

Giovanni Di Giacomo • Nicole Pouliart  
Alberto Costantini • Andrea De Vita

# Atlas of Functional Shoulder Anatomy

*Foreword by*  
James C. Esch

*Preface by*  
W. Ben Kibler

 Springer

---

# ATLAS OF FUNCTIONAL SHOULDER ANATOMY

---

Giovanni Di Giacomo • Nicole Pouliart • Alberto Costantini • Andrea De Vita  
Editors

# Atlas of Functional Shoulder Anatomy

 Springer

Giovanni Di Giacomo  
Concordia Hospital for Special Surgery  
Rome, Italy

Nicole Pouliart  
Vrije Universiteit Brussels  
Universitair Ziekenhuis Brussel  
Brussel, Belgium

Alberto Costantini  
Concordia Hospital for Special Surgery  
Rome, Italy

Andrea De Vita  
Concordia Hospital for Special Surgery  
Rome, Italy

Library of Congress Control Number: 2008522466

ISBN 978-88-470-0758-1 Springer Milan Berlin Heidelberg New York e-ISBN 978-88-470-0759-8

Springer is a part of Springer Science+Business Media  
springer.com  
© Springer-Verlag Italia 2008

This work is subject to copyright. All rights are reserved, whether the whole or part of the material is concerned, specifically the rights of translation, reprinting, re-use of illustrations, recitation, broadcasting, reproduction on microfilms or in other ways, and storage in data banks. Duplication of this publication or parts thereof is only permitted under the provisions of the Italian Copyright Law in its current version, and permission for use must always be obtained from Springer. Violations are liable for prosecution under the Italian Copyright Law.

The use of general descriptive names, registered names, trademarks, etc., in this publication does not imply, even in the absence of a specific statement, that such names are exempt from the relevant protective laws and regulations and therefore free for general use.

Product liability: The publisher cannot guarantee the accuracy of any information about dosage and application contained in this book. In every individual case the user must check such information by consulting the relevant literature.

Cover design: Simona Colombo, Milan, Italy  
Typesetting: Graphostudio, Milan, Italy  
Printing: Grafiche Porpora, Segrate, Italy

*Printed in Italy*  
Springer-Verlag Italia S.r.l., Via Decembrio 28, I-20137 Milan, Italy

*To my father Dr. Sergio Di Giacomo, and in memory  
of my friends Dr. Richard B. Caspari, and Dr. Douglas T. Harryman, II*  
Giovanni Di Giacomo

*To teachers and mentors who have inspired me  
to keep delving deeper for knowledge*  
Nicole Pouliart

*To my family, to my love Andrea and Stefano*  
Alberto Costantini

*To my family and to my teachers Giovanni and Alberto*  
Andrea De Vita

*We wish to express our grateful thanks to Mauro Fermariello for providing the scientific images,  
and to Valeria Di Spirito, Barbara Pucci and Sonia Errera for their editorial assistance.  
Credit must be given to Prof. Dr. F. Anderhuber of the Anatomical Institute of Karl-Franzens-University, Graz,  
and Prof. Dr. W. Firbas of the Institute of Anatomy of the University of Vienna (Austria) for their support  
to the realization of the book images.*

---

## Foreword

*Functional Anatomy of the Shoulder* gives the shoulder surgeon a fresh look and feel for shoulder anatomy. The endless energy and the inquisitive nature that characterise Dr. Di Giacomo and his team are evident in every dissection and image in this book. His meticulous dissections and crisp photography give the reader a clear insight into the functional anatomical relationships of this elegant piece of machinery called the shoulder. He shows us how the stabilization and movement muscles provide power and motion and how it is that the ligament changes, which send signals to the brain, masterfully regulate the freedom of movement we enjoy throughout our lives with a minimal amount of pain and problems. The discerning clear photography of clean dissections gives new life to anatomical structures.

I have had the opportunity of viewing all the excellent images and listening to the Authors' descriptions of the biceps pulley and shoulder proprioception over the past several years. It pleases me that they have taken it upon their shoulders to share their expertise and enthusiasm. This is an exciting, essential book for everyone who is interested in the shoulder.

*James C. Esch, MD*  
President, San Diego Shoulder Institute  
Assistant Clinical Professor, Department of Orthopaedics  
University of California  
San Diego, School of Medicine  
Tri-City Orthopaedics  
Oceanside, CA, USA

---

## Preface

Dr. Di Giacomo and his team have undertaken a very important task – the production of a book on shoulder anatomy that relates the static description of the anatomy to the dynamic function of the shoulder. This book has done an excellent job of showing the anatomy of the individual structures around the shoulder in a beautiful series of pictures and then relating this anatomy to the developing knowledge of how the shoulder functions as a dynamic, integrated whole. In addition, this book emphasizes the relation of shoulder anatomy and function to the larger kinetic chain that supports, guides, and provides force for shoulder function.

This book will serve two purposes. It is the newest and freshest addition to shoulder anatomy books, and it will serve to show the clinician the importance of a deep knowledge of functional anatomy as a basis for understanding how the shoulder works in function. With this knowledge, the clinician can better understand dysfunction – the combination of structural deficits that brings the patient to treatment. In addition, this knowledge of function will allow a framework of treatment that will restore the pertinent anatomy.

I am glad Dr. Di Giacomo's team has produced this work. It should become a standard reference for clinicians who will treat shoulder injuries. It will give doctors much more information with which they can effectively treat patients.

*W. Ben Kibler, MD FACSM*  
Medical Director  
Lexington Clinic Sports Medicine Center  
Lexington, KY, USA

---

# Contents

<b>List of Contributors</b> .....	XV
-----------------------------------	----

## **PART 1 - SCAPULOTHORACIC JOINT**

*Andrea De Vita, W. Ben Kibler, Nicole Pouliart, Aaron Sciascia*

<b>1.1 Muscles for Scapulothoracic Control: Role of the Scapula</b> .....	2
1.1.1 Serratus Anterior Muscle .....	4
1.1.2 Trapezius Muscle .....	6
1.1.3 Pectoralis Minor Muscle .....	8
1.1.4 Biomechanics and Functional Anatomy .....	8
1.1.5 Clinical Relevance .....	14
<b>1.2 Latissimus Dorsi Muscle</b> .....	16
<b>1.3 Pectoralis Major Muscle</b> .....	18
1.3.1 Biomechanics and Functional Anatomy .....	18
1.3.2 Clinical Relevance .....	20
<b>References</b> .....	24

## **PART 2 - ACROMIOCLAVICULAR JOINT AND SCAPULAR LIGAMENTS**

*Alberto Costantini*

<b>2.1. Introduction</b> .....	28
2.1.1 Acromioclavicular and Coracoclavicular Ligaments .....	32
2.1.2 Biomechanics and Functional Anatomy .....	34
2.1.3 Clinical Relevance (Acromioclavicular Joint Separations) .....	40
<b>2.2. Scapular Ligaments</b> .....	48
2.2.1 The Coracoacromial Ligament ( <i>Ligamentum Coracoacromial</i> ) .....	48
2.2.2 The Superior Transverse Ligament ( <i>Ligamentum Transversum Scapulae Superius</i> ; Transverse or Suprascapular Ligament) .....	52



2.2.3 The Inferior Transverse Ligament ( <i>Ligamentum Transversum Scapulae Inferius</i> ; Spinoglenoid Ligament) .....	56
References .....	58

## PART 3 - GLENOHUMERAL JOINT (MUSCLE-TENDON)

<b>3.1 Deltoid Muscle</b> .....	62
<i>Andrea De Vita</i>	
3.1.1 Biomechanics and Functional Anatomy .....	64
3.1.2 Clinical Relevance .....	68
<b>3.2 Rotator Cuff</b> .....	70
<i>Alberto Costantini, Hiroshi Minagawa</i>	
3.2.1 The Subscapularis (Muscle-Tendon) .....	72
3.2.2 The Supraspinatus (Muscle-Tendon) .....	74
3.2.3 The Infraspinatus (Muscle-Tendon) .....	86
3.2.4 The Teres Minor (Muscle-Tendon) .....	86
3.2.5 Anatomy of the Rotator Cuff Insertion .....	88
3.2.6 Biomechanics and Functional Anatomy of the Rotator Cuff .....	90
3.2.7 Clinical Relevance .....	96
<b>3.3 The Long Head of the Biceps</b> .....	100
<i>Alberto Costantini</i>	
References .....	106

## PART 4 - GLENOHUMERAL CAPSULE

<b>4.1 Fibrotendinous Cuff of the Capsule</b> .....	110
<i>Giovanni Di Giacomo</i>	
<b>4.2 Superior (Glenohumeral Ligament) Complex</b> .....	114
<i>Giovanni Di Giacomo, Nicole Pouliart</i>	
4.2.1 Coracohumeral Ligament .....	120
4.2.2 Superior Glenohumeral Ligament .....	126
4.2.3 Coracoglenoid Ligament .....	130
4.2.4 Posterosuperior Glenohumeral Ligament .....	132

4.2.5	Rotator Cable .....	134
4.2.6	Rotator Cuff Interval .....	138
4.2.7	Biceps Pulley .....	142
4.2.8	Arthroscopic Description of the Anterosuperior Structures .....	146
4.2.9	Biomechanics and Functional Anatomy of Superior Glenohumeral Ligament Complex .	150
4.2.10	Clinical Relevance of the Superior Glenohumeral Capsule .....	158
<b>4.3</b>	<b>Anterior and Inferior Glenohumeral Capsuloligamentous Complex .....</b>	<b>162</b>
	<i>Nicole Pouliart</i>	
4.3.1	Middle Glenohumeral Ligament .....	162
4.3.2	Fasciculus Obliquus .....	164
4.3.3	Inferior Glenohumeral Ligament Complex .....	166
4.3.4	Synovial Recesses .....	170
4.3.5	Biomechanics and Functional Anatomy of the Anteroinferior Glenohumeral Complex ....	176
4.3.6	Clinical Relevance .....	180
4.3.7	Glenoid and Humeral Insertion of the Capsule .....	182
4.3.8	Glenoid Labrum .....	186
4.3.9	Biomechanics of the Glenoid Labrum .....	188
4.3.10	Clinical Relevance .....	192
4.3.11	Conclusions .....	194
	<b>References .....</b>	<b>198</b>

## PART 5 - NEUROMUSCULAR CONTROL AND PROPRICEPTION OF THE SHOULDER

### Introduction

*Scott M. Lephart*

<b>5.1</b>	<b>Mechanoreceptors of the Shoulder Joint: Structure and Function .....</b>	<b>206</b>
	<i>Zdenek Halata, Klaus L. Baumann</i>	
5.1.1	Innervation of the Shoulder Joint .....	206
5.1.2	Sensory Nerve Endings in Muscles .....	210
5.1.3	Sensory Nerve Endings in the Joint Capsule .....	212
<b>5.2</b>	<b>The Role of “Proprioception” in Shoulder Disease .....</b>	<b>216</b>
	<i>Giovanni Di Giacomo, Todd S. Ellenbecker</i>	
	<b>References .....</b>	<b>228</b>

---

## List of Contributors

Klaus L. Baumann

Institute of Experimental Morphology, University of Hamburg, Hamburg, Germany

Alberto Costantini, MD

Arthroscopic Surgery Department, Concordia Hospital for Special Surgery, Rome, Italy

Andrea De Vita, MD

Assistant

Arthroscopic Surgery Department, Concordia Hospital for Special Surgery, Rome, Italy

Giovanni Di Giacomo, MD

Director

Arthroscopic Surgery Department, Concordia Hospital for Special Surgery, Rome, Italy

Todd S. Ellenbecker, DPT, MS, SCS, OCS, CSCS

Clinic Director

Physiotherapy Associates Scottsdale Sports Clinic, Scottsdale, Arizona USA

National Director of Clinical Research, Physiotherapy Associates, Philadelphia, PA, USA

Zdenek Halata

Institute of Experimental Morphology, University of Hamburg, Hamburg, Germany

Department of Anatomy, First Faculty of Medicine, Charles University Prague, Prague, Czech Republic

W. Ben Kibler, MD FACSM

Medical Director

Lexington Clinic Sports Medicine Center, Lexington, KY, USA

Scott M. Lephart, PhD

Director

Neuromuscular Research Laboratory, Department of Sports Medicine and Nutrition,  
School of Health and Rehabilitation Sciences, University of Pittsburgh, PA, USA

## **XVI** List of Contributors

---

Hiroshi Minagawa, MD

Department of Orthopedic Surgery, Akita University School of Medicine, Akita, Japan

Nicole Pouliart, MD, PhD

Department of Human Anatomy, Vrije Universiteit Brussel

Department of Orthopaedics and Traumatology, Universitair Ziekenhuis Brussel, Brussel, Belgium

Aaron Sciascia, MS, ATC, NS

Program Coordinator

Lexington Clinic Sports Medicine Center, KY, USA

---

# **PART 1 - SCAPULOTHORACIC JOINT**

*Andrea De Vita, W. Ben Kibler, Nicole Pouliart, Aaron Sciascia*

## 1.1 Muscles for Scapulothoracic Control: Role of the Scapula

The scapula is anatomically and biomechanically involved in shoulder function and movement of the arm [1]. During the process of shoulder and arm movement to achieve a change in glenohumeral position and during movements required in athletic and daily activities, the two are linked (Fig. 1.1).

To obtain a correct three-dimensional (3D) movement of the shoulder girdle and upper arm the scapula rotates upwards, tilts to the back and rotates externally [2, 3], the clavicle elevates and retracts [3, 4] and the humerus elevates and rotates externally [5].

Scapula, shoulder and arm are either stabilised in or moved into a certain position to generate, absorb and transfer forces that accomplish work or athletic tasks. An alteration in the scapular position at rest or during arm movement is commonly associated with injuries that create clinical dysfunction of the shoulder. These alterations, which may be the result of injury or may exacerbate an existing injury, are called scapular dyskinesis [6], a generic term describing the loss of scapular motion and position control observed upon clinical examination.

The scapula has four roles in the shoulder complex. The first is as an integral part of the glenohumeral articulation, which

cinematically is a ball-and-socket configuration. To maintain this configuration, the scapula must move in coordination with the moving humerus, so that the instant centre of rotation is constrained within a physiological pattern throughout the full range of shoulder motion [7, 8].

The second role of the scapula is to provide motion along the thoracic wall. Scapular retraction creates a stable base so that the abducted or elevated arm can perform tasks requiring actions such as reaching, pushing or pulling.

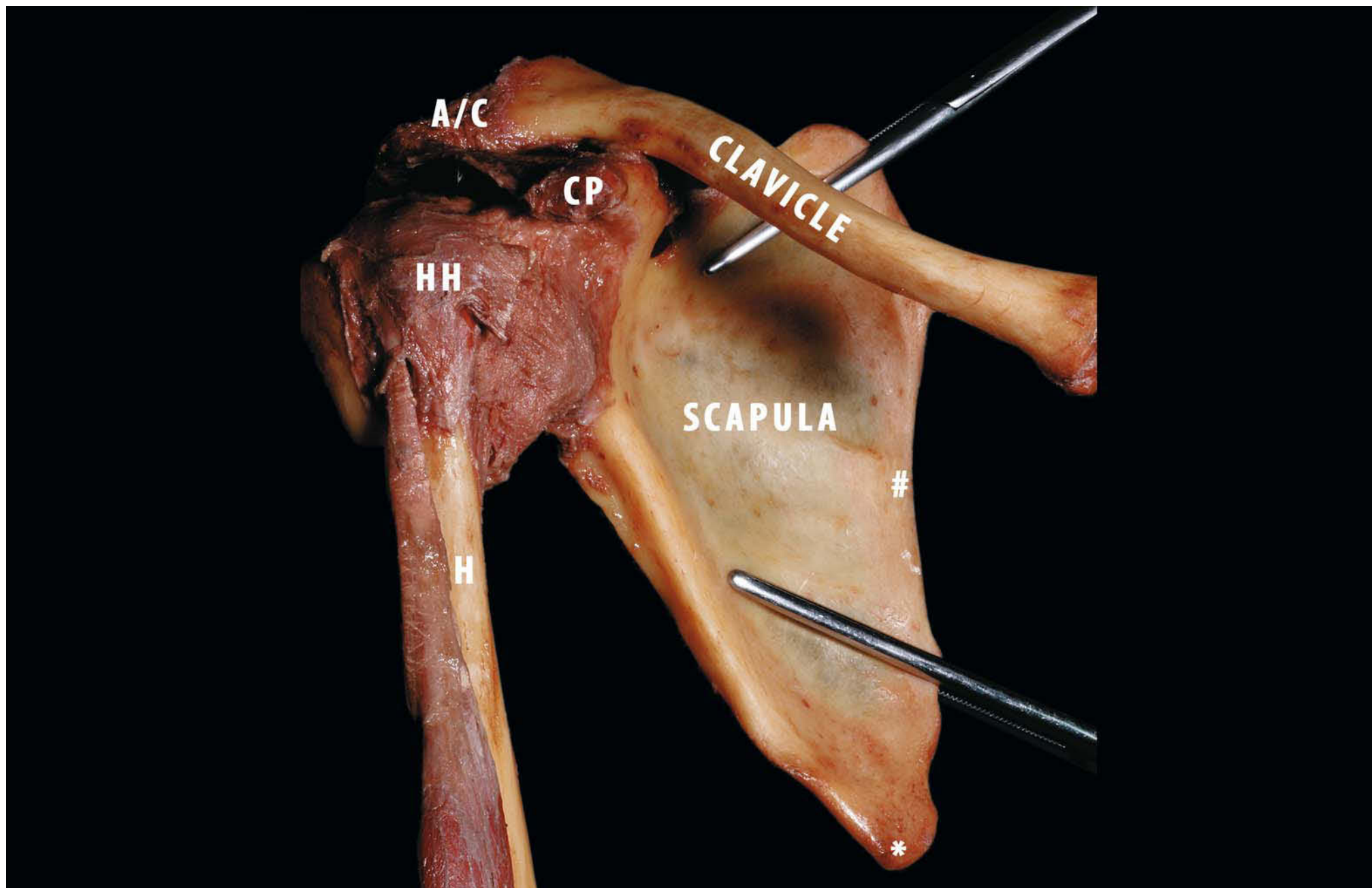
The third role of the scapula in shoulder function is the elevation of the acromion, which occurs during the cocking and acceleration phases of throwing or elevation of the arm, so as to separate it from the rotator cuff during movement and to decrease impingement and coracoacromial arch compression [9, 10].

The scapula's final role in shoulder function is to act as a link between proximal and distal parts of the body in order to transfer large forces and high energy from the legs, back and trunk to delivery points, such as the arm and the hand [11, 12].

It is absolutely necessary that the scapula have a good system of muscle activation in order to best perform these functions.

The serial muscle activation patterns stabilise the scapula and increase control over its movement and position as the arm is moved [1].

**Fig. 1.1.** Anterior view of the right shoulder. This view illustrates the three bones of the shoulder girdle: the scapula, the humerus (*H*), and the clavicle. The scapula is the link between the thorax and the superior arm (*HH* humeral head, *A/C* acromioclavicular joint, *CP* coracoid process, \*inferior angle of the scapula; #medial border of the scapula)



### 1.1.1 Serratus Anterior Muscle

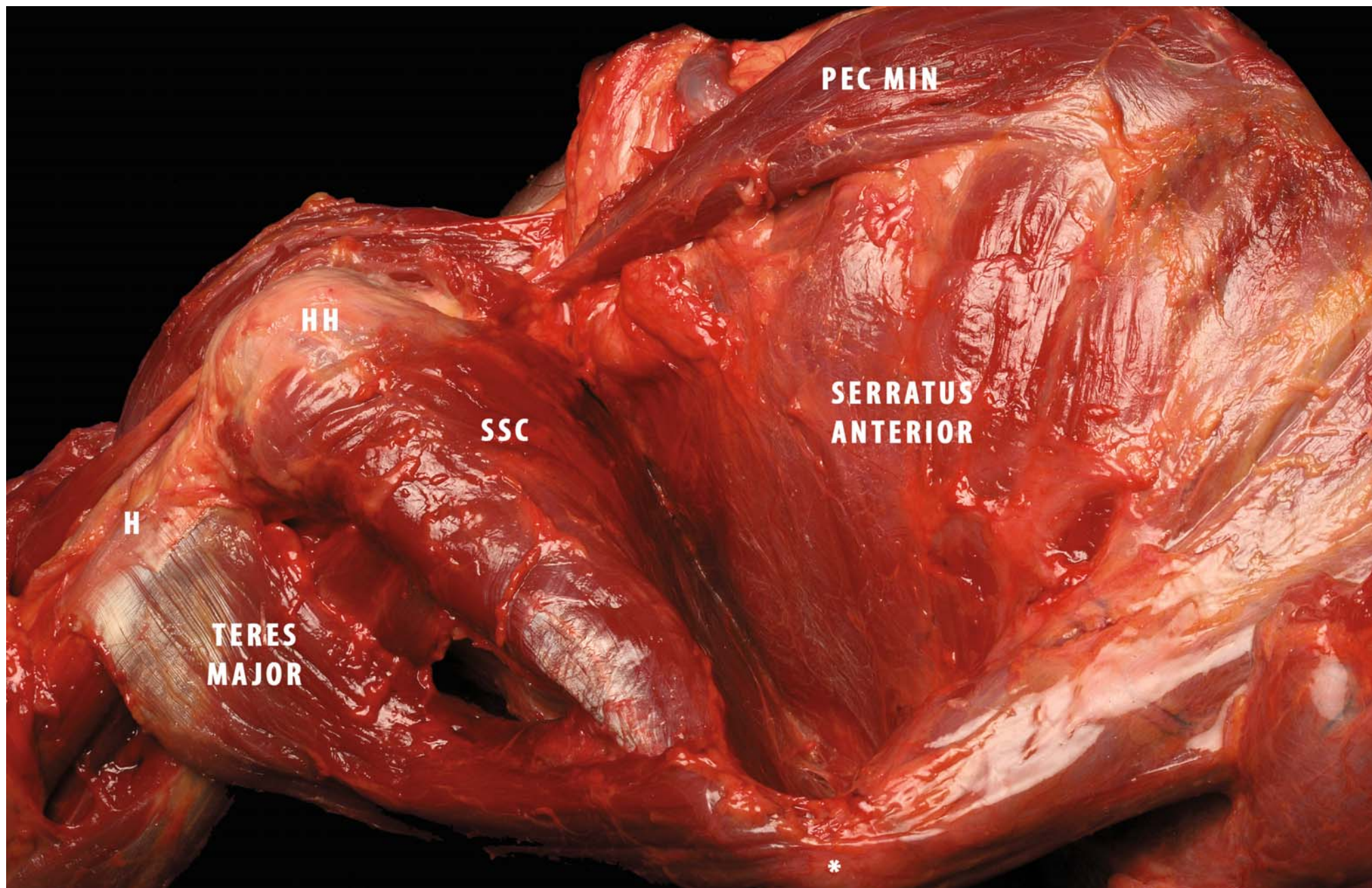
The serratus anterior muscle is a large muscle covering much of the lateral aspect of the thorax (Fig. 1.2). In bipedal animals, the serratus anterior complex acts together with the trapezius to provide a very strong, mobile base of support designed to optimise the glenoid position so that maximally effective use of the entire upper extremity is attained [17]. Its fleshy fibres arise from the outer surfaces of the upper nine ribs. There are three major functional portions to this muscle.

Concealed in the axilla by the pectoralis major muscle, the superior cylindrical mass accounts for 40-50% of the wet weight of the serratus anterior muscle. Attached to the main rotation axis at the superior medial border of the scapula, this large, powerful mass is a necessary anchor allowing the rotation required to lift the arm over the head. This portion of the serratus anterior muscle arises from the first, second and part of the third ribs, and the intervening fascia. It travels laterally, insert-

ing in the superior medial angle of the scapula, where it forms the ventral part of the rotation axis. This scapular axis is completed by the trapezius muscles situated in the back and attached to the acromial spine base. The second portion of the serratus anterior is a long, thin, wide band of muscle originating from the third, fourth and fifth ribs and inserting in the vertebral border of the scapula. The fibres of this part of the muscle help to draw the scapula forward. The third functional part of the serratus anterior made up of the lower five slips. These originate from the sixth to the tenth ribs, run up and down along the chest wall and converge on the inferior angle of the scapula. These lower slips are subcutaneous and easily visible in muscular individuals. Innervation is supplied by the long thoracic nerve (C5, C6, C7) [18]. The blood supply to the serratus muscle is classically stated to come through the lateral thoracic artery. There is often a large contribution from the thoracodorsal artery, especially when the lateral thoracic artery is small or absent [19].

**Fig. 1.2.** Lateral view of the thorax (right side). This view illustrates the origin of the serratus anterior muscle from the ribs and its insertion to the medial border of the scapula. The inferior angle of the scapula (\*) is the common insertion for different scapulothoracic and glenohumeral muscles (*PEC MIN* pectoralis minor, *SSC* subscapularis muscle, *HH* humeral head, *H* humerus)



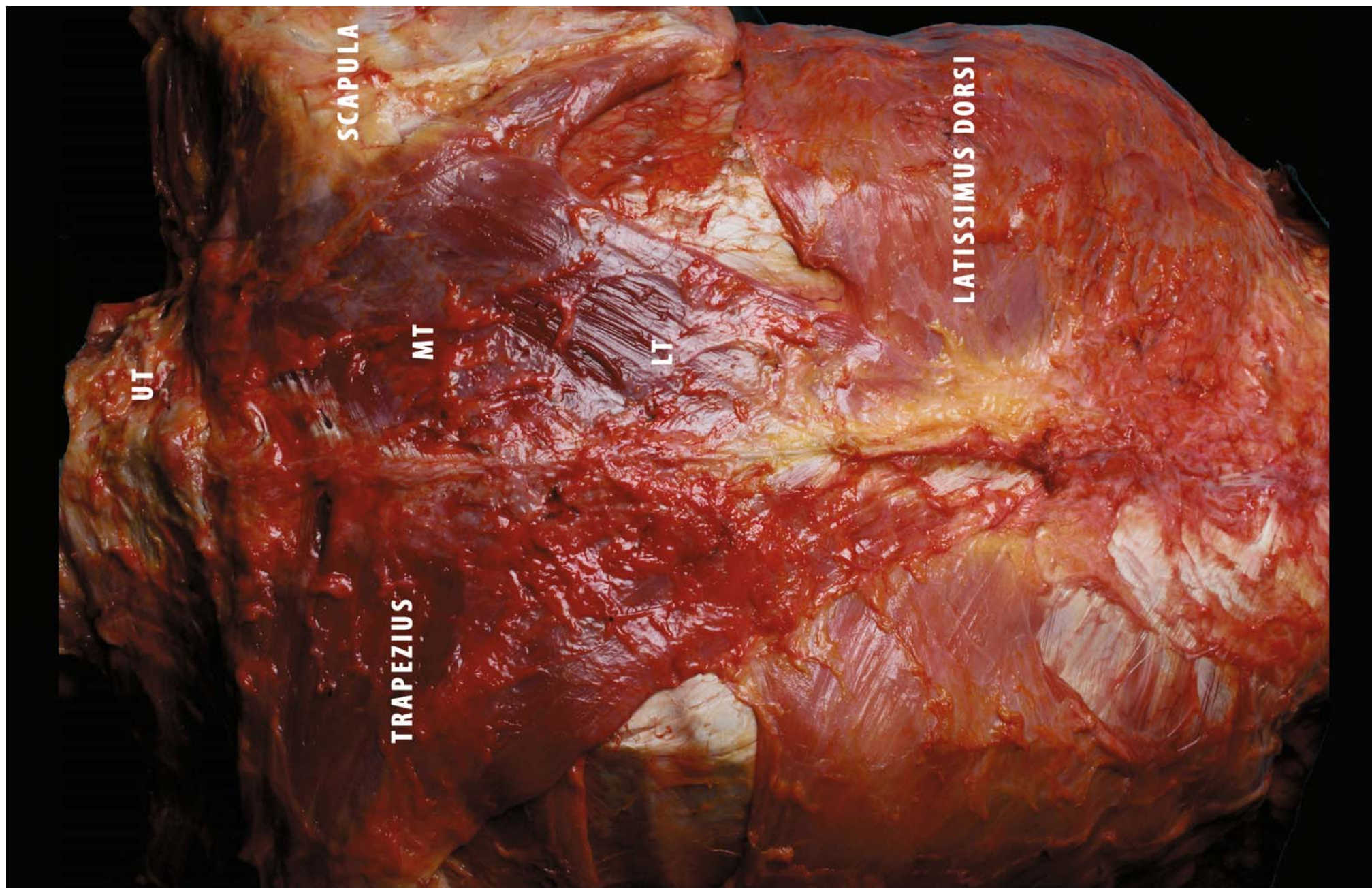


### 1.1.2 Trapezius Muscle

The trapezius muscle is the largest and most superficial scapulothoracic muscle on the back of the thorax (Fig. 1.3). Many authors have been confused about the anatomical description and functions of this muscle. Little attention is paid to the morphology of the trapezius and its lines of action in biomechanics literature. Its origin comes from the nuchal ligament through the T-12 vertebra. The muscle is subdivided into upper, middle and lower portions. The upper portion originates from the occiput and the nuchal ligament, as far as C-6. Beyond the C-7 level all fascicles are directed to the clavicle. They are attached along the posterior border of the distal third of the bone, as seen in the case of the fascicle from the superior nuchal line. This last assumes the most anterior attachment, followed in sequence by the fascicles from the upper and then the lower half of the nuchal liga-

ment. The fibres arising from the C-6 spinous process insert into the distal corner of the clavicle as far as the acromioclavicular joint. The middle and lower portions originate from the dorsal spines of the C-7 through T-12 vertebra. The lower cervical and upper thorax fibres (C7–T1) insert in the inner border of the acromion (C-7) and the spine of the scapula (T-1). The lower portion of the muscle inserts at the base of the scapular spine. The fascicles from T-2 to T-5 converge in a common aponeurotic tendon attached to the deltoid tubercle of the scapula. Fascicles from T-6 to T-12 insert in the medial border of the deltoid tubercle. The deep surface of the trapezius muscle touches the rhomboid and other muscles; on the back it is covered by fat and skin [20]. The blood supply usually derives from the transverse cervical artery or from the dorsal scapular artery. The accessory spinal nerve (CN XI) provides motor support, with some sensory branches contributed by C-2, C-3 and C-4 [19].

**Fig. 1.3.** Posterior view of the thorax. This view illustrates the trapezius muscle. The origin comes from the nuchal ligament to T-12. The wide origin of the large muscle is closely related to other muscles on the back of the thorax (*UT* upper trapezius, *MT* middle trapezius, *LT* lower trapezius)



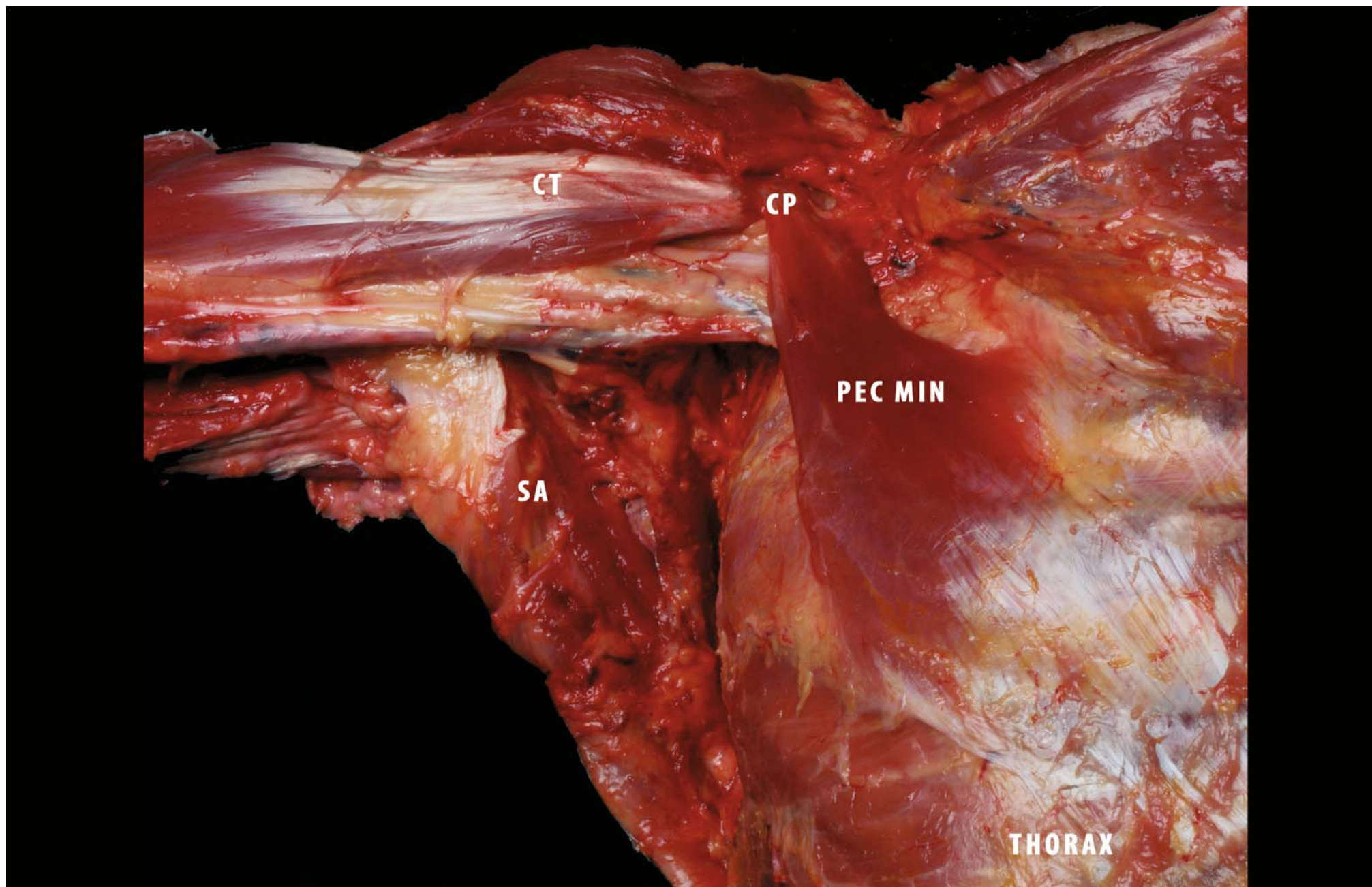
### 1.1.3 Pectoralis Minor Muscle

The pectoralis minor muscle is triangular. It is positioned under the pectoralis major muscle on each side of the thorax (Fig. 1.4). The origin of the pectoralis minor is at the external surfaces of the third, fourth and fifth ribs, and occasionally the second to sixth ribs. The muscle, running superolaterally, and the tendon insert in the medial and superior surfaces of the coracoid process of the scapula. The fibres of the tendon seem to continue into the coracoglenoid and/or coracohumeral ligaments (see Chapter 4, section 4.2.3). Several authors have reported frequent (15%) aberrant slips of the tendon to the humerus, glenoid, clavicle or scapula. Innervation is from the medial pectoral nerve, which passes through this muscle, which also receives motor supply from the lateral pectoral nerve. The blood supply comes through the pectoral branch of the thoracoacromial artery [19].

### 1.1.4 Biomechanics and Functional Anatomy

Scapular stabilisation on the thorax involves coupling of the upper and lower fibres of the trapezius muscle with the serratus anterior and pectoralis minor muscles [15]. Elevation of the scapula with arm elevation is accomplished through activation and coupling of the serratus anterior and lower trapezius muscles with the upper trapezius and pectoralis minor muscles [15, 16]. Divisions situated in the lower and in the middle part of the serratus anterior muscle are key contributors to normal and abnormal scapular motion and control [17, 21]. The serratus anterior muscle's insertion into the scapular vertebral border and inferior angle results in larger moment arms for production of scapular upward rotation and posterior tilting than in any of the other muscles linking scapula and thorax [21]. Thus, the serratus anterior muscle has been described as the prime mover of the scapula [20, 21]. This muscle has been historically identified

**Fig. 1.4.** Anterior view of the thorax (right side). This view illustrates the pectoralis minor muscle after removal of the pectoralis major muscle. The pectoralis minor is a triangular muscle on the deep surface of the pectoralis major. Its insertion is on the coracoid process (*CP*) with other tendons and ligaments (*CT* common tendon, *SA* serratus anterior muscle)

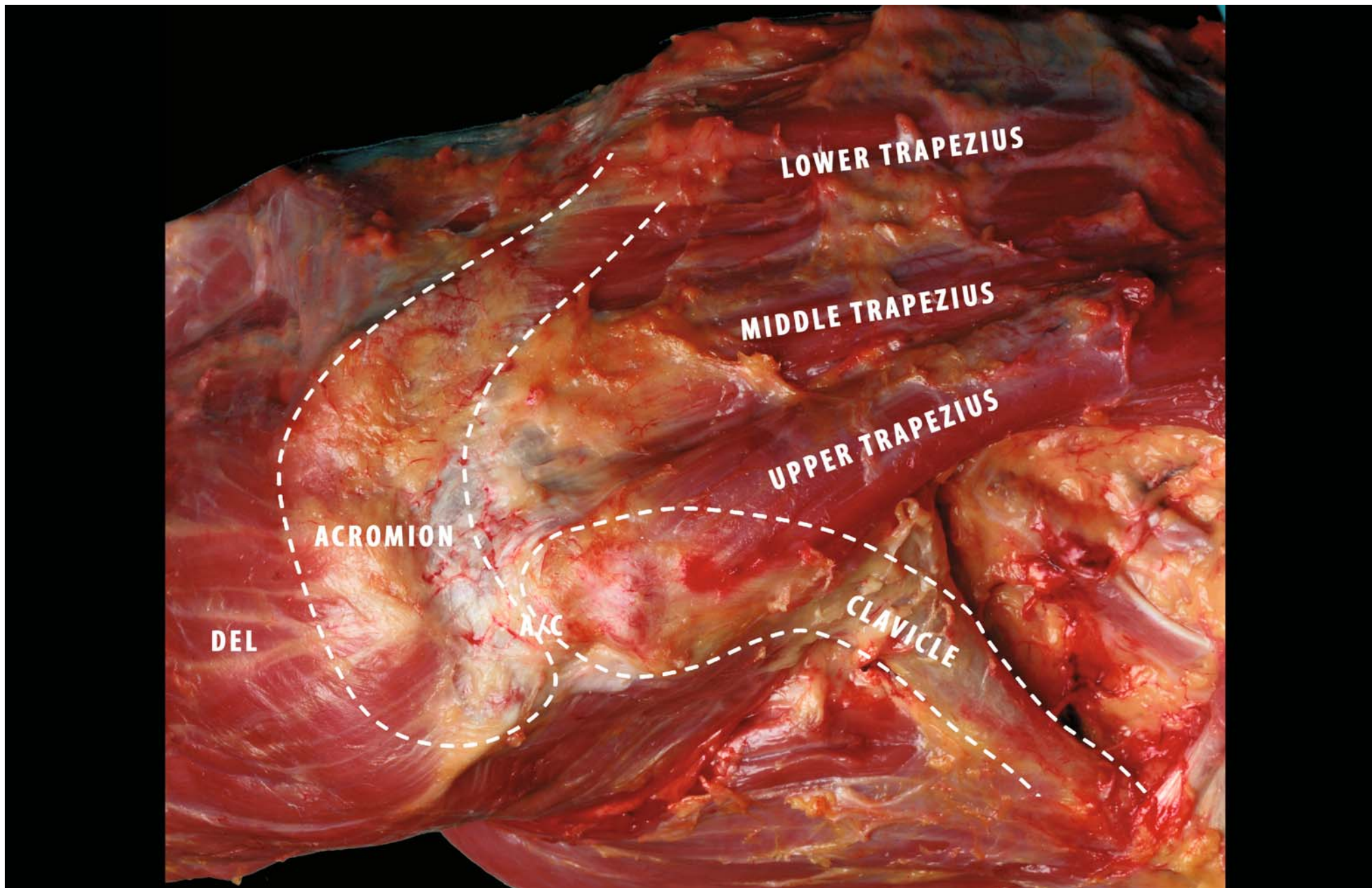


as a protractor of the scapula owing to high EMG activity elicited during various push-up manoeuvres [23, 24]. The serratus anterior is actually multi-faceted, and it contributes to all components of 3D motion of the scapula during arm elevation [2, 25]. Specifically, this muscle can produce upward rotation, posterior tilt and external rotation of the scapula while stabilising the vertebral border and inferior angle of the scapula to the thorax and preventing scapular “winging” [22]. The serratus anterior also has a role as a stabiliser of the scapula. The highest level of serratus anterior activation occurs in both the cocking phase of the throwing motion [25, 26] and the earliest stages of arm elevation [27]. It appears that a prime role of the serratus in these activities is as an external rotator/stabiliser of the scapula in arm motion.

It is generally accepted that the three parts of the trapezius muscle, together with the serratus anterior muscle, are important in so far as they act as a force couple providing movement and dynamic stability of the scapula [16, 17, 28, 29]. However, within this force couple, the upper, middle and lower parts of the trapezius muscle are involved in different ways [20].

As the serratus anterior muscle contracts, its force tends to draw the scapula laterally around the chest wall, but lower fibres of the trapezius muscle, which operate at a constant length to stabilise the rotation axis, resist this displacement. The role of the upper part of the trapezius muscle is uncertain. It is evident from this pattern that the nuchal portion of the trapezius is not involved in elevating the scapula, as its fibres act on the clavicle and not on the scapula. Even so, its fibres are oriented transversely as if drawing the clavicle backwards or medially, but not upwards. In an anatomical study by Johnson et al. [20], the authors suppose that the transverse orientation of the fibres of the trapezius muscle can exert a medially directed moment on the clavicle on this axis, which would draw the lateral end of the clavicle medially and upwards. A consequence of this mechanism is that the sternoclavicular joint must sustain substantial compression loads and permit upward rotation of the scapula (in the same way as a fulcrum mechanism) (Fig. 1.5), enhancing the force of the serratus anterior muscle. The middle trapezius muscle fibres, although strong, lie very close to the rotation axis of the scapula.

**Fig. 1.5.** Superior view of the shoulder complex (right side). This view illustrates the insertion of the upper trapezius on the posterior border of the third distal of the clavicle. The *dotted line* shows the bony profile of the clavicle and the acromion. Biomechanical function of the upper portion of the trapezius helps to rotate the scapula upwards during arm elevation (A/C acromion/clavicular joint, DEL deltoid muscle)



Therefore, their ability to generate an upward rotator moment is compromised by relatively short moment arms. On the basis of their data, several authors have concluded that the middle and lower fibres maintain horizontal and vertical equilibrium of the scapula rather than generating net torque. This stabilising role of the middle and lower trapezius muscle parts has also been suggested by several authors [29, 30–32].

The pectoralis minor muscle has an important role, in conjunction with the serratus anterior and trapezius muscles, in stability and motion of the scapula. The force couple created from three muscles is important to obtain the correct orientation of the scapula on the thoracic wall.

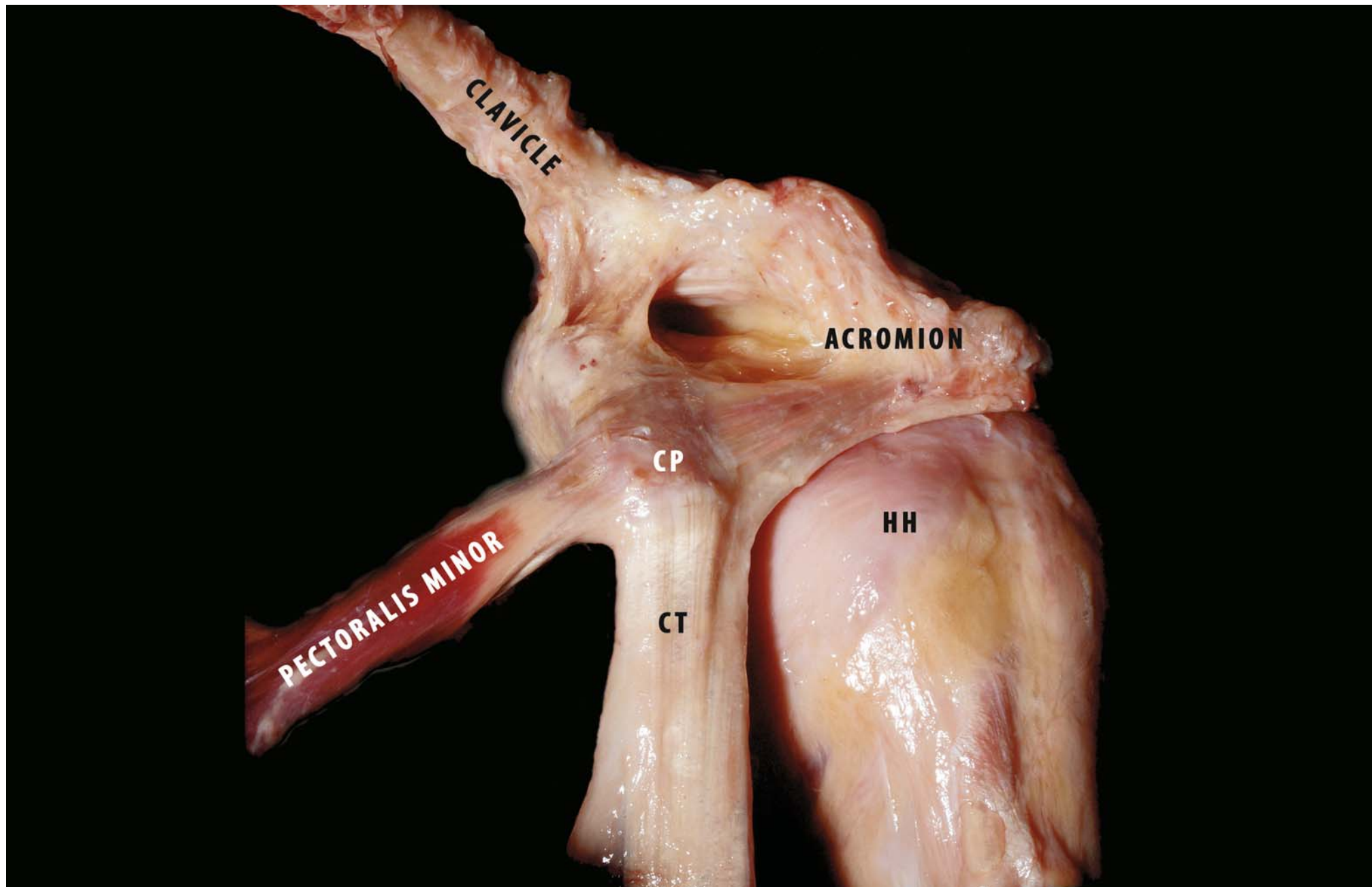
The main action of the pectoralis minor is the protraction of the scapula around the thorax. It works in conjunction with the serratus anterior muscle to keep the scapula close to the thorax as the latter draws it forward. Normally the pectoralis minor muscle elongates during arm elevation, allowing the scapula to rotate upwards and outwards and tilt backwards [33, 34] (Fig. 1.6). Optimal functioning of the stabilising muscles depends not only on the force production of these muscles in relation to synergists, antagonists, and prime movers of the

joint, but also on the correct timing of muscle activation [32]. The scapular position that allows optimal muscle activation to occur is the retraction and external rotation. Scapular retraction is an essential and integral part of normal scapulohumeral rhythm in coupled shoulder motions and functions [14, 34, 35]. It results from synergistic muscle activation in patterns from the hip and trunk through the scapula to the arm, which then facilitates maximal muscle activation of the muscles attached to the scapula [1, 36]. The retracted scapula can then act as a stable base for the origins of all the rotator cuff muscles [1, 37].

Protraction has been shown to limit both muscle strength and motion [38, 39]. Kebatse et al. [38] have shown that excessive scapular protraction, which is frequently seen in injured patients as part of scapular dyskinesis, decreases maximum rotator cuff activation by 23%. Smith et al. [40] report that maximal rotator cuff strength is achieved in association with a position of “neutral scapular protraction/retraction” and that positions of excessive protraction or retraction demonstrate decreased rotator cuff abduction strength. Kibler et al. [37] have shown that the strength of the supraspinatus increases by up to 24% in a position of scapular retraction in patients with shoulder pain.

**Fig. 1.6.** Anterolateral view of the left shoulder. View of insertion of the pectoralis minor muscle on the coracoid process (CP) on the anterior aspect of the shoulder. The pectoralis minor pulls the scapula in the anterior direction. During arm elevation the muscle is relaxed to permit correct positioning of the scapula around the chest wall (CT common tendon, HH humeral head)





### 1.1.5 Clinical Relevance

An alteration in muscle activation causes “scapular dyskinesis.” Scapular dyskinesis has been defined as an abnormal static scapular position or dynamic scapular motion (2nd Scapula Summit, Lexington, KY 2006) characterised by:

- a) Medial border prominence or inferior angle prominence and/or
- b) Early scapular elevation or shrugging and/or
- c) Rapid downward rotation during lowering (Fig. 1.7).

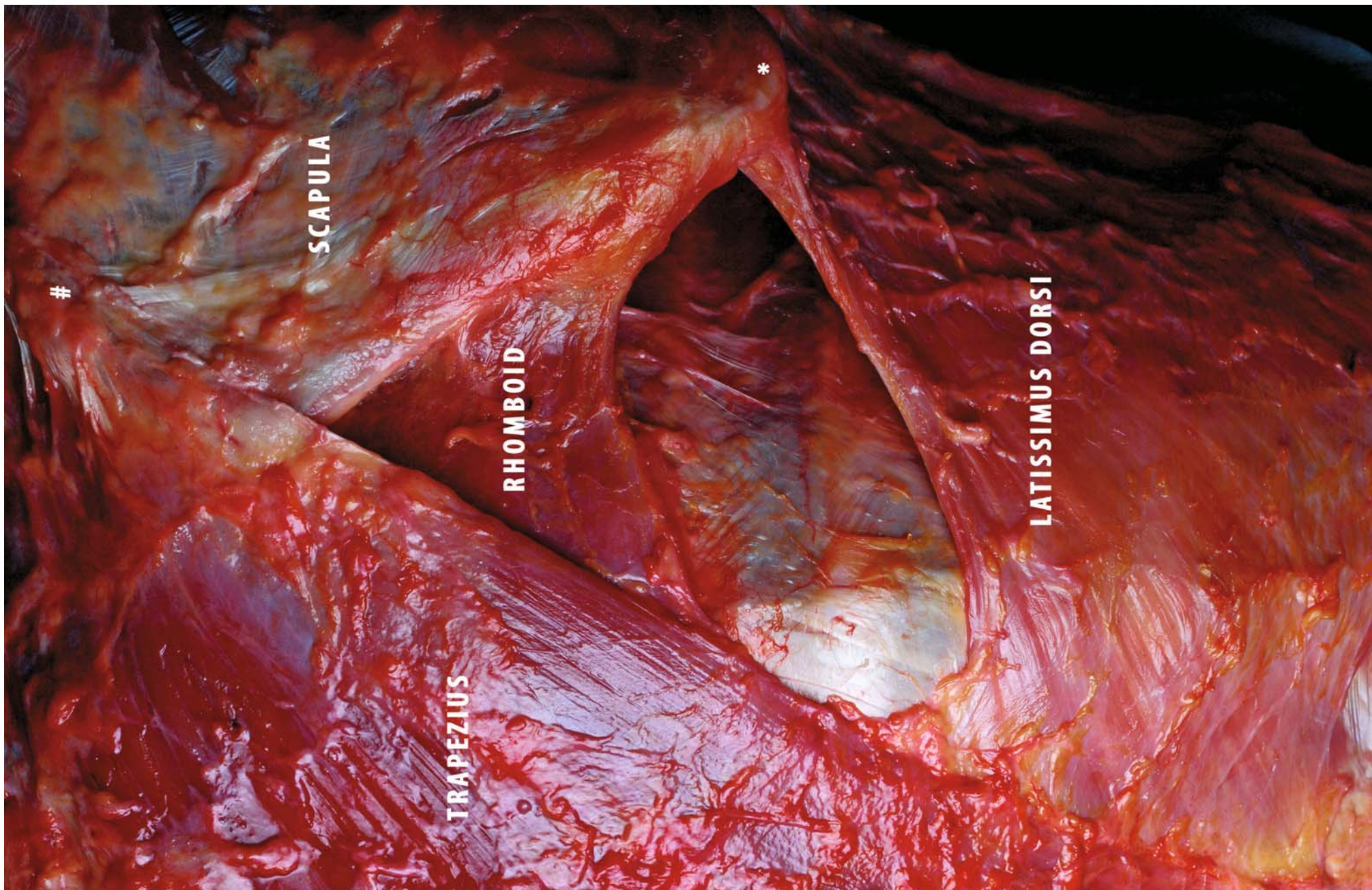
There are many possible causes of such an alteration, and they can be loosely grouped into proximal (to the shoulder) and distal causes [41]. Most proximal causes are due to nerve or muscle injury, while the majority of distal causes result from glenohumeral joint injury.

While each muscle attached to the scapula makes a specific contribution to scapular function, the lower trapezius and serratus anterior muscles appear to play the major role in stabilisation of the scapula during arm movement [9, 15]. Weakness, fatigue, or injury in either of these muscles may cause disruption of the dynamic stability, which can lead to abnormal kinematics [9, 25, 29, 32, 40]. Injury to the spinal accessory nerve can alter the function of the trapezius, while injury to the long thoracic nerve can alter muscle function of the serratus anterior muscle, which can cause abnormal stabilisation and control. Muscle inhibition or weakness has been seen in cases of glenohumeral instability, labral pathology [42], rotator cuff tear and

arthrosis [25, 43]. The lower trapezius and serratus anterior muscles are the most susceptible to the effects of inhibition and fatigue [5, 9, 43]. Inhibition is seen as a decreased ability of the muscles to exert torque and stabilise the scapula together with disorganisation of normal muscle firing patterns [25, 43]. The exact nature of the inhibition is unclear. The nonspecific response and the altered motor patterns suggest a proprioceptively based mechanism [44, 45].

Scapular dyskinesis is often the result of altered muscle activation patterns. Increased trapezius activity with decreased serratus anterior activity has been reported in patients with impingement [9]. A relatively short pectoralis minor muscle, as a result of adaptation, would demonstrate less total excursion than a relatively longer muscle [34, 46], limiting full scapular motion [33]. Similar studies examining patients with shoulder pain demonstrate decreased serratus activity and suggest that an improperly functioning serratus anterior muscle may be a contributory factor in shoulder dysfunction [25, 47]. Other authors who have reported demonstrable serratus activity have also reported excessive upper trapezius muscle activity [9, 10]. The imbalance between the upper trapezius and serratus anterior muscles creates an alteration in muscle activation, which allows excessive superior translation of the scapula or shrugging to occur during arm elevation [48]. Shrugging essentially creates an environment in which impingement can arise, accounting for the existence of shoulder pain.

**Fig. 1.7.** Posterior view of the thorax (right side). View of the scapula during arm elevation. The serratus anterior muscle pulls the scapula laterally around the thorax, and the lower trapezius stabilises the scapula to perform upward rotation (\*inferior angle of the scapula, #deltoid tubercle of the scapula)



## 1.2 Latissimus Dorsi Muscle

The latissimus dorsi muscle is a long muscle on the back of the thorax, which has a very important role in shoulder stability (Fig. 1.8a). The proximal origin of the muscle is on the spinous processes of thoracic vertebrae 7–12, the thoracolumbar fascia, the iliac crest, and the lower ribs [49].

The main blood supply to the latissimus dorsi muscle is from the thoracodorsal artery, which is a maximum of 9 cm and a minimum of 6 cm in length. The muscle is innervated through the thoracodorsal nerve (C-6 and C-7) [19].

The most interesting part of the muscle is its attachment on the anterior part of the humerus. The tendon is attached to the humerus anteriorly on the lateral border of the crest of the lesser tubercle. The tendon is either wing-like or quadrilateral. The distal tendon structure is 41.4–62.8 mm wide, and the upper border of the tendon is 50.4–98.4 mm long (Fig. 1.8b). For biomechanical reasons, it is important to know the distance between the proximal border of the latissimus dorsi tendon and the cartilaginous rim of the humeral head.

The distance between the upper border of the tendon and the cartilage is 12.6–31.6 mm (mean  $21.1 \pm 5.11$  mm).

Most of the deep surface of the tendon of the latissimus dorsi is separated from the underlying tendon of the teres major muscle by a bursa. The teres major tendon inserts more medially on the lesser tubercle crest. The teres major muscle originates from the inferolateral part of the dorsal surface of

the scapula. In the same manner as the latissimus dorsi, it runs from its origin on the back to its humeral insertion. It winds round on itself and around the teres major [49–56].

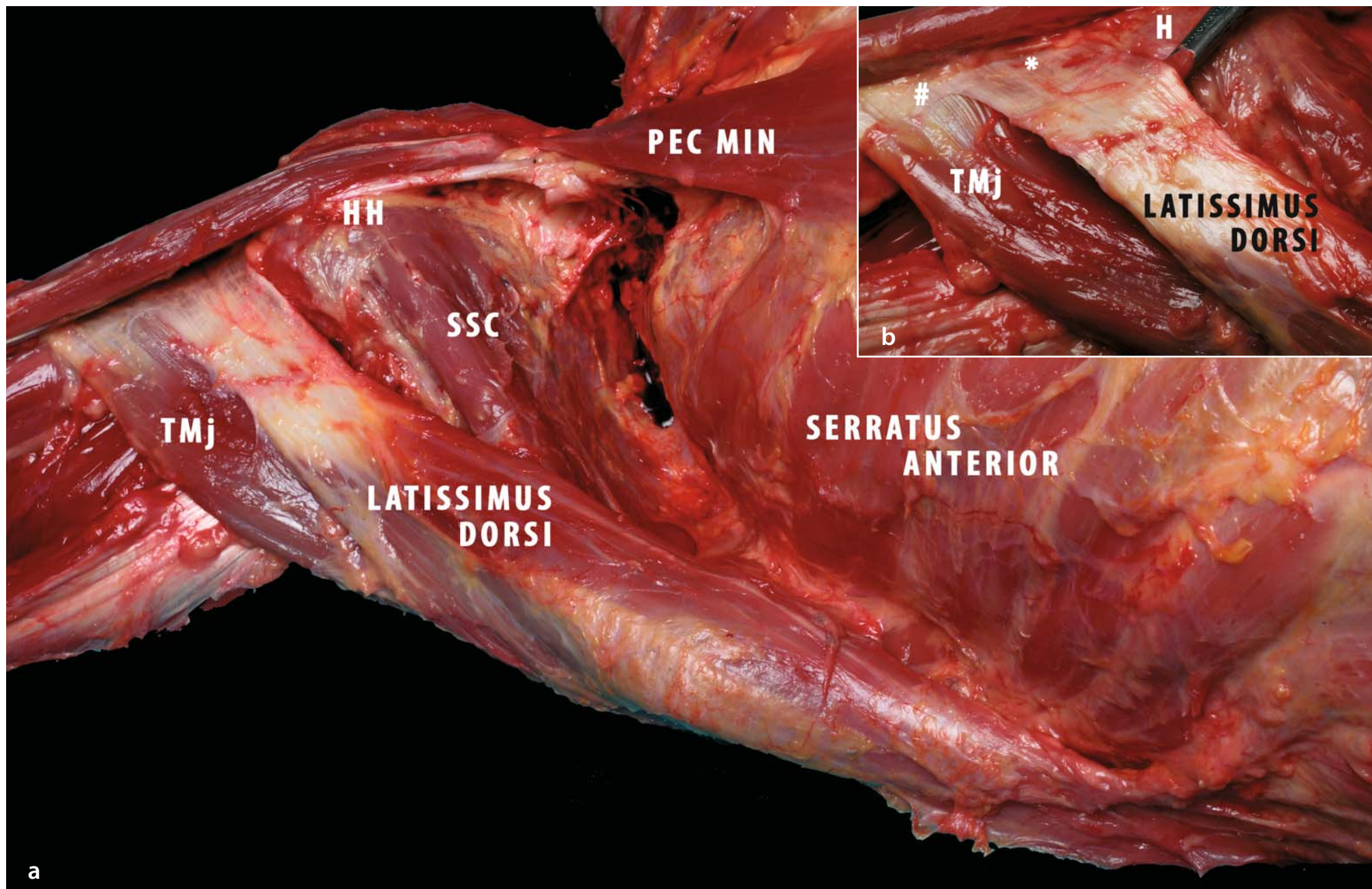
In an anatomical study published by Pouliart and Gagey [57] in *Clinical Anatomy*, the positions of the latissimus dorsi relative to the scapula in 100 specimens dissected is described.

The latissimus dorsi crosses the inferior angle of the scapula. The authors observed three different variants in the relative positions of the latissimus dorsi muscle and the inferior angle of the scapula. They described type 1, type 2a and type 2b scapular connections [57].

In 43 of the 100 specimens studied, a substantial amount of muscular fibres of latissimus dorsi origin and from the inferior angle of the scapula (type 1) was found, while in the other 57 of the 100 specimens there were few muscular fibres or none at all from the scapula to the latissimus dorsi muscles. In these specimens, there was either a soft fibrous link between the bulk of latissimus dorsi and inferior angle of the scapula (36 specimens; type 2a), or a bursa and no connecting tissue between the two structures (remaining 21 shoulders; type 2b) [19, 49, 50, 51, 55, 56, 58, 59].

Unfortunately, anatomical studies of the latissimus dorsi muscle seem to be limited to the form of its belly and its neurovascular supply [49], the reason being the use of this muscle in plastic surgery as a free vascularised transfer flap for the treatment of severe soft tissue defects.

**Fig. 1.8a, b.** **a** Anterolateral view of the thorax (right side). This view illustrates the latissimus dorsi, a large muscle that runs from the back to the medial side of the humerus, inserting on the lesser tubercle. Its relationship with the subscapularis muscle is interesting. In some cases they combine to form a functional hammock below the humeral head (*HH*; *PEC MIN* pectoralis minor, *SSC* subscapularis, *TMj* teres major muscle). **b** Magnification of lateral insertion of latissimus dorsi (and teres major) (right side). This view illustrates the insertion of the latissimus dorsi and teres major muscles on the lesser tubercle of the humerus. The latissimus dorsi tendon is quadrilateral, and it partially covers the teres major tendon (*H* humerus, \*insertion of the latissimus dorsi, #insertion of the teres major)



## 1.3 Pectoralis Major Muscle

The pectoralis major is a large muscle in the anterior part of the thorax and consists of three portions (Fig. 1.9a).

The upper part originates in the medial one-half to two-thirds of the clavicle and inserts along the lateral border of the bicipital groove. The middle part takes its origin in the manubrium and upper two-thirds of the body of the sternum and ribs 2, 3 and 4. It inserts directly behind the clavicular portion and maintains a parallel fibre arrangement.

The inferior part of the pectoralis major takes its origin in the distal body of the sternum, ribs 5 and 6 and the external oblique fascia. It has the same insertion as the other two parts, but the fibres rotate 180° so that the inferior fibres insert at a higher point on the humerus.

The muscle is innervated by the lateral pectoral nerve (C5–7), which innervates the clavicular part, and the medial pectoral nerve (C-8 to –T-1), which innervates the remaining part of the muscle.

The major blood supply of the muscle derives from the deltoid branch of the thoracoacromial artery for the clavicular part and from the pectoral artery for the sternocostal part.

The superior lateral border of the muscle is the deltopectoral interval, and the inferior border is the border of the axillary fold. It is important to bear in mind the close relationship between the insertion of the pectoralis major muscle and the long head of the bicipital tendon as we retain that this relationship influences the role both muscles play in glenohumeral stability [19].

### 1.3.1 Biomechanics and Functional Anatomy

The latissimus dorsi muscle acts as an internal rotator and adductor of the humerus. It also extends the shoulder and indi-

rectly rotates the scapula downwards by its pull on the humerus [19].

The relationships between the different humeral attachments of the latissimus dorsi muscle and the different connections to the scapula play an important role in glenohumeral joint stability.

In the apprehension position of the arm (abduction and external rotation), when the distance from distal insertion of latissimus dorsi to the cartilage is small and there are type 1 scapular connections, the muscle is tensed, the distal tendon has a more vertical course and the lateral border of the subscapularis tendon is covered. In this case the latissimus dorsi muscle forms an anteroinferior hammock for the humeral head.

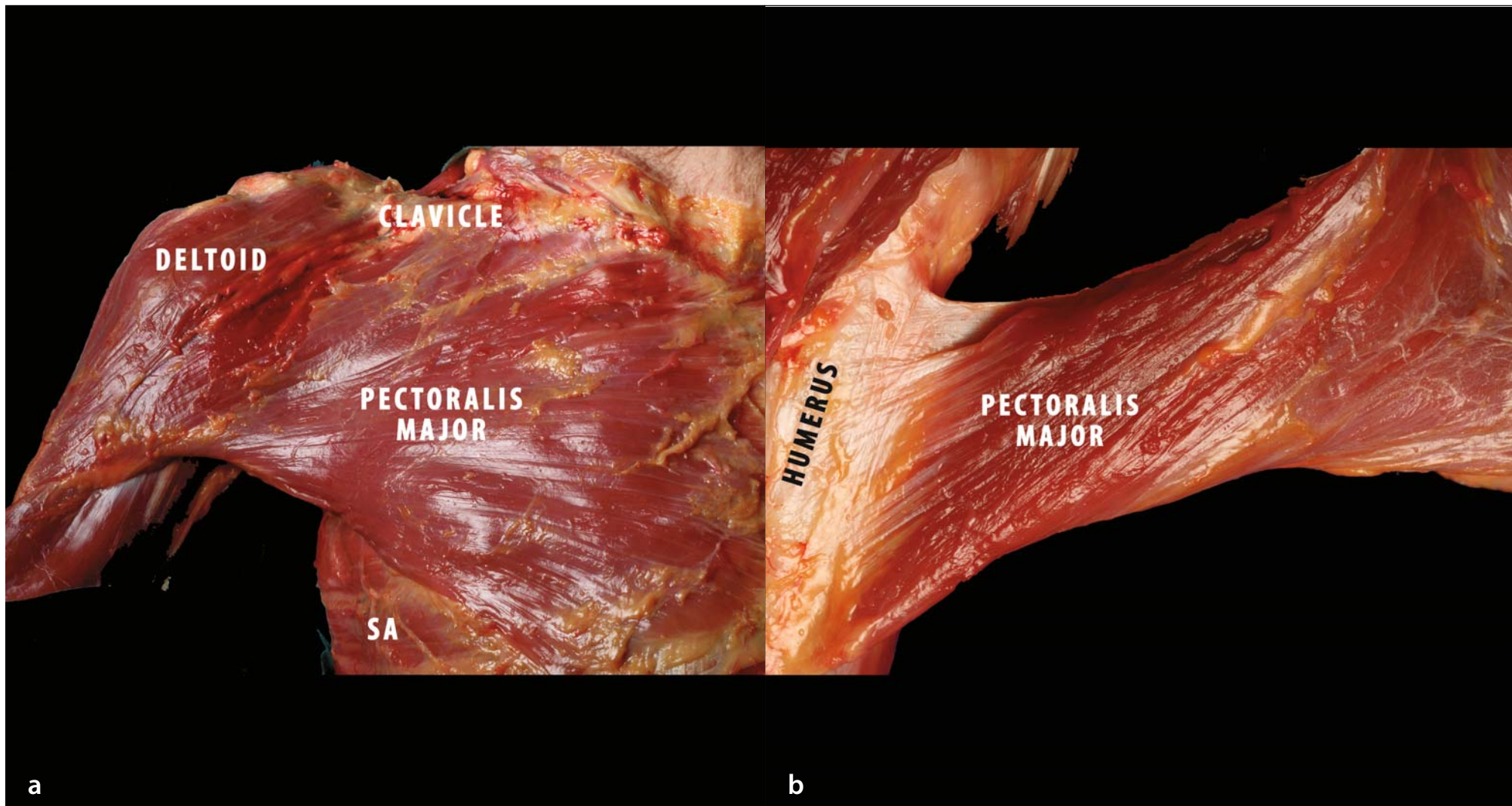
With the arm in the same position, if the distance between the distal insertion of the latissimus dorsi and the cartilage is large and there are type 2 (a and b) scapular connections, the latissimus dorsi muscle does not cover the subscapularis muscle and the two tendons diverge from another one even in abduction, leaving a gap between them so that there is no hammock effect [49, 60].

The action of the pectoralis major muscle depends on its starting position. It is interesting to see the structure of the lateral attachment of this muscle. In fact, when the fibres of the tendon insert on the lateral side of the bicipital groove they are exactly inverted relative to the origin of the three parts of the muscle, thus forming a ‘twisting tendon’ (Fig. 1.9b).

The muscle is active in internal rotation against resistance. In flexion, the clavicular portion is involved to some degree with the anterior part of the deltoid muscle, while the lower fibres are antagonistic. This muscle is also a powerful adductor of the glenohumeral joint and works indirectly as a depressor of the lateral angle of the scapula [19].

The pectoralis major and the latissimus dorsi muscles work together to provide glenohumeral stability of the shoulder and good arm movement.

**Fig. 1.9a, b.** **a** Anterior view of the thorax (right side). This view illustrates the pectoralis major muscle. The muscle originates from the clavicle, sternum and the ribs. Laterally it forms the anterior part of the axillary fold. The prime role of the pectoralis major muscle is internal rotation of the arm (SA serratus anterior). **b** Magnification of lateral insertion of pectoralis major muscle (right side). Detail of shape of lateral insertion of pectoralis major. The three portions of the muscle (superior, middle and inferior) insert in exactly the opposite order to the origin, forming a ‘twisting tendon’. This shape suggests different actions of the three portions of the muscle during arm motion



### 1.3.2 Clinical Relevance

Shoulder muscle forces are usually powerful stabilisers of the glenohumeral joint. However, muscle forces can also contribute to instability. Certain muscle forces decrease glenohumeral joint stability in end-range positions. We believe this to be the case with both active and passive pectoralis major forces. Improved understanding of the contribution of muscle forces not only to stability but also to instability will improve rehabilitation protocols for the shoulder and prove useful in the treatment of joint instability throughout the body [61].

Increased action of the pectoralis major muscle has also been shown to decrease the stability of the glenohumeral joint.

Shoulder muscle activity stabilises the glenohumeral joint by compressing the humeral head against the concave glenoid surface, allowing concentric rotation of the humeral head on the glenoid [8, 62–64]. Through this mechanism, termed concavity-compression, shoulder muscles may be the primary stabilisers of the glenohumeral joint in the middle ranges of motion, where the capsuloligamentous structures are lax [65]. Concavity-compression may also be important in the end-ranges of motion, where forces acting on the glenohumeral joint are increased [66–69]. In end-range positions, shoulder muscle activity protects the capsuloligamentous structures by limiting the joint's range of movement [63, 70] and by decreasing strain in these structures [70, 71]. Shoulder muscle forces may be defined by their magnitude and direction (line of action). Shoulder muscle forces can be resolved into three com-

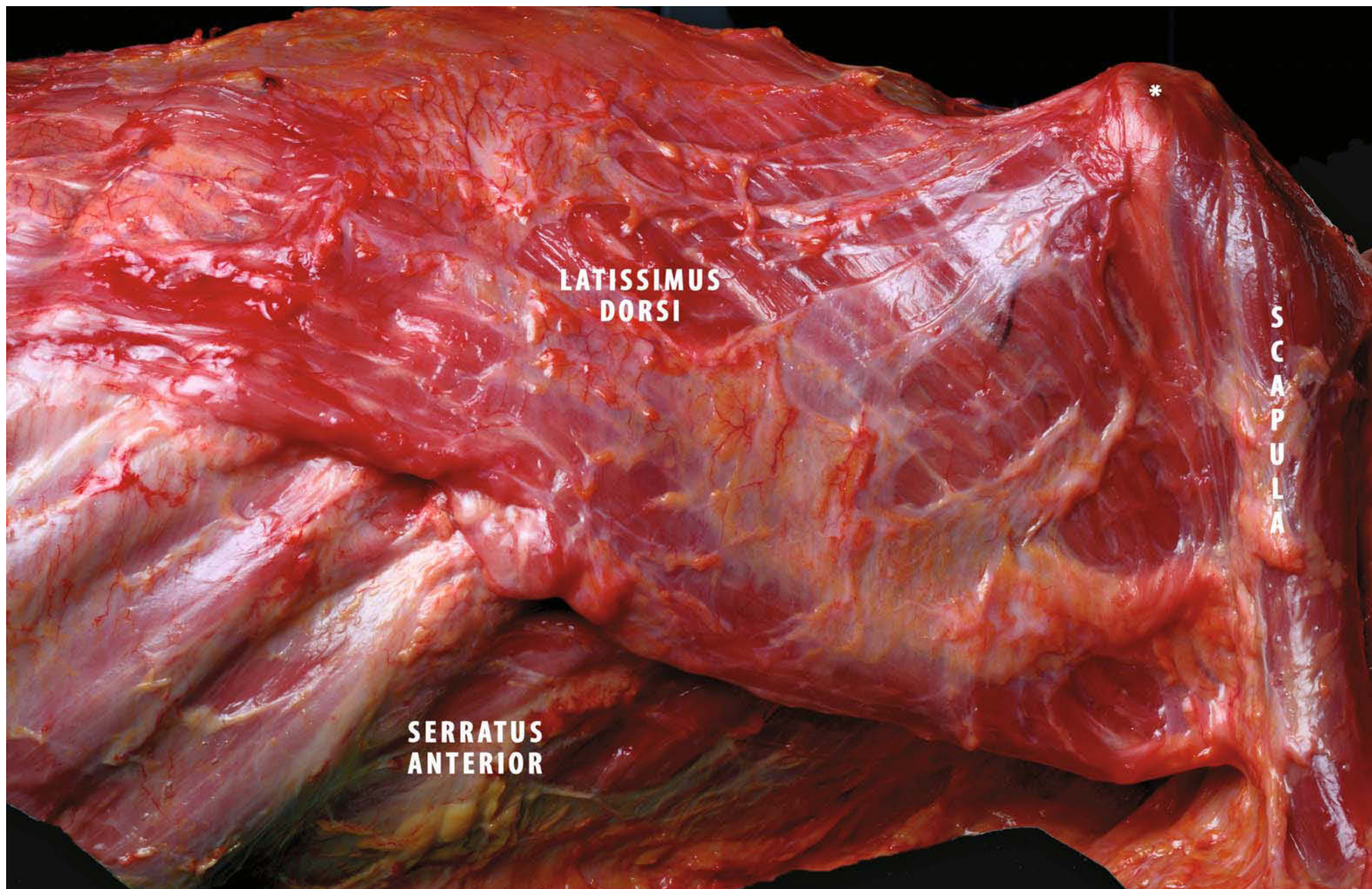
ponents: compressive, superoinferiorly directed and anteroposteriorly directed forces. Whereas compressive forces stabilise the glenohumeral joint, forces directed anteriorly, posteriorly, inferiorly, and superiorly are termed translational forces and destabilise the joint. Glenohumeral joint stability can be quantified by the ratio between the translational forces in any direction and the compressive forces [65, 72, 73]. As the ratio between the translational forces and compressive forces decreases, stability of the glenohumeral joint increases and vice versa.

Labriola et al. [74] studied the contributory effects of each shoulder muscle to glenohumeral joint stability. They established the effect of increasing the magnitude of individual muscle forces on the lines of action of the resultant forces. When pectoralis major activity was increased, compressive forces increased by 12%, while anteriorly directed forces increased by 1180%. However, they concluded that if the lines of action were more directly anterior, increasing pectoralis major muscle forces, they would diminish the stability of the glenohumeral joint. Changing the magnitude of the teres major and the subscapularis had no effect on the lines of action of the resultant force. In a study conducted by Pouliart [49], specimens with capsuloligamentous lesions after glenohumeral dislocation showed different outcomes according to whether they had a small or a large distance between the latissimus dorsi insertion and cartilage of the humeral head and the various connections from the latissimus dorsi muscle to the scapula.

She observed, via a load and shift test, that in specimens with small tendon–cartilage distance and type 1 scapula (Fig. 1.10),

**Fig. 1.10.** Lateral view of the thorax (prone decubitus, right side). View of latissimus dorsi muscle. For biomechanical reasons the relationships of this muscle with the scapula are important for the stability of the joint. In this specimen (type 1) some fibres originate directly from the inferior angle of the scapula (\*)






glenohumeral dislocation was unlocked; in the case of large tendon–cartilage distance and type 2 scapula (Fig. 1.11), humeral head dislocation was locked.

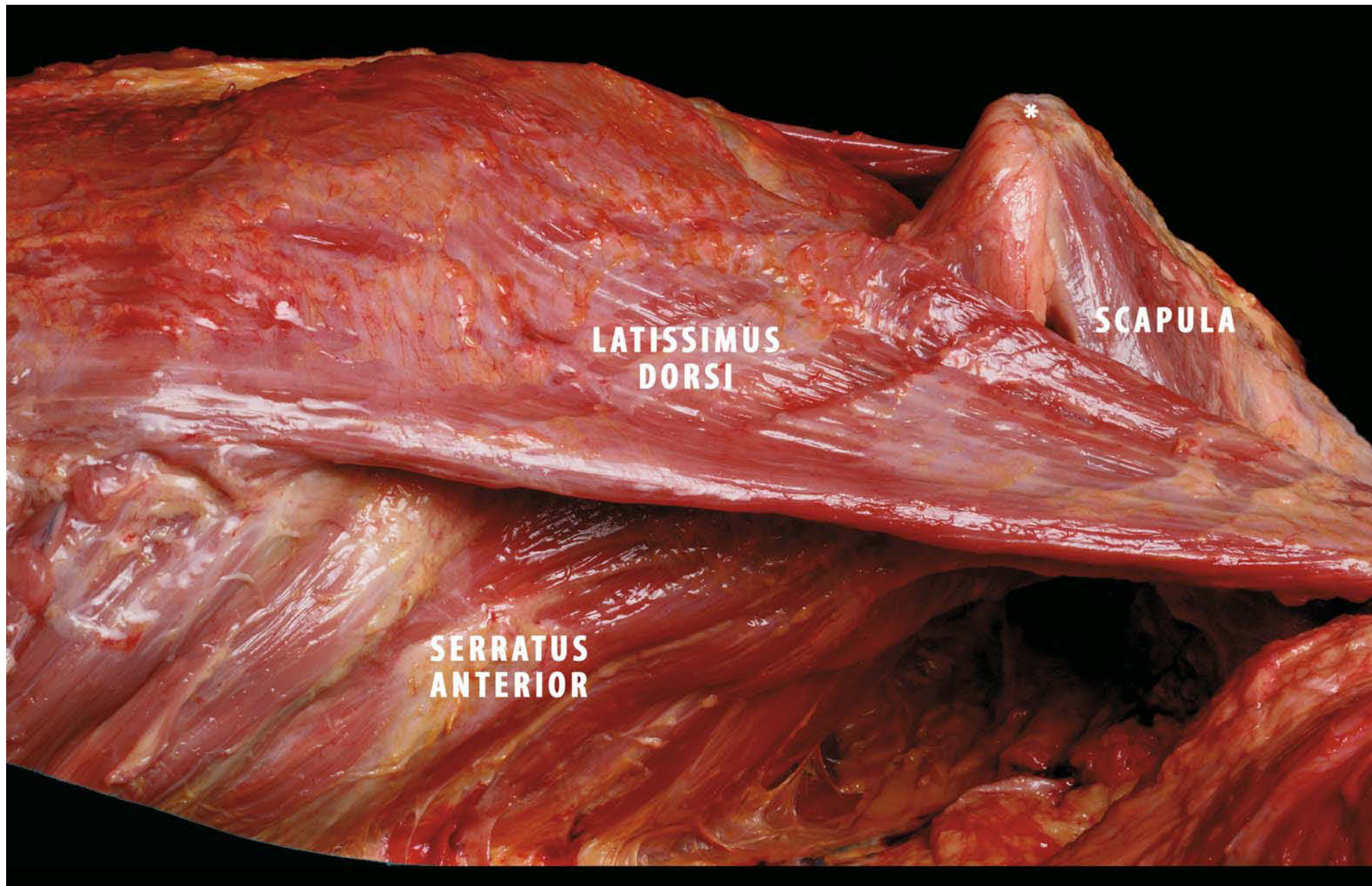
She concludes that the space between subscapularis and latissimus dorsi (inferior interval) may have some significance for anteroinferior stability, as in the case of the rotator cuff interval between subscapularis and supraspinatus [61].

In conclusion, the latissimus dorsi muscle influences the dislocation of the glenohumeral joint and limits the movement of the humeral head in patients with shoulder instability after a capsuloligamentous tear.

The action of the latissimus dorsi helps other musculotendinous structures around the shoulder to maintain stability [49].



**Fig. 1.11.** Lateral view of the thorax (prone decubitus, right side). View of latissimus dorsi muscle. This is long and wide and has its origin in the back of the thorax (from T-7 to T-12, thoracolumbar fascia, iliac crest, lower ribs) and its insertion on the humerus. In this specimen (type 2) there is no connection between the muscle and the inferior angle of the scapula (\*)



## References

1. Kibler WB, McMullen J (2003) Scapular dyskinesis and its relation to shoulder pain. *J Am Acad Orthop Surg* 11:142-151
2. Ludewig PM, Cook TM, Nawoczenski DA (1996) Three-dimensional scapular orientation and muscle activity at selected positions of humeral elevation. *J Orthop Sports Phys Ther* 24:57-65
3. McClure P, Michener LA, Sennett B et al (2001) Direct 3-dimensional measurement of scapular kinematics during dynamic movements in vivo. *J Shoulder Elbow Surg* 10:269-277
4. Ludewig PM, Behrens SA, Meyer SM (2004) Three-dimensional clavicular motion during arm elevation: reliability and descriptive data. *J Orthop Sports Phys Ther* 34:140-149
5. Ebaugh DD, McClure PW, Kardura AR (2006) Effect of shoulder muscle fatigue caused by repetitive overhead activities on scapulothoracic and glenohumeral kinematics. *J Elect Kinemat* 16:224-235
6. Warner JJ, Micheli LJ, Arslanian LE et al (1992) Scapulothoracic motion in normal shoulders and shoulders with glenohumeral instability and impingement syndrome: a study using moire topographic analysis. *Clin Orthop* 285:191-199
7. Doukas WC, Speer KP (2000) Anatomy, pathophysiology, and biomechanics of shoulder instability. *Oper Tech Sports Med* 8:179-187
8. Poppen NK, Walker PS (1976) Normal and abnormal motion of the shoulder. *J Bone Joint Surg Am* 58:195-201
9. Ludewig PM, Cook TM (2000) Alteration in shoulder kinematics and associated muscle activity in people with symptoms of shoulder impingement. *Phys Ther* 80: 276-291
10. Lukasiewicz AC, McClure P, Michener L et al (1999) Comparison of 3-dimensional scapular position and orientation between subjects with and without shoulder impingement. *J Orthop Sports Phys Ther* 29: 574-586
11. Kibler WB (1995) Biomechanical analysis of the shoulder during tennis activities. *Clin Sports Med* 14:79-85
12. Kennedy K (1993) Rehabilitation of the unstable shoulder. *Oper Tech Sports Med* 1:311-324
13. Nieminen H, Niemi J, Takala EP et al (1995) Load-sharing patterns in the shoulder during isometric flexion tasks. *J Biomech* 28:555-566
14. Happee R, Van der Helm FC (1995) The control of shoulder muscles during goal directed movements: an inverse dynamic analysis. *J Biomech* 28:1179-1191
15. Speer KP, Garrett WE, Jr (1993) Muscular control of motion and stability about the pectoral girdle. In: Matsen FA III, Fu FH, Hawkins RJ (eds) *The shoulder: a balance of mobility and stability*. American Academy of Orthopedic Surgery, Rosemont, Ill, pp 159-172
16. Bagg SD, Forrest WJ (1986) Electromyographic study of the scapular rotators during arm abduction in the scapular plane. *Am J Phys Med* 65:111-124
17. Inman VT, Saunders JB, Abbott LC (1944) Observations on the function of the shoulder joint. *J Bone Joint Surg* 26:1-30
18. Greg MD, Labosky D et al (1979) Serratus anterior paralysis in the young athlete. *J Bone Joint Surg Am*; 61(6A):825-32
19. Jobe CM (1998) Gross anatomy of the shoulder. In: Rockwood CA Jr, Matsen FA III (eds) *The shoulder*. WB Saunders, Philadelphia, pp 34-97
20. Johnson G, Bogduk N, Nowitzke A (1994) Anatomy and actions of the trapezius muscle. *Clin Biomech* 9:44-50
21. Dvir Z, Berme N (1978) The shoulder complex in elevation of the arm: a mechanism approach. *J Biomech* 11:219-225
22. Ludewig PM, Molly S (2004) Relative balance of serratus anterior and upper trapezius muscle activity during push-up exercises. *Am J Sports Med* 32:484-493
23. Moseley JB, Jobe FW, Pink M et al (1992) EMG analysis of the scapular muscles during a shoulder rehabilitation program. *Am J Sports Med* 20:128-134
24. Decker MJ, Hintermeister RA, Faber KJ et al (1999) Serratus anterior muscle activity during selected rehabilitation exercises. *Am J Sports Med* 27:784-791
25. Glousman R, Jobe FW, Tibone J et al (1988) Dynamic electromyographic analysis of the throwing shoulder with glenohumeral instability. *J Bone Joint Surg Am* 70:220-226
26. DiGiovine NM, Jobe FW, Pink M et al (1992) An electromyographic analysis of the upper extremity in pitching. *J Shoulder Elbow Surg* 1:15-25
27. Kibler WB, Chandler TJ, Shapiro R et al (2007) Muscle activation in coupled scapulohumeral motion in the high performance tennis serve. *Br J Sports Med* 41:745-749
28. Kamkar A, Irrgang JJ, Whitney SL (1993) Nonoperative management of secondary shoulder impingement syndrome. *J Orthop Sports Phys Med* 17:212-224
29. Kibler WB (1998) The role of the scapula in athletic shoulder function. *Am J Sports Med* 26:325-337
30. Mottram SL (1997) Dynamic stability of the scapula. *Man Ther* 2:123-131
31. Wadsworth DJ, Bullock-Saxton JE (1997) Recruitment patterns of the scapular rotator muscles in freestyle swimmers with subacromial

- impingement. *Int J Sports Med* 18:618-624
32. Cools A, Witvrouw E, DeClercq G et al (2003) Scapular muscle recruitment pattern: trapezius muscle latency in overhead athletes with and without impingement symptoms. *Am J Sports Med* 31:542-549
  33. Borstad JD, Ludewig PM (2006) Comparison of three stretches for pectoralis minor muscle. *J Sports Elbow Surg* 15 (3): 324-30
  34. Williams PE, Goldspink G (1973) The effect of immobilization on the longitudinal growth of striated muscle fibres. *J Anat* 116:45-55
  35. Bagg SD, Forrest WJ (1988) A biomechanical analysis of scapular rotation during arm abduction in the scapular plane. *Am J Phys Med* 67:238-245
  36. Prilutsky B, Zatsiorsky VM (2002) Optimization based models of muscle coordination. *Exerc Sports Sci Rev* 30:32-38
  37. Kibler WB, Sciascia AD, Dome DC (2006) Evaluation of apparent and absolute supraspinatus strength in patients with shoulder injury using the scapular retraction test. *Am J Sports Med* 34:1643-1647
  38. Kebaetse M, McClure PW, Pratt NA (1999) Thoracic position effect on shoulder range of motion, strength, and three-dimensional scapular kinematics. *Arch Phys Med Rehabil* 80:945-950
  39. Smith J, Dietrich CT, Kotajarvi BR et al (2006) The effect of scapular protraction on isometric shoulder rotation strength in normal subjects. *J Shoulder Elbow Surg* 15:339-343
  40. Smith J, Kotajarvi BR, Padgett DJ (2002) Effect of scapular protraction and retraction on isometric shoulder elevation strength. *Arch Phys Med Rehabil* 83:367-370
  41. Rubin B, Kibler WB (2002) Fundamental principles of shoulder rehabilitation: conservative to postoperative management. *Arthroscopy* 18 [Suppl]:29-39
  42. Burkhart SB, Craig DM, Kibler WB (1998) The disabled throwing shoulder: spectrum of pathology. III. The SICK scapula, scapular dyskinesis, the kinetic chain and rehabilitation. *Arthroscopy* 14:553-565
  43. McQuade KJ, Dawson J, Smidt GL (1998) Scapulothoracic muscle fatigue associated with alterations in scapulohumeral rhythm kinematics during maximum resistive shoulder elevation. *J Orthop Sports Phys Ther* 28:74-80
  44. Tripp B, Boswell L, Gansneder BM (2004) Functional fatigue decreases 3-dimensional multijoint position reproduction acuity in the overhead-throwing athlete. *J Athletic Training* 39:316-320
  45. Tripp B, Uhl TL, Mattacola CG et al (2006) Functional multijoint position reproduction acuity in overhead athletes. *J Athletic Training* 41:146-153
  46. Williams PE, Goldspink G (1978) Changes in sarcomere length and physiological properties in immobilized muscle. *J Anat* 3:459-468
  47. Scovazzo ML, Browne A, Pink M et al (1991) The painful shoulder during freestyle swimming. *Am J Sports Med* 19:577-582
  48. Ludewig PM, Hoff MS, Osowski EE et al (2004) Relative balance of serratus anterior and upper trapezius muscle activity during push-up exercises. *Am J Sports Med* 32:484-493
  49. Pouliart N (2005) Shoulder instability: experimental model and related anatomy. Doctoral thesis, Free University of Brussels, Faculty of Medicine and Pharmacy
  50. Beaunis H, Bouchard A (1868) *Nouveaux elements d'anatomie descriptives et d'embryologie*. Baillière, Paris, pp 161-164; 220-222
  51. Debierre C (1890) *Traité élémentaire d'anatomie de l'homme, vol 1: Manuel de l'amphithéâtre*. Ancienne librairie Germer Baillière, Paris, pp 222-229; 330-334
  52. Hartman R (1881) *Handbuch der Anatomie des Menschen*. Schultz, Strasbourg, pp 142-144; 210-229
  53. Hyrtl J (1871) *Handbuch der topographischen Anatomie und ihrer medicinisch-chirurgischen Anwendungen, vol 2*. Wilhelm Braumuller, Vienna, pp 260-262; 350-368
  54. Krause CFT (1879) *Handbuch der menschlichen Anatomie, vol 2: Spezielle und macroscopische Anatomie*. Hahn'sche Buchhandlung, Hanover, pp 92-98; 193-221
  55. Testut L (1884) *Les anomalies musculaires chez l'homme*. Masson, Paris, pp 110-125
  56. Testut L, Latarjet A et al (1948) *Traité d'anatomie humaine, vol 1: Ostéologie-Arthropologie-Myologie*. Dion, Paris, pp 564-581; 868-871; 1022-1027
  57. Pouliart N, Gagey O (2005) Significance of the latissimus dorsi for shoulder instability. I. Variations in its anatomy around the humerus and scapula. *Clin Anat* 18:493-499
  58. Bergman RA, Thompson SA, Afifi AK, Saadeh FA (1988) *Compendium of human anatomic variation 7-10*. Urban & Schwarzenberg, Baltimore
  59. Williams P, Warwick R (1980) *Gray's anatomy*. Churchill Livingstone, Edinburgh
  60. Williams GR Jr, Shakil M, KlimKiewicz J et al (1999) Anatomy of the scapulothoracic articulation. *Clin Orthop* 359:237-246
  61. Soslowsky LJ, Malicky DM, Blasler RB (1997) Active and passive factors in inferior glenohumeral stabilization: a biomechanical model. *J Shoulder Elbow Surg* 6:371-379
  62. Howell SM, Galinat BJ, Renzi AJ et al (1988) Normal and abnormal mechanics of the glenohumeral joint in the horizontal plane. *J Bone Joint Surg Am* 70:227-232

63. Karduna AR, Williams GR, Williams JL et al (1991) Kinematics of the glenohumeral joint: influences of muscle forces, ligamentous constraints, and articular geometry. *J Orthop Res* 14:986-993
64. Kelkar R, Wang VM, Flatow EL et al (2001) Glenohumeral mechanics: a study of articular geometry, contact, and kinematics. *J Shoulder Elbow Surg* 10:73-84
65. Lippett S, Vanderhoof J, Harris SL et al (1993) Glenohumeral stability from concavity-compression: a quantitative analysis. *J Shoulder Elbow Surg* 2:27-34
66. Apreleva M, Parsons IM, Pfaeffle J et al (1998) 3-D joint reaction forces at the glenohumeral joint during active motion. *Adv Bioeng* 39:33-34
67. Parsons IM, Apreleva M, Fu FH et al (2002) The effect of rotator cuff tears on reaction forces at the glenohumeral joint. *J Orthop Res* 20:439-446
68. Poppen NK, Walker PS (1978) Forces at the glenohumeral joint in abduction. *Clin Orthop* 135:165-170
69. Wuelker N, Korell M, Thren K (1998) Dynamic glenohumeral joint stability. *J Shoulder Elbow Surg* 7:43-52
70. Cain PR, Mutschler TA, Fu FH et al (1987) Anterior stability of the glenohumeral joint. A dynamic model. *Am J Sports Med* 15:144-148
71. Rodosky MW, Harner CD, Fu FH (1994) The role of the long head of the biceps muscle and superior glenoid labrum in anterior stability of the shoulder. *Am J Sports Med* 22:121-30
72. Lazarus MD, Sidles JA, Harryman DT et al (1996) Effect of a chondral-labral defect on glenoid concavity and glenohumeral stability. A cadaveric model. *J Bone Joint Surg Am* 78:94-102
73. Matsen FA (ed) (1994) Practical evaluation and management of the shoulder. Saunders, Philadelphia, p 242
74. Labriola JE, Lee TQ, Debski RE et al (2005) Stability and instability of the glenohumeral joint: the role of shoulder muscles. *J Shoulder Elbow Surg* 14:32S-38S

---

## **PART 2 - ACROMIOCLAVICULAR JOINT AND SCAPULAR LIGAMENTS**

*Alberto Costantini*

## 2.1 Introduction

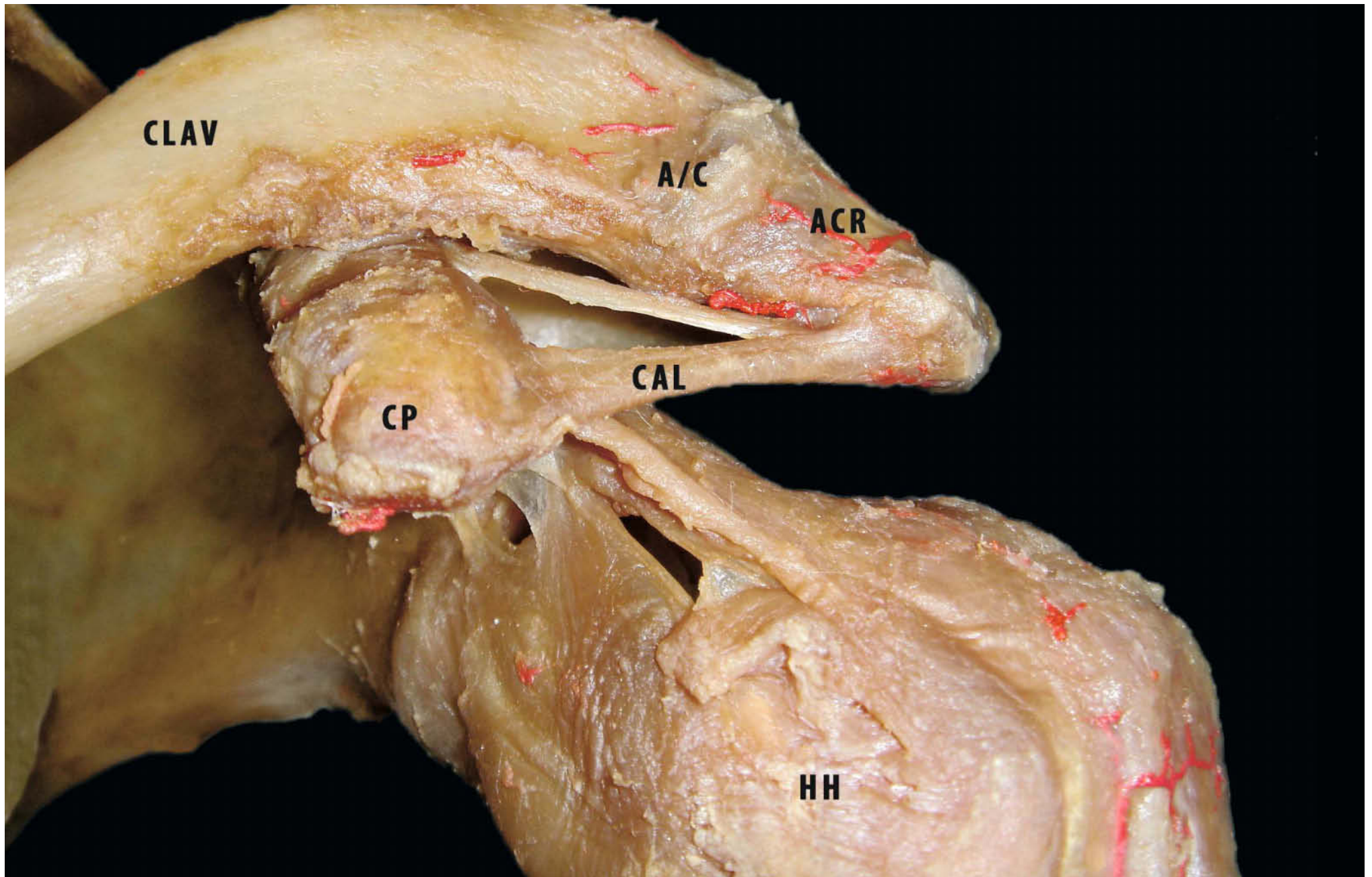
The acromioclavicular (AC) joint is a diarthrodial joint ostensibly connecting the acromion and the distal clavicle, but in reality suspending the entire arm, via the clavicle and sternoclavicular joint, from the axial skeleton. Using the AC joint as a pivot point, the scapula (acromion) can protract and retract. The AC joint, which is approximately 9 mm by 19 mm, is formed by the distal clavicle and the acromion process of the scapula (Fig. 2.1). The articular surface of the acromion is concave (relative to the subacromial space) and has an anterior and medial orientation toward the convex, distal, end of the clavicle. The joint allows gliding, shearing and rotational motion. The articular surface of the acromial end of the clavicle is hyaline cartilage until 17 years of age, at which time it acquires the structure of fibrocartilage. Similarly, the articular surface of the clavicular side of the acromion becomes fibrocartilage at approximately 23 years of age [1]. The angle of the AC joint on AP view is variable. Urist found it was inclined from superolateral to inferomedial in 49% of cases, vertically oriented in 27%, incongruous in 21% and laterally oriented in 3% [2]. The joint is also inclined a few degrees from anterolateral to posterior medial on the axillary view.

Viewed anteriorly, the inclination of the joint may be almost vertical or downward medially, the clavicle overriding the acromion by an angle of as much as 50°.

Because of the small area of the AC joint and the high compressive loads transmitted from the humerus to the chest by muscles such as the pectoralis major, the stresses on the AC joint can be very high. As a result, the articular surface of the distal clavicle is prone to compressive failure, as seen in osteolysis of the distal clavicle in weightlifters. Failure of the disc to accommodate both articular surfaces congruently may explain the high rate of early degenerative changes observed in this joint [3]. The intraarticular disc (meniscus) varies in size and shape. DePalma et al. [4], Petersson [5] and Salter et al. [6] have all demonstrated that with age this meniscal homologue undergoes rapid degeneration, until it is no longer functional beyond the 4th decade [7]. The meniscus of the AC joint is poorly understood, and little is known of its biomechanical role. The AC joint is stabilised by both static and dynamic stabilisers. The static stabilisers include the AC ligaments (superior, inferior, anterior and posterior), the coracoclavicular ligaments (trapezoid and conoid) and the coracoacromial ligament.

**Fig. 2.1.** Left shoulder: anterior view of the acromioclavicular joint (*A/C* acromioclavicular joint, *CAL* coraco acromial ligament, *ACR* acromion, *CLAV* clavicle, *CP* coracoid process, *HH* humeral head)



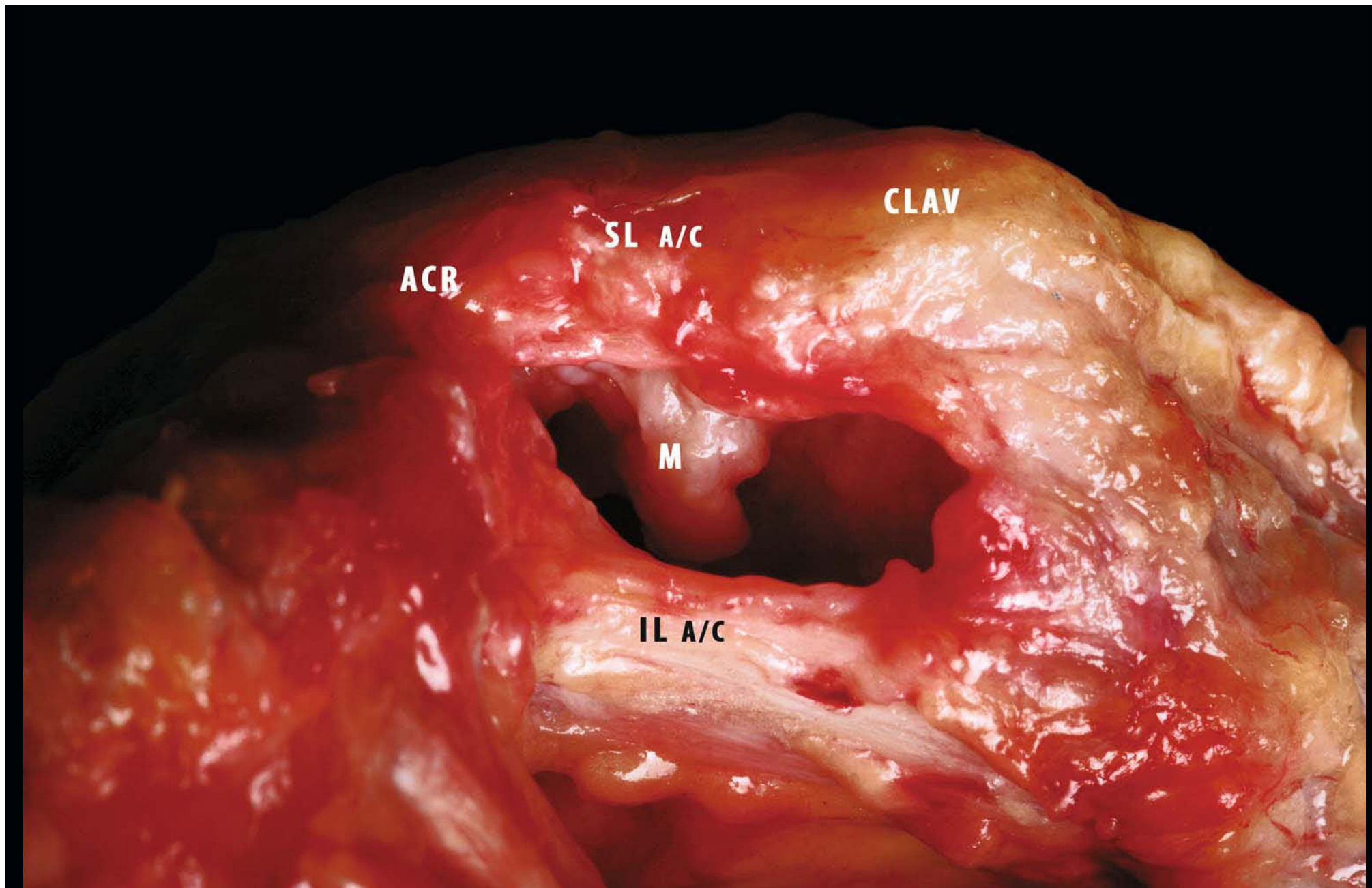


The dynamic stabilisers include the deltoid and trapezius muscles. The trapezius and serratus anterior muscles form a force couple that dynamically stabilises the joint. Fibres from the superior AC ligament blend with the fascia of the trapezius and deltoid muscles, adding stability to the joint when they contract or stretch.

The AC ligaments surrounding the joint are defined as superior, inferior, anterior and posterior acromioclavicular ligaments. (The superior ligaments are thick and strong, while the inferior capsular thickenings are weaker [8].) The posterior and superior portions of the capsule play the most important part in limiting anterior and posterior translation of the distal clavicle [9]. The superior acromioclavicular ligament and the capsule are continuous with the aponeuroses of the deltoid and trapezius muscles and are consistently thicker than the inferior

AC ligament [10] (Fig. 2.2). These muscle attachments are important in strengthening the AC ligaments and adding stability to the AC joint [11]. The two coracoclavicular ligaments (the conoid and the trapezoid) attach the coracoid to the distal end of the clavicle and have an average length of about 1.3 cm [12]. The distance from the lateral edge of the clavicle to the centre of the trapezoid and conoid tuberosities is  $25.9 \pm 3.9$  mm and  $35 \pm 5.9$  mm, respectively [13]. Several biomechanical studies have recently examined the function of the conoid and trapezoid ligaments in human cadaveric models [14–16]. The function of the coracoclavicular ligaments is to stabilise the clavicle at the scapula, with the conoid ligament primarily preventing anterior and superior clavicular displacement. The trapezoid ligament is the primary constraint against compression of the distal clavicle into the acromion.

**Fig. 2.2.** Right shoulder: frontal view. The anterior capsule has been opened, and the A/C meniscus is now visible (*IL a/c* inferior acromioclavicular ligament, *M* meniscus, *SL a/c* superior acromioclavicular ligament)



## 2.1.1 Acromioclavicular and Coracoclavicular Ligaments

### 2.1.1.1 The Superior Acromioclavicular Ligament (*Ligamentum Acromioclaviculare*)

This is a quadrilateral band covering the superior part of the joint and extending between the upper part of the acromial end of the clavicle and the adjoining part of the upper surface of the acromion. It is composed of parallel fibres, which interlace with the aponeuroses of the trapezius and deltoideus muscles; below, it is in contact with the articular disc when this is present.

### 2.1.1.2 The Inferior Acromioclavicular Ligament

This is somewhat thinner than the superior acromioclavicular ligament; it covers the lower part of the joint and is attached to the adjoining surfaces of the two bones. Its upper part is in relation with the articular disc in rare cases and the lower part, with the tendon of the supraspinatus muscle.

The length of the posterior portion of the acromioclavicular

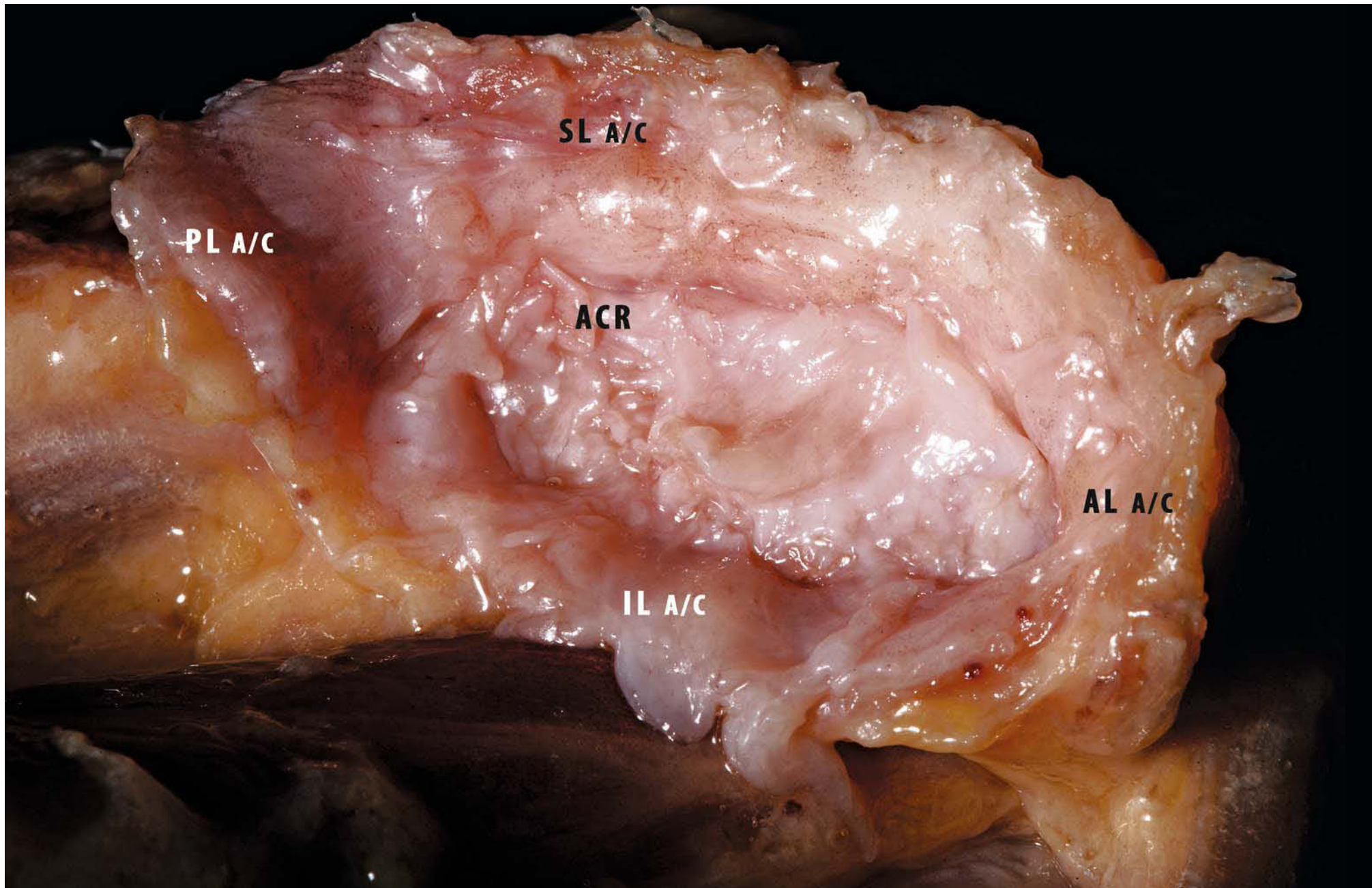
ligament increases when the free sternal end of the clavicle is rotated anteriorly about the vertical axis of the acromioclavicular joint. When the clavicle is rotated posteriorly about the frontal axis, the posterior portion of the acromioclavicular ligament becomes slack and the anterior portion of the acromioclavicular ligament stretches.

The acromioclavicular ligaments act as a primary constraint for posterior displacement of the clavicle and posterior axial rotation (Fig. 2.3).

### 2.1.1.3 The Trapezoid Ligament (*Ligamentum - Trapezoideum*)

The anterior and lateral fasciculus is wide, thin and quadrilateral: it is placed obliquely between the coracoid process and the clavicle. It is attached, below, to the upper surface of the coracoid process and, above, to the oblique ridge on the under surface of the clavicle. Its anterior border is free; its posterior border is joined with the conoid ligament, the two forming, by their junction, an angle projecting backward. The width of the clavicular origin of the trapezoid ligament is  $11.8 \pm 1.0$  mm.

**Fig. 2.3.** Left shoulder: acromial side of the A/C joint. The entire capsule, detached from the clavicular side, is still attached at the acromial side, making the acromioclavicular ligaments visible (*ACR* acromion, articular side, *AL a/c* anterior acromioclavicular ligament, *IL a/c* inferior acromioclavicular ligament, *PL a/c* posterior acromioclavicular ligament *SL a/c* superior acromioclavicular ligament)



### 2.1.1.4 The Conoid Ligament (*Ligamentum Conoideum*)

The posterior and medial fasciculus is a dense band of fibres, conical in form, with its base directed upward. It is attached by its apex to a rough impression at the base of the coracoid process, medial to the trapezoid ligament; above, by its expanded base, to the coracoid tuberosity on the lower surface of the clavicle, and to a line proceeding medialward from it for 1.25 cm. The conoid width at its clavicular origin is  $25.3 \pm 4.9$  mm. The broad conoid ligament is not reliably centred over the most prominent aspect of the conoid tuberosity.

These ligaments are in relation, in front, with the subclavius and deltoid muscle; and behind, with the trapezius. The coracoclavicular ligaments have two major functions: first, they guide synchronous scapulohumeral motion by attaching the clavicle to the scapula and second, they strengthen the AC joint.

Harris et al. [17], working with cadaver models, found three distinct anatomical variations of the conoid ligament based on their inferior attachment sites (Fig. 2.4a-d).

In type 1, the most common form, the conoid ligament originates from an area encompassing the posterior aspect of the coracoid dorsum and an area just beyond the posterior coracoid precipice.

In type 2 the confluence of the conoid ligament and the transverse scapular ligament form one continuous structure from the medial scapular notch via the coracoid to the clavicle. In this type, the inferior attachment area of the complex includes the dorsum and posterior coracoid precipice and the superior border of the scapula.

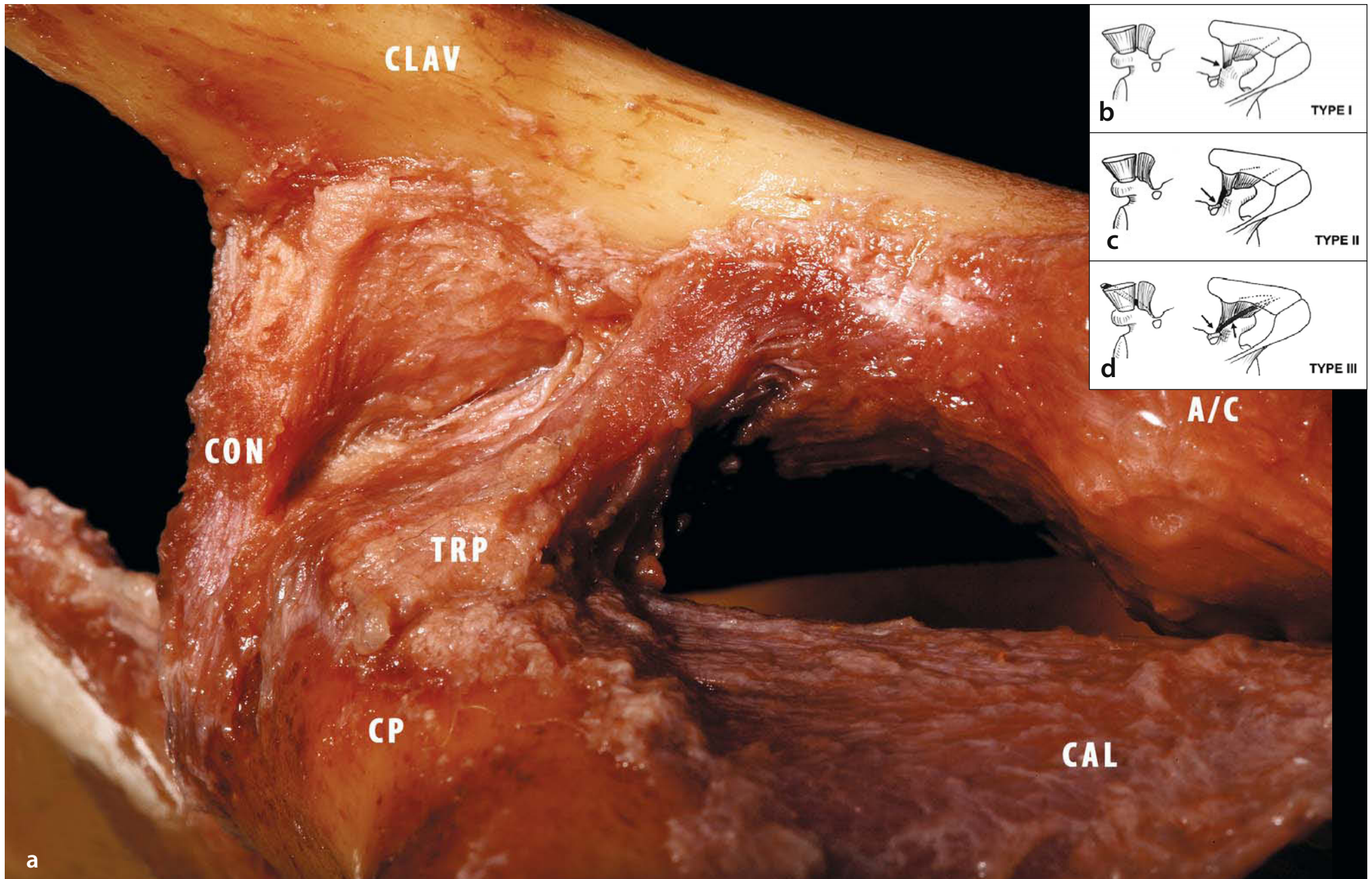
Type 3, with the accessory fascicle, is a variant of type 2 but with an accessory conoid lateral fascicle arising inferomedially from the lateral border of the scapular notch at the junction of the conoid and superior transverse scapular ligament. Although there is a description of this variant in Testut's classic textbook of anatomy [18], it remains unclear whether this configuration is considered anomalous.

The clinical implications of these variations are questionable. The strength and load-sharing capabilities of the coracoclavicular ligament, and the stability of the acromioclavicular joint, may be affected by a differing course and configuration of ligament attachments. Another possibility is that the morphologic arrangement may predispose a patient to suprascapular nerve entrapment, although the variations noted do not appear to narrow the suprascapular notch, which has been suggested as a cause of nerve compression [19] (Fig. 2.4b-d).

### 2.1.2 Biomechanics and Functional Anatomy

Worcester and Green [20] described three types of motion at the normal AC joint: anterior and posterior gliding of the scapula on the clavicle, a hinge-like abduction and adduction of the scapula on the clavicle, and rotation of the scapula about the long axis of the clavicle (perpendicular to the long axis of the body). All of these motions are limited to between  $5^\circ$  and  $8^\circ$  in each direction. This rotational motion, along with shear and compressive forces of the deltoid, probably contributes to degenerative changes of the AC joint. Another important factor to consider is the distance between the articular surfaces of the acromion and the clavicle. The first reported measurement of

**Fig. 2.4a-d.** **a** Left shoulder: anterior view of the coracoclavicular ligament (A/C acromioclavicular joint, CAL coracoclavicular ligament, CLAV clavicle, CON conoid ligament, CP coracoid process, TRP trapezoid ligament) **b-d** Proposed classification of the coracoclavicular ligament based on its variant scapular attachments (types I-III). Courtesy of Sonnabend [17]



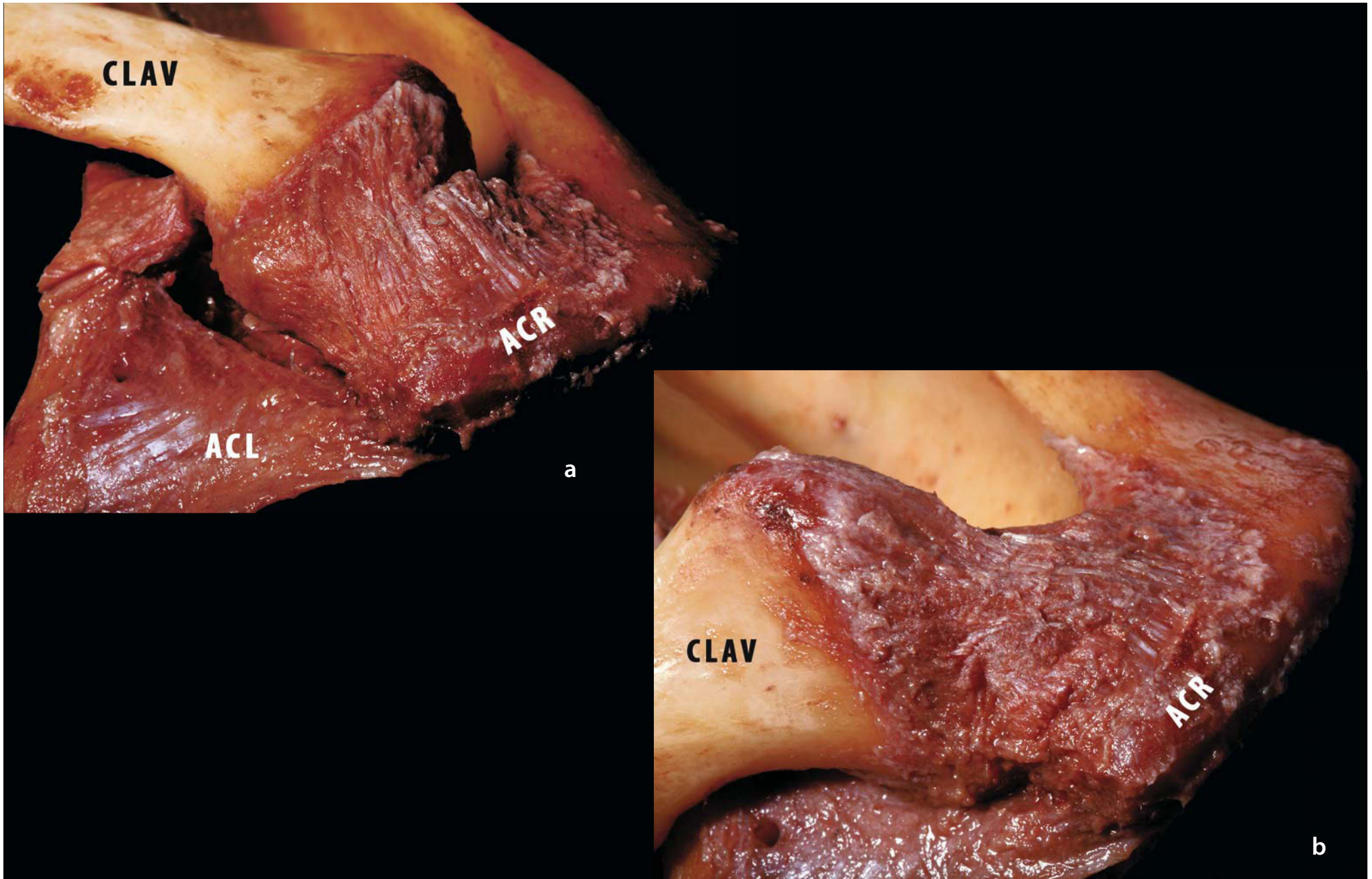
this width was published by Zanca [21]. He found a width of 1–3 mm in 1,000 normal anteroposterior X-rays of shoulder joints with no evidence of arthritic changes. Petersson and Redlund-Jonell [22] found similar results in 151 patients with no underlying shoulder pathology. They also recorded a diminution of this joint space with advancing age: some patients over 60 have an AC joint width less than 5 mm. Men were found to have wider AC joints than women. Nevertheless, AC joints wider than 7 mm in men and wider than 6 mm in women should be considered pathologic. An increased space may reflect distal clavicle osteolysis or inflammatory joint changes.

The lengths of the conoid and trapezoid ligaments show moderate increases with increasing anterior rotation. When the clavicle is rotated superiorly along the anterior-posterior axis of the acromioclavicular joint, the length of the conoid ligament, especially the medial portion, increases greatly. With inferior rotation of the clavicle along the anterior-posterior axis, the lengths of the conoid and trapezoid ligaments decrease and the length of the acromioclavicular ligament increases slightly. With anterior axial rotation of the clavicle, the conoid ligament

acts as a fulcrum, and the anterolateral part of the trapezoid ligament becomes slack. Posterior axial rotation of the clavicle causes the length of the medial portion of the conoid ligament and the anterolateral portion of the trapezoid ligament to increase. The anterior portion of the acromioclavicular ligament increases in length with posterior axial rotation, and the posterior portion of the acromioclavicular ligament becomes taut with anterior axial rotation (Fig. 2.5a, b). In the physiological loads encountered through the range of motion required in daily living the acromioclavicular ligament was the major contributor, providing a resisting force of as much as 50% of the total resisting force to anterior displacement. With increasing displacement, the force contribution of the conoid ligament increased and reached 70% of the total force. Through the entire range of posterior displacement, the acromioclavicular ligament played the primary role in providing a resisting force to prevent posterior subluxation of the distal end of the clavicle. In anterior rotation, the conoid ligament was found to be the main contributor in the provision of force to resist anterior rotation through the entire range of motion.

**Fig. 2.5a, b.** Left shoulder: superior view of the A/C joint. Modification of the tension of the acromioclavicular ligament with clavicular rotation (*ACL* acromioclavicular ligament, *ACR* acromion, *CLAV* clavicle)

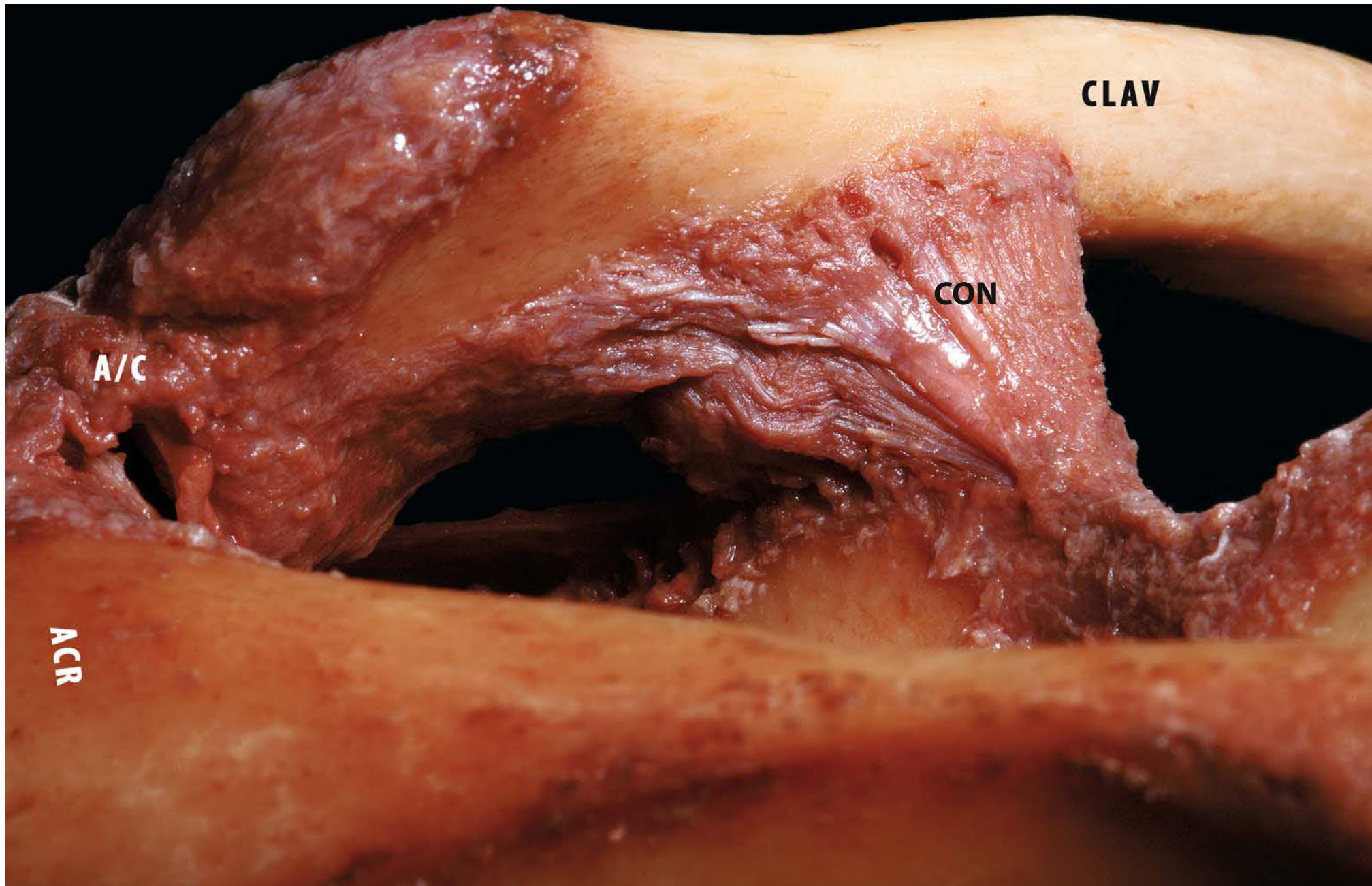




In posterior rotation, the conoid ligament provides the major constraining force in the initial phase of displacement, while at small displacements in superior rotation, the acromioclavicular and conoid ligaments contribute equal amounts of torque to resist rotation. With further rotation, the conoid ligament surpasses the acromioclavicular ligament and becomes the major contributor of torque, with an average of 82% of the total. Superior displacement within the range of small displacements is primarily resisted (65%) by forces produced by the acromioclavicular ligament. The force contribution of the conoid ligament to resisting superior displacement increases significantly, to 60% of the total, with further displacement. The trapezoid ligament contributes the least resistance to superior displacement. In axial distraction at small displacements, the conoid ligament contributes about 35% of the induced force, and this contribution decreases with further distraction. The acromioclavicular ligament acts as a primary constraint for posterior displacement of the clavicle and posterior axial rotation. The conoid ligament has a primary role in constraining both anterior and superior rotation and anterior and superior displacement of the clavicle. The trapezoid ligament contributes less constraint to movement of the clavicle in both the horizontal and the vertical planes, except when the clavicle moves in axial compression toward the acromion process. The various contributions of different

ligaments to constraint change not only with the direction of joint displacement but also with the amount of loading and displacement. For many directions of displacement, the acromioclavicular joint makes a greater contribution to constraint at smaller degrees of displacement, while the coracoclavicular ligaments, primarily the conoid ligament, contribute a greater amount of constraint with larger amounts of displacement (Fig. 2.6). Rockwood et al. [23] have reported that approximately 5–8° of rotation (in line with the scapula) is detected at the AC joint with forward elevation and abduction to 180°. Ludewig et al. [24] report that during elevation of the arm, the clavicle, with respect to the thorax, undergoes elevation (11–15°) and retraction (15–29°). Codman [25] reports that with an intact AC joint, scapular motion (3 planes, 2 translations) is synchronously coupled with arm motion by the clavicle. This motion is guided by the coracoclavicular ligaments. Because of the obligatory coupling of clavicle rotation with scapular motion and arm elevation, the AC joint should not be fixed, whether by fusion with joint-spanning hardware (screws, plates, pins) or by coracoclavicular screws. Motion will be lost, limiting shoulder function, or the hardware may fail. Normal scapular motion consists in substantial rotations around three axes and not simply upward rotation [26]. Motion of the scapula (protraction–retraction) plays a major part in the motion at the AC joint.

**Fig. 2.6.** Left shoulder. Posterior view of the conoid ligament (*A/C* acromioclavicular joint, *ACR* acromion, *CLAV* clavicle, *CON* conoid ligament)



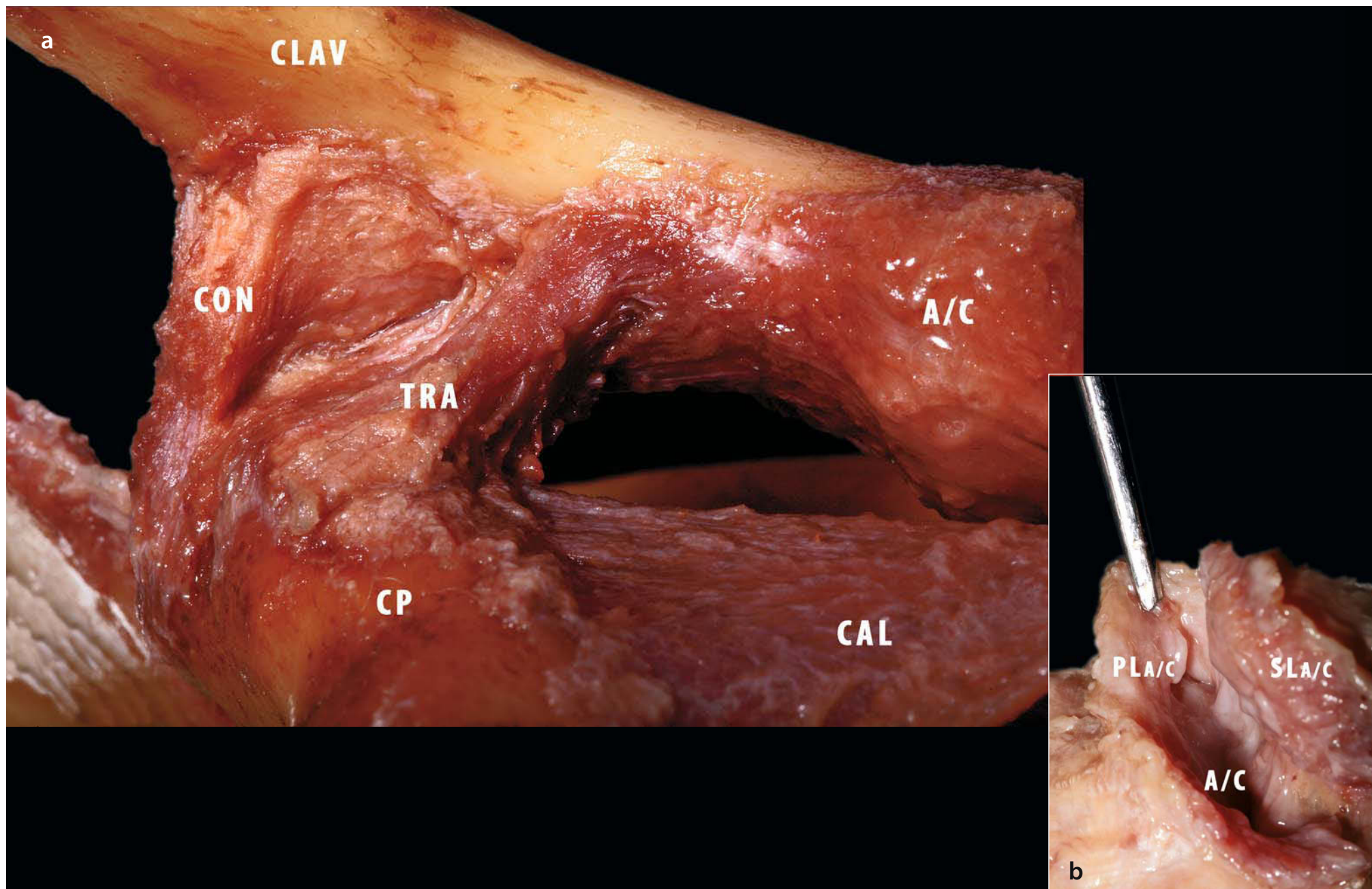
### 2.1.3 Clinical Relevance (Acromioclavicular Joint Separations)

Injury to the AC joint is most commonly the result of direct force produced by the patient falling on the point of the shoulder onto the ground or a firm object with the arm at the side in the adducted position. These injuries are very common in athletes, especially those engaged in contact sports; they can be responsible not only for aesthetically unpleasing deformities of the clavicle but also for pain, fatigue and muscle weakness. The direct force of the blow to the point of the shoulder drives the acromion downwards. Bearn [27] has shown that the downward displacement of the clavicle is primarily resisted through interlocking of the sternoclavicular ligaments. The clavicle remains in its normal anatomical position, and the scapula and shoulder girdle are driven downward. The result, then, of a downward force applied to the superior aspect of the acromion is either a lesion of the AC and coracoclavicular ligaments or clavicle fracture. There may be an additional anteroposterior direction to the force. AC joint injuries vary along a continuum of ligament injuries, beginning with a mild sprain of the AC ligaments and progressing through AC ligament tears, followed by stresses on the coracoclavicular ligament; and finally, if the downward force continues, tears of the deltoid and trapezius muscle attachments occur from the clavicle, as do ruptures of the coracoclavicular ligament (Fig. 2.7a, b). When these structures tear,

the upper extremity has lost its ligamentous support from the distal end of the clavicle, and it droops downward. The classification scheme described by Rockwood and Young [23] for AC grading is well accepted. Six types of injury are classified according to the degree of displacement of the distal clavicle, the involvement of the AC and coracoclavicular ligaments, and the integrity of the fascia overlying the deltoid and trapezius musculature:

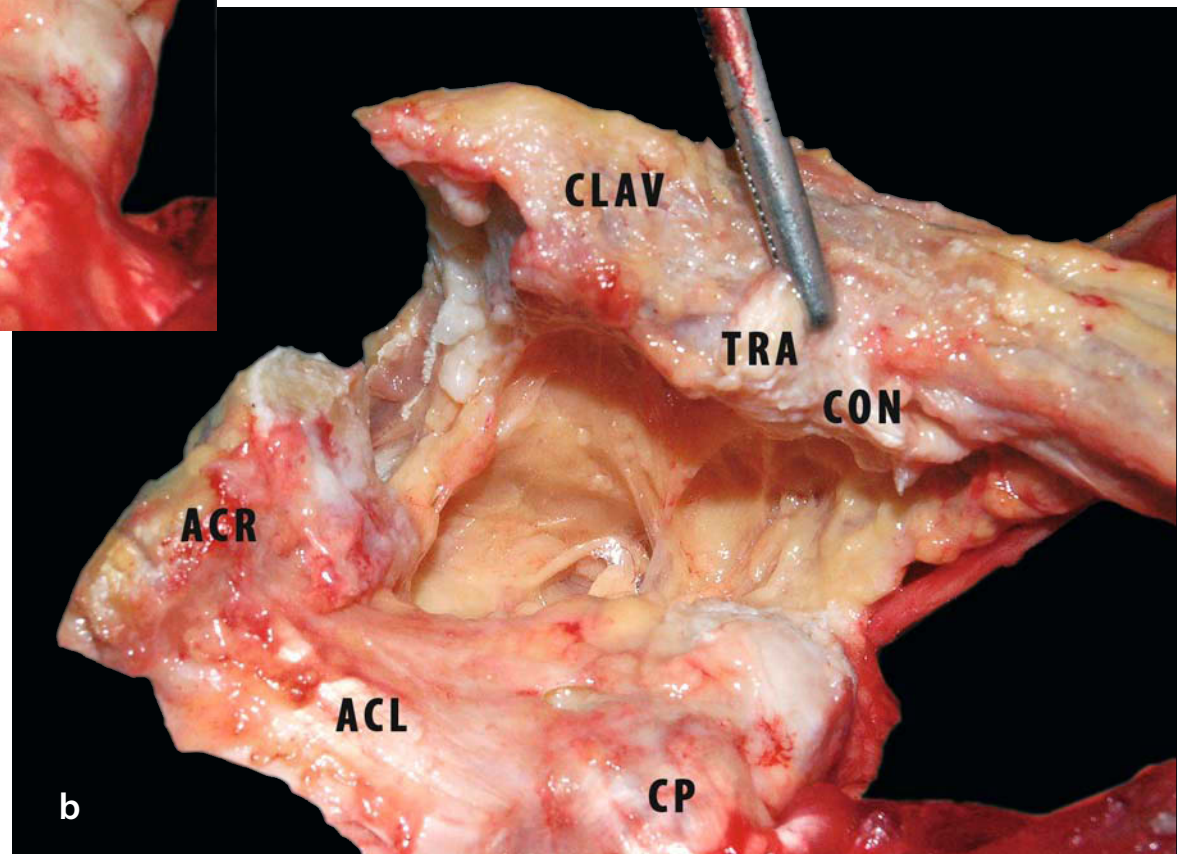
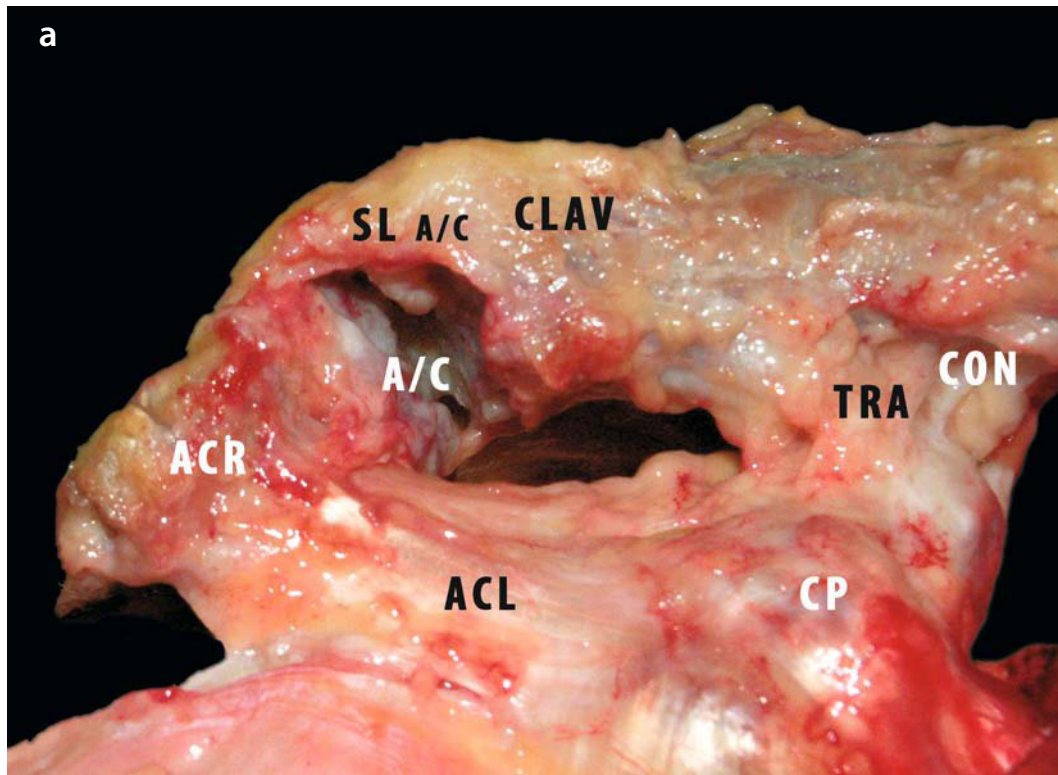
- *Type I:* Direct force to the shoulder produces a minor strain to the fibres of the AC ligaments. The coracoclavicular and AC ligaments are all intact and the AC joint remains stable.
- *Type II:* In type II injuries, a greater force to the point of the shoulder is severe enough to rupture the AC ligaments yet not severe enough to rupture or affect the coracoclavicular ligaments. In this case the distal end of the clavicle is unstable and may be slightly superior to the acromion. The scapula may rotate medially, widening the AC joint.
- *Type III:* This injury involves complete disruption of both AC and coracoclavicular ligaments without significant disruption of the deltoid or trapezoid fascia. The upper extremity is usually held in an adducted position with the acromion depressed, while the clavicle appears “high riding.” The clavicle is unstable in both the horizontal plane and the vertical plane, and stress views on radiographic examination are abnormal. Pain on movement is severe, typically for the first 1–3 weeks.

**Fig. 2.7a, b.** Left shoulder. **a** Anterior view, **b** detail of the coracoclavicular ligaments and of the acromioclavicular ligaments (superior view), which are involved in A/C joint stability (A/C acromioclavicular joint, *ACR* acromion, *CLAV* clavicle, *CON* conoid ligament, *TRA* trapezoid ligament, *CP* coracoid process, *CAL* coracoacromial ligament, *PL A/C* posterior acromionclavicular ligament, *SL A/C* superior acromionclavicular ligament)



- *Type IV*: This injury is similar to a type III AC separation except that the distal clavicle is displaced posteriorly and may even be locked within the fibres of the trapezius muscle. It is important to evaluate the sternoclavicular joint, because there can be an anterior dislocation of the sternoclavicular joint and posterior dislocation of the AC joint. A manual reduction manoeuvre is not possible in this type of injury, which helps to distinguish it from a type III injury (Fig. 2.8a, b).
- *Type V*: This is a more severe form of a type III injury, with the trapezius and deltoid fascia stripped from both the acromion and the clavicle. It is manifested by a 2- to 3-fold increase in the coracoclavicular distance, or a 100–300% increase in the clavicle-to-acromion radiographic distance. The shoulder is affected by a severe droop secondary to downward displacement of the scapula and humerus resulting from loss of the clavicular strut. The weight of the arm and the geometry of the chest wall cause anterior-inferior translation of the scapula around the thorax, which is referred to as the third translation of the scapula.
- *Type VI*: A type VI injury is very rare and involves inferior dislocation of the distal clavicle. Gerber and Rockwood have reported three cases. This injury is associated with severe trauma and frequently accompanied by multiple other injuries. (Associated fractures of the clavicle and upper ribs and injury to the brachial plexus must be carefully sought owing to the significant amount of trauma required to cause a type VI injury). The mechanism is thought to be severe hyperabduction and external rotation of the arm, combined with retraction of the scapula. The distal clavicle is found in two orientations, either subacromial or subcoracoid. With the subcoracoid dislocation, the clavicle becomes lodged behind the intact conjoined tendon. The posterior superior AC ligaments, which often remain attached to the acromion, are displaced into the AC interval, making anatomical reduction difficult. The tissue needs to be surgically cleared and then reattached after reduction. Most patients with type VI injuries have paresthesia, which resolves after relocation of the clavicle.

**Fig. 2.8a, b.** Right shoulder: anterior view. Specimen simulation of the acromioclavicular and coracoclavicular ligaments lesion (A/C joint dislocation) (A/C acromioclavicular joint, *ACR* acromion, *CLAV* clavicle, *CON* conoid ligament) (*TRA* trapezoid ligament, *SL A/C* superior coracoclavicular ligament, *ACL* coracoacromial ligament)

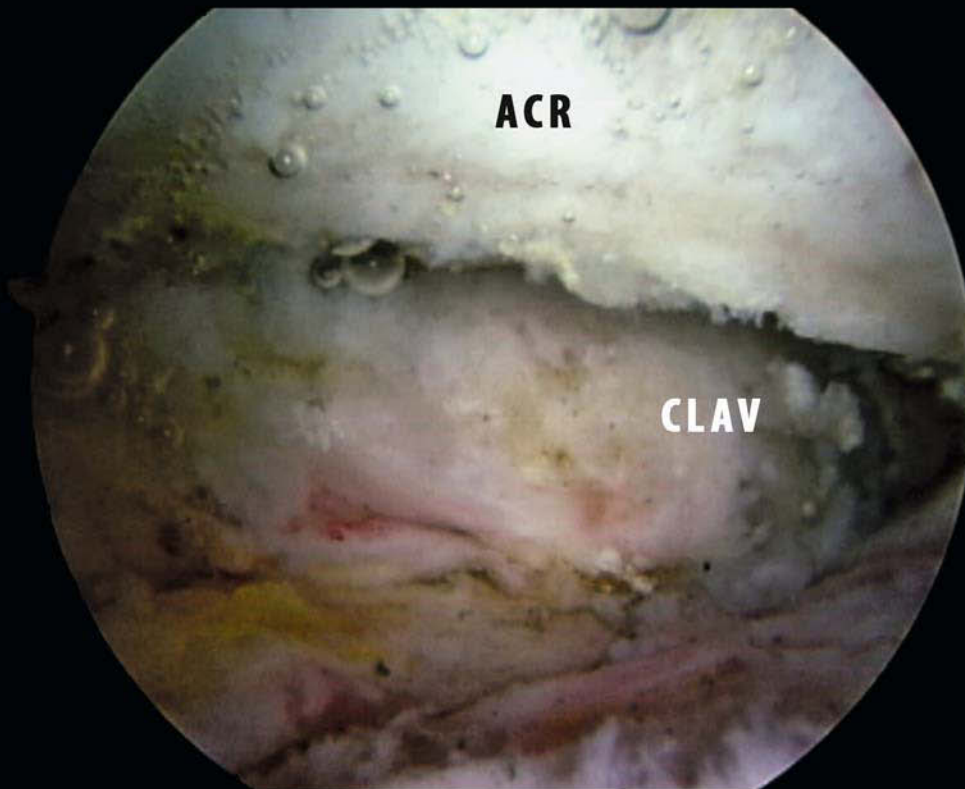
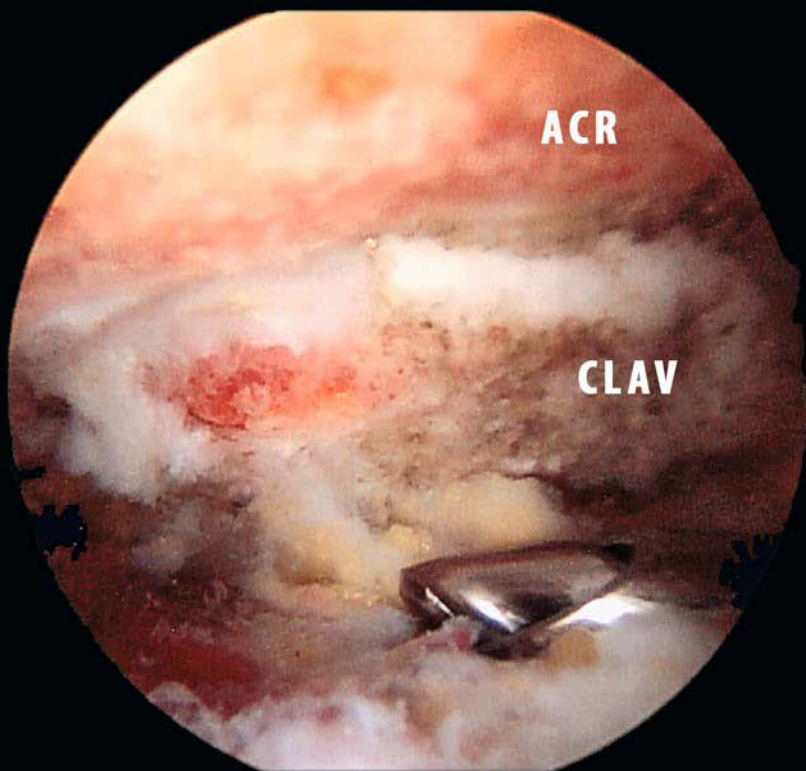


One of the surgical techniques most frequently used to address symptomatic AC joint arthritis is the arthroscopic Mumford procedure (Fig. 2.9a, b). The technique involves excising a minimal portion (about 10 mm) of the lateral end of the clavicle [28]. This bone removal eliminates contact between the arthritic articular surfaces of the acromion and the clavicle. Because of the important stabilising effect of the soft tissues around this joint, the goal is to leave the superior and posterior ligaments of the AC joint intact to prevent gross instability. Another technique frequently used in conjunction with an arthroscopic Mumford procedure is subacromial decompression, in which the subacromial bursa is removed, together with any osteophytes of the anterolateral acromion [29, 30]. These techniques can alter the normal biomechanics of the AC joint significantly; removal of the distal end of the clavicle is not without its biomechanical consequences. Klimkiewicz et al. [31] have demonstrated that loss of function of the superior ligament increases posterior translation of the clavicle by 56%, while loss of the posterior ligament increases posterior translation by 25%. This agrees with Branch et al.'s [32] description of increased rotational instability of the joint after a Mumford procedure that is associated with transverse division of the superior AC ligament. The length of distal clavicle removed is also important, but minimal resection is recommended. Renfree and Wright [10] subjected fresh-frozen cadaveric shoulders to

serial sectioning of the AC joint. The clavicular insertion of the superior AC capsular ligament was completely removed in some preparations by resecting as little as 2.6 cm of the distal clavicle in men and 2.3 cm in women. Branch et al. recorded large increases in the range of motion of the distal clavicle after superior and/or inferior ligament resection combined with a 5-mm clavicle resection. This group demonstrated not only increases in anteroposterior and superoinferior translation, but also a significant increase in rotational instability. This rotatory instability, coupled with the strength of the humeral internal rotators (e.g. pectoralis major, subscapularis, pectoralis minor), could anteromedially sublax the scapula with respect to the clavicle. This sublaxation can be a cause of increased tension at the posterior aspect of the AC joint, and can be a source of persistent pain. Corteen and Teitge [28] report that after resection, the remaining capsule (the remaining superior and posterior ligaments) is not capable of stabilising the clavicle. They have demonstrated a 32% increase in posterior translation of the clavicle after AC capsule resection. Renfree and Wright state that resecting less than 11 mm of the distal clavicle should never violate any portion of the trapezoid ligament in 98% of men and women, and a resection of less than 24 mm should never violate any portion of the conoid ligament in either group, meaning there is probably no need to worry about such violations during resection of these lengths.

**Fig. 2.9a, b.** Right shoulder. **a** Arthroscopic view. The shaver has been inserted from the anterosuperior portal and used to resect the inferior portion of the acromioclavicular ligament. **b** The acromioclavicular joint is now visible





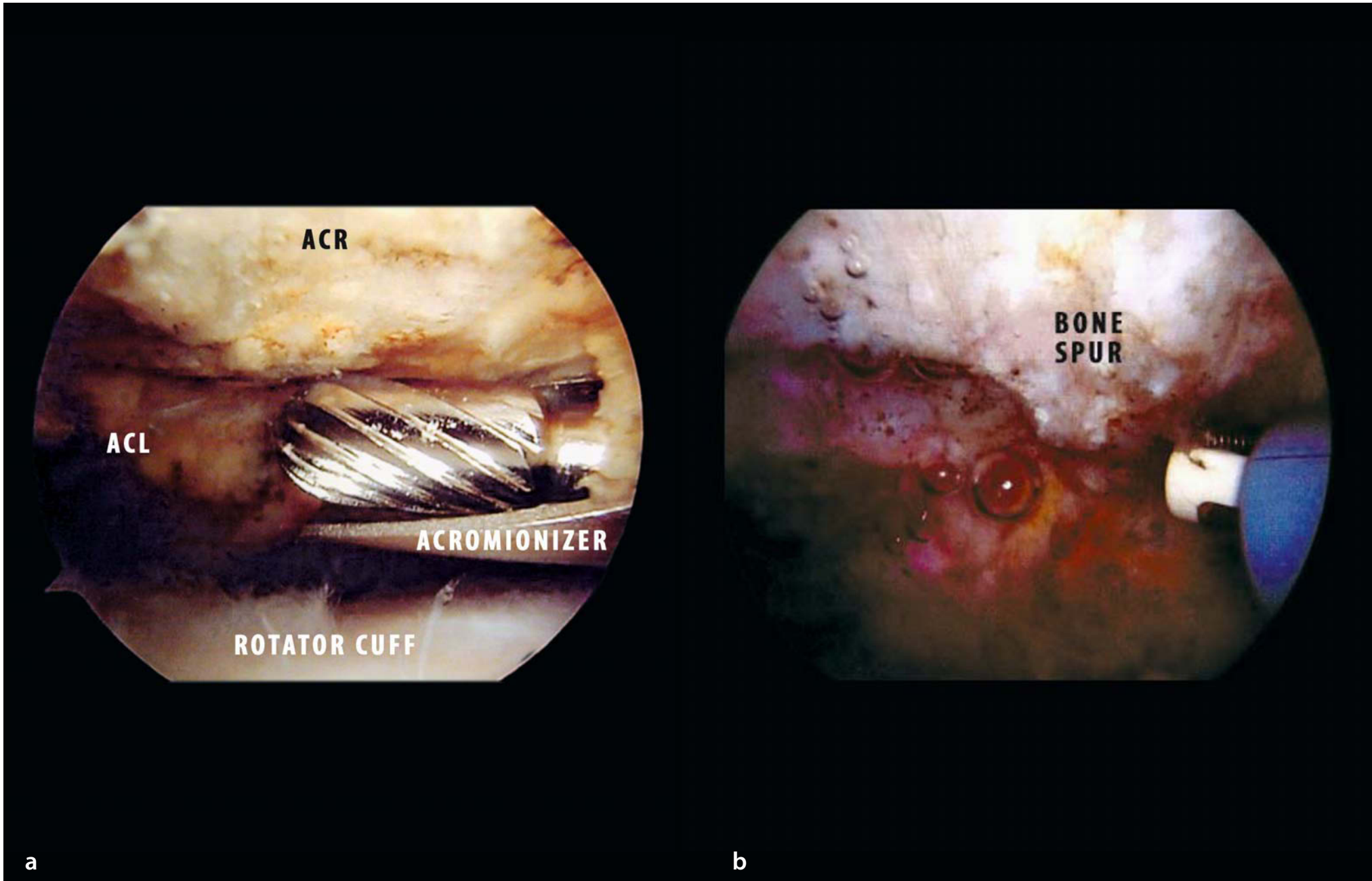
a

b

There is a theoretical advantage to performing an arthroscopic resection rather than an open one. With an arthroscopic resection the superior AC ligament can usually—not always—be preserved. However, any resection, either arthroscopic or open, of greater than 5.2 mm in women and 7.6 mm in men can disrupt this structure. Corteen and Teitge propose a minimal resection of both the distal clavicle and the distal acromion, in preference to excision of the clavicle alone, in order to avoid damage to the trapezoid and conoid ligaments. This may be beneficial clinically, although it has not been tested extensively. Another common surgical procedure performed near the AC joint is subacromial decompression (Fig. 2.10a, b). Although this procedure successfully attenuates or eliminates pain associated with arm elevation, one report [33] notes increased radiographic AC joint instability and tenderness in patients who have undergone arthroscopic subacromial decompression. The concern is that this procedure may destabilise the AC joint. Deshmukh et al. [34] found that AP compliance increased by 13% and superi-

or compliance increased by 32% after arthroscopic subacromial decompression. From a practical standpoint, it is impossible to avoid injury to the inferior AC ligament during arthroscopic or open subacromial decompression, even if an acromioplasty is performed without any invasion of the AC joint. Both distal clavicle excision (Mumford procedure) and subacromial decompression are frequently performed in patients over 40. Not infrequently both AC joint resection and subacromial decompression are performed in the same surgical session. In general, the surgical outcomes of these procedures are satisfactory, although in some cases residual pain has been reported. Postsurgical instability may be the cause of this residual pain, although this cannot be confirmed without more research. It is important to study the normal biomechanics of any joint to achieve a better understanding of the changes that happen in a pathologic setting. This is especially true in the case of the shoulder, where the function of one element in the articulation affects the overall function of the joint.

**Fig. 2.10a, b.** **a** Right shoulder: arthroscopic view. Acromioplasty is performed with the acromionizer inserted from the lateral portal. **b** One of the most common pitfall is start the acromioplasty medially and leave a bone spur laterally



## 2.2 Scapular Ligaments

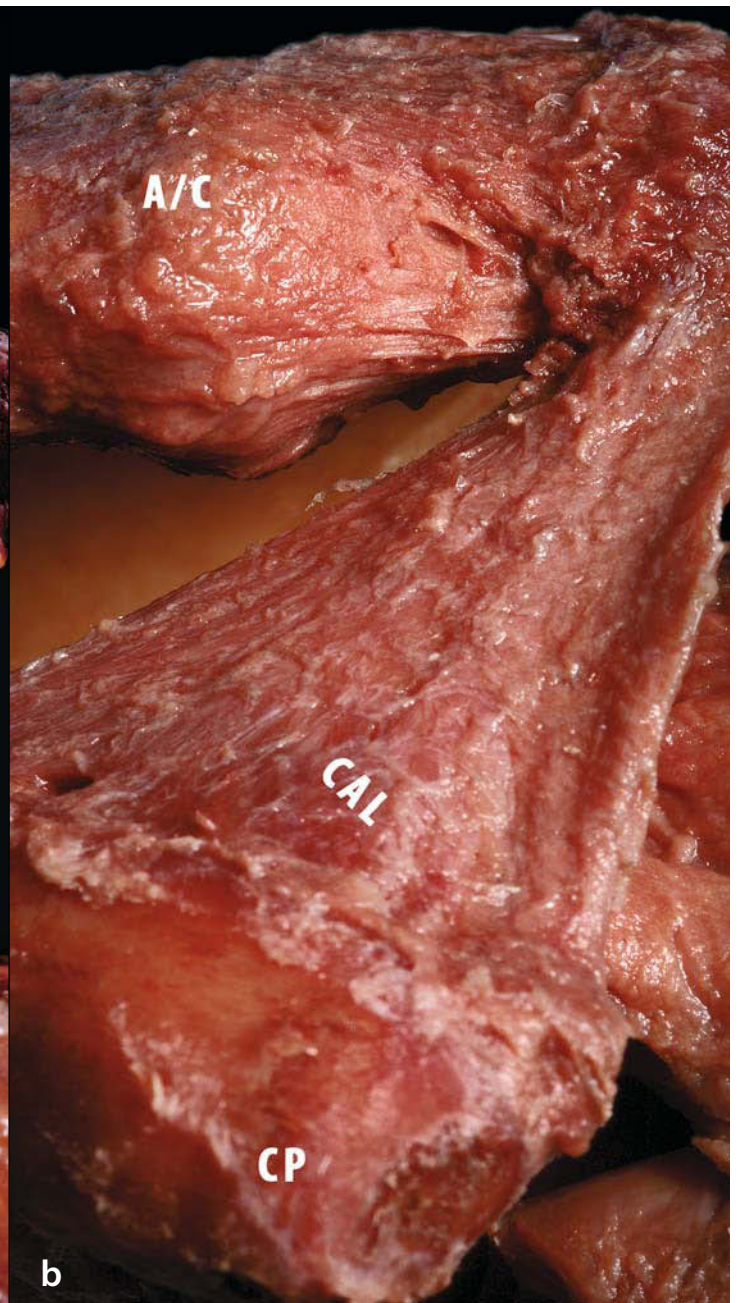
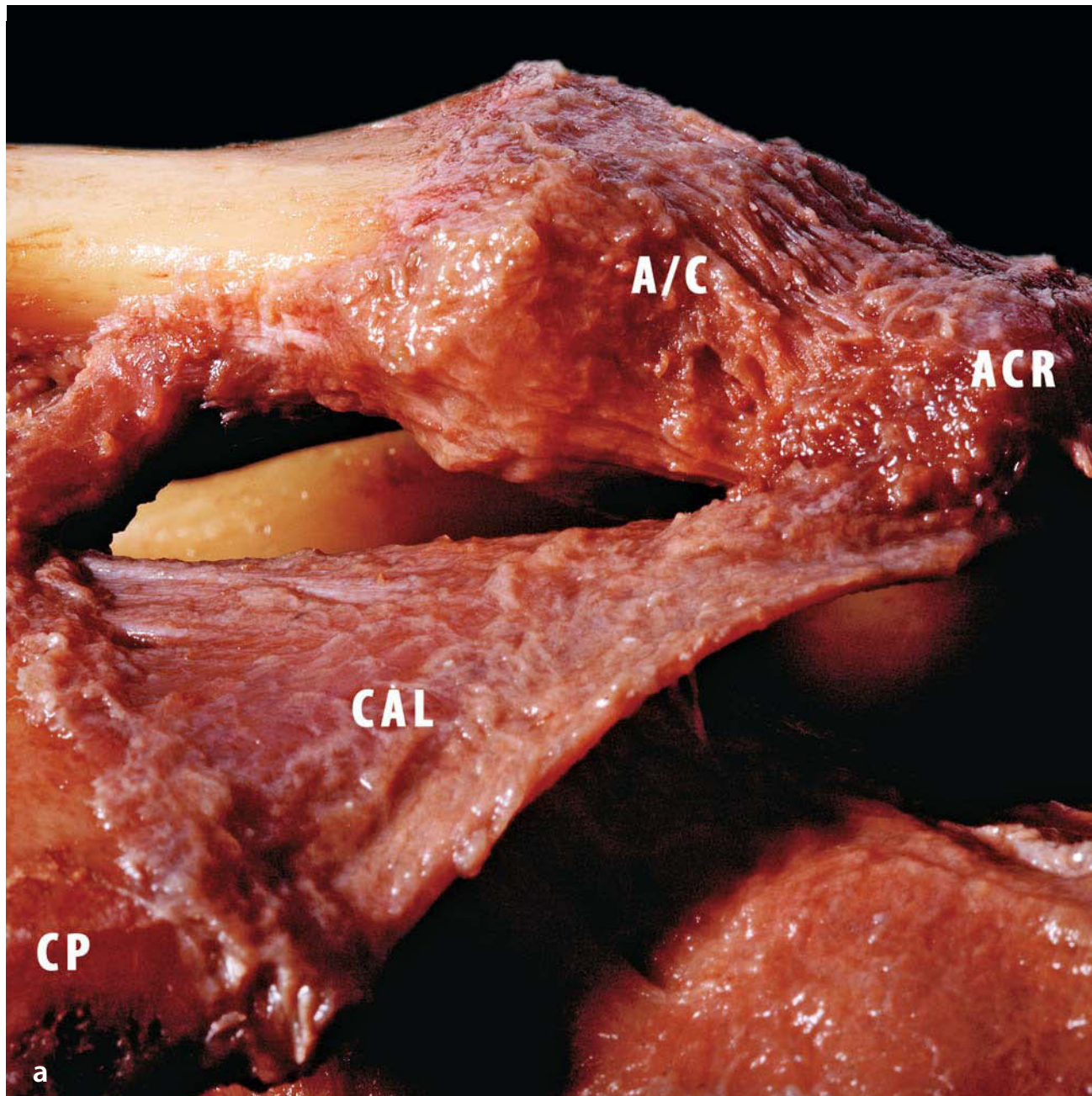
### 2.2.1 The Coracoacromial Ligament (*Ligamentum Coracoacromial*)

This ligament is a strong triangular band extending between the coracoid process and the acromion. It is attached, by its apex, to the summit of the acromion just in front of the articular surface for the clavicle; and by its broad base to the whole length of the lateral border of the coracoid process (Fig. 2.11). The ligament is moderated by twisting into a helix downward and to the exterior as far as the insertion on the coracoid apophysis. In particular, the subacromial portion of the ligament is variable in thickness, varying from 2 mm to 5.6 mm (average 3.9 mm). An arterial vessel is constantly present on

the posterior surface of the ligament, coming from the coracoid and circulating upward; this is a branch of the suprascapular artery. It is in relation, above, with the clavicle and the lower surface of the deltoid muscle; below, it is indirectly in contact with the tendon of the supraspinatus muscle, a bursa being interposed. Its lateral border is continuous with a dense lamina that passes beneath the deltoid on the tendons of the supraspinatus and infraspinatus. Holt et al. [35] performed cadaveric anatomical dissections of 50 shoulders with measurement and histological analysis of the coracoacromial ligament.

In subjects older than 50 years of age the coracoacromial ligament does not have a constant form. Three main types have been identified [35]: quadrangular, Y-shaped, consisting of two marginal bands and a thinner intervening portion, the two bands being attached respectively to the apex and the base of

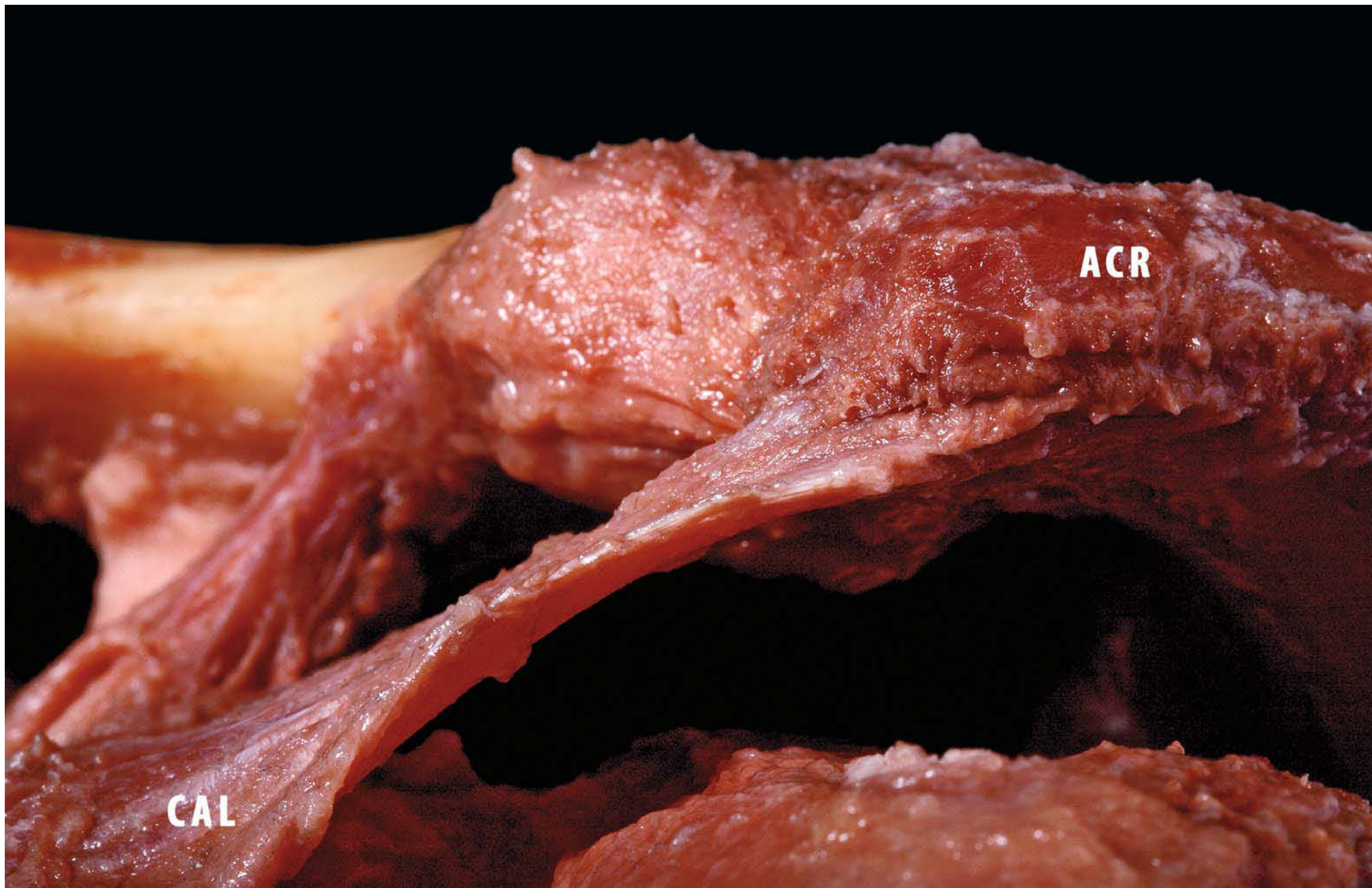**Fig. 2.11a, b.** Left shoulder. **a** Coracoid insertion of coracoacromial ligament. **b** Triangular morphology of coracoacromial ligament (*CON* conoid ligament, *CAL* coracoacromial ligament, *A/C* acromioclavicular joint, *CP* coracoid process)



the coracoid process and joining together at the acromion (Fig. 2.12), and a broad band. A previously unreported type of coracoacromial ligament defined as a multiple-banded ligament, has the largest coracoid attachment. This ligament was similar to the Y form, but with an additional band extending inferiorly and medially toward the base of the coracoid. Histological analysis indicates that the multiple-banded type could be more common than this study suggests. When the pectoralis minor inserts, as occasionally is the case, into the capsule of the shoulder-joint instead of into the coracoid process, it passes between these two bands, and the intervening portion of the ligament is then deficient. This ligament, together with the coracoid process and the acromion, forms a vault for the protection of the head of the humerus. The assumption that the coracoacromial ligament acts as a stabiliser arises from reports of superior humeral dislocation after hemiarthroplasty in patients with irreparable rotator cuff tears who have previously had a procedure in which the coracoacromial ligament was excised [36]. This assumption may also arise from studies on the impingement syndrome, which implicate the coracoacromial ligament as a causative factor [37]. Two studies defining the role of the coracoacromial ligament in normal shoulder function have been presented [38, 39]. Their authors performed cadaver studies in which superior translation was measured in rotator cuff-deficient shoulders before and after coracoacromial ligament resection. In both studies with a given force, the humerus

could be displaced further in the superior direction after coracoacromial ligament release. These studies are consistent with the previous notion that the coracoacromial ligament may act as an anterosuperior restraint [40]. Some reflections [41] are possible on the biomechanical role of the ligament, on the basis of the pathogenesis of the impingement syndrome. According to the biomechanical studies of Tillmann [42], the acromion and the coracoid are under opposite directional forces exerted by the muscle inserted to them. The coracoacromial ligament acts as a tension band within the humeral fossa, and this reduces the bending movement of the coracoid process and of the acromion, counteracting the action of the pectoralis minor, the coracobrachialis and the caput brevis of the biceps. With this view, the coracoacromial ligament seems to have a role in transmitting forces from pectoralis minor to acromion, and its greater or lesser extension may be consistent with more or less tension. Increased tone of the pectoralis minor, related to the external rotators of the upper arm, would lead to anterior positioning and internal rotation of the scapula (protraction) [43], and the ligament tension will also increase. Another possibility is an increase in the thickness of the ligament, leading to a further increase in friction. The anterior spur develops from the acromial edge within the substance of the coracoacromial ligament, as a result of the transmission of the tensile forces through it; this is a possible expression of the passage from a dysfunctional syndrome to an organic stenosis [44].

**Fig. 2.12.** Left shoulder: lateral view. Detail of the acromial insertion of the coracoacromial ligament



### 2.2.2 The Superior Transverse Ligament (*Ligamentum Transversum Scapulæ Superius*; Transverse or Suprascapular Ligament)

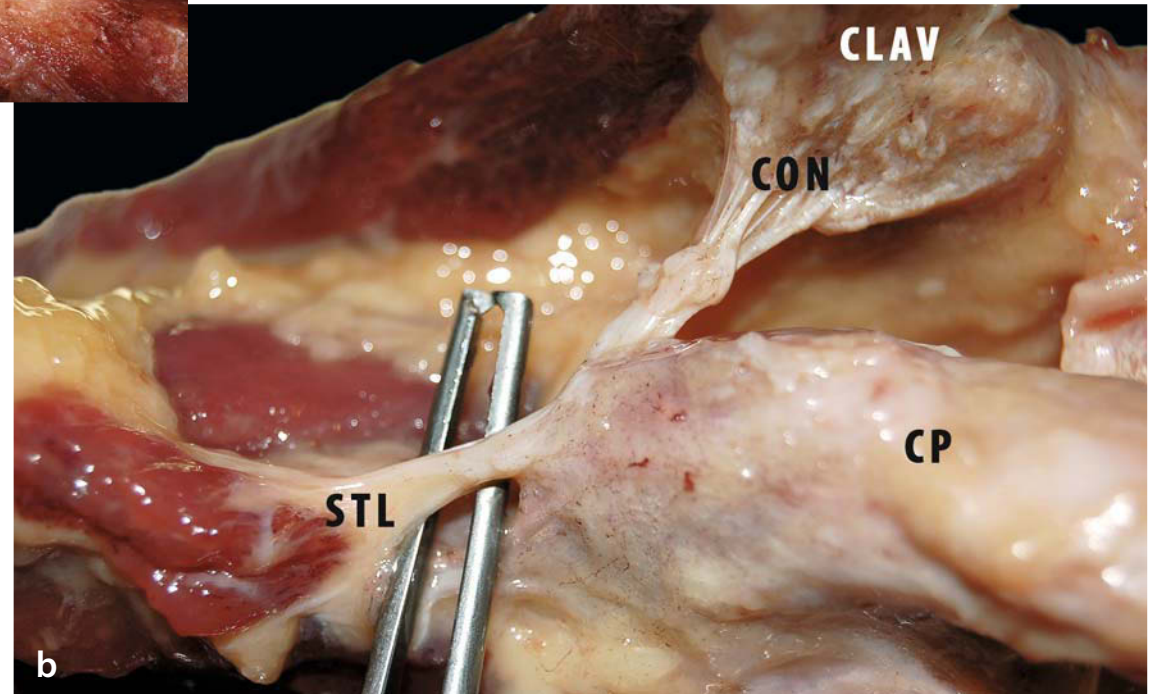
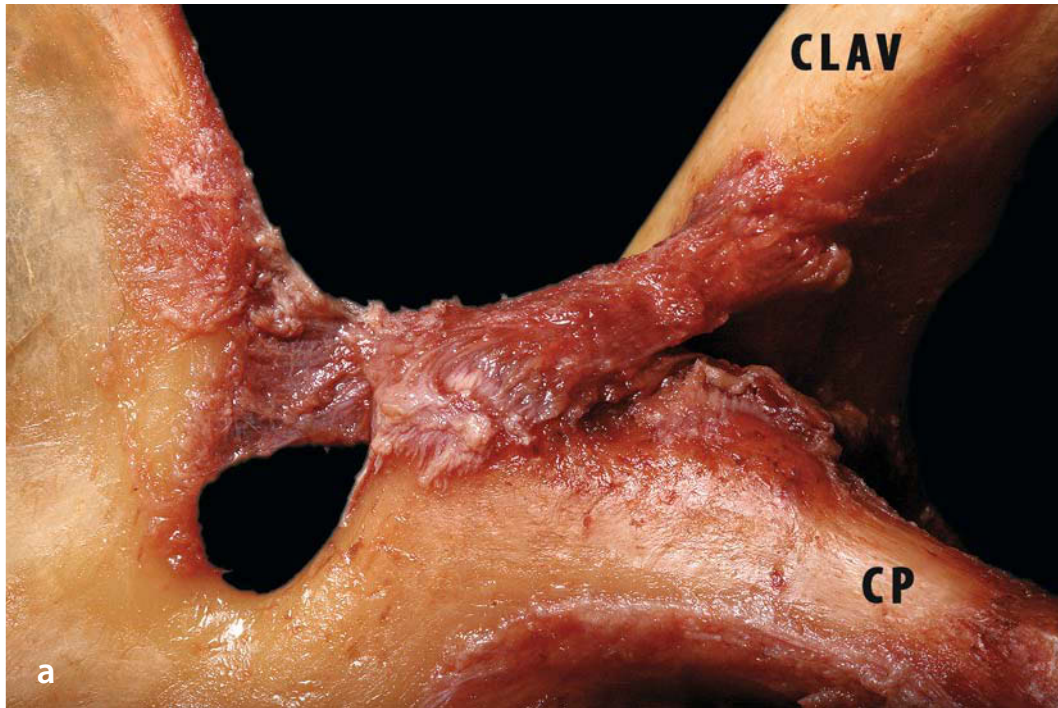
The suprascapular ligament converts the suprascapular notch into a foramen separating the vessels and nerve of the same name (Fig. 2.13a, b). It is a thin, flat fasciculus, narrower in the middle than at the ends and attached by one end to the base of the coracoid process and at the other to the medial end of the scapular notch. The suprascapular nerve runs through the foramen; the transverse scapular vessels cross over the ligament. Nevertheless, variations in its thickness and length and its tendency to ossify suggest that the ligament responds to changes in mechanical load. The fibrocartilaginous character of the entheses suggests that the insertion sites of the ligament are subject to both compressive and tensile loading and are regions of stress concentration. This probably reflects the complex shape of the scapula and the presence of a conspicuous indentation (the suprascapular notch) near the ligament. The loading patterns may reflect either the attachment of muscles and/or the forces transmitted to the suprascapular ligament from the neighbouring coracoclavicular ligament [45]. With an incidence of 1–2% of all cases of shoulder pain, suprascapular nerve entrapment is a rare entity that is often missed in clinical practice [46]. The suprascapular nerve arises from the superior

trunk of the brachial plexus at Erb's point and runs an oblique course through the posterior cervical triangle toward the suprascapular notch, where it arrives together with the suprascapular vein and artery. The suprascapular nerve enters the suprascapular fossa beneath the superior transverse scapular ligament, while the artery and vein travel above the ligament and laterally in relation to the nerve.

From its origin at the brachial plexus, the suprascapular nerve runs as a mixed motor and sensory peripheral nerve toward the suprascapular notch, where it passes underneath the superior transverse ligament. Here, the suprascapular nerve releases a motor branch that usually innervates the supraspinatus muscle with two branches. The suprascapular nerve then travels around the lateral margin of the base of the scapular spine, passing the spinoglenoid notch, and enters the infraspinatus fossa. At the spinoglenoid notch the nerve may be covered with the spinoglenoid ligament, also known as the inferior transverse scapular ligament. Thereafter, it divides into two, three or four motor branches [47] innervating the infraspinatus muscle. All motor branches to the infraspinatus muscle are of the same length and diameter. The motor branches to the infraspinatus are significantly longer and slightly thicker than those to the supraspinatus. Therefore, cases of suprascapular nerve entrapment must be divided into those with proximal lesions at the suprascapular notch and those with distal lesions at the spinoglenoid notch [48, 49].

**Fig. 2.13a,b.** Left shoulder. **a** Antero-inferior view. The scapular notch is closed by the superior transverse ligament (STL). Note there is continuity between the fibres of the conoid ligament and the STL. **b** Magnification of the suprascapular notch





Whereas the former type of entrapment generally involves compression at the suprascapular notch with resultant denervation of both the supraspinatus and infraspinatus muscles, suprascapular nerve compression at the spinoglenoid notch is not uncommon and involves only the infraspinatus muscle. Entrapment or injury of the suprascapular nerve can be caused by fracture, overuse, anatomical variations, excessive scapular motion or massive spinoglenoid cysts [50]. Sometimes the ligament is ossified [51, 52].

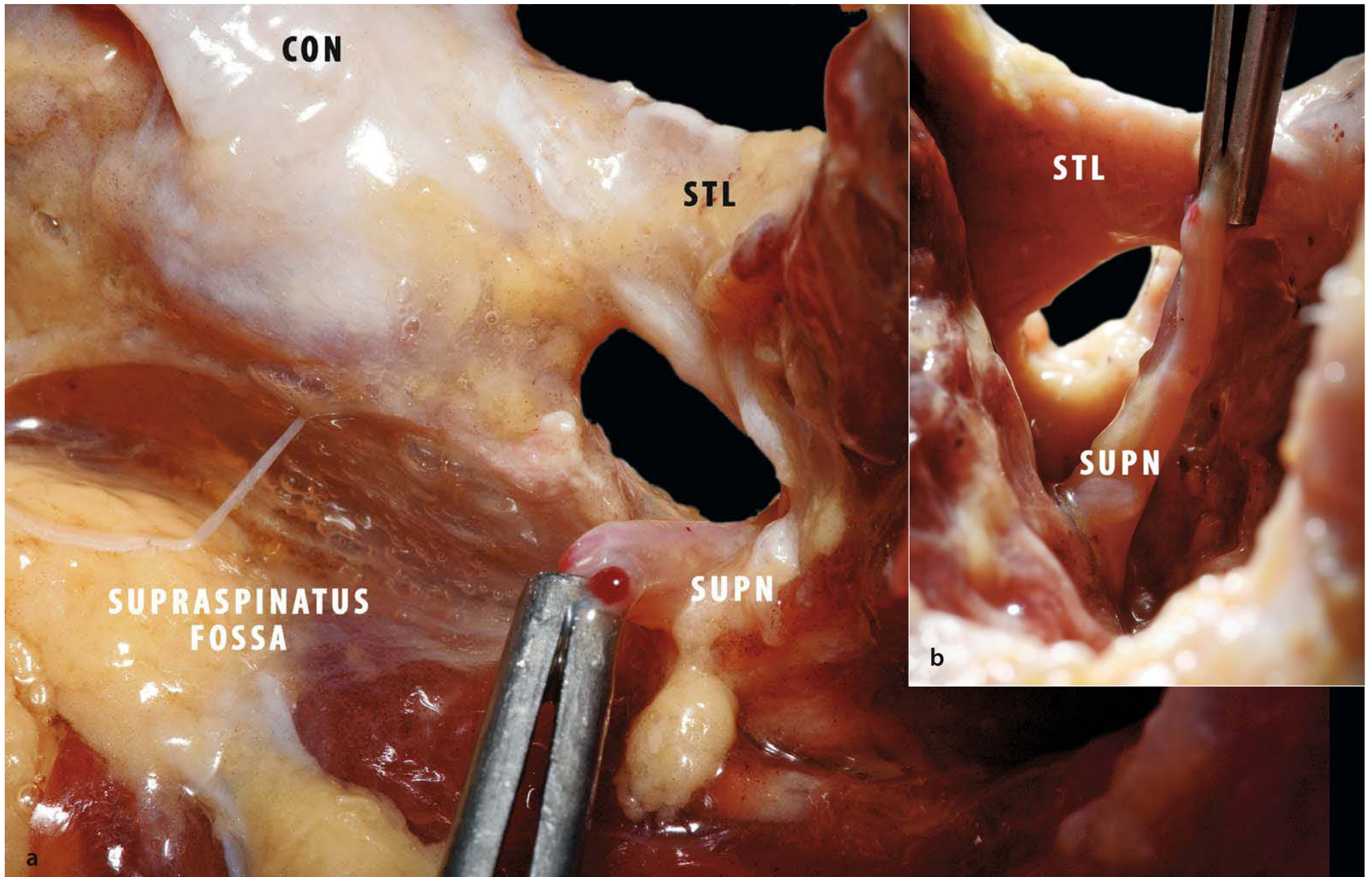
Arthroscopic release of the superior transverse ligament is a technically demanding but effective method of decompressing the suprascapular nerve at the suprascapular notch with minimal morbidity [53–55], in contrast to an open approach.

Variations in morphology around the suprascapular notch have been identified. Rengachary et al. [56] have classified the suprascapular notch and reported on six types, depending on their configuration and enclosure. The most common type was a U-shaped notch, which was identified in 48% of their cadavers. A

small V-shaped notch was identified in only 3% [57]. Several variations in the suprascapular ligament morphology have been reported. At the suprascapular notch and in the supraspinatus fossa no significant movement of the suprascapular nerve is possible because the neurovascular pedicle is fixed to the periosteum. This results in the vulnerability of the motor branches of suprascapular nerve [58]. Rengachary et al., in their study, evaluated motion of the suprascapular nerve relative to the suprascapular notch with various movements of the arm and shoulder and noted that the nerve was often apposed to the sharp inferior margin of the superior transverse scapular ligament. They term this mechanism of injury the “sling effect” [56, 59].

Anatomical variants of the suprascapular vessel’s passage through the suprascapular notch have been described. An anomalous suprascapular artery (2.5%) or its prominent branch (32%) may pass under the suprascapular ligament along with the nerve [57, 60]. The vessel always runs lateral to the nerve and is thus closer to the glenoid rim [47] (Fig. 2.14a, b).

**Fig. 2.14a, b.** Right shoulder. **a** Posterior view of the suprascapular notch. **b** Magnification of suprascapular notch

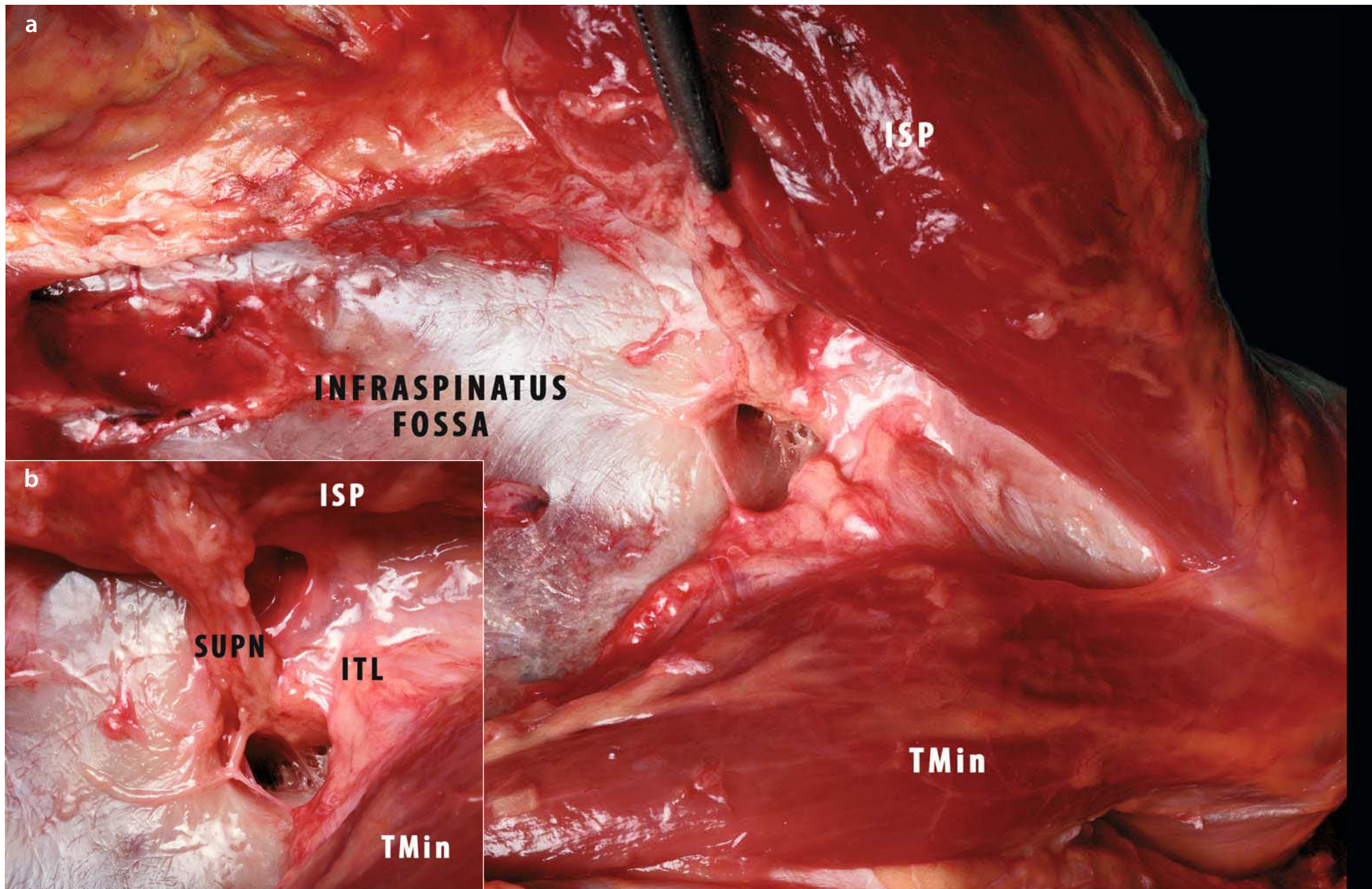


### 2.2.3 The Inferior Transverse Ligament (*Ligamentum Transversum Scapulæ Inferius*; Spinoglenoid Ligament)

This ligament is a weak membranous band, situated behind the neck of the scapula and stretching from the lateral border of the spine to the margin of the glenoid cavity. It forms an arch under which the transverse scapular vessels and suprascapular nerve enter the infraspinatus fossa (Fig. 2.15a, b). The spinoglenoid ligament, also known as the inferior transverse scapular ligament, has been identified as a site of entrapment of the suprascapular nerve resulting in isolated weakness of the infraspinatus muscle [61]. The infraspinatus muscle is elevated inferiorly out of the infraspinatus fossa from medial to lateral to expose the suprascapular nerve and the spinoglenoid ligament, if present. Cummins et al. [62] classified the ligament as absent or insubstantial, as a thin fibrous band (type I), or as a distinct ligament (type II). Type I and type II ligaments differ from each other only in terms of thickness. The reported prevalence of the spinoglenoid ligament varies widely. Mestdagh et al. [63] iden-

tified the spinoglenoid ligament in 10 of 20 cadavers and described it as “an aponeurotic band” separating the supra- and infraspinatus muscles. Kaspi et al. [64] found the ligament in 5 of 10 female cadavers and 13 of 15 male cadavers in their study; overall, they identified the ligament in 18 (72%) of the 25 cadavers. Demaio et al. [65] found the ligament in only 2 of 75 shoulders. An aponeurosis, described as “a condensation of fascia distinct from surrounding tissues,” was identified in 10 other shoulders. The aponeurosis did not extend to the glenoid neck. The presence of the spinoglenoid ligament is of potential clinical importance, for two reasons. First, the ligament may limit the advancement of the infraspinatus tendon during repair of a massive tear of the rotator cuff, placing the distal part of the suprascapular nerve at risk. Second, the spinoglenoid ligament represents a potential site for entrapment of the suprascapular nerve, particularly with the added stress of traction that can occur with overhead athletic activities. If other possible causes of weakness of the infraspinatus muscle have been excluded and nonoperative treatment has failed, exploration and operative release of the spinoglenoid ligament may be indicated [62].

**Fig. 2.15a, b.** Right shoulder, *posterior view*. **a** After elevation of the infraspinatus muscle the inferior transverse ligament (*ITL*), which closes the spinoglenoid notch, is visible at the border of the spine (*SUPN* suprascapular nerve). **b** Magnification of suprascapular notch (*TMin* teres minor)



## References

1. Tyurina TV (1985) Age related characteristic of the human acromioclavicular joint. *Arkh Anat Gistol Embriol* 89:75-81
2. Urist MR (1946) Complete dislocation of the acromioclavicular joint. *J Bone Joint Surg* 28:813-837
3. Ernberg LA, Potter HG (2003) Radiographic evaluation of the acromioclavicular and sternoclavicular joints. *Clin Sports Med* 22:255-275
4. DePalma A, Callery G, Bennett G (1949) Variational anatomy and degenerative lesions of the shoulder joint. *Instr Course Lect* 6:255-281
5. Petersson C. (1983) Degeneration of the acromioclavicular joint: a morphological study. *Acta Orthop Scand* 54:434-438
6. Salter EJ, Nasca R, Shelley B (1987) Anatomical observations on the acromioclavicular joint and supporting ligaments. *Am J Sports Med* 15:199-206
7. Richards RR (1993) Acromioclavicular joint injuries. *Instr Course Lect* 42:259-269
8. Buttaci CJ, Stitik TP, Yonclas PP et al (2004) Osteoarthritis of the acromioclavicular joint: a review of anatomy, biomechanics, diagnosis, and treatment. *Am J Phys Med Rehabil* 83:791-797
9. Klimkiewicz J, Sher J et al (1997) Biomechanical function of acromioclavicular ligaments in limiting anterior posterior translation of the acromioclavicular joint. Paper presented at the open meeting of the American Shoulder and Elbow Surgeons, San Francisco, Calif
10. Renfree KJ, Wright TW (2003) Anatomy and biomechanics of the acromioclavicular and sternoclavicular joints. *Clin Sports Med* 22:219-238
11. Rockwood CA Jr, Young DC (1990) Disorders of the acromioclavicular joint. In: Rockwood CA Jr, Matsen FA III (eds) *The shoulder*. Saunders, Philadelphia, Penn, pp 413-476
12. Renfree KJ, Riley MK, Wheeler D et al (2003) Ligamentous anatomy of the distal clavicle. *J Shoulder Elbow Surg* 12:355-359
13. Rios CG, Arciero RA, Mazzocca AD (2007) Anatomy of the clavicle and coracoid process for reconstruction of the coracoclavicular ligaments. *Am J Sports Med* 35:811-817
14. Fukuda K, Craig EV, An KN et al (1986) Biomechanical study of the ligamentous system of the acromioclavicular joint. *J Bone Joint Surg Am* 68:434-440
15. Harris RI, Wallace AL, Harper GD et al (2000) Structural properties of the intact and reconstructed coracoclavicular ligament complex. *Am J Sports Med* 28:103-108
16. Motamedi AR, Blevins FT, Willis MC et al (2000) Biomechanics of the coracoclavicular ligament complex and augmentations used in its repair and reconstruction. *Am J Sports Med* 28:380-384
17. Harris RI, Vu DH, Sonnabend DH et al (2001) Anatomic variance of the coracoclavicular joints. *J Shoulder Elbow Surg* 10:585-588
18. Testut L (1909) *Traité d'anatomie humaine*, vol 1. Octave Doin, Paris, pp 475-480
19. Rengachary SS, Burr D, Lucas S et al (1979) Suprascapular entrapment neuropathy: a clinical, anatomical, and comparative study. 2. Anatomical study. *Neurosurgery* 5:447-451
20. Worcester JN Jr, Green DP (1968) Osteoarthritis of the acromioclavicular joint. *Clin Orthop Relat Res* 58:69-73
21. Zanca P (1971) Shoulder pain: involvement of the acromioclavicular joint. *Am J Roentgenol Radium Ther Nucl Med* 112:493-506
22. Petersson CJ, Redlund-Jonnell I (1983) Radiographic joint space in normal acromioclavicular joints. *Acta Orthop Scand* 54:431-433
23. Rockwood CJ, Williams G, Young D (1998) Disorders of the acromioclavicular joint. In: Rockwood CJ, Matsen FA III (eds) *The shoulder*, 2nd edn. Saunders, Philadelphia
24. Ludwig PM, Behrens SA, Meyer SM et al (2004) Three-dimensional clavicular motion during arm elevation: reliability and descriptive data. *J Orthop Sports Phys Ther* 34:140-149
25. Codman EA (1934) *The shoulder*. Robert E. Krieger, Malabar, Fla
26. McClure PW, Michener LA, Sennett BJ et al (2001) Direct 3-dimensional measurement of scapular kinematics during dynamic movements in vivo. *J Shoulder Elbow Surg* 10:269-277
27. Bearn JG (1967) Direct observations on the function of the capsule of the sternoclavicular joint in clavicle support. *J Anat* 101:159-170
28. Corteen DP, Teitge RA (2005) Stabilization of the clavicle after distal resection. A biomechanical study. *Am J Sports Med* 33:61-67
29. Neer CS (1972) Anterior acromioplasty for the chronic impingement syndrome in the shoulder. A preliminary report. *J Bone Joint Surg Am* 54:41-50
30. Sachs RA, Stone ML, Devine S (1994) Open vs. arthroscopic acromioplasty: a prospective, randomized study. *Arthroscopy* 10:248-254
31. Klimkiewicz JJ, Karduna A, Sher JS et al (1999) The acromioclavicular capsule as a restraint to posterior translation of the clavicle: a biomechanical analysis. *J Shoulder Elbow Surg* 8:119-124
32. Branch TP, Burdette HL, Shahriari AS et al (1996) The role of the acromioclavicular ligaments and the effect of distal clavicle resection. *Am J Sports Med* 24:293-297
33. Kuster MS, Hales PF, Davis SJ (1998) The effects of arthroscopic acromioplasty on the acromioclavicular joint. *J Shoulder Elbow Surg* 7:140-143
34. Deshmukh AV, Perlmutter GS, Zilberfarb JL et al (2004) Effect of subacromial decompression on laxity of the acromioclavicular joint: biomechanical testing in a cadaveric model. *J Shoulder Elbow Surg* 13:338-343
35. Holt EM, Allibone RO (1995) Anatomic variants of the coracoacromial ligament. *J Shoulder Elbow Surg* 4:370-375
36. Soslowky LJ, An CH, Johnston SP et al (1994) Geometric and mechanical properties of the coracoacromial ligament and their relationship to rotator cuff disease. *Clin Orthop* 304:10-17
37. Soslowky LJ, An CH, DeBano CM et al (1996) Coracoacromial ligament: in situ load and viscoelastic properties in rotator cuff disease. *Clin Orthop* 330:40-44

38. Moorman CT III, Deng XH, Warren RF et al (1995) Role of the coracoacromial ligament in normal shoulder function. Presented at the American Academy of Orthopedic Surgeons, 62nd Annual Meeting, 16–21 February 1995, Orlando, Fla
39. Lazarus MD, Ynug SW, Sidles JA et al (1995) Anterosuperior humeral displacement: limitation by the coracoacromial arch. Presented at the American Academy of Orthopedic Surgeons, 62nd Annual Meeting, 16–21 February 1995, Orlando, Fla
40. Hockman DE, Lucas GL, Roth CA (2004) Role of the coracoacromial ligament as restraint after shoulder hemiarthroplasty. *Clin Orthop Relat Res* 419:80-82
41. Gallino M, Battiston B, Annaratone G et al (1995) Coracoacromial ligament: a comparative arthroscopic and anatomic study. *Arthroscopy* 11:564–567
42. Tilmann B (1990) Functional anatomy of the shoulder. Communication at the Fourth Congress of the European Society of Knee Surgery and Arthroscopy, 25-30 June 1990, Stockholm
43. Pujadas GM (1970) Coracoacromial ligament syndrome. *J Bone Joint Surg Am* 52:126
44. Ogata S, Unthoff HK (1990) Acromial enthesopathy and rotator cuff tear: A radiologic and histologic post-mortem investigation of the coracoacromial arch. *Clin Orthop* 254:39-48
45. Moriggl B, Jax P, Milz S et al (2001) Fibrocartilage at the entheses of the suprascapular (superior transverse scapular) ligament of man—a ligament spanning two regions of a single bone. *J Anat* 199:539-545
46. Zehetgruber H, Noske H, Lang T et al (2002) Suprascapular nerve entrapment (a meta-analysis). *Int Orthop* 26:339–343
47. Warner JP, Krushell RJ, Masquelet A et al (1992) Anatomy and relationships of the suprascapular nerve: anatomical constraints to mobilization of the supraspinatus and infraspinatus muscles in the management of massive rotator-cuff tears. *J Bone Joint Surg Am* 74:36–45
48. Vastamaki M, Goransson H (1993) Suprascapular nerve entrapment. *Clin Orthop Relat Res* 297:135–143
49. Fabre T, Piton C, Leclouerec G et al (1999) Entrapment of the suprascapular nerve. *J Bone Joint Surg Br* 81:414–419
50. Chen AL, Ong BC, Rose DJ (2003) Arthroscopic management of spinoglenoid cysts associated with SLAP lesions and suprascapular neuropathy. *Arthroscopy* 19:E15–E21
51. Osuagwu FC, Imosemi IO, Shokunbi MT (2005) Complete ossification of the superior transverse scapular ligament in a Nigerian male adult. *Int J Morphol* 23:121-122
52. Cohen SB, Dines DM, Moorman CT (1997) Familial calcification of the superior transverse scapular ligament causing neuropathy. *Clin Orthop Relat Res* 334:131-135
53. Barwood SA, Burkhart SS, Lo IKY (2007) Arthroscopic suprascapular nerve release at the suprascapular notch in a cadaveric model: an anatomic approach. *Arthroscopy* 23: 221-225
54. Mok WY (2003) Case report of spontaneous dissolution of ganglion cyst following arthroscopic stabilisation of a type 2 SLAP lesion. Literature review of the treatment of ganglion cyst causing suprascapular nerve entrapment. Abstract presented at the Biennial Congress, Auckland, N Z, p 5, no 160
55. Post M, Mayer J (1987) Suprascapular nerve entrapment. Diagnosis and treatment. *Clin Orthop Relat Res* 126-136
56. Rengachary SS, Neff JP, Singer PA et al (1979) Suprascapular entrapment neuropathy: a clinical, anatomical and comparative study. 1. Clinical study. *Neurosurgery* 5:441-446
57. Safran MR (2004) Nerve injury about the shoulder in athletes. 1. Suprascapular nerve and axillary nerve. *Am J Sports Med* 32:803-819
58. Greiner A, Golser K, Wambacher M et al (2003) The course of the suprascapular nerve in the supraspinatus fossa and its vulnerability in muscle advancement. *J Shoulder Elbow Surg* 12:256-259
59. Cummins CA, Messer TM, Number GW (2000) Suprascapular nerve entrapment. *J Bone Joint Surg Am* 82:415-24
60. Tubbs RS, Smyth MD, Salter G et al (2003) Anomalous traversement of the suprascapular artery through the suprascapular notch: a possible mechanism for undiagnosed shoulder pain? *Med Sci Monit* 9:BR116-119
61. Aiello I, Serra G, Traina GC et al (1982) Entrapment of the suprascapular nerve at the spinoglenoid notch. *Ann Neurol* 12:314-316
62. Cummins CA, Anderson K, Bowen M (1998) Anatomy and histological characteristics of the spinoglenoid ligament. *J Bone Joint Surg* 80:1622-1625
63. Mestdagh H, Drizenko A, Ghestem P (1981) Anatomical bases of suprascapular nerve syndrome. *Anat Clin* 3:67-71
64. Kaspi A, Yanai J, Pick CG et al (1988) Entrapment of the distal suprascapular nerve. An anatomical study. *Int Orthop* 12:273-275
65. Demaio M, Drez D Jr, Mullins RC (1991) The inferior transverse scapular ligament as a possible cause of entrapment neuropathy of the nerve to the infraspinatus. A brief note. *J Bone Joint Surg Am* 73:1061-1063

---

## **PART 3 - GLENOHUMERAL JOINT (MUSCLE-TENDON)**



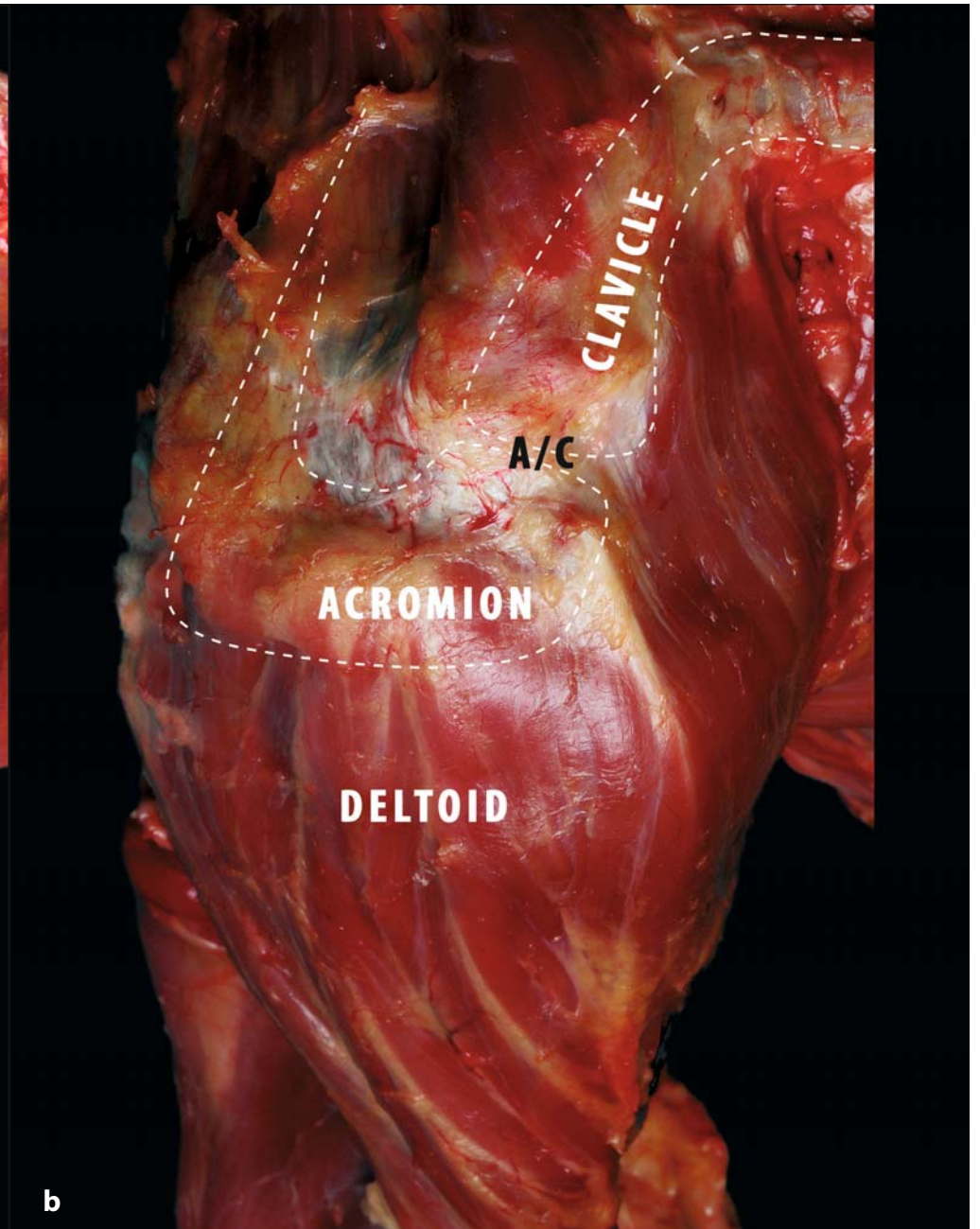
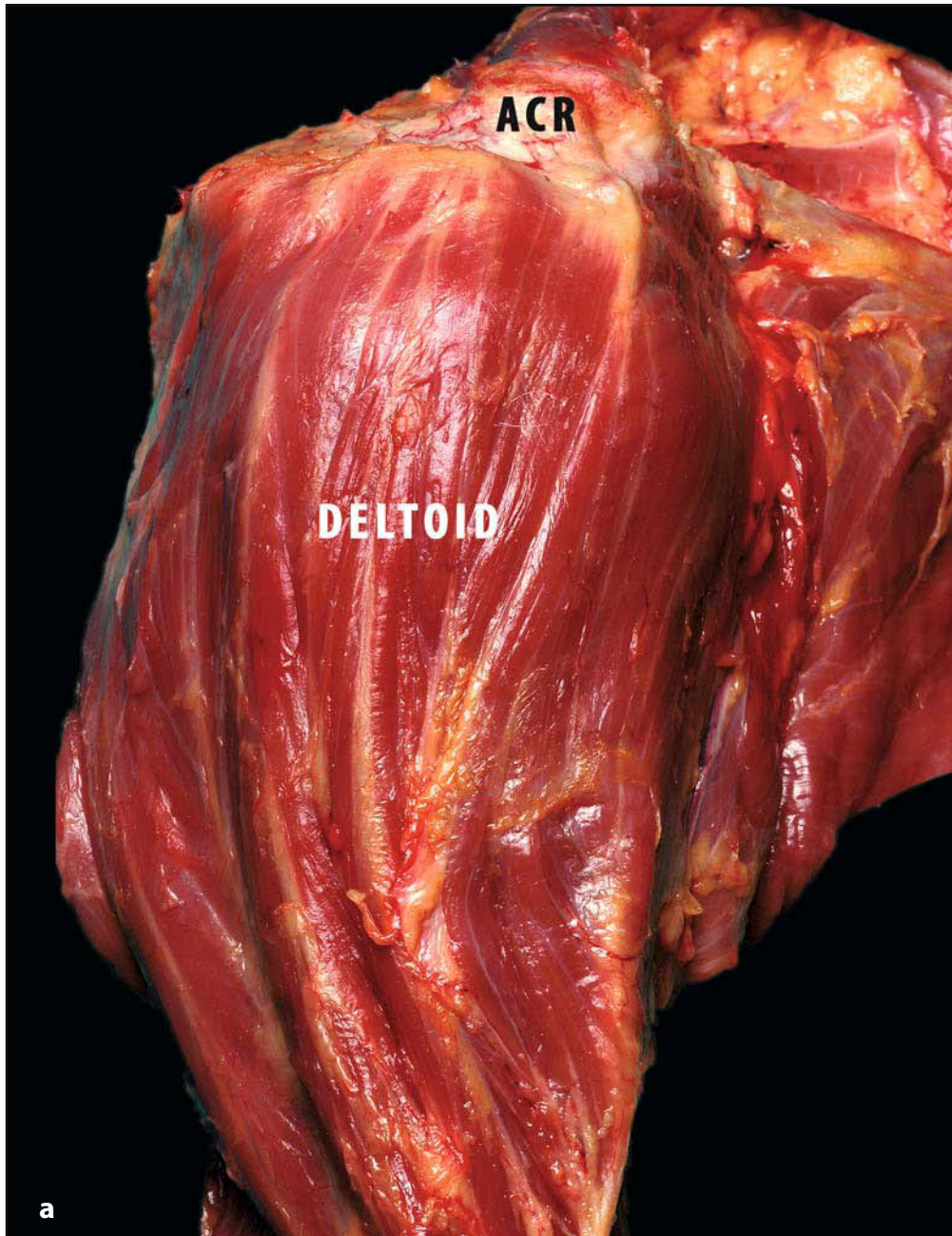
### 3.1 Deltoid Muscle

*Andrea De Vita*

The deltoid is the largest and perhaps most important muscle in the shoulder girdle (Fig. 3.1a). It is made up of three major parts: the anterior deltoid taking its origin from the anterior and superior surfaces of the outer third of the clavicle and anterior acromion; the middle deltoid, originating from the lateral margin of the acromion; and the posterior deltoid, originating from almost the entire scapular spine. The deltoid covers the proximal portion of the humerus and converges into a thick tendinous

insertion at the lateral surface of the humeral shaft [1, 2]. The most important function of the deltoid is forward elevation on the scapular plane. However, differences in activity of the three portions of the deltoid related to arm position have been observed by electromyographic analysis [3]. The function of the deltoid is highly differentiated and is not restricted to only abducting moment of the arm. Although its integrity is critical to shoulder function, it has not been extensively studied with reference to its stabilising function [4]. The axillary nerve and posterior humeral circumflex artery are the only nerve and the major blood supply of this muscle [2] (Fig. 3.1b).

**Fig. 3.1. a** Lateral view of the upper superior arm (right side): lateral view of the deltoid muscle. This is a powerful muscle and has an important role in arm elevation. Its origins are common to other muscle insertions in shoulder girdle. The insertion (\*) is on the lateral surface of the humerus (ACR acromion)  
**b** Superior view of the right shoulder: superior view of the origin of the deltoid muscle. The *dotted lines* describe the bony profiles of acromion and the clavicle. The anterior part of the muscle comes from the clavicle, the middle part from the acromion and the posterior part from the scapular spine (AC acromioclavicular joint)



### 3.1.1 Biomechanics and Functional Anatomy

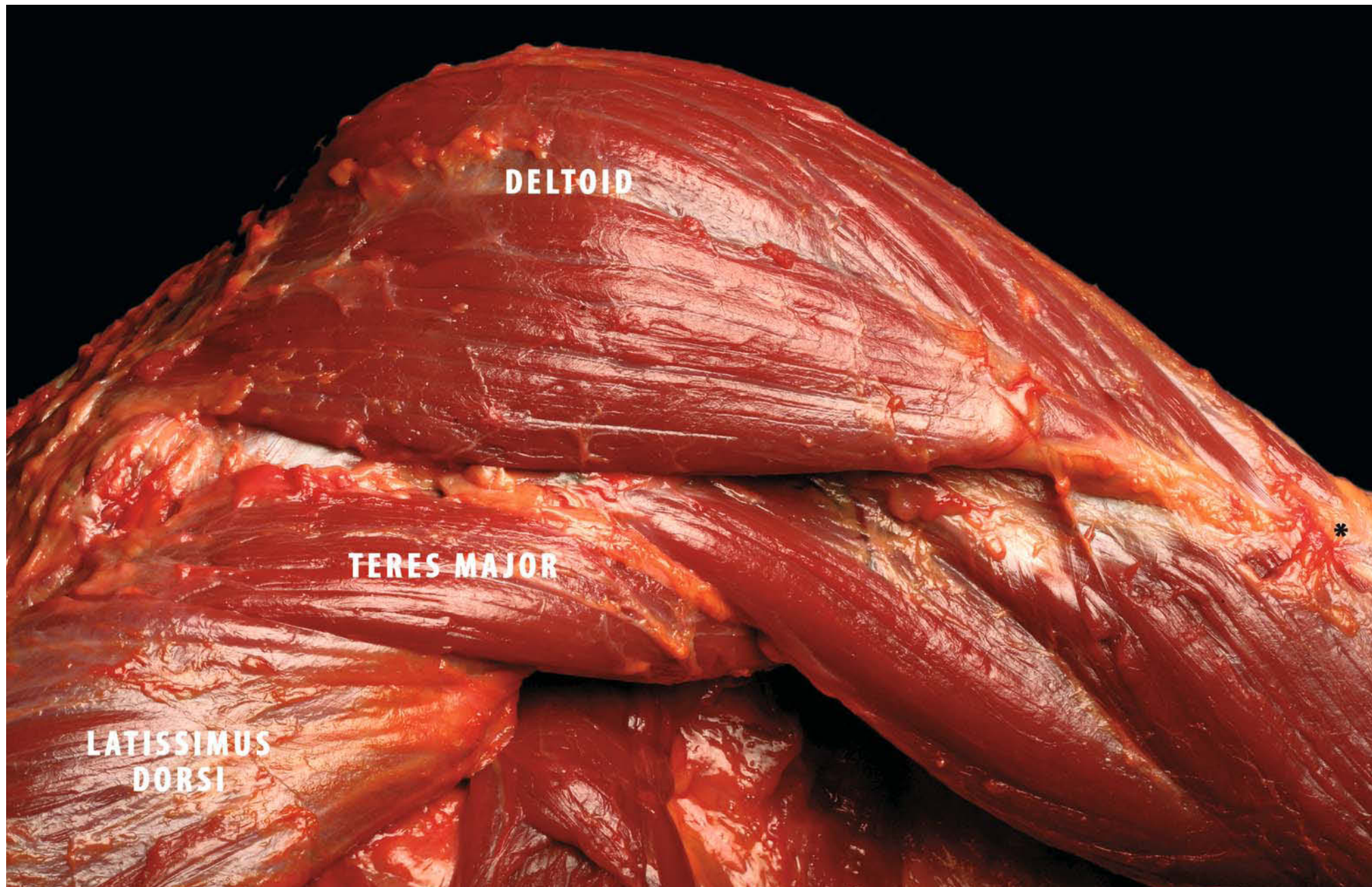
As the deltoid muscle has the largest moment of all the shoulder muscles during arm elevation [5] and is also the largest in cross-sectional area [6], it is thought to be the primary elevator of the shoulder. The three sections of the deltoid differ in internal structure and function. The anterior and the posterior deltoid both have parallel fibres and a longer excursion than the middle third, which is multipennate and stronger and has a shorter excursion (1 cm). The middle third of the deltoid takes part in all elevation movements of the humerus [7]. With its abundant collagens, it is the portion of the muscle most frequently involved in contraction. Elevation on the scapular plane is the product of the anterior and middle third of the deltoid, with some actions by the posterior third, especially for those movements over 90° [4]. This biomechanical principle is reflected in EMG data, as the anterior and middle deltoid demonstrate consistently high activity throughout the range of motion and the posterior deltoid shows extremely low activity until the final phase of motion, where it reveals only a small increase [8] (Fig. 3.2).

Abduction on the coronal plane decreases contribution of the anterior third and increases the contribution of the posterior deltoid. Flexion is a product of the anterior and middle thirds of the deltoid and the clavicular portion of the pectoralis major, with some contribution from the biceps [2].

Although the deltoid muscle's function as a mover has been thoroughly studied, little attention has been paid to this muscle as a

stabiliser of the shoulder. Several studies have shown that contraction of muscles across a joint can lead to increased stability [7, 9–13]. Although dynamic stability mechanisms could potentially operate throughout the range of movement (ROM), its importance may vary according to the position of the glenohumeral joint. Motzkin et al. [14] studied the static relative stabilising effect of the passive bulk tissues and the deltoid muscle on inferior humeral displacement in cadaver shoulders by simulating two techniques used in clinical examinations: the sulcus test and the abducted inferior stability test. In their conclusion, they report that the static deltoid muscle does not provide significant inferior stability in the shoulder. Markhede et al. [15] report that five shoulders in five different patients whose deltoid muscle had been removed because of soft tissue tumours showed no significant functional impairment, although they did not specifically mention stability or instability of the shoulder. A study by Kido et al. [16] has clearly demonstrated the anterior stabilising function of each portion of the deltoid muscle. It is an anterior stabiliser of the shoulder with the arm in abduction and in external rotation. Each portion contributes equally to anterior stability under constant loading conditions. As far as we know, this is the first study showing the deltoid muscle as an anterior stabiliser of the shoulder. There are four mechanisms for dynamic stabilisation through muscles: (1) passive tension from the bulk effect of the muscle itself; (2) contraction, causing related compression of the articular surfaces; (3) joint movement that secondarily tightens the passive ligament constraints; (4) a barrier effect of the contracted muscle [17].

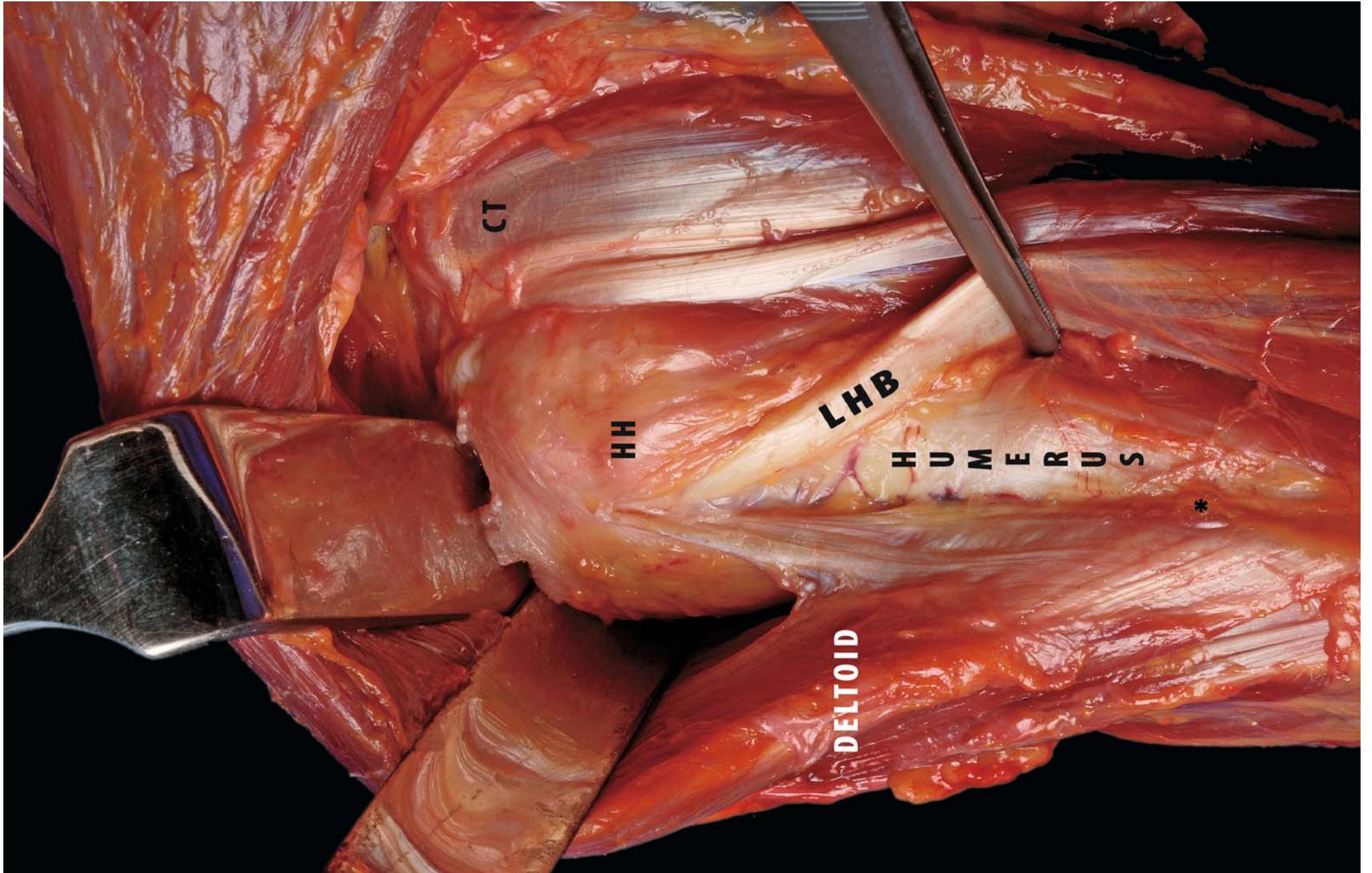
**Fig. 3.2.** Posterior view of the right shoulder: this view illustrates the fibres of the deltoid muscle on the posterior aspect of the shoulder. During arm elevation the posterior part of the muscle is less highly activated. To obtain the stability of the glenohumeral joint the three parts of the muscle work as a whole (\*insertion of deltoid muscle on humerus)



When the arm is elevated, contraction of the deltoid muscle produces more compression force acting on the glenohumeral joint than when the arm is at the subject's side (mechanism 2) [17]. Furthermore, with the arm in external rotation, the deltoid muscle insertion is located further posterior than with the arm in neutral rotation. Thus, it is quite likely that the deltoid muscle, which is located in the posterior aspect of the shoulder joint, works through the passive tension mechanism (mechanism 1) rather than through the barrier effect (mechanism 4). Because there are no differences in stabilising effect among the three portions of the deltoid muscle, the main mechanism seems to be compression of the humeral head against the glenoid fossa, rather than passive tension from the bulk effect. The position used in this experiment was 90° of abduction and external rotation, simulating a position in which anterior instability is com-

monly observed in the clinical setting. This position is also observed during the pitching motion, between late cocking and acceleration. Having conducted an EMG study, Di Giovine et al. [18] report that the three portions of the deltoid muscle are highly active during early cocking, but that the activity decreases to moderate levels during late cocking and acceleration. Thus, moderate contraction of the deltoid muscle does occur during late cocking and acceleration, which may contribute to anterior stability of the shoulder. In his report on a biomechanics study [4], the author, Lee, describes the important function of the deltoid in shoulder stability. The deltoid generates significant shear force and compressive force in the position of anterior shoulder instability. It provides dynamic stability with the arm in the scapular plane, and it only decreases the stability of the shoulder when the arm is in the coronal plane [4] (Fig. 3.3).

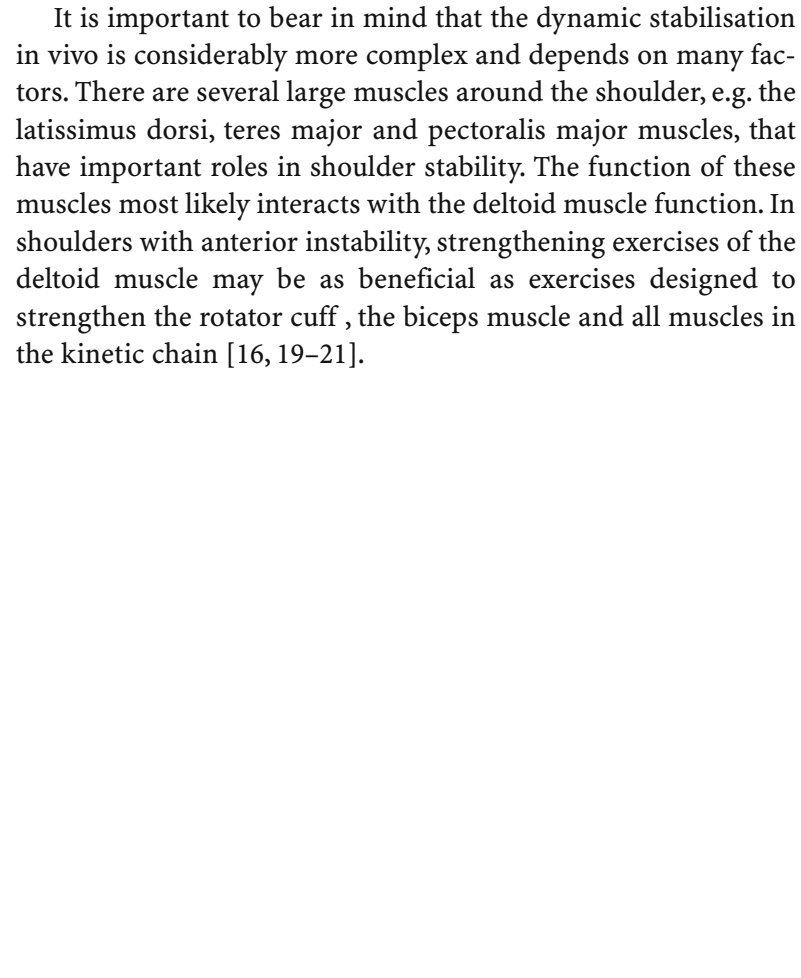
**Fig. 3.3.** Anterior view of the right shoulder: the deltoid covers the rotator cuff muscles and the long head of the biceps (*LHB*). These muscles work together for glenohumeral motion and stability (*CT* common tendon, *HH* humeral head, \*insertion of the deltoid)



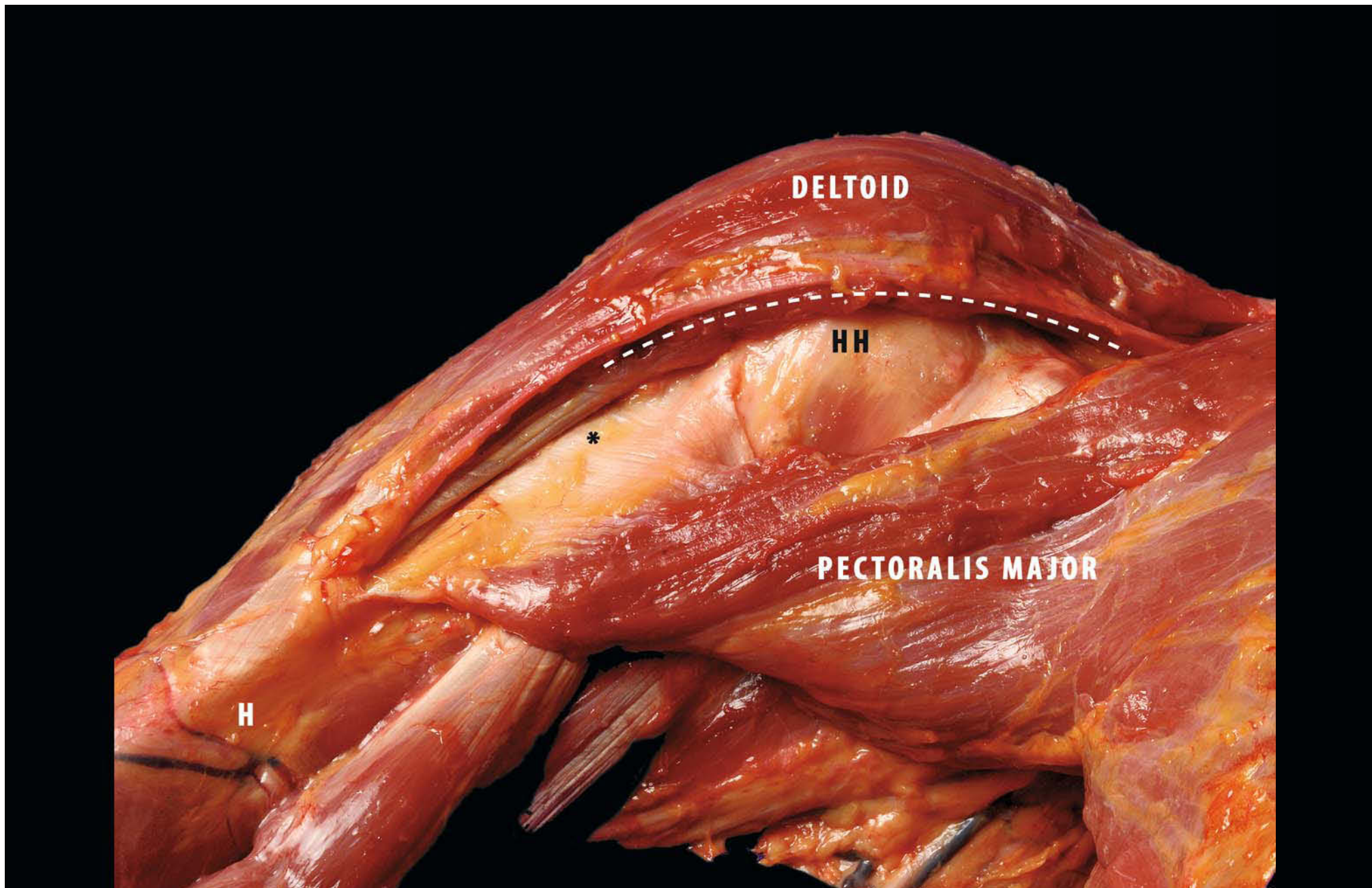
### 3.1.2 Clinical Relevance

In conclusion, we have found that the deltoid muscle is an anterior stabiliser and its function becomes more prominent when the shoulder becomes unstable [16] (Fig. 3.4). The mid- and posterior heads are vigorously strengthened in anterior shoulder instability, because they provide more stability, generating higher compressive force and lower shear force than the anterior head, especially when the glenohumeral joint is working in the scapular plane. This is in contrast to the rotator cuff, which provides substantial stability in all positions of the glenohumeral joint.

It is important to bear in mind that the dynamic stabilisation *in vivo* is considerably more complex and depends on many factors. There are several large muscles around the shoulder, e.g. the latissimus dorsi, teres major and pectoralis major muscles, that have important roles in shoulder stability. The function of these muscles most likely interacts with the deltoid muscle function. In shoulders with anterior instability, strengthening exercises of the deltoid muscle may be as beneficial as exercises designed to strengthen the rotator cuff, the biceps muscle and all muscles in the kinetic chain [16, 19–21].



**Fig. 3.4.** Anterior view of the right shoulder: this view illustrates the anterior portion of the deltoid muscle. The *dotted line* describes the deltopectoral interval, i.e. the space between the medial margin of the deltoid muscle and the superior margin of the pectoralis major muscle (\*lateral insertion of the pectoralis major, *H* humerus, *HH* humeral head)





### 3.2 Rotator Cuff

*Alberto Costantini, Hiroshi Minagawa*

Many muscles are attached to different parts of the shoulder, and they are used to move the arm in space. Underneath the deltoid muscle are the rotator cuff muscles. The rotator cuff is a group of four muscles that form a strong cuff around the shoulder joint and help to control the rotation and position of the arm. Each of these muscles has a tendon at the end that attaches to the humerus. These four muscles are:

The *subscapularis*

The *supraspinatus*

The *infraspinatus*

The *teres minor*

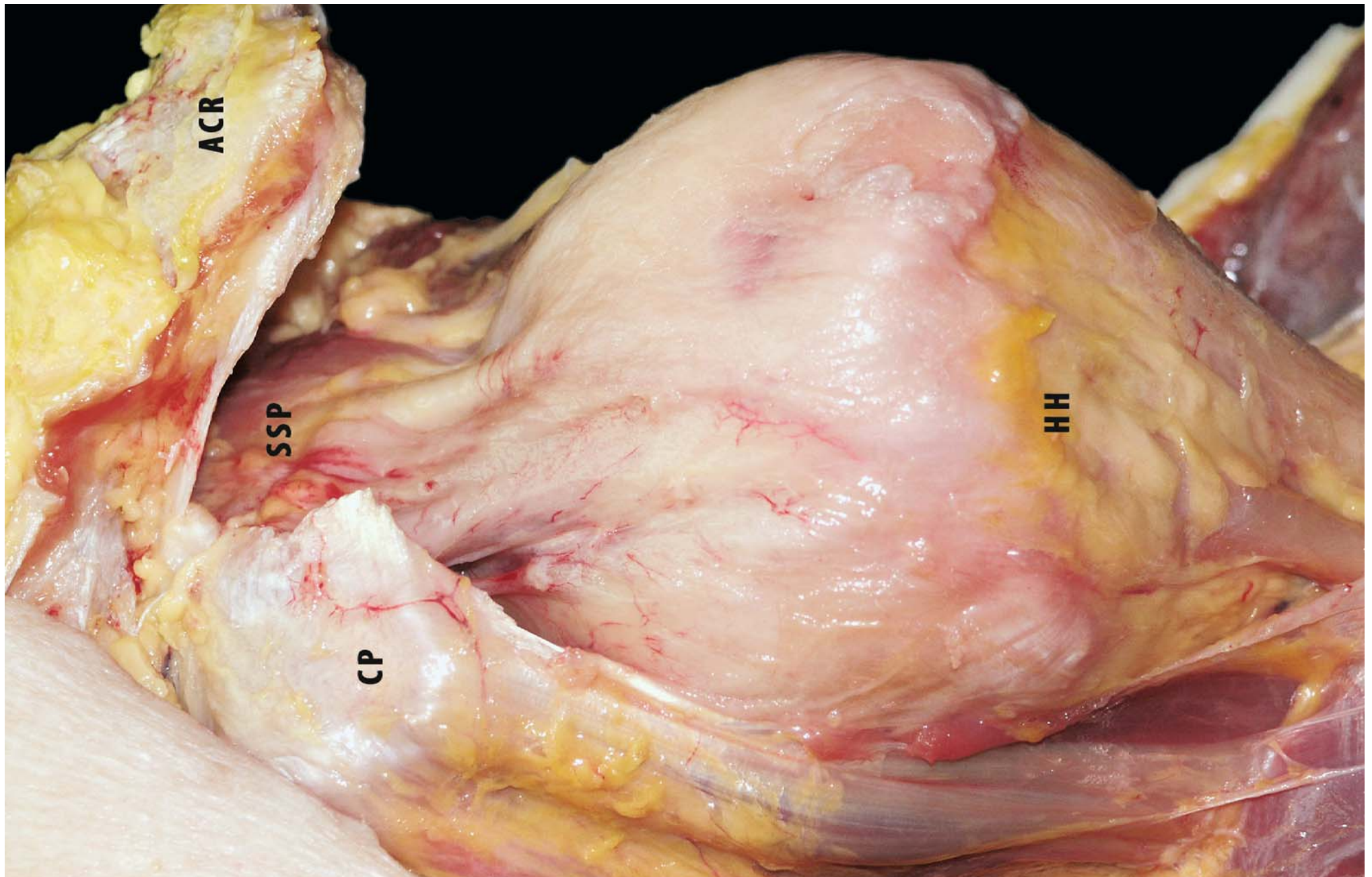
The tendons of the rotator cuff are seen to fuse into a single structure near their insertions into the tubercles of the humerus (Fig. 3.5). This fusion is apparent when the two surfaces of the intact cuff are exposed by removal of the overlying bursa and the underlying capsule. The supraspinatus and infraspinatus tendons join about 15 mm proximal to their insertions on the humerus and cannot be separated by additional blunt dissection. Although there is an interval between the muscular portions of teres minor and infraspinatus, these muscles merge inseparably just proximal to the musculotendinous junction. The teres minor and the subscapularis have muscular insertions on the surgical neck of the humerus, which extends approximately 2 cm down-

ward beyond their tendinous attachment on the tubercles.

The tendons of the cuff are reinforced near their insertions on the tubercles of the humerus by fibrous structures that are located both superficial and deep to the tendons. The superficial aspects of the infraspinatus and supraspinatus tendons are covered by a thick sheet of fibrous tissue that lies directly beneath the deep layer of the subdeltoid bursa but is not part of the bursa itself.

In a paper published in 2006, Ward et al. [22] report on their examination of the architectural properties of the rotator cuff muscles in ten cadaveric specimens, which they performed in the hope of understanding their functional design. Based on physiological cross-sectional area, the subscapularis have the greatest force-producing capacity, followed in declining order by the infraspinatus, supraspinatus, and teres minor. Based on fibre length, the supraspinatus operates over the widest range of sarcomere lengths. The supraspinatus and infraspinatus have relatively long sarcomere lengths in the anatomical position and are under relatively high passive tensions at rest, indicating that they are responsible for glenohumeral resting stability. However, the subscapularis contributes passive tension at maximum abduction and lateral rotation, indicating that it plays a critical part in glenohumeral stability in the position of apprehension. This information illustrates the exquisite coupling of muscle architecture and joint mechanics, which allows the rotator cuff to produce near-maximal active tensions in the midrange and to produce passive tensions in the various end-range positions.

**Fig. 3.5.** Superior view of the left shoulder: the anterosuperior portion of the rotator cuff is visible following removal of the coracoacromial ligament



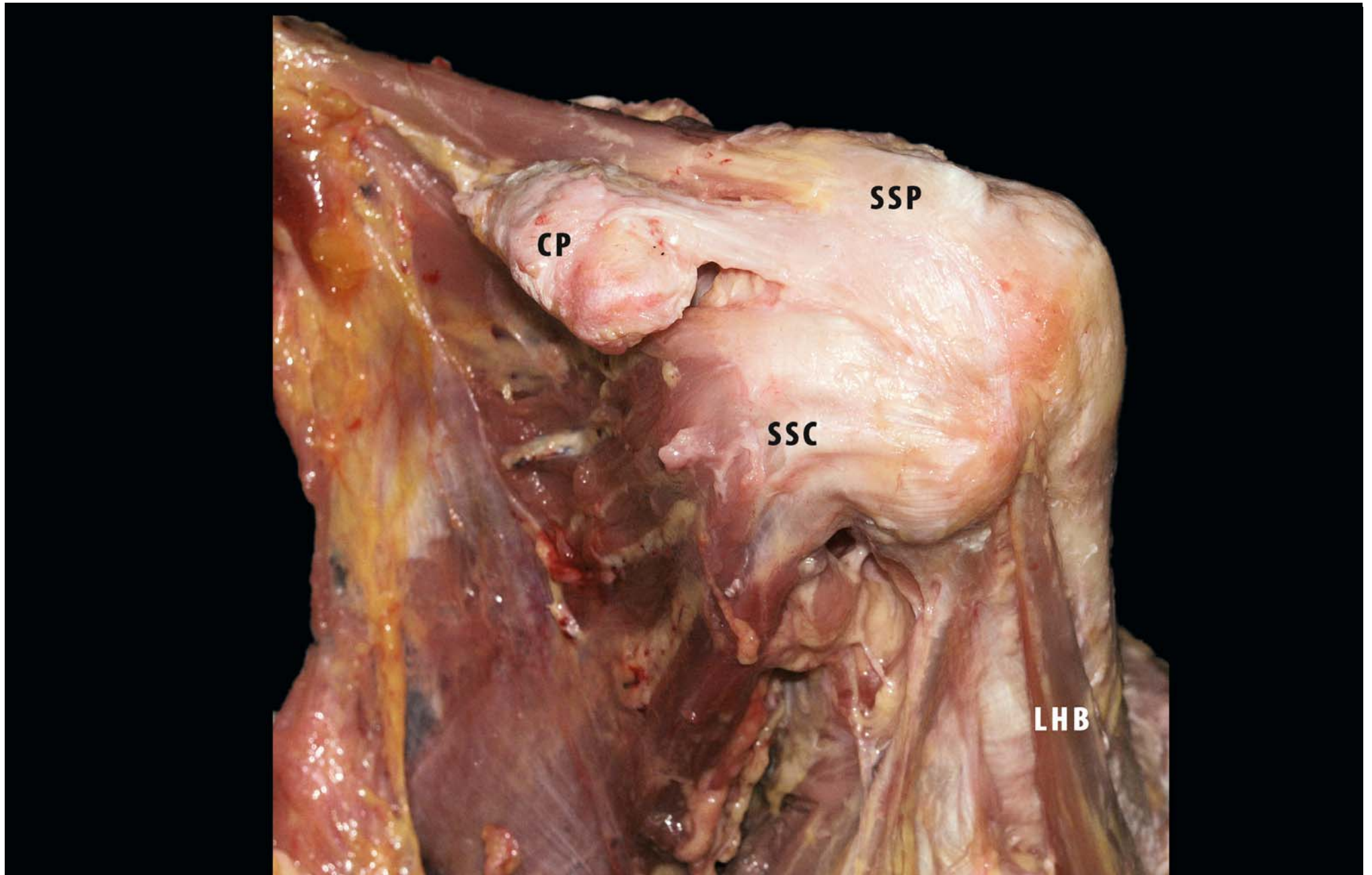
### 3.2.1 The Subscapularis (Muscle-Tendon)

The subscapularis muscle (SSC) is the largest and most powerful rotator cuff muscle. It arises from the anterior surface of the scapula. In the upper two thirds of the subscapularis there are tendinous bands that are interspersed in the midportion of the muscle and are condensed laterally into a single large, flat tendon, the lower one third remaining muscular and inserting along the humeral metaphysis. The upper fibres of the subscapularis tendon interdigitate with the anterior fibres of the supraspinatus tendon to contribute to the structure of the rotator cuff interval and of the transverse humeral ligament.

The subscapularis tendon extends over the bicipital groove, interdigitating with the supraspinatus tendon over the greater tuberosity of the humerus. There is no visible separation between the tissue band and the supraspinatus tendon laterally or between the tissue band and the subscapularis tendon medially (types 2 and 3 as described by Cash et al. [23]). It seems, that the macroscopic appearance of subscapularis tendon insertions correlates well with the MRI appearance presented in this paper, where the authors report that the majority of the subscapularis tendon fibres are types 2 and 3 (80%); more precisely, the fibres that insert in the region of the bicipital groove are type 2, and the fibres that insert on the greater tuberosity of the humerus are type 3, although it is widely thought that the tendon usually inserts in the lesser tuberosity (type 1). Macroscopic study does

not reveal convincingly that the fibres actually attach to the greater tuberosity, suggesting rather that they blend with those of the supraspinatus, supporting the notion of a rotator cuff extension suggested by Jost et al. [24]. The microscopic results confirm the macroscopic findings: the direction of collagen fibres in the direction of the subscapularis extension over the lesser tuberosity and the direction of the tendon of the supraspinatus toward the bicipital groove facilitate their biomechanical function of stabilising the shoulder joint [23]. Clark and Harryman [25] report that the subscapularis has between five and six tendon slips, arising from deep within the muscle belly to the lesser tuberosity. Totterman et al. [26], in a magnetic resonance imaging study of the shoulder, note that the subscapularis has approximately four to six tendon slips arising medially and deep within the muscle. The slips converge superiorly and laterally to form a stout main tendon that lies within the upper third of the muscle and inserts along the superior aspect of the lesser tuberosity (Fig. 3.6). Klapper et al. sectioned subscapularis specimens in four zones and describe a constant histological pattern in the distribution of the tendinous bands within the muscle. They note superior migration of the bands as they traverse laterally, eventually coming to lie within the superior one third of the subscapularis at its insertion. These bands serve to increase the surface area to which the muscle fibres attach and to concentrate the vector of the muscle pull [26].

**Fig. 3.6.** Anterolateral view of left shoulder. The subscapularis has approximately 4–6 tendon slips arising medially deep within the muscle. The slips converge superiorly and laterally to form a stout main tendon that lies within the upper third of the muscle and inserts along the superior aspect of the lesser tuberosity (*CP* coracoid process, *LHB* long head of biceps, *SSC* subscapularis, *SSP* supraspinatus)



Cooper et al. [27] observed that the superior portion of the subscapularis tendon was intraarticular (IASS) when it was viewed arthroscopically (Fig. 3.7). The IASS constitutes only 86% of the sagittal diameter of the entire subscapularis [28]. When viewed arthroscopically, the muscle is always visualised after complete release of the IASS. This observation was confirmed histologically in representative sections throughout the entire height of the tendon. In addition, the IASS constitutes only 25% of the entire cephalad–caudad dimension of the subscapularis tendon. Although the subscapularis muscle plays a critical part in maintaining anterior glenohumeral stability, this study found that the release of the intra-articular component of the subscapularis constitutes only a small portion of the entire muscle, with minimal symptoms of instability. The subscapularis was the largest muscle–tendon unit. It inserted in a comma-shaped pattern from 7 to 11 o'clock around the tuberosity (right shoulder as point of reference). Its footprint has an average maximum length of 40 mm (range: 35–55 mm), and the average maximum width is 20 mm (range: 15–25 mm). It inserts along the medial aspect of the biceps groove, and its distance from the articular surface tapers from 0 mm superiorly to 18 mm inferiorly. The most superior intraarticular margin is purely tendinous. The

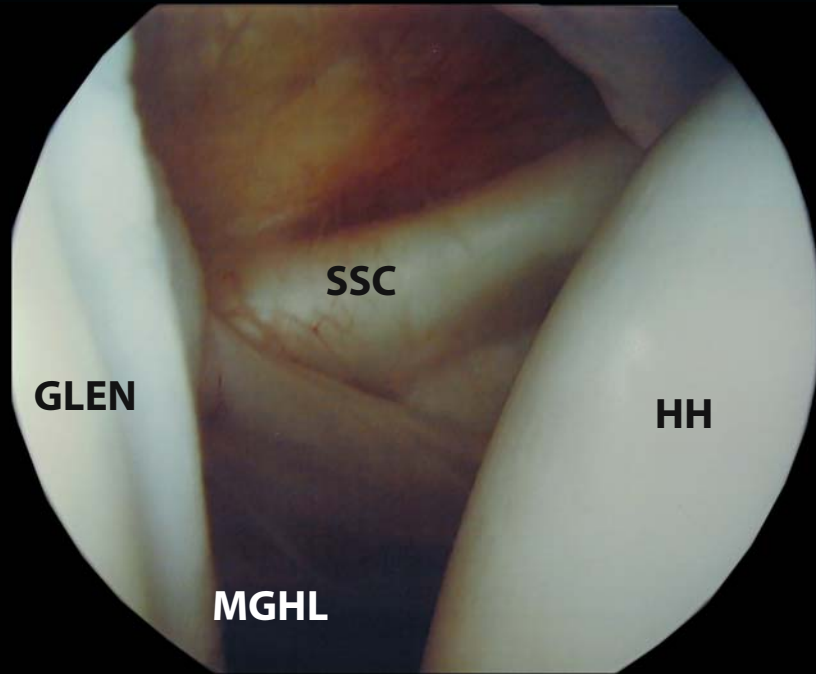
subscapularis insertion tapers as it runs inferiorly, to end as a purely muscle–capsular attachment [29]. The muscle is covered by a thick fibrous aponeurosis, which separates it and is partly involved with the thoracoscapular joint. A subscapularis bursa is located between the muscle and the joint capsule, which always communicates with the cavity of the joint capsule.

### 3.2.2 The Supraspinatus (Muscle-Tendon)

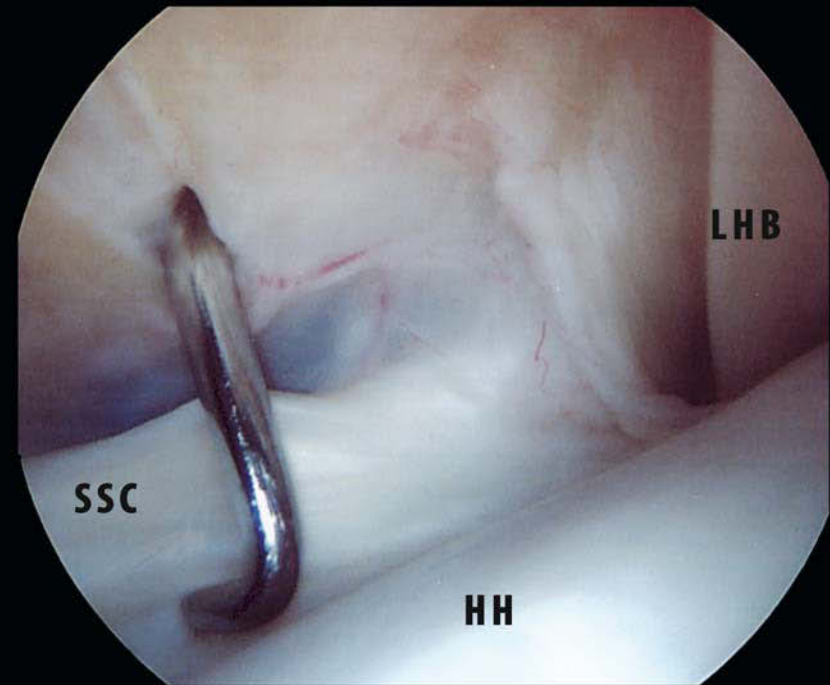
The supraspinatus (SSP) muscle lies in the supraspinatus fossa of the scapula. It is a long, thin muscle, whose muscle fibres arise from the medial portion and base of the fossa to converge into a tendinous portion that interdigitates with the subscapularis and infraspinatus to form a common continuous insertion on the humerus. The supraspinatus acts as a superior stabiliser of the humeral head, preventing its impingement against the undersurface of the acromion. Any tears of the rotator cuff most often begin in the supraspinatus [30].

Traditionally, the supraspinatus muscle has been described as fusiform, bipennate, multipennate, or circumpennate [31–33]. However, closer inspection of the supraspinatus muscle and tendon reveals a more complex architecture.

**Fig. 3.7a, b.** Arthroscopic view of right shoulder: posterior view. **a** Intraarticular portion of subscapularis tendon is visible behind the middle glenohumeral ligament (*GLEN* glenoid, *HH* humeral head, *MGHL* middle glenohumeral ligament, *SSC* subscapularis). **b** Close view of subscapularis insertion on the lesser tuberosity



a



b

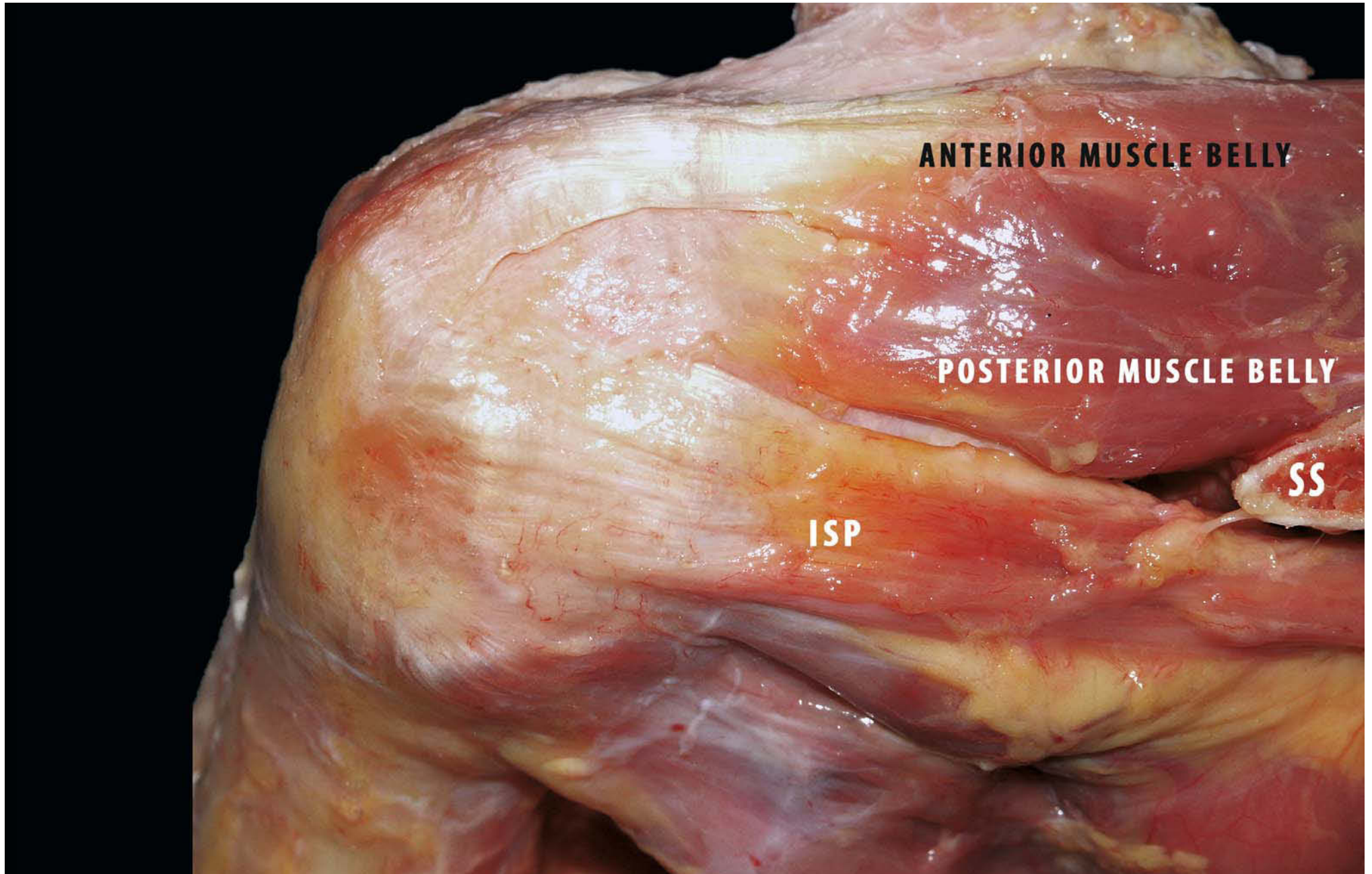
It is generally thought that the supraspinatus inserts into the major tubercle only with few variations, which are usually not described [34], but in fact Kolts [35] found a lesser tubercle insertion. Although the part of the tendon that runs to the lesser tubercle is weaker than the common tendon, the fact of accessory insertion might be of functional and clinical importance. For this reason the region between the subscapularis and supraspinatus tendons is occupied not only by the coracohumeral ligament [36] but also by the accessory part of the supraspinatus tendon. The anterior edge of the supraspinatus forms the superior border of the rotator interval [37].

The average length of the supraspinatus is 14.5 cm (range, 12.4–16.8 cm), the average length of the posterior tendinous portion from the insertion being 2.8 cm (range, 2–3.7 cm). There is a distinct anterior tendinous portion of the supraspinatus extending medially and averaging 5.4 cm in length (range,

4.2–7.7 cm). In some cases, the tendon is separate, with associated muscle fibres from the rest of the muscle. These fibres originate from the anteromedial part of the supraspinatus fossa, whereas medially the bulk of the tendon originate from the posterior part of the fossa.

The anterior muscle belly, with its larger muscle size, is essentially fusiform, originating entirely from the supraspinous fossa. The anterior supraspinatus fusiform structure, and intramuscular tendinous core, is responsible for the bulk of the supraspinatus contractile force. An internal tendon runs within the centre of the muscle belly, forming a tendinous, intramuscular core on which the larger anterior muscle mass inserts. As it nears its insertion, this internal tendon thickens and continues into a tubular, extramuscular tendon. This anterior external tendon accounts for approximately 40% of the overall width of the supraspinatus tendon (Fig. 3.8).

**Fig. 3.8.** Posterosuperior view of left shoulder. Two distinct tendinous portions of the supraspinatus (*SSP*). Anterior muscle belly, with larger muscle size, is essentially fusiform, originating entirely from supraspinatus fossa. Posterior muscle belly is a smaller, unipennate muscle that has no intramuscular tendon and originates mostly from the scapular spine and glenoid neck (*ISP* infraspinatus) (*SS* scapular spine)



**ANTERIOR MUSCLE BELLY**

**POSTERIOR MUSCLE BELLY**

**ISP**

**SS**



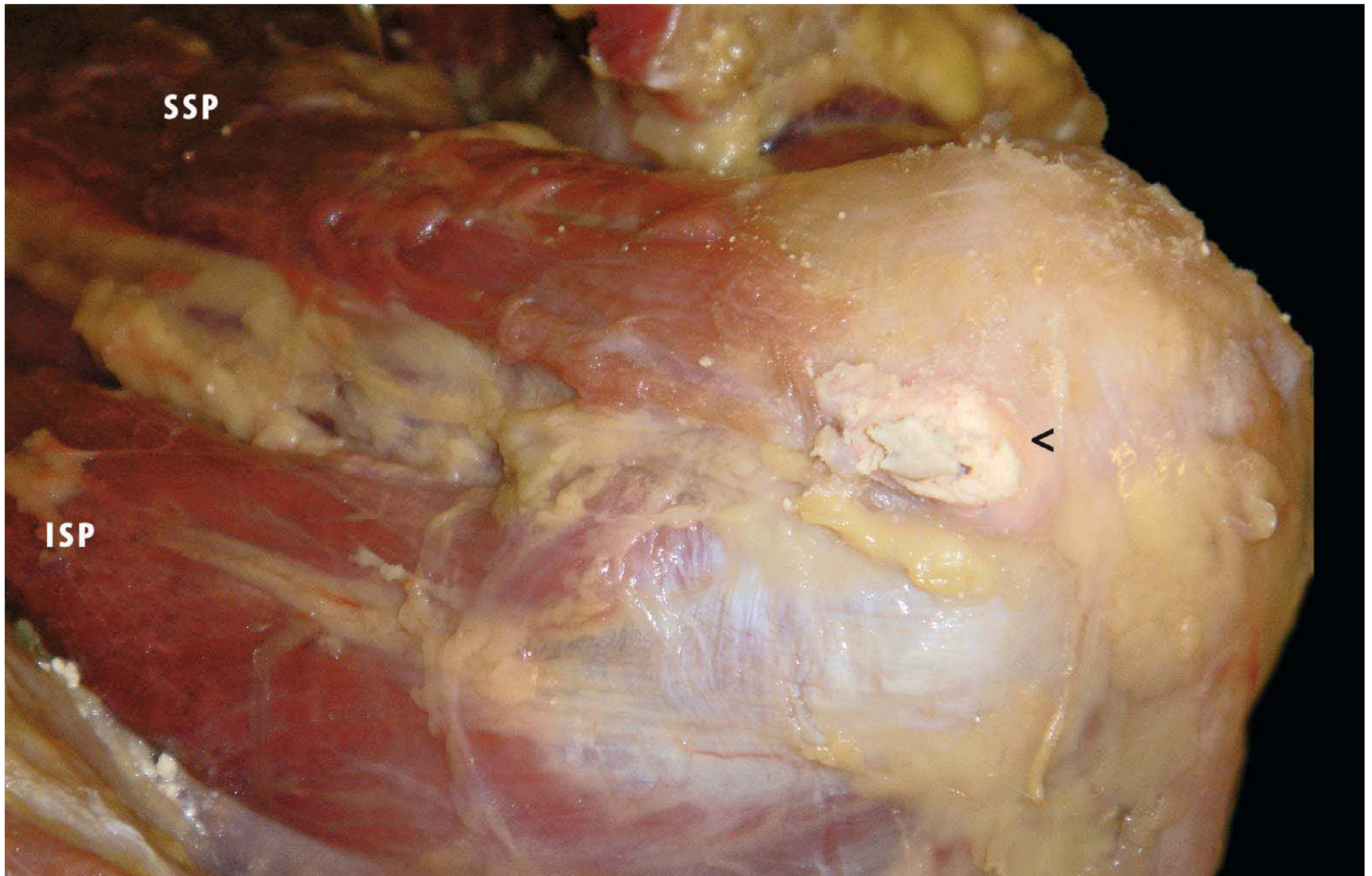
The posterior muscle belly, which Vahlensieck et al. [38] describe as “straplike”, is a smaller, unipennate muscle with no intramuscular tendon, and its architecture thus does not appear to be suited to generating large contractile loads; it is a smaller “strap” muscle that originates mostly from the scapular spine and glenoid neck. It contains no tendinous core, and therefore its fibres insert directly on the flatter, wider, posterior tendon. The posterior external tendon is responsible for approximately 60% of the width of the supraspinatus tendon, and as the supraspinatus tendon thins in the posterior direction it is overlapped by the infraspinatus tendon (Fig. 3.9).

The coronal histological analysis of the supraspinatus showed greater tendinous structures in the anterior sections and more muscular tissue in the posterior sections. This is consistent with the gross anatomy. Histological cross sections show a prominent medial anterior tendon that gradually blends into the rest of the tendinous supraspinatus at the lateral humeral insertion posteriorly [39].

The greater PCSA (muscle physiological cross-sectional area) of the anterior muscle belly is structurally consistent with the thicker, more robust anterior tendon, which may have adapted to better withstand the greater contractile loads transmitted through it. Itoi et al. [40] found, after arbitrarily dividing the

supraspinatus tendon into thirds, that the anterior third of the tendon is significantly stronger than the middle and posterior thirds. Subsequently, Minagawa et al. [41] observed the close relationship between the internal and the anterior one third of external supraspinatus tendon, though no quantitative assessments of relative contractile loading were made. It was interesting to note that though the posterior tendon is thinner, it is sufficiently wide for the overall cross-sectional area to be significantly greater in the posterior tendon than in the anterior tendon (26.4 mm<sup>2</sup> vs 31.1 mm<sup>2</sup>). All this reveals 2.88 times greater stress in the anterior supraspinatus tendon. This finding may be evidence of an additional intrinsic risk factor for rotator cuff tearing of the anterior supraspinatus tendon, either through intratendinous failure or through pull-off at the insertion site in the course of tendon degeneration [42, 43]. It is likely that tensile load is shared through the interface between the anterior and posterior tendons, given the interweaving fibre arrangement of the middle tendon layer [25]. Separation of the anterior and posterior tendons in this anatomical study, however, facilitates an approximation of relative tendon stress. Indeed, histological evidence of double-layered, intertwining fibres in the anterior tendon versus thin, dispersed fibres in the posterior tendon indicates that intratendinous structural differences exist to support these theories [44].

**Fig. 3.9.** Lateral view of right shoulder. Tendons of the rotator cuff fuse into one structure near their insertions into the tubercles of the humerus. A calcium deposit is present near the insertion of supra (*SSP*) and infraspinatus (*ISP*) tendon



The anterior supraspinatus tendon transmits the majority of the contractile load suggest that to allow the best functional outcome, surgical repair should incorporate the anterior tendon whenever possible. Although the wider, “straplike” posterior tendon may offer greater coverage of the humeral head, the shoulder abduction and head depression actions of the supraspinatus are best effected by its contractile function [45, 46], for which the anterior muscle and tendon are primarily responsible. Although it has also been suggested that shoulder weakness occurs with rotator cuff tearing because of decrease tendon length [32], it may also occur secondary to anterior tendon failure and loss of the primary transmitter of the supraspinatus contractile load [47].

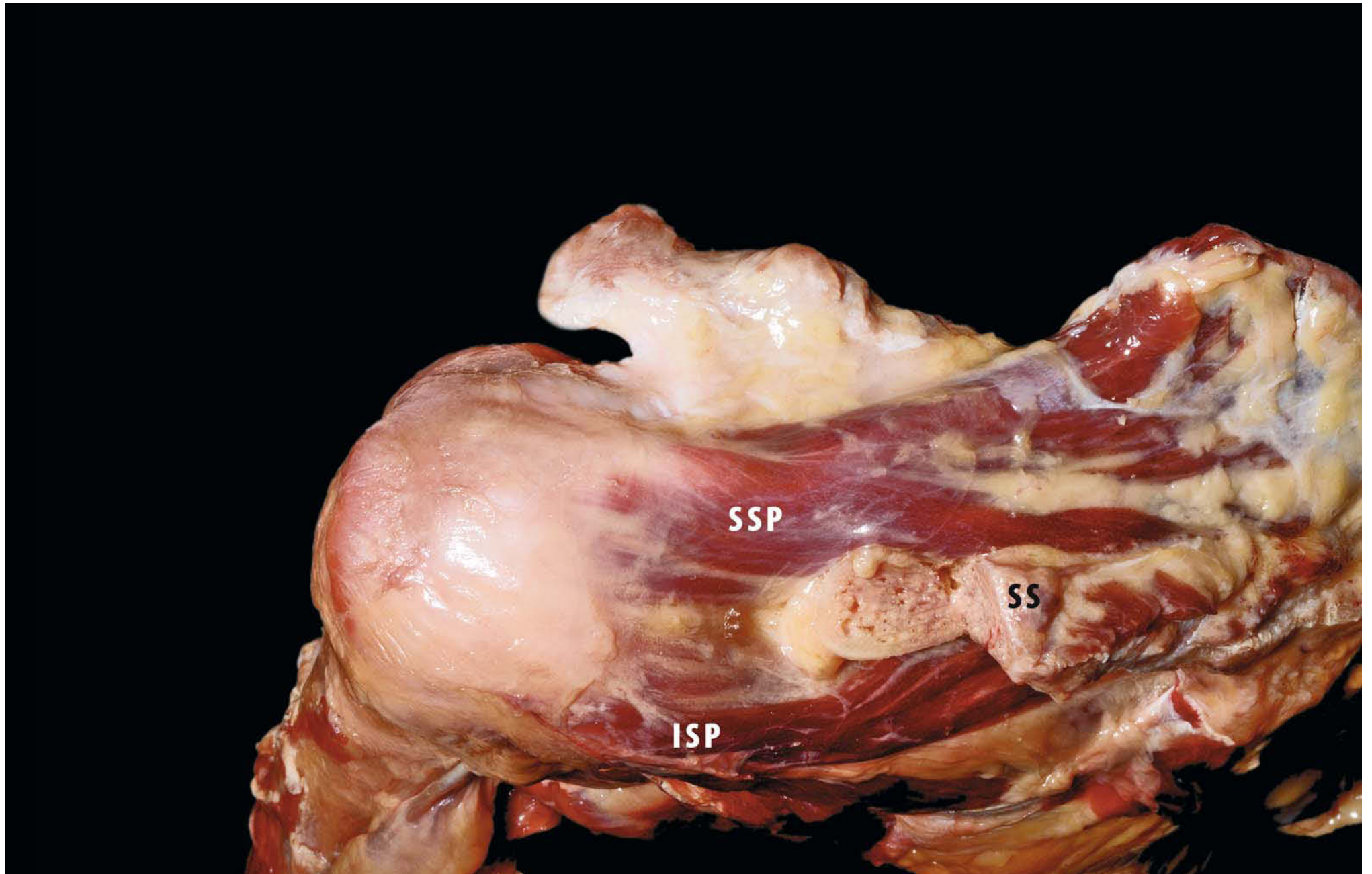
The supraspinatus tendon is strengthened by the infraspinatus and subscapularis tendons through the formation of a functional unit, which makes the structure stronger from a mechanical point of view (Fig. 3.10). Thus, a single contraction of the supraspinatus would not be enough to cause a tear in an intact supraspinatus tendon if it is assumed the force is transmitted evenly through the tendon. The tension on the deep fibres become higher than that on superficial fibres in abduction, whereas the two are under equal tension in adduction. Although it cannot be determined on which side the tear first occurred and no differences in the modulus of elasticity can be observed between the superficial and deep surfaces, it may be possible to show some difference by changing the direction of pull [40].

The most common site of rotator cuff tear is the “critical zone” of the supraspinatus tendon, approximately 1 cm proximal to the insertion of its central portion [27]. The weaker area is the cen-

tral insertional area of the tendon compared with the anterior strip. The tear may expand to the weak posterior portion in the interval between the supraspinatus and infraspinatus. Clinical observation has demonstrated that among tears involving multiple tendons, the prevalence of combined tear of the supraspinatus and subscapularis is 14% [48].

Nakajima et al. performed histological and biomechanical studies on the supraspinatus tendon and found differences in tensile strengths between the bursal and joint surfaces [49]. Four structurally independent subunits were identified: the *tendon proper* extends from the musculotendinous junction to approximately 2.0 cm medial to the greater tuberosity. It is composed of parallel collagen fascicles oriented along the tensional axis and separated by a prominent endotenon region. There is no interdigitation of fascicles, and there is an 18% incidence of fascicle convergence as the fascicles course from muscle to greater tuberosity. The *attachment fibrocartilage* extends from the tendon proper to the greater tuberosity, consisting of a complex basket-weave of collagen fibres. The densely packed unidirectional collagen fibres of the *rotator cable* extend from the coracohumeral ligament (CH) posteriorly to the infraspinatus, running both superficial and deep to the tendon proper. The *capsule* is composed of thin collagen sheets, each with its own uniform fibre alignment that differs slightly from that of the other sheets. These data describe a specialised tendon capable of compensating internally for changing joint angles through fascicles that are structurally independent and can slide past one another. The tendon attachment exhibits a structure adapted to tensional load dispersion and resistance to compression [50].

**Fig. 3.10.** Superior view of left shoulder. Posterosuperior aspect of the rotator cuff. Spine and acromion have been removed. Supraspinatus tendons (SSP) are strengthened by the infraspinatus tendon (ISP) giving a functional unit, which makes the structure stronger mechanically (SS scapular spine)



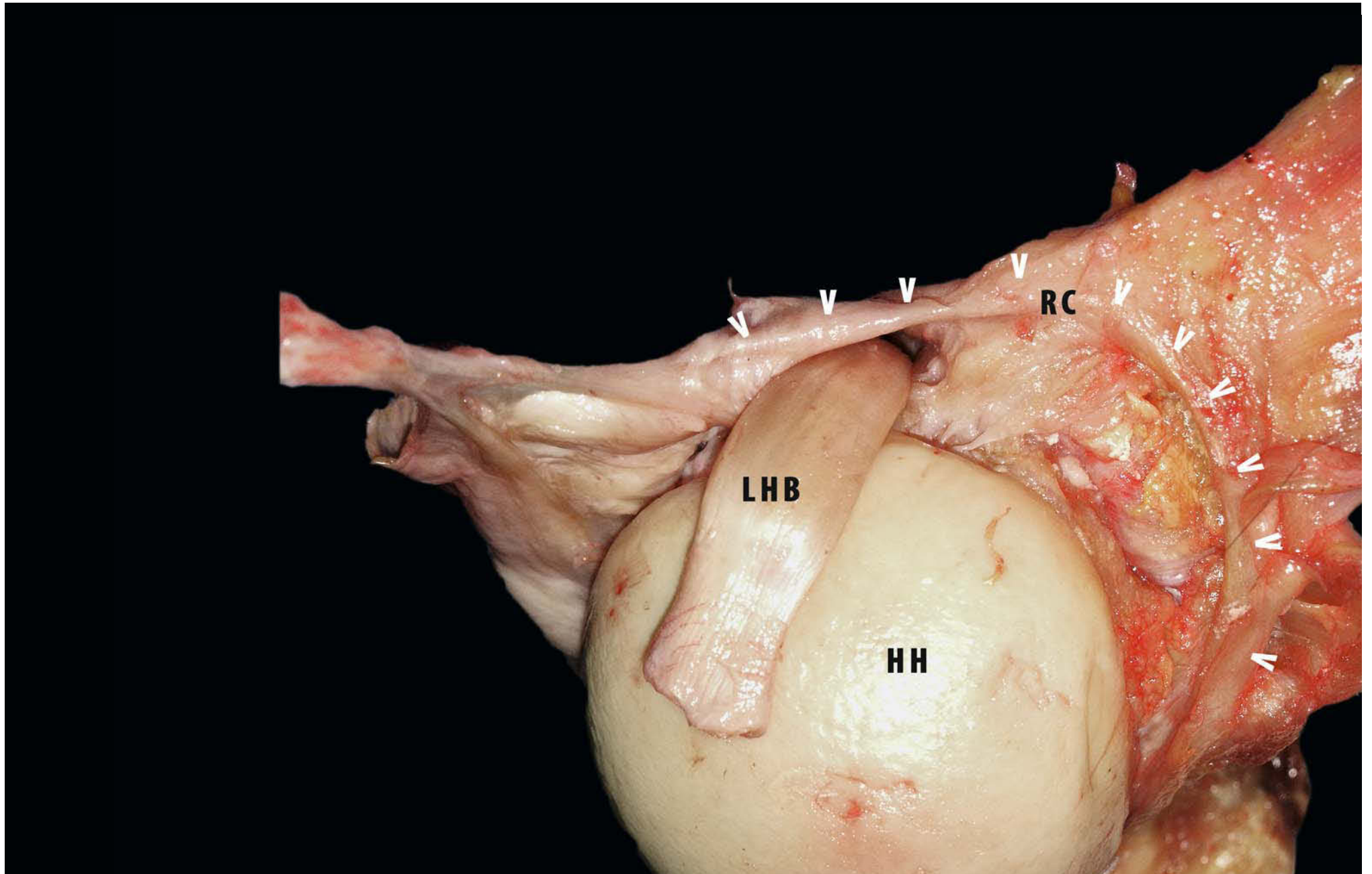
The crescent, meaning the rotator crescent, comprises supraspinatus and infraspinatus insertions that are contained within the avascular zone. On arthroscopic examination, the margin of the crescent is seemed to have thick bundles of fibres that are perpendicular to the axis of the supraspinatus tendon and arch anteriorly and posteriorly to attach on the humerus.

Independent confirmation of a crescentic thickening of the joint capsule beneath the infraspinatus and supraspinatus tendons has come from a detailed anatomical study performed by Clark and Harryman [25]. Their report describes a strip of fibrous tissue 1 cm wide running posteriorly perpendicular to the fibres of the supraspinatus tendon and extending to the posterior edge of the infraspinatus. They describe this strip as a deep extension of the coracohumeral ligament. This strip of fibrous tissue corresponds in size and location to the cable that forms the margin of the rotator crescent. Failure always occurs through the soft tissues of the suspension bridge rather than through the bone insertions of the rotator cuff fibres. Therefore, one would not expect unrepaired tears in the rotator crescent to propagate anteriorly or posteriorly on a mechanical basis alone. Significant biological weakening would have to occur before fibre failure would be anticipated.

The marked differences in thickness between the rotator cable (4.72 mm) and the rotator crescent bordered by the cable (1.82 mm) is striking (Fig. 3.11). This finding supports the concept of the rotator cable as a functional cable system in which there is stress transfer from the cuff to the thick cable and stress-

shielding of the thin capsular tissue distal to the cable and within the crescent. In younger shoulders with thick rotator crescents, the crescent is not stress-shielded by the cable. The older shoulders (>60 years of age) with thin crescent tissue again demonstrate stress-shielding of the crescent by the cable. These findings suggest that there may be two different functional classes of rotator cuff based on the behaviour of the cable-crescent complex under load: *cable dominant* (in which the crescent is stress-shielded by the cable) and *crescent dominant* (in which there is no stress-shielding of the crescent by the cable). The arthroscopic view of the rotator cable and crescent often shows that the flimsy crescent tissue has a redundant invagination adjacent to the rotator cable, suggesting that the rotator crescent is not under tension. These arthroscopic findings give additional support to the concept of stress-shielding of the rotator crescent by the rotator cable in some shoulders. One can then postulate that rotator cuff tears within the crescent are biomechanically inconsequential in cable-dominant shoulders. Therefore, a patient with an intact cable system and intact force couples in the transverse and coronal planes can have a rotator cuff that is biomechanically intact even though it is anatomically deficient [51]. This hypothesis suggests that the location of a rotator cuff tear is much more important than the size of the tear in terms of its effect on shoulder function. That is to say that a tear involving the rotator cable may be biomechanically much more significant than a tear that involves only the rotator crescent.

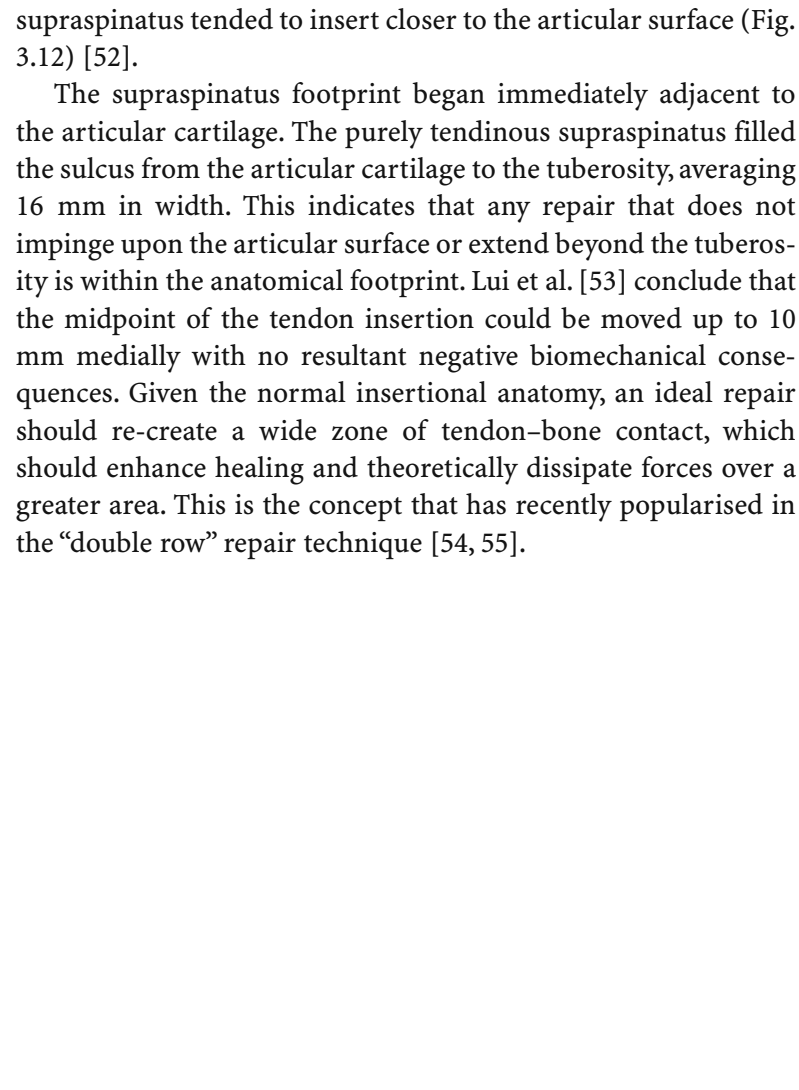
**Fig. 3.11.** Superior view of right shoulder. The cable (*arrowheads*) is a thick structure of fibres oriented perpendicular to the axis of the supraspinatus tendon and arching anteriorly and posteriorly to attach on the humerus (*RC* rotator cable, *HH* humeral head, *LHB* long head of bicep)



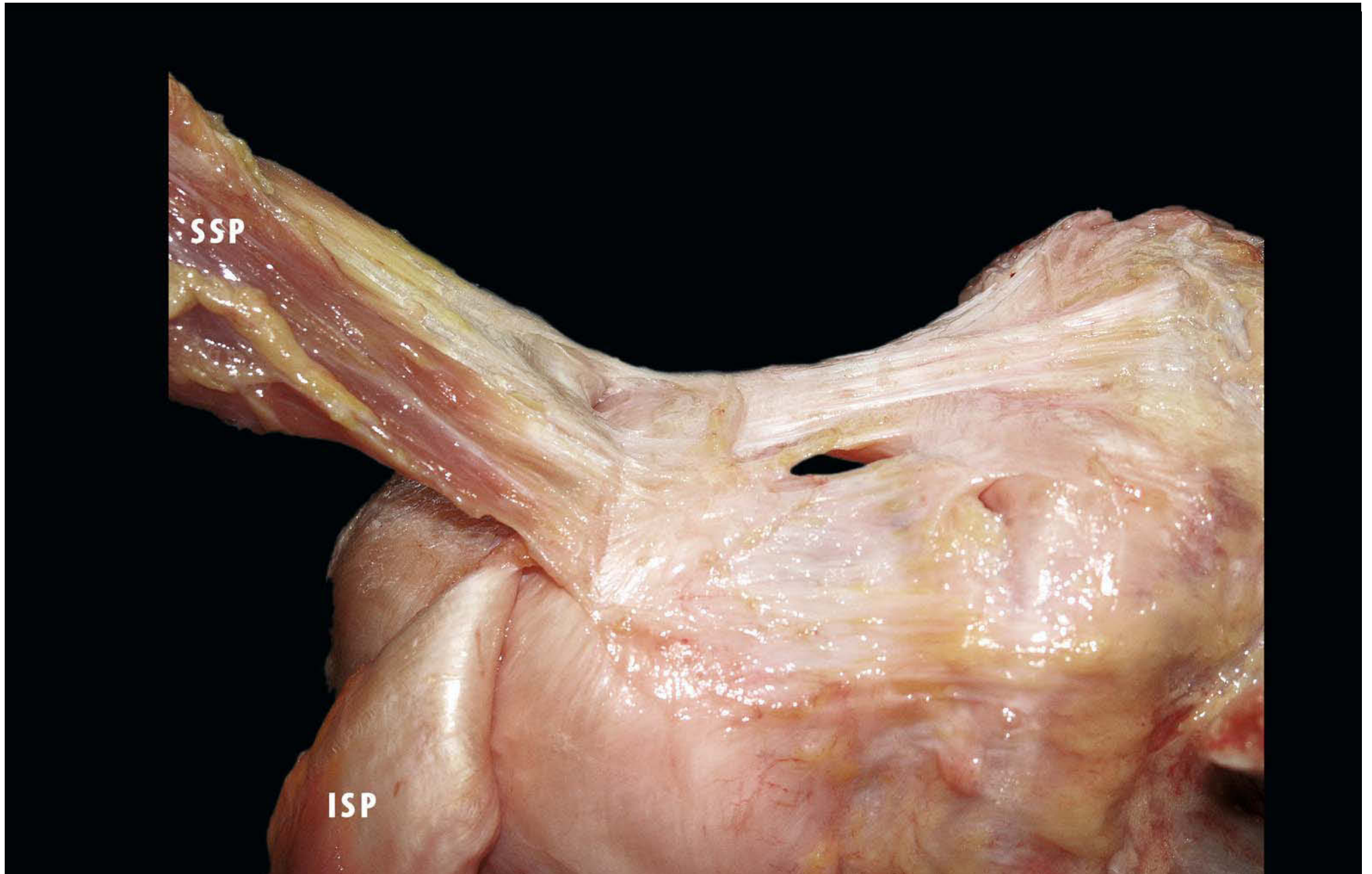The supraspinatus tendon is third in size. Its footprint filled the sulcus between the biceps groove and the bare area in a trapezoidal shape that was wider proximally along the articular surface than at the more distal insertion around the tuberosity. The insertion was located from 11 to 1 o'clock. It had an average maximum length of 23 mm (range: 18–33 mm) and an average maximum width of 16 mm (range: 12–21 mm). The insertion appeared at an average of 0.9 mm (range: 0–4 mm) from the edge of the articular surface, with most specimens having the supraspinatus insertion directly on the articular surface throughout the entire length of the tendon. The lateral-most attachment actually continued over the lip of the greater tuberosity. The posterior border of the insertion was overlapped by the anterior border of the infraspinatus tendon. Although it was difficult to distinguish the beginning of one and the end of the other, the

supraspinatus tended to insert closer to the articular surface (Fig. 3.12) [52].

The supraspinatus footprint began immediately adjacent to the articular cartilage. The purely tendinous supraspinatus filled the sulcus from the articular cartilage to the tuberosity, averaging 16 mm in width. This indicates that any repair that does not impinge upon the articular surface or extend beyond the tuberosity is within the anatomical footprint. Lui et al. [53] conclude that the midpoint of the tendon insertion could be moved up to 10 mm medially with no resultant negative biomechanical consequences. Given the normal insertional anatomy, an ideal repair should re-create a wide zone of tendon–bone contact, which should enhance healing and theoretically dissipate forces over a greater area. This is the concept that has recently popularised in the “double row” repair technique [54, 55].



**Fig. 3.12.** Posterior view of right shoulder. Posterior border of the insertion of supraspinatus overlapped by the anterior border of the infraspinatus tendon (*SSP* supraspinatus tendon, *ISP* infraspinatus tendon)





### 3.2.3 The Infraspinatus (Muscle-Tendon)

The Infraspinatus (ISP) is a thick triangular muscle, which occupies the chief part of the infraspinatous fossa. The muscle has three pennate origins (80%). Bipennate and monopennate muscle origins were only observed in five cases (20%). It arises as fleshy fibres from its medial two-thirds, and as tendinous fibres from the ridges on its surface; it also arises from the infraspinatus fascia, which covers it and separates it from the teres major and minor (Fig. 3.13). The fibres converge to a tendon, which glides over the lateral border of the spine of the scapula and, passing across the posterior part of the capsule of the shoulder joint, inserts into the middle impression on the greater tubercle of the humerus. The tendon of this muscle is sometimes separated from the capsule of the shoulder joint by a bursa, which may communicate with the joint cavity. The supraspinatus and infraspinatus tendons are composed of five layers [25]: *layer 1*, the fibres of the coracohumeral ligament; *layer 2*, the most densely packed tendon fibres running parallel from the muscle belly to the humerus; *layer 3*, smaller tendon fibres with less uniform orientation; *layer 4*, loose connective tissue; and *layer 5*, the joint capsule.

To expose layer 2, layer 1 of the supraspinatus and infraspinatus tendons needs to be removed to allow a clear view. Layer 2 is identifiable as thick and parallel fibre bundles. The superior margin of the anatomical neck without articular cartilage, or the so-called sulcus [54], is the only landmark to identify the

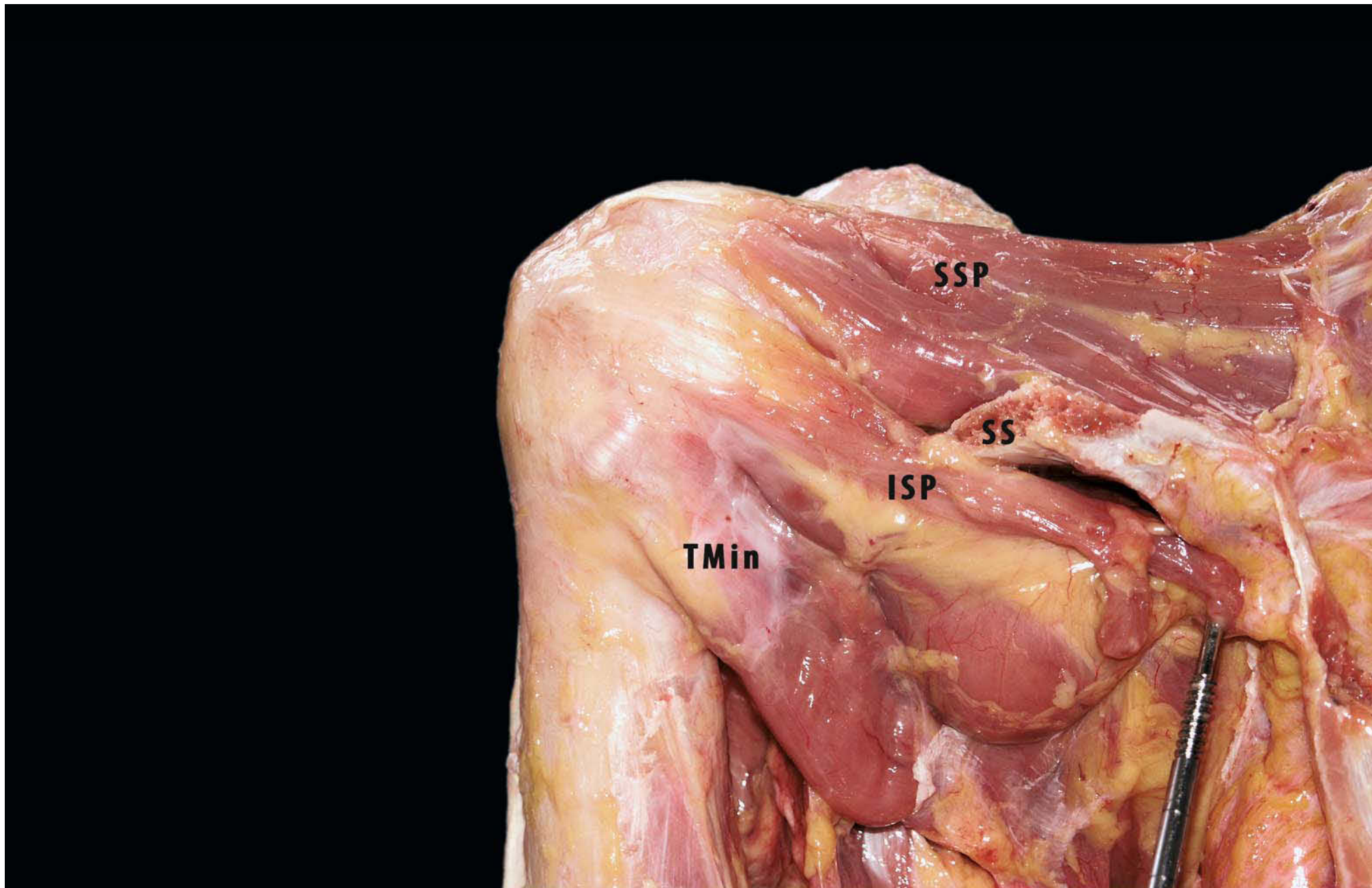
supraspinatus and infraspinatus from the articular side [55], and there are no landmarks from the bursal side.

The insertional area (footprint) of the infraspinatus was second in size, inserting from approximately 1 to 3 o'clock. Superiorly, it interdigitated and wrapped around the posterior aspect of the supraspinatus tendon. The bipennate muscle tapered into a trapezoidal footprint with an average maximum length of 29 mm (range: 20–45 mm) and width of 19 mm (range: 12–27 mm). The insertion tapered away from the articular surface, from 0 mm superiorly to 16 mm inferiorly. The gap between the articular surface and the inferior insertion formed the “bare area”. The tendon of the infraspinatus shortened and became more muscular as it ran toward the teres minor [52].

### 3.2.4 The Teres Minor (Muscle-Tendon)

The teres minor (TMin) is a narrow, elongated muscle that arises from the dorsal surface of the axillary border of the scapula for the upper two thirds of its extent, and from two aponeurotic laminæ, one of which separates it from the infraspinatus and the other from the teres major. Its fibres run obliquely upward and lateral; the upper ones end in a tendon inserting in the lowest of the three impressions on the greater tubercle of the humerus; the lowest fibres are inserted directly into the humerus immediately below this impression. The tendon of this muscle passes across, and is united with, the posterior part of the capsule of the shoulder joint.

**Fig. 3.13.** Posterior view of right shoulder. Posterior aspect of rotator cuff (*Tmin* teres minor muscle) (*SSP* supraspinatus tendon, *ISP* infraspinatus tendon, *SS* supraspinatus spine)



### 3.2.5 Anatomy of the Rotator Cuff Insertion

As rotator cuff tears are interpreted as a failure of force transmission generated by muscle fibres, the location of the tear is evaluated by the strength in shoulder abduction, external rotation, and internal rotation. However, it is difficult to decide the precise location of the tear by MRI, ultrasound imaging and intraoperative observation without bony landmark, so-called facets of the greater tuberosity. The relationship between each tendon of the rotator cuff and facets of the greater tuberosity may provide useful information in the clinical evaluation of the prognostic and diagnostic data for both operative and nonoperative patients. Locating the tear site is especially important for selecting treatment options and predicting prognosis, because one tear can be more devastating than another that is the same size but in a different location [56].

#### *Intramuscular Tendons of the Rotator Cuff*

According to the arrangements of muscle fibres, skeletal muscles are divided into fusiform and pennate muscle. The fascicles in fusiform muscle are parallel to the long axis of the muscle, whereas those in pennate muscle are oblique and attach to the intramuscular tendon. Pennate muscle contains shorter and more numerous muscle fibres than does fusiform muscle of the

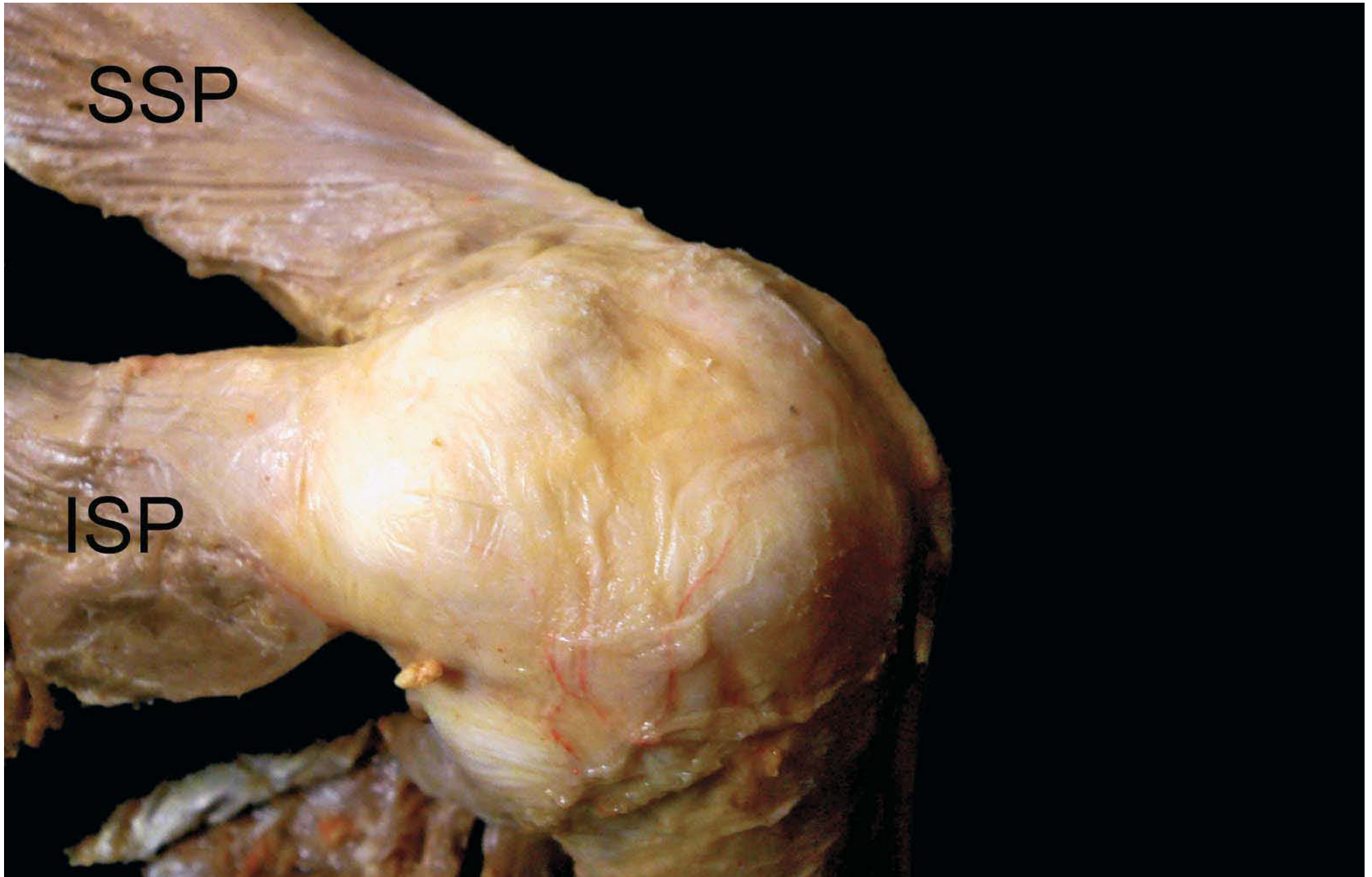same size; as a result it provides more tension than does a parallel muscle. Muscle tension generated by muscle fibres is transmitted to the extramuscular tendon via the intramuscular tendon in pennate muscle.

The supraspinatus, infraspinatus, and teres minor muscles are pennate muscles each with a single intramuscular tendon, and they act as external rotators. On the other hand, subscapularis is a multipennate muscle with several intramuscular tendons and acts as an internal rotator [57]. These findings indicate that rotator cuff muscle may provide a stable fulcrum as a transverse force couple. According to the study on the physiological cross-sectional area of each cuff muscle, it is known that the force-generating capacity of the subscapularis is equal to that of the other three muscles (subscapularis 53%, supraspinatus 14%, infraspinatus 22%, and teres minor 10% of the cuff moment) [58].

#### *Extramuscular Tendons of the Rotator Cuff*

Macroscopically, it is difficult to distinguish the separate extramuscular tendons. However, after removal of the superficial layer of the extramuscular tendons to expose the tendon fibres from intramuscular tendons, tendon fibres peculiar to the infraspinatus can be observed covering those of the supraspinatus from the bursal side [59] (Fig. 3.14).

**Fig. 3.14.** Macroscopic findings. It is difficult to distinguish each cuff tendon. However, after removal of the superficial layer of the cuff tendons, tendon fibres peculiar to infraspinatus can be observed covering those of supraspinatus from the bursal side (*ISP* infraspinatus, *SSP* supraspinatus)



Microscopically, dense fibre bundles peculiar to the supraspinatus and infraspinatus are observed in a transverse section of the extramuscular tendon. In longitudinal section, extramuscular tendon is composed of five layers [25]. As the intramuscular tendon of the supraspinatus and infraspinatus are contiguous to layer 2, this layer is the most important part for force transmission [41].

#### *Anatomical Relationship Between Rotator Cuff Tendons and Facets of the Greater Tuberosity*

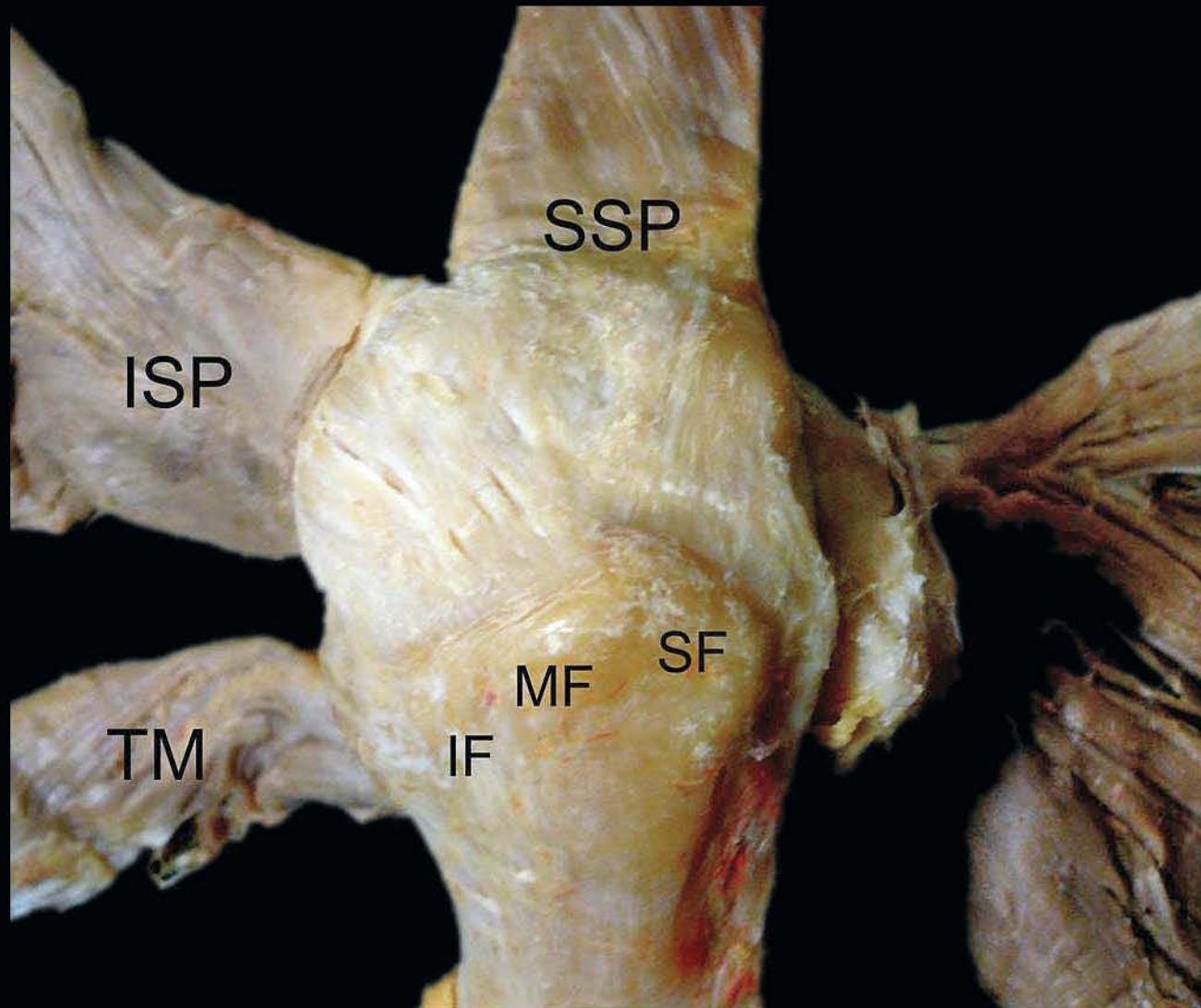
There are three facets on the greater tuberosity; superior, middle and inferior (Fig. 3.15). Layer 2 of the supraspinatus tendon attaches not only to the superior facet but also to the superior half of the middle facet, whereas that of the infraspinatus tendon attaches to the entire length of the middle facet, covering the posterior half of the supraspinatus tendon from the bursal side [41]. Facets of the greater tuberosity may become useful bony landmarks that can help in locating the tear, because most tears of the

rotator cuff are observed at the tendon insertion corresponding to the facets of the great tuberosity.

### 3.2.6 Biomechanics and Functional Anatomy of the Rotator Cuff

The shoulder complex is comprised of several joints, including the sternoclavicular joint, acromioclavicular joint, glenohumeral (GH) joint and scapulothoracic (ST) joint. These articulations work together to carry out normal shoulder motion. Most motion occurs in the GH and ST joints. The GH-to-ST motion ratio of total shoulder motion is 2 : 1, i.e. 180° of abduction, 120° being GH motion and 60°, ST motion. The 2 : 1 ratio is an average over the entire arc of motion, changing through the arc of motion, so that it is not constant. In the initial portion of abduction, GH motion predominates and the ratio is 4 : 4 (GH-to-ST). As the shoulder moves beyond 90° of abduction, the GH-to-ST motion ratio becomes 1 : 1.

**Fig. 3.15.** Tendon attachments on the greater tuberosity. Supraspinatus tendon attaches to superior facet and superior half of middle facet, while infraspinatus tendon attaches to entire length of the middle facet, covering posterior half of supraspinatus tendon from bursal side (*ISP* infraspinatus, *SSP* supraspinatus, *TM* teres minor, *SF* superior facet, *MF* middle facet, *IF* inferior facet)



The rotator cuff muscles are associated with and assist with some shoulder motion; however, their main function is to provide stability to the joint by pressing the humeral head on the glenoid. Because of the limited stabilisation afforded by the shallow glenoid and the variety of shoulder positions, it seems intuitively that the joint would require robust yet adaptable soft tissue stabilisation over a range of joint positions.

The shoulder can maintain a stable fulcrum of motion only when it maintains balanced force couples (i.e. balanced moments) in both the coronal and the transverse planes (Fig. 3.16) [51, 59].

### ***Coronal Plane Force Couple***

The deltoid and supraspinatus contribute equally to abduction. As the arm is abducted the resultant joint reaction force is directed towards the glenoid. This ‘compresses’ the humeral head against the glenoid and improves the stability of the joint when the arm is abducted and overhead. Throughout the range of

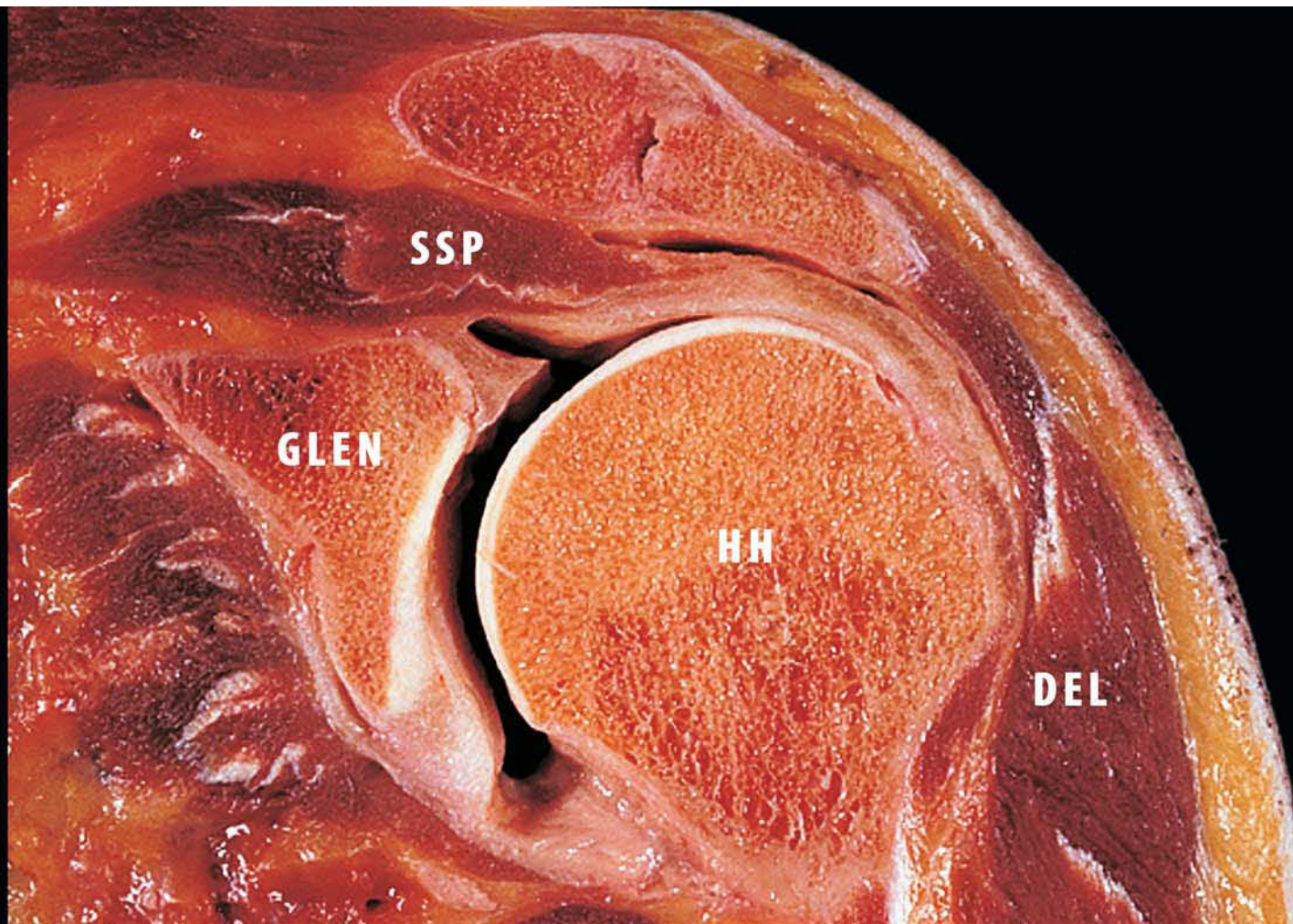
motion the compressive resultant joint reaction force in the transverse plane contributes to joint stability.

### ***Transverse Plane Force Couple***

This is the predominant mechanism resisting superior humeral head displacement with cuff tears. As long as the force couple between subscapularis and infraspinatus remains balanced the joint remains centred and functional [60].

The intact rotator cuff demonstrates an arching, cable-like thickening surrounding a thinner crescent of tissue that inserts into the greater tuberosity of the humerus; this is known as the cable–crescent complex [61]. This cable-like structure represents a thickening of the coracohumeral ligament and is consistently located at the margin of the avascular zone [25]. The rotator cable extends from its anterior attachment just posterior to the biceps tendon to its posterior attachment near the inferior border of the infraspinatus tendon.

**Fig. 3.16.** Left shoulder, frontal view. Coronal plane force couple: deltoid and supraspinatus each contribute equally to abduction (*DEL* deltoid, *GLEN* glenoid, *HH* humeral head, *SSP* supraspinatus). (Courtesy of Dr. Pau Golanò)





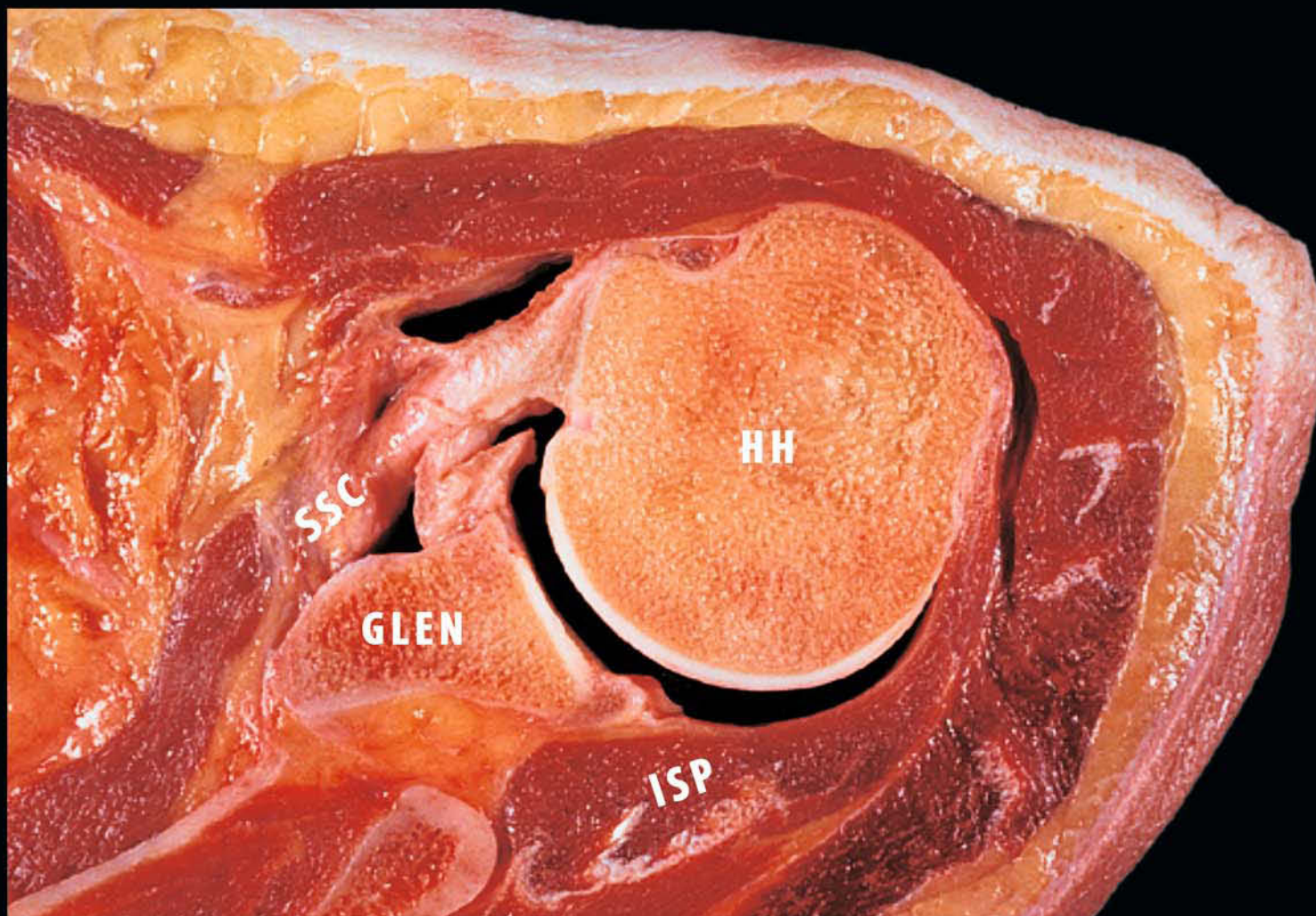
This rotator cable may function in a way analogous to the functioning of a load-bearing suspension bridge. By this model, stress is transferred from the cuff muscles to the rotator cable as a distributed load, thereby stress-shielding the thinner, avascular crescent tissue, particularly in older individuals. A rotator cuff tear can be similarly modelled after a suspension bridge, with the free margin of the tear corresponding to the cable and the anterior and posterior attachments of the tear corresponding to the supports at each end of the cable's span [62].

By this model, the supraspinatus muscle, even with a supraspinatus tendon tear, can still exert its compressive effect on the shoulder joint by means of its distributed load along the span of the suspension bridge configuration. Halder et al. [63] have confirmed the validity of this suspension bridge model in an in vitro biomechanical study.

The architectural arrangement of the rotator cuff muscle fibres indicates that they are designed for force production rather than excursion, which is consistent with their proposed role of stabilising the humeral head in the glenoid (Fig. 3.17). Based on architecture alone, the short and relatively homogeneous fibre lengths of these muscles imply they would function efficiently over a relatively narrow range of sarcomere lengths. However, the combination of short fibres and long resting sarcomere lengths make this muscle relatively sensitive to stretch, so that small perturbations would result in relatively high restoring forces [64, 65].

Contractile function may be compromised if the muscle is moved to the descending limb of its length-tension curve (e.g. if sarcomeres are stretched so that myofilament overlap is critically decreased) [66]. This concept has important implications for current strategies of rotator cuff repair. During traditional repairs, the retracted muscle and tendon are often mobilised and stretched to permit reattachment as close to the original insertion site as possible. This is based on the assumption that stretching the musculotendinous unit to its original length restores normal anatomy and native function. In the acute setting, this may restore optimal gross and ultrastructural muscle length if the musculotendinous length is maintained and extensive debridement is not necessary. However, this technique may be detrimental to muscle function in the common condition of retraction and reorganisation, as observed in chronic tears. Chronic rotator cuff tears are commonly associated with changes including fatty infiltration, loss of muscle volume, and retraction [67]. These changes may accompany remodelling in the muscle by subtraction of serial sarcomeres, as reported after tenotomy in other systems [68]. Hypothetically, the sensitivity of the supraspinatus to stretch would be compounded in a chronically retracted muscle with sarcomere subtraction. If the repair requires muscle advancement, then one can reasonably expect the sarcomere length-joint angle and relative tension-joint angle curves to shift to very long lengths, resulting in profound muscle weakness [68].

**Fig. 3.17.** Axial view of right shoulder: transverse plane force couple. This is the predominant mechanism resisting superior humeral head (*HH*) displacement with cuff tears. As long as the force couple between subscapularis (*SSC*) and infraspinatus (*ISP*) remains balanced the joint remains centred and functional. (Courtesy of Dr. Pau Golanò)



### 3.2.7 Clinical Relevance

Arthroscopic evaluation allows a much more accurate assessment of cuff tear configuration than does open inspection. Tears can be viewed through various arthroscopic portals to afford 3-dimensional views of tear patterns that are generally superior to the views obtained by an open approach, particularly in the case of large tears. Rotator cuff tears can be broadly classified into two patterns: crescent-shaped tears and U-shaped tears. Crescent-shaped tears, even large ones, typically pull away from bone but do not retract far. Therefore, they can be repaired with reattachment to bone with minimal tension. U-Shaped tears generally extend much farther medially than crescent-shaped tears, usually extending as far as the glenoid or even beyond it to end medial to the glenoid. It is important to realise that this medial extension of a tear does not represent retraction, but is rather the shape that an L-shaped tear assumes under physiological load from its muscle-tendon components [69].

From the clinical point of view, Burkhart divided the clinical presentation of rotator cuff tear on the basis of fluoroscopic comparison into:

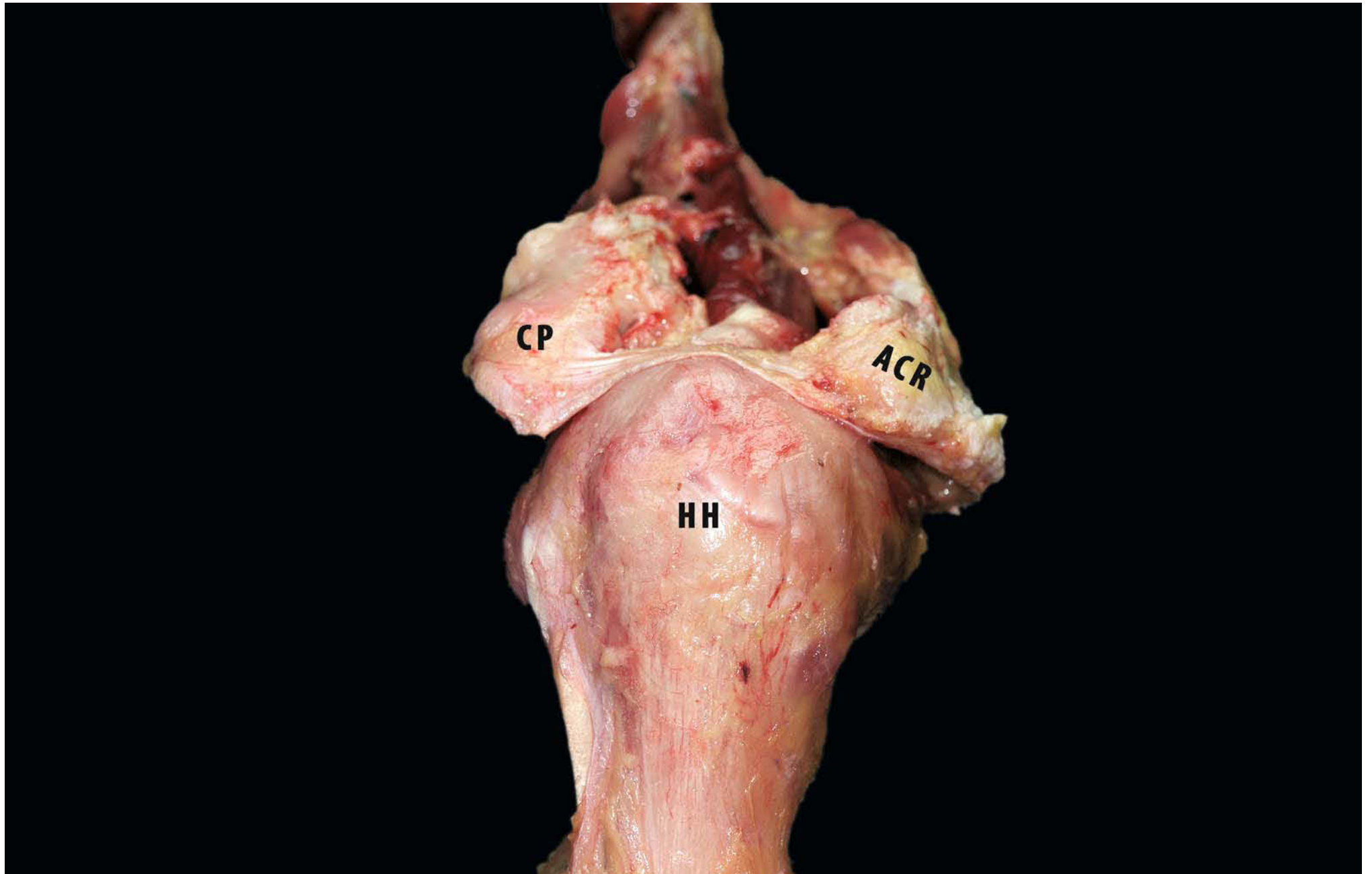
*Stable fulcrum kinematics.* These patients had normal shoulder motion with a stable glenohumeral fulcrum. Patients in this category had tears of the superior portion of the rotator cuff,

meaning the supraspinatus and various portions of the infraspinatus. This pattern of tear allowed for the preservation of essential force couples in the coronal and transverse planes. These patients had good strength and normal motion.

*Unstable fulcrum kinematics.* These patients had an unstable fulcrum of glenohumeral motion that allowed anterior and superior translation of the humeral head on attempted active elevation of the shoulder. These patients had massive tears that involved virtually all of the superior and posterior rotator cuff. Their active motion consisted of little more than a shoulder shrug. This pattern of tear exhibited uncoupling of essential force couples with the inability to create a stable fulcrum of motion.

*Captured fulcrum kinematics.* In these patients, the humerus became anatomically captured under the acromion or the adjacent anterior deltoid, in such a way that an acromiohumeral fulcrum was created. These patients had massive tears that involved all of the supraspinatus, a major portion (greater than one third) of the posterior cuff, and at least one half of the subscapularis. In these patients, the coronal plane force couple could not adequately keep the humeral head centred in the glenoid, and the humerus subluxed superiorly. These patients had enough deltoid strength to allow them to elevate the shoulder about the fulcrum that the humeral head developed on the undersurface of the acromion or at the anterior acromiodeltoid origin (Fig. 3.18).

**Fig. 3.18.** Left shoulder, lateral view: model of fulcrum captured. In these circumstances the humerus becomes anatomically captured under the coracoacromial arch (fulcrum) or the adjacent anterior deltoid (*CP* coracoid process, *ACR* acromion, *HH* humeral head)

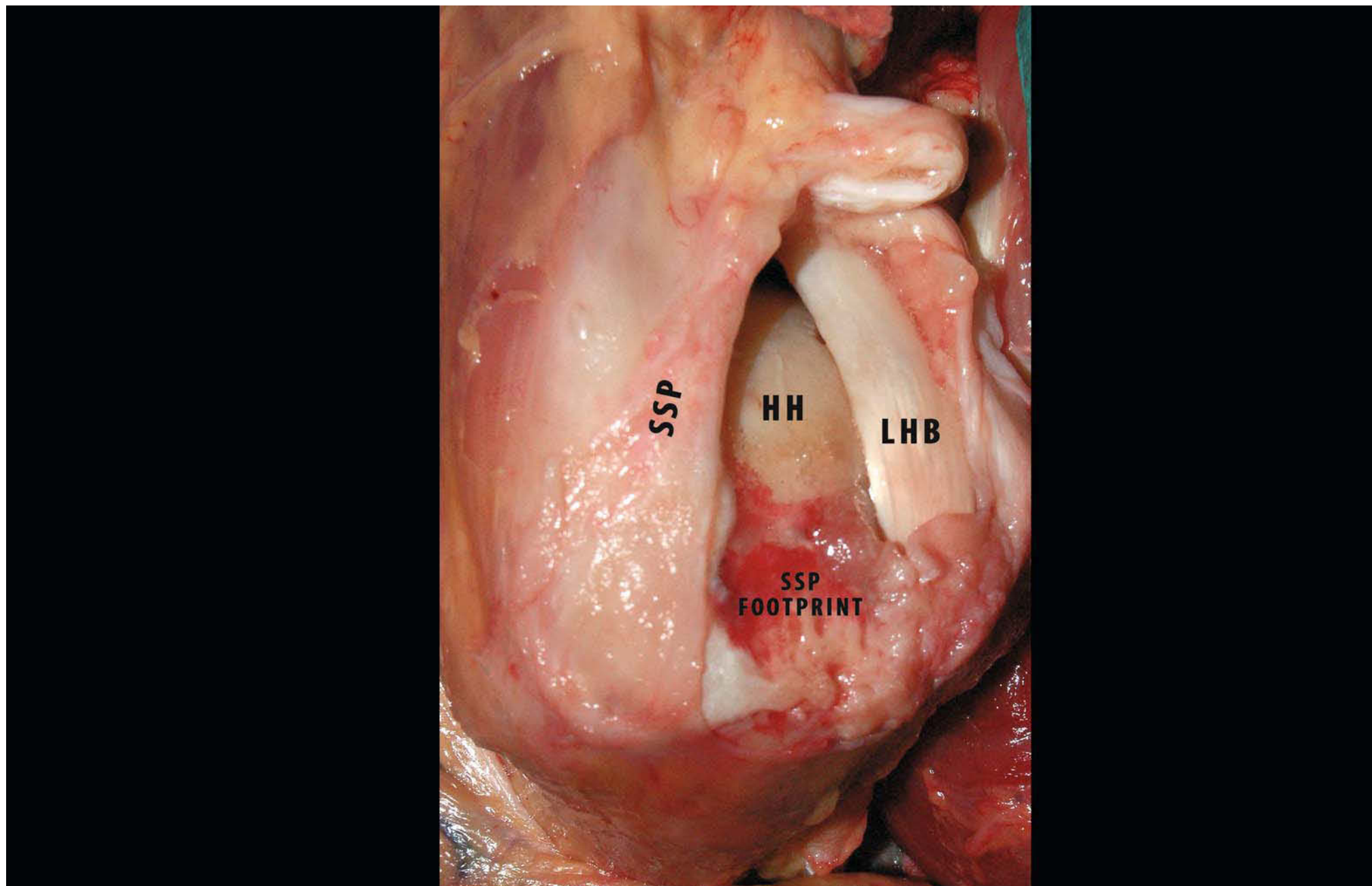


Patients with captured fulcrum kinematics fall into two groups, which are characterized by the anteroposterior coverage of the humeral head by the acromion. The acromion acts as an awning over the top of the humeral head. Patients with a short “awning” obtain a fulcrum of motion at the anterior border of the acromion that allows for full forward elevation. In contrast, in patients with a long “awning” the proximal humerus would impinge on the anterior acromion on attempted elevation, so that full forward elevation would not be possible.

The location of the rotator cuff tear is a key element in shoulder kinematics and seems to be much more important than the size of the tear. It is unusual for rotator cuff tears to extend anteriorly, most instead involving the supraspinatus tendon and varying amounts of the posterior rotator cuff. If the posterior cuff is spared to the degree that the normal transverse plane force couple is intact normal function is possible. If the posterior cuff is torn a stable fulcrum cannot be established. The same applies to tears that extend anteriorly to involve a significant portion of the subscapularis. This lesion is the reverse of the usual lesion of

unstable fulcrum kinematics, with a relative deficiency of the anterior cuff. This pattern of tear also results in an unstable fulcrum with potential superior migration of the humeral head. Anterior rotator cuff deficiency (subscapularis tear) can be suspected in patients with positive results in various muscular tests (i.e. lift-off, belly-off press, bear-hug test, etc.) [70–72]. This classification is important for the treatment to be selected for the rotator cuff tears (Fig. 3.19), particularly in older patients. There is a subset of older, active individuals with rotator cuff tears who have normal motion and good strength and whose only symptom is pain. Many of these patients have normal shoulder kinematics. In such patients, it seems reasonable to address their pain with rehabilitation and perhaps arthroscopic debridement of the free margin of the tendon, tenodesis or tenotomy of the long head of the biceps, etc. If the orthopaedic principle of using the most conservative treatment to accomplish our goals is followed, then this treatment for selected rotator cuff tears changes its complexion from radical to rational [62].

**Fig. 3.19.** Lateral view of right shoulder: anterosuperior rotator cuff lesion. It is possible to see extension of supraspinatus (*SSP*) footprint just posterior to posterior pulley (*HH* head of humerus, *LHB* long head of biceps)



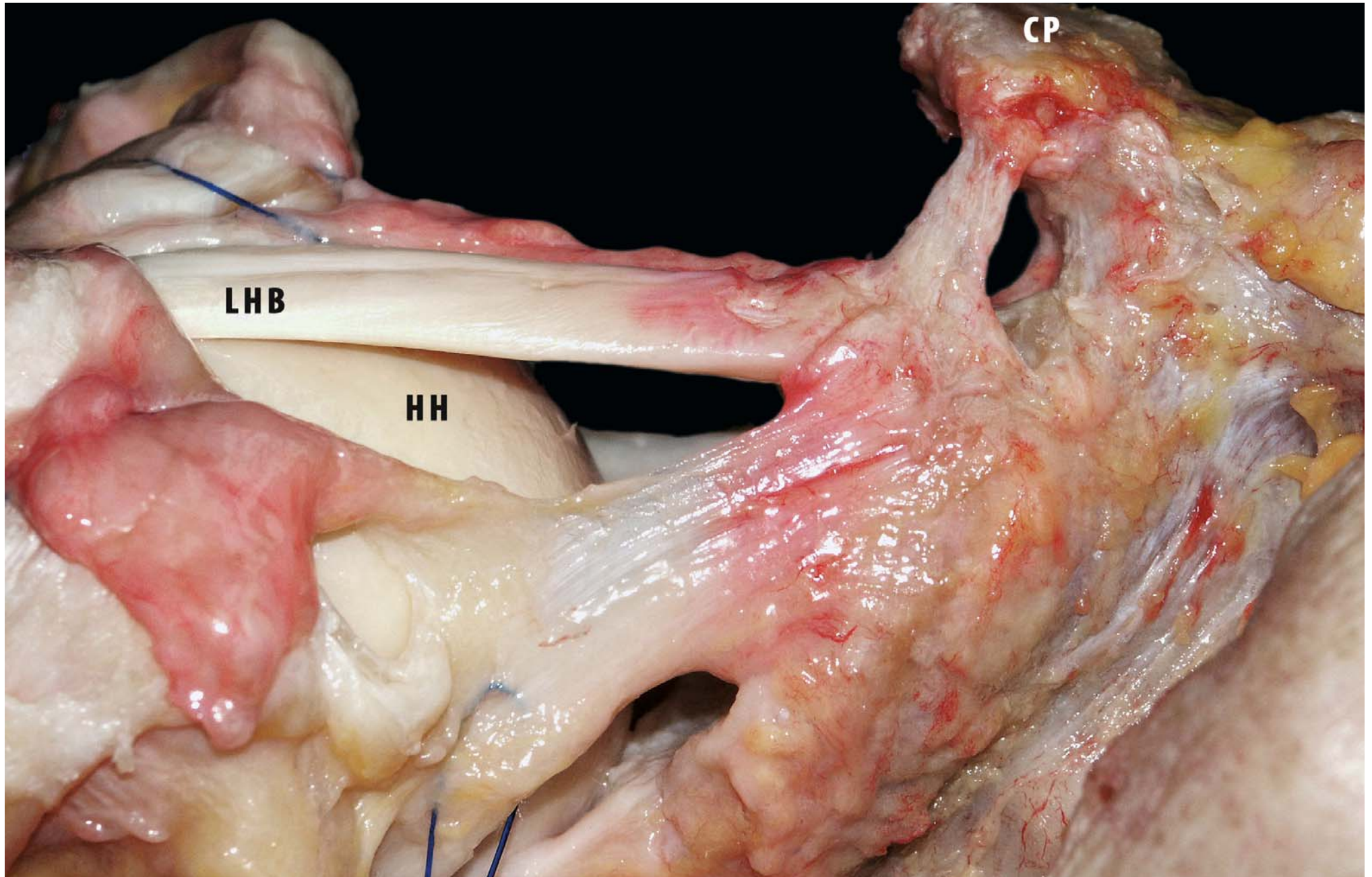
### 3.3 The Long Head of the Biceps

*Alberto Costantini*

The tendon of the long head of the biceps muscle (LHB) is intraarticular but extrasynovial. The synovial sheath, which communicates directly with the glenohumeral joint, ends in a blind pouch at the distal end of the bicipital groove. The chief restraint on medial dislocation of this tendon within the proximal end of the groove is the medial portion of the coracohumeral ligament, which usually merges with the subscapularis tendon close to the insertion of the latter tendon into the lesser tuberosity [73]. The main structure restraining the tendon of the long head of the biceps muscle within the distal part of the groove is the tendinous expansion from the insertion of the sternocostal portion of the pectoralis major muscle (the falci-form ligament), which crosses the biceps tendon and is inserted predominantly into the lateral lip of the groove (Fig. 3.20) [74]. The maximum thickness of the tendon of the long head of the biceps muscle is 3.3–4.7 mm, depending on the sex and athletic activity of the patient [75]. The glenoid origin of the long tendon of the biceps varies. In 30% of the shoulders its anatomical origin is the supraglenoid tubercle; in 45% it originates in a Y-form directly from the glenoid labrum with fibres visible from

both the ventral and the dorsal aspects of the labrum. In 25% of shoulders the tendon originates from both the supraglenoid tubercle and from the labrum. On average the total length of the tendon is 102 mm (range 89–146 mm). There are no differences between the right and left shoulders. In men the average length of the tendon is 108 mm, and in women it is 95 mm. There is a positive correlation between tendon length and body height in each patient. The greater the height, the longer the tendon. The cross-sectional area and shape of the tendon change along its course. Near the glenoid the diagonal and oval origins of the tendon have an average cross-sectional area of 8.4 mm x 3.4 mm. As the tendon enters the intertubercular groove it tapers to an average cross-sectional area of 5.1 mm x 2.7 mm. As it exits from the groove its cross-sectional area decreases to 4.5 mm x 2.1 mm. The cross-sectional area of the tendon in men and women shows comparable changes along the course of the tendon; the respective cross sections of the female group are a little smaller. The calculated means in women (men's in brackets) are 7.2 mm x 2.9 mm at the glenoid origin, 4.5 mm x 2.4 mm at the entrance to the intertubercular groove, and 4 mm x 2 mm at the exit from the groove [76]. The long head of the biceps stabilises the humeral head on the glenoid by counteracting against to displace the humeral head upward during elbow flexion and forearm supination [77].

**Fig. 3.20.** Anterior view of right shoulder: Long head of biceps (*LHB*) is visible after detachment of rotator cuff from scapula (*CP* coracoid process, *HH* head of humerus)

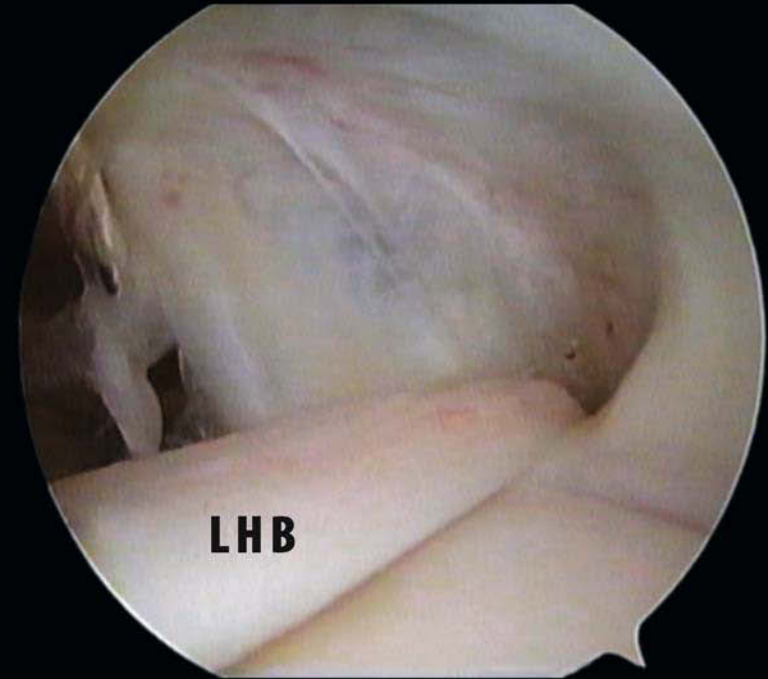
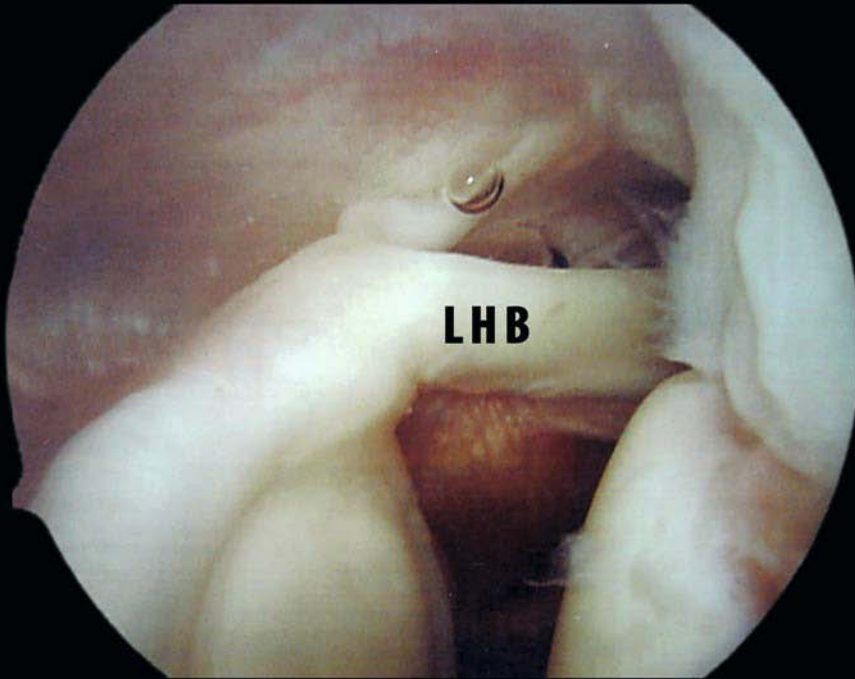




The superior glenohumeral ligament and coracohumeral ligament stabilise the LHB pulley system [78, 79]. We will describe the intraarticular portion of the LHB, starting from the emergency at the pulley system level and going on to the insertion on the supraglenoid tubercle. In the rotator interval proximal to the bicipital groove, the biceps tendon is surrounded by the coracohumeral ligament as a superficial layer and the superior glenohumeral ligament as an internal reflection pulley. The two ligaments have a common insertion at the opening of the bicipital groove. The function of the biceps pulley is thought to be to protect the LHB tendon against anterior shearing stress. From the biomechanical point of view, the orientation of the fibres in ligaments and tendons reflects the direction of the tensile stresses. Fibre orientation of the superior glenohumeral ligament toward the LHB tendon indicates anterior shearing stress. Werner et al. [80] and Gohlke et al. [81] suggest that a lesion in the pulley system might lead to anterior instability of the long head of the biceps tendon in external rotation and therefore cause shoulder pain. On arthroscopical examination, the intraarticular length of

the LHB is increased with the arm at the side and in neutral rotation. The macroscopic attachment of the biceps to the glenoid labrum (Fig. 3.21) is often depicted as an inverted Y shape. Macroscopically, Vangness et al. [82], studying 100 shoulders, have classified the attachment of the biceps tendon into four types: entirely posterior, posterior-dominant, equal, and entirely anterior. The percentages of these four types are 22%, 33%, 37% and 8%, respectively. According to this classification, the type depends on the fibre distribution of the biceps tendon to the anterior superior labrum. It is less likely that an inverted Y-shape occurs in the entirely posterior type, because none of the biceps fibres go to the anterior superior labrum, whereas in the other types they usually do, because the anterior superior labrum contains at least a part of the tendon fibres of the biceps. However, Vangness et al. did not perform histological examinations; nor did they investigate the fibre distribution of the glenohumeral ligaments to the anterior superior labrum, even though the anterior superior labrum is the common attachment site of the glenohumeral ligaments [83].

**Fig. 3.21a, b.** Arthroscopic view of right shoulder posterior view. **a** Glenoid insertion of long head of biceps (LHB). **b** Articular emergency of long head biceps (LHB)



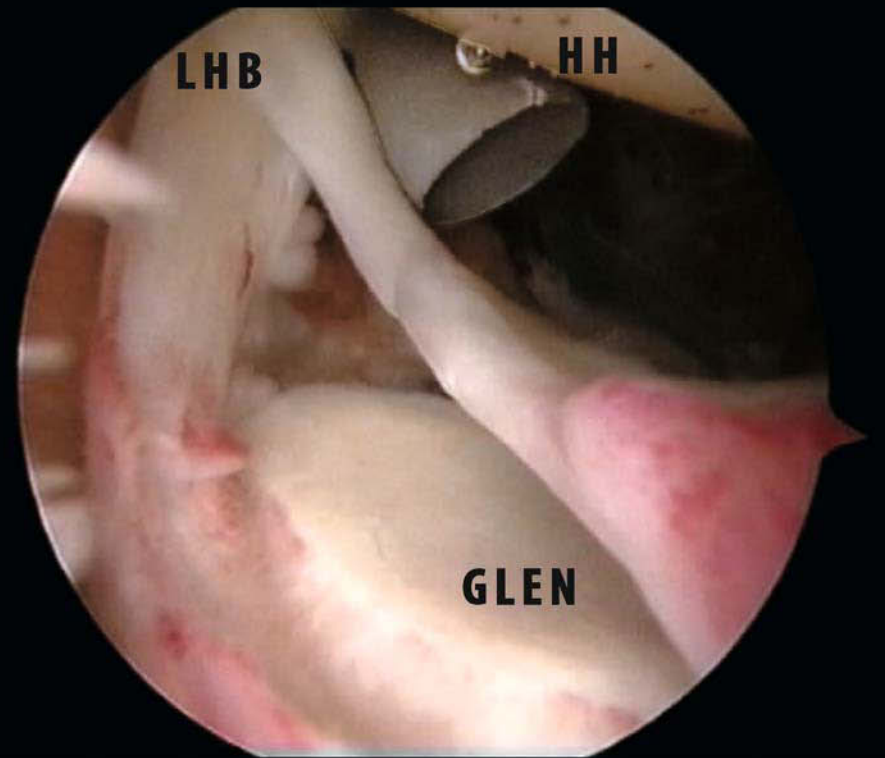
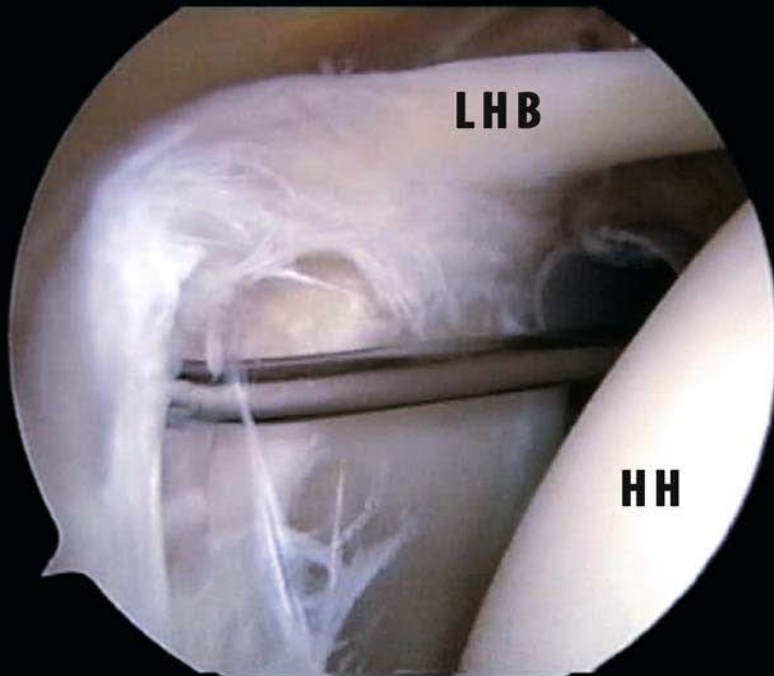
a

b

Huber et al. [84] have shown that the anterior superior labrum is mainly composed of the fibres of the inferior glenohumeral ligament. However, they did not study the relationship between the fibre orientation of the inferior glenohumeral ligament and the macroscopic pattern of the biceps tendon attachment. It seems that the formation of an inverted Y-shape not only relates to the fibre distribution of the biceps tendon but also depends on the fibre distribution of the inferior glenohumeral ligament to the anterior superior labrum. Therefore, it would be interesting to observe the relationship between the biceps tendon and the inferior glenohumeral ligament in terms of their fibre distributions to the anterior superior labrum. Tuoheti et al. [85] hypothesised that the fibre distribution of the biceps tendon to the anterior superior labrum would differ according to the types of biceps attachment to the superior labrum. If the size of the anterior superior labrum is constant, it is likely that the more biceps fibres the anterior superior labrum receives from the biceps tendon, the fewer fibres it receives from the inferior glenohumeral ligament [85]. They conclude that the labral attachment of the long head of the biceps tendon is posterior regardless of its macroscopic appearance. The macroscopic attachment pattern of the biceps

tendon results from the different attachment height of the IGHL. The IGHL attachment site is lower than 4 o'clock in the entirely posterior type, whereas it is higher than 4 o'clock in other types. In other words, the biceps attachment is basically posterior, with or without a few fibres extending into the anterior superior labrum, but it may appear posterior or anteroposterior because of the difference in the attachment site of the inferior glenohumeral ligament. Because glenoid labrum tears and the lesions of the biceps anchor on the superior glenoid, known as SLAP lesions [86], are common both in cadavers and in patients, histological understanding of the fibre orientation of the labrum–biceps complex is of great importance for the treatment of these lesions. A type II SLAP lesion was formerly believed to affect the long head of the biceps tendon alone (Fig. 3.22). However, judging from this study, a type II SLAP lesion affects not only the glenoid attachment of the biceps tendon, but also the glenohumeral ligaments. Therefore, in patients with various types of SLAP lesions, especially throwing athletes, not only the posterior labrum but also the anterior superior labrum should be firmly fixed. This may be helpful in reducing the instability associated with SLAP lesions.

**Fig. 3.22a,b.** Arthroscopic view of right shoulder. **a** Type II SLAP lesion with posterior extension. **b** Type IV SLAP lesion (*LHB* long head of bicep, *HH* humeral head, *GLEN* glena)



a

b

## References

1. Grant J, Smith C (1953) The musculature. In: Schaeffer J (ed) *Morris' Human Anatomy: A Complete Systematic Treatise*. Blakiston, New York, pp 399–609
2. Jobe CM (1998) Gross anatomy of the shoulder. In: Rockwood CA Jr, Matsen FA III (eds) *The shoulder*. Saunders, Philadelphia, pp 34–97
3. Sher JS, Iannotti JP, Warner JJ et al (1997) Surgical treatment of post-operative deltoid origin disruption. *Clin Orthop* 343:93–98 [Ovid Full Text Bibliographic Links \[Context Link\]](#)
4. Lee S-B, An K-N (2002) Dynamic glenohumeral stability provided by three heads of the deltoid muscle. *Clin Orthop* 400:40–47
5. Kuechle DK, Newman SR, Itoi E et al (1997) Shoulder muscle moment arms during horizontal flexion and elevation. *J Shoulder Elbow Surg* 6:429–439
6. Bassett RW, Browne AO, Morrey BF et al (1990) Glenohumeral muscle force and moment mechanics in a position of shoulder instability. *J Biomech* 23:405–415
7. Matsen III FA, Harryman DT II, Sidles JA (1991) Mechanics of glenohumeral instability. *Clin Sports Med* 10:783–788 [Bibliographic Links \[Context Link\]](#)
8. Alpert SW, Pink MM, Jobe FW et al (2000) Electromyographic analysis of deltoid and rotator cuff function under varying loads and speeds. *J Shoulder Elbow Surg* 9:47–58
9. Blasler RB, Guldborg RE, Rothman ED (1992) Anterior shoulder stability: Contributions of rotator cuff forces and the capsular ligaments in a cadaver model. *J Shoulder Elbow Surg* 1:140–150 [\[Context Link\]](#)
10. Cain RR, Mutschler TA, Fu FH et al (1987) Anterior stability of the glenohumeral joint: a dynamic model. *Am J Sports Med* 15:144–148 [Bibliographic Links \[Context Link\]](#)
11. Matsen FA III, Lippitt SB, Sidles JA et al (1994) Stability. In: Matsen FA III, Lippitt SB, Sidles JA, Harryman II DT (eds) *Practical evaluation and management of the shoulder*. Saunders, Philadelphia, pp 59–109 [\[Context Link\]](#)
12. Symeonides PP (1972) The significance of the subscapularis muscle in the pathogenesis of recurrent anterior dislocation of the shoulder. *J Bone Joint Surg Br* 54:476–483 [\[Context Link\]](#)
13. Thompson WO, Debski RE, Boardman ND III (1996) A biomechanical analysis of rotator cuff deficiency in a cadaveric model. *Am J Sports Med* 24:286–292 [Bibliographic Links \[Context Link\]](#)
14. Motzkin NE, Itoi E, Morrey BF et al (1994) Contribution of passive bulk tissues and deltoid to static inferior glenohumeral stability. *J Shoulder Elbow Surg* 3: 313–319
15. Markhede G, Monastyrski J, Stener B (1985) Shoulder function after deltoid muscle removal. *Acta Orthop Scand* 56:242–244
16. Kido T, Itoi E, Lee SD et al (2003) Dynamic stabilizing function of the deltoid muscle in shoulders with anterior instability. *Am J Sports Med* 31:399
17. Morrey B, Itoi E, An K (1998) Biomechanics of the shoulder. In: Rockwood C Jr, Matsen FA III (eds) *The shoulder*, 2nd edn. Saunders, Philadelphia, pp 890–896
18. DiGiovine MN, Jobe FW, Pink M et al (1992) An electromyographic analysis of the upper extremity in pitching. *J Shoulder Elbow Surg* 1:15–25
19. Burkhead WZ Jr, Rockwood CA Jr (1992) Treatment of instability of the shoulder with an exercise program. *J Bone Joint Surg Am* 74:890–896
20. Itoi E, Kuechle DK, Newman SR et al (1993) Stabilising function of the biceps in stable and unstable shoulders. *J Bone Joint Surg Br* 75:546–550
21. Matsen FA III, Thomas SC, Rockwood CA Jr et al (1998) Glenohumeral instability. In: Rockwood CA Jr, Matsen F III (eds) *The shoulder*, 2nd edn. Saunders, Philadelphia, pp 611–754
22. Ward SR, Hentzen ER, Smallwood LH et al (2006) Rotator cuff muscle architecture: implications for glenohumeral stability. *Clin Orthop Relat Res* 448:157–163
23. Cash CJC, Dixon AK, Bearcroft PWP et al (2002) Variations in the MRI appearance of the subscapularis tendon insertion of the shoulder joint (abstract). *Clin Anat* 15:72
24. Jost B, Koch PP, Gerber C (2000) Anatomy and functional aspects of the rotator interval. *J Shoulder Elbow Surg* 9:336–341
25. Clark JM, Harryman DT (1992) Tendons, ligaments, and capsule of the rotator cuff. *J Bone Joint Surg Am* 74:713–725
26. Totterman S, Miller R, Meyers S (1994) Basic anatomy of the shoulder by magnetic resonance imaging. *Top Magn Reson Imaging* 6:86–93
27. Cooper D, O'Brien S, Warren R (1993) Supporting layers of the glenohumeral joint: an anatomic study. *Clin Orthop Relat Res* 289:144–159
28. Pearsall AW, Holovacs TF, Speer KP (2000) The intra-articular component of the subscapularis tendon: anatomic and histological correlation in reference to surgical release in patients with frozen-shoulder syndrome. *Arthroscopy* 16:236–242
29. Curtis AS, Burbank KM, Tierney JJ et al (2006) The insertional footprint of the rotator cuff: an anatomic study. *Arthroscopy* 22:603–609
30. Paulos LE, Tibone JE (1991) Operative techniques in shoulder surgery.

- Aspen, Gaithersburg, Md
31. Basmajian JV (1976) Supraspinatus muscle. Primary anatomy. Williams & Wilkins, Baltimore, pp 158-159
  32. Itoi E, Hsu HC, Carmichael SW et al (1995) Morphology of the torn rotator cuff. *J Anat* 186:429-434
  33. McMinn RMH (1990) Last's anatomy: regional and applied. Churchill-Livingstone, New York, p 72
  34. Williams PL, Warwick R (eds) (1980) Gray's anatomy. Churchill-Livingstone, Edinburgh
  35. Kolts I (1992) A note on the anatomy of the supraspinatus muscle. *Arch Orthop Trauma Surg* 111:247-249
  36. Edelson JG, Taitz C, Grishkan A (1991) The coracohumeral ligament. *J Bone Joint Surg Br* 73:150-153
  37. Ho CP (1999) MR imaging of rotator interval, long biceps, and associated injuries in the overhead-throwing athlete. *Magn Reson Imaging Clin North Am* 7:23-37
  38. Vahlensieck M, Pollack M, Lang P et al (1993) Two segments of the supraspinous muscle: cause of high signal intensity at MR imaging? *Radiology* 186:449-454
  39. Volk AG, Vangsness CT Jr (2001) An anatomic study of the supraspinatus muscle and tendon. *Clin Orthop* 384:280-285
  40. Itoi E, Berglund LJ, Grabowski JJ et al (2004) Tensile properties of the supraspinatus tendon. *J Musculoskel Res* 8:29-34
  41. Minagawa H, Itoi E, Sato T et al (1996) Morphology of the transitional zone of intramuscular to extramuscular tendons of the rotator cuff. *Katakansetsu* 20:103-110
  42. Sano H, Ishii H, Yeadon A et al (1997) Degeneration at the insertion weakens the tensile strength of the supraspinatus tendon: a comparative mechanical and histologic study of the bone-tendon complex. *J Orthop Res* 15:719-726
  43. Uthoff HK, Sano H (1997) Pathology of failure of the rotator cuff tendon. *Orthop Clin North Am* 28:31-41
  44. Nakajima T, Fukuda H (1993) Fiber arrangements of the supraspinatus tendon. *J Shoulder Elbow Surg* 3:S49
  45. Howell SM, Imobersteg AM, Seger DH et al (1986) Clarification of the role of the supraspinatus muscle in shoulder function. *J Bone Joint Surg Am* 68:398-404
  46. Soslowsky LJ, Carpenter JE, Bucchieri JS et al (1997) Biomechanics of the rotator cuff. *Orthop Clin North Am* 28:17-30
  47. Roh MS, Wang VM, April EW et al (2000) Supraspinatus muscle-tendon: anterior and posterior musculotendinous anatomy of the supraspinatus. *JBJS* 9:436-440
  48. Gschwend N, Ivosevic-Radavanovic D, Patte D (1992) Rotator cuff tear: relationship between clinical and anatomopathological findings. *Arch Orthop Trauma Surg* 107:7-15
  49. Nakajima T, Rokuuma N, Hamada K et al (1994) Histologic and biomechanical characteristics of the supraspinatus tendon: reference to rotator cuff tearing. *J Shoulder Elbow Surg* 3:79-87
  50. Fallon J, Blevins FT, Vogel K et al (2002) Functional morphology of the supraspinatus tendon. *J Orthop Res* 20:920-926
  51. Burkhart SS (1991) Arthroscopic treatment of massive rotator cuff tears: clinical results and biomechanical rationale. *Clin Orthop* 267:45-56
  52. Curtis AS, Burbank KM, Tierney JJ et al (2006) The insertional footprint of the rotator cuff: an anatomic study. *Arthroscopy* 22:603-609
  53. Lui J, Hughes RE, O'Driscoll SW et al (1998) Biomechanical effect of medial advancement of supraspinatus tendon. *J Bone Joint Surg Am* 80:853-859
  54. Codman EA (1934) The shoulder. Boston: Thomas Todd
  55. Ellman H, Gartsman GM, Hengst TC (1993) Arthroscopic shoulder surgery and related procedures. Philadelphia: Lea & Febiger
  56. Itoi E, Konno N, Kido T et al (1997) Function of the anterior one-third of the supraspinatus tendon (anterior tendinous band). *J Jpn Orthop Assoc* S161
  57. Itoi E, Hsu HC, Carmichael SW et al (1995) Morphology of the torn rotator cuff. *J Anat* 186: 429-34
  58. Keating JF, Waterworth P, Shaw-Dunn J et al (1993) The relative strength of the rotator cuff muscles. A cadaver study. *J Bone Joint Surg* 75B: 137-40
  59. Minagawa H, Itoi E, Konno N et al (1998) Humeral attachment of the supraspinatus and infraspinatus tendons: an anatomic study. *Arthroscopy* 14: 302-6
  60. Parsons IM, Apreleva M, Fu FH et al (2002) The effect of rotator cuff tears on reaction forces at the glenohumeral joint. *J Orthop Res* 20:439-446
  61. Burkhart SS, Esch JC, Jolson RC (1993) The rotator crescent and rotator cable: an anatomic description of the shoulder's "suspension bridge." *Arthroscopy* 9: 611-616
  62. Burkhart SS (1992) Fluoroscopic comparison of kinematic patterns in massive rotator cuff tears: A suspension bridge model. *Clin Orthop Relat Res* 284: 144-152
  63. Halder AM, O'Driscoll SW, Heers G (2002) Biomechanical comparison of effects of supraspinatus tendon detachments, tendon defects, and muscle retractions. *J Bone Joint Surg Am* 84: 780-785

64. Petit J, Filippi GM, Emonet-Dénand F et al (1990) Changes in muscle stiffness produced by motor units of different types in peroneus longus muscles of cat. *J Neurophysiol* 63: 190-197
65. Petit J, Filippi GM, Gioux M et al (1990) Effects of tetanic contraction of motor units of similar type on the initial stiffness to ramp stretch of the cat peroneus longus muscle. *J Neurophysiol* 64:1724-1732
66. Gordon AM, Huxley AF, Julian FJ (1966) The variation in isometric tension with sarcomere length in vertebrate muscle fibres. *J Physiol* 184:143-169
67. Williams GR Jr, Iannotti JP, Rosenthal A et al (1996) Anatomic, histologic, and magnetic resonance imaging abnormalities of the shoulder. *Clin Orthop Relat Res* 330:66-74
68. Abrams RA, Tsai AM, Watson B et al (2000) Skeletal muscle recovery after tenotomy and 7-day delayed muscle length restoration. *Muscle Nerve* 23:707-714
69. McLaughlin HL (1944) Lesions of the musculotendinous cuff of the shoulder: The exposure and treatment of tears with retraction. *J Bone Joint Surg Am* 26:31-51
70. Gerber C (1991), Krushell R (1991) Isolated rupture of the tendon of the subscapularis muscle. *J. Bone Joint Surg Br* 73:389
71. Scheibel M, Magosch P, Pritsch M, Lichtenberg S, Habermeyer P (2005) The belly-off sign: a new clinical diagnostic sign for subscapularis lesions. *Arthroscopy*. 21:1229-1235
72. Barth JR, Burkhart SS, De Beer JF (2006) The bear-hug test: a new and sensitive test for diagnosing a subscapularis tear. *Arthroscopy* 22:1076-1084
73. Slatys P, Aalto K (1979) Medial dislocation of the tendon of the long head of the biceps brachii. *Acta Orthop Scand* 50:73-77
74. Rockwood CA Jr, Matsen FA (1990) *The shoulder*, 1st edn, vol. 2. Philadelphia: Saunders 565-660
75. Van Holsbeek M, Introcaso JH (1990) *Musculoskeletal ultrasound*, 1st ed. St. Louis: Mosby-Year Book, pp 265-284, 316
76. Refior H.J, Sowa D (1995) Long tendon of the biceps brachii: sites of predilection for degenerative lesions. *J Shoulder Elbow Surg* 4:436-440
77. Eakin CL, Faber KJ, Hawkins RJ et al (1999) Biceps tendon disorders in athletes. *J Am Acad Orthop Surg* 7:300-308
78. Ferrari DA (1990) Capsular ligaments of the shoulder. Anatomical and functional study of the anterior superior capsule. *Am J Sports Med* 18:20-24
79. Walch G, Josserand LN, Levigne C et al (1994) Tears of the supraspinatus tendon associated with "hidden" lesions of the rotator interval. *J Shoulder Elbow Surg* 3:353-360
80. Werner A, Mueller T, Boehm D et al (2000) The stabilizing sling for the long head of the biceps tendon in the rotator cuff interval. *Am J Sports Med* 28:28-31
81. Gohlke F, Essigkrug B, Schmitz F (1994) The patterns of the collagen fiber bundles of the capsule of the glenohumeral joint. *J Shoulder Elbow Surg* 3:111-128
82. Vangsness CT, Jorgenson SS, Watson T et al (1994) The origin of the long head of the biceps from the scapula and glenoid labrum. *J Bone Joint Surg Br* 76:951-953
83. O'Brien SJ, Neves MC, Arnoczky SP et al (1990) The anatomy and histology of the inferior glenohumeral ligament complex of the shoulder. *Am J Sports Med* 18:449-456
84. Huber WP, Putz RV (1997) Periarticular fiber system of the shoulder. *Arthroscopy* 13:680-691
85. Tuoheti Y, Itoi E, Minagawa H, Yamamoto N et al (2005) Attachment types of the long head of the biceps tendon to the glenoid labrum and their relationships with the glenohumeral ligaments. *Arthroscopy* 21:1242-1244
86. Snyder SJ, Karzel RP, Del Pizzo W et al (1990) SLAP lesions of the shoulder. *Arthroscopy* 6:274-279

---

## **PART 4 - GLENOHUMERAL CAPSULE**



## 4.1 Fibrotendinous Cuff of the Capsule

*Giovanni Di Giacomo*

The influence of arthroscopy over the last 30 years has induced an evolution towards closer visualisation of the commonly recognised ligaments (superior, middle and inferior glenohumeral), leading them to be seen as clearly defined bands or folds rather than as parts of a larger complex; on the other hand, microscopic and histological techniques have resulted in an expansion of our knowledge of both the inferior glenohumeral ligament and the superior structures, enabling anyone to become aware of the intimate relationships between coracohumeral and superior glenohumeral ligaments, rotator cuff tendons and the transverse band.

It is commonly assumed that the configuration of the myotendinous cuff and the capsular and ligamentous components is capable of withstanding physiological load and minimising the concentration of stress. The main purpose of the previous and following chapters is to formulate an “*integrated vision*” of the anatomical structures that enable the rotator cuff to work effectively throughout life, namely the glenohumeral capsule and the rotator cuff tendons (Fig. 4.1).

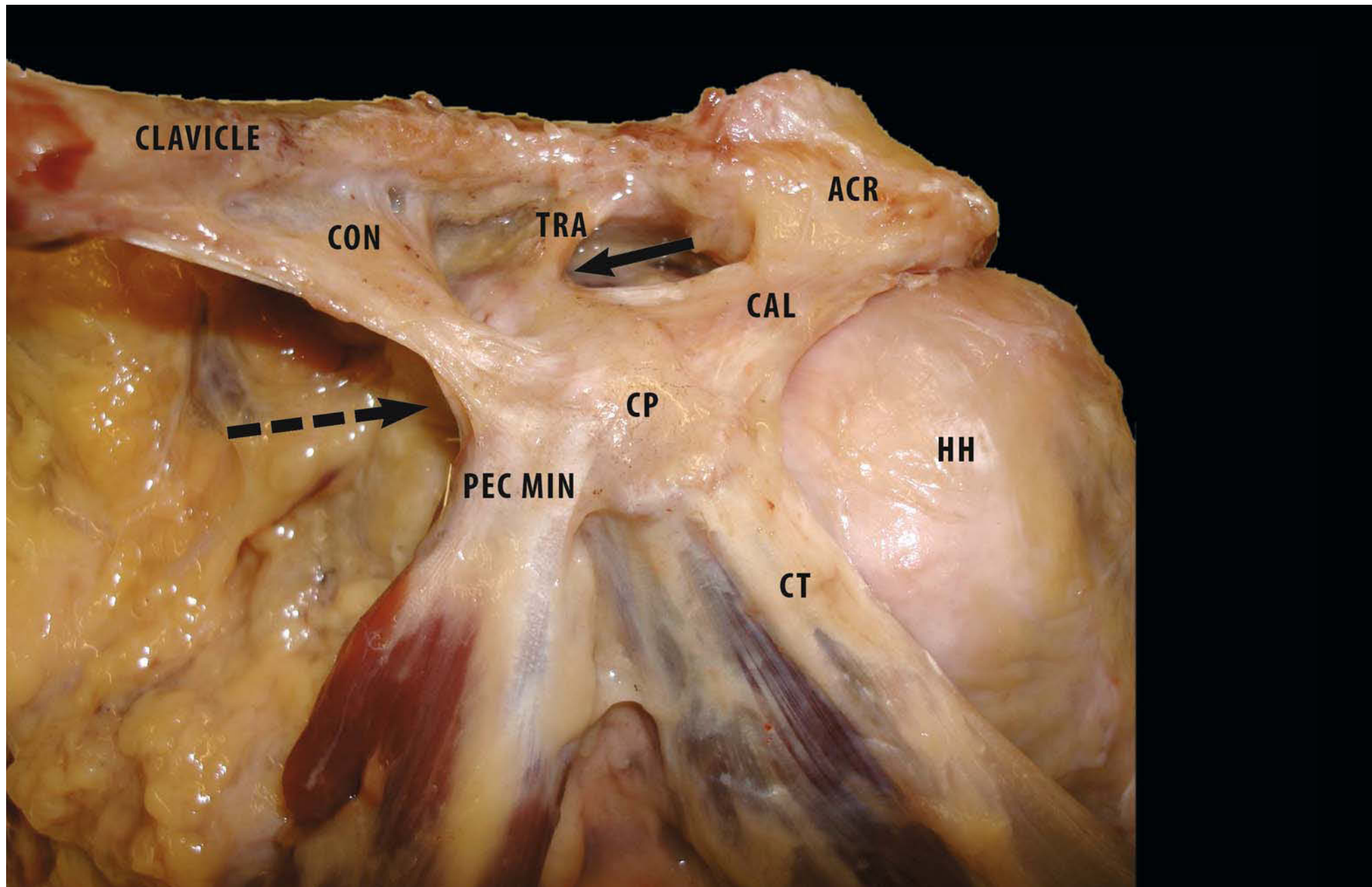
The tendons of the rotator cuff are seen to fuse into one structure near their insertions onto the tubercles of the

humerus. This fusion is apparent when the two surfaces of the intact cuff are exposed by removal of the overlying bursa and the underlying capsule. The supraspinatus and infraspinatus tendons join about 15 mm proximal to their insertions on the humerus and cannot be separated by additional blunt dissection. Although there is an interval between the muscular portions of the teres minor and the infraspinatus muscles, these muscles merge inseparably just proximal to the musculotendinous junction. The teres minor and the subscapularis muscles have muscular insertions on the surgical neck of the humerus, which extend to approximately 2 cm below their tendinous attachment on the tubercles.

The tendons of the cuff are reinforced near their insertions on the tubercles of the humerus by fibrous structures with both *superficial* and deep locations.

- The “*superficial*” aspect of the tendons is covered by a thick sheet of fibrous tissue that lies beneath the deep layer of the subdeltoid bursa. This sheet is a fan-like posterolateral extension of a broad and thick fibrous band that extends from the lateral edge of the coracoid process over the supraspinatus and infraspinatus tendons to the humerus.
- This band also sends slips (CHL) along the surface of the capsule into the interval between the subscapularis and supraspinatus tendons that attach to both tubercles underneath both tendons [1–4].

**Fig. 4.1.** Anterior view of left shoulder: image of entire shoulder, illustrating different connections between ligament and ligament (←) and ligament and tendon (---→) (ACR acromion, CAL coracoclavicular ligament, CON conoid ligament, CP coracoid process, CT conjoined tendon, HH humeral head, PEC MIN pectoralis minor, TRA trapezoid)



Additional components of the coracohumeral ligament are revealed when the tendons of the rotator cuff are dissected from the underlying capsule of the shoulder and reflected laterally or when the cuff and capsule are resected together and their *deep* surfaces are examined. When viewed from these perspectives, the tendons are seen to adhere tightly to the joint capsule near their insertions on the humerus [2].

The capsule beneath the supraspinatus and the infraspinatus tendons is thickened by a 1-cm-wide band of fibrous tissue running posteriorly in a direction perpendicular to the fibres of the tendons; the band extends to the posterior edge of the infraspinatus tendon and appears to be a deep extension of the coracohumeral ligament, which passes through an interval between the capsule and the cuff tendons (Fig. 4.2).

The capsule is firmly attached to the deep surface of the rotator cuff near the insertion on the humerus (first region). Adjacent to the tendon-to-capsule area of tight adherence there is a second region of looser attachment between cuff muscle and capsule; a third region, adjacent to the rim of the glenoid, is free of attachments to the cuff. The axillary pouch of the capsule is not crossed by tendons of the rotator cuff, but a lateral muscular part of the long head of the triceps is consistently found emerging on its medial side. The insertions of both the subscapularis and the teres minor muscles extend distally to the level of the inferior capsule insertion on the humerus. Fibres of these muscles insert on the front and back of the axillary pouch. The capsule is thicker (>2 mm) in the interval between the subscapularis and the supraspinatus, where it continues in the fibrous band mentioned before. The capsule is thicker where it is most stably attached to the tubercles and thinner (<1 mm) where it has no attachments, namely posteroinferiorly and inferiorly [5, 6].

The joint capsule of the shoulder is a complex structure reinforced by bands of “specifically oriented fibres”. It carries out several distinct functions, providing:

1. Support for the synovial membrane;
2. Restraint;
3. A watertight seal;
4. Extension of the periarticular tendon insertion.

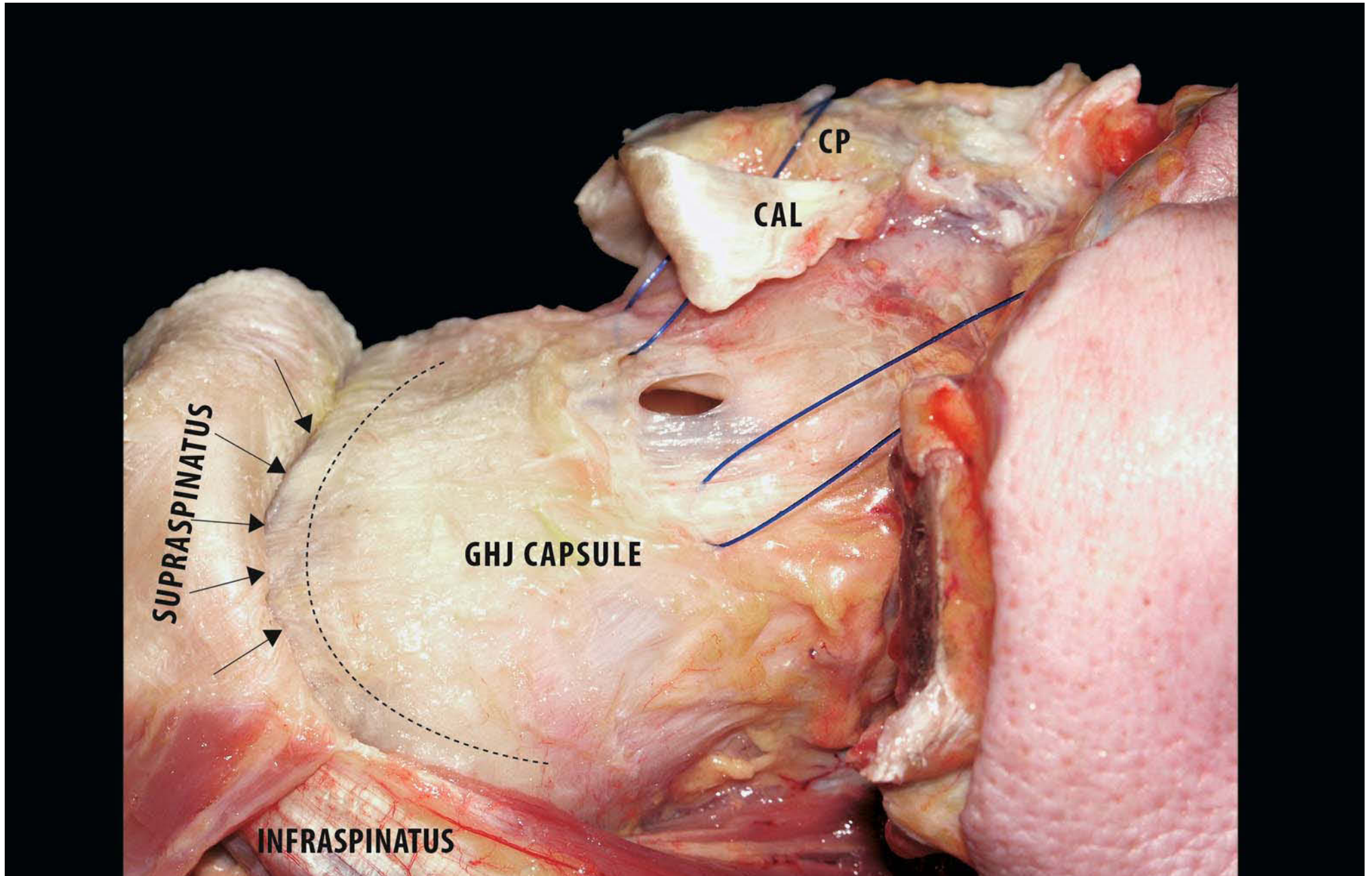
Clark [5] found that a number of structural characteristics of the capsule are closely related to the overlying myotendinous unit known as the rotator cuff. The capsule and cuff generally interact through two functions: mechanical and proprioceptive. The loose muscle attachments probably draw back redundant capsular portions in the same way as the articularis genu muscle retracts the suprapatellar pouch. One of the functions of tight tendinous attachments to the capsule adjacent to the humerus may be to ensure that the tension generated by cuff muscle is evenly distributed into the capsule.

The unique attribute of the glenohumeral joint (GHJ), namely maintaining the humeral head precisely in the centre of the glenoid and, at the same time, allowing a vast range of motion, is achieved by a combination of dynamic and static mechanisms. The rotator cuff and biceps brachii muscles are the main structures responsible for the dynamic stabilisation of the GHJ. They work through two key mechanisms:

1. Joint compression, resulting from synchronous active muscle contraction: this keeps the articular surfaces congruent in different arm positions. At the same time these muscles depress the humeral head, forming a fulcrum that allows the deltoid to raise the arm.
2. Dynamisation of the glenohumeral ligaments through direct attachments onto the rotator cuff tendons adjacent to the humeral tubercles.

The dynamic shoulder model developed by Warner et al. [7] demonstrates that the orientation of ligaments is indeed affected by rotator cuff contraction. Intensifications of these dynamic mechanisms are balanced by scapulothoracic/scapulohumeral rhythm and proprioception.

**Fig. 4.2.** Posterosuperior view of the left shoulder: after acromionectomy note “melding” of cuff and capsule. In the glenohumeral joint are several ligamento-muscular reflex arcs; existence of such arcs suggests that ligaments and muscles function synergistically in both “mechanical” and “proprioceptive” fashion. Under supraspinatus and infraspinatus tendons a strip of fibrous tissue runs posteriorly and perpendicular to the fibres of the tendons (----- fibrous tissue, →supraspinatus fibres, CAL coracoacromial ligament, CP coracoid process, GHJ glenohumeral joint)



Several studies [7] have demonstrated that the fibres of the tendons of the short rotator muscles (subscapularis, supraspinatus, infraspinatus and teres minor) intermingle with each other and with fibres of the glenohumeral capsule (Fig. 4.3). This interaction is such that the tendons reinforce the capsule [4], but also the capsular fibres [8], specifically the “transverse band”, may hold the tendons together, thereby protecting them from tears at their edges, and also dissipate some of the tension generated in the cuff.

At least half of the capsule receives reinforcing fibres from the surrounding muscles: the most evident connection is with supraspinatus and subscapularis, but there is also a connection with the infraspinatus, the teres minor and the long tendon of the triceps [5]. Clark and Harryman [6] and Gohlke et al. [9] recognised five distinct layers on histological examination of the capsule and superior rotator cuff:

1. Directly under the synovial layer was a thin layer of fibres organised into an interwoven network.
2. The second layer was thicker and consisted mainly of interwoven bands of stronger fibres derived from the circular and coracohumeral systems of the actual joint capsule. The coracohumeral ligament was seen to extend along the rotator cuff interval, where it formed the part of the fibrous roof for the long tendon of the biceps muscle, around the edges of both the supraspinatus and the subscapularis muscles and into the capsule up to 1 cm underneath both tendons. The coracohumeral ligament also extended into a fibrous sheath that was part of the deep layer of the subdeltoid bursa. The superior glenohumeral ligament merged with the anterior edge of the coracohumeral ligament beneath the superior edge of the subscapularis muscle near the humeral insertion of both ligaments. The superior and middle glenohumeral ligaments were located around the superior and inferior edges of the subscapularis muscle in a layer between capsule and tendons.
3. The intermediate layer contained a loose pattern of crossing

tendinous fibres that became denser towards the tendinous insertion and connected the capsular layer to the deeper layer and to the tendons.

4. In the actual tendon layer, there were fibre bundles from the supraspinatus tendon connecting to the infraspinatus tendon and to the fibrous canal surrounding the biceps tendon. Gagey et al. [10] have demonstrated that the fibrous structure of the supraspinatus muscle is much denser and stronger along its anterior border, whereas that of the subscapularis muscle converges towards its superolateral border. This fibrous lock provides an additional reinforcement around the rotator cuff interval.
5. Finally, a superficial layer of fibre bundles ran from the coracoid process and over the tendons as part of the deep layer of the bursa subacromialis.

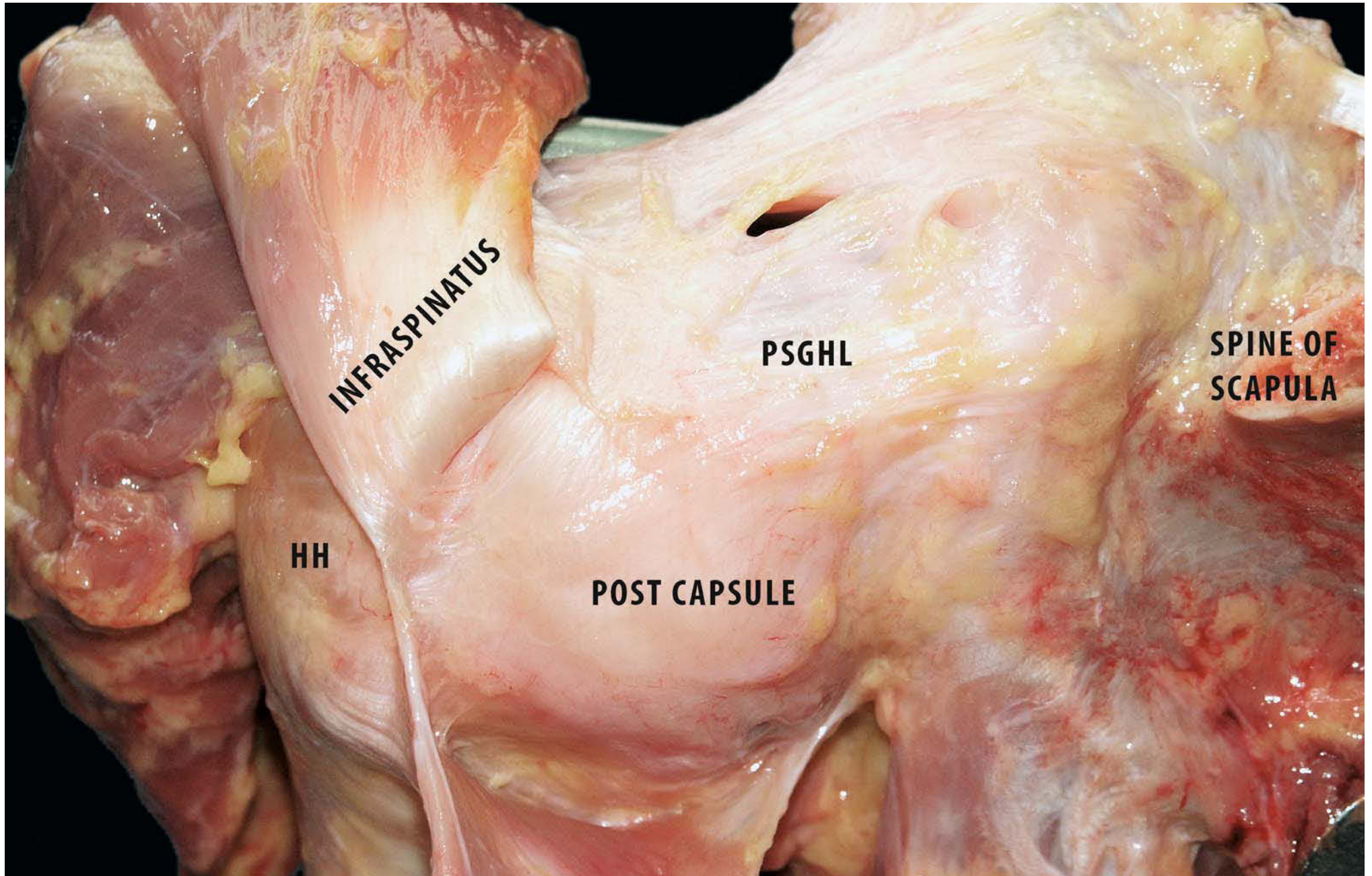
## 4.2 Superior (Glenohumeral Ligament) Complex

*Giovanni Di Giacomo, Nicole Pouliart*

Coracohumeral and superior glenohumeral ligaments (SGHL) have been described by most authors. In addition, the rotator cable, the rotator cuff interval and the adjacent ligaments are currently receiving more attention than formerly because of their importance in glenohumeral instability and adhesive capsulitis, as well as for their proprioceptive role in normal glenohumeral function.

Nevertheless, there seems to be not a little confusion about the anatomy of this particular region. On the basis of recent data, the fibrous structure of the superior part of the glenohumeral capsule is even more complex than thus far described. The integrated structures of the superior capsule can be summarised as follows:

**Fig. 4.3.** Posterior view of left shoulder: infraspinatus muscle is separated from posterosuperior joint capsule and reflected laterally. Spine of scapula has been cut at its base. Fibres of the rotator muscles tendons intermingle with each other and with fibres of the glenohumeral capsule (*PSGHL* posterosuperior glenohumeral ligament)



1. An anterior limb, formed by the coracohumeral, the superior glenohumeral and coracoglenoid ligaments (Fig. 4.4a).
  2. A posterior limb, formed by the posterosuperior glenohumeral ligament (Fig. 4.4b).
  3. Both limbs fusing into the transverse band before anchoring down onto the humerus anteriorly and posteriorly.
  4. Merging of the ligaments with the tendons of the supraspinatus and the infraspinatus muscles at the level of the transverse band.
  5. The fibrous reinforcement of the superior part of the glenohumeral capsule is completed by the transverse humeral ligament (THL), which merges with the superior glenohumeral ligament and the coracohumeral ligament to form the roof of the “biceps pulley”.
  6. The superior complex is linked with the inferior one by a number of diagonal and circular fibrous bands, formed by the glenoid labrum, the fasciculus obliquus, the transverse band and the middle glenohumeral ligament.
- e. Superior complex with a “medium-sized gap” between the posterosuperior glenohumeral ligament and the anterior limb of the complex: the superior glenohumeral ligament, the coracohumeral ligament and the coracoglenoid ligament cannot be separated (Fig. 4.4a);
  - f. Superior complex with a “wide gap” between the posterosuperior glenohumeral ligament and the anterior limb of the complex: the superior glenohumeral ligament and the coracohumeral ligament cannot be separated, and there is a distinct coracoglenoid ligament (Fig. 4.4e);
  - g. Superior complex with a “very wide gap” between the posterosuperior glenohumeral ligament and the anterior limb of the complex, the superior glenohumeral ligament and the coracohumeral ligament (Fig. 4.4f);
  - h. Superior complex with a “very wide” posterosuperior glenohumeral ligament but “thin coracohumeral and superior glenohumeral ligament”: the coracoglenoid ligament merges into the posterosuperior glenohumeral ligament.

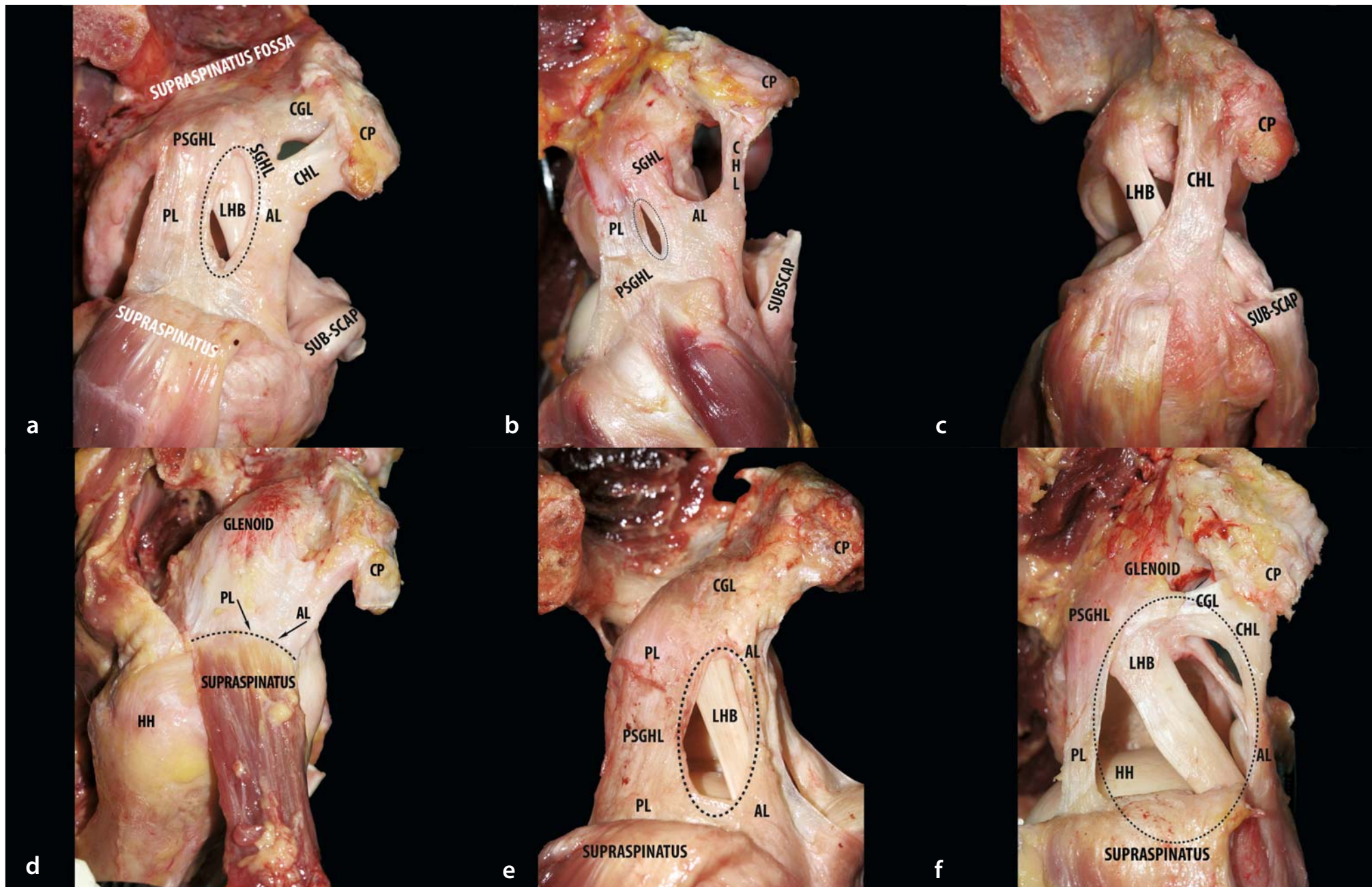
### Various Types of Superior Complex

According to Pouliart et al. [55, 56]

- a. “Absent” posterosuperior glenohumeral ligament (Fig. 4.4c);
- b. “Broad” and “confluent” superior complex (Fig. 4.4d);
- c. Superior complex with a “small gap” between the posterosuperior glenohumeral ligament and the anterior limb of the complex (AL): the superior glenohumeral ligament and the coracohumeral ligament merge in the middle third; there is no coracoglenoid ligament (Fig. 4.4b);
- d. Superior complex with a “medium-sized gap” between the posterosuperior glenohumeral ligament and the anterior limb of the complex: the superior glenohumeral ligament and the coracohumeral ligament merge in the medial third; there is no coracoglenoid ligament;

Ferrari [11] has described the coracohumeral ligament as having a single broad origin from the base but not from the tip of the coracoid process. The coracohumeral ligament arises from under the coracoacromial ligament, blends posteriorly along its length with the fascia of the supraspinatus muscle and blends anteriorly with the insertion of the subscapularis tendon. The lateral insertion is doubled into both the greater and the lesser tubercle, thereby forming a tunnel for the biceps tendon. The superior glenohumeral ligament arises from the supraglenoid tubercle, just anterior to the long tendon of the biceps muscle. Laterally, the coracohumeral and the superior glenohumeral ligaments join each other at their midportion, which renders it difficult to separate both ligaments laterally. Both ligaments insert into the so-called *fovea capitis humeri*. This description of coracohumeral and superior glenohumeral

**Fig. 4.4a–f.** Lateral view of right shoulder. **a** Superior complex with medium-sized gap between anterior limb (SGHL and CHL) and posterior limb (PSGHL); **b** Superior complex with small gap between anterior (AL) and posterior (PL) limbs; **c** Absent posterior limb; **d** Broad and confluent anterior and posterior limb; **e** superior complex with broad gap; **f** Superior complex with very broad gap. (CP coracoid process, LHB long head of biceps, HH humeral head)





ligaments can also be found in other texts [12–15]. Boardman et al. [16] found that the superior glenohumeral coracohumeral ligaments were funnel-shaped and could easily be separated from origin to insertion. The coracohumeral ligament was broader than the superior glenohumeral ligament. The coracohumeral ligament had a broader lateral base and the superior glenohumeral ligament had a broader medial base. In their description only the coracohumeral ligament merged with the rotator cuff tendons.

As long ago as in 1910, Delorme [8] gave a detailed description of the three components of the anterior limb of the superior glenohumeral ligament complex.

The origin of the coracohumeral ligament from the posterolateral border of the coracoid process, under and between the two branches of the coracoacromial ligament, and in most instances also from the base of the coracoid process, has a variable form, with a width ranging from 1 to over 2.5 cm (Fig. 4.5). In general, it forms a solid plate that courses laterally over the capsule with a free ventral border. Finally, it runs towards the tendon of the subscapularis and inserts into the lesser tubercle. Often, fibres from the coracohumeral ligament run in a curve towards the supraglenoid tubercle and then constitute a so-called coracoglenoid ligament. These latter fibres fuse posteriorly with that part of the capsule that arises from the supraglenoid tubercle and that bridges over the long tendon of the biceps muscle. This dorsal part is covered by the tendon of the supraspinatus muscle with which it intertwines and with which it has a common insertion into the greater tubercle. Two fibre systems branch off from the dorsal part shortly before this humeral insertion. These additional fibre systems run anteriorly and posteriorly along the anatomical neck in the glenohumeral capsule and are variably labelled the transverse band

or the rotator cable. The double humeral insertion into both the greater and the lesser tubercle forms a tunnel for the long tendon of the biceps.

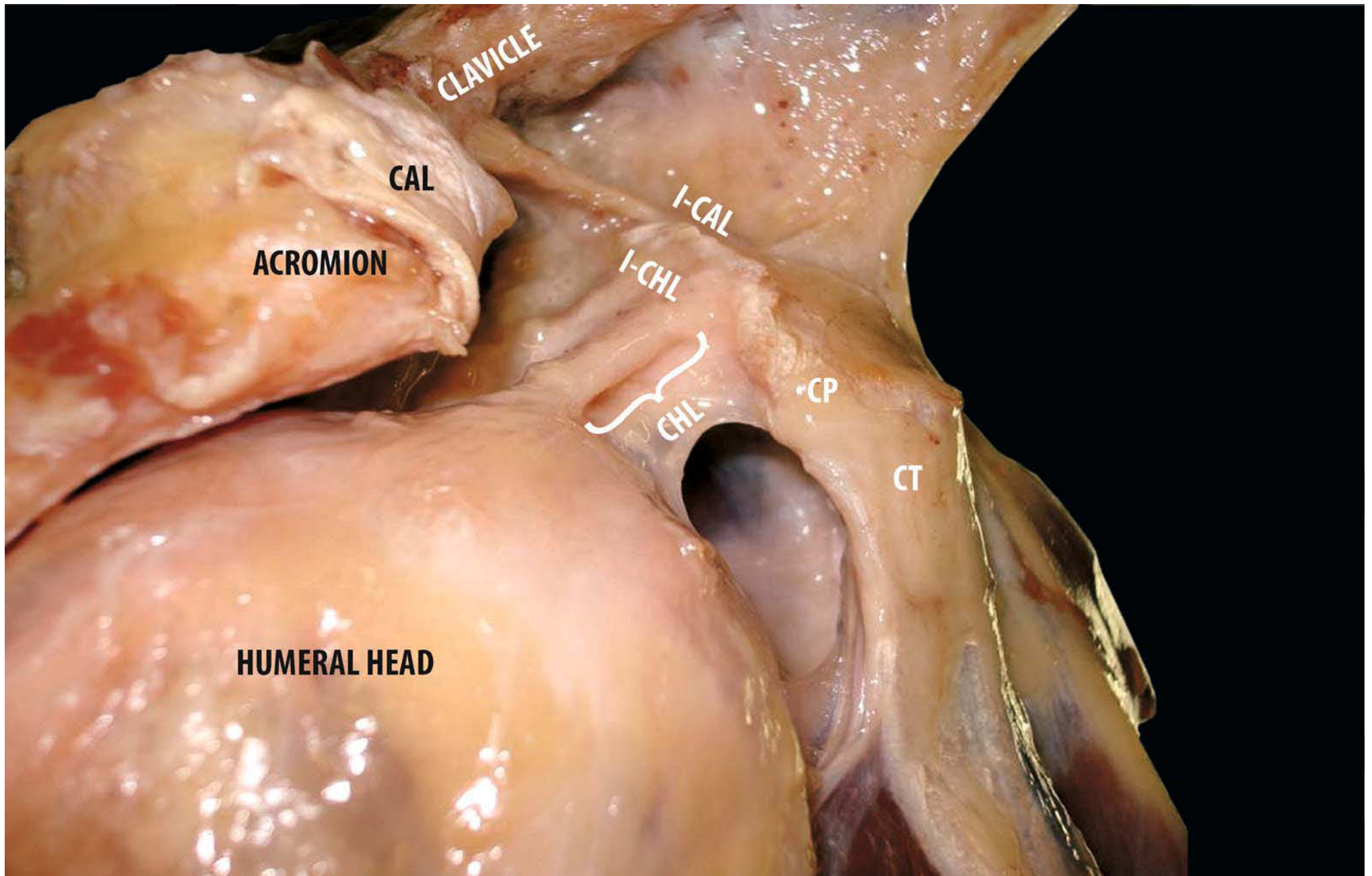
The superior glenohumeral ligament arises from the upper pole of the glenoid labrum and has a few fibres coming from the supraglenoid tubercle ventral to the origin of the biceps tendon. At their origin, biceps tendon and ligament may be intertwined and the ligament follows the tendon laterally together with a small artery. Here it may have the aspect of no more than a thin, band-like fold in the synovial membrane. Finally, the superior glenohumeral ligament inserts in the small depression of the humeral articulating surface just above the lesser tubercle (fovea capitis humeri). In contrast to Welcker [17] and in agreement with Fick [18], the superior glenohumeral ligament was a constant finding in the dissections done by Delorme [8].

Because the coracohumeral ligament, the superior glenohumeral ligament and the coracoglenoid ligament seem to merge with each other to a variable extent, we believe that they should be considered as one functional unit, the coracoglenohumeral ligament. In this section, the three ligaments are nevertheless described separately in detail.

This section deals with the structures of the superior (glenohumeral ligament) complex:

- 1) Coracoglenohumeral ligament with its components
  - a. Coracohumeral ligament
  - b. Superior glenohumeral ligament
  - c. Coracoglenoid ligament
- 2) Posterosuperior glenohumeral ligament
- 3) Rotator cable or transverse band
- 4) Rotator cuff interval
- 5) Biceps pulley

**Fig. 4.5.** Lateral view of right shoulder: coracohumeral ligament (*CHL*) originates from lateral border of coracoid process, just below distal insertion of coracoacromial ligament (*CAL*) (*I-CAL* distal insertion of coracoacromial ligament, *I-CHL* distal insertion of coracohumeral ligament) (*CP* coracoid process, *CT* common tendon)



### 4.2.1 Coracohumeral Ligament

A variety of descriptions of the coracohumeral ligament (Fig. 4.6) can be found in the literature.

According to Schlemm [19], the coracohumeral ligament has two roots: one superior, and stronger, proceeding from the lateral border of the coracoid process to the posterior margin of the posterior groove, and an inferior, weaker one, going from the glenoid labrum and rim, close to the origin of long tendon of the biceps to the anterior margin of the biceps groove. The coracohumeral ligament courses between supraspinatus and subscapularis forming a gutter that cradled the long tendon of the biceps muscle. The coracohumeral ligament attaches to the inner and outer margin of the intertubercular bicipital groove and both humeral tubercles. This description was shared by several others [17, 18, 21, 22]. Other texts [8, 17, 23–26] only mention the coracohumeral part of the coracohumeral ligament with a single origin from the base of the coracoid process. According to Delorme [8], most authors and surgical textbooks of the late nineteenth and early twentieth centuries have omitted to mention the origin of the coracohumeral ligament from the tip of the coracoid process. Often the superior and middle glenohumeral and the coracohumeral ligaments have been mixed up and considered as a single structure, usually referred to as the “coracohumeral ligament”.

Kocher [27] describes a Y-shaped coracohumeral ligament emerging from the base of the coracoid process immediately before the origin of the long tendon of the biceps muscle and then diverging into two parts. The “weaker posterosuperior” branch runs towards the greater tubercle, where some of it intertwines with the tendon of the supraspinatus muscle next to

its insertion, while some of its fibres continue downwards within the capsule. While the insertion of this part does relate to the coracohumeral ligament described by most authors, its origin actually corresponds to that of the superior glenohumeral ligament. The “stronger anteroinferior” branch, in contrast, inserts mainly on the lesser tubercle but also has some fibres descending into the capsule. This branch actually corresponds to the middle glenohumeral ligament described by most authors.

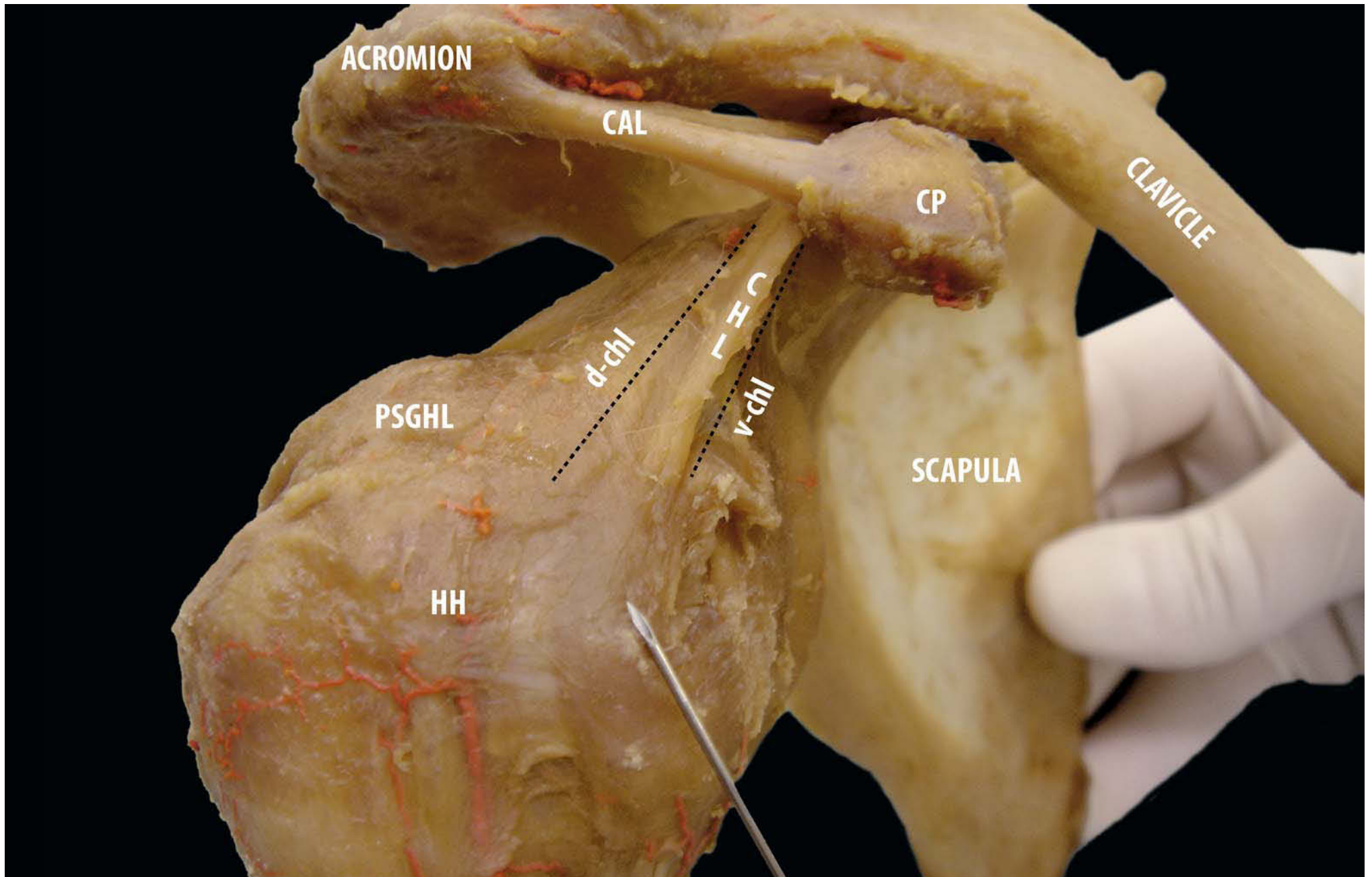
Debierre [28], Sappey [29] and Testut and Latarjet [12] describe a “superficial coracohumeral” ligament going from the coracoid process to the greater tubercle and merging there with the fibres of the circular capsule. They have added the notion of a “deep part”, the coracoglenoid ligament, extending from the coracoid process to the supraglenoid tubercle and along the insertion of the long tendon of the biceps muscle and the glenoid labrum.

Debierre [28], nevertheless, thinks that this latter deep part runs towards both tubercles, to merge with the superficial part. The continuation of the deep part corresponds to the superior glenohumeral ligament described by most authors.

Hoffman [30] agrees with others descriptions of the coracohumeral ligament as made up of two parts, a “columna anterior”—the coracohumeral ligament itself—and a “columna posterior” corresponding to the superior glenohumeral ligament, although this author did not recognise separate ligaments in the glenohumeral capsule.

Meckel [31] and Langer [20] also only describe a superior fibre bundle that reinforced the capsule, although Meckel describes a fibrous contribution to the labrum coming from the coracoid process and corresponding to the “coracoglenoid ligament”.

**Fig. 4.6.** Anterolateral view of right shoulder: the coracohumeral ligament (CHL) in the context of the glenohumeral capsule “as a whole” (*v-chl* ventral [inferior] coracohumeral ligament, *d-chl* dorsal [superior] coracohumeral ligament)

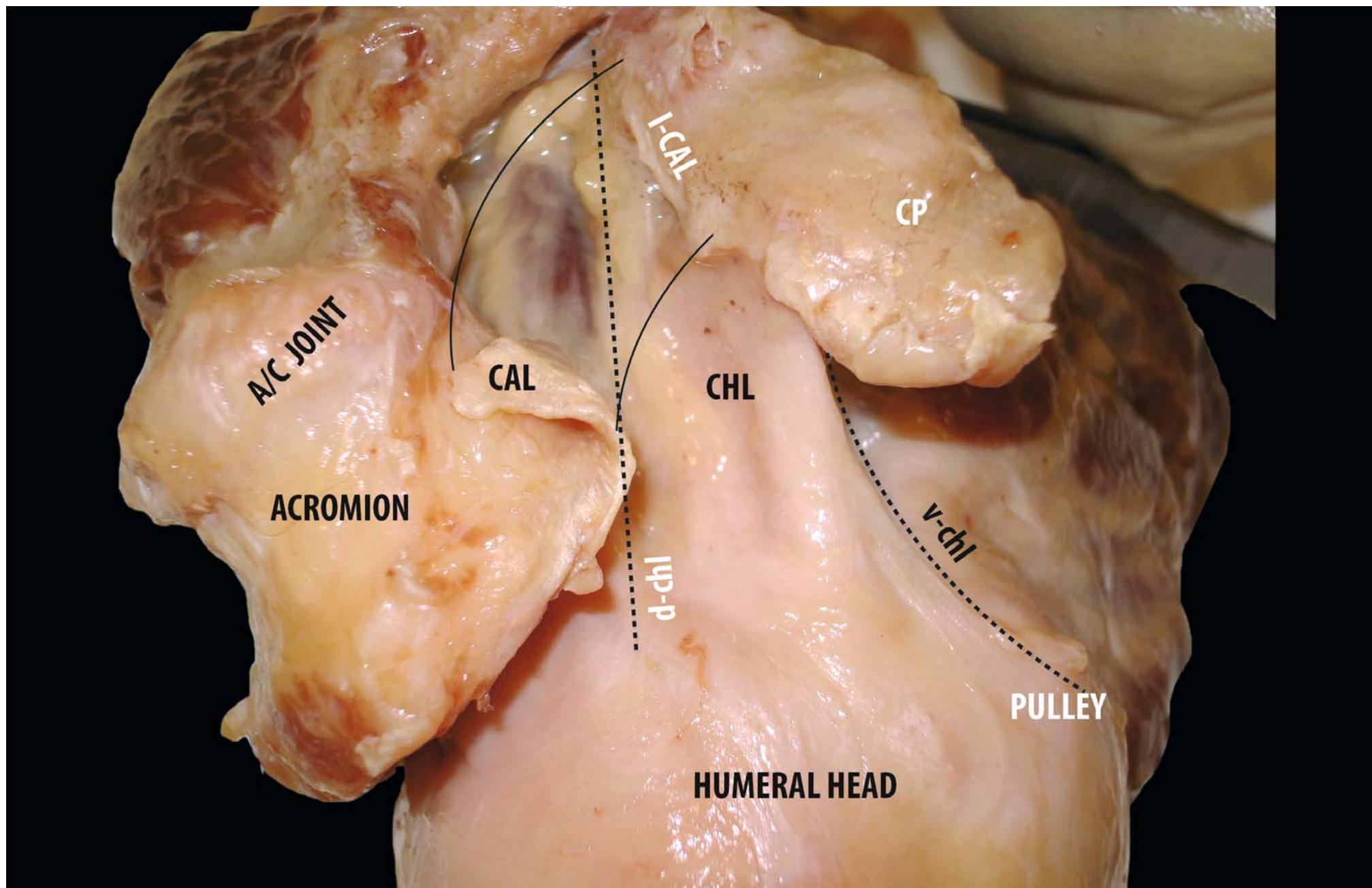


The origin of the coracohumeral ligament from the posterolateral border of the coracoid process, under and between the two branches of the coracoacromial ligament, and, in most instances, also from the base of the coracoid process, has a variable shape, with its width ranging from 1 to over 2.5 cm.

Some authors [9, 32–34, 35, 36, 37] have found that the ligament represents a thickening of the capsule or a capsular fold, but that it is rarely consistent with a clearly defined histological structure; most describe a relatively broad origin ranging from the posterior edge of the base of the coracoid process and extending as far as 24 mm anterior to this edge (Fig. 4.7). According to Cooper et al. [32, 33], the origin is usually V-shaped. Kolts' group found a partial origin from the coracoglenoid ligament [35, 38] and also found two distinct parts closely corresponding to the two parts of Debierre and Sappey, but inserting laterally on a broad semicircular band spanning the humeral head from the anterior border of the supraspinatus tendon to the posterior border of the infraspinatus tendon, but not inserting directly onto the bone [39].

The coracohumeral ligament underlies the rotator cuff interval formed by the supraspinatus and subscapularis tendons, as shown by Clark and Harryman [6] and Cooper et al. [32, 33]. According to their description, the coracohumeral ligament has a broad, thin origin, 1–2 cm wide, along the proximal third of the dorsolateral aspect of the coracoid or, more rarely, represents the continuation of the pectoralis minor tendon [32–41]. In some specimens [5, 16, 42–46], the tendon of the pectoralis minor is portrayed either crossing over the coracoid process, continuing between both parts of the coracoacromial ligament and inserting directly onto the coracohumeral ligament, or continuing into the coracoglenoid ligament, at times even further laterally up to the tendon of the supraspinatus. These observations have led several authors to believe that the coracohumeral ligament might be the phylogenetic remnant of the tendon of the pectoralis minor. Landsmeer [47] describes the coracohumeral ligament as part of the osteofibrous arch that limits the subscapularis fascia in the cranial direction.

**Fig. 4.7.** Lateral view of right shoulder: magnification of Fig. 4.6. (CAL coracoacromial ligament, D-CHL dorsal coracohumeral ligament, V-CHL ventral coracohumeral ligament, I-CAL distal insertion of coracoacromial ligament) (A/C acromion clavicular joint, CP coracoid process)



According to various results, both parts of the coracohumeral ligament are attached onto the “ligament semicirculare humeri” and, therefore, its fibres do not reach the greater and lesser tubercles directly (Fig. 4.8). Our arthroscopic and anatomical observations indicate that the coracohumeral ligament has two main bands: the *ventral* one (referred to by Kolts as the inferior, and by Gohlke as the circular system) originates from the furthest anterior part of the dorsolateral aspect of the coracoid process: some fibres insert on the cable, whereas others intermingle with the superior glenohumeral ligament to form the “internal reflection pulley”. The *dorsal* (referred to by Kolts as superior, and by Gohlke as radial) band originates from the base of the coracoid process, runs toward the cable anterior to the posterosuperior glenohumeral ligament and forms the roof and the lateral wall of the pulley.

Several variations have been found in the insertion of the coracohumeral ligament [32–36, 38, 40]:

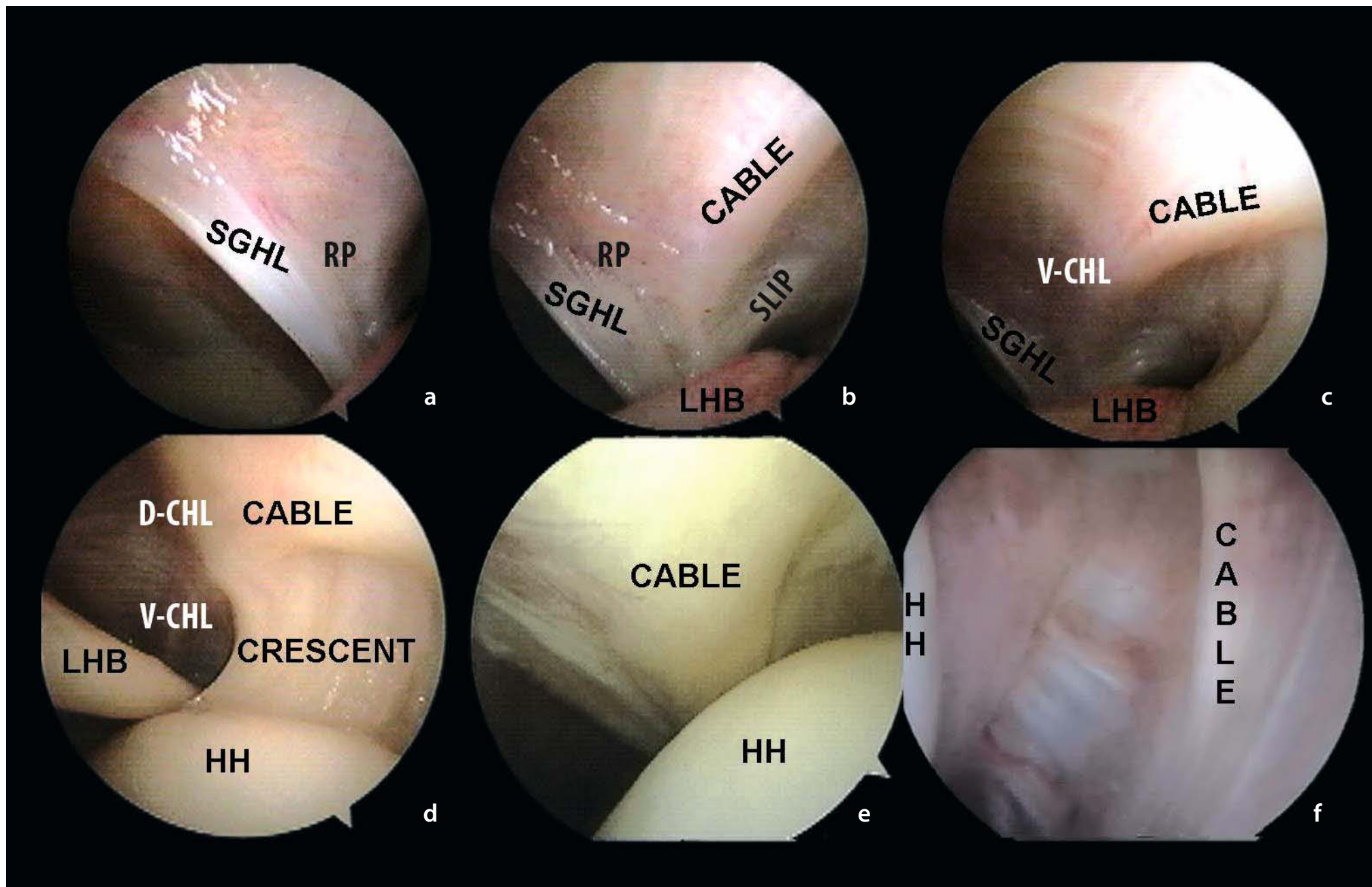
1. Most often, insertion on either the rotator cuff interval or the tendon of the supraspinatus, or the transverse band, rather than a discrete insertion on the humerus as in the majority of specimens, sometimes with a secondary slip from the coracohumeral ligament fusing with the tendon of

the subscapularis;

2. Frequently, a double insertion on both humeral tubercles on either side of the bicipital groove;
3. Rarely, a vestigial or absent coracohumeral ligament, usually associated with a large rotator cuff tear.

Again according to Harryman et al. [1] and Cooper et al. [32, 33], the coracohumeral ligament can be divided into two layers of *superficial* and *deep fibres*. The majority of the *superficial fibres* insert with their broader part on the greater tubercle, with 15–50% of their width inserting on the lesser tubercle. Most of the *deep fibres* insert under the supraspinatus tendon on the greater tubercle, while a smaller proportion cross over the biceps tendon and insert at the most proximal portion of the lesser tubercle, thus forming an anterior covering band around the long tendon of the biceps (medial coracohumeral ligament). Further fibres insert on the superior border of the subscapularis and the transverse humeral ligament. These insertions are intimately interlaced and cannot be distinguished from those of the capsule. Adjacent to their humeral attachments, capsule, coracohumeral ligament, superior glenohumeral ligament and rotator cuff tendons merge with one another [9].

**Fig. 4.8a–f.** Arthroscopic view of the right shoulder from posterior portal: the superior glenohumeral ligament (SGHL) (a); ventral fibres of CHL intermingles with SGHL to form the “internal reflection pulley” (RP) (b); a component of ventral fibres of CHL run in the cable (c, d); Arthroscopic view of the right shoulder from anterior portal: the cable in the postero-inferior capsula (e, f)





#### 4.2.2 Superior Glenohumeral Ligament

Flood [48] assumed he was the first to describe a superior ligament in the glenohumeral joint, running parallel to the long tendon of the biceps muscle. Delorme [8] deemed that the superior glenohumeral ligament [12, 18, 46, 49] was equivalent to Welcker's [17] fifth ligament, the one he had named "nutritional *ligamentum interarticulare [sic] seu teres humeri*". Flood [48] and Welcker [17] thought that this ligament might well be compared to the round ligament of the head of the femur (*ligamentum capitis femoris*), as it inserts into the cartilaginous surface, but nonetheless creates a dimple of varying width on it (*fovea capitis humeri*) (Fig. 4.9, magnification). This is a small depression of the humerus articular surface just above the lesser tubercle.

In contrast to Welcker, who reported the superior glenohumeral ligament as a rare occurrence, several other authors [4, 16, 50, 51] have found it to be a constant finding, present in 94–98% of specimens. In addition, Fick's observations [18] have confirmed that it is one of the usual components of the GH capsule.

The superior glenohumeral ligament emerges from the upper pole of the glenoid labrum and has a few fibres deriving from the supraglenoid tubercle, ventral to the origin of the biceps tendon (Fig. 4.9).

At their origin, the biceps tendon and the ligament may be intertwined, and the ligament can then follow the tendon laterally, together with a small artery. Here it may look like no more than a thin, stripe-like fold in the synovial membrane.

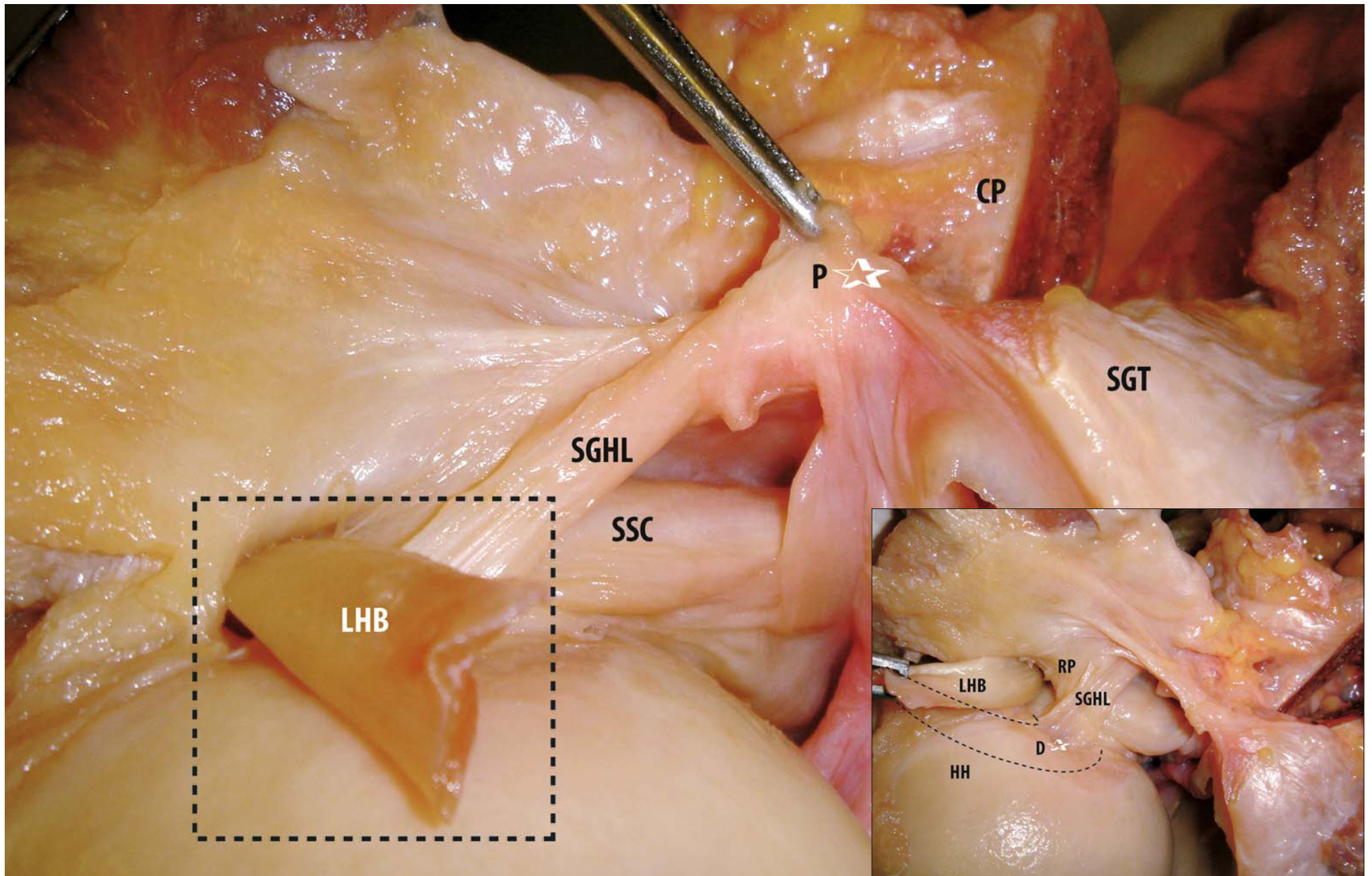
However, there seems to be some disagreement about its origin [17]. Most authors have found that it emerges from the upper part of the glenoid neck next to the biceps tendon, usually running underneath the biceps tendon towards the lesser

tubercle. Some authors [4, 43, 51, 52] think it is attached to the glenoid labrum, in contact with the long tendon of the biceps muscle, at least in some specimens. Turkel et al. [51] reckon that the superior glenohumeral ligament has a second origin from the base of the coracoid process. In a variable percentage of cases, 17–76%, the origin of the superior glenohumeral ligament partially merges with that of the middle glenohumeral ligament [4, 53].

Most authors agree that the superior glenohumeral ligament inserts on the anterior margin of the bicipital groove and the upper part of the lesser tubercle. Others [50] report that the superior glenohumeral ligament merges laterally with the coracohumeral ligament. Turkel et al. [51] are apparently alone in believing that the humeral attachment is located on the anterior aspect of the anatomical neck. Sutton [54] reckons that the superior glenohumeral ligament may be the phylogenetic remnant of the split tendon of the subclavius. Support for this theory is given by observations in birds, whose subclavius continues onto the humeral head even now [55].

Pouliart et al. [55, 56] have also described variations in how the superior glenohumeral ligament relates to the coracohumeral ligament: in 41% of specimens it merges with the coracohumeral ligament medially, within 2 cm of its origin; in 23% the two ligaments join at their mid-portion; and in 25% they fuse laterally, within 2 cm of the biceps pulley. In 11%, the superior glenohumeral ligament does not merge with the coracohumeral ligament, instead inserting on the anterior margin of the biceps groove, contributing to the transverse humeral ligament; moreover, it may also fuse with the fasciculus and the tendon of the subscapularis close to or together with the middle glenohumeral ligament. The superior glenohumeral ligament varies in width from 6 mm to 12 mm.

**Fig. 4.9.** Left shoulder: proximal origin of the superior GHL (SGHL) (P-★). Left shoulder from posterior to anterior: LHB has been moved from medial to lateral to show magnification of distal insertion of the SGHL (D-★) (RP internal reflection pulley, SGT supraglenoid tubercle, SSC subscapularis tendon)



Werner et al. [57] noted two anatomical variations: 70% of specimens show a thin superior glenohumeral ligament inserting at a flat angle on the posterior part of the bicipital groove (type I), whereas the remainder reveal a thicker ligament with a steep insertion on the anterior edge of the access to the groove (type II).

Furthermore, in type I specimens, the insertion of the ligament is closer to the posterior edge of the intertubercular groove, thus covering a larger portion of the inferior aspect of the long head of the biceps tendon than in type II samples.

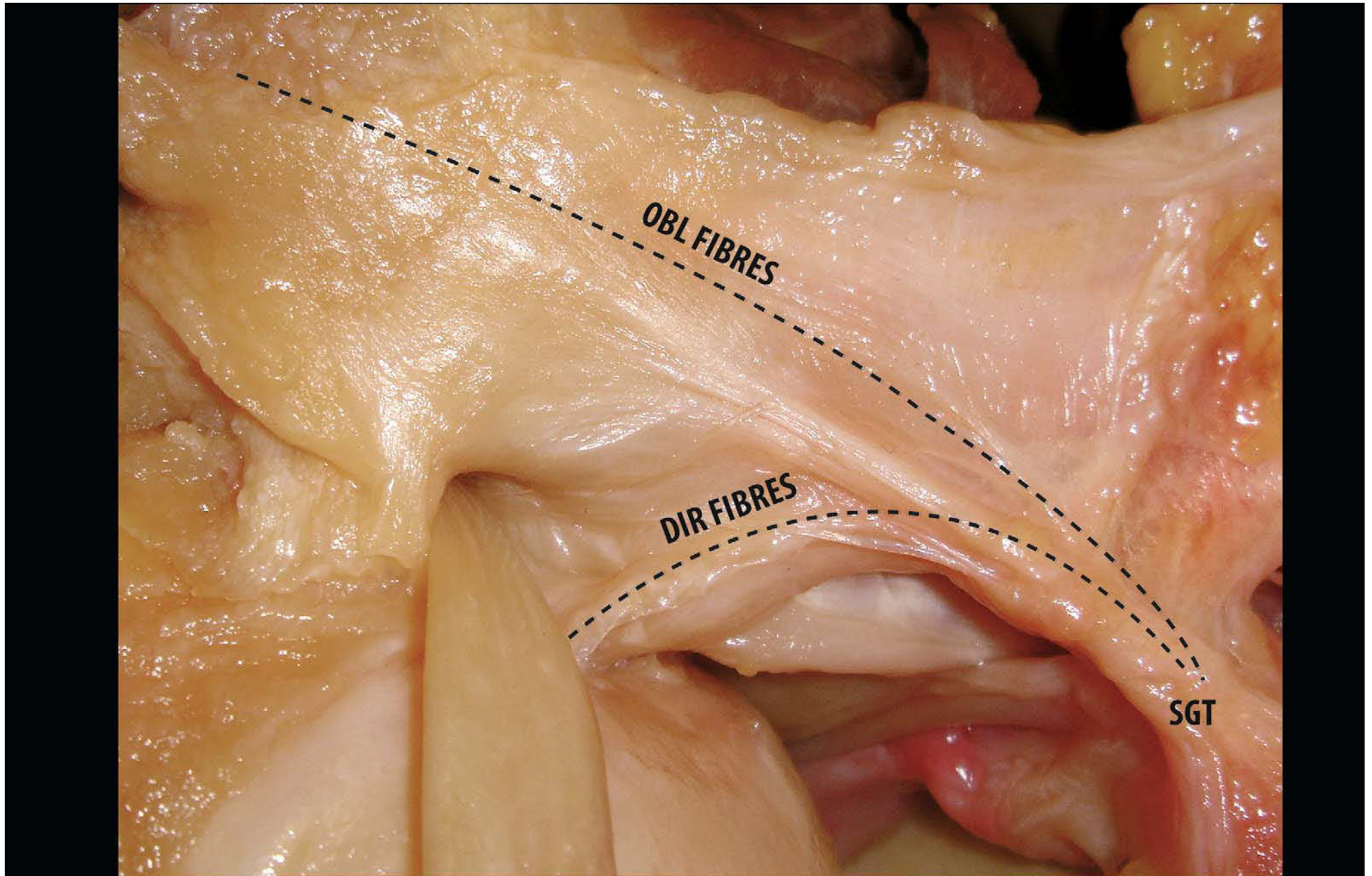
When the coracoid process is cut at its base and shifted backwards together with the “coracoglenoid” and coracohumeral ligaments, collagen fibres of the superior and medial glenohumeral ligament oriented in parallel are exposed. The fibres emerge from the supraglenoid tubercle region and run in mediolateral and craniocaudal directions.

The mediolaterally oriented fibres fashion the superior glenohumeral ligament, while those running craniocaudally form the medial glenohumeral ligament.

The superior glenohumeral ligament is classically described as the second main structural component of the rotator interval. Kolts et al. [53] and Welcker [17] have shown that structures of the rotator interval make up a stabilising network for the biceps tendon. The *direct fibres* in this ligament begin from the region of the supraglenoid tubercle, anteriorly bordered by the tendon of the long head of the biceps (LHB), and run towards the lesser tubercle. In addition, the *oblique fibres* cross over the tendon of the long head of the biceps and insert onto the transverse band (Kolts’ ligamentum semicirculare humeri), together with fibres from the coracohumeral ligament, strengthening the rotator interval above the intraarticular portion of the tendon of the long head of the biceps (Fig. 4.10).

The present result supports the previous statements: structures of the rotator interval make up a stabilizing network for the biceps tendon [61]. The insertion of the oblique fibres of the Lig. Glenohumerale superius together with the Lig. Coracohumerale onto the “Lig. Semicirculare humeri” explains the tight connection between the two ligaments before their attachment [53].

**Fig. 4.10.** Left shoulder from posterior to anterior: “direct” (-----) and “oblique” (-----) fibres (SGT supraglenoid tubercle)



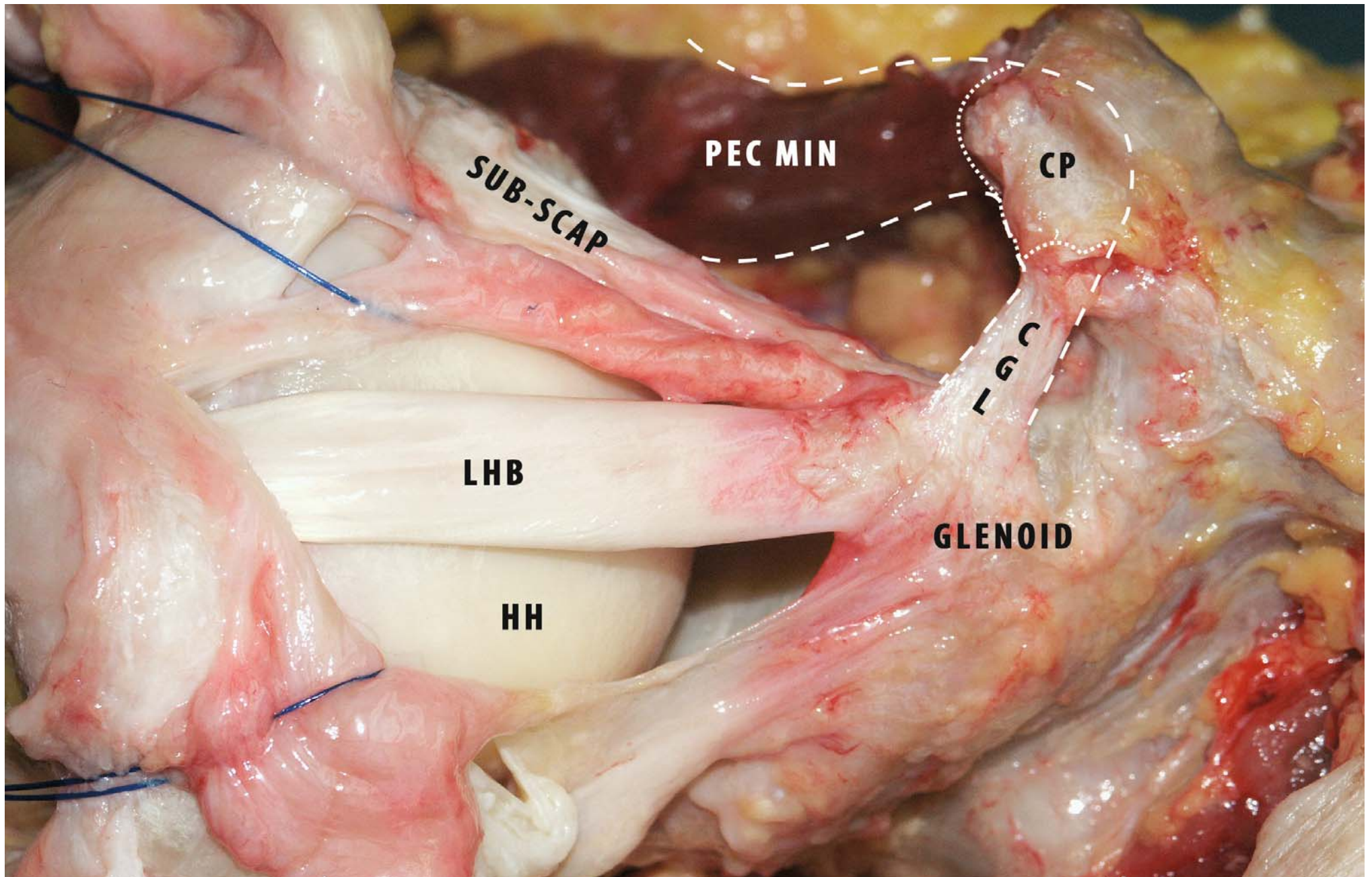
### 4.2.3 Coracoglenoid Ligament

The coracoglenoid ligament (CGL) was apparently first described in 1866 by Sappey [29], who alleged it was the deep part of the coracohumeral ligament, and in 1867 by Macalister [58], who believed it was part of the insertion of the pectoralis minor. According to LeDouble [59] and Testut [60], the pectoralis minor in primates is generally composed of two distinct portions, the superior one of which inserts on the humerus, the glenohumeral capsule or the acromion. Testut [60] also revealed insertions lateral to the coracoid process in rabbits, sheep, kangaroos, horses, cows and bears. In lower apes, the insertion on the humerus has been confirmed as a constant finding. Although several authors [12, 14, 15, 18] have referred to the coracoglenoid ligament as a small fibre bundle extending from the middle of the coracoid origin of the coracohumeral ligament to the posterosuperior part of the glenoid labrum and capsule, only Weinstabl et al. [61] and Kolts et al. [35] seem to have studied it in detail. The coracoglenoid ligament was seen to originate superior to the coracohumeral ligament in 86% of Weinstabl's 126 cadaver shoulders. It was perceived as a strong

rounded ligament in 47% and as a membranous structure in 39% of specimens. In the remaining 14%, the coracohumeral and coracoglenoid ligaments could not be separated at their coracoid origin (Fig. 4.11). In 16% of Weinstabl's and in 36 of 53 of Kolts' samples, fibre bundles from the pectoralis minor muscle were noted to continue over the coracoid process into the coracoglenoid ligament. In most instances, the coracoglenoid ligament was observed to insert on the top of the glenoid rim, the labrum and the long tendon of the biceps muscle. Pouliart et al. observed a distinct coracoglenoid ligament in 56% of specimens, but could not identify any in 13% [55, 56].

The coracoglenoid ligament originates from the middle of the upper or posterior surface of the coracoid process, between the anterior and posterior limbs of the acromioclavicular ligament, and inserts posterior to the supraglenoid tubercle on the neck of the scapula, separating the "inferior part" of the coracohumeral ligament from the base of the coracoid process. It forms the superomedial border of the rotator interval and separates the inferior part of the coracohumeral ligament from the base of the coracoid process [35].

**Fig. 4.11.** Posterosuperior view of left shoulder: (CGL coracoglenoid ligament) continues course of fibres of pectoralis minor tendon (PEC MIN pectoralis minor, LHB long head biceps, HH humeral head, CP coracoid process)



#### 4.2.4 Posterosuperior Glenohumeral Ligament

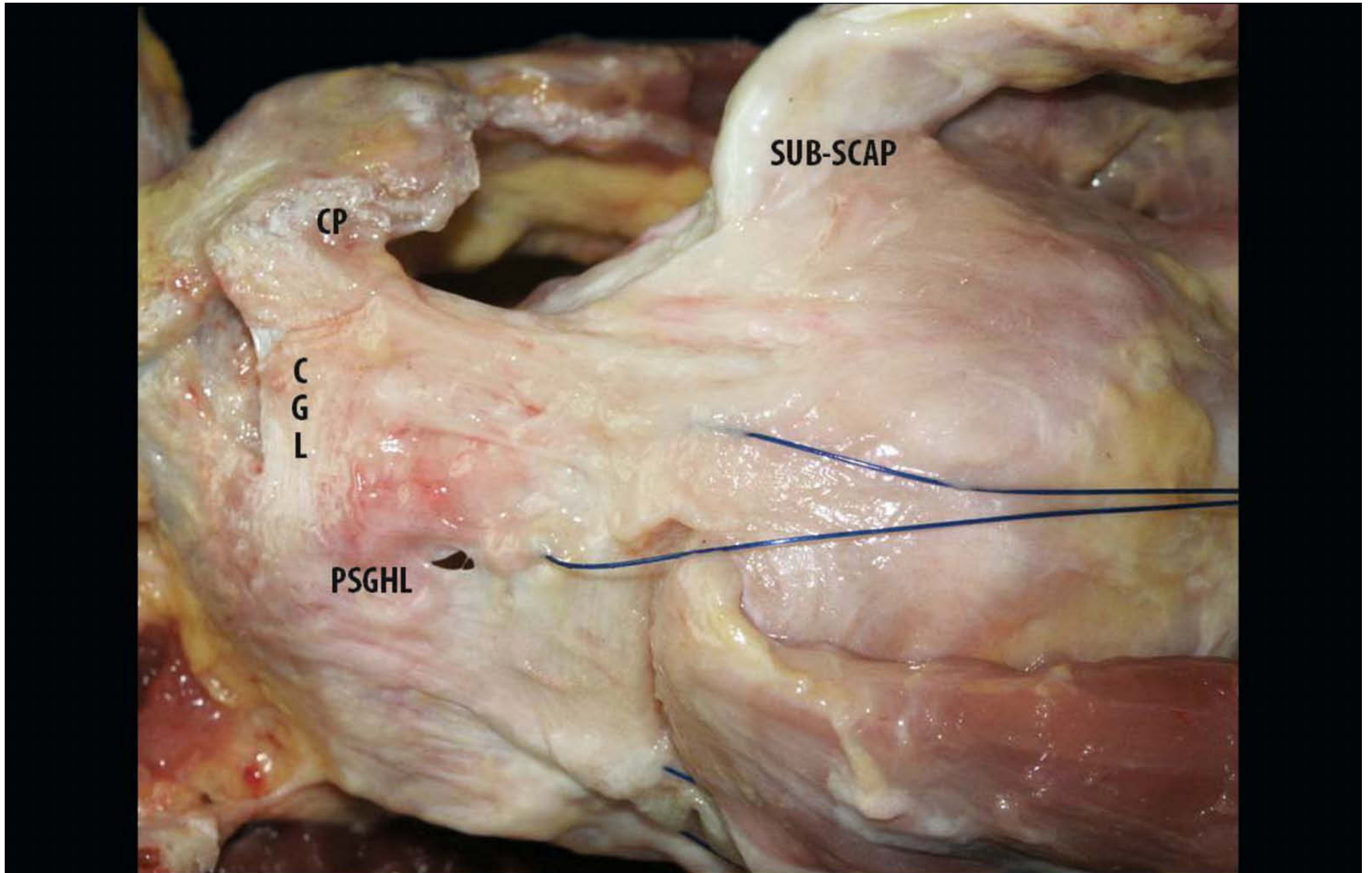
The posterosuperior glenohumeral ligament originates from a ridge on the posterosuperior aspect of the glenoid neck, medial to the glenoid labrum and medial and posterior to the origin of the long tendon of the biceps.

Laterally, these fibres fan out and merge with the “circular fibrous” structure, whereas a small part of them inserts posteriorly on the greater tubercle together with the tendon of the infraspinatus (Fig. 4.12). These posterior fibres form a complex superior network together with the coracohumeral ligament, the circular band, and the coracoglenoid and the superior glenohumeral ligaments.

Pouliart et al. [55, 56] are the first to describe this ligament and the variations of the superior complex. Four main types are distinguished. In 43% of shoulders, the posterior fibrous structure and the coracoglenohumeral ligament were seen to be distinct, with a broad gap between them. The long tendon of the biceps was visible through this gap, being 1.5- to 2-fold the

width of the gap. In 20% of specimens, the gap was appreciably smaller but was still distinct, corresponding approximately to the width of the biceps tendon. No posterior fibrous structure was found in 10% of specimens. In these cases, the fibre bundles were perceived to be either too scarce to form a fibrous sheath or macroscopically completely absent owing to degenerative phenomena. In the remaining 27% of shoulders, the gap was found to be very small or absent, resulting in a confluent superior complex. In the case of small gaps, fibres of the posterior structure and the coracohumeral ligament were perceived to cross over and mingle. When the posterior structure was separate from the anterior limb, it was seen to range in width from 6 to 26 mm in its middle portion. When the superior complex was confluent it was found to range in width from 34 to 46 mm. Histological examination confirmed the presence of well-organised fibrous structures with a longitudinal orientation, corresponding to both the superior glenohumeral and coracohumeral ligaments and the macroscopic posterosuperior fibrous structure.

**Fig. 4.12.** Superior view of right shoulder: myotendinous cuff muscles have been dissected away from shoulder capsule and reflected laterally, with attachments to humerus left intact showing (PSGHL posterosuperior glenohumeral ligament)





#### 4.2.5 Rotator Cable

The coracohumeral ligament and the posterosuperior glenohumeral ligament merge laterally with a broad fibrous “band”. This transverse band runs in a crescent shape from the middle facet of the greater tubercle—underneath the infraspinatus tendon—and reaches the biceps groove where it merges with the transverse humeral ligament before continuing anteriorly into the fasciculus obliquus. It was first described as a “*transverse band*” by Clark [5]; Burkhart [62, 63] renamed it the “*rotator cable*”; and finally, Kolts [38] called it the “*ligamentum semicirculare humeri*”. We believe that the “(semi)circular band”, the “transverse band”, the “rotator cable”, and the “circular fibre system” described by Gohlke et al. [9] are all one and the same. The capsule and its ligaments are closely attached to the rotator cuff tendons at the level of the rotator cable (Fig. 4.13a, b).

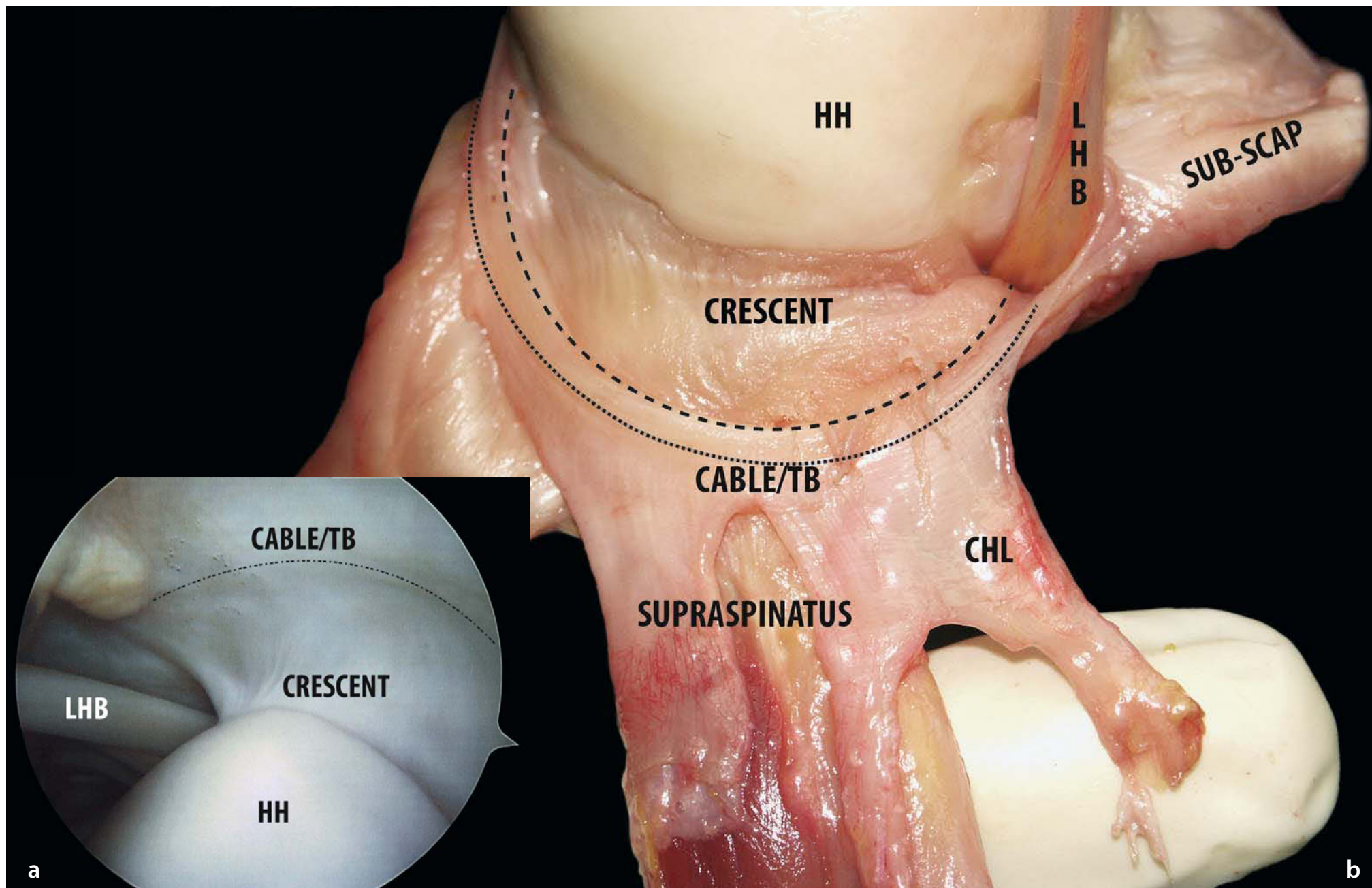
Burkhart et al. [62, 63] defined the suspension bridge model for the rotator cuff. In 12 shoulders with massive rotator cuff tears, they observed that normal kinematics were maintained when the tears involved only the supraspinatus tendon and a

small portion of the infraspinatus tendon. In all these shoulders with stable fulcrum kinematics, the free margin of the rotator cuff tear was thick and rind like.

In a second study, the same authors found a *rotator cable–crescent* complex in cadaver shoulders, corresponding to the free margin of a tear. The rotator crescent was found to measure an average of 41.35 mm in the anteroposterior direction and of 14.08 mm in the mediolateral direction, with an average thickness of 1.82 mm. The average width of the rotator cable surrounding the rotator crescent was seen to be 12.05 mm, with an average thickness of 4.72 mm.

Biomechanical tests have confirmed that this thick rotator cable works in the same way as the functional cable system of a suspension bridge: thereby, stress is transferred from the cuff to the cable, providing stress-shielding to the thinner capsular tissue and the cuff tendons within the rotator crescent. Comparison of the crescent and the rotator cable shows that in young people the former looks thicker than the latter, whereas in the elderly the opposite is true [62]. Moreover, the stress-shielding effect is less evident in young people than in the elderly.

**Fig. 4.13a, b.** **a** Lateral view of right shoulder: articular view of “cable” and “crescent.” Deep (capsular) aspect of rotator cuff, showing capsule overlying cuff after dissection of cuff-capsule complex away from scapula. **b** Arthroscopic posterior view of right shoulder: arthroscopic “cable” and “crescent.” (TB transverse band)



The coracohumeral and superior glenohumeral ligaments form the deeper layer of the capsule, although the coracohumeral ligament is less distinct microscopically than macroscopically. The part of the circular system (Fig. 4.14) that actually anchors down the long tendon of the biceps muscle into its intertubercular bicapital groove has been named the “transverse humeral ligament” of Gordon Brodie [12, 14, 15, 18, 64]. According to Paturet [14], this ligament may go as far down as the upper border of insertion of the tendons of teres major and latissimus dorsi muscle. French authors call the larger anterior band of the coracohumeral ligament the *faisceau trochitérien* and the smaller posterior part of it the *faisceau trochinien*. Moreover, they have coined the term “expansion trochinienne du sus-épineux” for the reinforcement sometimes proceeding from the supraspinatus tendon to the transverse humeral ligament.

Microscopically, Gohlke et al. [9] found a predominant circular orientation of fibre bundles in the superior capsule. Between the teres minor and the posterior limit of the inferior glenohumeral ligament, the capsule has a relatively simple structure made up of crossing radial and circular fibre bundles. In all the other capsular areas, the structure is formed by a complex network of different layers. The capsular layer forms a strong fibre system with a circular orientation where its fibres intermingle with those of the tendinous insertion of supraspinatus and infraspinatus muscles. This circular system forms the fibrous roof of the biceps muscle’s long tendon and continues into the superficial layer of the anterior capsule. The circular part of the

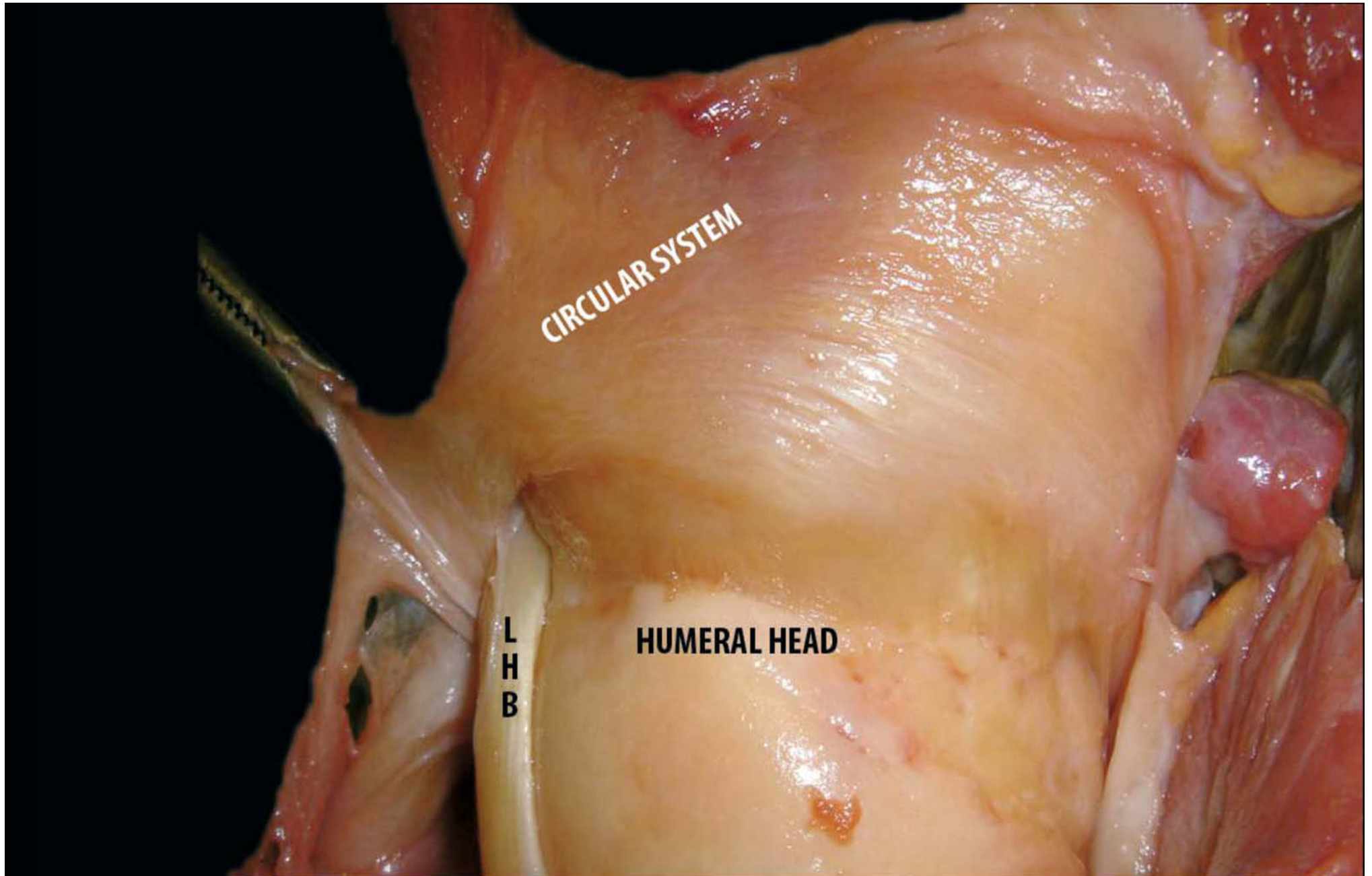
capsular layer can be compared to a sling spanning from the teres minor to the subscapularis muscles and reinforcing the insertion of the rotator cuff and the tendons.

According to Kolts’s studies [35, 38], the semicircular ligament of the humerus is an approximately 1-cm-wide band of capsular collagen fibres oriented in parallel, running transverse to the longitudinal axis of the supraspinatus muscle tendon. Its anterior attachment is located on the superior facets of the greater and lesser tubercles, the fibres of the band bridge the sulcus intertubercularis, above the transverse ligament of the humerus, proceeding within the joint capsule posteriorly and eventually inserting on the posterior side of the greater tubercle between the insertion tendons of the infraspinatus and teres minor muscles.

The anterior fibres of the supraspinatus tendon fuse with the semicircular ligament of the humerus and follow its course. In 9 out of 19 preparations, an additional insertion of the anterior fibres of the supraspinatus tendon on the lesser tubercle was clearly recognisable macroscopically.

The fusion between the anterior part of the supraspinatus tendon and the semicircular ligament of the humerus is obvious even when the anterior portion of the supraspinatus tendon is not macroscopically obvious. This means that this fusion ensures the direct insertion of the supraspinatus tendon fibres above the transverse humeral ligament and on the greater and lesser tubercles. The link of the intraarticular portion of the long head of the biceps within the joint cavity is one of the focal functional properties of the intricate structure.

**Fig. 4.14.** Superior view of right shoulder: magnification of circular system; two-fibre-bundle system making up structure of capsule is obvious: one has circular orientation (running around the joint) and lies mainly in superficial stratum; other, mostly with radial orientation (running from the glenoid to the humerus) and distinctly stronger, is located in deeper layer on articular side. While radial elements dominate in anteroinferior part, circular elements are predominant in superior part



#### 4.2.6 Rotator Cuff Interval

The rotator cuff interval is the space between the anterior border of the supraspinatus tendon and the superior border of the subscapularis tendon. The base of this triangular space is formed by the coracoid process, and at its apex lies the transverse humeral ligament at the intertubercular sulcus for the long tendon of the biceps. The coracohumeral and the superior glenohumeral ligaments constitute the capsular bottom of the musculotendinous rotator cuff interval [9]. (Fig. 4.15)

The rotator interval has begun to figure significantly in the recent literature, because of its apparent importance in antero-superior/posteroinferior stability and in frozen shoulder. Owing to an increasing interest in shoulder arthroscopy, there has been a shift in the identification of the rotator cuff interval. From the intraarticular view, too, the triangular space between the superior glenohumeral and the middle glenohumeral ligaments (Weitbrecht's foramen) is generally considered the rotator cuff interval. This consistent synovial recess, which varies in size and which leads into the subscapular bursa, underlies the space between the supraspinatus and the subscapularis tendons and the muscle bellies. In the clinical literature, the term *rotator*

*cuff interval* can therefore refer to two entities, depending on the pathological situation:

- As the tendinous connection between the supraspinatus and the subscapularis muscles in the case of rupture of the rotator cuff;
- As the triangular space in the glenohumeral joint capsule between the superior and middle glenohumeral ligaments underneath both tendons in the case of glenohumeral instability.

The capsular rotator interval will now be discussed in detail:

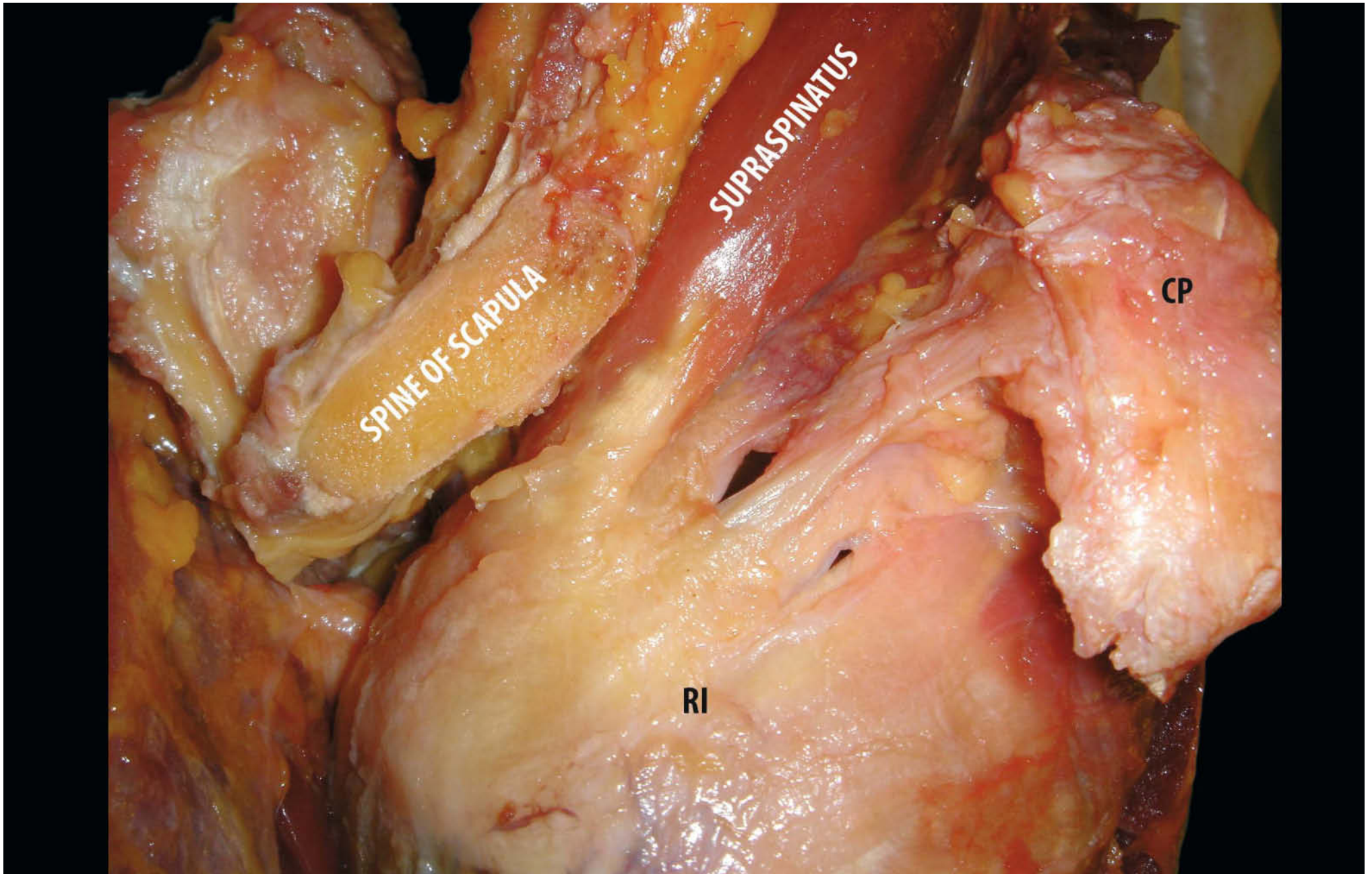
Fealy et al. [41] has found that this capsular recess is already quite distinct in fetal specimens at 14 weeks of gestation.

The capsular "rotator cuff interval" (RI) is bordered by [13, 38]:

- The coracoid process and the coracoglenoid ligament medially;
- The intertubercular groove of the humerus, the transverse humeral ligament and the fasciculus obliquus laterally;
- The coracohumeral and superior glenohumeral ligaments superiorly;
- The middle glenohumeral ligament inferiorly.

In contrast with the musculotendinous rotator cuff interval, the apex of this capsular area is medially at the glenoid neck, while

**Fig. 4.15.** Superolateral view of the right shoulder: Acromion is separated from the spine scapula to show the rotator cuff interval (RI)



the base is lateral. At its glenoid border it is 2 to 8 mm wide and at its lateral margin 13 to 25 mm. The observed size also depends on the position of the humerus. In internal rotation, the interval is almost obliterated, whereas it spreads out in external rotation.

Histologically, the rotator interval has two zones of different composition. (Fig. 4.16):

The *lateral part*, covering the fovea capitis (lateral to the cartilage-bone transition of the humeral head), consists of four layers: [13]

- Layer 1: superficial fibres of the coracohumeral ligament covering the interval and extending to the insertions of supraspinatus and subscapularis;
- Layer 2: fibres from the tendons of supraspinatus and subscapularis muscles, forming a network and blending with each other and with parts of the coracohumeral ligament;
- Layer 3: deep fibres of the coracohumeral ligament, the majority of them inserting on the greater tubercle and the minority, on the lesser tubercle;
- Layer 4: the superior glenohumeral ligament and the capsule.

The *medial part*, covering the articular cartilage of the humeral head, has only two layers:

- Layer 1: superficial, composed of the coracohumeral ligament;
- Layer 2: deep, composed of the superior glenohumeral ligament and the capsule.

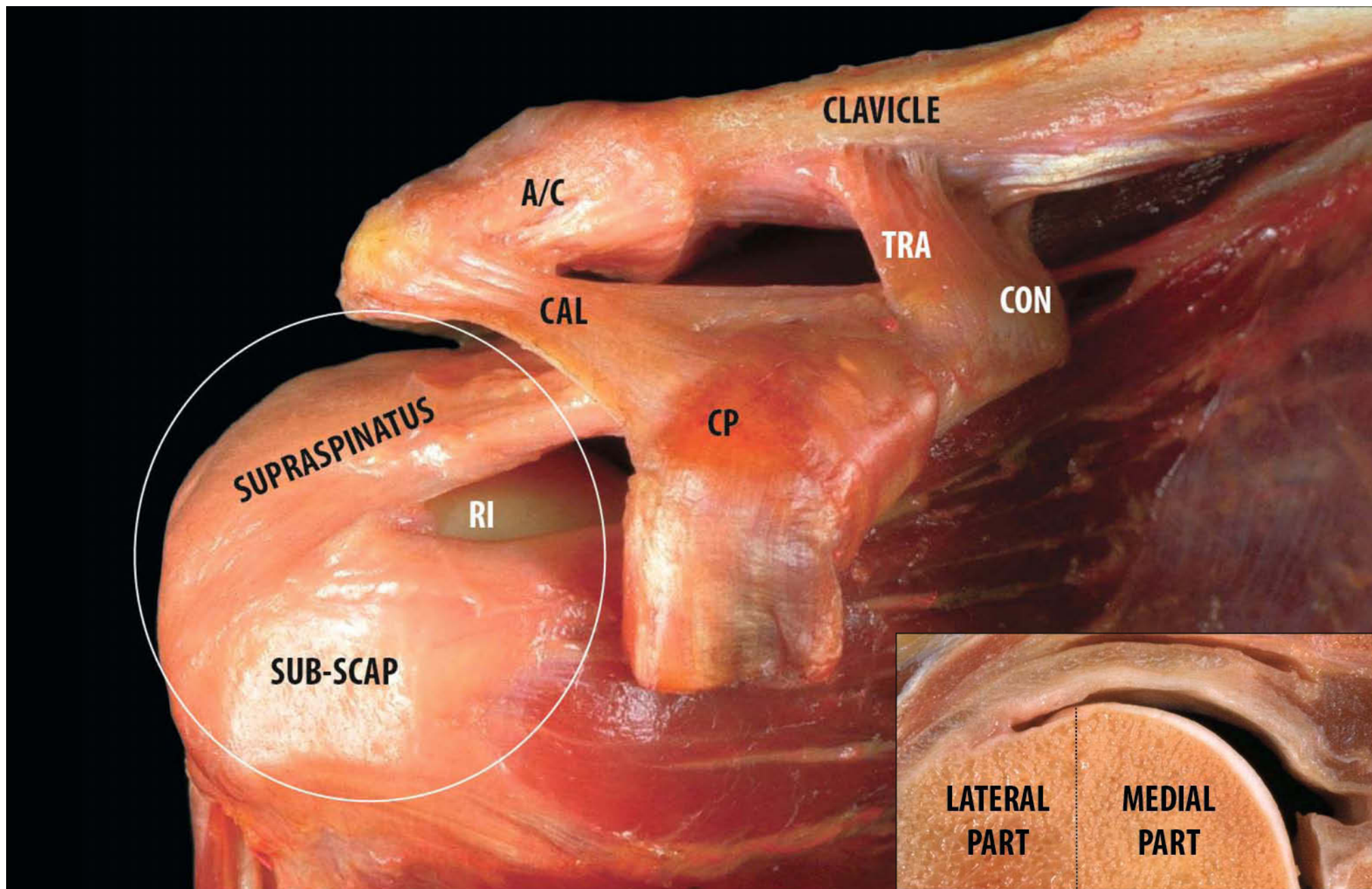
The *medial part* of the fibrous plate of the rotator cuff interval and, in particular, the coracohumeral ligament, mostly control inferior translation of the adducted arm and, to a much lesser extent, external rotation. In contrast, the lateral part mainly

affects external rotation of the adducted arm. Therefore, it is not surprising that the amplitude of external rotation is reduced when the divided lateral part of the RI is closed in experimental studies.

The function of the rotator cuff interval capsule is to limit the range of flexion, extension, adduction, and external rotation as well as to limit inferior translation of the glenohumeral joint in the adducted shoulder. Additionally, it provides stability to the joint against posterior dislocation in the position of flexion or external rotation in adduction [13].

Another interesting description of the rotator cuff interval was given by Kolts, who divided this capsular space into three parts: lateral, mediosuperior and medioinferior. All of them are composed of different macroscopical structures and their lateral and medial segments occupy approximately equal parts of the RI. The lateral part of the capsule is strengthened by the transverse band (ligamentum semicircular humeri) and the anterior fibres of the supraspinatus tendon. The coracohumeral and coracoglenoid ligaments are the macroscopical elements of the mediosuperior part. The medioinferior part is reinforced by the superior and middle glenohumeral ligaments. This author considers the transverse band (ligamentum semicircular humeri) as the key because laterally it ensures the insertion of the anterior fibres of the supraspinatus muscle tendon above the transverse ligament of the humerus and on the greater and lesser tubercles, and medially it represents the attachment of the coracohumeral ligament and the oblique fibres of the superior glenohumeral ligament. The RI is not a weak capsular region, but, in contrast, a complex network of macroscopically recognizable tendinous and ligamentous structures.

**Fig. 4.16.** Anterior view of the right shoulder: borders of the rotator cuff interval (CAL coracoacromion ligament, TRA trapezoid ligament, CON conoid, RI rotator interval, A/C acromion clavicular joint, CP coracoid process)





## 4.2.7 Biceps Pulley

The “*biceps pulley*” is a stabilising sling for the long head of the biceps tendon against anterior shearing stress in the rotator cuff interval, as emphasised by Habermeyer [65], who states that this is its most important function.

The pulley system, a tendoligamentous sling, represents a significant part of the rotator interval and consists of four major structures: the coracohumeral ligament, the superior glenohumeral ligament, fibres of the supraspinatus tendon (slip) and fibres of the subscapularis tendon.

### 4.2.7.1 Medial Wall

This structure needs to be described in detail, as it includes the medial sheath of the bicipital groove (ventral coracohumeral ligament or internal reflection of the coracohumeral ligament) [66] formed by the SGHL–CHL complex and the insertion of the subscapularis tendon (Fig. 4.17).

The superior glenohumeral ligament, in its medial part, moulds a crease parallel to the long head of the biceps tendon, while in its lateral part the crease changes into a U-shaped sling crossing beneath the biceps tendon and inserting on the proximal aspect of the lesser tubercle just above the insertion of the subscapularis tendon [61]. At the access to the bicipital groove, the superior glenohumeral ligament incorporates the medial aspect of the coracohumeral ligament and inserts on the superior lateral portion of the lesser tubercle. This insertion is initially wide, inferiorly oblique and vertical on the internal margin of the bicipital groove. The change in direction is indicated by the beginning of the bony groove. The superior fibres form a fold limiting the biceps, thus creating a pulley for the biceps tendon before it penetrates into the bicipital groove; the inferior fibres define the superior aspect of the bicipital groove. The

coracohumeral ligament and the superior glenohumeral ligament form a unique and indivisible structure at their insertion onto the humerus. The coracohumeral ligament is the superficial portion, which covers the long head of the biceps, and the superior glenohumeral ligament is the deep part, which inserts onto the humerus, thus forming a *reflection pulley* for the biceps tendon.

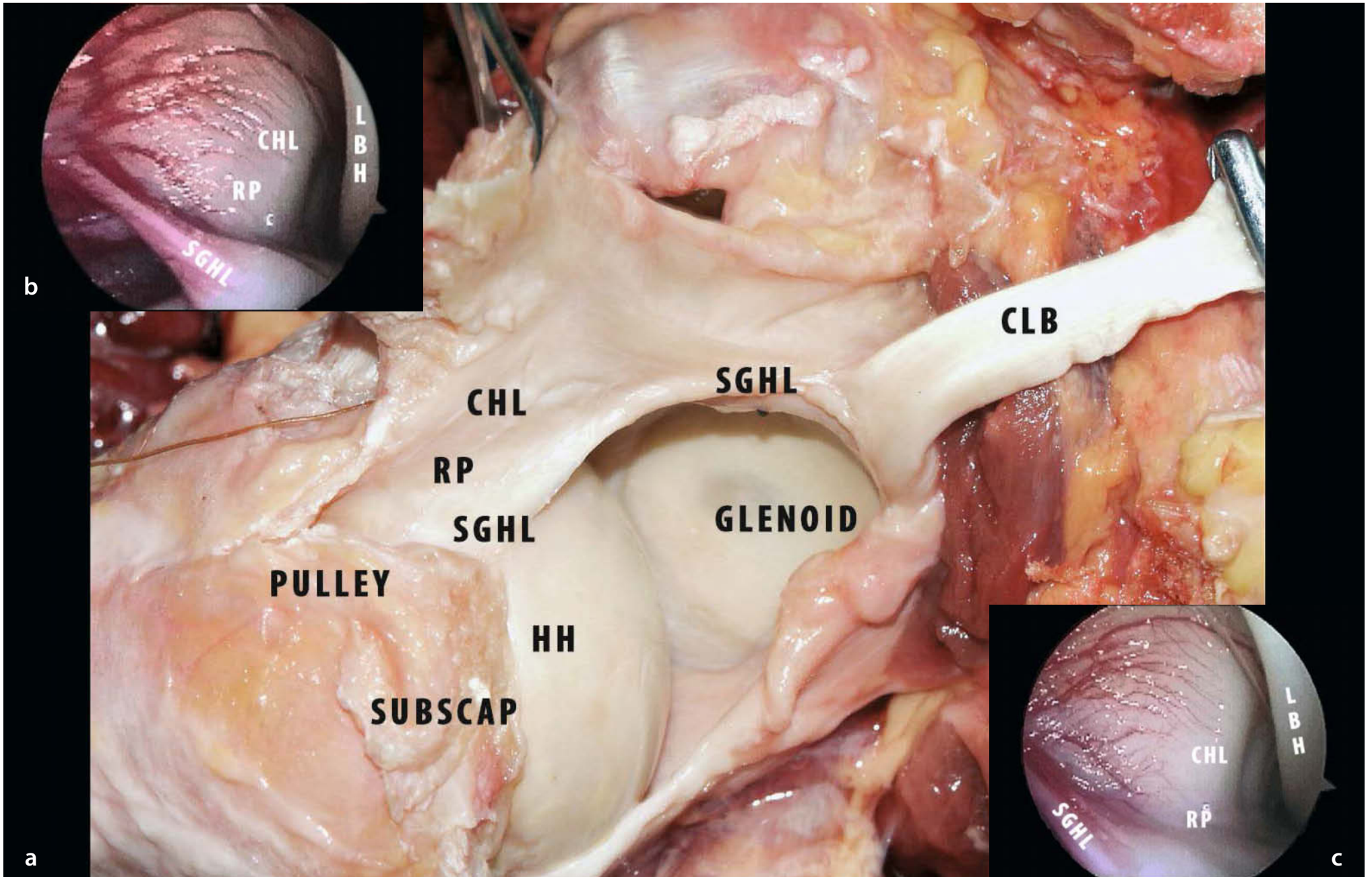
This pulley is also in direct contact with the insertion of the subscapularis, positioned on its internal border [65]. Therefore, the superior glenohumeral ligament appears to form a semicircular anterior support for the lateral part of the intraarticular long head of the biceps tendon.

The subscapularis tendon inserts onto the lesser tubercle, anterior to the superior glenohumeral ligament. Laterally, at the level of the access into the bicipital groove between the two structures, there is a transition zone, where posterior fibres of the subscapularis tendon, anterior fibres of the superior glenohumeral ligament and some fibres of the ventral coracohumeral ligament intermingle at their insertion. Altogether, these structures contribute to the medial wall of the bicipital sheath (the triad: superior glenohumeral ligament, coracohumeral ligament, slip).

Arthroscopic patterns reveal that the outer surface of the subscapularis tendon is in close relationship with the coracohumeral ligament, as the superior glenohumeral and coracohumeral ligaments and the subscapularis tendon all insert by means of interdigitating fibres [67].

Just medial to the insertion of the SGHL–CHL complex is the insertion of the subscapularis tendon, which normally inserts in a small trough just inferior to the articular cartilage margin [67]. In some patients there is no evidence of any well-formed superior glenohumeral ligament and their medial-superior biceps pulley system relies solely on the internal reflection of the coracohumeral ligament (MCHL). On the lateral side, sever-

**Fig. 4.17a-c.** **a** Anterosuperior view of the right shoulder: the CHL and SGHL run laterally and blend together, forming the “internal reflection pulley” (RP) for the biceps before they enter the bicipital groove; **b, c** arthroscopic view of the right shoulder (CHL coracohumeral ligament, RP reflection pulley, SGHL superior glenohumeral ligament)



al authors [8, 32, 57] have demonstrated that the coracohumeral ligament-superior glenohumeral ligament complex inserting around the bicipital groove is central in retaining the long tendon of the biceps and in preventing its subluxation. We deem that the coracoglenohumeral ligament inserts on both margins of the groove, together with the anterior limb of the rotator cable. The tendons of the supraspinatus and subscapularis rarely cover the groove. Werner et al. [57] report that the fasciculus obliquus makes an important contribution to the biceps pulley, together with the superior glenohumeral ligament. Lesions of the so-called biceps pulley may be destabilising for two reasons: first, because the long tendon of the biceps may subluxate and, second, because the head-depressing effect of the rotator cable is diminished.

#### 4.2.7.2 Roof and Lateral Wall (Fig. 4.18)

The ventral portion of the coracohumeral ligament (circular system) emerges from the posterolateral border of the coracoid process and fans out laterally. Traditionally, it has been visualised from the subacromial space. Gohlke et al. [9], in a superb electron microscope study, have shown that the coracohumeral ligament and the collagen fibres of the “circular” system contribute to the intraarticular SGHL–CHL complex (internal reflection pulley).

In addition, the dorsal coracohumeral (radial system) fibres cross the bicipital groove superiorly and, near the articular surface on the lateral side of the bicipital groove, they meet the circular system of collagen fibres (cable) or the leading edge of the

supraspinatus tendon insertion. Besides this, a tendinous slip extends anterolaterally from the supraspinatus tendon to form part of the roof of the sheath [5, 9].

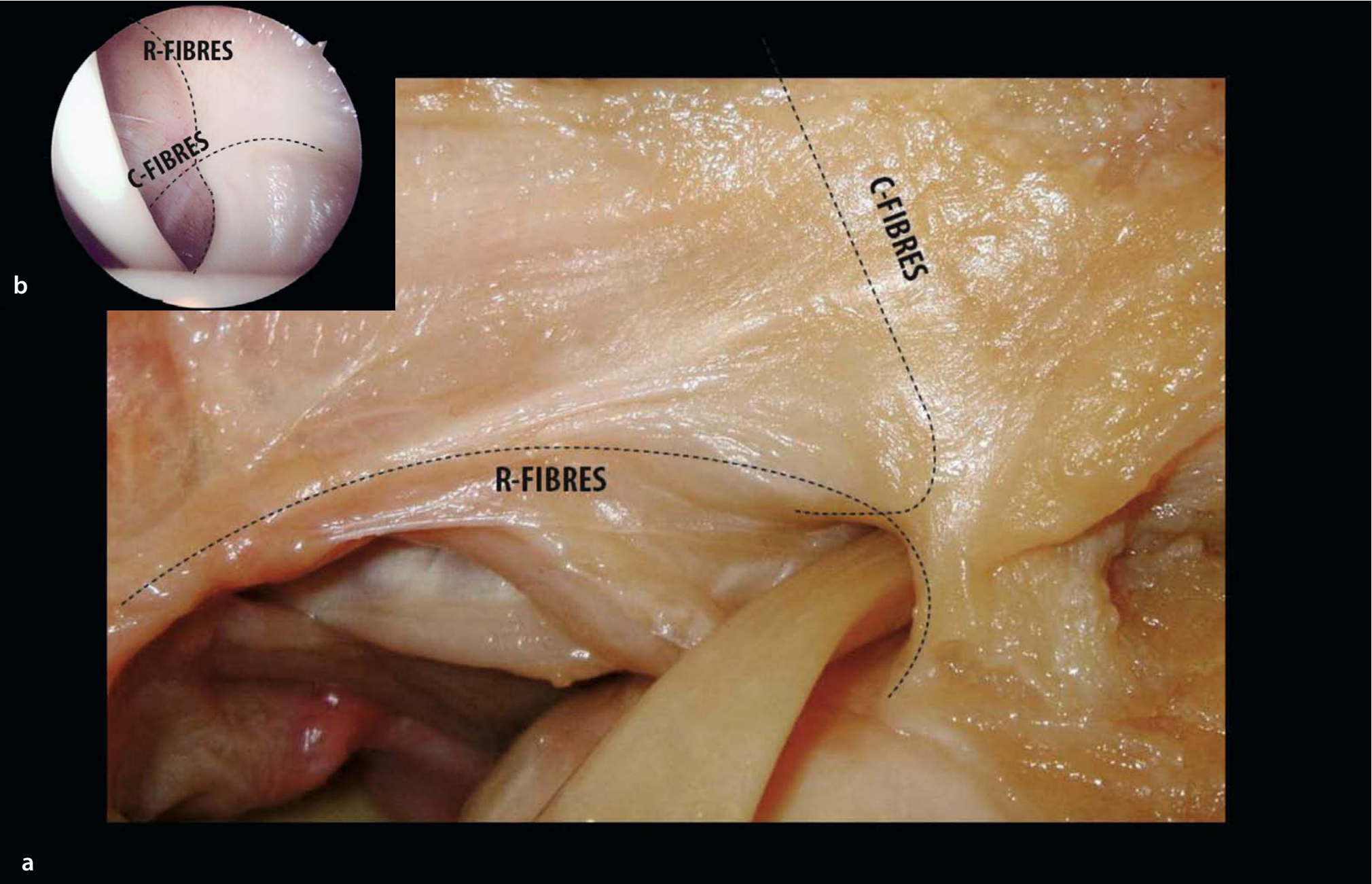
Kolts [68] also observed an accessory insertion going from the supraspinatus onto the lesser tubercle in 10 out of 31 specimens. One part of the muscle splits from the anterior part of the “common” tendon, runs downwards anterior to the greater tubercle, crosses the anterolateral part of the joint capsule and inserts on the cranial part of the lesser tubercle. Moreover, in some cases a connection with the subscapular tendon is noticed.

Although the part of the tendon running to the lesser tubercle is weaker than the “common” tendon, the presence of accessory insertions might be of some functional and clinical importance. According to Kolts [35], the region between the subscapular and supraspinatus tendon is filled not only by the coracohumeral ligament but also by the accessory part of supraspinatus.

In the development of rotator cuff tears, the additional insertion into the lesser tubercle may have a compensatory role, since ruptures occur in the part of the tendon inserting on the greater tubercle. After most of the tendon has been destroyed, this appears to be divided into two parts, showing a y-shaped insertion. Then, the rest of the common part inserts on the posterior part of the greater tubercle, while the “accessory” part inserts on the lesser tubercle.

We reckon that this accessory bundle corresponds to the anterior limb of the CHL–SGHL complex and its continuation into the rotator cable and the fasciculus obliquus. This opinion is supported by the studies of LeDouble [59] and Testut [60], who found the supraspinatus was singularly invariable.

**Fig. 4.18a, b.** **a** Posterior view of the right shoulder: roof and lateral wall of the pulley is formed by circular (C-FIBRES) and radial systems (R-FIBRES); **b** arthroscopic view of the right shoulder from posterior porta/: radial and circular systems



b

a

### 4.2.7.3 Floor

The floor is made of fibres deriving from the posterior aspect of the subscapularis. These fibres blend together again with parts of the superior glenohumeral ligament and coracohumeral ligament at the point of access to the groove [57]. As mentioned above, in type I variation of the superior glenohumeral ligament (Fig. 4.19a) the ligament inserts at a flat angle on the posterior edge of the intertubercular groove, thus covering a larger part of the inferior aspect of the long head of the biceps tendon than in type II (Fig. 4.19b), where the thicker ligament has a steep insertion on the anterior edge of the access to the groove. In the region of the subscapularis tendon, the portion of the cuff–capsule complex is made up of four to six thick bundles of collagen fibres extending from the muscle belly to the lesser tubercle. These bundles run parallel to one another but splay before their insertion on the lesser tubercle, being tightly packed in the superficial part of the tendon. The deeper bundles, adjacent to the capsule, are separated by loose connective tissue. The most proximal group of bundles passes underneath the biceps tendon to form the floor of the bicipital groove together with fibres from the supraspinatus. However, most of the fibres making up the floor of the groove derive from the subscapularis. Within the groove, these intermingled tendinous elements become fibrocartilaginous, with cuboidal cells and metachromatic ground substance dispersed among thick collagen fascicles; this sheath extends for approximately 7 mm.

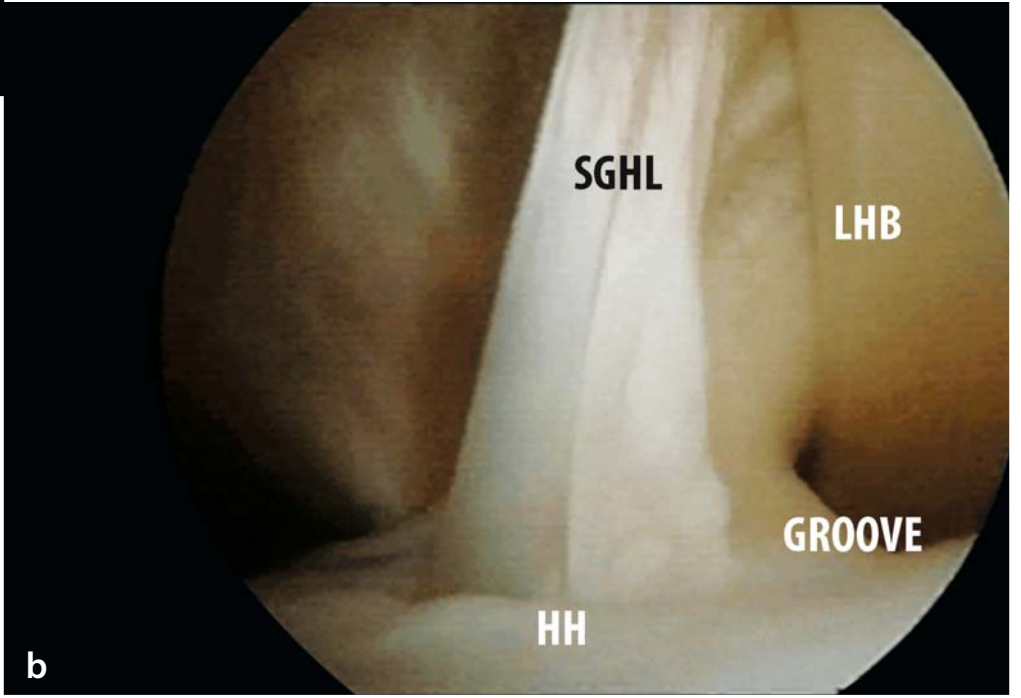
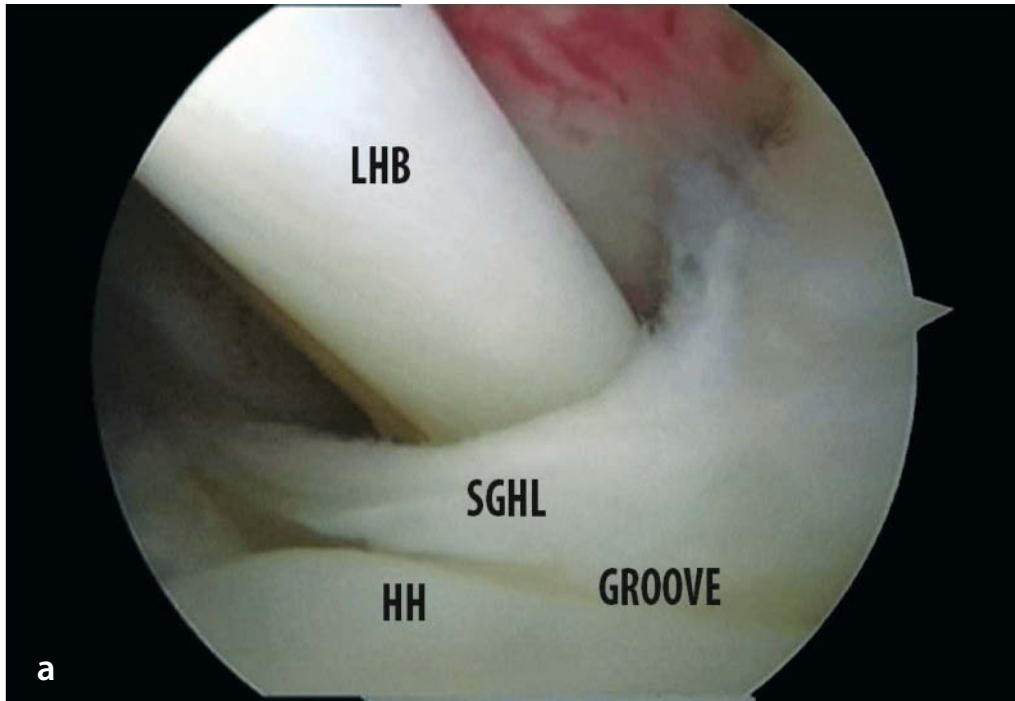
### 4.2.8 Arthroscopic Description of the Anterosuperior Structures

For evaluation of the rotator interval, pulley system and cable, we advise starting with a 30° arthroscope, moving it to the anterior portion of the glenohumeral joint so that the SGHL–CHL complex can be visualised. Given the difficulty of observing the insertions of the SGHL–CHL complex with the patient’s arm at his/her side, we elevate the arm forward, adding internal rotation to improve the view: that helps to slacken the subscapularis and the coracohumeral ligament. The coracohumeral ligament can hide tears in the subscapularis tendon [66].

The biceps tendon at the level of the bicipital groove can be visualised by flexing the elbow, elevating the shoulder and using the neuroprobe to pull the biceps tendon into glenohumeral joint. Inflammation and/or fraying of the biceps tendon can then be seen.

The structures to be visualised and evaluated consist of the medial sheath of the bicipital groove (MCHL or internal reflection of the CHL), i.e. the SGHL–CHL complex and the insertion of the subscapularis tendon. Together, these structures combine to fashion the medial wall of the bicipital sheath. The superior glenohumeral ligament, when present, and the middle coracohumeral ligament make up a stronger medial-superior pulley system. Superiorly the SGHL–CHL complex penetrates the articular portions of the glenohumeral joint. In addition, immediately medial to the insertion of the SGHL–CHL complex is the

**Fig. 4.19a, b.** Arthroscopic view of the right shoulder from posterior portal: anatomical variations of (SGHL superior glenohumeral ligament): **a** flat insertion; **b** steep insertion



insertion of the subscapularis tendon, which normally inserts into a small trough just inferior to the articular cartilage margin. Using the same technique, the lateral head of the CHL complex is easily seen. Its fibres cross the bicipital sheath horizontally and insert on the supraspinatus fibres. However, with forward elevation and internal rotation, it is actually possible to look into the bicipital sheath.

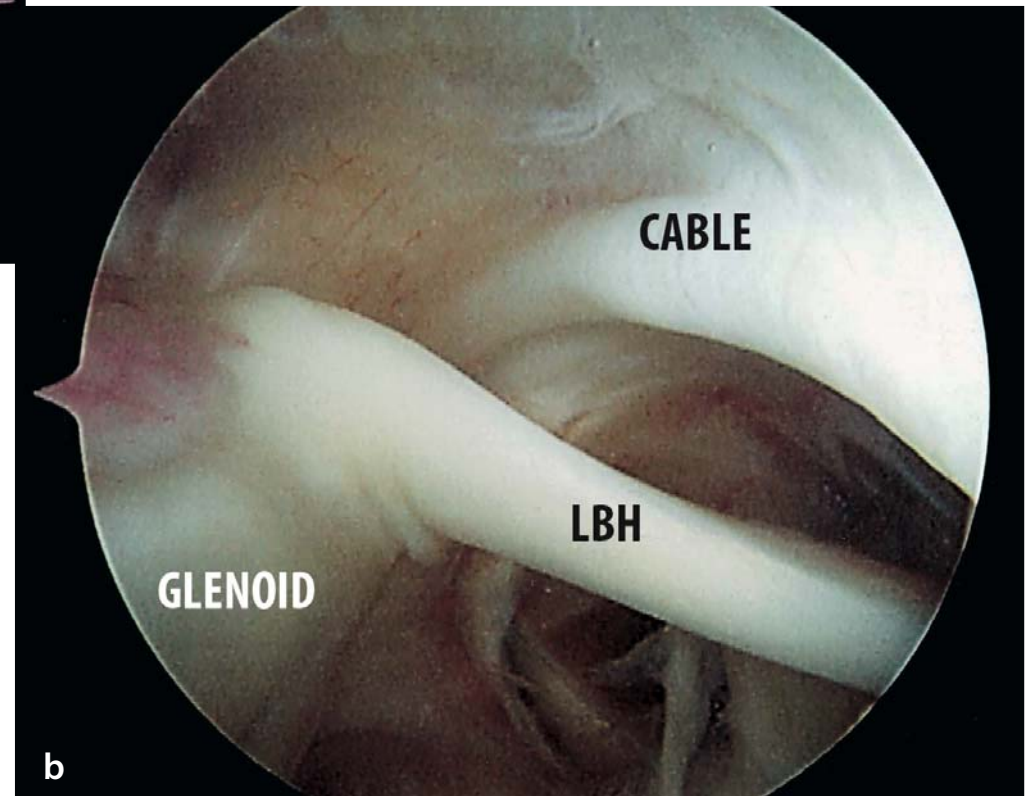
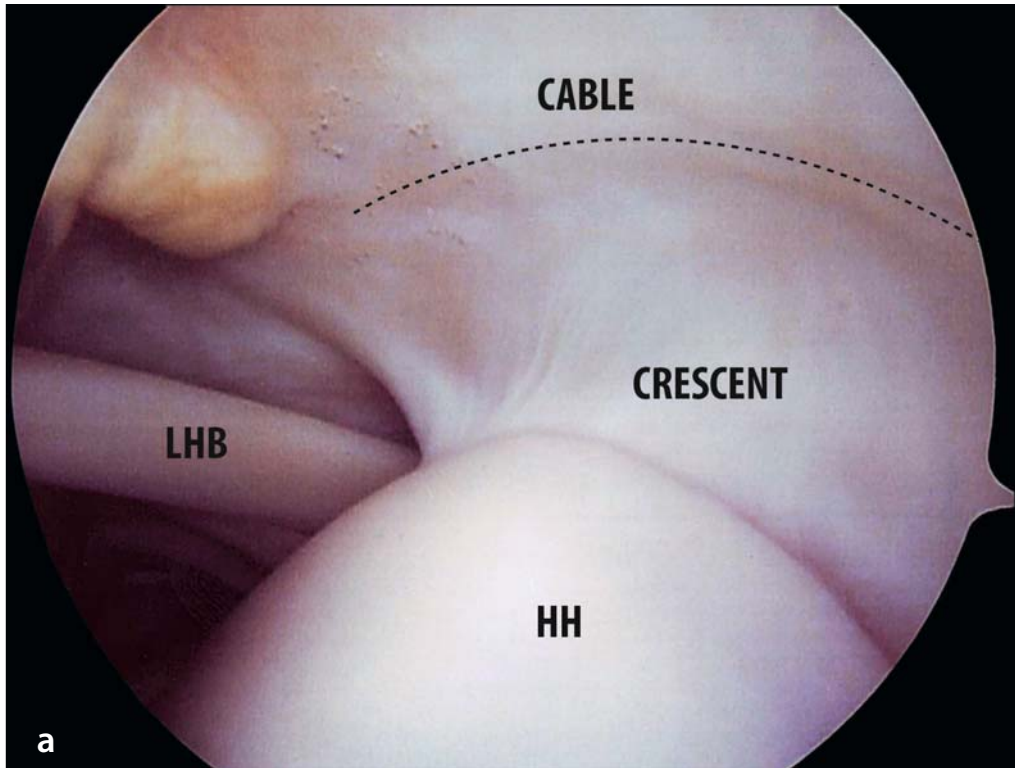
Arthroscopy shows that the outer surface of the subscapularis tendon is intimately associated with the coracohumeral ligament: in fact, the insertions of the superior glenohumeral and coracohumeral ligaments and the subscapularis tendon appear to be attached by interdigitating fibres. The SGHL–CHL system complex (pulley) is central to prevention of subluxation of the biceps tendon.

Partial subscapularis tears can remain in a relatively anatomical position when they occur; this is seen especially in chronic rotator cuff tears, when the CHL scars at the outer edge of the

subscapularis tendon. Occasionally the subscapularis tendon insertion and SGHL–CHL complex can tear together. Because the CHL inserts both medial and lateral to the bicipital groove, having a medial and lateral head, the subscapularis tendon can appear in a relatively anatomical position unless the arm is brought into internal rotation and *relaxation* is achieved [67].

Pouliart et al. [55, 56] have observed a distinct *rotator cable* surrounding a distinct rotator crescent in about 50% of specimens. “*The rotator cable* (Fig. 4.20 a, b) spans from anterolateral to posterolateral above the biceps groove. In about 25% of shoulders the rotator cable is less obvious but might be identified by adding traction to the arm or rotating the humerus. In these shoulders, the rotator crescent is not visible. In the rest, the rotator cable and crescent cannot be discerned despite manipulations, and the rotator crescent therefore cannot be marked. In adduction and external rotation, a longitudinal anterosuperior capsular fold with a distinct anterior leading edge develops in all cases.

**Fig, 4.20. a** Arthroscopic view of the right shoulder: the crescent. **b** Arthroscopic view of the right shoulder: “the cable”





This leading edge corresponds to the superior border of the foramen described by Weitbrecht. This capsular fold runs from the anterosuperior glenoid rim, adjacent to the long tendon of the biceps, to the biceps pulley. In specimens in which a rotator cable is observed, the capsular fold joins the anterior leg of the cable (Fig. 4.21). In adduction and internal rotation the longitudinal anterior capsular fold is no longer seen, although the anterosuperior part of the capsule had a tendency to fold up in the transverse direction.

With reversed rotation, the same observation of transverse folding and unfolding and longitudinal folding can be made for the posterosuperior part of the capsule. In adduction and internal rotation, the posterosuperior capsule becomes tight enough to squeeze the arthroscope downwards and out. The longitudinal posterosuperior fold appears just superior to the posterior arthroscopic portal and runs from the posterosuperior glenoid rim, medial and posterior to the origin of the long tendon of the biceps and the glenoid labrum, to the posterior part of the greater tubercle. Here it merges with the posterior leg of the rotator cable when this is visible. Since both longitudinal superior folds are always seen during either external or internal rotation, they may as well be assessed with the arthroscopic technique in all cases [55, 56]”.

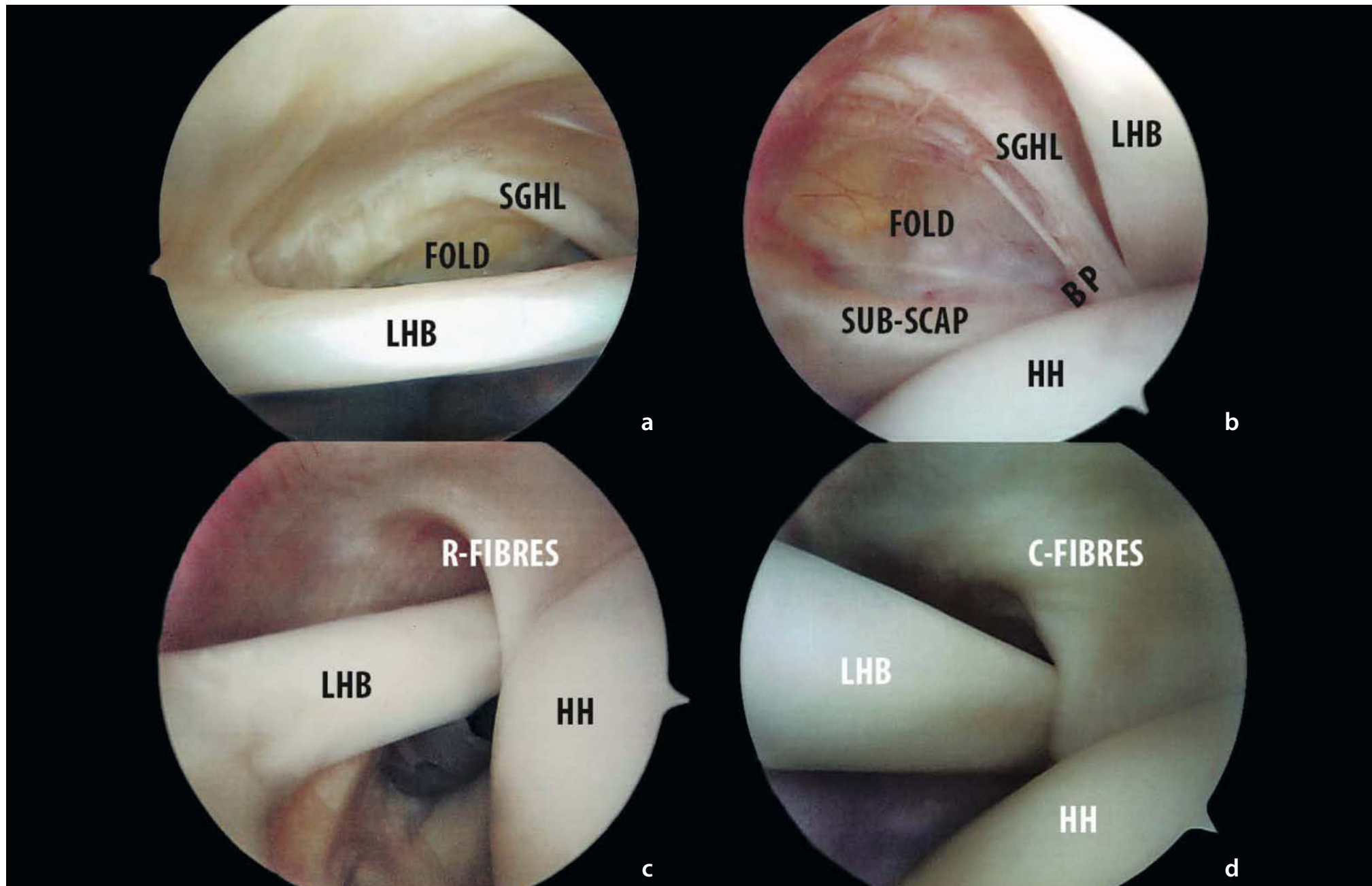
#### 4.2.9 Biomechanics and Functional Anatomy of Superior Glenohumeral Ligament Complex

A few biomechanical studies [6, 16, 69 - 75] have been devoted to the coracoglenohumeral ligament. Boardman et al. [16] determined that the coracohumeral ligament is significantly greater in cross-sectional area at its midportion than the superior glenohumeral ligament. The coracohumeral ligament also had greater stiffness, greater ultimate load and was capable of absorbing six times the amount of energy before failure with only 1.5 times as much elongation as the superior glenohumeral ligament. The coracohumeral ligament always breaks down medially, whereas the superior glenohumeral ligament always fails near its humeral insertion.

The coracohumeral ligament's tensile properties are about 150% those of the inferior glenohumeral and coracoacromial ligaments, corresponding to about 15% of those of the anterior cruciate ligament. The superior glenohumeral ligament's tensile properties are comparable to those of the inferior glenohumeral ligament.

The coracohumeral ligament plays an important part in inferior stability during external rotation with the arm in the lowest ranges of abduction. On the other hand, it does not seem signifi-

**Fig. 4.21a–d.** Arthroscopic view of the right shoulder (posterior portal): the superior complex (*R-FIBRES* radial fibres, *C-FIBRES* circular fibres). The capsular fold runs from the anterosuperior glenoid rim to the biceps pulley. (*BP* biceps pulley)



cant in neutral and internal rotation; nor does it appear to contribute to superior stability [74]. Delorme [8] states that the superior glenohumeral ligament cannot work as a true capsular ligament-limiting motion (Hemmungsband), as it usually appears to be too thin and proceeds with an accompanying blood vessel. He modified his statement by declaring that this definite function of the coracohumeral ligament is useful only when the shoulder muscles are paralysed. Conversely, these muscles hold the articular surfaces together in concurrence with atmospheric pressure. Fick [18,76] and Delorme [8] report that the coracohumeral ligament inhibits external rotation but not internal rotation of the adducted humerus. According to Delorme [8], the coracohumeral ligament reaches its maximal limiting function when the humerus is externally rotated, adducted and retroflexed. Turkel et al. [50] suggest that the superior glenohumeral ligament may play a part in preventing anterior translation with the arm in adduction and external rotation. Most authors agree that the coracohumeral ligament acts against inferior displacement of the humeral head and that the coracohumeral ligament limits external rotation in the lower ranges of abduction (up to 60°) but does not play a role in internal rotation. [36, 77, 78]

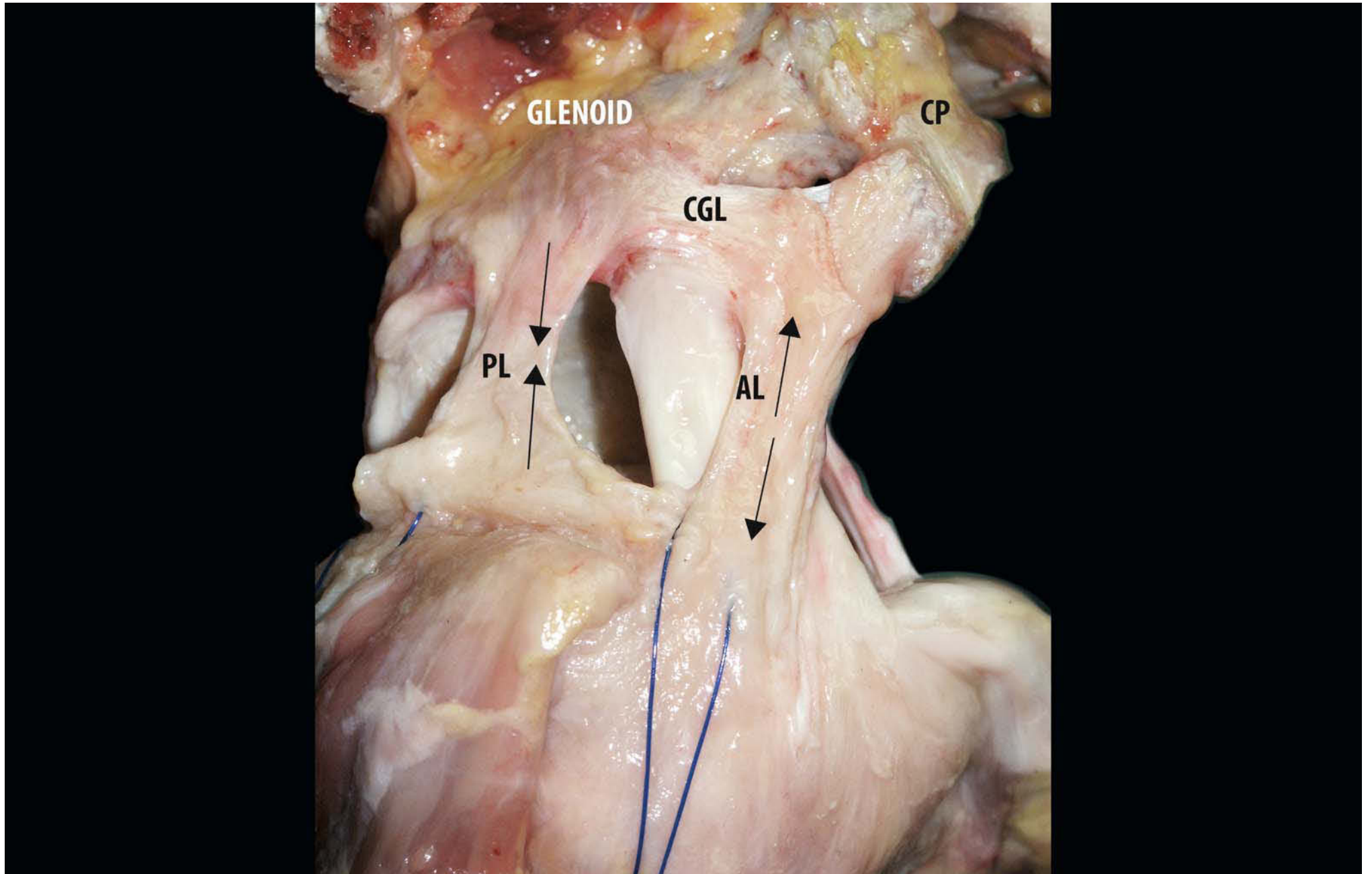
The results of another study [77, 78] have demonstrated that the coracohumeral ligament limits flexion (sagittal plane) of the humerus to an average of 75° when the humerus is in neutral rotation. The length of the coracohumeral ligament forces the

humerus out of the sagittal plane when further elevation is attempted. Throughout flexion, tension in the coracohumeral ligament occurs at an earlier degree in external rotation and at a later stage in internal rotation. Castaing et al. [79] find that rotation in maximal abduction does not increase either after resection of the acromion or after the rotator cuff tendons have been cut, and only slightly after section of the superior glenohumeral and coracohumeral ligaments. Free rotation is only seen after additional severance of the inferior glenohumeral ligament.

Lee et al. [80] state that the anterior band of the coracohumeral ligament becomes tighter during external rotation (Fig. 4.22), whereas the posterior band tightens with increasing internal rotation. The posterior band described by these authors probably corresponds to the posterosuperior glenohumeral ligament observed by Pouliart et al. [55,56]. The coracohumeral ligament also seems to limit external rotation in abduction according to Kuhn et al. [70], who have shown that cutting it has the same effect for this movement as cutting the entire inferior glenohumeral ligament. The coracohumeral and superior glenohumeral ligaments also operate against inferior displacement of the humeral head [1, 11, 34, 69, 72, 81, 82].

Even when the coracohumeral ligament, the anterosuperior glenohumeral capsule and the subscapularis are cut, the posterosuperior glenohumeral ligament can still prevent inferior displacement of the humeral head in internal rotation, and up to 60° abduction [69]. Imbrications or contraction of the

**Fig. 4.22.** Superolateral view of the right shoulder: anterior limb of superior complex humeral ligament (anterior limb) becomes taut with increasing external rotation. (*PL* posterior limb, *CGL* coracoglenoid ligament)



coracoglenohumeral ligament (as in adhesive capsulitis) limit external rotation [1, 11, 34, 81, 83–100] as much as sealing the rotator cuff interval, whereas increased external rotation follows the release of a contracted coracohumeral ligament.

As previously described, the rotator cable works in the same way as the functional cable system of a suspension bridge and provides stress-shielding to the thinner capsular tissue and cuff tendons within the rotator crescent by transferring stress from cuff to cable. Given their fusion into the rotator cable, the coracoglenohumeral ligament and posterosuperior glenohumeral ligament provide the medial anchorage for the rotator cable function. This probably allows the superior complex to maintain its depressing and centring effect as long as one of the medial and one of the lateral points of bony attachment are preserved [55, 56].

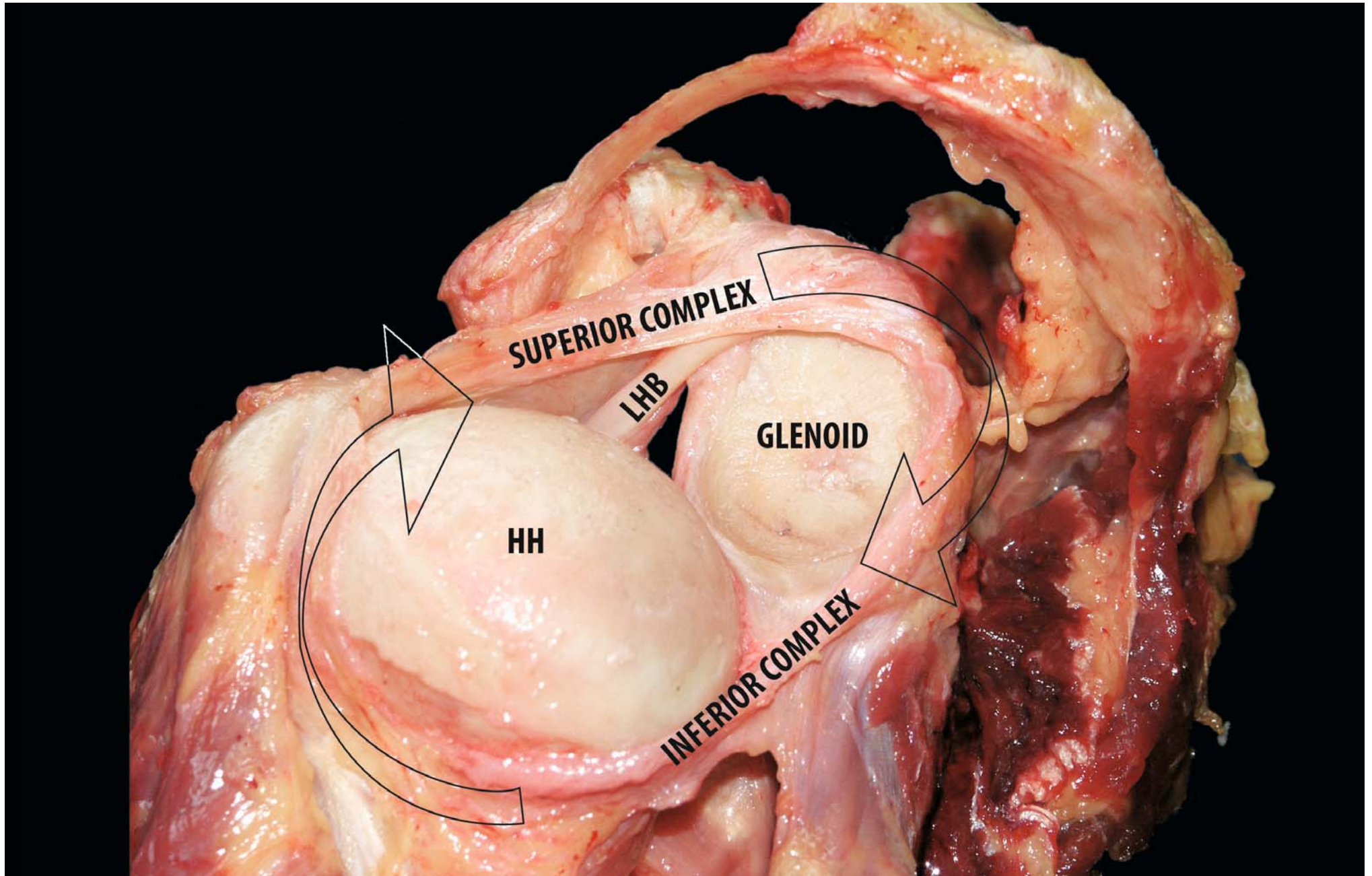
With its four-point anchorage and its anterior and posterior limbs, giving reciprocal tightening during rotation, the superior complex works as a suspension sling for the humeral head. In fact, it mirrors the hammock formed by the inferior gleno-

humeral ligament complex. The superior complex appears to be more effective in adduction, although it might work as a secondary restraint in abduction, whereas the inferior complex works in the opposite way [54, 103].

Further to these observations, we can conclude that coracohumeral, coracoglenoid and superior glenohumeral ligaments exist as distinctive entities in the majority of cases. However, they are thin, broad sheet-like structures rather than rope-like. Given that the extent of merging, fusion or even confluence of these three ligaments varies considerably, we assume that it might be better to consider them all as one single ligamentous structure with a number of parts. This also makes sense from a functional point of view.

The superior capsuloligamentous structure works in synergy with the inferior complex (Fig. 4.23): the former represents the primary restraint against excessive translation and rotation of the humeral head in adduction and is a secondary restraint in abduction. The latter, instead, works as primary restraint in abduction and secondary restraint in adduction.

**Fig. 4.23.** Posterolateral view of the left shoulder: superior capsule ligamentous structure acts in synergy with the inferior complex

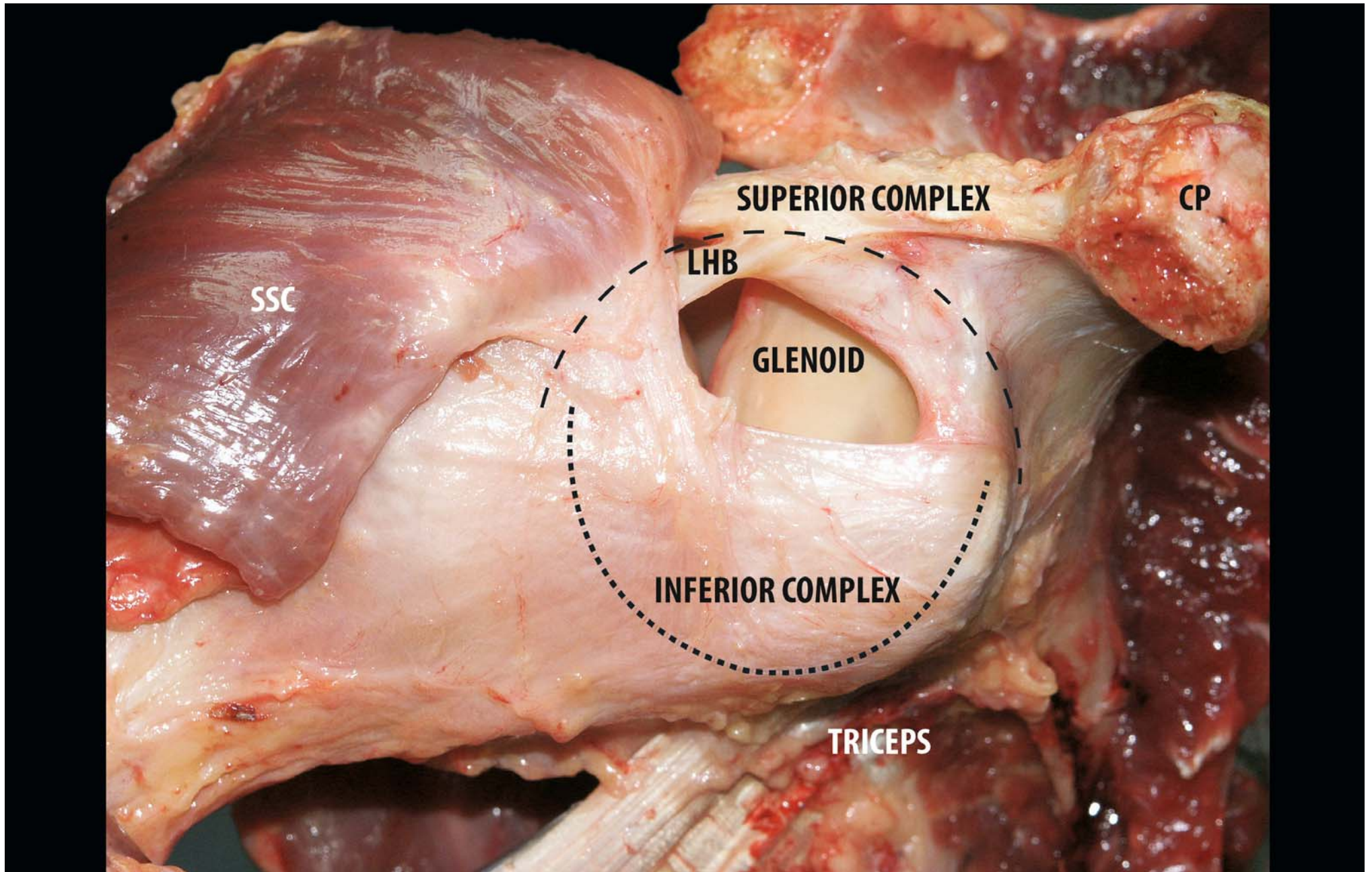


The superior half of the glenohumeral joint also contains several ligamentous structures and we would suggest that the superior glenohumeral and the inferior glenohumeral ligament complexes are nothing but parts of a single functional structure. The superior complex consists of the coracohumeral ligament and the superior and the middle glenohumeral ligaments set in a radial orientation and the coracoglenoid ligament, the transverse humeral ligament and the transverse band (semicircular humeral ligament or rotator cable) set in circular orientation. The middle glenohumeral ligament and the fasciculus

obliquus (spiral glenohumeral ligament) form an anterior cross-link between both complexes. Furthermore, we deem that the two complexes are linked to each other by the circular fibrous structure of the glenoid labrum.

Finally, the tendons of the rotator cuff muscles—subscapularis, supraspinatus, infraspinatus and teres minor—help to anchor down and reinforce the capsuloligamentous structures on the humeral side. On the glenoid side of the capsuloligamentous complex, this anchoring mechanism is improved by the origin of the long tendons of biceps and triceps muscles (Fig. 4.24).

**Fig. 4.24.** Anterolateral view of the right shoulder: superior and inferior GHL complexes are parts of the same functional structure (existing in conjunction, in anatomical, mechanical and proprioceptive fashion)





#### 4.2.10 Clinical Relevance of the Superior Glenohumeral Capsule [55, 56]

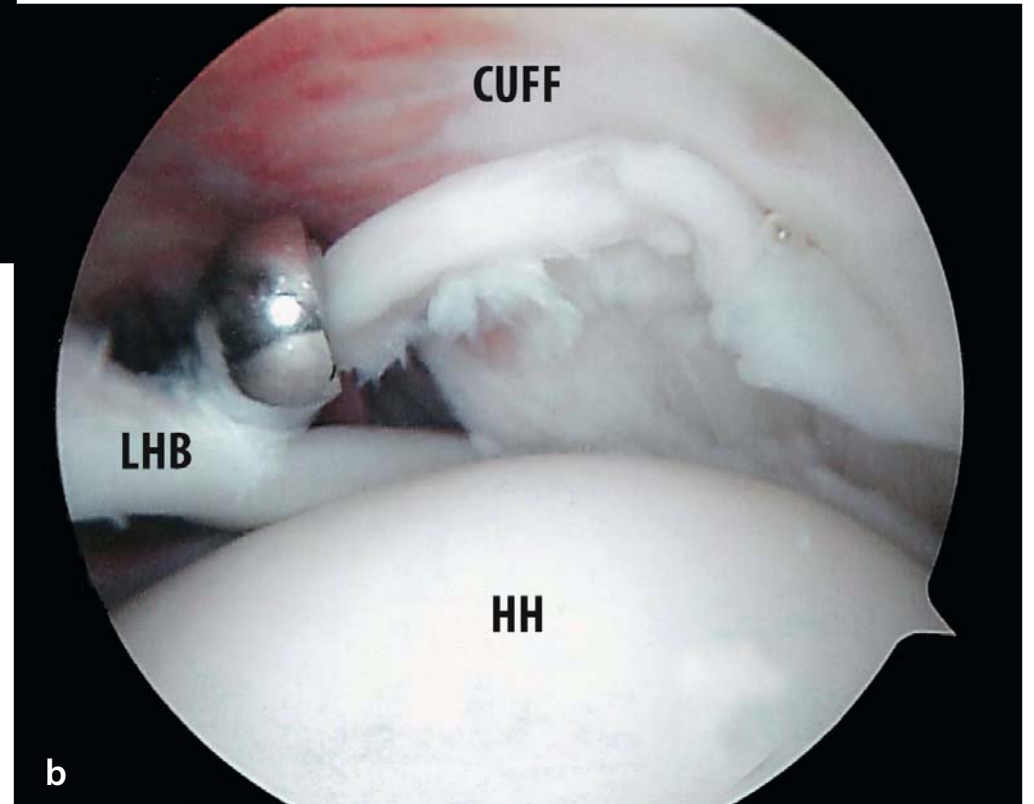
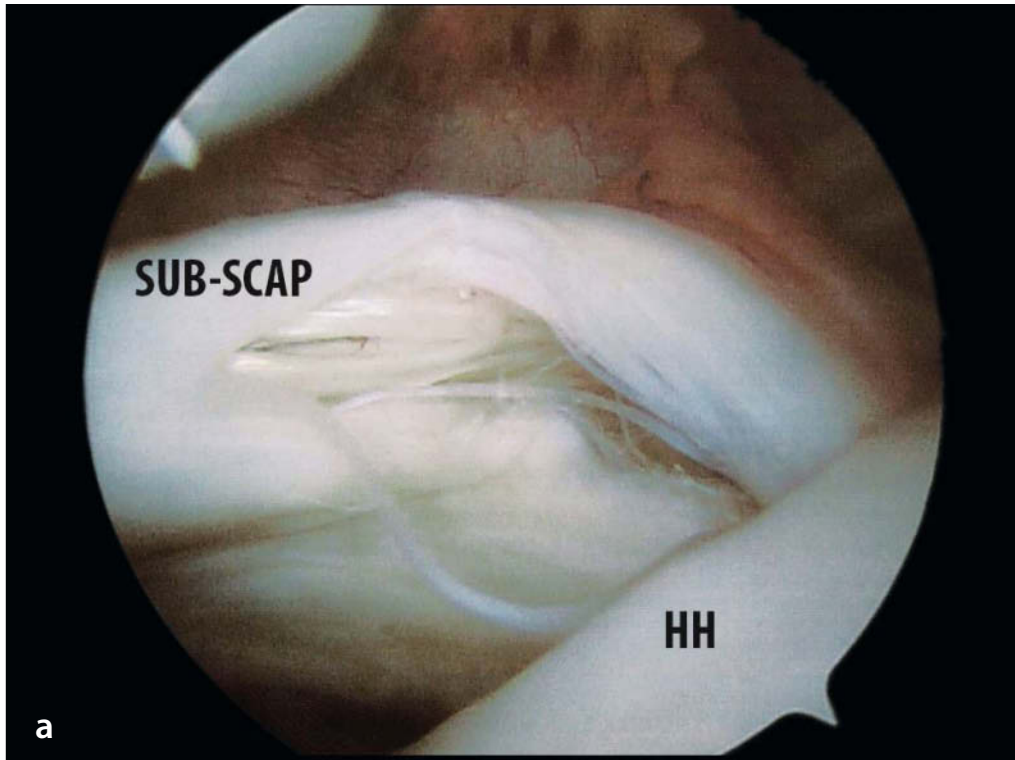
“The superior glenohumeral capsule is involved in several subsets of pathology: internal anterosuperior and posterosuperior impingement, subscapularis lesions (hidden lesions, Fig. 4.25a) [66], rotator cuff interval lesions, articulation-side rotator cuff tears, Fig. 4.25b) and adhesive capsulitis. A specific sort of instability is present where no overt clinical signs of instability are evident but where faulty control, slight laxity or increased ranges of motion, with possible opposing contracture, cause impingement of intraarticular structures. Usually, this *functional instability* is associated with anterosuperior and/or posterosuperior labral lesions [101–105].

Several authors [65, 106–108] have more recently given accounts of anterosuperior impingement. In this case, lesions either to the common insertion of the coracohumeral and superior glenohumeral ligaments—the so-called *pulley lesion*—or to the rotator cuff interval or the long biceps tendon itself, an articulation-side partial subscapularis tear or a combination of these lesions can occur owing to repetitive trauma to these structures against the anterosuperior labrum or the coracoid process in

flexion and internal rotation. Anterosuperior impingement and rotator cuff interval lesions can also be associated with coracoid impingement [109–112]. Savoie et al. [113] describe a variant of anterosuperior impingement in which combined lesions of the superior labrum and the anterior cuff (SLAC lesion), in the form of a partial anterior supraspinatus tear, were obvious. Posterosuperior internal impingement, first described by Walch [114], has been associated with posterior articular-side partial-thickness rotator cuff tears and posterosuperior labral lesions [110, 111, 113, 115–118]. Nevertheless, posterosuperior impingement is not necessarily related to increased laxity and instability [115, 118]. Superficial articulation-side rotator cuff tears should probably be regarded more as capsuloligamentous injuries attributable to impingement or instability, rather than as damage to the rotator cuff tendons themselves. This is very significant in the rehabilitation period, when close attention should be paid to stabilising and preventive exercises.

Although rotator cuff interval lesions are most frequently seen in overhead athletes with slight instability or anterosuperior impingement, they can also easily be associated with other capsuloligamentous lesions and more overt instability [31, 40, 83, 87, 119–122].

**Fig. 4.25a, b.** Arthroscopic view of right shoulder: **a** “hidden lesion” of the subscapularis; **b** partial-thickness rotator cuff tear



A small to large gap between the superior and the middle glenohumeral ligaments should alert the surgeon to the possibility of a rotator cuff interval lesion, although caution is mandatory to avoid overdiagnosis. Closure of an actually normal interval may result in an undesired limitation of external rotation. When an interval is closed, external rotation should therefore always be checked to prevent this complication.

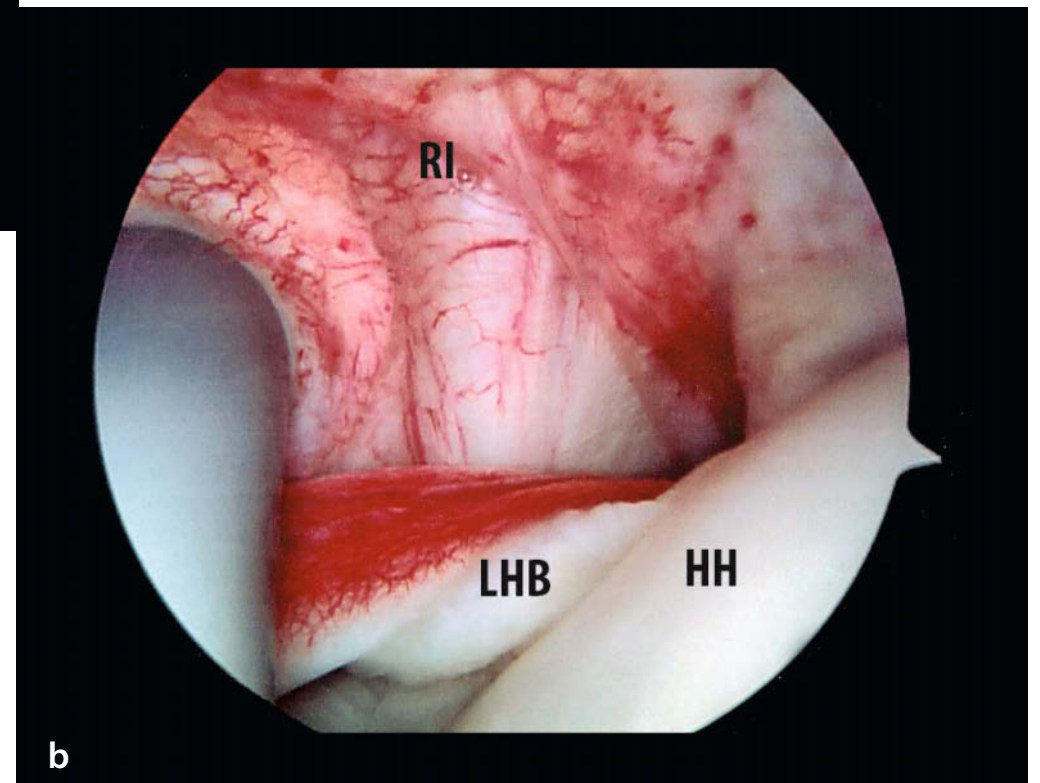
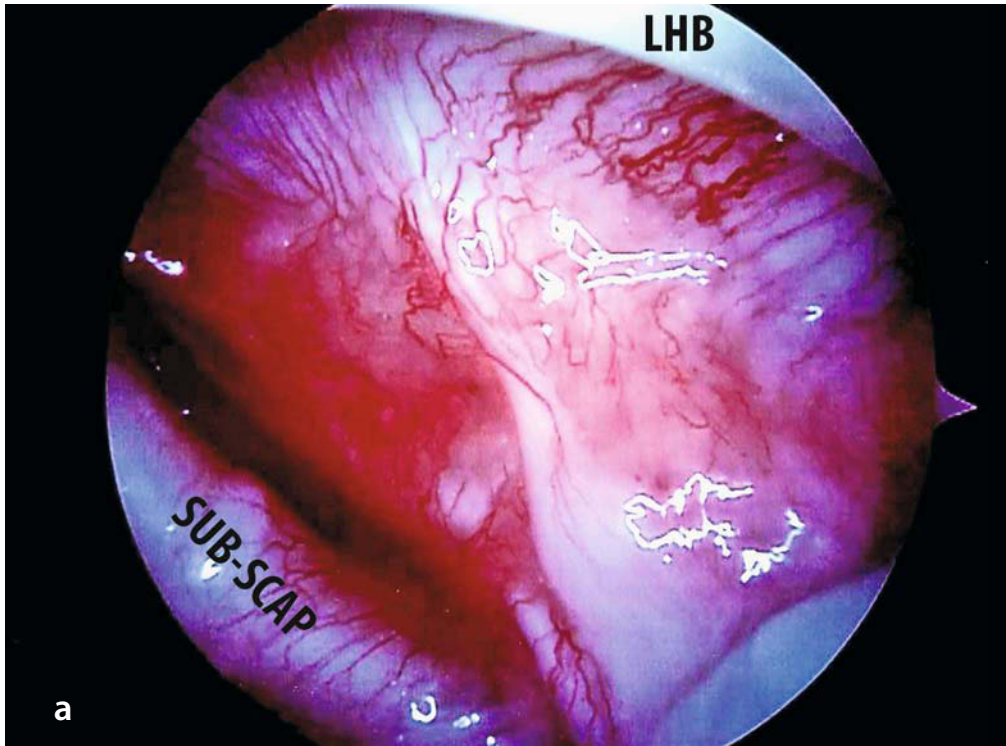
In patients with adhesive capsulitis (Fig. 4.26 a, b), external rotation can be improved by releasing the rotator cuff interval and cutting the coracoglenohumeral ligament. This can be done by open [36, 85, 86, 90, 91, 100] or arthroscopic surgery [83, 84, 123, 124, 93–100].

Similarly, internal rotation can be increased by extending the release of the posterosuperior portion of the glenohumeral capsule up to the 9 o'clock position, thereby cutting the posterosuperior ligament [90, 96, 98, 99, 123].

We reckon that true superficial articular-sided rotator cuff

tears actually reflect damage to the superior complex rather than to the rotator cuff tendons themselves. This damage compromises the head-depressing and centring effect normally performed by the superior complex. When the superior complex remains intact or is only partially damaged, it may limit the retraction of the toren rotator cuff tendons. This effect has already been demonstrated in the studies of Burkhart et al. [62, 63], who proved that the *rotator cable* is pivotal in maintaining normal kinetics in the presence of massive rotator cuff tears. Burkhart et al. [62, 63] and Kolts et al. [38] do not recognise the fusion of the coracoglenohumeral and superior glenohumeral ligaments into the *rotator cable* or *transverse band*. Furthermore, superior and inferior complexes may be linked to each other medially, through the glenoid labrum, as well as laterally through the fasciculus obliquus. The potential implications of the superior complex and the linkage between both *complexes* in glenohumeral stability require further study”.

**Fig. 4.26. a** Arthroscopic view of right shoulder: in patient with capsulitis, **b** Arthroscopic view of right shoulder: irritation of the rotator interval and LHB (LHB long head bicep, RI rotator interval, HH humeral head)



## 4.3 Anterior and Inferior Glenohumeral Capsuloligamentous Complex

Nicole Pouliart

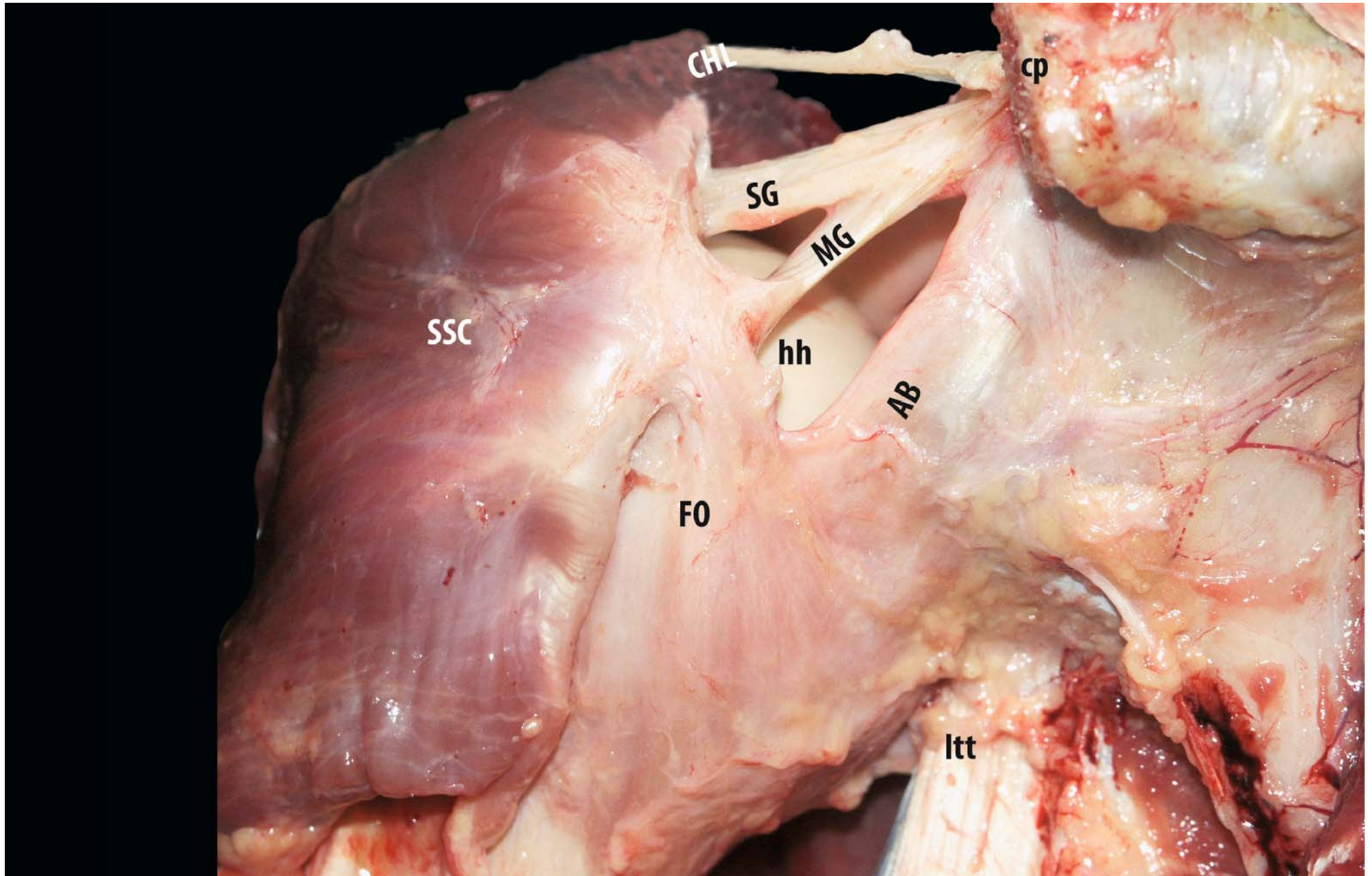
### 4.3.1 Middle Glenohumeral Ligament

The middle glenohumeral ligament (ligamentum glenohumerales medium seu internum, ligament sus-gléno-pré-huméral) [4, 11, 12, 14, 15, 18, 19, 46, 51, 52–55, 125–130] arises from the upper periphery of the glenoid cavity and from the glenoid labrum, together with the coracohumeral ligament, and then runs diagonally downwards to the humerus, diverging from the latter ligament, to join the inferior part of the tendon of the subscapularis and the fasciculus obliquus before inserting together on the lesser tubercle. The glenoid origin can sometimes be as high as the supraglenoid tubercle and the scapular neck at the level of the base of the coracoid process, in which case the middle glenohumeral ligament may be fused

with the superior glenohumeral ligament at this point. The middle glenohumeral ligament is usually a well-formed distinct structure, although some variations, such as an origin only from the glenoid labrum, no attachment to the labrum at all, a complete bony origin without labral attachment or an origin conjoined with that of the superior glenohumeral ligament, are described. In rare specimens, the middle glenohumeral ligament exists as a double structure without any connection to labrum, scapula or superior glenohumeral ligament.

Its superior border is readily identifiable arthroscopically because it is separated from the superior glenohumeral ligament by the subscapular recess (foramen of Weitbrecht) and because it crosses the intraarticular tendon of the subscapularis. The inferior border can only be clearly identified arthroscopically when an inferior subscapular bursa (foramen of Rouvière) is present [11, 55, 127–129]. In a small percentage of specimens, the middle glenohumeral ligament is only a thin thread or is even absent [11, 55, 127–129] (Fig. 4.27).

**Fig. 4.27.** Anterior extraarticular view of the anterior glenohumeral capsule of a right shoulder in neutral rotation and slight abduction: the tip of the coracoid process (*cp*) has been resected to allow a better view of the glenoid origin of the capsular ligaments. The subscapularis (*ssc*) has been detached from the underlying capsule as far laterally as possible and is shown reflected laterally. The capsular tissue without fibrous components has been removed so that the individual ligaments become visible in front of the humeral head (*hh*). In this specimen, the coracohumeral ligament (*CHL*) is rather thin and fuses with the superior GHL (*SG*) far laterally. The superior GHL and the middle GHL (*MG*) have a common origin from the glenoid rim and neck and are seen to be fused over half of their length. The middle GHL fuses laterally with the subscapularis and the fasciculus obliquus (*FO*), which has its origin from the inferior glenoid rim and from the tendon of the long head of the triceps (*LTT*). In this position, the fasciculus obliquus has an almost vertical course. It is anterior to the anterior band of the inferior GHL (*AB*), with which it fuses laterally. In this specimen, the fusion appears in the lateral third (pattern 4, see text for details)



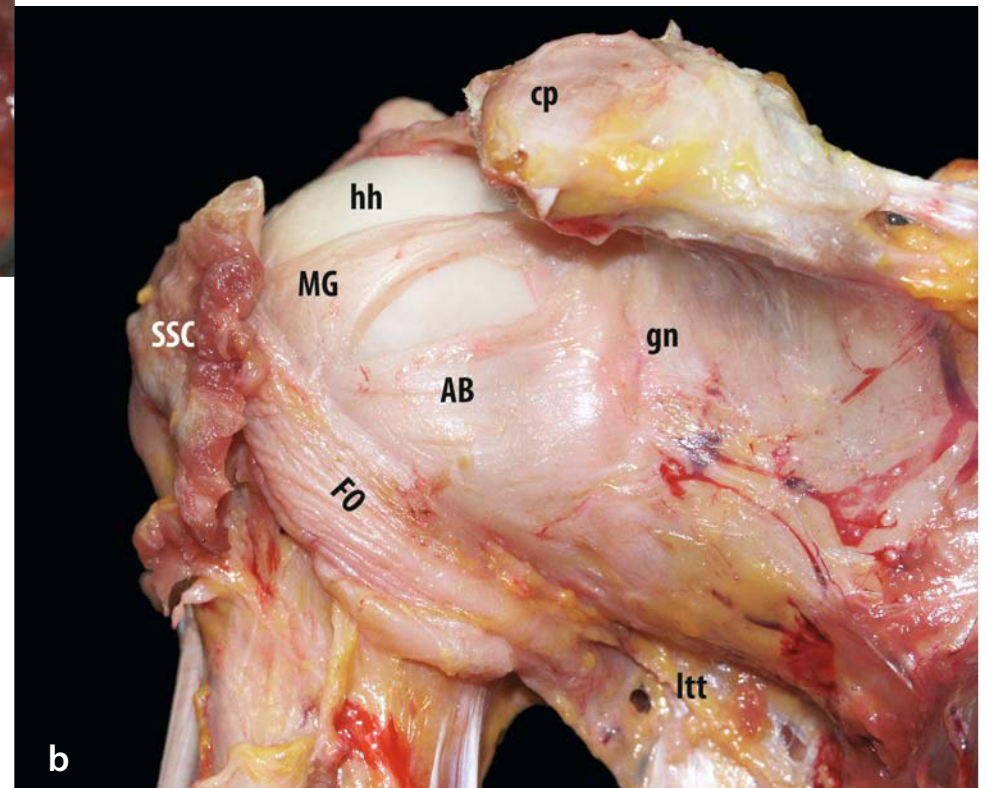
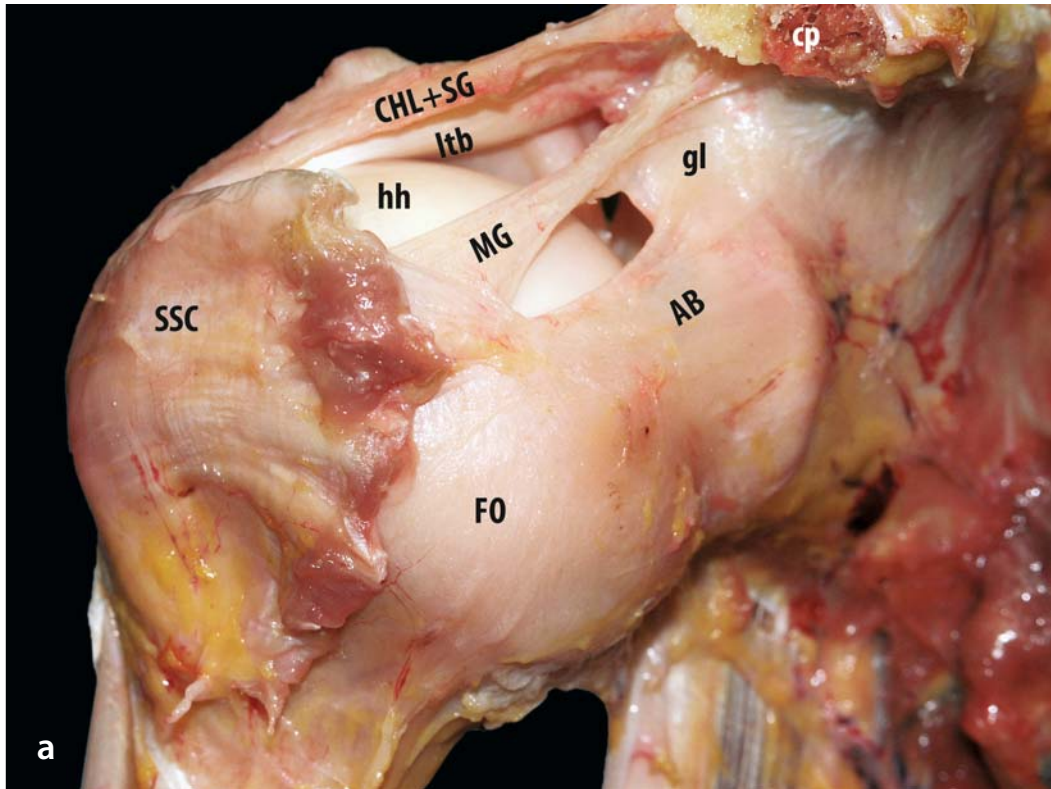
### 4.3.2 Fasciculus Obliquus

The fasciculus obliquus (longitudinal-oblique system, ascending fibres, spiral glenohumeral ligament) [47, 51, 53, 126, 128–130], originally described by Delorme [8], attaches to the glenoid from 5 to 7 o'clock, as does the origin of long head of the triceps over 1–1.5cm laterally. From there it crosses up words in front of the joint, to merge with the tendon of the subscapularis and the middle glenohumeral ligament.

The macroscopic description of the fasciculus obliquus and the inferior glenohumeral ligament by Delorme [8] has recently been corroborated by the histological study of Gohlke et al. [9]. The most superficial of the three layers they describe is

composed of circular elements that run wing-like from the insertion of the long tendon of the triceps towards the tendon of the subscapularis. This layer therefore corresponds with the fibre orientation of the fasciculus obliquus. Although O'Brien et al. [131] describe the histology of the inferior glenohumeral ligament complex beautifully, they unfortunately fail to recognise that their axillary pouch, with less well-organised fibre bundles and intermingling of fibres from the inner and intermediate layers, is actually formed by the medial part of the fasciculus obliquus on the glenoid side. Gohlke et al. [9] found that the axillary pouch was formed both by a layer of intermingling radial and circular fibres and by fibres from the insertion of the triceps muscle (Fig. 4.28a, b).

**Fig. 4.28a, b.** Anteroinferior extraarticular view of the anterior glenohumeral capsule of a right shoulder in external rotation and slight abduction: the tip of the coracoid process (*cp*) has been resected to allow a better view of the origin of the capsular ligaments from the glenoid labrum (*gl*) and neck (*gn*). The subscapularis (*ssc*) has been detached from the underlying capsule as far laterally as possible and resected at that point. In this view, the coracohumeral ligament (*CHL*) and the superior GHL (*SG*) cannot be separated and are seen to run parallel with the tendon of the long head of the biceps (*LTB*), superior to the humeral head (*hh*). The middle GHL (*MG*) is relatively broad near its fusion with the fasciculus obliquus (*FO*). The anterior band of the inferior GHL (*AB*) is also quite broad, with a high origin from the glenoid labrum, and it almost crosses with the fasciculus obliquus over its entire length (pattern 5, see text for details). **a** In this position, the anterior band of the inferior GHL and the fasciculus obliquus are under maximal tension; **b** anteroinferior extraarticular view of the same specimen (right shoulder) in internal rotation and adduction. The superior structures now lie behind the humeral head. The fasciculus obliquus now runs obliquely from its insertion on the tendon of the long head of the triceps to its fusion with the middle GHL and the subscapularis. In this position, the anterior band of the inferior GHL runs horizontally





### 4.3.3 Inferior Glenohumeral Ligament Complex

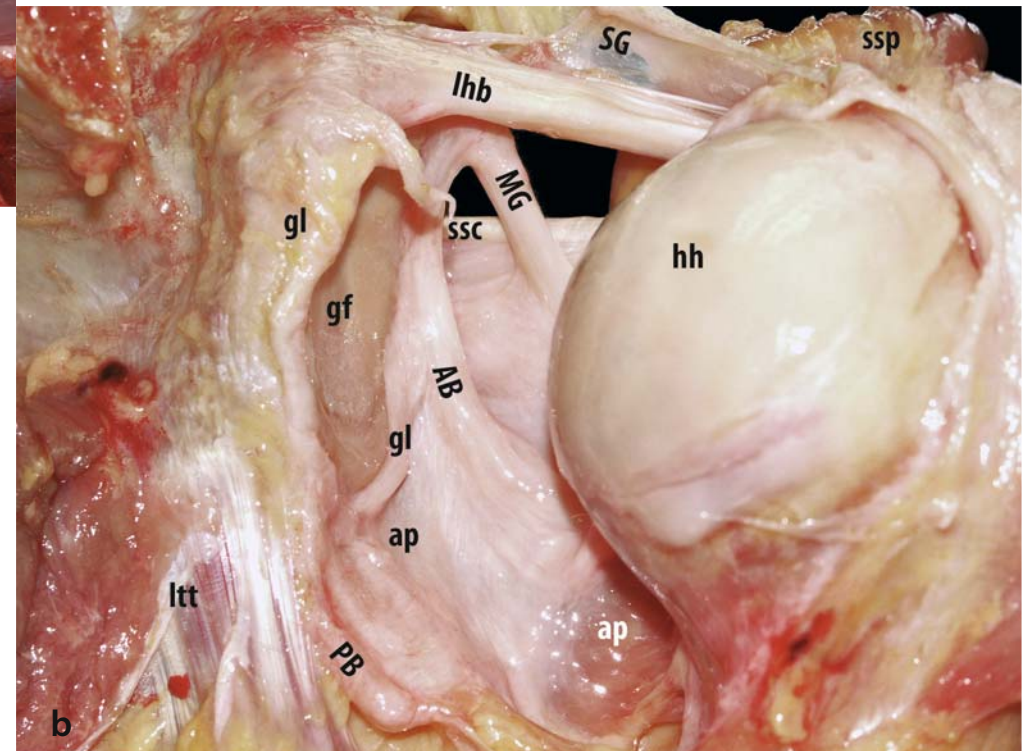
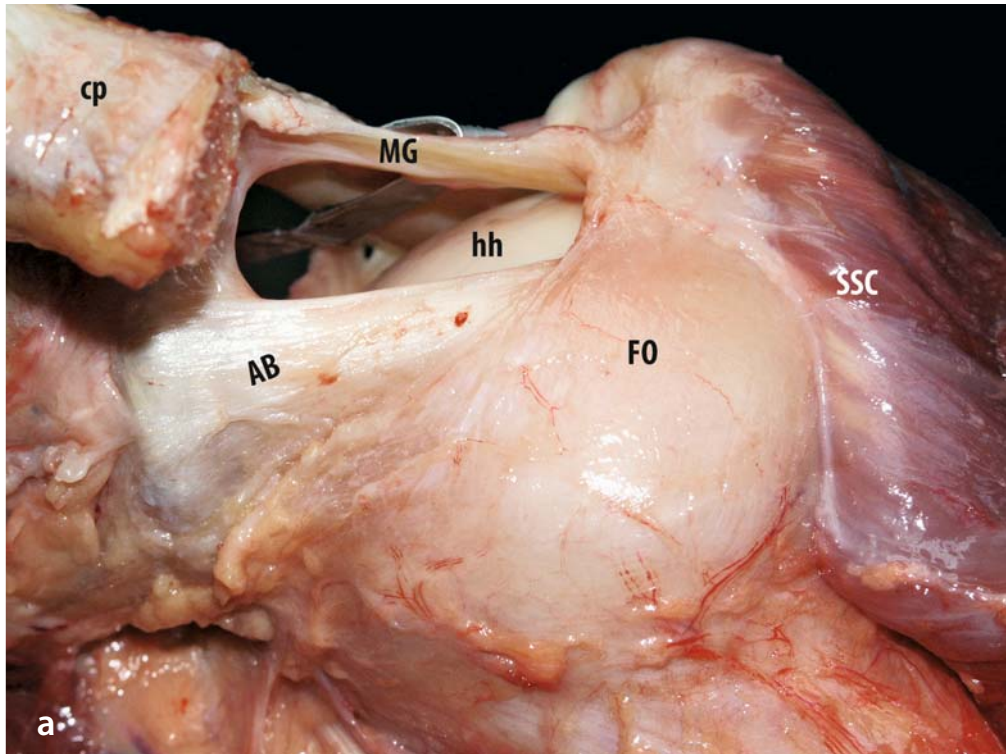
The term inferior glenohumeral complex was coined by O'Brien et al. [131] to denote the inferior ligamentous reinforcement of the capsule consisting of the anterior and posterior bands of the inferior glenohumeral ligament and the intervening axillary pouch. The fasciculus obliquus also forms part of this complex on the medial side [10, 55, 127–129]. The inferior glenohumeral complex forms a hammock that cradles the humeral head and acts as the primary static restraint against anterior translation in abduction [51, 131].

A distinct inferior glenohumeral ligament can be observed even in fetal specimens as early as 14 weeks of gestation [41]. O'Brien et al. [131] and Gohlke et al. [9] describe the histology of the inferior and the anteroinferior capsule, respectively. Both groups recognise three layers of fibre orientation. The fibres of the inner and outer layers are oriented radially from glenoid to humerus, whereas the fibres of the intermediate layer are oriented perpendicular to those of the other two layers and therefore have a circular orientation. The anterior and posterior bands seem to be abrupt thickenings of the inner layer with densely packed fibre bundles. The predominantly radially ori-

ented fibre bundles of this thickest part of the capsule radiate spirally into the labrum and the glenoid rim in three layers. The fibres of the inferior capsule connect in an acute angle to the circular fibre system of the labrum. The deeper layer has fibre bundles that are either diagonal or radial in orientation, depending on the height at which they are anchored on the glenoid labrum. This deeper layer corresponds with what is commonly designated the anterior part of the inferior glenohumeral ligament. Posteriorly, the fibre bundles of the outer and intermediate layers appear so intermingled that these two layers cannot be distinguished (Fig. 4.29a, b).

When historical texts are considered in association with recent developments, a picture of the inferior glenohumeral capsuloligamentous structures emerges [4, 8, 19, 14, 15, 51, 52, 55, 126–129]. The anterior part of the inferior glenohumeral ligament complex (anterior band, ligamentum glenohumerale inferius seu latum, ligament pré-gleno-sous-humerale) [4, 8, 14, 15, 19, 47, 51, 52, 55, 126–129, 131] can easily be identified, even arthroscopically, through its superior border, which usually appears as a thickened band, especially in internal rotation with little abduction, attaching to the glenoid at 2–4 o'clock in a right shoulder and running diagonally downwards to the humerus.

**Fig. 4.29a, b.** **a** Anteroinferior view of the anterior glenohumeral capsule of a left shoulder in maximal external rotation and abduction. In this position, the middle GHL (*MG*) lies superior to the humeral head (*hh*). Again its fusion laterally with the fasciculus obliquus (*FO*) and the subscapularis (*ssc*) is clearly visible. The fasciculus obliquus is fully stretched and cradles the humeral head, thereby contributing to stability in the position at risk. The anterior band of the inferior GHL (*AB*) is also taut in this position and lies horizontal. It can clearly be seen that this ligament limits external rotation in abduction (*cp* coracoid process). **b** Posterior intraarticular view on the anterior glenohumeral capsule of a right shoulder in neutral rotation and adduction: the reflected supraspinatus (*ssp*) can be seen. In this position, the tendon of the long head of the biceps (*ltb*) and superior GHL (*SG*) run parallel over the top of the humeral head. The middle GHL obliquely crosses the intraarticular portion of the tendon of the subscapularis. The anterior band of the inferior GHL has a relatively high origin on the glenoid labrum (*gl*) and runs obliquely downwards from the glenoid to attach inferiorly on the humeral neck. In this posterior part, its course is parallel to that of the posterior band of the inferior GHL (*PB*) (*gf* glenoid fossa, *ltt* tendon of the long head of the triceps, *ap* axillary pouch)



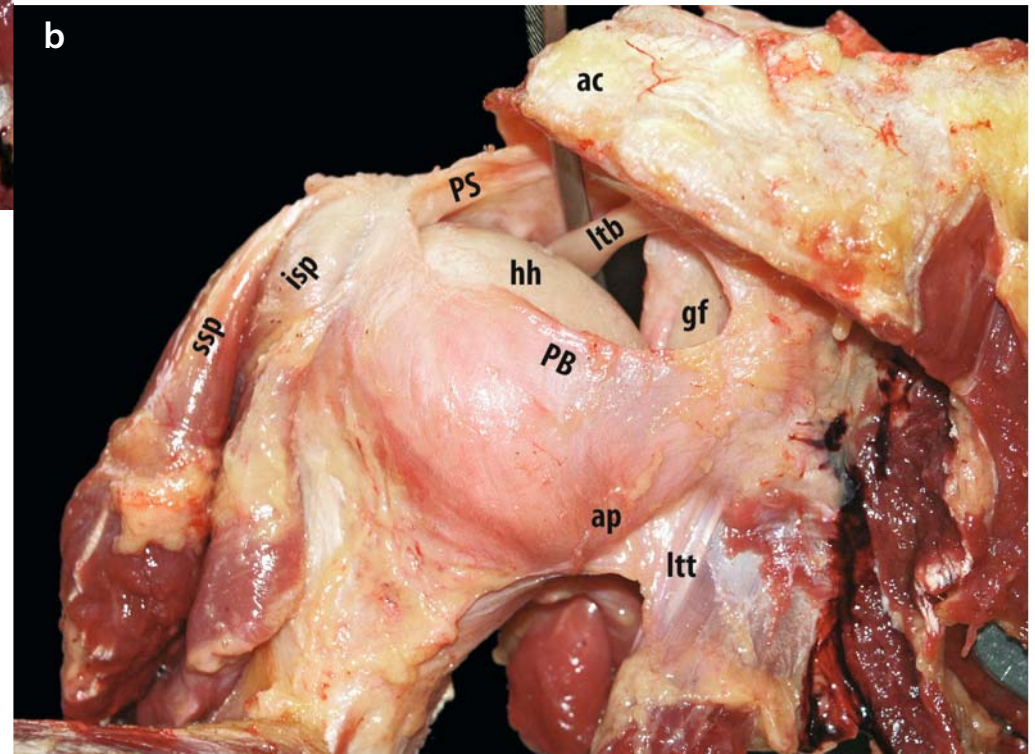
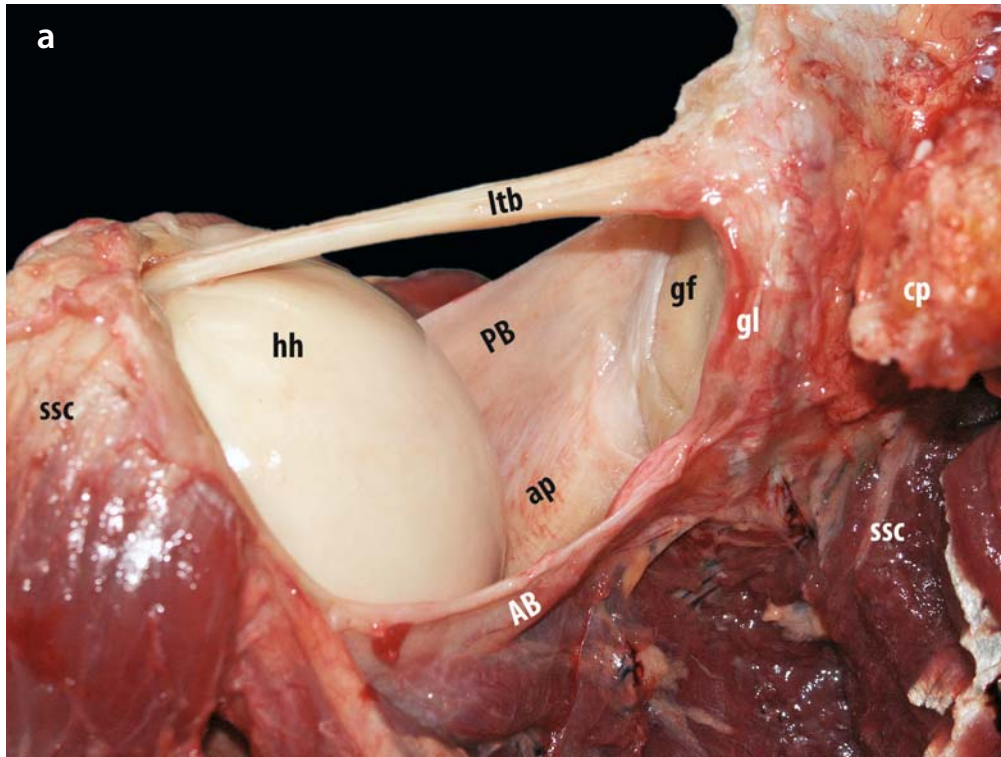
The posterior band of the inferior glenohumeral ligament complex usually originates at 7–9 o'clock on the glenoid [127, 128]. Its superior edge is somewhat more difficult to discern than that of the anterior band, although rotating the slightly abducted humerus externally may help in its identification. The posterior band runs diagonally downward to form the posteroinferior part of the humeral insertion.

The intervening axillary pouch is actually formed by the fasciculus obliquus medially and by the junction of the anterior and posterior bands of the inferior glenohumeral ligament on the humerus laterally [55, 127–129, 132] (Fig. 4.30a, b).

The fasciculus obliquus crosses diagonally over and anterior to the anterior band of the inferior glenohumeral ligament. In the area where they cross, the two ligaments cannot be separated from each other. This configuration can be compared to a baby-bundler. On the basis of the anterior extraarticular aspect of the fasciculus obliquus in relation to the anterior band of the inferior GHL, six patterns can be discerned [55, 129]:

- In pattern 1, the anterior band is not in evidence as a fibrous sheet, and this may be due to degeneration of the capsule in older cadaver specimens. This pattern is relatively rare.
- In pattern 2, the superior borders of both ligaments cross in the medial third, which leaves a small strip of the anterior band visible from the outside.

**Fig. 4.30a, b.** **a** Anterior view on the inferior GHL complex of a right shoulder in slight internal rotation and abduction with some distraction. The inferior GHL complex cradles the humeral head (*hh*) like a hammock. It is composed of the posterior band of the inferior GHL (*PB*), the anterior band of the inferior GHL (*AB*) and the axillary pouch (*ap*). The latter is actually formed by the fasciculus obliquus (*FO*) on the medial side, where it attaches to the glenoid labrum (*gl*) and the tendon of the long head of the triceps (*ltt*), and by the anterior band of the inferior GHL, where it attaches to the humeral neck. The middle and superior GHL (*SG*) have been cut away to allow a better view of the hammock. The subscapularis (*ssc*) has been transected (*cp* coracoid process, *gf* glenoid fossa, *gl* glenoid labrum). **b** Posterior view of the posterior glenohumeral capsule of a left shoulder in internal rotation and slight abduction: the tendons of the supraspinatus (*ssp*) and the infraspinatus (*isp*) have been dissected free of the underlying capsule as far laterally as possible and have then been reflected laterally. In this position the posterior band of the inferior GHL cradles the humeral head posteriorly, much as the fasciculus obliquus cradles it anteriorly in external rotation. In this specimen, the posterior band of the inferior GHL reaches as far up as to the equator of the glenoid fossa. Together with the medial part of the axillary pouch (formed by the fasciculus obliquus), it has a partial origin from the tendon of the long head of the triceps. The tendon of the long head of the biceps (*ltb*) is mostly obscured from view by the acromion (*AC*). The posterosuperior GHL (*PS*) appears relatively anteriorly due to the positioning of the humeral head in internal rotation

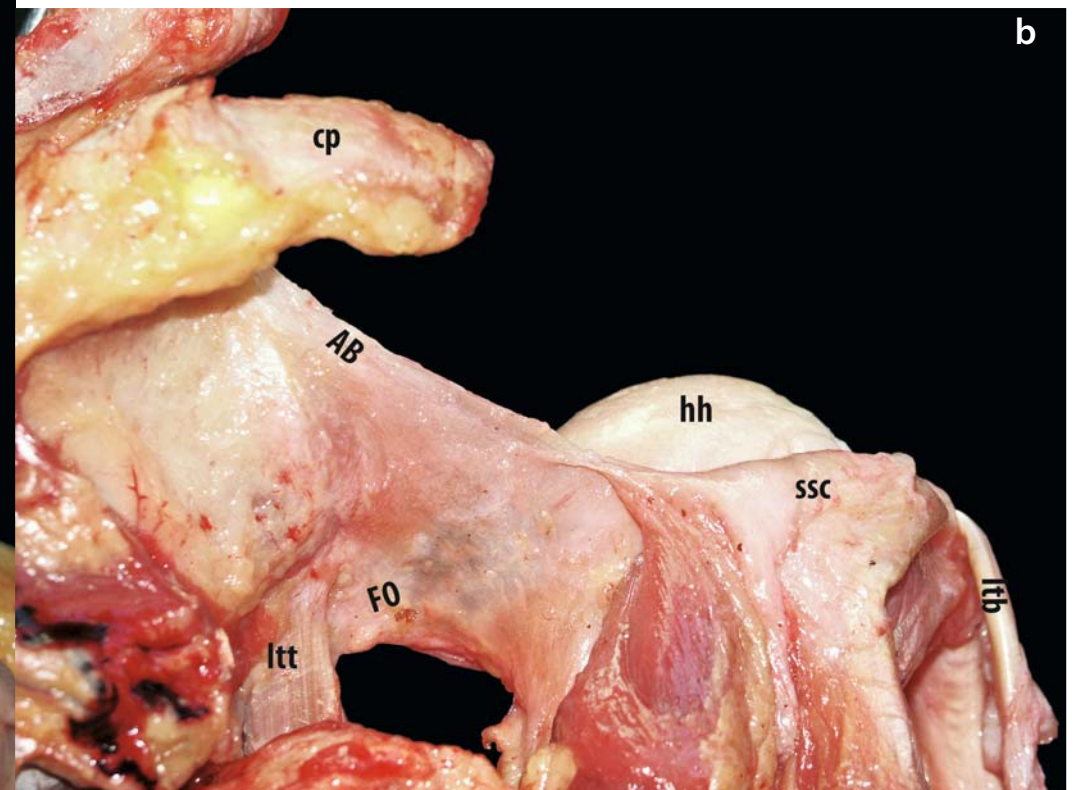
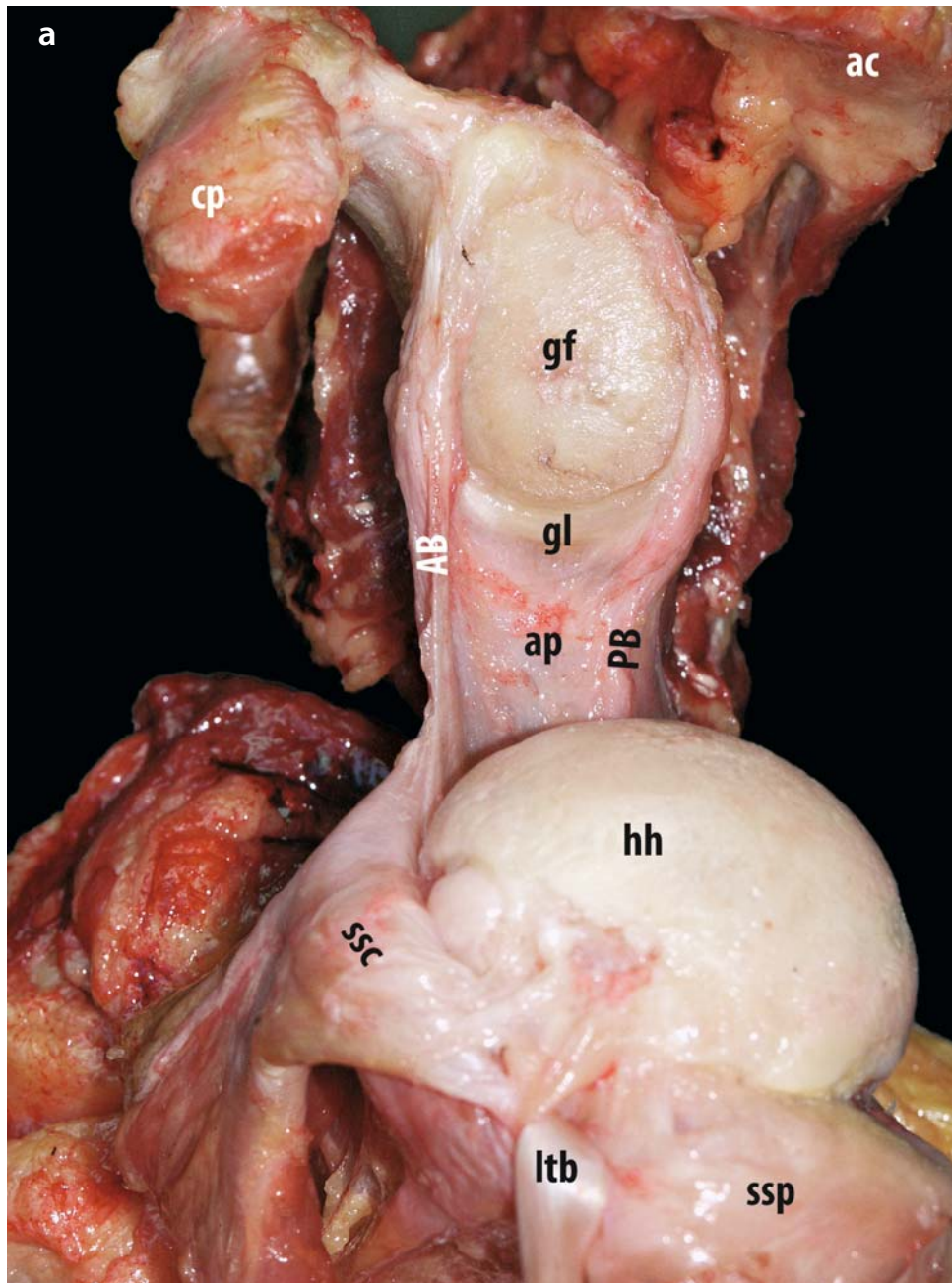


- In pattern 3, an intermediate width of the anterior band is visible, with both ligaments crossing in the middle third. This seems to be the most frequent pattern.
- In pattern 4, the anterior band appears as a broad structure, and the crossing is in the lateral third. This seems to be the second most common pattern.
- In pattern 5, a very broad anterior band crosses the fasciculus obliquus over its entire length. This pattern is also rarely observed.
- Finally, pattern 6 has both ligaments crossing in their lateral third, but there is a gap between them in the middle and/or third. This gap corresponds with the foramen of Rouvière and is rarely seen (Fig. 4.31a, b).

#### 4.3.4 Synovial Recesses

Cicccone et al. [133] determined that the glenohumeral capsule varied in thickness from 1.32 to 4.47 mm and in overall length (glenoid to humerus) from 25 to 45 mm. There was a general thinning from medial (average 3.03 mm at the glenoid side) to lateral (average 2.17 mm at the humeral side) and from inferior to superior. The midposterior area seemed to be the thinnest part of the capsule. In this relatively uniform distribution of capsular thickness several weaker and thinner areas have been observed. These occur in the capsular areas between the ligamentous reinforcements.

**Fig. 4.31a, b.** **a** Superior view of the inferior GHL complex of a left shoulder in slight external rotation and distraction: the superior GHL complex has been resected. The tendon of the long head of the biceps (*ltb*) has been cut loose from the glenoid labrum (*gl*) and reflected laterally. The subscapularis (*ssc*) and the supraspinatus (*ssp*) have also been reflected laterally. The superior border of the anterior band of the inferior GHL (*AB*) is sharply delineated and under full tension. The anterior band of the inferior GHL lies anterior to the humeral head (*hh*) in external rotation. In this specimen, the anterior band of the inferior GHL has an origin from the glenoid labrum reaching the 8 o'clock position. The posterior band of the inferior GHL (*PB*) only reaches 5 o'clock position and almost runs under the humeral head in this position (*cp* coracoid process, *gf* glenoid fossa, *ac* acromion). **b** Anteroinferior view of the inferior GHL complex of a left shoulder in internal rotation and abduction with full distraction: the anterior band of the inferior GHL and the fasciculus obliquus (*FO*) cradle the humeral head. Both ligaments are under maximal tension in this position. The fasciculus obliquus, with its partial origin from the tendon of the long head of the triceps (*ltt*), forms the axillary pouch on the medial side, while the anterior band of the inferior GHL forms the lateral side. The subscapularis (*ssc*) and the tendon of the long head of the biceps (*ltb*) have been reflected laterally (*cp* coracoid process)



DePalma et al. [4] classified the synovial recesses by the morphological variation of the glenohumeral ligaments. The synovial recess above the middle glenohumeral ligament was designated the superior subscapularis recess and the synovial recess below the middle glenohumeral ligament, the inferior subscapularis recess. The size of both these recesses varies extremely widely, and with increasing age the recesses have a tendency to become smaller or even obliterated.

The synovial membrane that coats the entire fibrous capsule, the glenohumeral ligaments and the long tendon of the biceps muscle was slightly wider at the level of the recesses. In a later publication, DePalma et al. [134] started some confusion with the idea that the presence of large synovial recesses indicates the absence of the middle glenohumeral ligament. The six types of arrangement of the synovial recesses according to DePalma et al. [4, 134] were (Fig. 4.32a, b):

Type I: one recess above middle glenohumeral ligament

Type II: one recess below middle glenohumeral ligament

Type III: two recesses, one superior above and one inferior below the middle glenohumeral ligament

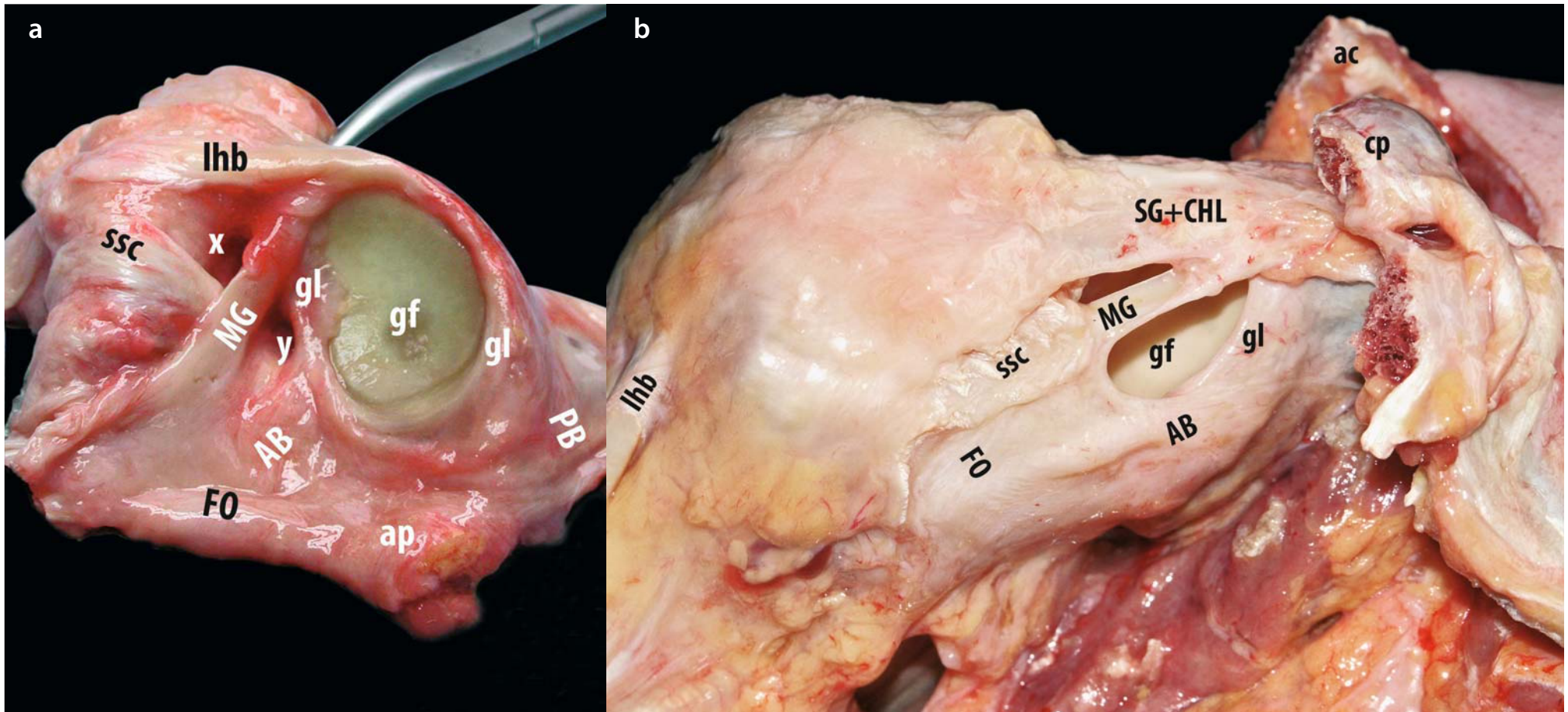
Type IV: one large recess above inferior glenohumeral ligament, lacking middle glenohumeral ligament

Type V: middle glenohumeral ligament in the form of two small synovial folds

Type VI: no recesses

The superior subscapular recess is in contact with and sometimes actually opens into the subscapular bursa. This bursa is present in 80–89% of cases and extends along the superior tendinous border of the subscapularis muscle. Medially, the bursa lies between muscle and coracoid process, and it extends 4–8 cm onto the scapula. The bursa is instrumental in allowing smooth gliding of the subscapularis tendon and muscle along the coracoid process during humeral motion [126, 135].

**Fig. 4.32a, b.** **a** Glenoid block specimen of a left shoulder: the glenoid has been cut at the scapula and the glenohumeral capsule has been dissected free along its humeral insertion. The middle GHL (*MG*) can always be identified because it crosses the intraarticular portion of the tendon of the subscapularis diagonally (*ssc*). The foramen of Weitbrecht (*x*) is almost always present superior to both structures. It leads to the subscapular bursa (medial continuation indicated by *clamp*) and lies inferior to the superior GHL, which is obscured by the tendon of the long head of the biceps (*lhb*). The foramen of Weitbrecht (*x*) should not be confused with a rotator cuff interval lesion. In some specimens, one can also observe a second recess (*y*) beneath the middle GHL and above the anterior band of the inferior GHL (*AB*). This recess has been called the foramen of Rouvière (*y*) (*FO* fasciculus obliquus, *ap* axillary pouch, *PB* posterior band of the inferior GHL, *gf* glenoid fossa, *gl* glenoid labrum). **b** Anterior extraarticular view of a right shoulder showing synovial recesses between the superior GHL (*SG*) with conjoined coracohumeral ligament (*CHL*) and middle GHL (*MG*), as well as between the middle GHL and the anterior band of the inferior GHL (*AB*) (*cp* coracoid process, *ac* acromion, *ssc* subscapularis)



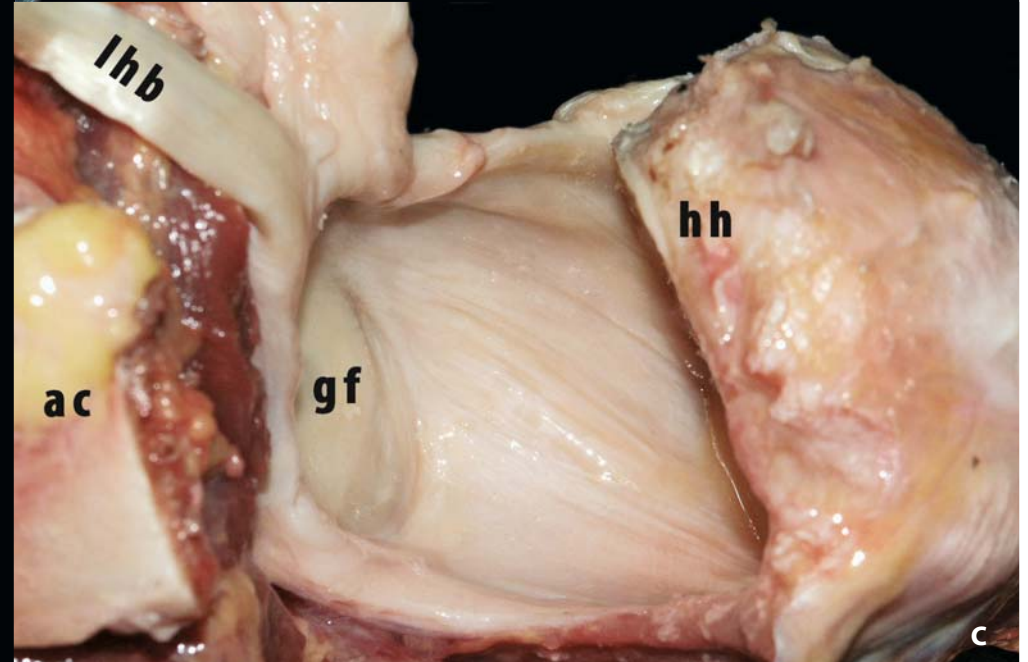
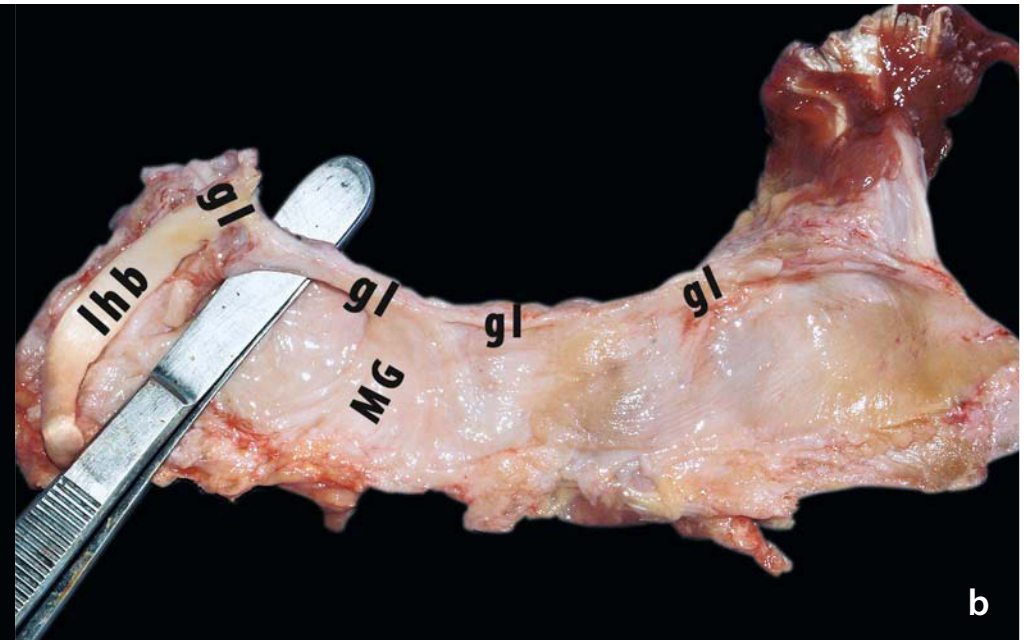
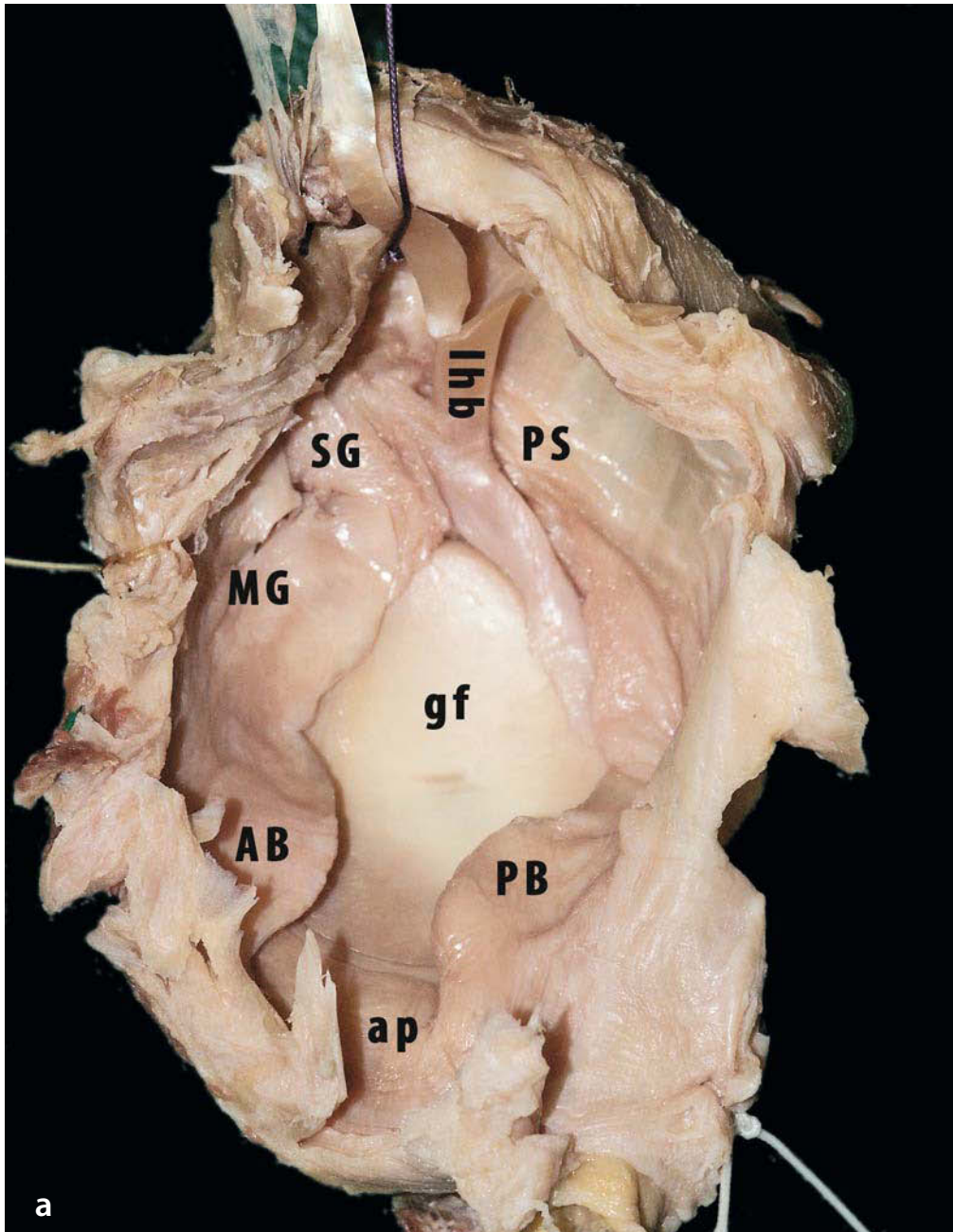


The superior subscapularis recess has also been called the foramen ovale of Weitbrecht [12, 14, 15, 28], whereas the inferior recess corresponds with the subcoracoid foramen of Rouvière [14, 15]. Landsmeer and Meyers [47] give a very detailed anatomical description of both bursae and clearly state that they are separated by the middle glenohumeral ligament. According to Rouvière and Delmas [15], the subcoracoid foramen was observed in half of their cases and it was situated either between the middle and the inferior glenohumeral ligament or between glenoid and labrum at the level of these ligaments. In the latter case, it actually corresponded with a sublabral hole.

Alternatively, the capsular region between superior and middle glenohumeral ligament that comprises the foramen of Weitbrecht has also been referred to as the rotator cuff interval. This has been described in a previous chapter.

In embalmed specimens and during arthroscopy, folds and recesses are usually observed in the anterior and inferior parts of the capsule. Most authors and surgeons have interpreted these folds as the ligaments of the glenohumeral capsule. While these folds and recesses may aid in localising the underlying ligaments, they are actually only the borders of the ligaments, as discussed in section 4.3.5. In contrast, when flattened capsular specimens or the anterior capsule are examined during dissection, it often happens that no folds or recesses can be distinguished (Fig.4.33a–c).

**Fig. 4.33a–c.** Glenoid block specimen of an embalmed left shoulder. **a** The glenoid has been cut at the scapula and the glenohumeral capsule has been dissected free along its humeral insertion. Folds and recesses do not necessarily correspond with the individual capsular ligaments, which are difficult to identify separately (*SG* superior GHL, *MG* middle GHL, *AB* anterior band of the inferior GHL, *ap* axillary pouch, *PB* posterior band of the inferior GHL, *PS* posterosuperior GHL, *lhb* tendon of the long head of the biceps, *gf* glenoid fossa). **b** Detached glenohumeral capsule laid out flat. No individual ligaments can be discerned. The foramen of Weitbrecht (indicated by *forceps*) can be identified. The thickened band next to it is probably the middle GHL (*MG*). **c** Posterior intraarticular view of the anterior glenohumeral capsule of a left shoulder in external rotation, abduction and distraction: the humeral head (*hh*) has been resected. When the individual ligaments have not been dissected out, no folds or recesses can be observed (*lhb* tendon of the long head of the biceps, *gf* glenoid fossa, *ac* acromion)



### 4.3.5 Biomechanics and Functional Anatomy of the Anteroinferior Glenohumeral Complex

The middle glenohumeral ligament limits motion when the position of the humerus is in neutral to slight abduction associated with external rotation and slight retroflexion. It has been observed [8, 11, 51, 126] that the middle glenohumeral ligament resists external rotation in up to 90° of abduction and that the middle glenohumeral ligament works together with the coracohumeral ligament to resist external rotation below 60° of abduction and to resist inferior displacement of the humeral head.

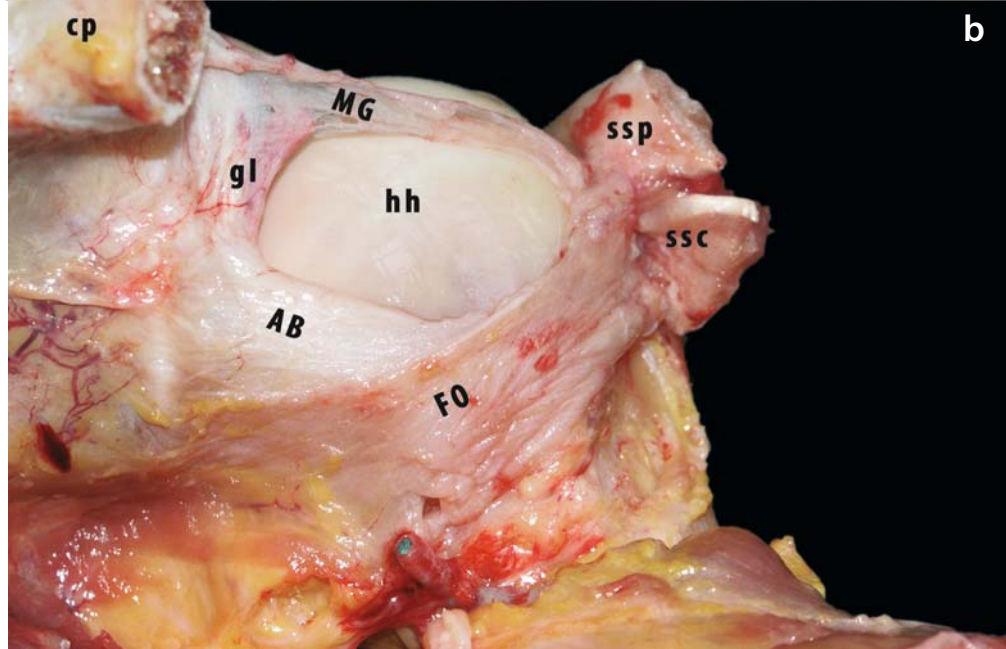
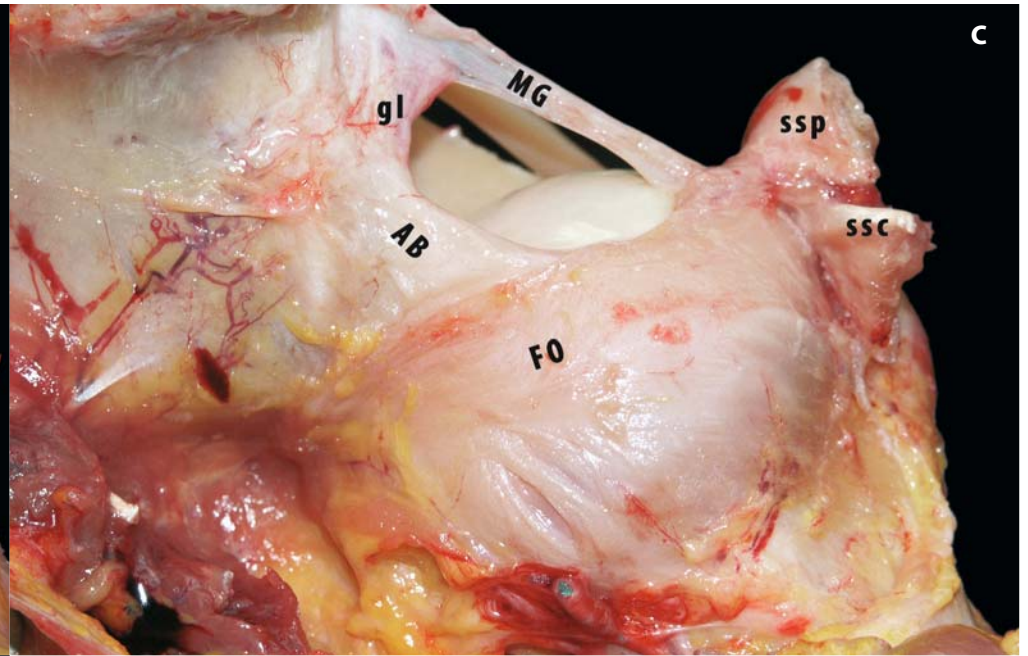
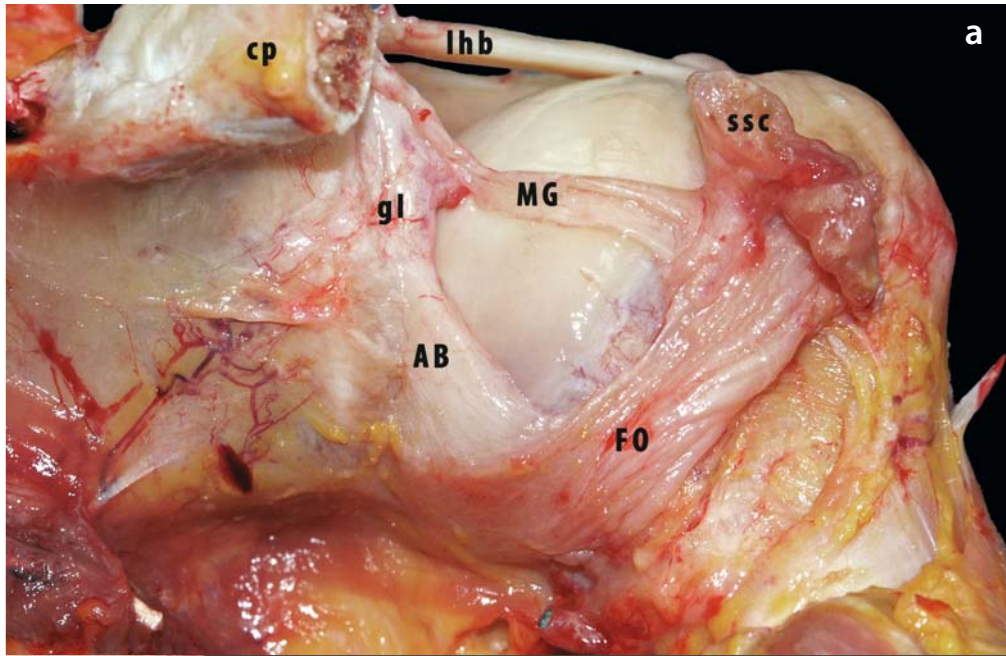
The fasciculus obliquus limits external rotation with the humerus in anteflexion. Together with the middle glenohumeral, the fasciculus obliquus stabilises the humeral head against anterior translation both in external rotation in adduction and in neutral rotation in abduction, especially when there is associated retropulsion. It also aids the anterior band of the inferior glenohumeral ligament in supporting the humeral head during abduction with neutral to external rotation [8, 55, 79, 129].

In abduction and external rotation, the anterior band of the inferior glenohumeral ligament comes under tension, fans out and seems to expand into a more discrete structure that forms a buttress against anterior translation. In contrast, the anterior band becomes slack and folded, and thereby more easily identifiable as a thickened band, in internal rotation. The posterior band of the inferior glenohumeral ligament appears as a more variable fold that cradles the humeral head in adduction and external to neutral rotation. With abduction or forward flexion and internal rotation, the posterior band is put under tension, the fold is obliterated and the humeral head is pushed forward.

Together the anterior and posterior bands and the axillary pouch form a hammock for the humeral head. This hammock appears redundant in adduction and becomes progressively tighter with increasing abduction. The anterior and posterior bands display reciprocal tightening with rotation. Similarly, the inferior and superior glenohumeral ligament complexes show reciprocal tension within the abduction range. The inferior glenohumeral ligament limits external rotation motion when the humerus is in abduction associated with slight retroflexion, the upper fibres being more involved in low abduction, the lower ones more in higher abduction and both parts in mid-abduction (about 30–60°) [8, 51, 55, 75, 127–129, 131, 132] (Fig. 4.34a-c).

Both Turkel et al. [51] and Warner et al. [138] have labelled various components of the glenohumeral capsule to evaluate their orientation and relative length during motion. The anterior and posterior bands of the inferior glenohumeral ligament have a cruciate orientation in the anteroposterior glenoid plane that is maintained in all positions of abduction except at 90° of abduction, where the bands are parallel. The cruciate orientation seems to be due to the difference in humeral insertion and glenoid origin, with the posterior band located lower on the glenoid and higher on the humerus. This configuration may allow reciprocal tightening of each band during rotation. The superior glenohumeral ligament tightens more in adduction, while the middle glenohumeral ligament tightens more in abduction. The superior glenohumeral ligament seems to form the primary check against external rotation in adduction and against inferior translation in adduction combined with neutral to external rotation. The superior glenohumeral ligament has no effect in abduction.

**Fig. 4.34a-c.** Sequence (anterior view of left shoulder) illustrating functional anatomy of the inferior GHL complex with an anterior band of the inferior GHL (AB) that crosses the fasciculus obliquus (FO) in the middle third (pattern 3, see text for details). **a** In full internal rotation and adduction, the anterior band of the inferior GHL and the fasciculus obliquus are slack and folded up. Both follow an oblique course to cross over below the humeral head (*hh*). The middle GHL (*MG*) runs horizontally over the middle of the humeral head (*hh*) and is slack in this position. **b** In external rotation and slight abduction, the anterior band of the inferior GHL and the middle GHL are unfolded under tension and both have an almost parallel horizontal course. **c** In full external rotation with abduction, the fasciculus obliquus is also fully stretched over the humeral head. The middle GHL (*mg*) now lies superior to the humeral head (*ltb* tendon of the long head of the biceps, *ssc* subscapularis, *ssp* supraspinatus, *gl* glenoid labrum, *cp* coracoid process)



Malicky et al. [137, 138] discovered that during subluxation forces in abduction and external rotation, high strain tends to occur on the glenoid side, but failure tends to occur on the humeral side. The maximum principal strain vectors are generally not oriented along the anterior band of the inferior glenohumeral ligament, but rather diagonally from the inferior rim of the glenoid to the superior humeral insertion of the anteroinferior capsule, which is along the course of the fasciculus obliquus.

The entire capsule and the interplay between its ligaments has apparently not been a frequent subject of biomechanical studies. Debski et al. [139] and Terry et al. [140] have demonstrated that the ligamentous restraints transfer and share the

tension required to stabilise the glenohumeral joint during loading. In addition, attempts at simple motion in one plane always result in coupled motion in two additional planes. Other studies [71, 141–143] have measured the strain that develops in a specific part of the glenohumeral capsule during application of a given torque or a given translatory force. Their results can be summarised to give the following conclusion. When an external rotation torque is applied to the humerus, the maximal strain of loading is progressively shifted from the superior and middle glenohumeral ligament at 0° of abduction to the anterior band of the inferior and the middle glenohumeral ligament in 30–60° of abduction, with a maximum strain in the anterior band at 90° of abduction (Fig. 4.35a, b).

**Fig. 4.35a, b.** **a** Superior intraarticular view of a left shoulder in slight external rotation and distraction. The superior GHL complex has been resected. The anterior band of the inferior GHL (*AB*) and the middle GHL (*MG*) are under tension in front of the humeral head (*hh*). The major part of posterior band of the inferior GHL (*PB*) lies under the humeral head (*hh*) together with the axillary pouch (*ap*) (*cp* coracoid process, *ac* acromion, *gf* glenoid fossa, *gl* glenoid labrum, *ssc* subscapularis, *ssp* supraspinatus, *isp* infraspinatus). **b** Anterior view of a right shoulder in neutral rotation and distraction. The superior structures and the middle GHL have been resected. The anterior band of the inferior GHL is taut and the axillary pouch lies centrally under the humeral head. The inferior GHL complex functions as a hammock under the humeral head (*lth* tendon of the long head of the triceps, *isp* infraspinatus)



### 4.3.6 Clinical Relevance

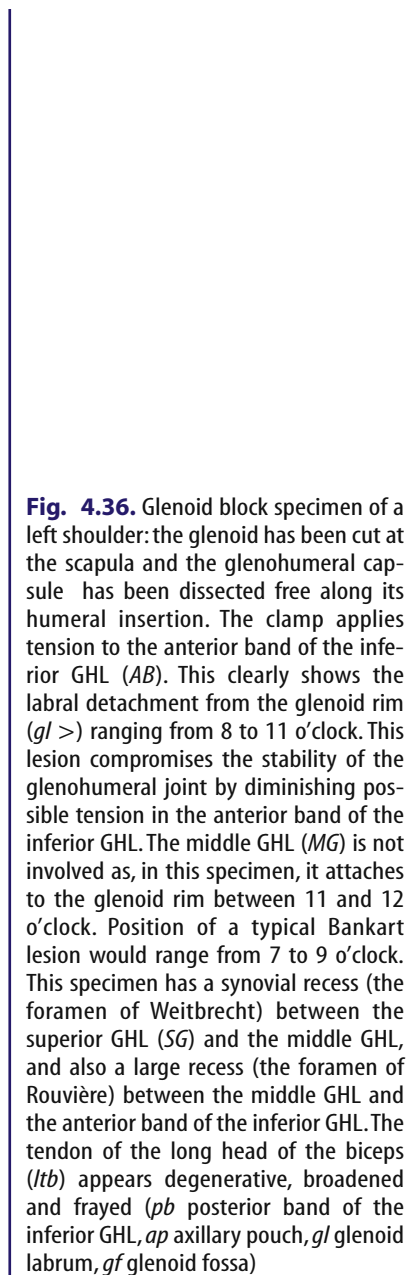
In the clinical situation, instability with recurrent dislocation most frequently occurs in abduction with external rotation. Therefore, the anterior band of the inferior glenohumeral ligament and its insertions on the labrum and the humerus (see later) will most often be involved. When lesions are present, repair needs to follow the fibre orientation of this ligamentous reinforcement. An anterior band that has been detached from the glenoid side, either with or without the labrum—a Bankart lesion—will usually be retracted laterally and downwards. Its surgical reattachment should, therefore, not only be directed medially—back to the glenoid rim—but also upwards, with its superior border back to the midglenoid position.

Patients may suffer from less classic forms of instability, that is in other positions than abduction with external rotation, or in cases of subtle instability often without frank dislocation. In these cases, one should consider damage to other structures

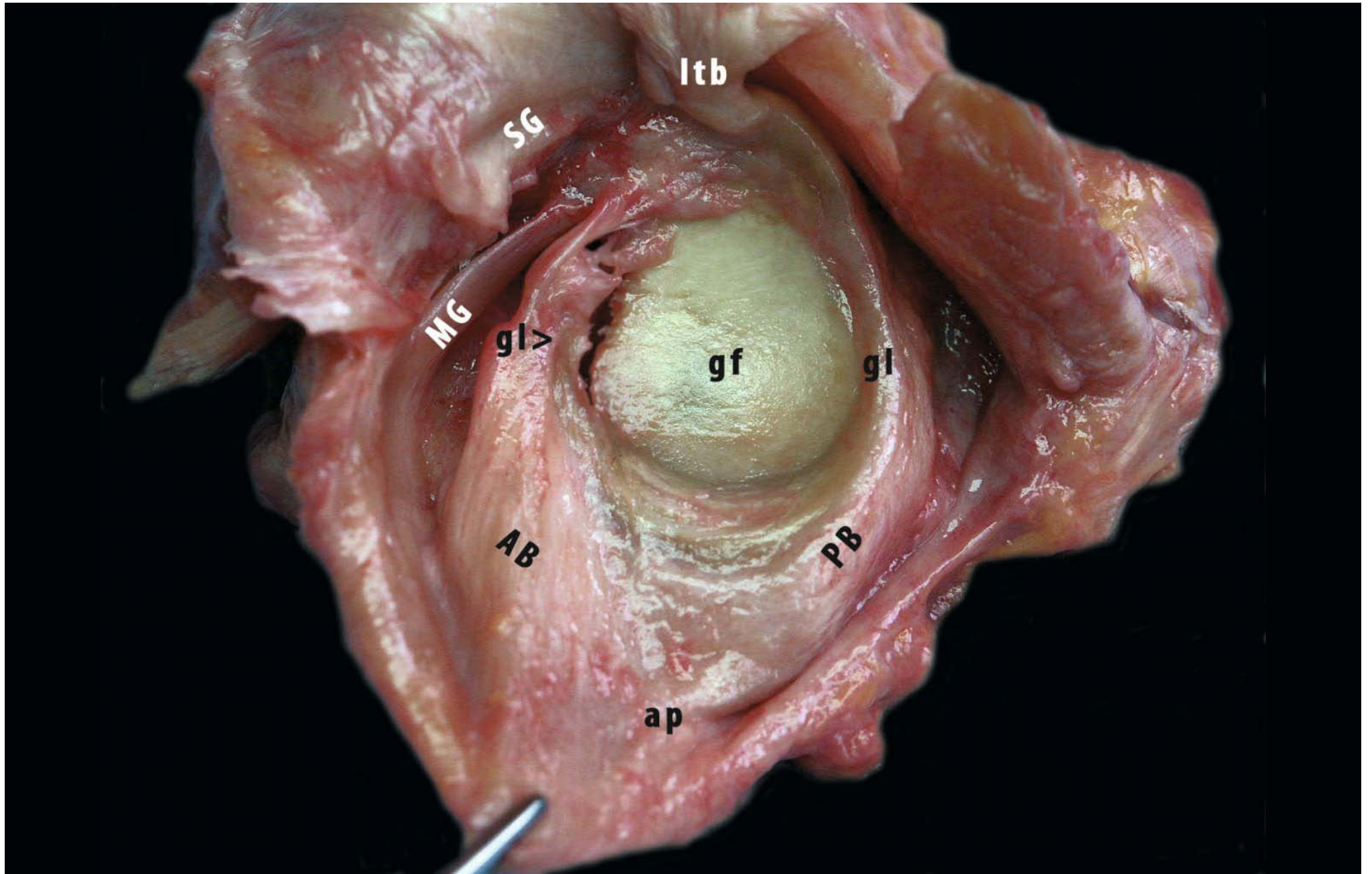
than the anterior band of the inferior glenohumeral ligament. The middle glenohumeral ligament and the fasciculus obliquus may be involved in cases of straight anterior instability. This may be characterised by increased anterior translation in neutral rotation rather than external rotation associated with retropulsion in 30–90° of abduction. This kind of instability may be underdiagnosed because it can more easily be compensated by a well-functioning subscapularis muscle.

On the other hand, “Bankart” lesions that run far inferiorly and HAGL lesions of the anteroinferior part of the capsular insertion actually involve the fasciculus obliquus. Again, repairs have to reattach this structure according to its normal fibre orientation from inferiorly on the glenoid to anterior on the humerus.

Open capsular shift procedures should address the anterior band of inferior glenohumeral ligament as well as the fasciculus obliquus (Fig. 4.36).



**Fig. 4.36.** Glenoid block specimen of a left shoulder: the glenoid has been cut at the scapula and the glenohumeral capsule has been dissected free along its humeral insertion. The clamp applies tension to the anterior band of the inferior GHL (*AB*). This clearly shows the labral detachment from the glenoid rim (*gl >*) ranging from 8 to 11 o'clock. This lesion compromises the stability of the glenohumeral joint by diminishing possible tension in the anterior band of the inferior GHL. The middle GHL (*MG*) is not involved as, in this specimen, it attaches to the glenoid rim between 11 and 12 o'clock. Position of a typical Bankart lesion would range from 7 to 9 o'clock. This specimen has a synovial recess (the foramen of Weitbrecht) between the superior GHL (*SG*) and the middle GHL, and also a large recess (the foramen of Rouvière) between the middle GHL and the anterior band of the inferior GHL. The tendon of the long head of the biceps (*ltb*) appears degenerative, broadened and frayed (*pb* posterior band of the inferior GHL, *ap* axillary pouch, *gl* glenoid labrum, *gf* glenoid fossa)





### 4.3.7 Glenoid and Humeral Insertion of the Capsule

The *humeral insertion* of the superior capsule has been described together with the superior complex.

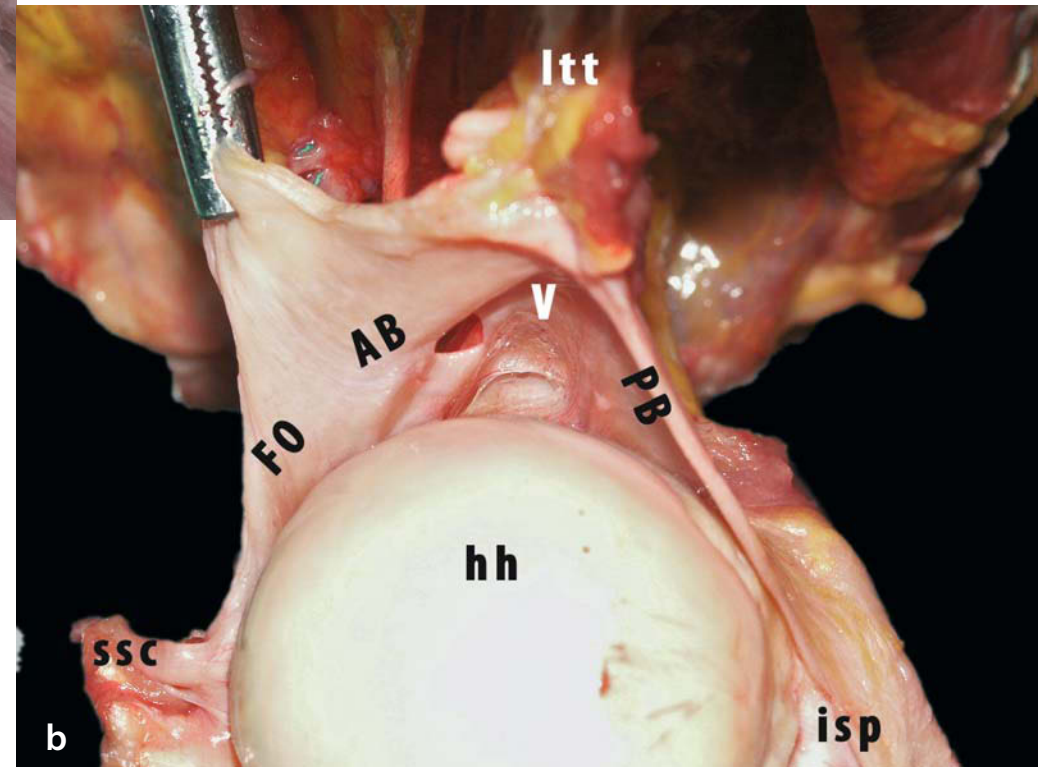
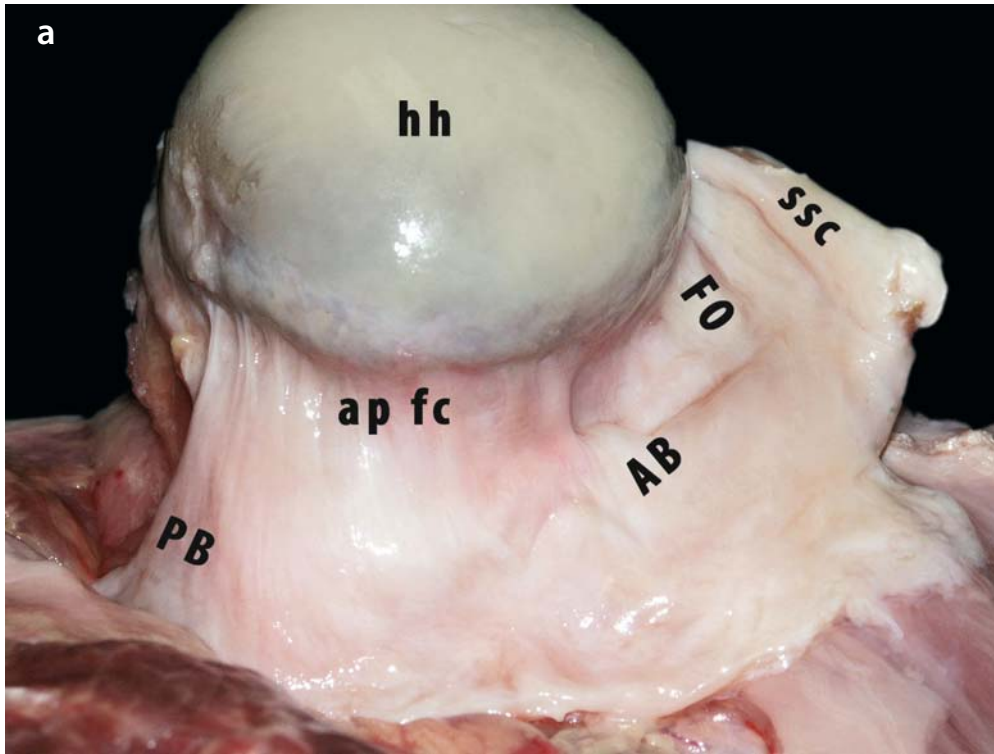
Two variations of the humeral insertion of the inferior glenohumeral ligament are described: a *collar-like* attachment close to the articular cartilage [131, 144] and a *V-shaped* attachment with its base close to the cartilage rim and its point more inferiorly on the humeral metaphysis [14, 15, 131, 144–147].

O'Brien et al. [131] (11 cadaver shoulders) and Ticker et al. [144] (8 cadaver shoulders) observed a collar-like insertion immediately inferior to the cartilaginous margin of the humeral head in half of their cases. The other half of the specimens in both studies had a V-shaped insertion. This description corresponds more closely to that found in classic anatomy textbooks, although only three of these [14, 15, 147] give extensive descriptions of the humeral insertion of the glenohumeral capsule. The capsular attachment closely follows the articular margin on the anatomical neck of the humerus, except in its inferior part. Here it descends away from the articular margin up to 1 cm lower than the inferior pole of the humeral head. This is in contrast to the synovial lining that follows the capsule onto the bone and then covers the anatomical neck up to the cartilage rim even inferiorly. Some recurrent fibres of the inferior capsule—the *frenula capsulae*—do attach to the inferior cartilage rim of the

humeral head [14, 15, 148] and may lift up the synovial membrane. The arterial circle of the blood supply to the humeral head described by Duparc et al. [149] passes along these *frenula capsulae*.

Recent studies [55, 127–129] combining observation by dissection and by arthroscopy in 200 cadaver shoulders and also by arthroscopy in 100 living subjects have shown that the inferior insertion of the glenohumeral capsules is consistently V-shaped when viewed from the outside. In over 90% of specimens, this V looked more or less rounded off from the inside because of connecting synovial bands. In only 8% of all shoulders that were examined from the inside, whether arthroscopically or by open dissection, was a V-shape observed by intraarticular inspection. The impression of a shallow V without a true V-like shape of the synovial lining can be gained when the humeral insertion is inspected arthroscopically in certain positions of humeral rotation or when the inferior capsule is examined through an anterosuperior incision. Sugalski et al. [150] have recently reported that the humeral insertion consists of two leaves, the outer, anterosuperior, leaf probably corresponding with the exterior V-shaped limb of the anterior insertion formed by the *fasciculus obliquus* while the inner, anteroinferior, leaf probably corresponds with the interior collar-like part of the inferior insertion formed by the anterior band of the inferior glenohumeral ligament (Fig. 4.37a, b).

**Fig. 4.37a, b.** **a** Intraarticular view of a collar-like inferior humeral insertion in a left shoulder: the glenohumeral capsule has been detached from the glenoid. *Frenula capsulae* (*fc*) obliterate the axillary pouch (*ap*). **b** Intraarticular view of a V-shaped humeral insertion in a left shoulder. The anterior band of the inferior GHL (*AB*) and the posterior band of the inferior GHL (*PB*) are seen to converge in a V when inserting on the humeral neck (*FO* *fasciculus obliquus*, *ssc* *subscapularis*, *isp* *infraspinatus*, *lth* *tendon of the long head of the triceps*, *hh* *humeral head*)



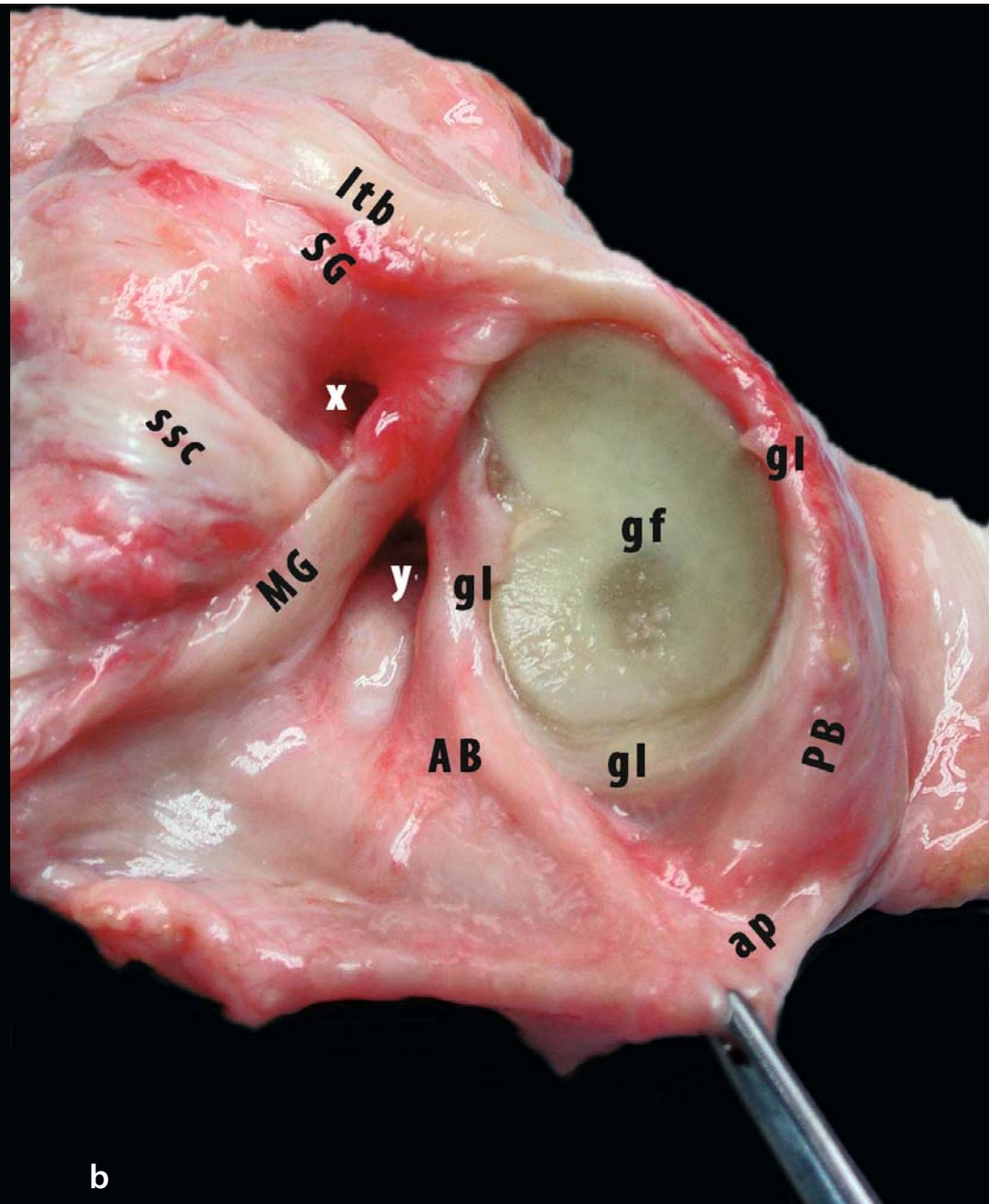
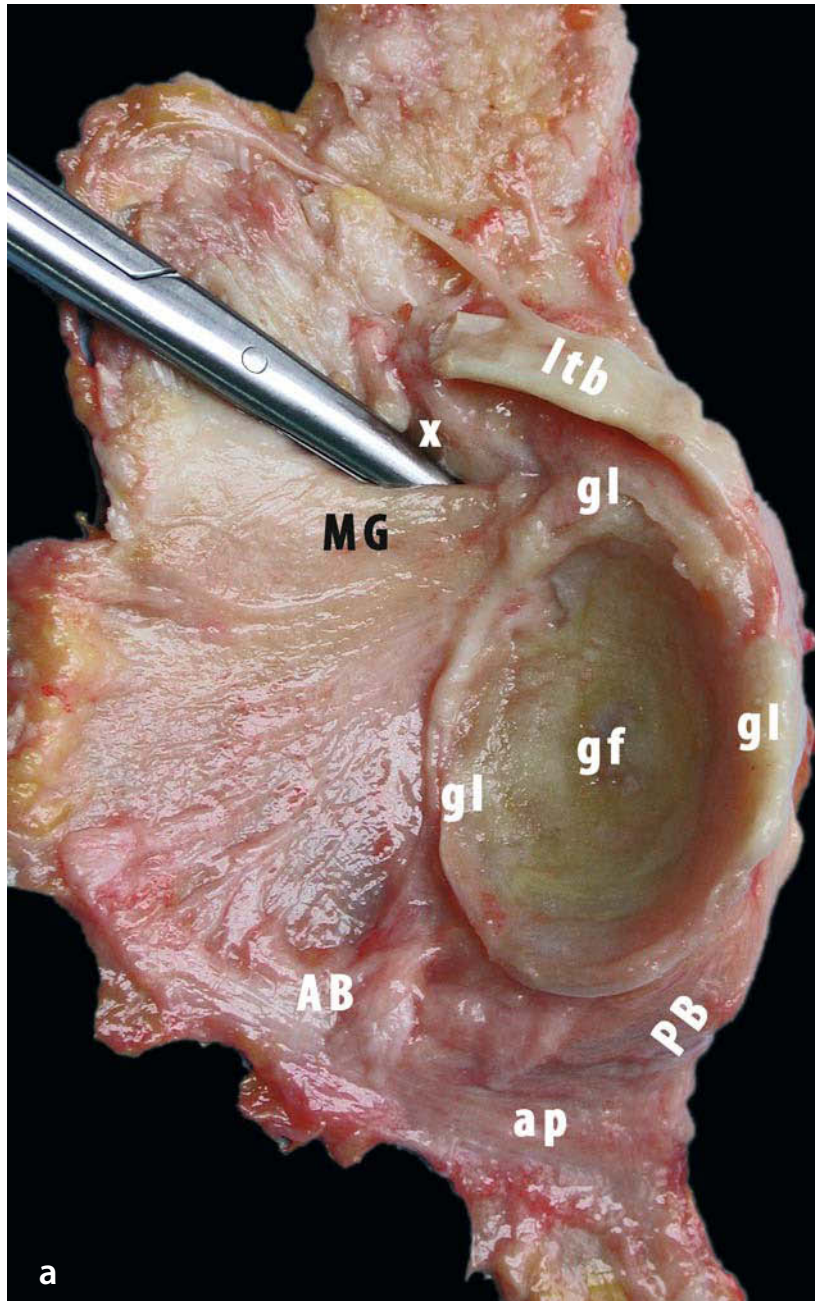
On the *glenoid* side, the inferior glenohumeral ligament is said to invariably attach on the inferior third of the labrum. Additionally, there is always a contribution of the triceps to the posteroinferior capsule through a fibrous extension of the bony origin [55, 127–129, 151].

Two types of attachment of the glenohumeral capsule to the scapula are usually described [152, 153]. In type I, which has been observed in about 80% of specimens, the anterior capsule is inserted into the labrum, sometimes with the appearance of an anterior capsular fold in internal rotation and a posterior fold in external rotation. This type has a primary attachment from the glenoid labrum with a fibrocartilaginous transition zone. In type II, observed in 23% of specimens, the capsule is inserted on the neck of the scapula without obvious attachment to the glenoid labrum. Here, some collagen fibres attach directly to bone and others blend with the periosteum. Most fibres run in a longitudinal direction before attaching to the bone or

periosteum at an acute angle. In the inferior zones, the fibre orientation is primarily radial, so that these fibres are involved in the circular collagen bundle system of the glenoid labrum. These studies indicate that one should be very careful in attributing any capsular redundancy to instability-induced pathology, as it may be a developmental variant. McMahon et al. [154] find that the anterior band of the inferior glenohumeral ligament apparently has a double type of attachment to the glenoid rim. Poorly organised collagen fibres insert on the labrum, whereas dense collagen fibres attach to the front of the glenoid neck.

The middle glenohumeral ligament is usually attached to the labrum, but may occasionally insert directly into the glenoid neck. The superior glenohumeral ligament complex arises from the glenoid neck, immediately medial to the labrum. The superior labrum is continuous with the long tendon of the biceps (Fig. 4.38a, b).

**Fig. 4.38a, b.** Glenoid block specimens of two left shoulders illustrating the appearance of synovial recesses in the anterior part of the glenohumeral capsule. **a** The glenoid has been cut at the scapula and the glenohumeral capsule dissected free along its humeral insertion. A synovial recess between the superior GHL (*SG*) and the middle GHL (*MG*) is almost always present. This foramen of Weitbrecht (*x*) gives access to the subscapular bursa, which may reach far medially on the scapular body (indicated by *scissors*). In this specimen, the anterior capsule from middle GHL to anterior band of the inferior GHL (*AB*) is smooth without additional recesses. **b** The foramen of Weitbrecht (*x*) can usually easily be located in the triangle formed by the superior GHL, the middle GHL and the intraarticular part of the tendon of the subscapularis (*ssc*). The area immediately lateral to the foramen is the rotator cuff interval. This specimen also displays a pronounced foramen of Rouvière (*y*), which may give access to an inferior subscapular bursa and is situated between the middle GHL and the anterior band of the inferior GHL (*PB* posterior band of the inferior GHL, *ap* axillary pouch, *ltb* tendon of the long head of the biceps, *gl* glenoid labrum, *gf* glenoid fossa)



a

b

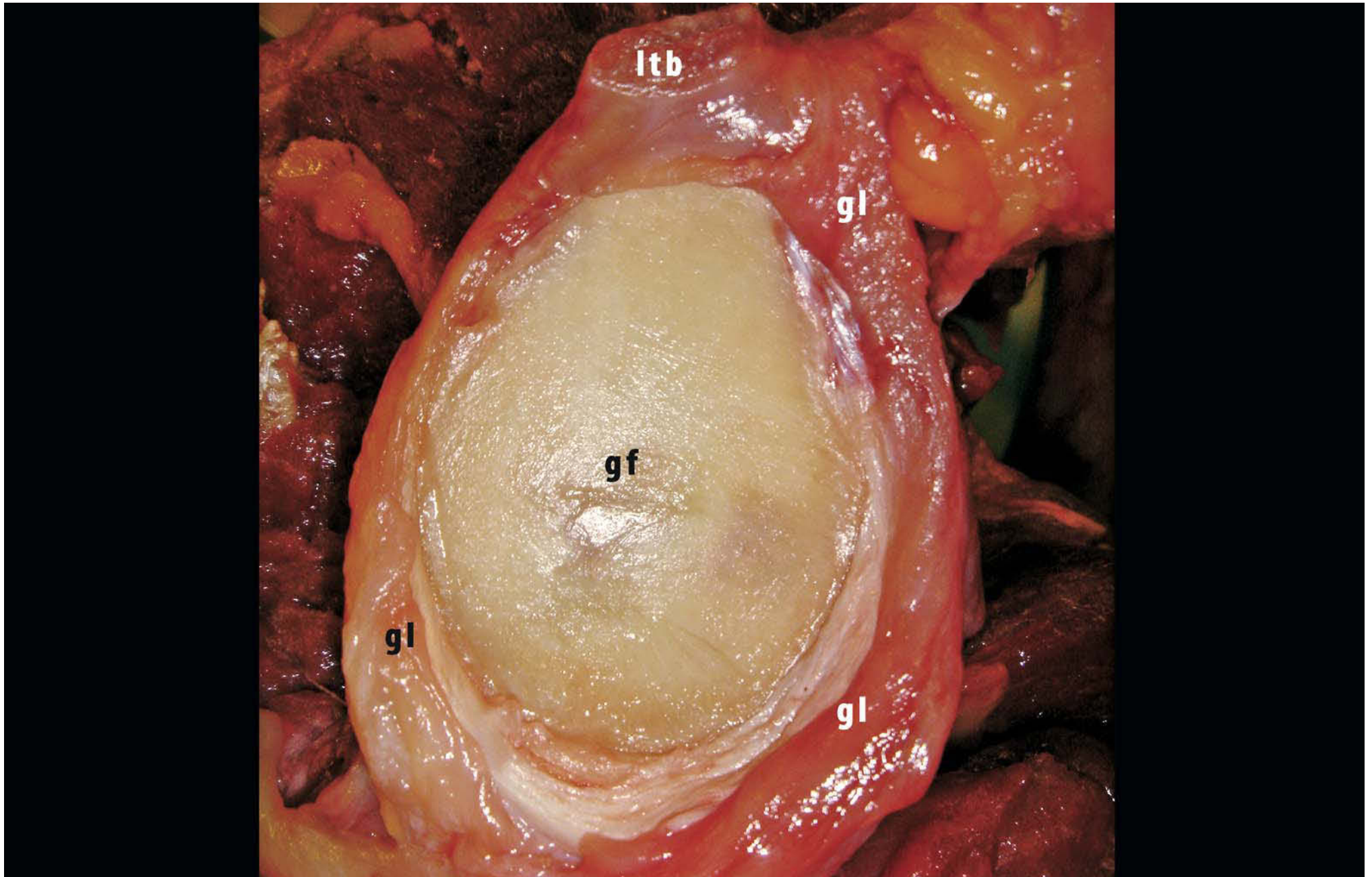
### 4.3.8 Glenoid Labrum

Vesalius [155] described the glenoid labrum long ago: “[L]imbus cartilagineus foveae glenoidalis luxandi promptitudinem corrigit.” According to most anatomy textbooks [12, 28, 131, 156], the glenoid labrum is triangular in shape with a free articular edge. The anterosuperior part of the labrum is usually thought to be meniscal in appearance, with a groove of varying depth between the labrum and the articular cartilage. The labrum usually forms a bridge over the glenoid notch, with a more or less pronounced opening between labrum and glenoid rim. In contrast, the inferior half of the labrum is usually described as more intimately connected to the glenoid rim and more continuous with the articular cartilage. Although most recent authors [4, 126, 157, 158] agree that the inferior part of the labrum appears as a rounded, fibrous and immobile extension of the articular cartilage with a fibrocartilaginous transition zone, there is more discussion about the superior part. Moseley and Övergaard [126] and Townley [157] believe that the labrum does not resemble the meniscus of the knee in any way, but should rather be considered as a redundant fold of the

capsular tissue. In contrast, Cooper et al. [158] report that the superior part of the glenoid labrum has a more or less meniscal pattern with a relatively loose and mobile attachment to the glenoid bone, but is closely associated with the long tendon of the biceps muscle. Nishida et al. [159] and Tamai et al. [160] discerned three layers in the labrum by scanning electron microscopic examination: a superficial layer with a randomised, mesh like fibril organisation, a stratified second layer with multidirectional fibrils forming the major part of the labrum, and a deep layer with dense fibre bundles including the area of insertion into articular cartilage and glenoid rim.

Hertz et al. [161] and Huber and Putz [162] have studied the fibre orientation and attachment of the glenoid labrum with a combination of several techniques. The labrum is mainly formed by a circular, periarticular system of fibre bundles that receives fibre bundles from the surrounding ligaments and tendons. From this study, Huber and Putz [162] conclude that the periarticular fibre system including the long tendons of the biceps and the triceps muscles and the glenohumeral ligaments should be considered as a single functional unit (Fig. 4.39).

**Fig. 4.39.** Medial view of the glenoid fossa (gf) of a left shoulder: the tendon of the long head of the biceps (*ltb*) has been transected at the level of its origin from the glenoid neck. This illustrates that the biceps anchor appears continuous with the superior labrum. Often, a small recess can be found under the biceps anchor, which should not be confused with a SLAP lesion. Another frequent location for a sublabral recess is anterosuperiorly. This sublabral hole usually occurs in association with a more explicit glenoid notch and should not be confounded with a labral lesion. In this specimen, the glenoid labrum (*gl*) is well attached to the glenoid rim around the entire circumference of the glenoid. The glenoid notch cannot be identified



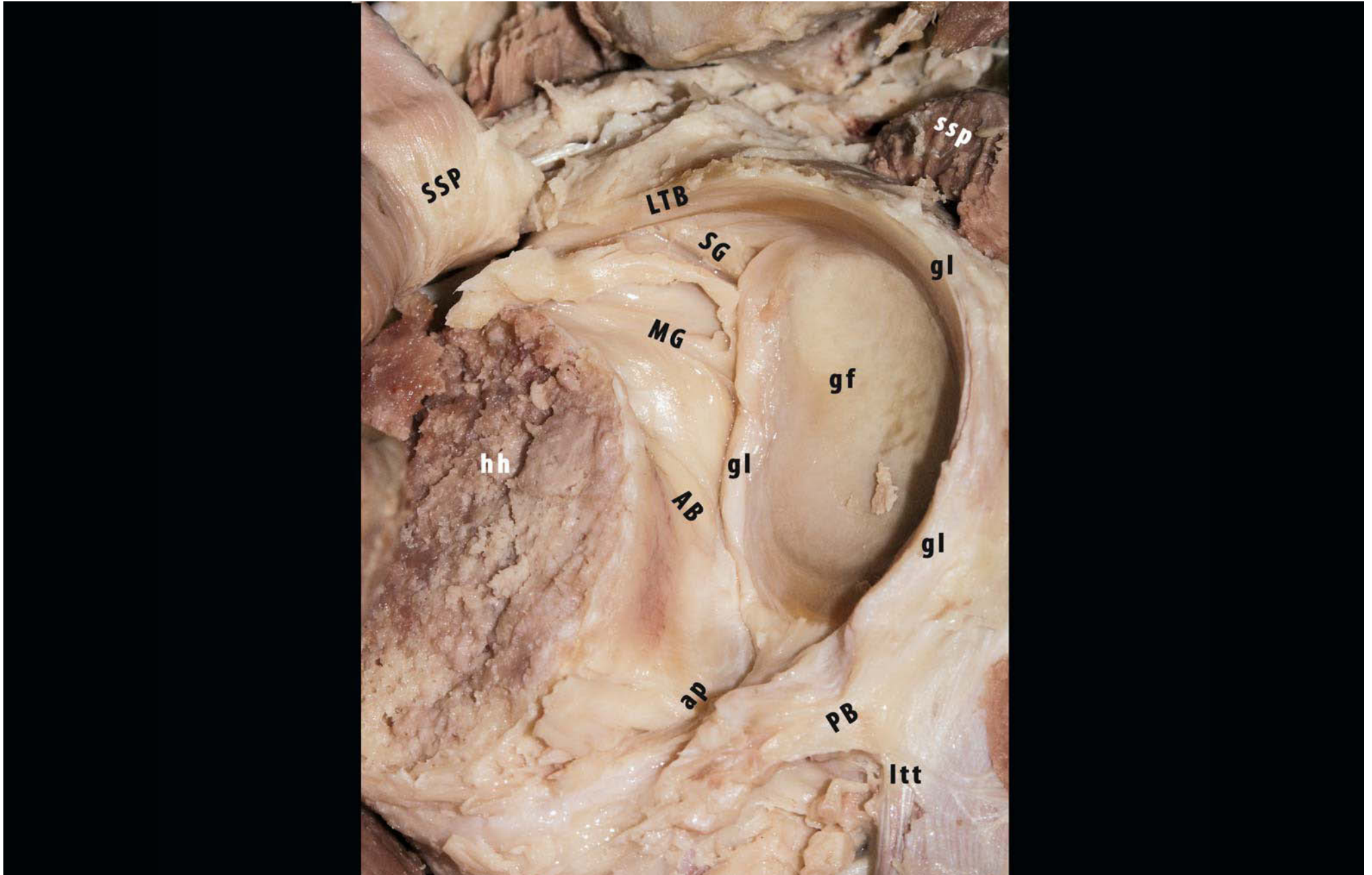
### 4.3.9 Biomechanics of the Glenoid Labrum

Although the glenoid labrum has received a great deal of attention in the literature, there is still much discussion about its role in stabilising the glenohumeral joint. The labrum certainly aids in anchoring the capsuloligamentous structures to the glenoid rim. In the inferior half, capsule and ligaments are continuous with the glenoid labrum and difficult to separate from one another. The presence of subcoracoid and subscapularis bursae make it especially clear that the continuity of capsule and labrum is not uniform in the superior half [126, 131, 163–167]. By increasing the depth of the glenoid concavity, the labrum contributes 10–40% of the concavity-compression effect and thereby increases the stability of the glenohumeral coupling [168–172]. Excising the labrum reduces the effectiveness of concavity-compression in resisting a translatory force by 20–65% [168, 173, 174].

The labrum is also believed to aid in creating negative intraarticular pressure by functioning as a valve block, sealing the glenohumeral joint against atmospheric pressure [175].

Compression of the humeral head against the glenoid by active muscle function and by passive capsuloligamentous restraint is facilitated by negative intraarticular pressure, and its role seems to be most prominent in preventing inferior translation when abduction is less than 45° [81, 176–179]. When capsulolabral or rotator cuff lesions are present negative intraarticular pressure diminishes [176, 180, 181]. We have observed that the elimination of negative intraarticular pressure may increase translation as a result of applied forces and diminish the force required to obtain a specific displacement, but by itself does not lead to any appreciable degree of instability on clinical testing manoeuvres [182] (Fig. 4.40).

**Fig. 4.40.** Posteromedial view on the glenoid fossa (gf) of an embalmed left shoulder: the humeral head (*hh*) has been resected and the posterior capsule detached from the humeral neck. The supraspinatus (*ssp*) has been transected at the level of the glenoid neck and the lateral part then reflected superolaterally. The tendon of the long head of the biceps (*ltb*) is left intact. In this specimen, the microscopic periarticular fibre system as described by Huber and Putz [162] is translated into a macroscopic impression: the tendon of the long head of the biceps appears to continue into the posterior glenoid labrum (*gl*) and to diverge posteroinferiorly into the posterior band of the inferior GHL (*PB*) and into the tendon of the long head of the triceps (*LTT*). A small glenoid notch can be seen at the level of the origin of the middle GHL (*MG*). The superior GHL (*SG*) has its origin on the glenoid neck medial to the glenoid labrum and the biceps anchor. In this embalmed specimen, folds create the impression that the middle GHL and the superior part of the anterior band of the inferior GHL (*AB*) also attach to the glenoid neck rather than to the glenoid labrum. A synovial recess (foramen of Weitbrecht) is visible between the superior GHL and the middle GHL (*ap* axillary pouch)





The labrum has also been likened by Howell and Galinat [183] to a wedge that forms a passive restraint to translation of the humeral head, much as a chock block prevents a wheel from rolling away. However, the relatively loose attachment of the labrum in its superior part [146, 167, 184] precludes the blocking wedge effect in this area. Cooper et al. [167] have described the labrum as more meniscoid in this area. Anatomical variations or degenerative changes in this (antero)superior area, which do not lead to instability, may be falsely interpreted as labral tears [167, 185]. In the inferior part, the labrum is more fibrous and is securely attached to the glenoid rim [127, 167].

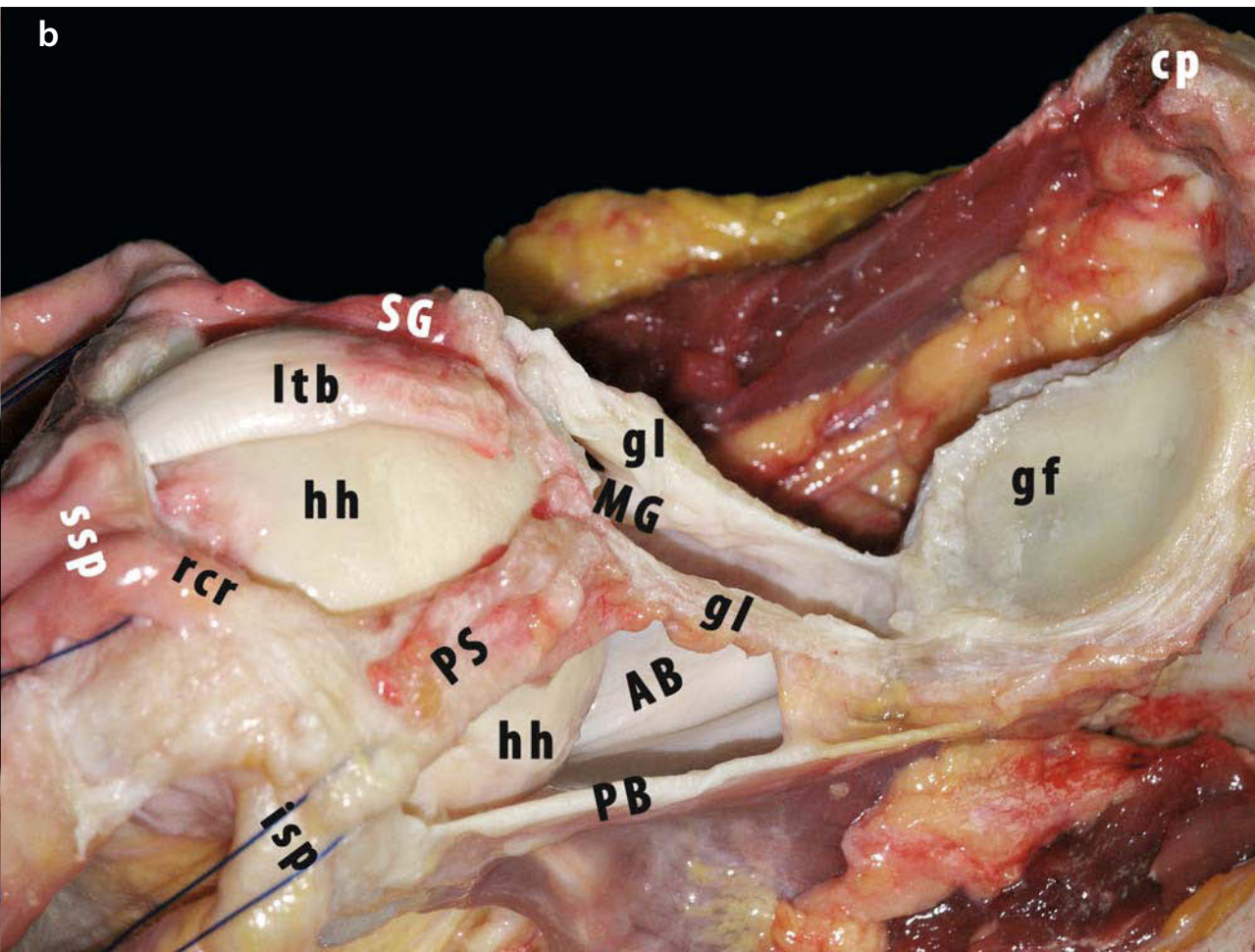
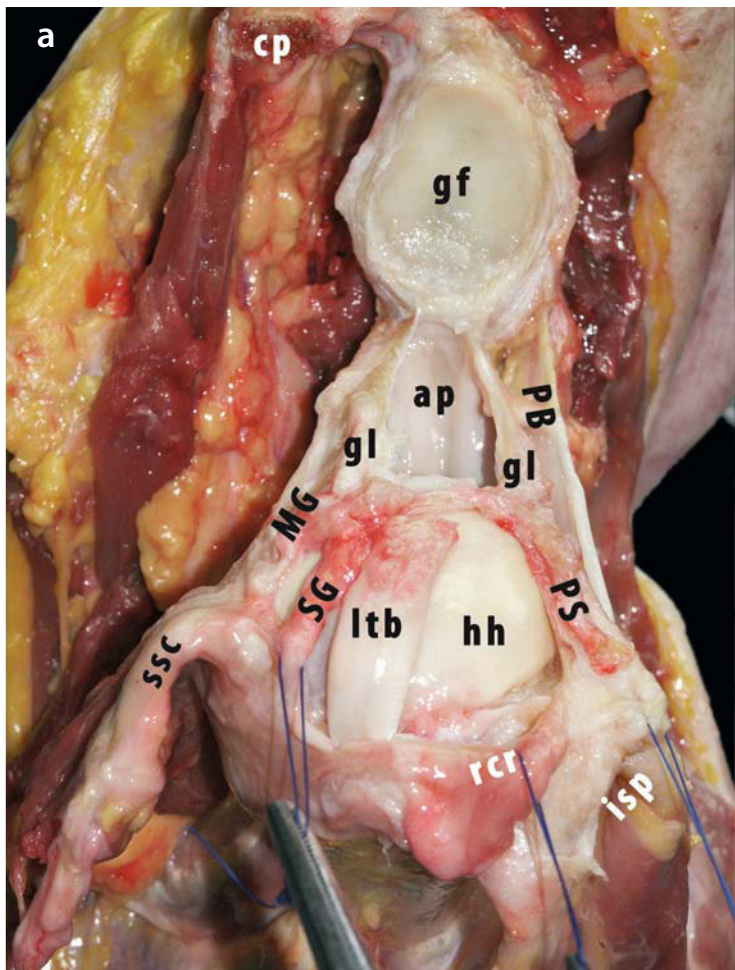
Here, it is easier to believe that the immobile labrum can act as a passive restraint in itself. This inferior area is also where the middle and inferior glenohumeral ligaments are located. That capsuloligamentous and labral lesions are predominantly found in this anteroinferior zone in clinical series of patients with shoulder instability reinforces the blocking wedge theory.

Labral resection with intact capsuloligamentous structures does not seem to have important consequences as far as clinically detectable instability is concerned. Our study [182] seems to indicate that the chock-block effect of the labrum and its relevance for concavity-compression are not major contributory factors for stability in 90° of external rotation with 90° of abduction. We believe that capsuloligamentous tension is the more important static stabiliser in this position.

Some experimental studies on labral lesions have been published [182, 185–189]. These indicate that small increases in translation and altered contact pressures, but not dislocation, can be due to labral and Bankart lesions, but that these increases may remain within the normal variation of inferior and anterior translation observed in asymptomatic shoulders [190–192].

Torsional resistance does decrease with increasing depth of a Bankart lesion [193]. In combination with glenoid cartilage lesions [174] anteroinferior stability is compromised (Fig. 4.41a, b).

**Fig. 4.41a, b.** **a** Superior intraarticular view of a left shoulder in neutral rotation and abduction, with the humeral head (*hh*) inclined away from the glenoid. **b** Posterior view of the same shoulder in the same position except for some external rotation. The superior GHL complex composed of the superior GHL (*SG* left marker suture) and the posterosuperior GHL (*PS* right marker suture) have been dissected out and detached from the glenoid neck. In this specimen, both ligamentous structures were partially attached to the glenoid labrum (*gl*). This connection was preserved. The tendon of the long head of the biceps (*ltb*) and the glenoid labrum were then carefully peeled off from the glenoid rim, leaving the inferior labrum attached to the glenoid rim and the tendon of the long head of the triceps. This illustrates that the glenoid labrum serves as a circumferential anchor linking the superior GHL complex, forming a crown on top of the humeral head together with the rotator crescent (*rcr*), with the inferior GHL complex, cradling the humeral head as a hammock (*PB* posterior band of the inferior GHL, *ap* axillary pouch, *AB* anterior band of the inferior GHL, *MG* middle GHL, *ssc* subscapularis, *ssp* supraspinatus, *isp* infraspinatus, *gf* glenoid fossa)



### 4.3.10 Clinical Relevance

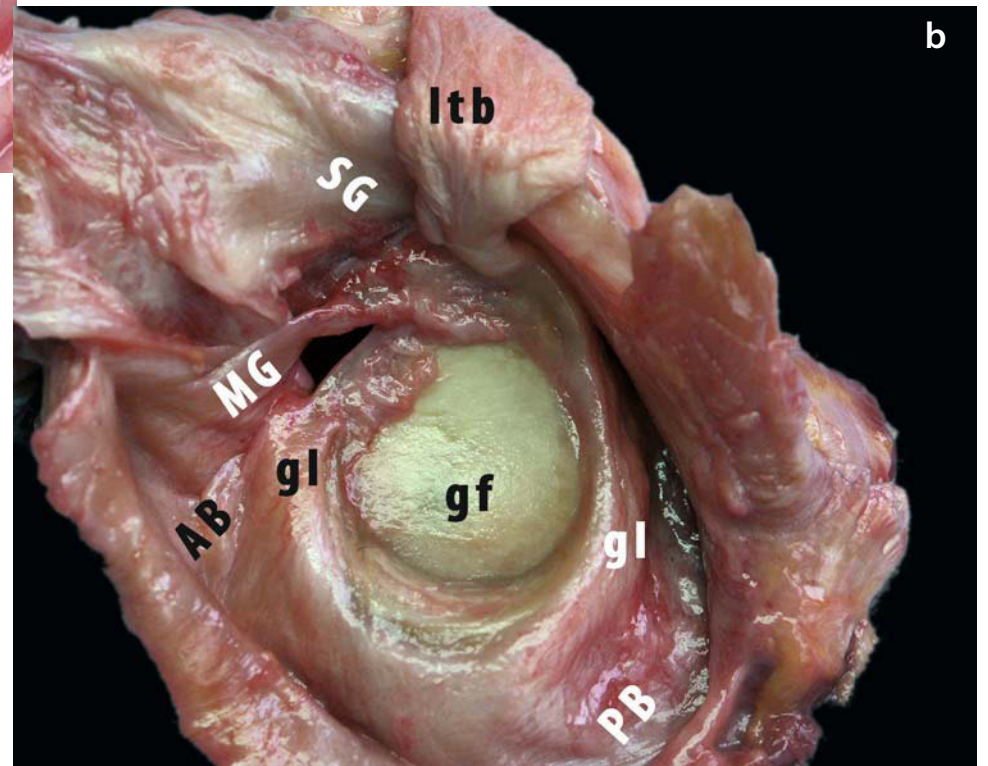
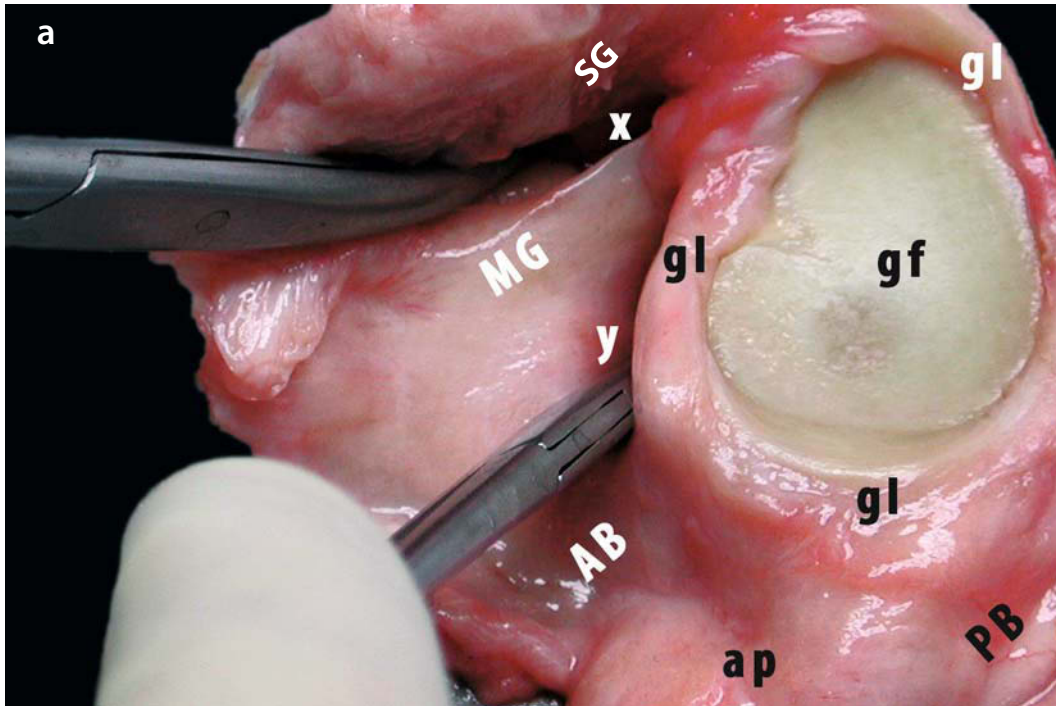
The clinician needs to be aware of possible normal variations in the shape of the glenoid labrum and in the attachment of the labrum to the glenoid bone, as well as in the attachment of the capsule and its ligaments to the labrum. The variations may be mistaken for capsulolabral tears and erroneously repaired, entailing a risk of narrowing the range of motion. A careful examination of the patient and his/her history combined with scrupulous attention to any other signs of trauma may help in differentiating the normal from the pathologic variant.

The combined collar-like and V-shaped nature of the inferior humeral insertion has two major implications. On the one hand, tears of the inferior recess—the frenula capsulae—visualised during arthroscopy may not necessarily signify a humeral avulsion of the (inferior) glenohumeral ligaments (HAGL). On the other hand, when HAGL is diagnosed, the inferior cap-

sule is probably best reattached in its original V-form if the intention is to restore adequate length and tension to the capsular structures and, more specifically, the various components of the inferior glenohumeral ligament. Both components of the double-leaved structure of the anteroinferior insertion—the anterior band of the inferior glenohumeral ligament and the fasciculus obliquus—need to be addressed in humerus-based capsular shift procedures [55, 127, 129].

The intricate interweaving of the lateral part of the superior complex and the superior tendons of the rotator cuff may in part explain why small rotator cuff tears within the confines of the rotator cable have limited functional consequences. Adequate restoration of the pillars of the suspension bridge may be sufficient to restore function in the case of tears that compromise the insertion of the rotator cable (Fig. 4.42a, b) [55, 56].

**Fig. 4.42a, b.** Glenoid block specimens of two left shoulders. In both specimens, it is impossible to separate the axillary pouch of the inferior GHL complex clearly from the glenoid labrum (*gl*). Similarly, it appears difficult to demarcate the transition from glenoid labrum to the posterior band of the inferior GHL (*PB*). In both specimens, the glenoid labrum appears to be attached to the bone along the entire circumference of the glenoid fossa (*gf*). Both specimens have a clearly visible glenoid notch. The middle GHL (*MG*) and also the anterior band of the inferior GHL (*AB*) attach directly on the glenoid neck, rather than on the labrum. **a** There seems to be a synovial recess at the level of the anterior band of the inferior GHL, although the two ligaments form a continuous sheet of anterior glenohumeral capsule. When this recess reaches to the midpoint of the glenoid neck, as indicated by the *clamp* (*y*), this may be regarded as a foramen of Rouvière. The second clamp indicates a relatively deep subscapular bursa with a distinct foramen of Weitbrecht (*x*). The synovial proliferation of the labrum at the level of the glenoid notch may hide a sublabral hole. **b** The anterior band of the inferior GHL is continuous with the glenoid labrum. A synovial recess can be observed inferior to the middle GHL, but it is continuous with the recess superior to the ligament and not truly a foramen of Rouvière. This cordlike middle GHL is separate from the other ligaments. Because of the gap between the middle GHL and the anterior band of the inferior GHL at the level of their glenoid origin, the anterosuperior glenoid labrum has a sharp free border and a wedge-like meniscoid appearance (*ltb* tendon of the long head of the biceps, *SG* superior GHL)



### 4.3.11 Conclusions

The glenohumeral capsule contains a superior capsuloligamentous structure with its fibrous reinforcements:

- Superior glenohumeral ligament
- Coracohumeral ligament
- Posterosuperior glenohumeral ligament
- Coracoglenoid ligament
- Transverse band

that is least as intricate as the better known inferior glenohumeral ligament complex with its fibrous reinforcements:

- Anterior band of the inferior glenohumeral ligament
- Posterior band of the inferior glenohumeral ligament

- Fasciculus obliquus.

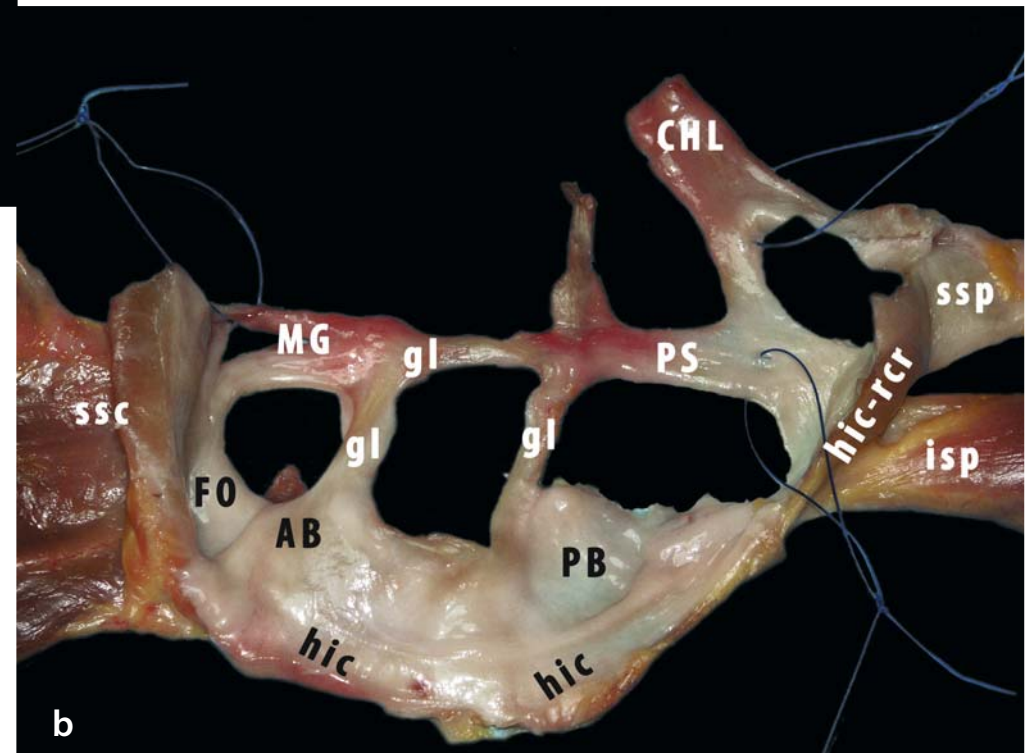
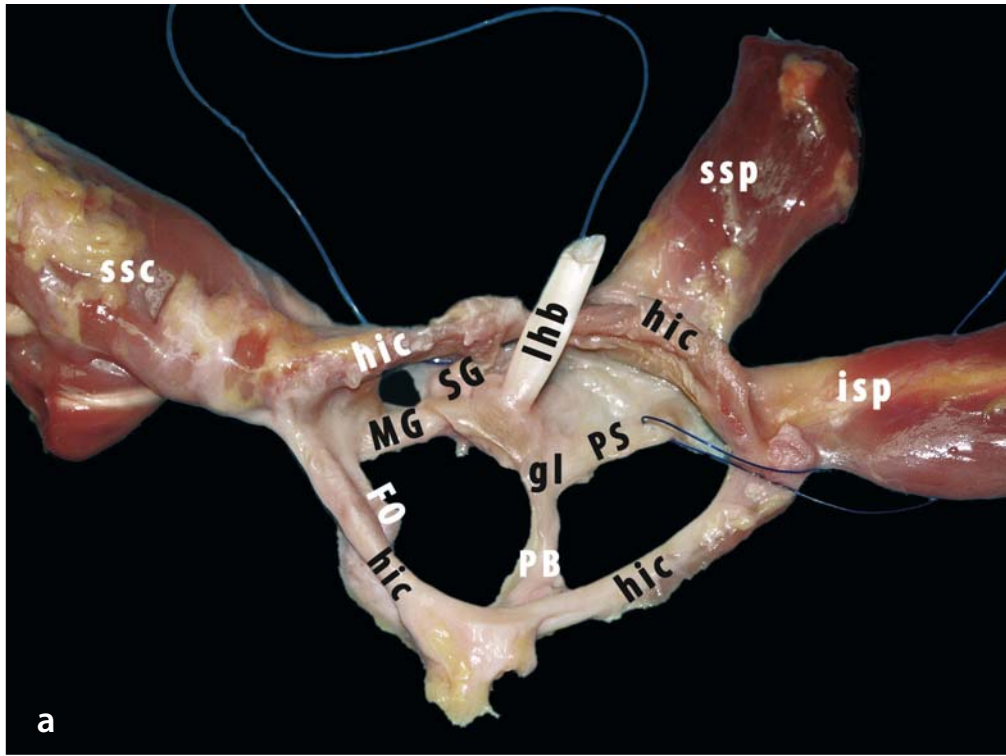
The superior complex serves as a primary restraint in adduction and as a secondary restraint in abduction. The inferior complex is the primary restraint in abduction. In addition, both systems are linked by:

- A *circular system* on the medial side (the glenoid labrum),
- A *semicircular system* on the humeral side (the rotator cuff tendons, the fasciculus obliquus, the transverse band), and
- Two diagonal cross-links (the fasciculus obliquus and the middle glenohumeral ligament).

Finally, the ligamentous reinforcements play an important part in stabilising the long tendon of the biceps in its gutter through their complex interaction to form the biceps pulley (Fig. 4.43a, b).

scapular level. The ligaments were dissected to separate them (*PS* posterosuperior GHL, *chl* coracohumeral ligament, *SG* superior GHL, *MG* middle GHL, *AB* anterior band of the inferior GHL, *FO* fasciculus obliquus, *PB* posterior band of the inferior GHL). The glenoid labrum (*gl*) was detached from the glenoid rim together with the ligaments. Finally, the ligaments were detached at their humeral insertion, together with the rotator cuff tendons. The tendon of the long head of the biceps (*lhb*) was transected at the level of the biceps pulley. **a** This specimen centres on the ring formed by the humeral insertion of the capsule (*hic*). The inferior humeral insertion, formed by the confluence of anterior band of the inferior GHL (obscured by *hic* and *FO*) and the posterior band of the inferior GHL (*PB*), is oriented inferiorly. The top can be oriented by the origin of the tendon of the long head of the biceps on the glenoid labrum for the glenoid ring system and the supraspinatus for the humeral ring system. Anterior is indicated by the subscapularis. The *right superior suture* marks the superior GHL, and the left suture marks the posterosuperior GHL (*PS*). **b** This specimen centres on the ring formed by the glenoid labrum (*gl*). The humeral ring was cut through the rotator cuff interval between superior GHL and middle GHL to make it possible to flatten it completely. The subscapularis again orientates the specimen anteriorly. The left suture marks the middle GHL. The superior right suture marks the coracohumeral ligament (*CHL*) and the superior GHL, the inferior right suture marks the posterosuperior GHL. Both superior structures and also the supraspinatus and infraspinatus are linked by the rotator crescent

**Fig. 4.43a, b.** Two specimens illustrating the fibrous framework of the glenohumeral capsule with its interlinked system of rings formed by the ligaments, their glenoid and humeral insertions, and the rotator cuff tendons. These tendons—subscapularis (*ssc*), supraspinatus (*ssp*) and infraspinatus (*isp*)—were carefully separated from the underlying capsule as far laterally as possible after transection at the mid-



The glenohumeral ligaments are the most important static stabilisers for the shoulder joint, but their material and structural properties are much weaker than those of the knee ligaments [194–197]. Some studies have indicated that the different glenohumeral ligaments should not be considered separately, as they seem to form a complex network of structures that distribute and share the stresses that are applied to the joint. The glenohumeral ligaments seem to exert their restraining effect mainly at the extremes of motion, although they are able to restrict translation in other positions as well. In summary, the main restraints to translation are [6, 51, 70, 72, 73, 142, 143, 198–204]:

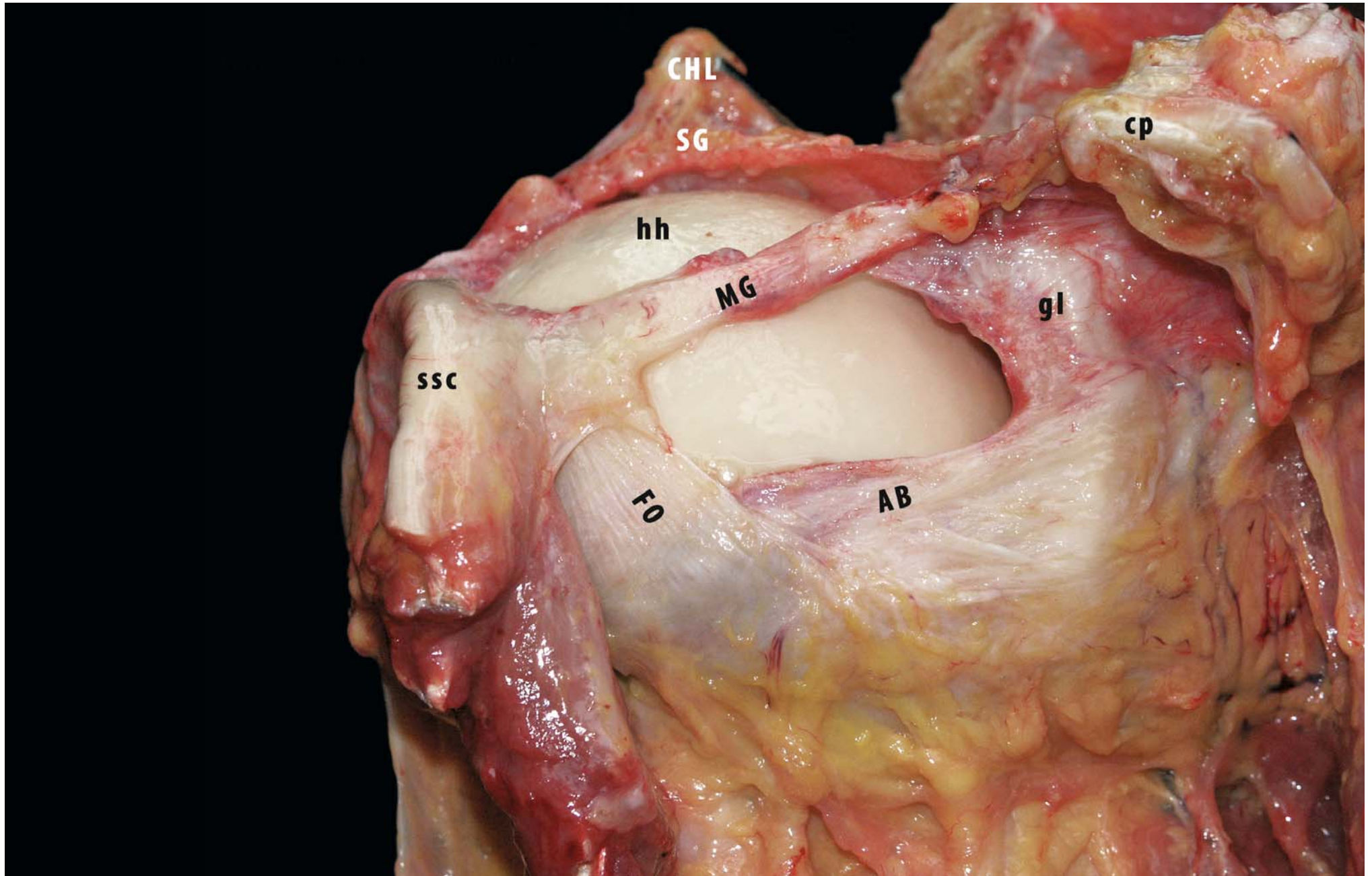
1. The coracohumeral and superior glenohumeral ligaments, which work
  - a) Mainly against inferior translation in the lower ranges of abduction
  - b) To a lesser extent against anterior translation, especially with additional external rotation, and
  - c) Against posterior translation in forward flexion and abduction with external rotation
2. The middle glenohumeral ligament, which works
  - a) Mainly against anterior translation in the midrange of abduction
  - b) To a lesser extent against inferior translation, especially with additional external rotation, and
  - c) Limits external rotation in the lower ranges of abduction
3. The inferior glenohumeral ligament
  - a) The anterior band restrains internal rotation
  - b) The posterior band restrains internal rotation and forward flexion
  - c) To a lesser extent, works against inferior translation, especially in the midrange of abduction
  - d) Limits abduction and external rotation
4. The posterior capsule, which
  - a) Works against posterior translation
  - b) Limits internal rotation during abduction

Although the glenoid labrum in itself is probably not able to prevent dislocation, it is important for stability through a variety of mechanisms, including:

- Augmentation of the articular arc length
- Increasing the effect of concavity-compression
- Maintaining negative intraarticular pressure
- Anchoring the capsuloligamentous complex

The bony structure of the glenohumeral joint offers little stability, but variations and defects of the glenoid cavity as well as of the humeral head may contribute to instability (Fig. 4.44).

**Fig. 4.44.** Anteroinferior extraarticular view of a right shoulder in external rotation and adduction: the coracoid process (*cp*) has been transected to show the anterosuperior structures from the glenoid neck onwards. The subscapularis (*ssc*) has been dissected from the underlying ligaments as far laterally as possible and then reflected laterally. The tendon of the long head of the biceps cannot be seen in this specimen. Because of the anteroinferior incidence, the superior GHL (*SG*) and the coracohumeral ligament (*CHL*, detached from the coracoid process) seem to lie posterior to the humeral head (*hh*). The superior GHL and the middle GHL (*MG*) have a separate origin from the glenoid neck. In this specimen, the middle GHL has an origin on the glenoid labrum (*gl*) as well as on the glenoid neck. It runs over the anterosuperior aspect of the humeral head to fuse laterally with the fasciculus obliquus (*FO*) and the subscapularis (*ssc*) before inserting on the humerus. The fasciculus obliquus and the anterior band of the inferior GHL (*AB*) are fused in their lateral part with a crossing in the middle third (pattern 3). In this position, all three anterior and inferior ligaments are under tension





## References

1. Harryman DT, Sidles JA, Harris SL (1992) The role of the rotator interval capsule in passive motion and stability of the shoulder. *J Bone Joint Surg Am* 74:53-66
2. Grant JCB (1962) *An atlas of anatomy*, 6th edn. Williams & Wilkins, Baltimore, MD, p 26ff
3. Hawkins R, Bokor DJ (1990) Clinical evaluation of shoulder problems. In: Rockwood CA, Matsen FA (eds) *The shoulder*, vol III/4, pp 167-171
4. DePalma AF, Callery G, Bennett GA (1949) Variational anatomy and degenerative lesions of the shoulder joint. *Instr Course Lect* 6:255-281
5. Clark J, Sidles JA, Matsen FA (1990) The relationship of the glenohumeral joint capsule to the rotator cuff. *Clin Orthop* 254:29-34
6. Clark JM, Harryman DT II (1992) Tendons ligaments and capsule of the rotator cuff. Gross and microscopic anatomy. *J Bone Joint Surg Am* 74:713-725
7. Warner JJ, Deng XH, Warren RF (1992) Static capsuloligamentous restraints to superior-inferior translation of the glenohumeral joint. *Am J Sports Med* 20:675-685
8. Delorme DHD (1910) Die Hemmungsbänder des Schultergelenks und ihre Bedeutung für die Schulterluxationen. *Arch Klin Chir* 92:72-101
9. Gohlke F, Essigkrug B, Schmitz F (1994) The pattern of collagen fiber bundles of the capsule of the glenohumeral joint. *J Shoulder Elbow Surg* 3:111-127
10. Gagey O, Arcache J, Welby F (1993) Fibrous frame of the rotator cuff. The concept of fibrous lock. *Rev Chir Orthop Reparatrice Appar Mot* 79:452-455
11. Ferrari DA (1990) Capsular ligaments of the shoulder. Anatomical and functional study of the anterior superior capsule. *Am J Sports Med* 18:20-24
12. Testut L, Latarjet A (1948) *Traité d'anatomie humaine*, vol I: Osteologie—arthrologie—myologie. Doin, Paris, pp 48, 564-581, 868-871, 1022-1027
13. Jost B, Koch PP, Gerber C (2000) Anatomy and functional aspects of the rotator interval. *J Shoulder Elbow Surg* 9:336-341
14. Paturet G (1951) *Traité d'anatomie humaine*, vol II: Membres Supérieur et inférieur. Masson, Paris
15. Rouvière H, Delmas A (1997) *Traité d'anatomie humaine*, vol III: Descriptive, topographique et fonctionnelle. Masson, Paris
16. Boardman ND, Debski RE, Warner JJ et al (1996) Tensile properties of the superior glenohumeral and coracohumeral ligaments. *J Shoulder Elbow Surg* 5:249-254
17. Welcker H (1877) Nachweis eines Ligamentum interarticulare ("teres") humeri, sowie eines Lig. sessile femoris. *Z Anat Entwicklungsgesch* 2:98-107
18. Fick R (1904) *Handbuch der Anatomie und Mechanik der Gelenke unter Berücksichtigung der bewegenden Muskeln*. Part 1. Anatomie der Gelenke. Gustav Fischer, Jena, pp 163-187
19. Schlemm F (1853) Über die Verstärkungsbänder am Schultergelenk. *Arch Anat* 23:45-48
20. Langer C (1865) *Lehrbuch der Anatomie des Menschen*. Wilhelm Braumüller, Vienna
21. Hartmann R (1881) *Handbuch der Anatomie des Menschen*. Schultz, Strasbourg, pp 142-144; 210-229
22. von Luschka H (1865) *Die Anatomie des Menschen in Rücksicht auf die Bedürfnisse der praktischen Heilkunde*, vol 3: Die Anatomie der Glieder des Menschen. Verlag der H. Laupp'shen Buchhandlung, Tübingen, pp 149-159, 122-127
23. Alvimalm A, Furness A, Wellington L (1996) Measurement of shoulder joint kinaesthesia. *Man Ther* 1:140-145
24. Brösicke (1910) *Lehrbuch der Anatomie*. Cited in: Delorme [8]
25. Stieda (1900) *Grundriss der Anatomie des Menschen*. Cited in: Delorme [8]
26. Harryman DT II (1993) Shoulders: frozen and stiff. *Instr Course Lect* 42:247-257
27. Kocher (1870) Eine neue Reductionsmethode der Schulterverrenkungen. *Berl Klin Wochenschr* 7:101-105
28. Debierre C (1890) *Traité élémentaire d'anatomie de l'homme*. Manuel de l'amphithéâtre. Ancienne librairie Germer Baillière, Paris, pp 222-229; 330-334
29. Sappey PC (1866) *Ostéologie*, vol I: *Traité d'anatomie descriptive*. Adrien Delahaye, Paris, pp 600-611
30. Hoffman CEE (1877) *Lehrbuch der Anatomie des Menschen*, vol 1/I: Äussere Körperform, einfache Körperbestandtheile und Bewegungsorgane. Eduard Besold, Erlangen, pp 264-266
31. Meckel JF (1816) *Besondere Anatomie*. Knochenlehre. Bänderlehre. Muskellehre (Handbuch der menschlichen Anatomie, vol 2). Buchhandlungen des hallischen Waisenhauses, Halle Berlin
32. Cooper DE, O'Brien SJ, Arnoczky SP et al (1993) The structure and function of the coracohumeral ligament: a anatomic and microscopic study. *J Shoulder Elbow Surg* 2:70-77
33. Cooper DE, O'Brien SJ, Warren RF (1993) Supporting layers of the glenohumeral joint. An anatomic study. *Clin Orthop* 289:144-155
34. Edelson JG, Taitz C, Grishkan A (1991) The coracohumeral ligament. Anatomy of a substantial but neglected structure. *J Bone Joint Surg Br* 73:150-153
35. Kolts I, Busch LC, Tomusk H et al (2000) Anatomy of the coracohumeral and the coracoglenoidal ligaments. *Ann Anat* 182:563-566
36. Neer CS II, Satterlee CC, Dalsey RM et al (1992) The anatomy and potential effects of contracture of the coracohumeral ligament. *Clin Orthop* 280:182-185
37. Lane JG, Sachs RA, Riehl B (1993) Arthroscopic staple capsulorrhaphy: a long-term follow-up. *Arthroscopy* 9:190-194
38. Kolts I, Busch LC, Tomusk H et al (2002) Macroscopical anatomy of the so-called "rotator interval". A cadaver study on 19 shoulder joints. *Ann Anat* 184:9-14
39. Kolts I, Busch LC, Tomusk H et al (2001) Anatomy of the coracohumeral and coracoglenoidal ligaments. *Ann Anat* 2000; 182: 563-566

40. Bennett WF (2001) Subscapularis, medial, and lateral head coracohumeral ligament insertion anatomy. Arthroscopic appearance of "hidden" rotator interval lesions. *Arthroscopy* 17:173-180
41. Fealy S, Rodeo SA, Dicarlo EF et al (2000) The developmental anatomy of the neonatal glenohumeral joint. *J Shoulder Elbow Surg* 9:217-222
42. Beaunis H, Bouchard A (1868) *Nouveaux éléments d'anatomie descriptive et d'embryologie*. Baillière et Fils, Paris, pp 161-164;220-222
43. Blachut PA (1989) Arthroscopic anatomy of the shoulder. *Arthroscopy* 5:1-10
44. Coughlin L, Rubinovich M, Johansson J et al (1992) Arthroscopic staple capsulorrhaphy for anterior shoulder instability. *Am J Sports Med* 20:253-256
45. Romanes GJ (ed) (1964) *Cunningham's Textbook of anatomy*, 10th edn. Oxford University Press, London New York, pp 232-235
46. Browne AO, Hoffmeyer P, Thanaka S et al (1990) Glenohumeral elevation studied in three dimensions. *J Bone Joint Surg Br* 72:843-845
47. Landsmeer JMF (1959) The shoulder region exposed by anatomical dissection. *Arch Chir Neerl* 11:274-296
48. Flood V (1829) Discovery of a new ligament of the shoulder joint. *Lancet* 1:672-673
49. Quain J (1828) *Elements of descriptive and practical anatomy*. Cited in: Delorme [8]
50. Langer-Toldt (1897) *Lehrbuch der systematischen und topographischen Anatomie*. Cited in: Delorme [8]
51. Turkel SJ, Panio MW, Marshall JL, Girgis FG (1981) Stabilizing mechanisms preventing anterior dislocation of the glenohumeral joint. *J Bone Joint Surg Am* 63:1208-1217
52. Steinbeck J, Lijencqvist U, Jerosch J (1998) The anatomy of the glenohumeral ligamentous complex and its contribution to anterior shoulder stability. *J Shoulder Elbow Surg* 7:122-126
53. Kolts I, Busch LC, Tomusk H et al (2001) Anatomical composition of the anterior shoulder joint capsule. A cadaver study on 12 glenohumeral joints. *Ann Anat* 183:53-59
54. Sutton JB (1884) On the nature of ligaments. *J Anat Physiol [II]* 19:27
55. Pouliart N (2005) *Shoulder instability: Experimental model and related anatomy*. Doctoral thesis, Brussels, Vrije Universiteit, Faculty of Medicine and Pharmacy
56. Pouliart N, Eid S, Somers K et al (2007) Variations in the superior capsuloligamentous complex and description of a new ligament. *J Shoulder Elbow Surg* (published Online First)
57. Werner A, Mueller T, Boehm D et al (2000) The stabilizing sling for the long head of the biceps tendon in the rotator cuff interval. A histoanatomic study. *Am Sports Med* 28:28-31
58. Macalister A (1867) Notes on an instance of irregularity in the muscles around the shoulder joint. *J Anat Physiol* 1:316 (cited in: Delorme [8])
59. LeDouble AF (1897) *Traité des variations du système musculaire de l'homme et de leur signification au point de vue de l'anthropologie zoologique*, 2nd edn, vol I. Schleicher Frères, Paris, pp 250-255
60. Testut (1884) *Les anomalies musculaire chez l'homme*. Masson, Paris, pp 110-125
61. Weinstabl R, Hertz H, Firbas W (1986) Zusammenhang des ligamentum coracoglenoidale mit dem musculus pectoralis minor. *Acta Anat* 125:126-131
62. Burkhart SS (1992) Fluoroscopic comparison of kinematic patterns in massive rotator cuff tears. A suspension bridge model. *Clin Orthop* 284:144-152
63. Burkhart SS, Esch JC, Jolson RS (1993) The rotator crescent and rotator cable: an anatomic description of the shoulder's "suspension bridge". *Arthroscopy* 9:611-616
64. Federative Committee on Anatomical Terminology (1998) *International anatomical terminology (Terminologia Anatomica)* Thieme, Stuttgart
65. Habermeyer P, Magosch P, Pritsch M et al (2004) Anterosuperior impingement of the shoulder as a result of pulley lesions: a prospective arthroscopic study. *J Shoulder Elbow Surg* 13:5-12
66. Walch G, Nove-Josserand L, Levigne C et al (1994) Tears of the supraspinatus tendon associated with "hidden" lesions of the rotator interval. *J Shoulder Elbow Surg* 3:353-360
67. Bennett WF (2001) Visualization of the anatomy of the rotator interval and bicipital sheath. *Arthroscopy* 17:107-111
68. Kolts I (1992) A note on the anatomy of the supraspinatus muscle. *Arch Orthop Trauma Surg* 111:247-249
69. Helmig P, Sojbjerg JO, Kjaersgaard-Andersen P et al (1990) Distal humeral migration as a component of multidirectional shoulder instability. An anatomical study in autopsy specimens. *Clin Orthop* 252:139-143
70. Kuhn JE, Bey MJ, Huston LJ, et al (2000) Ligamentous restraints to external rotation of the humerus in the late-cocking phase of throwing. A cadaveric biomechanical investigation. *Am J Sports Med* 8:200-205
71. O'Connell PW, Nuber GW, Mileski RA (1990) The contribution of the glenohumeral ligaments to anterior stability of the shoulder joint. *Am J Sports Med* 18:579-584
72. Ovesen J, Nielsen S (1985) Experimental distal subluxation in the glenohumeral joint. *Arch Orthop Trauma Surg* 104:78-81
73. Ovesen J, Nielsen S (1985) Stability of the shoulder joint. Cadaver study of stabilizing structures. *Acta Orthop Scand* 56:149-151
74. Slätis P, Aalto K (1979) Medial dislocation of the tendon of the long head of the biceps brachii. *Acta Orthop Scand* 50:73-77
75. Itoi E, Berglund LJ, Grabowski JJ et al (1998) Superior-inferior stability of the shoulder: role of the coracohumeral ligament and the rotator interval capsule. *Mayo Clin Proc* 73:508-515
76. Fick R (1911) *Handbuch der Anatomie und Mechanik der Gelenke unter Berücksichtigung der bewegenden Muskeln*. III. Spezielle Gelenk- und Muskelmechanik. Gustav Fischer, Jena, pp 247-283
77. Gagey O, Bonfait H, Gillot C et al (1987) Anatomic basis of ligamentous control of elevation of the shoulder. *Surg Radiol Anat* 9:19-26

78. Gagey O, Bonfait H, Gillot C et al (1988) Anatomie fonctionnelle et mécanique de l'élevation du bras. *Rev Chir Orthop Reparatrice Appar Mot* 74:209-217
79. Castaing J, Gouazé A, Soutoul J-H et al (1963) Les éléments anatomiques du blocage de la rotation de l'humérus en abduction maximale de l'articulation scapulo-humérale. *Bull Assoc Anat* 117:426-435
80. Lee TQ, Black AD, Tibone JE et al (2001) Release of the coracoacromial ligament can lead to glenohumeral laxity: a biomechanical study. *J Shoulder Elbow Surg* 10:68-72
81. Harryman DT II, Sidles JA, Clark JM et al (1990) Translation of the humeral head on the glenoid with passive glenohumeral motion. *J Bone Joint Surg Am* 72:1334-1343
82. Warner JJP, Deng XH, Warren RF et al (1993) Superoinferior translation in the intact and vented glenohumeral joint. *J Shoulder Elbow Surg* 2:99-105
83. Field LD, Warren RF, O'Brien SJ et al (1995) Isolated closure of rotator interval defects for shoulder instability. *Am J Sports Med* 23:557-563
84. Jerosch J (2001) 360 degrees arthroscopic capsular release in patients with adhesive capsulitis of the glenohumeral joint—indication, surgical technique, results. *Knee Surg Sports Traumatol Arthrosc* 9:178-186
85. Neviasser RJ, Neviasser TJ (1987) The frozen shoulder. Diagnosis and management. *Clin Orthop* 223:59-64
86. Neviasser TJ (1987) Adhesive capsulitis. *Orthop Clin North Am* 18:439-443
87. Nobuhara K, Ikeda H (1987) Rotator interval lesion. *Clin Orthop* 223:44-50
88. Nobuhara K, Sugiyama D, Ikeda H et al (1990) Contracture of the shoulder. *Clin Orthop* 254:104-110
89. Ogilvie-Harris DJ, Myerthall S (1997) The diabetic frozen shoulder: arthroscopic release. *Arthroscopy* 13:1-8
90. Omari A, Bunker TD (2001) Open surgical release for frozen shoulder: surgical findings and results of the release. *J Shoulder Elbow Surg* 10:353-357
91. Ozaki J, Nakagawa Y, Sakurai G et al (1989) Recalcitrant chronic adhesive capsulitis of the shoulder. Role of contracture of the coracohumeral ligament and rotator interval in pathogenesis and treatment. *J Bone Joint Surg Am* 71:1511-1515
92. Pearsall AW IV, Holovacs TF, Speer KP (2000) The intra-articular component of the subscapularis tendon: anatomic and histological correlation in reference to surgical release in patients with frozen-shoulder syndrome. *Arthroscopy* 16:236-242
93. Pearsall AW IV, Osbahr DC, Speer KP (1999) An arthroscopic technique for treating patients with frozen shoulder. *Arthroscopy* 15:2-11
94. Pollock RG, Duralde XA, Flatow EL et al (1994) The use of arthroscopy in the treatment of resistant frozen shoulder. *Clin Orthop* 304:30-36
95. Segmuller HE, Taylor DE, Hogan CS (1995) Arthroscopic treatment of adhesive capsulitis. *J Shoulder Elbow Surg* 4:403-408
96. Warner JJ (1997) Frozen shoulder: diagnosis and management. *J Am Acad Orthop Surg* 5:130-140
97. Warner JJ, Allen A, Marks PH et al (1996) Arthroscopic release of chronic, refractory adhesive capsulitis of the shoulder. *J Bone Joint Surg Am* 78:1808-1816
98. Warner JJ, Allen AA, Marks PH et al (1997) Arthroscopic release of postoperative capsular contracture of the shoulder. *J Bone Joint Surg Am* 79:1151-1158
99. Yamaguchi K, Sethi N, Bauer GS (2002) Postoperative pain control following arthroscopic release of adhesive capsulitis: a short-term retrospective review study of the use of an intra-articular pain catheter. *Arthroscopy* 18:359-365
100. Leffert RD (1985) The frozen shoulder. *Instr Course Lect* 34:199-203
101. Garth WP Jr, Allman FL Jr, Armstrong WS (1987) Occult anterior subluxations of the shoulder in noncontact sports. *Am J Sports Med* 15:579-585
102. Martin DR, Garth WP Jr (1995) Results of arthroscopic debridement of glenoid labral tears. *Am J Sports Med* 23:447-451
103. McGlynn FJ, Caspari RB (1984) Arthroscopic findings in the subluxating shoulder. *Clin Orthop* 183:173-178
104. Pappas AM, Goss TP, Kleinman PK (1983) Symptomatic shoulder instability due to lesions of the glenoid labrum. *Am J Sports Med* 11:279-288
105. Protzman RR (1980) Anterior instability of the shoulder. *J Bone Joint Surg Am* 62:909-918
106. Gerber C, Sebesta A (2000) Impingement of the deep surface of the subscapularis tendon and the reflection pulley on the anterosuperior glenoid rim: a preliminary report. *J Shoulder Elbow Surg* 9:483-490
107. Kim TK, McFarland EG (2004) Internal impingement of the shoulder in flexion. *Clin Orthop* 421:112-119
108. Struhl S (2002) Anterior internal impingement: an arthroscopic observation. *Arthroscopy* 18:2-7
109. Dumontier C, Sautet A, Gagey O et al (1999) Rotator interval lesions and their relation to coracoid impingement syndrome. *J Shoulder Elbow Surg* 8:130-135
110. Jobe CM (1996) Superior glenoid impingement. *Clin Orthop* 330:98-107
111. Jobe CM (1997) Superior glenoid impingement. *Orthop Clin North Am* 28:137-143
112. Radas CB, Pieper HG (2004) The coracoid impingement of the subscapularis tendon: a cadaver study. *J Shoulder Elbow Surg* 13:154-159
113. Savoie FH III, Field LD, Atchison S (2001) Anterior superior instability with rotator cuff tearing: SLAC lesion. *Orthop Clin North Am* 32:457-461
114. Walch G, Liotard JP, Boileau P et al (1991) Le conflit glénoïdien postéro-supérieur: Un autre conflit de l'épaule. *Rev Chir Orthop Reparatrice Appar Mot* 77:571-574
115. Davidson PA, Elattrache NS, Jobe CM et al (1995) Rotator cuff and posterior-superior glenoid labrum injury associated with increased glenohumeral motion: a new site of impingement. *J Shoulder Elbow Surg* 4:384-390
116. Jobe CM (1995) Posterior superior glenoid impingement: expanded spectrum. *Arthroscopy* 11:530-536
117. Liu SH, Boyton E (1993) Posterior superior impingement of the rotator cuff on the glenoid labral tears. *Arthroscopy* 9:697-699

118. McFarland EG, Hsu CY, Neira C et al (1999) Internal impingement of the shoulder: a clinical and arthroscopic analysis. *J Shoulder Elbow Surg* 8:458-460
119. Altchek DW, Hobbs WR (2001) Evaluation and management of shoulder instability in the elite overhead thrower. *Orthop Clin North Am* 32:423-430
120. Fitzpatrick MJ, Powell SE, Tibone JE et al (2003) The anatomy, pathology, and definitive treatment of rotator interval lesions (Current concepts [Suppl 19]). *Arthroscopy* 1:70-79
121. Rowe CR (1987) Recurrent transient anterior subluxation of the shoulder. The "dead arm" syndrome. *Clin Orthop* 223:11-19
122. Rowe CR, Zarins B (1981) Recurrent transient subluxation of the shoulder. *J Bone Joint Surg Am* 63:863-872
123. Berghs BM, Sole-Molins X, Bunker TD (2004) Arthroscopic release of adhesive capsulitis. *J Shoulder Elbow Surg* 13:180-185
124. Holloway GB, Schenk T, Williams GR et al (2001) Arthroscopic capsular release for the treatment of refractory postoperative or post-fracture shoulder stiffness. *J Bone Joint Surg Am* 83:1682-1687
125. Gerber C, Espinosa N, Perren TG (2001) Arthroscopic treatment of shoulder stiffness. *Clin Orthop* 390:119-128
126. Moseley H, Övergaard B (1962) The anterior capsular mechanism in recurrent anterior dislocation of the shoulder. Morphological and clinical studies with special reference to the glenoid labrum and the glenohumeral ligaments. *J Bone Joint Surg Br* 44:913-927
127. Pouliart N, Gagey OJ (2005) Reconciling arthroscopic and anatomic morphology of the humeral insertion of the inferior glenohumeral ligament. *Arthroscopy* 21:979-984
128. Pouliart N, Gagey OJ (2005) The arthroscopic view of the glenohumeral ligaments compared with anatomy: fold or fact? *J Shoulder Elbow Surg* 14:324-328
129. Pouliart N, Somers K, Gagey OJ (2006) Arthroscopic glenohumeral folds and microscopic glenohumeral ligament: the fasciculus obliquus is the missing link (abstract). Paper presented at the 20th Congress of the European Society for Surgery of the Shoulder and Elbow, Athens, September 2006
130. Merila M, Leibecke T, Gehl HB et al (2004) The anterior glenohumeral joint capsule: macroscopic and MRI anatomy of the fasciculus obliquus or so-called ligamentum glenohumeral spirale. *Eur Radiol* 14:1421-1426
131. O'Brien SJ, Neves MC, Arnoczky SP et al (1990) The anatomy and histology of the inferior glenohumeral ligament complex of the shoulder. *Am J Sports Med* 18:449-456
132. Caspari RB, Geissler WB (1993) Arthroscopy manifestations of shoulder subluxation and dislocation. *Clin Orthop* 291:54-66
133. Ciccone WJ II, Hunt TJ, Lieber R et al (2000) Multi-quadrant digital analysis of shoulder capsular thickness. *Arthroscopy* 16:457-461
134. DePalma AF, Cooke AJ, Prabhakar M (1967) The role of the subscapularis in recurrent anterior dislocation of the shoulder. *Clin Orthop* 54:35-49
135. Colas F, Nevoux J, Gagey OJ (2004) The scapular and subcoracoid bursae: descriptive and functional anatomy. *J Shoulder Elbow Surg* 13:454-458
136. Warner JJP, Caborn DNM, Berger R et al (1993) Dynamic capsuloligamentous anatomy of the glenohumeral joint. *J Shoulder Elbow Surg* 2:115-133
137. Malicky DM, Soslowky LJ, Kuhn JE et al (2001) Total strain fields of the antero-inferior shoulder capsule under subluxation: a stereoradiogrammetric study (abstract). *J Biomech Eng* 123:425-431
138. Malicky DM, Kuhn JE, Frisancho JC et al (2002) Neer award 2001: Nonrecoverable strain fields of the antero-inferior glenohumeral capsule under subluxation. *J Shoulder Elbow Surg* 11:529-540
139. Debski RE, Wong EK, Woo SL et al (1999) An analytical approach to determine the in situ forces in the glenohumeral ligaments. *J Biomech Eng* 121:311-315
140. Terry GC, Hammon D, France P et al (1991) The stabilizing function of passive shoulder restraints. *Am J Sports Med* 19:26-34
141. Jerosch J, Moersler M, Castro WH (1990) Über die Funktion der passiven Stabilisatoren des glenohumeralen Gelenkes—eine biomechanische Untersuchung. *Z Orthop Ihre Grenzgeb* 128:206-212
142. Urayama M, Itoi E, Hatakeyama Y et al (2001) Function of the 3 portions of the inferior glenohumeral ligament: a cadaveric study. *J Shoulder Elbow Surg* 10:589-594
143. Brenneke SL, Reid J, Ching RP et al (2000) Glenohumeral kinematics and capsuloligamentous strain resulting from laxity exams. *Clin Biomech* 15:735-742
144. Ticker JB, Bigliani LU, Soslowky LJ et al (1996) Inferior glenohumeral ligament: geometric and strain-rate dependent properties. *J Shoulder Elbow Surg* 5:269-279
145. Jobe CM (1998) Gross anatomy of the shoulder. In: Rockwood CA Jr, Matsen FA III (eds) *The shoulder*, vol 1. Saunders, Philadelphia, PA, pp 34-97
146. Detrisac D, Johnson LL (1986) Arthroscopic shoulder anatomy. Pathological and surgical implications. Slack, Thorofare NJ
147. Williams PL, Warwick R (1980) *Grey's anatomy*, 36th edn. Churchill Livingstone, Edinburgh
148. Bigliani LU (1996) *The unstable shoulder*. American Academy of Orthopedic Surgeons, Rosemont, IL
149. Duparc F, Muller JM, Freger P (2001) Arterial blood supply of the proximal humeral epiphysis. *Surg Radiol Anat* 23:185-190
150. Sugalsky MT, Wiater GM, Levine WL (2005) An anatomic study of the humeral insertion of the inferior glenohumeral capsule. *J Shoulder Elbow Surg* 14:91-95
151. Eiserloh H, Drez D, Guanche CA (2000) The long head of the triceps: a detailed analysis of its capsular origin. *J Shoulder Elbow Surg* 9:332-335
152. Uthoff HK, Piscopo M (1985) Anterior capsular redundancy of the shoulder: congenital or traumatic? An embryological study. *J Bone Joint Surg Br* 67:363-366
153. Eberly VC, McMahon PJ, Lee TQ (2002) Variation in the glenoid origin of the antero-inferior glenohumeral capsulolabrum. *Clin Orthop* 400:26-31
154. McMahon PJ, Dettling J, Sandusky MD, et al (1999) The anterior band of the inferior glenohumeral ligament. Assessment of its permanent deformation

- and the anatomy its glenoid attachment. *J Bone Joint Surg Br* 81:406-413
155. Vesalius A (1543) *De humani corporis fabrica*. Opporinus, Basel (Warnock Library book [CD-ROM]. Octavo Cooperation—Digital Rare Books, Palo Alto, CA)
  156. Henle FGJ (1855) *Handbuch der systematischen Anatomie des Menschen, vol I: Handbuch der Knochenlehre des Menschen*. Vieweg & Sohn, Braunschweig, pp 26-30, 66-72, 176-178
  157. Townley C (1950) The capsular mechanism in recurrent dislocation of the shoulder. *J Bone Joint Surg Am* 32:370-380
  158. Cooper DE, Arnoczky SP, O'Brien SJ et al (1992) Anatomy, histology, and vascularity of the glenoid labrum. An anatomical study. *J Bone Joint Surg Am* 74:46-52
  159. Nishida K, Hashizume H, Toda K et al (1996) Histologic and scanning electron microscopic study of the glenoid labrum. *J Shoulder Elbow Surg* 5:132-138
  160. Tamai K, Higashi A, Tanabe T (1999) Recurrences after the open Bankart repair: a potential risk with use of suture anchors. *J Shoulder Elbow Surg* 8:37-41
  161. Hertz H, Weinstabl R, Grundschober F (1986) Zur makroskopischen und mikroskopischen Anatomie der Schultergelenkspfanne und des Limbus glenoidalis. *Acta Anat* 125:96-100
  162. Huber WP, Putz RV (1997) Periarticular fiber system of the shoulder joint. *Arthroscopy* 13:680-691
  163. Ogilvie-Harris DJ, Wiley AM (1986) Arthroscopic surgery of the shoulder. A general appraisal. *J Bone Joint Surg Br* 68:201-207
  164. Bankart ASB (1938) The pathology and treatment of recurrent dislocation of the shoulder joint. *Br J Surg* 26:23-29
  165. Bankart ASB (1923) Recurrent or habitual dislocation of the shoulder joint. *Br Med J II*:1132-1133
  166. Bankart ASB, Cantab MC (1993) Recurrent or habitual dislocation of the shoulder joint. *Clin Orthop* 291:3-6
  167. Cooper RA, Brems JJ (1992) The inferior capsular-shift procedure for multidirectional instability of the shoulder. *J Bone Joint Surg Am* 74:1516-1521
  168. Lippitt S, Matsen F (1993) Mechanisms of glenohumeral joint stability. *Clin Orthop* 291:20-28
  169. Hata Y, Nakatsucki Y, Saitoh S et al (1992) Anatomic study of the glenoid labrum. *J Shoulder Elbow Surg* 1:207-214
  170. Warner JP (1993) The gross anatomy of the joint surfaces, ligaments, labrum, and capsule. In: Matsen FA 3, Fu FH, Hawkins RJ (eds) *The shoulder: a balance of mobility and stability*, chap 1. AAOS, Rosemont, pp 7-28
  171. Habermeyer P, Schuller U (1990) Significance of the glenoid labrum for stability of the glenohumeral joint. An experimental study. *Unfallchirurg* 93:19-26
  172. Halder AM, Kuhl SG, Zobitz ME et al (2001) Effects of the glenoid labrum and glenohumeral abduction on stability of the shoulder joint through concavity-compression: an in vitro study. *J Bone Joint Surg Am* 83:1062-1069
  173. Matsen FA, Harryman DT, Sidles JA (1991) Mechanics of glenohumeral instability. *Clin Sports Med* 10:783-788
  174. Lazarus MD, Sidles JA, Harryman DT et al (1996) Effect of a chondral-labral defect on glenoid concavity and glenohumeral stability. A cadaveric model. *J Bone Joint Surg Am* 78:94-102
  175. Habermeyer P, Schuller U, Wiedemann E (1992) The intra-articular pressure of the shoulder: an experimental study on the role of the glenoid labrum in stabilizing the joint. *Arthroscopy* 8:166-172
  176. Gibb TD, Sidles JA, Harryman DT et al (1991) The effect of capsular venting on glenohumeral laxity. *Clin Orthop* 268:120-127
  177. Warner JP, Bowen MK, Deng XH et al (1999) Effect of joint compression on inferior stability of the glenohumeral joint. *J Shoulder Elbow Surg* 8:31-36
  178. Wuelkerr N, Brewes F, Sperverlage C (1994) Passive glenohumeral joint stabilization: a biomechanical study. *J Shoulder Elbow Surg* 3:129-134
  179. Itoi E, Motzkin NE, Morrey BF et al (1994) Stabilizing function of the long head of the biceps in the hanging arm position. *J Shoulder Elbow Surg* 3:135-142
  180. Hashimoto T, Suzuky K, Nobuhara K (1995) Dynamic analysis of intraarticular pressure in the glenohumeral joint. *J Shoulder Elbow Surg* 4:209-218
  181. Kumar VP, Balasubramaniam P (1985) The role of atmospheric pressure in stabilising the shoulder. An experimental study. *J Bone Joint Surg* 67:719-721
  182. Pouliart N, Gagey OJ (2006) The effect of isolated labrum resection on shoulder stability. *Knee Surg Sports Traumatol Arthrosc* 14:301-308
  183. Howell SM, Galinat BJ (1989) The glenoid-labral socket. A constrained articular surface. *Clin Orthop* 243:122-125
  184. Andrews JR, Carson WG, McLeod WD (1985) Glenoid labrum tears related to the long head of the biceps. *Am J Sports Med* 13:337-341
  185. Pegnami MJ, Deng XH, Warren RF et al (1995) Effect of lesions of the superior portion of the glenoid labrum on glenohumeral translation. *J Bone Joint Surg Am* 77:1003-1010
  186. Speer KP, Deng XH, Borrero S et al (1994) Biomechanical evaluation of simulated Bankart lesion. *J Bone Joint Surg Am* 76:1819-1826
  187. Fehringer EV, Schimdt GR, Boorman RS et al (2003) The anteroinferior labrum helps center the humeral head on the glenoid. *J Shoulder Elbow Surg* 12:53-58
  188. Greis PE, Scuderi MG, Mohr A (2002) Glenohumeral articular contact areas and pressures following labral and osseous injury to the anteroinferior quadrant of the glenoid. *J Shoulder Elbow Surg* 11:442-451
  189. Hawkins RJ, Schutte JP, Janda DH (1996) Translation of the glenohumeral joint with the patient under anesthesia. *J Shoulder Elbow Surg* 5:286-292
  190. Sauers EL, Borsa PA, Herling DE et al (2001) Instrumented measurement of glenohumeral joint laxity and its relationship to passive range of motion and generalized joint laxity. *Am J Sports Med* 29:143-150
  191. Sauers EL, Borsa PA, Herling DE et al (2001) Instrumented measurement of glenohumeral joint laxity: reliability and normative data. *Knee Surg Sports Traumatol Arthrosc* 9:34-41

192. Lippitt SB, Harris SL, Harryman DT et al (1994) In vivo quantification of the laxity of normal and unstable glenohumeral joints. *J Shoulder Elbow Surg* 1:215-223
193. Klein AH, Harner CD, Fu FH (1995) The Bankart lesion of the shoulder a biomechanical analysis following repair. *Knee Surg Sports Arthrosc* 3:117-120
194. Woo SL, Orlando CA, Gomez MA et al (1986) Tensile properties of the medial collateral ligament as a function of age. *J Orthop Res* 4:133-141
195. Woo SL, Newton PO, McKenna DA et al (1992) A comparative evaluation of the mechanical properties of the rabbit medial collateral and anterior cruciate ligaments. *J Biomech* 25:277-386
196. Woo SL, Hollis JM, Adams DJ (1991) Tensile properties of the human femur-anterior cruciate ligament-tibia complex. The effects of specimen age and orientation. *Am J Sports Med* 19:217-225
197. Woo SL, Gomez MA, Inoue M et al (1977) New experimental procedures to evaluate the biomechanical properties of healing canine medial lateral ligaments. *J Orthop Res* 5:425-432
198. Balvanyosy P (1990) Static stabilizers of the shoulder joint. *Unfallchirurg* 93:27-31
199. Blasier RB, Gulberg RE, Rothman ED (1992) Anterior shoulder instability: Contributions of rotator cuff forces and the capsular ligaments in a cadaver model. *J Shoulder Elbow Surg* 1:140-150
200. Harryman DT, Sidles JA, Harris SL (1992) Laxity of the normal glenohumeral joint: a quantitative in vivo assessment. *J Shoulder Elbow Surg* 1:66-76
201. Lee SB, Kim KJ, O'Driscoll SW et al (2000) Dynamic glenohumeral stability provided by the rotator cuff muscles in the mid-range and end-range of motion. A study in cadavera. *J Bone Joint Surg Am* 82:849-857
202. Weiser WM, Lee TQ, McMaster WC et al (1999) Effects of simulated scapular protraction on anterior glenohumeral stability. *Am J Sports Med* 27:801-805
203. Gagey OJ, Gagey N (2001) The hyperadduction test. *J Bone Joint Surg Br* 83:69-74
204. Ovesen J, Sojbjerg JO (1986) Posterior shoulder dislocation. Muscle and capsular lesions in cadaver experiments. *Acta Orthop Scand* 57:535-536

---

## PART 5 - NEUROMUSCULAR CONTROL AND PROPRICEPTION OF THE SHOULDER

### Introduction

Stability of the shoulder joint emanates from numerous mechanisms including articular geometry, static restraints (capsuloligamentous tissue), dynamic (muscular) stabilizers, and intra-articular forces. Capsuloligamentous structures not only provide mechanical restraint to joint subluxation, but also provide vital sensory feedback information that regulates involuntary muscular activation for joint stability (neuromuscular control).

The role of proprioception in mediating this sensory feedback mechanism is a critical element linking the synergistic role between the static and dynamic stabilizers required for functional shoulder stability.

Proprioceptive deficits arising from deafferentation of peripheral mechanoreceptors has been reported in patients with various pathological shoulder conditions, while restoration of such proprioceptive deficits has also been reported and related to restoration of shoulder function.

Although the relationship between proprioception, neuromuscular control and shoulder stability has not been fully elucidated this synergistic mechanism is clearly vital to functional joint stability.

*Scott M. Lephart, PhD*  
Chair and Associate Professor  
Director, Neuromuscular Research Laboratory  
Department of Sports Medicine and Nutrition  
School of Health and Rehabilitation Sciences  
Associate Professor of Orthopaedic Surgery  
University of Pittsburgh  
Pittsburgh, PA, USA

## 5.1 Mechanoreceptors of the Shoulder Joint: Structure and Function

Zdenek Halata, Klaus L. Baumann

In general, there are three ways of controlling joint movement: limitations through bone structure, ligaments and muscles. The joint between the humerus and ulna (*articulatio humero-ulnaris*) is a typical example of a joint in which movement is limited by the way the articulating bones interact with each other. In contrast, movement of the knee joint (*articulatio genus*) is limited by ligaments, while movement of the shoulder joint (*articulatio humeri*) is controlled by muscles. A large majority of joints combine the different controlling mechanisms to variable degrees. The anatomical structure, the degree of mobility and the way movement is limited are determining factors for the innervation of joints.

Depending on how movement is controlled, different types of mechanoreceptors around joints provide the CNS with information on the position of the articulating bones (*kinaesthesia*). Receptors in muscles are particularly important in the joints that are mainly or exclusively guided by muscles, while in joints controlled by ligaments, sensory nerve endings in the ligaments (e.g. the cruciate ligaments in the knee joint) play an important part [1, 2]. The sense of position in joints limited by the structure of the articulating bones relies mainly on sensory receptors in the surrounding muscles, whereas the sensory innervation of ligaments and joint capsule has only a minor role.

### 5.1.1 Innervation of the Shoulder Joint

The shoulder joint is a typical example of a joint secured by muscles. The socket (*cavitas glenoidalis* with *labrum glenoidale*) is rather small, covering only one quarter to one third

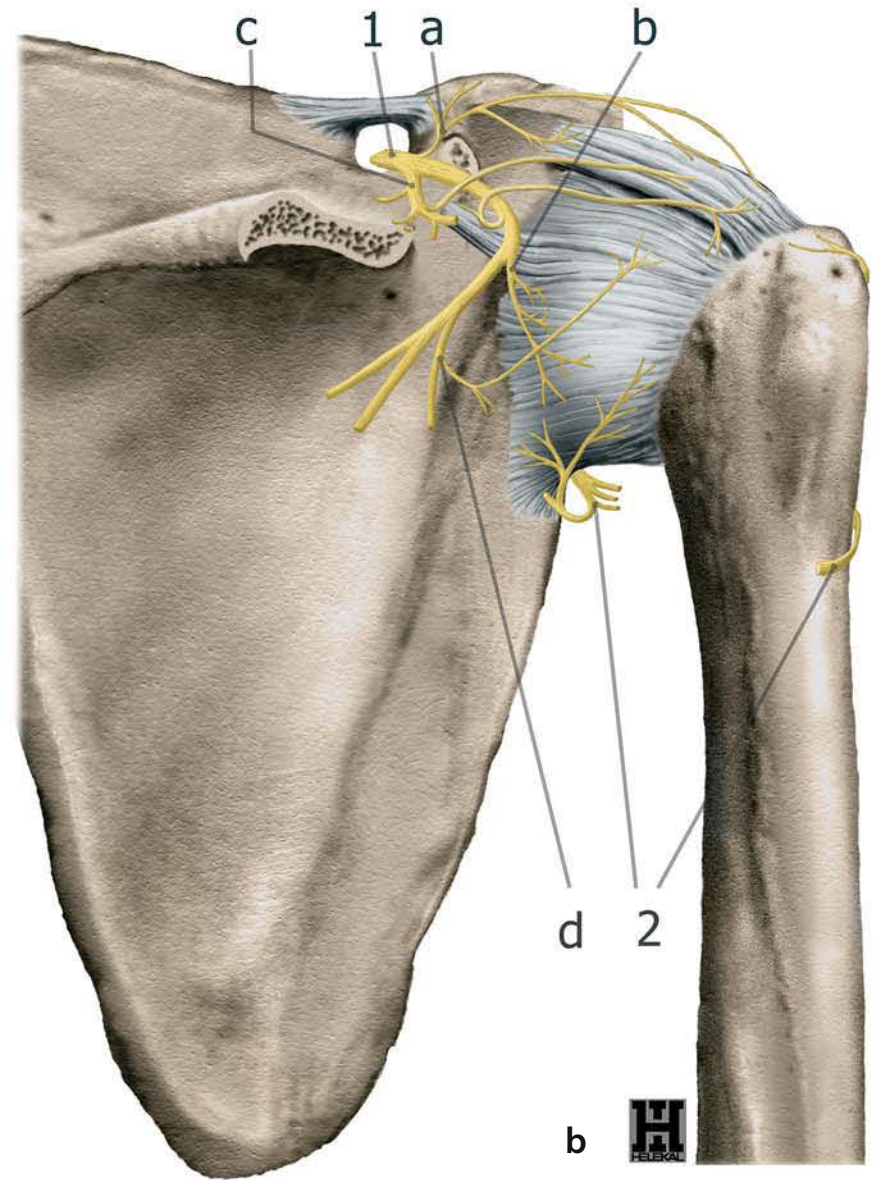
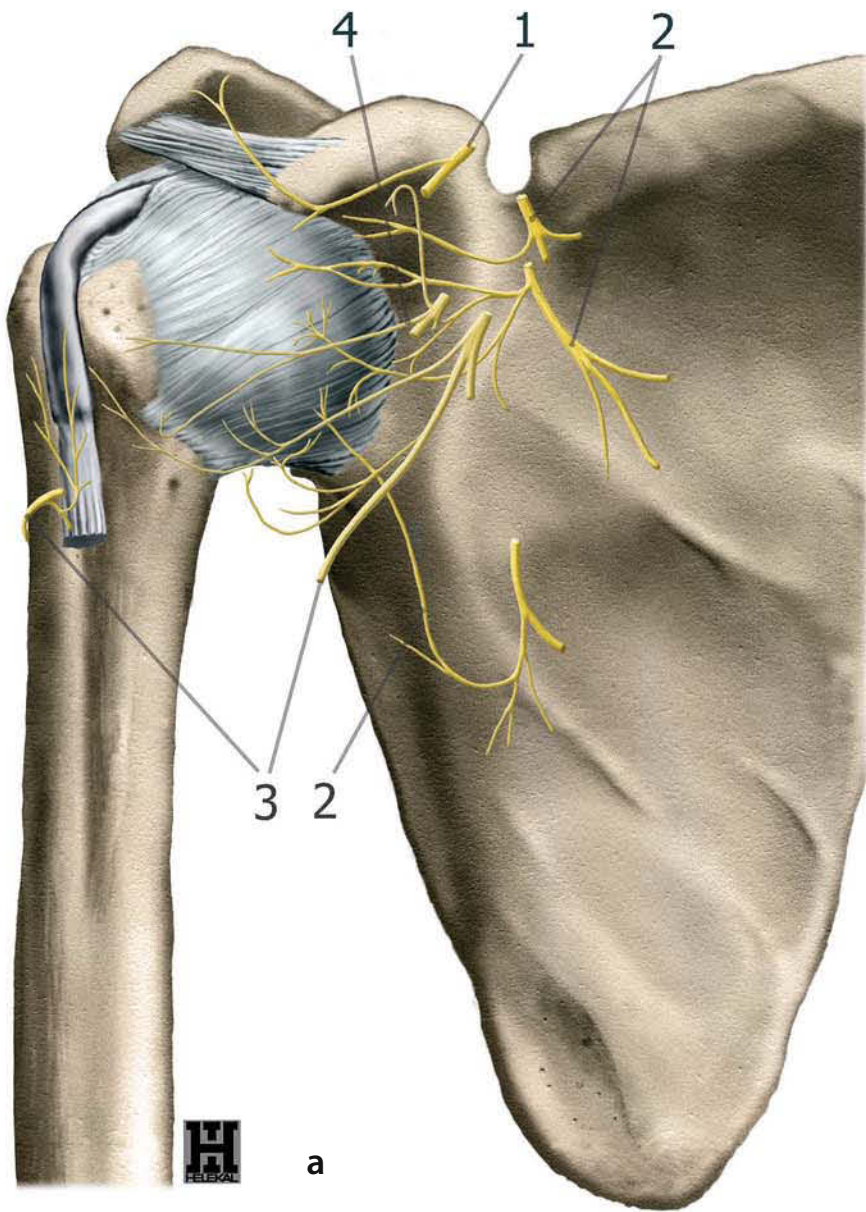
of the surface of the humeral head (*caput humeri*). The joint capsule is relatively flaccid, originating from the rim of the *cavitas glenoidalis* of the scapula—leaving the *glenoid labrum* inside the joint cavity—and inserting at the *collum anatomicum* along the border between articular cartilage and bone. A large fold, the *recessus axillaris*, enables good movement of the joint. Several relatively weak ligaments reinforce the joint capsule: these are the superior, middle and inferior *glenohumeral ligaments* and the *coracohumeral ligament*. These can best be visualised from the inside of the joint during arthroscopy.

To keep the head of the humerus in close contact with the *cavitas glenoidalis*, a number of muscles blend with the capsule to form the *rotator cuff*, which consists of the following four muscles: ventrally, the *subscapularis* muscle, originating from the anterior face of the scapula and inserting at the smaller tubercle (*tuberculum minus humeri*); on the cranial side the *supraspinatus* muscle, originating from the *fossa supraspinata* and inserting at the proximal part of the greater tubercle (*tuberculum majus humeri*); on the middle part of the greater tubercle is the insertion of the *infraspinatus* muscle, originating from the *fossa infraspinata* of the scapula and strengthening the dorsal part of the joint capsule; the last muscle of the *rotator cuff* is the *teres minor* muscle, which originates from the lateral margin of the scapula and gives support to the dorsal part of the joint capsule before inserting on the distal part of the greater tubercle. All four of these muscles are firmly connected to the joint capsule. Between the upper margin of the *subscapularis* muscle and the anterior margin of the *supraspinatus* muscle is a cleft. In this region, the capsule is strengthened by the superior *glenohumeral* and *coracohumeral* ligaments.

The *suprascapular nerve* is the main sensory nerve for the dorsal part of the joint capsule (no. 1 in Fig. 5.1a). Only a small part of the joint capsule in the region of the *recessus axillaris* is supplied by a branch of the *axillary nerve* (*R. articularis dorso-caudalis*) (no. 2 in Fig. 5.1b). The ventral part of the joint cap-

**Fig. 5.1a,b.** Sensory innervation of the human shoulder joint and capsule. **a** Ventral aspect: 1 lateral pectoral nerves (*Nn. pectorales laterales*); 2 subscapular nerve (*N. subscapularis*); 3 axillary nerve (*N. axillaris*); 4 musculocutaneous nerve (*N. musculocutaneus*). **b** Dorsal aspect: 1 subscapular nerve (*N. subscapularis*) with: *a* cranial and *b* caudal articular branch and muscular branches for *c* *supraspinatus* muscle and *d* *infraspinatus* muscle; 2 Axillary nerve (*N. axillaris*)





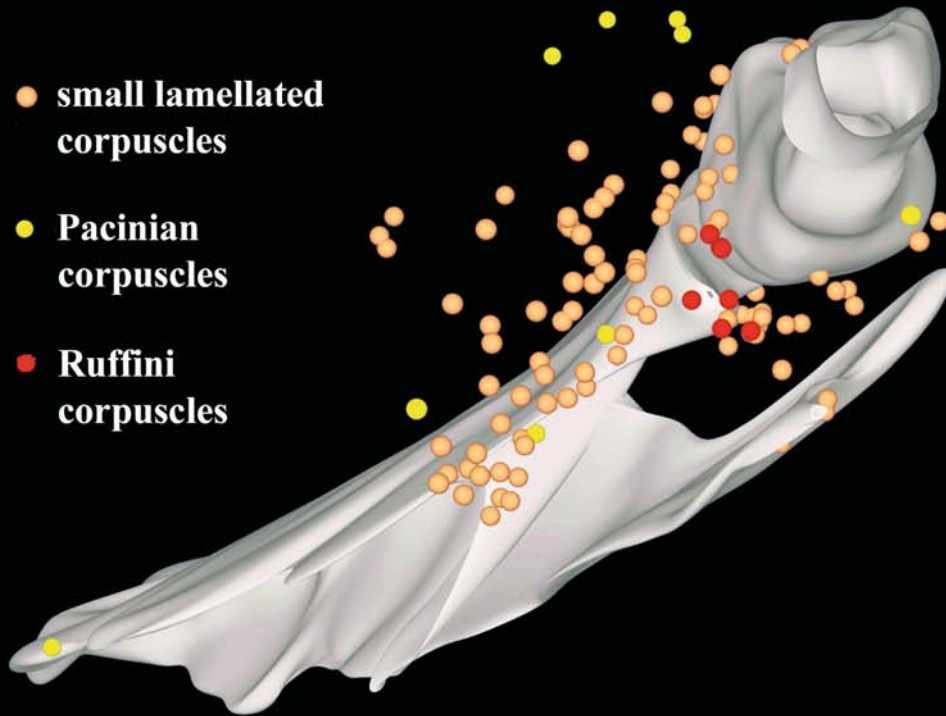
sule is supplied by several nerve branches. The upper part in the region of the fornx humeri (consisting of the acromion scapulae, the coracoid process and the coracoacromial ligament) is supplied by the thoracic ventral cranial nerve (no. 1 in Fig. 5.1a). The subscapular (no. 2) and the axillary (no. 3 in Fig. 5.1a) nerves have branches extending to the lower parts of the joint capsule (e.g. R. articularis ventrocaudalis of the axillary nerve). The rotator cuff muscles receive their innervation from the subscapular nerve (C6 and C7; no. 2 in Fig. 5.1a) for the subscapular muscle; from the suprascapular nerve (C4–C6; no. 1 in Fig. 5.2b) for the supraspinatus and infraspinatus muscles; and from the axillary nerve for the teres minor muscle. The other muscles involved in movement of the shoulder joint are: the deltoideus (axillary nerve), the latissimus dorsi (thoracodorsal nerve), the biceps brachii (musculocutaneous nerve), the triceps brachii—caput longum (radial nerve), the pectoralis major (pectoral nerves) and the teres minor (thoracodorsal nerve) muscles. All nerves innervating the joint capsule or the aforementioned muscles are involved in supplying information about the position of the joint. To a lesser extent, mechanoreceptors in the skin may also have a role.

Considering the size of the human shoulder joint, it is not surprising that quantitative studies on the number and distribution of sensory nerve endings are lacking. It was therefore necessary to find a good animal model. Quadruped animals are not very suitable for such studies as their shoulder joints are designed to cope with a rather different type of load. However, a small laboratory marsupial, *Monodelphis domestica*, has a similar degree of freedom of movement in the shoulder joint to humans and is sufficiently small to allow complete topographic examination of the shoulder region [3, 4]. The shoulder joint capsule in this species is well supplied with different types of mechanoreceptors—most of them are small lamellated corpuscles corresponding to Pacinian corpuscles in man (Fig. 5.2) [3]. Accumulations of lamellated corpuscles have been found in the ventral part of the joint capsule, where the capsule is attached to the glenoid labrum and the scapula, and also in the axillary fold. In addition, the flaccid part of the capsule in the recessus axillaris also contains a small number of Ruffini corpuscles. In contrast, the rotator cuff region of the joint capsule contains only a small number of lamellated corpuscles, while numerous Golgi tendon organs are found in the area where the tendons of the rotator cuff muscles insert into the joint capsule (Fig. 5.2) [4]. Muscle spindles are spread throughout the shoulder muscles, mostly at some distance from the shoulder joint (Fig. 5.2).

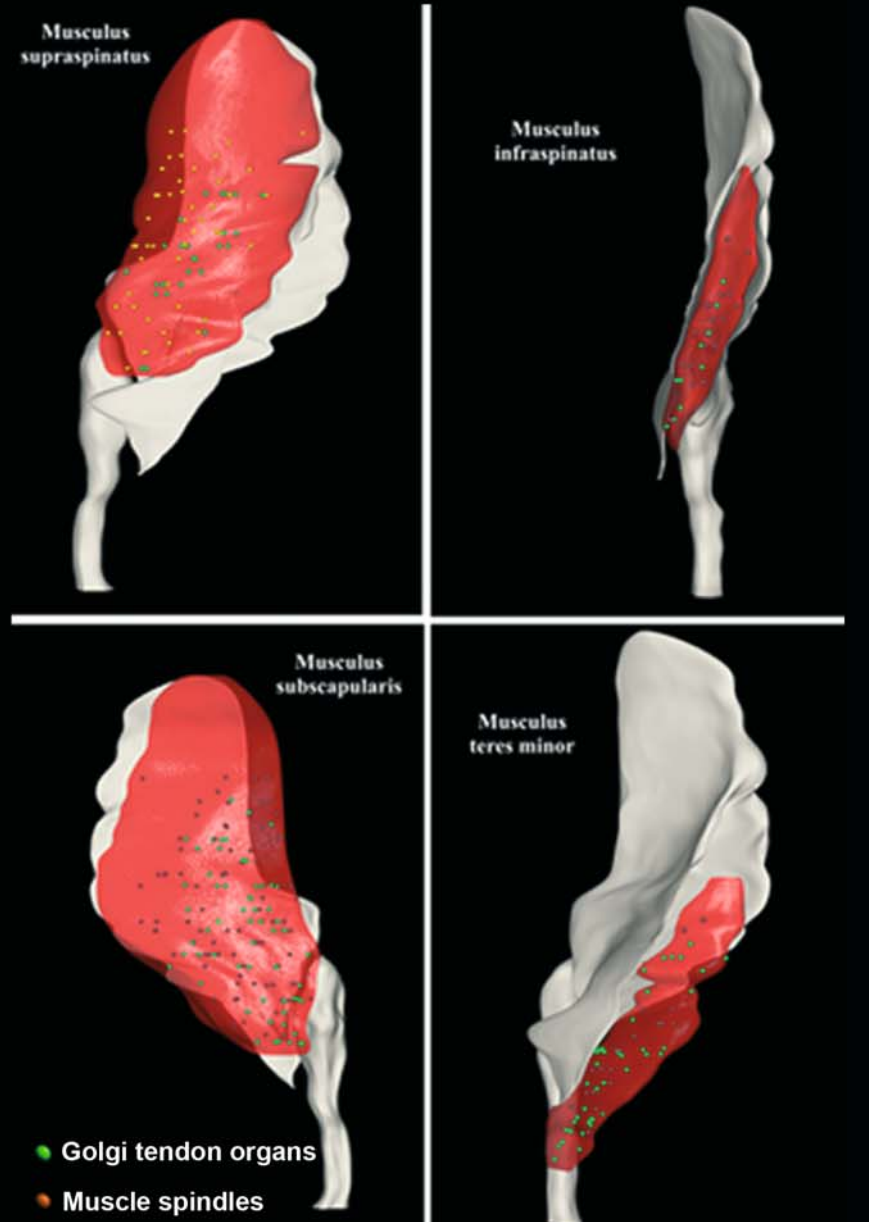
**Fig. 5.2.** Mechanoreceptors in the capsule and rotator cuff of the shoulder joint of *Monodelphis domestica*. (Modified from [3])

### Mechanoreceptors in the capsule of the shoulder joint

- small lamellated corpuscles
- Pacinian corpuscles
- Ruffini corpuscles



### Mechanoreceptors in the rotator cuff



### 5.1.2 Sensory Nerve Endings in Muscles

Functionally, two major types of receptors have to be distinguished: mechanoreceptors, which are designed to monitor the length of muscles and the tension of tendons, and polymodal nociceptors, which are specialised in thermal and chemical and stimuli that are potentially damaging to the tissues.

*Nociceptors* are found in the connective tissue of muscles (endomysium, perimysium and epimysium). They are fine branches of thin myelinated (A $\delta$ -) or unmyelinated (C-) nerve fibres forming numerous free nerve endings [5]. They play an important part in muscle soreness [6] and may affect muscle tone and shoulder movement through reflexes. Polymodal nociceptors are not regarded as mechanoreceptors and are thus outside the focus of this chapter.

Two types of *mechanoreceptors* are found in muscles: muscle spindles and Golgi tendon organs. *Muscle spindles* are the largest mechanoreceptors found in man. They can reach a length of several millimetres and a diameter of about 0.2 mm. Their number varies widely between different types of muscles [7]. The number of muscle spindles is usually larger in muscles that are involved mainly in postural control than in muscles performing mainly fast movements. The number of muscle spindles appears to be relatively constant throughout life [8].

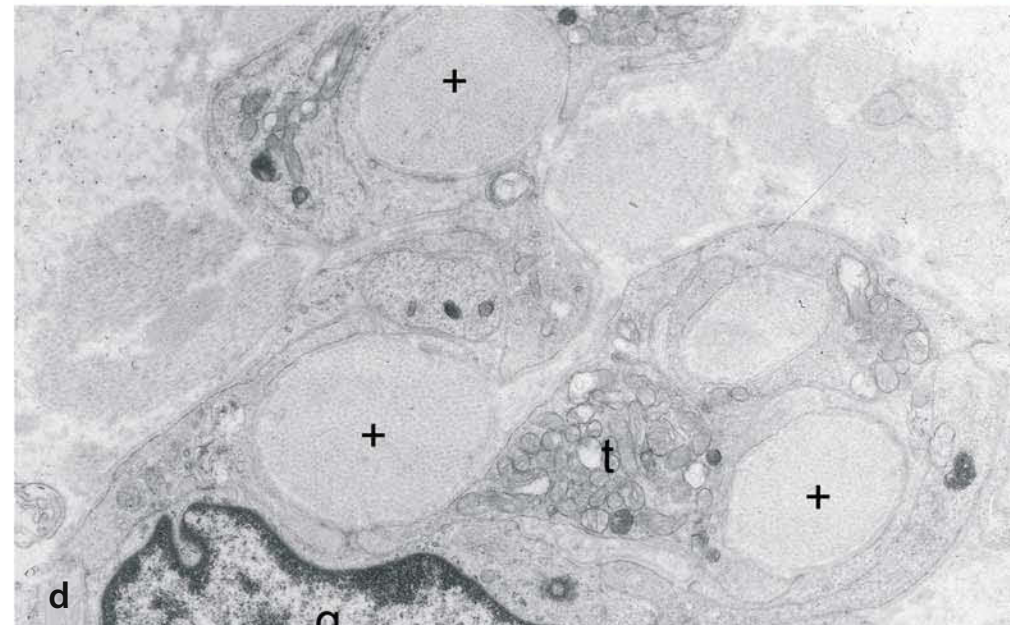
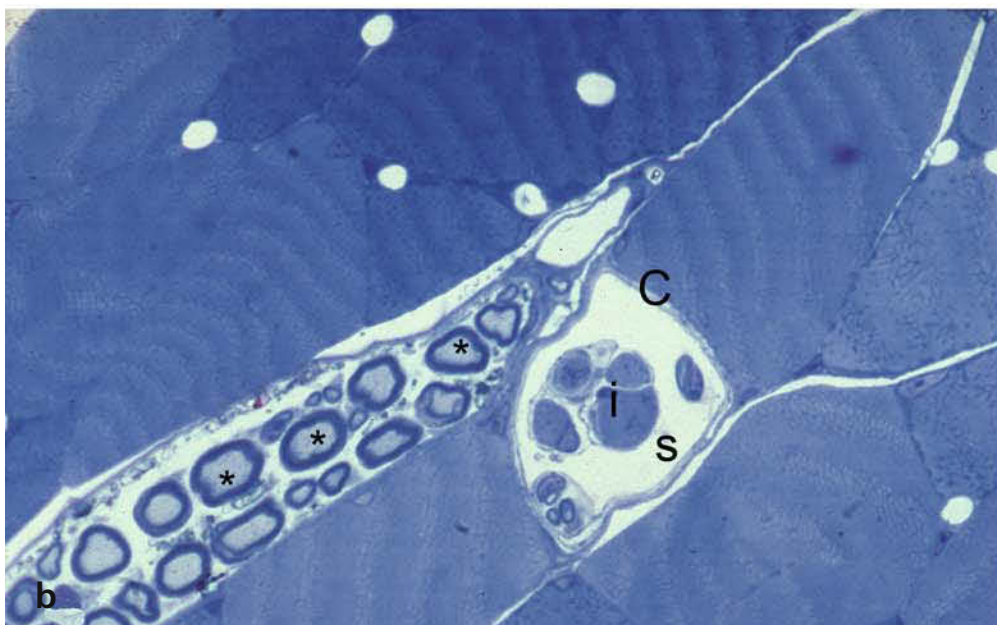
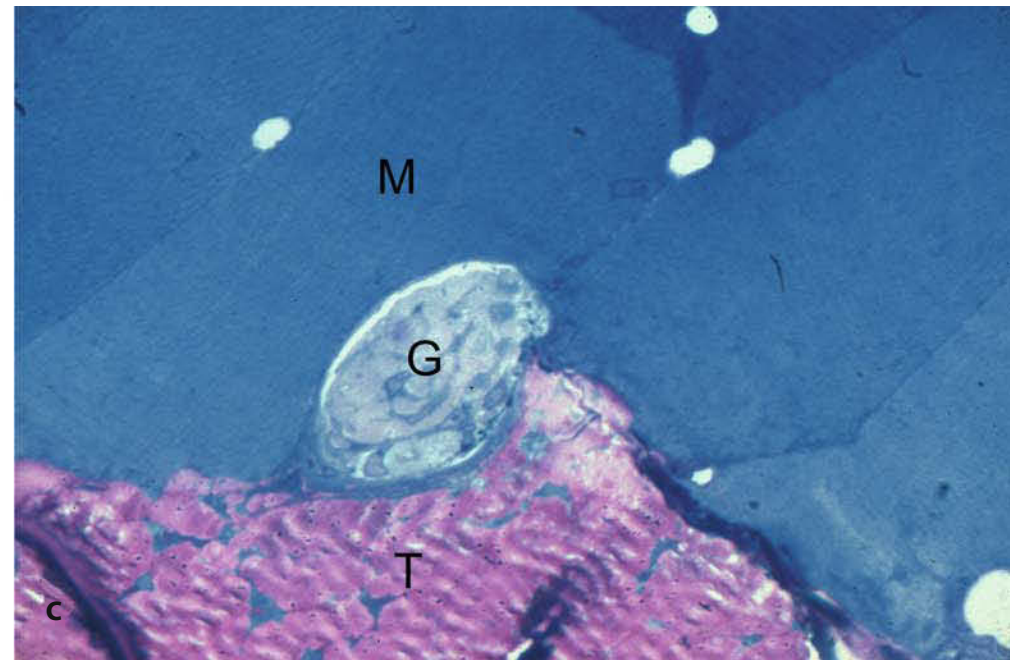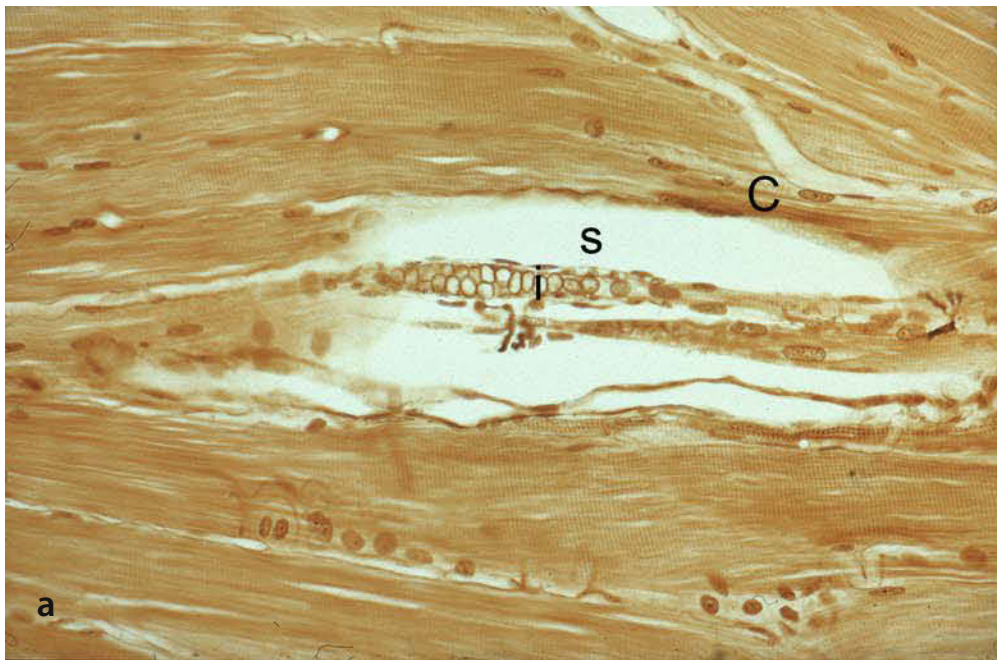
In longitudinal sections (Fig. 5.3a), the equatorial region can be distinguished from the two thinner polar regions. Muscle spindles contain intrafusal muscle fibres and sensory, motor and autonomic nerve fibres with the corresponding nerve endings, and they are surrounded by a capsule formed as an extension of the perineurium of the supplying nerve. The intrafusal fibres and the axons are covered by a spindle sheath consisting of endomysial cells. Between spindle sheath and capsule is a periaxial cleft (“s” in Fig. 5.3a, b). Depending on the

arrangement of the nuclei of the intrafusal muscle fibres, nuclear chain fibres and nuclear bag fibres can be distinguished [9, 10]. The numbers of intrafusal muscle fibres per muscle spindle vary between 1 and 5 for nuclear bag fibres and between 2 and 11 for nuclear chain fibres.

The sensory nerve fibres are myelinated, with diameters of 6–15  $\mu\text{m}$  (type Ia fibres) or about 6  $\mu\text{m}$  (type II fibres). Each muscle spindle is usually supplied by one Ia and one type II fibre. The Ia fibre loses its myelin sheath in the equatorial region and forms primary “anulospiral” nerve endings. The type II fibres form secondary nerve endings outside the equatorial region in the shape of anulospiral or flower-spray endings. Motor nerve fibres of the A $\gamma$ - or, occasionally, the A $\beta$ -type supply the intrafusal muscle fibres. In this way the sensitivity of the sensory fibres can be adjusted to monitor not only the length of muscle but also small sudden changes (for review see [11]).

*Golgi tendon organs (GTO)* are found almost exclusively (94%) at the junction between muscle and tendon (Fig. 5.3c), while only about 6% are seen in the main tendons [12]. Their number depends again on the type of muscle: in “fast” muscles, (e.g. the gastrocnemius) there are usually fewer GTOs than in “slow” muscles (e.g. the soleus muscle). GTOs are usually spindle shaped, with diameters of about 0.16 mm and a maximum length of 1.6 mm, running into pointed ends on both sides. The muscular end is normally about 25% thicker than the end facing the tendon. Most GTOs consist of only one cylinder, while in about one third, more than one can be found. Histologically, GTOs are surrounded by a perineural capsule, which is lacking at the pointed ends. The sensory nerve fibres of 5–15  $\mu\text{m}$  diameter (type Ib) branch intensively, forming enlarged nerve terminals between bundles of collagen fibres (Fig. 5.3d) running through the capsule of the GTO. GTOs are designed to monitor the tension in the muscles [13–15].

**Fig. 5.3a-d.** Muscle spindles and Golgi tendon organs from the shoulder of *Monodelphis domestica*. **a** Silver-stained longitudinal section of a muscle spindle of supraspinatus muscle (*i* intrafusal muscle fibre, *s* subcapsular space, *C* perineural capsule; magnification x400) **b** Semithin cross section of a muscle spindle from supraspinatus muscle. Close to the muscle spindle is a bundle of myelinated nerves marked with an asterisk. (x1200) **c** Semithin cross section of a Golgi tendon organ (GTO). The GTO is between the muscle and tendon of teres minor muscle (*M* striated muscle, *T* tendon, *G* Golgi tendon organ); (x1200) **d** Detail of a Golgi tendon organ. Bundles of collagen fibres (marked +) run between nerve terminals (*t*). The nerve terminals are covered by a terminal glial cell (*g*) (x10,000)



### 5.1.3 Sensory Nerve Endings in the Joint Capsule

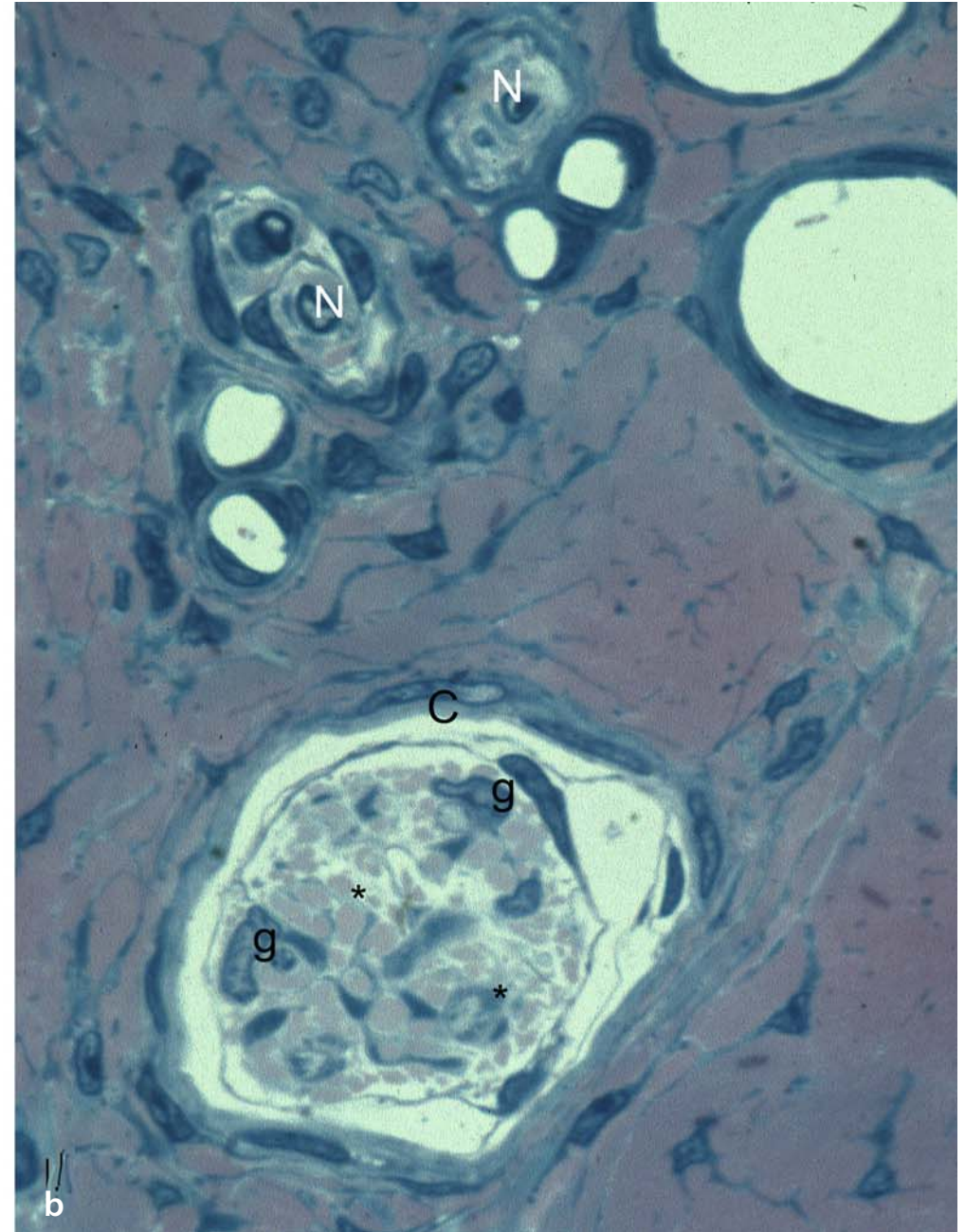
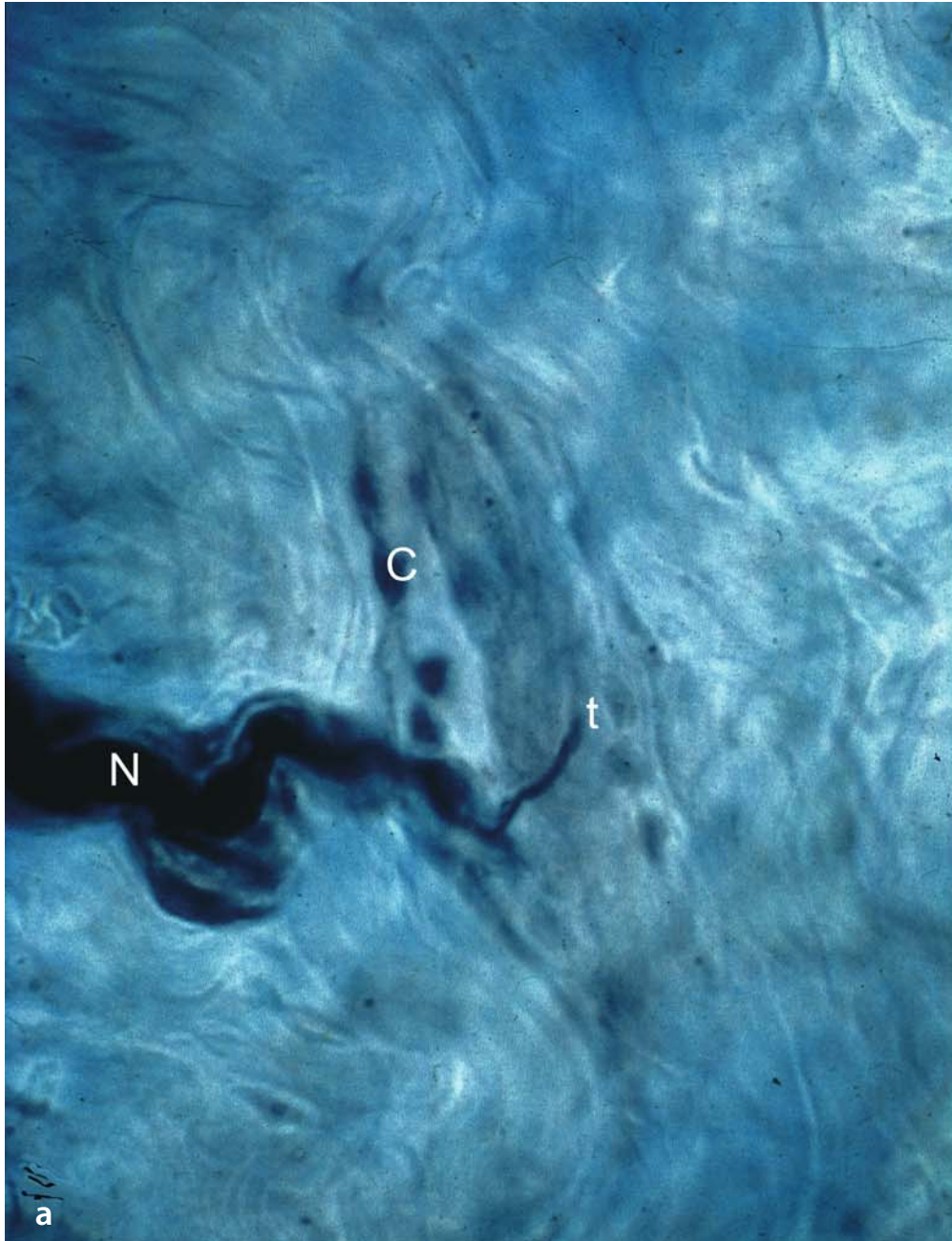*Free nerve endings, or nociceptors*, are found in large numbers inside joint capsules [16]. They are mainly terminal branches of thin myelinated fibres (about 2  $\mu\text{m}$  diameter), losing their myelin sheath in the fibrous layer of the capsule before branching intensively to form networks of nerve terminals between collagen fibrils. The nerve terminals are only partly covered by glial cells and contain accumulations of mitochondria. Like those in muscles, they are not primarily involved in mechanoreception.

Only small numbers of *Ruffini corpuscles* are found in the capsule of the shoulder joint (see Fig. 5.2), mainly in areas without muscles, such as the axillary fold [3].

Morphologically, three types of Ruffini corpuscles can be distinguished: corpuscles without a capsule, corpuscles with a capsule formed by connective tissue and perineural cells, and

corpuscles resembling Golgi tendon organs [17, 18]. The last type is only found in the fibrous layer of the joint capsule. Perineural cells form cylinders with open ends through which bundles of collagen fibres enter, running through the cylinder (Fig. 5.4a). Myelinated nerve fibres 4–6  $\mu\text{m}$  in diameter enter the cylinder on the long side. Their perineural sheath merges with the perineural sheath of the cylinder. Within the cylinder the nerve fibre loses its myelin sheath and branches several times before forming terminal enlargements anchoring it between bundles of collagen fibres (Fig. 5.4b). The nerve terminals are only incompletely covered by terminal glial cells. Stretching of the collagen fibres results in deformation of the nerve terminals, opening mechanically gated channels resulting in receptor potentials and eventually causing the characteristic slowly adapting discharge pattern of action potentials [19]. In this way, Ruffini corpuscles are designed to monitor tissue stretch [20–22].

**Fig. 5.4a, b.** Ruffini corpuscles from the joint capsule of a cat knee joint. **a** Silver stained longitudinal section (*N* myelinated nerve fibre, *t* terminal nerve fibre, *C* perineural capsule; x 600). **b** Semithin cross section from collateral lateral ligament of a dog knee joint (*N* myelinated nerve fibres, \*nerve terminal, *C* perineural capsule, *g* terminal glial cells; x1200)



*Pacinian corpuscles* (also referred to as Vater-Pacini corpuscles) have a longish oval shape, with a long diameter of 0.2–1.0 mm (Fig. 5.5a). The afferent axon in the centre of the corpuscle is surrounded by an inner core of lamellae formed by terminal glial cells and an outer perineural capsule (Fig. 5.5b). The myelinated afferent axon has a diameter of 6–10  $\mu\text{m}$ . In typical Pacinian corpuscles there is only one axon. The corpuscles with two or more axons and corresponding inner cores are often referred to as Golgi–Mazzoni corpuscles. Reinnervation following lesions of the afferent nerve can also result in multiple axons supplying one corpuscle [23, 24].

Within the inner core, the axon loses its myelin sheath and the nerve terminal is characterised by accumulations of empty vesicles and mitochondria (Fig. 5.5c). Finger-like protrusions are often seen extending from the axon between the cells of the inner core. Clear vesicles are found at the origin of these “spikes” from the nerve terminal. Within the inner core, the terminal glial cells are arranged in the form of symmetrical lamellae around the nerve terminal. The number of layers varies with the size of the corpuscle, and there can be as many

as 70 in large Pacinian corpuscles. The glial cells have their nuclei in the peripheral part of the inner core. The cytoplasmic lamellae are covered with basal lamina, sometimes with small clefts left between adjoining basal laminae. The axon is placed like a “hot dog” between two lamellar systems, leaving a cleft on either side into which the aforementioned “spikes” extend.

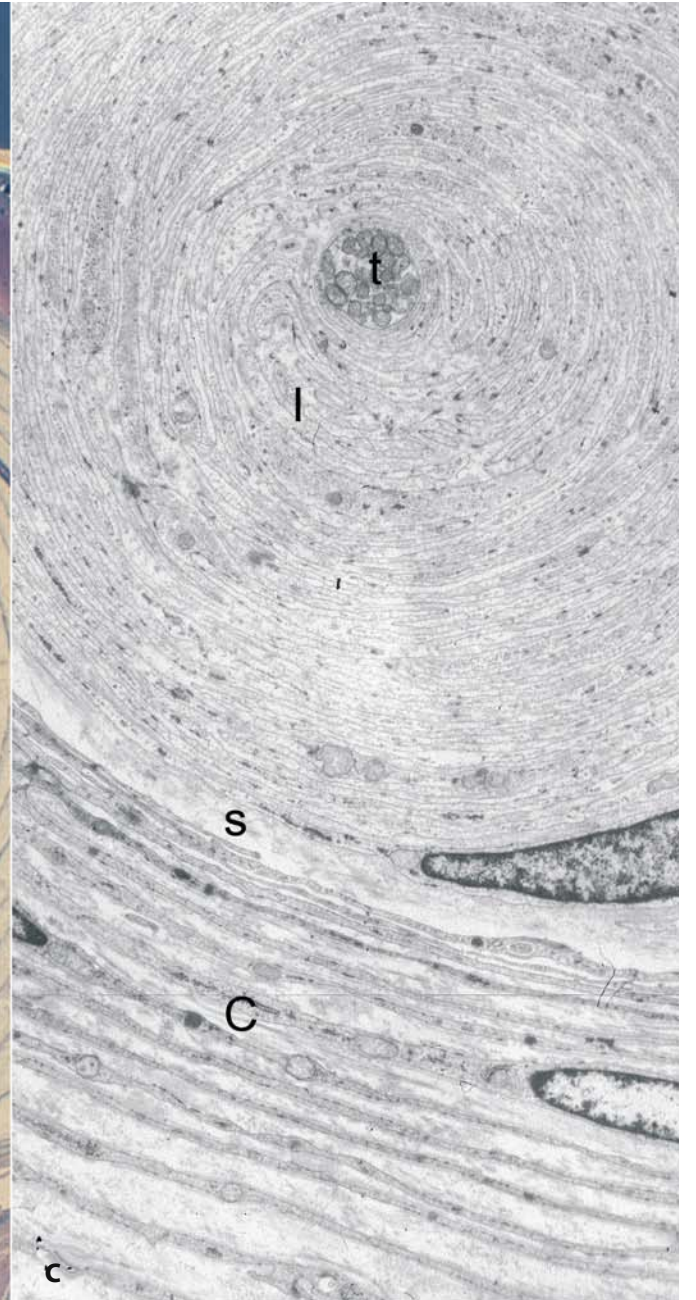
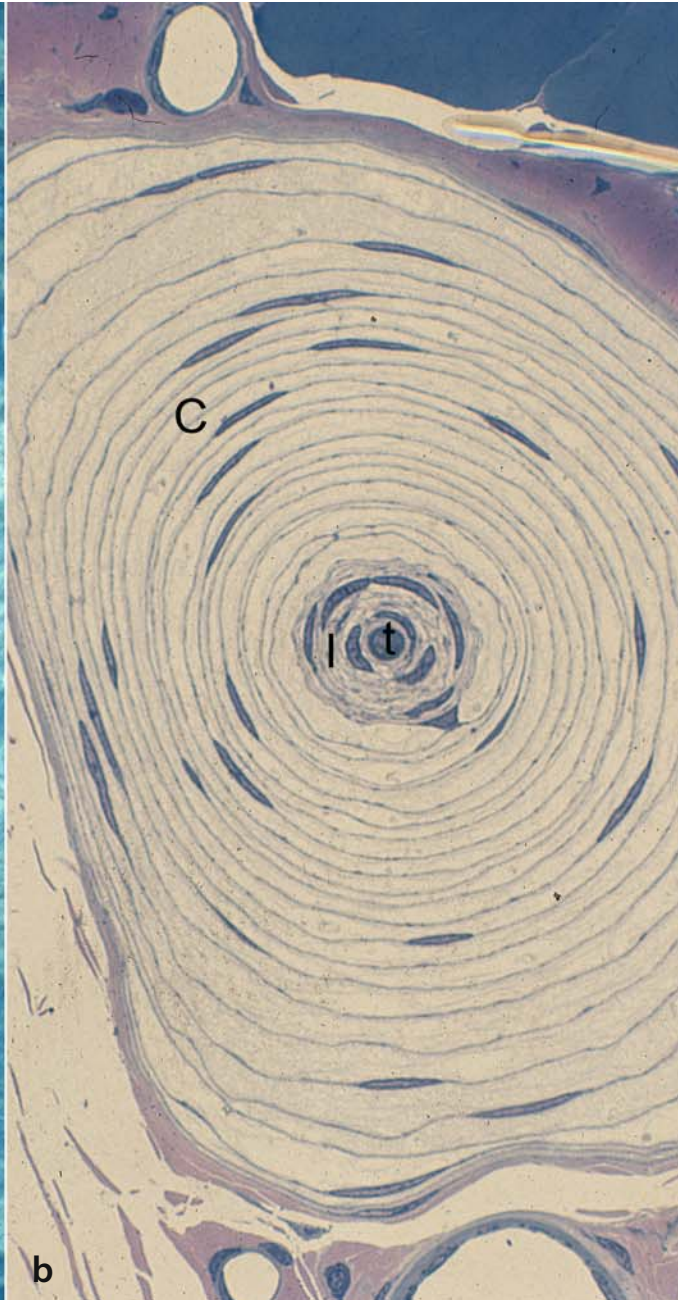
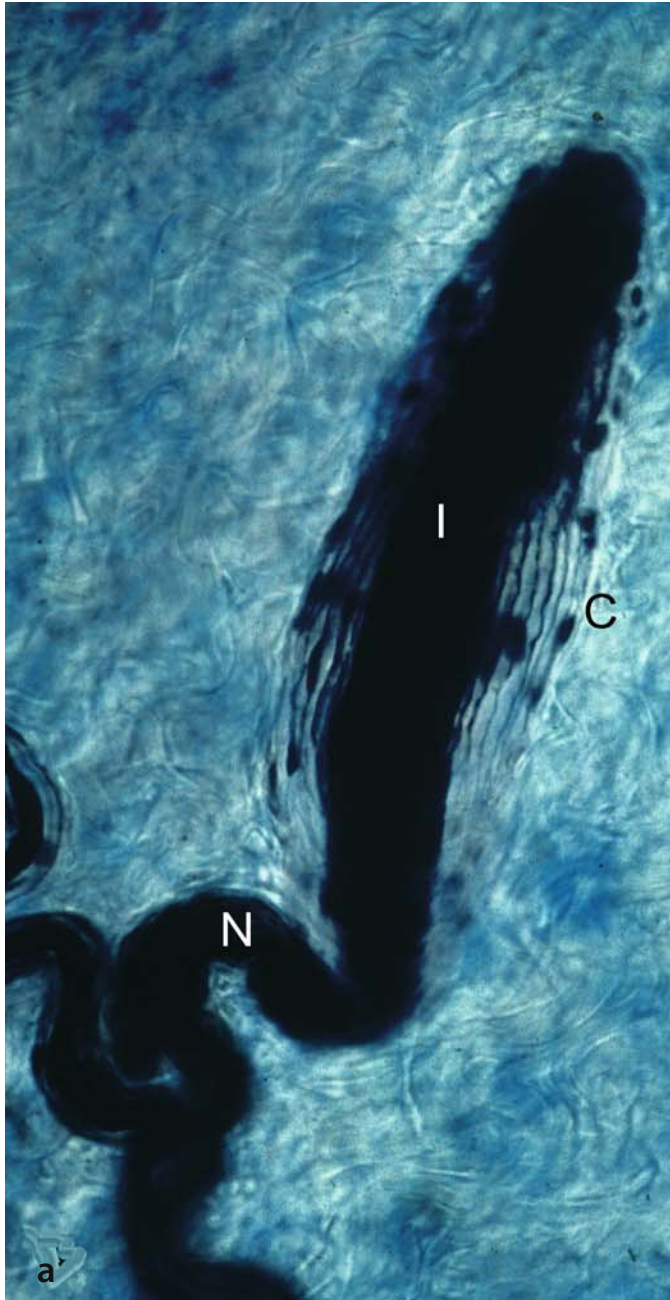
The perineural capsule consists of layers of flat perineural cells (Fig. 5.5c) extending from the perineurium of the afferent axon [25]. Structurally, they are similar to cells of the perineurium and are covered on both sides with basal lamina. Thin collagen fibrils run through the clefts between adjacent basal laminae. Capillaries can be found in the subcapsular cleft between inner core and perineural capsule [26]. Functionally, Pacinian corpuscles respond best to vibration stimuli in the frequency range of 200–300 Hz and with extremely small amplitudes that can be as low as 1  $\mu\text{m}$  [27, 28].

#### Acknowledgements:

The authors thank Ms. Brigitte Asmus, Hamburg for excellent technical assistance and Mr. Ivan Helekal, Prague for drawing Fig. 5.1.

**Fig. 5.5a-c.** Pacinian corpuscles. **a** Silver-stained longitudinal section of a Pacinian corpuscle from a cat knee joint. The middle dark cylinder is an inner core (*I*) covered by a perineural capsule (*C*) consisting of several layers (x400). **b** Electron microscopic (EM) cross section of a Pacinian corpuscle from the interosseous membrane of the leg of *Monodelphis domestica*. In the middle the inner core (*I*) with the axon terminal (*t*) can be seen. The perineural capsule (*C*) contains about 25 layers of thin perineural cells (x1200). **c** Detail from a Pacinian corpuscle in EM. Inner core with axon terminal (*t*) packed with mitochondria is placed between thin lamellae of inner core cells. In the lower part of the picture details of the subcapsular space (*s*) and the perineural capsule (*C*) cells can be seen (x6000)





## 5.2 The Role of “Proprioception” in Shoulder Disease

*Giovanni Di Giacomo, Todd S. Ellenbecker*

The *shoulder* functions both as a *funnel*, transferring the proximally developed forces efficiently, and as a ball-and-socket joint allowing rapid arm rotation. This rotation, termed “*long axis rotation*”, refers to internal rotation within the shoulder and forearm pronation coupled around a stable ball-and-socket articulation [29]. The biomechanical function of the rotator cuff is to maximise concavity/compression ball-and-socket kinematics rather than to provide rotary motion and force. The rotator cuff has been shown to develop only 18% of the forward motion of the arm [30].

The physiological model for basic arm activity and striker sports is a “*motor programme*” [31]. Motor programmes activate muscles in coordinated sequences that simplify and allow movement tasks for voluntary upper extremity performance. These motor programmes include lower extremity and trunk muscle activation before and during arm motion. In addition to generating and transferring force to the distal segments, these programmes create a stable proximal base for voluntary arm movements. The motor programmes rely on specific sensory and proprioceptive feedback for integration and activation [32]. A thorough study of the shoulder’s intraarticular anatomy is one of the several opportunities arthroscopy has provided to surgeons, and an array of anatomical observations and considerations has allowed us to assume possible roles for some structures and their interconnections, not only from a biomechanical point of view, but also as a neural drive to the muscles as afferent and efferent neuromuscular pathways in the proprioceptive control of this joint. Over the past few years the international literature has focused on the role of scapular dyskinesis and capsular

pathology, referring to them as “starters” of a cascade of events potentially triggering more complex and known lesions of the capsulolabral complex, such as glenohumeral joint instability and rotator cuff impingement syndrome.

Owing to the shoulder’s unconstrained nature and its role in the kinetic chain, the glenohumeral joint must have several mechanisms to regulate its position in space.

Up to the 1970s, the view on sensory feedback of active human movements was that once voluntary movement was initiated by the cerebral cortex, only low-level control was presented by the receptors in the muscles and tendons. This sensory information from the muscles and tendons was passed on to the spinal cord and some subcortical extrapyramidal parts of the brain, such as the cerebellum, but made no contribution to conscious sensation, which remained the province of the joint receptors [33]. In the early 1970s, however, important research by Goodwin et al. [34] and Eklund [35] independently demonstrated the important role that muscular receptors have in contributing to sensations of active movement qualitatively. The current view is that the articular structures of the body act as sensory chambers, which relay proprioceptive information between specific neural pathways within the peripheral nervous system (PNS) and the CNS. These “neural pathways” transport the necessary sensorimotor information, which modulates muscle function. These articular structures include the ligamentous tissue within and surrounding movable joints, and the adjoining musculotendinous tissues that cross and insert around these joints. The pericapsular tissues, both active and passive, must therefore make a significant contribution to stability and coordination [36]. This balance is accomplished by force generation within the muscles and is partially controlled by neuromuscular feedback [36–38]. This reaction requires afferent information from neural elements located within muscles, tendons, and other periarticular structures [38–40]. An essential part of this interaction would

be information emanating from a joint (afferent supply) to control a given action. This afferent feedback would be attributable to the neuroreceptors present within the joint's soft tissues [36, 40, 41]. In essence, the afferent feedback would serve as an element of coordination for the nervous system.

The *sensorimotor system* controls the contributions of the dynamic restraints for functional joint stability and coordination [32]. The term 'sensorimotor system' describes the sensory, motor, and central integration and processing components involved in maintaining joint homeostasis during body movements, including all the afferent, efferent and central integration and processing components involved in maintaining functional joint stability and kinetic chain coordination. Although visual and vestibular input provides a significant contribution, the peripheral mechanoreceptors are the most important from a clinical and orthopaedic perspective. The process of maintaining functional joint stability is accomplished through a complementary relationship between static and dynamic components. Ligaments, joint capsule, cartilage and the bony geometry within the articulation comprise the static component [42, 43]. Dynamic contributions arise from feedforward and feedback neuromotor control over the skeletal muscles crossing the joint. The term 'proprioception' has been adopted to refer to the afferent information arising from 'proprioceptors' located in the 'proprioceptive field'. The proprioceptive field is specifically defined as the area of the body "screened from the environment" by the surface cells, which contains receptors especially adapted for the changes that occur inside the organism independently of the 'interoceptive field' [32]. In contrast to proprioception, the term 'somatosensory' is more global and encompasses all of the mechanoreceptive, thermoreceptive, and pain information arising from the periphery. Conscious appreciation of somatosensory information leads to the sensations of pain, temperature, touch, pressure, etc., and the conscious submodality proprioception sensations. Proprioception is a subcomponent of soma-

tosensation, and the terms should not therefore be used interchangeably.

Neuromuscular control, specifically as considered from the aspect of joint stability, is defined as the unconscious activation of dynamic restraints in preparation for and in response to joint motion, and loading for the purpose of maintaining and restoring functional joint stability. Stimulation of a corrective response within the corresponding system after sensory detection is often considered '*feedback control*'. In contrast, '*feedforward control*' has been described as anticipatory actions occurring before the sensory detection of a homeostatic disruption. Feedback control is characterised by continual processing of afferent information and provision of response control on a moment-to-moment basis. In contrast, afferent information during feedforward control is used intermittently until feedback controls are initiated [32]. Feedforward neuromuscular control involves planning movements based on sensory information from past experiences [44]. The feedback process regulates motor control continuously through reflex pathways. Feedforward mechanisms are responsible for preparatory muscle activity: feedback processes are associated with reactive muscle activity.

Owing to skeletal muscle's orientation and activation characteristics, a diverse array of movement capabilities can be coordinated, involving concentric, eccentric and isometric contractions, while excessive joint motion is restricted. Therefore, dynamic restraint is achieved through preparatory and reflexive neuromuscular control. The level of muscle activation, whether preparatory or reactive, greatly modifies its stiffness properties. From a mechanical perspective, muscle stiffness is the ratio of the change in force to the change in length. In essence, muscles that are stiffer resist stretching episodes more effectively, have higher tone, and provide more effective dynamic restraint to joint displacement.

*Mechanoreceptors* are sensory neurons or peripheral affer-

ents located within joint capsular tissues, ligaments, tendons, muscle and skin [45, 46]. Deformation or stimulation of the tissues in which the mechanoreceptors lie produces gated release of sodium, eliciting an action potential [47]. In general, mechanoreceptors are specialised sensory receptors responsible for quantitatively transducing the mechanical events occurring in their host tissues to neural signals [45] that are transmitted via afferent and efferent pathways. With the identification of a large spectrum of receptors and knowledge of their function, it now appears that the soft tissue structures of muscles and joints contain the neural components necessary for the awareness of joint motion, joint position, pain and touch. This combination of both muscle and joint receptors forms an integral component of a complex sensorimotor system that plays a part in the proprioceptive mechanism belonging to a feedback–feedforward system initiated by the activation of mechanoreceptors. Research [48] has confirmed a rich nerve supply to the glenohumeral capsule. Furthermore, specific nerve branches appear to supply the various regions of the glenohumeral capsule in consistent patterns. This regional confirmation completes the circuit between the passive and active components of any given joint. The sensory (afferent) input from the mechanoreceptors is relayed by the PNS to the CNS. The CNS responds to the afferent stimulus by discharging a motor (efferent) signal that modulates effector muscle function by controlling joint motion and/or position. The distribution indicates a difference in receptor concentration depending on the given site. It remains to be seen, however, whether specific receptor distribution patterns vary between individuals and, more importantly, between varying pathologies. These variations in concentration and type of neural elements may have specific implications for pathologic entities of the glenohumeral joint. Several studies [49, 50] indirectly suggest that there is a reflex arc based on intraarticular mechanoreceptors that aids in dynamic control of the shoulder joint. Several authors [46, 51] have also studied the receptors in the

shoulder labrum and subacromial bursa (see section 5.1).

Vangsness et al. [52] have studied the neural histology of the human shoulder joint, including the glenohumeral ligaments, labrum, and subacromial bursa. Two types of slowly adapting Ruffini end-organs and rapidly adapting Pacini corpuscle are identified in the superior, middle and inferior glenohumeral ligaments. The most common mechanoreceptor is the classic Ruffini end-organ in the glenohumeral joint capsular ligaments. Pacinian corpuscles are less abundant overall; however, Shimoda [54–55] reports that the type II Pacinian corpuscles are more commonly found in the human glenohumeral joint capsular ligaments than in the human knee. Analysis of the coracoclavicular and acromioclavicular ligaments shows equal distribution of type I and II mechanoreceptors. Morisawa et al. [56] identified types I, II, III and IV of mechanoreceptors in human coracoacromial ligaments. Their review shows how the glenohumeral joint capsular ligaments aid in the provision of afferent proprioceptive input by their inherent distributions of type I Ruffini mechanoreceptors along with the more rapidly adapting Pacinian receptors. A rapidly adapting receptor such as the Pacinian type can identify changes in tension in the joint capsular ligaments, but it quickly decreases its input once the tension becomes constant [52]. In this way, the type II receptor has the ability to monitor acceleration and deceleration of a ligament's tension.

Vangsness et al. [52] report finding no evidence of mechanoreceptors in the glenoid labrum but noted free nerve endings in the fibrocartilaginous tissue in the peripheral half. The subacromial bursa was found to have diffuse, yet copious, free nerve endings, with no evidence of larger, more complex, mechanoreceptors. Ide et al. [48] also studied subacromial bursa, taken in their case from three cadavers, and found a copious supply of free nerve endings, most of which were found on the roof side of the subacromial arch, which is exposed to impingement type stresses. Unlike Vangsness et al. [52], Ide et al. [48] do report

evidence of both Ruffini and Pacinian mechanoreceptors in the subacromial bursa. Their findings suggest that the subacromial bursa receives both nociceptive stimuli and proprioception and may play a part in the regulation of shoulder movement. Further research into the exact distribution of these important structures in the human shoulder is indicated, to give clinicians further information and enhance our understanding of the proprioceptive function of the shoulder. The movement of the shoulder is the expression of a kinetic chain, which is activated in a proximal-to-distal direction and shows a glenohumeral-scapular-thoracic rhythm modulated by fine proprioceptive activity. In theory, any disturbance of one or more of the structures responsible for the control and transmission of proprioceptive information may, by altering arthrokinematics, produce lesions and disturbances in the subacromial soft tissues and glenohumeral joint.

In addition to the afferent structures found in the human shoulder's noncontractile tissues (joint, capsule, subacromial bursa, and intrinsic and extrinsic ligaments), significant contributions to the regulation of human proprioceptive feedback are obtained from receptors located in contractile structures. Two of the primary mechanisms for afferent feedback from the muscle tendon unit are the muscle spindle mechanism and the Golgi tendon organ [47, 57]. The main components of the muscle spindle are intrafusal muscle fibres, afferent sensory fibre endings and efferent motor fibre endings. The intrafusal fibres are specialised muscle fibres with central regions that are not contractile. The sensory fibre endings spiral around the central regions of the intrafusal fibres and are responsive to stretch. Gamma ( $\gamma$ ) motor neurons innervate the contractile polar regions of the intrafusal fibres. Contraction of the intrafusal fibres pulls on the central regions from both ends and changes the sensitivity of the sensory fibre endings to stretch [58]. Research classifying muscle spindles has traditionally grouped intrafusal muscle fibres into two groups based on the type of afferent projections [57,

59]. These two groups consist of nuclear bag and nuclear chain fibres. Nuclear chain fibres project from large afferent axons [57, 59]. Nuclear bag fibres are innervated by  $\gamma$ -1 (dynamic) motor neurons and are more sensitive to the rate of muscle length change such as occurs during a rapid stretch of a muscle during an eccentric contraction or passive stretch [57]. Intrafusal nuclear chain fibres are innervated by  $\gamma$ -2 (static) motor neurons and are more sensitive to static muscle length. The combination of the nuclear chain and nuclear bag fibres allows the afferent communication from the muscle tendon unit to remain sensitive over a wide range of motion, during both reflex and voluntary activation [58].

Muscle spindles provide much of the primary information needed for motor learning in terms of muscle length and joint position. Upper levels of the central nervous system can bias the sensitivity of muscle spindle input and sampling [57]. Muscle spindles are not present in similar densities in all muscles in the human body. Their density is most probably related to muscle function, with greater densities of muscle spindles reported in muscles that initiate and control fine movements or maintain posture. Muscles that cross the front of the shoulder, such as the pectoralis major and biceps, have a very high number of muscle spindles per unit of muscle weight [60]. Muscles with attachment to the coracoid, such as the biceps, pectoralis minor and coracobrachialis, also have high spindle densities. Lower spindle densities have been reported for the rotator cuff muscle tendon units, the subscapularis and infraspinatus having greater densities than the supraspinatus and teres minor [60]. This lower rotator cuff spindle density most probably indicates synergistic mechanoreceptor activation with the scapulothoracic musculature during glenohumeral joint movement [57, 61]. This coupled, or shared, mechanoreceptor activation is an example of a kinetic link or proximal-to-distal sequencing, which occurs with predictable or programmed movement patterns in the human body [62]. This kinetic link activation concept is further demonstrated

by the deltoid/rotator cuff force couple [61] and other important biomechanical features of the human glenohumeral joint that have been discussed in this *Atlas*.

Recently it has also become clear that reflexes from joint afferents may be transmitted via pathways other than those projecting directly to the skeletal motor neurons [63]. Thus, the pathways from joint afferents to the muscle spindles via the  $\gamma$ -motor neurons have attracted increasing attention, particularly since the effects on the  $\gamma$ -motor neurons often seem to be more potent and elicited at lower stimulation thresholds. Since the primary muscle spindle afferents are of great importance for the regulation of muscle stiffness and for position and movement sense, it seems obvious that reflexes from peripheral afferents to the  $\gamma$ -muscle spindle system may also be important for these functions. Information mediated by the MSAs (muscle spindle afferents) are shaped not only by variations in muscle length, but also, and to a large extent, by the signals from descending pathways and from ipsilateral and contralateral peripheral nerves. In other words, descending messages and peripheral receptor information are integrated into the fusimotor neurons and then transmitted to the muscle spindles, where this integrated information undergoes final adjustments according to ongoing length/tension changes of the parent muscle. Thus, the  $\gamma$  muscle-spindle system is viewed as an integrative system that converts polymodal feedback to the CNS. Therefore, owing to its intricate reflex regulation, it may be well suited to dealing with the sophisticated coordination between different muscles and, since there are indications that muscles might be functionally partitioned [64], perhaps also between intramuscular compartments [65].

*The concept attributing neurologic synergy* between ligaments and muscles for the common purpose of maintaining joint stability and coordination was first described in 1900 by Payr [66]. Researchers have shown that mechanoreceptors exist in the ligaments [51, 67], that a reflex arc exists from the recep-

tors to muscles crossing the joints [49, 68], and that the muscles are able to improve knee and shoulder stability or stiffness over certain segments of the range of motion [69, 70–72]. The musculature's contribution has also been shown to have clinical significance in the absence of ligamentous structures [49, 73–75]. Several additional concepts demonstrate the important shared role of the static and dynamic structures of the glenohumeral joint in providing an optimal relationship between the glenoid and the humeral head with respect to the rhythm between the scapulothoracic joint and distal segments of the upper extremity. Since the glenohumeral joint is not stabilised by isometric articular ligaments [76], stability in the mid-range positions must be achieved by a mechanism other than capsuloligamentous restraints [58, 77].

The existence of a “*reflex arc*” from the mechanoreceptors within the glenohumeral capsule to muscles crossing the joint confirms and extends the concept of synergism between the passive (ligaments) and active (muscle) restraints on the glenohumeral joint. Solomonow et al. [49, 50], in an interesting investigation on the feline shoulder, have shown the existence of a ligamentous-muscular reflex arc in the glenohumeral joint, confirming the synergy between ligaments and muscles. Gardner and Wrete [78, 79] indicate that some nerve twigs from the capsular region have been traced to the sympathetic system. Gardner [78] dismisses these as vasomotor control in the capsular region, as opposed to innervation of receptors in the capsule, since these nerve twigs always travel along blood vessels. The mechanoreceptors seem to be positioned in the appropriate locations to detect excessive loads at the extremes of motion. Their activity, therefore, could conceivably trigger a reflex that could prevent a subluxation or dislocation episode. Additionally, a reflex arc also exists from the capsule to the muscles crossing the shoulder. This reflex arc could be mediated independently by each of the three branches of the axillary nerve terminating in the capsule. The existence of direct reflex arcs from the capsule

to the musculature confirms and extends the concept that joint stability is not an exclusive or separate function of the ligaments and muscles, but a synergistic affair between the ligaments and the associated muscles [77].

It has been documented that the inferior capsule is subjected to strain during glenohumeral movements that require overhead elevation and external or internal rotation. In such circumstances, the large number of mechanoreceptors can create a relatively sensitive feedback response to this strain of the capsular tissue through the reflex arc and, thus, preserve joint stability.

The biceps, infraspinatus, and supraspinatus muscles are not always the prime mover muscles for a given activity, but it is nonetheless well understood that a mild to moderate increase in their contractile force significantly improves joint stability. Their dynamic relationship to stress the glenohumeral ligaments via the reflex arc thus produces an additional important mechanism that protects the glenohumeral joint from damage. The confirmation that mechanoreceptors are present within the capsule indicates the existence of tissue capable of generating impulses for such reflexes. The presence of this important reflex may lead to a modification of surgical repairs of the capsule, and specifically to preservation of as many neurological structures as possible. This may form the foundation for new postsurgical therapeutic modalities used in the treatment of shoulder dysfunction [50].

Assuming that the reflex arc originates from the mechanoreceptors found in the capsule to the various muscles, some implications remain unclear. Researchers have not yet determined whether such a neurological relationship provides stability to the shoulder in all daily activities or only at the extremes of stress in the capsule to activate the reflex. It can be assumed that the glenohumeral reflex is a spinal reflex deployed automatically upon application of certain levels of stress in the capsular structures and that it does not require voluntary decision or effort from the individual's higher CNS structures [50]. The

spinal stretch reflex is a monosynaptic, two-neuron pathway that is "the simplest, best-defined, most accessible, fastest, and scientifically most productive stimulus-response model in the vertebrate central nervous system" [80, 80a]. The spinal stretch reflex is regarded as an innate spinal segmental reflex that evolves during normal neuromuscular development from a hyperexcitable and prominent state during infancy to a less prominent, or quiescent, state during adulthood [81]. This evolution occurs through modification, inhibition or integration (or all three) of the spinal stretch reflex into programmed motor activity by higher control mechanisms in the course of normal neuromuscular development [82–88] and correlates with changes in spinal or supraspinal structures (or both) during the acquisition of motor skill [84–96].

With a history of an increased level of muscle activity, the spinal stretch reflex often displays a lowered response amplitude to similar controlled stimuli [80, 88, 90, 91, 93, 94, 95, 97]. The spinal stretch reflex response characteristics vary between subjects, with variations in muscle-activity levels or coordination patterns [90, 91, 93, 98]. Through neurological maturation, a higher development of central descending motor control mechanisms would obviate the need for the maintenance and importance of primitive reflexes such as the spinal stretch reflex in neuromuscular activity [86, 87, 90, 91, 93, 95, 97]. The retention of obligatory reflex-induced motor stereotypes would not allow the necessary flexibility in neural development for skill acquisition [84]. As is observed clinically, the motor skill (control) that athletes exhibit is often reflected by a less prominent spinal stretch reflex response in various deep tendon reflexes and implies less spinal stretch reflex influence than other established mechanisms [82–88].

In the patient with multidirectional instability, the prominence of the spinal stretch reflex may reflect a pathologic state. For instance, although the spinal stretch reflex may not always have a significant effect on limb position [80], an altered spinal

stretch reflex can manifest as inappropriate muscle activity during voluntary or reactionary movement [99, 100]. Abnormal developmental changes in excitability of the spinal stretch reflex may reflect factors such as functionally disorganised segmental spinal pathways, inappropriate descending signals or changes in the spinal stretch reflex itself, which can translate into movement deficits or disorders [80, 81, 84–86, 90, 99–101]. Whether this represents decreased development of motor control or neural circuitry or the retention of a more primitive state is unclear. On the other hand, the prominent spinal stretch reflex response of subjects with multidirectional instability may simply reflect a different history of muscle activity (training effect). The subject with multidirectional instability may avoid shoulder use during certain activities or positions, whereas a subject with a normal shoulder would not, and indeed, an athlete would practice these activities or position during training [103].

*Neuromuscular control and proprioception* coordinate the complex movements of the kinetic chain in which the shoulder is an integral part. A disturbance of these systems can present with clinical and subclinical pictures noted in the literature with glenohumeral instability and subacromial impingement. Functional stability and shoulder activity is dependent both on coactivation of the musculature (core, scapulothoracic, rotator cuff) and on reactive neuromuscular characteristics. Biomechanically, the body is a series of links recruited and utilised not only during athletic activities, but during most movements in the shoulder girdle. These movements are not accomplished by individual links, but by sequential activation of the links to achieve a desired function.

For throwing or serving activities, this sequence starts as the leg motions create a ground reaction force. The activation and force development then proceed through the knees and hips to the trunk, then through the shoulder to the arm and hand and whatever implement is held in the hand. These sequences are commonly referred to as the kinetic chain. The largest propor-

tion of kinetic energy and force development in the throwing or serving kinetic chain is developed from the ground reaction force and the larger proximal links comprised of the legs, hips and trunk. Research has shown that 54% of the force and 51% of the kinetic energy delivered to the racquet in the tennis serve is generated by the legs and trunk [103].

Stability at the glenohumeral joint, which can be defined as control of the path of the instant centre of rotation of the humerus in a specific path during the full spectrum of motion, is more dynamic than static. In the mid-ranges of motion there is minimal movement of the instantaneous centre of rotation or none at all, indicating a true ball-and-socket joint. At the end-ranges, antero–posterior and supero–inferior translations of 4–10 mm do occur. These translations are coupled with specific motions of internal or external rotation. Glenohumeral stability in the mid-ranges of motion is the result of several biomechanical actions. The first is concavity/compression, which combines anatomical curvature of the humerus and glenoid, the extra depth created by the glenoid labrum, negative intraarticular pressure and muscle coactivation force couples to create a vector that keeps the humerus directed into the glenoid. Secondly, the angle between the glenoid and the moving humerus must be maintained within a ‘safe zone’ of 30° of angulation in either direction to decrease shear and translatory forces. This requires that the scapula be actively positioned in relation to the moving humerus to maintain the safe zone. At the same time, the scapula must be stabilised to allow it to act as a stable base of muscle origin for the rotator cuff, deltoid, biceps, and triceps. Normal biomechanical function of the shoulder is the result of distant force and energy development through kinetic chain sequencing, providing the mobility to allow movements and positions of the joint, and stability to control and transfer force in a funnel-like fashion to the arm and hand. Muscle activity in certain physiological patterns is the mechanism that allows this function. The primary dynamic stabilisers of the glenohumeral joint are



the rotator cuff and long head of the biceps. The important stabilising influence of the rotator cuff has been studied and outlined by Blaiser et al. [104]. Four mechanisms of stability provision that have been proposed characterise the encompassing influence of the rotator cuff. These mechanisms are:

- 1) The passive bulk of the rotator cuff;
- 2) Development of muscle tensions that compress the joint surfaces together;
- 3) Movement of the humerus relative to the glenoid and resultant tightening of the static restraints;
- 4) Limitation of the arc of motion of the glenohumeral joint by muscle tensions.

Each of these important roles directly affects glenohumeral joint stability and also provides for stimulation of afferent activity in both the contractile and the noncontractile stabilising tissues. Clarke et al. [105] have demonstrated that the glenohumeral joint capsular and ligamentous structures are actually adherent and merged with portions of the rotator cuff tendons (fibrotendinous). Therefore, tension created in the rotator cuff during muscular activation directly affects capsular tension and orientation, and may influence afferent mechanoreceptor activation (dynamic instability control) [58]. Further evidence of the important part the rotator cuff muscles play in glenohumeral joint stability is provided by Lee et al. [76]. Their research examined the role of the dynamic stabilisers in both mid-range and end-range positions of the glenohumeral joint. In mid-range, where the static stabilisers have a lesser role in ultimately providing stabilisation for the glenohumeral joint, the supraspinatus and subscapularis had the highest dynamic stability indices of all portions of the rotator cuff. In a simulation of end-range motion (60° of abduction and up to 90° of external rotation), the subscapularis, teres minor, and infraspinatus provided higher stability indices than the supraspinatus [76]. This study shows the important role of the dynamic stabilisers in providing both mid-range and end-range stabilisation for the glenohumeral joint.

Knowledge of the dynamic muscular relationships in the human shoulder is imperative for clinicians, to improve their understanding of the important part played by optimal muscle balance and joint biomechanics in the rehabilitation of a patient with shoulder girdle dysfunction. Major components governing normal shoulder movements are the muscular force couples. A force couple can be defined as a pair of forces that when acting on an object tends to produce rotation, even though the forces may act in opposing directions [61]. An example of this force couple in the human shoulder is the deltoid-rotator cuff force couple, which was originally described by Inman [61]. The breakdown of force vectors in this force couple includes the pull of the deltoid in an upward or superior direction. This superiorly directed muscle force can lead to superior migration, if the pull of the deltoid is unopposed from the other portions of the rotator cuff force couple [61]. The supraspinatus muscle-tendon unit has a compressive function when contracting, creating an approximation of the humeral head into the glenoid [61]. The infraspinatus/teres minor and subscapularis produce a caudal and compressive force that resists the upward migration or superiorly directed pull of the deltoid. The scapula has a major and pivotal role in normal shoulder function. Its motion and position create the parameters that allow normal physiology and biomechanics of the shoulder. Its roles include being a stable part of the glenohumeral articulation, retraction and protraction around the thoracic wall, active acromial elevation, a base for muscle origin and insertion, and being a link in the kinetic chain delivering energy and force from the trunk and legs to the hand. Abnormalities in scapular position and motion are very common and can be seen in a variety of pathologic states (dynamic impingement), some intrinsic to the glenohumeral joint and scapula and some far distant from the scapula. These abnormalities alter the roles of the scapula and can decrease performance, or cause or contribute to shoulder abnormalities.

*Impingement syndrome* or *SIS (subacromial impingement syndrome)* is one of the most commonly diagnosed shoulder conditions. It is characterised by mechanical compression of the soft tissues in the subacromial space, with symptoms that typically include shoulder pain, stiffness, tenderness and weakness. The diagnosis of impingement syndrome is identified in the typical patient with pain localised over the supraspinatus insertion on the greater tuberosity and pain on forward flexion [106]. The complete aetiology of SIS is not understood, and a number of hypotheses have been suggested. Structures and contributing factors have included the acromion [107], specifically the shape of the acromion [108], the os acromiale [107], the coracoacromial ligament [109], the superior aspect of the glenoid fossa [110, 111], hypermobility and instability of the glenohumeral joint [112, 113], glenohumeral capsular contracture [114], rotator cuff tendinitis [107, 115] and intrinsic rotator cuff tendinosis [116–118]. Fu et al. [119] propose that, if the synchronous pattern of motion between the scapula and humerus is disrupted, the rotator cuff tendons become impinged under the coracoacromial arch. It has also been suggested that functional limitations caused by evolutionary changes that have occurred within the human shoulder girdle may also contribute to SIS [120]. It is our opinion that many factors contribute to SIS and that in many cases this impingement is secondary to other findings. Several of the most prevalent findings are abnormal scapulohumeral rhythm, posterior capsule tightness and underlying glenohumeral joint instability. Identifying the presence of each of these contributing factors may be important in both treating and preventing secondary shoulder impingement.

Functional mobility of the shoulder is accomplished through three processes. The first is the motion of the glenohumeral joint. The second is protraction and retraction of the scapula, which increases the area of access of the humerus. The third is elevation of the acromion; which consists of upward scapular rotation, posterior scapular tilting and scapular external rota-

tion, which allows more space for the supraspinatus tendon and lessens compressive forces, allowing greater overhead access. Altered neuromuscular control mechanisms (from deafferentation) also result in abnormal scapular posturing, consisting of decreased upward rotation with elevation, increased anterior tipping and increased medial rotation. These scapular modifications are thought to be contributing factors in rotator cuff impingement and demonstrate the importance of optimal and coordinated muscular control of the scapulothoracic and glenohumeral joints [58]. Functionally, the kinetic chain is interrupted, as the unstable scapula aberrantly transmits the large forces generated from the ground through the lower extremities and torso to the shoulder and arm. The maximum force transferred to the arm and hand is diminished, and all the distal linkages of the chain are forced to generate increased muscle contraction forces, in effect catching up, to compensate for the loss of proximally generated force. Kibler et al. [121] have calculated that a loss of 20% of kinetic energy to the arm requires a compensatory increase of 80% in mass or a 34% increase in rotational velocity at the shoulder to achieve the same amount of force. Poor upper body posture, such as forward head posture (FHP), has been cited as a potential aetiological factor in the pathogenesis of SIS [122, 123]. This is because a FHP has been associated with an increase in the angle of thoracic kyphosis, a forward shoulder posture (FSP) and a scapula that is positioned in more elevation, protraction, downward rotation and anterior tilt [122, 124, 125]. The effect of these changes leads to a loss of glenohumeral flexion and abduction range of motion [121, 122, 124], compression and irritation of the superior (bursal) surface of the supraspinatus tendon and a reduction in the range of glenohumeral elevation [121, 123, 124, 126]. This may be due in part to the fact that alterations in scapular orientation can affect the amount of clearance in the subacromial space, as demonstrated by magnetic resonance imaging (MRI). Ludewig and Cook [127] found less posterior tilting in patients with impingement syndrome and

suggest that this may have a negative effect, because of the small confines of the subacromial space and the fact that even a subtle change in dimension could result in compression of the subacromial tissues during glenohumeral elevation. We believe that shoulder movement patterns, especially those of the scapula, may have a key role in the impingement syndrome. If the relationship between scapular motion and SIS can be determined, it is possible that novel methods for modifying motion patterns may be developed, which may relieve patient symptoms and potentially help prevent the progression of rotator cuff disease.

An additional factor that affects glenohumeral and scapulothoracic mechanics is glenohumeral inflexibility. As far as glenohumeral inflexibility is concerned, it is important to make a distinction between the classic presentation of an athlete's shoulder and the posterior inferior and/or anterior inferior capsular contractures that occur in the over-40 patient who presents with classic clinical signs of subacromial impingement. The concept of GIRD (glenohumeral internal rotation deficit) in athletes is characterised by a deficit of internal rotation in abduction that is greater than the acquired external rotation of the dominant limb. GIRD can create abnormal biomechanics of the glenohumeral joint and scapula. Posterior shoulder inflexibility because of capsular or muscular tightness can affect both glenohumeral and scapulothoracic biomechanics (mostly in a position of abduction and external rotation), allowing the scapula to be pulled in an antero-inferior direction during arm motion. This increase in protraction is thought to interfere with overhead activities by altering the scapula's position enough to cause a decrease in subacromial clearance and increase the risk of subacromial impingement as the scapula rotates down and forward. In addition, it is believed that the serratus anterior and the lower trapezius muscles are at risk as the effects of inhibition and are commonly involved at even the initial stages of injury. Ludewig and Cook [127] and others [58] have found the serratus anterior to be inhibited in patients with both glenohumeral joint instabil-

ity and impingement. Inhibition of the scapular stabilisers decreases the ability of the muscles to exert torque and result in a more random firing pattern of the shoulder girdle musculature. An imbalance in muscle strength within the shoulder girdle may change the force of opposing muscles along the normal biomechanical vectors and change the relative position of the glenohumeral and scapulothoracic joints. This positional change may manifest as shoulder pain, asymmetrical wear of the articular surfaces, capsulolabral lesions and partial rotator cuff tears.

Although associated loss of internal rotation in patients over 40 has been described, extensive range of motion loss is usually not considered to be a common feature in impingement syndrome, and adhesive capsulitis is regarded as a separate and different condition. Recent biomechanical work has shown that contracture of the posterior or anterior inferior capsule can alter normal glenohumeral kinematics, resulting in anterosuperior translation of the humeral head during arm elevation. This can cause a form of a nonoutlet impingement as the humeral head is forced into the coracoacromial arch. It is important to emphasise the importance of stretching a stiff or hypomobile shoulder during physical therapy as one important part of the overall nonoperative treatment for impingement syndrome. The effect of tight capsular and musculotendionous structures of the shoulder on the normal range of motion in the shoulder has been well documented. Clinically, much attention has been given to how a tight posterior capsule might affect normal glenohumeral arthrokinematics. The posterior capsular structures have been shown to play a significant role in allowing and controlling normal arthrokinematics between the humeral head and the glenoid. Harryman and Clark [40] state that oblique glenohumeral translations are not the result of ligament insufficiency or laxity; rather, translation results when the capsule is asymmetrically tight. Asymmetrical tightness is thought to cause anterior and superior migration of the humeral head during forward elevation of the shoulder, possibly contributing to or exacerbating the

impingement response. There is a relationship between posterior capsule tightness, limitation in glenohumeral range of motion and shoulder dysfunction. However, it is not known which adaptation came first. It is possible that patients may avoid putting their arm in a position of internal rotation to avoid pain caused by a mechanical impingement of the greater tuberosity on the subacromial arch and structures. This restriction of internal rotation motion may result in posterior capsule tightness. Conversely, posterior capsule tightness that is already present may be forcing the humeral head forward, causing mechanical impingement and a loss of range of motion as a result of the avoidance of painful movements. All this means that it is not clear which comes first, secondary shoulder impingement or posterior capsule tightness. In fact, in our clinical experience, many patients have unilateral posterior capsule tightness but do not have an impingement symptom.

The *neural innervation of articular structures* is supplied by *peripheral receptors* located within the tissue that surrounds these structures. These receptors include nociceptive free nerve endings that signal pain and touch, and mechanoreceptors that signal mechanical deformation of soft tissue, also referred to as “deep touch”. The afferent and efferent pathways involved with this complex system mediate proprioception at three distinct levels within the CNS. At the spinal level, proprioception operates unconsciously with reflexes subserving movement patterns that are received from higher levels of the nervous system. The second level of motor control is at the brain stem (basal ganglia, and cerebellum), where joint afference is relayed to maintain posture and balance of the body. The final aspect of motor control includes the highest level of CNS function, the motor cortex, and is mediated by cognitive awareness of body position and motion. Proprioception at this level functions consciously and is essential for proper muscle and joint function in sports, activities of daily living, and occupational tasks. These higher centres initiate and programme motor commands for voluntary move-

ments. Movement patterns that are repetitive in nature can be stored in the subconscious as central commands and can be performed without continuous reference to consciousness. The disruption of muscles and joint mechanoreceptors from physical trauma results in ‘partial deafferentation’ of the joint and surrounding musculature, thus resulting in diminished proprioception. Partial deafferentation and sensory deficits can predispose to further injury, and contribute to the aetiology of degenerative disease of the tendons, capsulolabral complex and the joint through pathologic wear on a joint with poor sensation. It is unclear whether the proprioceptive deficits that accompany these diseases are a result of, or contribute to the aetiology of, the pathologic process. In addition, scientists speculate that mechanoreceptor function has a genetic component (genetic profile), which can influence proprioceptive acuity in certain individuals. Contemporary research has investigated these hypothetical models, and some interesting findings have been revealed.

It is possible to hypothesise that altered proprioception in unstable shoulders and impingement syndrome can influence the dynamic mechanisms of joint restraint and alter the G/H and S/T rhythms. This would indicate the necessity of integrating shoulder kinaesthesia and joint position sensing exercises as a part of shoulder rehabilitation. It is logical to assume that methods used to improve proprioception in patients with shoulder disorders could improve shoulder function and decrease the risk of reinjury. The role of proprioception in allowing feedback mechanisms to work, which in turn allows a synergistic contraction of muscle groups, may be vital both for normal functioning of the muscle groups of the shoulder joint and in protecting the shoulder against potential instability and degenerative disease. Multiple studies have demonstrated that after injury to the shoulder capsule and ligaments, glenoid labrum or pericapsular muscle-tendon units, there is a related deficit in joint proprioception [53, 128, 129]. Functional instability that occurs after

injury to the capsuloligamentous structures is partly the result of partial deafferentation. Deafferentation may result in disruption of afferent signals altering transmission to the central nervous system. Injury to any of these structures could cause a disruption of this neuromuscular mechanism. This neuromuscular deficit can result in diminished joint position sense, kinaesthetic awareness, and abnormal humero-scapular and scapulo-thoracic muscular firing patterns [129, 130].

Whether mechanoreceptors are mechanically deformed or just 'switch off' after injury to the capsule and/or labrum, they may not be sufficiently stimulated in a lax or injured capsule and/or muscle-tendon unit. After surgery or rehabilitation, it is controversial and not completely understood whether this mechanical deformity is reversed or whether a 'switch on' phenomenon of the mechanoreceptors occurs on restoration of the proper tension in the capsule and ligaments. Lephart et al. [32, 131] have shown that after surgery proprioception is restored in the shoulder, and this may be related to the repopulation of receptors in the capsule and the ligaments [128]. Approximately 80% of all muscle afferents stem from free nerve endings and are distributed throughout muscle bellies and their connective tissue sheaths and tendons. Approximately 40% of these free nerve endings are nonnociceptive pressure and contraction receptors; 40% mechanical, chemical and/or thermal nociceptors; and 20%, nonnociceptive temperature receptors.

In our clinical experience, deafferentation may be 'direct', when the disturbance of the proprioceptive field is produced by a direct trauma or a microtrauma (traumatic lesion), or 'indirect', when the anatomical lesions are produced slowly over time as an expression of disturbed articular mechanics owing to a deficiency of peripheral information influenced by muscular fatigue, pain, the use of ice, and aging. In inflamed, ischaemic or fatigued muscle, chemical substances including lactic acid, bradykinins, prostaglandins and potassium are produced, which

sensitise the free nerve endings. In these circumstances a much larger proportion of muscular free nerve endings have a resting discharge, and a larger proportion respond to physiological joint movements. The small-diameter group III and IV afferents from these hyperactive free nerve endings may stimulate the  $\gamma$  efferents, leading in turn to abnormal afferent output from the muscle spindles. The end-result may be disturbed joint position, movement sense, and kinetic chain alteration. Recent research has demonstrated abnormal muscle spindle afferent activity in the masseter muscle of adult cats following intramuscular pain-inducing (saline) injections, and several human clinical studies have found abnormal position sense associated with muscle fatigue [32, 131]. Lephart et al. [128] have proposed a further hypothesis: that proper dynamic control is mediated by a proprioceptive feedback loop provided by tension that develops in the joint capsule and ligaments. Many studies done on joint position sense measured both before and after injury to the shoulder capsule and ligaments, glenoid labrum or pericapsular muscles have revealed a related deficit in joint proprioception.

*This new information enhances the orthopaedic sciences* by improving our understanding of shoulder function, leading to optimisation of surgical procedures and the design of new treatment modalities for rehabilitation of patients with shoulder pathology. The application of the basic scientific information on the neurobiology of the glenohumeral and scapulothoracic joints presented here serves to provide the framework for a better understanding of how each of these specific structures allows for the function of the shoulder and scapula in the upper extremity kinetic chain.

## References

1. Grigg P (1975) Mechanical factors influencing response of joint afferent neurons from cat knee. *J Neurophysiol* 38:1473-1484
2. Halata Z, Wagner C, Baumann KI (1999) Sensory nerve endings in the anterior cruciate ligament (Lig. cruciatum anterius) of sheep. *Anat Rec* 254:13-21
3. Maass S, Baumann KI, Halata Z (2001) Topography of corpuscular mechanoreceptors in the shoulder joint region of *Monodelphis domestica*. *Anat Rec* 263:35-40
4. Maass S, Baumann KI, Halata Z (2001) Topography of muscle spindles and Golgi tendon organs in shoulder muscles of *Monodelphis domestica*. *Ann Anat* 183:237-242
5. Mense S (1977) Muscular nociceptors. *J Physiol (Paris)* 73:233-240
6. Mense S (1990) Physiology of nociception in muscles. In: Friction JR, Awad E (eds) *Advances in pain research and therapy*, vol 17. Raven Press, New York, pp 67-85
7. Voss H (1971) Tabelle der absoluten und relativen Muskelspindelzahlen der menschlichen Skelettmuskulatur. *Anat Anz* 129:562-572
8. Hartung V, Asmussen G (1988) Age related changes of muscle spindles of rat soleus muscle. In: Hnik P, Soukup T, Vejsada R, Zelena J (eds) *Mechanoreceptors: development, structure and function*. Plenum Press, New York London, pp 89-90
9. Cheney PD, Preston JB (1976) Classification and response characteristics of muscle spindle afferents in the primate. *J Neurophysiol* 39:1-8
10. Hunt CC (1990) Mammalian muscle spindle—peripheral mechanisms. *Physiol Rev* 70:643-663
11. Proske U, Wise AK, Gregory JE (2000) The role of muscle receptors in the detection of movements. *Prog Neurobiol* 60:85-96
12. Barker D (1974) The morphology of muscle receptors. In: Hunt CC (ed) *Muscle receptors (Handbook of sensory physiology, vol. 3, pt 2)*. Springer, Heidelberg New York, pp 2-190
13. Gregory JE (1990) Relations between identified tendon organs and motor units in the medial gastrocnemius muscle of the cat. *Exp Brain Res* 81:602-608
14. Moore JC (1984) The Golgi tendon organ—a review and update. *Am J Occup Ther* 38:227-236
15. Proske U (1981) The Golgi tendon organ: properties of the receptor and reflex action of impulses arising from tendon organs. *Int Rev Physiol* 25:127-171
16. Heppelmann B, Messlinger K, Neiss WF, Schmidt RF (1990) The sensory terminal tree of “free nerve endings” in the articular capsule of the knee. In: Zenker W, Neuhuber WL (eds) *The primary afferent neuron. A survey of recent morpho-functional aspects*. Plenum Press, New York London, pp 73-85
17. Halata Z (1993) Die Sinnesorgane der Haut und der Tiefensensibilität. In: Niethammer J, Schliemann H, Starck D, Wermuth H (eds) *Handbook of zoology, vol. 8, part 57*. De Gruyter, Berlin New York
18. Polacek P (1966) Receptors of the joints. Their structure, variability and classification. *Acta Fac Med Univ Brunensis* 23:1-107
19. Chambers MR, Andres KH, von Düring M, Iggo A (1972) The structure and function of the slowly adapting type II mechanoreceptor in hairy skin. *Q J Exp Physiol* 57:417-445
20. Eklund G, Skoglund S (1960) On the specificity of the Ruffini like joint receptors. *Acta Physiol Scand* 49:184-191
21. Ferrell WR (1987) The effect of acute joint distension on mechanoreceptor discharge in the knee of the cat. *Q J Exp Physiol* 72:493-499
22. Grigg P, Hoffman AH (1984) Ruffini mechanoreceptors in isolated joint capsule: response correlated with strain energy density. *Somatosens Res* 2:149-162
23. Jirmanova I (1987) Pacinian corpuscle in rats with carbon disulphide neuropathy. *Acta Neuropathol (Berl)* 72:341-348
24. Zelena J (1984) Multiple axon terminals in reinnervated Pacinian corpuscles of adult rat. *J Neurocytol* 13:665-684
25. Shanthaveerappa TR, Bourne GH (1964) The perineural epithelium of sympathetic nerves and ganglia and its relation to the pia arachnoid of the central nervous system and perineural epithelium of the peripheral nervous system. *Z Zellforsch* 61:742-753
26. Pallie W, Nishi K, Oura C (1970) The Pacinian corpuscle, its vascular supply and the inner core. *Acta Anat* 77:508-552
27. Bolanowski SJ Jr. (1988) Transduction mechanisms in Pacinian corpuscles. In: Hnik P, Soukup T, Vejsada R, Zelena J (eds) *Mechanoreceptors: development, structure and function*. Plenum Press, New York London, pp 201-207
28. Loewenstein WR (1971) Mechano-electric transduction in the Pacinian corpuscle. Initiation of sensory impulses in mechanoreceptors. In: Loewenstein WR (ed) *Principles of sensory physiology*. Springer, Berlin, pp 269-290
29. Marshall RN, Elliot BC (2000) Long axis rotation: the missing link in proximal to distal segmental sequencing. *J Sports Sci* 18:247-254
30. Happee R, Van der Helm FC (1995) Control of shoulder muscles during goal-directed movements, an inverse dynamic analysis. *J Biomech* 28:1179-1191
31. Shumway-Cook A, Woollacott MH (1995) *Theories of motor control*. Mo-

- tor control: theory and practical applications. Williams & Wilkins, Baltimore, MD, pp 3-18
32. Lephart SM, Pinciuro DM, Giraldo JL (1997) The role of proprioception in the management and rehabilitation of athletic injuries. *Am J Sports Med* 25:130-137
  33. Roland PE, Ladegaard-Pedersen H (1977) A quantitative analysis of sensations of tension and of kinaesthesia in man: evidence for a peripherally originating muscular sense and for a sense of effort. *Brain* 100:671-692
  34. Goodwin GM, McCloskey DI, Matthews PBC (1972) The contribution of muscle afferents to kinaesthesia shown by vibration induced illusions of movement and by the effects of paralysing joint afferents. *Brain* 95:705-748
  35. Eklund G (1972) Position sense and state of contraction; the effects of vibration. *J Neurol Neurosurg Psychiatry* 35:606-611
  36. Cerlstend CA, Nordin M (1989) Basic biomechanics of the musculoskeletal system, 2nd edn, chapter: Biomechanics of tendons and ligaments. Lea & Febiger, Philadelphia, pp 59-74
  37. Basmajian JV, Bazant FJ (1959) Factors preventing downward dislocation of the adducted shoulder joint. An electromyographic and morphologic study. *J Bone Joint Surg Am* 41:1180-1186
  38. Clark J, Sidles JA, Matsen FA (1990) The relationship of glenohumeral joint capsule to the rotator cuff. *Clin Orthop* 254:29-34
  39. Bowen MK, Warren RF (1991) Ligament control of shoulder stability based on selective cutting and static translation experiments. *Clin Sports Med* 10:757-782
  40. Clark JM, Harryman DT (1992) Tendons, ligament, and capsule of the rotator cuff. *J Bone Joint Surg Am* 74:713-725
  41. Cooper DE, O'Brein SJ, Arnoczky SP et al (1993) The structure and function of the coracohumeral ligament: an anatomic and microscopic study. *J Shoulder Elbow Surg* 2:70-77
  42. Diener H, Dichgans J, Guschlbauer B et al (1984) The significance of proprioception on postural stabilization as assessed by ischemia. *Brain Res* 296:103-109
  43. Inglis JT, Horak FB, Shupert CL et al (1994) The importance of somatosensory information in triggering and scaling automatic postural responses in humans. *Exp Brain Res* 101:159-164
  44. Lephart S (1999) Reestablishing neuromuscular control. In: Prentice WE (ed) *Rehabilitation techniques in sports medicine*, 3rd edn, vol 6. WCB McGraw-Hill, Boston MA, pp 89-90
  45. Grigg P (1994) Peripheral neural mechanisms in proprioception. *J Sports Rehabil* 3:2-17
  46. Wyke B (1972) Articular neurology—a review. *Physiotherapy*. 58:94-99
  47. Myers JB, Lephart SM (2000) The role of the sensorimotor system in the athletic shoulder. *J Athletic Training* 35:351-363
  48. Ide K, Shirai Y, Ito H et al (1996) Sensory nerve supply in the human subacromial bursa. *J Shoulder Elbow Surg* 5:371-382
  49. Solomonow M, Baratta R, Zhou B et al (1987) The synergistic action of the ACL and thigh muscles in maintaining joint stability. *Am J Sports Med* 15:207-213
  50. Solomonow M, Guanche C, Wink C et al (1996) Mechanoreceptors and reflex arc in the feline shoulder. *J Shoulder Elbow Surg* 5:139-146
  51. Zimny M, Schutte M, Dabezies E (1986) Mechanoreceptors in the human cruciate ligaments. *Anat Rec* 214:204-209
  52. Vangsnest CT, Ennis M, Taylor JG et al (1995) Neural anatomy of the glenohumeral ligaments, labrum and subacromial bursa. *Arthroscopy* 11:180-184
  53. Wyke BD (1967) The neurology of joints. *Ann R Coll Surg Engl* 41:25
  54. Shimoda F (1955) Innervation, especially sensory innervation of the knee joint and motor organs around it in early stage of human embryo. *Arch Hisol Jpn* 9:91-108
  55. Kikuchi T (1968) Histological studies on the sensory innervation of the shoulder joint. *J Iwate Med Assoc* 20:554-567
  56. Morisawa Y, Kawakami T, Uermura H et al (1994) Mechanoreceptors in the coraco-acromial ligament. A study of the aging process. *J Shoulder Elbow Surg* 3:S45
  57. Nyland JA, Caborn DNM, Johnson DL (1998) The human glenohumeral joint: a proprioceptive and stability alliance. *Knee Surg Sports Traumatol Arthrosc* 6:50-61
  58. Ellenbecker TS (2001) Proprioception and neuromuscular control of the glenohumeral joint. In: Wilk KE (ed) *Sports and physical therapy home study course (Basic science to clinical application)*. APTA, Alexandria, VA, pp 1-3459
  59. Barker D, Banks RW, Harker DW et al (1976) Studies of the histochemistry, ultrastructure, motor innervation, and regeneration of mammalian intrafusal muscle fibers. *Exp Brain Res* 44:67-88
  60. Voss H (1971) Tabelle der absoluten und relativen Muskel-Spindelzahlen der menschlichen Skelettmuskulatur. *Anat Anz* 129:562-572
  61. Inman VT, Saunders JB, Abbot LC (1944) Observations on the function of the shoulder joint. *J Bone Joint Surg* 26:1-30
  62. Marshall RN, Elliot BC (2000) Long-axis rotation: The missing link in proximal to distal segmental sequencing. *J Sports Sci* 18:247-254
  63. Johansson H, Pederson J, Bergenheim M, Djupsjobacka M (2000) Peripheral afferents of the knee: their effects on central mechanisms regulat-

- ing muscle stiffness, joint stability, and proprioception and coordination. In: Lephart SM, Fu FH (eds) *Proprioception and neuromuscular control in joint stability*, vol 1. Human Kinetics, Champaign IL, pp 5-22
64. Windhorst U, Hamm TM, Stuart DG (1989) On the function of muscle and reflex partitioning. *Behav Brain Sci* 12:629-681
  65. Johansson H (1985) *Reflex integration in the gamma motor system*. Macmillan Press, London, pp 297-301
  66. Payr E (1900) Der heutige Stand der Gelenkchirurgie. *Arch Klin Chir* 148:404-451
  67. Schultz R. (1984) Mechanoreceptors in the human cruciate ligaments. *J Bone Joint Surg Am* 66:1072-1076
  68. Palmer I (1958) Pathophysiology of the medial ligament of the knee joint. *Acta Chir Scand* 115:312-318
  69. Hirokawa S, Solomonow M, Luo Z et al (1991) Muscular co-contraction and control of knee stability. *J Electromyogr Kinesiol* 1:199-208
  70. Louis J, Mote C (1987) Contribution of the musculature to rotary laxity and torsional stiffness at the knee. *J Biomech* 20:281-300
  71. Markhoff K, Mensh J, Amstutz H (1976) Stiffness and laxity of the knee: contribution of the supporting structures. *J Bone Joint Surg Am* 58:583-594
  72. Rentsrom P, Arms S, Stanwyck T et al (1986) Am J Sports Med Strain within the ACL during hamstrings and quadriceps activity. *Am J Sports Med* 14:83-87
  73. Giove TP, Miller SJ, Kent BE et al (1983) Non-operative treatment of the torn anterior cruciate ligament. *J Bone Joint Surg Am* 65:184-192
  74. McDaniels W, Dameron T (1983) Untreated ACL ruptures. *Clin Orthop* 172:158-163
  75. Walla DJ, Albright JP, McAuley E et al (1985) Hamstring control and the unstable anterior cruciate ligament-deficient knee. *Am J Sports Med* 13:34-39
  76. Lee SB, Kim KJ, O'Driscoll SW et al (2000) Dynamic glenohumeral stability provided by the rotator cuff muscles in the mid-range and end-range of motion. *J Bone Joint Surg Am* 82:849-857
  77. Guanche C, Solomonow M (1995) The synergistic action of the shoulder muscles. *Am J Sports Med* 23:301-306
  78. Gardner E (1948) The innervation of the shoulder joint. *Anat Rec*:102:1-18
  79. Wreth M (1949) The innervation of the shoulder joint in man. *Acta Anat* 7:173-190
  80. Wolpaw JR (1994) Acquisition and maintenance of the simplest motor skill: investigation of CNS mechanisms. *Med Sci Sports Exerc* 26:1475-1479
  - 80a. Wolpaw JR (1985) Adaptive plasticity in the spinal stretch reflex: an accessible substrate of memory? *Cell Mol Neurobiol* 5:147-165
  81. Myklebust BM, Gottlieb GL, Penn RD et al (1982) Reciprocal excitation of antagonistic muscles as a differentiating feature in spasticity. *Ann Neurol* 12:367-374
  82. Barnes MR, Crutchfield CA, Heriza CB et al (1990) Reflex and vestibular aspects of motor control, motor development, and motor learning. Stokesville Publishing Co., Atlanta, GA
  83. Beger W, Altenmueller E, Dietz V (1984) Normal and impaired development of children's gait. *Hum Neurobiol* 3:163-170
  84. Matthews PBC (1990) The knee jerk: still an enigma? *Can J Physiol Pharmacol* 68:347-354
  85. Myklebust BM (1990) A review of myotatic reflexes and the development of motor control and gait in infants and children (special communication). *Phys Ther* 70:188-203
  86. Myklebust BM, Gottlieb GL (1993) Development of the stretch reflex in the newborn: reciprocal excitation and reflex irradiation. *Child Dev* 64:1036-1045
  87. Myklebust BM, Gottlieb GL, Agarwal GC (1986) Stretch reflexes of the normal infant. *Dev Med Child Neurol* 28:440-449
  88. Wolpaw JR, Lee CL, Carp JS (1991) Operantly conditioned plasticity in spinal cord. *Ann N Y Acad Sci* 627:338-348
  89. Bawa P (1981) A neurophysiological study. *Electroencephalogr Clin Neurophysiol* 52:249-256
  90. Edgerton VR, Hutton RS (1990) Nervous system and sensory adaptation. In Bouchard C, Shephard RJ, Stephens T et al (eds) *Exercise, fitness, and health: a consensus of current knowledge*. Human Kinetics Books, Champaign, IL, pp 363-376
  91. Evatt ML, Wolf SL, Segal RL (1989) Modification of human spinal stretch reflexes: preliminary studies. *Neurosci Lett* 105:350-355
  92. Forssberg H, Nashner LM (1982) Ontogenetic development of postural control in man: adaptation to altered support and visual conditions during stance. *J Neurosci* 2:545-552
  93. Goode DJ, van Hoven J (1982) Loss of patellar and Achilles tendon reflexes in classical ballet dancers. *Arch Neurol* 39:323
  94. Hutton RS (1984) Acute plasticity in spinal segmental pathways with use: implications for training. In: Kimamoto M (ed) *Neural and mechanical control of movement*. Yamaguchi Shoten, Kyoto
  95. Hutton RS, Doolittle TL (1987) Resting electromyographic triceps activity and tonic vibration reflexes in subjects with high and average-low maximum oxygen uptake capacities. *Res Q Exerc Sports* 58:280-285



96. Lynch SA, Eklund U, Gottlieb D et al (1996) Electromyographic latency changes in the ankle musculature during inversion moments. *Am J Sports Med.* 24:362-369
97. Sale DG (1987) Influence of exercise and training on motor unit activation. *Exerc Sport Sci Rev* 15:95-151 *Neurobiol* 5:147-165
98. Huston LJ, Wojtys EM (1996) Neurolomuscular performance characteristics in elite female athletes. *Am J Sports Med* 24:427-436
99. Pierrot-Deseilligny E (1983) Patholophysiology of spasticity. *Triangle* 22:165-174
100. Segal RL, Wolf SL (1994) Operant conditioning of spinal stretch reflexes in patients with spinal cord injuries. *Exp Neurol* 130:202-213
101. Corcos DM, Gottlieb GL, Penn RD et al (1986) Movement deficits caused by hyperexcitable stretch reflexes in spastic humans. *Brain* 109:1043-1058
102. Wayne K, Augè, David S, Morrison (2000) Assessment of the infraspinatus spinal stretch reflex in the normal, athletic, and multidirectionally unstable shoulder. *Am J Sports Med* 28:206-213
103. Ben Kibler W (1998) The role of the scapula in athletic shoulder function. *Am J Sports Med* 2:325-337
104. Blaiser RB, Guldberg RE, Rothman ED (1992) Anterior shoulder stability: contributions of rotator cuff forces and the capsular ligaments in a cadaver model. *J Shoulder Elbow Surg* 1:40-50
105. Clarke J, Sidles JA, Matsen FA (1990) The relationship of the glenohumeral joint capsule to the rotator cuff. *Clin Orthop* 254:29-34
106. Lewis JS, Green A, Wright C (2005) Subacromial impingement syndrome: the role of posture and muscle imbalance. *J Shoulder Elbow Surg* 14:385-392
107. Neer CS II (1972) Anterior acromioplasty for the chronic impingement syndrome in the shoulder. A preliminary report. *J Bone Joint Surg Am* 54:41-50
108. Biglini LU, Marrison DS, April EW (1986) The morphology of the acromion and its relationship to rotator cuff tears. *Orthop Trans* 10:228
109. Soslowsky L, An C, Johnston S et al (1994) Geometric and mechanical properties of the coracohumeral ligament and their relationship to rotator cuff disease. *Clin Orthop* 304:10-17
110. Edelson J, Teitz C (2000) Internal impingement of the shoulder. *J Shoulder Elbow Surg* 9:308-315
111. Jobe CM (1997) Superior glenoid impingement. *Orthop Clin North Am* 28:137-143
112. Maister K, Andrews J (1993) Classification and treatment of rotator cuff injuries in the overhand athlete. *J Orthop Sports Phys Ther* 18:413-421
113. Warner JJP, Micheli LJ, Arslanian LE et al (1990) Patterns of flexibility, laxity and strength in normal shoulders and shoulders with instability and impingement. *Am J Sports Med* 18:366-375
114. Matsen FA, Arntz CT (1990) Subacromial impingement. *Shoulder* 2:623-646
115. Neer CS (1983) Impingement lesions. *Clin Orthop* 173:70-77
116. Budoff JE, Nirschl RP, Guidi J (1998) Debridement of partial-thickness tears of the rotator cuff without acromioplasty. *J Bone Joint Surg Am* 80:733-748
117. Ozaki J, Fujimoto S, Nakagawa Y et al. (1988) Tears of the rotator cuff of the shoulder associated with pathological changes in the acromion. *J Bone Joint Surg Am* 70:1224-1230
118. Uthoff HK, Sono H (1997) Pathology of failure of the rotator cuff tendon. *Orthop Clin North Am* 28:31-41
119. Fu FH, Harner CD, Klein AH (1991) Shoulder impingement syndrome: a critical review. *Clin Orthop* 269:162-173
120. Lewis J, Green A, Yizhat Z (2001) Subacromial impingement syndrome: has evolution failed us? *Physiotherapy* 87:191-198
121. Kibler WB (1998) The role of the scapula in athletic shoulder function. *Am J Sports Med* 26:325-337
122. Grisby O, Gray JC (1997) *Clinics in physical therapy.*
123. Sahrman SA (2002) *Diagnosis and treatment of movement impairment syndromes.* Mosby, London
124. Calliet R (1991) *Shoulder.* FA Davis, Philadelphia, Pa
125. Kendall FP, McCreery EK, Provance PG (1993) *Muscles testing and function.* Williams & Wilkins, Baltimore, MD
126. Ayub E (1991) Posture and the upper quarter. *Phys Ther Shoulder* 2:81-90
127. Ludewig PM, Cook TM (2000) Alterations in shoulder kinematics and associated muscle activity in people with symptoms of shoulder impingement. *Phys Ther* 80:276-291
128. Lephart MS, Warner JP, Fu FH et al (1994) Proprioception of the shoulder joint in healthy, unstable and surgically repaired shoulders. *J Shoulder Elbow Surg* 3:371-380
129. Lephart MS, Henry TJ (1996) The physiological basis for open and closed kinetic chain rehabilitation for the upper extremity. *J Sports Rehabil* 5:71-78
130. Borsa PA, Lephart MS, Kocher MS (1994) Functional assessment and rehabilitation of shoulder proprioception for glenohumeral instability. *J Sports Rehabil* 3:84-104
131. Gholke F, Muller T, Janben E et al. (1996) Distribution and morphology of mechanoreceptors in the shoulder joint. *J Shoulder Elbow Surg* 5:104