

**MEDICAL
RADIOLOGY**

**Diagnostic
Imaging**

A. L. Baert
K. Sartor

Vascular Embolotherapy

A Comprehensive Approach

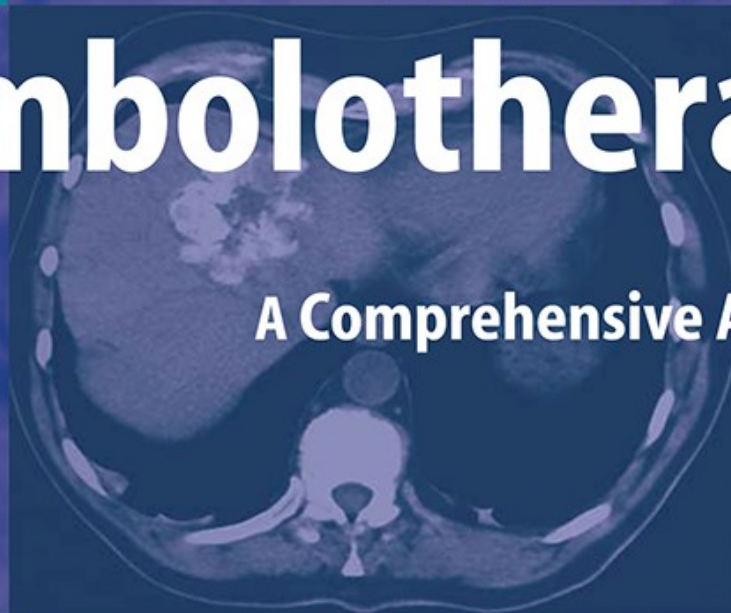
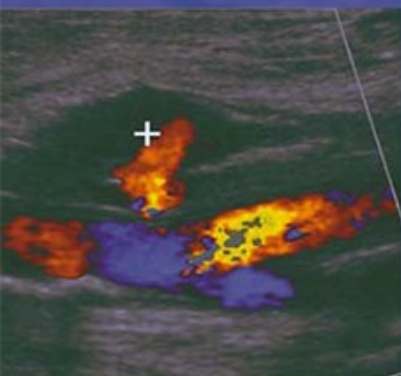
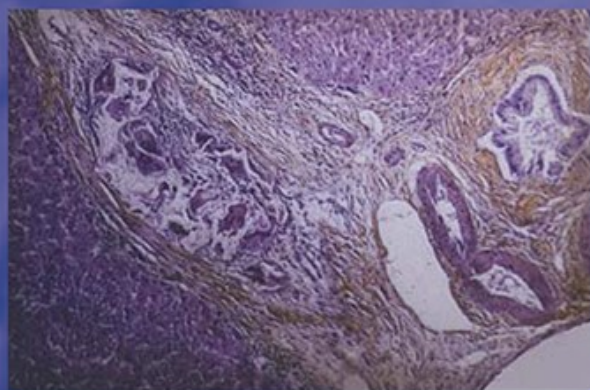
Volume 2

**Oncology, Trauma, Gene Therapy,
Vascular Malformations, and Neck**

J. Golzarian
Editor

S. Sun
M. J. Sharafuddin
Co-Editors

 Springer



MEDICAL RADIOLOGY

Diagnostic Imaging

Editors:

A. L. Baert, Leuven

K. Sartor, Heidelberg

J. Golzarian · S. Sun · M. J. Sharafuddin (Eds.)

Vascular Embolotherapy

A Comprehensive Approach

Volume 2

**Oncology, Trauma, Gene Therapy,
Vascular Malformations, and Neck**

With Contributions by

K. Ahrar · H. Alvarez · J. C. Chaloupka · M. D. Darcy · J. Dubois · J. R. Duncan · D. Elias · L. Garel
J.-F. Geschwind · C. B. Glaiberman · C. Georgiades · J. Golzarian · M. Hayakawa · S. Heye
S.-W. Hsu · M. S. Johnson · J. R. Kachura · N. M. Khilnani · P. Klurfan · P. Lasjaunias · S. K. Lee
E. Liapi · W. S. Lesley · D. C. Madoff · G. Maleux · F. Marshalleck · R. J. Min · A. C. Roberts
A. J. Roche · G. Rodesch · R. Salem · M. Sharafuddin · G. P. Siskin · S. Sun · K. T. Tan · M. Thijs
K. G. Thurston · R. Verma · L. Wibbenmeyer · J. J. Wong

Foreword by

A. L. Baert

With 139 Figures in 368 Separate Illustrations, 26 in Color and 56 Tables

JAFAR GOLZARIAN, MD
Professor of Radiology, Department of Radiology
University of Iowa Hospitals and Clinics
Carver College of Medicine
200 Hawkins Drive
Iowa City, IA 52242
USA

SHILIANG SUN, MD
Associate Professor of Radiology
University of Iowa Hospitals and Clinics
Carver College of Medicine
200 Hawkins Drive
Iowa City, IA 52242
USA

M. J. SHARAFUDDIN, MD
Departments of Radiology and Surgery
University of Iowa Hospitals and Clinics
Carver College of Medicine
200 Hawkins Drive
Iowa City, IA 52242
USA

MEDICAL RADIOLOGY · Diagnostic Imaging and Radiation Oncology
Series Editors: A. L. Baert · L. W. Brady · H.-P. Heilmann · M. Molls · K. Sartor

Continuation of Handbuch der medizinischen Radiologie
Encyclopedia of Medical Radiology

Library of Congress Control Number: 2005923494

ISBN 3-540-21491-7 Springer Berlin Heidelberg New York
ISBN 978-3-540-21491-5 Springer Berlin Heidelberg New York

This work is subject to copyright. All rights are reserved, whether the whole or part of the material is concerned, specifically the rights of translation, reprinting, reuse of illustrations, recitations, broadcasting, reproduction on microfilm or in any other way, and storage in data banks. Duplication of this publication or parts thereof is permitted only under the provisions of the German Copyright Law of September 9, 1965, in its current version, and permission for use must always be obtained from Springer-Verlag. Violations are liable for prosecution under the German Copyright Law.

Springer is part of Springer Science+Business Media

<http://www.springer.com>

© Springer-Verlag Berlin Heidelberg 2006

Printed in Germany

The use of general descriptive names, trademarks, etc. in this publication does not imply, even in the absence of a specific statement, that such names are exempt from the relevant protective laws and regulations and therefore free for general use.

Product liability: The publishers cannot guarantee the accuracy of any information about dosage and application contained in this book. In every case the user must check such information by consulting the relevant literature.

Medical Editor: Dr. Ute Heilmann, Heidelberg

Desk Editor: Ursula N. Davis, Heidelberg

Production Editor: Kurt Teichmann, Mauer

Cover-Design and Typesetting: Verlagsservice Teichmann, Mauer

Printed on acid-free paper – 21/3150xq – 5 4 3 2 1 0

To my parents
a wellspring of love and support without limit.
I owe you everything.

To my wonderful wife, *Elham*
and my children *Sina* and *Sadra*

Dr. Golzarian

To my wife, *Shuzhen*, and daughter, *Yue*
for their selfless support

Dr. Sun

To my wife *Lucy*, and children *Jacob* and *Evan*

Dr. Sharafuddin

To all our teachers

Foreword

Percutaneous image-guided treatment is now well recognized as an effective minimally invasive treatment modality in modern medicine. Its field of application is growing every year due to the availability of more and more sophisticated materials, tools and devices, but also because of the technical progress in reduction of the dose of ionizing irradiation incurred by both patient and radiologist during fluoroscopy.

Vascular embolotherapy is now one of the main forms of endovascular percutaneous treatment of diseases of the vascular system.

The editors of the two volumes of “Vascular Embolotherapy: a Comprehensive Approach”, J. Golzarian, S. Sun and M.J. Sharafuddin, leading experts in the field, were successful in obtaining the collaboration of many other internationally renowned interventional radiologists. I am particularly indebted to Professor Golzarian for his original concept for these books and his relentless efforts to complete the project in good time.

I would like to congratulate the editors and authors on producing these well-written, superbly illustrated and exhaustive volumes covering all aspects of vascular embolotherapy. The readers will find comprehensive up-to-date information as a source of knowledge and as a guideline for their daily clinical work.

These two outstanding books will certainly meet with high interest from interventional radiologists and vascular surgeons. They – and therefore their patients – will greatly benefit from its contents. Also referring physicians may find these books very useful to learn more about the indications, possibilities and limitations of modern vascular embolotherapy

I am confident that these two volumes will encounter the same success with readers as the previous books in this series.

Leuven

ALBERT L. BAERT

Preface

Therapeutic embolization has now become a major part of modern interventional practice, and its applications have become an integral component of the modern multimodality management paradigms in trauma, gastrointestinal hemorrhage and oncology, and the endovascular therapy of vascular malformations and aneurysms. The past decade has also marked the emergence of several new indications for therapeutic embolization, such as uterine fibroid embolization, and the widespread acceptance of embolization therapy as an effective non-operative management modality for major hepatic, splenic and renal injuries that once posed tremendous challenge to the trauma surgeon. Embolization therapy has also become an integral facet of the modern oncology center, offering solid-organ chemoembolization, preoperative devascularization, hepatic growth stimulation prior to resection, and direct gene therapy delivery.

Despite this remarkable growth, there are currently few references available to summarize this major field in vascular interventional therapy. The purpose of our two-volume book was to organize and present the current state of the art of embolotherapy in a comprehensive yet manageable manner. Our goal was to provide a user-friendly, well-illustrated, and easy-to-browse resource to enable both experts and novices in this field to quickly derive high-yield clinically relevant information when needed. In addition to standard applications of embolotherapy, we have also included a number of closely related applications that have become intimately associated with the field of therapeutic embolization, such as stent-graft placement and radiofrequency ablation. The two volumes constitute the combined experience of many of the leading experts in the field and have been generously supplemented with helpful tables, illustrations and detailed imaging material. We have also striven to include insightful discussions and a “cookbook” segment in each topic to provide a quick outline of procedural preparation and technique. We have included a chapter on monitoring and resuscitation of the hemorrhaging patient that should be a “must-read” for the interventionist who is not well versed in surgical critical care. Readers will also find important coverage of pathophysiology and of diagnostic clinical as well as imaging workup.

We hope this reference will meet the needs of physicians providing therapeutic embolization, whether they are trainees, recent graduates or even well-established interventionists who wish to refresh their memory or learn the opinion of some of the field’s renowned experts before embarking on a difficult case or trying a new technique or approach.

Iowa City

JAFAR GOLZARIAN
SHILIANG SUN
MELHEM J. SHARAFUDDIN

Contents

Vascular Malformation	1
1 Percutaneous Management of Hemangiomas and Vascular Malformations FRANCIS MARSHALLECK and MATTHEW S. JOHNSON	3
2 Predominantly Venous Malformation JOSÉE DUBOIS	21
Trauma and Iatrogenic Lesions	33
3 Recognition and Treatment of Medical Emergencies in the Trauma Patient LUCY WIBBENMEYER and MELHEM J. SHARAFUDDIN	35
4 Visceral and Abdominal Solid Organ Trauma GARY SISKIN and JAFAR GOLZARIAN	43
5 Embolization and Pelvic Trauma JEFFREY J. WONG and ANNE C. ROBERTS	59
6 Postcatheterization Femoral Artery Injuries GEERT MALEUX, SAM HEYE, and MARIA THIJS	69
7 Iatrogenic Lesions MICHAEL DARCY	79
Visceral Aneurysm	97
8 Embolization of Visceral Arterial Aneurysms CRAIG B. GLAIBERMAN and D. MICHAEL D. DARCY	99
Venous Ablation	117
9 Endovenous Thermal Ablation of Incompetent Truncal Veins in Patients with Superficial Venous Insufficiency NEIL M. KHILNANI and ROBERT J. MIN	119
Embolotherapy Applications in Oncology	127
10 Chemo-Embolization for Liver CHRISTOS GEORGIADES and JEAN FRANCOIS GESCHWIND	129

11	Radioactive Microspheres for the Treatment of HCC CHRISTOS GEORGIADIS, RIAD SALEM, and JEAN-FRANCOIS GESCHWIND.	141
12	Yttrium-90 Radioembolization for the Treatment of Liver Metastases RIAD SALEM, KENNETH G. THURSTON, and JEAN-FRANCOIS GESCHWIND	149
13	Portal Vein Embolization ALAIN J. ROCHE and DOMINIQUE ELIAS.	163
14	Embolotherapy for Neuroendocrine Tumor Hepatic Metastases KONG TENG TAN and JOHN R. KACHURA.	177
15	Bone Metastases from Renal Cell Carcinoma: Preoperative Embolization SHILIANG SUN	189
16	Embolotherapy for Organ Ablation DAVID C. MADOFF, RAJIV VERMA, and KAMRAN AHRAR	201
17	Research and Future Directions in Oncology Embolotherapy ELENI LIAPI and JEAN-FRANCOIS H. GESCHWIND.	221
	External Carotid	233
18	Technical and Anatomical Considerations of the External Carotid System PAULA KLURFAN and SEON KYU LEE	235
19	Endovascular Management for Head and Neck Tumors PAULA KLURFAN and SEON-KYU LEE.	247
20	Embolization of Epitaxis GEORGES RODESCH, HORTENSIA ALVAREZ, and PIERRE LASJAUNIAS	257
21	Diagnosis and Endovascular Surgical Management of Carotid Blowout Syndrome JOHN C. CHALOUPKA, WALTER S. LESLEY, MINAKO HAYAKAWA, and SHIH-WEI HSU.	271
	Gene Therapy and Pediatrics	293
22	Embolotherapy Applications in Gene Therapy JAMES R. DUNCAN.	295
23	Embolotherapy in Pediatrics JOSÉE DUBOIS and LAURENT GAREL	303
	Subject Index	321
	List of Contributors.	331
	Contents and List of Contributors of Volume 1	335

Vascular Malformation

1 Percutaneous Management of Hemangiomas and Vascular Malformations

FRANCIS MARSHALLECK and MATTHEW S. JOHNSON

CONTENTS

1.1	Classification	3
1.1.1	Hemangioma	4
1.1.1.1	Clinical Presentation	4
1.1.1.2	Diagnostic Imaging	4
1.1.1.3	Treatment	5
1.1.2	Kaposiform Hemangioendothelioma	5
1.1.3	Hepatic Hemangioendothelioma	7
1.2	Vascular Malformations	8
1.2.1	Arteriovenous Malformations	8
1.2.1.1	Clinical Presentation	8
1.2.1.2	Diagnostic Imaging	9
1.2.1.3	Treatment	10
1.2.2	Arteriovenous Fistulae	11
1.2.2.1	Treatment	12
1.2.3	Venous Malformations	12
1.2.4	Lymphatic Malformations	12
1.2.4.1	Clinical Presentation	12
1.2.4.2	Diagnostic Imaging	13
1.2.4.3	Treatment	13
1.2.5	Capillary Malformations	16
1.3	Complications of Embolization and Sclerotherapy	16
1.4	Preprocedural Preparation	16
1.5	Post-Procedural Care and Follow-Up	16
1.6	Conclusion	17
	References	18

1.1 Classification

Vascular birthmarks have intrigued physicians for centuries. Many attempts have been made to classify vascular birthmarks, resulting in much confusion. Historically, various classifications have been developed, each with its own shortcomings. Initially, classifications were largely descriptive [1].

F. MARSHALLECK, MD

Assistant Professor of Radiology, Indiana University School of Medicine, Indiana University Hospital, Room 0279, 550 North University Boulevard, Indianapolis, IN 26202, USA

M. JOHNSON, MD

Associate Professor of Radiology, Director, Section of Interventional Radiology, Indiana University Hospital, UH0279, Department of Radiology, 550 University Boulevard, Indianapolis, IN 46202-5253, USA

Although the descriptive classification allowed differentiation between benign and more serious forms of vascular malformations, because many different malformations can have similar external appearances, it was limited in its value in differentiating between them. The histopathological classification [1] represented an improvement in the attempt to classify vascular malformations. Its broad use of the word “hemangioma” and lack of clinical correlation limited its usefulness because hemangiomas and vascular malformations differ in pathology and are treated differently. The embryological classification [1] was based on the theory that vascular malformations were due to improper development of various cellular lines (arteries, veins, capillaries, and lymphatics). Although the premise was sound, the embryological classification was not clinically useful to direct treatment. To date, the most pertinent classification of vascular birthmarks has been published by John MULLIKEN and Julie GLOWAKI [1–3]. This biological classification separates vascular birthmarks into hemangiomas (vascular tumors) and vascular malformations (malformed vessels) (Table 1.1). Hemangiomas are characterized by a proliferating phase and subsequent involution phase, distinguishing them from vascular malformations which do not spontaneously involute. Vascular malformations may be high-flow lesions (e.g. arteriovenous malformations, arteriovenous fistulae) or low-flow lesions (e.g. venous malformations, capillary malformations, lymphatic malformations, combined or mixed lesions). Vascular malformations are best managed by a vascular anomalies team in a facility equipped and experienced in the management of vascular anomalies. Such a vascular anomalies team might include a vascular interventionalist, dermatologist, plastic surgeon, orthopedic surgeon and/or neurosurgeon, pediatrician, and physiotherapist. The percutaneous management of these lesions including clinical diagnosis, radiological diagnosis, percutaneous treatment (embolization, sclerotherapy) and post-procedure care will be discussed.

Table 1.1. Classification of vascular birthmarks

<i>Hemangiomas</i>	
Proliferating	
Involuting	
<i>Vascular malformations</i>	
High-flow	
	Arteriovenous malformations
	Arteriovenous fistulae
Low-flow	
	Venous malformations
	Lymphatic malformations
	Capillary malformations
	Mixed malformations

1.1.1

Hemangioma

A hemangioma is a benign vascular endothelial cell neoplasm characterized by a period of intense cellular and endothelial proliferation resulting in the formation of a cellular mass. During the proliferation phase, there is formation of new feeding and draining vessels similar to that of a high-flow vascular malformation. Proliferation is followed by involution and finally regression. This distinguishes a hemangioma from a vascular malformation.

1.1.1.1

Clinical Presentation

Unlike vascular malformations, hemangiomas are not commonly present at birth but usually become evident during the first month of life. They are more common in Caucasians, females, and premature infants and have a predilection for the head and neck. Hemangiomas are the most common tumor of infancy with a reported incidence of 10%–12% [4, 5].

A hemangioma's location determines its presentation. When it is superficial, it typically presents as a small red macule or patch which proliferates at a rapid rate during the first 6–12 months of life. A superficial lesion may produce a mass (a “strawberry” lesion) which can grow so large as to become disfiguring. The strawberry appearance is produced by the presence of multiple reddened superficial vessels which result in an irregular raised “pebbly” surface ([4]Fig. 1.1). When the hemangioma is deeper in location, the overlying skin may in fact be normal in color or may show bluish discoloration. The mass is usually warm and may be pulsatile during the proliferative phase. After the first 12 months of life, the majority of hemangiomas undergo an involution phase which



Fig 1.1. Typical “strawberry” hemangioma. (Image provided through the courtesy of Dr. Phillip John, MD)

can last more than 5 years. Complete resolution of hemangiomas occurs in greater than 50% of children by age 5 years and in over 70% by the age of 7 years [1]. As the hemangioma involutes, it softens, shrinks, loses its red color and becomes dull grey due to its replacement with fibrofatty tissue. Depending on the original size of the hemangioma, the overlying skin may become loose with a “crepe paper”-like appearance. Occasionally, scars or telangiectasias are seen at the site of an involuted hemangioma [4].

Complications of hemangiomas usually occur during the first 6 months of life. The most common complication is ulceration, which occurs in up to 10% of patients, especially when the lips or genital areas are involved [1, 4]. Occasionally, there may be associated bleeding, which is usually not significant. Hemangiomas may also result in congestive cardiac failure (e.g. hepatic hemangioendotheliomas) or platelet consumption (Kasabach-Merritt phenomenon). Both entities will be discussed later in this chapter. When diffuse, hemangiomas may compromise the airway, obstruct vision, or impair hearing [1]. Associated osseous deformities are uncommon [1]. Rarely, hemangiomas may be associated with other anomalies, such as posterior fossa malformations, right aortic arch, coarctation of the aorta, genitourinary anomalies, and spinal dysraphism [6].

1.1.1.2

Diagnostic Imaging

Hemangiomas, when superficial, are easily diagnosed clinically as previously discussed. Appropriate treatment of a symptomatic hemangioma,

however, requires delineation of its extent. Diagnostic imaging is also useful when the diagnosis is in doubt. On CT and MR imaging, hemangiomas are well-circumscribed lobulated masses that demonstrate intense parenchymal enhancement following the administration of intravenous contrast (Fig. 1.2a,b). During the proliferating phase, dilated vessels representing feeding arteries and draining veins are seen. MR is the optimal modality for the diagnosis and evaluation of hemangiomas [5]. The vessels are seen as flow voids on T1- and T2 (spin echo)-weighted MR images. A proliferating hemangioma is hypointense to muscle on T1-weighted images and hyperintense on T2-weighted images. During involution, there may be a preponderance of fat (high signal on T1-weighted images) with lack of flow voids. If a lesion lacks the classic clinical and imaging findings already discussed for a hemangioma, then a biopsy should be performed to exclude other potentially more serious tumors such as rhabdomyosarcoma, infantile fibrosarcoma, or neurofibroma.

1.1.1.3

Treatment

About 75% of hemangiomas will regress on their own without treatment [1, 4]. Multiple factors will determine whether a hemangioma requires treatment, including the child's age and emotional needs, the location of the lesion, and symptomatology. When hemangiomas are small or are already decreasing in size before the child enters school, observation and reassurance are all that is needed. When treatment is deemed necessary, systemic corticosteroids have been the therapeutic mainstay, with a nearly 90% response [8]. Side effects of systemic steroids include gastrointestinal symptoms, weight gain, hypertension, immunosuppression, and growth retardation [7–9]. Intralesional corticosteroids have been used to treat rapidly growing hemangiomas with the dose limited by the size of the hemangioma [7–9]. When steroids fail to cause adequate response, alpha interferon, chemotherapeutic agents, and radiotherapy have also been used [10–12]. The use of α -interferon is now limited to refractory cases due to its effects on the central nervous system such as spastic diplegia [13]. Laser therapy has been used to treat areas of ulceration, bleeding, telangiectasias, and skin discoloration [14].

Surgical removal becomes warranted in cases of ocular hemangioma unresponsive to medical ther-

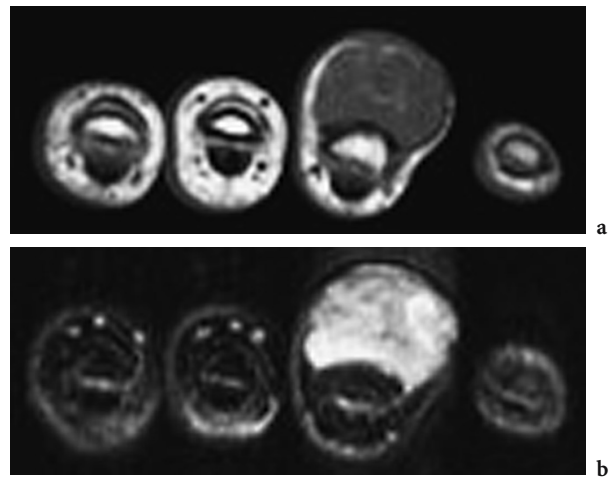


Fig 1.2a,b. Proliferating hemangioma of the finger demonstrating: a low signal on T1-weighted image and b intense parenchymal enhancement with gadolinium

apy and for airway compromise. Cosmetic needs may dictate surgical removal depending on the parents' and patient's wishes especially for head and neck hemangiomas. After involution, surgical resection may be required to remove excess skin and fibrofatty tissue [4]. In the minority of cases in which a hemangioma fails to involute (noninvoluting hemangioma) despite medical management, surgical resection of the lesion, if possible, is indicated [15]. Percutaneous embolization prior to surgical resection has also been successful [16].

Rarely, arterial embolization is required to treat life-threatening hemorrhage, high-output cardiac failure, or platelet consumption (Kasabach-Merritt phenomenon) ([17], Fig. 1.3a–c).

1.1.2

Kaposiform Hemangioendothelioma

Kaposiform hemangioendothelioma is an infiltrative variant of pediatric hemangioma. It commonly affects the trunk and extremities, producing an edematous mass of variable size with purple skin discoloration (Fig.1.4a,b). It proliferates and involutes like a typical hemangioma but persists, infiltrates, and consumes platelets (Kasabach-Merritt phenomenon) resulting in hemorrhage [18, 19]. Rarely, it may resemble a classic hemangioma [20]. Platelets decrease to low levels (< 5000) despite repeated transfusions. Management involves a multidisciplinary approach [21]. Chemotherapy, ste-

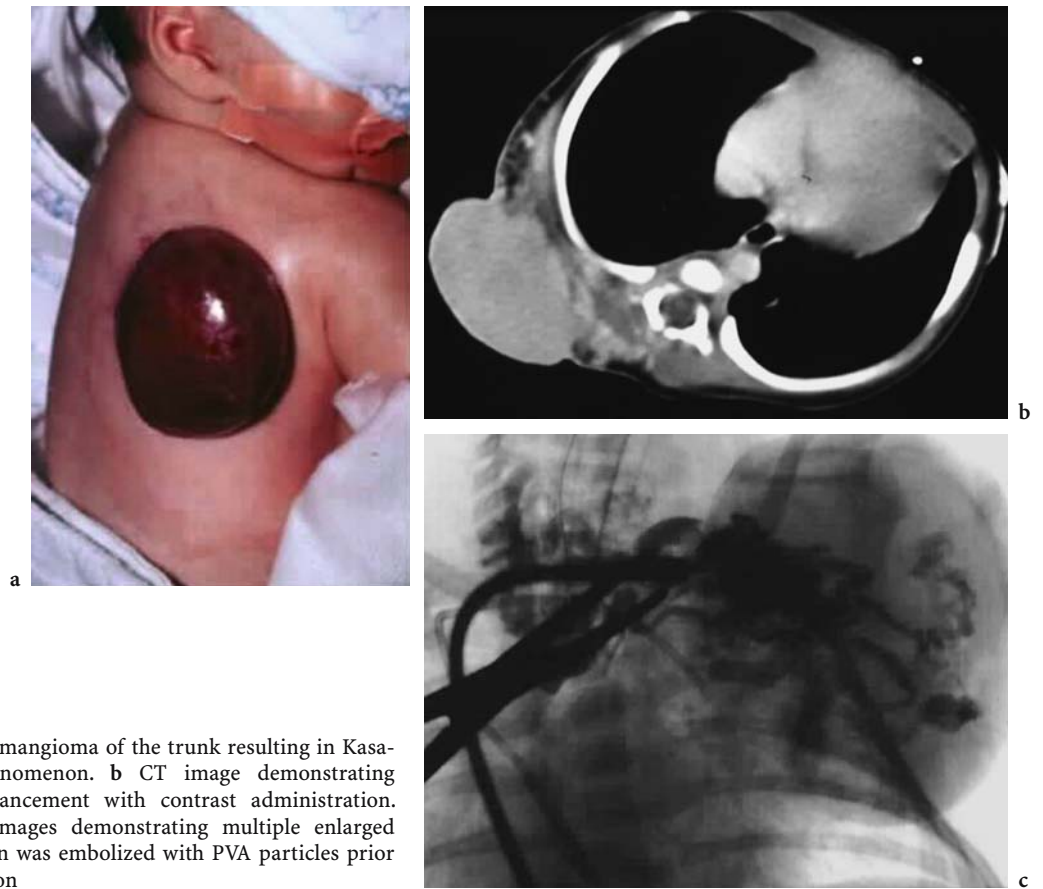


Fig 1.3. a Giant hemangioma of the trunk resulting in Kasabach-Merritt phenomenon. **b** CT image demonstrating parenchymal enhancement with contrast administration. **c** Angiographic images demonstrating multiple enlarged feeders. This lesion was embolized with PVA particles prior to surgical resection

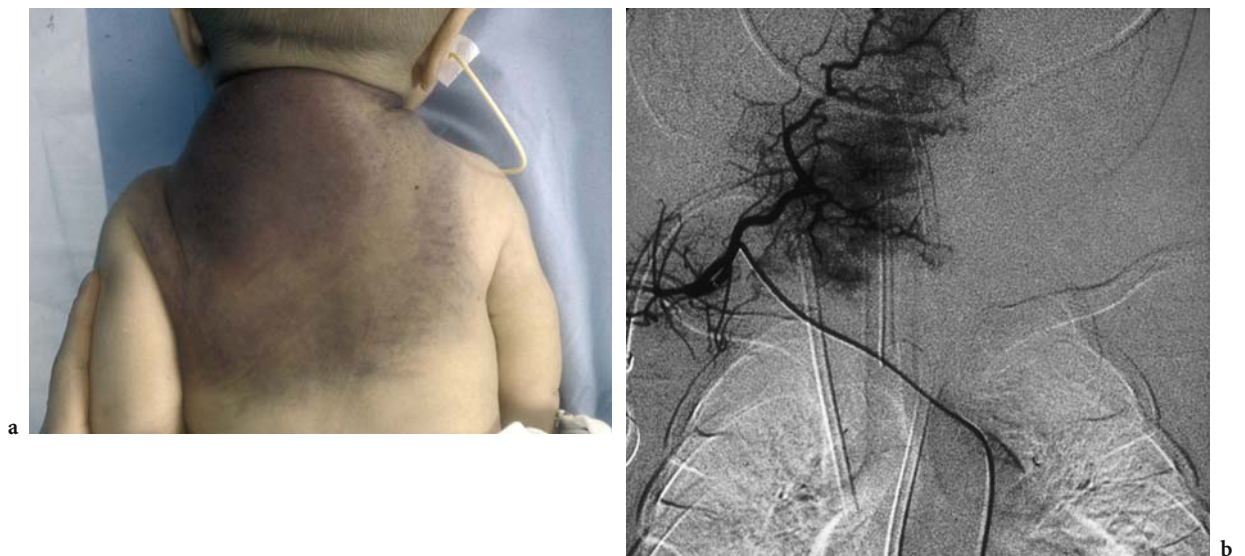

Fig 1.4. a Kaposiform Hemangioendothelioma presenting as an edematous purple discoloration of the trunk. **b** Angiographic findings in the same patient demonstrating a diffuse parenchymal blush with multiple enlarged feeders. (Images provided by Dr. Phillip John, MD)

roids, α -interferon, and radiation have all been tried [22, 23]. Surgical resection can be curative [24] but, in many cases, may not be possible due to the risk of hemorrhage. Interventional management comprises treatment of the associated platelet consumption by endovascular embolization using a microcatheter technique. PVA (polyvinyl alcohol) particles and/or absolute alcohol are typically used [25–27]. These cases are usually difficult to treat and time-consuming due to the presence of multiple feeders. The long-term effects of endovascular embolization have not yet been established.

1.1.3

Hepatic Hemangioendothelioma

Hepatic hemangioendothelioma (multiple hepatic hemangiomas, congenital hepatic hemangioma) of the newborn is characterized by a liver mass, an audible bruit, and congestive heart failure with or without cutaneous hemangiomata ([1], Fig. 1.5a–c). The high-output cardiac state could be fatal. First-line management is medical with the use of steroids, interferon,

or chemotherapy. Endovascular embolization can be performed as a temporizing measure to liver transplantation if surgical treatment (hepatic resection, hepatic artery ligation) is not possible and if medical therapy fails [28]. The vascular anatomy may be complex with multiple collaterals and various shunts (arteriovenous, arterioportal, portovenous) resulting in the high-output state [29, 30]. In order to treat the severe AV shunting in the liver, endovascular embolization can be performed. Selective hepatic arterial embolization has been used to treat arteriovenous shunts. Coils [31, 32], detachable balloons [47], and PVA particles [33] have been used. Coils and detachable balloons result in permanent occlusion and their use depends on personal preference. The hepatic artery can be accessed via the femoral artery, a central vein, or femoral vein by way of a patent foramen ovale [32] or via a patent ductus arteriosus in neonates [34]. In cases of portovenous shunts, the portal vein can be accessed using a transjugular approach, transhepatic approach or via the umbilical vein in neonates [34] to allow for coil embolization. In cases where portovenous shunts are dominant, hepatic arterial embolization alone may not prove to be of benefit

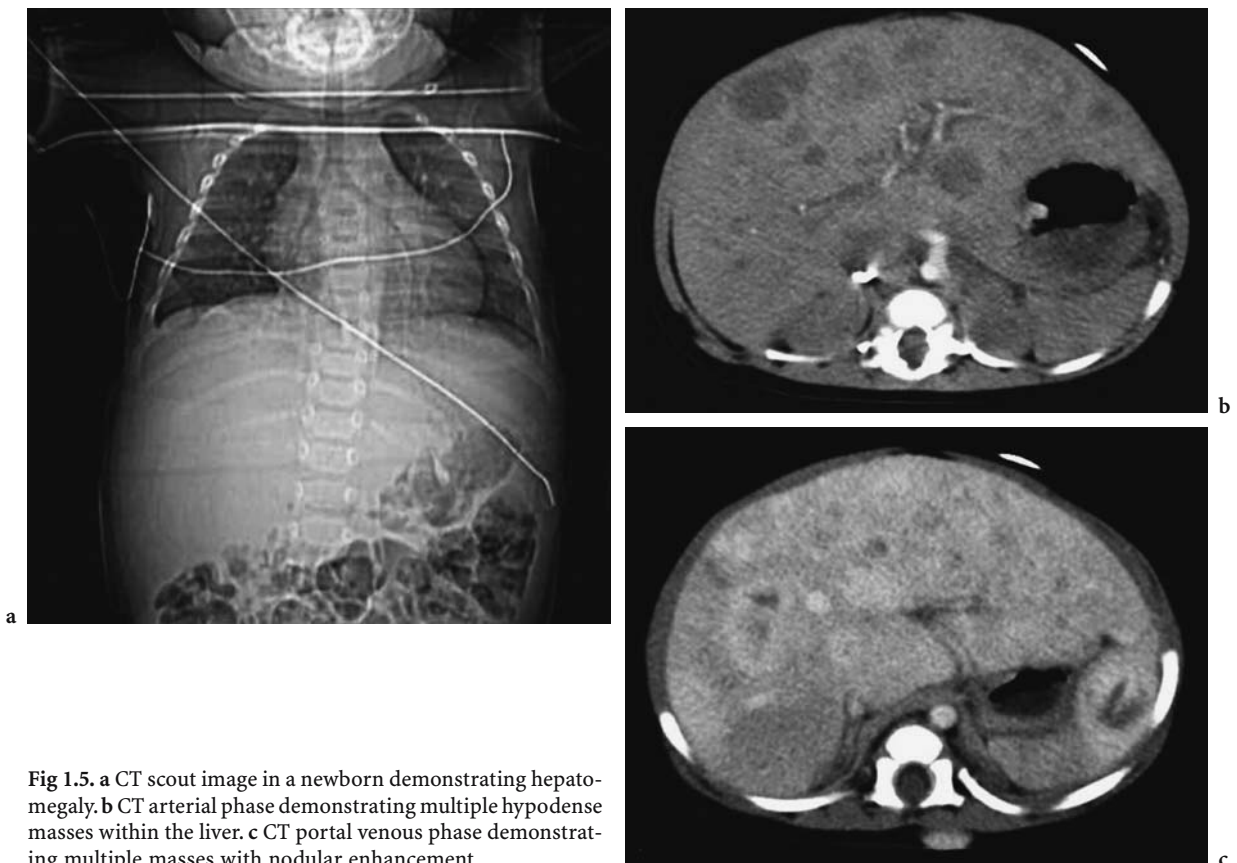


Fig 1.5. a CT scout image in a newborn demonstrating hepatomegaly. b CT arterial phase demonstrating multiple hypodense masses within the liver. c CT portal venous phase demonstrating multiple masses with nodular enhancement

and may result in hepatic necrosis [30, 35]. It is therefore imperative to perform an angiographic study to include the portal venous circulation and potential collateral vessels to allow for careful planning before embolization is performed [29].

1.2 Vascular Malformations

Vascular malformations, unlike hemangiomas, are not neoplasms, but instead represent errors of vascular morphogenesis resulting in abnormal blood vessels and lymphatics [1]. They are classified into high-flow and low-flow lesions based on their hemodynamic properties. High-flow lesions include arteriovenous malformations (AVMs) and arteriovenous fistulae (AVFs). Low-flow lesions include venous malformations, lymphatic malformations, capillary malformations, and combined malformations. Vascular malformations tend to be present at birth and grow commensurate with the growth of the child. The majority of vascular malformations can be diagnosed with history and physical examination and confirmed by diagnostic imaging.

1.2.1 Arteriovenous Malformations

Arteriovenous malformations (AVMs) consist of multiple small abnormal connections (nidi) connecting large arterial feeding arteries to large draining veins without an intervening capillary bed.

1.2.1.1 Clinical Presentation

AVMs affect males and females equally. Their growth is known to be stimulated from hormonal changes during puberty, hormonal therapy, and pregnancy [1]. AVMs are classified into four clinical stages according to the International Society for the Study of Vascular Anomalies (ISSVA) Schobinger classification [36]. Stage 1 represents a dormant AVM which present like a capillary skin stain or a small pulsatile skin mass. In stage 2, an AVM is larger and presents as a warm, tender, red, pulsatile mass with visible large draining veins and an audible bruit. In stage 3, the AVM is complicated by ulceration, bleeding, and associated destructive osseous changes. In

stage 4 (2.5% of cases), the AVM results in congestive cardiac failure due to increased arteriovenous shunting. AVMs may affect the head and neck, extremities, and viscera (e.g. lungs, liver, kidneys, spleen, and pancreas). AVMs may be focal, but more frequently are diffuse and cross tissue planes. AVMs become symptomatic when they bleed, ulcerate, or exhibit mass effect on nearby structures.

In the extremities, AVMs typically present as a soft tissue mass with hyperthermia, redness, tenderness, and swelling (Fig. 1.6a). The draining veins are usually visibly distended and associated with a palpable thrill and an audible bruit. There is usually associated tissue ischemia and edema which can lead to ulceration. It has been postulated that the skin necrosis is due in part to arteriovenous shunting but also due to associated venous hypertension and mass effect [1]. Ulceration can ultimately lead to life-threatening hemorrhage and can also be complicated by infection. Spontaneous bleeding is uncommon in the absence of ulceration or trauma. When intramuscular, AVMs may produce significant pain [1]. Pelvic AVMs are rare and typically present with pelvic pain, pedal edema, menorrhagia, hemorrhage (antepartum, postpartum) or a pulsatile mass on pelvic exam. In males, dysuria, frequency, impotence, tenesmus, and hematuria can occur [37–39]. AVMs may produce lytic osseous lesions or result in limb overgrowth. Congestive heart failure can result if the AVM is large or if it occurs in infancy.

When affecting the brain, an AVM can present with hemorrhage, stroke, seizures, or focal neurological deficits. Spinal AVMs present with hemorrhage or a myeloradiculopathy. Dental AVMs can present with life-threatening hemorrhage after tooth extraction, eruption, or infection [1].

AVMs of the abdominal viscera are uncommon, but when they do occur, they have an increased probability of bleeding due to the proximity to mucosa. True AVMs of the liver in the newborn will present with a clinical picture similar to hepatic hemangioendothelioma already discussed. Pancreatic AVMs [40, 41] are usually associated with Osler-Weber-Rendu syndrome. Splenic vascular malformations are usually asymptomatic and found incidentally at autopsy. They can also present with splenomegaly, pain, bleeding, portal hypertension, and hypersplenism [42]. Vascular malformations of the kidney are rare.

Pulmonary AVMs can occur sporadically (15%) or as part of the autosomal dominant disorder (60%–90%) known as Osler-Weber-Rendu syndrome or Hereditary Hemorrhagic Telangiectasia (an autosomal dominant disease characterized by telangiecta-

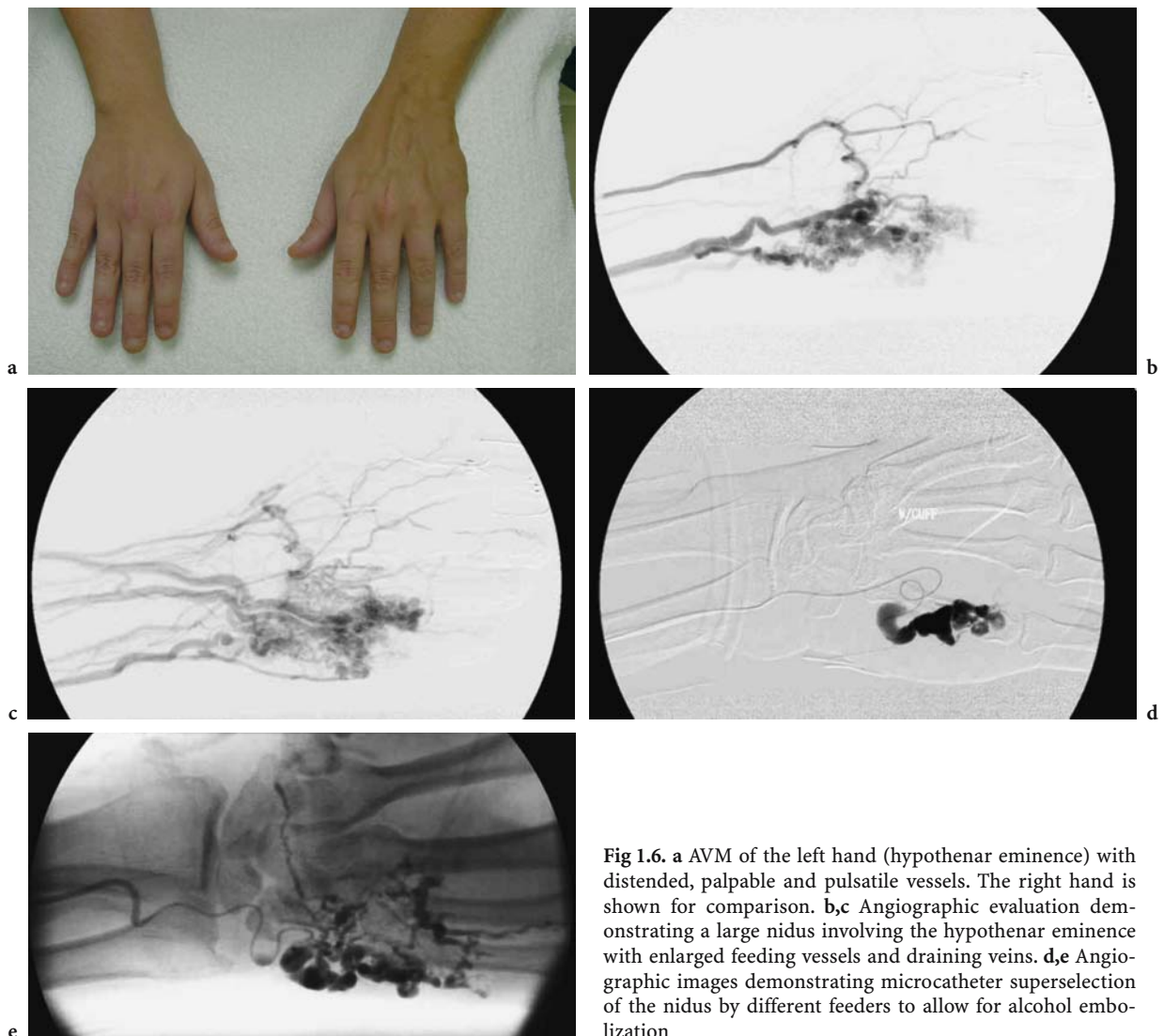


Fig 1.6. a AVM of the left hand (hypothenar eminence) with distended, palpable and pulsatile vessels. The right hand is shown for comparison. b,c Angiographic evaluation demonstrating a large nidus involving the hypothenar eminence with enlarged feeding vessels and draining veins. d,e Angiographic images demonstrating microcatheter superselection of the nidus by different feeders to allow for alcohol embolization

sias, recurrent epistaxis, and a family history of telangiectasia). Pulmonary AVMs are multiple in up to 55%, bilateral in 40%, and occur mainly in the lower lobes. The AVMs are usually simple with a single feeding artery (80%) but may be complex with multiple feeding arteries (20%). Patients present with symptoms of hypoxia due to arteriovenous shunting (e.g. dyspnea and cyanosis), paradoxical embolization resulting in CVA, TIA, or brain abscess and/or congestive heart failure [50, 51].

1.2.1.2

Diagnostic Imaging

The characteristic imaging findings of AVMs include dilated feeding arteries and draining veins. On CT

imaging, the vessels enhance after the administration of intravenous contrast while on MR imaging the vessels are seen as multiple prominent flow voids on T1- and T2-weighted spin echo sequences [5]. The vessels will be bright on gradient echo sequences. Unlike a hemangioma, there is no parenchymal mass and the nidus is usually not visible. Various signal changes indicative of blood products may be seen if the AVM has bled. Associated soft tissue (edema) and bony changes may also be seen. History and physical examination will usually suffice in the diagnosis of AVMs affecting the extremities with imaging performed to document the extent of the lesion. CT imaging is superior to MR in the delineation of pulmonary AVMs. Visceral lesions may be investigated with CT and MR imaging. Angiography is usually not required for diagnosis, but is

performed for treatment planning, at the time of percutaneous embolization, or if the diagnosis is in doubt. Angiography is superior to delineate the nidi and also clearly demonstrates the large feeding vessels and early draining veins (Fig. 1.6b,c).

1.2.1.3

Treatment

The vast majority of AVMs will cross surgical planes to involve the deep tissues, making surgical resection impossible due to the risk of significant hemorrhage or of damage to associated tissues or organs. Excisional surgery becomes more feasible after successful embolization. Percutaneous management of AVMs is difficult, with complete lasting obliteration of the AVM usually not possible even with current techniques. Percutaneous treatment is performed mainly to control symptoms such as pain, distal ischemia leading to ulceration, hemorrhage, and congestive cardiac failure [5]. Amputation may be the necessary end result in cases of extensive AVM of the extremity when embolization fails to control the symptoms [43].

For those patients where treatment is indicated, an initial diagnostic arteriogram is performed. Although treatment of the lesion might be performed at that time, the diagnostic and therapeutic procedures may be performed separately, to minimize contrast volume and to ensure that appropriate equipment is available. In young children, the procedures might be combined to decrease the number of times the patient needs to be placed under general anesthesia. Superselective arterial embolization is usually performed using microcatheter techniques. The aim is to selectively embolize the feeders to the nidus without compromising blood supply to essential nearby structures. This often proves to be difficult and time-consuming because the majority of AVMs will have numerous feeding arteries and draining veins. Occluding a feeding vessel too proximally will only lead to development of new feeders and is thus ineffective. This will ultimately lead to recurrence and distal ischemia as new vessels are recruited [44]. Additionally, proximal occlusion may make subsequent attempts at embolization more difficult.

In order to attempt embolization of the nidus within an AVM, various agents such as PVA particles, absolute alcohol, and tissue adhesives (glue) have been used. PVA particles are available in sizes ranging from 50 μm to 1000 μm . They are useful

when multiple microfistulous connections exist within the nidus. The size of the particles must be larger than the connections to avoid escape into the venous system. The effects of PVA particles are usually temporary with a high rate of recurrence due to subsequent development of collaterals compromising future percutaneous management [44]. PVA particles are therefore best suited for preoperative embolization to minimize bleeding during surgical resection [45].

Absolute alcohol is a very effective embolization agent because it destroys the walls of the blood vessels by inciting a strong inflammatory reaction. In order to maximize the effect on AVMs and simultaneously prevent effects on vital structures, alcohol is delivered directly into the nidus by superselective catheterization or via direct puncture ([47, 48], Fig. 1.6d,e). Occluding inflow arteries or outflow veins maximizes the effect on the nidus. The objective is to confine the injected alcohol within the nidus. Inflow occlusion can be achieved with the use of balloon catheters. If inflow occlusion is not possible, then outflow occlusion can be achieved with the use of orthopedic tourniquets, blood pressure cuffs (inflated to suprasystolic pressures), or manual compression depending on the location of the lesion [44]. Contrast is injected into the nidus during inflow occlusion until the draining veins are seen. This reflects the volume of alcohol needed to fill the nidus without spilling into the draining veins. Following each infusion of alcohol (retained for several minutes within the lesion prior to releasing the inflow or outflow obstruction), contrast injection should be repeated to follow the effects of alcohol, with stasis within the nidus being the ultimate goal. Some authors have advocated that alcohol should be the only agent used in the treatment of AVMs and that alcohol therapy can be curative [44]. While we agree, it is important to consider the risk of necrosis of nearby vital tissues and of the skin need to be considered when alcohol is administered by a percutaneous or endovascular route. Also, the risk of systemic toxicity increases in doses above 1 ml/kg or if a volume greater than 60 ml is used. Complications can be as high as 15% of patients treated with absolute alcohol [44]. Most complications are self-limiting or may be successfully treated (e.g., with skin grafting in the case of skin necrosis); however, neurologic complications can be permanent. Some authors advocate that general anesthesia should be used when embolization will be carried out using alcohol, due to its possible local and systemic effects [25]. We agree that gen-

eral anesthesia should be used in children when embolization is performed with absolute alcohol. In adults, by keeping the patient awake with conscious sedation, the local effects of absolute alcohol can be assessed clinically (e.g. assessing for neuropathy in the extremities during absolute alcohol therapy).

Tissue adhesives work by forming a cast within a blood vessel resulting in occlusion. It is available as an injectable liquid that immediately polymerizes when it contacts ionic fluids such as blood. It can also be diluted or modified to polymerize after variable periods. Tissue adhesives are of value in the treatment of very high-flow AVMs where instant polymerization is advantageous to avoid entry into the draining veins. The disadvantage of tissue adhesives is that, unlike absolute alcohol, they may not totally destroy the nidus resulting in eventual recanalization. Coils and detachable balloons produce too proximal an embolization and should be avoided in the treatment of extremity AVMs unless the arteriovenous connections are quite large and glue is unavailable [46]. When a transarterial route to the nidus is not possible, the nidus can be directly injected with absolute alcohol or glue [47, 48] or accessed via a transvenous route [44, 49].

Approximately 80% of pulmonary AVMs will be of the simple type with a single feeding artery making them amenable to percutaneous embolization with coils or detachable balloons (Fig. 1.7a,b).

Cure of up to 84% of pulmonary AVMs with a single procedure has been reported [50–52].

Renal AVMs are rare and are typically small in size but can be quite large. Percutaneous embolization has been documented in the treatment of symptomatic lesions (hematuria, congestive cardiac failure, or hypertension). Percutaneous embolization using coils, Gelfoam, PVA particles, and glue (N-butyl-cyanoacrylate) has been reported [53–55]. Uterine AVMs have successfully been embolized with PVA particles, Gelfoam, glue, and coils [56].

1.2.2 Arteriovenous Fistulae

Arteriovenous fistulas (AVFs), like AVMs, are high-flow vascular malformations but consist of a single macrofistulous communication between an artery and a vein (Fig. 1.8a–c). They are not common in childhood and are considered to be posttraumatic in origin. They are, however, still found in the absence of a history of trauma [26]. Like AVMs, they can produce CHF due to arteriovenous shunting. Small AVFs may close spontaneously and larger lesions can enlarge over time presenting in the extremity as a pulsatile lesion with a palpable thrill and audible bruit. Angiography easily demonstrates the single large interconnection. Visceral AVF are usually iatrogenic and can present with hemorrhage.

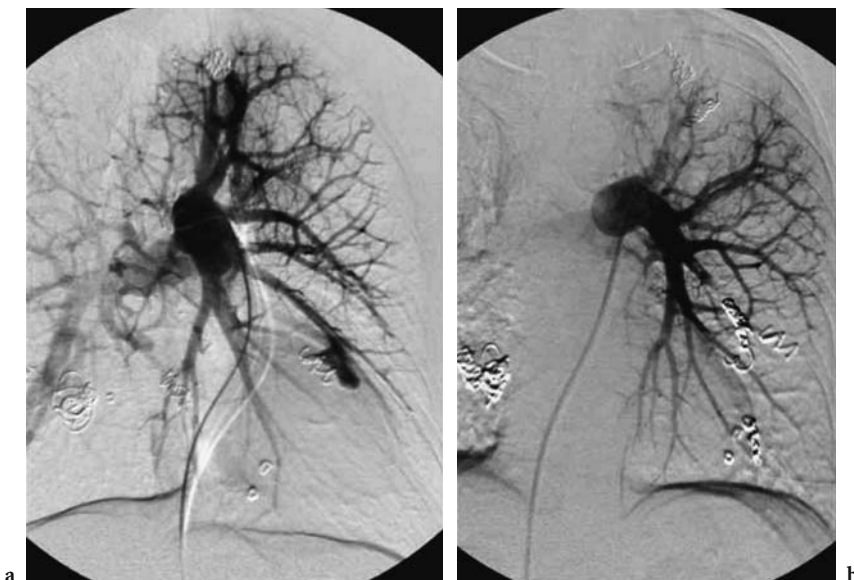

Fig 1.7a,b. Left pulmonary arteriogram in a patient with Hereditary Hemorrhagic Telangiectasia. **a** Formation of new pulmonary AVM years after treatment of prior malformations. **b** Successful coil embolization of a new pulmonary AVM

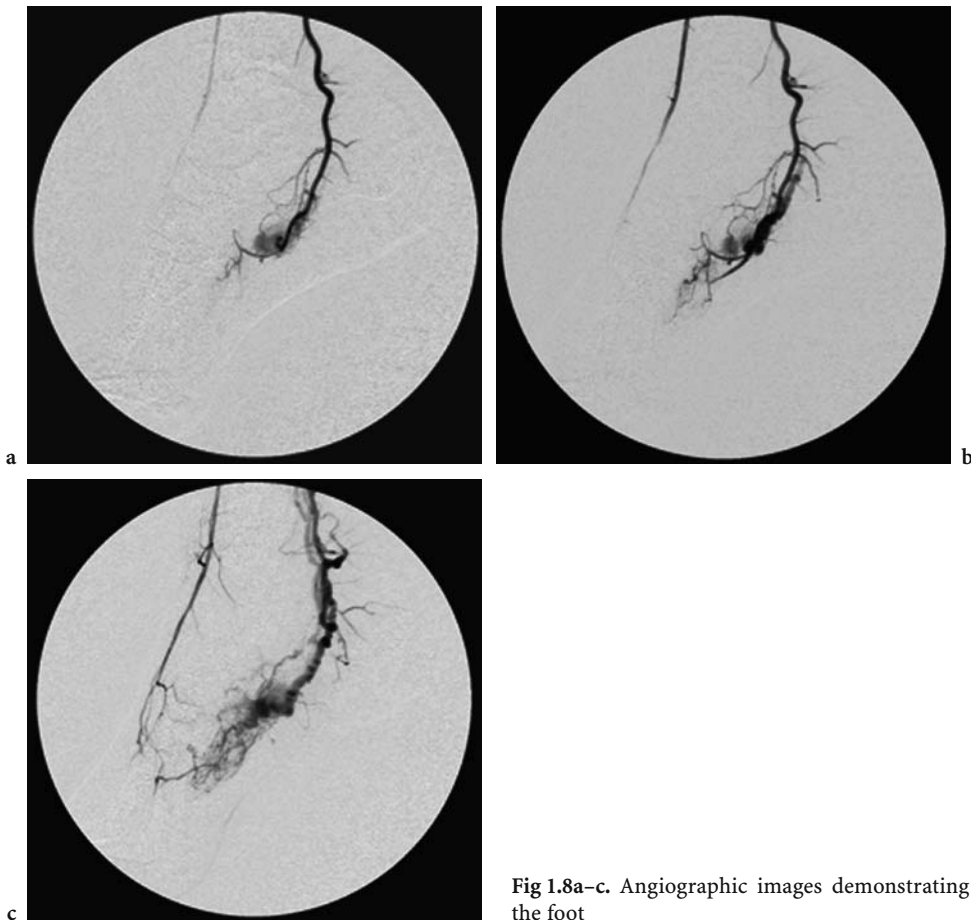


Fig 1.8a–c. Angiographic images demonstrating a posttraumatic AVF of the foot

1.2.2.1

Treatment

AVFs are amenable to percutaneous endovascular embolization with coils and detachable balloons [57–59] or ethanol [60]. The aim is to embolize the macrofistulous connection or the immediate draining vein. When this is not possible, a stent graft or covered stent can be percutaneously placed within the feeding vessel to cover the AVF [61]. If the feeding vessel can be sacrificed, it can be occluded using coils, detachable balloons, or glue [26]. In occluding large AVFs, migration of a deployed device can be prevented with the use of balloon catheters, snares, and tourniquets.

1.2.3

Venous Malformations

The management of VMs is discussed in its entirety in the next Chapter.

1.2.4

Lymphatic Malformations

Lymphatic malformations (formerly known as cystic hygroma or lymphangiomas) are maldevelopments of the various components of the lymphatic system. They are localized malformations affecting the various layers of the subcutaneous tissue and exhibit low-flow characteristics. They are usually multiloculated and are divided into microcystic (cysts <2 cm in diameter), macrocystic, and mixed categories.

1.2.4.1

Clinical Presentation

Lymphatic malformations (LMs), like other vascular malformations, are commonly present at birth with a predilection for the head, neck and axilla (Fig. 1.9). They affect both sexes equally. They are less common than venous malformations and are usually subcutaneous [1, 5, 68].

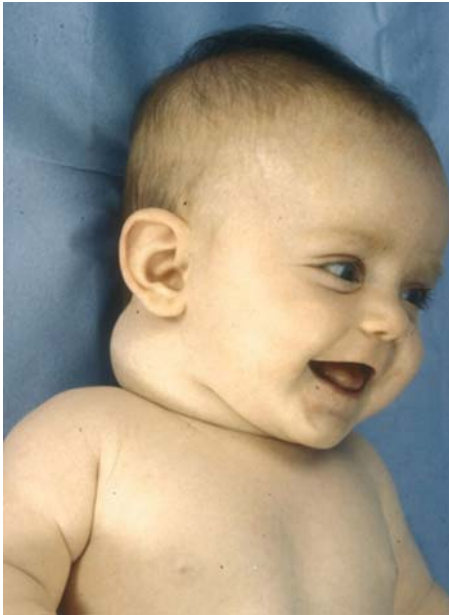

Fig 1.9. Lymphatic malformation of the neck. (Image provided by Dr. Phillip John, MD)

They can enlarge significantly and extend through various tissue planes to dissect into the mediastinum thus making surgical removal difficult. Mass effect can lead to airway compromise and osseous overgrowth [1]. LMs can occur with other malformations such as capillary and venous malformations. The most superficial form of LM is referred to as lymphangioma circumscriptum (LC) and consists of visible thin-walled clear lymphatic vesicles on the skin that, on occasion, exude lymph. If hemorrhagic, the LC may become pink in appearance. It is seen most commonly at the shoulder, buttocks, neck, or mouth. Optimal treatment, to control persistent leakage of lymph and for cosmetic reasons, is operative resection [1].

The classic LM presents at birth as a soft translucent mass at birth that, unlike some venous malformations, cannot be manually decompressed. Also, unlike venous malformations, LMs do not enlarge during the Valsalva maneuver. They may be associated with overlying lymphangioma circumscriptum. When complicated by hemorrhage, the mass becomes firm. LMs can also become secondarily infected causing them to become tender, warm, and erythematous [62]. They frequently enlarge during a viral illness. When the LM is extensive and becomes secondarily infected, the result can be airway compromise [63, 64]. Other complications include SVC obstruction, chylothorax, pulmonary hypoplasia, and death [65–67].

1.2.4.2 Diagnostic Imaging

MR imaging of macrocystic LMs shows multiple large cysts isointense to muscle on T1-weighted images and hyperintense on T2-weighted images, with peripheral rim enhancement, septal enhancement, or no enhancement with gadolinium (Fig. 1.10a–e). There may be fluid–fluid levels and signal characteristics presenting blood products (Fig. 1.11a–c). Edematous changes may be seen in the surrounding subcutaneous tissue [5]. Osseous distortion and overgrowth are best demonstrated on CT. The microcystic variety demonstrates similar characteristics; however, the hyperintensity on T2-weighted images is more diffuse due to the presence of microcysts. Cysts are also readily demonstrated by ultrasound with low-flow dynamics seen on Doppler imaging [5].

1.2.4.3 Treatment

Treatment is indicated to relieve symptoms such as pain or airway compromise or to improve cosmetically. The macrocystic form of LM responds favorably to surgery and sclerotherapy with sclerotherapy having similar success rates but less morbidity [68]. Sclerotherapy is performed using direct percutaneous puncture using a variety of agents, e.g. ethanol [68], doxycycline [69–71], bleomycin [72], Ethibloc and OK-432 [73–76]. Bleomycin, a chemotherapeutic agent, may be used for sclerotherapy of LM, but has systemic side effects such as pulmonary fibrosis. OK-432 is a superantigen produced from *Streptococcus A* and is not yet available in the USA. Ethibloc is composed of Zein protein, contrast and ethanol and is also not available in the USA. Doxycycline has been used to treat microcystic LM, in neonates where the use of alcohol is limited due to the patient's weight and in the treatment of very large lymphatic malformations in which a large volume of sclerosant is needed. It is available in powder form (100 mg) and is mixed with saline in a concentration of 10 or 20 mg/ml. Volumes up to 100 ml can be used. Doxycycline produces pain during injection, is nontoxic, and may result in only mild adverse reactions, e.g. fever [68]. The most commonly used sclerosant for macrocystic LM is ethanol with a maximum dose of 1 ml/kg or a maximum volume of 60 ml [5].

Depending on the size of the cysts, their contents can be drained using single or multiple angiocatheters, a catheter with multiple side holes, or a pig-

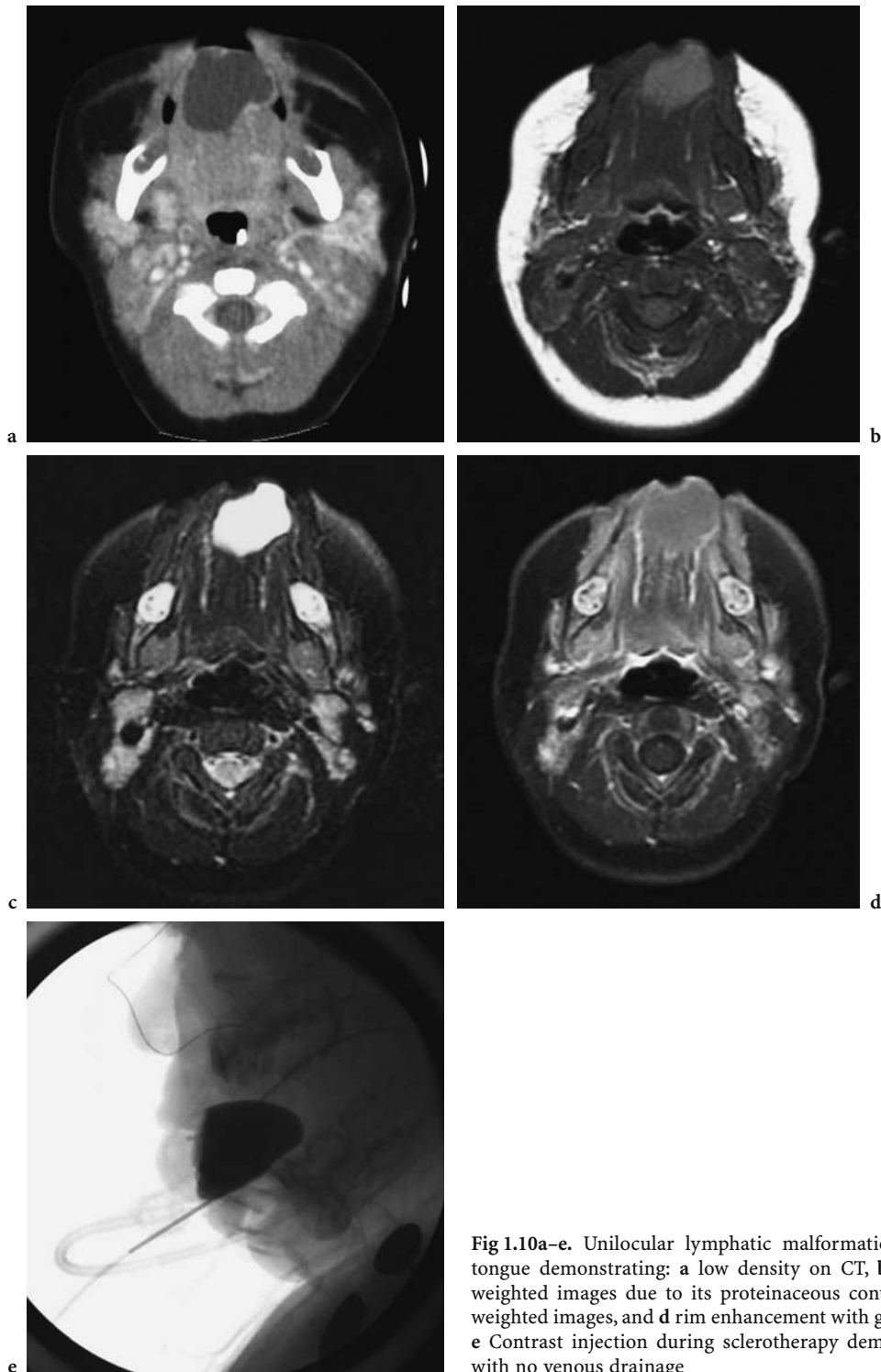


Fig 1.10a-e. Unilocular lymphatic malformation involving the anterior tongue demonstrating: **a** low density on CT, **b** increased signal on T1-weighted images due to its proteinaceous content, **c** high signal on T2-weighted images, and **d** rim enhancement with gadolinium administration. **e** Contrast injection during sclerotherapy demonstrating a single cavity with no venous drainage

tail catheter. The volume aspirated will determine the volume of sclerosant to be used. Various authors report using a volume of sclerosant equal to 30%–100% of the aspirated volume [70]. Contrast injec-

tion confirms the location of the needle and catheter. The contrast is aspirated and then the sclerosant is instilled. To minimize the use of contrast and concomitant potential dilution of the sclerosant, access

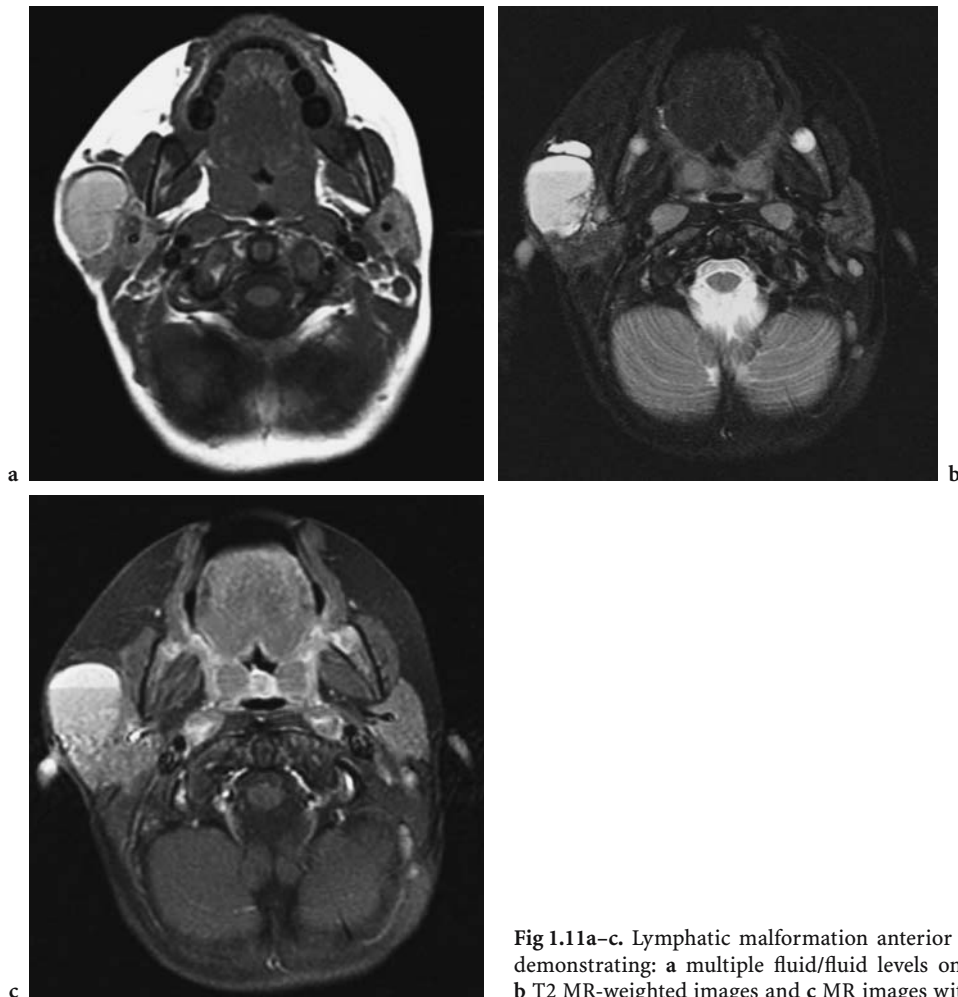


Fig 1.11a-c. Lymphatic malformation anterior to the right parotid gland demonstrating: a multiple fluid/fluid levels on T1 MR-weighted images, b T2 MR-weighted images and c MR images with gadolinium

into the cyst can be achieved using sonographic guidance. CT can also be used to guide sclerotherapy [69]. The sclerosant is injected with a tiny amount of contrast with subsequent CT scanning to confirm opacification of the cysts. Some authors will mix the sclerosant with a small amount of contrast and utilize fluoroscopy during injection to evaluate for venous escape [26]. When alcohol is the sclerosant of choice, it is instilled, left to dwell for up to 15 min, and then drained with subsequent needle removal. In order to increase dwell time when doxycycline is used, aspiration of the sclerosant is not performed. A pressure dressing is applied to minimize leakage following the procedure.

SHEILS et al. describes a coaxial technique for large cysts using a coaxial system consisting of a 14G angiocatheter and 5F pigtail catheter. The cyst is accessed with the 14F angiocatheter and the 5F pigtail catheter is advanced through the existing angiocatheter into the cyst. Contrast is injected to opacify the LM. After

the contrast is aspirated, 1% Lidocaine is injected and left to dwell for 10 min. After aspiration, 3% sodium tetradecyl sulfate, a detergent sclerosant, is injected and left to dwell for 1–2 min. After aspiration, alcohol is injected and left to dwell for 15 min. At each step, 50% cyst volume is utilized. After the alcohol is aspirated, the catheter is connected to a Jackson Pratt suction bulb system and suction is performed for up to three days while the patient is on oral antibiotics. Pigtail catheter drainage can be followed up with repeated injections of the sclerosant until there is no further drainage. Ultrasound evaluation performed one month following sclerotherapy has shown complete ablation in 95% of patients where catheter drainage has been used [70].

Fluid aspiration and contrast injection may not be feasible when treating the microcystic form of LM. Ultrasound imaging is therefore useful to monitor the injection of microcysts. Due to the local effects of alcohol such as tissue necrosis and nerve injury,

doxycycline is usually the sclerosant of choice in the treatment of microcystic LM [45].

1.2.5

Capillary Malformations

Capillary malformations (CMs), because of their appearance, have traditionally been referred to as port wine stains and incorrectly as capillary hemangiomas. They represent maldevelopment of capillaries and present as well demarcated skin discoloration. CMs initially have a pink or red color and become more purple as children age. CMs frequently occur with other vascular anomalies. In Klippel-Trenaunay syndrome, they occur on the trunk or lower extremity and are associated with limb hypertrophy and widespread venolymphatic malformations. In Sturge-Weber syndrome, the CM is typically in the V1 (first division of the trigeminal nerve) distribution on the face and is associated with underlying ophthalmologic and leptomeningeal VMs and CMs.

Treatment options for CMs include mainly pulsed dye laser therapy and also corticosteroids, interferon, and surgery [77–79]. The interventional radiologist may be called upon only to treat the associated lesions such as VM and LM in order to alleviate symptoms.

1.3

Complications of Embolization and Sclerotherapy

The percutaneous treatment of arteriovenous malformations can be quite challenging. Embolization can fail if the nidus cannot be reached or if the malformation is not adequately treated. Additional complications include embolization to distal tissues or organs, thrombosis of normal vessels, nausea/vomiting, pain, fever, swelling, and post embolization syndrome. Although absolute alcohol can be effective in the management of vascular malformations, the complication rate can be as high as 10%–15%. Local effects of alcohol include tissue necrosis, neuropathy, and skin ulceration. Systemic effects include CNS depression, hypoglycemia, systemic hypertension, pulmonary hypertension, cardiac arrhythmias, bradycardia, pulmonary vasoconstriction, disseminated intravascular coagulation due to fibrinogen consumption [80], hemoglobinuria, pulmonary embolism, and car-

diovascular collapse resulting in the patient's demise [81].

1.4

Preprocedural Preparation

The indications for treatment are clearly delineated. Treatment may be performed only to alleviate symptoms, since in many cases a cure is not possible. The risks and benefits are clearly explained to the patient. Lab studies are performed as in many interventional procedures to test clotting parameters and renal function. When small focal malformations are treated with agents other than ethanol, the procedure can be performed using conscious sedation. It is generally recommended that when a significant volume of alcohol is to be used in the treatment of a large AVM, especially in patients with pre-existent cardiac compromise, that general anesthesia is performed. Pulmonary arterial pressures may be monitored. Some authors advocate hydration before the procedure to protect the kidney from the effects of hemolysis [68]. A Foley catheter may be inserted. Proper equipment (sheaths, microcatheters, wires, and embolic agents) is essential. Anti-inflammatory medications such as corticosteroids are given just before and continued after the procedure to minimize swelling. Antibiotics (e.g. cephalexin) are usually given for 10 days after sclerotherapy of LMs due to the risk of infection. Antiemetics, antibiotics and analgesics may also be administered especially for transarterial embolization cases.

1.5

Post-Procedural Care and Follow-Up

In addition to routine vascular postprocedural care, several post-embolization-specific procedures should be employed: The treated extremity should be elevated to alleviate edema. Pain control is usually necessary and may require intravenous narcotics: A patient-controlled-anesthesia (PCA) pump works very well for the majority of patients. Whenever absolute alcohol is used, the overlying skin should be observed for blanching or blistering, which, if present, suggest skin injury. Mild cases can be treated with topical antibiotics or Silvadene cream. Plastic surgeons should be consulted early, as necrosis might ensue, and skin grafting might be required. Neuro-

Table 1.2. Basic materials and equipment

IR clinic with ancillary staff (clerks, nurses, physician assistants, nurse practitioners), and time for physician to go to the clinic

Portable Doppler ultrasound machine, to allow evaluation of vascular status prior to and following treatment of some vascular lesions

Imaging equipment and expertise: MRI/MRA, CT/CTA, US with color flow, high-speed DSA

Cook Micropuncture sheath: A very versatile sheath which can be used as primary vein or artery access set in preparation for angiography and/or embolization, or, as described above, as a direct access device, e.g., in the treatment of a VVM.

Catheters

- Standard array of 4F and 5F catheters
- Hydrophilic catheters: May be necessary if standard catheters cannot be advanced through small feeding vessels to lesion
- Microcatheters: The Transit catheter (Cordis) is quite useful
- Guidewires: Standard array; if microcatheter is used, will need appropriate guidewire. The Transcend guidewire (BSC) is a good choice
- Balloon catheters: E.g., the Cook Over-the-wire Fogarty balloon catheter: Such catheters can be used as proximal occlusion catheters, through which microcatheters can be advanced, and through which alcohol (e.g.) can be infused. The use of proximal occlusion as with these devices is especially valuable in treatment of high-flow lesions.

Blood pressure cuffs: Pediatric, standard, and large. Suprasystolic inflation of BP cuffs can be used (as can direct pressure and/or tourniquets) to prevent outflow from lesions to be embolized or sclerosed.

Embolization materials

- Absolute alcohol
- Glue
- +/- Sotradecol (may be of some value in treating very superficial lesions, as it may be less likely to cause skin necrosis)
- Coils: Although usually not necessary and usually contraindicated in the treatment of AVMs and VVMs (because coils are unlikely to be successful in the treatment of those lesions and they interfere with subsequent access), coils are invaluable in the treatment of PAVMs and AVFs. A wide range of coils should be available for such lesions.
- Balloons: May be necessary in the treatment of high-flow lesions

Silvadene cream: In the unfortunate event that a person develops skin breakdown after a procedure, appropriate would care will include the use of such an ointment.

Point 1: Be prepared. Ascertain that the patient and his/her family understand what to expect from the procedure; ensure that adequate analgesia is available; ensure that all necessary equipment (including ultrasound) is readily available.

Point 2: Don't lose access. Always use a sheath when approaching a lesion from the inside. Co-axial access (sheath and catheter, or sheath and catheter and microcatheter) is mandatory. Similarly, although you can treat a lesion with direct injection through a needle, a flexible sheath, e.g., the 3F inner portion of a Cook 4F Micropuncture transitional dilator provides better stability.

Point 3: Be prepared for all outcomes, both successful and otherwise; e.g., prompt discussion with a plastic surgeon can be of enormous benefit in patients who develop skin breakdown.

logic examination of the treated extremity is essential to evaluate for neuropathy. Most peripheral malformations will visibly swell soon after treatment, reach a peak a few days later, and subside over the next few weeks. The degree of expansion is expected to subside over the next two weeks. Overnight stay is indicated if large lesions are treated especially if airway compression can occur. ICU admission may be necessary with intubation to protect the airway. In the presence of hemoglobinuria, the urine needs to be alkalinized with sodium bicarbonate to protect the kidneys from crystallization [68]. When pigtail catheters are placed e.g. in LMs, the patient are hospitalized for a few days. Follow-up appointments may be made in 4–6 weeks to evaluate response to treatment and determine if repeat embolization or sclerosis is necessary. Lesions are followed clinically and with MR imaging as indicated.

1.6 Conclusion

As discussed, the most useful classification of vascular malformations to date is the one by MULLIKEN and GLOWAKI. The majority of vascular malformations can be diagnosed clinically with MRI now the gold standard to delineate the extent of the lesion or in cases where the diagnosis is in doubt.

The majorities of hemangiomas are best left alone and will regress either spontaneously or with medical treatment. Endovascular embolization can be helpful in the cases of noninvoluting hemangiomas, Kaposiform hemangioendotheliomas, and hepatic hemangioendotheliomas. This can prove to be quite challenging. The aim is not to cure but to stabilize deleterious effects such as hemorrhage and thrombocytopenia.

Endovascular embolization of high-flow malformations requires proper planning and the use of microcatheter techniques. Although alcohol may produce the best result, it should be used with extreme caution due to its local and systemic effects. Although a cure may not be possible, relief of symptoms can be achieved in the majority of patients.

Percutaneous sclerotherapy of low-flow vascular malformations can be technically straightforward, but requires pre-procedure and post-procedure planning in order to avoid serious complications.

References

- Mulliken JB, Young A (1988) *Vascular birthmarks: hemangiomas and malformations*. Saunders, Philadelphia
- Mulliken J, Glowaki J (1982) Hemangiomas and vascular malformations in infants and children: a classification based on endothelial characteristics. *Plast Reconstr Surg* 69:412
- Mulliken, JB, Fishman SJ, Burrows PE (2000) Vascular anomalies. *Curr Probl Surg* 37:517–584
- Witt PD, Mulliken JB (1999) Hemangiomas and vascular malformations. Publications committee, Cleft Palate Foundation
- Burrows PE, Laor T, Paltiel H et al. (1998) Diagnostic Imaging in the evaluation of vascular birthmarks. *Pediatr Derm* 16:455–488
- Frieden IJ, Reese V, Cohen D (1996) PHACE syndrome. The association of posterior fossa brain malformations, hemangiomas, arterial anomalies, coarctation of the aorta, cardiac defects and eye abnormalities. *Arch Dermatol* 132:307–311
- Gangopadhyay AN, Sinha CK, Gopal SC et al. (1997) The role of steroids in childhood hemangioma: a 10 year review. *Int Surg* 82:49–51
- Bennett ML, Fleischer AB, Chamlin SL et al. (2001) Oral corticosteroids are effective for cutaneous hemangiomas: an evidence based evaluation. *Arch Dermatol* 137:1208–1213
- Akyuz C, Yaris N, Kutluk MT et al. (2001) Management of cutaneous hemangiomas: a retrospective analysis of 1109 cases and comparison of conventional prednisolone with high-dose methylprednisolone therapy. *Pediatr Hematol Oncol* 18:47–55
- Deb G, Donfresco A, De Sio L et al. (1996) Treatment of hemangiomas in infants and babies with interferon alfa-2a: preliminary results. *Int J Pediatr Hematol Oncol* 3:1–16
- Enjolras O, Riche MC, Merland JJ et al. (1990) Management of alarming hemangiomas in infancy: a review of 25 cases. *Pediatrics* 85:491
- Ezekowitz RAB, Mulliken JB, Folkman J (1992) Interferon alpha-2a therapy for life threatening hemangiomas of infancy. *N Engl J Med* 326:1456–1463
- Barlow CF, Priebe CL, Mulliken JB et al. (1998) Spastic diplegia as a complication of interferon alpha-2a treatment of hemangiomas of infancy. *J Pediatr* 132:527–530
- Achauer MB, Chang CJ, Vander Kam VM (1997) Management of hemangioma in infancy: review of 245 patients. *Plast Reconstr Surg* 99:1301–1308
- Chiaverini C, Kurzenne JY, Rogopoulos A et al. (2002) Non-involuting congenital hemangioma: 2 cases. *Ann Dermatol Venerol* 129:735–737
- Leikensohn JR, Epstein LI, Vasconez LO (1981) Superselective embolization and surgery of noninvoluting hemangiomas and A-V malformations. *Plast Reconstr Surg* 68:143–152
- Hosono S, Ohno T, Kimoto H et al. (1999) Successful transcatheter embolization of a giant hemangioma associated with high output cardiac failure and Kasabach-Merritt syndrome in a neonate: a case report
- Zukerberg LR, Nickoloff BJ, Weiss SW (1993) Kaposiform Hemangioendothelioma of infancy and childhood, an aggressive neoplasm associated with Kasabach-Merritt syndrome and lymphangiomatosis. *Am J Surg Pathol* 17:321–328
- Sarkar M, Mulliken JB, Kozakewich HP et al. (1997) Thrombocytopenic coagulopathy (Kasabach-Merritt phenomenon) is associated with Kaposiform Hemangioendothelioma and not with common infantile hemangioma. *Plast Reconstr Surg* 100:1377–1386
- Vin-Christian K, McCalmont TH, Frieden IJ (1997) Kaposiform hemangioendothelioma. An aggressive, locally invasive vascular tumor that can mimic hemangioma of infancy. *Arch Derm* 133:1573–1578
- Shin HY, Ryu KH, Ahn HS (2000) Stepwise multimodal approach in the treatment of Kasabach-Merritt syndrome. *Pediatr Int* 42:620–624
- Haisley-Royster CA, Enjolras O, Frieden IJ et al. (2002) Kasabach-Merritt phenomenon: a retrospective study of treatment with vincristine. *J Pediatr Hematol Oncol* 24:459–462
- Ogino I, Torikai K, Kobayasi S et al. (2001) Radiation therapy for life- or function- threatening infant hemangioma. *Radiology* 218:834–839
- Drolet BA, Scott LA, Esterly NB et al. (2001) Early surgical intervention in a patient with Kasabach Merritt phenomenon. *J Pediatr* 138:756–758
- Yakes WF, Rossi P, Odink H (1996) Arteriovenous malformation management. *Cardiovasc Interv Radiol* 19:65–71
- Armstrong DC, Brugge K (2000) Selected interventional procedures for pediatric head and neck vascular lesions. *Neuroimaging Clin North Am* 10:271–292
- Yakes WF (2004) Endovascular management of malignant pediatric hemangioma and kaposiform hemangioendothelioma. Presented at the 2004 SIR 29th annual scientific meeting
- Daller JA, Bueno J, Gutierrez J et al. (1999) Hepatic Hemangioendothelioma: clinical experience and management strategy. *J Pediatr Surg* 34:98–106
- McHugh K, Borrows PE (1992) Infantile hepatic hemangioendotheliomas: significance of portal venous and systemic collateral supply. *J Vasc Interv Radiol* 3:337–344
- Kassarjian A, Dubois J, Burrows PE (2002) Angiographic classification of Hepatic Hemangiomas in Infants. *Radiology* 222:693–698
- Larcher VF, Howard ER, Mowat AP (1981) Hepatic hemangioma: diagnosis and management. *Arch Dis Child* 56:7–14
- Warman S, Bertram H, Kardoff R et al. (2003) Interventional therapy of Infantile Hepatic Hemangioma. *J Pediatr Surg* 38:1177–1181

33. Stanley P, Grinnell VS, Stanton RE et al. (1983) Therapeutic embolization of infantile hepatic hemangioma with PVA. *AJR* 141:1047–1051
34. Peuster M, Windhagen-Mahnet B, Fink F et al. (1998) Interventional therapy for hemangioendothelioma of the liver in a newborn infant using a central venous approach. *Z Kardiol* 87:832–836
35. Burke DR, Verstandig A, Edwards O et al. (1986) Infantile hemangioendothelioma: angiographic features and factors determining the efficacy of hepatic arterial embolization. *Cardiovasc Interv Radiol* 9:154–157
36. Enjolras O, Mulliken JB (1997) Vascular tumors and vascular malformations, new issues. *Adv Dermatol* 13:375–423
37. Beggs I, Garvin DD (1983) Pelvic arteriovenous malformation in a man. *Br J Clin Pract* 37:186
38. Neifeld JP, Doppman JL, Chretien PB (1975) Congenital pelvic arteriovenous fistulas: report of a case and review of literature. *J Urol* 114:648
39. Flye MW, Jordan BP, Schwartz MZ (1983) Management of congenital arteriovenous malformations. *Surgery* 94:740
40. Brinley JL, Palubinskas AJ (1977) Congenital arteriovenous malformation of the pancreas. *Br J Radiol* 50:219
41. Mizutani N, Masudo U, Naito N et al. (1981) Pancreatic arteriovenous malformation in a patient with gastrointestinal hemorrhage. *Am J Gastroenterol* 76:141
42. Pinkas J, Djaldetti M, DeVries A et al. (1968) Diffuse angiomatosis with hypersplenism: Splenectomy followed by polycythemia. *Am J Med* 45:795
43. Frieden I, Enjolras O, Esterly N Vascular birthmarks and other abnormalities of blood vessels and lymphatics, chap 20 (www.harcourt-international.com/e-books/pdf/569.pdf)
44. Vogelzang R (2003) High-flow AVMs: modern therapy with absolute alcohol. Presented at the 2003 Midwest Institute for Interventional Therapy (MIIT) conference
45. Burrows PE (coordinator) Vascular anomalies: interventions and patient management. Presented at the 2004 SIR 29th annual scientific meeting
46. Kaufman SL, Kumar AAJ, Roland JMA (1980) Transcatheter embolotherapy in the management of congenital arteriovenous malformations. *Radiology* 137:21–29
47. Yakes WF, Peosner PH, Reed MD et al. (1996) Serial embolizations of an extremity arteriovenous malformation with alcohol via direct percutaneous puncture. *AJR* 146:1038–1040
48. Doppman JL, Pevsner P (1983) Embolization of arteriovenous malformations by direct percutaneous puncture. *AJR* 140:773–778
49. Abe FJ, TenBroek FW, van Schaik JJP et al. (1997) Transvenous embolization of an arteriovenous malformation of the mandible via a femoral approach. *Pediatr Radiol* 27:855–857
50. White RI, Pollack JS, Wirth JA (1996) Pulmonary arteriovenous malformations: diagnosis and transcatheter embolotherapy. *JVIR* 7:787–804
51. Pollack J, White R (1996) Pulmonary arteriovenous malformations. *SCVIR syllabus thoracic and visceral vascular malformations*
52. Lee DW, White Jr. RI, Egglin TK et al. (1997) Embolotherapy of large pulmonary arteriovenous malformations: long term results. *Ann Thorac Surg* 64:930–939
53. Clouse ME, Levin DC, Desautels RE (1983) Transcatheter embolotherapy for congenital renal arteriovenous malformations. Long term follow-up. *Urology* 22:360–365
54. Nakai M, Nakamura N, Suzuki Y et al. (2003) Transcatheter arterial embolization with n-butyl 2-cyanoacrylate (hystoacryl) for renal arteriovenous malformation: case report. *Hinyokika Kyo* 49:51–53
55. Morita T, Uekado Y, Kyoku et al. (1989) Transcatheter arterial embolization in patients with renal arteriovenous malformation: a report of two cases. *Honyokika Kyo* 35:1761–1765
56. Ghai S, Rajan DK, Asch MR et al. (2003) Efficacy of embolization in traumatic uterine vascular malformations. *J Vasc Interv Radiol* 14:1401–1408
57. Ricolfi F, Valiente E, Bodson F et al. (1995) Arteriovenous fistulae complicating central venous catheterization: value of endovascular treatment based on a series of seven cases. *Intensive Care Med* 21:1043–1047
58. DeSouza NM, Reidy JF (1992) Embolization with detachable balloons – applications outside the head. *Clin Radiol* 46:170–175
59. Herbreteau D, Aymard A, Khayata MH et al. (1993) Endovascular treatment of arteriovenous fistulas arising from branches of the subclavian artery. *J Vasc Interv Radiol* 4:237–240
60. Yakes WF, Luethke JM, Merland JJ et al. (1990) Ethanol embolization of arteriovenous fistulae: a primary mode of therapy. *J Vasc Interv Radiol* 1:89–96
61. Sprouse LR 2nd, Hamilton IN Jr (2002) The endovascular treatment of a renal arteriovenous fistula: placement of a covered stent. *J Vasc Surg* 36:1066–1068
62. Ninh TN, Ninh TX (1974) Cystic hygroma in children: report of 126 cases. *J Pediatr Surg* 9:191
63. Sumner TE, Volberg FM, Kiser PE et al. (1981) Medistinal cystic hygroma in children. *Pediatr Radiol* 11:160
64. Grosfeld JL, Weber TR, Vane DW (1982) One stage resection for massive cervicomedistinal hygroma. *Surgery* 92:693
65. Groves LK, Effler DB (1954) Primary chylopericardium. *N Engl J Med* 250:520
66. Stratton VC, Grant RN (1958) Cervicomedistinal cystic hygroma associated with chylopericardium. *Arch Surg* 77:887
67. Csicsko JF, Grisfeld JL (1974) Cervicomedistinal hygroma with pulmonary hypoplasia in the newborn. *Am J Dis Child* 128:557
68. Burrows PE, Mason KP (2004) Percutaneous treatment of low flow vascular malformations. *J Vasc Interv Radiol* 15:431–450
69. Molitch HI, Unger EC, Witte CL et al. (1995) Percutaneous sclerotherapy of lymphangiomas. *Radiology* 194:343–347
70. Sheils WE. Sclerotherapy of Lymphatic Malformations. Presented at the 2004 annual scientific meeting of the Society of Interventional Radiology
71. Gericke KR (1989) Doxycycline as a sclerosing agent. *Ann Pharmacother* 26:648–649
72. Sung MW, Chang SO, Choi JH et al. (1995) Belomycin sclerotherapy in patients with congenital lymphatic malformation of the head and neck. *Am J Otolaryngol* 16:236–241
73. Giguere CM, Bauman NM, Sato Y et al. (2002) Treatment of lymphangiomas with OK-432 (Picibanil) sclerotherapy: a prospective multi-institutional trial. *Arch Otolaryngol Head Neck Surg* 128:1137–1144
74. Laranne J, Keski-Nisula L, Rautio R et al. (2002) OK-432 therapy for lymphangiomas in children. *Eur Arch Oto-Rhino-Laryngol* 259:274–278

75. Luzatto C, Midrio P, Tchaprassian Z et al. (2000) Sclerosing treatment of lymphangiomas with OK-432. *Arch Dis Childhood* 82:316–318
76. Smith RJ, Burke DK, Sato Y et al. (1996) OK-432 therapy for lymphangiomas. *Arch Otolaryngol Head Neck Surg* 122:1195–1199
77. Lanigan SW (2001) Treatment of vascular nevi in children. *Hosp Med* 62:144–147
78. Lam SM, Williams EF (2004) Practical considerations in the treatment of capillary vascular malformations, or port wine stains. *Facial Plast Surg* 20:71–76
79. Richards KA, Garden JM (2000) The pulsed dye laser for cutaneous and nonvascular lesions. *Semin Cutan Med Surg* 19:276–286
80. Mason KP, Neufeld EJ, Karian VE et al. (2001) Coagulation abnormalities in pediatric and adult patients after sclerotherapy or embolization of vascular anomalies. *Radiology* 217:1359–1363
81. Hammer FD, Boon LM, Mathurin P et al. (2001) Ethanol Sclerotherapy of venous malformations: evaluation of systemic ethanol contamination. *J Vasc Interv Radiol* 12:595–600

2 Predominantly Venous Malformation

JOSÉE DUBOIS

CONTENTS

2.1	Introduction	21
2.2	Genetics	21
2.3	Clinical Features	21
2.4	Focal and Diffuse Venous Malformations	22
2.5	Associated Syndromes	22
2.5.1	Blue Rubber Bleb Nevus Syndrome	22
2.5.2	Mucocutaneous Familial Venous Malformations	22
2.5.3	Glomovenous Malformations	22
2.5.4	Maffucci's Syndrome	22
2.6	Coagulopathies	22
2.7	Histopathology	22
2.8	Imaging	23
2.8.1	Plain Radiograph	23
2.8.2	Doppler Ultrasound	23
2.8.3	Computed Tomography	24
2.8.4	Magnetic Resonance Imaging	24
2.8.5	Arteriography	24
2.8.6	Direct Percutaneous Venography	25
2.8.7	Peripheral Venography	25
2.9	Management	26
2.9.1	Medical Treatment	26
2.9.2	Sclerotherapy	26
2.9.2.1	Technique	27
2.9.2.2	Sclerosing Agents	28
2.9.3	Laser	29
2.9.4	Surgery	29
2.9.5	Pharmacologic Treatment	29
2.10	Intensive Care Unit Management	29
2.11	Follow-up	31
2.12	Outcome	31
	References	31

2.1

Introduction

Vascular anomalies are divided into vascular tumours and vascular malformations. Vascular malformation classification is based on the anomalous channels: arterial, venous, lymphatic, or capillary. The most frequent vascular anomalies are venous malformations. The incidence is estimated to be around 1 in 10,000 [1]. The reader must be made aware of the numerous confusing misnomers such as glomangioma, cavernous haemangioma, and haemangioma that have also been used in prior literature.

2.2

Genetics

Venous malformations are sporadic in most cases but can be inherited. A locus for autosomal-dominant multiple cutaneous and mucosal venous malformations, VMCM1, was identified on chromosome 9p21 [2–4]. A mutation was found in the endothelial cell-specific receptor tyrosine kinase TIE-2 [5]. This mutation is likely to occur in vascular malformations.

2.3

Clinical Features

Generally, venous malformations are noted at birth but can also appear during infancy. They involve any tissue or organ in all anatomic locations. Venous malformations grow with the patient. Exacerbations can occur during puberty or pregnancy. Indeed, hormonal modulations of venous malformations can be seen during the menstrual cycle or under anovulant therapy. Surgery or trauma can also lead to the progression of venous

J. DUBOIS, MD

Professor of Radiology, Pediatric and Interventional Radiologist, Department of Medical Imaging, Hôpital Ste-Justine, 3175 Côte Ste-Catherine Road, Montreal, Quebec H3T 1C5, Canada

malformations. At clinical exam, venous malformations appear as soft tissue lesions that are compressible, and increase with Valsalva manoeuvre or gravity. The overlying skin can be normal, bluish, or purple in colour. The lesion is cold and not pulsatile. Bleeding is uncommon. Hematologic evaluation is important and must include complete blood count, fibrinogen, and d-dimer dosage. Localized intravascular consumption can be observed, especially in extensive venous malformations [6]. Coagulopathy can be exacerbated by sclerotherapy or surgery [7–9]. Extensive facial venous malformations are frequently associated with intracranial developmental venous anomalies [10].

2.4 Focal and Diffuse Venous Malformations

Venous malformations are either focal or diffuse, and may involve the skin, the mucosae, the muscles, the bones. In cases of extensive venous malformations, associated distal sites of involvement are likely.

2.5 Associated Syndromes

2.5.1 Blue Rubber Bleb Nevus Syndrome

Blue rubber bleb nevus syndrome, a rare disorder, is characterized by continuous development of multiple focal venous malformations of the skin, musculoskeletal tissue, and mucosa throughout the body, including the gastrointestinal tract. These venous malformations can be treated by sclerotherapy or surgery. In some cases of blue rubber bleb nevus, it has been shown that the mutation may occur on chromosome 9p.

2.5.2 Mucocutaneous Familial Venous Malformations

The characteristics of mucocutaneous familial venous malformations are the same as those of the blue rubber bleb nevus syndrome except for the lack of gastrointestinal involvement.

2.5.3 Glomovenous Malformations

Glomovenous malformations are venous malformations associated with glomus cells. The smooth layer is formed by glomus cells, which are smooth muscle precursor cells [11]. Glomovenous malformations frequently recur. Sclerotherapy can be useful for their treatment.

2.5.4 Maffucci's Syndrome

Maffucci's syndrome consists in the association of venous malformations and multiple enchondromas. Intraosseous venous malformations as well as enchondromas are responsible for the bony defects [12].

2.6 Coagulopathies

Localized intravascular coagulopathy is reported in venous malformations. Most patients with venous malformations have no clinical signs or symptoms at presentation. A chronic form of consumptive coagulopathy is however possible as shown by positive d-dimer levels, and normal or low platelets and fibrinogen values. Consumptive coagulopathy must be corrected prior to initiating the treatment of vascular malformations. Low-molecular-weight heparin and elastic stockings are recommended [8]. Administration of cryoprecipitate, platelets, or fresh frozen plasma to patients with chronic coagulopathy has proved to be helpful before performing sclerotherapy or embolization in order to obtain a successful thrombolysis [9].

2.7 Histopathology

Venous malformations are due to the abnormal development of the vein wall. Microscopy shows multiple thin-walled vessels with flattened endothelial cells, lacking proliferative features [1] (quiescent endothelium), and wall smooth muscle deficiency. The deficient smooth muscle layer leads to the inability of the affected veins to constrict normally,

inducing stagnation of blood, thrombosis, thrombolysis, swelling, and pain [13]. Venous malformations do not exhibit up-regulation of angiogenic factors or matrix enzymes [14].

2.8 Imaging

2.8.1 Plain Radiograph

Plain radiographs can show phleboliths (Fig. 2.1) that are suggestive of venous malformation but rarely present. Soft tissue swelling and bone deformity can be seen.

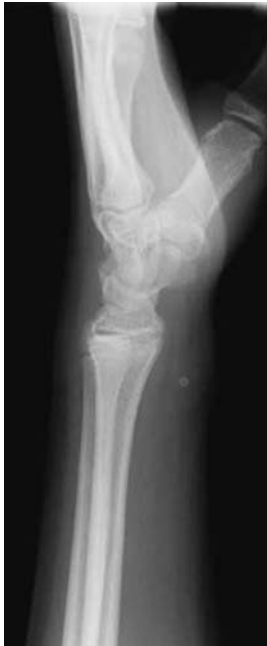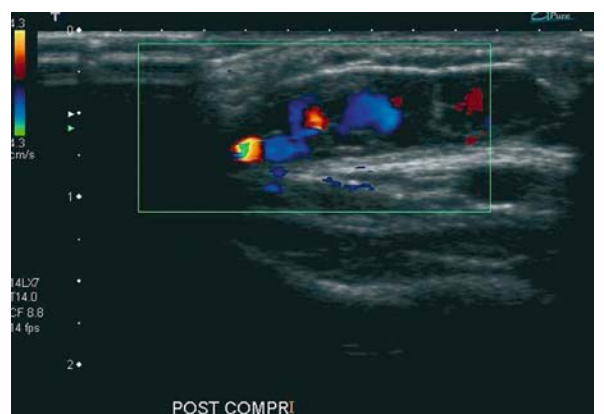
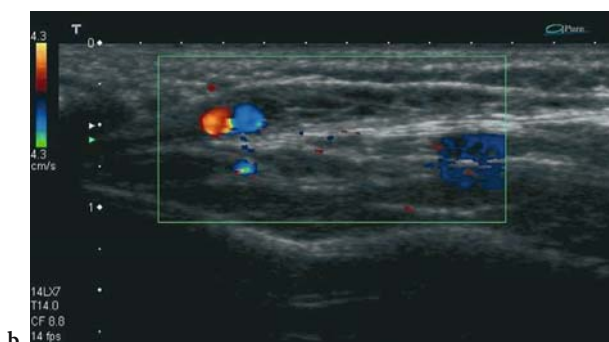
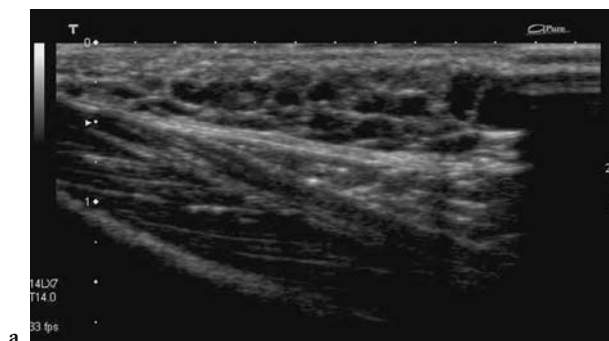


Fig. 2.1. Sixteen-year-old male. Lateral X-ray of the left wrist shows a ventral soft tissue mass associated with typical phlebolith in a case of venous malformation

2.8.2 Doppler Ultrasound

Doppler ultrasound is the initial modality of choice to differentiate venous malformations from other vascular abnormalities. Ultrasound is performed with a high-frequency linear array transducer (5–12 MHz). On grey-scale images, venous malformations appear as compressible hypoechoic or heterogeneous lesions [15, 16] (Fig. 2.2a–c). Calcifications (demonstrated in less than 20% of cases), are quite specific of venous malformation; anechoic channels can be seen. Doppler examination displays a monophasic low-velocity flow (Fig. 2.3). In 20% of venous malformations, no flow can be demonstrated. Dynamic manoeuvres such as Valsalva or manual compression are sometimes necessary to induce a visible Doppler flow.

Fig. 2.2a–c. Six-year-old boy with a stable soft tissue mass of the right temporal region. **a** US shows an heterogeneous hypoechoic well-delimited superficial lesion containing anechoic structures. **b** The same lesion is compressible and seems not vascularized. **c** Low velocity flow is detected when the compression is released (venous malformation)



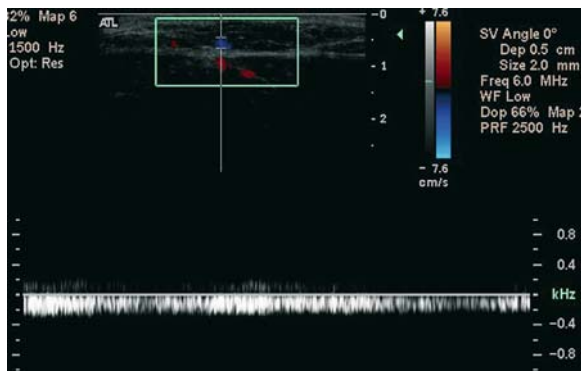


Fig. 2.3. Doppler US in another patient with a superficial venous malformation shows typical venous flow on pulsed Doppler

2.8.3

Computed Tomography

Computed tomography (CT) demonstrates the extension of venous malformations but the contrast resolution is less than with MRI. The lesion is hypodense or heterogeneous with a slow contrast enhancement after injection of contrast material (Fig. 2.4a,b). Phleboliths, when present, are easily seen.

2.8.4

Magnetic Resonance Imaging

Magnetic resonance imaging (MRI) is the best modality to evaluate the extension of vascular malformations. The MRI protocol includes spin-echo

or fast spin-echo T1-weighted sequences and T2-weighted sequences with fat suppression (Fig. 2.5a–d). T2-weighted gradient-echo sequences can be useful to demonstrate calcification or hemosiderin. On gradient-echo sequences, the absence of intravascular signal suggests a slow-flow malformation [17]. T1-weighted sequences with fat suppression and gadolinium injection have to be performed to evaluate the perfusion of the malformation. 3D-FISP (Fast Imaging with Steady Precision) phlebographic sequence allows the evaluation of draining veins [18]. On T1-weighted sequence, venous malformations are hypo- or isointense. The signal is heterogeneous when haemorrhage or thrombosis is present. On T2-weighted sequence, the venous malformation is hyperintense. Areas of hypointensity are related to thrombosis, phleboliths, or septa, most evident on gradient images. Small fluid-fluid levels can be seen. After sclerotherapy, the lesion becomes heterogeneous on both T1- and T2-weighted sequences. Postgadolinium sequences are useful to evaluate the residual perfusion. MRI is very helpful for the delimitation and assessment of the extension, but is not specific of venous malformations. MRI results have to be correlated with clinical findings and Doppler examination to reinforce the diagnosis.

2.8.5

Arteriography

Arteriography of the affected limb is not clinically useful, showing either no anomalies or the late opacifi-

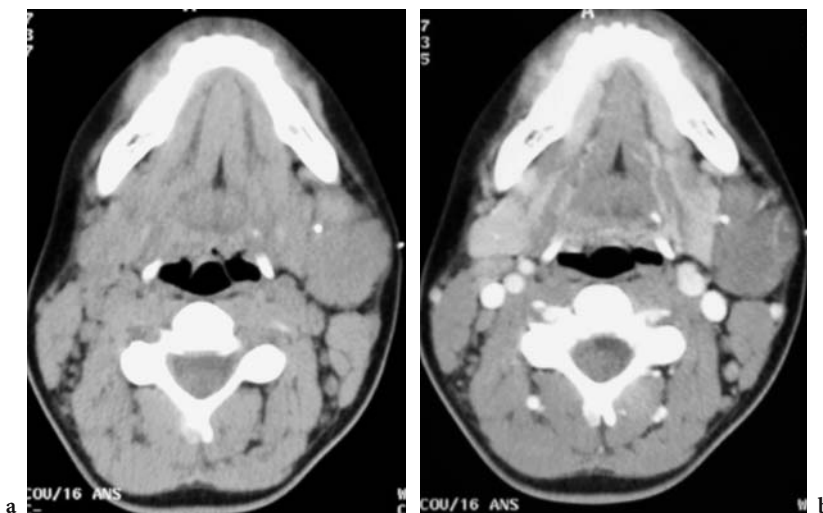


Fig. 2.4. a Axial unenhanced cervical CT of a 16-year-old female shows a slightly hypodense mass containing a calcified phlebolith in the left parotid region. b After contrast injection, the venous malformation slightly enhances, remains hypodense and is better delineated

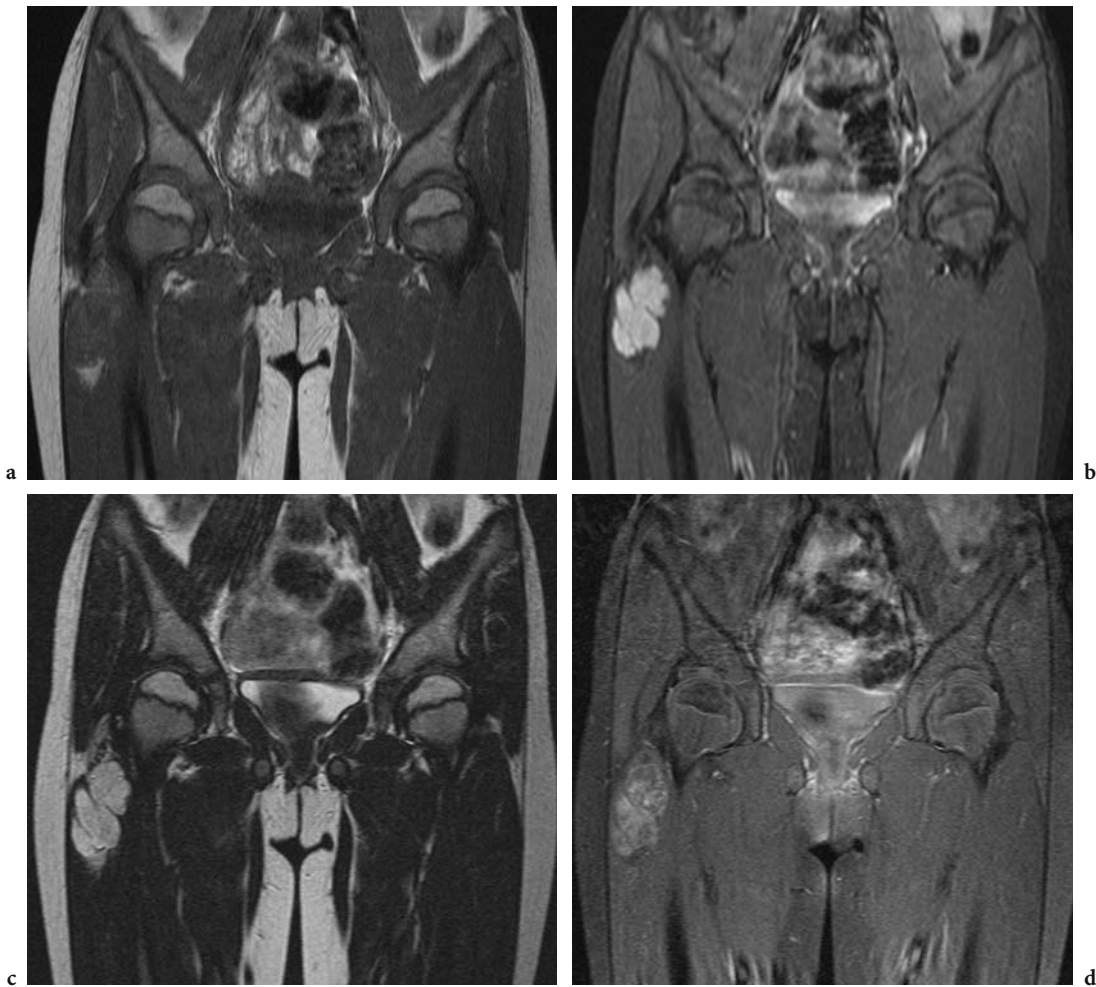


Fig. 2.5. **a** Coronal T1-weighted MRI shows a slightly hyperintense mass in the right quadriceps. **b** In short time inversion recovery (STIR) sequence, the well-delineated mass is hyperintense. **c** In T2-weighted image, the lesion remains hyperintense to the muscle. **d** Coronal T1-weighted scan after gadolinium injection and fat saturation shows slight and heterogeneous enhancement

cation of venous spaces with or without dysplastic channels. However, angiography is sometimes performed to rule out the presence of an arterial microfistula.

2.8.6

Direct Percutaneous Venography

Direct percutaneous phlebography is useful in some atypical venous malformations to allow a precise diagnosis and mapping of the malformation. Under ultrasonography, direct puncture of the malformation is performed with a 20- or 21-gauge needle. The needle is connected to a syringe through an extension tubing and is progressively withdrawn while applying slight suction. Once blood return is

obtained, the opacification with a low osmolarity iodinated contrast is recorded, as a phlebogram. Three different patterns can be seen: a cavitary pattern with late filling of normal draining veins (Fig. 2.6), a spongy appearance with tiny cavities and late venous drainage (Fig. 2.7), and the dysmorphic veins pattern (Fig. 2.8).

2.8.7

Peripheral Venography

This technique is useful in the presence of complex venous malformations to evaluate the communication between the dysmorphic veins and the normal venous system.

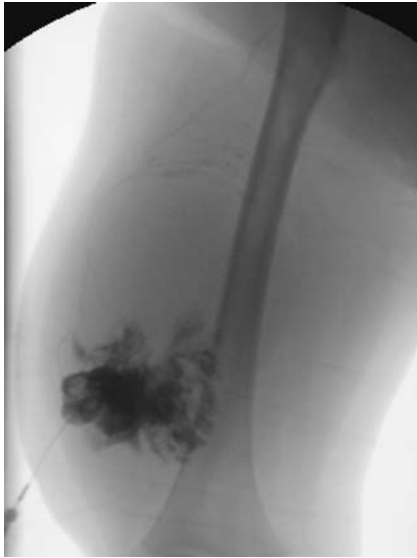

Fig. 2.6. Percutaneous Venography opacifies large cavities with late filling of normal draining veins

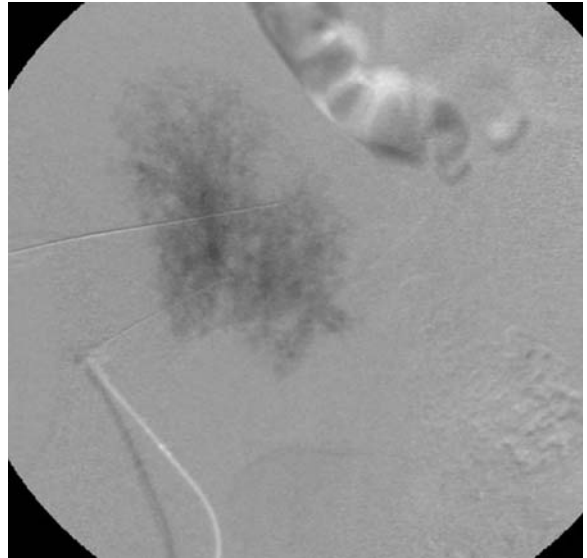

Fig. 2.7. Percutaneous phlebography of a large spongy venous malformation of the right iliac fossa

2.9 Management

A multidisciplinary approach is essential to plan a treatment strategy specific to each patient. The modalities of treatment depend on: the localization, the size, the extension, the functional repercussion, and the aesthetic impact of the venous malformation. The goal is to lessen the symptoms and improve the functional consequences. The management of venous malformations includes compression, resection, and obliteration of the channels lumen by sclerosing injection or laser photocoagulation.

2.9.1 Medical Treatment

Asymptomatic venous malformations should be treated conservatively. Counselling regarding the hazards of puberty, oral contraceptive medication, and pregnancy has to be provided. Extensive arm or leg venous malformations should be treated with elastic stockings. Anti-inflammatory drugs are helpful during the symptomatic thrombosis-related episodes. Cyclooxygenase-2 (COX-2) inhibitors (such as Celebrex) have also proved to be effective against pain. Low-molecular-weight heparin may also be used to decrease the disseminated intravascular consumption and is recommended in the preoperative preparation prior to resection. Corticosteroids,

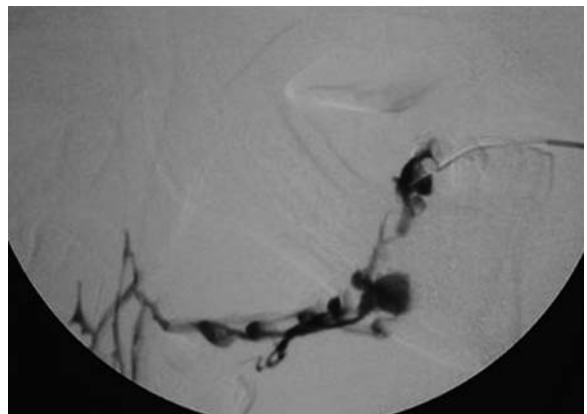


Fig. 2.8. Percutaneous phlebography of dysmorphic veins in a case of facial venous malformation

interferon, and other antiangiogenic drugs have proven useless in the treatment of venous malformations.

2.9.2 Sclerotherapy

Sclerotherapy, with or without surgery, is the treatment of choice for symptomatic venous malformations. Sclerosants destroy the vascular endothelium through different mechanisms depending on the agents: chemical agents (iodine or absolute alcohol);

osmotic effect (salicylates or hypertonic saline); detergents (morrhuate sodium, sotradecol, polidocanol, and diatrizoate sodium) [13] (Fig. 2.9a–d).

2.9.2.1

Technique

Sclerotherapy is performed under fluoroscopic control. The puncture with a 24 or 22 Cathlon or 20-gauge Teflon intravenous cannula or other needle system can be done under ultrasound, CT, or MRI guidance. It is necessary to venographically assess the draining veins before injecting sclerosing agents

in order to prevent complications. Indeed, an appropriate opacification is essential to evaluate the pattern of the lesion, its volume, and the draining veins. The amount of agent injected is estimated by the initial amount of contrast medium needed to opacify the lesion before the visualization of the draining veins. Additional sclerosant can be needed in order to obtain a firm lesion on palpation or to dry up the blood return on aspiration of the cannula. A tourniquet can be useful. An automated orthopaedic tourniquet inflated to a pressure below systolic arterial pressure, provides the most effective method of control [13]. The cuff pressure can be adjusted with test injections of contrast medium until the drain-

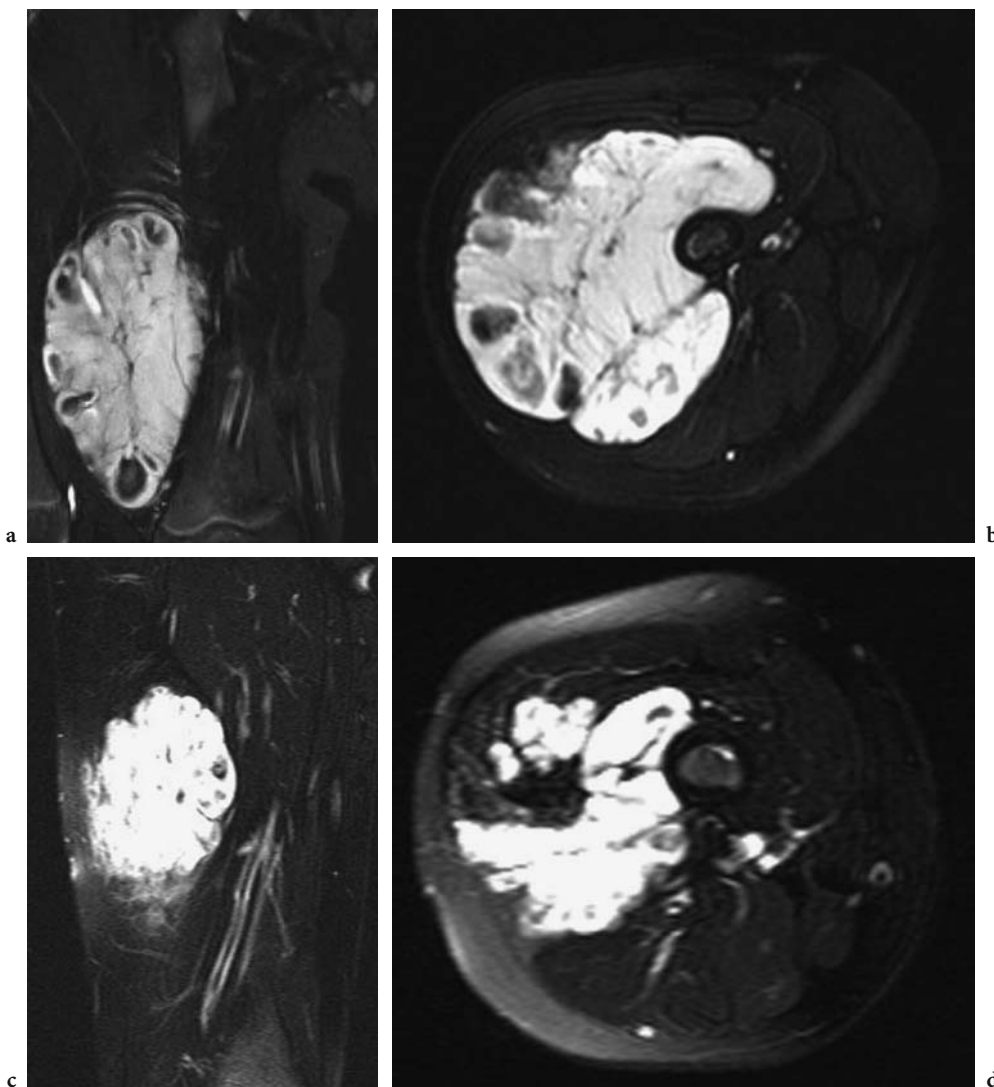


Fig. 2.9a-d. Four-year-old boy with venous malformation of the thigh. **a** Coronal and **b** axial T2SE MRI show a well delimited intramuscular venous malformation. Six months after three sessions of sclerosing treatment with alcohol **c** coronal and **d** axial T2SE show an important regression

ing veins no longer fill. After injection of moderate amounts of absolute ethanol into sequestered venous malformations of the limb, the tourniquet is kept inflated for 20–30 min, to minimize the risk of egress of ethanol or clot into the draining veins. It is wise to release the tourniquet slowly [13]. The tourniquet use is controversy. Some groups prefer to use a manual compression with a gradual decompression to avoid pulmonary emboli.

2.9.2.2

Sclerosing Agents

Ethanol (95%–98%)

Absolute ethanol is the most frequently used agent, and is also the most potent and destructive on the vascular endothelium. Ethanol causes an instant precipitation of endothelial cells proteins and rapid thrombosis. **Injection:** An undiluted form of ethanol, or opacified ethanol with oily contrast medium (9:1 or 10:2), or opacified ethanol with metrizamide power under fluoroscopy monitoring [19]. **Dose:** The total dose of 1ml/kg (or 60 cc) per session should never be exceeded [13]. Ethanol blood levels correlate directly with the amount of ethanol injected. **Complications:** Ethanol is the most effective sclerosant available but it also results in the most serious side effects. The most common complication of ethanol is local tissue injury, such as skin necrosis (in 10%–15% of cases) [13] or peripheral nerve damage (in approximately 1% of cases) [13, 17, 20, 21]. Most complications are transient, but permanent injury has been reported [20, 22, 23]. Complications rate for ethanol embolization ranges from 7.5% to 23%. Severe complications have been reported (cardiac arrest, pulmonary embolus) [23, 24]. YAKES et al. [23] reported four cases of cardiopulmonary collapse in out of over 50,000 embolizations or sclerotherapy procedures. The mechanism remains unknown and may include pulmonary vasospasm, pulmonary embolism and direct cardiotoxicity. Central nervous system depression, hypoglycemia, hypertension, hyperthermia, haemolysis, pulmonary embolism, pulmonary vasospasm, cardiac arrhythmias, and electromechanical dissociation [9, 13, 17, 21] have been reported in the literature [23, 25, 26]. Continuous cardiovascular monitoring during the procedure is paramount. When large malformations are being treated, some have advocated that such procedures be performed under general anaesthesia. Some authors also recommend the use of

continuous pulmonary artery pressure monitoring during the procedures [23, 26].

Detergent-Type Sclerosants

The detergent-type of sclerosants includes: aetoxisclerol (polidocanol 1%–3%, sodium tetradecyl sulfate (STS), sodium morrhuate, and ethanolamine. These detergents can be used in liquid or foam.

Aetoxisclerol (Polidocanol) (3%)

This agent is used for the small venous malformations. Polidocanol is effective by altering the vascular wall. The emulsion of aetoxisclerol would allow for the visualization of the draining veins, thanks to the bubbles; accordingly, this emulsion could direct the compression to the involved veins, sparing then the normal adjacent veins. **Injection:** Some authors used it mixed with a lidocaine solution to minimize pain after injection. **Dose:** The quantity is 1cc per cavity [25] up to a total of 6 cc of polidocanol with 0,2–1,0 cc of 1% lidocaine solution. **Complications:** Skin necrosis, sciatic neurolysis, and infections were reported in 6–8% of cases [25, 27]. One cardiac arrest was also reported [28].

Sodium Tetradecyl Sulfate

(Sotradecol – Elkins-Sinn, Cherry Hill, New Jersey)

Sodium tetradecyl sulfate damages the endothelium resulting in thrombosis and fibrosis. This agent can be used in a liquid solution or by creating foam with air. The main difference between liquid solution and foam is the long life of the foam in the vein and by the clear separation obtained between the blood and the sclerosant [29]. **Injection:** We mix 5 cc of sotradecol with 2 cc of Lipiodol and 5–10 cc of air. TESSARI described a stable and compact foam quality using two plastic syringes and a three-way stopcock, mixing ratio for sclerosant to air is 1:4 to 1:5 [30–32]. The foam is obtained by mixing the agents (STS or polidocanol: air) through multiple passages between two syringes. **Dose:** The maximum dose is not well established. **Complications:** Skin necrosis was reported by O'DONOVAN [33] in three out of 15 patients.

Ethanolamine Oleate

Ethanolamine oleate is a mixture of 5% ethanolamine oleate (Keuk Dong, Inchon, Korea) and iodized oil (Lipiodol) (ratio 5:1–5:2); the amount

used ranges from 2 to 20 ml within 1 to 10 sessions. This salt of an unsaturated fatty acid has been used as a sclerosing agent because it has excellent thrombosing properties [34]. Approximately 50% of oleic acid combines with serum proteins within 30 minutes [21]. This can cause renal toxicity in association with a marked intravascular haemolysis and hemoglobinuria and hepatotoxicity [34]. To prevent these complications, haptoglobin can be administered intravenously during and after the injection of the sclerosant into the lesion [35]. Effective in 92% (23 out of 25) of cases, KONEZ et al. [36] reported the conjoint use of coils embolization as well as inflated balloons within the internal jugular vein in cases of cervicofacial venous malformations in order to prevent the systemic passage of the sclerosant. Trismus in two patients, abated completely within 1 week.

Ethibloc (Ethicon, Hamburg)

Ethibloc is not available in the United States. Ethibloc is a mixture of zein (corn protein), alcohol, and contrast medium. The sclerosing effect is due to the giant cell inflammatory reaction. **Injection:** The product is available in a preloaded syringe. **Complications:** No significant lasting complication, except for the extrusion of the agent in 10% of cases [25]. DUBOIS et al. [37] reported 74% of good or excellent results in 28 out of 38 patients.

Histoacryl

Histoacryl is a biological product that undergoes polymerization on contact with an ionic substance, inducing then a permanent occlusion. Mostly used as a pre-surgical step, it was reported for the treatment of venous malformations of the orbit [38]. Delay in healing up may be due to the extrusion of the Histoacryl when left in place.

Coils

In the presence of rapid venous drainage or massive venous spaces, placement of coils can be useful to retain sclerosing agent and avoid pulmonary embolus, particularly in a venous malformations close to normal veins. Coils can be delivered directly through the access needle into the venous spaces or via the femoral or jugular vein (Fig. 2.10a–e). For limb superficial venous malformations, a peripheral intravenous catheter can be useful to perform a phlebography during sclerotherapy for assess-

ing the ischemic changes. Applying cold sterile saline onto the surface of the skin to induce local vasoconstriction seems to reduce the risk of skin damage [13].

2.9.3

Laser

Effective intralesional laser therapy was reported by DERBY and LOW [39] in cases of facial venous malformations. Pulse dye laser operation has been found to be most successful in removing hundred of lesions in cases of blue rubber bleb nevus syndrome, without recurrence [40].

2.9.4

Surgery

In the majority of cases, successful sclerosing treatment will obviate the need for surgery [41]. Surgery alone is only effective in well-defined and easily accessible lesions of moderate size in which the anatomy will allow for a maximal functional restoration. Serious complications such as bleeding and nerve injury can occur with surgery.

2.9.5

Pharmacologic Treatment

Corticosteroids, interferon, other antiangiogenic drugs are useless in cases of venous malformations.

2.10

Intensive Care Unit Management

Airway obstruction in the case of neck lesions, and compartment syndrome in extremities lesions should be carefully observed and managed accordingly (tracheostomy, fasciotomy). Systemic corticosteroid (dexamethasone 0.1 mg/kg intravenously every 8 h), and ice packs can be helpful to minimize the swelling. Gross hemoglobinuria can occasionally occur and is managed by hydration and urine alkalization (95% dextrose and water mixed with 75 mEq/L of sodium bicarbonate), administered at twice the maintenance rate. Urine is monitored visually and usually clears within 6 h.

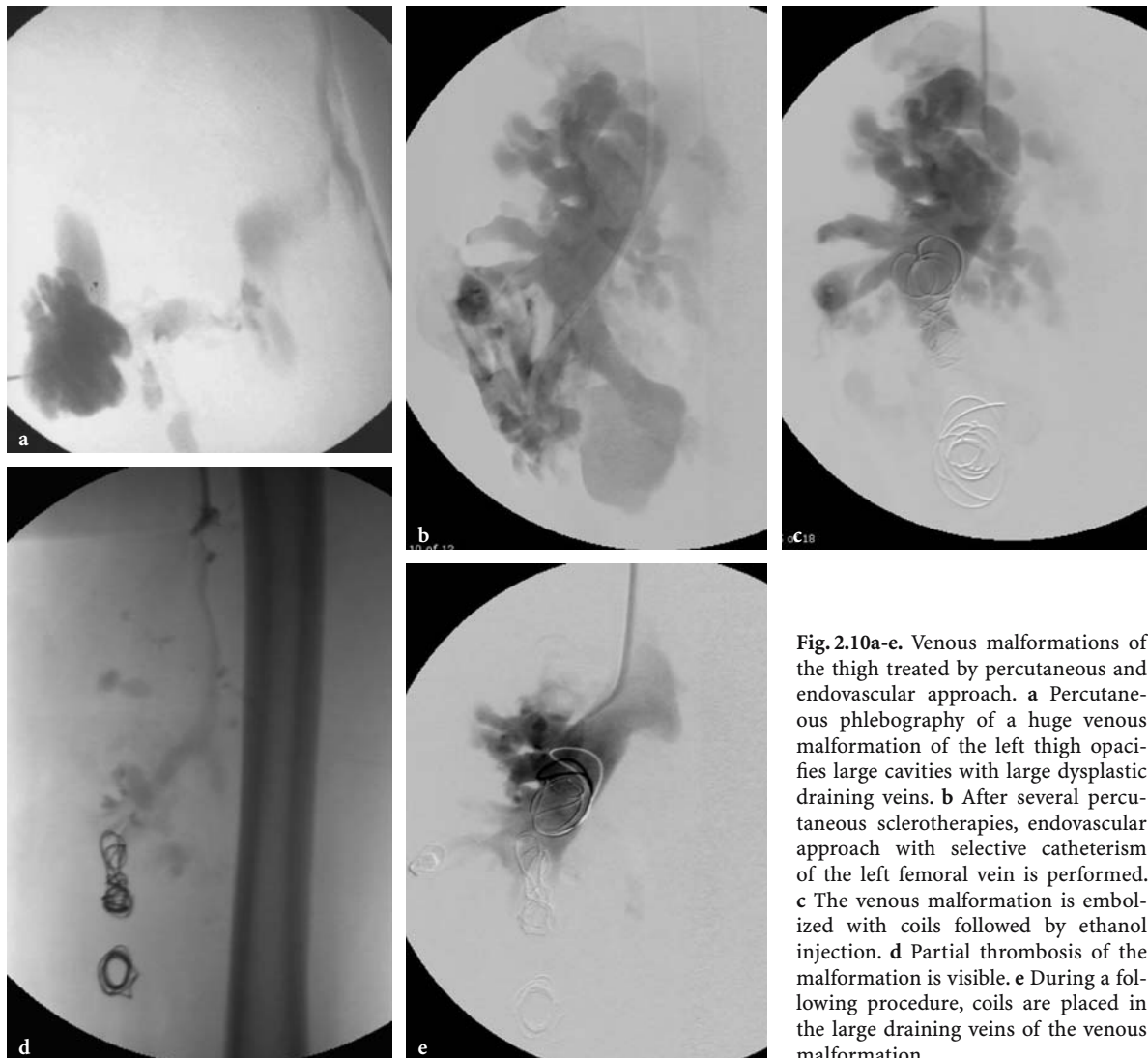


Fig. 2.10a-e. Venous malformations of the thigh treated by percutaneous and endovascular approach. **a** Percutaneous phlebography of a huge venous malformation of the left thigh opacifies large cavities with large dysplastic draining veins. **b** After several percutaneous sclerotherapies, endovascular approach with selective catheterism of the left femoral vein is performed. **c** The venous malformation is embolized with coils followed by ethanol injection. **d** Partial thrombosis of the malformation is visible. **e** During a following procedure, coils are placed in the large draining veins of the venous malformation

Table 2.1. Materials for sclerotherapy

- Puncture needles
- Butterfly needle: 25G or
- Jelco 20G, 22G, 24G
- Sclerosing agents

Agents	How to use (opacification)	Dose
Ethanol	7 cc ethanol with metrizamide powder (3.75 g) or With nonionic contrast medium	Max: 1 cc/kg
3% Sodium Tetradecyl Sulfate (Sotradecol)	With metrizamide powder or Diluted contrast medium	Max:30 cc/session
Foam = (Fig. 2.11)	Mix: • 5 cc Sotradecol • 2 cc Lipiodol • 5–10 cc air	Maximum: not well established Our recommendation 20 cc/session
Ethibloc (Fig. 2.12)	Syringe: 7.5 cc Diluted with 2 cc ethanol	Max: 14 cc/session Intramuscular: max 7.5 cc

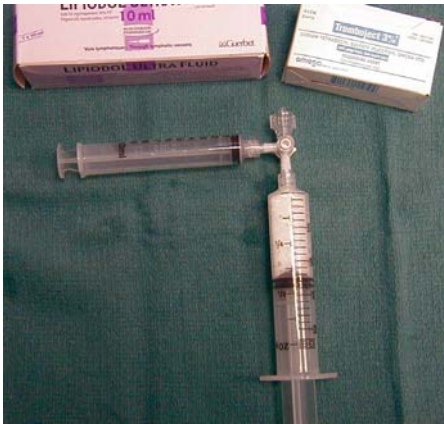

Fig. 2.11. Foam

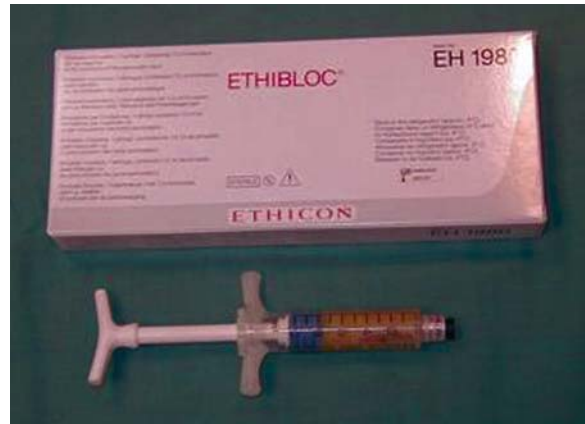

Fig. 2.12. Ethibloc

2.11 Follow-up

In case of skin necrosis, weekly surveillance is recommended, to exclude superimposed infection. When necessary, the referral to a specialized wound centre is mandatory for possible debridement and/or skin grafting. In the absence of complications, a 6-week post-procedure follow-up is indicated to evaluate the need for other sessions.

2.12 Outcome

The reported outcome of endovascular treatment of venous malformation has been extremely variable from one series to another. No series has been reported based upon strict MRI documentation and sufficient follow-up. No predictors of success have been clearly outlined. Overall, it appears that favourable results may depend on the extension of the venous malformations and the number of sclerotherapy sessions. Recurrence due to recanalization of treated venous malformations is more likely in cases of diffuse involvement with associated coagulopathy [13].

References

- Vikkula M, Boon LM, Mulliken JB (2001) Molecular genetics of vascular malformations. *Matrix Biol* 20:327–335
- Boon LM, Mulliken JB, Vikkula M et al. (1994) Assignment of a locus for dominantly inherited venous malformations to chromosome 9p. *Hum Mol Genet* 3:1583–1587
- Brouillard P, Vikkula M (2003) Vascular malformations: localized defects in vascular morphogenesis. *Clin Genet* 63:340–351
- Gallione CJ, Pasyk KA, Boon LM et al. (1995) A gene for familial venous malformations maps to chromosome 9p in a second large kindred. *J Med Genet* 32:197–199
- Vikkula M, Boon LM, Carraway KL 3rd et al. (1996) Vascular dysmorphogenesis caused by an activating mutation in the receptor tyrosine kinase TIE2. *Cell* 87:1181–1190
- Mazoyer E, Enjolras O, Laurian C et al. (2002) Coagulation abnormalities associated with extensive venous malformations of the limbs: differentiation from Kasabach-Merritt syndrome. *Clin Lab Haematol* 24:243–251
- Aronoff DM, Roshon M (1998) Severe haemorrhage complicating the Klippel-Trenaunay-Weber syndrome. *South Med J* 91:1073–1075
- Enjolras O, Ciabrini D, Mazoyer E et al. (1997) Extensive pure venous malformations in the upper or lower limbs: a review of 27 cases. *J Am Acad Dermatol* 36:219–225
- Mason KP, Neufeld EJ, Karian VE et al. (2001) Coagulation abnormalities in pediatric and adult patients after sclerotherapy or embolization of vascular anomalies. *AJR Am J Roentgen* 177:1359–1363
- Boukobza M, Enjolras O, Guichard JP et al. (1996) Cerebral developmental venous anomalies associated with head and neck venous malformations. *AJNR Am J Neuroradiol* 17:987–944
- Brouillard P, Boon LM, Mulliken JB et al. (2002) Mutations in a novel factor, glomulin, are responsible for glomuvenous malformations (“glomangiomas”). *Am J Hum Genet* 70:866–874
- Mulliken JB, Fishman SJ, Burrows PE (2000) Vascular anomalies. *Curr Probl Surg* 37:517–584
- Burrows PE, Mason KP (2004) Percutaneous treatment of low flow vascular malformations. *J Vasc Interv Radiol* 15:431–445
- Takahashi K, Mulliken JB, Kozakewich HP et al. (1994) Cellular markers that distinguish the phases of hemangioma during infancy and childhood. *J Clin Invest* 93:2357–2364
- Paltiel HJ, Burrows PE, Kozakewich HP et al. (2000) Soft-tissue vascular anomalies: utility of US for diagnosis. *Radiology* 214:747–754
- Trop I, Dubois J, Guibaud L et al. (1999) Soft-tissue venous

- malformations in pediatric and young adult patients: diagnosis with Doppler US. *Radiology* 212:841–845
17. Siegel MJ (2001) Magnetic resonance of musculoskeletal soft tissue masses. *Radiol Clin North Am* 39:701–720
 18. Li W, David V, Kaplan R et al. (1998) Three-dimensional low dose gadolinium-enhanced peripheral MR venography. *J Magn Reson Imaging* 8:630–633
 19. Suh JS, Shin KH, Na JB et al. (1997) Venous malformations: sclerotherapy with a mixture of ethanol and lipiodol. *Cardiovasc Intervent Radiol* 20:268–273
 20. Lee BB, Kim DI, Huh S et al. (2001) New experiences with absolute ethanol sclerotherapy in the management of a complex form of congenital venous malformation. *J Vasc Surg* 33:764–772
 21. Sukigara M, Omoto R, Miyamae T (1985) Systemic dissemination of ethanolamine oleate after injection sclerotherapy for esophageal varices. *Arch Surg* 120:833–836
 22. Rautio R, Saarinen J, Laranne J et al. (2004) Endovascular treatment of venous malformations in extremities: results of sclerotherapy and the quality of life after treatment. *Acta Radiol* 45:397–403
 23. Yakes WF, Engelwood CO, Baker R (1993) Cardiopulmonary collapse: sequelae of ethanol embolotherapy. *Radiology* 189:145
 24. Hanafi M, Orliaguet G, Meyer P et al. (2001) Embolie pulmonaire au cours de la sclerotherapie percutanee d'un angiome veineux sous anesthesie generale chez un enfant. *Ann Fr Anesth Reanim* 20:556–558
 25. Blum L, Gallas S, Cottier JP et al. (2004) Sclerose percutanee des malformations veineuses superficielles: etude retrospective de 68 cas. *J Radiol* 85:107–116
 26. Hammer FD, Boon LM, Mathurin P et al. (2001) Ethanol sclerotherapy of venous malformations: evaluation of systemic ethanol contamination. *J Vasc Interv Radiol* 12:595–60027.
 27. Cabrera J, Cabrera J Jr, Garcia-Olmedo A et al. (2003) Treatment of venous malformations with sclerosant in micro-foam form. *Arch Dermatol* 139:1409–1416
 28. Marrocco-Trischitta MM, Guerrini P, Abeni D et al. (2002) Reversible cardiac arrest after polidocanol sclerotherapy of peripheral venous malformation. *Dermatol Surg* 28:153–155
 29. Frullini A (2002) Sclerosing foam in the treatment of recurrent varicose veins. In: Henriot JP (ed) *Foam sclerotherapy state of the art*. Editions Phlebologiques Francaises, Paris, pp 73–78
 30. Tessari L (2000) Nouvelle technique d'obtention de la sclero-mousse. *Phlébographie* 53:129
 31. Tessari L, Cavezzi A, Frullini A (2001) Preliminary experience with a new sclerosing foam in the treatment of varicose veins. *Dermatol Surg* 27:58–60
 32. Rabe E, Pannier-Fischer F, Gerlach H et al. (2004) Guidelines for sclerotherapy of varicose veins (ICD 10: I83.0, I83.1, I83.2, and I83.9). *Dermatol Surg* 30:687–693
 33. O'Donovan JC, Donaldson JS, Morello FP et al. (1997) Symptomatic hemangiomas and venous malformations in infants, children, and young adults: treatment with percutaneous injection of sodium tetradecyl sulfate. *AJR Am J Roentgenol* 169:723–729
 34. Choi YH, Han MH, O-Ki K et al. (2002) Craniofacial cavernous venous malformations: percutaneous sclerotherapy with use of ethanolamine oleate. *J Vasc Interv Radiol* 13:475–482
 35. Hashizume M, Kitano S, Yamaga H et al. (1988) Haptoglobin to protect against renal damage from ethanolamine oleate sclerosant. *Lancet* 2:340–341
 36. Konez O, Burrows PE, Mulliken JB (2002) Cervical venous malformations: MRI features and interventional strategies. *Interventional Neuroradiology* 8:227–234
 37. Dubois J, Sebag GH, De Prost Y et al. (1991) The treatment of soft tissue venous malformation in children: percutaneous sclerotherapy with Ethibloc. *Radiology* 180:195–198
 38. Gobin JP (2001) The sclerotherapy position in recurrent varicose veins treatment. *Int Angiol* 20(2 Suppl 1):336
 39. Derby LD, Low DW (1997) Laser treatment of facial venous vascular malformations. *Ann Plast Surg* 38:371–378
 40. Olsen TG, Milroy SK, Goldman L et al. (1979). Laser surgery for blue rubber bleb nevus. *Arch Dermatol* 115:81–82
 41. Hein KD, Mulliken JB, Kozakewich HP et al. (2002) Venous malformations of skeletal muscle. *Plast Reconstr Surg* 110:1625–1635

Trauma and Iatrogenic Lesions

3 Recognition and Treatment of Medical Emergencies in the Trauma Patient

LUCY WIBBENMEYER and MELHEM J. SHARAFUDDIN

CONTENTS

3.1	Introduction	35
3.2	Airway Compromise	35
3.2.1	Recognition	35
3.2.2	Treatment Adjuncts	36
3.2.3	Definitive Control	37
3.3	Circulatory Shock	38
3.3.1	Recognition	38
3.3.2	Resuscitation	39
3.3.3	Pitfalls of Resuscitation	40
	Cookbook: Recognition and Treatment of Medical Emergencies in the Trauma Patient	40
	References	41

3.1 Introduction

The role of interventional radiology (IR) is expanding in the care of the acutely injured polytrauma patient. The interventional radiologist is often asked to perform therapeutic embolization of active bleeding from intraabdominal solid organ injuries and pelvic arterial injuries to provide initial control [1–3]. These patients are often accompanied by a traumatologist while in the interventional suite. They are often ventilated and actively receiving blood products. When these patients are critically ill and potentially unstable, the interventionist can delegate their critical care to the traumatologist. However, the challenge to the interventionist occurs in the setting of the “presumed stable” trauma patient with compensated shock. The intervention-

ist may occasionally be the only physician available to provide timely recognition and prompt, systematic treatment of life-threatening emergencies. Adequate treatment of these emergencies is essential for optimizing the care of the trauma patient. This chapter will discuss recognition and treatment of two common life-threatening emergencies that the interventional radiologist may be the first physician to encounter in the trauma patient. Definitive treatment will be presented for completeness and further study.

3.2 Airway Compromise

3.2.1 Recognition

The airway of an acutely unstable patient should be addressed first. The American College of Surgeons addresses the airway as the initial step of the primary survey in the Advance Trauma Life Support Protocol for evaluation of trauma patients (Table 3.1) [4]. The primary survey addresses all life-threatening injuries in an expedient manner by systematic review of all the systems. The primary survey protocol also works well to address any acutely decompensating patient. Airway emergencies in a previously stable patient can occur as a result of on-going cervical edema or hematoma from soft tissue injury or fractures. It can also accompany mental status deterior-

Table 3.1. The primary survey of the trauma patient. From [37], with permission

A	Airway maintenance with cervical spine protection
B	Breathing and ventilation
C	Circulation with hemorrhage control
D	Disability: Neurologic status
E	Exposure/environmental control: Completely undress the patient, but prevent hypothermia

L. A. WIBBENMEYER, MD
University of Iowa Hospitals and Clinics, Department of Radiology, 200 Hawkins Dr., Iowa City, IA 52242, USA
M. SHARAFUDDIN, MD
University of Iowa Hospitals and Clinics, Department of Radiology, 200 Hawkins Dr., 3957 JPP, Iowa City, IA 52242, USA

ration, circulatory decompensation, or administration of procedural conscious sedation medications. It is therefore imperative that the interventionist be familiar with the signs and symptoms of impending respiratory collapse and the treatment.

Airway compromise may be insidious in onset. Recognition of the signs and symptoms of airway obstruction can enable controlled airway access and prevent a respiratory arrest. Table 3.2 lists the signs of impending respiratory embarrassment secondary to airway obstruction. Stridor or inspiratory wheezing heard over the cervical region is a sensitive marker for impending respiratory compromise. Signs of increased labored breathing should also be observed. Flaring of the nasal alae, retraction of cervical soft tissues, and retraction of the ribs on inspiration all are signs of increased work of breathing. Paradoxical movement of the chest (abdominal distention on inspiration) is an ominous sign suggesting impending airway compromise.

Adequate oxygenation and ventilation should be assessed. The pulse oximeter data is readily available to the interventionist during the procedure and can provide quantitative data reflecting the patient's ability to oxygenate. Saturations above 95% are usually adequate to ensure sufficient oxygenation [4]. However, due to the sigmoidal shape of the oxyhemoglobin desaturation curve, factors that shift the curve to the left such as hypothermia, alkalosis, and a decrease in 2,3-diphosphoglycer-

aldehyde (old banked blood) may impair sufficient oxygen unloading from oxyhemoglobin. Therefore, all trauma patients should receive supplemental oxygen by nasal cannula or mask. Unlike oxygenation, adequate ventilation can only be accurately accessed by arterial blood gas analysis demonstrating normal carbia. Inadequate or marginal oxygenation or ventilation accompanied by increased signs of labored breathing should prompt consideration for intubation.

3.2.2 Treatment Adjuncts

Several options are available for the initial management of suspected airway obstruction. If neurologic deterioration secondary to closed head injury or administration of sedative agents is suspected, a soft plastic nasopharyngeal airway (trumpet) can be inserted (Fig. 3.1) [5–7]. Its counterpart the oropharyngeal should be avoided in the conscious patient because of excessive irritation of the upper airway. The nasopharyngeal airway will lift the tongue and accompanying soft tissues off the back of the airway, enabling ventilation. In addition, a gentle chin lift or jaw thrust can alleviate upper airway obstruction (Fig. 3.2). These maneuvers alone may be sufficient if only upper airway obstruction is the problem. It should be remembered that extension of the neck

Table 3.2. Symptoms and signs of respiratory obstruction graded according to severity. Modified from [38,39], with permission. First published in the British Medical Journal, 1964

Stage	Signs and Symptoms
1. Mild or Potential Obstruction	Hoarseness Cough No stridor at rest Stridor on moderate exertion
2. Moderate Obstruction	Dyspnea Rib retraction on inspiration Use of accessory muscles of aspiration Stridor on slight exertion
3. Severe Obstruction	Apprehension Restlessness Sweating and pallor Increased blood pressure and heart rate Paradoxical movement of chest Stridor at rest
4. Total Obstruction	Slowed respirations Marked cyanosis Impaired consciousness Slowing heart rate Hypotension No longer stridorous

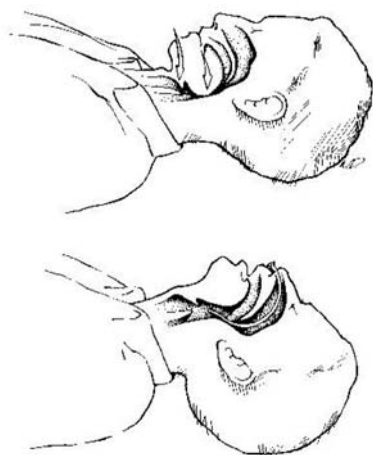


Fig. 3.1. The mechanism of oropharyngeal obstruction in the supine position and the proper placement of the nasopharyngeal airway. Modified from [42], with permission. Copyright, American Heart Association

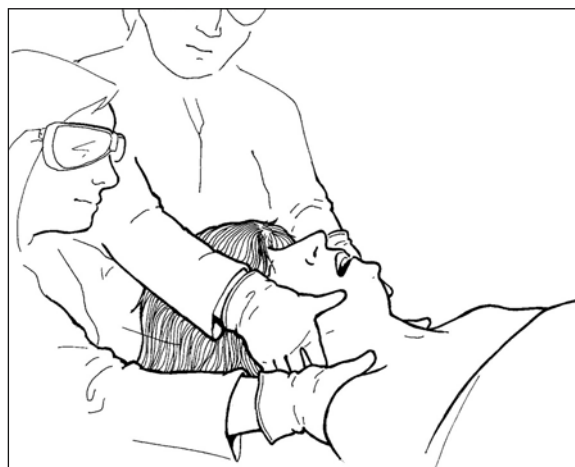

Fig. 3.2. Manual in-line stabilization is provided as the patient's airway is opened with the two-handed jaw thrust airway opening technique

should be avoided in all trauma patients until their cervical spine is radiographically and clinically cleared. These patients will almost invariably have hard cervical collars for neck immobilization, and these should never be removed without proper consultation with the trauma team.

3.2.3 Definitive Control

If the patient continues to show signs of airway obstruction or compromise, despite the insertion of a nasopharyngeal airway or manual airway opening procedure, a definitive airway needs to be established. Trauma patients have challenging airways due to the need to maintain manual in-line neck stabilization (MILS) and the presence of the cervical collar. Normally patients are placed in the sniffing position with the head and upper neck fully extended and the occiput slightly elevated. This position aligns the oral, pharyngeal, and laryngeal airways. MILS places the head in the neutral position, displacing the larynx anteriorly and impairing visualization [8,9]. The anterior faceplate of the cervical collar restricts mouth opening, further complicating access to the larynx [9]. Removal of the anterior faceplate as long as MILS is maintained is safe and will facilitate intubation. When available, an experienced provider should attempt definitive control of the airway. However, as the interventionist may occasionally be the only one immediately

available, a systematic approach to the definitive airway will be presented.

A systematic approach to the airway consists of assessment of the level of airway difficulty, preparation of the patient, collection of airway equipment and pharmacologic medication, and development of a back-up plan. A back-up plan is essential prior to any intubation attempt. Preparation is critical to avoid failed attempts resulting in airway trauma impairing subsequent laryngoscopies.

The first step, assessment of the level of airway difficulty, is critical. An unanticipated difficult airway can lead to a no intubation–no ventilation crisis where only a surgical airway can correct the situation. It is estimated that anywhere from 1.5%–8.5% of airways are difficult [10]. Despite a number of scoring systems that rate airway difficulty, only 50% of these difficult airways can be accurately predicted [11–13]. In general, patients who are difficult to intubate often have limited mouth opening, protruding teeth, receding chins, short necks, or limited neck extension. The existing difficult airway scoring systems take into account these factors. If a difficult airway is anticipated, other options such as an awake intubation, Laryngeal Mask Airway, gum bougie, or a lighted stylet can be considered [7,14].

Patients need to be preoxygenated prior to intubation. Preoxygenation washes out the nitrogen and ensures adequate oxygenation if prolonged laryngoscopy is needed. In the spontaneously breathing trauma patient, this is done by giving them high flow oxygen via a non-rebreathing mask or a bag

valve mask device. In the case of the non-ventilating patient, their ventilation must be provided through manual compression of a bag valve mask device. This is best done using a two-person technique. The mask is placed over the bridge of the nose with the thumbs and then secured over the mouth and chin area with the index and middle fingers. The ring and little fingers support the jaw in the jaw thrust position. An additional person is needed to compress the ventilating bag.

Necessary equipment and pharmacologic medication then needs to be made available to ensure smooth intubation. Essential equipment is listed in Table 3.3. Pharmacologic medications consist of hypnotic and paralytic agents and are listed in Table 3.4. All patients should have cardiopulmonary monitoring with cardiac, blood pressure, and pulse oximeter monitors. Intravenous lines should be checked for their patency. The choice of sedative or hypnotic agents will depend on the patient's hemodynamic status, with etomidate and ketamine usually preferred in the hemodynamically unstable patient. The administration of a paralytic agent has

been demonstrated to help with successful intubation [15,16]. However, the choice of a paralytic will depend on the difficulty of the airway and the ability of the airway provider. A depolarizing paralytic (succinylcholine) is ideal as it results in rapid induction and has the shortest half-life of all the paralytics. However, its use should be restricted in patients with known neuromuscular disease, massive muscular trauma, burn injuries over 24 hours old, or suspected elevation in serum potassium. Non-depolarizing paralytics should be reserved for patients with easy airways and experienced airway providers, since paralysis can last up to 120 minutes.

Conscious trauma patients are intubated by the technique of rapid sequence intubation (RSI) with MILS. Unconscious patients can be intubated without medication. RSI calls for administration of a sedative or hypnotic agent followed by a paralytic agent. Another team member provides MILS by cradling the trauma victim's neck between their arms, effectively preventing neck extension (Fig 3.2). External cricoid pressure (8 kg of pressure applied with three fingers over the cricoid ring) is applied prior to the administration of medication to decrease the risk of aspiration. The patient is then intubated, and verification of correct positioning of the tube is performed by physical exam and disposable capnography to assess for exhaled carbon dioxide. Further discussion of intubation techniques is beyond the scope of this chapter; the interested reader is referred to several references [14,17–19].

Table 3.3. Essential airway management equipment. Modified from [40], p. 6, with permission

- Supply of 100% oxygen
- Face mask
- Bag valve device
- Suction equipment
 - Suction catheters
 - Large-bore tonsil suction apparatus (Yankauer)
- Stylet
- Oral airways
- Nasal airways
- Laryngoscope handle and blades (curved, straight, various sizes)
- Endotracheal tubes (various sizes)
- Tongue depressors
- Syringe for cuff inflation
- Tape
- Tincture of benzoin

Table 3.4. Pharmacologic therapy for intubation. Modified from [41], with permission

Drug	Dose	Onset	Offset
Propofol	1–2 mg/kg	22–125 sec	5–10 min
Etomidate	0.25–0.5 mg/kg	< 60 sec	5 min
Ketamine	1–3 mg/kg	< 60 sec	10–15 min
Midazolam	0.1–0.3 mg/kg	30–60 sec	6–15 min
Succinylcholine	1–1.5 mg/kg	30–60 sec	5–10 min
Cisatracurium	0.4 mg/kg	60–90 sec	75–100 min
Vecuronium	0.3 mg/kg	60–90 sec	> 120 min
Rocuronium	0.9–1.2 mg/kg	60 sec	> 60 min

3.3 Circulatory Shock

3.3.1 Recognition

Once an adequate airway and breathing of the trauma patient is achieved, the primary survey of the trauma patient addresses the circulatory system. A number of perfusion endpoints must be analyzed to determine whether the patient is adequately resuscitated or declining into circulatory shock. The predominate cause of shock in the trauma patient is under-perfusion secondary to bleeding. The treatment of shock is to replace the volume lost. By and large, the treatment of shock in the trauma patient has remained unchanged for the past few decades.

The recognition of shock, however, can be challenging. Blood pressure and pulse are neither sensi-

tive nor specific markers for the diagnosis of early hemodynamic shock [20–22]. In fact, hypotension can be a late finding in shock after which circulatory collapse can occur. In general, the signs and symptoms of shock are directly related to the blood volume lost [4]. The American College of Surgeons divides hemorrhage into four categories (Table 3.5). Most patients tolerate class-1 hemorrhage or 10% blood volume loss with little change in vital signs, due to a number of compensatory mechanisms, the earliest of which are tachycardia and narrowed pulse pressure (the difference between the systolic and the diastolic pressures). If loss continues, the patient will demonstrate a decrease in cardiac output and blood pressure. As a result pallor, cool extremities, delayed capillary perfusion, decreased urine output, and mental status changes (agitation and anxiety) may develop. Although these signs may occur before, they are usually manifested in adults following around 20%–40% blood volume loss and therefore are late markers of shock. Children, on the other hand, may not manifest these signs until around 40% volume loss. Children with hypotension and tachycardia are significantly volume-depleted and can rapidly decompensate.

Biochemical markers may better quantify the initial and on-going magnitude of the shock state [22–26]). Both the base deficit and serum lactic acid level measure the acidosis produced by the anaerobic state during inadequate delivery of substrate to tissues [27]. Shock impairs nutritive blood flow to tissues, shifting cellular metabolism into the less efficient anaerobic glycolysis pathway. The formation of ATP from ADP is slowed, resulting in accumulation of hydrogen ion (H^+) in the cytosol and extracellular fluid. This accumulation of the H^+ in the cytosol is quantified by the base deficit measured on the arterial blood gas. Base deficit

(the quantity of strong acid or base that would be required to titrate the patient to a normal pH assuming a $PaCO_2$ of 40 mmHg and a hemoglobin of 5 g/dl) reflects the metabolic component of shock. Initial and subsequent base deficit measurements provide markers to assess the severity and recovery of the shock state. Initial base deficit < -6 has been associated with the need for transfusion [25]. Similar to the base deficit, lactic acid accumulates in the shock state. Under anaerobic conditions, pyruvate accumulates and is dehydrogenated in the cytosol to lactate. Lactate buffers H^+ , resulting in lactic acid. Serial measurement of serum lactate can also help achieve a better follow-up of the compensated shock state and reduce the need for on-going resuscitation. Persistent serum lactate elevation following resuscitation in trauma has been reported to portend a worse outcome [23].

3.3.2 Resuscitation

Once shock is identified, resuscitation needs to be instituted to prevent on-going perfusion mismatch, which can lead to multiple system organ failure and death. Although there is some controversy regarding resuscitating penetrating trauma victims to normal blood pressure before surgical control of their bleeding, resuscitation to normal volemia is the current paradigm in bluntly injured patients [28]. In penetrating trauma victims, normotension may lead to worsened hemorrhage, whereas blunt trauma patients often have accompanying head injuries that can be significantly worsened by hypotension. Trauma patients in shock are first resuscitated with crystalloid, namely Lactated Ringers or normal saline. ATLS protocol dictates a 2-liter rapid bolus

Table 3.5. Estimated fluid and blood losses based on hemorrhagic shock severity class on patient's initial presentation. From [42], with permission

	Class I	Class II	Class III	Class IV
Blood loss (ml)	Up to 750	750-1500	1500-2000	> 2000
Blood loss (% blood volume)	Up to 15%	15%–30%	30%–40%	> 40%
Pulse rate	< 100	> 100	> 120	> 140
Blood pressure	Normal	Normal	Decreased	Decreased
Pulse pressure (mmHg)	Normal or increased	Decreased	Decreased	Decreased
Respiratory rate	14–20	20–30	30–40	> 35
Urine output (ml/h)	> 30	20–30	5-15	Negligible
CNS/mental status	Slightly anxious	Mildly anxious	Anxious, confused	Confused, lethargic
Fluid replacement (3:1 rule)	Crystalloid	Crystalloid	Crystalloid and blood	Crystalloid and blood

in an adult and a 20 cc/kg bolus in a child. Non-responders or transient hemodynamic responders usually have lost > 25% of their blood volume or have on-going bleeding and need to receive blood. As typing and cross-matching require time, type O negative blood is preferentially transfused. It is crucial to remember that the ability to provide adequate resuscitation is also dependent on catheter dynamics. ATLS protocol dictates the placement of two large-bore (14–16 gauge) peripheral catheters. With short intravenous tubing (< 3 feet) and 300 mmHg external compression, these catheters can provide flow rates of 249–500 cc/min [29]. Central access is required if peripheral access is inadequate. The location of the placement of catheters is also important. The lower extremities should be avoided if intra-abdominal injury is suspected.

3.3.3 Pitfalls of Resuscitation

The two main pitfalls of rapid resuscitation and massive transfusion are hypothermia and coagulopathy. Along with acidosis of the shock state, hypothermia and coagulopathy compose the “triangle of death” well known to the trauma surgeon [30,31]. When these three conditions are present in the emergency room or operating room, only stabilizing procedures are performed and the patient is transferred to the intensive care unit for resuscitation. With resolution of the triad, the patient is returned to the operating room if necessary.

Hypothermia in the trauma patient is multifactorial, resulting from exposure to cold environment, bleeding, and infusion of cold fluids. Mild to moderate hypothermia (34°C to 30°C) can be associated with coagulopathy that can impair the patient’s response to ongoing resuscitation and at times be refractory to treatment [32]. During massive resuscitation, hypothermia can be avoided by administration of warmed fluids, either by means of an in-line warmer, or rapid infuser. The ambient room temperature should be maintained at 21°C. Additionally, patients can also be actively warmed by one of the commercially available convective blankets.

Coagulopathy can also be multifactorial in the multiple injured trauma patients. In addition to hypothermia-related coagulopathy, massive resuscitation and massive transfusion are other important causes. Massive resuscitation can lead to thrombocytopenia, prolonged prothrombin times, and decreased fibrinogen [32,33]. The incidence of coag-

ulopathy during resuscitation is variable, and therefore its treatment remains controversial. Although some formulas have been proposed for replacement of coagulation factors and platelets based on the number of units of blood received, several studies have failed to show their reliability [34,35]. Without obvious microvascular bleeding, many recommend that fresh frozen plasma and platelet replacement be guided by laboratory abnormalities [33,36].

Cookbook: Recognition and Treatment of Medical Emergencies in the Trauma Patient

Suspect Airway Compromise

- Perform Primary Survey
- Assess Airway for Patency
- Open Airway
 - Airway Opening Procedure
 - Insertion of Naso- or Oropharyngeal Airway
- Prepare for Definitive Airway
 - Assessment of Airway Difficulty
 - Preoxygenation
 - Collection of Equipment
 - Development of a Back-up Plan
- Provide Definitive Airway-Intubation
- Confirm Placement of Airway
 - Auscultation
 - Capnography
 - Chest Radiograph

Suspect Circulatory Compromise

- Perform Primary Survey
- Assess Circulation
 - Look for signs of perfusion abnormalities
 - Hypotension, tachycardia, diaphoresis, agitation, pallor
 - Obtain biochemical markers of perfusion abnormalities (base deficit and lactic acid)
- Provide Resuscitation
 - Crystalloid (Ringer lactate) bolus
 - Packed red blood cells for non-responders
- Avoid hypothermia
 - Warm room to 20°C
 - Warm fluids
 - Warm patient with a convective blanket
- Assess for secondary coagulopathy during massive resuscitation
 - Obtain blood for PT, INR, PTT, Fibrinogen

References

- Dondelinger RF, Trotteur G et al. (2002) Traumatic injuries: radiological hemostatic intervention at admission. *Eur Radiol* 12:979–993
- Velmahos GC, Toutouzas KG et al. (2002) A prospective study on the safety and efficacy of angiographic embolization for pelvic and visceral injuries. *J Trauma Injury Infect Crit Care* 53:303–308
- Santucci RA, Wessells H et al. (2004) Evaluation and management of renal injuries: consensus statement of the renal trauma subcommittee. *BJU Int* 93:937–954
- American College of Surgeons (1997) *Advanced trauma life support manual*, 6th edn. ACS, Chicago
- Kaur S, Heard SO (1996) Airway management and endotracheal intubation. In: Rippe JM, Irwin RS, Fink MP, Cerra FB (eds) *Intensive care medicine*, vol 1. Little Brown, New York, pp 1–15
- Hillman DR, Platt PR et al. (2003) The upper airway during anaesthesia. *Br J Anaesth* 91:31–39
- Nolan JP, Wilson ME (1993) Orotracheal intubation in patients with potential cervical spine injuries. An indication for the gum elastic bougie (see comment). *Anaesthesia* 48:630–633
- Heath KJ (1994) The effect of laryngoscopy of different cervical spine immobilisation techniques (see comment). *Anaesthesia* 49:843–845
- Crosby ET, Cooper RM et al. (1998) The unanticipated difficult airway with recommendations for management (see comment). *Can J Anaesth* 45:757–776
- Oates JD, Macleod AD et al. (1991) Comparison of two methods for predicting difficult intubation (see comment). *Br J Anaesth* 66:305–309
- Savva D (1994) Prediction of difficult tracheal intubation (see comment). *Br J Anaesth* 73:149–153
- Rosenblatt WH (2004) Preoperative planning of airway management in critical care patients (see comment). *Crit Care Med* 32 [Suppl 4]
- Blanda M, Gallo UE (2003) Emergency airway management. *Emerg Med Clin North Am* 21:1–26
- Criswell JC, Parr MJ et al. (1994) Emergency airway management in patients with cervical spine injuries (see comment). *Anaesthesia* 49:900–903
- Li J, Murphy-Lavoie H et al. (1999) Complications of emergency intubation with and without paralysis. *Am J Emerg Med* 17:141–143
- Behringer EC (2002) Approaches to managing the upper airway. *Anesthesiol Clin North Am* 20:813–832
- Orebaugh SL (2002) Difficult airway management in the emergency department. *J Emerg Med* 22:31–48
- Butler KH, Clyne B (2003) Management of the difficult airway: alternative airway techniques and adjuncts. *Emerg Med Clin North Am* 21:259–289
- Luna GK, Eddy AC et al. (1989) The sensitivity of vital signs in identifying major thoracoabdominal hemorrhage. *Am J Surg* 157:512–515
- Thompson D, Adams SL et al. (1990) Relative bradycardia in patients with isolated penetrating abdominal trauma and isolated extremity trauma. *Ann Emerg Med* 19:268–275
- Wilson M, Davis DP et al. (2003) Diagnosis and monitoring of hemorrhagic shock during the initial resuscitation of multiple trauma patients: a review. *J Emerg Med* 24:413–422
- Abramson D, Scalea TM et al. (1993) Lactate clearance and survival following injury. *J Trauma Injury Infect Crit Care* 35:584–588
- Manikis P, Jankowski S et al. (1995) Correlation of serial blood lactate levels to organ failure and mortality after trauma. *Am J Emerg Med* 13:619–22
- Davis JW, Parks SN et al. (1996) Admission base deficit predicts transfusion requirements and risk of complications (see comment). *J Trauma Injury Infect Crit Care* 41:769–774
- Davis JW, Kaups KL et al. (1998) Base deficit is superior to pH in evaluating clearance of acidosis after traumatic shock. *J Trauma Injury Infection & Crit Care* 44:114–118
- Mullins R (2000) Management of shock. In: Mattox KL, Feliciano DV, Moore EE (eds) *Trauma*. McGraw-Hill, New York, pp 195–232
- Bickell WH, Wall MJ Jr et al. (1994) Immediate versus delayed fluid resuscitation for hypotensive patients with penetrating torso injuries (see comment). *N Engl J Med* 331:1105–1109
- Millikan JS, Cain TL et al. (1984) Rapid volume replacement for hypovolemic shock: a comparison of techniques and equipment. *J Trauma Injury Infect Crit Care* 24:428–431
- Stone HH, Strom PR et al. (1983) Management of the major coagulopathy with onset during laparotomy. *Ann Surg* 197:532–535
- Danks RR (2002) Triangle of death. How hypothermia acidosis and coagulopathy can adversely impact trauma patients. *J Emerg Med Serv* 27:61–66
- Ferrara A, MacArthur JD et al. (1990) Hypothermia and acidosis worsen coagulopathy in the patient requiring massive transfusion. *Am J Surg* 160:515–518
- Faringer PD, Mullins RJ et al. (1993) Blood component supplementation during massive transfusion of AS-1 red cells in trauma patients. *J Trauma Injury Infect Crit Care* 34:481–485
- Harrigan C, Lucas CE et al. (1985) Serial changes in primary hemostasis after massive transfusion. *Surgery* 98:836–844
- Wudel JH, Morris JA Jr et al. (1991) Massive transfusion: outcome in blunt trauma patients. *J Trauma Injury Infect Crit Care* 31:1–7
- Reed RL 2nd, Johnson TD et al. (1992) The disparity between hypothermic coagulopathy and clotting studies. *J Trauma Injury Infect Crit Care* 33:465–470
- Bell RM (2000) Initial assessment. In: Mattox KL, Feliciano DV, Moore EE (eds) *Trauma*, 4th edn. McGraw-Hill, New York
- Mattox KL, Feliciano DV, Moore EE (eds) (2000) *Trauma*, 4th edn. McGraw-Hill, New York
- Robinson RJS, Mulder DS, Forbes JA (1964) Airway control. *Br Med J* 1:369
- Rippe JM, Irwin RS, Fink MP, Cerra FB (1996) *Intensive care medicine*, 3rd edn. Little Brown, Boston
- Hartmannsbruber (2000) The traumatic airway: the anesthesiologist's role in the emergency room. *Int Anesthesiol Clin* 38:87–104
- Cummins RO (ed) (1994) *Textbook of advance cardiac life support*. American Heart Association, Dallas, Texas

4 Visceral and Abdominal Solid Organ Trauma

GARY SISKIN and JAFAR GOLZARIAN

CONTENTS

4.1	Splenic Artery Embolization	43
4.1.1	Introduction	43
4.1.2	Patient Selection	43
4.1.3	Diagnosis	44
4.1.3.1	The Role of Abdominal CT	44
4.1.3.2	Diagnostic Angiography	44
4.1.4	Splenic Artery Embolization	45
4.1.4.1	Technique	45
4.1.4.2	Results	47
4.1.4.3	Post-Embolization Follow-up	48
4.2	Hepatic Artery Embolization	48
4.2.1	Patient Selection	48
4.2.2	Diagnosis	49
4.2.3	Hepatic Artery Embolization	49
4.2.3.1	Technique	49
4.2.3.2	Results	49
4.2.3.3	Post-Embolization Follow-up	51
4.3	Renal Artery Embolization	51
4.3.1	Patient Selection	51
4.3.2	Diagnosis of Renal Vascular Injury	52
4.3.3	Renal Artery Embolization	52
4.3.3.1	Technique	52
4.3.3.2	Results	52
4.3.3.3	Post-Embolization Follow-up	54
	Cookbook	54
	References	55

4.1 Splenic Artery Embolization

4.1.1 Introduction

During the past 10–15 years, there has been a clear trend among trauma surgeons toward the use of bed rest and observation for hemodynamically stable

patients after blunt injury to the spleen [1]. However, well-defined criteria are still not available to apply to these patients in order to determine who is best suited for nonoperative management and who will ultimately require surgery. We do know that hemodynamically unstable patients with multisystem trauma and significant intraperitoneal bleeding will likely not be successfully managed with observation and splenic salvage. All other hemodynamically stable patients are now considered candidates for nonoperative treatment consisting of observation with serial physical examination, frequent hematocrit determinations, bed rest, and limited oral intake [2].

The trend toward nonoperative management after splenic injury has significant benefits for this patient population. These include eliminating the risks for immediate and late complications associated with open surgery as well as preserving the immunologic functions provided by the spleen [1, 3–5]. Immunologically, the spleen is best known for its filtering function, which serves to remove particulate antigens, bacteria, and old erythrocytes from circulation [6]. In addition to this, the spleen produces mediators such as immunoglobulin M, tuftsin, and properdin [6, 7]. The importance of these functions manifests itself after splenectomy with a significant post-surgical infection rate, which is what initially prompted surgeons to increase their interest in splenic salvage [6–9].

4.1.2 Patient Selection

With the benefits of splenic salvage rarely questioned, it makes sense that this is most desirable option for most, if not all, hemodynamically stable patients. However, it is still not known with certainty which patients will be successfully managed with nonoperative management and which will ultimately require surgery despite initially being considered candidates for observation. Patient age, injury severity

G. SISKIN, MD

Albany Medical College, Vascular Radiology, A113, 47 New Scotland Avenue, Albany, NY 12208-3479, USA

J. GOLZARIAN, MD

Professor of Radiology, Director, Vascular and Interventional Radiology, University of Iowa, Department of Radiology, 200 Hawkins Drive, 3957 JPP, Iowa City, IA 52242, USA

score, neurologic status, grade of injury on abdominal CT, and quantity of hemoperitoneum have all been cited as factors that may affect the success of nonoperative management [10–15]. Hemodynamic stability as a reflection of injury severity is likely the most important factor to consider; PEITZMAN et al. found that nonoperative management was more likely to be successful in patients with higher blood pressure, higher hematocrit levels, less severe injury, and smaller quantity of hemoperitoneum [15]. Early on, it was recommended that patients older than age 55 be excluded from nonoperative management of blunt splenic injuries [10, 16]. However, more recent data suggest that the decision to pursue nonoperative management should be based on clinical and hemodynamic factors, and not necessarily on age [11, 17].

Despite the benefits of splenic salvage and the trend towards nonoperative management for these patients, there are those that advocate a more aggressive approach to the treatment of splenic injuries. These investigators cite the potential for delayed rupture or progression of injury that may require urgent transfusion or emergency splenectomy. FEDERLE et al. did note in the review of their institutional experience with splenic trauma patients that 15% of patients selected for nonoperative management initially ultimately required surgery, most commonly within 48 hours of presentation [18]. One problem with managing patients with delayed rupture or injury progression is the difficulty utilizing techniques to preserve splenic tissue, such as partial splenectomy and splenorrhaphy, depending on clinical severity [19–22].

4.1.3 Diagnosis

4.1.3.1 The Role of Abdominal CT

Abdominal CT has become an integral part of the evaluation of patients experiencing blunt traumatic injury. For stable patients with splenic trauma, CT is needed before a decision is made to proceed with nonoperative therapy because it is important to identify and characterize not only the degree of splenic injury, but also any concomitant abdominal injury [19, 23, 24]. There have been several CT-based classification systems for splenic injury, based on the morphologic grade of splenic injury and the amount of intraperitoneal hemorrhage, to guide therapy and predict success for nonoperative management [18,

25–29]. One example of a grading system for splenic injury is the modified criteria of the American Association for the Surgery of Trauma (AAST), which grades splenic injuries from 1 to 5 on the basis of increasing severity of parenchymal damage based on radiologic assessment [18, 27] (Table 4.1). Despite the widespread use of this and other classification systems, their use remains controversial since several studies have shown that they do not necessarily correlate well with clinical outcome [26, 27, 30–32] and may not provide sufficient information regarding vascular injuries to be useful [23, 33]. However, FEDERLE et al. studied this issue and found that CT can effectively recognize vascular injury and active extravasation from splenic arterial branches [18].

In 2000, SHANMUGANATHAN et al. evaluated the potential role of contrast-enhanced spiral CT in predicting the need for splenic angiography and embolization by correlating them with results from subsequent splenic angiograms [19]. In their study, contrast extravasation at CT was highly predictive of the need for embolization, regardless of the CT grade of injury. The presence of a pseudoaneurysm or arteriovenous fistulas on CT, both of which are seen as focal areas of high attenuation, was a less sensitive finding, with only 58% of patients with these CT findings requiring embolization or splenectomy. The angiograms of the remaining 42% of patients with CT findings suggestive of a pseudoaneurysm or arteriovenous fistula did not reveal any focal vascular abnormalities. These false-positive CT findings were attributed to islands of enhancing splenic parenchyma surrounded by low-attenuating splenic lacerations or contusions and intact intrasplenic vessels traversing parenchymal lacerations simulating hemorrhage surrounding a focal pseudoaneurysm [19]. The finding of a splenic vascular lesion on contrast-enhanced spiral CT was 83% sensitive in predicting the need for splenic angiography and subsequent embolization or surgery. Using this approach, 94% of patients were successfully selected at presentation for conservative management. This study demonstrated that the use of contrast-enhanced spiral CT and splenic angiography improves early diagnosis and potentially increases the number of patients with blunt splenic injuries who are treated successfully without surgery.

4.1.3.2 Diagnostic Angiography

The role of diagnostic angiography in the evaluation of patients experiencing blunt splenic trauma

Table 4.1. AAST Splenic Injury Scale

Grade	Type of Injury	Description
1	Hematoma	Subcapsular, <10% surface area
	Laceration	Capsular tear, < = 1 cm parenchymal depth
2	Hematoma	Subcapsular, 10–50% surface area, intraparenchymal, <5 cm in diameter
	Laceration	1–3 cm parenchymal depth that does not Involve a trabecular vessel
3	Hematoma	Subcapsular, >50% surface area or expanding; ruptured subcapsular or parenchymal hematoma; intraparenchymal, >5 cm or expanding
	Laceration	>3 cm parenchymal depth or involving Trabecular vessels
4	Laceration	Involving segmental or hilar vessels producing major devascularization (>25% of the spleen)
5	Laceration	Completely shattered spleen
	Vascular	Hilar vascular injury that devascularizes the spleen

remains controversial. While some believe that all patients with splenic injuries should undergo diagnostic angiography, others are more selective and prefer angiography for patients with high-grade parenchymal injury, vascular injury, or a large volume of hemoperitoneum on admission CT scan [6, 16, 23, 33–35]. It has been well established that selective splenic angiography is successful at identifying vascular injuries, with positive findings including active extravasation of contrast and the presence of a pseudoaneurysm [33, 36]. It is the early work of SCLAFANI et al. and HAGIWARA et al. that supports the angiographic evaluation of stable patients with CT evidence of splenic injury [23, 33]. A positive angiogram is a strong predictor of nonoperative failure, necessitating the use of embolization or surgery to allow for continued splenic viability [1, 23, 33, 37–39]. Conversely, a negative angiogram can successfully predict the success of observation for these patients [33, 39].

However, others consider the use of angiography in all patients with documented splenic injury is aggressive. SCLAFANI et al. reported a 70% incidence of negative angiograms in this population [39]. DENT et al. recommend angiography for patients with persistent tachycardia despite fluid resuscitation, splenic vascular blush on CT, severe splenic injury on CT, or decreasing hematocrit that cannot be explained [40]. Using these criteria, angiography was only necessary in 7% of patients with blunt splenic injury and ultimately, the success of nonoperative management was similar to studies in which there was more liberal use of angiography. Similarly, LIU et al. argue against the use of routine angiography since most patients with blunt splenic injury can be successfully managed by bed rest and observation [6, 7]. These

findings therefore need to be considered when exposing patients to the inherent risks and cost of angiography [12].

4.1.4 Splenic Artery Embolization

The use of splenic artery embolization was originally described in 1973 in patients with hypersplenism [41]. In 1981, SCLAFANI first reported the splenic artery infusion of Pitressin, Gelfoam pledget embolization, and coil occlusion of the proximal splenic artery to treat splenic injury [36]. Since that time, the findings of many studies have supported the use of splenic artery embolization in patients managed nonoperatively after blunt splenic trauma [2, 12, 19, 23, 33, 37, 39]. In general, embolization is reserved for patients with documented vascular injury at the time of diagnostic angiography, but the success and ease of performing this procedure has led some to utilize embolization in all patients with higher grade injuries [2].

4.1.4.1 Technique

It must be stated that the goal of embolization in the setting of splenic trauma is to reduce arterial flow to the spleen so that hemostasis can take place at the site of arterial injury. However, the importance of maintaining splenic viability must not be forgotten and therefore, continued perfusion of splenic parenchyma from collateral vessels must also be maintained during a successful embolization procedure.

Technically, an abdominal aortogram is recommended prior to selective splenic artery catheterization in order to visualize the exact point of origin of the splenic artery and to demonstrate the presence or absence of variant anatomy. Most interventionalists then favor either a superselective approach with distal embolization of the injured splenic artery branches, or a relatively nonselective approach with proximal embolization of the main splenic artery, utilizing the angiographic appearance of the splenic vasculature to make that decision. While one can certainly make the argument that patients with active branch vessel extravasation should have clinical signs that should have necessitated immediate surgery, the expanding use of angiography and embolization at our institution frequently puts us in the position of treating patients that seem to require distal embolization for adequate treatment. In these patients, it often makes intuitive sense to select and embolize the injured branch vessels, a feat made easier by advances in microcatheter and microcoil technology [6]. In these patients, however, consideration must be given to the balance between superselective control of bleeding, the fluoroscopy exposure time required for selective catheterization, and the volume of splenic parenchyma put at risk for ischemia and subsequent infarction (Fig. 4.1).

An alternative to superselective catheterization of splenic artery branches is the use of proximal splenic artery embolization [23, 33, 39]. In this technique, the main splenic artery is embolized,

beyond the origin of the dorsal pancreatic artery but proximal to the splenic hilum, with appropriately sized coils [33]. The reason behind this technique is to decrease perfusion pressure to the spleen while maintaining the ability of the spleen to receive arterial inflow from collateral vessels, including gastric, omental, and pancreatic vessels [1, 42]. Therefore, the splenic artery should be measured prior to introducing coils and care should be taken to use coils that are large enough so that they do not migrate into the hilum of the spleen since this will increase the risk of splenic infarction. The maintenance of splenic perfusion was demonstrated by HAGIWARA et al. who demonstrated preservation of splenic function by arteriography and scintigraphy in patients who underwent proximal splenic artery embolization [23].

Patients with multiple vascular injuries are candidates for either proximal coil embolization or combined therapy, which utilizes selective catheterization and embolization of the most significantly injured vessels followed by proximal coil embolization [2]. In these patients, distal embolization since this may require extensive fluoroscopic exposure times to catheterize multiple small vessels with subsequent infarction of too large a percentage of splenic parenchyma. HAAN et al. found no difference in failure rate when proximal embolization was compared with more selective, distal embolization. Interestingly, however, the largest failure rate was found when both techniques were utilized in

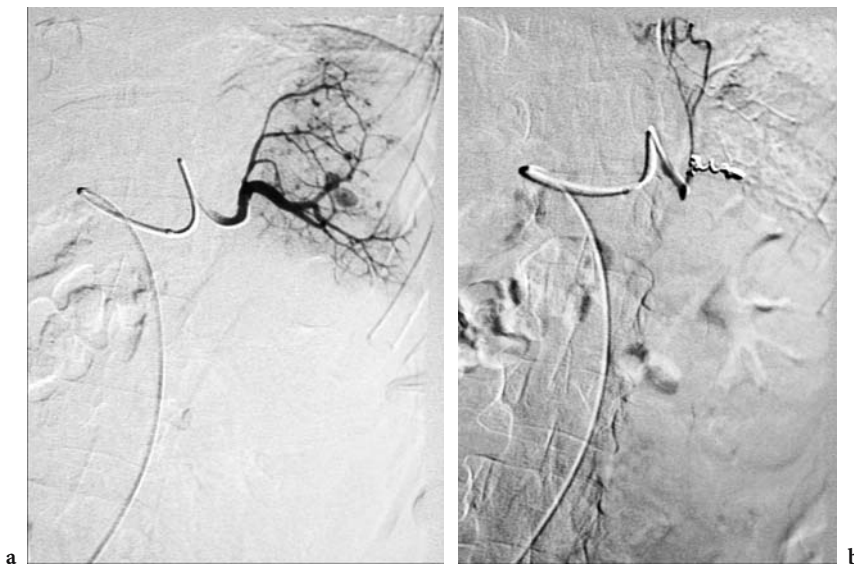

Fig 4.1. **a** Selective splenic angiogram demonstrating a pseudoaneurysm arising from an upper pole branch after blunt trauma. **b** Selective splenic angiogram after coil embolization of the upper pole branch of the splenic artery supplying the injured splenic parenchyma

the same patient, possibly due to the fact that these patients had the most severe injuries [2].

4.1.4.2

Results

SCLAFANI et al. were the first to report that the use of splenic angiography and embolization expanded the number of patients that could be managed non-surgically [33]. In 1995, SCLAFANI et al. reported a nonoperative success rate of 83%, with a splenic salvage rate of 88% by performing angiography on every patient with a splenic injury who did not require urgent operation and proximally embolizing the main splenic artery of the 40% of patients who had evidence of splenic vascular injury on angiography [39]. HAGIWARA et al. embolized 15 patients due to extravasation within or beyond the splenic parenchyma or disruption of terminal arteries without extravasation [23]. In this study, it was noted that patients requiring embolizing required larger volumes of fluid for resuscitation than those who were not embolized, implying that the angiographic findings indicating the need for embolization correlated with a greater degree of hemodynamic instability at presentation, which may therefore be an additional indication for embolization. In addition, the CT grades for patients who did not undergo embolization were significantly lower than those for patients who were embolized.

In 1998, DAVIS et al. evaluated their experience with 524 consecutive patients with blunt splenic injury over a 4½ year period [37]. A focal area of high attenuation on CT, confirmed with angiography to represent a pseudoaneurysm, was seen in 26 patients; 20 of these patients were successfully embolized and did not require further surgery while 6 patients were not embolized due to either free arterial extravasation, early filling of the splenic vein due to a traumatic AV fistula, and multiple pseudoaneurysms. Given the fact that the appearance of some pseudoaneurysms will be delayed, DAVIS et al. emphasized the importance of obtaining follow-up CT scans in patients that are being managed nonoperatively [37].

HAAN et al. [12] more recently reported their experience with the use of angiography in stable patients with CT-proven blunt splenic injury. In their series, 352 patients presented after blunt splenic trauma with 64% requiring immediate surgery. The remaining 36% of patients underwent splenic angiography. Patients with negative angiograms were observed. Embolization was performed in 32% of those under-

going angiography due to positive findings including contrast extravasation, arteriovenous fistula, or pseudoaneurysm. Of these, 8% required laparotomy (2 for bleeding and 1 for abscess formation), for a splenic salvage rate of 92%, despite the presence of high-grade injuries in many of these patients.

SEKIKAWA et al. reported on factors that support use of a nonoperative approach using splenic artery embolization [34]. They found that injury severity score and shock index had no significant correlation with outcome, implying that more severe injuries do not necessarily predict failure of nonoperative management with embolization. However, hemodynamic instability (as evidenced by low hemoglobin, low hematocrit, and low blood pressure) was associated with a poor clinical outcome after embolization. Based on their data, a patient's age, in addition to the presence of head or solid abdominal organ injury in hemodynamically stable patients, should not preclude the use of embolization although concomitant pelvic injury was associated with a poor clinical outcome. Importantly, the time interval from injury to arrival at the hospital and from arrival at the hospital to the start of the embolization procedure did not significantly affect clinical outcome.

The experience of HAAN et al. [12] confirms that embolization improved splenic salvage rates for all CT grades of injury, including grades 3–5. This was true even with patients that were at least as severely injured based on transfusion requirements, injury severity score, length of stay, and ICU stay [12]. Their data also offers additional support for the use of embolization in patients with concomitant neurologic injury, stating that angiography may be associated with a statistically and clinically significant decrease in mortality in patients with neurologic injury when compared with operative therapy [12]. They went on to theorize that patients with neurologic injury pursuing nonoperative management are spared the risk of intraoperative or postoperative hypotension. It has been stated that a single episode of hypotension can increase neurologic mortality by 50–80% and intraoperative hypotension during splenectomy is a frequent occurrence [12, 43]. Therefore, utilizing angiography and embolization for these patients potentially avoids this risk and may lead to less secondary brain injury and lower mortality.

HAAN et al. also reported the results of a multicenter review of patients undergoing splenic artery embolization for splenic trauma and this represents the largest collection of splenic artery embolization patients studied to date [2]. In this review, 140 patients undergoing splenic artery embolization at

one of four institutions over a 5-year period were retrospectively evaluated. They found that splenic artery embolization is used for patients with high-grade splenic injury with an average grade of injury of 3.5 in this series. Despite significant injury severity, splenic salvage of patients selected for embolization was 87% in this series. This series documented a failure rate for embolization of 10% with 17% of patients demonstrating active contrast extravasation failing [2]. In this series, patients with AV fistulae had the worst outcome and they hypothesized that proximal coil embolization may not be enough in these patients since the drop in perfusion pressure may not be sufficient to provide hemostasis [2]. This same multicenter center found a 19% rate of major complications and 23% rate of minor complications. Taking overlap of these patients into account, there was a 32% complication rate. The most common complication, seen in 60% of patients, was blood loss or continued blood loss. True infection is rare but significant splenic infarction was common, with a rate of 20–27% [2]. The vast majority of patients experiencing splenic infarction, however, were asymptomatic and able to continue being managed nonoperatively.

4.1.4.3

Post-Embolization Follow-up

Following nonoperative management and splenic artery embolization for blunt splenic trauma, most patients typically require continued observation in a monitored setting since there continues to be a risk of bleeding or sepsis. It is generally accepted that these patients should be followed with abdominal CT until resolution of the injury is seen [44]. KILLEEN et al. performed a retrospective study to evaluate the CT findings after splenic artery embolization in 53 patients [1]. They found that splenic infarcts described as small, multiple, and peripheral were seen in 63% of patients after a proximal splenic embolization while infarcts were seen in 100% of patients after a distal embolization. The infarcts seen after both proximal and distal embolization tend to resolve without sequelae [1]. In these patients, the infarcts tended to be larger, single, and located just distal to the embolization material. Gas within splenic parenchyma was seen in only 13% of patients but was shown to more commonly occur when Gelfoam was used as the embolization agent [1]. The presence of gas, however, is concerning because it is difficult to exclude

a splenic abscess clinically or based on CT findings [1].

HAAN et al. further explored the CT finding of air within areas of infarction after splenic artery embolization [45]. They found that air in areas of splenic infarction was associated with infection in only 17% of patients but that this rate increased to 33% in symptomatic patients [45]. Clearly, this implies that air is not pathognomonic of infection and that further investigation must be performed in these patients prior to splenectomy. While asymptomatic patients can likely be observed, patients with symptoms and a minimal amount of air should be treated with antipyretics. Aspiration and percutaneous drainage should be considered, as should splenectomy, in patients with large areas of infarct air and/or severe symptoms [45].

4.2

Hepatic Artery Embolization

4.2.1

Patient Selection

In a manner similar to how splenic injuries are being treated, there has been a trend in recent years towards the nonoperative management of hepatic injuries, especially in hemodynamically stable patients [46–52]. Given its large size, the liver is obviously susceptible to injury in association with blunt trauma. In addition, iatrogenic trauma due to biopsies and other procedures can lead to vascular injury potentially requiring embolization as treatment. The vascular injuries seen are similar to those seen with other solid organ injury, including arterial laceration with extravasation in addition to pseudoaneurysm formation but unique to the liver is the potential for fistulas to develop between any of the intrahepatic vascular structures and the biliary system.

Almost two decades ago, MEYER et al. recommended the following criteria for nonsurgical management of blunt liver trauma: hemodynamic stability, CT scans showing simple parenchymal lacerations or intrahepatic hematoma, <250 cc of free intraperitoneal blood, no other significant intraabdominal injury, and availability of close monitoring [53]. The absence of associated injury must be determined with the use of abdominal CT, since it has been estimated that 35% of patients may have associated injuries requiring surgery [52]. When these criteria are utilized, it has been estimated that

80–90% of all blunt liver injuries may be managed without laparotomy [54, 55]. Certainly, embolization and other interventional radiologic procedures have contributed to this success [56].

4.2.2

Diagnosis

For years, contrast-enhanced CT has been the imaging technique of choice to evaluate hemodynamically stable patients with blunt abdominal trauma. It is considered a reliable way to detect hepatic injuries and has therefore been used to grade injuries (Table 4.2) and assess whether surgery or more conservative treatment will be necessary and successful [57]. Importantly, the severity of hepatic injuries may be underestimated on CT scans but the decision to pursue nonoperative management has been shown to not be dependent on the grade of liver injury [50, 54]. Successful management of hemodynamically stable patients of all grades has been demonstrated [55, 59–61]. In general, if the patient is considered stable after resuscitation and the hepatic injury is either isolated or in combination with other injuries that do not themselves require surgery, then a nonoperative approach to management is utilized [61].

4.2.3

Hepatic Artery Embolization

Embolization has been shown to be an effective treatment to offer patients that respond to resuscitation but rapidly become unstable if resuscitation is withdrawn [61]. While it certainly would be appropriate to operate on these patients, an understandable desire to avoid the potential complications associated with surgery has increased the utilization of embolization in this setting [61].

4.2.3.1

Technique

Flush aortography is typically required before selective catheterization of the common hepatic artery, similar to that required before splenic artery catheterization. Even more so in the case of the hepatic arterial circulation is the potential for variant anatomy. Once the origin of the hepatic artery has been identified, selective catheterization can be performed. Whereas the goal in splenic artery embolization is to potentially embolize proximally and preserve flow to the spleen via collateral circulation, a more distal and selective embolization is often the goal when it comes to the treatment of hepatic arterial injury. However, in some situation, the embolization of the right or left hepatic artery might be necessary. In those situations, Gelfoam embolization can be performed with larger particles and torpedoes (Fig. 4.2). Fortunately, the contribution of the portal vein to the hepatic circulation enables the liver parenchyma to tolerate hepatic arterial embolization without significant ischemic injury. Given the more distal nature of this embolization, microcatheters and microcoils are often required for these procedures, although success has been reported using a variety of embolic agents including Gelfoam, polyvinyl alcohol, and coils (Fig. 4.2).

4.2.3.2

Results

Reports dating back to 1977 have demonstrated the effectiveness of embolization for patients experiencing blunt hepatic trauma [62–65]. HAGIWARA et al. [66] demonstrated that nonsurgical management of Grade III or IV using angiography and Gelfoam embolization was successful in all patients. In a later study, HAGIWARA et al. [67] prospectively evaluated

Table 4.2. Mirvis Computed Tomographic Scan Hepatic Injury Severity Scale For Blunt Hepatic Trauma [69]

Grade	CT Criteria
1	Capsular avulsion; superficial laceration(s) <1 cm deep, or subcapsular hematoma <1 cm maximal thickness, periportal blood tracking only
2	Parenchymal laceration(s) 1–3 cm deep; central or subcapsular hematoma(s) 1–3 cm in diameter
3	Laceration(s) >3 cm deep; central or subcapsular hematoma (3) >3 cm in diameter
4	Massive central/subcapsular hematoma >10 cm in diameter, lobar tissue destruction (maceration) or devascularization
5	Bilobar tissue destruction (maceration) or devascularization

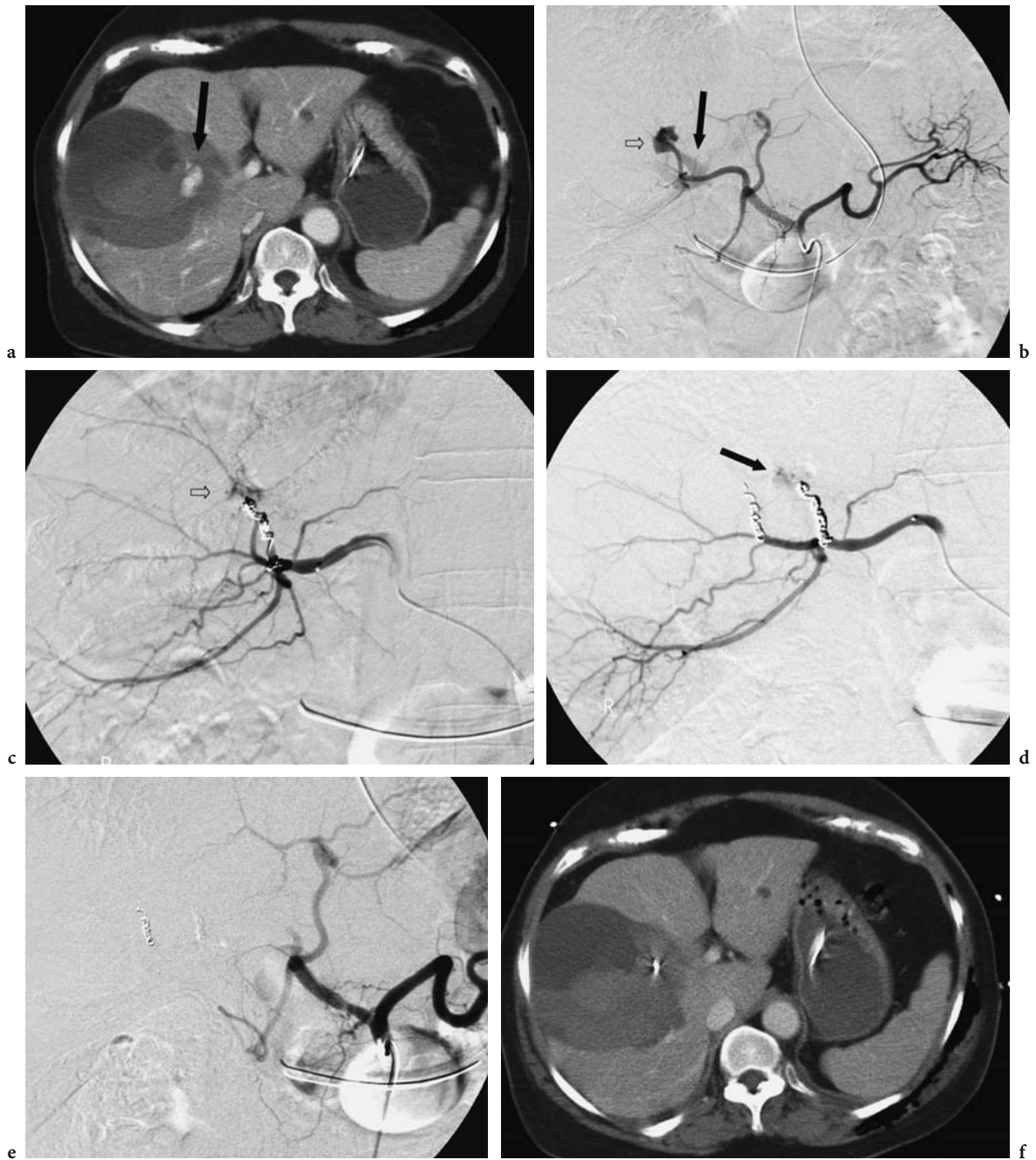


Fig. 4.2a-f. 42 year-old man with abdominal and pelvis trauma. **a** Contrast-enhanced CT of the upper abdomen demonstrates a hematoma and active bleeding (*arrow*) in the right hepatic parenchyma. **b** Celiac trunk angiogram shows the arterial lesion (*short arrow*) with early venous drainage (*black arrow*). **c** Selective microcatheter placement in the feeding artery and embolization with coils is performed. Angiogram demonstrates the persistence of extravasation (*arrow*). **d** Hepatic angiogram, oblique view, after embolization of another feeding artery demonstrates the extravasation (*arrow*). **e** 20 minutes after embolization, there was a persistent extravasation from hepatic artery. The right hepatic artery is then embolized using Gelfoam torpedoes. **f** Contrast enhanced CT obtained 24 hours after embolization shows no more bleeding

patients with Grade III-V injury who were treated with angiography and embolization. They concluded that embolization should be used to manage

hemodynamically stable patients in whom contrast-enhanced CT shows extravasation of contrast, even when the injury is severe. Since embolization obvi-

ously has no effect on bleeding from juxtahepatic venous injuries, HAGIWARA et al. advocate the use of surgery in these patients. They found that all patients with juxtahepatic venous injury required >2,000 ml/hour of fluid for resuscitation. Therefore, they consider the combination of a Grade IV or V lesion and fluid requirements >2,000 ml/hour to maintain normotension an absolute indication for surgery. The success of hepatic artery embolization was also demonstrated by PACTER et al. [59], CARILLO et al. [60], MOHR et al. [68], and SUGIMOTO et al. [69], who successfully performed embolization on patients after blunt liver trauma who were considered stable after resuscitation. CIRAULO et al. [61] evaluated their experience utilizing embolization in patients with severe hepatic injury and found that embolization with Gelfoam and coils was successful in patient whose stability was maintained only by aggressive continuous resuscitation. In these patients, embolization resulted in a reduction from continuous resuscitation to maintenance fluids, which inferred an improvement in hemodynamic stability.

4.2.3.3

Post-Embolization Follow-up

Once the decision has been made to pursue nonoperative management for patients with blunt hepatic trauma, an additional decision concerning follow-up imaging needs to be made as well. Typically, follow-up CT scans have been performed to detect complications, to document healing of the liver injury, and to guide patients' activity restrictions [54]. However, some have advocated a selective approach to the performance of follow-up CT scans [70]. CIRAULO et al. [71] reviewed their experience in 95 patients with blunt hepatic injury to determine if follow-up scan altered management or discharge decisions. They found that follow-up CT scans did not alter the decision to discharge stable patients with Grade I–III injuries. CUFF et al. [54], agreed with this finding and concluded that follow-up CT scans may not always be necessary in patients being treated nonoperatively. In their study, only two patients were found to have significant CT findings during their hospitalization: one patient had a bile leak and biloma while another patient had a hepatic artery to portal vein fistula. Both of these patients had Grade IV injuries and both continued to be managed nonoperatively. Based on this study, CUFF et al. concluded that follow-up CT scans are

unnecessary in stable patients with Grade I, II, or III injuries. Instead, the need for follow-up imaging should depend on the results of serial clinical evaluations with CT scans indicated in stable patients with persistent abdominal pain, sudden change in clinical examination, unexplained tachycardia, fever, jaundice, or decreasing hemoglobin [54].

Complications after embolization include delayed hemorrhage, hepatic necrosis, infection/sepsis, and biliary fistula. They manifest with abnormal physical findings, elevated liver function tests, or findings on imaging studies such as ultrasound or CT (Fig. 4.3) [56, 61, 68]. Fever is common after hepatic artery embolization, occurring in as many as 69–100% of patients [60, 68]. HAGIWARA et al. found bilomas in 4 of 54 patients and these were associated with pseudoaneurysms in 3 of these 4 patients [66]. They propose that the presence of bile delays healing of liver injury and causes an inflammatory reaction that can ultimately lead to rupture of blood vessels and delayed hemorrhage. MOHR et al. reported on five patients with hepatic necrosis after embolization, all of whom required operative debridement or resection with one of these patients ultimately dying after the procedure [68]. 80% of the patients with hepatic necrosis also experience infarction of the gallbladder that required cholecystectomy. These patients required embolization of right hepatic artery branches during their initial procedure. MOHR et al. also noted a 23% incidence of biliary leakage after embolization and these patients typically required biliary drainage for a median of 1 month. In total, MOHR found that 21% of patients required a return to the operating room for hepatic complications while KNUDSON et al. reported a rate of 18% [72]. Of note, CARRILLO demonstrated the importance of other interventional radiologic techniques such as percutaneous drainage and biliary drainage in managing several of these complications, contributing to the continued nonoperative management of these patients [60].

4.3

Renal Artery Embolization

4.3.1

Patient Selection

As stated throughout this chapter, there is a continuing movement towards nonoperative management for patients experiencing significant solid organ

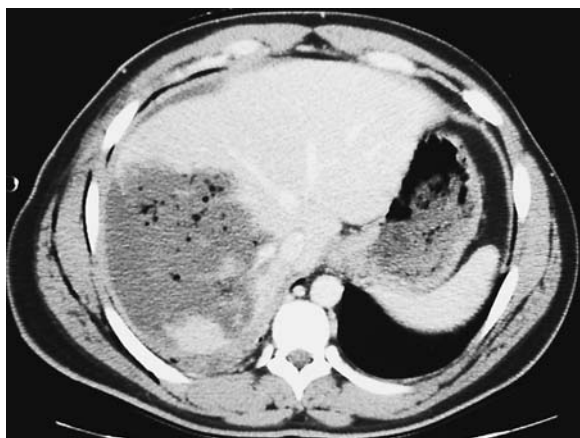

Fig. 4.3. CT scan of the liver 1 week after hepatic artery embolization as treatment for a traumatic liver laceration. The CT reveals a subcapsular fluid collection and an intraparenchymal, air-containing abscess in the right lobe of the liver

injury after trauma. This has been seen concerning the nonoperative management for patients experiencing renal vascular trauma as well [73]. While some believe that surgical exploration is warranted because it ultimately improves the nephrectomy rate [73–75], other believe that nonoperative management is more effective at preventing the need for nephrectomy [76–80]. Accepted indications for surgery include avulsion of the renal pelvis, injuries to the vascular pedicle, and life-threatening hemodynamic instability while embolization can be considered in patients with continuous hematuria or massive hemorrhage due to renal vascular injury [81].

4.3.2 Diagnosis of Renal Vascular Injury

The diagnosis of renovascular injury may be difficult in some patients, especially because hematuria, which is thought to be present in most patients, can be absent in up to 33% of patients with injuries to the renal artery [82]. This is why imaging is often necessary in these patients. In addition, patients with renal vascular injuries typically have other significant intraperitoneal and retroperitoneal injury [83], supporting the need for imaging evaluation. These other injuries can lead to the elevated injury severity scores and increased transfusion requirements often seen in these patients [83].

At the present time, contrast-enhanced spiral CT is the best imaging modality for assessing the renal

parenchyma, grading the severity of injury [84] and confirming the presence of active bleeding and other peritoneal or retroperitoneal injuries [85]. It is effective at diagnosing injuries ranging from contusions and hematomas to shattered kidneys (Fig. 4.4) or avulsion of the renal pedicle [86, 87]. CT findings indicative of an arterial occlusion include a lack of renal enhancement in the presence of a normal renal contour, rim enhancement, central hematoma, and abrupt cut-off of an enhancing renal artery [88]. Segmental arterial injury should be suspected when an area of decreased parenchymal enhancement corresponds to an area perfused by one of the segmental arteries [83].

4.3.3 Renal Artery Embolization

4.3.3.1 Technique

As has been the case with the embolization of other solid organs as described in this chapter, it is recommended that these procedures start with a non-selective abdominal aortogram. Variations in the number of arteries supplying one or both kidneys are numerous and therefore must be documented before attempts at selective catheterization are made. In addition, the angle of origin between the abdominal aorta and renal arteries will help guide catheter selection for catheterization. Aortography is also important to rule out traumatic disruption or dissection of the renal artery before selective catheterization is attempted. Embolization is typically performed as distal as possible, or as close as possible to the site of arterial injury, in order to minimize the amount of devascularized renal parenchyma after the procedure. This typically requires the use of microcatheters and microcoils (Fig. 4.4).

4.3.3.2 Results

Renal vascular injuries, caused by both blunt and penetrating trauma, can be effectively treated with arterial embolization from a superselective catheter position, resulting in organ salvage and tissue preservation [86, 89–92]. HAGIWARA et al. evaluated 46 trauma patients with evidence of renal injury on abdominal CT [93]. Twenty-one of these patients had grade 3 or higher injuries and underwent angi-

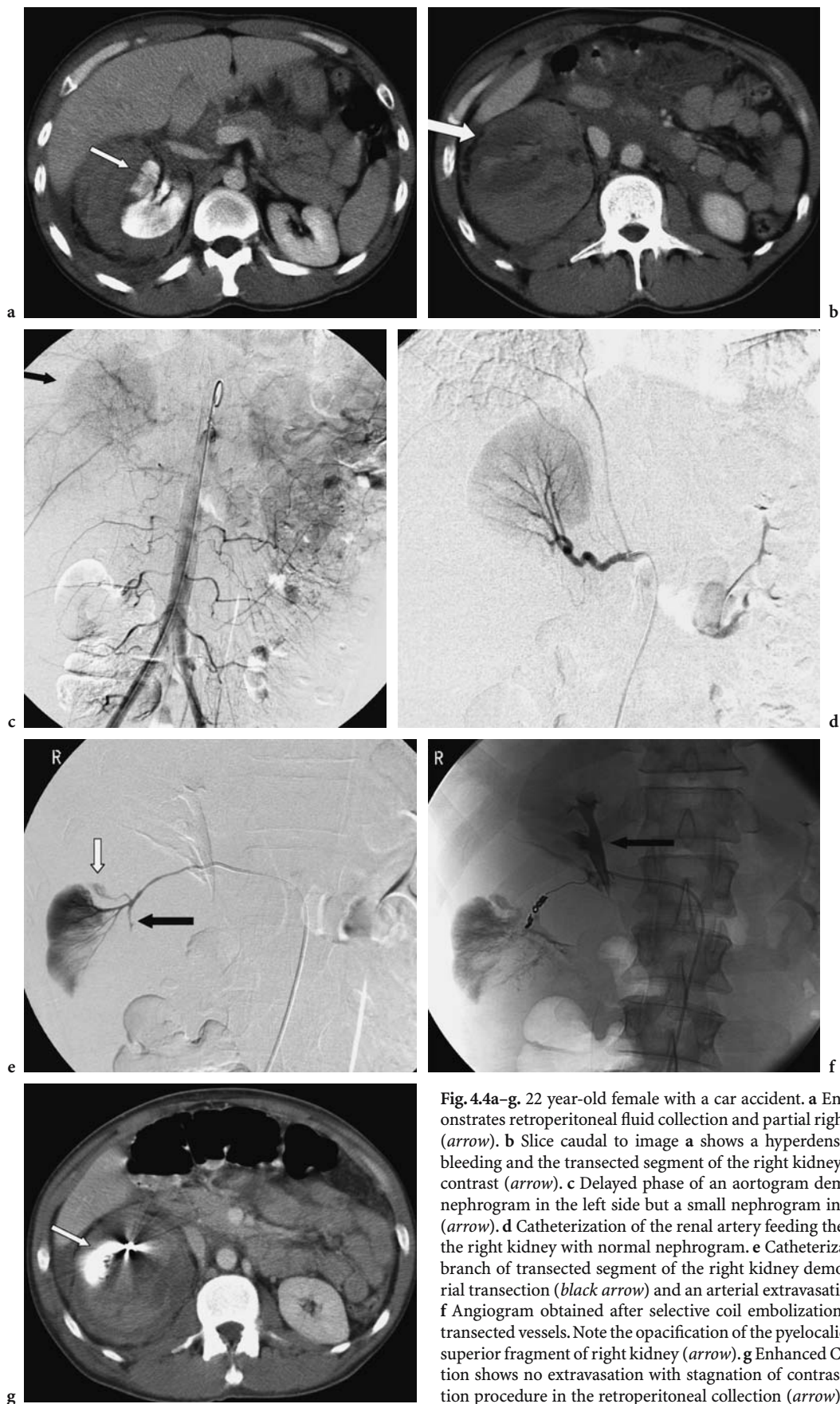

Fig. 4.4a-g. 22 year-old female with a car accident. **a** Enhanced CT demonstrates retroperitoneal fluid collection and partial right kidney fracture (*arrow*). **b** Slice caudal to image **a** shows a hyperdense retroperitoneal bleeding and the transected segment of the right kidney that is taking up contrast (*arrow*). **c** Delayed phase of an aortogram demonstrate normal nephrogram in the left side but a small nephrogram in the right kidney (*arrow*). **d** Catheterization of the renal artery feeding the superior part of the right kidney with normal nephrogram. **e** Catheterization of the renal branch of transected segment of the right kidney demonstrates an arterial transection (*black arrow*) and an arterial extravasation (*white arrow*). **f** Angiogram obtained after selective coil embolization proximal to the transected vessels. Note the opacification of the pyelocaliceal system of the superior fragment of right kidney (*arrow*). **g** Enhanced CT after embolization shows no extravasation with stagnation of contrast from embolization procedure in the retroperitoneal collection (*arrow*)

Table 4.3. Organ Injury Score for Blunt Renal Trauma*

Grade	Type	Description of Trauma
1	Contusion	Hematuria, imaging studies normal
	Hematoma	Subcapsular hematoma (nonexpanding)
2	Hematoma	Perirenal hematoma (contained, nonexpanding)
	Laceration	Cortical laceration (<1 cm) without urinary extravasation, nonexpanding perirenal hematoma
3	Hematoma	Perirenal hematoma (contained, nonexpanding)
	Laceration	Corticomedullary laceration deeper than 1 cm without extravasation
4	Laceration	Corticomedullary laceration deeper than 1 cm with collecting system injury
	Vascular	Injury to main renal artery or vein with contained Hemorrhage
5	Laceration	Completely shattered kidney, ureteropelvic avulsion
	Vascular	Avulsion of renal hilum, devascularizing kidney

*From the American Association for the Surgery of Trauma (AAST) [99].

ography. One patient had venous extravasation and ultimately required surgery; this was the only patient in this series who required surgery. Eight patients demonstrated arterial extravasation and were treated successfully with embolization. Success with embolization has been demonstrated in hemodynamically unstable patients presenting with gross hematuria, active bleeding, and symptoms of shock. These patients are at risk for significant morbidity and mortality with surgery supporting the use of embolization during their care. It has been shown that in these patients, embolization can help control bleeding without nephrectomy [94].

Embolization is also well suited to patients that are initially stable after trauma but develop delayed bleeding over the course of days, weeks, or months [86]. In these patients, the delayed bleeding is most likely due to the formation of a traumatic pseudoaneurysm or arteriovenous fistula, which is more common in patients experiencing penetrating trauma than blunt trauma [95]. Pseudoaneurysms form after blunt trauma due to rapid deceleration-induced injuries to renal arteries [96, 97]. As they form, pseudoaneurysms can contact the collecting system, which can lead to the delayed hematuria often seen in these patients [95]. These pseudoaneurysms can be successfully treated with selective embolization.

4.3.3.3

Post-Embolization Follow-up

There are potential complications associated with the surgical management of patients with renal vascular injuries. These include azotemia and persistent hypertension, which may possibly require nephrectomy for management [83, 98, 99]. At the present time, significant and persistent hypertension has

not been reported after superselective renal embolization [86]. The post-embolization syndrome that is commonly seen after solid organ embolization for other indications and consists of pain, leukocytosis, and fever, is uncommon after selective renal artery embolization in the setting of trauma [100].

Cookbook

Splenic Artery Embolization

- **Proximal Embolization:** In the absence of active contrast extravasation, the splenic artery is proximally embolized. We typically utilize either a 5F Cobra catheter or a 5F Omni-2 catheter to catheterize the celiac axis. Depending on the tortuosity of the vessel, we then either use the Cobra catheter or a microcatheter with a 0.021" inner luminal diameter for more selective catheterization. Once the catheter is in place, just distal to the dorsal pancreatic artery, coils are deposited. The size of the coils chosen depends on the size of the vessel.
- **Distal Embolization:** If active extravasation is present, we find it desirable to selectively catheterize and embolize the injured branch vessel. This requires the use of a microcatheter (0.021" inner luminal dia.) and appropriate guidewire. Once the microcatheter is as distal as it can be, microcoils (either straight or helical, depending on vessel size) are used for embolization.

Hepatic and Renal Artery Embolization

- In patients with hepatic or renal arterial injury, our goal is to embolize as distally as possible, with the intent of sparing as much parenchyma as possible. This typically requires the use of microcatheter and microcoils as above.

References

- Killeen KL, Shanmuganathan K, Boyd-Kranis R et al. (2001) CT findings after embolization for blunt splenic trauma. *J Vasc Interv Radiol* 12:209–214
- Haan JM, Biffl W, Knudson MM et al. (2004) Splenic embolization revisited: a multicenter review. *J Trauma* 56:542–547
- Chaudry IH, Tabata Y, Schleck S et al. (1980) Effect of splenectomy on reticuloendothelial function and survival following sepsis. *J Trauma* 20:649–656
- Rabbinate CD, Frumenti JF (1977) Splenectomy and subsequent mortality in veterans of the 1939–1945 War. *Lancet* 2:127–129
- Green JB, Shackford SR, Sise MJ et al. (1986) Late septic complications in adults following splenectomy for trauma. *J Trauma* 26:999–1004
- Liu PP, Lee WC, Cheng YF et al. (2004) Use of splenic artery embolization as an adjunct to nonsurgical management of blunt splenic injury. *J Trauma* 56:768–773
- Knudson MM, Maull KI. (1999) Nonoperative management of solid organ injuries: past, present, and future. *Surg Clin North Am* 79:1357–1371
- King H, Shumacker HB Jr (1952) Splenic studies 1: susceptibility to infection after splenectomy performed in infancy. *Ann Surg* 136:239
- Pachter HL, Grau J (2000) The current status of splenic preservation. *Adv Surg* 34:137–174
- Godley CD, Warren RL, Sheridan RL et al. (1996) Nonoperative management of blunt splenic injury in adults: age over 55 years as a powerful indicator for failure. *J Am Coll Surg* 183:133–139
- Cocanour CS, Moore FA, Ware DN et al. (2000) Age should not be a consideration for nonoperative management of blunt splenic injury. *J Trauma* 48:606–612
- Haan J, Scott J, Boyd-Kranis RL et al. (2001) Admission angiography for blunt splenic injury: advantages and pitfalls. *J Trauma* 51:1161–1165
- Lucas CE (1991) Splenic trauma: choice of management. *Ann Surg* 213:98–112
- Koury HI, Peschiera JL, Welling RE (1991) Non-operative management of blunt splenic trauma: a 10-year experience. *Injury* 22:349–352
- Peitzman AB, Heil B, Rivera L et al. (2000) Blunt splenic injury in adults: multi-institutional study of the Eastern Association for the Surgery of Trauma. *J Trauma* 49:177–189
- Smith JS Jr, Cooney RN, Mucha P Jr (1996) Nonoperative management of the ruptured spleen: a revalidation of criteria. *Surgery* 120:745–751
- Albrecht RM, Schermer CR, Morris A (2002) Nonoperative management of blunt splenic injuries: factors influencing success in age >55 years. *Am Surg* 68:227–230
- Federle MP, Courcoulas AP, Powell M et al. (1998) Blunt splenic injury in adults: clinical and CT criteria for management, with emphasis on active extravasation. *Radiology* 206:137–142
- Shanmuganathan K, Mirvis SE, Boyd-Kranis R et al. (2000) Nonsurgical management of blunt splenic injury: use of CT criteria to select patients for splenic arteriography and potential endovascular therapy. *Radiology* 217:75–82
- Molin MR, Shackford SR (1990) The management of splenic trauma in a trauma system. *Arch Surg* 125:840–843
- Feliciano PD, Mullins RJ, Trunkey DD et al. (1992) A decision analysis of traumatic splenic injuries. *J Trauma* 33:340–348
- Godley CD, Warren RL, Sheridan RL et al. (1996) Nonoperative management of blunt splenic injury in adults: age over 55 years as a powerful indicator of failure. *J Am Coll Surg* 183:133–139
- Hagiwara A, Yukioka T, Ohta S et al. (1996) Nonsurgical management of patients with blunt splenic injury: efficacy of transcatheter arterial embolization. *Am J Roentgenol* 167:159–166
- Gavant ML, Schurr M, Flick PA et al. (1997) Predicting clinical outcome of nonsurgical management of blunt splenic injury: using CT to reveal abnormalities of splenic vasculature. *AJR* 168:207–212
- Buntain WL, Gould WR, Maull KL (1988) Predictability of splenic salvage by computed tomography. *J Trauma* 28:24–29
- Mirvis SE, Whitley NO, Gens DR (1989) Blunt splenic trauma in adults: CT-based classification and correlation with prognosis and treatment. *Radiology* 171:33–39
- Umlas SL, Cronan JJ (1991) Splenic trauma: can CT grading systems enable prediction of successful nonsurgical treatment? *Radiology* 178:481–485
- Moore EE, Cogbill TH, Jurkovich GH et al. (1995) Organ injury scaling: spleen and liver (1994 revision). *J Trauma* 38:323–324
- Resciniti A, Flink MP, Raptopoulous V et al. (1988) Nonoperative treatment of adult splenic trauma: development of a computed tomographic scoring system that detects appropriate candidates for expectant management. *J Trauma* 28:828–831
- Kohn JS, Clark DE, Isler RJ et al. (1994) Is computed tomographic grading of splenic injury useful in the nonsurgical management of blunt trauma? *J Trauma* 36:385–390
- Becker CD, Spring P, Glatli A et al. (1994) Blunt splenic trauma in adults: can CT findings be used to determine the need for surgery? *AJR* 162:343–347
- Sutyak JP, Chiu WC, D'Amelio LF et al. (1995) Computed tomography is inaccurate in estimating the severity of adult splenic injury. *J Trauma* 39:514–518
- Sclafani SJA, Weisberg A, Scalea T et al. (1991) Blunt splenic injuries: nonsurgical treatment with CT, arteriography, and transcatheter arterial embolization of the splenic artery. *Radiology* 181:189–196
- Sekikawa Z, Takebayashi S, Kurihara H et al. (2004) Factors affecting clinical outcome of patients who undergo transcatheter arterial embolisation in splenic injury. *Br J Radiol* 77:308–311
- Gaunt WT, McCarthy MC, Lambert CS et al. (1999) Traditional criteria for observation of splenic trauma should be challenged. *Am Surg* 65:689–691
- Sclafani SJA (1981) The role of angiographic hemostasis in salvage of the injured spleen. *Diag Radiol* 141:645–650
- Davis KA, Fabian TC, Croce MA et al. (1998) Improved success in nonoperative management of blunt splenic injuries: embolization of splenic artery pseudoaneurysms. *J Trauma* 44:1008–1013

38. James CA, Emanuel PG, Vasquez WD et al. (1996) Embolization of splenic artery branch pseudoaneurysms after blunt abdominal trauma. *J Trauma* 40:835–837
39. Sclafani SJA, Shaftan GW, Scalea TM et al. (1995) Nonoperative salvage of computed tomography-diagnosed splenic injuries: utilization of angiography for triage and embolization for hemostasis. *J Trauma* 39:818–827
40. Dent D, Alsabrook G, Erickson BA et al. (2004) Blunt splenic injuries: high nonoperative management rate can be achieved with selective embolization. *J Trauma* 56:1063–1067
41. Maddison F (1973) Embolic therapy of hypersplenism. *Invest Radiol* 8:280–281
42. Anderson JH, VuBan A, Wallace S et al. (1977) Transcatheter splenic arterial occlusion: an experimental study in dogs. *Radiology* 125:95–102
43. Pietropaoli JA, Rogers FB, Shackford SB et al. (1992) The deleterious effects of intraoperative hypotension on outcome in severe head injuries. *J Trauma* 33:403–407
44. Cocanour CS, Moore FA, Ware DN et al. (1998) Delayed complications of nonoperative management of blunt adult splenic trauma. *Arch Surg* 1998; 133:619–625
45. Haan J, Bochicchio G, Kramer M et al. (2003) Air following splenic embolization: infection or incidental finding? *Am Surg* 69:1036–1039
46. Hiatt JR, Harrier HD, Koeing BV et al. (1990) Nonoperative management of major blunt liver injury with hemoperitoneum. *Arch Surg* 125:101–103
47. Pachter HL, Spencer Fc, Hofstetter SR et al. (1992) Significant trends in the treatment of hepatic trauma. *Ann Surg* 215:492–502
48. Hammond JC, Canal DE, Broadie TA (1992) Nonoperative management of adult blunt hepatic trauma in a municipal trauma center. *Am Surg* 58:551–555
49. Meredith JW, Young JS, Bowling J et al. (1994) Nonoperative management of blunt hepatic trauma: the exception or the rule? *J Trauma* 36:529–535
50. Croce MA, Fabian TC, Menke PG et al. (1995) Nonoperative management of blunt hepatic trauma is the treatment of choice for hemodynamically stable patients. *Ann Surg* 221:744–755
51. Knudson MM, Maull KI (1999) Nonoperative management of solid organ injuries. *Surg Clin North Am* 79:1357–1371
52. Durham RM, Buckley J, Keegan M et al. (1992) Management of blunt hepatic injuries. *Am J Surg* 164:477–481
53. Meyer AA, Crass RA, Lim RC et al. (1985) Selective nonoperative management of blunt liver injury using computed tomography. *Arch Surg* 120:550–554
54. Cuff RE, Cogbill TH, Lambert PJ (2000) Nonoperative management of blunt liver trauma: the value of follow-up abdominal computed tomography scans. *Am Surg* 66:332–336
55. Brasel KJ, DeLisle CM, Olson CJ et al. (1997) Trends in the management of hepatic injury. *Am J Surg* 174:674–677
56. Harper HC, Maull KI (2000) Transcatheter arterial embolization in blunt hepatic trauma. *South Med J* 93:663–665
57. Becker CD, Gal I, Baer HU, Vock P (1996) Blunt hepatic trauma in adults: correlation of CT injury grading with outcome. *Radiology* 201:215–220
58. Mirvis SE, Whitley NO, Vainwright JR et al. (1989) Blunt hepatic trauma in adults: CT-based classification and correlation with prognosis and treatment. *Radiology* 11:27–32
59. Pachter HL, Knudson MM, Esrig B et al. (1996) Status of nonoperative management of blunt hepatic injuries in 1995; a multicenter experience with 404 patients. *J Trauma* 40:31–38
60. Carrillo EH, Spain DA, Wohltmann CD et al. (1999) Interventional techniques are useful adjuncts in nonoperative management of hepatic injuries. *J Trauma* 46:619–624.
61. Ciraulo DL, Luk S, Palter M et al. (1996) Selective hepatic arterial embolization of grade IV and V blunt hepatic injuries: an extension of resuscitation in the nonoperative management of traumatic hepatic injuries. *J Trauma* 45:353–358
62. Rubin BE, Katzen BT (1977) Selective hepatic artery embolization to control massive hepatic hemorrhage after trauma. *AJR* 129:253–256
63. Sclafani SJR (1985) Angiographic control of intraperitoneal hemorrhage caused by injuries to the liver and spleen. *Semin Intervent Radiol* 2:139–147
64. Hashimoto S, Hiramatsu K, Ido K et al. (1990) Expanding role of emergency embolization in the management of severe blunt hepatic trauma. *Cardiovasc Intervent Radiol* 13:193–199
65. Bass EM, Crosier JH (1977) Percutaneous control of post-traumatic hepatic hemorrhage by gelfoam embolization. *J Trauma* 17:61–63
66. Hagiwara A, Yukioka T, Ohta S et al. (1997) Nonsurgical management of patients with blunt hepatic injury: efficacy of transcatheter embolization. *Am J Radiol* 169:1151–1156
67. Hagiwara A, Murata A, Matsuda T et al. (2002) The efficacy and limitations of transarterial embolization for severe hepatic injury. *J Trauma* 52:1091–1096
68. Mohr AM, Lavery RF, Barone A et al. (2003) Angiographic embolization for liver injuries: low mortality, high morbidity. *J Trauma* 55:1077–1082
69. Sugimoto K, Horiike S, Hirata M et al. (1994) The role of angiography in the assessment of blunt liver injury. *Injury* 25:283–287
70. Allins A, Ho T, Nguyen TH et al. (1996) Limited value of routine follow up CT scans in nonoperative management of blunt liver and splenic injuries. *Am Surg* 62:883–886
71. Ciraulo DL, Nikkanen HE, Palter M et al. (1996) Clinical analysis of the utility of repeat computed tomographic scan before discharge in blunt hepatic injury. *J Trauma* 41:821–824
72. Knudson MM, Lim RC, Olcott EW (1994) Morbidity and mortality following major penetrating liver injuries. *Arch Surg* 129:256–261
73. Nash PA, Bruce JE, McAninch JW (1995) Nephrectomy for traumatic renal injuries. *J Urol* 153:609–611
74. Cass AS, Luxenberg M (1983) Conservative or immediate surgical management of blunt renal injuries. *J Urol* 130:11–16
75. Carroll PR, Klosterman PW, McAninch JW (1988) Surgical management of renal trauma: analysis of risk factors, technique and outcome. *J Trauma* 28:1071–1077
76. Thompson IM, Latourette H, Montie JE et al. (1977) Results of non-operative management of blunt renal trauma. *J Urol* 118:522–524
77. McGopnigal MD, Lucas CE, Ledgerwood AM (1987) The effects of treatment of renal trauma on renal function. *J Trauma* 27:471–476
78. Husmann DA, Morris JS (1990) Attempted nonopera-

- tive management of blunt renal lacerations extending through the corticomedullary junction: the short-term and long-term sequelae. *J Urol* 143:682–684
79. Altman AL, Haas C, Dinchman KH et al. (2000) Selective nonoperative management of blunt grade 5 renal injury. *J Urol* 164:27–30
 80. Danuser H, Wille S, Zoscher G et al. (2001) How to treat blunt kidney ruptures: primary open surgery or conservative treatment with deferred surgery when necessary? *Eur Urol* 39:9–14
 81. McAninch JW, Carroll PR, Klosterman PW (1991) Renal reconstruction after injury. *J Urol* 145:932–937
 82. Grablowsky OM, Weichert RF, Goff JB et al. (1970) Renal artery thrombosis following blunt trauma: report of 4 cases. *Surgery* 67:895–900
 83. Carroll PR, McAninch JW, Klosterman P et al. (1990) Renovascular trauma: risk assessment, surgical management, and outcome. *J Trauma* 30:547–555
 84. Moore EE, Shackford SR, Pachter HL et al. (1989) Organ injury scaling: spleen, liver, and kidney. *J Trauma* 29:1664–1666
 85. Becker CD, Mentha G, Schmidlin F et al. (1998) Blunt abdominal trauma in adults: role of CT in the diagnosis and management of visceral injuries. II. Gastrointestinal tract and retroperitoneal organs. *Eur Radiol* 8:772–780
 86. Dinkel HP, Danuser H, Triller J (2002) Blunt renal trauma: minimally invasive management with microcatheter embolization – experience in nine patients. *Radiology* 223:724–730
 87. Kristjansson A, Pedersen J (1993) Management of blunt renal trauma. *Br J Urol* 72:692–696
 88. Sclafani SJA, Goldstein AS, Panetta T et al. (1985) CT diagnosis of renal pedicle injury. *Urol Radiol* 7:63–68
 89. Fisher RG, Ben Menachem Y, Whigham C (1989) Stab wounds of the renal artery branches: angiographic diagnosis and treatment by embolization. *AJR* 152:1231–1235
 90. Corr P, Hacking G (1991) Embolization in traumatic intrarenal vascular injuries. *Clin Radiol* 43:262–264
 91. Velmahos GC, Chahwan S, Falabella A et al. (2000) Angiographic embolization for intraperitoneal and retroperitoneal injuries. *World J Surg* 24:539–545
 92. Velmahos GC, Demetriades D, Chahwan S et al. (1999) Angiographic embolization for arrest of bleeding after penetrating trauma to the abdomen. *Am J Surg* 178:367–373
 93. Hagiwara A, Sakaki S, Goto H et al. (2001) The role of interventional radiology in the management of blunt renal injury: a practical protocol. *J Trauma* 51:526–531
 94. Baron BJ, Scalea TM, Sclafani SJ et al. (1993) Nonoperative management of blunt abdominal trauma: the role of sequential diagnostic peritoneal lavage, computed tomography, and angiography. *Ann Emerg Med* 22:1556–1562
 95. Miller DC, Forauer A, Faerber GJ (2002) Successful angiographic embolization of renal artery pseudoaneurysms after blunt abdominal trauma. *Urology* 59:444xiii–444xv
 96. Jebra VA, El Rassi I, Achouh PE et al. (1998) Renal artery pseudoaneurysm after blunt abdominal trauma. *J Vasc Surg* 27:362–365
 97. Swana HS, Cohn SM, Burns GA et al. (1996) Renal artery pseudoaneurysm after blunt abdominal trauma: case report and literature review. *J Trauma* 40:459–461
 98. Grant P, Gifford RW, Pudvan WR et al. (1971) Renal trauma and hypertension. *Am J Cardiol* 27:173–176
 99. Mounger EJ (1973) Hypertension resulting from segmental renal artery infarction. *Urology* 1:189–190
 100. Larsen DW, Pentecost MJ (1992) Embolotherapy in renal trauma. *Semin Intervent Radiol* 9:13–18

5 Embolization and Pelvic Trauma

JEFFREY J. WONG and ANNE C. ROBERTS

CONTENTS

5.1	Introduction and Background	59
5.1.1	Penetrating vs Blunt Trauma	59
5.1.2	Causes and Epidemiology	59
5.1.3	Sources of Bleeding: Arterial vs Venous vs Marrow	60
5.1.4	Why Not Surgery?	60
5.1.5	Role of Interventional Radiology	60
5.2	Presentation	60
5.2.1	Shock/Active Hemorrhage	61
5.2.2	Pelvic Fracture & Plain AP Radiographs	61
5.3	Guiding/Directing Therapy and the Laparotomy	61
5.3.1	Diagnostic Peritoneal Aspiration, Ultrasound, and Contrast-Enhanced CT	61
5.3.2	External Fixation	62
5.3.3	Laparotomy	62
5.4	Endovascular Therapy	63
5.4.1	Access to Vessels	63
5.4.2	The Initial Pelvic Arteriogram and Further Studies	63
5.4.3	Angiographic Appearance of Hemorrhage	64
5.4.4	Embolization Agents	64
5.4.5	What To Do If No Bleeding Is Seen? The "Check" Arteriogram	66
5.5	Complications	66
5.6	Conclusion	67
	Cookbook:	66
	References	67

5.1 Introduction and Background

5.1.1 Penetrating vs Blunt Trauma

Like all traumatic injuries, trauma to the pelvis can be classified into either penetrating or blunt. Penetrating mechanisms, such as stab wounds, gunshot wounds biopsies, or surgical or percuta-

neous spine procedures, may directly injure pelvic organs, nerves, or the blood vessels. Blunt trauma exerts its effects through vessels being sheared against fixed ligamentous structures and avulsion of vessels attached to displaced bony pelvic structures. Pelvic fractures also damage adjacent pelvic or retroperitoneal structures. The interventionist's primary concerns are vascular injuries, notably hemorrhage from the branches of the internal iliac arteries.

5.1.2 Causes and Epidemiology

Pelvic fractures account for 3% of all skeletal injuries and are associated with a substantial mortality, with reported figures varying from 5% to 60% [1–21]. Mechanisms for pelvic fractures include motor vehicle accidents (57%), pedestrians hit by motor vehicles (18%), motorcycle accidents (9%), falls (9%), crush injuries (4%), and sports/recreational mechanisms (3%) [22]. Pelvic fractures are grouped based on the direction of the causative force. These forces include lateral compression, anteroposterior compression, vertical shear, and combinations of these three [23]. Most injuries to the infrarenal aorta are caused by seat belts compressing the lower abdomen in the anteroposterior aspect during car accidents.

A closed stable fracture with stable vital signs offers the best prognosis, while patients with an open fracture and hemodynamic instability have a higher mortality. This latter subgroup only represents 1%–2% of all pelvic injuries seen in Level 1 trauma centers [24] but no other skeletal injury carries such a high mortality rate.

As hemorrhage is the most common treatable cause of death in this population of patients, it is imperative that vascular injuries are treated swiftly and decisively. CLARKE et al. [25] suggested that the risk of mortality increases by 1% every 3 minutes that a patient remains hemodynamically unstable.

J. J. WONG, MB ChB, BMedSc; A. C. ROBERTS, MD
University of California, San Diego Medical Center, Division of
Vascular and Interventional Radiology, 200 West Arbor Drive,
San Diego, California, 92103-8756, USA

5.1.3

Sources of Bleeding:

Arterial vs Venous vs Marrow

Direct bleeding from the fractured cancellous bones or from injured pelvic arteries and veins can cause pelvic bleeding. The anatomy of the retroperitoneum and its contents provides a natural tamponading effect on the fragile venous plexus adjacent to the pelvic bones and osseous bleeding. However, in the event of pelvic disruption and an unstable pelvic fracture, this tamponading effect is lost. A 3-cm diastasis of the symphysis pubis will increase the potential volume of the pelvis from 4 liters to 8 liters [26]. The lack of valves between the inferior vena cava and the pelvic veins allows for potential catastrophic blood loss if the retroperitoneum is violated. Pelvic fixation, be it invasive or noninvasive, will re-establish and maintain the tamponading effect, thus controlling bleeding from the venous and osseous structures. A dog model has been used to show that ligation of multiple pelvic arteries had no effect on the pelvic venous pressure [27]. Because the source of pelvic hemorrhage is from venous structures 80%–90% of the time [28,29], there is a strong argument for starting with pelvic fixation and intrapelvic compression. Clinically, it is not possible to determine the source of pelvic hemorrhage without the aid of radiographic studies. Thus there remains much debate as to whether a patient who has presumed pelvic hemorrhage undergoes angiography or pelvic fixation, since fixation can only temporize small vessel hemorrhage [28, 30]. If the bleeding source is arterial, angiography and embolization is necessary. Miller et al. [31] showed that if patients present with hypotension from a pelvic fracture, poor response to resuscitative efforts indicates the presence of arterial bleeding in over 70% of patients. Meanwhile, responsive patients are unlikely to have arterial bleeding, with a negative predictive value of 100%.

5.1.4

Why Not Surgery?

An open surgical approach to retroperitoneal bleeding is not a treatment for retroperitoneal pelvic bleeding. Dissection into the retroperitoneum and pelvis results in the loss of the internal compression effect provided by adjacent anatomic structures, resulting in increased bleeding. The rich collateral

pathways, as well as large hematomas obscuring the surgical field further complicate the technical aspect of surgical control of arterial hemorrhage. An obscured field of view increases the likelihood of complications such as nerve injury. The primary operative option for controlling pelvic bleeding consists of packing and correction of coagulopathy. Temporary aortic clamping has been suggested to improve access to the site of bleeding [32].

5.1.5

Role of Interventional Radiology

The interventional radiologist has become the central figure in treating traumatic pelvic and retroperitoneal arterial hemorrhage, and with impressive results. Angiographic embolization has a success rate between 85% and 100% when bleeding sites can be identified [33, 34]. The first-line therapy for an unstable patient with a pelvic fracture should be immediate angiographic evaluation and embolization.

5.2

Presentation

All trauma patients should be initially assessed following standard Advanced Trauma Life Support (ATLS) guidelines, the details of which cannot be covered in this text. However, as interventional radiologists, we are most concerned with signs and symptoms that will raise our suspicion of pelvic fractures and hemodynamic compromise. As the presentation of patients with life-threatening hemorrhage can vary from exsanguinating shock to subtle innocuous signs, a detailed knowledge of the presentations of pelvic trauma is necessary.

5.2.1

Shock/Active Hemorrhage

Evidence of shock consists of hypotension, tachycardia (pulse > 100 beats per min), tachypnea, cool extremities, low urine output, and a progressive decline in the level of consciousness. A normal blood pressure may be misleading in young patients, because the blood pressure may be maintained by a compensatory increased heart rate. In these patients, hypotension occurs only when this mechanism fails and usually indicates impending cardiovascular collapse.

The hemoglobin level is not a specific marker of hemorrhage as, in the acute stages, the hemoglobin or hematocrit is likely to be normal. A few hours are required before extravascular fluids equilibrate with the blood and for laboratory values to reflect blood loss. It is imperative to obtain two intravenous accesses with large bore cannulas and start an infusion of intravenous fluids as soon as possible. O-negative blood should be readily available, and blood samples should be sent early for cross matching.

5.2.2 Pelvic Fracture & Plain AP Radiographs

The suspicion for a pelvic fracture should start with a history of a high-energy impact such as a motor vehicle accident or a fall from a substantial height. Careful inspection may reveal leg length discrepancies (Roux sign), flank ecchymosis (Grey-Turners sign), blood at the urethral meatus, rectal bleeding and/or vaginal bleeding. Hematomas observed on the proximal thigh superficial to the inguinal ligament or over the perineum are also suggestive of a pelvic fracture (Destot's sign). Tenderness with gentle pressure on the iliac wings bilaterally also supports the diagnosis of a pelvic fracture. Care must be taken not to apply too much pressure as this may aggravate hemorrhage in an as-yet-undiagnosed unstable fracture. Rectal examination may reveal a high-riding prostate or a large hematoma or palpable fracture line (Earle's sign). Examination of the lower limbs may also show neurovascular deficits.

Most patients will usually have plain films of the chest and pelvis, regardless of their hemodynamic situation. Anteroposterior (AP) pelvic films, although only 68% sensitive for diagnosing all fractures [35], will reveal and define any large fractures which would raise our suspicion of retroperitoneal bleeding. It has been shown if an unstable fracture pattern is seen or suspected, the probability of pelvic arterial bleeding is approximately 52% [11, 14, 34, 19, 21, 36, 37]. NIWA et al. [38] showed that AP pelvic films can be useful in predicting hemorrhage sites based on the location and severity of the fracture. Interestingly, stable pelvic fractures have shown to be more strongly associated with abdominal bleeding rather than pelvic bleeding [21].

Kane's classification of pelvic radiograph's helps to convey the gravity of the bony injury (See Table 5.1).

5.3 Guiding/Directing Therapy and the Laparotomy

Once the suspicion of pelvic hemorrhage has been raised, one must systematically follow a protocol that will ensure injuries and sources of bleeding are addressed in order of gravity. HEETVELD et al. [39] published an evidence-based algorithm for the management of *hemodynamically unstable* pelvic fracture patients (Table 5.2).

5.3.1 Diagnostic Peritoneal Aspiration, Ultrasound, and Contrast-Enhanced CT

The initial examination of the patient may elicit signs of peritoneal irritation on abdominal palpation. As the laboratory and plain film investigations fail to address the abdominal cavity, these clinical signs will point the trauma team to proceed with further investigations. An acute abdomen in the setting of hemodynamic instability should result in either a diagnostic peritoneal lavage (DPL) or focused abdominal sonography for trauma (FAST). These investigations will reveal blood/free fluid in the abdominal cavity suggesting intra-abdominal hemorrhage and, in the presence of hemodynamic instability may indicate the need for a laparotomy.

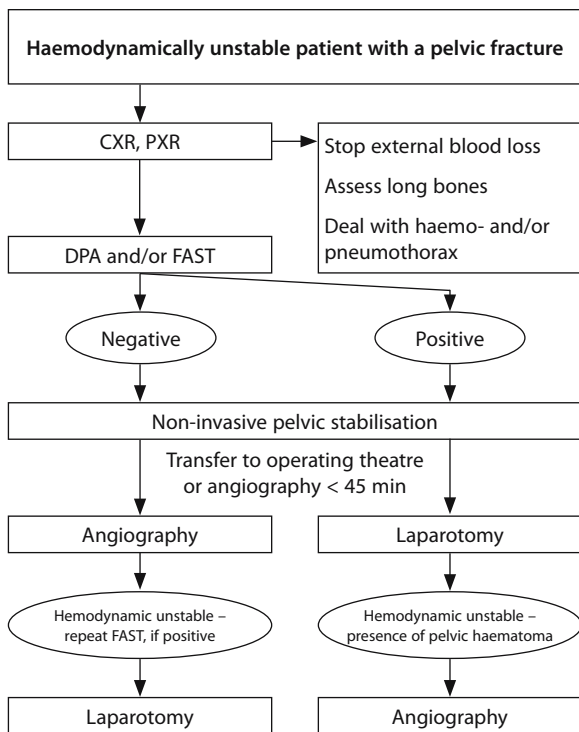
It is not recommended that hemodynamically unstable patients undergo a computed tomography (CT) scan. However, in those patients stable enough to be transported, contrast-enhanced CT of the abdomen and pelvis can help distinguish actively extravasating contrast material from clotted blood [40] and thus guide surgical or angiographic therapy.

In the hemodynamically stable patient, CT is the preferred method of investigation [41]. CERVA et al. [42] in 1996 showed that using angiography as a gold

Table 5.1. Kane's classification of pelvic fractures

Kane's classification type	Definition
I	Fracture of only 1 pelvic bone with no interruption of the anatomic ring
II	Single breaks in the ring near the pubic symphysis or a sacroiliac joint
III	Double breaks in the ring
IV	Acetabular fractures

Table 5.2. Algorithm for the management of hemodynamically unstable pelvic fracture patients



standard, contrast enhanced CT was 85% specific, 84% sensitive and 90% accurate. This study used 10-mm collimation at 20-mm intervals. However, a more recent study by PEREIRA et al. [43] found a sensitivity of 90%, specificity of 99% and accuracy of 98 with helical CT using 10-mm intervals with a pitch of 1.0:1 to 1.5:1. They suggested its use as a method for screening polytrauma patients with pelvic fractures to accurately identify patients who would benefit from emergent angiographic embolization. It is important that patients who may be going on to angiography not receive oral contrast material that would interfere with the angiographic evaluation.

With improving technology resulting in faster image acquisition and higher-resolution images, contrast-enhanced multi-detector CT has become increasingly accurate and may even surpass conventional angiography in sensitivity. In one study, four hemodynamically stable patients exhibiting contrast extravasation on CT did not require embolization during hospitalization [43]. An example of this clinical scenario is seen in Fig. 5.1, which involved a hemodynamically stable trauma patient with visible extravasation on CECT which was undetectable

on catheter angiography. This posed a challenging therapeutic dilemma. As she was hemodynamically stable and there were no signs of hypovolemia, the eventual decision was not to embolize. The patient returned to the intensive care unit and did well.

5.3.2 External Fixation

Following DPL or FAST, HEETVELD et al. [39] suggest using external fixation to provide a tamponading effect. Internal pelvic fixation is an open surgical procedure that consumes precious time that may be better spent on laparotomy or angiography. Noninvasive methods of pelvic fixation include a pelvic sling, pelvic binder, C-clamp, military anti-shock trousers (MAST), and external fixation. The latter two options are most relevant to the interventionist because they impair access to the femoral arteries [44]. A hole can be cut with scissors into the upper edge of a pelvic binder to allow access into the groin.

5.3.3 Laparotomy

Following HEETVELD et al.'s guidelines [39], if evidence of intra-abdominal hemorrhage is found, a laparotomy is indicated. As a general rule, intra-abdominal hemorrhage takes priority over retroperitoneal pelvic bleeding. So, in the face of detected abdominal free fluid, a pelvic fracture and hemodynamic compromise or catastrophic exsanguination, a laparotomy is first-line therapy. If, after achieving abdominal hemostasis [intra-abdominal repair], retroperitoneal pelvic bleeding is detected and hemodynamic instability continues pelvic packing with large sponges should be performed and the patient be taken to angiography. EASTRIDGE et al. [21], however, suggest considering angiography over laparotomy with unstable pelvic fractures, despite the presence of hemoperitoneum.

Ligation of the internal iliac artery has been shown not to lead to satisfactory reduction in bleeding [45–48]. This is thought to be due to the rich collateral blood supply to the pelvic region and the loss of the tamponading effect of the retroperitoneum. Following surgery, angiography is warranted if the patient requires transfusions of 4 units or greater in 24 hours or hemodynamic instability persists [36, 49].

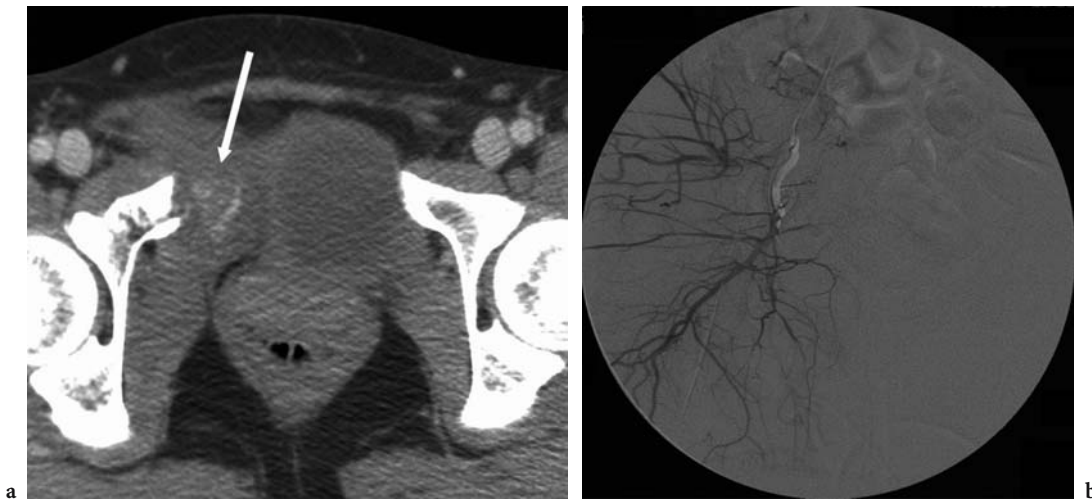


Fig 5.1a,b. Fifty-year-old female was a restrained driver involved in a road traffic accident traveling at 50 mph. She was hemodynamically stable when the initial pelvic CT was performed. **a** Contrast-enhanced CT of the pelvis shows right pelvic fractures and active contrast extravasation (*arrow*) with mass effect on the bladder. This finding prompted angiographic study of the internal iliac arteries. **b** Selective angiogram of the right internal iliac shows no contrast extravasation. As the patient was hemodynamically stable, no embolization was performed.

5.4 Endovascular Therapy

Once abdominal hemorrhage has been ruled out by FAST, CT, or DPL with continued hemodynamic instability or if contrast extravasation is demonstrated on CT the patient should be transferred to the angiography suite. It is imperative that the resuscitative process is not impeded by this transfer, and that a full complement of clinical staff accompany the patient during angiography and embolization.

It is important that angiographic evaluation is not delayed, since patients who have experienced significant blood loss are at risk of becoming coagulopathic. It is vital, therefore, to have a variety of blood products available, and coagulation/hematologic studies should be performed before, during, and after the resuscitation phase.

5.4.1 Access to Vessels

A femoral approach is preferred. If the side of the pelvic injury is known, the contralateral femoral artery should be used. This is because it is easier to catheterize 2nd- and 3rd-order vessels on the contralateral side, over the aortic bifurcation. If bilateral femoral artery access is impaired, an axillary or brachial approach can be used. An upper extremity

approach is sometimes useful if an external pelvic fixator has already been placed or there are bilateral pelvic injuries. Ultrasound guidance may be helpful in patients with large hematomas involving the groin.

5.4.2 The Initial Pelvic Arteriogram and Further Studies

The angiographic search for bleeding should start with a pelvic arteriogram with a 5 F pigtail catheter positioned above the aortic bifurcation. The most commonly injured vessels include the superior gluteal, internal pudendal, obturator, inferior gluteal, lateral sacral, and iliolumbar arteries. The arteries that are injured tend to be associated with the bony injury; thus sacral fractures and sacroiliac joint disruption are associated with superior gluteal, iliolumbar, and lateral sacral arterial injury. Fractures of the pubic ramus and acetabulum tend to cause injury to the internal pudendal and obturator arteries. Therefore, one should pay attention to the plain films or CT to direct the angiographic evaluation. If no bleeding is observed, selective right and left internal iliac arteriograms should be performed. Oblique views frequently help “open up” the branches of the internal iliac.

Access to either the contralateral or ipsilateral internal iliac arteries can be facilitated using a Waltman's loop technique with a Cobra 2 catheter; alternatively, a long reverse curve catheter can be used. Care must be taken not to catheterize too distally so as to ensure visualization of the lateral sacral and iliolumbar arteries [50]. Carbon dioxide offers an alternative contrast agent that has the benefits of no allergic reactions, nephrotoxicity, or volume limitations, low cost and flexibility of use with different sized catheters [51–53]. High-pressure contrast injections should be avoided since they may potentially dislodge newly formed clots and result in loss of hemostasis [54].

5.4.3 Angiographic Appearance of Hemorrhage

See Table 5.3 for the angiographic manifestations of vessel injury [54]. Care must be taken not to confuse the normal uterine blush or bulbospongiosal stain with the blush associated with contrast extravasation (Fig. 5.2). Reported causes of false negative arteriograms include intermittent vasospasm, spontaneous vaso-occlusion of a bleeding artery by thrombus formation, venous bleeding that is not shown by arteriography, and technical difficulties selectively catheterizing the bleeding artery [54]. Arteriovenous fistulas and pseudoaneurysm are recognized late complications of pelvic trauma.

5.4.4 Embolization Agents

Embolization of visualized bleeding site(s) in the pelvis is typically performed using Gelfoam. Gelfoam pledgets have excellent properties for trauma

use because they usually dissolve over several weeks and may allow for recanalization of the vessel following healing. The size of the particles is also optimal because they are large enough not to invade the capillary bed, while small enough to prevent flow from collateral vessels and stop bleeding. Gelfoam powder, which has a much smaller diameter, should not be used for pelvic bleeding since it has the potential to cause ischemia and has been implicated in nerve damage [55].

“Scatter” embolization using a Gelfoam ‘slurry’ provides a rapid solution in the face of multiple bleeding points and a hemodynamically unstable patient who cannot tolerate the time required for subselective catheterization. In this scenario, the catheter is placed proximally in the internal iliac trunk to allow flow of the embolic material to all bleeding points. If the patient is hemodynamically stable, further subselection can take place in search for the bleeder. However, it must be stressed that an ideal subselective embolization must take second place to the cardiovascular status of the patient.

To protect the gluteal arteries from inadvertent embolization, spring coils can be placed at their origins. Coils can also be added for larger lacerations in higher-caliber proximal vessels. In this scenario, Gelfoam may flow straight out of the vessel and into the pelvic cavity, but a large-caliber, proximally placed coil would not. Gelfoam may then be placed on top of the coil, which acts as a scaffolding, and if necessary, a second coil may be placed creating a “Gelfoam sandwich”. Ideally, the injured segment should be crossed so a distal coil can be placed which will have the beneficial effect of preventing retrograde flow from collateral vessels beyond the injury. Coils can be used to treat AVFs and pseudoaneurysms, closely packed up to and proximal to any observed lesion.

Absolute alcohol and particulate polyvinyl alcohol (PVA) emboli have no role in the trauma patient.

Table 5.3. The angiographic manifestations of vessel injury [54]

Angiographic manifestations of vessel injury	Angiographic manifestations of bleeding
Arterial cut-off	Free-flow contrast extravasation
Mural irregularities or flap	Stagnant intraparenchymal accumulation of contrast
Laceration	Disruption of visceral contour
Thrombosis	Displaced organ
Dissection	Intraparenchymal avascular zones
Free-flow contrast extravasation	
Stagnant intraparenchymal accumulation of contrast	
Parenchymal blush	
Stagnant arterial or venous flow	
Diffuse vasoconstriction	
Pseudoaneurysm	
Arteriovenous fistula	
Vessel displacement	

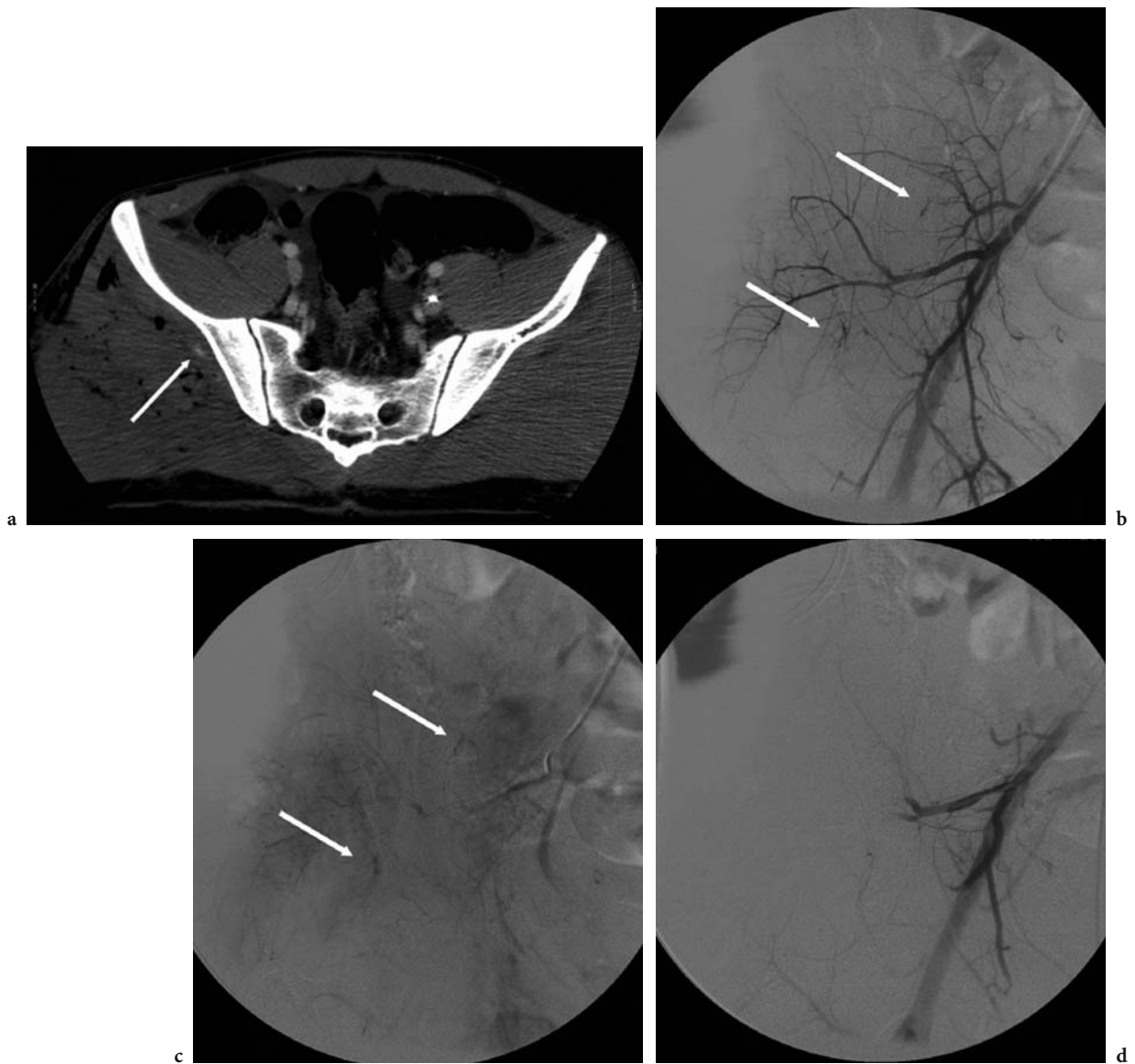


Fig 5.2a–d. Thirty-one-year-old male involved in a motorcycle accident collision and suffered multiple injuries including right femur fracture and a laceration of the right buttock. The patient was hypotensive and no definite pelvic fractures were seen on plain film. **a** Pelvic CT demonstrated active extravasation of contrast from a right superior gluteal artery branch and an expanding right side. **b** Arterial phase angiogram of the right internal iliac demonstrates two areas of extravasation. **c** Venous phase angiogram shows retention of contrast in the suspected areas. **d** Post-Gelfoam embolization angiogram shows truncation of the distal branches of the superior gluteal artery.

Unlike Gelfoam, which spares the capillary bed vessels, alcohol causes sclerosis of all vessels it comes into contact with, including those at the capillary level. This results in irreversible end-organ ischemia and necrosis.

Angiography may reveal injuries to larger more proximal vessels, such as the common iliac or external iliac arteries, traditionally treated surgically. However, with the advent of covered stents, inter-

ventional radiologists may be able to offer a less invasive endovascular solution [42, 56]. In some unusual circumstances, temporary occlusion balloons can be used to obtain hemostasis allowing for surgical repair.

Following embolization of a bleeding site, the internal iliac artery should be checked proximally to make sure there are no other bleeding sites that were not recognized earlier. Because of the rich cross-

pelvic collateral supply, the contralateral internal iliac artery should then be evaluated and embolized as necessary. Once embolization is felt to be complete, it may be reasonable to perform a final flush pelvic arteriogram.

5.4.5

What To Do If No Bleeding Is Seen? The “Check” Arteriogram

In the setting of hemodynamic instability and undetectable extravasation from the pelvis on angiography, further investigation of other vessels including the lumbar branches, branches of the common femoral artery, superficial femoral artery, and profunda femoral artery should be performed. If there is potential for splenic, hepatic, or renal injury, these vessels should also be evaluated. If all other potential arterial sources have been excluded and the patient remains hemodynamically unstable, then empiric embolization of the internal iliac arteries may be performed.

5.5

Complications

Although a post-embolization arteriogram may show complete hemostatic control, a second embolization may be needed. Vessels that had previously “clamped down”/vasoconstricted due to shock may re-open following reperfusion from the ensuing resuscitation and increased systemic blood pressure [54]. These vessels may have initially been injured, but were not detectable on initial arteriogram and therefore provide a new source of hemorrhage.

Embolization, by definition, reduces blood flow distally. Therefore, it is no surprise that distal necrosis is a recognized complication of trauma embolization. However, unintentional reflux of embolization material from the internal iliac into the femoral artery can cause inadvertent ischemia in the leg. Sciatic palsy with associated foot drop and sacral plexus palsy has been reported [57]. Embolization of the superior gluteal artery in a patient who will be subjected to prolonged bedrest may cause sacral and buttock ischemia leading to skin break down [58]. Sexual dysfunction seems not to be a complication of bilateral internal iliac artery embolization, but is more likely a result of nerve injury secondary to the fracture or pelvic trauma [59].

5.6

Conclusion

Endovascular therapy is now established as the treatment modality of choice for retroperitoneal and pelvic bleeding secondary to trauma. Despite evidence to support earlier involvement of the interventional radiologist, some trauma centers still fail to consider angiographic study until much later into the resuscitative process. The adoption of an evidence-based trauma algorithm (Table 5.2) is vital to ensure rapid and decisive treatment.

Cookbook:

For selective angiogram

- 5 French Sheath
- Glidewire (Terumo)
- Long reverse curve catheter (RUC – Cook, Inc) an excellent catheter for trauma as it is for fibroid embolization

Alternative catheters

- C2 catheter, can be used to as is, or used to form a Waltman Loop
- Microcatheters if patient stability and vessel bleeding would allow subselective catheterization

Embolization materials

- Gelfoam – may be constituted as pledgets, torpedoes, or slurry. Do *not* use Gelfoam powder
- Coils – may be used particularly for larger vessels
- May use in combination with Gelfoam for “Gelfoam sandwich”
- Very occasionally, for large vessel trauma, occlusion balloons or covered stents may be appropriate

Tips

- Never forget that a less selective embolization and a live patient is preferable to a technical tour de force and a dead patient!
- Long reverse curve catheter allows for a very fast way to access the internal iliacs and to perform subselective embolization quickly with large pieces of Gelfoam or large coils
- Make sure if embolization done on one side, that the other iliac artery is evaluated to make sure no collateral flow
- If iliac arteries are ok, but patient still hemodynamically unstable, check for lumbar bleeding or for bleeding from branches of femoral arteries

References

1. Trunkey DD, Chapman MW et al. (1974) Management of pelvic fractures in blunt trauma injury. *J Trauma* 14(11):912-23
2. Rothenberger D, Velasco R et al. (1978) Open pelvic fracture: a lethal injury. *J Trauma* 18(3):184-7
3. Rothenberger DA, Fischer RP et al. (1978) The mortality associated with pelvic fractures. *Surgery* 84(3):356-61
4. McMurtry R, Walton D et al. (1980) Pelvic disruption in the polytraumatized patient: a management protocol. *Clin Orthop*(151):22-30
5. Gilliland MD, Ward RE et al. (1982) Factors affecting mortality in pelvic fractures. *J Trauma* 22(8):691-3
6. Richardson JD, Harty J et al. (1982) Open pelvic fractures. *J Trauma* 22(7):533-8
7. Naam NH, Brown WH et al. (1983) Major pelvic fractures. *Arch Surg* 118(5):610-6
8. Mucha P Jr and Welch TJ (1988) Hemorrhage in major pelvic fractures. *Surg Clin North Am* 68(4):757-73
9. Panetta T, Sclafani SJ et al. (1985) Percutaneous transcatheter embolization for massive bleeding from pelvic fractures. *J Trauma* 25(11):1021-9
10. Moreno C, Moore EE et al. (1986) Hemorrhage associated with major pelvic fracture: a multispecialty challenge. *J Trauma* 26(11):987-94
11. Cryer HM, Miller FB et al. (1988) Pelvic fracture classification: correlation with hemorrhage. *J Trauma* 28(7):973-80
12. Evers BM, Cryer HM et al. (1989) Pelvic fracture hemorrhage. Priorities in management. *Arch Surg* 124(4):422-4
13. Flint L, Babikian G et al. (1990) Definitive control of mortality from severe pelvic fracture. *Ann Surg* 211(6):703-6; discussion 706-7
14. Poole GV, Ward EF et al. (1991) Pelvic fracture from major blunt trauma. Outcome is determined by associated injuries. *Ann Surg* 213(6):532-8; discussion 538-9
15. Gruen GS, Leit ME et al. (1994) The acute management of hemodynamically unstable multiple trauma patients with pelvic ring fractures. *J Trauma* 36(5):706-11; discussion 711-3
16. Poole GV and Ward EF (1994) Causes of mortality in patients with pelvic fractures. *Orthopedics* 17(8):691-6
17. Eastridge BJ and Burgess AR (1997) Pedestrian pelvic fractures: 5-year experience of a major urban trauma center. *J Trauma* 42(4):695-700
18. Bassam D, Cephas GA et al. (1998) A protocol for the initial management of unstable pelvic fractures. *Am Surg* 64(9):862-7
19. Hamill J, Holden A et al. (2000) Pelvic fracture pattern predicts pelvic arterial haemorrhage. *Aust N Z J Surg* 70(5):338-43
20. Ertel W, Keel M et al. (2001) Control of severe hemorrhage using C-clamp and pelvic packing in multiply injured patients with pelvic ring disruption. *J Orthop Trauma* 15(7):468-74
21. Eastridge BJ, Starr A et al. (2002) The importance of fracture pattern in guiding therapeutic decision-making in patients with hemorrhagic shock and pelvic ring disruptions. *J Trauma* 53(3):446-50; discussion 450-1
22. Dalal SA, Burgess AR et al. (1989) Pelvic fracture in multiple trauma: classification by mechanism is key to pattern of organ injury, resuscitative requirements, and outcome. *J Trauma* 29(7):981-1000; discussion 1000-2
23. Burgess AR, Eastridge BJ, et al. (1990) Pelvic ring disruptions: effective classification system and treatment protocols. *J Trauma* 30(7):848-56
24. Tscherne HPT (1998) *Unfallchirurgie: Becken und Acetabulum*. Berlin, Springer
25. Clarke JR, Trooskin SZ et al. (2002) Time to laparotomy for intra-abdominal bleeding from trauma does affect survival for delays up to 90 minutes. *J Trauma* 52(3):420-5
26. Agnew SG (1994) Hemodynamically unstable pelvic fractures. *Orthop Clin North Am* 25(4):715-21
27. Ger R, Condrea H et al. (1969) Traumatic intrapelvic retroperitoneal hemorrhage. An experimental study. *J Surg Res* 9(1):31-4
28. Huittinen VM and Slativ P (1973) Postmortem angiography and dissection of the hypogastric artery in pelvic fractures. *Surgery* 73(3):454-62
29. Kadish LJ, Stein JM et al. (1973) Angiographic diagnosis and treatment of bleeding due to pelvic trauma. *J Trauma* 13(12):1083-5
30. Ben-Menachem Y, Coldwell DM et al. (1991) Hemorrhage associated with pelvic fractures: causes, diagnosis, and emergent management. *AJR Am J Roentgenol* 157(5):1005-14
31. Miller PR, Moore PS et al. (2003) External fixation or arteriogram in bleeding pelvic fracture: initial therapy guided by markers of arterial hemorrhage. *J Trauma* 54(3):437-43
32. Buhner V and Trentz O (1989) [Intraluminal balloon occlusion of the aorta in traumatic massive hemorrhage]. *Unfallchirurg* 92(7):309-13
33. Mucha P Jr and Farnell MB (1984) Analysis of pelvic fracture management. *J Trauma* 24(5):379-86
34. Agolini SF, Shah K et al. (1997) Arterial embolization is a rapid and effective technique for controlling pelvic fracture hemorrhage. *J Trauma* 43(3):395-9
35. Guillaumondegui OD, Pryor JP et al. (2002) Pelvic radiography in blunt trauma resuscitation: a diminishing role. *J Trauma* 53(6):1043-7
36. Velmahos GC, Chahwan S et al. (2000) Angiographic embolization for intraperitoneal and retroperitoneal injuries. *World J Surg* 24(5):539-45
37. Velmahos GC, Toutouzas KG et al. (2002) A prospective study on the safety and efficacy of angiographic embolization for pelvic and visceral injuries. *J Trauma* 53(2):303-8; discussion 308
38. Niwa T, Takebayashi S et al. (2000) The value of plain radiographs in the prediction of outcome in pelvic fractures treated with embolisation therapy. *Br J Radiol* 73(873):945-50
39. Heetveld MJ, Harris I et al. (2004) Guidelines for the management of haemodynamically unstable pelvic fracture patients. *ANZ J Surg* 74(7):520-9
40. Shanmuganathan K, Mirvis SE et al. (1993) Value of contrast-enhanced CT in detecting active hemorrhage in patients with blunt abdominal or pelvic trauma. *AJR Am J Roentgenol* 161(1):65-9
41. Pryor JP and Reilly PM (2004) Initial care of the patient with blunt polytrauma. *Clin Orthop*(422):30-6
42. Balogh Z, Voros E et al. (2003) Stent graft treatment of an external iliac artery injury associated with pelvic fracture. A case report. *J Bone Joint Surg Am* 85-A(5):919-22
43. Pereira SJ, O'Brien PD et al. (2000) Dynamic helical computed tomography scan accurately detects hemorrhage in patients with pelvic fracture. *Surgery* 128(4):678-85
44. Gansslen A, Giannoudis P et al. (2003) Hemorrhage in

- pelvic fracture: who needs angiography? *Curr Opin Crit Care* 9(6):515–23
45. Ravitch MM (1964) Hypogastric Artery Ligation in Acute Pelvic Trauma. *Surgery* 56:601–2
 46. Seavers R, Lynch J et al. (1964) Hypogastric Artery Ligation for Uncontrollable Hemorrhage in Acute Pelvic Trauma. *Surgery* 55:516–9
 47. Hauser CW and Perry JF Jr. (1965) Control of Massive Hemorrhage from Pelvic Fractures by Hypogastric Artery Ligation. *Surg Gynecol Obstet* 121:313–5
 48. Saueracker AJ, McCroskey BL et al. (1987) Intraoperative hypogastric artery embolization for life-threatening pelvic hemorrhage: a preliminary report. *J Trauma* 27(10):1127–9
 50. Kerr A (2002) Pelvic and Obstetric Hemorrhage. *Vascular and Interventional Radiology: Principles and Practice*. Curtis JES, Bakal W, Cynamon J, and Sprayregen S, New York, NY, Thieme. 1:297–313
 49. Velmahos GC, Chahwan S et al. (2000) Angiographic embolization of bilateral internal iliac arteries to control life-threatening hemorrhage after blunt trauma to the pelvis. *Am Surg* 66(9):858–62
 51. Sato MFH, Hagiwara A et al. (1991) Traumatic hemorrhage of the spleen diagnosed by CO₂ DSA. *Journal of Japanese Association of Acute Medicine* 2:728–732
 52. Hashimoto SHK, Sato M (1997) CO₂ as an intra-arterial digital subtraction angiography agent in the management of trauma. *Seminars in Interventional Radiology* 14:162–173
 53. Hawkins IF Jr., Caridi JG, Weichmann BN, Kerns SR (1997) Carbon dioxide, digital subtraction angiography in trauma patients. *Seminars in Interventional Radiology* 14:175–180
 54. Dondelinger RF, Trotteur G et al. (2002) Traumatic injuries: radiological hemostatic intervention at admission. *Eur Radiol* 12(5):979–93
 55. Hare WS and Holland CJ (1983) Paresis following internal iliac artery embolization. *Radiology* 146(1):47–51
 56. Sternbergh WC, 3rd, Connors MS, 3rd et al. (2003) Acute bilateral iliac artery occlusion secondary to blunt trauma: successful endovascular treatment. *J Vasc Surg* 38(3):589–92
 57. Perez JV, Hughes TM et al. (1998) Angiographic embolisation in pelvic fracture. *Injury* 29(3):187–91
 58. Uflakcer R (2002) 8. Embolization in Trauma. *Visceral and Nonvascular Percutaneous Therapy: A Teaching File*, Lippincott Williams & Wilkins. 2:134–141
 59. Ramirez JI, Velmahos GC et al. (2004) Male sexual function after bilateral internal iliac artery embolization for pelvic fracture. *J Trauma* 56(4):734–9; discussion 739–41

6 Postcatheterization Femoral Artery Injuries

GEERT MALEUX, SAM HEYE, and MARIA THIJS

CONTENTS

6.1	Introduction	69
6.2	Incidence of Postcatheterization Vascular Injuries	69
6.3	Pseudoaneurysm	69
6.3.1	Clinical Features	69
6.3.2	Radiological Diagnosis	70
6.3.3	Treatment	70
6.3.3.1	Surgery	70
6.3.3.2	Ultrasound-Guided Compression Repair	70
6.3.3.3	Transcatheter Endovascular Techniques	71
6.3.3.4	Ultrasound-guided Thrombin Injection	71
6.4	Arteriovenous Fistula	74
6.4.1	Prevalence and Natural History	74
6.4.2	Diagnosis	75
6.4.3	Treatment	75
6.5	Thromboembolic Lesions	75
	References	76

6.1 Introduction

The number of percutaneous femoral arterial catheterizations has increased exponentially in recent years with several million procedures performed worldwide annually. A direct consequence of that explosion in number of percutaneous diagnostic and interventional catheterizations is the increasing number of vascular complications due to the percutaneous creation of that vascular access mainly using the femoral artery. Potential complications are pseudoaneurysm, arteriovenous fistula, uncontrollable groin and/or retroperitoneal bleeding, in situ arterial thrombosis, and peripheral embolization. In order to deal with these complications, there is an increasing need for quick and optimal diagnosis and for efficient and, by preference, minimally invasive treatment.

G. MALEUX, MD; S. HEYE, MD; M. THIJS, MD
Department of Radiology, University Hospitals Gasthuisberg,
Herestraat 49, 3000 Leuven, Belgium

6.2 Incidence of Postcatheterization Vascular Injuries

Among these iatrogenic femoral arterial injuries, the formation of a pseudoaneurysm is the most common entity. The reported incidence of iatrogenic pseudoaneurysms ranges from 2% to 8% after coronary angioplasty and stent placement and from 0.2% to 0.5% after diagnostic angiography [1]. These clear differences in complication rates are basically due to the use of larger sheaths and catheters and due to the aggressive postprocedural anticoagulation therapy routinely used in interventional cardiological units [2]. Arteriovenous fistulas are less common and occur in about 1% of all percutaneous coronary procedures. Uncontrollable groin hemorrhage, in situ arterial thrombosis, and peripheral embolization are rare entities; their incidence is less than 1%.

6.3 Pseudoaneurysm

6.3.1 Clinical Features

Among iatrogenic femoral arterial injuries, the formation of a pseudoaneurysm is the most common entity. Clinical symptoms are pain and swelling at the site of a recent arterial puncture, and physical examination can reveal a palpable mass in case of a large pseudoaneurysm. In a study by TOURSARKISSIAN et al., monitoring patients with a pseudoaneurysm of less than 3 cm in diameter, spontaneous closure was noted in 86% of cases with a mean of 23 days [3]. Adversely KENT et al. found spontaneous closure unusual in pseudoaneurysms larger than 1.8 cm in diameter [4]. These contradictory findings can probably be explained by the anticoagulation status of the patient: spontaneous thrombosis of a

pseudoaneurysm is probably unlikely in an anticoagulated patient. As the vast majority of patients presenting with a postcatheterization pseudoaneurysm in our institution is anticoagulated, we routinely treat every pseudoaneurysm with a diameter of more than 1 cm.

6.3.2 Radiological Diagnosis

Duplex ultrasound is a simple, cheap, and effective tool to correctly diagnose a pseudoaneurysm. Real-time ultrasound imaging shows an echo-poor soft tissue mass anterior to the femoral artery and distal to the puncture site. The surrounding fatty tissues can be echogenic due to the hemorrhagic infiltration. Doppler evaluation shows the classic triad of swirling color flow in a mass separate from the underlying artery, color flow signal in a track leading from the artery to the mass (pseudoaneurysmal neck), and a to-and-fro Doppler waveform in the pseudoaneurysmal neck [5] (Fig. 6.1). Additionally, duplex ultrasound is also the imaging tool of preference to guide treatment like compression repair or thrombin injection, and it can also be used to perform follow-up studies after treatment. Of course, MR and CT imaging are also valuable tools, but these techniques are expensive and need additional contrast medium administration. Catheter angiography can also diagnose a pseudoaneurysm, but because of the invasiveness of the procedure, this technique is no longer considered a valuable option.

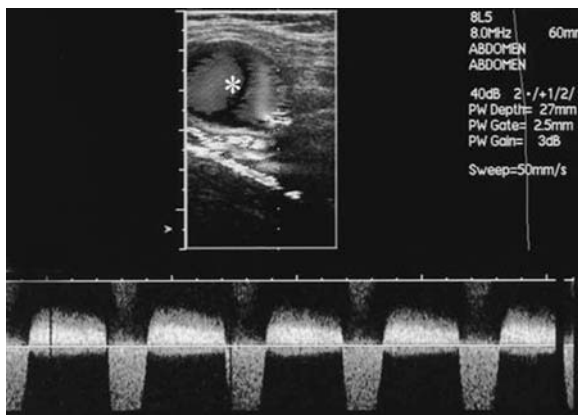


Fig. 6.1. Color Doppler ultrasound of the groin shows a pseudoaneurysm (*asterisk*) with a diameter of 2 cm and color flow centrally in the pseudoaneurysmal cavity. Duplex scanning of the pseudoaneurysmal neck demonstrates a typical to-and-fro signal

6.3.3 Treatment

6.3.3.1 Surgery

Surgery has been the classical treatment of iatrogenic groin pseudoaneurysms for many years but since the publication of new, less invasive techniques, the number of surgical corrections has diminished significantly in most institutions. Briefly, the surgical technique consists of opening the groin, dissection of the pseudoaneurysm and injured vessel above and below the puncture point, evacuating the surrounding hematoma, and suturing the bleeding point with or without placement of any absorbable synthetic graft material over the bleeding point. Despite the significant decrease in number of surgically repaired pseudoaneurysms, there are still some strict indications for surgery (and these surgical indications are contraindications for percutaneous repair):

- a) rapidly expanding pseudoaneurysm due to continuous bleeding,
- b) infected pseudoaneurysm,
- c) symptoms of compression of the pseudoaneurysm on surrounding tissues like the femoral artery (distal ischemia), femoral nerve (neuropathy), overlying skin (skin lesions),
- d) pseudoaneurysm not responding to percutaneous treatment.

The results of surgical repair are nearly 100%, but this treatment is not free of morbidity or even mortality, in most cases due to the significant cardiac comorbidity of the affected patients. In a cohort study of 55 patients presenting with arterial injuries produced by percutaneous femoral procedures, FRANCO et al. reported nine postoperative wound complications, five myocardial infarctions, and two deaths [6]. These numbers result in a postoperative morbidity rate of 25% and a postoperative mortality of 3.5%.

6.3.3.2 Ultrasound-Guided Compression Repair

This technique, first described by FELLMETH et al., consists in placing an ultrasound probe directly over the neck of the pseudoaneurysm followed by downward pressure of the probe, which will result in occlusion of the neck of the pseudoaneurysm [7]. Duplex examination will demonstrate absence of

flow into the pseudoaneurysmal lumen. The pressure must be continued for at least 10 minutes and then controlled by duplex ultrasound. If there is still a residual flow into the pseudoaneurysm, continued pressure for 20 minutes is mandatory. This technique, which was very popular in the last decade, has some important drawbacks. It is a time-consuming and painful technique, mostly requiring oral or intravenous analgesics to avoid excessive patient discomfort. Additionally, the procedure can be contraindicated, not only when one of the above-mentioned indications for surgery is present, but also when there is an anatomy unsuitable for compression repair: when the neck, which must be compressed, is located above or near the inguinal ligament, no underlying tough structure is present that would enable occlusion of the neck when anterior compression is performed. Other disadvantages of ultrasound-guided compression repair are the limited success rate in anticoagulated patients and in patients presenting with large pseudoaneurysms 4–6 or more cm in diameter [8,9].

6.3.3.3

Transcatheter Endovascular Techniques

Several transcatheter endovascular techniques have been described to treat iatrogenic groin pseudoaneurysms, all of them in the form of case reports and some small series. Basically, two main techniques should be mentioned, but they have only historical value: coil embolization and placement of a stent-graft [10–12] across the pseudoaneurysmal neck. The main reasons that these techniques have been omitted are the cost of the devices, the exclusion of later femoral artery puncture in the presence of an overlying stent-graft, potential metallic stent-fractures, and the disappointing long-term results of primary and secondary patency rates of femoral artery stent-grafts [13,14]. The long-term outcome of subcutaneously placed vascular coils is unknown.

6.3.3.4

Ultrasound-guided Thrombin Injection

6.3.3.4.1

History

COPE and ZEIT first described the potential interest of thrombin as an effective embolic agent in 1986

[15]. They reported the successful direct needle-injection of thrombin to thrombose peripheral pseudoaneurysms such as common iliac, peroneal, and hepatic pseudoaneurysms. Despite this interesting report, it was not until a decade later that the first report of ultrasound-guided direct thrombin-injection to close iatrogenic groin pseudoaneurysms was published, by LIAU et al. [16].

6.3.3.4.2

Biochemical Working Mechanism

Thrombin is an active enzyme in the blood-clotting cascade. It is formed from prothrombin (factor II clotting cascade) and it converts inactive fibrinogen into fibrin, which actively participates in the formation of thrombus. When injecting thrombin into the pseudoaneurysmal lumen, thrombus formation will be clearly accelerated as the blood flow in the pseudoaneurysm is turbulent or even nearly static. These phenomena will lead to a high concentration of thrombin in the pseudoaneurysm over a period of time, long enough to activate the clotting cascade into a definitive direction of clot formation. This activation of the clotting cascade due to the injection of thrombin will not be restrained or stopped when the patient is anticoagulated by heparin or warfarin-derivatives or when the patient is anti-aggregated. However, KRÜGER et al. demonstrated the increase of thrombin-antithrombin III complexes in the peripheral circulation 2, 5, and 10 minutes after thrombin injection in the pseudoaneurysm, indicating that some amount of thrombin passed into the circulation [17]. No transcatheter occlusion of the neck of the pseudoaneurysm was performed during injection. Possible pathways of this passage are a direct flow of thrombin from the lumen of the pseudoaneurysm into the feeding artery and here binding to antithrombin III; another possible mechanism is the formation of thrombin-antithrombin III complexes in the pseudoaneurysm and then passage of the whole complex into the feeding artery. A third pathway is that thrombin is partially absorbed from the surface of the pseudoaneurysmal cavity into the venous drainage. This increase in thrombin-antithrombin III complexes does not lead to a higher risk of peripheral clot formation, neither in the arterial nor in the venous system. Today, thrombin is available in the form of human thrombin and as bovine thrombin. Due to production costs, human thrombin is more expensive than bovine, but the latter is a non-human substance which potentially may induce allergic or even anaphylactic reactions [18].

6.3.3.4.3

Technique of Percutaneous Embolization

Thrombin injection can be performed in an interventional suite or even in an ultrasound room, but precautions must be taken in order to avoid potential infection during the procedure. Therefore the patient's affected groin must be cleaned and disinfected with povidone-iodine and covered with a sterile drape. Before starting the procedure the distal pulses of the affected limb are examined. A sterilized 7.5- or a curved 3.5-MHz array transducer is used to guide the whole procedure. A 3.5-MHz array probe can be helpful when treating an obese patient or when the pseudoaneurysm is surrounded by massive hematoma or by massively infiltrated subcutaneous fatty tissues. Although most interventional radiologists inject some local anesthetics before introducing the puncture needle, the embolization procedure can also be done without any anesthetics and without any discomfort for the patient [19]. A 21-gauge puncture needle is clearly large enough to inject the thrombin, avoiding the use of larger (20- or 19-gauge) needles. Under ultrasound guidance

using a freehand technique, the puncture needle (e.g., spinal needle) is placed in the middle of the pseudoaneurysmal lumen (Fig. 6.2a,b). Injection of thrombin is done safely when the ultrasound probe is directed longitudinally to the femoral arteries for having a correct view on the pseudoaneurysmal neck and lumen (Table 6.1). After switching the gray-scale imaging to color Doppler imaging, thrombin can be injected very slowly and under continuous color Doppler control. After each injection of 0.10 ml of thrombin, the residual flow in the pseudoaneurysm is evaluated and when no more Doppler signal can be depicted, the injection is stopped (Fig. 6.2c). In the case of a multilocular (or complex) pseudoaneurysm, repositioning of the needle into another,

Table 6.1. My cookbook (materials) for ultrasound-guided thrombin injection

- 7.5 or 3.5 MHz array ultrasound probe
- Povidone-iodine
- 21-gauge spinal needle (Terumo Europe, Leuven, Belgium)
- Human thrombin (Tissucol Duo, Baxter Hyland Immuno, Vienna, Austria)

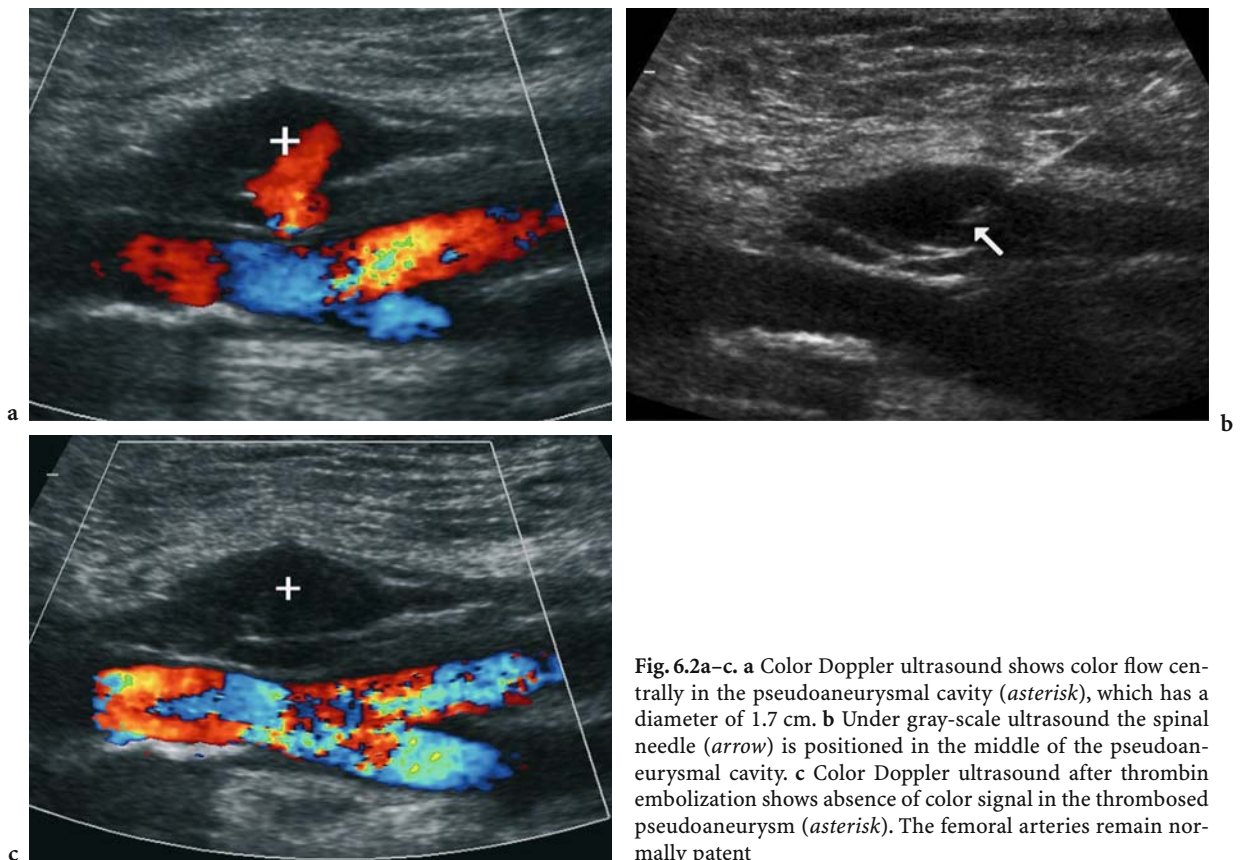


Fig. 6.2a-c. a Color Doppler ultrasound shows color flow centrally in the pseudoaneurysmal cavity (*asterisk*), which has a diameter of 1.7 cm. b Under gray-scale ultrasound the spinal needle (*arrow*) is positioned in the middle of the pseudoaneurysmal cavity. c Color Doppler ultrasound after thrombin embolization shows absence of color signal in the thrombosed pseudoaneurysm (*asterisk*). The femoral arteries remain normally patent

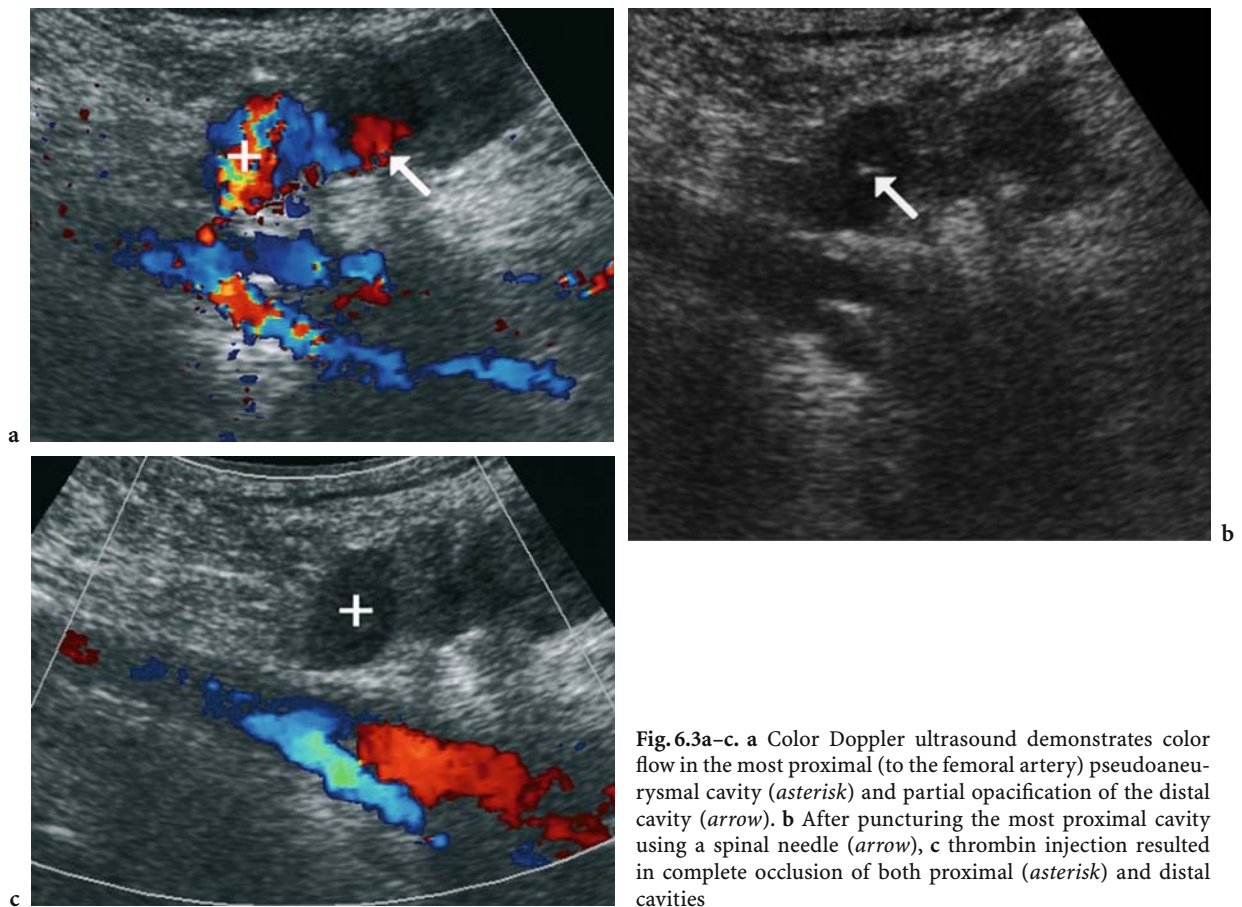


Fig. 6.3a–c. a Color Doppler ultrasound demonstrates color flow in the most proximal (to the femoral artery) pseudoaneurysmal cavity (*asterisk*) and partial opacification of the distal cavity (*arrow*). b After puncturing the most proximal cavity using a spinal needle (*arrow*), c thrombin injection resulted in complete occlusion of both proximal (*asterisk*) and distal cavities

still reperfused lobe can be necessary to completely close the pseudoaneurysm, but we advise starting the embolization procedure by puncturing the most proximal (to the femoral artery) cavity. In the majority of cases embolization of the most proximal cavity will lead to concomitant occlusion of the distal cavities, as these are in direct connection with the proximal one (Fig. 6.3a–c). Some residual flow signals in the neck of the pseudoaneurysm, but without any signal in the lumen, can be considered a successful embolization. After the procedure, physical examination of the distal pulses is indicated to exclude distal embolization.

Variants of the above-described technique are also mentioned in the literature, but they are more complex and more expensive and no longer promoted today. A technique of ultrasound-guided thrombin injection after transcatheter balloon occlusion of the neck of the pseudoaneurysm was promoted in the United Kingdom a few years ago [20, 21] but this technique needs additional, contralateral puncture, contrast medium administration, and manipulation under X-ray guidance. Transcatheter injection

of thrombin into the cavity of the pseudoaneurysm is another complex procedure with the same drawbacks as the balloon occlusion technique. Another variant technique is the ultrasound-guided injection of saline beneath the neck of the pseudoaneurysm [22]. This particular technique, described by GEHLING et al., should result in rapid occlusion of the neck and subsequently will thrombose the pseudoaneurysmal cavity [22]. Unfortunately no large series or confirmations from other centers are reported.

6.3.3.4.4 Results

Immediate success defined as complete thrombosis of the pseudoaneurysmal cavity following thrombin injection is very high, and most series report an immediate success rate in between 90 and 100% (Table 6.2). Failure of percutaneous embolization can occur in multiloculated pseudoaneurysms, when one or more lobes are not punctured; SHEIMAN et al. sought the predictors of failure [23]. They concluded that the volume of the pseudoaneurysm,

Table 6.2. Overview of results of published series on percutaneous thrombin injection to treat iatrogenic postcatheterization pseudoaneurysms

Author	Number of patients	Technical success	Complications
KANG et al. [35]	21	95%	–
PAULSON et al. [8]	114	96%	4
TAYLOR et al. [36]	29	93%	–
PEZZULLO et al. [37]	23	95%	1
LAPERNA et al. [38]	70	94%	1
GALE et al. [39]	20	100%	–
BROPHY et al. [40]	15	100%	–
MALEUX et al. [19]	100	98%	–
KHOURY et al. [25]	131	96%	3/131
FRIEDMAN et al. [41]	40	97.5%	1
OWEN et al. [20]	25	100%	1
MATSON et al. [21]	28	85%	1

the neck diameter, and the thrombin dose were not predictive criteria. They only found that failure of treatment may indicate an occult vascular injury and that surgical repair rather than reinjection of thrombin should be considered. Percutaneous thrombin-injection, even without additional transcatheter occlusion of the pseudoaneurysmal neck, is also very safe; the reported complication rates vary between 0% and 5% (Table 6.2). Complications are rare and can occur immediately or long after the embolization procedure [24]. Distal embolization is reported and can be due to passage of clot into the arterial circulation, but most probably will occur due to needle misplacement in the femoral artery and subsequently direct thrombin injection into the femoral artery [25]. Another rare complication is allergic or even anaphylactic reaction, but only when bovine thrombin is used [18]. Mid- and long-term results of percutaneous thrombin injection are also very good. In a study by MALEUX et al., 70% of previously occluded pseudoaneurysms disappeared completely whereas in 25% of cases a small, residual hematoma was found; in 3.5% a partial reperfusion of a previously thrombosed pseudoaneurysm was revealed by color-duplex ultrasound after a mean follow-up of 99 days [19] (Fig. 6.4).

The simplicity and reproducibility of the procedure as well as the high efficacy and very low complication rate of percutaneous thrombin injection under ultrasound guidance have made it the treatment of choice for postcatheterization pseudoaneurysms in many institutions [19, 26].

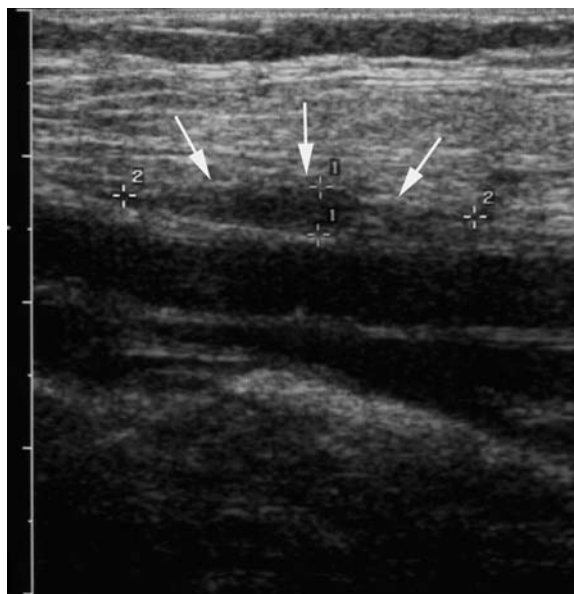

Fig. 6.4. Ultrasound of the groin, 90 days after thrombin injection reveals a small, residual hematoma (arrows), anterior to the femoral arteries

6.4 Arteriovenous Fistula

6.4.1 Prevalence and Natural History

Iatrogenic, postcatheterization arteriovenous fistulae are by far less frequent than postcatheterization pseudoaneurysms. KELM et al. and PERINGS et al. found an incidence of 1% in a prospective study including more than 10,000 patients who underwent cardiac catheterization [27,28]. This study also revealed five significant and independent risk factors for developing an iatrogenic arteriovenous fistula: procedural administration of heparin $\geq 12,500$ IU, coumadin therapy, puncture of the left groin, arterial hypertension, and female gender. Follow-up of these patients demonstrated that one-third of all arteriovenous fistulae closed spontaneously within one year and the majority even within the first four months. Additionally, the authors found that the majority of patients who suffer from an iatrogenic arteriovenous fistula do not develop clinical signs of hemodynamic significance during follow-up, and subsequently in most cases invasive treatment is not needed.

**6.4.2
Diagnosis**

Auscultation of the groin classically reveals a (new) continuous bruit after sheath removal, and in most cases a concomitant hematoma and/or pseudoaneurysm can be found. The clinical diagnosis must be confirmed by duplex ultrasonography, which will show a triad of typical signs: (1) a colorful “speckled” mass at the level of the puncture site, (2) an increased venous flow with a lack of respiratory variation and a pulsatile arterial component in the affected vein, and (3) decreased arterial flow distal to the suspected fistula. As for pseudoaneurysms, an arteriovenous fistula can also be detected by more sophisticated imaging tools like MR-, CT- and catheter angiography, but the standard imaging tool is still duplex-ultrasound.

**6.4.3
Treatment**

According to the study results of KELM et al., in the majority of patients suffering from an iatrogenic arteriovenous fistula, no invasive treatment is needed or even indicated [27]. In case of clinical symptoms due to the fistula, surgical repair, covered

stents, or compression repair are the therapeutic options [11, 12, 29]. The last one has a rather low success rate. Covered stents seem to be an attractive and minimally invasive alternative (Fig. 6.5a,b), although many questions about long-term patency, stent and graft fatigue still exist. Open surgical repair is very effective and durable, but is not free of perioperative morbidity and mortality.

**6.5
Thromboembolic Lesions**

In situ thrombosis of the common femoral artery due to catheterization or manual compression afterwards are rare lesions but, if diagnosed late, can have a tragic outcome. Caution must be the rule when puncturing and certainly when compressing too much and too long a graft (e.g., in patients with an aortofemoral graft). When performing catheterization in children or young adults, persistent spasms of the femoral or brachial artery can induce an in situ thrombosis and potentially provoke distal embolization of a part of the clot. Small-sized sheaths and catheters as well as administration of vasoactive drugs can avoid this complication. In situ thrombosis of the punctured artery is also described in

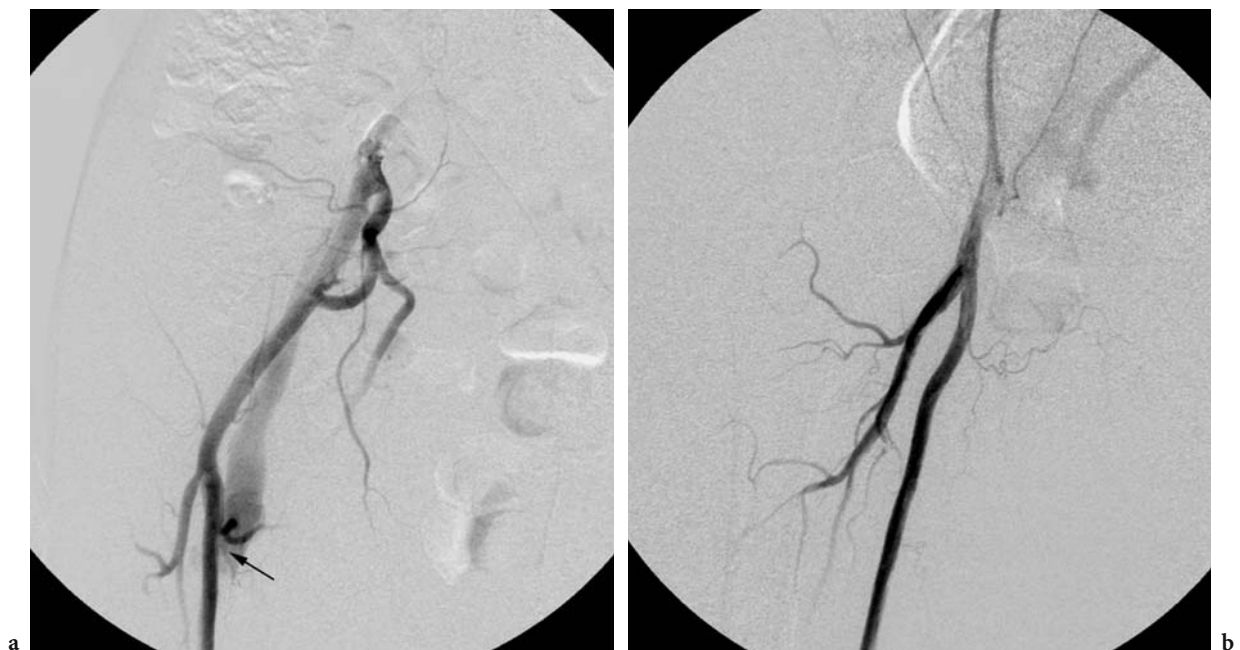

Fig. 6.5a,b. Selective angioplasty of the right femoral bifurcation **a** reveals an arteriovenous fistula (*arrow*) originating postostially from the deep femoral artery. **b** After insertion of a covered stent (Viabahn 8x25 mm, W.L. Gore and Assoc., Flagstaff, AZ, USA), the arteriovenous fistula is completely excluded

patients treated with closure devices at the end of an endovascular procedure [30–32]. In most instances these complications must be corrected surgically, although interventional, endovascular management such as transcatheter thrombolysis or wire recanalization and balloon dilatation can be successful [33, 34] (Fig. 6.6a,b).

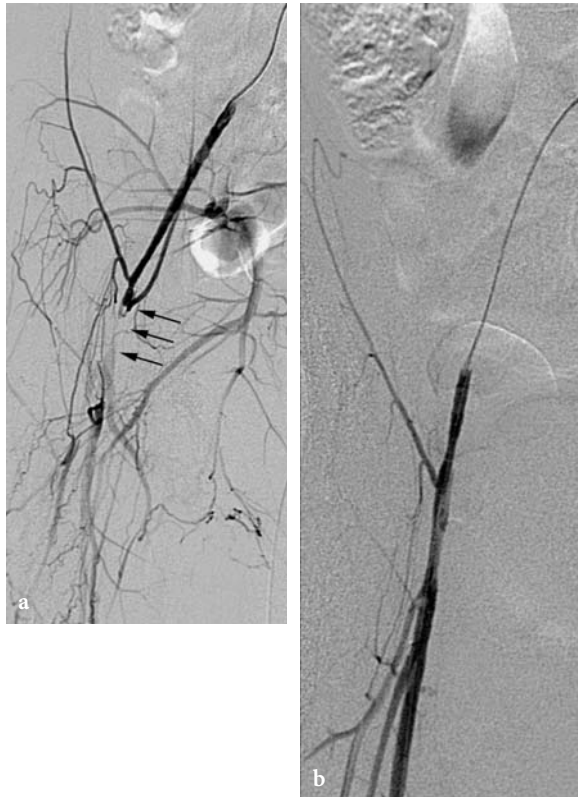

Fig. 6.6a,b. A 9-year-old girl presented with progressive claudication, Fontaine stage 2b, for the past 3 months. She previously underwent multiple cardiac catheterizations from the right groin. **a** Selective angiography of the right femoral bifurcation demonstrates total occlusion of the proximal part of the right common femoral artery (arrows). **b** After wire recanalization and balloon angioplasty (Wanda balloon 5×40 mm, Boston Scientific, Natick, MA, USA) an acceptable patency of the common femoral artery is obtained. Clinical follow-up showed absence of claudication and normal distal pulses

References

- Lumsden AB, Miller JM, Kosinski AS, Allen RC, Dodson TF, Salam AA, Smith RB (1994) A prospective evaluation of surgically treated groin complications following percutaneous cardiac procedures. *Am Surg* 60:132–137
- Topol EJ (1998) Coronary-artery stents: gauging, gorging, and gouging. *N Engl J Med* 339:1702–1704
- Toursarkissian B, Allen BT, Petrincic D, Thompson RW, Rubin BG, Reilly JM, Anderson CB, Flye MW, Sicard GA (1997) Spontaneous closure of selected iatrogenic pseudoaneurysms and arteriovenous fistulae. *J Vasc Surg* 25:803–809
- Kent KC, McArdle CR, Kennedy B, Baim DS, Anninos E, Silkman JJ (1993) A prospective study of the clinical outcome of femoral pseudoaneurysms and arteriovenous fistulas induced by arterial puncture. *J Vasc Surg* 17:125–133
- Abu-Yousef MM, Wiese JA, Shamma AR (1988) The “to-and-fro” sign: duplex Doppler evidence of femoral artery pseudoaneurysm. *AJR* 150:632–634
- Franco CD, Goldsmith J, Veith FJ, Calligaro KD, Gupta SK, Wengerter KR (1993) Management of arterial injuries produced by percutaneous femoral procedures. *Surgery* 113:419–425
- Fellmeth BD, Roberts AC, Bookstein JJ, Freischlag JA, Forsythe JR, Buckner NK, Hye RJ (1991) Postangiographic femoral artery injuries: nonsurgical repair with US-guided compression. *Radiology* 178:671–675
- Paulson EK, Nelson RC, Mayes CE, Sheafor DH, Sketch MH, Kliewer MA (2001) Sonographically guided thrombin injection of iatrogenic femoral pseudoaneurysms: further experience of a single institution. *AJR* 177:309–316
- Eisenberg L, Paulson EK, Kliewer MA, Hudson MP, DeLong DM, Carroll BA (1999) Sonographically guided compression repair of pseudoaneurysms: further experience from a single institution. *AJR* 173:1567–1573
- Lemaire JM, Dondelinger RF (1994) Percutaneous coil embolization of iatrogenic femoral arteriovenous fistula or pseudo-aneurysm. *Eur J Radiol* 18:96–100
- Waigand J, Uhlich F, Gross CM, Thalhammer C, Dietz R (1999) Percutaneous treatment of pseudoaneurysms and arteriovenous fistulas after invasive vascular procedures. *Catheter Cardiovasc Interv* 47:157–166
- Thalhammer C, Kirchgasser AS, Uhlich F, Waigand J, Gross CM (2000) Postcatheterization pseudoaneurysms and arteriovenous fistulas: repair with percutaneous implantation of endovascular covered stents. *Radiology* 214:127–131
- Kessel DO, Wijesinghe LD, Robertson I, Scott DJ, Raat H, Stockx L, Nevelsteen A (1999) Endovascular stent-grafts for superficial femoral artery disease: results of 1-year follow-up. *J Vasc Interv Radiol* 10:289–296
- Saxon RR, Coffman JM, Gooding JM, Natuzzi E, Ponc DJ (2003) Long-term results of ePTFE stent-graft versus angioplasty in the femoropopliteal artery: single center experience from a prospective, randomized trial. *J Vasc Interv Radiol* 14:303–311
- Cope C, Zeit R (1986) Coagulation of aneurysms by direct percutaneous thrombin injection. *AJR* 147:383–387
- Liau CS, Ho FM, Chen MF, Lee YT (1997) Treatment of iatrogenic femoral artery pseudoaneurysm with percutaneous thrombin injection. *J Vasc Surg* 26:18–23
- Krüger K, Zähringer M, Söhngen F-D, Gossmann A, Schulte O, Feldmann C, Strohe D, Lackner K (2003) Femoral pseudoaneurysms: management with percutaneous thrombin injections – success rates and effects on systemic coagulation. *Radiology* 226:452–458
- Pope M, Johnston KW (2000) Anaphylaxis after thrombin injection of a femoral pseudoaneurysm: recommendations for prevention. *J Vasc Surg* 32:190–191
- Maleux G, Hendrickx S, Vaninbrouckx J, Lacroix H, Thijs M, Desmet W, Nevelsteen A, Marchal G (2003) Percutaneous

- injection of human thrombin to treat iatrogenic femoral pseudoaneurysms: short- and midterm ultrasound follow-up. *Eur Radiol* 13:209–212
20. Owen RJT, Haslam PJ, Elliott ST, Rose JDG, Loose HW (2000) Percutaneous ablation of peripheral pseudoaneurysms using thrombin: a simple and effective solution. *Cardiovasc Intervent Radiol* 23:441–446
 21. Matson MB, Morgan RA, Belli AM (2001) Percutaneous treatment of pseudoaneurysms using fibrin adhesive. *Br J Radiol* 74:690–694
 22. Gehling G, Ludwig J, Schmidt A, Daniel WG, Werner D (2003) Peripheral vascular disease. Percutaneous occlusion of femoral artery pseudoaneurysm by para-aneurysmal saline injection. *Cathet Cardiovasc Intervent* 58:500–504
 23. Sheiman RG, Mastromatteo M (2003) Iatrogenic femoral pseudoaneurysms that are unresponsive to percutaneous thrombin injection: potential causes. *AJR* 181:1301–1304
 24. Kurz DJ, Jungius K-P, Lüscher TF (2003) Delayed femoral vein thrombosis after ultrasound-guided thrombin injection of a postcatheterization pseudoaneurysm. *J Vasc Interv Radiol* 14:1067–1070
 25. Khoury M, Rebecca A, Greene K, Rama K, Colaiuta E, Flynn L, Berg R (2002) Duplex scanning-guided thrombin injection for the treatment of iatrogenic pseudoaneurysms. *J Vasc Surg* 35:517–521
 26. Morgan R, Belli A-M (2003) Current treatment methods for postcatheterization pseudoaneurysms. *J Vasc Interv Radiol* 14:697–710
 27. Kelm M, Perings SM, Jax T, Lauer T, Schoebel FC, Heintzen MP, Perings C, Strauer BE (2002) Incidence and clinical outcome of iatrogenic femoral arteriovenous fistulas. Implications for risk stratification and treatment. *J Am Coll Cardiol* 40:291–297
 28. Perings SM, Kelm M, Jax T, Strauer BE (2003) A prospective study on incidence and risk factors of arteriovenous fistulae following transfemoral cardiac catheterization. *Int J Cardiol* 88:223–228
 29. Önal B, Kosar S, Gumus T, Ilgit ET, Akpek S (2004) Postcatheterization femoral arteriovenous fistulas: endovascular treatment with stent-grafts. *Cardiovasc Intervent Radiol* 27:453–458
 30. Brown DB, Crawford ST, Norton PL, Hovsepian DM (2002) Angiographic follow-up after suture-mediated femoral artery closure. *J Vasc Interv Radiol* 13:677–680
 31. Nehler MR, Lawrence WA, Whitehill TA, Charette SD, Jones DN, Krupski WC (2001) Iatrogenic vascular injuries from percutaneous vascular suturing devices. *J Vasc Surg* 33:943–947
 32. Abando A, Hood D, Weaver F, Katz S (2004) The use of the angioseal device for femoral artery closure. *J Vasc Surg* 40:287–290
 33. Geschwind JF, Dagli MS, Lambert DL, Kobeiter H (2003) Thrombolytic therapy in the setting of arterial line-induced ischemia. *J Endovasc Ther* 10:590–594
 34. Gemmete JJ, Dasika N, Forauer AR, Cho K, Williams DM (2003) Successful angioplasty of a superficial femoral artery stenosis caused by a suture-mediated closure device. *Cardiovasc Intervent Radiol* 26:410–412
 35. Kang SS, Labropoulos N, Mansour MA, Baker WH (1998) Percutaneous ultrasound guided thrombin injection: a new method for treating postcatheterization femoral pseudoaneurysms. *J Vasc Surg* 27:1032–1038
 36. Taylor BS, Rhee RY, Muluk S, Trachtenberg J, Walters D, Steed DL, Makaroun MS (1999) Thrombin injection versus compression of femoral artery pseudoaneurysms. *J Vasc Surg* 30:1052–1059
 37. Pezzullo JA, Dupuy DE, Cronan JJ (2000) Percutaneous injection of thrombin for the treatment of pseudoaneurysms after catheterization: an alternative to sonographically guided compression. *AJR* 175:1035–1040
 38. La Perna L, Olin JW, Goines D, Childs MB, Ouriel K (2000) Ultrasound-guided thrombin injection for the treatment of postcatheterization pseudoaneurysms. *Circulation* 102:2391–1295
 39. Gale SS, Scissons RP, Jones L, Salles-Cunha SX (2001) Femoral pseudoaneurysm thrombinjection. *Am J Surg* 181:379–383
 40. Brophy DP, Sheiman RG, Amatulle P, Akbari CM (2000) Iatrogenic femoral pseudoaneurysms: thrombin injection after failed US-guided compression. *Radiology* 214:278–282
 41. Friedman SG, Pellerito JS, Scher L, Faust G, Burke B, Safa T (2002) Ultrasound-guided thrombin injection is the treatment of choice for femoral pseudoaneurysms. *Arch Surg* 137:462–464

7 Iatrogenic Lesions

MICHAEL D. DARCY

CONTENTS

7.1	Introduction	79
7.2	Physiopathology	79
7.3	Clinical Considerations	81
7.4	Anatomy	82
7.5	Techniques and Equipment	83
7.5.1	Access and Delivery	83
7.5.2	Embolic Agents	85
7.5.3	Alternative Techniques	87
7.5.3.1	Balloon Tamponade	87
7.5.3.2	Uncovered Stents	87
7.5.3.3	Stent Grafting	88
7.6	Results	89
7.6.1	Hepatic	89
7.6.2	Renal	90
7.6.3	Miscellaneous Injuries	91
7.7	Complications	91
7.8	Future Development and Research	93
7.9	Conclusion	94
	References	94

7.1 Introduction

Since the beginning of both surgery and percutaneous interventions, vascular injury has always been one of the potential complications. Bleeding can complicate a wide range of procedures from simple biopsies or venous access cases up to more complex angioplasty, drainage procedures, or surgeries. This can be a primary injury that occurs at the site of the pathology that is being treated, such as arterial rupture during percutaneous transluminal angioplasty (PTA). Alternatively, vascular damage can be a secondary effect such as when a hepatic arterial branch is injured along a percutaneous tract to the bile ducts (Fig. 7.1).

M. D. DARCY, MD

Professor of Radiology and Surgery, Division of Diagnostic Radiology, Chief, Interventional Radiology Section, Washington University School of Medicine, Mallinckrodt Institute of Radiology, 510 S. Kingshighway Blvd., St. Louis, MO 63110, USA

Fortunately, the interventionist often has the ability to manage these complications, and embolization is one of the primary techniques utilized.

Throughout the 1970s numerous case reports appeared demonstrating the ability to successfully embolize iatrogenic bleeding in a variety of organs [1–4]. While these reports demonstrated the proof of concept, these embolizations were done with large 6 to 7 Fr catheters and often the arteries were occluded at a fairly proximal level. With the development of smaller catheters and improved embolization materials, it is now possible to advance super-selectively and occlude the artery right at the site of injury. Since modern embolization techniques allow effective control of bleeding while posing less of a risk to the target organ, embolization has become the method of choice for managing many forms of iatrogenic hemorrhage.

7.2 Physiopathology

Iatrogenic vascular injuries that require embolization are most often arterial in origin. Venous injuries rarely cause clinically significant bleeding since local hematoma caused by bleeding from the injury will often compress the low-pressure vein and tamponade the bleeding. An exception to this is when a large vein is disrupted along a drainage catheter tract. In this setting, bleeding may wick along the catheter or enter the catheter itself if the catheter side-holes are inappropriately positioned in the parenchyma. Aside from the low frequency of major venous bleeding, venous bleeding is also difficult to diagnose arteriographically, plus access to the vein for embolization may be limited. For these practical reasons, embolization techniques to correct iatrogenic hemorrhage have focused on arterial bleeding.

Iatrogenic lesions tend to be simple traumatic disruptions of the artery, so unlike true aneurysms, the

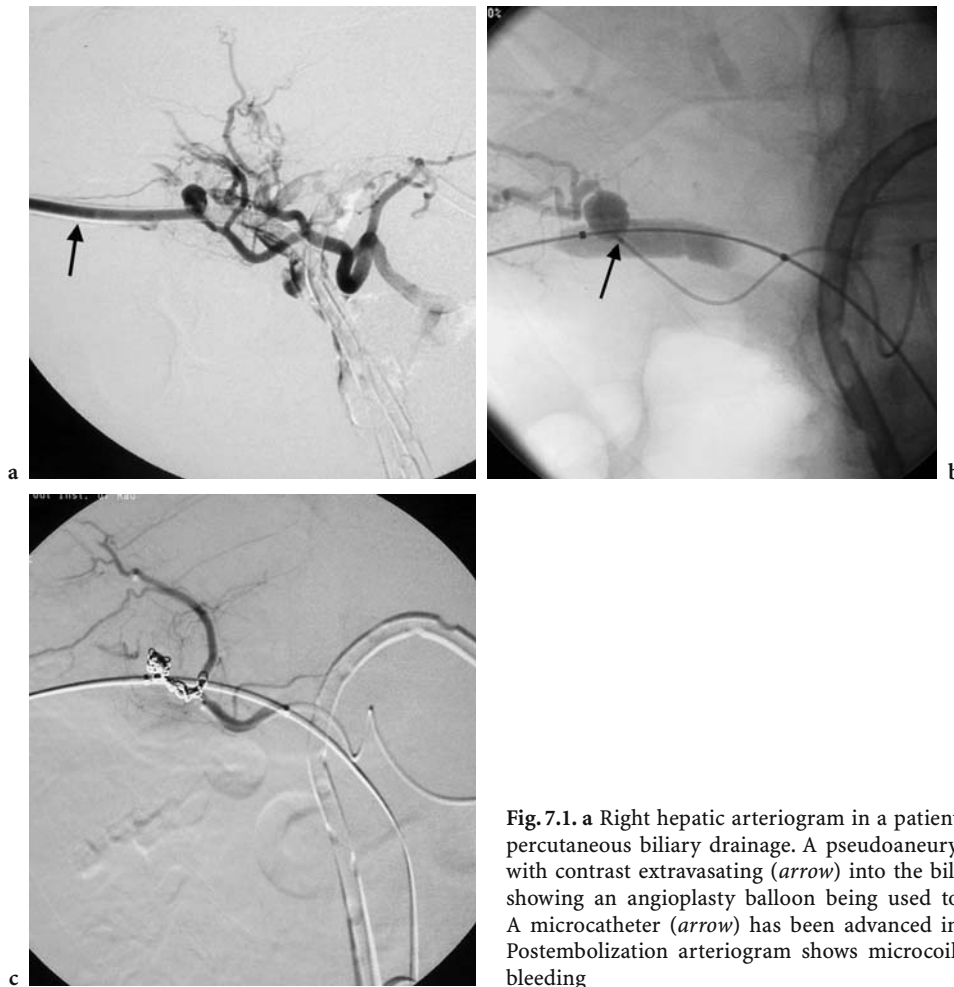


Fig. 7.1. a Right hepatic arteriogram in a patient with severe bleeding after percutaneous biliary drainage. A pseudoaneurysm is seen along the tract with contrast extravasating (*arrow*) into the biliary catheter. b Spot image showing an angioplasty balloon being used to tamponade the bleeding. A microcatheter (*arrow*) has been advanced into the pseudoaneurysm. c Postembolization arteriogram shows microcoils in place and no further bleeding

defect usually extends through all layers of the arterial wall. The size of the defect may vary with the mechanism of injury. An artery damaged by a needle pass during biopsy may have a very focal wall defect. On the other hand, an artery split during a PTA may have a long linear defect. The size of the defect may alter the ease with which embolization can control the bleeding. The size of the defect can alter the presentation. Injury to a small hepatic branch may present remote in time from the original procedure that caused it and may present only with annoying persistent bleeding into the biliary drainage catheter without any signs of hemodynamic instability. A large rupture of a main hepatic or renal artery however will usually lead to immediate pain, tachycardia, and hypotension.

The signs and presentation of an arterial injury will also vary depending on the location of the injury with respect to the surrounding tissue. If the damaged artery is deep inside a solid organ like the liver, the bleeding may be relatively contained by the surround-

ing tissue and a pseudoaneurysm may form without signs of major hemorrhage (tachycardia, hypotension) being present. Instead the presentation may be more of a chronic low-grade bleeding into a drainage tube or adjacent structure (e.g. into a calyx causing hematuria or into a bile duct causing hemobilia). In some cases intrarenal or intrahepatic pseudoaneurysms may even be found incidentally on cross-sectional imaging done for other reasons. However, if the injured artery is only surrounded by loose areolar tissue or fat, the bleeding may not be constrained and considerable hemorrhage may ensue. Aside from surrounding native tissue, one must remember that the bleeding may be partially tamponaded by the presence of the tube that caused the injury in the first place. In fact some pseudoaneurysms or even gross hemorrhage will not be evident on the initial arteriogram with the drainage catheter in place and will only become evident once the arteriogram is repeated after removing the drainage catheter over a guidewire (Fig. 7.2).

The location of the iatrogenic injury (i.e. how central or peripheral it is) will have a significant effect on the choice of therapy. A central lesion may be less amenable to embolization for several reasons. Embolization of a main arterial trunk may threaten the viability of the organ supplied by the injured vessel. It also may be difficult to embolize a main arterial trunk without risking nontarget embolization. In these settings, alternative techniques like stent-grafting may be more useful.

Fortunately, injuries in solid organs like kidneys and liver often tend to be in more peripheral branches. These lesions are often inaccessible to the surgeon for direct repair and so surgical therapy involves very aggressive approaches such as main arterial ligation or partial resection of the organ. This provides a unique advantage for embolotherapy since a peripheral, focal source of bleeding can often be embolized while sacrificing only a small portion of the organ. Thus repair by embolization will preserve a much greater percentage of the organ than would be possible with surgical repair.

7.3 Clinical Considerations

Some bleeding is natural after placing a catheter through a very vascular organ such as a kidney or liver. Therefore one of the first tasks is to decide when to proceed to arteriography. In some cases, iat-

rogenic hemorrhage is profound with rapid onset of tachycardia and hypotension. In this setting immediate arteriography is clearly warranted. The presence of pulsatile blood flow out of the tract during a tube exchange is another indication that angiography is needed. The decision is less clear when there is just low-grade continued bleeding such as bloody output from a nephrostomy catheter that fails to clear after a few days.

One should first insure that the patient does not have a coagulopathy or thrombocytopenia that could account for the continued bleeding. Venous oozing that might normally be inconsequential can become quite troublesome in coagulopathic patients. The patient's medication list should also be checked for anticoagulant or antiplatelet medications that may have accidentally not been stopped before the procedure. The other reason to carefully assess the coagulation status is that embolization has been shown to be less effective in coagulopathic patients [5, 6]. This is because coils and other embolic agents do not by themselves provide complete occlusion to flow but rather provide a substrate for the formation of thrombus which occludes the vessel. If coagulation tests are normal or corrected and bleeding persists a week or more or if continued bleeding causes a significant drop in the hematocrit, then angiography may be indicated.

The hemodynamic status of the patient should be carefully assessed. If the patient is clearly actively bleeding, one should proceed to angiography as soon as possible even if the patient is hypotensive.

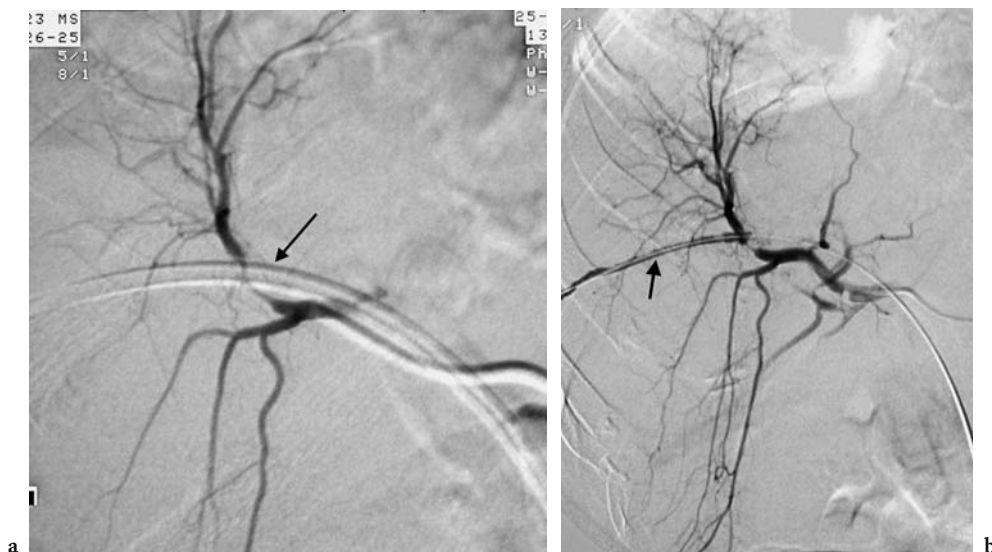

Fig. 7.2. a Right hepatic arteriogram after percutaneous biliary drainage shows spasm where the biliary catheter crosses the artery (arrow), but no bleeding or pseudoaneurysm. b After removing the biliary catheter over a guidewire, repeat arteriogram shows extravasation of contrast along the tract (arrow)

Waiting for the patient to stabilize may waste precious time, and in fact it may not be possible to stabilize the patient until the bleeding is stopped. Although a few steps are necessary to try to stabilize the patient, resuscitation efforts should be carried on concurrently with the angiographic efforts to stop the bleeding. The patient should have several large-bore venous lines for fluid resuscitation and blood transfusion. Blood should be typed, crossed, and readily available. Drugs and equipment needed to start a vasopressor infusion should be at hand.

Even if the patient does not appear to be actively bleeding at the start of the arteriogram, one must assume that they may develop significant blood loss during the case. Wire manipulation or pressure injections in the injured artery may stimulate increased bleeding. Also if biliary or nephrostomy catheter removal is necessary to demonstrate the pseudoaneurysm, massive bleeding may suddenly occur upon removal of the catheter. Therefore some of the same precautionary steps (large IVs, type and cross, etc.) should be taken with the patients with more chronic low-grade bleeding. One should remember to check the baseline hematocrit, since a patient who has been chronically bleeding may be starting out with a low hematocrit and may not tolerate even a modest amount of bleeding.

If the bleeding is secondary to an indwelling catheter such as a nephrostomy or biliary drain, one should determine whether the catheter is still necessary. If so, one may need to place a new catheter via a different access. At a minimum, you should be prepared to temporarily remove the catheter over a guidewire during the diagnostic arteriogram. The catheter may tamponade the bleeding, and extravasation may only be seen with the catheter removed. In a series of 13 patients with severe hemobilia after biliary drainage, five (38%) of the vascular injuries could only be identified after removing the catheter over a wire [7]. Maintaining guidewire access is crucial to allow replacement of the catheter or a PTA balloon to tamponade the bleeding once the diagnosis has been made.

Depending on the organ being embolized and the level of embolization, some tissue ischemia or even necrosis may occur. Prophylactic antibiotics may be indicated to prevent bacterial seeding of the infarcted tissue from developing into an abscess. This may be more of a concern when the embolized artery is in an infected organ such as a renal pseudoaneurysm that occurs after a nephrostomy done for pyonephrosis. Certainly if the patient has known bacteremia, antibiotic coverage should be started prior to the embolization.

7.4 Anatomy

Since vessels can be injured anywhere in the body, it is not possible to discuss the specific anatomy of all arterial beds. But there are some general anatomic assessments common to all regions and questions that must be answered prior to treating an iatrogenic vascular injury.

The first important question is whether or not the injured vessel can be sacrificed. The answer to this partially depends on whether you would expect the tissue distal to the target artery to remain viable or become ischemic after embolization. If sufficient collaterals are available, the tissue supplied by the target vessel may not be affected. So for example, embolizing a gastric branch to stop post-gastrotomy bleeding (Fig. 7.3) is unlikely to cause any ischemia due to the rich collateral supply around the stomach. Tissue distal to the injured vessel may also be safe from ischemia if there is an alternate blood supply. For example, portal venous flow into the liver allows safe embolization of even major trunks of the hepatic artery.

If good collateral perfusion is unlikely, one then must consider whether one can afford to let the tissue become ischemic. As an example, it would be very reasonable to embolize a peripheral renal artery branch that was injured during a biopsy and sacrifice a small section of renal parenchyma, since it would have negligible effect on renal function. However if the main renal artery was ruptured during PTA, you would not want to embolize this artery except in dire situations since it would sacrifice the entire kidney.

Thorough understanding of the anatomy, in particular potential collateral pathways, is also critical when planning at what level to embolize the artery in order to insure an adequate therapeutic result. If the target vessel is an end-artery (such as a renal arterial branch) it probably suffices to deposit emboli proximal to the injured arterial segment. However, if there are well known collateral pathways beyond the target artery, then it is necessary to advance the catheter beyond the point of extravasation and occlude the artery both distal and proximal to the injury. Otherwise collateral flow could lead to persistent bleeding.

Knowledge of collateral pathways is also critical to allow the interventionist to check the appropriate vessels after what appears to be a successful embolization. Thus, after a gastroduodenal embolization for post-biopsy pancreatic head bleeding, it is

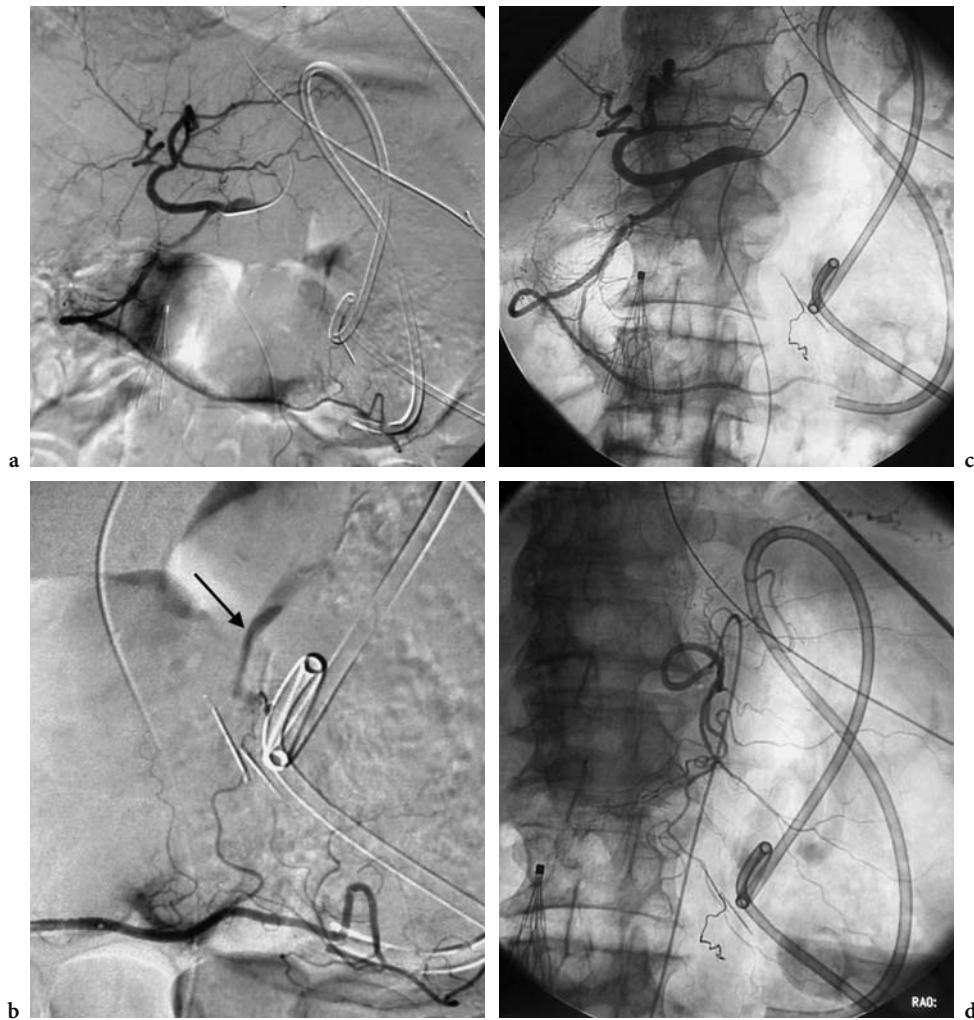


Fig. 7.3. a Selective gastroduodenal arteriogram in a patient with upper gastrointestinal bleeding after placement of a single lumen gastrojejunostomy (which has backed up into the stomach). b Magnified view better showing the bleeding (*arrow*) coming from the gastrojejunostomy access site in the mid-body of the stomach. c Postembolization study arteriogram shows a microcoil in the branch that was bleeding and no further extravasation. d Left gastric arteriogram showing good perfusion to the mid-body thus preventing gastric ischemia

important to do both a celiac arteriogram to look for pancreatic collaterals from the splenic artery and a superior mesenteric arteriogram to look for inferior pancreatico-duodenal collaterals.

7.5 Techniques and Equipment

Again given that iatrogenic injuries can occur anywhere in the body, a complete discussion of specific techniques and equipment for all areas is not possible, but there are some general principles (Table 7.1).

7.5.1 Access and Delivery

An arterial access sheath is crucial to maintain access in case the embolization catheter becomes occluded. The sheath will also facilitate catheter exchanges. Typically a standard short sheath will work. A longer curved sheath like the Balkan sheath (Cook Inc.; Bloomington, IN) or a guiding catheter may be useful to engage the main arterial trunk, especially if additional support will be needed to ease passage of the embolization catheter across a severely angled or tortuous artery. A guiding catheter may also be useful for embolizations done from an axillary approach so that multiple catheter

Table 7.1. Cookbook: Sample embolization equipment list**1. Embolization of large accessible artery**

- 5-Fr Cobra catheter
- 0.035-in. Bentson or Glidewire to help engage artery
- Gianturco coils (size to match vessel) or Gelfoam pledgets
- LLT wire to push coils
- Alternative catheters depending on vessel shape
 - 5-Fr Sos or Simmon catheter to engage artery
 - Rosen guidewire or stiff-shaft glidewire for exchange
 - MPA or Cobra catheter to advance more peripherally

2. Embolization of small peripheral artery

- 5-Fr Cobra, Sos, or Simmons catheter to engage arterial trunk
- MassTransit or Renegade microcatheter to advance peripherally
- Transend guidewire to guide microcatheter
- 0.018-in. microcoils or PVA
- 0.025-in. glidewire to push microcoils through microcatheter

3. Direct puncture for visceral aneurysm

- 21-g Micropuncture needles
- 0.018-in microcoils or thrombin (1,000–2,000 units)
- Alternatives
 - 22-g Chiba needle and thrombin when smaller access desired
 - 18-g Trocar needle for better control of needle and more choices of embolic agent to use (can use larger 0.038-in. coils)

exchanges are not done across the origin of the vertebral artery.

The size and type catheter used for embolization must be tailored to the type of lesion to be embolized, the anatomy, and how peripheral the lesion is. If the size of the defect is large (as with wide neck pseudoaneurysms) or if there is potential for the embolic material to migrate through the arterial defect (as with an arteriovenous fistula), then larger coils or large Gelfoam pledgets may be needed. In that case a 5 Fr catheter is necessary to deliver the larger emboli. The 5 Fr catheter chosen will depend on the shape of the arteries. A Sos Omni (Angiodynamics; Queensbury, NY) is a good initial catheter for selecting a variety of arterial trunks including renal, celiac, and mesenteric trunks. However the recurved shape may not allow the catheter to be advanced more peripherally unless a very stiff wire is advanced out into the target artery. A Cobra-shaped catheter is sometimes less stable when engaging a main visceral trunk, but it tends to be easier to advance more peripherally. Alternatively a recurved catheter such as a Sos or a Simmons 2 can be used to securely engage the trunk and then pass a stiffer wire out into the periphery to allow an exchange for

a straighter catheter (e.g. an MPA catheter; Cook Inc.) that will track better peripherally. Although a hydrophilic coated catheter may be more easily passed out to the peripheral aspects of an artery, we do not tend to use hydrophilic catheters because in our experience coils tend to get stuck in hydrophilic catheters.

For more focal defects in smaller arteries, a 3 Fr microcatheter such as the Mass Transit (Cordis; Miami, FL) or Renegade (Boston Scientific) has several advantages. Because they are small and very flexible, they can be advanced very peripherally into branches that would be too small for a larger 5 Fr catheter. More peripheral embolization minimizes the amount of tissue that must be sacrificed (Fig. 7.4). Microcatheters do have several disadvantages. They are more cumbersome to use, require a higher level of technical skill, and only allow delivery of smaller emboli which may not occlude the target artery as effectively.

As an alternative to catheterization, an iatrogenic pseudoaneurysm can be directly punctured percutaneously with a needle for delivery of the embolic agent. This is most commonly done for post-angiography femoral artery pseudoaneurysms, which are discussed more fully in another chapter. However, direct puncture can also be used to access deep abdominal lesions that cannot be reached with an intra-arterial catheter due to tortuosity, small vessel size, or obstruction by emboli from a prior attempted embolization. This technique has been applied to various hepatic and splanchnic pseudoaneurysms using either thrombin or coils as the embolic agents [8–12]. The puncture is done with long 22- or 21-gauge needles when planning to use thrombin alone as the embolic agent. Although microcoils can be introduced through a 21-g needle, using an 18-g needle for access gives you the option of introducing larger 0.038-in. fibered coils. For deep intra-abdominal pseudoaneurysms, needle placement can be guided by ultrasound, CT, or fluoroscopic visualization of injected arterial contrast. Once the needle has been inserted, confirmation of proper position in the pseudoaneurysm is confirmed by aspiration of blood and injecting contrast directly through the needle. Thrombin or coils can then be introduced directly through the needle into the pseudoaneurysm.

In solid organs such as the liver, major iatrogenic bleeding is sometimes due to communication between the tract and a major venous structure. Arteriography will usually not reveal any abnormality nor provide an access for therapy. In most cases of venous bleeding, simply leaving the drainage cath-

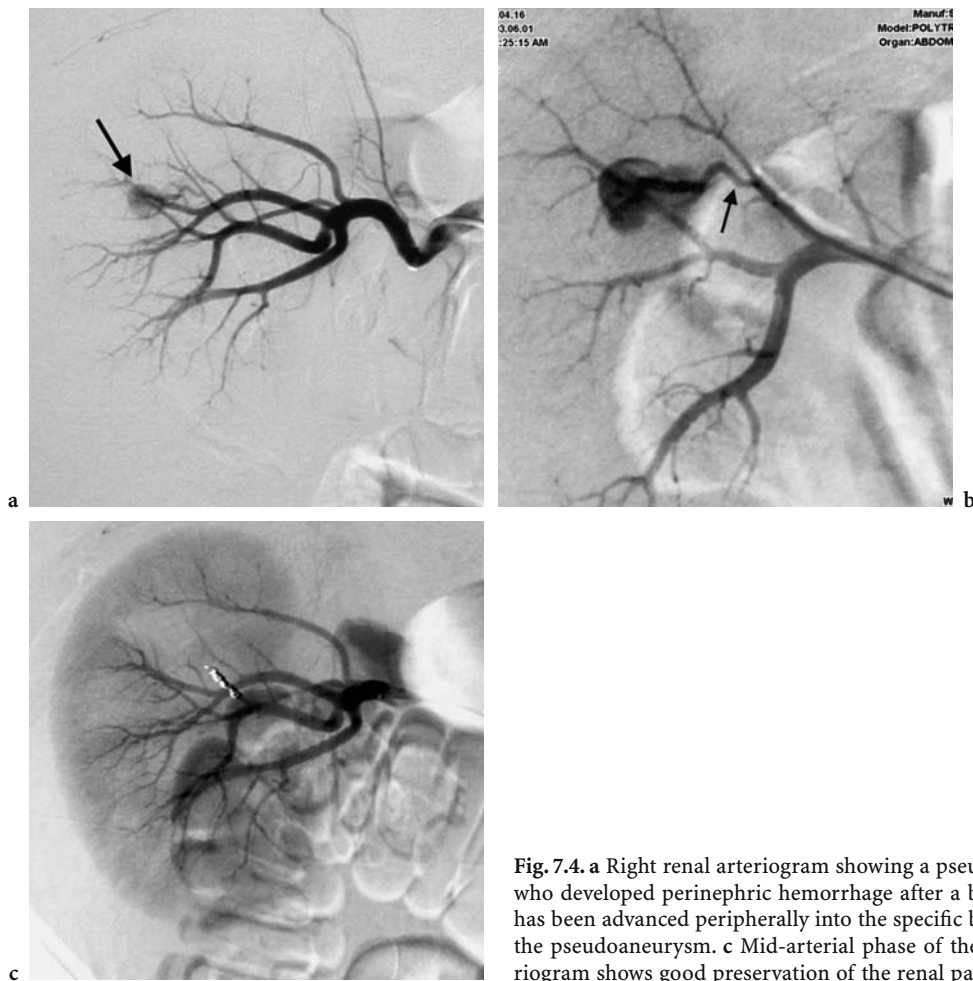


Fig. 7.4. **a** Right renal arteriogram showing a pseudoaneurysm in a patient who developed perinephric hemorrhage after a biopsy. **b** A microcatheter has been advanced peripherally into the specific branch (*arrow*) leading to the pseudoaneurysm. **c** Mid-arterial phase of the post embolization arteriogram shows good preservation of the renal parenchyma

eter in place or sometimes upsizing the catheter will effectively tamponade the smaller venous bleeds. If tamponade fails to control the bleeding because of the large size of the vein that was transgressed, embolization can be done via the tract itself (Fig. 7.5). The drainage catheter is first replaced with a sheath with a side arm adaptor or a Lieberman catheter (Cook Inc.) with an attached hemostatic valve with a side-arm adaptor (Merit Medical; South Jordan, UT). The sheath or catheter is pulled into the tract and contrast is injected into the tract while acquiring digital subtracted images. Once the venous connection is identified, coils are placed in the tract across the point where the tract and vein intersect. After tract embolization, it may not be possible (or desirable) to re-advance a drainage catheter down the tract. Therefore a new access for draining the biliary tree should be secured before starting the tract embolization. Although rarely needed in our practice, tract embolization has been effective at stopping the bleeding when this technique was used.

7.5.2 Embolic Agents

Coils are possibly the most commonly used devices for embolization of iatrogenic bleeding because they are readily visible during fluoroscopy, they can be deposited very precisely, and they generally provide effective occlusion. Larger coils (0.035–0.038 in.) must be passed through 5 Fr catheters, but in our experience these coils occlude arteries more effectively than the smaller 0.025-in. coils or 0.018-in. microcoils. Thus 0.038-in. coils are preferred whenever vessel size permits passage of a 5-Fr catheter. However, even 0.038-in. coils may not effectively occlude blood flow if the patient has a coagulopathy. One of the main functions of a coil is to provide a nidus for thrombus formation. If coagulopathy prevents thrombus formation, then blood may continue to flow around coils, especially if they are not tightly packed. Correction of the coagulopathy should be a priority but may not be possible. Alternatively Gel-

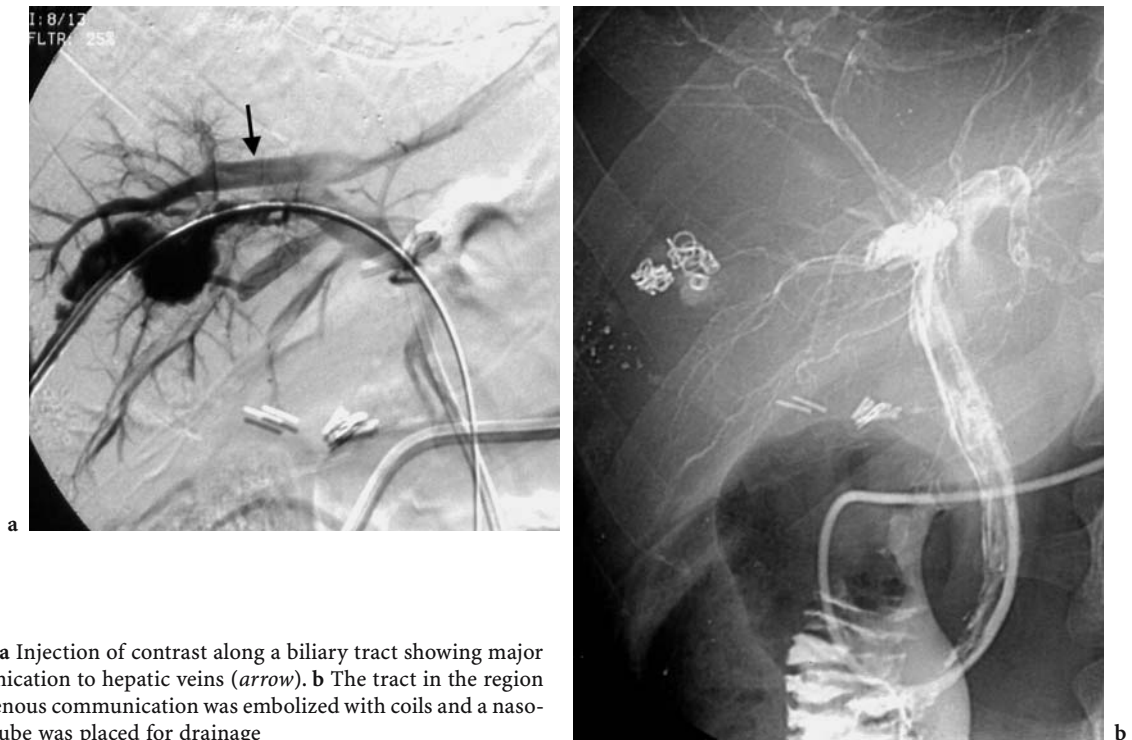


Fig. 7.5. a Injection of contrast along a biliary tract showing major communication to hepatic veins (*arrow*). b The tract in the region of the venous communication was embolized with coils and a nasobiliary tube was placed for drainage

foam can be injected on top of the framework of coils; this will provide more complete obstruction to blood flow.

Gelfoam is another commonly used agent but unlike coils it is injected and relies on flow direction. This is useful when the catheter cannot be advanced close enough to the bleeding site to allow placement of a coil. It is a versatile embolic agent. It comes in sheets and is cut into appropriate-size pieces for each case, which allows the emboli to be easily tailored to the situation. For large arterial defects or bleeding from large vessels, Gelfoam can be cut into large torpedoes. For smaller vessels it can be cut into smaller cubes. To embolize multiple branches at once it can also be made into a slurry by rapidly injecting it back and forth through a three-way stopcock. Because it is a flow-directed embolic agent, careful fluoroscopic monitoring of injections is critical to avoid reflux into nontarget vessels. For this reason, Gelfoam must be suspended in contrast. Since Gelfoam dissolves after a couple of weeks, it has the theoretic benefit of allowing vessel recanalization, although in some organs (such as kidney) the distal tissue has already infarcted long before the vessel recanalizes.

Polyvinyl alcohol (PVA) is a semipermanent flow-directed injectable particulate agent that can also be useful for treating iatrogenic hemorrhage.

Its main benefit over Gelfoam is the smaller size of the particles, making it easier to use them through a microcatheter. Because of their small size they are mostly useful for bleeding from small arteries. With large arterial defects or arteriovenous fistulas, the PVA can just flow out through the defect or into the venous circulation. For iatrogenic bleeding, larger PVA particles (>500 microns) are typically used since smaller particles are more likely to travel into very peripheral arterioles and are more likely to cause tissue ischemia.

PVA has several disadvantages. Like Gelfoam, the particles themselves are not fluoroscopically visible, and only the contrast they are suspended in allows you to monitor the injection. This is an indirect method of monitoring the embolization since the number or density of particles is not always uniform in any given injection. Care must be taken to avoid reflux and nontarget embolization. The particles also can occlude catheters requiring forceful and less controlled injections to clear the catheter, or the occlusion may even be firm enough to require removal of the catheter. Avoiding excessive particle density in the embolic mixture and frequent flushing with saline can help prevent this problem. PVA particles may also clump together, leading to premature occlusion of a vessel proximal to the injury. Newer formulations of PVA engi-

neered into more spherical shapes such as Contour SE (Boston Scientific) may reduce clumping and catheter occlusion.

Thrombin has been used for embolization with increased frequency, especially for management of post-catheterization pseudoaneurysms [13,14]. Occluding pseudoaneurysms with thrombin was first described in 1986 by COPE and ZEIT [15], and even in that initial report the technique was also used for an intrahepatic lesion, not just femoral lesions. Being a liquid agent it is readily delivered through even small-caliber catheters or needles. Usually only 1–2 ml of thrombin (1000 units/ml) is needed to thrombose a pseudoaneurysm. It must be injected carefully, since over-injection of the pseudoaneurysm can lead to nontarget downstream thrombosis. Most often the effect of thrombin injection is monitored in real time using color-flow ultrasound. In addition to its use as the primary embolic agent, thrombin can be used to augment the efficacy of coils. In situations where it is difficult to control hemorrhage due to a high rate of blood flow, it can be useful to soak the coils in thrombin to increase their thrombogenic potential.

The liquid tissue adhesive n-butyl cyanoacrylate (NBCA) has been utilized in an increasing number of applications and was recently proposed for use in stopping active hemorrhage. In a series of 16 patients with arterial hemorrhage (one of which was an iatrogenic injury), the authors reported being able to stop active bleeding in 75% of patients without any complications related to the embolic agent [16]. Although this is not a tremendous success rate, 10 of the 16 patients had already previously failed prior embolization with coils or particles.

NBCA does have some attractive properties. Since it is mixed with ethiodized oil, the mixture is radio-opaque, which should aid fluoroscopic control of the embolization. By varying the ratio of ethiodized oil and NBCA, the polymerization rate can be adjusted, thus providing the ability to customize how far peripherally the agent will penetrate. Finally, although it is a liquid, it does not penetrate out into the capillaries, and thus the risk of infarction should be low. Further investigation into the use of this agent is warranted.

7.5.3

Alternative Techniques

In some cases the damaged artery is critical and patency cannot be sacrificed. Thus alternate tech-

niques that stop bleeding without leaving behind emboli to occlude the lumen should be considered.

7.5.3.1

Balloon Tamponade

Balloon tamponade is the simplest technique and involves inflating either a compliant occlusion balloon (Balloon Wedge Pressure Catheter; Arrow Intl.; Reading, PA) or an appropriately sized angioplasty balloon across the injured segment of artery. If using an angioplasty balloon, it is recommended that low-pressure inflation be done to avoid further tearing of the artery. Some recommend using a balloon that is 1 mm smaller than the size of the balloon that caused the rupture [17]. Balloon occlusion can be used as a temporary measure to stop hemorrhage while planning definitive therapy, or in some instances it has been used as the definitive treatment. The theory behind balloon occlusion as the sole therapy is that the balloon will prevent continued extravasation and allow the perivascular thrombus time to organize and seal the leak.

There have been a number of reports of using temporary balloon tamponade to repair arterial ruptures both in the iliac and renal arteries [17–20]. With this technique, a balloon is left inflated across a ruptured artery anywhere from a few minutes up to an hour. Repeat arteriography is done after the balloon is deflated and if the leak persists the balloon is reinflated. With shorter inflation times this cycle may have to be repeated several times. One problem with this approach is that the tissues may not tolerate the ischemia for the length of time needed to finally stop the bleeding. This is why some authors only inflate for a few minutes at a time in order to allow reperfusion of the tissue in-between inflations, even though additional bleeding may occur during the deflation periods. Although longer inflation times may be associated with less bleeding, intraluminal thrombus can form while the balloon is arresting blood flow [20].

7.5.3.2

Uncovered Stents

Standard uncovered stents can occasionally be used to seal a vascular defect [21] (Fig. 7.6). While it seems counterintuitive that a bare stent would seal an arterial leak, this can work if the defect runs obliquely through the arterial wall. In this setting,

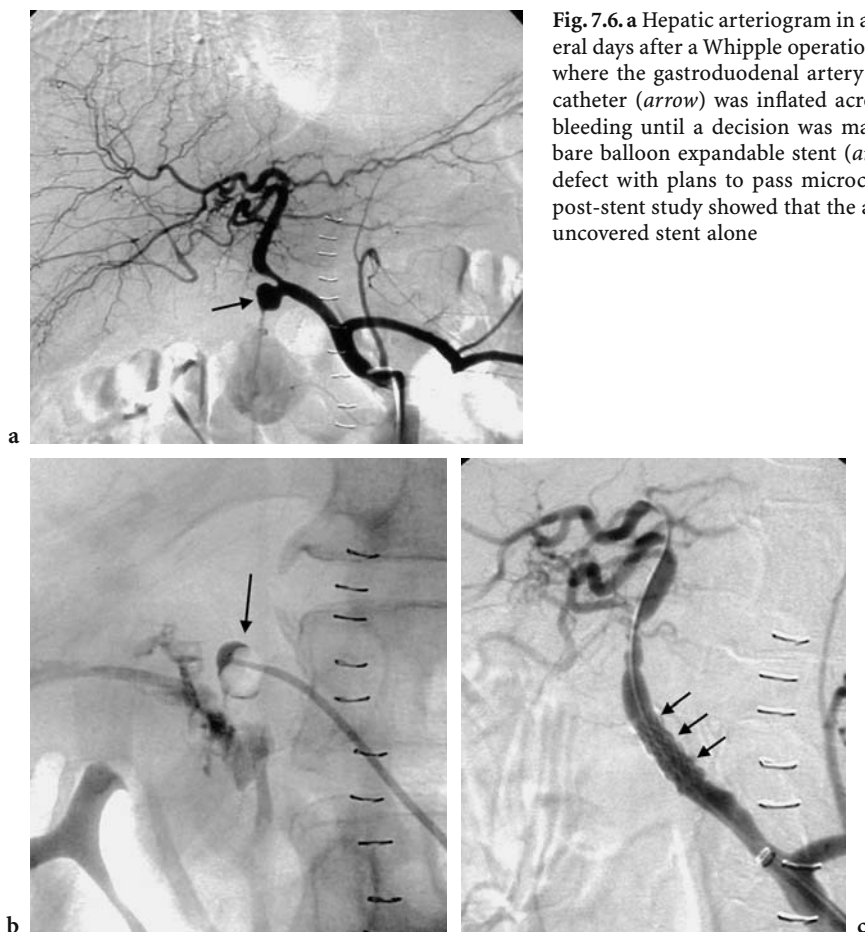


Fig. 7.6. **a** Hepatic arteriogram in a patient who developed bleeding several days after a Whipple operation. A pseudoaneurysm (*arrow*) is seen where the gastroduodenal artery was resected. **b** A balloon occlusion catheter (*arrow*) was inflated across the arterial defect to tamponade bleeding until a decision was made regarding definitive therapy. **c** A bare balloon expandable stent (*arrows*) was placed across the arterial defect with plans to pass microcoils through the stent; however, this post-stent study showed that the arterial defect had been sealed by the uncovered stent alone

the expanded stent forces together the two sides of the oblique tear, thus sealing the defect. This maneuver is a little risky since it can be difficult to tell whether the tear runs obliquely through the arterial wall. If it does not, placing a stent may simply hold open the defect and promote continued hemorrhage. However if the stent by itself does not stop the bleeding, the stent can be used as a gate to trap coils out in the pseudoaneurysm. A catheter can be passed through the stent interstices allowing coils to be deployed out in the pseudoaneurysm.

7.5.3.3 Stent Grafting

A potentially simpler and more secure method is deployment of a stent graft across the arterial defect. There are currently several commercially available stent grafts. Some, like the Fluency (Bard Peripheral Vascular; Tempe, AZ) and the Viabahn (W.L. Gore; Flagstaff, AZ) have a polytetrafluoroethylene

(PTFE) layer that would seal the hole in the vessel wall. The Wallgraft (Boston Scientific) has a woven Dacron graft material and although this is more porous, it will still effectively seal a hole and prevent further bleeding.

Currently most of these devices are fairly large and are best suited for repair of larger vessels such as subclavian, iliac, femoral, or splenic arteries (Fig. 7.7). There is also a smaller stent graft originally designed for coronary applications, the Jostent (Jomed; Helsingborg, Sweden), that has been used in smaller hepatic and renal arteries [17, 22–28]. Currently this device is still in trial and is not readily available in the United States. It is important with all these devices to carefully match the device diameter to the vessel diameter. Choosing a device that is too small for the vessel will yield a poor seal and potentially could allow continued hemorrhage. On the other hand with the Viabahn, if the device is significantly over-sized for the vessel, some of the graft material will fold into the device lumen and may compromise blood flow.

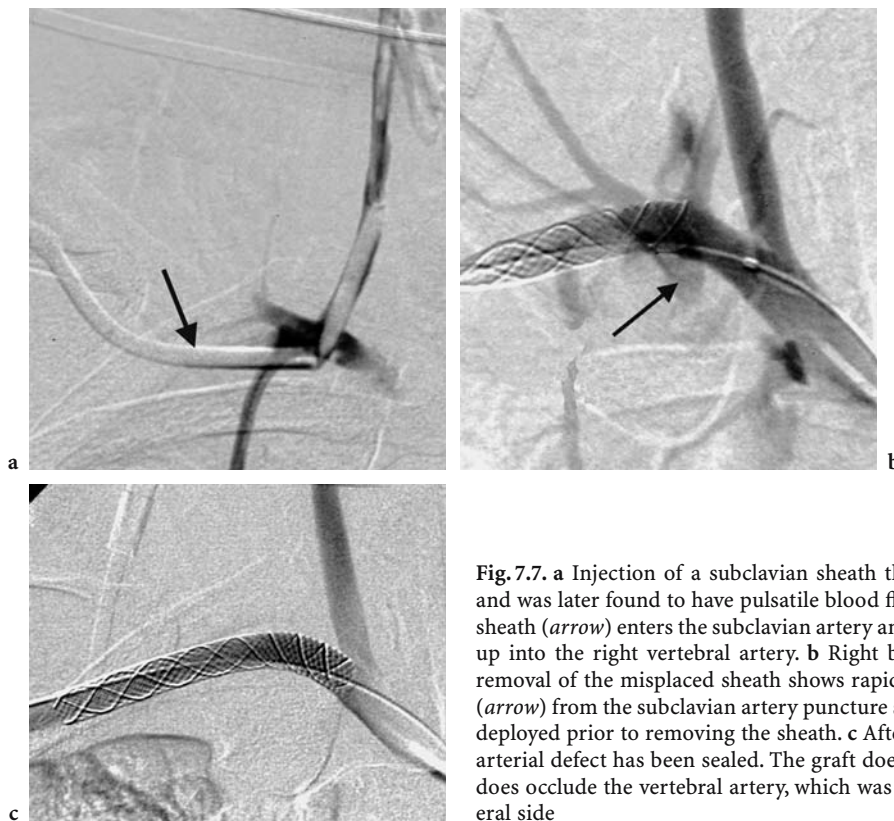

Fig. 7.7. a Injection of a subclavian sheath that had been placed on the ward and was later found to have pulsatile blood flow coming out of the sheath. The sheath (*arrow*) enters the subclavian artery and had been accidentally advanced up into the right vertebral artery. b Right brachiocephalic arteriogram after removal of the misplaced sheath shows rapid contrast extravasation/bleeding (*arrow*) from the subclavian artery puncture site. A Wallgraft has been partially deployed prior to removing the sheath. c After repositioning the Wallgraft, the arterial defect has been sealed. The graft does not compromise the carotid but does occlude the vertebral artery, which was well perfused from the contralateral side

7.6 Results

7.6.1 Hepatic

Hepatic iatrogenic bleeding can be divided into intrahepatic and extrahepatic varieties. Intrahepatic bleeding and pseudoaneurysms can result from any of the interventional hepatic procedures including percutaneous biopsy, transjugular biopsy [29], percutaneous biliary drainage or stenting, and even transjugular intrahepatic portosystemic shunts (Fig. 7.8). Extrahepatic lesions are often postsurgical in nature due to injury to a vessel or breakdown of a vascular anastomosis. Extrahepatic lesions may cause pain by mass effect and may be more likely to cause hemoperitoneum since they have less surrounding tissue to help contain the bleeding. Intrahepatic lesions are more likely to cause pain or hemobilia but may go undetected for a long time, with some patients not presenting until several months after the injury [30].

The locations also tend to dictate the therapy used. Since intrahepatic lesions often involve a peripheral branch, the artery can generally be sac-

rificed. Thus when the lesion can be reached with a catheter, standard coils or Gelfoam embolization is usually the primary therapy. Embolization of intrahepatic lesions is usually highly successful. In one study [31], hemobilia was controlled in 100% of eight cases. HIDALGO et al. [30] controlled hemobilia in 11 of 12 patients, however, several of the patients had recurrent bleeding 2 weeks to 2 months later. Although Tessier et al. had a success rate of only 86% for embolization, they noted that mortality was only 14% in patients treated with embolization but was 25% after surgery [32]. Results of direct puncture have been very favorable with effective occlusion of the lesions; however there are no large series and only scattered case reports of treating hepatic and pancreatic lesions with this technique [8, 9, 33–35]. One recurrence 2 months after initially successful direct puncture embolization has been reported [8].

Extra-hepatic pseudoaneurysms are usually not treated with coil embolization since it would sacrifice a major branch to a lobe or even the entire liver. Successful percutaneous thrombin injection of an anastomotic pseudoaneurysm has been described [12]. Recently, a number of case reports have been published on the use of stent grafts to repair these

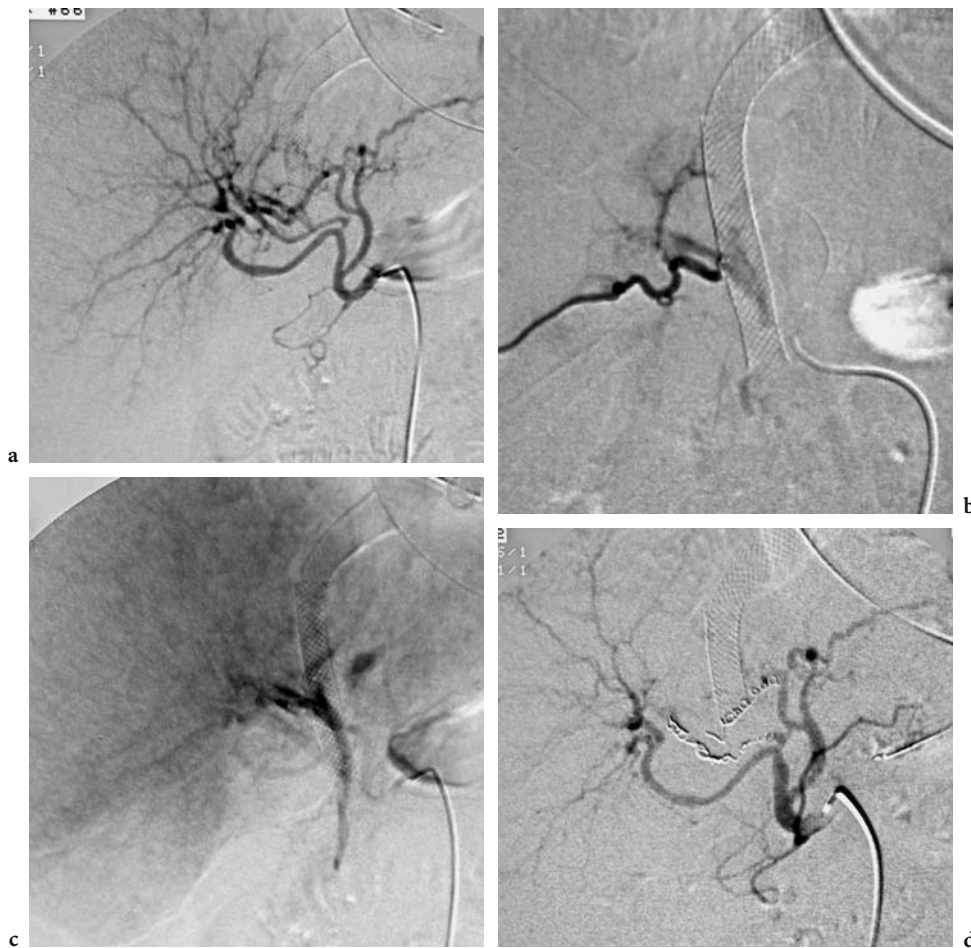

Fig. 7.8. **a** Arterial phase of a hepatic arteriogram in a patient with hemobilia 5 days after TIPS. **b** Later phase of the same study shows prominent opacification of the bile ducts. **c** Magnified super-selective arteriogram through a microcatheter shows rapid flow into the bile ducts from this arterial branch. **d** Post-embolization arteriogram shows no further flow to the arterio-biliary fistula

extrahepatic lesions [27, 28, 36, 37]. While successful in all cases, larger series are needed to validate this technique.

7.6.2 Renal

Pseudoaneurysms or arteriovenous fistulas occur after 0.2–2% of biopsies in transplant kidneys. Similarly after percutaneous nephrostomy the incidence of significant arterial injury is around 1%. Although vascular injuries typically manifest within the first week or so, delayed presentations out to 21 months after initial nephrostomy have been reported [38]. Although most papers report only a few patients [39, 40], embolization is well accepted as the preferred

method to deal with vascular injuries after renal biopsy and nephrostomies [41].

Technical success of embolization for intrarenal vascular injury is quite high, around 95–100% [42–44]. Typically the recurrence rate is nearly 0%; however, in one series a second embolization session was needed in 2 (15%) of 13 patients to fully occlude arteriovenous fistulas and achieve true technical success [44]. An analysis of the effect on renal function of selective embolization for traumatic renal lesions revealed that the mean volume of infarcted kidney was only 6% (range 0–15%) and 1 week postembolization the serum creatinine was normal in all their patients [42]. A series of renal transplants estimated that the maximal volume of infarcted kidney after embolization for biopsy-related injuries was always less than 30% [44]. Also, while renal function dete-

riorated in three patients, the serum creatinine significantly improved in 10 of 13 (77%).

The incidence of rupture after renal PTA has ranged from 1.6% to 5%. This is clearly a situation where traditional embolization is undesirable since it will lead to infarction of the entire kidney. However, if the patient is not a surgical candidate and they have another well functioning kidney, embolization with sacrifice of the kidney can be used as a life-saving maneuver if no other options are available. Stent graft use in the renal arteries has been described in a number of small case reports [17, 22–26, 45, 46]. They have been mostly used for exclusion of renal aneurysms but have occasionally been used to treat ruptures. In a series of five renal ruptures [17], all were able to be managed nonsurgically. Some were treated by balloon occlusion alone but one patient required a stent-graft. The stent-graft used in this setting was a home-made device of thin-walled PTFE mounted on a Palmaz stent. Another patient had a second bare stent placed within the original stent that caused the rupture, and this was followed by 2 minutes of balloon tamponade with successful sealing of the leak. There are no good series with long-term follow-up reported; however, a trial with 12 renal stent grafts showed reasonable patency with a restenosis rate of only 7.3% at 6 months [23].

7.6.3

Miscellaneous Injuries

Outside of the liver and kidneys, there are innumerable other types of iatrogenic arterial injuries that can occur. Of course the commonest iatrogenic injury is post-catheterization femoral artery pseudoaneurysms, but this is discussed in another chapter.

One type of injury that may be increasing in frequency (due to the increased use of central venous lines) is damage to the subclavian or carotid arteries or branches during line placement. If the injury involves a small artery such as a thyrocervical branch, selective embolization will typically solve the problem. If the subclavian artery itself is punctured or has a catheter placed into it, management becomes more difficult. Surgical repair carries high risks and may even require a thoracotomy, whereas standard embolization is not practical because of the arm ischemia it would cause. Placing a stent-graft is probably the preferred way to deal with this, assuming that the arterial defect is

in a location that allows a graft to be placed without compromising the carotid artery. In fact, the first reported application of an intravascular stent graft was to close a large hole (10 Fr) in the subclavian artery caused by an improperly placed Port catheter [47].

Arterial rupture is a feared complication of iliac PTA but fortunately is uncommon, with a 0.2–0.4% incidence [18]. However when it does occur it can be life-threatening, with the patient rapidly becoming hypotensive. This kind of injury has traditionally been managed surgically. Embolization is not typically done since it will likely make the leg severely ischemic. However embolization can be combined with a femoral-femoral cross-over graft. This type of graft has lower patency than a direct aortofemoral bypass, however it can be a useful option in patients who are high surgical risks since it is an extra-abdominal operation and can be accomplished without general anesthesia. It does, however, require that there is good inflow into the opposite iliac artery. With the increasing availability of commercially available covered stents, stent-grafting is now considered by some to be the treatment of choice [48].

Embolization techniques have been applied to iatrogenic hemorrhage throughout the entire body. There are numerous case reports of embolization successfully terminating bleeding after a wide variety of operation or procedures as varied as prostatectomy [49], orthopedic osteotomy [50], salpingo-oophorectomy [51], bone marrow biopsy [52], and pelvic abscess drainage [53]. KWON and KIM [54] reported a particularly large series of 24 cases of iatrogenic arterial injuries in the uterus after curettage or cesarean section. Gelfoam embolization of the uterine arteries successfully stopped bleeding in all cases. Interestingly, four patients desired to become pregnant after undergoing bilateral uterine embolization, and all four were able to deliver full-term babies. A theme running through all these reports is successful cessation of bleeding with no or minimal complications, enforcing the idea that embolization should be the first approach to treat iatrogenic arterial hemorrhage.

7.7

Complications

Arterial puncture site complications such as hematoma, pseudoaneurysm, arteriovenous fistula, dis-

section, and arterial occlusion can all certainly occur but are not unique to embolization cases. Trauma from the catheters and guidewires can also cause spasm or dissection in the main trunk or branches leading to the arterial defect that one is attempting to treat. This can prevent being able to advance the catheter to the bleeding site, or if the catheter can be advanced beyond the spasm / dissection there may be no flow to carry flow-directed embolic particles more distally. Spasm by itself may decrease blood flow to the arterial defect sufficiently that the bleeding will stop. However, this is a less secure method of managing the iatrogenic lesion. If the spasm resolves, bleeding may recur once the injured segment is again subjected to normal arterial pressure. Also any pseudoaneurysm or fistula would not be directly occluded and the permanence of the occlusion of that lesion would be questionable. If there are any collateral communications beyond the spasm or dissection, the pseudoaneurysm would likely remain patent.

If spasm occurs, local injection of vasodilators (e.g. 50–100 microgram boluses of nitroglycerin) may relieve the spasm. The best approach is to try to avoid the spasm in the first place. Minimizing the manipulation of guidewires and being very gentle will help reduce spasm. Also if it is anticipated that advancing the catheter will be difficult, prophylactic boluses of nitroglycerin can be employed. If dissection occurs, it may be possible to tack down the flap with a stent or PTA depending on the location and the caliber of the artery.

As emboli are being delivered to the target, the next complication that may be encountered is nontarget embolization. When using flow-directed emboli such as Gelfoam or PVA, overly vigorous injection can lead to reflux of emboli out of the target artery. The risk of reflux is increased as the end of the embolization approaches, since there will be increased resistance to flow in the target artery. The chance of particle reflux can be minimized by gentle injection, having the emboli suspended in contrast, and careful fluoroscopic monitoring of the injection.

Nontarget embolization can also occur when using coils. Rarely do coils migrate to a remote location, but they can cause undesirable occlusion of arteries or branches adjacent to the target vessel (Fig. 7.9). Having the catheter securely positioned well into the target artery before pushing out the coils will help prevent nontarget embolization. However it is not always possible to have the catheter advanced well into the target artery, especially

if the injury is close to the vessel origin. Maintaining good manual control of the catheter close to the groin access will allow one to move the catheter in or out slightly to help form the coils in situ. A gentle tapping motion of the pushing wire will also help the coil to form in a tight configuration. Rapidly pushing the coil out often elongates the coil and forces the delivery catheter back out of the target artery. Choosing appropriately sized coils is also critical to prevent this complication since pushing in oversized coils will also tend to back the catheter out of the target artery.

If a coil does get misplaced, retrieval with snares can be attempted. This can be quite difficult since the errant coil may often wedge itself into the peripheral aspect of another branch. That plus the spasm that frequently occurs from excessive manipulation makes it difficult to open a snare sufficiently to get around the coil. An unusual form of nontarget embolization is delayed migration of coils from the original point of deployment into another structure. Coils placed in an intrahepatic pseudoaneurysm have been reported in two cases to migrate (presumably via erosion of the adjacent structures) into the bile ducts [8, 55]. In these cases biliary obstruction resulted and required percutaneous or surgical removal of the coils.

Tissue infarction can range in severity from an expected inconsequential occurrence up to a fatal complication. When embolizing end-arteries such as renal branches, it is expected that the parenchyma distal to the embolized segment will infarct. However if the embolization is done peripherally enough, only a small segment of the kidney will infarct with no effect on renal function, and sometimes it will cause only minimal symptoms (pain and fever). In the liver, the consequences depend partially on the degree of intrahepatic collateral flow beyond the embolized artery. HASHIMOTO et al. [31] found that no hepatic infarction occurred when there was good collateral flow, but all four patients with poor collateral flow developed infarction. Three of these four had no symptoms and had infarcted segments seen on CT scans done to evaluate transient transaminase elevations. However, one patient did progress to hepatic failure. Such severe ischemia is uncommon in embolization for iatrogenic bleeding but has been reported by others [30]. Clinically significant ischemia can be minimized by super-selective embolizations with 3 Fr catheters and by avoiding the use of very small particles or liquid embolic agents that penetrate out to the capillary level.

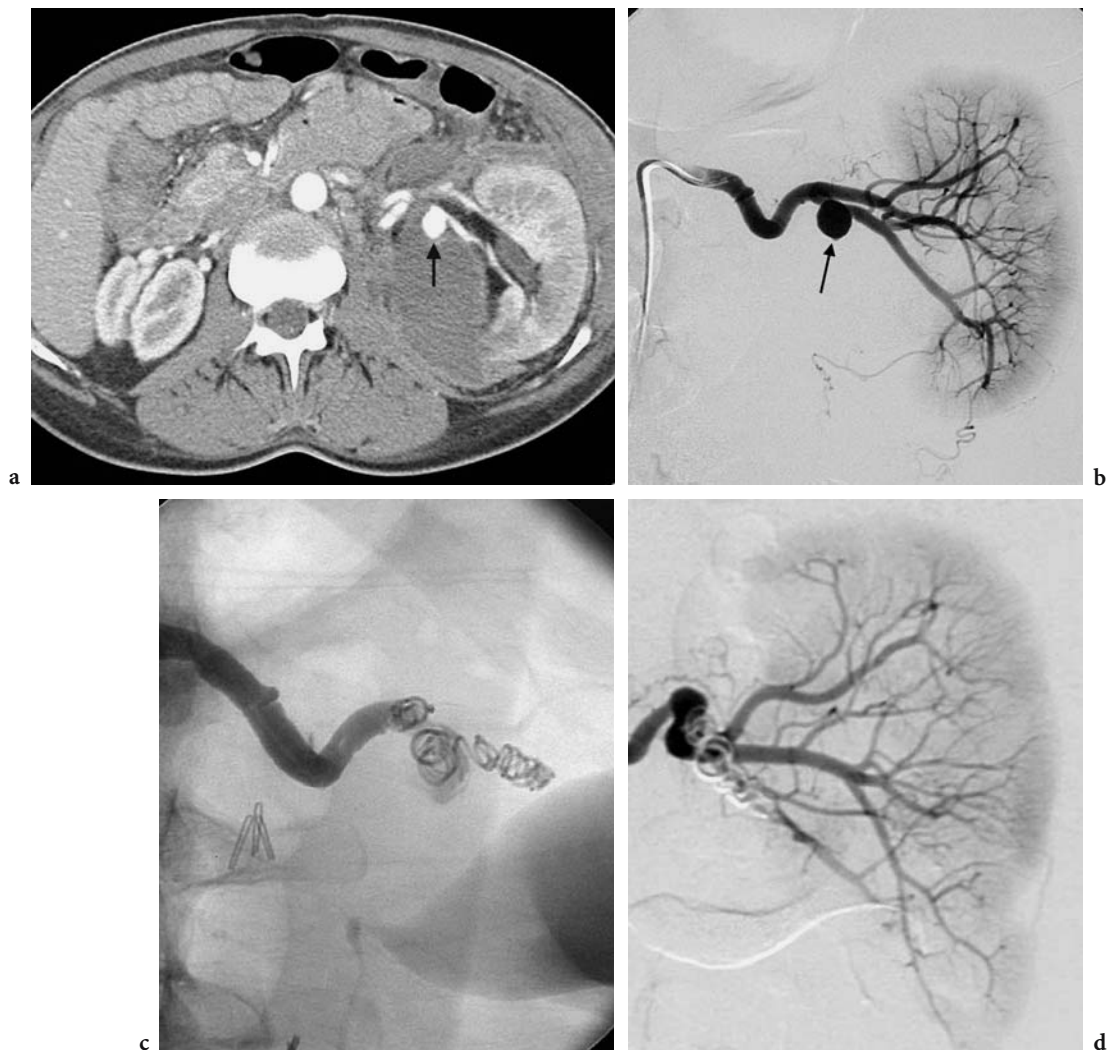


Fig. 7.9. **a** CT of a 38-year-old female who had flank pain after a partial nephrectomy. A hematoma and a pseudoaneurysm (*arrow*) are seen. **b** Left renal arteriogram shows a pseudoaneurysm near the origin of the inferior branch of the renal artery. **c** Coils were placed distal and into the pseudoaneurysm, and an attempt was made to place the final coils just proximal to the pseudoaneurysm. These last coils moved out into the main renal artery occluding all renal artery flow. **d** An arteriogram done 3 months later shows some recanalization through the displaced coils with some perfusion to the kidney

7.8 Future Development and Research

Areas for potential research include development of new embolic agents and improving existing embolic devices. Gelfoam and PVA are less than ideal embolic agents. Some of the newer embolic agents such as Embospheres (Biosphere Medical; Rockland, MA) may be more easily injected through small catheters, but they also may be more prone to causing tissue ischemia since they can travel more peripherally. Studies will need to be done to see whether this agent is appropriate for treating iatrogenic bleeding

and to determine what size spheres should be used. Liquid agents have some potential benefits in terms of ease of use and control. The initial studies with NBCA [16] are a step in the right direction, but some of the other new liquid embolic agents will also need to be evaluated.

Nontarget embolization can ruin an otherwise good result and while coils are one of the most commonly used embolic devices, they can be difficult to form properly. Better control over the coils is desirable. The Guglielmi detachable coils (Target Therapeutics; Fremont, CA) do provide the ability to redo the deployment if it is unsatisfactory, and they have

been applied to closure of iatrogenic vascular lesions [56]. However, they are expensive and the electrolytic detachment is more complex than the use of standard coils. There should be investigation into new embolic devices with better control and possibly different shapes that might enhance both placement and control of bleeding.

Although stent-grafting is an increasingly attractive therapy for some cases of iatrogenic bleeding, smaller, better devices and more ready availability are necessary. Bifurcated or fenestrated devices similar to those developed for aortic aneurysms might widen the application of visceral stent-grafts, since the presence of critical side branches sometimes limits the use of stent-grafts.

7.9

Conclusion

Embolization has become one of the primary techniques for treating iatrogenic bleeding. However since by default it causes vessel occlusion, it is mostly applicable to small, less important arteries or in peripheral branches that can be readily sacrificed. Proper technique generally allows a high degree of clinical success with minimal risk. With the ongoing development of stent grafts, endovascular treatment may also become the primary means of repairing larger, more critical vessels that must remain patent.

References

1. Tisnado J, Beachley MC, Amendola MA (1979) Transcatheter embolization of traumatic renal arteriovenous fistula. *Urol Radiol* 1:175-177
2. Walter JF, Paaso BT, Cannon WB (1976) Successful transcatheter embolic control of massive hematemesis secondary to liver biopsy. *Am J Roentgenol* 127:847-849
3. Gunther R, Jonas U, Jacobi GH (1977) Kidney damage during translumbar aortography treated by selective catheter embolisation. *Rofo* 126:426-429
4. Athanasoulis CA, Waltman AC, Barnes AB, Herbst AL (1976) Angiographic control of pelvic bleeding from treated carcinoma of the cervix. *Gynecol Oncol* 4:144-150
5. Encarnacion CE, Kadir S, Beam CA, Payne CS (1992) Gastrointestinal bleeding: treatment with gastrointestinal arterial embolization. *Radiology* 183:505-508
6. Schenker MP, Duszak R Jr, Soulen MC, Smith KP, Baum RA, Cope C et al. (2001) Upper gastrointestinal hemorrhage and transcatheter embolotherapy: clinical and technical factors impacting success and survival. *J Vasc Interv Radiol* 12:1263-1271
7. Savader SJ, Trerotola SO, Merine DS, Venbrux AC, Osterman FA (1992) Hemobilia after percutaneous transhepatic biliary drainage: treatment with transcatheter embolotherapy. *J Vasc Interv Radiol* 3:345-352
8. Araoz PA, Andrews JC (2000) Direct percutaneous embolization of visceral artery aneurysms: techniques and pitfalls. *J Vasc Interv Radiol* 11:1195-1200
9. Capek P, Rocco M, McGahan J, Frey C (1992) Direct aneurysm puncture and coil occlusion: a new approach to peripancreatic arterial pseudoaneurysms. *J Vasc Interv Radiol* 3:653-656
10. Kemmeter P, Bonnell B, VanderKolk W, Griggs T, van Erp J (2000) Percutaneous thrombin injection of splanchnic artery aneurysms: two case reports. *J Vasc Interv Radiol* 11:469-472
11. Lukancic SP, Nemcek AA Jr, Vogelzang RL (1991) Posttraumatic intrahepatic arterial pseudoaneurysm: treatment with direct percutaneous puncture. *J Vasc Interv Radiol* 2:335-337
12. Patel JV, Weston MJ, Kessel DO, Prasad R, Toogood GJ, Robertson I (2003) Hepatic artery pseudoaneurysm after liver transplantation: treatment with percutaneous thrombin injection. *Transplantation* 75:1755-1757
13. Brophy DP, Sheiman RG, Amatulle P, Akbari CM (2000) Iatrogenic femoral pseudoaneurysms: thrombin injection after failed US-guided compression. *Radiology* 214:278-282
14. Morgan R, Belli AM (2003) Current treatment methods for postcatheterization pseudoaneurysms. *J Vasc Interv Radiol* 14:697-710
15. Cope C, Zeit R (1986) Coagulation of aneurysms by direct percutaneous thrombin injection. *AJR Am J Roentgenol* 147:383-387
16. Kish JW, Katz MD, Marx MV, Harrell DS, Hanks SE (2004) N-butyl cyanoacrylate embolization for control of acute arterial hemorrhage. *J Vasc Interv Radiol* 15:689-695
17. Morris CS, Bonnevie GJ, Najarian KE (2001) Nonsurgical treatment of acute iatrogenic renal artery injuries occurring after renal artery angioplasty and stenting. *AJR Am J Roentgenol* 177:1353-1357
18. Cooper SG, Sofocleous CT (1998) Percutaneous management of angioplasty-related iliac artery rupture with preservation of luminal patency by prolonged balloon tamponade. *J Vasc Interv Radiol* 9:81-83
19. Joseph N, Levy E, Lipman S (1987) Angioplasty-related iliac artery rupture: treatment by temporary balloon occlusion. *Cardiovasc Intervent Radiol* 10:276-279
20. Smith TP, Cragg AH (1989) Non-surgical treatment of iliac artery rupture following angioplasty. *J Vasc Interv Radiol* 4:16-18
21. Kelly AJ (1995) Case report: iliac artery rupture-percutaneous treatment by stent insertion. *Clin Radiol* 50:876-877
22. Bisschops RH, Popma JJ, Meyerovitz MF (2001) Treatment of fibromuscular dysplasia and renal artery aneurysm with use of a stent-graft. *J Vasc Interv Radiol* 12:757-760
23. Gaxotte V, Laurens B, Haulon S, Lions C, Mounier-Vehier C, Beregi JP (2003) Multicenter trial of the Jostent balloon-expandable stent-graft in renal and iliac artery lesions. *J Endovasc Ther* 10:361-365
24. Pershad A, Heuser R (2004) Renal artery aneurysm: successful exclusion with a stent graft. *Catheter Cardiovasc Interv* 61:314-316

25. Schneiderreit NP, Lee S, Morris DC, Chen JC (2003) Endovascular repair of a ruptured renal artery aneurysm. *J Endovasc Ther* 10:71–74
26. Tan WA, Chough S, Saito J, Wholey MH, Eles G (2001) Covered stent for renal artery aneurysm. *Catheter Cardiovasc Interv* 52:106–109
27. Venturini M, Angeli E, Salvioni M, de Cobelli F, Trentin C, Carlucci M, et al. (2002) Hemorrhage from a right hepatic artery pseudoaneurysm: endovascular treatment with a coronary stent-graft. *J Endovasc Ther* 9:221–224
28. Sakai H, Urasawa K, Oyama N, Kitabatake A (2004) Successful covering of a hepatic artery aneurysm with a coronary stent graft. *Cardiovasc Intervent Radiol* 27:274–277
29. Roche CJ, Lee WK, Duddalwar VA, Nicolaou S, Munk PL, Morris DC (2001) Intrahepatic pseudoaneurysm complicating transjugular biopsy of the liver. *AJR Am J Roentgenol* 177:819–821
30. Hidalgo F, Narvaez JA, Rene M, Dominguez J, Sancho C, Montanya X (1995) Treatment of hemobilia with selective hepatic artery embolization. *J Vasc Interv Radiol* 6:793–798
31. Hashimoto M, Akabane Y, Heianna J, Tate E, Ishiyama K, Nishii T et al. (2004) Hepatic infarction following selective hepatic artery embolization with microcoils for iatrogenic biliary hemorrhage. *Hepatol Res* 30:42–50
32. Tessier DJ, Fowl RJ, Stone WM, McKusick MA, Abbas MA, Sarr MG et al. (2003) Iatrogenic hepatic artery pseudoaneurysms: an uncommon complication after hepatic, biliary, and pancreatic procedures. *Ann Vasc Surg* 17:663–669
33. Merhav H, Zajko AB, Dodd GD, Pinna A (1993) Percutaneous transhepatic embolization of an intrahepatic pseudoaneurysm following liver biopsy in a liver transplant patient. *Transpl Int* 6:239–241
34. Millonig G, Graziadei IW, Waldenberger P, Koenigsrainer A, Jaschke W, Vogel W (2004) Percutaneous management of a hepatic artery aneurysm: bleeding after liver transplantation. *Cardiovasc Intervent Radiol* 27:525–528
35. Chan RP, David E (2004) Reperfusion of splanchnic artery aneurysm following transcatheter embolization: treatment with percutaneous thrombin injection. *Cardiovasc Intervent Radiol* 27:264–267
36. Larson RA, Solomon J, Carpenter JP (2002) Stent graft repair of visceral artery aneurysms. *J Vasc Surg* 36:1260–1263
37. Paci E, Antico E, Candelari R, Alborino S, Marmorale C, Landi E (2000) Pseudoaneurysm of the common hepatic artery: treatment with a stent-graft. *Cardiovasc Intervent Radiol* 23:472–474
38. Kaufman JA, Edelstein RA (1994) Arterioalical fistula from prolonged nephrostomy tube drainage. *J Urol* 151:1616–1618
39. Peene P, Wilms G, Baert AL (1990) Embolization of iatrogenic renal hemorrhage following percutaneous nephrostomy. *Urol Radiol* 12:84–87
40. Ueda J, Furukawa T, Takahashi S, Miyake O, Itatani H, Araki Y (1996) Arterial embolization to control renal hemorrhage in patients with percutaneous nephrostomy. *Abdom Imaging* 21:361–363
41. Zagoria RJ, Dyer RB (1999) Do's and don'ts of percutaneous nephrostomy. *Acad Radiol* 6:370–377
42. Chatziioannou A, Brountzos E, Primetis E, Malagari K, Sofocleous C, Mourikis D et al. (2004) Effects of superselective embolization for renal vascular injuries on renal parenchyma and function. *Eur J Vasc Endovasc Surg* 28:201–206
43. Perini S, Gordon RL, LaBerge JM, Kerlan RK Jr, Wilson MW, Feng S et al. (1998) Transcatheter embolization of biopsy-related vascular injury in the transplant kidney: immediate and long-term outcome. *J Vasc Interv Radiol* 9:1011–1019
44. Maleux G, Messiaen T, Stockx L, Vanrenterghem Y, Wilms G (2003) Transcatheter embolization of biopsy-related vascular injuries in renal allografts. Long-term technical, clinical and biochemical results. *Acta Radiol* 44:13–17
45. Liguori G, Trombetta C, Bucci S, Pozzi-Mucelli F, Bernobich E, Belgrano E (2002) Percutaneous management of renal artery aneurysm with a stent-graft. *J Urol* 167:2518–2519
46. Majwal TK, Ismail A, Alaqlly R (2002) Renal artery stenosis associated with saccular aneurysm and arterio-venous fistula. *J Invasive Cardiol* 14:411–413
47. Becker GJ, Benenati JF, Zemel G, Sallee DS, Suarez CA, Roeren TK et al. (1991) Percutaneous placement of a balloon-expandable intraluminal graft for life-threatening subclavian arterial hemorrhage. *J Vasc Interv Radiol* 2:225–229
48. Allaire E, Melliere D, Poussier B, Kobeiter H, Desgranges P, Becquemin JP (2003) Iliac artery rupture during balloon dilatation: what treatment? *Ann Vasc Surg* 17:306–314
49. Ibarra R, Magee C, Ferral H, Thompson IM (2003) Post-prostatectomy bleeding managed by endovascular embolization. *J Urol* 169:276–277
50. Rickman M, Saleh M, Gaines PA, Eyres K (1999) Vascular complications of osteotomies in limb reconstruction. *J Bone Joint Surg Br* 81:890–892
51. Mariano RT, Stein B, Vine HS, Rosshirt W, Sussman SK, Ohki SK (2000) Angiographic diagnosis and transarterial embolization of iatrogenic ovarian artery injury. *J Vasc Interv Radiol* 11:625–628
52. Arellano-Rodrigo E, Real MI, Muntanola A, Burrel M, Rozman M, Fraire GV et al. (2004) Successful treatment by selective arterial embolization of severe retroperitoneal hemorrhage secondary to bone marrow biopsy in post-polycythemic myelofibrosis. *Ann Hematol* 83:67–70
53. Harisinghani MG, Gervais DA, Maher MM, Cho CH, Hahn PF, Varghese J et al. (2003) Transgluteal approach for percutaneous drainage of deep pelvic abscesses: 154 cases. *Radiology* 228:701–705
54. Kwon JH, Kim GS (2002) Obstetric iatrogenic arterial injuries of the uterus: diagnosis with US and treatment with transcatheter arterial embolization. *Radiographics* 22:35–46
55. Ozkan OS, Walser EM, Akinci D, Nealon W, Goodacre B (2002) Guglielmi detachable coil erosion into the common bile duct after embolization of iatrogenic hepatic artery pseudoaneurysm. *J Vasc Interv Radiol* 13:935–938
56. Angle JF, Matsumoto AH, McGraw JK, Hagspiel KD, Spinosa DJ, McCullough CS (1999) Percutaneous embolization of a high-flow pancreatic transplant arteriovenous fistula. *Cardiovasc Intervent Radiol* 22:147–149

Visceral Aneurysm

8 Embolization of Visceral Arterial Aneurysms

CRAIG B. GLAIBERMAN and MICHAEL D. DARCY

CONTENTS

8.1	Introduction	99
8.2	Pathophysiology	100
8.3	Clinical Considerations	101
8.4	Anatomy	103
8.5	Technique	104
8.6	Hepatic	105
8.6.1	Incidence	105
8.6.2	Causes	105
8.6.3	Risks Posed by the Aneurysm	106
8.6.4	Management	106
8.6.4.1	Anatomic/Physiologic Considerations	106
8.6.4.2	Technique	106
8.6.4.3	Results of Embolization	106
8.6.4.4	Complications	106
8.7	Splenic	107
8.7.1	Incidence	107
8.7.2	Risks Posed by the Aneurysm	107
8.7.3	Management	107
8.7.3.1	Anatomic/Physiologic Considerations	107
8.7.3.2	Technique	107
8.7.3.2	Results of Embolization	108
8.7.3.3	Complications	109
8.8	Mesenteric	109
8.8.1	Incidence	109
8.8.2	Causes	111
8.8.3	Risks Posed by the Aneurysm	111
8.8.4	Management	111
8.8.4.1	Anatomic/Physiologic Considerations	111
8.8.4.2	Technique	111
8.8.4.3	Results of Embolization	112
8.8.4.4	Complications	112
8.9	Renal	112
8.9.1	Incidence	112
8.9.2	Causes	112
8.9.3	Risks Posed by the Aneurysm	112

8.9.4	Management	113
8.9.4.1	Anatomic/Physiologic Considerations	113
8.9.4.2	Technique	113
8.9.4.3	Results of Embolization	113
8.9.4.4	Complications	113
8.10	Complications	114
8.11	Future Development and Research	114
8.12	Conclusion	115
	References	115

8.1 Introduction

Visceral arterial aneurysms (VAAs) are rare with incidence rates ranging between 0.01% and 0.2% at autopsy. However, they are important entities to recognize due to disastrous outcomes that result should rupture occur. Most visceral aneurysms are asymptomatic and are either overlooked clinically or found incidentally. Roughly 25% of symptomatic patients with VAAs will present with rupture [1]. Depending on the literature, reported mortality rates of ruptured aneurysms range from 10% to 50% [1–4]. It is important to note that aneurysm location contributes to the varying morbidity and mortality.

VAAs occur in the splenic, hepatic, superior mesenteric, gastroduodenal, pancreaticoduodenal, and renal arteries. Classically, splenic artery aneurysms have been found to account for 60% of all VAAs. Interestingly, SHANLEY et al. reviewed the literature from 1985 to 1995 and found that hepatic artery aneurysms were more common [5]. This finding may reflect an increase in the number of percutaneous hepatic and biliary interventions being performed. Furthermore, the routine use of computed tomographic imaging after trauma also attributes to the increased discovery of hepatic artery pseudoaneurysms. Because VAAs occur infrequently, it must be remembered that much of the current literature consists of retrospective reviews of small cohorts that span as many as 10 to 15 years of experience. Therefore, much of what has been reported is either anecdotal or based on collective case reports.

C. B. GLAIBERMAN, MD

Instructor, promoted to assistant professor of radiology, Radiology, Division of Interventional Radiology, Washington University School of Medicine, Mallinckrodt Institute of Radiology, 510 S. Kingshighway, St. Louis, MO 63110, USA

M. D. DARCY, MD

Professor, Radiology and Surgery Division of Diagnostic Radiology, Chief, Interventional Radiology Section, Washington University School of Medicine, Mallinckrodt Institute of Radiology, 510 S. Kingshighway Blvd, St. Louis, MO 63110, USA

A brief review of our experience over the last two years demonstrates that our group has embolized 21 VAAs. By far, the majority of cases (nine) were performed urgently for traumatic liver and splenic lacerations. This was followed closely by seven iatrogenic pseudoaneurysms that were caused by percutaneous biopsy, biliary intervention, or from previous laparotomy. Three pseudoaneurysms resulted from inflammatory causes such as pancreatitis, diverticulitis, and peptic ulcer disease. Two aneurysms were treated in patients with angiomyolipomas. A variety of techniques including coil, Gelfoam, and PVA embolization were used. No stent grafts were placed in this time period. Immediate technical success was achieved in all cases; however, the long-term outcomes are currently unknown.

Historically, visceral aneurysms have been treated surgically by resection, ligation, and bypass, as well as vein patch angioplasty. Today, the interventional radiologist is particularly well suited to perform less invasive forms of treatment with high technical success and less patient morbidity. VAAs have been treated with transcatheter techniques such as coil embolization, thrombin injection, or stent graft placement. Although the literature is relatively scant regarding the long-term outcomes of embolization or stent graft placement, the trend has been toward minimally invasive therapies. Preemptive treatment of these lesions with percutaneous methods has become more popular due to the high mortality associated with rupture and the reduced morbidity that embolization procedures offer.

8.2 Pathophysiology

The arterial wall is composed of three layers. The outer serosal covering is the adventitia, the muscular middle layer is the media, and the inner lining is the intima. True aneurysms are distinguished from false or pseudoaneurysms based on which layers of the arterial wall are present in the aneurysm itself. In order to classify an aneurysm as being “true,” it must be comprised of all three layers. Pseudoaneurysms have any combination less than all three of the arterial wall components.

Aneurysms can be either saccular or fusiform. Saccular aneurysms are typically spherical in shape and have a small communication or “neck” arising from the parent vessel (Fig. 8.1). Fusiform implies longitudinal dilatation along the course of the

artery. True fusiform aneurysms of visceral arteries are rare. The most common place for a fusiform aneurysm to occur is in the superior mesenteric artery distribution; it is typically the result of post-stenotic dilatation from atherosclerotic disease.

More commonly, VAAs are saccular pseudoaneurysms resulting from an insult to the arterial wall. Historically, one of the most common causes of saccular aneurysm formation has been from bacterial endocarditis. Originally described by Osler, aneurysms caused by an infectious etiology have been termed mycotic. Direct infection of the vaso vasorum in the adventitial lining has been postulated as a cause of mycotic aneurysm formation. The resulting inflammatory response typically results in saccular pseudoaneurysm formation. The incidence of this type of aneurysm has diminished over time due to earlier detection and treatment with antibiotics. Today, mycotic aneurysms in the presence of endocarditis have a high association with intravenous drug abuse and can occur in visceral and peripheral arteries.

Similarly, adjacent inflammatory changes such as pancreatitis can cause compromise of vessel wall integrity. Proteolytic degradation can occur if pancreatic enzymes come in contact with arteries. Gastroduodenal and pancreaticoduodenal pseudoaneurysms are especially prone to rupture in the presence of duodenal ulceration, pancreatitis, or pseudocyst formation [6, 7]. These should be treated regardless of size.

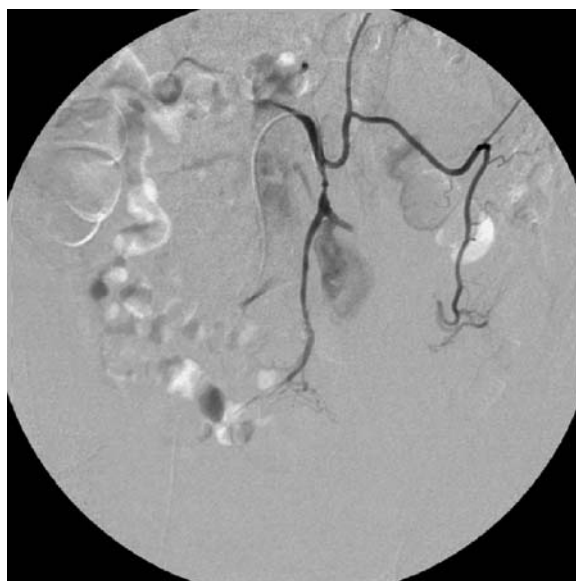


Fig. 8.1. Large saccular pseudoaneurysm arising from a sigmoid branch of the IMA demonstrating a short, well-defined neck. (Courtesy of Jennifer E. Gould, MD)

Other causes of saccular aneurysm formation include trauma and iatrogenic injury from percutaneous or surgical interventions. Any focal insult, perforation, or laceration can lead to pseudoaneurysm formation. These aneurysms are often symptomatic due to hemorrhage, pain, and hypotension that occur. Iatrogenic injuries will be discussed in a separate chapter of this text.

Multiple saccular microaneurysms are commonly seen with vasculitis caused by polyarteritis nodosa (PAN). Amphetamine abuse can also lead to multiple renal and hepatic microaneurysms similar to those seen with PAN. The small size and diffuse nature of these lesions often precludes embolization.

Inherent weaknesses caused by acquired or congenital etiologies may lead to VAAs. Congenital weakness of the arterial wall from a collagen disorder such as Ehlers-Danlos or Marfan's Syndrome can result in either saccular or fusiform aneurysms. Angiography should not be performed in patients with Ehlers-Danlos due to the high risk of arterial rupture. Therefore, embolization would be extremely dangerous to execute in these patients.

Fibromuscular dysplasia (FMD) is an inherent arterial wall abnormality that classically affects the media of the renal arteries and can be associated with renal artery aneurysms. Several subtypes of FMD have been described and the disorder can affect other medium-sized vessels including the carotid, vertebral, brachial, and visceral arteries. For the angiographer, FMD has the classic beaded appearance often described as a "string of pearls." Both aneurysms and dissections can be seen with this disorder. The treatment for FMD is angioplasty of the intraluminal webs, which results in significant remodeling.

Renal artery aneurysms can also be seen in patients with angiomyolipomas (AMLs) (Fig. 8.2). Classically, AMLs occur in elderly females and patients with tuberous sclerosis. The entire lesion can often be embolized in addition to coiling the aneurysms. A combination of coils and PVA or simply ethanol infusion with a balloon occlusion catheter can be performed as definitive treatment or if surgical resection is anticipated.

Although atherosclerosis has been implicated, there is debate as to whether it is the cause or the result of aneurysm formation. The heavy calcification seen in splenic artery aneurysms may be due to altered hemodynamics. For example, splenic artery aneurysms can be seen with portal hypertension (Fig. 8.3). Saccular or "berry" aneurysms associated with hypertension and atherosclerosis arise at

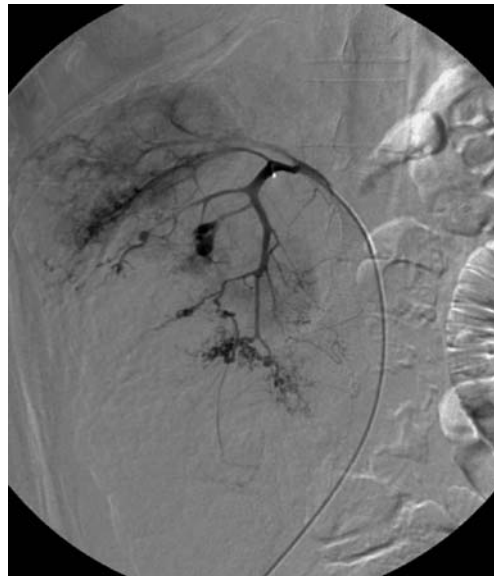


Fig. 8.2. Selective right renal angiogram demonstrating a huge AML with aneurysms that displaces the kidney laterally and superiorly. The patient has tuberous sclerosis

branch points where intrinsic weakness of the wall may exist.

Aneurysm configuration should influence treatment planning. Proximal and distal control should be obtained if the aneurysm itself cannot be occluded. It is typically easier to occlude short necks seen with the saccular form; therefore many different treatment options exist. These will be discussed later in the chapter. Fusiform aneurysms may not allow for both proximal and distal control and are often better treated with surgical ligation or reconstruction.

8.3 Clinical Considerations

Appropriate patient work up includes consent, a brief review of current and past medical history, pertinent imaging, a limited physical exam with evaluation of the pulses, and basic laboratory parameters. Endocarditis, vasculitis, pancreatitis, prior trauma, and congenital arteriopathies such as Ehlers-Danlos are important entities to be aware of. Knowing the past surgical history and whether prior percutaneous biopsy was performed would be relevant for iatrogenic causes. Since asymptomatic patients have VAAs that are often discovered incidentally and symptomatic patients often have vague

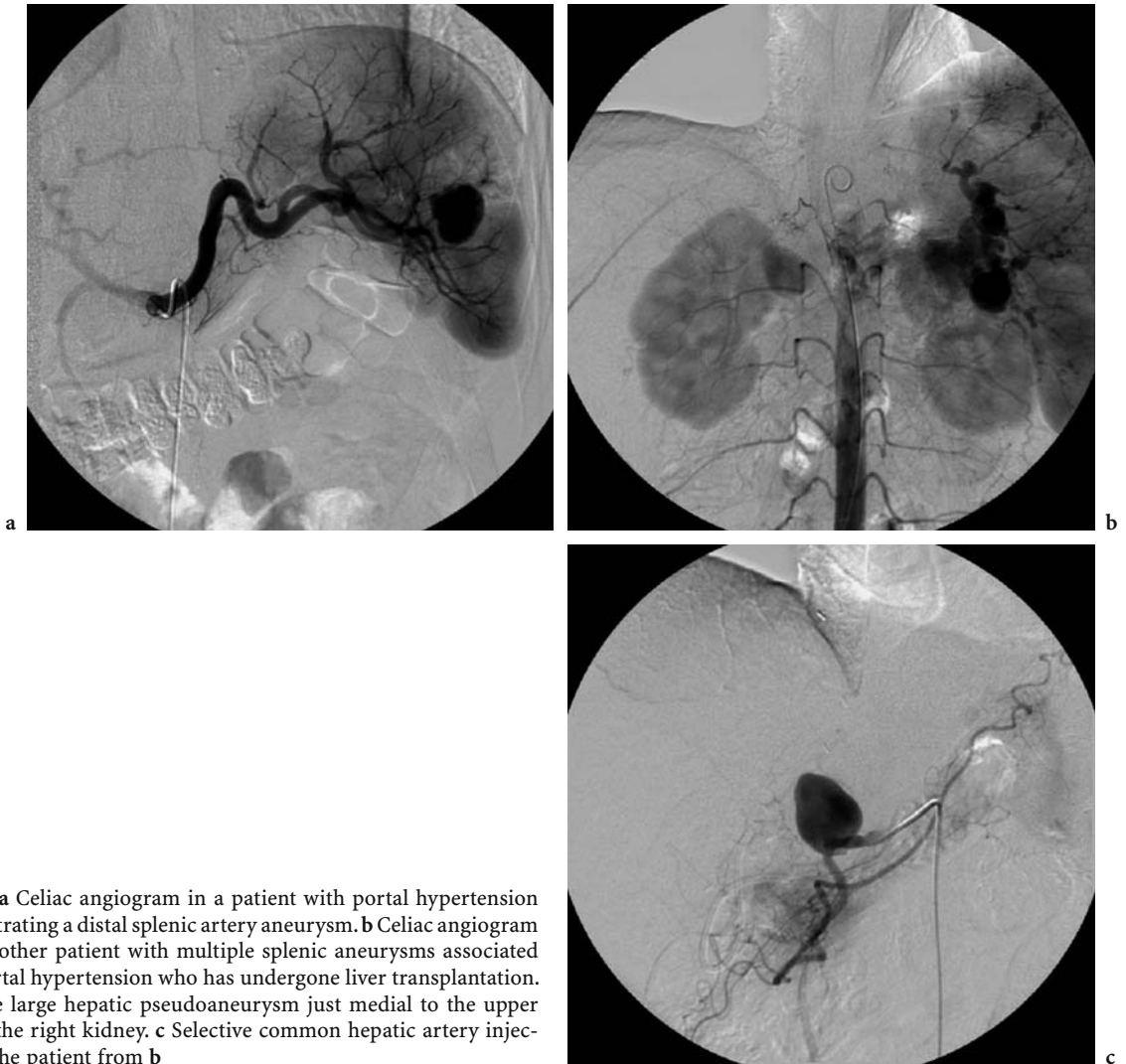

Fig. 8.3. **a** Celiac angiogram in a patient with portal hypertension demonstrating a distal splenic artery aneurysm. **b** Celiac angiogram from another patient with multiple splenic aneurysms associated with portal hypertension who has undergone liver transplantation. Note the large hepatic pseudoaneurysm just medial to the upper pole of the right kidney. **c** Selective common hepatic artery injection in the patient from **b**

abdominal pain, CT or MR imaging has typically been performed looking for other etiologies prior to referral to the Interventional Radiologist. Reviewing the images and examining the patient in the Interventional clinic are important steps in formulating a successful treatment plan. A complete blood cell count, prothrombin time with INR, and a basic or complete metabolic profile should be available prior to the procedure. Acceptable lab value limits vary depending on the institution.

Diabetics and patients with borderline renal function should be prehydrated to reduce the chances of contrast-induced nephropathy. A recent randomized controlled trial suggested that prehydration with sodium bicarbonate is more effective than sodium chloride in preventing contrast-induced renal failure [8]. For those patients with contrast allergies, prophylactic

steroids are typically administered at least 12 hours prior to intervention. If access from a brachial artery is required, a pre-procedure neurologic exam including mental status is vital to document any change during or after the procedure since catheters will cross the origin of at least one cerebral vessel.

Ideally, monitored conscious sedation should be administered by a registered nurse with intensive care experience or training. Continuous assessment of vital signs and oxygenation is important to maintain a comfortable level of sedation without respiratory or cardiovascular suppression. Typically, fast-onset, short-acting agents are used. In our practice, we use a benzodiazepine such as Versed (Roche Pharmaceuticals, Manati, PR) and the narcotic analgesic Fentanyl (Sublimaze; Abbott Laboratories, North Chicago, IL).

Patients with active bleeding should be vigorously transfused to maintain hemodynamic stability, and there should be no delay in transportation to the angiography suite for treatment. Severe coagulopathy should be corrected with fresh frozen plasma and platelet transfusion because hemorrhage can persist despite a technically successful embolization. Coagulation factors are required to maximize the effectiveness of the embolization materials and are responsible for the ensuing thrombus at the site of embolization. Plasma can infuse throughout the procedure, and the need for transfusion should not delay treatment if the patient is actively bleeding.

Periprocedural antibiotics should be considered if end-organ ischemia is a possibility. This is more common with the small permanent agents such as PVA and in organs where there is poor collateral flow. Tissue necrosis and hematoma can lead to abscess formation. When total occlusion of the splenic artery occurs and infarction results, patients should receive the pneumococcal vaccine. They should also take prophylactic antibiotics for future procedures as if they underwent a surgical splenectomy.

At our institution, outpatients are typically observed overnight and hematocrit levels are checked to watch for postprocedural complications. Postembolization syndrome consisting of pain, fever, and nausea can be seen in the first 24 hours following intervention. Follow-up Doppler ultrasound can be used to assess the success of embolization. However, the timing and frequency of reimaging are debatable. There are reports in the literature demonstrating that recanalization of treated aneurysms can occur.

For those patients who present emergently and require fluid and blood product resuscitation, transfer to the intensive care unit for close monitoring is a must. If coagulopathy exists, or there is concern for further bleeding, the sheath can be left in the access site should there be need for repeat angiography and embolization.

8.4 Anatomy

It is vital to understand the arterial anatomy and know the vascular supply distal to the planned embolization. In some VAAs, tissue ischemia can occur if the parent vessel is completely occluded. However, if good collateral flow exists, such as in

the stomach and duodenum, permanent embolization of entire vessels can be performed with some degree of impunity.

The hepatic and splenic arteries typically arise from the celiac axis, which has its origin at the T12/L1 level of the abdominal aorta. The three main branches of the celiac include the splenic, left gastric, and common hepatic arteries. The splenic artery is typically large and tortuous and supplies small branches to the pancreas. The common hepatic branches into the gastroduodenal and proper hepatic arteries. There is significant variant anatomy of the hepatic arteries that the interventionist should be aware of. The most common variation is the replaced right hepatic artery, which arises from the superior mesenteric artery (SMA). This occurs in 12%–15% of the population. Other less frequent variations include the replaced left hepatic from the left gastric artery (11%) and the completely replaced common hepatic from the SMA (2%).

The gastroduodenal artery arises from the common hepatic artery and supplies branches to the pancreatic head via the superior pancreaticoduodenal arcade (SPDA) and greater curvature of the stomach via the gastroepiploic. It is an excellent collateral vessel connecting the celiac to the SMA if either one becomes occluded.

The SMA arises at the L1 level and supplies the small bowel via jejunal and ileal branches, the right and middle colon via the ileocolic, right and middle colic arteries, as well as the pancreatic head via the inferior pancreaticoduodenal arcade (IPDA).

The inferior mesenteric artery (IMA) arises from the aorta at the level of the left pedicle of L3 and supplies the left colon, sigmoid, and rectum. It is frequently occluded in older populations. Collateral flow to this distribution can come from the marginal artery of Drummond or from branches of the internal iliacs.

The renal arteries originate from the aorta at the L2 level. A third of the population has multiple renal arteries. The main renal arteries are 5 to 6 mm in diameter and typically bifurcate into anterior and posterior divisions. There is further subdivision into segmental, interlobar, arcuate, and interlobular arteries before termination in glomeruli. Capsular and adrenal arteries take their origin from the main renal arteries.

The concept of collateral and end-organ vascular supply is vital to understand when considering embolization of visceral vessels. Choice of embolic agents for these vascular distributions and applications is described elsewhere in this book.

8.5 Technique

After arterial access is obtained, a sheath with heparinized saline flush through the side port should be placed to maintain access throughout the case. Typically a 5 or 6 French short vascular sheath such as a Flexor Check-flo (Cook Inc., Bloomington, IN) is used. Sometimes sheath upsize or exchange is required based on the arterial anatomy or type of intervention to be performed. For example, guiding catheters such as a Balkin Up and Over (Cook Inc.) may offer the advantage of a more secure access around corners during coil deployment. Certain devices such as stent grafts may mandate the use of larger sheaths for delivery.

Catheter selection is based upon individual preference and experience, but is typically guided by patient anatomy. It is often wise to perform a non-selective aortogram with a pigtail catheter (Merit Medical Systems Inc., Salt Lake City, UT) to identify vessel origins, assess patency, and look for potential stumbling blocks such as variant anatomy or stenosis from atherosclerotic disease. A reverse curve catheter such as a Sos (Angiodynamics Inc., Queensbury, NY) can often be used to select visceral and renal arteries. A floppy tipped wire, such as a Bentson (Medi-Tech/Boston Scientific, Watertown, MA) is used to select visceral branches and advance the catheter into the origin to perform selective angiography. Other catheter considerations include the Simmons (Cook Inc.), Roche Celiac (RC-1) (Roche Inc., Indianapolis, IN), Cobra (Merit Medical Inc., South Jordan, UT), Roche Inferior Mesenteric (RIM) (Cook Inc.), or even a Multipurpose Angiographic Catheter (MPA) (Cook Inc.) if approaching from the arm. Often, the coaxial use of microcatheters is advantageous when attempting to occlude vessels as peripherally as possible. Being as selective as possible is important when embolizing tissues that have poor or no collateral supply.

In our experience, the Sos catheter can be used to select the origin of nearly every visceral vessel including the renals. Once selective angiography is performed and access is secured by passing a wire distally, the Sos can be exchanged for a more appropriate catheter to fit the anatomy, or a microcatheter can be used coaxially through the Sos. Hydrophilic coated wires and catheters are useful for navigating tortuous vessels. The secondary curve of the Cobra catheter can help to select more peripheral branches as well as provide a “backstop” to keep it from buckling out of the origin of the desired vessel.

Another trick is the formation of a Waltman loop if a reverse curve catheter is unavailable or unsuccessful at cannulating the origin of visceral arteries. This is typically formed over the aortic bifurcation with the tip of a Cobra or hockey-stick catheter in the contralateral external iliac artery. Using the back end of a Bentson wire, the loop is formed by pushing cephalad and twisting. The back end of the wire must be positioned in the ipsilateral common iliac segment of the catheter to provide the stiffness required to advance the entire loop into the distal aorta. The wire is then reversed so that the floppy tip can be used to select the desired vessel origin. An alternative way to form a Waltman loop was described by Shlansky-Goldberg and Cope and uses a stitch and guidewire combination to physically pull the catheter into a reverse curve formation [9].

Prior to intervention, selective angiography of the target vessel is performed. Access is secured and tested by passing a wire through the catheter to ensure that it does not buckle out of the origin and lead to nontarget embolization. Permanent occlusion is the goal of treatment for VAAs due to high morbidity and mortality should they rupture. Permanent materials include, but are not limited to, coils, thrombin, glue, and stent grafts. Distal to proximal embolization should be performed to prevent recanalization of the aneurysm from retrograde flow through collaterals. If the aneurysm neck is amenable, packing with coils can be performed. Care must be taken not to rupture the aneurysm with this type of intervention, which is far more challenging and time-consuming than simply embolizing the supplying vessel.

If both distal and proximal occlusion cannot be obtained because the aneurysm neck is too close to a vessel origin or distal occlusion would result in undesirable end-organ ischemia, a bare metal stent can be deployed across the neck of the aneurysm. A guidewire is then passed between the interstices of the stent and into the aneurysm sac. Selective coil embolization of the aneurysm can then be performed using a microcatheter and microcoils. Alternatively, a stent graft can be considered for this situation.

Due to the small size and tortuosity of the visceral vessels, stent graft placement is often prohibitive. In the appropriate situation, stent grafts offer the benefit of occlusion of the aneurysm neck while maintaining distal perfusion [2]. Although an elegant solution, the anatomy must be such that there is enough of a landing zone proximal and distal to obtain an effective seal on both ends of the graft to exclude the aneurysm. Further device development and experience are needed to perfect this therapy.

If the aneurysm is amenable to direct percutaneous puncture, another option includes direct thrombin injection or coiling via an 18-gauge needle. Simultaneous balloon occlusion of the aneurysm neck via arterial access can be performed to prevent nontarget embolization.

8.6 Hepatic

8.6.1 Incidence

Hepatic artery aneurysms comprise 20% of all visceral aneurysms [4, 10–12]. Eighty percent are extrahepatic and 20% are intrahepatic. The majority affect the common hepatic artery. Males are affected

twice as often as females, and patients are typically in their fifties. Hepatobiliary and intraperitoneal rupture occur with equal propensity. These lesions tend to be solitary although they can be multiple in conditions such as polyarteritis nodosa [4,12]. Multiplicity is also seen with amphetamine abuse and trauma.

8.6.2 Causes

Mycotic aneurysms from bacterial endocarditis were initially the most common cause of hepatic artery aneurysm [11]. However, traumatic and iatrogenic causes are likely the most common etiology today. Medial degeneration and atherosclerotic changes have also been implicated. However, atherosclerosis is more likely the result rather than the cause of the

First and Second Line Tools for Embolization

Celiac (Splenic, Hepatic, GDA, Pancreaticoduodenal):

- First choice:
 - 6 F sheath in common femoral artery
 - 5 F Sos to engage the celiac artery
 - 3 F microcatheter and guidewire coaxially
 - microcoils appropriately sized to fit the target hepatic artery
- Second choice:
 - 5 F Sos to select the celiac
 - exchange groin sheath for a Balkin sheath or guiding catheter to maintain access to the celiac artery
 - Bentson or hydrophilic wire to gain peripheral access using a 5 F Cobra catheter (can be 4 F hydrophilic)
 - Coaxial use of a microcatheter or direct embolization through Cobra

SMA

- First choice:
 - 6 F sheath in common femoral artery
 - 5 F Sos to engage the superior mesenteric artery
 - 3 F microcatheter and guidewire coaxially
 - microcoils appropriately sized to fit the target mesenteric artery
- Second choice:
 - 5 F sheath in the left brachial artery
 - 5 F MPA to engage the SMA
 - 3 F microcatheter and guidewire coaxially
 - microcoils appropriately sized to fit the target mesenteric artery

IMA

- First choice:
 - 6 F sheath in common femoral artery
 - 5 F RIM catheter to engage the inferior mesenteric artery

- 3 F microcatheter and guidewire coaxially
- microcoils appropriately sized to fit the target mesenteric artery
- Second choice:
 - 5 F sheath in the left brachial artery
 - 5 F MPA or vertebral artery catheter (for the length) to engage the IMA
 - 3 F microcatheter and guidewire coaxially
 - microcoils appropriately sized to fit the target mesenteric artery

Renal

- First choice:
 - 6 F sheath in common femoral artery
 - 5 F Sos to engage the renal artery
 - 3 F microcatheter and guidewire coaxially
 - microcoils appropriately sized to fit the target renal artery
- Second choice:
 - 5 F Cobra to select the renal artery
 - exchange groin sheath for a Balkin sheath or guiding catheter to maintain access to the renal artery over a Rosen wire
 - obtain peripheral access with the 5 F Cobra (can be 4 F hydrophilic)
 - Coaxial use of a microcatheter or direct embolization through Cobra
- Other options:
 - 500–700 or 700–900 micron PVA/embospheres/Contour SE in vascular beds with good collateral flow
 - Bare stent with microcoils through the interstices
 - Stent-graft where anatomy is favorable
 - Direct puncture with an 18-g needle for coil, thrombin, or glue injection

aneurysm. Inflammatory processes and vasculitis also cause hepatic artery aneurysms. Polyarteritis nodosa, systemic lupus erythematosus, Takayasu's arteritis, and Wegener's granulomatosis have all been implicated in published case reports [11–13]. Congenital arteriopathies such as Marfan syndrome, Ehlers-Danlos syndrome, and hereditary hemorrhagic telangiectasia can lead to aneurysm formation [14].

8.6.3

Risks Posed by the Aneurysm

Intrahepatic rupture can result in hemobilia with or without biliary obstruction. These patients can present with right upper quadrant pain, jaundice, fever, melena, or hematemesis. Extrahepatic rupture usually presents acutely and can lead to exsanguination due to massive intraperitoneal hemorrhage. They can erode into adjacent structures such as the stomach, common bile duct, duodenum, or portal vein. Due to the high mortality from rupture, elective treatment of small asymptomatic aneurysms has been advocated.

8.6.4

Management

8.6.4.1

Anatomic/Physiologic Considerations

The liver receives a “dual” blood supply from both the hepatic arteries and the portal vein. Although good collateral flow exists, necrosis can occur if enough arterial supply is occluded at the time of embolization. Therefore, it is wise to assess the direction of blood flow in the portal vein because hepatofugal flow may increase the risk of infarction. One should be cautious and superselective when embolizing in the presence of portal vein thrombosis.

There have been reports of recanalization of pseudoaneurysms after percutaneous embolization. Follow-up ultrasound, CT, or MRI can be performed to assess success of embolization [4,15]. One must be aware of the relatively frequent anatomic variation seen in the hepatic artery distribution.

8.6.4.2

Technique

Typically, the celiac axis is selected with either a Sos or Cobra catheter from the groin and nonselec-

tive angiography is performed. Portal vein patency should be confirmed prior to occluding any vessel supplying the hepatic parenchyma. Approach from the left brachial artery may be required if the celiac axis cannot be catheterized due to an unfavorable angle off the aorta. Furthermore, if the origin of the celiac is occluded, retrograde catheterization of the GDA can be attempted from the SMA. Hydrophilic or microcatheters are helpful to navigate tortuosity. Once securely positioned within the origin of the common or proper hepatic artery, the microcatheter can be used to perform selective angiography and embolization. Distal to proximal coil deposition should be performed for small intrahepatic aneurysms in peripheral vessels. In cases of multiple traumatic pseudoaneurysms, Gelfoam embolization can be used to temporarily tamponade bleeding.

Treatment of saccular aneurysms that arise from the common, proper, or extrahepatic right and left hepatic arteries require more planning. Selective coil or percutaneous thrombin injection are options that can allow for continued perfusion distal to the aneurysm. Tortuosity and small caliber may preclude stent graft placement. The GDA can be sacrificed if absolutely necessary due to collateral flow from the SMA.

8.6.4.3

Results of Embolization

Review of the relatively limited literature reveals that embolization with coils, Gelfoam, detachable balloons, or glue and placement of stent grafts is technically successful in 95%–100% of cases [6,10,16–22]. Failures were typically discovered early when patients tended to rebleed. In cases where follow-up imaging was performed, a small number were found to recanalize [19,22]. In some cases of recanalization, successful thrombosis was obtained percutaneously with glue using the coils as a target in the series by PARILDAR et al. [22].

8.6.4.4

Complications

Complications of the embolization procedure include those of diagnostic angiography with the addition of aneurysm rupture, nontarget embolization, ischemia or infarction, abscess formation, and rarely sepsis. In earlier literature, spontaneous

rupture occurred in as many as 44% of cases [23]. It is likely that this rate is much lower today due to earlier discovery with frequent and improved imaging. However, mortality associated with rupture is still nearly 35% [24]. Although small case numbers, rupture during manipulation has not been reported in the current literature [25–27]. In 1986, UFLACKER reported successful treatment of 11 cases of visceral artery aneurysms by coiling feeding vessels both distally and proximally, thus reducing the risk of rupturing the fragile pseudoaneurysm wall by directly coiling the sac [28].

8.7 Splenic

8.7.1 Incidence

Considered the most common, the splenic artery aneurysm has been reported to comprise approximately 60% of all VAAs [1,2]. This entity affects females four times as often as males. Typically seen in multiparous women, this aneurysm has a high propensity to rupture in the third trimester of pregnancy [29]. Asymptomatic aneurysms can often be seen as round calcified masses in the left upper quadrant on plain films and computed tomography. This type of aneurysm has been associated with portal hypertension. Many causes exist and include pancreatitis, portal hypertension, endocarditis, cystic medial necrosis, iatrogenic, and collagen vascular diseases such as Ehlers-Danlos.

8.7.2 Risks Posed by the Aneurysm

Life-threatening rupture, which commonly occurs in the third trimester of pregnancy, is a serious risk of splenic aneurysms. The small 2–3 cm asymptomatic lesions typically pose no immediate threat and can be observed with serial CT. There is some debate regarding the size of aneurysm that can be observed. However, patients who develop left upper quadrant or abdominal pain with no other identifiable source would likely benefit from elective embolization even if in the 2–3 cm range. Although not defined, rapid interval growth should also be an impetus to embolize because the morbidity from rupture is significant.

8.7.3 Management

8.7.3.1 Anatomic/Physiologic Considerations

The splenic artery arises from the celiac axis and is often tortuous. Therefore, glide wires and hydrophilic catheters are helpful in gaining peripheral access to this vessel. It has a long course from the aorta to the splenic hilum, making it one of the most amenable arteries for stent graft placement. It supplies branches to the body and tail of the pancreas. If necessary, complete occlusion of the main splenic artery distal and proximal to the aneurysm neck can be performed. If the artery is completely thrombosed, collaterals can be parasitized resulting in a splenic remnant or even hypertrophy of splenules after an embolization.

8.7.3.2 Technique

Typically a groin approach is used and the celiac axis is selected with a Sos catheter. Selective angiography is performed to lay out the splenic artery. A guidewire is then passed distally and either the Sos or a Cobra catheter is advanced. Embolization can be performed through the 5 French catheter at this point. If too tortuous, then a microcatheter can be passed coaxially. (Fig. 8.4) We use either a Mass Transit® (Cordis, Miami, FL) or Renegade® (Boston Scientific, Boston, MA) microcatheter. These catheters can withstand a power injection of 2–3 cc per second if needed.

Coil embolization is technically easy and successful. Coils should be sized slightly larger than the vessel lumen. Smaller coils or Gelfoam can be used to sandwich or “nest” between the flanking coils. This will ensure a compact and occlusive embolus. Patients should be observed for splenic infarction, although short gastric or other small collateral vessels can perfuse portions of the spleen distal to the occluded main renal artery.

A long guiding catheter can be used to secure access or to upsize from the standard 6 F short sheath used in the common femoral artery, should a stent graft be chosen. The splenic artery is probably the most amenable to stent graft insertion due to its long length and relative lack of branch vessels feeding other organs. Although tortuous, the vessel will often straighten out when a wire is passed distally.

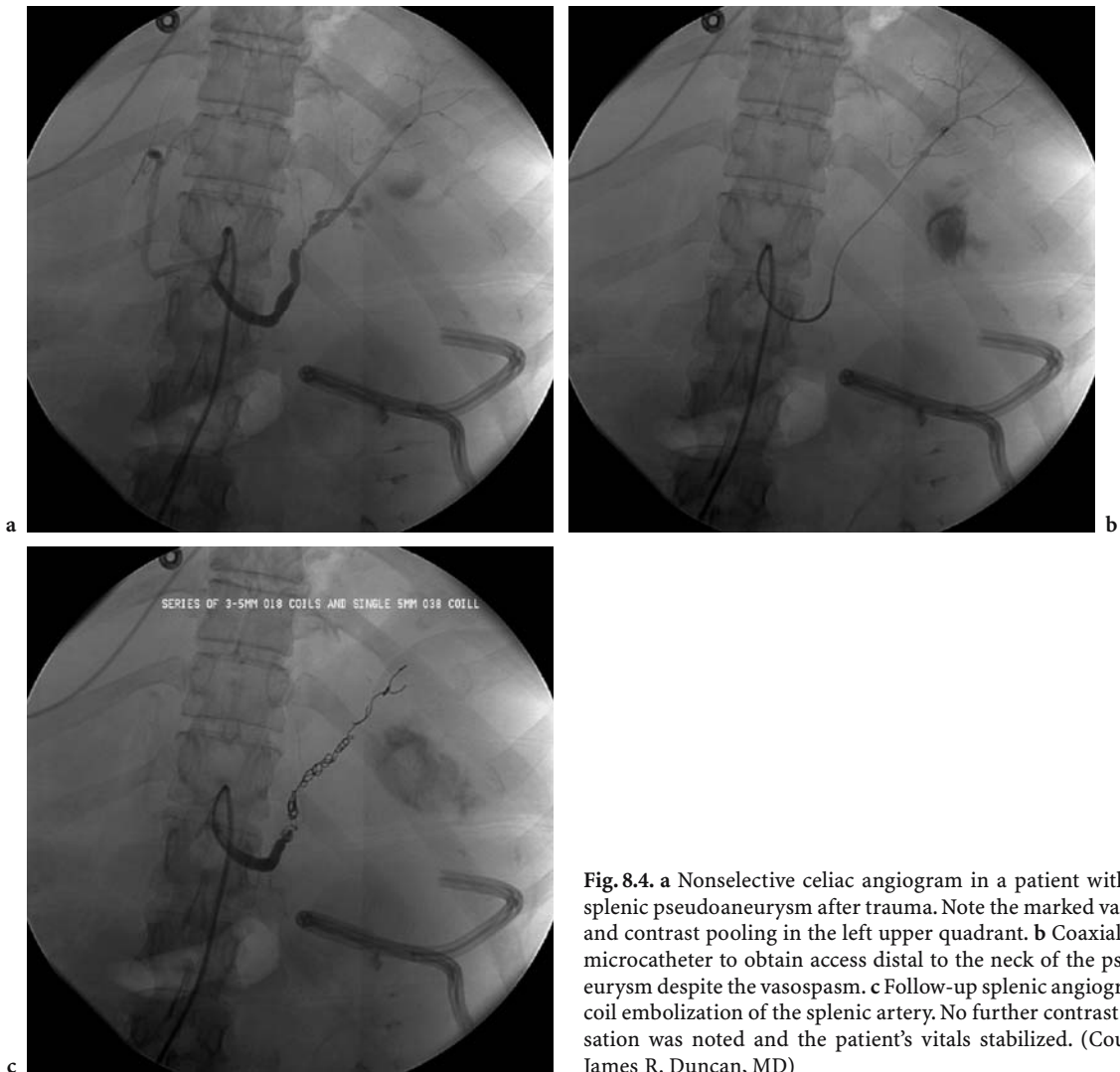


Fig. 8.4. **a** Nonselective celiac angiogram in a patient with a large splenic pseudoaneurysm after trauma. Note the marked vasospasm and contrast pooling in the left upper quadrant. **b** Coaxial use of a microcatheter to obtain access distal to the neck of the pseudoaneurysm despite the vasospasm. **c** Follow-up splenic angiogram after coil embolization of the splenic artery. No further contrast extravasation was noted and the patient's vitals stabilized. (Courtesy of James R. Duncan, MD)

A good landing zone of at least 1 to 2 cm is required on either side of the aneurysm neck to obtain a seal. Self-expanding stent grafts such as the Viabahn (Gore Inc., Flagstaff, AZ) are readily available, but are far too large for use in the visceral vessels. Smaller coronary stent grafts such as the balloon mounted Jostent® (Abbott Laboratories, Inc., Abbott Park, Illinois) have been used, but are not readily available or approved for this indication. Although delivery is more precise, balloon-mounted stents are less flexible. Flexibility is desirable for passing catheters through tortuous vessels. Currently, there is little published on stent graft use for VAAs, and more investigation is warranted.

8.7.3.2 Results of Embolization

Technical success is high, approaching 100%. On the rare occasion that the celiac axis is occluded or too stenotic, access to the splenic artery can be obtained by retrograde cannulation of the gastroduodenal artery from the SMA. The GDA is often hypertrophied if the celiac has been chronically occluded. In this case, getting coils through multiple turns may not be possible. However, if the catheter tip is in a secure enough position, particles such as PVA or a Gelfoam slurry can be used to stop acute bleeding prior to taking the patient to the operating room.

8.7.3.3

Complications

Complications of the embolization procedure include those of diagnostic angiography with the addition of aneurysm rupture, nontarget embolization, splenic infarction, abscess formation, and rarely sepsis (Fig. 8.5). Total splenic infarction can occur, which puts the patient at an increased risk of infection with encapsulated bacteria such as pneumococcus. Older literature suggests that bland splenic artery aneurysms rupture at a rate of approximately 2% [30]. However, in pregnant patients, rupture occurs in nearly every case with mortality rates for mother and fetus 70% and 95% respectively [31]. Obviously, any aneurysm in the pregnant female should be addressed since over 95% will rupture if left untreated [30, 32].

After a retrospective review of ten years of experience, CARR et al. found that 42% of their cases of VAAs presented with rupture [33]. Half of all the VAAs were splenic artery aneurysms. Of the splenic artery aneurysms that were observed, 33% went on to rupture. This is much higher than the previously reported 2% rupture rate and reflects the fact that

the patients in the series by CARR et al. suffered from associated conditions such as hypersplenism, pancreatitis, abscess, and PAN. The overall mortality rate after rupture was 25% despite surgical intervention [33]. This would suggest that intervention should be pursued in cases due to associated conditions since a high rupture rate exists during observation. Incidental aneurysms can be watched. Again, no case reports of rupture during manipulation were encountered in the current literature.

8.8

Mesenteric

8.8.1

Incidence

The superior mesenteric artery aneurysm is the third most common VAA but only accounts for 6% of all splanchnic aneurysms. It is typically associated with an infectious etiology such as endocarditis. Thrombosis and dissection can be seen with these lesions and patients can present with symptoms of mesen-

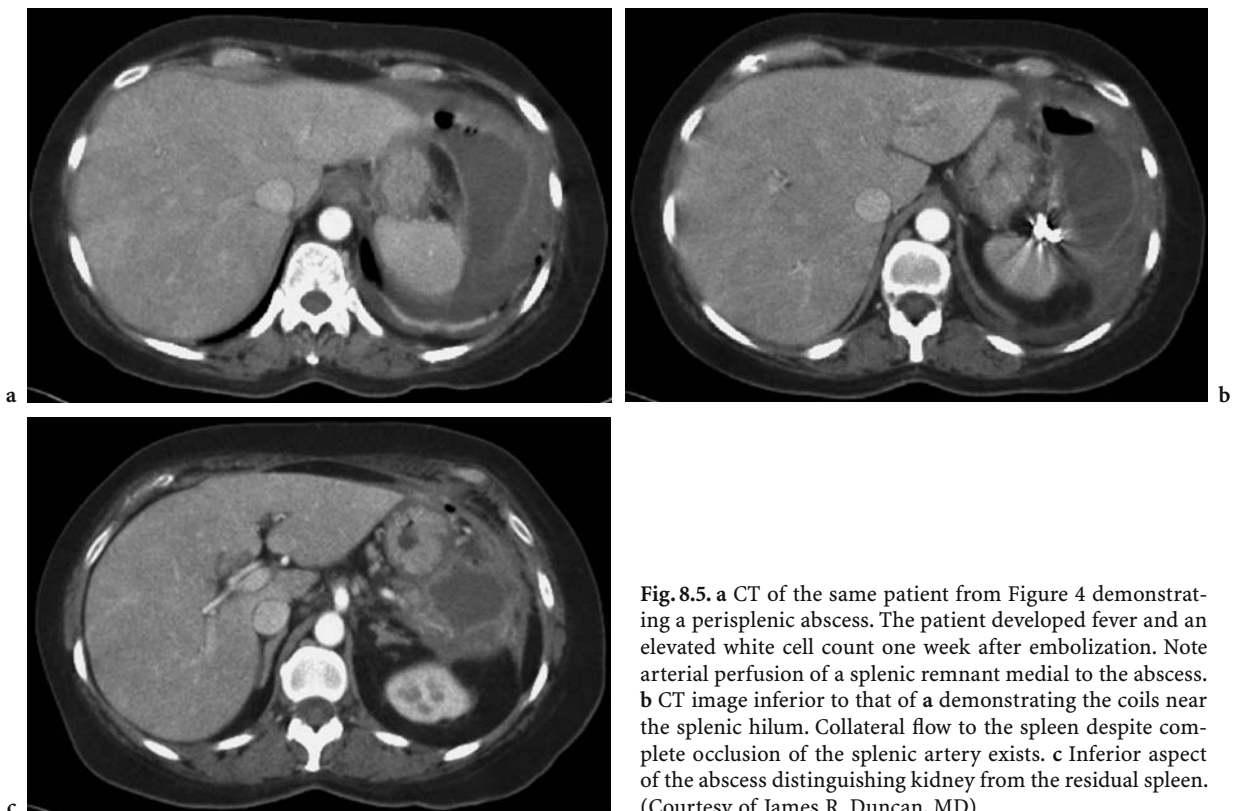


Fig. 8.5. a CT of the same patient from Figure 4 demonstrating a perisplenic abscess. The patient developed fever and an elevated white cell count one week after embolization. Note arterial perfusion of a splenic remnant medial to the abscess. b CT image inferior to that of a demonstrating the coils near the splenic hilum. Collateral flow to the spleen despite complete occlusion of the splenic artery exists. c Inferior aspect of the abscess distinguishing kidney from the residual spleen. (Courtesy of James R. Duncan, MD)

teric ischemia or intestinal angina. Aneurysms and pseudoaneurysms of the remaining mesenteric vessels are rare and present in descending frequency: celiac, gastroduodenal (GDA) (Fig. 8.6), gastric,

gastroepiploic, and pancreaticoduodenal. There is no significant gender predilection for mesenteric aneurysms, and the age range typically spans the sixth and seventh decades.

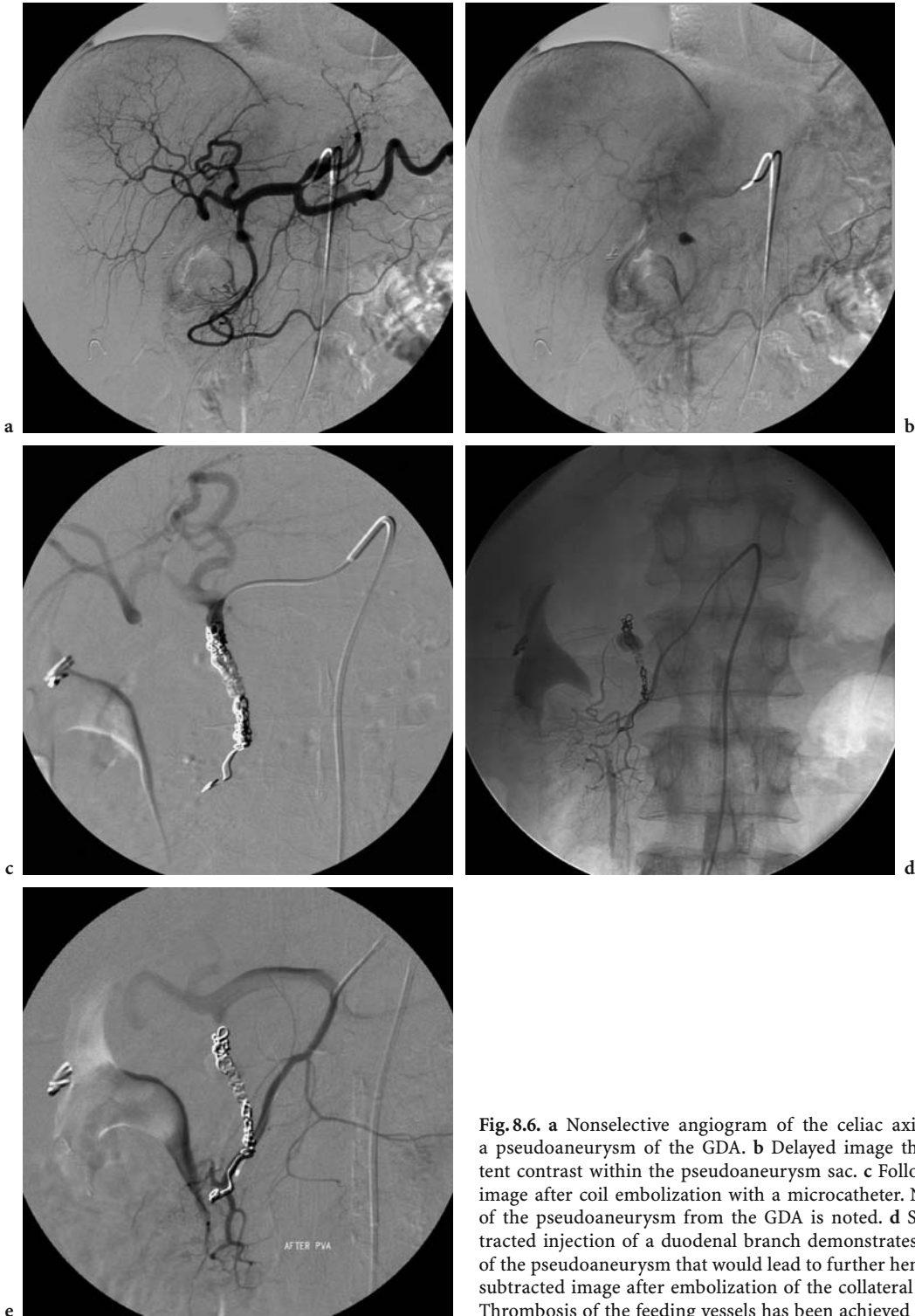

Fig. 8.6. a Nonselective angiogram of the celiac axis demonstrating a pseudoaneurysm of the GDA. b Delayed image that shows persistent contrast within the pseudoaneurysm sac. c Follow-up subtracted image after coil embolization with a microcatheter. No further filling of the pseudoaneurysm from the GDA is noted. d Selective non-subtracted injection of a duodenal branch demonstrates collateral filling of the pseudoaneurysm that would lead to further hemorrhage. e Final subtracted image after embolization of the collateral vessel with PVA. Thrombosis of the feeding vessels has been achieved

8.8.2

Causes

Generally, SMA aneurysms are mycotic, celiac aneurysms develop from cystic medial degeneration, GDA pseudoaneurysms occur in the presence of duodenal ulceration, and gastropiploic and pancreaticoduodenal aneurysms arise secondary to inflammatory changes from pancreatitis. Other causes include polyarteritis nodosa, amphetamine abuse, and connective tissue disorders.

8.8.3

Risks Posed by the Aneurysm

Ischemia from proximal thrombosis or distal embolization and rupture are significant risks posed by these types of VAAs. Local infection of adjacent hematomas and generalized sepsis can occur. Subsequent bowel resection may be required if ischemia from thrombosis or embolization is severe or revascularization is not possible.

8.8.4

Management

8.8.4.1

Anatomic/Physiologic Considerations

Due to good collateral flow, complete occlusion of splenic, peripheral hepatic, and gastroduodenal

arteries is well tolerated. Ischemia, stricture, and infarction of the bowel can result from embolization in the peripheral SMA and IMA distributions. Because of the rich arcade around the pancreatic head, the GDA can easily reconstitute the celiac axis via retrograde flow from the SMA. This is beneficial for preventing ischemia, but can allow persistent perfusion of aneurysms if both distal and proximal control is not achieved at the time of embolization.

Often, pseudoaneurysm formation in the pancreaticoduodenal, SMA, and IMA distributions is due to adjacent inflammatory processes such as pancreatitis or diverticulitis. (Fig. 8.7) Hematomas in the mesentery can become abscesses. Even though microcoils are used in these instances, it is unwise to implant a stent graft into a potentially infected bed.

8.8.4.2

Technique

Technique will vary significantly depending on the vascular distribution of the mesenteric aneurysm. Typically, celiac and proximal SMA aneurysms are best treated surgically.

Although a common femoral approach is preferable to that of the brachial artery, a left upper extremity puncture may be required to negotiate the acute angles the visceral arteries take from the aorta. A Sot catheter works well from the groin, and an MPA is typically all one needs from the arm. Guiding catheters or sheaths offer support and directionality if access is difficult to maintain.

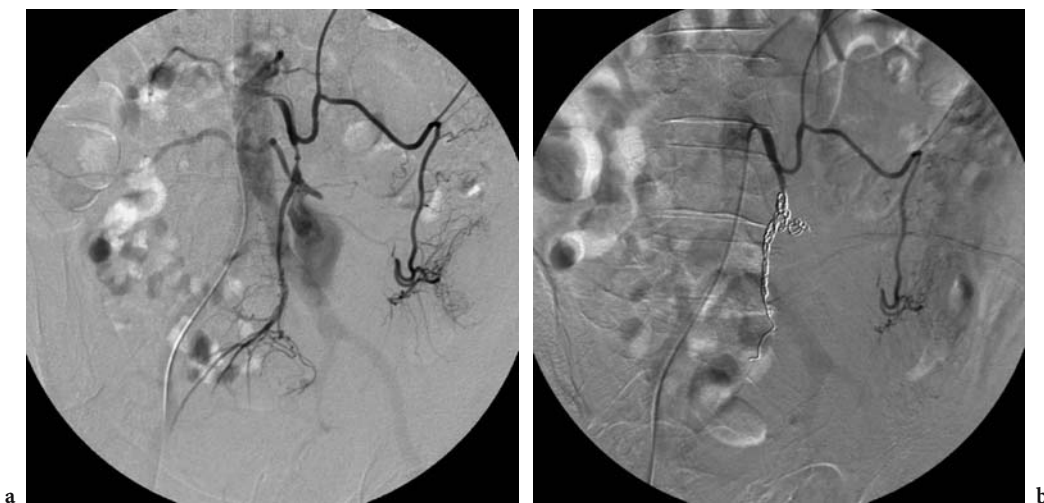


Fig. 8.7. **a** Selective angiogram demonstrating a pseudoaneurysm of the sigmoid branch of the IMA due to diverticulitis. **b** Follow-up subtracted image demonstrating coil occlusion of both branches that were supplying the large pseudoaneurysm. No ischemia resulted due to collateral flow from internal iliac branches via the hemorrhoidal arteries. (Courtesy of Jennifer E. Gould, MD)

As long as there is no celiac, proper hepatic, or SMA origin occlusion, the GDA can be sacrificed. If the GDA is required to maintain perfusion of the liver or, if flow into the SMA is dependent upon the celiac, then direct coiling of GDA pseudoaneurysms is preferable. This can be accomplished with stent placement over the aneurysm neck and microcoil deposition through the interstices via a microcatheter. A small-caliber stent graft such as a Jostent could theoretically be used in this situation. However, use of this device is still not approved by the FDA. APPEL et al. described the placement of a 26-mm stent graft for humanitarian treatment of a traumatic pseudoaneurysm of the SMA [34].

The RIM catheter was specifically designed for the inferior mesenteric artery. This catheter typically seats well in the origin, which arises at the level of the left pedicle of L3. A microcatheter can then be passed coaxially into the desired branch and microcoils deposited. Superselective technique is desired. Although some collateral flow is supplied to the distal colon via internal iliac branches, care must be taken when occluding more proximal vascular territories.

8.8.4.3 Results of Embolization

Results of transcatheter embolization of mesenteric aneurysms appear favorable in the literature, and technical success has been reported to range from 75% to 100% [1,3,15,18,19,24–27,33,35–42]. However, many of these studies are not only retrospective and small, but the mesenteric VAAs are often lumped in with splenic and hepatic artery aneurysms, making it difficult to isolate effective treatment rates for SMA, IMA, and GDA aneurysms independently. The anatomy and location of the lesion will often dictate the success of embolization. Furthermore, some case series report the use of different methods, such as percutaneous thrombin or coil injection versus transcatheter embolization.

8.8.4.4 Complications

The major complicating factor of embolization in the mesenteric distribution is bowel ischemia and infarction. Ischemia can cause strictures and obstruction whereas infarction can lead to perforation and sepsis from dead gut. Dissection and

thromboembolic phenomenon can occur during manipulation. Smaller emboli not seen during the embolization procedure may become evident a few hours later and manifest as abdominal pain. This typically resolves with heparinization, pain management, bowel rest, and time. If hemorrhage occurs in the mesentery, abscesses can develop and percutaneous drainage may be required.

8.9 Renal

8.9.1 Incidence

Incidence rates of aneurysm formation differ for the various etiologies of renal artery aneurysms. However, the literature suggests that incidence rates range between 0.015% and 9.7% [43]. A classification scheme divided into saccular, fusiform, dissecting, and pseudoaneurysms has been described by POUTASSE [44,45]. The natural history of these aneurysms is not well defined in the literature. However, there are small and large case series that demonstrate low rupture rates ranging from 0% to 14% [46–50]. HUBERT et al. followed some patients with solitary aneurysms as large as 4.0 cm for as long as 17 years without rupture [50]. Renal artery aneurysms that are treated surgically are approached by nephrectomy, ex vivo repair, and auto-transplantation.

8.9.2 Causes

Typically pseudoaneurysm formation in the renal artery distribution is iatrogenic or traumatic. Other causes of aneurysm formation include fibromuscular dysplasia, polyarteritis nodosa, amphetamine abuse, angiomyolipoma in the presence or absence of tuberous sclerosis, and neurofibromatosis.

8.9.3 Risks Posed by the Aneurysm

Rupture is a rare risk of these aneurysms. However, pregnant women are more prone to rupture just as with splenic artery aneurysms. SCHORN et al. provided a succinct review of the literature regarding the

risk of rupture of these lesions [51]. They found one dated series that described the risk of rupture as high as 14%. However, many subsequent large autopsy series demonstrated no instances of rupture when renal artery aneurysms were present. In their review of the literature, they also discovered that noncalcified aneurysms were more at risk of rupture.

In cases of FMD, distal embolization and dissection can be seen. Malignant hypertension may be the presenting symptom as a result of embolization of clot from the aneurysm or occlusion from a dissection flap.

8.9.4 Management

8.9.4.1 Anatomic/Physiologic Considerations

The vascular supply to the kidney is considered end-organ, and infarction is common after embolization. Therefore, in patients with renal insufficiency or underlying diseases such as tuberous sclerosis or von Recklinghausen's disease, nephron-sparing procedures are vital. Superselective embolization is advisable in all cases of renal artery embolization unless partial or total nephrectomy is planned.

8.9.4.2 Technique

The renal arteries arise at the L2 level from the abdominal aorta. A 10° LAO view during a flush injection of the aorta will often provide the best view of the origins. Careful examination for accessory renal arteries is necessary. A Sos or Cobra catheter will easily select the main renal ostium. A Rosen wire is an atraumatic guidewire that allows for secure exchange or upsizing to a guiding catheter or Balkin sheath. Selective injection should be performed to identify the feeding vessel or vessels. This can be done through the sheath.

Many embolization techniques can be used in this setting depending on the type, number, and location of the aneurysms. For example, aneurysms of the main renal artery may be amenable to stent graft placement, thus allowing distal perfusion to be maintained [52–56]. However, until stent graft placement is perfected, surgical repair by resection, aneurysmorrhaphy, and autotransplantation is more commonly performed in this setting.

More peripheral aneurysms can be selectively coil embolized using microcatheter techniques. Both distal and proximal control is not always possible, and may not be necessary due to the vascular anatomy. In the presence of multiple aneurysms from a lesion such as an angiomyolipoma, a combination of particle and coil embolization can be performed. If actively bleeding, the aneurysms are coiled first, followed by occlusion of the feeding vessels to the tumor with PVA or embospheres. Gelfoam can be sandwiched between coil nests to assist thrombolysis.

If surgical resection is planned, ablation of entire lobar or main renal arteries can be performed with ethanol. This requires the use of a balloon occlusion catheter such as a single lumen Balloon Wedge-Pressure Catheter (Arrow International, Reading, PA) to prevent systemic spread of alcohol. Ethanol ablation should be performed within one or two days of the planned resection. This will help to avoid a prolonged post-embolization syndrome, which can be quite uncomfortable for patients and can reduce the risk of abscess formation from the ensuing infarction.

8.9.4.3 Results of Embolization

The technical success is quite high once the renal artery is securely accessed. If superselective techniques are used, very little ischemia results and there is very little chance of inducing renal failure. The small number of reported cases in the literature makes it difficult to assess the long-term success of transcatheter embolization.

8.9.4.4 Complications

Although rare, dissection or perforation of the renal arteries and their branches can occur. Rupture may lead to rapid development of retroperitoneal hemorrhage. Both dissection flaps and rupture can be immediately controlled with balloon tamponade. Although dissection flaps can often be tacked down, rupture typically requires emergent surgery. Even perforation of smaller branch vessels can occur if a guidewire is passed too far into the periphery. Hematoma and abscess can develop.

Embolization of plaque from heavily calcified arteries or aorta is a risk when manipulating

sheaths or catheters in the origins of these vessels. Even though richly vascular, the renal parenchyma is prone to ischemia and infarction due to its end-organ supply. Every attempt should be made to become as selective as possible to preserve distal flow and prevent nontarget embolization.

Care must be taken when embolizing with absolute ethanol due to the vigorous thrombosis it causes by denaturing proteins. Ethanol can cause seizures and intoxication if it reaches the systemic circulation. It can also permeate the tissues and cause injury to adjacent structures such as bowel and nerves.

8.10 Complications

Access site complications include hematoma, pseudoaneurysm formation, and arterial dissection. Although sometimes unavoidable, good technique should keep these complications at an acceptable level. Brachial punctures are slightly more prone to complication, especially neural compression from hematoma. It should also be remembered that working from the left arm entails a catheter crossing the origin of the left vertebral artery, and a sheath will be nearly occlusive in the brachial artery. If possible, using a smaller sheath such as a 4 or 5 French system can help diminish post-procedure complications. Microcatheters will work coaxially through 4 French catheters.

Placement of a vascular sheath serves two important purposes. It protects the access artery from injury if multiple catheter exchanges occur, and it maintains access to the artery should the working catheter become occluded.

Aneurysm rupture during vigorous contrast injection or direct manipulation can occur. Emergent tamponade can be achieved by inflating a balloon either across the neck of the aneurysm or in the origin of the feeding vessel. Having an appropriately sized balloon occlusion catheter ready on the back table can be useful should rupture occur during the procedure. Emergent surgery may be necessary if the bleeding cannot be controlled or if permanent embolization of the parent vessel is not technically feasible. The ruptured aneurysm may continue to bleed if distal occlusion is not achieved.

One of the feared complications of deploying coils, injecting thrombin or glue, or infusing particulate embolics is nontarget embolization. Stringent technique to ensure satisfactory positioning

of catheters is vital to prevent nontarget embolization. Before embolizing, catheter stability should be tested by passing a wire through it. Catheters are more apt to buckle out of vessel origins and cause nontarget embolization or loss of access in the presence of extremely tortuous courses. Should a coil become lodged in the catheter, a forceful injection with a 1- or 3-cc syringe can be attempted to torpedo it free. However, this maneuver may back the catheter out of the target vessel. If nontarget embolization of a coil occurs, a snare can be used in an attempt to retrieve it if it lodges in an undesirable location.

Since miniscule amounts of thrombin are required to thrombose aneurysms, great care should be taken when injecting this embolic. Distal embolization during thrombin injection usually resolves without significant sequelae. Although not always possible with VAAs, the use of real-time ultrasound can help to monitor the progress of thrombosis. Obtaining arterial access provides the ability to balloon occlude the origin of the aneurysm when injecting the aneurysm percutaneously.

8.11 Future Development and Research

Coil embolization has been one of the mainstays of VAA treatment and has been augmented with direct glue or thrombin injection. Coil design has not changed significantly. However, extremely precise deployment mechanisms such as electrolytic detachment are available today.

Many different agents, both temporary and permanent (Gelfoam, glue, thrombin, PVA, detachable balloons, and ethanol) can be used depending on the situation and the desired end result. There has been no significant change of these materials in the last few years. Refinement of PVA into embolic "spheres" has been achieved, and is thought to provide a more uniform embolization rather than the clumping that can occur with regular PVA. A newer nonadhesive liquid embolic agent called Onyx (Micro Therapeutics, Inc., Irvine, CA) has been used in some neurointerventional and neurosurgery applications. Because Onyx is nonadhesive, care must be taken when using this product due to the propensity of the embolic to migrate into the parent vessel.

The future may lie with stent graft placement, which has been performed with good technical success in the last four years, albeit in small case reports [16, 34, 52, 54–67]. However, no long-term data exist,

and further investigation is warranted. The capacity to occlude aneurysm necks while maintaining distal perfusion in a single step would seem to make stent grafts the ideal therapy. However, small vessel diameter, short landing zones, frequent bifurcations, and tortuosity provide ample hurdles for placement of stent grafts in the visceral arteries. Furthermore, the paucity of these cases makes it difficult to collect statistically significant data and gain experience in a short period of time. Therefore, there is little to drive the market to further develop this technology.

8.12 Conclusion

Although quite rare, visceral artery aneurysms are life-threatening when hemorrhage occurs. Aggressive management by the interventional radiologist is paramount. Often, these patients are too sick for major revascularization procedures, making endovascular techniques a more desirable approach. Surgical morbidity and mortality is fairly high after aneurysm rupture.

The asymptomatic lesions are being discovered more regularly due to the increased demand for cross-sectional imaging. The timing of treatment depends on aneurysm size and location. For example, some authors have suggested treating asymptomatic splenic artery aneurysms while others have argued that observation is adequate [60, 68, 69]. However observation is the exception rather than the rule with visceral artery aneurysms. All splenic artery aneurysms in women of child-bearing age should be treated due to the high incidence of rupture in the third trimester. All mesenteric aneurysms should be treated due to a high likelihood of complications from rupture, thrombosis, or embolization.

A variety of methods for embolization of VAAs are described in the literature. The type of treatment should be tailored to each individual case as the anatomy will typically dictate the therapy best suited.

Despite the fact that minimally invasive embolization procedures have been performed for over twenty years, very few long-term data on VAA occlusion are available. Further investigation and development of newer techniques such as stent graft placement are needed. Coil, glue, thrombin, and particle embolization will continue to be effective methods for treatment of visceral artery aneurysms in both the elective and emergent settings. Good

technique and a firm understanding of the visceral vascular supply are vital, just as in any embolization procedure.

References

1. Lookstein RA, Guller J (2004) Embolization of complex vascular lesions. *Mt Sinai J Med* 71:17–28
2. Larson RA, Solomon J, Carpenter JP (2002) Stent graft repair of visceral artery aneurysms. *J Vasc Surg*, 36:1260–1263
3. Melissano G, Chiesa R (1998) Successful surgical treatment of visceral artery aneurysms. After failure of percutaneous treatment. *Tex Heart Inst J* 25:75–78
4. Abbas MA et al. (2003) Hepatic artery aneurysm: factors that predict complications. *J Vasc Surg* 38:41–45
5. Shanley CJ, Shah NL, Messina LM (1996) Common splanchnic artery aneurysms: splenic, hepatic, and celiac. *Ann Vasc Surg* 10:315–322
6. Deshmukh H et al. (2004) Transcatheter embolization as primary treatment for visceral pseudoaneurysms in pancreatitis: clinical outcome and imaging follow up. *Indian J Gastroenterol* 23:56–58
7. Carr JA et al. (2000) Visceral pseudoaneurysms due to pancreatic pseudocysts: rare but lethal complications of pancreatitis. *J Vasc Surg* 32:722–730
8. Merten GJ et al. (2004) Prevention of contrast-induced nephropathy with sodium bicarbonate: a randomized controlled trial. *JAMA* 291:2328–2334
9. Shlansky-Goldberg R, Cope C (2001) A new twist on the Waltman loop for uterine fibroid embolization. *J Vasc Interv Radiol* 12:997–1000
10. Salcuni PF et al. (1995) Hepatic artery aneurysm: an ever present danger. *J Cardiovasc Surg (Torino)* 36:595–599
11. Lal RB et al. (1989) Hepatic artery aneurysm. *J Cardiovasc Surg (Torino)* 30:509–513
12. O'Driscoll D, Olliff SP, Olliff JF (1999) Hepatic artery aneurysm. *Br J Radiol* 72:1018–1025
13. Chan RJ et al. (1998) Segmental mediolytic arteriopathy of the splenic and hepatic arteries mimicking systemic necrotizing vasculitis. *Arthritis Rheum* 41:935–938
14. Erskine JM (1973) Hepatic artery aneurysm. *Vasc Surg* 7:106–125
15. Messina LM, Shanley CJ (1997) Visceral artery aneurysms. *Surg Clin North Am* 77:425–442
16. Venturini M et al. (2002) Hemorrhage from a right hepatic artery pseudoaneurysm: endovascular treatment with a coronary stent-graft. *J Endovasc Ther* 9:221–224
17. Thomas DE, Leon LM (1998) Hepatic artery aneurysm rupture: case report, imaging findings, and literature review. *S D J Med* 51:413–416
18. Stambo GW, Hallisey MJ, Gallagher JJ Jr (1996) Arteriographic embolization of visceral artery pseudoaneurysms. *Ann Vasc Surg* 10:476–480
19. Salam TA et al. (1992) Nonoperative management of visceral aneurysms and pseudoaneurysms. *Am J Surg* 164:215–219
20. Rokke O et al. (1996) Hepatic artery aneurysm. Diagnosis and treatment. *Tidsskr Nor Laegeforen* 116:487–489
21. Reber PU et al. (1998) Life-threatening upper gastroin-

- testinal tract bleeding caused by ruptured extrahepatic pseudoaneurysm after pancreatoduodenectomy. *Surgery* 124:114–115
22. Parildar M, Oran I, Memis A (2003) Embolization of visceral pseudoaneurysms with platinum coils and N-butyl cyanoacrylate. *Abdom Imaging* 28:36–40
 23. Stanley JC, Thompson NW, Fry WJ (1970) Splanchnic artery aneurysms. *Arch Surg* 101:689–697
 24. Busuttill RW, Brin BJ (1980) The diagnosis and management of visceral artery aneurysms. *Surgery* 88:619–624
 25. Hossain A et al. (2001) Visceral artery aneurysms: experience in a tertiary-care center. *Am Surg* 67:432–437
 26. Kasirajan K et al. (2001) Endovascular management of visceral artery aneurysm. *J Endovasc Ther* 8:150–155
 27. Rokke O et al. (1997) Successful management of eleven splanchnic artery aneurysms. *Eur J Surg* 163:411–417
 28. Uflacker R (1986) Transcatheter embolisation of arterial aneurysms. *Br J Radiol* 59:317–324
 29. Angelakis EJ et al. (1993) Splenic artery aneurysm rupture during pregnancy. *Obstet Gynecol Surv* 48:145–148
 30. Stanley JC, Fry WJ (1974) Pathogenesis and clinical significance of splenic artery aneurysms. *Surgery* 76:898–909
 31. Barrett JM, Caldwell BH (1981) Association of portal hypertension and ruptured splenic artery aneurysm in pregnancy. *Obstet Gynecol* 57:255–257
 32. Macfarlane JR, Thorbjarnarson B (1966) Rupture of splenic artery aneurysm during pregnancy. *Am J Obstet Gynecol* 95:1025–1037
 33. Carr SC et al. (2001) Visceral artery aneurysm rupture. *J Vasc Surg* 33:806–811
 34. Appel N, Duncan JR, Schuerer DJ (2003) Percutaneous stent-graft treatment of superior mesenteric and internal iliac artery pseudoaneurysms. *J Vasc Interv Radiol* 14:917–922
 35. Araoz PA, Andrews JC (2000) Direct percutaneous embolization of visceral artery aneurysms: techniques and pitfalls. *J Vasc Interv Radiol* 11:1195–1200
 36. Carr SC et al. (1996) Current management of visceral artery aneurysms. *Surgery* 120:627–633; discussion 633–634
 37. Gabelmann A, Gorich J, Merkle EM (2002) Endovascular treatment of visceral artery aneurysms. *J Endovasc Ther* 9:38–47
 38. Lauschke H et al. (2002) Visceral artery aneurysms. *Zentralbl Chir* 127:538–542
 39. Masciarriello S et al. (1997) Aneurysms of the splanchnic arteries. *Minerva Chir* 52:45–52
 40. Muscari F et al. (2002) Management of visceral artery aneurysms. Retrospective study of 23 cases. *Ann Chir* 127:281–288
 41. Panayiotopoulos YP, Assadourian R, Taylor PR (1996) Aneurysms of the visceral and renal arteries. *Ann R Coll Surg Engl* 78:412–419
 42. Smith JA, Macleish DG, Collier NA (1989) Aneurysms of the visceral arteries. *Aust N Z J Surg* 59:329–334
 43. Martin RS 3rd et al. (1989) Renal artery aneurysm: selective treatment for hypertension and prevention of rupture. *J Vasc Surg* 9:26–34
 44. Poutasse EF (1966) Renal artery aneurysms: their natural history and surgery. *J Urol* 95:297–306
 45. Poutasse EF (1975) Renal artery aneurysms. *J Urol* 113:443–449
 46. Henriksson C et al. (1985) Natural history of renal artery aneurysm elucidated by repeated angiography and patho-anatomical studies. *Eur Urol* 11:244–248
 47. Hageman JH et al. (1978) Aneurysms of the renal artery: problems of prognosis and surgical management. *Surgery* 84:563–572
 48. Harrow BR, Sloane JA (1959) Aneurysm of renal artery: report of five cases. *J Urol* 81:35–41
 49. McCarron JP Jr, Marshall VE, Whitsell JC 2nd (1975) Indications for surgery on renal artery aneurysms. *J Urol* 114:177–180
 50. Hubert JP Jr, Pairolo PC, Kazmier FJ (1980) Solitary renal artery aneurysm. *Surgery* 88:557–565
 51. Schorn B et al. (1997) Kidney salvage in a case of ruptured renal artery aneurysm: case report and literature review 1. *Cardiovasc Surg* 5:134–136
 52. Bruce M, Kuan YM (2002) Endoluminal stent-graft repair of a renal artery aneurysm. *J Endovasc Ther* 9:359–362
 53. Liguori G et al. (2002) Percutaneous management of renal artery aneurysm with a stent-graft. *J Urol* 167:2518–2519
 54. Pershad A, Heuser R (2004) Renal artery aneurysm: successful exclusion with a stent graft. *Catheter Cardiovasc Interv* 61:314–316
 55. Rundback JH et al. (2000) Percutaneous stent-graft management of renal artery aneurysms. *J Vasc Interv Radiol* 11:1189–1193
 56. Schneidereit NP et al. (2003) Endovascular repair of a ruptured renal artery aneurysm. *J Endovasc Ther* 10:71–74
 57. Marx M et al. (2002) Treatment of a splenic artery aneurysm with use of a stent-graft. *J Vasc Interv Radiol* 13:1282
 58. Brountzos EN et al. (2003) Pancreatitis-associated splenic artery pseudoaneurysm: endovascular treatment with self-expandable stent-grafts. *Cardiovasc Intervent Radiol* 26:88–91
 59. Henry M et al. (2000) Percutaneous endovascular treatment of peripheral aneurysms. *J Cardiovasc Surg (Torino)* 41:871–883
 60. Arepally A et al. (2002) Treatment of splenic artery aneurysm with use of a stent-graft. *J Vasc Interv Radiol* 13:631–633
 61. Atkins BZ, Ryan JM, Gray JL (2003) Treatment of a celiac artery aneurysm with endovascular stent grafting – a case report. *Vasc Endovasc Surg* 37:367–373
 62. Atar E et al. (2004) Percutaneous treatment of a celiac artery aneurysm using a stent graft. *Isr Med Assoc J* 6:370–371
 63. Millonig G et al. (2004) Percutaneous management of a hepatic artery aneurysm: bleeding after liver transplantation. *Cardiovasc Intervent Radiol* 27:525–528
 64. Paci E et al. (2000) Pseudoaneurysm of the common hepatic artery: treatment with a stent-graft. *Cardiovasc Intervent Radiol* 23:472–474
 65. Rocek M et al. (2002) Percutaneous treatment of a superior mesenteric artery pseudoaneurysm using a stent-graft. *AJR Am J Roentgenol* 178:1459–1461
 66. Seriki DM et al. (2004) Endovascular stent graft: treatment of pseudoaneurysm of the superior mesenteric artery. *Cardiovasc Intervent Radiol* 27:271–273
 67. Yoon HK et al. (2001) Stent-graft repair of a splenic artery aneurysm. *Cardiovasc Intervent Radiol* 24:200–203
 68. Trastek VF et al. (1982) Splenic artery aneurysms. *Surgery* 91:694–699
 69. Dave SP et al. (2000) Splenic artery aneurysm in the 1990s. *Ann Vasc Surg* 14:223–229

Venous Ablation

9 Endovenous Thermal Ablation of Incompetent Truncal Veins in Patients with Superficial Venous Insufficiency

NEIL M. KHILNANI and ROBERT J. MIN

CONTENTS

9.1	Introduction	119
9.2	Pathophysiology and Epidemiology	119
9.3	Anatomy	119
9.4	EVTA: Background	120
9.5	Evaluation Prior to EVTA	121
9.6	EVTA Technique	121
9.7	Clinical Data	123
9.8	Summary	125
	References	125

9.1 Introduction

Endovenous thermal ablation has become an accepted option to eliminate the reflux caused by incompetent saphenous veins. In this chapter, a review of the clinical problems and anatomy precedes a review of this exciting new venous occlusion technique.

9.2 Pathophysiology and Epidemiology

Lower-extremity chronic venous insufficiency (CVI) is caused by venous hypertension [1]. Most patients develop venous hypertension from the hydrostatic forces produced by reflux that results from primary valvular insufficiency [2]. Venous obstruction, muscular pump failure, and congenital anomalies are much less common causes. In addition, 85%–90%

of patients with all forms of CVI have significant superficial venous insufficiency (SVI). If present, treatment of CVI begins with elimination of this reflux. Reflux in the saphenous (truncal) veins is the most common cause of venous hypertension. Pathophysiologically significant reflux in the great saphenous vein (GSV) or in one of its primary tributaries is present in 70%–80% of patients with CVI. Small saphenous vein (SSV) reflux is found in 10%–20% and non-saphenous superficial reflux is identified in 10%–15% of patients [2, 3].

SVI is certainly the most prevalent medical condition treated by interventional radiologists. Up to 25% of women and 10% of men in the U.S. are affected, with 50% of people >50 years old having some form of SVI [3]. Most patients with SVI have symptoms, which include aching, fatigue, throbbing, heaviness, and night cramps. A minority of patients develop skin injury from chronic venous hypertension, which includes eczema, edema, pigmentation, lipodermatosclerosis, and ulceration. Heredity is the primary risk factor for developing SVI; 85% of patients are affected if both parents are involved, 47% if one parent is involved, and 20% if neither parent is involved [4]. Prolonged standing and multiparity increase the risk of expressing this heritable risk.

9.3 Anatomy

The superficial venous system of the lower extremities is composed of innumerable subcutaneous collecting veins, the saphenous trunks and their tributaries. The GSV begins on the anterior and medial portion of the foot, runs anterior to the medial malleolus, and ascends the medial aspect of the calf and thigh to ultimately join the femoral vein at the fossa ovale (saphenofemoral junction, SFJ) several centimeters below the inguinal ligament (Fig. 9.1). The GSV is adjacent to the saphenous nerve (sensory)

N. M. KHILNANI, MD; R. J. MIN, MD
Cornell Vascular, Weill Medical College of Cornell University,
416 East 55th Street, New York, NY 10022, USA

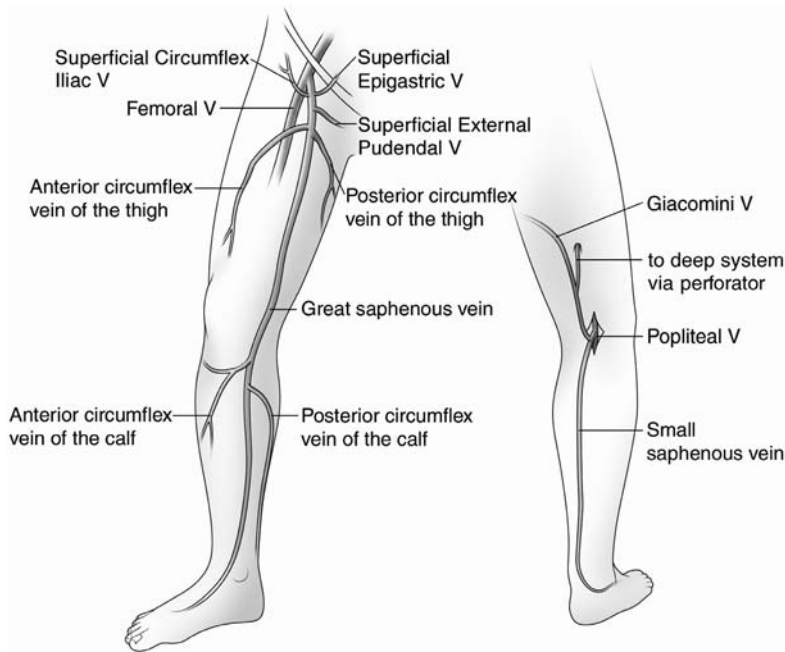


Fig. 9.1. Frontal and posterior diagrams of the lower extremity demonstrating the great and small saphenous veins and their named tributaries. The two saphenous systems can be connected via the vein of Giacomini

from about 6 cm below the knee to the ankle. The GSV and its major named branches run superficial to the deep and deep to the superficial fascia within the saphenous space. The GSV has two important and named tributaries above and below the knee: the anterior and posterior circumflex veins of the calf and thigh. In addition there are three smaller tributaries at the groin which are important in that they are often a source of recurrent varicose veins following their surgical ligation along with the GSV (high ligation). A common variant, the anterior accessory GSV (AAGSV), runs more laterally than the GSV within the saphenous space and often is erroneously termed a duplication of this trunk. This vein is frequently present and can be responsible for varicose veins on the anterior aspect of the thigh. An extrafascial tributary vein that communicates with the GSV but runs parallel to the GSV course and is relatively straight should be described as a superficial accessory GSV.

The SSV begins on the lateral aspect of the foot, ascends posterior to the lateral malleolus and then up the midline of the calf, between the same fascial planes as the GSV. The SSV runs adjacent to the sural nerve (sensory) from just below the popliteal crease to the foot. In about two thirds of cases, the SSV drains into the popliteal vein at or just above the popliteal crease. In about one third of cases it has a cephalad extension with or without a saphenopopliteal junction (SPJ) to ultimately drain into

a posterior thigh perforating vein, or into the posterior circumflex vein of the thigh via the vein of Giacomini (Fig. 9.1).

9.4 EVTA: Background

Treatment of SVI is indicated for symptoms unrelied by conservative methods such as graduated compression stockings (GCS), exercise, and avoiding prolonged standing. It is also indicated for complications from chronic venous hypertension such as bleeding varices, superficial thrombophlebitis, and skin injury. Treatment begins with elimination of any truncal incompetence. The treatment modalities available to accomplish this include high ligation, truncal vein stripping along with a high ligation, endovenous thermal ablation (EVTA), and duplex ultrasound (DUS)-guided sclerotherapy.

In the last 5 years, EVTA has developed into a successful option for obliterating truncal incompetence. Its main advantages over surgery are that there is no need for anesthesia or sedation and no recovery or down time following the procedure. The underlying mechanism of this procedure is to endovascularly deliver sufficient thermal energy to the wall of an incompetent vein segment to produce irreversible occlusion. The first modern report of EVTA

was made using laser-delivered energy to ablate the saphenofemoral junction [6]. Since that time several devices have been approved by the U.S. Food and Drug Administration. The currently available tools utilize radiofrequency or laser energy of a variety of different wavelengths to deliver the required thermal dose.

As mentioned, the goal of EVTA is to endovenously deliver sufficient thermal energy to the wall of an incompetent vein to irreversibly occlude it. A catheter inserted into the venous system either by percutaneous access or by open venotomy delivers the thermal energy. The procedure can be performed on an ambulatory basis with local anesthetic and generally require little or no sedation. The patients are generally fully ambulatory following treatment and the recovery time is short.

The associated varicose tributary and reticular veins and telangiectasias are treated separately with adjunctive therapies such as compression sclerotherapy or microphlebectomy. Some physicians will perform microphlebectomy for varicose veins at the same time as EVTA. Other physicians elect to perform phlebectomy or compression sclerotherapy of the varicose veins at a later time. Almost all physicians will defer therapy of spider veins to a later time.

In our practice, phlebectomy is generally recommended at the same time as EVTA when varicose tributaries are larger than 8–10 mm in diameter or when EVTA will occlude their inflow and outflow. If such veins are left untreated they may thrombose in 5%–10% of cases and become painful, erythematous, and possibly result in skin pigmentation. Also, if they thrombose, their complete eradication may be made more difficult and certainly will be delayed. For smaller varicose veins and all reticular and spider veins, we offer compression sclerotherapy beginning 4 weeks after EVTA. By this point the veins have substantially decompressed, making their eradication with injections easier.

9.5

Evaluation Prior to EVTA

Treatment for patients with CVI begins with a careful history and directed physical exam. All patients with visible varicose veins or symptoms suggesting venous insufficiency should be evaluated with DUS [7, 8]. In patients with spider veins near the medial ankle (corona phlebectasia) or along the medial

calf or thigh, a DUS of the GSV is recommended to identify truncal reflux. The goal of the DUS is to determine which veins are normal and which veins are incompetent to create a map of the pathways of reflux in a given patient. Such a map is necessary to define the best combination of treatments which are available. In some cases, it may be possible to identify the abnormal vein segments by physical exam. However, the different pathways of incompetence overlap sufficiently such that reliance on physical examination alone will lead to frequent diagnostic errors.

Reflux in truncal veins must be treated prior to addressing any visible abnormalities. EVTA is a treatment option for endovenously eliminating such reflux. The indications for ablation of incompetent truncal veins are identical to those for surgical ligation and stripping. Absolute contraindications have yet to be identified for the laser procedure. For RF ablation, a pacemaker or implantable defibrillator is a contraindication. Relative contraindications for EVTA include absent pedal pulses limiting GCS use, liver abnormalities limiting local anesthesia use, pregnancy, nursing, and uncorrectable coagulopathies.

9.6

EVTA Technique

Once the pathways of incompetence are established, EVTA can be utilized to treat incompetent truncal veins and straight segments of their tributary veins. In almost all cases venous access is directly into the vein to be treated or directly into one of its principle tributaries, if the tributary vein is straight. Generally the access is at or just below the lowest level of reflux in the treated truncal vein as defined by DUS. This is generally recognized as the level where the diameter of the truncal vein decreases just peripheral to a large incompetent tributary. In many cases, segmental great saphenous vein incompetence can occur in two separate portions of this vein. The reflux can completely spill out into a tributary vein only to re-enter the GSV at a lower level. It is important to determine if the intervening portion of the GSV is hypoplastic or normal. Hypoplastic segments occur commonly [9] and cannot be traversed by a guidewire. In this circumstance, venous access will be required into the most peripheral part of both segments and the segments are subsequently ablated sequentially. Normal intervening segments can be

crossed and allow the operator to treat all incompetent segments of the GSV through one venous access.

Prior to treatment, the treated veins are mapped and the courses of the treated segments as well as important landmarks such as junctions, venous aneurysms and large perforator inflows are drawn on the patient's skin with a surgical marker. The patient is then placed horizontal on the table allowing full access to the treated segments. In general, patients being treated for GSV reflux are placed supine. Patients being treated for reflux in the SSV are placed prone with their feet hanging off the end of the table to relax the calf. Posterior medial tributary and Giacomini vein ablations may require more challenging positions.

Venous access is accomplished with either a 19- or 21-G needle using real-time US guidance and a one-wall technique. The incompetent truncal vein can become much smaller when the patient lies down. Placing the patients in the reverse Trendelenburg position and keeping the procedure room warm can dilate the vein to make access easier. Also, when the puncture is directed into a tributary vein or the AAGSV, care must be taken to avoid venospasm, which is much more common with missed punctures of these veins.

The details of the laser and RF treatments vary at this point but the ultimate treatment goals and techniques are similar. With RF ablation, the RF catheter is withdrawn only after its tines are exposed to allow contact with the vein wall. The catheter is withdrawn maintaining the vein wall temperature at or above 85°C as measured by a thermocouple embedded in its tip. For laser ablation the fiber is withdrawn at a rate determined by the energy deposition per length of vein treated. For the remainder of this presentation on technique, the laser procedure will be discussed. The details of the RF venous ablation can be reviewed in the references cited in the results section.

For laser EVTA, a 5F sheath is inserted through the entire abnormal segment and into a more central vein. A bare tipped laser fiber is inserted to the end of the sheath, which is then withdrawn exposing the tip of the fiber. The sheath and fiber are then withdrawn to place the tip at the starting point of the ablation. For the GSV this is usually about 1 cm below the SFJ and for the SSV about 2 cm below the SPJ where the SSV turns parallel to the skin just below the popliteal fossa (Fig. 9.2). With the laser, confirmation of the position can be made with localization of the light which comes from the red aiming beam

which can almost always be visualized through the skin.

The most time consuming part of the procedure is the US-guided delivery of perivenous tumescent anesthesia (TA). TA is a form of local anesthesia delivery which was popularized by plastic surgeons which utilizes large volumes of dilute anesthetic solutions which are infiltrated to anesthetize large regions for treatment. TA can make EVTA painless obviating the risks and additional monitoring associated sedation or anesthesia. In fact, it can be argued that sedation adds risk to EVTA by blunting the patients' response to pain making them potentially more susceptible to extravenous thermal injury as well as delaying immediate ambulation after the procedure.

TA is also necessary for safety and efficacy of the procedure as well. Large volumes are utilized to compress the truncal vein to maximize the transfer of energy to the surrounding vein wall. Even though venospasm frequently occurs soon after sheath insertion, it is usually still necessary to empty the vein further with TA to ensure adequate treatment. Also important is that the large volume of fluid around the vein is necessary to insulate the vein from the surrounding structures. This part of the procedure

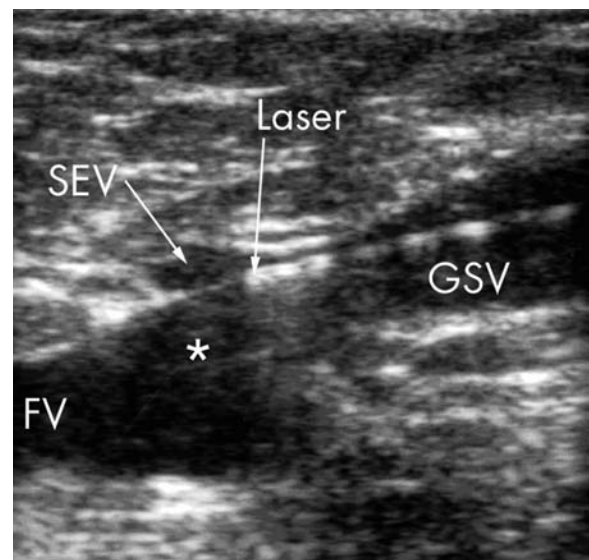


Fig. 9.2. Longitudinal view of the saphenofemoral junction (SFJ) during positioning of a laser fiber prior to EVTA. The left of the image is toward the patient's head. A thin arrow points to the tip of the laser fiber approximately 5–10 mm below the SFJ at the takeoff of the superficial epigastric vein. The (*) identifies the SFJ, FV the femoral vein, GSV the great saphenous vein and SEV the superficial epigastric vein

minimizes potential thermal injury to the skin or adjacent nerves or arteries. In practice a 1-cm-diameter cylinder of TA surrounding the treated vein and 1 cm separation of the treated vein from the skin is adequate.

For EVTA, we generally use 100–200 ml of a 0.1% lidocaine solution buffered with sodium bicarbonate. Utilizing these volumes we can get close to the 4.5-mg lidocaine/kg dose without epinephrine and 7-mg/kg doses with epinephrine. In plastic surgery these doses are routinely safely exceeded. The argument for this safety is that the large volumes of fluid containing this drug are absorbed slowly avoiding high systemic levels. However, in an outpatient environment, it is best to avoid reaching these dose thresholds. In our practice, we also avoid the use of epinephrine to avoid any toxicity related to this drug.

After placing the patient in a Trendelenburg position to further empty the vein of blood, the sheath and fiber are withdrawn as a unit through the treated vein segment as the laser is activated. With DUS, gas bubbles can be seen to emanate from the tip of the laser fiber which serves as additional confirmation of the tip position at the appropriate location.

Suggested parameters vary slightly with the different laser devices but are under the control of the operator. In our practice, using the 810-nm diode laser (Diomed, Andover, MA) 14-watt continuous mode is selected. The amount of energy necessary to effect reliable vein ablation seems to be an average of 80 J/cm throughout the treated segment [10]. The average pullback rate to accomplish this is about 2 mm/s. In practice for the GSV we generally pull back at 1 mm/s for the first 10 cm or so of treatment since failures, if they occur, will happen at this location. We also pull back at this rate near the inflow of incompetent perforators or pudendal veins or the take off of large incompetent tributaries to maximize successful occlusion at these important locations. When treating the GSV or a superficial accessory saphenous vein when the vein is superficial, when treating the SSV or the GSV below Boyd's perforator, we withdraw the fiber at 3 mm/s to minimize skin or nerve injuries.

Following the procedure, patients should be placed into a Class II (30–40 mmHg) graduated compression stocking (GCS) usually for 2 weeks. The purpose of this is to keep the variceal tributaries as empty as possible in case they occlude to minimize the amount of resultant thrombus. The GCS also increases the velocity of blood flow in the deep veins decreasing the likelihood of deep vein throm-

bosis. Anticoagulation with low-molecular-weight heparins is routinely used after EVTA in Europe but not in the US.

After EVTA, most patients will develop an ecchymosis over the entire treated segment. This generally develops the day after the procedure but fades by about 2–3 weeks. Most patients will comment about some mild discomfort over the treated vein which begins hours after the procedure but resolves within 24–48 h. The GCS helps minimize this discomfort; some patients use acetaminophen with good response. With laser ablation, patients will also develop a discomfort over the vein about 7–10 days after the procedure, which is generally described as being similar to a pulled muscle. This is most likely caused by transverse and longitudinal retraction of the vein as the acute inflammation transitions to cicatrization. This resolves with movement, occasional NSAID use and continued use of the GCS. No further treatment has been necessary in our experience.

Periodic follow-up DUS is suggested to monitor for the response to therapy. In general, at about 4 weeks following EVTA, one will identify a smaller-diameter, thick-walled truncal vein likely the result of significant vein wall injury and its inflammatory response. Little or no lumen or intraluminal thrombus is typically identified and no flow will be found in the treated segment. By 6–12 months the vein will continue to shrink in size so that in successfully treated cases the vein can no longer be visualized [11–13]. If the vein shrinks to this extent further follow-up is probably not necessary.

Most patients will require adjunctive treatment of the branch varicosities. Compression sclerotherapy and micro-phlebectomy are the most commonly used techniques to accomplish this. Occasionally, deeper tributary veins may require DUS-guided sclerotherapy, and rarely, large variceal clusters will require conventional phlebectomy.

9.7 Clinical Data

The technical success of EVTA is defined as a procedure with successful access, crossing the segment to be treated, delivery of tumescent anesthesia and delivery of thermal energy to the entire incompetent segment. Clinical success is defined as the permanent occlusion of the treated vein segments and successful elimination of related varicose veins and

an improvement in the clinical classification of the patients by at least one grade at a certain time interval after the procedure. As previously mentioned, in practice most patients will also be treated with either adjunctive micro-phlebectomy or compression sclerotherapy and as a result the clinical success data for the different clinical reports can be confounded by the success of the adjunctive procedures and by enthusiasm by which they are utilized by the treating physician.

Duplex ultrasound is essential to document the permanent occlusion of truncal veins treated with EVTA [11–13]. A successful procedure will result in non-thrombotic circumferential vein wall injury from the highest level of the incompetent segment and through its treated course on early evaluation. On late follow-up the vein segment will ideally be obliterated and impossible to find or at least will be significantly smaller in cross section than prior to treatment and will have no flow throughout the treated segment.

RF ablation was the first approved device for EVTA. Several single-center reviews have been published and are presented in Table 9.1. These studies have consistently demonstrated a high degree of success in occluding the target vein. Complication rates have been low, with paresthesias and skin burns being the most common and vexing problem with RF ablation. DVT is an uncommon problem in these series [19]. The imaging follow-up of these patients (median 25 months) has demonstrated truncal occlusion of the GSV in 90% with persistent patency without reflux of the SFJ in the overwhelming majority of cases [12].

An industry-sponsored registry is being accumulated with published 2-year follow-up data [17]. The patients in this trial were selected to have GSV ≤ 12 mm and without significant tortuosity. In this review 142 limbs were followed up at 2 years with DUS. Reflux was demonstrated absent in 90% with significant reductions in pain, fatigue and edema and 94.6% improvement in symptoms overall. There

were no cases of neovascularization. Complications were minor, with DVT in 0.7%, PE in 0.3%, skin burns in 4.2% of the early cases and 0% after the use of TA, and paresthesias persistent at 2 years in 5.6% of patients (Table 9.1).

A single-center pilot randomized trial was performed early in the RF experience comparing procedure related success and complications of ligation and stripping to RF EVTA of the GSV [20]. Fifteen patients were randomized to RF and 13 to surgery and all patients were followed for a mean of 50 days. The technical and clinical success and complication rates were similar. The RF technique was performed without tumescent anesthesia and many of the described complication would likely have been avoided with its utilization. Using a visual analogue pain scale, clear advantages were noted for EVTA most marked from days 5–14 following treatment. Less analgesics and days off from work were required by the EVTA group. Health related quality of life assessments ultimately improved to a similar extent but the EVTA group reached maximum benefit earlier.

Another small multi-center randomized trial comparing RF ablation to surgical stripping of the GSV with high ligation has been performed [21]. The data collected at a mean of 4-month follow-up and demonstrated that the recovery following RF ablation was shorter than following surgery with a significantly higher fraction of patients back to their usual level of activity at one day following the ablations. Of note was that the recovery was significantly quicker in those patients treated with RF ablation using only TA than in those treated with TA along with any other form of anesthesia. QOL as assessed using a standardized instrument was found to be significantly better immediately after RFA than after surgery, although by 4 months this difference was becoming significantly smaller.

Endovenous laser ablation of the great saphenous vein, short saphenous vein and other saphenous-related trunks has been approved by the FDA. The

Table 9.1. Clinical data evaluating the use of RF ablation of the GSV

Author	Limbs	Follow-up	Success (occluded vein/partly open, no reflux)	Parasthesias	DVT	Burns	Ref #
WEISS	140	6 wks–2 years	96%	8% / 1% @ 6 mos.	0	0	14
KISTNER	300	1 year	97%	NR	0.7%	0.3%	15
GOLDMAN	41	6–24 mos.	68%/22%	0	0	NR	16
MERCHANT (VNUS registry)	232@12 mos./ 142@24 mos.	12–24 mos.	84%/6%@12 mos., 85%/4%@24 mos.	15%/6%@24 mos.	1%	2.1%	17
WAGNER	24	3–12 mos.	21/21@3 mos. And 3/3 @ 12 mos.	0	1/24	0	18

Table 9.2. Data evaluating the use of laser ablation of the GSV

Author	Limbs	Follow-up	Success	Parasthesias	DVT	SVT	Burns	Ref #
MIN	121	24 mos.	93%	0	0	NR	0	22
PROEBSTLE (GSV)	104	12 mos.	90%	0	0	10%	0	23
SADICK	30	24 mos.	97%	0	0	0	0	24
TODD	291	12 mos.	96%	NR	NR	NR	NR	25
ROIZENTAL	150	12 mos.	99%	NR	NR	NR	NR	26

reported success rates reported in several single-center series laser ablation for GSV are presented in Table 9.2. In these series there were no restrictions to vein size or degree of tortuosity. These data have consistently shown successful nonthrombotic occlusion of the target truncal vein in >90% of cases with very rare recanalizations of previously occluded vein segments. Clinical improvement was noted in almost all of the cases with successful truncal vein occlusion. The incidence of DVT, paresthesias and skin burns was almost 0% in these series. Most patients have bruising over the region treated probably related to the needle injections for tumescent anesthesia. Many also describe a pulling sensation about 1 week after the procedure which is thought to be secondary to the evolution of the inflammatory response from vein wall injury maturing into a cicatrization phase. Superficial phlebitis was reported in 5–12% of patients after laser treatment noted primarily in cohorts of patients treated with delayed compression sclerotherapy rather than in those treated with immediate ambulatory phlebectomy of the larger tributary varicosities.

Optimization of the laser technique has prompted an evaluation of outcomes related to treatment parameters. Zimmet has suggested a lower rate of bruising and discomfort associate with continuous as opposed to pulsed laser energy delivery [27]. Timperman [10] has shown that the success of laser EVTA is unity when energy delivery is maintained on average as greater than 80 J/cm of vein treated. Further optimization is likely to influence the outcome and side effects somewhat. However, given the high degree of success comparisons of large numbers of patients will likely be necessary to establish any expected subtle difference.

Although speculation exists regarding differences between laser and RF EVTA success and side effects, there is no significant published experience comparing these two technologies. The important thing to recognize is that both of these technologies represent exciting, minimally invasive, low-risk, quick-recovery options for patients with symptoms or complications of superficial venous insufficiency.

Re-canalization of a treated vein presenting within the first few months after EVTA likely results from insufficient thermal energy delivery. This is either because of excessively rapid pull back of the thermal device or inadequate TA resulting in poor transfer of thermal energy to the wall. Vein diameter probably has no bearing on the success assuming adequate TA is applied, regardless of whether RFA or laser is the source of this energy. Late recurrences can be related to re-canalization of a previously occluded vein but are more likely related to development of incompetence in previously untreated vein segments.

9.8 Summary

EVTA should be considered a scientifically acceptable option to eliminate truncal reflux. The procedures can be performed without sedation in an ambulatory setting and are very effective, safe and associated with virtually immediate recovery. EVTA appears to be associated with a lower rate of recurrent SVI due to a virtual absence of the high rate of groin neovascularity seen with high ligation and stripping of the GSV. EVTA procedures have already begun to supplant traditional surgery for truncal incompetence.

References

1. Nicolaides AN, Hussein MK, Szendro G, Christopoulos D, Vasdekis S, Clarke H (1993) The relation of venous ulceration with ambulatory venous pressure measurements. *J Vasc Surg* 17:414–419
2. Labropoulos N, Delis K, Nicolaides AN, Leon M, Ramaswami G, Volteas N (1996) The role of the distribution and anatomic extent of reflux in the development of signs and symptoms in chronic venous insufficiency. *J Vasc Surg* 23:504–510.
3. Labropoulos N Clinical correlation to various patterns of reflux. *J Vasc Surg* 31:242–248
4. Cornu-Thenard A (1994) *J Dermatol Surg Oncol* 20(5): 318–326

5. Mullane DJ (1952) Varicose veins of pregnancy. *Am J Obstet Gynecol* 63: 620–628
6. Navarro L, Min RJ, Bone C (2001) Endovenous laser: a new minimally invasive method of treatment for varicose veins—preliminary observations using an 810 nm diode laser. *Dermatol Surg* 27(2):117–22
7. Khilnani NM, Min RJ (2003) Duplex ultrasound for superficial venous insufficiency. *Tech Vasc Interv Radiol* 6:111–115
8. Min RJ, Khilnani NM, Golia P (2003) Duplex ultrasound of lower extremity venous insufficiency. *J Vasc Interv Radiol* 14:1233–1241
9. Caggiati A, Mendoza E (2004) *Eur J Vasc Endovasc Surg* 28(3): 257–261
10. Timperman PE, Sichlau M, Ryu RK (2004) Greater energy delivery improves treatment success of endovenous laser treatment of incompetent saphenous veins. *J Vasc Interv Radiol* 15:1061–1063
11. Min RJ, Khilnani NM, Golia P (2003) Duplex ultrasound of lower extremity venous insufficiency. *J Vasc Interv Radiol* 14:1233–1241
12. Pichot O, Kabnick LS, Creton D, Merchahant RF, Schuller-Petroviae S, Chandler JG (2004) Duplex ultrasound scan findings two years after great saphenous vein radiofrequency obliteration. *J Vasc Surg* 39(1):189–195
13. Khilnani NM, Min RJ (2005) Imaging of superficial venous insufficiency. *Sem Interv Radiol* (in press)
14. Weiss RA, Weiss MA (2002) Controlled radiofrequency endovenous occlusion using a unique radiofrequency catheter under duplex guidance to eliminate saphenous varicose vein reflux: A 2-year follow-up. *Dermatol Surg* 28:38–42
15. Kistner, (2003) Endovascular obliteration of the greater saphenous vein: The Closure procedure. *J Phlebology* 13:325–333
16. Goldman MP, Amiry S (2002) Closure of the greater saphenous vein with endoluminal radiofrequency thermal heating of the vein wall in combination with ambulatory phlebectomy: 50 patients with more than 6-month follow-up. *Dermatol Surg* 28:29–31
17. Merchant RF, DePalma RG, Kabnick LS (2002) Endovascular obliteration of saphenous reflux: a multicenter study. *J Vasc Surg* 3(6):1190–1196
18. Wagner WH, Levin PM, Crossman DV, Lauterbach SR, Cohen JL, Farber A. (2004) Early experience with radiofrequency ablation of the greater saphenous vein. *Ann Vasc Surg* 18:42–47
19. Merchant R Jr., Kistner RL, Kabnick LS (2003) Is there an increased risk for DVT with the VNUS procedure? *J Vasc Surg* 38(3):628
20. Rautio T, Ohinmaa P, Perala J, Ohtonen P, Heikkinen T, Wiik H, Karljalainen P, Haukipuro K, Juvonen T (2002) Endovenous obliteration versus conventional stripping operation in the treatment of primary varicose veins: a randomized controlled trial with comparison of costs. *J Vasc Surg* 35:958–965
21. Lurie F, Cretin D, Eklof B, Kabnick LS, Kistner RL, Pichot O, Schuller-Petrovic S, Sessa C (2003) Prospective randomized study of endovenous radiofrequency obliteration (closure procedure) versus ligation and stripping in a selected patients population (EVOLVE Study). *J Vasc Surg* 38:207–214
22. Min RJ, Khilnani N, Zimmet SE (2003) Endovenous laser treatment of saphenous vein reflux: long term results. *J Vasc Interv Radiol* 14:991–996
23. Proebstle TM, Gul D, Lehr HA, et al. (2003) Infrequent early recanalization of GSV after endovenous laser treatment. *J Vasc Surg* 38:511–516
24. Sadick NS, Wasser S (2004) Combined endovascular laser with ambulatory phlebectomy for the treatment of superficial venous incompetence: a 2-year perspective. *J Cosmet Laser Ther* 6(1): 44–49
25. Todd K, Fronek H, Isaacs M, Mackay E, Pearson D () Endovenous laser treatment: a twelve month evaluation of 291 patients. *J Vasc Interv Radiol* supplement: S144
26. Roisental M () EVLT for the incompetent greater and lesser saphenous veins; *JVIR* supplement S211
27. Zimmet SE, Min RJ (2003) Temperature changes in perivenous tissue during endovenous laser treatment in a swine model. *J Vasc Interv Radiol* 14:911–915

Embolotherapy Applications in Oncology

10 Chemo-Embolization for Liver

CHRISTOS S. GEORGIADES and JEAN-FRANCOIS GESCHWIND

CONTENTS

10.1	Introduction	129
10.2	Clinical Considerations	130
10.2.1	Patient Selection and Preparation	130
10.2.2	Pathophysiology and Anatomical Considerations	132
10.3	Technique	132
10.3.1	Procedure	132
10.3.2	Recovery	135
10.3.3	Follow-up	137
10.4	Results	138
10.5	Conclusion	139
	References	140

10.1 Introduction

Chemoembolization is being used with increasing frequency in the treatment of solid hepatic tumors. Continued refinements of the technique and better designed studies have confirmed the survival benefit imparted by chemoembolization on patients with unresectable liver cancer, though still being considered a palliative option. While no conclusive data exist as to a survival benefit for patients with hepatic tumors other than hepatocellular carcinoma (HCC), this procedure is rapidly gaining favor over other nonsurgical alternatives (see below). HCC is the most common solid, nonskin cancer in the world, with an especially high prevalence in Southeast Asia and Sub-Saharan Africa. The main predisposing factor in these geographic regions is Hepatitis B (the strongest risk factor associated with developing HCC), whereas in Europe and the USA the increasing incidence is attributable to a concomitant increase

in the incidence of Hepatitis C (three-fold from 1993 to 1998) and alcoholic cirrhosis [1]. Epidemiologic analyses project increasing incidence in cirrhosis and HCC in the USA for the foreseeable future [2,3] and the trend is expected to eclipse the 70% increase in incidence of HCC over the last twenty years [1]. Though less frequent, the incidence of cholangiocellular carcinoma (CCC) in the USA is also on the increase with approximately 4,000 new cases per year. HCC and CCC comprise the overwhelming majority of primary malignant hepatic neoplasms. Secondary or metastatic hepatic neoplasms are especially common owing to the blood filtration function of the liver. With prolonged life expectancy, more people develop cancer and with improved cancer treatments patients live longer and thus have a greater chance of developing liver metastases. These factors have contributed to the ever-increasing incidence of patients with secondary hepatic neoplasms, especially in the Western World. Whether primary (HCC, CCC) or secondary however, hepatic malignancies carry a dismal prognosis with overall long-term survival percentage rates in the single digits. Both HCC and CCC are slow-growing tumors and even when the presence of risk factors initiates some sort of surveillance (cross-sectional imaging or tumor markers such as alpha-feto protein (AFP)) the majority of patients are unresectable at presentation. Of the 10%–20% of patients with HCC who are deemed resectable most will recur even with optimum treatment either due to residual tumor or metachronous lesions that eventually will develop in a cirrhotic liver. Liver involvement with metastatic disease from solid tumor imparts an equally dismal prognosis. A patient with resectable liver metastases and controlled primary disease who can benefit from such aggressive treatment is the rare exception. Median survival for patients with unresectable liver cancer is disappointingly short irrespective of histology. Survival ranges from a short two months for patients with adenocarcinoma of unknown primary to a maximum median survival of 15 months for colon metastases. Carcinoid patients in particular,

C. S. GEORGIADES MD, PhD

Assistant Professor of Radiology and Surgery, Johns Hopkins Medical Institutions, Blalock 545, 600 N. Wolfe Street, Baltimore, MD 21287, USA

J.-F. GESCHWIND, MD

Associate Professor of Radiology, Surgery and Oncology, Johns Hopkins Medical Institutions, Blalock 545, 600 N. Wolfe Street, Baltimore, MD 21287, USA

have very slow disease progression and despite the presence of liver metastases may survive for years. Survival for unresectable disease from hepatocellular carcinoma, cholangiocarcinoma, and metastases from pancreatic, breast cancer, and melanoma are between 4 and 9 months [3–9].

These disappointing results coupled with the poor response of HCC to traditional chemotherapy have provided the impetus for the development of a variety of nonsurgical techniques for the treatment of hepatic neoplasms (Table 10.1). Such techniques are generally divided into transarterial interventions versus percutaneous ones. The latter group is further subdivided into thermal ablation techniques versus chemical ablation techniques.

Transarterial chemoembolization (TACE) has become the most popular locoregional technique for the treatment of unresectable HCC. LLOVET et al. [10.] showed for the first time that TACE imparts a survival benefit to patients with unresectable HCC. It should be mentioned that some institutions do not routinely use chemotherapy during embolization for primary or secondary unresectable liver cancers. Though data show such patients who receive TACE have a longer survival and/or better response than those receiving blunt transarterial embolization (TAE) only with Lipiodol (Savage Laboratories, Melville, NY), Gelfoam (Pharmacia and Upjohn, Kalamazoo, Michigan) or particles (PVA by Boston Scientific or Embospheres by Biosphere Medical Corp., Boston, MA), the difference is not statistically significant [10–13]. The reason that the differences in patient survival between chemoembolization and blunt embolization are not significant is probably the small number of patients in the relevant studies. Chemoembolization should reasonably be expected to effect greater response not only pathophysiologically; studies (despite lack of statistical significance) always show greater survival for patients treated with TACE versus TAE.

10.2 Clinical Considerations

10.2.1 Patient Selection and Preparation

In addition to improved survival for patients who undergo TACE for unresectable disease, there have been reports of patients whose tumor has shrunk enough to permit resection or liver transplantation and provide a chance for cure. Despite these benefits, TACE is considered a palliative treatment option. Surgical resection is the only procedure that can be performed with curative intention, therefore, TACE should be reserved for patients who are not surgical candidates. This is the only absolute contraindication to TACE. Table 10.2 summarizes a list of relative contraindications.

Prior to TACE all patients should undergo a gadolinium-enhanced [Omniscan, GE Healthcare, Princeton, NJ] MRI of the liver, preferably with perfusion/diffusion sequences (Fig. 10.1). CT, without and even with contrast cannot adequately delineate viable tumor and differentiate it from necrosis, scar, or inflammatory tissue. CT can follow the tumor response as far as size goes, but we believe this is inadequate, whereas enhancement on MRI perfusion imaging provides more accurate information on which part of the tumor is viable and which is dead.

Dual phase, contrast-enhanced MRI with perfusion sequence will not only delineate the extent and viability of tumor but also serve as a baseline study to plan future treatment. A simple dual-phase MRI or CT is acceptable as well but inferior to MRI perfusion in quantifying viable tumor. In addition to information regarding tumor viability and morphology, cross-sectional provides information regarding the tumor’s vascular supply and anatomy. For example, knowing the presence of portal vein thrombosis

Table 10.1. Nonsurgical treatment options for unresectable hepatic malignancies

Nonsurgical treatment options for mass-forming hepatic neoplasms							
Percutaneous				Intra-arterial			
Thermal ablation			Chemical ablation			TACE	TARE
MCT	RFA	LIPC	Cryo	PEI	PAAI	PCI	

All of the percutaneous techniques are limited by the size and number of the lesions (up to three lesions each measuring up to 4 cm) as well as their location. Subdiaphragmatic lesions may be percutaneously inaccessible, and lesions close to large vascular structures respond poorly to thermal ablation techniques (RFA, MCT, Cryo, and LIPC). On the contrary, intra-arterial techniques are not limited by the number, size, or location of the lesions; rather by the hepatic function reserve, as shown in Table 10.2. TACE, trans-arterial chemo-embolization; TARE, trans-arterial radio-embolization; MCT, microwave coagulation therapy; RFA, radio frequency ablation; LIPC, laser interstitial photocoagulation; Cryo, cryo-ablation; PEI, percutaneous ethanol injection; PAAI, percutaneous acetic acid injection; PCI, percutaneous chemotherapy injection

Table 10.2. Contraindications to TACE

Contraindications to TACE	Mitigating action
1. Borderline liver function	1–3. Superselective TACE of a hepatic segment may be considered
2. Total bilirubin > 4 mg/dl	4. TACE may be performed if encephalopathy was minimal.
3. Albumin < 2	Consider lactulose.
4. Encephalopathy	5. Give FFP or platelets as indicated
5. Coagulopathy	6,7. See below ^a
6. Poor general health	8. Mucormist p.o. and i.v. fluids if creatinine > 1.2 but < 1.8.
7. Significant arteriovenous shunting through the tumor	Avoid TACE if Cr > 1.7
8. Elevated creatinine	

^aBorderline liver function, encephalopathy, and poor general health are subjective factors, and the complete clinical picture must be considered prior to deciding whether to proceed with TACE. Child-Pugh C liver disease patients show poor response to TACE, and in general we avoid TACE in such patients. On the other hand, Child-Pugh A liver disease patients seem to obtain the maximum benefit from TACE, exhibiting the longest survival. Though we do use TACE for Child-Pugh B liver disease patients, their survival benefit is less than that of their stage A counterparts. Total bilirubin of 4 mg/dl is currently used at our institution as the cut-off. We have recently increased this from 3 mg/dl without any adverse effects. Unpublished data again from our institution have shown that portal vein thrombosis does not increase the risk of complications, at least in Child-A patients. Finally, arteriovenous shunting through the tumor can result in nontarget embolization. This is evident on the initial angiogram, and blunt Gelfoam embolization can eliminate the shunting and allow the patient to proceed with TACE. At our institution arterial access is avoided if INR > 1.7 or APTT > 1.7 or platelet count < 50,000.

and/or variant vascular anatomy may obviate the use of embospheres during treatment or reduce the procedure time and contrast load. Patients are premedicated depending on the tumor histology, renal function, and prior surgical and medical history. For example, patients with carcinoid will have to be premedicated with Sandostatin to prevent possible carcinoid crisis after TACE. At our institution we have thus far performed TACE in patients with carcinoid metastases to the liver more than a few hundred times without witnessing any carcinoid crisis.

Patients whose sphincter of Oddi function has been eliminated, i.e. hepatojejunostomy, sphincterotomy patients or patients with percutaneous or internal biliary stents, are at high risk (> 50%) for developing a hepatic abscess after TACE. Stringent 24-h bowel preparation and i.v. administration of broad-spectrum intravenous antibiotics prior to the procedure is recommended, but abscess formation is still likely. This is thought to be a result of colonization of the biliary tree secondary to a resected or incompetent sphincter of Oddi. TACE causes ischemia to the biliary tree which, unlike liver parenchyma, is exclusively supplied by the peribiliary plexus via the hepatic artery. The necrotic tumor bed may become infected and abscessed, which can be particularly difficult to eradicate even with percutaneous drainage and i.v. antibiotics. This complication should always be discussed with the patient, with an overall risk of abscess formation of 50%–70% mentioned. Laboratory values should be obtained prior to TACE, including: A comprehensive metabolic panel (NA, K, glucose, creatinine, BUN, total

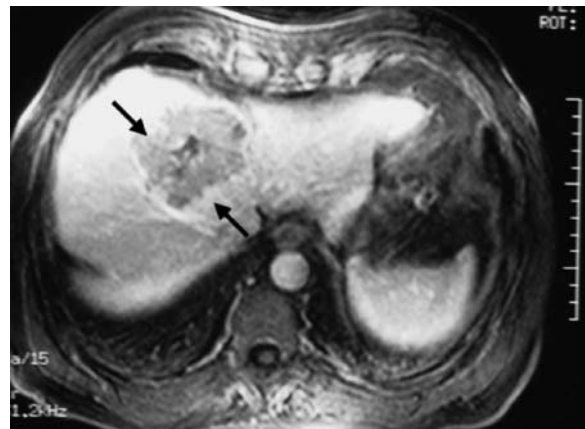


Fig. 10.1. Axial, venous phase, gadolinium-enhanced MRI of a patient with unresectable HCC showing a peripherally enhanced lesion (arrows) in the medial segment of the left lobe. Solid, well demarcated lesions such as this one respond better to TACE than do diffuse or multifocal lesions. Additionally, hypervascular tumors appear to respond better to TACE showing a higher degree of necrosis on follow-up MRI

bilirubin, AST, ALT, alkaline phosphatase, albumin, total protein), hematology panel (hematocrit and/or hemoglobin, white blood cell count, platelet count, coagulation profile (INR, APTT) and tumor markers (i.e. AFP for HCC, CEA for colon cancer). These values serve not only to ensure a safer procedure (i.e. normal coagulation) but also to allow for proper follow-up of hepatic and renal function and monitor response (using tumor marker levels). Finally, since the procedure is performed under sedation, an 8-h NPO status is required.

10.2.2 Pathophysiology and Anatomical Considerations

Chemoembolization takes advantage of the fact that, while normal liver parenchyma receives most of its blood supply (60%–80%) from the portal venous system, malignant hepatic tumors, whether primary or metastatic, are nearly exclusively supplied by branches of the hepatic artery. Cancer angiogenesis (a.k.a. neovascularization) is a process by which neoplastic cells recruit new blood vessels in order to ensure adequate local oxygen tension. Due to their relatively higher metabolic demands cancer cells live in a nearly constant state of hypoxia. They respond by secreting chemotactic factors that promote the formation of new blood vessels. Arterial epithelial cells are much more responsive to these factors, which explains why such malignant tumors are supplied by the hepatic artery. Chemoembolization then selectively targets the tumor while liver parenchyma is mostly (but not entirely) spared. Theoretically then, chemoembolization can be used to treat any solid malignant hepatic neoplasm whether primary or metastatic, solitary or multifocal, and irrespective of size. Of course exclusion criteria do exist and are described in detail below. Accessory and/or replaced right or left hepatic arteries are common (up to 20%–30%). Usually such variations are inconsequential, but rarely they may render catheter-selection of the hepatic artery to be treated with the 5 Fr catheter difficult (see Technique section below). Even then a 3 Fr microcatheter is usually a successful alternative. In addition, common origins of the left hepatic and left gastric as well as right hepatic and right gastric arteries may be added complicating factors. Such associations are important insofar as they increase the risk of nontarget embolization, mainly the stomach, proximal small bowel, and/or pancreas. Though self-limiting gastritis, duodenitis and pancreatitis have been reported, no deaths have yet been documented from nontarget embolization. Vigilance during the initial diagnostic arteriogram and intimate knowledge of the related vascular anatomy and its possible normal variations is a must in order to minimize the chances of complications. Recently, a few published reports have described extrahepatic supply of liver cancers. For example, intercostal or diaphragmatic arteries can be recruited by neoplasms. If repeated TACE fails to show the appropriate response or if a section of the tumor remains viable while the rest shows significant necrosis, search for such extrahepatic supply

is indicated. Selective arteriograms of intercostal and diaphragmatic arteries or a 3-dimensional CT angiogram can determine whether indeed this is the case. Currently, portal vein thrombosis (PVT) (Fig. 10.2) is considered by most physicians as a contraindication to TACE for fear of causing hepatic ischemia/infarction and possible decompensation. However, unpublished data from our institution confirm that for Child-Pugh A or B patients TACE is a safe intervention even in the presence of PVT. We had no mortality of significant morbidity for 30 days post-procedure in these patients. In addition we showed a survival advantage compared to historical controls.

10.3 Technique

10.3.1 Procedure

After a treatment plan is formulated based on image findings and the patient's clinical situation, informed consent is obtained. Informed consent should disclose the following risks: Injury to blood vessels and/or organs (which may require blood transfusion or surgery), anaphylactic reaction to contrast, worsening of renal function, infection, liver function worsening or liver failure and possibly death. Appropriate i.v. antibiotic prophylaxis is administered (cefotaxime 2 g i.v. once, at our institution) immediately pre-procedure. Preprocedure documentation of femoral, dorsalis pedis and posterior tibial pulses is mandatory in order to choose the appropriate access site (strongest pulse between right or left common femoral artery, CFA) and compare with the post-procedure exam for any changes. The patient is placed on the fluoroscopy table supine and both groins are prepared and draped in a sterile fashion. Sedation is provided according to the local nursing protocol (i.e. Versed and Fentanyl, supplemented as needed with Phenergan and/or Benadryl).

- Step 1—Obtaining vascular access. In most cases access using an 18 g, single-wall needle followed by an 0.035" guide-guide wire is successful. In difficult cases a 0.018" micropuncture set can be of help, with or without the use of ultrasound guidance.
- Step 2—Maintaining access. A 5-Fr short vascular sheath providing access in the right or left (strongest pulse) CFA is used at our institution.

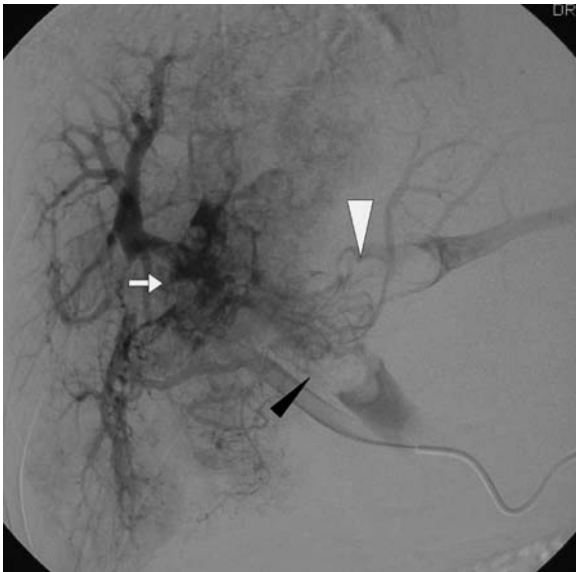


Fig. 10.2. Antero-posterior, digital subtraction angiogram of the abdomen of a patient with unresectable HCC showing clot in portal veins. This arterial phase hepatic angiogram shows early arterial-portal venous shunting through a hypervascular tumor (*white arrow*). The shunting into the portal veins uncovered a filling defect (clot) in the main (*black arrowhead*) and left (*white arrowhead*) portal veins. Embolization with 1 cc of Gelfoam slurry shut down the shunt while the tumor supply was preserved. This allowed us to proceed with TACE. The presence of portal vein thrombosis should not be considered by itself as a contraindication to TACE. Unpublished data from our institution shows TACE to be a safe and effective procedure in Child-Pugh A and B patients

A 4 Fr access set can be used in cases where less traumatic arterial access is needed (i.e. slightly abnormal coagulation profile, severe peripheral vascular disease), however smaller catheters may be a bit less controllable.

- Step 3—Abdominal aortogram. (Optional). A flush aortogram via a multisideholed, pig-tailed catheter at the level of the celiac artery will delineate the vascular anatomy, tumor supply and provide a road-map for more selective access. For the most part this step can be skipped. In rare cases and after failing to easily select the SMA and celiac axis with a selective catheter (see step 4), which may suggest variant anatomy, one may revert to an abdominal aortogram. If performed, a 15 cc per second injection for a total of 50 cc (15/50) is adequate.
- Step 4—Selective arteriograms. First, a 5-Fr glide catheter (Simmons-1 or Cobra glide-catheters, Terumo Medical, Somerset, NJ) is used to select the superior mesenteric artery (SMA) and perform a prolonged angiogram that is carried well into the venous phase (Fig. 10.3).

- An injection rate of 6 cc per second for a total of 40 cc (6/40) is what we use. If the portal vein is proven patent on recent MRI, CT or previous angiogram, the portal venous phase can be skipped, lowering the injection rate to 6 cc per second for a total of 20 cc (6/20). Then the celiac artery is selected (again Simmons's I or Cobra glide catheters) and a selective arteriogram is performed with an injection rate of 6 cc per second for a total of 20 cc (6/20). In most cases the celiac axis arteriogram will show the tumor blush to best advantage (Fig. 10.4). Prior to power-injection angiography using a mechanical injector, one should perform a gentle, short contrast injection by hand. This will serve many purposes: (1) it will ensure the catheter is in the right position, (2) that its tip is not in a small side branch (inadvertent power-injection in a small branch may cause dissection and/or thrombosis), and (3), it will give an idea on how fast (or slow) the flow is in the vessel of interest. The above-mentioned injection rates can be tailored to the flow observed within the vessel of interest. If for example the blood flow in the SMA appears to be very slow, instead of the usual 6/20 injection rate one can lower it to 5/15. Likewise, if the flow is fast or vessel caliber large the injection rate can be increased to 7/35.

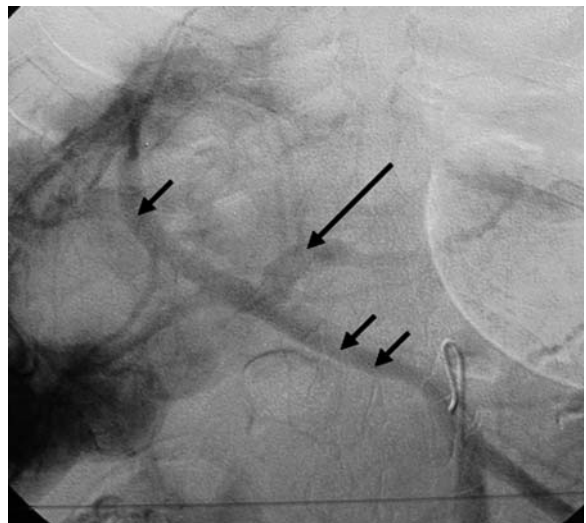


Fig. 10.3. Antero-posterior, digital subtraction angiogram of the abdomen of a patient with multifocal HCC in the venous phase shows a patent main (*double arrows*) as well as right (*arrow*) and left (*long arrow*) portal veins. Though only a relative contraindication, portal vein thrombosis demands extra precautions to avoid complete cessation of flow in the hepatic artery and to limit the use of embolization material (such as Gelfoam or particles) during TACE

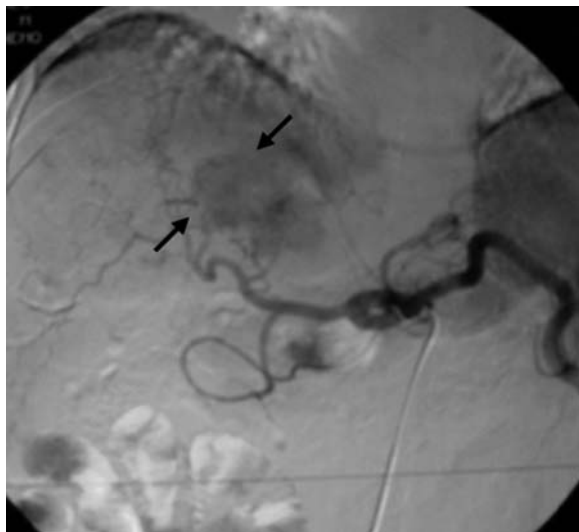


Fig. 10.4. Antero-posterior, digital subtraction angiogram in the arterial phase during celiac artery contrast injection in a patient with HCC (same as Fig 10.1) shows an enhancing lesion (*arrows*) supplied by the left hepatic artery. High tumor vascularity ("blush") is a marker for successful TACE

- **Step 5—Selecting the final catheter position.** A glide 0.035" wire is advanced through the glide catheter followed by the catheter itself. Though one wants to be as selective as possible to avoid chemoembolizing normal liver, being too selective will result in parts of the tumor not being treated. In general, either the right or left main hepatic artery is the optimal position for the treatment catheter. In cases where there is tumor in both lobes, the one showing more tumor blush during the diagnostic celiac (or SMA) arteriogram should be targeted. If the 5 Fr glide catheter cannot be advanced to the desired location because of unfavorable anatomy, a 3 Fr microcatheter (Renegade, Boston Scientific) over an 0.018" guide-wire (i.e. Transend, Boston Scientific) can be used coaxially. If one is targeting a peripheral solitary lesion, then one can be as selective as possible provided the whole lesion is targeted. In our experience the more selective the catheter is the higher the degree of necrosis. During this step, the radiologist may observe arteriovenous shunting through the tumor. If one proceeds with TACE, one risks nontarget embolization (lungs, since the most common type of shunting is hepatic artery to hepatic vein) and inadequate tumor treatment. Instead, the operator should treat first with blunt embolization using Gelfoam until the shunting resolves. If at the end of blunt embolization the tumor is still

enhanced by contrast then one can proceed with TACE. Otherwise a 2-week wait period is recommended at which time a repeat arteriogram will decide whether TACE is possible.

- **Step 6—Treatment.** TACE is performed slowly by hand-injection under continuous, real-time fluoroscopy to ensure there is no reflux of chemotherapy back around the catheter that may result in nontarget embolization. Though nontarget embolization of the contralateral hepatic artery may not be a serious problem, inadvertent embolization of the gastroduodenal artery can have serious consequences including gastroduodenal necrosis. Single, double, or triple agent chemotherapy mixtures are used with varying frequency depending on institutional preference. At our institution we use triple chemotherapy mixture composed of 100 mg Cisplatin (Bristol Myers Squibb, Princeton, NJ), 10 mg Mitomycin C (Bedford Laboratories, Bedford, OH) and 50 mg Doxorubicin Hydrochloride (Adriamycin; Pharmacia-Upjohn, Kalamazoo, MI). Currently there is no data as to the relative efficacy of specific chemotherapy mixtures. The chemotherapy is mixed 1:1 with Lipiodol (Savage Laboratories, Malville, NY) (2:1 if slow flow is noted in the artery to be treated). Lipiodol has been shown to concentrate within the tumor neovasculature and reside there for weeks. This increases the concentration of chemotherapy in the tumor by up to 100-fold compared to systemic chemotherapy. After chemotherapy infusion, 10–20 cc of nonbuffered lidocaine can be infused through the same catheter for pain control. This provides not only immediate pain relief in case the patient complains of intra-procedural pain but has also been shown to help in the immediate post-procedural period and until patient-control anesthesia can be initiated (see below). Additional embolization with 150–300 micrometer particles (PVA, Boston Scientific or Embospheres, Biosphere Medical, Boston, MA) until the flow in the treated artery is slowed down, further increases the chemotherapy residence time within the tumor, though data related to actual benefit are lacking. At our institution, complete embolization is avoided for two reasons: (1) we want to ensure patency of the artery for future treatments, and (2), *in vitro* experiments have shown that prolonged hypoxia induces selection for more aggressive neoplastic cells. Table 10.3 shows the list of materials required for TACE and Table 10.4 shows the possible complications and associated mitigating measures.

Table 10.3. The basic materials needed for TACE

Step	Objective	Primary materials	Alternative materials
1	Obtaining arterial access	18-g single-wall needle (Cook ^a) and 0.035" guide wire (Bentson, Cook)	Micropuncture set (Cook)
2	Maintaining arterial access	5 Fr, 11-cm vascular sheath (Cordis ^a)	4 Fr, 11-cm vascular sheath (Cordis)
3	Performing abdominal aortogram	5 Fr, Pigtail-flush catheter (Angiodynamics ^a)	4 Fr, Pigtail-flush catheter (Angiodynamics)
4	Performing selective SMA & celiac arteriogram	5 Fr, hook, endhole glide catheter (Simmon's 1, Terumo ^a)	Cobra (Terumo) or Michelson (Angiodynamics)
5	Selecting the final catheter position	Simmon's 1 or Cobra (Terumo) glide catheter over 0.035" glide wire (Terumo)	3 Fr microcatheter (Renegade, Boston Scientific ^a) coaxially through the 5 Fr or 4 Fr catheter over a 0.018"-wire (Transend, Boston Scientific)
6	Treatment	3-cc syringes and chemotherapy resistant 3-way stop-cock	1-cc syringes may be necessary if high resistance in microcatheter
7	Finishing	Manual hemostasis	Closure device

The microcatheter (step 5) is used only if the Simmons 1 glide cannot be advanced far enough to safely infuse the chemotherapy mixture. Once ready to infuse, the chemotherapy and related supplies should be manipulated at a table separate from the main one, to avoid inadvertent chemotherapy contamination of unrelated supplies.

^a Cook, Bloomington, IN; Cordis, Miami, FL; Angiodynamics, Queensbury, NY; Terumo, Somerset, NJ; Boston Scientific, Boston, MA

- **Step 7–Finishing.** A single high-resolution exposure of the liver is obtained to document distribution of Lipiodol (along with chemotherapy). The catheter and sheath are removed and hemostasis is achieved with manual pressure or the use of a closure device. Peripheral pulses are rechecked and documented to make sure they are stable. Though exceedingly rare with proper technique, significant changes may signify complications such as access artery dissection or distal thrombosis.

10.3.2 Recovery

After removal of the common femoral artery vascular sheath and proper hemostasis is achieved, the patient is placed on monitoring for 4–5 h and patient controlled analgesia (PCA) pump and i.v. hydration are initiated. At the end of the monitoring period and if no untoward events are noted the patient is sent to the floor. Routine nursing checks and care are adequate thereafter. P.R.N. medication should include (in addition to the morphine or fentanyl PCA pump), anti-nausea and additional pain medication for breakthrough pain. Hydration is critical not only because of the patient's NPO status prior to the procedure and possible nausea, but more importantly to mitigate the consequences of a possible tumor

lysis syndrome such as acute renal failure. After the 4-h observation period the patient is encouraged to ambulate, initially under supervision. Table 10.5 shows a sample admission order sheet. The use of arterial puncture closure devices can cut down the observation period to 2 h. As soon as the patient ambulates, the Foley catheter (If one was placed) is removed. At the same time p.o. intake is advanced as tolerated. When the patient is ambulatory a noncontrast CT of the abdomen is obtained to document the distribution of Lipiodol and the degree to which the tumor has taken up the chemoembolization mixture (Fig. 10.5). Uniform Lipiodol uptake by the tumor correlates with a higher degree of necrosis compared to spotty or lack of Lipiodol uptake. Likewise, region with high Lipiodol uptake post-TACE correlate with a higher degree of necrosis on follow-up imaging examinations (Fig. 10.6).

After a 24-h period of observation and symptomatic control, the patient is discharged to home, barring continued significant symptoms and with appropriate instructions to exercise vigilance for possible infection or groin hematoma. A sample discharge form is shown in Table 10.6. More than 90% of TACE patients are discharged to home after this period. Cases which require one more day of hospitalization are rare and even longer stays are exceedingly rare. Discharge medications should include a 7-day course of oral antibiotics (i.e., Ciprofloxacin 250 mg p.o. bid) and P.R.N. pain medication.

Table 10.4. Possible complications and mitigating interventions associated with TACE

Possible complication of TACE	Mitigating intervention/notes
Nontarget embolization or Post-embolization syndrome (Pain, fever, nausea/vomiting)	Supportive measures (Pain control, hydration, and gastric acidity reduction)
Tumor lysis syndrome	Pre- and post-procedure hydration Follow creatinine
LFT elevation	Follow as outpatient if mild and asymptomatic
Liver failure	Avoid TACE in patients with Child-Pugh C liver disease. Do not perform TACE from proper hepatic artery. Select right or left. May be irreversible and fatal

In our experience at least half the patients undergoing TACE will exhibit symptoms related to postembolization to a lesser or greater degree. The vast majority (> 90%) of patients will recover enough to be discharged the next morning. The rest may require a second hospital day. Fatalities related to TACE are exceedingly rare and related to limited hepatic function reserve and ensuing liver decompensation and acute failure. It is thus crucial to document the patient's liver function reserve and follow the contraindications indicated in Table 10.2.

Table 10.5. Sample admission orders for patients after TACE

- Admit: (Attending name and service)
- Diagnosis: Liver neoplasm, s/p chemoembolization
- Condition: (i.e. stable)
- Vitals: Q 15 min x 4, then q 30 x 2, then hour x 2, then floor routine
- Allergies: (i.e. NKDA)
- Activity: Right (or left) leg straight x 4 h and head flat x 2 h. Then ambulate under supervision x 15 min. Then patient may walk but avoid stairs/straining
- Nursing: Right (or left) groin checks q 15 min x 4, then q 30 min x 2, then q hour x 2 for possible hematoma/bleed
- Diet: Advance as tolerated (tailor per patient, i.e. diabetic, low cholesterol etc)
- IVF: 100 cc/h x 24 h, then d/c if patient tolerates p.o. intake (tailor per patient)
- Medications: Patient controlled anesthesia pump (PCA pump, separate order sheet)
 - (i.e. fentanyl 20 mcg i.v., q 10 min, lock out at maximum 6 times per h)
 - Oxycodone
 - Tylox 1-2 tablets q 4–6 h prn breakthrough pain
 - Zofran 8 mg p.o. q8 h prn nausea
 - Ciprofloxacin 250 mg p.o. bid
- Laboratories: None necessary (tailor to patient)
- Studies: CT abdomen without i.v. or oral contrast after patient able to ambulate

Orders should be tailored according to specific patient needs. For example, medications should be compatible with the patient's allergies; the amount of i.v. fluids should take into account the patient's renal function and cardiac status, and laboratories should be used to follow suspected TACE toxicities (i.e. an elevated bilirubin should be followed, as should an elevated creatinine)

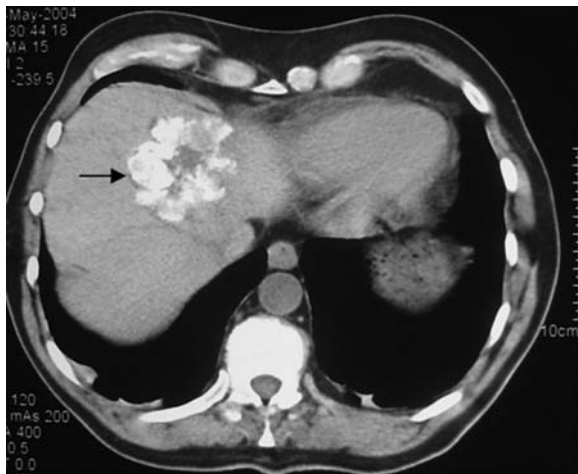


Fig. 10.5. Axial, nonenhanced CT of a patient with HCC (same as in Figs. 10.1 and 10.4) obtained one day following TACE, shows the lesion retaining the radio-opaque Lipiodol (arrow) in its most vascular regions. The retention of Lipiodol – and consequently chemotherapy since the two are mixed – can persist for weeks after TACE and correlates with tumor necrosis

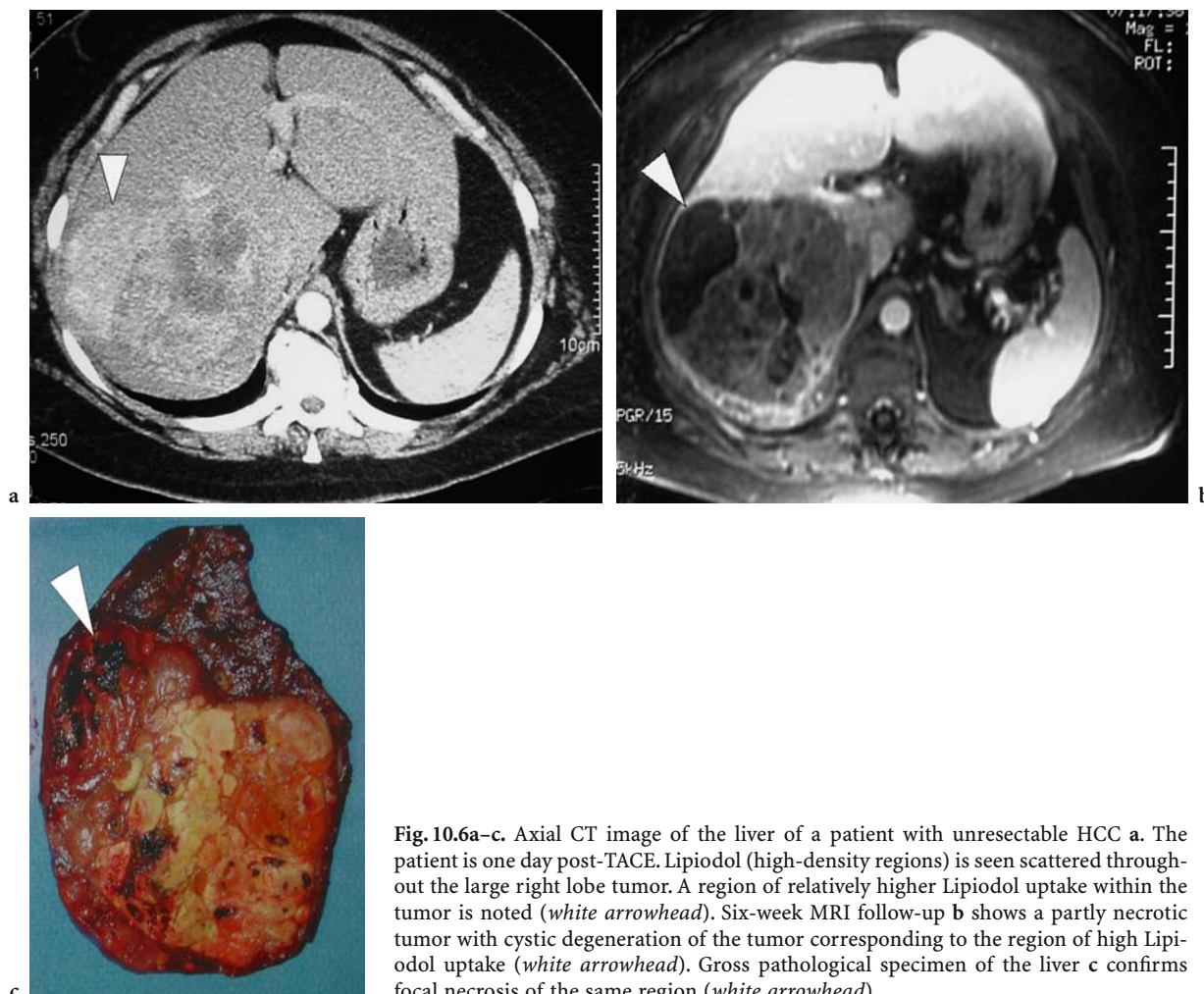


Fig. 10.6a–c. Axial CT image of the liver of a patient with unresectable HCC **a**. The patient is one day post-TACE. Lipiodol (high-density regions) is seen scattered throughout the large right lobe tumor. A region of relatively higher Lipiodol uptake within the tumor is noted (*white arrowhead*). Six-week MRI follow-up **b** shows a partly necrotic tumor with cystic degeneration of the tumor corresponding to the region of high Lipiodol uptake (*white arrowhead*). Gross pathological specimen of the liver **c** confirms focal necrosis of the same region (*white arrowhead*)

**10.3.3
Follow-up**

For maximum benefit, patients should be seen at regular intervals, a perfusion MRI of the liver obtained (Figs. 10.7 and 10.8) and compared to the baseline or previous MRI. Six-week intervals between successive TACEs is currently the standard at our institution. Prior to each TACE the MRI will establish tumor viability (or necrosis). Necrosis is quantified as 0%–25%, 25%–50%, 50%–75%, and 75%–100% based on perfusion (or contrast enhancement) MRI. If no residual viable tumor is noted, a follow-up MRI is scheduled for 6 weeks later and no TACE is performed. Lack of satisfactory response after one TACE does not predict eventual response, and additional TACE should target the same tumor. We have observed many times patients having “failed” to respond to the first TACE, responding very favorably after the second or third

TACE. Before TACE is called a “failure” we believe the patient should be treated at least 2–3 times targeting the same region. The emergence of any contraindications to TACE between successive TACEs precludes repeat treatment; thus prior to each procedure the relevant laboratory values should be obtained and the patient re-evaluated. In some cases where the patient was precluded from having surgery solely due to tumor size, adequate reduction in size following TACE may render the patient operable. Though rare, we have had at least five patients in the last 2 years who became resectable or candidates for liver transplantation after TACE reduced the tumor burden or shrunk it away from vital structure such as portal/hepatic veins. Thus continuous re-evaluation and consultation with oncology and surgery is vital so that such patients do not miss a chance for cure. Finally it should be noted that TACE-associated toxicity is significantly less than that of peripherally administered

Table 10.6. Sample discharge instructions for patients after TACE^a

- Discontinue all i.v. lines
- Discharge to home
- Medications:
 - Ciprofloxacin 250 mg p.o. bid x 7 days
 - Oxycotin 10 mg p.o. q12 h prn pain
 - Oxycodone 5–10 mg p.o. q 4-6 h prn breakthrough pain
 - Zofran 8 mg p.o. q8 h prn nausea
- Instructions:
 - No straining, stair climbing, or driving x 48 h
 - If groin swelling or bruising, or fever, nausea/vomiting, or worsening abdominal pain call (on call number)
- Diet:
 - As tolerated
- Follow up:
 - Contrast-enhanced MRI of liver and same day clinic appointment with (Interventional Radiologist) in 4–6 weeks
- Send copy of discharge summary to (referring physician's name)

^a These are general guidelines. Specific instructions should be tailored to patient's needs, allergies, and clinical situation

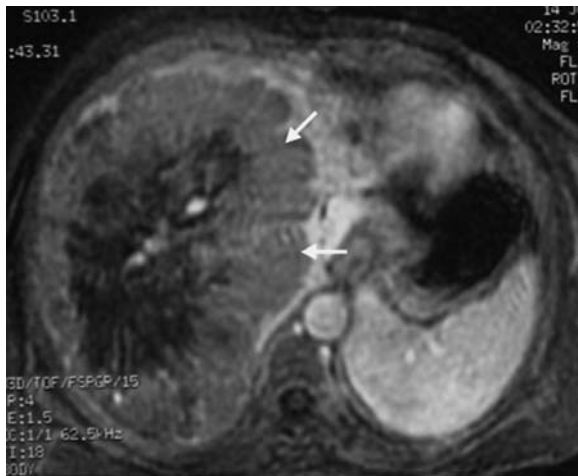


Fig. 10.7. Axial, gadolinium enhanced MRI of the liver of a patient with HCC shows a large, peripherally enhanced lesion (arrows) replacing the right lobe. The patient was unresectable owing to the size of the tumor. Decision was made to treat the patient with TACE for palliative reasons

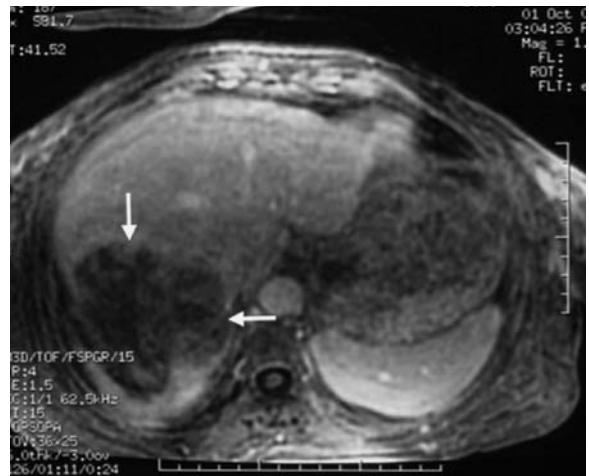


Fig. 10.8. Axial, gadolinium-enhanced MRI of the liver of the same patient as in Fig. 10.7 after two TACE treatments shows a dramatically decreased in size tumor with decreased enhancement (arrows). Though many tumors may not decrease in size significantly after TACE, most will show a degree of necrosis as measured on contrast-enhanced MRI

chemotherapy (unpublished data, C. S. GEORGIADES, K. HONG, M. W. D'ANGELO, J. F. GESCHWIND). Of course the main drawback of TACE is that it does not treat metastases outside the liver, which are in any case rare for HCC. For many secondary hepatic neoplasms, liver metastases are indeed the life-limiting disease aspect and such patients may benefit despite the presence of extrahepatic metastases.

10.4 Results

TACE is one of the most popular techniques available and one that is rapidly gaining favor. Despite the

fact that it has been used world-wide for many years, there has been, until recently, a lack of prospective randomized trials regarding its efficacy. Because of this, the procedure generated considerable discussion and dissent among physicians. Skepticism has been finally put aside by one randomized controlled trial and a recent meta-analysis that concluded that TACE significantly improves survival of patients with nonresectable HCC compared to nonactive treatment. LLOVET et al. [10.] performed a prospective randomized trial that recorded a 1-, 2- and 3-year survival of 82%, 63%, and 29% for patients undergoing TACE vs. 63%, 27%, and 17% for patients treated symptomatically. As a matter of fact, the trial was terminated early when the significant survival benefit of the TACE group became

evident. CAMMA et al. [14] performed a meta-analysis of randomized controlled trials looking at the two-year survival of patients with unresectable HCC who underwent TACE, transarterial chemotherapy (TAC) or transarterial embolization (TAE) versus nonactive treatment. Patients who underwent transarterial treatment had significantly improved survival with a pooled odds-ratio of 0.54 (95% CI). The TACE and TAE groups had an odds-ratio of 0.45 (95% CI) and the TAC group an odds-ratio of 0.65 (95% CI).

Prospective, randomized trials investigating possible survival benefits of TACE for metastatic neoplastic disease to the liver are lacking, as are such trials for cholangiocarcinoma. From our own experience however (accepted for publication, March 2005, JVIR), patients with unresectable cholangiocarcinoma treated with TACE had a median survival of 23 months, compared to only 6 months for historical controls receiving supportive treatment alone, 9 months for those receiving systemic chemotherapy and 16 months for those receiving chemoradiation. Metastatic colon cancer to the liver has proven to be less responsive than hoped for to TACE, with reported median survival of 10–12 months. Still, patients with colorectal metastases to the liver resistant to systemic chemotherapy may obtain benefit from TACE [15–17]). Other metastatic neoplasms to the liver that are amenable to TACE include carcinoid, breast cancer, adrenal cancer, sarcomas etc. From our own experience, though technically feasible for all types of pathology, TACE appears to be more effective in tumors which are highly vascular. Such observations have been reported by other authors as well [18] We have found sarcomas and carcinoid to be especially responsive but (as mentioned above) colon cancer to be less responsive to TACE in keeping with being relatively less vascular. In the latter case, we are currently investigating the efficacy of radioembolization (Yttrium-90, see Chapter 11) for colorectal metastases to the liver, and preliminary results appear to be more hopeful than those previously collected for TACE.

10.5 Conclusion

With concerns regarding the survival benefits of TACE for patients with inoperable hepatocellular carcinoma finally being put to rest [10,14], all such patients should be considered for TACE. The

median survival of patients with inoperable HCC is 4–7 months (which can be extended with maximal supportive care to approximately 10 months). TACE prolongs median survival to more than two years and, though rarely, converts some patients into candidates for resection or transplantation. Preliminary unpublished data from our institution confirm a significant survival advantage of TACE in patients with inoperable mass-forming cholangiocarcinoma. Nearly uniformly fatal, this disease imparts a median survival of 4–8 months. Such patients who have been treated with TACE (Protocol identical to that of HCC) show an extended median survival up to 20 months. The benefit of TACE on patients with other histological types of inoperable liver cancer has not been evaluated by prospective, randomized trials. Given the low toxicity rate, lack of alternatives and encouraging results for HCC and CCC, it is reasonable to offer this treatment to such patients. Indeed, not doing so would deprive them of a reasonably expected survival benefit. Though TACE can be applied to any morphologic type of liver cancer (from solitary lesions to diffuse bilobar disease), it must compete with percutaneous ablation techniques for patients with up to three lesions each less than 4 cm each. These percutaneous ablation techniques (Table 10.1) under optimal conditions provide benefits similar to surgical resection but suffer from their own specific limitations. The most commonly used percutaneous ablation techniques are radiofrequency ablation (RFA) and alcohol injection (PAI). In experienced hands these techniques have excellent results for up to three lesions with a maximum diameter of 3–4 cm each. However, their efficacy rapidly tapers for larger lesions. Table 10.7 shows the typical response/recurrence rates of HCC treated with RFA. Radioembolization with Yttrium-90 microspheres is an alternative to TACE as an intra-arterial treatment for unresectable HCC, CCC, or secondary liver cancer, but efficacy data are more scarce. TACE is an evolving technique and many questions remain unanswered. For example, what is the best chemotherapy “cocktail”? What TACE protocol yields maximum survival benefit? Can it be combined with systemic chemotherapy or other ablation techniques? Will the addition of novel pharmaceuticals (i.e. anti-angiogenesis drugs or drugs that target catabolic pathways uniquely) improve survival? If so, what is the best regimen? We are years and many studies away from answering these questions, but the prospect of transforming inoperable liver cancer into a chronic disease managed by a protocol of surveillance and regular interventions

is a matter of time. As treatment options change and as more and more patients receive multiple different treatments for their disease (i.e. RFA and TACE, or systemic chemotherapy and TACE) we must also evolve in how we view this disease. One of the salient points is the definition of response, which according to current criteria, depends on tumor size alone. The advancement of imaging methods and their ability to distinguish between necrosis and cystic change versus viable tumor has rendered this view antiquated and inappropriate in our opinion. We believe the most appropriate method to measure response is to quantify the percent viable tumor remaining after treatment. Currently the best way to achieve this is by contrast-enhanced MRI or PET scanning (the latter somewhat limited by its relatively lower spatial resolution).

This final point is probably the most crucial. Surgeons, hepatologists, oncologists, and interventional and diagnostic radiologists bring their unique and important input to the treatment planning for these complex cases. Treatment planning should be reviewed after every intervention whether this is

Table 10.7. Radiofrequency ablation is an alternative technique for the treatment of unresectable HCC

Tumor size	Complete response rate	Six-month recurrence rate
< 2 cm	~100%	~0%
2–3 cm	80%	20%
3–5 cm	50%–75%	~50%
> 5 cm	< 25%	> 75%

As indicated above, response and recurrence rates are inversely proportional to lesion size. Up to three separate lesions of up to 4 cm each can be treated with RFA, TACE, or both for that matter with good results. Lesions larger than 5 cm or more than three lesions of any size should preferentially be treated with TACE. Percutaneous ethanol or acetic acid injection has similar response rates to RFA and suffers from the same limitations pertaining to lesion size and number

partial hepatectomy, TACE, systemic chemotherapy or percutaneous ablation therapy, as the clinical situation may change for the better or worse. A multidisciplinary team approach to treating primary or secondary liver cancer is a development that affords such patients maximum benefit from what medicine currently has to offer.

References

- Achenbach T et al. (2002) Chemoembolization for primary liver cancer. *Eur J Surg Oncol* 28:37–41
- Adam R (2003) Chemotherapy and surgery: new perspectives on the treatment of unresectable liver metastases. *Ann Oncol* 14 [Suppl 2]:II13–II16
- Camma C et al. (2002) Transarterial chemoembolization for unresectable hepatocellular carcinoma: meta-analysis of randomized controlled trials. *Radiology* 224:47–54
- El-Serag HB, Mason AC (2000) Risk factors for the rising primary liver cancer in the United States. *Arch Intern Med* 27:3227–3230
- Feldman ED et al. (2004) Regional treatment options for patients with ocular melanoma metastatic to the liver. *Ann Surg Oncol* 11:290–297
- Georgiades CS et al. (2001) New non-surgical therapies in the treatment of hepatocellular carcinoma. *Techn Vasc Intervent Radiol* 4:193–199
- Hogan BA et al. (2002) Hepatic metastases from an unknown primary (UPN): survival, prognostic indicators and value of extensive investigations. *Clin Radiol* 57:1073–1077
- Inoue Y et al. (1994) Hypervascular liver metastases of gastric cancer completely responding to transcatheter oily chemoembolization using epirubicin hydrochloride, mitomycin C and lipiodol. *Gan To Kagaku Ryoho* 21:1665–1667
- Kawai S et al. (1992) Prospective and randomized clinical trial for the treatment of hepatocellular carcinoma—a comparison of lipiodol-transcatheter arterial embolization with and without adriamycin (first cooperative study). The Cooperative Study Group for Liver Cancer Treatment of Japan. *Cancer Chemother Pharmacol* 31 [Suppl]:S1–S6
- Kawai S et al. (1997) Prospective and randomized trial of lipiodol-transcatheter arterial chemoembolization for treatment of hepatocellular carcinoma: a comparison of epirubicin and doxorubicin (second cooperative study). The Cooperative Study Group for Liver Cancer Treatment of Japan. *Semin Oncol* 24 [Suppl 6]:S6–38–S6–45
- Llovet JM et al. (2002) Arterial embolization or chemoembolization versus symptomatic treatment in patients with unresectable hepatocellular carcinoma: a randomised controlled trial. *Lancet* 359:1734–1739
- Nakahashi C et al. (2003) The impact of liver metastases on mortality in patients initially diagnosed with locally advanced or resectable pancreatic cancer. *Int J Gastrointest Cancer* 33:155–164
- Sanz-Altamira PM et al. (1997) Selective chemoembolization in the management of hepatic metastases in refractory colorectal carcinoma: a phase II trial. *Dis Colon Rectum* 40:770–775
- Seong J et al. (1999) Combined transcatheter arterial chemoembolization and local radiotherapy of unresectable hepatocellular carcinoma. *Int J Radiat Oncol Biol Phys* 43:393–397
- Tanada M et al. (1996) Intrahepatic arterial infusion chemotherapy for the colon cancer patients with liver metastases - a comparison of arterial embolization chemotherapy versus continuous arterial infusion chemotherapy. *Gan To Kagaku Ryoho* 23:1440–1442
- Tarazov PG (2000) Arterial chemoembolization for metastatic colorectal cancer in the liver. *Vopr Onkol* 46:561–566
- Wyd L et al. (2003) Prognostic factors for patients with hepatic metastases from breast cancer. *Br J Cancer* 89:284–290
- Yu MC et al. (2000) Epidemiology of hepatocellular carcinoma. *Can J Gastroenterol* 14:703–709

11 Radioactive Microspheres for the Treatment of HCC

CHRISTOS S. GEORGIADIS, RIAD SALEM and JEAN-FRANCOIS GESCHWIND

CONTENTS

11.1	Introduction	141
11.2	Clinical Considerations	142
11.2.1	Patient Selection & Preparation	142
11.3	Technique	142
11.3.1	Calculation of the Total Dose To Be Delivered	142
11.3.2	Calculation of the Shunt-Ratio	143
11.3.3	Anatomical Considerations	143
11.3.4	⁹⁰ Y-Microsphere Embolization	144
11.3.5	Patient Recovery	145
11.3.6	Follow-up	147
11.4	Conclusion	147
	References	148

11.1 Introduction

As in the case for transarterial chemoembolization (TACE, Chapter 10), radioembolization takes advantage of the preferential hepatic arterial supply of hepatocellular carcinoma (HCC) to deliver targeted therapy to the tumor, relatively sparing the liver parenchyma, which is mostly supported by the portal venous system. Radioembolization is effected via intra-arterial delivery of carrier spheres onto which radioactive particles are attached. There are two types of radioactive microspheres that can be used in the treatment of primary (and metastatic for that matter) liver disease. They both contain Yttrium-90 (⁹⁰Y) as the active element but differ in the type of carrier particle. The first is ⁹⁰Y glass

microspheres (Theraspheres, MDS Nordion, Ottawa, Ontario, Canada), which are glass spheres with a diameter of 25±10 μm, impregnated with ⁹⁰Y, a radioactive element. Following intra-arterial infusion, most Theraspheres embolize at the arteriole level because of their relative size. ⁹⁰Y is a pure beta emitter (937 KeV) that decays to Zirconium-90 with a half-life of 64.2 h. The emitted electrons have an average tissue penetration of 2.5 mm (effective max 10 mm) [1–5]. These physical properties stimulated interest in the use of Theraspheres for the treatment of HCC as well as metastatic liver lesions. Unlike TACE, the effectiveness of ⁹⁰Y-microsphere embolization has not been established; however it is seen as a viable alternative for patients whose hepatic neoplasm does not respond to TACE. Histological studies have shown that there is a disproportionate accumulation of ⁹⁰Y-microspheres along the vascular periphery of the hepatic tumor, with a relative concentration of 2.4 to 50 times more than in the normal liver parenchyma [6,7]. Though the exact reason for this is not understood (perhaps the altered blood vessel flow and diameter that results from tumor angiogenesis allows preferential embosphere flow), this phenomenon can be used to deliver large doses of radiation to the tumor, while relatively sparing the normal liver. After lodging in the distal arteriolar circulation, the microsphere radiation has a maximum effective tissue penetration of 10 mm, thereby sparing the normal liver parenchyma beyond this limit. Radiation essentially ceases 10 days after embolization but even before that it poses no threat to others. These advantages are exploited in this type of novel treatment and the process is described below.

The second type of ⁹⁰Y carrier is resin-based microspheres with a diameter of 29–35 μm and are also infused via the appropriate hepatic artery branch to provide selective internal radiation (SIR). These SIR-Spheres (Sirtex, Medical Limited) have an average activity of 40 Bq per sphere and can be suspended in sterile water and contrast media to the desired total activity [8, 9]. Since the radioactive element is the same as that on glass microspheres,

C. S. GEORGIADIS MD, PhD

Assistant Professor of Radiology and Surgery, Johns Hopkins Medical Institutions, Blalock 545, 600 N. Wolfe Street, Baltimore, MD 21287, USA

R. SALEM, MD

Assistant Professor of Radiology and Oncology, Northwestern Memorial Hospital, Department of Radiology, 676 North St. Claire, Chicago, IL 60611, USA

J.-F. GESCHWIND, MD

Associate Professor of Radiology, Surgery and Oncology, Johns Hopkins Medical Institutions, Blalock 545, 600 N. Wolfe Street, Baltimore, MD, 21287, USA

the tissue penetration and decay characteristics are identical, as are patient selection, preparation, technique, and recovery.

11.2 Clinical Considerations

11.2.1 Patient Selection & Preparation

Selection criteria are similar to those for TACE and are listed in section 10.2.1 (“Chemoembolization for Liver”). As with TACE, candidates must have unresectable solid, primary or secondary hepatic tumors. However, one crucial difference is the degree of shunting between the hepatic artery and hepatic vein. The detection of shunting during the pre-TACE arteriogram needs to be addressed but not necessarily quantified. Gelfoam embolization and repeat arteriogram immediately or 7–14 days later to document lack of visible shunting allows for TACE to proceed. However, in the case of ^{90}Y -microsphere embolization, shunting can result in life-threatening complications and must be accurately quantified. Radiation pneumonitis can result from ^{90}Y -microsphere shunting to the lungs with significant morbidity and possible mortality ensuing, especially if the total lung dose approaches 30–50 Gy [3]. The method for quantifying shunting is described in the following section.

Okuda stage and ECOG score should be obtained prior to treatment, as severe liver dysfunction is a contraindication to any form of hepatic artery embolization including ^{90}Y -microsphere embolization. Laboratory values should be obtained prior to embolization, including: a comprehensive metabolic panel (NA, K, glucose, creatinine, BUN, total bilirubin, AST, ALT, alkaline phosphatase, albumin, total protein), hematology panel (hematocrit and/or hemoglobin, white blood cell count, platelet count, coagulation profile (INR, APTT) and tumor markers (i.e. AFP for HCC, CEA for colon cancer). These values serve not only to ensure a safer procedure (i.e. normal coagulation) but also to allow for proper follow-up of hepatic and renal function and monitor response (using tumor marker levels). A baseline gadolinium-enhanced MRI with diffusion/perfusion sequence should be obtained as part of staging, for establishing response to treatment and for future treatment planning. Based on current evidence, the patients should be informed that though it may

prolong survival, ^{90}Y -microsphere (either glass- or resin-based) embolization is not considered a curative treatment option.

11.3 Technique

Once the patient has been deemed a candidate for ^{90}Y -microsphere embolization one has to calculate two important values:

1. The total dose of radiation to be delivered which is related to the efficacy of the treatment
2. The hepatic artery-to-vein shunt percentage, which is related to the safety of the treatment.

11.3.1 Calculation of the Total Dose To Be Delivered

The total dose to be delivered depends not on the tumor burden but on the total volume of the liver (normal parenchyma plus tumor) to be embolized. A CT or MRI should be obtained, based on which the liver volume to be embolized is calculated. The same MRI (which should include contrast-enhanced and diffusion/perfusion sequences) can be used as baseline to quantify the response to treatment. Studies have shown that a total dose of 120–150 Gy yields better results than lower doses [1,4,8]. The total activity to be injected is calculated by:

$$A(\text{GBq}) = \frac{D(\text{Gy}) \times V(\text{L}) \times \text{SGL}(\text{Kg/L})}{50\text{Gy/Kg.GBq} \times [1 - F]}$$

where,

- A is the total activity to be injected (in gigabecquerels)
- D is the desired dose to the volume of the liver to be treated (in grays)
- V is the total liver volume to be treated (in liters)
- SGL is the specific gravity of the liver (1.03 kg/l)
- F is the percent hepatic artery-to-vein shunting, and
- The factor 50 results from the fact that for soft tissue (liver) the absorbed dose is 50 Gy per GBq per Kg

Therasphere vials are supplied with predetermined doses fractionated at 3, 5, 7, 10, 15 and 20 GBq, therefore a tailored combination should be used for each patient depending on the desired dose.

In addition to the above dose calculation, in the case of resin-based Yttrium-90 treatment, some authors [10] calculate the tumor to normal liver uptake ratio (T/N) and treat only if the T/N ratio is equal or greater than 2.

$$T / N = \frac{At / Mt}{An / Mn}$$

Where,

- At/An is the ratio of activity in the tumor divided by the activity in nontumorous liver and can be calculated from the images obtained for the calculation of the shunt ration (see next section)
- Mt/Mn is the ratio of the tumor to nontumorous liver volume calculated from CT or MRI studies

11.3.2

Calculation of the Shunt-Ratio

From the above equation the only factor that needs to be independently quantified is the percent hepatic artery-to-vein shunting. This is accomplished by performing a perfusion study of the liver with ⁹⁹Tm macroaggregated albumin (⁹⁹Tm MAA) particles, which are routinely used to perform a ventilation/perfusion scan for the diagnosis of pulmonary embolism. Commercially available MAA particles have a diameter of 50±13 μm (i.e. more than 90% are within 10 and 90 μm in diameter) [11]. Because a slightly larger percentage of ⁹⁰Y-microspheres are smaller than the diameter of the capillaries (compared to MAA particles), the use of MAA to calculate the shunt percentage tends to slightly underestimate the shunt. Therefore one should be rather conservative in cases where the shunt percentage is borderline and err on the side of safety. The initial diagnostic hepatic arteriogram has a dual purpose: first, to plan which hepatic artery branch will be used to treat the tumor; second, to calculate the shunt related to that vessel. Though most commonly the main right or left hepatic artery is used, occasionally a secondary branch may suffice if it supplies the entire tumor. Once the diagnostic catheter is in the branch that will be used to deliver the ⁹⁰Y-microspheres during the future treatment, 2–6 mCi (75–220 MBq) of ⁹⁹Tm MAA is infused. Following this, a perfusion study with antero-posterior planar images is obtained whose field of view includes the liver and chest. Steps 1–5 described below are followed. After Step 5, the patient is taken to the nuclear medicine department and the planar images

of the liver/lungs are obtained. The shunt percentage is calculated by

$$S\% = \frac{ALng}{ALng + ALvr} \times 100\%$$

where,

- S is the shunt percentage (percent of the total activity that will be shunted to the lungs)
- ALng is the activity calculated over the lung fields, and
- ALvr is the activity calculated over the liver field

Normal lungs can tolerate a total lung dose of 30 Gy [3], above which severe morbidity and possibly mortality may result from radiation pneumonitis. Thus, if for example, a total liver dose of 150 Gy is desired the shunt should be less than approximately 20%. A safety factor can be introduced arbitrarily to increase the safety margin. Figures 11.1 and 11.2 show two planar images of two patients who underwent such a shunt study. The first patient was deemed a candidate for radioembolization having shown negligible shunting to the lungs. The second patient showed significant shunting and would have suffered complications related to radiation pneumonitis had he received radioembolization.

11.3.3

Anatomical Considerations

Radioembolization takes advantage of the fact that, while normal liver parenchyma receives most of its

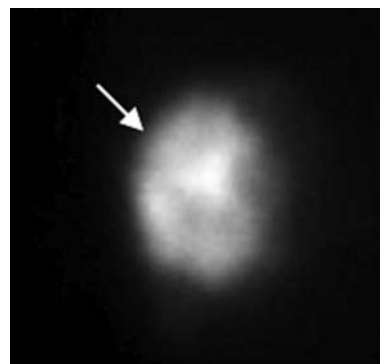


Fig. 11.1. Planar gamma camera view of the liver and chest following ⁹⁹Tm MAA infusion in the right hepatic artery of a patient with unresectable HCC. Activity is seen in the liver (arrow) without any pulmonary activity. The shunt percentage was calculated to be 2%; thus the patient is a candidate for ⁹⁰Y-microsphere treatment

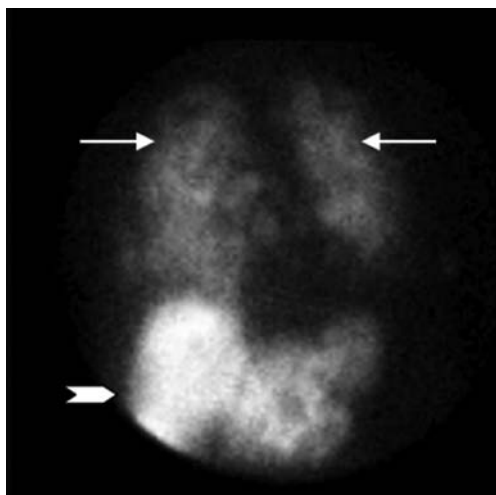


Fig. 11.2. Planar gamma camera view of the liver and chest following $^{99}\text{Tc-m}$ MAA infusion in the hepatic artery of a patient with unresectable HCC. Significant pulmonary activity is seen (arrows) indicating a shunt. The liver activity is indicated by an arrowhead. The shunt percentage was prohibitive; thus the patient could not safely receive ^{90}Y -microsphere treatment

blood supply (60%–80%) from the portal venous system, malignant hepatic tumors, whether primary or metastatic, are nearly exclusively supplied by branches of the hepatic artery. Cancer angiogenesis (a.k.a. neovascularization) is a process by which neoplastic cells recruit new blood vessels in order to ensure adequate local oxygen tension. Due to their relatively higher metabolic demands, cancer cells “live” in a nearly constant state of hypoxia. They respond by secreting chemotactic factors that promote the formation of new blood vessels. Arterial epithelial cells are much more responsive to these factors, which explains why such malignant tumors are supplied by the hepatic artery. Radioembolization then selectively targets the tumor while liver parenchyma is mostly (but not entirely) spared.

Accessory and/or replaced right or left hepatic arteries are common (up to 20%–30%). In addition, common origins of the left hepatic and left gastric as well as right hepatic and right gastric arteries may be added complicating factors. Such associations are important insofar as they increase the risk of nontarget embolization, mainly the stomach, proximal small bowel, and/or pancreas. Though self-limiting gastritis, duodenitis, and pancreatitis have been reported, no deaths have yet been documented from nontarget embolization (excluding pneumonitis). Irrespective of this, it is important to clearly delineate vascular anatomy during the initial arteriogram in order to minimize morbidity. If ^{90}Y -micro-

sphere treatment cannot be given safely due to left or right gastric or gastroduodenal vascular anatomic relationships, one should consider coil-embolizing these vessels and then proceeding with ^{90}Y -microsphere embolization.

11.3.4 ^{90}Y -Microsphere Embolization

The treatment plan having been decided upon, written informed consent is obtained and the patient’s groin regions are prepared and draped in a sterile fashion on the fluoroscopy table. Informed consent should disclose the following risks: Injury to blood vessels and/or organs, anaphylactic reaction to contrast, worsening of renal function, infection, worsening liver function or liver failure, and possibly death. One must document the pre-procedural peripheral pulses and choose the femoral artery with the strongest pulse for initial access. Sedation with i.v. versed and fentanyl is used at our institution, occasionally needing to be enhanced with Phenergan and/or Benadryl.

- Step 1—Obtaining vascular access. In most cases access using an 18-g, single-wall needle followed by an 0.035" guide wire is successful. In difficult cases a 0.018" micropuncture set can be of help, with or without the use of ultrasound guidance.
- Step 2—Maintaining access. A 5 Fr short vascular sheath providing access in the right or left (strongest pulse) common femoral artery is used at our institution. A 4 Fr access set can be used in cases where less traumatic arterial access is needed (i.e. slightly abnormal coagulation profile), however the smaller catheters may be a bit less controllable.
- Step 3—Abdominal aortogram. A flush aortogram via a multisideholed, pig-tailed catheter at the level of the celiac artery will delineate the vascular anatomy, tumor supply and provide a road-map for more selective access. For the most part this step can be skipped. In rare cases and after failing to easily cannulate the SMA and celiac access with a selective catheter (see step 4), which may suggest variant anatomy, one may fall back to it. If performed, a 15 cc per s injection for a total of 50 cc is adequate.
- Step 4—Selective arteriograms. First, a 5 Fr catheter (Simmons 1 or Cobra glide catheters, Terumo) is used to select the superior mesenteric artery (SMA) and an arteriogram is performed using an injection rate of 6 cc per s for 3–4 s. Then the celiac

artery is selected (again Simmon's 1 or Cobra glide catheters, Terumo) and a selective arteriogram is performed with a similar injection rate as above. In most cases the celiac axis arteriogram will show the tumor blush to best advantage.

- Step 5—Selecting the final catheter position. A glide wire 0.035" is advanced through the glide catheter followed by the catheter itself. Though one wants to be as selective as possible to avoid treating normal liver, being too selective will result in parts of the tumor not being treated. In general, either the right or left main hepatic artery is the optimal position for the treatment catheter. In cases where there is tumor in both lobes, the one showing more tumor blush on the diagnostic arteriogram should be targeted. If the 5 Fr glide catheter cannot be advanced to the desired location because of unfavorable anatomy, a 3 Fr microcatheter (Renegade, Boston Scientific) over an 0.018" guidewire (i.e. Transend, Boston Scientific) can be used coaxially.
- Step 6a—If the objective is to calculate the future dose to be delivered, then once the diagnostic catheter is in the branch that will be used to deliver the ^{90}Y -microspheres in the future, 2–6 mCi (75–220 MBq) of $^{99\text{Tc}}\text{m}$ MAA is infused. As described above, the patient is then taken to the nuclear medicine department and the shunt ratio is calculated (see section 11.3.2).
- Step 6b—If the dose has been previously calculated and the patient has been deemed a candidate for radioembolization, then the dose is delivered using the set-up shown in Figure 11.3. Extreme care regarding the set-up (tubing connections, stop-cock positions, etc) must be exercised as the volume to be injected is small (a few milliliters) and errors are usually irreversible.
- Step 7—The catheter and sheath are removed and hemostasis is achieved with manual pressure or the use of a closure device. Peripheral pulses are rechecked and documented to make sure they are stable. Though exceedingly rare, significant changes may signify complications such as access artery dissection or distal thrombosis.

The infusion set-up system is shown in Figure 11.3. Careful set-up and inspection of the system is crucial prior to infusion to avoid inadvertent spillage or misadministration of the Theraspheres. A list of basic materials needed is shown in Table 11.1.

Close coordination between the Interventional Radiologist, Oncologist and Radiation Safety Officer is a must for an uneventful treatment. Even then,

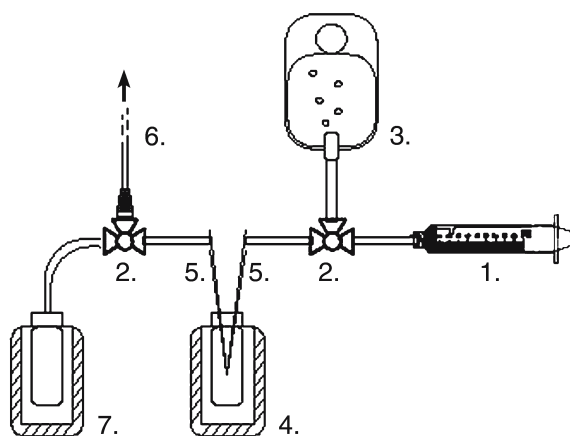


Fig. 11.3. Schematic of the set-up for the treatment apparatus for ^{90}Y -microsphere embolization. 1, syringe; 2, three-way stop cock; 3, saline bag; 4, shielded vial containing the ^{90}Y -microsphere solution; 5, needles; 6, outflow infusion catheter; 7, excess ^{90}Y -microsphere solution collection vial, shielded

one must abide by the ALARA (As Low As Reasonably Achievable) principle to limit radiation exposure. The process must be speedy without sacrificing quality control, with proper shielding and radiation dosimetry and utilizing the minimum number of personnel possible. The infusion is given under continuous fluoroscopic guidance to ensure proper delivery. Once the total dose is given the catheter is flushed with a few milliliters of saline to extrude any particles remaining in it. The catheter and arterial access sheath are removed, hemostasis is achieved and the patient recovered.

11.3.5 Patient Recovery

^{90}Y -microsphere embolization for liver tumors is generally an outpatient procedure with minimal complications. Patients are recovered and observed for 4–6 h, essentially a post-arteriogram recovery. Possible complications and mitigating interventions are shown in Table 11.2. Mild pain and minimal nausea are not uncommon and if controlled with medication should not prevent the patient's discharge. A small minority of patients will develop post-embolization syndrome and require overnight admission to control their pain, nausea and fever. Even then, almost all will be discharged the next day. The vast majority of patients report no symptoms and return home the same day. A sample discharge order sheet is shown in Table 11.3. They present no

Table 11.1. The basic materials needed for ^{90}Y -microsphere embolization

Step	Objective	Primary materials	Alternative
1	Obtaining arterial access	18 g-single wall needle (Cook ^a) and 0.035" guide wire (Bentson, Cook)	Micropuncture set (Cook)
2	Maintaining arterial access	5 Fr, 11 cm vascular sheath (Cordis ^a)	4 Fr, 11 cm vascular sheath (Cordis)
3	Performing abdominal aortogram	5 Fr, pigtail-flush catheter (Angiodynamics ^a)	4 Fr, pigtail-flush catheter (Angiodynamics)
4	Performing selective SMA & celiac arteriogram	5 Fr, hook, endhole glide catheter (Simmon's 1, Terumo ^a)	Cobra (Terumo) or Michelson (Angiodynamics)
5	Selecting the final catheter position	Simmon's 1 or Cobra glide catheter over 0.035" glide wire (Terumo)	3 Fr microcatheter (Renegade, Boston Scientific ^a) coaxially through the 5 Fr or 4 Fr catheter above over a 0.018" wire (Transend, Boston Scientific)
6a	MAA infusion	2–6 mCi (75–220 MBq) of $^{99\text{Tm}}$ MAA	–
6b	Treatment	Yttrium-90 dose (see Fig. 11.3 for additional supplies)	–
7	Finishing	Manual hemostasis	Closure devices

The microcatheter (step 5) is used only if the Simmons 1 glide cannot be advanced to the desired location due to unfavorable vascular anatomy. Prior to treatment the shunt ratio through the tumor to be treated must be calculated to avoid nontarget embolization. Steps 1–6a are performed during the patient's first visit followed by a planar gamma-camera image that is used to calculate this ratio. If deemed a candidate for embolization, the patient returns at a later time and steps 1–5 and 6b–7 are followed to perform the embolization. ^a[Cook, Bloomington, IN; Cordis, Cordis Corp., Miami, FL; Angiodynamics, Queensbury, NY; Terumo, Terumo Medical Corp., Somerset, NJ; Boston Scientific, Boston, MA]

Table 11.2. Possible complications associated with ^{90}Y -microsphere embolization for liver tumors and mitigating interventions

Possible complications of radio-embolization	Mitigating intervention
Nontarget embolization - radiation gastritis/duodenitis	Anti-ulcer, antacid medication x 2 weeks Admit if severe
Tumor lysis syndrome	Pre- and post-procedure hydration Follow creatinine
Post-embolization syndrome (Pain, fever, nausea/vomiting)	Symptomatic support
Radiation pneumonitis	Admission-supportive measures

Such complications from radioembolization are exceedingly rare allowing the vast majority of patients to have this procedure on an outpatient basis. Rarely, treatment may be complicated by post-embolization syndrome and symptomatic support may be necessary. Nontarget embolization can be all but eliminated by meticulous technique and pre-procedure planning

Table 11.3. Sample discharge instructions for patients after radioembolization^a

- Discontinue all i.v. lines
 - Discharge to home
 - Medications:
 - Ciprofloxacin 250 mg p.o. bid x 7 days
 - Oxycontin 10 mg p.o. q 12 h prn pain
 - Oxycodone 5–10 mg p.o. q 4–6 h prn breakthrough pain
 - Zofran 8 mg p.o. q 8 h prn nausea
 - Instructions:
 - No straining, stair climbing, or driving x 48 h
 - If groin swelling or bruising, or fever, nausea/vomiting, or worsening abdominal pain call (on call number)
 - Diet:
 - As tolerated
 - Follow-up:
 - Contrast-enhanced MRI of liver and same day clinic appointment with (Interventional Radiologist) in 4–6 weeks
- Send copy of discharge summary to (referring physician's name)

^a These are general guidelines. Specific instructions should be tailored to patient's needs, allergies, and clinical picture

radiation risk to others and thus no special precautions are required. Mild and self-limiting transaminase elevation is often seen but usually of no clinical significance. Upon discharge, the patient is placed on a 7-day oral antibiotic regimen (i.e. Ciprofloxacin 250 mg p.o. bid) and given PRN oral pain medication for possible abdominal pain. One must remember that occasionally, a patient who has been discharged to home without complaints may develop pain, nausea and/or fever within a few days afterwards. Therefore the above medications are recommended for all patients regardless of symptomatology.

11.3.6

Follow-up

At approximately four to six weeks, the patient is seen at the clinic and a contrast-enhanced, perfusion/diffusion MRI is obtained. At that time, one should address two issues. First, what is the tumor's response to treatment and second, has the patient's overall condition changed? The answers to these questions will dictate whether the patient still remains a candidate for embolization and if so, should he or she continue with ^{90}Y -microsphere embolization or change the treatment plan. In establishing response to treatment, the pertinent factor is the percent enhancement of the tumor in the MRI scan, and not as classically thought, the size of the tumor. Many times the tumor is killed entirely and replaced by an indolent cyst or necrotic/fibrotic tissue of similar size. Additionally, it is not uncommon to see a lack of response after the first treatment and a good response after the second or third treatment, and thus at least two or three embolizations are recommended before one decides on a change of venue. ECOG score and laboratory values should be retested to ensure that the patient remains a candidate for further embolization. Finally, re-evaluation of the patient's clinical status, including re-staging of the disease if relevant changes are observed, is necessary. Such re-evaluations may require the input of surgery or hepatology in case adequate down-staging renders the patient a surgical candidate.

11.4

Conclusion

With few if any surgical options for hepatocellular carcinoma patients, many nonsurgical techniques

have been developed to attempt to improve survival in these patients. Intra-arterial embolization with ^{90}Y -microspheres has shown promise in early clinical studies for the treatment of unresectable HCC. Such patients are expected to live for about 5–7 months with symptomatic treatment alone. Glass ^{90}Y -microsphere embolization has been shown to extend the median survival to 12 months for Okuda stage II disease and 23 months for Okuda stage I [4, 12]. Significant tumor shrinkage has also been reported [6], which again requires the constant re-evaluation of patients in case surgical resection or transplantation becomes an option. Additional, combination treatments as well as treatment for colorectal metastatic disease are beginning to appear, i.e. ^{90}Y -microsphere embolization followed by hepatic arterial chemotherapy (HAC). The 1-, 2-, 3-, and 5-year survival rates of patients treated with glass ^{90}Y -microsphere embolization followed by HAC are reported at 72%, 39%, 17%, and 3.5%, versus 68%, 29%, 6.5%, and 0% for HAC alone [13]. ^{90}Y -microsphere treatment has the added advantage of very minimal toxicity/side effects and quick recovery. Additionally, glass ^{90}Y -microsphere embolization appears to yield similar survival benefit to those of TACE for unresectable HCC, with GESCHWIND et al. [2] reporting a 1-year survival of about 63% for both and significantly better than supportive treatment alone. Resin-based ^{90}Y -microsphere embolization has also been shown to provide a survival benefit, with LAU et al. [10] reporting a median survival of 9.4 months (1.8–46.4 months), with four of 71 patients becoming resectable after treatment. LAU et al. [8] in phase I & II clinical trials reported a median survival of 55.9 weeks for patients who received a tumor dose > 120 Gy. Similarly, benefit has been shown for patients with colorectal metastases treated with SIR spheres. GRAY et al. [14] and BLANCHARD et al. [15] showed that about 50% of patients have exhibited more than 50% shrinkage of the tumor with a concomitant decrease in CEA levels. Given the large number of nonsurgical treatment options, patient selection is of paramount importance. In this context, ^{90}Y -microsphere embolization has a definite niche. In the end, a multidisciplinary approach that includes Interventional & Diagnostic Radiologists, Oncologists, Hepatologists, and Surgeons is a must, in order to choose and tailor the optimum treatment protocol and offer the patient the best hope for extended survival.

References

1. Carr IB (2004) Hepatic arterial ^{90}Y trium glass microspheres (therasphere) for unresectable hepatocellular carcinoma: interim safety and survival data on 65 patients. *Liver Transplant* 10 [Suppl 1]:S107–S110
2. Geschwind JF et al. (2004) Yttrium-90 microspheres for the treatment of hepatocellular carcinoma. *Gastroenterology* 127:S194–S205
3. Salem R et al. (2002) Yttrium-90 microspheres: radiation therapy for unresectable liver cancer. *J Vasc Interv Radiol* 13:S223–S229
4. Salem R et al. (2004) Use of yttrium-90 glass microspheres (therasphere) for the treatment of unresectable hepatocellular carcinoma in patients with portal vein thrombosis. *J Vasc Interv Radiol* 15:335–345
5. Sarfaraz M et al. (2003) Physical aspects of Yttrium-90 microsphere therapy for nonresectable hepatic tumors. *Med Phys* 30:199–203
6. Cao X et al. (1999) Hepatic radioembolization with yttrium-90 glass microspheres for the treatment of primary liver cancer. *Chin Med J* 112:430–432
7. Campbell AM et al. (2000) Analysis of the distribution of intra-arterial microspheres in human liver following hepatic Yttrium-90 microsphere therapy. *Phys Med Biol* 45:1023–1033
8. Lau WY et al. (1994) Treatment of inoperable hepatocellular carcinoma with intrahepatic arterial Yttrium-90 microspheres: a phase I and II study. *Br J Cancer* 70:994–999
9. Van Hazel G et al. (2004) Randomized phase 2 trial of SIR-spheres plus fluorouracil/leucovorin chemotherapy versus fluorouracil/leucovorin chemotherapy alone in advanced colorectal cancer. *J Surg Oncol* 88:78–85
10. Lau WY et al. (1998) Selective internal radiation therapy for nonresectable hepatocellular carcinoma with intraarterial infusion of ^{90}Y trium microspheres. *Int J Radiat Oncol Biol Phys* 40:583–592
11. Hung JC et al. (2000) Evaluation of macroaggregated albumin particle sizes for use in pulmonary shunt studies. *J Am Pharm Assoc* 40:46–51
12. Keng GH, Sundram FX (2003) Radionuclide therapy for hepatocellular carcinoma. *Ann Acad Med Singapore* 32:518–524
13. Gray B et al. (2001) Randomized trial of sir-spheres plus chemotherapy vs. chemotherapy alone for treating patients with liver metastases from primary large bowel cancer. *Ann Oncol* 12:1711–1720
14. Gray B et al. (1992) Regression of liver metastases following treatment with Yttrium-90 microspheres. *Aust NZ J Surg* 62:105–110
15. Blanchard RJ et al. (1989) Treatment of liver tumors with Yttrium-90 microspheres alone. *Can Assoc Radiol J* 40:206–210

12 Yttrium-90 Radioembolization for the Treatment of Liver Metastases

RIAD SALEM, KENNETH G. THURSTON, and JEAN-FRANCOIS GESCHWIND

CONTENTS

12.1	Introduction	149
12.2	Pathophysiology and Therapeutic Principle	149
12.3	Clinical Considerations	150
12.4	Anatomic and Technical Considerations	151
12.4.1	TheraSphere Administration	153
12.4.1.1	Dosimetry for TheraSphere	153
12.4.1.2	Infusion Technique	154
12.4.2	SIR-Spheres Administration	154
12.4.2.1	Dosimetry for SIR-Spheres	154
12.4.2.2	Infusion Technique	155
12.4.3	Calculation of Lung Dose	155
12.5	Results	156
12.5.1	TheraSphere: Clinical Experience, Response, and Survival	156
12.5.2	SIR-Spheres®: Clinical Experience, Response, and Survival	157
12.6	Complications	159
12.7	Conclusion	159
	References	159

12.1 Introduction

The liver is the most frequent site of metastases, primarily due to the spread of cancer cells through the portal circulation. Approximately 60% of patients diagnosed with colorectal carcinoma will eventually experience liver disease as the predominant site. As with hepatocellular carcinoma (HCC), surgical resection of colorectal metastases offers the only chance for cure. However, this option is only available to a small percentage of patients. Many patients with other primaries such as breast, lung, and neuroendocrine will develop liver metastases during the course of the dis-

ease. Therefore, there is a need for novel liver-directed treatments for patients with unresectable metastases to the liver. Current therapies for the treatment of liver metastases parallel those for HCC and include: hepatic arterial infusion of chemotherapy (HAI), trans-arterial chemoembolization (TACE), radiofrequency ablation (RFA), and combinations of these treatments. These treatments have displayed some effectiveness in prolonging life for patients with liver metastases, but are often associated with toxicities such as abdominal pain, fever, nausea, and vomiting.

Yttrium-90 (^{90}Y) microspheres (TheraSphere, MDS Nordion, Ottawa, Canada and SIR-Spheres, Sirtex Medical, Lake Forest, Illinois) represent an intra-arterial therapy, infused via a catheter placed in the hepatic arterial system. The microspheres are selectively delivered to the tumor bed due to the hypervascularity of tumor relative to normal liver parenchyma, where they become entrapped in the arterioles feeding the tumor. Since ^{90}Y emits beta radiation with a maximum average penetration of approximately 1 cm, the majority of the radiation effect is directed to tumorous tissue while sparing normal liver parenchyma. This results in a maximum tumoricidal effect, while minimizing potential compromise to normal liver function. The therapeutic benefit derived as a result of effecting tumor kill while sparing radiosensitive normal tissue provides a significant treatment alternative for patients who have limited treatment options available. TheraSphere was approved by the FDA for unresectable hepatocellular carcinoma in December 1999 under a Humanitarian Device Exemption, while SIR-Spheres was approved in March 2002 for colorectal cancer metastatic to the liver in conjunction with infusion of intra-hepatic floxuridine (FUDR).

R. SALEM, MD, MBA

Assistant Professor of Radiology and Oncology, Northwestern Memorial Hospital, Department of Radiology, 676 North St. Claire, Chicago, IL 60611, USA

K. G. THURSTON, MA

17 Bramble Lane, West Grove, PA 19390, USA

J.-F. GESCHWIND, MD

Associate Professor of Radiology, Surgery and Oncology, Johns Hopkins Medical Institutions, Blalock 545, 600 N. Wolfe Street, Baltimore, MD 21287, USA

12.2 Pathophysiology and Therapeutic Principle

The rationale for intra-arterial delivery of ^{90}Y microspheres for metastatic disease to the liver involves

anatomic and physiologic aspects of hepatic tumors that can be exploited for the delivery of a therapeutic agent. Hepatic tumors derive at least 90% of their blood supply from the hepatic artery, while liver parenchyma obtains between 70%–80% of its blood supply from the portal vein [1–8]. This differential pattern of vascular perfusion provides an intrinsic advantage for hepatic arterial regional therapies delivered selectively to liver tumors. Additionally, many liver tumors, both primary and secondary, are hypervascular relative to normal liver parenchyma as determined by contrast angiography. Thus, selective arterial delivery, as practiced in hepatic arterial chemotherapy and chemoembolization, delivers therapeutic doses of radiation that are preferentially retained in the liver tumor, theoretically sparing the surrounding nonmalignant liver tissue. It has been shown, using hepatic arterial injection of radiolabeled microspheres in experimental tumors, that tumor microcirculatory blood vessel density is 3–4 times greater than that of surrounding liver parenchyma [9, 10]. In particular, single photon emission computed tomography (SPECT) with hepatic arterial injection of ^{99m}Tc -macroaggregated albumin (MAA) has been used to investigate the patterns of microcirculation in patients with liver tumors and confirm findings in experimental animal liver tumor models [11]. The incorporation of an appropriate therapeutic radioactive isotope into nondegradable microspheres can potentially be utilized to capitalize upon the selective advantage afforded by hepatic arterial administration and by the increased arteriolar density of malignant tissue within the liver to deliver a highly localized dose of radiation directly to the intrahepatic tumor(s). It has been known for some time that it is possible to inject the liver and other organs with doses of nondegradable (glass or resin) microspheres without producing overt ischemic damage [1, 9, 12].

Radiation pneumonitis is a concern with hepatic-directed radiation treatment. Previous preclinical and clinical studies with ^{90}Y microspheres demonstrated that up to 30 Gy to the lungs could be tolerated with a single injection, and up to 50 Gy for multiple injections [13]. For this reason, patients with ^{99m}Tc -MAA evidence of potential shunting to the lungs leading to lung doses greater than 30 Gy should not be treated. Similarly, any flow of ^{90}Y microspheres to the gastrointestinal system that cannot be corrected by percutaneous coil embolization techniques, as predicted on ^{99m}Tc -MAA, is contraindicated because of potential adverse gastrointestinal events.

12.3 Clinical Considerations

The selection process for patients undergoing radioembolization is multifactorial. Patients with metastatic disease to the liver might have undergone one or several courses of systemic chemotherapy, surgical resection, and/or radiofrequency ablation. Relevant clinical history having an impact on the safety and efficacy of radioembolization might include surgically placed intrahepatic chemotherapy pumps (causing chemical vasculitis), the use of radiosensitizers (such as capecitabine or irinotecan), as well as treatment with growth factor inhibitors, such as bevacizumab. These patients have image findings of progressive liver-dominant metastatic disease, regardless of any therapeutic benefit afforded by the aforementioned therapies.

For all patients, one of the most important factors in determining eligibility for radioembolization is ECOG performance status. Patients presenting with clearly compromised functional status (ECOG 2–4; see Table 12.1) are at high risk for rapid onset of liver failure and associated morbidity with treatment. Notwithstanding this precaution, each patient deserves individual consideration given the favorable toxicity profile of radioembolization; some patients with limited ECOG performance may still benefit from therapy.

Liver metastases present with relatively consistent findings on MRI, CT, or ultrasound. If a mass is identified, pathologic confirmation of malignancy metastatic to the liver is necessary. If ultrasound is the initial diagnostic modality, additional cross-sectional imaging should be obtained. Triple-phase CT is highly sensitive in detecting hepatic malignancies. Since the majority of liver tumors are angiographically hypervascular, scanning in the early phases results in the maximum likelihood of detection.

Table 12.1. ECOG performance status and Karnofsky score

ECOG Scale	Characteristics	Equivalent Karnofsky score
0	Asymptomatic and fully active	100%
1	Symptomatic; fully ambulatory; restricted in physically strenuous activity	80%–90%
2	Symptomatic; ambulatory; capable of self-care; more than 50% of waking hours are spent out of bed	60%–70%
3	Symptomatic; limited self-care; spends more than 50% of time in bed	40%–50%
4	Completely disabled; no self-care; bedridden	20%–30%

Later phase imaging is necessary to detect other less vascular lesions, the degree of multifocality, and to identify portal vein patency. MRI is also a sensitive modality to identify and characterize lesions, given specific attention to diffusion weighted imaging sequences.

One of the most important clinical parameters that must be assessed when treating patients with radioembolization is the status of overall liver function. In the absence of biliary obstruction, drug toxicity (e.g., capecitabine) or metabolic abnormality (e.g., Gilbert's syndrome), it is extremely unusual for patients with metastatic disease to the liver to exhibit elevated liver functions. In particular, total bilirubin is usually normal in this patient population. In cases where total bilirubin is elevated and all of the abovementioned factors have been excluded, it is likely that tumor infiltration within the hepatic parenchyma is the causative agent, thereby implying a grim prognosis for the patient. The decision to treat such patients should be based on the thorough assessment of the possibility of extending survival or palliating pain.

The pretreatment evaluation of a patient with metastatic disease to the liver should include:

1. History, physical examination, assessment of performance status
2. Clinical laboratory tests (complete blood count with differential, blood urea nitrogen, serum creatinine, serum electrolytes, liver function, albumin, LDH, PT)
3. Chest X-ray, tumor marker assay (CEA, AFP)
4. CT/MRI scan of the abdomen and pelvis with assessment of portal vein patency

Similar to hepatic artery chemoembolization, patients with bilobar disease should be treated in a lobar fashion at staged time intervals, usually 30–60 days following the first treatment. Patients' eligibility for repeat radioembolization should be evaluated following every treatment. Patients on chemotherapy should have this therapy discontinued two weeks prior to radioembolization. Chemotherapy may be restarted two weeks following radioembolization.

12.4 Anatomic and Technical Considerations

Although recent implementation of CT, MRI, and ultrasound with 3-D reconstruction for the iden-

tification of first- and second-order variants have proven effective for the identification of large variant mesenteric vessels, these techniques are not a replacement for conventional angiography. During the evaluation of the patient for radioembolization, mesenteric angiography and ^{99m}Tc -MAA lung shunting scan must be performed [14–16]. Complications as a result of inadequate assessment for radioembolization and nontarget embolization include unplanned/unexpected necrosis in undesirable arterial beds, such as the cystic artery, GI, cutaneous and phrenic capillary beds [17–22].

All patients being evaluated for radioembolization should have the following angiographic evaluation [14]:

Abdominal aortogram-injection of 15–20 cc/sec for a total of 30–40 cc. This allows for the assessment of aortic tortuosity, mural atherosclerotic disease, and facilitates proper visceral catheter selection.

Superior mesenteric angiogram-injection of 3–4 cc/sec for 30 cc. This allows assessment of any variant vessels to the liver (accessory or replaced right hepatic), as well as visualization and identification of a patent portal vein. This injection rate allows for the opacification of the mesenteric system without unnecessary reflux of contrast into the aorta.

1. Celiac angiogram-injection of 4 cc/sec for 12–15 cc. This allows for the assessment of normal hepatic branch anatomy, the presence of a replaced left hepatic artery, or other variant arteries without reflux of contrast into the aorta.
2. Selective left hepatic arteriogram-injection of 2 cc/sec for 8 cc. In cases of normal anatomy, this allows for the assessment of flow to segments 2, 3, 4A, and 4B. Special attention should be paid to the falciform, phrenic, right or accessory gastric arteries.
3. Selective right hepatic arteriogram-injection of 3 cc/sec for 12 cc. Normally, the right hepatic artery provides flow to segments 1 (caudate lobe may have other blood supply), 5, 6, 7, and 8. Particular attention should be paid to the supraduodenal, retroduodenal, retroportal and cystic arteries.
4. Selective gastroduodenal arteriogram-injection of 2 cc/sec for 8–10 cc. The gastroduodenal artery normally provides flow to the pancreas, stomach, small bowel, and omentum. Attention should be paid to the identification of an accessory right hepatic artery feeding segment 6. The threshold for prophylactic embolization of this vessel during radioembolization should be quite low. Two examples of prophylactic embolization in preparation for radioembolization are demonstrated in Figures 12.1 and 12.2.

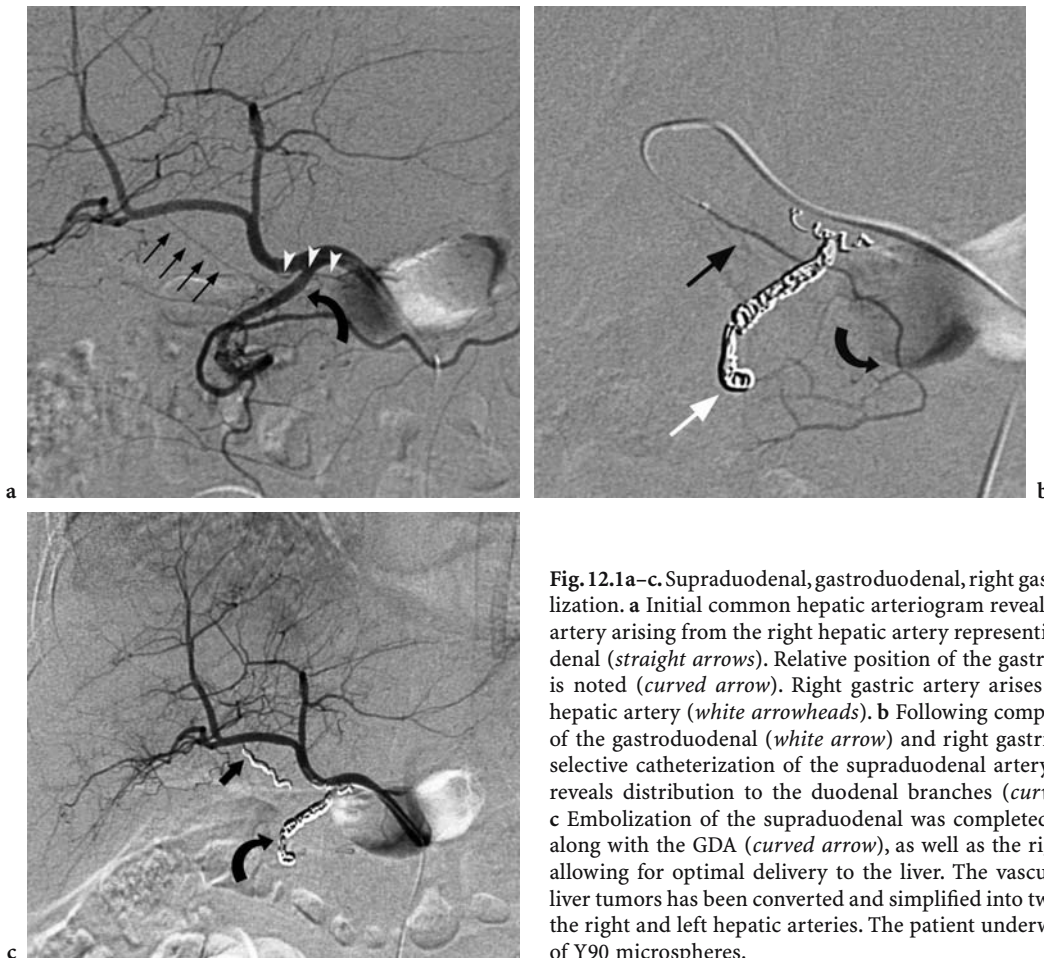


Fig. 12.1a–c. Supraduodenal, gastroduodenal, right gastric artery embolization. **a** Initial common hepatic arteriogram revealing a small vessel arising from the right hepatic artery representing the supraduodenal (*straight arrows*). Relative position of the gastroduodenal artery is noted (*curved arrow*). Right gastric artery arises from the proper hepatic artery (*white arrowheads*). **b** Following complete embolization of the gastroduodenal (*white arrow*) and right gastric arteries, superselective catheterization of the supraduodenal artery (*straight arrow*) reveals distribution to the duodenal branches (*curved black arrow*). **c** Embolization of the supraduodenal was completed (*straight arrow*) along with the GDA (*curved arrow*), as well as the right gastric artery allowing for optimal delivery to the liver. The vascular supply to the liver tumors has been converted and simplified into two feeding vessels, the right and left hepatic arteries. The patient underwent safe infusion of Y90 microspheres.

As described above, in order to visualize small vessels as well as vessels that may demonstrate reversal of flow (e.g., result of flow shunt, or sumping secondary to hypervascular tumor), dedicated microcatheter injection with relatively high rates (2–3cc/sec for 8–12cc) should be performed. Without adequate contrast bolus, many ancillary vessels (which have profound effect on hemodynamics and directed therapy) may go unnoticed, resulting in toxicities including post embolization syndrome, distal embolization, and/or end nontarget organ necrosis or ulceration. Although it may be argued that high injection rates may represent suprphysiologic flow dynamics, the potential changes induced as a result of regional therapy with radioembolization (spasm, ischemia, stasis, and vessel injury) may result in altered physiologic states and thus reflux into these vessels. Every attempt must be made to avoid this scenario.

Arteriovenous connections responsible for radioactive particle delivery from the liver to the lungs arise from cancers rather than from normal liver. Thus, in the presence of liver cancers (particularly hepatocellular carcinoma), a significant amount of ^{90}Y microspheres may shunt to the lungs. Hence, during the angiographic evaluation of a patient for ^{90}Y , 4–5 mCi of $^{99\text{m}}\text{Tc}$ -MAA must be injected in the vessel of interest, followed by imaging for lung shunt fraction in Nuclear Medicine. Given that the likelihood of shunting is low with metastatic disease, we favor whole liver (i.e., proper hepatic) MAA injection in order to assess the entire liver at one time. Lung shunt fraction (LSF) is defined as total lung counts/(total lung counts + total abdomen counts). The lung shunt fraction that is obtained must now be factored into the dosimetry portion of the treatment plan.

The technical aspects of radioembolization are quite complex and should not be undertaken lightly.

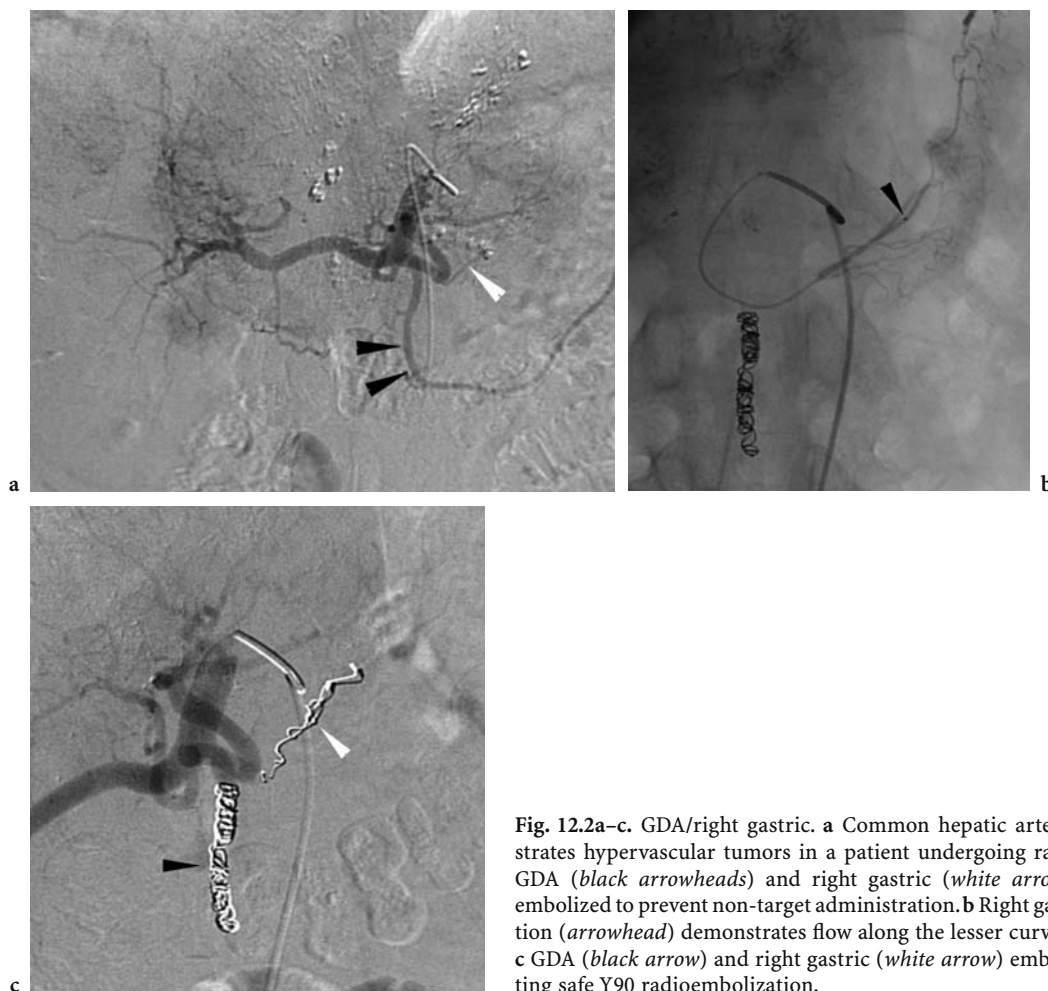


Fig. 12.2a–c. GDA/right gastric. **a** Common hepatic arteriogram demonstrates hypervascular tumors in a patient undergoing radioembolization. GDA (*black arrowheads*) and right gastric (*white arrowhead*) must be embolized to prevent non-target administration. **b** Right gastric catheterization (*arrowhead*) demonstrates flow along the lesser curve of the stomach. **c** GDA (*black arrow*) and right gastric (*white arrow*) embolization permitting safe Y90 radioembolization.

Furthermore, the delivery of TheraSphere and SIR-Spheres are distinctly different. Unlike SIR-Spheres, the embolic effects of the 20–40 micrometer TheraSphere ^{90}Y particles are angiographically negligible. As described in this chapter, unrecognized collateral vessels with consequent infusion of radioactive microspheres are certain to result in clinical toxicities if proper angiographic techniques are not adopted (see package insert TheraSphere[®], SIR-Spheres[®]). These might include gastrointestinal ulceration, pancreatitis, and skin irritation as well as other nontarget radiation. For this reason, aggressive prophylactic embolization of vessels prior to therapy is highly recommended such that all hepatico-enteric arterial communications are completely eliminated. These vessels include the gastroduodenal, right gastric, esophageal, accessory phrenic, and falciform as well as variant arteries such as the supra/retroduodenal. At our institution, where over 400 radioembolizations have been performed, we have found our

GI toxicity rate to be well below 1%. This is due to our standard practice of: (a) aggressive prophylactic embolization of GDA/right gastric and other variant vessels, (b) use of nonembolic TheraSpheres[®] in a lobar and segmental fashion, and (c) use of SIR-Spheres[®] in a lobar, segmental, and dose-fractionated method (several small doses rather than one larger dose) without reaching a completely embolic state.

12.4.1 TheraSphere Administration

12.4.1.1 Dosimetry for TheraSphere

As described in the product insert, TheraSphere consists of insoluble glass microspheres where Yttrium-90 is an integral constituent of the glass.

The mean sphere diameter ranges from 20 to 30 μm . Each milligram contains between 22,000 and 73,000 microspheres. TheraSphere is supplied in 0.05 ml of sterile, pyrogen-free water contained in a 0.3-ml vee-bottom vial secured within a 12-mm clear acrylic vial shield. TheraSphere is available in six activity sizes: 3 GBq (81 mCi), 5 GBq (135 mCi), 7 GBq (189 mCi), 10 GBq (270 mCi), 15 GBq (405 mCi), and 20 GBq (540 mCi) [23]. The corresponding number of microspheres per vial is 1.2, 2, 2.8, 4, 6, and 8 million, respectively. The activity per microsphere is approximately 2500 Bq [24].

Assuming TheraSphere ^{90}Y microspheres distribute in a uniform manner throughout the liver and ^{90}Y undergoes complete decay in situ, radioactivity required to deliver the desired dose to the liver can be calculated using the following formula [15]:

$$\text{TheraSphere: } A \text{ (GBq)} = [D \text{ (Gy)} \times M \text{ (kg)}] / 50$$

When lung shunt fraction (LSF) is taken into account, the actual dose delivered to the target volume becomes [15]:

$$D \text{ (Gy)} = [A \text{ (GBq)} \times 50 \times (1 - \text{LSF})] / M \text{ (kg)}$$

A is the activity delivered to the liver, D is the absorbed delivered dose to the target liver mass, M is target liver mass. Liver volume (cc) is estimated with CT, and then converted to mass using a conversion factor of 1.03 kg/cc.

As an example, an authorized user wishes to treat a patient with the following characteristics: target volume 1000 cc (1.030 kg), desired dose 120 Gy, LSF=5%.

$$\text{Activity required} = (120 \times 1.030) / 50 = 2.47 \text{ GBq}$$

The patient receives an infusion of 2.47 GBq to the target volume. Given a 5% LSF, the actual delivered dose was:

$$D \text{ (Gy)} = [2.47 \times 50 \times (1 - 0.05)] / 1.030 = 114 \text{ Gy}$$

The lung dose calculation is:

$$D \text{ (Gy)} = 50 \times (2.47 \times 0.05) = 6 \text{ Gy}$$

12.4.1.2

Infusion Technique

The TheraSphere Administration Set consists of one inlet set, one outlet set, one empty vial, and two interlocking units consisting of a positioning needle

guide, and a priming needle guide, all contained in a Lucite shield. A MONARCH™ 25 cc syringe (Merit Medical) is used to infuse saline containing the TheraSphere ^{90}Y microspheres through a catheter placed in the hepatic vasculature.

Once the catheter is in place and the authorized user is ready for delivery, the catheter is connected to the outlet tubing. Delivery of TheraSphere is accomplished by pressurizing the MONARCH syringe. For 3 French catheter systems, the infusion pressure should range from 20 to 40 PSI, while for 5 French systems, the infusion pressure should not usually exceed 20 PSI. It is essential that, irrespective of the infusion pressure utilized, pressure and flow of microspheres closely mimic that observed angiographically with gentle, hand injection of contrast. The authorized user should familiarize himself with the actual flow dynamics of the vessel being infused and use a correspondingly lowered infusion pressure where necessary, such as might be seen in patients with decreased cardiac output. Given the small volume of microspheres contained in a given activity of TheraSphere (typically 27–90 mg), a low volume of saline is required to infuse a vial of TheraSphere; the majority of the microspheres are infused once a few milliliters of saline are injected. Furthermore, given the low number of microspheres infused with TheraSphere (typically 1.2–4.0 million), the entire vascular bed is never saturated. Hence, live fluoroscopic guidance while the infusion is occurring is not necessary. A complete infusion usually requires 20–40 cc.

12.4.2

SIR-Spheres Administration

12.4.2.1

Dosimetry for SIR-Spheres

As described in the product insert, SIR-Spheres® consist of biocompatible resin-based microspheres containing ^{90}Y with a size between 20 and 40 microns in diameter. SIR-Spheres® is a permanent implant and is provided in a vial with water for injection. Each vial contains 3 GBq of yttrium-90 (at the time of calibration) in a total of 5 cc water for injection. Each vial contains 40–80 million microspheres [25]. The corresponding activity per microsphere for SIR-Spheres is much lower than that of TheraSphere (50 Bq vs. 2500 Bq respectively) [24].

Just as with TheraSphere, assuming SIR-Spheres ^{90}Y microspheres distribute in a uniform manner

throughout the liver and undergo complete decay in situ, radioactivity delivered to the liver can be calculated using one of two available methods:

The first method incorporates body surface area and estimate of tumor burden as follows:

$$A \text{ (GBq)} = \text{BSA (m}^2\text{)} - 0.2 + (\% \text{ tumor involvement}/100) \quad [26]$$

where BSA is body surface area.

The second method is based on a broad estimate of tumor burden as described in Table 12.2 [25]:

For either SIR-Spheres® dosimetry models, A (GBq) is decreased depending on the extent of LSF (<10% LSF no reduction, 10%–15% LSF-20% reduction, 15%–20% LSF-40% reduction, >20% LSF no treatment).

As an example, an authorized user wishes to treat a patient with the following characteristics: total weight 91 kg, height 1.83 meters (6 ft), target volume 1000 cc, tumor volume 300 cc, LSF=5%.

Using the first method, the formula for BSA as described by Dubois and Dubois [27] is:

$$\text{BSA} = 0.20247 \times \text{height}^{0.725} \text{ (m)} \times \text{weight}^{0.425} \text{ (kg)}$$

Therefore,

$$A \text{ (GBq)} = 2.13 - 0.2 + (30/100) = 2.23 \text{ GBq}$$

would be required using the BSA formula.

Alternatively, given the tumor burden of 25%–50%, the patient could be prescribed 2.5 GBq in activity based on Table 12.2 [25]. Given the 5% LSF, no reduction in activity would be required. It should be noted that for SIR-Spheres, the dosimetry described in the product insert is based on whole liver infusion. If a lobar infusion is intended, the infused activity should be calculated assuming whole liver volume, and then “corrected” to the proportional volume of the target lobe. For example, if the right lobe is the target and represents 70% of the entire liver volume, the calculated activity to be delivered should be multiplied by 0.7.

12.4.1.2

Infusion Technique

The SIR-Spheres administration set consists of a Perspex shield, the dose vial, inlet and outlet tubing with needles. Standard 10- or 20-cc injection syringes preloaded with sterile water are required

Table 12.2. Radioactivity delivered to the liver with SIR-Spheres, based on a broad estimate of tumor burden

Percent involvement by the tumor in the liver	Recommended SIR-Spheres dose
> 50 %	3.0 GBq
25%–50 %	2.5 GBq
< 25 %	2.0 GBq

to infuse the microspheres into the delivery catheter.

Given the larger number of microspheres (40–80 million) and lower activity of SIR-Spheres (50 Bq per microsphere) compared to TheraSphere, the delivery of SIR-Spheres is distinctly different than that for TheraSphere. Once the catheter is in place and the authorized user is ready for delivery, the catheter is connected to the outlet tubing. Given the very large number of SIR-Spheres microspheres required to deliver the intended dose, it is not uncommon for the entire vascular bed to become saturated with microspheres and an embolic state to be reached. For this reason, fluoroscopic guidance is essential during the infusion. The technique of SIR-Spheres infusion involves the alternating infusion of sterile water and contrast, never allowing direct SIR-Spheres contact with contrast. This allows the authorized user to adequately monitor the injection and ensure that vascular saturation has not been reached. In cases where unrecognized vascular saturation occurs and microsphere infusion continues, reflux of microspheres and nontarget radiation become a distinct possibility. The infusion is complete if either (1) the entire intended dose has been infused without reaching stasis, or (2) stasis has been reached and only a portion of the dose has been infused. Given the risk of reflux and nontarget radiation once stasis has been reached, the continued infusion of SIR-Spheres is not recommended.

12.4.3

Calculation of Lung Dose

Radiation pneumonitis is a concern with hepatic-directed radiation treatment. Previous preclinical and clinical studies with ⁹⁰Y microspheres demonstrated that up to 30 Gy to the lungs could be tolerated with a single injection, and up to 50 Gy for multiple injections [13]. For this reason, patients with ^{99m}Tc-MAA evidence of potential pulmonary shunting resulting in lung doses greater than 30 Gy should not be treated.

The absorbed lung radiation dose is the total cumulative dose of all treatments [28]):

Cumulative absorbed lung radiation dose =

$$50 \times \text{lung mass} \sum_{i=1}^n A_i * \text{LSF}_i$$

where A_i = activity infused, LSF_i = lung shunt fraction during infusion, n = number of infusions, approximate vascular lung mass (for both lungs, including blood) = 1 kg [29].

This dose should not exceed the limit of 30 Gy per single infusion and 50 Gy cumulatively. In patients who require more than two treatments to achieve tumor coverage or in patients being retreated in the same target volume after progression, repeat ^{99m}Tc -MAA LSF should be performed before each treatment and calculation of cumulative absorbed lung radiation dose included from all previous treatments.

12.5 Results

12.5.1

TheraSphere: Clinical Experience, Response, and Survival

ANDREWS et al. [12] presented data on 24 patients including 17 with colorectal metastases to the liver, six with metastatic neuroendocrine tumors, and one HCC patient. Imaging at week 16 indicated a partial response in five patients, minimal response in four, stable disease in seven, and progressive disease in the remaining eight patients. Other than mild gastrointestinal symptoms in four patients (unrelated to TheraSphere), no hematologic, hepatic, or pulmonary toxicities were observed. The authors considered the hepatic tolerance to radiation delivered by ^{90}Y to be excellent at doses of up to 150 Gy used in the study. HERBA and THIRLWELL [30] performed a prospective dose-escalation study with TheraSphere starting at 50 Gy and escalating in 25 Gy increments to 150 Gy. There were 37 patients with liver metastases, 33 of whom had colorectal metastases to the liver. The authors observed no major hematological or pulmonary complications but did observe some gastroduodenal ulceration, which occurred early in their clinical experience with TheraSphere, due to inadvertent deposition of spheres in the GI tract. There was a beneficial response observed by CT in cases where tumors could be resolved. Stabili-

zation or decrease in tumor size was observed in 22/30 patients (73%). Due to the small sample size of the study, no statistically significant relationship between dose and clinical or radiological beneficial effects was observed. However, the authors concluded that TheraSphere treatment was a feasible and safe technique with beneficial effects. WONG et al. [31] presented data on TheraSphere treatment of eight patients with unresectable colorectal liver metastases. Tumor response was evaluated using imaging (CT/MRI) and metabolic evaluation via ^{18}F -FDG-PET and serum CEA. Five of the eight patients had an improvement in their tumor activity, as assessed by a decrease in ^{18}F -FDG-PET metabolic activity and confirmed by parallel changes in serum CEA. However, as observed in other studies, the use of imaging by CT/MRI illustrated that only some of the tumors that responded by metabolic criteria revealed a corresponding decrease in size. This study suggested that using tumor size as an indication of treatment response would lead to an underestimate of the effect of TheraSphere. The authors concluded that there was a significant metabolic response to TheraSphere treatment in patients with unresectable colorectal liver metastases. This treatment appeared to provide significant palliation for patients with otherwise incurable disease. In a subsequent study, WONG et al. [32] presented data on TheraSphere treatment of 27 patients with metastatic colorectal cancer to the liver. Tumor response was evaluated via ^{18}F -FDG-PET and serum CEA. The study evaluated the use of ^{18}F -FDG-PET to quantify the metabolic response to treatment comparing visual estimates to standardized hepatic uptake values. Visual estimates were graded as: progression, no change, mild, moderate or dramatic improvement. Visual estimates indicated 20 patients responded to treatment while seven patients experienced progression or no change in their disease. There was a significant correlation ($r=0.75$, $p<0.0001$) between the response group identified through visual estimation and as determined by hepatic standardized uptake values. There was no statistically significant correlation observed with CEA values ($p=0.13$), which was attributed to the effect of extrahepatic lesions. The authors concluded that treatment significantly reduced hepatic tumor metabolism and appeared to be palliative in patients with unresectable liver metastases.

GOIN et al. [33] performed a dose-escalation study with TheraSphere in 43 colorectal metastases patients. The study assessed dose-related effects on survival,

tumor response and toxicity. There were no life-threatening or fatal toxicities. The median survival was 408 (95% CI=316–565) days. Tumor response was evaluated by decrease in tumor size assessed by CT imaging. By these criteria, two patients had a complete response, eight had a partial response, and 35 (81%) were at least stable. Higher doses were associated with greater tumor response and increased survival ($p=0.05$). In addition, tumor hypervascularity ($p=0.01$), higher performance status [baseline] ($p=0.002$) and less liver involvement ($p=0.004$) were associated with enhanced response or survival. Clinical toxicities included duodenal/gastric ulcers in six patients (14%) that resolved with medical management. These were most likely due to inadvertent deposition of microspheres into the GI tract via unappreciated collateral vessels. Other related complications included single occurrences of mild fever and fatigue. There was no dose-relationship to toxicities observed in the study.

SALEM et al. [34] presented data on 27 patients with colorectal metastases treated with TheraSphere. Patients who had life-threatening colorectal metastases to the liver for whom other therapies were judged to be inappropriate or had failed were treated. The majority of patients entering the study had extrahepatic lesions (85%), 89% of patients had undergone prior systemic chemotherapy, 52% had bilobar disease, and 22% had >25% of their liver replaced by tumor. Patients underwent baseline CT and ^{18}F -FDG-PET imaging and follow-up imaging for determination of efficacy. Metabolic response was also evaluated by CEA levels. Greater than 80% of patients displayed response to treatment assessed by ^{18}F -FDG-PET. The response observed via CT imaging was less dramatic but paralleled the ^{18}F -FDG-PET results. Almost all (96%) of patients showed stabilization or response by one of the two imaging methods. There was an increase in survival for patients with <25% tumor replacement (339 [95% CI=250–481] days) versus those with >25% (162 [CI=153–237], $p=0.0001$). The overall median survival was 286 [CI=218–406] days, likely as a result of the prevalence of extrahepatic lesions in the majority of the patients (23/27). However, patients with an ECOG of 0 ($n=17$) had a median survival of 406 [CI=250–490] days. Treatments were well tolerated with most events being transient (mild fatigue [$n=13$], nausea [$n=4$], and abdominal pain [$n=5$]) and resolving without medical intervention. Six patients (22%) experienced non-treatment-related ascites/pleural effusion or laboratory toxicities as a consequence of liver failure in advanced-stage, met-

astatic disease. The response rate compared favorably to hepatic arterial chemotherapy and fewer complications were anticipated due to the relatively simple procedure required and the minimal toxicity associated with TheraSphere treatment. The authors concluded that TheraSphere appeared to provide therapeutic benefit with minimal toxicity in patients with progressive metastases following failure on systemic chemotherapy. In an ongoing study at our institution, a cohort of 65 patients with metastatic disease to the liver from diverse primaries including colorectal, pancreatic, melanoma, lymphoma, bladder, breast, and neuroendocrine were treated with TheraSphere. All patients were treated on an outpatient basis. Tumor response rate using RECIST criteria was approximately 35%, while the ^{18}F -FDG-PET response rate was significantly higher. Response rates were accentuated in those patients who underwent systemic chemotherapy following a full course of liver-directed therapy with TheraSphere.

12.5.2

SIR-Spheres[®]: Clinical Experience, Response, and Survival

GRAY et al. [35] published a phase III randomized clinical trial of 74 patients conducted to assess whether a single injection of ^{90}Y in combination with intrahepatic FUDR could increase the tumor response rate, time to disease progression in the liver, and survival compared to FUDR alone. Treatment-related toxicities or change in quality of life were also examined. All patients had undergone complete surgical resection of a primary adenocarcinoma of the large bowel, and only those with nonresectable metastases limited to the liver and lymph nodes in the porta hepatis were included in the study. In addition, patients were required to have a WHO performance status of 0–2, adequate hematological and hepatic function, and not have evidence of cirrhosis or ascites. Both treatment arms received 12-day cycles of continuous infusion floxuridine (FUDR) at 0.3 mg/kg of body wt/day that were repeated at four weekly intervals, and continued for 18 cycles (or until evidence of tumor progression, extrahepatic metastases requiring a systemic chemotherapy change, unacceptable toxicity, port failure, or at the patient's request). The SIR-Spheres treatment arm also received a predetermined quantity of ^{90}Y that varied (2 GBq, 2.5 GBq, or 3 GBq) depending on the size of the tumor. Yttrium-90 microspheres were administered one time only,

within four weeks of insertion of the hepatic artery access port. The mean ^{90}Y dose administered was 2.156 ± 0.32 GBq. There was no difference between the ^{90}Y arm and control arm in the mean chemotherapy dose ($1,863 \pm 1,735$ mg FUDR vs. $1,822 \pm 1,323$ FUDR per patient) or the mean number of cycles of chemotherapy (8.7 ± 5.6 vs. 8.0 ± 5.0 cycles per patient). Six of 34 patients (18%) in the hepatic artery chemotherapy (HAC) arm had at least a PR, while 16/36 patients (44%) in the HAC + SIRT arm had at least a PR. ($p = 0.01$).

STUBBS et al. [36] published a clinical trial of 50 patients with extensive colorectal liver metastases not suitable for either resection or cryotherapy. The study compared experience with ^{90}Y alone ($n = 7$) and in combination ($n = 43$) with fluorouracil (5-FU). For all patients, ^{90}Y microspheres were administered as a single treatment within 10 days of hepatic artery port placement. The dose was titrated to the estimated extent of disease (< 25% liver replacement: 2 GBq, 25–50% liver replacement: 2.5 GBq, and > 50% liver replacement: 3 GBq) and given over 10 minutes, a few minutes after 50 mcg angiotensin II. Forty-three of the 50 enrolled patients also received 5-FU given at the time of ^{90}Y continuously over 4 days (1 gm/day), every 4 weeks. Prior to administration of ^{90}Y , a $^{99\text{m}}\text{Tc}$ -labeled macroaggregated albumin ($^{99\text{m}}\text{Tc}$ -MAA) test was conducted to discern the percentage of lung shunting and assess the risk of radiation pneumonitis. Acute pain and/or nausea was experienced in 14 patients (28%) at the time of administration of ^{90}Y , and was managed with narcotics and antiemetics. Six patients (12%) developed an acute duodenal ulcer within 2 months after ^{90}Y therapy and the initial cycle of 5-FU that was due to misperfusion of the duodenum by either ^{90}Y , 5-FU, or both. Antitumor effect was assessed by tumor marker (CEA) and CT response. Median CEA levels were reduced to 25% of baseline values at one month post-treatment with ^{90}Y , and remained < 30% of baseline when followed for 6 months. Median survival for all liver metastases patients from the time of diagnosis was 14.5 months (range 1.9 to 91.4) and from the time of treatment was 9.8 months (range 1.0 to 30.3).

STUBBS et al. [37] published on 38 patients with extensive colorectal liver metastases who received SIR-Spheres. Liver involvement was < 25% in 19 patients, 25%–50% in 9 and > 50% in 10. Patients received ^{90}Y in the hepatic artery via an arterial port and subsequent 4-weekly cycles of hepatic artery chemotherapy with 5-fluorouracil. The treatments were well tolerated, and no treatment-related mor-

tality was observed. Response to SIR-Spheres therapy, as indicated by decreasing tumor markers and serial 3-monthly CT scans were seen in over 90% of patients. Estimated survival at 6, 12, and 18 months was 70%, 46% and 46%, respectively, and was principally determined by the development of extrahepatic metastases. The authors concluded that SIR-Spheres was well tolerated in patients with extensive colorectal liver metastases and achieved encouraging liver tumor responses, which are well maintained by hepatic artery chemotherapy.

VAN HAZEL et al. [26] published a randomized clinical trial of 21 patients with untreated advanced colorectal liver metastases (with or without extrahepatic metastases) that compared the response rate, time to progressive disease, and toxicity of systemic 5-fluorouracil/leucovorin chemotherapy versus 5-fluorouracil/leucovorin plus a single administration of ^{90}Y . Systemic chemotherapy consisted of 425 mg/m^2 fluorouracil + 20 mg/m^2 leucovorin IV bolus for 5 days, and repeated in 4 weekly cycles. Mean SIR-Spheres activity infused was 2.25 GBq. There were five cases of grade 3 / 4 toxicity following FU/LV and 13 cases following combined SIRT + FU/LV, which were primarily elevated liver function tests. Tumor response rates using RECIST criteria were 10/11 (91%) and 0/10 (0%) for the combined chemotherapy/ ^{90}Y and chemotherapy only arms respectively ($p < 0.001$). The time to progression was significantly greater in those receiving combination therapy compared to the chemotherapy arm (18.6 vs. 3.6 months, $p < 0.0005$). Survival was significantly improved in the combination arm compared to chemotherapy (29.4 vs. 12.8 months, $p = 0.02$). The authors concluded that a single administration of ^{90}Y significantly increased both tumor response and time to progressive disease when added to systemic FU/LV chemotherapy, with acceptable toxicity. Studies are now underway to assess the efficacy of combining SIR-Spheres with oxaliplatin, irinotecan and bevacizumab based therapies.

RUBIN et al. [38] presented a case report of a patient with metastatic breast cancer to the liver treated with SIR-Spheres. The authors concluded that using an integrative approach to cancer treatment including SIR-Spheres was successful in palliating a patient with metastatic breast cancer. BOAN et al. [39] presented data on a nine-patient cohort with primary and metastatic disease to the liver treated with SIR-Spheres. Although no response, toxicity or long-term data was presented, the authors concluded that SIR-Spheres was well-tolerated by all patients and that further evaluation was underway.

COLDWELL et al. [40] presented an abstract describing 84 patients receiving 127 infusions for colorectal metastases to the liver. The target dose was 90 Gy to the tumor and 30 Gy to the normal parenchyma. Objective response rates were 35% by CT, 70% by CEA, and 90% by ^{18}F FDG-PET. Mean follow-up time was 12 months, with median survival not having been reached at the time of presentation. No life-threatening toxicities were noted. All patients who exhibited fluoroscopic cessation of blood flow (stasis) during ^{90}Y infusion experienced post-embolization syndrome. The authors concluded that radioembolization provides encouraging response rates with an improvement in overall survival with acceptable toxicity in the group of patients treated.

12.6 Complications

The most common complications of radioembolization include nontarget radiation (GI ulceration, pancreatitis), radiation pneumonitis, and radiation induced liver disease (radiation hepatitis). The incidence of nontarget radiation should be minimized if the above-described technical principles are followed, including aggressive embolization of collateral vessels and the use of fluoroscopic guidance. The risk of radiation pneumonitis is mitigated if dosimetry planning incorporates the 30-Gy lung limit. The last possible complication of radioembolization is radiation hepatitis. This mechanism involves the irradiation of normal parenchyma beyond that which is tolerated. INGOLD et al. [41] published a landmark series on radiation hepatitis in a cohort of patients treated with whole abdomen external beam radiation for gynecologic malignancies. The classical findings of anicteric ascites, elevated alkaline phosphatase, thrombocytopenia, and veno-occlusive disease occurred in those patients receiving greater than 30 Gy to the liver. Although the mechanism of selective “internal” microsphere radioembolization is distinctly different than external beam radiation, liver failure in this unique form of radiation hepatitis is a possibility. When radioembolization with microspheres is undertaken, the objective is to administer the microspheres to the tumor without affecting the normal parenchyma. However, if the normal parenchyma receives a threshold dose above a yet undetermined amount for this mode of therapy, irreversible liver failure will invariably ensue. Systemic steroid treatment may

control the progression of radiation hepatitis. With radioembolization, care must be taken to ensure that the normal parenchyma is not receiving excessive radiation to a level where radiation induced liver disease might occur. Finally, it must be stated that the true mechanism of radiation hepatitis from radioembolization is not currently understood. Any evidence of radiation hepatitis (e.g. anicteric ascites, elevated alkaline phosphatase, elevated transaminases [42] represents an extension of the knowledge gained from external beam radiation.

12.7 Conclusion

There is a significant body of evidence supporting the safety and effectiveness of radioembolization in the treatment of metastases to the liver. The aforementioned studies representing the collective clinical experience supporting the safety and therapeutic benefit of TheraSphere and SIR-Spheres in patients with metastatic disease to the liver suggest further investigation for additional applications. Disease states where further work should be initiated include HCC (primary therapy, randomization against TACE, bridge to transplantation, tumor downstaging), colorectal (combination with radiosensitizers [capecitabine, CPT-11] or newer agents [oxaliplatin, bevacizumab, cetuximab]), and metastatic neuroendocrine cancer to the liver. Furthermore, this technology appears to be ideal for extrahepatic applications, such as the treatment of renal cell carcinomas, meningiomas, as well as other malignancies that are readily accessible angiographically. There is also much to be gained from a more rigorous approach to investigating patient selection criteria, presentation of disease, and optimal dosimetry to obtain the desired therapeutic effect given these factors.

References

1. Breedis C, Young G (1954) The blood supply of neoplasms in the liver. *Am J Pathol* 30:969–985
2. Schenk WG, McDonald JR, McDonald K, Drapanas T (1962) Direct measurement of hepatic blood flow in surgical patients. *Ann Surg* 156:463
3. Lin G, Junderquist A, Hågerstrand I, Boijesen E (1984) Post-mortem examination of the blood supply and vascular pattern of small liver metastases in man. *Surgery* 96:517–526

4. Grindlay JH, Herrick JF, Mann FC (1941) Measurement of the blood flow of the liver. *Am J Physiol* 132:489–496
5. Tystrup N, Winklker K, Mellemegaard K, et al. (1962) Determination of the hepatic arterial blood flow and oxygen supply in man by clamping the hepatic artery during surgery. *J Clin Invest* 41:447–454
6. Almersjo O, Bengmark S, Engevik L et al. (1966) Hepatic artery ligation as pretreatment for liver resection of metastatic cancer. *Rev Surg* 23:377–380
7. Bierman HR, Byron RL, Kelley KH et al. (1951) Studies on the blood supply of tumor in man III. Vascular patterns of the liver by hepatic arteriography in vivo. *JNCI* 12:107–131
8. Healy JE (1965) Vascular patterns in human metastatic liver tumors. *Surg Gynecol Obstet* 120:1187–1193
9. Blanchard RJ, Grotenhuis I, Lafaye JW et al. (1965) Blood supply to hepatic V2 carcinoma implants as measured by radioactive microspheres. *Proc Soc Exp Biol Med* 118:465–468
10. Sundqvist K, Hafstrom L, Persson B (1978) Measurements of total and regional tumor blood flow and organ blood flow using Tc99m labelled microspheres. *Eur J Surg Res* 10:433–443
11. Gyves J, Ziessman HA, Ensminger WD et al. (1984) Definition of hepatic tumor microcirculation by single photon emission computerized tomography (SPECT). *J Nucl Med* 25:972–977
12. Andrews JC, Walker SC, Ackerman RJ, Cotton LA, Ensminger WD, Shapiro B (1967) Hepatic radioembolization with yttrium-90 containing glass microspheres: Preliminary results and clinical follow-up. *J Nucl Med* 35:1637–1644
13. Leung TWT, Lau WY, Ho SKW et al. (1995) Radiation pneumonitis after selective internal radiation treatment with intra-arterial 90-yttrium-microspheres for inoperable hepatic tumors. *Int J Radiation Biol Phys* 33:919–924
14. Liu D, Salem R, Bui. JT, Courtney A, Barakat O, Sergie Z, Atassi B, Barrett K, Lewandowski RJ, Wong CO, Gates VL, Thurston KG Angiographic considerations in patients undergoing liver-directed therapy with yttrium-90 microspheres and chemoembolization: a comprehensive review. *J Vasc Interv Radiol* 2005, in press
15. Salem R, Thurston KG, Carr BI, Goin JE, Geschwind JF (2002) Yttrium-90 microspheres: Radiation therapy for unresectable liver cancer. *J Vasc Interv Radiol* 13: 223S–229S
16. Salem R, Lewandowski RJ, Roberts C, Goin JE, Thurston KG, Abouljoud M, Courtney A (2004) Use of Yttrium-90 Glass Microspheres (TheraSphere) for the Treatment of Unresectable Hepatocellular Carcinoma in Patients with Portal Vein Thrombosis. *J Vasc Interv Radiol* 15:335–345
17. Carr BI (2002) Hepatic artery chemoembolization for advanced stage HCC: experience of 650 patients. *Hepato-gastroenterology* 49:79–86
18. Chun HJ, Byun JY, Yoo SS, Choi BG (2003) Added benefit of thoracic aortography after transarterial embolization in patients with hemoptysis. *AJR Am J Roentgenol* 180:1577–1581
19. Chung JW, Park JH, Han JK, Choi BI, Han MC, Lee HS et al. (1996) Hepatic tumors: predisposing factors for complications of transcatheter oily chemoembolization. *Radiology* 198:33–40
20. Inaba Y, Arai Y, Matsueda K, Takeuchi Y, Aramaki T (2001) Right gastric artery embolization to prevent acute gastric mucosal lesions in patients undergoing repeat hepatic arterial infusion chemotherapy. *J Vasc Interv Radiol* 12:957–963
21. Ueno K, Miyazono N, Inoue H, Miyake S, Nishida H, Nakajo M (1995) Embolization of the hepatic falciform artery to prevent supraumbilical skin rash during transcatheter arterial chemoembolization for hepatocellular carcinoma. *Cardiovasc Intervent Radiol* 18:183–185
22. Arora R, Soulen MC, Haskal ZJ. Cutaneous complications of hepatic chemoembolization via extrahepatic collaterals (1999) *J Vasc Interv Radiol* 10:1351–1356
23. Yttrium-90 microspheres (TheraSphere) Package Insert, MDS Nordion, Kanata, Canada 2004
24. Kennedy AS, Nutting C, Coldwell D, Gaiser J, Drachenberg C (2004) Pathologic response and microdosimetry of ⁹⁰Y microspheres in man: Review of four explanted whole livers. *Int. J Radiation Oncology Biol Phys* 60:1552–1563
25. Yttrium-90 microspheres (SIR-Spheres) Package Insert, Sirtex Medical, Lake Forest, IL 2002
26. Van Hazel G, Blackwell A, Anderson J, Price D, Moroz P, Bower G, Cardaci G, Gray B (2004) Randomised phase 2 trial of SIR-Spheres plus fluorouracil/leucovorin chemotherapy versus fluorouracil/leucovorin chemotherapy alone in advanced colorectal cancer. *J Surg Oncol* 88:78–85
27. Medical College of Wisconsin. <http://www.intmed.mcw.edu/clinical/body.html> 2005
28. Berger, M.J (1971) Distribution of absorbed dose around point sources of electrons and beta particles in water and other media. *Journal of Nuclear Medicine Suppl* 5: 5–23
29. Synder WS, Ford MR, Warner GC, Waston SB. Absorbed dose per unit cumulated activity for selected radionuclides and organs., in *MIRD Pamphlet Number 11*. New York, NY: Society of Nuclear Medicine, 1975–1976
30. Herba MJ, Thirlwell MP (2002) Radioembolization for hepatic metastases. *Semin Oncol* 29:152–159
31. Wong CYO, Salem R, Roman S et al. (2002) Evaluating ⁹⁰Y-glass microsphere treatment response of unresectable colorectal liver metastases by [¹⁸F] FDG PET: a comparison with CT or MRI. *Eur J Nucl Med* 29:815
32. Wong C-YO, Salem R, Qing F, Wong KT, Barker D, Gates V et al. (2004) Metabolic response after intraarterial ⁹⁰Y-Glass microsphere treatment for colorectal liver metastases: A comparison of quantitative and visual analyses by ¹⁸F-FDG PET. *J Nucl Med* 45:1892–97
33. Goin JE, Dancy JE, Hermann GA, Sickles CJ, Roberts CA, Macdonald JS (2003) Treatment of unresectable metastatic colorectal carcinoma to the liver with intrahepatic Y-90 microspheres: dose-ranging study. *World J of Nuc Med* 2:216–225
34. Salem R, Thurston KG, Goin JE, Wong CO, Lewandowski RJ, Gates VL et al. (2005) TheraSphere for unresectable metastatic carcinoma to the liver: treatment response at targeted doses of 135–150 Gy as measured by FDG-PET and CT imaging, in press
35. Gray B, Van Hazel G, Hope M, Burton M, Moroz P, Anderson J, Gebiski V (2001) Randomized trial of SIR-Spheres plus chemotherapy vs chemotherapy alone for treating patients with liver metastases from primary large bowel. *Annals of Oncology* 12:1711–1120
36. Stubbs RS, Cannan RJ, Mitchell AW (2001) Selective Internal Radiation therapy with Yttrium-90 microspheres for extensive colorectal metastases. *J Gastrointest Surg* 5:294–302

37. Stubbs RS, Cannan RJ, Mitchell AW (2001) Selective internal radiation therapy (SIRT) with ⁹⁰Yttrium microspheres for extensive colorectal liver metastases. *Hepatogastroenterology* 48:333–337
38. Rubin D, Nutting C, Jones B (2004) Metastatic Breast Cancer in a 54 year old woman: Integrative Treatment with Yttrium-90 Radioembolization. *Integrative Cancer Therapies* 3: 262–267
39. Boan JF, Marti-Climont JM, Martinez A, Sangro B, Rodriguez J, Penuelas I, Richter JA (2004) Abstract P954, *European Journal of Nuclear Medicine and Molecular Imaging* Vol 31, Suppl. 2
40. Coldwell D, Nutting C, Kennedy A (2004) Initial clinical results in the treatment of unresectable hepatic tumors with resin-based yttrium-90 radioembolization. Presented at the Cardiovascular and Interventional Radiological Society of Europe (CIRSE) conference. September 25–29
41. Ingold JA, Reed GB, Kaplan HS, Bagsjaw MA (1965) Radiation hepatitis. *Am J Roentgen* 93:200–208
42. Cheng JC, Wu JK, Huang CM, Huang DY, Cheng SH, Lin YM, Jian JJ, Yang PS, Chuang VP, Huang AT (2002) Radiation-induced liver disease after radiotherapy for hepatocellular carcinoma: clinical manifestation and dosimetric description. *Radiother Oncol* Apr;63(1):41–45

13 Portal Vein Embolization

ALAIN J. ROCHE and DOMINIQUE ELIAS

CONTENTS

13.1	Introduction	163
13.2	Physiopathology	163
13.2.1	Portal Blood and Liver Regeneration	163
13.2.2	Portal Vein Embolization and Liver Regeneration	164
13.2.2.1	Mechanisms Inducing Regeneration After PVE	164
13.2.2.2	Is Volume Increase Correlated to Functional Increase?	164
13.3	Indications for Portal Vein Embolization	164
13.3.1	Calculation of FRL/Total Functional Liver Volume Ratio	165
13.3.2	Hepatocellular Carcinoma	165
13.3.3	Cholangiocarcinoma	166
13.3.4	Liver Metastasis	166
13.3.5	Other Indications	166
13.4	Anatomy	166
13.5	Technique	166
13.5.1	Personal Technique	166
13.5.2	Other Techniques	168
13.5.2.1	Approaches	168
13.5.2.2	Distal Embolization or Proximal Ligation?	168
13.5.2.3	Embolic Agents	169
13.6	Complications	169
13.6.1	Tolerance	169
13.6.2	Complications	170
13.6.3	Does PVE Accelerate Growth Rate of Liver Metastases?	170
13.7	Results	171
13.7.1	Liver Hemodynamic Effects of Portal Vein Embolization	171
13.7.2	Induced Hypertrophy, Delay to Surgery	171
13.7.3	Hypertrophy in Patients with Underlying Liver Disease	171
13.7.4	Is Hypertrophy Predictable?	172
13.7.5	Is Liver Failure After Surgery Predictable?	172
13.7.6	Long-term Results and Survival	172
13.8	Future Developments and Research	172
13.9	Conclusion	173
	References	173

A. J. ROCHE, MD

Head of Interventional Radiology Section, Professor, Institut Gustave Roussy, 39 Rue Camille Desmoulins, 94800 Villejuif Cedex, France

D. ELIAS, MD

Head of Digestive Surgery Section, Institut Gustave Roussy, 39 Rue Camille Desmoulins, 94800 Villejuif Cedex, France

13.1

Introduction

One of the prerequisites for partial hepatic resection is the presence of enough remaining functional liver parenchyma to avoid life-threatening postoperative liver failure. Therefore, the possibilities of curative resection of liver tumors are strongly dependent on the volume of the future remnant liver (FRL). In clinical practice, these possibilities are frequently limited when an extended right hepatectomy is mandatory since the left lobe is small, or when major liver surgery is indicated in patients with impaired liver function, whatever the cause (cirrhosis, cholestasis, noncirrhotic fibrous disease, or severe fatty steatosis). The aim of portal vein embolization (PVE) is to selectively induce hypertrophy of the FRL during the preoperative period. This is achieved by embolization of the intrahepatic portal branches of the future resected liver, therefore leading to distribution of the entire portal blood flow, containing hepatotrophic factors, exclusively towards the FRL. This technique was first applied for patients with hepatocellular carcinoma [29] with the double goal to induce hypertrophy of the FRL and to prevent retrograde intraportal tumor dissemination from the tumor lobe. Few years later, PVE was proposed in patients with hilar cholangiocarcinoma carcinoma who frequently require major hepatectomy in relation to their tumor location [39], and in patients with liver metastasis where PVE extends the indications for curative surgery [47].

13.2

Physiopathology

13.2.1

Portal Blood and Liver Regeneration

It has been demonstrated for a long time that portal branch ligation resulted in shrinkage of the corresponding lobe and hypertrophy of the contralateral

one. Moreover, it is well known in clinical practice that liver trophicity closely depends on hepatic portal blood perfusion. Liver atrophy after surgical or spontaneous portocaval shunting, hypertrophy of the remnant liver after partial hepatectomy, Spiegel lobe hypertrophy in Budd-Chiari disease where the caudate lobe remains the only one to still have hepatopetal portal blood flow, occlusion of portal veins from cholangiocarcinoma giving rise to hypertrophy of the unaffected lobe, are some examples illustrating this very close relationship. It was established along the seventies that portal venous blood flow promoted hepatic cell regeneration [8] and that blood arising from duodenopancreatic area had strong hepatotrophic properties [50]. Insulin and glucagon were then soon recognized as growth-regulatory factors which, when infused concomitantly, synergistically stimulated hepatic regeneration. More recently, hepatocyte growth factor (HGF) could be isolated in different laboratories and described to rise after partial hepatectomy. Multiple other factors such as cytokines or transforming growth factor- α (TGF- α), have also been demonstrated to play a role in hepatic regeneration.

13.2.2

Portal Vein Embolization and Liver Regeneration

13.2.2.1

Mechanisms Inducing Regeneration After PVE (Table 13.1)

Occlusion of portal branches of the liver parenchyma to be resected redistributes the totality of its portal blood flow, and consequently all its hepatotrophic contents, towards the FRL. This is the basic rationale of the method that triggers off regenerative activity of the nonembolized portion of the liver. Moreover, PVE dilates the portal branches in the FRL, exposing liver vasculature to stretch stress which act as a trigger for IL-6 release from endothelial cells and contribute to the activation of regenerative cascade in the FRL [26]. Induction of heat shock protein in the nonembolized lobe is supposed to have similar effects [40]. PVE also acts through two potentially complementary pathways specifically related to embolization: ischemia and inflammation. With most of the embolic agents, PVE induces a mild ischemia: apoptosis or necrosis of some hepatocytes, and intercellular disjunction.

These lesions lead liver cells of the embolized liver to produce regenerating factors [35]. Moreover, the injection of embolic material induces a foreign body reaction and a cascade of inflammatory phenomena with production of cytokines and liver growth factors by Kupffer cells and granulocytes. This pathway may be more or less predominant, depending on the intensity of the inflammatory reaction induced by the embolic agent used for PVE. Consequently, embolic agents inducing a strong inflammatory reaction, such as cyanoacrylate or ethanol, should induce more hypertrophy than others.

13.2.2.2

Is Volume Increase Correlated to Functional Increase?

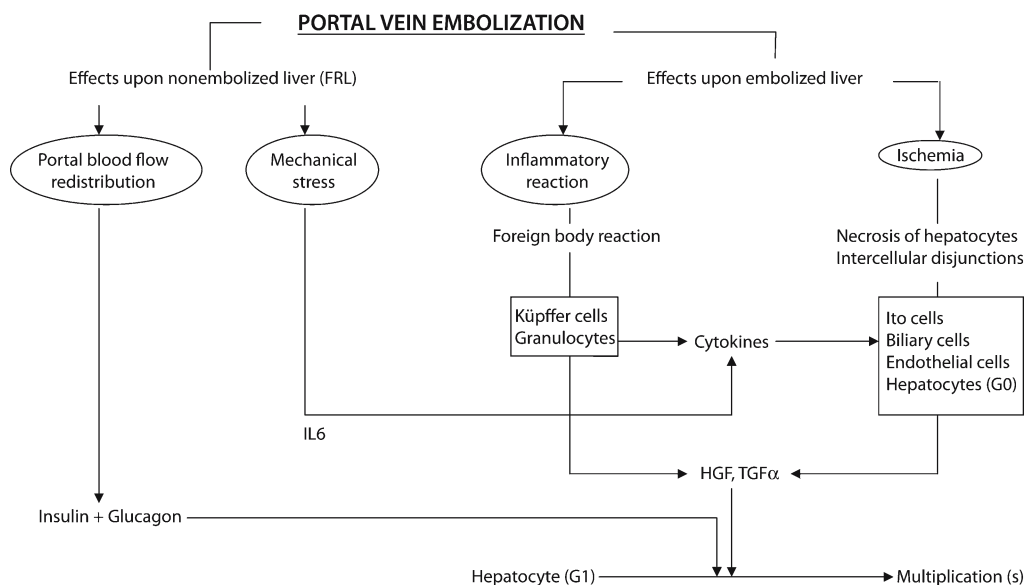
Even if volume increase of the FRL after PVE was demonstrated by all the first publications, it had to be proved that it corresponded to a functional increase. Nowadays it has been clearly demonstrated by the mean of many different techniques that volume increase did parallel function increase. PVE produces a significant increase in bile volume and biliary indocyanine green concentration in the FRL [53]. Histology examination of FRL and assessment of volumetric, cell kinetic and morphometric parameters attributed to PVE a gain of functional hepatocyte mass and early induction of hepatocyte proliferation following hepatectomy [19]. Levels of erythrocyte polyamine, that is known to be related to liver regeneration, increase along the seven days following PVE [52]. Hepatic energy charge levels in the FRL remain comparable to that of normal liver [9], hepatic plasma clearance of sorbitol and antipyrine were stable after PVE [48], while the percentage of FRL to total liver volume increased, thereby demonstrating that the functional reserve of FRL increased. Functional improvement after PVE has also been demonstrated through evaluation of the first-pass lidocaine extraction [51] and (99m)Tc-galactosyl serum albumin scintigraphy [34].

13.3

Indications for Portal Vein Embolization

Limits for hepatic resections, and consequently for PVE, depend on multiple factors. The age of the patient is one of these: the younger the patient is, the larger a resection is tolerated. Liver function

Table 13.1. Mechanisms involved in hypertrophy after PVE. Cytokines and growth factors produced by the embolized liver need recirculation to be effective upon FRL.



is obviously a predominant factor for determining the limit for a safe resection. Bilirubin level, indocyanine green clearance and presence or not of a cirrhosis are widely used as parameters for evaluating liver function before hepatic resection. Liver function is considered as normal if there is no jaundice and indocyanine green clearance at 15 min is <10%. Presence of jaundice or ICG clearance 10%–20% indicates mild liver dysfunction. ICG clearance >20% indicates more severe compromised liver, also meaning that PVE should not be followed by dramatic increase in FRL volume. At last, it is the FRL/Total functional liver ratio for a given patient (with or without compromised liver function) that determines possibilities for a safe and complete resection. Depending on the authors, PVE is considered when this ratio is expected to be <25%–40% in patients with normal liver function and <40%–50% in patients with liver dysfunction [3, 12, 32].

13.3.1 Calculation of FRL/Total Functional Liver Volume Ratio

Many studies have demonstrated that CT estimations of liver volumes in vivo were correctly correlated to real volumes despite partial volume effect, respiratory phase, or inter-observer variations. It is widely admitted that tumors do not contain functional hepatocytes. Consequently, tumor volume

must be subtracted from that of liver. Preoperative radiofrequency ablation (RFA) has been widely developed along the recent years. When RFA is planned for treating a tumor located in the FRL simultaneously to the hepatectomy, one should pay attention to subtract the supposed volume of the future RFA lesion (tumor volume + safety margin) from the total FRL volume.

13.3.2 Hepatocellular Carcinoma

PVE was initially proposed in HCC at least for controlling retrograde tumor thrombus invasion in the portal vein [29], but today there is little evidence to support this supposed interest of the technique. On the contrary, some authors pointed out that the compensatory increase in arterial flow in the embolized lobe might accelerate the tumor growth [54]. Most of hepatocellular carcinomas occur in patients with compromised liver. Thereby this dramatically increases the risk of severe postoperative complications and limits the possibilities for major curative liver resections. Consequently, PVE is actually proposed in selected cases to extend indications for curative surgery and increase its safety. Apart from increasing the FRL volume and function, minimizing the sudden increase in portal pressure at resection in these cirrhotic patients may also be an advantage of preoperative PVE.

13.3.3 Cholangiocarcinoma

Radical surgery of hilar cholangiocarcinoma generally necessitates major liver resection, mainly an extensive right hepatectomy. Such a major intervention is frequently impeded by a too small left lobe, which consequently indicates preoperative PVE. Moreover, the patient frequently develops obstructive jaundice that may severely injured functionality of the FRL. Preoperative PVE is performed in these patients after biliary drainage of the FRL. Ideally patients should undergo PVE only when decrease in the serum bilirubin level is obtained, which facilitate hypertrophy of the nonembolized sector. On the contrary, biliary drainage of the future resected parenchyma should not be performed in the preoperative period to allow a more important shrinkage of the embolized territory.

13.3.4 Liver Metastasis

Curative resection of liver metastases is mainly performed in patients presenting with colorectal primary cancer. Liver metastases are found in 40%–70% of patients with a colorectal cancer. In about one third of cases, the liver is shown to be the only site of cancer spread, even at autopsy. There is no spontaneous long-term survival in untreated patients, whose median survival time range from 6 to 18 months. Furthermore, liver involvement is the most important factor associated with decreased patient survival. However, at time of diagnosis, the majority of patients present unresectable tumors, and resection can be performed in <20% of all patients with colorectal liver metastases. The main limitation for resectability is the impossibility to be curative while leaving a sufficient residual amount of functional liver parenchyma. Consequently, preoperative PVE may dramatically improve the possibilities for a curative (R0) resection of liver metastases by increasing the volume and the function of the future remnant liver.

13.3.5 Other Indications

PVE has been reported prior to resection of multiple benign adenomas which dissemination in the liver parenchyma impeded curative surgery [11],

huge benign adenoma (personal data), or even for allowing resection in primary sclerosing cholangitis [43].

13.4 Anatomy

A thorough knowledge of hepatic segmentation and portal venous anatomy is essential before performing PVE. *Variations* frequently occur and must be well known. One may remember that almost all variations concern right branches, making left branches remarkably constant in their disposition. The most frequent variation is slipping from right to left of segment V and VIII branches, separately or together. Therefore two main variations are frequently encountered: (i) trifurcation of the portal vein in left branch, segments V + VIII branch and segments VI + VII branch, when the slipping is limited; (ii) bifurcation of the portal vein in a right vein limited to segments VI + VII and left vein giving also rise to segments V + VIII branch, when the slipping is complete. Segmental branches of the right liver may also slip separately, but the most frequent variations concern segment VIII branch that may slip to the left as well as to the right.

13.5 Technique

13.5.1 Personal Technique

The procedure may be performed under intravenous sedation and analgesia but most of the teams prefer general anesthesia that provides more comfort for the patient as for the operator. When the goal of PVE is occlusion of right branches, the preferred access of the portal vein is mostly the anterior subxiphoid left route that allows antegrade catheterization of all right branches to be occluded and free flow embolization, thereby providing safer maneuvers. The puncture is achieved under sonographic guidance with a 5F-needle catheter (Table 13.2). When branches for segment IV have not to be occluded, the entry point in portal veins may be the Reix recess. If segment IV is concern by PVE, it is recommended to enter the segment III branch, upstream from the recess, to facilitate catheterization of segment IV

Table 13.2. Personal cookbook

First choice	Second choice
Puncture: 5F-needle catheter, 27 cm (Cook)	Echotip needle, 18 G, 20 cm (Allegiance)
Catheterization: 5F catheter from the needle catheter Guide wire: Kayak 0.035 J glide wire (Boston Scientific)	Same catheter with on demand shaping of the tip 0.035 shapeable glide wire (Terumo)
Embolic agent: Cyanoacrylate: Histoacryl, 0.5 ml vials (B. Braun) Lipiodol Ultrafluide, 10 ml (Guerbet)	Embogold (700–900 µm) (Biosphere Medical)
Embolization technique: Three-way stopcock resistant to Lipiodol (Cook) isotonic glucose solution, Two 1-ml syringes (Terumo) 20 ml syringe	

branches. Retrograde catheterization of the portal vein for performing a portography is the first step of the procedure in order to identify individual intrahepatic branches and anatomical variations. In all patients with a known or suspected compromised liver, the portal pressure must be measured prior to embolization as it represents a prognostic parameter. Catheterization of every branch to be embolized is then performed with the 5F catheter of the needle catheter device, with the help of a J shaped 0.035 glide wire. In case of left approach and very tightened portal bifurcation, catheterization of the right portal vein may necessitate to extemporaneously shape the catheter tip. Depending on individual anatomy, a 1–2 cm length and 30°–90° angulated tip is then shaped under steam to make further maneuvers easier. Every main trunk to be occluded is selectively catheterized for performing a distal and free flow embolization. The degree of selectivity (sectorial, segmental, or subsegmental) before each embolization depends on individual anatomy and local hemodynamic. It is chosen for each vein to ensure a stable selective positioning of the catheter, providing best conditions for free flow embolization and preventing from inadvertent reflux of embolic material. Massive reflux of embolic agent in the FRL would annihilate its hypertrophy, or induce almost total portal occlusion and thereby fatal portal hypertension when the rest of the portal vasculature has already been totally embolized. Consequently, right branches originating close to the portal bifurcation should be hyperselectively catheterized. Caution should also be exercised to avoid reflux into left lobe veins when occluding veins in segment IV. Due to this potential risk, segment IV portal veins should be occluded first for added safety, and sometimes even with particulate embolic agent instead of cyanoacrylate. As many authors, we mostly perform emboliza-

tion with a mixture of cyanoacrylate and Lipiodol. Safe use of this embolic agent necessitates following a very strict technique but, to our point of view, presents multiple advantages. It permits to achieve complete and durable occlusion. Its radio-opacity increases safety at time of embolization. Histoacryl and Lipiodol are mixed in a ratio of 1 part of Histoacryl for 1 to 3 parts of Lipiodol, the more Lipiodol in the mixture, the longer the polymerization time of the glue. Consequently, it allows distal embolization in every case since the polymerization time can be adapted to individual and instant hemodynamic variations. Furthermore, the cyanoacrylate induces a very strong inflammatory reaction, involving vessels as well as bile ducts, that is thought to increase production of hepatotrophic factors. The mixture (Histoacryl/Lipiodol ratio close to 1/2) is prepared in an insulin syringe, immediately prior to the first embolization. If needed during the procedure, it is possible to increase the dilution by adding Lipiodol. The mixture is pushed with isotonic glucose, following the “sandwich technique”: the volume of every injection of mixture being lower than the catheter content. This is repeated as many times as necessary for obtaining a distal and complete occlusion. The total dose of Histoacryl will be 1–3 cc, administered in 4–6 successive injections of mixture. Catheter occlusion along repetitive injections of glue is a risk of this technique. Pushing the 0.035 glide wire through the catheter still in position, immediately after each injection of glue minimizes it. This cleans the inner wall of the catheter from residual glue/Lipiodol mixture, and gently push it out in the embolized vein under fluoroscopic control. The three-way stopcock also needs to be cleared from residual glue after each injection. Anyway, both three-way stopcock and catheter must be exchanged in time before occlusion, at least every 3–5 injections. A

control portography is performed at the end of the procedure and postembolization portal pressure is registered. In our experience, the transhepatic tract does not need to be embolized.

13.5.2 Other Techniques

13.5.2.1 Approaches

Prior to complex hepatectomies PVE may concern left and right portal branches. A right transhepatic access may be then chosen, giving preference to entering a vein not to be occluded (Fig. 13.1). Some authors advocate a right transhepatic approach in all cases, using double- or triple-lumen balloon catheters for embolization [42]. Recently, the transjugular approach has

been successfully used in cases of impossibility to perform the conventional transhepatic technique, due to tumor interposition or severely impaired hemostasis [46]. The surgical transileocolic approach needs laparotomy but for some authors allows tumor extension to be better assessed preoperatively [21]. Nevertheless most of the surgeons actually prefer the transhepatic approaches.

13.5.2.2 Distal Embolization or Proximal Ligation?

Distal embolization is achieved with particulate agents, cyanoacrylate or other liquid agents. Proximal ligation is surgically performed or may be done percutaneously with steel coils or detachable balloons. Considering that the intrahepatic portal vasculature was classically considered as terminal

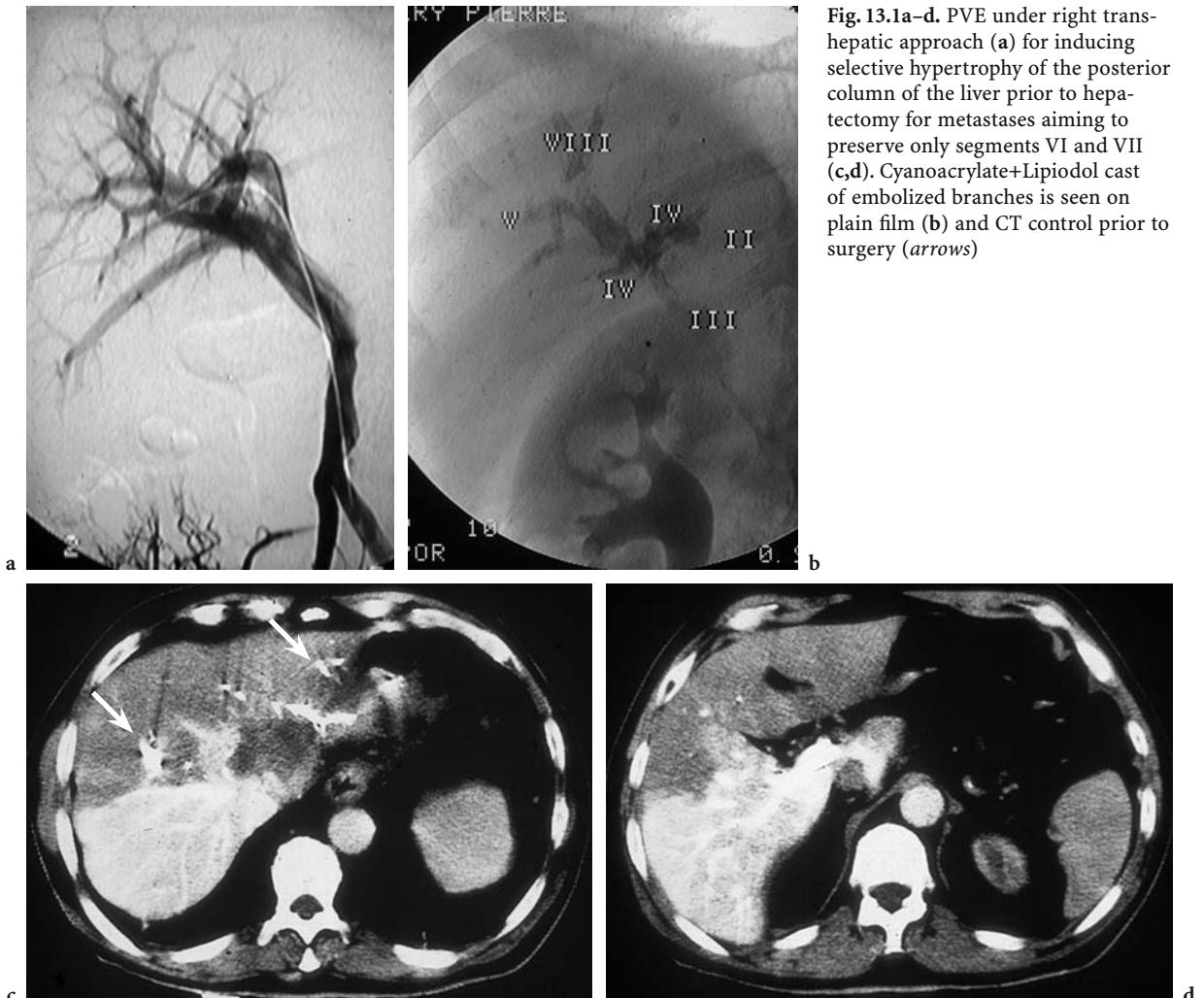


Fig. 13.1a–d. PVE under right transhepatic approach (a) for inducing selective hypertrophy of the posterior column of the liver prior to hepatectomy for metastases aiming to preserve only segments VI and VII (c,d). Cyanoacrylate+Lipiodol cast of embolized branches is seen on plain film (b) and CT control prior to surgery (arrows)

type, interest of performing a distal embolization rather than a proximal surgical ligation has been contested. Therefore, nowadays there are strong arguments for preferring a distal occlusion. The efficacy of PVE vs. right portal vein ligation before extended right hepatectomy has been recently demonstrated [6]. The increase in FRL volume was significantly higher with PVE (188 +/- 81 ml vs. 123 +/- 58 ml; $P=0.012$). A strictly proximal occlusion allows distal reentry through the intra-parenchymatous vascular shunts opening [57]. After having controlled patients with a previous proximal ligation we also encountered antegrade porto-portal collateral circulation bypassing the ligation and supposed to be parabiliary veins homologue to the parabiliary arteries well known to play a predominant role in the development of intrahepatic arterial collateral circulation's. Lastly, in rare cases we encountered macroscopic distal intra hepatic porto-portal anastomosis (Fig. 13.2) that could also minimize the efficacy of a too proximal occlusion in some patients.

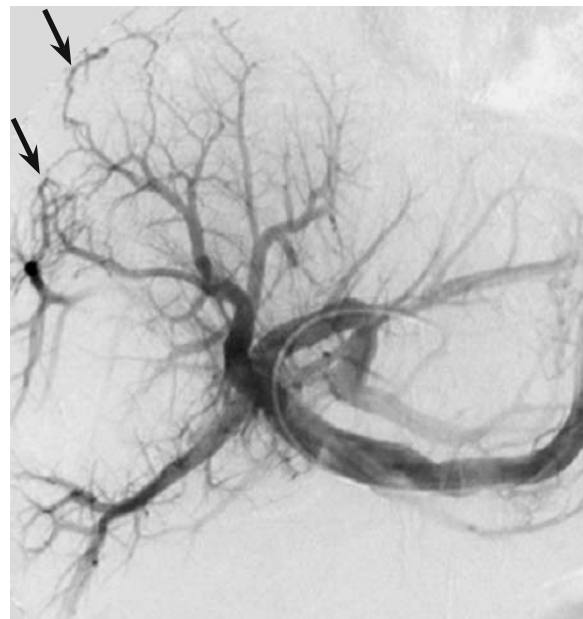


Fig. 13.2. Spontaneous intrahepatic porto-portal anastomosis in the right liver (arrows), demonstrated during a direct transhepatic portography under left approach

13.5.2.3

Embolic Agents

Many embolic agents have been used and compared, either in animal experiments or clinical use. There is no definitive argument in the literature in favor of one specific type of embolus, excepted that the embolic agent must provide a distal occlusion (Table 13.3). Among particulate and liquid embolus, the actual tendency is to favor agents inducing complete, distal and durable occlusion as well as a strong inflammatory reaction. Most of teams actually seem to prefer Histoacryl/Lipiodol mixture. Absolute ethanol has also been experimentally assessed and clinically used by several teams [49, 57, 58]. Fifteen to 65 ml of ethanol had to be injected to induce an adequate occlusion, either in right portal vein or at a segmental or subsegmental level. Technical easiness of its use and efficacy to inducing hypertrophy are clear advantages of ethanol. On the opposite, its clinical and hepatic biological tolerance appeared to be much poorer than that of cyanoacrylate. Consequently, one should be very careful in using this embolic agent, especially in patients with compromised liver. Recently, new agent have been studied in attempt to benefit from ethanol advantages while limiting its adverse effects [30] or using sclerosing agents combined with gelatin sponge [25]. Coils do not induce distal occlusion and are generally used combined with a distal embolus [38] or in rare cases where

Table 13.3. Compared efficacy of different usual embolic agents

	Embolic agents	Induced hypertrophy
DE BAERE et al. [10] (hypertrophy at 4 weeks)	Gelatin sponge	53%
	Coils	44%
	Cyanoacrylate	68%
KANEKO et al. [25] (hypertrophy at 2 weeks)	Gelatin sponge	21.9%
	Fibrin glue	13.5%
	Cyanoacrylate	25.0%

an efficient and safe occlusion is not feasible with cyanoacrylate or particulate embolus. Particulate calibrated agents may also be used: polyvinyl alcohol particles [7] or Embospheres (personal data).

13.6 Complications

13.6.1 Tolerance

Clinical tolerance is generally excellent with only mild abdominal pain or discomfort and slight fever which disappear in less than 3 days. A flush syndrome may occur in the post embolization period in patients with carcinoid primary, and should be systematically prevented. During the post PVE period,

prothrombin time remains above 70% of the baseline value. Serum aspartate transaminase and alanine transaminase slightly increase and may reach a maximum value of threefold the normal value on the first day post PVE, excepted when using ethanol that induces a greater cytotoxicity. Alterations in the total bilirubin level are insignificant. Normally, the total duration of hospitalization for the procedure does not exceed 3 days.

At histopathological study, there is no macroscopic difference between embolized and nonembolized liver. In patients embolized with gelatin sponge, small vessels remain patent even though the main portal branches are obstructed. In patients embolized with Histoacryl (Fig. 13.3), portal vein walls are damaged with their lumen filled with embolic material and macrophage cells and periportal inflammatory reaction and fibrosis are constantly associated. A massive peribiliary fibrosis, as encountered in sclerosing cholangitis, is also observed in most of the cases treated with cyanoacrylate. Specimens contain very rare and small foci of necrotic tissue, excepted for ethanol embolization where there are more important.

13.6.2 Complications

In the literature from experienced teams, complications rate rarely exceed 1.5%, without any reported mortality. Main reported complications include pneumothorax, subcapsular hematoma, arterial pseudoaneurysm after inadvertent arterial puncture and portal vein thrombosis [31]. The risks are higher in patients with portal hypertension and/or blood

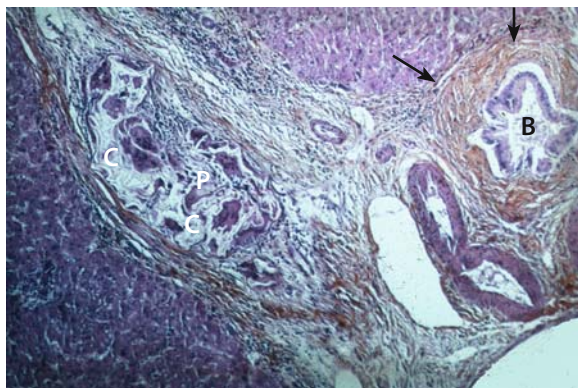


Fig. 13.3. Liver histopathology of the resected parenchyma 4 weeks after portal embolization with Histoacryl. Portal branch (P) filled with cyanoacrylate (C). Bile duct (B) presenting a massive periductal fibrosis (arrows)

coagulation disorders. In patients who underwent a duodenopancreatectomy and who chronically present an infected biliary tree, the PVE can be done without risk of hepatic abscess, contrarily to that occurs after intra-arterial chemoembolization or after radiofrequency ablation.

13.6.3 Does PVE Accelerate Growth Rate of Liver Metastases?

It is well known that partial hepatectomy accelerates local tumor growth [45]. Some of the cytokines and growth factors involved in liver regeneration or hypertrophy may also be involved in tumor burden. For example, transforming growth factor- α is a strong stimulator of liver regeneration but has also been demonstrated to have stimulatory effects on tumor growth in vitro [36]. Consequently, one could suppose PVE to accelerate tumor growth of lesions located in the FRL. Our group studied volumetry of the FRL and that of liver metastases located in the FRL in five cases [13]. Volumes measurement prior to PVE and one month later showed that increase of the normal liver varied to 59%–127%, compared with 60%–970% for the metastases. The ratio between the growth rate of the left lobe and the liver metastases varied from 1.0 to 15.6. However, the spontaneous growth rate of metastases prior to PVE, that should be subtracted to the total tumor growth to define the exact potential enhancement by PVE, was unknown in this study. More recently, Kokudo et al. demonstrated an increase in proliferative activity of intrahepatic colorectal metastases in patients who underwent PVE compared with a control non-PVE group [33]. The Ki-67 labeling index of metastatic lesions was significantly higher in the PVE group. Long-term survival was similar in the two groups but disease-free survival was significantly poorer in the PVE group. To overpass this potential adverse effect, some have proposed a two-stage hepatectomy, PVE being performed after a primary resection of metastases that are present in the FRL [22]. Radiofrequency ablation of lesions located in the FRL, prior or simultaneously to PVE, is also an alternative option (Fig. 13.4). To conclude, complementary studies are still needed but it is logical to consider that PVE accelerates tumor growth in some patients and some tumors. However, clinical experience demonstrates that this rare and probably limited adverse effect remains negligible compared to advantages of PVE in widely extending indications for curative surgery.

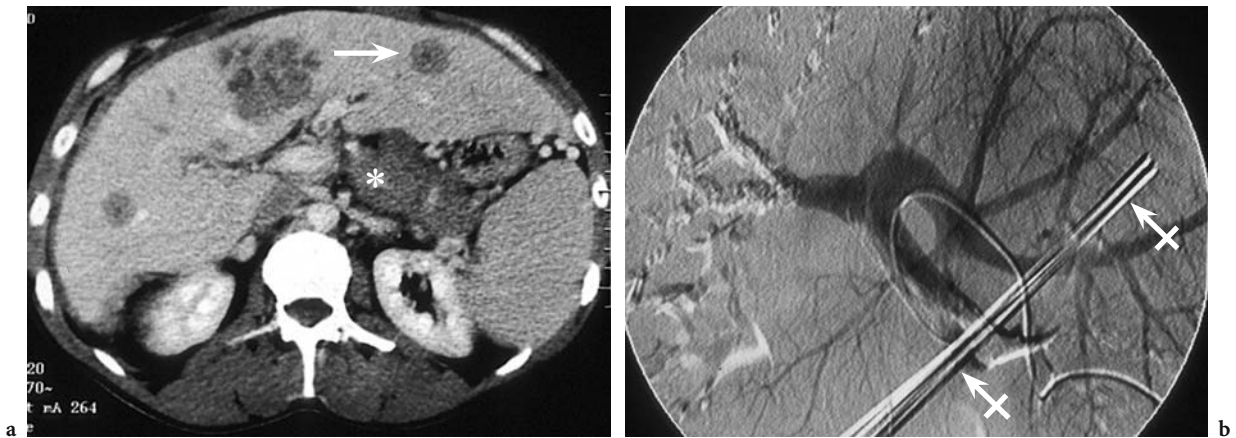


Fig. 13.4a,b. PVE under left transhepatic approach prior to right hepatectomy extended to segment IV for liver metastases from pancreatic carcinoid tumor (*asterisk*). Percutaneous radiofrequency ablation of a left lobe single lesion (*arrow*) is performed along the same session. Control portography (b) after PVE, the triple cooled RF needle being in place (*crossed arrow*)

13.7

Results

13.7.1

Liver Hemodynamic Effects of Portal Vein Embolization

When performed on a normal liver, right portal vein embolization induces an immediate mild increase in portal pressure, from 2 to 5 cm of saline. However, some minutes or even seconds after embolization, the portal pressure comes back to its initial value. In patients with abnormal liver parenchyma, portal pressure increase tends to be greater and more durable. Interestingly, in both cases, the portal pressure registered immediately after PVE is similar to levels registered after hepatectomy, and subsequently may have a diagnostic interest in predicting the hemodynamic surgical outcome [55].

13.7.2

Induced Hypertrophy, Delay to Surgery

Along the last 10-year period we have performed PVE in 108 patients, before right hepatectomy in 43 cases, right extended hepatectomy in 58 cases and more complex hepatectomy in 7 cases (6.4%). We have reported a mean increase of 70% in the size of the FRL and a ratio of FRL/Total liver that increased by 12.4% and measured 32% four weeks after PVE [12]. Main series report increases in volume of 30 to 42 % and FRL/Total liver ratio increases from 19%–36% to 31%–59%. Disparities may be explained

by different delays before surgery (2–4 weeks), use of diverse embolic agents and different proportion of patients with compromised liver in the respective studies [1, 21, 27, 28, 37, 58]. In animals, complete hypertrophy of the contralateral hepatic lobe occurs 3–6 months after portal branch ligation. Hepatic regeneration follows an exponential curve, with a 250% increase in the remnant volume during the first week after resection of 80% of the liver. Delay between PVE and surgery should be as short as possible to preclude any tumor growth. In our experience, all patients reached the critical FRL/Total functional liver volume ratio of 25% after 4–5 weeks. Consequently, as several other teams, we consider a 4–5 weeks delay before surgery to be a good compromise between hepatic hypertrophy and tumor dissemination. Other teams consider the hypertrophy gain negligible after 2–3 weeks and prefer to perform the resection earlier. Interest of PVE prior to large resections was evaluated through retrospective [2, 16, 20] or prospective [15] comparisons with non-PVE series. In all retrospective studies, FRL were significantly smaller at presentation in PVE group and thank to PVE were similar at surgery.

13.7.3

Hypertrophy in Patients with Underlying Liver Disease

Almost all patients with normal liver experience hypertrophy after PVE since only 86% develops hypertrophy in patients with chronic liver disease [15]. Furthermore, in most of the studies, hyper-

trophy is milder and slower (35%–40% increase in volume of the FRL at 1 month) than in normal liver. In damaged liver due to viral hepatitis, increase in volume of the FRL was 25% at 2 weeks, compared with a 34% value in normal liver [56]. In HCC with injured liver, Ji et al. recently reported FRL/Total liver ratio increasing from 36% to 40.8% at 1 week and 47.3% at 3 week [23]. More and more frequently, major hepatectomy for metastases has to be done in patients with liver fibrosis following long-term systemic chemotherapy or intraarterial infusion. We have reported that hypertrophy can also be achieved in such cases of liver injury [12].

13.7.4

Is Hypertrophy Predictable?

Patients with diabetes mellitus have lower hypertrophy [41]. Imamura et al. showed that diabetes mellitus, a high total bilirubin level at time of PVE and being male each reduced the extent of hypertrophy in FRL and that cholestasis accelerated the process of atrophy in the embolized lobe [21]. The hypertrophy rate has a significant correlation with the absolute value of portal blood flow velocity on day 1 post PVE [18] and Doppler evaluation of left portal branch velocity along the post PVE period seems to easily predict the hypertrophy rate of the nonembolized left lobe [17]. The parenchymal volumetric rate of the FRL before PVE in patients with damaged liver parenchyma due to viral hepatitis, and both this volumetric rate and prothrombin time have been showed as independent parameters predicting the hypertrophic ratio of FRL after PVE [56]. Indocyanine green retention rate at 15 min is an adverse predicting factor for all patients and platelet count is significantly correlated with the hypertrophic ratio in hepatocellular patients [24].

13.7.5

Is Liver Failure after Surgery Predictable?

Patient selection criteria for hepatectomy following PVE are still under investigation. For WAKABAYASHI et al. postoperative liver failure appears to be more severe in patients having high portal pressure and hypertrophy of the FRL lower than 20% [55]. In another study, the same team founded that portal pressure and serum level of hyaluronate measured before and after PVE were the most useful parameters in prediction of the outcome of the following

hepatectomy [56]. The cut-off points of significance for serum hyaluronate were 130 ng/ml and 160 ng/ml before and after PVE respectively. Cut-off for portal pressures was 16 cm and 25 cm of saline, measured before and immediately after PVE respectively. Consequently, high initial portal pressure and important elevation after PVE both indicate limited resection, and an initially elevated pressure should be considered as a poor indication for PVE. Preoperative ^{99m}Tc-galactosyl serum albumin has been reported as a useful tool for predicting residual liver function before hepatectomy [44]. In patients who needed major hepatectomy for biliary tract malignancy and presenting with jaundice, skeletonization of the hepatoduodenal ligament was significantly correlated to postoperative hyperbilirubinemia, even after PVE [16]. Anyway, in high risk group of patients, PVE suppresses rise in total bilirubin and thrombin-antithrombin complex, decreases the incidence of postoperative complications and reduces intensive care unit or total hospital stay after hepatectomy [15, 16].

13.7.6

Long-term Results and Survival

In patients presenting hepatobiliary malignancies without chronic liver disease, ABDALLA et al. reported equivalent median survival durations when they underwent PVE or not prior to extended hepatectomy (> or = 5 segments), respectively 40 and 52 months [2]. We have reported 5-year survival and 5-year disease-free survival of 34% and 24% respectively in 60 patients who underwent PVE for liver metastases, that was comparable with the survival rates obtained after resection without PVE [14]. Compared long-term results from the literature, in specific groups of patients presenting with liver metastases from colorectal primary or with hepatocellular carcinoma, are summarized in Table 13.4. All these studies demonstrated equivalence in 5-year survival and 5-year disease-free survival between groups of patients preoperatively treated by PVE or not (Table 13.4).

13.8

Future Developments and Research

Cyanoacrylate, the main efficient embolic agents for PVE, necessitates sophisticated manipulations and

Table 13.4. Long-term survival of patients with liver metastases from colorectal cancer or hepatocellular carcinoma: statistical equivalence in long-term survival rates between groups of patients who underwent preoperative PVE (PVE) or not (NPVE)

	Metastases from colorectal cancer					Hepatocellular carcinoma			
		Number of resected patients	% of patients resected after PVE	5-year survival rate (%)			Overall actuarial survival rate (%)		
						1-year	3-year	5-year	
AZOULAY et al.[4]	PVE	19	63	40	AZOULAY et al. [5]	PVE	89	67	44
	NPVE	88	-	38		NPVE	60	53	53
ELIAS et al. [14]	PVE	41	87	37.3	WAKABAYASHI et al. [56]	PVE	72.2	72.2	39.9
	NPVE	357	-	38.1		NPVE	86.8	80.2	44.1

very specific training for its safe use. Ethanol is also efficient in inducing hypertrophy but carries out poorer tolerance that limit its use at least in compromised liver. Therefore, researches for improving embolic agents for PVE are certainly still required. Accessibility to a combined Angio-CT suite allows real time precise intrahepatic portal mapping during the procedure and increases possibilities for on-demand atypical and hyperselective PVE, adapted to the most complex types of hepatectomies. A FRL/Total functional liver ratio of more than 30% is widely admitted as a requested condition for allowing a safe hepatectomy in patients with normal liver. However, curative resection is frequently discussed in patients presenting with an injured liver: liver cirrhosis and any type of liver fibrosis, previous intra-arterial (or even systemic) long-term chemotherapy, severe fatty steatosis, chronic hepatitis, or previous hepatic resection. The cut-off of liver volume to be preserved remains still unclear in these patients with compromised liver and should be clarified through prospective studies. Computer simulation of liver resection or radiofrequency ablation, for preoperative assessment of volumes and function (possibly based on the indocyanine green clearance) should also be developed.

13.9 Conclusion

PVE is a safe technique allowing efficient preoperative hypertrophy of the FRL in selected cases. It is recommended to perform distal embolization rather than proximal occlusion or ligation. Embolic agents producing high local inflammatory reaction induce greater hypertrophy than others do.

PVE neither improves nor worsens long-term prognosis but it allows curative resection in patients that otherwise are considered as unresectable. Nowadays,

it may be frequently combined with multiple other efficient therapeutic modalities (systemic or intra-arterial chemotherapy, chemoembolization, radiofrequency ablation) in order to lead more patients with malignant liver tumor to radical surgery.

References

1. Abdalla EK, Hicks ME, Vauthey JN (2001) Portal vein embolization: rationale, technique and future prospects. *Br J Surg* 88:165-175
2. Abdalla EK, Barnett CC, Doherty D et al. (2002) Extended hepatectomy in patients with hepatobiliary malignancies with and without preoperative portal vein embolization. *Arch Surg* 137:675-680
3. Adam R, Lucidi V, Bismuth H (2004) Hepatic colorectal metastases: methods of improving resectability. *Surg Clin North Am* 84:659-671
4. Azoulay D, Castaing D, Smail A et al. (2000a) Resection of nonresectable liver metastases from colorectal cancer after percutaneous portal vein embolization. *Ann Surg* 231:480-486
5. Azoulay D, Castaing D, Krissat J et al. (2000b) Percutaneous portal vein embolization increases the feasibility and safety of major liver resection for hepatocellular carcinoma in injured liver. *Ann Surg* 232:665-672
6. Broering DC, Hillert C, Krupski G et al. (2002) Portal vein embolization vs. portal vein ligation for induction of hypertrophy of the future liver remnant. *J Gastrointest Surg* 6:905-913
7. Brown KT, Brody LA, Decorato DR et al. (2001) Portal vein embolization with use of polyvinyl alcohol particles. *J Vasc Interv Radiol* 12:882-886
8. Bucher NLR, Swaffield MN (1975) Regulation of hepatic regeneration in rats by synergistic action of insulin and glucagon. *Proc Natl Acad Sci USA* 72:1157-1160
9. Chijiwa K, Saiki S, Noshiro H et al. (2000) Effect of preoperative portal vein embolization on liver volume and hepatic energy status of the nonembolized liver lobe in humans. *Eur Surg Res* 32:94-99
10. De Baere T, Roche A, Elias D et al. (1996) Preoperative portal vein embolization for extension of hepatectomy indications. *Hepatology* 24:1386-1391
11. Denys AL, Abehsera M, Leloutre B et al. (2000) Intrahepatic hemodynamic changes following portal vein embolization.

- lization: a prospective Doppler study. *Eur Radiol* 10:1703–1707
12. Elias D, de Baere T, Roche A et al. (1998) Preoperative selective portal vein embolizations are an effective means of extending the indications of major hepatectomy in normal and injured liver. *Hepatogastroenterology* 45:170–177
 13. Elias D, de Baere T, Roche A et al. (1999) During liver regeneration following right portal embolization the growth rate of liver metastases is more rapid than that of the liver parenchyma. *Br J Surg* 86:784–788
 14. Elias D, Ouellet JF, de Baere T et al. (2002) Preoperative selective portal vein embolization before hepatectomy for liver metastases: long-term results and impact on survival. *Surgery* 131:294–299
 15. Farges O, Belghiti J, Kianmanesh R et al. (2003) Portal vein embolization before right hepatectomy: prospective clinical trial. *Ann Surg* 237:208–217
 16. Fujii Y, Shimada H, Endo I et al. (2003) Effects of portal vein embolization before major hepatectomy. *Hepatogastroenterology* 50:438–442
 17. Gerunda GE, Bolognesi M, Neri D et al. (2002) Preoperative selective portal vein embolization (PSPVE) before major hepatic resection. Effectiveness of Doppler estimation of hepatic blood flow to predict the hypertrophy rate of non-embolized liver segments. *Hepatogastroenterology* 49:1405–1411
 18. Goto Y, Nagino M, Nimura Y (1998) Doppler estimation of portal blood flow after percutaneous transhepatic portal vein embolization. *Ann Surg* 228:209–213
 19. Harada H, Imamura H, Miyagawa S et al. (1997) Fate of the human liver after hemihepatic portal vein embolization: cell kinetic and morphometric study. *Hepatology* 26:1162–1170
 20. Hemming AW, Reed AI, Howard RJ et al. (2003) Preoperative portal vein embolization for extended hepatectomy. *Ann Surg* 237:686–691
 21. Imamura H, Shimada R, Kubota M et al. (1999) Preoperative portal vein embolization: an audit of 84 patients. *Hepatology* 29:1099–1105
 22. Jaeck D, Bachellier P, Nakano H et al. (2003) One or two-stage hepatectomy combined with portal vein embolization for initially nonresectable colorectal liver metastases. *Am J Surg* 185:221–229
 23. Ji W, Liu WH, Ma KS et al. (2003) Preoperative selective portal vein embolization in two-step hepatectomy for hepatocellular carcinoma in injured livers: a preliminary report. *Hepatobiliary Pancreat Dis Int* 2:216–220
 24. Kaido T, Aarii S, Shimada Y et al. (2003) Portal embolization in various types of liver: novel variables to predict hypertrophy. *Hepatogastroenterology* 50:140–145
 25. Kaneko T, Nakao A, Takagi H (2002) Clinical studies of new material for portal vein embolization: comparison of embolic effect with different agents. *Hepatogastroenterology* 49:472–477
 26. Kawai M, Naruse K, Komatsu S et al. (2002) Mechanical stress-dependent secretion of interleukin 6 by endothelial cells after portal vein embolization: clinical and experimental studies. *J Hepatol* 37:240–246
 27. Kawasaki S, Makuuchi M, Kahazu T et al. (1994a) Resection for multiple metastatic liver tumors after portal embolization. *Surgery* 115:674–677
 28. Kawasaki S, Makuuchi M, Miyagawa S et al. (1994b) Radical operation after portal embolization for tumor of hilar bile duct. *J Am Coll Surg* 178:480–486
 29. Kinoshita H, Sakai K, Hirohashi K et al. (1986) Preoperative portal vein embolization for hepatocellular carcinoma. *World J Surg* 10:803–808
 30. Ko GY, Sung KB, Yoon HK et al. (2003) Preoperative portal vein embolization with a new liquid embolic agent. *Radiology* 227:407–413
 31. Kodama Y, Shimizu T, Endo H et al. (2002) Complications of percutaneous transhepatic portal vein embolization. *J Vasc Interv Radiol* 13:1233–1237
 32. Kokudo N, Makuuchi M (2004) Current role of portal vein embolization/hepatic artery chemoembolization. *Surg Clin North Am* 84:643–657
 33. Kokudo N, Tada K, Seki M et al. (2001) Proliferative activity of intrahepatic colorectal metastases after preoperative hemihepatic portal vein embolization. *Hepatology* 34:267–272
 34. Kubo S, Shiomi S, Tanaka H et al. (2002) Evaluation of the effect of portal vein embolization on liver function by (99m)tc-galactosyl human serum albumin scintigraphy. *J Surg Res* 107:113–118
 35. Kusaka K, Imamura H, Tomiya T et al. (2004) Factors affecting liver regeneration after right portal vein embolization. *Hepatogastroenterology* 51:532–535
 36. Lee GE, Merlino G, Fausto N (1992) Development of liver tumors in transforming growth factor alpha transgenic mice. *Cancer Res* 52:5162–5170
 37. Lee KG, Kinoshita H, Hirohashi K et al. (1993) Extension of surgical indications for hepatocellular carcinoma by portal vein embolization. *World J Surg* 17:109–115
 38. Madoff DC, Hicks ME, Abdalla EK et al. (2003) Portal vein embolization with polyvinyl alcohol particles and coils in preparation for major liver resection for hepatobiliary malignancy: safety and effectiveness—study in 26 patients. *Radiology* 227:251–260
 39. Makuuchi M, Thai BL, Takayasu K et al. (1990) Preoperative portal embolization to increase safety of major hepatectomy for hilar bile duct carcinoma: a preliminary report. *Surgery* 107:521–527
 40. Miyake H, Fujii M, Sasaki K et al. (2003) Heat shock protein 70 induction in hepatocytes after right portal vein embolization. *Hepatogastroenterology* 50:2084–2087
 41. Nagino M, Nimura Y, Kamiya J et al. (1995) Changes in hepatic lobe volume in biliary tract cancer patients after right portal vein embolization. *Hepatology* 21:434–439
 42. Nagino M, Nimura Y, Kamiya J et al. (1996) Selective percutaneous transhepatic embolization of the portal vein in preparation for extensive liver resection: the ipsilateral approach. *Radiology* 200:559–563
 43. Nagino M, Kamiya J, Kanai M et al. (2000) Right trisegment portal vein embolization for biliary tract carcinoma: technique and clinical utility. *Surgery* 127:155–160
 44. Nishiyama Y, Yamamoto Y, Hino I et al. (2003) 99mTc galactosyl human serum albumin liver dynamic SPET for pre-operative assessment of hepatectomy in relation to percutaneous transhepatic portal embolization. *Nucl Med Commun* 24:809–817
 45. Panis Y, Ribeiro J, Chretien F et al. (1992) Dormant liver metastases: an experimental study. *Br J Surg* 79:221–223
 46. Perarnau JM, Daradkeh S, Johann M et al. (2003) Transjugular preoperative portal embolization (TJPE) a pilot study. *Hepatogastroenterology* 50:610–613
 47. Roche A, Soyer P, Elias D et al. (1991) Preoperative portal vein embolization for hepatic metastases. *J Intervent Radiol* 6:63–66

48. Shimada R, Imamura H, Nakayama A et al. (2002) Changes in blood flow and function of the liver after right portal vein embolization. *Arch Surg* 137:1384–1388
49. Shimamura T, Nakajima Y, Une Y et al. (1997) Efficacy and safety of preoperative percutaneous transhepatic portal embolization with absolute ethanol: a clinical study. *Surgery* 121:135–141
50. Starzl TE, Francavilla A, Halgrimson CG (1973) The origin, hormonal nature and action of hepatotrophic substances in portal venous blood. *Surg Gynecol Obst* 137:179–199
51. Tominaga M, Ku Y, Iwasaki T et al. (2002) Effect of portal vein embolization on function of the nonembolized lobes of the liver: evaluation by firstpass hepatic lidocaine extraction in dogs. *Surgery* 132:424–430
52. Tsukamoto T, Kinoshita H, Hirohashi K et al. (1999) Human erythrocyte polyamine levels after portal vein embolization. *Hepatogastroenterology* 46:3178–3183
53. Uesaka K, Nimura Y, Nagino M (1996) Changes in hepatic lobar function after right portal vein embolization. An appraisal by biliary indocyanine green excretion. *Ann Surg* 223:77–83
54. Wakabayashi H, Ishimura K, Okano K et al. (2001) Is preoperative portal vein embolization effective in improving prognosis after major hepatic resection in patients with advanced-stage hepatocellular carcinoma? *Cancer* 92:2384–2390
55. Wakabayashi H, Yachida S, Maeba T et al. (2002a) Evaluation of liver function for the application of preoperative portal vein embolization on major hepatic resection. *Hepatogastroenterology* 49:1048–1052
56. Wakabayashi H, Ishimura K, Okano K et al. (2002b) Application of preoperative portal vein embolization before major hepatic resection in patients with normal or abnormal liver parenchyma. *Surgery* 131:26–33
57. Yamakado K, Takeda K, Nishide Y et al. (1995) Portal vein embolization with steel coils and absolute ethanol: a comparative experimental study with canine liver. *Hepatology* 22:1812–1818
58. Yamakado K, Takeda K, Matsumura K et al. (1997) Regeneration of the un-embolized liver parenchyma following portal vein embolization. *J Hepatol* 27:871–880

14 Embolotherapy for Neuroendocrine Tumor Hepatic Metastases

KONG TENG TAN and JOHN R. KACHURA

CONTENTS

14.1	Introduction	177
14.2	Pathophysiology and Clinical Considerations	178
14.3	Technique	179
14.3.1	Patient Selection	179
14.3.2	Embolization Protocols	180
14.3.3	Pre-Embolization Preparation	180
14.3.4	Embolization Technique (Table 14.2)	180
14.3.5	Post-Embolization and Follow-up	181
14.4	Results	184
14.5	Complications (Table 14.3)	184
14.5.1	Angiographic Complications	184
14.5.1.1	Nontarget Embolization	184
14.5.1.2	Embolization complications	185
14.6	Pitfalls	185
14.7	Conclusion	186
	References	186

14.1 Introduction

Neuroendocrine tumors comprise an interesting group of rare neoplasms, which are derived from neuroendocrine cells interspersed within the gastrointestinal system and throughout the body. In the gastrointestinal tract, they mainly manifest as pancreatic islet-cell tumors and carcinoid tumors which are essentially serotonin-secreting tumors that originate from enterochromaffin cells. Due to its rarity, the epidemiology of malignant neuroen-

docrine tumors was not well established until relatively recently. A large population-based registry in France documented incidences of 7.6 and 5.0 cases per million population for men and women, respectively, with increasing incidence over time for both sexes [1]. All together, these tumors account for 1% of all gastrointestinal tumors. The small bowel is the most common primary site (40%), followed by the large bowel (30%) and the pancreas (20%) [1].

Although these tumors are well known for producing various hormonal syndromes, approximately half are nonfunctioning or do not produce hormones of clinical significance. In addition, these tumors are often indolent, described by MOERTEL [2] as “cancers in slow motion”, with which patients may live for many years. Indeed at the time of diagnosis, the duration of symptoms attributable to the tumor frequently exceeds several years. Nevertheless, patients with carcinoid tumor metastatic to the liver have a median survival of only 3 years, with at most 30% of them still alive 5 years after diagnosis [2,3]. Therefore, the index of suspicion must be high in order to diagnose these tumors prior to the development of metastases in a timely fashion. When these tumors present clinically, the symptoms are caused by either hormonal excess, local tumor growth, or metastatic spread. Although surgical extirpation remains the only curative modality, it is feasible merely in patients presenting with local disease, which accounts for <30% of all cases. On the other hand, visceral or lymph node metastases already are present in >70% of patients at first clinical presentation, with liver metastases accounting for 60% of all secondaries [1,4,5].

The main prognostic factors of these tumors are the stage of disease at presentation, anatomical location of tumor, histological subtype, and adequacy of surgical resection [6–8]. Five-year survival of patients with and without metastatic carcinoid tumors are 0%–40% and 75%–99%, respectively [2,3,9,10]. The corresponding figures for the second most common gastrointestinal neuroendocrine tumor, i.e. gastrinoma, are 20% and 65% [11].

K. T. TAN, MB, BCh, FRCS, FRCR
Division of Vascular and Interventional Radiology,
Department of Medical Imaging, Toronto General Hospital,
585 University Avenue, NCSB 1C-563, Toronto, Ontario,
Canada M5G 2N2
J. R. KACHURA, MD, FRCPC
Division of Vascular and Interventional Radiology,
Department of Medical Imaging, Toronto General Hospital,
200 Elizabeth Street, Eaton South 1-454d, Toronto, Ontario,
Canada M5G 2C4

14.2 Pathophysiology and Clinical Considerations

Gastrointestinal neuroendocrine tumors often develop extensive hepatic metastases that remain clinically silent until the liver's metabolic capacity is overtaken by the increasing serotonin and neuropeptides produced by these tumors [12]. When tumor burden overtakes hepatic metabolic function, the excess hormones are released into the systemic circulation producing a variety of syndromes, the commonest of which is the carcinoid syndrome, characterized by flushing, diarrhea, cardiac valvular damage, bronchoconstriction, and pellagra. Although these symptoms are usually well-controlled using somatostatin analogues (octreotide), tolerance generally occurs which eventually leads to a decrease and finally absence of therapeutic effectiveness [13,14]. Furthermore, the use of octreotide remains solely as a palliative measure, as this therapy has no significant effect on the neuropeptide production nor reduces metastatic load [15,16]. Hence, since the introduction of somatostatin analogues, the commonest cause of death in these patients is liver failure from tumor progression [17].

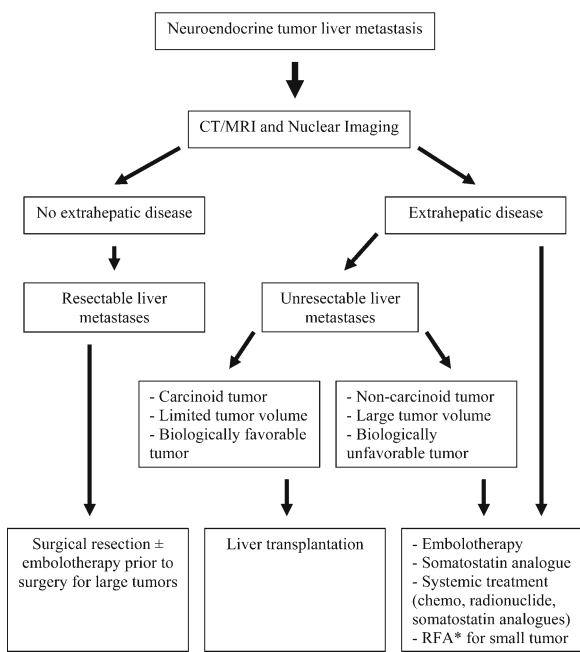
Liver metastases from neuroendocrine tumors may be found synchronously with the primary tumor, may occur following resection of a primary tumor, or may occur in the absence of a detectable primary tumor. Imaging modalities available for the localization of both primary neuroendocrine tumors and their metastases include ultrasonography (US), computed tomography (CT), magnetic resonance imaging (MRI), endoscopic ultrasonography (EUS), scintigraphy, portal venous sampling, and arteriography. Conventional cross sectional imaging studies (US, CT, MRI) individually have poor accuracy in locating the primary tumor, with reported sensitivities of less than 30% [18–20]. When combined with somatostatin receptor scintigraphy, however, the detection rate improves significantly to 70% [19]. For primary islet cell tumor detection, EUS is the method of choice with reported sensitivities of 80–90% [21,22]. Although reported to have good sensitivity, both portal venous sampling and selective arteriography are invasive diagnostic tests. As with the detection of primary tumors, the diagnosis of neuroendocrine tumor hepatic metastases improves when somatostatin receptor scintigraphy is added to US, CT or MRI, with the resultant sensitivity exceeding 90% in comparison to 40%–50% with cross sectional imaging alone [18–21]. In addi-

tion, scintigraphy is also the best screening test for extrahepatic metastases, the presence of which has significant impact on the treatment planning and outcome [23].

Surgical management of metastatic neuroendocrine tumors remains a significant challenge. A few authors have advocated hepatic resection for resectable hepatic metastases, with results supporting palliation and prolonged survival in these patients [24–33]. However, most patients (> 90%) with metastatic disease are unresectable at diagnosis; other treatment options such as aggressive chemotherapy, cytoreductive procedures, interferon, and symptomatic control with conventional pharmacological methods, all have disappointing results and cure is rare [34–40].

Although neuroendocrine tumors vary in behavior, these tumors share the clinical tendency to metastasize diffusely to the liver and to be extremely vascular [41]. Therefore, it seems logical to target the liver with regional treatment when metastatic neuroendocrine cancers have a substantial hepatic component. The unique dual blood supply of the liver allows interruption of the arterial supply without major risk of hepatic infarction, as normal liver parenchyma derives approximately 75% of its blood supply and one-third of its oxygen supply from the portal venous system. Tumors, however, derive their blood supply entirely from the arterial system. Some authors recommend bland liver embolization whereas others suggest chemoembolization for neuroendocrine tumor hepatic metastases. In chemoembolization, an intra-arterial chemotherapeutic agent is an added component to the embolization procedure, with the premise that such an agent may achieve a drug concentration greater than is possible using an intravenous route, with a long exposure of the tumor to the drug [42] while attaining low systemic toxicity. Furthermore, ischemia from the embolization may render the tumor cells more sensitive to the chemotherapeutic agent [43].

Detailed clinical management of patients with liver metastases from neuroendocrine tumors is beyond the scope of this chapter. A suggested treatment algorithm is shown in Figure 14.1 [44]. Briefly, candidates for treatment can be divided into three groups: (1) those with surgically resectable liver metastases with no extrahepatic disease, (2) those with unresectable liver metastases with no extrahepatic disease, and (3) those with liver metastases as well as extrahepatic disease [44]. Group 1 patients could be offered surgical metastasectomy as this provides the potential for symptomatic improvement, as



*RFA = Radiofrequency ablation

Fig. 14.1. Treatment algorithm for patients with neuroendocrine tumor liver metastases

well as an increase in 5 year survival from 20%–30% without surgical excision to 50%–80% with resection [45,46]. In those patients with large liver metastases, pre-resection hepatic artery embolization can be performed to reduce tumor bulk and hence may facilitate complete resection [47,48]. In addition, pre-resection portal vein embolization of the lobe/segments to be resected can be used to induce compensatory hypertrophy and increase function of the future liver remnant in patients with questionable hepatic reserve. For group 2 and 3 patients, conventional anti-hormonal pharmacological therapies are still considered first line treatment although this is being challenged by newer treatment alternatives. Systemic chemotherapy such as streptozocin has been used on its own or in combination with other agents. The results are variable and often not long lasting, however, with significant systemic toxicity [39, 49]. Although early results with the therapeutic use of I131 metaiodobenzylguanidine (MIBG) are encouraging, as a 5-year survival of 85% and symptomatic relief in a majority of patients with metastatic neuroendocrine malignancy can be achieved, only approximately 50% of patients are receptor positive for MIBG [50]. Moreover, a complete response is rare and the long-term outcome and side effects of MIBG are currently unknown [51–54]. Similarly,

intra-arterial infusion of Indium111 pentetreotide has been used in a small number of patients with encouraging result [55]. Orthotopic liver transplant for hepatic metastases of neuroendocrine tumor is controversial. Early transplant aiming for cure has been suggested for group 2 patients [44]. With the perpetual donor organ shortage and variable results, however, this approach requires further evaluation [56–60].

Hepatic artery embolotherapy (with or without chemotherapeutic agent) has been established as an effective method in long-term control of hormonal symptoms and pain, and in the reduction of tumor growth in patients who are not suitable for surgical excision and refractory to medical therapy [48, 61–65]. Recently, Roche and coworkers proposed the use of chemoembolization as the primary line of treatment in patients with unresectable neuroendocrine liver metastases [64]. The authors reported a 90% symptomatic and a 75% hormonal response in comparison to the 30%–75% response rate with somatostatin analogues, 43% objective tumor reduction in comparison to 5%–15% with somatostatin analogues, and a 5- and 10-year survival of 83% and 56%, respectively, which are considerably better than the previously reported survival rates of 0%–40% in patients who received only conventional medical treatment [2,3,9,10].

14.3 Technique

14.3.1 Patient Selection

Eligibility requirements for hepatic artery embolotherapy for neuroendocrine tumor metastases are summarized in Table 14.1. They include adequate hepatic and renal function, acceptable coagulation parameters, and hepatopedal portal venous flow. While what constitutes an adequate amount of residual uninvolved liver is not clear, in most published series 50% to 60% tumor replacement is considered as the acceptable upper limit. It is well recognized that over 75% tumor replacement is associated with higher incidence of hepatic failure post embolization [48]. In those patients with borderline liver and/or renal function, superselective embolization using smaller amounts of embolic agent and iodinated contrast could be considered.

14.3.2 Embolization Protocols

Unfortunately, due to the rarity of neuroendocrine tumors, there is no consensus on the best embolotherapy protocol. A variety of methods have been used, and no prospective comparative studies have been conducted: (1) particles (bland) embolization including polyvinyl alcohol (PVA), tris-acryl gelatin microspheres, or pledgets of absorbable gelatin sponge, (2) chemoembolization using a cytotoxic agent (such as doxorubicin, mitomycin C, or cisplatin) and Lipiodol (ethiodized oil) with or without a bland embolic agent, (3) cyanoacrylate embolization, and, more recently, (4) selective intra-arterial Indium111 pentetretotide infusion [27, 30, 42, 43, 47, 48, 55, 61–66]. STOKES and colleagues in 1993 suggested that chemoembolization is associated with a shorter recovery period (pain and liver enzyme elevations) in comparison to particle occlusion while producing similar efficacy or response rate [67]. They compared 20 patients treated with hepatic arterial chemoembolization to their prior experience using gelatin sponge powder alone for embolization of metastatic endocrine tumors. Gelatin sponge powder, however, has fallen out of favor as an embolic agent as it penetrates distally and causes tissue necrosis. Also, BROWN and colleagues remind us that no study has demonstrated superiority of adding either chemotherapeutic agents or Lipiodol for the treatment of neuroendocrine tumor hepatic metastases, and that these agents may increase the risk of severe complications [48]. Most published series reported good symptomatic palliation, with response rates ranging from 75% to 100%, following all of the above embolization protocols. At our center, we use PVA or tris-acryl gelatin microspheres for embolotherapy of patients with neuroendocrine tumor hepatic metastases.

For chemoembolization, the most widely used agent is doxorubicin (50 mg/m² body surface area) mixed with iodinated contrast agent and Lipiodol. The amounts of contrast and Lipiodol used have varied, ranging from 0–10 ml and 10–20 ml, respectively. Following intra-arterial chemotherapeutic injection, many routinely occlude the feeding artery with particulate agents such as PVA or gelatin sponge. In our experience, we have not been able to predict the volume of Lipiodol and/or embolic material that a right or left hepatic arterial system can accommodate, based on tumor size, number, and vascularity.

Table 14.1. Inclusion and exclusion criteria for embolotherapy of neuroendocrine tumor liver metastases

Inclusion criteria	
Unresectable tumor	
Patent portal venous system	
Satisfactory liver function	
Satisfactory renal function	
Normal coagulation	
Exclusion criteria	
Occluded portal venous system	
Hepatofugal portal venous flow	
> 75% of hepatic parenchyma replaced by tumor	
Hepatic encephalopathy	
Poor liver function	
Biliary obstruction	
Biliary-enteric anastomosis	
Renal failure	
Uncorrectable coagulopathy	
Life expectancy < 3 months	

14.3.3 Pre-Embolization Preparation

All patients undergo analysis of baseline liver function, electrolytes, renal function, complete blood count, and coagulation studies within 1–4 weeks prior to the procedure. CT or MRI is performed prior to treatment primarily for assessment of portal vein patency and to document lesion size and distribution.

In order to decrease the risk of carcinoid crisis in those patients with symptomatically active tumors, 150–500 micrograms of somatostatin may be given the day before embolotherapy and continued for 3 to 5 days post-treatment [35]. Despite pre-medication, however, carcinoid crisis can occur during the procedure, often manifested by hemodynamic instability. For noncarcinoid or islet cell tumors, treatment of underlying endocrinopathy must be initiated before referral for embolotherapy. In our institution, prophylactic intravenous antibiotic coverage with cefazolin 1 g q8h and metronidazole 500 mg q8h is used routinely during the inpatient stay. In some centers, allopurinol and lactulose are also administered to prevent urate-induced renal failure and post-embolization hepatic encephalopathy.

14.3.4 Embolization Technique (Table 14.2)

The patient is usually admitted the day before or on the morning of the procedure after overnight fast-

ing. Blood pressure, pulse, and oxygen saturation are continuously monitored throughout the procedure, and intravenous sedation (midazolam) and analgesia (fentanyl) are administered as required. Access to the common femoral artery is achieved using Seldinger technique following the infiltration of local anesthesia. A 4 or 5 French vascular sheath is then inserted into the artery. Selective arteriography of the celiac and superior mesenteric arteries is performed to evaluate the anatomy of these vessels, to assess portal venous flow, and to identify the distribution of the metastases (Fig. 14.2). Once the arterial anatomy is clearly understood, a catheter is advanced selectively into the right or left hepatic artery, depending upon which lobe has the greatest tumor burden. If both lobes of the liver have a similar metastatic load, then the hepatic artery that is the easier to catheterize is embolized. A 4 French hydrophilic cobra catheter used with an hydrophilic guidewire usually suffices. Embolic and/or chemotherapeutic material is injected into the selected hepatic artery. It is imperative that the tip of the catheter is beyond any visceral branches, such as gastric arteries, the cystic artery, and the gastroduodenal artery, in order to minimize the risk of nontarget embolization. Small vessels and branches unable to be accessed with a standard angiographic catheter may be selected with a microcatheters (3 French or smaller). To minimize the risk of post-embolization hepatic failure, only one lobe of the liver is treated on each occasion. We use PVA particles or tris-acryl gelatin microspheres > 100 μm diameter, switching to larger particles (e.g. 300–500 μm) when arteriographic tumor blush decreases, and terminating embolization when there is flow stasis throughout the targeted artery distribution. Although manufacturers have

specific instructions for preparation of the particle suspension, we find a 20-ml mixture of 50% full strength nonionic contrast and 50% normal saline satisfactory for any standard vial of embolic agent. A 10-ml syringe is filled with this particle suspension, and is attached to an empty 10-ml syringe and to the catheter by means of a three-way stopcock. By injecting the suspension from one syringe to the other intermittently between embolization injections into the catheter, a uniform suspension of particles can be nicely maintained. Some advocate the administration of lidocaine (10 mg bolus) directly into the treated artery during embolization, in an effort to reduce the pain experienced during or after the procedure [68].

14.3.5 Post-Embolization and Follow-up

Following the embolotherapy, most patients will have some degree of right upper quadrant pain, nausea, vomiting, and low-grade pyrexia due to post-embolization syndrome. The pain, nausea, and vomiting usually resolve within 24 hours. Complete blood counts, coagulation status, electrolytes, liver and renal function tests are performed on daily basis until the patient is discharged. Liver enzymes typically become elevated immediately, peaking in 24–36 hours, and then decrease to pre-embolization levels in less than one week. In those patients with hormonally active tumors, production of 5-hydroxyindoleacetic acid, gastrin or glucagon diminishes considerably (by 90%) within two weeks of treatment, along with associated symptomatic relief [69].

Triphasic contrast-enhanced CT scans of the liver are obtained 1 day, 1 month, 3 months, 6 months, and yearly after embolization, or as required, depending on the clinical status of the patient (Fig. 14.3). The CT scans reveal changes in tumor morphology, tumor size, overall liver size, and the development of new lesions or metastases. Appropriate biochemical tumor markers such as 5-hydroxyindoleacetic acid for carcinoid tumor may be measured before and after embolization at the similar intervals.

Most patients with neuroendocrine tumor liver metastasis have extensive bilobar involvement. As only one lobe is treated during each embolization session, most patients require a minimum of two treatment sessions in order to treat the entire liver, depending on the hepatic arterial anatomy. An interval of 4 to 6 weeks is recommended between treatment sessions to allow for liver function recovery.

Table 14.2. Cookbook. Primary tools for embolization of neuroendocrine tumor liver metastases

Options for celiac artery and superior mesenteric artery catheterization, in preferential order:

- 4 French Cobra 2 hydrophilic catheter and angled hydrophilic guidewire
- 4 or 5 French Sos Omni catheter to engage the origin, then exchange for a 4 French Cobra 2 hydrophilic catheter over a 035 straight Bentson wire or hydrophilic wire
- 4 or 5 French Simmons 1 or 2 catheter
- 4 French Simmons 2 hydrophilic catheter
- Sos Omni or Simmons catheter to engage the celiac origin, and use microcatheter for superselective catheterization

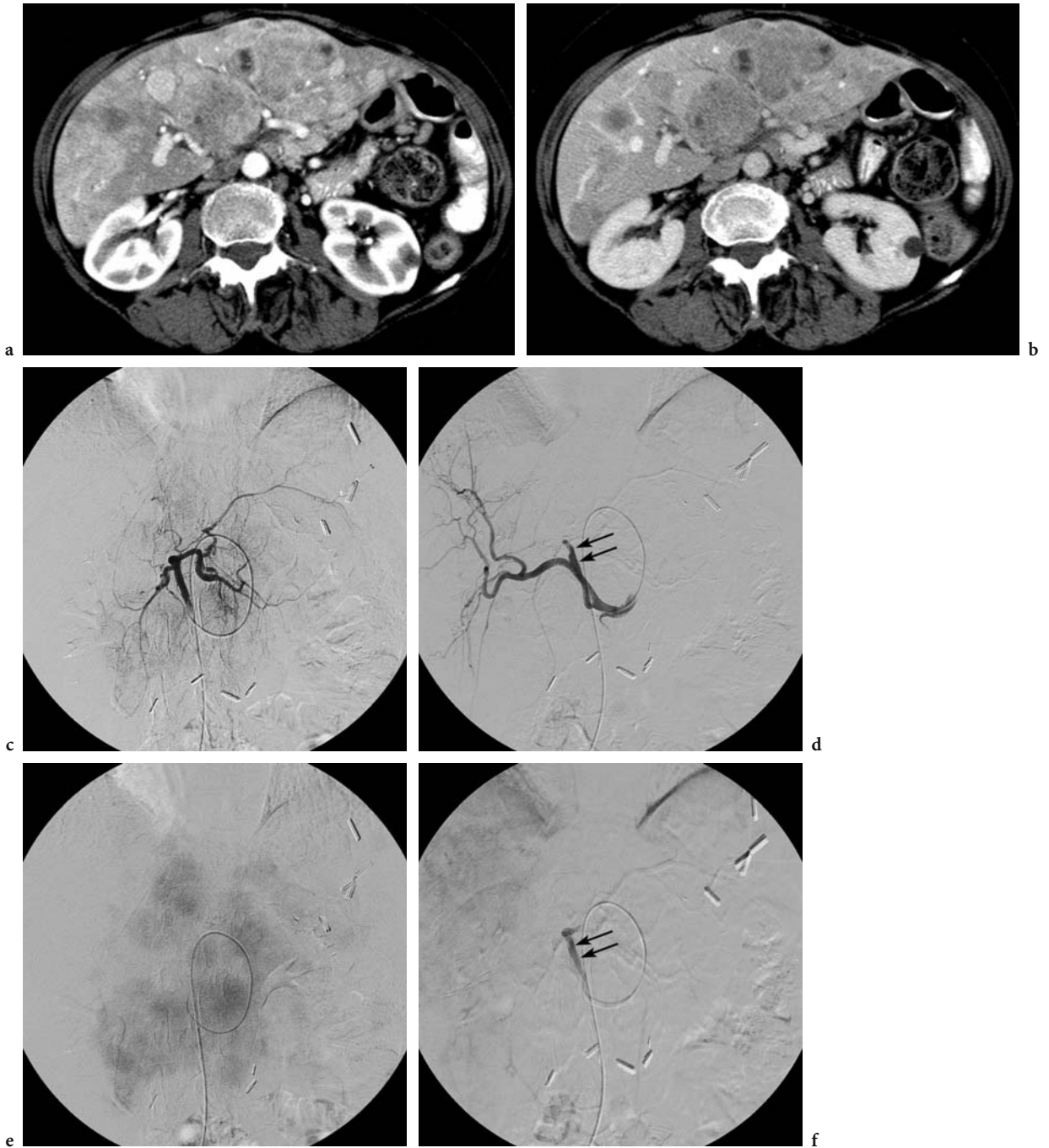


Fig. 14.2a–h. Sixty-four-year-old female with rapidly progressing carcinoid liver metastases. The gastroduodenal artery was surgically ligated at the time of resection of the primary tumor at the gastroduodenal junction 2 years before. Arterial-phase (a) and venous-phase (b) CT images of liver show greater metastatic burden in the left lobe. Selective early (c,d) and delayed (e,f) arteriographic images of left hepatic artery (LHA), before (c,e) and after (d,f) embolization using 5 vials of 100–300 μm tris-acryl gelatin microspheres via a 4 French Cobra II hydrophilic catheter. Arrows denote stagnant contrast column in proximal aspect of embolized LHA. Most of the injected contrast is seen refluxing into the right hepatic artery in (d). Celiac arteriographic images before (g) and after (h) LHA embolization

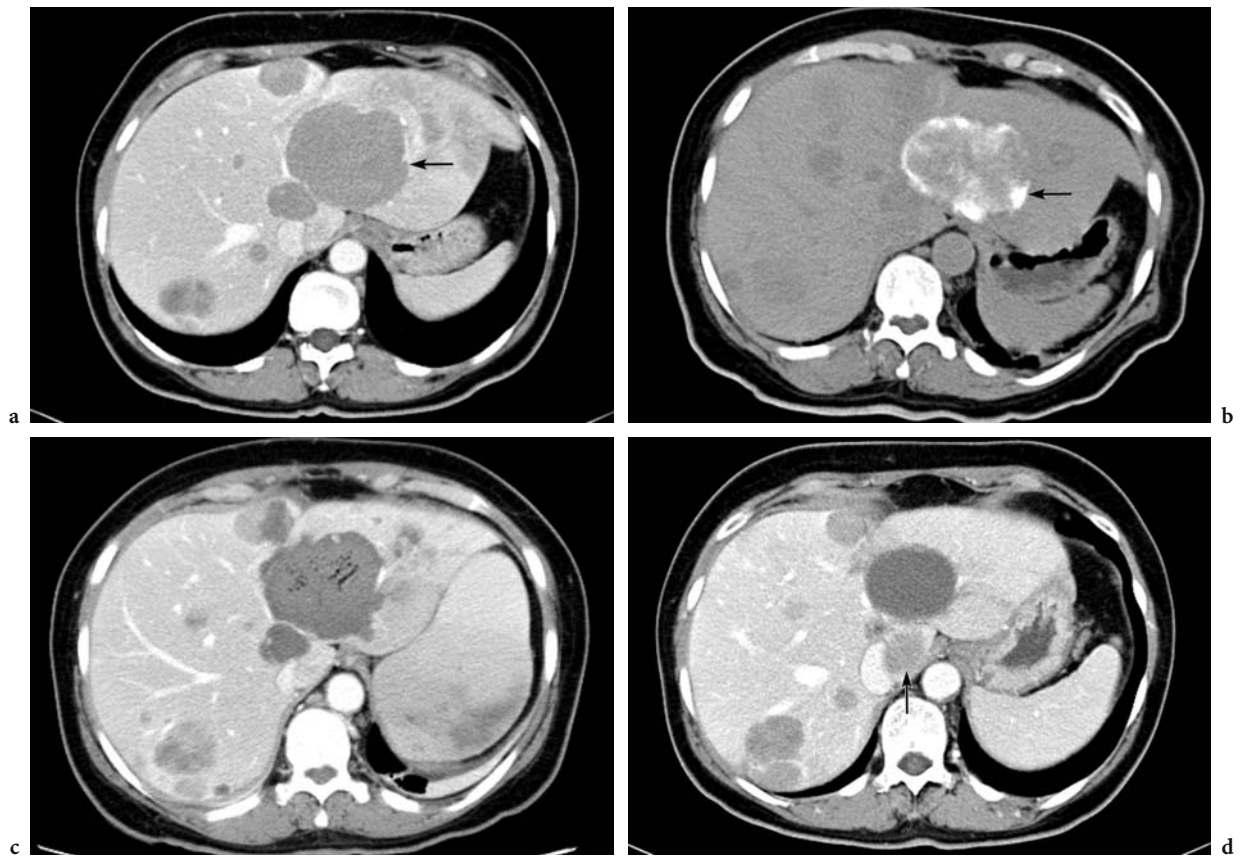
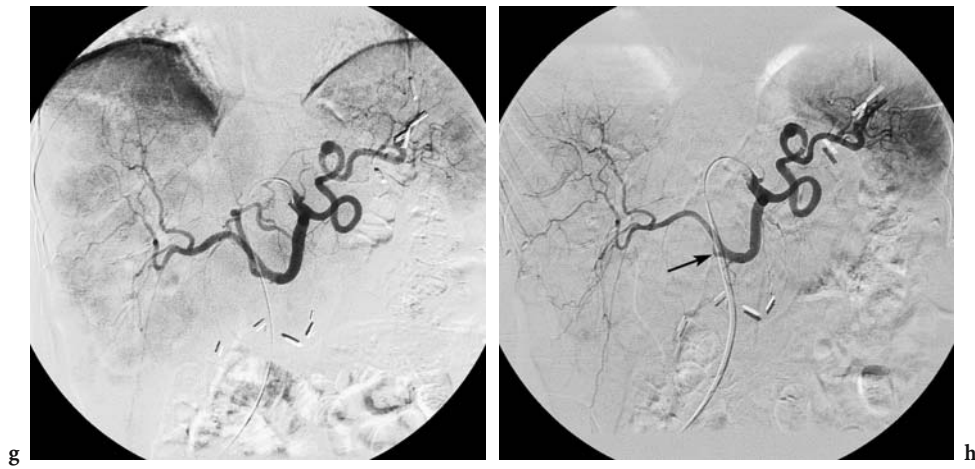

Fig. 14.3a–d. Fifty-six-year-old female with nonfunctioning rectal carcinoid tumor metastatic to liver, complained of upper abdominal pain and hormonal symptoms. (a) Pre-embolization venous-phase CT image of the liver shows the largest metastasis in the left lobe (*arrow*). (b) CT image without intravenous contrast injection, obtained immediately after LHA embolization using 4.5 vials of tris-acryl gelatin microspheres, shows retained arterially injected contrast within the largest metastasis (*arrow*). (c) Venous-phase CT image 3 days post-embolization shows decreased attenuation and a small amount of gas within the largest metastasis, consistent with necrosis. (d) Venous phase CT image 3 months post-embolization shows a significant decrease in size of the largest metastasis, but growth of a new metastasis in the caudate lobe (*arrow*)

14.4 Results

At present, there is no conclusive data regarding the effectiveness of embolotherapy for liver metastasis from neuroendocrine tumor in comparison to other methods of treatment due to various reasons. It is an uncommon condition with a wide spectrum of clinical presentations and severity in addition to multiple treatment options. Hence, it is highly unlikely that randomized trials will ever be conducted to investigate this matter. All results for embolotherapy published so far are case series involving small numbers of subjects ranging from 14 to 41 patients with a wide range of disease severity. Despite this, allowing for different stages of disease and method of treatments, these series show a good clinical response rate (reduction of symptoms, somatostatin requirement, tumor size) of between 50 to 100%, with symptom-free intervals of 5–10 months in 90%–100% of patients [43, 47, 48, 61–75]. Interestingly, the reported 5-year survival of 53% to 83% post-embolotherapy is superior in comparison to historical controls receiving medical treatment alone (0%–40%) [2, 3, 9, 10]. However, there is no definitive evidence that any particular embolic agent is more superior to others.

Our center recently prospectively evaluated 11 patients with metastatic neuroendocrine tumors treated with 20 hepatic artery embolizations using tris-acryl gelatin microspheres for pain, hormonal symptoms, and/or rapid tumor growth. On follow-up CT scanning, 90% of lesions showed reduction in vascularity suggesting tumor necrosis. All patients had amelioration of original pain and/or hormonal symptoms (mean 31% decrease in pain score) lasting 3–15 months. There was one major complication: encephalopathy for which no etiology was found and which resulted in a prolonged hospital stay [70].

14.5 Complications (Table 14.3)

Serious complications following embolization of metastatic neuroendocrine tumor are uncommon with careful patient selection, thorough pre-procedure preparation, and meticulous angiographic technique [72]. Reported major complication rates and death rates after embolotherapy for neuroendocrine tumor hepatic metastases range from 1% to 10%, and 0% to 3%, respectively.

14.5.1 Angiographic Complications

Access site complications are unusual as a large-diameter common femoral artery access is rarely required for the embolization. Iatrogenic arterial dissection occasionally occurs at the celiac artery origin during difficult catheterization. In patients with borderline hepatic or renal function, the risk of contrast induced nephropathy and hepatorenal syndrome can usually be prevented with optimal hydration and by limiting the volume of liver embolized.

14.5.1.1 Nontarget Embolization

Inadvertent extrahepatic deposition of embolic material is relatively common. Although any nontarget embolization is undesirable and may cause complications, the frequency of significant clinical sequela is low [72]. Asymptomatic deposition of embolic material may be seen in the lung, stomach, pancreas, duodenum, gallbladder, diaphragm, and

Table 14.3. Complications of embolotherapy for neuroendocrine tumor liver metastases

Angiographic complications

Access-related

- Dissection / thrombosis
- Distal embolization
- Hemorrhage / hematoma / false aneurysm
- Arteriovenous fistula
- Nerve damage
 - Contrast media
 - Allergic / anaphylactoid
 - Nephrotoxicity
- Catheter and general complications
 - Air embolism / thromboembolism
 - Fracture of guide wire or catheter

Nontarget embolization

- Cholecystitis
- Pancreatitis
- Splenic infarct
- Gastric or bowel infarction
- Pulmonary embolism

Embolization complications

Severe/prolonged post-embolization syndrome

Carcinoid crisis

- Anemia, neutropenia, and thrombocytopenia (due to cytotoxic agent)
 - Liver abscess
 - Liver failure

spleen. Some patients may develop significant complications, however, from such deposition of embolic material. Acalculous cholecystitis, gangrenous cholecystitis, acute pancreatitis, and splenic infarction have all been reported. Fortunately, most of these complications can be treated conservatively and they rarely require surgical interventions.

14.5.1.2

Embolization complications

Although the main objective of embolotherapy is to cause tumor cell death, this by itself may have undesirable effects. Post-embolization syndrome (pain, nausea, vomiting, pyrexia, and malaise) practically occur in all patients and can last for 1 to 2 weeks. Anemia, neutropenia, and thrombocytopenia are invariable if a cytotoxic agent is used. Secondary infection of the necrotic liver/tumor can occur and may lead to the formation of liver abscess (Fig. 14.4), which may require percutaneous drainage. Previous biliary tract surgery such as enterobiliary anastomosis or sphincterotomy is associated with a greater incidence of liver abscess, and this is likely due to the colonization of the biliary tree by gut organisms [76–78]. There is some evidence to suggest that bowel preparation combined with tazobactam/piperacillin given intravenously for 3 days reduces the incidence of this complication in high risk patients [79].

Until the introduction of somatostatin analogues, exacerbation of the symptoms of carcinoid or frank carcinoid crisis was common with embolization of

carcinoid metastases. Now, with somatostatin analogues used routinely for hormonally active tumors, both during and after embolization, carcinoid crisis occurs in only a small percentage of patients. Treatment of these patients, who often have severe disease of the pulmonary and tricuspid valves, is difficult because there is little room for error when reducing preload to treat pulmonary edema. Right atrial pressure must be maintained to ensure adequate flow through the diseased tricuspid valve. Maintenance of right atrial pressure requires close collaboration with an experienced anesthesiologist or cardiologist.

14.6

Pitfalls

There are many potential variations of the anatomy of the arterial supply to the liver. Scrupulous attention to hepatic arterial anatomy, variants, and nontarget branches is necessary to avoid potentially devastating complications. In addition, hypervascular metastases can create a sump effect, reversing the flow in the gastroduodenal artery (GDA). Thus a superior mesenteric artery injection may fill the hepatic artery via an enlarged GDA, which could be mistaken for a replaced right hepatic. Furthermore, a celiac injection in such a case may fail to opacify the GDA because of the flow reversal and may give the impression of an occluded GDA. After embolization of the tumor, the flow will revert to antegrade

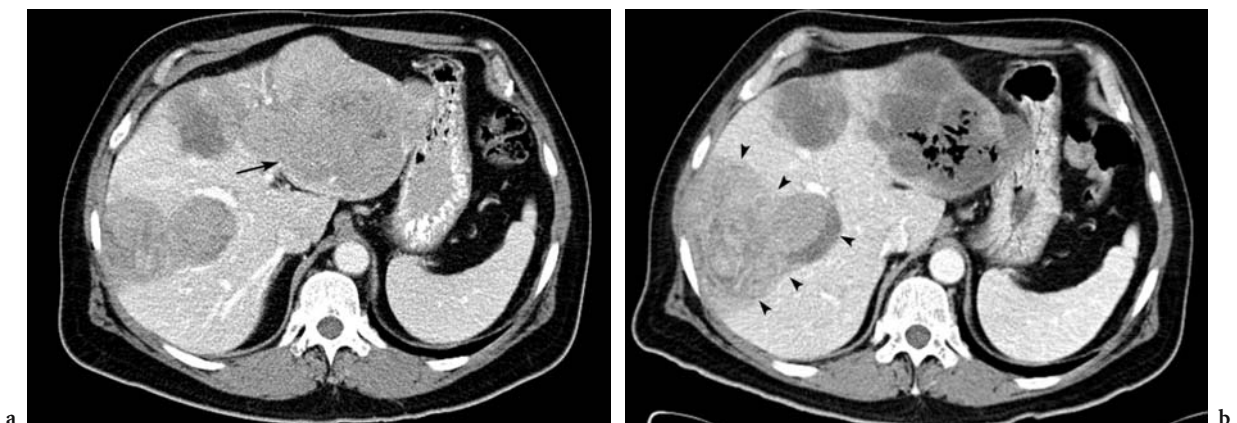


Fig. 14.4a,b. Fifty-four-year-old male with metastatic neuroendocrine tumor of unknown primary. (a) Pre-embolization venous-phase CT image of the liver shows the largest metastasis in the left lobe (*arrow*). (b) Venous-phase CT image of the liver obtained 7 wks post-embolization of the LHA using 6 vials of tris-acryl gelatin microspheres shows that the largest metastasis has decreased in size and enhancement, but contains a moderate amount of gas. The patient complained of fever and vomiting, which resolved with antibiotic therapy. The lesion was not aspirated or drained. We suggest percutaneous drainage only if a patient becomes septic or if there is no response to antibiotics. *Arrowheads* denote interval growth of a right lobe metastasis

in the GDA. Thus it is important to have the catheter tip distal to the origin of the GDA to avoid nontarget embolization.

Some advanced or superficial tumors may parasitize arterial supply from the arteries of adjacent organs, especially after multiple prior embolization procedures. Such parasitization may require embolization of branches arising from such arteries as the right renal, colonic, gastric, phrenic, internal thoracic, and intercostal arteries. It is important to recognize that not all such parasitized vessels can be safely treated without risk to other important organs.

A patent portal venous system with hepatopedal flow is essential to minimize the risk of possible liver necrosis/failure post-embolization. In patients with occluded or reversed flow (hepatofugal) portal venous systems, embolization can still be performed using a modified technique of superselective injection and reduced amounts of embolic material [71].

14.7 Conclusion

Current management strategies for neuroendocrine tumor hepatic metastases have relied on data from anecdotal evidence and retrospective studies involving small numbers of patients. It is unlikely that this situation will change in the near future, since prospective studies are difficult to perform in such a relatively rare and biologically heterogeneous disease. Embolotherapy is a widely accepted method of treatment for nonresectable hepatic metastases from neuroendocrine tumors. Long-term palliation of pain and hormonal symptoms is possible using repeated treatment. Both bland hepatic artery embolization and chemoembolization have been used, and there is no conclusive data to indicate which embolization method and which embolic agents are most efficacious.

References

- Lepage C, Bouvier AM, Phelip JM, et al. (2004) Incidence and management of malignant digestive endocrine tumours in a well defined French population. *Gut* 53:549–553
- Moertel CG (1987) An odyssey in the land of small tumors. *J Clin Oncol* 5:1503–1522
- Soreide O, Berstad T, Bakka A (1992) Surgical treatment as a principle in patients with advanced abdominal carcinoid tumors. *Surgery* 111:48
- Hemminki K, Li X (2001) Incidence trends and risk factors of carcinoid tumors: a nationwide epidemiologic study from Sweden. *Cancer* 92:2204–10
- Quaedvlieg PF, Visser O, Lamers CB, et al. (2001) Epidemiology and survival in patients with carcinoid disease in The Netherlands. An epidemiological study with 2391 patients. *Ann Oncol* 12:1295–300
- Hochwald SN, Zee S, Conlon KC, et al. (2002) Prognostic factors in pancreatic endocrine neoplasms: an analysis of 136 cases with a proposal for low-grade and intermediate-grade groups. *J Clin Oncol* 20:2633–42
- Shebani KO, Souba WW, Finkelstein DM, et al. (1999) Prognosis and survival in patients with gastrointestinal tract carcinoid tumors. *Ann Surg* 229:815–21
- Madeira I, Terris B, Voss M, et al. (1998) Prognostic factors in patients with endocrine tumours of the duodenopancreatic area. *Gut* 43:422–7
- Godwin JD II (1975) Carcinoid tumors: An analysis of 2837 cases. *Cancer* 36:560–569
- Zeitels J, Naunheim K, Kaplan EL, et al. (1982) Carcinoid tumors: A 37 year experience. *Arch Surg* 117:732–737
- Mignon M, Ruzsniowski P, Haffar S, et al. (1986) Current approach to the management of tumoral process in patients with gastrinoma. *World J Surg* 10:703–710
- Creutzfeldt W (1996) Carcinoid tumors: development of our knowledge. *World J Surg* 20:126–131
- Arnold R, Frank M, Kajdan U (1994) Management of gastroenteropancreatic endocrine tumors: The place of somatostatin analogues. *Digestion* 55 (Suppl 3):107–113
- Öberg K, Erikson B (1989) Medical treatment of neuroendocrine gut and pancreatic tumors. *Acta Oncol* 28:425–431
- Ruzsniowski P, Ducreux M, Chayvialle JA, et al. (1996) Treatment of the carcinoid syndrome with the long acting somatostatin analogue lanreotide: a prospective study in 39 patients. *Gut* 39:279–283
- Arnold R (1996) Medical treatment of metastasizing carcinoid tumors. *World J Surg* 20:203–207
- Eriksson B, Skogseid B, Lundqvist G, et al. (1990) Medical treatment and long-term survival in a prospective study of 84 patients with endocrine pancreatic tumors. *Cancer* 65:1883–1890
- Chiti A, Fanti S, Savelli G, et al. (1998) Comparison of somatostatin receptor imaging, computed tomography and ultrasound in the clinical management of neuroendocrine gastroentero-pancreatic tumours. *Eur J Nucl Med* 25:1396–1403
- Gibril F, Reynolds JC, Doppman JL, et al. (1996) Somatostatin receptor scintigraphy: its sensitivity compared with that of other imaging methods in detecting primary and metastatic gastrinomas. A prospective study. *Ann Intern Med* 125:26–34
- Frucht H, Doppman JL, Norton JA, et al. (1989) Gastrinomas: comparison of MR imaging with CT, angiography, and US. *Radiology* 171:713–717
- Zimmer T, Ziegler K, Bader M, et al. (1994) Localization of neuroendocrine tumours of the upper gastrointestinal tract. *Gut* 35:471–475
- Zimmer T, Stolzel U, Bader M, et al. (1996) Endoscopic ultrasonography and somatostatin receptor scintigraphy in the preoperative localization of insulinomas and gastrinomas. *Gut* 39:562–568
- Anthuber M, Jauch KW, Briegel J, et al. (1996) Results of liver transplantation for gastroenteropancreatic tumor metastases. *World J Surg* 20:73–76

24. Ahlman H, Westberg G, Wangberg B, et al. (1996) Treatment of liver metastases of carcinoid tumors. *World J Surg* 20:196–202
25. Chamberlain RS, Canes D, Brown KT, et al. (2000) Hepatic neuroendocrine metastases: Does intervention alter outcomes? *J Am Coll Surg* 190:432–445
26. Chen H, Hardacre JM, Uzar A, et al. (1998) Isolated liver metastases from neuroendocrine tumors: does resection prolong survival? *J Am Coll Surg* 187:88–93
27. Dominguez S, Denys A, Menu Y, et al. (1999) Hepatic arterial chemoembolization in the management of advanced digestive endocrine tumours. *Ital J Gastroenterol Hepatol* 31(Suppl 2):213–215
28. McEntee GP, Nagorney DM, Kvols LK, et al. (1990) Cytoreductive hepatic surgery for neuroendocrine tumors. *Surgery* 108:1091–1096
29. Soreide O, Berstad T, Bakka A, et al. (1992) Surgical treatment as a principle in patients with advanced abdominal carcinoid tumors. *Surgery* 111:48–54
30. Yao KK, Talamonti MS, Nemcek A, et al. (2001) Indications and results of liver resection and hepatic chemoembolization for metastatic gastrointestinal neuroendocrine tumors. *Surgery* 130:677–685
31. Benevento A, Boni L, Frediani L, et al. (2000) Result of liver resection as treatment for metastases from noncolorectal cancer. *J Surg Oncol* 74:24–29
32. Grazi GL, Cescon M, Pierangeli F, et al. (2000) Highly aggressive policy of hepatic resections for neuroendocrine liver metastases. *Hepatogastroenterology* 47:481–486
33. Que FG, Nagorney DM, Batts KP, et al. (1995) Hepatic resection for metastatic neuroendocrine carcinomas. *Am J Surg* 169:36–42
34. Akerstrom G (1996) Management of carcinoid tumors of the stomach, duodenum, and pancreas. *World J Surg* 20:173–182
35. Faiss S, Scherubl H, Riecken EO, et al. (1996) Drug therapy in metastatic neuroendocrine tumors of the gastroenteropancreatic system. *Recent Results Cancer Res* 142:193–207
36. di Bartolomeo M, Bajetta E, Buzzoni R, et al. (1996) Clinical efficacy of octreotide in the treatment of metastatic neuroendocrine tumors. A study by the Italian Trials in Medical Oncology Group. *Cancer* 77:402–408
37. Moertel CG, Hanley JA (1979) Combination chemotherapy trials in metastatic carcinoid tumor and the malignant carcinoid syndrome. *Cancer Clin Trials* 2:327–334
38. Oberg K, Norheim I, Lundqvist G, et al. (1987) Cytotoxic treatment in patients with malignant carcinoid tumors. Response to streptozocin—alone or in combination with 5 FU. *Acta Oncol* 26:429–432
39. Moertel CG, Lefkopoulo M, Lipsitz S, et al. (1992) Streptozocin-doxorubicin, streptozocin-fluorouracil, or chlorozotocin in the treatment of advanced islet-cell carcinoma. *N Engl J Med* 326:519–523
40. Rivera E, Ajani JA (1998) Doxorubicin, streptozocin, and 5-fluorouracil chemotherapy for patients with metastatic islet-cell carcinoma. *Am J Clin Oncol* 21:36–38
41. Gray RK, Rosch J, Grollman JH (1970) Arteriography in the diagnosis of islet-cell tumors. *Radiology* 97:39–44
42. Andersson M, Aronsen F, Balch C, et al. (1989) Pharmacokinetics of intra-arterial mitomycin-c with or without degradable starch microspheres (DSM) in the treatment of non-resectable liver cancer. *Acta Oncol* 28:219–222
43. Ruzsniwski P, Malka D (2000) Hepatic arterial chemoembolization in the management of advanced digestive endocrine tumors. *Digestion* 62(suppl 1):79–83
44. Sutcliffe R, Maguire D, Ramage J, et al. (2004) Management of neuroendocrine liver metastases *Am J Surg* 187:39–46
45. Norton JA, Warren RS, Kelly MG, et al. (2003) Aggressive surgery for metastatic liver neuroendocrine tumors. *Surgery* 134:1057–1063
46. Sarmiento JM, Heywood G, Rubin J, et al. (2003) Surgical treatment of neuroendocrine metastases to the liver: a plea for resection to increase survival. *J Am Coll Surg* 197:29–37
47. Eriksson BK, Larsson EG, Skogseid BM, et al. (1998) Liver embolizations of patients with malignant neuroendocrine gastrointestinal tumors. *Cancer* 83:2293–2301
48. Brown KT, Koh BY, Brody LA, et al. (1999) Particle embolization of hepatic metastases for control of pain and hormonal symptoms. *J Vasc Interv Radiol* 10:397–403
49. Rivera E, Ajani JA (1998) Doxorubicin, streptozocin, and 5-fluorouracil chemotherapy for patients with metastatic islet-cell carcinoma. *Am J Clin Oncol* 21:36–38
50. Faiss S, Pape UF, Bohmig M, et al. (2003) Prospective, randomized, multicenter trial on the antiproliferative effect of lanreotide, interferon alfa, and their combination for therapy of metastatic neuroendocrine gastroenteropancreatic tumors—The International Lanreotide and Interferon Alfa Study Group. *J Clin Oncol* 21:2689–2696
51. De Jong M, Breeman WA, Bernard HF, et al. (1999) Therapy of neuroendocrine tumors with radiolabeled somatostatin analogues. *Q J Nucl Med* 43:356–66
52. Mukherjee JJ, Kaltsas GA, Islam N, et al. (2001) Treatment of metastatic carcinoid tumours, pheochromocytoma, paraganglioma and medullary carcinoma of the thyroid with (131)I-meta-iodobenzylguanidine [(131)I-mIBG]. *Clin Endocrinol* 55:47–60
53. Castellani MR, Chiti A, Seregni E, et al. (2000) Role of 131I-metaiodobenzylguanidine (MIBG) in the treatment of neuroendocrine tumours. Experience of the National Cancer Institute of Milan. *Q J Nucl Med* 44:77–87
54. Chatal JF, Le Bodic MF, Kraeber-Bodere F, et al. (2000) Nuclear medicine applications for neuroendocrine tumors. *World J Surg* 24:1285–9
55. Chatziioannou A, Ladopoulos C, Limouris GS, et al. (2004) Selective intraarterial injection of ¹¹¹In-pentetreotide in the treatment of somatostatin positive (receptors II, SSTR₂) neuroendocrine metastatic disease in the liver. *CIRSE 2004, Barcelona*. Poster 150
56. Le Treut YP, Delpero JR, Dousset B, et al. (1997) Results of liver transplantation in the treatment of metastatic neuroendocrine tumors. A 31-case French multicentric report. *Ann Surg* 225:355–364
57. Dousset B, Houssin D, Soubrane O, et al. (1995) Metastatic endocrine tumors: is there a place for liver transplantation? *Liver Transpl Surg* 1:111–117
58. Knechtel SJ, Kalayoglu M, D'Alessandro AM, et al. (1997) Proceed with caution: liver transplantation for metastatic neuroendocrine tumors. *Ann Surg* 225:345–346
59. Lang H, Oldhafer KJ, Weimann A, et al. (1997) Liver transplantation for metastatic neuroendocrine tumors. *Ann Surg* 225:347–354
60. Coppa J, Pulvirenti A, Schiavo M, et al. (2001) Resection versus transplantation for liver metastases from neuroendocrine tumors. *Transplant Proc* 33:1537–1539
61. Perry LJ, Stuart K, Stokes KR, et al. (1994) Hepatic arte-

- rial chemoembolization for metastatic neuroendocrine tumors. *Surgery* 116:1111–1116
62. Drougas JG, Antony LB, Blair TK, et al. (1998) Hepatic artery chemoembolization for management of patients with advanced metastatic carcinoid tumors. *Am J Surg* 175:408–412
 63. Kim YH, Ajani JA, Carrasco CH, et al. (1999) Selective hepatic arterial chemoembolization for liver metastases in patients with carcinoid tumor or islet cell carcinoma. *Cancer Invest* 17:474–478
 64. Roche A, Girish BV, de Baere T, et al. (2003) Trans-catheter arterial chemoembolization as first-line treatment for hepatic metastases from endocrine tumors. *Eur Radiol* 13:136–140
 65. Schell SR, Camp RE, Caridi JG, et al. (2002) Hepatic Artery Embolization for Control of Symptoms, Octreotide Requirements, and Tumor Progression in Metastatic Carcinoid Tumors. *J Gastrointest Surg* 6:664–670
 66. Winkelbauer FW, Niederle B, Pietschmann F (1995) Hepatic artery embolotherapy of hepatic metastases from carcinoid tumors: value of using a mixture of cyanoacrylate and ethiodized oil. *Am J Roentgenol* 165:323–327
 67. Stokes KR, Stuart K, Clouse ME (1993) Hepatic arterial chemoembolization for metastatic endocrine tumors. *J Vasc Interv Radiol* 4:341–345
 68. Hartnell GG, Gates J, Stuart K, et al. (1999) Hepatic chemoembolization: effect of intraarterial lidocaine on pain and postprocedure recovery. *Cardiovasc Intervent Radiol* 22:293–297
 69. Clouse ME, Perry L, Stuart K, et al. (1994) Hepatic arterial chemoembolization for metastatic neuroendocrine tumors. *Digestion* 55(suppl 3):92–97
 70. Lem SL, Asch M, Kachura JR, et al. (2004) Toronto hepatic artery embolization study. *J Vasc Interv Radiol* 15:S245 [Poster No. 297 presented at 29th Annual Scientific Meeting of the Society of Interventional Radiology, Phoenix, Arizona, March 25–30, 2004]
 71. Pentecost MJ, Daniels JR, Teitelbaum GP, et al. (1993) Hepatic chemoembolization: safety with portal vein thrombosis. *J Vasc Intervent Radiol* 4:347–351
 72. Gates J, Hartnell GG, Stuart KE, et al. (1999) Chemoembolization of hepatic neoplasms: safety, complications, and when to worry. *Radiographics* 19:399–414
 73. Carrasco CH, Charnsangavej C, Ajani J, et al. (1986) The carcinoid syndrome: palliation by hepatic artery embolization. *Am J Roentgenol* 147:149–154
 74. Marlink RG, Lokich JJ, Robins JR, et al. (1990) Hepatic arterial embolization for metastatic hormone-secreting tumors. Technique, effectiveness, and complications. *Cancer* 65:2227–2232
 75. Hajarizadeh H, Ivancev K, Mueller CR, et al. (1992) Effective palliative treatment of metastatic carcinoid tumors with intra-arterial chemotherapy/chemoembolization combined with octreotide acetate. *Am J Surg* 163:479–483
 76. Ishikawa H, Kanai T, Ono T, et al. (1994) Analysis of cases with liver abscess following transcatheter arterial chemoembolization (TAE) for malignant hepatic tumors (Japanese). *Gan To Kagaku Ryoho* 21:2233–2236
 77. Song SY, Chung JW, Han JK, et al. (2001) Liver abscess after transcatheter oily chemoembolization for hepatic tumors: incidence, predisposing factors, and clinical outcome. *J Vasc Interv Radiol* 12:313–320
 78. Kim W, Clark TW, Baum RA, et al. (2001) Risk factors for liver abscess formation after hepatic chemoembolization. *J Vasc Interv Radiol* 12:965–968
 79. Geschwind JF, Kaushik S, Ramsey DE, et al. (2002) Influence of a new prophylactic antibiotic therapy on the incidence of liver abscesses after chemoembolization treatment of liver tumors. *J Vasc Interv Radiol* 13:1163–1166

15 Bone Metastases from Renal Cell Carcinoma: Preoperative Embolization

SHILIANG SUN

CONTENTS

15.1	Introduction	189
15.2	Clinical Features and Physiopathology	190
15.3	Angiography and Embolization Technique	190
15.3.1	Indications	190
15.3.2	Preprocedural Preparation	191
15.3.3	Angiographic Technique	191
15.3.4	Embolization Technique	191
15.4	Results	193
15.4.1	Obliteration of Tumor Blush / Estimated Blood Loss	193
15.4.2	Osseous Healing and Survival	196
15.4.3	Complications	196
15.5	Conclusion	198
	References	199

15.1 Introduction

The American Cancer Society estimates that there will be approximately 36,160 new cases of kidney and other urinary carcinomas in the U.S. in 2005. Renal cell carcinoma (RCC) is the most common type of kidney cancer in adults, accounting for 70% of the tumors, i.e., approximately 25,312 new cases. Furthermore, since the 1970s, incidence rates for RCC have been increasing an average of 2% per year, but recently this increase appears to be leveling off [1, 2]. Up to one-third of patients with RCC have metastases at presentation [3]. Eighty percent of patients with RCC eventually have metastases, and nearly one-half of these patients have metastases to the bone [4–6]. However, more recent reports indicated that with the significant improvement of imaging techniques, such as ultrasonography, computerized tomography (CT), magnetic resonance imaging (MRI), and positron emission tomography (PET),

asymptomatic RCC is more frequently detected and detected at lower stages of disease, when tumors may be resected with curative intent or when a metastatic lesion is in the early stage [7, 8]. As a result, fewer than 20% of patients with RCC have overt metastasis at the initial presentation [7].

Treatments for RCC includes radiation therapy, chemotherapy, and surgical intervention. RCC is relatively radioresistant. The response rate to radiation therapy is 50% at best, and symptomatic recurrences are common [4–9]. Despite extensive evaluation of many different treatment modalities, RCC remains highly resistance to systemic therapy, and the median survival of RCC patients is ~8 months. About 10% to 20% of patients exhibit complete or partial response to interferon and/or interleukin-2 with/without chemotherapy or each therapy alone, with a durable response of >2 years in 5% or less [3]. In patients with localized disease, surgical resection of the primary tumor remains the mainstay of therapy [7, 8].

Although metastasis to the bone represents an advanced stage of underlying disease, it may be associated with relatively prolonged survival. However, reports of survival conflict in a range of less than 15% to more than 50% [4, 10]. Therefore, indications for surgical intervention and the appropriate extent of surgery remain controversial. Wide excision of metastatic lesions was advocated because of the unresponsiveness of RCC to noninvasive measures, such as chemotherapy and radiation therapy, and the possibility that survival may be relatively prolonged in treated patients [10]. Existing reports on the surgical management of metastatic RCC of bone have limited value since they are based on only a small number of patients or failed to mention the surgical technique and its effect on local tumor control [10].

Most metastases from RCC are hypervascular and tend to bleed massively during surgery [11]. Biopsies, open reductions, internal fixations, and resections have been associated with an average intraoperative blood loss of 1.5–3 L [12]. A blood loss of 2000–18,500 ml (mean 6800 ml) was reported in

S. SUN, MD

Associate Professor of Radiology, Department of Radiology, University of Iowa, College of Medicine, 200 Hawkins Dr., 3955 JPP, Iowa City, IA 52242, USA

20 patients operated on during the pre-embolization era [13]. Preoperative embolization of these lesions appears to be a safe and effective technique to decrease intraoperative blood loss and the duration of surgery, and thus reduce the surgical morbidity/mortality and hospital stay [11–20]. Preoperative embolization has become a standard measure for this type of patient before surgical intervention.

15.2 Clinical Features and Physiopathology

Due to its visceral location and the existence of a second functional kidney, RCC is characterized by a lack of early warning signs, resulting in a high proportion of patients with either locally advanced disease or metastases already present at the time of diagnosis [3, 21]. RCC metastases take place via the lymphatic or venous routes. The lung parenchyma, bone, liver, and brain are the most common sites of metastases [3, 21, 22]. Although metastasis to the bone from RCC ranks as approximately the sixth most common site, compared to other tumors, this tumor has several unique features that increase its significance: (1) the metastases may occur many years (up to 10 years) after the primary tumor has been treated surgically; (2) the metastases may occur as a solitary lesion and as such an *en bloc* surgical resection may render the patient free of cancer and offer hope for a cure; (3) even though the incidence of RCC is proportionally small, the tumor has a high avidity for the skeletal system and thus produces a relatively large number of bone lesions; and (4) the bone lesions can be large, with an average size of 7 cm in diameter, and have an aggressive appearance [3, 19, 21, 22].

Pain is the most common presenting symptom. Pathological fracture rarely occurs without a history of a few weeks or months of increasingly severe pain.

Systemic symptoms may also occur, such as hypocalcaemia. Occasionally, patients may have hypertension from the tumor affecting the rennin-angiotensin pathway. RCC metastases most commonly affect the spine, proximal long bone, pelvis, ribs, sternum, and skull [3, 22, 23]. Since the kidney is comprised of mostly blood vessels, RCC is normally a hypervascular tumor. RCC metastases usually mimic the primary tumor in vascularity, being hypervascular in 65%–75% of patients, and bleeding extensively (even audibly) after a simple biopsy [3, 8].

15.3 Angiography and Embolization Technique

15.3.1 Indications

Due to the fact that most embolization procedures were performed preoperatively, surgical indications dictate the number and extent of the procedures. Indications for surgery are divided into two groups according to signs of mechanical skeletal failure (Table 15.1). For patients who required amputation or wide radical resection due to massive tumor extension to the soft tissue with invasion of the major neurovascular bundle of the extremity, preoperative embolization may not be indicated [10]. Similarly, for patients with a small, easily accessed lesion or with an angiography-proven very hypovascular tumor, preoperative embolization may not be necessary [18]. Otherwise, all other patients should undergo preoperative embolization with the intent to obliterate all tumor feeders and decrease intraoperative blood loss. General indications for transcatheter embolization of bone metastasis are listed in Table 15.2. Even though listed, practically, the applications of this technique in the indications other than preoperative emboliza-

Table 15.1. Indications for surgery

Without mechanical bone failure	<ul style="list-style-type: none"> • Solitary bone metastasis • Intractable pain
With mechanical bone failure	<ul style="list-style-type: none"> • Impending or pathological fracture

Table 15.2. Indications for embolization of bone metastasis from RCC

Preoperative embolization (72%)
Control of hemorrhage
Inhibition of tumor growth
Reducing viable tumor volume to facilitate radiation or chemotherapy

tion have been limited, with only sporadic reports in the literature [11–20].

15.3.2

Preprocedural Preparation

Due to the preoperative nature of the procedure, the orthopedic surgeon should do a complete work-up of the patient to rule out all potential major medical contraindications for surgery. Interventional radiologists should review every document available and focus on issues related to the embolization procedure. One should perform and document findings of physical examination in terms of the patient's general condition, the status of affected limb, and circulation of the extremities in order to set up a baseline and compare with postembolization findings later. For patients who have a history of contrast allergy, premedication should be given according to the institutional protocol. Routine preprocedure lab tests include CBC, coagulation tests, and renal function tests. Patients may have impaired renal function due to previous nephrectomy for RCC. These patients need to be sufficiently hydrated before the embolization procedure. The amount of contrast media given during the procedure should also be limited if possible. For patients who have significant coagulopathy, correction is necessary with Vitamin K or transfusion of fresh frozen plasma or platelets. Placing a Foley catheter may be helpful, as the embolization procedure can be lengthy if multiple tumor feeders need to be embolized, and since the patient may have a pathological fracture, ambulation could be difficult. Furthermore, for patients with a pending pathological fracture, early ambulation postembolization may complicate the pathological fracture [19]. A review of available imaging studies is imperative for choosing a treatment plan. Consents for the procedure and conscious sedation are obtained routinely. Whether or not one should give prophylactic antibiotics routinely before the procedure is controversial. Most authors do not prescribe antibiotics for the purpose of prophylaxis [18–20].

15.3.3

Angiographic Technique

Most preoperative embolizations can be performed under intravenous conscious sedation via a transfemoral approach. Lesions in the proximal femur are treated from the contralateral approach. Lesions in

the distal femur may be accessed in an ipsilateral antegrade fashion to facilitate catheter manipulation [19]. For lesions located in the pelvis and upper extremities, a right femoral approach is routinely used. A 5-F sheath is used for most procedures. A 5-F Davis catheter, JB-1 or Cobra visceral catheter is commonly used for selective catheterization. Microcatheters such as the 2.9-F Renegade Super-flow (Boston Scientific) through a coaxial system are used for superselective catheterization that allows a safe and effective embolization of the tumor feeders.

The pre-embolization arteriogram should be started at the main territory artery in order to cover the entire area and identify all tumor feeders. For example, a distal abdominal aortogram or common iliac arteriogram should be performed when a tumor is located in the proximal femur, because the tumor may derive blood from superior/inferior gluteal arteries, medial/lateral circumflex femoral arteries, and descending muscular branches from the profunda femoris artery. In rare situations, the obturator and internal pudendal arteries from the anterior group of the internal iliac artery may also provide blood supply to the tumor. The postembolization arteriogram should include all possible collateral pathways, because untreated collaterals may become more prominent after occlusion of other feeders (Fig. 15.1a–c). The amount of contrast medium given during an arteriogram must be sufficient to make all possible tumor feeders well-opacified. Therefore, in addition to an appropriate injection rate, the period of injection should be long enough (lasting more than 3 sec). The acquisition should be long enough to cover all phases of the arteriogram (arterial, capillary, and venous phase) to document tumor vascularity and arterial to venous shunting. Frequently, multiple selective arteriograms in different projections may be necessary in order to show the origin of a tumor feeder in profile and facilitate superselective catheterization. The fluoro-fade, or road mapping, technique is available for use with most modern digital arteriographic equipment. This is very helpful for superselective catheterization, especially when a tumor is located in the extremities (reduced artifacts caused by movements of breathing and bowel peristalses).

15.3.4

Embolization Technique

Thus far, there has been no single embolic agent that is ideal for preoperative embolization of bone

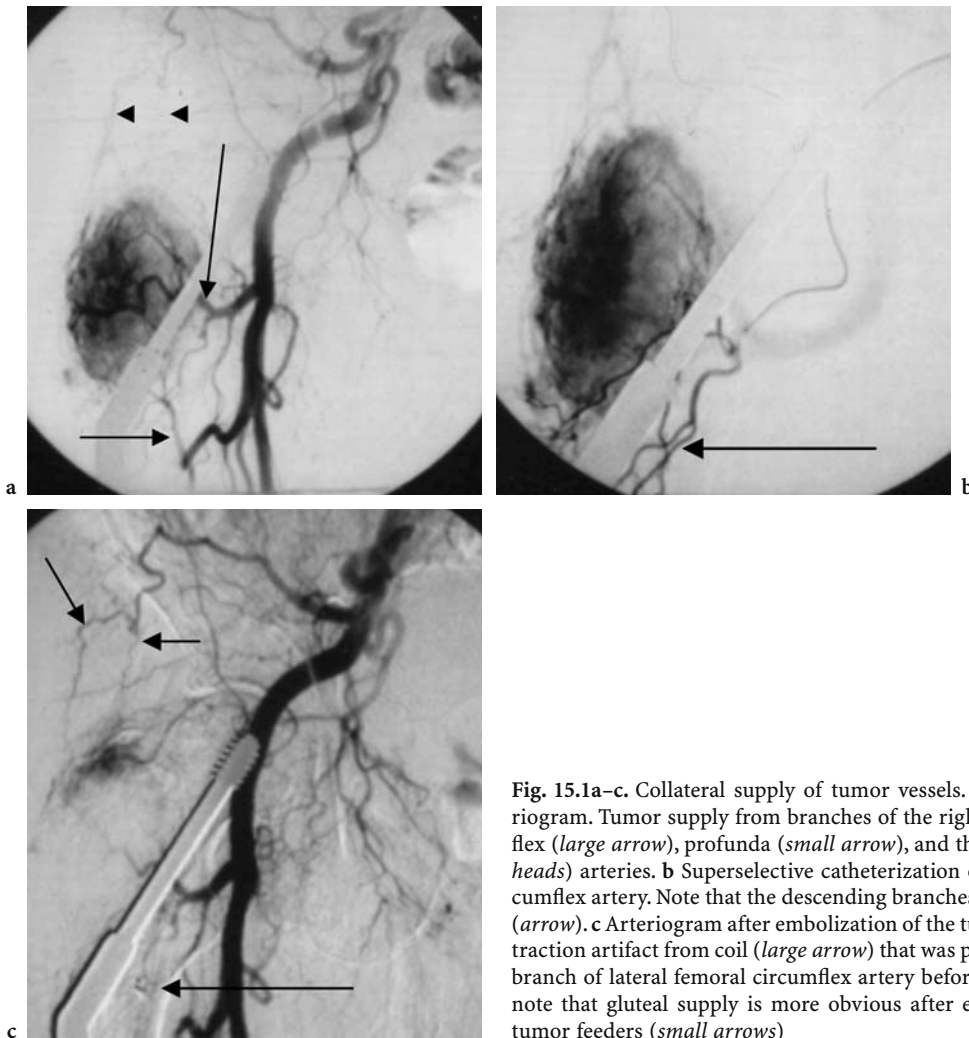


Fig. 15.1a-c. Collateral supply of tumor vessels. **a** Pre-embolization arteriogram. Tumor supply from branches of the right lateral femoral circumflex (*large arrow*), profunda (*small arrow*), and the superior gluteal (*arrow heads*) arteries. **b** Superselective catheterization of the lateral femoral circumflex artery. Note that the descending branches do not supply the tumor (*arrow*). **c** Arteriogram after embolization of the tumor with PVA. Note subtraction artifact from coil (*large arrow*) that was placed into the descending branch of lateral femoral circumflex artery before PVA embolization. Also note that gluteal supply is more obvious after embolization of the main tumor feeders (*small arrows*)

metastases from RCC. An ideal embolic agent should be easily delivered through a microcatheter, should reach and permanently occlude small blood vessels deep within the tumor, and should be nontoxic and easy to prepare and control during delivery. Different embolic agents have been used for preoperative embolization of bone metastases from RCC, including absolute alcohol, tissue adhesives, coils, gelatin sponge, Embospheres, and polyvinyl alcohol particles (PVA) [11–20, 24–31]. The use of liquid embolic agents (e.g., ethanol, tissue adhesive) was not advocated for preoperative embolization of bone metastasis since they may be associated with a high rate of complications (even in experienced hands) such as tissue ischemia, skin necrosis, and neurologic impairment when used for spinal metastasis [13]. Coils are a permanent embolic agent, but they induce relatively proximal occlusion of target vessels, and thus are less effective for decreasing

estimated blood loss (EBL), because bone metastasis from RCC shows angiomatous vascularization that may reconstitute collaterals within hours. Practically, it is not uncommon to find new tumor feeders that were not evident on the preembolization angiogram, immediately after the major feeders were occluded. Coil embolization made no significant difference in EBL compared with a control group in hypervascular spinal lesions [13, 19]. The same studies also suggested that the additional use of coils after PVA particles provides no further benefit.

Gelfoam particles have been used in the early stage of preoperative embolization of bone metastasis. Due to the fact that it is biologically degradable and not definite in size, Gelfoam pledge only creates proximal and temporary occlusion of target vessels. Early recanalization and revascularization of embolized vessels have been observed, which resulted in unfavorable outcomes regarding EBL. Therefore, compared

with PVA particles, Gelfoam pledge is less reliable in controlling intra-operative bleeding [10, 13, 19], and it should be avoided in preoperative embolization for bone metastasis from RCC, especially when surgery is not to be performed within 48 h [19].

PVA particles are considered a permanent peripheral embolic agent, and have been used successfully for the treatment of hemorrhage, vascular malformations, and tumors throughout the body [31, 32]. PVA particles in sizes between 250 and 1,000 μm were used for preoperative embolization in the majority of published series [14, 19–21, 32]. The technical requirements are more demanding for PVA than for larger embolization materials that can be deployed more proximally, e.g. coils or Gelfoam pledges. Selective and superselective catheterization can provide a safer environment for deploying PVA and reduce the possibility of errant embolization, but caution must be taken. Large anastomoses, such as those between the inferior gluteal or the obturator arteries and the femoral artery, may provide an escape route for particles into nontarget territories [33]. The size of the embolic material needs to be adjusted to the size of these potential collateral vessels and the size of existing A-V shunts, which are often present in hypervascular metastases (Fig. 15.2a–g).

However, smaller particles ($\sim 200 \mu\text{m}$ in size) should be used when a catheter or microcatheter can be superselectively positioned in a small, peripheral feeder that supplies the tumor only. Smaller PVA particles can also be used when branches from a tumor feeder that supply surrounding normal tissue are protectively embolized with coils (Fig. 15.1a,c). Occasionally, a main tumor feeder gives many branches that supply most of the tumor, but bifurcates from a major branch supplying normal tissue. In order to make the embolization safer, superselective embolization of each of tumor feeders will be required, but is very time-consuming. Under such a situation, coil embolization of the major normal branch will make the procedure much easier and safer. Embolization with smaller PVA particles by means of a coaxial microcatheter system is more effective, and complete obliteration of all tumor blushes can be expected [13, 19]. This is partially due to the fact that smaller particles make immediate revascularization from vessels distal to the embolized pedicles through existing collaterals less likely. Immediate revascularization is frequently seen when larger particles or proximal embolization was conducted, which may give one the impression that complete obliteration of the tumor blush can never be achieved. It is also frustrating for the

operator because the new tumor feeders are usually too small to be catheterized, not to mention the time one has to spend.

Nonetheless, when embolizing an artery that may supply important structures with a smaller size of PVA, great care must be taken to avoid nontarget embolization. For example, internal iliac artery branches (mostly inferior and superior gluteal artery) and deep femoral artery branches may supply the sciatic nerve, buttock, and leg muscles. Embolization of these arteries may result in an inadvertent event [33]. The embolization should begin with the major pedicles and then proceed to the accessory ones to avoid embolization through backflow of any neighboring area. It is not uncommon to see that the accessory feeders have already partially or completely occluded through the communication with the major feeder when the major feeder has been embolized (Fig. 15.3a–e). PVA is mixed with contrast medium for better fluoroscopic detectability and more controlled PVA particle delivery. To keep the PVA particles in suspension during the delivery, many methods have been used. The most commonly used technique is to perform, as frequently as possible, mechanical exchanges of the solution containing PVA particles between two syringes on a three-way stopcock. Ex vivo experiments showed that the best PVA particle suspension could be achieved when the ratio of contrast medium and normal saline was 6:4, i.e., 60% contrast and 40% saline [28]. For better fluoroscopic visualization during the particles' delivery, full-strength contrast was also used with the delivery syringe held upwards to keep the particles floating on the top of the syringe [19]. The mixture of PVA is manually delivered under fluoroscopic observation. When the flow slows down or stagnation is observed, the delivery is halted and residual PVA is slowly flushed forward with normal saline. Saline clearly defines the contrast material interface and emptying of the catheter from particles [19].

15.4 Results

15.4.1 Obliteration of Tumor Blush / Estimated Blood Loss

Intra-operative blood loss is the major criterion in evaluating the efficacy of preoperative embolization. Significant intra-operative blood loss was defined as

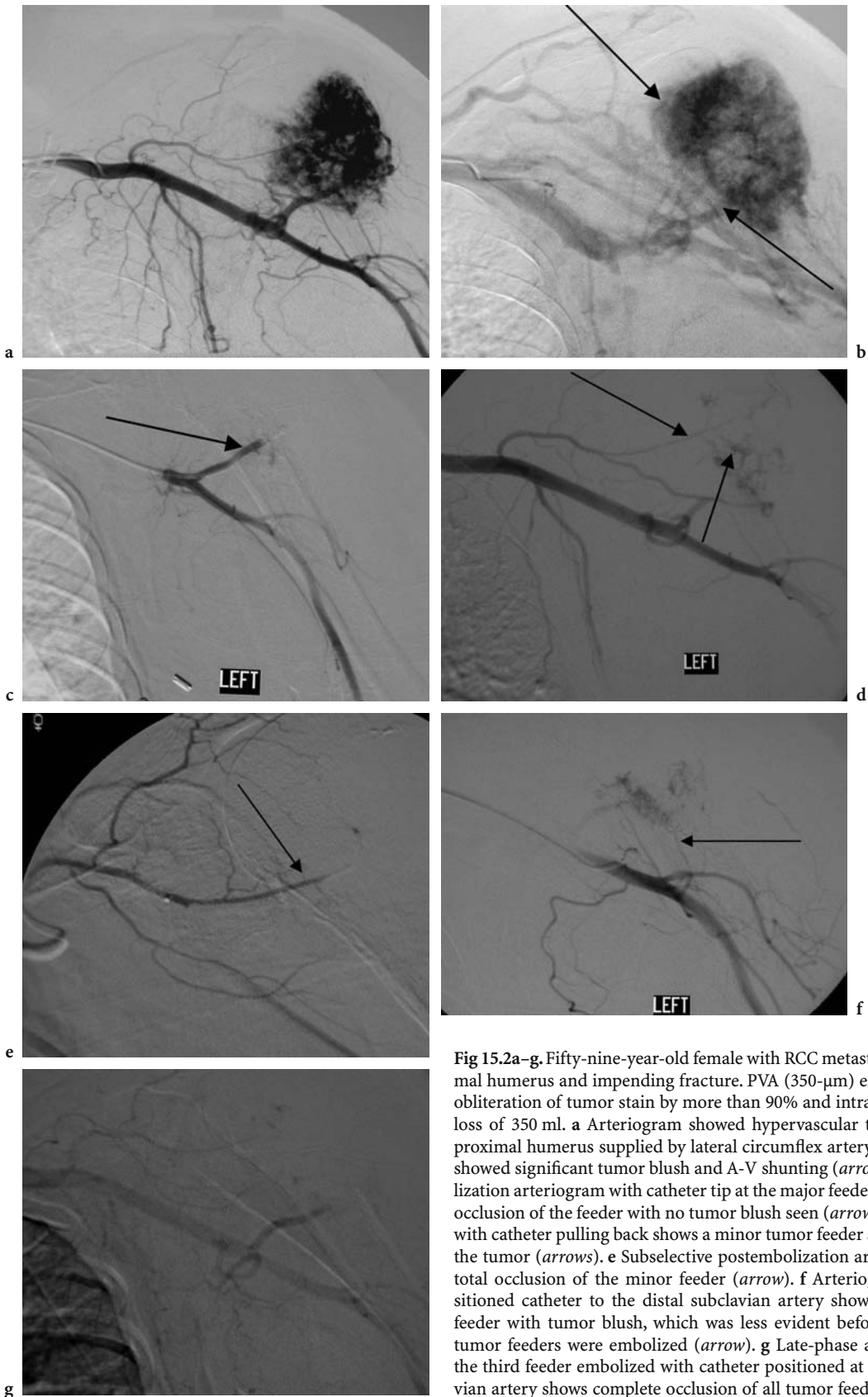


Fig 15.2a-g. Fifty-nine-year-old female with RCC metastasis of left proximal humerus and impending fracture. PVA (350- μ m) embolization with obliteration of tumor stain by more than 90% and intra-operative blood loss of 350 ml. **a** Arteriogram showed hypervascular tumor in the left proximal humerus supplied by lateral circumflex artery. **b** Venous phase showed significant tumor blush and A-V shunting (*arrows*). **c** Postembolization arteriogram with catheter tip at the major feeder shows complete occlusion of the feeder with no tumor blush seen (*arrow*). **d** Arteriogram with catheter pulling back shows a minor tumor feeder supplying part of the tumor (*arrows*). **e** Subselective postembolization arteriogram shows total occlusion of the minor feeder (*arrow*). **f** Arteriogram after repositioned catheter to the distal subclavian artery shows another minor feeder with tumor blush, which was less evident before the other two tumor feeders were embolized (*arrow*). **g** Late-phase arteriogram after the third feeder embolized with catheter positioned at proximal subclavian artery shows complete occlusion of all tumor feeders

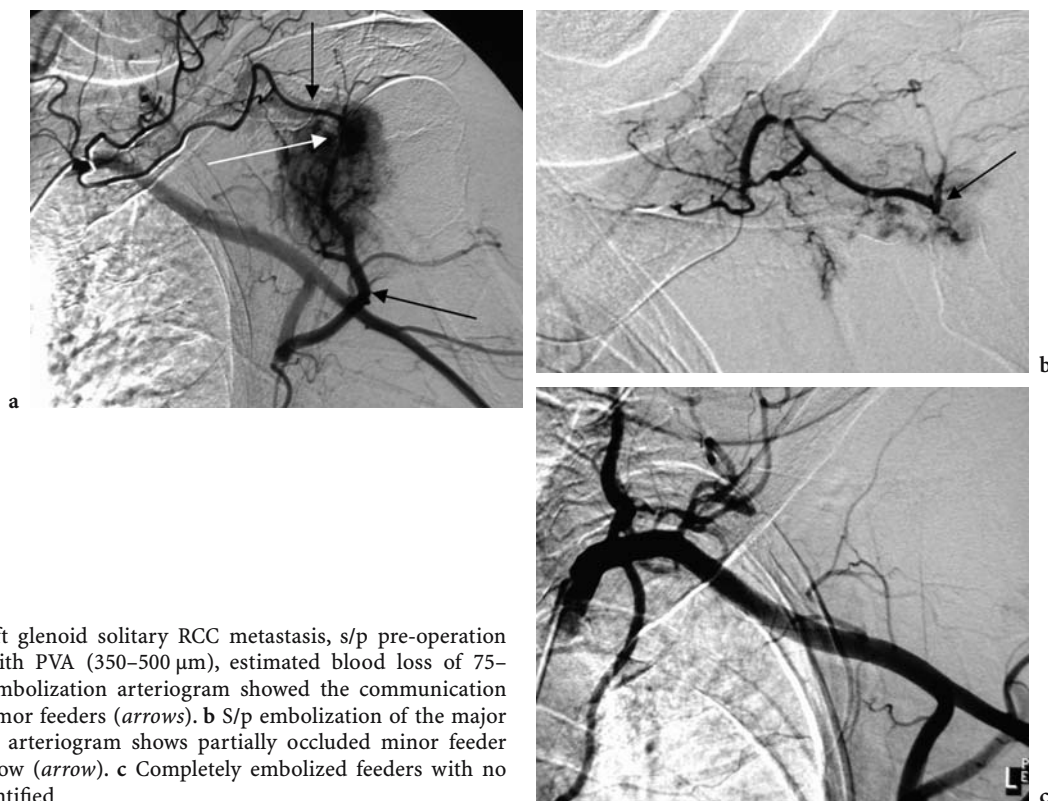


Fig 15.3a-c. Left glenoid solitary RCC metastasis, s/p pre-operation embolization with PVA (350–500 μ m), estimated blood loss of 75–100 ml. **a** Pre-embolization arteriogram showed the communication between two tumor feeders (*arrows*). **b** S/p embolization of the major feeder, selective arteriogram shows partially occluded minor feeder with sluggish flow (*arrow*). **c** Completely embolized feeders with no tumor stain identified

a loss of more than 600 ml of blood from a lesion of extremities or 1,200 ml from a pelvic lesion [10]. The amount of blood loss has been positively correlated with the percentage of obliteration of tumor blush (OTB) postembolization. The more tumor feeders embolized, the better EBL results that could be achieved. Different categories for rating OTB that resulted in a significant difference in EBL have been used [13, 15, 19, 20]. Achieving greater than 70% or 75% of OTB was recommended in order to effectively reduce intra-operative blood loss [15, 19]. For peripheral lesions, patients with OTB >70% had an average of 550 ml EBL, which was significantly less than patients with OTB <70% [15, 19]. With proper embolization technique, sufficient OTB could be obtained in more than 75% of patients who underwent preoperative embolization [19]. Some authors used the criterion of complete/incomplete OTB to indicate the success of the procedure [13, 20]. An average of 535 ml EBL (ranging from 200–1600 ml) was observed in patients who had complete OTB. However, complete OTB could be obtained only in 36% of all patients [20]. EBL did not significantly correlate with tumor size or vascularity prior to embolization [19]. The effect of embolotherapy on OTB was based on a planimetric comparison of pre-

and postembolization arteriograms [19]. Causes for patients with <70% of OTB were multifold: (1) severe tortuosity and irregularity of vessels secondary to remarkable atherosclerotic disease precluded super-selective catheterization; (2) tumor feeding vessels that arose directly from a limb-supplying artery were so small that a microcatheter could not be seated well enough for embolization without risk of nontarget ischemia (Fig. 15.4a,b); and (3) proximal embolization with coils or Gelfoam pledge [19].

It is generally recommended that surgery be performed within 24 h after embolization, since flow reconstitution through collaterals increases with time [14]. For patients who were embolized with coils only and who were operated more than 48 h after embolization, significant intraoperative blood loss was encountered during the surgery. This high blood loss was observed although more than 70% obliteration of tumor blush had been achieved in some patients [19]. The small number of patients makes it difficult to assess whether this result is related to the type of embolization material or the timing of surgery. In patients who were embolized with smaller-sized PVA, the timing of surgery may not be critical; there was no significant difference in EBL between the patients who were operated on

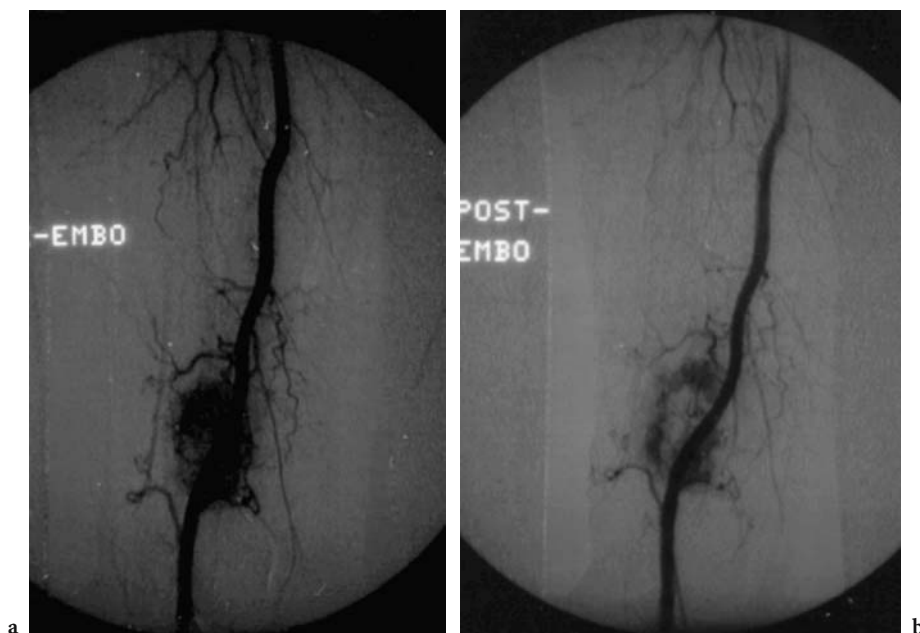


Fig 15.4a,b. Obliteration of tumor stain by <math><50\%</math>, 700 ml of estimated blood loss, survival 6 months. **a** Pre-embolization arteriogram showing a hypervascular lesion in the right distal femur. The branches supplied a tumor arising directly from the popliteal artery; many of them were too small for safe embolization (*arrows*). **b** Postembolization arteriogram with residual tumor stain

within 24 h and those who had surgery 36 to 120 h after embolization. Use of PVA in cases of an anticipated delay in surgery is therefore recommended [19].

15.4.2 Osseous Healing and Survival

Bone healing can be affected adversely by many variables, such as presence of tumor cells, poor local blood supply, systemic disease, malnutrition, corticosteroid therapy, and iatrogenic inference [34, 35]. Preoperative embolization has the potential to induce ischemic changes in the tissues adjacent to the tumor and may theoretically interfere with osseous union. However, there has been no evidence of delayed postoperative healing or nonhealing reported in the literature [10, 19, 34, 35]. In all reported patients, bone healing ensued as evidenced by radiography, progressive callus formed at 3 and 6 months, and hardware was in place without complication (Fig. 15.5a–e). When bone healing was evident, functional recovery largely depended on the type of surgery the patients received.

The oncological objective of excising metastatic RCC of bone is the achievement of local tumor control. Patient survival is determined by metastatic

disease at other sites, inherent biological behavior of the tumor, and tumor response to adjuvant treatment modalities. Therefore, the rate of local recurrence is the most appropriate criterion by which to evaluate the oncological adequacy of resection margin [10].

The appropriate goal of pre-operative embolization is to decrease intra-operative blood loss, followed by reduction of the amount of blood transfusion and surgical morbidity/mortality. As a result, shortened duration of surgery and hospital stay can be expected [10, 19, 25]. A median hospital stay of 8 days was reported with minimal surgical complications in a relative large surgical series [10]. Restoration of musculoskeletal function and release of pain therefore are paramount for the quality of life of these patients [19].

15.4.3 Complications

Postembolization syndrome (PES) is a common occurrence after pre-operative embolization of bone metastases. It was reported that PES is not necessarily regarded as a complication [36]. Marked PES may indicate a successful embolization and has been associated with a good clinical response to the embo-

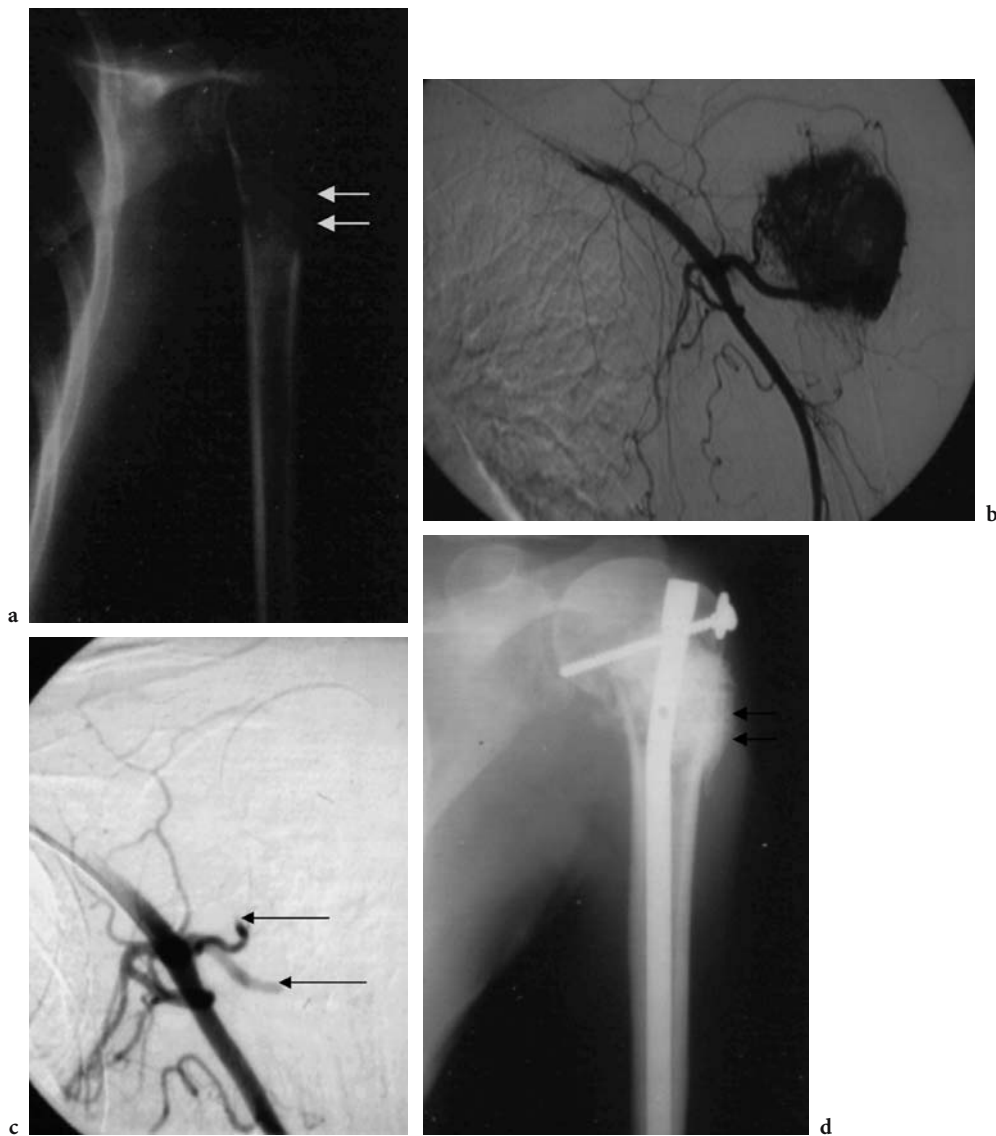


Fig 15.5a–d. Obliteration of tumor stain by more than 95%. Intraoperative blood loss of 100 ml, survival 3-1/2 years with normal healing and unimpaired function of her left upper extremity. **a,b** Pre-embolization; **c,d** postembolization. **a** Plain radiograph with large osteolytic lesion of the left humerus and pathologic fracture (*arrows*). **b** Early arterial phase showing hypervascular metastasis. **c** Arteriogram after superselective embolization of the left circumflex humeral arteries with 500- μ m PVA particles (*arrows*). **d** Radiograph 6 months after embolization and surgical repair shows normal bone healing with hardware in place (*arrows*)

lization [36]. Common symptoms are fever (usually below 38°C), malaise, and pain. PES usually subsides within 3–5 days without treatment. However, severe PES may deter a surgeon from immediate intervention. When PVA particle is used, such a delay should not have adverse effects on intraoperative blood loss. Reported complications include nontarget embolization, skin necrosis, and ischemic ulcer [36]. One spontaneous pathologic fracture was reported 12 h after the embolization with PVA and additional

coils. More than 95% of obliteration of tumor blush had been achieved by superselective embolization in this patient (Fig. 15.6a–e). The patient reported no apparent external forces on his leg after the embolization. It is conceivable that acute ischemic changes following embolization in a hypervascular tumor may cause volume changes eliciting a spontaneous cortical collapse. Although patients with pending fractures are already handled carefully, extra caution during patient transport and immobilization of

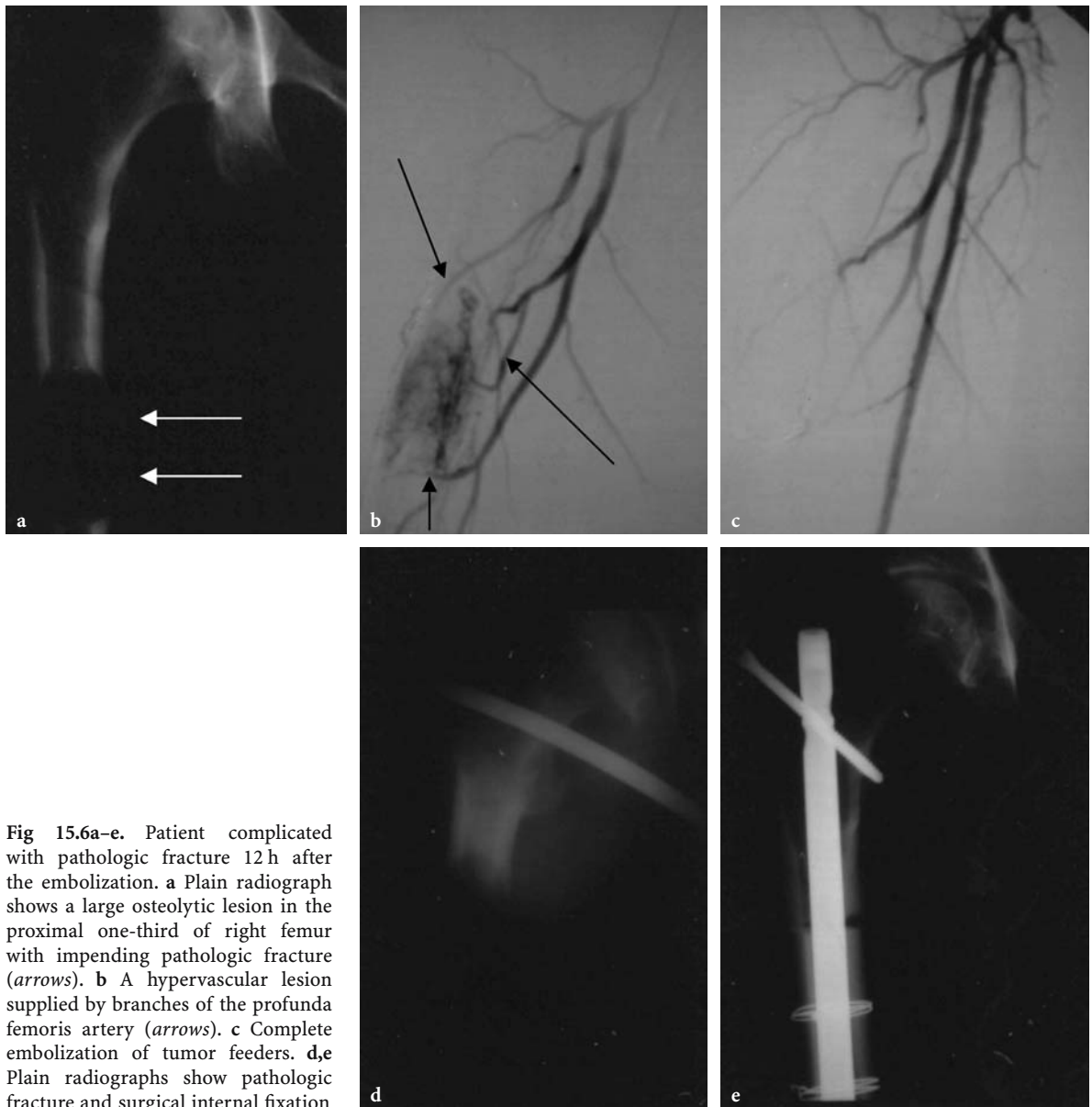


Fig 15.6a–e. Patient complicated with pathologic fracture 12 h after the embolization. **a** Plain radiograph shows a large osteolytic lesion in the proximal one-third of right femur with impending pathologic fracture (*arrows*). **b** A hypervascular lesion supplied by branches of the profunda femoris artery (*arrows*). **c** Complete embolization of tumor feeders. **d,e** Plain radiographs show pathologic fracture and surgical internal fixation

the affected extremity is recommended after embolization [19].

While complications can be reduced through abiding by proper technique, risks are higher in certain anatomic locations. During pelvic embolization, occlusion of blood vessels supplying the sciatic nerve may cause ischemic neuropathy, which can be avoided by sparing the inferior gluteal artery during embolization. Also, muscle branches of the superior gluteal artery or deep femoral artery should be spared to prevent claudication or necrosis. Coil embolization should be performed before emboliza-

tion of tumor feeders with smaller particles to avoid inadvertent embolization.

15.5 Conclusion

Retrospective studies are of limited value in determining the exact effect of a certain form of treatment. Intra-operative blood loss depends not only on the type of surgery, but the individual skills of

surgeon as well. Theoretically, a prospective and randomized study would be desirable for precisely evaluating the effects of pre-operative embolization. However, according to the nature of clinical studies, the necessity and possibility of conducting such a study are in question. Practically, pre-operative embolization of hypervascular bone metastases from renal cell carcinoma is a safe and minimally invasive procedure in experienced hands. Best results can be achieved with the use of PVA particles and when >70% of tumor blush is obliterated. This has become a standard pre-operative procedure for patients with hypervascular metastatic disease of bone from RCC.

References

- Parker SL, Tong T, Bolden S and Wingo PA (2005) Cancer statistics, 2005. *CA Cancer J Clin* 65:5-27
- Devesa SS, Silverman DT, McLaughlin JK et al. (1990) Comparison of the descriptive epidemiology of urinary tract cancer. *Cancer Causes and Control* 1:133-141
- Russo, P (2000) Renal cell carcinoma: Presentation, staging and surgical treatment. *Semin Oncol* 27:160-176
- Swanson DA, Orovan WL, Johnson DE, Giacco G (1981) Osseous metastases secondary to renal cell carcinoma. *Urology* 18:556-561
- Selli O, Hinshaw WM, Woodard BH, Paulson DF (1983) Stratification of risk factors in renal cell carcinoma. *Cancer* 52:899-903
- King GJ, Kostuik JP, McBroom RJ, Richardson W (1991) Surgical management of metastatic renal carcinoma of the spine. *Spine* 16:265-271
- Kessler O, Mukamel E, Hadar H et al. (1994) Effect of improved diagnosis of renal cell carcinoma on the course of the disease. *J Surg Oncol* 57:201
- Maldazys JD and deKernio JB (1986) Prognostic factors in metastatic renal carcinoma. *J Urol* 136:376
- Kollender Y, Bickels J, Price WM. et al. (2000) Metastatic renal cell carcinoma of bone: Indications and technique of surgical intervention. *J Urol* 164:1505-1508
- Bowers TA, Murray JA, Charnssngavej C, Soo CS, Chuang VP Wallace S (1982) Bone metastases from renal carcinoma: The pre-operative use of transcatheter arterial occlusion. *J Bone Joint Surg (Am)* 64-A:749-754
- Carpenter PR, Ewing JW, Cook AJ, Kuster AH (1977) Angiographic assessment and control of potential operative hemorrhage with pathologic fractures secondary to metastasis. *Clin Orthop* 123:6-8
- Manke C, Bretschneider T, Lenhart M et al. (2001) Spinal metastases from renal cell carcinoma: Effect of preoperative particle embolization on intraoperative blood loss. *Am J Neuroradiol* 22:997-1003
- Carrasco CH (1991) Embolotherapy of bone and soft-tissue tumors. In: Kadir S (ed) *Current practice of interventional radiology*. Decker, Philadelphia
- Gellad FE, Sadato N, Numaguchi Y, Levine AM (1990) Vascular metastatic lesion of the spine: preoperative embolization. *Radiology* 176: 683-686
- Keller FS, Rosch J, Bird CB (1983) Percutaneous embolization of bony pelvic neoplasms with tissue adhesive. *Radiology* 147:21-27
- Rowe DM, Becker GJ, Rabe FE et al. (1984) Osseous metastases from renal cell carcinoma: embolization and surgery for restoration of function. *Radiology* 150:673-676
- Barton PP, Waneck RE, Karnel FJ et al. (1996) Embolization of bone metastases. *J Vasc Interv Radiol* 7:81-88
- Sun S, Lang EV (1998) Bone metastases from renal cell carcinoma: Preoperative embolization. *J Vasc Interv Radiol* 9:263-269
- Chatziioannou AN, Johnson ME, Pneumaticos SG et al. (2000) Preoperative embolization of bone metastases from renal cell carcinoma. *Eur Radiol* 10:593-596
- Lavrenkov K, Meller I, Cohen Y (2002) Solitary bone metastasis of renal cell carcinoma treated with limb-sparing surgery followed by radiotherapy. *Isr Med Assoc* 4:385-386
- Motzer RJ, Bander NH, Nanus, DM (1996) Renal-cell carcinoma. *N Engl J Med* 335:865
- Tuncay IC, Condrad EU (1993) Metastatic bone disease. *J Arthroplasty Arthrosc Surg* 7:80-8218
- Rossi C, Ricci S, Boriani S et al. (1990) Percutaneous transcatheter arterial embolization of bone and soft tissue tumors. *Skeletal Radiol* 19:555-560
- Berkefeld J, Scale D, Kirchner J et al. (1999) Hypervascular spinal tumors: influence of the embolization technique on perioperative hemorrhage. *Am J Neuroradiol* 20:757-763
- Olerud C, Johnson H Jr, Lofberg AM et al. (1993) Embolization of spinal metastases reduces perioperative blood loss. *Acta Orthop Scand* 64:9-12
- Smith TP, Gray L, Weinstein JN et al. (1995) Preoperative transarterial embolization of spinal column neoplasms. *J Vasc Interv Radiol* 6:863-869
- Siskin GP, Englander M, Stainken BF et al. (2000) Embolic agents used for uterine fibroid embolization. *Am J Roentgenol* 175:767-773
- Kunstlinger F, Brunelle F, Chaumont P, Doyon D (1981) Vascular occlusive agents. *Am J Roentgenol* 136:151-156
- White RI, Stranberg JV, Gross G, Barth K (1977) Therapeutic embolization with long term occluding agents and their effects on embolized tissues. *Radiology* 125:677-687
- Horton JA, Marano GD, Kerber CW et al. (1983) Polyvinyl alcohol foam-gelfoam for therapeutic embolization: A synergistic mixture. *Am J Neuroradiol* 4:143-147
- Pisco JM, Martins JM, Correia MG (1989) Internal iliac artery: Embolization to control hemorrhage from pelvic neoplasms. *Radiology* 172:337-339
- Merland J-J, Charas J (1981) *Arteriography of the pelvis. Diagnostic and Therapeutic Procedures*. pp. 3-4, Springer Verlag, Berlin
- Buckwalter JA, Cruess RL (1991) Healing of the musculoskeletal tissues. In: Rockwood CA Jr, Green DP, Bucholz RW, eds. *Rockwood and Green's fractures in adults*, 3rd ed., pp 181, Lippincott, Philadelphia
- Hulth A (1989) Current concepts of fracture healing. *Clin Orthop* 249:265-284
- Hemingway AP and Allison DJ (1988) Complications of embolization: analysis of 410 procedures. *Radiology* 166:609-672

16 Embolotherapy for Organ Ablation

DAVID C. MADOFF, RAJIV VERMA and KAMRAN AHRAR

CONTENTS

16.1	Embolotherapy in Management of Renal Tumors	201
16.1.1	Introduction	201
16.1.2	Anatomic and Angiographic Considerations	203
16.1.3	Technical Considerations	203
16.1.4	Results	207
16.1.4.1	Embolotherapy for Renal Cell Carcinoma	207
16.1.4.2	Embolotherapy for Angiomyolipoma	210
16.1.5	Future Directions	211
16.2	Embolotherapy in Management of Hypersplenism	211
16.2.1	Introduction	211
16.2.2	Anatomic Considerations	212
16.2.3	Technical Considerations	212
16.2.4	Results	214
16.2.5	Future Development and Research	215
16.3	Conclusion	216
	References	217

16.1 Embolotherapy in Management of Renal Tumors

16.1.1 Introduction

Malignant tumors of the kidney and renal pelvis account for ~3% of all adult malignancies. There were ~31,200 new cases in 2000 contributing to ~11,900 deaths in the United States [1]. Renal cell carcinoma is the most common primary malignant tumor of the kidney and occurs in both sporadic and hereditary forms [2]. Most cases are sporadic, but at

least four forms of hereditary renal carcinoma have been identified. The most studied form of hereditary renal cancer is von Hippel-Lindau syndrome, in which affected individuals have a predisposition to develop tumors in various organs, including the kidneys. In the hereditary syndromes, kidney cancer is often bilateral and tends to occur in younger patients. Renal cell carcinoma may remain clinically occult for most of its course; the classic presentation of pain, hematuria, and palpable mass occurs in only 9% of patients. Approximately 30% of patients with renal cell carcinoma present with metastatic disease, 25% with locally advanced tumor, and 45% with localized disease. Widespread use of routine abdominal imaging has led to increasing detection of smaller lower stage renal tumors [3]. Therefore, the natural history of renal cell carcinoma may be changing [3]. Historically, radical nephrectomy was considered the only effective treatment for patients with renal cell carcinoma. More recently, nephron-sparing surgery has been accepted as an alternative for smaller tumors (less than 4 cm) localized to the kidney [3]. Although promising for the management of smaller tumors, energy ablative therapies, including cryotherapy and radiofrequency ablation, are investigational and are reserved for patients who are not good surgical candidates, patients with only one kidney, and those with multiple bilateral tumors [4, 5]. Metastatic renal cell carcinoma is unresponsive to conventional chemotherapy used to treat other metastatic solid tumors, but treatment with immunotherapy has resulted in durable responses in selected patients [3]. Before the era of immunotherapy, the course of metastatic renal cancer was not affected by debulking nephrectomy, and surgery was reserved only for palliation of symptoms. Recent trials of nephrectomy and immunotherapy versus immunotherapy alone have demonstrated statistically significant improvement in overall survival in patients with metastatic renal cell carcinoma [6]. In light of these findings, nephrectomy has become the initial component of multimodality therapy for metastatic renal cancer.

D. C. MADOFF, MD; R. VERMA, MD; K. AHRAR, MD
Section of Interventional Radiology, Division of Diagnostic Imaging, The University of Texas, MD Anderson Cancer Center, 1515 Holcombe Boulevard, Unit 325, Houston, TX 77030-4009, USA

Surgical resection of larger renal cell carcinoma is challenging because both the kidney and the tumor are extremely vascular and dissection of the tumor may lead to clinically significant blood loss, necessitating replacement of a large volume of blood. In addition, renal hilar lymph nodes may interfere with visualization and access to the vascular pedicle [7]. Early ligation of the renal artery is necessary to avoid substantial bleeding, but the renal vein lies anterior to the artery and may be encountered before the renal artery. For these reasons, starting in the 1970s, the technique of renal artery embolization was popularized as an adjunct to surgery. Since that time, embolization has been used before resection of larger tumors and tumors invading the renal vein or inferior vena cava [8, 9]. When used appropriately and in the right setting, the technique purportedly decreases intraoperative blood loss and creates a plane of edema that facilitates the dissection of the tumor [8]. The same technique has been used for palliation of patients who may not be surgical candidates. Renal artery embolization has been used to alleviate tumor-related symptoms like hematuria, flank pain, paraneoplastic symptoms such as hypercalcemia or polycythemia, congestive heart failure, and hypotension [10, 11]. Other potential, but as of yet unproven, benefits of renal artery embolization include inhibition of tumor growth and improved survival [12].

Angiomyolipoma is generally a benign tumor of the kidney, although a more aggressive subtype (epithelioid angiomyolipoma) has also been described [13]. The tumor is composed of mature fat cells, vascular tissue, and smooth muscle in various proportions. Clinically, angiomyolipoma appears in one of two distinct settings. It may be

associated with the tuberous sclerosis complex, which is an autosomal dominant disease with incomplete penetrance. The triad of seizures, mental retardation, and adenoma sebaceum characterizes tuberous sclerosis in its classic clinical presentation. More commonly, angiomyolipoma is encountered sporadically in individuals who otherwise have no clinical features of tuberous sclerosis. Angiomyolipoma is also associated with pulmonary lymphangiomyomatosis. The clinical presentation of angiomyolipoma may be similar to that of renal cell carcinoma. Patients may present with flank pain, a palpable tender mass, or gross hematuria, and possibly nausea, fever, hypertension, or anemia. In patients with tuberous sclerosis and multiple angiomyolipomas, renal insufficiency or failure may be the initial sign of the tumor. The most dramatic and life-threatening presentation of angiomyolipoma is spontaneous retroperitoneal hemorrhage. Angiomyolipomas associated with the tuberous sclerosis complex are often multiple, bilateral, and larger at presentation. These tumors are more prone to spontaneous hemorrhage than their sporadic counterparts (Table 16.1).

Before 1976, 93% of reported angiomyolipomas not associated with tuberous sclerosis were treated with total nephrectomy, whereas in 1984, only 50% of all angiomyolipomas reported in the literature were treated with total nephrectomy [14]. Because of advances in embolization and partial nephrectomy techniques, most angiomyolipomas are now treated conservatively where the goal is control of symptoms, prevention of life-threatening hemorrhage, and preservation of renal function. Other than patients who present with spontaneous bleeding and require urgent treatment, the timing of intervention for angiomyolipoma remains a subject of debate. In one study, 90% of symptomatic tumors were 4 cm or larger and 64% of asymptomatic tumors were smaller than 4 cm [14]. In another study, small (less than 4 cm), medium (4–8 cm), and large (greater than 8 cm) tumors were symptomatic in 10%, 54%, and 100% of cases, respectively [15]. Primary indications for intervention include pain, retroperitoneal hemorrhage, and hematuria regardless of tumor size, but prophylactic intervention is reserved for larger tumors in high-risk patients, in females of childbearing age, and for those patients for whom follow-up or access to emergency care may be inadequate. Regardless of the indication, preserving renal tissue and function is a significant concern when treatment is contemplated.

Table 16.1. Clinical characteristics of angiomyolipoma in contemporary surgical series

	Tuberous sclerosis-associated angiomyolipoma	Sporadic angiomyolipoma	<i>p</i> -value (chi-square test)
Mean age	30.3	52.1	
Tumor diameter (cm)	8.9	5.4	
% Multiple tumors	97	13	<0.0001
% At presentation:			
– Symptomatic	64	73	0.2584
– Acute hemorrhage	44	14	<0.0001

From: NELSON and SANDA [13] -(printed with permission)

16.1.2 Anatomic and Angiographic Considerations

A thorough understanding of the renal vascular anatomy is a prerequisite for successful embolization of renal tumors and helps minimize inadvertent nontarget embolization. Most commonly, a single renal artery to each kidney arises from the abdominal aorta at the level of L1–L2 disc space. Multiple renal arteries to one or both kidneys may be present in 12%–32% of individuals [16]. The main renal artery frequently divides into anterior and posterior branches. Because of the location of the kidney in the retroperitoneum, the ventral or anterior division of the renal artery supplies the lateral border of the kidney in an anteroposterior angiogram, whereas the dorsal or posterior division provides blood supply to the medial border of the kidney. Furthermore, the anterior division appears as a direct continuation of the main renal artery, whereas the posterior division is smaller in caliber and appears as a branch of the main renal artery [17]. Branching of the renal arteries continues to form segmental, lobar, interlobar, and arcuate arteries. The arcuate arteries are end arteries and do not anastomose with one another; instead, they subdivide into interlobular arteries, which in turn give rise to afferent glomerular arterioles [18].

Perforating arteries, an important collateral pathway to the kidney, arise from the intraparenchymal branches of the renal artery and exit from the kidney to anastomose with various retroperitoneal arteries [18]. In addition to the main renal artery and perforating arteries, the superior, middle, and inferior capsular arteries should be considered as well. The superior capsular artery may arise from the inferior adrenal artery, main renal artery, or aorta. The middle capsular artery, which may consist of one or more branches, arises from the main renal artery. The inferior capsular artery may originate from the gonadal artery, an accessory or aberrant lower pole, or even the main renal artery. These vessels form a rich capsular network that anastomoses freely with perforating arteries and other retroperitoneal (especially lumbar) arteries and also with internal iliac, intercostal, and mesenteric arteries [18].

Angiography is no longer performed in the diagnostic workup of renal masses and is reserved for therapeutic interventions only. The study should start with an abdominal aortogram to determine the number and location of arteries supplying the kidney and the tumor. Selective catheterization and angiography of each feeding artery is performed to assess

the extent of neovascularity, degree of arteriovenous shunting, and risk of nontarget embolization.

Most renal cell carcinomas appear hypervascular on angiography (Fig. 16.1) and demonstrate tumor vessels that are irregular, tortuous, randomly distributed, variable in size, and unpredictable in branching [19]. Other findings may include pooling of contrast in dilated vessels, arteriovenous shunting, staining of the tumor during the capillary phase, and renal vein invasion or occlusion by the tumor.

The angiographic appearance of angiomyolipoma is that of a hypervascular mass with a large feeding artery [19]. The vascular components of the tumor are thick-walled arteries characterized by the absence of the internal elastic membrane and a disordered adventitial cuff of smooth muscle, which results in the numerous saccular aneurysms frequently seen on arteriograms. Tortuous vessels may be circumferentially arranged in the arterial phase. Overall, a sunburst or whorled appearance in the nephrographic and venous phases is suggestive of these tumors. Arteriovenous shunting is not a prominent feature of angiomyolipomas.

16.1.3 Technical Considerations

The size and extent of the tumor, the need to preserve any of the renal parenchyma, and the overall goal of embolization should be considered in planning embolotherapy of renal tumors. Historically, the choice of embolic agents depended on the experience and preference of the operator. Although more than twenty embolic agents have been used (Table 16.2), it is most worthwhile to consider three classes of embolic agents currently used for embolizations of renal tumors: liquid agents (the prototype of which is absolute ethanol), particulate materials (the prototype of which is polyvinyl alcohol foam), and metallic coils.

A recent review of the literature demonstrated a trend toward the use of ethanol for embolization of renal tumors [20]. Ethanol is a nonviscous liquid, and after it is injected into the main renal artery, it diffuses into the distal vascular bed of the tumor, potentially causing tumor necrosis rather than simple occlusion of the embolized artery [21]. Transcatheter administration of ethanol is technically easy, and theoretically, reflux of a small amount of ethanol may not be as toxic as other embolic agents to other organs of the body because alcohol dilutes rapidly in a large volume of blood [22]. In reality,

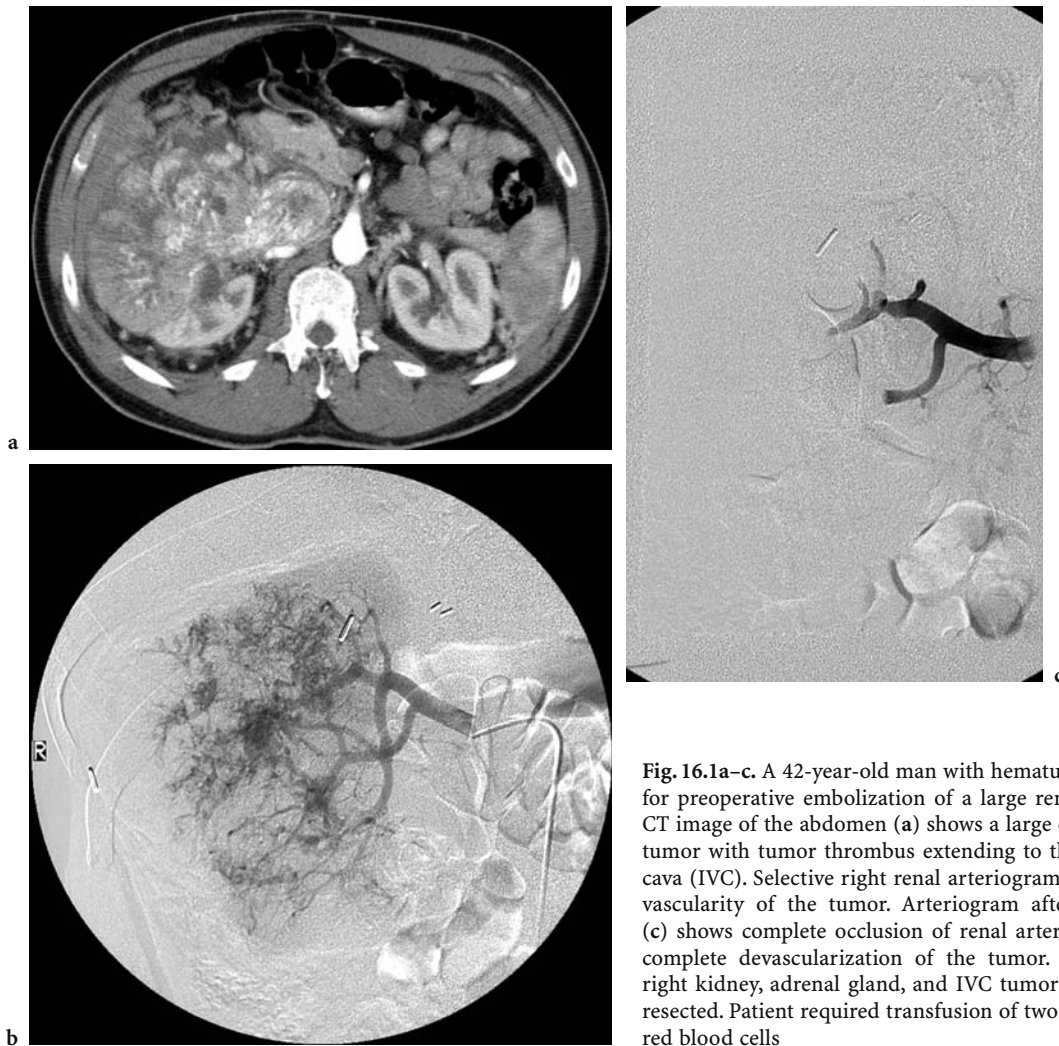


Fig. 16.1a–c. A 42-year-old man with hematuria was referred for preoperative embolization of a large renal tumor. Axial CT image of the abdomen (a) shows a large enhancing renal tumor with tumor thrombus extending to the inferior vena cava (IVC). Selective right renal arteriogram (b) shows neovascularity of the tumor. Arteriogram after embolization (c) shows complete occlusion of renal artery branches and complete devascularization of the tumor. At surgery, the right kidney, adrenal gland, and IVC tumor thrombus were resected. Patient required transfusion of two units of packed red blood cells

however, reflux of ethanol can lead to nontarget embolization of the inferior mesenteric artery and the lumbar arteries [11, 23–26].

Ellman et al. [21] first described ablation of renal tumors with absolute ethanol. On the basis of their experience with an animal model and six patients, they recommended selective injection of ethanol at a rate of 2 ml/s in as many tumor arteries as possible. They hypothesized that injection of ethanol at a rate of 1 to 5 ml/s results in tissue toxicity, thereby leading to necrosis in the perivascular areas, “sludging” of erythrocytes in small arteries and glomeruli, and spasm of these small arteries; subsequently, the endothelium is damaged and sloughs over several hours, resulting in complete occlusion of damaged vessels. ELLMAN et al. further elaborated that slow injection of ethanol (0.1 ml/s) results in little direct tissue toxicity and that instead, small clumps of

damaged erythrocytes and denatured proteins lead to proximal occlusion of the arteries. The desired angiographic end points were described as occlusion of all arteries smaller than major segmental branches, stagnation of flow in patent major arteries, and extravasation of contrast material into the renal parenchyma. According to their report, injection of 1 ml of ethanol per 4 lb (1.8 kg) of body weight results in a systemic blood ethanol level of about 50 mg/dl, which is half the intoxicating level of 100 mg/dl and far below the toxic level of 500 mg/dl.

In a modification of the technique of ELLMAN et al., RABE et al. [22] used an occlusion balloon catheter in eight patients. In this technique, the occlusion balloon is inflated in the main renal artery (Fig. 16.2), and ethanol is injected at a rate of 1 to 5 ml/s. The balloon is kept inflated for 10 s to 2 min, and after 10 min, the catheter is aspirated to

Table 16.2. Agents used for therapeutic embolization of renal cell carcinoma, in alphabetical order

Absolute ethanol
Autologous muscle particles
Avitene (microfibrillar collagen hemostat)
Coils (metal / steel / mini / Gianturco / GAW)
Collagen
Detachable balloons
Dura particles
Ethibloc (oily contrast-labeled amino acid)
Fibrosputum
Gelatin foam / Gelfoam
Gelatin sponge / Gelaspon
Gelfoam prepared with BCG
Histoacryl
Ivalon (polyvinyl alcohol)
ICBA (isobutyl-2-cyanoacrylate)
Lydura
MMC (microencapsulated or nonencapsulated mitomycin C)
Palacos (methylmethacrylate)
Spongostan
Tachotyp flocculi
Thrombin
Vilan

From: KALMAN and VARENHORST [20] (printed with permission)

remove residual alcohol from it. After the catheter is flushed, a test injection is performed with contrast material. This sequence is repeated until total occlusion of the main renal artery is achieved. The advantages of using an occlusion balloon catheter are several: the balloon interrupts renal blood flow, markedly prolonging the contact time of ethanol with the endothelium and thereby reducing the volume of ethanol needed for complete ablation of the target tissue; the balloon inhibits reflux into the aorta; and with the use of a balloon catheter, the main renal artery can be injected with ethanol and selective catheterization of segmental branches is not necessary. RABE et al. also suggested that injection of ethanol in the main renal artery without an occlusion balloon is ineffective because ethanol dilutes rapidly in a large volume of blood. Instead, they endorsed the technique of ELLMAN et al. with selective catheterization and embolization of segmental arteries when a balloon occlusion catheter could not be used.

BAKAL et al. [7] described a variation of the balloon occlusion technique. They performed all renal embolizations during selective placement of an occlusion balloon catheter in the distal main renal artery. Estimates of ethanol volume needed for embolization were made by test injecting contrast material during balloon occlusion. After infusion of the ethanol, the balloon was left inflated for 5 min. As the balloon was deflating, gentle suction through the distal endhole of the catheter prevented reflux of

residual ethanol or thrombus into the aorta. Unlike the study by RABE et al., no attempts were made to selectively catheterize or embolize other tumor vessels; embolization of the kidney rather than the tumor was the intended effect. The retrospective analysis of BAKAL et al. demonstrated that complete ablation of large, hypervascular tumors was associated with a significantly reduced blood transfusion requirement at nephrectomy, whereas tumors that were partially ablated (accessory renal arteries, polar branches, or lumbar arteries were not embolized) required larger amount of blood transfusion than the control group did.

Absolute ethanol is readily available, inexpensive, and easy to handle, but its major drawback is that it is not radiopaque. Early experiments in mixing ethanol with radiographic contrast resulted in precipitation of the mixture [22]. However, ethanol may be mixed with iodized oil (Lipiodol or Ethiodol) in a 1:3 mixture for successful embolization of angio-myolipomas [27]. KONYA et al. [28] suggested that a 1:1 mixture of ethanol and iodized oil followed by absolute ethanol may be an effective embolic agent for ablation of renal tissue.

Particulate materials, such as absorbable gelatin sponge (Gelfoam) and polyvinyl alcohol foam (Ivalon), have been used alone and with metallic coils [29]. Newer embolic agents such as EmboGold Microspheres (BioSphere Medical, Rockland, MA) and Contour SE (Boston Scientific; Natick, MA) are also used for embolization of renal masses, but no reports of their effectiveness or lack thereof are available in the literature; theoretically, these newer agents should not be any less effective than Gelfoam or Ivalon. There is no scientific evidence pointing to a particular particle size for embolization of renal masses. Despite the lack of information, some recommendations can be made here. In general, distal embolization of the tumor bed rather than proximal occlusion is desirable; therefore, embolization should start with particles small enough to avoid proximal occlusion. Hypervascular renal tumors may have considerable arteriovenous shunting, and nontarget embolization of the pulmonary bed is a concern. In tumors with rapid arteriovenous shunting, the use of a sclerosing agent such as ethanol or larger particles may be prudent. The use of coils for palliation of tumors is discouraged because renal tumors in advanced stages often have an extensive collateral blood supply, rendering proximal occlusion of the feeding arteries ineffective. Furthermore, many tumors require additional interventions, so arterial access

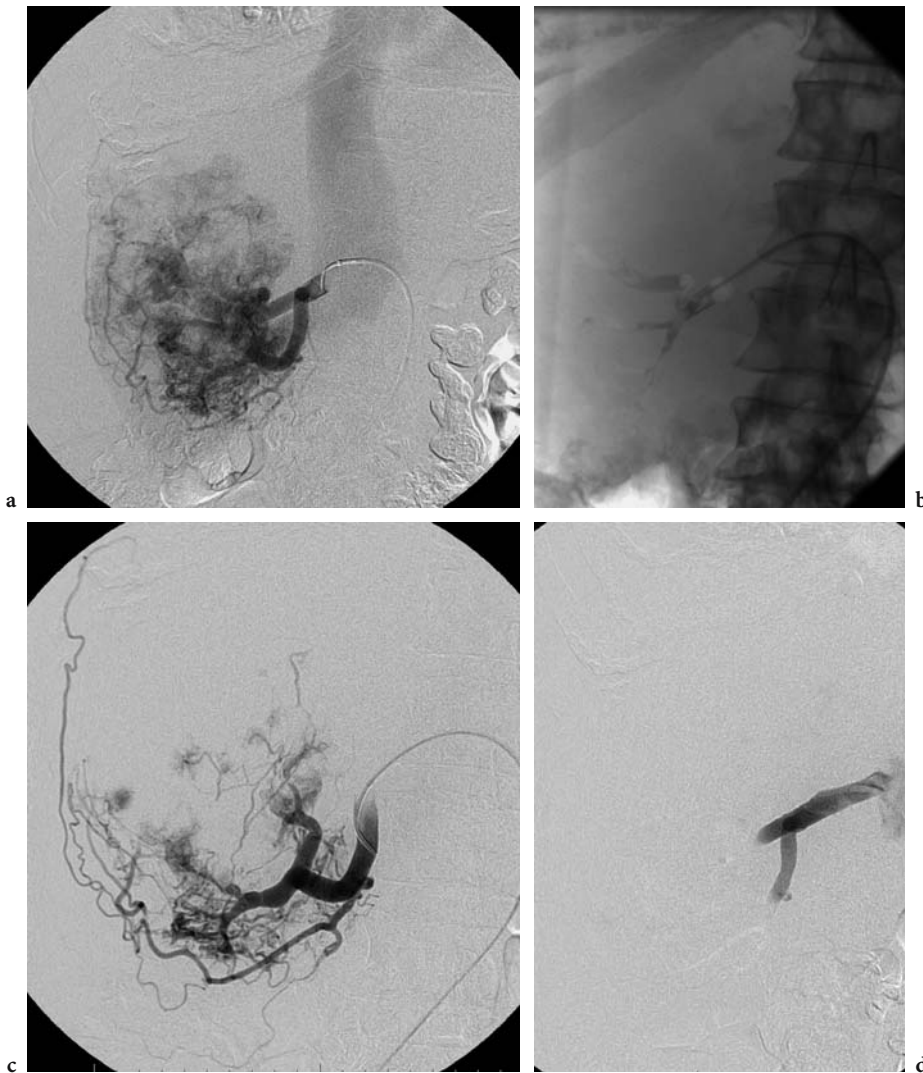


Fig. 16.2a–d. A 64-year-old man with history of metastatic renal cell carcinoma and right flank pain was referred for palliative embolization. Selective digital subtraction angiogram of the right main renal artery (a) shows early bifurcation of the renal artery, neovascularity, tumor stain, and substantial arteriovenous shunting. The inferior vena cava is opacified in the background. After placement of an occlusion balloon catheter (b), the anterior branch of the renal artery was embolized with 10 ml of dehydrated alcohol (absolute ethanol). Selective angiogram of the posterior branch of the right renal artery (c) shows blood supply to the remainder of the tumor. Embolization of this branch was completed using EmboGold Microspheres. Selective angiogram of the main renal artery (d) shows complete occlusion of both anterior and posterior branches. The tumor is completely devascularized

to the neoplasm must remain intact [30]. If coils are used for preoperative embolization, they should be sized and placed appropriately to minimize the risk of dislodgment at the time of surgery and to avoid difficulties with renal artery clamping or ligation [29].

Although firm scientific evidence is lacking, complete embolization of the renal tumors may be a desirable end point both for preoperative and pal-

liative purposes [7, 11, 27, 31]. Because most renal cell carcinomas are hypervascular and often recruit collateral blood supply from other sources as well, many operators use a combination of techniques and embolic agents to achieve complete embolization (Fig. 16.2). Therefore, it seems appropriate for the operator to be familiar with various techniques and have access to a full complement of different embolic agents.

16.1.4 Results

16.1.4.1 Embolotherapy for Renal Cell Carcinoma

Renal artery embolization was popularized by Almgård in the early 1970s. Over the next two decades, investigators debated the usefulness of embolotherapy in the management of renal cell carcinoma, but the decreasing number of reports in the literature since then indicates a loss of interest in this technique over time, particularly in the last decade. Most of the published reports are now over 20 years old. Angiography, catheterization, and embolization

techniques have evolved over the last three decades. A review of this older literature, which may not be reflective of the current practice of embolotherapy, is nevertheless warranted to elucidate the evolution of the technique, point out some of the shortcomings of previous studies, and highlight questions that remain to be answered.

In 1999, KALMAN and VARENHORST [20] published a survey of the pertinent literature which appeared during 1973–1997 on renal artery embolization for management of renal cell carcinoma (Table 16.3). Each one of the selected articles presented a minimum of 20 embolization cases, and each study aimed to investigate the clinical effect of embolization. All reports were scrutinized for study

Table 16.3. Case series published in the English literature, in order of year of publication, agents used for therapeutic embolization, number of patients, and indication for embolization

First Author	Year of publication	Method	Number of patients	Pre-operative	Palliative	Not specified
ALMGÅRD [45]	1977	Muscle particles	38	29	9	
FRASSON [49]	1978	Gelfoam	45	35	10	
SCHULMAN [141]	1980	Coils	3			
		Gelfoam	10			
		Gelfoam + coils	9	26	2	
		ICBA	4			
FRASSON [50]	1981	Coils	6			
		Gelfoam	226			
		Gelfoam + coils	3	241	41	
		ICBA	7			
		Muscle particles	2			
GIULIANA [53]	1981	Coils	1			
		Gelatin foam	14	40		
		ICBA	25			
KATO [142]	1981	Encaps MMC + gel	33	23	10	
		Sponge				
MOBILIO [48]	1981	Gelfoam	41	41		
		ICBA	1	1		
WALLACE [29]	1981	Gelfoam + coils	100	74	26	
LE GUILLOU [143]	1982	Not specified	247	203	44	
TEASDALE [144]	1982	Coils	3			
		Gelfoam	22	26	2	
		Gelfoam + coils	3			
BONO [39]	1983	Avitene	47	47		
		Gelfoam	48	48		
		ICBA	4			4
NAKANO [36]	1983	Gelatin sponge	21	12	9	
		ICBA				
EKELUND [40]	1984	Ethanol	20	6	14	
KAISARY [35]	1984	Coils				
		Gelatin sponge				
		Lyodura	55	49	6	
		Thrombin				
		Combinations of the above				
KURTH [32]	1984	Coils				
		Ethanol				
		Gelfoam	25	25		
		ICBA				
		Thrombin				

Table 16.3. Continued

First Author	Year of publication	Method	Number of patients	Pre-operative	Palliative	Not specified
MCIVOR [33]	1984	Coils				
		Dura particles	29	29		
		Gelfoam				
		Thrombin				
MEBUST [52]	1984	Coils + gelatin sponge	41	40	6	
		Ethanol	5			
CHRISTENSEN [42]	1985	Coils	36	36		
GOTTESMAN [41]	1985	Coil + Gelfoam	30	30		
KLIMBERG [8]	1985	Ethanol	25	21	4	
LAMMER [24]	1985	Coils	4			
		Ethanol	7			
		Gelfoam	85	81	40	
		Ivalon	25			
LEINONEN [38]	1985	Ethanol	12	10	2	
		Gelfoam	18	11	7	
WEIGEL [34]	1985	Coils				
		Ethanol	22	22		
		Gelfoam				
CHUDACEK [145]	1986	Ethibloc				
		Gelaspon	30		30	
		Vilan				
KARWOWSKI [146]	1987	Gelfoam	81		39	
		Gelfoam + coils	39	30		
KURTH [37]	1987	Coils				
		Ethanol				
		Gelfoam	33	33		
		ICBA				
NURMI [11]	1987	Ethanol	4			
		Ethanol + coils	3			
		Gelfoam	3			
		Gelfoam + coils	2		25	
		ICBA	10			
		ICBA + coils	2			
		ICBA + coils + Gelfoam	1			
STÖSSLEIN [147]	1988	Detachable balloons				
		Histoacryl				
		Ivalon	147	100	47	
		Combinations				
SWANSON [148]	1988	Coils				
		Gelfoam	134	145		
		Ivalon				
		Gelfoam + BCG	11			
KATO [46]	1989	Encaps MMC	44	99	74	
		Encaps MMC + Gelfoam	129			
LANIGAN [43]	1992	Ethanol	35	35		
BAKAL [7]	1993	Ethanol	22	22		
		Ethanol + coils	1	1		
		Ethanol + Gelfoam	1	1		
PARK [44]	1994	Ethanol	27	27		

From: KALMAN and VARENHORST [20]-(with modification, printed with permission)

design, control-comparison group, recruitment, patient selection, tumor stage, method of embolization, delay between embolization and operation, measurement of intended outcome, adverse outcome of treatment, and assessment of the extent to which therapeutic embolization provided a solution to the clinical problem.

Of the 51 publications, only 7 were prospective studies [8, 32–37]. The remainder were retrospective studies, or the study design was not specified. Most studies were from observation, and only four had historical control groups. As of 2004, no prospective randomized clinical trial of renal artery embolization has been reported. The methodologic

weaknesses of the published studies make it difficult to compare the reports and draw firm conclusions; therefore, evidence regarding renal artery embolization in the literature is weak and must be interpreted with caution.

Recruitment of patients to the studies on preoperative embolization varied widely. Some investigators included patients with “large primary tumors”, and others recruited patients with tumors larger than a specified diameter [34, 38, 39]; one study did not consider tumor size as a selection criterion [24]. Eligibility criteria for palliative embolization were more commonly reported as palliation of pain, hematuria, or life-threatening endocrine tumor activity [11, 24, 37, 38, 40, 41]. In one study, palliation was not defined with respect to any symptoms but as an alternative therapy for patients with advanced disease who were not surgical candidates [24]. Several of the 51 papers reported on patients who underwent either preoperative or palliative embolization. Overall, the studies varied greatly in their patient selection criteria, and details regarding patient condition and tumor stage were often lacking.

Over the span of three decades, more than 20 embolic agents have been used. Few authors used one agent only for embolization in their study [8, 40, 42–45]; most introduced combinations of agents or used different agents for embolization in their trials. Earlier studies used absorbable gelatin sponge and coils, which are still used in preoperative devascularization of renal tumors. For palliation, more permanent agents such as Ivalon and ethanol are preferred. More recently, absolute alcohol has become the recommended agent for embolization of renal tumors for all indications [7, 43, 44].

The time between embolization and nephrectomy was reported in 34 of the 45 studies on preoperative embolization. This interval varied from 8 hours [8] to 183 days [46]. In one study, a planned delayed nephrectomy was thought to result in development of edema and facilitate dissection [9], whereas another study reported a more difficult dissection 3 days or longer after embolization because of increasing collateral circulation [47]. On the basis of the results of the reviewed articles, KALMAN and VARENHORST [20] concluded that the optimal delay between embolization and operation was less than 48 hours.

Several variables have been considered in measurement of the intended outcome, including intraoperative blood loss. Twelve studies evaluated intraoperative blood loss after renal artery embolization. In three studies, blood loss was based on subjective estimation only [48–50]. One study compared

blood loss after embolization using ethanol and Gelfoam and found no significant difference [38]. In three studies, the difference in the amount of blood loss in embolized and nonembolized patients was not statistically significant [42, 43, 51]. One study reported greater blood loss for embolized patients compared with historical data, but an appropriately matched control group was not selected [52]. BAKAL et al. [7] demonstrated that estimated blood loss is an unreliable measurement and used instead the transfused volume as a measure of successful preoperative embolization. They demonstrated that the transfusion volume was statistically significantly lower after embolization for patients with large, hypervascular renal cell carcinoma (volume greater than 250 ml, diameter larger than 7.8 cm) than for smaller or hypovascular tumors. Another group recorded a statistically significantly lower volume of blood transfused in T3 and T4 tumors than in a historical control group [53]. Some groups believe that resection of renal cell carcinoma is facilitated by preoperative embolization [8, 47]. Reportedly, a plane of edema develops after embolization, making dissection of the tumor easier. In tumors with extension into inferior vena cava, embolization causes the tumor to shrink and facilitates its resection from the vena cava [9]. In addition, in larger tumors extending to the renal hilum and perihilar lymph nodes, preoperative embolization allows for ligation of the renal vein before the renal artery, alleviating some of the technical difficulties with resection of these bulky tumors [8].

Only four studies reported duration of surgery as an objective measure of intended outcome. One study found a shorter operating time compared with nonembolized patients in other published reports [8], and three trials found no benefit from preoperative embolization [42, 51, 52].

Immunologic response was also evaluated as a measurement of intended outcome. WALLACE et al. [47] suggested that angioinfarction of the tumor may result in release of tumor antigens, resulting in enhanced immunity against the tumor, and also that embolization prolonged survival in a selected group of patients. Although several reports showed distorted immunologic homeostasis after renal artery embolization, there was no conclusive evidence that embolization provided immunotherapeutic benefits in the management of advanced renal cell carcinoma [36, 40, 46]. In one study, patients with metastatic renal cell carcinoma who were treated with embolization and nephrectomy had a longer survival than patients who underwent embolization only [35]. In

a more recent study not included in the review by KALMAN and VARENHORST, preoperative embolization resulted in improved survival after nephrectomy: the overall 5- and 10-year survival rates were 62% and 47%, respectively, for 118 patients embolized before nephrectomy and 35% and 23%, respectively, for a matched group of 116 patients treated with surgery alone ($p = 0.01$) [12]. But this optimism is not shared by the experience of other researchers [11, 41, 42].

Palliation of symptoms in nonoperable patients was also included in some outcome analyses. The details of symptoms and therapeutic effects of renal artery embolization are generally lacking, but studies generally reported that hematuria, pain, and paraneoplastic symptoms were alleviated. In one study, severe hematuria resolved in 11 of 14 patients, and incomplete embolization of the tumor blood supply from parasitized lumbar arteries resulted in persistent hematuria in 3 of 14 patients [11]. In another study, malignant hypercalcemia resolved after embolization [10]. KALMAN and VARENHORST concluded that a small group of patients with specific, tumor-related symptoms may benefit from embolization. However, the palliative effect of embolization cannot be evaluated from the available data, and the effectiveness of the procedure awaits validation.

The most common side effect of embolotherapy is the post-embolization syndrome, which consists of low-grade fever, pain, nausea, and vomiting that start shortly after embolization and may last several days [32, 39, 47, 49]. These symptoms are often self-limiting and require only supportive therapy. Although solid evidence was not provided, some studies suggested that ablation of tumors with ethanol may result in a lower frequency of nausea and vomiting and an overall milder post-embolization syndrome than ablation of tumors with other particulate embolic agents will [8, 21, 38]. More serious complications have been reported as a result of nontarget embolization of the large bowel, spinal cord, contralateral kidney, or gonadal artery [23–26]. Contrast-induced nephropathy, renal abscess, and hypertension have also been reported [47]. In their initial description of the technique, RABE et al. [22] recommended the use of broad-spectrum antibiotics before and after embolization to prevent superinfection of necrotic tumor. Many reports lack specifics, but the need for prophylactic antibiotics does not seem to be universally accepted. In 1985, LAMMER et al. [24] reported a 9.9% overall complication rate in 121 renal tumor embolizations and a mortality rate of 3.3%. The most common complications in

this series were renal failure and nontarget embolization. The complication rate was four times higher in the palliative embolization procedures than in the preoperative embolizations. The authors attributed this discrepancy to the larger embolized tumor mass and the severely impaired health of patients who underwent palliative embolization [24]. A decade later, BAKAL et al. [7] reported a puncture site hematoma as the sole complication in a group of 24 patients who underwent preoperative embolization. It appears that with advancements in technology and experience in embolotherapy, complication rates have decreased substantially.

In a recent review of our database, we identified 30 consecutive patients (20 males, 10 females) with a mean age of 65 years (range, 42–85), who underwent embolization and surgical resection of their renal tumors. The mean tumor size was 11.5 cm. At surgery, tumor thrombus was removed from IVC in 25 patients (83%) and from the right atrium in 3 patients (10%). The surgeons reported substantial bleeding from venous collaterals in 8 patients (27%), marked inflammatory response around kidney in 6 patients (20%), and ascites in 1 patient (3%). Median blood transfusion requirement was 2 units of packed red blood cells. Mean tumor size was reduced to 10.5 cm after resection (p -value, 0.003). In 3 patients (10%) a significant reduction in size of IVC thrombus was noted during surgery.

16.1.4.2 Embolotherapy for Angiomyolipoma

Nelson and Sanda [13] summarized contemporary advances relevant to the clinical management of renal angiomyolipoma. Among other factors, the authors cited refinement of embolization and partial nephrectomy techniques as major developments in the management of these benign tumors. Their review of the literature identified 24 reports [22, 27, 31, 54–74] of a total of 76 patients regarding therapeutic embolization for angiomyolipoma (Table 16.4). The most common indication for embolization was acute hemorrhage. Other indications were symptomatic tumors in patients who were poor surgical candidates or had limited renal reserve and asymptomatic tumors for which prophylactic treatment was deemed appropriate. Post-embolization syndrome was recorded for 85% of patients, other complications were reported in 10% of cases including renal abscess (5%) and pleural effusion (3%). Over a median follow-up of 23 months (range,

0–204 months), 17% of patients had recurrent symptoms or hemorrhage that required repeat embolization or surgery.

16.1.5

Future Directions

Preoperative and palliative embolization of renal cell carcinoma may benefit a large number of patients. However, because of a paucity of scientific evidence, the technique remains underutilized. Similarly, although embolization is an accepted treatment for acute hemorrhage in patients with angiomyolipoma, it is not widely used to treat asymptomatic patients with this condition. Patient selection, technical details, expected complications, and outcomes all remain unclear at this time. Prospective clinical trials and randomized clinical trials are necessary to evaluate the true value of embolotherapy in the management of renal tumors.

16.2

Embolotherapy in Management of Hypersplenism

16.2.1

Introduction

Surgical removal or transcatheter ablation of splenic parenchyma is often performed for the management of hypersplenism, a pathologic condition in which there is increased pooling or destruction of the corpuscular elements of the blood by the spleen, resulting in reticuloendothelial hyperplasia [75]. Hypersplenism may be seen in many disorders,

including cirrhosis with portal hypertension [76, 77]; hematologic abnormalities such as idiopathic thrombocytopenic purpura, thalassemia major, and hereditary spherocytosis [78–82]; and diffuse splenic infiltration from primary malignancies such as leukemia and lymphoma [83–86]. Signs of hypersplenism include splenomegaly, thrombocytopenia, leukopenia, and anemia, and symptoms may include abdominal discomfort, pain, respiratory distress, and early satiety [87, 88]. Removal of functional splenic tissue may also improve hematologic abnormalities related to bone marrow suppression from systemic chemotherapeutic and immunosuppressive agents so that optimal doses of such medications can be maintained [88–90].

Total splenectomy may be an effective treatment for hypersplenism, but it impairs the body's ability to produce antibodies against encapsulated microorganisms and predisposes patient to sepsis [91]. Partial splenectomy has been proposed as a way to avoid this life-threatening complication [92, 93]. Despite surgery (total or partial splenectomy), the patient's condition for which the operation is performed may relapse, resulting in the need for a second operation or additional transfusions [81, 92–96]. Other patients may not be considered surgical candidates because of their underlying medical condition and severe cytopenia.

During the past three decades, splenic arterial embolization has been advocated in the nonoperative treatment of patients with these difficult clinical scenarios by intentionally infarcting splenic tissue and reducing its consumptive activity. In 1973, MADDISON [97] reported the initial clinical experience of splenic artery embolization, but severe complications that resulted from complete splenic infarction prevented acceptance of the technique as a viable treatment option. Since this initial descrip-

Table 16.4. Results of embolotherapy for angiomyolipoma

Reference	No. of patients	% Complications	% Recurrent symptoms or hemorrhage	% Repeat embolization	% Surgery	Median. follow-up (mos.) (range)
MOURIKIS [54]	5	0	60	40	20	18 (0–29)
KESSLER [55]	7	0	0	0	14	24 (12–48)
LEE [27]	15	7	13	13	0	24 (3–96)
HAMLIN [56]	5	20	80	80	20	15 (1–204)
HAN [57]	14	0	7	14	7	28 (8–72)
SOULEN [58]	5	0	29	0	0	20 (2–84)
Others [22, 31, 59–74]	25 (fewer than 5/report)	22	8	4	27	5 (0–60)
Totals	76	10	17	14	16	23 (0–204)

From: NELSON and SANDA [13] (printed with permission)

tion, many authors have advocated incomplete or partial splenic embolization (PSE), a method by which a portion of the splenic parenchyma is left viable, thus preserving the spleen's immunologic function and limiting complications while still managing the underlying condition [78–82, 87–90, 98, 99]. PSE has also been advocated as a preoperative tool to improve the safety of and reduce intraoperative blood loss during open or laparoscopic splenectomy [100–103].

16.2.2 Anatomic Considerations

The splenic artery supplies the spleen as well as substantial portions of the stomach and pancreas [104]. The splenic artery courses superior and anterior to the splenic vein along the superior edge of the pancreas. Near the splenic hilum, the artery usually divides into superior and inferior terminal branches, and each branch further divides into four to six segmental intrasplenic branches. The superior terminal branches are usually longer than the inferior terminal branches and provide the major splenic arterial supply. A superior polar artery usually arises from the distal splenic artery near the hilum, but it may originate from the superior terminal artery. The inferior polar artery usually provides the left gastroepiploic artery, but it may arise from the distal splenic or inferior terminal artery. The left gastroepiploic artery then runs along the greater curvature of the stomach. Numerous short gastric branches arise from the terminal splenic or left gastroepiploic artery to supply the gastric cardia and fundus. In addition, the splenic artery has many branches to the body and tail of the pancreas; the largest of these are the pancreatic magna and dorsal pancreatic artery. When PSE is considered, knowledge and visualization of these arteries is essential to reduce the risk for nontarget embolization.

16.2.3 Technical Considerations

PSE refers to partial obliteration of the peripheral intrasplenic vascular bed by injection of embolic material through the angiographic catheter placed within the splenic artery. This technique evolved as initial attempts to treat hypersplenism by proximal splenic arterial occlusion proved unsuccessful. Response failure was attributed to the abundant

collateral circulation from the short gastric and gastroepiploic arteries that reestablish the blood supply to the spleen around the occluded segment of the splenic artery [105–107]. Proximal arterial occlusion, although ineffective for management of hypersplenism, is a useful technique for reducing intraoperative blood loss in thrombocytopenic patients undergoing splenectomy [108, 109].

Because of the need for more enduring and effective hemodynamic and hematologic responses, total infarction of the spleen was performed with autologous clots or particles in single or staged procedures [83, 97, 110, 111]. However, the widespread use of this technique was limited because of the severity and high incidence of complications such as splenic abscess, splenic rupture, septicemia, splenic vein thrombosis, and unremitting bronchopneumonia [83, 110–115]. Several mechanisms may cause complications after complete infarction of the spleen: induced immunocompromised state of the patient, predisposition of anaerobic bacterial growth within the hypoxic ischemic tissues, introduction of exogenous bacteria through the angiographic catheter or embolic agents, and contamination of the devascularized splenic tissue with organisms originating within the intestines by retrograde portal blood flow [83, 106, 112, 116, 117].

Hemodynamic and hematologic responses and the severity of complications correlate with the amount of splenic tissue that is infarcted after embolization [110]. Therefore, PSE has been advocated to reduce complication rates after splenic infarction. Ablation of more than 80% of the splenic mass has been reported, but most authors have attempted to embolize 60%–70% of the parenchyma [115, 118–120]. This amount of embolization allows for reduced sequestration and destruction of the blood elements while maintaining the spleen's immunologic function and preserving antegrade flow within the splenic vein.

SPIGOS et al. [112] adopted a strict protocol that resulted in a remarkably low number of complications. The protocol included broad-spectrum antibiotics started 8–12 hours before the procedure and continued for 1–2 weeks, local antibiotics (such as gentamicin) suspended in the solution used to deliver the particulate embolic agents and administered through the angiographic catheter, strict attention to sterility (whole-body povidone-iodine bath or wide surgical scrub at the site of catheter insertion), selective catheterization with the catheter tip beyond pancreatic branches, effective pain control with narcotics or epidural anesthesia for 48 hours (which prevents the splinting that may

lead to pulmonary complications), and avoidance of overembolization. A Pneumovax vaccine was also administered before the procedure to help prevent pneumococcal infection.

More recently, HARNED et al. [99] evaluated the effect of PSE where only 30%–40% of the splenic mass was ablated and found that the reduced infarction volume still led to increased platelet counts, albeit the increase was less impressive in those patients than in patients in whom 70%–80% of the spleen was ablated. However, their technique also resulted in significantly lower morbidity. Therefore, a more conservative embolization procedure with lower complication rates may be prudent, and a second embolization can be performed if necessary.

PSE can be performed by two methods. In one approach, a few distal branches of the splenic artery are selectively catheterized and embolized to complete stasis, and several other branches are

left untreated (Fig. 16.3). Parenchymal phase of angiogram may be used to estimate the volume of remaining viable splenic tissue. Additional branches can be catheterized and embolized until the desired effect is achieved. In the second method, the working catheter tip is placed more proximally in the main splenic artery but beyond the origin of major pancreatic branches. Embolic particles are injected until the parenchymal blush is reduced angiographically to the desired amount. Contrast-enhanced CT scan may be used for follow up purposes (Fig. 16.4).

In patients undergoing splenectomy, distal or proximal splenic arteries can be completely occluded to reduce the risk of intraoperative hemorrhage. After the embolization, if patients have thrombocytopenia, a femoral arterial closure device may help promote hemostasis at the puncture site. Patients commonly experience fever, leukocytosis, and ele-

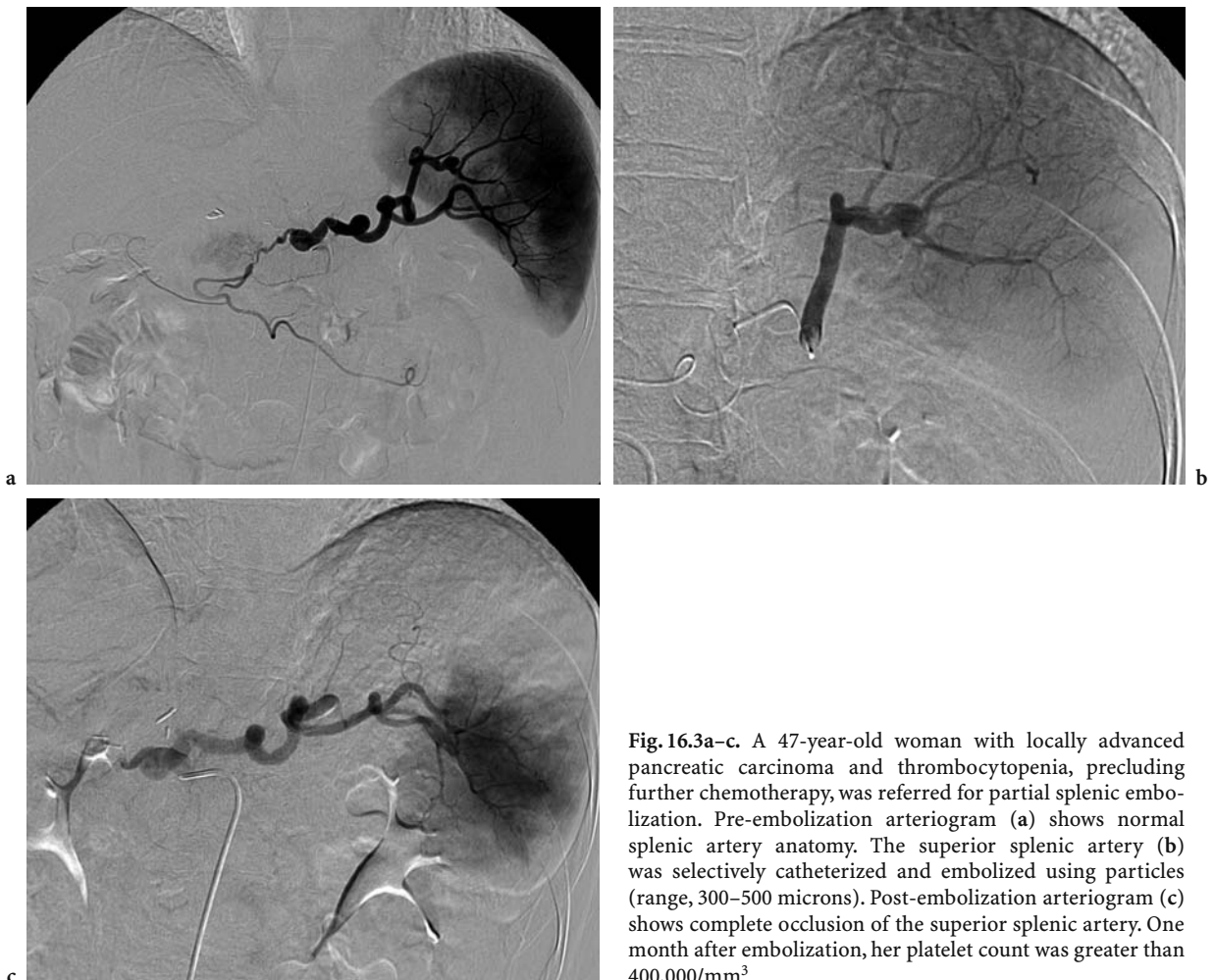


Fig. 16.3a-c. A 47-year-old woman with locally advanced pancreatic carcinoma and thrombocytopenia, precluding further chemotherapy, was referred for partial splenic embolization. Pre-embolization arteriogram (a) shows normal splenic artery anatomy. The superior splenic artery (b) was selectively catheterized and embolized using particles (range, 300–500 microns). Post-embolization arteriogram (c) shows complete occlusion of the superior splenic artery. One month after embolization, her platelet count was greater than $400,000/\text{mm}^3$

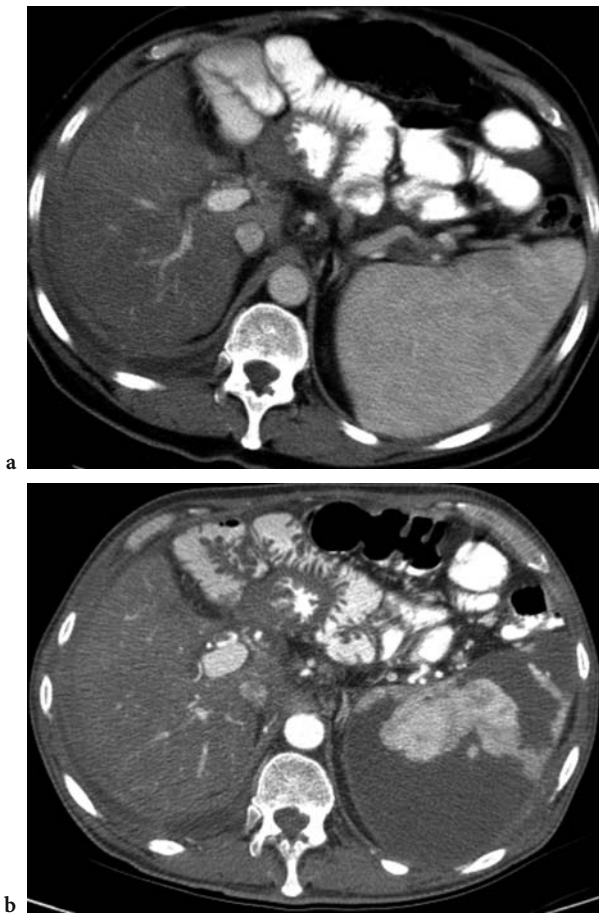


Fig. 16.4a,b. A 48-year-old man with pancreatic cancer presented with persistent neutropenia and thrombocytopenia. Patient was referred for partial splenic embolization (PSE) in an attempt to increase white blood cell and platelet counts prior to additional chemotherapy. Pre-embolization axial CT image of the abdomen (a) shows splenomegaly. CT scan performed 4 months after PSE (b) shows massive necrosis of splenic parenchyma. Within 2 weeks of partial splenic embolization, the platelet count normalized ($379,000/\text{mm}^3$)

vated serum amylase levels, but these complications are transient.

The embolic agents most commonly used for splenic ablation are Gelfoam pledgets and polyvinyl alcohol particles. YOSHIOKA et al. [105] also showed excellent increases in platelet counts when coils were placed within the intrasplenic branches, and HICKMAN et al. [108] successfully used Gelfoam, polyvinyl alcohol particles, and coils alone or in combination for preoperative embolization. In animal studies, additional materials that have been used for this purpose are absolute ethanol [121, 122], microfibrillar collagen [123], tissue adhesives [124], balloon catheters [125], silicone particles [126], and

others [127], but none of these agents have been widely accepted for use in humans.

The techniques developed and used at different centers vary greatly, but some general recommendations can be made here. Pre-procedure antibiotics are highly recommended. Povidone-iodine baths are not commonly used, but careful attention to sterile preparation is warranted. Embolization can be performed through the diagnostic catheter placed in the splenic artery only if the catheter tip can be advanced beyond the origin of major pancreatic branches; a coaxial system with the use of a microcatheter often facilitates catheterization of the appropriate branches. Adequate pain control after the procedure with the use of patient-controlled analgesic pumps is warranted to minimize the severity and possibly duration of the post-embolization syndrome and to decrease the risk of pulmonary complications (such as atelectases and pneumonia).

Similar to complete splenic arterial embolization, PSE is prone to complications and adverse effects, but PSE is much better tolerated than complete splenic ablation. In addition to those mentioned above, patients might develop pancreatitis (likely a result of nontarget embolization of dorsal pancreatic and pancreatic magna arteries), pleural effusions requiring thoracentesis, paralytic ileus, or the post-embolization syndrome consisting of fever, leukocytosis, and abdominal pain [119].

After PSE, the spleen retains its ability to regenerate. KUMPE et al. [120] found substantial regeneration of splenic tissue in 9 of 11 patients despite 70%–80% embolization, as visualized on Tm-99m sulfur colloid liver-spleen scans performed 4 to 16 months later. In contrast, WATANABE et al. [128] reported that PSE of 80% or more resulted in initial increases in spleen size followed by substantial and stable reductions by 4 months. Despite these conflicting results, a repeat PSE procedure can be performed with similar effectiveness should symptoms recur [98].

16.2.4 Results

Few studies have compared splenectomy with PSE in a randomized, prospective fashion. In a series by MOZES et al. [118], 53 patients who were to later undergo renal transplant with azathioprine immunosuppressive therapy (which causes leukopenia and thrombocytopenia) were randomly assigned to a splenectomy group (25 patients) or a PSE group (28 patients). For patients in the PSE group, a mean of

65.4% ± 16.6% of the splenic mass was ablated. The early postoperative morbidity rate and the duration of hospital stay were similar in the two study groups. Abscess and splenic rupture were not encountered. The two cases of severe pancreatitis resulting in death occurred in the splenectomy group, and one death from pneumococcal pneumonia occurred 3 months after PSE. Equivalent numbers of renal transplantation were carried out in both groups and resulted in similar long-term (2.5–4.0 years) graft survival (60% vs. 66%) and long-term patient mortality. However, splenic regeneration occurred in most patients after PSE, and doubling of splenic parenchyma was seen in 40% of them. As demonstrated in this study, PSE may be an effective alternative to splenectomy, especially for patients who are not suitable surgical candidates.

Numerous retrospective studies have demonstrated that PSE is an effective short-term therapeutic alternative to splenectomy for a wide spectrum of patients with hypersplenism [77,78,80,82,88–90]. KIMURA et al. [80] reported the results of initial and repeated PSE in patients with chronic idiopathic thrombocytopenic purpura. Thirty-nine patients underwent initial PSE, and 12 underwent a repeat PSE. The therapeutic effects of initial and repeat PSE were classified as complete response if the patient's platelet count rose to more than 100,000/mm³ without steroids 1 year after the initial or repeat embolization, as partial response if the platelet count increased by 50,000–100,000 under similar circumstances, or as no response. Twenty patients (51% responded to the initial PSE (11 complete response, 9 partial response) with significantly higher peak platelet response ($p = 0.029$). Differences between responders and nonresponders in terms of age, sex, lowest platelet count, and steroid response before PSE were nonsignificant. Of the 11 patients with complete response (median follow-up, 58 months; range 21–156 months), one relapsed after 32 months and underwent repeat PSE. Of the 9 patients with partial response, four maintained a platelet count of more than 50,000/mm³ without relapse during a median follow-up period of 73 months (range, 14 to 42 months), and five relapsed after a median follow-up period of 34 months (range, 15–123 months). Repeat PSE resulted in four partial responses and one no response. However, in 6 of 19 patients who had no response to the initial PSE (median follow-up, 8 months; range, 3–22 months), repeat PSE elicited only one partial response. The 51% remission rate was maintained by means of repeat PSE for a median follow-up of 76 months (range, 14–147 months) after

the initial PSE. KIMURA et al. concluded that PSE combined with repeat embolization may be an effective alternative to splenectomy in patients with chronic idiopathic thrombocytopenic purpura.

PALSSON et al. [129] reviewed 26 severely ill patients (median age, 63.5 years) who were treated with PSE a total of 52 times, mainly because of bleeding esophageal varices and thrombocytopenia. The mean hemoglobin values, leukocyte counts, and platelet counts increased significantly after PSE, and the frequency of bleeding episodes from esophageal varices was statistically significantly reduced. As defined by the authors, the integrated PSE effect was judged as improved in 19 patients, unchanged in five, and worse in two. Median survival time was 50.5 months (range, 0.5–272 months). Complications consisted mainly of fever, atelectasis, and abdominal pain, although two patients died of PSE-related complications. Thus, a standardized and graded PSE is reasonably safe even in patients with advanced disease in whom it is hazardous to perform splenectomy. PALSSON et al. concluded that PSE maintains long-term effects on hematologic parameters, esophageal variceal hemorrhage, and may substantially improve patients' clinical status.

Nio et al. [130] published a retrospective study in which 41 PSE procedures were performed in 36 children with liver disease and thrombocytopenia resulting from hypersplenism. The average volume embolized was 70.1%, and the mean follow-up was 71 months (range, 20 days–182 months). Eleven patients (30.6%) had recurring thrombocytopenia (defined as fewer than 100,000/mm³). There were no significant differences in the volume embolized or platelet count before PSE between the patients with and without recurring thrombocytopenia. However, the peak platelet counts after PSE was significantly lower in the patients with recurring thrombocytopenia ($p = 0.0091$). In 17 of 24 survivors who did not undergo liver transplantation, platelet counts remained normal throughout the follow-up period. Hematologic indices improved in all 36 patients after PSE, and its long-term efficacy was shown in 70% of the survivors.

16.2.5 Future Development and Research

External beam radiation therapy is an alternative treatment for patients with splenomegaly [131–135]. Similarly, transcatheter arterial brachytherapy using yttrium-90 microspheres has been reported

[136, 137]. At the time of this writing, the cost associated with intraarterial brachytherapy and the complexity of the delivery system discourage its widespread use. When intraarterial brachytherapy becomes more widely available, further investigation of its usefulness in patients with hypersplenism may be warranted. Thermal ablation therapy, which has received considerable attention over the last decade, has been used to treat patients with hepatic malignancies, small renal cell carcinoma, and lung tumors [138, 139]. More recently, radiofrequency ablation has been proposed as an alternative treatment for hypersplenism [140]; the safety and usefulness of this approach remains to be carefully evaluated in clinical setting.

16.3 Conclusion

Embolotherapy for organ ablation, as highlighted in this chapter for treatment of patients with renal tumors and hypersplenism, was developed in the 1970s and enjoyed a period of intense activity over the next two decades. During that period, numerous articles describing single-center experiences with small series of patients appeared in the medical literature. Retrospective studies of small series of cases demonstrated the safety and potential benefits of embolotherapy for organ ablation in selected patients. During the same period, technological advancements have elevated the fields of angiography, vascular catheterization, and

Table 16.5. Catheters and embolic agents used for organ ablation

Renal Artery Embolization	
Abdominal aortogram	
Pigtail catheter, 5 Fr	Cook, Bloomington, IN
Selective renal arteriogram	
C2 Cobra Visceral, 5 Fr	Cook, Bloomington, IN
Sos Omni Selective (2), 5 Fr	Angiodynamics, Queensbury, NY
Occlusion balloon catheter, 5 Fr	Boston Scientific Medi-Tech, Natick, MA
Subselective renal arteriogram	
Renegade HI-FLO, 3 Fr	Boston Scientific Medi-Tech, Natick, MA
Embolic agents	
Dehydrated alcohol	American Regent, Shirley, NY
EmboGold microspheres	Biosphere Medical, Rockland, MA
Contour.SE Microspheres	Boston Scientific, Natick, MA
Absorbable Gelatin Sponge	Ethicon, Somerville, NJ
Splenic artery embolization	
Selective splenic arteriogram	
C2 Cobra Visceral, 5 Fr	Cook, Bloomington, IN
Sos Omni Selective (2), 5 Fr	Angiodynamics, Queensbury, NY
Subselective splenic arteriogram	
Renegade HI-FLO, 3 Fr	Boston Scientific Medi-Tech, Natick, MA
Embolic agents	
Absorbable Gelatin Sponge	Ethicon, Somerville, NJ
EmboGold Microspheres	Biosphere Medical, Rockland, MA
Contour.SE Microspheres	Boston Scientific, Natick, MA

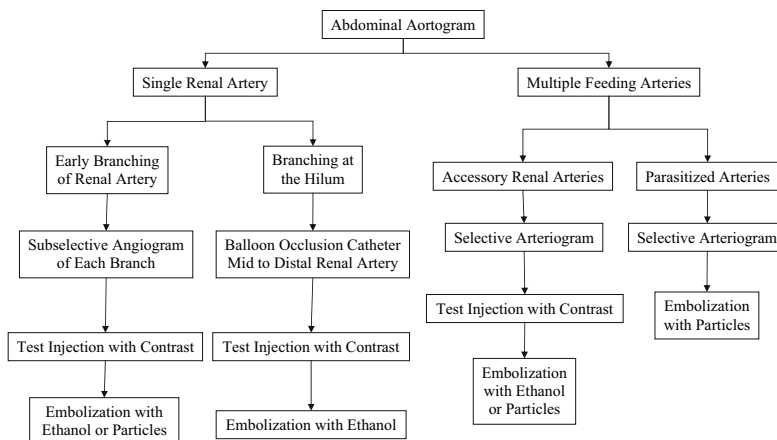


Fig. 16.5. A simple and useful algorithm for planning embolization of renal tumors. Interventional radiologist should be familiar with various embolic agents including ethanol and solid particles and different methods for delivery of these agents. Nevertheless, the algorithm may be modified to suite individual expertise and available embolic agents

embolotherapy to new heights. Table 16.5 provides a short list of supplies currently used for embolotherapy at our institution. A simple algorithm for embolization of renal tumors is also suggested (Fig. 16.5). In this era of evidence-based medicine, advanced embolotherapy techniques warrant reevaluation and validation in the management of renal tumors and hypersplenism.

References

- Greenlee RT, Murray T, Bolden S, Wingo PA (2000) Cancer statistics, 2000. *CA Cancer J Clin* 50:7–33
- Linehan WM, Zbar B, Bates SE, Zelefsky MJ, Yang JC (2001) Cancer of the kidney and ureter. In: DeVita VT, Hellman S, Rosenberg SA (eds) *Cancer principles and practice of oncology*. Lippincott Williams and Wilkins, Philadelphia, PA, pp 1362–1396
- Pantuck AJ, Zisman A, Beldegrun AS (2001) The changing natural history of renal cell carcinoma. *J Urol* 166:1611–23
- Lowry PS, Nakada SY (2003) Renal cryotherapy: 2003 clinical status. *Curr Opin Urol* 13:193–197
- Gervais DA, McGovern FJ, Arellano RS, McDougal WS, Mueller PR (2003) Renal cell carcinoma: clinical experience and technical success with radio-frequency ablation of 42 tumors. *Radiology* 226:417–424
- Flanigan RC, Mickisch G, Sylvester R, Tangen C, van Poppel H, Crawford ED (2004) Cytoreductive nephrectomy in patients with metastatic renal cancer: a combined analysis. *J Urol* 171:1071–1076
- Bakal CW, Cynamon J, Lakritz PS, Sprayregen S (1993) Value of preoperative renal artery embolization in reducing blood transfusion requirements during nephrectomy for renal cell carcinoma. *J Vasc Interv Radiol* 4:727–731
- Klimberg I, Hunter P, Hawkins IF, Drylie DM, Wajzman Z (1985) Preoperative angioinfarction of localized renal cell carcinoma using absolute ethanol. *J Urol* 133:21–24
- Craven WM, Redmond PL, Kumpe DA, Durham JD, Wetlaufer JN (1991) Planned delayed nephrectomy after ethanol embolization of renal carcinoma. *J Urol* 146:704–708
- Jacobs JA, Ring EJ, Wein AJ (1981) New indications for renal infarction. *J Urol* 125:243–245
- Nurmi M, Satokari K, Puntala P (1987) Renal artery embolization in the palliative treatment of renal adenocarcinoma. *Scand J Urol Nephrol* 21:93–96
- Zielinski H, Szmigielski S, Petrovich Z (2000) Comparison of preoperative embolization followed by radical nephrectomy with radical nephrectomy alone for renal cell carcinoma. *Am J Clin Oncol* 23:6–12
- Nelson CP, Sanda MG (2002) Contemporary diagnosis and management of renal angiomyolipoma. *J Urol* 168:1315–1325
- Oesterling JE, Fishman EK, Goldman SM, Marshall FF (1986) The management of renal angiomyolipoma. *J Urol* 135:1121–1124
- Dickinson M, Ruckle H, Beagler M, Hadley HR (1998) Renal angiomyolipoma: optimal treatment based on size and symptoms. *Clin Nephrol* 49:281–286
- Kadir S (1986) *Diagnostic angiography*, 1st edn. Saunders, Philadelphia, PA, pp 445–495
- Boijsen E (1997) Renal agraphography. In: Baum S (ed) *Abram's angiography*, 4th edn. Little Brown, New York, NY, pp 1101–1131
- Kadir S (1991) *Atlas of normal and variant angiographic anatomy*, 1st edn. Saunders, Philadelphia, PA, pp 387–428
- Abrams HL, Grassi CJ (1997) Renal tumor versus renal cyst. In: Baum S (ed) *Abram's angiography*, 4th edn. Little Brown, New York, NY, pp 1132–1177
- Kalman D, Varenhorst E (1999) The role of arterial embolization in renal cell carcinoma. *Scand J Urol Nephrol* 33:162–170
- Ellman BA, Parkhill BJ, Curry TS 3rd, Marcus PB, Peters PC (1981) Ablation of renal tumors with absolute ethanol: a new technique. *Radiology* 141:619–626
- Rabe FE, Yune HY, Richmond BD, Klatte EC (1982) Renal tumor infarction with absolute ethanol. *AJR Am J Roentgenol* 139:1139–1144
- Cox GG, Lee KR, Price HI, Gunter K, Noble MJ, Mebust WK (1982) Colonic infarction following ethanol embolization of renal-cell carcinoma. *Radiology* 145:343–345
- Lammer J, Justich E, Schreyer H, Pettek R (1985) Complications of renal tumor embolization. *Cardiovasc Intervent Radiol* 8:31–35
- Mulligan BD, Espinosa GA (1983) Bowel infarction: complication of ethanol ablation of a renal tumor. *Cardiovasc Intervent Radiol* 6:55–57
- Teertstra HJ, Winter WA, Frensdorf EL (1984) Ethanol embolization of a renal tumor, complicated by colonic infarction. *Diagn Imaging Clin Med* 53:250–254
- Lee W, Kim TS, Chung JW, Han JK, Kim SH, Park JH (1998) Renal angiomyolipoma: embolotherapy with a mixture of alcohol and iodized oil. *J Vasc Interv Radiol* 9:255–261
- Konya A, Van Pelt CS, Wright KC (2004) Ethiodized oil-ethanol capillary embolization in rabbit kidneys: temporal histopathologic findings. *Radiology* 232:147–153
- Wallace S, Charnsangavej C, Carrasco CH, Richli WR, Swanson D (1990) Therapeutic angiographic techniques, renal tumors: clinical results. In: Dondelinger RF, Rossi P, Kurdziel JC, Wallace S (eds) *Interventional radiology*. Thieme Medical, New York, NY, pp 468–477
- Ray CE, Waltman AC (2002) General principles of embolization and chemoembolization. In: Bakal CW, Silberzweig JE, Cynamon J, Sprayregen S (eds) *Vascular and interventional radiology principles and practice*. Thieme, New York, NY, pp 89–100
- Zerhouni EA, Schellhammer P, Schaefer JC, Drucker JR, Jaffe AH, Gonzales JE et al. (1984) Management of bleeding renal angiomyolipomas by transcatheter embolization following CT diagnosis. *Urol Radiol* 6:205–209
- Kurth KH, Cinqualbre J, Oliver RT, Schulman CC (1984) Embolization and subsequent nephrectomy in metastatic renal cell carcinoma. *Prog Clin Biol Res* 153:423–436
- McIvor J, Kaisary AV, Williams G, Grant RW (1984) Tumour infarction after pre-operative embolisation of renal carcinoma. *Clin Radiol* 35:59–64
- Weigel JW, Mebust WK, Foret JD, Noble MJ, Votapka T, Krishnan EC et al. (1985) Treatment of renal cell carcinoma with renal infarction, delayed nephrectomy, medroxyprogesterone, and xenogeneic immune RNA. *Urology* 25:103–105
- Kaisary AV, Williams G, Riddle PR (1984) The role of preoperative embolization in renal cell carcinoma. *J Urol* 131:641–646
- Nakano H, Nihira H, Toge T (1983) Treatment of renal

- cancer patients by transcatheter embolization and its effects on lymphocyte proliferative responses. *J Urol* 130:24–27
37. Kurth KH, Debruyne FM, Hall RR, Denis L, Verbaes A, Bollack C et al. (1987) Embolization and postinfarction nephrectomy in patients with primary metastatic renal adenocarcinoma. *Eur Urol* 13:251–255
 38. Leinonen A (1985) Embolization of renal carcinoma. Comparison between the early results of Gelfoam and absolute ethanol embolization. *Ann Clin Res* 17:299–305
 39. Bono AV, Caresano A (1983) The role of embolization in the treatment of kidney carcinoma. *Eur Urol* 9:334–337
 40. Ekelund L, Ek A, Forsberg L, Haukaas S, Henrikson H, Kalland T et al. (1984) Occlusion of renal arterial tumor supply with absolute ethanol. Experience with 20 cases. *Acta Radiol Diagn (Stockh)* 25:195–201
 41. Gottesman JE, Crawford ED, Grossman HB, Scardino P, McCracken JD (1985) Infarction-nephrectomy for metastatic renal carcinoma. Southwest oncology group study. *Urology* 25:248–250
 42. Christensen K, Dyreborg U, Andersen JF, Nissen HM (1985) The value of transvascular embolization in the treatment of renal carcinoma. *J Urol* 133:191–193
 43. Lanigan D, Jurriaans E, Hammonds JC, Wells IP, Choa RG (1992) The current status of embolization in renal cell carcinoma—a survey of local and national practice. *Clin Radiol* 46:176–178
 44. Park JH, Kim SH, Han JK, Chung JW, Han MC (1994) Transcatheter arterial embolization of unresectable renal cell carcinoma with a mixture of ethanol and iodized oil. *Cardiovasc Intervent Radiol* 17:323–327
 45. Almgard LE, Slezak P (1977) Treatment of renal adenocarcinoma by embolization: a follow-up of 38 cases. *Eur Urol* 3:279–281
 46. Kato T, Sato K, Abe R, Moriyama M (1989) The role of embolization/chemoembolization in the treatment of renal cell carcinoma. In: Alan R (ed) *Tehrapeutic progress in urological cancers*. Liss, New York, pp 697–705
 47. Wallace S, Chuang VP, Swanson D, Bracken B, Hersh EM, Ayala A et al. (1981) Embolization of renal carcinoma. *Radiology* 138:563–570
 48. Mobilio G, Cavalli A, Bianchi G (1981) Preoperative arterial occlusion in renal tumors: 3 years experience. *Int Urol Nephrol* 13:25–33
 49. Frasson F, Fugazzola C, Bianchi G, Franzolin N, Caresano A, del Favero C et al. (1978) Selective arterial embolization in renal tumors. *Radiol Clin (Basel)* 47:239–251
 50. Frasson F, Roversi RA, Simonetti G, Ziviello M (1981) Embolization of renal tumors. A survey of the Italian experience : 282 patients. *Ann Radiol (Paris)* 24:396–399
 51. Fishedick AR, Peters PE, Kleinhaus G, Pfeifer E (1987) Preoperative renal tumor embolization. A useful procedure? *Acta Radiol* 28:303–306
 52. Mebust WK, Weigel JW, Lee KR, Cox GG, Jewell WR, Krishnan EC (1984) Renal cell carcinoma-angioinfarction. *J Urol* 131:231–235
 53. Giuliani L, Carmignani G, Belgrano E, Puppo P, Quattrini S (1981) Usefulness of preoperative transcatheter embolization in kidney tumors. *Urology* 17:431–434
 54. Mourikis D, Chatziioannou A, Antoniou A, Kehagias D, Gikas D, Vlahos L (1999) Selective arterial embolization in the management of symptomatic renal angiomyolipomas. *Eur J Radiol* 32:153–159
 55. Kessler OJ, Gillon G, Neuman M, Engelstein D, Winkler H, Baniel J (1998) Management of renal angiomyolipoma: analysis of 15 cases. *Eur Urol* 33:572–575
 56. Hamlin JA, Smith DC, Taylor FC, McKinney JM, Ruckle HC, Hadley HR (1997) Renal angiomyolipomas: long-term follow-up of embolization for acute hemorrhage. *Can Assoc Radiol J* 48:191–198
 57. Han YM, Kim JK, Roh BS, Song HY, Lee JM, Lee YH et al. (1997) Renal angiomyolipoma: selective arterial embolization-effectiveness and changes in angiogenic components in long-term follow-up. *Radiology* 204:65–70
 58. Soulen MC, Faykus MH Jr, Shlansky-Goldberg RD, Wein AJ, Cope C (1994) Elective embolization for prevention of hemorrhage from renal angiomyolipomas. *J Vasc Interv Radiol* 5:587–591
 59. Ciancio SJ, Vira M, Simon MA, Lerner SP, Schulam PG (2001) Giant bilateral renal angiomyolipomas associated with tuberous sclerosis. *Urology* 57:554
 60. Barbalius GA, Siablis D, Liatsikos EN, Yarmenitis S, Karnabatidis D, Dimopoulos J (1998) Renal angiomyolipoma with haemorrhage treated by urgent embolization. *Scand J Urol Nephrol* 32:54–55
 61. Henslee D, Ross G Jr, Beale G (1991) Bilateral angiomyolipomas: the benefits and limitation of embolization for renal salvage. A case report. *Mo Med* 88:292–294
 62. Jonsson E, Sueoka BL, Spiegel PK, Richardson JR Jr, Heaney JA (1991) Angiographic management of retroperitoneal hemorrhage from renal angiomyolipoma in polycystic kidney disease. *J Urol* 145:1248–1250
 63. Ou YC, Wu HC, Yang CR, Chang CL, Hwang TI, Chang CH (1991) Renal angiomyolipoma: experience of 23 patients. *Zhonghua Yi Xue Za Zhi (Taipei)* 48:217–223
 64. Edelman MA, Mitty HA, Dan SJ, Birns DR (1990) Angiomyolipoma: postembolization liquefaction and percutaneous drainage. *Urol Radiol* 12:145–147
 65. Van Baal JG, Lips P, Luth W, Bakker P, Davis G, Karthaus P et al. (1990) Percutaneous transcatheter embolization of symptomatic renal angiomyolipomas: a report of four cases. *Nether J Surg* 42:72–77
 66. Uchino A, Itoh K, Egashira K, Ohno M (1987) Therapeutic embolization for renal angiomyolipoma: case report and review of the literature. *Radiat Med* 5:191–194
 67. Earthman WJ, Mazer MJ, Winfield AC (1986) Angiomyolipomas in tuberous sclerosis: subselective embolotherapy with alcohol, with long-term follow-up study. *Radiology* 160:437–441
 68. Sanchez FW, Vujic I, Ayres RI, Curry NS, Gobien RP (1985) Hemorrhagic renal angiomyolipoma: superselective renal arterial embolization for preservation of renal function. *Cardiovasc Intervent Radiol* 8:39–42
 69. Adler J, Greweldinger J, Litzky G (1984) “Macro” aneurysm in renal angiomyolipoma: two cases, with therapeutic embolization in one patient. *Urol Radiol* 6:201–203
 70. Rosen RJ, Schlossberg P, Roven SJ, Rothberg M (1984) Management of symptomatic renal angiomyolipomas by embolization. *Urol Radiol* 6:196–200
 71. Lingeman JE, Donohue JP, Madura JA, Selke F (1982) Angiomyolipoma: emerging concepts in management. *Urology* 20:566–570
 72. Bagley D, Appell R, Pingoud E, McGuire EJ (1980) Renal angiomyolipoma: diagnosis and management. *Urology* 15:1–5
 73. Moorhead JD, Fritzsche P, Hadley HL (1977) Management of hemorrhage secondary to renal angiomyolipoma with selective arterial embolization. *J Urol* 117:122–123

74. Eason AA, Cattolica EV, McGrath TW (1979) Massive renal angiomyolipoma: preoperative infarction by balloon catheter. *J Urol* 121:360-361
75. Peck-Radosavljevic M (2001) Hypersplenism. *Eur J Gastroenterol Hepatol* 13:317-323
76. Sangro B, Bilbao I, Herrero I, Corella C, Longo J, Beloqui O et al. (1993) Partial splenic embolization for the treatment of hypersplenism in cirrhosis. *Hepatology* 18:309-314
77. Romano M, Gjojelli A, Capuano G, Pomponi D, Salvatore M (2004) Partial splenic embolization in patients with idiopathic portal hypertension. *Eur J Radiol* 49:268-273
78. Stanley P, Shen TC (1995) Partial embolization of the spleen in patients with thalassemia. *J Vasc Interv Radiol* 6:137-142
79. Kimura F, Ito H, Shimizu H, Togawa A, Otsuka M, Yoshidome H et al. (2003) Partial splenic embolization for the treatment of hereditary spherocytosis. *AJR Am J Roentgenol* 181:1021-1024
80. Kimura F, Itoh H, Ambiru S, Shimizu H, Togawa A, Yoshidome H et al. (2002) Long-term results of initial and repeated partial splenic embolization for the treatment of chronic idiopathic thrombocytopenic purpura. *AJR Am J Roentgenol* 179:1323-1326
81. Kumar S, Diehn FE, Gertz MA, Tefferi A (2002) Splenectomy for immune thrombocytopenic purpura: long-term results and treatment of postsplenectomy relapses. *Ann Hematol* 81:312-319
82. Miyazaki M, Itoh H, Kaiho T, Ohtawa S, Ambiru S, Hayashi S et al. (1994) Partial splenic embolization for the treatment of chronic idiopathic thrombocytopenic purpura. *AJR Am J Roentgenol* 163:123-126
83. Wholey MH, Chamorro HA, Rao G, Chapman W (1978) Splenic infarction and spontaneous rupture of the spleen after therapeutic embolization. *Cardiovasc Radiol* 1:249-253
84. Athale UH, Kaste SC, Bodner SM, Ribeiro RC (2000) Splenic rupture in children with hematologic malignancies. *Cancer* 88:480-490
85. Gardner RV, Warrior RP, Loe W, Ward K, Haymon M, Craver R (2003) Splenic artery embolization as emergency treatment of splenic rupture in a child with T-cell acute lymphocytic leukemia having t(8;14) translocation. *Med Pediatr Oncol* 41:492-493
86. Bird MA, Amjadi D, Behrns KE (2002) Primary splenic lymphoma complicated by hematemesis and gastric erosion. *South Med J* 95:941-942
87. Pringle KC, Spigos DG, Tan WS, Politis C, Pang EJ, Reyez HM et al. (1982) Partial splenic embolization in the management of thalassemia major. *J Pediatr Surg* 17:884-891
88. Jonasson O, Spigos DG, Mozes MF (1985) Partial splenic embolization: experience in 136 patients. *World J Surg* 9:461-467
89. Lokich J, Costello P (1983) Splenic embolization to prevent dose limitation of cancer chemotherapy. *AJR Am J Roentgenol* 140:159-161
90. Gerlock AJ Jr, MacDonell RC Jr, Muhletaler CA, Parris WC, Johnson HK, Tallent MB et al. (1982) Partial splenic embolization for hypersplenism in renal transplantation. *AJR Am J Roentgenol* 138:451-456
91. Zarrabi MH, Rosner F (1984) Serious infections in adults following splenectomy for trauma. *Arch Intern Med* 144:1421-1424
92. Rice HE, Oldham KT, Hillery CA, Skinner MA, O'Hara SM, Ware RE (2003) Clinical and hematologic benefits of partial splenectomy for congenital hemolytic anemias in children. *Ann Surg* 237:281-288
93. De Buys Roessingh AS, de Lagausie P, Rohrlich P, Berrebi D, Aigrain Y (2002) Follow-up of partial splenectomy in children with hereditary spherocytosis. *J Pediatr Surg* 37:1459-1463
94. Schwartz J, Leber MD, Gillis S, Giunta A, Eldor A, Bussel JB (2003) Long term follow-up after splenectomy performed for immune thrombocytopenic purpura (ITP). *Am J Hematol* 72:94-98
95. Kahn MJ, McCrae KR (2004) Splenectomy in immune thrombocytopenic purpura: recent controversies and long-term outcomes. *Curr Hematol Rep* 3:317-323
96. McMillan R, Durette C (2004) Long-term outcomes in adults with chronic ITP after splenectomy failure. *Blood* 104:956-960
97. Maddison FE (1973) Embolic therapy of hypersplenism (abstract). *Invest Radiol* 8:280
98. Brandt CT, Rothbarth LJ, Kumpe D, Karrer FM, Lilly JR (1989) Splenic embolization in children: long-term efficacy. *J Pediatr Surg* 24:642-644; discussion 644-645
99. Harned RK 2nd, Thompson HR, Kumpe DA, Narkewicz MR, Sokol RJ (1998) Partial splenic embolization in five children with hypersplenism: effects of reduced-volume embolization on efficacy and morbidity. *Radiology* 209:803-806
100. Hiatt JR, Gomes AS, Machleder HI (1990) Massive splenomegaly. Superior results with a combined endovascular and operative approach. *Arch Surg* 125:1363-1367
101. Poulin EC, Mamazza J, Schlachta CM (1998) Splenic artery embolization before laparoscopic splenectomy. An update. *Surg Endosc* 12:870-875
102. Totte E, Van Hee R, Kloeck I, Hendrickx L, Zachee P, Bracke P et al. (1998) Laparoscopic splenectomy after arterial embolisation. *Hepatogastroenterology* 45:773-776
103. Iwase K, Higaki J, Mikata S, Tanaka Y, Yoshikawa M, Hori S et al. (1999) Laparoscopically assisted splenectomy following preoperative splenic artery embolization using contour emboli for myelofibrosis with massive splenomegaly. *Surg Laparosc Endosc Percutan Tech* 9:197-202
104. Kadir S, Lundell C, Saeed M (1991) Celiac, superior and inferior mesenteric arteries. In: Kadir S (ed) *Atlas of normal and variant angiographic anatomy*. Saunders, Philadelphia, PA, pp 204-237
105. Yoshioka H, Kuroda C, Hori S, Tokunaga K, Tanaka T, Nakamura H et al. (1985) Splenic embolization for hypersplenism using steel coils. *AJR Am J Roentgenol* 144:1269-1274
106. Anderson JH, VuBan A, Wallace S, Hester JP, Burke JS (1977) Transcatheter splenic arterial occlusion: an experimental study in dogs. *Radiology* 125:95-102
107. Thanopoulos BD, Frimas CA (1982) Partial splenic embolization in the management of hypersplenism secondary to Gaucher disease. *J Pediatr* 101:740-743
108. Hickman MP, Lucas D, Novak Z, Rao B, Gold RE, Parvey L et al. (1992) Preoperative embolization of the spleen in children with hypersplenism. *J Vasc Interv Radiol* 3:647-652
109. Levy JM, Wasserman P, Pitha N (1979) Presplenectomy transcatheter occlusion of the splenic artery. *Arch Surg* 114:198-199
110. Castaneda-Zuniga WR, Hammerschmidt DE, Sanchez R,

- Amplatz K (1977) Nonsurgical splenectomy. *AJR Am J Roentgenol* 129:805–811
111. Vujic I, Lauer JW (1981) Severe complications from partial splenic embolization in patients with liver failure. *Br J Radiol* 54:492–495
 112. Spigos DG, Jonasson O, Mozes M, Capek V (1979) Partial splenic embolization in the treatment of hypersplenism. *AJR Am J Roentgenol* 132:777–782
 113. Witte CL, Ovitt TW, van Wyck DB, Witte MH, O'Mara RE, Woolfenden JM (1976) Ischemic therapy in thrombocytopenia from hypersplenism. *Arch Surg* 111:1115–1121
 114. Alwmark A, Bengmark S, Gullstrand P, Joelsson B, Lunderquist A, Owman T (1982) Evaluation of splenic embolization in patients with portal hypertension and hypersplenism. *Ann Surg* 196:518–524
 115. Owman T, Lunderquist A, Alwmark A, Borjesson B (1979) Embolization of the spleen for treatment of splenomegaly and hypersplenism in patients with portal hypertension. *Invest Radiol* 14:457–464
 116. Sclafani SJ (1981) The role of angiographic hemostasis in salvage of the injured spleen. *Radiology* 141:645–650
 117. Tsapogas MJ, Karmody AM, Peabody RA, Chuntrasakul C (1971) The fate of the spleen after partial or total dearterialization. *Br J Surg* 58:866–867
 118. Mozes MF, Spigos DG, Pollak R, Abejo R, Pavel DG, Tan WS et al. (1984) Partial splenic embolization, an alternative to splenectomy—results of a prospective, randomized study. *Surgery* 96:694–702
 119. Spigos DG, Tan WS, Mozes MF, Pringle K, Iossifides I (1980) Splenic embolization. *Cardiovasc Intervent Radiol* 3:282–287
 120. Kumpe DA, Rumack CM, Pretorius DH, Stoecker TJ, Stelling GP (1985) Partial splenic embolization in children with hypersplenism. *Radiology* 155:357–362
 121. Latshaw RF, Pearlman RL, Schaitkin BM, Griffith JW, Weidner WA (1985) Intraarterial ethanol as a long-term occlusive agent in renal, hepatic, and gastrosplenic arteries of pigs. *Cardiovasc Intervent Radiol* 8:24–30
 122. Mineau DE, Miller FJ Jr, Lee RG, Nakashima EN, Nelson JA (1982) Experimental transcatheter splenectomy using absolute ethanol. *Radiology* 142:355–359
 123. Kaufman SL, Strandberg JD, Barth KH, White RI Jr (1978) Transcatheter embolization with microfibrillar collagen in swine. *Invest Radiol* 13:200–204
 124. Goldman ML, Skorapa V Jr, Galambos JT, Oen KT, Jove DF, Silberman M (1978) Intra-arterial tissue adhesives for medical splenectomy in dogs. *Am J Gastroenterol* 70:489–495
 125. Mazer M, Smith CW, Martin VN (1985) Distal splenic artery embolization with a flow-directed balloon catheter. *Radiology* 154:245
 126. Yamauchi T, Furui S, Irie T, Kusano S (1994) Partial splenic embolization with Y-shaped silicone particles. *Acta Radiol* 35:335–339
 127. Wright KC, Anderson JH, Gianturco C, Wallace S, Chuang VP (1982) Partial splenic embolization using polyvinyl alcohol foam, dextran, polystyrene, or silicone. An experimental study in dogs. *Radiology* 142:351–354
 128. Watanabe Y, Todani T, Noda T (1996) Changes in splenic volume after partial splenic embolization in children. *J Pediatr Surg* 31:241–244
 129. Palsson B, Hallen M, Forsberg AM, Alwmark A (2003) Partial splenic embolization: long-term outcome. *Langenbecks Arch Surg* 387:421–426
 130. Nio M, Hayashi Y, Sano N, Ishii T, Sasaki H, Ohi R (2003) Long-term efficacy of partial splenic embolization in children. *J Pediatr Surg* 38:1760–1762
 131. Galbraith PR (1967) The mechanism of action of splenic irradiation in chronic myelogenous leukemia. *Can Med Assoc J* 96:1636–1641
 132. Abrams RA, Liu PJ, Ambinder RF, Haulk TL, Korman LT, Herman MG et al. (1997) Hodgkin and non-Hodgkin lymphoma: local-regional radiation therapy after bone marrow transplantation. *Radiology* 203:865–870
 133. Elliott MA, Chen MG, Silverstein MN, Tefferi A (1998) Splenic irradiation for symptomatic splenomegaly associated with myelofibrosis with myeloid metaplasia. *Br J Haematol* 103:505–511
 134. Schratte-Sehn AU, Cerveny M, Simmel H, Schlogl E, Schratte A (2003) Short-time splenic irradiation for splenomegaly. *Onkologie* 26:21–24
 135. McFarland JT, Kuzma C, Millard FE, Johnstone PA (2003) Palliative irradiation of the spleen. *Am J Clin Oncol* 26:178–183
 136. Ariel IM, Padula G (1973) Irradiation of the spleen by the intra-arterial administration of 90 yttrium microspheres in patients with malignant lymphoma. A preliminary report. *Cancer* 31:90–96
 137. Becker CD, Rosler H, Biasiutti FD, Baer HU (1995) Congestive hypersplenism: treatment by means of radioembolization of the spleen with Y-90. *Radiology* 195:183–186
 138. Nahum Goldberg S, Dupuy DE (2001) Image-guided radiofrequency tumor ablation: challenges and opportunities, part I. *J Vasc Interv Radiol* 12:1021–1032
 139. Dupuy DE, Goldberg SN (2001) Image-guided radiofrequency tumor ablation: challenges and opportunities, part II. *J Vasc Interv Radiol* 12:1135–1148
 140. Liu QD, Ma KS, He ZP, Ding J, Huang XQ, Dong JH (2003) Experimental study on the feasibility and safety of radiofrequency ablation for secondary splenomegaly and hypersplenism. *World J Gastroenterol* 9:813–817
 141. Schulman CC, Struyven J, Giannakopoulos X, Mathieu J (1980) Preoperative embolization of renal tumors—Comparison of different methods. *Eur Urol* 6:154–157
 142. Kato T, Nemoto R, Mori H, Takahashi M, Tamakawa Y (1981) Transcatheter arterial chemoembolization of renal cell carcinoma with microencapsulated mitomycin C. *J Urol* 125:19–24
 143. LeGuillou M, Merland JJ (1982) The indications of embolization in renal tumor: what remains to be said? *Prog Clin Biol Res* 100:603–607
 144. Teasdale C, Kirk D, Jeans WD, Penry JB, Tribe CT, Slade N (1982) Arterial embolisation in renal carcinoma: a useful procedure? *Br J Urol* 54:616–619
 145. Chudacek Z, Zavazal V (1986) Palliative embolization of renal tumors. I. Immunologic reaction to the embolization. *Radiol Diagn (Berl)* 27:211–213
 146. Karwowski A, Wojtowicz J (1987) Long-term results of embolization in renal tumors. *Radiol Diagn (Berl)* 28:533–535
 147. Stoesslein F, Schwenke A, Muenster W (1988) Percutaneous transluminal embolization for improved prognosis of renal cell carcinoma—dependence on tumor stages. *Cardiovasc Intervent Radiol* 11:91–96
 148. Swanson DA, Wallace S (1988) Surgery of metastatic renal cell carcinoma and use of renal infarction. *Semin Surg Oncol* 4:124–128

17 Research and Future Directions in Oncology Embolotherapy

ELENI LIAPI and JEAN-FRANCOIS H. GESCHWIND

CONTENTS

17.1	Introduction	221
17.2	Advances in Chemotherapeutic Agents	222
17.2.1	Conventional Chemotherapeutic Agents	222
17.2.2	Novel Drug Regimens	222
17.3	Update on Current Use and Development of Embolic Agents	223
17.3.1	Ethiodol	223
17.3.2	Gelfoam	224
17.3.3	Polyvinyl Alcohol (PVA) Particles	225
17.3.4	N-Butyl-2-Cyanoacrylate	225
17.3.5	Spherical Embolic Agents	226
17.3.5.1	Plain Spherical Agents	226
17.3.5.2	Drug-Loaded Embolic Agents	228
17.4	Advancements in Embolization Technique	229
17.5	Conclusion	229
	References	230

17.1 Introduction

Oncology embolotherapy consists of a catheter-based group of treatments where embolic agents are intravascularly directed to target cancerous lesions. This group of therapies is mainly represented by transcatheter arterial chemoembolization (TACE) for primary and metastatic hepatic lesions; however, oncology embolotherapy has been applied beyond liver for palliative treatment of bone, pulmonary, renal, oral cavity or anterior oropharynx lesions [11, 29, 30, 71]. The underlying principle for

the procedure is selective and precise delivery of high doses of chemotherapeutic agents to malignant hepatic lesions, so as to achieve local tumor control, while minimizing systemic toxicity. While exploiting the well-known arterial blood supply of malignant hepatic lesions, oncology embolotherapy involves the infusion of chemotherapeutic and embolic agents.

In practice, despite its promising concept of design, TACE has not shown yet to be as effective and potent as in theory. Several challenging obstacles that have not been exceeded yet include chemotherapeutic dose-limiting toxicity, development of mechanisms for drug resistance and tumor revascularization. Moreover, the techniques and agents used for intra-arterial treatment of primary and metastatic liver cancer are very heterogeneous. This hinders a more systematic approach and interpretation of the results of clinical trials as well as implementation of meta-analyses.

Despite its heterogeneity and limitations, transcatheter arterial chemoembolization has gained wide acceptance over the past 20 years and is currently considered as the mainstay therapy for unresectable primary and metastatic liver cancer [64, 67]. Recent advances in infusible drug regimens, embolic agents and embolization design, as well as the positive results of two recent randomized controlled trials and a meta-analysis, have boosted investigators' optimism to further develop this method of local tumor control [7, 38, 39]. The extent of tumor necrosis after chemoembolization has been reported to range from 60% to 100% [58]. However, these data need to be further supported by conducting prospective randomized clinical trials, with use of standardized interventional oncologic protocols. Moreover, adequate knowledge on the molecular basis of hepatic tumorigenesis may lead to a consensus on optimal treatment of primary and metastatic liver cancer. New developments and research activities on hepatic oncology embolotherapy represent an amalgamation of its evolutionary course with future trends in chemotherapeutic agents, embolic agents and embolization techniques.

E. LIAPI, MD

The Russell H. Morgan Department of Radiology and Radiological Sciences, Johns Hopkins Medical Institutions, Baltimore, MD, USA

J.-F. H. GESCHWIND, MD

Associate Professor of Radiology, Surgery and Oncology, Division of Vascular and Interventional Radiology, 600 N Wolfe Street, Blalock 545 Baltimore, MD, 21287, USA

Following, we present a comprehensive approach to recent advances on hepatic embolotherapy. Advances on radioactive microspheres embolization are not included, as they are thoroughly discussed in a previous chapter.

17.2 Advances in Chemotherapeutic Agents

17.2.1 Conventional Chemotherapeutic Agents

Currently, there is no good evidence for the best chemotherapeutic agent. A number of chemotherapeutic cocktails have been used for chemoembolization in the past decade, and controversy persists regarding the selection of the most potent of these drugs. A large variety of drugs including mitomycin C, doxorubicin, epirubicin, cisplatin have been used with TACE. The most common chemotherapeutic drug used as a sole agent is doxorubicin, whereas the combination of cisplatin, doxorubicin, and mitomycin C is the most common combination drug regimen for treatment of HCC [6]. All of these drugs exhibit preferential extraction when delivered intrahepatically and they can achieve favorable tumor drug concentration with concurrent low systematic drug load. Despite their favorable and high intratumoral concentrations, most randomized controlled trials have failed to demonstrate advantage of one agent over another [51]. In one study, cisplatin was shown to be more effective than doxorubicin as a single agent against HCC; however, this improved effectiveness could not be correlated with improved survival [9]. Recent data suggest that injectable volumes of chemotherapy and long-term arterial patency were improved by embolizing the tumor-feeding vessel(s) only after the entire dose of chemotherapy had been delivered [20]. In our institution, a standardized regimen of chemotherapeutic agents, based on the Hospital of the University of Pennsylvania protocol, regardless of tumor type, is currently used. This regimen comprises of cisplatin 100 mg (Bristol Myers Squibb, Princeton, NJ), doxorubicin 50 mg (Adriamycin; Pharmacia-Upjohn, Kalamazoo, MI) and mitomycin C 10 mg (Bedford Laboratories, Bedford, OH) mixed in 10 ml of water-soluble contrast medium (Omnipaque; Winthrop Pharmaceuticals, New York, NY). This cocktail is then mixed with an equivalent volume of lipiodol.

17.2.2 Novel Drug Regimens

Advances in the knowledge of the molecular pathogenesis of HCC and hepatic tumorigenesis have led to the testing of some novel cytostatic agents that may interact upon some disrupted pathways. Among their significant properties is their ability to overcome drug resistance, inhibit angiogenesis and limit chemotherapeutic dose-related toxicity. Phase I/II/III studies are currently being conducted to explore whether anti-angiogenesis agents, inhibitors of growth-factor-signaling and cell cycle enzymes, nonspecific growth inhibitory agents, specific antagonists of HCC tumor markers, and anti-inflammatory agents, may have a role in the treatment of liver cancer [8].

Among those agents, bevacizumab (Avastin, Genentech Inc., San Francisco, CA), a humanized monoclonal antibody that binds vascular endothelial growth factor (VEGF) and prevents its interaction to receptors on the surface of endothelial cells, has been recently added to the triple chemoembolization cocktail for patients with primary and metastatic liver cancer. A recent pilot study, in selected HCC patients undergoing TACE who additionally received intravenous bevacizumab, showed encouraging results with good drug tolerance and prolonged disease control [4]. Currently, there are two phase II trials evaluating the safety and efficacy of bevacizumab in patients with primary and metastatic unresectable liver cancer [47, 48]. The combination of bevacizumab with this TACE regimen seems challenging, as the formation of new blood vessels may effectively be reduced while the targeted tumor may maintain high cytotoxic chemotherapeutic concentrations.

3-Bromopyruvate (3-BrPa) is another example of a drug disrupting a metabolic pathway, which has been recently tested via transcatheter infusion. 3-BrPa is a hexokinase II specific inhibitor, which potentially abolishes cell ATP production via the inhibition of glycolysis [19]. Preliminary experiments on the rabbit VX-2 tumor model for liver cancer with direct intraarterial infusion of 3-BrPa showed very specific necrosis of the implanted lesions [19, 21]. Additionally, intraarterial injection did not affect the viability of surrounding normal liver tissues, nor damaged the animals' major tissues during systemic infusion [19]. The mechanism of innate resistance of normal cells against 3-BrPa treatment has not yet been clarified, though it might be related to the difference of hexokinase II expression levels between normal and malignant cells [17].

Recombinant adenoviral vectors, such as those expressing recombinant b-galactosidase or human hepatocyte growth factor, soaked in gelatin sponge pledgets, have been recently tested for transcatheter delivery in canines [53]. The intratumoral injection of oncolytic adenovirus seems to be a promising approach for the treatment of tumors resistant to other modalities, but its intra-arterial infusion warrants additional research. To date, the published clinical experience with these agents has been almost exclusively limited to intratumoral injection on Phase I and II studies [62, 63].

The ideal chemotherapeutic agent for transcatheter treatment of primary and metastatic liver cancer is yet to be developed. This agent should combine effectiveness against the tumor and reduced toxicity to the normal or cirrhotic liver. In the near future, some of the above novel drugs are expected to enter the clinical arena and be prospectively tested, whereas some of the currently used chemotherapeutic agents such as doxorubicin, cisplatin and mitomycin C are expected to be tested in a more systematic and prospective way.

17.3 Update on Current Use and Development of Embolic Agents

Several embolic agents have been employed over the past two decades in order to enhance the effects of transcatheter intraarterial drug delivery for hepatic malignancies. These agents may produce different effects on vasculature, resulting in permanent or transient obstruction, by acting at different levels in the arterial system. Usually, the injection of embolic particles follows the injection of the chemotherapeutic mixture, yet, some centers favor mixing the particles in slurry with the chemotherapeutic drugs and oil [20]. Embolization without chemotherapy (transarterial embolization) has often been categorized as a form of chemoembolization [58]. This form of embolotherapy has been occasionally described in the literature. Arterial embolization alone has been investigated in two randomized trials from Barcelona, which failed to demonstrate a survival benefit [5, 38].

Despite the extensive research that is available on hepatic embolization, the precise effects of embolization on tumor cells remain largely unknown. In fact, recent data suggest that hypoxia, generated by arterial embolization, may activate several genes, including those for vascular endothelial growth

factor (VEGF) and hexokinase II, leading therefore to compensatory angiogenesis and tumor growth [24]. A direct link among the degree of embolization, tumor hypoxia, and the stimulation of new blood vessels has been suggested in a number of recent studies. KOBAYASHI et al. found that blood levels of VEGF were markedly increased in patients who had been treated with embolization [27]. POON et al. reported that serum VEGF level was significantly elevated in patients with HCC, and significantly high serum VEGF levels were associated with the absence of tumor capsule, the presence of venous invasion and microsatellite modules, and advanced TNM stage [56]. More recently, high serum level of VEGF was found to be a predictor of poor outcome after resection of HCC [57]. VEGF may also help in predicting treatment response and monitoring disease course after chemoembolization [35].

From a different standpoint, similar simple observations have already confirmed the angiogenesis theory by the formation of early revascularization after proximal and temporary embolization induced with gelfoam [20]. Moreover, it has been demonstrated that proximal embolization of tumor-feeding arteries in hepatic metastases with large particles or coils may lead to immediate peripheral hepatic circulation reconstitution through collateral vessels. It seems that the earlier the revascularization of the tumor occurs, the more incomplete the necrosis will be. An occlusion of more peripheral vessels generates a nearly complete tumor necrosis and current trends in oncology embolotherapy seem to favor distal occlusion. Gelatin sponge powder and pledgets and polyvinyl alcohol are the most commonly used agents for chemoembolization [20]. Combinations of ethiodol with other embolic agents have also been reported for transcatheter use. Autologous clots, coils and microcoils, or collagen have also been used for oncology embolotherapy, but few reports have assessed their efficacy [37]. An overview of characteristics, current use and future perspective of some commonly used embolic agents is next presented, as well as an introduction to some novel embolic agents (Table 17.1). The latter new category of new embolic agents may lead to more accurate tumor targeting and ultimately, improve patients' survival.

17.3.1 Ethiodol

This oily medium is a key ingredient to the chemoembolization procedure due to its unique combina-

Table 17.1. Size of embolic agents used for oncology embolotherapy

Embolic Agents	Particle Size
Polyvinyl alcohol foam	150–500 μm
Gelfoam (gelatin sponge particles)	1–2 μm
Tris-acryl gel microspheres (Embogold and Embosphere Microspheres)	40–1200 μm
Polyvinyl alcohol microspheres (Contour SE)	45–1180 μm
Polyvinyl alcohol hydrogel microspheres (Bead Block)	100–1200 μm

tion of properties as a drug-carrier, tumor-seeking and embolic agent. Since the observation that this poppy seed oil accumulates preferentially in hepatocellular carcinoma (HCC) and other hepatic malignancies, ethiodized oil or lipiodol (Ethiodol; Savage Laboratories, Melville, NY) has been successfully used as a suspension medium for chemotherapeutic agents [13, 28, 45]), as a radiolabeling means by labeling part of its iodine with ^{131}I to deliver targeted radiotherapy, or as a plain embolic agent [2, 28, 50, 60]. In most cases, ethiodol is used along with a chemotherapeutic cocktail and constitutes the basis of most TACE procedures.

Although ethiodol has been used for more than 20 years for chemoembolization of HCC and hepatic metastatic lesions, the mechanism of its uptake by cancer cells is not clearly understood. A biochemical pump in the tumor cell wall recognizes ethiodol and transfers the emulsion in the intracellular space, and this pump is subsequently disabled by hypoxia, thus trapping the ethiodol emulsion within the cell. Ethiodol localizes in hepatic tumors when administered via the hepatic artery, and is retained by HCC for many weeks, even up to 1 year, while it is cleared from normal or cirrhotic liver within 4 weeks. When injected into the hepatic artery, it traverses the peribiliary plexus to the portal veins resulting in a dual embolization [69]. The amount of lipiodol emulsion has been shown to proportionally depend on the tumor size. However, hepatic parenchymal damage or bile duct ischemia have been reported by use of large amounts of lipiodol [12]. Individualized adjustment of lipiodol dose, according to blood supply pattern and tumor diameter as measured on CT, has been recently suggested in a controlled randomized trial [10]. The degree of lipiodol accumulation at computed tomography has been shown to be an independent indicator of better prognosis [44].

Labeling part of lipiodol's iodine with ^{131}I attracted researchers' interest early in the course of investigating lipiodol's potential for hepatic embolotherapy [75]. Intra-arterial ^{131}I -lipiodol has been successfully used to treat inoperable hepatocellular carcinoma and is well tolerated and effective in small tumors (<5 cm) [42, 76]. Randomized studies have shown

that treatment with ^{131}I -lipiodol is at least as effective as but less toxic than chemoembolization and that there is a significant increase in the survival of patients presenting with an HCC with portal thrombosis [61]. Moreover, it may lead to a 50% reduction in the recurrence rate 3 years after a resection [31]. Nevertheless, the administration of ^{131}I -lipiodol has limitations related to radiation protection issues. Following treatment with ^{131}I -lipiodol, patients are not eligible for surgery for up to 4 weeks, due to the relatively long physical half-life of ^{131}I (8 days) [31]. Another drawback is the required hospitalization of up to 7 days, due to the high energy of the gamma-ray emission of ^{131}I (365 keV) and its physical half-life.

There have been various attempts to label lipiodol with other isotopes, in particular ^{90}Y , ^{188}Re and recently $^{99\text{m}}\text{Tc}$ [31, 77, 78]. Currently, the best approach seems to be the labeling of a lipophilic chelating agent with ^{188}Re , which is then put into solution secondarily with the Lipiodol [77]. ^{188}Re is a radionuclide with a higher energy of the beta-emission (2120 keV and 1960 keV for ^{188}Re versus 606 keV for ^{131}I) and its use, with its physical half-life of 17 h, avoids most of the radioprotection problems and allows for a shorter hospitalization, as well as further dose escalations. Following ^{188}Re -lipiodol treatment, patients are eligible for transplantation after an interval of only 1 week. However, certain problems remain, such as the relatively weak labeling efficiency, and further studies to determine the maximum tolerated dose and potential hepatotoxicity should be assessed.

17.3.2 Gelfoam

Gelatin bioabsorbable embolic agents, in the form of gelfoam sponge or powder, have been extensively used as an intravascular embolization agent for TACE. Gelatin sponge, which blocks circulation transiently and is absorbed within 48–72 h, is currently the most commonly employed material. Gelatin sponge causes temporary vascular occlusion,

with recanalization occurring in approximately 2 weeks [20]. When compared to powder, gelfoam sponge provides a more proximal obstruction to blood supply. However, proximal obstruction may enhance the development of revascularization of treated lesions through aberrant collaterals and limit the efficacy of further embolization. On the other hand, gelfoam powder can induce ischemic bile duct necrosis. Improved overall patient survival rates with the addition of gelfoam sponge to the lipiodol emulsion were initially described by NAKAO et al. in a retrospective study on 343 patients [46]. In this study, no dose–response relationship was found and based on these data, the combination of lipiodol and gelfoam sponge was further suggested for transcatheter treatment of hepatic malignancies. The use of gelatin-sponge allows repetitive chemoembolization procedures, which in some centers is desirable [20]. Today, gelfoam is still widely used and new applications of its use, such as its soaking in recombinant adenoviral vectors may shed new light in the use of this traditional embolic agent [53].

17.3.3

Polyvinyl Alcohol (PVA) Particles

Polyvinyl alcohol (PVA) particles have been successfully used since 1974 as an intravascular embolic agent and for many years, it has been considered the standard embolic agent for TACE [68]. The earliest method of its preparation for use as an embolic agent first involved its conversion into foam that can absorb water and become readily compressible. According to this preliminary method, PVA particles were prepared by scraping a compressed block or by cutting off pieces, which were then filtered through different sizes of sieves. Their irregular shape, however, did not ensure uniformity of the final compound, as large particles were likely to pass through small holes depending on their orientation during filtration. This problem created variability in size and shape; however, later on, changes were made to ensure improved uniformity.

Polyvinyl alcohol is considered to be a permanent embolic agent because it is not biodegradable. The histologic effects of PVA particles embolization have been well documented, varying from inflammatory and foreign body reactions to focal angionecrosis of the vessel wall [36]. The duration of the vascular occlusion induced by PVA is variable. Occlusions may last for several months as a result of organization of the thrombus, with recanalization attributed




Fig. 17.1. Polyvinyl alcohol particles. Their irregular shape does not guarantee precise vessel occlusion. (Courtesy of Biosphere Medical Inc.)

to thrombus resorption and angiogenesis [36]. Unexpected and non-targeted embolization has been reported, creating some uncertainty over their use. In a study testing the effects of embolization protocol on injectable volume of chemotherapy and subsequent arterial patency, the type of chemoembolization protocol rather than the type of embolic material had a significant impact on the rate of arterial recanalization or arterial patency [20]. Surprisingly, the assumption that PVA particles result in deeper penetration, when compared to gelfoam pledgets, was not confirmed in this study [20].

17.3.4

N-Butyl-2-Cyanoacrylate

This glue, first used for bleeding control, has been successfully utilized for preoperative portal vein embolization [15]. This adhesive, that polymerizes on contact with blood and endothelium, does not affect the peribiliary arterial plexus, and this property led to the assumption that it can be used for transcatheter arterial embolization [55]. Mixed with radiopaque lipiodol, the polymerization time can be prolonged to 10–15 s, depending on dilution. Therefore, a more peripheral and permanent embolization can be achieved.

In an initial short report, patients with carcinoid hepatic metastases treated with a mixture of *N*-butyl-2-cyanoacrylate/ethiodol, showed complete and long-lasting relief of symptoms, with significant decrease or normalization of levels of 5-HIAA in the urine, and a reduction of metastatic tumor in the liver [72]. Another study demonstrated promising results in the treatment of metastatic hepatic

insulinomas [73]. Other retrospective studies have shown that TACE with use of cyanoacrylate and lipiodol for unresectable HCC and neuroendocrine hepatic metastases is feasible [41, 42]. Cyanoacrylate was recently used in a retrospective study of patients treated for unresectable HCC, combined with other embolic agents without concurrent addition of chemotherapy [59]. Still, this type of embolic material is used for bland embolization and assessment of its effectiveness compared to the use of other embolotherapy regimens is rather complicated.

17.3.5 Spherical Embolic Agents

Investigations on the mechanisms of actions of commercially available embolic agents demonstrated that novel embolic materials should possess a combination of certain mechanical and physicochemical properties in order to maximize their efficiency and minimize potential side effects. First, they must be spherical in shape to allow for accurate calibration, optimal and complete geometric vessel occlusion. Spherical particles have a single dimension; moreover, depending on their size, they may block tightly and gradually seal the vascular lumen, whereas non-spherical particles produce a more incomplete occlusion. Second, the particles must not aggregate, which may lead to catheter obstruction and proximal arterial occlusion. Other desirable properties include unproblematic fabrication, controlled deformability, good biocompatibility and in vivo stability when mixed with chemotherapeutic agents. Moreover, potential drug-loading combined with sustained drug release seem to be very attractive properties that may lead to the establishment of a new category of embolic agents and transform the profile of oncology embolotherapy.

With the recent bloom in nanotechnology, several types of microspheres have been developed [3]. Some of these new types of spherical agents, such as polyvinyl alcohol and tris-acryl microspheres are non-degradable, resulting in more permanent occlusion. Others, such as gelatin, albumin, polysaccharides (dextran), starch, ethyl cellulose, and poly-(D,L lactide/glycoside)-copolymer include a resorbable component, and are not suitable for permanent vascular occlusion [18]. The optimal size of these embolic agents for chemoembolization has yet to be established. Spherical embolic agents may be categorized into plain (unloaded) and drug-loaded (or drug-eluting) spheres.

17.3.5.1 Plain Spherical Agents

17.3.5.1.1 Tris-acryl Gelatin Microspheres

Tris-acryl gel microspheres were the first spherical embolic agents to be commercially available [32]. Tris-acryl is an entirely synthetic, hydrophilic, and nonresorbable material. It has been demonstrated that this material produces non-toxic tissue reaction, thus allowing absorption and cellular adhesion [32]. Colored and non-colored tris-acryl gelatin microspheres (Embogold and Embosphere Microspheres; Biosphere Medical, Rockland, MA) are currently commercially available.

These microspheres are precisely calibrated, spherical, hydrophilic, microporous beads made of tris-acryl co-polymer coated with gelatin. They come in defined range of sizes, ranging from 40 to 1200 μm in diameter. Their smooth hydrophilic surface, deformability and minimal aggregation tendency have been shown to result in a lower rate of catheter occlusion and more distal penetration into the small vessels [32]. Their efficacy has been evaluated in several conditions, and when compared to the standard polyvinyl alcohol particles (PVA) particles, a deeper penetration and embolization of smaller and more peripheral vessels may be achieved. This distal embolization may limit the development of any collateral blood supply. Also, in a study where PVA particles and tris-acryl microspheres of similar size were compared, the level of vascular occlusion with calibrated tris-acryl microspheres precisely correlated with particle size whereas the level of vascular occlusion with PVA particles did not. Another study has demonstrated that in embolized tumors,

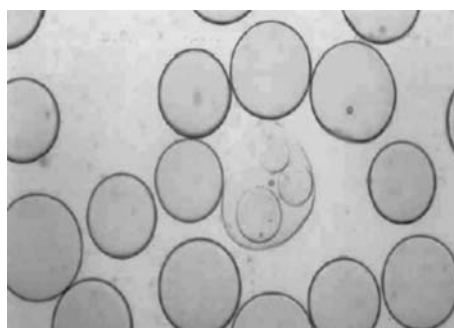


Fig. 17.2. Embosphere microspheres. These tris-acryl gelatin microspheres are precisely calibrated, spherical, hydrophilic, microporous beads. (Courtesy of Andy Lewis, Biocompatibles, UK, Ltd, Surrey, UK)

a great majority of occluded vessels were located within the tumoral tissue, and vessels located outside the tumor were rarely occluded [33]. Interestingly, the median diameter of the occluded vessels located within the tumors was 210 μm . However, the authors avoided suggesting this number as a threshold for the penetration, due to tumor vessel variability and histological processing pitfalls.

Tris-acryl gelatin microspheres have been proven to be stable in a standard chemoembolization solution and some centers have adopted their use [1]. Tris-acryl gelatin microspheres have been also tested for compatibility with several chemotherapeutic agents and can be mixed with carboplatin, mitomycin C, 5-fluorouracil, or pirarubicin for chemoembolization without any risk of harmfully altering their morphology, dimensions, or geometric characteristics [70].

17.3.5.1.2

Polyvinyl Alcohol Microspheres

A long track record of safety and efficacy of polyvinyl alcohol led to the design of spherical PVA. PVA (Contour SE Microspheres; Boston Scientific/Mediatech, Natick, MA) and PVA hydrogel (Bead Block, Terumo Medical Corp., Somerset, NJ) are currently available for transcatheter use.

Interestingly, PVA microspheres have been observed to result in a very mild inflammatory response [65]. This finding seems rather counterintuitive and unexpected, considering the aggressive inflammatory reactions that have been described with PVA particles. Further studies, however, should be conducted to assess whether this reduced intravascular and perivascular inflammation may have significant favorable clinical implications [65].

17.3.5.1.3

Other Types of Plain Microspheres

Poly-L-lactic acid (PLLA) microspheres have also been tested for transcatheter delivery, but they are biodegradable and tend to clog microcatheters, like PVA particles. The diameter of these particles can be changed according to the polymerization time and therefore, various sizes of PLLA microspheres can be prepared [74]. Loading of these particles with neutron-activated radioactive holmium 166 (^{166}Ho) has also been tested for transcatheter administration in an animal HCC model [49]. A recent study demonstrated that the Ho on the surface of neutron-irradiated Ho-PLLA-micro-

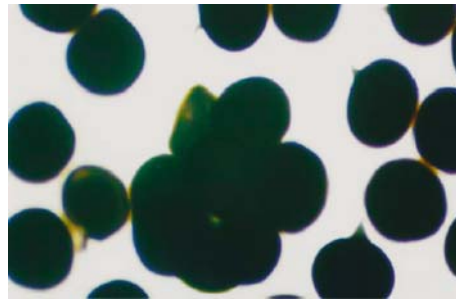


Fig. 17.3. Contour SE microspheres. PVA microspheres with smooth, hydrophilic surface and standardized caliber of size. (Courtesy of Andy Lewis, Biocompatibles, UK, Ltd, Surrey, UK)

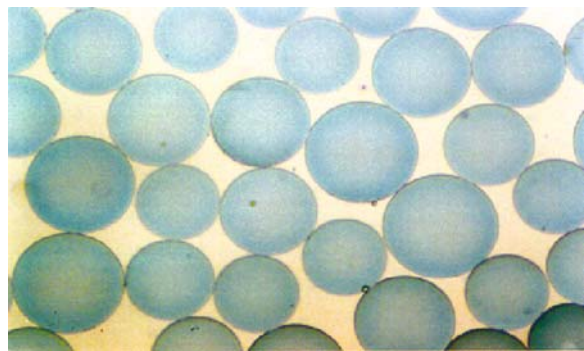


Fig. 17.4. Bead Block (Terumo Medical Corp., Somerset, NJ). PVA hydrogel microspheres (Courtesy of Andy Lewis, Biocompatibles UK, Ltd, Surrey, UK)

spheres is probably the reason for their poor suspending ability in saline and that a pharmaceutically acceptable solvent (1% pluronic F68 or F127 in 10% ethanol) can be used for the formulation of a homogeneous suspension, making these systems feasible for further clinical evaluation [79].

Radiopaque microbeads made of polyacrylonitrile (PAN) hydrogel have also been evaluated in vitro and in vivo for transcatheter embolization on a swine model showing potential for future use [23].

Superabsorbent polymer microspheres is another example of nontoxic and non-biodegradable solid particle with a spherical shape that has been recently tested in Japan [52]. The particle size is precisely calibrated in 50- μm increments ranging from 53 to 350 μm and initial experience suggests that embolization with use of these particles leads to extensive tumor necrosis of large nodular HCC, sparing use of chemotherapeutic agents [52].




Fig. 17.5. a Stable solution of Doxorubicin-eluting beads (PRECISION Beads) in saline. Note that red-colored doxorubicin does not leak outside the bead. b Confocal laser microscopy image, showing doxorubicin distribution in the bead. Progressive sectioning shows that the drug is concentrated in the outer portions of the bead. (Courtesy of Andy Lewis, Biocompatibles, UK, Ltd, Surrey, UK)

17.3.5.2 Drug-Loaded Embolic Agents

The concept of drug-loaded microspheres for chemoembolization is not new, and several attempts have been made over the past decade to design microspheres loaded with chemotherapeutic agents suitable for intraarterial delivery. Cisplatin-loaded poly(D,L-lactide) microspheres for chemoembolization [66], doxorubicin incorporated into albumin microspheres [26], poly (benzyl L-glutamate) (PBLG) microspheres containing cisplatin [34], 5-fluorouracil-loaded chitosan microspheres [16] are some examples of initial attempts to create vehicles of chemotherapeutic agents for precise tumor targeting. Today, the development of nanotechnology combined with the robust research activity in tumor pathophysiology has boosted up the production of novel drug carriers for systematic or local tumor targeting. A promising example of this new category of embolic materials is the doxorubicin-eluting beads, which will be further analyzed.

17.3.5.2.1 Polyvinyl Alcohol Hydrogel Drug-Eluting Beads

PVA hydrogels are non-biodegradable and relatively biocompatible and can be easily fabricated since they possess high stability under a range of temperature and pH conditions [43]. Their structural mechanical properties are similar to those of human soft tissues and provoke a limited inflammatory response [54].

Because of the amphiphilic nature and microporous architecture of hydrogels, drugs can be incorporated in hydrogel coatings and can be typically released within hours to weeks [54]. The release of the loaded drugs in acidic environment represents another important property of these polymers.

Recent development of a new PVA hydrogel bead has enabled accurate doxorubicin loadings to be achieved, with subsequent slow first order release. This novel drug-delivery system has been recently evaluated for intraarterial treatment of hepatic lesions [22]. Doxorubicin-eluting beads (DC Bead for loading by the physician and PRECISION Bead preloaded with doxorubicin, Biocompatibles UK Ltd, Surrey, UK), are designed for intraarterial infusion and selective tumor targeting [14].

The significant advance of these beads is the demonstration of an effective process for consistent drug release that controls local tissue response. Recent animal studies on a model of liver cancer have confirmed the *in vivo* slow release of doxorubicin over time within the tumor, with maintenance of a high concentration of drug for up to 14 days. Pharmacokinetic data of this study showed near complete absence of doxorubicin within plasma, while intratumoral doxorubicin concentrations remained high [22].

Clinical studies that are necessary to support this initial report of efficacy are currently in progress in Europe and Hong Kong. These beads are not currently available in the US market. Irinotecan-eluting beads for metastatic colon cancer are also under development.

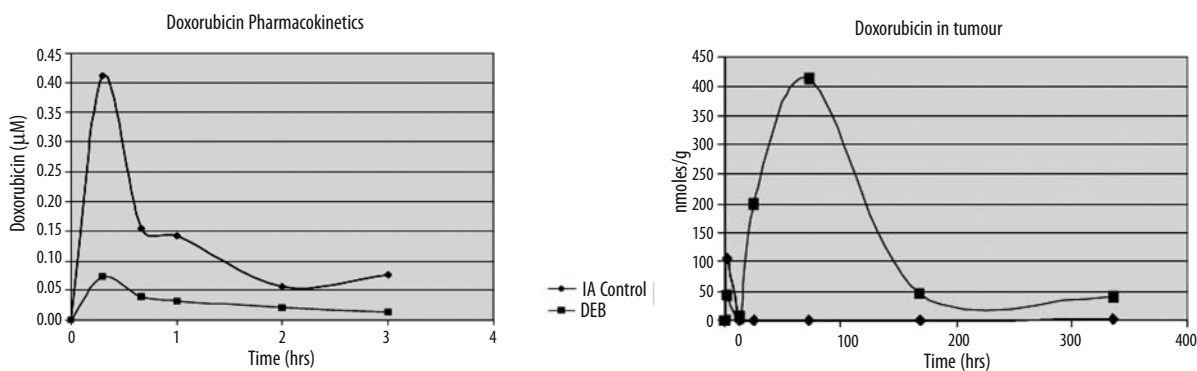


Fig. 17.6. Pharmacokinetic study results of doxorubicin-eluting beads (DEB) in a VX-2 rabbit model of liver tumor show high intratumoral drug concentration with minimal systemic toxicity. Note the significantly higher levels of doxorubicin found in the tumor, peaking 3 days after treatment. Sustained levels of doxorubicin measured in the tumor 14 days after treatment

A future approach on this category of embolic agents would include a sophisticated regimen of timed release drugs appropriate to the pathologic stage of cancer, followed by a treatment that suppresses angiogenesis (such as bevacizumab) or disrupts a neoplastic metabolic pathway (like 3-BrPa).

17.4 Advancements in Embolization Technique

Several variations in the techniques of embolotherapy have been reported. Some of the common steps of the procedure include the patient's overnight fasting and volume loading, administration of conscious sedation and a visceral angiogram to identify the arterial anatomy of the liver, the size and locations of the tumors, and their feeding vessels and portal venous potency. A catheter is advanced beyond the gastroduodenal artery (to avoid extrahepatic embolization), and depending on tumor location and institution's protocol to lobar, segmental, or subsegmental branches feeding the target lesion(s).

A common objective of every interventional oncologist is to preserve as much functional liver tissue as possible. Currently, there is no consensus on how selective (lobar vs. segmental) chemoembolization should be. Many centers prefer to focus on one lobe of the liver at each treatment session, regardless of the extent or number of tumors, so as to avoid a prolonged postembolization syndrome or postinterventional liver failure. Others may choose an even more selective approach, by engaging a segmental or subsegmental feeding artery. Longer survival seems to be related to multiple TACE sessions,

which require, however, long-term maintenance of arterial patency. Further research though is required to assess the effectiveness of long-term arterial patency [25]. Controversy also exists over the best treatment scheme for repetitive treatments and over the timing for repetition of the treatment session. Some centers prefer to treat patients at fixed timing, whereas others upon disease progression after the initial response. In our institution, the decision to re-treat is made on the basis of imaging and clinical assessment of tumor response. Appointments for imaging and clinical evaluation though are scheduled within a fixed interval of time after treatment. In the future, a better knowledge of genetics and causes of hepatic malignancies may result in significant modifications of hepatic artery embolization techniques.

17.5 Conclusion

Several questions remain unanswered, such as which is the best embolization agent, which is the best chemotherapeutic drug, or how can we increase the intratumoral concentration of the drug. The lack of large prospective randomized trials and the current difficulty in conducting meta-analyses on hepatic oncology embolotherapy, along with the absence of effective systemic therapy for unresectable primary and metastatic liver disease, urge intense efforts and the continuation of research on oncology embolotherapy. New developments in drug regimens, embolization materials and new variations in the embolization technique are rapidly changing the image of oncology embolotherapy and hopefully,

will positively influence the outcome of treatment and patient survival.

The interventional radiologist should also bear in mind that successful embolotherapy depends on factors beyond the embolic agent selection, or the choice chemotherapeutic cocktail. Technical skills, experience, familiarity with the underlying pathologic processes, and appreciation of the importance for constructive collaboration with other specialties, are also essential for every successful oncology embolotherapy treatment.

References

- Ball DS, Heckman R, et al. (2003) In vitro stability of tris-acryl gelatin microspheres in a multipharmaceutical chemoembolization solution. *J Vasc Interv Radiol* 14:83–88
- Bretagne JF, Raoul JL, et al. (1988) Hepatic artery injection of I-131-labeled lipiodol. Part II. Preliminary results of therapeutic use in patients with hepatocellular carcinoma and liver metastases. *Radiology* 168:547–550
- Brigger I, Dubernet C, et al. (2002) Nanoparticles in cancer therapy and diagnosis. *Adv Drug Deliv Rev* 54:631–651
- Britten C, Finn RS, Gomes AS, Amado R, Yonemoto L, Bentley G, Mass R, Bussutil RW, Slamon DJ (2005) A pilot study of IV bevacizumab in hepatocellular carcinoma patients undergoing chemoembolization. 2005 ASCO Annual Meeting, Orlando, Florida
- Bruix J, Llovet JM, et al. (1998) Transarterial embolization versus symptomatic treatment in patients with advanced hepatocellular carcinoma: results of a randomized, controlled trial in a single institution. *Hepatology* 27:1578–1583
- Bruix J, Sala M, et al. (2004) Chemoembolization for hepatocellular carcinoma. *Gastroenterology* 127[Suppl 1]:S179–S188.
- Camma C, Schepis F, et al. (2002) Transarterial chemoembolization for unresectable hepatocellular carcinoma: meta-analysis of randomized controlled trials. *Radiology* 224:47–54
- Carr BI (2004) Hepatocellular carcinoma: current management and future trends. *Gastroenterology* 127:S218
- Chang JM, Tzeng WS, et al. (1994) Transcatheter arterial embolization with or without cisplatin treatment of hepatocellular carcinoma: a randomized controlled study. *Cancer* 74:2449
- Cheng HY, Shou Y, et al. (2004) Adjustment of lipiodol dose according to tumor blood supply during transcatheter arterial chemoembolization for large hepatocellular carcinoma by multidetector helical CT. *World J Gastroenterol* 10:2753–2755
- Chiras J, Adem C, et al. (2004) Selective intra-arterial chemoembolization of pelvic and spine bone metastases. *European Radiology* 14:1774
- Chung JW, Park JH, et al. (1996) Hepatic tumors: predisposing factors for complications of transcatheter oily chemoembolization. *Radiology* 198:33–40
- Clouse ME, Perry L, et al. (1994) Hepatic arterial chemoembolization for metastatic neuroendocrine tumors. *Digestion* 55[Suppl 3]:92–97
- Constantin M, Fundueanu G, et al. (2004) Preparation and characterisation of poly(vinyl alcohol)/cyclodextrin microspheres as matrix for inclusion and separation of drugs. *Int J Pharm* 285:87–96
- de Baere T, Roche A, Elias D, Lasser P, Lagrange C, Bousson V (1996) Preoperative portal vein embolization for extension of hepatectomy indications. *Hepatology* 24:1386–1391
- Denkbas EB, Seyyal M, et al. (1999) 5-Fluorouracil loaded chitosan microspheres for chemoembolization. *J Microencapsul* 16:741–749
- Foubister V (2002) Energy blocker to treat liver cancer. *Drug Discovery Today* 7:934
- Fujimoto S, Miyazaki M, et al. (1985) Biodegradable mitomycin C microspheres given intra-arterially for inoperable hepatic cancer. With particular reference to a comparison with continuous infusion of mitomycin C and 5-fluorouracil. *Cancer* 56:2404–2410
- Geschwind J-F H, Ko YH, et al. (2002) Novel therapy for liver cancer: direct intraarterial injection of a potent inhibitor of ATP production. *Cancer Res* 62:3909–3913
- Geschwind JF, Ramsey DE, et al. (2003) Transcatheter arterial chemoembolization of liver tumors: effects of embolization protocol on injectable volume of chemotherapy and subsequent arterial patency. *Cardiovasc Intervent Radiol* 26:111
- Geschwind JF, Georgiades CS, et al. (2004) Recently elucidated energy catabolism pathways provide opportunities for novel treatments in hepatocellular carcinoma. *Expert Rev Anticancer Ther* 4:449–457
- Geschwind JF, Khwaja A, Hong K (2005) New intraarterial drug delivery system: Pharmacokinetics and tumor response in an animal model of liver cancer. 2005 ASCO Annual Meeting, Orlando, Florida.
- Gobin YP, Vinuela F, et al. (2000) Embolization with radiopaque microbeads of polyacrylonitrile hydrogel: evaluation in swine. *Radiology* 214:113–119
- Hanahan D, Folkman J (1996) Patterns and emerging mechanisms of the angiogenic switch during tumorigenesis. *Cell* 86:353–364
- Horst JJ, Ulrich-Martin M, et al. (1996) Sequential transarterial chemoembolization for unresectable advanced hepatocellular carcinoma. *Cardiovasc Intervent Radiol* 19:388
- Kerr DJ, Willmott N, et al. (1988) Target organ disposition and plasma pharmacokinetics of doxorubicin incorporated into albumin microspheres after intrarenal arterial administration. *Cancer* 62:878–883
- Kobayashi N, Ishii M, et al. (1999) Co-expression of Bcl-2 protein and vascular endothelial growth factor in hepatocellular carcinomas treated by chemoembolization. *Liver* 19:25–31
- Konno T, Maeda H, et al. (1983) Effect of arterial administration of high-molecular-weight anticancer agent SMANCS with lipid lymphographic agent on hepatoma: a preliminary report. *Eur J Cancer Clin Oncol* 19:1053–1065
- Konya A, Van Pelt CS, et al. (2004) Ethiodized oil-ethanol capillary embolization in rabbit kidneys: temporal histopathologic findings. *Radiology* 232:147–153
- Kovacs AF (2005) Chemoembolization using Cisplatin crystals as neoadjuvant treatment of oral cancer. *Cancer Biother Radiopharm* 20:267–279
- Lambert B, Praet M, et al. (2005) Radiolabeled lipiodol therapy for hepatocellular carcinoma in patients awaiting liver transplantation: pathology of the explant livers and clinical outcome. *Cancer Biother Radiopharm* 20:209–214

32. Laurent A, Beaujeux R, et al. (1996) Trisacryl gelatin microspheres for therapeutic embolization, I: development and in vitro evaluation. *AJNR Am J Neuroradiol* 17:533–540
33. Laurent A, Wassef M, et al. (2004) Location of vessel occlusion of calibrated tris-acryl gelatin microspheres for tumor and arteriovenous malformation embolization. *J Vasc Interv Radiol* 15:491–496
34. Li C, Yang DJ, et al. (1994) Formation and characterization of cisplatin-loaded poly(benzyl l-glutamate) microspheres for chemoembolization. *Pharm Res* 11:1792–1799
35. Li X, Feng GS, et al. (2004) Expression of plasma vascular endothelial growth factor in patients with hepatocellular carcinoma and effect of transcatheter arterial chemoembolization therapy on plasma vascular endothelial growth factor level. *World J Gastroenterol* 10:2878–2882
36. Link DP, Strandberg JD, et al. (1996) Histopathologic appearance of arterial occlusions with hydrogel and polyvinyl alcohol embolic material in domestic swine. *J Vasc Interv Radiol* 7:897–905
37. Llovet JM (2005) Updated treatment approach to hepatocellular carcinoma. *J Gastroenterol* 40:225
38. Llovet JM, Real MI, et al. (2002) Arterial embolisation or chemoembolisation versus symptomatic treatment in patients with unresectable hepatocellular carcinoma: a randomised controlled trial. *Lancet* 359:1734–1739
39. Lo CM, Ngan H, et al. (2002) Randomized controlled trial of transarterial lipiodol chemoembolization for unresectable hepatocellular carcinoma. *Hepatology* 35:1164–1171
40. Loewe C, Cejna M, et al. (2002) Arterial embolization of unresectable hepatocellular carcinoma with use of cyanoacrylate and lipiodol. *J Vasc Interv Radiol* 13:61–69
41. Loewe C, Schindl M, et al. (2003) Permanent transarterial embolization of neuroendocrine metastases of the liver using cyanoacrylate and lipiodol: assessment of mid- and long-term results. *Am J Roentgenol* 180:1379–1384
42. Maini CL, Scelsa MG, et al. (1996) Superselective intra-arterial radiometabolic therapy with I-131 lipiodol in hepatocellular carcinoma. *Clin Nucl Med* 21:221
43. McNair AM (1996) Using hydrogel polymers for drug delivery. *Med Device Technol* 7:16–22
44. Mondazzi L, Bottelli R, et al. (1994) Transarterial oily chemoembolization for the treatment of hepatocellular carcinoma: a multivariate analysis of prognostic factors. *Hepatology* 19:1115–1123
45. Nakakuma K, Tashiro S, et al. (1983) Studies on anticancer treatment with an oily anticancer drug injected into the ligated feeding hepatic artery for liver cancer. *Cancer* 52:2193–2200
46. Nakao N, Uchida H, et al. (1992) Effectiveness of Lipiodol in transcatheter arterial embolization of hepatocellular carcinoma. *Cancer Chemother Pharmacol* 31[Suppl]: S72–76
47. National Cancer Institute (2002) Chemoembolization and Bevacizumab in treating patients with liver cancer that cannot be removed with surgery. NCI trials database (record first received November 12, 2002)
48. National Cancer Institute (2003) Bevacizumab in treating patients with unresectable nonmetastatic liver cancer. NCI trials database (record first received March 6, 2003)
49. Nijsen JF, Seppenwoolde JH, et al. (2004) Liver tumors: MR imaging of radioactive holmium microspheres – phantom and rabbit study. *Radiology* 231:491–499
50. Novell JR, Dusheiko G, et al. (1991) Selective regional chemotherapy of unresectable hepatic tumours using lipiodol. *HPB Surg* 4:223–234; discussion 234–236
51. Okamura J, Kawai S, et al. (1992) Prospective and randomized clinical trial for the treatment of hepatocellular carcinoma – a comparison of L-TAE with Farmorubicin and L-TAE with Adriamycin (second cooperative study). *Cancer Chemother Pharmacol (Historical Archive)* 31:S20
52. Osuga K, Khankan AA, et al. (2002) Transarterial embolization for large hepatocellular carcinoma with use of superabsorbent polymer microspheres: initial experience. *J Vasc Interv Radiol* 13:929–934
53. Park BH, Lee JH, et al. (2005) Vascular administration of adenoviral vector soaked in absorbable gelatin sponge particles (GSP) prolongs the transgene expression in hepatocytes. *Cancer Gene Ther* 12:116–1121
54. Peppas NA, Huang Y, et al. (2000) Physicochemical foundations and structural design of hydrogels in medicine and biology. *Annu Rev Biomed Eng* 2: 9–29
55. Peter B, Franz P, et al. (1998) Arterial hepatic embolization of unresectable hepatocellular carcinoma using a cyanoacrylate/lipiodol mixture. *Cardiovasc Intervent Radiol* 21:214
56. Poon RT, Ng IO, et al. (2001) Serum vascular endothelial growth factor predicts venous invasion in hepatocellular carcinoma: a prospective study. *Ann Surg* 233:227–235
57. Poon RT, Ho JW, et al. (2004) Prognostic significance of serum vascular endothelial growth factor and endostatin in patients with hepatocellular carcinoma. *Br J Surg* 91:1354–1360
58. Ramsey DE, Kernagis LY, et al. (2002) Chemoembolization of hepatocellular carcinoma. *J Vasc Interv Radiol* 13:211S–2221
59. Rand T, Loewe C, et al. (2005) Arterial embolization of unresectable hepatocellular carcinoma with use of microspheres, lipiodol, and cyanoacrylate. *Cardiovasc Intervent Radiol* 28:313–318
60. Raoul JL, Bourguet P, et al. (1988) Hepatic artery injection of I-131-labeled lipiodol. Part I. Biodistribution study results in patients with hepatocellular carcinoma and liver metastases. *Radiology* 168:541–545
61. Raoul JL, Guyader D, et al. (1997) Prospective randomized trial of chemoembolization versus intra-arterial injection of I-131-labeled-iodized oil in the treatment of hepatocellular carcinoma. *Hepatology* 26:1156–1161
62. Reid T, Galanis E, et al. (2001) Intra-arterial administration of a replication-selective adenovirus (dl1520) in patients with colorectal carcinoma metastatic to the liver: a phase I trial. *Gene Ther* 8:1618–1626
63. Reid T, Galanis E, et al. (2002) Hepatic arterial infusion of a replication-selective oncolytic adenovirus (dl1520): phase II viral, immunologic, and clinical endpoints. *Cancer Res* 62:6070–6079
64. Roche A, Girish B, et al. (2003) Trans-catheter arterial chemoembolization as first-line treatment for hepatic metastases from endocrine tumors. *European Radiology* 13:136
65. Siskin GP, Dowling K, et al. (2003) Pathologic evaluation of a spherical polyvinyl alcohol embolic agent in a porcine renal model. *J Vasc Interv Radiol* 14:89–98
66. Spenlehauer G, Veillard M, et al. (1986) Formation and characterization of cisplatin loaded poly(D,L-lactide) microspheres for chemoembolization. *J Pharm Sci* 75:750–755
67. Stuart K (2003) Chemoembolization in the management of liver tumors. *Oncologist* 8:425–437

68. Tadavarthy SM, Knight L, et al. (1974) Therapeutic transcatheter arterial embolization. *Radiology* 112:13–16
69. Tancredi T, McCuskey PA, et al. (1999) Changes in rat liver microcirculation after experimental hepatic arterial embolization: comparison of different embolic agents. *Radiology* 211:177–181
70. Vallee JN, Lo D, et al. (2003) In vitro study of the compatibility of tris-acryl gelatin microspheres with various chemotherapeutic agents. *J Vasc Interv Radiol* 14:621–628
71. Vogl TJ, Wetter A, et al. (2005) Treatment of unresectable lung metastases with transpulmonary chemoembolization: preliminary experience. *Radiology* 234:917–922
72. Winkelbauer FW, Niederle B, et al. (1995) Hepatic artery embolotherapy of hepatic metastases from carcinoid tumors: value of using a mixture of cyanoacrylate and ethiodized oil. *AJR Am J Roentgenol* 165:323–327
73. Winkelbauer FW, Niederle B, et al. (1995) Malignant insulinoma: permanent hepatic artery embolization of liver metastases – preliminary results. *Cardiovasc Intervent Radiol* 18:353–359
74. Yamamoto T, Hayakawa K, et al. (2003) Transcatheter arterial embolization using poly-L-lactic acid microspheres. *Radiat Med* 21:150–154
75. Yoo HS, Park CH, et al. (1989) Radioiodinated fatty acid esters in the management of hepatocellular carcinoma: preliminary findings. *Cancer Chemother Pharmacol* 23[Suppl]: S54–58
76. Yoo HS, Park CH, et al. (1994) Small hepatocellular carcinoma: high dose internal radiation therapy with superselective intra-arterial injection of I-131-labeled Lipiodol. *Cancer Chemother Pharmacol* 33: S128
77. Yoon CJ, Chung JW, et al. (2004) Transcatheter arterial embolization with 188Rhenium-HDD-labeled iodized oil in rabbit VX2 liver tumor. *J Vasc Interv Radiol* 15:1121–1128
78. Yu J, Hafeli UO, et al. (2003) 90Y-oxine-ethiodol, a potential radiopharmaceutical for the treatment of liver cancer. *Appl Radiat Isot* 58:567–573
79. Zielhuis SW, Nijsen JF, et al. (2005) Surface characteristics of holmium-loaded poly(-lactic acid) microspheres. *Biomaterials* 26:925

External Carotid

18 Technical and Anatomical Considerations of the External Carotid System

PAULA KLURFAN and SEON KYU LEE

CONTENTS

- 18.1 ECA Anatomy 235
- 18.2 Embryological Development 235
- 18.3 External Carotid System 237
- 18.4 Technical Aspects of Head and Neck Embolization 240
- 18.5 Therapeutic Techniques and Materials 241
- 18.6 Medication 245
- References 245

The external carotid system (ECS) is a key arterial supply for the craniofacial and neck regions. Even though the internal carotid artery, the thyrocervical, costocervical, and vertebral arteries are also supplying these territories, this chapter will focus on the anatomical aspects of the ECS and the technical implications of the endovascular management of these regions.

18.1 ECA Anatomy

The external carotid artery (ECA) is in general the smaller branch of the two terminal arteries of the common carotid artery. The site of the carotid bifurcation is variable; however, between the C4–C5 and the C3–C4 is the most common levels. Despite its great anatomical variability, this artery is classically described as having eight main branches. The main

trunk of the ECA decreases in size as it gives off branches to the tongue, deep face, and neck. The arterial termination is located at the level of the parotid gland, where it is divided into the superficial temporal artery and the internal maxillary artery. Initially the ECA lies anterior and medial to the internal carotid artery (ICA), then it courses posterolaterally as it ascends in the carotid sheath in front of the internal jugular vein. During its cervical course it is covered by the sternomastoid muscle and crossed by the hypoglossal nerve, lying anterolaterally to the vagus nerve.

18.2 Embryological Development

The wide variety in the anatomical disposition of the arterial tree of the head and the neck is explained by the embryological development of the vessels in these anatomical areas. The specific supply to every territory is related to a general hemodynamic balance in the whole region. This relationship is established between the territory and several potential nutrient vessels.

During ontogenesis, the arterial supply to every territory will be the result of this hemodynamic balance, achieved by anastomosis, annexation, and involution of blood vessels.

Initially, at early embryonic stages, the ventral and dorsal aortas communicate by a certain number of arterial bridges, the aortic arches (1 to 4 in the craniocaudal direction). Other embryonic arteries are the primitive maxillary artery, dorsal ophthalmic artery, ventral ophthalmic artery, anterior cerebral artery and the longitudinal neural arteries (Fig. 18.1).

During the subsequent stages, some of these arteries undergo modifications through regression in the regions of the ventral ophthalmic artery, dorsal aorta and the ventral portion of the first two aortic arches.

P. KLURFAN, MD

Interventional Neuroradiology Clinical Fellow, Department of Medical Imaging, University of Toronto, Toronto Western Hospital, University Health Network, Suite 3MC-429, #399 Bathurst Street, Toronto, Ontario, M5T 2S8, Canada

S. K. LEE, MD, PhD

Assistant Professor, Staff Interventional and Diagnostic Neuroradiologist, Division of Neuroradiology, Department of Medical Imaging, University of Toronto, Toronto Western Hospital, University Health Network, Suite 3MC-429, #399 Bathurst Street, Toronto, Ontario, M5T 2S8, Canada

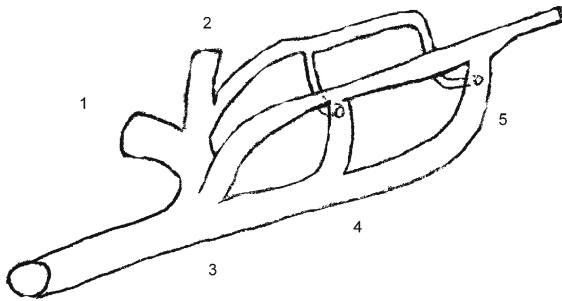


Fig. 18.1. ECA embryonic development at early stage. 1, proatlantal artery; 2, hypoglossal artery; 3, third aortic arch; 4, second aortic arch; 5, first aortic arch

The dorsal aorta will give rise to the third aortic arch which, subsequently, will reach the remnant of the ventral pharyngeal artery, becoming the external carotid artery. As the proximal dorsal aorta involutes, the ventral aorta becomes the definitive common carotid artery dividing into a primitive internal carotid artery and external carotid artery (Fig. 18.2).

The original ventral pharyngeal artery turns into the facio-lingual system, while the hyoid artery and the stapedia artery will evolve to become the internal maxillary artery and the middle meningeal artery (Figs. 18.3, 18.4)

The caroticotympanic artery originates from the proximal segment of the hyostapedial trunk, while the inferolateral trunk (ILT) is a remnant of the dorsal

ophthalmic artery. The definitive ophthalmic artery originates from the primitive ophthalmic artery.

Some implications of this vascular development rely on the fact that every vascular segment lies between the origin of two embryonic vessels, and therefore they may be the point of entry of vascular rerouting in cases of segmental agenesis of part of the ICA proximal to the embryonic vessel: rerouting via the hyoid artery through the ascending pharyngeal artery at a cervical ICA agenesis, otic or trigeminal artery in a cervical or petrous agenesis or even primitive maxillary artery originating from the carotid siphon on the contralateral side. In combined cervical, petrous and cavernous agenesis, rerouting through a complex cavernous network belonging to the internal maxillary artery has been described.

Anatomic variants result from errors in the multiple steps during the development of these arteries. The hemodynamic balance of the internal carotid, maxillary and external carotid arteries can produce very different anatomic variants.

Two types of craniofacial branches arise from the external carotid artery:

- The arteries that supply the muscular and tegmental structures, arising on the whole from the external carotid artery.
- The arteries that supply the peripheral cranioencephalic system (cranial nerves), which evolve from internal carotid to external carotid arteries, like the maxillary system that arises originally from the stapedia artery.

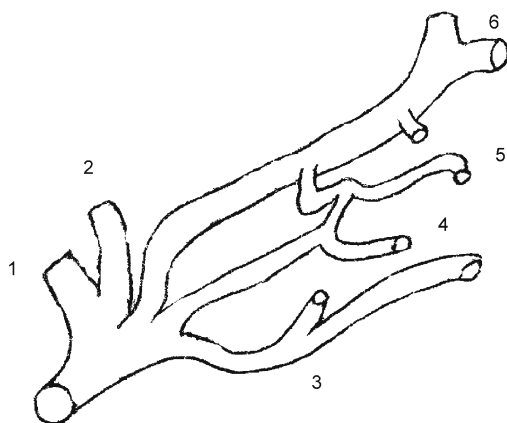


Fig. 18.3. Final appearance of the external carotid artery. 1, occipital artery; 2, ascending pharyngeal artery; 3, inferior tympanic artery; 4, internal carotid artery; 5, lingual artery; 6, facial artery; 7, posterior auricular artery; 8, superficial temporal artery; 9, petrous branch; 10, middle meningeal artery; 11, maxillary artery; 12, transverse facial artery

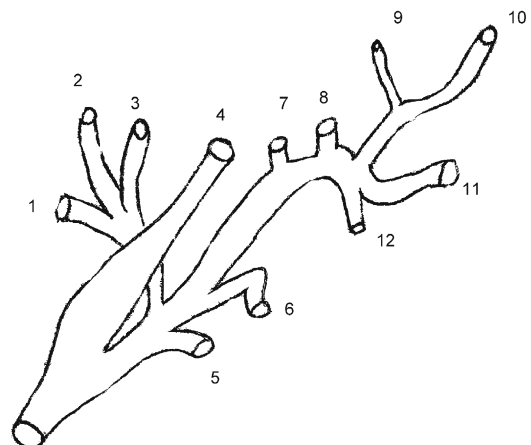


Fig. 18.2. ECA embryonic development at a later stage. 1, occipital artery; 2, ascendant pharyngeal artery; 3, faciolingual artery; 4, maxillomandibular artery; 5, supraorbital artery; 6, internal carotid artery

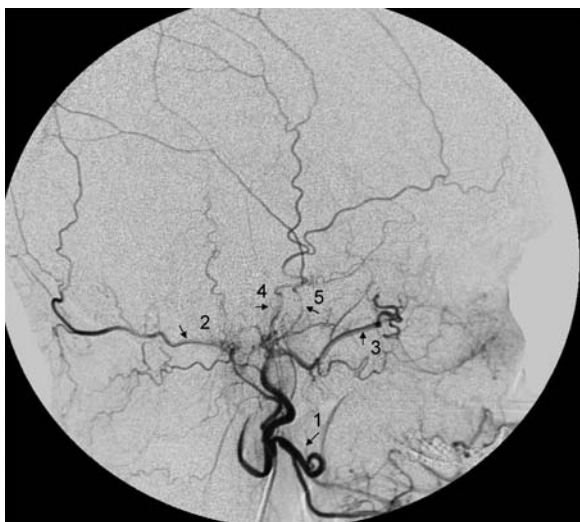

Fig. 18.4. Angiographic view of the external carotid artery. 1, faciolingual trunk; 2, occipital artery; 3, internal maxillary artery; 4, superficial temporal artery; 5, middle meningeal artery

The rest of the craniofacial supply is the one involved in the vascularization of the central nervous system, and arises on the whole from the ICA.

18.3 External Carotid System

It is important to understand that all the ECA branches are in a hemodynamic balance. The internal maxillary system consists of two groups of branches, whether their course is intracranial or extracranial.

The ophthalmic artery arises originally from the supraorbital branch of the stapodial artery which later becomes the middle meningeal artery. In addition, the orbital artery will also anastomose with the primitive (and later definitive) ophthalmic artery, from the supracavernous internal carotid artery. Because of the different variants in the involution of the proximal segment of the orbital or ophthalmic arteries, the supply to the orbit will finally arise exclusively from the ICA, the stapodial system (ECA) or both.

The embryologic hemodynamics makes it possible to predict the arterial variants that can be observed in the orbital region. The role of the middle meningeal artery in supplying the orbit can be seen to vary from one individual to another and from one side to the other in the same individual (Fig. 18.5a,b). In

the lacrimal variant, the orbital supply is limited to an anastomosis across the superior orbital fissure, while in the meningolacrimal variant; the middle meningeal artery is responsible for the supply of a portion of the intraorbital territory.

Other branches of the maxillary artery to the orbit include the anterior deep temporal, the infra-orbital and the sphenopalatine arteries. These arteries correspond to remnants of vessels arising from the infraorbital artery of the vertebrates, which gives rise to the orbital artery.

There are multiple anastomoses between the intraorbital branches with the external carotid system only supplying the periorbital region. This includes the internal maxillary, superficial temporal arteries and the facial system.

Supply to the cavernous sinus region may arise from the ECA. Arterial branches arise from the different segments of the cavernous carotid artery and course medially, laterally and in the direction of the posterior cranial fossa. These branches will anastomose with branches of the external carotid artery, which will allow a functional approach to this region. The ILT always anastomoses with the artery of the foramen rotundum, the middle meningeal artery and the accessory meningeal artery. It is also called the inferolateral trunk of the cavernous sinus.

The significance of these various arrangements lies in the fact that the anastomoses at the cavernous segment of the internal carotid artery constitutes the most common pathway of reestablishing blood supply in acquired occlusions of the internal carotid artery. The acquired constraint re-orientates the hemodynamic balance in order to support and preserve the territory distal to the acquired occlusion.

Embryologically, the dorsal ophthalmic artery, the stapodial artery, the trigeminal artery and the primitive maxillary artery are involved in this anastomosis.

The primitive maxillary artery originates from the medial surface of the C5 portion of the carotid siphon. It supplies the posterior hypophysis where it anastomoses with its counterpart on the other side. It may arise from a common trunk with the trigeminal artery and their common remnant is then a single artery that arises from C5 and gives off all the meningeal, hypophyseal and neural branches of this region. This variant seems to be rather rare. The primitive maxillary artery also gives rise to a meningeal branch for the dorsum sellae (the medial artery of the clivus). This branch anastomoses with its counterpart on the contralateral side and inferi-

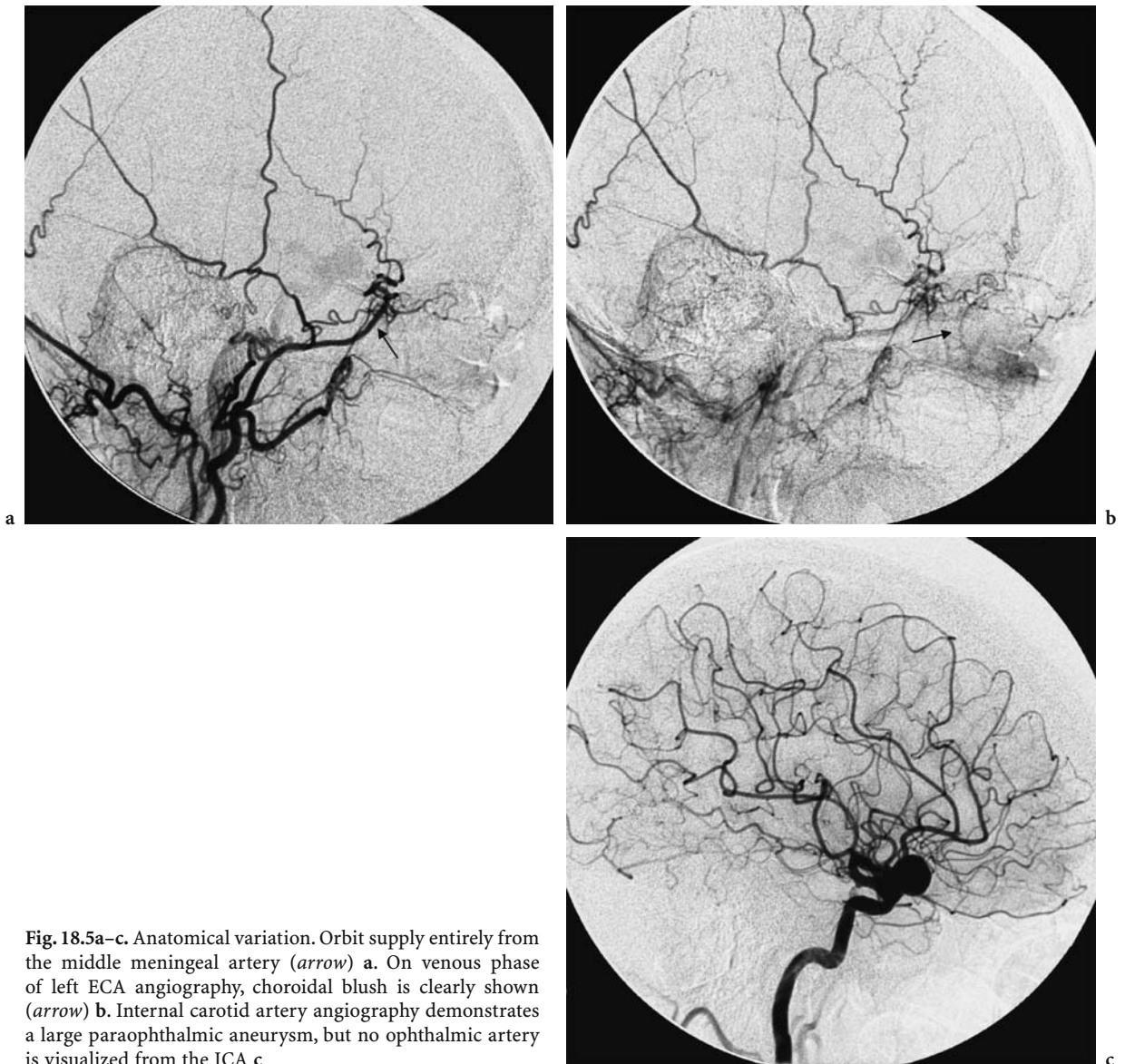


Fig. 18.5a–c. Anatomical variation. Orbit supply entirely from the middle meningeal artery (*arrow*) **a**. On venous phase of left ECA angiography, choroidal blush is clearly shown (*arrow*) **b**. Internal carotid artery angiography demonstrates a large paraophthalmic aneurysm, but no ophthalmic artery is visualized from the ICA **c**

only with the clival branch of the hypoglossal branch of the ascending pharyngeal artery. The persistence or unusual origin of the primitive maxillary artery may be demonstrated in certain variants. For example, when there is a cervical internal carotid artery agenesis, the internal carotid artery may arise from the contralateral internal carotid artery through a trans-sellar anastomosis of the persistence primitive maxillary artery system. The contralateral intracavernous origin of the internal carotid artery can be developed through the embryological remnants of the primitive maxillary artery that include posterior-inferior hypophyseal artery (anterior to the clivus) and medial clival artery (posterior to the clivus).

Other ICA branches arising from the C5 segments are the posteroinferior hypophyseal artery, the lateral artery of the clivus and the recurrent artery of the foramen lacerum. These are constant vessels that are anastomosed with the external carotid system through the ascending pharyngeal artery and in some cases with middle meningeal artery branches.

The ECA is mainly responsible for supplying the supratentorial dura which covers the convexity. The anterior ethmoidal artery or the frontal branch of the middle meningeal artery supplies anterior aspect of dura mater. These arteries are the main suppliers for the anterior parietal regional dura of the convexity, but the blood supply may also come from the

ophthalmic or intraorbital lacrimal artery which reaches its territory passing through the superior orbital fissure. The parieto-occipital trunk of the middle meningeal artery supplies the meninges of this region and the petrosquamosal trunk courses in the groove of the petrous and squamous portions of the temporal bone. These vessels are branches of the middle meningeal artery reaching the midline where they participate in the supply to the superior sagittal sinus and give descending branches to the falx cerebri.

Anastomoses to the cortical pial (cerebral) arteries from these dural arteries are rare and are mainly found in occlusive diseases of the ICA.

The extracranial branches of the maxillary artery include arteries that supply the nasal cavity, the choana and the nasal part of the pharynx and its walls. The blood supply of this region is particularly rich and presents multiple anastomoses to vital structures.

The accessory meningeal artery is the main branch of the extracranial middle meningeal artery and anastomoses with the mandibular artery remnant of the ICA and the superior pharyngeal branch of the ascending pharyngeal artery. The accessory meningeal artery anastomoses with the Eustachian tube meatus arterial branch of the ascending pharyngeal artery and the pterygovaginal artery inferomedially, and with the descending and/or ascending palatine arteries inferiorly. This variety of territories supplied by the accessory meningeal artery makes it potentially responsible for the arterial supply for numerous lesions arising in this region.

The pterygovaginal and vidian arteries are also supplying these territories with multiple anastomoses. The pterygovaginal artery anastomoses with the accessory meningeal, ascending pharyngeal and the mandibular branch of the ICA when it is present. The vidian artery is rarely visible during the maxillary artery angiography, probably due to the bone density through which it courses. The vidian artery may anastomose with a corresponding branch of the petrous segment of the internal carotid artery.

The sphenopalatine artery, the terminal branch of the internal maxillary artery enters the nasal cavity where it is divided into a septal, medial branch and a lateral branch that supplies the conchae. These two arteries have a distinctive appearance on the angiographic views. These branches usually anastomose with the anterior and posterior ethmoidal arteries, which arise from the ophthalmic artery system, at the anterior and posterior ethmoidal cells, and eventually connects the external and internal carotid

systems. Other anastomoses are the septal branch of the superior labial artery (medially) and laterally with the alar arteries, also branches of the facial artery. There is also a septal anastomosis of the anterior branch of the greater palatine artery with the posterior ethmoidal artery and the olfactory artery (a branch of the anterior cerebral artery).

The upper arch of the mouth and the mandibulozygomatic area branches supply the maxillomandibular region. This system provides connections between superficial (cutaneous) and deep structures (bone and mucosa).

The pharyngo-occipital system consist of an occipital artery, which supplies the cutaneomuscular elements and an ascending pharyngeal artery that is responsible for the meningeal and neural territory. The latter vessel is a metameric artery that has numerous anastomoses with the ICA and its branches are in hemodynamic balance with the suboccipitocervical system.

The caroticovertebral anastomoses can be found as the persistence of the embryonic segmental vessels in adult. The type II proatlantal artery corresponds to the second segmental artery. It arises from the future external carotid artery and courses posteriorly to the second cervical vertebral canal, where it supplies C2. This embryonic artery regresses to give the C2 occipito-vertebral anastomosis. However, when it persists, it runs into the cervical canal from C2 to C1 and penetrates the dura at the C1 level, similar to the conventional vertebral artery. Additional variants can be seen, including the occipital artery origin of PICA at C2 that is corresponding to an equivalent of the radiculopial artery for the cord.

Most often, the occipital artery arises from the external carotid artery, in some cases as a common trunk with the ascending pharyngeal artery. In other cases they may arise from the origin of the internal carotid artery. The occipital artery may also arise from the vertebral system via the branch of the first or the second vertebral body level or, more rarely, from the cervical arteries or from the vertebral artery at C3 level.

The ascending pharyngeal artery arises posteriorly from the inferior part of the external carotid artery. It may also arise from the occipital artery or from the origin of the internal carotid artery. More rarely both ascending pharyngeal artery and occipital artery may arise from the ascending cervical artery. Three pharyngeal branches of the ascending pharyngeal artery are usually seen including inferior, middle and superior branches. They supply the medial and paramedian mucosa of the naso- and

oropharynx. They anastomose on the midline with their counterparts and with the adjacent pharyngeal branches on the same side. The superior pharyngeal (or Eustachian) branch reaches the Eustachian tube's meatus on its medial side, lateral to the pharyngeal recess. It anastomoses with the corresponding branches of the accessory meningeal and pterygogingival arteries as well as forming a more medial and superior anastomosis with the mandibular vestige of the first aortic arch from the petrous segment of the internal carotid artery.

From the superior pharyngeal branch, the carotid branch arises to the carotid canal. This carotid branch ascends through the foramen lacerum and accompanies the internal carotid artery up to the cavernous sinus, where it anastomoses with the inferolateral trunk and with the recurrent artery of the foramen lacerum, arising from the C5 portion of the carotid siphon, which supplies the internal carotid artery wall and sympathetic nerve fibers.

The inferior tympanic branch has certain distinctive features. This artery accompanies the tympanic branch of the 9th cranial nerve in the inferior part of the tympanic cavity, where it usually divides into three branches. The ascending branch anastomoses with the petrosal branch of the middle meningeal artery, accompanying the major deep petrosal nerve. An anterior branch joins the caroticotympanic artery, following the neural anastomosis between the tympanic branch to the ninth cranial nerve and the pericarotid nervous plexus. The posterior branch that courses towards the facial canal, where it anastomoses with the stylomastoid artery.

The neuromeningeal branch gives rise to hypoglossal and jugular branches. It enters the hypoglossal canal and supplies the 12th cranial nerve and the meninges of the posterior cranial fossa, where it is in balance with the other arteries of this region. This artery gives off medially a descending branch which anastomoses with the vertebral artery at the third cervical space. The jugular branch, which arises from the same neuromeningeal trunk as the hypoglossal branch, enters the cranial cavity through the jugular foramen, where it supplies the ninth, tenth, and eleventh cranial nerves.

In order to be able to perform endovascular embolization procedures in the external carotid artery it is important to understand the physiological characteristics of the blood flow of this particular vessel.

The normal hemodynamic characteristics of the ECA are the absence of diastolic forward flow. This represents an important risk during embolization

procedure due the possibility of material reflux. Thus, it is highly recommended to perform the embolization procedure during the systolic phase with a small volume on each injection of embolic materials.

Autoregulation mechanisms have been described to be more effective in the internal maxillary artery and the pharyngo-occipital system, whereas the facial artery has not shown to respond as effectively. Vasoconstriction as a response for hypertension or mechanical trauma is observed in large or medium sized arteries whereas small distal arteries seem to react with true regulatory mechanisms.

18.4 Technical Aspects of Head and Neck Embolization

Preoperative medication is usually not needed, aside for anesthesia drugs or those used for other medical conditions. A urinary catheter is recommended for an accurate measurement of fluids output and will prevent any discomfort for the patient in prolonged procedures.

General anesthesia is necessary in most of the endovascular procedures for head and neck conditions, particularly in the pediatric population, in ethanol injections (painful procedures) and patients with lesions located near the airway where swelling may obstruct the airway.

Where the lesions are located at or near the airway, and combined procedures are schedule (surgery) a prophylactic tracheostomy may be considered.

Neuroleptic analgesia is a useful tool for diagnostic angiography, when neurological monitoring throughout the procedure is necessary and when general anesthesia is contraindicated in the older or medically compromised patients. Usually a combination of an analgesic (opiate derivatives) with sedative drugs (benzodiazepines) is useful to allow the patient to tolerate the procedure.

Conventional Seldinger technique is generally used for the majority of the procedures, and a femoral sheath with hemostatic valve (4 to 9 French) is placed into the femoral artery to allow the exchange of the catheters, reducing the trauma to the artery.

Diagnostic procedures are performed with 4 to 5 French diagnostic catheters: single (Berenstein) or double curve (Sidewinder) depending on the tortuosity of the vessels. These catheters are used in combination with guidewires (0.035") (Fig. 18.6).




Fig. 18.6. Diagnostic catheters with simple (Berenstein), double curve (Sidewinder) and guide wire with curved tip

18.5 Therapeutic Techniques and Materials

A great variety of microcatheters, microwires, embolic agents and drugs are available for the management of a number of indications and purposes. The success in the endovascular technique and the achievement of the treatment goals not only depend on the technical skills of the operator but also in the appropriate selection of the endovascular material, based on the knowledge and the experience of the interventional neuroradiologist.

Microcatheters are manufactured in different sizes: 0.018", 0.014", 0.010" systems allow to navigate the arterial branches with different flexibility. These microcatheters are used in combination with 0.018" to 0.010" outer diameter microwires that gives the required support to the system as well as a torque control to direct the tip of the catheter. Most of these catheters are performed with polyethylene and allow shaping the catheter tip. This is usually performed by exposing the end of the microcatheter to the steam source. Some of these microcatheters are available with a pre-shaped tip with different angles.

Flow guided microcatheters are a second type of microcatheters designed to navigate with the blood flow with a much smaller outer diameter (0.012" – 0.018") achieving a more distal selective catheterization. The development of these microcatheters has permitted interventional neuroradiologist to treat a more extensive variety of craniofacial and neck lesions that were beyond the reach of the endovascular techniques with the previous generation of microcatheters.

Balloon catheters are divided into two main groups: those used for blood flow control and test

occlusion, and those used as the embolic agent themselves, detachable balloons.

Single lumen balloon catheters (Hyperform, Hyperglide) are available in 4–7 mm in diameter and 10 to 30 mm in length. To inflate this balloon, a microwire should pass the balloon and stay beyond the microcatheter. A 50% iodine contrast material is used for the balloon inflation.

Serbinenko first designed and introduced the detachable balloon for the clinical usage in 1974. With the evolving designs and materials, they have been a good embolic device for single high flow fistulas of major arteries in the trauma or congenital types. These are made of latex or Silicone with an Inflation diameter of 4 to 35 mm and are provided with a radiopaque marker which permits the balloon location under fluoroscopy before the inflation of the balloon. Detachable balloons can be hand assembled and be used with high reliability for closing the selected vessel at a precise location. They can be removed and changed if the position or size of the balloon is incorrect (Fig. 18.7a–e) before its detachment. Once the desired position is reached, gentle and continuous traction is applied on the delivery catheter until the detachment occurs.

The selection of the embolic agents is determined by the goal of the procedure, vascular territory and type of lesion. Classically they are divided into solid or liquid agents.

Among the solid agents, particles are precut agents used for mechanical blockage of a selected territory. Several materials and sizes are available depending on the result required.

Absorbable particles consist mainly is Gelfoam (gelatine sponge) powder (40–60 μm) or particles (any size), the use of autologous clot or Avitene has also been described. The occlusion achieved with this material is not permanent and vascularization is reconstituted in 7 to 21 days after the procedure. The Gelfoam can be easily cut, and placed in contrast material to be injected through small lumen catheters.

Gelfoam powder can be used for tumor preoperative embolization, in highly vascularized lesion. This material is used also for endovascular management of the epistaxis due to the fact that the embolic occlusion occurs at the capillary or precapillary level. The Gelfoam is mixed with contrast material and is injected under fluoroscopic monitoring with a 1–3 cc Luer-lock syringe held in horizontal position.

This embolic agent should be used carefully with a good positioning of the catheter and continuous

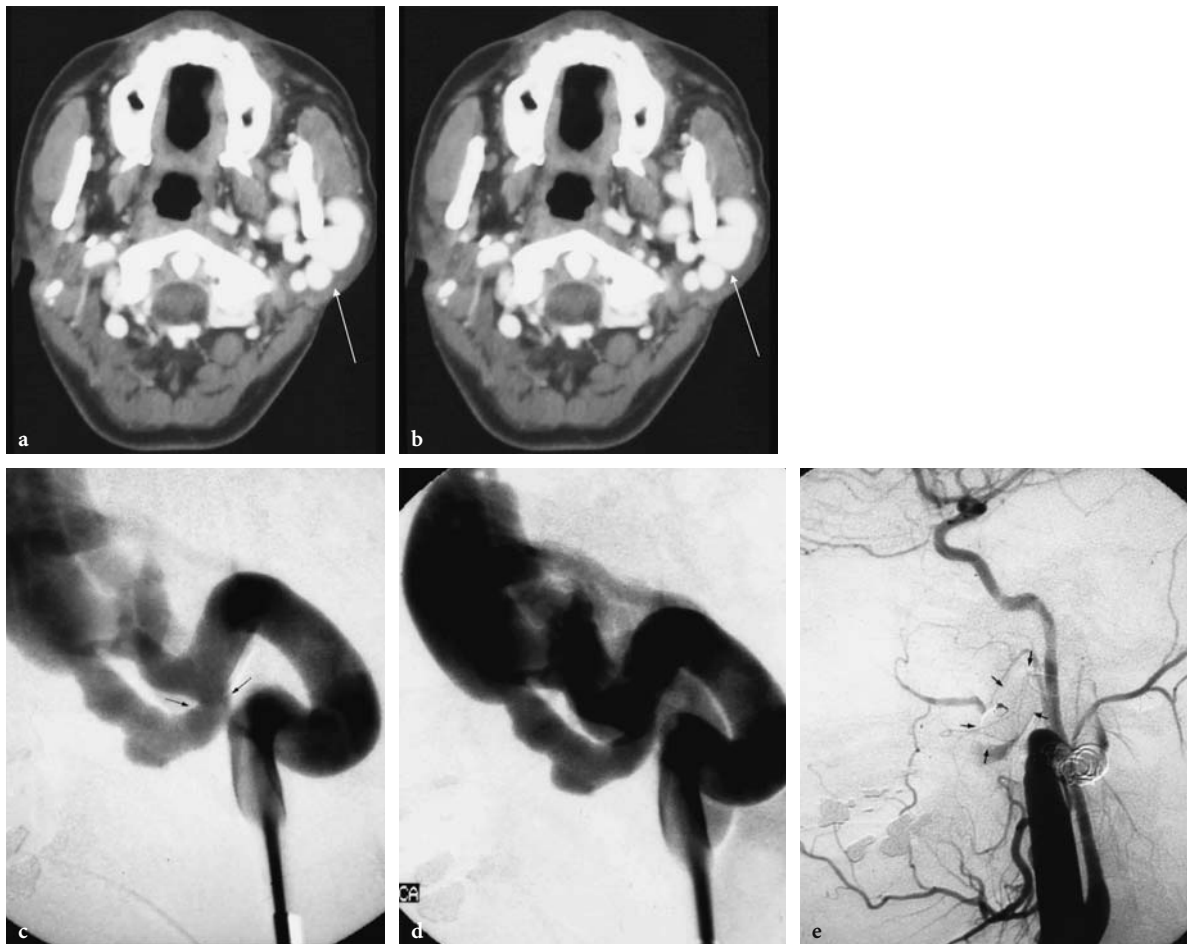


Fig. 18.7a–e. Contrast enhanced CT scans **a, b** in 12-year-old boy with slowly enlarging pulsatile mass lesion involving the left cheek region demonstrate prominent vascular channels left preauricular area (*arrows*). Left lateral external carotid angiogram in early **c** and late arterial phase **d** demonstrated single hole fistulous communication (*arrows*) between proximal internal maxillary artery and adjacent facial vein. Transarterial arterial single balloon detachment was performed at the fistulous site resulting in immediate complete obliteration of the fistula and several coils were deposited in the proximal external carotid artery for added protection. Post-embolization left lateral common carotid angiogram **e** demonstrated closure of the AVF. Note the cast of the single balloon (*arrows*) and the discrepancy between the grossly enlarged proximal trunk of the external carotid artery versus the size of the internal carotid artery

fluoroscopic monitoring due to multiple anastomosis between the external carotid system and the intracerebral circulation as well as the cranial nerves arterial supply from the ECA branches.

Gelfoam pellets are mainly used for preoperative hemostasis, however, they do not reach the tumoral capillary bed, and therefore no necrosis is observed in the treated territory.

When you cannot reach to the target vessel (so called superselectivity) but a permanent agent must be used, a Gelfoam particle 1×2 or 1×3 mm or even larger sized particles can be used to occlude the proximal part of a normal vessel. This method will protect a normal vessel by preserving its distal part

and should be able to change the hemodynamics of the involved territory so that embolic agents would only reach the pathological vessels. Later on, the absorption of the Gelfoam particle should restore the normal flow into these arteries. In some other cases, Gelfoam can be safely used as an occlusive agent. These include traumatic arterial hemorrhage or traumatic aneurysms.

Among the nonabsorbable embolic materials, Polyvinyl Alcohol particle (PVA) is one of the most widely used. This consists of a water-soluble, biocompatible material made by a reaction of polyvinyl alcohol foam with formaldehyde. When it is moisturized, it expands its volume up to 20% more

than its dry volume. PVA suspensions are available as dried particles measuring 140–250 to 590–1000 microns in size. These particles are mixed with contrast material. PVA has a high coefficient of friction and its injection may be difficult. For this reason, it is recommended to continuously mix the suspension in between the material injection and to intermittent flush the system to prevent PVA deposits on the catheter hub.

The PVA has been described to have an embolic effect not only by occluding distal small to medium size vessels but also by slowing the flow in the treated vessel producing stagnation and, therefore clot formation. Even though this material is known to be non-reabsorbable, recanalization occurs, mainly because of clot reabsorption and re-endothelialization of the PVA deposits on the vessel walls. PVA is a useful embolic material for preoperative devascularization for tumors, some vascular malformations such as dural arteriovenous fistulas or flow rerouting in preparation for IBCA or ethanol injections. A catheter that was previously used for particle embolization should never be used for an angiogram of intracerebral arteries (ICA or Vertebral artery).

NBCA (N-Butyl-2-Cyanoacrylate) is a vinyl monomer of the alkyl-2-cyanoacrilates. This material is the most widely used liquid embolic agent and is characterized by being non-reabsorbable, producing almost immediate solidification when it reaches a polarized fluid such as saline and blood. Polymerization of the NBCA occurs when it combines with an ionic solution such as contrast material, saline, blood or endothelium producing an exothermal reaction in a few seconds. Polymer retardants are generally used to achieve the ideal setting time for a particular injection. Iodized Ethyl Esters (Lipiodol) are usually a good combination as a polymer retardant for the NBCA. It has been shown to maintain a good dilution retarding polymerization in 4 to 8 seconds for every 0.2 to 0.5 cc in 1 cc of NBCA. The viscosity of this material may be a concern but usually it can be injected in the smallest catheters used in interventional procedures.

Due to the radio-opacity of the Iodized Ethyl Esters, it can be used with NBCA without the use of an opacifying agent unless the NBCA concentration is over 50% of the mixture. In those cases Tantalum powder is recommended using 1 gram for every 1 cc of NBCA. Before the injection of the NBCA mixture, a 5% dextrose solution should be used to rinse the catheter. This will prevent the NBCA to solidify before reaching the targeting tis-

sues. Injection of NBCA must be done under continuous fluoroscopic control after the superselective placement of the microcatheter. Depending on the therapeutic goal, NBCA/retardant mixture will be prepared to achieve venous/capillary penetration or arterial occlusion (endovascular ligation) (Fig. 18.8a–d). When a high flow vessel of fistula is to be treated, combined technique may be used with using liquid coils.

Ethyl Alcohol (95% Ethanol) is an effective and aggressive liquid embolic agent. Its does not produce a mechanical occlusion of the vessels but produces an immediate tissue reaction due to the cytotoxicity on the blood and endothelium. The use of Ethyl Alcohol results in a systemic distribution but the use of up to 60 cc of alcohol in an adult is below the toxic blood concentration. Ethanol is an effective embolic material to induce necrosis and endothelial damage but may not be indicated for high flow conditions or when a mechanical occlusion is expected. The control of the Ethanol during its injection is very poor especially its distribution in the vascular territory. Therefore, its use is generally limited to venous malformation and some limited territories of the ECA. In some cases it can be combined with the use of PVA particles or Gelfoam. Ethanol procedures must be performed under general anesthesia as it causes severe pain during the injections. In addition, special attention should be taken regarding the venous outflow of the malformation witch may involve the ophthalmic vein, cavernous sinus or the vertebral epidural plexus. After the ethanol injection the area indurates and swells, starting a few minutes after the infusion and lasting 3–7 days. Final result may be expected after 1 to 5 weeks. Local skin necrosis may be seen after but usually is limited and heals spontaneously.

Other materials have an important role in the endovascular management of the ECA. Detachable or pushable coils represent a safe option when arterial occlusion is required: arterial ligation, hemorrhagic emergencies (carotid blowout), blood flow rerouting techniques or combined endovascular embolization with other embolic agents. Several types of coils are widely available. Detachable bare platinum coils (Fig. 18.9) allow very precise coil deployment, and can be removed if the size is incorrect or coil placement. Pushable coils are directly deployed into the vessel while fibered coils have filaments that induce stagnation and local thrombosis. The 2nd generation of coils have been designed with combined material that may induce inflammatory reaction in the surrounding vascular tissue (GDC Matrix® coils) or a

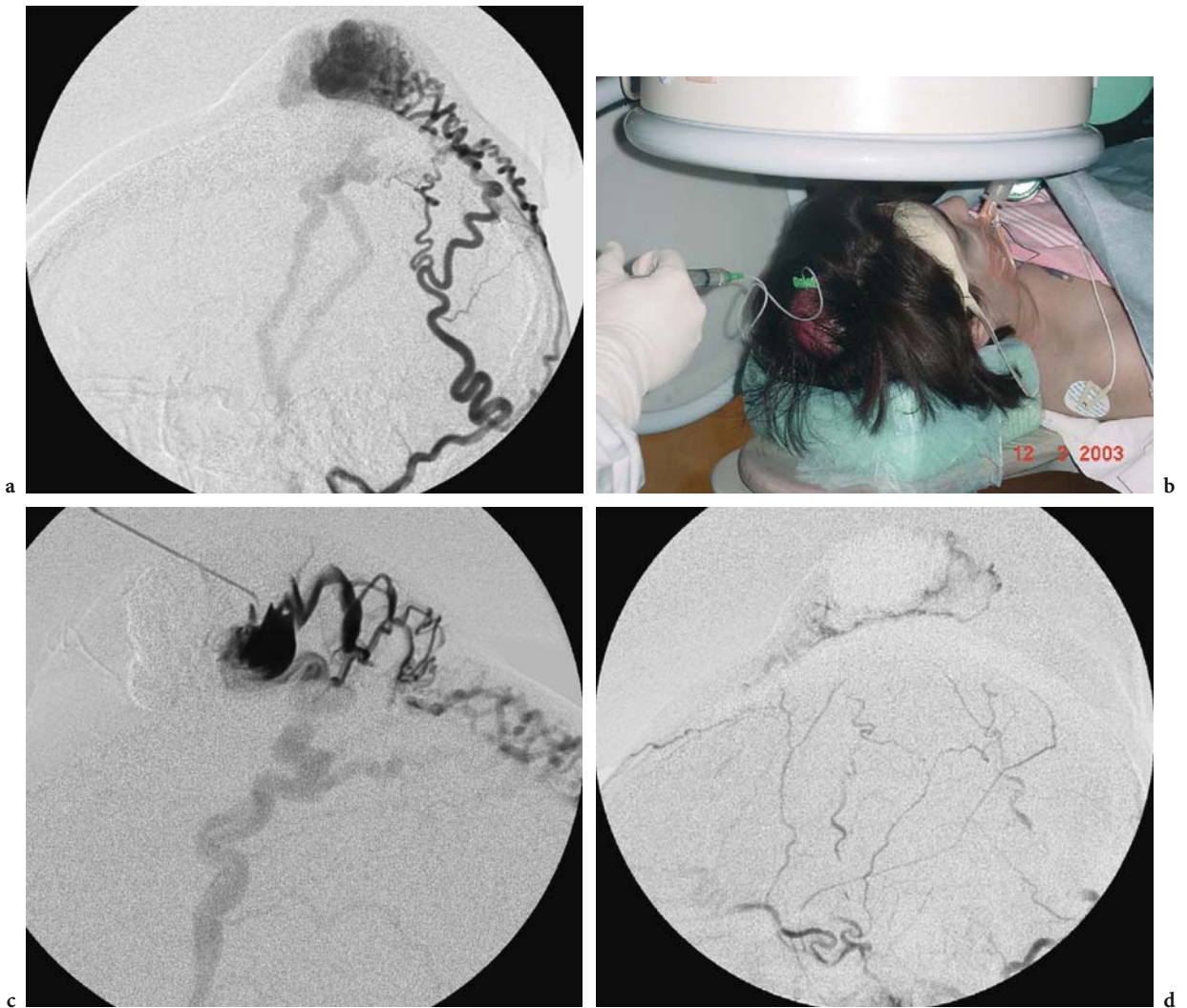


Fig. 18.8a-d. Selective occipital angiogram in lateral view **a** demonstrates high-flow scalp AVM which was also supplied by branches of the ipsilateral and contralateral superficial temporal arteries and contralateral occipital artery (*not shown*). Following transarterial partial embolization with glue and particles of PVA into these vessels a percutaneous approach was performed **b,c** with injection of glue (50% NBCA/ 50% Lipiodol) resulting in complete obliteration of the AVM nidus as shown on the post embolization left external carotid angiogram **d**




Fig. 18.9. Detachable coils are available in several model an shapes. 2D and 3D coils may be used for vascular occlusion

hydrophilic component that allow the coil to expand 4 to 20 times its volume to achieve a better vascular occlusion (Hydrocoils®).

The selection of the embolic material will vary depending on the vascular territory, the vascular or tumoral lesion, the therapeutic goal and the previous experience of the interventional neuroradiologist.

18.6 Medication

Heparinization is usually recommended when coaxial catheter assembly systems are used to prevent fibrin clot formation. Initial prothrombin time, partial thromboplastin time and activation coagulation time is recommended to use as a baseline to calculate the dose of the protamine sulfate dosage when heparinization is to be reversed. Complete heparinization of the patient can be achieved with a bolus dose (50 IU/Kg) and a maintenance infusion (500 UI/Kg in 24 hours) that is initiated once the arterial access is obtained.

Flushing solutions are prepared with heparin using 2000 IU/ 1000 ml of 2.5 D/W in children and 4000 UI/ 1000 ml of 2.5 D/W.

Corticosteroids are not generally used during the endovascular management of the ECS. Its use is limited to very prolonged procedures, or when significant inflammation or swelling is expected such as maxillofacial alcohol injection. In these cases, dexamethasone 10 mg is given intravenously (bolus) followed by a maintenance dose of 8 mg every 8 hours for the following 3 days.

Catheter induced vascular spasm can be an undesirable event during endovascular procedures in the ECS and it is usually triggered by mechanical stimulus. Percutaneous administration of nitroglycerin

(nitropaste) is a useful treatment without significant systemic reaction such as hypotension.

References

- Allen WE, Kier EL, Rothman SLG (1973) The maxillary artery – normal arteriography anatomy. *Am J Roentgenol* 118:517–527
- Berenstein A, Graeb D (1982) Convenient preparation of ready-to-use polyvinyl alcohol foam suspension for embolization. *Radiology* 145:846–850
- Berenstein A, Kreber C, Edwards JH, Bank WO, Kricheff II, Cromwell L (1980) Complications of therapeutic transarterial embolization: cooperative study. *AJNR Am J Neuro-radiol* 1:128
- Berenstein A, Kricheff II (1978) Therapeutic vascular occlusion. *J Dermatol Surg Oncol* 4:874–880
- Berenstein A, Kricheff II (1981) Neuroradiologic interventional procedures. *Semin Roentgenol* 16:79–94
- Berenstein A, Lasjaunias P, Kricheff I (1983) Functional anatomy of the facial vasculature in pathological conditions and its therapeutic applications. *AJNR* 5:149–153
- Connors J, Wojak J (1999) *Interventional neuroradiology strategies and practical techniques*. Saunders, Philadelphia
- Countee TW, Vijayanathan (1979) External carotid artery in internal carotid artery occlusion: angiographic, therapeutic and prognostic considerations. *Stroke* 10:450–460
- Djindjian R, Merland JJ (1978) *Superselective arteriography of the external carotid artery*. Springer, Berlin Heidelberg New York
- Kuru Y (1967) Meningeal branches of the ophthalmic artery. *Acta Radiol* 6:241–251
- Lasjaunias P (1986) The external carotid artery: functional anatomy. In: Taveras JM, Ferruci JT (eds) *Radiology*, chap 99. Lippincott, Philadelphia
- Lasjaunias P, Berenstein A, Doyon D (1979) Functional anatomy of the facial artery. *Radiology* 133:631–638
- Lasjaunias P, Doyon D (1978) The ascending pharyngeal artery and the blood supply of the lower cranial nerves. *J Neuro-radiol* 5:287–301
- Lasjaunias P, Berenstein A, Ter Brugge K (eds) (2001) *Surgical neuroangiography, clinical vascular anatomy and variations*, vol 1. Springer, Berlin Heidelberg New York
- Osborne A (ed) (1994) *Diagnostic neuroradiology*. Mosby, St Louis

19 Endovascular Management for Head and Neck Tumors

PAULA KLURFAN and SEON KYU LEE

CONTENTS

19.1	Nasopharyngeal Tumors	247
19.2	Juvenile Angiofibroma	248
19.2.1	Classification	248
19.2.2	Anatomic Features	248
19.2.3	Imaging Features	248
19.2.4	Natural History	249
19.2.5	Diagnosis	250
19.2.6	Treatment	250
19.2.7	Embolization Technique	250
19.3	Paragangliomas	251
19.3.1	Classification	251
19.3.2	Pathology	251
19.3.3	Imaging	252
19.3.4	Treatment	252
19.4	Thyrolaryngeal Tumors	254
19.5	Craniofacial Tumors	254
19.6	Miscellaneous Applications of Embolization Therapy in the Head and Neck	254
19.6.1	Preoperative Embolization	254
19.6.2	Pain Management	255
19.6.3	Hemorrhagic Emergencies	255
	Cookbook	255
	References	256

Head and neck tumors consist of primary tumors arising from various regional tissues including lymph nodes and metastatic lesions. Most of these lesions are highly vascularized due to both abundant vascularities of the head and neck region and their histological types.

Magnetic resonance imaging (MRI) is the most useful imaging study for the initial evaluation of head and neck tumors. Computed tomography (CT) is also helpful in defining the anatomical disposition of these lesions. In addition, the CT can pro-

vide important complementary information such as the presence of calcifications and the extent of bony involvement. Diagnostic angiography is hardly used as a diagnostic purpose. In fact, its main role is a carrier for the endovascular procedures for head and neck tumor managements. Endovascular procedures for head and neck tumors consist of (1) selective devascularization procedures of the feeding arteries such as transcatheter arterial embolization and (2) adjunctive embolotherapy including intra-arterial chemoembolization. Functional vascular embolization such as intra-arterial chemotherapy for malignant head and neck cancers to maximize local concentration with minimized toxic effect has also been studied, however, further investigations are necessary for its clinical application.

19.1 Nasopharyngeal Tumors

Juvenile angiofibroma (JAF) represents 0.5% of the head and neck tumors [1] and 15% of nonepithelial tumors of the nasal and paranasal cavities [2]. It is the most common benign tumor of the nasopharynx and is typically diagnosed on adolescent males, with a peak age of 14–17 years. However, up to 20% of these tumors are diagnosed after the age of 20 [3]. The most frequent clinical presentations of juvenile angiofibroma are nasal obstruction and recurrent nose bleeding. These symptoms can be followed by sinusitis, otitis, hearing loss, or anosmia. Life-threatening massive nose bleeding can occur and is often difficult to control with nasal packing. In these cases, it requires urgent endovascular treatment after blood transfusion and establishment of diagnosis. The growth of JAF seems to be influenced by hormonal activity, although tumor samples fail to show the presence of estrogen, progesterone, or androgen receptors.

Tumors developing in the nasopharyngeal region in the adult population are most likely to be malig-

P. KLURFAN, MD

Interventional Neuroradiology Clinical Fellow, Department of Medical Imaging, University of Toronto, Toronto Western Hospital, 399 Bathurst Street, Toronto, Ontario, Canada, M5T 2S8
S. K. LEE, MD, PhD

Assistant Professor and Staff Neuroradiologist, Department of Medical Imaging, University of Toronto, Toronto Western Hospital, 399 Bathurst Street, Toronto, Ontario, Canada, M5T 2S8

nant. Intra-arterial embolization may play a significant role when performed prior to diagnostic biopsy, radical excision or palliative treatment.

The angiographic and therapeutic protocols described for JAFs are applicable to other hypervascular tumors of this region. Percutaneous embolization has also been described to be effective in the treatment of severe or recurrent epistaxis from nasopharyngeal carcinomas previously irradiated.

Benign tumors including paragangliomas, neuroblastomas, esthesioneuroblastomas, hemangiopericytomas, and hemangioendotheliomas (most of them are considered malignant) may be diagnosed in the nasopharyngeal region. These tumors are all generally highly vascularized and have a relatively benign course. The treatment strategy for these lesions is a radical surgery whenever possible and therefore they will also be benefited from presurgical embolization.

Extracranial meningiomas are very rare (1%). In some cases they may be located in the parapharyngeal space even though most of the tumors within this location are benign salivary gland tumors or neurogenic tumors like schwannomas.

19.2 Juvenile Angiofibroma

19.2.1 Classification

Several grading systems of JAF have been presented but the Fisch classification [] is the most extensively used one. Fisch classifies JAF into four types. Fisch type 1 is when the tumor is limited to the nasopharynx and nasal cavity without bony erosion. Fisch type 2 defines a JAF that invades the pterygomaxillary fossa and the maxillary, ethmoid and parasellar region but remains lateral to the cavernous sinus. Type 3 is defined as JAF tumors that invade the infratemporal fossa, orbit and parasellar region but remain lateral to the cavernous sinus. Finally, the type 4 tumors are those that show massive invasion of the cavernous sinus, the optic chiasm region, or the pituitary fossa.

19.2.2 Anatomic Features

JAF is a highly vascular and locally invasive tumor. It is usually originated from the superolateral aspect of the choana, near the sphenopalatine foramen, but may also arise more medially, near the vomer, from the pharyngeal roof where it involves the body of the sphenoid bone, or from the adjacent pterygoid plates.

Regardless the uncertain histological origin, this tumor has a significant vascularity and proliferative activity. It may cause significant bone erosion, even though the JAF does not invade the bone tissues directly. Attached to the neighboring osseous structures, it extends through the submucosal space into the adjacent open spaces. Macroscopically, JAF is reddish-gray or red purple in color and has a firm rubbery consistency with a lobulated shape. Multifocal tumors have never been reported.

19.2.3 Imaging Features

Imaging (CT, MRI) studies usually show the presence of an expansible lobulated lesion located at the nasopharynx. Due to the local extension of the JAF, it can show significant bony erosion expanding into the surrounding nasopharyngeal cavities, maxillary sinus, and sphenoid sinus and infrequently to the anterior skull base and the orbit (extra-capsular and extraconal). MRI is an excellent complementary study for JAF evaluation. Intracranial invasion and intradural tumor extension can be evaluated and certainly is a decisive factor to determine radical treatment. MRI is also useful to differentiate tumor extension into the sinuses from sinusitis. The contrast enhanced MRI also shows extensive enhancement of tumor due to its hypervascularity (Fig. 19.1a). Contrast enhancement is essential for the JAF CT examination. Reviewing CT scans with both soft tissue and bone window setting is necessary to evaluate the extent of the tumor as well as bony erosions. Coronal and axial views provide good anatomical information regarding the relationships among tumor, nasopharyngeal soft tissues and osseous structures of skull base. On CT, the JAF usually shows displacement and thinning of bony structures without definite bony destructions considering the size of main mass (Fig. 19.1 b). These are useful radiologic findings to differentiate the JAF from other malignant tumors in children

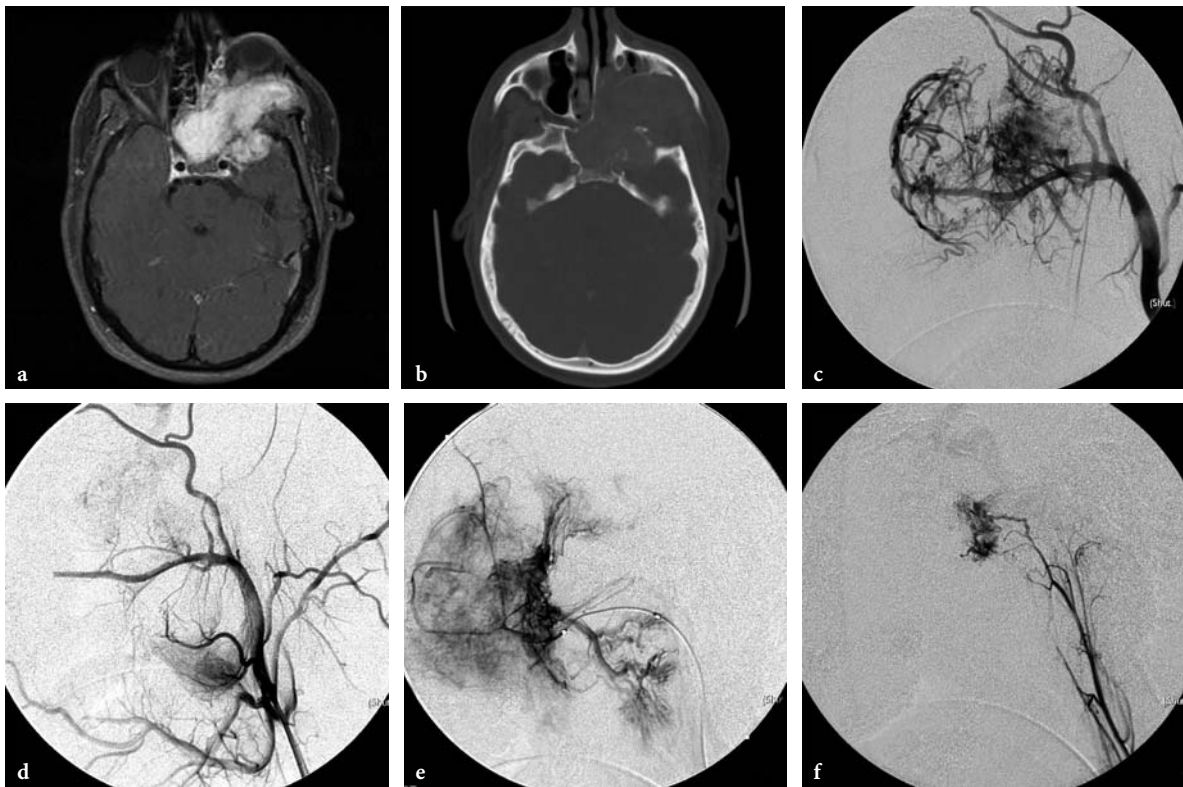


Fig. 19.1a-f. JAF: An 18-year-old male presenting with epistaxis. The MRI and the CT scan shows orbital and intracranial (left temporal fossa) extension of tumor with significant bony erosion (a,b). Angiogram shows tumoral blush arising from the internal maxillary artery, the facial artery and the ascending pharyngeal artery (c-f). Preoperative embolization with particles was performed after selective catheterization of the feeding arteries. Courtesy of Dr. K. terBrugge

such as rhabdomyosarcoma that typically destroys adjacent bony structures.

On angiography, the JAF presents with a dense tumor blush (Fig. 19.1c), and this is highly accurate to delimit tumor extension. Although it has intense hypervascularity, angiographic findings of arteriovenous shunting or early venous drainage have not been reported. Feeding arteries of JAF are mainly external carotid artery (ECA) branches such as distal internal maxillary branches, accessory meningeal artery, superior pharyngeal division of the ascending pharyngeal artery and the ascending palatine artery.

Internal carotid artery (ICA) may supply the JAF without having intracranial portion of the tumor. However, if angiographic tumor blush is located above the skull base on AP and/or lateral views and has vascular supply from the ICA branches and/or from ascending pharyngeal and/or proximal internal maxillary arteries, it might represent intracranial extension of the tumor. However, the subarachnoid space extension of tumor is exclusively

supplied by the ICA branches. The evaluation of the venous phase of the internal carotid angiography is an essential part of diagnostic angiography, since it will demonstrate the patency of the cavernous sinuses and adjacent venous plexus those will affect surgical respectability of the tumor.

19.2.4 Natural History

OSBORN and FRIEDMAN suggested that repeated hemorrhages within the tumor could stimulate the formation of granulation tissue and a fibrous reaction (1). This would explain some cases presenting spontaneous regression and tumors that tend to have a slower rate of growth after adolescence due to a higher proportion of fibrous tissue and less tendency to bleed. As the disease progresses, facial deformities, proptosis, blindness and cranial nerve palsy may occur. Thus, complete spontaneous regression of these tumors should not be expected

and treatment should not be delayed due to the tumor's potential to behave aggressively.

The recruitment of new vascular supply is probably related to the production of angiogenic factors and it may explain the local invasiveness of some types of the JAF.

19.2.5

Diagnosis

The diagnosis of JFA is mainly based on a careful clinical history and nasal endoscopic examination in addition to the imaging studies (CT and MRI). Biopsy to establish histological diagnosis is not indicated, and definitive diagnosis can be established by angiography, which certainly will play an important role in the patient management and treatment.

19.2.6

Treatment

The objective of the treatment is complete resection of the tumor. Surgical removal and radiation therapy are considered as the best therapeutic options. Controversy still exists as to how patients with recurrent or residual disease should be treated and how large tumors of the skull base should be managed.

Surgical techniques have been mostly successful by using advancing endonasal techniques with the use of the microscope for limited midface degloving procedures but in a small group of cases: transpalatal, lateral rhinotomy and craniofacial approaches can be used.

Tumoral resection of JAF may be challenging and can be limited due to the risk of profuse intraoperative bleeding and the size and extension of the tumor.

To diminish these risk factors and to facilitate the surgical resection, preoperative intra-arterial embolization, radiation therapy and exogenous estrogens has been largely used.

Preoperative exogenous estrogens have shown to produce positive effects on the bleeding rate. However, the morbidity cause by the administration of such drugs to an adolescent male population is very high, with consequences on the gonadal development and function, which turns this treatment into an undesirable choice.

Radiation therapy is known to produce partial tumoral mass reduction or at least a significant

arrest of the tumor growth (80%), but functional morbidity and the high rate of long term secondary neoplasm induction place this treatment option in a secondary role. Thus, in general, radiation therapy for JNF is restricted to certain cases where intracranial extension prevents a complete resection of the lesion. Its effects are secondary to post radiation vasculitis and not the targeting of the cellular component. The use of radiation as a sole treatment has shown an overall rate of recurrence of 20%.

Intra-arterial embolization has resulted in a helpful and reliable technique in preparation for surgery, and currently is the preferred combined treatment. This procedure, when performed by an experienced team carries no significant morbidity or mortality. Reported complications or unsatisfactory results are likely related to insufficient training or knowledge or poor judgment during the procedure itself.

Based on the classification of Fisch, most surgeons in the international literature tend to operate on stages 1 and 2, some on stage 3 and few on stage 4. The overall mortality of JFA is 3% and the rate of recurrence after surgery varies from 12% to 35% and is likely owing to inadequate surgical removal.

Radiation therapy should be reserved for bilateral cavernous sinus involvement and for the situation where adequate surgical or therapeutic angiographic teams are not available in a given geographic location.

The use of surgical tumor resection precede by intra-arterial embolization has shown strong evidence in terms of reducing the number of recurrences and repeated recurrences as a consequence of a reduction of the tumoral size and intraoperative bleeding, and therefore a higher rate of complete surgical resection of the JFA.

19.2.7

Embolization Technique

During preoperative angiography, major feeding vessels arising from the external carotid system are superselectively embolized and subsequent surgery can be scheduled within 12 to 48 hours after embolization.

The goal of the endovascular procedure is to devascularize the tumor at the level of capillary bed, not just proximal occlusion. Arterial supply of the tumor may vary depending on the site of the tumor and these vessels can only be moderately enlarged. The internal carotid artery supply to the tumor is usually the most important factor to limit the capacity of pre-operative

embolization. Therefore it is recommended to begin the study by performing a contralateral injection of the ICA with cross compression in the Caldwell view followed by an ipsilateral ICA injection. This will show the tumor's ethmoidal, sphenoidal and middle cranial fossa extension. If the ICA branches can be purchased easily and can get a safe position for the embolization, there cannot be any restriction for the procedure. However, in general, it is technically challenging to obtain a safe enough position to embolize JNF thru the ICA branches.

Regarding the ECA branches embolization. Special precaution has to be taken to identify potential anastomosis between branches of the internal maxillary and ascending pharyngeal arteries and the intracranial or intraorbital arteries, and internal carotid artery supply to the tumor.

For the last years, 150–250 μm in size polyvinyl alcohol (PVA) has been the material of choice to reach the tumor capillary bed during the endovascular procedure. Smaller particles (50 μm) have shown to pass through the capillary vessels reaching the lungs with no therapeutic impact. Embolization can be completed by the injection of Gelfoam pledgets (3 mm in caliber and up to 1 cm in length) to achieve a transient devascularization of the region (ligation) and in addition facilitate the distal thrombosis within the tumor itself.

Strong evidence indicates that presurgical embolization facilitates surgical resection of JNF. Furthermore, either embolization alone or embolization associated with estrogens favors patients that present surgically unresectable tumors due to size or location.

The endovascular management may require the usage of other techniques such as injection of fluid materials such as NBCA or alcohol with flow control thru the internal maxillary artery or ascending pharyngeal branches. Sacrifice of the ICA can be considered on an individual basis in patients with intracavernous extension.

In this last case neurologic examination as well as a transitory carotid occlusion test should always be carried out before the procedure.

The endovascular treatment results in a significant benefit for the JAF treatment whether it is preoperative or palliative. Usually shrinkage of the tumor mass can be observed both radiological and clinically within 12 hours after the procedure and breathing is usually improved indicating the return of nasal patency.

19.3 Parangliomas

19.3.1 Classification

Parangliomas, glomus tumors, chemodectomas, neurocristopathic tumors or nonchromaffin parangliomas are several names that have been given to the neuroendocrine neoplasms arising from the neural crest derivatives.

These tumors present with a wide range of locations: tympanic, jugular, carotid, vagal, laryngeal, nasopharyngeal and orbital. Tympanic and Jugular parangliomas are classified as temporal parangliomas.

Branchial parangliomas are found in a variety of locations in the head or the neck with almost one half arising in the temporal bone. These are the most common tumors of the middle ear. Its features include multicentricity and frequent association with other neural crest tumors. Other frequent locations are: jugular, carotid, vagal, laryngeal, nasopharyngeal and orbital, but pure single localization is uncommon and parangliomas are usually found to extend to multiple regions. Almost all of the parangliomas located in the head and neck develop from a pre-existing normal paranglion.

The clinical presentation of parangliomas is related to the location of the tumor (mass, bruit, pain or cranial nerve palsy) and is usually progressive.

The malignant potential of paranglioma is reported as between 10% and 18% on the vagal, carotid and laryngeal locations while in the temporal area is about 3%. Spontaneous regression of parangliomas has never been reported. It usually has a slow growing rate but in some cases can be rapid or associated with additional tumors in other locations.

19.3.2 Pathology

Depending on the location, the paranglioma may be lobulated or oval in shape and histologically it consists of a capsulated, highly vascular stroma with a paranglion structure and epithelial cells (Fig. 19.2h). An irregular narrowing of the internal carotid artery can be seen in some cervical parangliomas but is similar to tumoral encasement and is probably not specific.

The ascending pharyngeal artery is a unique link between parangliomas in various territories.

The tympanic, jugular, vagal, carotid and laryngeal locations of paragangliomas are supplied by different branches of the ascending pharyngeal artery. The internal maxillary artery and the superior and inferior laryngeal arteries are also responsible for supplying paragangliomas in their respective territories.

19.3.3 Imaging

CT and MRI are important methods for the initial evaluation of a paraganglioma. Even though the findings are usually not specific for this tumor and may mimic other nerve sheath neoplasms, these studies are highly effective to demonstrate the extension of the tumor into different regions like the carotid canal, the inner and middle ear, mastoid process, posterior fossa or pterygoid muscles. (Fig. 19.2a,d,e)

These studies should always be performed with and without contrast enhancement and a bone windowed as well as a soft tissue windowed evaluation of the CT scan of the lesion should be done. Direct coronal images are indispensable in the presence of cervical or skull base mass lesion and 1 to 3 mm sections are required for the petrous temporal bone evaluation. Due to the hypervascularity of the paragangliomas, intense homogeneous enhancement of these tumors occurs following the contrast administration.

Superselective angiography still represents the most reliable study for pre treatment evaluation of paragangliomas. If the diagnosis is suspected, the angiogram should be performed before any biopsy attempt. (Fig. 19.2b,c,f,g)

The topography of the lesion will always indicate the arterial supply to the tumor. This could consist of a single artery or multiple vascular supplies. Angiographic findings are usually an intense tumoral blush, enlargement of the arterial feeders and rapid venous filling. Just like in JAF, it is recommended to perform the endovascular treatment at the time of the diagnostic angiogram, whenever it is possible.

The principal arteries that should be studied include the ipsilateral vertebral artery, the internal carotid artery, the distal external carotid, the posterior auricular, the occipital arteries and bilateral ascending pharyngeal arteries. It is important to visualize the venous drainage pattern and recognize the presence of a venous thrombosis.

Diagnosis of a carotid canal invasion can be performed by detecting expansive mass and bone destruction on the carotid canal on the CT scan associated with a narrowing of the intrapetrosal carotid artery at the angiography.

19.3.4 Treatment

Interdisciplinary management has shown to be critical for the optimal treatment of paragangliomas. Even though complete surgical excision has shown to be the treatment of choice, radiotherapy and endovascular embolization have become important therapeutic options for treating unresectable tumors and perform palliative treatment. Preoperative procedures such as embolization to reduce the surgical procedure timing and the bleeding risk contemplated in surgery have become an important therapeutic tool for these tumors. Endovascular embolization, when performed by an experienced operator, is a highly efficient and a low-risk method.

The efficacy of radiotherapy is not clear. Several studies have shown a tumor control rate as different as 90% and 25%. The mechanism of treatment is due to its effect on the vascular component causing vascular arteritis and fibrosis rather than affecting the tumoral cells. Brain tissue necrosis is an undesirable side effect related with this method and is usually detectable by CT or MRI.

Embolization of these tumors is usually performed with 200–350 microns in size polyvinyl alcohol (PVA). After particle injection, ligation of the arterial supply can be performed with Gelfoam strip injection. This will facilitate the intratumoral thrombosis. Liquid embolic agents are usually reserved for palliative lesions and only when strict flow control can be achieved.

As in any endovascular embolization of the craniofacial region, special regards must be taken towards the multiple anastomosis channels between the ICA and the orbit, middle meningeal or occipital arteries. As was previously described, the embolization of the ascending pharyngeal artery with fluid agent may induce lower cranial nerve palsy.

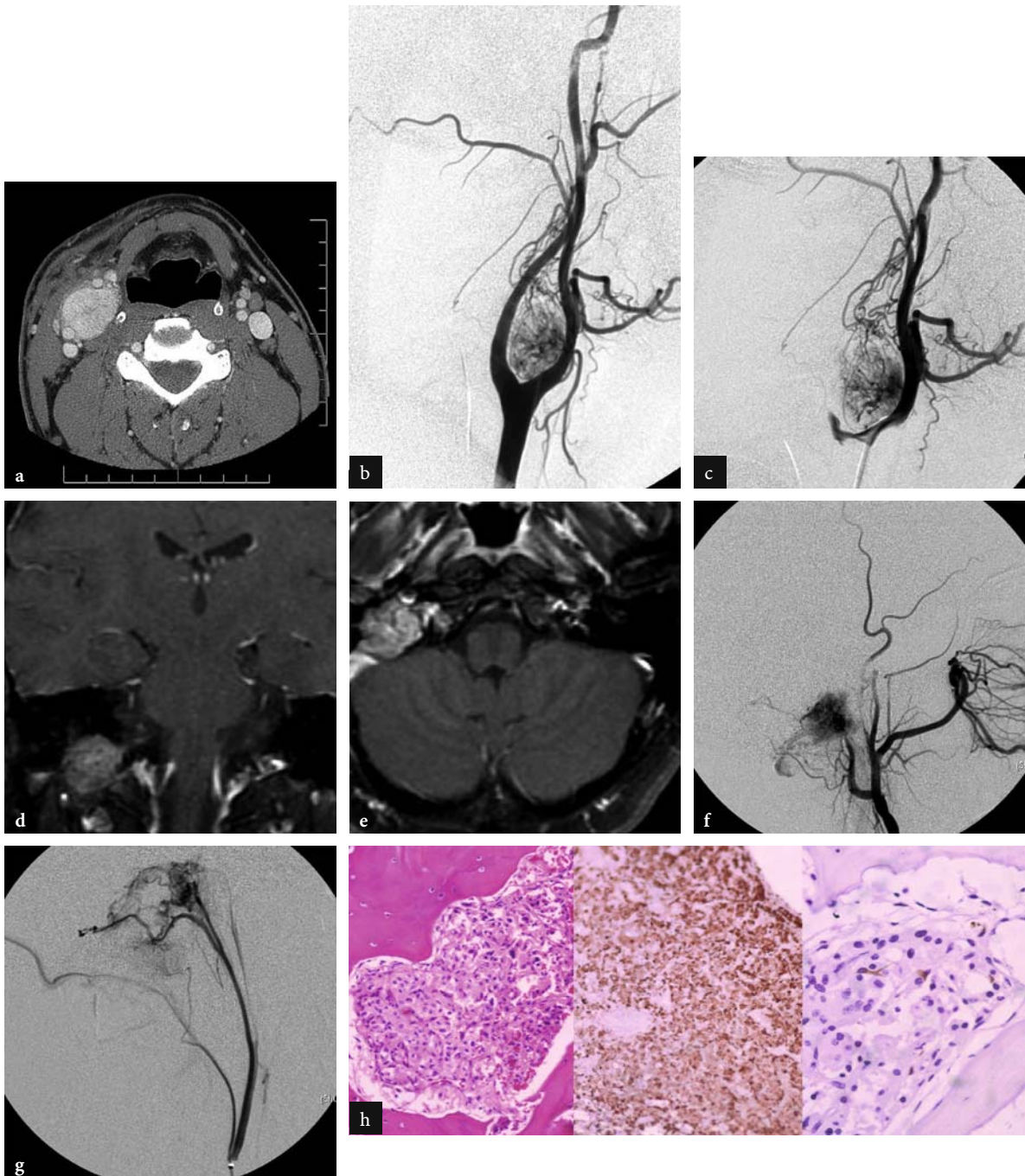


Fig. 19.2a-h. Carotid body tumor (a-c). CT scan a shows the anatomical relationship of the tumor with the carotid artery. Glomus tumor typically shows enhancement after contrast administration. Selective angiography b,c shows tumor blush arising from small ECA branches. Glomus jugulare (d-h) MRI shows the tumor location in relationship with the petrous bone and the jugular bulb d,e. Selective angiography shows tumor blush supplied by the posterior auricular artery (f) and the ascending pharyngeal artery (g). Pathologic examination (h) demonstrates tumor tissue with the typical capsulated structure and epithelial cells surrounded with a vascularized stroma. Courtesy of Dr. K. terBrugge

19.4 Thyrolaryngeal Tumors

Tumors located in the thyrolaryngeal region are usually malignant and highly vascularized. Even though cerebral angiography and endovascular embolization can offer a significant help for the management of these tumors, most of cases are not referred for either diagnostic or therapeutic angiography.

Pretherapeutic evaluation of the thyrolaryngeal tumors should include conventional radiograms, CT, ultrasound and radionuclide scanning. The highly vascularized tumors of this region are usually supplied by the superior and inferior thyroidal arteries and are the most likely involved in the endovascular treatment. These arteries are usually widely selected for endovascular embolization of other head and neck tumors due to the collateral supply to the floor of the mouth and the carotid region.

They even may be the only supply to the floor of the mouth when there is a proximal ligation of the linguo-facial system.

Except for large tumors, the non-invasive techniques have shown little help in anatomical localization of parathyroid tumors, especially through the detection of secreting hormones at the neck veins.

Endovascular management techniques for these tumors include the superselective injection of 2 to 30 ml of contrast material [] with a higher dose of iodine compared to the conventional dose for cerebral angiography. The persistence of the tumoral stain indicates the local damage of the tissue, and can be noticed for hours or days. After the procedure, a reduction in the calcium level in the blood can be found as a result of the released hormone from the cellular granules. Even though a significant result can be obtained from this technique, the endovascular procedure should be considered incomplete without a surgical excision. Experience on particle embolization for parathyroid adenomas has shown only a temporary effect and recurrence is always noticed. No evidence has been reported on the use of selective injection of cytotoxic agents.

Some of the vascularized tumors that have shown to be benefited by a preoperative embolization include: soft tissue and bony hemangiomas in adults, capillary hemangiomas in children and malignant synoviomas.

As previously described, some paragangliomas may be presented in the pharyngeal and thyroidal regions and may require preoperative endovascu-

lar embolization for complete excision. Particles of liquid agents may be used as an only treatment for palliative management of these lesions.

19.5 Craniofacial Tumors

Endovascular techniques certainly have a role in the management of craniofacial tumors. Most of these lesions are metastasis or primary malignant tumors. The main impact of the procedure is the necrotic changes in the tumor territory and this leads to a significant size reduction in its mass. Rarely in these cases, embolization is used as a single treatment, like recurrent or non-surgical lesions, and reaching as much of the area of the tumor with minimal side effects is the main goal.

Some techniques can be used to maximize the effect of particle embolization, like rearrangement of the vascular supply to the lesion. For this technique a lateralized tumor may be selectively embolized to give priority to a single feeder. The feasibility of this technique varies depending on the tumor extent, accessibility of the vessels and potential vascular anastomosis. For example, either the ipsilateral ascending pharyngeal or the internal maxillary artery can be embolized with particles. The remaining feeder is deliberately left open. Repeated angiogram after a few weeks will verify the redirection of the tumor supply, witch can now be used for a more aggressive treatment: liquid adhesive, powder, cytotoxics, ethanol, loaded microcapsules, etc. Although little experience has been reported with these materials, significant decrease in the tumor masses has been reported.

19.6 Miscellaneous Applications of Embolization Therapy in the Head and Neck

19.6.1 Preoperative Embolization

Embolization has been described for the prevention of hemorrhagic complications from a planned tumoral biopsy. Particle embolization preserves the histoarchitecture and immunohistoanalysis and therefore is a safe material for the preservation of the tissue for diagnostic purposes.

19.6.2

Pain Management

Embolization for control of tumor related pain could be performed in selected cases where decongestion or tumoral mass reduction is thought to decompress the surrounding tissues, resulting in a local pain relief.

19.6.3

Hemorrhagic Emergencies

Craniofacial and neck malignant tumors usually present with a highly aggressive local activity. Bone destruction and ulceration are not uncommon findings especially as a secondary effect of radiotherapy. In some cases, invasion of vascular structures may lead to a recurrent bleeding or severe hemorrhages.

In these emergencies initial clinical management and manual external compression is usually required until the patient can be treated (Fig. 19.3a). Diagnostic angiography is a priority to determine the cause for the carotid ‘Blow out’ syndrome. Aggressive tumor invasion or pseudoaneurysm formation of the neck or nasopharynx vessels are usual angiographic findings (Fig. 19.3b-c). These are life-threatening situations and special consideration must be taken for the overall clinical status of the patient (shock management, blood replacement, etc.) Mild to moderate hemorrhagic event may be temporarily treated with particles in the tumor capillary bed. In some cases ligation of a terminal branch (nasopharynx) or even the external or internal carotid artery by endovascular means is required (Fig. 19.3). For these purposes different kinds of material such as detachable or pushable coils, detachable balloons or liquid adhesives are highly effective.

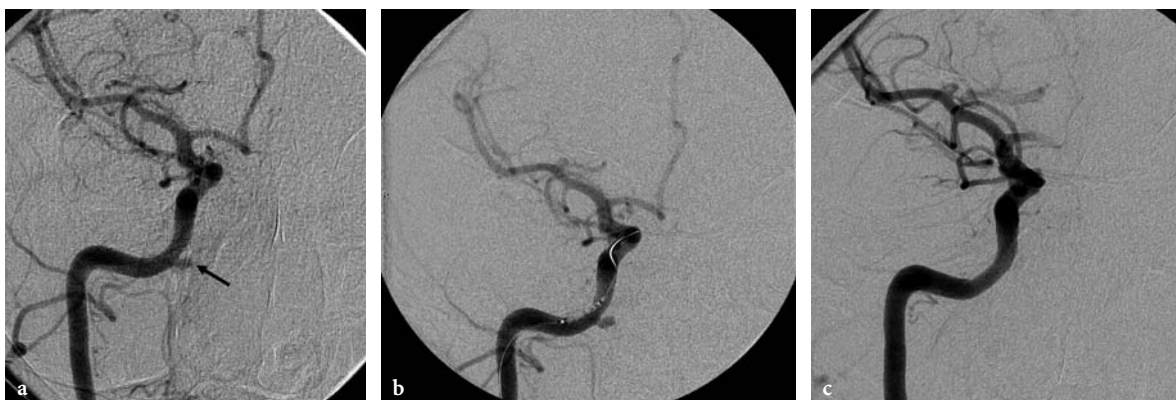

Fig. 19.3a–c. Nasopharyngeal cancer with profuse bleeding treated with covered stent (Jomed®). A 54-year-old female with advanced nasopharyngeal cancer presented with intractable oral and nasal bleeding. Right ICA angiogram a shows pseudoaneurysm of distal petrosal segment (*arrow*). Covered stent is introduced and adjusted its position across the pseudoaneurysm. b A post-stent angiogram. c shows complete occlusion of pseudoaneurysm

Cookbook:

1. Anesthesia: General anesthesia preferred but the tumor embolization can be performed under neuroleptic anesthesia if the patient is stable and cooperative. In case of emergency such as carotid blow-out syndrome or profuse and active nose bleeding, you may perform the procedure under the local anesthesia.

2. Femoral arterial sheath: 5 or 6 Fr, 11 cm. If the patient has a very tortuous abdominal aorta, you can use longer arterial sheaths (30 ~ 45 cm).

3. Diagnostic catheter: 4 or 5 Fr angled Glider (Boston Scientific®) or Berenstein (Cordis®)

4. Guide wire: 0.035 or 0.038 inch Glider (Terumo®)

5. Guiding catheter: 5 or 6 Fr Envoy (Cordis®) or Guider (Boston Scientific®) 90 cm
6. Microcatheter:
 - a. Prowler 14 (0.014 inch) or 18 (0.018 inch) microcatheter (Cordis®) for the particle embolization.
 - b. Elite 1.5 (0.018 inch proximal and 0.011 inch distal end) or 1.8 (0.018 inch proximal and 0.013 inch distal end) (Boston Scientific®) for the NBCA embolization.
7. Microwire:
 - a. Transend Ex 14 (0.014 inch) (Boston Scientific®) for the Prowler microcatheter
 - b. Mirage (0.010 inch) (MTI®) for the Elite microcatheter
8. Embolization procedure should always be performed under simultaneous subtracted fluoroscopic control.
9. Particle Embolization:
 - a. A bottle of 150 ~ 250 μm -sized PVA particles mixed with 10~15 cc of contrast media
 - b. Inject the particle mixture with 1cc Luer-Lok syringe.
 - c. Intermittent flushing of microcatheter with saline using another 1 or 3cc Luer-Lok syringe.
 - d. If you have any resistance during the embolization or flushing, do not forcefully inject the PVA particle mixture or flushing saline but remove the microcatheter completely and use a new one if needed.
10. NBCA (N-butyl cyanoacrylate) embolization:
 - a. Mix the NBCA with Lipiodol according to the vascularity and the degree of arteriovenous shunting.
 - b. For the tumor without significant arteriovenous shunting, less than 50% (usually 30%–50%) of the NBCA mixture can be used.
 - c. For the NBCA embolization of the head and neck lesions, you should obtain a safe microcatheter position and know potential external carotid-internal carotid communication pathways to prevent disastrous internal carotid territorial embolization.

References

1. Mann WJ, Jecker P, Amedee RG (2004) Juvenile Angiofibromas: Changing surgical concept over the last 20 years. *Laryngoscope* 114
2. Lasjaunias P, Berenstein A, Ter Brugge K () *Surgical Neuroangiography*, Vol. 2, Springer
3. Osborne A (1994) *Diagnostic Neuroradiology*; Mosby
4. Rosenwasser H (1974) Glomus jugulare tumors. *Proc Roy Soc Med* 67:259–164
5. Apostol JV, Frazell E (1965) Juvenile Nasopharyngeal Angiofibroma: a clinical study. *Cancer* 18:869–978
6. Aufdemorte TB (1981) Hemangiopericytoma-like tumor of the nasal cavity. *Arch Otolaryngol* 107:172–174
7. Batsakis JG (1979) Tumor of the head and neck, clinical and pathological considerations. Williams & Wilkins, 2nd edn. pp 296–301
8. Batsakis JG, Jacobs JB, Templeton AC (1983) Hemangiopericytoma of the nasal cavity: Electron-optic study and clinical correlations. *J Laryng Otol* 97:361–368
9. Berg NO (1950) Tumors arising from the tympanic gland (glomus jugularis) and their differential diagnosis. *Acta Pathol Microbiol Scand* 27:194–221
10. Casasco A, Herbreteau E, George E, Tran Ba Huy P, Defresne D, Merland JJ (1994) Devascularization of craniofacial tumors by percutaneous tumor puncture. *AJNR Am J Neuroradiol* 15:1233–1239
11. Christiansen TA, Duvall AJ, Roseberg Z, Carley TB (1980) Juvenile nasopharyngeal angiofibroma. *Trans Am Acad Ophthalmol Otolaryngol* 78:140–147
12. Cummings BJ (1980) Relative risk factors in the treatment of juvenile nasopharyngeal angiofibroma. *Head Neck Surg* 3:21–26
13. Cummings BJ, Blend R, Fitzpatrick P, Clark R, Harwood A, Keane T, Beale F, Garrett P, Payne D, Rider W (1984) Primary radiation therapy for juvenile nasopharyngeal angiofibroma. *Laryngoscope* 94:1599–1605
14. Doppman JL (1980) The localization and treatment of parathyroid adenomas by angiographic techniques. *Ann Radiol* 23:253–258
15. Erickson D, Kudva YC, Ebersold MJ, Thompson GB, Grant CS, Van Heerden JA, Young WF (2001) Benign paragangliomas: Clinical presentation and treatment outcomes in 236 patients. *J Clin Endocrinol Metab* 86:5210–5216
16. Ewing JA, Shively EH (1981) Angiofibroma: a rare case in an elderly female. *Otolaryngol Head Neck Surg* 89:602–603
17. Farrior JB, Hyams VJ, Benke RH (1980) Carcinoid apudoma arising in a glomus jugulare tumor: review of endocrine activity in glomus jugulare tumors. *Laryngoscope* 90:110–118
18. Goncalves CG, Briant TDR (1978) Radiologic findings in nasopharyngeal angiofibromas. *J Can Assoc Radiol* 29:209–215
19. Harrison K (1974) Glomus jugulare tumors: their clinical behavior and management. *Proc Roy Soc Med* 67:264–267
20. Hertzanu Y, Mendelson DB, Kassner G, Hockman M (1982) Haemangiopericytoma of the larynx. *Brit J Radiol* 55:870–873

20 Embolization of Epistaxis

GEORGES RODESCH, HORTENSIA ALVAREZ and PIERRE LASJAUNIAS

CONTENTS

20.1	Introduction	257
20.2	Etiologies and Origins of ENT Bleedings	257
20.3	Clinical Presentation and Initial Management	258
20.4	Vascular Anatomy and Angiographic Protocol of the Nasomaxillary Region	259
20.5	Technique of Embolization	259
20.6	Idiopathic Epistaxis	262
20.7	Traumatic Epistaxis	264
20.8	Tumor-Related Epistaxis	264
20.9	Epistaxis in Hereditary Hemorrhagic Telangiectasia	266
20.10	Results of Embolization Therapy in Epistaxis	267
20.11	Conclusions	267
20.12	“Endovascular management of EPX from a Practical Point of View”	268
20.12.1	What Has to Be Expected from Angiography in EPX?	268
20.12.2	What Causes of Epistaxis Require Emergent Treatment?	268
20.12.3	When Is Embolization Required in HHT Disease?	268
	Cookbook: Embolization of ENT bleeding	269
20.12.4	What Is the Place of Surgery in Epistaxis?	269
	References	270

20.1 Introduction

Epistaxis (EPX) is a nosebleed that can result from various etiologies. This condition is rather common, often benign and self-limiting [23]. It may however be the symptom of an underlying pathological condition; and it is therefore mandatory to diagnose properly its origin in order to propose an adequate treatment [20]. Traumatic EPX is another common cause of serious epistaxis resulting from maxillofacial trauma, and can lead to massive life-threatening intractable hemorrhage from associated vascular tears.

G. RODESCH, MD

Service de Neuroradiologie Diagnostique et Thérapeutique, Hôpital Foch, 40 rue Worth, 92150 Suresnes, France

H. ALVAREZ MD; P. LASJAUNIAS, MD PhD

Service de Neuroradiologie Diagnostique et Thérapeutique, Hôpital Bicêtre, 78 rue du Général Leclerc, 94275 Le Kremlin Bicêtre, France

EPX has been described as the most frequently observed symptom leading to emergency room consultation in an ENT clinic [21]. Only 6%–10 % of EPX require medical attention [19, 22]. Embolization should only be reserved to patients who have been preselected by a proper initial medical and/or ENT evaluation and management trial [6] as well as a radiological evaluation.

20.2 Etiologies and Origins of ENT Bleedings

The various reported causes of EPX are listed in Table 20.1. They can be also distinguished according to the age group in which they develop (Table 20.2)

Broadly speaking, one can categorize EPX into two main groups [23]:

- Instances where an organic lesion is the source of the bleed. Different pathological entities can be recognized and specific treatments can be offered. This requires a multidisciplinary approach to achieve palliation or cure. Embolization is then often only part of the global therapeutic management required.
- Instances where *no underlying vascular or tumoral pathology can be identified* [2]. Inconsistent association with arterial hypertension, smoking, alcohol consumption, or hypercholesterolemia can be found. Most of these patients have been previously healthy until presenting with acute EPX requiring therapy. In those idiopathic EPX cases, the goal of treatment is to control and stop the bleeding.

Another way to categorize EPX is based on the bleeding site, with two distinct types of EPX:

- *Anterior EPX*: This is the most frequent type, and is usually less severe than the posterior one. It often resolves spontaneously. The bleeding site is

Table 20.1. Most frequent origins of EPX

Idiopathic	30%
Hereditary hemorrhagic telangiectasia (HHT1)	27%
Arterial hypertension	12%
Traumatism	8.5%
Coagulation disorder	7.5%
Benign tumor	7.5%
Iatrogenic (surgical) vascular tear or traumatism	3%
Malignant tumor	3%
Aneurysm	0.4%
Arteritis	0.4%
Intracranial vascular malformation	0.4%

Table 20.2. EPX: populations and most frequent related causes

Pediatric population	Trauma Tumors Maxillo-facial surgery Coagulation disorders
Elderly population	Anticoagulant treatment Arterial hypertension
Average age population	Idiopathic HHT Tumors Trauma Aneurysm (cavernous, petrous, etc...)

located in the anterior septum (on the plexus of Kisselbach). If treatment is required, simple procedures such as compression, anterior packing, or cauterization can usually easily arrest the hemorrhagic episode.

- *Posterior EPX:* This type requires more aggressive or active treatment. Cauterization, anterior and posterior packing, local sclerosis, local injections of haemostatic agents, electrocoagulation, surgical clipping, and ligation have all been described to control the hemorrhage [5, 13, 17, 23, 24]. The patients usually poorly tolerate posterior packing. They still belong however to the panel of necessary ENT procedures that has to be attempted before performing any embolization.

20.3 Clinical Presentation and Initial Management

A recurrent EPX that does not stop spontaneously usually leads to consultation with an ENT surgeon or at the emergency room staff. Careful endoscopic evaluation is then performed in order to delineate the site and type of bleeding. A first treatment (cauterization or packing) is attempted. Even such simple procedures can control the bleed, even though tem-

porarily. In severe facial trauma, anterior and posterior packing might allow stabilization of unsteady hemodynamic situations. This allows further clinical evaluation, correction of the coagulation profile, careful history and physical examination, and additional radiological investigations to be performed to better delineate the etiology and precise location of the hemorrhage [23]. EPX can have other origins than the nasal fossa: lesions in the frontal, sphenoidal (Fig. 20.5), or maxillary sinuses can present with EPX; middle ear hemorrhage can also be externalized via the Eustachian tube. Initial proper clinical examination is thus mandatory combined with evaluation of the angiographic findings and careful analysis of the potential collateral circulation. Careful preliminary evaluation will be more likely to lead to a satisfactory diagnosis and treatment.

Packing stops the EPX but is often poorly tolerated by the patient and, if prolonged, can lead to serious complications such as aspiration, sinus infection, and necrosis by intranasal balloon pressure [23]. It has to be therefore limited in duration. Packing is however often a necessary step in the therapeutic management of nosebleed and further therapeutic procedures should be performed only if these initial ENT treatments fail, and EPX recurs. Failure rates up to 25%–50% and complications rates of 20%–60% have been described [17, 23, 24]. In these situations, one considers the EPX to be intractable and mandates other managements. External carotid artery ligation has been proposed in the past but should currently be avoided as the rich maxillo-facial collateral supply will rapidly reconstitute distally the sacrificed arterial trunk, leading then to clinical recurrences [1, 2, 10]. Moreover, further endovascular treatment will then be more complex or impossible because of indirect arterial supplies. Internal maxillary clipping or ligation have also been reported [5,23], but with a complication rate of up to 47% and clinical failures of 15 % [13,17,23]. Rebleed can easily be explained by the developments of anatomical collateral pathways. Anterior and posterior ethmoidal arteries (arising from the ophthalmic artery), internal carotid artery branches (inferolateral trunk, vidian artery) and nasopharyngeal vessels (ascending pharyngeal artery, descending palatine artery, ascending palatine artery, accessory meningeal artery) will participate to restore the flow distal to the ligated internal maxillary artery. However, the mere fact that proximal disconnection alone might be successful suggests that the decrease of pressure and indirect flow to the nasal mucosa might play a role in the physiologic hemostasis that will occur [23].

Endovascular therapies have gained much popularity nowadays. Embolization of EPX has to be performed according to strict angiographic protocols taking in consideration the clinical situation and the cause of the bleed [9]. This will be further illustrated below.

20.4 Vascular Anatomy and Angiographic Protocol of the Nasomaxillary Region

The cavum and the nasal fossa, both located on the midline, need **bilateral explorations** even if the symptom or the disease seems to be unilateral (Fig. 20.1). Exploration of adjacent territories will help in delineating with accuracy the vascular limits of a given lesion. A unilateral vascular approach should therefore be avoided [1, 9, 10].

The distal internal maxillary artery is the main arterial trunk supplying lesions in the nasomaxillary area [9, 10, 23]. Vascular supply is via the *sphenopalatine artery* of the internal maxillary artery, the *alar and septal branches of the facial artery*.

The *sphenopalatine artery* originates from the pterygopalatine segment of the internal maxillary artery. It exits the pterygopalatine fossa through the sphenopalatine foramen and penetrates in the nasal fossa behind and above the middle concha. It divides then in two trunks: a *posterior lateral nasal artery* (or *conchal artery*) supplying the turbinates and parts of the maxillary, ethmoidal and sphenoidal sinuses, and a *posterior medial nasal artery* (or *septal artery*) supplying the nasal septum. Anterior and posterior ethmoidal arteries arising from the ophthalmic artery beyond its second intra-orbital portion also supply this midline structure. Ethmoidal arteries supply the superior parts of the septum at the level of anterior and posterior ethmoidal cells; they will build a rich anastomotic network with septal arteries.

In its distal portion, the septal artery of the sphenopalatine artery abandons the *nasopalatine artery* that anastomoses with the terminal branches of the greater palatine artery through the distal hard palate. The arterial supply to the inferior and anterior portion of the nasal cavity is thus accomplished.

The contribution of the distal facial artery to the vascularization of the nasomaxillary region depends from *alar arteries*, and from *anterior septal arteries* (branches of the superior labial arteries). This anterior and inferior portion of the septum (the plexus of

Kisselbach) is thus an arterial junction between the facial, nasopalatine and descending palatine arteries [23].

Accessory supply to the nasal fossa and to the cavum has been described in vascular lesions or after proximal ligation via the *accessory meningeal arteries* and *ascending pharyngeal arteries* [3, 23].

The nasal cavity is therefore a difficult area to control by endovascular procedures because of the complex arterial supply belonging to two systems: the internal carotid artery via the ethmoidal arteries, and the external carotid system mainly via the sphenopalatine artery. Transarterial approach to this region will mainly use the external carotid artery vascular channels.

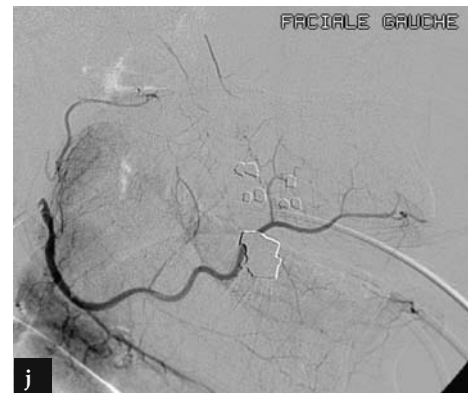
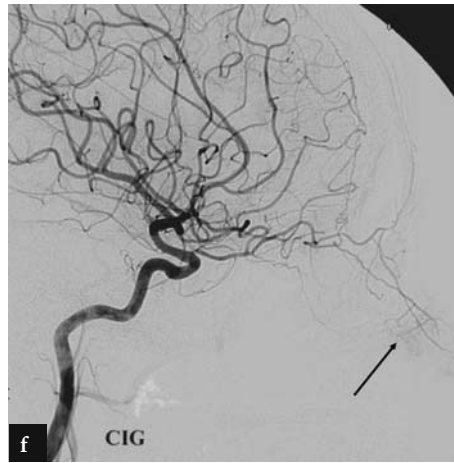
20.5 Technique of Embolization

Diagnostic and therapeutic angiography is performed in the angiography suite, the nasal packing being kept in place and always after thorough clinical examination of the patient by an ENT doctor [23]. The whole procedure is performed under general anesthesia (GA) for the patient's comfort. GA also allows suppression of breathing during angiographic runs, and eliminates agitation and uncontrolled motion. In addition, the patient airway and ventilation are secured despite the nasal packing. Indirectly, these measures lower the risk of vasospasm due to intra-arterial catheter manipulation. Conscious sedation and neuroleptic analgesia are less frequently used because they lack the above advantages of GA; it will be reserved mostly to patients with contraindications to GA.

An introducer sheath is placed into the femoral artery; its size will depend on the pathology suspected: in case of rupture of the internal carotid artery in adults, a large 6 or 7 F introducer sheath should be initially placed to allow the use of large size guiding catheters for the manipulation of detachable balloons. In children, the smallest possible introducer size is initially inserted. In our experience, all major nasomaxillary arteries and main branches, which invariably represent the pathology responsible for the EPX, can be catheterized with a 4F or 5F catheter [23] (Fig. 20.1). Direct puncture of the arterial branches or of the internal or external carotid artery should not be considered [1]. The embolization (usually with particles) is performed through the same catheter, except if specific

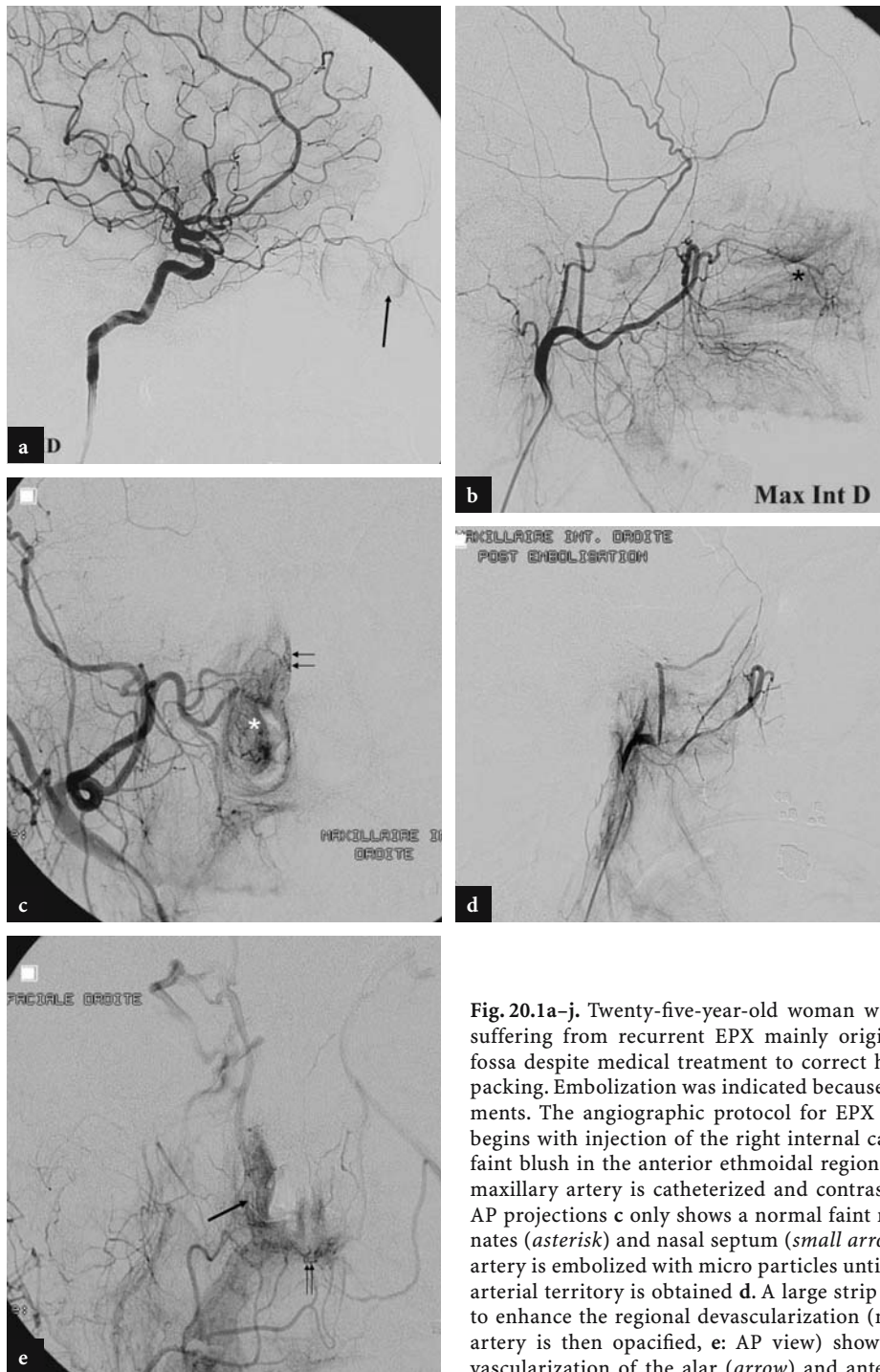

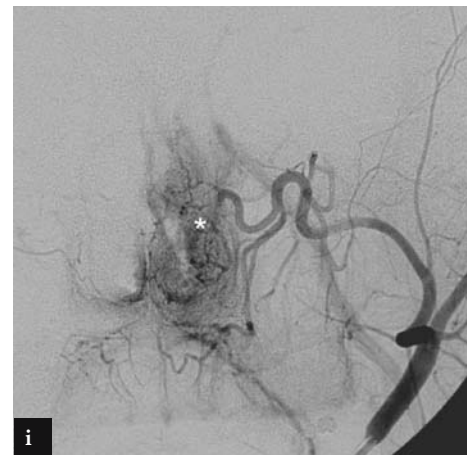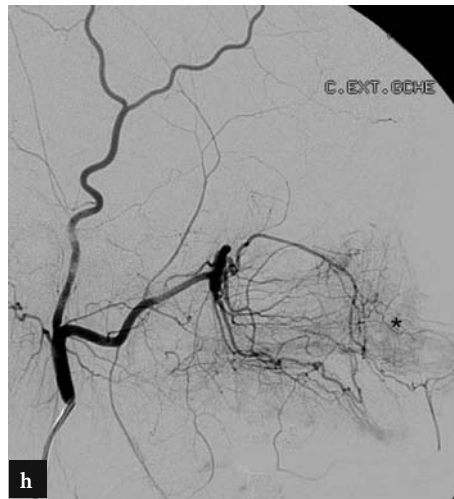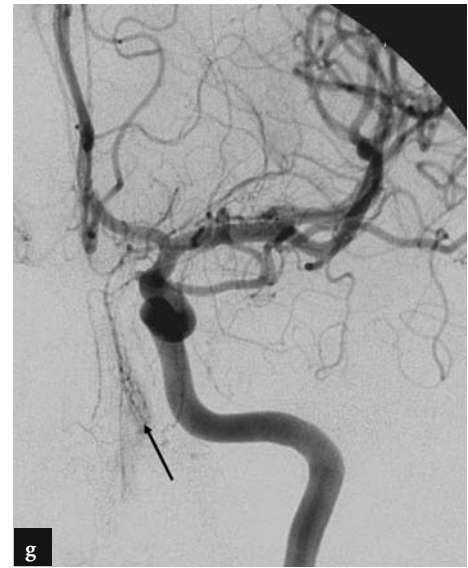Fig. 20.1a-j. Twenty-five-year-old woman with von Willebrand disease suffering from recurrent EPX mainly originating from the left nasal fossa despite medical treatment to correct her coagulopathy, and nasal packing. Embolization was indicated because of failure of all other treatments. The angiographic protocol for EPX is followed. The procedure begins with injection of the right internal carotid artery a that shows a faint blush in the anterior ethmoidal region (*arrow*). The right internal maxillary artery is catheterized and contrast injection in lateral b and AP projections c only shows a normal faint mucosal blush on the turbinates (*asterisk*) and nasal septum (*small arrows*). The internal maxillary artery is embolized with micro particles until distal disconnection of the arterial territory is obtained d. A large strip of Gelfoam is then injected to enhance the regional devascularization (not shown). The right facial artery is then opacified, e: AP view) showing its contribution to the vascularization of the alar (*arrow*) and anterior septal regions (*double*



arrow). The right facial artery is embolized with the same material following the same rules. The nasomaxillary region on the left side is then studied, with injection of the internal carotid artery showing faint septal hyperemia supplied by the anterior ethmoidal arteries [f (lateral view) and g (AP view): *arrow*]. The left internal maxillary artery supplied the left nasal fossa [h (lateral view) and i (AP view): *asterisk*], and is then embolized in the same manner. The left facial artery (j, lateral view) is not embolized because of its hypoplastic territory that does not participate to the vascularization of the alar zone. Note that embolization was carried out despite the fact that no clear-cut abnormality was detected in the vascular tree or at the level of the nasal fossa. The ENT surgeon was told that he might have to clip the ethmoidal arteries in case of recurrence of EPX because of the prominent aspect of these vessels. The nasal packing was removed 24 hrs later; the patient did not present with recurrent EPX anymore

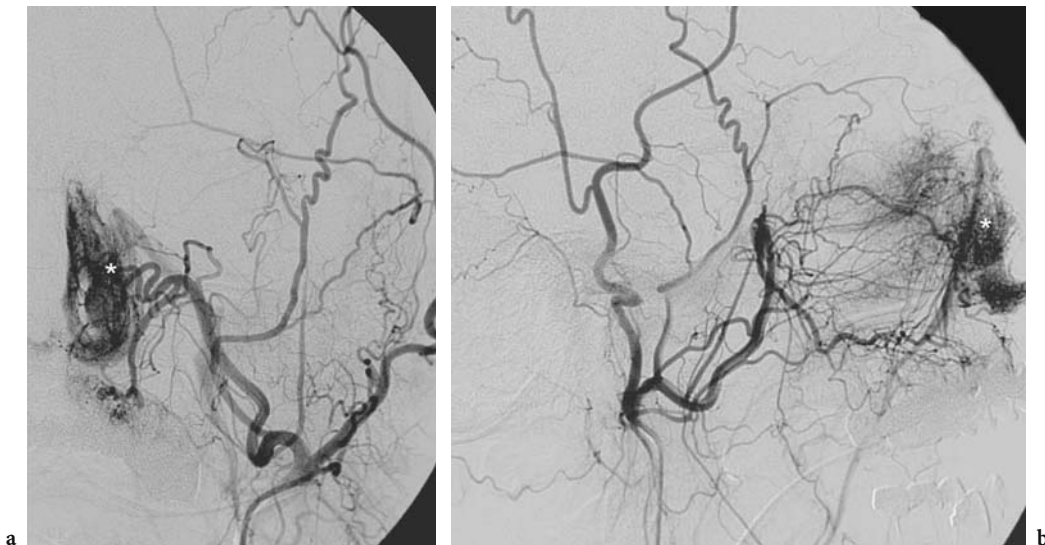


Fig. 20.2a,b. Young woman with a tumor of the cheekbone. Angiography was performed in order to disclose any hypervascularity before surgery. The lesion was avascular but opacification of the internal maxillary artery in the AP **a** and lateral views **b** showed intense nasal fossa mucosal blush (*asterisk*) corresponding to a normal appearance in a woman in the premenstrual period, with no EPX

embolic materials are necessary (balloons or coils) or if superselective catheterization is required in case of anatomic variations that have to be respected (e.g. meningo-ophthalmic artery). Other investigators [23] recommend routine superselective embolization after catheterization of the sphenopalatine artery; however, no differences in the immediate outcomes and clinical follow-ups have been noted between these techniques. Undoubtedly, the superselective approach is associated with higher cost, and more time and labor, which is why we have continued to favor the simpler regionally selective approach since 1979.

20.6 Idiopathic Epistaxis

The initial study in idiopathic EPX should involve the internal carotid artery ipsilateral to the bleed, using both lateral and AP views in order to detect any lesion of the petrous or cavernous segment of this vessel. This also allows the evaluation of nasal fossa vascularity that originates from the ethmoidal arteries. Angiography of internal maxillary artery is then performed in lateral views to depict any culprit anastomoses with the internal carotid system, as the external carotid origin of the ophthalmic artery. These

anatomical variations do not contraindicate endovascular therapy but will require superselective catheterizations in order to avoid any erratic emboli in the internal carotid territory. Embolization is performed with small size particles (250–350 micron) that will be injected within the flow at each systolic pulsation until stagnation of contrast is detected in the vessel. Large strips of Gelfoam are secondarily injected in the internal maxillary artery in order to increase the distal devascularization. Embolization should always begin first with the most distal territory [2]. Second, angiography of the ipsilateral facial artery is performed. If contribution to the nasomaxillary territory is noted, the facial artery is then embolized with large strips of Gelfoam in order to reduce the flow in its distal region and participate to the hemostasis.

The same studies are repeated in the contralateral vessels, and embolization performed according to the same rules. As a rule, proximal ligation or occlusions with coils must be avoided, as they will not properly control the bleed and will favor the development of collaterals.

In our experience, the nasal packs are usually kept in place for 24 hours and then withdrawn by the ENT surgeon. Some teams advocate removal of the packing at the end of the procedure in the angiographic suite [23]. The patient will be seen for follow up in consultation both by the referring physician and by the interventional neuroradiologist.

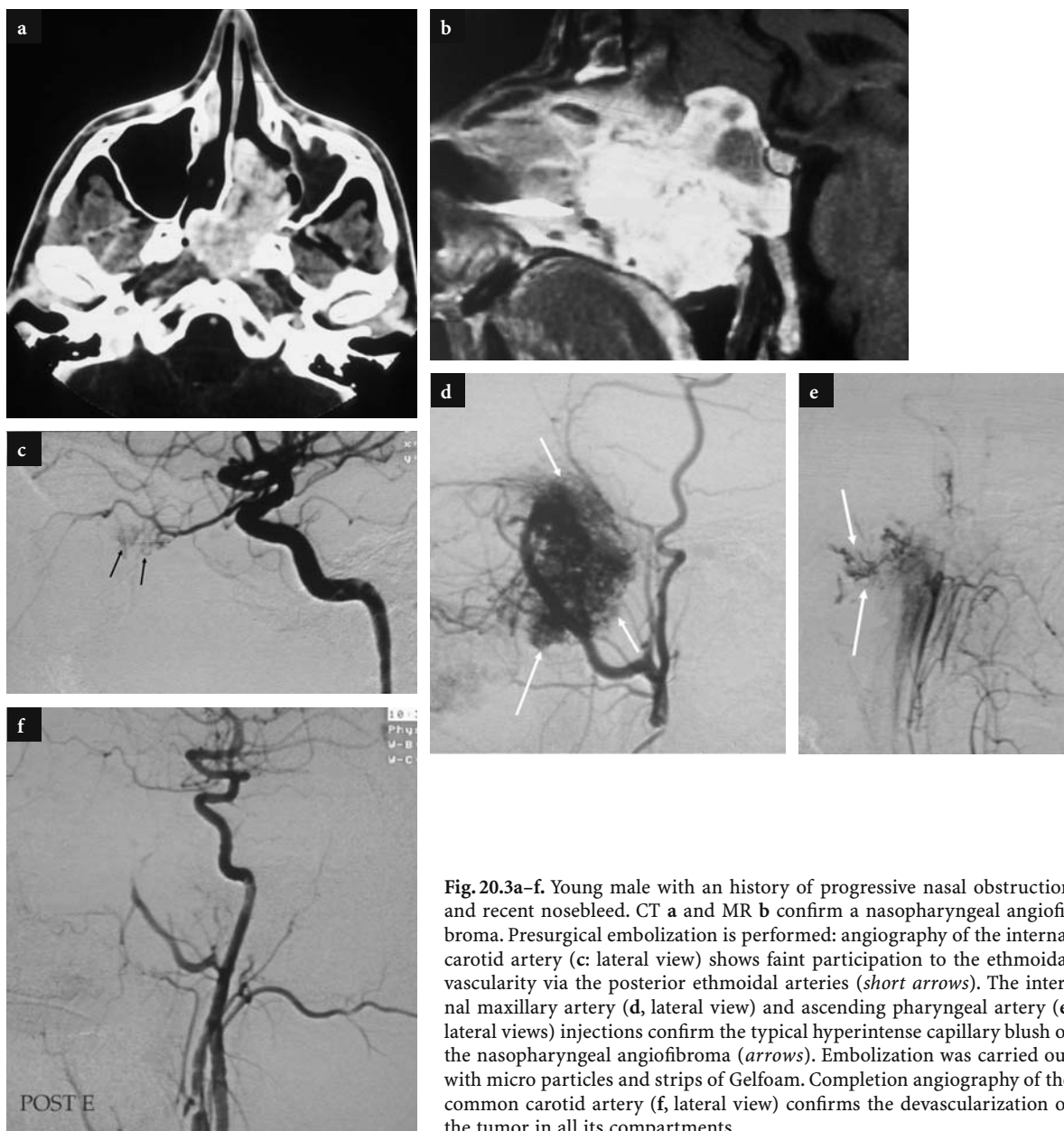


Fig. 20.3a–f. Young male with an history of progressive nasal obstruction and recent nosebleed. CT **a** and MR **b** confirm a nasopharyngeal angiofibroma. Presurgical embolization is performed: angiography of the internal carotid artery (**c**: lateral view) shows faint participation to the ethmoidal vasculature via the posterior ethmoidal arteries (*short arrows*). The internal maxillary artery (**d**, lateral view) and ascending pharyngeal artery (**e**, lateral views) injections confirm the typical hyperintense capillary blush of the nasopharyngeal angiofibroma (*arrows*). Embolization was carried out with micro particles and strips of Gelfoam. Completion angiography of the common carotid artery (**f**, lateral view) confirms the devascularization of the tumor in all its compartments

Persistence of prominent ethmoidal arteries seen on the post embolization angiogram may predict further bleeding, requiring surgical clipping of these arteries, as this type of recurrence can not be managed properly by additional endovascular therapy.

EPX is a frequent complication of *coagulopathy* mainly in the pediatric population. Angiography

usually shows a normal blush of the nasal mucosa. Embolization is performed according to the same rules than described above combined with correction of the underlying coagulopathy will help control the bleeding [11]. Particular attention has to be paid to the orbital anastomosis, usually patent in children, in order to avoiding erratic embolus that could give rise to visual complications.

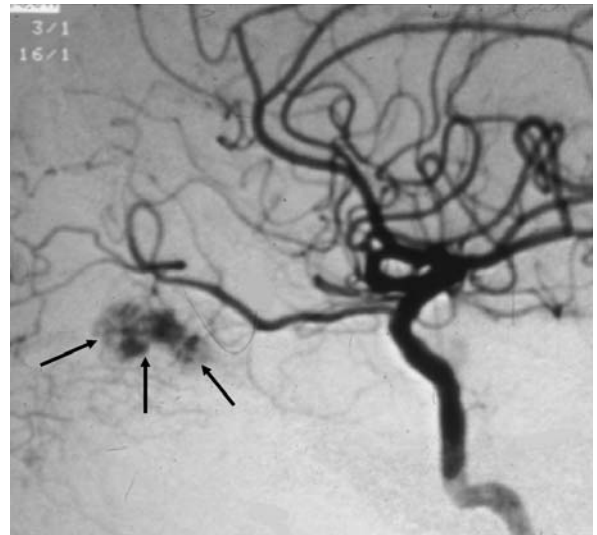
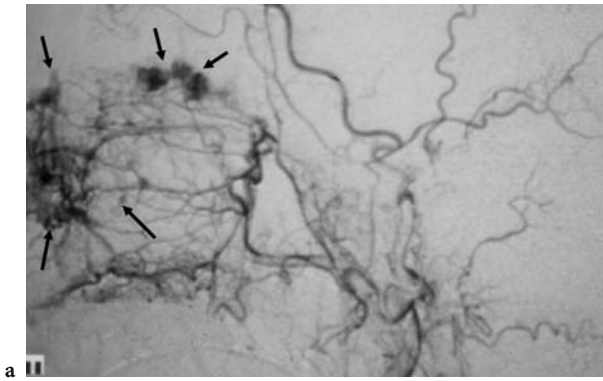


Fig. 20.4a,b. Patient with HHT disease suffering from recurrent EPX. Nasal fossa telangiectasias are vascularized by both septal and turbinate branches of the internal maxillary artery (lateral view **a**, *small arrows*) and by ethmoidal branches of the ophthalmic artery (lateral view **b**, *small arrows*)

20.7 Traumatic Epistaxis

Traumatic EPX requires initial CT imaging to rule out any skull base or maxillo-facial fracture that could be linked to a vascular tear responsible for the bleed (Fig 20.6 and 20.7). Damage to the internal carotid artery could be diagnosed if the fracture involves the carotid canal, or if a subarachnoid hemorrhage is associated to the osseous trauma, where rupture of the supracavernous portion of the internal carotid artery should be suspected. Traumatic EPX is a life-threatening emergency, and can be associated with severe hemodynamic instability. If a history of serious vascular trauma is evoked in the setting of severe EPX, superselective diagnostic angiography should be avoided in order to prevent rupture of a potentially associated arterial false aneurysm, which is effectively the unclotted portion of the hematoma associated with the vascular injury. This represents a weak point that could rupture if subjected to sudden increased pressurization or forceful injection. Instead, we recommend in these situations that a nonselective runs in the common carotid artery territory be obtained in order to depict angiographic signs of a vascular tear on the internal or external carotid artery, including presence of a pseudo-aneurysm, localized vasospasm of the affected artery, or truncation or even no filling of the traumatized artery. It is important to know that the exact localization of the rupture is best visualized via the collateral circulation: an angiographic protocol studying internal carotid, vertebral and external carotid artery branches helps to built up

the regional vascular cartography and points thus to the arterial leakage.

If the external carotid artery territory is affected, sacrifice of the traumatized arterial segment is best performed with glue in our experience. N-butyl 2-cyanoacrylate (NBCA) is gently deposited proximally to the arterial tear or at the level of the stump of the traumatized artery after superselective microcatheterization. Traumatic rupture of the internal carotid artery is usually treated by sacrifice with balloons and coils [7]. The recent availability of covered stents offers another endovascular alternative, especially when occlusion of the internal carotid artery is poorly tolerated [4].

20.8 Tumor-Related Epistaxis

Tumors of various types have been associated with EPX, both *benign* (juvenile angiofibromas (Fig. 20.3), angiomatous polyps, capillary hemangiomas etc...) and *malignant* (primary head and neck carcinomas, epitheliomas, metastatic lesions etc...). Tumor-related bleeding tends to be recurrent and moderate in severity. It may occur at night leading to anemia [2], or be can associated with breathing difficulties due to nasal obstruction. Life-threatening hemorrhage is rare in these conditions but has been reported [2]. In the diagnosis of recurrent tumor-related EPX, the patient usually first undergoes an MRI in order to delineate the tumor location and extension. Angiography and embolization are performed usually as a

pre-surgical procedure, or to control hemorrhage in the rare occasions of life-threatening EPX associated with head and neck tumors. The goal of the endovascular procedure is to devascularize the tumoral capillary bed. All the vessels supplying the lesion are studied according to an angiographic protocol [9]. Angiographic patterns of primary and collateral vascular supply are predictable in most cases, and the location of the arterial feeders depends on the site of origin of the lesion [2]. The moderately enlarged vessels supplying the tumoral hypervascularization should be embolized with particles and Gelfoam: we currently use small size particles (150-350 microns) to embolize the tumor bed, as smaller particles may pass through the tumoral capillaries and reach the

lungs [18]. The embolization is concluded by injection of large strips of Gelfoam in order to produce a transient devascularization of the region and enhance distal thrombosis in the tumor. In case of intracranial extension of the tumor, glue can be used in order to selectively occlude any tumoral feeders originating from the internal carotid artery. Balloon occlusion of the internal carotid artery (to be considered only after proper evaluation of the collateral circulation on arterial and venous phases) can be utilized if radical surgical exclusion is planned in large otherwise unresectable lesions [2, 23].

In our practice, we perform catheterization and embolization using preset procedural sequences that are applied in every external carotid artery

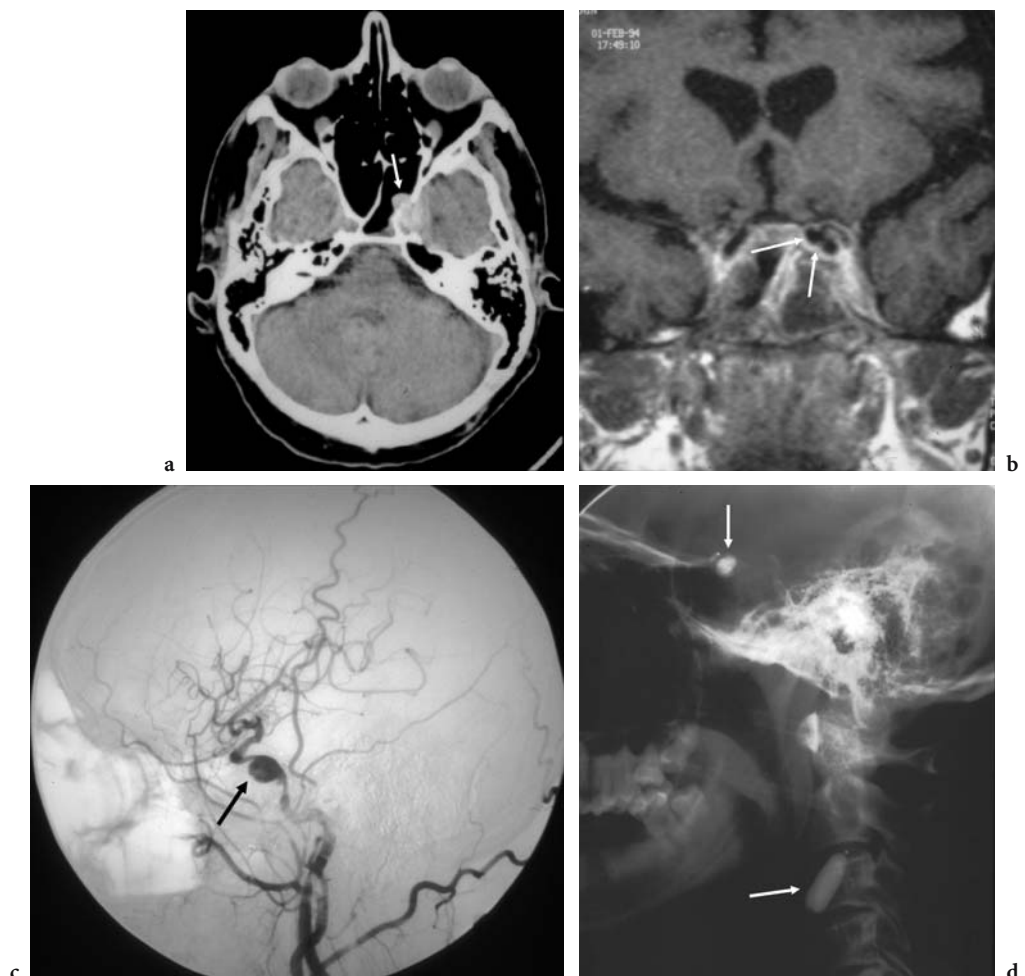


Fig. 20.5a–d. A patient with sphenoid sinusitis treated by antibiotics therapy who developed sudden EPX. CT **a** and MR **b** showed enlargement of the left cavernous sinus with a structure bulging into the sphenoid sinus (**a**: arrow) and an irregular aspect of the internal carotid artery (**b**: arrows). An infectious false aneurysm was suspected and the patient underwent emergent angiography. A left common carotid artery injection (**c**, lateral view) confirmed the lesion (**c**: arrow) on the cavernous portion of the internal carotid artery, which was also stenosed. Sacrifice of the internal carotid artery (with trapping of the pathological zone) was performed with occlusion balloons (arrows) after a satisfactory tolerance test **d**

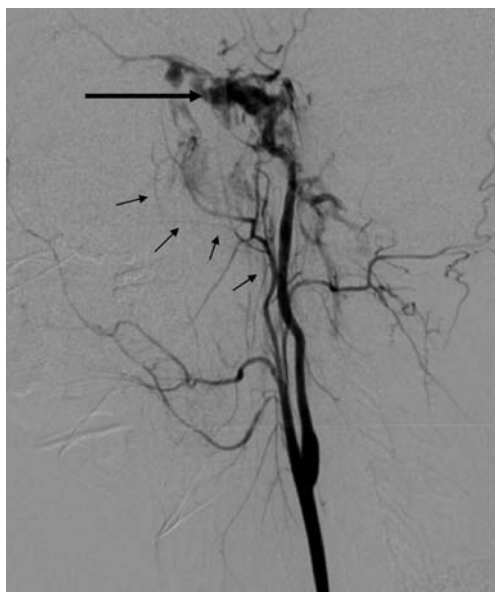


Fig. 20.6. Intractable EPX following maxillofacial and skull base trauma. A common carotid artery injection (lateral view) shows rupture of the internal carotid artery (*large arrow*) and a spastic posttraumatic aspect of the distal external carotid artery (*small arrows*)

endovascular embolization procedure [2]. If several branches must be embolized, one should always tackle the most distal target first to avoid later loss of access due to vasospasm. The next artery (arteries) to be catheterized should include possible sources of collateral circulations to the region embolized in order to provide an alternate route to reach the territory in case the embolization was too proximal. Superselective catheterization of distal pathological arteries is in our daily practice only performed if dangerous anastomoses are open.

20.9 Epistaxis in Hereditary Hemorrhagic Telangiectasia

Hereditary hemorrhagic telangiectasia (HHT) or Rendu-Osler-Weber disease (ROW) is a disorder that presents with recurrent episodes of EPX. These episodes are difficult to manage because of the recurring nature of telangiectasias (Fig. 20.4).

HHT is a dominant autosomal disease with variable expressivity that evolves usually in four stages: latency, hemorrhages, telangiectasias, and anemia. There are two genotypes recognized to date, HHT1

and HHT2, with a third one suspected (HHT3). Endoglin is the gene that maps to chromosome 9q33, which is mutated in HHT1, and which is thought to be responsible for the telangiectasia, pulmonary arterio-venous fistulas (AVFs) and cerebral AV shunts [12]. Lack of endoglin, a binding protein for transforming growth factor β protein, compromises normal vascular remodeling in endothelial cells. EPX is the commonest presentation of HHT both in adults and children; however it may be not given enough importance in HHT families and it needs to be inquired about specifically. Cutaneous lesions are accountable for 66.7% of the adults and 27.3% of the pediatric population in our series, which is keeping with its acquired nature and presentation in the 2nd and 3rd decade [14]. Usually by the 4th decade the telangiectasias will be visible [8]. The localization in the mucous membrane is usually the one giving rise to hemorrhages. The hemorrhagic manifestations in HHT have the following distributions: EPX 85%, oral 20%, digestive 20%, genitourinary 10%, lungs 17% [11]. Epistaxis is the major cause of death in 4%–27% according to the series. The diagnosis of the disease is mainly clinical, two of four criteria being required: spontaneous recurrent EPX, typical mucocutaneous telangiectasias, positive family history and typical visceral AVMs (cerebral, pulmonary or gastro-intestinal [14]. Telangiectasias have to be searched for carefully as they may be located under the nails or on the tip of fingers or toes [11]. The family history may be poor as the penetrance of the disease is variable, some families being not affected by the disease but only transmitting it. Appreciation of the evolution of the disease is difficult but of importance for the selection of the best treatment. Complete cure is not possible nowadays for this systemic disease; the only therapeutic objective is the stabilization of the bleedings.

We generally distinguish three stages in HHT, which primarily reflect the disease impact on the patient's daily life [11]. Stage 1: episodic EPX that resolve spontaneously. Stage 2: periodic EPX sometimes following mechanical trauma, requiring no more than one hospitalization and transfusion per year, and allowing normal professional activity, Stage 3: frequent spontaneous EPX requiring multiple hospitalization and transfusions per year with resulting incapacitation or inability to lead a normal life. The therapeutic approach will depend on the stage of presentation.. Stage 1 does not require any treatment. Stage 2 should be treated whenever blood transfusions are necessary. Stage 3 represents an indication for therapy and usually requires a combi-

nation of both conventional ENT procedures (local treatments and scleroses, clipping of ethmoidal arteries, etc...) and embolization that is currently generally considered the better therapeutic alternative, albeit still palliative in nature, unless it has been proven that collateral supply (mainly via ethmoidal arteries) has developed.

Non symptomatic telangiectasias should not be treated. In symptomatic HHT-related telangiectasias, embolization with particles gives a satisfactory immediate result with immediate hemostasis, lasting from 3 weeks to 2 years in our experience. This reflects the high angiogenetic activity of the disease and the continued development of new telangiectasias. Failure to stabilize stage 2 patients, or to transform stage 3 patients to stage 2, will require the addition of more aggressive treatments [11]. Estrogen therapy (at a dose of 1–2 mg/day) has proven to be effective in the treatment of EPX in this disease because of the specific nature of nasal mucosa. Careful clinical and biological follow up has to be performed in order to prevent the side effects or complications of the treatment such as gynecomastia in men, cancers of the endometrium in women, phlebothrombosis, alterations of cholesterol levels, etc...

Treatment of associated lesions in the brain, cord or lungs has to be debated taking in consideration

the natural history of the disease linked to HHT. For example, the risk for hemorrhage seems to be less for unruptured brain AVMs linked to HHT (0.7%/year) compared to non-syndromic brain AVMs (2%–4%/year)[12]. Endovascular treatment of HHT-associated spinal cord arterio-venous fistulae (AVF) in the pediatric population has to be offered, because of potential for neurologic sequelae that can be linked to these lesions [15, 16]. Pulmonary AVF also require treatment because of the hemodynamic symptoms they create, and the potential for devastating neurological deficit associated with thromboembolic diseases (strokes and abscesses).

20.10 Results of Embolization Therapy in Epistaxis

If properly performed, embolization allows immediate hemostasis (about 97% of all patients in our series) [1]. Recurrences occurred more commonly in HHT patients, requiring either additional endovascular treatments, or surgical clipping of the ethmoidal arteries. Satisfactory stable long-term results with no EPX are achieved in 86.3% of patients [1]. “Therapeutic Failures” with recurrence of EPX is seen in 13.7% of embolized cases, 75% of them being HHT patients, which only reflects the aggressive angiogenetic potential in HHT.

Procedure-related morbidity is rare, as are neurological complications. Proper anatomic evaluation can minimize the risks of stroke [23]. Careful fluoroscopic monitoring, low pressure injection of the embolic material and consideration of the potentially dangerous anastomoses and vascular supply to cranial nerves are mandatory to obtain safe and effective results. In our series, complications occurred during the phase of diagnostic angiography in older patients (0.4% and 1% permanent and transient deficits, respectively) but were never related to erratic emboli due to poor technical control during delivery of the embolic material, or to lack of recognition of dangerous arterial anastomoses. Necrosis of the nasal septum occurred in 0.4% of cases. Non-neurological complications include pain, trismus or facial edema that can be sometimes described after these interventions but have always regressed rapidly with analgesics and/or corticosteroids.

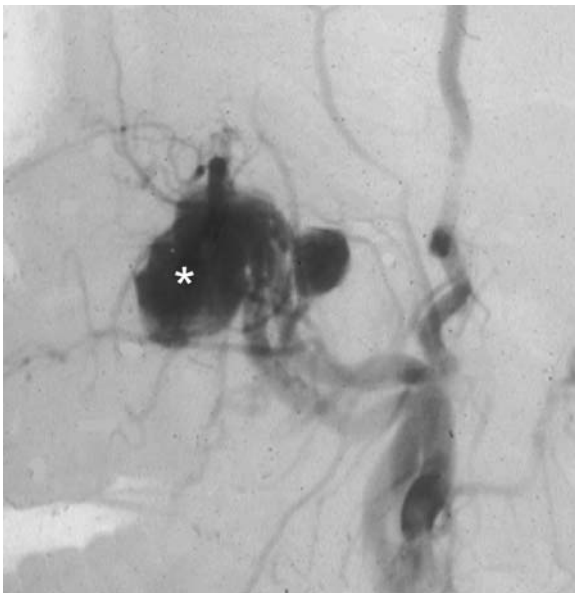


Fig. 20.7. Massive EPX with hemodynamic instability following maxillofacial trauma. A large false aneurysm due to a vascular laceration of the distal internal maxillary artery (*asterisk*) is detected. After microcatheterization of the pathological arterial segment, it is embolized with proximal glue deposition, with rapid hemodynamic stabilization and control of the EPX

20.11 Conclusions

Management of patients with EPX should involve a multidisciplinary approach. An escalating cascade of treatment modalities offers these patients a tailored approach yielding a high success rate with minimal recurrences and low complication rates [23]. Proximal vascular occlusion has to be avoided, as are proximal surgical clippings. They may reduce perfusion pressure to the nasal mucosa but will not avoid reconstitution of the flow by the rich collateral circulation. Distal bilateral embolization to achieve blockage at the arteriolar-capillary bed level are essential for successful endovascular managements of EPX. The effectiveness and safety of the embolization procedure in trained hands has currently rendered it the preferential modality of treatment in intractable EPX. In idiopathic EPX, devascularization of the posterior septal area is emphasized, as this is the usual source of bleeding hardly reachable for examination and cauterization [23].

20.12 “Endovascular management of EPX from a Practical Point of View”

20.12.1 What Has to Be Expected from Angiography in EPX?

- Angiography will rarely show active bleeding or its cause. This should not preclude embolization where clinical indications exist.
- A unilateral bleed, or a unilateral angiographic localization of bleed should not preclude bilateral embolization.
- The clinical, biological and imaging data orient the diagnosis and will help to choose the appropriate material to use.
- In idiopathic EPX secondary to hypertension or coagulation disorders, angiography is most often negative. The aim of an angiography is then to study the vascular anatomy of the skull base and the inter-territorial and inter-regional anastomoses.
- In the case of HHT disease, telangiectasias are detected at the level of the nasal mucosa. Bilateral embolization will also need to be performed in these conditions. Ethmoidal arteries are often well developed in these patients and it is always

necessary to assess them properly in order to manage appropriately these patients, by either endovascular or surgical methods.

- Less frequently, mucosal hyperemia can occur in women during the premenstrual period (Fig. 20.2). EPX in those cases is usually modest and does not require therapy most of the time. Intracranial vascular malformations draining towards the cavernous sinus and secondarily through orbital veins may give rise to EPX: treatment of these malformations relieves the bleedings thanks to the secondary venous decongestion.
- In traumatic EPX the imaging signs are usually more helpful and may help localize the bleeding site. One has to look for a pseudoaneurysm, arterial spasm or a missing artery. Endovascular treatment should be targeted in priority towards the bleeding zone.

20.12.2 What Causes of Epistaxis Require Emergent Treatment?

- The clinical suspicion of a ruptured internal carotid artery (by trauma, surgical damage or secondary to a cavernous aneurysm) is an absolute emergency, as is also the rupture of the external carotid artery, even if the patient is hemodynamically stable.
- In older patients suffering of hypertension or coagulation disorders (due to hepatic or hematological disorders or to anticoagulation therapy), nasal packing and correction of the causative disease are usually sufficient to achieve hemostasis. Failure of initial treatment requires complementary endovascular therapy, usually performed in a less urgent context.
- Presentation of idiopathic EPX will often allow a deferred embolization procedure.

20.12.3 When Is Embolization Required in HHT Disease?

Repeated embolization is usually necessary. In our experience clinical remissions can last from few weeks to years, and recurrences will usually require new treatment. We perform embolization during the acute phases of hemorrhage, when the bleeds are too frequent and interfere with the quality of daily professional or personal life, or when blood transfusions are necessary [1, 11]. The long-term

Cookbook:**Embolization of ENT bleeding**

Common EPX	(Idiopathic, coagulopathy, tumors, HHT..)
Introducer:	5F Terumo (children) 6F Terumo (adults)
Catheter:	4F Vertebral (Terumo) In the case of failure (tortuous vessels e.g.): 4F Simons type II (Terumo)
Guide:	Glidewire 35 (Terumo)
Embolic material:	Contour particles 250-350 microns (Boston Scientific–Target) Gelfoam (cut in strips)

If superselective catheterization is needed:

Guiding catheter:	Envoy (Cordis) 5 or 6F Guider (Boston Scientific–Target) 5 or 6F
Microcatheter:	Excelsior 18 or Excel 14
Microguide:	Terumo 12 (45° or 90° angulation) Mirage 008 (MTI)
Embolic material:	Contour particles (Boston Scientific –Target) 150–250 µm 250–350 µm

Rupture of ICA

Introducer:	5F Terumo (children) 6F Terumo (adults)
Guiding catheter:	Envoy (Cook) 5 or 6F Guider (Boston Scientific–Target) 5 or 6F
Guide:	Glidewire 35 (Terumo)
Microcatheter:	Minitorquer C1FN 130 (Mynvaxis)
Embolic material:	Detachable Gold Valve Balloons 16 (Mynvaxis)

If to be used in children, according to age, weight, and size:

	Eventually 4F introducer and 4F guiding catheter
	If not: 5F introducer and 5F guiding catheter
	Preload system with minitorquer and detachable balloons

Traumatic false aneurysm on external carotid artery

Introducer:	5F Terumo (children) 6F Terumo (adults)
Guiding catheter:	Envoy (Cook) 5 or 6F Guider (Boston Scientific–Target) 5 or 6F

If needed in children, according to age, weight, and size:

	Possibly 4F introducer and 4F guiding catheter (4F Vertebral, Terumo)
Guide:	Glidewire 35 (Terumo)
Microcatheter:	Magic 1.8 or 1.5 (Balt) Excelsior 18 or Excel 14 (Boston Scientific–Target)
Microguide:	Terumo 12 (45° or 90° angulation) Mirage 008 (MTI)
Embolic material:	NBCA (Braun Aesculap, Germany)

success of embolization is unpredictable. Embolization will be repeated as often as necessary and possible. Clipping of the ethmoidal arteries and estrogen therapy will be proposed when the vessels responsible for the bleeds are inaccessible to endovascular therapy.

20.12.4**What Is the Place of Surgery in Epistaxis?**

- Clipping of the ethmoidal arteries is an effective and relatively easy procedure to perform. It should however be offered only after emboliza-

tion, or when the technical or anatomic conditions are inadequate for success in endovascular therapy, such as when the size of the ophthalmic artery does not allow safe distal catheterization.

- Ligature of the internal maxillary artery should be avoided. The unilateral and proximal aspect of the procedure will allow the development of ipsi- and contra-lateral anastomoses that will distally reconstruct the vessel, and will continue to favor rebleeding but without allowing subsequent selective catheterizations.

References

1. Alvarez H, Theobald ML, Rodesch G, Attal P, Magufis G, Bobin S, Lasjaunias P (1998) Traitement endovasculaire des epistaxis. *J Neuroradiol*, 25: 15–18
2. Berenstein A, Lasjaunias P, Terbrugge K (2004) Nasopharyngeal tumors. In: *Surgical neuroangiography*, vol 2.1. Springer, Berlin Heidelberg New York, pp 201–226
3. Breda SC, Choi IS, Persky NS, Weiss M (1989) Embolization in the treatment of epistaxis after failure of internal maxillary artery ligation. *Laryngoscope* 99: 809–815
4. Celil G, Engin D, Orhan G, Barbaros C, Hakan K, Adil E (2004) Intractable epistaxis related to cavernous carotid artery pseudoaneurysm: treatment of a case with covered stent. *Auris Nasus Larynx* 31: 275–278
5. Chandler JR, Serrins AJ (1965) Transantral ligation of the internal maxillary artery for epistaxis. *Laryngoscope* 75: 1151–1160
6. Evans AS, Young D, Adamson R (2004) Is the nasal tampon a suitable treatment for epistaxis in accident and emergency? A comparison of outcomes for ENT and A&E packed patients. *J Laryngol Otol* 118:12–4
7. Hadfield PJ, Gane SB, Leighton SE (2002) Epistaxis due to traumatic internal carotid artery aneurysm. *Int J Pediatr Otorhinolaryngol* 66: 193–196
8. Guttmacher A, Marchuk D, White RI Jr (1995) Hereditary haemorrhagic telangiectasia. *N Engl J Med* 333:918–924
9. Lasjaunias P, Berenstein A (1987) Angiographic protocol of the nasomaxillary region. In: *Surgical neuroangiography*, vol 1. Springer, Berlin Heidelberg New York, pp 371–382
10. Lasjaunias P, Berenstein A, Terbrugge K (1987) Skull base and maxillo-facial region. In: *Surgical neuroangiography*, vol 1, Clinical vascular anatomy and variations. Springer, Berlin Heidelberg New York, pp 261–385
11. Lasjaunias P, Berenstein A (1987) Craniofacial hemangiomas, vascular malformations and angiomatosis: specific aspects. In: *Surgical neuroangiography*, vol 2, Endovascular treatment of craniofacial lesions. Springer, Berlin Heidelberg New York, pp 341–397
12. Mahadevan J, Ozanne A, Yoshida Y, Weon YC, Alvarez H, Rodesch G, Lasjaunias P (2004) Hereditary hemorrhagic telangiectasia cerebrospinal localization in adults and children. Review of 39 cases. *Interventional Neuroradiology* 10: 27–35
13. Metson R, Lane R (1988) Internal maxillary ligation for epistaxis: an analysis of failures. *Laryngoscope* 98: 760–764
14. Plauchu H, DE Chadarevian JP, Bideau A, Robert JM (1989) Age related clinical profile of hereditary hemorrhagic telangiectasia in an epidemiologically recruited population. *Am J Med Genet* 32: 291–297
15. Rodesch G, Hurth M, Alvarez H, Tadie M, Lasjaunias P (2002) Classification of spinal cord arteriovenous shunts: proposal for a reappraisal. The Bicêtre experience with 155 consecutive patients treated between 1981 and 1999. *Neurosurgery* 51: 374–380
16. Rodesch G, Hurth M, Alvarez H, Ducot B, Tadie M, Lasjaunias P (2004) Angioarchitecture of spinal cord arteriovenous shunts at presentation. Clinical correlations in adults and children. *Acta Neurochir (Wien)*, 16; 146: 217–227
17. Schaitkin B, Strauss M, Houck JK, Hershey PA (1987) Epistaxis: medical surgical therapy—a comparison of efficacy, complications and economic considerations. *Laryngoscope* 97: 1392–1397
18. Schroth G, Haldemann AR, Mariani L, Remonda L, Raveh J (1996) Preoperative embolization of paragangliomas and angiofibromas. Measurements of intratumoral arteriovenous shunts. *Arch Otolaryngol Head Neck Surg* 122:1320–1325
19. Small M, Murray J, Maran A (1982) A study of patients with epistaxis requiring admission to hospital. *Health Bull (Edinb)* 40: 24–29
20. Sparacino LL (2000) Epistaxis management: what's new and what's noteworthy. *Lippincotts Prim Care Pract* 4: 498–507
21. Timsit CA, Bouchene K, Olfatpour B, Hermann P, Tran Ba Huy P (2001) Epidemiology and clinical findings in 20563 patients attending Lariboisière Hospital ENT Adult Emergency Clinic. *Ann Otolaryngol Chir Cervicofac*, 118: 215–224
22. Vaamonde Lago P, Martin Martin C, Lechuga Garcia MR, Minguez I, Labella Caballero T (2004) Epidemiological notes on nasal bleeding. *An Otorinolaringol Ibero Am*, 31:123–132
23. Valavanis A, Setton A (1003) Embolization of epistaxis. In: Valavanis A (ed) *Interventional neuroradiology*. Springer, Berlin Heidelberg New York, pp 55–62
24. Wang L, Vogel DM (1981) Posterior epistaxis: comparison of treatment. *Otolaryngol Head Neck Surg* 89: 1001–1006

21 Diagnosis and Endovascular Surgical Management of Carotid Blowout Syndrome

JOHN C. CHALOUKKA, WALTER S. LESLEY, MINAKO HAYAKAWA, and SHIH-WEI HSU

CONTENTS

21.1	Background	271
21.2	Definition	273
21.3	Pathoetiology	274
21.4	Diagnostic Evaluation	277
21.5	Endovascular Techniques	277
21.5.1	“Deconstructive” Techniques	276
21.5.2	“Reconstructive” Techniques	279
21.6	Outcomes	285
21.7	Future Directions	289
	References	290

21.1 Background

The apoplectic consequences of a ruptured carotid artery have been well recognized for centuries, dating back to antiquity. In both the distant and near past, this catastrophe was exclusively the result of a penetrating injury derived from an act of warfare or accident. Surgical intervention for treatment of carotid rupture is also historically relatively old, predating “modern” neurosurgical practice for more than 100 years [1]. JOHN ABERNATHY, a former pupil

J. C. CHALOUKKA, MD

Director of Interventional Neuroradiology, Professor of Radiology and Neurosurgery, University of Iowa Hospitals and Clinics, University of Iowa Carver College of Medicine, 200 Hawkins Dr, 3893 JPP, Iowa City, IA 52242, USA

W. S. LESLEY, MD

Chief, Section of Surgical Neuroradiology, Assistant Professor of Radiology, The Texas A&M University Health Science Center

M. HAYAKAWA, MD

Visiting Assistant Professor of Radiology, University of Iowa Hospitals and Clinics, University of Iowa Carver College of Medicine, 200 Hawkins Dr, 3893 JPP, Iowa City, IA 52242, USA

S. W. HSU, MD

Visiting Scholar, University of Iowa Hospitals and Clinics, University of Iowa Carver College of Medicine, 200 Hawkins Dr, 3893 JPP, Iowa City, IA 52242, USA

and

Assistant Professor, Department of Diagnostic Radiology, Chang Gung Memorial Hospital, Kaohsiung, Taiwan

and successor of the famed surgeon John Hunter, probably can be credited with the first well described published account of successful surgical treatment of a ruptured carotid artery in the late eighteenth century [2]. The case involved a patient who suffered a laceration of the internal carotid artery after being gored in the neck by a bull's horn. Dr. Abernathy successfully arrested the hemorrhage by simple ligation of the artery, which fortunately was well tolerated by the patient.

Although penetrating mechanisms of injury to the carotid arterial tree still occur today, in more recent times, physicians have been increasingly confronted with carotid rupture or so-called “blow-out” as an iatrogenic complication of surgical management of cervical neoplasms [3, 4]. The first well described cases of carotid rupture occurring in association with head and neck surgery date back to isolated reports in 1962 by BORSZDANY [5], followed by the first large case series published by KETCHAM and HOYE in 1965 [6]. The term “carotid blowout” also was first coined during this time period by RUTLEDGE and CAGLE [7].

The reasons for developing carotid blowout in patients with head and neck cancer are potentially multifold, being closely linked to the advent of aggressive operative resections, flap mobilizations, and adjuvant therapies for both primary and recurrent neoplasms. Occasionally, these interventions may produce either direct or indirect trauma to the carotid arterial tree, resulting in a cascade of events that produce progressive structural fatigue and eventual rupture of the affected artery. Owing to the usual loss of anatomic fascial planes and barriers from surgery, catastrophic hemorrhage through various external and oropharyngeal pathways ultimately ensues [4–6, 8–12].

Despite anecdotal reports of technical and clinical success of simple operative ligation for the treatment of carotid rupture, most open surgical series reported over the last few decades have shown exceedingly high rates of mortality and morbidity associated with this complication. Emergent opera-

tive ligation or attempts at primary repair/reconstruction of the common or internal carotid artery had been traditionally the only therapeutic maneuver available for treating carotid blowout [3, 5, 7, 13–20]. These approaches, however, generally resulted in unacceptably high rates of major stroke and mortality. A review of cumulative published outcomes whereby carotid blowout was managed by surgical ligation or repair/reconstruction revealed an average mortality of approximately 40%, and an average major neurologic morbidity of approximately 60% [3, 4, 6, 11, 12].

Several general limitations of operative management of patients with carotid blowout may explain this high morbidity and mortality. Patients suffering a carotid blowout often are hemodynamically unstable, particularly in situations of uncontrollable or protracted hemorrhage. In such scenarios severe reductions in mean arterial blood pressure and cardiac output may be encountered, which in turn can lead to regional and global cerebral ischemia in susceptible patients (e.g. dysfunctional autoregulation, lack of anatomic and/or physiologic collaterals). Adverse reductions in cerebral perfusion pressure can be further exacerbated by induction of general anesthesia, particularly in patients with depleted intravascular volumes who not infrequently will develop profound transient hypotension in response to anesthetic. Extreme blood loss from a carotid rupture not infrequently produces a depletion coagulopathy that leads to further uncontrolled bleeding (particularly in a fresh operative wound). Extensive, often multiple, previous surgeries in combination with either external beam or intraoperative brachytherapy radiation can make operative dissection extremely challenging [4, 12, 15].

Another important limitation of past operative series managing carotid blowout syndrome (CBS) is that they were invariably performed without the benefit of diagnostic angiography. Consequently, the type and precise location of the hemorrhage was often unknown, being mostly inferred from the physical examination. Based upon our past cumulative experience, a wide spectrum of anatomic locations for pseudoaneurysm formation involving the carotid circulation likely would have been encountered in these series [4, 21]. This likely would have resulted in frequently inadequate therapy of the actual pathoetiologic mechanisms of hemorrhage by empiric common carotid ligation.

An additional compounding problem associated with conventional proximal carotid ligation is the

increased risk of thromboembolic complications that may occur from the phenomenon of propagating thrombus within long arterial segments. DANDY was one of the first to recognize that thromboembolic stroke may occur after carotid ligation from a growing tail of thrombus that often develops within the large intravascular “dead space” distal to the site of occlusion [22]. Historically, extensive clinical experience with both open surgical and endovascular parent artery occlusion techniques (mostly for treatment of giant intracranial aneurysms) has shown that “proximal” occlusions of the carotid artery within the neck are associated with a relatively high risk of thromboembolic stroke [23–27]. The risk of stroke from such a proximal occlusion of the carotid artery also is likely to be increased without the use of systemic anticoagulation for some period of time immediately after carotid occlusion [27, 28]. In the past it was likely that systemic anticoagulation was not used in the previously published surgical series for postoperative management of therapeutic carotid occlusion.

Fortunately, an excellent alternative to open surgical management of CBS has become available, consisting at first of various endovascular techniques for occluding major brachiocephalic arteries [25, 27, 29–36]. Furthermore, within the last several years, endovascular revascularization techniques utilizing stent technology also have become more readily available, providing additional options for the successful treatment of CBS without sacrifice of the carotid circulation [37–43].

There are several distinct advantages of endovascular versus open surgical management of carotid blowout. Although patients managed by endovascular approach also may be hemodynamically unstable, there is usually no need to place the patient under general anesthesia with the additional inherent risks of diminished cerebral perfusion pressure. Because only a relatively small arteriotomy is used for many types of endovascular operations, there are generally less difficulties with iatrogenic hemostasis that frequently complicates a large surgical wound. Since the therapeutic interventions are directed through endovascular navigation, dissection through scarred and deformed tissue planes altered by prior radical neck dissection and irradiation is completely avoided.

As shown by earlier publications by our group [3, 4], precise localization of the pathoetiology of hemorrhage can be readily identified in most patients through meticulous diagnostic angiography performed just prior to endovascular surgery. This

permits specific targeting of the most likely site of potential or actual bleeding, as well as better selection of the most appropriate endovascular device and/or technique. Finally, the added risk of postoperative thromboembolic stroke after carotid sacrifice can be substantially reduced by use of both intra-operative and postoperative systemic anticoagulation, which can be done more safely in patients undergoing endovascular operations.

Interestingly, the application of these endovascular techniques specifically for the management of carotid rupture is a relatively recent development. The first reports of successful treatment of CBS using endovascular therapeutic techniques date back to the mid-1980s [29, 33, 34]. However, a rigorous evaluation of the specific indications and technical approaches to this problem did not occur until 1995, when our group at Yale published a preliminary clinical series on the first 15 patients managed by an interdisciplinary protocol centered on endovascular surgery [3]. At that time we also recognized that the various scenarios of carotid rupture actually manifest in a few discrete and well recognizable patterns of clinical presentations, which we coined the “carotid blowout syndrome” [3, 4]. This permitted the creation of a simple classification scheme that provided a means of rapidly communicating the nature, severity, and urgency of a given clinical presentation, which greatly facilitated triage and therapeutic planning [4]. Our subsequent work and that of others have shown that CBS can be effectively managed by a well-coordinated, multidisciplinary protocol centered on deconstructive endovascular techniques [3, 4, 21, 29, 35, 36].

Although our results with deconstructive endovascular management of CBS have been overall significantly better than previous open surgical series, there is considerable room for improvement, owing to a combination of acute complications, technical limitations, and recurrent disease. Problems such as delayed collateral failure resulting in stroke, acute intolerance to balloon occlusion of the internal carotid artery, and recurrent hemorrhages, remain as significant challenges to still overcome when utilizing so called deconstructive techniques. Consequently, we have begun to aggressively pursue an alternate management strategy using so-called endovascular reconstructive techniques centered on stenting with or without adjunctive measures. Our recently published case series experience with this approach has been indeed very favorable, and has now led us to consider fully adopting this change in treatment paradigm [43].

This chapter will review some of these issues and present both diagnostic and therapeutic strategies for managing carotid blowout using modern endovascular approaches as the centerpiece of a well coordinated multidisciplinary paradigm.

21.2 Definition

Based upon a combination of our previous review of the literature and cumulative clinical experience, our group proposed that the varying presentations of actual or potential hemorrhage arising from the carotid circulation can be conveniently classified within a broad clinical diagnostic scheme termed the “carotid blowout syndrome” [3, 4]. CBS can be operationally defined as either an episode of acute hemorrhage (usually trans-oral or trans-cervical), or exposure of a portion of the carotid arterial system (e.g. wound dehiscence, devitalized musculocutaneous flap), that occurs in a patient who previously had undergone a surgical resection of a craniocervical neoplasm. Although this classification scheme derives mostly from the commonly encountered clinical scenarios of carotid hemorrhage in head and neck cancer patients, it is equally valid for accidental, intentional, or other iatrogenic penetrating injuries to the cervical carotid circulation [4].

The clinical spectrum of CBS can be sub-classified into three distinct groups of affected patients. This nosologic scheme originally was created out of a need for enhanced clarity and uniformity in describing certain clinical scenarios that would frequently arise, which in turn could permit more efficient communication and triage between the clinical services responsible for the care of these patients. Based upon extensive review of the literature, these group definitions are equivalent to many previously described variations of carotid blowout [3, 12, 18, 29].

The first distinctive type of presentation of CBS is in patients who develop wound dehiscence from prior radical neck dissection or flap mobilization, resulting in a visibly exposed carotid artery. In such a setting it is well recognized that the exposed artery will inevitably rupture if it is not promptly covered with well-vascularized, viable tissue (e.g. free pedicle flap, rotated musculocutaneous flap, etc.). For such a scenario, although rupture of the carotid artery has not occurred at this point in time, there

is a considerable threat of eventual rupture, leading to the designation: threatened carotid blowout (or Group 1 CBS).

A second commonly encountered group of CBS patients are those who present with a short lived acute hemorrhage that resolves either spontaneously or with simple surgical packing. The hemorrhage is typically either transoral or transcervical through a surgical wound or fistula. These events may be episodic, and are considered sentinel hemorrhages occurring from a ruptured vessel with a pseudoaneurysm that intermittently leaks. Because there is no real wall with supporting structural elements around the pseudoaneurysm, unconfined rupture is almost always certain to eventually occur. Such a scenario may be described as an impending carotid blowout (or Group 2 CBS).

The final group of patients with CBS is those who present with an apoplectic, profuse hemorrhage that is not self-limiting and is not well controlled with surgical packing. This presentation often, but not always is preceded by the above mentioned sentinel hemorrhage of impending carotid blowout. In this scenario, there has been complete rupture of the affected artery and lack of confinement by the organized hematoma surrounding the associated pseudoaneurysm. These patients rapidly deteriorate from exsanguination, unless intensive resuscitation measures and therapeutic occlusion of the ruptured artery is implemented immediately. It is this most catastrophic scenario that is best designated as acute carotid blowout (or Group 3 CBS).

21.3 Pathoetiology

There are a variety of causes of carotid rupture, which can be broadly grouped into the following three categories: traumatic, non-traumatic (related to “spontaneous” carotid dissection), and those related to head and neck surgical management of cervical cancers. Traumatic carotid rupture or blowout can occur from various penetrating insults (e.g. ballistic missiles, knives, impalements, etc.) or blunt trauma (e.g. dissecting aneurysm). Iatrogenic traumatic injury to the carotid not associated with head and neck cancer surgery is also an occasional cause of delayed rupture, typically occurring in the setting of carotid endarterectomy (CEA). In fact the original term “carotid blowout” was probably first

applied in the well-known complication of delayed rupture of a venous graft used for patch angioplasty after CEA [7].

It has also become increasingly recognized that non-traumatic or “spontaneous” carotid dissection can occasionally result in significant pseudoaneurysm formation and growth, which arguably may pose a subsequent risk of a catastrophic, life-threatening hemorrhage. In the past conventional teaching has contended that in the absence of disruption of the normal fascial planes within the neck (as in the case of penetrating trauma or surgical intervention), the expanding hematoma that constitutes a pseudoaneurysm should stay well contained within the carotid sheath, and therefore pose an unlikely hazard of exsanguination. However, our group and others have noted rare anecdotal cases of “breakthrough” hemorrhages occurring in non-traumatic carotid dissection that resulted in Group 3 CBS. This has in part lead to more of an impetus toward active intervention when dissecting pseudoaneurysms are now diagnosed, although admittedly there is little known about the true natural history and risk of these lesions to provide strong evidence-based support of such a management strategy.

Although recently our group at UIHC has seen an unexplained rise in traumatic and spontaneous etiologies of CBS, our overall cumulative experience has revealed that most cases are an iatrogenic complication of aggressive multimodality treatment of malignant cervical neoplasms. It has been previously hypothesized that there are numerous putative mechanisms of injury to the carotid artery that ultimately lead to CBS in head and neck cancer patients [3, 4–6, 8–12, 27]. Both the cellular and extracellular matrix components of the carotid arterial wall may be directly damaged from a wide spectrum of insults commonly encountered with contemporary head and neck surgical management of cervical carcinomas. These include iatrogenic surgical manipulation during functional neck dissections or radical tumor resections, radiation induced necrosis (from either an external beam source or intra-operative brachytherapy), exposure desiccation after breakdown of a reconstructive flap, secondary wound infections producing fasciitis, direct tumor invasion, and enzymatic degradation from oropharyngocutaneous fistulae.

21.4 Diagnostic Evaluation

Many patients with CBS present in an unstable condition, which obviously requires emergent triage and immediate basic resuscitative measures. However, at some point early in the evaluation of any CBS patient who is to be considered for possible intervention, a focused, yet detailed history with particular attention to the specific types and anatomic sites of previous surgical intervention, is critical for considering not only where the likely source(s) of bleeding may be located, but also what treatment options may be most realistically considered. For example, patients with previous bilateral functional neck dissections and flap reconstructions are more likely to harbor multi-focal (and unfortunately bilateral) disease, making deconstructive intervention less favorable, if not impossible. This is also the case in patients with a previous history of CBS that required deconstructive intervention, who return with so-called recurrent carotid blowout syndrome (rCBS). Again, consideration of realistic treatment options will largely depend on whether an internal carotid artery already has been therapeutically occluded, and where the suspected source of recurrent bleeding is originating.

A quick and directed otolaryngologic examination is also an essential preliminary step for evaluating any patient with CBS. Of particularly paramount importance is the ability to localize and/or lateralize the site of bleeding, which will enable a more focused search for the precise pathoanatomic substrate when the patient is subsequently studied by catheter angiography. Furthermore, prospective identification of the most likely potential pathoetiology of the CBS, such as a flap breakdown with carotid exposure, presence of a pharyngo-cutaneous fistula and/or infection, or recurrent tumor can facilitate therapeutic decision making when treatment options are considered.

Often in the setting of Group 2 and 3 CBS, the use of cross sectional imaging studies are of limited utility, owing to the emergent nature of these presentations and need for prompt and definitive intervention. However, in patients who are clinically stable or who present with threatened CBS, CT or MR imaging may serve the dual purpose of not only helping to elucidate the likely source of active or potential bleeding, but also assessing open surgical options for the overall management of the patient's disease. In our experience, close scrutiny of either contrast enhanced CT or MRI scans of the neck in the set-

ting of CBS not infrequently shows evidence of one or more of the following features: pseudoaneurysm formation, pockets of extravasation, fistulae, tumor encasement of a large carotid vessel, or prominent tumor enhancement (secondary to neoangiogenic hypervascularity). These cross-sectional imaging studies may be supplemented with three-dimensional reconstruction CT angiography or MR angiography to better define the relevant cervical and cranial vasculature. These non-invasive imaging modalities have improved substantially over the last few years, and are increasing supplanting catheter angiography for initial diagnostic work up of a variety of vascular diseases. However, in our experience we have found that both CTA and MRA have limited capability in detecting the likely pathoetiological sources of bleeding in the setting of CBS, particularly lesions involving the external carotid system. Therefore, at our institution we do not routinely utilize either of these modalities in the preoperative evaluation of CBS.

As in the case of obtaining a good directed clinical history and physical examination, recognition of the critical imaging findings relevant to optimal multidisciplinary management can greatly facilitate the localization of pathology to target for intervention. With regards to open surgical planning, demonstration of the presence and extent of recurrent neoplasia by cross-sectional imaging will to a large degree determine whether this is not only a therapeutic option, but also what endovascular approaches may be preferable to manage the CBS. For example, a patient who has been previously "disease-free" or "disease-stable", but develops a flap breakdown that results in threatened carotid blowout, may also harbor an unrecognized primary or nodal recurrence that is amenable to salvage resection. In such cases (particularly if the mass is attached to or encasing the carotid artery) it may be preferable to perform therapeutic occlusion of the artery (providing that the patient tolerates balloon test occlusion) above and below the expected margins of resection in order to simplify such an operation.

Ultimately, the gold standard for diagnostic evaluation of a patient with CBS is a meticulously performed catheter angiography study of the head and neck, using modern high resolution (1024×1024 pixel matrix) and preferably biplane digital subtraction imaging (DSA) of the cervical and intracranial carotid circulation. This requires selective catheterization and injection of each common carotid, external carotid, and not

infrequently internal carotid artery performed in at least three different projections. Frequently the pathology is obvious [4, 27], such as large pseudoaneurysm formation, active extravasation, or fistula formation arising from the ICA, ECA or CCA (Figs. 21.1–21.3). In some cases the source of bleeding is not from a ruptured vessel within the carotid tree, but rather from a recurrent tumor arising from primary or nodal metastatic sites. The mechanism of such bleeding may be either secondary to invasion and/or erosion through an oro-pharyngeal or cutaneous anatomic barrier or from stimulation of tumor neoangiogenesis resulting in hypervascularity [27].

It must be emphasized, however, that obvious pathology is not always apparent, requiring one to maintain a very high index of suspicion when scrutinizing the angiographic images. In such cases we have frequently observed very subtle, and/or non-specific alterations in endoluminal contour on close inspection of selective (and occasionally superselective) injection DSA runs that have ultimately turned out to be the source of bleeding in patients with Groups 2 and 3 CBS (Fig. 21.4a). The areas that require the closest scrutiny are around the common carotid bifurcation, including the external carotid trunk and its lower branches (e.g. superior thyroid, facial and lingual branches), and the internal carotid bulb.

If bleeding is encountered within the lower neck (particular when involving a tracheostomy site), bilateral selective arteriography of the subclavian, costocervical, and thyrocervical arteries also must be performed. Angiographic study of these vessels usually can be closely correlated with the actual site of bleeding (which should be marked by a radio-opaque object). In our experience, the tracheostomy site or underlying distal margins of a surgical neopharynx are the most commonly affected structures, which typically bleed from tumor recurrences, erosions, and radiation-induced necrosis.

The anatomic substrate of potential collateral pathways (particularly involving the circle of Willis) must also be assessed, which requires angiographic study of the intracranial circulation from selective carotid and vertebral injections. Prospective identification of major breaks within the circle of Willis that result in partial or complete isolation of the cerebral circulation [e.g. ipsilateral absent A1 segment and posterior communicating artery (PCoA)], is often enough to dissuade one from performing a balloon test

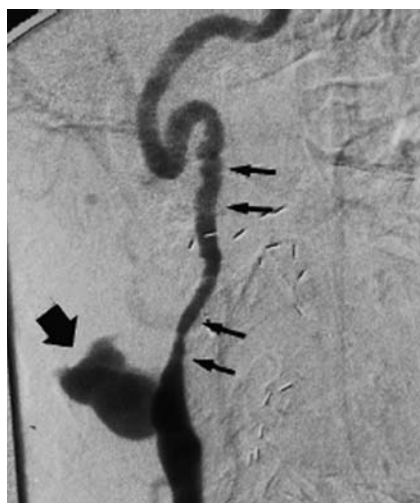


Fig. 21.1. Angiogram shows a large pseudoaneurysm of the common carotid artery (*large arrow*). Narrowing of the internal carotid artery (*small arrows*) is also present, most likely related to postoperative cicatrization, radiation-induced changes, or tumor encasement

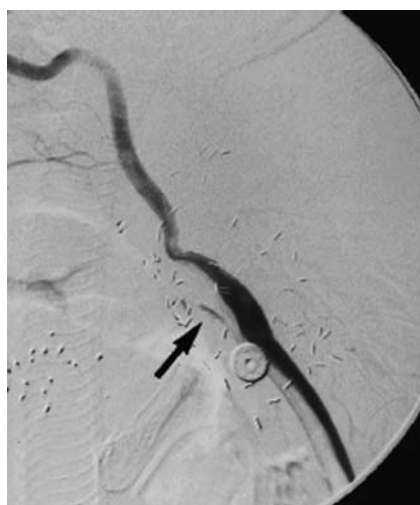


Fig. 21.2. Left common carotid artery (CCA) angiogram shows a small amount of extravasation from the CCA into the oropharynx (*arrow*) from a fistula that developed after rupture of a pseudoaneurysm

occlusion in consideration for a deconstructive intervention. Other anatomic variants, such as a persistent trigeminal artery are also likely to discourage consideration of a therapeutic occlusion of the ipsilateral carotid artery.

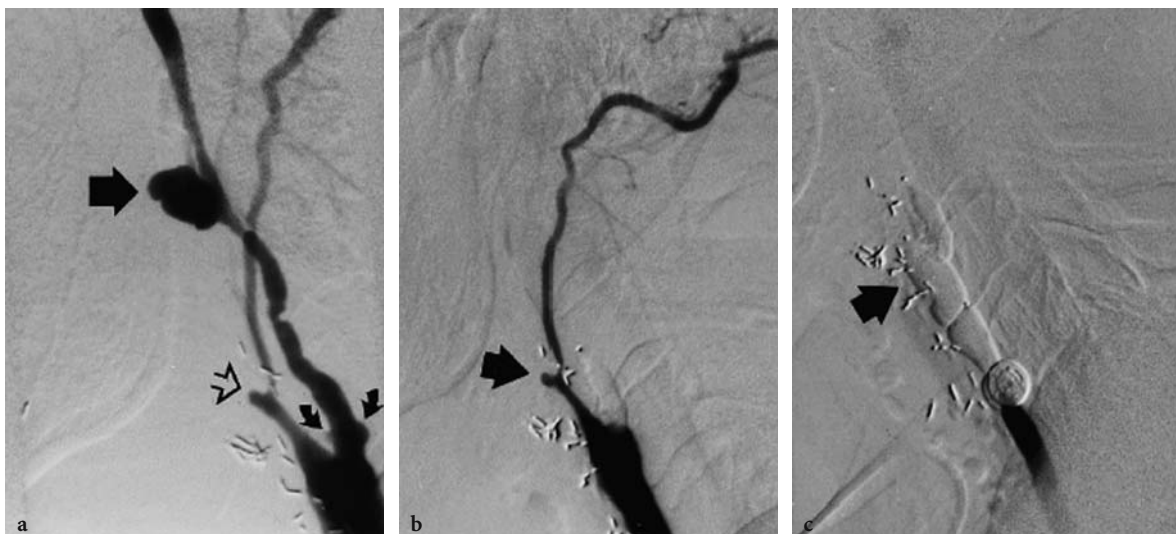


Fig. 21.3. **a** Right common carotid artery angiogram shows a large pseudoaneurysm of the mid-cervical right internal carotid artery (ICA) (*large solid arrow*). Small concurrent pseudoaneurysms of the proximal right ICA (*curved arrows*) and right external carotid artery (ECA) (*open arrow*) are also present. **b** Right common carotid artery injection after balloon occlusion of right ICA shows the pseudoaneurysm of the right ECA (*arrow*) still fills. **c** Angiogram obtained after composite permanent balloon occlusion shows embolization of the carotid system. A balloon had been positioned across the origin of the right ECA (*arrow*)

21.5 Endovascular Techniques

Over the last decade, dramatic technical and technological progress in endovascular surgery has greatly expanded its role in the management of many types of intracranial and extracranial cerebrovascular diseases. These advances have been particularly significant in two categories: (i) new micro-catheterization technologies and (ii) new endovascular stent systems. Both have yielded devices that are safer, easier, and ultimately more effective to use. For now nearly two decades it has been increasingly recognized that the acquired arterial injuries of CBS are often readily amenable to endovascular intervention. However, the specific indications and appropriate selection of techniques and technology had only recently become better defined in the past decade [3, 4, 21]. This definition is already undergoing substantial revision and evolution in response to inherent limitations and complications of various endovascular approaches [21, 43] and our expanded technical and technological capabilities.

Endovascular management of CBS can now be broadly defined into the two following categories: “deconstructive” and “reconstructive” approaches. The former consists of various techniques and technology used to produce therapeutic occlusion or

“sacrifice” of an affected artery. In contrast, the latter category consists of various techniques and technology for eliminating bleeding while preserving the patency of an affected carotid artery.

21.5.1 “Deconstructive” Techniques

Therapeutic occlusion of major brachiocephalic arteries is one of the oldest neuroendovascular therapeutic techniques, originally having been developed for the treatment of inoperable aneurysms of the cranial base using simple open ligation or gradual clamping (e.g. Seleverstone clamp) of the carotid arteries. Both SERBINENKO [30, 31] and DEBRUN [32, 44] are credited with pioneering the endovascular equivalent of such an approach through their use of detachable balloons for the treatment of certain types of giant aneurysms (e.g. cavernous segment in the mid and late 1970s). Today, besides detachable balloons, a wide variety of embolic devices and endovascular techniques may be employed for deconstructive therapy of CBS. The selection of a particular device or technique for therapeutic arterial occlusion may be based upon a variety of factors, including: the specific pathoetiologic lesion identified on angiography, prevailing cerebrovas-

cular hemodynamics, perceived tolerance to internal carotid artery occlusion based upon balloon test occlusion (BTO), access to the lesion, urgency for rapid and definitive occlusion, and availability and/or comfort level with certain techniques/technologies.

Detachable latex (Goldvalve, Nycomed) or silicone detachable (DSB, Boston Scientific-Target) balloons remain as one of the easiest and most reliable means of achieving rapid occlusion of a large vessel, such as the common or internal carotid arteries, and therefore in my view continue to be essential embolic devices for such applications. These devices can be readily mounted on various conventional microcatheters (e.g. Tracker 18 HiFlo Unibody, Boston Scientific-Target, or Prowler 14 (Cordis Neurovascular, Miami Lakes, FL), and once navigated into the targeted vasculature, rapidly inflated and deployed by simple traction detachment (Figs. 21.3, 21.4) As a general rule it is most desirable to place the first balloon into a fairly distal purchase within the ICA (typically the petrous segment), owing to the risk of thromboembolism that may occur from the creation of a long propagating thrombus in case of more proximal placement of the balloon within the cervical carotid [4]. A second important rule for therapeutic carotid occlusion is to always use a second so-called “safety” balloon (Figs. 21.3c, 21.4b) to ensure permanent occlusion, since detachable balloons on occasion are well know to prematurely deflate. Optimal placement of the second balloon will largely depend upon the location of the breach within the carotid artery, since trapping of the

defect is the effective means of stopping/preventing further hemorrhage [4]. In some cases, therapeutic occlusion of the entire carotid system (ICA, CCA, and ECA origin) is necessary or desirable, such as in cases of multifocal pseudoaneurysms and fistulae or in patients with Group 1 CBS who are candidates for salvage surgical resection of local recurrent disease. In such case performance of a so-called composite carotid occlusion is indicated [4, 21, 27].

Unfortunately, the use and availability of detachable balloons has been steadily on the decline over the last few years, which just recently were markedly amplified by the abrupt discontinuation of the only FDA approved detachable balloon in the United States (DSB; Target-BSC). Currently, it remains unclear if this device will be reintroduced, which has created a new impetus in utilizing alternative techniques and technology.

Many centers have been using various types of embolic coils (e.g. non-retrievable fibered platinum, detachable bare platinum) as an alternative or adjunct to balloon occlusion of the carotid arteries. Our group was first to propose using detachable coils in combination with detachable balloons in cases where composite carotid occlusion was needed [4]. Although these conventional embolic coils can produce therapeutic occlusion of large caliber vessels, such as the common and internal carotid arteries, there are several intrinsic disadvantages in using them as the sole embolic agent. These disadvantages include: (i) lack of precision in deposition within the distal targeted vessel segment; (ii) frequent instability of the first “framing coils” in large caliber arter-

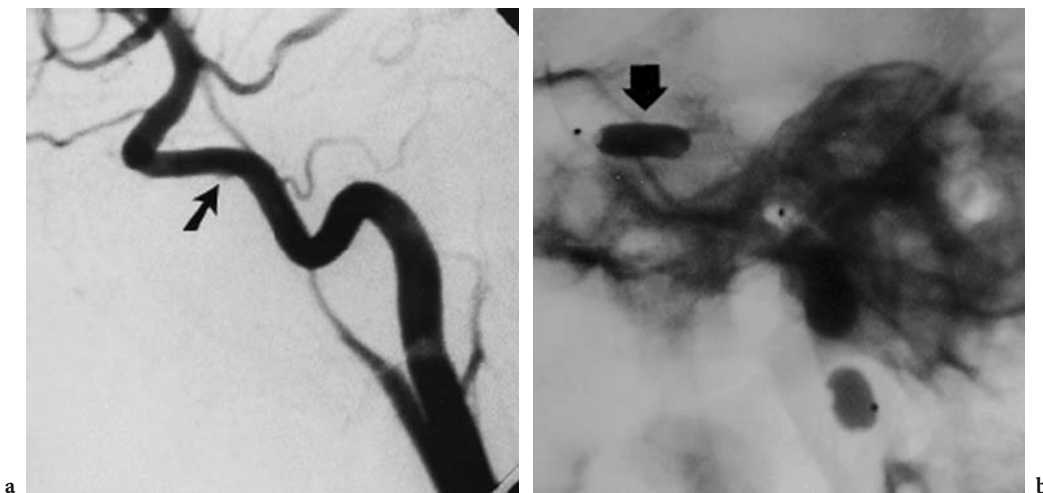


Fig. 21.4. **a** Right common carotid artery angiogram shows a subtle pseudoaneurysm of the cavernous internal carotid artery (ICA) (*arrow*). **b** Lateral radiograph shows three detachable balloons used in permanent balloon occlusion of the right ICA. The most distal balloon covers the orifice of the pseudoaneurysm (*arrow*)

ies that are typically carrying high volumetric blood flow; (iii) need to use a relatively large number of coils to achieve occlusion; (iv) increased procedure time and expense owing to the typically long times required to achieve arterial occlusion; and (v) possible increased risk of artery to artery thromboembolism as progressive thrombosis within the coils occurs when there is still antegrade flow within the artery.

A new detachable platinum coil coated with a hydrogel polymer recently has been introduced for intracranial aneurysm therapy (HydroCoil, Microvention), which our group and others have found to be also useful for carotid occlusion, at least in potentially decreasing the number of coils needed to occlude the targeted artery. Unfortunately these coils still suffer from many of the same above-mentioned disadvantages. Although no definite prototypes have been revealed, a few device companies have indicated some interest in creating more novel large vessel occlusion devices that may incorporate certain already existing technologies, such as downstream embolic filtering devices, stent grafts, and hydrogel polymers.

In cases requiring smaller vessel occlusion, such as pseudoaneurysms or tears to the ECA and brachio-cervical branches, both nonretrievable platinum microcoils (e.g. Tornado, Cook, Indianapolis, IN; Vortex, Boston Scientific-Target, Fremont, CA), and various retrievable/detachable platinum microcoils (e.g. GDC, Boston Scientific-Target) can be used. Owing to the enhanced control and safety of the latter type systems, our group has long switched over to using them exclusively. Occasionally, our group has utilized careful injections of small aliquots of cyanoacrylate-iodinized oil embolic mixtures (Trufill-nBCA, Cordis Neurovascular) to very effectively obliterate small distal pseudoaneurysms of the ECA circulation [45] (Fig. 21.5).

Occasionally some cases of CBS are ultimately found to be the result of hemorrhage from a hypervascular neoplasm (typically in our experience from transformed squamous cell carcinomas that have exuberant induction of angiogenesis after multimodality treatment). Endovascular therapeutic devascularization can be achieved with superselective transarterial embolization using either conventional embolic agents such as polyvinyl alcohol (PVA) particles (Contour, ITC/Target Therapeutics/Boston Scientific, Fremont, CA) or more recently with the slow polymerizing cyanoacrylate 2-octyl cyanoacrylate (e.g. Dermabond) [46]. Additionally, in cases where superselective catheterization of sup-

plying arteries is not feasible, we have successfully utilized direct puncture tumor embolization with either absolute alcohol or cyanoacrylate embolic mixtures [47].

21.5.2 "Reconstructive" Techniques

In lieu of the inherent risks of unilateral therapeutic ICA occlusion, the unfeasibility of bilateral therapeutic ICA occlusion in most patients who have already undergone a previous carotid occlusion, and the high rate of recurrent disease resulting in future episodes of CBS, there has been a growing impetus to alternatively consider endovascular repair of the damaged arterial segment, in an effort to preserve flow within the vessel. Therefore an alternative strategy for the management of CBS is to reconstruct the damaged artery through the various mechanical and biological effects of endovascular stents [38, 40–43, 48].

With the increasing use of stent-assisted angioplasty for the treatment of extracranial carotid occlusive disease, it is becoming more widely acknowledged that such endovascular reconstructive techniques can be performed with a relatively low rate of peri-operative cerebral ischemic complications [42, 49–52]. These ischemic complications, on average appear to be lower than those for therapeutic occlusion of the carotid artery using either open or endovascular techniques.

There are clearly a few important theoretical advantages afforded by stent reconstruction of the carotid artery that may ultimately enhance the overall efficacy of endovascular management of CBS. First and foremost, such techniques are aimed at preservation of the affected carotid artery, thereby having the combined effect of broadening application of endovascular intervention (for example in patients who outright fail carotid BTO or possess an isolated circulation from an incomplete circle of Willis), and reducing delayed ischemic complications (which can be both thrombo-embolic and hemodynamic) Second, the scaffolding and positive remodeling force induced by placement of one or more self expanding stents not only maintains endoluminal patency, but likely reinforces the mechanical integrity of the arterial wall, which in the case of CBS has been damaged by the previously described processes developing as a consequence of therapy. This ultimately should result in an artery that is more resistant to future spontaneous rup-

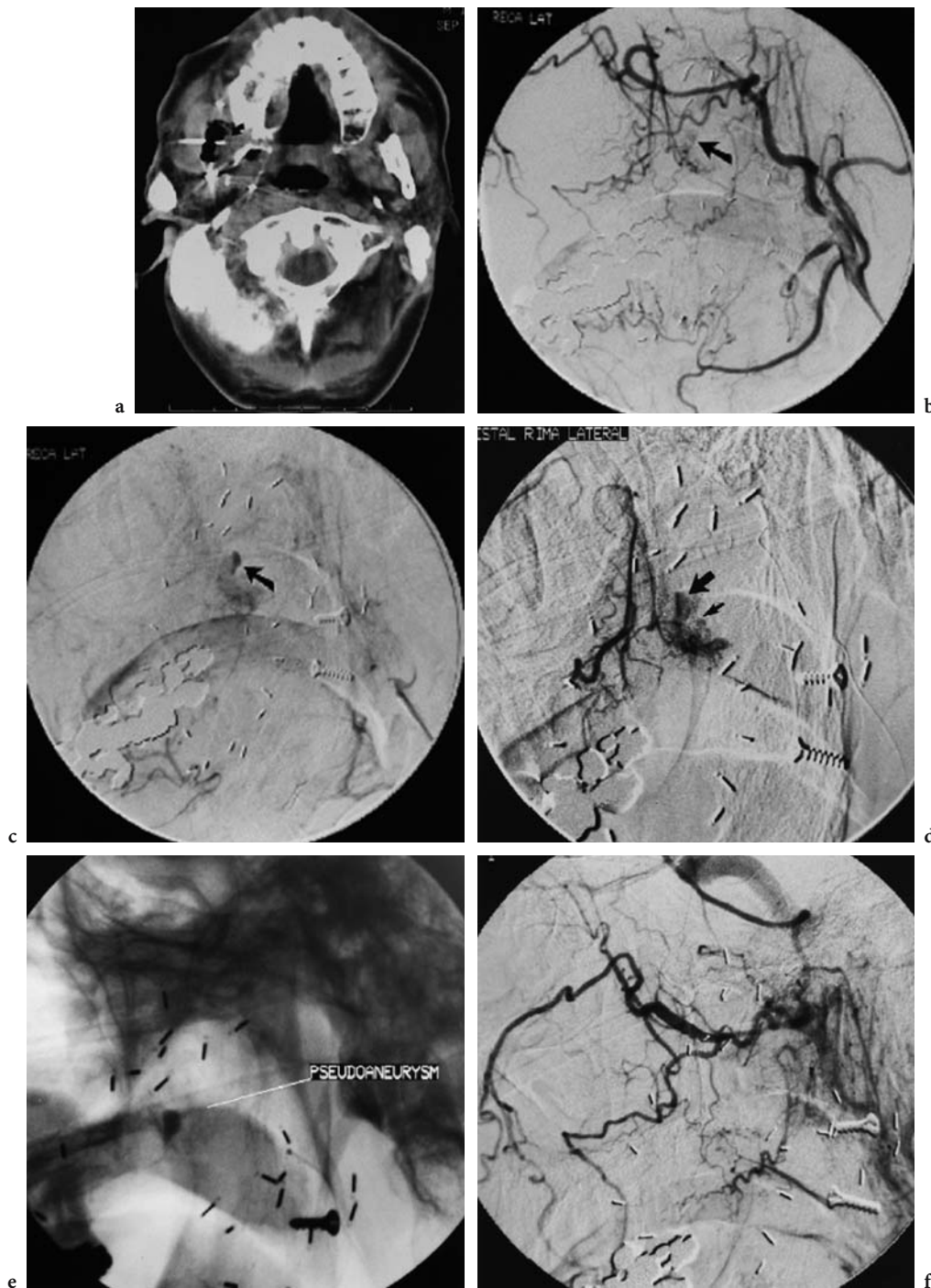


Fig. 21.5a-f. Iatrogenic pseudoaneurysm of an external carotid artery branch after CT-guided biopsy. **a** Axial nonenhanced CT image shows the tip of a 22-gauge Chiba needle within the anterior aspect of a soft-tissue abnormality (*curved arrow*) that was concerning for recurrent squamous cell carcinoma. Histologic analysis showed only inflammatory changes. **b,c** Two weeks later the patient presents with arterialized epistaxis. **b** Selective right external carotid arteriogram, lateral projection, shows mild irregularity of the distal internal maxillary artery and focal dilatation of the distal buccal branch (*arrow*). **c** Delayed image from same injection shows filling of a 5-mm pseudoaneurysm (*arrow*). **d-f** Endovascular surgical management. **d** Superselective arteriogram, lateral projection after catheterization of the common trunk of the descending palatine and buccal arteries, shows filling of the pseudoaneurysm (*large arrow*) and adjacent extravasation (*small arrow*). **e** Delayed image (unsubtracted) from same injection shows persistent filling of the pseudoaneurysm. **f** Selective right external carotid arteriogram immediately after embolization shows complete occlusion of the buccal branch pseudoaneurysm

ture. Another putative benefit of stent-assisted reconstruction of an affected carotid artery is the favorable alteration in flow mechanics that lead to a reduction in disturbed blood flow and eddy formation that has been linked to cerebral artery-to-artery thromboembolism [42,52]. Such favorable alterations in hemodynamics may translate into a significant risk reduction of thromboembolic ischemic complications.

Consequently, over the last 6 years our group has progressively moved from a primarily “deconstructive” to a primarily “reconstructive” paradigm for the endovascular management of CBS. This approach first originated in the mid 1990s at Yale, when we occasionally encountered patients who were not candidates for therapeutic carotid occlusion owing to outright failure of a balloon test occlusion or angiographic demonstration of an isolated anterior hemispheric circulation (i.e. hypoplasia/aplasia of the ipsilateral A1 segment and posterior communicating artery). During this time our experience with carotid stenting was starting to evolve, providing an opportunity to try this alternative technique in a few selected patients [39, 43]. Over time we broadened inclusion criteria to all patients presenting with CBS who were at high risk of a stroke from therapeutic carotid occlusion. This included patients with advanced age (>65 years), significant cardiovascular and/or pulmonary co-morbidities, significant relative reduction of CBF ($\geq 20\%$) based on cerebral SPECT imaging during BTO, and contralateral carotid occlusive disease. Within the last 3 years at UIHC, we have now shifted to attempting a reconstructive procedure whenever feasible if the affected arterial segment involves the common or internal carotid artery, with the expectation that such a shift in therapeutic strategy could serve the primary purpose of reducing overall risk of peri-operative stroke, while at the very least keeping the rates of immediate and delayed hemorrhagic arrest at the same level of our previous experience with deconstructive techniques [43]. Arterial injuries involving the external carotid tree or rarely branches arising from the subclavian arteries continue to be managed by deconstructive techniques as was originally conceived in our early experience.

We have successfully utilized a few different techniques of stent-reconstruction for the management of CBS, which can be broadly classified as follows. First, in a similar fashion to techniques developed for the treatment of wide-neck aneurysms of the intracranial circulation [37,53–56], endovascular stenting across a pseudoaneurysm can be per-

formed for neck-bridging scaffolding to eventually support endosaccular embolization [38,39,43,48] (Figs. 21.6, 21.7). The rationale for such an approach originally derived from animal studies of experimentally constructed side-wall aneurysms, which showed that stent placement alone could result in sufficient flow diversion and altered recirculation that ultimately produces thrombosis and neointimalization of the aneurysm sac and ostium, respectively [53–55,57]. However, the time required for aneurysm obliteration can be substantial in such circumstances, which prompted the idea of trying to conjointly use thrombogenic coils placed within the aneurysm after deployment of the stent, in order to promote rapid thrombotic occlusion [37,55]. This strategy has indeed been used successfully in an increasing number of clinical cases [39,43,48], although its application in the treatment of large pseudoaneurysms is questionable [39]. We have also experimented with use of alternative embolic agents, such as liquid adhesives [39], which can be delivered either by endovascular catheterization or direct puncture (Fig. 21.7e) of the pseudoaneurysm. Although we have had success with such techniques in a small number of cases, widespread adaptation has been limited owing to concerns of proper control and stability of the liquid embolic agent.

The second technical strategy that we have successfully employed for management of CBS is the use of overlapping, self-expanding stents deployed across the neck of a pseudoaneurysm or along a weakened segment of the affected artery [43,58]. The major advantage of such a strategy is that the effective porosity of the stent cell configuration is substantially decreased, resulting in a combination of additional flow diversion away from the aneurysm sac, and markedly reduced bulk flow out of the aneurysm sac. Such alterations in fluid mechanics may diminish growth and re-rupture of the pseudoaneurysm, as well as promote its thrombotic occlusion (both spontaneously and iatrogenically with the assistance of embolic agents). Furthermore, the added relative coverage and scaffolding afforded by placement of a second stent allows for better bridging of a pseudoaneurysm neck, which in turn facilitates more secure placement of embolic agents (particularly coils). In fact this approach has overall been so successful that it has now become essentially a standard strategy in all our cases when utilizing uncovered stents for endovascular reconstruction (Fig. 21.6).

For reconstruction of the common carotid or proximal cervical internal carotid artery, we have

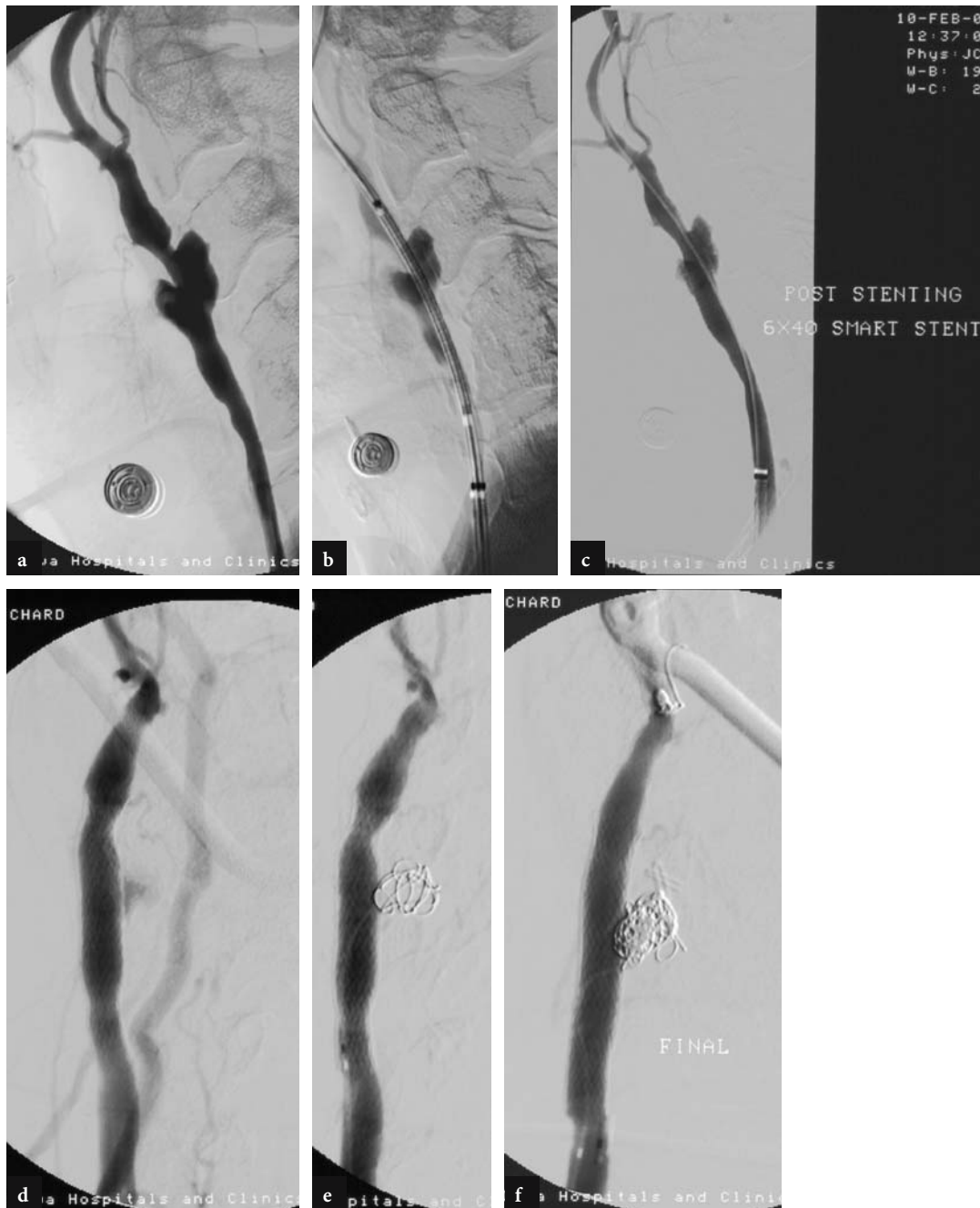


Fig. 21.6a–f. Stent-assisted coiling of pseudoaneurysm. **a** Pre-treatment angiogram, right common carotid injection (lateral projection) shows two large pseudoaneurysms of the right common carotid artery in a patient with Group 2 CBS. Note that the internal carotid artery had been previously occluded from an earlier episode of CBS. **b** Control angiogram during stent navigation confirms proper positioning of the stent over the diseased segment of the right common carotid artery. **c** Delayed control angiogram after placement of a single Smart Stent. Note the markedly diminished filling of the ventral pseudoaneurysm and moderately reduced filling of the dorsal aneurysm. Active bleeding stopped shortly after deployment. **e–f** Right common carotid injection 48 h after first intervention. **d** The patient developed a second episode of CBS 2 days later, in which the angiogram shows persistence of the dorsal aneurysm after stent placement. **e** The pseudoaneurysm is entered through a stent cell with a microcatheter, and a framing detachable coil is placed. **f** The final control angiogram shows complete obliteration of the pseudoaneurysm. No recurrent bleeding was subsequently encountered. A 66-year-old woman with recurrent carotid blowout syndrome in whom a large pseudoaneurysm developed

avored using Nitinol self-expanding stents (e.g. Precise, Cordis Endovascular or Acculink, Guidant), owing to a combination of factors that include: ease of access with a long (90-cm) 6-F sheath, high precision and accuracy of delivery, good conformity within tapering segments, and relatively high positive remodeling force after deployment. Our preferred techniques for carotid stenting are similar to those used for extracranial atherosclerotic revascularization [42]. For initial access into the carotid circulation, there are two basic techniques commonly employed. In both cases, a large inner diameter guiding catheter or sheath must be positioned into the common carotid (or occasionally the innominate artery). It has been our experience that placement of a long arterial sheath from a percutaneous common femoral artery puncture is preferable from multiple perspectives, including enhanced stability, ease of coaxial delivery of PTA and stent catheters, and minimization of the size of arteriotomy. This technique is performed as follows. A standard 6-F arterial sheath is inserted into the common femoral artery after single wall percutaneous puncture and guide wire insertion. A 5-F diagnostic catheter is carefully positioned within the appropriate great vessel (usually the external carotid artery origin during internal carotid artery PTA/Stenting), for subsequent placement of an exchange length (260 cm) 0.035" or 0.038" (e.g. Amplatz regular or extra-stiff) wire. The diagnostic catheter and sheath are carefully removed, while maintaining the distal purchase of the guide wire. For extracranial stent cases where a 0.018" SmartStent (O.D. = 2.3 mm) or Wallstent (O.D. = 2.4 mm) will be deployed, a 7-F, 90 cm Shuttle Sheath (I.D. = 0.10", O.D. = 0.131") is carefully advanced over the stiff exchange wire, until a stable position within the parent lesion vessel (distal common carotid artery) is obtained. We prefer the final sheath position to be at least 1–2 cm below the lowest planned stent placement to minimize potential stent deployment difficulty. We also find that placing a wide arcing curve on the Shuttle inner dilator and distal sheath, as well as removal of the intervening rotating hemostatic valve facilitates navigation of tortuous aortic arches and brachiocephalic vessels. Care must be taken to hold both components (dilator and sheath) together during initial advancement. Subsequently, the outer sheath is independently advanced into position over the dilator and guide wire within the proximal brachiocephalic vessels. This latter maneuver is critical, since the dilator is poorly seen on fluoroscopy (without a marker band), and therefore may be inadvertently

advanced too far distally into the stenotic lesion if both components are advanced in tandem. An alternative approach that may be employed requires a coaxial technique utilizing a diagnostic catheter (5-F, 120-cm) and guide wire (0.035" or 0.038") within the 90 cm Shuttle sheath, and subsequent staged advancement of each into the appropriate position. The diagnostic catheter and its associated curves may assist in distal navigation, while also minimizing wire/catheter/sheath transitions. Following stabilization, the sheath is then connected to a large bore rotating hemostatic valve, and continuous pressurized heparinized saline infusion. In some cases, smaller delivery devices may be utilized, such as coronary PTCA and stent microcatheters, in which case a 6- or 7-F thin walled guiding catheter with larger internal diameters (e.g. Envoy, Guider, Platform) may be placed primarily or over an exchange guide wire. Appropriate testing of device/catheter compatibility is recommended before attempting therapy.

Generally, self-expanding stents (Smart Stent, Wallstent, Precise stent) are preferred within the extracranial vessels, especially at the level of the common carotid bifurcation. The Wallstent has a greater strut density, but has a tendency to foreshorten significantly during deployment, which makes accurate sizing and placement more difficult. Although more porous, the Smart Stent deploys with relative precision and minimal foreshortening. The Precise and Acculink stents have a much lower profile than the Smartstent, allowing facile, less traumatic passage through tortuous anatomy or stenotic segments. Of the two, the Acculink has somewhat less radial force (positive remodeling force), which may be an advantage for treating pseudoaneurysms (i.e. less risk of iatrogenic rupture). Appropriate measurements of the parent vessel diameter and length of desired coverage are required. For the management of CBS, we prefer to use a stent of 1- to 2-mm greater diameter than the parent vessel (e.g. a 6-mm ICA would receive a 7- to 8-mm diameter stent). Slight oversizing of the stent ensures adequate radial tension and approximation of the device to the endoluminal surface, preventing migration and early thrombosis. This oversizing also may promote a delayed mechanical and biological remodeling of the diseased segment through gradual continued dilatation, and stimulation of various growth factors and extracellular matrix proteinases (occurring over days to weeks). Excessive oversizing of the self-expanding stents should be avoided, since this may result in vessel wall necrosis, and pro-

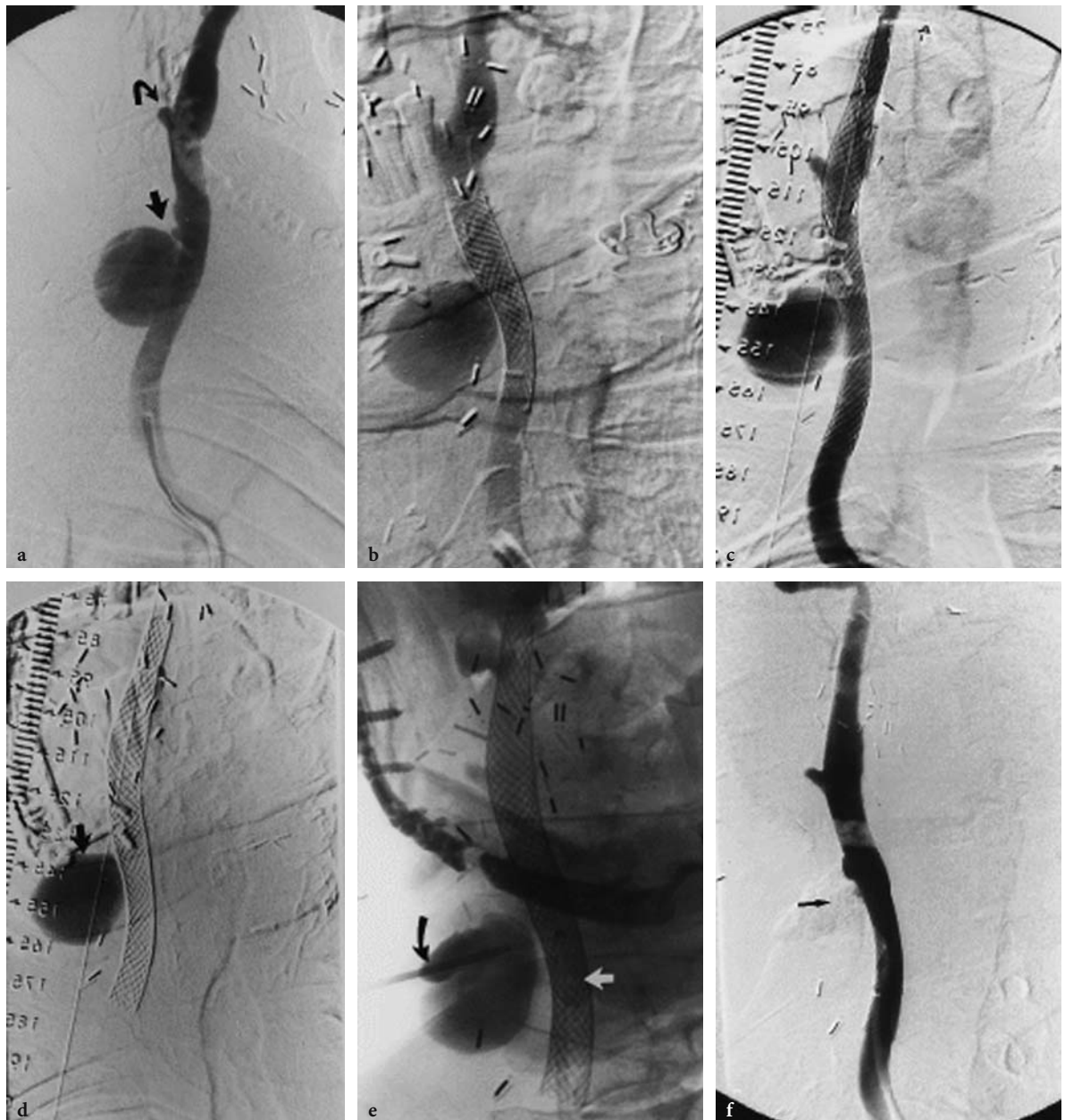


Fig. 21.7. **a** Oblique view of a right common carotid artery injection shows large pseudoaneurysm (*straight arrow*). Note evidence of prior surgery, including ligation of the external carotid artery (*curved arrow*). **b** Angiogram after deployment of an 8×20-mm Wallstent across the rent in the carotid artery shows good distal runoff but persistent filling of the pseudoaneurysm. **c** Repeat angiogram after deployment of a second, overlapping (8×60-mm) Wallstent shows slower filling of the pseudoaneurysm. **d** Delayed image shows stagnation of contrast material within the pseudoaneurysm (*arrow*). **e** Fluoroscopic spot film shows a balloon occlusion catheter within the stents, with the balloon partially inflated (*straight arrow*). This allowed some retrograde flow of opacified blood to fill the pseudoaneurysm, which was percutaneously punctured with a 200-gauge needle (*curved arrow*). **f** Control angiogram after two direct-puncture acrylic embolizations shows complete obliteration of the pseudoaneurysm with patency of the carotid artery. Subtraction artifact is seen where NBCA was injected at the site of rupture (*arrow*). Endovascular treatment of a head and neck cancer-related CBS by use of the self-expanding, covered Wallgraft stent

tracted carotid body stimulation of varying severity and clinical sequelae. We also prefer to use a stent 5-10 mm longer than the lesion, to ensure adequate coverage of both the distal and proximal stenotic segments. Often it is necessary to cross the external carotid artery with a stent, owing to extension of disease into the common carotid bifurcation that needs revascularization. Our group and others have observed that this can be done with impunity, since the ECA in most cases remains patent on follow-up examinations. In the rare cases when the ECA does occlude (usually from severe coexistent atherosclerotic disease), patients always remain asymptomatic secondary to the presence of abundant collaterals. If a second stent is required, a self-expanding stent of equal or greater diameter is overlapped with the primary stent and appropriately deployed. If a self-expanding stent of a smaller diameter is positioned within a larger self-expanding stent, the risk of delayed dilatation and subsequent migration of the inner stent arises. On occasion, self-expanding coronary stents (e.g. Radius, Magic Wallstent, Boston Scientific), balloon expandable coronary stents (e.g. S7-Medtronic AVE, Vision-Guidant), or the recently FDA approved self-expanding neurovascular stent (Neuroform, Boston Scientific) may be required for use in smaller arteries (e.g. distal cervical or skull base portions of the internal carotid) or in challenging anatomy (e.g. excessive tortuosity or loops). Great care in proper sizing is requiring preventing excessive trauma (e.g. oversizing balloon expanding stents) or stent migration (undersizing both balloon expandable and self-expanding stents). On post-deployment angiography, the stent margins should approximate the luminal diameter and geometry of the parent vessels, proximal and distal to the diseased segment. If poor approximation of the stent margins is observed, post stent dilatation or “flaring” using PTA balloons may be required, although in the setting of CBS may entail additional risk of carotid rupture. An alternative strategy is to use telescoping “bridging” stents (typically self-expanding) to remodel variations in contour and diameter of an arterial segment [58].

Finally, our group has slowly begun to utilize covered stents or “stent grafts”, as a third alternative technical strategy for endovascular reconstruction of CBS (Fig. 21.8). These devices have slowly evolved over the last several years in which both balloon expandable and more recently, self-expanding designs have been devised using either native venous grafts or synthetic materials (e.g. PTFE) sewn into the inner portion of the metallic stent frame. Such

devices have the major advantage of being more likely to produce immediate exclusion of an aneurysm from the parent arterial blood flow, which effectively results in an endoluminal bypass of the aneurysm. As with bare stent reconstruction for the management of CBS, proper sizing and precision of deployment are critical for technical and clinical success. However, unfortunately there remain significant major disadvantages of covered stents at this time. In general both balloon expandable and self-expanding designs are inherently larger in profile for a given targeted vessel diameter, therefore requiring larger access sheaths and delivery systems. These larger profile systems can be very difficult, if not impossible to safely navigate into the cervical carotid system. The balloon expandable stent grafts also suffer from problems related to the need for an open surgical harvesting of a vein graft, increased danger of pseudoaneurysm/parent artery rupture from high pressure inflation, poorer flexibility for navigation into carotid arteries, and less availability. Finally, all current stent-graft designs suffer from inherent increased thrombogenicity, resulting in increased risk of immediate or delayed in-stent thrombosis or thromboembolic cerebral ischemia. Unfortunately, although aggressive anti-thrombotic adjunctive therapy using systemic anticoagulation and anti-platelet drugs diminishes this risk, there is a commensurate increased risk of perioperative hemorrhage (often catastrophic) from the CBS.

Despite these limitations our group [43] and others [59–63] have successfully treated a limited number of pseudo-aneurysms of the common and internal carotid arteries. It is anticipated that future advances in material sciences and engineering will result in lower profile and more flexible self-expanding stent-graft systems that will pose comparable technical demands to bare stents. Partially porous synthetic graft materials also hold the promise of less acute and subacute thrombogenicity, since they will be composed of more biologically inert compounds and may more readily permit neointimalization.

21.6 Outcomes

Since 1993, the senior author has managed over 150 CBS events by various endovascular approaches, likely representing the largest single operator experience in the world. With this greater than a decade of cumulative experience, much has been learned in

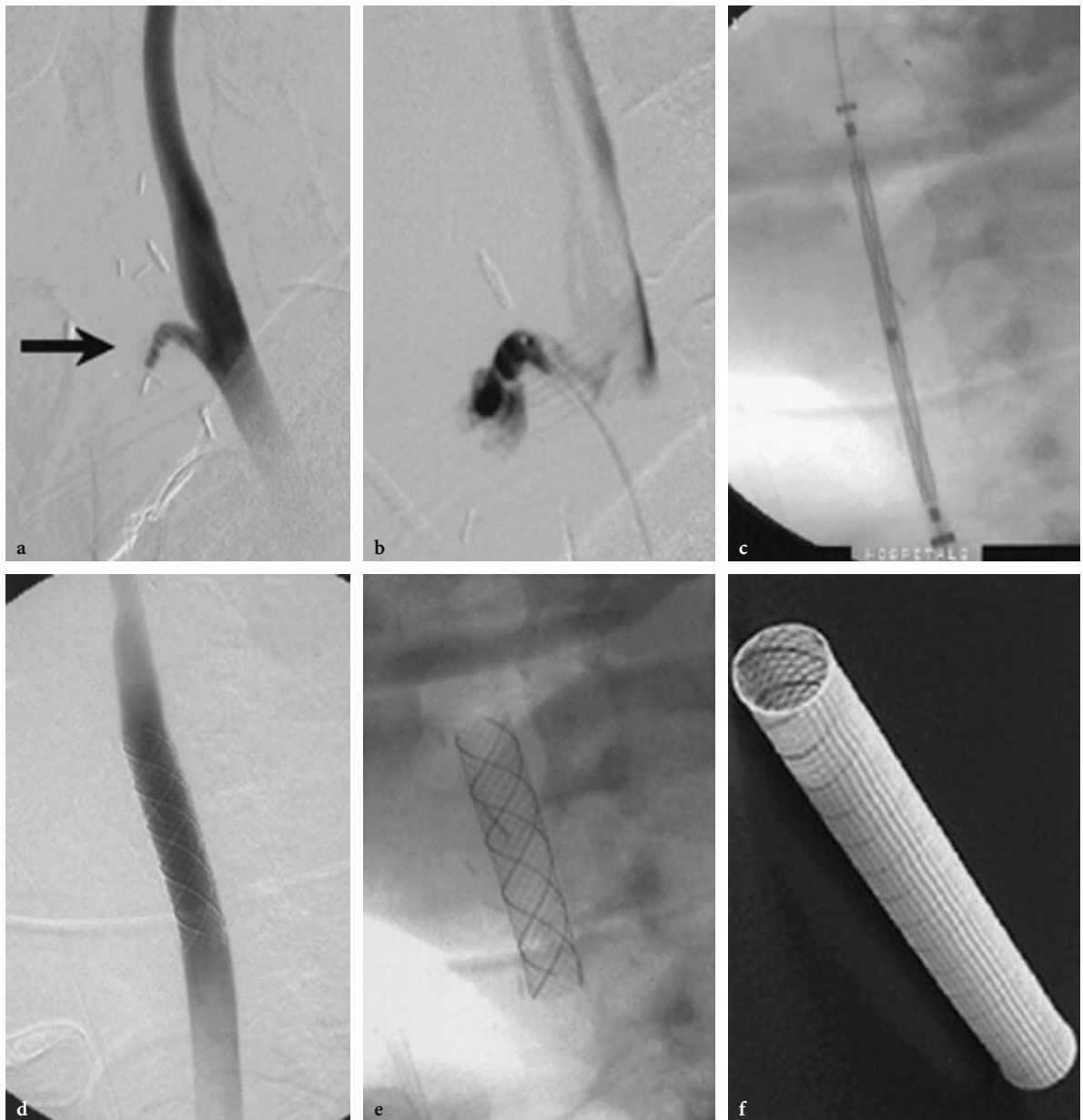

Fig. 21.8a–f. **a** Initial angiogram reveals a stump (*arrow*) at the proximal external carotid artery. **b** Microcatheter injection of the stump during endovascular exploration confirms a pseudoaneurysm as the source of hemorrhage. **c** An 8×30-mm Wallgraft stent is positioned within the common carotid artery and ICA junction, bridging the external carotid artery origin. **d** After deploying the stent, angiography shows exclusion of the pseudoaneurysm and normal caliber of the parent, stented artery. **e** Digital subtraction angiogram mask is shown for detail. **f** Photograph of the Wallgraft stent is shown for detail

recognizing the relative strengths and weaknesses of various endovascular strategies.

Deconstructive techniques founded in sound basic endovascular principles rapidly proved to be quite effective in achieving short-term hemorrhagic arrest in patients with Group 2 and Group 3 CBS, which approached a rate of over 95% for the first two

case series reported by our group at Yale [3, 4]. In particular, composite occlusion of the internal and common carotid segments affected by pseudoaneurysm formation using multiple detachable balloons and embolic coils immediately proved to be a superior approach to historical cumulative experience with open surgical repair of the carotid artery. Peri-

operative major morbidity (neurologic and hemorrhagic) and mortality was surprisingly low, initially in the range of 10% and 2%, respectively. With increasing experience, the types of deconstructive techniques applied to the management of CBS narrowed to mostly combined detachable balloon and coil embolization of the larger arterial segments (i.e. composite parent artery occlusion of the common, internal and external carotid arteries), liquid or coil embolization of pseudoaneurysms of the external carotid artery branches, and tumor embolization using either particulates or liquid adhesives.

Our group's first large cumulative case series [21] evaluated 46 consecutive patients with a clinical diagnosis of CBS between 1993 and 1997, who were referred for a total of 62 events for evaluation and intervention. Of these patients 43 had undergone extensive primary and/or salvage radical resections and had received additional adjuvant therapy/intervention (e.g. external beam and brachytherapy irradiation, and chemotherapy) that is believed to be associated with increased risk of CBS. Again, overall, the short-term safety and efficacy of endovascular management of CBS remained excellent, consisting of 100% initial hemorrhagic arrest, 7% minor neurologic morbidity (0% major neurologic morbidity) and 2% mortality. However, we discovered a disturbing new problem of additional events of CBS occurring in previously treated patients that we coined "recurrent carotid blowout syndrome" (rCBS). Our group was indeed the first to describe rCBS, having recognized this previously undescribed complication while reviewing our cumulative first 4 years of experience with endovascular management of CBS [21]. We specifically defined rCBS as either a repeat episode of self-limited or uncontrollable bleeding (i.e. Groups 2 and 3) occurring within 12 h of completed therapy for a previous episode of CBS, or a newly exposed portion of the carotid system (Group 1) occurring any time after completed therapy for a previous episode of CBS. In this series we found an astonishing 26% rate of rCBS in treated patients, with an average number of episodes of almost three per affected patient. Also interestingly, there was considerable variability between episodes of rCBS, ranging from 1 day to as long as 6 years.

Upon reviewing patterns of recurrence in CBS patients, we observed two readily discernible categories that could be linked to either proven or presumptive pathoetiologic mechanisms of recurrent hemorrhage. The first category could be broadly defined on the basis of what we hypothesized to

be so-called progressive disease (PD). All patients within this group developed new events of either potential or actual hemorrhagic recurrence, attributable to one or more putative etiologies: (1) surgical wound dehiscence, (2) free pedicle or mobilized musculocutaneous flap necrosis, (3) iatrogenic mechanical vascular injury, (4) radiation induced arteriopathy, (5) tumor invasion of a major arterial segment, and (6) recurrent tumor growth and invasion into adjacent mucosal surfaces.

In terms of prognosis and management strategy, rCBS attributable to PD could be further classified into bleeding arising from vasculature that is either ipsilateral or contralateral to the pathoetiologic lesion causing the index event (i.e. original CBS episode). This was the most commonly encountered type of rCBS, occurring in approximately 65% of cases. In the PD group 54% had recurrent ipsilateral disease and the remaining 46% had recurrent contralateral disease.

The second category of rCBS was best defined simply as events attributable to treatment failures (TF) (i.e. rCBS attributable to same affected arterial segment or territory that had been previously treated). This included recurrent bleeding from a previously treated arterial pseudoaneurysm, arterial fistula, or tumor neovasculture. Interestingly, the time course between recurrent events attributable to TF tended to be relatively short, varying between 1 and 10 days. In our cumulative series we found that approximately 32% rCBS could be attributable to treatment failures.

Despite our short-term ability to arrest or prevent hemorrhagic complications in patients presenting with CBS, the various pathoetiologic substrates that originally may have been responsible for the index event often persist chronically in this patient population. This persistence of pathoetiologic factors, which frequently occur bilaterally, would explain the frequent occurrence of rCBS attributable to both ipsilateral and contralateral PD. It is interesting to note that within the PD group of patients, nearly half had an episode of rCBS attributable to disease occurring contralateral to the index event. This surprisingly high rate of contralateral events has the potential of creating serious longitudinal complications, particularly in situations where a new pseudoaneurysm develops on the common and/or internal carotid artery contralateral to a previously occluded internal carotid artery. In such cases, therapeutic parent artery occlusion of the remaining carotid artery carries a very high risk of catastrophic cerebral ischemia.

Although less common than PD, TFs also constitute a major cause of rCBS. This group of patients develops recurrent events that are directly attributable to repetitive bleeding occurring in the same previously treated arterial segment or territory. Unlike the PD group, the time intervals between events for rCBS attributable to TFs are usually fairly short (typically in the range of 1–10 days). Several specific limitations of therapy may explain the associated high incidence of rCBS attributable to TF. Occasional technical failures (e.g. inability to cross the ostium of a pseudoaneurysm for endovascular trapping) or device failures (e.g. premature balloon deflation) may occur. More commonly, endovascular TF may be the result of recurrent tumor hemorrhages that were previously treated by partial transarterial embolization with particulates. This technical approach to tumor devascularization has a higher probability of short-term failure due to the frequent inability to achieve ideal superselective microcatheterization of all arterial pedicles supplying the tumor. This type of limitation may be overcome with the application of direct puncture embolization techniques using either cyanoacrylate or ethanol [27, 47].

The apparent high incidence of recurrent CBS observed in our patient population raised important issues regarding assumptions of durability and optimization of endovascular therapeutic management, and served as the fundamental impetus to try alternative endovascular management paradigms. Unfortunately, we are more frequently encountering situations in which patients may not be candidates for conventional therapeutic ICA occlusion, owing to one or more of the following factors: (1) clinical or CBF imaging failure of BTO, (2) spontaneous occlusion of the contralateral ICA/CCA secondary to concurrent occlusive arteriopathy, and (3) prior contralateral therapeutic ICA occlusion in rCBS. The option of extracranial to intracranial bypass in such individuals is usually not favorable due to the combination of technical limitations in performing this surgery in patients with prior radical neck surgery and irradiation, and the frequent urgency of presentation [21, 43]. Our group first described one such patient [39] in whom we initially attempted to treat a large pseudoaneurysm by endoluminal exclusion using overlapping self-expanding stents. Although this was initially successful in arresting the index event of acute CBS (Group 3), the patient rebled 24 h later. This prompted us to attempt an unconventional heroic intervention (i.e. direct puncture acrylic embolization), which fortunately was successful. However, such a technical

approach has potential limitations and risks that make it unsuitable for a routine primary therapeutic modality [43].

Our center's preliminary experience with selective use of stent-assisted carotid reconstruction consisted of 16 CBS events in 12 patients who fulfilled one or more of the above defined case selection criteria. These included seven patients with an incomplete circle of Willis on catheter angiography, two patients with a contralateral carotid occlusion, and three patients who failed BTO. Ten patients had underlying head and neck cancer (83%), whereas two suffered post-traumatic CBS (17%). Acute hemorrhagic arrest was initially achieved in all Group-2 and -3 patients; however, there were four patients (33%) who each had one episode of rCBS that necessitated additional endovascular intervention. Fortunately in all cases of rCBS, durable hemostasis was ultimately achieved after re-treatment. A total of 26 stents were used, in which 22 (85%) of the stents were uncovered, and the remaining four stents were covered. There was a 96% technical success rate in placing the stents; the sole technical failure occurred when an autologous vein-covered Palmaz stent failed to deploy in the carotid artery. In six of the 16 procedures (37.5%), pseudoaneurysm embolization was also performed using adjuvant acrylic glue or platinum coils.

One patient developed post-procedural transient ischemia (TIA), but no permanent neurological complications occurred in this series. No deaths were attributable to ERCA although one death occurred within the 30-day perioperative period. Specifically, one patient with advanced HNC (Group III) died from complications of disease progression (pulmonary embolus) on the fourth post-operative day. These complication rates were comparable or lower than those previously reported for endovascular deconstructive techniques and stent-assisted carotid angioplasty of atherosclerotic disease [4, 21, 51].

Unfortunately the rate of rCBS in this series (33%) was similar to that of our cumulative experience using deconstructive techniques, highlighting the continued major shortcoming of endovascular management of CBS in completely preventing recurrent hemorrhages. In all cases, rCBS occurred in the same carotid vasculature that was originally targeted for reconstruction, thus representing initial treatment failures as previously defined. Of interest however, is that these events of rCBS only occurred when either uncovered stenting or adjuvant embolization was performed alone. When

these techniques were combined together, efficacy appeared to be relatively better in preventing future hemorrhages.

Based upon our experience in the current series, as well as extensive cumulative experience with endovascular revascularization of carotid occlusive disease in general [42], we strongly believe that a self-expanding stent is highly preferable to a balloon-mounted stent for the treatment of CBS, owing to a variety of technical and biomechanical factors. Self-expanding stents (e.g., Wallgraft, Wallstent, Precise, SMART) easily accommodate varying diameters of the carotid tree, especially at the transition from CCA to ICA, and are more forgiving when determining the proper diameter size needed. These stents tend to have decreased porosity compared to balloon mounted stents, which improves vessel support and promotes pseudoaneurysm thrombosis. They also have superior flexibility in conforming to tortuous segments of the carotid anatomy, permitting more facile and less traumatic deployment. Furthermore, the selection of a self-expanding stent is preferable to a balloon-mounted stent owing to the potential for arterial injury resulting from the requisite high balloon inflation pressures needed for deployment. This is especially relevant in the setting of CBS, since the target arterial segment by definition has been weakened from a variety of processes that predispose to CBS. These concerns have indeed been confirmed recently by Kwok et al. [64], who presented an example of HNC-related CBS in which a covered stent (Jostent) offered no protection to high-pressure balloon-stent expansion; extravasation at both ends of the stent with persistent transoral hemorrhage required endovascular occlusion of the common carotid artery [64].

We recently have experienced excellent results with the currently available Wallgraft in, rapid deployment of this polytetrafluoroethylene-covered stent produced immediate exclusion of the targeted pseudoaneurysm, while simultaneously providing reconstructive preservation of the carotid artery (Fig. 21.8). However, it must be emphasized that the safe and effective use of the Wallgraft stent for CBS requires a variety of favorable anatomic and pathophysiologic factors that were present in both of our patients. These factors include common femoral and iliac arterial anatomy that will permit placement of a large caliber (9- or 10-F) vascular sheath, simple curvature of the aortic arch, relatively straight carotid and brachiocephalic arteries, and the lack of coexistent atherosclerotic or post-radiation stenoses. Therefore, more widespread use of self-expanding, covered stents for the management of CBS will not be possible until significant technologi-

cal improvements are realized, such as the creation of lower profile delivery systems, increased overall flexibility, and enhanced deliverability.

21.7 Future Directions

Endovascular management of CBS has evolved considerably over the last 15 years, paralleling the evolution of the specialty as a result of various technical, technological, and intellectual innovations. Over this period of time we have seen a paradigm shift emphasis from deconstructive to reconstructive techniques. It must be stressed, however, that the full armamentarium of endovascular techniques should always be considered when confronted by each case of CBS, since often the “less elegant” deconstructive techniques may still be the best option for definitive management. This is especially true when dealing with pseudo-aneurysms or fistulae of the external carotid system and tumor hemorrhages, which really remain preferably managed by conventional or unconventional embolization techniques. Unfortunately, extensive, multi-focal disease of the common and internal carotid arteries also remains difficult to reconstruct, and as such may be only amenable to composite parent artery occlusion procedures, using current techniques and technology.

However, clearly our group and others have shown the feasibility in managing more cases of CBS with reconstructive endovascular surgery than what was originally predicted. As stent-assisted angioplasty has become increasingly utilized for a variety of diseases affecting the extracranial carotid system, major advances in technology and technique have permitted more facile, safe, and effective placement of stents into the carotid arteries. Consequently, techniques described previously such as stent-assisted coiling and overlapping stent remodeling are now being routinely used at our center, with at least equivalent (and possibly superior) clinical efficacy compared to conventional deconstructive techniques. We continue to modify and refine these approaches as increased experience and improved technology is gained.

As noted earlier, stent-grafts will likely become more “user-friendly” for management of CBS, and may be the better technological solution to the problems and limitations that remain with current endovascular reconstructive techniques. In particular the

promise of lower profile, more flexible and trackable devices will enable broader application of this technology. We can also expect further enhancements in the mechanical and biologic properties of future graft materials, which will likely translate into better short- and long-term outcomes.

Finally, it is predicted that modification/manipulation of biological response to implanted stents will also improve technical and clinical efficacy of endovascular reconstruction of CBS. As drug eluting technology has already made an enormous impact on diminishing neointimal hyperplastic restenosis in stented coronary arteries, we are likely to see similar technology using synthetic pharmaceuticals, growth factors, cytokines or other biologic agents that will be applied to bare or covered stents. These bioactive agents will be utilized to manipulate specific molecular and/or cellular processes that could promote certain desirable responses, such as rapid healing, neointimalization, and enhanced structural support of the affected artery.

With the advent of these improvements, it is almost certain that constructive endovascular approaches, without adjuvant embolization, will become the treatment of choice for repairing both the common and internal carotid arteries affected by CBS. We predict that the use of such devices will not only substantially diminish the immediate perioperative complications, but also decrease the rate of rCBS attributable to treatment failure that has remained a problem with uncovered stents.

References

1. Hamby WB (1952) Intracranial aneurysms. Charles C. Thomas, Springfield, IL, p 45
2. Abernathy J (1815) Surgical observations. Longmans, London, p 193
3. Citardi MJ, Chaloupka JC, Son YH, Sasaki CT (1995) Management of carotid artery rupture by monitored endovascular therapeutic occlusion (1988–1994). *Laryngoscope* 105:1086–1092
4. Chaloupka JC, Putman CM, Citardi MJ, Ross DA, Sasaki CT (1996) Endovascular therapy of carotid blowout syndrome in head and neck surgical patients: evolving diagnostic and management considerations. *Am J Neuroradiol* 17:843–852
5. Borsanyi SJ (1962) Rupture of the carotids following radical neck surgery in irradiated patients. *Evol Psychiatr (Paris)* 41:531–533
6. Ketcham AS, Hoye RC (1965) Spontaneous carotid artery hemorrhage after head and neck surgery. *Am J Surg* 110:649–655
7. Rutledge RH, Cagle JE (1966) Vein wrap for carotid blowout in endarterectomized carotid artery. *Arch Surg* 92:94–95
8. Marchetta FC, Sako K, Maxwell W (1967) Complications after radical head and neck surgery performed through previously radiated tissues. *Am J Surg* 114:835–838
9. Swain RE, Biller HF, Ogura JH (1974) An experimental analysis of causative factors and protective methods in carotid artery rupture. *Arch Otolaryngol* 99:235–241
10. Huvos AG, Learning RH, Moore OS (1973) Clinicopathologic study of the resected carotid artery: analysis of 64 cases. *Am J Surg* 126:570–574
11. Ariyan S, Marfaggi RA, Harden G, et al. (1980) An experimental model to determine the effects of adjuvant therapy on the incidence of postoperative wound infection. I. Evaluating Preoperative Radiation Therapy. *Plast Reconstr Surg* 65:328–337
12. Sanders EM, Davis KR, Whelan CS, Deckers KR (1986) Threatened carotid rupture: a complication of radical neck surgery. *J Surg Onc* 33:190–193
13. Shumrick DA (1973) Carotid artery rupture. *Laryngoscope* 83:1051–1061
14. Heller KS, Strong EW (1979) Carotid artery hemorrhage after radical head and neck surgery. *Am J Surg* 138:607–610
15. Razack MS, Sako K (1982) Carotid artery hemorrhage and ligation in head and neck cancer. *J Surg Oncology* 19:189–192
16. Coleman JJ (1985) Treatment of the ruptured or exposed carotid artery: a rational approach. *South Med J* 78:262–267
17. Porto DP, Adams GL, Foster C (1986) Emergency management of carotid artery rupture. *Am J Otolaryng* 7:213–217
18. Maran AGD, Amin M, Wilson JA (1989) Radical neck dissection: a 19 year experience. *J Laryngol Otol* 103:760–764
19. Koch WM (1993) Complications of surgery of the neck. In: Eisele D (ed) *Complications in head and neck surgery*. Mosby, Philadelphia, PA, pp 393–413
20. Ditmars ML, Klein SR, Bongard FS (1997) Diagnosis and management of zone III carotid injuries. *Injury* 28:515–520
21. Chaloupka JC, Roth TC, Putman CM, Mitra S, Ross DA, Sasaki CT (1999) Recurrent carotid blowout syndrome: diagnostic and therapeutic challenges in a newly recognized subgroup of patients. *AJNR Am J Neuroradiol* 20:1069–1077
22. Dandy WE (1938) Intracranial aneurysm of the internal carotid artery. Cured by operation. *Ann Surg* 107:654–659
23. Dandy WE (1942) Results following ligation of the internal carotid artery. *Arch Surg* 45:521–533
24. Chaloupka JC, Awad IA (1995) Strategies and armamentarium of treatment options. In: Awad IA, Barrow DL (eds) *Giant intracranial aneurysms*. AANS Publications, Park Ridge, IL, pp 91–116
25. Fox AJ, Viñuela F, Pelz DM, et al. (1987) Use of detachable balloon for proximal artery occlusion in the treatment of unclippable cerebral aneurysms. *J Neurosurg* 66:40–46
26. Berenstein A, Ransohoff J, Kupersmith M, Flamm E and Graeb D (1984) Transvascular treatment of giant aneurysms of the cavernous carotid and vertebral arteries. Functional investigation and embolization. *Surg Neurol* 21:3–12
27. Chaloupka JC, Putman CM (1995) Endovascular therapy of surgical diseases of the cranial base. *Clin Plastic Surg* 22:417–450

28. Dare AO, Chaloupka JC, Putman CM, Fayad PB, Awad IA (1998) Failure of the hypotensive provocative test during temporary balloon test occlusion of the internal carotid artery to predict delayed hemodynamic ischemia after therapeutic carotid occlusion. *Surg Neurol* 50:147–155
29. Zimmerman MC, Mickel RA, Kessler DJ, et al. (1987) Treatment of impending carotid rupture with detachable balloon embolization. *Arch Otolaryngol Head Neck Surg* 113:1169–1175
30. Serbinenko FA (1974) Balloon catheterization and occlusion of major vessels. *J Neurosurg* 41:125–145
31. Serbinenko FA, Faltov JM, Spallone A, et al. (1990) Management of giant intracranial ICA aneurysms with combined extracranial intracranial anastomosis and endovascular occlusion. *J Neurosurg* 73:57–63
32. Debrun G, Lacour P, Viñuela F, et al. (1981) Treatment of 54 traumatic carotid-cavernous fistulas. *J Neurosurg* 55:678–692
33. Osguthorpe JD, Hungerford GD (1984) Transarterial carotid occlusion: case report and review of the literature. *Arch Otolaryngol Head Neck Surg* 110:694–696
34. Khoo CTK, Molyneux AJ, Rayment R, Saad MN (1986) The control of carotid arterial haemorrhage in head and neck surgery by balloon catheter tamponade and detachable balloon embolisation. *Br J Plast Surg* 39:72–75
35. Morrissey DD, Andersen PE, Nesbit GM, Barnwell SL, Everts EC, Cohen JI (1997) Endovascular management of hemorrhage in patients with head and neck cancer. *Arch Otolaryngol Head Neck Surg* 123:15–19
36. Macdonald S, Gan J, McKay AJ, Edwards RD (2000) Endovascular treatment of acute carotid blow-out syndrome. *J Vasc Interv Radiol* 11:1184–1188
37. Szikora I, Guterman LR, Wells KM, Hopkins LN (1994) Combined use of stents and coils to treat experimental wide-neck carotid aneurysms: preliminary results. *AJNR Am J Neuroradiol* 15:1091–1102
38. Matsuura JH, Rosenthal D, Jerius H, Clark MD, Owens DS (1997) Traumatic carotid artery dissection and pseudoaneurysm treated with endovascular coils and stent. *J Endovasc Surg* 4:339–343
39. Roth TC, Chaloupka JC, Putman CM, Weaver EM, Tarro J, Wecht DA, Sasaki CT (1998) Percutaneous direct puncture acrylic embolization of a pseudoaneurysm after failed carotid stenting for the treatment of acute carotid blowout. *Am J Neuroradiol* 19:912–916
40. Simionato F, Righi C, Melissano G, Rolli A, Chiesa R, Scotti G (2000) Stent-graft treatment of a common carotid artery pseudoaneurysm. *J Endovasc Ther* 7:136–140
41. Coldwell DM, Novak Z, Ryu RK, et al. (2000) Treatment of posttraumatic internal carotid arterial pseudoaneurysms with endovascular stents. *J Trauma* 48:470–472
42. Chaloupka JC, Weigele JB, Mangla S, Lesley WS (2001) Cerebrovascular angioplasty and stenting for the prevention of stroke. *Curr Neurol Neurosci Rep* 1:39–53
43. Lesley WS, Chaloupka JC, Weigele JB, Mangla S, Dogar MA (2003) Preliminary experience with endovascular reconstruction for the management of carotid blowout syndrome. *AJNR Am J Neuroradiol* 24:975–981
44. Debrun G, Fox A, Drake C (1981) Giant unclippable aneurysms: treatment with detachable balloons. *AJNR Am J Neuroradiol* 2:167–173
45. Walker AT, Chaloupka JC, Putman CM, Abrahams JJ, Ross DA (1996) Sentinel transoral hemorrhage from a pseudoaneurysm of an internal maxillary artery branch; a complication of CT guided biopsy of the masticator space. *AJNR Am J Neuroradiol* 17:377–381
46. Weigele JB, Chaloupka JC, Lesley WS, Dogar MA, Bemporad JA (2002) Octyl-2-cyanoacrylate: an effective agent for head and neck tumor embolization [abstract]. 40th Annual Meeting of the American Society of Neuroradiology, May, Vancouver, BC, Canada
47. Chaloupka JC, Mangla S, Huddle DC, Mitra S, Ross DA, Sasaki CT (1999) Evolving experience with direct puncture therapeutic embolization for adjunctive and palliative management of head and neck hypervascular neoplasms. *Laryngoscope* 109:1864–1872
48. Horowitz MB, Miller G, Meyer Y, Carstens G, Purdy PD (1996) Use of intravascular stents in the treatment of internal carotid and extracranial vertebral artery pseudoaneurysms. *AJNR Am J Neuroradiol* 16:693–696
49. Diethrich EB, Ndiaye M, Reid DB (1996) Stenting in the carotid artery: initial experience in 110 patients. *J Endovasc Surg* 3:42–62
50. Yadav JS, Roubin GS, Iyer S, Vitek J, King P, Jordan WD, Fisher WS (1996) Elective stenting of the extracranial carotid arteries. *Circulation* 5:1–6
51. Wholey MH, Wholey M, Mathias K, et al. (2000) Global experience in cervical carotid artery stent placement. *Catheter Cardiovasc Interv* 50:160–167
52. Phatouros CC, Higashida RT, Malek AM, et al. (2000) Carotid artery stent placement for atherosclerotic disease – rationale, technique, and current status. *Radiology* 217:26–41
53. Wakhloo AK, Schellhammer F, de Vries J, Haberstroh J, Schumacher M (1994) Self-expanding and balloon-expandable stents in the treatment of carotid aneurysms: an experimental study in a canine model. *AJNR Am J Neuroradiol* 15:493–502
54. Geremia G, Haklin M, Brennecke L (1994) Embolization of experimentally created aneurysms with intravascular stent devices. *AJNR Am J Neuroradiol* 15:1223–1231
55. Turjman F, Massoud TF, Ji C, Guglielmi G, Vinuela F, Robert J (1994) Combined stent implantation and endosaccular coil placement for treatment of experimental wide-neck aneurysms: a feasibility study in swine. *AJNR Am J Neuroradiol* 15:1087–1090
56. Higashida RT, Smith W, Gress D, Urwin R, Dowd CF, Balousek PA, Halbach VV (1997) Intravascular stent and endovascular coil placement for a ruptured fusiform aneurysm of the basilar artery. Case report and review of the literature. *J Neurosurg* 87:944–949
57. Graves VB, Strother CM, Partington CR, Rappe A (1992) Flow dynamics of lateral carotid artery aneurysms and their effects on coils and balloons: an experimental study in dogs. *AJNR Am J Neuroradiol* 13:189–196
58. Lesley WS, Weigele JB, Chaloupka JC (2004) Outcomes for overlapping stents in the extracranial carotid artery. *Catheter Cardiovasc Interv* 62:375–379
59. Parodi JC, Ferreira M, Estol CJ (1996) Treatment of carotid artery disease with an endoluminal stent-venous graft. *J Neurovasc Dis* 1:27–31
60. Ruebben A, Merlo M, Verri A, et al. (1997) Exclusion of an internal carotid aneurysm by a covered stent. *J Cardiovasc Surg* 38:301–303
61. Marotta TR, Buller C, Taylor D, Morris C, Zwimpfer T

- (1998) Autologous vein-covered stent repair of a cervical internal carotid artery pseudoaneurysm: technical case report. *Neurosurgery* 42:408–412
62. Scavee V, De Wispelaere JF, Mormont E, Coulier B, Trigaux JP, Schoevaerds JC (2001) Pseudoaneurysm of the internal carotid artery: treatment with a covered stent. *Cardiovasc Intervent Radiol* 24:283–285
63. Alexander MJ, Smith TP, Tucci DL (2002) Treatment of an iatrogenic petrous carotid artery pseudoaneurysm with a Symbiot covered stent: technical case report. *Neurosurgery* 50:658–662
64. Kwok PC, Cheung JY, Tang KW, Wong WK (2001) Endovascular treatment of acute carotid blow-out syndrome. *J Vasc Interv Radiol* 12:895–896

Gene Therapy and Pediatrics

22 Embolotherapy Applications in Gene Therapy

JAMES R. DUNCAN

CONTENTS

22.1	Introduction	295
22.1.1	Background	295
22.2	Embolization and Gene Therapy	296
22.2.1	Embolization by Infusion of Genetically Altered Cells	296
22.2.2	Embolization as a Prelude to Gene Therapy	298
22.2.3	Embolization as an Adjunct to Gene Therapy	300
22.3	Future Directions for Embolization and Gene Therapy	300
22.3.1	Cell Transplantation	300
22.3.2	Embolization to Promote Gene Therapy	301
22.3.3	Gene Therapy to Promote Embolization	301
	References	301

22.1 Introduction

Gene therapy is an emerging technology that will likely yield a wide variety of treatments. Initially gene therapy focused on rare diseases such as inborn errors of metabolism, but it is increasingly being applied to common conditions such as cancer and peripheral vascular disease [4, 12, 13, 22]. Human gene therapy trials in the United States can be reviewed online at www.gemcris.od.nih.gov, and many of these trials include interventional procedures. As summarized in Table 22.1, interventional procedures include direct arterial injection, direct injection into tumors, stent placement, and infusion through a central venous catheter. While Interventional Radiology will certainly play a role in this field, this chapter will concentrate on the interplay between embolization and gene therapy.

J. R. DUNCAN, MD, PhD
Assistant Professor of Radiology and Surgery, Mallinckrodt Institute of Radiology and Washington University School of Medicine, 510 S. Kingshighway Blvd, St. Louis, MO 63110, USA

22.1.1 Background

By its nature, gene therapy is an indirect treatment method. In most cases, the gene (DNA) must be transcribed into RNA, the RNA translated into protein, and it is the protein product that achieves the desired clinical effect. The transformations from DNA to RNA and then RNA to protein require access to the internal machinery of the cell. Delivering the gene to the cell's interior has been a significant barrier to successful gene therapy. A series of different strategies have been used; these are summarized in Table 22.2.

The clinical condition dictates what method might be used to deliver the gene to the cell's interior. For example, correcting an inborn error of metabolism by gene replacement would ideally entail a single treatment that confers lifelong production of a protein. This requirement excludes the brute force and hybrid strategies, because these only result in short-term expression of the therapeutic protein. This requirement also excludes most viral vectors and leaves only retroviral and adeno-associated viral vectors. On the other hand, short-term expression (days to weeks) may be sufficient for other therapies such as combating atherosclerosis by angiogenesis or killing tumor cells. Since a wide variety of vectors confer short-term expression, choosing a vector then requires balancing factors such as level of expression with untoward attributes such as immunogenicity.

22.2 Embolization and Gene Therapy

Three different gene therapy strategies have employed embolization (Table 22.3). In the first, cells containing the desired gene are infused and this method can lead to embolization since the altered cells are large enough to occlude vessels. In the second, embolization is used to facilitate gene therapy by preparing

Table 22.1. Interventional techniques used for gene therapy

Interventional method	Example	Selected references
Direct injection into lesion	Inject adenoviral vector containing gene which selectively kills tumor cells	NEMUNAITIS et al. [14]
Direct injection into tissue	Inject adenoviral vector with gene for vascular growth factor	RAJAGOPALAN [16, 17]
Selective intra-arterial injection	Inject adenoviral vector containing gene which selectively kills tumor cells	SZE [21]
Biomaterials	Attach adenoviral vector to stent	KLUGHERZ [11]

Table 22.2. Gene delivery vehicles

Strategy	Premise	Vector	Pros	Cons
Brute force	When cells are bathed in large amounts of DNA, some DNA crosses cell's membrane	None – inject DNA directly into tissue	Easy to produce the gene in large quantities; low immunogenicity	Very inefficient means of transferring gene into cells; gene is expressed for day-weeks
Elegant	Genetically engineered viruses provide a highly evolved method of inserting genetic material (DNA or RNA) into mammalian cells	Adenovirus, adeno-associated virus, retrovirus, lentivirus	Efficient; long term expression is possible with selected vectors	Large-scale production of the viral vectors can be difficult; viruses can induce or be destroyed by immune response; immune response can cause systemic illness
Hybrid	Construct agents which mimic the biologic methods used by viruses	Cationic liposomes; peptide fusion domains	Low immunogenicity, potential cell specific delivery	Transient expression

Adapted from GIANNOUKAKIS and TRUCCO [6]

the tissue to receive the gene therapy vector or by helping target the gene therapy vector to the cells of interest. Examples are portal vein embolization as a method of stimulating hepatocyte replication in the nonembolized segments of the liver and using Ethiodol embolization to help target a viral gene therapy vector to hepatocellular carcinomas. In the third case, gene therapy is used as an adjunct to embolization. An example is tethering adenoviral particles to embolization coils.

22.2.1 Embolization by Infusion of Genetically Altered Cells

The first human gene therapy experiments used this approach [18]. Cells were collected, genetically altered and then infused back into the patient. The advantage of this approach is that the difficult task of inserting the gene into cells was performed in the laboratory where conditions could be optimized. This approach also minimized the possible risks since the patient was not directly exposed to the gene therapy vector. In these experiments, circulating lymphocytes were collected, modified and then

infused. Subsequent studies have used a wide variety of cell types.

An early therapeutic trial that involved embolization was a complex protocol that is summarized in Fig. 22.1. In this protocol, patients with familial hypercholesteremia caused by mutations in the low density lipoprotein receptor (LDL receptor) were treated with the hope of normalizing cholesterol metabolism [8, 9]. For treatment to be successful, long term expression of LDL receptors was desired and this requirement prompted the investigators to use a retroviral vector because these vectors had the advantage of inserting the LDL-R gene into the genome of the harvested hepatocytes (Fig. 22.2). Other vectors offered only a short-term solution because genes that are not incorporated into a cell's chromosomes are lost over a period of days to weeks.

In this experiment, gene expression was assessed by several methods. Liver biopsies found hepatocytes which expressed the LDL receptor. In addition, small changes in cholesterol metabolism were found. However, the clinical effect was negligible and the investigators concluded that the *ex vivo* method was limited by the "low efficiency of genetic reconstitution".

Table 22.3. Interplay between embolization and gene therapy

Strategy	Example
Part and parcel	Infusion of genetically altered mammalian cells
Embolization facilitates gene therapy	Portal vein embolization stimulates hepatocyte replication
	Ethiodol embolization helps target viral vector to tumor
Gene therapy as adjunct to embolization	Embolize using bifunctional agent – part embolization and part gene therapy

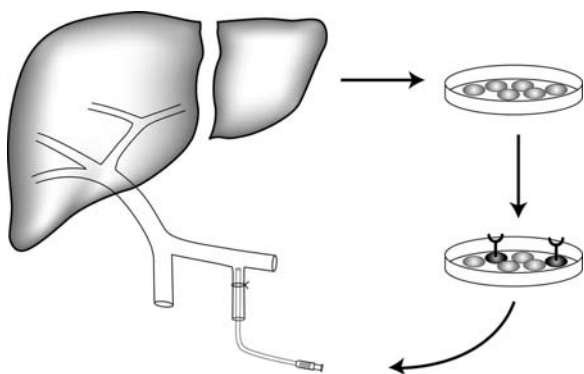


Fig. 22.1. Protocol schematic for ex vivo hepatic gene therapy. The lateral segment of the patient’s liver was removed by a subcostal incision, and a Hickman catheter was placed by sacrificing the inferior mesenteric vein. The liver specimen (~250 gm) was then perfused with collagenase to release hepatocytes (~3 billion) which were then divided into 800 culture dishes. Two days later, a retrovirus containing the sequence for the LDL receptor was added to the culture media. The hepatocytes were harvested 12–18 hrs later and divided into three aliquots. Each aliquot was infused slowly (2 cc/min) back into the patient’s portal circulation using the Hickman catheter. Adapted from GROSSMAN [8]

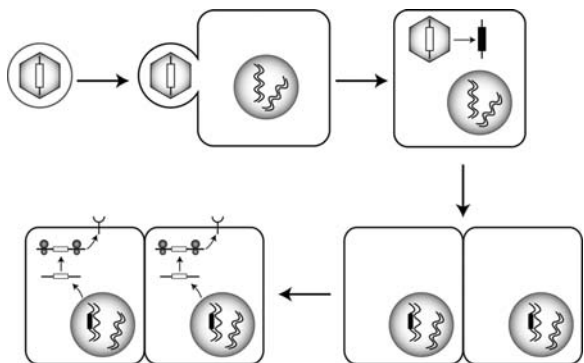


Fig. 22.2. Schematic for retroviral gene therapy. Retroviral particles containing RNA that encodes the gene of interest are prepared and added to the recipient cells. The retroviral vector is internalized and then releases its genetic material into the cytoplasm. Reverse transcriptase uses the viral template to produce a DNA copy of the desired gene and this gene can then be integrated into the recipient cell’s genome. The integrated gene then serves as a template for transcription into mRNA and translation into protein.

Numerous factors limited the efficiency of genetic reconstitution. First was the number of cells that were recovered from the liver specimen. A 250-gm liver specimen was resected, and from this only 3 billion hepatocytes were isolated for culture. A typical liver contains approximately 100 million hepatocytes per milliliter and thus the 250-gm specimen could have provided approximately 25 billion hepatocytes. Second, only 2 billion hepatocytes were viable, and only 20% of them expressed the LDL-R after transfection with the retrovirus. Even if these 400 million hepatocytes expressed the normal number of LDL receptors, they would have only the number of receptors typically found in 4 ml of liver. Since the average liver volume is slightly more 1600 ml [24], even if the methods were improved 100-fold, the result would be a LDL receptor levels that would still only be 25% of normal. Cholesterol metabolism is clearly sensitive to the number of LDL receptors since patients with one half the number of LDL receptors (heterozygotes for familial hypercholesterolemia) have markedly elevated levels of LDL cholesterol and develop premature atherosclerosis [7].

Even if more hepatocytes could be isolated by either resecting more liver or improving the yield per gm of resected liver, infusing more of the genetically altered hepatocytes into the portal vein carries real risks. Hepatocyte infusion causes occlusions at the microvascular level and transient increases in portal venous pressure were observed during the infusions.

Ex vivo gene therapy followed by infusion of the altered cells clearly illustrates the promise and problems of gene therapy for inborn errors of metabolism. While it is difficult to conceive how the transplantation method might provide more than a few percent of normal levels for any protein, there are diseases where restoring low levels of the missing protein significantly ameliorates the clinical condition. One such example is hemophilia A where achieving 1% of normal levels for Factor VIII substantially lowers the risk of severe hemorrhage [3].

Even with integration of the target gene into a cell's genome, the durability of the treatment will be limited by the lifespan of the altered cell unless the cell divides and passes the desired gene to its progeny. Hence there is interest in genetic manipulation of stem cells. If the genetically altered stem cell has a survival advantage over its endogenous counterparts, this could lead to increasing levels of gene expression over time.

22.2.2 Embolization as a Prelude to Gene Therapy

The limitations of cell transplantation for hepatic gene therapy prompted Kathy Ponder, Marshall Hicks, and this author to study how embolization might be used as a preparatory step for gene therapy. This project stemmed from the fact that retroviral vectors could integrate genes into the hepatocyte genome only if the hepatocytes were dividing. In adult animals, far fewer than 1% of hepatocytes were replicating under normal conditions. However based on data from partial hepatic resections and hepatic embolization, we postulated that occluding the portal vein branches supplying two thirds of the liver might be a safe and effective means of stimulating hepatocyte replication in the remaining third of the liver (Fig. 22.3).

A series of animal experiments confirmed that embolizing two thirds of the portal branches stimulated hepatocytes in the spared portion of the liver to divide [5]. These experiments also determined the timing and timing and extent of hepatocyte replication. The embolized liver segments atrophied and the atrophy was not accompanied by evidence of hepatocyte lysis. Instead, it was found that hepatocytes underwent apoptosis. Finally, these experiments also demonstrated the feasibility of maintaining a catheter in the portal vein for several days.

Attempts to build upon this groundwork were less encouraging. Large doses of the retroviral vector were prepared and infused into the liver after embolization using the portal venous catheter. Subsequent blood samples revealed only low levels of the gene product. Later experiments in a dog model encountered additional technical issues. Specifically, it was more difficult to obtain and maintain portal vein access. Finally a severe immune response was encountered during retrovirus infusion. These and other issues prompted Kathy Ponder to study the feasibility of neonatal hepatic gene therapy. Those experiments found that a sizable fraction of hepatocytes are dividing in neonates without any added stimulus. Subsequent work by her group has found that intravenous infusions led to successful gene therapy in neonates and the immune response seen in adult animals was not reproduced [15, 20, 23].

We next hypothesized that portal vein infusion in neonates might have additional advantages over intravenous infusion. For these experiments, we attempted to use the umbilical vein for access and then select the portal vein. Infusing the vector into the portal vein might prove more efficient than intravenous infusion. The approach is summarized in Fig. 22.4. The small size of the animals and sharp angles between the umbilical vein and main portal vein forced us to abandon this model. However, we still expect that there may be a role for this method of portal vein infusion that might be best studied in future human trials.

Since embolization alters tissue blood flow, embolization could potentially be used to facilitate gene delivery to cells of interest. Embolization could improve the target to background ratio by altering blood flow (Table 22.4). Embolization could also increase the likelihood that the vector will interact with the individual cells in the target tissue. This dwell time argument is often cited to explain the efficacy of chemoembolization.

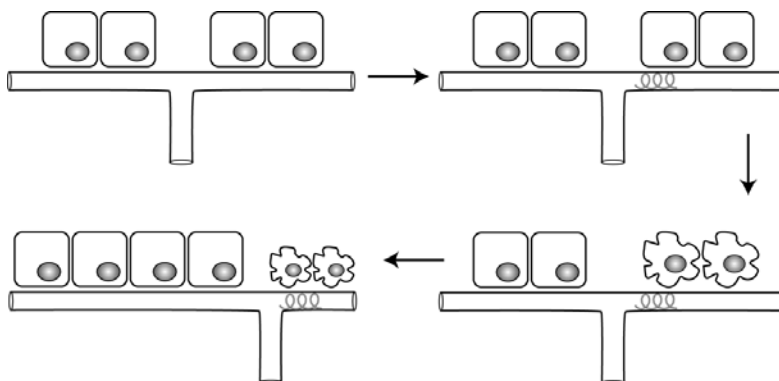


Fig. 22.3. Portal vein embolization stimulates hepatocyte replication. Hepatocytes and their portal vein branches are shown. If the portal vein branch supplying a portion of the liver is occluded, the hepatocytes supplied by that branch undergo apoptosis. The embolized segment of the liver atrophies while hepatocytes in nonembolized liver replicate.

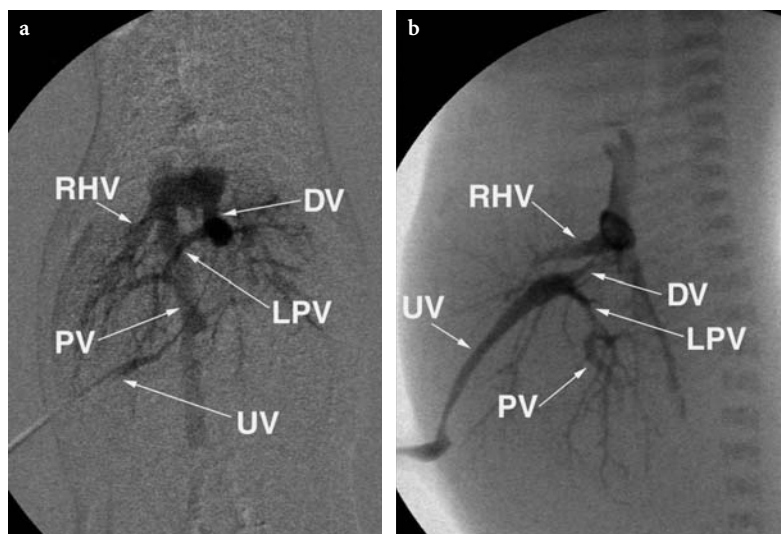


Fig. 22.4. a 200-gm pup was delivered by caesarean section, and the umbilical vein was cannulated with a 20-g Angio-cath. Diluted contrast was injected and images recorded in either anteroposterior (a) or lateral (b) planes. Vessels are labeled as follows: umbilical vein (UV), main portal vein (PV), left portal vein (LPV), ductus venosus (DV), right hepatic vein (RHV). a A digital subtraction image; b is nonsubtracted. Attempts to select the portal vein from the umbilical vein access were hindered by the angles between the left portal vein and umbilical vein as well as the angle between the left portal vein and main portal vein

Table 22.4. Strategies for improving target to background ratios via embolization

Method	Possible clinical example	Flow to target*	Flow to Nontarget	Target/background
Selectively embolize vessels to nontarget tissue	Selectively embolize gastroduodenal artery to protect normal tissue, then infuse vector via common hepatic artery catheter	No change	Decreased	Increased
Embolize vessels supplying lesion and surrounding tissue	Embolize hepatic artery branch using Ethiodol	Decrease	Large decrease	Increased

*Increasing delivery to the target tissue by embolization is not considered because it is unlikely that embolization could cause an increase in blood flow to the target tissue.

SHIBA et al. [19] tested whether embolization could improve gene delivery to hepatocellular carcinomas. They induced spontaneous hepatocellular carcinomas in rats using chemical carcinogens and performed hepatic artery embolization using Lipiodol. It is noteworthy that most animal studies have used models where tumors are implanted in the liver and it is a considerable leap of faith to believe that the blood flow to a tumor 5–21 days after implantation will accurately simulate the blood flow of primary or metastatic tumors in humans. SHIBA et al. then tested gene transfer using an adenovirus carrying a marker gene. The adenoviral vector could be mixed with Lipiodol without destroying the vector because adenovirus lacks a lipid membrane. This mixture was injected into the hepatic artery and the efficiency of gene transfer was assessed by staining for the marker protein and calculating the percentage of stained tissue in normal liver, small tumors and large tumors. In control animals, the adenoviral vector without Lipiodol was injected into the hepatic artery.

A substantial increase in tumor to background ratio was found when the adenoviral vector was coinjected with Lipiodol (Table 22.5). This reflected an increase in the percentage of tumor cells which expressed the gene therapy marker as well a decrease in the percentage of normal hepatocytes that expressed the marker. The latter is an expected consequence of embolization. The increase in tumor cell staining suggests that the dwell time effect more than overcame the decrease in blood flow caused by embolization.

The finding that tumor cell staining exceeded staining in normal liver by approximately sixfold is remarkable because the available data indicates that tumors are almost uniformly underperfused [2]. While hepatomas appear hypervascular on angiography, at the microscopic level, the tumor vasculature is disorganized. Furthermore, even if a tumor possessed a well organized microvascular network, tumor interstitial pressure would reduce perfusion. The mechanism by which Lipiodol improved the target to background ratio is uncertain. Prior work

Table 22.5. Marker gene expression following gene transfer

Injection	Tumors <5 mm	Tumors >5 mm	Normal liver
Vector after iodized oil (n=9)	37.4 +/- 6.0	35.6 +/- 9.3	5.7 +/- 1.3
Vector alone (n=15)	14.0 +/- 3.6	7.0 +/- 1.9	14.4 +/- 2.3

The adenoviral vector containing the gene for β -galactosidase was injected into the hepatic artery of tumor bearing animals either by itself or immediately following injection of iodized oil. Animals were sacrificed 2 days later and liver sections were prepared. Expression of the marker gene was determined by staining for β -galactosidase. The area of staining in small tumors (<5mm), large tumors (>5mm) and normal liver was determined. Results are expressed as mean percentages +/- standard error of the mean. Nine animals received the vector after iodized oil; 15 animals received the vector alone. Adapted from SHIBA et al. [15]

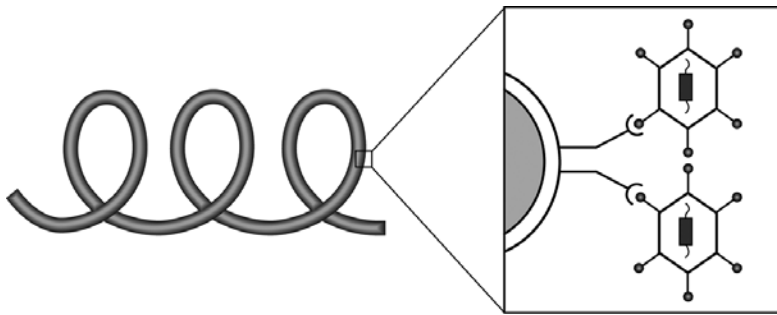


Fig. 22.5. Attaching adenoviral particles to embolization coils. Platinum and bio-degradable coils were coated with collagen to provide a surface for subsequent attachment of an anti-adenovirus antibody. The derivatized coils were then incubated with the adenoviral vector which contained the gene for green fluorescent protein

has shown that injection of Lipiodol into hepatic arterial branches results in Lipiodol deposition in both normal liver and hepatic tumors. The initial deposition in tumors is felt to reflect the large extracellular spaces within tumors and the different pressures within the arterial and portal systems [10].

22.2.3 Embolization as an Adjunct to Gene Therapy

Endovascular treatment of aneurysms has focused on the mechanical aspects of the procedures but the prevalence of endoleaks and incomplete obliteration of intracranial aneurysms indicates there is ample room for improvement. An integrated approach where the mechanical device also serves as a scaffold for drug delivery has been proposed. In this scheme, the coils deployed within the aneurysm might also be coated with a drug which promotes intimal hyperplasia and the intimal hyperplasia helps seal the aneurysm neck.

ABRAHAMS et al. [1] recently reported linking an adenoviral vector to embolization coils. A diagram of the attachment strategy is shown as Figure 22.5. These initial experiments tested the feasibility of this approach both in vitro and in an animal model of intracranial aneurysms. A marker gene was used and expression of the marker protein was found in cells which were in contact with the coil. The animal experiments detected the marker protein in leuko-

cytes that were embedded in the thrombus adjacent to the coil. Interestingly, there was no evidence of gene transfer to smooth muscle cells or endothelial cells.

22.3 Future Directions for Embolization and Gene Therapy

22.3.1 Cell Transplantation

Research in cell based gene therapy represents the leading edge of how gene therapy and embolization can overlap. The field remains in its infancy and the research thus far has focused on the feasibility of transferring genes into cells and gene expression after infusion of the altered cells. The nuances of embolization are largely ignored because most infusions are by an intravenous route and also because it is desirable to keep these early experiments as simple as possible. As the technology matures, there will be increasing interest in embolization techniques. Catheter directed infusion into specific tissue beds could be used to improve the therapeutic window by both by concentrating the cells in the target tissue and sparing nontarget organs. Most of these targeted embolizations would be from arterial access but it is also likely that infusion into

the portal venous system and selected branches of the pulmonary vasculature will be advantageous in certain circumstances.

Delivering these cells to the site of interest is only the first step. The duration of therapy will be dependent upon the survival of cells following injection. That survival will depend upon adequate delivery of nutrients and removal of waste products. This might seem trivial since the cells will initially reside in the intravascular space but this location does not guarantee perfusion especially since the cells themselves will likely occlude the vessel in which they reside. This mechanical occlusion would likely lead to thrombosis, especially if the transplanted cells lack the cell surface moieties found on normal endothelial cells. A transplanted cell within a cocoon of thrombus is unlikely to survive. If this is true, anticoagulation either by inhibiting the coagulation cascade or platelet deposition might improve survival of the transplanted cells.

22.3.2

Embolization to Promote Gene Therapy

The need to induce hepatocyte replication by portal vein embolization is fading into the past. Neonatal infusions, new vectors and other strategies circumvent the need for embolization. Further work is needed to determine if hepatic embolization with oil based agents can indeed improve target to background ratios for gene therapy vectors. If this is possible, it will be critical to establish the mechanisms responsible so that the technique might be applied to other organs.

22.3.3

Gene Therapy to Promote Embolization

Gene therapy could be used to improve embolization outcomes. Interventional Radiology has traditionally concentrated on the mechanical aspects of our procedures but it is clear that biological coatings that alter tissue response will become increasingly important. The same strategy that has been used to link adenoviral particles to embolization coils could easily be adapted to link gene therapy vectors to embolization particles. This technology clearly illustrates that the key to a successful marriage of embolization and gene therapy will be understanding both embolization and gene therapy at the cellular and molecular levels.

References

1. Abrahams JM, Song C, DeFelice S et al. (2002) Endovascular microcoil gene delivery using immobilized anti-adenovirus antibody for vector tethering. *Stroke* 33:1376-1382
2. Carmeliet P, Jain RK (2000) Angiogenesis in cancer and other diseases. *Nature* 407:249-257
3. Chuah MK, Collen D, VandenDriessche T (2004) Clinical gene transfer studies for hemophilia A. *Semin Thromb Hemost* 30:249-256
4. Collinson DJ, Donnelly R (2004) Therapeutic angiogenesis in peripheral arterial disease: can biotechnology produce an effective collateral circulation? *Eur J Vasc Endovasc Surg* 28:9-23
5. Duncan JR, Hicks ME, Cai SR et al. (1999) Embolization of portal vein branches induces hepatocyte replication in swine: a potential step in hepatic gene therapy. *Radiology* 210:467-477
6. Giannoukakis N, Trucco M (2003) Current status and prospects for gene and cell therapeutics for type 1 diabetes mellitus. *Rev Endocr Metab Disord* 4:369-380
7. Goldstein JL, Hobbs HH, Brown MS (1995) Familial hypercholesterolemia. In: Scriver CR, Beaudet AL, Sly WS et al. (eds) *The metabolic and molecular bases of inherited diseases*. McGraw-Hill, New York, pp 1981-2030
8. Grossman M, Raper SE, Kozarsky K et al. (1994) Successful ex vivo gene therapy directed to liver in a patient with familial hypercholesterolaemia. *Nat Genet* 6:335-341
9. Grossman M, Rader DJ, Muller DW et al. (1995) A pilot study of ex vivo gene therapy for homozygous familial hypercholesterolaemia. *Nat Med* 1:1148-1154
10. Kan Z, Wallace S (1994) Sinusoidal embolization: impact of iodized oil on hepatic microcirculation. *J Vasc Interv Radiol* 5:881-886
11. Klugherz BD, Song C, DeFelice S et al. (2002) Gene delivery to pig coronary arteries from stents carrying antibody-tethered adenovirus. *Hum Gene Ther* 13:443-454
12. Manninen HI, Makinen K (2002) Gene therapy techniques for peripheral arterial disease. *Cardiovasc Intervent Radiol* 25:98-108
13. Mulligan RC (1993). The basic science of gene therapy. *Science* 260:926-932
14. Nemunaitis J, Ganly I, Khuri F et al. (2000) Selective replication and oncolysis in p53 mutant tumors with ONYX-015, an E1B-55kD gene-deleted adenovirus, in patients with advanced head and neck cancer: a phase II trial. *Cancer Res* 60:6359-6366
15. Ponder KP, Melniczek JR, Xu L et al. (2002) Therapeutic neonatal hepatic gene therapy in mucopolysaccharidosis VII dogs. *Proc Natl Acad Sci USA* 99:13102-13107
16. Rajagopalan S, Mohler ER 3rd, Lederman RJ et al. (2003a) Regional angiogenesis with vascular endothelial growth factor in peripheral arterial disease: a phase II randomized, double-blind, controlled study of adenoviral delivery of vascular endothelial growth factor 121 in patients with disabling intermittent claudication. *Circulation* 108:1933-1938
17. Rajagopalan S, Mohler E 3rd, Lederman RJ et al. (2003b) Regional Angiogenesis with Vascular Endothelial Growth Factor (VEGF) in peripheral arterial disease: Design of the RAVE trial. *Am Heart J* 145:1114-1118
18. Rosenberg SA, Aebbersold P, Cornetta K et al. (1990) Gene

- transfer into humans-immunotherapy of patients with advanced melanoma, using tumor-infiltrating lymphocytes modified by retroviral gene transduction. *N Engl J Med* 323:570-578
19. Shiba H, Okamoto T, Futagawa Y et al. (2001) Efficient and cancer-selective gene transfer to hepatocellular carcinoma in a rat using adenovirus vector with iodized oil esters. *Cancer Gene Ther* 8:713-718
20. Sleeper MM, Fornasari B, Ellinwood NM et al. (2004) Gene therapy ameliorates cardiovascular disease in dogs with mucopolysaccharidosis VII. *Circulation* 110:815-820
21. Sze DY, Freeman SM, Slonim SM et al. (2003) Dr. Gary J. Becker Young Investigator Award: intraarterial adenovirus for metastatic gastrointestinal cancer: activity, radiographic response, and survival. *J Vasc Interv Radiol* 14:279-290
22. Wadhwa PD, Zielske SP, Roth JC et al. (2002) Cancer gene therapy: scientific basis. *Annu Rev Med* 53:437-452
23. Xu L, Gao C, Sands MS et al. (2003) Neonatal or hepatocyte growth factor-potentiated adult gene therapy with a retroviral vector results in therapeutic levels of canine factor IX for hemophilia B. *Blood* 101:3924-3932
24. Yu HC, You H, Lee H et al. (2004) Estimation of standard liver volume for liver transplantation in the Korean population. *Liver Transpl* 10:779-783

23 Embolotherapy in Pediatrics

JOSÉE DUBOIS and LAURENT GAREL

CONTENTS

23.1	Introduction	303
23.2	Embolotherapy	303
23.2.1	Pre-procedure	303
23.2.1.1	Indications	303
23.2.1.2	Consent	304
23.2.1.3	Prior Laboratory Tests	304
23.2.1.4	Preparation	304
23.2.1.5	Anesthesia	304
23.2.1.6	Setting – Equipment	304
23.2.2	Procedure	305
23.2.2.1	Fluids	305
23.2.2.2	Contrast Medium	305
23.2.2.3	Arterial Access	305
23.2.2.4	Arterial Spasm During Catheterization	305
23.2.2.5	Arterial Spasm Following Withdrawal of the Introducer	305
23.2.2.6	Embolizing Agents	305
23.2.3	Post-procedure	306
23.3	Main Indications in Pediatrics	306
23.3.1	Trauma	306
23.3.2	Pelvic fracture	306
23.3.3	Vascular anomalies	306
23.3.3.1	Hemangiomas Refractory to Medical Treatment	308
23.3.3.2	Kaposiform Hemangioendothelioma	308
23.3.3.3	Liver Hemangiomas	308
23.3.3.4	Arteriovenous Malformations	311
23.3.4	Renal Embolization	311
23.3.5	Epistaxis	311
23.3.5	Hemoptysis	315
23.3.6	Gastrointestinal Bleeding	316
23.3.7	Embolization or Sclerotherapy of Varicoceles	316
23.3.8	Hypersplenism	317
23.3.9	Thrombolysis	317
23.3.10	Chemoembolization	318
23.4	Conclusion	319
	References	319

J. DUBOIS, MD

Professor of Radiology, Pediatric and Interventional Radiologist, Department of Medical Imaging, Hôpital Ste-Justine, 3175 Côte Ste-Catherine Road, Montreal, Quebec H3T 1C5, Canada

L. GAREL, MD

Professor of Radiology, Pediatric and Interventional Radiologist, Department of Medical Imaging, Hôpital Ste-Justine, 3175 Côte Ste-Catherine Road, Montreal, Quebec H3T 1C5, Canada

23.1

Introduction

Pediatric interventions differ from adult interventions in several ways: both the setting and the equipment must be adapted to infants and children. The disease processes and the indications for treatment are clearly distinct in this age group.

Interventional procedures have been slower to gain acceptance in pediatrics because physicians were more conservative, training centers were few in number, and the equipment not designed for small patients.

Nowadays, pediatric embolotherapy has become feasible, thanks to the availability of microcatheters. Such procedures must be performed in tertiary pediatric centers, because newborns, infants, and children require special attention in the choice of general anesthesia versus sedation, control of temperature, fluids, radiation hazards, and dedicated equipment. These procedures rely upon a team of trained nurses, radiology technicians, interventional radiologists, and anesthesiologists.

The aim of this chapter is to outline our approach regarding the environment (setting, sedation, equipment), and to share our experience in pediatric endovascular procedures.

23.2

Embolotherapy

23.2.1

Pre-procedure

23.2.1.1

Indications

It is important to ensure the relevance of the procedure. The advantages of embolization by arterial route over a surgical procedure must be well established. The potential hazards must be discussed with the attending staff. A clinician and surgeon must be available as back-up to face any potential complication.

23.2.1.2**Consent**

Informed consent is obtained from the parent or guardian. In Quebec (Canada), a child over age 14 has the legal right to sign for him/herself. The procedure and all potential complications must be fully explained and discussed.

23.2.1.3**Prior Laboratory Tests**

Blood tests, including a standard coagulation work-up, are mandatory [1].

23.2.1.4**Preparation**

Patients must be fasting for the appropriate duration as determined by age and health condition. No prophylactic antibiotic is administered before embolotherapy except in children with congenital heart defects for bacterial endocarditis prophylaxis [2]. Sedation at the bedside is prescribed by the anesthesiologist for anxious children and adolescents.

23.2.1.5**Anesthesia**

The majority of simple interventions – biopsy, venous access, and drainage – are performed under sedation.

With the exception of embolotherapy for varicoceles, the majority of embolotherapies by arterial route are performed under general anesthesia for the following reasons: (a) to prevent the child from moving during a long procedure, (b) to focus fully on the technique while the patient is monitored by the anesthesiologist. Besides, embolization with alcohol carries definite risks, which are well described in the literature, and for which general anesthesia is mandatory.

23.2.1.6**Setting – Equipment**

The angiography room must be warm, especially for newborns and infants. Pediatric anesthesiologists must have the necessary means to maintain the child at a constant body temperature: covers, hat, Bear Hugger, heat lamp, and warming blanket. The solutions as well as the contrast medium are heated.

Table 23.1. Materials for pediatric angiography and embolotherapy

Introducer sheath: 4Fr (for patients weighing less than 8 kg)
 Introducer sheath: 5Fr (for patients weighing over 8 kg)

Catheters – 5Fr AND 4Fr (selected according to the introducer sheath):

Celiac trunk catheterization: Hook (Cook) (RIM - second choice)
 Superior mesenteric artery: Hook (Cook) (RIM - second choice)
 Inferior mesenteric artery: RIM (Cook)
 Bronchial artery: Hook (Cook)
 Inferior and superior limbs: Hook (second choice: Tracker, Boston Scientific)
 Common carotid: Harwood Nash (Cook)

Microcatheters (used with the following none tapered catheters)

Fast Tracker 18 (Boston Scientific): Coaxial 5Fr
 Renegade 18 (Boston Scientific): Coaxial 5Fr
 Excel 14 (Boston Scientific): Coaxial 4Fr
 Fast Tracker 10 (Boston Scientific): Coaxial 4Fr

Guides

Terumo guidewire (the most often used in our institution):

Available in different angle shapes (45° and 90°) selected according to arteries angulation.

Transend 14 (Boston Scientific):

The tip of this guidewire has the distinctive feature of being malleable and therefore it can be reshaped before catheterization. For this reason, this guidewire is often used to perform difficult catheterization.

Mizzen Soft (0.012) (Boston Scientific):

The tip of this guide is smaller than Transend and is sometime useful for distal catheterization.

Pulsed fluoroscopy, low mA, filters, videocapture, and coning are mandatory in pediatric practice for decreasing radiations.

23.2.2

Procedure

Although partially modified for children (mainly for shortening their length) the catheters used are basically the same as those used for adults. The catheterization technique and the embolizing agents are similar. However, certain details specific to children must be discussed: fluids, contrast medium, and equipment.

23.2.2.1

Fluids

The fluids administered must be closely monitored in order to avoid rapid pulmonary overload, particularly in an infant weighing under 10 kg. It is important to inform the anesthesiologist of the quantity and nature of the fluids that are injected during the procedure. Specific attention must be given to the infusion via the introducer, which must be regulated by a counter to 20 cc/hr. The quantity of rinsing fluid must be minimized.

23.2.2.2

Contrast Medium

A maximum of 5 cc/kg must be the rule. It is better to perform an embolotherapy in several steps than to exceed the maximum dose of contrast. Aspirating surplus contrast medium remaining in the catheter helps to reduce the volume administered. Hydration should be maintained. Reported rate of minor reactions is 0.9% for non-ionic contrast media [3].

23.2.2.3

Arterial Access

Arterial spasm is frequent in children, especially when having difficulty with the arterial puncture. In children, it is preferable to puncture an artery with a Cathlon rather than a metal needle to lessen the risk of arterial spasm. A 20-G Cathlon is used for children weighing less than 10 kg, and an 18-G Cathlon for children over 10 kg. An introducer is

always used: 4-F for under 10 kg and 5-F above. Occasionally, when there are specific technical demands, a 5-F introducer may be used for children under 10 kg. Heparin therapy of 50–100 units/kg is recommended for all infants weighing less than 10 kg, with the exception of those with bleeding problems [4].

23.2.2.4

Arterial Spasm During Catheterization

The medications used are intraarterial papaverine (1 mg/kg) or nitroglycerin (2–3 µg/kg – which may be repeated 3 times, maximum 20 µg/kg), and xylocaine.

23.2.2.5

Arterial Spasm Following Withdrawal of the Introducer

We recommend keeping the limb warm. A nitro ointment can be applied to the puncture site. Occasionally, a nerve block may be done. The patient must be on heparin and, if necessary, an intravenous infusion of rtPA can be used under the supervision of a hematologist.

Thrombolysis by arterial route is seldom recommended, particularly for newborns and babies weighing less than 5 kg, given the risk of damaging other vessels. Infants have a well-developed collateral network which, in most cases, enables revascularization of the affected limb.

23.2.2.6

Embolizing Agents

The embolizing agents are the same as those used for adults. The gelatin sponge particles (Surgifoam, Ethicon, Johnson & Johnson Co., Somerville, New Jersey) are used for a temporary occlusion, and the polyvinyl alcohol particles (Contour, Boston Scientific Corp., Fremont, CA) for a permanent occlusion. Tissue adhesive: N-butyl-2-cyanoacrylate (Indermil, Tyco, Norwalk, USA) or enbucrilate (Histoacryl, Braun, Aesculap) opacified with oily contrast media and alcohol can also be used in pediatrics.

Specific precautions are needed for alcohol use. A maximum dose of 1 ml/kg (or 60 ml) per session should never be exceeded [5].

23.2.3 Post-procedure

As soon as the interventional procedure is over, the pediatric patient is taken to the recovery room and then transferred to his/her room. He/she must be monitored and the catheter entry site checked every 15 minutes for the first 2 hours, and then every 30 minutes for an additional 2 hours. Bed rest for eight hours is recommended with special attention given to the limb involved.

23.3 Main Indications in Pediatrics

23.3.1 Trauma

Organ injuries occur following a blunt or a penetrating trauma, including biopsy. Hematuria, hemobilia, or intraabdominal bleeding are the relevant clinical symptoms indicating traumatic injuries. Delayed or recurrent hemorrhage is the most common complication of trauma occurring in 3-8% of hepatic injuries, 1.5% of liver-spleen injuries, 6% of liver-spleen and pancreas injuries, and 31% of isolated pancreas injuries [6]. Pseudoaneurysm with expanding hematoma and subsequent rupture is the most serious evolutive complication. CT-scan is able to identify arterial injuries or fistulae. Angiography is indicated in unstable patients with dropping hemoglobin or in patients in whom a vascular lesion is questioned on CT-scan [7].

The embolization should be done as close as possible to the injury site to preserve the functional parenchyma. The embolization can be performed by an endovascular route with a coaxial microcatheter system (Tracker 18, Target Therapeutics, Fremont, Ca) to reach the vascular lesion or by a percutaneous approach under Doppler ultrasonography guidance. There are several options regarding the embolic agents: polyvinyl alcohol particles, isobutyl-2-cyanoacrylate, alcohol, and microcoils (Figs. 23.1a-d, 23.2a,b). The first choice for the occlusion of pseudoaneurysms is microcoils deposition on both sides of the pseudoaneurysm neck [8] followed by in-situ deposition of tissue adhesive, alcohol, or particles. We do not use Gelfoam because it is a temporary occluding agent and it carries the risk of future recanalization.

For pseudoaneurysm accessible by percutaneous approach, the procedure can be performed under Doppler guidance (Fig. 23.3a,b). The adequate needle placement is confirmed by contrast injection. Thrombostat (Thrombin, Parke-Davis, Scarborough, On., Canada), 1000 units/cc, is the most commonly used agent. We start with an initial bolus of 200 units. If the flow in the pseudoaneurysm is still present on Doppler ultrasound, we repeat the injection up to a maximal dose of 1000 units. Since there is a possible risk of contamination with Thrombostat, we elected to use human thrombin 500 which is included in a kit available at the blood bank of our institution (Tissel Kit VH, Baxter, USA). Tissue adhesive, Gelfoam, or coils can also be used percutaneously.

23.3.2 Pelvic fracture

Although rare in pediatric patients, severe hemorrhage is a significant complication of pelvic fractures and pelvic crush injuries, and a leading cause of early mortality. Angiography and embolization of bleeding vessels have been recommended for the management of pelvic bleeding in patients in whom hypotension is unresponsive to resuscitation and/or surgical exploration [9]. The pelvic vessels are accessed by femoral or axillary approach using Seldinger technique. Once the extravasation is identified and selectively cannulated, the embolization is performed with Gelfoam or coils.

23.3.3 Vascular anomalies

MULLIKEN and GLOWACKI [10] proposed a classification that was accepted by the Workshop on Vascular Anomalies in Rome in June 1996. The vascular anomalies are divided into vascular tumors (hemangioma, hemangioendothelioma, and other vascular tumors) and vascular malformations. Hemangiomas are the most frequent tumors in infancy. They are characterized by initial rapid growth of endothelial cells and subsequent slow involution. Vascular malformations are made of malformed or dysplastic vessels. They never regress. These vascular malformations are subcategorized based on the type of channel abnormality (arterial, capillary, venous or lymphatic) and flow rate (high- or low-flow malformations).

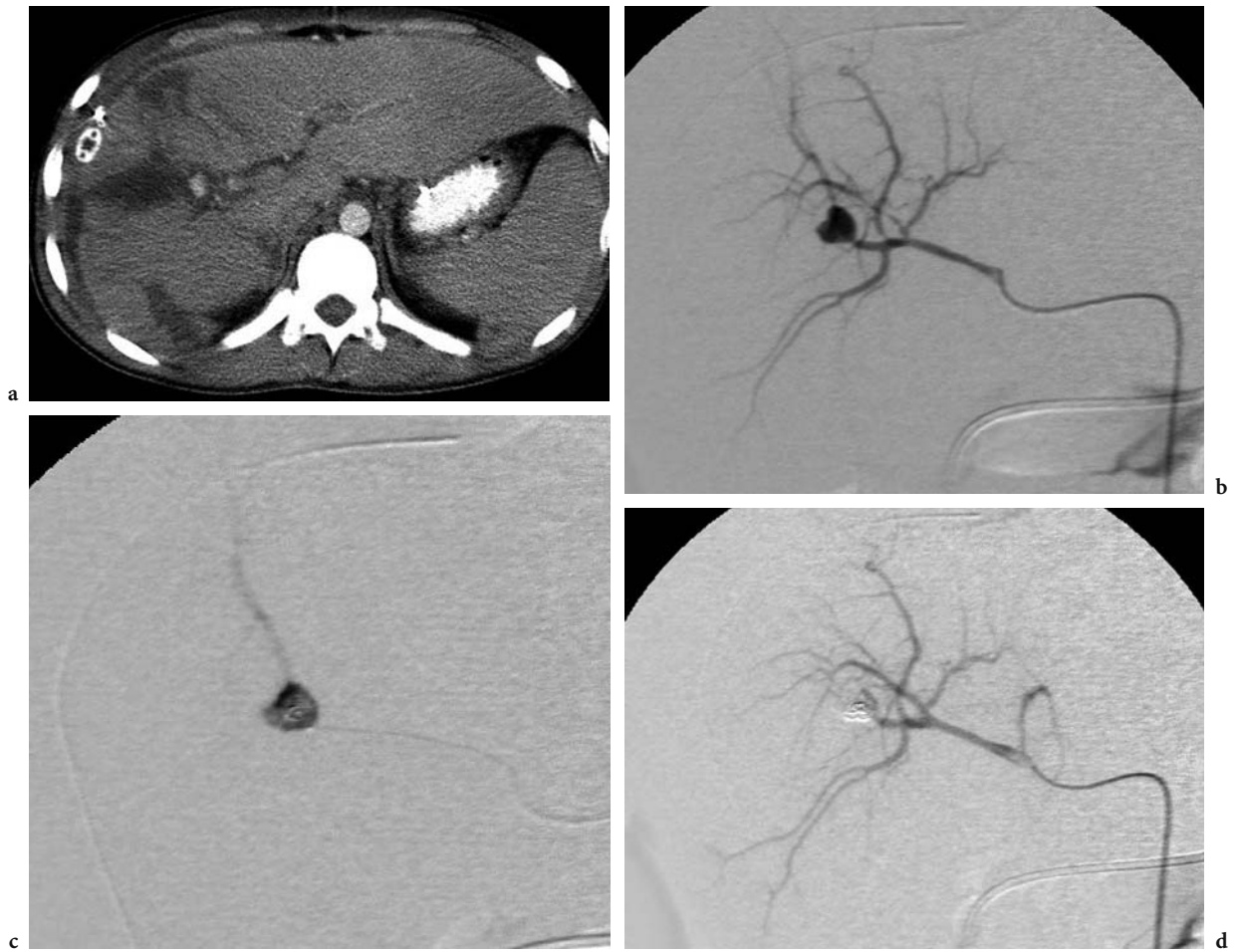

Fig. 23.1a–d. Liver trauma in a 15-year-old boy. **a** CT-scan revealed the presence of an arterial pseudoaneurysm. **b** Selective catheterization of the hepatic artery confirmed the pseudoaneurysm. **c** With a coaxial system (Tracker: Renegade) we overpass the pseudoaneurysm and occlude the exit branch with a coil. Then, we occlude the pseudoaneurysm with glue followed by the occlusion of the afferent artery by a coil. **d** Control angiogram revealed a complete occlusion of the pseudoaneurysm

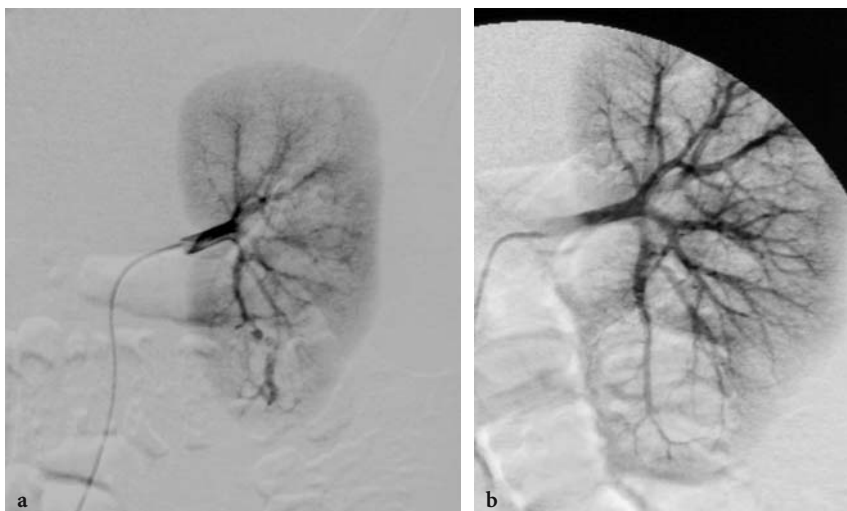


Fig. 23.2a,b. A 10-year-old girl with severe hematuria post renal transplant biopsy. **a** Angiogram shows the presence of a pseudoaneurysm. **b** With a coaxial system, a selective catheterization of the pseudoaneurysm was performed. The occlusion was performed with a coil

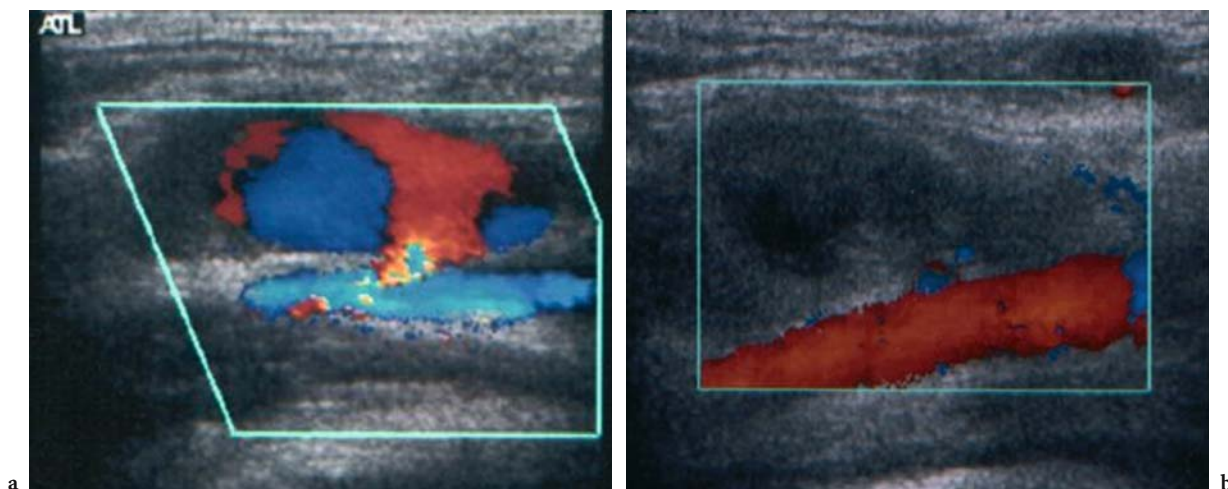


Fig. 23.3a,b. A 10-year-old boy with a pseudoaneurysm of the femoral artery related to cardiac catheterization. **a** Color ultrasonography shows the presence of a pseudoaneurysm. **b** Under ultrasonography, direct puncture of the pseudoaneurysm was performed with a 22-G Cathlon. 800 units of Thrombostat permit to occlude the pseudoaneurysm

The indications of embolotherapy in vascular anomalies are: (1) hemangiomas refractory to medical treatment, (2) hemangioendotheliomas with Kasabach-Merritt phenomenon, (3) liver hemangioma with cardiac failure, and (4) arteriovenous malformations.

23.3.3.1 Hemangiomas Refractory to Medical Treatment

Ten to 20% of hemangiomas need to be treated [11]. Medical treatment is the first choice using steroids, interferon, or vincristine. Embolotherapy is only indicated in cases of ineffective medical treatment. Embolization is mostly performed in cases of hepatic hemangioma with cardiac failure, hemangioendothelioma complicated by Kasabach-Merritt phenomenon, and uncontrolled proliferative hemangioma with functional disorder (e.g. tongue with feeding problem).

The embolization provides the control of the growth of hemangioma in its proliferative phase.

23.3.3.2 Kaposiform Hemangioendothelioma

MUELLER [12] and ENJOLRAS [13] reported that Kasabach-Merritt phenomenon (KMP) is caused by kaposiform hemangioendothelioma (KHE) or tufted angioma. The KMP consists of thrombocy-

topenia, microangiopathic hemolytic anemia, and localized consumption coagulopathy in association with rapid evolutive hemangioendothelioma. This syndrome requires an aggressive treatment, and carries a mortality rate of 20 to 30%.

Aspirin, dipyridamole, antifibrinolytic agents, aminocaproic acid, corticosteroid, interferon, embolization, cyclophosphamide, pentoxifylline, radiotherapy, and antiplatelet aggregating agents have been tried with variable success [12–14]. Heparin has been shown to boost the growth of KHE [12] and worsens the clinical situation [15, 16].

Embolization aims at reducing the high flow. Embolization is performed by arterial approach using polyvinyl alcohol particles or alcohol (Fig. 23.4a–d).

23.3.3.3 Liver Hemangiomas

The differential diagnosis of hemangioma of the liver include hepatic angiosarcoma, hepatic epithelioid hemangioendothelioma, or metastatic disease like neuroblastoma. No treatment is required in case of asymptomatic hepatic hemangiomas. The main indications for treatment of hepatic hemangiomas are congestive heart failure, patients who requires mechanical ventilatory support, feeding problem, or Kasabach-Merritt phenomenon. Steroid is the initial drug. Interferon or vinblastine is reserved for refractory cases. We believe that embolization

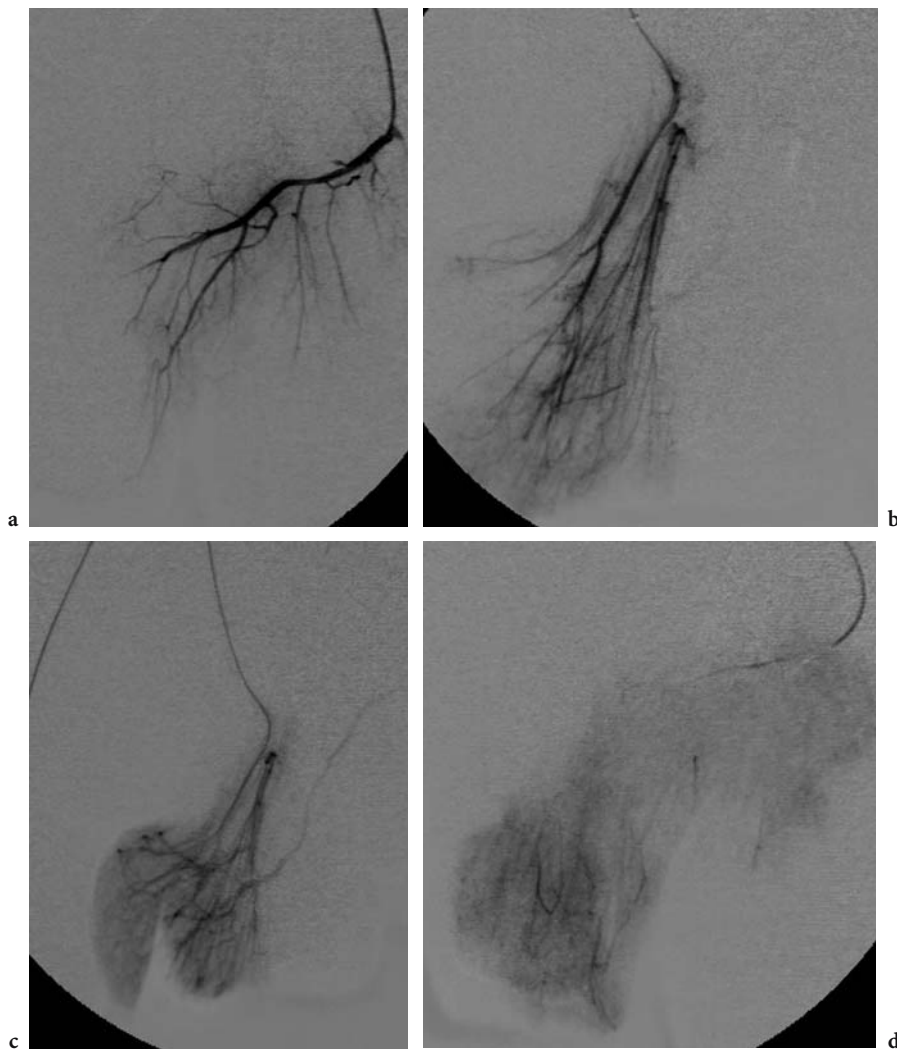


Fig. 23.4a–d. A 10-year-old boy with refractory scrotal and perineal hemangioendothelioma with recurrent scrotal bleeding. **a** Selective catheterization of the perineal branch from the internal pudendal artery through an anastomosis from the common femoral artery was performed. The opacification demonstrates an important stagnation of contrast in the tumor. **b** The embolization was performed with Gelfoam. **c** Catheterization of the hypogastric artery with selective catheterization of the perineal branch from the internal pudendal artery shows a tumor blush. **d** (Control) angiogram after devascularization of the tumor with particles

in combination with medical treatment is the best alternative in symptomatic liver hemangiomas. Pre-embolization mapping is mandatory, assessing the potential involvement of intercostal or phrenic arteries in addition to the hepatic artery and the portal system [17–19].

Five patterns of angiographic findings had been described by KASSARJIAN et al. [20]. Embolic material is selected depending on the vascular type. The first type, the most classical appearance, is early filling of abnormal vascular channels, stagnation of contrast material, and no evidence of a direct shunting (Fig. 23.5a–h). Type 2 shows high-flow nodules

without direct shunts. Large particles can be used in type 1 and 2. Type 3 is made of arteriovenous shunts, type 4 of portovenous shunt, and type 5 of both arteriovenous and portovenous shunts.

The embolization is performed by arterial approach for types 1, 2, 3, and 5, and by transhepatic transvenous approach for portovenous shunts in type 4. Platinum fiber microcoils are generally safe in types 3, 4 and 5, and permit the occlusion of the shunts. Glue (n-butyl-2-cyanoacrylate) is the most effective material in patients with direct arteriovenous and arteriportal shunting arising from multiple sources [21]. Medical antiangiogenesis drugs

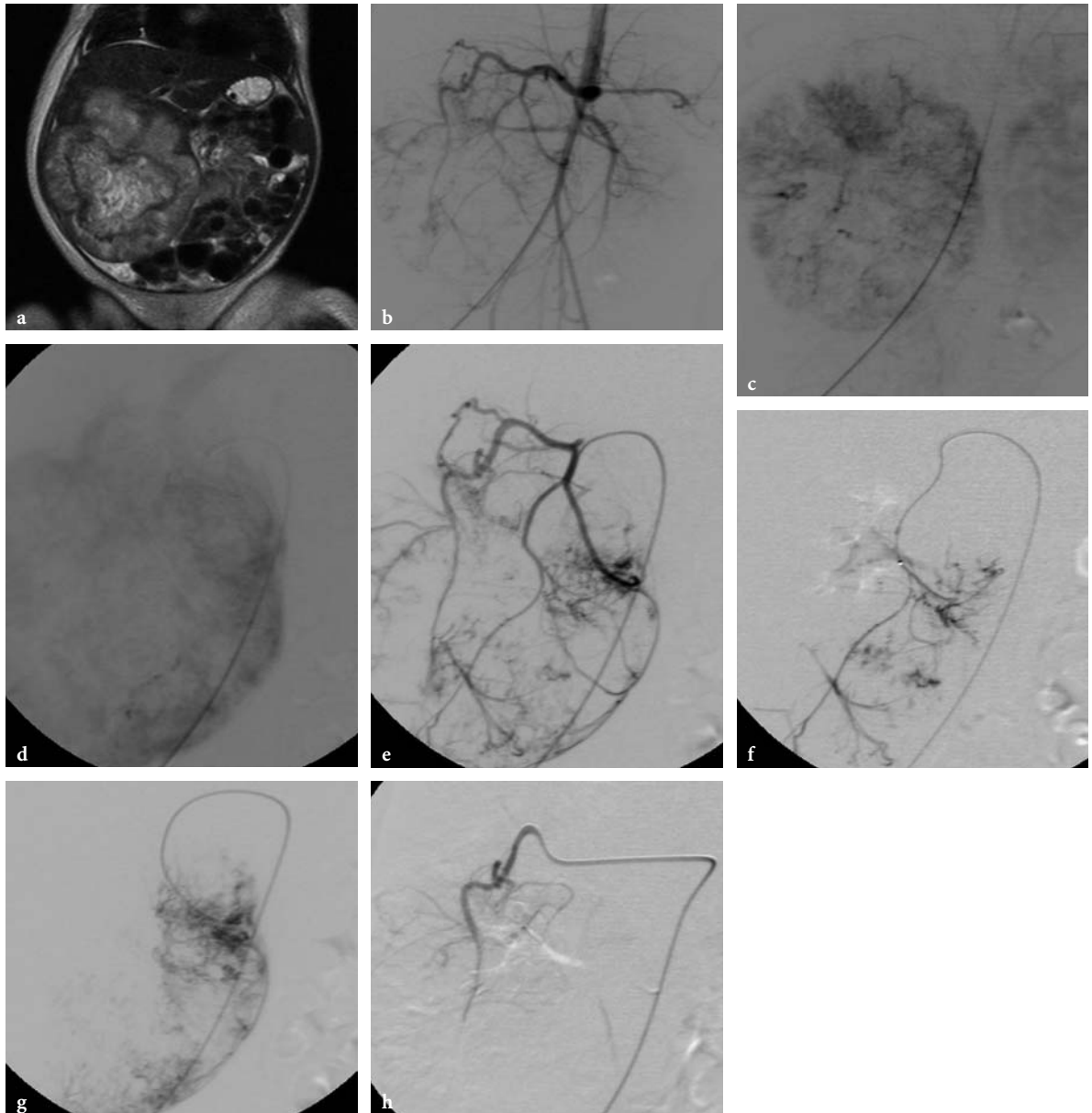


Fig. 23.5a-h. A 2-month-old girl on steroid treatment with progressive liver hemangioma and feeding problem. **a** MR imaging shows a large liver mass in the right lobe of the liver. **b-d** The aortogram demonstrates a vascular tumor supplied by the right branch of the hepatic artery with stagnation of the contrast and normal draining vein, illustrative of type 1 liver hemangioma. **e** Selective catheterization of the right hepatic artery was performed. **f,g** With a coaxial system, multiple feeders were catheterized followed by an embolization with particles. **h** Postembolization opacification of the right hepatic artery shows a significant devascularization of the tumor

should be maintained after embolization until nearly complete regression of the lesions.

Vascular malformations of the liver are rare, except for the venous malformations misnamed hemangioma in adults. Most arteriovenous malformations of the liver are seen in hereditary hemorrhagic telangiectasia (Rendu-Weber-Osler) with hepatic ischemia, congestive heart failure, and

portal hypertension. Because of the risk of increasing the hepatic failure, embolization is not recommended in diffuse lesions. Liver transplantation is indicated in such instances.

Arterioportal fistula in cases of hereditary hemorrhagic telangiectasia, Ehlers-Danlos syndrome, or patients with biliary atresia and cirrhosis can be treated by embolization.

Pure venous malformations are rare and asymptomatic in children. Most of them are seen specifically in patients with blue rubber bleb nevus syndrome which is a familial condition with multiple venous malformations of the skin, musculoskeletal system, and viscera.

23.3.3.4

Arteriovenous Malformations

Arteriovenous malformations (AVM) are an important challenge for interventional angiographers. These high flow vascular malformations are abnormal communications between arteries and veins. We do not understand exactly why some AVMs respond well to embolization while other AVMs progress ineluctably despite embolotherapy. That is the reason why we favor a conservative management for quiescent, stable, and non-bleeding AVM with an annual MRI and cardiac ultrasound. If the AVM progresses, bleeds, or disfigures, angiography is essential to provide the road-map necessary for embolization. The angiographic characteristics of AVMs are dilatation and lengthening of afferent arteries, with early opacification of enlarged efferent veins [22]. To destroy the AVM and reduce the risk of recurrence, a superselective catheterization with microcatheters is necessary combined with percutaneous puncture when feasible [23]. The best agent to destroy the nidus is dehydrated alcohol. The amount of ethanol needed and the pressure of injection are evaluated with contrast media test injections. The maximum dose is 1 ml/kg. Over 1 ml/kg, the elevated serum ethanol levels put the patients at risk for respiratory depression, cardiac arrhythmias, seizures, rhabdomyolysis, and hypoglycemia [24]. The ethanol penetrates to the capillary level and totally devitalizes normal tissues. Balloon occlusion, tourniquets, blood pressure cuffs inflated above systolic pressure, or a combination of these can be useful if vascular occlusion is necessary to induce stasis. Temporary compression of the venous drainage during the injection slows the blood flow, but one should relieve the occlusion slowly to avoid a significant modification of the pressure within the AVM. Coagulation disturbances have been reported in response to dehydrated alcohol that could increase the risk of bleeding, thrombosis, or hematoma. In these patients, in which the embolization is followed by surgery, the use of glue or coils as a substitute for dehydrated alcohol is recommended [25]; further studies are

needed to evaluate the specific changes that occur with the dehydrated alcohol. N-butyl-2-cyanoacrylate or coils are used for large AVM or to avoid neuropathy when the AVM is close to nerves.

Many complications are reported particularly with alcohol embolization, such as pulmonary embolus, cardiovascular collapse, neuropathy, skin blisters, radiculopathy, finger numbness, and focal skin necrosis [23, 24]. Arterial line monitoring and Swan-Ganz catheters are recommended for large AVM embolization [24] (Figs. 23.6a–d, 23.7a–d).

AVM can be associated with hereditary hemorrhagic telangiectasia (HHT), also known as Osler-Weber-Rendu syndrome. It is an autosomal dominant inherited disease of the vascular connective tissue characterized by epistaxis, telangiectasia, and visceral arteriovenous malformation. The organs mostly affected are the lungs (Fig. 23.8a–c), liver, brain, and the gastrointestinal tract. HHT is difficult to treat and requires a multidisciplinary approach for its management.

23.3.4

Renal Embolization

Renal scarring secondary to vesicoureteral reflux may be the cause of renovascular hypertension. Renal ablation is an alternative to nephrectomy to remove the involved kidney. The selective embolization should be performed with alcohol to prevent collateral revascularization. The efficacy is debated considering that embolization may delay the definitive treatment [26]. Gelfoam and coils are less valuable than alcohol because of collateral revascularization (Fig. 23.9a,b).

Selective renal embolization can be useful and effective in cases of refractory urinoma following partial nephrectomy or blunt trauma. The goal of the embolization is to ablate the fragment of renal parenchyma that is producing and leaking urine [27]. The embolization is done through selective catheterization of the vessel adjacent to the leakage. We recommend the use of particles (polyvinyl alcohol) as embolic agent.

23.3.5

Epistaxis

The differential diagnoses of epistaxis in children includes trauma, foreign-body impaction, bleeding diathesis, vascular disorder, vascular anomalies

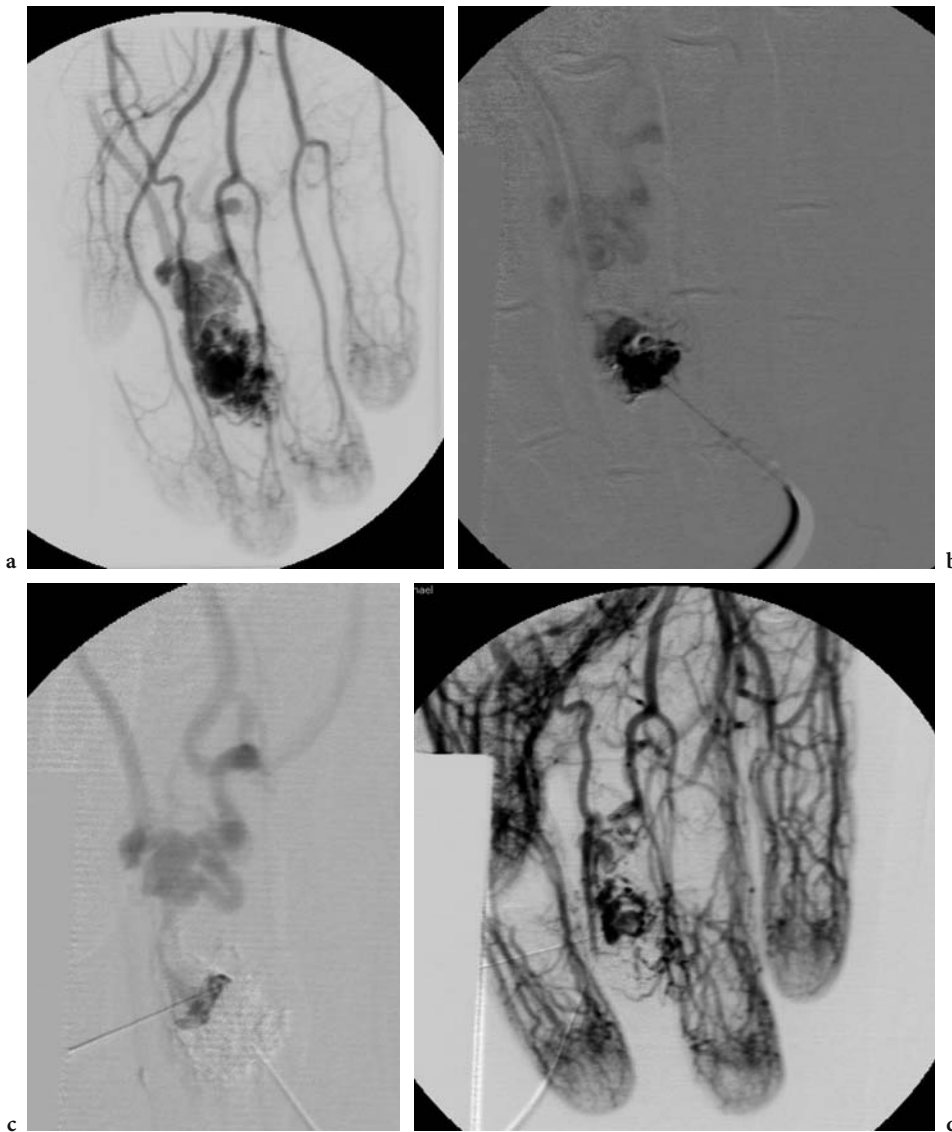


Fig. 23.6a–d. A 17-year-old boy with arteriovenous malformation (AVM) of the third digit. **a** Selective catheterization of the brachial artery was performed and showed an AVM of the third digit. **b,c** Percutaneous approach was performed. Under fluoroscopy, with prior mapping of the AVM from the arterial side, we puncture directly the AVM with a 25-G butterfly needle at two sites. The acquisition shows the opacification of the AVM. We injected 2 cc of alcohol. **d** Control angiogram by arterial approach shows a significant devascularization of the AVM but a severe arterial spasm. We monitored the coloration and skin temperature. No arterial ischemia was seen; because of the significant venous congestion, a nail resection was performed without any sequelae

(reported but rare in Sturge-Weber syndrome), and nasal hemangioma. The most common indication of embolotherapy in children presenting with epistaxis is nasopharyngeal angiofibroma. A benign tumor, most often seen in the adolescent boy, juvenile angiofibromas originate from the sphenopalatine foramen and extend into the paranasal sinuses, the infratemporal fossa, the middle fossa, and the orbit. The optimal treatment consists of preoperative embolization followed by radical surgical excision.

CT-scan and MR are essential both for the diagnosis and the assessment of the tumoral extent.

The arteries supplying juvenile angiofibromas arise from branches of the external carotid artery (ECA). The tumor blush is intense and persistent. There is no arteriovenous shunting within the lesion. The contralateral ECA should be explored in all cases that reach the midline. The distal internal maxillary artery is the first vessel to investigate. Large tumors are also supplied by other branches

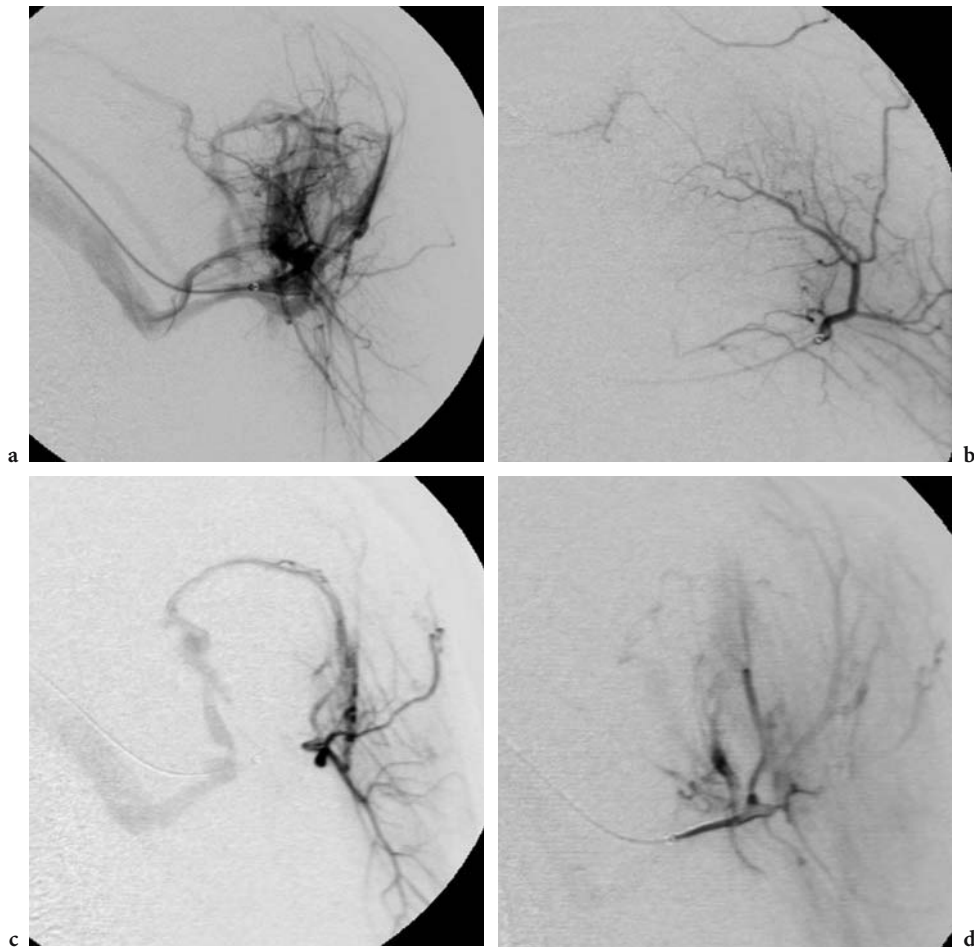


Fig. 23.7a–d. An 11-year-old boy with an arteriovenous malformation (AVM) of the left shoulder. **a** Selective catheterization of the posterior circumflex artery from the humeral artery was performed with a Tracker 38. Angiogram demonstrated multiple dilated arteries with early venous drainage. **b** A Tracker 18 was introduced through the Tracker 38 for selective catheterization of the arterial feeders. Alcohol was used for embolization. The control angiogram revealed a complete devascularization of the AVM. **c** 8 weeks later a residual AVM was seen at the control angiogram. **d** We used the same coaxial system and alcohol for the devascularization of the residual AVM with a good result

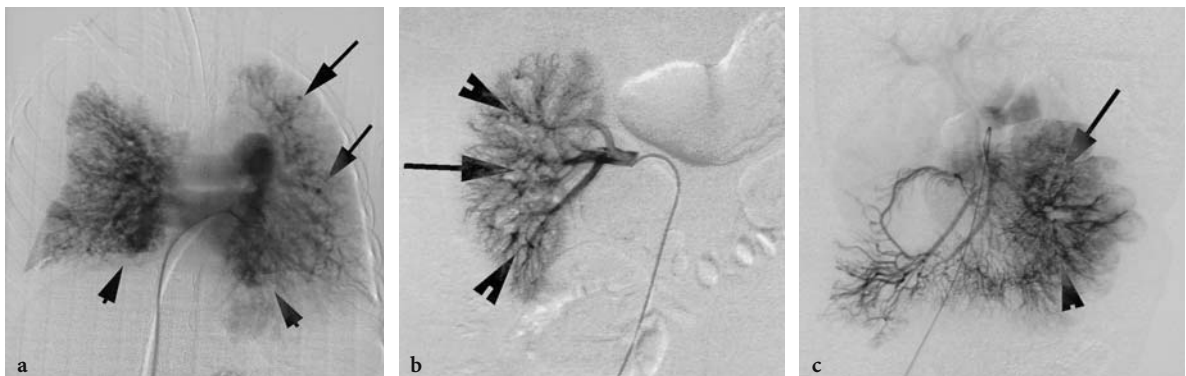

Fig. 23.8a–c. A 6-year-old girl with Rendu-Weber-Osler syndrome. **a** At pulmonary angiogram, small aneurysms (*arrows*) are seen in the left lung. Multiple areas of telangiectasia with diffuse arteriovenous shunting are seen predominantly in both lower lobes (*arrowhead*). **b** On selective injection of the right renal artery, several small aneurysms (*arrowhead*) associated with telangiectasia (*arrows*) are seen. **c** After selective injection of the superior mesenteric artery, a small aneurysm (*arrow*) and diffuse area of telangiectasia are demonstrated in the proximal jejunum

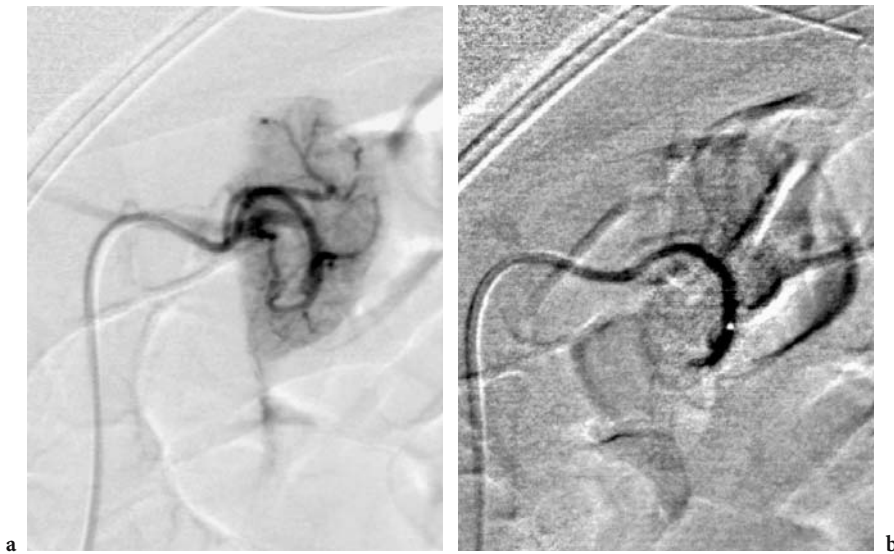

Fig. 23.9a,b. Alcohol embolization of atrophic kidney for refractory hypertension. **a** Selective catheterism of left renal artery. **b** Renal artery opacification after alcohol embolization shows a complete devascularization of the kidney. Normalization of blood pressure was noted

such as the accessory meningeal, the ascending pharyngeal, and the ascending palatine arteries. In case of intracranial tumor extension, the hemodynamics (anastomoses) between the internal maxillary system and the ipsilateral internal carotid artery must be analyzed carefully. Distal embolization (proximal occlusion would result in tumor

revascularization) is usually performed with particles or tissue adhesive (Fig. 23.10a,b). When the tumor has invaded the cavernous sinus, the pituitary fossa, the suprasellar area, or the intracranial intradural area, permanent preoperative balloon occlusion of the internal carotid artery could be helpful [28, 29].

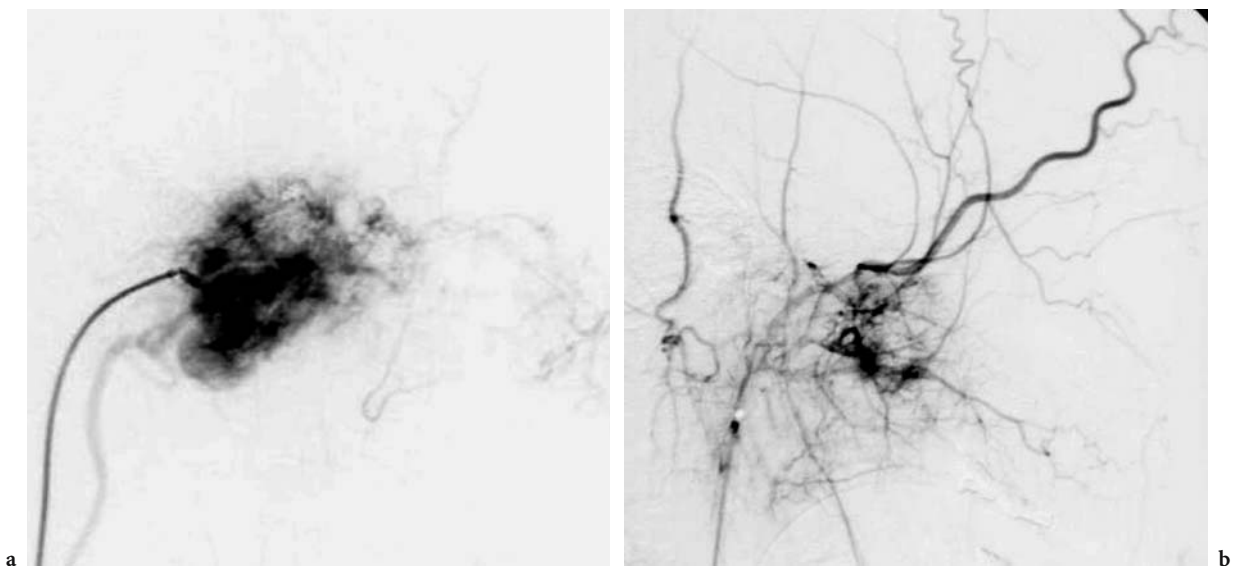


Fig. 23.10a,b. Juvenile nasopharyngeal angiofibroma in an 11-year-old boy. Preoperative embolization with particles of the arterial branches of the internal maxillary artery. **a** Selective external carotid angiogram shows a vascular tumor fed by multiple branches of the internal maxillary artery. **b** After multiple selective catheterization with a coaxial system (Tracker 38 and Tracker 18), embolization was performed with particles. Postembolization angiogram shows significant devascularization

23.3.5 Hemoptysis

Most patients who may benefit from bronchial artery embolization are teenagers with cystic fibrosis (CF) and major hemoptysis. The hazards of general anesthesia with positive pressure ventilation in CF patients have been addressed recently in the literature. A fatal pulmonary hemorrhage during induction was reported by MCDUGAL and SHERRINGTON [30]. The technique is well established: femoral artery access, 5-F catheter, precise vascular mapping, coaxial technique with Tracker 18 catheters, secure catheter placement prior to performing embolization, and use of polyvinyl alcohol particles (size: 355–500 microns or 500–710 microns if microfistulas are observed)

(Fig. 23.11a–d). Coil embolization or surgical ligation of bronchial arteries should be avoided because they hinder subsequent catheterization of the proximally occluded vessel. Careful attention should be paid for the identification of spinal arteries arising from the bronchial or intercostal arteries. The localizing value of emergency bronchoscopy or multidetector CT scanning prior to embolization remains to be evaluated.

Bronchial artery embolization in CF patients is very effective immediately and on short-term basis. Many patients will require repeated embolizations during the follow-up [31]. Despite the reported severe complications of bronchial artery embolization, the procedure has proved to be safe if performed by experienced angiographers.

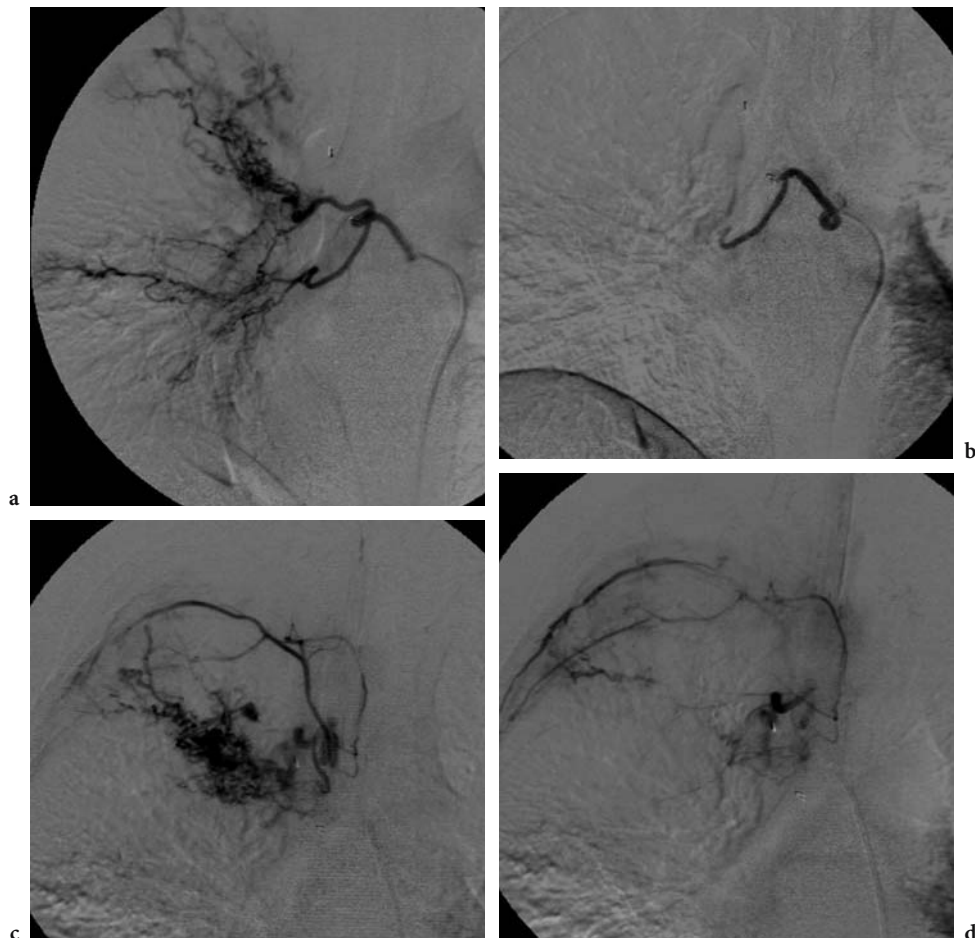


Fig. 23.11a–d. Hemoptysis in a 17-year-old boy with cystic fibrosis. **a** Selective catheterization of the right bronchial artery with a 5-F hook catheter shows dilated and tortuous arteries in the superior and middle pulmonary lobes. **b** With a coaxial system (Renegade 18), an embolization was performed with particles (Contour 500-700 microns). Postembolization angiogram shows devascularization of the bleeding site. **c** Selective catheterization of the bronchointercostal trunk. Multiple dilated and tortuous arteries are seen. **d** Selective catheterization with the same coaxial system. Embolization was performed with particles. Postembolization angiogram shows complete devascularization

23.3.6 Gastrointestinal Bleeding

In children, localized gastrointestinal bleeding is usually secondary to duodenal ulcer and less frequently to gastric ulcer, Meckel's diverticulum, and vascular malformations. Diffuse bleeding can occur in vasculitis and coagulopathy.

Gastrointestinal vascular anomalies are often associated with known syndromes such as Klippel-Trenaunay, Rendu-Osler-Weber, blue rubber bleb nevus, and Proteus syndromes.

In our experience, venous malformations are the more common vascular anomaly encountered in cases of bleeding (Fig. 23.12a,b).

In children with gastrointestinal arteriovenous malformations, the angiographic examination confirms the diagnosis and the extent of the AVMs. Embolization is usually not recommended in small bowel and colonic lesions because of the risk of necrosis [32, 33]. Embolotherapy is sometimes considered preoperatively to lower the risk of operative bleeding.

23.3.7 Embolization or Sclerotherapy of Varicoceles

Varicoceles are present in 15%–20% of preadolescents and adolescents. The treatment of varicoceles

in this age group is controversial. The treatment can be surgical, endoscopic or radiological (sclerotherapy or embolization of the internal spermatic vein). Most of the varicoceles are seen on the left side. BÄHREN et al. [34] described five types of left varicoceles according to the anatomy of the internal spermatic vein (ISV).

Irrespective of the type of varicocele, the sclerotherapy procedure is the same. Our technical protocol for percutaneous endovascular occlusion of the ISV is as follows: IV sedation by Ketamine/Midazolam, femoral vein approach, 7-F Cobra catheter with coaxial 3-F or Tracker 18 for distal sclerotherapy by sodium tetradecyl sulfate (STS) followed by more proximal coil occlusion, bed-rest for 4 hours, and discharge 6 hours post-procedure (Fig. 23.13a,b). Results are assessed by the referring surgeon 2 months later.

In our series, we have found a high incidence (44%) of anatomical variants in the pediatric population. Technical difficulties of retrograde sclerotherapy were seen in type IVb, collaterals from segmental renal veins to the internal spermatic vein with a competent ostial valve (12% of our cases, failure rate 50%) and in type V, double renal veins (14% of our cases, failure rate 33%). Our overall results (failure rate 10%) are comparable to the recently reported pediatric series [35, 36], in the radiological and surgical literature. The issue of radiation related to interventional procedure has been addressed in the literature. If the

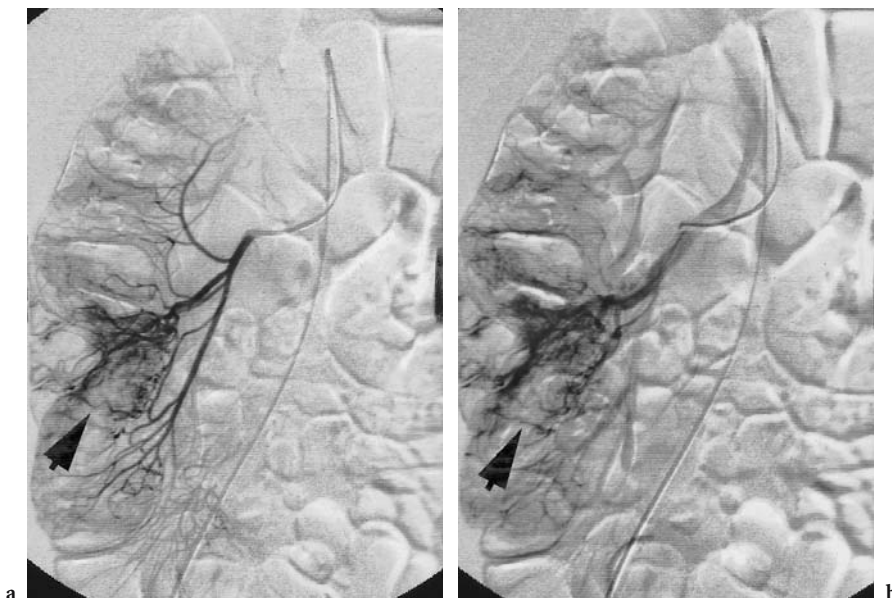


Fig. 23.12a,b. A 13-year-old boy presented with recurrent lower gastrointestinal bleeding. Lower gastrointestinal endoscopy was normal. a,b Selective injection of the right colic artery shows dysplastic veins (arrowhead) in the ascending colon

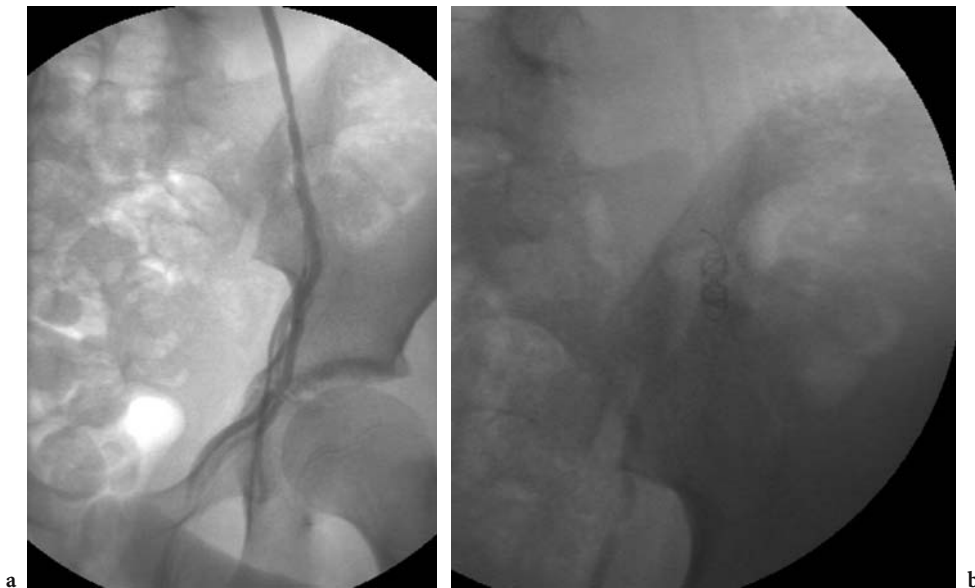


Fig. 23.13a,b A 12-year-old boy with left varicocele. **a** Selective catheterization of the left spermatic vein with a 7-F cobra and a coaxial 3-F catheters. **b** Injection of 4 cc of sodium tetradecyl sulfate with proximal coil occlusion

usual principles of radioprotection are observed, the gonad-dose (0.01 mSv) is negligible.

23.3.8 Hypersplenism

The causes of hypersplenism in children are cirrhosis secondary to cystic fibrosis or biliary atresia, portal vein thrombosis, thalassemia, and idiopathic thrombocytopenic purpura. Hypersplenism is treated by surgical resection with subsequent increased risk of infection in the pediatric age group.

Partial splenic embolization is an alternative to splenectomy. Preprocedural and postprocedural antibiotic prophylaxis is recommended. Under general anesthesia, the embolization is performed with a femoral 5-F catheter. The catheter is advanced through the femoral artery to the mid splenic artery. Subsequent catheterization into the intrasplenic arterial branches is performed either with the 5-F catheter or if necessary, coaxially with a microcatheter. The embolization is done with an injection of polyvinyl alcohol particles and antibiotic solution containing 0.2 mg of ampicillin (Fig. 23.14a,b). Splenic embolization is monitored angiographically. The procedure is completed after approximately 70% of the splenic parenchyma is devascularized [6]. Aggressive pain control is needed for 7-10 days post-procedure. In children, HARNED [37] demonstrated

that 30%–40% embolization of splenic blood flow is enough to improve the platelet count and white blood cells with a shorter hospitalization, faster recovery, and fewer complications. Complications of splenic embolization include fever, leucocytosis, pain, pleural effusion, splenic abscess, and peritonitis. The long-term results after partial splenic embolization have not been well established [38]. Up to now, partial splenic embolization as treatment of hypersplenism in children has not gained wide acceptance in western countries.

23.3.9 Thrombolysis

Experience with thrombolysis in children is limited but the need for this procedure has increased because of the need to treat complications of cardiac catheterization and systemic arterial intervention. Agents used include urokinase and rtPA. Effective dose schedules for children have been extrapolated from adult studies. Coagulation and fibrinolysis are probably different in pediatrics, particularly in neonates. Plasminogen levels are known to be low in neonates, and it has been proposed that plasminogen or fresh plasma be given to enhance fibrinolytic therapy. Most centers favor rTPA, and this may be locally delivered via a selective catheter. Local low-dose therapy is unlikely to produce systemic

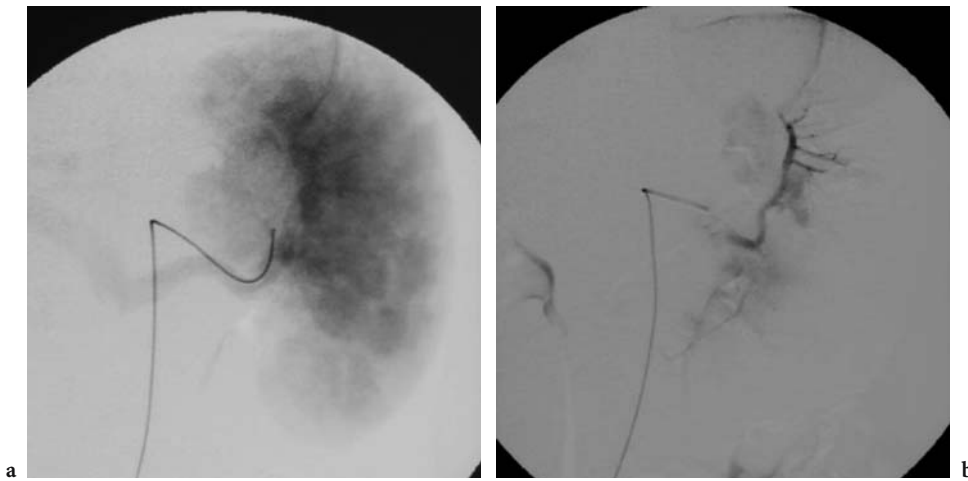


Fig. 23.14a,b. A 7-year-old boy with spherocytosis and hypersplenism. **a** Selective catheterization of the spleen shows the parenchymogram of the spleen. **b** Postembolization angiogram with the residual parenchyma

changes in coagulation, whereas systemic therapy will and therefore has greater risk and more contraindications. In all systemic therapies, the fibrinogen level, thrombin time, prothrombin time, and activated partial thromboplastin time are monitored at regular intervals, and the children are observed in an intensive care unit or neonatal nursery. Systemic therapy with heparin is recommended for indwelling catheters, but its role in the neonate is uncertain. The trend in thrombolytic therapy is toward higher-dose, shorter-duration treatment given locally, which often produces rapid clearing of thrombus. Failures may be related to delays in implementing therapy, going to maturation of the thrombus.

The most common lesion treated in the authors' center is femoral artery thrombosis complicating catheterization, especially for balloon angioplasty of the aortic arch or aortic valve. These procedures require the insertion of a large balloon, which is currently mounted on large shafts. Initially a local low-dose approach from the opposite groin was preferred, but now systemic therapy is frequently used if there are no contraindications. Local low-dose thrombolysis is used for thrombosis of Blalock-Taussig shunts, dialysis fistula, pulmonary artery thrombosis, iliofemoral thrombophlebitis, aortic thrombosis in neonates, and brachial artery occlusion after supracondylar fracture.

Bleeding is the most serious complication of thrombolytic therapy. Cerebral hemorrhage is a concern in the neonate, and in this age group the authors elect local low-dose treatment. Bleeding from recent surgical sites is also a well-known complication of thrombolysis.

23.3.10 Chemoembolization

We have no personal experience of chemoembolization and the pediatric literature on the topic is scarce.

According to the International Society of Pediatric Oncology and the Pediatric Oncology Group, the standard therapeutic protocol for childhood primary malignant tumors of the liver is based on the association of systemic chemotherapy and surgery [39–44]. Such an approach has improved significantly the outcome of hepatoblastomas, especially when the tumor is unresectable at presentation. Some case reports and a few series have outlined the interest of preoperative hepatic artery infusion of cisplatin and/or doxorubicin and of TACE (transcatheter arterial chemoembolization) in advanced hepatoblastomas [45–51]. According to these reports, the results were more than encouraging, with a much lower toxicity than conventional systemic chemotherapy. To the best of our knowledge, however, no study has demonstrated the superiority of preoperative TACE over preoperative systemic chemotherapy in increasing the resectability of initially inoperable hepatoblastomas. Besides hepatoblastomas, TACE has been reported also in pediatric cases of hepatocarcinoma [52] and even hepatic metastases [53]. According to the proponents of the technique, TACE appears feasible in children and can be performed in cases of unresectable tumor confined to the liver, when the portal vein is patent, and in the absence of biliary obstruction.

Inadvertent pulmonary lipiodol embolism during TACE has been reported in adults [54] and children [55].

Transarterial catheter chemotherapy and/or embolization in the management of advanced hepatic malignancies is still a work in progress and has not been endorsed by the international pediatric oncologic societies. On the other hand, the future development of gene therapy in children delivered through a vascular route can already be anticipated.

23.4 Conclusion

Embolotherapy of small vessels in small patients needs well-trained pediatric radiologists and a dedicated environment. Networking between the few centers performing such procedures in children is paramount for continuously optimizing both their indications and their techniques, and for assessing their effectiveness.

References

- MacPherson DS (1993) Preoperative laboratory testing: should any tests be "routine" before surgery? *Med Clin North Am* 77:289–308
- Saker MC, Uejima T (2002) Management of the pediatric patient for interventional radiologic procedures. *Semin Intervent Radiol* 19:3–12
- American College of Radiology Committee on Drugs and Contrast Media (1998) *Manual on contrast media*, 4th edn. Reston, VA
- Freed MD, Keane JF, Rosenthal A (1974) The use of heparinization to prevent arterial thrombosis after percutaneous cardiac catheterization in infants. *Circulation* 50:565–569
- Burrows PE, Mason KP (2004) Percutaneous treatment of low flow vascular malformations. *J Vasc Intervent Radiol* 15:431–445
- Spigos DG, Tan WS, Mozes MF, et al. (1980) Splenic embolization. *Cardiovasc Intervent Radiol* 3:282–287
- Vane DW (2002) Imaging of the injured child: important questions answered quickly and correctly. *Surg Clin N Am* 82:315–323
- Goffette PP, Laterre PF (2002) Traumatic injuries: imaging and intervention in post-traumatic complications (delayed intervention) *Eur Radiol* 12:994–1021
- Cook RE, Keating JF, Gillespie I (2002) The role of angiography in the management of haemorrhage from major fractures of the pelvis. *J Bone Joint Surg* 84-B:178–182
- Mulliken JB, Glowacki J (1982) Hemangiomas and vascular malformations in infants and children: a classification based on endothelial characteristics. *Plast Reconstr Surg* 69:412–422
- Enjolras O, Riche CM, Merland JJ, et al. (1990) Management of alarming hemangiomas in infancy: a review of 25 cases. *Pediatrics* 85:491–498
- Mueller BU, Mulliken JB (1999) The infant with a vascular tumor. *Semin Perinatol* 23:332–340
- Enjolras O, Wassef M, Mazoyer E, et al. (1997) Infants with Kasabach-Merritt syndrome do not have "true" hemangiomas. *J Pediatr* 130:631–640
- Hu B, Lachman R, Phillips J, et al. (1998) Kasabach-Merritt syndrome-associated kaposiform hemangioendothelioma successfully treated with cyclophosphamide, vincristine, and actinomycin D. *J Pediatr Hematol Oncol* 20:567–569
- Folkman J, Klagsbrun M, Sasse J, et al. (1988) A heparin-binding angiogenic protein – basic fibroblast growth factor – is stored within basement membrane. *Am J Pathol* 130:393–400
- Folkman J, Mulliken JB, Ezekowitz RAB (1997) Antiangiogenic therapy of hemangiomas with interferon-alpha. In: Stuart-Harris R, Penny RD (eds) *Clinical applications of the interferons*. Chapman Hall Medical, London, pp 255–265
- Burrows PE (1991) Variations in the vascular supply to infantile hepatic hemangioendotheliomas. *Radiology* 181:631–632
- Fellows KE, Hoffer FA, Markowitz RI, O'Neil JA Jr (1991) Multiple collaterals to hepatic infantile hemangioendotheliomas and arteriovenous malformations: effect of embolization. *Radiology* 181:813–818
- McHugh K, Burrows PE (1992) Infantile hepatic hemangioendotheliomas: significance of portal venous and systemic collateral arterial supply. *J Vasc Intervent Radiol* 3:337–344
- Kassarjian A, Dubois J, Burrows PE (2002) Angiographic classification of hepatic hemangiomas in infants. *Radiology* 222:693–698
- Burrows PE, Dubois J, Kassarjian A (2001) Pediatric hepatic vascular anomalies. *Pediatr Radiol* 31:533–545
- Burrows PE, Mulliken JB, Fellows KE, et al. (1983) Childhood hemangiomas and vascular malformations: angiographic differentiation. *AJR Am J Roentgenol* 141:483–488
- Yakes WF, Luethke JM, Parker SH, et al. (1990) Ethanol embolization of vascular malformations. *Radiographics* 10:787–796
- Mason KP, Michna E, Zurakowski D, et al. (2000) Serum ethanol levels in children and adults after ethanol embolization or sclerotherapy for vascular anomalies. *Radiology* 217:127–132
- Mason KP, Neufeld EJ, Karian VE, et al. (2001) Coagulation abnormalities in pediatric and adult patients after sclerotherapy or embolization of vascular anomalies. *AJR Am J Roentgen* 177:1359–1363
- Ognjanovic MV, Richardson D, de la Hung M, et al. (2002) Selective renal embolisation for renovascular hypertension? *Arch Dis Child* 86:127–129
- Horikami K, Matsuoka Y, Nagaoki K, et al. (1997) Treatment of post-traumatic urinoma by means of selective arterial embolization. *J Vasc Interv Radiol* 8:221–224
- Lasjaunias P (1980) Nasopharyngeal angiofibromas: hazards of embolization. *Radiology* 136:119–123
- Valavanis A (1993) Embolization of intracranial and skull base tumors. In: Valavanis A (ed) *Interventional neuroradiology*. Springer-Verlag, Berlin; New York, pp 77–83
- McDougall RJ, Sherrington CA (1999) Fatal pulmonary haemorrhage during anaesthesia for bronchial artery embolization in cystic fibrosis. *Paediatr Anaesth* 9:345–348

31. Barben J, Robertson D, Olinsky A, et al. (2002) Bronchial artery embolization for hemoptysis in young patients with cystic fibrosis. *Radiology* 224:124–130
32. Fremont B, Yazbeck S, Dubois J, et al. (1997) Intestinal vascular anomalies in children. *J Pediatr Surg* 32:873–877
33. Fishman SJ, Burrows PE, Leichtner AM, et al. (1998) Gastrointestinal manifestations of vascular anomalies in childhood: varied etiologies require multiple therapeutic modalities. *J Pediatr Surg* 33:1163–1167
34. Bähren W, Lenz M, Porst H, et al. (1983) Side effects, complications and contraindications for percutaneous sclerotherapy of the internal spermatic vein in the treatment of idiopathic varicocele. *ROFO* 128:172–179
35. Lopez C, Serres-Cousine O, Averous M (1998) Varicocele in adolescents. Treatment by sclerotherapy and percutaneous embolization: reflections on the method. A propos of 23 cases. *Prog Urol* 8:382–387
36. Ficarra V, Porcaro AB, Righetti R, et al. (2002) Antegrade scrotal sclerotherapy in the treatment of varicocele: a prospective study. *BJU Int* 89:264–268
37. Harned RK 2nd, Thompson HR, Kumpe DA, et al. (1998) Partial splenic embolization in five children with hypersplenism: effects of reduced-volume embolization on efficacy and morbidity. *Radiology* 209:803–806
38. Kimura F, Itoh H, Ambiru S, et al. (2002) Long-term results of initial and repeated partial splenic embolization for the treatment of chronic idiopathic thrombocytopenic purpura. *AJR Am J Roentgenol* 179:1323–1326
39. Carceller A, Blanchard H, Champagne J, et al. Surgical resection and chemotherapy improve survival rate for patients with hepatoblastoma. *J Pediatr Surg* 36:755–759
40. Czauderna P, Mackinlay G, Perilongo G, et al. (2002) Hepatocellular carcinoma in children: results of the first prospective study of the International Society of Pediatric Oncology group. *J Clin Oncol* 20:2798–2804
41. Pritchard J, Brown J, Shafford E, et al. (2000) Cisplatin, doxorubicin, and delayed surgery for childhood hepatoblastoma: a successful approach – results of the first prospective study of the International Society of Pediatric Oncology. *J Clin Oncol* 18:3819–3828
42. Sasaki F, Matsunaga T, Iwafuchi M, et al. (2002) Outcome of hepatoblastoma treated with the JPLT-1 (Japanese Study Group for Pediatric Liver Tumor) Protocol-1: A report from the Japanese Study Group for Pediatric Liver Tumor. *J Pediatr Surg* 37:851–856
43. Schnater JM, Aronson DC, Plaschkes J, et al. (2002) Surgical view of the treatment of patients with hepatoblastoma: results from the first prospective trial of the International Society of Pediatric Oncology Liver Tumor Study Group. *Cancer* 94:1111–1120
44. Suita S, Tajiri T, Takamatsu H, et al. (2004) Improved survival outcome for hepatoblastoma based on an optimal chemotherapeutic regimen – a report from the study group for pediatric solid malignant tumors in the Kyushu area. *J Pediatr Surg* 39:195–208
45. Arcement CM, Towbin RB, Meza MP, et al. (2000) Intrahepatic chemoembolization in unresectable pediatric liver malignancies. *Pediatr Radiol* 30:779–785
46. Gerber DA, Arcement C, Carr B, et al. (2000) Use of intrahepatic chemotherapy to treat advanced pediatric hepatic malignancies. *J Pediatr Gastroenterol Nutr* 30:137–144
47. Han YM, Park HH, Lee JM, et al. (1999) Effectiveness of preoperative transarterial chemoembolization in presumed inoperable hepatoblastoma. *J Vasc Interv Radiol* 10:1275–1280
48. Malogolowkin MH, Stanley P, Steele DA, et al. (2000) Feasibility and toxicity of chemoembolization for children with liver tumors. *J Clin Oncol* 18:1279–1284
49. Ohtsuka Y, Matsunaga T, Yoshida H, et al. (2004) Optimal strategy of preoperative transcatheter arterial chemoembolization for hepatoblastoma. *Surg Today* 34:127–133
50. Oue T, Fukuzawa M, Kusafuka T, et al. (1998) Transcatheter arterial chemoembolization in the treatment of hepatoblastoma. *J Pediatr Surg* 33:1771–1775
51. Tashjian DB, Moriarty KP, Courtney RA, et al. (2002) Preoperative chemoembolization for unresectable hepatoblastoma. *Pediatr Surg Int* 18:187–189
52. Uemura S, Todani T, Watanabe Y, et al. (1993) Successful left hepatectomy for hepatocellular carcinoma in a child after transcatheter arterial chemoembolization: report of a survival. *Eur J Pediatr Surg* 3:54–56
53. Mutabagani KH, Klopfenstein KJ, Hogan MJ, et al. (1999) Metastatic paraganglioma and paraneoplastic-induced anemia in an adolescent: treatment with hepatic arterial chemoembolization. *J Pediatr Hematol Oncol* 21:544–547
54. Tajima T, Honda H, Kuroiwa T, et al. (2002) Pulmonary complications after hepatic artery chemoembolization or infusion via the inferior phrenic artery for primary liver cancer. *J Vasc Interv Radiol* 13:893–900
55. Yamaura K, Higashi M, Akiyoshi K, et al. (2000) Pulmonary lipidol embolism during transcatheter arterial chemoembolization for hepatoblastoma under general anaesthesia. *Eur J Anaesthesiol* 17:704–708

Subject Index

A

abdominal
– aorta 103
– pain 112
absolute
– alcohol 11, 192
– ethanol 169, 204, 205
acalculous cholecystitis 185
accessory 144
– meningeal artery 239, 259
– renal artery 113
– right hepatic artery 151
active bleeding 103
acute pancreatitis 185
adenoviral vector 299
aetoxisclerol 28
airway
– compromise 35
– management
– – equipment 38
– – pharmacologic therapy for intubation 38
alar artery 259
alcohol 251, 314
allopurinol 180
alpha-fetoprotein 129
anatomy 82
ancillary vessel 152
anemia 185
aneurysm
– arterial wall 100
– configuration 101
– fusiform 100
– mycotic 100
– pseudoaneurysm 100
– rupture 109, 114
– saccular 100
– true aneurysm 100
angiomatous
– polyps 264
– vascularization 192
angiomyolipoma 101, 113, 202, 210
angionecrosis 225
angioneogenesis 225
anosmia 247
anterior
– cerebral artery 235
– EPX 257
– septal artery 259
antiangiogenesis agent 222
anticoagulation 123
apoptosis 164

arrow 53
arterial
– access 104
– spasm 305
arteriovenous
– fistula (AVF) 3, 11, 12, 64, 69, 74, 90
– malformation 3, 311, 313
– – clinical stages 8
– – complication rate 16
– – congestive cardiac failure 8
– – CT 9
– – MR imaging 9
– – percutaneous management 10
– – soft tissue mann 8
– shunting 134
atherosclerosis 101
autopsy 113
autosomal dominant disease 202
AVE 285
AVF, see arteriovenous fistula
avitene 242
AVM 9, 243, 311

B

bacterial endocarditis 304
balloon 278
– balloon-mounted stent 289
– catheter 241
– occlusion 273
– tamponade 87
bare metal stent 104
beta emitter 141
bevacizumab 222
biliary
– atresia 317
– indocyanine green concentration 164
biochemical pump 224
biopsy 90
birthmark 3
bleeding diathesis 311
blue rubber bleb nervus syndrome 22, 316
bone
– healing 196
– metastases 189
– – embolization 191
– – estimated blood loss 193
– – obliteration of tumor blush 193, 195
– – post-embolization syndrome 196
bowel
– ischemia 112
– preparation 185

- breast 149
 3-bromopyruvate (3-BrPa) 222
 bronchial artery embolization 315
 Budd-Chiari disease 164
- C**
- cancer angiogenesis 132, 144
 capecitabine 150
 capillary
 – hemangioma 264
 – malformation 16
 carcinoid 131, 139, 169
 – liver metastases 182
 – syndrome 178
 – tumor 177
 – – metastatic 183
 cardiac arrhythmia 16
 caroticotympanic artery 236
 caroticovertebral anastomose 239
 carotid
 – blowout 244, 271
 – dissection 274
 – occlusion 272
 – rupture 271
 – tumor 253
 causative agent 151
 cauterization 258
 CCC, see cholangiocellular carcinoma
 celiac axis 103
 cell cycle enzyme 222
 cell transplantation 300
 chemical carcinogen 299
 chemodectoma 251
 chemotactic factor 132
 chemotherapy 130
 – mixture
 – – admission orders 136
 – – cisplatin 134
 – – complications 136
 – – doxorubicin 134
 – – hydrochloride 134
 – – lipiodol 134
 – – materials 135
 – – mitomycin C 134
 cholangiocellular carcinoma (CCC) 129
 chronic idiopathic thrombocytopenic purpura 215
 cicatrization phase 125
 circle of Willis 276
 circulatory shock 38
 cirrhosis 211
 cisplatin 222
 – cisplatin-loaded poly(d,l-lactide) microsphere 228
 classification of Fisch 250
 clinical toxicity 157
 clival artery 238
 CNS depression 16
 coagulopathy 263
 coil 29, 49, 64, 81, 85, 92, 114, 192, 214, 262, 311
 – deposition 106
 – embolization 107
 collateral
 – pathway 82
 – perfusion 82
 colorectal carcinoma 149
 common iliac 71
 complication 212
 congestive heart failure 202
 connective tissue disorder 111
 contour SE 205
 contrast-induced nephropathy 210
 corpuscular element 211
 corticosteroid 5, 245
 – therapy 196
 covered stent 285
 cranial nerve 236, 267
 craniofacial tumor 254
 critical FRL 171
 cryotherapy 158, 201
 CVI, see lower-extremity chronic venous insufficiency
 cyanoacrylate 167, 168, 180
 cystic
 – fibrosis 315, 317
 – medial degeneration 111
 cytokine 164, 170
 cytolysis 170
 cytoreductive procedure 178
- D**
- debulking nephrectomy 201
 dehydrated alcohol 311
 detachable
 – balloon 114, 241, 277
 – bare platinum coil 244
 – latex 278
 – platinum coil 279
 diabetes mellitus 172
 diaphragmatic artery 132
 direct thrombin injection 105
 disseminated intravascular coagulation 16
 distal internal maxillary artery 259
 diverticulitis 111
 dominant autosomal disease 266
 dorsal
 – aorta 236
 – ophthalmic artery 235
 doxorubicin 180, 222
 – doxorubicin-eluting bead 228
 drug-carrier 224
 drug-eluting 226
 drug-loaded embolic agent 228
 duodenal ulceration 100
 duplex ultrasound 70
 DVT 124
- E**
- ecchymosis 123
 Ehlers-Danlos syndrome 101, 310
 electrolytic detachment 114
 EmboGold microsphere 205
 embolic agent 192
 embolization
 – equipment list 84
 – of the superior gluteal artery 66

embosphere 93, 130, 134, 192
 – microsphere 226
 enbucrilate 305
 encapsulated microorganism 211
 endoglin 266
 endorgan supply 114
 endothelium 204
 endovenous thermal ablation
 – clinical success 123
 – complication rates 124
 – epinephrine 123
 – extravenous thermal injury 122
 – laser 121
 – RF ablation 121
 – venospasm 122
 ENT bleeding 257, 269
 enterobiliary anastomosis 185
 enterochromaffin cell 177
 epidemiology 177
 epidural anesthesia 213
 epirubicin 222
 episodic EPX 266
 epistaxis 257, 311
 epithelioid angiomyolipoma 202
 epithelioma 264
 errant embolization 193
 erythrocyte 204
 – polyamine 164
 esthesioneuroblastoma 248
 estimated blood loss 192, 209
 ethanol 28, 30, 203
 – ablation 113
 ethanolamine oleate 28
 ethibloc 29–31
 ethiodol 223, 225
 ethyl alcohol 243
 eustachian tube 258
 external carotid artery 235, 236, 264
 extracranial meningioma 248
 extrahepatic
 – metastases 138
 – supply of liver cancer 132

F
 familial hypercholesteremia 296
 fatal toxicity 157
¹⁸F-DG-PET 159
 femoral artery 73
 – injury
 – – percutaneous embolization 72
 – – postcatheterization 69
 – – surgery 70
 – – techniques 71
 – – thrombin injection 71
 – – transcatheter 71
 – – ultrasound-guided compression 70
 – pseudoaneurysm 84
 fibromuscular dysplasia 101
 fibrosis 170
 Fisch classification 248
 flap breakdown 275
 floxuridine (FUDR) 149

fluoro-fade 191
 fluorouracil (5-FU) 158
 flush syndrome 169
 foam 30, 31
 fracture of the pubic ramus 63
 frequent spontaneous EPX 266
 fresh frozen plasma 191
 FRL, see future remnant liver
 5-FU, see fluorouracil
 FUDR, see floxuridine
 future remnant liver (FRL) 163

G

^{99m}Tc-galactosyl serum albumin 172
 gangrenous cholecystitis 185
 gastrin 181
 gastrinoma 177
 gastroduodenal
 – artery 103, 151, 185
 – necrosis 134
 gastroepiploic 212
 gastrointestinal bleeding 83
 gastrojejunostomy 83
 – tube
 – – bleeding 83
 – – complication 83
 gastrostomy tube
 – bleeding 83
 – complication 83
 GCS, see graduated compression stocking
 GDC matrix® coil 244
 gelatin sponge 192
 – powder 180, 223
 gelfoam 64, 86, 91, 130, 205, 224, 262, 265, 311
 – embolization 49
 – pledget 214
 – powder 64, 242
 gene (DNA) 295
 – therapy vector 296
 – transfer 299
 general anesthesia 240
 genetic reconstitution 297
 genotype 266
 Giacomini vein ablation 122
 giant hemangioma 6
 gigabec-querel 142
 Gilbert's syndrome 151
 glomeruli 204
 glomovenous malformation 22
 glomus tumor 251
 glucagon 164, 181
 glue 309
 graduated compression stocking (GCS) 123
 grays 142
 great saphenous vein (GSV) 119
 groin bleeding 69
 growth factor 170
 – inhibitor 150
 GSV, see great saphenous vein
 Guglielmi detachable coil 93

H

HCC, see hepatocellular carcinoma
 hemangioendothelioma 248, 306
 hemangioma 306, 308
 – arterial embolization 5
 – complete resolution 4
 – complications 4
 – CT 5
 – MR 5
 – proliferating hemangioma 5
 – strawberry lesion 4
 – superficial 4
 – surgical removal 5
 hemangiopericytoma 248
 hematologic purpura 211
 hematoma 111
 hematuria 202
 hemorrhagic shock 35
 – severity class 39
 hepatectomy 170
 hepatic 103
 – artery
 – – iatrogenic embolization 81
 – artery aneurysms
 – – common hepatic artery 105
 – – multiple 105
 – – solitary 105
 – artery embolization 48, 50, 52
 – biological tolerance 169
 – encephalopathy 180
 – epithelioid hemangioendothelioma 308
 – hemangioendothelioma 7
 – injury
 – – CT 49
 – – hepatic injury severity scale 49
 – pseudoaneurysm 71
 – tumorigenesis 221
 hepatic-enteric arterial communication 153
 hepatitis 129
 – B 129
 hepatoblastoma 318
 hepatocellular carcinoma (HCC) 129, 141
 hepatocyte
 – genome 298
 – growth factor (HGF) 164, 223
 hepatojejunostomy 131
 hepatotrophic
 – content 164
 – factor 163
 hereditary
 – spherocytosis 211
 – syndrome 201
 hereditary hemorrhagic telangiectasia 8, 11, 310
 hexokinase II
 – expression 222
 – specific inhibitor 222
 HGF, see hepatocyte growth factor
 5-HIAA 225
 histoacryl 29, 167, 305
 holmium 166 (–166–Ho) 227
 hormonal syndrome 177
 human gene therapy 295
 hyaluronate 172

hydrocoil 244
 hypercalcemia 202
 hypersplenism 211
 hypertension 190, 210
 hypertrophy 163
 hypervascular tumor 190
 hypervascularity 149
 hypocalcaemia 190
 hypophyseal artery 238
 hypotension 202
 hypovascular tumor 190
 hypoxia 223

I

iatrogenic 34
 – injury 79, 101
 – – arterial puncture 91
 – – arterial rupture 91
 – – carotid arteries 91
 – – femoral artery 69
 – – gastrointestinal bleeding 83
 – – hepatic 88–90
 – – hepatic veins 86
 – – intrahepatic pseudoaneurysm 80
 – – renal 85, 90, 93
 – – renal PTA 91
 – – renal transplants 90
 – – subclavian 89
 – – subclavian arteries 91
 – pseudoaneurysm 100
 idiopathic
 – epistaxis 262
 – thrombocytopenic purpura 317
 iliolumbar artery 63
 IMA, see inferior mesenteric artery
 immunologic response 209
 immunotherapy 201
 incidental aneurysm 109
 independent indicator 224
 indium¹¹¹ pentetreotide 179
 indocyanine green retention rate 172
 indolent cyst 147
 infarction of the bowel 111
 inferior
 – capsular artery 203
 – gluteal 63
 – – artery 191
 – mesenteric artery (IMA) 103
 – polar artery 212
 – tympanic branch 240
 inflow artery 10
 inhibitor of growth-factor-signaling 222
 in-line stabilization 37
 insulin 164
 intercellular disjunction 164
 intercostal artery 132
 interferon 178, 189, 308
 interleukin-2 189
 internal
 – artery 64
 – carotid artery 235, 238, 249, 273
 – iliac artery 62, 64, 65

- maxillary artery 235
- maxillary system 237
- pudendal 63
- intestinal angina 110
- intraarterial brachytherapy 216
- intrahepatic rupture 106
- intraoperative blood loss 189, 209
- iodized ethyl ester 242
- irinotecan 150
 - irinotecan-eluting bead 228
- irreversible failure 159
- ischemia 111
- ischemic neuropathy 198
- isotonic glucose 167
- ivalon 205

J

- jaw thrust, in-line stabilization 37
- juvenile
 - angiofibroma 247, 264, 312
 - nasopharyngeal angiofibroma 314

K

- kaposiform hemangioendothelioma 5, 6
- Kasabach-Merritt phenomenon 4, 6, 308
- Ki-67 labeling index 170
- kidney
 - fracture 53
 - renal embolization 53
 - renal injury
 - embolization 51
- Klippel-Trenaunay syndrome 316

L

- lactulose 180
- landing zone 108
- laser 29
- lateral
 - circumflex femoral artery 191
 - sacral 63
- LDL receptor 296
- left gastroepiploic artery 212
- leucovorin 158
- leukemia 211
- lidocaine 181
- ligation 62
- lipiodol 130, 180, 222, 299
 - ¹³¹I-lipiodol 224
- liver 106, 149
 - abscess 185
 - embolization 50
 - hepatic trauma 48
 - trophicity 164
 - volume 165
- longitudinal neural artery 235
- lower-extremity chronic venous insufficiency (CVI)
 - GSV 119
 - sphenous space 120

- SSV 120
- superficial venous insufficiency 119
- LSF, see lung shunt fraction
- lung 149
 - shunt fraction (LSF) 152
- lymphatic malformation 12, 14, 15
- lymphoma 211

M

- ^{99m}Tc-MAA 143
 - lung shunting 151
- ^{99m}Tc-MAA 150
- macroaggregated albumin 143
- macrophage cell 170
- Maffucci's syndrome 22
- magic wallstent 285
- malignant hypertension 113
- Marfan's syndrome 101
- mechanical skeletal failure 190
- medial
 - circumflex femoral artery 191
 - emergency 35
- metaiodobenzylguanidine (MIBG) 179
- microcirculation 150
- microcoil 49
- microphlebectomy 121
- middle capsular artery 203
- mitomycin 222
- mucocutaneous familial venous malformation 22
- multiple renal artery 203
- mycotic aneurysm 105

N

- nanotechnology 228
- nasopalatine artery 259
- nasopharyngeal angiofibroma 312
- native venous graft 285
- NBCA, see n-butyl cyanoacrylate
- n-butyl cyanoacrylate (NBCA) 87, 93, 242, 251
 - N-butyl-2-cyanoacrylate 225, 242, 305, 309
- neointimal hyperplastic restenosis 290
- nephron-sparing procedure 113, 201
- nerve
 - block 305
 - injury 66
- neural compression hematoma 114
- neuroblastoma 248
- neurocristopathic tumor 251
- neuroendocrine tumor 177
 - complication 184
 - exclusion criteria 180
 - hepatic artery embolotherapy 179
 - inclusion criteria 180
 - pitfalls 185
 - results 184
 - survival 184
 - tools 181
 - treatment algorithm 179
- neuroform 285

- neuroleptic analgesia 240
- neuropathy 16,70
- neuropeptide 178
- neutropenia 185
- nidus 16
- nitroglycerin 245,305
- nitropaste 245
- nonchromaffin paraganglioma 251
- nontarget
 - embolization 114, 144, 184, 210
 - radiation 155

- O**
- obstructive jaundice 166
- obturator 63
- occipital artery 239,243
- occlusion balloon 205
 - catheter 204
- ontogenesis 235
- onyx 114
- ophthalmic artery 237,259
- organ
 - ablation 201
 - injury 306
- oropharyngeal obstruction 37
- Osler-Weber-Rendu syndrome 8
- outflow vein 10

- P**
- packing 258
- palliative embolization 209
- pancreatic islet-cell tumor 177
- pancreatitis 100, 111, 114
- papaverine 305
- paraganglioma 248, 251
- paraneoplastic symptom 202
- parathyroid adenoma 254
- paresthesia 124
- partial
 - hepatic resection 163
 - splenectomy 211
 - splenic embolization 212
- patient work up 101
- patient-controlled-anesthesia (PCA) 16
- PCA, see patient-controlled-anesthesia
- PCoA, see posterior communicating artery
- pediatric intervention 303
- pelvic
 - arteriogram 63
 - fracture 63, 65, 306
 - - algorithm for the management 62
 - - classification 61
 - - external fixation 62
 - - Kane's classification 61
 - - laparotomy 62
 - - mechanism of injury 59
 - - radiographs 61
 - - sources of bleeding 60
 - trauma
 - - hemorrhage 59
 - - mortality 59
 - - shock 60
 - - surgery 60
 - - therapy 63
- percutaneous
 - biliary drainage 80, 81
 - venography 26
- perforating artery 203
- perfusion MRI 137
- peribiliary fibrosis 170
- periodic EPX 266
- periprocedural antibiotic 103
- peritoneal lavage 61
- peroneal 71
- pharyngo-cutaneous fistula 275
- piperacillin 185
- platinum fiber microcoil 309
- pledget 223
- polidocanol 28
- poly(benzyl l-glutamate) (PBLG) microsphere 228
- polyacrylonitrile (PAN) hydrogel 227
- polycythemia 202
- polyethylene 241
- poly-L-lactic acid (PLLA) microsphere 227
- polymerization 167
- polyvinyl alcohol (PVA) 49, 86, 223, 225, 226, 251
 - hydrogel drug-eluting bead 228
 - particle 192, 214, 242, 305
 - hydrogel 227
 - particle 6
- portal
 - hypertension 211
 - pressure 167
 - vein embolization 163
 - - embolic agents 169
 - - growth rate of liver 170
 - - long-term survival 173
 - - surgical transileocolic approach 168
 - vein patency 106
 - vein thrombosis (PVT) 132
- porto-anastomosis 169
- postcatheterization 69
- postembolization syndrome 103, 145, 196, 210
- posterior
 - communicating artery (PCoA) 276
 - EPX 258
 - lateral nasal 259
 - medial nasal artery 259
- postoperative
 - bleeding 88
 - liver failure 172
- posttraumatic AVF 12
- precise stent 283
- primitive maxillary artery 237
- profunda femoris artery 191
- prognostic factor 177
- prominent ethmoidal artery 263
- prophylactic
 - embolization 151
 - intervention 202
- Proteus syndrome 316
- protracted hemorrhage 272
- pseudoaneurysm 69, 70, 80
 - of the common carotid artery 276

- pterygovaginal artery 239
- pulling sensation 125
- pulmonary
 - AVM year 8, 11
 - lipiodol embolism 318
 - lymphangiioleiomyomatosis 202
- PVA, see polyvinyl alcohol
- PVT, see portal vein thrombosis
- pyrexia 181

- R**
- radiation
 - dosimetry 145
 - hepatitis 159
 - pneumonitis 142, 150, 155
 - therapy 250
- radical nephrectomy 201
- radioembolization 139
 - calculation of lung dose 155
 - complications 146, 159
 - discharge instructions 146
 - duodenal ulcers 157
 - follow up 147
 - gastric ulcers 157
 - HCC 141
 - insoluble glass microspheres 153
 - liver metastases 149
 - materials 146
 - resin-based microspheres 154
 - results 156
- radiofrequency ablation 140, 170, 201
- radiosensitizer 150
- radiotherapy 252
- radius 285
- rCBS, see recurrent carotid blowout syndrome
- RCC metastase 190
- recanalization 106
 - of pseudoaneurysm 106
- recombinant
 - adenoviral vector 223
 - β -galactosidase 223
- recurrent carotid blowout syndrome (rCBS) 275
- refractory hypertension 314
- renal
 - abscess 210
 - artery 103
 - artery aneurysm
 - angiomyolipoma 112
 - balloon occlusion catheter 113
 - classification 112
 - iatrogenic 112
 - incidence 112
 - natural history 112
 - neurofibromatosis 112
 - post-embolization syndrome 113
 - surgical repair 113
 - traumatic 112
 - artery embolization 51, 52, 207, 216
 - cell carcinoma 201, 207
 - bone metastases 189
 - failure 113
 - trauma
 - organ injury score 54
 - vascular injury 52
- renal
 - Renou-Osler-Weber syndrome 266, 310, 313, 316
 - Renegade 145
 - renin-angiotensin 190
 - replaced
 - left hepatic artery 144
 - right hepatic artery 144, 185
 - resin-based microsphere 141
 - respiratory obstruction grade 36
 - resuscitation 39, 40
 - reticuloendothelial hyperplasia 211
 - retroperitoneal bleeding 53, 69
 - RF ablation 124
 - rhabdomyosarcoma 249
 - right
 - gastric artery 144
 - hepatic artery 144
 - RNA 295
 - road mapping 191
 - rtPA 317

 - S**
 - saccular
 - microaneurysm
 - amphetamine abuse 101
 - polyarteritis nodosa 101
 - pseudoaneurysm 100
 - sacral fracture 63
 - sandwich technique 167
 - saphenous
 - nerve 119
 - vein reflux 119
 - sarcoma 139
 - sciatic nerve 193
 - sclerosing agent 28
 - sclerotherapy 27, 30, 316
 - seizure 114
 - selective internal radiation (SIR) 141
 - sphere 141, 149, 154
 - self-expanding stent 281, 283
 - sepsis 48
 - serotonin 178
 - serotonin-secreting tumor 177
 - sexual dysfunction 66
 - shock 35, 60
 - silicone detachable 278
 - single photon emission computed tomography 150
 - SIR, see selective internal radiation
 - skeletonization 172
 - skin
 - burn 124
 - ulceration 16
 - SMA 103
 - small saphenous vein 119
 - smart stent 283
 - sodium tetradecyl sulfate 316
 - solid hepatic tumor 129
 - solitary lesion 190
 - somatostatin
 - analogue 178
 - receptor 178

- sotradecol 28
 - spasm 81
 - sphenopalatine artery 239, 259
 - sphere 226
 - spherical PVA 227
 - sphincter of Oddi 131
 - sphincterotomy 131, 185
 - spider vein 121
 - splanchnic aneurysm 109
 - spleen 46, 49
 - splenic 103
 - angiogram 46
 - artery 212, 214
 - artery aneurysm
 - - calcified masses 107
 - - rupture 107
 - artery embolization 43, 45, 47, 48, 216
 - infarction 48, 109, 185
 - injury 45
 - - scale 45
 - trauma
 - - AV fistula 47, 48
 - - CT grades 47
 - - CT-based classification 44
 - - pseudoaneurysm 45, 47
 - - splenic injury scale 45
 - spontaneous
 - pathologic fracture 197
 - retroperitoneal hemorrhage 202
 - stem cell 298
 - stent
 - angioplasty 279
 - fracture 71
 - graft 71, 88, 89, 104, 113, 114, 285
 - strawberry hemangioma 4
 - streptozocin 179
 - Sturge-Weber syndrome 312
 - subclavian artery injury 89
 - sunburst 203
 - superficial temporal artery 235, 243
 - superior
 - capsular artery 203
 - gluteal 63
 - gluteal artery 191
 - mesenteric artery aneurysm 109
 - polar artery 212
 - surgical metastasectomy 178
 - survival benefit 139
 - synthetic material 285
 - systemic steroid treatment 159
- T**
- TAC, see transarterial chemotherapy
 - TACE, see transarterial chemoembolization
 - TAE, see transarterial embolization
 - tamponade 114
 - tazobactam 185
 - telangiectasia 121, 267
 - TGF- α , see transforming growth factor-alpha
 - thalassemia 317
 - major 211
 - TheraSphere 141, 149, 154
 - thermal ablation therapy 216
 - thrombin 71, 87
 - injection 74
 - thrombocytopenia 185
 - thrombolysis 317
 - thyrolaryngeal tumor 254
 - tissue
 - adhesive 11, 192, 305
 - necrosis 16
 - topography 252
 - torpedo 49
 - total splenectomy 211
 - toxic level 204
 - transarterial
 - chemoembolization (TACE)
 - - blunt embolization 134
 - - contrast-enhanced MRI 130
 - - discharge instructions 138
 - - dual phase 130
 - - follow up 137
 - - procedure 132
 - - results 138
 - chemotherapy (TAC) 139
 - embolization (TAE) 139
 - transcatheter arterial chemoembolization 221
 - transforming growth factor-alpha (TGF- α) 164
 - transient ischemia 288
 - transitory carotid occlusion 251
 - transplant kidney 90
 - trauma 35, 101, 306
 - blunt 48
 - iatrogenic 48
 - kidneys 52
 - liver 48
 - pelvic 59
 - solid organ 43
 - splenic 43
 - visceral 43
 - traumatic epistaxis 264
 - treatment
 - of saccular aneurysm 106
 - of SVI 120
 - Trendelenburg position 123
 - tris-acryl gelatin microsphere 180
 - truncal vein 120
 - tuberous sclerosis 202
 - tufted angioma 308
 - tumescent anesthesia 122
 - tumor
 - antigen 209
 - dissemination 171
 - growth 165
 - lysis syndrome 135
 - marker 142
 - tumor-related epistaxis 264
 - vessel 203
 - viability 137
 - volume 165
- U**
- uncovered stent 87
 - urate-induced renal failure 180
 - urokinase 317

V

- VAA, see visceral arterial aneurysm
- valvular insufficiency 119
- varicocele 316
- varicose vein 121
- vascular
 - anomaly 21
 - endothelial growth factor (VEGF) 222, 223
 - injury 69
 - malformation 3, 83, 306
 - supply to the kidney 113
 - tumor 306
- VEGF, see vascular endothelial growth factor
- venous malformation 3, 12, 23
 - arteriography 24
 - classification 21
 - coagulopathies 22
 - computed tomography 24
 - diffuse 22
 - direct percutaneous venography 25
 - endovascular approach 30
 - focal 22
 - genetics 21
 - magnetic resonance imaging 24
 - management 26
 - MRI 25, 27
 - percutaneous approach 30
 - peripheral venography 25
 - predominantly venous malformation 21
 - sclerotherapy 26
 - ultrasound 23

ventral

- aorta 236
- ophthalmic artery 235
- pharyngeal artery 236
- vidian artery 239
- viral hepatitis 172
- visceral arterial aneurysm (VAA)
 - incidence 99
 - mortality 99
- visceral AVM 266
- vitamin K 191
- von Hippel-Lindau syndrome 201
- von Recklinghausen's disease 113
- von Willebrand disease 260
- wallgraft 286, 289
- wallstent 283
- Waltman loop 104
- Whipple procedure 88
- whorled appearance 203

X

- xylocaine 305

Y

- yttrium-90 (-90-Y) 141
 - glass microsphere 141
 - microsphere 149

Z

- zirconium-90 141

List of Contributors

Volume 2

KAMRAN AHRAR, MD
 Section of Interventional Radiology
 Division of Diagnostic Imaging
 The University of Texas
 MD Anderson Cancer Center
 1515 Holcombe Boulevard, Unit 325
 Houston, TX 77030-4009
 USA

HORTENSIA ALVAREZ, MD
 Service de Neuroradiologie Diagnostique
 et Thérapeutique
 Hôpital Bicêtre
 78 rue due Général Leclerc
 94275 Le Kremlin Bicêtre
 France

JOHN C. CHALOUPIKA, MD, FAHA, FACA
 Director of Interventional Neuroradiology
 Professor of Radiology and Neurosurgery
 University of Iowa Hospitals and Clinics
 University of Iowa Carver College of Medicine
 200 Hawkins Dr, 3893 JPP
 Iowa City, IA 52242
 USA

MICHAEL D. DARCY, MD
 Professor of Radiology and Surgery
 Division of Diagnostic Radiology
 Chief, Interventional Radiology Section
 Washington University School of Medicine
 Mallinckrodt Institute of Radiology
 510 South Kingshighway, 6th Floor
 St. Louis, MO 63110
 USA

JOSÉE DUBOIS, MD
 Professor of Radiology
 Pediatric and Interventional Radiologist
 Department of Medical Imaging
 Hôpital Ste-Justine
 3175 Côte Ste-Catherine Road
 Montreal, Quebec H3T 1C5
 Canada

JAMES R. DUNCAN, MD, PhD
 Assistant Professor of Radiology and Surgery
 Mallinckrodt Institute of Radiology and
 Washington University School of Medicine
 510 S. Kingshighway Blvd
 St. Louis, MO 63110
 USA

DOMINIQUE ELIAS, MD
 Head of Digestive Surgery Section
 Institut Gustave Roussy
 39, Rue Camille Desmoulins
 94800 Villejuif Cedex
 France

LAURENT GAREL, MD
 Professor of Radiology
 Pediatric and Interventional Radiologist
 Department of Medical Imaging
 Hôpital Ste-Justine
 3175 Côte Ste-Catherine Road
 Montreal, Quebec H3T 1C5
 Canada

CHRISTOS S. GEORGIADIS, MD, PhD
 Assistant Professor of Radiology and Surgery
 Johns Hopkins Medical Institutions
 Blalock 545, 600 North Wolfe Street,
 Baltimore, MD 21287
 USA

JEAN-FRANCOIS H. GESCHWIND, MD
 Associate Professor of Radiology, Surgery and Oncology
 Division of Vascular and Interventional Radiology
 The Russell H. Morgan Department of Radiology
 and Radiological Sciences
 Johns Hopkins Medical Institutions
 Blalock 545, 600 North Wolfe Street
 Baltimore, MD 21287
 USA

CRAIG B. GLAIBERMAN, MD
 Instructor, Radiology
 Division of Interventional Radiology
 Washington University School of Medicine
 Mallinckrodt Institute of Radiology
 510 South Kingshighway, 6th Floor
 St. Louis, MO 63110
 USA

JAFAR GOLZARIAN, MD
 Professor of Radiology
 Director, Vascular and Interventional Radiology
 University of Iowa
 Department of Radiology
 200 Hawkins Drive, 3957 JPP
 Iowa City, IA 52242
 USA

MINAKO HAYAKAWA, MD
 Visiting Assistant Professor of Radiology
 University of Iowa Hospitals and Clinics
 University of Iowa Carver College of Medicine
 200 Hawkins Dr, 3893 JPP
 Iowa City, IA 52242
 USA

SAM HEYE, MD
 Department of Radiology
 University Hospitals Gasthuisberg
 Herestraat 49
 3000 Leuven
 Belgium

SHIH-WEI HSU, MD
 Visiting Scholar, University of Iowa Hospitals
 and Clinics
 University of Iowa Carver College of Medicine
 200 Hawkins Dr, 3893 JPP
 Iowa City, IA 52242
 USA

and
 Assistant Professor, Department of Diagnostic
 Radiology
 Chang Gung Memorial Hospital
 Kaohsiung
 Taiwan

MATTHEW S. JOHNSON, MD
 Associate Professor of Radiology
 Director, Section of Interventional Radiology
 Indiana University Hospital, UH0279
 Department of Radiology
 550 University Boulevard
 Indianapolis, IN 46202-5253
 USA

JOHN R. KACHURA, MD, FRCPC
 Division of Vascular and Interventional Radiology
 Department of Medical Imaging
 Toronto General Hospital
 200 Elizabeth Street, Eaton South 1-454d
 Toronto, ON M5G 2C4
 Canada

NEIL M. KHILNANI, MD
 Cornell Vascular
 Weill Medical College of Cornell University
 416 East 55th Street
 New York, NY 10022
 USA

PAULA KLURFAN, MD
 Interventional Neuroradiology Clinical Fellow
 Department of Medical Imaging
 University of Toronto
 Toronto Western Hospital
 399 Bathurst Street
 Toronto, Ontario M5T 2S8
 Canada

PIERRE LASJAUNIAS, MD, PhD
 Service de Neuroradiologie Diagnostique et Thérapeutique
 Hôpital Bicêtre
 78 rue due Général Leclerc
 94275 Le Kremlin Bicêtre
 France

SEON KYU LEE, MD, PhD
 Assistant Professor and Staff Neuroradiologist
 Department of Medical Imaging
 University of Toronto
 Toronto Western Hospital
 #399 Bathurst Street
 Toronto, Ontario M5T 2S8
 Canada

WALTER S. LESLEY, MD
 Chief, Section of Surgical Neuroradiology
 Assistant Professor of Radiology
 The Texas A&M University Health Science Center
 USA

ELENI LIAPI, MD
 The Russell H. Morgan Department of Radiology
 and Radiological Sciences
 Johns Hopkins Medical Institutions
 Baltimore, MD
 USA

DAVID C. MADOFF, MD
 Section of Interventional Radiology
 Division of Diagnostic Imaging
 The University of Texas
 MD Anderson Cancer Center
 1515 Holcombe Boulevard, Unit 325
 Houston, TX 77030-4009
 USA

GEERT MALEUX, MD
 Department of Radiology
 University Hospitals Gasthuisberg
 Herestraat 49
 3000 Leuven
 Belgium

FRANCIS MARSHALLECK, MD
 Assistant Professor of Radiology
 Indiana University School of Medicine
 Indiana University Hospital
 Room 0279, 550 North University Boulevard
 Indianapolis, IN 46202
 USA

ROBERT J. MIN, MD
Cornell Vascular
Weill Medical College of Cornell University
416 East 55th Street
New York, NY 10022
USA

ANNE C. ROBERTS, MD
University of California, San Diego Medical Center
Division of Vascular and Interventional Radiology
200 West Arbor Drive
San Diego, CA 92103-8756
USA

ALAIN J. ROCHE, MD
Head of Interventional Radiology Section
Professor, Institut Gustave Roussy
39, Rue Camille Desmoulins
94800 Villejuif Cedex
France

GEORGES RODESCH, MD
Service de Neuroradiologie Diagnostique et Thérapeutique
Hôpital Foch
40 rue Worth
B.P. 36
92150 Suresnes
France

RIAD SALEM, MD, MBA
Assistant Professor of Radiology and Oncology
Northwestern Memorial Hospital
Department of Radiology
676 North St. Claire, Suite 800
Chicago, IL 60611
USA

MELHEM J. SHARAFUDDIN, MD
University of Iowa Hospitals and Clinics
Department of Radiology
200 Hawkins Dr, 3957 JPP
Iowa City, IA 52242
USA

GARY SISKIN, MD
Albany Medical College
Vascular Radiology, A113
47 New Scotland Avenue
Albany, NY 12208-3479
USA

SHILIANG SUN, MD
Associate Professor of Radiology
Department of Radiology
University of Iowa, College of Medicine
200 Hawkins Dr., 3955 JPP
Iowa City, IA 52242
USA

KONG TENG TAN, MB, BCH, FRCS, FRCR
Division of Vascular and Interventional Radiology
Department of Medical Imaging
Toronto General Hospital
585 University Avenue, NCSB 1C-563
Toronto, ON M5G 2N2
Canada

MARIA THIJS, MD
Department of Radiology
University Hospitals Gasthuisberg
Herestraat 49
3000 Leuven
Belgium

KENNETH G. THURSTON, MD
17 Bramble Lane
West Grove, PA 19390
USA

RAJIV VERMA, MD
Section of Interventional Radiology
Division of Diagnostic Imaging
The University of Texas
MD Anderson Cancer Center
1515 Holcombe Boulevard, Unit 325
Houston, TX 77030-4009
USA

LUCY A. WIBBENMEYER, MD
University of Iowa Hospitals and Clinics
Department of Radiology
200 Hawkins Dr.
Iowa City, IA 52242
USA

JEFFREY J. WONG, MB ChB, BMedSc
University of California, San Diego Medical Center
Division of Vascular and Interventional Radiology
200 West Arbor Drive
San Diego, CA 92103-8756
USA

Contents – Volume 1

General Principles	1
1 Embolotherapy: Basic Principles and Applications MELHEM J. SHARAFUDDIN, SHILIANG SUN, and JAFAR GOLZARIAN	3
2 Embolization Tools JAFAR GOLZARIAN, GARY P. SISKIN, MELHEM J. SHARAFUDDIN, HIDEFUMI MIMURA, and DOUGLAS M. COLSWELL	15
3 Controlled Delivery of Pushable Fibered Coils for Large Vessel Embolotherapy ROBERT I. WHITE JR. and JEFFREY S. POLLAK	35
4 Work-up and Follow-up after Embolization JIM A. REEKERS	43
GI	47
5 Upper GI Bleeding LUC DEFREYNE	49
6 Embolization for Lower GI Bleeding MICHAEL DARCY	73
7 Haemobilia and Bleeding Complications in Pancreatitis TONY A. NICHOLSON	87
8 Balloon-occluded Retrograde Transvenous Obliteration of Gastric Varices in Portal Hypertension KOJI TAKAHASHI and SHILIANG SUN	99
Gynecology and Obstetrics	105
9 Interventional Management of Postpartum Hemorrhage HICHAM T. ABADA, JAFAR GOLZARIAN, and SHILLIANG SUN	107
10 Fibroids GARY P. SISKIN, JEFFREY J. WONG, ANNE C. ROBERTS, JEAN PIERRE PELAGE, ARNAUD FAUCONNIER, PASCAL LACOMBE, ALEXANDRE LAURENT, and JAFAR GOLZARIAN	119
10.1 Uterine Fibroid Embolization: Practice Development GARY P. SISKIN	119
10.2 Pre-op Work-Up and Post-op Care of Uterine Fibroid Embolization JEFFREY J. WONG and ANNE C. ROBERTS	125
10.3 Fibroid Embolization: Anatomy and Technical Considerations ANNE C. ROBERTS	141

10.4 Results and Complications JEAN PIERRE PELAGE, ARNAUD FAUCONNIER, and PASCAL LACOMBE	157
10.5 How to Minimize Failure after UFE JAFAR GOLZARIAN and JEAN PIERRE PELAGE	177
10.6 Perspectives ALEXANDRE LAURENT, JEAN PIERRE PELAGE and JAFAR GOLZARIAN	187
11 Pelvic Congestion Syndrome LINDSAY MACHAN	199
Genitourinary	213
12 Varicocele Embolization DAVID HUNTER and GALIA T. ROSEN	215
13 Embolization Therapy for High-Flow Priapism JIM A. REEKERS	227
Aortic-Iliac	233
14 Endoleak: Definition, Diagnosis, and Management DAVID VALENTI and JAFAR GOLZARIAN	235
15 Internal Iliac Artery Embolization in the Stent-Graft Treatment of Aortoiliac Aneurysms MAHMOOD K. RAZAVI	253
Respiratory System	261
16 Bronchial Artery Embolization JOS C. VAN DEN BERG	263
17 Pulmonary Arteriovenous Malformations JEAN PIERRE PELAGE, PASCAL LACOMBE, ROBERT I. WHITE, JR., and JEFFRAY S. POLLAK	279
Subject Index	297
List of Contributors	303
Contents and List of Contributors of Volume 2	305

List of Contributors – Volume 1

HICHAM T. ABADA, MD
 Department of Imaging and Interventional Radiology
 Centre Hospitalier René Dubos
 6, Avenue de L'Île-de-France
 95303 Cergy Pontoise Cedex
 France

DOUGLAS M. COLDWELL, MD
 Professor of Radiology
 University of Texas Southwestern Medical Center
 5323 Harry Hines Blvd.
 Dallas, TX 75390-8834
 USA

MICHAEL D. DARCY, MD
 Professor of Radiology and Surgery
 Mallinckrodt Institute of Radiology
 Washington University School of Medicine
 510 South Kingshighway Boulevard
 Saint Louis, MO 63110-1076
 USA

LUC DEFREYNE, MD
 Department of Vascular and
 Interventional Radiology
 Ghent University Hospital
 De Pintelaan 185
 9000 Ghent
 Belgium

ARNAUD FAUCONNIER, MD, PhD
 Department of Obstetrics and Gynecology,
 Centre Hospitalier de Poissy,
 10, rue du Champ Gaillard,
 78300 Poissy Cedex,
 France

JAFAR GOLZARIAN, MD
 Professor of Radiology
 Director, Vascular and Interventional Radiology
 University of Iowa
 Department of Radiology
 200 Hawkins Drive, 3957 JPP
 Iowa City, IA 52242
 USA

DAVID W. HUNTER, MD
 Department of Radiology
 J2-447 Fairview-University Medical Center
 University of Minnesota
 500 Harvard Street S.E.
 Minneapolis, MN 55455
 USA

PASCAL LACOMBE, MD
 Department of Radiology Hôpital Ambroise Pare
 9, Avenue Charles De Gaulle
 92104 Boulogne Cedex
 France

ALEXANDRE LAURENT, MD, PhD
 Associate Professor
 Center for Research in
 Interventional Imaging (Cr2i APHP-INRA)
 Jouy en Josas, 78352
 France

LINDSAY MACHAN, MD
 Department of Radiology
 University of British Columbia Hospital
 2211 Wesbrook Mall
 Vancouver, BC V6T 2B5
 Canada

HIDEFUMI MIMURA, MD
 Associate Professor of Radiology
 University of Iowa Hospitals and Clinics
 Department of Radiology
 200 Hawkins Dr, 3957 JPP
 Iowa City, IA 52242
 USA

TONY A. NICHOLSON, BScM, Sc, MB, ChB, FRCR
 Consultant Vascular Radiologist & Senior Lecturer
 Leeds Teaching Hospitals NHS Trust
 Great George Street
 Leeds, LS13EX
 UK

JEAN-PIERRE PELAGE, MD, PhD
 Department of Radiology
 Hôpital Ambroise Pare
 9, Avenue Charles De Gaulle
 92104 Boulogne Cedex
 France

JEFFREY S. POLLAK, MD
 Yale University School of Medicine
 Department Diagnostic Radiology
 PO Box 20842
 New Haven, CT 06504-8042
 USA

MAHMOOD K. RAZAVI, MD
 Director
 Center for Research and Clinical Trials
 St. Joseph Vascular Institute
 Orange, CA 92868
 USA

JIM A. REEKERS, MD, PhD
Department of Radiology, G1-207
Academic Medical Center
University of Amsterdam
Meibergdreef 9
AZ 1105 Amsterdam
The Netherlands

ANNE C. ROBERTS, MD
University of California, San Diego Medical Center
Division of Vascular and
Interventional Radiology
200 West Arbor Drive
San Diego, CA 92103-8756
USA

GALIA T. ROSEN, MD
Department of Radiology
J2-447 Fairview-University Medical Center
University of Minnesota
500 Harvard Street S.E.
Minneapolis, MN 55455
USA

MELHEM J. SHARAFUDDIN, MD
Departments of Radiology and Surgery, 3JPP
University of Iowa Hospitals and Clinics
200 Hawkins Drive
Iowa City, IA 52242-1077
USA

GARY P. SISKIN, MD
Associate Professor of Radiology and
Obstetrics & Gynecology
Albany Medical College
47 New Scotland Avenue, MC-113
Albany, NY 12208-3479
USA

SHILIANG SUN, MD
Associate Professor of Radiology
University of Iowa Hospitals and Clinics
200 Hawkins Dr, 3955 JPP
Iowa City, IA 52242
USA

KOJI TAKAHASHI, MD
Department of Radiology
Asahikawa Medical College
2-1-1-1 Midorigaoka
Asahikawa, 078-8510
Japan

JOS C. VAN DEN BERG, MD, PhD
Head of Service of Interventional Radiology
Ospedale Regionale di Lugano, sede Civico
Via Tesserete 46
6900 Lugano
Switzerland

DAVID A. VALENTI, MD
Royal Victoria Hospital
McGill University Health Centre
McGill University
687 Pine Avenue West, Suite A451
Montreal, Quebec H3A 1A1
Canada

ROBERT I. WHITE, Jr., MD
Yale University School of Medicine
Department of Diagnostic Radiology
333 Cedar Street, Room 5039 LMP
New Haven, CT 06520
USA

JEFFREY J. WONG, MB ChB, BMedSc
Senior House Officer
Royal National Orthopaedic Hospital
London
UK

MEDICAL RADIOLOGY Diagnostic Imaging and Radiation Oncology

Titles in the series already published

DIAGNOSTIC IMAGING

Innovations in Diagnostic Imaging

Edited by J. H. Anderson

Radiology of the Upper Urinary Tract

Edited by E. K. Lang

The Thymus - Diagnostic Imaging, Functions, and Pathologic Anatomy

Edited by E. Walter, E. Willich, and W. R. Webb

Interventional Neuroradiology

Edited by A. Valavanis

Radiology of the Pancreas

Edited by A. L. Baert, co-edited by G. Delorme

Radiology of the Lower Urinary Tract

Edited by E. K. Lang

Magnetic Resonance Angiography

Edited by I. P. Arlart, G. M. Bongartz, and G. Marchal

Contrast-Enhanced MRI of the Breast

S. Heywang-Köbrunner and R. Beck

Spiral CT of the Chest

Edited by M. Rémy-Jardin and J. Rémy

Radiological Diagnosis of Breast Diseases

Edited by M. Friedrich and E.A. Sickles

Radiology of the Trauma

Edited by M. Heller and A. Fink

Biliary Tract Radiology

Edited by P. Rossi, co-edited by M. Brezi

Radiological Imaging of Sports Injuries

Edited by C. Masciocchi

Modern Imaging of the Alimentary Tube

Edited by A. R. Margulis

Diagnosis and Therapy of Spinal Tumors

Edited by P. R. Algra, J. Valk, and J. J. Heimans

Interventional Magnetic Resonance Imaging

Edited by J.F. Debatin and G. Adam

Abdominal and Pelvic MRI

Edited by A. Heuck and M. Reiser

Orthopedic Imaging

Techniques and Applications

Edited by A. M. Davies and H. Pettersson

Radiology of the Female Pelvic Organs

Edited by E. K. Lang

Magnetic Resonance of the Heart and Great Vessels

Clinical Applications

Edited by J. Bogaert, A.J. Duerinckx, and F. E. Rademakers

Modern Head and Neck Imaging

Edited by S. K. Mukherji and J. A. Castelijns

Radiological Imaging of Endocrine Diseases

Edited by J. N. Bruneton in collaboration with B. Padovani and M.-Y. Mourou

Trends in Contrast Media

Edited by H. S. Thomsen, R. N. Muller, and R. F. Mattrey

Functional MRI

Edited by C. T. W. Moonen and P. A. Bandettini

Radiology of the Pancreas

2nd Revised Edition
Edited by A. L. Baert. Co-edited by G. Delorme and L. Van Hoe

Emergency Pediatric Radiology

Edited by H. Carty

Spiral CT of the Abdomen

Edited by F. Terrier, M. Grossholz, and C. D. Becker

Liver Malignancies

Diagnostic and Interventional Radiology

Edited by C. Bartolozzi and R. Lencioni

Medical Imaging of the Spleen

Edited by A. M. De Schepper and F. Vanhoenacker

Radiology of Peripheral Vascular Diseases

Edited by E. Zeitler

Diagnostic Nuclear Medicine

Edited by C. Schiepers

Radiology of Blunt Trauma of the Chest

P. Schnyder and M. Wintermark

Portal Hypertension

Diagnostic Imaging-Guided Therapy

Edited by P. Rossi
Co-edited by P. Ricci and L. Broglia

Recent Advances in Diagnostic Neuroradiology

Edited by Ph. Demaerel

Virtual Endoscopy and Related 3D Techniques

Edited by P. Rogalla, J. Terwisscha Van Scheltinga, and B. Hamm

Multislice CT

Edited by M. F. Reiser, M. Takahashi, M. Modic, and R. Bruening

Pediatric Uroradiology

Edited by R. Fötter

Transfontanelar Doppler Imaging in Neonates

A. Couture and C. Veyrac

Radiology of AIDS

A Practical Approach

Edited by J.W.A.J. Reeders and P.C. Goodman

CT of the Peritoneum

Armando Rossi and Giorgio Rossi

Magnetic Resonance Angiography

2nd Revised Edition
Edited by I. P. Arlart, G. M. Bongartz, and G. Marchal

Pediatric Chest Imaging

Edited by Javier Lucaya and Janet L. Strife

Applications of Sonography in Head and Neck Pathology

Edited by J. N. Bruneton in collaboration with C. Raffaelli and O. Dassonville

Imaging of the Larynx

Edited by R. Hermans

3D Image Processing

Techniques and Clinical Applications
Edited by D. Caramella and C. Bartolozzi

Imaging of Orbital and Visual Pathway Pathology

Edited by W. S. Müller-Forell

Pediatric ENT Radiology

Edited by S. J. King and A. E. Boothroyd

Radiological Imaging of the Small Intestine

Edited by N. C. Gourtsoyiannis

MEDICAL RADIOLOGY Diagnostic Imaging and Radiation Oncology

Titles in the series already published

Imaging of the Knee

Techniques and Applications

Edited by A. M. Davies
and V. N. Cassar-Pullicino

Perinatal Imaging

From Ultrasound to MR Imaging

Edited by Fred E. Avni

Radiological Imaging of the Neonatal Chest

Edited by V. Donoghue

Diagnostic and Interventional Radiology in Liver Transplantation

Edited by E. Bücheler, V. Nicolas,
C. E. Broelsch, X. Rogiers,
and G. Krupski

Radiology of Osteoporosis

Edited by S. Grampp

Imaging Pelvic Floor Disorders

Edited by C. I. Bartram
and J. O. L. DeLancey
Associate Editors: S. Halligan,
F. M. Kelvin, and J. Stoker

Imaging of the Pancreas

Cystic and Rare Tumors

Edited by C. Procacci
and A. J. Megibow

High Resolution Sonography of the Peripheral Nervous System

Edited by S. Peer and G. Bodner

Imaging of the Foot and Ankle

Techniques and Applications

Edited by A. M. Davies,
R. W. Whitehouse,
and J. P. R. Jenkins

Radiology Imaging of the Ureter

Edited by F. Joffre, Ph. Otal,
and M. Soulie

Imaging of the Shoulder

Techniques and Applications

Edited by A. M. Davies and J. Hodler

Radiology of the Petrous Bone

Edited by M. Lemmerling
and S. S. Kollias

Interventional Radiology in Cancer

Edited by A. Adam, R. F. Dondelinger,
and P. R. Mueller

Duplex and Color Doppler Imaging of the Venous System

Edited by G. H. Mostbeck

Multidetector-Row CT of the Thorax

Edited by U. J. Schoepf

Functional Imaging of the Chest

Edited by H.-U. Kauczor

Radiology of the Pharynx and the Esophagus

Edited by O. Ekberg

Radiological Imaging in Hematological Malignancies

Edited by A. Guermazi

Imaging and Intervention in Abdominal Trauma

Edited by R. F. Dondelinger

Multislice CT

2nd Revised Edition

Edited by M. F. Reiser, M. Takahashi,
M. Modic, and C. R. Becker

Intracranial Vascular Malformations and Aneurysms

From Diagnostic Work-Up
to Endovascular Therapy

Edited by M. Forsting

Radiology and Imaging of the Colon

Edited by A. H. Chapman

Coronary Radiology

Edited by M. Oudkerk

Dynamic Contrast-Enhanced Magnetic Resonance Imaging in Oncology

Edited by A. Jackson, D. L. Buckley,
and G. J. M. Parker

Imaging in Treatment Planning for Sinonasal Diseases

Edited by R. Maroldi and P. Nicolai

Clinical Cardiac MRI

With Interactive CD-ROM

Edited by J. Bogaert,
S. Dymarkowski, and A. M. Taylor

Focal Liver Lesions

Detection, Characterization,
Ablation

Edited by R. Lencioni, D. Cioni,
and C. Bartolozzi

Multidetector-Row CT Angiography

Edited by C. Catalano
and R. Passariello

Paediatric Musculoskeletal Diseases

With an Emphasis on Ultrasound
Edited by D. Wilson

Contrast Media in Ultrasonography

Basic Principles and Clinical Applications

Edited by Emilio Quaia

MR Imaging in White Matter Diseases of the Brain and Spinal Cord

Edited by M. Filippi, N. De Stefano,
V. Dousset, and J. C. McGowan

Diagnostic Nuclear Medicine

2nd Revised Edition

Edited by C. Schiepers

Imaging of the Kidney Cancer

Edited by A. Guermazi

Magnetic Resonance Imaging in Ischemic Stroke

Edited by R. von Kummer and T. Back

Imaging of the Hip & Bony Pelvis

Techniques and Applications

Edited by A. M. Davies, K. J. Johnson,
and R. W. Whitehouse

Imaging of Occupational and Environmental Disorders of the Chest

Edited by P. A. Gevenois and
P. De Vuyst

Contrast Media

Safety Issues and ESUR Guidelines

Edited by H. S. Thomsen

Virtual Colonoscopy

A Practical Guide

Edited by P. Lefere and S. Gryspeerdt

Vascular Embolotherapy

A Comprehensive Approach

Volume 1

Edited by J. Golzarian. Co-edited by
S. Sun and M. J. Sharafuddin

Vascular Embolotherapy

A Comprehensive Approach

Volume 2

Edited by J. Golzarian. Co-edited by
S. Sun and M. J. Sharafuddin

Head and Neck Cancer Imaging

Edited by R. Hermans

Vascular Interventional Radiology

Current Evidence in Endovascular
Surgery

Edited by M. G. Cowling

MEDICAL RADIOLOGY Diagnostic Imaging and Radiation Oncology

Titles in the series already published

RADIATION ONCOLOGY

Lung Cancer

Edited by C.W. Scarantino

Innovations in Radiation Oncology

Edited by H. R. Withers
and L. J. Peters

Radiation Therapy of Head and Neck Cancer

Edited by G. E. Laramore

Gastrointestinal Cancer – Radiation Therapy

Edited by R.R. Dobelbower, Jr.

Radiation Exposure and Occupational Risks

Edited by E. Scherer, C. Streffer,
and K.-R. Trott

Radiation Therapy of Benign Diseases A Clinical Guide

S. E. Order and S. S. Donaldson

Interventional Radiation Therapy Techniques – Brachytherapy

Edited by R. Sauer

Radiopathology of Organs and Tissues

Edited by E. Scherer, C. Streffer,
and K.-R. Trott

Concomitant Continuous Infusion Chemotherapy and Radiation

Edited by M. Rotman
and C. J. Rosenthal

Intraoperative Radiotherapy – Clinical Experiences and Results

Edited by F. A. Calvo, M. Santos,
and L.W. Brady

Radiotherapy of Intraocular and Orbital Tumors

Edited by W. E. Alberti and
R. H. Sagerman

Interstitial and Intracavitary Thermoradiotherapy

Edited by M. H. Seegenschmiedt
and R. Sauer

Non-Disseminated Breast Cancer

Controversial Issues in Management
Edited by G. H. Fletcher and
S.H. Levitt

Current Topics in Clinical Radiobiology of Tumors

Edited by H.-P. Beck-Bornholdt

Practical Approaches to Cancer Invasion and Metastases

**A Compendium of Radiation
Oncologists' Responses to 40 Histories**
Edited by A. R. Kagan with the
Assistance of R. J. Steckel

Radiation Therapy in Pediatric Oncology

Edited by J. R. Cassady

Radiation Therapy Physics

Edited by A. R. Smith

Late Sequelae in Oncology

Edited by J. Dunst and R. Sauer

Mediastinal Tumors. Update 1995

Edited by D. E. Wood
and C. R. Thomas, Jr.

Thermoradiotherapy and Thermochemotherapy

Volume 1:
Biology, Physiology, and Physics
Volume 2:
Clinical Applications

Edited by M.H. Seegenschmiedt,
P. Fessenden, and C.C. Vernon

Carcinoma of the Prostate

Innovations in Management
Edited by Z. Petrovich, L. Baert,
and L.W. Brady

Radiation Oncology of Gynecological Cancers

Edited by H.W. Vahrson

Carcinoma of the Bladder

Innovations in Management
Edited by Z. Petrovich, L. Baert,
and L.W. Brady

Blood Perfusion and Microenvironment of Human Tumors

**Implications for
Clinical Radiooncology**
Edited by M. Molls and P. Vaupel

Radiation Therapy of Benign Diseases A Clinical Guide

2nd Revised Edition
S. E. Order and S. S. Donaldson

Carcinoma of the Kidney and Testis, and Rare Urologic Malignancies

Innovations in Management
Edited by Z. Petrovich, L. Baert,
and L.W. Brady

Progress and Perspectives in the Treatment of Lung Cancer

Edited by P. Van Houtte,
J. Klastersky, and P. Rocmans

Combined Modality Therapy of Central Nervous System Tumors

Edited by Z. Petrovich, L. W. Brady,
M. L. Apuzzo, and M. Bamberg

Age-Related Macular Degeneration Current Treatment Concepts

Edited by W. A. Alberti, G. Richard,
and R. H. Sagerman

Radiotherapy of Intraocular and Orbital Tumors

2nd Revised Edition
Edited by R. H. Sagerman,
and W. E. Alberti

Modification of Radiation Response Cytokines, Growth Factors, and Other Biological Targets

Edited by C. Nieder, L. Milas,
and K. K. Ang

Radiation Oncology for Cure and Palliation

R. G. Parker, N. A. Janjan,
and M. T. Selch

Clinical Target Volumes in Conformal and Intensity Modulated Radiation Therapy

A Clinical Guide to Cancer Treatment
Edited by V. Grégoire, P. Scalliet,
and K. K. Ang

Advances in Radiation Oncology in Lung Cancer

Edited by Branislav Jeremić

New Technologies in Radiation Oncology

Edited by W. Schlegel, T. Bortfeld,
and A.-L. Grosu