

Antonio Cardesa
Pieter J. Slootweg
Editors

Pathology of the Head and Neck



 Springer

Antonio Cardesa · Pieter J. Slootweg (Eds.)

Pathology of the Head and Neck

Antonio Cardesa · Pieter J. Slootweg (Eds.)

Pathology of the Head and Neck

With 249 Figures in 308 separate Illustrations
and 17 Tables

 Springer

Professor Dr. Antonio Cardesa

Department of Pathological Anatomy
Hospital Clinic
University of Barcelona
Villarroel 170
08036 Barcelona
Spain

Professor Pieter J. Slootweg

Department of Pathology
University Medical Center St. Radboud
P.O. Box 9101
6500 HB Nijmegen
The Netherlands

Library of Congress Control Number: 2006922731

ISBN-10 3-540-30628-5 Springer Berlin Heidelberg New York
ISBN-13 978-3-540-30628-3 Springer Berlin Heidelberg New York

This work is subject to copyright. All rights are reserved, whether the whole or part of the material is concerned, specifically the rights of translation, reprinting, reuse of illustrations, recitation, broadcasting, reproduction on microfilms or in any other way and storage in data banks. Duplication of this publication or parts thereof is permitted only under the provisions of the German Copyright Law of September 9, 1965, in its current version, and permission for use must always be obtained from Springer-Verlag. Violations are liable for prosecution under German Copyright Law.

Springer is a part of Springer Science+Business Media
springer.com

© Springer-Verlag Berlin Heidelberg 2006
Printed in Germany

The use of general descriptive names, trademarks, etc. in this publication does not imply, even in the absence of a specific statement, that such names are exempt from the relevant protective laws and regulations and therefore free for general use.

Product liability: the publishers cannot guarantee the accuracy of any information about dosage and application contained in this book. In every individual case the user must check such information by consulting the relevant literature.

Editor: Gabriele Schröder, Heidelberg
Desk Editor: Ellen Blasig, Heidelberg
Production: LE-TeX, Jelonek, Schmidt & Vöckler GbR, Leipzig
Typesetting: Satz-Druck-Service, Leimen
Cover: Frido Steinen-Broo, eStudio Calamar, Spain
Printed on acid-free paper 24/3100/YL 5 4 3 2 1 0

To
*Gerhard Seifert and to Leslie Michaels,
great pioneers of Head and Neck Pathology
in Europe and founding members
of the Working Group
on Head and Neck Pathology
of the European Society of Pathology.*

Foreword

Pathology of the Head and Neck is an easy sounding title for a complex subject matter. This title stands for an accumulation of diverse diseases occurring in different organs whose relationship to each other consists in the fact that they are located between the base of the skull and the thoracic aperture. One reason for assembling all these different organs under the title "Pathology of the Head and Neck" is that the proximity of the organs of the head and neck region makes it difficult for the surgical pathologist to focus on one of these organs and neglect the pathology of others, which are only a centimetre apart. A second reason, however, is that the upper digestive tract and the upper respiratory tract, which meet in the larynx, have some basic diseases in common, notably squamous cell carcinoma. Thus pathology of the head and neck is both an arbitrary compilation of diseases and, at least to some extent, a group of disease entities with a common morphological and pathogenetic trunk.

The past years have seen remarkable advances in many fields of pathology, including that of the head and neck. There is a need for a book that integrates surgical pathology with molecular genetics, epidemiology, clinical behaviour and biology. This book provides a comprehensive description of the manifold aspects of the morphology and pathology of the organs of the head and neck region. These description, as comprehensive as they may be, also show that there are some areas of the

pathology of the head and neck that remain an unexplored world. Examples include the never-ending problem of prognostication of tumour diseases, the pathogenetic significance of tumour precursor lesions and the validation of appropriate sets of tumour markers as meaningful predictors of malignancy.

The editors of the book, Professor Antonio Cardesa and Professor Pieter Slootweg, are leading experts in the field of the pathology of the head and neck. As such they are the main members of the Working Group on Pathology of the Head and Neck of the European Society of Pathology, one of the first European working groups to be founded under the auspices of the European Society of Pathology. In this multi-author book the expertise of outstanding experts on the pathology of the head and neck in Europe is reflected. The chapters are characterised by the desire to correlate pathology with all necessary information on clinical features, epidemiology, pathogenesis and molecular genetics. The authors of these chapters have not attempted to be encyclopaedic, but rather have aimed at providing concise, yet adequate knowledge. They are therefore to be warmly commended for providing us with an excellent book, which will prove useful to surgical pathologists involved in the pathology of the head and neck.

Kiel, Germany
March 2006

Günter Klöppel

Preface

This book was initially conceived as a unitary group of chapters on “Pathology of the Head and Neck”, to be published in German within the series of volumes of Remmele’s Textbook of Pathology. From the outset, the editorial approach was to concentrate on pathological entities that are either unique to or quite characteristic of the head and neck. At the same time, we strove to avoid as much as possible unnecessary details on systemic diseases that, although involving the head and neck region, have their main focus of activity in other organs. Thus, “Pathology of the Head and Neck” encompasses the wide range of diseases encountered in the complex anatomic region extending proximally from the frontal sinuses, orbits, roof of the sphenoidal sinuses and clivus to distally the upper borders of the sternal manubrium, clavicles and first ribs. This includes the eyes, ears, upper aerodigestive tract, salivary glands, dental apparatus, thyroid and parathyroid glands, as well as all the epithelial, fibrous, fatty, muscular, vascular, lymphoid, cartilaginous, osseous and neural tissues or structures related to them.

The contents have been divided into ten chapters. The first covers the spectrum of precursor and neoplastic lesions of the squamous epithelium. It is followed by chapters devoted to the nasal cavities and paranasal sinuses, oral cavity, maxillofacial skeleton and teeth, salivary glands, nasopharynx and Waldeyer’s ring, larynx and hypopharynx, ear and temporal bone, neck and neck dissection, as well as eye and ocular

adnexa. The pathology of the thyroid and parathyroid glands and lymph nodes is covered in greater detail elsewhere.

Since the authors selected for writing the different chapters are international experts and members of the Working Group on Head and Neck Pathology of the European Society of Pathology, the chief editors of the series, Prof. Wolfgang Remmele, Prof. Hans Kreipe and Prof. Günter Klöppel, accepted that all manuscripts should be in English. After the original texts had been submitted, it became clear to the editors and publisher that, in addition to their translation to fit into Remmele’s Textbook, the work warranted publication in English as a separate book. Therefore, we want to thank the chief editors and the publisher Springer for their stimulating support and trust. We add our special thanks to the authors who produced such an excellent work, as well as to those secretaries, photographers and others who helped them.

Finally, we should like to express our wish that this book on “Pathology of the Head and Neck”, the first ever written as a joint project by a Working Group of the European Society of Pathology, could serve as an example for new books written by other Working Groups.

Barcelona, Spain

Prof. Antonio Cardesa

Nijmegen, The Netherlands
March 2006

Prof. Pieter J. Slootweg

Contents

1	Benign and Potentially Malignant Lesions of the Squamous Epithelium and Squamous Cell Carcinoma	1		
	N. GALE, N. ZIDAR			
1.1	Squamous Cell Papilloma and Related Lesions	2		
1.1.1	Squamous Cell Papilloma, Verruca Vulgaris, Condyloma Acuminatum and Focal Epithelial Hyperplasia	2		
1.1.2	Laryngeal Papillomatosis	3		
1.2	Squamous Intraepithelial Lesions (SILS)	4		
1.2.1	General Considerations	4		
1.2.2	Terminological Problems	4		
1.2.3	Aetiology	5		
1.2.3.1	Oral Cavity and Oropharynx.	5		
1.2.3.2	Larynx	5		
1.2.4	Clinical Features and Macroscopic Appearances	6		
1.2.4.1	Oral and Oropharyngeal Leukoplakia, Proliferative Verrucous Leukoplakia and Erythroplakia	6		
1.2.4.2	Laryngeal and Hypopharyngeal Leukoplakia and Chronic Laryngitis	7		
1.2.5	Histological Classifications	8		
1.2.5.1	WHO Dysplasia System	8		
1.2.5.2	The Ljubljana Classification	9		
1.2.5.3	Comparison Between the Ljubljana Classification and WHO 2005 Classification	11		
1.2.6	Biomarkers Related to Malignant Potential of SILs Recognised by Auxiliary and Advanced Molecular Methods.	12		
1.2.7	Treatment and Prognosis	12		
1.2.7.1	Oral Cavity and Oropharynx.	12		
1.2.7.2	Larynx	13		
1.3	Invasive Squamous Cell Carcinoma	13		
1.3.1	Microinvasive Squamous Cell Carcinoma	13		
1.3.2	Conventional Squamous Cell Carcinoma	13		
1.3.2.1	Aetiology	14		
1.3.2.2	Pathologic Features	14		
1.3.2.3	Grading	14		
	1.3.2.4 Invasive Front	15		
	1.3.2.5 Stromal Reaction	15		
	1.3.2.6 Differential Diagnosis	15		
	1.3.2.7 Treatment and Prognosis	15		
	1.3.3 Spindle Cell Carcinoma	16		
	1.3.3.1 Aetiology	16		
	1.3.3.2 Pathologic Features	16		
	1.3.3.3 Differential Diagnosis	17		
	1.3.3.4 Treatment and Prognosis	17		
	1.3.4 Verrucous Carcinoma	17		
	1.3.4.1 Aetiology	17		
	1.3.4.2 Pathologic Features	18		
	1.3.4.3 Differential Diagnosis	18		
	1.3.4.4 Treatment	18		
	1.3.4.5 Prognosis	19		
	1.3.5 Papillary Squamous Cell Carcinoma.	19		
	1.3.5.1 Aetiology	19		
	1.3.5.2 Pathologic Features	19		
	1.3.5.3 Differential Diagnosis	20		
	1.3.5.4 Treatment and Prognosis	20		
	1.3.6 Basaloid Squamous Cell Carcinoma	20		
	1.3.6.1 Aetiology	20		
	1.3.6.2 Pathologic Features	20		
	1.3.6.3 Differential Diagnosis	21		
	1.3.6.4 Treatment and Prognosis	21		
	1.3.7 Adenoid Squamous Cell Carcinoma	22		
	1.3.7.1 Pathologic Features	22		
	1.3.7.2 Differential Diagnosis	22		
	1.3.7.3 Treatment and Prognosis	22		
	1.3.8 Adenosquamous Carcinoma	23		
	1.3.8.1 Aetiology	23		
	1.3.8.2 Pathologic Features	23		
	1.3.8.3 Differential Diagnosis	23		
	1.3.8.4 Treatment and Prognosis	24		
	1.3.9 Lymphoepithelial Carcinoma	24		
	1.3.9.1 Aetiology	24		
	1.3.9.2 Pathologic Features	24		
	1.3.9.3 Differential Diagnosis	25		
	1.3.9.4 Treatment and Prognosis	25		
	1.4 Second Primary Tumours	25		
	1.5 Tumour Spread and Metastasising	25		
	1.5.1 Invasion of Lymphatic and Blood Vessels	26		

1.5.2	Perineural Invasion	26	2.6.2	Mucormycosis	44
1.5.3	Regional Lymph Node Metastases	26	2.6.3	Rhinosporidiosis	44
1.5.3.1	Extracapsular Spread in Lymph Node Metastases	26	2.7	HIV-Related Infections	44
1.5.3.2	Metastases in the Soft Tissue of the Neck	27	2.8	Mid-Facial Necrotising Granulomatous Lesions	45
1.5.4	Distant Metastasis	27	2.8.1	Wegener's Granulomatosis	45
1.5.5	Micrometastasis	27	2.8.2	Lepromatous Leprosy	45
1.6	Molecular Pathology of Squamous Cell Carcinoma	28	2.8.3	Tuberculosis	45
1.6.1	Detecting Tumour Cells	28	2.8.4	Sarcoidosis	45
1.6.2	Clonal Analysis	28	2.8.5	Rhinoscleroma	45
1.6.3	Assessment of Risk for Malignant Progression	29	2.8.6	Leishmaniasis	45
1.6.4	DNA/RNA Profiling in Predicting Metastatic Disease	29	2.8.7	Cocaine Abuse	46
	References	29	2.8.8	Local Steroid Injections	46
2	Nasal Cavity and Paranasal Sinuses	39	2.9	Benign Epithelial Neoplasms	46
	A. CARDESA, L. ALOS		2.9.1	Sinonasal Papillomas	46
2.1	Introduction	40	2.9.1.1	Squamous Cell Papilloma	46
2.1.1	Embryology	40	2.9.1.2	Exophytic Papilloma	46
2.1.2	Anatomy	40	2.9.1.3	Inverted Papilloma	46
2.1.3	Histology	40	2.9.1.4	Oncocytic Papilloma	47
2.2.	Acute and Chronic Rhinosinusitis	40	2.9.2	Salivary-Type Adenomas	48
2.2.1	Viral Infections (Common Cold)	40	2.9.3	Pituitary Adenomas	48
2.2.2	Bacterial Infections	40	2.10	Benign Sinonasal Soft Tissue Neoplasms	48
2.2.3	Allergic Rhinitis	40	2.10.1	Haemangiomas	48
2.2.4	Atrophic Rhinitis	41	2.10.2	Haemangiopericytoma	48
2.2.5	Hypertrophic Rhinitis	41	2.10.3	Solitary Fibrous Tumour	48
2.2.6	Non-Suppurative Chronic Sinusitis	41	2.10.4	Desmoid Fibromatosis	49
2.3	Sinonasal Polyps	41	2.10.5	Fibrous Histiocytoma	49
2.3.1	Allergic Polyposis	41	2.10.6	Leiomyoma	49
2.3.2	Polyposis in Mucoviscidosis	41	2.10.7	Schwannoma and Neurofibroma	49
2.3.3	Polyposis in Immotile Cilia Syndrome and in Kartagener's Syndrome	41	2.10.8	Meningioma	50
2.3.4	Antrochoanal Polyps	41	2.10.9	Paraganglioma	50
2.4	Sinonasal Hamartomatous and Teratoid Lesions	42	2.10.10	Juvenile Angiofibroma	50
2.4.1	Hamartomas	42	2.11	Malignant Sinonasal Tumours	50
2.4.2	Teratoid Lesions	42	2.11.1	Keratinising Squamous Cell Carcinoma	51
2.5	Pseudotumours	43	2.11.2	Cylindrical Cell Carcinoma	52
2.5.1	Mucocele	43	2.11.3	Sinonasal Undifferentiated Carcinoma	53
2.5.2	Organising Haematoma	43	2.11.4	Small Cell (Neuroendocrine) Carcinoma	54
2.5.3	Amyloidosis	43	2.11.5	Primary Sinonasal Nasopharyngeal-Type Undifferentiated Carcinoma	54
2.5.4	Myospherulosis	43	2.11.6	Malignant Melanoma	55
2.5.5	Eosinophilic Angiocentric Fibrosis	43	2.11.7	Olfactory Neuroblastoma	57
2.5.6	Heterotopic Brain Tissue	43	2.11.8	Primitive Neuroectodermal Tumour	58
2.6	Fungal Diseases	44	2.11.9	High-Grade Sinonasal Adenocarcinomas	58
2.6.1	Aspergillosis	44	2.11.9.1	Intestinal-Type Adenocarcinoma	58
			2.11.9.2	Salivary-Type High-Grade Adenocarcinoma	60

2.11.10	Low-Grade Sinonasal Adenocarcinomas	60	3.4.7	Hairy Tongue	85
2.11.10.1	Non-Salivary-Type Low-Grade Adenocarcinomas	60	3.4.8	Hairy Leukoplakia	85
2.11.10.2	Salivary-Type Low-Grade Adenocarcinomas	61	3.4.9	Geographic Tongue	85
2.11.11	Sinonasal Malignant Lymphomas	61	3.4.10	Frictional Keratosis	86
2.11.12	Extramedullary Plasmacytoma	62	3.5	Pigmentations	86
2.11.13	Fibrosarcoma	62	3.5.1	Amalgam Tattoo	86
2.11.14	Malignant Fibrous Histiocytoma	63	3.5.2	Localised Melanotic Pigmentation	86
2.11.15	Leiomyosarcoma	63	3.5.2.1	Oral Melanotic Macules	86
2.11.16	Rhabdomyosarcoma	63	3.5.2.2	Melanoacanthoma	87
2.11.17	Malignant Peripheral Nerve Sheath Tumour	63	3.5.2.3	Pigmented Naevi	87
2.11.18	Teratocarcinosarcoma	63	3.5.3	Premalignant Oral Melanoses and Oral Melanoma	87
	References	64	3.5.4	Addison Disease	88
3	Oral Cavity	72	3.5.5	Peutz Jeghers Syndrome	89
	J.W. EVESON		3.5.6	Racial Pigmentation	89
3.1	Embryonic Rests and Heterotopias	72	3.5.7	Laugier Hunziker Syndrome	89
3.1.1	Fordyce Granules/Spots	72	3.5.8	Smoker's Melanosis	89
3.1.2	Juxtaoral Organ of Chievitz	72	3.5.9	Drug-Associated Oral Pigmentation	90
3.2.	Vesiculo-Bullous Diseases	72	3.6	Hyperplastic Lesions	90
3.2.1	Herpes Simplex Infections	72	3.6.1	Fibrous Hyperplasias	90
3.2.2	Chickenpox and Herpes Zoster	73	3.6.2	Papillary Hyperplasia	90
3.2.3	Hand-Foot-and-Mouth Disease	73	3.6.3	Generalised Gingival Fibrous Hyperplasia	91
3.2.4	Herpangina	74	3.6.4	Crohn's Disease	91
3.2.5	Pemphigus Vulgaris	74	3.6.5	Orofacial Granulomatosis	92
3.2.6	Pemphigus Vegetans	74	3.6.6	Chronic Marginal Gingivitis and Localised Gingival Fibrous Hyperplasia	92
3.2.7	Paraneoplastic Pemphigus	75	3.6.7	Peripheral Giant Cell Granuloma (Giant Cell Epulis)	93
3.2.8	Mucous Membrane Pemphigoid	75	3.6.8	Pyogenic Granuloma	93
3.2.9	Dermatitis Herpetiformis	76	3.6.9	Pulse (Vegetable) Granuloma	93
3.2.10	Linear IgA Disease	76	3.7	Benign Tumours and Pseudotumours	94
3.2.11	Erythema Multiforme	77	3.7.1	Giant Cell Fibroma	94
3.3	Ulcerative Lesions	77	3.7.2	Lingual Thyroid	94
3.3.1	Aphthous Stomatitis (Recurrent Aphthous Ulceration)	77	3.7.3	Verruciform Xanthoma	95
3.3.2	Behçet Disease	78	3.7.4	Haemangiomas	95
3.3.3	Reiter Disease	78	3.7.5	Lymphangioma	95
3.3.4	Median Rhomboid Glossitis	78	3.7.6	Benign Nerve Sheath Tumours	95
3.3.5	Eosinophilic Ulcer (Traumatic Ulcerative Granuloma with Stromal Eosinophilia)	79	3.7.6.1	Neurofibroma	96
3.3.6	Acute Necrotising Ulcerative Gingivitis	79	3.7.6.2	Schwannoma	96
3.3.7	Wegener's Granulomatosis	80	3.7.6.3	Neurofibromatosis	96
3.3.8	Tuberculosis	81	3.7.6.4	Multiple Neuromas in Endocrine Neoplasia Syndrome	96
3.4	White Lesions	81	3.7.7	Granular Cell Tumour (Granular Cell Myoblastoma)	96
3.4.1	Candidosis	81	3.8	Squamous Cell Carcinoma	96
3.4.2	Lichen Planus	82	3.8.1	Introduction	96
3.4.3	Lupus Erythematosus	83	3.8.2	Clinical Features	97
3.4.4	Oral Epithelial Naevi	84	3.8.2.1	Buccal Mucosa	97
3.4.5	Smoker's Keratosis	84	3.8.2.2	Tongue	97
3.4.6	Stomatitis Nicotina	84	3.8.2.3	Floor of Mouth	97

3.8.2.4	Gingiva and Alveolar Ridge	97	4.4.3.6	Calcifying Odontogenic Cyst	118
3.8.2.5	Hard Palate	98	4.4.4	Odontogenic Tumours –	
3.8.2.6	Retromolar Trigone	98		Malignant	119
3.8.3	Staging	98	4.4.4.1	Malignant Ameloblastoma	119
	References	98	4.4.4.2	Ameloblastic Carcinoma	119
4	Maxillofacial Skeleton		4.4.4.3	Primary Intraosseous Carcinoma	119
	and Teeth	104	4.4.4.4	Clear Cell Odontogenic Carcinoma	120
	P.J. SLOOTWEG		4.4.4.5	Malignant Epithelial Odontogenic	
4.1	Introduction	104		Ghost Cell Tumour	120
4.1.1	Embryology	104	4.4.4.6	Odontogenic Sarcoma	120
4.1.2	Tooth Development	104	4.5	Fibro-Osseous Lesions	121
4.2	Inflammatory Diseases		4.5.1	Fibrous Dysplasia	121
	of the Maxillofacial Bones	104	4.5.2	Ossifying Fibroma	121
4.3	Cysts of the Jaws	105	4.5.3	Osseous Dysplasia	123
4.3.1	Odontogenic Cysts –		4.6	Giant Cell Lesions	124
	Inflammatory w	105	4.6.1	Central Giant Cell Granuloma	124
4.3.1.1	Radicular Cyst	105	4.6.2	Cherubism	124
4.3.1.2	Paradental Cyst	106	4.7	Neoplastic Lesions	
4.3.2	Odontogenic Cysts –			of the Maxillofacial Bones,	
	Developmental	106		Non-Odontogenic	125
4.3.2.1	Dentigerous Cyst	106	4.7.1	Osteoma	125
4.3.2.2	Lateral Periodontal Cyst	107	4.7.2	Chordoma	125
4.3.2.3	Glandular Odontogenic Cyst	107	4.7.3	Melanotic Neuroectodermal Tumour	
4.3.2.4	Odontogenic Keratocyst	107		of Infancy	126
4.3.2.5	Gingival Cyst	108		References	126
4.3.3	Non-Odontogenic Cysts	109	5	Major and Minor	
4.3.3.1	Nasopalatine Duct Cyst	109		Salivary Glands	132
4.3.3.2	Nasolabial Cyst	109		S. DI PALMA, R.H.W. SIMPSON,	
4.3.3.3	Surgical Ciliated Cyst	109		A. SKALOVA, I. LEIVO	
4.3.4	Pseudocysts	109	5.1	Introduction	132
4.3.4.1	Solitary Bone Cyst	109	5.1.1	Normal Salivary Glands	132
4.3.4.2	Focal Bone Marrow Defect	109	5.1.2	Developmental Disorders	132
4.4	Odontogenic Tumours	109	5.2	Obstructive Disorders	132
4.4.1	Odontogenic Tumours –		5.2.1	Mucus Escape Reaction	132
	Epithelial	110	5.2.2	Chronic Sclerosing Sialadenitis	
4.4.1.1	Ameloblastoma	110		of the Submandibular Gland	
4.4.1.2	Calcifying Epithelial			(Küttner Tumour)	133
	Odontogenic Tumour	112	5.3.	Infections	133
4.4.1.3	Adenomatoid Odontogenic Tumour	112	5.3.1	Bacteria, Fungi	133
4.4.1.4	Squamous Odontogenic Tumour	113	5.3.2	Viruses	133
4.4.2	Odontogenic Tumours –		5.4	Miscellaneous Inflammatory	
	Mesenchymal	114		Disorders	133
4.4.2.1	Odontogenic Myxoma	114	5.5	Miscellaneous Non-Inflammatory	
4.4.2.2	Odontogenic Fibroma	115		Disorders	133
4.4.2.3	Cementoblastoma	116	5.5.1	Necrotising Sialometaplasia	
4.4.3	Odontogenic Tumours –			(Salivary Gland Infarction)	133
	Mixed Epithelial and Mesenchymal	117	5.5.2	Sialadenosis	133
4.4.3.1	Ameloblastic Fibroma	117	5.5.3	Adenomatoid Hyperplasia	
4.4.3.2	Ameloblastic Fibro-Odontoma	117		of Mucous Salivary Glands	134
4.4.3.3	Odontoma – Complex Type	118	5.5.4	Irradiation Changes	134
4.4.3.4	Odontoma – Compound Type	118			
4.4.3.5	Odonto-Ameloblastoma	118			

5.5.5	Tissue Changes Following Fine Needle Aspiration	134	5.9.11.3	Metastasising Pleomorphic Adenoma	157
5.6	Oncocytic Lesions	134	5.9.12	Sebaceous Carcinoma	158
5.6.1	Focal and Diffuse Oncocytosis	134	5.9.13	Lymphoepithelial Carcinoma	158
5.6.2	Ductal Oncocytosis	134	5.9.14	Small Cell Carcinoma	158
5.6.3	Multifocal Nodular Oncocytic Hyperplasia	135	5.9.15	Higher Grade Change in Carcinomas	159
5.7	Cysts	135	5.9.16	Metastatic Malignancies	159
5.7.1	Salivary Polycystic Dysgenetic Disease	135	5.10	Hybrid Carcinoma	160
5.7.2	Mucocele	135	5.11	Endodermal Sinus Tumour	160
5.7.3	Simple Salivary Duct Cysts	135	5.12	Sialoblastoma	160
5.7.4	Lymphoepithelial Cystic Lesions	135	5.13	Alterations in Gene Expression and Molecular Derangements in Salivary Gland Carcinoma	160
5.7.4.1	Benign Lymphoepithelial Cyst	135	5.13.1	Predominantly Myoepithelial Malignancies	161
5.7.4.2	Cystic Lymphoid Hyperplasia of AIDS	136	5.13.2	Predominantly Epithelial Malignancies	161
5.7.5	Sclerosing Polycystic Sialadenopathy (Sclerosing Polycystic Adenosis)	136	5.14	Benign and Malignant Lymphoid Infiltrates	162
5.7.6	Other Cysts	137	5.14.1	Non-Autoimmune Lymphoid Infiltrates	162
5.8	Benign Tumours	137	5.14.2	Benign Autoimmune Lymphoid Infiltrates	162
5.8.1	Pleomorphic Adenoma	137	5.14.3	Malignant Lymphoma	163
5.8.1.1	Salivary Gland Anlage Tumour (“Congenital Pleomorphic Adenoma”)	140	5.15	Other Tumours	163
5.8.2	Benign Myoepithelioma	140	5.16	Unclassified Tumours	163
5.8.3	Basal Cell Adenoma	141		References	164
5.8.4	Warthin’s Tumour	142	6	Nasopharynx and Waldeyer’s Ring	171
5.8.5	Oncocytoma	143		S. REGAUER	
5.8.6	Canalicular Adenoma	143	6.1	Embryological Development of the Nasopharynx and Waldeyer’s Ring	172
5.8.7	Sebaceous Adenoma	144	6.2	Nasopharynx	173
5.8.8	Sebaceous Lymphadenoma	144	6.2.1	Anatomy and Histology	173
5.8.9	Ductal Papilloma	144	6.2.2	Congenital Developmental Anomalies	173
5.8.10	Cystadenoma	144	6.2.2.1	Nasopharyngeal Branchial Cleft Cysts	173
5.9	Malignant Epithelial Tumours	144	6.2.2.2	Tornwaldt’s Cyst	173
5.9.1	Acinic Cell Carcinoma	144	6.2.2.3	Rathke’s Cleft Cyst/ Ectopic Pituitary Tissue	174
5.9.2	Mucoepidermoid Carcinoma	146	6.2.2.4	Craniopharyngioma	174
5.9.3	Adenoid Cystic Carcinoma	147	6.2.2.5	Heterotopic Brain Tissue/ Encephalocele	174
5.9.4	Polymorphous Low-Grade Adenocarcinoma	148	6.2.3	Congenital Tumours	174
5.9.4.1	Cribriform Adenocarcinoma of the Tongue	149	6.2.3.1	Salivary Gland Anlage Tumour	175
5.9.5	Epithelial-Myoepithelial Carcinoma	150	6.2.3.2	Hairy Polyp	175
5.9.6	Hyalinising Clear Cell Carcinoma	151	6.2.3.3	Congenital Nasopharyngeal Teratoma	175
5.9.7	Basal Cell Adenocarcinoma	151	6.2.4	Benign Tumours and Tumour-Like Lesions	175
5.9.8	Myoepithelial Carcinoma (Malignant Myoepithelioma)	152			
5.9.9	Salivary Duct Carcinoma	154			
5.9.10	Oncocytic Carcinoma	155			
5.9.11	Malignancy in Pleomorphic Adenoma Malignant Mixed Tumour	156			
5.9.11.1	Carcinoma (True Malignant Mixed Tumour) Ex Pleomorphic Adenoma	156			
5.9.11.2	Carcinosarcoma Ex Pleomorphic Adenoma	157			

6.2.4.1	Nasopharyngeal Angiofibroma	175	7.2	Laryngocele, Cysts, Heterotopia	199
6.2.4.2	Respiratory Epithelial Adenomatoid Hamartoma	178	7.2.1	General Considerations	199
6.2.4.3	Nasopharyngeal Inverted Papilloma	178	7.2.2	Laryngocele	199
6.2.4.4	Solitary Fibrous Tumour	179	7.2.3	Saccular Cyst	199
6.2.4.5	Paraganglioma	179	7.2.4	Ductal Cyst	199
6.2.4.6	Meningioma	179	7.2.5	Oncocytic Cyst	200
6.2.4.7	Glandular Retention Cysts	179	7.2.6	Zenker's Hypopharyngeal Diverticle	201
6.2.5	Nasopharyngeal Carcinoma	180	7.2.7	Aberrant Thyroid Tissue	201
6.2.5.1	Non-Keratinising Nasopharyngeal Carcinoma	180	7.2.8	Tracheopathia Osteochondroplastica	202
6.2.5.2	Keratinising Nasopharyngeal Carcinoma	182	7.3	Inflammatory Lesions	202
6.2.6	Nasopharyngeal Adenocarcinoma	182	7.3.1	Acute Infections	202
6.2.6.1	Salivary Gland-Type Adenocarcinoma of the Nasopharynx	182	7.3.1.1	Epiglottitis	202
6.2.6.2	Papillary Adenocarcinoma of the Nasopharynx	182	7.3.1.2	Laryngotracheobronchitis	202
6.2.7	Malignant Non-Epithelial Tumours of the Nasopharynx	183	7.3.1.3	Diphtheria	202
6.2.7.1	Chordoma	183	7.3.2	Chronic Infections	202
6.2.7.2	Sarcoma	183	7.3.2.1	Tuberculosis	202
6.3	Waldeyer's Ring	183	7.3.2.2	Fungal Infections	203
6.3.1	Anatomy and Histology of Waldeyer's Ring	183	7.3.2.3	Other Rare Infections	203
6.3.2	Congenital Anomalies of Waldeyer's Ring	184	7.3.3	Non-Infectious Inflammatory Lesions	203
6.3.3	Tonsillitis	184	7.3.3.1	Wegener's Granulomatosis	203
6.3.3.1	Bacterial Tonsillitis	184	7.3.3.2	Sarcoidosis	204
6.3.3.2	Viral Tonsillitis	185	7.3.3.3	Rheumatoid Arthritis	204
6.3.4	Benign Tumours of Waldeyer's Ring	187	7.3.3.4	Relapsing Polychondritis	205
6.3.4.1	Squamous Papilloma	187	7.3.3.5	Gout	206
6.3.4.2	Lymphangiomatous Tonsillar Polyp	187	7.3.3.6	Teflon Granuloma	206
6.3.5	Carcinomas of Waldeyer's Ring	187	7.3.3.7	Idiopathic Subglottic Laryngeal Stenosis	206
6.3.6	Malignant Lymphomas of Waldeyer's Ring	189	7.3.3.8	Angioneurotic Oedema	207
6.3.6.1	Mantle Cell Lymphoma	189	7.4	Degenerative Lesions	207
6.3.6.2	Extranodal Marginal Zone B-Cell Lymphoma of Mucosa-Associated Lymphoid Tissue	190	7.4.1	Oculopharyngeal Muscular Dystrophy	207
6.3.6.3	Extranodal NK/T-Cell Lymphoma, Nasal Type	190	7.5	Pseudotumours	207
6.3.6.4	Hodgkin's Lymphoma	190	7.5.1	Exudative Lesions of Reinke's Space	207
6.3.6.5	Extramedullary Plasmacytoma	190	7.5.1.1	Reinke's Oedema	208
6.3.7	Systemic Disease Affecting Waldeyer's Ring	190	7.5.1.2	Vocal Cord Polyp and Nodule	208
	References	191	7.5.2	Contact Ulcer and Granuloma, Intubation Granuloma	210
7	Larynx and Hypopharynx	196	7.5.3	Necrotising Sialometaplasia	211
	N. GALE, A. CARDESA, N. ZIDAR		7.5.4	Metaplastic Elastic Cartilaginous Nodules	211
7.1	Summary of Anatomy, Histology and Embryology	198	7.5.5	Amyloidosis	211
			7.5.6	Sinus Histiocytosis with Massive Lymphadenopathy and Other Rare Pseudotumours	212
			7.5.7	Inflammatory Myofibroblastic Tumour	213
			7.6	Benign Neoplasms	214
			7.6.1	Squamous Cell Papilloma	214
			7.6.2	Salivary Gland-Type Tumours	214
			7.6.2.1	Pleomorphic Adenoma	214
			7.6.2.2	Oncocytoma	214
			7.6.3	Haemangioma (Neonatal and Adult Types)	214

7.6.4	Paranglioma	215	8.2.2.2	First Branchial Cleft Cyst	238
7.6.5	Granular Cell Tumour	216	8.2.3	Tumour-Like Lesions	239
7.6.6	Chondroma	217	8.2.3.1	Chondrodermatitis Nodularis Helicis	239
7.7	Malignant Neoplasms	217	8.2.3.2	Keratosis Obturans and Cholesteatoma of External Canal	239
7.7.1	Potentially Malignant (Precancerous) Lesions	217	8.2.3.3	Keratin Granuloma	239
7.7.2	Invasive Squamous Cell Carcinoma	218	8.2.3.4	Angiolymphoid Hyperplasia with Eosinophilia and Kimura's Disease	239
7.7.2.1	Epidemiology	218	8.2.3.5	Accessory Tragus	240
7.7.2.2	Aetiology	218	8.2.3.6	Keloid	240
7.7.2.3	Anatomic Sites	218	8.2.4	Benign Neoplasms	240
7.7.2.4	Histological Variants	219	8.2.4.1	Adenoma of Ceruminal Glands	240
7.7.2.5	TNM Grading	220	8.2.4.2	Pleomorphic Adenoma of Ceruminal Glands	241
7.7.3	Neuroendocrine Carcinoma	220	8.2.4.3	Syringocystadenoma Papilliferum of Ceruminal Glands	241
7.7.3.1	Well-Differentiated Neuroendocrine Carcinoma (Carcinoid)	220	8.2.4.4	Bony Lesions	241
7.7.3.2	Moderately Differentiated Neuroendocrine Carcinoma (Atypical Carcinoid)	220	8.2.5	Malignant Neoplasms	242
7.7.3.3	Poorly Differentiated Neuroendocrine Carcinoma (Small Cell Carcinoma)	221	8.2.5.1	Adenocarcinoma of Ceruminal Glands	242
7.7.4	Adenocarcinoma	222	8.2.5.2	Adenoid Cystic Carcinoma of Ceruminal Glands	242
7.7.4.1	Adenoid Cystic Carcinoma	222	8.2.5.3	Basal Cell Carcinoma	242
7.7.4.2	Mucoepidermoid Carcinoma	222	8.2.5.4	Squamous Cell Carcinoma	243
7.7.5	Sarcomas	223	8.2.5.5	Melanotic Neoplasms	243
7.7.5.1	Chondrosarcoma	223	8.3	Middle Ear and Mastoid	244
7.7.5.2	Other Sarcomas	224	8.3.1	Inflammatory Lesions	244
7.7.6	Other Malignant Neoplasms	224	8.3.1.1	Acute and Chronic Otitis Media	244
7.7.6.1	Malignant Lymphoma	224	8.3.1.2	Cholesteatoma	244
7.7.6.2	Extraosseus (Extramedullary) Plasmacytoma	224	8.3.1.3	Unusual Inflammatory Lesions	247
7.7.6.3	Primary Mucosal Melanoma	225	8.3.2	Neoplasms and Lesions Resembling Neoplasms	247
7.7.6.4	Metastases to the Larynx	225	8.3.2.1	Choristoma (Salivary Gland, Glial and Sebaceous Types)	247
	References	226	8.3.2.2	Adenoma	247
8	Ear and Temporal Bone	234	8.3.2.3	Papillary Tumours	248
	L. MICHAELS		8.3.2.4	Jugulotympanic Paranglioma	249
8.1	Summary of Embryology, Anatomy and Histology	236	8.3.2.5	Squamous Carcinoma	250
8.1.1	Embryology	236	8.3.2.6	Meningioma	251
8.1.2	Anatomy	236	8.3.2.7	Rhabdomyosarcoma	251
8.1.3	Histology	237	8.3.2.8	Metastatic Carcinoma	252
8.2	External Ear and Auditory Canal	237	8.4	Inner Ear	252
8.2.1	Inflammatory and Metabolic Lesions	237	8.4.1	Bony Labyrinth	252
8.2.1.1	Diffuse External Otitis	237	8.4.1.1	Otosclerosis	252
8.2.1.2	Perichondritis	237	8.4.1.2	Paget's Disease	253
8.2.1.3	Malignant Otitis Externa	237	8.4.1.3	Osteogenesis Imperfecta	254
8.2.1.4	Relapsing Polychondritis	238	8.4.1.4	Osteopetrosis	254
8.2.1.5	Gout	238	8.4.2	Membranous Labyrinth and Cranial Nerves	254
8.2.1.6	Ochronosis	238	8.4.2.1	Viral, Bacterial and Mycotic Infections	254
8.2.2	Pseudocystic and Cystic Lesions	238	8.4.2.2	Lesions of the Vestibular System	256
8.2.2.1	Idiopathic Pseudocystic Chondromalacia	238	8.4.2.3	Tumours and Tumour-Like Lesions	257

8.4.2.4	Presbycusis	260	9.7.3	Histologic Evaluation of Neck Dissection	279
8.4.2.5	Malformations	260		References	280
	References	260			
9	Cysts and Unknown Primary and Secondary Tumours of the Neck, and Neck Dissection	262	10	Eye and Ocular Adnexa	282
	M. A LUNA, K. PINEDA-DABOIN			M.R. CANNINGA-VAN DIJK	
9.1	Introduction	264	10.1	Summary of Anatomy and Histology	284
9.2.	Anatomy	264	10.1.1	Conjunctiva	284
9.2.1	Triangles of the Neck	264	10.1.2	Cornea	284
9.2.2	Lymph Node Regions of the Neck	264	10.1.3	Intraocular Tissues	284
9.3	Cysts of the Neck	264	10.1.4	Optic Nerve	284
9.3.1	Developmental Cysts	265	10.1.5	Lacrimal Glands and Lacrimal Passages	284
9.3.1.1	Branchial Cleft Cysts, Sinuses and Fistulae	265	10.1.6	Eyelids	284
9.3.2	Branchiogenic Carcinoma	267	10.1.7	Orbit	285
9.3.3	Thyroglossal Duct Cyst and Ectopic Thyroid	268	10.2	Conjunctiva	285
9.3.4	Cervical Thymic Cyst	269	10.2.1	Developmental Anomalies	285
9.3.5	Cervical Parathyroid Cyst	270	10.2.1.1	Dermoid, Dermolipoma and Complex Choristoma	285
9.3.6	Cervical Bronchogenic Cyst	270	10.2.2	Cysts	285
9.3.7	Dermoid Cyst	271	10.2.2.1	Inclusion cysts	285
9.3.8	Unclassified Cervical Cyst	271	10.2.3	Degeneration	286
9.3.9	Non-Developmental Cysts	271	10.2.3.1	Pinguecula and Pterygium	286
9.3.9.1	Ranula	271	10.2.4	Inflammatory Processes	286
9.3.9.2	Laryngocele	271	10.2.4.1	Acute Conjunctivitis	286
9.4	Cystic Neoplasms	272	10.2.4.2	Chronic Non-Granulomatous Conjunctivitis	287
9.4.1	Cystic Hygroma and Lymphangioma	272	10.2.4.3	Granulomatous Conjunctivitis	287
9.4.2	Haemangioma	272	10.2.4.4	Ligneous Conjunctivitis	287
9.4.3	Teratoma	272	10.2.4.5	Chlamydia Trachomatis (TRIC Agent) Infection	287
9.4.4	Cervical Salivary Gland Cystic Neoplasms	273	10.2.5	Dermatologic and Systemic Diseases	288
9.4.5	Miscellaneous Lesions	273	10.2.5.1	Keratoconjunctivitis Sicca	288
9.5	Paraganglioma	273	10.2.5.2	Dermatologic Diseases	288
9.6	Unknown Primary and Secondary Tumours	274	10.2.5.3	Metabolic Diseases	288
9.6.1	Definition	274	10.2.6	Tumours and Tumour-Like Conditions	288
9.6.2	Clinical Features	275	10.2.6.1	Epithelial	288
9.6.3	Search for the Primary Tumour	275	10.2.6.2	Melanocytic	290
9.6.4	Common Location of the Primary Tumour	276	10.2.6.3	Other Neoplasms	291
9.6.5	Histologic Type of Metastases and Immunohistochemical Features	276	10.3	Cornea	292
9.6.6	Differential Diagnosis	276	10.3.1	Keratitis and Corneal Ulcers	292
9.6.7	Treatment and Results	278	10.3.1.1	Herpes Simplex Keratitis	292
9.7	Neck Dissection	278	10.3.1.2	Corneal Ulceration Due to Systemic Disease	292
9.7.1	Classification of Neck Dissections	278	10.3.2	Keratoconus	292
9.7.2	Gross Examination of Neck Dissection Surgical Specimens	279	10.3.3	Hereditary Corneal Dystrophies	293
			10.3.3.1	Epithelial Dystrophies	293
			10.3.3.2	Stromal Dystrophies	293
			10.3.3.3	Endothelial Dystrophies	293
			10.3.4	Failed Previous Grafts	294

10.4	Intraocular Tissues	294	10.5.4	Tumours	302
10.4.1	Developmental Anomalies	294	10.5.4.1	Glioma	302
10.4.1.1	Congenital Glaucoma	294	10.5.4.2	Meningioma	302
10.4.1.2	Retinopathy of Prematurity	294	10.6	Lacrimal Gland and Lacrimal Passages	302
10.4.1.3	Persistent Primary Hyperplastic Vitreous	294	10.6.1	Inflammatory Processes	302
10.4.1.4	Retinal Dysplasia	294	10.6.2	Tumours and Tumour-Like Conditions	303
10.4.1.5	Aniridia	294	10.7	Eyelids	303
10.4.1.6	Congenital Rubella Syndrome	294	10.7.1	Cysts	303
10.4.2	Inflammatory Processes	295	10.7.1.1	Dermoid Cyst	303
10.4.2.1	Acute Inflammation	295	10.7.1.2	Epidermal Cyst	303
10.4.2.2	Chronic Non-Granulomatous Inflammation	295	10.7.1.3	Hydrocystoma	303
10.4.2.3	Granulomatous Inflammation	295	10.7.2	Inflammatory Processes	303
10.4.3	Trauma	296	10.7.2.1	Chalazion and Other Ruptured Cysts	304
10.4.4	Degeneration	296	10.7.2.2	Deep Granuloma Annulare	304
10.4.4.1	Glaucoma	296	10.7.2.3	Necrobiotic Xanthogranuloma	304
10.4.4.2	Cataracts	297	10.7.3	Amyloidosis	305
10.4.4.3	Phtisis Bulbi	298	10.7.4	Tumours and Tumour-Like Conditions	305
10.4.4.4	Retinal Vascular Disease	298	10.7.4.1	Xanthelasmata	305
10.4.4.5	Retinal Detachment	298	10.8	Orbit	305
10.4.4.6	Retinitis Pigmentosa	298	10.8.1	Inflammatory Processes	305
10.4.5	Tumours and Tumour-Like Conditions	298	10.8.1.1	Dysthyroid Ophthalmopathy	305
10.4.5.1	Melanocytic	298	10.8.1.2	Cellulitis	305
10.4.5.2	Lymphoid	300	10.8.1.3	Pseudotumour	306
10.4.5.3	Retinoblastoma and Pseudoretinoblastoma	300	10.8.2	Tumours and Tumour-Like Conditions	306
10.4.5.4	Glial	301	10.8.2.1	Developmental Cysts	306
10.4.5.5	Vascular	301	10.8.2.2	Optic Nerve and Meningeal Tumours	306
10.4.5.6	Other Primary Tumours	301	10.8.2.3	Metastatic Tumours	307
10.4.5.7	Metastatic Tumours	302		References	307
10.5	Optic Nerve	302		Subject Index	311
10.5.1	Papilloedema	302			
10.5.2	Optic Neuritis	302			
10.5.3	Optic Atrophy	302			

List of Contributors

Llucia Alos

(e-mail: lalos@clinic.ub.es)
Department of Pathological Anatomy,
Hospital Clinic, University of Barcelona,
Villarroel 170, 08036 Barcelona, Spain

M.R. Canning-Van Dijk

(e-mail: m.r.canningavandijk@azu.nl)
Department of Pathology,
University Medical Centre Utrecht, H04-312,
P.O. Box 85500, 3508 GA, Utrecht, The Netherlands

Antonio Cardesa

(e-mail: acardesa@clinic.ub.es)
Department of Pathological Anatomy,
Hospital Clinic, University of Barcelona,
Villarroel 170, 08036 Barcelona, Spain

Silvana Di Palma

(e-mail: silvana.dipalma@royalsurrey.nhs.uk)
Department of Histopathology,
University of Surrey, Royal Surrey County Hospital,
Egerton Road, Guildford, GU2 7XX, UK

John Wallace Eveson

(e-mail: j.w.eveson@bristol.ac.uk)
Division of Oral Medicine,
Pathology and Microbiology,
University of Bristol Dental School,
Lower Maudlin Street, Bristol, BS1 2LY, UK

Alessandro Franchi

(e-mail: franchi@unifi.it)
Department of Human Pathology and Oncology,
University of Florence,
Viale Morgagni 85, 50134 Florence, Italy

Nina Gale

(e-mail: nina.gale@mf.uni-lj.si)
Institute of Pathology, Faculty of Medicine,
University of Ljubljana,
Korytkova 2, 1000 Ljubljana, Slovenia

Ilmo Leivo

(e-mail: ilmo.leivo@helsinki.fi)
Department of Pathology, Haartman Institute,
P.O. Box 21 (Haartmaninkatu 3)
00014 University of Helsinki, Helsinki, Finland

Mario A. Luna

(e-mail: mluna@mdanderson.org)
Department of Pathology, The University of Texas,
M.D. Anderson Cancer Center,
1515 Holcombe Blvd, Box 85,
Houston, Texas 77030, USA

Leslie Michaels

(e-mail: l.michaels@ucl.ac.uk)
Department of Histopathology,
Royal Free and UCL Medical School,
Rockefeller Building,
University Street, London WC1E 6JJ, UK

Keyla Pineda-Daboin

Department of Pathology,
Military Hospital "Carlos Arvelo"
and Institute of Anatomical Pathology,
University Central of Venezuela, Caracas, Venezuela

Sigrid Regauer

(e-mail: sigrid.regauer@meduni-graz.at)
Institute of Pathology,
Karl Franzens University of Graz,
Auenbruggerplatz 25, 8036 Graz, Austria

Roderick H.W. Simpson

(e-mail: roderick.simpson@virgin.net)
Department of Histopathology,
Church Lane Exeter, EX2 5AD, UK

Alena Skalova

(e-mail: skalova@fnplzen.cz)
Department of Pathology,
Medical Faculty Hospital,
Dr. E Benese 13, 305 99 Plzen, Czech Republic

Pieter J. Slootweg

(e-mail: p.slootweg@pathol.umcn.nl)

Department of Pathology,
University Medical Center St. Radboud, HP 437,
P.O. Box 9101, 6500 HB Nijmegen, The Netherlands

Nina Zidar

(e-mail: nina.zidar@mf.uni-lj.si)

Institute of Pathology, Faculty of Medicine,
University of Ljubljana,
Korytkova 2, 1000 Ljubljana, Slovenia

Benign and Potentially Malignant Lesions of the Squamous Epithelium and Squamous Cell Carcinoma

N. Gale · N. Zidar

Contents

1.1	Squamous Cell Papilloma and Related Lesions	2	1.3.4.3	Differential Diagnosis	18
1.1.1	Squamous Cell Papilloma, Verruca Vulgaris, Condyloma Acuminatum and Focal Epithelial Hyperplasia	2	1.3.4.4	Treatment	18
1.1.2	Laryngeal Papillomatosis	3	1.3.4.5	Prognosis	19
1.2	Squamous Intraepithelial Lesions (SILS)	4	1.3.5	Papillary Squamous Cell Carcinoma	19
1.2.1	General Considerations	4	1.3.5.1	Aetiology	19
1.2.2	Terminological Problems	4	1.3.5.2	Pathologic Features	19
1.2.3	Aetiology	5	1.3.5.3	Differential Diagnosis	20
1.2.3.1	Oral Cavity and Oropharynx	5	1.3.5.4	Treatment and Prognosis	20
1.2.3.2	Larynx	5	1.3.6	Basaloid Squamous Cell Carcinoma	20
1.2.4	Clinical Features and Macroscopic Appearances	6	1.3.6.1	Aetiology	20
1.2.4.1	Oral and Oropharyngeal Leukoplakia, Proliferative Verrucous Leukoplakia and Erythroplakia	6	1.3.6.2	Pathologic Features	20
1.2.4.2	Laryngeal and Hypopharyngeal Leukoplakia and Chronic Laryngitis	7	1.3.6.3	Differential Diagnosis	21
1.2.5	Histological Classifications	8	1.3.6.4	Treatment and Prognosis	21
1.2.5.1	WHO Dysplasia System	8	1.3.7	Adenoid Squamous Cell Carcinoma	22
1.2.5.2	The Ljubljana Classification	9	1.3.7.1	Pathologic Features	22
1.2.5.3	Comparison Between the Ljubljana Classification and WHO 2005 Classification	11	1.3.7.2	Differential Diagnosis	22
1.2.6	Biomarkers Related to Malignant Potential of SILS Recognised by Auxiliary and Advanced Molecular Methods	12	1.3.7.3	Treatment and Prognosis	22
1.2.7	Treatment and Prognosis	12	1.3.8	Adenosquamous Carcinoma	23
1.2.7.1	Oral Cavity and Oropharynx	12	1.3.8.1	Aetiology	23
1.2.7.2	Larynx	13	1.3.8.2	Pathologic Features	23
1.3	Invasive Squamous Cell Carcinoma	13	1.3.8.3	Differential Diagnosis	23
1.3.1	Microinvasive Squamous Cell Carcinoma	13	1.3.8.4	Treatment and Prognosis	24
1.3.2	Conventional Squamous Cell Carcinoma	13	1.3.9	Lymphoepithelial Carcinoma	24
1.3.2.1	Aetiology	14	1.3.9.1	Aetiology	24
1.3.2.2	Pathologic Features	14	1.3.9.2	Pathologic Features	24
1.3.2.3	Grading	14	1.3.9.3	Differential Diagnosis	25
1.3.2.4	Invasive Front	15	1.3.9.4	Treatment and Prognosis	25
1.3.2.5	Stromal Reaction	15	1.4	Second Primary Tumours	25
1.3.2.6	Differential Diagnosis	15	1.5	Tumour Spread and Metastasising	25
1.3.2.7	Treatment and Prognosis	15	1.5.1	Invasion of Lymphatic and Blood Vessels	26
1.3.3	Spindle Cell Carcinoma	16	1.5.2	Perineural Invasion	26
1.3.3.1	Aetiology	16	1.5.3	Regional Lymph Node Metastases	26
1.3.3.2	Pathologic Features	16	1.5.3.1	Extracapsular Spread in Lymph Node Metastases	26
1.3.3.3	Differential Diagnosis	16	1.5.3.2	Metastases in the Soft Tissue of the Neck	27
1.3.3.4	Treatment and Prognosis	17	1.5.4	Distant Metastasis	27
1.3.4	Verrucous Carcinoma	17	1.5.5	Micrometastasis	27
1.3.4.1	Aetiology	17	1.6	Molecular Pathology of Squamous Cell Carcinoma	28
1.3.4.2	Pathologic Features	18	1.6.1	Detecting Tumour Cells	28
			1.6.2	Clonal Analysis	28
			1.6.3	Assessment of Risk for Malignant Progression	29
			1.6.4	DNA/RNA Profiling in Predicting Metastatic Disease	29
				References	29

1.1 Squamous Cell Papilloma and Related Lesions

Benign, exophytic, papillary or verrucous lesions of the squamous epithelium of the oral cavity, oropharynx and larynx include similar entities such as squamous cell papilloma (SCP), verruca vulgaris (VV), condyloma acuminatum (CA), and focal epithelial hyperplasia (FEH). However, not every papillary lesion in these areas can be placed into one of the listed categories. It seems that the majority of lesions are similar variants of mucosal proliferations, frequently induced by infections by human papillomaviruses (HPV). They show more or less overlapping clinical and morphological properties, but different biological behaviour, ranging from rather inconspicuous to potentially life threatening. Classification of these changes into infectious (VV, CA, FEH), and neoplastic (SCP), is thought to be rather inconsistent and not well founded. Papillary lesions, except for laryngeal papillomatosis, generally have a favourable outcome.

1.1.1 Squamous Cell Papilloma, Verruca Vulgaris, Condyloma Acuminatum and Focal Epithelial Hyperplasia

ICD-O:8052/0

Squamous cell papilloma, the most frequent papillary lesion of the oral cavity and oropharynx, is usually a single, pedunculated, white or pink lesion, consisting of finger-like mucosal projections (Fig. 1.1). It may occasionally be sessile with a granular or verrucous surface. The lesion, usually smaller than 1 cm, grows rapidly and has predilections for the hard and soft palate and lateral border of the tongue [2, 285]. Multiple sessile lesions in children are characteristic of VV; they are found on the lips, palate and gingiva. CAs are usually larger than SCPs, multiple dome-shaped nodular lesions that mainly appear on the lips and soft palate. FEHs are characterised by multiple sessile or elevated papules, usually distributed over the buccal, labial and tongue mucosa.

Aetiologically, it is extremely difficult to establish their accurate relationship to HPV infection due to variations in tissue samplings, the ethnic and geographic origin of patients, and the use of non-molecular vs. molecular methods for HPV detection with different levels of sensitivity [285, 374]. However, more than 20 HPV genotypes have been detected in oral papillary lesions [285]. SCPs are mainly related to HPV genotypes 6 and 11 [386], VV to HPV genotypes 2, 4, 6, 11, and 16 [142, 244], CA to HPV genotypes 6, 11, 16, and 18 [100, 201] and FEH to HPV genotypes 13 and 32 [285, 286]. Only a few cases of VV have been described in the larynx. Barnes and co-workers studied a single case and unexpectedly found it to contain HPV genotypes 6 and 11 and

not genotypes 2 and 4, which are characteristic of mucosal VV [22]. Other, non-infectious aetiological factors are not well known for oral papillary lesions (Fig. 1.1).

Histologically, SCPs are composed of narrow papillary projections of soft fibrous stroma covered by keratotic or parakeratotic squamous epithelium (Fig. 1.2).

Koilocytosis, the only visible cytopathic effect of HPV infection, which is caused by viral replication in the upper intermediate and superficial zone of the squamous epithelium, is rarely visible in SCPs. VV shows similar histological features, but peripheral papillary projections are usually centrally bend, and koilocytosis and the granular layer are prominent. The characteristics of CAs are obvious: koilocytosis and bulbous rete ridges of the covering epithelium [100, 285]. Koilocytosis, apoptotic bodies and epithelial hyperplasia are significant in FEH [61, 285].

In the differential diagnosis of squamous cell oral papillary lesions, verrucous carcinoma is the most important consideration. An evident downgrowth of bulbous epithelial projections favours a diagnosis of verrucous carcinoma. Oral SCPs in patients with acquired im-

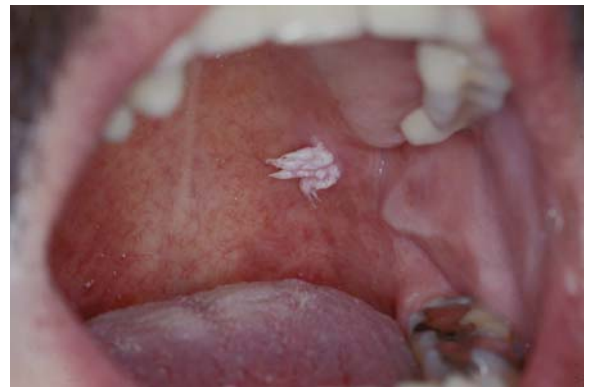

Fig. 1.1. Whitish papillary lesion of the palate. Courtesy of Dr. J. Fischinger, Ljubljana, Slovenia

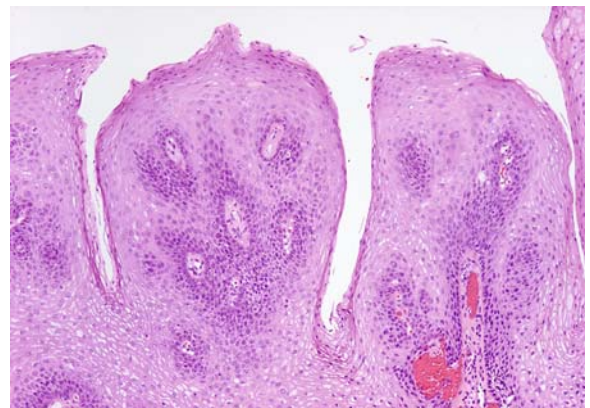


Fig. 1.2. Oral squamous cell papilloma. Projections of fibrovascular stroma are covered by parakeratotic squamous epithelium

munodeficiency syndrome (AIDS) may show a certain amount of epithelial atypia. In these cases SCPs have to be differentiated from squamous cell carcinoma [295].

The treatment for SCPs and related papillary lesions is surgical removal. The infectivity of HPV in SCPs is very low and recurrence uncommon, except in lesions associated with human immunodeficiency virus (HIV) infections. On the other hand, recurrence is more common in CAs. No special treatment is required for FEH unless the lesions are extensive.

1.1.2 Laryngeal Papillomatosis

ICD-O:8060/0

Laryngeal squamous cell papillomas (LSCPs) are the most frustrating benign lesions in the head and neck region. Because of their clinical specificities, such as multiplicity, recurrence and the propensity to spread to adjacent areas, it has been suggested that LSCPs should be renamed recurrent respiratory papillomatosis (RRP) [34, 89, 91, 187].

Recurrent respiratory papillomatosis is aetiologicaly related to HPV [4, 212, 283, 289, 352]. HPV-6 and -11 are the most frequent genotypes associated with RRP (Fig. 1.4b) [4, 126, 212, 284, 289, 330].

Characteristically, LSCPs show a bimodal age distribution: the first peak is before the age of 5 years with no gender predominance; the second peak occurs between the ages of 20 and 40 years with a male to female ratio of 3:2 [34, 87, 91, 189, 216].

Human papillomavirus transmission in children is associated with perinatal transmission from an infected mother to the child [34, 88, 217]. The mode of HPV infection in adults remains unclear. The reactivation of a latent infection acquired perinatally or a postpartum infection with orogenital contacts has been suggested [4, 188]. In contrast to RRP, a solitary keratinising squamous papilloma or papillary keratosis of adults appears not to be associated with viral infection, although it may recur or be occasionally associated with malignant transformation [20].

Recurrent respiratory papillomatosis almost invariably involves the larynx, especially the true and false vocal cords, subglottic areas and ventricles [4]. An extralaryngeal spread may occur successively to the oral cavity, trachea and bronchi. Although RRP has been traditionally divided into juvenile and adult groups [87, 189, 216, 352], the prevailing opinion has recognised the disease as a unified biological entity with differences in clinical courses, caused by HPV genotypes 6 or 11 [28, 126, 189, 218, 321]. For children, multiple and extensive growth with rapid recurrence after excision is characteristic. The small diameter of the airways in children may cause dangerous or even fatal airway obstruction. The clinical course in adults is usually not so dramat-

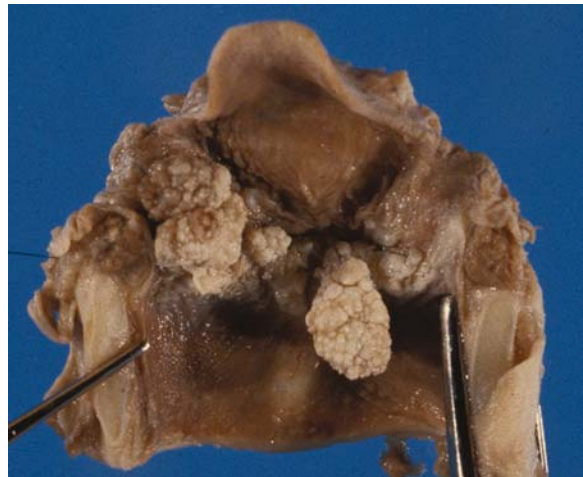

Fig. 1.3. Laryngeal papillomatosis. Numerous clusters of papillomas obliterate the laryngeal lumen

ic, although RRP can be aggressive with multiple recurrences [43, 284]. Most children present with dysphonia and stridor, and less commonly with a chronic cough, recurrent pneumonia, dyspnoea, and acute life-threatening events [34, 43, 88]. Affected adults present mostly with dysphonia and hoarseness [43, 181].

Grossly, papillomas are exophytic, branching, pedunculate or sessile masses, pink or reddish in colour, with a finely lobulated surface, presenting either singly or in clusters (Fig. 1.3).

Histologically, RRP is composed of finger-like projections of the squamous epithelium, covering thin fibrovascular cores. A basal and parabasal hyperplasia of the squamous epithelium is most frequently seen, usually extending up to the mid-portion (Fig. 1.4a). Mitotic features may be prominent within this area. Irregularly scattered clusters of koilocytes are seen in the upper part of the epithelium. Epithelial changes, such as mild to moderate nuclear atypia and hyperchromatism, increased nuclear cytoplasmic ratio, increased mitotic activity with pathological features, and prominent surface keratinisation are rarely found in RRP [181].

Various lesions with a papillary structure must be considered in the differential diagnosis of RRP. In verrucous carcinomas, the squamous fronds are thicker and are covered by a prominent keratotic layer, bulbous rete pegs infiltrate fibrous stroma in a blunt, pushing manner and koilocytosis is usually absent. The papillary squamous carcinoma usually shows an architectonic similarity to RRP. In contrast to RRP, papillary structures in the papillary squamous carcinoma are covered by a clearly neoplastic epithelium showing invasive growth.

The clinical course of RRP is unpredictable, characterised by periods of active disease and remissions. HPV present in apparently normal mucosa serves as a virus reservoir responsible for repeated recurrence of papillo-

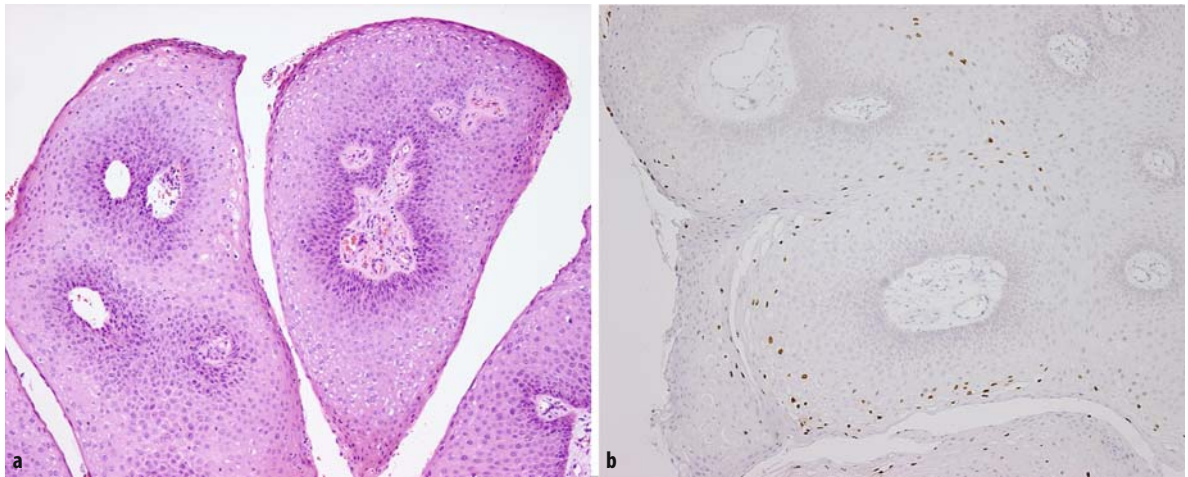


Fig. 1.4. Laryngeal papillomatosis. **a** Branches of laryngeal papilloma are covered with hyperplastic squamous cell epithelium. Numerous koilocytes are seen in the upper part of the epithelium.

b Positive in situ hybridisation signal for HPV genotypes 6 and 11 in an adult laryngeal papilloma

mas [301, 330]. The presence of RRP in the neonatal period is a negative prognostic factor with a greater need for tracheotomy and likelihood of mortality [88]. One report on the spontaneous disappearance of the disease, especially during puberty, has not been further supported [4]. Increased histologic changes (atypia of epithelial cells) are reported to be associated with increased severity and recurrence of RRP [75, 288]. Others have suggested that the histologic changes of RRP are not a good predictor of eventual malignant transformation [133].

Malignant transformation occurs mainly in patients with a history of previous irradiation or heavy smoking [290], and rarely without any predisposing factors [143, 296]. In children, carcinomas preferentially appear in the bronchopulmonary tree, and in adults in the larynx [141]. HPV genotype 11 is assumed to be most frequently associated with malignant transformation of RRP [70, 206, 218, 290], followed by HPV-16 [92] and HPV-18 [311].

The overall mortality rate of patients with RRP ranges from 4 to 14% [20], and is mostly causally related to asphyxia, pulmonary complications and cancer development [17, 20, 338].

1.2 Squamous Intraepithelial Lesions

1.2.1 General Considerations

Histological changes of the squamous epithelium that occur in the process of oral, oro- and hypopharyngeal and laryngeal carcinogenesis, are cumulatively designated squamous intraepithelial lesions (SILs). The term SILs has been proposed as an all-embracing ex-

pression of the whole spectrum of epithelial changes ranging from squamous cell hyperplasia to carcinoma in situ.

It has been widely accepted that the transition from normal mucosa to invasive squamous cell carcinoma (SCC) is a comprehensive and multistage process, causally related to a progressive accumulation of genetic changes leading to the selection of a clonal population of transformed epithelial cells [144]. Between six and ten independent genetic events are required for progression to SCC [300]. In their evolution, some cases of SIL are self-limiting and reversible, some persist, and some of them progress to SCC in spite of treatment [78]. Particular interest has been focused on potentially malignant or risky (precancerous) lesions [48, 181, 200, 223]. These lesions have been defined as histomorphological changes of the squamous epithelium from which invasive cancer develops in a higher percentage than from other epithelial lesions [125, 179, 181, 223]. A fundamental enigma of potentially malignant lesions remains when and under what conditions these changes turn to malignant growth [180, 223].

Various aetiological, clinical, histological and molecular genetic aspects are significant for the evaluation, adequate treatment and predictive behaviour of SILs, particularly of potentially malignant lesions.

1.2.2 Terminological Problems

An exact and uniform terminology of SILs is a prerequisite for successful cooperation among pathologists as well as adequate understanding with clinicians. A considerable overlapping of clinical and histological terms relating to SILs has been widely noticed due to inade-

quate definitions in the past. In an attempt to avoid such misunderstandings, the most inconsistently used terms are discussed here and their use recommended strictly within the scope of definitions.

Various suggestions have been made that the terms “precancerous”, “pre-malignant” or “precursor” lesions should be replaced with the expression “potentially malignant” signifying only an increased possibility and not necessarily a transition to malignant growth [125, 150, 181, 223, 297].

The most controversial term remains leukoplakia. In the oral cavity, it has only a clinical meaning: white plaque that cannot be scraped off and cannot be given a specific diagnosis [14]. Over the decades, the definition of leukoplakia has changed considerably and has come to be properly called *gallimaufry* [342]. It has been generally accepted that leukoplakia should be used only as a clinical term without a specific histopathological connotation. Analogically, erythroplakia is a clinical term defining a red lesion that cannot be identified as another, specific lesion. Both expressions have also been applied for clinical use in the pharynx and larynx as merely clinical terms without consideration of their aetiology and histological features [181].

Keratosis is a histological term and denotes an increased amount of keratin on the surface of the squamous epithelium, often accompanied by granular cell layer [180, 181]. However, keratosis has been also used as a common term for classifying different grades of SIL, which does not seem to be appropriate, since not all cases of SIL display keratinising epithelium.

Dysplasia is a widely used histological term directly transferred from the uterine cervix to oral and laryngeal pathology indicating the architectural disturbance of squamous epithelium accompanied by cytologic atypia; it is divided into three groups: mild, moderate and severe [381]. Dysplasia has been replaced in the last two decades with new invented classifications, such as keratosis [20, 78], squamous intraepithelial neoplasia [79], oral intraepithelial neoplasia [200], laryngeal intraepithelial neoplasia [122], etc. to list only the most frequently used terminologies. These classifications contain only additional synonyms for dysplasia. They do not enhance our understanding of classification problems, but introduce other confusing terms for clinicians to deal with [20]. The only classification not based on cervical dysplasia or the subsequently introduced cervical intraepithelial system, is the Ljubljana classification of laryngeal SILs. The Ljubljana classification recognises four grades: squamous (simple) hyperplasia and basal and parabasal cell hyperplasia (abnormal hyperplasia) are benign categories; atypical hyperplasia (risky epithelium) is potentially malignant; and carcinoma in situ is a malignant lesion [125, 150, 183, 242].

1.2.3 Aetiology

1.2.3.1 Oral Cavity and Oropharynx

Squamous intraepithelial lesions in the oral cavity and oropharynx are associated with tobacco, whether smoked, chewed or used as snuff, which seems to be the major carcinogen in this region [165, 171, 247, 298, 316, 389]. Smoking 20 or more cigarettes per day, particularly non-filtered, as well as drinking alcohol, particularly fortified wines and spirits, is an important risk for the development of oral dysplasia in the European population. Tobacco is a stronger independent risk factor for oral SILs than alcohol [165]. The use of smokeless tobacco in the western world has a rather lower correlation with oral precancerous and cancerous lesions than south-east Asia, where chewing habits, including betel quid, strongly correlate with oral precancer and cancer development [298]. Alcohol has been considered the second most important risk factor for oral and pharyngeal cancer development [247], and its synergistic effect with tobacco is particularly evident [170, 171]. The risk of the development of oral dysplasia is increased six to 15 times in smokers and heavy drinkers compared with non-smokers and non-drinkers [371].

The significance of *Candida albicans* as a possible aetiological factor of oral leukoplakia (OL) remains disputable [24, 303], as does the role of HPV in oral carcinogenesis. The involvement of HPV in the initiation and progression of oral neoplasia is still a matter of debate. Different studies have generated conflicting results concerning the prevalence of HPV, ranging from 0 to 90% [45, 345, 386]. The discrepancy observed may be related to the varying sensitivity of the methodologies applied for HPV detection and the epidemiologic factors of the patient groups examined. A recent study on 59 oral SCCs showed that the occasional findings of HPV DNA (8.4%) may be the result of incidental HPV colonisation of the oral mucosa rather than viral infection. In the same study, HPV DNA was detected in 6.6% in the control group of healthy people who matched the subjects with oral SCCs in various clinical parameters. HPVs, therefore, probably play a limited role in the aetiopathogenesis of the majority of oral SCCs [186]. In contrast, SCCs of the tonsil seem to be strongly aetiologically linked to the HPV infection [97, 214].

1.2.3.2 Larynx

Laryngeal SILs, like their oral counterparts, are most likely related to cigarette smoking and alcohol abuse, and especially a combination of these two [38, 55, 86, 115, 138, 228, 249, 252, 351]. The risk of SIL was found

to increase with the duration of smoking, the quality of tobacco, the practice of deep inhalation and the inability to stop smoking, and inversely with the age of the patient at the start of smoking.

Additional aetiological factors are: industrial pollution, chronic infections, voice abuse, obstruction of the upper respiratory tract, vitamin deficiency, and hormonal disturbance [115, 181, 184, 185, 228, 276]. The role of HPV infection in laryngeal carcinogenesis remains unclarified [331]. The prevalence of HPV infection in laryngeal carcinomas varies significantly among various studies, ranging from 0 to 54.1% [346]. The overall prevalence of HPV infection in nine studies of SILs [16, 54, 118, 128, 136, 137, 219, 281, 302] was found to be 12.4%. However, HPV DNA was also detected in a clinically and histologically normal larynx in 12–25% of individuals [267, 302]. Definite evidence of an aetiological role of HPV in SIL, at least at present, is lacking, and HPV infection in SILs may represent an incidental HPV colonisation rather than true infection of the laryngeal mucosa.

1.2.4 Clinical Features and Macroscopic Appearances

1.2.4.1 Oral and Oropharyngeal Leukoplakia, Proliferative Verrucous Leukoplakia and Erythroplakia

Both oral leukoplakia (OL) and oral erythroplakia (OE) have generally been defined as premalignant lesions, mainly on the basis of their clinical appearance [14, 371]. It seems more reasonable to disregard clinically based premalignant connotations, especially for OL, without knowing the histological features [200, 297, 342]. The risk of OL becoming malignant is relatively low and quite unpredictable [342]. In contrast, OE is a much more worrisome lesion than OL and always requires histological evaluation.

Oral leukoplakia is a clinical diagnosis of exclusion. If any oral white patch can be diagnosed as some other condition, such as candidiasis, leukoedema, white sponge naevus, lichen planus, frictional keratosis, nicotine stomatitis, etc. then the lesion should not be considered a case of OL [263]. The white appearance of OL is most often related to an increase in the surface keratin layer. OL affects approximately 3% of white adults [46]. It is most frequently seen in middle-aged and older men with an increasing prevalence with age, reaching 8% in men over 70 years [48, 49]. However, recent studies reported a tendency towards a lower prevalence of OL, compared with the past, which might be the result of the massive public health education campaign against tobacco [314].

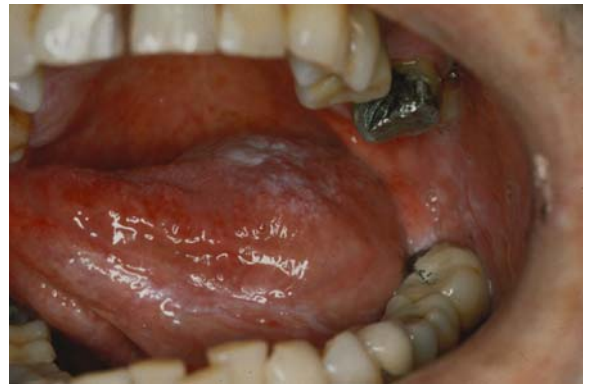

Fig. 1.5. Leukoplakia of the dorsal tongue. The microscopic diagnosis was basal and parabasal cell hyperplasia. Courtesy of Dr. J. Fischinger, Ljubljana, Slovenia

The most common sites of lesions are the buccal and alveolar mucosa and the lower lip. Lesions in the floor of the mouth, lateral tongue and lower lip more often show epithelial atypia or even malignant growth [263]. A consensus has been attained to divide OL clinically into homogenous and non-homogenous types [14]. The former type is characterised as a uniform, flat, thin lesion with a smooth or wrinkled surface showing shallow cracks, but a constant texture throughout (Fig 1.5). The latter type is defined as a predominantly white or white and red lesion that may be irregularly flat, nodular or exophytic. Nodular lesions have slightly raised rounded, red and/or whitish excrescences. Exophytic lesions have irregular blunt or sharp projections [14]. The term non-homogenous is applicable to the aspect of both colour (a mixed white and red lesion) and texture (exophytic, papillary or verrucous) of the lesions (Fig. 1.6).

With regard to verrucous lesions, there are no reproducible clinical criteria to distinguish among verrucous hyperplasia, proliferative verrucous hyperplasia and verrucous carcinoma [371]. Any persisting lesion with no apparent aetiology should be considered suspicious [235]. A period of 2–4 weeks seems acceptable to observe the regression or disappearance of the OL after the elimination of possible causative factors. After that time a biopsy is obligatory [371].

Proliferative verrucous hyperplasia (PVL) is a special type of OL with a proven high risk of becoming malignant [32, 322]. Initially, it is relatively benign-looking, a homogenous solitary patch that turns gradually to an exophytic, diffuse or multifocal, progressive and irreversible lesion [32, 322, 390]. The diagnosis is made retrospectively after evidence of a progressive clinical course, accompanied by a particular deterioration in histological changes. Women predominate over men in PVL by 4 to 1, with a mean age at diagnosis of 62 years [322]. The epidemiology of PVL

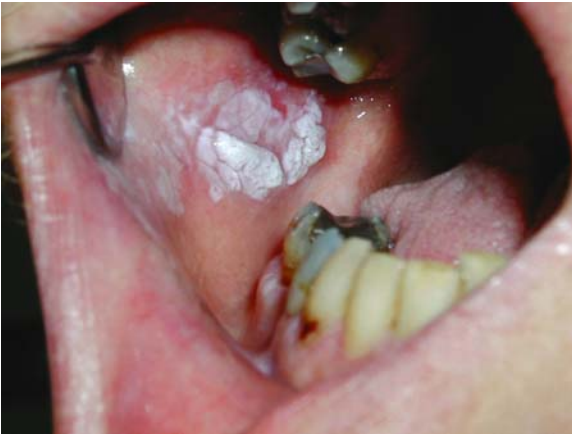

Fig. 1.6. Erythroleukoplakia of the buccal mucosa. The microscopic diagnosis was atypical hyperplasia. Courtesy of Dr. D. Dovšak, Ljubljana, Slovenia

does not highlight a particular causal agent and the lesion would appear to be multifactorial [114, 342]. The relatively common absence of well-known risk factors associated with oral cancer and a preponderance of elderly female patients, may indicate a different pathogenesis of PVL-related, compared with non-PVL-related, cancer [32]. It appears most frequently in the buccal mucosa, followed by the gingiva, tongue, and floor of the mouth [322]. The severity of histologic features correlates with duration of lesion, from benign keratotic lesion to verrucous hyperplasia, and finally, up to one of three forms of SCC: verrucous, conventional or papillary types [32]. PVL should be considered a possible diagnosis when a specific discrepancy between bland histological features and aggressive clinical course is established [114]. Whether verrucous hyperplasia forms a separate stage in this series of histological features shown by PVL is debatable, as there seems to be considerable histological overlap between this lesion and verrucous carcinoma. Thus, there are no convincing arguments that verrucous hyperplasia is anything other than a variant of verrucous carcinoma [327, 371, 390]. A mean time of 7.7 years was found from the diagnosis of PVL to cancer development in 70.3% of patients [322]. The treatment of PVL continues to be an unsolved problem with high rates of recurrence, since total excision is rarely possible because of the widespread growth [32].

Oral erythroplakia is much less common than OL. OE occurs most frequently in older men as a red macula or plaque with a soft, velvety texture, quite sharply demarcated and regular in coloration. The disease was found to have no apparent sex predilection and is most frequent in the 6th and 7th decades [319].

The floor of the mouth, the ventral and lateral tongue, the retromolar region and the soft palate are the most

frequently involved sites [47, 263]. OEs that are intermixed with white areas are called erythroleukoplakia or speckled mucosa and are believed to behave similarly to pure OE. The red appearance of OE may be related to an increase in subepithelial blood vessels, a lack of surface keratin and thinness of the epithelium. Prior to a clinical diagnosis of OE numerous entities should be excluded, such as: median rhomboid glossitis, all kinds of injuries, infectious and allergic lesions, haemorrhages, vessel tumours, Wegener's granulomatosis, etc. [47]. Although OE is a rare lesion, it is much more likely to show dysplasia or carcinoma. Shafer and Waldron reviewed their biopsy experiences with 65 cases of OE: 51% of cases showed invasive SCC, 40% were carcinomas in situ or severe dysplasia, and the remaining 9% showed mild to moderate dysplasia [319]. In all red lesions of the oral mucosa that do not regress within 2 weeks of the removal of possible aetiological factors, biopsy is, therefore, mandatory.

1.2.4.2 Laryngeal and Hypopharyngeal Leukoplakia and Chronic Laryngitis

Squamous intraepithelial lesions appear mainly along the true vocal cords, and rarely in other parts of the larynx, such as the epiglottis. Two-thirds of vocal cord lesions are bilateral [48, 178, 181]. They can extend over the free edge of the vocal cord to its subglottic surface. An origin in, or extension along the upper surface of the vocal cord is less common [181, 194]. The commissures are rarely involved [48]. Hypopharyngeal lesions are rarely found and are poorly defined [364].

Laryngeal SILs do not have a single distinctive or characteristic clinical appearance and are variously described as leukoplakia, chronic hyperplastic laryngitis or rarely erythroplakia. A circumscribed thickening of the mucosa covered by whitish patches (Fig. 1.7), or an irregularly growing, well-defined warty plaque may be seen. A speckled appearance of lesions can also be present, caused by unequal thickness of the keratin layer.

However, the lesions are commonly more diffuse, with a thickened appearance, and occupy a large part of one or both vocal cords (Fig. 1.8). A few leukoplakic lesions are ulcerated (6.5%) or combined with erythroplakia (15%) [48]. Leukoplakic lesions, in contrast to erythroplakic ones, tend to be well demarcated.

The macroscopic features of hypopharyngeal and laryngeal SILs are not as well defined as their counterparts in the oral cavity and their relative importance is not generally accepted. Most patients with SILs present with a history of a few months or more of symptoms; an average duration of 7 months has been reported [48]. Symptoms depend on the location and sever-

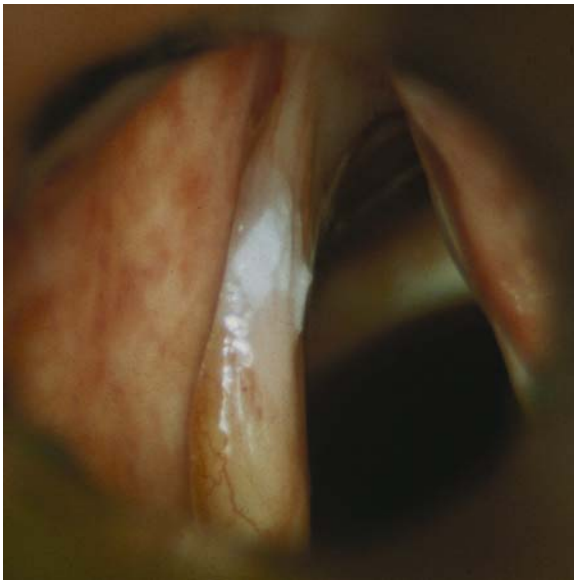


Fig. 1.7. Leukoplakia of the left vocal cord. The microscopic diagnosis was squamous cell hyperplasia

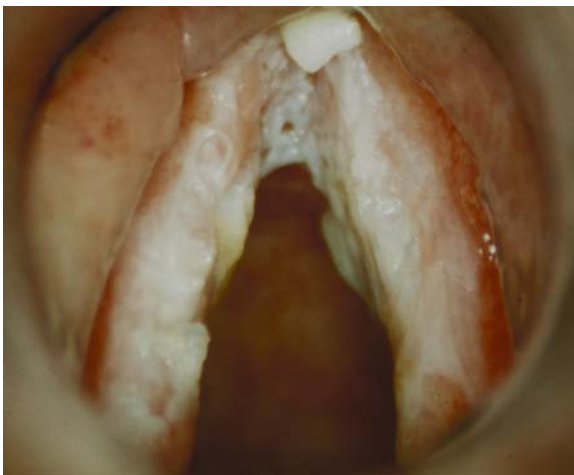

Fig. 1.8. Chronic laryngitis. Both vocal cords are irregularly thickened and covered by whitish plaques. The microscopic diagnosis was atypical hyperplasia

ity of the disease. Patients may complain of fluctuating hoarseness, throat irritation, sore throat, and/or a chronic cough.

1.2.5 Histological Classifications

Traditional light microscopic examination, in spite of certain subjectivity in interpretation, remains the most reliable method for determining an accurate diagnosis of a SIL. The clinical validity of any histological grad-

ing system depends on the degree of accord with the biological behaviour of the lesions. Worldwide, there are no generally accepted criteria for a histological grading system in the head and neck region with regard to severity of SILs and propensity to malignant transformation. It is, therefore, not surprising to find in the literature more than 20 classifications of laryngeal SILs [39, 125, 150, 180, 181, 242]. The majority of the classifications have followed similar criteria to those in common use for epithelial lesions of the uterine cervix, such as the dysplasia or cervical intraepithelial neoplasia systems.

The World Health Organisation (WHO) has recently readopted the dysplasia system for classifying SILs of the oral cavity and larynx [381]. However, due to different standpoints concerning this important problem of oral and laryngeal carcinogenesis, the dysplasia system was reviewed simultaneously with two additional classifications: the squamous intraepithelial neoplasia system and the Ljubljana classification [381]. Here, the WHO dysplasia system and the Ljubljana classification will be reviewed.

1.2.5.1 WHO Dysplasia System

Precursor lesions are designated as altered epithelium with an increased likelihood of progression to SCC. The altered epithelium shows a variety of architectural and cytological changes that have been grouped under the term dysplasia. The following architectural changes are required to diagnose epithelial dysplasia: irregular epithelial stratification, loss of polarity of basal cells, drop-shaped rete ridges, increased number of mitoses, superficial mitoses, dyskeratosis and keratin pearls within rete pegs. The cytological abnormalities of dysplasia are: anisonucleosis, nuclear pleomorphism, anisocytosis, cellular pleomorphism, increased nuclear cytoplasmic ratio, atypical mitotic figures, increased number and size of nucleoli, and hyperchromatism.

The dysplasia system includes the following categories:

A. Hyperplasia with increased number of cells. This may be in the spinous layer (acanthosis) or in the basal and parabasal cell layer (basal cell hyperplasia). The architecture of the epithelium is preserved, and there is no cellular atypia.

B. Dysplasia with three grades:

1. Mild dysplasia: architectural disturbance is limited to the lower third of the epithelium, accompanied by cytological atypia.
2. Moderate dysplasia: architectural disturbance extends into the middle third of the epithelium, accompanied by an upgraded degree of cytological atypia.

3. Severe dysplasia: architectural disturbance is greater than two-thirds of the epithelium with associated cytological atypia or architectural disturbance in the middle third of the epithelium with sufficient cytological atypia to upgrade from moderate to severe dysplasia.

C. **Carcinoma in situ:** full or almost full thickness of the epithelium shows architectural disturbance, accompanied by pronounced cytological atypia. Atypical mitotic figures and abnormal superficial mitoses are present [381].

1.2.5.2 The Ljubljana Classification

The Ljubljana grading system does not follow the criteria used for cervical SILs, but was devised to cater for the special clinical and histological problems related to laryngeal conditions. Briefly, the different aetiology of SILs in the upper aerodigestive tract in comparison with cervical lesions probably triggers a different pathway of genetic events from those established in cervical lesions. Additionally, different anatomic specificities, various clinical approaches to obtaining adequate biopsy specimens, as well as different treatment modalities for high-risk lesions of cervical and upper aerodigestive tract SILs, were the basis for establishing the Ljubljana classification more than three decades ago and this was further formulated in 1997 by the working group on SILs of the European Society of Pathology [125, 150, 178, 181, 182, 183, 242].

The main feature of the Ljubljana classification is that it separates the group of lesions with a minimal risk of progression to invasive carcinoma, including squamous and basal-parabasal cell hyperplasia on the one hand, and the potentially malignant group, i.e. those lesions more likely to progress to invasive carcinoma (atypical hyperplasia or risky epithelium), on the other. Carcinoma in situ is considered a separate entity within the spectrum of SILs.

The general principles of the classification presented, which hold for all of its grades, are the following: the epithelium is generally thickened, although in a minority of cases the epithelium may show areas of diminished thickness, but even these cases show basal-parabasal cell hyperplasia; the basement membrane is generally preserved at all grades, with no definite evidence of even minimal invasion. The presence of a surface keratin layer, which is often present in all grades of SIL, is of no importance in this classification.

Group of Reactive Lesions with a Minimal Risk of Progression to Invasive Carcinoma

Squamous (simple) hyperplasia is a benign hyperplastic process with retention of the normal architectural and cytological pattern of the squamous epithelium.

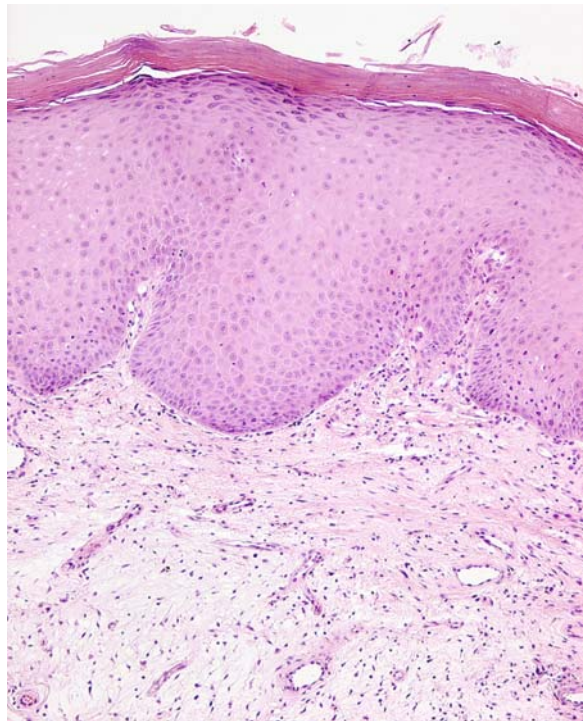


Fig. 1.9. Squamous cell hyperplasia. Thickened epithelium shows increased prickle cell layer, the basal layer remains unchanged

The epithelium is thickened as a result of an increased prickle cell layer. The cells of the basal and parabasal region, which comprise one to three layers, remain unchanged. There is no cellular atypia; infrequent, regular mitoses are seen in the basal layer (Fig. 1.9).

Basal and parabasal cell hyperplasia (abnormal hyperplasia) can be defined as a benign augmentation of basal and parabasal cells in the lower part of the epithelial layer while the upper part, containing regular prickle cells, remains unchanged.

Stratification of the laryngeal squamous epithelium, characterised by its layered construction, is seen as a smooth transition from an epithelial layer composed of basal cells that are aligned perpendicular to the basement membrane to the more superficial part in which the prickle cells are orientated horizontal to the basement membrane. Thickened epithelium consists of an increased number of basal and parabasal cells occupying up to one-half or occasionally slightly more of the entire epithelium. These cells do not show significant nuclear changes and are aligned perpendicularly with preservation of normal polarity and organisation. Basal and parabasal cells contain moderately enlarged nuclei and uniformly distributed chromatin, slightly more cytoplasm than those of the basal layer and, in addition, few or no intercellular prickles or bridges. Rare, regular mitoses may be seen, always located in or near the basal layer. Less than 5% of epithelial cells show characteristics of

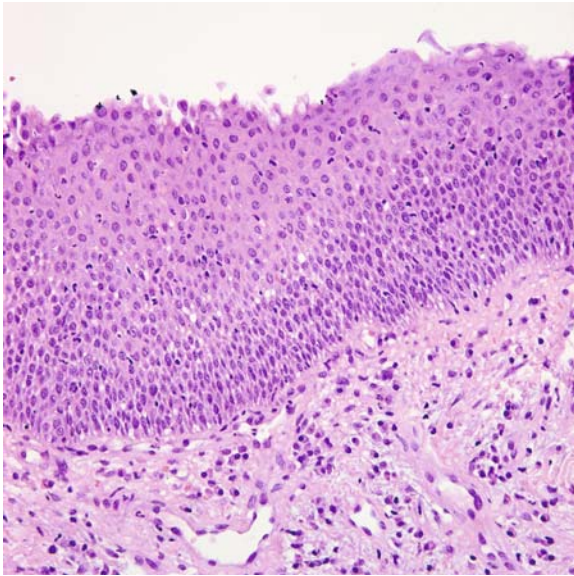


Fig. 1.10. Basal and parabasal cell hyperplasia. Augmented cells of the basal and parabasal cell layer extend up to the midportion of the epithelium. Occasional mitoses are seen in the lower part of the epithelium

dyskeratosis, a premature and abnormal keratinisation of individual cells or groups of cells that have no prickles and strongly eosinophilic cytoplasm (Fig. 1.10).

Group of Potentially Malignant Lesions

Atypical hyperplasia (risky epithelium), considered to be a potentially malignant lesion, i.e. a lesion with a definitely increased risk of progressing to invasive carcinoma, is characterised by preservation of stratification in the epithelium, by alterations of epithelial cells with mild to moderate degrees of cytological atypia occupying the lower half or more of the epithelial thickness, and by increased mitotic activity.

Stratification is still preserved in the epithelium. There is an increased number of epithelial cells that are frequently orientated perpendicular to the basement membrane. The nuclei of many of them show mild to moderate changes of atypia, such as: enlargement, irregular contours, and marked variations in staining intensity with frequent hyperchromaticity; nucleoli are increased in number and size, showing enhanced staining characteristics. The nuclear/cytoplasmic ratio is generally increased. This type of epithelial cell may occupy the lower half, or more of the entire epithelial thickness. Mitoses are moderately increased. They are usually found in the lower two-thirds of the epithelium, although they may occasionally appear at a higher level. Mitoses are rarely, if ever, abnormal. Dyskeratotic cells are frequent within the entire epithelium. Apoptotic cells may be present; they are smaller in size and with hyaline eosinophilic cytoplasm and conspicuous nuclear chromatin

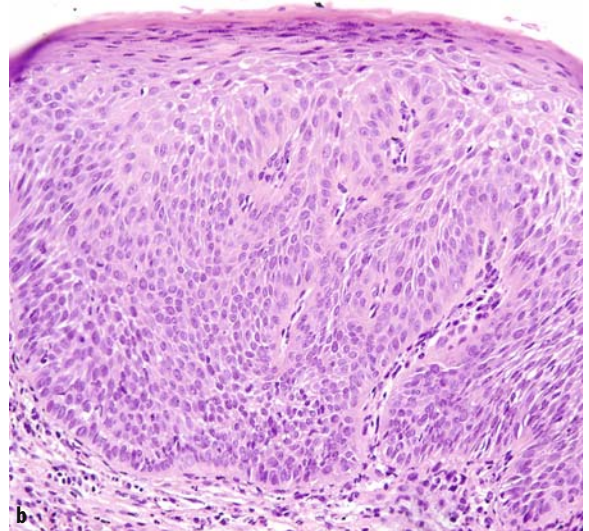
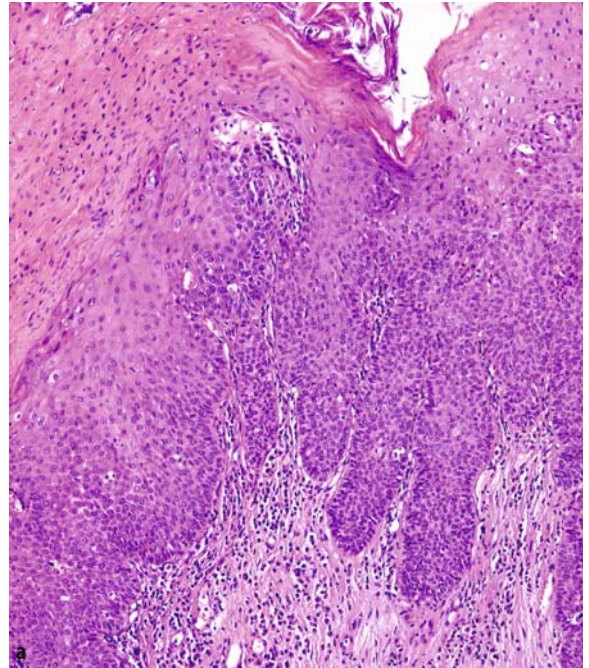


Fig. 1.11. **a** Atypical hyperplasia. Augmented epithelial cells showing mild to moderate grades of atypia, preserved stratification and some regular mitoses. **b** Augmented epithelial cells with increased nuclear/cytoplasmic ratio and some regular mitoses. The cells are aligned perpendicularly to the basement membrane

condensation or nuclei crumbled into smaller fragments (Fig. 1.11). Two subdivisions of atypical hyperplasia are recognised: (a) The more frequent “basal cell type” with no intercellular prickles and no cytoplasmic eosinophilia, and the cells aligned perpendicularly or at an acute angle to the basement membrane, and (b) The less frequent “spinous cell type” (analogous to so-called “keratinising dysplasia” by Crissman and Zarbo [79]) with intercellular prickles and increased cytoplasmic eosino-

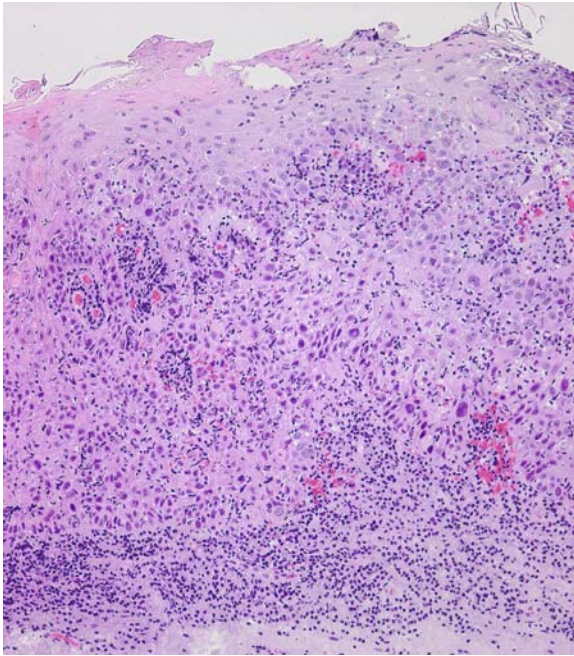


Fig. 1.12. Carcinoma in situ. The lesion shows loss of stratification, malignant cells with increased mitotic activity replace the entire epithelial thickness

philia. The cells may be aligned horizontal to the basement membrane.

Group of Actually Malignant Lesions

The term squamous cell carcinoma in situ (CIS) is reserved for lesions showing the features of carcinoma without invasion. Three distinct morphologic characteristics are usually present:

- Loss of stratification or maturation of the epithelium as a whole; however, the surface of the epithelium may be covered by one or at most a few layers of compressed, horizontally stratified, and sometimes keratinised cells.
- Epithelial cells may show all the cytologic characteristics of invasive squamous cell carcinoma.
- Mitotic figures are usually markedly increased throughout the whole epithelium, often more than

five per high power field. Abnormal mitoses are frequently seen. Hyaline bodies and dyskeratotic cells are present, often in high numbers (Fig. 1.12).

In CIS, as in atypical hyperplasia, the lesion may fall within one or the other of the two subdivisions of atypical hyperplasia:

- Basal cell type with no intercellular prickles and no cytoplasmic eosinophilia;
- Spinous cell type with intercellular prickles and increased cytoplasmic eosinophilia [125, 150, 242].

In the differential diagnosis of SILs, regenerative changes of the squamous epithelium after trauma, inflammation or irradiation therapy may simulate various cyto-architectural disturbances resembling different grades of SILs.

Clinical data are always of considerable help in distinguishing different grades of SILs from regenerative processes in which epithelial abnormalities are generally less pronounced than in atypical hyperplasia or CIS, and atypical mitoses are almost never present.

1.2.5.3 Comparison Between the Ljubljana Classification and WHO 2005 Classification

Comparing the two classifications, one should be aware that there is no simple relationship and overlapping between the WHO 2005 and the Ljubljana classifications (Table 1.1).

The group of the so-called benign lesions, including squamous and basal-parabasal cell (abnormal) hyperplasia is comparable in both classifications. Disagreement starts with the presumption of the WHO 2005 classification [381] that each grade of the whole series of dysplasia is considered to be a precursor or potentially malignant lesion. Histologically, however, there are some similarities between the basal and parabasal cell hyperplasia of the Ljubljana classification and the mild dysplasia of the WHO 2005 [381]. Mild dysplasia, in contrast to basal and parabasal cell hyperplasia, was classified as the initial grade within a potentially malignant group,

Table 1.1. Comparison between two classifications of squamous intraepithelial lesions: WHO 2005 and Ljubljana classification [381]

WHO dysplasia system	Ljubljana classification of squamous intraepithelial lesions
Hyperplasia*	Squamous cell hyperplasia
Mild dysplasia	Hyperplasia of basal and parabasal cell layers
Moderate dysplasia	Atypical hyperplasia – risky epithelium
Severe dysplasia	Carcinoma in situ
Carcinoma in situ	

*Hyperplasia may be in the spinous and/or in the basal/parabasal cell layers

whereas in the Ljubljana classification, basal-parabasal hyperplasia is considered a benign lesion with a minimum risk of malignant transformation. Atypical hyperplasia of the Ljubljana classification is similar to moderate dysplasia, but also partially includes severe dysplasia. The analogy is, thus, only approximate [150]. Carcinoma in situ is equal to the carcinoma in situ of the WHO 2005 classification. However, some cases of severe dysplasia would fall into the category of carcinoma in situ of the Ljubljana classification, and the analogy is again only approximate [150].

The Ljubljana classification was devised to satisfy the specific clinical and histological requirements of the diagnosis of SILs in the regions of the upper aerodigestive tract where common aetiological, clinical and morphological aspects are found. Recently, the Ljubljana classification has also been successfully applied to oral SILs, which share the same aetiology, and similar clinical and histological specificities with laryngeal lesions [225].

Over the many years in practical use, it has been found to be more precise for daily diagnostic work than other grading systems and provides data that have been shown to be closely correlated with the biological behaviour of the lesions [125].

1.2.6 Biomarkers Related to Malignant Potential of SILs Recognised by Auxiliary and Advanced Molecular Methods

A genetic progression model with specific genetic alterations for different stages of laryngeal SILs has increased the possibilities of recognising potential biomarkers in correlation with histopathologic changes that might signal a stage of carcinogenesis from initiation to invasive growth [60]. This model has revealed that both oncogenes and tumour suppressor genes are involved in tumour progression with a distinct order of progression starting with loss of heterozygosity (LOH) at 9p21 and 3p21 as the earliest detectable events, followed by 17p13 loss. Additional genetic alterations, which tend to occur in severe dysplasia (atypical hyperplasia), or even in SCC, are cyclin D1 amplification, pTEN inactivation, and LOH at 11q13, 13q21, 14q32, 6p, 8q, 4q27, and 10q23 [60, 117]. For some chromosomal areas involved the target genes have been recognised, such as tumour suppressor genes p16 at 9p21, p53 at 17p13, and cyclin D1 oncogene at 11q13 [60, 117, 381].

A similar genetic basis, associated with histopathological stages, has been designed for oral carcinogenesis, based on LOH, gene mutations and telomerase reactivation [231]. Recent approaches to identifying genetic changes as predictors of malignancy risk for low grade oral dysplasia show that LOH at 3p and 9p could serve

as an initial screening marker for the cancer risk of early lesions [306]. Additionally, telomerase reactivation has been shown to be an early event of laryngeal and oral carcinogenesis, already detectable at the stage of atypical hyperplasia in 75% and 43% respectively. However, for progression towards invasive SCC other genetic events seem to be necessary [225, 226].

Special attention has been recently devoted to molecular genetic studies of potentially malignant lesions in an attempt to establish their risk of progression more reliably than static conventional histological diagnosis enables. In terms of prognostic value, genetic events such as LOH of 3p, 9p21 and 17q13 and DNA aneuploidy are considered a substantial risk of malignant transformation [344, 381].

Predictive factors of different grades of SILs in head and neck carcinogenesis have also been widely studied at the level of abnormal protein expression of the oncogenes and tumour suppressor genes involved. Overexpression of p16, p21waf1, p27, p53, epidermal growth factor receptor (EGFR), and cyclin D1 proteins have been examined in an attempt to increase diagnostic sensitivity and predictive values of SILs [12, 64, 102, 127, 156, 162, 169, 199, 251, 255, 282, 363, 369].

Additionally, various proliferation and differentiation markers, including keratins and carbohydrate antigens, are widely used as predictive factors for determining the biological behaviour of oral and laryngeal SILs [297]. The detection of proliferative activity, such as the counting of nucleolar organiser regions (Ag-NORs) and immunohistochemical labelling for proliferating cell nuclear antigen (PCNA) and Ki-67 antigen are useful adjuncts to light microscopy and may provide predictive information on the clinical outcome of SILs in the larynx and oral cavity [73, 129, 181, 251, 279, 357, 394].

The expression of lectins and cytokeratins, particularly those of low molecular weight, has been shown to be a good marker of epithelial maturation in normal and pathologic conditions, and may thus facilitate a more precise evaluation of SIL [152, 182, 229, 365].

1.2.7 Treatment and Prognosis

1.2.7.1 Oral Cavity and Oropharynx

Surgical excision, performed either classically with a cold knife or a CO₂ laser, is the treatment of choice for oral SILs. However, in highly suspicious lesions as in OE on the floor of the mouth, an incisional biopsy is always the preferred method for establishing a microscopic diagnosis. Surgical treatment is only the beginning of therapy for such lesions; the long-term follow-

up and avoidance of exposure to known risk factors is important due to the risk of malignant transformation [47, 263, 334]. Recurrences of high-risk SILs are not infrequent events, being reported in 18% of lesions that had been excised with free surgical margins [366]. If the size or other clinical obstacles make surgical treatment of oral SILs difficult, various antioxidants, such as beta-carotene and the retinoids, are most commonly used for chemoprevention [191].

The occurrence of the higher grades (moderate and severe dysplasia, atypical hyperplasia) of oral SILs is considered the most important risk of SCC development. The reported frequency of malignant transformation of OL ranges from 3.1% [373] to 17.5% [323]. Several locations of OL, together with histological abnormalities, are linked with higher malignant transformation. The floor of the mouth is, thus, the highest risk site, followed by the tongue and lip [319].

The clinical appearance of non-homogenous or speckled OL may correlate with the likelihood that the lesion will show epithelial changes or malignant transformation. In a study by Silverman and Gorsky the overall malignant transformation of OL was 17.5%, for the homogenous form only 6.6%, and for speckled OL 23.4%. A special subtype of OL, PVL, was found to develop SCC in 70.3% of patients [322]. Compared with OL, OE has significantly worse biological behaviour, with 51% proceeding to malignant transformation [319].

1.2.7.2 Larynx

The main task of the pathologist dealing with laryngeal SILs is to separate non-risky or a minimally risky from risky changes. Patients with benign hyperplastic lesions (simple and basal-parabasal hyperplasia) do not require such a close follow-up after excisional biopsies as those with atypical hyperplasia and CIS, although elimination of known detrimental influences is advised [125, 150]. Diagnosis of atypical hyperplasia in laryngeal lesions requires close follow-up and often repeated histological assessment to detect any possible persistence or progression of the disease [125, 150, 178, 181]. Patients with CIS may require more extensive surgical treatment or radiotherapy, although this is controversial [79, 181, 254, 299, 336].

The histopathologic degree of severity of laryngeal SILs is still used as the most reliable predictive factor [39, 125, 150, 178, 181, 239]. The frequency of subsequent malignant alteration markedly increases from squamous (simple) and basal-parabasal (abnormal) hyperplasia (0.9%), compared with atypical hyperplasia (11 %) [150]. Barnes's review of the literature shows that the risk of SCCs developing in mild, moderate and severe laryngeal dysplasia ranges from 5.5% to 22.5% and 28.4% respectively [20].

1.3 Invasive Squamous Cell Carcinoma

1.3.1 Microinvasive Squamous Cell Carcinoma

ICD-O:8076/3

Microinvasive squamous cell carcinoma (SCC) is a SCC with invasion beyond the epithelial basement membrane, extending into the superficial stroma. There is little consensus among pathologists on the maximum depth of invasion in microinvasive SCCs, but it generally ranges from 0.5 mm [20] to 2 mm [77]. The depth of invasion must be measured from the basement membrane of the adjacent (non-neoplastic) surface epithelium, because of the great variations in epithelial thickness.

Microinvasive SCC is a biologically malignant lesion capable of gaining access to lymphatic and blood vessels, which may result in metastases. However, metastases are rare in microinvasive SCCs and the prognosis is excellent. Studies on SCCs of the floor of the mouth have shown that there is little or even no metastatic potential for SCCs penetrating less than 2 mm beyond the basement membrane, and a substantially higher risk of metastases in more deeply invasive SCCs at this site [74, 77, 246]. The prognosis is also excellent in microinvasive SCCs of the laryngeal glottis because of the poor lymphatic and vascular network in this location. Some authors have therefore recommended more conservative treatment of these lesions, such as endoscopic removal, with a careful follow-up [80, 308, 341].

The reliable diagnosis of microinvasive SCC can only be made with certainty if the whole lesion is examined. It should not be made in small, tangentially cut biopsy specimens.

1.3.2 Conventional Squamous Cell Carcinoma

ICD-O:8070/3

Squamous cell carcinoma (SCC) is a malignant epithelial tumour with evidence of squamous differentiation such as intercellular bridges and keratin formation. It originates from the surface squamous epithelium, or from ciliated respiratory epithelium that has undergone squamous metaplasia [242].

Squamous cell carcinoma of the head and neck is the sixth most prevalent cancer worldwide, accounting for 5% of all new cancers, with a global annual incidence of 500,000 [42]. The vast majority of SCCs are the conventional type of SCC, accounting for more than 90% of cases. The remaining cases belong to the variants of SCC, which will be discussed later in this chapter.

Squamous cell carcinoma of the head and neck occurs most frequently in the oral cavity and lip, in the

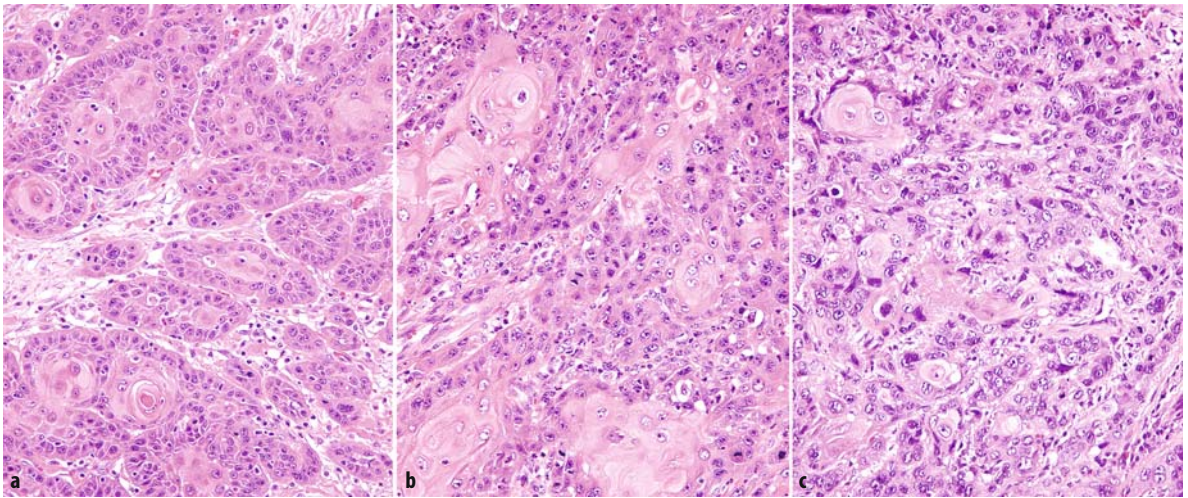


Fig. 1.13. **a** Well-differentiated squamous cell carcinoma. **b** Moderately differentiated squamous cell carcinoma. **c** Poorly differentiated squamous cell carcinoma

oropharynx, larynx and hypopharynx. Less frequently, it arises in the nasopharynx, nasal cavities and paranasal sinuses. The predilection sites in the oral cavity are the lateral tongue and floor of the mouth. In the oropharynx, the most commonly involved sites are the base of the tongue and the tonsils. In the larynx, there are geographic differences in the topographic distribution, the glottis being the most frequent location in some countries, and the supraglottis in others [20, 117].

1.3.2.1 Aetiology

Smoking and alcohol abuse are the greatest risk factors for the development of SCCs of the head and neck. Much attention has been paid to the possible role of viral infection, particularly the Epstein-Barr virus (EBV), and the human papillomavirus (HPV), in the pathogenesis of the head and neck carcinoma.

The EBV is aetiopathogenetically strongly related to nasopharyngeal carcinomas [265], and to rare cases of lymphoepithelial carcinoma of the salivary glands [153, 160]. HPV has been aetiologically linked to SCCs of the tonsil [97, 214]. Apart from tonsillar SCC and nasopharyngeal SCC, it appears that EBV and HPV play little, if any, role in the pathogenesis of SCCs in other locations in the head and neck [93, 153, 227, 392].

1.3.2.2 Pathologic Features

The macroscopic appearance of invasive SCCs is variable, and includes flat lesions with a well-defined, raised

edge, polypoid exophytic and papillary lesions, as well as endophytic infiltrative lesions. The surface of the tumour is frequently ulcerated.

Microscopically, SCCs are characterised by an invasive growth and evidence of squamous differentiation. Invasive growth is manifested by interruption of the basement membrane and the growth of islands, cords, or single (dyscohesive) tumour cells in the subepithelial stroma; large tumours may invade deeper structures, i.e. muscle, cartilage and bone. Perineural invasion and invasion of lymphatic and blood vessels may be present and are reliable proof of invasive cancer. Squamous differentiation is demonstrated by intercellular bridges and/or keratinisation, with keratin pearl formation.

Immunohistochemically, SCCs express epithelial markers, such as cytokeratins and epithelial membrane antigen (EMA). The patterns of expression of cytokeratin subtypes are related to the degree of SCC differentiation and to the degree of keratinisation [229].

The pattern of cytokeratin expression in low-grade SCCs is similar to that observed in non-neoplastic squamous epithelium, and is characterised by medium and high molecular weight cytokeratins, and the lack of expression of the low molecular weight cytokeratins. High-grade SCCs tend to lose the expression of medium and high molecular weight cytokeratins and express low molecular weight cytokeratins [229].

Of the various cytokeratin subtypes, cytokeratins 8, 18 and 19, recognised by the antibody CAM5.2, could be used as an indicator of malignant transformation. In a study by Mallofré et al., 40% of SCCs were positive for CAM5.2, but it was never positive in non-neoplastic squamous epithelium [229]. In poorly differentiated SCCs, expression of vimentin may appear [367].

1.3.2.3 Grading

Squamous cell carcinomas are traditionally graded into well-, moderately, and poorly differentiated SCC. The criteria for grading are: the degree of differentiation, nuclear pleomorphism and mitotic activity. Well-differentiated SCCs closely resemble normal squamous epithelium and contain varying proportions of large, differentiated keratinocyte-like squamous cells, and small basal-type cells, which are usually located at the periphery of the tumour islands. There are intercellular bridges and usually full keratinisation; mitoses are scanty (Fig. 1.13a). Moderately differentiated SCCs exhibit more nuclear pleomorphism and more mitoses, including abnormal mitoses; there is usually less keratinisation (Fig. 1.13b). In poorly differentiated SCCs, basal-type cells predominate, with a high mitotic rate, including abnormal mitoses, barely discernible intercellular bridges and minimal, if any, keratinisation (Fig. 1.13c). Although keratinisation is more likely to be present in well- or moderately differentiated SCCs, it should not be considered an important histological criterion for grading SCCs.

1.3.2.4 Invasive Front

Tumour growth at the invasive front (tumour–host interface) shows an expansive pattern, an infiltrative pattern, or both. An expansive growth pattern is characterised by large tumour islands with well-defined pushing margins, whereas an infiltrative pattern is characterised by small scattered irregular cords or single tumour cells, with poorly defined infiltrating margins. It has been demonstrated that the growth pattern at the invasive front has prognostic implications: an infiltrative pattern is associated with a more aggressive course and poorer prognosis than an expansive pattern [57, 58, 76, 382].

1.3.2.5 Stromal Reaction

Invasive SCCs are almost always associated with a desmoplastic stromal reaction, which consists of proliferation of myofibroblasts, excessive deposition of extracellular matrix and neovascularisation [63, 94, 221]. In our experience, desmoplastic stromal reaction is present only in invasive SCCs and never in SILs, regardless of their grade, and may be considered as an additional marker of invasion [395, 396].

Desmoplastic stromal reaction tends to be pronounced in well- and moderately differentiated SCCs and weak or absent in poorly differentiated SCCs and in lymphoepithelial carcinomas. The intensity of desmoplasia is inversely related to the density of stromal lymphocytic infiltration. In SCCs with marked desmoplasia,

lymphocytic infiltration is focal and scarce, while intense lymphocytic infiltration is found in SCCs with little or no desmoplasia.

1.3.2.6 Differential Diagnosis

The diagnosis of SCC must be confirmed by a biopsy, which must be taken from the clinically most suspicious area, avoiding the central necrotic area. In well-oriented, adequate biopsy samples, the diagnosis does usually not present a diagnostic problem, as evidence of invasive growth and of squamous differentiation is easily found.

However, well-differentiated SCCs must be distinguished from verrucous carcinomas and papillary SCCs, as well as from benign conditions, such as pseudoepitheliomatous hyperplasia. Verrucous carcinomas lack atypia, which are always present in SCCs. Papillary SCCs are characterised by papillae formation, which is not the prevailing feature in conventional SCCs.

Pseudoepitheliomatous hyperplasia is a benign condition associated with granular cell tumours, mycotic infection or tuberculosis. It consists of deep irregular tongues and rete pegs, but there are no abnormal mitoses or atypia, as in SCCs. Identifying the associated condition (granular cell tumour or infection) may be helpful in establishing the diagnosis of pseudoepitheliomatous hyperplasia.

Poorly differentiated SCCs must be differentiated from malignant melanomas, malignant lymphomas, neuroendocrine carcinomas, adenocarcinomas, and adenosquamous carcinomas. The correct diagnosis is best achieved by the use of appropriate immunohistochemistry and special stains for the demonstration of mucin production.

Malignant melanomas are distinguished from SCCs by the expression of S-100, HMB-45 and melan-A. Neuroendocrine carcinomas express neuroendocrine markers (synaptophysin, chromogranin) and do not show evidence of squamous differentiation, while SCCs do not express neuroendocrine markers. Malignant lymphomas are differentiated from SCCs by the presence of leukocyte common antigen, and markers of B- or T-cell differentiation. Adenocarcinomas and adenosquamous carcinomas can be distinguished from SCCs by the presence of glands and mucin secretion within the tumour cells.

1.3.2.7 Treatment and Prognosis

Squamous cell carcinomas of the head and neck have an overall death risk of 40% [328]. The most important prognostic factor is the TNM stage based on the size of the primary tumour, the presence of regional lymph node metastases, and distant metastases [332].

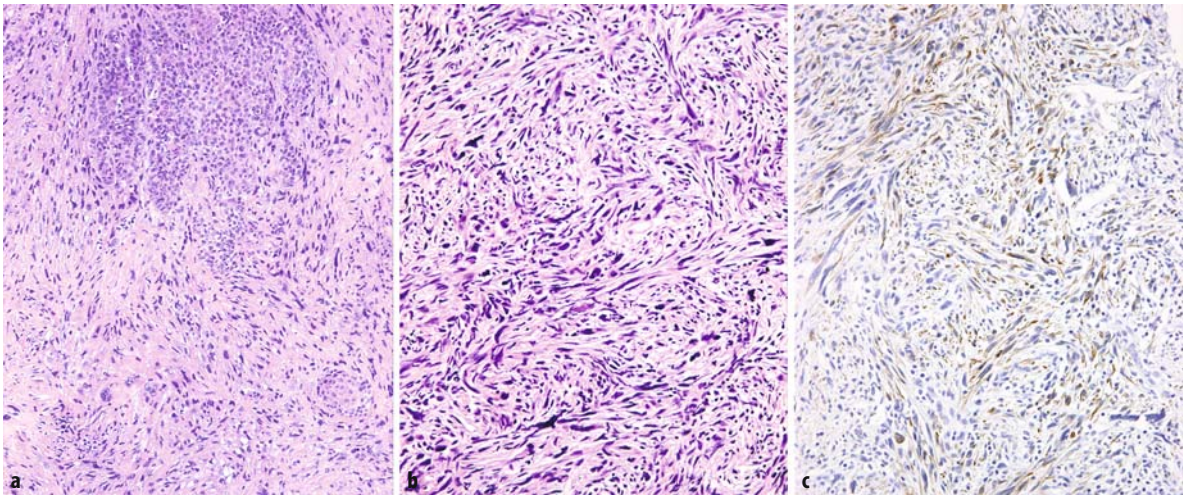


Fig. 1.14. Spindle cell carcinoma. **a** Squamous cell carcinoma in association with pleomorphic spindle cells. **b** Pure spindle cell

component: pleomorphic cells with large hyperchromatic nuclei. **c** Positive staining for cytokeratin in spindle cells

Additional important prognostic features are: localisation and depth of the tumour [74, 77, 130, 233, 246], presence of extracapsular spread in lymph node metastases [85, 109, 155, 335], and pattern of tumour growth at the invasive front [57, 58, 76, 382].

The prognostic value of some other parameters, i.e. differentiation of the tumour [166, 280, 376] and DNA ploidy [23, 98, 350, 378], is controversial.

The treatment of choice is complete excision of the tumour. For small tumours at some locations, such as the glottic larynx, the primary treatment is radiation. In large tumours, surgery is usually followed by radiotherapy. Patients with advanced, unresectable tumours, with or without metastases, are treated by concurrent chemotherapy and radiotherapy [117].

giving rise to both epithelial and mesenchymal components [66, 354].

1.3.3.1 Aetiology

Similar to conventional SCCs, SpCCs have been aetiologically related to cigarette smoking and alcohol consumption [356]. It has been suggested that SpCCs may develop after radiation exposure; however, some authors believe that this is not a major aetiological factor [356]. The reported incidence of radiation-induced SpCCs of the head and neck is between 7.7 and 9.1%; they develop after a latent period of 1.2 to 16 years after radiation exposure [210, 356].

1.3.3 Spindle Cell Carcinoma

ICD-O:8074/3

Spindle cell carcinoma (SpCC) is a biphasic tumour composed of conventional SCC and a malignant spindle cell component. Synonyms for SpCC are sarcomatoid carcinoma, carcinosarcoma, collision tumour and pseudosarcoma.

It has been described in various sites of the body including the upper and lower respiratory tract, breast, skin, urogenital and gastrointestinal tracts, and salivary glands [31]. In the head and neck, SpCC occurs most frequently in the larynx [36, 108, 213, 356] and oral cavity [13, 96, 304], followed by the skin, tonsils, sinonasal tract and the pharynx [13, 375].

The histogenesis of this tumour is controversial, but there is mounting evidence that SpCC is a monoclonal neoplasm originating from a non-committed stem cell

1.3.3.2 Pathologic Features

Macroscopically, SpCCs are usually exophytic polypoid or pedunculated tumours, with frequent surface ulceration. Less often, SpCCs manifest as sessile, endophytic or ulcero-infiltrative tumours [31, 356].

Microscopically, SpCCs consist of a SCC component and a spindle cell component. The former is represented by in situ carcinoma or by an invasive SCC, and is often small, requiring multiple sections for demonstration (Fig. 1.14a) [210].

The spindle cell component usually forms the bulk of the tumour. Spindle cells are often pleomorphic, with large hyperchromatic nuclei, prominent nucleoli, and numerous mitoses (Fig. 1.14b). They are arranged in fascicles or whorls and can assume many histologic patterns, the most common being that of a malignant fibrous histiocytoma or fibrosarcoma [213, 356]. Foci of

osteosarcomatous, chondrosarcomatous, or rhabdomyosarcomatous differentiation may be present, particularly in patients who had been previously treated by radiotherapy [203, 213, 356]. Sometimes, only spindle cells are present; in such cases, a SpCC can be mistaken for a true sarcoma.

However, occasional cases of SpCC may be less cellular, closely resembling a reactive fibroblastic proliferation and can thus be mistaken for a pseudosarcomatous reaction in a SCC or for radiation-induced stromal atypia [13].

Metastases usually contain SCCs alone or both SCC and spindle cell components, and rarely, only a spindle cell component [205, 232, 340].

Electron microscopy has revealed evidence of epithelial differentiation in spindle cells, such as desmosomes and tonofilaments [33, 151, 349, 391].

Immunohistochemically, tumour cells in SpCC often express epithelial and mesenchymal markers; moreover, keratin and vimentin coexpression has been observed on individual tumour cells [241, 391]. Cytokeratin expression can be demonstrated in spindle cells in 40–85.7% of cases (Fig. 1.14c), depending on the number of antikeratin antibodies used [96, 241, 329, 349, 360, 391]. The most sensitive/reliable epithelial (keratin) markers for SpCC seem to be keratin (AE1/AE3, K1) K1, K18 and epithelial membrane antigen (EMA) [356].

Spindle cells always express vimentin and often other mesenchymal filaments, such as myogenic markers (smooth muscle actin, muscle specific actin, desmin). The presence of S-100 protein has been reported in rare cases of SpCC [356]. SpCCs do not express glial-fibrillary acid protein (GFAP), chromogranin or HMB-45 [356]. p63 has been recently suggested as an alternative epithelial marker in SpCCs [213a].

1.3.3.3 Differential Diagnosis

The diagnosis of a SpCC is based on the demonstration of an invasive or in situ SCC and a malignant spindle cell component. However, when a SCC component cannot be demonstrated, the diagnosis is more difficult, and the SpCC must be distinguished from a number of benign and malignant processes, such as spindle cell sarcomas, nodular fasciitis, inflammatory myofibroblastic tumour and malignant melanoma.

In the head and neck, true sarcomas (with the exclusion of chondrosarcomas) and benign mesenchymal tumours are very rare; if present, they are usually located in deep structures [356]. It is therefore a general view that in the mucosa of the upper aerodigestive tract a malignant spindle cell tumour is probably a SpCC and not a sarcoma.

Negative reaction for S-100 protein and HMB45 helps to distinguish SpCCs from malignant melanomas [96].

1.3.3.4 Treatment and Prognosis

Wide surgical excision, alone or with radical neck dissection is the most successful treatment for SpCC. Radiation therapy is generally considered less effective.

The prognosis is similar to that for conventional SCCs and depends on the location of the tumour and the stage: glottic SpCCs have a good prognosis, while SpCCs in the oral cavity and paranasal sinuses behave more aggressively [29, 31]. Prognostic significance has been also suggested for the gross appearance of the tumour, i.e. polypoid lesions having a better prognosis than flat ulcerative tumours [375].

The reported 5-year survival is between 63 and 94%; the overall lethality of the tumour is 30–34% [29, 356].

1.3.4 Verrucous Carcinoma

ICD-O:8051/3

Verrucous carcinoma (VC; Ackerman's tumour) is a variant of well-differentiated SCC that was originally described by Ackerman in 1948 [5]. It is characterised by an exophytic warty growth that is slowly but locally invasive and can cause extensive local destruction if left untreated. It rarely, if ever, metastasises.

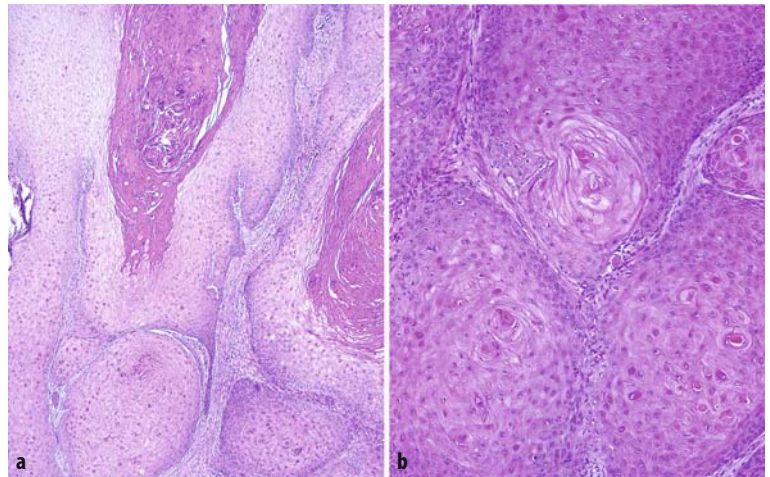
The majority of VCs (75%) occurs in the oral cavity and 15% in the larynx. In the oral cavity, the buccal mucosa and gingiva are most frequently involved, and in the larynx, the most frequent site of occurrence is the vocal cords. It rarely occurs in other locations in the head and neck, such as the nasal cavity, sinonasal tract and nasopharynx. It has been also described elsewhere in the body, i.e. the skin, anus, genitalia, urinary bladder and oesophagus [339].

1.3.4.1 Aetiology

Verrucous carcinomas have been aetiologically related to the use of chewing tobacco or snuff. The habitual chewing of “pan”, a mixture of betel leaf, lime, betel nuts and tobacco has been implicated in the high incidence of VC of the oral cavity in India [197]. However, tobacco usage is not a reasonable explanation for VC in the skin, genitourinary tract and other non-aerodigestive sites [107].

A possible aetiological factor is also human papillomavirus (HPV), as HPV types 16 and 18, and rarely 6 and 11, have been found in some, but not all cases of VC [52, 56, 116, 172, 190].

Fig. 1.15. Verrucous carcinoma. **a** Projections and invaginations lined by thick, well-differentiated squamous epithelium with marked surface keratinisation, invading the stroma with well-defined pushing margins. **b** Squamous epithelial cells are large and lack the usual cytologic criteria of malignancy. There are numerous dyskeratotic cells



1.3.4.2 Pathologic Features

Macroscopically, VC usually presents as a large, broad based exophytic tumour with a white keratotic and warty surface. On the cut surface, it is firm or hard, tan to white, and may show keratin-filled surface clefts. It is usually large by the time of diagnosis, measuring up to 10 cm in its greatest dimension.

Microscopically, VCs consist of thickened club-shaped filiform projections lined with thick, well-differentiated squamous epithelium with marked surface keratinisation (“church-spire” keratosis). The squamous epithelial cells in VCs are large [71] and lack the usual cytologic criteria of malignancy. Mitoses are rare, and are only observed in the suprabasal layer; there are no abnormal mitoses. VCs invade the subjacent stroma with well-defined pushing rather than infiltrative borders (Fig. 1.15). A lymphoplasmacytic inflammatory response is common in the stroma.

Hybrid (mixed) tumours also exist composed of VC and conventional well-differentiated SCC; the reported incidence for the oral cavity and the larynx is 20 and 10% [274] respectively. It is important to recognise such hybrid tumours as foci of conventional SCC in an otherwise typical VC indicate a potential for metastasis. Orvidas et al. reported that a patient with a hybrid carcinoma of the larynx died of the disease [274]. Patients with hybrid carcinomas must be treated aggressively as if they had conventional SCCs [274].

Verrucous carcinoma is characterised by a high frequency of initial misdiagnosis; Orvidas et al. reported a series of 53 laryngeal VCs; 16 out of 31 patients (52%) had received an incorrect diagnosis of a benign lesion [274]. This emphasises the need for close cooperation between the pathologist and the clinician in order to establish the diagnosis of VC. An adequate, full-thickness biopsy specimen must be taken when a clini-

cian suspects a VC [274]; moreover, multiple biopsies may be needed to rule out a conventional SCC component in a VC.

1.3.4.3 Differential Diagnosis

Differential diagnosis includes verrucous hyperplasia, well-differentiated SCC, papillary SCC, and squamous papilloma.

Invasion below the level of the basal cell layer of the neighbouring normal squamous epithelium distinguishes VC from verrucous hyperplasia. Whether this feature, however, adequately discriminates between VC and verrucous hyperplasia is debatable, as verrucous hyperplasia could be an exophytic form of VC as well [327].

Lack of atypia helps to rule out the conventional SCC and papillary SCC. The VC also lacks the well-formed, wide papillary fronds of a squamous cell papilloma.

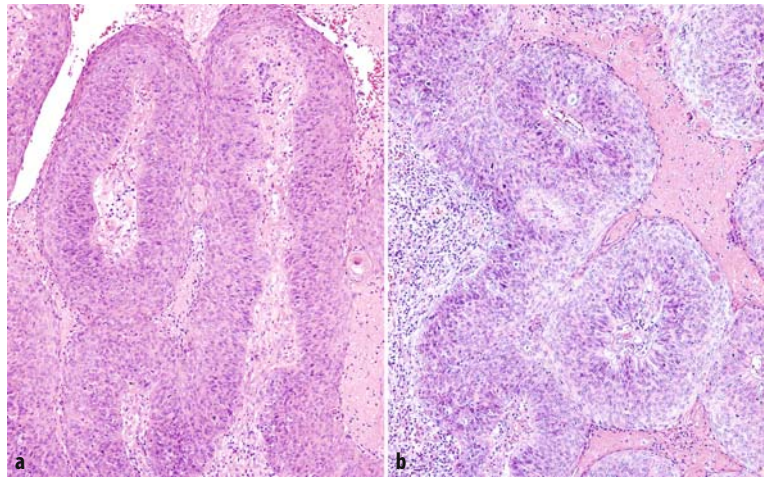
An additional feature supporting the diagnosis of a VC is the enlarged spinous cells by morphometrical analysis [71].

1.3.4.4 Treatment

Verrucous carcinoma may be treated by excision (by laser or surgery), and by radiotherapy. It appears that surgery is a more effective treatment for VC [236, 274]. Hagen et al. reported a 92.4% cure rate for primary surgery in patients with laryngeal VC [145]. In contrast, Ferlito and Recher reported a 29% cure rate for radiotherapy in laryngeal VC [107]. Other studies have shown a 46–57% rate of failure for primary radiation therapy in VCs [224, 243, 353].

Furthermore, early reports suggested anaplastic transformation following radiotherapy [95, 107, 145,

Fig. 1.16. Papillary squamous cell carcinoma. **a** Tumour consists of papillae with a central fibrovascular core, covered by neoplastic squamous epithelium. **b** The covering epithelium is composed of pleomorphic cells resembling carcinoma in situ



278, 287, 309]. However, recent studies do not support this notion. It appears that some of the reported cases of transformation of VC to SCC after radiotherapy were of mixed (hybrid) tumours. Moreover, similar transformation can also occur after surgical treatment of VC [237, 240, 275, 353]. Radiotherapy is now believed to be an appropriate mode of treatment for oral VC [177] and laryngeal VC [275].

1.3.4.5 Prognosis

In his original report, Ackerman noted metastasis in the regional lymph node in only one of the 31 patients, and no distant spread was observed in his series [5]. Further studies confirmed his observation that pure VCs do not metastasise [107, 274]; cases of VC with metastases were really a hybrid carcinoma that had not been detected at initial biopsy.

Verrucous carcinomas therefore have a good prognosis; the overall 5-year survival rate is 77% [196]. It is important to recognise hybrid tumours, as foci of a conventional SCC in a VC indicate the potential for metastasis. Orvidas et al. reported that a patient with a hybrid carcinoma of the larynx died of the disease [274]. Patients with hybrid carcinomas must be treated aggressively as if they had a conventional SCC [274].

1.3.5 Papillary Squamous Cell Carcinoma

ICD-O:8052/3

Papillary squamous cell carcinoma (PSCC) is an uncommon variant of SCC originally described by Crissman et al. in 1988 [75]. Its main characteristics are a papillary growth pattern and a good prognosis.

In the head and neck, PSCCs show a predilection for the oropharynx, hypopharynx, larynx, and the sinusal tract [75, 99, 110, 161, 343, 355]. They also occur in other parts of the body, such as the skin [15], uterine cervix [292], conjunctiva [215], and thymus [209].

1.3.5.1 Aetiology

It has been postulated that human papillomavirus (HPV) infection might be an important aetiological factor in PSCCs, similar to squamous papillomas [343]. However, the reported prevalence of HPV infection in PSCCs varies from 0 [75] to 48% [30, 343] and does not differ significantly from the reported overall prevalence of HPV infection in head and neck SCCs [238]. Therefore, the significance of HPV infection in the pathogenesis of PSCCs remains unclear.

1.3.5.2 Pathologic Features

Macroscopically, PSCCs present as papillary, friable and soft tumours, ranging in size from 2 mm to 4 cm. The main histologic feature of PSCCs is the papillary growth pattern that comprises the majority of the tumour (Fig. 1.16a). Papillae consist of a central fibrovascular core covered by neoplastic squamous epithelium. The covering epithelium may be composed of immature basaloid cells or may be more pleomorphic, resembling carcinoma in situ (Fig. 1.16b). It is usually non-keratinising or minimally keratinising.

Multiple lesions can be found, consisting either of invasive PSCCs or mucosal papillary hyperplasia. Stromal invasion is often difficult to demonstrate in biopsy specimens, and sometimes additional biopsies are needed to make the diagnosis of an invasive PSCC. A dense lym-

phoplasmacellular infiltration is usually present in the stroma at the base of the carcinoma, but is scarce within the papillae. If no stromal invasion is found, the lesion is called papillary atypical hyperplasia, PSCC in situ, or non-invasive PSCC [328].

1.3.5.3 Differential Diagnosis

Differential diagnosis includes squamous papilloma, VC, and SCC with an exophytic or fungating pattern. Papillomas and VCs share with PSCCs similar architecture, but PSCCs are differentiated from both VCs and papillomas by the presence of atypia of the squamous epithelium covering the papillae. The differentiation between exophytic and papillary SCCs can be more difficult as the histologic criteria for the diagnosis of exophytic SCCs are not clearly defined [30, 355].

1.3.5.4 Treatment and Prognosis

Treatment of PSCCs is similar to that of conventional SCCs. Patients with PSCCs are generally believed to have a better prognosis than those with conventional SCCs, although reports in the literature are controversial [343, 355]. It appears that, because of a relatively small number of cases published in the literature, PSCCs possibly remain the least understood of the several variants of SCC of the head and neck [30].

1.3.6 Basaloid Squamous Cell Carcinoma

ICD-O:8083/3

A basaloid squamous cell carcinoma (BSCC) is a poorly differentiated SCC composed of basaloid cells and squamous cell carcinoma, characterised by an aggressive clinical course. It was first described by Wain et al. in 1986 [372]. It has a predilection for the upper aerodigestive tract, but also occurs in other locations such as the uterine cervix [140], oesophagus [202], lung [51], and anus [90].

In the upper aerodigestive tract, BSCC shows a predilection for the hypopharynx (pyriform sinus), base of the tongue, and supraglottic larynx [195, 293]; it has also been described in the oropharynx [195, 293], oral cavity [69, 72, 159] and trachea [277, 312]. The suggested precursor of the BSCC is a totipotent primitive cell located in the basal cell layer of the surface epithelium, or within the seromucinous glands [293, 372].

1.3.6.1 Aetiology

Tobacco and alcohol use are strong risk factors for the development of BSCCs [19].

1.3.6.2 Pathologic Features

Macroscopically, the tumour usually appears as a white, firm, poorly defined, exophytic, polypoid, and centrally ulcerated mass with peripheral submucosal infiltration [21].

Microscopically, BSCCs are composed of small, closely packed basaloid cells, with hyperchromatic nuclei with or without nucleoli, and scant cytoplasm (Fig. 1.17a). The tumour grows in a solid pattern with a lobular configuration, with a frequent peripheral palisading of nuclei. Large central necroses of the comedo type are frequent. Distinctive features of BSCCs that are not found in conventional SCCs are small cystic spaces containing para aminosalicylate (PAS)- and Alcian blue-positive material and focal stromal hyalinisation [19, 372].

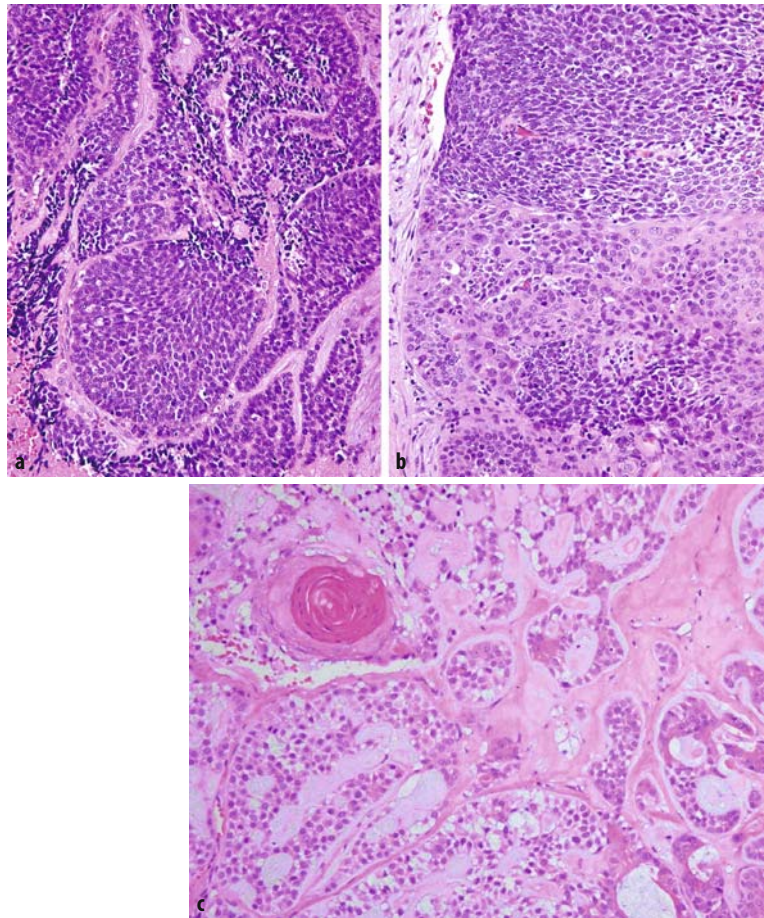
BSCCs are always associated with an SCC component, which can present either as an in situ or invasive SCC. The invasive SCC is usually located superficially, and is typically well- to moderately differentiated. It may also present as focal squamous differentiation within the basaloid tumour islands. The transition between the squamous cells and the basaloid cells is often abrupt (Fig. 1.17b), or there may be a narrow zone of transition.

If there is extensive ulceration, only dysplastic changes may be identifiable in the intact surface epithelium [19, 21]. Rarely, BSCCs exhibit a malignant spindle cell component [21, 250]. Metastases may demonstrate basaloid carcinoma, squamous carcinoma, or both [21].

By electron microscopy, desmosomes and tonofilaments were demonstrated in basaloid cells and in squamous cells. There were no neurosecretory granules, myofilaments or secretory granules [154, 372].

Immunohistochemically, BSCCs express keratin and epithelial membrane antigen, but the percentage of positive cells varies among different reports. It is advised to use a cocktail of keratin antibodies (i.e. CAM 5.2, AE1-AE3) to avoid false-negative results [21]. Some cases express carcinoembryonic antigen and neuron-specific enolase [19, 195, 318], while expression of S-100 protein, vimentin and muscle-specific actin varied among different reports. Vimentin was negative in some studies [69, 195], while Barnes et al. [21] described positive staining in the majority of basaloid cells, with a peculiar pattern of staining, forming a delicate perinuclear rim. Varying results have also been reported for S-100 immunoreactivity. Some authors described focal immunoreactivity in a few cases [19, 21], while others did not find any S-100-positive tumour cells [69, 195, 248]. However, most cases displayed numerous S-100-positive dendritic cells intermingled with the tumour cells [9, 21, 195, 248]. BSCCs do not express chromogranin, synaptophysin and GFAP [19, 21, 195].

Fig. 1.17. Basaloid squamous cell carcinoma. **a** Closely packed basaloid cells with hyperchromatic nuclei and scant cytoplasm, with focal peripheral palisading of nuclei. **b** Abrupt transition between squamous and basaloid cells. **c** Focal squamous differentiation in adenoid cystic carcinoma. Courtesy of Dr. Pieter J. Slootweg



1.3.6.3 Differential Diagnosis

Differential diagnosis includes neuroendocrine carcinoma, adenoid cystic carcinoma, adenocarcinoma and adenosquamous carcinoma.

Neuroendocrine carcinomas express various neuroendocrine markers that help to distinguish neuroendocrine carcinomas from BSCCs. However, as 60–75% of cases of BSCC have been reported to express neuron-specific enolase [19, 65, 318] the application of other neuroendocrine markers, including chromogranin, CD56, and synaptophysin, is advised [19, 65].

Adenoid cystic carcinomas, especially the solid variant, may resemble BSCCs but adenoid cystic carcinomas rarely show squamous differentiation (Fig. 1.17C). Immunohistochemistry may also be helpful: tumour cells in adenoid cystic carcinomas express S-100 protein and vimentin, while tumour cells in BSCCs usually do not express either of the two markers [21, 195].

Adenocarcinomas and adenosquamous carcinomas can be distinguished from BSCCs by the presence

of gland formation and mucin secretion within the tumour cells.

1.3.6.4 Treatment and Prognosis

A BSCC is an aggressive, rapidly growing tumour characterised by an advanced stage at the time of diagnosis and a poor prognosis. Metastases to the regional lymph nodes have been reported in two-thirds of patients [19, 195, 277, 293], and distant metastases involving lungs, bone, skin and brain in 37–50% of patients [19, 195, 293].

It is generally believed that BSCCs are more aggressive than conventional SCCs [103, 108, 195, 372, 377]. However, some studies indicate that BSCCs exhibit behaviour similar to that of high-grade conventional SCCs of the head and neck [19, 134, 222, 376].

The treatment of choice is radical surgical excision and, because of early regional lymph node and distant visceral metastases, radical neck dissection and supplementary radio- and chemotherapy [21, 372, 375].

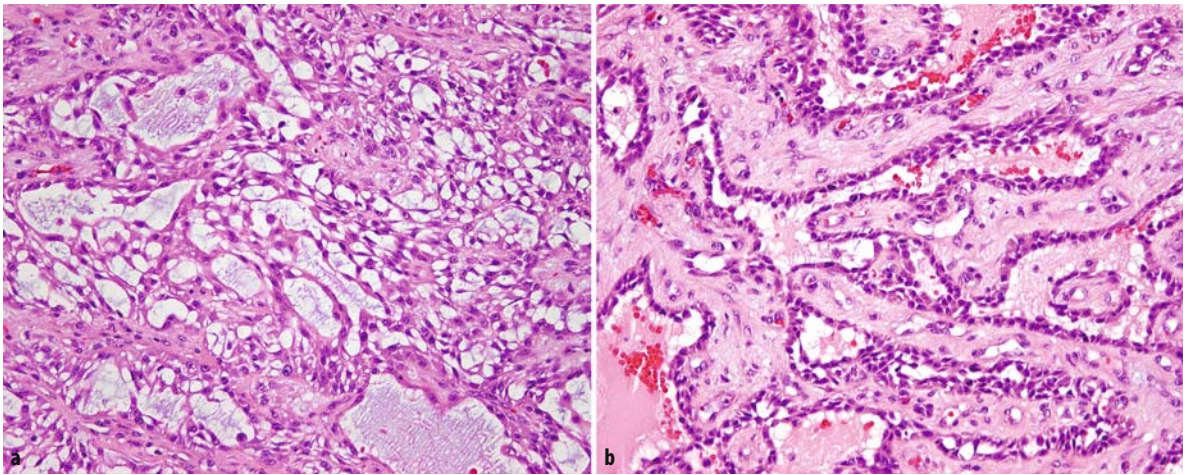


Fig. 1.18. Adenoid squamous cell carcinoma. **a** Islands of squamous cell carcinoma with pseudoglandular (adenoid) structures

due to acantholysis of neoplastic cells. **b** Anastomosing spaces and channels mimicking an angiosarcoma.

1.3.7 Adenoid Squamous Cell Carcinoma

ICD-O:8075/3

Adenoid squamous cell carcinoma (adenoid SCC) is an uncommon histopathologic type of SCC that was first recognised by Lever in 1947 [211]. It resembles an ordinary SCC, but because of the acantholysis of malignant squamous cells, pseudoluminae are formed, creating the appearance of glandular differentiation. There is no evidence of true glandular differentiation or mucin production.

Adenoid SCC has been referred to by a variety of names such as pseudoglandular SCC, acantholytic SCC, SCC with gland-like features and adenoacanthoma.

In the head and neck it arises most frequently in the skin (especially in sun-exposed areas) [259, 260], and less frequently in mucosal sites of the upper aerodigestive tract, including the lip, oral cavity, tongue and nasopharynx [27, 37, 105, 135, 173, 348, 375, 388].

1.3.7.1 Pathologic Features

Adenoid SCCs are composed of islands and cords of keratinising SCC; because of the acantholysis of neoplastic cells, pseudoglandular (adenoid) structures are formed that have central lumina containing detached acantholytic neoplastic cells, necrotic debris, or they may be empty (Fig. 1.18a). The conventional squamous cell carcinoma component is nearly always present.

Acantholysis may lead to the formation of anastomosing spaces and channels, thus mimicking an angiosarcoma (Fig. 1.18b). This variant of adenoid SCC is termed pseudovascular adenoid SCC or angiosarcoma-

like SCC, and has been reported in the skin of the head and neck [260], as well as in other organs, such as breast and lungs [18].

Immunohistochemically, adenoid SCCs are positive for epithelial markers, such as cytokeratins and epithelial membrane antigen (EMA); it may also express carcinoembryonic antigen (CEA) and vimentin [105].

Ultrastructural analysis revealed hemidesmosomes and attached tonofilaments, with no glandular features, thus supporting the squamous origin of the adenoid SCC [388].

1.3.7.2 Differential Diagnosis

Adenoid SCCs must be differentiated from adenocarcinomas, particularly adenoid cystic carcinomas, adeno-squamous carcinomas, and mucoepidermoid carcinomas. This is best achieved by demonstrating that there is no true gland formation and that stains for mucin are negative in adenoid SCCs.

Differential diagnosis also includes angiosarcoma, but immunohistochemistry helps to distinguish between the two tumours. Angiosarcomas typically express vascular antigens (CD31, CD34, von Willebrand factor) that are negative in adenoid SCCs. Cytokeratin, however, may also be positive in some angiosarcomas [139].

1.3.7.3 Treatment and Prognosis

Treatment and prognosis are similar to those for adenoid SCCs and conventional SCCs. Some authors, however, believe that adenoid SCCs have aggressive behaviour

and a worse prognosis than conventional SCCs [27, 105, 348, 388], but the number of patients reported so far is too small to draw firm conclusions [328].

1.3.8 Adenosquamous Carcinoma

ICD-O:8560/3

Adenosquamous carcinoma (ASC) is a rare malignant epithelial tumour characterised by the presence of both SCC and adenocarcinoma, and aggressive behaviour. It occurs in various sites, such as the pancreas [68], lung [262], uterine cervix [132], prostate [310], stomach [44] and breast [305]. In the head and neck, it was first reported by Gerughty et al. [131] who described a series of 10 patients with nasal, oral and laryngeal ASC.

Since then, over 150 cases of ASC of the head and neck have been reported; the most frequent site of occurrence is the larynx [8, 83, 124, 192], followed by the nose and paranasal sinuses [8, 245], oral cavity [8, 192, 258, 317, 385], upper lip [234], nasopharynx [234], oropharynx [234] and hypopharynx [83, 234, 313].

The histogenesis of the ASC has not yet been completely elucidated. Some authors have suggested that it originates from the salivary and/or mucoserous glands [131] while others favour a surface epithelial derivation or a combined glandular and surface epithelial derivation [83]. However, it is becoming increasingly accepted that the basal cells of the surface squamous epithelium, which are capable of divergent differentiation, are the sole origin of ASCs [8, 258, 264, 317].

1.3.8.1 Aetiology

Aetiology has not been defined, but cigarette smoking and alcohol consumption probably play an important role in the pathogenesis of ASCs, similar to other types of SCC in the upper aerodigestive tract [8, 131, 192].

1.3.8.2 Pathologic Features

Adenosquamous carcinomas do not differ macroscopically from conventional SCCs. Microscopically, they are characterised by the presence of both adenocarcinoma and SCC. The two components occur in close proximity, but are generally distinct and separate, and are not closely intermingled as in the mucoepidermoid carcinoma. The SCC component can present either as an in situ or as an invasive SCC, manifesting intercellular bridges, keratin pearl formation or dyskeratosis. The adenocarcinomatous component is usually located in the deeper parts of the tumour; it consists of tubular, alveolar or ductular structures (Fig. 1.19).

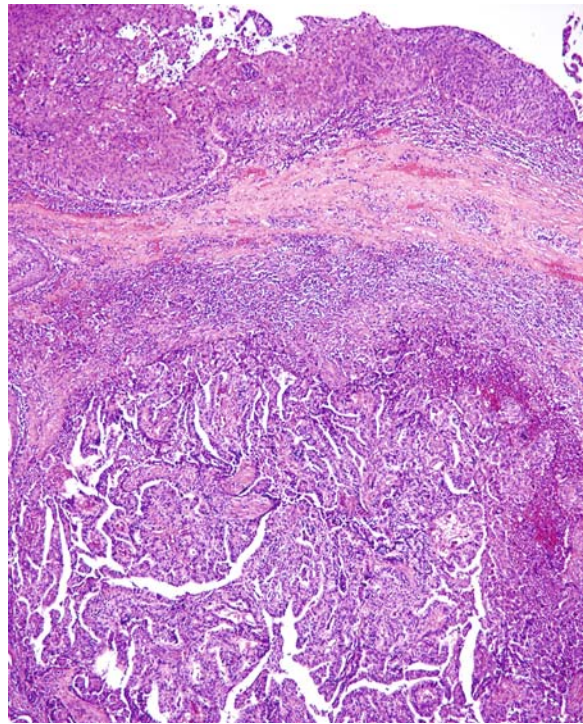


Fig. 1.19. Adenosquamous carcinoma: squamous cell carcinoma in situ and the adenocarcinomatous component in the deeper part of the tumour. The two components are in close proximity, though separate

The presence of intracytoplasmic mucin can be demonstrated by special techniques, such as PAS, Alcian blue and Mayer mucicarmine. Necroses and mitoses are common [8, 192].

Immunohistochemistry has demonstrated positive staining for cytokeratins with high molecular weight in both the SCC and the adenocarcinomatous components, and positive staining for carcinoembryonic antigen (CEA) and cytokeratins with low molecular weight in the adenocarcinomatous component [8, 234].

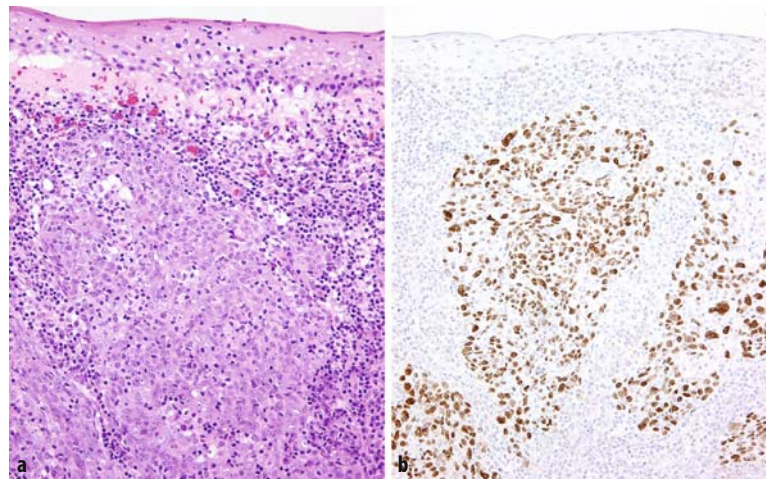
By electron microscopy, features of both squamous and adenocarcinomatous differentiation have been demonstrated [41, 164].

1.3.8.3 Differential Diagnosis

Differential diagnosis includes mucoepidermoid carcinoma, adenoid SCC, conventional SCC invading the normal salivary glands, and necrotising sialometaplasia.

It is important to differentiate ASCs from mucoepidermoid carcinomas because ASCs have a worse prognosis than mucoepidermoid carcinomas [131, 192, 313]. The histopathologic features favouring the diagnosis of ASC are: separate and distinct areas of SCC and adeno-

Fig. 1.20. Nasopharyngeal carcinoma.
a Islands of poorly differentiated carcinoma beneath the surface epithelium, with dense lymphocytic infiltration of the stroma.
b In situ hybridisation reveals Epstein-Barr virus RNA transcripts in the nuclei of all tumour cells



carcinomatous components, and the involvement of the surface epithelium exhibiting atypical hyperplasia, carcinoma in situ, or invasive SCC.

The presence of mucin in true glandular spaces helps to distinguish ASCs from adenoid SCCs.

Conventional SCCs invading or entrapping the normal salivary or mucoserous glands can be confused with ASC, especially in small biopsy specimens. In such cases, preservation of lobular gland architecture and lack of significant atypia are observed, helping to distinguish conventional SCCs from ASCs.

Finally, ASCs must be differentiated from necrotising sialometaplasia, which is a benign condition. The histopathologic features suggesting the diagnosis of necrotising sialometaplasia are: surface ulceration, localisation in minor salivary glands, lobular architecture, partial necrosis of the salivary gland, and squamous metaplasia of the salivary ducts.

ated with dense lymphocytic stromal infiltration. It is morphologically indistinguishable from nasopharyngeal carcinoma type 3 (WHO classification) [381]. It was originally described in the nasopharynx in 1921 by Regaud and Reverchon [294], and independently by Schmincke [315]. Synonyms for LEC include lymphoepithelioma, nasopharyngeal-type carcinoma, Regaud and Schmincke-type lymphoepithelioma, and undifferentiated carcinoma. The specific features of the nasopharyngeal carcinoma are extensively discussed in Chap. 6.

Apart from the nasopharynx, it rarely occurs in other locations in the head and neck, such as the oropharynx, salivary glands, tonsils, tongue, soft palate, uvula, floor of the mouth, sinonasal tract, larynx and hypopharynx [67, 93, 120, 227, 392], as well as elsewhere in the body including the lung, urinary bladder, uterine cervix, breast, skin and stomach [113].

1.3.8.4 Treatment and Prognosis

The ASC has a more aggressive course than the conventional SCC [131, 258, 313], with a tendency toward early lymph node metastases, frequent local recurrences, and occasional dissemination [192]. The reported 5-year survival rate is between 13 and 25% [124, 131, 192].

The treatment of choice is radical surgical excision. Irradiation alone has had poor results [124, 192, 313]. Some reports indicate that radical surgery combined with irradiation may improve the survival rate [6].

1.3.9 Lymphoepithelial Carcinoma

ICD-O:8082/3

Lymphoepithelial carcinoma (LEC) is a poorly differentiated SCC or undifferentiated carcinoma, associ-

1.3.9.1 Aetiology

Nasopharyngeal carcinomas are aetiopathogenetically associated with the Epstein-Barr virus (EBV; Fig. 1.20b) [265]. Apart from nasopharyngeal carcinomas, EBV has been also implicated in the pathogenesis of LECs of the salivary glands, as well as undifferentiated carcinomas of the stomach, lung and thymus [153, 160]. In contrast, it seems that EBV plays little, if any role in the pathogenesis of LEC in other locations in the head and neck [93, 153, 227, 392].

1.3.9.2 Pathologic Features

The LEC is composed of small clusters or aggregates (Schmincke pattern) or large syncytial masses (Regaud pattern) of cells. Tumour cells have oval or round ve-

sicular nuclei, and one to three prominent nucleoli (Fig. 1.20a). The cytoplasm is sparse and poorly defined. Normal and abnormal mitoses may be numerous. Necroses may be present.

The LEC may exist in two histological forms: as a pure LEC and as a mixed form, composed of both LEC and conventional SCC; such a mixture has been observed both in primary and metastatic tumours [227].

The stroma in LECs is densely infiltrated by T lymphocytes; stromal inflammatory infiltration may also contain plasma cells, follicular dendritic cells and eosinophils.

1.3.9.3 Differential Diagnosis

Differential diagnosis includes malignant lymphoma, in particular diffuse large B-cell lymphoma, as well as malignant melanoma and rhabdomyosarcoma. Differentiation is achieved by the use of appropriate immunohistochemical staining. The vast majority of LECs are positive for cytokeratin and negative for leukocyte common antigen as well as other lymphocyte antigens. Cytokeratin positivity has been reported in rare lymphomas [123], but leukocyte common antigen positivity in the tumour cells of LECs has not yet been reported. A negative reaction to S-100, HMB-45 and melan-A helps to differentiate LECs from malignant melanomas.

1.3.9.4 Treatment and Prognosis

Lymphoepithelial carcinomas are more aggressive than conventional SCCs, with a higher incidence of cervical lymph node metastases, and a propensity for distant metastases, mostly to the lung, liver and bones [93, 227]. In a series of 34 patients with LECs, 76% of patients had lymph node metastases at the time of diagnosis, and 36% had distant metastases [93].

The LEC is a radiosensitive tumour and radiotherapy is an appropriate initial therapy for patients with LECs. Surgical treatment should be reserved for patients with persistent disease after completing radiotherapy. In those patients adjuvant chemotherapy is also recommended in an attempt to decrease the rate of distant metastases [93].

1.4 Second Primary Tumours

Patients with SCCs of the upper aerodigestive tract are at high risk of developing a second primary tumour (SPT) at a separate anatomic site from the index (first) tumour. The SPT is synchronous if it is diagnosed

within 6 months after the index tumour, or metachronous if it is diagnosed more than 6 months after the index tumour. Synchronous tumours are simultaneous if they are discovered at the same time as the index tumour.

The median prevalence of SPT in patients with an index tumour in the upper aerodigestive tract is 9% [149, 291, 337]. The site of the SPT is affected by the site of the index tumour. In patients with an index tumour in the oral cavity, pharynx and oesophagus, the SPT tends to arise in the same location. In patients with index tumours in the larynx, the SPT tends to be located in the lungs [174].

The risk of developing an SPT closely correlates with the use of tobacco and alcohol abuse, and is more than doubled in patients who smoke and drink compared with those who do not smoke and drink [207]. Moreover, there is a direct dose-dependent relationship between tobacco and alcohol exposure and the risk of SPT.

It is now accepted that long-term exposure to tobacco and/or alcohol causes extensive and diffuse DNA changes leading to widespread genetic damage or “field cancerisation” of the whole respiratory tract and the upper digestive tract [324].

The prognosis for patients with SPTs is poor, being worse for synchronous SPTs than for metachronous tumours. They generally present with a more advanced T stage, and have a much lower 5-year survival than the index tumour [291].

It is therefore imperative for a panendoscopy to be performed at the time of diagnosis of the index tumour, not only as a part of the staging procedure, but also to look for an SPT [291].

1.5 Tumour Spread and Metastasis

Squamous cell carcinomas may spread directly to contiguous structures, as well as via lymphatic and blood vessels, giving rise to regional lymph node and distant metastases, or metastases along the nerves. The behaviour and spread of SCCs are affected by various factors, the most important being the site of the primary tumour. This has been attributed to the rich vascular and lymphatic network in certain areas, such as the base of the tongue, where metastatic rates are significantly higher than for similar-sized tumours on the oral tongue. Similarly, poorly vascularised areas, such as the glottis, are associated with a lower rate of metastases [106].

Other factors important for the spread and behaviour of SCCs include the size and the differentiation of the tumour, as well as poorly defined factors of the host, i.e. the immune status and genetic susceptibility [130].

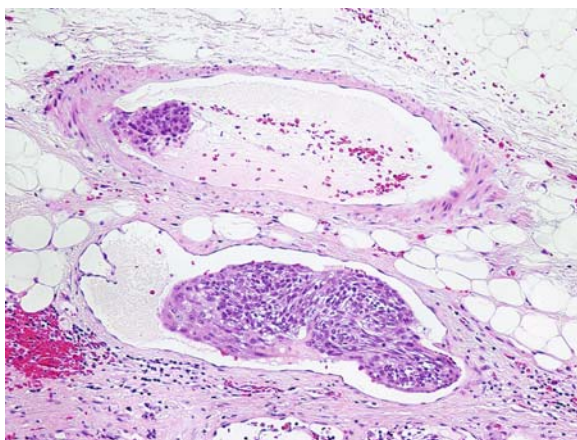


Fig. 1.21. Tumour emboli in a lymph vessel and vein

1.5.1 Invasion of Lymphatic and Blood Vessels

Experimental studies have shown that metastatic progression is initiated by local invasion: select tumour cells are released from the tumour where they gain entry to the lymphatic system or circulation, mainly via the production of tumour-derived proteolytic enzymes and angiogenic factors [220].

Cancer cells commonly invade thin-walled lymphatic vessels, capillaries and veins (Fig. 1.21), whereas thicker-walled arterioles and arteries are relatively resistant. The appearance of vascular invasion should not be considered synonymous with metastasis, because most of the tumour cells that enter the lymphatic system and circulation are destroyed [1]. However, the penetration of tumour cells in the lymphatic and blood vessels is associated with a high probability of regional lymph node and distant metastases. Furthermore, it allows the tumour to spread beyond the apparent margins. The presence of vascular invasion is therefore associated with an increased incidence of recurrence and poor survival [383].

1.5.2 Perineural Invasion

In perineural invasion, the tumour cells enter the perineural space and spread both proximally and distally along the nerve fibre. Even though a perineural spread of more than 2 cm is unusual, the travelling of tumour cells up to 12 cm away from the primary tumour site along the perineural space has been described [101, 370].

Patients with perineural invasion may be asymptomatic, or may experience pain and paresthesia [40]. It appears that perineural invasion is a poor prognostic sign,

associated with an increased risk of local recurrence, regional lymph node metastases and decreased survival [101, 233, 333, 383].

1.5.3 Regional Lymph Node Metastases

Squamous cell carcinomas of the head and neck have a high tendency to metastasise to the regional lymph nodes. The localisation and frequency of the lymph node metastases depend upon the site and size of the primary tumour. Large metastases can be detected clinically by examination or using ultrasound or radiographic methods. Smaller metastases evade clinical detection, but are detected by light microscopy [111].

Routine analysis of neck dissection specimens is usually limited to the examination of a few sections of each node stained by haematoxylin-eosin. During such routine analysis, small metastases can easily be missed. It has been demonstrated that with more sensitive techniques, nodal metastases can be detected in 8–20% of patients in whom metastases had not been found during routine histologic examination [11, 146, 147]. The most commonly used sensitive techniques for the detection of small metastases are serial section light microscopy, immunohistochemistry and molecular analysis [130, 273, 307, 379].

The prognostic significance of lymph node metastases has been extensively studied. Metastasis in the lymph nodes is the most significant adverse prognostic factor in head and neck SCCs. The 5-year survival is decreased by approximately 50% in patients with lymph node metastases compared with patients without nodal involvement [10, 25, 320]. The number and size of positive nodes, their level in the neck and the presence of extracapsular spread are the most important prognostic parameters for nodal status [10, 85, 109, 230].

1.5.3.1 Extracapsular Spread in Lymph Node Metastases

Cancer cells initially lodge in the marginal sinus, and then extend throughout the lymph node. Metastases may be confined to the lymph node, or may penetrate the capsule and infiltrate the perinodal tissue; this pattern of growth has been referred to as extracapsular spread (ECS). Extracapsular spread is further divided into macroscopic and microscopic ECS [62]; macroscopic ECS is evident to the naked eye during the laboratory dissection of the surgical specimen and is later confirmed by histological assessment. It usually involves not only the perinodal fibro-adipose tissue, but also the surrounding structures. Microscopic ECS is only evident on histologic examination and is usually limited to the adjacent perinodal fibro-adipose tissue.

Extracapsular spread is a significant predictor of both regional recurrence and the development of distant metastases resulting in decreased survival [109, 155, 175, 335, 337]. In some studies, ECS has been shown as a better predictor than the resection margins. It has therefore been suggested that ECS should be incorporated into the staging system for surgically managed patients [380]. Some studies, on the contrary, have not confirmed the independent prognostic significance of extracapsular spread [230, 280].

1.5.3.2 Metastases in the Soft Tissue of the Neck

In some patients, an SCC in the soft tissue of the neck is found, with no evidence of lymph nodes being present. These soft tissue metastases may be the result of either total effacement of a lymph node by the SCC, or extra-lymphatic spread of the SCC [176].

It has been shown that the presence of soft tissue metastases is associated with an aggressive clinical course and poor survival [176, 368]. In a study of 155 patients, survival was significantly shorter for patients with soft tissue metastases than those without nodal metastases and those with nodal metastases without extracapsular spread; it was similar to that for patients with lymph node metastases with extracapsular spread [176].

1.5.4 Distant Metastasis

Distant metastases in patients with head and neck cancer are usually defined as metastases below the clavicle, and may be the result of lymphogenic or haematogenous spread. Lymphogenic spread results in distant lymph node metastases; the most commonly affected distant nodes are the mediastinal, axillary and inguinal nodes [7]. Haematogenous spread results in distant metastases, most commonly to the lung, liver and bones, followed by the skin and brain [84, 157, 198, 208, 337, 362, 387]. Metastases have been also described in the small intestine [384], spleen [3] and the cavernous sinus [362].

Distant metastases in head and neck SCCs are infrequent, but may occur in the late stages of the disease, with the reported incidence between 3 and 8.5% [337, 387]. Postmortem studies have shown a higher incidence of distant metastases, ranging from 24 to 57% [266, 325, 393].

The incidence of distant metastases depends on the site of the primary tumour, as well as the initial size of the tumour and the presence of nodal metastases [59, 198, 253]. The highest incidence of distant metastases has been reported in hypopharyngeal SCCs, followed by the SCCs of the tongue [198].

Most distant metastases become clinically apparent 2 years after diagnosis of the initial tumour. The average survival once distant metastases are diagnosed ranges between 4 and 7 months [208].

1.5.5 Micrometastasis

Micrometastasis is defined as a microscopic deposit of malignant cells, smaller than 2–3 mm, that are segregated spatially from the primary tumour [193]. The fate of micrometastases is uncertain; the majority of them are probably destined for destruction or dormancy, and only a small percentage of circulating tumour cells survive and initiate a metastatic focus [1].

The fundamental characteristic of micrometastasis is the absence of a specific blood supply. Micrometastases are thus dependent on passive diffusion for oxygen and nutrient supply. Experimental studies have shown that without new blood vessel formation (neovascularisation), the growth of tumour cells is limited to 2–3 mm and may remain dormant for months or even years. During dormancy, the proliferation is balanced by an equivalent rate of cell death by apoptosis. After induction of neovascularisation, apoptosis is significantly reduced, but the proliferation rate remains unchanged, and the growth of the clinically overt metastasis can occur because of the increased survival of the tumour cells [158].

Micrometastases can be detected anywhere in the body, but most frequently in the lymph nodes, in the surgical margins, in the blood and in bone marrow [112]. Their detection can be accomplished by serial sectioning light microscopy, immunohistochemistry, and/or molecular analysis [35, 112, 130, 146].

The clinical and prognostic implication of micrometastases is still uncertain. It has been suggested that residual micrometastatic tumour cells may increase the risk of tumour recurrence, thus resulting in failure of the primary treatment. Furthermore, the presence of tumour cells in the blood and/or bone marrow may be an indicator of a generalised disease with possible dissemination to many organs [163]. Several studies have demonstrated that lymph node micrometastases are associated with a high risk of recurrence and poor survival in patients with carcinoma of the breast, oesophagus, stomach, colon and lung [163], but few studies have been focused on the clinical significance of micrometastases in SCCs of the head and neck [112, 379].

It appears that the detection of micrometastases is a promising approach that might enable us to identify candidates for adjuvant treatment strategies [163]. However, further studies are needed to define more precisely the clinical implication of micrometastases, as well as the most appropriate method for their detection.

1.6 Molecular Pathology of Squamous Cell Carcinoma

Malignant tumours arise clonally from transformed cells that have undergone specific genetic alterations in tumour suppressor genes and proto-oncogenes [117], as well as telomerase re-activation [225, 226, 256]. Loss of chromosomal region 9p21 is the most common genetic change in head and neck carcinogenesis with consequent inactivation of the p16 gene [168, 169]. A frequent event is also mutation of the p53 gene located at 17p13; it occurs in approximately 50% of patients with SCCs of the head and neck [255, 257, 270]. Loss of retinoblastoma gene (Rb1) expression is seen in less than 20% of cases, although LOH at 13q14 is present in 60% or more of SCCs, suggesting the existence of (an)other tumour suppressor gene(s) neighbouring Rb1 [256].

The activation of oncogenes also occurs, such as cyclin D1 amplification, which has been described in one-third of patients with SCCs of the head and neck, and is associated with advanced disease [167, 272]. Amplification of other oncogenes, e.g. c-myc and epidermal growth factor receptor, has also been described in 6–25% of patients with SCCs of the head and neck [119, 121, 269], while ras mutations probably do not play a significant role in the development of head and neck SCCs [119].

Molecular pathology has significantly deepened our insight into genetic alterations occurring in and being probably responsible for cancer development. Moreover, it offers the opportunity for tissue characterisation, i.e. detection of tumour cells, distinction between multiple primary tumours and metastatic disease, and the risk of progression of premalignant lesions, going beyond morphological techniques that have been used in pathology until now. The question remains, however, whether there is any practical impact of these new techniques regarding diagnosis, prognosis and management.

1.6.1 Detecting Tumour Cells

The introduction of methods more sensitive than histology for detecting tumour cells in surgical margins and lymph nodes could be helpful in obtaining better treatment results for patients with SCCs of the head and neck [53, 261, 361]. Their application, however, requires some critical remarks.

First, if histology is inadequate for reliable margin assessment, a lot of cases of SCC of the head and neck that have been classified as tumour-free after surgery by this method should nevertheless show recurrence at the site from which the tumour was removed.

Secondly, the usefulness of molecular detection of tumour cells in lymph nodes should be demonstrated by transferring patients from the histopathologically assessed N0 stage to the N+ stage. Merely detecting addi-

tional positive nodes in patients already classified as N+ is of debatable value.

In the third place, genetically altered cells are not always tumour cells. The whole epithelial lining of the upper aerodigestive tract bears the genetic burden of the carcinogenetic agents that cause SCCs and, therefore, these cells could have arisen independently from the invasive tumour [50, 268].

Also, there is no uniformity as to what constitutes a positive or negative surgical margin [26]. There is a broad spectrum of histological appearance between normal epithelium and fully developed SCC. If genetically altered cells are found in areas free of tumour but with atypical hyperplasia (severe dysplasia), molecular pathology does not provide any information compared with conventional microscopical examination.

In a recently published study, the value of molecular pathology was compared with traditional histology in the assessment of surgical margins and neck nodes in patients with SCCs of the head and neck [326]. It was found that from patients with microscopically positive margins, 22% had recurrence at the primary site. In contrast, of the cases with histologically tumour-free margins, only 4% showed recurrence of the tumour at the primary site. The authors concluded that conventional histology adequately identifies patients with SCCs of the head and neck at risk of local recurrence, leaving only very limited room for improvement using more sophisticated methods.

Regarding the neck, local recurrence was observed in 12 out of 107 cases in which a previous neck dissection was reported to be tumour-free. These neck recurrences could be due to the presence of micrometastases not detected by microscopy and improved methods for detecting them may reduce this number. However, it is still uncertain whether micrometastatic disease has the same clinical significance as metastatic disease detected by conventional methods [104].

The authors concluded that the added clinical value of molecular pathology over histology in detecting tumour cells in surgical margins in SCCs of the head and neck does not justify the effort. For lymph nodes, such an added value is still under discussion [326].

1.6.2 Clonal Analysis

Patients with SCCs of the head and neck are at risk of the development of multiple primary SCCs, not only in the head and neck region, but also in the lung. Therefore, it is not always clear whether a patient who has multiple lesions either synchronically or metachronically suffers from one single disseminated disease or from multiple primary cancers. If all tumour deposits show SCC, histology cannot distinguish between both possibilities whereas both situations require different treatment approaches. If histologically similar tumours differ geneti-

cally, molecular pathology could be decisive in making the distinction. Such a clonal marker should be different in different tumours and not subject to alterations during tumour progression and metastasis. The p53 gene meets these requirements; other markers such as loss of heterozygosity analysis are less stable [271, 347, 358, 359]. Only in tumours lying close to each other p53 mutation analysis may be unreliable as separate tumours developing within a single neoplastic field may have the same p53 mutation [50]. This, however, does not detract from the main value of p53 gene analysis as a tool to distinguish between lung lesions as distant metastasis from SCCs of the head and neck or second primary cancer in the lung.

1.6.3 Assessment of Risk of Malignant Progression

Squamous cell carcinomas of the head and neck may be preceded by premalignant alterations showing epithelial changes of varying degrees. Molecular pathology has been shown to be helpful in identifying lesions at risk of further malignant progression. Chromosomal losses at loci 3p and 9p have been shown to occur in mucosal lesions that subsequently turned into cancer, but as not all of the lesions with these genetic alterations progress, other changes also play a role: additional chromosomal losses, chromosomal polysomies and p53 protein expression [204, 306]. Also, suprabasal expression of p53 protein and the presence of cells with abnormal DNA content predict malignant transformation, even in the absence of overt morphologic epithelial alterations [82, 344].

1.6.4 DNA/RNA Profiling in Predicting Metastatic Disease

DNA alterations and RNA expression profiles could be useful in distinguishing between patients with SCCs of the head and neck with and without lymph node metastasis, thus diminishing the number of elective neck dissections in N0 patients. Data on this issue are just beginning to appear. Their application in patient management lies in the future [81, 148].

References

- Abati A, Liotta LA (1996) Looking forward in diagnostic pathology. The molecular superhighway. *Cancer* 78:1–3
- Abbey LM, Page DG, Sawyer DR (1980) The clinical and histopathologic features of a series of 464 oral squamous cell papillomas. *Oral Surg Oral Med Oral Pathol* 49:419–428
- Abramson AL, Parisier SC, Zamansky MJ, Sulka M (1971) Distant metastases from carcinoma of the larynx. *Laryngoscope* 81:1503–1511
- Abramson AL, Steinberg BM, Winkler B (1987) Laryngeal papillomatosis: clinical, histopathologic and molecular studies. *Laryngoscope* 97:678–685
- Ackerman LV (1948) Verrucous carcinoma of the oral cavity. *Surgery* 23:670–678
- Aden KK, Niehans G, Adams GL, Abdel-Fattah HM (1988) Adenosquamous carcinoma of the larynx and hypopharynx with five new case presentations. *Trans Am Laryngol Assoc* 109:216–221
- Alavi S, Namazie A, Sercarz JA, Wang MB, Blackwell KE (1999) Distant lymphatic metastasis from head and neck cancer. *Ann Otol Laryngol* 108:860–863
- Alos L, Castillo M, Nadal A, Caballero M, Mallofre C, Palacin A, Cardesa A (2004) Adenosquamous carcinoma of the head and neck: criteria for diagnosis in a study of 12 cases. *Histopathology* 44:1–10
- Altavilla G, Mannara GM, Rinaldo A, Ferlito A (1999) Basaloid squamous cell carcinoma of oral cavity and oropharynx. *ORL J Otorhinolaryngol Relat Spec* 61:169–173
- Alvi A, Johnson JT (1996) Extracapsular spread in the clinically negative neck (N0): implications and outcome. *Otolaryngol Head Neck Surg* 114:65–70
- Ambrosch P, Bricbeck U (1996) Detection of nodal micrometastasis in head and neck cancer by serial sectioning and immunostaining. *Oncology* 10:1221–1226
- Ambrosch P, Schlott T, Hilmes D, Ruschenburg I (2001) p16 alterations and retinoblastoma protein expression in squamous cell carcinoma and neighboring dysplasia from the upper aerodigestive tract. *Virchows Arch* 438:343–349
- Ansari-Lari MA, Hoque MO, Califano J, Westra WH (2002) Immunohistochemical p53 expression patterns in sarcomatoid carcinomas of the upper respiratory tract. *Am J Surg Pathol* 26:1024–1031
- Axell T, Pindborg JJ, Smith CJ, van der Waal I (1996) Oral white lesions with special reference to precancerous and tobacco-related lesions: conclusions of an international symposium held in Uppsala, Sweden, May 18–21 1994. International Collaborative Group on Oral White Lesions. *J Oral Pathol Med* 25:49–54
- Azarin D, Rodriguez-Peralta JL, Garcia-Garcia E, Salamanca J (2003) Cutaneous papillary squamous cell carcinoma. Report of three new cases and review of the literature. *Virchows Arch* 442:298–302
- Azzimonti B, Hertel L, Aluffi P, Pia F, Monga G, Zocchi M, Landolfo S, Gariglio M (1999) Demonstration of multiple HPV types in laryngeal premalignant lesions using polymerase chain reaction and immunohistochemistry. *J Med Virol* 59:110–116
- Balažic J, Mašera A, Poljak M (1997) Sudden death caused by laryngeal papillomatosis. *Acta Otolaryngol* 527:111–113
- Banerjee SS, Eyden BP, Wells S, McWilliam LJ, Harris M (1992) Pseudoangiosarcomatous carcinoma – a clinicopathological study of 7 cases. *Histopathology* 21:13–23
- Banks ER, Frierson HF, Mills SE, George E, Zarbo RJ, Swanson PE (1992) Basaloid squamous cell carcinoma of the head and neck. *Am J Surg Pathol* 16:939–946
- Barnes L (2001) Diseases of the larynx, hypopharynx, and esophagus. In: Barnes' surgical pathology of the head and neck, 2nd edn. Dekker, New York, pp 128–237
- Barnes L, Ferlito A, Altavilla G, MacMillan C, Rinaldo A, Doglioni C (1996) Basaloid squamous cell carcinoma of the head and neck: clinicopathologic features and differential diagnosis. *Ann Otol Rhinol Laryngol* 105:75–82
- Barnes L, Yunis EJ, Krebs FJ III, Sonmez-Alpan E (1991) Veruca vulgaris of the larynx. Demonstration of human papillomavirus types 6/11 by in situ hybridization. *Arch Pathol Lab Med* 115:895–899
- Barona de Guzman R, Martorell MA, Basterra J, Armengot M, Montoro A, Montoro J (1993) Analysis of DNA content in supraglottic epidermoid carcinoma. *Otolaryngol Head Neck Surg* 108:706–710
- Barrett AW, Kingsmill VJ, Speight PM (1998) The frequency of fungal infection in biopsies of oral mucosal lesions. *Oral Dis* 4:26–31

25. Barzan L, Talamini R (1996) Analysis of prognostic factors for recurrence after neck dissection. *Arch Otolaryngol Head Neck Surg* 122:1299–1302
26. Batsakis JG (1999) Review article. Surgical excision margins. A pathologist's perspective. *Adv Anat Pathol* 3:140–148
27. Batsakis JG, Huser J (1990) Squamous carcinomas with glandlike (adenoid) features. *Ann Otol Rhinol Laryngol* 99:87–88
28. Batsakis JG, Raymond AK, Rice DH (1983) The pathology of head and neck tumors: papillomas of the upper aerodigestive tracts. *Head Neck Surg* 5:332–344
29. Batsakis JG, Rice DH, Howard DR (1982) The pathology of head and neck tumors: spindle cell lesions (sarcomatoid carcinomas, nodular fasciitis and fibrosarcoma) of the aerodigestive tracts. *Head Neck Surg* 4:499–513
30. Batsakis JG, Suarez P (2000) Papillary squamous carcinomas: will the real one please stand up? *Adv Anat Pathol* 7:2–8
31. Batsakis JG, Suarez P (2000) Sarcomatoid carcinomas of the upper aerodigestive tract. *Adv Anat Pathol* 7:282–293
32. Batsakis JG, Suarez P, el-Naggar AK (1999) Proliferative verrucous leukoplakia and its related lesions. *Oral Oncol* 35:354–359
33. Battifora H (1976) Spindle cell carcinoma: ultrastructural evidence of squamous origin and collagen production by tumor cells. *Cancer* 37:2275–2282
34. Bauman NM, Smith RJ (1996) Recurrent respiratory papillomatosis. *Pediatr Clin North Am* 43:1385–1401
35. Becker MT, Shores CG, Yu KK, Yarbrough WG (2004) Molecular assay to detect metastatic head and neck squamous cell carcinoma. *Arch Otolaryngol Head Neck Surg* 130:21–27
36. Berthelet E, Shenouda G, Black MJ, Picariello M, Rochon L (1994) Sarcomatoid carcinoma of the head and neck. *Am J Surg* 168:455–458
37. Blackburn TK, Macpherson D, Conroy B (1999) Primary adenoid squamous cell carcinoma of the upper lip associated with locoregional metastasis: a case report and review of the literature. *J Oral Maxillofac Surg* 57:612–616
38. Blackwell KE, Calcaterra TC, Fu YS (1995) Laryngeal dysplasia: epidemiology and treatment outcome. *Ann Otol Rhinol Laryngol* 104:596–602
39. Blackwell KE, Fu YS, Calcaterra TC (1995) Laryngeal dysplasia. A clinicopathologic study. *Cancer* 75:457–463
40. Boerman RH, Maasen EM, Joonsten J, Kaanders HAM, Marres AM, van Overbeek J, De Wilde P (1999) Trigeminal neuropathy secondary to perineural invasion of head and neck carcinomas. *Neurology* 53:213–217
41. Bombi JA, Riverola A, Bordas JM, Cardesa A (1991) Adenosquamous carcinoma of the esophagus. A case report. *Pathol Res Pract* 187:514–519
42. Boring CC, Squires TS, Tong T (1991) Cancer statistics, 1991. *CA Cancer J Clin* 41:19–36
43. Boston M, Derkey CS (2003) Recurrent respiratory papillomatosis. *Clin Pulm Med* 10:10–16
44. Boswell JT, Helwig EB (1965) Squamous cell carcinoma and adenoacanthoma of the stomach. A clinicopathologic study. *Cancer* 18:181–192
45. Bouda M, Gorgoulis VG, Kastrinakis NG, Giannoudis A, Tsoli E, Danassi-Afentaki D, Foukas P, Kyrouti A, Laskaris G, Herrington CS, Kittas C (2000) "High risk" HPV types are frequently detected in potentially malignant and malignant oral lesions, but not in normal oral mucosa. *Mod Pathol* 13:644–653
46. Bouquot JE (1994) Oral leukoplakia and erythroplakia: a review and update. *Pract Periodontics Aesthet Dent* 6:9–17
47. Bouquot JE, Ephros H (1995) Erythroplakia: the dangerous red mucosa. *Pract Periodontics Aesthet Dent* 7:59–67
48. Bouquot JE, Gnepp DR (1991) Laryngeal precancer: a review of the literature, commentary, and comparison with oral leukoplakia. *Head Neck* 13:488–497
49. Bouquot JE, Gorlin RJ (1986) Leukoplakia, lichen planus, and other oral keratoses in 23,616 white Americans over the age of 35 years. *Oral Surg Oral Med Oral Pathol* 61:373–381
50. Braakhuis BJM, Tabor MP, Leemans CR, Waal I van der, Snow GB, Brakenhoff RH (2002) Second primary tumours and field cancerization in oral and oropharyngeal cancer: molecular techniques provide new insights and definitions. *Head Neck* 24:198–206
51. Brambilla E, Moro D, Veale D, Brichon PY, Stoeber P, Paramelle B, Brambilla C (1992) Basal cell (basaloid) carcinoma of the lung: a new morphologic and phenotypic entity with separate prognostic significance. *Hum Pathol* 23:993–1003
52. Brandsma JL, Steinberg BM, Abramson AL, Winkler B (1986) Presence of human papillomavirus type 16 related sequences in verrucous carcinoma of the larynx. *Cancer Res* 46:2185–2188
53. Brennan JA, Mao L, Hruban RH, Boyle JO, Eby YJ, Koch WM, Goodman SN, Sidransky D (1995) Molecular assessment of histopathological staging in squamous-cell carcinoma of the head and neck. *N Eng J Med* 332:429–435
54. Brito H, Vassallo J, Altemani A (2000). Detection of human papillomavirus in laryngeal squamous dysplasia and carcinoma. An in situ hybridization and signal amplification study. *Acta Otolaryngol* 120:540–544
55. Browson RC, Chang JC (1987) Exposure to alcohol and tobacco and the risk of laryngeal cancer. *Arch Environ Health* 42:192–196
56. Bryan RL, Bevan IS, Crocker J, Young LS (1990) Detection of HPV 6 and 11 in tumors of the upper respiratory tract using the polymerase chain reaction. *Clin Otolaryngol* 15:177–180
57. Bryne M (1998) Is the invasive front of an oral carcinoma the most important area for prognostication? *Oral Dis* 4:70–77
58. Bryne M, Jenssen N, Boysen M (1995) Histologic grading in the deep invasive front of T1 and T2 glottic squamous cell carcinomas has high prognostic value. *Virchows Arch* 427:277–281
59. Calhoun KH, Fulmer P, Weiss R, Hokanson JA (1994) Distant metastases from head and neck squamous cell carcinomas. *Laryngoscope* 104:1199–1205
60. Califano J, van der Riet P, Westra W, Nawroz H, Clayman G, Piantadosi S, Corio R, Lee D, Greenberg B, Koch W, Sidransky D (1996) Genetic progression model for head and neck cancer: implications for field cancerization. *Cancer Res* 56:2488–2492
61. Carlos R, Sedano HO (1994) Multifocal papilloma virus epithelial hyperplasia. *Oral Surg Oral Med Oral Pathol* 77:631–635
62. Carter RL, Barr LC, O'Brien CJ, Soo KC, Shaw HK (1985) Transcapsular spread of metastatic squamous cell carcinoma from cervical lymph nodes. *Am J Surg* 150:495–499
63. Cazorla M, Hernandez L, Nadal A, Balbin M, Lopez JM, Vizoso F, Fernandez PL, Iwata K, Cardesa A, Lopez-Otin C, Campo E (1998) Collagenase-3 expression is associated with advanced local invasion in human squamous cell carcinomas of the larynx. *J Pathol* 186:144–150
64. Chen YK, Hsue SS, Lin LM (2003) Immunohistochemical demonstration of p63 in DMBA-induced hamster buccal pouch squamous cell carcinogenesis. *Oral Dis* 9:235–240
65. Cho KJ, Jang JJ, Lee SS, Zo JI (2000) Basaloid squamous carcinoma of the oesophagus: a distinct neoplasm with multipotential differentiation. *Histopathology* 36:331–340
66. Choi HR, Sturgis EM, Rosenthal DI, Luna MA, Batsakis JG, El-Naggar AK (2003) Sarcomatoid carcinoma of the head and neck. Molecular evidence for evolution and progression from conventional squamous cell carcinoma. *Am J Surg Pathol* 27:1216–1220
67. Chow TL, Chow TK, Lui YH, Sze WM, Yuen NWF, Kwok SPY (2002) Lymphoepithelioma-like carcinoma of oral cavity: report of three cases and literature review. *Int J Oral Maxillofac Surg* 31:212–218
68. Cihak RW, Kawashima T, Steer A (1972) Adenoacanthoma (adenosquamous carcinoma) of the pancreas. *Cancer* 29:1133–1140
69. Coletta RD, Cotrim P, Almeida OP, Alves VAF, Wakamatsu A, Vargas PA (2002) Basaloid squamous carcinoma of oral cavity: a histologic and immunohistochemical study. *Oral Oncol* 38:723–729

70. Cook JR, Hill DA, Humphrey PA, Pfeifer JD, El-Mofty SK (2000) Squamous cell carcinoma arising in recurrent respiratory papillomatosis with pulmonary involvement: emerging common pattern of clinical features and human papillomavirus serotype association. *Mod Pathol* 13:914–918
71. Cooper JR, Hellquist H, Michaels L (1992) Image analysis in the discrimination of verrucous carcinoma and squamous papilloma. *J Pathol* 166:383–387
72. Coppola D, Catalano E, Tang CK, Efenbein IB, Harwick R, Mohr R (1993) Basaloid squamous cell carcinoma of floor of mouth. *Cancer* 72:2299–2305
73. Cör A, Gale N, Kambič V (1997) Quantitative pathology of laryngeal epithelial hyperplastic lesions. *Acta Otolaryngol* 527:57–61
74. Crissman JD, Gluckman JL, Whitely J, Quernelle D (1980) Squamous cell carcinoma of the floor of the mouth. *Head Neck Surg* 3:2–7
75. Crissman JD, Kessis T, Shah KV, Fu YS, Stoler MH, Zarbo RJ, Weiss MA (1988) Squamous papillary neoplasia of the adult upper aerodigestive tract. *Hum Pathol* 19:1387–1396
76. Crissman JD, Liu MY, Gluckman J, Cummings G (1984). Prognostic value of histopathologic parameters in squamous cell carcinoma of the oropharynx. *Cancer* 54:2995–3001
77. Crissman JD, Sakr WA (2001) Squamous neoplasia of the upper aerodigestive tract. In: Pilch BZ (ed) *Head and neck surgical pathology*. Lippincott Williams & Wilkins, Philadelphia, pp 34–52
78. Crissman JD, Visscher DW, Sakr W (1993) Premalignant lesions of the upper aerodigestive tract: pathologic classification. *J Cell Biochem* 17:49–56
79. Crissman JD, Zarbo RJ (1989) Dysplasia, in situ carcinoma, and progression to invasive squamous cell carcinoma of the upper aerodigestive tract. *Am J Surg Pathol* 13:5–16
80. Crissman JD, Zarbo RJ, Drozdowicz S, Jacobs J, Ahmad K, Weaver A (1988) Carcinoma in situ and microinvasive squamous carcinoma of the laryngeal glottis. *Arch Otolaryngol Head Neck Surg* 114:299–307
81. Cromer A, Carles A, Millon R, Ganguli G, Chalmel F, Lemaire F, Young J, Dembélé D, Thibault C, Muller D, Poch O, Abecassis J, Wasyluk B (2004) Identification of genes associated with tumorigenesis and metastatic potential of hypopharyngeal cancer by microarray analysis. *Oncogene* 23:2484–2498
82. Cruz IB, Snijders PJF, Meijer CJ, Braakhuis BJ, Snow GB, Walboomers JM, van der Waal I (1998) P53 expression above the basal cell layer in oral mucosa is an early event of malignant transformation and has predictive value for developing oral squamous cell carcinoma. *J Pathol* 184:360–368
83. Damiani JM, Damiani KK, Hauck K, Hyams VJ (1981) Mucoepidermoid-adenosquamous carcinoma of the larynx and hypopharynx: a report of 21 cases and a review of the literature. *Otolaryngol Head Neck Surg* 89:235–243
84. De Bree R, Mehta DM, Snow GB, Quak JJ (2001) Intracranial metastases in patients with squamous cell carcinoma of the head and neck. *Otolaryngol Head Neck Surg* 124:217–221
85. De Carvalho MB (1998) Quantitative analysis of the extent of extracapsular invasion and its prognostic significance: a prospective study of 170 cases of carcinoma of the larynx and hypopharynx. *Head Neck* 20:16–21
86. De Stefani E, Oreggia F, Rivero S, Fierro L (1992) Hand-rolled cigarette smoking and risk of cancer of the mouth, pharynx and larynx. *Cancer* 70:679–682
87. Derkay CS (2001) Recurrent respiratory papillomatosis. *Laryngoscope* 111:57–69
88. Derkay CS, Darrow DH (2000) Recurrent respiratory papillomatosis of the larynx: current diagnosis and treatment. *Otolaryngol Clin North Am* 33:1127–1142
89. Derkay CS, Rimell FL, Thompson JW (1998) Recurrent respiratory papillomatosis. *Head Neck* 20:418–424
90. Dougherty BG, Evans HL (1985) Carcinoma of the anal canal: a study of 79 cases. *Am J Clin Pathol* 83:159–164
91. Doyle DJ, Gianoli GJ, Espinola T, Miller RH (1994) Recurrent respiratory papillomatosis: juvenile versus adult forms. *Laryngoscope* 104:523–527
92. Doyle DJ, Henderson LA, LeJeune FE Jr, Miller RH (1994) Changes in human papillomavirus typing of recurrent respiratory papillomatosis progressing to malignant neoplasm. *Arch Otolaryngol Head Neck Surg* 120:1273–1276
93. Dubey P, Ha CS, Ang KK, El-Naggar AK, Knapp C, Byers RM, Morrison WH (1998) Nonnasopharyngeal lymphoepithelioma of the head and neck. *Cancer* 82:1556–1562
94. Dvorak HF (1986) Tumors: wounds that do not heal. *N Engl J Med* 315:1650–1659
95. Edstrom S, Johansson SL, Lindstrom J, Sandin I (1987) Verrucous squamous cell carcinoma of the larynx: evidence for increased metastatic potential after irradiation. *Otolaryngol Head Neck Surg* 97:381–384
96. Ellis GL, Langloss JM, Heffner DK, Hyams VJ (1987) Spindle-cell carcinoma of the aerodigestive tract. An immunohistochemical analysis of 21 cases. *Am J Surg Pathol* 11:335–342
97. El-Mofty SK, Lu DW (2003) Prevalence of human papillomavirus type 16 DNA in squamous cell carcinoma of the palatine tonsil, and not the oral cavity, in young patients: a distinct clinicopathologic and molecular disease entity. *Am J Surg Pathol* 27:1463–1470
98. El-Naggar AK, Dinh M, Tucker S, Luna MA, Goepfert H, Hsu P, Batsakis JG (1996) Genotypic analysis of primary head and neck squamous carcinoma by combined fluorescence in situ hybridization and DNA flow cytometry. *Am J Clin Pathol* 105:102–108
99. Ereño C, Lopez JJ, Sanchez JM, Bilbao FJ (2001) Papillary squamous cell carcinoma of the larynx. *J Laryngol Otol* 115:164–166
100. Eversole LR, Laipis PJ, Merrell P, Choi E (1987) Demonstration of human papillomavirus DNA in oral condyloma acuminatum. *J Oral Pathol* 16:266–272
101. Fagan JJ, Collins B, Barnes L, D'Amico F, Myers EN, Johnson JT (1998) Perineural invasion in squamous cell carcinoma of the head and neck. *Arch Otolaryngol Head Neck Surg* 124:637–640
102. Faridoni-Laurens L, Bosq J, Janot F, Vayssade M, Le Bihan ML, Kaghad M, Caput D, Benard J, Ahomadegbe JC (2001) P73 expression in basal layers of head and neck squamous epithelium: a role in differentiation and carcinogenesis in concert with p53 and p63? *Oncogene* 20:5302–5312
103. Ferlito A, Altavilla G, Rinaldo A, Doglioni C (1997) Basaloid squamous cell carcinoma of the larynx and hypopharynx. *Ann Otol Rhinol Laryngol* 106:1024–1035
104. Ferlito A, Devaney KO, Devaney SL, Rinaldo A, Carbone A (1999) Clinicopathological consultation. Micrometastases: have they an impact on prognosis? *Ann Otol Rhinol Laryngol* 108:1185–1189
105. Ferlito A, Devaney KO, Rinaldo A, Milroy CM, Carbone A (1996) Clinicopathological consultation. Mucosal adenoid squamous cell carcinoma of the head and neck. *Ann Otol Rhinol Laryngol* 105:409–413
106. Ferlito A, Partridge M, Brennan J, Hamakawa H (2001) Lymph node micrometastasis in the head and neck cancer: a review. *Acta Otolaryngol* 121:660–665
107. Ferlito A, Recher G (1980) Ackerman's tumor (verrucous carcinoma) of the larynx: a clinicopathologic study of 77 cases. *Cancer* 46:1617–1630
108. Ferlito A, Rinaldo A, Devaney KO, Devaney SL, Milroy CM (1998) Impact of phenotype on treatment and prognosis of laryngeal malignancies. *J Laryngol Otol* 112:710–714
109. Ferlito A, Rinaldo A, Devaney KO, MacLennan K, Myers JN, Petruzzelli GJ, Shaha AR, Genden EM, Johnson JT, de Carvalho MB, Myers EN (2002) Prognostic significance of microscopic and macroscopic extracapsular spread from metastatic tumor in the cervical lymph nodes. *Oral Oncol* 38:747–751
110. Ferlito A, Rinaldo A, Devaney KO, Putzi MT (1999) Papillary squamous cell carcinoma versus verrucous squamous cell carcinoma of the head and neck. *Ann Otol Rhinol Laryngol* 108:318–322
111. Ferlito A, Rinaldo A, Robbins KT, Leemans CR, Shah JP, Shaha AR, Andersen PE, Kowalski LP, Pellitteri PK, Clayman GL, Rogers SN, Medina JE, Byers RM (2003) Changing con-

- cepts in the surgical management of the cervical node metastasis. *Oral Oncol* 39:429–435
112. Ferlito A, Shaha AR, Silver CE, Rinaldo A, Mondin V (2001) Incidence and sites of distant metastases from head and neck cancer. *ORL J Otorhinolaryngol Relat Spec* 63:202–207
 113. Ferlito A, Weiss CM, Rinaldo A, Carbone A, Devaney KO, MacMillan C, Barnes L (1997) Clinicopathologic consultation. Lymphoepithelial carcinoma of the larynx, hypopharynx and trachea. *Ann Otol Rhinol Laryngol* 106:437–444
 114. Fetting A, Pogrel MA, Silverman S Jr, Bramanti TE, Da Costa M, Regezi JA (2000) Proliferative verrucous leukoplakia of the gingiva. *Oral Surg Oral Med Oral Pathol Oral Radiol Endod* 90:723–730
 115. Fiorella R, Di Nicola V, Resta L (1997) Epidemiological and clinical relief on hyperplastic lesions of the larynx. *Acta Otolaryngol Suppl* 527:77–81
 116. Fliss DM, Noble-Topham SE, McLachlin CM, Freeman JL, Noyek AM, van Nostrand AWP, Hartwick WJ (1994) Laryngeal verrucous carcinoma: a clinicopathologic study and detection of human papillomavirus using polymerase chain reaction. *Laryngoscope* 104:146–152
 117. Forastiere A, Koch W, Trotti A, Sidransky D (2001) Head and neck cancer. *N Engl J Med* 345:1890–1900
 118. Fouret P, Dabit D, Sibony M, Alili D, Commo F, Saint-Guilly JL, Callard P (1995) Expression of p53 protein related to the presence of human papillomavirus infection in precancer lesions of the larynx. *Am J Pathol* 146:599–604
 119. Fracchiolla NS, Pignataro L, Capaccio P, Trecca D, Boletini A, Ottaviani A, Polli E, Maiolo AT, Neri A (1995) Multiple genetic lesions in laryngeal squamous cell carcinomas. *Cancer* 75:1292–1301
 120. Frank DK, Cheron F, Cho H, DiConstanzo D, Sclafani AP (1995) Nonnasopharyngeal lymphoepitheliomas (undifferentiated carcinomas) of the upper aerodigestive tract. *Ann Otol Rhinol Laryngol* 104:305–310
 121. Freier K, Joos S, Flechtenmacher C, Devens F, Benner A, Bosch FX, Lichter P, Hafele C (2003) Tissue microarray analysis reveals site-specific prevalence of oncogene amplifications in head and neck squamous cell carcinoma. *Cancer Res* 63:1179–1182
 122. Friedmann I, Ferlito A (1993) Precursors of squamous cell carcinoma. In: Ferlito's neoplasms of the larynx. Churchill Livingstone, Edinburgh, pp 97–111
 123. Frierson HF, Bellafiore FJ, Gaffey MJ, McCary WS, Innes DJ, Williams ME (1994) Cytokeratin in anaplastic cell large cell lymphoma. *Mod Pathol* 7:317–321
 124. Fujino K, Ito J, Kanaji M, Shiomi Y, Saiga T (1995) Adenosquamous carcinoma of the larynx. *Am J Otolaryngol* 16:115–118
 125. Gale N, Kambič V, Michaels L, Cardesa A, Hellquist H, Zidar N, Poljak M (2000) The Ljubljana classification: a practical strategy for the diagnosis of laryngeal precancerous lesions. *Adv Anat Pathol* 7:240–251
 126. Gale N, Poljak M, Kambič V, Ferluga D, Fischinger J (1994) Laryngeal papillomatosis: molecular, histopathological, and clinical evaluation. *Virchows Arch* 425:291–295
 127. Gale N, Zidar N, Kambič V, Poljak M, Cör A (1997) Epidermal growth factor receptor, c-erbB-2 and p53 overexpressions in epithelial hyperplastic lesions of the larynx. *Acta Otolaryngol* 527:105–110
 128. Gallo O, Bianchi S, Giannini A, Boccuzzi S, Calzolari A, Fini-Storchi O (1994) Lack of detection of human papillomavirus (HPV) in transformed laryngeal keratosis by in situ hybridization (ISH) technique. *Acta Otolaryngol* 114:213–217
 129. Gallo O, Franchi A, Chiarelli I, Porfirio B, Grande A, Simonetti L, Bocciolini C, Fini-Storchi O (1997) Potential biomarkers in predicting progression of epithelial hyperplastic lesions of the larynx. *Acta Otolaryngol Suppl* 527:30–38
 130. Genden EM, Ferlito A, Bradley PJ, Rinaldo A, Scully C (2003) Neck disease and distant metastases. *Oral Oncol* 39:207–212
 131. Gerughty RM, Hennigar GR, Brown FM (1968) Adenosquamous carcinoma of the nasal, oral and laryngeal cavities: a clinicopathologic survey of ten cases. *Cancer* 22:1140–1155
 132. Gluckmann A, Cherry CP (1956) Incidence, histology, and response to radiation of mixed carcinomas (adenocarcinomas) of the uterine cervix. *Cancer* 9:971–979
 133. Go C, Schwartz MR, Donovan DT (2003) Molecular transformation of recurrent respiratory papillomatosis: viral typing and p53 overexpression. *Ann Otol Rhinol Laryngol* 112:298–302
 134. Goes FCGD, Oliviera DT, Dorta RG, Nishimoto IN, Landman G, Kowalski LP (2004) Prognoses of oral basaloid squamous cell carcinoma and squamous cell carcinoma – a comparison. *Arch Otolaryngol* 130:83–86
 135. Goldman RL, Klein HZ, Sung M (1977) Adenoid squamous cell carcinoma of the oral cavity: report of the first case arising in the tongue. *Arch Otolaryngol* 103:496–498
 136. Gorgoulis V, Rassidakis G, Karameris A, Giatromanolaki A, Barbatis C, Kittas C (1994) Expression of p53 protein in laryngeal squamous cell carcinoma and dysplasia: possible correlation with human papillomavirus infection and clinicopathological findings. *Virchows Arch* 425:481–489
 137. Gorgoulis VG, Zacharatos P, Kotsinas A, Kyroutdi A, Rassidakis AN, Ikonomopoulos JA, Barbatis C, Herrington CS, Kittas C (1999) Human papilloma virus (HPV) is possibly involved in laryngeal but not in lung carcinogenesis. *Hum Pathol* 30:274–283
 138. Grasl MCH, Neuwirth-Riedl K, Vutuc C, Horak F, Vorbeck F, Banyai M (1990) Risk of vocal cord dysplasia in relation to smoking, alcohol intake and occupation. *Eur J Epidemiol* 6:45–48
 139. Gray MH, Rosenberg AE, Dickersin GR, Bhan AK (1990) Cytokeratin expression in epitheloid vascular neoplasms. *Hum Pathol* 21:212–217
 140. Grayson W, Cooper K (2002) A reappraisal of “basaloid carcinoma” of the cervix, and the differential diagnosis of basaloid cervical neoplasms. *Adv Anat Pathol* 5:290–300
 141. Green GE, Bauman NM, Smith RJ (2000) Pathogenesis and treatment of juvenile onset recurrent respiratory papillomatosis. *Otolaryngol Clin North Am* 33:187–207
 142. Green TL, Eversole LR, Leider AS (1986) Oral and labial verruca vulgaris: clinical, histologic and immunohistochemical evaluation. *Oral Surg Oral Med Oral Pathol* 62:410–416
 143. Guillou L, Sahli R, Chaubert P, Monnier P, Cuttat JF, Costa J (1991) Squamous cell carcinoma of the lung in a nonsmoking, nonirradiated patient with juvenile laryngotracheal papillomatosis. Evidence of human papillomavirus-11 DNA in both carcinoma and papillomas. *Am J Surg Pathol* 15:891–898
 144. Ha PK, Califano JA (2002) The molecular biology of laryngeal cancer. *Otolaryngol Clin North Am* 35:993–1012
 145. Hagen P, Lyons GD, Haindel C (1993) Verrucous carcinoma of the larynx: role of human papillomavirus, radiation, and surgery. *Laryngoscope* 103:253–257
 146. Hamakawa H, Fukizumi M, Bao Y, Sumida T, Onishi A, Tanioka H, Sato H, Yumoto E (1999) Genetic diagnosis of micrometastasis based on SCC antigen mRNA in cervical lymph nodes of head and neck cancer. *Clin Exp Metastasis* 17:593–599
 147. Hamakawa H, Takemura K, Sumida T, Kayahara H, Tanioka H, Sogawa K (2000) Histological study on pN upgrading of oral cancer. *Virchows Arch* 437:116–121
 148. Hannen EJM, Macville MVE, Wienk SM, Slootweg PJ, Mani JJ, Hanselaar AGJM, de Wilde PCM (2004) Different chromosomal imbalances in metastasized and nonmetastasized tongue carcinomas identified by comparative genomic hybridization. *Oral Oncol* 40:364–371
 149. Haughey BH, Gates GA, Arkfen CL, Harvey J (1992) Meta-analysis of second tumours in head and neck cancer: the case for an endoscopic screening protocol. *Ann Otol Rhinol Laryngol* 101:105–112
 150. Hellquist H, Cardesa A, Gale N, Kambič V, Michaels L (1999) Criteria for grading in the Ljubljana classification of epithelial hyperplastic laryngeal lesions. A study by members of the Working group on Epithelial Hyperplastic Laryngeal Lesions of the European Society of Pathology. *Histopathology* 34:226–233

151. Hellquist H, Olofsson J (1989) Spindle cell carcinoma of the larynx. *APMIS* 97:1103–1113
152. Hellquist HB, Olofsson J (1988) Expression of low molecular weight cytokeratin proteins in laryngeal dysplasia. *APMIS* 96:971–978
153. Herrmann K, Niedobitek G (2003) Epstein-Barr virus-associated carcinomas; facts and fiction. *J Pathol* 199:140–145
154. Hewan-Lowe K, Dardick I (1995) Ultrastructural distinction of basaloid-squamous carcinoma and adenoid cystic carcinoma. *Ultrastruct Pathol* 19:371–381
155. Hirabayashi H, Koshii K, Uno K, Ohgaki H, Nakasone Y, Fujisawa T, Syouno N, Hinohara T, Hirabayashi K (1991) Extracapsular spread of squamous cell carcinoma in neck lymph nodes: prognostic factor of laryngeal cancer. *Laryngoscope* 101:501–506
156. Hirai T, Hayashi K, Takumida M, Ueda T, Hirakawa K, Yajin K (2003) Reduced expression of p27 is correlated with progression in precancerous lesions of the larynx. *Auris Nasus Larynx* 30:163–168
157. Hoffman GR, Hayter JP (2002) Widespread subcutaneous distant metastases from a head and neck squamous cell carcinoma. *J Oral Maxillofac Surg* 60:954–958
158. Holmgren L, O'Reilly S, Folkman J (1995) Dormancy of micrometastasis: balanced proliferation and apoptosis in the presence of angiogenesis. *Nat Med* 1:149–153
159. Ide F, Shimoyama T, Horie N, Kusama K (2002) Basaloid squamous cell carcinoma of the oral mucosa: new case and review of 45 cases in the literature. *Oral Oncol* 38:120–124
160. Iezzoni JC, Gaffey MJ, Weiss LM (1995) The role of Epstein-Barr virus in lymphoepithelioma-like carcinomas. *Am J Clin Pathol* 103:308–315
161. Ishiyama A, Eversole LR, Ross DA, Raz Y, Kerner MM, Fu YS, Blackwell KE, Feneberg R, Bell TS, Calcaterra TC (1994) Papillary squamous neoplasms of the head and neck. *Laryngoscope* 104:1446–1452
162. Izawa H, Yonemitsu N, Shin T, Sugihara H (1999) Histopathological analysis of apoptosis, and expression of p53, bcl-2, bax, and Ki-67 in laryngeal squamous cell carcinomas and dysplasia. *Auris Nasus Larynx* 26:317–330
163. Izbicki JR, Pantel K, Hosch SB (2002) Micrometastasis in solid epithelial tumors: impact on surgical oncology. *Surgery* 131:1–5
164. Izumi K, Nakajima T, Maeda T, Cheng J, Saku T (1998) Adenosquamous carcinoma of the tongue – report of a case with histochemical, immunohistochemical, and ultrastructural study and review of the literature. *Oral Surg Oral Med Oral Pathol Oral Radiol Endod* 85:178–184
165. Jaber MA, Porter SR, Gilthorpe MS, Bedi R, Scully C (1999) Risk factors for oral epithelial dysplasia – the role of smoking and alcohol. *Oral Oncol* 35:151–156
166. Janot F, Kljanienko J, Russo, Mamet JP, de Braud F, El-Nagar AK, Pignon JP, Luboinski B, Cvitkovic E (1996) Prognostic value of clinicopathologic parameters in head and neck squamous carcinoma: a prospective analysis. *Br J Cancer* 73:531–538
167. Jares P, Fernández PL, Campo E, Nadal A, Bosch F, Aiza G, Nayach I, Traserra J, Cardesa A (1994) PRAD-1/Cyclin D1 gene amplification correlates with messenger RNA overexpression and tumor progression in human laryngeal carcinomas. *Cancer Res* 54:4813–4817
168. Jares P, Fernández PL, Nadal A, Cazorla M, Hernández L, Pinyol M, Hernández S, Traserra J, Cardesa A, Campo E (1997) p16MTS1/CDK4I mutations and concomitant loss of heterozygosity at 9p21-23 are frequent events in squamous cell carcinoma of the larynx. *Oncogene* 15:1445–1453
169. Jares P, Nadal A, Fernandez PL, Pinyol M, Hernandez L, Cazorla M, Hernandez S, Bea S, Cardesa A, Campo E (1999) Disregulation of p16MTS1/CDK4I protein and mRNA expression is associated with gene alterations in squamous-cell carcinoma of the larynx. *Int J Cancer* 81:705–711
170. Johnson NW, Ranasinghe AW, Warnakulasuriya KA (1993) Potentially malignant lesions and conditions of the mouth and oropharynx: natural history-cellular and molecular markers of risk. *Eur J Cancer Prev* 2:31–51
171. Johnson NW, Warnakulasuriya S, Tavassoli M (1996) Hereditary and environmental risk factors; clinical and laboratory risk matters for head and neck, especially oral, cancer and precancer. *Eur J Cancer Prev* 5:5–17
172. Johnson TL, Plieth DA, Crissman JD, Sarkar FH (1991) HPV detection by polymerase chain reaction (PCR) in verrucous lesions of the upper aerodigestive tract. *Mod Pathol* 4:461–463
173. Jones AC, Freedman PD, Kerpel SM (1993) Oral adenoid squamous cell carcinoma: a report of three cases and review of the literature. *J Oral Maxillofac Surg* 51:676–681
174. Jones AS, Morar P, Phillips DE, Field JK, Husband D, Helliwell TR (1994) Second primary tumours in patients with head and neck cancer. *Cancer* 95:1343–1352
175. Jose J, Coatesworth AP, MacLennan K (2003) Cervical metastases in upper aerodigestive tract squamous cell carcinoma: histopathologic analysis and reporting. *Head Neck* 25:194–197
176. Jose J, Moor JW, Coatesworth AP, Johnston C, MacLennan K (2004) Soft tissue deposits in neck dissections of patients with head and neck squamous cell carcinoma. *Arch Otolaryngol Head Neck Surg* 130:157–160
177. Jyotirmayi R, Sankaranarayanan R, Varghese C, Jacob R, Krishnan Nair M (1997) Radiotherapy in the treatment of verrucous carcinoma of the oral cavity. *Oral Oncol* 33:124–128
178. Kambič V (1978) Difficulties in management of vocal cord precancerous lesions. *J Laryngol Otol* 92:305–315
179. Kambič V (1997) Epithelial hyperplastic lesions – a challenging topic in laryngology. *Acta Otolaryngol* 527:7–11
180. Kambič V, Gale N (1986) Significance of keratosis and dyskeratosis for classifying hyperplastic aberrations of laryngeal mucosa. *Am J Otolaryngol* 7:323–333
181. Kambič V, Gale N (1995) Epithelial hyperplastic lesions of the larynx. Elsevier, Amsterdam, pp 1–265
182. Kambič V, Gale N, Ferluga D (1992) Laryngeal hyperplastic lesions, follow-up study and application of lectins and anticytokeratins for their evaluation. *Pathol Res Pract* 188:1067–1077
183. Kambič V, Lenart I (1971) Our classification of hyperplasia of the laryngeal epithelium from the prognostic point of view. *J Fr Otorhinolaryngol Audiophonol Chir Maxillofac* 20:1145–1150
184. Kambič V, Radšel Z, Gale N (1989) Alterations in the laryngeal mucosa after exposure to asbestos. *Br J Ind Med* 46:717–723
185. Kambič V, Radšel Z, Preželj J, Žargi M (1984) The role of testosterone in laryngeal carcinogenesis. *Am J Otolaryngol* 5:344–349
186. Kinsky AA, Poljak M, Seme K, Kocjan BJ, Gale N, Luzar B, Golouh R (2003) Human papillomavirus DNA in oral squamous cell carcinomas and normal oral mucosa. *Acta Virol* 47:11–16
187. Kashima H, Mounts P, Leventhal B, Hruban RH (1993) Sites of predilection in recurrent respiratory papillomatosis. *Ann Otol Rhinol Laryngol* 102:580–583
188. Kashima HK, Mounts P, Shah K (1996) Recurrent respiratory papillomatosis. *Obstet Gynecol Clin North Am* 23:699–706
189. Kashima HK, Shah F, Lyles A, Glackin R, Muhammad N, Turner L, Van Zandt S, Whitt S, Shah K (1992) A comparison of risk factors in juvenile-onset and adult-onset recurrent respiratory papillomatosis. *Laryngoscope* 102:9–13
190. Kasperbauer JL, O'Halloran GL, Espy MJ, Smith TF, Lewis JE (1993) Polymerase chain reaction (PCR) identification of human papillomavirus (HPV) DNA in verrucous carcinoma of the larynx. *Laryngoscope* 103:416–420
191. Kaugars GE, Silverman S Jr, Lovas JG, Thompson JS, Brandt RB, Singh VN (1996) Use of antioxidant supplements in the treatment of human oral leukoplakia. *Oral Surg Oral Med Oral Pathol Oral Radiol Endod* 81:5–14
192. Keelawat S, Liu CZ, Roehm PC, Barnes L (2002) Adenosquamous carcinoma of the upper aerodigestive tract: a clinicopathologic study of 12 cases and review of the literature. *Am J Otolaryngol* 23:160–168

193. Kell MR, Winter DC, O'Sullivan GC, Shanaha F, Redmond HP (2000) Biological behaviour and clinical implications of micrometastasis. *Br J Surg* 87:1629–1639
194. Kleinsasser O (1988) Tumors of the larynx and hypopharynx. Thieme, Stuttgart, pp 61–123
195. Klijanienko J, El-Naggar A, Ponzio-Prion A, Marandas P, Micheau C, Caillaud JM (1993) Basaloid squamous carcinoma of the head and neck. Immunohistochemical comparison with adenoid cystic carcinoma and squamous cell carcinoma. *Arch Otolaryngol Head Neck Surg* 119:887–890
196. Koch BB, Trask DK, Hoffman HT, Karnell LH, Robinson RA, Zhen W, Menck HR (2001) National survey of head and neck verrucous carcinoma: pattern of presentation, care, and outcome. *Cancer* 92:110–120
197. Kolbusz RV, Goldberg LH (1994) Verrucous carcinoma of the oral cavity. *Int J Dermatol* 33:618–622
198. Kotwall C, Sako K, Razack MS, Rao U, Bakamjian V, Shedd DP (1987) Metastatic patterns in squamous cell cancer of the head and neck. *Am J Surg* 154:439–442
199. Krecicki T, Jelen M, Zalesska-Krecicka M, Szkudlarek T, Szajowski K (1999) Immunohistochemically stained markers (p53, PCNA, bcl-2) in dysplastic lesions of the larynx. *Cancer Lett* 143:23–28
200. Küffer R, Lombardi T (2002) Premalignant lesions of the oral mucosa. A discussion about the place of oral intraepithelial neoplasia (OIN). *Oral Oncol* 38:125–130
201. Kui LL, Xiu YZ, Ning LY (2003) Condyloma acuminatum and human papilloma virus infection in the oral mucosa of children. *Pediatr Dent* 25:149–153
202. Lam KY, Law S, Luk JM, Wong J (2001) Oesophageal basaloid squamous cell carcinoma: a unique clinicopathological entity with telomerase activity as a prognostic indicator. *J Pathol* 195:435–442
203. Lambert PR, Ward PH, Berci G (1980) Pseudosarcoma of the larynx: a comprehensive analysis. *Arch Otolaryngol* 106:700–708
204. Lee JJ, Hong WK, Hittelman WN, Mao L, Lotan R, Shin DM, Benner SE, Xu XC, Lee JS, Papadimitrakopoulou VM, Geyer C, Perez C, Martin JW, El-Naggar AK, Lippman SM (2000) Predicting cancer development in oral leukoplakia: ten years of translational research. *Clin Cancer Res* 6:1702–1710
205. Leifer C, Miller AS, Putong PB, Min BH (1974) Spindle cell carcinoma of oral mucosa: a light and electron microscopic study of apparent sarcomatous metastasis to cervical lymph nodes. *Cancer* 34:597–605
206. Lele SM, Pou AM, Ventura K, Gatalica Z, Payne D (2002) Molecular events in the progression of recurrent respiratory papillomatosis to carcinoma. *Arch Pathol Lab Med* 126:1184–1188
207. León X, Quer M, Diez S, Orús C, López-Pousa A, Burgués J (1998) Second neoplasm in patients with head and neck cancer. *Head Neck* 21:204–210
208. León X, Quer M, Orús C, del Prado Venegas M, López M (2000) Distant metastases in head and neck cancer patients who achieved loco-regional control. *Head Neck* 22:680–688
209. Leong AS, Brown JH (1984) Malignant transformation in a thymic cyst. *Am J Surg Pathol* 8:471–475
210. Leventon GS, Evans HL (1981) Sarcomatoid squamous cell carcinoma of the mucous membranes of the head and neck: a clinicopathologic study of 20 cases. *Cancer* 48:994–1003
211. Lever WF (1947) Adenoacanthoma of sweat glands: carcinoma of sweat glands with glandular and epidermal elements. Report of 4 cases. *Arch Dermatol Syphilol* 56:157–171
212. Levi JE, Delcelo R, Alberti VN, Torloni H, Villa LL (1989) Human papillomavirus DNA in respiratory papillomatosis detected by in situ hybridization and the polymerase chain reaction. *Am J Pathol* 135:1179–1184
213. Lewis JE, Olsen KD, Sebo TJ (1997) Spindle cell carcinoma of the larynx: review of 26 cases including DNA content and immunohistochemistry. *Hum Pathol* 28:664–673
- 213a. Lewis Jr JS, Ritter JH, El-Mofty S (2005) Alternative epithelial markers in sarcomatoid carcinomas of the head and neck, lung and bladder – p63, MOC-31, and TT-F1. *Modern Pathology* 18:1471–1481
214. Li W, Thompson CH, O'Brien CJ, McNeil EB, Scolyer RA, Cossart YE, Veness MJ, Walker DM, Morgan GJ, Rose BR (2003) Human papillomavirus positivity predicts favourable outcome for squamous carcinoma of the tonsil. *Int J Cancer* 106:553–558
215. Li WW, Pettit TH, Zakka KA (1980) Intraocular invasion by papillary squamous cell carcinoma of the conjunctiva. *Am J Ophthalmol* 90:697–701
216. Lindeberg H, Elbrond O (1989) Laryngeal papillomas: clinical aspects in a series of 231 patients. *Clin Otolaryngol* 14:333–342
217. Lindeberg H, Elbrond O (1990) Laryngeal papillomas: the epidemiology in a Danish subpopulation 1965–1984. *Clin Otolaryngol* 15:125–131
218. Lindeberg H, Elbrond O (1991) Malignant tumours in patients with a history of multiple laryngeal papillomas: the significance of irradiation. *Clin Otolaryngol* 16:149–151
219. Lindeberg H, Krogdahl A (1997) Laryngeal dysplasia and the human papillomavirus. *Clin Otolaryngol* 22:382–386
220. Liotta LA (1992) Cancer cell invasion and metastasis. *Sci Am* 266:54–59; 62–63
221. Liotta LA, Rao CN, Barsky SH (1983) Tumor invasion and the extracellular matrix. *Lab Invest* 49:636–649
222. Luna MA, El Naggar A, Parichatikanond P, Weber SR, Batsakis JG (1990) Basaloid squamous carcinoma of the upper aerodigestive tract. Clinicopathologic and DNA flow cytometric analysis. *Cancer* 66:537–542
223. Luna MA, Pineda-Daboin K (2001) Upper aerodigestive tract. In: Henson and Albores-Savedra's Pathology of incipient neoplasia, 3rd edn. Oxford, New York, pp 57–85
224. Lundgren JAV, van Nostrand AWP, Harwood AR, Cullen RJ, Bryce DP (1986) Verrucous carcinoma (Ackermans's tumor) of the larynx: diagnostic and therapeutic considerations. *Head Neck Surg* 9:19–26
225. Luzar B, Poljak M, Marin IJ, Eberlinc A, Klopčič U, Gale N (2004) Human telomerase catalytic subunit gene re-expression is an early event in oral carcinogenesis. *Histopathology* 45:13–19
226. Luzar B, Poljak M, Marin IJ, Gale N (2003) Telomerase re-activation is an early event in laryngeal carcinogenesis. *Mod Pathol* 16:841–848
227. MacMillan C, Kapadia SB, Finkelstein SD, Nalesnik MA, Barnes L (1996) Lymphoepithelial carcinoma of the larynx and hypopharynx: study of eight cases with relationship to Epstein-Barr virus and p53 gene alterations, and review of the literature. *Hum Pathol* 27:1172–1179
228. Maier H, Tisch M (1997) Epidemiology of laryngeal cancer: results of the Heidelberg case-control study. *Acta Otolaryngol Suppl* 527:160–164
229. Mallofré C, Cardesa A, Campo E, Condom E, Palacin A, Garrin-Chesa P, Traserra J (1993) Expression of cytokeratins in squamous cell carcinomas of the larynx: immunohistochemical analysis and correlation with prognostic factors. *Pathol Res Pract* 189:275–282
230. Mabelle G, Pampurik J, Luboinski B, Lancar R, Lusinchi A, Bosq J (1994) Lymph node prognostic factors in head and neck squamous cell carcinomas. *Am J Surg* 168:494–498
231. Mao L (1997) Leukoplakia: molecular understanding of premalignant lesions and implications for clinical management. *Mol Med Today* 3:442–448
232. Martin MR, Kahn LB (1977) So-called pseudosarcoma of the esophagus: nodal metastases of the spindle cell element. *Arch Pathol Lab Med* 101:604–609
233. Martinez-Gimeno C, Rodriguez EM, Villa CN, Varela CL (1995) Squamous carcinoma of the oral cavity: a clinicopathologic scoring system for evaluating risk of cervical lymph node metastasis. *Laryngoscope* 105:107–114
234. Martinez-Madrigal E, Baden E, Casiraghi O, Micheau C (1991) Oral and pharyngeal adenosquamous carcinoma. A report of four cases with immunohistochemical studies. *Eur Arch Otorhinolaryngol* 248:255–258
235. Mashberg A, Samit A (1995) Early diagnosis of asymptomatic oral and oropharyngeal squamous cancers. *CA Cancer J Clin* 45:328–351

236. McCaffrey TV, Witte M, Ferguson MT (1998) Verrucous carcinoma of the larynx. *Ann Otol Rhinol Laryngol* 107:391–395
237. McDonalds JS, Crissman JD, Gluckman JL (1982) Verrucous carcinoma of the oral cavity. *Head Neck Surg* 5:22–28
238. McKaig RG, Baric RS, Olshan AF (1998) Human papillomavirus and head and neck cancer. *Epidemiology and molecular biology. Head Neck* 20:250–265
239. McLaren KM, Burnett RA, Goodland JR, Howatson SR, Lang S, Lee FD, Lessells AM, Ogston S, Robertson AJ, Simpson JG, Smith GD, Tavadia HB, Walker F; The Scottish Pathology Consistency Group (2000) Consistency of histopathological reporting of laryngeal dysplasia. *Histopathology* 37:460–463
240. Medina JE, Dichtel W (1984) Verrucous carcinoma of the head and neck. *Arch Otolaryngol* 110:437–440
241. Meijer JW, Ramaekers FC, Manni JJ, Slooff JJ, Aldeweireldt J, Vooys GP (1988) Intermediate filament proteins in spindle cell carcinoma of the larynx and tongue. *Acta Otolaryngol* 106:306–313
242. Michaels L, Hellquist HB (2001) Ear, nose and throat histopathology, 2nd edn. Springer, London, pp 15–51
243. Milford CA, O'Flynn PE (1991) Management of verrucous carcinoma of the larynx. *Clin Otolaryngol* 16:160–162
244. Miller CS, White DK, Royse DD (1993) In situ hybridization analysis of human papillomavirus in orofacial lesions using a consensus biotinylated probe. *Am J Dermatopathol* 15:256–259
245. Minić AJ, Stajčić Z (1994) Adenosquamous carcinoma of the inferior turbinate: a case report. *J Oral Maxillofac Surg* 52:764–767
246. Mohit-Tabatabai MA, Sobel HJ, Rush BF, Mashberg A (1986) Relation of thickness of floor of mouth stage-I and stage-II cancers to regional metastases. *Am J Surg* 152:351–353
247. Moreno-Lopez LA, Esparza-Gomez GC, Gonzalez-Navarro A, Cerero-Lapiedra R, Gonzalez-Hernandez MJ, Dominguez-Rojas V (2000) Risk of oral cancer associated with tobacco smoking, alcohol consumption and oral hygiene: a case-control study in Madrid, Spain. *Oral Oncol* 36:170–174
248. Morice WG, Ferreiro JA (1998) Distinction of basaloid squamous cell carcinoma from adenoid cystic and small cell undifferentiated carcinoma by immunohistochemistry. *Hum Pathol* 29:609–612
249. Müller KM, Krohn RB (1980) Smoking habits and their relationship to precancerous lesions of the larynx. *J Cancer Res Clin Oncol* 96:211–217
250. Muller S, Barnes L (1995) Basaloid squamous cell carcinoma of the head and neck with a spindle cell component. An unusual histologic variant. *Arch Pathol Lab Med* 119:181–182
251. Munck-Wikland E, Edström S, Jungmark E, Kuylenstierna R, Lindholm J, Auer G (1994) Nuclear DNA content, proliferating-cell nuclear antigen (PCNA) and p53 immunostaining in predicting progression of laryngeal cancer in situ lesions. *Int J Cancer* 56:95–99
252. Muscat JE, Wynder EL (1992) Tobacco, alcohol, asbestos, and occupational risk factors for laryngeal cancer. *Cancer* 69:2244–2251
253. Myers EN, Alvi N (1996) Management of the carcinoma of the supraglottic larynx: evolution, current concepts, and future trends. *Laryngoscope* 106:559–567
254. Myssiorek D, Vambutas A, Abramson AL (1994) Carcinoma in situ of the glottic larynx. *Laryngoscope* 104:463–467
255. Nadal A, Campo E, Pinto J, Mallofre C, Palacin A, Arias C, Traserra J, Cardesa A (1995) p53 expression in normal, dysplastic, and neoplastic laryngeal epithelium. Absence of a correlation with prognostic factors. *J Pathol* 175:181–188
256. Nadal A, Cardesa A (2003) Molecular biology of laryngeal squamous cell carcinoma. *Virchows Arch* 442:1–7
257. Nadal A, Jares P, Cazorla M, Fernández PL, Sanjuan X, Hernández L, Pinyol M, Aldea M, Mallofré C, Muntané J, Traserra J, Campo E, Cardesa A (1997) p21WAF1/Cip1 expression is associated with cell differentiation but not with p53 mutations in squamous cell carcinomas of the larynx. *J Pathol* 183:156–163
258. Napier SS, Gormley JS, Newlands C, Ramsay-Baggs P (1995) Adenosquamous carcinoma. A rare neoplasm with an aggressive course. *Oral Surg Oral Med Oral Pathol Oral Radiol Endod* 79:607–611
259. Nappi O, Pettinato G, Wick MR (1989) Adenoid (acantholytic) squamous cell carcinoma of the skin. *J Cutan Pathol* 16:114–121
260. Nappi O, Wick MR, Pettinato G, Ghiselli RW, Swanson PE (1992) Pseudovascular adenoid squamous cell carcinoma of the skin. A neoplasm that may be mistaken for angiosarcoma. *Am J Surg Pathol* 16:429–438
261. Nathan CAO, Sanders K, Abreo FW, Nassar R, Glass J (2000) Correlation of p53 and the proto-oncogene eIF4E in larynx cancers: prognostic implications. *Cancer Res* 60:3599–3604
262. Naunheim KS, Taylor JR, Skosey C, Hoffman PC, Ferguson MK, Golomb HM, Little AG (1987) Adenosquamous lung carcinoma, clinical characteristics, treatment and prognosis. *Ann Thorac Surg* 44:462–466
263. Neville BW, Day TA (2002) Oral cancer and precancerous lesions. *CA Cancer J Clin* 52:195–215
264. Newman J, Antonakopoulos GN, Darnton J, Matthews HR (1992) The ultrastructure of oesophageal carcinoma: multidirectional differentiation. A transmission microscope study of 43 cases. *J Pathol* 167:192–198
265. Niedobitek G, Hansmann ML, Herbst H, Young LS, Diemann D, Hartmann CA et al. (1991) Epstein-Barr-virus and carcinomas – undifferentiated carcinomas but not squamous-cell carcinomas of the nasopharynx are regularly associated with the virus. *J Pathol* 165:17–24
266. Nishijima W, Takooda S, Tokita N, Takayama S, Sakura M (1993) Analyses of distant metastases in squamous cell carcinoma of the head and neck and lesions above the clavicles at autopsy. *Arch Otolaryngol Head Neck Surg* 119:65–68
267. Nunez DA, Astley SM, Lewis FA, Wells M (1994) Human papilloma viruses: a study of their prevalence in the normal larynx. *J Laryngol Otol* 108:319–320
268. Oijen MCGT van, Leppers vd Straat FGJ, Tilanus MGJ, Slootweg PJ (2000) The origin of multiple squamous cell carcinomas in the aerodigestive tract. *Cancer* 88:884–893
269. Oijen MG van, Rijkse G, ten Broek FW, Slootweg PJ (1998) Increased expression of epidermal growth factor receptors in normal epithelium adjacent to head and neck carcinomas independent of tobacco and alcohol abuse. *Oral Dis* 4:4–8
270. Oijen MGCT van, Slootweg PJ (2000) Gain-of-function mutations in the tumor suppressor gene p53. *Clin Cancer Res* 6:2138–2145
271. Oijen MGCT van, Slootweg PJ (2000) Review. Oral field cancerization. Carcinogen-induced independent events or micrometastatic deposits? *Cancer Epidemiol Biomarkers Prev* 9:249–256
272. Oijen MGCT van, Tilanus MG, Medema RH, Slootweg PJ (1998) Expression of p21 (Waf1/Cip1) in head and neck cancer in relation to proliferation, differentiation, p53 status. *J Oral Pathol Med* 27:367–375
273. Onishi A, Nakashiro K, Mihara M, Sumida T, Kawamata H, Shintani S, Aida T, Tachikawa T, Kamakawa H (2004) Basic and clinical studies on quantitative analysis of lymph node micrometastasis in oral cancer. *Oncol Rep* 11:33–39
274. Orvidas LJ, Kerry DK, Lewis JE, Suman VJ (1998) Verrucous carcinoma of the larynx. *Head Neck* 20:197–203
275. O'Sullivan B, Warde P, Keane T, Irish J, Cummings B, Payne D (1995) Outcome following radiotherapy in verrucous carcinoma of the larynx. *Int J Radiat Oncol Biol Phys* 32:611–617
276. Parnes SM (1990) Asbestos and cancer of the larynx: is there a relationship? *Laryngoscope* 100:254–261
277. Paulino AFG, Singh B, Shah JP, Huvos AG (2000) Basaloid squamous cell carcinoma of the head and neck. *Laryngoscope* 110:1479–1482
278. Perez CA, Kraus FT, Evans JC, Powers WE (1966) Anaplastic transformation in verrucous carcinoma of the oral cavity after radiation therapy. *Radiology* 86:108–115
279. Piattelli A, Rubini C, Fioroni M, Iezzi G, Santinelli A (2002) Prevalence of p53, bcl-2, and Ki-67 immunoreactivity and

- of apoptosis in normal oral epithelium and in premalignant and malignant lesions of the oral cavity. *J Oral Maxillofac Surg* 60:532–540
280. Pinsolle J, Pinsolle V, Majoufre C, Duroux S, Demeaux H, Siberchicot F (1997) Prognostic value of histologic findings in neck dissections for squamous cell carcinoma. *Arch Otolaryngol Head Neck Surg* 123:145–148
 281. Poljak M, Gale N, Kambič V (1997) Human papilloma viruses: a study of their prevalence in the epithelial hyperplastic lesions of the larynx. *Acta Otolaryngol Suppl* 527:66–69
 282. Poljak M, Gale N, Kambič V, Ferluga D, Fischinger J (1996) Overexpression of p53 protein in benign and malignant laryngeal epithelial lesions. *Anticancer Res* 16:1947–1951
 283. Poljak M, Seme K, Gale N (1998) Detection of human papillomaviruses in tissue specimens. *Adv Anat Pathol* 5:216–234
 284. Pou AM, Rimell FL, Jordan JA, Shoemaker DL, Johnson JT, Barua P, Post JC, Ehrlich GD (1995) Adult respiratory papillomatosis: human papillomavirus type and viral coinfections as predictors of prognosis. *Ann Otol Rhinol Laryngol* 104:758–762
 285. Praetorius F (1997) HPV-associated diseases of oral mucosa. *Clin Dermatol* 15:399–413
 286. Premoli-De-Percoco G, Cisternas JP, Ramirez JL, Galindo I (1993) Focal epithelial hyperplasia: human-papillomavirus-induced disease with a genetic predisposition in a Venezuelan family. *Hum Genet* 91:386–388
 287. Proffitt SD, Spooner TR, Kosek JC (1970) Origin of undifferentiated neoplasm from verrucous epidermal carcinoma of oral cavity following irradiation. *Cancer* 26:389–393
 288. Quick CA, Foucar E, Dehner LP (1979) Frequency and significance of epithelial atypia in laryngeal papillomatosis. *Laryngoscope* 89:550–560
 289. Quiney RE, Wells M, Lewis FA, Terry RM, Michaels L, Croft CB (1989) Laryngeal papillomatosis: correlation between severity of disease and presence of HPV 6 and 11 detected by *in situ* DNA hybridisation. *J Clin Pathol* 42:694–698
 290. Rady PL, Schnadig VJ, Weiss RL, Hughes TK, Tying SK (1998) Malignant transformation of recurrent respiratory papillomatosis associated with integrated human papillomavirus type 11 DNA and mutation of p53. *Laryngoscope* 108:735–740
 291. Rafferty MA, O'Dwyer TP (2001) Secondary primary malignancies in head and neck squamous cell carcinoma. *J Laryngol Otol* 115:988–991
 292. Randall ME, Andersen WA, Mills SE, Kim JA (1986) Papillary squamous cell carcinoma of uterine cervix: a clinicopathologic study of nine cases. *Int J Gynecol Pathol* 5:1–10
 293. Raslan WF, Barnes L, Krause JR, Contis L, Killeen R, Kapadia SB (1994) Basaloid squamous cell carcinoma of the head and neck: a clinicopathologic and flow cytometric study of 10 new cases with review of the English literature. *Am J Otolaryngol* 15:204–211
 294. Regaud C, Reverchon L (1921) Sur un cas d'epithelioma epidermoide developpe dans le massif maxillaire superieure etendu aux ligaments de la face, aux cavities buccale, nasale et orbitaire ainsi que aux ganglions du cou gueri par la radiotherapie. *Rev Laryngol Otol Rhinol (Bord)* 42:369–378
 295. Regezi JA, Sciubba JJ, Jordan RCK (2003) Oral pathology. Clinical pathologic correlations, 4th edn. Saunders, St. Louis, pp 143–156
 296. Rehberg E, Kleinsasser O (1999) Malignant transformation in non-irradiated juvenile laryngeal papillomatosis. *Eur Arch Otorhinolaryngol* 256:450–454
 297. Reibel J (2003) Prognosis of oral pre-malignant lesions: significance of clinical, histopathological, and molecular biological characteristics. *Crit Rev Oral Biol Med* 14:47–62
 298. Reichart PA (2001) Identification of risk groups for oral pre-cancer and cancer and preventive measures. *Clin Oral Investig* 5:207–213
 299. Reid BC, Winn DM, Morse DE, Pendry DG (2000) Head and neck *in situ* carcinoma: incidence, trends, and survival. *Oral Oncol* 36:414–420
 300. Renan MJ (1993) How many mutations are required for tumorigenesis? Implications from human cancer data. *Mol Carcinog* 7:139–146
 301. Rihkanen H, Aaltonen LM, Syrjanen SM (1993) Human papillomavirus in laryngeal papillomas and in adjacent normal epithelium. *Clin Otolaryngol* 18:470–474
 302. Rihkanen H, Peltomaa J, Syrjänen S (1994) Prevalence of human papillomavirus DNA in vocal cords without laryngeal papillomas. *Acta Otolaryngol* 114:348–351
 303. Rindum JL, Stenderup A, Holmstrup P (1994) Identification of *Candida albicans* types related to healthy and pathological oral mucosa. *J Oral Pathol Med* 23:406–411
 304. Rizzardi C, Frezzini C, Maglione M, Tirelli G, Melato M (2003) A look at the biology of spindle cell squamous carcinoma of the oral cavity: report of a case. *J Oral Maxillofac Surg* 61:264–268
 305. Rosen PP, Ernsberger D (1987) Low-grade adenosquamous carcinoma. A variant of metaplastic mammary carcinoma. *Am J Surg Pathol* 11:351–358
 306. Rosin MP, Cheng X, Poh C, Lam WL, Huang Y, Lovas J, Berean K, Epstein JB, Priddy R, Le ND, Zhang L (2000) Use of allelic loss to predict malignant risk for low-grade oral epithelial dysplasia. *Clin Cancer Res* 6:357–362
 307. Ross GL, Soutar DS, MacDonald DG, Shoaib T, Camilleri IG, Robertson AG (2004) Improved staging of cervical metastases in clinically node-negative patients with head and neck squamous cell carcinoma. *Ann Surg Oncol* 11:213–218
 308. Rotfield RE, Myers EN, Johnson JT (1991) Carcinoma *in situ* and microinvasive squamous cell carcinoma of the vocal cord. *Ann Otol Rhinol Laryngol* 100:793–796
 309. Ryan RE, de Santo LW, Devine KD, Weiland LH (1977) Verrucous carcinoma of the larynx. *Laryngoscope* 87:1989–1994
 310. Saito R, Davis BK, Ollapathy EP (1984) Adenosquamous carcinoma of the prostate. *Hum Pathol* 15:87–89
 311. Sakakura A, Yamamoto Y, Takasaki T, Makimoto K, Nakamura M, Takahashi H (1996) Recurrent laryngeal papillomatosis developing into laryngeal carcinoma with human papilloma virus (HPV) type 18: a case report. *J Laryngol Otol* 110:75–77
 312. Saltarelli MG, Fleming MV, Wenig BM, Gal AA, Mansour KA, Travis WD (1995) Primary basaloid squamous cell carcinoma of the trachea. *Am J Clin Pathol* 104:594–598
 313. Sanderson RJ, Rivron PR, Wallace WA (1991) Adenosquamous carcinoma of the hypopharynx. *J Laryngol Otol* 105:678–680
 314. Scheifele C, Reichart PA, Dietrich T (2003) Low prevalence of oral leukoplakia in a representative sample of the US population. *Oral Oncol* 39:619–625
 315. Schmincke A (1921) Über lympho-epitheliale Geschwülste. *Beitr Pathol Anat* 68:161–170
 316. Sciubba JJ (1995) Oral leukoplakia. *Crit Rev Oral Biol Med* 6:147–160
 317. Scully C, Porter SR, Speight PM, Eveson JW, Gale D (1999) Adenosquamous carcinoma of the mouth: a rare variant of squamous cell carcinoma. *Int J Oral Maxillofac Surg* 28:125–128
 318. Seidman JD, Berman JJ, Yost BA, Iseri OA (1991) Basaloid squamous carcinoma of the hypopharynx and larynx associated with second primary tumors. *Cancer* 68:1545–1549
 319. Shafer WG, Waldron CA (1975) Erythroplakia of the oral cavity. *Cancer* 36:1021–1028
 320. Shah JP (1990) Patterns of cervical lymph node metastases from squamous carcinomas of the upper aerodigestive tract. *Am J Surg* 160:405–409
 321. Shah KV, Stern WF, Shah FK, Bishai D, Kashima HK (1998) Risk factors for juvenile onset recurrent respiratory papillomatosis. *Pediatr Infect Dis J* 17:372–376
 322. Silverman S Jr, Gorsky M (1997) Proliferative verrucous leukoplakia: a follow-up study of 54 cases. *Oral Surg Oral Med Oral Pathol Oral Radiol Endod* 84:154–157
 323. Silverman S Jr, Gorsky M, Lozada F (1984) Oral leukoplakia and malignant transformation. A follow-up study of 257 patients. *Cancer* 53:563–568

324. Slaughter DP, Southwick HW, Smejkal W (1953) "Field cancerization" in oral stratified squamous epithelium: clinical implication of multicentric origin. *Cancer* 6:963–968
325. Slootweg PJ, Hordijk GJ, Koole R (1996) Autopsy findings in patients with head and neck squamous cell cancer and their therapeutic relevance. *Oral Oncol Eur J Cancer* 32B:413–415
326. Slootweg PJ, Hordijk GJ, Schade Y, Es RJJ van, Koole R (2002) Treatment failure and margin status in head and neck cancer. A critical view on the potential value of molecular pathology. *Oral Oncol* 38:500–503
327. Slootweg PJ, Muller H (1983) Verrucous hyperplasia or verrucous carcinoma. An analysis of 27 patients. *J Maxillofac Surg* 11:13–19
328. Slootweg PJ, Richardson M (2001) Squamous cell carcinoma of the upper aerodigestive system. In: Gnepp DR (ed) *Diagnostic surgical pathology of the head and neck*. Saunders, Philadelphia, pp 19–78
329. Slootweg PJ, Roholl PJM, Müller H et al. (1987) Spindle cell carcinoma of the oral cavity and larynx. Immunohistochemical aspects. *J Craniomaxfac Surg* 17:234–236
330. Smith EM, Pignatari SS, Gray SD, Haugen TH, Turek LP (1993) Human papillomavirus infection in papillomas and nondiseased respiratory sites of patients with recurrent respiratory papillomatosis using the polymerase chain reaction. *Arch Otolaryngol Head Neck Surg* 119:554–557
331. Smith EM, Summersgill KF, Allen J, Hoffman HT, McCulloch T, Turek LP, Haugen TH (2000) Human papillomavirus and risk of laryngeal cancer. *Ann Otol Rhinol Laryngol* 109:1069–1076
332. Sobin LH, Wittekind C (2002) *TNM: classification of malignant tumours*, 6th edn. Wiley, New York
333. Soo KC, Carter RL, O'Brien CJ, Barr L, Bliss JM, Shaw HJ (1986) Prognostic implication of perineural spread in squamous carcinomas of the head and neck. *Laryngoscope* 96:1145–1148
334. Sood S, O'Hara J, Quraishi HS (2002) The significance of oral leukoplakia. *Curr Opin Otolaryngol Head Neck Surg* 10:80–84
335. Souglu Y, Erdamar B, Katircioglu OS, Karatay MC, Sunay T (2002) Extracapsular spread in ipsilateral neck and contralateral neck metastases in laryngeal cancer. *Ann Otol Rhinol Laryngol* 111:447–454
336. Spayne JA, Warde P, O'Sullivan B, Payne D, Liu FF, Waldron J, Gullane PJ, Cummings BJ (2001) Carcinoma in situ of the glottic larynx: results of the treatment with radiation therapy. *Int J Radiat Oncol Biol Phys* 49:1235–1238
337. Spector JG, Sessions DG, Haughey BH, Chao KSC, Simpson J, Al Mofty S, Perez CA (2001) Delayed regional metastases, distant metastases, and second primary malignancies in squamous cell carcinomas of the larynx and hypopharynx. *Laryngoscope* 111:1079–1087
338. Sperry K (1994) Lethal asphyxiating juvenile laryngeal papillomatosis. *Am J Forensic Med Pathol* 15:146–150
339. Spiro RH (1998) Verrucous carcinoma, then and now. *Am J Surg* 176:393–397
340. Staley CJ, Ujiki GT, Yokoo H (1977) "Pseudocarcinoma" of the larynx: independent metastasis of carcinomatous and sarcomatous elements. *Arch Otolaryngol* 94:458–465
341. Stutsman AC, McGavran MH (1971) Ultraconservative management of superficially invasive epidermoid carcinoma of the true vocal cord. *Ann Otol Rhinol Laryngol* 80:506–512
342. Suarez P, Batsakis JG, el-Naggar AK (1998) Leukoplakia: still a gallimaufry or is progress being made? A review. *Adv Anat Pathol* 5:137–155
343. Suarez PA, Adler-Storthz K, Luna MA, El-Naggar AK, Abdul-Karim FW, Batsakis JG (2000) Papillary squamous cell carcinoma of the upper aerodigestive tract: a clinicopathologic and molecular study. *Head Neck* 22:60–368
344. Sudbo J, Kildal W, Risberg B, Koppang HS, Danielsen HE, Reith A (2001) DNA content as a prognostic marker in patients with oral leukoplakia. *N Engl J Med* 344:1270–1278
345. Sugiyama M, Bhawal UK, Dohmen T, Ono S, Miyauchi M, Ishikawa T (2003) Detection of human papillomavirus-16 and HPV-18 DNA in normal, dysplastic, and malignant oral epithelium. *Oral Surg Oral Med Oral Pathol Oral Radiol Endod* 95:594–600
346. Syrjänen K, Syrjänen S (2000) *Papillomavirus infections in human pathology*. Wiley, Chichester, pp 1–615
347. Tabor MP, Houten VMM van, Kummer JA, Vosjan MJWD, Vlasblom R, Snow GB, Leemans CR, Braakhuis BJM, Brakenhoff RH (2002) Discordance of genetic alterations between primary head and neck tumors and corresponding metastases associated with mutational status of the TP53 gene. *Genes Chromosomes Cancer* 33:168–177
348. Takagi M, Sakota Y, Takayama S, Ishikawa G (1977) Adenoid squamous cell carcinoma of the oral mucosa. Report of two autopsy cases. *Cancer* 40:2250–2255
349. Takata T, Ito H, Ogawa I, Miyaguchi M, Iljuhin N, Nikai H (1991) Spindle cell squamous carcinoma of the oral region. An immunohistochemical and ultrastructural study on the histogenesis and differential diagnosis with a clinicopathologic analysis of six cases. *Virchows Arch* 419:177–182
350. Takes RP, Baatenburg de Jong RJ, van Blommestein R, Hermans J, van Krieken HHJM, Cornelisse CJ (2002) DNA ploidy status as a prognostic marker and predictor of lymph node metastasis in laryngeal carcinoma. *Ann Otol Rhinol Laryngol* 111:1015–1020
351. Tavani A, Negri E, Franceschi S, Barbone F, La Vecchia C (1994) Attributable risk for laryngeal cancer in northern Italy. *Cancer Epidemiol Biomarkers Prev* 3:121–125
352. Terry RM, Lewis FA, Robertson S, Blythe D, Wells M (1989) Juvenile and adult laryngeal papillomata: classification by in situ hybridization for human papillomavirus. *Clin Otolaryngol* 14:135–139
353. Tharp ME, Shidnia H (1995) Radiotherapy in the treatment of verrucous carcinoma of the head and neck. *Laryngoscope* 105:391–396
354. Thompson L, Chang B, Barsky SH (1996) Monoclonal origins of malignant mixed tumors (carcinosarcomas). Evidence for a divergent histogenesis. *Am J Surg Pathol* 20:277–285
355. Thompson LDR, Wenig BM, Heffner DK, Gnepp DR (1999) Exophytic and papillary squamous cell carcinomas of the larynx: a clinicopathologic series of 104 cases. *Otolaryngol Head Neck Surg* 120:718–724
356. Thompson LDR, Wieneke JA, Miettinen M, Heffner DK (2002) Spindle cell (sarcomatoid) carcinomas of the larynx: a clinicopathologic study of 187 cases. *Am J Surg Pathol* 26:153–170
357. Thomson PJ, Soames JV, Booth C, O'Shea JA (2002) Epithelial cell proliferative activity and oral cancer progression. *Cell Prolif* 1:110–120
358. Tjebbes GWA, Kreijveld PA, Tilanus MGJ, Hordijk GJ, Slootweg PJ (2002) P53 tumor suppressor gene mutations in laryngeal cancer and in recurrent disease following radiation therapy. *Oral Oncol* 38:296–300
359. Tjebbes GWA, Leppers FGJ, Hordijk GJ, Tilanus MGJ, Slootweg PJ (1999) p53 tumor suppressor gene as a clonal marker in head and neck squamous cell carcinoma. p53 mutations in primary tumor and matched lymph node metastases. *Oral Oncol* 35:384–389
360. Toda S, Yonemitsu N, Miyabara S, Sugihara H, Maehara N (1989) Polypoid squamous cell carcinoma of the larynx. An immunohistochemical study for ras p21 and cytokeratin. *Pathol Res Pract* 185:860–866
361. Toorn PP van der, Veltman JA, Bot FJ, de Jong JM, Manni JJ, Ramaekers FC, Hopman AH (2001) Mapping of resection margins of oral cancer for p53 overexpression and chromosome instability to detect residual (pre)malignant cells. *J Pathol* 193:66–72
362. Traserra J, Comas J, Conde C, Cuchi A, Cardesa A (1990) Metastatic involvement of the cavernous sinus from primary pharyngolaryngeal tumors. *Head Neck* 12:426–429
363. Uhlman DL, Adams G, Knapp D, Aeppli MM, Niehans G (1996) Immunohistochemical staining for markers of future neoplastic progression in the larynx. *Cancer Res* 56:2199–2205
364. Uzcudun AE, Bravo Fernández P, Sánchez JJ, García Grande A, Rabanal Retolaza I, González Baron M, Gavilán Bouzas J (2001) Clinical features of pharyngeal cancer: a retrospective

- study of 258 consecutive patients. *J Laryngol Otol* 115:112–118
365. Vaidya MM, Sawant SS, Borges AM, Ogale SB, Bhisey AN (1998) Cytokeratin expression in precancerous lesions of the human oral cavity. *Oral Oncol* 34:261–264
 366. Vedtofte P, Holmstrup P, Hjorting-Hansen E, Pindborg JJ (1987) Surgical treatment of premalignant lesions of the oral mucosa. *Int J Oral Maxillofac Surg* 16:656–664
 367. Velden LA van der, Schaafsma HE, Manni JJ, Ruiter DJ, Ramaekers FCS, Kuijpers W (1997) Cytokeratin expression in normal epithelium and squamous cell carcinomas of the larynx. *Eur Arch Otorhinolaryngol* 254:376–383
 368. Violaris NS, O'Neill D, Helliwell TR, Caslin AW, Roland NJ, Jones AS (1994) Soft tissue cervical metastases of squamous carcinoma of the head and neck. *Clin Otolaryngol* 19:394–399
 369. Volavšek M, Bračko M, Gale N (2003) Distribution and prognostic significance of cell cycle proteins in squamous carcinoma of the larynx, hypopharynx and adjacent epithelial hyperplastic lesions. *J Laryngol Otol* 117:286–293
 370. Vural E, Hutcheson J, Korourian S, Kechelava S, Hanna E (2000) Correlation of neural cell adhesion molecules with perineural spread of squamous cell carcinoma of the head and neck. *Otolaryngol Head Neck Surg* 122:717–720
 371. Waal I van der, Schepman KP, van der Meij EH, Smelee LE (1997) Oral leukoplakia: a clinicopathological review. *Oral Oncol* 33:291–301
 372. Wain SL, Kier R, Volmer RT, Bossen EH (1986) Basaloid-squamous carcinoma of the tongue, hypopharynx, and larynx. Report of 10 cases. *Hum Pathol* 17:1158–1166
 373. Waldron CA, Shafer WG. Leukoplakia revisited (1975) A clinicopathologic study 3256 oral leukoplakias. *Cancer* 36:1386–1392
 374. Ward KA, Napier SS, Winter PC, Maw RD, Dinsmore WW (1995) Detection of human papilloma virus DNA sequences in oral squamous cell papillomas by the polymerase chain reaction. *Oral Surg Oral Med Oral Pathol Oral Radiol Endod* 80:63–66
 375. Wenig BM (2002) Squamous cell carcinoma of the upper aerodigestive tract: precursors and problematic variants. *Mod Pathol* 15:229–254
 376. Wiernik G, Millard PR, Haybittle JL (1991) The predictive value of histological classification into degrees of differentiation of squamous cell carcinoma of the larynx and hypopharynx compared with the survival of patients. *Histopathology* 19:411–417
 377. Winzenburg SM, Niehans GA, George E, Daly K, Adams GL (1997) Basaloid squamous carcinoma: a clinical comparison of two histologic types with poorly differentiated squamous cell carcinoma. *Otolaryngol Head Neck Surg* 119:471–475
 378. Wolf GT, Fisher SG, Truelson JM, Beals TF (1994) DNA content and regional metastases in patients with advanced laryngeal squamous carcinoma. *Laryngoscope* 104:479–483
 379. Woolgar JA (1999) Micrometastasis in oral/oropharyngeal squamous cell carcinoma: incidence, histopathological features and clinical implications. *Br J Oral Maxillofac Surg* 37:181–186
 380. Woolgar JA, Rogers SN, Lowe D, Brown JS, Vaughan ED (2003) Cervical lymph node metastasis in oral cancer: the importance of even microscopic extracapsular spread. *Oral Oncol* 39:130–137
 381. World Health Organization Classification of Tumours (2005) Pathology and genetics of tumours of the head and neck. IARC, Lyon
 382. Yilmaz T, Hoşal AŞ, Gedikoğlu G, Kaya S (1999) Prognostic significance of histopathological parameters in cancer of the larynx. *Eur Arch Otorhinolaryngol* 256:139–144
 383. Yilmaz T, Hoşal AS, Gedikoğlu G, Önerci M, Gürsel B (1998) Prognostic significance of vascular and perineural invasion in cancer of the larynx. *Am J Otolaryngol* 19:83–88
 384. Yoshihara T, Yamamura Y (1997) An unusual case of laryngeal carcinoma metastasizing to the small intestine. *J Laryngol Otol* 111:575–577
 385. Yoshimura Y, Mishima K, Obara S, Yoshimura H, Maruyama R (2003) Clinical characteristics of oral adenosquamous carcinoma: report of a case and an analysis of the reported Japanese cases. *Oral Oncol* 39:309–315
 386. Young SK, Min KW (1991) In situ DNA hybridization analysis of oral papillomas, leukoplakias, and carcinomas for human papillomavirus. *Oral Surg Oral Med Oral Pathol* 71:726–729
 387. Yucel OT, Yilmaz T, Unal OF, Turan E (1999) Distant metastases in laryngeal squamous cell carcinoma. *J Exp Clin Cancer Res* 18:285–288
 388. Zaatari GS, Santoianni RA (1986) Adenoid squamous cell carcinoma of the nasopharynx and neck region. *Arch Pathol Lab Med* 110:542–546
 389. Zain RB (2001) Cultural and dietary risk factors of oral cancer and precancer – a brief overview. *Oral Oncol* 37:205–210
 390. Zakrzewska JM, Lopes V, Speight P, Hopper C (1996) Proliferative verrucous leukoplakia: a report of ten cases. *Oral Surg Oral Med Oral Pathol Oral Radiol Endod* 82:396–401
 391. Zarbo RJ, Crissman JD, Venkat H, Weiss MA (1986) Spindle-cell carcinoma of the upper aerodigestive tract mucosa. An immunohistochemical and ultrastructural study of 18 biphasic tumors and comparison with seven monophasic spindle-cell tumors. *Am J Surg Pathol* 10:741–753
 392. Zbären P, Borisch B, Lang H, Greiner R (1997) Undifferentiated carcinoma of nasopharyngeal type of the laryngopharyngeal region. *Otolaryngol Head Neck Surg* 117:688–693
 393. Zbären P, Lehmann W (1987) Frequency and sites of distant metastases in head and neck squamous cell carcinoma. An analysis of 101 cases at autopsy. *Arch Otolaryngol Head Neck Surg* 11:762–764
 394. Zidar N, Gale N, Cör A, Kambič V (1996) Expression of Ki-67 antigen and proliferative cell nuclear antigen in benign and malignant epithelial lesions of the larynx. *J Laryngol Otol* 110:440–445
 395. Zidar N, Gale N, Kambič V, Fischinger J (2001) Expression of tenascin and fibronectin in benign epithelial hyperplastic lesions and squamous carcinoma of the larynx. *Anticancer Res* 21:451–454
 396. Zidar N, Gale N, Kambič V, Fischinger J (2002) Proliferation of myofibroblasts in the stroma of epithelial hyperplastic lesions and squamous carcinoma of the larynx. *Oncology* 62:381–385

Nasal Cavity and Paranasal Sinuses

A. Cardesa · L. Alos · A. Franchi

Contents

2.1	Introduction	40	2.9.1.1	Squamous Cell Papilloma	46
2.1.1	Embryology	40	2.9.1.2	Exophytic Papilloma	46
2.1.2	Anatomy	40	2.9.1.3	Inverted Papilloma	46
2.1.3	Histology	40	2.9.1.4	Oncocytic Papilloma	47
2.2	Acute and Chronic Rhinosinusitis	40	2.9.2	Salivary-Type Adenomas	48
2.2.1	Viral Infections (Common Cold)	40	2.9.3	Pituitary Adenomas	48
2.2.2	Bacterial Infections	40	2.10	Benign Sinonasal Soft Tissue Neoplasms	48
2.2.3	Allergic Rhinitis	40	2.10.1	Haemangiomas	48
2.2.4	Atrophic Rhinitis	41	2.10.2	Haemangiopericytoma	48
2.2.5	Hypertrophic Rhinitis	41	2.10.3	Solitary Fibrous Tumour	48
2.2.6	Non-Suppurative Chronic Sinusitis	41	2.10.4	Desmoid Fibromatosis	49
2.3	Sinonasal Polyps	41	2.10.5	Fibrous Histiocytoma	49
2.3.1	Allergic Polyposis	41	2.10.6	Leiomyoma	49
2.3.2	Polyposis in Mucoviscidosis	41	2.10.7	Schwannoma and Neurofibroma	49
2.3.3	Polyposis in Immotile Cilia Syndrome and in Kartagener's Syndrome	41	2.10.8	Meningioma	50
2.3.4	Antrochoanal Polyps	41	2.10.9	Paraganglioma	50
2.4	Sinonasal Hamartomatous and Teratoid Lesions	42	2.10.10	Juvenile Angiofibroma	50
2.4.1	Hamartomas	42	2.11	Malignant Sinonasal Tumours	50
2.4.2	Teratoid Lesions	42	2.11.1	Keratinising Squamous Cell Carcinoma	51
2.5	Pseudotumours	43	2.11.2	Cylindrical Cell Carcinoma	52
2.5.1	Mucocele	43	2.11.3	Sinonasal Undifferentiated Carcinoma	53
2.5.2	Organising Haematoma	43	2.11.4	Small Cell (Neuroendocrine) Carcinoma	54
2.5.3	Amyloidosis	43	2.11.5	Primary Sinonasal Nasopharyngeal-Type Undifferentiated Carcinoma	54
2.5.4	Myospherulosis	43	2.11.6	Malignant Melanoma	55
2.5.5	Eosinophilic Angiocentric Fibrosis	43	2.11.7	Olfactory Neuroblastoma	57
2.5.6	Heterotopic Brain Tissue	43	2.11.8	Primitive Neuroectodermal Tumour	58
2.6	Fungal Diseases	44	2.11.9	High-Grade Sinonasal Adenocarcinomas	58
2.6.1	Aspergillosis	44	2.11.9.1	Intestinal-Type Adenocarcinoma	58
2.6.2	Mucormycosis	44	2.11.9.2	Salivary-Type High-Grade Adenocarcinoma	60
2.6.3	Rhinosporidiosis	44	2.11.10	Low-Grade Sinonasal Adenocarcinomas	60
2.7	HIV-Related Infections	44	2.11.10.1	Non-Salivary-Type Low-Grade Adenocarcinomas	60
2.8	Mid-Facial Necrotising Granulomatous Lesions	45	2.11.10.2	Salivary-Type Low-Grade Adenocarcinomas	61
2.8.1	Wegener's Granulomatosis	45	2.11.11	Sinonasal Malignant Lymphomas	61
2.8.2	Lepromatous Leprosy	45	2.11.12	Extramedullary Plasmacytoma	62
2.8.3	Tuberculosis	45	2.11.13	Fibrosarcoma	62
2.8.4	Sarcoidosis	45	2.11.14	Malignant Fibrous Histiocytoma	63
2.8.5	Rhinoscleroma	45	2.11.15	Leiomyosarcoma	63
2.8.6	Leishmaniasis	45	2.11.16	Rhabdomyosarcoma	63
2.8.7	Cocaine Abuse	46	2.11.17	Malignant Peripheral Nerve Sheath Tumour	63
2.8.8	Local Steroid Injections	46	2.11.18	Teratocarcinosarcoma	63
2.9	Benign Epithelial Neoplasms	46	References	64	
2.9.1	Sinonasal Papillomas	46			

2.1 Introduction

2.1.1 Embryology

The midface, or area between the upper lip and forehead, develops at between 4 and 8 weeks' gestation [219]. The frontal prominence forms during the 4th postovulatory week and gives rise to the superior and middle portions of the face. The maxillary and nasal swellings form beneath the frontal prominence. At the end of the 4th week surface thickening of the nasal swellings forms the nasal placodes, which are of ectodermal origin and give rise to the epithelial lining of the nasal cavity and paranasal sinuses. The placodes invaginate, producing the nasal pits that become the anterior choanae (nostrils) and, less superficially, the primitive posterior choanae. The medial nasal and frontal processes give rise to the nasal septum, frontal bones, nasal bones, ethmoid sinus complexes and upper incisors. The lateral nasal and maxillary processes fuse to form the philtrum and columella. The cartilaginous nasal capsule forms deep to the nasal and frontal bones from the chondrocranium (skull base) during the 7th and 8th postovulatory weeks. The paranasal sinuses develop from the lateral nasal walls at the 6th foetal week, and their growth continues after birth, throughout childhood and adolescence.

2.1.2 Anatomy

The nasal cavities are separated by the nasal septum, and limited by a roof, which is formed by the cribriform plate of the ethmoid, and a floor, which is formed by the hard palate [261]. The lateral walls have three turbinates or conchae, and three horizontal spaces, or meatus, on each side. The nasolacrimal duct opens in the inferior meatus, whereas the middle meatus receives drainage from the frontal, anterior ethmoid and maxillary sinuses. Below the superior turbinate is the sphenothmoid recess, with the openings of the sphenoid and posterior ethmoid sinuses. Each nasal cavity communicates posteriorly with the nasopharynx through the choanae. The paranasal sinuses are a group of cavities within the corresponding craniofacial bones (maxilla, sphenoid, ethmoid and frontal) that communicate with the nasal cavities through an ostium.

2.1.3 Histology

The nasal vestibule and skin share a similar histology. At the level of the limen nasi, the keratinising squamous epithelium gradually changes first to cuboidal or columnar epithelium, and then to ciliated respiratory-type epithelium, which lines most of the nasal cavity and all the

paranasal sinuses, with the exception of the roof [261]. Numerous goblet cells are interspersed in the respiratory-type epithelium. The lamina propria contains several seromucous glands, lymphocytes, monocytes, and a well-developed vascular network, particularly evident in the inferior and middle turbinate. The olfactory epithelium is predominantly made of columnar non-ciliated sustentacular cells, with scattered bipolar sensory neurons and basal cells.

2.2 Acute and Chronic Rhinosinusitis

2.2.1 Viral Infections (Common Cold)

Infectious rhinitis is typically viral and is often referred to as the "common cold". It is more common in children than in adults, and the most frequently identified agents are rhinovirus, myxovirus, coronavirus and adenovirus [67, 271]. Swelling of the mucosa may cause obstruction of a sinus ostium, with subsequent secondary bacterial infection (acute bacterial sinusitis). The histologic findings include marked oedema and a non-specific mixed inflammatory infiltrate of the lamina propria.

2.2.2 Bacterial Infections

Bacterial rhinosinusitis usually follows a viral infection or allergic rhinitis, and the most commonly involved agents are *Streptococcus pneumoniae*, *Haemophilus influenzae* and *Moraxella catarrhalis* [11, 34]. A dense inflammatory infiltrate mainly made of neutrophils occupies the lamina propria. Acute bacterial rhinosinusitis usually resolves with antibiotic therapy. Complications are rare and include contiguous infectious involvement of the orbit or central nervous system.

2.2.3 Allergic Rhinitis

Allergic rhinitis (hay fever) is part of an inherited syndrome, which may also manifest as atopic eczema and asthma. In allergic rhinitis, airborne particles, such as grass pollens, moulds and animal allergens, are deposited on the nasal mucosa giving rise to acute and chronic reactions. Allergens combine with the IgE antibodies produced by the plasma cells of the nasal mucosa, which are avidly bound to the Fc-epsilon receptors on mast cells. This triggers degranulation of mast cells and releases the inflammatory mediators of the type I hypersensitivity reaction, causing rhinorrhoea and nasal obstruction. Microscopically, the nasal mucosa shows numerous eosinophils, abundant plasma and in some cases an increased number of mast cells. There is goblet cell

hyperplasia of the respiratory epithelium and the basement membrane, which is destroyed in the acute phase, appears considerably thickened in the chronic phase.

2.2.4 Atrophic Rhinitis

Atrophic rhinitis is a chronic inflammation of the nasal mucosa of unknown aetiology characterised by progressive nasal mucosal atrophy and by a thick, dense secretion, with a foetid smell and crusting [178]. Multiple factors may be involved in the pathogenesis, including chronic bacterial infections and nutritional deficiencies. Its incidence has markedly decreased in the last century, and nowadays most cases are secondary to trauma, surgery, granulomatous diseases, infection and radiation exposure [178]. Histologically, there is non-specific chronic inflammatory infiltrate, squamous metaplasia of the surface epithelium and of glandular excretory ducts, and atrophy of mucoserous glands [1, 69].

2.2.5 Hypertrophic Rhinitis

This term is applied to a condition of unknown aetiology, characterised by thickening of the sinonasal mucosa resulting from chronic inflammatory diseases [28, 71]. Frequently, these patients have undergone several sinus operations, each time with limited success and subsequent recurrence. Recurrent nasal polyposis is often associated.

2.2.6 Non-Suppurative Chronic Sinusitis

Chronic sinusitis is a complex, multifactorial disorder resulting from persistent acute inflammation or repeated episodes of acute or subacute sinusitis. There are usually predisposing factors like small sinus ostia, repeated episodes of common cold, allergy or acute sinusitis determining obstruction of the sinus ostia, reduction of ciliary activity (immotile cilia syndrome) and cystic fibrosis. The mucosal changes observed are variable and include basement membrane thickening, goblet cell hyperplasia, oedema of varying extent, inflammation (mostly lymphocytes and plasma cells) and polypoid change of the mucosa [242].

2.3 Sinonasal Polyps

2.3.1 Allergic Polyposis

Allergic sinonasal polyps consist largely of myxoid oedematous tissue with pseudocysts containing eo-

sinophilic proteinaceous fluid and infiltrates of inflammatory cells [115]. They are covered by respiratory epithelium with variable ulceration, goblet cell hyperplasia, squamous metaplasia and thickening of the basement membranes. Seromucous glands and mucin-containing cysts may also occur. They arise most frequently in the ethmoidal region and the upper part of the nasal cavity. Allergic polyps usually exhibit heavy infiltration by eosinophils (Fig. 2.1a), marked thickening of the basement membranes and goblet cell hyperplasia. Most sinonasal polyps are of allergic origin. Epithelial dysplasia is present in a few cases. Granulomas may be present in polyps treated with intranasal injection, application of steroids or other oily medications. Atypical fibroblasts with abundant cytoplasm, poorly defined cell borders and large pleomorphic nuclei are present in a small proportion of cases [183]. These atypical cells occur individually and are more frequently found close to blood vessels (Fig. 2.1b) or near the epithelial surface. Such stromal atypia is a reactive phenomenon and it should not be confused with sarcoma.

2.3.2 Polyposis in Mucoviscidosis

Nasal polyps in mucoviscidosis show cystic glands filled with inspissated mucoid material and thickening of the basement membranes that surround the glands [22, 189]. Some other polyps are of infective or chemical aetiology. The histological appearances of nasal polyps do not always correlate well with their aetiology.

2.3.3 Polyposis in Immotile Cilia Syndrome and Kartagener's Syndrome

Immobile cilia syndrome (or primary ciliary dyskinesia) is a genetic disease affecting ciliary movement and resulting in respiratory infections and male infertility. Situs inversus may be associated (Kartagener's syndrome). About 15% of patients develop nasal polyps histologically indistinguishable from other nasal polyps. Ultrastructural analysis of nasal biopsies is needed to identify the alterations in the architecture of the cilium [177].

2.3.4 Antrochoanal Polyps

Antrochoanal polyps are polyps that arise in the maxillary antrum and extend into the middle meatus projecting posteriorly through the ipsilateral choana [106]. Antrochoanal polyps typically have prominent fibrous stroma surrounding thick-walled blood vessels

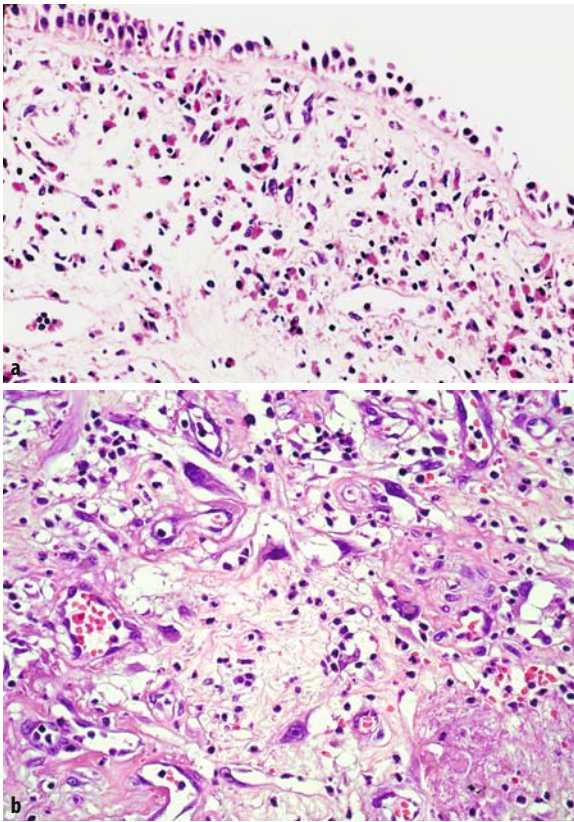


Fig. 2.1. **a** Allergic polyp with marked oedema of the stroma and heavy infiltration by eosinophils. **b** Atypical fibroblasts in an inflammatory allergic polyp: enlarged fibroblasts with bizarre nuclei and occasional prominent nucleoli appear interspersed in granulation tissue

[7]. In addition, scattered, enlarged, stromal cells with hyperchromatic nuclei are not an uncommon finding in this type of polyp [235]. Those polyps that arise in the maxillary antrum and extend into the middle meatus projecting anteriorly are known as antronsal polyps.

2.4 Sinonasal Hamartomatous and Teratoid Lesions

2.4.1 Hamartomas

Sinonasal hamartomas are benign polypoid lesions in which well-developed branching glands and/or stroma with variable participation of different mesenchymal components are present [266]. These lesions may result from an exuberant hyperplastic reaction within the context of an inflammatory polyp. When the glands are mainly covered by ciliated respiratory epithelium the le-

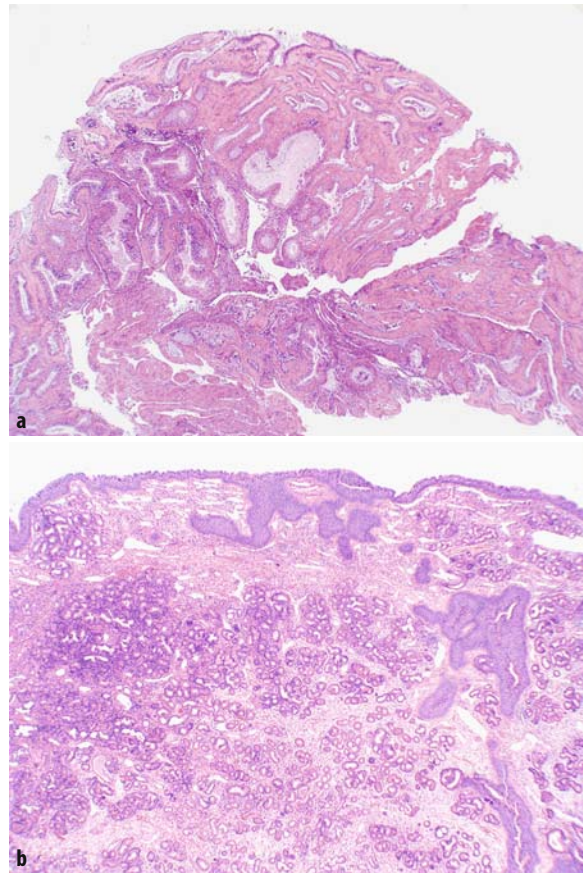


Fig. 2.2 a Respiratory epithelial adenomatoid hamartoma: glandular-like spaces lined by respiratory epithelium and supported by fibrous stroma. **b** Glandular hamartoma: abundant nodular aggregates of modified seromucous glands supported by slightly oedematous stroma

sion is termed “respiratory epithelial adenomatoid hamartoma” (Fig. 2.2a). If the glandular component consists of seromucous glands they are known as “glandular hamartomas” (Fig. 2.2b). “Mesenchymal hamartomas” show predominance of skeletal muscle or of other mesenchymal elements.

2.4.2 Teratoid Lesions

Dermoid cysts of the nose constitute 5.5–12% of those of the head and neck region. More than half are detected in children 6 years old or less, and approximately a third are present at birth. They occur most commonly in the bridge of the nose and always in the midline [33, 63, 88, 254, 278]. Dermoid cysts are lined with mature keratinising squamous epithelium and contain appendages of the skin in the cyst wall, but no endoderm. The lumen is filled with cheesy, yellow-white material.

This lesion is differentiated from the very rare sinonasal teratoma by the limited variety of tissue types and the absence of endodermal components [100]. Epidermal inclusion cysts do not contain adnexa. Dermoid cysts of the nose should also be distinguished from encephalocele. We are unaware of hairy polyps occurring in the nose.

2.5 Pseudotumours

2.5.1 Mucocele

Mucocele is a cyst filled with mucus that develops within a sinus cavity as the result of occlusion of the ostium. Most commonly it is due to infection, but may also result from trauma or be congenital [109]. Retained secretions cause expansion of the sinus and bone erosion. The most common sites of occurrence are the frontal and the sphenoidal sinuses. The cyst is lined by respiratory epithelium that shows prominent goblet-cell hyperplasia [158, 184]. Expansion of the cyst may cause atrophy and metaplasia of the epithelium.

2.5.2 Organising Haematoma

Organising haematoma, also known as “cholesterol granuloma” or “rhinitis caseosa”, is in most cases the result of occult submucosal haemorrhage in the maxillary sinus due to external trauma or tooth extraction [147]. Resolution of the haematoma produces the formation of cholesterol granulomas and fibrosis, simulating a foreign body reaction.

2.5.3 Amyloidosis

Isolated amyloid deposition in the sinonasal mucosa is a rare event, with about 20 cases reported in the English-language literature [180, 258]. Grossly, the lesion appears as a friable tumour-like mass, with a tendency to bleed. Histologically, there is a deposition of intensely eosinophilic material in the stroma, around blood vessels and around ducts of the mucoserous glands, which is often associated with diffuse chronic inflammation and foreign body granulomatous reaction. Amyloid stains orange with Congo red, and showed apple green birefringence under polarised light examination. Immunohistochemistry may help to identify the type of amyloid deposition.

2.5.4 Myospherulosis

Myospherulosis is characterised by the presence of cyst-like spaces lined by flattened histiocytes and containing clusters of brownish spherules resembling fungi [198, 217, 230]. They lie loosely or within sacs formed by thin refractile membranes. The brownish spherules do not stain with PAS or Gomori methanamine silver and their morphology does not correspond to any known fungus [228]. They are found within fibrous granulation tissue, which may show a foreign body reaction. The lesion is usually found in patients who have had previous operations [145]. It is now recognised that the spherules are extravasated red cells that have been altered by interaction with traumatised fat or petrolatum-based ointments and gauzes used in surgical procedures.

2.5.5 Eosinophilic Angiocentric Fibrosis

Eosinophilic angiocentric fibrosis is a rare, chronic, benign, idiopathic condition of the upper respiratory tract occurring predominantly in adult women [214, 248]. Initially, the histologic picture is characterised by non-necrotising eosinophilic vasculitis involving capillaries and venules of the sinonasal mucosa, accompanied by an inflammatory infiltrate with lymphocytes, plasma cells, histiocytes and occasional neutrophils [214]. In late lesions there is a characteristic obliterative perivascular onion-skin fibrosis, while the inflammatory infiltrate is less dense and eosinophils predominate [214]. The differential diagnosis includes reactive processes of the sinonasal mucosa, like Wegener's granulomatosis, Churg-Strauss syndrome, Kimura disease, and angiolymphoid hyperplasia with eosinophilia.

2.5.6 Heterotopic Brain Tissue

This lesion mostly occurs in young children, usually the result of a congenital abnormality related to a variant of meningoencephalocele [136, 196]. Commonly used synonyms are glial heterotopia and nasal glioma, although the latter is a misnomer. The lesion mainly arises at the base of the nose or in the upper part of the nasal cavity, and grossly may be polypoid. Histologically, it is mostly composed of a mixture of astrocytes, glial fibres and fibrous connective tissue. Multinucleated glial cells are frequently found. Some glial cells can have large nuclei resembling nerve cells. Immunostaining for glial fibrillary acidic protein is a helpful diagnostic adjunct. A few true nerve cells or even ependymal elements can rarely be identified. Mitoses are not found.

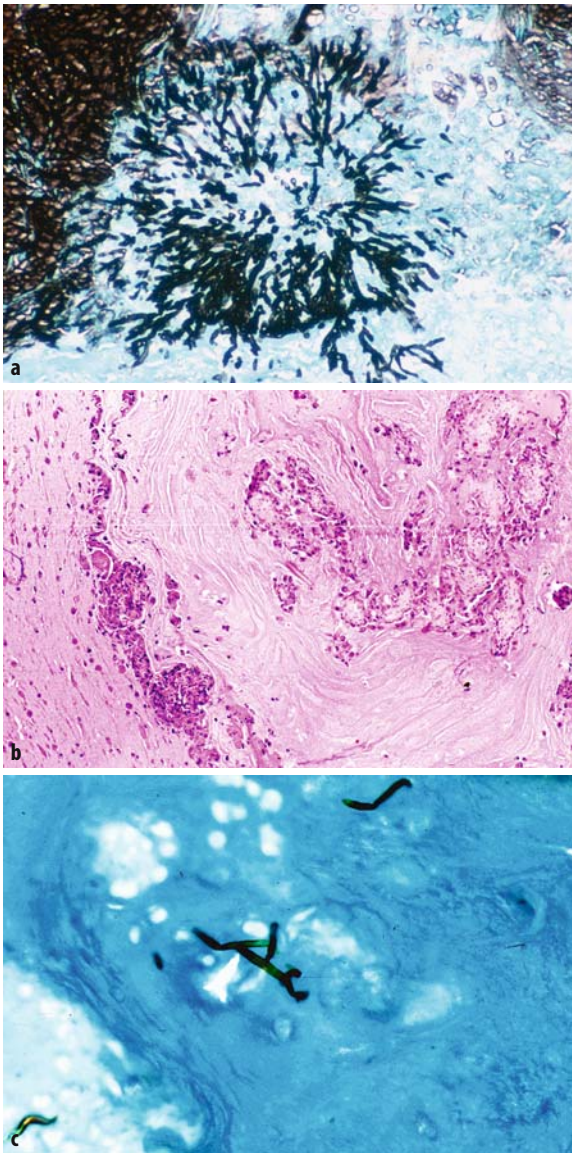


Fig. 2.3. **a** Sinonasal aspergilloma: densely packed branching hyphae of aspergillus forming a fungal ball. (Gomori's methenamine silver). **b** Sinonasal allergic mucinosis: dense aggregates of eosinophilic leukocytes distributed between pools of mucin. At the centre, one Charcot-Leyden crystal. **c** Allergic fungal sinusitis: scarce fungal hyphae found after diligent search in a lake of mucin (Gomori's methenamine silver)

2.6 Fungal Diseases

2.6.1 Aspergillosis

Aspergillosis is caused by *Aspergillus fumigatus*, *Aspergillus niger* and other species. In sections stained with

PAS or Gomori methanamine silver the fungi appear as dichotomously branching septate hyphae 6–8 μm wide. Aspergillosis may occur as a non-invasive disease in which a mass of fungal hyphae (fungal ball) is present in a sinus (Fig. 2.3a). Invasive aspergillosis is seen more often in immunocompromised patients, associated with destructive inflammation of the sinonasal tissues [223]. The disease may also occur as an allergic mucinous sinusitis in which the sinuses contain masses of inspissated mucus with abundant eosinophils, Charcot-Leyden crystals (Fig. 2.3b), necrotic cell debris and scarce fungal hyphae (Fig. 2.3c) [137, 172]. The sinus mucosa shows inflammatory changes without fungal invasion.

2.6.2 Mucormycosis

Mucormycosis is caused by fungi of the class *Zygomycetes* and order *Mucorales* [73]. The most common species causing sinonasal infection are *Rhizopus arrhizus* and *Rhizopus oryzae*. In sections stained with PAS or Gomori methanamine silver the fungi are seen as non-septate hyphae measuring 10- to 20- μm wide, usually branching at right angles. Infection is usually opportunistic and causes rapidly progressive disease in poorly controlled diabetics and immunocompromised patients. The fungus has a tendency to invade blood vessels causing thrombosis; the affected tissues may exhibit coagulative necrosis and haemorrhage.

2.6.3 Rhinosporidiosis

Rhinosporidiosis is caused by the endosporulating fungus *Rhinosporidium seeberi*. The lesions are polypoid and occur principally in the nasal cavity [21, 161]. They are characterised by the presence of thick-walled sporangia measuring 50–350 μm in diameter and containing numerous mucicarminophilic spores. They are associated with a heavy chronic inflammatory reaction with occasional foci of suppuration and foreign body giant cell reaction.

2.7 HIV-Related Infections

Sinonasal infections are frequently observed in HIV patients, are often asymptomatic and tend to be recurrent or refractory [281]. They are due to various pathogens including cytomegalovirus [164], *Staphylococcus aureus*, fungi (*Aspergillus*) [170] and parasites (*Microsporidium*, *Cryptosporidium*) [66].

2.8 Mid-Facial Necrotising Granulomatous Lesions

2.8.1 Wegener's Granulomatosis

Wegener's granulomatosis is an immunologically mediated inflammatory disease characterised by granulomatous vasculitis of the upper and lower respiratory tracts together with glomerulonephritis. Variable degrees of disseminated vasculitis involving both small arteries and veins may also occur. The lesions in the upper respiratory tract are ulcerative and destructive and occur mainly in the nasal cavity and paranasal sinuses. The hallmarks of Wegener's granulomatosis are the presence of geographic necrosis surrounded by palisaded histiocytes, granulomas and scattered giant cells, vasculitis with fibrinoid necrosis or infiltration of vessel walls by inflammatory cells, neutrophilic microabscesses and a mixed inflammatory infiltrate with variable fibrosis [57, 165]. Stains for acid fast bacilli and fungi are negative. There is no cytological atypia. The classic histological features of Wegener granulomatosis are not present in many biopsy specimens. Repeat biopsies and clinical correlations are often essential for early diagnosis. The disease may be restricted to the upper respiratory tract in the early stages. A high percentage of patients develop c-ANCA. More details are to be found in Chap. 3.

2.8.2 Lepromatous Leprosy

Lepromatous leprosy is the most frequent form of this type of disease involving the nasal cavity [101]. It is characterised by nodular masses of foamy macrophages (lepra cells) in which large numbers of acid fast bacilli (*Mycobacterium leprae*) are demonstrable by the modified Ziehl-Neelsen method. Tuberculoid leprosy is characterised by non-caseating granulomas and the indeterminate variant by a non-specific chronic inflammatory reaction; acid fast bacilli are seldom demonstrable in these types.

2.8.3 Tuberculosis

Tuberculosis of head and neck occurs infrequently and involvement of the nose is rare, representing in most cases a secondary event to pulmonary involvement [231]. In most cases there is a polyp of the nasal septum or an ulcerated granular lesion. Presence of intracranial extension may lead to a clinical diagnosis of malignancy [19]. Microscopically, there are caseating giant cell granulomas in which acid-fast bacilli may occasionally be identified. The definitive diagnosis is made by iso-

lating *Mycobacterium tuberculosis* from tissue removed during biopsy.

2.8.4 Sarcoidosis

Sarcoidosis is a chronic multisystem granulomatous disorder that has a predilection for pulmonary and upper respiratory tract mucosa. The sinonasal mucosa is rarely involved, and most patients have generalised disease [143]. Discrete non-caseating granulomata composed predominantly of epithelioid histiocytes with multinucleated giant cells and a peripheral rim of lymphocytes are present in the mucosa. Stains for acid-fast bacilli are negative. The differential diagnosis includes other granulomatous disorders, like tuberculosis, leprosy, Wegener's granulomatosis and cholesterol granuloma [57].

2.8.5 Rhinoscleroma

Rhinoscleroma is caused by *Klebsiella rhinoscleromatis* [21], a capsulated gram-negative bacillus. Large nodular tumour-like masses are found in the nasal cavity and less often in other parts of the upper respiratory tract. They contain large macrophages with abundant clear or vacuolated cytoplasm (Mikulicz cells). The causative organism may be identified by the Warthin-Starry staining method or by immunostaining for the *Klebsiella* capsular antigen. There is heavy infiltration by chronic inflammatory cells, mainly plasma cells showing numerous Russell bodies.

2.8.6 Leishmaniasis

Leishmaniasis of the nasal region, when seen in Mediterranean countries, is mostly in the form of an "oriental sore" caused by *Leishmania tropica*. In Central and South America it is mostly seen in the form of mucocutaneous leishmaniasis caused by *Leishmania braziliensis* [153, 197]. The protozoan parasite is seen in the cytoplasm of histiocytes or extracellularly, measures 1.5–3.0 µm in its maximum dimension and has a nucleus and a rod-shaped kinetoplast that stains positively with Giemsa. The kinetoplast is more readily identified in Giemsa-stained smears of exudates or scrapings than in paraffin sections. The lesions, commonly found in the nasal mucosa and facial skin, are associated with chronic inflammatory reaction and granuloma formation. They are in general circumscribed and self-involutive in the case of the "oriental sore" and markedly destructive in mucocutaneous leishmaniasis.

2.8.7 Cocaine Abuse

Cocaine abuse may be associated with severe nasal necrotising inflammation [225]. Endoscopically, there is atrophy of the inferior and middle turbinates and ulceration of the nasal septum. Histologically, areas of acute and chronic inflammation are found; however, vasculitis is minimal or absent and granulomas may be present. The lesion may be confused with Wegener's granulomatosis.

2.8.8 Local Steroid Injections

A granulomatous lesion of the nasal mucous membranes has been observed in patients treated with injections of steroid preparations [272]. There is a central deposition of amorphous material bordered by histiocytes and foreign body giant cells. Occasional particles of birefringent crystalline material may be present. Special stains should be performed to exclude the presence of micro-organisms.

2.9 Benign Epithelial Neoplasms

2.9.1 Sinonasal Papillomas

Sinonasal papillomas may be divided into squamous cell papillomas of the nasal vestibule and schneiderian papillomas of the nasal cavity and paranasal sinuses [121]. The first are covered by epithelium of the skin surface. The latter are lined by well-differentiated respiratory epithelium (referred to as the schneiderian membrane) and comprise three histopathological types: exophytic, inverted and oncocytic. The histopathological features that clearly differentiate between the three types of schneiderian papillomas have been well documented [173]. Human papilloma virus (HPV) types 6 and 11 are involved in the pathogenesis of exophytic papillomas, but not in the other two variants of schneiderian papillomas [35, 89, 128]. All oncocytic papillomas examined have been HPV-negative [35, 128, 221].

2.9.1.1 Squamous Cell Papilloma

ICD-O:8052/0

Squamous cell papillomas are located in the nasal vestibule and are formed by keratinising stratified squamous epithelium of the skin surface [122]. They are exophytic and consist of a thickened layer of differentiated squamous epithelium, without evidence of atypia or mitoses, which is supported by arborescent stalks of fibrovascular stroma. Varying degrees of keratinisation are present and either hyperkeratosis, parakeratosis or both may be

seen. They are benign, rarely recur after simple excision. Its main differential diagnosis is the exophytic schneiderian papilloma.

2.9.1.2 Exophytic Papilloma

ICD-O:8121/0

Exophytic papilloma, also known as “everted” or “fungiform” papilloma, is a single, warty tumour measuring up to 1.5 cm in diameter, arising most frequently at the nasal septum and only very rarely in the lateral nasal walls or in paranasal sinuses [122]. Males are predominantly affected. Patients tend to be younger than with other types of schneiderian papilloma. Exophytic papillomas are almost always unilateral [54]. No side is preferred and bilaterality is exceptional. The tumour is composed of branching papillary structures, with papillae covered by stratified non-keratinising squamous epithelium, admixed with intermediate or transitional cells and with ciliated respiratory epithelium that contains interspersed mucin-secreting cells. Koilocytosis is not infrequently found in the squamous epithelium. Seromucinous glands are abundantly found when the underlying submucosa is removed.

The two main differential diagnoses are inverted papilloma and oncocytic papilloma. Neither the invaginated pattern of growth of inverted papillomas nor the oncocytic columnar epithelium of oncocytic papillomas are found in exophytic papillomas [173]. Cylindrical cell carcinoma can be easily ruled out by the lack of atypia and invasion. Wide surgical excision is the best choice of treatment to avoid recurrences. Recurrences occur in about 20–40% of cases, which is less than in inverted papillomas. Malignant transformation almost never occurs in exophytic papillomas.

2.9.1.3 Inverted Papilloma

ICD-O:8121/0

Inverted papilloma is the most common type of schneiderian papilloma. This lesion occurs almost exclusively in the lateral wall of the nasal cavity and in the paranasal sinuses, although on rare occasions it may also arise on the nasal septum [226]. Grossly, they frequently have a polypoid appearance, but they differ from nasal polyps of the common type by their histological features. Inverted papillomas are composed of invaginating crypts, cords and nests covered by non-keratinising squamous epithelium, which alternates with columnar ciliated respiratory epithelium and with intermediate or transitional epithelium (Fig. 2.4a). This newly formed duct system is similar to the embryonic development of the nasal mucosa [240]. The multilayered epithelium typically contains mucous cells and mucin-filled micro-

cysts. The invagination of the mucosa may result in the presence of apparently discontinuous cell masses lying deep to the epithelial surface, but the basement membrane is intact and may be shown in continuity with that of the surface epithelium [226]. An inverted growth is the hallmark of inverted papilloma, but varying degrees of papillary growth may be seen at the surface [54]. The surface is characteristically lined by a respiratory type of epithelium; nevertheless, foci of surface keratinisation are occasionally present [122]. A few regular mitoses may be found in the basal and parabasal layers. Although the nuclei may show mild nuclear irregularities and hyperchromatism, no disturbances of the cellular polarity are found. An abundant and oedematous connective tissue stroma is a common feature of inverted papillomas. It usually contains macrophages and neutrophils, but eosinophils may also be present. This inflammatory infiltrate may also be present between the epithelial cells, within the dilated lumens of invaginated crypts, and within the numerous microcysts that usually occur in the respiratory epithelium. Seromucinous glands are absent, but branching gland ducts are often present. The tumour grows by extension to involve the contiguous sinonasal epithelium.

If treated only by local surgical excision, recurrence occurs in up to 75% of cases. Therefore, lateral rhinotomy and medial maxillectomy are advisable for tumours of the lateral nasal wall [236]. Carcinoma develops in about 10–15% of inverted papillomas [122, 211, 236]. Carcinoma may coexist with inverted papilloma at the initial presentation or originate subsequently [122, 273]. According to the experience of Michaels and Hellquist [171], carcinoma does not usually develop in the course of recurrences of inverted papilloma. In the presence of severe atypia or marked keratinisation in an inverted papilloma malignant transformation is always suspected (Fig. 2.4b). In these instances the entire specimen should be thoroughly examined to exclude an associated carcinoma. Most associated carcinomas are squamous [204], although other types may also occur such as verrucous carcinoma [192].

2.9.1.4 Oncocytic Papilloma

ICD-O:8121/1

Oncocytic papilloma, also known as “columnar” or “cylindrical” cell papilloma [226], is the least common type of schneiderian papilloma. It constitutes less than 5% of all sinonasal papillomas [18, 122, 173, 262]. Both sexes are equally affected. Bilaterality has not been documented. Tumours are in general small, although occasionally may reach various centimetre measurements in their greatest dimension. They are composed of exophytic fronds and endophytic invaginations lined by pseudostratified or multilayered columnar cells with prominent onco-

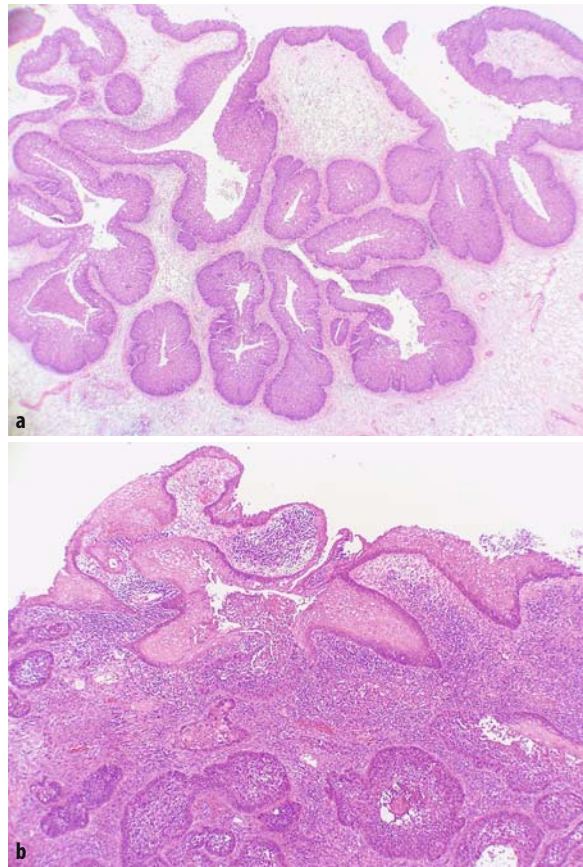


Fig. 2.4. **a** Inverted papilloma: prominent invaginating crypts lined by hyperplastic respiratory epithelium are supported by oedematous connective tissue. **b** Squamous cell carcinoma ex inverted papilloma: remnants of benign invaginating crypts are seen between invasive cords of squamous epithelium

cytic features. The cells have uniform hyperchromatic nuclei and abundant eosinophilic, occasionally granular, cytoplasm that contains abundant mitochondria and stains for the mitochondrial enzyme cytochrome C oxidase [59]. Goblet cells are not found. Cilia may be occasionally encountered on the superficial epithelial layer. Intraepithelial microcysts containing mucin and neutrophils are usually present. These microcysts are larger than the similar structures also seen in inverted papilloma. The tumour resembles inverted papilloma in its sites of occurrence, the lateral wall of the nasal cavity and the maxillary antrum. The rate of recurrence is considered to be 36%, which is lower than in inverted papilloma. The low frequency of this tumour makes it difficult to evaluate its true malignant potential, which seems to be similar to that of inverted papilloma [262]. Atypical hyperplasia and carcinoma *in situ* changes can be occasionally found (Fig. 2.5). Surgical excision with wide margins is the treatment of choice. Invasive squamous cell carcinoma, high-grade mucoepidermoid

carcinoma and undifferentiated carcinoma have been reported in association with oncocytic papilloma [18, 122, 135, 265, 274].

2.9.2 Salivary-Type Adenomas

Pleomorphic adenoma is the most frequent benign glandular tumour of the sinonasal region. Most arise on the nasal septum and the rest on the lateral nasal wall or turbinates. Origin in the maxillary antrum is rare. The recurrence rate of sinonasal pleomorphic adenoma is much lower than for its counterpart in the major salivary glands [56, 109]. Rare examples of sinonasal oncocytoma, myoepithelioma and basal cell adenoma have been reported [27, 55, 103, 277], as well as one case of sinonasal myoepithelioma transformed into myoepithelial carcinoma after various recurrences [9].

2.9.3 Pituitary Adenomas

The rare pituitary adenomas of the sinonasal region are in most instances extensions from intrasellar tumours. Very unusually, they arise from ectopic pituitary tissue as tumours from the sphenoid sinus or the nasal cavity. Histologically, they are similar to tumours within the sella [61, 151].

2.10 Benign Sinonasal Soft Tissue Neoplasms

2.10.1 Haemangiomas

Haemangiomas of the upper respiratory tract may be of the capillary, cavernous or venous types [90]. The most common type is the capillary haemangioma which consists of lobules of blood-filled capillaries separated by loose connective tissue. The lesion should be distinguished from granulation tissue and from the vascular ectasias found in Rendu-Weber-Osler disease.

2.10.2 Haemangiopericytoma (Glomangiopericytoma)

ICD-O:9150/1

Haemangiopericytoma is characterised by the proliferation of oval, polyhedral or spindle-shaped cells enmeshed by collagen type IV fibres and arranged around vascular channels that are lined by a single layer of endothelial cells. The tumour contains numerous thin-walled blood vessels and the tumour cells, typically arranged around the blood vessels, are of uniform size with regular oval

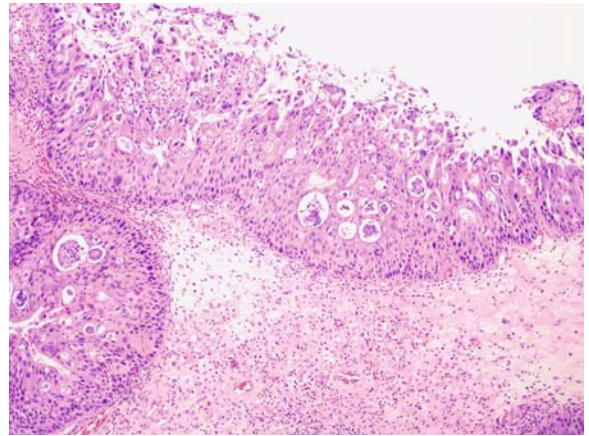


Fig. 2.5. Oncocytic papilloma with atypical cells: papillary stalks covered by columnar cells with frequent atypical nuclei and oncocytic cytoplasm-forming microcysts

or elongated nuclei and pale cytoplasm (Fig. 2.6). The cells may also be arranged in short, haphazard fascicles or in sheets of closely packed cells containing compressed capillaries. Areas of poor cellularity, myxoid change and fibrosis are not uncommon. The tumour cells are entirely situated outside the capillaries, which are lined by a single layer or normal-looking endothelium. This feature, well shown by reticulin staining or by anti-collagen IV antibodies, helps to distinguish the tumour from angiosarcoma. The distinction from other well-vascularised mesenchymal tumours is usually made by exclusion. Haemangiopericytomas of the nasal cavity are generally less aggressive than those occurring elsewhere. They exhibit a more orderly structure with minimal mitotic activity, but tend to recur after removal and may rarely metastasise [249]. Muscle-specific actin is focally positive in tumour cells. The term glomangiopericytoma has been recently proposed for this entity [267a].

2.10.3 Solitary Fibrous Tumour

ICD-O:8815/0

Solitary fibrous tumour of the nose, paranasal sinuses and nasopharynx is in most instances a benign fibroblastic proliferation with variable cellularity and vascularity (Fig. 2.7) having features identical to those of solitary fibrous tumour of the pleura [8, 168, 279]. Its main differential diagnoses are sinonasal haemangiopericytoma and nasopharyngeal angiofibroma.

2.10.4 Desmoid Fibromatosis

ICD-O:8821/1

Desmoid fibromatoses are a group of non-metastasising unencapsulated fibrous tissue proliferations that have a

tendency towards local invasion and recurrence, which rarely arise in the sinonasal mucosa [96]. They comprise interlacing fascicles of bland spindle-shaped fibroblasts, in a collagenous or myxoid background. The main differential diagnoses are fibrosarcoma and reactive fibrosis. Desmoid fibromatosis of the sinonasal tract shows lower recurrence rates than desmoid fibromatoses arising in other locations.

2.10.5 Fibrous Histiocytoma

ICD-O:8830/0

Benign fibrous histiocytoma presents as a yellow-tan nodule or polyp, most commonly causing nasal obstruction or bleeding [201]. It is composed of spindle-shaped cells producing a storiform pattern admixed with histiocytic cells and multinucleated giant cells. Distinction from other benign sinonasal spindle cell proliferations is largely based on the immunohistochemical findings. Benign fibrous histiocytomas may recur if incompletely excised.

2.10.6 Leiomyoma

ICD-O:8890/0

Sinonasal leiomyoma is a rare tumour occurring in adults, preferentially involving the nasal cavities, with non-specific symptoms of nasal obstruction [91]. Its morphologic and immunohistochemical profile is identical to that of leiomyomas of other sites. It has been postulated that they may originate from blood vessel walls. Distinction from sinonasal leiomyosarcoma is based on the absence of atypia and mitoses. Huang and Antonescu have proposed separating a category of smooth muscle tumours of uncertain malignant potential, characterised by the presence of 1–4 mitotic figures/10 high power fields, that tend to pursue a more aggressive behaviour than leiomyomas [119].

2.10.7 Schwannoma and Neurofibroma

ICD-O:9560/0, 9540/0

About 4% of schwannomas of the head and neck region arise in the sinonasal tract [202]. They usually present as polypoid lesions involving the nasal cavity and/or a paranasal sinus, with non-specific symptoms of obstruction, compression, or extension in the surrounding structures [202]. Histologically, the tumour is composed of elongated wavy-shaped monomorphic spindle cells, with eosinophilic cytoplasm and oval nucleus. Antoni type A and type B areas usually coexist within the lesion, and nuclear palisading may be present. Focal degenerative nuclear atypia has been described [108], while mitotic activity is absent to low. A consistently reported

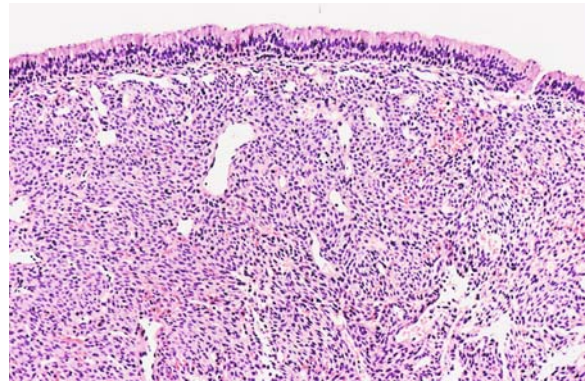


Fig. 2.6. Haemangiopericytoma: interconnected thin-walled blood vessels surrounded by uniform spindle-shaped cells with oval or elongated nuclei

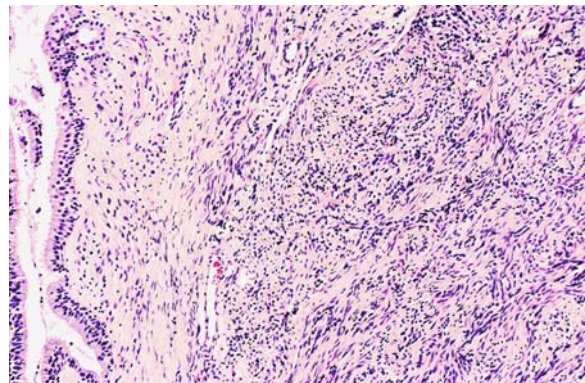


Fig. 2.7. Solitary fibrous tumour: fibroblastic proliferation, collagen production and dilated blood vessels. Identical features to the pleural counterpart

feature of sinonasal schwannomas is the lack of tumour encapsulation that determines an apparently infiltrative growth pattern [36, 108]. Immunohistochemically, sinonasal schwannoma is intensely reactive for S-100 protein [108]. The differential diagnosis includes other spindle cell lesions of the sinonasal mucosa, like juvenile angiofibroma, solitary fibrous tumour and leiomyoma. Particular care should be taken when evaluating cellular schwannomas with a predominance of Antoni type A areas, which should not be confused with malignant spindle cell neoplasms, like fibrosarcoma, leiomyosarcoma, malignant peripheral nerve sheath tumour, and spindle cell melanoma.

Neurofibromas of the sinonasal mucosa are usually not associated with the Von Recklinghausen syndrome, and appear as unencapsulated lesions composed of a mixture of Schwann cells and fibroblasts embedded in a predominantly myxoid stroma [117, 202]. Due to the overlapping of the histologic features, it may be difficult to differ-

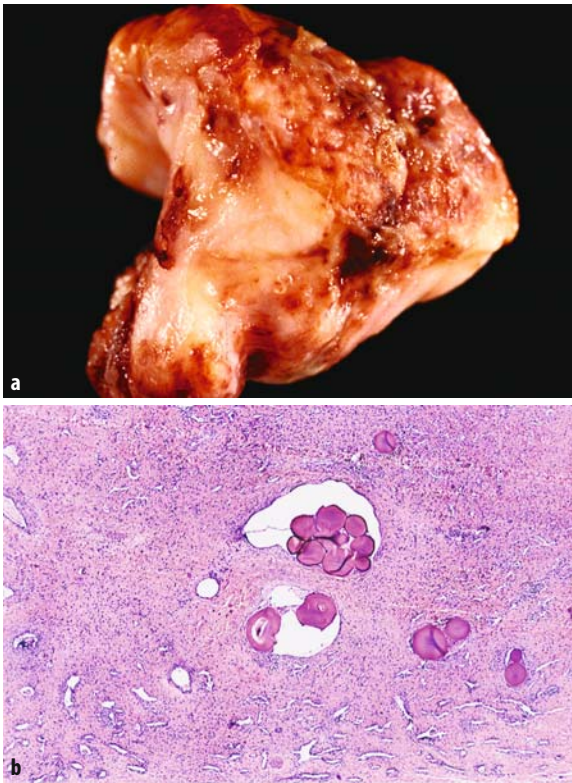


Fig. 2.8. Juvenile angiofibroma. **a** Polypoid mass of white-red cut surface and rubbery consistency. **b** Vascular elements embedded in fibrous tissue showing intravascular microembolisation, a treatment modality prior to surgery

entiate neurofibromas from schwannomas of the sinonasal mucosa. Neurofibromas should also be distinguished from myxomas, which are S-100 protein-negative.

2.10.8 Meningioma

ICD-O:9530/0

Meningiomas of the sinonasal tract may extend directly from the central nervous system or arise from ectopic extracranial tissue. Although always rare, they are more commonly seen in the orbit, ear and skin of the head and neck than in the sinonasal tract. Histologically, they are similar to meningiomas elsewhere, the meningothelial type being the most frequent. Sinonasal meningiomas tend to occur in younger patients than intracranial meningiomas [118, 203].

2.10.9 Paraganglioma

ICD-O:8680/1

There are few reports on nasal paragangliomas. The tumours originate in the middle turbinates and ethmoid

sinuses. Histologically, they are similar to paragangliomas elsewhere [12, 98, 187].

2.10.10 Juvenile Angiofibroma

ICD-O:9160/0

Juvenile nasopharyngeal angiofibroma arises in the confluence of the posterolateral nasal wall and the lateral nasopharynx and occurs almost exclusively in males during adolescence [90, 125]. The tumour is sessile or polypoid (Fig. 2.8a) and is histologically benign, but has a tendency to recur and is locally destructive, causing pressure necrosis of adjacent soft tissue and bone. It may occasionally extend into paranasal sinuses, orbit and cranial fossae. It is composed of vascular and fibrous elements in varying proportions. The vessels in the superficial portions of the tumour are mainly gaping capillaries that may become compressed with increasing stromal fibrosis. Thick-walled vessels without elastic membranes and with irregular, incomplete or absent muscle coats and focal intimal thickenings are usually present in the deeper portions of the tumour. These vessels resemble those normally seen in the submucosa of the nasal conchae. The vascular elements are embedded in fibrous tissue, which varies in cellularity and collagenisation. Stellate fibroblast-like cells are often present close to the blood vessels. The fibroblastic cells of nasopharyngeal angiofibroma are strongly positive for testosterone receptors [120]. Ultrastructurally, the nuclei of angiofibroma contain characteristic dense granules [251]. Occasionally, the fibroblasts may exhibit cytologic atypia, and some of these cells may be multinucleated, but mitosis is rare. Mast cells may be numerous. There may be focal thrombosis, haemorrhage and chronic inflammatory reaction. With the advent of preoperative selective embolisation, iatrogenic emboli (Fig. 2.8b) are increasingly encountered in resected specimens [232]. For more details on this tumour see Chap. 6.

2.11 Malignant Sinonasal Tumours

Malignant sinonasal tumours represent less than 1% of all cancers seen in humans and about 3% of all malignancies of the head and neck region [160]. Despite the low rate of malignancy arising in the sinonasal tract, a great variety of histological types of tumours may be found [216, 226]. The use of electron microscopy and more recent advances in immunohistochemistry and molecular biology have made it possible to refine the criteria for their correct recognition.

Geographical differences in the relative frequency of certain histological types of malignant sinonasal tumours may be related to variations in the exposure

Table 2.1. Malignant sinonasal tumours at the Hospital Clinic, University of Barcelona Medical School

Histological type of tumour	Frequency		Men		Women		Mean age	Age range
	n	%	n	%	n	%		
Squamous cell carcinoma	54	27	38	70	16	30	64	39–87
Undifferentiated carcinoma	26	13	19	73	7	27	60	41–87
Cylindrical cell carcinoma	19	9.5	15	79	4	21	59	26–84
Malignant lymphoma	19	9.5	15	79	4	21	59	9–89
Malignant melanoma	14	7	7	50	7	50	69	56–89
High-grade adenocarcinoma	13	7	10	77	3	23	59	16–81
Adenoid cystic carcinoma	11	5	7	64	4	36	58	22–69
Low-grade adenocarcinoma	10	5	4	40	6	60	64	28–92
Olfactory neuroblastoma	7	3	3	43	4	57	36	2–67
Mucoepidermoid carcinoma	4	2	3	75	1	25	55	50–61
Malignant fibrous histiocytoma	4	2	3	75	1	25	56	35–65
Plasmacytoma	4	2	3	75	1	25	51	50–65
Rhabdomyosarcoma	4	2	2	50	2	50	30	8–51
Malignant schwannoma	3	1.5	1	33	2	67	57	27–70
Adenosquamous carcinoma	2	1	2	100	–	–	66	61–71
Myoepithelial carcinoma	2	1	2	100	–	–	47	29–66
Kaposi's sarcoma	2	1	2	100	–	–	37	34–40
Teratocarcinosarcoma	1	0.5	1	100	–	–	76	–
Ewing's sarcoma (PNET)	1	0.5	–	–	1	100	23	–
Total	200	100	137	69	63	31	58	2–92

to environmental carcinogens (see epidemiological aspects Sect. 11.1.1). In Table 2.1 the histological types of malignant sinonasal tumours diagnosed at the Hospital Clinic of the University of Barcelona are presented in decreasing order of frequency. The most frequent histological types are: keratinising squamous cell carcinoma, undifferentiated carcinoma, cylindrical cell carcinoma, malignant lymphoma, malignant melanoma, intestinal-type adenocarcinoma, adenoid cystic carcinoma, low-grade adenocarcinomas and olfactory neuroblastoma.

A practical way to start classifying malignant sinonasal tumours is to separate them initially into large and small cell categories. Among the large cell malignant tumours the most common types are: squamous cell carcinoma, cylindrical cell carcinoma, malignant melanoma, intestinal-type adenocarcinoma, and low-grade adenocarcinomas. To the most common small cell tumours belong the sinonasal undifferentiated carcinoma, malignant lymphoma, adenoid cystic carcinoma and olfactory neuroblastoma. Large cell tumours account for approximately 75% of the malignant sinonasal tumours and the small cell tumours for the remaining 25% [41].

For staging of malignant sinonasal tumours the TNM classification of 2002 and the TNM atlas of 2004 are recommended, since nasal cavity tumours are now included [237, 271a].

2.11.1 Keratinising Squamous Cell Carcinoma

ICD-O:8071/3

At the nasal vestibule, keratinising squamous cell carcinoma is the most common malignancy [130, 167, 245]. Due to early recognition and easy access to treatment, they usually have a more favourable prognosis than their counterpart of the sinonasal region.

Sinonasal keratinising squamous cell carcinoma represents up to 45–50% of the malignant tumours of this region in several series [93, 259]. At the Hospital Clinic of the University of Barcelona, where non-keratinising squamous cell carcinomas (see Sect. 2.11.2 on cylindrical cell carcinomas) are grouped separately from keratinising squamous cell carcinomas, the latter account for only 27% of the sinonasal malignancies. They predominate in males and the great majority are seen in patients aged over 50 years. The maxillary antrum, the lateral nasal wall and the sphenoidal sinuses are the most common sites, whereas the frontal and sphenoid sinuses are rarely involved. These tumours grow by local extension, infiltrating the neighbouring structures, but lymph node metastases are rare [215]. For neoplasms circumscribed to the nasal cavity the 5-year survival is slightly above 50% [30], whereas in neoplasms of the maxillary antrum the 5-year survival may be as low as 25% [146].

The occupational epidemiology of sinonasal squamous cell carcinoma has been strongly related to exposure to nickel [141, 243, 252, 253] and to a lesser extent to chromium, isopropyl alcohol and radium [218]. As in other territories of the respiratory tract, a definite association between sinonasal squamous cell carcinoma and cigarette smoking has been documented [26, 146]. Chronic sinonasal inflammation is considered a predisposing factor. A case of carcinoma of the maxillary antrum after thorotrast exposure has been reported [97]. Nitrosamines and to a lesser extent formaldehyde are strong nasal carcinogens in laboratory rodents [44, 155].

Keratinising squamous cell carcinomas originate in the respiratory sinonasal mucosa from areas of pre-existing squamous metaplasia and manifest the same range of histological appearances as those arising in other sites. They are characterised by the proliferation of malignant epithelial cells with squamous differentiation and intercellular bridges. Malignancy is graded according to the degree of differentiation, cellular pleomorphism and mitotic activity. They are divided into well-differentiated, moderately differentiated and poorly differentiated forms. Well-differentiated carcinomas are uncommon in this territory and when encountered need to be differentiated from pseudoepitheliomatous types of hyperplasia and from verrucous carcinoma. Most conventional keratinising squamous cell carcinomas of the sinonasal tract present as moderately or poorly differentiated tumours. Special types, such as verrucous carcinoma [104], spindle cell carcinoma [205, 276], basaloid-squamous cell carcinoma [16, 269] and adenosquamous carcinoma [10, 94] are occasionally found in the sinonasal tract. Regional lymph node involvement is seen in about 17% of sinonasal squamous cell carcinomas and distant metastases in about 1.5% [215].

2.11.2 Cylindrical Cell Carcinoma

ICD-O:8121/3

Cylindrical cell carcinoma, also known as non-keratinising squamous cell carcinoma, transitional cell carcinoma or schneiderian carcinoma, is a tumour composed of malignant proliferating cells derived from sinonasal respiratory (schneiderian) epithelium. The name cylindrical cell carcinoma was first coined by Ringertz in 1938 [212] and recommended as the preferred term by Shanmugaratnam in the WHO classification of 1991 [226].

Grossly, the tumours grow in most cases as exophytic masses showing either a corrugated or a smooth surface. They may arise from the antrum, the lateral nasal wall or the ethmoid, the maxillary antrum being the most frequent site [193, 194]. They may occur concomitantly with other non-neoplastic polypoid formations. Microscopically, cylindrical cell carcinoma is composed of papillary fronds (Fig. 2.9a), thick ribbons

and polystratified masses of cells that give rise quite often to invaginations of the surface epithelium, which at low magnification may mimic inverted papilloma. The tumour cells are commonly cylindrical and have a tendency to form palisade arrangements perpendicular to the underlying basement membrane (Fig. 2.9b). The nuclei are atypical and show increased mitotic activity, as well as abnormal mitotic figures. The pattern of invasion is usually expansive, being characterised by pushing margins with focal infiltration of the stroma. The basement membrane remains in most cases conspicuous, despite stromal infiltration, which should not be regarded as carcinoma in situ. Foci of squamous metaplasia, with transition from cylindrical to squamous epithelium, are not uncommon and when extensive these tumours may be indistinguishable from squamous cell carcinoma. This resulted in denominations such as “transitional cell carcinoma” and “non-keratinising squamous cell carcinoma”, which may be confusing. The first because the term transitional has also been applied to carcinomas of the lymphoepithelial type, and the second due to the fact that tumours called “non-keratinising squamous cell carcinoma” also have foci of keratinisation [267a]. In addition, the term cylindrical cell carcinoma should be preferred to non-keratinising squamous cell carcinoma because “pure” cylindrical cell carcinomas, without any squamous cell component, carry a better prognosis than conventional squamous cell carcinomas [84]. Very recent observations suggest a strong etiologic relationship of cylindrical cell carcinoma to high-risk human papillomavirus [69a]. A high proportion of these tumours show marked immunoreactivity for p16.

More aggressive types of carcinoma, such as sinonasal undifferentiated carcinoma (SNUC) or high-grade adenocarcinoma, may appear occasionally intermingled with cylindrical cell carcinoma [226]. Two cases of cylindrical cell carcinoma with endodermal sinus-like features have been reported [162]. A full examination of the resected specimen is therefore mandatory before labeling a tumour a “pure cylindrical cell carcinoma”.

The two main differential diagnoses of cylindrical cell carcinoma are the schneiderian papillomas of the inverted and oncocytic types, especially when they have concomitant carcinomatous changes. Both types of papilloma lack the atypical cellularity constantly seen in cylindrical cell carcinoma. When schneiderian papillomas coexist with cylindrical cell carcinomas, or with other types of carcinoma, the two components usually appear demarcated from one another although in contiguity. When the invaginating crypts of an inverted papilloma are filled with the cords and ribbons of a keratinising or non-keratinising squamous cell carcinoma, the lesion represents a conventional squamous cell carcinoma arising in an inverted papilloma, which implies a worse prognosis than that of cylindrical cell carcinoma.

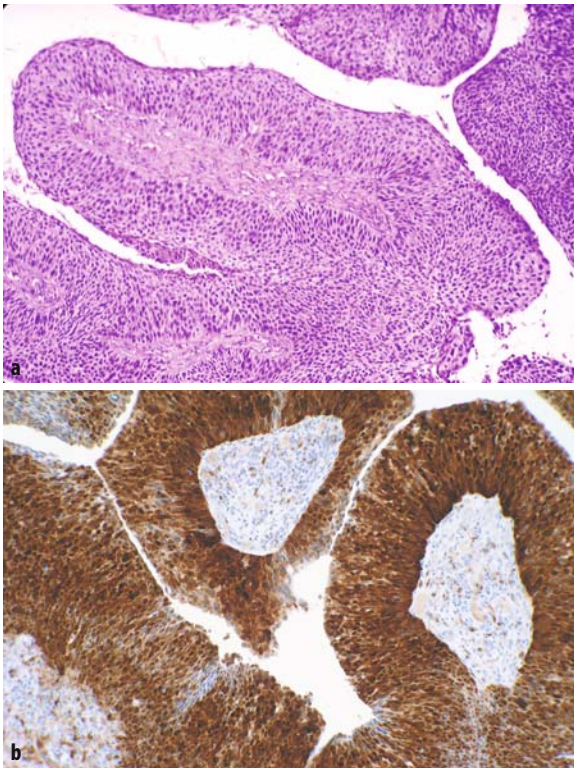


Fig. 2.9. Cylindrical cell carcinoma. **a** Papillary structures covered by malignant cells with cylindrical cytoplasm and basal nuclei arranged in palisades. **b** Marked immunoreactivity of the epithelial neoplastic cells for p16, which is related to high-risk HPV

2.11.3 Sinonasal Undifferentiated Carcinoma

ICD-O:8020/3

Sinonasal undifferentiated carcinoma (SNUC) is defined as a high-grade malignant epithelial neoplasm of the nasal cavity and paranasal sinuses, composed of small to medium-sized cells, lacking evidence of squamous or glandular differentiation and of rosette formation [48, 86, 114]. Cigarette smoking [86] and nickel exposure [252] have been associated with SNUC. Epstein-Barr virus (EBV) and the deletion of the retinoblastoma gene have been ruled out as factors involved in the development of this tumour [127]. Ionising radiation is another aetiological factor, as radiotherapy either for retinoblastoma or for nasopharyngeal carcinoma has been associated with SNUC [127].

Sinonasal undifferentiated carcinoma occurs in both sexes over a wide age range, with a median in the 6th decade of life. It commonly originates from the ethmoidal region as a large fungating mass. Grossly, the tumours are quite frequently extensive le-

sions, obstructing the nasal cavity either unilaterally or bilaterally and invading the adjacent sinonasal structures (Fig. 2.10a), as well as the orbit, skull base and the brain. Microscopically, SNUC is composed of small to medium-sized, undifferentiated cells, which arise via dysplastic changes from the basal cells of the surface epithelium. The cells are polygonal with distinct borders, showing round to oval, hyperchromatic or vesicular nuclei, with either inconspicuous or slightly prominent nucleoli, surrounded by a moderate amount of either amphophilic or eosinophilic cytoplasm (Fig. 2.10b). Mitotic figures are common. The tumour forms nests, cords and sheets of cells that show frequent areas of central necrosis and tendency to vascular (Fig. 2.10c) and perineural invasion. Ultrastructural studies demonstrate poorly formed desmosomes in quite a number of cells, while the presence of tiny bundles of tonofilaments is very rare. Neurosecretory granules are very rarely found. SNUC are immunoreactive with epithelial markers, such as CAM 5.2 and epithelial membrane antigen (EMA). Variable reactivity can be seen with neuron-specific enolase (NSE), whereas there is negative reactivity for synaptophysin, chromogranin and other neuroendocrine markers. SNUC are also negative for EBV [48, 127].

The two main differential diagnoses of SNUC are small cell (neuroendocrine) carcinoma (SCC) and high-grade olfactory neuroblastoma (ONB). All three entities may share some clinical and light microscopic features. However, SNUC and SCC show a marked immunoreactivity for cytokeratins that is not seen in ONB, and SNUC lacks the neuroendocrine immunoreactivity seen in SCC and ONB. Most lesions categorised in the past as grade IV ONB are now considered to be either SNUC or SCC. This is important because SNUC and SCC have a worse prognosis than ONB. In addition, SNUC needs to be distinguished from other primary sinonasal tumours, such as solid adenoid cystic carcinoma, microcytic malignant melanoma, cylindrical cell carcinoma, primary sinonasal nasopharyngeal-type undifferentiated carcinoma, lymphoma and others (Table 2.2).

Sinonasal undifferentiated carcinomas are very aggressive tumours. In most instances, the tumour is so large and the infiltration is so extensive that complete surgical resection cannot be achieved. Radiotherapy and chemotherapy are additional options, either single or combined. High-dose chemotherapy and autologous bone marrow transplantation have been considered as a form of treatment [241]. Prognosis of SNUC is dismal, with a median survival of 4 months to 1 year [86, 114]. In our experience survival after 2 years is less than 40%.

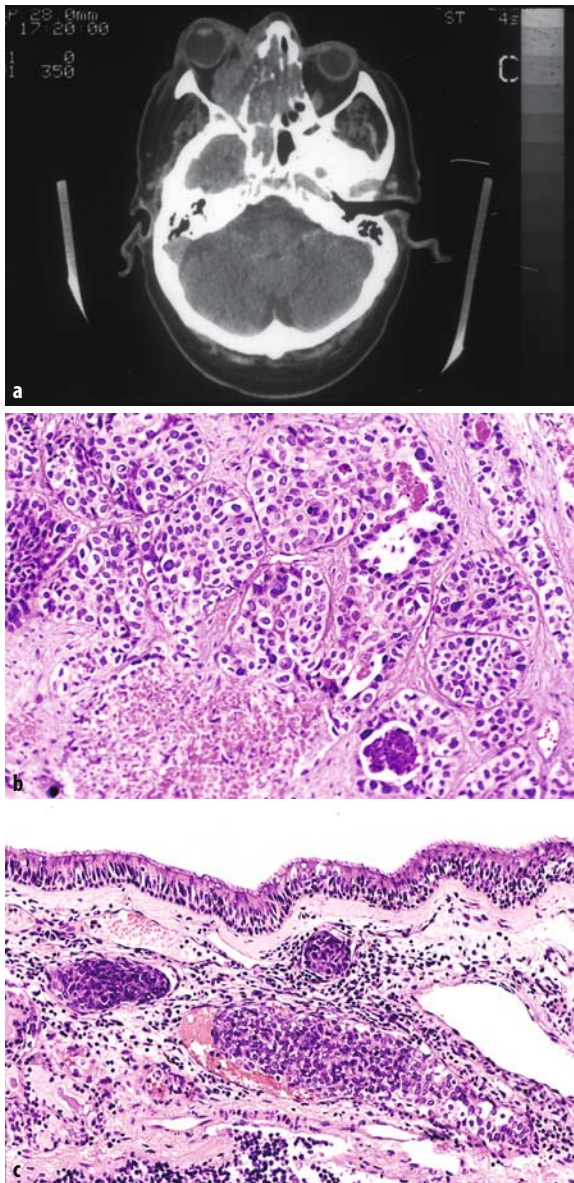


Fig. 2.10. Sinonasal undifferentiated carcinoma (SNUC) **a** Extensive neoplastic growth invading ethmoid, orbit and sphenoid at the left and also the right ethmoid. Courtesy of Prof. J. Traserra, Barcelona, Spain. **b** Nests of small to intermediate epithelial cells showing markedly atypical nuclei and areas of necrosis. **c** Frequent foci of intra-vascular invasion

2.11.4 Small Cell (Neuroendocrine) Carcinoma

ICD-O:8041/3

This is a high-grade malignant epithelial tumour with histological features similar to small cell carcinoma of the lung [226]. Variable degrees of neuroendocrine differentiation may be demonstrable by electron microscopy or immunohistochemistry, but have not always been

required for diagnosis [176]. Before placing a tumour within this category, a differential diagnosis of a primary tumour from the lung must be ruled out.

This type of tumour has been well documented in various head and neck territories, mainly in the parotid gland and in the larynx. In the sinonasal tract, where they are distinctly uncommon, small cell neuroendocrine carcinomas have been less precisely characterised, and so far no unanimous consensus has been reached with regard to the way they have to be separated from other small cell tumours, either round or undifferentiated, occurring in this region [51, 132, 151, 191, 208, 210, 229, 264]. Table 2.2 provides the current criteria most widely accepted for their recognition.

Small cell neuroendocrine carcinoma of the sinonasal region is considered to derive from cells with neuroendocrine differentiation occasionally found in the seromucous glands. In some cases the tumour grows surrounding the seromucous glands of the lamina propria, as if it were originating from them. They give rise to nests, cords and sheets of small, undifferentiated cells, with moulded nuclei and scanty cytoplasm. Immunohistochemistry exhibits a positive reaction for low molecular weight cytokeratins and EMA, as well as variable positivity for neuron-specific enolase, Leu-7, CD56, synaptophysin and chromogranin. At least two neuroendocrine markers should demonstrate positivity [199]. Diligent searching and expert hands usually demonstrate neurosecretory granules by electron microscopy.

Although its prognosis seems to be somewhat better than that of SNUC, or for similar tumours of the lung, small cell neuroendocrine carcinoma is a high-grade malignancy. Treatment should be a combination of surgery and radiotherapy, plus chemotherapy.

2.11.5 Primary Sinonasal Nasopharyngeal-Type Undifferentiated Carcinoma

ICD-O:8082/3

Although nasopharyngeal carcinoma (NPC), also known as lymphoepithelioma, almost invariably arises in the nasopharynx, “bona fide” primary sinonasal nasopharyngeal-type undifferentiated carcinomas (PSNPC) have recently been reported [127]. Due to the undifferentiated appearance of cells in NPC and PSNPC, these tumours may be lumped together with SNUC if unaware of their differences [48, 80, 127]. SNUC does not arise in the nasopharynx, but bulky lesions may extend into this region. Also, NPC may extend from the nasopharynx into the sinonasal region. The distinction between these tumours can generally be made on purely histological grounds, since SNUC lacks the lymphoplasmacytic cell infiltrate seen in most cases of NPC and PSNPC. Immunohistochemistry and in

Table 2.2. Sinonasal undifferentiated tumors. Immunohistochemistry and genetics.

	CK	NSE	S-100	CG	SYN	NF	EBV	L	MIC-2	t11;22	Ampl N-myc
SNUC	+	±	-	-	-	-	-	-	-	-	-
SCC	+	+	-	±	+	-	-	-	-	-	-
PSNPC	+	-	-	-	-	-	+	-	-	-	-
SNML	-	-	-	-	-	-	+	+	-	-	-
PNET	-	+	+	±	+	-	-	-	+	+	-
ONB	-	+	(+)	+	+	+	-	-	-	-	-
MNB	-	+	-	+	+	+	-	-	-	-	+

SNUC sinonasal undifferentiated carcinoma, SCC small cell (neuroendocrine) carcinoma, PSNPC primary sinonasal nasopharyngeal-type carcinoma, SNML sinonasal malignant lymphoma, PNET primitive neuroectodermal tumour, ONB olfactory neuroblastoma, MNB metastatic neuroblastoma, CK cytokeratin, NSE neuronal specific enolase, S-100 Protein S-100, CG chromogranin, SYN synaptophysin, NF neurofilaments, EBV Epstein-Barr virus, L lymphoma markers, MIC-2 CD99, t(11;22) EWS-FLI1, Ampl amplification, (+) positive only in sustentacular cells

situ hybridisation are of great help in difficult cases. All three, NPC, PSNPC, and SNUC, react positively for low molecular weight cytokeratins and EMA. In contrast, NPC and PSNPC are positive for EBV, whereas SNUC is negative. Until very recently, confusion of NPC and PSNPC with SNUC has led to the belief that some SNUC were related to EBV. The sharp distinction of these entities is crucial because NPC and PSNPC have a better prognosis and are more responsive to radiation therapy than SNUC.

2.11.6 Malignant Melanoma

ICD-O:8720/3

Sinonasal melanomas represent between 0.5 and 1.5% of all melanomas [25, 82, 157] and between 3 and 20% of sinonasal malignant neoplasms [25, 74]. They most frequently develop after the fifth decade of life [25, 42, 250] and seem to originate from melanocytes present in the mucosa of the respiratory tract [25, 58, 275]. In our experience, it is not uncommon to see melanomas arising in an area of squamous metaplasia. In contrast to Caucasians, black Africans often show visible pigmentation at sites corresponding with the common locations of intranasal melanomas, of which they have a higher incidence [148]. Although there is not a significant sex predilection, men seem to be affected more than women [25, 29, 42]. The signs and symptoms of presentation of sinonasal melanomas are not specific. Epistaxis and nasal obstruction are frequent when located in the nasal cavity.

Grossly sinonasal malignant melanomas are either pigmented (black-brown) or non-pigmented (pink-tan) lesions. In the nasal cavity, they commonly arise in the anterior portion (Fig. 2.11a) of the septum and present as tan-brown polypoid formations, with occasional ulcerated and hemorrhagic areas. When arising within

sinuses, they present as extensive and widely infiltrative tumours. The development of an intranasal malignant melanoma in an inverted papilloma has been reported [99].

The histological features of sinonasal melanomas may be as polymorphic as in their cutaneous counterpart. Metastatic disease needs to be ruled out, before they are labelled as primary tumours. Primary melanomas may be recognised by the presence of junctional activity (Fig. 2.11c) or by the finding of an intraepithelial component in the adjacent mucosa; nevertheless, these features are usually lost in advanced stages of the disease. Histologically, melanomas are composed of medium to large cells that may be polyhedral, round, fusiform (Fig. 2.11b), pleomorphic, microcytic, or a mixture of them. Usually, they have finely granular cytoplasm and nuclei with one or more eosinophilic nucleoli. Mitotic activity is prominent. A rare balloon cell variant with clear cytoplasm may mimic various types of clear cell tumours (see Chap. 5). Osteocartilaginous differentiation has also been observed [244]. The cells of sinonasal melanoma grow in solid, loosely cohesive, storiform, pseudo-alveolar or organoid patterns [25]. Two-thirds of sinonasal melanomas contain some intracytoplasmic brown pigment (Fig. 2.11d) [25], which has to be confirmed as melanin by Masson-Fontana or Grimelius silver stains. However, in the sinonasal tract non-pigmented melanomas are not uncommon; in our Barcelona series up to 40% of the sinonasal melanomas are amelanotic. When melanin is scarce or is not found, diagnosis may be difficult, and special techniques are mandatory. Immunohistochemically, the cells of amelanotic melanomas are negative for cytokeratin and positive for vimentin, S-100 protein and HMB-45 [65, 82, 209], as well as anti-tyrosinase and other newly reported markers [207]. Electron microscopy reveals the presence of pre-melanosomes and/or melanosomes.

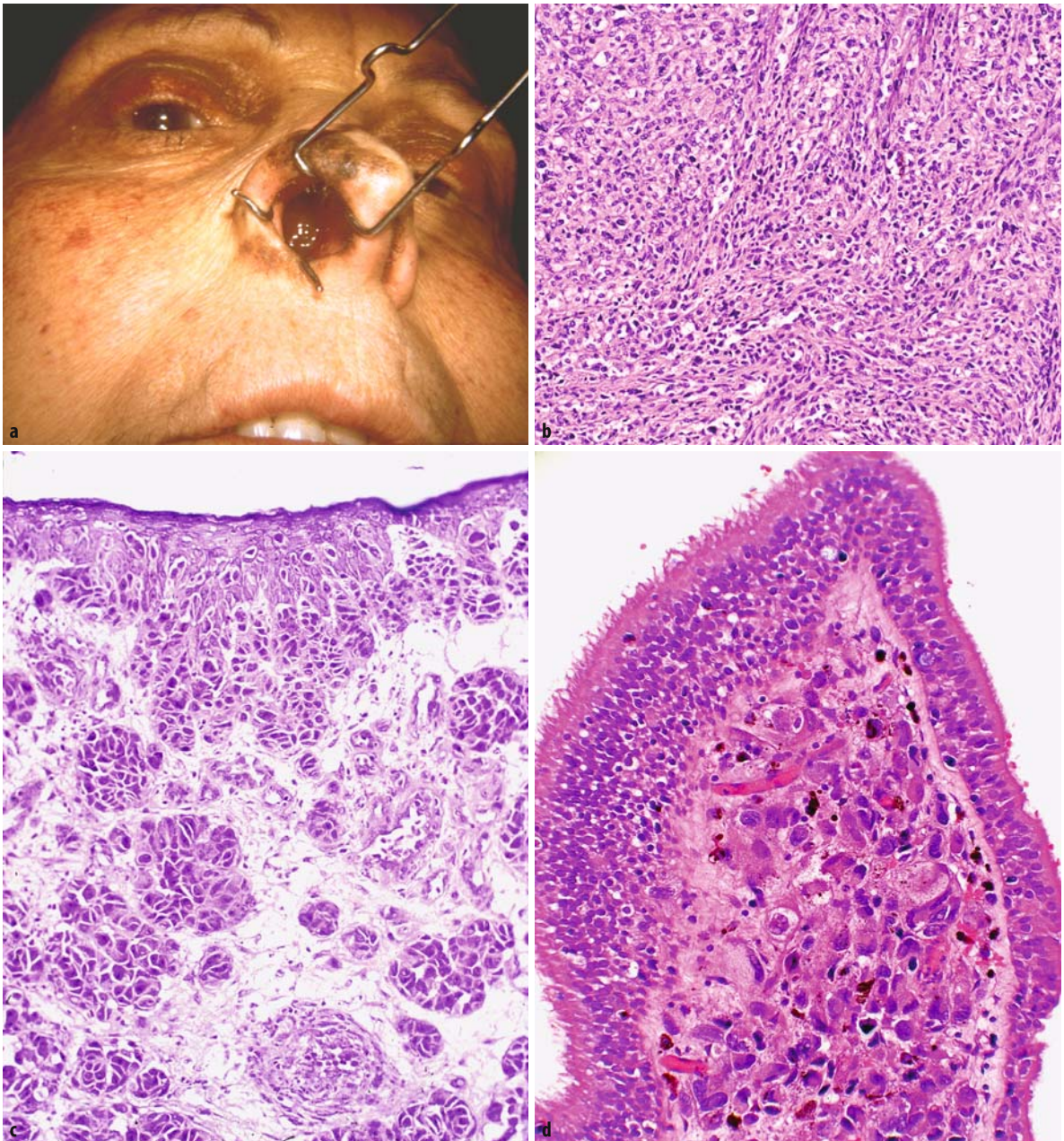


Fig. 2.11. Sinonasal malignant melanoma. **a** Darkly pigmented polypoid lesion of the anterior nasal cavity in contiguity with a pigmented lesion of nasal skin. Courtesy of Prof. J. Traserra, Barcelona, Spain. **b** Spindle cell non-pigmented malignant melano-

cytes with storiform pattern. **c** Nests of non-pigmented, invasive malignant melanocytes arising from metaplastic squamous epithelium showing junctional activity. **d** Pigmented malignant melanocytes underneath ciliated respiratory epithelium

The differential diagnosis of amelanotic malignant melanoma of the sinonasal tract comprises a long list of entities. Epithelioid melanomas mainly have to be distinguished from non-keratinising squamous cell carcinomas, but also from other large cell carcinomas as well as from epithelioid malignant schwannomas [76] and from metastases. Microcytic melanoma may mimic SNUC and other small round cell tumours (Table 2.2).

Spindle-cell melanoma may be mistaken for a variety of spindle-cell sarcomas (see Sects. 2.11.13 to 2.11.17).

The prognosis and management is related to the peculiar biology of the tumour. The prognostic significance of the level of local invasion, as established for cutaneous melanomas, does not apply to mucosal melanomas because of the absence of histological landmarks analogous to the papillary and reticular dermis; nevertheless, inva-

sion deeper than 0.5 mm is associated with decreased survival [25].

Although many of the patients do not show initial lymph node involvement or disseminated metastases [25, 83, 107] and have stage I disease at the time of initial diagnosis, the prognosis is bad due to a high recurrence rate [250]. This recurrence appears to be related to the multicentricity of the tumours and to the anatomic characteristics of the region that preclude adequate resection, which is the treatment of choice [29, 256]. The utility of radiotherapy is controversial, but it can be of use in unresectable cases or to control recurrences [29, 95]. Immunotherapy and chemotherapy are also used for metastatic disease [256]. Five-year survival of sinonasal melanoma is reportedly under 35% [29, 250, 256]. The mean survival has not improved during the past 15 years [32]. In our Barcelona series, the 5-year survival rate of 35% is similar to that of sinonasal squamous cell carcinoma. Patients with primary nasal melanomas had a significantly better 5-year survival rate than patients with melanomas from other head and neck sites [154].

2.11.7 Olfactory Neuroblastoma

ICD-O:9522/3

Olfactory neuroblastoma (ONB) is defined as a malignant tumour composed of neuroblasts derived from the olfactory membrane [14, 175, 246, 257]. Synonyms include early terminology such as esthesioneuroepithelioma, esthesioneurocytoma and esthesioneuroblastoma. The site of origin of ONB is confined to the olfactory mucosa that lines the upper part of the nasal cavity [181]. On rare occasions ONB predominantly involves the superior aspect of the cribriform plate and grow as intracranial masses [15, 186]. Before establishing a diagnosis of the extremely rare entity known as “ectopic” olfactory neuroblastoma, which implies absence of involvement of the olfactory membrane, other sinonasal small round cell tumours have to be carefully ruled out (Table 2.2).

Olfactory neuroblastoma has a bimodal age distribution with peaks in the 2nd and 6th decades [70]. This clearly differs from adrenal neuroblastoma, with most cases arising in children under 4 years of age. Both sexes are equally affected. Nasal obstruction, rhinorrhoea and epistaxis are the most common presenting symptoms.

Grossly, the tumours are often unilateral, presenting as smooth polypoid or fungating masses of fleshy consistency and yellow to pink colour (Fig. 2.12a).

At low magnification, ONB exhibits one of two main patterns of growth [176]. Most often, it presents a lobular arrangement with well-defined groups of tumour cells separated by abundant oedematous stroma. Less frequently, the tumour grows as diffuse sheets of cells with scanty, but highly vascular stroma. The neoplastic neuroblasts are typically small, showing round to oval nu-

clei with stippled chromatin, absent or small nucleoli, and minimal cytoplasm. They are commonly separated by a neurofibrillary matrix formed by neuronal cell processes in which axons may be demonstrable by conventional silver stains. This background, seen in about 85% of ONBs, is the most helpful diagnostic feature (Fig. 2.12b). The Homer-Wright type of rosettes is quite characteristic of ONB; however, they are less commonly seen. They form when the tumour cells surround the neurofibrillary matrix in collar-like arrangements. Even more rare are the true olfactory Flexner-Wintersteiner type of rosettes, which depict well-defined lumina lined by columnar cells resembling olfactory epithelium. These cells generally have basally located nuclei and merge with the adjacent neuroblasts without any intervening basal lamina. Perivascular pseudorosettes, formed by tumour cells arranged around capillaries, are of no diagnostic value, for they may be found in several types of neoplasms.

The scheme proposed by Hyams [122] to grade ONB into four groups carries diagnostic and prognostic implications (Table 2.3). The differential diagnosis of ONB includes a wide variety of small round cell tumours arising in the sinonasal region (Table 2.2). Immunohistochemically, ONB shows diffuse positivity for NSE and synaptophysin, but is less often positive for chromogranin. In tumours with a nesting pattern, sustentacular cells are positive for S-100 protein, but generally negative for cytokeratin, although in ONB with a nesting pattern a few tumours may exhibit focal staining for low molecular weight cytokeratins. They are negative for EMA. Neurofilament protein and other markers of neural differentiation are more often expressed in tumours with diffuse, sheet-like patterns [53, 87, 246, 268]. Electron microscopy shows evidence of neuroblastic differentiation, demonstrating neuritic processes, neurotubules and membrane-bound dense-core granules [131, 159, 247]. The human analogue of achaete-scute gene (HASH1), expressed in immature olfactory neurons, is also expressed in ONB [45]. Conversely, the olfactory marker protein [182], expressed exclusively in mature olfactory neurons, is not. ONB lacks CD 99 (MIC-2) expression, as well as the t(11;22) translocation characteristic of primary neuroectodermal tumour (PNET) [13, 263]. It also lacks the molecular genetic changes of sympathetic neuroblastoma, which, in children, may be metastatic to the sinonasal region.

Staging of ONB is based on the Kadish system [129], in which stage A disease is confined to the nasal cavity, stage B to the nasal cavity and paranasal sinuses, and stage C shows local or distant spread beyond the nasal cavity or sinuses. This correlates with prognosis [70]. Necrosis is the single histological feature that seems to correlate with poor survival [175]. About two-thirds of recurrences are in the form of local disease, whereas locoregional recurrences, with intracranial extension or involvement of cervical lymph nodes, represent about 20%, and distant

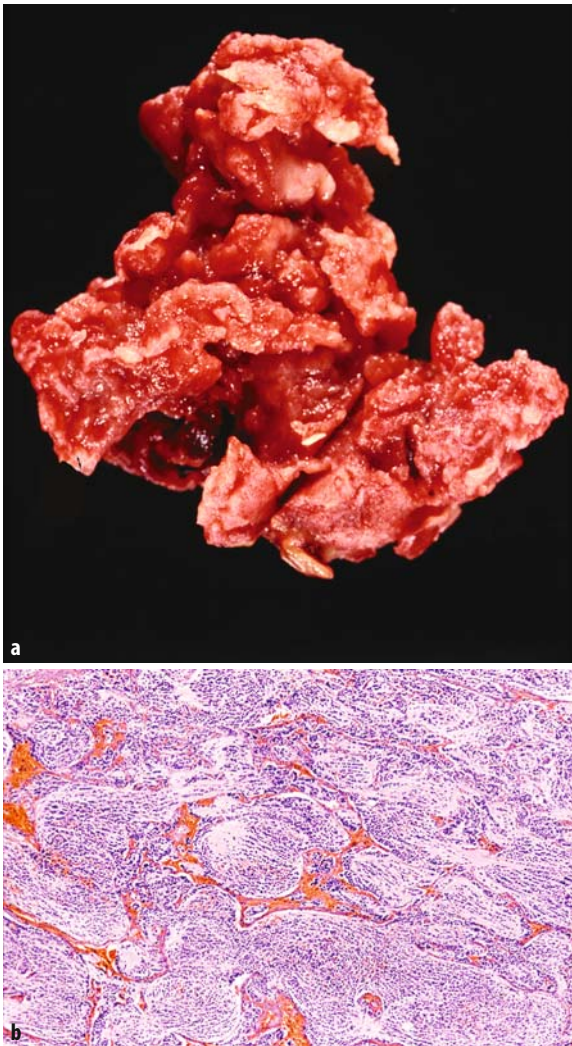


Fig. 2.12. **a** Olfactory neuroblastoma: polypoid mass of fleshy consistency and pink colour. **b** Well-differentiated olfactory neuroblastoma: nests of small round neuroblasts embedded in a neurofibrillary matrix are surrounded by delicate networks of capillary blood vessels

metastases account for the rest [70]. Distant metastases mainly involve bone and lung [68]. Complete surgical excision, often followed by radiation therapy and/or chemotherapy, seems to be the treatment of choice [14, 179]. In advanced ONB, high-dose chemotherapy and autologous bone marrow transplantation has been used [68, 188].

2.11.8 Primitive Neuroectodermal Tumour

ICD-O:9364/3

Approximately 9% of extrasosseous Ewing's sarcoma/primitive neuroectodermal tumour (PNET) arise in the head and neck region [176]. This tumour is composed

of uniform, small, undifferentiated, primitive neuroectodermal cells (Fig. 2.13a) [149]. The great majority of these tumours will react strongly with antibodies against the MIC-2 (CD99) protein product (Fig. 2.13b). This marker is of considerable value, but it is by no means specific. A growing number of other neoplasms expressing this protein have been documented. Among these are T-cell lymphomas [263]. The standard translocation t(11; 22) (q24; q12) of PNET [260] results in the fusion of the EWS-FLI1 genes. The detection of the chimeric transcript by techniques of molecular biology confirms the diagnosis [238]. We have seen one example of PNET arising from the maxillary antrum [39], which ultrastructurally showed rudimentary neuritic differentiation, as well as scanty microtubule formation. This raised the differential diagnostic dilemma of "ectopic olfactory neuroblastoma"; nevertheless, the tumour cells were positive for MIC-2 and showed the t(11;22)(q24;q12) translocation, findings that are characteristically negative in ONB [13].

2.11.9 High-Grade Sinonasal Adenocarcinomas

2.11.9.1 Intestinal-Type Adenocarcinoma

ICD-O:8144/3

This is a tumour with histological features resembling colorectal adenocarcinoma [126, 220]. It is considered to originate through intestinal metaplasia of the ciliated respiratory cells lining the schneiderian membrane. This tumour is the most common type of sinonasal adenocarcinoma, representing about 6–13% of malignancies developing in the sinonasal tract [41, 105, 216]. Metastasis from gastrointestinal adenocarcinoma should be ruled out before a tumour is labelled as a primary of this region. These tumours are strongly associated with exposure to different types of dust, mainly hardwood, but also softwood dusts, as well as leather dust [4, 5, 47, 102, 123, 124, 142]. About 20% of sinonasal intestinal-type adenocarcinomas seem to be sporadic, without evidence of exposure to industrial dusts [4].

Grossly, they have a fungating appearance with either polypoid or papillary features. Occasionally, they may have a gelatinous consistency resembling a mucocele. The most common location is the ethmoidal region [17]. Histologically, the tumour is mainly composed of columnar mucin-secreting cells and goblet cells [17]. Some well-differentiated tumours may also contain desmoplastic cells, argentaffin cells and Paneth cells. Endocrine-amphicrine enteric differentiation may occasionally be found [222]. Metaplastic and atypical changes have been observed in adjacent pre-neoplastic epithelium [270]. These tumours

Table 2.3. Olfactory neuroblastoma. Hyams Grading Scheme [122].

Histologic grades	1	2	3	4
Lobular architecture	Present	Present	±	±
Mitotic activity	Absent	Present	Prominent	Marked
Nuclear pleomorphism	Absent	Moderate	Prominent	Marked
Fibrillary matrix	Prominent	Moderate	Slight	Absent
Rosettes	H-W ±	H-W ±	Flexner ±	Absent
Necrosis	Absent	Absent	Occasional	Common
Calcification	±	±	Absent	Absent

H-W Homer-Wright rosettes, ± present or absent

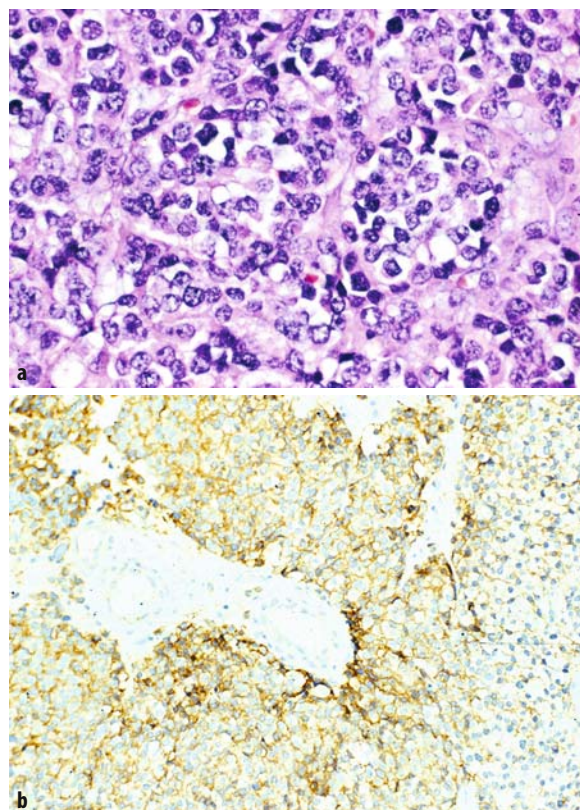


Fig. 2.13. Primitive neuroectodermal tumour (PNET). **a** Monotonous proliferation of small, round, undifferentiated cells. **b** CD99-positive immune reaction at the cellular membrane

depict different histological patterns that may be predominantly papillary, glandular, compact, mucinous or mixed [17, 23]. Papillary tumours mainly consist of elongated outgrowths lined by intestinal-type cells with markedly atypical pseudostratified nuclei (Fig. 2.14a). Although most of them are high-grade tumours, low-grade forms (Fig. 2.14b) mimicking colonic villous adenoma may occasionally occur [174]. The glandular pattern resembles

common-type intestinal adenocarcinoma. Compact or solid forms show poorly differentiated nests of cells in which glandular formation is rarely seen. In the mucinous pattern, more than 50% of the tumour is composed of dilated mucin-filled glands lined by columnar mucin-secreting epithelium, and lakes of mucin containing fragmented epithelial elements (Fig. 2.14c). Other mucinous tumours show mucin-filled cells with the pattern of “signet-ring” cell carcinoma. Various attempts have been made to correlate histopathological grading and typing with clinical behaviour [78, 81, 140].

Features such as cytologic atypia, high mitotic rate and areas of necrosis, which are common findings in most intestinal-type adenocarcinomas, help to distinguish the high-grade variants from rare low-grade intestinal-type adenocarcinomas and from mucoceles. The lack of epidermoid and squamous differentiation separates these tumours from mucoepidermoid and adenosquamous carcinomas. Immunohistochemistry and electron microscopy have confirmed the enteric differentiation of the tumour cells [24]. These tumours are positive for a wide spectrum of cytokeratin markers, whereas they are only occasionally positive for carcinoembryonic antigen [166]. Intestinal-type adenocarcinomas are frequently but not always positive for cytokeratin 7, while most express cytokeratin 20 and CDX-2, two markers related to intestinal differentiation [79]. The prognosis for high-grade intestinal-type adenocarcinoma is poor. Recurrences and subsequent deeply invasive local growth are frequent; however, lymph node and distant metastases are rare [17, 78, 142]. Treatment of choice is complete surgical resection followed by radiotherapy.

2.11.9.2 Salivary-Type High-Grade Adenocarcinomas

Adenoid Cystic Carcinoma ICD-O:8200/3

Adenoid cystic carcinoma (see Chap. 5) is the most common malignant salivary-type of tumour of the upper

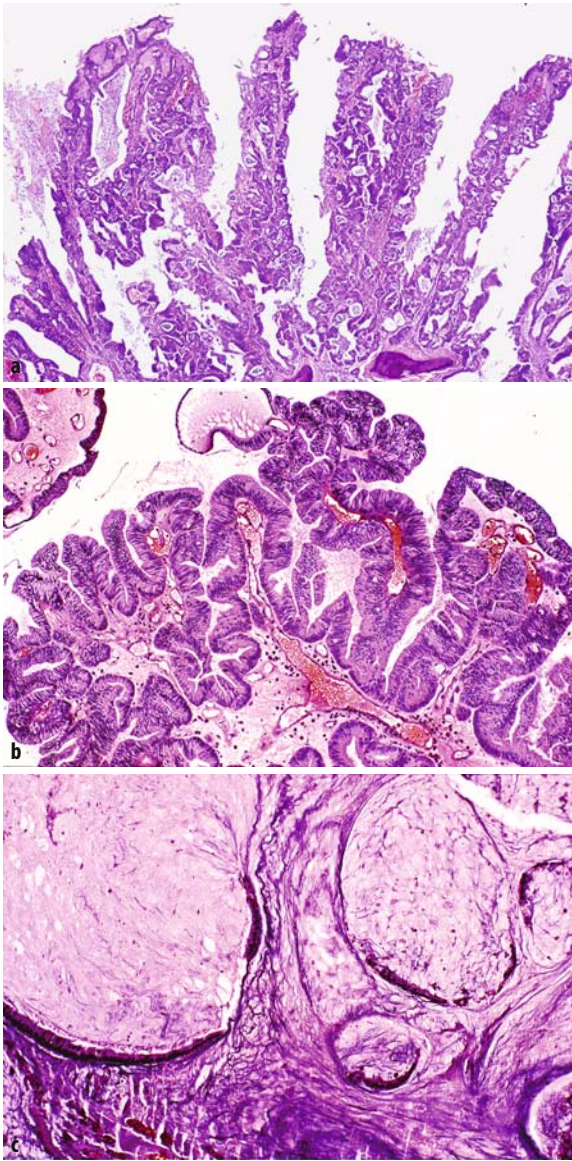


Fig. 2.14. Intestinal-type adenocarcinoma. **a** Papillary outgrowth of intestinal-like malignant epithelium. Destruction of sinonasal bone at the bottom. **b** Low-grade variant mimicking villous adenoma of the colon. **c** Mucinous variant mimicking mucocele

respiratory tract and constitutes 5–10% of all sinonasal malignancies [43, 105, 206]. It is most common in the maxillary antrum, followed by the nasal cavity [60], although ethmoid, sphenoid and frontal sinuses may also be involved [110, 169, 255].

Other Salivary-Type High-Grade Adenocarcinomas

With the exception of adenoid cystic carcinoma, these tumours are quite rare in the sinonasal region. Although most salivary duct carcinomas (SDCs) arise from the major salivary glands, the development of this highly

aggressive tumour from the seromucous glands of the upper respiratory tract may occasionally occur. We have seen one example of SDC originating in the maxillary antrum, in which the characteristic ductal pattern, with comedo-type necrosis, was only evident in the metastases to the submandibular lymph nodes. The primary tumour was initially classified as adenocarcinoma not otherwise specified (NOS) due to the absence of convincing diagnostic features [40]. Carcinoma ex pleomorphic adenoma may also occur in the sinonasal tract [110].

2.11.10 Low-Grade Sinonasal Adenocarcinomas

Low-grade adenocarcinomas arising primarily within the sinonasal tract are an uncommon and heterogeneous group of tumours [23, 113, 139, 150]. Some of these neoplasms show apparent histological continuity with the normal surface epithelium of the sinonasal mucosa, whereas others are of salivary gland origin. All have better prognosis and different clinical presentation than their high-grade counterpart. With the exception of the well-differentiated, low-grade, adenocarcinomas of intestinal type, no correlation with occupational activities has been found in these tumours.

2.11.10.1 Non-Salivary-Type Low-Grade Adenocarcinomas

Non-salivary-type low-grade sinonasal adenocarcinomas are a distinctive group of tumours comprising well-differentiated tubular or papillary structures, or a combination of both. They are lined by a single layer of cuboidal or columnar cells that display uniform round or oval nuclei, inconspicuous nucleoli, minimal cytologic atypia and scarce mitotic figures. They are locally infiltrative and have a tendency towards local recurrence [113].

Different histological patterns may be recognised: papillary, glandular, mucinous, trabecular, cribriform and clear cell. The papillary pattern is characterised by complex papillary fronds lined by bland columnar cells that may occasionally mimic oncocyctic (columnar) cell papilloma. Quite similar tumours also develop in the nasopharynx [267]. The glandular pattern may simulate adenoma; nevertheless, the presence of closely packed glands, forming back-to-back arrangements, indicates the true malignant nature. Mucinous tumours have to be distinguished from mucoceles and from mucinous adenocarcinoma of intestinal or salivary type [20, 224]. The trabecular pattern may resemble acinic cell carcinoma [200]. The cribriform arrangements have to be distinguished from low-grade salivary duct carcinoma of salivary glands [62]. The clear cell type has to be separated from the salivary-type tumours with clear cells and

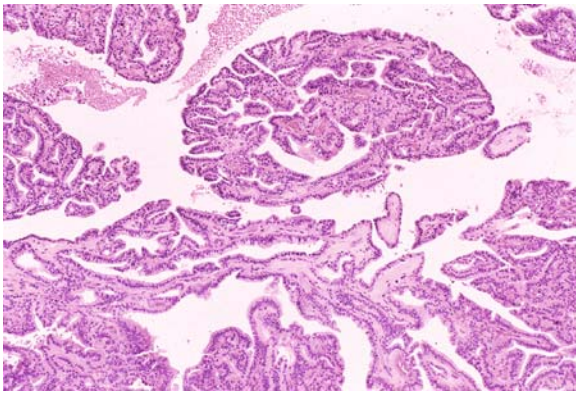


Fig. 2.15. Tubulopapillary carcinoma: low-grade proliferation of cuboidal to columnar epithelial cells forming tubules at the centre and papillae at the surface

from metastatic renal cell carcinoma [31, 280]. A tubulopapillary variant has recently been reported (Fig. 2.15) [234] that has to be differentiated from terminal tubulus adenocarcinoma of the nasal seromucous glands [139].

2.11.10.2 Salivary-Type Low-Grade Adenocarcinomas

Mucoepidermoid carcinoma, polymorphous low-grade adenocarcinoma (Fig. 2.16) and acinic cell carcinoma originate only on rare occasions from the seromucous glands of the sinonasal mucosa [43, 110, 150, 190, 200, 239]. Most mucoepidermoid carcinomas of the sinonasal tract are low-grade. Some large oncocytic tumours of the sinonasal tract may behave in a locally aggressive fashion and are better classified as low-grade adenocarcinomas [55, 103, 110]. All these tumours are dealt with in detail in Chap. 5 on salivary glands. Their main differential diagnoses are other salivary- or non-salivary-type low-grade adenocarcinomas.

2.11.11 Sinonasal Malignant Lymphomas

Malignant lymphomas of the sinonasal region comprise approximately 6% of all sinonasal malignancies [134]. In our Barcelona series, they account for 9.5% (Table 2.1). In western countries, about 50% of sinonasal lymphomas are of B-cell type, whereas the other 50% mostly showed NK/T-cell lineage [38]; nevertheless, other reports point to more variable rates [3, 72, 77, 85]. Conversely, in oriental populations most primary lymphomas of the nasal cavity and nasopharynx are of NK/T cell lineage [49, 50, 52, 92, 233].

Sinonasal B-cell lymphomas are in general composed of a diffuse proliferation of large lymphoid cells, or of a

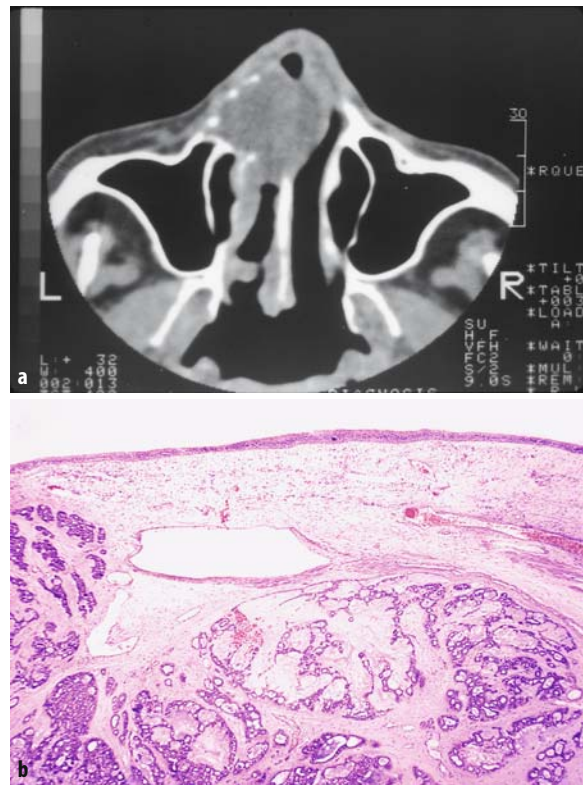


Fig. 2.16. Polymorphous low-grade adenocarcinoma. **a** CT scan showing an irregularly nodular lesion destroying the anterior nasal septum. Courtesy of Prof. J. Traserria, Barcelona, Spain. **b** Variegated glandular arrangements composed of tubules with bland cellularity are seen beneath respiratory epithelium

diffuse mixed pattern of small and large cells. They infiltrate and expand the subepithelial soft tissue and may extend into the underlying bone. Sinonasal B-cell lymphomas lack epitheliotropism, polymorphous cell infiltrate, angiocentricity, prominent necrosis, and fibrosis. They are usually positive for B-cell markers (CD20 and CD79a) and negative for NK/T cell markers. κ light chain restriction is seen more often than λ restriction. They are often negative for EBV markers. Radiotherapy and chemotherapy is the standard treatment for advanced tumours [213].

Sinonasal NK/T cell lymphomas were labelled in past decades with terms such as “lethal midline granuloma”, “polymorphic reticulosis” and “angiocentric T-cell lymphoma”, among others. Until quite recently, non-B cell sinonasal lymphomas were considered as other forms of T-cell lymphoma, frequently displaying angiocentricity. Patients may present either with an obstructive mass or with mid-facial destructive lesions. Histologically, an angiocentric and angiodestructive infiltrate with extensive necrosis (Fig. 2.17a) is frequently seen. In NK/T-cell lymphoma, cells may be small, medium-sized, large, or anaplastic, and may show a conspicuous admixture of

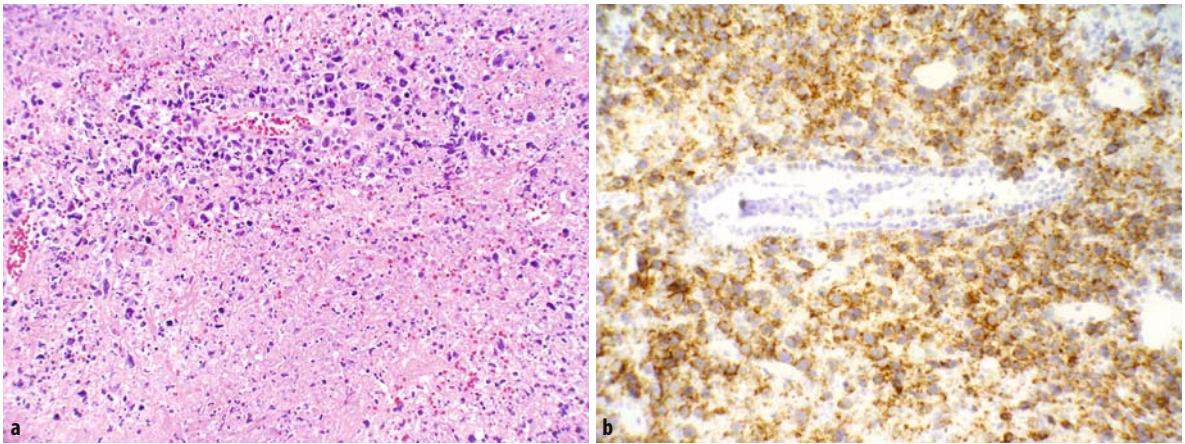


Fig. 2.17. Sinonasal NK/T lymphoma. **a** Angiocentric infiltrate of atypical lymphocytes with extensive necrotic areas. **b** Strongly positive CD56 immunoreaction

inflammatory cells. Pseudoepitheliomatous hyperplasia of the covering epithelium may occur [49]. NK/T cell lymphoma is almost always associated with EBV positivity. The most typical immunophenotypes are CD2+, CD56+ (Fig. 2.17b), surface CD3-, and cytoplasmic CD3epsilon+. Most cases are also positive for cytotoxic granule-associated proteins (granzyme B, TIA-1 and perforin). They are usually negative for other T and NK-cell associated markers. Sinonasal lymphomas demonstrating CD3epsilon+, CD56-, cytotoxic molecule+, and EBV+ are also included within the NK/T category. The commonest cytogenetic abnormality found in NK/T-cell lymphoma is the 6q-22-23 deletion [233]. The prognosis of nasal NK/T-cell lymphoma is variable. Some patients respond well to therapy and others die of disease despite aggressive therapy [52].

Sinonasal malignant lymphomas of either B-cell or T-cell derivation need a careful differential diagnosis with other small round cell tumours (Table 2.2) and with extramedullary plasmacytoma [6, 46], as well as with extramedullary tumours composed of myeloid or lymphoid blasts [133].

2.11.12 Extramedullary Plasmacytoma

ICD-O:9731/3

Plasmacytoma of the sinonasal tract appears as a diffuse infiltration of mature plasma cells of the mucosa; occasionally, tumour cells are less differentiated, and diagnosis may be difficult on a histologic basis [2, 6, 46, 185]. Immunohistochemical staining for CD138 and κ and λ chains may be helpful. Full examination of the patient is required to exclude disseminated disease.

2.11.13 Fibrosarcoma

ICD-O:8810/3

Fibrosarcoma of the sinonasal tract occurs across a wide age range, most commonly causing obstruction or epistaxis. The histologic appearance is that of a spindle cell lesion, with fascicles or bundles of neoplastic cells intersecting at various angles, sometimes with a herringbone pattern. Most sinonasal fibrosarcomas have a low-grade appearance, with moderate cellularity and a low mitotic rate [111]. In accordance, the behaviour is more often characterised by repeated local recurrences, while distant metastases are rare. The differential diagnosis includes desmoid fibromatosis, leiomyosarcoma, nerve sheath tumours, spindle cell carcinoma and melanoma.

2.11.14 Malignant Fibrous Histiocytoma

ICD-O:8830/3

Malignant fibrous histiocytoma is a high-grade sarcoma of adulthood histologically consisting of a proliferation of spindle cells arranged in a storiform pattern, intermixed with atypical pleomorphic, often multinucleated giant cells. In the sinonasal tract it presents as a highly aggressive and destructive lesion, with bone invasion and extension in adjacent structures [201]. Before a diagnosis of malignant fibrous histiocytoma is rendered, other pleomorphic malignant tumours, like leiomyosarcoma, osteosarcoma and sarcomatoid carcinoma should be excluded by means of immunohistochemical or ultrastructural analysis.

2.11.15 Leiomyosarcoma

ICD-O:8890/3

Leiomyosarcoma of the sinonasal tract is an extremely rare neoplasm, with identical histological appearance and immunoprofile to the soft tissue counterpart [91]. If the tumour is limited to the nasal cavity the prognosis is good, and according to Kuruvilla et al. [144], sinonasal leiomyosarcoma can be regarded as a locally aggressive neoplasm with limited metastatic potential that should be treated by surgery alone. Distinction from sinonasal leiomyoma is based on mitotic activity and cellular atypia.

2.11.16 Rhabdomyosarcoma

ICD-O:8900/3

Rhabdomyosarcoma is the most common sinonasal malignancy of the paediatric age, but it is also observed in adults [37, 116]. The most common histologic subtypes are the embryonal and the alveolar [37]. The overall 5-year survival is around 40%; adult age and alveolar subtype are adverse prognostic factors. Treatment includes a combination of radiotherapy and chemotherapy, with surgical resection reserved for residual disease. The risk of neck involvement is high.

2.11.17 Malignant Peripheral Nerve Sheath Tumour

ICD-O:9560/3

Malignant peripheral nerve sheath tumour (MPNST) of the sinonasal tract is a very rare neoplasm [163] that is probably under-recognised due to the lack of reproducible histologic criteria and to the tendency of these tumours to be negative for the commonly used immunohistochemical markers of nerve sheath differentiation. Only in some cases can the diagnosis be based on the identification of a pre-existing neurofibroma. Histologically, MPNST is a moderately to highly cellular spindle cell proliferation, with variable mitotic activity and areas of necrosis. A variant composed of epithelioid cells has been described in the sinonasal cavities (Fig. 2.18) [76]. Some tumours may show morphologic and immunohistochemical features of skeletal muscle differentiation and are designated “malignant triton tumours” [138].

2.11.18 Teratocarcinosarcoma

ICD-O:8980/3

The term “teratocarcinosarcoma” is designated to an unusual entity in which a malignant sinonasal teratomatous tumour also shows features of carcinosarcoma

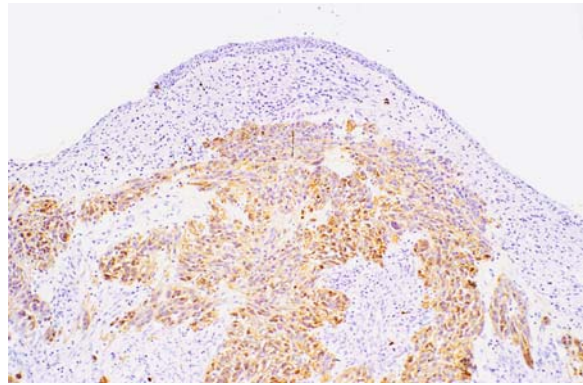


Fig. 2.18. Sinonasal malignant epithelioid schwannoma: marked S-100 protein positivity in a large cell malignant neoplasm, mimicking amelanotic melanoma

[112]. Patients suffering from this malignancy are exclusively adults (age range 18–79 years; mean 60 years) [64, 75, 112, 156, 195, 227]. There is a male predominance and symptoms are non-specific with nasal obstruction and epistaxis produced by a nasal cavity mass (Fig. 2.19a) [112].

Histologically, sinonasal teratocarcinosarcoma (SNTCS) comprises a multiplicity of cell types of varying maturity (Fig. 2.19b). The epithelial component includes keratinising squamous epithelium, pseudostratified columnar ciliated epithelium and glandular structures lined by cuboidal and columnar cells including mucus cells. Masses of immature epithelial cells, some containing glycogen or mucin, are frequently found. “Foetal-appearing” clear cell squamous epithelium is a common finding and a very important diagnostic clue for some authors [112]. Neuroepithelial elements with rosettes and neuroblastoma-like areas are in most instances present. These epithelial and neuroepithelial elements occur in close relationship with each other and with mesenchymal elements, the most prominent of which are immature cells with oval or elongated nuclei. The mesenchymal cells may exhibit skeletal muscle differentiation with cross striations (Fig. 2.19c). Foci of cartilage, smooth muscle, adipose tissue and fibrovascular tissues may also be present. In spite of the common occurrence of areas having a variety of mature tissues, mitotic activity and cytological features of malignancy are demonstrable in the undifferentiated areas of both the epithelial and mesenchymal elements [75].

In order to achieve the correct diagnosis of SNTCS a thorough sampling of the specimen is required. Inadequate sampling may lead to mistaken diagnoses of esthesioneuroblastoma, squamous cell carcinoma, undifferentiated carcinoma, adenocarcinoma, malignant craniopharyngioma, malignant mixed tumour of salivary gland type, mucoepidermoid carcinoma, adeno-

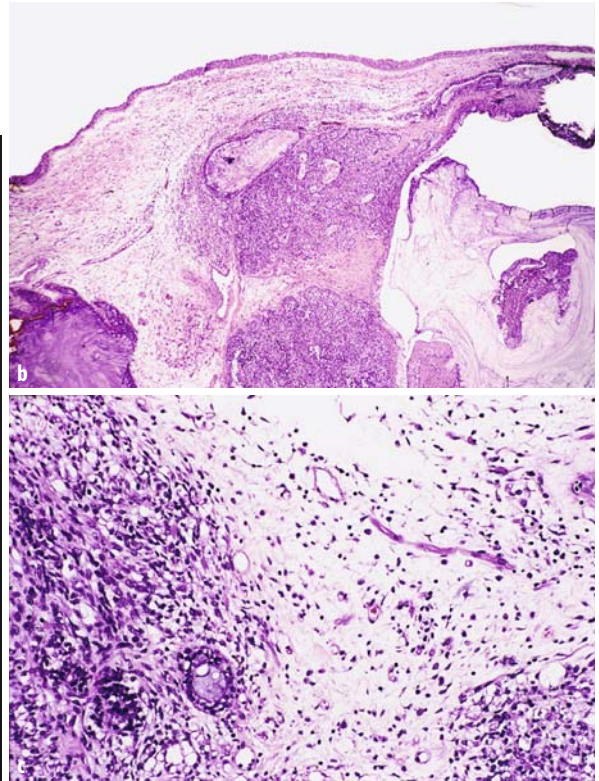
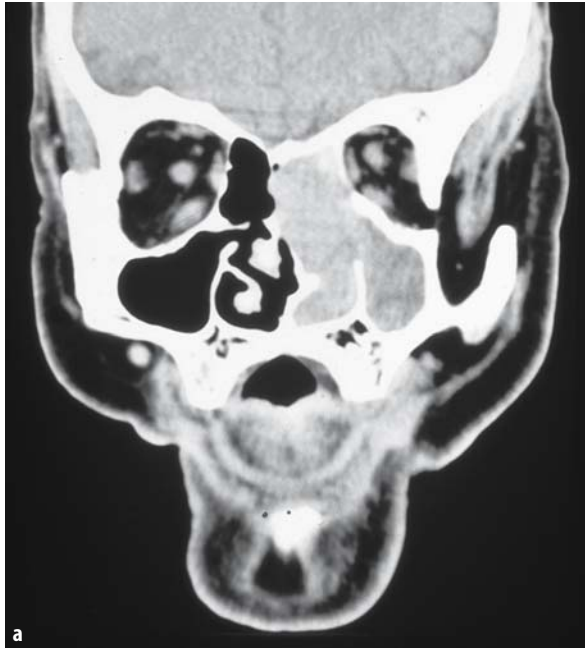

Fig. 2.19. Teratocarcinosarcoma. **a** CT scan showing massive destructive infiltration of the nasal cavity and maxillary sinus on the left. With permission [75] **b** Cystic spaces filled with mucin are partly covered by benign columnar epithelium and surrounded by

immature blastematos tissue. **c** Immature glands surrounded by blastematos elements at the *lower left*; presence of immature striated muscle, *upper right and centre*

squamous carcinoma and others [105]. In contradistinction to malignant gonadal teratomas, which are frequently found in patients at a younger age, sinonasal teratocarcinosarcoma does not contain areas of embryonal carcinoma, choriocarcinoma or germinoma (seminoma), as seen in many germ cell tumours. This makes a germ cell origin of SNTCS unlikely [112]. The histogenesis of sinonasal teratocarcinosarcoma is debatable. The presence of neural tissue in these neoplasms raises the possibility that the origin could be in some way related to the olfactory membrane, or alternatively to the sinonasal membrane as a whole, since the olfactory membrane also develops from it [112].

Sinonasal teratocarcinosarcomas are locally aggressive tumours, with rapid invasion of soft tissues and bone, and metastasise to regional lymph nodes and sites, such as the lung. The average survival of a patient with SNTCS is 1.7 years, with 60% of the patients not surviving beyond 3 years. The treatment of SNTCS is controversial, but an aggressive initial therapeutical approach with a combination of surgical resection, radiotherapy and chemotherapy is usually recommended [112].

References

1. Abdel-Latif SM, Baheeg SS, Aglan YI, Babin RW, Giltman LI (1987) Chronic atrophic rhinitis with fetor (ozena): a histopathologic treatise. *Rhinology* 25:117–120
2. Abemayor E, Canalis RF, Greenberg P, Wortham DG, Rowland JP, Sun NC (1988) Plasma cell tumors of the head and neck. *J Otolaryngol* 17:376–381
3. Abbondanzo SL, Wenig BM (1995) Non-Hodgkin's lymphoma of the sinonasal tract. A clinicopathologic and immunophenotypic study of 124 cases. *Cancer* 75:1281–1291
4. Acheson ED, Cowdell RH, Hadfield E, Macbeth RG (1968) Nasal cancer in woodworkers in the furniture industry. *Br Med J* 2:587–596
5. Acheson ED, Cowdell RH, Jolles B (1970) Nasal cancer in the Northamptonshire boot and shoe industry. *Br Med J* 1:385–393
6. Aguilera NS, Kapadia SB, Nalesnik MA, Swerdlow SH (1995) Extramedullary plasmacytoma of the head and neck: use of paraffin sections to assess clonality with in situ hybridization, growth fraction, and the presence of Epstein-Barr virus. *Mod Pathol* 8:503–508
7. Aktas D, Yetiser S, Gerek M, Kurnaz A, Can C, Kahramanyol M (1998) Antrochoanal polyps: analysis of 16 cases. *Rhinology* 36:81–85
8. Alobid I, Alos L, Blanch JL, Benitez P, Bernal-Sprekelsen M, Mullol J (2003) Solitary fibrous tumour of the nasal cavity and paranasal sinuses. *Acta Otolaryngol* 123:71–74
9. Alos L, Cardesa A, Bombí JA, Mallofré C, Cuchi A, Traserra J (1996) Myoepithelial tumours of salivary glands: a clinico-

- pathologic, immunohistochemical, ultrastructural and flow-cytometric study. *Semin Diagn Pathol* 13:138–147
10. Alos L, Castillo M, Nadal A, Caballero M, Mallofre C, Palacin A, Cardesa A (2004) Adenosquamous carcinoma of the head and neck: criteria for diagnosis in a study of 12 cases. *Histopathology* 44:1–10
 11. Anon JB (2003) Acute bacterial rhinosinusitis in pediatric medicine: current issues in diagnosis and management. *Paediatr Drugs* 5 [Suppl 1]:25–33
 12. Apple D, Kreines K (1982) Case report. Cushing's syndrome due to ectopic ACTH production by a nasal paraganglioma. *Am J Med Sci* 283:32–35
 13. Argani P, Perez-Ordóñez B, Xiao H, Caruana SM, Huvos AG, Ladanyi M (1998) Olfactory neuroblastoma is not related to the Ewing family of tumours. Absence of EWS/FLI1 gene fusion and MIC2 expression. *Am J Surg Pathol* 22:391–398
 14. Bailey BJ, Barton S (1975) Olfactory neuroblastoma management and prognosis. *Arch Otolaryngol* 101:1–5
 15. Banerjee AK, Sharma BS, Vashista RK, Kak VK (1992) Intracranial olfactory neuroblastoma: evidence for olfactory epithelial origin. *J Clin Pathol* 45:299–302
 16. Banks ER, Frierson HF, Mills SE et al. (1992) Basaloid squamous cell carcinoma of the head and neck. A clinicopathologic and immunohistochemical study of 40 cases. *Am J Surg Pathol* 16:939–946
 17. Barnes L (1986) Intestinal-type adenocarcinoma of the nasal cavity and paranasal sinuses. *Am J Surg Pathol* 10:192–202
 18. Barnes L, Bedetti C (1984) Oncocytic Schneiderian papilloma: a reappraisal of cylindrical cell papilloma of the sinonasal tract. *Hum Pathol* 15:344–351
 19. Batra K, Chaudhary N, Motwani G, Rai AK (2002) An unusual case of primary nasal tuberculosis with epistaxis and epilepsy. *Ear Nose Throat J* 81:842–844
 20. Batsakis JG (1970) Mucous gland tumors of the nose and paranasal sinuses. *Ann Otol Rhinol Laryngol* 79:557–562
 21. Batsakis JG, el-Naggar AK (1992) Rhinoscleroma and rhinosporidiosis. *Ann Otol Rhinol Laryngol* 101:879–882
 22. Batsakis JG, el-Naggar AK (1996) Cystic fibrosis and the sinonasal tract. *Ann Otol Rhinol Laryngol* 105:329–330
 23. Batsakis JG, Holtz F, Sueper RH (1963) Adenocarcinoma of the nasal and paranasal cavities. *Arch Otolaryngol* 77:625–633
 24. Batsakis JG, Mackay B, Ordóñez NG (1984) Enteric-type adenocarcinoma of the nasal cavity. An electron microscopic and immunocytochemical study. *Cancer* 54:855–860
 25. Batsakis JG, Regezi JA, Solomon AR, Rice DH (1982) The pathology of head and neck tumors: Mucosal melanomas. *Head Neck Surg* 4:404–418
 26. Beatty CW, Pearson BW, Kern EB (1982) Carcinoma of the nasal septum: experience with 85 cases. *Otolaryngol Head Neck Surg* 90:90–94
 27. Begin LR, Rochon L, Frenkel S (1991) Spindle cell myoepithelioma of the nasal cavity. *Am J Surg Pathol* 15:184–190
 28. Benninger MS, Ferguson BJ, Hadley JA, Hamilos DL, Jacobs M, Kennedy DW, Lanza DC, Marple BF, Osguthorpe JD, Stankiewicz JA, Anon J, Denny J, Emanuel I, Levine H (2003) Adult chronic rhinosinusitis: definitions, diagnosis, epidemiology, and pathophysiology. *Otolaryngol Head Neck Surg* 129:S1–S32
 29. Berthelsen A, Andersen AP, Jensen S, Hansen HA (1984) Melanomas of the mucosa in the oral cavity and the upper respiratory passages. *Cancer* 54:907–912
 30. Bosch A, Vallecillo L, Frias Z (1976) Cancer of the nasal cavity. *Cancer* 37:1458–1463
 31. Brandwein M (2002) Renal cell-like carcinoma of the sinonasal tract. XXIV International Congress of the International Academy of Pathology. Amsterdam. The Netherlands 2002. Slide Seminar 9, "Unusual Head and Neck Lesions". Case 6
 32. Brandwein MS, Rothstein A, Lawson W, Bodian C, Urken ML (1997) Sinonasal melanoma. A clinicopathologic study of 25 cases and literature meta-analysis. *Arch Otolaryngol Head Neck Surg* 123:290–296
 33. Brarsman FA (1980) The median nasal sinus and dermoid cyst. *Arch Otorhinolaryngol* 226:107–113
 34. Brook I, Frazier EH (2004) Microbiology of recurrent acute rhinosinusitis. *Laryngoscope* 114:129–131
 35. Buchwald C, Franzmann MB, Jacobsen GK, Lindeberg H (1995) Human papillomavirus (HPV) in sinonasal papillomas: a study of 78 cases using in situ hybridization and the polymerase chain reaction. *Laryngoscope* 105:66–71
 36. Buob D, Wacrenier A, Chevalier D, Aubert S, Quinchon JF, Gosselin B, Leroy X (2003) Schwannoma of the sinonasal tract: a clinicopathologic and immunohistochemical study of 5 cases. *Arch Pathol Lab Med* 127:1196–1199
 37. Callender TA, Weber RS, Janjan N, Benjamin R, Zaher M, Wolf P, el-Naggar A (1995) Rhabdomyosarcoma of the nose and paranasal sinuses in adults and children. *Otolaryngol Head Neck Surg* 112:252–257
 38. Campo E, Cardesa A, Alos L, Palacin A, Cobarro J, Traserri J, Montserrat E (1991) Non-Hodgkin's lymphomas of nasal cavity and paranasal sinuses. An immunohistochemical study. *Am J Clin Pathol* 96:184–190
 39. Cardesa A (1998) Peripheral primitive neuroectodermal tumour, left maxillary sinus. XXII International Congress of the International Academy of Pathology. Nice. France 1998. Slide Seminar 18, "Head and Neck Pathology". Case 12
 40. Cardesa A (1998) Sinonasal salivary duct carcinoma metastatic to right cervical lymph nodes. XXII International Congress of the International Academy of Pathology. Nice. France 1998. Slide Seminar 18, "Head and Neck Pathology". Case 6
 41. Cardesa A, Alos L (2002) Special tumours of the head and neck region: characterization of undifferentiated sinonasal tumours. *Histopathology* 41 [Suppl 2]:473–477
 42. Cardesa A, Alos LL, Bombi JA, Palacin A, Traserri J (1991) Relative frequency and diagnoses of sinonasal malignant melanoma (SNMM). *Lab Invest* 64:63A
 43. Cardesa A, Bombi JA, Alos L (1993) The classification of tumours of the minor salivary glands. *Arquivos de Patologia, Univ. Coimbra, Portugal* 25:75–85
 44. Cardesa A, Pour P, Haas H, Althoff J, Mohr U (1976) Histogenesis of tumors from the nasal cavities induced by diethylnitrosamine. *Cancer* 37:346–355
 45. Carney ME, O'Reilly RC, Sholevar B et al. (1995) Expression of the human Achaete-scute 1 gene in olfactory neuroblastoma (esthesioneuroblastoma). *J Neurooncol* 26:35–43
 46. Castro EB, Lewis JS, Strong EW (1973) Plasmacytoma of paranasal sinuses and nasal cavity. *Arch Otolaryngol* 97:326–329
 47. Cecchi F, Buiatti E, Kriebel D, Nastasi L, Santucci M (1980) Adenocarcinoma of the nose and paranasal sinuses in shoemakers and woodworkers in the province of Florence, Italy (1963–77). *Br J Ind Med* 37:222–225
 48. Cerilli LA, Holst VA, Brandwein MS, Stoler MH, Mills SE (2001) Sinonasal undifferentiated carcinoma. Immunohistochemical profile and lack of EBV association. *Am J Surg Pathol* 25:156–163
 49. Chan JK (1998) Natural killer cell neoplasms. *Anat Pathol* 3:77–145
 50. Chan JK, Ng CS, Lau WH, Lo ST (1987) Most nasal/nasopharyngeal lymphomas are peripheral T-cell neoplasms. *Am J Surg Pathol* 11:418–429
 51. Chaudry MR, Aktar S, Kim DS (1994) Neuroendocrine carcinoma of the ethmoid sinus. *Eur Arch Otorhinolaryngol* 251:461–463
 52. Cheung MM, Chan JK, Lau WH et al. (1998) Primary non-Hodgkin's lymphoma of the nose and nasopharynx: clinical features, tumor immunophenotype, and treatment outcome in 113 patients. *J Clin Oncol* 16:70–77
 53. Choi HS, Anderson PJ (1986) Olfactory neuroblastoma: an immuno-electron microscopic study of S-100 protein-positive cell. *J Neuropathol Exp Neurol* 45:576–587
 54. Christensen WN, Smith RL (1986) Schneiderian papillomas: a clinicopathologic study of 67 cases. *Hum Pathol* 17:393–400
 55. Cohen MA, Batsakis JG (1968) Oncocytic tumors (oncocytomas) of minor salivary glands. *Arch Otolaryngol* 88:97–99

56. Compagno J, Wong RT (1977) Intranasal mixed tumours (pleomorphic adenomas). A clinicopathologic study of 40 cases. *Am J Clin Pathol* 68:213–218
57. Coup AJ, Hopper IP (1980) Granulomatous lesions in nasal biopsies. *Histopathology* 4:293–308
58. Cove H (1994) Melanosis, melanocytic hyperplasia, and primary malignant melanoma of the nasal cavity. *Cancer* 44:1424–1433
59. Cunningham MJ, Brantley S, Barnes L, Schramm VL (1987) Oncocytic Schneiderian papilloma in a young adult: a rare diagnosis. *Otolaryngol Head Neck Surg* 97:47–51
60. Da-Quan M, Guang-Yan Y (1987) Tumours of the minor salivary glands. A clinicopathologic study of 243 cases. *Acta Otolaryngol (Stockh)* 103:325–331
61. Davis JM, Weber AL (1980) Pituitary adenoma presenting as a sphenoid sinus lesion. *Ann Otol Rhinol Laryngol* 89:883–884
62. Delgado R, Klimstra D, Albores-Saavedra J (1996) Low grade salivary duct carcinoma. A distinctive variant with low grade histology and a predominant intraductal growth pattern. *Cancer* 78:958–967
63. Denoyelle F, Ducroz V, Roger G, Garabedian EN (1997) Nasal dermoid sinus cysts in children. *Laryngoscope* 107:795–800
64. Devgan BK, Devgan M, Gross CW (1978) Teratocarcinoma of the ethmoid sinus: review of literature plus a new case report. *Otolaryngol Head Neck Surg* 86:689–695
65. Drier JK, Swanson PE, Cherwitz DL, Wick MR (1987) S100 protein immunoreactivity in poorly differentiated carcinomas. Immunohistochemical comparison with malignant melanoma. *Arch Pathol Lab Med* 111:447–452
66. Dunand VA, Hammer SM, Rossi R, Poulin M, Albrecht MA, Doweiko JP, DeGirolami PC, Coakley E, Piessens E, Wanke CA (1997) Parasitic sinusitis and otitis in patients infected with human immunodeficiency virus: report of five cases and review. *Clin Infect Dis* 25:267–272
67. Dykewicz MS (2003) 7. Rhinitis and sinusitis. *J Allergy Clin Immunol* 111:S520–S529
68. Eden BV, Debo RF, Larner JM et al. (1994) Esthesioneuroblastoma. Long term outcome and patterns of failure – the University of Virginia experience. *Cancer* 73:2556–2562
69. El-Barbary AE-S, Yassin A, Fouad H, Shennawy ME (1976) Histopathological and histochemical studies in atrophic rhinitis. *J Laryngol Otol* 84:1103–1111
- 69a. El-Mofty SK, Lu DW (2005) Prevalence of high-risk human papillomavirus DNA in non-keratinising (cylindrical cell) carcinoma of the sinonasal tract. A distinct clinicopathologic and molecular disease entity. *Am J Surg Pathol* 29:1367–1372
70. Elkon D, Hightower SI, Lim ML, Cantrell RW, Constable WC (1979) Esthesioneuroblastoma. *Cancer* 44:1087–1094
71. Fang SY, Shen CL (1998) Neuropeptide innervation and neuroendocrine cells in allergic rhinitis and chronic hypertrophic rhinitis. *Clin Exp Allergy* 28:228–232
72. Fellbaum C, Hansmann ML, Lennert K (1989) Malignant lymphomas of the nasal cavity and paranasal sinuses. *Virchows Archiv A Pathol Anat Histopathol* 414:399–405
73. Ferguson BJ (2000) Mucormycosis of the nose and paranasal sinuses. *Otolaryngol Clin North Am* 33:349–365
74. Fernandez PL, Cardesa A, Alos L (1995) Malignant melanoma of the sinonasal tract. Check Sample. APII. *Am J Clin Pathol* 19:45–58
75. Fernandez PL, Cardesa A, Alos L, Pinto J, Traserra J (1995) Sinonasal teratocarcinosarcoma: an unusual neoplasm. *Pathol Res Pract* 191:166–171
76. Fernandez PL, Cardesa A, Bombi JA, Palacin A, Traserra J (1993) Malignant sinonasal epithelioid schwannoma. *Virchows Arch* 423:401–405
77. Ferry JA, Sklar J, Zukerberg RL, Harris NL (1991) Nasal lymphoma. A clinicopathologic study with immunophenotypic and genotypic analysis. *Am J Surg Pathol* 15:268–279
78. Franchi A, Gallo O, Santucci M (1999) Clinical relevance of the histological classification of sinonasal intestinal-type adenocarcinomas. *Hum Pathol* 30:1140–1145
79. Franchi A, Massi D, Palomba A, Biancalani M, Santucci M (2004) CDX-2, cytokeratin 7 and cytokeratin 20 immunohistochemical expression in the differential diagnosis of primary adenocarcinomas of the sinonasal tract. *Virchows Arch* 445:63–67
80. Franchi A, Moroni M, Massi D, Paglierani M, Santucci M (2002) Sinonasal undifferentiated carcinoma, nasopharyngeal-type undifferentiated carcinoma, and keratinizing and nonkeratinizing squamous cell carcinoma express different cytokeratin patterns. *Am J Surg Pathol* 26:1597–1604
81. Franquemont DW, Fehner RE, Mills SE (1991) Histologic classification of sinonasal intestinal-type adenocarcinoma. *Am J Surg Pathol* 15:368–375
82. Franquemont DW, Mills SE (1991) Sinonasal malignant melanoma. A clinicopathologic and immunohistochemical study of 14 cases. *Am J Clin Pathol* 96:689–697
83. Freedman HM, DeSanto LW, Devine KD, Weiland LH (1973) Malignant melanoma of the nasal cavity and paranasal sinuses. *Arch Otolaryngol* 97:322–325
84. Friedmann I, Osborn DA (1982) Carcinoma of the surface epithelium (including ameloblastoma). In: Friedmann I, Osborn D (eds) *Pathology of granulomas and neoplasms of the nose and paranasal sinuses*. Churchill Livingstone, Edinburgh, pp 118–132
85. Frierson HF Jr, Innes DJ Jr, Mills SE, Wick M (1989) Immunophenotypic analysis of sinonasal non-Hodgkin's lymphomas. *Human Pathol* 20:636–642
86. Frierson HF, Mills SE, Fehner RE, Taxy JB, Levine PA (1986) Sinonasal undifferentiated carcinoma. An aggressive neoplasm derived from Schneiderian epithelium and distinct from olfactory neuroblastoma. *Am J Surg Pathol* 10:771–779
87. Frierson HF Jr, Ross GW, Mills SE, Frankfurter A (1990) Olfactory neuroblastoma. Additional immunohistochemical characterization. *Am J Surg Pathol* 94:547–553
88. Frodel JL, Larrabee WF, Raisis J (1989) The nasal dermoid. *Head Neck Surg* 101:392–396
89. Fu YS, Hoover L, Franklin M, Cheng L, Stoler MH (1992) Human papillomavirus identified by nucleic acid hybridization in concomitant nasal and genital papillomas. *Laryngoscope* 102:1014–1019
90. Fu YS, Perzin KH (1974) Non-epithelial tumors of the nasal cavity, paranasal sinuses, and nasopharynx: a clinicopathologic study. I. General features and vascular tumors. *Cancer* 33:1275–1288
91. Fu YS, Perzin KH (1975) Nonepithelial tumors of the nasal cavity, paranasal sinuses, and nasopharynx: a clinicopathologic study. IV. Smooth muscle tumors (leiomyoma, leiomyosarcoma) *Cancer* 35:1300–1308
92. Gaal K, Sun NCJ, Hernandez AM, Arber DA (2000) Sinonasal NK/T-cell lymphomas in the United States. *Am J Surg Pathol* 24:1511–1517
93. Gadeberg CC, Hjeltn-Hansen M, Sögaard H et al. (1984) Malignant tumors of the paranasal sinuses and nasal cavity. A series of 180 patients. *Acta Radiol Oncol* 23:181–187
94. Gerughty RM, Hennigar GR, Brown FM (1984) Adenosquamous carcinoma of the nasal, oral and laryngeal cavities. A clinicopathologic survey of ten cases. *Cancer* 22:1140–1155
95. Ghamrawi KAE, Glennie JM (1974) The value of radiotherapy in the management of malignant melanoma of the nasal cavity. *J Laryngol Otol* 88:71–75
96. Gnepp DR, Henley J, Weiss S, Heffner D (1996) Desmoid fibromatosis of the sinonasal tract and nasopharynx. A clinicopathologic study of 25 cases. *Cancer* 78:2572–2579
97. Goren AD, Harley N, Eisenbud L, Levin S, Cohen N (1980) Clinical and radiobiologic features of Thorotrast-induced carcinoma of the maxillary sinus. A case report. *Oral Surg Oral Med Oral Pathol* 49:237–242
98. Gosavi DK, Moidekar AT (1978) Chemodectoma of the nose and sphenoid sinus. *J Laryngol Otol* 92:813–816
99. Gouldsbrough DR, Martin-Hirsch DP, Lannigan F (1992) Intranasal malignant melanoma arising in an inverted papilloma. *Histopathology* 20:523–526
100. Guarisco JL, Butcher RB (1990) Congenital cystic teratoma of the maxillary sinus. *Otolaryngol Head Neck Surg* 103:1035–1038

101. Gupta A, Seiden AM (2003) Nasal leprosy: case study. *Otolaryngol Head Neck Surg* 129:608–610
102. Hadfield EH, Macbeth RG (1971) Adenocarcinoma of ethmoids in furniture workers. *Ann Otol Rhinol Laryngol* 80:699–703
103. Handler SD, Ward PH (1979) Oncocytoma of the maxillary sinus. *Laryngoscope* 69:372–376
104. Hanna GS, Ali MH (1987) Verrucous carcinoma of the nasal septum. *J Laryngol Otol* 101:184–187
105. Harbo G, Grau C, Bundgaard T, Overgaard M, Elbrond O, Sogaard H, Overgaard J (1997) Cancer of the nasal cavity and paranasal sinuses. A clinicopathological study of 277 patients. *Acta Oncol* 36:45–50
106. Hardy G (1957) The choanal polyp. *Ann Otol Laryngol Rhinol* 66:306–326
107. Harrison DFN (1976) Malignant melanomata arising in the nasal mucous membrane. *J Laryngol Otol* 90:993–1005
108. Hasegawa SL, Mentzel T, Fletcher CD (1997) Schwannomas of the sinonasal tract and nasopharynx. *Mod Pathol* 10:777–784
109. Heffner DK (1983) Problems in pediatric otorhinolaryngic pathology. I. Sinonasal and nasopharyngeal tumors and masses with myxoid features. *Int J Pediatr Otorhinolaryngol* 5:77–91
110. Heffner DK (1991) Sinonasal and laryngeal salivary gland lesions. In: Ellis GL, Auclair PL, Gnepp DR (eds) *Surgical pathology of salivary glands*. Saunders, Philadelphia, pp 544–559
111. Heffner DK, Gnepp DR (1992) Sinonasal fibrosarcomas, malignant schwannomas, and “Triton” tumors. A clinicopathologic study of 67 cases. *Cancer* 70:1089–1101
112. Heffner DK, Hyams VJ (1984) Teratocarcinoma (malignant teratoma?) of the nasal cavity and paranasal sinuses. *Cancer* 53:2140–215
113. Heffner DK, Hyams VJ, Hauck KW, Lingeman C (1982) Low-grade adenocarcinoma of the nasal cavity and paranasal sinuses. *Cancer* 50:312–322
114. Helliwell TR, Yeoh LH, Stell PM (1986) Anaplastic carcinoma of the nose and paranasal sinuses. Light microscopy, immunohistochemistry, and clinical correlation. *Cancer* 58:2038–2045
115. Hellquist HB (1996) Nasal polyps update. *Histopathology. Allergy Asthma Proc* 17:237–242
116. Herrmann BW, Sotelo-Avila C, Eisenbeis JF (2003) Pediatric sinonasal rhabdomyosarcoma: three cases and a review of the literature. *Am J Otolaryngol* 24:174–180
117. Hillstrom RP, Zarbo RJ, Jacobs JR (1990) Nerve sheath tumors of the paranasal sinuses: electron microscopy and histopathologic diagnosis. *Otolaryngol Head Neck Surg* 102:257–263
118. Ho KL (1980) Primary meningioma of the nasal cavity and paranasal sinuses. *Cancer* 46:1442–1447
119. Huang HY, Antonescu CR (2003) Sinonasal smooth muscle cell tumors: a clinicopathologic and immunohistochemical analysis of 12 cases with emphasis on the low-grade end of the spectrum. *Arch Pathol Lab Med* 127:297–304
120. Hwang HC, Mills SE, Patterson K, Gown AM (1998) Expression of androgen receptors in nasopharyngeal angiofibroma: an immunohistochemical study of 24 cases. *Mod Pathol* 11:1122–1126
121. Hyams VJ (1971) Papillomas of the nasal cavity and paranasal sinuses. A clinicopathologic study of 315 cases. *Ann Otol Rhinol Laryngol* 80:192–206
122. Hyams VJ, Batsakis JG, Michaels L (1988) Tumors of the upper respiratory tract and ear. In: *Atlas of Tumor Pathology*, 2nd series. Fascicle 25. Armed Forces Institute of Pathology, Washington, D.C.
123. Imbus HR, Dyson WL (1987) A review of nasal cancer in furniture manufacturing and woodworking in North Carolina, the United States, and other countries. *J Occup Med* 29:734–740
124. Ironside P, Matthews J (1975) Adenocarcinoma of the nose and paranasal sinuses in woodworkers in the state of Victoria, Australia. *Cancer* 36:1115–1124
125. Jacobsson M, Petruson B, Svendsen P, Berthelsen B (1988) Juvenile nasopharyngeal angiofibroma. A report of eighteen cases. *Acta Otolaryngol* 105:132–139
126. Jarvi O (1945) Heterotopic tumors with an intestinal mucous membrane structure in the nasal cavity. *Acta Otolaryngol* 33:471–85
127. Jeng YM, Sung MT, Fang CL, Huang HY, Mao TL, Cheng W, Hsiao CH (2002) Sinonasal undifferentiated carcinoma and nasopharyngeal-type undifferentiated carcinoma. Two clinically, biologically, and histopathologically distinct entities. *Am J Surg Pathol* 26:371–376
128. Judd R, Zaki SR, Coffield LM, Evatt BL (1991) Sinonasal papillomas and human papillomavirus: human papillomavirus 11 detected in fungiform schneiderian papillomas by in situ hybridization and the polymerase chain reaction. *Hum Pathol* 22:550–556
129. Kadish S, Goodman M, Wang CC (1976) Olfactory neuroblastoma. A clinical analysis of 17 cases. *Cancer* 37:1571–1576
130. Kagan AR, Nussbaum H, Rao A, Chan P, Gilbert H, Hintz B, Ryou M, Miles J, Rice D (1981) The management of carcinoma of the nasal vestibule. *Head Neck Surg* 4:125–128
131. Kahn LB (1974) Esthesioneuroblastoma. A light and electron microscopic study. *Hum Pathol* 5:364–371
132. Kameya T, Shimosato Y, Adachi I, Abe K, Ebihara S, Ono I (1980) Neuroendocrine carcinoma of the paranasal sinus. A morphological and endocrinological study. *Cancer* 45:330–339
133. Kapadia SB (1985) Hematologic diseases: malignant lymphomas, leukemias, plasma cell dyscrasias, histiocytosis X, and reactive lymph node lesions. In: Barnes L (ed) *Surgical pathology of the head and neck*, vol 2. Dekker, New York
134. Kapadia SB, Barnes L, Deutsch M (1981) Non-Hodgkin's lymphoma of the nose and paranasal sinuses: a study of 17 cases. *Head Neck Surg* 3:490–499
135. Kapadia SB, Barnes L, Pelzman K, Mirani N, Heffner DK, Bedetti C (1993) Carcinoma ex oncocytic Schneiderian (cylindrical cell) papilloma. *Am J Otolaryngol* 14:332–338
136. Karma P, Rasanen O, Karja J (1977) Nasal gliomas. A review and report of two cases. *Laryngoscope* 87:1169–1179
137. Katzenstein AL, Sale SR, Greenberger PA (1983) Pathologic findings in allergic aspergillus sinusitis. A newly recognized form of sinusitis. *Am J Surg Pathol* 7:439–443
138. Kim ST, Kim CW, Han GC, Park C, Jang IH, Cha HE, Choi G, Lee HM (2001) Malignant triton tumor of the nasal cavity. *Head Neck* 23:1075–1078
139. Kleinsasser O (1985) Terminal tubulus adenocarcinoma of the nasal seromucous glands. A specific entity. *Arch Otorhinolaryngol* 241:183–193
140. Kleinsasser O, Schroeder HG (1988) Adenocarcinoma of the inner nose after exposure to wood dust. Morphological findings and relationships between histopathology and clinical behavior in 79 cases. *Arch Otorhinolaryngol* 245:1–15
141. Klein-Szanto AJ, Boysen M, Reith A (1987) Keratin and involucrin in preneoplastic and neoplastic lesions. Distribution in the nasal mucosa of nickel workers. *Arch Pathol Lab Med* 111:1057–1061
142. Klintonberg C, Olofsson J, Hellquist H, Sokjer H (1984) Adenocarcinoma of the ethmoid sinuses. A review of 28 cases with special reference to wood dust exposure. *Cancer* 54:482–488
143. Krespi YP, Kuriloff DB, Aner M (1995) Sarcoidosis of the sinonasal tract: a new staging system. *Otolaryngol Head Neck Surg* 112:221–227
144. Kuruvilla A, Wenig BM, Humphrey DM, Heffner DK (1990) Leiomyosarcoma of the sinonasal tract. A clinicopathologic study of nine cases. *Arch Otolaryngol Head Neck Surg* 116:1278–1286
145. Kyriakos M (1977) Myospherulosis of the paranasal sinuses, nose and middle ear. A possible iatrogenic disease. *Am J Clin Pathol* 67:118–130
146. Larsson LG, Martensson G (1972) Maxillary antral cancers. *JAMA* 219:342–345
147. Lee BJ, Park HJ, Heo SC (2003) Organized hematoma of the maxillary sinus. *Acta Otolaryngol* 123:869–872

- 2
148. Lewis MG, Martin JAM (1967) Malignant melanoma of the nasal cavity in Ugandan Africans: relationship of ectopic pigmentation. *Cancer* 20:1699–1705
 149. Llombart-Bosch A, Terrier-Lacombe J, Peydro-Olaya A, Contesso G (1989) Peripheral neuroectodermal sarcoma of soft tissue (peripheral neuroepithelioma): a pathologic study of ten cases with differential diagnosis regarding other small, round-cell sarcomas. *Hum Pathol* 20:273–280
 150. Lloreta J, Serrano S, Corominas JM, Ferrer-Padro E (1995) Polymorphous low-grade adenocarcinoma arising in the nasal cavities with an associated undifferentiated carcinoma. *Ultrastruct Pathol* 19:365–370
 151. Lloreta-Trull J, Mackay B, Troncoso P, Ribalta-Farres T, Smith T, Khorana S (1992) Neuroendocrine tumors of the nasal cavity: an ultrastructural study of 24 cases. *Ultrastruct Pathol* 16: 165–175
 152. Lloyd RV, Chandler WF, Kovaks K, Ryan N (1986) Ectopic pituitary adenomas with normal anterior pituitary glands. *Am J Surg Pathol* 108:546–552
 153. Lohuis PJ, Lipovsky MM, Hoepelman AI, Hordijk GJ, Huizing EH (1997) Leishmania braziliensis presenting as a granulomatous lesion of the nasal septum mucosa. *J Laryngol Otol* 111:973–975
 154. Loree TR, Mullins AP, Spellman J, North JH Jr, Hicks WL Jr (1999) Head and neck mucosal melanoma: a 32-year review. *Ear Nose Throat J* 78:372–375
 155. Luce D, Gerin M, Leclerc A, Morcet JF, Brugere J, Goldberg M (1993) Sinonasal cancer and occupational exposure to formaldehyde and other substances. *Int J Cancer* 53:224–231
 156. Luna MA (1995) Critical commentary to “Sino nasal teratocarcinoma”. *Pathol Res Pract* 191:172
 157. Lund V (1982) Malignant melanoma of the nasal cavity and paranasal sinuses. *J Laryngol Otol* 96:347–355
 158. Lund VJ, Milroy CM (1991) Fronto-ethmoidal mucocoeles: a histopathological analysis. *J Laryngol Otol* 105:921–923
 159. Mackay B, Luna MA, Butler JJ (1976) Adult neuroblastoma. Electronmicroscopic observations in nine cases. *Cancer* 37:1334–1351
 160. Majumdar B, Kent S (1983) Malignant neoplasms of the nose and paranasal sinuses. A survey of cases treated in a regional centre. *Clin Otolaryngol* 8:97–102
 161. Makannavar JH, Chavan SS (2001) Rhinosporidiosis. A clinicopathological study of 34 cases. *Indian J Pathol Microbiol* 44:17–21
 162. Manivel C, Wick MR, Dehner LP (1986) Transitional (cylindrical) cell carcinoma with endodermal sinus tumor-like features of the nasopharynx and paranasal sinuses. Clinicopathologic and immunohistochemical study of two cases. *Arch Pathol Lab Med* 110:198–202
 163. Mannan AA, Singh MK, Bahadur S, Hatimota P, Sharma MC (2003) Solitary malignant schwannoma of the nasal cavity and paranasal sinuses: report of two rare cases. *Ear Nose Throat J* 82:634–646
 164. Marks SC, Upadhyay S, Crane L (1996) Cytomegalovirus sinusitis. A new manifestation of AIDS. *Arch Otolaryngol Head Neck Surg* 122:789–791
 165. McDonald TJ, DeRemee RA, Kern EB, Harrison EG Jr (1974) Nasal manifestations of Wegener’s granulomatosis. *Laryngoscope* 84:2101–2112
 166. McKinney CD, Mills SE, Franquemont DW (1995) Sinonasal intestinal-type adenocarcinoma. Immunohistochemical profile and comparison with colonic adenocarcinoma. *Mod Pathol* 8:421–426
 167. Mendenhall WM, Stringer SP, Cassisi NJ, Mendenhall NP (1999) Squamous cell carcinoma of the nasal vestibule. *Head Neck* 21:385–393
 168. Mentzel T, Bainbridge TC, Katenkamp D (1997) Solitary fibrous tumour: clinicopathological, immunohistochemical, and ultrastructural analysis of 12 cases arising in soft tissues, nasal cavity and nasopharynx, urinary bladder and prostate. *Virchows Arch* 430:445–453
 169. Mesara BW, Batsakis JG (1966) Glandular tumors of the upper respiratory tract. A clinicopathologic assessment. *Arch Surg* 92:872–878
 170. Meyer RD, Gaultier CR, Yamashita JT, Babapour R, Pitchon HE, Wolfe PR (1994) Fungal sinusitis in patients with AIDS: report of 4 cases and review of the literature. *Medicine (Baltimore)* 73:69–78
 171. Michaels L, Hellquist HB (2001) Ear, nose and throat histopathology. Springer, Berlin Heidelberg New York
 172. Michaels L, Lloyd G, Phelps P (2000) Origin and spread of allergic fungal disease of the nose and paranasal sinuses. *Clin Otolaryngol* 25:518–525
 173. Michaels L, Young M (1995) Histogenesis of papillomas of the nose and paranasal sinuses. *Arch Pathol Lab Med* 119:821–826
 174. Mills SE, Fechner RE, Cantrell RW (1982) Aggressive sinonasal lesion resembling normal intestinal mucosa. *Am J Surg Pathol* 6:803–809
 175. Mills SE, Frierson HF (1985) Olfactory neuroblastoma. A clinicopathologic study of 21 cases. *Am J Surg Pathol* 9:317–327
 176. Mills SE, Gaffey MJ, Frierson HF (2000) Tumors of the upper aerodigestive tract and ear. Atlas of tumor pathology. Third Series. Fascicle 26. Armed Forces Institute of Pathology. Washington D.C.
 177. Min YG, Shin JS, Choi SH, Chi JG, Yoon CJ (1995) Primary ciliary dyskinesia: ultrastructural defects and clinical features. *Rhinology* 33:189–193
 178. Moore EJ, Kern EB (2001) Atrophic rhinitis: a review of 242 cases. *Am J Rhinol* 15:355–361
 179. Morita A, Ebersold MJ, Olsen KD, Foote RL, Lewis JE, Quast LM (1993) Esthesioneuroblastoma: prognosis and management. *Neurosurgery* 32:706–715
 180. Mufarrij AA, Busaba NY, Zaytoun GM, Gallo GR, Feiner HD (1990) Primary localized amyloidosis of the nose and paranasal sinuses. A case report with immunohistochemical observations and a review of the literature. *Am J Surg Pathol* 14:379–383
 181. Nakashima T, Kimmelman CP, Snow JB Jr (1984) Structure of human fetal and adult olfactory neuroepithelium. *Arch Otolaryngol* 110:641–646
 182. Nakashima T, Kimmelman CP, Snow JB Jr (1985) Olfactory marker protein in the human olfactory pathway. *Arch Otolaryngol* 111:294–297
 183. Nakayama M, Wenig BM, Heffner DK (1995) Atypical stromal cells in inflammatory nasal polyps: immunohistochemical and ultrastructural analysis in defining histogenesis. *Laryngoscope* 105:127–134
 184. Natvig K, Larsen TE (1978) Mucocoele of the paranasal sinuses. A retrospective clinical and histological study. *J Laryngol Otol* 92:1075–1082
 185. Navarrete ML, Quesada P, Pellicer M, Ruiz C (1991) Extramedullary nasal plasmacytoma. *J Laryngol Otol* 105:41–43
 186. Ng HK, Poon WS, Poon CY, South JR (1988) Intracranial olfactory neuroblastoma mimicking carcinoma: report of two cases. *Histopathology* 12:393–403
 187. Nguyen QA, Gibbs PM, Rice DH (1995) Malignant nasal paraganglioma: a case report and review of the literature. *Otolaryngol Head Neck Surg* 113:157–161
 188. O’Connor GT Jr, Drake CR, Johns ME, Cail WS, Winn HR, Niskanen E (1985) Treatment of advanced esthesioneuroblastoma with high-dose chemotherapy and autologous bone marrow transplantation. A case report. *Cancer* 55:347–349
 189. Oppenheimer EH, Rosenstein BJ (1979) Differential pathology of nasal polyps in cystic fibrosis and atopy. *Lab Invest* 40:455–449
 190. Ordóñez NG, Batsakis JG (1986) Acinic cell carcinoma of the nasal cavity: electron-optic and immunohistochemical observations. *J Laryngol Otol* 100:345–349
 191. Ordóñez NG, Mackay B (1993) Neuroendocrine tumors of the nasal cavity. *Pathol Annu* 28:77–111
 192. Orvidas LJ, Lewis JE, Olsen KD, Weiner JS (1999) Intranasal verrucous carcinoma; relationship to inverting papilloma and human papillomavirus. *Laryngoscope* 109:371–375
 193. Osborn DA (1956) Transitional cell growths of the upper respiratory tract. *J Laryngol Otol* 70:574–587
 194. Osborn DA (1970) Nature and behavior of transitional tumors in the upper respiratory tract. *Cancer* 25:50–60

195. Pai SA, Naresh KN, Masih K, Ramarao C, Borges AM (1998) Teratocarcinosarcoma of the paranasal sinuses: a clinicopathologic and immunohistochemical study. *Hum Pathol* 29:718–722
196. Patterson K, Kapur S, Chandra RS (1986) "Nasal gliomas" and related brain heterotopias: a pathologist's perspective. *Pediatr Pathol* 5:353–362
197. Patuano E, Carrat X, Drouet Y, Barnabe D, Vincey P, Berthelot B (1993) Mucocutaneous leishmaniasis in otorhinolaryngology. *Ann Otolaryngol Chir Cervicofac* 110:415–419
198. Paugh DR, Sullivan MJ (1990) Myospherulosis of the paranasal sinuses. *Otolaryngol Head Neck Surg* 103:117–119
199. Perez-Ordoñez B, Caruana SM, Huvos AG, Shah JP (1998) Small cell neuroendocrine carcinoma of the of the nasal cavity and paranasal sinuses. *Hum Pathol* 29:826–832
200. Perzin KH, Cantor JO, Johannessen JV (1981) Acinic cell carcinoma arising in the nasal cavity: report of a case with ultrastructural observations. *Cancer* 47:1818–1822
201. Perzin KH, Fu YS (1980) Non-epithelial tumors of the nasal cavity, paranasal sinuses and nasopharynx: a clinico-pathologic study. XI. Fibrous histiocytes. *Cancer* 45:2616–2626
202. Perzin KH, Panyu H, Wechter S (1982) Nonepithelial tumors of the nasal cavity, paranasal sinuses and nasopharynx. A clinicopathologic study. XII. Schwann cell tumors (neurilemoma neurofibroma, malignant schwannoma). *Cancer* 50:2193–2202
203. Perzin KH, Pushparaj N (1984) Nonepithelial tumors of the nasal cavity, paranasal sinuses, and nasopharynx. A clinicopathologic study. XIII. Meningiomas. *Cancer* 54:1860–1869
204. Phillips PP, Gustafson RO, Facer GW (1990) The clinical behavior of inverting papilloma of the nose and paranasal sinuses; report of 112 cases and review of the literature. *Laryngoscope* 100:468–469
205. Piscicoli F, Aldovini D, Bondi A, Eusebi V (1984) Squamous cell carcinoma with sarcoma-like stroma of the nose and paranasal sinuses: report of two cases. *Histopathology* 8:633–639
206. Pitman KT, Prokopakis EP, Aydogan B, Segas J, Carrau RL, Snyderman CH, Janecka IP, Hanna E, D'Amico F, Johnson JT (1999) The role of skull base surgery for the treatment of adenoid cystic carcinoma of the sinonasal tract. *Head Neck* 21:402–407
207. Prasad ML, Jungbluth AA, Iversen K, Huvos AG, Busam KL (2001) Expression of melanocytic differentiation markers in malignant melanomas of the oral and sinonasal mucosa. *Am J Surg Pathol* 25:782–787
208. Raychowdhuri RN (1965) Oat cell carcinoma and paranasal sinuses. *J Laryngol Otol* 79:253–255
209. Regauer S, Anderhuber W, Richtig E, Schachenreiter J, Ott A, Beham A (1998) Primary mucosal melanomas of the nasal cavity and paranasal sinuses. A clinicopathologic analysis of 14 cases. *APMIS* 106:403–404
210. Rejowski JE, Campanella RS, Block LJ (1982) Small cell carcinoma of the nose and paranasal sinuses. *Otolaryngol Head Neck Surg* 90:516–517
211. Ridolfi RL, Liberman PH, Erlandson RA, Moore OS (1977) Schneiderian papillomas; a clinicopathologic study of 30 cases. *Am J Surg Pathol* 1:43–53
212. Ringertz N (1938) Pathology of malignant tumours arising in the nasal and paranasal cavities and maxilla. *Acta Otolaryngol Suppl* 27:31–42
213. Robbins KT, Fuller LM, Vlasak M et al. (1985) Primary lymphomas of the nasal cavity and paranasal sinuses. *Cancer* 56:814–819
214. Roberts PF, McCann BG (1985) Eosinophilic angiocentric fibrosis of the upper respiratory tract: a mucosal variant of granuloma faciale? A report of three cases. *Histopathology* 9:1217–1225
215. Robin PE, Powell DJ (1980) Regional node involvement and distant metastases in carcinoma of the nasal cavity and paranasal sinuses. *J Laryngol Otol* 94:301–309
216. Robin PE, Powell DJ, Stassbie JM (1979) Carcinoma of the nasal cavity and paranasal sinuses: incidence and presentation of different histological types. *Clin Otolaryngol* 4:431–456
217. Rosai J (1978) The nature of myospherulosis of the upper respiratory tract. *Am J Clin Pathol* 69:475–481
218. Rousch GC (1979) Epidemiology of cancer of the nose and paranasal sinuses: current concepts. *Head Neck Surg* 2:3–11
219. Sadler TW (1985) Langman's medical embryology, 5th edn. Williams & Wilkins, Baltimore
220. Sanchez-Casis G, Devine KD, Weiland LH (1971) Nasal adenocarcinomas that closely simulate colonic carcinomas. *Cancer* 28:714–729
221. Sarkar FH, Visscher DW, Kintanar EB, Zarbo RJ, Crissman JD (1992) Sinonasal schneiderian papillomas: human papillomavirus typing by polymerase chain reaction. *Mod Pathol* 5:329–332
222. Schmid KO, Aubock L, Albegger K (1979) Endocrine-amphicrine enteric carcinoma of the nasal mucosa. *Virchows Arch A Pathol Anat Histol* 383:329–343
223. Schwartz S, Thiel E (1997) Clinical presentation of invasive aspergillosis. *Mycoses* 40 [Suppl 2]:21–24
224. Seifert G (1991) WHO histological typing of salivary gland tumours. Springer, Berlin Heidelberg New York
225. Seyer BA, Grist W, Muller S (2002) Aggressive destructive midfacial lesion from cocaine abuse. *Oral Surg Oral Med Oral Pathol Oral Radiol Endod* 94:465–470
226. Shanmugaratnam K (1991) WHO histological typing of tumours of the upper respiratory tract and ear. Springer, Berlin Heidelberg New York
227. Shanmugaratnam K, Kunaratnam N, Chia KB, Chiang GS, Sinniah R (1983) Teratoid carcinosarcoma of the paranasal sinuses. *Pathology* 15:413–419
228. Shimada K, Kobayashi S, Yamadori I, Ohmori M (1988) Myospherulosis in Japan. A report of two cases and an immunohistochemical investigation. *Am J Surg Pathol* 12:427–432
229. Silva EG, Butler JJ, Mackay B, Goepfert H (1982) Neuroblastomas and neuroendocrine carcinomas of the nasal cavity. A proposed new classification. *Cancer* 50:2388–2405
230. Sindwani R, Cohen JT, Pilch BZ, Metson RB (2003) Myospherulosis following sinus surgery: pathological curiosity or important clinical entity? *Laryngoscope* 113:1123–1127
231. Singhal SK, Dass A, Mohan H, Venkataramana Y (2002) Primary nasal tuberculosis. *J Otolaryngol* 31:60–62
232. Siniluoto TM, Luotonen JP, Tikkakoski TA, Leinonen AS, Jokinen KE (1993) Value of pre-operative embolization in surgery for nasopharyngeal angiofibroma. *J Laryngol Otol* 107:514–521
233. Siu LL, Chan V, Chan JK, Wong KF, Liang R, Kwong YL (2000) Consistent patterns of allelic loss in natural killer cell lymphoma. *Am J Pathol* 157:1803–1809
234. Skalova A, Cardesa A, Leivo I, Pfaltz M, Ryska A, Simpson R, Michal M (2003) Sinonasal tubulopapillary low grade adenocarcinoma. Histopathological, immunohistochemical and ultrastructural features of a poorly recognized entity. *Virchows Arch* 443:152–158
235. Smith CJ, Echevarria R, McLelland CA (1974) Pseudosarcomatous changes in antrochoanal polyps. *Arch Otolaryngol* 99:228–230
236. Smith O, Gullane PJ (1987) Inverting papilloma of the nose: analysis of 48 patients. *J Otolaryngol* 16:154–156
237. Sobin LH, Wittekind C (2002) UICC TNM classification of malignant tumours, 6th edn. Wiley-Liss, New York
238. Sorensen PH, Liu XF, Delattre O et al. (1993) Reverse transcriptase PCR amplification of EWS/FLI-1 fusion transcripts as a diagnostic test for peripheral primitive neuroectodermal tumors of childhood. *Diagn Mol Pathol* 2:147–157
239. Spiro RH, Koss LG, Hajdu SI, Strong EW (1973) Tumors of minor salivary gland origin: a clinicopathologic study of 492 cases. *Cancer* 31:117–129
240. Stammberger H (1983) Neue Aspekte zur Genese des invertierten Papilloms. *Laryngol Rhinol Otol* (Stuttg) 62:249–255
241. Stewart FM, Lazarus HM, Levine PA, Stewart KA, Tabbara IA, Spaulding CA (1989) High-dose chemotherapy and autologous marrow transplantation for esthesioneuroblastoma and sinonasal undifferentiated carcinoma. *Am J Clin Oncol* 12:217–221

242. Stierna P, Carlsoo B (1990) Histopathological observations in chronic maxillary sinusitis. *Acta Otolaryngol* 110:450–458
243. Sunderman FW Jr, Morgan LG, Andersen A, Ashley D, Frouhar FA (1989) Histopathology of sinonasal and lung cancers in nickel refinery workers. *Ann Clin Lab Sci* 19:44–50
244. Takeshita H, Miwa T, Furukawa M (2002) Osteochondriginous differentiation of mucosal melanoma in the sinonasal cavity. *Ann Otol Rhinol Laryngol* 111:1112–1115
245. Taxy JB (1997) Squamous carcinoma of the nasal vestibule. An analysis of five cases and literature review. *Am J Clin Pathol* 107:698–703
246. Taxy JB, Bharani NK, Mills SE, Frierson HF Jr, Gould VE (1986) The spectrum of olfactory neural tumors. A light-microscopic, immunohistochemical and ultrastructural analysis. *Am J Surg Pathol* 10:687–705
247. Taxy JB, Hidvegi DF (1977) Olfactory neuroblastoma: an ultrastructural study. *Cancer* 39:131–138
248. Thompson LD, Hefner DK (2001) Sinonasal tract eosinophilic angiocentric fibrosis. A report of three cases. *Am J Clin Pathol* 115:243–248
249. Thompson LD, Miettinen M, Wenig BM (2003) Sinonasal-type hemangiopericytoma: a clinicopathologic and immunophenotypic analysis of 104 cases showing perivascular myoid differentiation. *Am J Surg Pathol* 27:737–749
250. Thompson LD, Wieneke JA, Miettinen M (2003) Sinonasal tract and nasopharyngeal melanomas: a clinicopathologic study of 115 cases with a proposed staging system. *Am J Surg Pathol* 27:594–611
251. Topilko A, Zakrzewski A, Pichard E, Viron A (1984) Ultrastructural cytochemistry of intranuclear dense granules in nasopharyngeal angiofibroma. *Ultrastruct Pathol* 6:221–228
252. Torjussen W, Haug FM, Andersen I (1978) Concentration and distribution of heavy metals in nasal mucosa of nickel-exposed workers and of controls, studied with atomic absorption spectrophotometric analysis and with Timm's sulphide silver method. *Acta Otolaryngol* 86:449–463
253. Torjusen W, Solberg LA, Hogetvit AC (1979) Histopathologic changes of the nasal mucosa in nickel workers. A pilot study. *Cancer* 44:963–974
254. Torske KR, Benson GS, Warnock G (2001) Dermoid cyst of the maxillary sinus. *Ann Diagn Pathol* 5:172–176
255. Tran I, Sidrys J, Horton D et al. (1989) Malignant salivary gland tumors of the paranasal sinuses and nasal cavity. The UCLA experience. *Am J Clin Oncol* 12:387–392
256. Trapp TK, Fu YS, Calcaterra TC (1987) Melanoma of the nasal and paranasal sinus mucosa. *Head Neck Surg* 113:1086–1089
257. Trojanowski JQ, Lee V, Pillsbury N, Lee S (1982) Neuronal origin of human esthesioneuroblastoma demonstrated with anti-neurofilament monoclonal antibodies. *N Engl J Med* 307:159–161
258. Tsikoudas A, Martin-Hirsch DP, Woodhead CJ (2001) Primary sinonasal amyloidosis. *J Laryngol Otol* 115:55–56
259. Tufano RP, Mokadam NA, Montone KT, Weinstein GS, Chalian AA, Wolf PF, Weber RS (1999) Malignant tumors of the nose and paranasal sinuses: hospital of the University of Pennsylvania experience 1990–1997. *Am J Rhinol* 13:117–123
260. Turc-Carel C, Aurias A, Mugneret F, Lizard S, Sidaner I, Volk C, Thiery JP, Olschwang S, Philip I, Berger MP (1988) Chromosomes in Ewing's sarcoma. I. An evaluation of 85 cases of remarkable consistency of t(11;22)(q24;q12). *Cancer Genet Cytogenet* 32:229–238
261. Walike JW (1973) Anatomy of the nasal cavities. *Otolaryngol Clin North Am* 6:609–621
262. Ward BE, Fechner RE, Mills SE (1990) Carcinoma arising in oncocytic Schneiderian papilloma. *Am J Surg Pathol* 14:364–369
263. Weidner N, Tjoe J (1994) Immunohistochemical profile of monoclonal antibody O13: antibody that recognizes glycoprotein p30/32MIC2 and is useful in diagnosing Ewing's sarcoma and peripheral neuroepithelioma. *Am J Surg Pathol* 18:486–494
264. Weiss MD, deFies HO, Taxy JB, Braine H (1983) Primary small cell carcinoma of the paranasal sinuses. *Arch Otolaryngol* 109:341–343
265. Weissler MC, Montgomery WW, Montgomery SK, Turner PA, Joseph MP (1986) Inverted papilloma. *Ann Otol Rhinol Laryngol* 95:215–221
266. Wenig BM, Hefner DK (1995) Respiratory epithelial adenomatoid hamartomas of the sinonasal tract and nasopharynx: a clinicopathologic study of 31 cases. *Ann Otol Rhinol Laryngol* 104:639–645
267. Wenig BM, Hyams VJ, Hefner DK (1988) Nasopharyngeal papillary adenocarcinoma. A clinicopathologic study of a low-grade carcinoma. *Am J Surg Pathol* 12:946–953
- 267a. World Health Organization Classification of Tumours (2005) Pathology and genetics of tumours of the head and neck. IARC, Lyon
268. Wick MR, Stanley SJ, Swanson PE (1988) Immunohistochemical diagnosis of sinonasal melanoma, carcinoma, and neuroblastoma with monoclonal antibodies HMB-45 and antisynaptophysin. *Arch Pathol Lab Med* 112:616–620
269. Wieneke JA, Thompson LD, Wenig BM (1999) Basaloid squamous cell carcinoma of the sinonasal tract. *Cancer* 85:841–854
270. Wilhelmsson B, Hellquist H, Olofsson J, Klimentberg C (1985) Nasal cuboidal metaplasia with dysplasia. Precursor to adenocarcinoma in wood-dust exposed workers? *Acta Otolaryngol* 99:641–648
271. Winther B, Gwaltney JM Jr, Mygind N, Hendley JO (1998) Viral-induced rhinitis. *Am J Rhinol* 12:17–20
- 271a. Wittekind C, Greene FL, Hutter RVP, Klimpfing M, Sobin LH (2004) UICC TNM atlas. Illustrated guide to the TNM/pTNM classification of malignant tumours. 5th edn. Springer, Berlin
272. Wolff M (1974) Granulomas in nasal mucous membranes following local steroid injections. *Am J Clin Pathol* 62:775–782
273. Woodson GE, Robbins KT, Michaels L (1985) Inverted papilloma. Considerations in treatment. *Arch Otolaryngol* 111:806–811
274. Yang YJ, Abraham JL (1997) Undifferentiated carcinoma arising in oncocytic Schneiderian (cylindrical cell) papilloma. *J Oral Maxillofac Surg* 55:289–294
275. Zak FG, Lawson W (1974) The presence of melanocytes in the nasal cavity. *Ann Otol Rhinol Laryngol* 83:515–519
276. Zarbo RJ, Crissman JD, Venkat H, Weiss MA (1986) Spindle-cell carcinoma of the upper aerodigestive tract mucosa. *Am J Surg Pathol* 10:741–753
277. Zarbo RJ, Ricci A, Kowalczyk PD, Kartun RW, Knibbs DR (1985) Intranasal dermal analogue tumor (membranous basal cell adenoma). *Arch Otolaryngol* 111:333–337
278. Zerris VA, Annino D, Heilman CB (2002) Nasofrontal dermoid sinus cyst: report of two cases. *Neurosurgery* 51:811–814
279. Zukerberg LR, Rosenberg AE, Randolph G, Pilch BZ, Goodman ML (1991) Solitary fibrous tumor of the nasal cavity and paranasal sinuses. *Am J Surg Pathol* 15:126–130
280. Zur KB, Brandwein M, Wang B, Som P, Gordon R, Urken ML (2002) Primary description of a new entity; renal cell-like carcinoma of the nasal cavity. Van Meegeren in the house of Vermeer. *Arch Otolaryngol Head Neck Surg* 128:441–447
281. Zurlo JJ, Feuerstein IM, Lebovics R, Lane HC (1992) Sinusitis in HIV-1 infection. *Am J Med* 93:157–162

Contents

3.1	Embryonic Rests and Heterotopias	72	3.5.4	Addison Disease	88
3.1.1	Fordyce Granules/Spots	72	3.5.5	Peutz Jeghers Syndrome	89
3.1.2	Juxtaoral Organ of Chievitz	72	3.5.6	Racial Pigmentation.	89
3.2.	Vesiculo-Bullous Diseases	72	3.5.7	Laugier Hunziker Syndrome.	89
3.2.1	Herpes Simplex Infections	72	3.5.8	Smoker's Melanosis	89
3.2.2	Chickenpox and Herpes Zoster	73	3.5.9	Drug-Associated Oral Pigmentation	90
3.2.3	Hand-Foot-and-Mouth Disease.	73	3.6	Hyperplastic Lesions	90
3.2.4	Herpangina.	74	3.6.1	Fibrous Hyperplasias	90
3.2.5	Pemphigus Vulgaris.	74	3.6.2	Papillary Hyperplasia.	90
3.2.6	Pemphigus Vegetans	74	3.6.3	Generalised Gingival Fibrous Hyperplasia	91
3.2.7	Paraneoplastic Pemphigus	75	3.6.4	Crohn's Disease	91
3.2.8	Mucous Membrane Pemphigoid	75	3.6.5	Orofacial Granulomatosis	92
3.2.9	Dermatitis Herpetiformis	76	3.6.6	Chronic Marginal Gingivitis and Localised Gingival Fibrous Hyperplasia	92
3.2.10	Linear IgA Disease	76	3.6.7	Peripheral Giant Cell Granuloma (Giant Cell Epulis)	93
3.2.11	Erythema Multiforme	77	3.6.8	Pyogenic Granuloma	93
3.3	Ulcerative Lesions.	77	3.6.9	Pulse (Vegetable) Granuloma	93
3.3.1	Aphthous Stomatitis (Recurrent Aphthous Ulceration).	77	3.7	Benign Tumours and Pseudotumours	94
3.3.2	Behçet Disease	78	3.7.1	Giant Cell Fibroma	94
3.3.3	Reiter Disease	78	3.7.2	Lingual Thyroid	94
3.3.4	Median Rhomboid Glossitis.	78	3.7.3	Verruciform Xanthoma.	95
3.3.5	Eosinophilic Ulcer (Traumatic Ulcerative Granuloma with Stromal Eosinophilia)	79	3.7.4	Haemangiomas	95
3.3.6	Acute Necrotising Ulcerative Gingivitis	79	3.7.5	Lymphangioma	95
3.3.7	Wegener's Granulomatosis.	80	3.7.6	Benign Nerve Sheath Tumours	95
3.3.8	Tuberculosis	81	3.7.6.1	Neurofibroma	96
3.4	White Lesions	81	3.7.6.2	Schwannoma.	96
3.4.1	Candidosis	81	3.7.6.3	Neurofibromatosis.	96
3.4.2	Lichen Planus	82	3.7.6.4	Multiple Neuromas in Endocrine Neoplasia Syndrome	96
3.4.3	Lupus Erythematosus.	83	3.7.7	Granular Cell Tumour (Granular Cell Myoblastoma)	96
3.4.4	Oral Epithelial Naevi	84	3.8	Squamous Cell Carcinoma.	96
3.4.5	Smoker's Keratosis.	84	3.8.1	Introduction	96
3.4.6	Stomatitis Nicotina	84	3.8.2	Clinical Features.	97
3.4.7	Hairy Tongue	85	3.8.2.1	Buccal Mucosa.	97
3.4.8	Hairy Leukoplakia	85	3.8.2.2	Tongue	97
3.4.9	Geographic Tongue	85	3.8.2.3	Floor of Mouth.	97
3.4.10	Frictional Keratosis	86	3.8.2.4	Gingiva and Alveolar Ridge	97
3.5	Pigmentations	86	3.8.2.5	Hard Palate.	98
3.5.1	Amalgam Tattoo.	86	3.8.2.6	Retromolar Trigone	98
3.5.2	Localised Melanotic Pigmentation	86	3.8.3	Staging	98
3.5.2.1	Oral Melanotic Macules	86	References	98	
3.5.2.2	Melanoacanthoma.	87			
3.5.2.3	Pigmented Naevi	87			
3.5.3	Premalignant Oral Melanoses and Oral Melanoma.	87			

3.1 Embryonic Rests and Heterotopias

3.1.1 Fordyce Granules/Spots

Fordyce granules are ectopic sebaceous glands in the oral mucosa [39, 119]. They appear as soft, creamy white or yellowish spots or clusters, typically a few millimetres in diameter. They are symmetrically distributed and tend to increase in size and number with age. The main site is the buccal mucosa, but they may also involve the vermilion border and labial mucosa, particularly in the upper lip. More rarely, the tongue, palatoglossal fold, tonsil and other intraoral sites may be affected, and the condition can then be confused with other lesions. Microscopy shows typical sebaceous glands opening directly onto the surface by short, keratinised ducts with no associated hair follicles.

3.1.2 Juxtaoral Organ of Chievitz

Chievitz's organ, or the bucco-temporal organ, is thought to be a vestigial neuroepithelial structure. It has also been suggested that the juxtaoral organ is an anlage of the parotid gland, or arises from Schwann cells that have undergone squamous metaplasia [132]. It has been demonstrated in neonates and children and can persist into adult life [16]. The organ is usually found between the temporalis muscle and the bucco-temporal fascia or pterygomandibular raphe, and is usually present bilaterally. It is seen fortuitously, generally in material taken from surgical resections, and is important as it can be misinterpreted as a squamous cell carcinoma. Very rare cases have presented as tumours in the infratemporal fossa [83]. It is usually only a few millimetres in size and microscopically forms a multilobulated mass of discrete cell nests that resemble squamous epithelium, but do not show obvious keratinisation. Occasionally, the cells have clear cytoplasm and form duct-like structures that may contain mucin-negative colloid. The cell nests are associated with nerve fibres, particularly at the periphery, and this may be mistakenly interpreted as a squamous carcinoma with perineural involvement, or sometimes mucoepidermoid carcinoma and thyroid carcinoma [103]. The central areas of the epithelial cell nests are positive for cytokeratin 19 and most cell nests are positive for vimentin and weakly positive for epithelial membrane antigen. They are negative for S-100 protein, glial acidic fibrillary protein, and neuroendocrine markers such as chromogranin, synaptophysin and neurone-specific enolase [132]. A similar appearance to the juxtaoral organ has rarely been described elsewhere in the mouth, including intraosseous locations [47].

3.2 Vesiculo-Bullous Diseases

3.2.1 Herpes Simplex Infections

Herpes simplex is a common virus that often causes subclinical infections. It is, however, a cause of serious and sometimes fatal illnesses in immunocompromised patients. In the orofacial tissues, clinically apparent infections can be primary or recurrent. The majority of cases of oral infections are due to *Herpes simplex* type 1, but an increasing proportion is being attributed to *Herpes simplex* type 2, which is typically more closely associated with genital infections. The virus is transmitted by close contact. Although in the past primary herpes affected children most frequently, in Western societies it is seen increasingly in young and middle-aged adults.

Primary herpes infection (primary herpetic gingivostomatitis) is characterised by widespread vesicular lesions of the oral mucosa [183]. Any site may be involved, but the hard palate and the dorsum of the tongue are the most common locations. The vesicles quickly rupture to leave shallow, painful, sharply demarcated ulcers that are 1–2 mm in diameter and have an erythematous halo. Ulcers frequently coalesce to form more irregular lesions. Gingivitis is a very characteristic feature of primary herpes. The gingivae are swollen and often strikingly erythematous, even in the absence of frank ulceration. There is often conspicuous cervical lymphadenopathy, together with mild fever and malaise. Oral lesions usually resolve spontaneously within 1–2 weeks. About a third of patients infected with *Herpes simplex*, either clinically or sub-clinically, are susceptible to recurrent infections.

It is uncommon for herpetic lesions to be biopsied (Fig 3.1). In the early stages there is intercellular oedema and ballooning and vacuolisation of keratinocytes due to intracellular oedema. This leads to intraepithelial vesiculation. Nuclei become enlarged, and occasionally basophilic or eosinophilic nuclear inclusions with a clear halo (Lipschutz bodies) can be identified. Cells may fuse to form multinucleated epithelial giant cells. The vesiculation is followed rapidly by epithelial necrosis and breakdown, leading to ulceration and more florid inflammatory infiltration.

Herpes simplex virus can persist in a latent form in the trigeminal ganglion and when re-activated causes recurrent infections. These are typically seen at the mucocutaneous junctions of the mouth or nasal cavity, and involvement of the lips, the most common site, is called herpes labialis. A variety of apparently disparate factors can trigger re-activation, including the common cold ("fever blister"), exposure to sunlight, menstruation, stress and others. There is usually a brief prodromal burning or prickling sensation in the

affected area, followed by the formation of a localised cluster of vesicles. These rapidly break down, ulcerate and crust. The lesions usually heal spontaneously in 1–2 weeks. Occasionally there may be intraoral recurrences, particularly in the hard palate. These may be triggered by local anaesthetic injections. Persistently recurrent intraoral herpes, however, should always raise the possibility of immunosuppression. Atypical and often very severe forms of intraoral herpes infections can be seen in patients who are immunocompromised [21].

3.2.2 Chickenpox and Herpes Zoster

Chickenpox is a highly contagious infection caused by the herpes virus *Varicella zoster*. It is typically seen in children where it causes crops of pruritic cutaneous vesicles. It is usually transmitted by direct contact and has an incubation period of 2–3 weeks. The exanthem is frequently preceded by a slight fever, malaise and mild headache. The cutaneous lesions start as an itchy macular rash, which progressively becomes vesicular and pustular before breaking down to form focal crusting lesions. They tend to erupt in crops, but lesions at all stages of evolution are frequently present. The back and chest are often the first sites of involvement, but later lesions appear on the face, neck and limbs. They can involve the nose, ears, conjunctiva and genital areas. In the mouth they form small, non-specific, scattered ulcers. The symptoms last from a few days to 2 weeks. In many cases the virus remains latent in dorsal root ganglia.

Herpes zoster (shingles) is due to reactivation of the *Varicella zoster* virus. In the orofacial region it is characterised by pain, a vesicular rash and stomatitis in the related dermatome. Unlike herpes labialis, repeated recurrences of zoster are very rare. Occasionally there is an underlying immunodeficiency. Herpes zoster is a hazard in organ transplant patients and can be an early complication of haematolymphoid neoplasms and HIV infections. Herpes zoster usually affects adults of middle age or older, but occasionally involves children. The first signs are often pain, irritation or tenderness in one or more divisions of the trigeminal nerve. The pain may be severe and can be misinterpreted as toothache, leading to inappropriate dental intervention. Malaise and low-grade fever are common constitutional symptoms. There is usually a strikingly unilateral, vesicular exanthem restricted to the affected dermatome. Intraorally, there may also be extensive unilateral ulceration in the distribution of the involved nerves. There is usually tender regional lymphadenopathy. The acute phase lasts about 7–10 days, but pain may continue until the lesions ul-

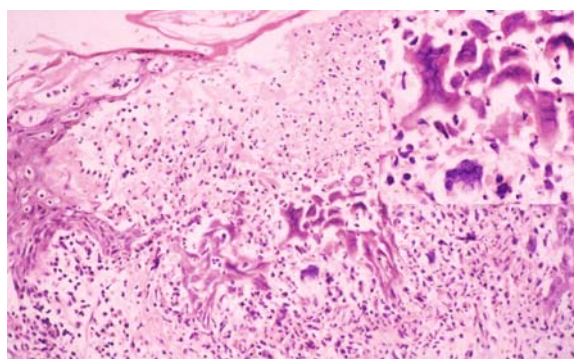


Fig. 3.1. Primary herpetic stomatitis showing intercellular vacuolation and multinucleated epithelial cells

cerate and crust over, which may take several weeks, especially if there is suppuration and subsequent scarring. In these circumstances a significant number of patients develop the most unpleasant consequence of post-herpetic neuralgia.

3.2.3 Hand-Foot-and-Mouth Disease

This is a common and usually mild viral infection that often causes local clusters of infections among groups of young children and is characterised by oral ulceration and a vesicular rash on the extremities. It is caused by a variety of strains of the coxsackie A16 virus and is highly infectious. Sporadic cases associated with Coxsackie A4–7, A9, A10, B1–B3, and B5 have also been reported. It frequently spreads through classrooms, schools and local communities in an epidemic manner. The incubation period is between 3 and 10 days. It presents clinically as small, scattered oral ulcers that often cause few symptoms. Although the initial lesions are vesicular, intact blisters are rarely seen. Unlike primary herpes infections, the gingivae are rarely affected. It is unusual for regional lymph nodes to be involved except in severe cases and constitutional symptoms tend to be mild or absent. The cutaneous exanthem consists of small vesicles or occasionally larger blisters that form mainly around the base of fingers or toes, but may extend to involve any part of the limb. In some outbreaks, either the mouth or the extremities alone may be affected. Although serological investigations can confirm the diagnosis, due to the relatively mild and transient nature of the disease, this investigation is rarely undertaken. Typically, the condition resolves spontaneously within a week to 10 days and does not recur. However, in some epidemics patients have developed severe complications, including interstitial pneumonitis, myocarditis and encephalitis, resulting in death [36].

3.2.4 Herpangina

Herpangina is also caused by a variety of group A coxsackie viruses including A1 to 6, 8, 10, and 22. Other causes include coxsackie group B (strains 1–4), echoviruses, and other enteroviruses [161]. It is highly contagious and tends to affect young children in the summer and early autumn period. Like hand-foot-and-mouth disease, it rapidly spreads through close-knit communities, such as schools, and presents with acute pharyngitis, anorexia and dysphagia, with or without cervical lymphadenopathy. Typically, the lesions are restricted to the soft palate, uvula, anterior pillars of the fauces and palatine tonsils. They consist of multiple, small vesicles that rapidly rupture to form superficial ulcers, which may coalesce. In addition, there is often more generalised oropharyngeal erythema. The condition usually lasts 1–2 weeks and is treated symptomatically.

3.2.5 Pemphigus Vulgaris

Pemphigus vulgaris is an uncommon, but potentially lethal, mucocutaneous disorder that occasionally also involves the eyes. It is an autoimmune disease due to circulating antibodies against the intercellular attachments of stratified squamous epithelia [163]. The specific target appears to be desmoglein 3 [2]. However, 50% of patients with pemphigus vulgaris also have autoantibodies to Dsg1, but cases that are predominantly oral have only Dsg3 antibodies [70]. Associations have been described between pemphigus vulgaris, myasthenia gravis and thymoma and a variety of drugs, including penicillamine, rifampicin and captopril. In addition, some cases are associated with internal malignancies, particularly of the haematolymphoid system, and the condition is then termed paraneoplastic pemphigus.

Pemphigus is more common in Asians and Ashkenazi Jews than other races and most patients are in the fourth or fifth decades. The mouth is the most common site of initial involvement and remains the only site affected in about half of patients. The oral features are very variable. It is uncommon to find intact vesicles and most patients present with painful, ragged superficial ulcers and areas of boggy and shredded mucosa. The buccal mucosa, gingiva and soft palate are the most common sites. In the tongue the condition may present as deep, non-healing fissures. Fluid from intact or recently ruptured blisters may contain acantholytic (Tzanck) cells, although this is rarely used as a diagnostic measure. The disease may be relatively mild or even regress, but some cases, particularly those with extensive cutaneous involvement, may be fulminant, either as a consequence of the disease itself, or as a complication of medical treatment.

Microscopy shows suprabasal clefting of the epithelium due to loss of intercellular attachments and acan-

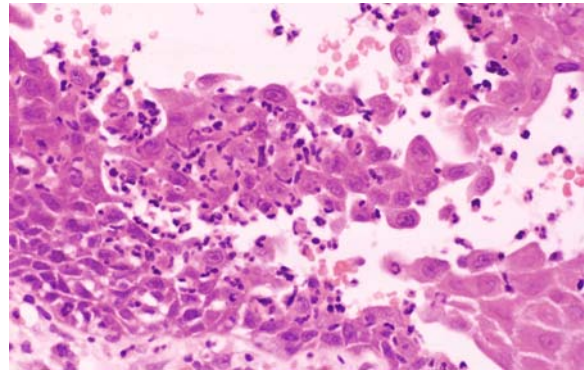


Fig. 3.2. Pemphigus vulgaris showing suprabasal clefting and acantholytic cells in an intraepithelial blister

tholysis (Fig 3.2). A single layer of keratinocytes may remain attached to the corium by their hemidesmosomes, but the cells are separated from each other laterally to form a characteristic “tombstone” appearance. The acantholytic cells floating in the vesicular fluid are rounded, with condensed cytoplasm surrounding hyperchromatic nuclei. The vesicles may contain acute and chronic inflammatory cells, and eosinophils may be a conspicuous feature. In many cases, the roof of the blister is lost during the biopsy procedure due to a positive Nikolsky phenomenon, but a row of keratinocytes remains adherent to the floor. Direct immunofluorescence on frozen tissue shows deposits of IgG and less frequently IgM and IgA in the intercellular junctions, producing a characteristic “chicken wire” appearance.

3.2.6 Pemphigus Vegetans

Pemphigus vegetans is considerably less common in the mouth than pemphigus vulgaris [15]. It usually presents clinically as serpyiginous ulcers that are most frequent on the dorsum of the tongue and lips [187]. The lingual lesions closely resemble those of erythema migrans. The papillomatous, proliferative lesions that characterise cutaneous pemphigus vegetans can sometimes be seen at the angles of the mouth. As in pemphigus vulgaris, drugs, particularly ACE inhibitors, have been invoked as possible causative agents in some cases [12, 137].

Microscopically, the epithelium tends to proliferate and become verruciform. Acantholytic cells may not be conspicuous and eosinophil microabscesses are said to be the most typical histological feature. However, the lesions frequently resemble pyostomatitis vegetans and conventional microscopy may not be diagnostic. The presence of typical skin lesions often helps in making the diagnosis and it may be differentiated from pyostomatitis by the clinical picture and appropriate immunocytochemical investigations [73].

3.2.7 Paraneoplastic Pemphigus

Although an occasional association between pemphigus and malignancy had been recognised for many years, it was not until 1990 that paraneoplastic pemphigus was recognised as a distinct clinical, histological and immunocytochemical entity [5]. The condition is seen predominantly in association with B-cell lymphoproliferative disorders, especially non-Hodgkin lymphoma, chronic lymphocytic leukaemia, Castleman disease, thymoma and Waldenström macroglobulinaemia [92]. Less commonly it is associated with non-lymphoid neoplasms, including some carcinomas of the bronchus, breast and pancreas. In some cases showing otherwise typical features of the disease, no underlying malignancy is found. Paraneoplastic pemphigus is characterised by the following features:

- Painful mucocutaneous vesiculo-bullous eruptions;
- Histopathologic features of intraepithelial acantholysis and vacuolar interface changes;
- Demonstration of intercellular epithelial IgG and C3, with or without granular linear deposition of complement along the BMZ;
- Presence of circulating autoantibodies that bind to the surfaces of stratified squamous epithelia as well as simple, columnar and transitional epithelia;
- Presence of a characteristic complex of proteins derived from keratinocytes and serum antibodies demonstrated by serum immunoprecipitation. These include desmoplakins I and II, bullous pemphigoid antigen I, envoplakin and periplakin [92].

In addition, paraneoplastic pemphigus tends to be extremely refractory to the usual immunosuppressant drugs used to control pemphigus vulgaris.

Paraneoplastic pemphigus is most common between the ages of 45 and 70 years and there appears to be a male predominance. The mouth is almost always involved and oral lesions present as a painful, intractable stomatitis that extends into the oropharynx and often beyond the vermilion borders of the lips. It causes blisters and irregular, ragged ulceration. The buccal mucosa and lips are the most common sites, but almost anywhere in the mouth, oropharynx and nasopharynx can be involved. About two-thirds of patients have conjunctival involvement characterised by frequently severe pseudomembranous conjunctivitis and symblepharon.

Microscopy shows intraepithelial acantholysis with suprabasal clefting, dyskeratotic keratinocytes, basal cell liquefaction, and epithelial inflammatory cell exocytosis [78]. In many cases, however, the condition cannot be distinguished from conventional pemphigus [89]. The overall appearances suggest that there is an overlap between paraneoplastic pemphigus and erythema multiforme. Indirect immunofluorescence

on the transitional epithelium of rat bladder appears to be a highly specific test for paraneoplastic pemphigus [100].

3.2.8 Mucous Membrane Pemphigoid

Mucous membrane pemphigoid is an uncommon, chronic blistering disorder affecting the mouth [186]. Other sites of involvement include the eyes, skin, and mucosa of the nasopharynx, anogenital region, oesophagus and larynx [32]. It has been defined as a group of putative autoimmune, chronic inflammatory, subepithelial blistering diseases predominantly affecting mucous membranes and characterised by linear deposition of IgG, IgA and C3 along the epithelial basement membrane [33]. It has also been called benign mucous membrane pemphigoid and cicatricial pemphigoid. However, it can be a severely disabling condition, and rarely causes scarring except in the eye and oesophagus/larynx, so these terms are not appropriate.

Mucous membrane pemphigoid is more common in women than men and most patients are in the 40–60-year age range. The mouth is often the first and only site of involvement. Oral lesions can be intact blisters that may contain clear or sero-sanguinous fluid, erythematous patches or superficial ulcers. Lesions are most common on the attached gingiva, usually buccally and labially, and the palatal mucosa. Less frequent sites include the labial, lingual and buccal mucosae. Ocular lesions are characterised by conjunctival inflammation, ulceration and symblepharon due to fusion of the palpebral and bulbar conjunctivae. There may be severe scarring, entropion and blindness. Skin lesions are uncommon and usually involve the scalp and upper torso.

Microscopy shows subepithelial blister formation with clean separation of the full thickness of the epithelium from the underlying connective tissue (Fig. 3.3). There is usually a dense mixed inflammatory infiltration of the corium. Due to the strongly positive Nikolsky phenomenon seen in mucous membrane pemphigoid, it is very common to receive a biopsy specimen where most or all of the epithelium has been lost or completely separated from the connective tissue. The specimen then consists of non-specifically inflamed connective tissue, which lacks the surface fibrinous slough that would be more typical of a non-specific oral ulcer. This type of appearance, though not diagnostic, is highly suggestive of mucous membrane pemphigoid.

Direct immunofluorescence on peri-lesional mucosal biopsies shows continuous deposits of IgG, IgA or C3, either singly or in combination, along the basement membrane zone (BMZ) in about 80% of cases. When present, these deposits help to distinguish mucous membrane

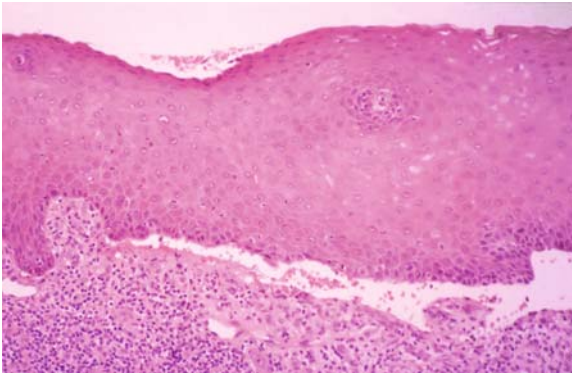


Fig. 3.3. Mucous membrane pemphigoid showing clean subepithelial blistering

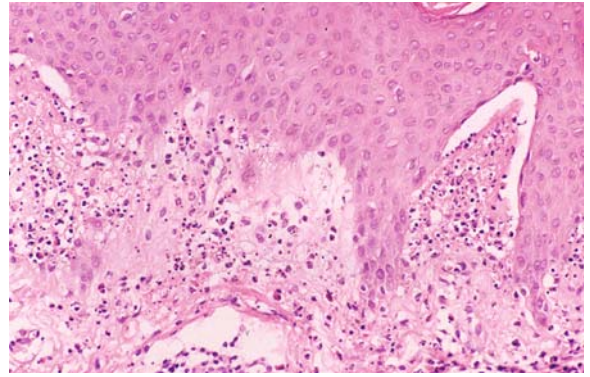


Fig. 3.4. Dermatitis herpetiformis showing polymorphonuclear leukocytes at the tips of the papillary corium

pemphigoid from several other common oral mucosal inflammatory disorders. For example, lichen planus does not have linear immunoglobulin deposits, but has linear and shaggy deposits of fibrin in the BMZ, and erythema multiforme has no linear BMZ deposits. However, these deposits do not distinguish mucous membrane pemphigoid from bullous pemphigoid, epidermolysis bullosa aquista or linear IgA bullous dermatosis. Such distinctions should be made on the basis of clinical findings.

Several possible target antigens have been identified in the sera of patients with mucous membrane pemphigoid. These include: bullous pemphigoid antigens 1 and 2; laminins 5 and 6; type VII collagen and $\beta 4$ integrin subunit [32].

3.2.9 Dermatitis Herpetiformis

Dermatitis herpetiformis is an uncommon, intensely pruritic mucocutaneous disorder related to coeliac disease that only occasionally involves the mouth [126]. Oral lesions present as areas of erythema and clusters of small, friable vesicles or superficial, painful ulcers. The lesions can involve both keratinised and non-keratinised mucosa and head and neck cutaneous lesions tend to affect the scalp and periorbital regions. Dermatitis herpetiformis is seen most frequently in teenagers and young adults, particularly males, and there is a predilection in people of Anglo-Saxon and Scandinavian origin. There is a strong association between dermatitis herpetiformis and gluten-sensitive enteropathy. The Class I antigen HLA-B8 is found in the large majority of patients with both dermatitis herpetiformis and coeliac disease, and HLA-DR3 is expressed in nearly 95% of patients.

Clinically, oral dermatitis herpetiformis presents as patches of mucosal erythema, clusters of small vesicles, herpetiform ulcers or more extensive areas of non-heal-

ing ulceration. In conventional gluten-sensitive enteropathy oral ulcers tend to be of the typical minor aphthous stomatitis type.

Microscopically, the lesions of dermatitis herpetiformis show polymorphonuclear leukocyte microabscesses in the tips of the papillary corium (Fig. 3.4). Initially, neutrophils predominate, but as the microabscesses enlarge eosinophils become more conspicuous. The microabscesses eventually fuse to form visible blisters that frequently rupture leaving superficial ulcers. Direct immunofluorescence shows granular deposits of IgA in the BMZ of the dermal papillae, in both affected and adjacent normal mucosa.

3.2.10 Linear IgA disease

Linear IgA disease is a rather poorly defined heterogeneous group of mucocutaneous blistering disorders that closely resemble mucous membrane pemphigoid clinically and microscopically [160, 191]. Like pemphigoid, the eyes may be involved. Linear IgA disease in adults has been separated from similar conditions in childhood such as bullous dermatosis of childhood and childhood cicatricial pemphigoid. Cutaneous linear IgA disease of adults has a strong association with a history of bowel disease. This association is much less clear in patients with oral lesions. However, patients with oral linear IgA disease appear to have a higher risk of severe ocular lesions. Some cases of oral lesions have been associated with drugs [51]. The condition is more common in women than men and it usually presents as a desquamative gingivitis with, or without, ulceration.

Microscopy shows subepithelial vesiculation and full thickness blister formation. Direct immunofluorescence shows linear deposition of IgA along the BMZ and a low titre of circulating IgA to the BMZ. Although small amounts of IgG, IgM and C3 may be seen, if these

are present in other than trace amounts mucous membrane pemphigoid is a much more likely diagnosis.

Linear IgA disease tends to be refractory to systemic steroids, but it may respond to dapsone or sulphonamides.

3.2.11 Erythema Multiforme

Erythema multiforme is a mucocutaneous inflammatory disorder, but sometimes the mouth is the only site of involvement [1, 8]. It can be relatively mild or manifest with fever, malaise and extensive skin, mucosal and ocular lesions when it is sometimes called Stevens Johnson syndrome or erythema multiforme major. It is thought to be an immunologically mediated disorder, but in many cases no precipitating factor is found. Triggering agents that have been implicated include infections with *Herpes simplex* virus [7] and *Mycoplasma pneumoniae* [99] and a wide range of drugs including sulphonamides, anticonvulsants, non-steroidal anti-inflammatory medications and antibiotics. Although patients may suffer a single episode, it is often recurrent.

Erythema multiforme is usually seen in young adults (20–40 years) and is more common in males. Oral lesions may be the only feature of the disease or cutaneous involvement may follow several attacks of oral ulceration. The lips are the most frequently involved site and typically show swelling and extensive haemorrhagic crusting. Within the mouth there are usually diffuse erythematous areas and superficial ulcers on the buccal mucosa, floor of the mouth, tongue, soft palate and fauces. It is uncommon for the gingiva to be involved and this sometimes helps to distinguish erythema multiforme from primary herpetic gingivostomatitis, where gingival inflammation is a conspicuous feature. The areas of mucosa involved frequently break down to form painful, shallow, irregular ulcers on a background of more generalised erythema. It is unusual to see intact blisters in the mouth.

The classical cutaneous manifestation of erythema multiforme is the development of so-called target or bull's eye lesions. These begin as dark red macules, usually 1–3 cm in diameter. They become slightly elevated and develop a characteristic bluish centre. These lesions are seen most frequently on the hands and lower limbs. In erythema multiforme major there may be ocular and genital involvement together with constitutional symptoms. A very severe and potentially lethal variant is toxic epidermal necrolysis, when there is widespread cutaneous and mucosal involvement with extensive blistering and epidermal loss leading to fluid and electrolyte loss and secondary infection.

Microscopy shows variable features and early epithelial breakdown of oral lesions frequently masks any

characteristic features [25]. In the early lesions there is apoptosis and necrosis of keratinocytes, intercellular oedema and inflammatory infiltration of the epithelium. This leads to intra- and sub-epithelial vesiculation and ultimately loss of the roof of the blister to form an ulcer. There is lymphohistiocytic and polymorphonuclear infiltration of the superficial corium and the inflammatory infiltrate can extend more deeply, often in a perivascular distribution. Patchy deposits of C3 and IgM may be found in the walls of blood vessels, but there is no frank vasculitis and the immune complex deposition appears to be non-specific.

3.3 Ulcerative Lesions

3.3.1 Aphthous Stomatitis (Recurrent Aphthous Ulceration)

This is the most common ulcerative disease of the oral mucosa and can affect as many as 15–20% of the population at some time in their lives [152]. It is characterised by persistently recurrent, painful oral ulcers [142, 143, 193]. The condition usually starts in early childhood and typically resolves spontaneously in the late teens or early adult life. When the condition develops in older individuals, predisposing causes such as haematinic deficiencies or smoking cessation are more likely to be associated.

There are three main clinical forms of the condition: minor, major and herpetiform ulceration, although a minority of patients may show various combinations of these types. Minor aphthae are by far the most common manifestation (~85%) and are characterised by the formation of one or several superficial ulcers, usually 2–8 mm in diameter with a yellowish-grey, fibrinous floor and an erythematous halo. The ulcers tend to involve the non-keratinised mucosa such as the lips, buccal mucosa, ventrum of the tongue and floor of the mouth. They usually heal within 7–10 days by regeneration of the epithelium across the floor of the ulcer, and without scarring. The ulcers frequently recur at regular intervals, typically of 2–3 weeks. Some patients, however, are virtually never ulcer free, as new crops appear before pre-existing ones have healed. A minority of cases are menstruation-related and the ulcers appear monthly in the premenstrual week. Major aphthae are less common (~10%) and ulcers can form on both keratinised and non-keratinised mucosae. The ulcers are usually single but can be several centimetres in diameter and are penetrating. Hence, healing is by secondary intention and characterised by granulation tissue formation and scarring. In severe cases the scarring following progressive ulceration can be so severe that it causes trismus and microstomia. Herpetiform aphthae are uncommon

(~5%) and are characterised by the formation of sometimes hundreds of small (~2 mm), superficial ulcers that frequently coalesce and may form on a background of more generalised mucosal erythema [154]. Any oral site may be involved, but the labial and ventral lingual mucosae are the sites of predilection.

Although most cases of recurrent aphthous stomatitis are idiopathic, a minority are caused, or exacerbated, by deficiencies in iron, vitamin B₁₂ or folate, and as such are potentially curable. Haematinic deficiencies are reported to be twice as common in patients with recurrent aphthous stomatitis compared with controls. The condition is often made worse by emotional stress. Occasional cases are said to be related to gastro-intestinal complaints such as coeliac disease, Crohn's disease and ulcerative colitis, but some of the data are conflicting [56, 164]. However, it is likely that in most instances any associations are secondary to haematinic deficiencies.

It is uncommon for recurrent aphthae to be biopsied, except when a major aphtha simulates malignancy [97]. Reported early changes include infiltration of the epithelium by lymphocytes and histiocytes and focal aggregates of lymphocytes in the superficial corium. This is followed by areas of epithelial cell apoptosis, degeneration and necrosis [77]. The epithelium is lost and the subsequent ulcer is covered by a fibrinous slough, heavily infiltrated by polymorphonuclear leukocytes. More deeply there is a mononuclear cell infiltration and perivascular cuffing is an inconsistent feature. The condition appears to be a T-cell mediated immunological response [62] and is thought to be a response to a keratinocyte-associated antigen that is yet to be identified.

3.3.2 Behçet Disease

This condition comprises recurrent oral ulceration together with genital ulceration and ocular lesions [56, 88, 109]. The ocular lesions include uveitis and retinal vasculitis. Behçet disease, however, is a multisystem disorder and can show a wide range of clinical manifestations. Features of more generalised disease include neurological disorders, arthralgia, and vascular, gastro-intestinal and renal lesions. The disease is uncommon the USA and UK, but has a much higher prevalence in southeast Asia, Japan and the eastern Mediterranean region. There is a strong association with the presence of HLA*B51 [116].

The oral lesions are clinically identical to recurrent aphthae [177]. Patients also have genital or perigenital cutaneous ulcers and erythema nodosum is common.

Microscopically, like recurrent aphthae, the ulcers associated with Behçet disease show essentially non-specific features. It has been suggested that perivascular inflammatory infiltration into the deeper corium may be

more characteristic of Behçet disease, but the significance of this observation is questionable.

3.3.3 Reiter Disease

Reiter disease comprises non-specific urethritis, arthritis and conjunctivitis, although the conjunctivitis is present in less than half of cases. It was initially thought to be only sexually transmitted, but many cases appear to result from enteric infections by a variety of organisms including Shigella, Salmonella and Campylobacter.

The disease is typically seen in young males and shows a strong association with HLA-B27 and has been reported in HIV-infected individuals [182]. Patients develop painful mono- or polyarticular arthropathy and occasionally the temporomandibular joint is involved. Patients can have fever, weight loss and CNS involvement, and facial nerve palsy has been described. Cutaneous and mucosal lesions are relatively common. The skin lesions include macules, vesicles, and pustules on the hands and feet particularly, and plaque-like hyperkeratotic lesions of the trunk and scalp. Oral lesions consist of circinate white or yellowish lesions surrounding macular areas that are erythematous or superficially ulcerated. They resemble circinate balanitis and the lesions of geographical tongue and geographical stomatitis [131]. They are painless and transient and are therefore rarely biopsied. Microscopy shows features similar to those seen in geographical tongue with spongiform pustules focally and diffusely dispersed in the superficial epithelium, but without evidence of psoriasiform hyperplasia.

3.3.4 Median Rhomboid Glossitis

Median rhomboid glossitis usually presents as a painless, reddened, sharply demarcated area of depapillation in the centre of the dorsum of the tongue anterior to the foramen caecum. In some cases the area is nodular or grooved. It was originally thought to be due to the persistence of the developmental eminence called the tuberculum impar, but now most cases are believed to be candidal in origin [180, 188]. Predisposing factors include smoking, wearing dentures, diabetes and using steroid inhalers. Sometimes there is a "kissing lesion" in the palate.

Microscopy typically shows elongation, branching and fusion of the rete ridges with mild epithelial atypia (Fig. 3.5). There may be spongiform pustules in the parakeratinised surface layers and evidence of candidal hyphae. Sometimes the epithelial hyperplasia is florid resulting in a pseudoepitheliomatous appearance. Some of these lesions have been misinterpreted as squamous

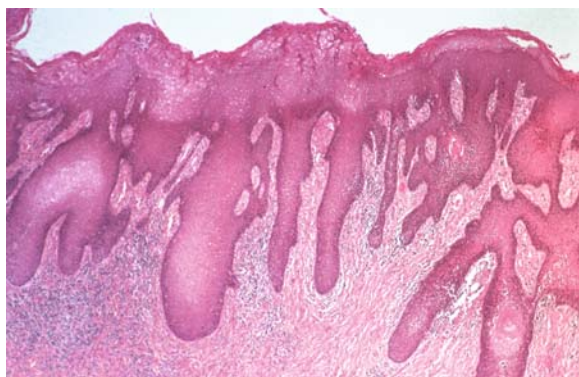


Fig. 3.5. Median rhomboid glossitis showing extensive epithelial hyperplasia and fusing of rete processes

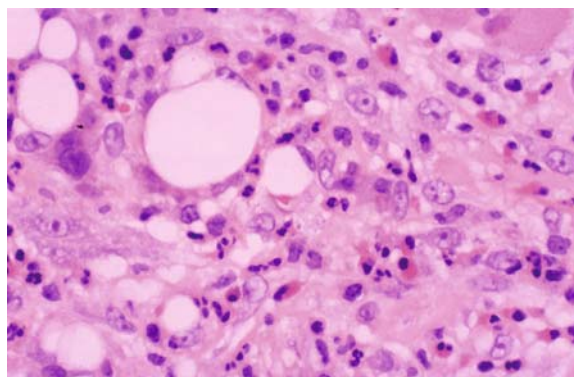


Fig. 3.6. Eosinophilic ulcers showing plump histiocytic nuclei and eosinophils

cell carcinomas, with significantly adverse clinical consequences [129]. Below the epithelium there is often a dense, band-like zone of hyalinisation that is sometimes mistaken for amyloidosis.

The lesion often responds to antifungal treatment, but almost invariably recurs if the patient continues to smoke. There does not appear to be any premalignant potential and the dorsum of the tongue is a very uncommon site for oral cancer.

3.3.5 Eosinophilic Ulcer (Traumatic Ulcerative Granuloma with Stromal Eosinophilia)

So-called eosinophilic ulcers are chronic but self-limiting lesions of a traumatic or reactive nature in which there is an intense inflammatory infiltration with a prominent eosinophilic component [45]. Despite their designation, about a third of these lesions do not undergo ulceration. Eosinophilic ulcers are seen most commonly in children and young adults and are frequently painless. In infants, particularly, the condition has been called Riga-Fede disease [46]. Although these ulcers can be seen anywhere in the oral mucosa, including the gingiva, they are most common on the tongue and buccal mucosa. About a third of patients have a history of trauma, particularly a crush injury of the lingual muscle due to biting [43]. The lesions are usually single and can be several centimetres in diameter. If left, most heal spontaneously within 2 months, and this may be accelerated by incisional biopsy. Although recurrence tends to be uncommon, in one report 6 out of 15 cases were recurrent or multiple [43]. On the basis of the clinical and immunocytochemical features it has been suggested that eosinophilic ulcers might be the oral equivalent of primary cutaneous CD30-positive lymphoproliferative disorders [54].

Microscopically, these lesions can be mistaken for malignancy. There is non-specific ulceration with underlying inflamed granulation tissue (Fig. 3.6). There is an associated dense inflammatory infiltrate that extends deeply into the underlying muscle. The infiltrate consists of lymphocytes and plasma cells, macrophages, polymorphonuclear leukocytes and mast cells. Eosinophils are particularly numerous and they may form microabscesses. Macrophages are frequently conspicuous and can form sheets of cells with poorly demarcated cytoplasm, but large, vesicular nuclei with prominent nucleoli and a high mitotic frequency. These macrophages, together with damaged muscle cells showing sarcolemmal nuclear degeneration and regeneration, can give the erroneous impression of a lymphoma. In addition, the prominent eosinophilic component can lead to a mistaken diagnosis of Langerhans cell histiocytosis. This erroneous diagnosis is particularly likely in lesions involving the gingiva, where there may be associated resorption of the underlying bone. Appropriate immunocytochemical characterisation should avoid this confusion.

3.3.6 Acute Necrotising Ulcerative Gingivitis

Acute necrotising ulcerative gingivitis (Vincent disease, trench mouth) is a relatively common oral disease. Although it is generally accepted that bacteria play a pivotal role in the development of the disease, a specific causal agent has not been established. In the past the Gram-negative anaerobes designated as *Treponema vincentii* and *Fusobacterium nucleatum* were strongly implicated and *Treponema denticola* [165] and *Prevotella intermedia* are some of the current candidate organisms.

A wide variety of factors predispose to the development of the disease. The most important local factors are cigarette smoking and poor oral hygiene. General

predisposing factors include emotional stress, malnutrition and immunosuppressive disorders. Recently, diabetes has also been implicated in the aetiology [102]. The condition is most common in young adult males and it starts with painful, punched out and crateriform ulcers developing on and permanently destroying the tips of the interdental papillae. It can spread to the marginal gingiva and progress to involve and destroy the underlying alveolar bone. Lesions sometimes develop in relation to an operculum overlying a partially erupted third molar tooth and occasionally they spread into the adjacent buccal mucosa. There is often severe halitosis and taste disturbances. Regional lymphadenopathy is common, but constitutional symptoms tend to be relatively mild.

It is very uncommon to receive a biopsy specimen from patients with active disease, but scrapings from the base of one of the ulcers typically show numerous polymorphs, fibrin and debris, and suitable staining reveals fusiform and spiral organisms.

The acute condition usually responds well to oral metronidazole or tinidazole.

3.3.7 Wegener's Granulomatosis

Wegener's granulomatosis (WG) is an uncommon but distinctive form of vasculitis characterised in its classical form by necrotising granulomatous inflammation of the upper and lower respiratory tracts and segmental necrotising glomerulonephritis [76]. It is now recognised that a wide variety of other organs and tissues may be involved. Rarely, a proliferative rather than a destructive response produces tumefactions [65]. Variants of WG include a limited form, which has few extrapulmonary manifestations, and a protracted superficial form, which is characterised by lesions restricted to the upper respiratory tract, mucosa and skin for a prolonged period, although it may eventually progress to renal involvement [58]. Wegener's granulomatosis limited to the respiratory system may respond to antibiotics such as co-trimoxazole and *Staphylococcus aureus* has been implicated as a triggering agent for this disease, but the evidence remains equivocal [141].

Head and neck manifestations, particularly in the sinonasal complex, are common and can affect as many as 90% of patients at presentation [50] (see Chap. 2). They include severe rhinorrhoea, sinusitis, otitis media and destruction of the nasal septum and cartilage to produce a saddle-nose deformity. By contrast, oral lesions are less common and affect only about 5% of patients [69]. They include oral ulceration, delayed healing of extraction wounds, tooth mobility and loss of teeth. Perforation of the palate is usually as a direct extension of sinonasal disease. Extraorally, head and neck manifestations include swelling and desquamation of the lips, parotid gland enlargement, and cranial nerve palsies.

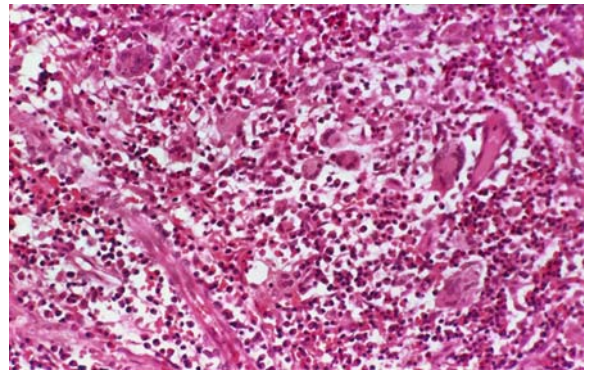


Fig. 3.7. Wegener's granulomatosis of gingiva showing intense inflammation, haemorrhage and scattered, small multinucleated giant cells

A rare, but particularly characteristic oral feature is so-called strawberry gums, which is considered to be virtually pathognomonic of Wegener's granulomatosis [111, 124]. There is a localised or generalised proliferative gingivitis with a mottled, purplish-red granular surface, which resembles an over-ripe strawberry. Disease localised to the gingiva tends to be fairly low-grade. Involvement of the underlying bone, however, may cause the related teeth to loosen or exfoliate.

Microscopy of the gingiva shows irregular epithelial hyperplasia with downgrowths of the rete processes into the underlying corium. The connective tissue shows vascular lakes of extravasated blood and haemosiderin-containing macrophages and there are neutrophil and eosinophil microabscesses, together with a more diffuse mixed inflammatory infiltration (Fig. 3.7). Small multinucleated giant cells are unevenly distributed in the lesion, and although considered to be characteristic, may be absent in many levels. Vasculitis is not usually seen, possibly because vessels of sufficient size to show this feature are rarely present in gingivectomy specimens. By contrast, biopsies of other oral lesions rarely show microabscesses or necrosis. Also, the granulomatous reaction characteristic of many other sites is uncommon [42].

Investigations of patients with suspected oral WG should include sinus and chest radiographs, full blood picture, erythrocyte sedimentation rate, C-reactive protein, autoantibody profile (including rheumatoid factor) and renal function tests. An important investigation is the titre of antineutrophil cytoplasmic antibody (ANCA), particularly cytoplasmic or cANCA. cANCA is a useful marker of WG and is found in up to 100% of patients with widespread, active disease [27], but only 60–70% of patients with limited forms of the disease [63]. Although cANCA has a very high specificity for WG, it is rarely found in other types of vasculitis [27]. Other ANCA-associated vasculitides include microscopic polyangiitis and Churg-Strauss syndrome [38], but

these do not affect the mouth. The titre of cANCA may be related to the severity of the disease and therefore can be a useful index of prognosis and efficacy of treatment. However, in patients with limited or protracted superficial forms of the disease, the ANCA may be negative for months or even years so that other clinicopathological criteria should not be ignored when making the diagnosis.

3.3.8 Tuberculosis

Oral tuberculosis is rare, but is important as it is usually a complication of advanced open pulmonary disease [155]. Tuberculosis is becoming increasingly more common in developed countries. This is partly due to HIV infections and the fact that multiple drug-resistant mycobacteria are becoming widespread.

The typical lesion is an ulcer, most commonly on the mid-dorsum of the tongue and gingiva, but other sites may be involved [122]. The ulcer usually has undermined edges, which may be stellate, and a pale granular floor. Occasionally it presents as a non-specific area of erythema or a chronic fissure [112]. It is painless in its early stages, but may become painful later. There is usually no regional lymph node involvement. The clinical features are often entirely non-specific and the diagnosis is initially suspected when the microscopy shows multiple epithelioid granulomas in the corium underlying an ulcer with undermined margins. The granulomas are usually non-caseating and it is unusual to demonstrate Mycobacteria, even using auramine and rhodamine staining. The organisms may be detected in the sputum (but rarely in the oral lesion) and chest radiographs typically show advanced disease. In patients who are immunosuppressed, the possibility of atypical mycobacterial infection needs to be considered.

3.4 White Lesions

3.4.1 Candidosis

Oral infections with candidal organisms are very common. The most frequent organism is *Candida albicans*, a yeast-like fungus [150]. It can cause acute and chronic white lesions and atrophic, red lesions. Candidal spores are present as commensal organisms in the mouths of as many as 70% of individuals. The infective phase of the organism is characterised by the presence of hyphae that can directly invade oral keratinocytes [31]. A wide variety of factors predispose to infection by candidal organisms, particularly depressed cellular immunity and inhibition of the normal oral flora by broad spectrum antibiotics.

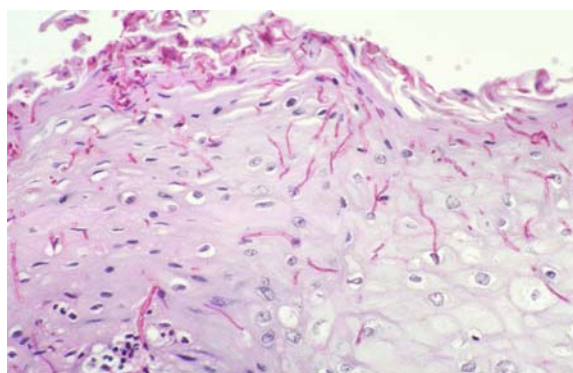


Fig. 3.8. Candidal hyphae penetrating the superficial layers (PAS/D stain)

Thrush, or acute hyperplastic candidosis, is seen most commonly in neonates whose immune systems are still developing and in debilitated patients at the extremes of life. It is also a feature of patients with xerostomia due to irradiation, Sjögren syndrome and a wide variety of medications, particularly the tricyclic antidepressants. In addition, it is now increasingly becoming a feature of immunosuppressed individuals. Other factors predisposing to the development of thrush include iron deficiency anaemia, broad spectrum antibiotics and steroid inhalers used for the control of asthma. It is characterised clinically by the formation of soft, creamy-white, friable plaques that can be easily wiped off to leave underlying erythematous areas of mucosa. The soft palate and areas protected from friction such as the vestibular reflections are the most common sites.

Microscopically, the characteristic plaque of thrush is due to invasion of the superficial epithelial layers by candidal hyphae and the subsequent proliferative epithelial response (Fig 3.8) [26]. The surface epithelium is parakeratinised, oedematous and infiltrated by numerous neutrophils. Candidal hyphae penetrate the epithelium vertically and extend downwards as far as the glycogen-rich layer. The hyphae may be inconspicuous in H&E sections unless the microscope condenser is lowered to increase their refractility, but they can be readily visualised with periodic acid Schiff or Grocott's silver stains. The epithelium may show hyperplastic but attenuated rete processes and there is variable but occasionally florid acute inflammation of the underlying corium.

Denture-induced stomatitis is a variant of atrophic candidosis. It is typically seen in the hard palate beneath a full or partial dental prosthesis, particularly one constructed from acrylic. There is a sharply demarcated area of bright red, often boggy erythema limited by the extent of the denture. Occasionally there may be a few flecks of thrush, but typically there is no plaque formation. Although sometimes referred to as "denture sore mouth" the condition rarely causes any symptoms un-

less it is associated with angular stomatitis. Microscopy shows intercellular oedema and chronic inflammatory infiltration of the corium. Candidal organisms may not be seen in biopsy specimens, as the fungus tends to proliferate within the microscopic interstices of the denture material.

Generalised mucosal erythema, often with depapillation of the filiform lingual papillae, can also be a feature of both broad-spectrum antibiotic use and HIV infection.

Candidal lesions may present as persistent, adherent, firm white plaques that may be solitary or multiple, particularly in mucocutaneous candidosis syndromes [30]. In the latter, the mouth is often the most severely affected site. These lesions are referred to as chronic hyperplastic candidosis or candidal leukoplakia. Most patients with isolated plaques are men of middle age or older and the majority smoke cigarettes. The most common sites of involvement are the dorsum of the tongue and the post-commissural buccal mucosa. The plaques are often thick with a rough, irregular surface that may be nodular. In many cases the lesion forms a variegated red and white patch producing a speckled appearance.

Microscopy shows a parakeratinised surface infiltrated by neutrophils forming spongiform pustules. The epithelium shows downgrowths of blunt or club-shaped rete ridges with thinning of the suprapapillary areas to produce a psoriasiform appearance. The BMZ may be thickened and prominent and there is variable but often severe inflammation in the underlying corium. In some cases there can be conspicuous peri-capillary fibrinous exudation, particularly in the papillary corium. Candidal hyphae may be remarkably sparse and not detected unless multiple sections and special stains are used. Electron microscopy shows that the hyphae are intracellular parasites that grow within the cytoplasm of the epithelial cells rather than along the intercellular spaces.

3.4.2 Lichen Planus

Lichen planus is a relatively common chronic inflammatory mucocutaneous disease that can also involve the hair and nails [162]. Although the majority of cases of cutaneous involvement resolve spontaneously within 2–3 years, oral lesions can be remarkably persistent and many cases never resolve. It can give rise to white lesions, atrophic areas or superficial ulcers (erosions). The aetiology is unknown, but the histological appearance, which shows T lymphocytes attacking the basal epithelium, suggests an autoimmune mechanism. A wide range of drugs can precipitate or exacerbate the disease and a similar reaction is seen in graft versus host disease.

Middle aged or older people are predominantly affected and the disease is rare in children and young adults. Women account for at least 65% of patients. White le-

sions are frequently asymptomatic, but in some patients lichen planus can lead to intractable oral ulceration that may persist for decades. The lesions have characteristic clinical appearances and distribution. The most common form is striae, which are sharply demarcated and form lace-like (reticular) or annular patterns. These may be interspersed with defined, small, elevated papules. The patient may complain that they feel a slight restriction on opening. Less common types of white lesions are confluent plaques, which some term homogeneous lichen planus. They are usually well demarcated, raised plaques and are frequently traversed by intersecting grooves producing a tessellated appearance. The latter appearance is particularly common on the dorsum of the tongue and other sites in long-standing disease. Atrophic areas, with redness due to mucosal thinning but without ulceration are usually combined with areas of striation. Erosions are shallow, irregular ulcers usually covered by a slightly raised, yellowish, fibrinous slough. Very rarely bullae form.

Oral lesions of lichen planus are very often symmetrical, sometimes strikingly so, but may be more prominent on one side than another. The most frequently affected sites are the buccal mucosae, particularly posteriorly, but lesions may extend to the commissures. The tongue is the next most commonly affected site. The lesions usually involve the lateral areas of the dorsum bilaterally or less frequently the centre of the dorsum. The ventrum is a relatively uncommon site. Atrophic lichen planus often involves the gingiva, but reticular lesions are relatively uncommon at this site. The lips, sometimes including the vermilion border, may be involved, but the palate is rarely affected; lesions of the floor of the mouth are exceptional.

Sometimes involvement of the gingiva may be the predominant or only manifestation of lichen planus. As such, it needs to be distinguished from a variety of other inflammatory gingival conditions. The most common appearance is gingival atrophy and the epithelial thinning leads to a shiny, red, smooth appearance. This is known clinically as *desquamative gingivitis*. It is important to appreciate that desquamative gingivitis is a clinical, descriptive term and not a diagnosis. Diseases other than lichen planus that can produce this appearance include mucous membrane pemphigoid, pemphigus and a condition called plasma cell gingivitis that is probably allergy based. Unlike marginal gingivitis, the inflammation can extend onto the alveolar mucosa, but in the absence of secondary plaque accumulation there is usually sparing of the marginal gingiva and interdental papillae. The condition may be generalised or only patchily distributed. Also, for unknown reasons, it is rare on the lingual and palatal gingiva.

Clinically, white lesions show parakeratosis or hyperorthokeratosis, sometimes with a prominent granular cell layer [4]. The keratosis may be patchily distrib-

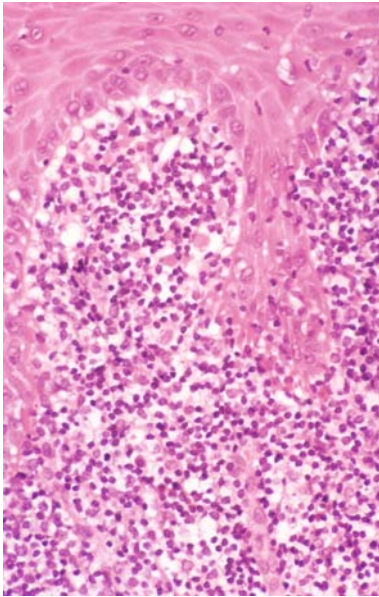


Fig. 3.9. Lichen planus showing basal cell degeneration and Civatte bodies

uted as might be expected in reticular or striated lesions. There is a characteristic band-like lymphohistiocytic infiltrate sharply localised to the superficial corium. Occasionally, germinal centres form within the lymphoid infiltrate. There is often conspicuous basal cell damage with apoptosis, ballooning degeneration due to intracellular oedema and the formation of colloid (Civatte) bodies (Fig. 3.9). Fibrinogen deposition along the BMZ is sometimes a conspicuous feature and there may be pigimentary incontinence secondary to the basal cell liquefaction and melanophages in the superficial corium. The rete ridge pattern is variable, but the saw-tooth pattern typical of cutaneous lichen planus is relatively uncommon in oral lesions. In lesions from the dorsum of the tongue in particular, the rete processes may be elongated with dense inflammatory infiltrates around their tips.

Atrophic lesions show conspicuous thinning and flattening of the epithelium, but the characteristic band-like inflammatory infiltrate is retained. In ulcerated lesions the inflammatory infiltrate contains polymorphonuclear leukocytes and plasma cells and extends into the deeper corium, often leading to a non-specific appearance.

As lichen planus is often treated with topical steroids it is not uncommon to find infestation of the superficial epithelial layers by candidal hyphae. These may or may not be associated with spongiform pustules. Some of these lesions may also show reactive cytological atypia.

A great variety of drugs can cause diseases resembling, or in some cases indistinguishable from, lichen planus. There may be a history relating the onset of lesions to the drug administration or exacerbation of pre-

viously quiescent disease [104, 105]. The oral lesions are often severely ulcerated and the dorsum of the tongue and palate appear to be sites of predilection. In some patients, there may be a lichenoid reaction in mucosa in direct contact with dental amalgam fillings and occasionally even composite filling material and gold restorations.

Microscopically, there are no absolute diagnostic criteria distinguishing lichen planus from lichenoid drug eruptions [104]. It is reported that in lichenoid reactions the inflammatory infiltrate is more dense. In addition, it is said to be more likely to show the presence of plasma cells in the infiltrate, particularly in the leading edge, and a greater likelihood of germinal follicle formation. In addition, the deep layer of the infiltrate is less defined and perivascular inflammatory infiltration extending into the deeper corium is seen more frequently. However, many of these features may reflect the more severe nature of the disease and be related merely to the effects of ulceration. It is therefore essential to examine areas well away from obvious ulceration when interpreting these biopsies.

3.4.3 Lupus Erythematosus

Lupus erythematosus is an autoimmune disease of unknown origin. The two main forms that affect the mouth are discoid lupus erythematosus (DLE; chronic cutaneous lupus erythematosus) and systemic lupus erythematosus (SLE). Oral lesions are present in over 20% of patients with SLE.

The clinical features of oral DLE closely resemble those of lichen planus [157]. They typically show a central area of atrophic, erythematous or granular mucosa with a surrounding radiating, striated white halo. The central area occasionally ulcerates. Lesions are most common in the centre of the palate and on the labial aspect of the upper lip, but they can be seen elsewhere in the mouth. Sometimes there are adjacent “kissing lesions” on the gingiva opposite labial lesions. The lesions of DLE lack the symmetrical distribution characteristic of oral lichen planus. Patients with SLE may have the classical photosensitive butterfly rash in the midface and show other evidence of a systematised disease. The mucosal lesions may resemble those of DLE or show evidence of more severe mucositis and non-specific ulceration. Shallow linear ulcers running parallel to the palatal gingiva are sometimes a striking feature.

Microscopy shows many similarities to lichen planus [90, 156]. There is either hyperorthokeratosis or hyperparakeratosis. The follicular plugging characteristic of cutaneous lesions has been described in oral lesions, but it is an inconsistent and frequently poorly defined feature (Fig. 3.10). The rete processes are hyperplastic and can form flame-like downgrowths into the

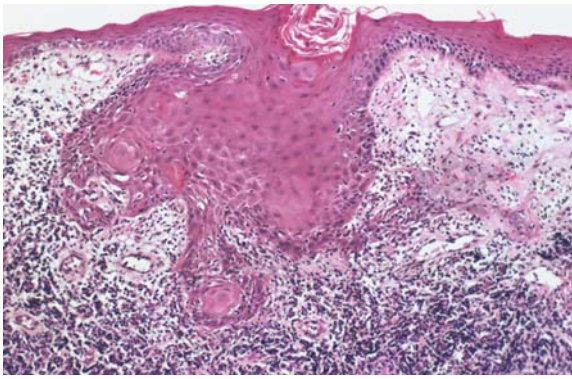


Fig. 3.10. Discoid lupus erythematosus showing irregular focal epithelial hyperplasia and follicular plugging

underlying corium. This feature is sometimes so florid that it produces a pseudoepitheliomatous appearance. The slender downgrowths can also show a tendency to fuse with each other producing an appearance simulating an embedding artefact. Dyskeratotic cells are an occasional feature. There is apoptosis and liquefaction degeneration of the basal cells, sometimes with Civatte body formation. The BMZ may become hyalinised and thickened and this is sometimes a notable feature. There is a band-like infiltrate of lymphohistiocytic cells in the superficial corium similar to that seen in lichen planus, but the lower border tends to be less well defined and the infiltrate often extends into the deeper tissues in a perivascular distribution. Reactive follicles may form in the lymphoid infiltrate. In cases of SLE there may be evidence of fibrinoid necrosis in vessels. Direct immunofluorescence of lesional tissue for IgG, IgM or IgA shows a granular deposit in the BMZ of about 75% of cases of oral DLE and all cases of SLE. A lupus band test in clinically normal skin or mucosa is diagnostic of systemic disease. The presence of C3 or fibrinogen in the BMZ is not specific and is frequently demonstrated in lichen planus.

3.4.4 Oral Epithelial Naevi

Non-pigmented epithelial naevi are rare in the oral cavity. They include white sponge naevus, oral epithelial naevi and naevi associated with naevus unius lateris.

White sponge naevus is an autosomal dominant inherited trait characterised by heaped up, sodden, irregular white plaques that can affect any part of the oral mucosa and may involve other mucosae including nasal, anal and vaginal (Cannon's syndrome). Microscopically, there is acanthosis with vacuolated cells in the stratum spinosum producing a basket weave appearance and irregular, shaggy parakeratosis. It is associated with a novel mutation in the keratin 4 gene [34].

Oral epithelial naevus was the term given to distinctive white plaques involving the ventral lingual mucosa and floor of the mouth [37]. These were sharply defined, irregularly butterfly shaped and had a uniformly wrinkled surface. However, a retrospective study of lesions of this type in the floor of the mouth suggested there was a substantial risk of malignant transformation in this lesion and it was renamed sublingual keratosis [94, 139]. Since that time there have been no other studies substantiating these observations and the status of these lesions needs to be re-established.

Naevus unius lateris typically involves the skin with unilateral linear, papillary or verrucous lesions, usually along the long axis of a limb or across the trunk. It has uncommonly been associated with oral lesions [74]. These are typically papillary, wart-like proliferations and have been described on the lips, tongue, buccal mucosa, palate and gingivae, usually on the left. Microscopy shows papilliferous proliferation with non-keratinised, hyperplastic epithelium covering connective tissue cores that may be patchily inflamed. Similar lesions have been described in the absence of cutaneous lesions, usually in the midline of the palate.

3.4.5 Smoker's Keratosis

Keratosis may be associated with both tobacco-smoking and -chewing. In smoker's keratosis the lesions appear to be a result of both thermal and chemical irritation. They rarely show significant dysplasia and appear to have a low pre-malignant potential. The affected mucosa may show diffuse whitening or more focal lesions and occasionally they are pigmented and have a slate-blue colour.

The epithelium can be hyperplastic or atrophic and is not dysplastic [136]. There is very variable parakeratosis or hyperorthokeratosis. Some cases show focal parakeratotic spikes ("chevrons"). Although such chevrons were thought to be most characteristic of smokeless tobacco-induced keratosis, only a minority of such lesions show this feature [40]. Pigmentary incontinence is common and may be florid in darkly pigmented individuals. Inflammatory infiltration is usually minimal.

3.4.6 Stomatitis Nicotina

Stomatitis nicotina is usually seen in the palates of pipe or cigar smokers and the overwhelming majority of patients are men [158]. Minor degrees of the condition may be seen in heavy cigarette smokers. Similar clinical appearances have been reported in patients who regularly drink excessively hot liquids. It is usually painless and asymptomatic. The initial lesion appears to be increased

keratosis of the palate exposed to the smoke. This leads to obstruction of the ducts of the underlying minor salivary glands, which then become inflamed. The classical clinical appearance, therefore, is whitening of the palatal mucosa, which may show tessellated plaque formation. The involved minor glands become swollen and have red, umbilicated centres.

Microscopy shows variable hyperkeratosis, acanthosis and duct dilatation. There is usually no evidence of epithelial dysplasia. There is variable submucosal chronic inflammation and there may be evidence of pigmentary incontinence. Keratinisation can extend down the salivary ducts and there is interstitial inflammation of the underlying minor mucous glands.

The condition will gradually resolve if the habit is discontinued and there appears to be minimal risk of malignant transformation. However, affected individuals have an increased risk of developing squamous cell carcinoma in other parts of the mouth, particularly the floor of the mouth and adjacent ventral lingual mucosa, and the retromolar trigone. Conversely, palatal keratosis due to “reverse smoking” where the lighted end of a cigarette or cigar is held in the mouth is associated with the development of carcinomas of the hard or soft palates in a very high number of patients practising the habit [148].

3.4.7 Hairy Tongue

Hairy tongue is due to hyperplasia and elongation of the filiform papillae, which form hair-like overgrowths on the dorsum. The filaments can be several millimetres long. The colour varies from pale brown to intense black. The discoloration is due to proliferation of chromogenic bacteria and fungi. Hairy tongue is usually seen in older individuals, and smoking, antiseptic mouthwashes, antibiotics and a diet lacking abrasive foodstuffs are the most common predisposing factors. The dorsum of the tongue may also become blackened without elongation of the filiform papillae by antibiotic mouthwashes such as tetracycline and iron compounds. Hairy tongue is rarely biopsied. Microscopically, it is characterised by irregular, hyperplastic filiform papillae showing hyperorthokeratosis or hyperparakeratosis with numerous bacterial conglomerates and filamentous organisms in the surface layers and more deeply between fronds of epithelium. It has been shown by immunocytochemical analysis of keratin expression that in black hairy tongue there is defective desquamation of cells in the central column of the filiform papillae. This results in the typical highly elongated, cornified spines that are the characteristic feature of the condition [110].

3.4.8 Hairy Leukoplakia

Patients infected with HIV, particularly homosexual males, may develop characteristic intraoral white lesions [149]. The lateral margins and underlying ventrum of the tongue are the most common sites. The lesion was called hairy leukoplakia, but typically it forms painless, vertical, white corrugations that may or may not have a rough or “hairy” surface. Some lesions are flat white plaques. Other sites may also be involved, especially the post-commissural buccal mucosa.

Microscopy shows acanthosis and parakeratosis, usually with verruciform, hair-like surface projections [168]. Invasion of the surface epithelium by candidal hyphae is common. Immediately below the parakeratotic layer there is a zone of vacuolated and enlarged epithelial cells with intense basophilic, pyknotic nuclei and perinuclear clearing (koilocytes). Epstein-Barr capsid viral antigen and viral particles can be demonstrated in the koilocytic nuclei [172]. There is usually little or no inflammatory infiltration of the epithelium or underlying corium. Similar lesions have occasionally been reported in patients receiving immunosuppressant drugs following organ transplantation. The early cases of hairy leukoplakia associated with HIV infection showed a very high rate of progression to full-blown AIDS. Lesions can resolve spontaneously and usually respond well to antiviral or anti-retroviral drug treatment; they appear to have no premalignant potential.

3.4.9 Geographic Tongue

Geographic tongue is a relatively common idiopathic condition typically characterised by migrating areas of depapillation on the dorsum of the tongue [6]. In many cases it is associated with fissuring. There is loss of filiform papillae often surrounded by a slightly raised yellowish-white and crenellated margin. These areas of depapillation tend to heal centrally and spread centrifugally. Occasionally, the ventrum is involved and in that site lesions consist of an area of erythema completely or partially surrounded by a circinate whitish halo. Identical lesions can occasionally be seen elsewhere in the mouth and have been called “ectopic geographical tongue”, although geographical stomatitis or benign migratory stomatitis would be more appropriate terms [81]. The majority of cases of geographical tongue are painless, but some patients complain bitterly of soreness and discomfort, which may or may not be associated with specific foods.

Geographic tongue is usually obvious clinically and is rarely biopsied. However, it has very typical microscopic features [114]. There is loss of filiform papillae and typically only a mild chronic inflammatory

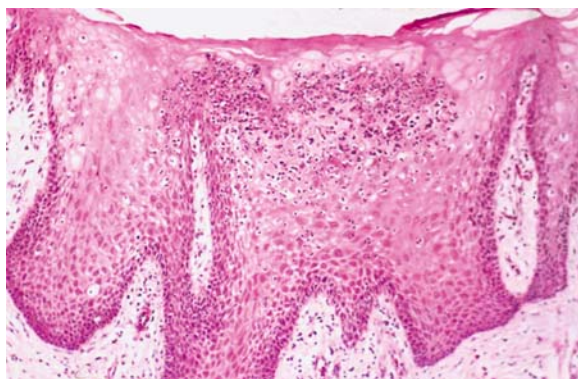


Fig. 3.11. Geographical tongue (erythema migrans) showing polymorphonuclear leukocyte microabscesses in the epithelium

reaction in the underlying corium. The striking feature is the presence of polymorphonuclear leukocytic microabscesses in the upper stratum spinosum (Fig. 3.11). These spongiform pustules are not pathognomonic of geographical tongue and can be seen in oral psoriasis, acute and chronic candidosis, Reiter syndrome and plasma cell gingivostomatosis. Some describe elongation of the rete ridges, but this is by no means a consistent observation. However, occasionally there may be psoriasiform hyperplasia in geographical tongue and it may be difficult or impossible to distinguish from psoriasis. Indeed, geographical tongue and migratory stomatitis are 4–5 times more common in patients with psoriasis and some believe that geographical tongue is the oral homology of psoriasis [179, 194]. The presence of spongiform pustules in oral biopsies should always prompt the search for candidal hyphae with a PAS or Grocott stain. These are not usually seen in geographical tongue and their presence would make a diagnosis of candidosis much more likely. Chronic hyperplastic candidosis can also show psoriasiform hyperplasia, but typically there is much more florid inflammatory infiltration of the corium and irregular surface parakeratosis.

3.4.10 Frictional Keratosis

Frictional keratosis of the oral mucosa is common and is usually a response to low-grade irritation by such causes as sharp edges of teeth or restorations, dental prostheses, abrasive foods, vigorous tooth brushing and playing wind instruments.

Clinically, the lesions tend to form diffuse keratotic plaques. In the early stages these are pale and translucent and merge imperceptibly into the surrounding normal mucosa. Later, they become more dense and white and may have an irregular, shaggy surface. The habit of cheek, lip and tongue chewing is a usually characteristic variant of frictional keratosis. It results in roughened or

shredded, often patchily erythematous white plaques limited to areas accessible to chewing. In typical frictional keratosis microscopy usually shows a thick orthokeratinised layer with a prominent granular cell layer. There is no significant dysplasia and inflammation of the underlying corium may be minimal in the absence of ulceration. In keratosis due to habitual chewing there is often acanthosis and the surface is usually irregular and parakeratinised. It frequently shows a covering of adherent basophilic cocci or more dense bacterial conglomerates.

3.5 Pigmentations

3.5.1 Amalgam Tattoo

Amalgam tattoo is the most common localised form of oral mucosal pigmentation [23]. Lesions usually form painless, bluish-black macules, which may be well defined or diffuse, and the most common sites are the gingiva, alveolar mucosa and floor of the mouth. They are caused by ingress of dental amalgam through a mucosal breach during a restorative procedure or tooth extraction and can also follow an apicectomy with retrograde root filling.

Microscopy shows dark, refractile particles of amalgam in the corium [44]. These may be coarse, but usually form fine, black or brownish granules. These are deposited along collagen and elastic fibres, and around small blood vessels, nerves and muscles. About half of cases show a fibrous and chronic inflammatory reaction, with or without multinucleated foreign body giant cells. Occasionally, there is a granulomatous reaction.

3.5.2 Localised Melanotic Pigmentation

3.5.2.1 Oral Melanotic Macules

These benign, ephelis-like pigmented macules are the most common melanocytic lesions of the oral mucosa. They are brownish-blue or black and may be single or multiple. They are typically well defined and rarely exceed 6 mm in diameter. They develop during early to middle adult life with a mean age at presentation of 41 years [22]. There is a female predilection of 2:1. They are most frequent in the anterior part of the mouth affecting the gingiva, buccal mucosa and, most commonly, the labial mucosa. Those involving the vermilion border (labial melanotic macules) often darken in strong sunlight and may cause cosmetic problems. Oral melanotic macules have been reported following radiotherapy [11],

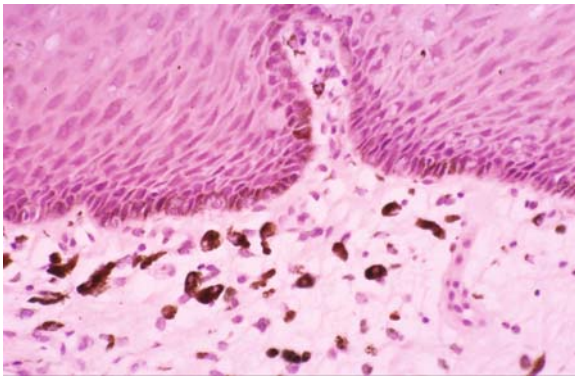


Fig. 3.12. Melanotic macule showing increased melanotic pigmentation of the basal keratinocytes and melanophages in the superficial corium

and in HIV infections, probably related to the administration of retroviral drugs [55].

Microscopy shows increased melanotic pigmentation in the basal and occasionally the immediately suprabasal keratinocytes. There is often pigmentary incontinence and melanophages in the superficial corium (Fig. 3.12).

3.5.2.2 Melanoacanthoma

Melanoacanthoma (melanoacanthosis) is a rare, probably reactive, proliferation of both keratinocytes and melanocytes [61, 64]. It is seen most commonly in adult black females, typically involving the labial or buccal mucosa. Lesions may be single or multiple [49] and are usually macular; less frequently, they are slightly raised or papilliferous. Trauma is thought to be the most likely cause and lesions can regress spontaneously or following incisional biopsy.

Microscopy shows acanthosis and frequently spongiosis that can be florid. There are strongly Fontana silver stain- and HMB45-positive, dendritic melanocytes extending throughout the full thickness of the epithelium (Fig. 3.13). As a consequence of a partial or complete block in pigment transfer the keratinocytes in melanoacanthoma contain little or no melanin in spite of the abundance of melanocytes.

3.5.2.3 Pigmented Naevi

Oral melanocytic naevi are much rarer than cutaneous lesions with a prevalence of 0.1% of the general population [75]. The most common sites are the hard palate, buccal mucosa and labial mucosa. Women are affected twice as frequently as men and most cases are seen in the third and fourth decades. They are usually single and

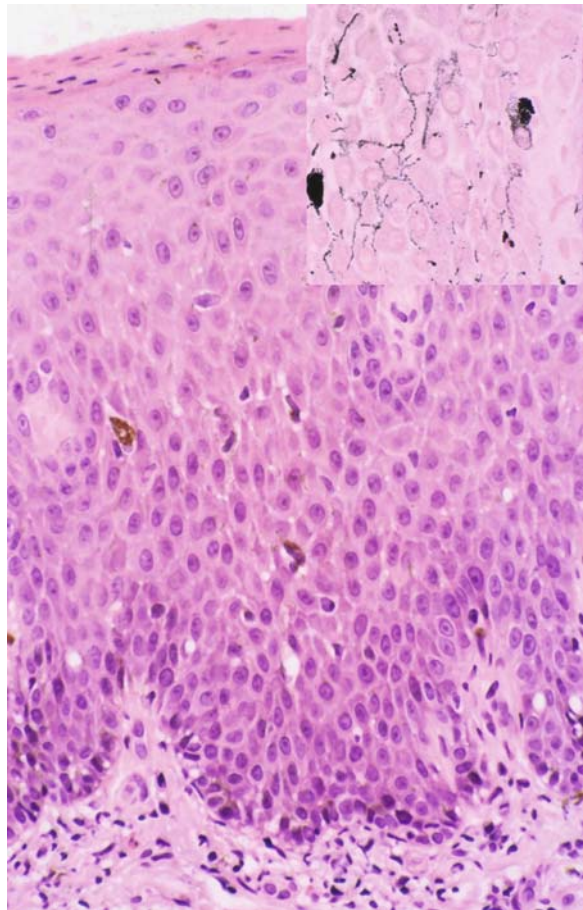


Fig. 3.13. Melanoacanthoma showing dendritic melanocytes extending throughout the epithelial thickness. *Inset* shows melanocytes stained with Masson-Fontana

form brown, bluish or black macules or sessile papules. Most are less than 6 mm in diameter [24]. Intramucosal (intradermal) naevi account for over half of the cases and junctional or compound naevi are uncommon. Blue naevi form 25–35% of cases and usually present in the palate. The large majority are of the common rather than the cellular type.

3.5.3 Premalignant Oral Melanoses and Oral Melanoma

ICD-O:8720/3

Oral mucosal melanomas are rare and account for about 0.5% of oral malignancies [35, 75]. However, they appear to be more common in Japan, India and Africa. Most arise in adults with a peak incidence between 40 and 60 years. Large series show a male predominance. About 80% of cases involve the palate and maxillary alveolus and gingivae. About a third of cases are preceded by

long-standing areas of oral hyperpigmentation, but they rarely arise from pre-existing benign melanocytic naevi. The majority of cases are painless in the early stages and form irregular, black or brownish flat, raised or nodular areas that are frequently multicentric. Rarely, they are amelanotic and may be reddish in colour. Nodular areas are usually a feature of more advanced tumours and may be ulcerated and associated with pain and bleeding. Invasion of the underlying bone is common and teeth involved may loosen or exfoliate. In most cases there is involvement of the cervical lymph nodes at presentation and half of patients have distant metastases.

Purely nodular melanomas are relatively rare and most tumours have a radial growth element similar to that seen in cutaneous acral lentiginous melanoma together with evidence of upward migration. Oral melanomas have been divided into:

1. In situ oral mucosal melanomas;
2. Invasive oral mucosa melanomas;
3. Mixed in situ and invasive oral mucosal melanomas.

About 15% of oral mucosal melanomas are in situ and 30% are invasive [9]. Fifty-five percent of melanomas have a combined pattern. Borderline lesions have been termed atypical melanocytic proliferations [75].

Microscopically, in situ melanomas show an increase in atypical melanocytes. Although these atypical melanocytes have angular and hyperchromatic nuclei, mitoses tend to be sparse. The melanocytes may form aggregates or be irregularly distributed in a junctional location. The characteristic nested or thecal pattern commonly seen in cutaneous melanomas is less frequently observed in mucosal lesions. Sometimes the melanocytes are dispersed throughout the epithelium and this may be combined with a junctional pattern (Fig. 3.14). Sequential biopsies have shown increases in the density of the junctional atypical melanocytes over time. Atypical melanocytes can extend down the excretory ducts of the underlying minor salivary glands. However, there is usually no inflammatory response to in situ lesions.

The melanocytes present in invasive melanomas show a variety of cell types including epithelioid, spindle and plasmacytoid. They typically have large, vesicular nuclei with prominent nucleoli. Mitoses may be present, but usually not in large numbers. They are usually aggregated into sheets or alveolar groups and less commonly neurotropic or desmoplastic configurations are seen. About 10% of cases are amelanotic. Over 95% of lesions are anti S-100 antigen-positive [10] and more specific markers include HMB45, Melan-A and antityrosinase [144].

Atypical melanocytic proliferation or hyperplasia is the term used for lesions with equivocal histopathological features, but the criteria for inclusion in this category are rather ill-defined [176]. These include oral mucosal lesions with melanocytes containing angular or hyper-

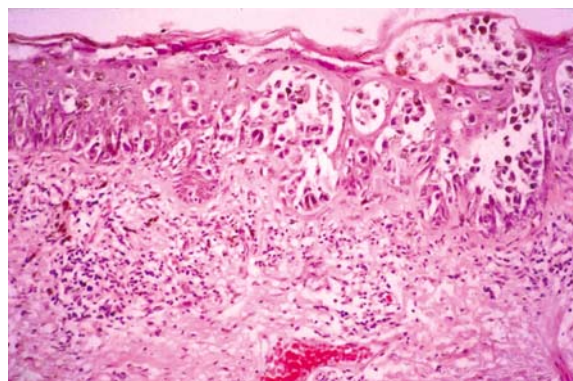


Fig. 3.14. In situ melanoma showing atypical melanocytes widely dispersed throughout the epithelium

chromatic nuclei with very infrequent mitoses. Melanocytic atypia can vary from mild to severe [75].

Oral melanomas are much more aggressive than their cutaneous counterparts. The prognosis of oral melanomas is poor with a 5-year survival rate of less than 20% [9], and even Stage I tumours have a 5-year survival rate of less than 50%. The conventional depth of invasion indicators such as Breslow thickness and Clark's levels tend to be of little value in mucosal melanomas, as many present at an advanced stage and most are deeper than 4 mm [145]. Histological features associated with a poor prognosis include evidence of vascular invasion, cellular pleomorphism, necrosis and amelanotic tumours [14, 75, 123, 145].

3.5.4 Addison Disease

Addison disease is rare with an estimated annual incidence of 0.8 cases per 100,000 of the population in Western societies. It is due to bilateral destruction of the adrenal cortex. Formerly, the most common cause was tuberculosis. Most cases now are due to organ-specific auto-immune destruction and opportunistic infections such as histoplasmosis in patients with AIDS. Due to this, it is likely that the number of patients with Addison disease will increase significantly. Addison disease may be associated with autoimmune polyglandular deficiency type I (Addison disease, chronic mucocutaneous candidosis, hypoparathyroidism) and autoimmune polyglandular deficiency type II (Addison disease, primary hypothyroidism, primary hypogonadism, insulin-dependent diabetes, pernicious anaemia, vitiligo) [130].

Clinically, there is usually slowly progressive weakness, lassitude and weight loss. Gastro-intestinal symptoms can include diarrhoea or constipation and anorexia, nausea and vomiting. Postural hypotension is a common symptom. An early sign is pigmentation of the skin and oral mucosa secondary to increased adrenocortico-

tropic hormone (ACTH) secretion. Parts of the skin exposed to the sun and areas subjected to trauma or friction become bronzed [85]. There is also increased pigmentation in skin folds and scars. About 10% of patients also show areas of vitiligo.

Oral pigmentation is variable and where present ranges from light brown to densely black [95]. The gingiva, lateral margins of the tongue, buccal mucosa and lips are the sites of predilection. Microscopy of the areas shows increased melanin predominantly in the basal keratinocytes.

3.5.5 Peutz Jeghers Syndrome

Peutz Jeghers syndrome (periorifacial lentiginosis) comprises melanotic spots of the face, mouth and less commonly the hands and feet, together with intestinal polyposis. It is inherited as an autosomal dominant trait with nearly complete penetrance [93], but new mutations occur in 40% of cases.

There are multiple ephelides on the face and melanotic macules in the mouth involving the lower labial and buccal mucosa in particular. Lesions are often present at birth. The facial pigmentation is around the mouth, nose and eyes and tends to progressively fade after puberty. The mucosal pigmentation persists into adult life.

There are hamartomatous polyps throughout the intestinal tract, but typically these are most numerous in the small intestine. They can give rise to abdominal pain and bleeding and intussusception is a rare complication. The polyps have a low malignant potential, with those in the colon having the highest risk. Patients also are at increased risk of malignancy at other sites including the uterus, ovary, pancreas and breast.

3.5.6 Racial Pigmentation

Racial pigmentation is the most common cause of intraoral pigmentation. It is seen predominantly in Blacks, Asians and people of Mediterranean origin, but about 5% of Caucasians also have significant intraoral pigmentation. The degree and extent of racial pigmentation is very variable and does not necessarily correlate with the depth of skin pigmentation. It can vary from light brown to almost black and the most commonly involved sites are the gingiva, palate and buccal mucosa. Sometimes when the tongue is involved the only areas affected are the fungiform papillae, producing an appearance of spotty pigmentation.

Microscopy shows increased melanocytic pigmentation of the basal and, to a much lesser degree, the immediately suprabasal keratinocytes. The denser pigmen-

tion is due to increased synthesis of melanin by melanocytes, which are otherwise normal in number and distribution.

3.5.7 Laugier Hunziker Syndrome

Laugier Hunziker syndrome is an acquired, benign macular hyperpigmentation of the lips and oral mucosa [118]. It typically starts in early to middle adult life and is more common in women than men. The pigmentation consists of brownish, circular or linear macules, that may be sharply circumscribed or more diffuse in nature, and lesions may coalesce. The lesions are seen most commonly on the buccal mucosa, lips and the hard and soft palates. Other less frequent sites include the tongue, gingiva and floor of the mouth. Occasionally, the pharynx and oesophagus are also involved [190]. About half of the cases also have nail involvement in the form of longitudinal pigmented bands in one or more fingers or toes. There are no known systemic associations.

Microscopy shows increased melanotic pigmentation of basal keratinocytes and melanophages in the superficial corium secondary to pigmentary incontinence. Ultrastructural studies show increased numbers of normal-appearing melanosomes in keratinocytes in the lower epithelial layers [118].

3.5.8 Smoker's Melanosis

Heavy smokers can sometimes develop areas of oral hyperpigmentation. It is more common in women than men. Although any part of the mouth can be affected the anterior gingivae are involved most frequently. The lesions vary in colour from light brown to bluish-black and the lesions may be focal or diffuse. Sometimes the overlying mucosa has a somewhat milky-white appearance, particularly in the buccal mucosa. The condition can slowly resolve if smoking is stopped or reduced [72]. Pigmentation of the soft palate has been reported in a significant number of patients with suppurative lung disease and malignancy [117]. Nearly a quarter of patients with confirmed bronchogenic carcinoma show this feature. Most patients have a long history of cigarette smoking and it is possible that in many cases these lesions were merely smoker's melanosis rather than being related directly to the pulmonary lesions.

Microscopy may show slightly increased melanotic pigmentation of the basal keratinocytes, but the most striking feature is usually pigmentary incontinence and accumulation of melanophages in the superficial corium.

3.5.9 Drug-Associated Oral Pigmentation

Gingival pigmentation due to heavy metals such as mercury, lead, bismuth, arsenic and others was not rare in the past due to industrial exposure and in some cases therapeutic administration, particularly for the treatment of syphilis. They caused blue, brown or black lines close to the gingival margins due to the deposition of sulphides as a result of reactions with products of the dental plaque. A wide range of drugs can cause more generalised oral pigmentation including antimalarials, phenothiazines and some contraceptive pills [98]. Drugs used in the treatment of HIV infection such as zidovudine and some antifungals such as ketoconazole have also been shown to cause oral pigmentation.

3.6 Hyperplastic Lesions

3.6.1 Fibrous Hyperplasias

The majority of fibrous and fibroblastic lesions within the mouth appear to be reactive rather than neoplastic. They are the most common tumour-like swelling of oral mucosa. Although these lesions are considered to be a response to low-grade irritation, the source of such irritation may not be immediately apparent. Fibroepithelial polyps tend to form smooth nodules or swellings that may be soft or firm and are usually covered by normal, pink mucosa unless ulcerated. The polypoid swellings may be sessile or pedunculated.

Fibrous overgrowths of the gingiva are a type of epulis (lit. – swelling of the gum). They can arise from the interdental papilla or gingival margin and tend to affect the anterior part of the mouth. They can grow to several centimetres in diameter. Fibrous epulides are frequently associated with local irritation from dental calculus, sharp edges of restorations or carious teeth. A very characteristic form of hyperplasia is associated with the edges of loose dentures. Such denture-induced fibrous hyperplasia has been termed denture granuloma and epulis fissuratum. The rocking backwards and forwards of the denture causes extensive overgrowth of fibrous tissue on either side of the edges, or flanges, of the denture. This often leads to the formation of a series of linear folds of hyperplastic tissue and the base of the grooves so formed is often ulcerated by the denture's edge. Other common sites for fibrous overgrowths are along the occlusal line of the buccal mucosa and lateral border of the tongue, and related to spaces where teeth have been extracted.

Microscopically most of these nodules consist of interlacing bundles of sparsely cellular fibrous tissue. The

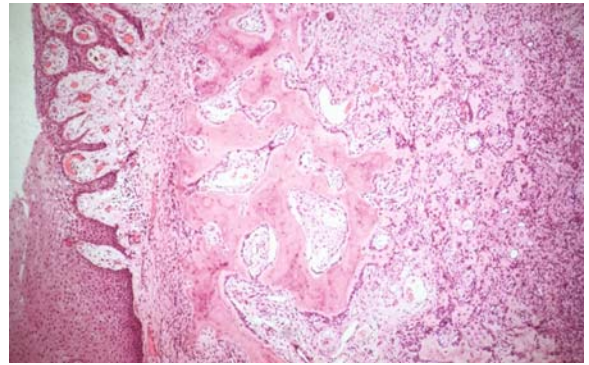


Fig. 3.15. Fibrous epulis showing osseous metaplasia

overlying epithelium is often hyperplastic with irregular rete processes extending sometimes deeply into the underlying fibrous tissue. There may be candidal infestation of the superficial epithelium. The degree of inflammatory infiltration is very variable, but tends to be mild unless there has been ulceration.

The microscopical appearances of fibrous epulides can differ from fibrous overgrowths seen elsewhere in the mouth. They typically show much more evidence of cellular fibroblastic proliferation. These lesions may consist predominantly or focally of a vascular stroma containing plump fibroblasts with large, vesicular nuclei and prominent nucleoli. There can be brisk mitotic activity. Ulceration is common and the lesions are often heavily inflamed. Calcifications are common in fibrous epulides and there may be florid osseous metaplasia or dystrophic calcification (Fig. 3.15). Sometimes the calcified masses are basophilic and they can also be laminated and resemble cementicles. Such lesions have been termed “peripheral ossifying fibromas”, but there is no evidence that they are neoplastic or have any relationship with central ossifying fibromas (see Chap. 4). Mineralisation tends to be uncommon in extra-gingival oral fibrous overgrowths.

Most fibrous overgrowths respond to conservative surgical removal, but a minority of fibrous epulides can recur, sometimes repeatedly.

3.6.2 Papillary Hyperplasia

Papillary hyperplasia is typically seen in the hard palate. In many cases it is related to dentures as part of the clinical spectrum of denture-induced stomatitis [174]. Although *Candida albicans* is frequently invoked as the causal agent, in a significant number of cases there is no evidence of fungal infection. The large majority of cases involve the hard palate, particularly when this is high-arched, but similar lesions are occasionally seen on the dorsum of the tongue. The lesions form painless, nodu-

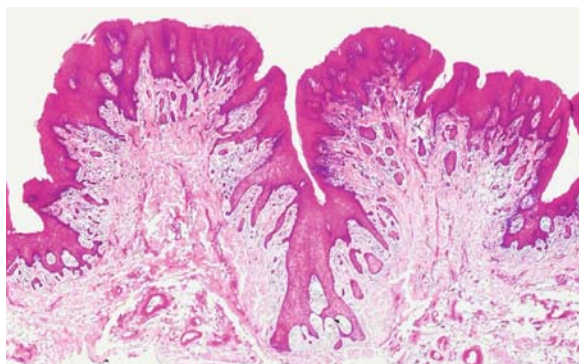


Fig. 3.16. Papillary hyperplasia of the palate showing long rete processes extending into the connective tissue cores

lar or papilliferous proliferations. Florid cases have been reported in immunocompromised patients [151].

Microscopy shows nodular, papilliferous hyperplasia of the epithelium and underlying fibrous connective tissue (Fig. 3.16). The surface usually shows parakeratosis or less commonly orthokeratosis. There may be evidence of candidal infestation such as spongiform pustules or obvious hyphae. The underlying hyperplastic rete ridges often extend into the cores of the papillae, resulting in a striking pseudoepitheliomatous appearance. The corium often contains a dense chronic inflammatory cell infiltrate. The condition then needs to be distinguished from oral papillary plasmacytosis [66].

3.6.3 Generalised Gingival Fibrous Hyperplasia

Generalised fibrous hyperplasia/hypertrophy of the gingiva can be familial or drug-induced.

Hereditary gingival fibromatosis is a rare condition that is usually inherited as an autosomal dominant trait [20]. It can affect all of the gingiva, often in a symmetrical manner. It may be associated with hypertrichosis, coarsening of the facial features and neurological problems such as epilepsy and mental retardation. The condition usually first affects adolescents, but occasionally it can involve the deciduous dentition. The enlargement is usually most conspicuous in the interdental areas and affects the palatal and lingual gingiva as well as the labial and buccal aspects. The overgrowths may be so florid that the teeth involved are almost completely buried (pseudo-anodontia). The overgrowths are rounded, smooth, firm and pale-coloured. Treatment is by surgical removal of the redundant fibrous tissue (gingivectomy), but the condition often recurs.

Drug-associated gingival hypertrophy is seen in about half of patients using the anti-epileptic drug phenytoin for long-term treatment [1]. Other drugs producing a similar reaction include cyclosporin (~30% of patients)

and calcium channel blockers such as nifedipine, amlodipine and verapamil (~10% patients). The enlargements may be generalised or more localised. The anterior interdental papillae tend to be the most severely affected areas, particularly on the labial aspect. The gingiva tend to enlarge laterally and this growth pattern may result in the formation of vertical clefts between adjacent overgrowths. The normal gingival stippling may be enhanced, producing an orange-peel appearance. The condition is exacerbated by poor oral hygiene and meticulous attention to tooth cleaning may help prevent the development of the condition.

Microscopy of generalised gingival fibrous hyperplasia tends to be the same irrespective of the cause. There is fibrous hypertrophy of the affected gingiva, often containing myofibroblastic cells. An increase in the amount of myxoid ground substance material is also common. In areas distant from the gingival sulcus there is usually no significant inflammatory component. There is often elongation and fusing of the rete process of the overlying epithelium. It is unusual for these lesions to become ulcerated

3.6.4 Crohn's Disease

Crohn's disease is a multisystem disorder characterised microscopically by non-caseating, epithelioid granulomas. Despite extensive investigations the cause remains unknown. Recently, genetic predisposition has been extensively investigated and among others, a susceptibility gene has been identified on chromosome 16q [18]. Smoking also appears to play a critical role in some patients [60]. Although an infective aetiology, particularly mycobacterial, has been long suspected, critical proof is lacking [173]. The most likely candidate organism is the *Mycobacterium avium* subspecies paratuberculosis [68]. Granulomatous vasculitis, possibly initiated by the measles virus, has been proposed as a significant factor in the pathogenesis [178]. However, blood vessel involvement may be a secondary phenomenon rather than a primary event [120]. Patients are usually children and young adults and there is a male preponderance. Associations between alterations in the intestinal microflora are also suspected and a statistically significant association between Crohn's disease and previous antibiotic use has been proposed [29]. The condition may be made worse by cigarette smoking [80].

Oral lesions are relatively common in patients with Crohn's disease of the lower gastro-intestinal tract [57, 185], but may be the presenting symptoms. They include swelling of the lips and cheeks (Fig. 3.17), recurrent aphthae, painful, indolent linear ulcers in the vestibular sulci, cobblestone thickening of the buccal mucosa, mucosal tags and hyperplastic, granular gingivitis [138]. The palate, tongue and pharynx, including the palatine ton-

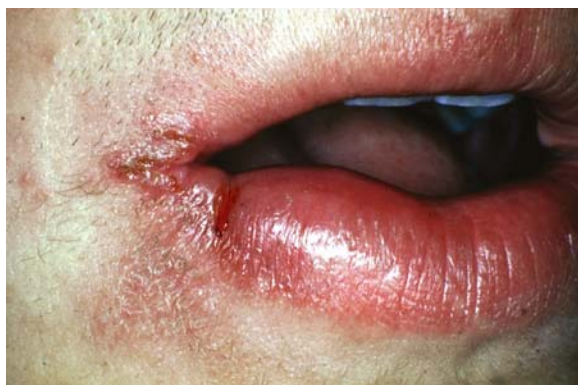

Fig. 3.17. Crohn's disease showing unilateral lip swelling with fissuring and peri-oral dermatitis

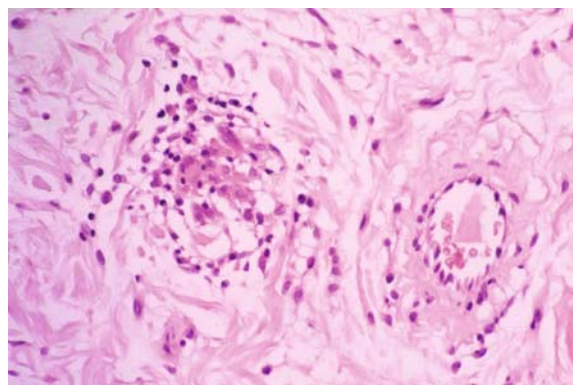


Fig. 3.18. Crohn's disease showing a small, irregular epithelioid granuloma and patchy chronic inflammation

sil, are only rarely involved [19]. Extraorally, there may be angular stomatitis and vertical fissuring of the lips, and perioral erythema and scaling.

Oral lesions may precede, or accompany, bowel symptoms, but in a significant number of cases intestinal disease is subclinical. In patients with active bowel disease there may be atrophic glossitis secondary to malabsorption of the haematinics iron, vitamin B₁₂ or folate.

Microscopy of oral lesions typically shows oedema of the superficial corium with lymphangiectasia and diffuse and focal aggregates of small lymphocytes. Non-caseating epithelioid granulomas with or without multinucleated giant cells are present in about 90% of cases [138]. However, granulomas may be small and poorly formed and may only be present in the underlying muscle so that they can be easily missed, especially if the biopsy is superficial (Fig. 3.18). Granulomas can also sometimes be seen in the minor salivary glands. Aggregates of mononuclear cells or granulomas may be seen bulging into or within the lumina of lymphatics. This feature has been termed endovasal granulomatous lymphangiitis [128]. Dilated lymphatics, with or without associated granulomas, are characteristic of Crohn's disease elsewhere in the alimentary tract [120].

3.6.5 Orofacial Granulomatosis

As many as 80–90% of patients with orofacial lesions that resemble those of Crohn's disease, both clinically and microscopically, have no gastro-intestinal signs or symptoms and do not develop gut disease [159]. The term orofacial granulomatosis (OFG) has been introduced to describe this group of patients [184]. OFG, therefore, is a diagnosis based on the exclusion of other causes of granulomatous inflammation, particularly sarcoidosis, tuberculosis and other mycobacterial infections, and Crohn's disease itself. Up to 60% of patients

with OFG are atopic [86] and some patients appear to show an idiosyncratic intolerance to a variety of foods or additives, including cinnamonaldehyde, carvone, carnosine, sun yellow, benzoates and monosodium glutamate [169], and to metallic compounds containing cobalt [146]. In many cases there is a partial or complete resolution of symptoms following withdrawal of the provoking agent.

OFG may be part of a spectrum of diseases that includes Melkersson Rosenthal syndrome (MRS) and cheilitis granulomatosa (Miescher's syndrome). MRS, in its complete form, is a triad of fissured tongue, labial or facial swelling due to granulomatous inflammation, and facial nerve palsy, which may be the first indication of the disease [192]. Cheilitis granulomatosa is probably merely an isolated manifestation of OFG.

3.6.6 Chronic Marginal Gingivitis and Localised Gingival Fibrous Hyperplasia

Chronic marginal gingivitis of variable degree is so common as to be almost universal. It represents a response of the gingival tissues to accumulation of dental microbial plaque around the teeth. If left untreated the inflammation can become more severe and extend into the underlying periodontal tissues causing loss of periodontal ligament attachment and a pocket develops between the tooth and the overlying gingiva exacerbating the tendency for plaque accumulation. Eventually, there is progressive resorption of the supporting alveolar bone leading to loosening or loss of the tooth.

Chronic marginal gingivitis is characterised microscopically by mild vascular hyperaemia and dense chronic inflammatory infiltration. The crevicular epithelium is ulcerated and may become hyperplastic with thin, irregular and anastomosing processes extending into the gingival connective tissue. There may be consid-

erable intercellular oedema and infiltration of the spongiform spaces by neutrophils, especially in the presence of gross dental plaque and calculus deposits. Many lymphocytes and plasma cells are present in the inflammatory infiltrate and dense, basophilic, granular deposits of extracellular immunoglobulin are common. Russell bodies may be a conspicuous feature. There is variable loss of collagen in areas of severe inflammation. However, in younger patients especially, there may be a proliferative response with extensive formation of new fibrous tissue leading to localised areas of fibrous hyperplasia. The enlarged gingiva may prevent effective cleaning of the related tooth, predisposing to further plaque accumulation and progressive inflammation. This type of localised inflammatory gingival hyperplasia is seen much more frequently on the buccal or labial aspects of the gingiva than in the palatal or lingual areas. Such overgrowths, although frequently removed as part of a gingivectomy procedure are not commonly sent for histological examination.

3.6.7 Peripheral Giant Cell Granuloma (Giant Cell Epulis)

This lesion is found on the gingiva or edentulous alveolus and is thought to originate from elements of the periodontal ligament. It is seen across a wide age range, but the peak incidence is between 30 and 50 years. Lesions tend to affect the area anterior to the permanent molars and are slightly more frequent in the mandible. The giant cell epulis usually forms a fleshy, bluish swelling that may be sessile or broadly pedunculated and the surface is often ulcerated. There may be erosion of the underlying bone or periodontium.

Microscopically, there is usually an uninvolved zone of fibrous tissue between the lesion and the overlying epithelium, but this is lost if there is inflammation or ulceration. The lesion consists of a matrix of plump, spindle-shaped cells with interspersed multinucleated and osteoclast-like giant cells. These can be numerous and may be confluent, blurring the distinction between each other and the stromal cells. The multinucleated cells are large and contain about 10–20 nuclei. There are two types: the most common have lightly eosinophilic cytoplasm and large vesicular nuclei with prominent nucleoli while the other type has much more densely stained cytoplasm, and pyknotic and densely haematoxyphilic nuclei. The latter are probably a degenerative form of the first type. The multinucleated cells are thought to be formed by fusion of bone marrow-derived mononuclear pre-osteoclasts [84, 101]. The lesion is usually very vascular and giant cells may be seen within the dilated vascular spaces. Red blood cell extravasation and haemosiderin deposition is common. Mitoses can often be seen in stromal and endothelial cells, but this observation has

no bearing on the likely behaviour. Osseous metaplasia and dystrophic calcification may be present, usually in the middle or deeper aspects of the lesion.

Giant cell epulis is indistinguishable microscopically from central giant cell granuloma and the brown tumour of hyperparathyroidism. Radiographs should be taken to exclude the possibility of a central bone lesion. If such a lesion is detected, hyperparathyroidism is excluded by assessing serum calcium, phosphate and alkaline phosphatase and measuring parathormone levels if necessary.

Treatment is usually by conservative surgical excision with curettage of the underlying bone, but about 10% of cases recur. Some cases in children have been treated by daily administration of calcitonin, delivered either by subcutaneous injections or nasal spray for up to 1 year. Although the treatment is protracted it appears to be effective [96].

3.6.8 Pyogenic Granuloma

Pyogenic granulomas are most common on the gingivae and less frequently in other intraoral sites, particularly the lip and tongue. They form solitary, soft, red and friable nodules that bleed readily. They frequently ulcerate and are covered by a fibrinous slough. Gingival lesions may be seen in pregnancy and appear to be a focal exacerbation of pregnancy gingivitis [113]. Pregnancy epulides (“pregnancy tumour”) usually manifest towards the end of the first trimester. They have a strong tendency to recur if removed before parturition and may show partial or complete spontaneous resolution if left following delivery. Occasionally, similar lesions are seen in other parts of the mouth during pregnancy, particularly the dorsum of the tongue, and they are termed granuloma gravidarum [52].

Microscopically, oral pyogenic granulomas consist of numerous large, thin-walled, anastomosing blood vessels in a loose, oedematous and moderately cellular stroma. Older lesions may show some fibrosis. Inflammation is very variable and can be minimal or absent. However, if the lesion ulcerates there may be an intense inflammatory infiltration. Foci of papillary endothelial hyperplasia are an occasional feature.

Although excision is usually curative, rare cases can show repeated recurrences and require more extensive surgery for their eradication.

3.6.9 Pulse (Vegetable) Granuloma

This unusual and uncommon chronic inflammatory lesion of oral tissues has been described under a variety of terms including chronic periostitis, giant-cell hyalin angiopathy, oral vegetable granuloma and hyaline ring

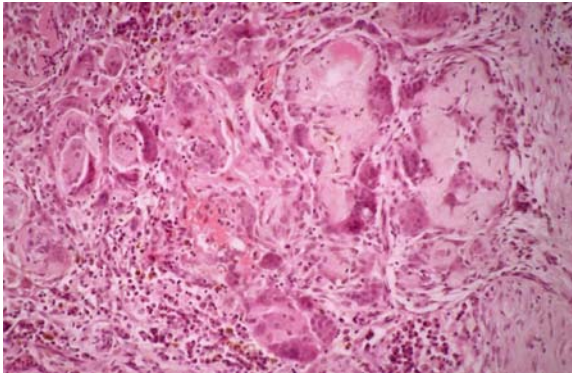


Fig. 3.19. Pulse granuloma showing chronic inflammation and eosinophilic, hyaline rings together with multinucleated foreign-body-type giant cells

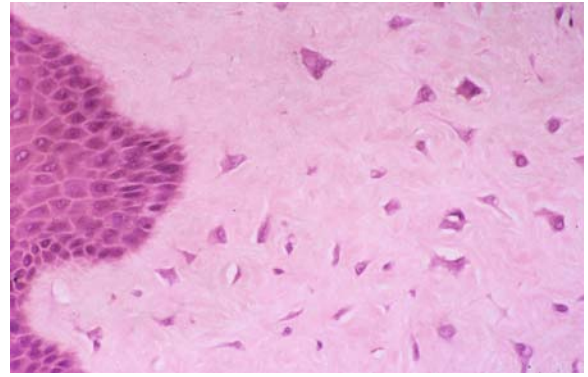


Fig. 3.20. Giant cell fibroma showing stellate and angular fibroblasts in collagenous matrix

granuloma [171]. Most cases are seen in the premolar/molar region of the edentulous mandible and the most common complaints are recurrent swelling and tenderness. Fifty-three percent of cases are extraosseous (peripheral) and radiographs often show a poorly defined erosion of the underlying alveolar bone. Intraosseous or central lesions (42%) show an irregular radiolucent area that is non-diagnostic. Occasionally, the lesion is found within the fibrous wall of an odontogenic or nasopalatine duct cyst [140].

Microscopy shows chronic inflammation and eosinophilic, hyaline rings together with multinucleated foreign-body-type giant cells (Fig. 3.19). The rings may be complete or horse-shoe shaped and may enclose giant cells, connective tissue and blood vessels. Haemosiderin within the centre of the rings is a frequent finding. The suggestion that the histological appearances are due to thickening and hyalinisation of the walls of blood vessels is not supported by most observers. Light and electron microscopical findings suggest that the rings are the cell walls of vegetable remains, often with collagen attached to their surface [71]. There does not appear to be any evidence that these appearances are exclusively due to pulses. Complete excision is curative.

3.7 Benign Tumours and Pseudotumours

3.7.1 Giant Cell Fibroma

Giant cell fibroma is an unusual but distinctive type of fibrous overgrowth. It is typically less than 5 mm in diameter and usually presents as a pedunculated polyp with a lobulated surface. Most are seen in the first three

decades of life. Although they can form anywhere in the oral mucosa, about half of cases are seen on the gingiva [79].

Microscopically, they consist of interweaving bundles of collagenous connective tissue with a prominent capillary network that surround stellate or angular fibroblastic giant cells with large vesicular nuclei (Fig. 3.20). Occasional cells may have several nuclei. These cells may have conspicuous dendritic processes and some contain melanin pigment. The giant cells are positive for vimentin, but negative for S-100, cytokeratin, leukocyte common antigen and neurofilament [107]. Conservative surgical excision is usually curative.

3.7.2 Lingual Thyroid

Ectopic lingual thyroid is a rare developmental anomaly due to failure of the thyroglossal duct to migrate caudally from the foramen caecum [13]. It is seen in females about four times more frequently than males and usually presents in middle age. The lingual gland is seen in the base of the tongue, deep to the foramen caecum. It is often asymptomatic, but may cause dysphagia, dysphonia or dyspnoea. Symptoms may coincide with puberty, pregnancy or the menopause due to hyperplasia secondary to raised levels of thyroid-stimulating hormone. In addition, any of the diseases involving the conventional thyroid gland, including inflammatory conditions, adenomas and carcinomas, can affect the ectopic thyroid tissue.

Microscopy typically shows normal thyroid tissue. As many as 70% of patients with lingual thyroid have no other thyroid tissue present, so it is essential that pre-surgical evaluation includes appropriate imaging and assessment of function using ^{131}I or $^{99\text{m}}\text{Tc}$ pertechnetate.

3.7.3 Verruciform Xanthoma

This rare but distinctive lesion, first described in 1971 [166], forms most commonly in the oral cavity [82, 135]. Extraoral locations include the male and female genitalia. There is no association with HPV in the vast majority of cases studied. Verruciform xanthomas are seen at all ages, but are most frequent in the fifth to seventh decades. Incidence is roughly equal between the sexes. They usually present as solitary, painless, discrete nodules that may be the colour of the surrounding mucosa, reddish or pink. They can be sessile or pedunculated and the surface can be domed or flat, and can be keratotic or papilliferous. They usually have sharply defined margins and are typically less than a centimetre in diameter. They do not appear to be related to any local irritating factors and most cases are asymptomatic. The gingival margin accounts for 85% of cases. Other common sites include the hard palate, tongue, buccal mucosa and a variety of other intraoral sites.

Microscopy typically shows corrugated, hyperplastic epithelium with elongated, broad rete ridges that extend to a straight, well-defined lower border [127]. There are deep clefts within the epithelium that often contain keratinised plugs. The surface shows parakeratinised spikes, which often stain a deep orange colour. There may be secondary candidal infestation of the surface keratin layers [125]. The characteristic feature is the presence of vacuolated, foamy xanthomatous cells, which fill the papillary corium. These xanthoma cells can occasionally extend into the overlying epithelium or into the deeper corium. The xanthoma cells have been shown to be derived from cells of monocyte/macrophage lineage [121].

The lesions are entirely benign and recurrence following even conservative surgery is very rare.

3.7.4 Haemangiomas

ICD-O:9120/0

Haemangiomas are vasoformative tumours that closely resemble normal vessels. They are amongst the most common soft tissue tumours and about a third of all cases involve the head and neck region. In this location congenital or neonatal lesions are relatively uncommon and tend to involve the lips and parotid glands. The majority of cases are seen in older individuals, and the most common sites are the lips and post-commissural buccal mucosa and the lateral border of the tongue. There is a male predominance of about 2:1. Haemangiomas typically form painless, flat or nodular, soft and purplish-red lesions. They are usually well circumscribed and may blanch on pressure. Congenital lesions behave like

hamartomas and increase in size in proportion to general somatic growth and tend to stabilise in size in early adult life. Those presenting in older individuals may show slow but progressive growth over several years. Their classification and microscopic aspects are discussed in the section on soft tissue tumours in Chap. 2 [3, 48, 53, 170, 175, 181].

3.7.5 Lymphangioma

ICD-O:9170/0

Lymphangioma is a benign, cavernous or cystic vascular lesion composed of dilated lymphatic channels. The head and neck region is the most common site of involvement. Many lesions are present at birth or develop within the first few years of life. There appears to be no sex predilection. They usually form painless swellings that are frequently superficial, but some extend deeply into the surrounding tissues and are ill-defined.

Oral lesions are seen most commonly in the tongue and lips where they may cause macroglossia and macrocheilia respectively. Involvement of underlying bone in oral lesions is uncommon [133]. Mucosal lymphangiomas usually have a pale, translucent surface, which is nodular or bossellated. It is common for black areas to appear in the lesion due to focal areas of haemorrhage.

In the neck, the lesions tend to be larger and show more extensive cystic dilatation. These lymphangiomas are then frequently called *cystic lymphangiomas* or *cystic hygromas* [91]. Some are associated with Turner syndrome (Monosomy X) [28]. The most common locations for cystic hygroma are the posterior triangle, submandibular region and floor of the mouth. It can extend upwards to involve the cheek and parotid gland, forwards into the anterior triangle or downwards into the mediastinum. Some cystic hygromas are severely disfiguring and they can compromise swallowing or breathing. The classification and microscopic aspects of oral lymphangiomas are discussed in Chap. 9.

3.7.6 Benign Nerve Sheath Tumours

Neurofibroma and schwannoma are the two most common benign tumours of nerve sheath origin. Although they both appear to be derived from Schwann cells they have distinctive clinical and microscopical features.

3.7.6.1 Neurofibroma

ICD-O:9540/0

Solitary neurofibromas are relatively uncommon in the orofacial region and tend to affect people in the 20–40 years age group [189]. Most tumours are sporadic, but the possibility of neurofibromatosis type 1 should always be considered when dealing with these lesions. They usually form small, painless, expansile submucosal nodules. The tongue is the most common intraoral site, but occasionally they develop on the inferior dental nerve and appear as a fusiform radiolucent area along the course of the inferior dental canal.

3.7.6.2 Schwannoma

ICD-O:9560/0

Schwannoma (neurilemmoma; neurinoma) is a benign neoplasm of Schwann cell origin. Patients are usually in the third or fourth decades and the tumour is more common in women than men. Lesions in the mouth tend to form small, painless and slow-growing swellings and the tongue is the most common site. However, occasional cases can be several centimetres in diameter [41, 87].

3.7.6.3 Neurofibromatosis

ICD-O:9540/0

Von Recklinghausen disease or neurofibromatosis type I is inherited as an autosomal dominant trait and the gene responsible is located on chromosome 17 [153]. It is relatively common and affects about 1 in 4,000 births. It is usually diagnosed before the age of 10 years because of the characteristic cutaneous lesions and the frequent family history.

Clinically, it is characterised by cutaneous neurofibromas that are usually associated with café au lait pigmentation of the skin. Lesions may be focal, but sometimes there can be thousands of tumours and the condition is then grossly disfiguring. The lesions are usually painless, but itching can be a serious problem. There can be overgrowth of bone and associated soft tissue leading to bizarre localised gigantism. Nearly a quarter of cases involve the head and neck, but only about 5% affect the oral cavity.

3.7.6.4 Multiple Neuromas in Endocrine Neoplasia Syndrome

ICD-O:9570/0

Multiple endocrine neoplasia syndrome type 2B is an autosomal dominant condition characterised by the presence of mucosal neuromas together with medullary carcinoma of the thyroid gland and pheochromocytoma [147]. Nearly 90% of patients with the condition have point mutations at codon 918 of the RET proto-oncogene.

Clinically, patients often have a Marfanoid habitus with arachnodactyly and a narrow face. Mucosal neuromas are the most consistent feature of the disease and may be pathognomonic. They tend to form on the lateral margins and dorsum of the tongue and appear as multiple, small, painless nodules. These nodules may be the first indication of the condition. The lips are sometimes enlarged and blubbery. Mucosal neuromas often affect the palpebral conjunctiva and can also involve the sclera.

Microscopy shows a partially encapsulated tangled mass of small nerve fibres, often with a thickened perineurium. These nerves lie in a loose fibrous stroma. The nerves usually stain with S-100 and may stain with epithelial membrane antigen indicating perineurial differentiation.

The mucosal neuromas themselves rarely cause clinical problems, but may act as indicators of the more serious aspects of the syndrome.

3.7.7 Granular Cell Tumour (Granular Cell Myoblastoma)

ICD-O:9580/0

Granular cell tumours are uncommon, but about half of all cases involve the head and neck region. The tongue, particularly the dorsum, is the most common site. The peak incidence is in middle life and 10–20% of cases are multiple. There is a female predominance of about 2:1. They usually form nondescript, painless swellings, but occasionally surface candidal infestation causes the lesion to present as a white plaque [59, 108]. See for this lesion also Chap. 7.

3.8 Squamous Cell Carcinoma

3.8.1 Introduction

Squamous cell carcinomas account for about 90% of all malignant neoplasms in the mouth and orophar-

ynx. It is important to consider the site of involvement as the epidemiological factors can vary considerably in tumours in different intraoral locations. There is typically a higher frequency in men than women, and this is attributed to the use of tobacco and alcohol [17]. It has been estimated that as many as 75% of cases of oral squamous cell carcinomas in Western countries and Japan can be ascribed to these factors. Globally, oral cancer accounts for 5% of all malignancies in men and 2% in women [134]. Much higher rates, however, are seen in both men and women in parts of southeast Asia, where they are usually associated with the habitual use of areca nut and tobacco products.

3.8.2 Clinical Features

Despite the fact that oral tumours frequently cause symptoms, and the mouth can be readily visualised with simple equipment, many oral cancers present at a relatively advanced stage where treatment may be disfiguring and prognosis is poor. This is often because many patients are elderly and frail and frequently wear dental prostheses and are accustomed to minor degrees of oral discomfort. In addition, early lesions may not be regarded as suspicious by the patient or the clinician and may therefore be treated empirically with antibacterial or antifungal preparations.

Any part of the oral mucosa can be the site of development of squamous cell carcinomas. The common oral locations can show wide variations in different geographical areas depending on the prevalent risk factors. The intraoral subsites include the buccal mucosa, tongue, floor of mouth, upper and lower gingivae and alveolar processes, the hard palate and retromolar trigone. As the clinical presentation can vary according to the specific sites of involvement, these will be discussed separately.

3.8.2.1 Buccal Mucosa

The buccal mucosa extends from the commissure anteriorly to the retromolar trigone posteriorly and from the upper and lower vestibular reflections. The majority of carcinomas arise from the posterior area where they are commonly traumatised by the molar teeth. They soon spread into the underlying buccinator muscle and though insidious initially they may eventually cause trismus. Bone, however, is generally involved only in advanced tumours. Tumours at this site often extend posteriorly into the palatoglossal fold and tonsillar fossa. Metastases are most common in the submandibular, submental, parotid and lateral pharyngeal lymph nodes.

3.8.2.2 Tongue

The tongue is the most common oral location of squamous cell carcinoma and can account for half of all cases. The majority affect the middle third of the lateral border and adjacent ventral surface. The dorsum is a very uncommon site and tumours arising there may be associated with precursor lesions such as lichen planus and candidal leukoplakia. Lingual tumours are often exophytic and ulceration is common. Even clinically small tumours can infiltrate deeply into the underlying muscle. With progressive growth tumours become indurated and frequently develop characteristic rolled, raised, everted margins. Infiltration of the lingual musculature may cause pain, dysphagia and dysphonia. Half of patients have regional lymph node metastases at presentation. Tumours towards the tip of the tongue drain to the submental and thence to the jugulo-digastric lymph node, and those located on the dorsum and lateral borders tend to involve the submandibular and jugulo-digastric nodes. Contralateral or bilateral spread is relatively common, particularly in tumours arising anteriorly.

3.8.2.3 Floor of Mouth

The floor of the mouth is a horseshoe-shaped mucosal trough extending between the lower lingual alveolar mucosa and the ventral lingual mucosa. It is the second most common site for intraoral squamous cell carcinomas and shows the highest frequency of small and symptomless tumours [115]. Tumours are most frequent in the anterior segment and tumours there tend to spread superficially rather than deeply. Involvement of the submandibular duct can cause obstructive sialadenitis and tumours can also extend down the duct itself. If the tumour extends to involve the mandible, there can be spread along the periodontal ligament and subperiostally [106]. Lymphatic involvement is early but less frequent than tumours of the tongue itself.

3.8.2.4 Gingiva and Alveolar Ridge

Tumours at this site can be exophytic resembling dental abscesses or epulides, or ulcerated and fixed to the underlying bone. They account for about 20% of oral tumours. In parts of the USA there is a very high frequency in women who practise snuff dipping. Related teeth are often loosened and there is extension along the periodontal ligament. On the alveolus tumours can re-

semble simple lesions like denture-induced hyperplasia or denture-related ulceration. The underlying bone may be eroded or invaded in 50% of patients and regional metastases are seen in over half the patients at presentation.

3.8.2.5 Hard Palate

This is a relatively uncommon site of involvement except in areas where reverse smoking is common [148]. Tumours at this site can be exophytic or ulcerative, but tend to spread superficially rather than deeply.

3.8.2.6 Retromolar Trigone

Tumours from this site spread to the buccal mucosa laterally and distally involve the tonsillar area. They can penetrate into the parapharyngeal area and may show extensive spread along the lingual and inferior alveolar nerves. In addition, tumours frequently erode or invade the adjacent mandible.

3.8.3 Staging

Staging of oral squamous cell carcinomas is undertaken using the current TNM Classification [67, 167].

References

- Abdollahi M, Radfar MA (2003) A review of drug-induced oral reactions. *J Contemp Dent Pract* 4:10–31
- Amagai M, Karpati S, Prussick R, Klaus-Kovtun V, Stanley JR (1992) Autoantibodies against the amino-terminal cadherin-like binding domain of pemphigus vulgaris antigen are pathogenic. *J Clin Invest* 90:919–926
- Amerigo J, Matilla A, Gonzalez-Campora R, Galera-Davidson H (1979) Vegetant intravascular hemangioendothelioma of the skin. Report of 3 cases with a critical pathogenetic study. *Dermatologica* 159:476–481
- Andreasen JO (1968) Oral lichen planus. II. A histologic evaluation of 97 cases. *Oral Surg Oral Med Oral Pathol* 25:158–166
- Anhalt GJ, Kim SC, Stanley JR, Korman NJ et al. (1990) Paraneoplastic pemphigus. An autoimmune mucocutaneous disease associated with neoplasia. *N Engl J Med* 320:1729–1735
- Assimakopoulos D, Patrikakos G, Fotika C, Elisaf M (2002) Benign migratory glossitis or geographic tongue: an enigmatic oral lesion. *Am J Med* 113:751–755
- Aurelian L, Ono F, Burnett J (2003) Herpes simplex virus (HSV)-associated erythema multiforme (HAEM): a viral disease with an autoimmune component. *Dermatol Online* 9:1
- Ayangco L, Rogers RS III (2003) Oral manifestations of erythema multiforme. *Dermatol Clin* 21:195–205
- Barker BF, Carpenter WM, Daniels et al. (1997) Oral mucosal melanomas: the WESTOP Banff workshop proceedings. Western Society of Teachers of Oral Pathology. *Oral Surg Oral Med Oral Pathol Oral Radiol Endod* 83:672–679
- Barrett AW, Bennett JH, Speight PM (1995) A clinicopathological and immunohistochemical analysis of primary oral mucosal melanoma. *Eur J Cancer B Oral Oncol* 31B:100–105
- Barrett AW, Porter SR, Scully C, Eveson JW, Griffiths MJ (1994) Oral melanotic macules that develop after radiation therapy. *Oral Surg Oral Med Oral Pathol* 77:431–434
- Bastiaens MT, Zwan NV, Verschuereen GL, Stooft TJ, Nieboer C (1994) Three cases of pemphigus vegetans: induction by enalapril – association with internal malignancy. *Int J Dermatol* 33:168–171
- Batsakis JG, El-Naggar AK, Luna MA (1996) Thyroid gland ectopias. *Ann Otol Rhinol Laryngol* 105:996–1000
- Batsakis JG, Suarez P (2000) Mucosal melanomas: a review. *Adv Anat Pathol* 7:167–180
- Becker BA, Gaspari AA (1993) Pemphigus vulgaris and vegetans. *Dermatol Clin* 11:429–452
- Benateau H, Rigau V, Comoz F, Benchemam Y, Galateau F, Compere JF (2003) Tumour of the juxtaoral organ. *Int J Oral Maxillofac Surg* 32:101–103
- Blot WJ, McLaughlin JK, Winn DM et al. (1988) Smoking and drinking in relation to oral and pharyngeal cancer. *Cancer Res* 48:3282–3287
- Bonen DK, Cho JH (2003) The genetics of inflammatory bowel disease. *Gastroenterology* 124:521–536
- Bozkurt T, Langer M, Fendel K, Lux G (1992) Granulomatous tonsillitis. A rare extraintestinal manifestation of Crohn's disease. *Dig Dis Sci* 37:1127–1130
- Bozzo L, Machado MA, de Almeida OP, Lopes MA, Coletta RD (2000) Hereditary gingival fibromatosis: report of three cases. *J Clin Pediatr Dent* 25:41–46
- Brooke AE, Eveson JW, Luker J, Oakhill A (1999) Oral presentation of a novel variant of herpes simplex infection in a group of bone marrow transplant patients: a report of five cases. *Br J Dermatol* 141:381–363
- Buchner A, Hansen LS (1979) Melanotic macule of the oral mucosa. A clinicopathologic study of 105 cases. *Oral Surg Oral Med Oral Pathol* 48:244–249
- Buchner A, Hansen LS (1980) Amalgam pigmentation (amalgam tattoo) of the oral mucosa. A clinicopathologic study of 268 cases. *Oral Surg Oral Med Oral Pathol* 49:139–147
- Buchner A, Leider AS, Merrell PW, Carpenter WM (1990) Melanocytic nevi of the oral mucosa: a clinicopathologic study of 130 cases from northern California. *J Oral Pathol Med* 19:197–201
- Buchner A, Lozada F, Silverman S Jr (1980) Histopathologic spectrum of oral erythema multiforme. *Oral Surg Oral Med Oral Pathol* 49:221–228
- Budtz-Jorgensen E (1990) Histopathology, immunology, and serology of oral yeast infections. Diagnosis of oral candidosis. *Acta Odontol Scand* 8:37–43
- Burrows NP, Lockwood CM (1995) Antineutrophil cytoplasmic antibodies and their relevance to the dermatologist. *Br J Dermatol* 132:173–181
- Byrne J, Blanc WA, Warburton D, Wigger J (1984) The significance of cystic hygroma in fetuses. *Hum Pathol* 15:61–67
- Card T, Logan RF, Rodrigues LC, Wheeler JG (2004) Antibiotic use and the development of Crohn's disease. *Gut* 53:246–250
- Cawson RA, Lehner T (1968) Chronic hyperplastic candidiasis – candidal leukoplakia. *Br J Dermatol* 80:9–16
- Cawson RA, Rajasingham KC (1972) Ultrastructural features of the invasive phase of *Candida albicans*. *Br J Dermatol* 87:435–443
- Chan LS (2001) Mucous membrane pemphigoid. *Clin Dermatol* 19:703–711
- Chan LS, Ahmed AR, Anhalt GJ et al. (2002) The first international consensus on mucous membrane pemphigoid: definition, diagnostic criteria, pathogenic factors, medical treatment, and prognostic indicators. *Arch Dermatol* 2002 138:370–379
- Chao SC, Tsai YM, Yang MH, Lee JY (2003) A novel mutation in the keratin 4 gene causing white sponge naevus. *Br J Dermatol* 148:1125–1128

35. Chaudhry AP, Hampel A, Gorlin RJ (1958) Primary malignant melanoma of the oral cavity: a review of 105 cases. *Cancer* 11:923–928
36. Chong CY, Chan KP, Shah VA et al. (2003) Hand, foot and mouth disease in Singapore: a comparison of fatal and non-fatal cases. *Acta Paediatr* 92:1163–1169
37. Cooke BED (1956) Leukoplakia buccalis and oral epithelial naevi: a clinical and histological study. *Br Dent J* 68:151–174
38. Csernok E (2003) Anti-neutrophil cytoplasmic antibodies and pathogenesis of small vessel vasculitides. *Autoimmun Rev* 2:158–164
39. Daley T (1993) Pathology of intraoral sebaceous glands. *J Oral Pathol Med* 22:241–245
40. Daniels TE, Hansen LS, Greenspan JS et al. (1992) Histopathology of smokeless tobacco lesions in professional baseball players. Associations with different types of tobacco. *Oral Surg Oral Med Oral Pathol* 73:720–725
41. Dayan D, Buchner A, Hirschberg A (1989) Ancient neurolipoma (Schwannoma) of the oral cavity. *J Craniomaxillofac Surg* 17:280–282
42. Devaney KO, Travis WD, Hoffman G et al. (1990) Interpretation of head and neck biopsies in Wegener's granulomatosis. A pathologic study of 126 biopsies in 70 patients. *Am J Surg Pathol* 14:555–564
43. Doyle JL, Geary W, Baden E (1989) Eosinophilic ulcer. *J Oral Maxillofac Surg* 47:349–352
44. Eley BM (1982) Tissue reactions to implanted dental amalgam, including assessment by energy dispersive x-ray microanalysis. *J Pathol* 138:251–272
45. El-Mofty SK, Swanson PE, Wick MR, Miller AS (1993) Eosinophilic ulcer of the oral mucosa. Report of 38 new cases with immunohistochemical observations. *Oral Surg Oral Med Oral Pathol* 75:716–722
46. Elzay RP (1983) Traumatic ulcerative granuloma with stromal eosinophilia (Riga-Fede's disease and traumatic eosinophilic granuloma). *Oral Surg Oral Med Oral Pathol* 55:497–506
47. Eversole LR, Leider AS (1978) Maxillary intraosseous neuroepithelial structures resembling those seen in the organ of Chievitz. *Oral Surg Oral Med Oral Pathol* 46:555–558
48. Eveson JW, Lucas RB (1979) Angiolympoid hyperplasia with eosinophilia. *J Oral Pathol* 8:103–108
49. Fatahzadeh M, Sirois DA (2002) Multiple intraoral melanoacanthomas: a case report with unusual findings. *Oral Surg Oral Med Oral Pathol Oral Radiol Endod* 94:54–56
50. Fauci AS, Wolff SM (1973) Wegener's granulomatosis: studies in eighteen patients and a review of the literature. *Medicine (Baltimore)* 52:535–561
51. Femiano F, Scully C, Gombos F (2003) Linear IgA dermatitis induced by a new angiotensin-converting enzyme inhibitor. *Oral Surg Oral Med Oral Pathol Oral Radiol Endod* 95:169–173
52. Fenton JE, Timon CI, McShane DP (1996) Lingual granuloma gravidarum. *Otolaryngol Head Neck Surg* 114:682–683
53. Fetsch JF (2002) Endothelioid haemangioma. In: Fletcher CDM, Unni KK, Mertens F (eds) *Pathology and genetics of tumours of soft tissue and bone. WHO Classification of Tumours*. IARC Press, Lyon, pp 159–160
54. Ficarra G, Prignano F, Romagnoli P (1997) Traumatic eosinophilic granuloma of the oral mucosa: a CD30+(Ki-1) lymphoproliferative disorder? *Oral Oncol* 33:375–379
55. Ficarra G, Shillitoe EJ, Adler-Storzh K et al. (1990) Oral melanotic macules in patients infected with human immunodeficiency virus. *Oral Surg Oral Med Oral Pathol* 70:748–755
56. Field EA, Allan RB (2003) Review article: oral ulceration – aetiopathogenesis, clinical diagnosis and management in the gastrointestinal clinic. *Aliment Pharmacol Ther* 18:949–962
57. Field EA, Tyldesley WR (1989) Oral Crohn's disease revisited – a 10-year-review. *Br J Oral Maxillofac Surg* 27:114–123
58. Fienberg R (1981) The protracted superficial phenomenon in pathergic (Wegener's) granulomatosis. *Hum Pathol* 12:458–467
59. Fine SW, Li M (2003) Expression of calretinin and the alpha-subunit of inhibin in granular cell tumors. *Am J Clin Pathol* 119:259–264
60. Fiocchi C (1998) Inflammatory bowel disease: etiology and pathogenesis. *Gastroenterology* 115:182–205
61. Fornatora ML, Reich RF, Haber S, Solomon F, Freedman PD (2003) Oral melanoacanthoma: a report of 10 cases, review of the literature, and immunohistochemical analysis for HMB-45 reactivity. *Am J Dermatopathol* 25:12–15
62. Freysdottir J, Lau S, Fortune F (1999) Gammadelta T cells in Behcet's disease (BD) and recurrent aphthous stomatitis (RAS). *Clin Exp Immunol* 118:451–457
63. Fukase S, Ohta N, Inamura K, Kimura Y, Koike Y (1994) Diagnostic specificity of anti-neutrophil cytoplasmic antibodies (ANCA) in otorhinolaryngological diseases. *Acta Otolaryngol Suppl* 511:204–207
64. Goode RK, Crawford BE, Callihan MD, Neville BW (1983) Oral melanoacanthoma. Review of the literature and report of ten cases. *Oral Surg Oral Med Oral Pathol* 56:622–628
65. Goulart RA, Mark EJ, Rosen S (1995) Tumor necrosis factor as an extravascular manifestation of Wegener's granulomatosis. *Am J Surg Pathol* 19:145–153
66. Grattan CE, Gentle TA, Basu MK (1992) Oral papillary plasmacytosis resembling candidosis without demonstrable fungus in lesional tissue. *Clin Exp Dermatol* 17:112–116
67. Greene FL, Page DL, Fleming ID, Fritz AG, Balch CM, Haller DG, Morrow M (2002) *American Joint Committee on Cancer, Cancer Staging Manual*. Springer, New York Berlin Heidelberg
68. Greenstein RJ (2003) Is Crohn's disease caused by a mycobacterium? Comparisons with leprosy, tuberculosis, and Johne's disease. *Lancet Infect Dis* 3:507–514
69. Handlers JP, Waterman J, Abrams AM, Melrose RJ (1985) Oral features of Wegener's granulomatosis. *Arch Otolaryngol* 111:267–270
70. Harman KE, Seed PT, Gratian MJ, Bhogal BS, Challacombe SJ, Black MM (2001) The severity of cutaneous and oral pemphigus is related to desmoglein 1 and 3 antibody levels. *Br J Dermatol* 144:775–780
71. Harrison JD, Maretin IC (1986) Oral vegetable granuloma: ultrastructural and histological study. *J Oral Pathol* 15:322–326
72. Hedin CA, Pindborg JJ, Axell T (1993) Disappearance of smoker's melanosis after reducing smoking. *J Oral Pathol Med* 22:228–230
73. Hegarty AM, Barrett AW, Scully C (2004) Pyostomatitis vegetans. *Clin Exp Dermatol* 29:1–7
74. Hickman RE, Eveson JW, Cawson RA (1988) Nevus unius lateris and intraoral verrucous nevi. *Oral Surg Oral Med Oral Pathol* 66:226–229
75. Hicks MJ, Flaitz CM (2000) Oral mucosal melanoma: epidemiology and pathobiology. *Oral Oncol* 36:152–169
76. Hoffman GS (1994) "Wegener's granulomatosis": The path travelled since 1931. *Medicine* 73:325–329
77. Honma T, Saito T, Fujioka Y (1985) Possible role of apoptotic cells of the oral epithelium in the pathogenesis of aphthous ulceration. *Oral Surg Oral Med Oral Pathol* 59:379–387
78. Horn TD, Anhalt GJ (1992) Histologic features of paraneoplastic pemphigus. *Arch Dermatol* 128:1091–1095
79. Houston GD (1982) The giant cell fibroma. A review of 464 cases. *Oral Surg Oral Med Oral Pathol* 53:582–587
80. Hume G, Radford-Smith GL (2002) The pathogenesis of Crohn's disease in the 21st century. *Pathology* 34:561–567
81. Hume WJ (1975) Geographic stomatitis: a critical review. *J Dent* 3:25–43
82. Hume WJ, Smith CJ, Franklin CD (1980) Verruciform xanthoma. *Br J Oral Surg* 18:157–161
83. Ide F, Mishima K, Saito I (2003) Juxtaoral organ of Chievitz presenting clinically as a tumour. *J Clin Pathol* 56:789–790
84. Itonaga I, Hussein I, Kudo O, Sabokbar A, Watt-Smith S, Ferguson D, Athanasou NA (2003) Cellular mechanisms of osteoclast formation and lacunar resorption in giant cell granuloma of the jaw. *J Oral Pathol Med* 32:224–231
85. Jabbour SA (2003) Cutaneous manifestations of endocrine disorders: a guide for dermatologists. *Am J Clin Dermatol* 4:315–331

86. James J, Patton DW, Lewis CJ et al. (1986) Oro-facial granulomatosis and clinical atopy. *J Oral Med* 41:29–30
87. Jordan RC, Regezi JA (2003) Oral spindle cell neoplasms: a review of 307 cases. *Oral Surg Oral Med Oral Pathol Oral Radiol Endod* 95:717–724
88. Jorizzo JL, Rogers RS III (1990) Behcet's disease. *J Am Acad Dermatol* 23:738–741
89. Kanitakis J, Wang YZ, Roche P, Cozzani E et al. (1994) Immunohistopathological study of autoimmune pemphigus. Lack of strictly specific histological and indirect immunofluorescence criteria for paraneoplastic pemphigus. *Dermatology* 188:282–285
90. Karjalainen TK, Tomich CE (1989) A histopathologic study of oral mucosal lupus erythematosus. *Oral Surg Oral Med Oral Pathol* 67:547–554
91. Kennedy TL (1989) Cystic hygroma-lymphangioma: a rare and still unclear entity. *Laryngoscope* 99:1–10
92. Kimyai-Asadi A, Jih MH (2001) Paraneoplastic pemphigus. *Int J Dermatol* 40:367–372
93. Kitagawa S, Townsend BL, Hebert AA (1995) Peutz-Jeghers syndrome. *Dermatol Clin* 13:127–133
94. Kramer IR, El-Labban N, Lee KW (1978) The clinical features and risk of malignant transformation in sublingual keratosis. *Br Dent J* 144:171–180
95. Lamey PJ, Carmichael F, Scully C (1985) Oral pigmentation, Addison's disease and the results of screening for adrenocortical insufficiency. *Br Dent J* 158:297–298
96. Lange J de, Rosenberg AJ, Akker HP van den, Koole R, Wirts JJ, Berg H van den (1999) Treatment of central giant cell granuloma of the jaw with calcitonin. *Int J Oral Maxillofac Surg* 28:372–376
97. Lehner T (1969) Pathology of recurrent oral ulceration and oral ulceration in Behcet's syndrome: light, electron and fluorescence microscopy. *J Pathol* 97:481–494
98. Lenane P, Powell FC (2000) Oral pigmentation. *J Eur Acad Dermatol Venereol* 14:448–465
99. Levy M, Shear NH (1991) Mycoplasma pneumoniae infections and Stevens-Johnson syndrome. Report of eight cases and review of the literature. *Clin Pediatr (Phila)* 30:42–49
100. Liu AY, Valenzuela R, Helm TN, Camisa C et al. (1993) Indirect immunofluorescence on rat bladder transitional epithelium: a test with high specificity for paraneoplastic pemphigus. *J Am Acad Dermatol* 28:696–699
101. Liu B, Yu SF, Li TJ (2003) Multinucleated giant cells in various forms of giant cell containing lesions of the jaws express features of osteoclasts. *J Oral Pathol Med* 32:367–375
102. Lopez R, Fernandez O, Jara G, Baelum V (2002) Epidemiology of necrotizing ulcerative gingival lesions in adolescents. *J Periodontol Res* 37:439–444
103. Lutman GB (1974) Epithelial nests in intraoral sensory nerve endings simulating perineural invasion in patients with oral carcinoma. *Am J Clin Pathol* 61:275–284
104. McCartan BE, McCreary CE (1997) Oral lichenoid drug eruptions. *Oral Dis* 3:58–63
105. McCartan BE, McCreary CE, Healy CM (2003) Studies of drug-induced lichenoid reactions: criteria for case selection. *Oral Dis* 9:163–164
106. McGregor AD, MacDonald DG (1988) Routes of entry of squamous cell carcinoma into the mandible. *Head Neck* 10:294–301
107. Magnusson BC, Rasmusson LG (1995) The giant cell fibroma. A review of 103 cases with immunohistochemical findings. *Acta Odontol Scand* 53:293–296
108. Maiorano E, Favia G, Napoli A, Resta L, Ricco R, Viale G, Altini M (2000) Cellular heterogeneity of granular cell tumours: a clue to their nature? *J Oral Pathol Med* 29:284–290
109. Main DM, Chamberlain MA (1992) Clinical differentiation of oral ulceration in Behcet's disease. *Br J Rheumatol* 31:767–770
110. Manabe M, Lim HW, Winzer M, Loomis CA (1999) Architectural organization of filiform papillae in normal and black hairy tongue epithelium: dissection of differentiation pathways in a complex human epithelium according to their patterns of keratin expression. *Arch Dermatol* 135:177–181
111. Manchanda Y, Tejasvi T, Handa R, Ramam M (2003) Strawberry gingiva: a distinctive sign in Wegener's granulomatosis. *J Am Acad Dermatol* 49:335–337
112. Mani NJ (1985) Tuberculosis initially diagnosed by asymptomatic oral lesions. Report of three cases. *J Oral Med* 40:39–42
113. Manus DA, Sherbert D, Jackson IT (1995) Management considerations for the granuloma of pregnancy. *Plast Reconstr Surg* 95:1045–1050
114. Marks R, Radden BG (1981) Geographic tongue: a clinicopathological review. *Australas J Dermatol* 22:75–79
115. Mashberg A, Samit A (1995) Early diagnosis of symptomatic oral and oropharyngeal squamous cancers. *CA Cancer J Clin* 45:328–351
116. Meador R, Ehrlich G, Von Feldt JM (2002) Behcet's disease: immunopathologic and therapeutic aspects. *Curr Rheumatol Rep* 4:47–54
117. Merchant HW, Hayes LE, Ellison LT (1976) Soft-palate pigmentation in lung disease, including cancer. *Oral Surg Oral Med Oral Pathol* 41:726–733
118. Mignogna MD, Lo Muzio L, Ruoppo E, Errico M, Amato M, Satriano RA (1999) Oral manifestations of idiopathic lenticular mucocutaneous pigmentation (Laugier-Hunziker syndrome): a clinical, histopathological and ultrastructural review of 12 cases. *Oral Dis* 1999 5:80–86
119. Miles AEW (1958) Sebaceous glands in the lip and cheek mucosa of man. *Br Dent J* 105:235–248
120. Mooney EE, Walker J, Hourihane DO (1995) Relation of granulomas to lymphatic vessels in Crohn's disease. *J Clin Pathol* 48:335–338
121. Mostafa KA, Takata T, Ogawa I, Ijuhin N, Nikai H (1993) Verruciform xanthoma of the oral mucosa: a clinicopathological study with immunohistochemical findings relating to pathogenesis. *Virchows Arch A Pathol Anat Histopathol* 423:243–248
122. Murray A, Gardiner DS, McGuinness RJ (1998) Primary mycobacterial infection of the uvula. *J Laryngol Otol* 112:1183–1185
123. Nandapalan V, Roland NJ, Helliwell TR, Williams EM, Hamilton JW, Jones AS (1998) Mucosal melanoma of the head and neck. *Clin Otolaryngol* 23:107–116
124. Napier SS, Allen JA, Irwin CR, McCluskey DR (1993) Strawberry gums: a clinicopathological manifestation diagnostic of Wegener's granulomatosis? *J Clin Pathol* 46:709–712
125. Neville BW, Weathers DR (1980) Verruciform xanthoma. *Oral Surg Oral Med Oral Pathol* 49:429–434
126. Nicolas ME, Krause PK, Gibson LE, Murray JA (2003) Dermatitis herpetiformis. *Int J Dermatol* 42:588–600
127. Nowparast B, Howell FV, Rick GM (1981) Verruciform xanthoma. A clinicopathological review and report of fifty-four cases. *Oral Surg Oral Med Oral Pathol* 51:619–625
128. Nozicka Z (1985) Endovasal granulomatous lymphangitis as a pathogenetic factor in cheilitis granulomatosa. *J Oral Pathol* 14:363–365
129. Ogun HD, Bennett MH (1978) Carcinoma of the dorsum of the tongue: a rarity or misdiagnosis. *Br J Oral Surg* 16:115–124
130. Obermayer-Straub P, Manns MP (1998) Autoimmune polyglandular syndromes. *Baillieres Clin Gastroenterol* 12:293–315
131. O'Keefe E, Braverman IM, Cohen I (1973) Annulus migrans. Identical lesions in pustular psoriasis, Reiter's syndrome, and geographic tongue. *Arch Dermatol* 107:240–244
132. Pantanowitz L, Balogh K (2003) Significance of the juxtaoral organ (of Chievitz). *Head Neck* 25:400–405
133. Park YW, Kim SM, Min BG, Park IW, Lee SK (2002) Lymphangioma involving the mandible: immunohistochemical expressions for the lymphatic proliferation. *J Oral Pathol Med* 31:280–283
134. Parkin DM, Whelan SL, Ferlay J et al. (2003) Cancer incidence in five continents, vol. VIII. IARC Press, Lyon
135. Philipsen HP, Reichart PA, Takata T, Ogawa I (2003) Verruciform xanthoma – biological profile of 282 oral lesions based on a literature survey with nine new cases from Japan. *Oral Oncol* 39:325–336

136. Pindborg JJ, Reibel J, Roed-Peterson B, Mehta FS (1980) Tobacco-induced changes in oral leukoplakic epithelium. *Cancer* 45:2330–2336
137. Pinto GM, Lamarao P, Vale T (1992) Captopril-induced pemphigus vegetans with Charcot-Leyden crystals. *Am Acad Dermatol* 27:281–284
138. Plauth M, Jess H, Meyle J (1991) Oral manifestations of Crohn's disease. An analysis of 79 cases. *J Clin Gastroenterol* 13:29–37
139. Pogrel MA (1979) Sublingual keratosis and malignant transformation. *J Oral Pathol* 8:176–178
140. Pola JG, de la Cruz, Bustillo F, Gallas M, Leston JS (2003) Pulse granuloma in the wall of an inflammatory radicular cyst. *Otolaryngol Head Neck Surg* 129:441–442
141. Popa ER, Tervaeert JW (2003) The relation between *Staphylococcus aureus* and Wegener's granulomatosis: current knowledge and future directions. *Intern Med* 42:771–780
142. Porter SR, Hegarty A, Kaliakatsou F, Hodgson TA, Scully C (2000) Recurrent aphthous stomatitis. *Clin Dermatol* 18:569–578
143. Porter SR, Scully C, Pedersen A (1998) Recurrent aphthous stomatitis. *Crit Rev Oral Biol Med* 9:306–321
144. Prasad ML, Jungbluth AA, Iversen K, Huvos AG, Busam KJ (2001) Expression of melanocytic differentiation markers in malignant melanomas of the oral and sinonasal mucosa. *Am J Surg Pathol* 25:782–787
145. Prasad ML, Patel S, Hoshaw-Woodard S et al. (2002) Prognostic factors for malignant melanoma of the squamous mucosa of the head and neck. *Am J Surg Pathol* 26:883–928
146. Pryce DW, King CM (1990) Orofacial granulomatosis associated with delayed hypersensitivity to cobalt. *Clin Exp Dermatol* 15:384–386
147. Pujol RM, Matias-Guiu X, Miralles J, Colomer A, de Moraes JM (1997) Multiple idiopathic mucosal neuromas: a minor form of multiple endocrine neoplasia type 2B or a new entity? *J Am Acad Dermatol* 37:349–352
148. Quigley LF, Cobb CM, Hunt EE, Williams P, Schoenfeld S (1964) Reverse smoking and its oral consequences in Caribbean and South American peoples. *J Am Dent Assoc* 69:426–442
149. Reichart PA, Langford A, Gelderblom HR et al. (1989) Oral hairy leukoplakia: observations in 95 cases and review of the literature. *J Oral Pathol Med* 18:410–415
150. Reichart PA, Samaranyake LP, Philipsen HP (2000) Pathology and clinical correlates in oral candidiasis and its variants: a review. *Oral Dis* 6:85–91
151. Reichart PA, Schmidt-Westhausen A, Samaranyake LP, Philipsen HP (1994) Candida-associated palatal papillary hyperplasia in HIV infection. *J Oral Pathol Med* 23:403–405
152. Rennie JS, Reade PC, Hay KD, Scully C (1985) Recurrent aphthous stomatitis. *Br Dent J* 159:361–367
153. Reynolds RM, Browning GG, Nawroz I, Campbell IW (2003) Von Recklinghausen's neurofibromatosis: neurofibromatosis type 1. *Lancet* 361:1552–1554
154. Rogers RS III (1997) Recurrent aphthous stomatitis: clinical characteristics and associated systemic disorders. *Semin Cutan Med Surg* 16:278–283
155. Sah SP, Raj GA, Bahadur T (1999) Chronic ulceration of the tongue and laryngitis: first clinical sign of asymptomatic pulmonary tuberculosis. *J Infect* 39:163–164
156. Schiodt M (1984) Oral discoid lupus erythematosus. III. A histopathologic study of sixty-six patients. *Oral Surg Oral Med Oral Pathol* 57:281–293
157. Schiodt M, Halberg P, Hentzer B (1978) A clinical study of 32 patients with oral discoid lupus erythematosus. *Int J Oral Surg* 7:85–94
158. Schwartz DL (1965) Stomatitis nicotina of the palate; report of two cases. *Oral Surg Oral Med Oral Pathol* 20:306–315
159. Sciubba JJ, Said-Al-Naief N (2003) Orofacial granulomatosis: presentation, pathology and management of 13 cases. *J Oral Pathol Med* 32:576–585
160. Scott JE, Ahmed AR (1998) The blistering diseases. *Med Clin North Am* 82:1239–1283
161. Scott LA, Stone MS (2003) Viral exanthems. *Dermatol Online J* 9:4
162. Scully C, Beyli M, Ferreiro MC et al. (1998) Update on oral lichen planus: etiopathogenesis and management. *Crit Rev Oral Biol Med* 9:86–122
163. Scully C, Challacombe SJ (2002) Pemphigus vulgaris: update on etiopathogenesis, oral manifestations, and management. *Crit Rev Oral Biol Med* 13:397–408
164. Sedghizadeh PP, Shuler CF, Allen CM, Beck FM, Kalmar JR (2002) Celiac disease and recurrent aphthous stomatitis: a report and review of the literature. *Oral Surg Oral Med Oral Pathol Oral Radiol Endod* 94:474–478
165. Sela MN (2001) Role of *Treponema denticola* in periodontal diseases. *Crit Rev Oral Biol Med* 12:399–413
166. Shafer WG (1971) Verruciform xanthoma. *Oral Surg Oral Med Oral Pathol* 31:784–789
167. Sobin LH, Wittekind C (2002) TNM: classification of malignant tumours, 6th edn. Wiley, New York
168. Southam JC, Felix DH, Wray D, Cubie HA (1991) Hairy leukoplakia – a histological study. *Histopathology* 19:63–67
169. Sweatman MC, Tasker R, Warner JO et al. (1986) Oro-facial granulomatosis. response to elemental diet and provocation by food additives. *Clin Allergy* 16:331–338
170. Sund S, Bang G (1990) Intramuscular hemangioma in the oral region: report of three cases. *Oral Surg Oral Med Oral Pathol* 70:765–768
171. Talacko AA, Radden BG (1988) Oral pulse granuloma: clinical and histopathological features. A review of 62 cases. *Int J Oral Maxillofac Surg* 17:343–346
172. Thomas JA, Felix DH, Wray D et al. (1991) Epstein-Barr virus gene expression and epithelial cell differentiation in oral hairy leukoplakia. *Am J Pathol* 139:1369–1380
173. Thompson DE (1994) The role of mycobacteria in Crohn's disease. *J Med Microbiol* 41:74–94
174. Tucker KM, Heget HS (1976) The incidence of inflammatory papillary hyperplasia. *J Am Dent Assoc* 93:610–613
175. Tsuboi H, Fujimura T, Katsuoka K (2001) Angiolymphoid hyperplasia with eosinophilia in the oral mucosa. *Br J Dermatol* 145:365–366
176. Umeda M, Komatsubara H, Shibuya Y, Yokoo S, Komori T (2002) Premalignant melanocytic dysplasia and malignant melanoma of the oral mucosa. *Oral Oncol* 38:714–722
177. Verpillieux MP, Bastuji-Garin S, Revuz J (1999) Comparative analysis of severe aphthosis and Behcet's disease: 104 cases. *Dermatology* 198:247–251
178. Wakefield AJ, Sankey EA, Dhillon AP et al. (1991) Granulomatous vasculitis in Crohn's disease. *Gastroenterology* 100:1279–1287
179. Wal N van der, Kwast WA van der, Dijk E van, Waal I van der (1988) Geographic stomatitis and psoriasis. *Int J Oral Maxillofac Surg* 17:106–109
180. Wal N van der, Waal I van der (1986) Candida albicans in median rhomboid glossitis. A postmortem study. *Int J Oral Maxillofac Surg* 15:322–325
181. Weiss SW, Golblum JR (2001) Benign tumors and tumor-like lesions of blood vessels. In: Enzinger and Weiss's soft tissue tumors, 4th edn. Mosby, St. Louis, pp 840–843
182. Weitzel S, Duvic M (1997) HIV-related psoriasis and Reiter's syndrome. *Semin Cutan Med Surg* 16:213–218
183. Whitley RJ (2002) Herpes simplex virus infection. *Semin Pediatr Infect Dis* 13:6–11
184. Wiesenfeld D, Ferguson MM, Mitchell DN et al. (1985) Orofacial granulomatosis – a clinical and pathological analysis. *Q J Med* 54:101–113
185. Williams AJ, Wray D, Ferguson A (1991) The clinical entity of orofacial Crohn's disease. *Q J Med* 79:451–458
186. Williams DM (1990) Vesiculo-bullous mucocutaneous disease: benign mucous membrane and bullous pemphigoid. *J Oral Pathol Med* 19:16–23
187. Woo TY, Solomon AR, Fairley JA (1985) Pemphigus vegetans limited to the lips and oral mucosa. *Arch Dermatol* 121:271–272
188. Wright BA, Fenwick F (1981) Candidiasis and atrophic tongue lesions. *Oral Surg Oral Med Oral Pathol* 51:55–61

189. Wright BA, Jackson D (1980) Neural tumors of the oral cavity. A review of the spectrum of benign and malignant oral tumors of the oral cavity and jaws. *Oral Surg Oral Med Oral Pathol* 49:509–522
190. Yamamoto O, Yoshinaga K, Asahi M, Murata I (1999) A Laugier-Hunziker syndrome associated with esophageal melanocytosis. *Dermatology* 199:162–164
191. Yeh SW, Ahmed B, Sami N, Razzaque Ahmed A (2003) Blistering disorders: diagnosis and treatment. *Dermatol Ther* 16:214–223
192. Zimmer WM, Rogers RS 3rd, Reeve CM, Sheridan PJ (1992) Orofacial manifestations of Melkersson-Rosenthal syndrome. A study of 42 patients and review of 220 cases from the literature. *Oral Surg Oral Med Oral Pathol* 74:610–619
193. Zunt SL (2003) Recurrent aphthous stomatitis. *Dermatol Clin* 21:33–39
194. Zunt SL, Tomich CE (1989) Erythema migrans – a psoriasisiform lesion of the oral mucosa. *J Dermatol Surg Oncol* 15:1067–1070

Maxillofacial Skeleton and Teeth

P.J. Slootweg

Contents

4.1	Introduction	104	4.4.3	Odontogenic Tumours – Mixed Epithelial and Mesenchymal	117
4.1.1	Embryology	104	4.4.3.1	Ameloblastic Fibroma	117
4.1.2	Tooth Development	104	4.4.3.2	Ameloblastic Fibro-Odontoma	117
4.2	Inflammatory Diseases of the Maxillofacial Bones	104	4.4.3.3	Odontoma – Complex Type	118
4.3	Cysts of the Jaws	105	4.4.3.4	Odontoma – Compound Type	118
4.3.1	Odontogenic Cysts – Inflammatory	105	4.4.3.5	Odonto-Ameloblastoma	118
4.3.1.1	Radicular Cyst	105	4.4.3.6	Calcifying Odontogenic Cyst	119
4.3.1.2	Paradental Cyst	106	4.4.4	Odontogenic Tumours – Malignant	119
4.3.2	Odontogenic Cysts – Developmental	106	4.4.4.1	Malignant Ameloblastoma	119
4.3.2.1	Dentigerous Cyst	106	4.4.4.2	Ameloblastic Carcinoma	119
4.3.2.2	Lateral Periodontal Cyst	107	4.4.4.3	Primary Intraosseous Carcinoma	119
4.3.2.3	Glandular Odontogenic Cyst	107	4.4.4.4	Clear Cell Odontogenic Carcinoma	120
4.3.2.4	Odontogenic Keratocyst	107	4.4.4.5	Malignant Epithelial Odontogenic Ghost Cell Tumour	120
4.3.2.5	Gingival Cyst	108	4.4.4.6	Odontogenic Sarcoma	120
4.3.3	Non-Odontogenic Cysts	109	4.5	Fibro-Osseous Lesions	121
4.3.3.1	Nasopalatine Duct Cyst	109	4.5.1	Fibrous Dysplasia	121
4.3.3.2	Nasolabial Cyst	109	4.5.2	Ossifying Fibroma	121
4.3.3.3	Surgical Ciliated Cyst	109	4.5.3	Osseous Dysplasia	123
4.3.4	Pseudocysts	109	4.6	Giant Cell Lesions	124
4.3.4.1	Solitary Bone Cyst	109	4.6.1	Central Giant Cell Granuloma	124
4.3.4.2	Focal Bone Marrow Defect	109	4.6.2	Cherubism	124
4.4	Odontogenic Tumours	109	4.7	Neoplastic Lesions of the Maxillofacial Bones, Non-Odontogenic	125
4.4.1	Odontogenic Tumours – Epithelial	110	4.7.1	Osteoma	125
4.4.1.1	Ameloblastoma	110	4.7.2	Chordoma	125
4.4.1.2	Calcifying Epithelial Odontogenic Tumour	112	4.7.3	Melanotic Neuroectodermal Tumour of Infancy	126
4.4.1.3	Adenomatoid Odontogenic Tumour	112	References	126	
4.4.1.4	Squamous Odontogenic Tumour	113			
4.4.2	Odontogenic Tumours – Mesenchymal	114			
4.4.2.1	Odontogenic Myxoma	114			
4.4.2.2	Odontogenic Fibroma	115			
4.4.2.3	Cementoblastoma	116			

4.1 Introduction

4.1.1 Embryology

The maxillofacial skeleton is partly derived from migrated cranial neural crest cells. These cells give rise to most connective tissues in the craniofacial region including the bones of the calvarium, face and jaws. So, the diseases to be discussed in this chapter occur in bones that are formed by mesenchymal cells with an ectodermal/neuroectodermal ancestry – that is why they are also known as ectomesenchyme – and are therefore different from bone and cartilage that have a mesodermal origin elsewhere in the body [145, 171].

4.1.2 Tooth Development

Teeth develop from epithelial cells from the mucosal lining of the oral cavity and cranial neural crest-derived ectomesenchymal cells. Under the influence of reciprocal inductive events, these cells develop into enamel-forming ameloblasts and dentin-producing odontoblasts (Fig. 4.1) [145, 171].

While ameloblasts and odontoblasts are depositing enamel and dentin, the epithelium proliferates downwards, thus creating a tube that maps out the form and size of the root of the teeth. This epithelial cuff is known as the sheath of Hertwig. Its remnants form a permanent component of the periodontal ligament; they are known as rests of Malassez and are the source of some cystic jaw lesions (Fig. 4.2). Other epithelial reminiscences of tooth development lie more superficially in the jaw tissues. These are the epithelial rests of Serres, which have their origin in the dental lamina.

4.2 Inflammatory Diseases of the Maxillofacial Bones

These include osteomyelitis, which mainly involves the mandible. It may occur through extension of infection of the dental pulp or as a complication after tooth extraction. When seen after irradiation, e.g. for head and neck cancer, it is called osteoradionecrosis.

There are five types: acute suppurative osteomyelitis, chronic suppurative osteomyelitis, chronic focal sclerosing osteomyelitis, chronic diffuse sclerosing osteomyelitis, and proliferative periostitis. Acute suppurative osteomyelitis shows bone marrow cavities infiltrated with neutrophils. The bony trabeculae are necrotic. Usually, this form of osteomyelitis evolves into chronic suppurative osteomyelitis, which also may arise de novo. Besides bone sequestrs surrounded by numerous neutrophilic

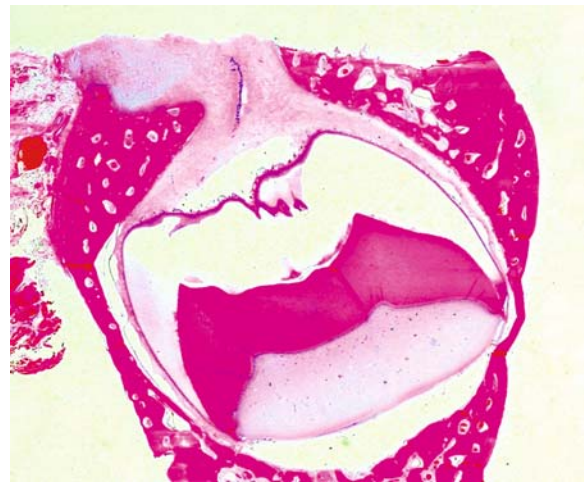

Fig. 4.1. Overview of normal tooth germ lying in its bony crypt. Odontogenic epithelium covers the enamel space from which the enamel is dissolved due to decalcification. An epithelial strand as remnant of the dental lamina can be seen in the fibrous tissue bridging the gap in the bony crypt

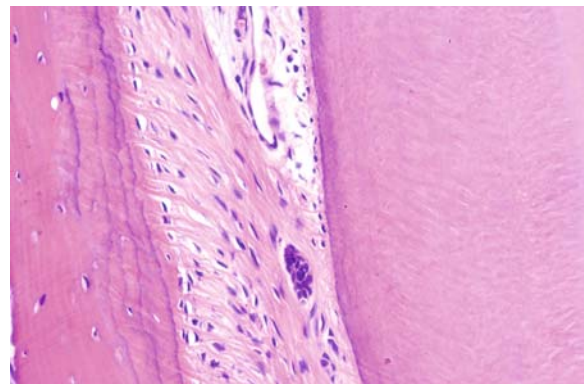


Fig. 4.2. The periodontal ligament connects the root surface (right side) with the bony socket (left side). An epithelial rest of Malassez is clearly visible

granulocytes granulation tissue is also present. Sinuses are formed partly lined by squamous epithelium from the oral mucosa. In less severe cases, fibrosis and development of a chronic inflammatory infiltrate may also be seen. Unless the sequestra are removed, the disease will not heal.

When the inflammation is mild, the jaw bone responds by bone formation. This form of osteomyelitis is known as chronic sclerosing, which may be focal as well as diffuse. Dense sclerotic bone masses are seen together with a bone marrow exhibiting oedema and small foci of lymphocytes and plasma cells. Both focal as well as diffuse chronic sclerosing osteomyelitis must be distinguished from other bone lesions, especially the fibro-osseous ones (see Sect. 4.5).

Table 4.1. Cysts of the jaws [73]

Odontogenic cysts – inflammatory	Radicular cyst
	Residual cyst
	Paradental cyst
Odontogenic cysts – developmental	Dentigerous cyst
	Lateral periodontal cyst
	Botryoid odontogenic cyst
	Glandular odontogenic cyst
	Odontogenic keratocyst (keratocystic odontogenic tumour [181])
	Gingival cyst
Non-odontogenic cysts	Nasopalatine duct cyst
	Nasolabial cyst
	Surgical ciliated cyst
Pseudocysts	Solitary bone cyst
	Focal bone marrow defect

When the inflammation mainly involves the periosteum, the disease is called proliferative periostitis, or called periostitis ossificans. Histologically, bony trabeculae that lie in a linear parallel pattern are seen. The intervening stroma is composed of fibrous connective tissue sparsely infiltrated with lymphocytes and plasma cells.

4.3 Cysts of the Jaws

Cysts of the jaws are classified into several categories depending on histogenesis and aetiology. Those that arise from odontogenic epithelium are called odontogenic, those that have their source in other epithelial structures are known as non-odontogenic. Among the odontogenic cysts, developmental and inflammatory types can be distinguished [73]. By definition, cysts are lined by epithelium. There are, however, also cavities in the jaw lacking such an epithelial investment that are also discussed under this heading. The various entities are listed in Table 4.1.

4.3.1 Odontogenic Cysts – Inflammatory

4.3.1.1 Radicular Cyst

Radicular cysts are located at the root tips of the teeth (Fig. 4.3). They arise from the epithelial rests of Malassez and are the cysts most frequently seen [34, 146].

They are lined by non-keratinising squamous epithelium. This epithelial lining may be thin and atrophic or show elongated rete processes. In many cysts, cholesterol clefts with adjacent giant cells occur. With-

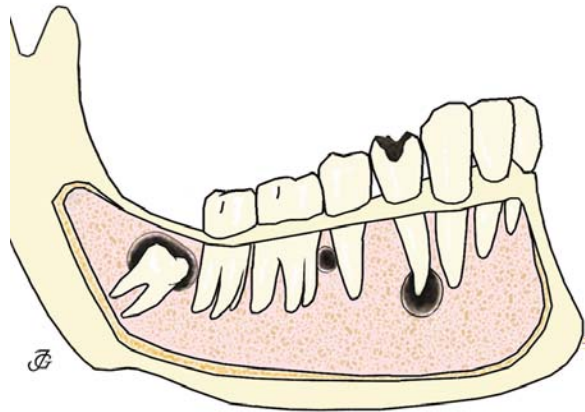


Fig. 4.3. Schematic drawing showing a bisected mandible. *Left to right:* examples of a dentigerous cyst, a lateral periodontal cyst and a radicular cyst (drawing by John de Groot)

in the cyst epithelium, hyaline bodies of various size and shape may be present (Fig. 4.4). The specific nature of these so-called Rushton bodies is unclear [95]. Occasionally, the lining squamous cells are admixed with mucous cells or ciliated cells (Fig. 4.5). Sometimes, the histologic pattern of the radicular cyst is complicated by extensive intramural proliferation of squamous epithelial nests of varying size, thus mimicking a squamous odontogenic tumour (see Sect. 4.4.1.4) [187]. The same histology may be shown by other jaw cysts, in particular when there are extensive inflammatory changes. When a radicular cyst is retained in the jaws after removal of the associated tooth, the lesion is called a *residual cyst*.

When complicated by inflammation, radicular cysts may cause pain and swelling. However, they may also be asymptomatic and fortuitously detected by radiographic examination of the dentition.

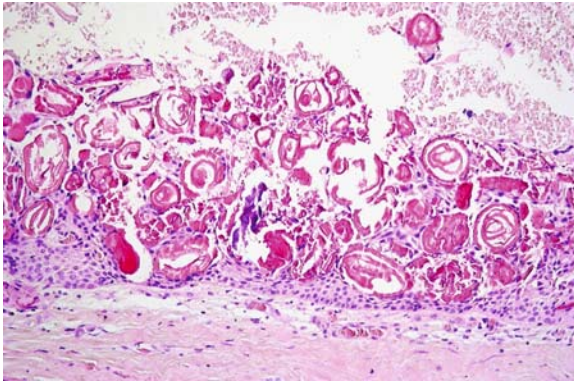


Fig. 4.4. Epithelial lining of a radicular cyst containing many Rushton bodies

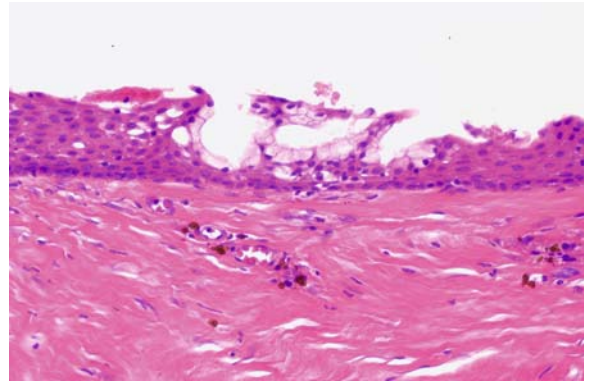


Fig. 4.5. Cyst lining composed of squamous as well as mucous epithelium. This can be found in radicular cysts as well as in dentigerous or residual cysts

4.3.1.2 Paradental Cyst

The paradental cyst is located on the lateral side of the tooth at the border between the enamel and root cementum. This cyst is secondary to an inflammatory process in the adjacent periodontal tissues that induces proliferation of neighbouring odontogenic epithelial rests, similar to the pathogenesis of the radicular cyst [88]. Histologically, it resembles the other inflammatory odontogenic cysts, the distinction being made by the specific clinical presentation. It is a rare lesion [128]. Treatment consists of excision with or without concomitant extraction of the involved tooth [45].

4.3.2 Odontogenic Cysts – Developmental

4.3.2.1 Dentigerous Cyst

A dentigerous cyst surrounds the crown of an unerupted tooth, mostly the maxillary canine or the mandibular third molar tooth (Fig. 4.3). They are quite common.

The cyst wall has a thin epithelial lining that may be only two to three cells thick. In case of inflammation, the epithelium becomes thicker and will show features similar to the lining of a radicular cyst. Also, mucous-producing cells as well as ciliated cells may be observed (Fig. 4.6). The connective tissue component of the cyst wall may be fibrous or fibromyxomatous. The cyst wall may also contain varying amounts of epithelial nests representing remnants of the dental lamina.

Radiologically, a lot of jaw diseases associated with unerupted teeth may have an appearance similar to that of a dentigerous cyst. Histologic examination, however, will be decisive in ruling out these possibilities among

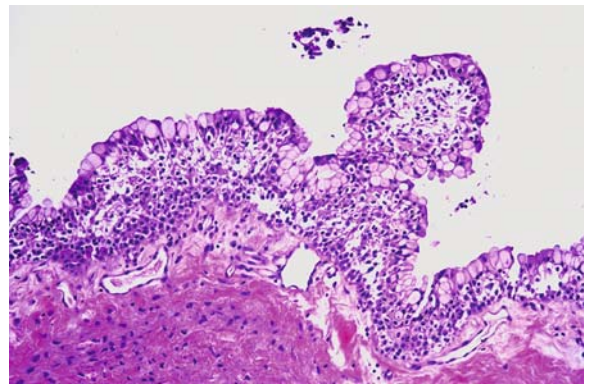


Fig. 4.6. Lining of a dentigerous cyst mainly composed of mucous cells

which keratocyst and unicystic ameloblastoma (see Sects. 4.3.2.4 and 4.4.1.1) are the most prevalent. Moreover, the radiologic picture of the dentigerous cyst may be mimicked by hyperplasia of the dental follicle, the connective tissue capsule that surrounds the unerupted tooth [33].

Fibromyxomatous areas in the connective tissue wall of the dentigerous cyst may resemble the odontogenic myxoma (see Sect. 4.4.2.1). The presence of odontogenic epithelial rests may lead to the erroneous diagnosis of one or another type of epithelial odontogenic tumour [71]. However, identification of the epithelial cyst lining will rule out these alternatives.

In most instances, dentigerous cysts are a fortuitous finding on oral radiographs. Only when excessively large may they cause swelling of the involved part of the jaw. If there is inflammation, they will cause pain and swelling. Removal of the cyst wall and the tooth involved will yield a permanent cure.

The *eruption cyst* is a specific type of dentigerous cyst located in the gingival soft tissues overlying the crown

of an erupting tooth. Mostly, these cysts are short-lived, rupturing with the progressive eruption of the associated tooth. They are lined by squamous epithelium that is thickened due to inflammatory changes in the underlying connective tissue and thus similar to the lining of a radicular cyst.

4.3.2.2 Lateral Periodontal Cyst

Lateral periodontal cysts are rare lesions, derived from odontogenic epithelial remnants, and occurring on the lateral aspect or between the roots of vital teeth (Fig. 4.3) [166]. They are lined by a thin, non-keratinising squamous or cuboidal epithelium with focal, plaque-like thickenings consisting of clear cells that may contain glycogen (Fig. 4.7) [150].

Lateral periodontal cysts do not cause any symptoms. They are fortuitous findings on radiographs where they present as a well-demarcated radiolucency on the lateral surface of a tooth root. Simple enucleation is adequate treatment.

The *botryoid odontogenic cyst* represents a multilocular form of the lateral periodontal cyst [54]. Treatment by curettage is the most appropriate treatment, but recurrences may occur [52].

4.3.2.3 Glandular Odontogenic Cyst

The glandular odontogenic cyst, also called *sialo-odontogenic cyst* is a rare cystic lesion characterised by an epithelial lining with cuboidal or columnar cells both at the surface and lining crypts or cyst-like spaces within the thickness of the epithelium [34, 73].

The lining epithelium is partly non-keratinising, squamous and with focal thickenings similar to the plaques in the lateral periodontal cyst and the botryoid odontogenic cyst. There may be a surface layer of eosinophilic cuboidal or columnar cells that can have cilia and may form papillary projections. Some superficial cells assume an apocrine appearance. Also, mucus-producing cells may be present. Focally, the epithelium shows areas of increased thickness in which glandular spaces are formed. Moreover, the epithelial cells may lie in spherical structures with a whorled appearance (Fig. 4.8).

Mucous cells and cuboidal cells with cilia may also occur in other jaw cysts, but the latter lack the other epithelial features described above. Mucous cells and non-keratinising squamous epithelium also occur in mucoepidermoid carcinoma [91, 177]. However, epithelial plaques consisting of clear cells are not a feature of this latter lesion.

The glandular odontogenic cyst most commonly affects the body of the mandible and the most prominent

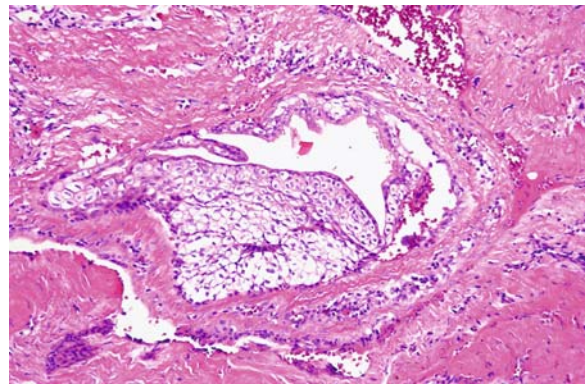


Fig. 4.7. Lateral periodontal cyst. The epithelial lining forms plaques consisting of clear cells

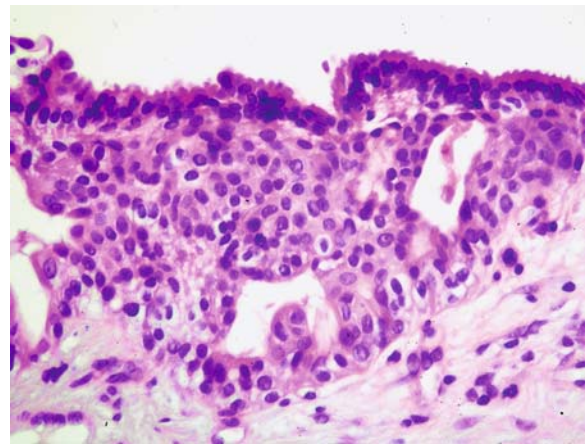


Fig. 4.8. Epithelial lining of glandular odontogenic cyst showing intraepithelial duct formation and apocrine differentiation at the surface

symptom is painless swelling [126]. Treatment may be conservative, but recurrence may occur [48].

4.3.2.4 Odontogenic Keratocyst

Odontogenic keratocyst, formerly also called *primordial cyst*, is defined by the presence of an epithelial lining not exceeding 10 cell layers in thickness, palisading of the basal cells, and a parakeratinised, corrugated surface [114].

Odontogenic keratocysts are common lesions [147, 148, 149]. They show a wide age range with a peak frequency in the 2nd and 3rd decades, are more common in males than in females and occur twice as frequently in the mandible as in the maxilla. Involvement of the gingival soft tissues has also been reported [26]. They also occur in cases of nevoid basal cell carcinoma syndrome and in patients with Marfan's syndrome [11, 50, 186].

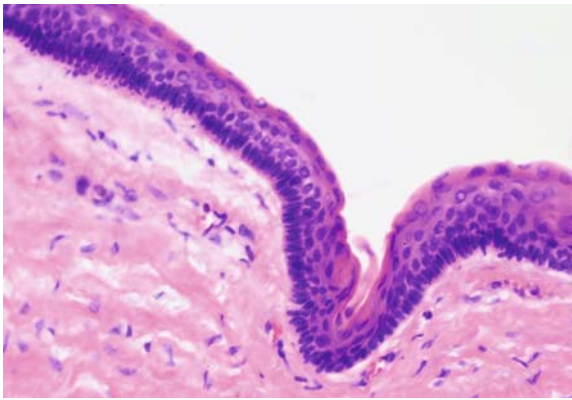


Fig. 4.9. Epithelial lining of a keratocyst. The basal palisading and the corrugated parakeratinised surface are unique to this lesion. Moreover, there is a striking parallel between the basal layer and the surface

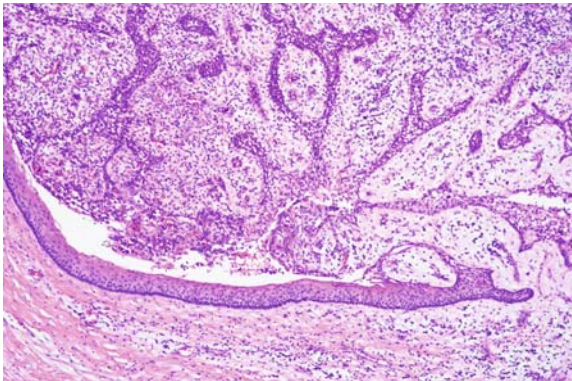


Fig. 4.10. In the event of inflammation, the epithelial lining of a keratocyst loses its typical pattern to transform into a lattice of spongiotic squamous epithelium

The odontogenic keratocyst shows a thin connective tissue wall lined by stratified squamous epithelium with a well-defined basal layer of palisading columnar or cuboidal cells and with a surface of a corrugated layer of parakeratin (Fig. 4.9). Mitotic figures can be identified in parabasilar and midspinous areas [12]. Rushton bodies similar to those seen in radicular cysts may also be present. The underlying cyst wall may contain tiny daughter cysts and solid epithelial nests. Also, epithelial proliferations similar to ameloblastoma have been reported. Daughter cysts and intramural epithelial nests are more common in cysts associated with the nevoid basal cell carcinoma syndrome [185]. When inflamed, the odontogenic keratocyst loses its typical histologic features, but shows a non-keratinising stratified epithelium exhibiting spongiosis and elongated rete pegs supported by a con-

nective tissue containing a mixed inflammatory infiltrate (Fig. 4.10). Rarely, odontogenic keratocysts show development of epithelial dysplasia and squamous cell carcinoma [87].

Immunohistochemical studies have not yielded data of diagnostic or prognostic significance [148, 149].

Odontogenic keratocysts may also contain mucous cells, melanin-producing cells, dentinoid and intramural cartilage [12, 74, 86, 105]. Ciliated cells may be seen, but in maxillary cases, they could also be the result of a communication with the maxillary sinus [122]. In addition, the cyst wall may contain intramural odontogenic epithelial remnants. Occasionally, intraosseous cysts are lined by orthokeratinised epithelium, thus having the appearance of an epidermoid cyst. Such cysts are known as orthokeratinised odontogenic cysts. Their differentiation from the odontogenic keratocyst with parakeratinisation is clinically important as recurrence of orthokeratinised cysts is rare [188]. Differential diagnosis with unicystic ameloblastoma (see Sect. 4.4.1.1) may be difficult. Odontogenic keratocyst exhibits a compact spinous layer and a corrugated superficial parakeratin layer, and ameloblastoma a spinous layer with intercellular oedema.

Keratocysts do not cause symptoms unless concomitant inflammation causes pain and swelling. Radiographs may reveal extensive uni- or multilocular radiolucent lesions that occupy the major part of the jaw without having caused any appreciable cortical expansion. When the odontogenic keratocyst forms part of the nevoid basal cell carcinoma syndrome, patients may show any of the other features of this syndrome [72].

Odontogenic keratocysts tend to recur after enucleation [147, 148, 149]. Sometimes, a partial jaw resection is needed to provide permanent cure [182]. If associated with the nevoid basal cell carcinoma syndrome, the chance of recurrence is even higher [18]. If located in the gingiva, the behaviour of the odontogenic keratocyst is less aggressive [65].

As there is sufficient evidence that this lesion actually represents a cystic neoplasm, the most recent WHO classification proposes the diagnostic designation *keratocystic odontogenic tumour* [181].

4.3.2.5 Gingival Cyst

Gingival cysts are divided in those occurring in adults and those in infants. They are located in the gingival tissues. *Gingival cysts of adults* are rarely larger than 1 cm and may be multiple. They are lined by either thin epithelium of one to three cell layers or thicker and exhibit keratinisation. Plaques similar to those occurring in the lateral periodontal cyst (see Sect. 4.3.2.2) may be seen [107].

Gingival cysts of infants occur either singularly or multiply on the edentulous alveolar ridge of the newborn infant. When occurring at the midline of the palate, they are known as *palatal cysts of infants*. These tiny lesions, usually not larger than 3 mm, disappear spontaneously within a short time. Histologically, they resemble epidermoid cysts [24, 94]. Historically, *Epstein's pearls* and *Bohn's nodules* are terms that have been used for these lesions.

4.3.3 Non-Odontogenic Cysts

4.3.3.1 Nasopalatine Duct Cyst

Nasopalatine duct cysts arise within the nasopalatine canal from epithelial remnants of the nasopalatine duct. Radiologically, they present as radiolucent lesions situated between the roots of both maxillary central incisor teeth. The cyst lining may be pseudostratified columnar ciliated epithelium, stratified squamous epithelium, columnar or cuboidal epithelium and combinations of these. As surgical treatment comprises emptying the nasopalatine canal, the specimen always includes the artery and nerve that run in this anatomic structure. These are seen within the fibrous cyst wall and form the most convincing diagnostic feature, as the specific epithelial structures may be obscured by inflammatory changes. Recurrences are rarely seen, and are probably due to incomplete removal [168].

4.3.3.2 Nasolabial Cyst

Nasolabial cysts are located in the soft tissue just lateral to the nose at the buccal aspect of the maxillary alveolar process and are thought to arise from the nasolacrimal duct. Non-ciliated pseudostratified columnar epithelium interspersed with mucous cells form the epithelial lining. These features may be lost through squamous metaplasia [180]. Apocrine metaplasia of the cyst lining has also been reported [83]. Treatment consists of enucleation.

4.3.3.3 Surgical Ciliated Cyst

Surgical ciliated cysts arise from detached portions of the mucosa that line the maxillary antrum and are buried within the maxillary bone. This may occur after trauma or surgical intervention in this area [93]. Mostly, the cyst is an incidental radiographic finding, observed as a well-defined unilocular radiolucency adjacent to the maxillary antrum.

The cyst lining is similar to the normal mucosal surface of the paranasal cavities: pseudostratified ciliated columnar epithelium with interspersed mucous cells. Treatment consists of simple enucleation.

4.3.4 Pseudocysts

4.3.4.1 Solitary Bone Cyst

The solitary bone cyst, also known as *traumatic bone cyst* or *simple bone cyst* is confined to the mandibular body. Its pathogenesis is ill-understood; a remnant of intraosseous haemorrhage is the most favoured hypothesis. Radiographs show a cavity that varies from less than 1 cm in diameter to one that occupies the entire mandibular body and ramus. At surgical exploration, one encounters a fluid-filled cavity. Material for histologic examination may be difficult to obtain as a soft tissue lining of the bony cavity may be entirely absent or very thin. If present, it usually consists only of loose fibrovascular tissue, although it may also contain granulation tissue with signs of previous haemorrhage such as cholesterol clefts and macrophages loaded with iron pigment [136]. Sometimes, this cyst develops simultaneously with a variety of fibro-osseous cemental lesions [62].

4.3.4.2 Focal Bone Marrow Defect

The focal bone marrow defect represents an asymptomatic radiolucent lesion of the jaws that contains normal hematopoietic and fatty bone marrow. It is also called *osteoporotic bone marrow defect*. This condition is mostly seen at the angle of the mandible where it reveals its presence as a radiolucency with more or less well-defined borders. Due to the lack of radiographic specificity, the lesion is usually biopsied. Then, histologic examination will reveal the presence of normal hematopoietic marrow [141]. Of course, further treatment is superfluous.

4.4 Odontogenic Tumours

Odontogenic tumours comprise a group of lesions that have in common that they arise from the odontogenic tissue. They develop from the epithelial part of the tooth germ, the ectomesenchymal part or from both. Their behaviour varies from frankly neoplastic, including metastatic potential, to non-neoplastic hamartomatous. Some of them may recapitulate normal tooth development including the formation of dental hard tissues such as enamel, dentin and cementum [129]. Table 4.2 gives

Table 4.2. Odontogenic tumours [73, 181]

Epithelial	Ameloblastoma Calcifying epithelial odontogenic tumour Adenomatoid odontogenic tumour Squamous odontogenic tumour
Mesenchymal	Odontogenic myxoma Odontogenic fibroma Cementoblastoma
Mixed epithelial and mesenchymal	Ameloblastic fibroma Ameloblastic fibro-odontoma Odontoma – complex type Odontoma – compound type Calcifying odontogenic cyst (calcifying cystic odontogenic tumour/ dentinogenic ghost cell tumour [181])
Malignant	Odonto-ameloblastoma Malignant ameloblastoma Ameloblastic carcinoma Primary intraosseous carcinoma Clear cell odontogenic carcinoma Malignant epithelial odontogenic ghost cell tumour Odontogenic sarcoma

an overview of the various entities encompassed under this heading.

4.4.1 Odontogenic Tumours – Epithelial

Epithelial odontogenic tumours are supposed to be derived from odontogenic epithelium: dental lamina, enamel organ and Hertwig's root sheath. As there is no contribution, either proliferative or inductive, from the odontogenic mesenchyme, these lesions do not contain dental hard tissues or myxoid tissue resembling the dental papilla.

4.4.1.1 Ameloblastoma

ICD-O:9310/0

Ameloblastomas closely resemble the epithelial part of the tooth germ. They behave aggressively locally, but do not metastasise.

It is the most common odontogenic tumour [34] and may occur at any age, although cases in the first decade are rare. Maxillary cases are far outnumbered by mandibular ones. Rarely, the sinonasal cavities are involved [130, 139].

The intraosseous lesions are solid, solid with cystic parts, multicystic or unicystic. In the gingiva, the tumours have a white fibrous appearance on the cut sur-

face, due to the preponderance of fibrous stroma of lesions at this site.

Ameloblastomas consist of either anastomosing epithelial strands and fields or discrete epithelial islands. The former pattern is called the *plexiform* type, the other the *follicular* (Figs 4.11, 4.12). Both may occur within one and the same lesion [73, 181]. The peripheral cells at the border with the adjacent fibrous stroma are columnar with nuclei usually in the apical half of the cell body away from the basement membrane. The cells lying more centrally are fusiform to polyhedral and loosely connected to each other through cytoplasmic extensions. Especially in the follicular type, an increase in intercellular oedema may cause cysts that coalesce to form the large cavities responsible for the multicystic gross appearance ameloblastomas may show. In the plexiform type, cyst formation is usually the result of stromal degeneration. Condensation of collagenous fibres may cause a juxta-epithelial eosinophilic hyaline band. At the periphery of the lesion, the tumour infiltrates the adjacent cancellous bone. The lower cortical border of the mandible and the periosteal layer usually expand, but will not be perforated, the periosteum in particular forming a barrier [99]. Spread into soft tissues is highly unusual; when observed, it is probably an ameloblastic carcinoma, a lesion to be discussed later on (see Sect. 4.4.4.2). Mitotic figures may occur within the peripheral columnar as well as in the stellate reticulum-like cells. In the absence of cytonuclear atypia and with a normal configuration, they are without prognostic significance.

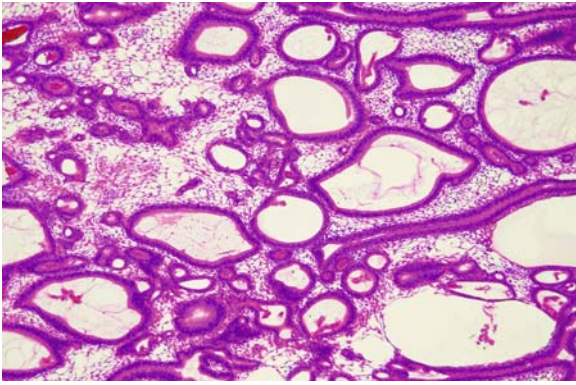


Fig. 4.11. Large epithelial areas of loosely structured spindle epithelium enclosing liquefying stromal areas are typical of a plexiform ameloblastoma. The epithelial cells facing the stroma show palisading

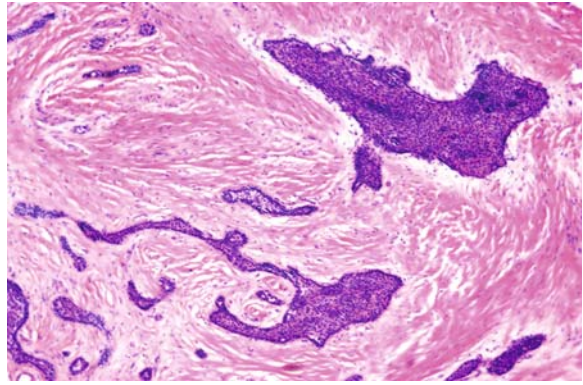


Fig. 4.13. Desmoplastic ameloblastoma consists of densely packed spindle cells lying in a fibrous stroma. Palisading of peripheral cells is not a conspicuous feature in this type of ameloblastoma

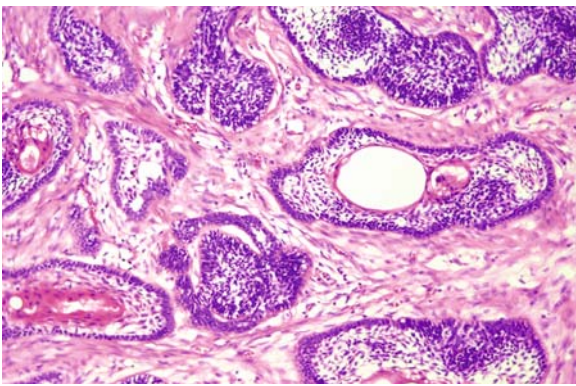


Fig. 4.12. In cases of follicular ameloblastoma, the tumour consists of epithelial islands with a loose oedematous centre and a peripheral rim of palisading cells. Liquefaction of their centre results in cyst formation

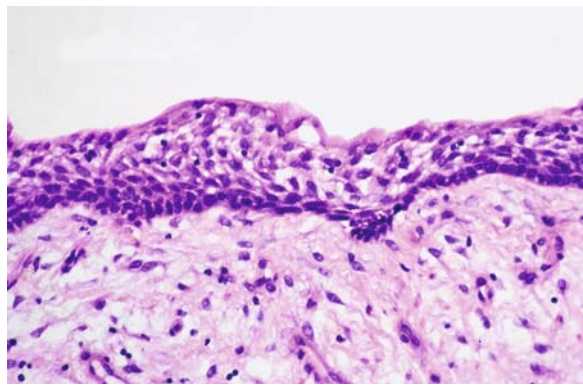


Fig. 4.14. In unicystic ameloblastoma, the tumour consists of cyst-lining epithelium that still shows the typical features of ameloblastoma: loose epithelium and a rim of palisading cells facing the stroma

Acanthomatous and *granular cell* type ameloblastoma are variants of follicular ameloblastoma with squamous metaplasia and granular cells respectively. If keratinisation is abundant, leading to large cavities filled with keratin, lesions are called *keratoameloblastoma* [135]. In these tumours acantholysis may lead to a pseudopapillary lining that characterises the variant called *papilliferous keratoameloblastoma*.

The *basal cell (basaloid) ameloblastoma* is composed of nests of basaloid cells with a peripheral rim of cuboidal cells and does not display a well-developed, loose oedematous centre.

Desmoplastic ameloblastoma shows a dense collagenous stroma, the epithelial component being reduced to narrow, compressed strands of epithelium. When these strands broaden to form larger islands, a peripheral rim of dark staining cuboidal cells and a compact centre in which spindle-shaped epithelial cells assume a whorling

pattern may be discerned (Fig. 4.13). Within the stromal component, active bone formation can be observed [119].

Unicystic ameloblastoma represents a cyst that is lined by ameloblastomatous epithelium (Fig. 4.14) [115]. This epithelium may proliferate to form intraluminal nodules with the architecture of plexiform ameloblastoma. Downward proliferation of this epithelium may lead to infiltration of the fibrous cyst wall by ameloblastoma nests. Sometimes, the cyst lining itself lacks any features indicative of ameloblastoma, these being confined to intramural epithelial nests [47]. Inflammatory alterations may obscure the specific histologic details to such an extent that none are left.

Ameloblastomas may also contain clear cells as well as mucous cells [100, 184].

Epithelial nests resembling ameloblastoma may be found in calcifying odontogenic cysts and ameloblas-

tic fibromas, lesions to be discussed under the appropriate headings (Sects. 4.4.3.1 and 4.4.3.6). Also, epithelial nests in the dental follicle that surrounds an impacted tooth and in the wall of odontogenic cysts may mimic ameloblastoma. Maxillary ameloblastomas may be mistaken for solid-type adenoid cystic carcinomas (see Chap. 5).

Ameloblastomas usually have swelling as the most prominent symptom. In the maxilla, growth into the paranasal sinuses allows tumours to attain a considerable size without causing any external deformity. Radiographically, ameloblastoma is a radiolucent lesion that is usually multilocular, the so-called soap bubble appearance, or unilocular with scalloped outlines [130].

Sometimes, ameloblastomas present as soft tissue swellings occurring in the tooth-bearing areas of the maxilla or mandible without involvement of the underlying bone. This *peripheral ameloblastoma* should not be confused with intraosseous ameloblastomas that spread from within the jaw into the overlying gingiva [117]. In the past, these lesions have also been described as *odontogenic gingival epithelial hamartoma* [6].

Clinically, some variants differ slightly from the prototypic ameloblastoma. Desmoplastic ameloblastoma occurs more often in the anterior parts of both maxilla and mandible than the other types, which favour the posterior mandible [119]. Unicystic ameloblastoma occurs at a lower mean age than the other types and often has a radiographic appearance similar to a dentigerous cyst because of its association with an impacted tooth [115].

Treatment of ameloblastoma consists of adequate tumour removal including a margin of uninvolved tissue. For peripheral ameloblastoma simple excision will be sufficient treatment [47, 115]. For unicystic ameloblastoma with the ameloblastomatous epithelium confined to the cyst lining, enucleation is adequate therapy, but in cases of intramural proliferation, treatment should be the same as for the other ameloblastoma types [133]. When adequately treated, ameloblastomas are not expected to recur. Adequate removal, however, may be difficult to realise in maxillary cases that grow postero-cranially. In that case, extension into the cranial cavity may be fatal [103]. In rare instances, metastatic deposits, mainly to the lung, have been observed. Lesions showing this behaviour are called malignant ameloblastoma (see Sect. 4.4.4.1).

4.4.1.2 Calcifying Epithelial Odontogenic Tumour

ICD-O:9340/0

The calcifying epithelial odontogenic tumour, also named *Pindborg tumour* occurs between the 2nd and 6th decade and mainly involves the posterior jaw area.

Also, cases located at the gingiva may be seen [63, 116].

The tumour consists of sheets of polygonal cells with ample eosinophilic cytoplasm, distinct cell borders and very conspicuous intercellular bridges. Nuclei are pleomorphic with prominent nucleoli; cells with giant nuclei and multiple nuclei are also present (Fig. 4.15). Mitotic figures, however, are absent. Clear cell differentiation may occur [58]. The epithelial tumour islands as well as the surrounding stroma frequently contain concentrically lamellated calcifications. The stroma contains eosinophilic material that stains like amyloid (Fig. 4.16) [73, 181]. The presence of bone and cementum in the tumour has also been reported [155]. There is no encapsulation. The tumour grows into the cancellous spaces of the adjacent jaw bone while causing expansion and thinning of the cortical bone.

Due to its pronounced nuclear pleomorphism, the tumour may be mistaken for a high-grade malignant carcinoma; the absence of mitotic figures should prevent this diagnostic error.

Swelling is the most common clinical symptom of this tumour. Radiographically, the tumour is characterised by a diffuse mixed radiodense and radiolucent appearance. Quite often, an unerupted tooth lies buried in the tumour mass. Surgery consists of removal with a margin of uninvolved tissue. Recurrences are occasionally seen, in particular with the clear cell variant [58]. Cases occurring in the extragnathic gingival tissue can be treated by simple excision as they are less aggressive than the intraosseous ones [63].

Metastatic disease is only seen in cases that combine the appearance of a calcifying epithelial odontogenic tumour with the presence of mitotic activity, suggesting malignant transformation [175]. Mitotic activity has also been seen in combination with perforation of cortical plates and invasion of blood vessels, both also highly unusual for calcifying epithelial odontogenic tumours [27]. Apparently, mitoses in this tumour indicate malignancy.

4.4.1.3 Adenomatoid Odontogenic Tumour

ICD-O:9300/0

Adenomatoid odontogenic tumour probably represents an odontogenic hamartoma rather than a neoplasm [73, 181]. The lesion is mostly seen in people in their 2nd decade. The anterior maxilla is the favoured site and the lesion is often associated with an impacted tooth [120]. Grossly, the adenomatoid odontogenic tumour is a cyst that embraces the crown of the involved tooth.

The lesion consists of two different cell populations: spindle-shaped and columnar. The spindle-shaped cells form whorled nodules that may contain drop-

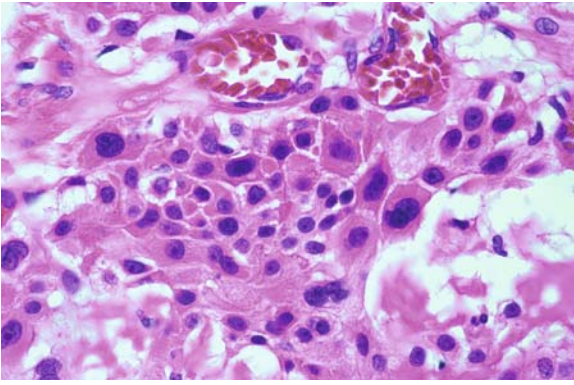


Fig. 4.15. Nuclear atypia, ample cytoplasm and pronounced intercellular bridging are typical of a calcifying epithelial odontogenic tumour

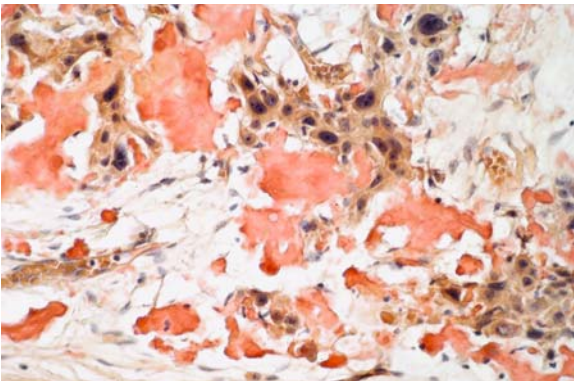


Fig. 4.16. Extracellular material staining for amyloid with congo red is another characteristic feature of a calcifying epithelial odontogenic tumour

lets of eosinophilic material. A lattice of thin epithelial strands may connect these nodules to each other. The columnar cells line duct-like spaces with a lumen either empty or containing eosinophilic material and may form curvilinear opposing rows with interposed eosinophilic material (Fig. 4.17). In the stroma, there are large aggregates of eosinophilic hyaline material, which is judged to be a dysplastic form of dentin, or cementum, or to be a metaplastic reaction of the stromal tissue [73, 120, 181]. Also, concentrically laminated calcified bodies similar to those seen in calcifying epithelial odontogenic tumours may occur.

In some adenomatoid odontogenic tumours, areas of eosinophilic cells with well-defined cell boundaries and prominent intercellular bridges similar to those observed in the calcifying epithelial odontogenic tumour are seen [110]. They do not influence the biologic behaviour of this tumour and are considered to be part of its histologic spectrum as is the presence of melanin pigment [78, 178].

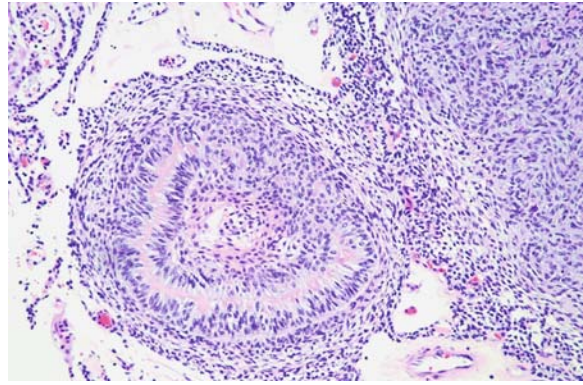


Fig. 4.17. Areas of small spindle cells and cylindrical cells facing extracellular material characterise the adenomatoid odontogenic tumour

Odontogenic adenomatoid tumour usually has swelling at the site of a missing tooth as a presenting symptom. Radiographically, this missing tooth is seen surrounded by a radiolucency that may contain multiple tiny opaque foci.

Treatment consists of simple enucleation.

4.4.1.4 Squamous Odontogenic Tumour

ICD-O:9312/0

Squamous odontogenic tumour is a rare lesion that mainly involves the periodontal tissues. There is no preference for either sex or jaw area [73, 181].

The lesion is composed of islands of well-differentiated squamous epithelium surrounded by mature fibrous connective tissue. There is no cellular atypia. There is spinous differentiation with well-defined intercellular bridges, but keratinisation is unusual. In the epithelial islands, cystic degeneration and calcification may occur. Invasion into cancellous bone may be present.

The absence of cytonuclear atypia rules out well-differentiated squamous cell carcinoma and the absence of peripheral palisading of columnar cells excludes ameloblastoma as an alternative diagnosis. Sometimes, intramural epithelial proliferation in jaw cysts may simulate squamous odontogenic tumour [187].

The lesion may cause loosening of the teeth involved. Radiographically, lucent areas are seen. Treatment consists of conservative removal of the tumour tissue. Occasionally, more extensive local spread may necessitate surgical excision with wider margins [142]. Sometimes, multicentric presentation may occur [79].

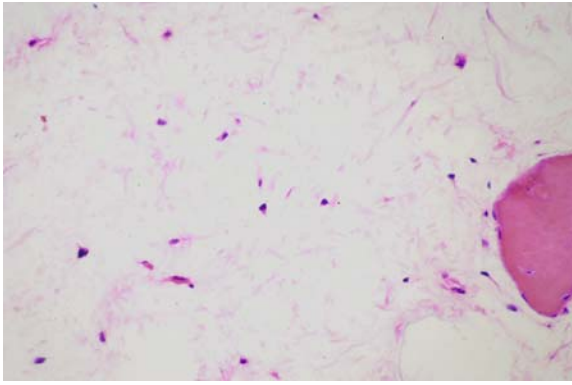


Fig. 4.18. Odontogenic myxoma is composed of poorly cellular myxoid material that surrounds pre-existing jaw bone

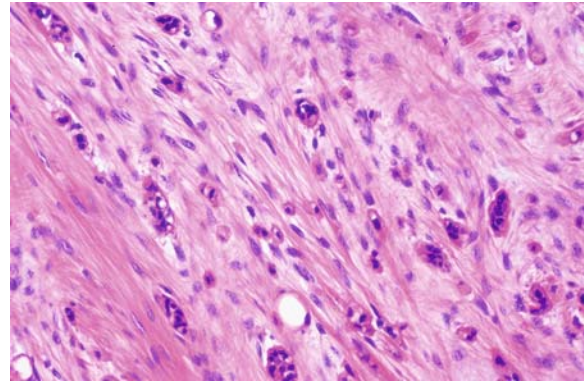


Fig. 4.19. Odontogenic fibroma consists of fibrous areas containing epithelial odontogenic nests

4.4.2 Odontogenic Tumours – Mesenchymal

Mesenchymal odontogenic tumours are derived from the ectomesenchymal part of the tissues that participate in the development of teeth and periodontal tissues. Odontogenic epithelial rests may be part of the histologic picture they show, but only fortuitously by tumour tissue-engulfed structures. They have no neoplastic or inductive potential.

4.4.2.1 Odontogenic Myxoma

ICD-O:9320/0

Odontogenic myxomas usually occur in the 2nd or 3rd decade of life, although cases occurring at a very young or old age have been reported. It is one of the more common odontogenic tumours [8].

Myxomas consist of rather monotonous cells with multipolar or bipolar slender cytoplasmic extensions that lie in a myxoid stroma. Nuclei vary from round to fusiform in appearance. Binucleated cells and mitotic figures are present, but scarce (Fig. 4.18). Occasionally, the lesion contains odontogenic epithelial rests. They are a fortuitous finding without any diagnostic or prognostic significance. Myxoma cells are positive for vimentin and muscle-specific actin, whereas positivity for S-100 is controversial [82, 102, 169].

Myxoma may be mimicked by dental follicle and dental papilla. Both contain myxoid areas [71, 101, 165]. Dental papilla tissue can be distinguished from myxoma by the presence of a peripheral layer of columnar odontoblasts. For both dental papilla and dental follicle clinical and radiographic data are decisive in avoiding misinterpretation of myxomatous tissue in jaw specimens: in the first case, a tooth germ lies in the jaw area from which the submitted tissue has been tak-

en whereas in the second case, the tissue sample covered the crown area of an impacted tooth.

Odontogenic myxomas occur in the maxilla as well as the mandible and in both anterior and posterior parts. Swelling may be the presenting sign as well as disturbances in tooth eruption or changes in position of teeth already erupted. In maxillary cases, nasal stuffiness may be the presenting sign due to tumour growth in nasal and paranasal cavities. Radiographically, lesions show a unilocular or soap-bubble appearance.

As the lesion lacks encapsulation, treatment usually consists of excision with a margin of uninvolved tissue [161]. Incidentally, cases with extremely aggressive local growth have been reported [35].

4.4.2.2 Odontogenic Fibroma

ICD-O:9321/0

Odontogenic fibroma is a controversial entity. Uncertainty exists about the broadness of histologic spectrum that these lesions may show, and about its distinction from other fibrous jaw lesions [73, 181].

Odontogenic fibroma has an age distribution of 9–80 years and occurs predominantly in females [55]. The lesion is seen within the jaw as well as in the gingiva [32].

Odontogenic fibroma consists of fibroblasts lying in a background of myxoid material intermingled with collagen fibres that may vary from delicate to coarse. Odontogenic epithelium, either scarce or abundant, may occur (Fig. 4.19). Only rarely is the epithelial component so conspicuous that differentiation between odontogenic fibroma and ameloblastoma may be difficult [66]. This histologic spectrum may expand to include cell-rich myxoid areas, a greater epithelial component and varying amounts of amorphous calcified globules or mineralised collagenous matrix. Tu-

mours with this more variegated histology have been referred to as *complex odontogenic fibroma* or *WHO-type odontogenic fibroma* [73, 181]. Odontogenic fibroma may also contain granular cells. These lesions have been called granular cell odontogenic fibromas or, alternatively, granular cell ameloblastic fibromas (see Sect. 4.4.3.1). This tumour, however, could also represent a unique entity: *central odontogenic granular cell tumour* [15, 170]. The granular cells are negative for epithelial markers and S-100 whereas positivity for CD68 suggests a histiocytic nature [15, 23]. Rarely, this tumour may show atypical histologic features including mitotic activity and aggressive behaviour [121].

There are also lesions that combine the histologic features of giant cell granuloma and central odontogenic fibroma [108]. Their aggressive nature suggests that the giant cell granuloma (see Sect. 4.6.1) component determines the clinical behaviour.

When odontogenic fibromas show a preponderance of myxoid material, distinguishing them from odontogenic myxomas may become problematic. It is probably best to consider such cases to be myxomas and to treat them accordingly.

Another significant diagnostic problem is the distinction between odontogenic fibroma and desmoplastic fibroma, which is clinically very important, as the former is benign whereas the latter shows aggressive behaviour [160]. Lesions with features of both odontogenic fibroma and desmoplastic fibroma may occur in patients with tuberous sclerosis [10].

Peripheral odontogenic fibroma should not be confused with peripheral ossifying fibroma, a gingival soft tissue lesion characterised by the presence of mineralised material of various appearances, but lacking odontogenic epithelium (see Chap. 3) [69]. Peripheral odontogenic fibroma has also to be distinguished from peripheral ameloblastoma, the former lesion lacking ameloblastomatous epithelium. Cases of peripheral odontogenic fibroma with an extensive epithelial component have in the past been reported with the designation *odontogenic epithelial hamartoma* [176].

All histologic features shown by odontogenic fibroma may also be displayed by the dental follicle [37, 71, 85, 165]. In these cases, the radiographic appearance of the lesion, a small radiolucent rim surrounding the crown of a tooth buried within the jaw, will make the distinction.

Central odontogenic fibromas may present as local bony expansions of the involved jaw area. Quite often, they are incidental findings on radiographs performed for other diagnostic purposes: demarcated unilocular radiolucencies located adjacent to the roots of the neighbouring teeth or surrounding an impacted tooth. Peripheral odontogenic fibromas are firm-elastic gingival swellings.

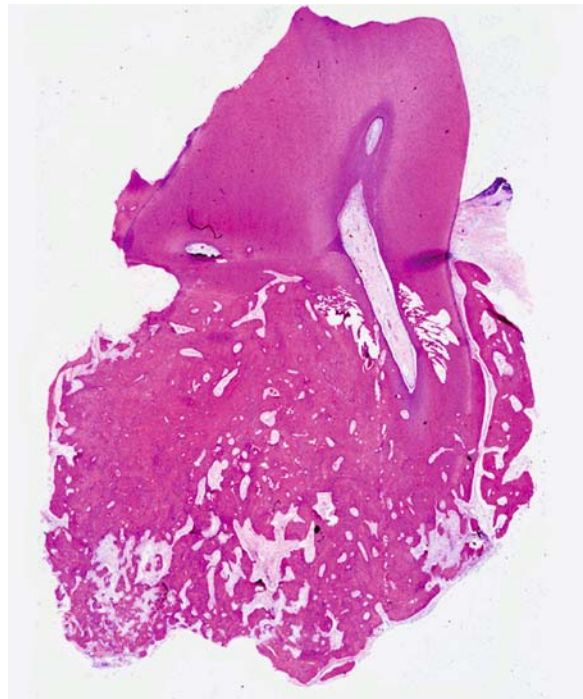

Fig. 4.20. A hard tissue mass firmly connected to the root surface of the tooth involved is diagnostic for cementoblastoma

Treatment consists of enucleation. Peripheral cases, however, may recur after excision [32].

4.4.2.3 Cementoblastoma

ICD-O:9273/0

Cementoblastomas are heavily mineralised cementum masses connected to the apical root part of a tooth (Fig. 4.20) [73, 181]. These tumours are most often seen in young adults and show a predilection for males [14].

They are composed of a vascular, loose-textured fibrous tissue that surrounds coarse trabeculae of basophilic mineralised material bordered by plump cells with ample cytoplasm and large but not atypical nuclei. Mitotic figures are rare. At the periphery, the mineralised material may form radiating spikes. Also, osteoclastic giant cells form part of the histologic spectrum. The hard tissue component is connected with the root of the involved tooth, which usually shows signs of external resorption. The sharp border between the tubular dentin of the root and the hard tissue component forms the hallmark of cementoblastomas (Fig. 4.21).

All features of the cementoblastoma may also be shown by the osteoblastoma, except the connection with the tooth root. Therefore, cases in which this connection cannot be demonstrated should be diagnosed as osteoblastoma and not cementoblastoma [156].

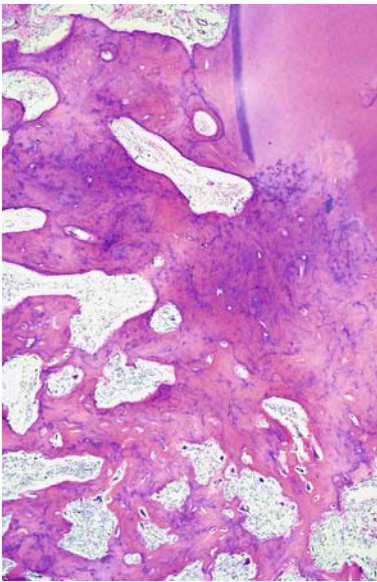


Fig. 4.21. Higher magnification of Fig. 4.20 shows the continuity between the root forming tubular dentin (*right side*) and the cemental masses of the cementoblastoma

Pain is the most common presenting symptom and the posterior jaw areas are the predilection site. Sometimes, the lesion is attached to multiple neighbouring teeth [156]. Radiographically, the lesion is demarcated with a mixed lucent and dense appearance and is continuous with the partially resorbed root of a tooth. As recurrence and continued growth are possible, treatment should consist of removal of the lesion along with the affected tooth or teeth, and should also include some adjacent jaw bone [14].

4.4.3. Odontogenic Tumours – Mixed Epithelial and Mesenchymal

Mixed odontogenic tumours are composed of both epithelial-derived and mesenchymal-derived tissues. These tumours recapitulate proliferation and differentiation as seen in the developing teeth. Deposition of the dental hard tissues – enamel and dentin – may also occur [73, 174, 181]. Lesions with an identical histology can show neoplastic as well as hamartomatous behaviour [118, 153].

4.4.3.1 Ameloblastic Fibroma

ICD-O:9330/0

Ameloblastic fibroma lacks a hard tissue component, only displaying soft tissues similar to those found in the immature tooth germ.

It is one of the less common lesions [34, 109, 127]. Mean age of occurrence is 14.8 years, but cases may be seen from as young as only 7 weeks up to as old as 62 years. Most cases are seen in the posterior mandible [96, 118].

The epithelial part of ameloblastic fibroma consists of branching and anastomosing epithelial strands that form knots of varying size. These knots have a peripheral rim of columnar cells that embraces a loosely arranged spindle-shaped epithelium. These epithelial strands lie in a myxoid cell-rich mesenchyme. The amount of epithelium may vary among cases and regionally within an individual case. There is no formation of dental hard tissues. Mitotic figures, either in epithelium or mesenchyme, are extremely rare; when easily found, they should raise concern about the benign nature of the case.

Ameloblastic fibroma may contain granular cells. Whether these lesions should be called *granular cell ameloblastic fibroma* or *granular cell odontogenic fibroma* is controversial (see also Sect. 4.4.2.2) [118, 170].

The epithelial component of ameloblastic fibroma closely resembles that of ameloblastoma. The stromal component, however, is entirely different: in ameloblastoma it is mature fibrous connective tissue whereas in the ameloblastic fibroma it is immature, embryonic, cell-rich myxoid tissue. Areas similar to ameloblastic fibroma may also be observed in the hyperplastic dental follicle [71, 165]. The radiographic appearance makes the distinction; a radiolucent rim surrounding an unerupted tooth in the case of a dental follicle and an expansive radiolucent jaw lesion in the case of an ameloblastic fibroma.

Most cases of ameloblastic fibroma present as painless swellings or are discovered due to disturbances in tooth eruption. Radiographically, the tumour presents as a well-demarcated expansive radiolucency, often in connection with a malpositioned tooth.

Treatment consists of enucleation and curettage. In some cases, recurrence may occur [118]. Sometimes, ameloblastic fibroma may progress to malignancy. These lesions are characterised by increased cellularity and mitotic activity of the mesenchymal component and therefore known as ameloblastic fibrosarcoma (see Sect. 4.4.4.6) [96].

4.4.3.2 Ameloblastic Fibro-Odontoma

ICD-O:9290/0

Ameloblastic fibro-odontomas are lesions that combine a soft tissue component, similar to ameloblastic fibroma, with the presence of dentin and enamel. In rare cases, only dentin is formed; those tumours are called *ameloblastic fibro-dentinoma* (ICD-O:9271/0) [73, 181].

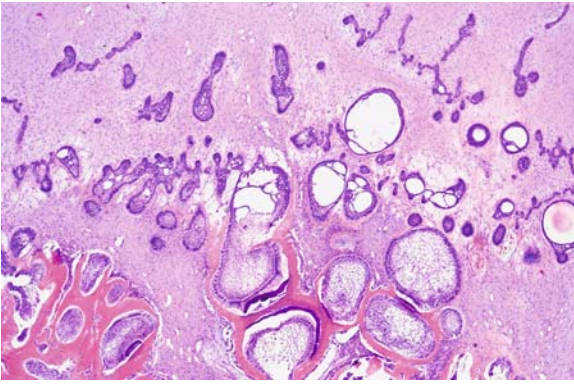


Fig. 4.22. Ameloblastic fibro-odontoma combines the soft tissue elements of an ameloblastic fibroma with the deposition of the dental hard tissues enamel and dentin. Cavities in the homogeneous eosinophilic dentin contain high-columnar ameloblasts lying down enamel matrix (*deep purple*)

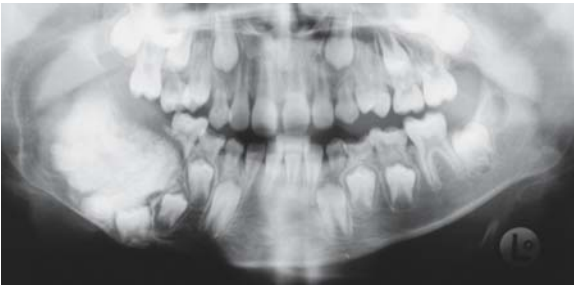

Fig. 4.23. Panoramic radiograph showing radiodense mass in connection with a tooth germ, a picture typical of complex odontoma

Ameloblastic fibro-odontomas are rare [34, 127]. They occur primarily within the first two decades and have the posterior jaw areas as sites of predilection, the mandible more often involved than the maxilla [118, 153].

The soft tissue component is identical to that of ameloblastic fibroma. Dentin may be formed either as eosinophilic mineralised material containing tubuli, just as in normal teeth, but it may also form as an homogeneous eosinophilic mass with sparse cells included. It always lies in close association with adjacent epithelium and forms the scaffold for the deposition of enamel matrix that is laid down at the epithelial–dentin interface by columnar epithelial cells that have reached their terminal differentiation as ameloblasts. The dental hard tissues are arranged haphazardly without any reminiscence of the orderly structure characterising normal teeth (Fig. 4.22).

Hyperplastic dental follicles may also show focal areas with the appearance of ameloblastic fibro-odontoma. Differential diagnostic considerations are the same

as those as already mentioned (see Sect. 4.4.3.1). Ameloblastic fibro-odontomas can be distinguished from ameloblastomas by the presence of cellular myxoid tissue and of dentin and enamel.

Most cases of ameloblastic fibro-odontoma present as painless swelling or are discovered due to disturbances in tooth eruption. Radiographically, the tumour presents as a well-demarcated expansive radiolucency with a radiopaque centre. Treatment consists of enucleation and curettage. Recurrence is rarely seen [46].

4.4.3.3 Odontoma – Complex Type

ICD-O:9282/0

Complex odontoma is a lesion composed of a haphazard conglomerate of dental hard tissues. This hamartoma is one of the more common odontogenic lesions [34, 127]. The posterior mandible is the favoured site (Fig. 4.23). Ages at which this lesion occurs are difficult to determine as lesions may be present unnoticed for a long time, the age distribution mentioned reflecting the age when the lesion was found rather than the age at which it formed. This explains the enormous range in age distribution reported: 2–74 years [118].

Complex odontomas consist of a usually well-delineated mass of dental hard tissues in a haphazard arrangement. The bulk of the lesion consists of dentin recognisable by the presence of tubuli. Enamel plays a minor role, usually confined to small rims in cavities in the dentin mass. The stroma consists of mature fibrous connective tissue.

Sometimes, odontomas may contain areas identical to the calcifying odontogenic cyst including ghost cells [22, 61, 80]. Odontoma-like structures may also occur in the hyperplastic dental follicle (see Sect. 4.4.2.1).

Complex odontomas may reveal their existence by disturbances in tooth eruption, missing teeth or jaw expansion. Quite often, they are incidental findings on radiographs taken for other purposes. In those cases, an amorphous calcified mass is seen that may be connected with the crown of an unerupted tooth. Treatment consists of conservative removal. Recurrences are not seen.

4.4.3.4 Odontoma – Compound Type

ICD-O:9281/0

Compound odontoma is a malformation consisting of tiny teeth that may vary in number from only a few to numerous. These teeth do not resemble the normal

teeth, but are usually cone-shaped. Histologically, they show the normal arrangement of centrally placed fibrovascular pulp tissue surrounded by dentin with an outer surface covered by enamel in the crown area and cementum in the root part.

Compound odontoma is one of the more frequently encountered odontogenic lesions [34, 127]. Data on age of occurrence show the same wide range as with complex odontoma: 0.5–73 years of age, which is due to the fact that compound odontomas may also remain unnoticed for a long time.

In contrast with almost all other odontogenic lesions that have the posterior mandible as the preferred site, compound odontomas have a definite predilection for the anterior maxilla [118, 153]. They may cause swelling or disturbed tooth eruption. Radiographically, a radiolucency containing multiple tooth-like radiopaque structures is seen. Treatment consists of enucleation and there is no recurrence.

Compound odontomas may contain areas identical to those of the calcifying odontogenic cyst including ghost cells (see Sect. 4.4.3.6) [22, 61, 80].

4.4.3.5 Odonto-Ameloblastoma

ICD-O:9311/0

Odonto-ameloblastoma is a very rare neoplasm that combines the features of ameloblastoma and odontoma, including the presence of enamel and dentin [73, 181]. The ameloblastoma component determines clinical presentation and behaviour. Radiographically, the soap-bubble appearance of ameloblastoma is combined with radiopaque masses due to the odontoma component [97].

4.4.3.6 Calcifying Odontogenic Cyst

ICD-O:9301/0

Calcifying odontogenic cysts occur both in the maxilla and in the mandible in equal proportions. They most commonly lie intraosseously, but cases in the gingiva are also seen. The lesion is most commonly found in the 2nd and 3rd decades [19, 20, 173].

In its most simple form, calcifying odontogenic cyst is a cavity with a fibrous wall and an epithelial lining. This epithelial lining closely mimics that seen in unicystic ameloblastoma, but, in addition, there are intraepithelial eosinophilic ghost cells lacking nuclei that may undergo calcification. Ghost cell masses may also herniate through the basal lamina to reach the underlying stroma where they can act as foreign material and evoke a giant cell reaction (Fig. 4.24). In the fibrous stroma adjacent to the basal epithelial cells, homogenous eosino-

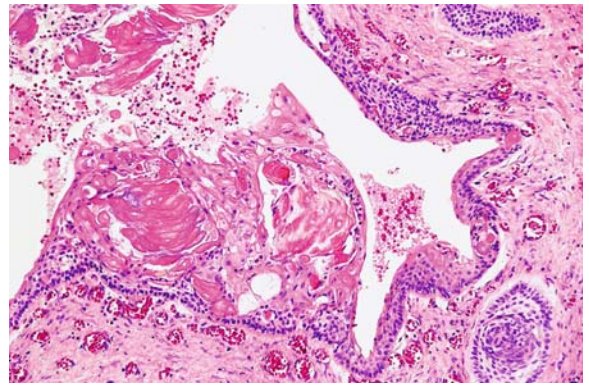


Fig. 4.24. Calcifying odontogenic cyst closely resembles ameloblastoma, but the presence of large intraepithelial aggregates of ghost cells rules out the latter diagnosis

philic material resembling dentin may be found in varying amounts. Dentin-like material and ghost cells together may form mixed aggregates.

To this simple unicystic structure other features may be added, thus creating different subtypes with different names [173].

The *proliferative calcifying odontogenic cyst* shows multiple intramural daughter cysts with an epithelial lining similar to the main cyst cavity. The *solid (neoplastic) calcifying odontogenic cyst* has been described by a variety of other terms: *dentinogenic ghost cell tumour*, *epithelial odontogenic ghost cell tumour*, *calcifying ghost cell odontogenic tumour*, and *cystic calcifying odontogenic tumour* [81]. This lesion combines the morphology of an ameloblastoma with intra-epithelial and stromal ghost cells with a dentin-like material. The most recent WHO classification proposes the diagnostic designations *calcifying cystic odontogenic tumour (ICD-O:9301/0)* and *dentinogenic ghost cell tumour (ICD-O:9302/0)* to discern between the cystic and the solid lesion [181].

Also, calcifying odontogenic cysts may occur in association with other odontogenic tumours, in most instances ameloblastoma and odontoma [124]. All variants of calcifying odontogenic cyst may show melanin pigment [60, 162].

Ghost cells, either intraepithelially or in the stroma, separate calcifying odontogenic cyst from ameloblastoma. The solid variant of calcifying odontogenic cyst is similar to craniopharyngioma [7, 111].

Intraosseous calcifying odontogenic cysts cause bony expansion. The peripheral type forms a gingival soft tissue swelling. Radiographically, the lesion shows a lucent appearance when located intraosseously, mostly with variable amounts of radiopacities. Treatment of the calcifying odontogenic cyst consists of enucleation in cases of intraosseous location or excision for peripheral ones.

Recurrences have been documented for both the cystic and the solid variant [124, 143]. If the lesion is combined with an ameloblastoma, this latter component dictates the most appropriate therapy, which consists of surgical excision including a margin of healthy tissue as already discussed [124].

4.4.4 Odontogenic Tumours – Malignant

Both odontogenic epithelium as well as odontogenic mesenchyme may show neoplastic degeneration, causing either odontogenic carcinomas or odontogenic sarcomas [73, 159, 181]. All entities to be mentioned show the clinical presentation and course as well as the radiographic appearance of an intraosseous malignant tumour.

4.4.4.1 Malignant Ameloblastoma

ICD-O:9310/3

Malignant (metastasising) ameloblastoma is an ameloblastoma that metastasises in spite of an innocuous histologic appearance. The primary tumour shows no specific features that are different from ameloblastomas that do not metastasise. Therefore, this diagnosis can only be made in retrospect, after the occurrence of metastatic deposits. It is thus clinical behaviour and not histology that justifies a diagnosis of malignant ameloblastoma [181]. This definition profoundly differs from that given in the previous WHO classification [73]. At that time a malignant ameloblastoma was described as a neoplasm in which the pattern of an ameloblastoma is combined with cytological features of malignancy, a definition not based on behaviour but on histology. It is obvious that disparate views on what represents a malignant ameloblastoma can give rise to confusion [41, 159]. It has to be emphasised that to avoid mixing up different entities, the term malignant ameloblastoma should be reserved for metastasising ameloblastomas whereas the ameloblastomas with atypia should be called ameloblastic carcinomas, a type of lesion to be discussed in Sect. 4.4.4.2 [104]. Confusion may also arise through the use of the term atypical ameloblastomas to denote lesions with a fatal outcome for various reasons, either metastasis, histologic atypia or relentless local spread [3].

Metastatic deposits of malignant ameloblastomas are mostly seen in the lung [76, 77, 159]. Apart from metastasis, malignant ameloblastoma shows no features that are different from conventional ameloblastoma (see Sect. 4.4.1.1).

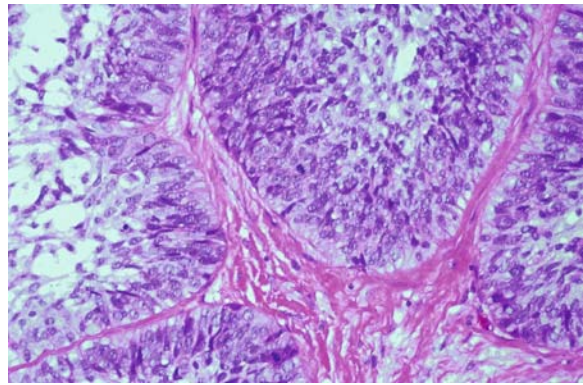


Fig. 4.25. Ameloblastic carcinoma combines the presence of epithelial nests with peripheral palisading and cytonuclear atypia

4.4.4.2 Ameloblastic Carcinoma

ICD-O:9270/3

Ameloblastic carcinoma, an entity that has only recently been recognised, is a lesion with the histologic features of both ameloblastoma and squamous cell carcinoma [42, 181]. This tumour may arise de novo or from a pre-existing benign odontogenic tumour or cyst [159].

Most cases of ameloblastic carcinoma occur in the mandible [30]. They show a wide age range with a mean of 30.1 years [30].

Ameloblastic carcinoma is characterised by cells that, although mimicking the architectural pattern of ameloblastoma, exhibit pronounced cytological atypia and mitotic activity, thus allowing the distinction between ameloblastic carcinoma and ameloblastoma (Fig. 4.25). Metastatic lesions are described in the lungs and in the lymph nodes [36, 151].

4.4.4.3 Primary Intraosseous Carcinoma

ICD-O:9270/3

Primary intraosseous carcinoma is a squamous cell carcinoma arising within the jaw, having no initial connection with the oral mucosa, and presumably developing from residues of the odontogenic epithelium [73, 181]. It ranges from well to poorly differentiated [42], mainly occurs in the posterior mandible and is more often seen in males [190].

The tumour may arise from a still recognisable precursor lesion such as the epithelial lining of an odontogenic cyst [67, 90]. Also, enamel epithelium has been documented as a tissue of origin [154].

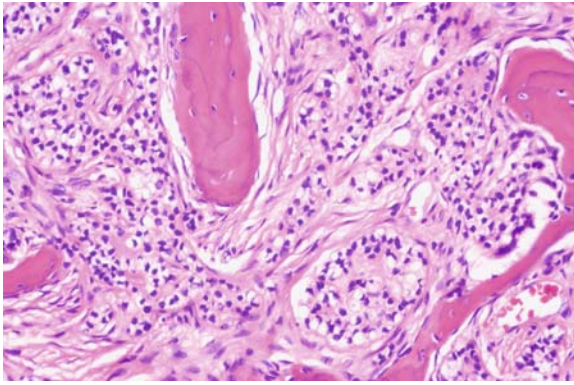


Fig. 4.26. Clear cell odontogenic carcinoma is characterised by clear cells forming epithelial nests

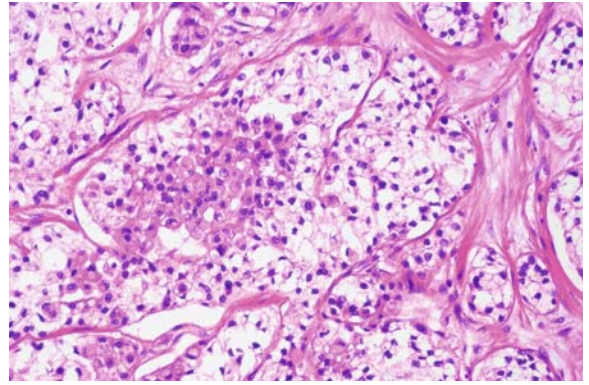


Fig. 4.27. At higher magnification, clear cell odontogenic carcinoma is seen to contain clear cells as well as eosinophilic cells

Swelling of the jaw and pain are most often the presenting signs. Surgery and postoperative radiotherapy seem to provide the best results. The tumour may metastasise to regional lymph nodes as well as lungs. Prognosis is poor with almost 50% of the patients failing loco-regionally within the first 2 years of follow-up [190].

4.4.4.4 Clear Cell Odontogenic Carcinoma

ICD-O:9341/1

Clear cell odontogenic carcinoma was initially reported as a clear cell odontogenic tumour [56]. As these lesions not only behave aggressively locally, but may also metastasise, the currently used diagnostic term clear cell odontogenic carcinoma appears to be more appropriate [43, 75]. The tumour is mostly seen in elderly patients [5].

The tumour is composed of cells with clear cytoplasm. These cells form nests and strands, intermingled with smaller islands of cells with eosinophilic cytoplasm (Figs. 4.26, 4.27). Also, squamous differentiation has been reported [17]. Cells at the periphery of the nests may show palisading. The clear cells stain positive for glycogen as well as for epithelial markers keratin AE1/AE3, cytokeratin 8/18, cytokeratin 19 and epithelial membrane antigen (EMA) [89].

The anterior mandible appears to be the site of predilection. Metastases are found in lymph nodes as well as in the lungs and the skeleton. Recurrent disease is seen in more than 50% of cases with documented follow-up. Death due to the tumour has also been reported [5, 89].

Differential diagnosis includes metastatic renal cell carcinoma, the clear cell variant of mucoepidermoid carcinoma, and ameloblastoma with clear cells. Metastatic renal cell carcinoma may be ruled out on clinical grounds. The clear cell variant of muco-epidermoid

carcinoma can be identified with stains for mucin production. Differentiation from ameloblastoma with clear cells may be problematic and it has been proposed that these lesions represent the same entity [16]. Clear cell carcinoma of minor salivary gland origin is another differential diagnosis (see Chap. 5).

4.4.4.5 Malignant Epithelial Odontogenic Ghost Cell Tumour

ICD-O:9270/3

Malignant epithelial odontogenic ghost cell tumour, also called *odontogenic ghost cell carcinoma* is a tumour that combines the elements of a benign calcifying odontogenic cyst with a malignant epithelial component. Only a few cases of this tumour have been reported, thus precluding any conclusions regarding clinicopathologic features. Malignancy has been demonstrated by local aggressive growth and distant metastasis [84]. The tumour apparently arises most often from malignant transformation of a pre-existing benign calcifying odontogenic cyst [81].

4.4.4.6 Odontogenic Sarcoma

ICD-O:9270/3

The WHO discerns between ameloblastic fibrosarcoma, ameloblastic fibrodentino- and fibro-odontosarcoma and odontogenic carcinosarcoma [73, 181]. The *ameloblastic fibrosarcoma* consists of malignant connective tissue admixed with epithelium similar to that seen in an ameloblastoma or ameloblastic fibroma [152]. If there is also dentin, this is known as an *ameloblastic fibrodentinosarcoma*, and if there is also enamel, it is called *ameloblastic fibro-odontosarcoma*. This subclassification has no prognostic significance [2]. These tumours may arise

Table 4.3. Fibro-osseous lesions [13, 181]

Fibrous dysplasia	
Ossifying fibroma	Conventional
	Juvenile trabecular
	Juvenile psammomatoid
Osseous dysplasia	Periapical osseous dysplasia
	Focal osseous dysplasia
	Florid osseous dysplasia
	Familial gigantiform cementoma

de novo or from a pre-existing ameloblastic fibroma or ameloblastic fibro-odontoma [98].

Those extremely rare lesions that combine carcinomatous and sarcomatous elements, but are recognisable as odontogenic from the epithelial component, resemble ameloblastic carcinomas, and have been called *odontogenic carcinosarcoma* or *odontogenic carcinoma with sarcomatous proliferation* [152].

4.5 Fibro-Osseous Lesions

The current classification of maxillofacial fibro-osseous lesions includes fibrous dysplasia, ossifying fibroma and osseous dysplasia [13, 158]. Table 4.3 gives an overview of the various entities in this group.

4.5.1 Fibrous Dysplasia

Fibrous dysplasia is composed of cellular fibrous tissue containing trabeculae of woven bone. It occurs in three clinical subtypes: monostotic, which affects one bone, polyostotic, which affects multiple bones, and Albright's syndrome, in which multiple bone lesions are accompanied by skin hyperpigmentation and endocrine disturbances [13]. Activating missense mutations of the gene encoding the α subunit of the stimulatory G protein are a consistent finding in the various forms of fibrous dysplasia [123].

Craniofacial fibrous dysplasia is usually of the monostotic type [44]. The disease mostly occurs during the first three decades, although cases are occasionally seen at an older age. The maxilla is more often involved than the mandible. In the maxilla, fibrous dysplasia may extend by continuity across suture lines to involve adjacent bones [13].

Fibrous dysplasia shows replacement of the normal bone by moderately cellular fibrous tissue containing irregularly shaped trabeculae consisting of woven bone without rimming osteoblasts that fuse with adjacent bone. Jaw lesions may also show lamellar bone (Fig. 4.28). Sometimes, tiny calcified spherules may be present [158].

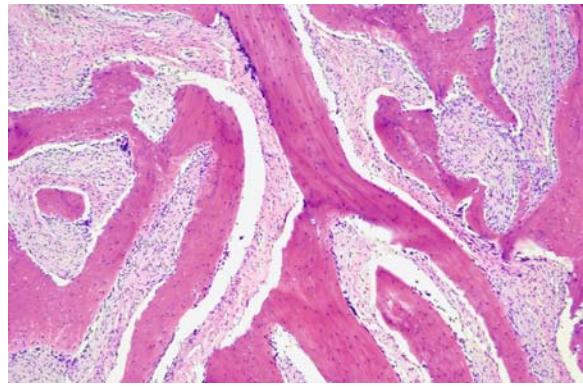


Fig. 4.28. In the jaws, fibrous dysplasia may consist of both woven and lamellar bone, as shown in this photomicrograph taken with the use of partly polarised light to enhance the collagenous scaffold of the bone

Fibrous dysplasia has to be distinguished from other lesions characterised by the combination of fibrous tissue and bone: ossifying fibroma, osseous dysplasia, low-grade osteosarcoma and sclerosing osteomyelitis. However, none of these is composed of woven bone trabeculae fusing with adjacent uninvolved bone. Ossifying fibroma and osseous dysplasia both show much variety in appearance of mineralised material and stromal cellularity, low-grade osteosarcoma invades through the cortical bone into soft tissues and sclerosing osteomyelitis shows coarse trabeculae of lamellar bone, whereas the intervening stroma is not cellular but oedematous with sprinkled lymphocytes [158].

Fibrous dysplasia clinically presents as a painless swelling of the bone involved. Radiographically, the classical appearance is described as orange-skin or ground-glass radiopacity without defined borders [13]. Usually, fibrous dysplasia is a self-limiting disease. Therefore, treatment is only required if there are problems due to local increase in size of the affected bone. Sometimes, an osteosarcoma may arise in fibrous dysplasia [39].

4.5.2 Ossifying Fibroma

ICD-O:9262/0, 9274/0

Ossifying fibroma, formerly also called *cemento-ossifying fibroma* is a well-demarcated lesion composed of fibrocellular tissue and mineralised material of varying appearance. It occurs most often in the 2nd through the 4th decades. The lesion shows a predilection for females, is mostly seen in the posterior mandible [13] and may occur multifocally [70].

Chromosomal abnormalities have been observed in ossifying fibromas [31, 49, 138]. Data are still too scarce to determine their pathogenetic significance.

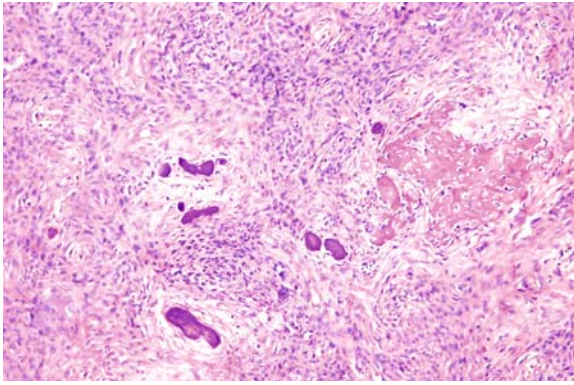


Fig. 4.29. Ossifying fibroma contains both cell-rich and cell-poor areas as well as well-structured bone and amorphous calcified material

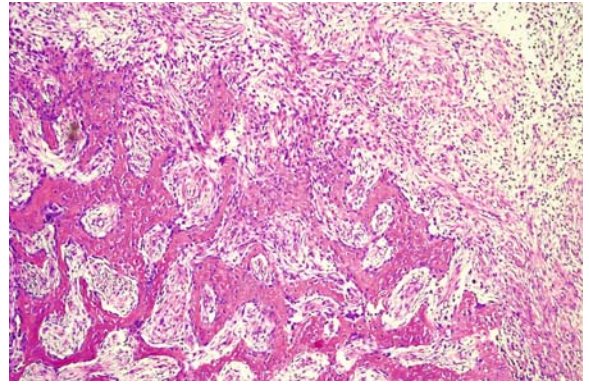


Fig. 4.31. Juvenile trabecular ossifying fibroma shows slender bony trabeculae rimmed with osteoblasts that merge with an extremely cellular stroma

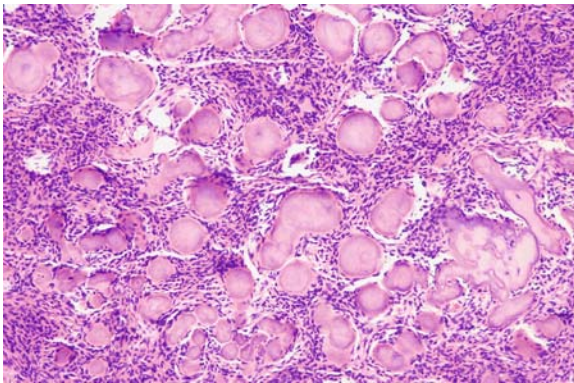


Fig. 4.30. Ossifying fibroma may also contain more smoothly contoured bony elements, formerly thought to represent cementum

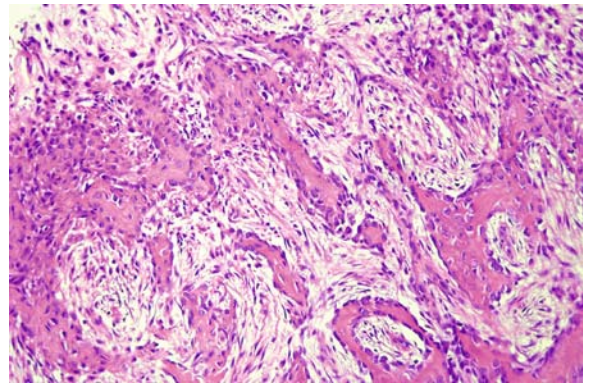


Fig. 4.32. At higher magnification, the plump osteoblasts that line the bony trabeculae in juvenile trabecular ossifying fibroma are shown to be a prominent feature

Ossifying fibroma is composed of fibrous tissue that may vary in cellularity from areas with closely packed cells displaying mitotic figures to almost acellular sclerosing parts within one and the same lesion. The mineralised component may consist of plexiform bone, lamellar bone and acellular mineralised material, sometimes all occurring together in one single lesion (Figs 4.29, 4.30).

Juvenile psammomatoid and *juvenile trabecular ossifying fibroma* are subtypes [40]. Juvenile trabecular ossifying fibroma consists of cell-rich fibrous tissue with bands of cellular osteoid together with slender trabeculae of plexiform bone lined by a dense rim of enlarged osteoblasts (Figs. 4.31, 4.32). Sometimes these trabeculae may anastomose to form a lattice. Mitoses are present, especially in the cell-rich areas. Also, multinucleated giant cells, pseudocystic stromal degeneration and haemorrhages may be present. Due to its cellularity and mitotic activity, the lesion may be confused with osteosarcoma. However, atypical cellular features or abnormal mitotic figures are not seen.

Moreover, the lesion is demarcated from its surroundings [73, 158, 181].

Juvenile psammomatoid ossifying fibroma is characterised by a fibroblastic stroma containing small ossicles resembling psammoma bodies, hence its name. The stroma varies from loose and fibroblastic to intensely cellular. The spherical or curved ossicles are acellular or include sparsely distributed cells (Fig. 4.33). They should not be confused with the cementum-like deposits that are present in conventional ossifying fibroma. These particles have a smooth contour whereas the ossicles in juvenile psammomatoid ossifying fibroma has a peripheral radiating fringe of collagen fibres. Ossicles may coalesce to form trabeculae. Sometimes, juvenile psammomatoid ossifying fibroma contains basophilic, concentrically lamellated particles, as well as irregular thread-like or thorn-like calcified strands in a hyalinised background (Fig. 4.34). Other features such as trabeculae of woven bone as well as lamellar bone, pseudocystic stromal degeneration and haemorrhages resulting

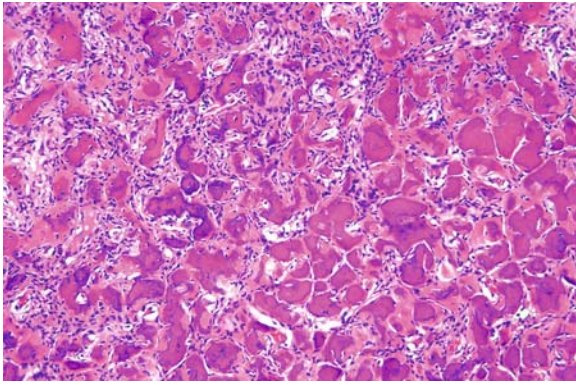


Fig. 4.33. Psammomatoid ossicles in a cellular stroma characterise juvenile psammomatoid ossifying fibroma. A comparison with Fig. 4.30 shows that these particles are not as smoothly outlined as those occurring in conventional ossifying fibromas

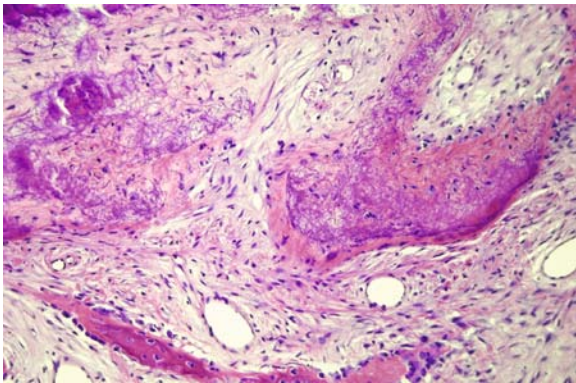


Fig. 4.34. Thread-like calcifications in an eosinophilic matrix are also often present in juvenile psammomatoid ossifying fibroma

in areas similar to an aneurysmal bone cyst, multinucleate giant cells, and mitotic figures can also be observed. Juvenile psammomatoid ossifying fibroma has the bony walls of the paranasal sinuses as site of predilection [179].

Ossifying fibroma may be confused with fibrous dysplasia. The most important distinguishing feature is the presence of demarcation and/or encapsulation in ossifying fibroma as opposed to the merging with its surroundings as shown by fibrous dysplasia. In addition, the variation in cellularity as well as in appearance of mineralised material distinguishes ossifying fibroma from fibrous dysplasia. To distinguish ossifying fibroma from osseous dysplasia, data on clinical presentation and radiographic appearance are indispensable (see Sect. 4.5.3).

Juvenile psammomatoid ossifying fibroma has to be differentiated from meningioma with psammoma bodies; immunohistochemistry positive for EMA rules out juvenile psammomatoid ossifying fibroma. Moreover,

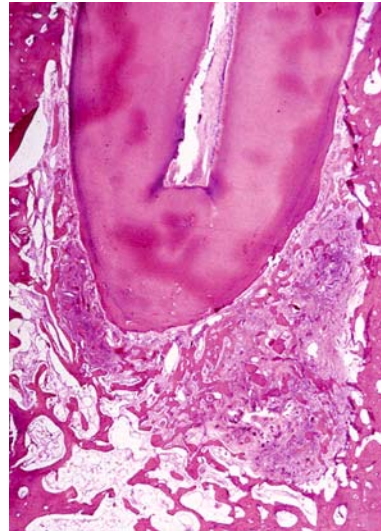


Fig. 4.35. Osseous dysplasia typically lies at the root tip. It consists of fibrous tissue containing mineralised material of varying appearance

the psammomatoid ossicles in juvenile psammomatoid ossifying fibroma are clearly different from the acellular spherical real psammoma bodies [172].

Clinically, ossifying fibroma causes expansion of the bone involved leading to a palpable swelling. Radiographically, a demarcated lesion is seen that may have radiodense as well as radiolucent areas depending on the various contributions of soft and hard tissue components to an individual lesion [13].

Excision of ossifying fibromas usually yields a permanent cure.

4.5.3. Osseous Dysplasia

ICD-O:9272/0

Osseous dysplasia is a pathologic process of unknown aetiology located in the tooth-bearing jaw areas in the vicinity of the tooth apices and is thought to arise from the proliferation of periodontal ligament fibroblasts that may deposit bone as well as cementum. The condition occurs in various clinical forms that bear different names. However, all have the same histomorphology: cellular fibrous tissue, trabeculae of woven as well as lamellar bone and spherules of cementum-like material (Fig. 4.35). The ratio of fibrous tissue to mineralised material may vary and it has been shown that these lesions are initially fibroblastic, but over the course of several years may show increasing degrees of calcification. This variation in ratio of soft tissue to hard tissue is reflected in the radiographic appearance; lesions are predominantly radiolucent, predominantly radiodense or mixed.

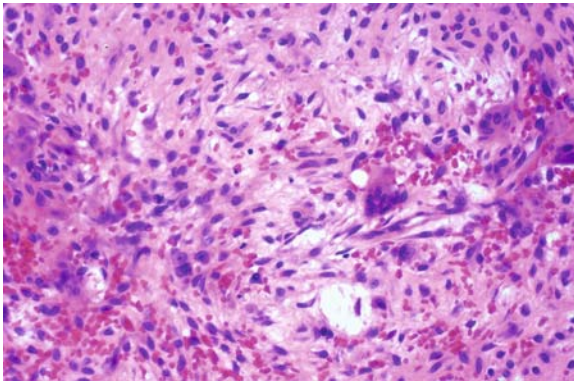


Fig. 4.36. Central giant cell granuloma shows osteoclast-like giant cells in a loose fibrocellular stroma. Cherubism has an identical appearance

Osseous dysplasia lacks encapsulation or demarcation, but tends to merge with the adjacent cortical or medullary bone [13].

The several subtypes of osseous dysplasia are distinguished by clinical and radiological features. *Periapical osseous dysplasia* occurs in the anterior mandible and involves only a few adjacent teeth. A similar limited lesion occurring in a posterior jaw quadrant is known as *focal osseous dysplasia* [167]. *Florid osseous dysplasia* is non-expansile, involves two or more jaw quadrants and occurs in middle-aged black females [13]. *Familial gigantiform cementoma* is expansile, involves multiple quadrants and occurs at a young age. This type of osseous dysplasia shows an autosomal dominant inheritance with variable expression, but sporadic cases without a history of familial involvement have also been reported [1, 189]. Simple bone cysts may be seen with florid and focal osseous dysplasia [59, 62].

Osseous dysplasia has to be distinguished from ossifying fibroma. Osseous dysplasia is a mixed radiolucent-radiodense lesion with ill-defined borders in the tooth-bearing part of the jaws, either localised or occupying large jaw areas depending on the type. In contrast, ossifying fibroma is usually a localised lesion that expands the jaw, and is predominantly radiolucent with radiodense areas [164].

Osseous dysplasia also has to be differentiated from sclerosing osteomyelitis [140]. Sclerotic lamellar bone trabeculae and well-vascularised fibrous tissue with lymphocytes and plasma cells define sclerosing osteomyelitis, whereas cementum-like areas and fibrocellular soft tissue are lacking [53].

The various forms of osseous dysplasia do not require treatment unless necessitated by complications such as infection of sclerotic bone masses, as may occur in florid osseous dysplasia, or facial deformity, as may be seen in familial gigantiform cementoma.

4.6 Giant Cell Lesions

Central giant cell granuloma, cherubism and aneurysmal bone cyst all show osteoclast-like giant cells lying in a fibroblastic background tissue. The fibroblastic tissue may vary in cellularity from very dense to cell-poor. Mitotic figures may be encountered but are usually not numerous and not atypical. The giant cells mostly cluster in areas of haemorrhage, but they may also lie more dispersed among the lesion (Fig. 4.36). Bone formation, if present, is usually confined to the periphery of the lesion. Radiologically, all three types of giant cell lesions have a lucent, quite often multilocular appearance. Multiple giant cell lesions may occur in association with Noonan's syndrome as well as with neurofibromatosis [38, 134]. Further discussion will only include giant cell granuloma and cherubism as they are confined to the jaws.

4.6.1 Central Giant Cell Granuloma

Central giant cell granuloma is mostly seen before the age of 30. The lesion is restricted to the jaws, the mandible being more often involved than the maxilla. Its aetiology is unknown. Lesions with a histologic appearance identical to that of the central giant cell granuloma may occur in the gingiva and are called giant cell epulis (see Chap. 3). Sometimes, lesions combine the appearance of a giant cell granuloma with that of an odontogenic fibroma [108].

Clinically, central giant cell granuloma manifests itself as a localised jaw swelling. Radiographically, it is a radiolucent lesion that may be either uni- or multilocular. As the lesion is not encapsulated, removal is sometimes followed by recurrence. If there is recurrence, hyperparathyroidism should be ruled out as the brown tumours associated with this latter disease are identical to giant cell granulomas. Also, distinction has to be made between giant cell granulomas and true giant cell tumours. There has been much discussion whether giant cell granulomas with more aggressive behaviour than usually observed could represent a gnathic manifestation of this latter lesion [4, 163].

4.6.2 Cherubism

In cases of cherubism, two or more jaw quadrants contain lesions histologically similar to giant cell granuloma. The disease occurs in young children, often with a history of other afflicted family members. The genetic defect responsible for cherubism has been localised to chromosome 4p16.3 [112].

The expansion of the affected jaw areas causes the angelic face leading to the lesion's designation: cherubism.

With the onset of puberty, the lesions lose their activity and may mature to fibrous tissue and bone.

There may also be a component consisting of immature odontogenic tissue due to developing tooth germs lying within the lesional tissue. This is a fortuitous finding without any clinical relevance.

4.7 Neoplastic Lesions of the Maxillofacial Bones, Non-Odontogenic

To be included in the following text, lesions should be mainly confined to the maxillofacial bones.

4.7.1 Osteoma

ICD-O:9180/0

Osteomas are lesions composed of compact lamellar bone with sparse marrow cavities filled with fatty or fibrous tissue. In the maxillofacial skeleton, they most commonly occur in the frontal and ethmoid sinus; less often, the maxillary antrum and the sphenoid sinus are involved [137]. They may also occur in the jaw bones as a manifestation of Gardner's syndrome [183].

Paranasal osteomas as a group are common lesions [92]. Clinically, they cause sinusitis and headache or other signs of sinonasal disease. Similar bony outgrowths at the palate or mandible are called *tori*.

4.7.2 Chordoma

ICD-O:9370/3

Chordomas are malignant tumours derived from embryonic remnants of the notochord. They mostly occur at either the cranial or caudal end of the vertebral column [57]. Chordomas show a slight male predominance; they may occur at any age [57].

Three different types of chordoma are discerned: conventional, chondroid, and dedifferentiated. Conventional chordoma consists of lobules separated from each other by fibrous bands. These lobules contain ovoid cells with small, dark nuclei and homogeneous eosinophilic cytoplasm. Other cells show large vesicular nuclei and abundant cytoplasm with vacuoles. Sometimes, these cells contain only one single vacuole causing a signet-ring appearance or vacuoles surrounding the nucleus: these latter cells represent the so-called physaliphorous cells thought to be pathognomonic for chordoma. In general, the cell density is maximal at the periphery of the lobules; more centrally, the cells lose their epithelial cohesion and may lie isolated in an abundant mucoid matrix (Fig. 4.37). Although there may be atypia, mitotic figures are infre-

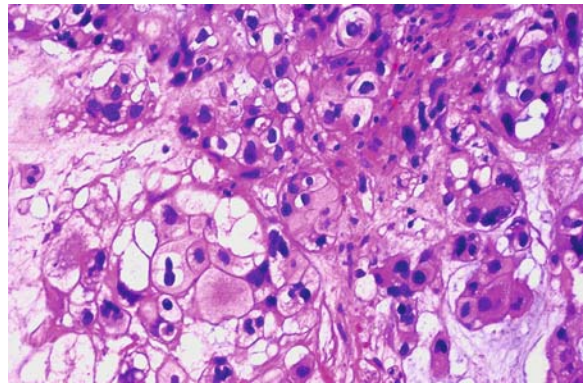


Fig. 4.37. At high magnification, the vacuolated nature of the chordoma cells are clearly visible, as is their epithelial cohesion

quent. The lesion invades adjacent structures. Immunohistochemically, chordoma is characterised by positivity for S-100 as well as vimentin and a broad variety of epithelial markers [131].

Chondroid chordoma (ICD-O:9371/3) denotes a variant of chordoma that contains cartilaginous areas indistinguishable from chondrosarcoma [57]. However, chondrocytic differentiation in chordomas probably represents a focal maturation process [51]. Neither has the distinction between conventional and chondroid chordoma any clinical significance [29]. Therefore, it is advocated that this designation be dropped. Dedifferentiated chordomas are those lesions that contain areas of chordoma as well as an additional malignant mesenchymal component that may be a fibrosarcoma, an osteosarcoma or, most likely, a poorly differentiated sarcoma [64].

Chordoma has to be distinguished from chondrosarcoma. Positivity for epithelial markers is a consistent feature in chordomas and is absent in chondrosarcoma [132]. Other look-alikes, such as extraskeletal myxoid chondrosarcoma, myxoid liposarcoma and myxopapillary ependymoma, also lack positivity for epithelial markers [28]. Chordoid meningiomas may also mimic chordomas, but there are no physaliphorous cells, nor is there positivity for cytokeratins in this meningioma subtype [125].

The differential diagnosis of chordoma should also include pleomorphic adenoma. Both lesions may show epithelial clusters as well as single cells with vacuolated cytoplasm lying in a mucoid matrix. Moreover, positivity for S-100, vimentin, and epithelial markers is displayed by both. Positivity for myoepithelial markers, however, is restricted to pleomorphic adenoma.

Chordomas manifest by destroying adjacent structures resulting in cranial nerve dysfunction. Rarely, they cause a swelling in the neck due to lateral growth. Their site precludes radical surgical treatment. Mostly, thera-

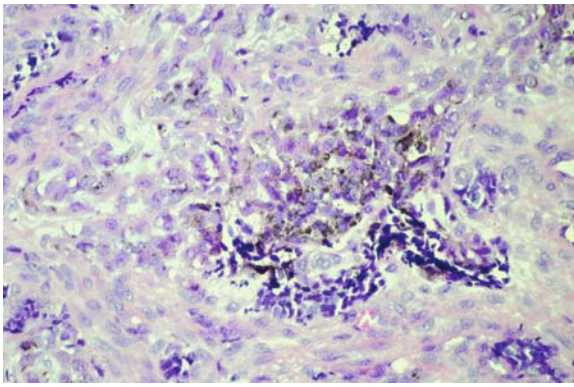


Fig. 4.38. Melanotic neuroectodermal tumour of infancy consists of small dark cells and larger cells with vesicular nuclei. Melanin is usually associated with the latter cell population

py consists of debulking and irradiation. Five-year survival rate is approximately 50%. Histologic features related with prognosis have not been identified [29]. Metastatic disease is unusual [25].

4.7.3 Melanotic Neuroectodermal Tumour of Infancy

ICD-O:9363/0

Cells derived from the neural crest play a major role in the formation of the jaws and teeth. These cells are also thought to be the source from which the melanotic neuroectodermal tumour of infancy develops [106]. Most of the lesions occur before the age of 1 year. The majority of them occur in the anterior maxilla [68].

The tumour shows dense fibrous stroma with nests composed of two different cell types: centrally placed small dark cells without any discernable cytoplasm and peripherally located larger cells with vesicular nuclei and ample cytoplasm with melanin pigment (Fig. 4.38) [9, 68, 113]. Maturation of the small cells to ganglion cells has been reported [144]. Although the cells may be atypical, mitotic figures are rare [9]. Sometimes, a transition of the large cells to osteoblasts forming tiny bony trabeculae can be observed [157]. The lesion is not encapsulated.

Immunohistochemically, the large cells are positive for a wide variety of cytokeratins, neuron-specific enolase, S-100, HMB45 and chromogranin. The small cells show positivity for CD56, neuron-specific enolase, synaptophysin and chromogranin [9]. This pattern can be summarised as evidence for neural, melanocytic and epithelial differentiation. In addition, the large cells have been shown to be positive for vimentin [157]. Ultrastructurally, the small cells show neurosecretory granules and the large cells show melanosomes at different stages of development [113].

Quite often, immature odontogenic tissues form part of the material excised or biopsied, due to the early age of occurrence and the close association of the tumour with tooth germs. This should not be mistaken as evidence of an odontogenic tumour. The highly characteristic histological pattern leaves no room for other differential diagnostic considerations.

Clinically, melanotic neuroectodermal tumour of infancy manifests as a rapidly growing blue tissue mass, usually at the anterior alveolar maxillary ridge. Radiologically, bone resorption may be seen, although this is difficult to evaluate in the delicate bony structures of the infantile maxilla. Tooth germs are displaced and may lie within the tumour mass. Conservative excision usually constitutes adequate treatment. Recurrences have been described, but metastases are exceptionally rare [113]. There are no histological features predicting more aggressive behaviour [9].

References

1. Abdelsayed RA, Eversole LR, Singh BS, Scarbrough FE (2001) Gigantiform cementoma: clinicopathologic presentation of 3 cases. *Oral Surg Oral Med Oral Pathol Oral Radiol Endod* 91:438–444
2. Altini M, Thompson SH, Lownie JF, Berezowski BB (1985) Ameloblastic sarcoma of the mandible. *J Oral Maxillofac Surg* 43:789–794
3. Ameerally P, McGurk M, Shaheen O (1996) Atypical ameloblastoma: report of 3 cases and a review of the literature. *Br J Oral Maxillofac Surg* 34:235–239
4. Auclair PL, Cuenin P, Kratochvil FJ, Slater LJ, Ellis GL (1988) A clinical and histomorphologic comparison of the central giant cell granuloma and the giant cell tumor. *Oral Surg Oral Med Oral Pathol* 66:197–208
5. August M, Faquin W, Troulis M, Kaban L (2003) Clear cell odontogenic carcinoma. Evaluation of reported cases. *J Oral Maxillofac Surg* 61:580–685
6. Baden E, Moskow BS, Moskow R (1968) Odontogenic gingival epithelial hamartoma. *J Oral Surg* 26:702–714
7. Badger JV, Gardner DG (1997) The relationship of adamantinomatous craniopharyngioma to ghost cell ameloblastoma of the jaws: a histopathologic and immunohistochemical study. *J Oral Pathol Med* 26:349–355
8. Barker BF (1999) Odontogenic myxoma. *Semin Diagn Pathol* 16:297–301
9. Barrett AW, Morgan M, Ramsay AD, Farthing PM, Newman L, Speight PM (2002) A clinicopathologic and immunohistochemical analysis of melanotic neuroectodermal tumor of infancy. *Oral Surg Oral Med Oral Pathol Oral Radiol Endod* 93:688–698
10. Barron RP, Kainulainen VT, Forrest CR, Krafchik B, Mock D, Sandor GKB (2002) Tuberous sclerosis: clinicopathologic features and review of the literature. *J Craniomaxillofac Surg* 30:361–366
11. Brannon RB (1976) The odontogenic keratocyst. A clinicopathologic study of 312 cases. I. Clinical features. *Oral Surg Oral Med Oral Pathol* 42:54–72
12. Brannon RB (1977) The odontogenic keratocyst. A clinicopathologic study of 312 cases. II. Histopathologic features. *Oral Surg Oral Med Oral Pathol* 43:233–255
13. Brannon RB, Fowler CB (2001) Benign fibro-osseous lesions: a review of current concepts. *Adv Anat Pathol* 8:126–143
14. Brannon RB, Fowler CB, Carpenter WM, Corio RL (2002) Cementoblastoma: an innocuous neoplasm? A clinicopathologic study of 44 cases and review of the literature with spe-

- cial emphasis on recurrence. *Oral Surg Oral Med Oral Pathol Oral Radiol Endod* 93:311–320
15. Brannon RB, Goode K, Eversole LR, Carr RF (2002) The central granular cell odontogenic tumor: report of 5 new cases. *Oral Surg Oral Med Oral Pathol Oral Radiol Endod* 94:614–621
 16. Braunshtein E, Vered M, Taicher S, Buchner A (2003) Clear cell odontogenic carcinoma and clear cell ameloblastoma. A single clinicopathologic entity? A new case and comparative analysis of the literature. *J Oral Maxillofac Surg* 61:1004–1010
 17. Brinck U, Gunawan B, Schulten HJ, Pinzon W, Fischer U, Fuezesi L (2001) Clear cell odontogenic carcinoma with pulmonary metastases resembling pulmonary meningothelial-like nodules. *Virchows Arch* 438:412–417
 18. Browne RM (1971) The odontogenic keratocyst. Histological features and their correlation with clinical behavior. *Br Dent J* 131:249–259
 19. Buchner A (1991) The central (intraosseous) calcifying odontogenic cyst: an analysis of 215 cases. *J Oral Maxillofac Surg* 49:330–339
 20. Buchner A, Merrell PW, Hansen LS, Leider AS (1991) Peripheral (extraosseous) calcifying odontogenic cyst. *Oral Surg Oral Med Oral Pathol* 72:265–270
 21. Buchner A, Hansen LS (1979) The histomorphologic spectrum of the gingival cyst in the adult. *Oral Surg Oral Med Oral Pathol* 48:523–539
 22. Budnick SD (1976) Compound and complex odontomas. *Oral Surg Oral Med Oral Pathol* 42:501–506
 23. Calvo N, Alonso D, Prieto M, Junquera L (2002) Central odontogenic fibroma granular cell variant: a case report and review of the literature. *J Oral Maxillofac Surg* 60:1192–1194
 24. Cataldo E, Berkman MD (1968) Cysts of the oral mucosa in newborns. *Am J Dis Child* 16:44–48
 25. Chambers PW, Schwinn CP (1979) Chordoma. A clinicopathologic study of metastasis. *Am J Clin Pathol* 72:765–776
 26. Chehade A, Daley TD, Wysocki GP, Miller AS (1994) Peripheral odontogenic keratocyst. *Oral Surg Oral Med Oral Pathol* 77:494–497
 27. Cheng YSL, Wright JM, Walstad WR, Finn MD (2002) Calcifying epithelial odontogenic tumor showing microscopic features of potential malignant behavior. *Oral Surg Oral Med Oral Pathol Oral Radiol Endod* 93:287–295
 28. Coffin CM, Swanson PE, Wick MR, Dehner LP (1993) An immunohistochemical comparison of chordoma with renal cell carcinoma, colorectal adenocarcinoma, and myxopapillary ependymoma: a potential diagnostic dilemma in the diminutive biopsy. *Mod Pathol* 6:531–538
 29. Colli B, Al-Mefty O (2001) Chordomas of the craniocervical junction: follow-up review and prognostic factors. *J Neurosurg* 95:933–943
 30. Corio RL, Goldblatt LI, Edwards PA, Hartman KS (1987) Ameloblastic carcinoma: a clinicopathologic study and assessment of eight cases. *Oral Surg Oral Med Oral Pathol* 64:570–576
 31. Dal-Cin PD, Sciort R, Fossion E, Damme B van, Berghe H van den (1993) Chromosome abnormalities in cementifying fibroma. *Cancer Genet Cytogenet* 71:170–172
 32. Daley TD, Wysocki GP (1994) Peripheral odontogenic fibroma. *Oral Surg Oral Med Oral Pathol* 78:329–336
 33. Daley TD, Wysocki GP (1995) The small dentigerous cyst. *Oral Surg Oral Med Oral Pathol Oral Radiol Endod* 79:77–81
 34. Daley TD, Wysocki GP, Pringle GA (1994) Relative incidence of odontogenic tumors and oral and jaw cysts in a Canadian population. *Oral Surg Oral Med Oral Pathol* 77:276–280
 35. Deron PB, Nikolovski N, Hollander JC den, Spoelstra HA, Knecht PP (1996) Myxoma of the maxilla; a case with extremely aggressive biologic behavior. *Head Neck* 18:459–464
 36. Dhir K, Sciuabba J, Tufano RP (2003) Case report. Ameloblastic carcinoma of the maxilla. *Oral Oncol* 39:736–741
 37. Dunlap CL (1999) Odontogenic fibroma. *Semin Diagn Pathol* 16:293–296
 38. Dunlap C, Neville B, Vickers RA, O'Neil D, Barker B (1989) The Noonan syndrome/cherubism association. *Oral Surg Oral Med Oral Pathol* 67:698–705
 39. Ebata K, Takeshi U, Tohnai I, Kaneda T (1992) Chondrosarcoma and osteosarcoma arising in polyostotic fibrous dysplasia. *J Oral Maxillofac Surg* 50:761–764
 40. El-Mofty SK (2002) Psammomatoid and trabecular juvenile ossifying fibroma of the craniofacial skeleton: two distinct clinicopathologic entities. *Oral Surg Oral Med Oral Pathol Oral Radiol Endod* 93:296–304
 41. Elzay RP (1982) Primary intraosseous carcinoma of the jaws. Review and update of odontogenic carcinomas. *Oral Surg Oral Med Oral Pathol* 54:299–303
 42. Eversole LR (1999) Malignant epithelial odontogenic tumors. *Semin Diagn Pathol* 16:317–324
 43. Eversole LR, Duffey DC, Powell NB (1995) Clear cell odontogenic carcinoma. A clinicopathologic analysis. *Arch Otolaryngol Head Neck Surg* 121:685–689
 44. Eversole LR, Sabes WR, Rovin S (1972) Fibrous dysplasia: a nosologic problem in the diagnosis of fibro-osseous lesions of the jaws. *J Oral Pathol* 1:180–220
 45. Fowler CB, Brannon RB (1989) The paradental cyst: a clinicopathologic study of six new cases and review of the literature. *J Oral Maxillofac Surg* 47:243–248
 46. Friedrich RE, Siegert J, Donath K, Jäkel KT (2001) Recurrent ameloblastic fibro-odontoma in a 10-year-old boy. *J Oral Maxillofac Surg* 59:1362–1366
 47. Gardner DG (1996) Some current concepts on the pathology of ameloblastomas. *Oral Surg Oral Med Oral Pathol Oral Radiol Endod* 82:660–669
 48. Gardner DG, Morency R (1993) The glandular odontogenic cyst; a rare lesion that tends to recur. *J Can Dent Assoc* 59:929–930
 49. Gollin SM, Storto PD, Malone PS, Barnes L, Washington JA, Chidambaram A, Janecka IP (1992) Cytogenetic abnormalities in an ossifying fibroma from a patient with bilateral retinoblastoma. *Genes Chromosomes Cancer* 4:146–152
 50. Gorlin RJ, Goltz RW (1960) Multiple nevoid basal cell epithelioma, jaw cysts and bifid rib. A syndrome. *N Engl J Med* 262:908–912
 51. Gottschalk D, Fehn M, Patt S, Saeger W, Kirchner T, Aigner T (2001) Matrix gene expression analysis and cellular phenotyping in chordoma reveals focal differentiation pattern of neoplastic cells mimicking nucleus pulposus development. *Am J Pathol* 158:1571–1578
 52. Greer RO, Johnson M (1988) Botryoid odontogenic cyst: clinicopathologic analysis of ten cases with three recurrences. *J Oral Maxillofac Surg* 46:574–579
 53. Groot RH, Merkesteyn JPR van, Bras J (1996) Diffuse sclerosing osteomyelitis and florid osseous dysplasia. *Oral Surg Oral Med Oral Pathol Oral Radiol Endod* 81:333–342
 54. Gurol M, Burkes EJ, Jacoway J (1995) Botryoid odontogenic cyst: analysis of 33 cases. *J Periodontol* 66:1069–1073
 55. Handlers JP, Abrams AM, Melrose RJ, Danfort R (1991) Central odontogenic fibroma. Clinicopathologic features of 19 cases and review of the literature. *J Oral Maxillofac Surg* 49:46–54
 56. Hansen LS, Eversole LR, Green TL, Powell NB (1985) Clear cell odontogenic tumor – a new histologic variant with aggressive potential. *Head Neck Surg* 8:115–123
 57. Heffelfinger MJ, Dahlin DC, MacCarty CS, Beabout JW (1973) Chordomas and cartilaginous tumors at the skull base. *Cancer* 32:410–420
 58. Hicks MJ, Flaitz CM, Wong ME, McDaniel RK, Cagle PT (1994) Clear cell variant of calcifying epithelial odontogenic tumor: case report and review of the literature. *Head Neck* 16:272–277
 59. Higuchi Y, Nakamura N, Tashiro H (1988) Clinicopathologic study of cemento-osseous dysplasia producing cysts of the mandible – report of four cases. *Oral Surg Oral Med Oral Pathol* 65:339–342
 60. Hirschberg A, Dayan D, Horowitz I (1987) Dentinogenic ghost cell tumor. *Int J Oral Maxillofac Surg* 16:620–625

61. Hirschberg A, Kaplan I, Buchner A (1994) Calcifying odontogenic cyst associated with odontoma: a possible separate entity (odontocalcifying odontogenic cyst). *J Oral Maxillofac Surg* 52:555–558
62. Horner K, Forman GH (1988) Atypical simple bone cysts of the jaws. II. A possible association with benign fibro-osseous (cemental) lesions of the jaws. *Clin Radiol* 39:59–63
63. Houston GD, Fowler CB (1997) Extrasosseous calcifying epithelial odontogenic tumor. Report of two cases and review of the literature. *Oral Surg Oral Med Oral Pathol Oral Radiol Endod* 83:577–583
64. Hruban RH, May M, Marcove RC, Huvos AG (1990) Lumbosacral chordoma with high-grade malignant cartilaginous and spindle cell components. *Am J Surg Pathol* 14:384–389
65. Ide F, Saito I (2003) Letter to the editor. Many faces of odontogenic keratocyst. *Oral Oncol* 39:204–205
66. Ide F, Sakshita H, Kusama K (2002) Ameloblastomatoid, central odontogenic fibroma: an epithelium-rich variant. *J Oral Pathol Med* 31:612–614
67. Johnson LM, Sapp JP, McIntire DN (1994) Squamous cell carcinoma arising in a dentigerous cyst. *J Oral Maxillofac Surg* 52:987–990
68. Kapadia SB, Frisman DM, Hitchcock CL, Popek EJ (1993) Melanotic neuroectodermal tumor of infancy. Clinicopathological, immunohistochemical, and flow cytometric study. *Am J Surg Pathol* 17:566–573
69. Kenney JN, Kaugars GE, Abbey LM (1989) Comparison between the peripheral ossifying fibroma and peripheral odontogenic fibroma. *J Oral Maxillofac Surg* 47:378–382
70. Khanna JN, Andrade NN (1993) Giant ossifying fibroma. Case report on a bimaxillary presentation. *Int J Oral Maxillofac Surg* 21:233–235
71. Kim J, Ellis GL (1993) Dental follicular tissue: misinterpretation as odontogenic tumors. *J Oral Maxillofac Surg* 51:762–767
72. Kimonis VE, Goldstein AM, Pastakia B, Yang ML, Kase R, DiGiovanna JJ, Bale AE, Bale SJ (1997) Clinical manifestations in 105 patients with nevoid basal cell syndrome. *Am J Med Genet* 69:299–308
73. Kramer IRH, Pindborg JJ, Shear M (1992) Histological typing of odontogenic tumours, 2nd edn. Springer, Berlin Heidelberg New York, pp 10–42
74. Kratochvil FJ, Brannon RB (1993) Cartilage in the walls of odontogenic keratocysts. *J Oral Pathol Med* 22:282–285
75. Kumar M, Fasanmade A, Barrett AW, Mack G, Newman L, Hyde NC (2003) Metastasizing clear cell odontogenic carcinoma: a case report and review of the literature. *Oral Oncol* 39:190–194
76. Kunze E, Donath K, Luhr HG, Engelhardt W, DeVivie R (1985) Biology of metastasizing ameloblastoma. *Pathol Res Pract* 180:526–535
77. Laughlin EH (1989) Metastasizing ameloblastoma. *Cancer* 64:776–780
78. Ledesma CM, Taylor AM, Romero de Leon E, Piedra Garza M de la, Jaukin PG, Robertson JP (1993) Adenomatoid odontogenic tumour with features of calcifying epithelial odontogenic tumour. (The so-called combined epithelial odontogenic tumour.) Clinico-pathological report of 12 cases. *Oral Oncol Eur J Cancer* 29B:221–224
79. Leider AS, Jonker LA, Cook HE (1989) Multicentric familial squamous odontogenic tumor. *Oral Surg Oral Med Oral Pathol* 68:175–181
80. Levy BA (1973) Ghost cells and odontomas. *Oral Surg Oral Med Oral Pathol* 36:851–855
81. Li TJ, Yu SF (2003) Clinicopathological spectrum of the so-called calcifying odontogenic cysts. A study of 21 intraosseous cases with reconsideration of the terminology and classification. *Am J Surg Pathol* 27:372–384
82. Lombardi T, Lock C, Samson J, Odell EW (1995) S100, α -smooth muscle actin and cytokeratin 19 immunohistochemistry in odontogenic and soft tissue myxomas. *J Clin Pathol* 48:759–762
83. Lopez-Rios F, Lassaletta-Atienza L, Domingo-Carrasco C, Martinez-Tello FJ (1997) Nasolabial cyst: report of a case with extensive apocrine change. *Oral Surg Oral Med Oral Pathol Oral Radiol Endod* 84:404–406
84. Lu Y, Mock D, Takata T, Jordan RC (1999) Odontogenic ghost cell carcinoma: report of four new cases and review of the literature. *J Oral Pathol Med* 28:323–329
85. Lukinmaa PL, Hietanen J, Anttinen J, Ahonen P (1990) Contiguous enlarged dental follicles with histologic features resembling the WHO type of odontogenic fibroma. *Oral Surg Oral Med Oral Pathol* 70:313–317
86. MacLeod RI, Fanibunda KB, Soames JV (1985) A pigmented odontogenic keratocyst. *Br J Oral Maxillofac Surg* 23:216–219
87. MacLeod RI, Soames JV (1988) Squamous cell carcinoma in an odontogenic keratocyst. *Br J Oral Maxillofac Surg* 26:52–57
88. Magnusson B, Borrmann H (1995) The paradental cyst: a clinicopathologic study of 26 cases. *Swed Dent J* 19:1–7
89. Maiorano E, Altini M, Viale G, Piatelli A, Favia G (2001) Clear cell odontogenic carcinoma. Report of two cases and review of the literature. *Am J Clin Pathol* 116:107–114
90. Makowski GJ, McGuff S, Sickels JE van (2001) Squamous cell carcinoma in a maxillary odontogenic keratocyst. *J Oral Maxillofac Surg* 59:76–80
91. Manojlovic S, Grguveric J, Knezevic G, Kruslin B (1997) Glandular odontogenic cyst: a case report and clinicopathologic analysis of the relationship to central mucoepidermoid carcinoma. *Head Neck* 19:227–231
92. Mehta BS, Grewal GS (1963) Osteoma of the paranasal sinuses along with a case of an orbito-ethmoid osteoma. *J Laryngol Otol* 77:601–610
93. Miller R, Longo J, Houston G (1988) Surgical ciliated cyst of the maxilla. *J Oral Maxillofac Surg* 46:310–322
94. Monteleone L, McLellan MS (1964) Epstein's pearls (Bohn's nodules) of the palate. *J Oral Surg* 22:301–304
95. Morgan PR, Johnson NW (1974) Histological, histochemical and ultrastructural studies on the nature of hyaline bodies in odontogenic cysts. *J Oral Pathol* 3:127–147
96. Mosby EL, Russell D, Noren S, Barker BF (1998) Ameloblastic fibroma in a 7-week-old infant; a case report and review of the literature. *J Oral Maxillofac Surg* 56:368–372
97. Mosqueda-Taylor A, Carlos-Bregni R, Ramirez-Amador V, Palma-Guzman JM, Esquivel-Bonilla D, Hernandez-Rojas LA (2002) Odontoameloblastoma. Clinico-pathologic study of three cases and critical review of the literature. *Oral Oncol* 38:800–805
98. Muller S, Parker DC, Kapadia SB, Budnick SD, Barnes L (1995) Ameloblastic fibrosarcoma of the jaws. A clinicopathologic and DNA analysis of five cases and review of the literature with discussion of its relationship to ameloblastic fibroma. *Oral Surg Oral Med Oral Pathol Oral Radiol Endod* 79:469–477
99. Müller H, Slootweg PJ (1985) The growth characteristics of multilocular ameloblastomas. A histological investigation with some inferences with regard to operative procedures. *J Maxillofac Surg* 13:224–230
100. Müller H, Slootweg PJ (1986) Clear cell differentiation in an ameloblastoma. *J Maxillofac Surg* 14:158–160
101. Müller H, Slootweg PJ (1988) A peculiar finding in Le Fort I osteotomy. *J Craniomaxillofac Surg* 16:238–239
102. Muzio LL, Nocini PF, Favia G, Procaccini M, Mignogna MD (1996) Odontogenic myxoma of the jaws. A clinical, radiologic, immunohistochemical, and ultrastructural study. *Oral Surg Oral Med Oral Pathol Oral Radiol Endod* 82:426–433
103. Nastri AL, Wiesenfeld D, Radden BG, Eveson J, Scully C (1995) Maxillary ameloblastoma: a retrospective study of 13 cases. *Br J Oral Maxillofac Surg* 33:28–32
104. Newman L, Howells GL, Coghlan KM, DiBase A, Williams DM (1995) Malignant ameloblastoma revisited. *Br J Oral Maxillofac Surg* 33:47–50
105. Ng KH, Siar CH (2003) Odontogenic keratocyst with dentinoid formation. *Oral Surg Oral Med Oral Pathol Oral Radiol Endod* 95:601–606
106. Nitta T, Endo T, Tsunoda A, Kadota Y, Matsumoto T, Sato K (1995) Melanotic neuroectodermal tumor of infancy: a molecular approach to diagnosis. *J Neurosurg* 83:145–148

107. Nxumalo TN, Shear M (1992) Gingival cysts in adults. *J Oral Pathol Med* 21:309–313
108. Odell EW, Lombardi T, Barrett AW, Morgan PR, Speight PM (1997) Hybrid central giant cell granuloma and central odontogenic fibroma-like lesions of the jaws. *Histopathology* 30:165–171
109. Odukoya O (1995) Odontogenic tumors: analysis of 289 Nigerian cases. *J Oral Pathol Med* 24:454–457
110. Okada Y, Mochizuki K, Sigimural M, Noda Y, Mori M (1987) Odontogenic tumor with combined characteristics of adenomatoid odontogenic and calcifying epithelial odontogenic tumors. *Pathol Res Pract* 182:647–657
111. Paulus W, Stöckel C, Krauss J, Sörensen N, Roggendorf W (1997) Odontogenic classification of craniopharyngiomas: a clinicopathological study of 54 cases. *Histopathology* 30:172–176
112. Petschler M, Stiller M, Hoffmeister B, Witkowski R, Opitz C, Bill JS, Peters H (2003) Klinische und molekulargenetische Befunde bei Familien mit Cherubismus über 3 Generationen. *Mund Kiefer Gesichtschir* 7:83–87
113. Pettinato G, Manivel C, d'Amore ES, Jaszcz W, Gorlin RJ (1991) Melanotic neuroectodermal tumor of infancy. A re-examination of a histogenesis problem based on immunohistochemical, flow cytometric, and ultrastructural study of 10 cases. *Am J Surg Pathol* 15:233–245
114. Philipsen HP (1956) Om keratocysts (kolesteatomer). *I Kaerborne, Tandlaegebladet* 60:963–980
115. Philipsen HP, Reichart PA (1998) Unicystic ameloblastoma. A review of 193 cases from the literature. *Oral Oncol* 34:317–325
116. Philipsen HP, Reichart PA (2000) Calcifying epithelial odontogenic tumour: biological profile based on 181 cases from the literature. *Oral Oncol* 36:17–26
117. Philipsen HP, Reichart PA, Nikai H, Takata T, Kudo Y (2001) Peripheral ameloblastoma: biological profile based on 160 cases from the literature. *Oral Oncol* 37:17–27
118. Philipsen HP, Reichart PA, Praetorius F (1997) Mixed odontogenic tumours and odontomas. Considerations on interrelationship. Review of the literature and presentation of 134 cases of odontomas. *Oral Oncol* 33:86–99
119. Philipsen HP, Reichart PA, Takata T (2001) Desmoplastic ameloblastoma (including “hybrid” lesion of ameloblastoma). Biological profile based on 100 cases from the literature and own files. *Oral Oncol* 37:455–460
120. Philipsen HP, Reichart PA, Zhang KH, Nikai AH, Yu QX (1991) Adenomatoid odontogenic tumor: biologic profile based on 499 cases. *J Oral Pathol Med* 20:149–158
121. Piatelli A, Rubini C, Goteri G, Fioroni M, Maiorano E (2003) Case report. Central granular cell odontogenic tumour. Report of the first malignant case and review of the literature. *Oral Oncol* 39:78–82
122. Piecuch JF, Eisenberg E, Segal D, Carlson R (1980) Respiratory epithelium as an integral part of an odontogenic keratocyst: report of a case. *J Oral Surg* 38:445–447
123. Pollandt K, Engels C, Kaiser E, Werner M, Delling G (2001) Gsa gene mutations in monostotic fibrous dysplasia of bone and fibrous dysplasia-like low-grade central osteosarcoma. *Virchows Arch* 439:170–175
124. Praetorius F, Hjørtting-Hansen E, Gorlin RJ, Vickers RA (1981) Calcifying odontogenic cyst. Range, variations and neoplastic potential. *Acta Odontol Scand* 39:227–240
125. Radner H, Katenkamp D, Reifenberger G, Deckert M, Pitsch T, Wiestler OD (2001) New developments in the pathology of skull base tumors. *Virchows Arch* 438:321–335
126. Ramer M, Montazem A, Lane SL, Lumerman H (1997) Glandular odontogenic cyst. Report of a case and review of the literature. *Oral Surg Oral Med Oral Pathol Oral Radiol Endod* 84:54–57
127. Regezi JA, Kerr DA, Courtney RM (1978) Odontogenic tumors: analysis of 706 cases. *J Oral Surg* 36:771–778
128. Reichart PA, Philipsen HP (2003) Entzündliche paradentale Zyste. Bericht von 6 Fällen. *Mund Kiefer Gesichtschir* 7:171–174
129. Reichart PA, Philipsen HP (2003) Revision der WHO-Klassifikation odontogener Tumoren von 1992. Ein Vorschlag. *Mund Kiefer Gesichtschir* 7:88–93
130. Reichart PA, Philipsen HP, Sonner S (1995) Ameloblastoma: biological profile of 3677 cases. *Oral Oncol Eur J Cancer* 31B:86–99
131. Rosenberg AE, Brown GA, Bhan AK, Lee JM (1994) Chondroid chordoma – a variant of chordoma. A morphologic and immunohistochemical study. *Am J Clin Pathol* 101:36–41
132. Rosenberg AE, Nielsen GP, Keel SB, Renard LG, Fitzek, Munzender JE, Liebsch NJ (1999) Chondrosarcoma of the base of the skull: a clinicopathologic study of 200 cases with emphasis on its distinction from chordoma. *Am J Surg Pathol* 23:1370–1378
133. Rosenstein T, Pogrel MA, Smith RA, Regezi JA (2001) Cystic ameloblastoma – behavior and treatment of 21 cases. *J Oral Maxillofac Surg* 59:1311–1316
134. Ruggieri M, Pavone V, Polizzi A, Albanese S, Magro G, Merino M, Duray PH (1999) Unusual form of recurrent giant cell granuloma of the mandible and lower extremities in a patient with neurofibromatosis type 1. *Oral Surg Oral Med Oral Pathol Oral Radiol Endod* 87:67–72
135. Saied-Al-Naief NAH, Lumerman H, Ramer M, Kopp W, Kringsstein GJ, Persenchino F, Torno R (1997) keratoameloblastoma of the maxilla. A case report and review of the literature. *Oral Surg Oral Med Oral Pathol Oral Radiol Endod* 84:535–539
136. Saito Y, Hoshina Y, Nagamine T, Nakajima T, Suzuki M, Hayashi T (1992) Simple bone cyst. A clinical and histopathologic study of fifteen cases. *Oral Surg Oral Med Oral Pathol* 74:487–491
137. Samy LL, Mostafa H (1971) Osteomata of the nose and paranasal sinuses with a report of twenty-one cases. *J Laryngol Otol* 85:449–469
138. Sawyer JR, Tryka AF, Bell JM, Boop FA (1995) Nonrandom chromosome breakpoints at Xq26 and 2q33 characterize cemento-ossifying fibromas of the orbit. *Cancer* 76:1853–1859
139. Schafer DR, Thompson LD, Smith BC, Wenig BM (1998) Primary ameloblastoma of the sinonasal tract: a clinicopathologic study of 24 cases. *Cancer* 82:667–674
140. Schneider LC, Mesa LM (1990) Differences between florid osseous dysplasia and chronic diffuse sclerosing osteomyelitis. *Oral Surg Oral Med Oral Pathol* 70:308–312
141. Schneider LC, Mesa ML, Fraenkel D (1988) Osteoporotic bone marrow defect: radiographic features and pathogenic factors. *Oral Surg Oral Med Oral Pathol* 65:127–129
142. Schwartz-Arad D, Lustmann J, Ulmansky M (1990) Squamous odontogenic tumor. Review of the literature and case report. *Int J Oral Maxillofac Surg* 19:327–330
143. Scott J, Wood GD (1989) Aggressive calcifying odontogenic cyst – a possible variant of ameloblastoma. *Br J Oral Maxillofac Surg* 27:53–59
144. Shah RV, Jambhekhar NA, Rana DN, Raje NS, Albuquerque KV, Mistry RC, Desai PB, Advani SH (1994) Melanotic neuroectodermal tumor of infancy: report of a case with ganglionic differentiation. *J Surg Oncol* 55:65–68
145. Sharpe PT (2001) Neural crest and tooth morphogenesis. *Adv Dent Res* 15:4–7
146. Shear M (1992) Cysts of the oral regions, 3rd edn. Wright, Oxford, p 6
147. Shear M (2002) The aggressive nature of the odontogenic keratocyst: is it a benign cystic neoplasm? I. Clinical and early experimental evidence of aggressive behaviour. *Oral Oncol* 38:219–226
148. Shear M (2002) The aggressive nature of the odontogenic keratocyst: is it a benign cystic neoplasm? II. Proliferation and genetic studies. *Oral Oncol* 38:323–331
149. Shear M (2002) The aggressive nature of the odontogenic keratocyst: is it a benign cystic neoplasm? III. Immunocytochemistry of cytokeratin and other epithelial markers. *Oral Oncol* 38:407–415
150. Shear M, Pindborg JJ (1975) Microscopic features of the lateral periodontal cyst. *Scand J Dent Res* 83:103–110

151. Simko EJ, Brannon RB, Eibling DE (1998) Ameloblastic carcinoma of the mandible. *Head Neck* 20:654–659
152. Slater LJ (1999) Odontogenic sarcoma and carcinosarcoma. *Semin Diagn Pathol* 16:325–332
153. Slootweg PJ (1981) An analysis of the interrelationship of the mixed odontogenic tumors – ameloblastic fibroma, ameloblastic fibro-odontoma, and the odontomas. *Oral Surg Oral Med Oral Pathol* 51:266–276
154. Slootweg PJ (1987) Carcinoma arising from reduced enamel epithelium. *J Oral Pathol* 16:479–482
155. Slootweg PJ (1991) Bone and cementum as stromal features in Pindborg tumor. *J Oral Pathol Med* 20:93–95
156. Slootweg PJ (1992) Cementoblastoma and osteoblastoma: a comparison of histologic features. *J Oral Pathol Med* 21:385–389
157. Slootweg PJ (1992) Heterologous tissue elements in melanotic neuroectodermal tumor of infancy. *J Oral Pathol Med* 21:90–92
158. Slootweg PJ (1996) Maxillofacial fibro-osseous lesions: classification and differential diagnosis. *Semin Diagn Pathol* 13:104–112
159. Slootweg PJ (2002) Malignant odontogenic tumors; an overview. *Mund Kiefer Gesichtschir* 6:295–302
160. Slootweg PJ, Müller H (1983) Central fibroma of the jaw, odontogenic or desmoplastic. *Oral Surg Oral Med Oral Pathol* 56:61–70
161. Slootweg PJ, Wittkamp ARM (1986) Myxoma of the jaws. An analysis of 15 cases. *J Maxillofac Surg* 14:46–52
162. Soames JV (1982) A pigmented calcifying odontogenic cyst. *Oral Surg Oral Med Oral Pathol* 53:395–400
163. Stolovitzky JP, Waldron CA, McConnel FMS (1994) Giant cell lesions of the maxilla and paranasal sinuses. *Head Neck* 16:143–148
164. Su L, Weathers DR, Waldron CA (1997) Distinguishing features of focal cemento-osseous dysplasias and cemento-ossifying fibromas. II. A clinical and radiologic spectrum of 316 cases. *Oral Surg Oral Med Oral Pathol Oral Radiol Endod* 84:540–549
165. Suarez PA, Batsakis JG, El-Naggar AJ (1996) Pathology consultation. Don't confuse dental soft tissues with odontogenic tumors. *Ann Otol Rhinol Laryngol* 105:490–494
166. Suljak JP, Bohay RN, Wysocki GP (1998) Lateral periodontal cyst: a case report and review of the literature. *J Can Dent Assoc* 64:58–51
167. Summerlin DJ, Tomich CE (1994) Focal cemento-osseous dysplasia: a clinicopathologic study of 221 cases. *Oral Surg Oral Med Oral Pathol* 78:611–620
168. Swanson KS, Kaugars GE, Gunsolley JC (1991) Nasopalatine duct cyst: an analysis of 334 cases. *J Oral Maxillofac Surg* 49:268–271
169. Takahashi H, Fujita S, Okabe H (1991) Immunohistochemical investigation in odontogenic myxoma. *J Oral Pathol Med* 20:114–119
170. Takeda Y (1999) Review. Ameloblastic fibroma and related lesions: current pathologic concept. *Oral Oncol* 35:535–540
171. Thesleff I, Keränen S, Jernvall J (2001) Enamel knots as signaling centers linking tooth morphogenesis and odontoblast differentiation. *Adv Dent Res* 15:14–18
172. Thompson LD, Gyure KA (2000) Extracranial sinonasal tract meningiomas: a clinicopathologic study of 30 cases with review of the literature. *Am J Surg Pathol* 24:640–650
173. Toida M (1998) So-called calcifying odontogenic cyst: review and discussion on the terminology and classification. *J Oral Pathol Med* 27:49–52
174. Tomich CE (1999) Benign mixed odontogenic tumors. *Semin Diagn Pathol* 16:308–316
175. Venness MJ, Morgan G, Collins AP (2001) Calcifying epithelial odontogenic (Pindborg) tumor with malignant transformation and metastatic spread. *Head Neck* 23:692–696
176. Villiers Slabbert H de, Altini M (1991) Peripheral odontogenic fibroma: a clinicopathologic study. *Oral Surg Oral Med Oral Pathol* 72:86–90
177. Waldron CA, Koh ML (1990) Central mucoepidermoid carcinoma of the jaws: report of four cases with analysis of the literature and discussion of the relationship to mucoepidermoid, sialodontogenic and glandular odontogenic cysts. *J Oral Maxillofac Surg* 48:871–877
178. Warter A, George-Diolombi G, Chazal M, Ango A (1990) Melanin in a dentigerous cyst and associated adenomatoid odontogenic tumor. *Cancer* 66:786–788
179. Wenig BM, Vinh TN, Smirniotopoulos JG, Fowler CB, Houston GD, Heffner DK (1995) Aggressive psammomatoid ossifying fibromas of the sinonasal region: a clinicopathologic study of a distinct group of fibro-osseous lesions. *Cancer* 76:1155–1165
180. Wesley RK, Scannel T, Nathan LE (1984) Nasolabial cyst: presentation of a case with a review of the literature. *J Oral Maxillofac Surg* 42:188–192
181. World Health Organization Classification of Tumours (2005) Pathology and genetics of tumours of the head and neck. IARC, Lyon
182. Williams TP, Connor FA Jr (1994) Surgical management of the odontogenic keratocyst: aggressive approach. *J Oral Maxillofac Surg* 52:964–966
183. Williams SC, Peller PJ (1994) Gardner's syndrome. Case report and discussion of the manifestations of the disorder. *Clin Nucl Med* 19:668–670
184. Wilson D, Walker M, Aurora N, Moore S (2001) Ameloblastoma with mucous cell differentiation. *Oral Surg Oral Med Oral Pathol Oral Radiol Endod* 91:576–578
185. Woolgar JA, Rippin JW, Browne RM (1987) A comparative histological study of odontogenic keratocysts in basal cell naevus syndrome and non-syndrome patients. *J Oral Pathol* 16:75–80
186. Woolgar JA, Rippin JW, Browne RM (1987) The odontogenic keratocyst and its occurrence in the nevoid basal cell carcinoma syndrome. *Oral Surg Oral Med Oral Pathol* 64:727–730
187. Wright JM (1979) Squamous odontogenic tumorlike proliferations in odontogenic cysts. *Oral Surg Oral Med Oral Pathol* 47:354–358
188. Wright JM (1981) The odontogenic keratocyst: orthokeratinized variant. *Oral Surg Oral Med Oral Pathol* 51:609–618
189. Young SK, Markowitz NR, Sullivan S, Seale TW, Hirschi R (1989) Familial gigantiform cementoma: classification and presentation of a large pedigree. *Oral Surg Oral Med Oral Pathol* 68:740–747
190. Zwetyenga N, Pinsolle J, Rivel J, Majoufre-Lefebvre C, Faucher A, Pinsolle V (2001) Primary intraosseous carcinoma of the jaws. *Arch Otolaryngol Head Neck Surg* 127:794–797

Major and Minor Salivary Glands

S. Di Palma · R.H.W. Simpson · A. Skalova · I. Leivo

Contents

5.1	Introduction	132	5.8.7	Sebaceous Adenoma	144
5.1.1	Normal Salivary Glands	132	5.8.8	Sebaceous Lymphadenoma	144
5.1.2	Developmental Disorders	132	5.8.9	Ductal Papilloma	144
5.2	Obstructive Disorders	132	5.8.10	Cystadenoma	144
5.2.1	Mucus Escape Reaction	132	5.9	Malignant Epithelial Tumours	144
5.2.2	Chronic Sclerosing Sialadenitis of the Submandibular Gland (Küttner Tumour)	133	5.9.1	Acinic Cell Carcinoma	144
5.3	Infections	133	5.9.2	Mucoepidermoid Carcinoma	146
5.3.1	Bacteria, Fungi	133	5.9.3	Adenoid Cystic Carcinoma	147
5.3.2	Viruses	133	5.9.4	Polymorphous Low-Grade Adenocarcinoma	148
5.4	Miscellaneous Inflammatory Disorders	133	5.9.4.1	Cribriiform Adenocarcinoma of the Tongue	149
5.5	Miscellaneous Non-Inflammatory Disorders	133	5.9.5	Epithelial-Myoepithelial Carcinoma	150
5.5.1	Necrotising Sialometaplasia (Salivary Gland Infarction)	133	5.9.6	Hyalinising Clear Cell Carcinoma	151
5.5.2	Sialadenosis	133	5.9.7	Basal Cell Adenocarcinoma	151
5.5.3	Adenomatoid Hyperplasia of Mucous Salivary Glands	134	5.9.8	Myoepithelial Carcinoma (Malignant Myoepithelioma)	152
5.5.4	Irradiation Changes	134	5.9.9	Salivary Duct Carcinoma	154
5.5.5	Tissue Changes Following Fine Needle Aspiration	134	5.9.10	Oncocytic Carcinoma	155
5.6	Oncocytic Lesions	134	5.9.11	Malignancy in Pleomorphic Adenoma Malignant Mixed Tumour	156
5.6.1	Focal and Diffuse Oncocytosis	134	5.9.11.1	Carcinoma (True Malignant Mixed Tumour) Ex Pleomorphic Adenoma	156
5.6.2	Ductal Oncocytosis	134	5.9.11.2	Carcinosarcoma Ex Pleomorphic Adenoma	157
5.6.3	Multifocal Nodular Oncocytic Hyperplasia	135	5.9.11.3	Metastasising Pleomorphic Adenoma	157
5.7	Cysts	135	5.9.12	Sebaceous Carcinoma	158
5.7.1	Salivary Polycystic Dysgenetic Disease	135	5.9.13	Lymphoepithelial Carcinoma	158
5.7.2	Mucoceles	135	5.9.14	Small Cell Carcinoma	158
5.7.3	Simple Salivary Duct Cysts	135	5.9.15	Higher Grade Change in Carcinomas	159
5.7.4	Lymphoepithelial Cystic Lesions	135	5.9.16	Metastatic Malignancies	159
5.7.4.1	Benign Lymphoepithelial Cyst	135	5.10	Hybrid Carcinoma	160
5.7.4.2	Cystic Lymphoid Hyperplasia of AIDS	136	5.11	Endodermal Sinus Tumour	160
5.7.5	Sclerosing Polycystic Sialadenopathy (Sclerosing Polycystic Adenosis)	136	5.12	Sialoblastoma	160
5.7.6	Other Cysts	137	5.13	Alterations in Gene Expression and Molecular Derangements in Salivary Gland Carcinoma	160
5.8	Benign Tumours	137	5.13.1	Predominantly Myoepithelial Malignancies	161
5.8.1	Pleomorphic Adenoma	137	5.13.2	Predominantly Epithelial Malignancies	161
5.8.1.1	Salivary Gland Anlage Tumour ("Congenital Pleomorphic Adenoma")	140	5.14	Benign and Malignant Lymphoid Infiltrates	162
5.8.2	Benign Myoepithelioma	140	5.14.1	Non-Autoimmune Lymphoid Infiltrates	162
5.8.3	Basal Cell Adenoma	141	5.14.2	Benign Autoimmune Lymphoid Infiltrates	162
5.8.4	Warthin's Tumour	142	5.14.3	Malignant Lymphoma	163
5.8.5	Oncocytoma	143	5.15	Other Tumours	163
5.8.6	Canalicular Adenoma	143	5.16	Unclassified Tumours	163
			References		164

5.1 Introduction

5.1.1 Normal Salivary Glands

The salivary glands include paired major glands (parotid, submandibular and sublingual) and minor glands throughout the upper aerodigestive tract.

The cellular component comprises serous and mucous acinar and ductal epithelial cells, myoepithelial cells and connective tissue components (e.g. fat, fibrous tissue, nerves and blood vessels). The parotid glands consist of predominantly serous acini, the submandibular glands of mixed, serous and mucous acini, while the sublingual glands contain mainly mucous acini. Minor salivary glands also have mixed serous and mucous acini in varying proportions.

Of particular interest are the myoepithelial cells. They are a normal constituent of the major and minor salivary glands, and are believed to have contractile properties that assist in the secretion of saliva. Similar cells are also found in the breast, tracheo-bronchial and sweat glands. They are plentiful in the salivary acini and intercalated ducts, but much less so in the larger excretory ducts of the major glands. Microscopic examination shows that myoepithelial cells are thin and spindle-shaped and situated between the basement membrane and epithelial cells, and ultrastructurally they are seen to possess a number of cytoplasmic processes that extend between and over the acinar and ductal lining cells. They display features of both smooth muscle and epithelium, such as numerous microfilaments with focal densities in the cytoplasmic processes, and desmosomes that attach the myoepithelial to the epithelial cells [62]. Similarly, immunohistochemistry shows that myoepithelial cells stain strongly with alpha smooth muscle actin (α SMA), calponin, smooth muscle myosin heavy chain (SMMHC) [164], h-caldesmon [74], S-100 protein [114] as well as with some cytokeratins (e.g. subtype 14). Maspin, p63 [8, 166] and CD 10 [143, 183] have recently been described as markers of breast myoepithelial cells, and may have a role in identifying their salivary equivalents. Preliminary studies show that p63 may well have practical value [166]. Scattered nests of sebaceous cells can be seen in normal parotid and minor salivary glands [62].

Serial sectioning has shown an average of 20 lymph nodes within each parotid [67], and they may be affected by inflammatory processes and neoplasms, both primary and metastatic. Their presence may hamper histologic evaluation of parotid gland lesions [6].

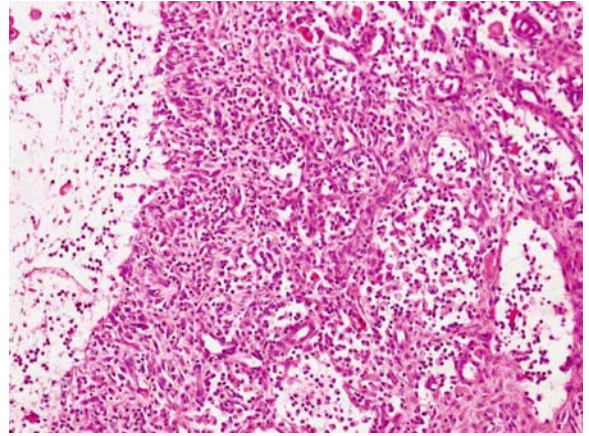


Fig. 5.1. Extravasation mucocele (mucous escape reaction): mucin-filled cavity lined with granulation tissue and macrophages

5.1.2 Developmental Disorders

Agensis, aplasia, hypoplasia and atresia of the main ducts are all extremely rare. In contrast, intra-parotid nodal heterotopias are very common [129], and epithelial tumours may arise from them [175]. Extranodal heterotopia is rare, and can be subdivided into high (involvement of the ear, pituitary, mandible, etc.) or low forms (lower neck, thyroid).

Accessory parotid glands comprising salivary tissue separate from the main gland, adjacent to Stenson's duct, are found in 20% of people.

5.2 Obstructive Disorders

5.2.1 Mucus Escape Reaction

This forms an extravasation mucocele, which is defined as the pooling of mucus in the connective tissue in a cavity not lined with epithelium. Most patients are under 30 years of age, and the minor glands are most often affected. The incidence by site is lower lip 65%, palate 4%, buccal mucosa 10%, and (in the major glands) parotid 0.6%, submandibular 1.2% and sublingual 1.1%. The pathogenesis is traumatic severance of a duct, leading to mucus pooling. It presents in the lip as a raised, often blue, dome shaped swelling of the mucosa, usually 2–10 mm in diameter, but it is generally larger in the sublingual gland in the floor of the mouth where it is known as a ranula. Microscopy shows a well-defined mucin-filled cavity lacking an epithelial lining, but lined with granulation tissue and macrophages (Fig. 5.1).

5.2.2 Chronic Sclerosing (Atrophic) Sialadenitis of the Submandibular Gland (Küttner Tumour)

In most if not all cases, this is secondary to calculi in the excretory ducts of the major salivary glands, particularly the submandibular gland. It can occur at any age, though the mean is 44 years. Patients present with pain and/or swelling associated with eating. Histology shows acinar atrophy and a chronic inflammatory infiltrate of variable intensity, but it can be heavy with lymphoid germinal centre formation. The end stage of destruction of the lobular architecture and scarring has been described as salivary gland cirrhosis [172].

5.3 Infections

5.3.1 Bacteria, Fungi

Tuberculosis may involve the gland itself or intra-parotid lymph nodes, and may present as a salivary mass. Other granulomatous infections such as cat-scratch, fungus, sarcoid, leprosy, syphilis, tularaemia, Brucella or toxoplasmosis can also occur in the salivary glands.

5.3.2 Viruses

Several viral diseases lead to infiltration by chronic inflammatory cells, but are rarely biopsied. This is especially true of mumps, and also in Cytomegalovirus infection, which may involve the salivary glands as part of a systemic infection in either the newborn or immunocompromised adults, particularly those with AIDS. The diagnosis is made by finding the characteristic enlarged cells with intranuclear inclusions [233]. Other viral infections include Epstein-Barr Virus (EBV), Coxsackie virus and influenza virus, as well as human immunodeficiency virus (HIV). Several lesions may be seen in the salivary glands in patients with AIDS, in particular cystic lymphoid hyperplasia (see Sect. 5.7.4.2).

5.4 Miscellaneous Inflammatory Disorders

There are a variety of non-infectious inflammatory conditions such as sarcoidosis [230], Rosai-Dorfman disease [75], xanthogranulomatous sialadenitis, amyloidosis [98] and Kimura's disease [155]. They will not be discussed here.

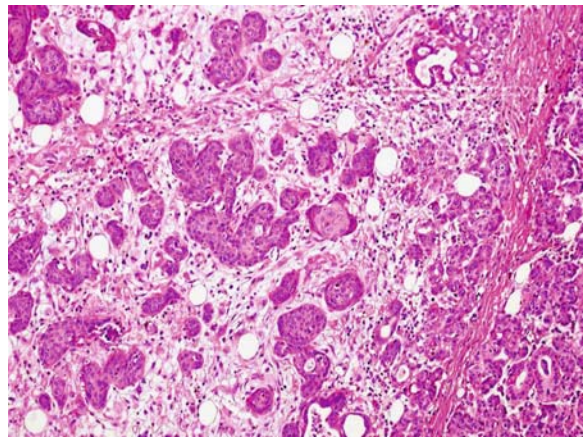


Fig. 5.2. Necrotising sialometaplasia. Most of the ducts and acini are replaced by mature non-keratinising squamous epithelium. The lobular architecture of the gland is preserved

5.5 Miscellaneous Non-Inflammatory Disorders

5.5.1 Necrotising Sialometaplasia (Salivary Gland Infarction)

Necrotising sialometaplasia (salivary gland infarction), is a benign, self-healing lesion, affecting especially the minor glands of the palate. Some cases follow surgery (about 1–8 weeks postoperatively) or even relatively minor trauma, such as from an ill-fitting denture, but often no predisposing factor is known, although the underlying process is generally considered to be ischaemic [172]. Microscopy shows lobular coagulative necrosis of acini (particularly in the early stages), squamous metaplasia of ducts, a chronic inflammatory cell infiltrate and pseudoepitheliomatous hyperplasia of the overlying surface [24]. There is a superficial resemblance to either mucoepidermoid or squamous cell carcinoma, but the overall lobular architecture of the involved gland is preserved. A similar reaction can be seen in the major glands after surgery or radiotherapy (Fig. 5.2) [17].

5.5.2 Sialadenosis

Sialadenosis [172] is a non-inflammatory process of the salivary glands due to metabolic and secretory disorders of the gland parenchyma accompanied by recurrent painless bilateral swelling of the parotid glands. The peak ages are the fifth and sixth decades [172]. It has been related to endocrine disorders (diabetes mellitus, ovarian and thyroid insufficiencies) as well as autonomic nervous system dysfunction; the

underlying process appears to be a disorder of salivary gland innervation. It is also seen in malnutrition, chronic alcoholism, bulimia, liver cirrhosis and has been linked to some drugs, such as antihypertensive agents [62].

It is rarely biopsied, but histologically there is enlargement of the serous acinar cells (two or three times the normal size) and slight compression of the duct system by the swollen acini.

5

5.5.3 Adenomatoid Hyperplasia of Mucous Salivary Glands

This nodular hyperplastic lesion is usually asymptomatic, often being noted on routine dental examination. Most cases occur on the palate, but sometimes other minor glands can be involved [25]. It can affect all ages, although most patients are between 30 and 60 years old. There is a slight male predominance. Examination reveals nodular mucosal swellings up to 30 mm in diameter. The aetiology is unknown, but possible relevant factors include local trauma due to dentures or tobacco smoking. The main histological feature of adenomatoid hyperplasia is the presence of hypertrophic and hyperplastic mucous lobules of minor salivary glands. Inflammation, fibrosis and cytological abnormality are not usually seen.

5.5.4 Irradiation Changes

Salivary glands are very sensitive to radiation, and xerostomia is a common complication. Acute radiation injury of salivary glands manifests with swelling, vacuolation and necrosis of acinar cells. Initial acute inflammatory response is later followed by chronic sclerosing sialadenitis characterised by loss of acini, focal squamous metaplasia, and fibrosis. When all the salivary glands are involved, the loss of saliva is progressive and irreversible.

5.5.5 Tissue Changes Following Fine Needle Aspiration

Fine needle aspiration (FNA) is an important technique in the investigation of salivary disease, particularly tumours, but the procedure itself can have adverse effects, causing difficulties in histological assessment and even simulating malignancy. The effects are classified as tissue injury with repair, infarction and reactive pseudomalignant changes [28]. Some or all of these can occur in any tumour [126] including pleomorphic adenoma, but are most frequent in Warthin's tumour, where in-

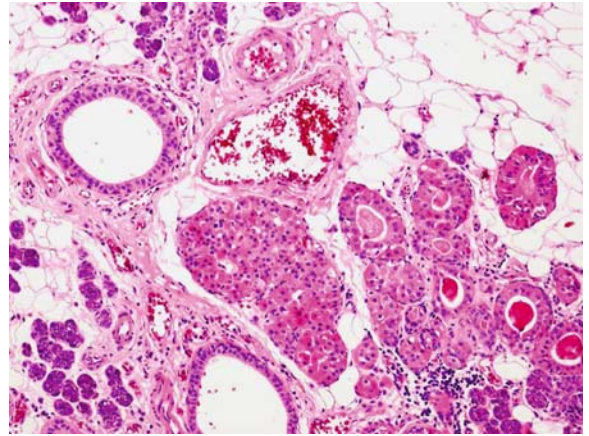


Fig. 5.3. Focal oncocytosis of the parotid gland. Some ducts and acinar cells show cytoplasmic oncocytic features

farction may be total and squamous metaplasia florid [55]. Possible causes include trauma by the needle [55] and an increased sensitivity of oncocytic cells to hypoxia [28].

5.6 Oncocytic Lesions

Oncocytic change is where cells develop intensely eosinophilic granular cytoplasm due, to increased numbers of mitochondria [180].

5.6.1 Focal and Diffuse Oncocytosis

Foci of oncocytic metaplasia, usually of ducts, but occasionally also acini, occur with increasing frequency with advancing age (Fig. 5.3). In contrast, diffuse oncocytosis of the parotid is extremely rare. Microscopic examination shows oncocytic metaplasia of ducts and acini involving virtually the whole gland. As with most other oncocytic lesions, diffuse oncocytosis comprises two types of cells, light and dark. The former are large and round or polygonal and have finely granular, pink cytoplasm and a single vesicular nucleus. The dark cells are usually more sparse and have deeply eosinophilic, compressed cytoplasm and densely hyperchromatic nuclei.

5.6.2 Ductal Oncocytosis

Oncocytic metaplasia of ducts often with cystic dilation (also known as oncocytic papillary cystadenoma) occurs mainly in the minor glands, particularly the larynx, and

only occasionally in the parotid (see Sect. 5.8.10). The lesions are often multifocal and usually small, but can reach 30 mm in diameter.

5.6.3 Multifocal Nodular Oncocytic Hyperplasia

This rare condition consists of nodules of varying size, composed of oncocytic cells, often with relatively clear cytoplasm. The nodules appear to engulf normal acini giving a false impression of invasion, but there is no stromal or other response by the acini. Multifocal nodular oncocytic hyperplasia (MNOH) can be mistaken for a clear cell neoplasm with satellite deposits when one nodule is much larger than the others. MNOH can also be bilateral, and it has been reported to co-exist with a pleomorphic adenoma, which itself showed oncocytic change [20, 158].

5.7 Cysts

Non-neoplastic cysts and pseudocysts accounted for about 6% of all lesions of the salivary glands in the Hamburg registry of salivary neoplasms and tumour-like lesions [172]. They can be classified as:

1. Dysgenetic, e.g. polycystic dysgenetic disease;
2. Acquired cysts lined with epithelium, e.g. lymphoepithelial cystic lesions, duct cysts;
3. Pseudocysts without an epithelial lining, e.g. extravasation mucocele, including ranula;
4. Cystic change in neoplasms, e.g. Warthin, variants of mucoepidermoid and acinic cell carcinomas, lymphoepithelial sialadenitis (LESA), lymphoma, and rarely, pleomorphic adenoma;
5. Miscellaneous other cysts.

The commonest are mucoceles, including ranula (80%), parotid duct cysts (11%), lymphoepithelial cystic lesions (7%) and dysgenetic cysts and congenital sialectasia (together 2%).

5.7.1 Salivary Polycystic Dysgenetic Disease

This very rare condition resembles cystic anomalies of other organs, such as the kidney, liver and pancreas, although no association has been described [62, 172, 177]. Some cases are familial [207], and almost all cases occurred in females. Most patients present in childhood, but some have not been recognised until adulthood. It only affects the parotid glands, usually bilaterally. Microscopically, the glands maintain their

lobular architecture, and some lobules are affected more severely than others. The cysts vary in size up to a few millimetres, and they are irregular in shape and often interconnect. The lining epithelium is flat, cuboidal to low columnar, sometimes with an apocrine-like appearance. The lumen contains secretion with spherical microliths. Remnants of salivary acini are seen between the cysts, and thick fibrous interlobular septa are often prominent.

5.7.2 Mucoceles

A mucocele is defined as the pooling of mucus in a cystic cavity [62]. Two types are recognised – extravasation and retention; extravasation mucocele is described in Sect. 5.2.1. Retention cysts can occur at any age, and the mucus pool is within an epithelium-lined cavity, likely to be a dilated excretory duct.

5.7.3 Simple Salivary Duct Cysts

Salivary duct cysts are acquired, and are due to dilatation of a salivary duct following obstruction, sometimes by a tumour [62]. They can occur at any age, although usually in patients over 30 years old. Most (85%) arise in the parotid and are unilateral and painless. They are well-circumscribed, unilocular and up to 100 mm in diameter (usually 10 to 30 mm). They contain fluid that is watery to viscous brown, occasionally with mucus. The wall comprises dense fibrous tissue, 1–3 mm thick, and there is often mild to moderate chronic inflammation, although not the dense lymphoid infiltrate of a lymphoepithelial cyst. The epithelium is stratified squamous, or a single layer of cuboidal or columnar cells, with occasional goblet cells and oncocytes.

5.7.4 Lymphoepithelial Cystic Lesions

Seven types of salivary lesions can be characterised by single or multiple epithelial-lined cysts surrounded by lymphoid tissue including germinal centres: benign lymphoepithelial cyst and cystic lymphoid hyperplasia of AIDS, in addition to Warthin's tumour, LESA and mucosa-associated lymphoid tissue (MALT lymphoma) each with cystically dilated ducts, low-grade cyst-forming mucoepidermoid carcinoma with a heavy lymphocytic response, and cystic metastases in intraparotid lymph nodes, each of which is discussed in Sect. 5.14.

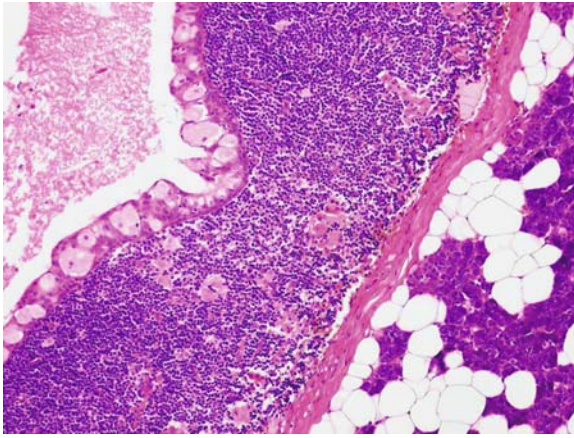


Fig. 5.4. Simple, benign lymphoepithelial cyst. The cavity is lined with columnar and cuboidal cells with scattered goblet cells. The surrounding tissue contains small lymphocytes and macrophages. Beyond this is a capsule and subcapsular space resembling that of a lymph node

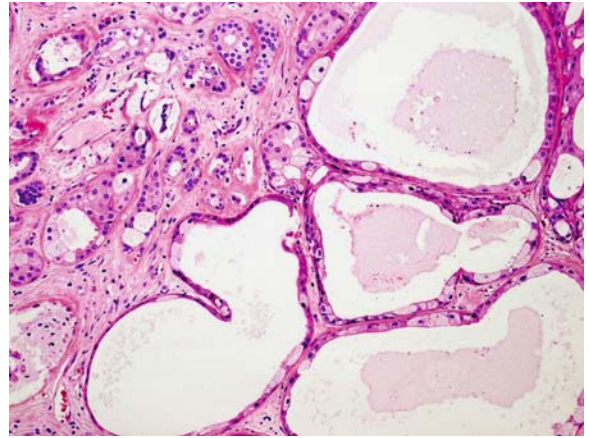


Fig. 5.5. Sclerosing polycystic adenosis. Cystic ducts of varying size with stromal fibrosis, resembling fibrocystic disease and sclerosis adenosis of the breast. There is also proliferation of ducts and acini in a lobular pattern

5.7.4.1 Benign Lymphoepithelial Cyst

Benign lymphoepithelial cysts are thought to arise either in intraparotid lymph nodes [60] or from remnants of the branchial apparatus [10]. There is no clinical association with Sjögren's syndrome, and they were described long before the AIDS epidemic. There is a slight male preponderance (1.6:1 in civilians in the Armed Forces Institute of Pathology [AFIP] series), and the mean age of onset is 46 years (range 18 to 79) [113]. They are usually solitary, but can occasionally be bilateral. The average diameter is 25 mm, but they may reach 70 mm. Microscopy shows the lining epithelium to be squamous, respiratory, cuboidal, columnar or a combination, and small numbers of goblet cells may also be present (Fig. 5.4). This lining is surrounded by abundant lymphoid tissue composed of small lymphocytes, plasma cells and germinal centres; lymphoepithelial lesions are not a feature. Benign lymphoepithelial cysts are not known to recur after surgical excision.

5.7.4.2 Cystic Lymphoid Hyperplasia of AIDS

A nodular or diffuse enlargement of particularly the parotid glands is often seen in HIV-positive patients – usually bilaterally. Microscopic examination shows a dense lymphoid infiltrate including follicular hyperplasia, sometimes displaying lysis of germinal centres and diminished mantle zones. There is an elaborate dendritic reticulum cell network within which there is evidence of active HIV replication, although the exact histogenesis of this lesion is not understood. Plasma cells (polytypic) are often numerous. The glandular parenchyma is

atrophic, and multiple cystic spaces are seen, filled with mucoid or gelatinous fluid. The cysts are dilated ducts, and the lining sometimes shows squamous metaplasia. The cysts are infiltrated by lymphoid cells, including variable numbers of marginal zone B-cells, and in time lymphoepithelial lesions are apparent.

There is considerable morphological overlap with LESA [60, 91], but only a minority of patients exhibit the clinical features of Sjögren's syndrome [105]. An important practical point is that this lesion can be the first clinical manifestation of HIV disease, and thus histological identification of it means a diagnosis of AIDS for the patient.

The lymphoid infiltrate is polyclonal and generally does not progress to lymphoma, although patients with HIV disease are at risk of developing aggressive B-cell lymphomas, most commonly of the Burkitt-type and diffuse large cell lymphoma [107]. An exception is that in children with AIDS, the infiltrate more closely resembles MALT lymphoma, and monoclonality may be demonstrated.

5.7.5 Sclerosing Polycystic Sialadenopathy (Sclerosing Polycystic Adenosis)

This is a benign pseudoneoplastic condition of major salivary glands [11, 84, 200], said to be analogous to fibrocystic disease of the breast [58]. It affects mainly females with a mean age of 28 years (range 12 to 63). Most cases have been described as slow-growing masses in the parotid gland, with a single example of submandibular gland involvement. The excised gland is largely replaced

by multiple discrete, firm, rubbery nodules. Microscopic examination shows a well-circumscribed, unencapsulated mass composed of a lobular arrangement of proliferating ducts and acini with cystic ducts containing viscous secretion and, on occasions, aggregates of foamy macrophages. There is often intraluminal epithelial proliferation occasionally with a cribriform pattern and these may contain small droplets of basement membrane material. The lining comprises a spectrum of apocrine, mucous, squamous cells and ballooned sebaceous-like cells, although true goblet cells are not seen. Some cells contain prominent large, intensely eosinophilic cytoplasmic granules of varying sizes, representing aberrant zymogen granules (Fig. 5.5). On occasion there is nuclear pleomorphism, even suggesting dysplasia [200], but there is no significant mitotic activity and no malignant cases have been described. Flattened myoepithelial cells are present around ductal and acinar structures, and there is periductal sclerosis and intense hyaline sclerosis of the surrounding soft tissue. Sometimes, a patchy lymphocytic infiltrate is noted. About one-third of cases recur, but none has metastasised.

5.7.6 Other Cysts

Other salivary cysts include dermoids [141], and a variety of epithelial and non-epithelial cysts including parasites and gas cysts in glass blowers [163]. Keratocystoma is a rare, recently described, benign parotid tumour characterised by multicystic keratin-filled spaces lined with stratified squamous epithelium with no atypical features [150].

5.8 Benign Tumours

There are various classifications. The revised WHO classification (Table 5.1) [171] has the merit of being easily applicable in practice [181].

5.8.1 Pleomorphic Adenoma

ICD-O:8940/0

Most authors accept that there is a spectrum of benign salivary adenomas, including pleomorphic adenoma. Benign myoepithelioma, which is composed almost entirely of myoepithelial cells represents one end of the spectrum, whereas basal cell adenoma and canalicul adenoma are at the other end [183, 236, 237]. The particular morphology of any particular tumour reflects the different proportions of the constituent cells (Fig. 5.6).

Pleomorphic adenoma (PA) is the most common tumour of the salivary glands. Although most often found in young to middle-aged women, they can occur in ei-

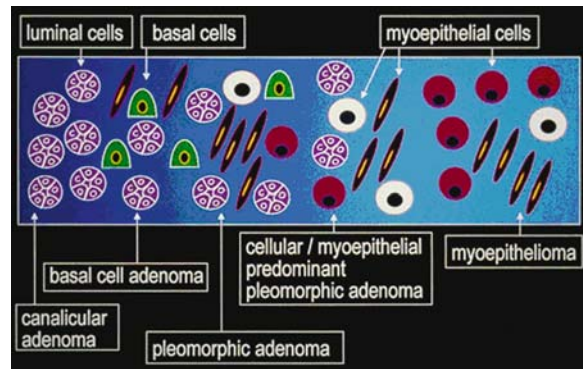


Fig. 5.6. Pleomorphic adenoma spectrum. Reproduced with permission from Zarbo et al. [236]

ther sex and at any age. Up to 80% occur in the superficial lobe of the parotid gland, and it typically presents as a painless swelling. When the deep lobe is involved, it often manifests as an intraoral parapharyngeal mass. Approximately 5% of PAs occur in the submandibular gland, 0.1% in the sublingual gland and about 10% in minor salivary glands [30, 228]. Similar tumours arise in extrasalivary locations including bronchi, ear, lacrimal gland, breast and skin.

Macroscopically, PAs are usually well-circumscribed masses of 20–40 mm. The cut surface is usually white, and grey glistening areas are commonly seen.

Histologically, PA was defined by the revised WHO Classification of 1991 as “a tumour [of the salivary glands] of variable capsulation characterised microscopically by architectural rather than cellular pleomorphism” [171], i.e. the pleomorphism refers to the variety of histological patterns, not the cytology.

The pattern varies from case to case, and also from area to area within any individual tumour. All are composed of a mixture of ductal epithelial cells, basal and myoepithelial cells and variable amounts of stroma, both hyaline and chondromyxoid. Attempts have been made to subclassify PA based on the proportions of cell types and stroma [176], but because of the variation in any tumour, this is difficult and probably has no prognostic value.

Ducts are lined with flat, cuboidal or columnar epithelial cells, with little or no atypia. The ducts are usually small tubules, but can be cystically dilated and also arranged in a cribriform pattern, resembling adenoid cystic carcinoma, but mitotic figures are rare and the proliferation index low (see Sect. 5.9.3). Squamous metaplasia with or without keratinisation is seen in up to 25% of PAs [65]. If associated with mucinous metaplasia, it may resemble mucoepidermoid carcinoma (Figs. 5.7, 5.8).

Myoepithelial cells are arranged in sheets, smaller islands and trabeculae, and also surround epithelial

Table 5.1. Revised WHO histological classification of salivary gland tumours [171]

Adenoma	Pleomorphic adenoma
	Myoepithelioma (myoepithelial adenoma)
	Basal cell adenoma
	Warthin's tumour (adenolymphoma)
	Oncocytoma (oncocytic adenoma)
	Canalicular adenoma
	Sebaceous adenoma
Ductal papilloma	Inverted ductal papilloma
	Intraductal papilloma
	Sialadenoma papilliferum
Cystadenoma	Papillary cystadenoma
	Mucinous cystadenoma
Carcinomas	Acinic cell carcinoma
	Mucoepidermoid carcinoma
	Adenoid cystic carcinoma
	Polymorphous low-grade adenocarcinoma (terminal duct adenocarcinoma)
	Epithelial-myoepithelial carcinoma
	Basal cell adenocarcinoma
	Sebaceous carcinoma
	Papillary cystadenocarcinoma
	Mucinous adenocarcinoma
	Oncocytic carcinoma
	Salivary duct carcinoma
	Adenocarcinoma (not otherwise specified)
	Malignant myoepithelioma (myoepithelial carcinoma)
	Carcinoma in pleomorphic adenoma
	Squamous cell carcinoma
	Small cell carcinoma
Undifferentiated carcinoma	
Other carcinomas	
Non-epithelial tumours	
Malignant lymphomas	
Secondary tumours	
Unclassified tumours	
Entities not included in the classification, but described or better characterised since 1991 [8a]	Sialoblastoma
	Hyalinising clear cell carcinoma
	Cribiform adenocarcinoma of the tongue
	Endodermal sinus tumour of the salivary glands

lium-lined spaces. As in benign myoepithelioma (see Sect. 5.8.2), neoplastic myoepithelial cells may take several forms – epithelioid, spindle, plasmacytoid, clear and oncocytic, as well as transitional forms with features of two or more of these types (Fig. 5.9).

The stroma varies in amount and is either dense eosinophilic hyaline material or chondromyxoid tissue. The former is composed of basement membrane material and stains with PAS diastase and collagen type IV; the chondromyxoid material only rarely resembles true cartilage and is Alcian blue-positive (Fig. 5.10). Calcification and bone formation can occur in long standing tumours. Occasionally, collagenous spherules and crys-

talloids are seen, particularly in tumours rich in myoepithelial cells of the plasmacytoid type (Fig. 5.11) [197]. Nuclear atypia is not common, but can be seen in tumours where epithelial or myoepithelial cells display oncocytic features [65]. Occasional myoepithelial cell nuclei are enlarged and bizarre, somewhat analogous to “ancient” change in schwannomas. Mitotic figures are generally sparse, but can occur as part of the repair process after FNA. Such tumours with these atypical features should be sampled thoroughly to exclude true intracapsular carcinoma.

Similarly, areas of necrosis or haemorrhage may follow surgical manipulation, FNA or other trauma, and

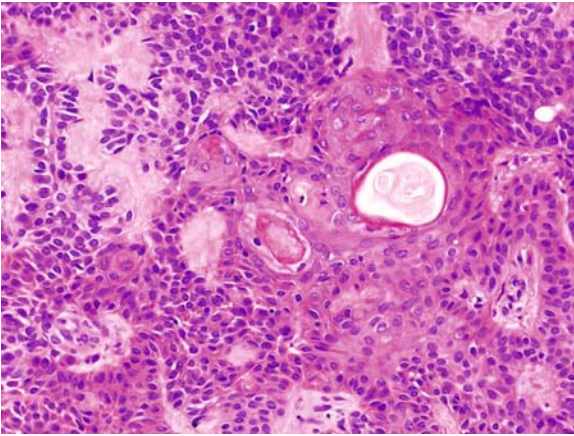


Fig. 5.7. Pleomorphic adenoma: myoepithelial cells with an epithelioid cytormorphology. These cells may also be spindle-shaped, plasmacytoid (hyaline) or have clear cytoplasm. Note also a small duct and a focus of squamous metaplasia. Keratinising squamous metaplasia is seen in up to a quarter of pleomorphic adenomas

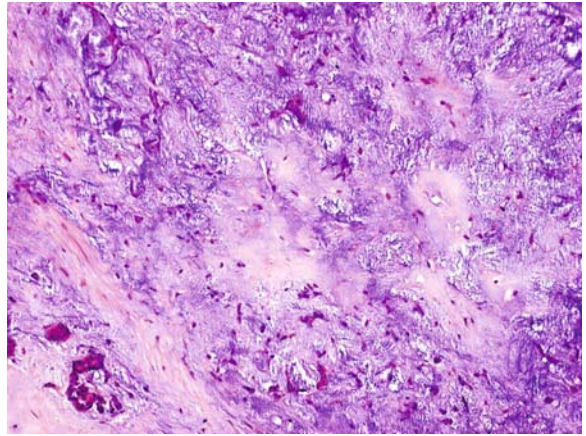


Fig. 5.10. Pleomorphic adenoma: chondromyxoid stroma containing isolated small and small aggregates of myoepithelial cells

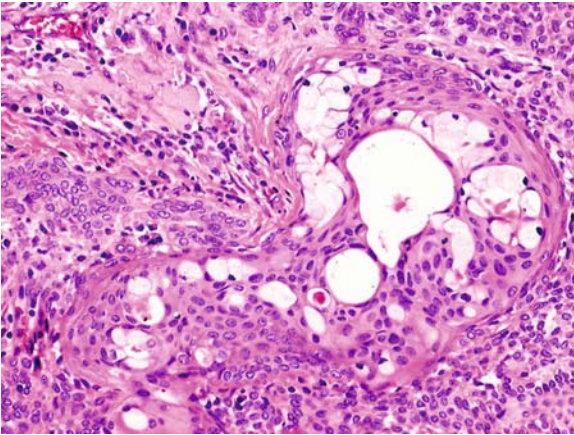


Fig. 5.8. Pleomorphic adenoma with squamous and focal mucinous metaplasia resembling mucoepidermoid carcinoma

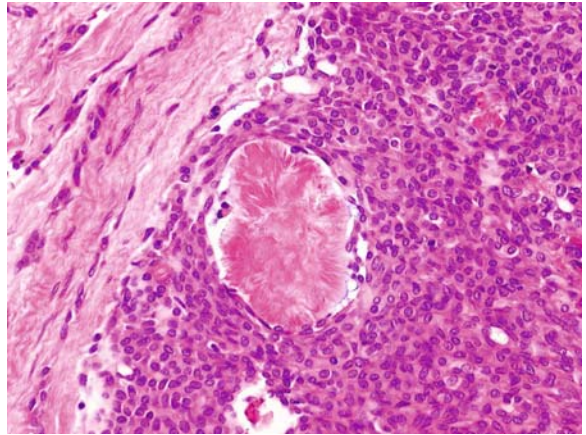


Fig. 5.11. Collagenous spherules can be seen in some benign myoepitheliomas and myoepithelium-rich pleomorphic adenomas

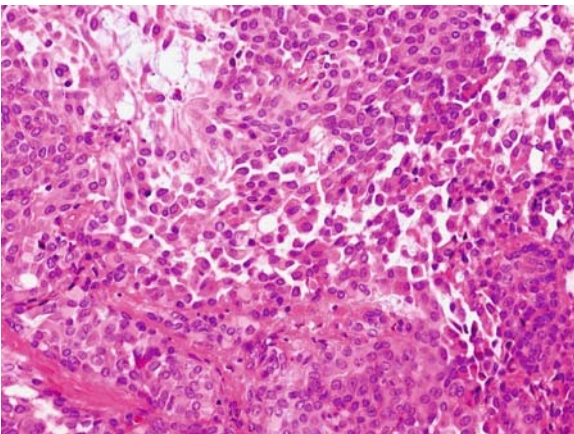


Fig. 5.9. Pleomorphic adenoma: myoepithelial cells showing an epithelioid and plasmacytoid appearance

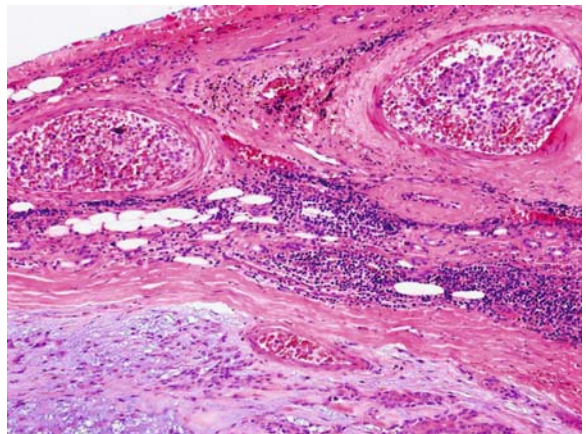


Fig. 5.12. Vascular “invasion” is a rare finding in benign pleomorphic adenoma, due to displacement of neoplastic cells into vascular spaces. It is not indicative of malignancy

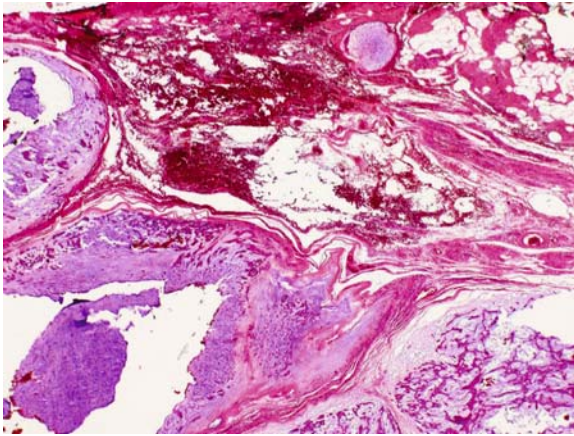


Fig. 5.13. Recurrent pleomorphic adenoma. Multiple and often well-separated tumour nodules of different sizes are seen in the periparotid soft tissue

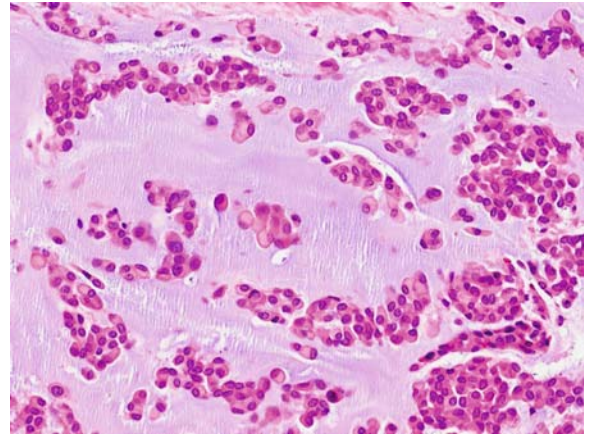


Fig. 5.14. Benign myoepithelioma composed of plasmocytoid (hyaline) and epithelioid cells with areas of myxoid stroma. Plasmocytoid cells have eccentric nuclei and dense eosinophilic cytoplasm

these neoplasms should also be sampled thoroughly. Tumour cells in lymphatics (“vascular invasion”) are occasionally seen in benign PAs, but this does not necessarily indicate malignancy (Fig. 5.12) [3]. None of the reported cases were followed by metastases.

Pleomorphic adenomas are often completely or partly surrounded by a fibrous capsule of variable thickness, but it can be absent, especially in tumours of the minor glands. Neoplastic elements may extend into and even through the capsule in the form of microscopic pseudopodia or apparent satellite nodules.

They may be the cause of future recurrence after apparent surgical removal [97], and their presence should be noted in the surgical pathology report. Special stains and immunohistochemistry are not necessary for the diagnosis in most cases, but can be used to identify the different cell types and also early malignant change (see Sect. 5.9.11).

Recurrent PA occurs after incomplete surgical excision and is usually composed of multiple nodules completely separate from each other. In the first recurrence the nodules are usually seen within salivary gland tissue, but in further recurrences tumours are found in the soft tissue of the surgical bed (Fig. 5.13). Histologically, the nodules show similar features to ordinary PA, and in particular they lack any cytological atypia. In spite of this, confluent nodules of recurrent PA can still kill the patient. As discussed later (see Sect. 5.9.11) multiply recurrent PAs may rarely metastasise to distant sites, and in addition are more prone to developing malignant changes.

5.8.1.1 Salivary Gland Anlage Tumour (“Congenital Pleomorphic Adenoma”)

ICD-O:8940/0

This is a rare, probably hamartomatous lesion in the nasopharynx of neonates [45]. Although potentially fatal due to its location, prognosis after surgery is good. It was not included in the 1991 WHO classification [171]. The microscopic features are a biphasic pattern of squamous nests and duct-like structures at the periphery, merging into solid, predominantly mesenchymal nodules, possibly of myoepithelial origin. Occasionally, there is necrosis and cyst formation [136].

5.8.2 Benign Myoepithelioma

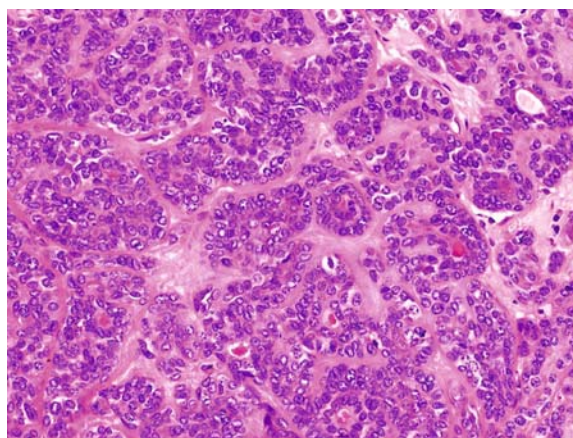
ICD-O:8982/0

Myoepithelial cells are found in several salivary gland neoplasms (Table 5.2). Benign myoepithelioma was first described in 1943 [179], and was included in the 1991 revised WHO classification [171]. It can be defined as a tumour composed totally, or almost totally, of myoepithelial cells. Whether or not it is truly a separate biological entity is debatable, but most commentators believe that it represents one end of a spectrum that also includes pleomorphic and at least some basal cell adenomas. Nevertheless, myoepithelioma displays particular microscopic features that pose specific practical problems in the identification and differential diagnosis, and on this basis it can be accepted as a separate diagnostic category [188, 189]. Most cases present as a well-circumscribed mass, usu-

Table 5.2. Salivary tumours with myoepithelial cell participation. Adapted from the WHO classification [171]

Benign	Pleomorphic adenoma Myoepithelioma Basal cell adenoma (some)
Malignant	Adenoid cystic carcinoma Polymorphous low-grade adenocarcinoma Epithelial-myoepithelial carcinoma Malignant myoepithelioma (myoepithelial carcinoma) Carcinoma ex pleomorphic adenoma (some)

ally 10–50 mm in diameter, in either major or minor salivary glands. Microscopically, there are several typical appearances, reflecting the different forms that neoplastic myoepithelial cells can take. Solid, myxoid and reticular growth patterns may be seen, and the component cells may be spindle-shaped, plasmacytoid (hyaline), clear, epithelioid or oncocyctic. Many tumours show more than one growth pattern or cell type, but myoepitheliomas of the minor glands are more often composed of plasmacytoid cells, and those of the parotid spindle cells [189]. Although most authors accept the plasmacytoid cells as myoepithelial, it has recently been suggested that these cells originate from luminal and not from myoepithelial cells [157], and thus the tumours should possibly be reclassified as plasmacytoid adenomas [157]. The clear cell variant can occur in both major and minor glands [182], but is relatively rare [43]. Unlike their malignant counterpart [52] (see Sect. 5.9.8), benign myoepitheliomas do not usually show invasiveness, necrosis, cytological pleomorphism, or more than an isolated mitotic figure. The stroma is usually scanty, fibrous or myxoid, and it may occasionally contain chondroid material or mature fat cells [203]. Extracellular collagenous crystalloids are seen in 10–20% of plasmacytoid cell-type myoepitheliomas, (as well as sometimes in myoepithelial-rich PAs); these structures are about 50–100 µm in diameter and consist of radially-arranged needle-shaped fibres composed of collagen types I and III, which stain red with the van Gieson method [197]. Scanty small ducts may be present (usually less than 10% of the tumour tissue) in otherwise typical myoepitheliomas (Fig. 5.14) [43]. Immunohistochemically, almost all tumours express S-100 protein, as well as some cytokeratins, especially subtype 14. Alpha smooth muscle actin positivity is seen to some degree in most spindle cell myoepitheliomas, but only occasionally in the plasmacytoid cell type [189]. Staining for calponin, smooth muscle myosin heavy chain (SMMHC) and CD10 is inconsistent in myoepithelial cells. The nuclear transcription factor p63 is positive in most benign myoepitheliomas [166]. Electron microscopic studies have also confirmed both epithelial

**Fig. 5.15.** Basal cell adenoma. The tumour is arranged in nests, islands and trabeculae or basal cells without cytological abnormality. Ductal differentiation is also noted

and smooth muscle differentiation [170], although focal densities in myofilaments are not usually found [43]. The behaviour of myoepithelioma is similar to that of pleomorphic adenoma, and complete excision should be curative. Neither growth pattern nor cell type appears to carry prognostic significance. Malignant change in a benign lesion has been described [2], but too little information is available about the percentage of cases involved. However, it is reasonable to postulate that it is probably not very different from that of pleomorphic adenoma.

5.8.3 Basal Cell Adenoma

ICD-O:8147/0

Most tumours previously described as monomorphic adenoma are now termed basal cell adenoma (BCA). The revised WHO [171] classification recognises four histopathological subtypes – solid, tubular, trabecular and membranous – but it is likely that, in reality, there are only two separate biological entities [16] – membranous and non-membranous (Figs 5.15, 5.16).

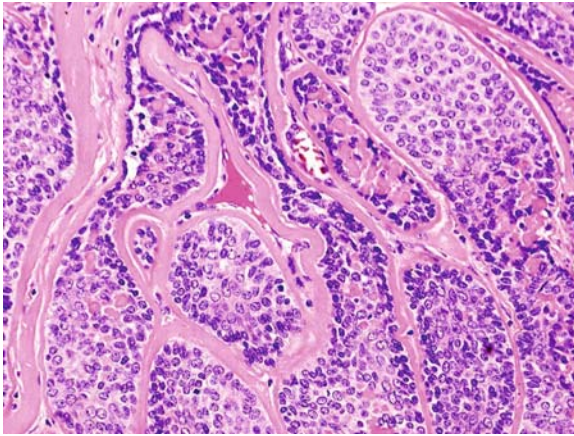


Fig. 5.16. Membranous basal cell adenoma: jigsaw like pattern: multiple epithelial islands surrounded by large amounts of basal membrane-like material. The latter is also present within the cytoplasm of some of the small dark hyperchromatic basal cells. There is little cellular pleomorphism

Non-membranous BCAs have an equal sex incidence and arise mostly in the major glands. They probably represent part of the spectrum of myoepithelioma and pleomorphic adenoma [70, 237]. The tumours are ovoid, well-circumscribed masses in which islands, nests and trabeculae of basaloid cells are each surrounded by a distinct thin PAS-positive basement membrane. The component cells may take two forms – small with scanty cytoplasm and a round, dark nucleus, and larger with amphophilic or eosinophilic cytoplasm and an ovoid paler staining nucleus. These two types are intermixed, but the smaller cells tend to be arranged around the periphery of the nests and trabeculae, giving the appearance of palisading. Ductal differentiation may or may not be apparent, but can be highlighted by EMA. There is little pleomorphism and mitotic figures are rare. The stroma varies in amount and cellularity, but S-100 protein-positive spindle cells may be numerous. S-100 positive cells are also present within the islands of epithelial cells, which react strongly with cytokeratins [220].

Membranous BCA (dermal analogue tumour) occurs predominantly in men, and can be multicentric. Most arise in the major glands, including within intraparotid lymph nodes [128]. Microscopically, they are not encapsulated and appear multinodular, often with a jigsaw-like pattern. The most characteristic feature is the deposition of large amounts of hyaline basement membrane material, which is brightly eosinophilic and PAS-positive. It surrounds the epithelial cell islands and blood vessels, and is present within the islands as small droplets. There is little pleomorphism or mitotic activity. In about 40% of cases, the salivary adenoma is associated with synchronous and often multiple skin appendage tumours of sweat gland

or hair follicle origin, usually cylindromas or eccrine spiradenomas.

The most important differential diagnosis of all types of BCA is adenoid cystic carcinoma. Useful pointers to adenoma include lack of invasiveness and cytological pleomorphism, low mitotic and proliferative activity, and whorled eddies of epithelial cells. S-100 protein positivity of spindled stromal cells may help, as this does not occur in adenoid cystic carcinoma [70]. BCA closely resembles basal cell adenocarcinoma, which may lack cytological pleomorphism and mitotic figures, the diagnosis then depending principally on the presence of genuine invasion (see Sect. 5.9.7).

The recurrence rate for non-membranous BCA is extremely low (0 out of 102 patients in one series) [16], and local excision with clear margins is sufficient treatment. There is a low rate of malignant transformation (about 4%) into basal cell adenocarcinoma [127]. In contrast, up to 24% of membranous BCAs recur after surgery [16], probably reflecting multicentricity and, in addition, malignancy (also as basal cell adenocarcinoma) develops in 28% [127]. Surgery for this subtype needs to be more extensive [16, 119, 130].

5.8.4 Warthin's Tumour

ICD-O:8561/0

Warthin's tumour (WT; adenolymphoma) is the second commonest neoplasm of the parotid gland, and is the easiest salivary tumour to diagnose by microscopy [66]. It arises almost exclusively in the parotid gland (usually the tail) and occasionally in periparotid lymph nodes. The mean age at diagnosis is 62 years (range 29–88), and WT is uncommon in blacks. Previously, there was a marked male predominance (as much as 26:1), but now there is an almost equal sex distribution. It is eight times more frequent in heavy smokers. WT is multicentric in 12% of patients, and bilateral in 6%.

There are two theories of its histogenesis [62] – a true epithelial neoplasm that attracts a heavy lymphoid reaction, or alternatively a non-neoplastic lesion arising from ectopic salivary inclusions in intraparotid lymph nodes. The latter theory is supported by a molecular genetic study using HUMARA analysis, which has shown that WT is not a clonal process [100].

Pathological examination shows a well-circumscribed oval mass, composed of slits or cystic spaces with papillary infoldings lined with two layers of oncocytic epithelium; the inner cells are columnar with nuclear palisading, deep to which are flattened or cuboidal basal cells (Fig. 5.17). Occasional mucous and squamous cells may be seen. The stroma comprises usually plentiful lymphoid tissue with germinal centre formation. Special stains and immunohistochemistry have little to offer in practice; myoepi-

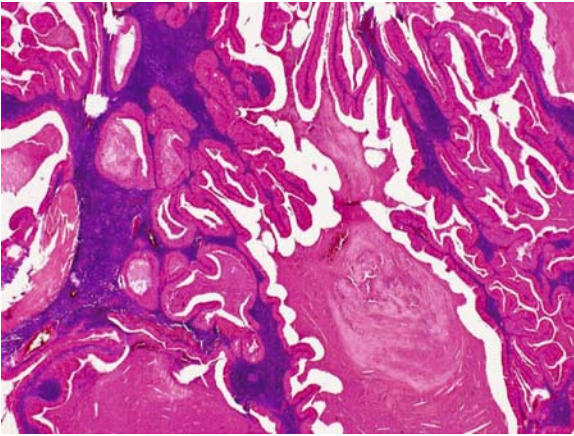


Fig. 5.17. Warthin's tumour. Cystic and slit-like spaces with papillary infolding lined with oncocytic cells. Lymphoid tissue occupies the cores of most papillae

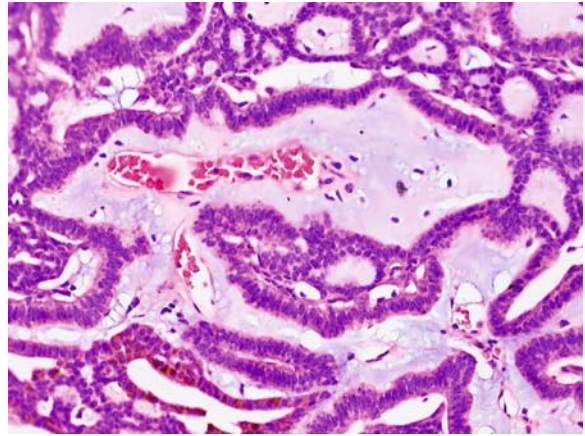


Fig. 5.20. Canalicular adenoma of the upper lip. It is composed of bi-layered strands of basal-like cells embedded in a loose oedematous stroma

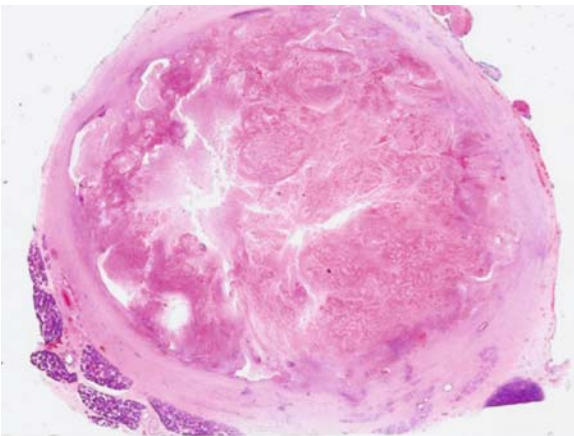


Fig. 5.18. Metaplastic (infarcted) Warthin's tumour. There is extensive necrosis. A surrounding thin rim of viable tissue shows squamous metaplasia

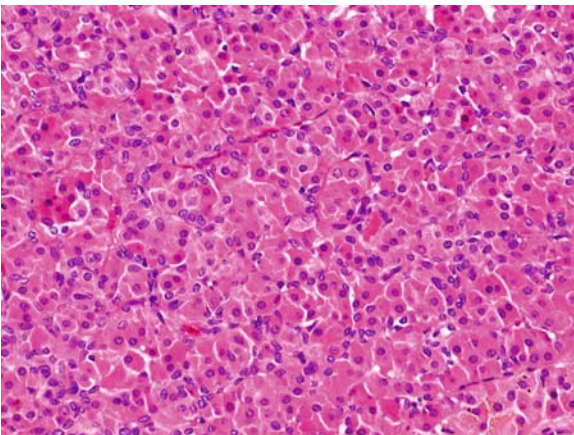


Fig. 5.19. Oncocytoma. Light and dark oncocytic cells are arranged in a solid, trabecular and tubular configuration

thelial markers are negative. Histological variants include a stroma-poor form, and metaplastic WT – in the latter, much of the original oncocytic epithelium has been replaced by squamous cells, and there is extensive necrosis, fibrosis, inflammation, and granuloma formation (Fig. 5.18) [66]. This not uncommon lesion follows trauma, particularly FNA [55], and can be mistaken for squamous or mucoepidermoid carcinomas (see Sect. 5.5.5). WT generally has a good outcome, with recurrence rates of about 2%. Malignancy occurs in less than 1% of cases, involving either epithelial or lymphoid elements leading to carcinomas or lymphomas [62].

5.8.5 Oncocytoma

ICD-O:8290/0

Oncocytic change in salivary tumours is common (see Sect. 5.6) [65]. Oncocytoma is a true benign neoplasm composed of oncocytes. It is rare and is often associated with MNOH (see Sect. 5.6) [158]. It comprises a well-demarcated mass of oncocytic cells (both light and dark) with a solid, trabecular, or tubular configuration (Fig. 5.19). There is a surrounding, usually incomplete fibrous capsule, and only a little internal fibrous stroma. There is a rare clear cell variant [61].

5.8.6 Canalicular Adenoma

ICD-O:8149/0

Canalicular adenoma also has a basaloid appearance. Its location is almost exclusively intraoral, particularly affecting the upper lip [119] and less often the palate. As a result, most tumours present when small

– rarely more than 20 mm in diameter. It has a characteristic morphology of branching and interconnecting bi-layered strands of darkly staining epithelial cells set in a loose vascular stroma (Fig. 5.20). There is no pleomorphism or significant mitotic activity. The cells express cytokeratins and S-100 protein. Not infrequently, they are multifocal [39], and can thus mimic the true invasiveness of cribriform adenoid cystic carcinoma. The lack of destructiveness and the presence of blood vessels in the cribriform spaces are good guides to canalicular adenoma, which is completely benign. Occasional recurrences are a result of multifocality [90].

5.8.7 Sebaceous Adenoma

ICD-O:8410/0

This rare, encapsulated epithelial tumour is composed of solid, variably shaped islands and cysts, both showing focal sebaceous differentiation with squamous areas; these are surrounded by a fibrous, hyalinised stroma. They do not recur after complete surgical excision [12, 62].

5.8.8 Sebaceous Lymphadenoma

ICD-O:8410/0

This lesion comprises irregular proliferating nests and islands of epithelium including solid and gland-like sebaceous elements, surrounded by a lymphoid stroma. It is possible that, like Warthin's tumour, sebaceous lymphadenoma develops from salivary inclusions within lymph nodes, and shows sebaceous rather than oncocyctic metaplasia [62, 171].

5.8.9 Ductal Papilloma

ICD-O:8503/0

There are three subtypes, all rare – inverted ductal papilloma (similar to the sinonasal tumour), intraductal papilloma and sialadenoma papilliferum (similar to skin syringocystadenoma papilliferum) [62]. Intraductal papilloma has a fibrovascular core lined with myoepithelial and ductal cells and it is usually seen in a dilated duct.

5.8.10 Cystadenoma

ICD-O:8440/0

The revised WHO classification recognises two histopathological subtypes – papillary cystadenoma (similar to lymphoid-poor Warthin's tumour) and mucin-

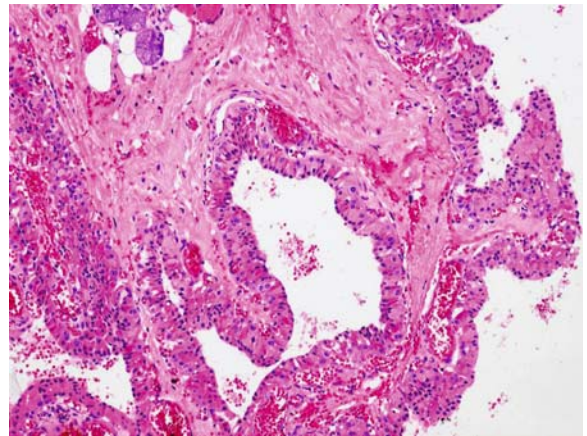


Fig. 5.21. Oncocytic (papillary) cystadenoma of the larynx. Cystically dilated ducts are lined with oncocytic cells

nous cystadenoma. Both are rare, benign tumours characterised by unicystic or multicystic growth patterns. The latter can be mistaken for mucinous malignancy, such as grade I mucoepidermoid carcinoma [62, 173]. Most cystadenomas are multilocular with individual cystic spaces separated by limited amounts of intervening stroma [229]. The lumina often contain eosinophilic material with scattered epithelial, foamy or inflammatory cells. Rarely, psammoma bodies and crystalloids have been described within the luminal secretion [199]. The lining epithelium of the cystic spaces is mostly columnar and cuboidal. Oncocytic, mucous and apocrine cells are sometimes present focally or may predominate. An oncocytic variant of papillary cystadenoma is composed of oncocytes present in unilayered or bilayered papillary structures (Fig. 5.21). Squamous epithelium may be present, but rarely predominates. The tumours are unlikely to recur, but rare cases of mucinous cystadenoma with malignant transformation have been described (Figs 5.22, 5.23) [135].

5.9 Malignant Epithelial Tumours

5.9.1 Acinic Cell Carcinoma

ICD-O:8550/3

Acinic cell carcinoma (AcCC) is defined as a malignant epithelial neoplasm in which some of the neoplastic cells demonstrate serous acinar cell differentiation.

It accounts for about 2–4% of salivary gland tumours, and 12–17% of malignancies [62]. It is slightly commoner in women and the mean age at presentation is 44 years, although AcCCs can affect children

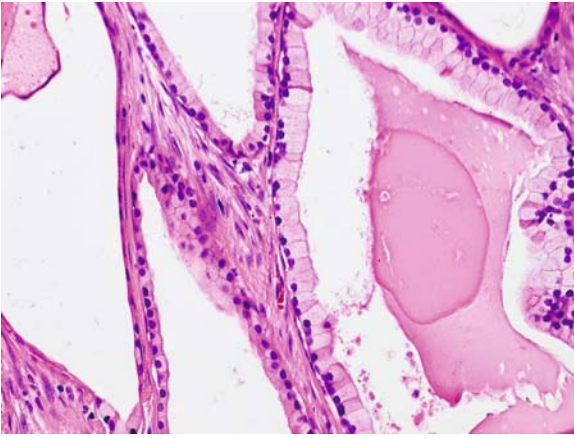


Fig. 5.22. Mucinous cystadenoma. Cysts are lined with mucosecreting cells without atypia

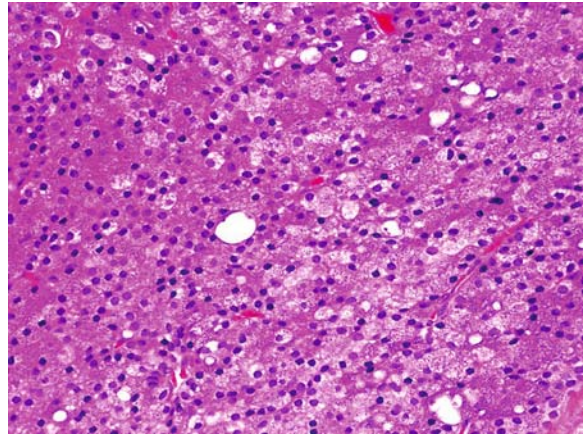


Fig. 5.24. Acinic cell carcinoma solid variant. The cells show granular cytoplasm and acinar differentiation similar to normal salivary gland acini

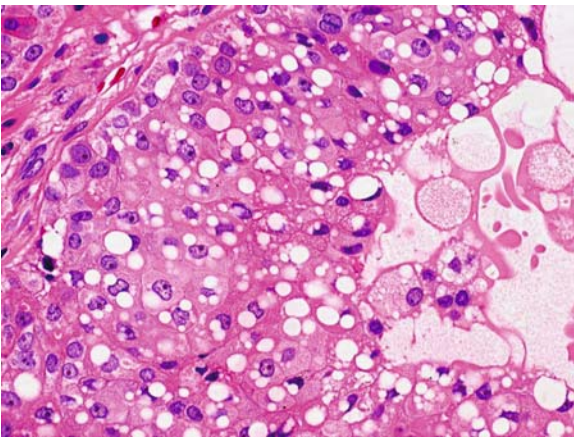


Fig. 5.23. Mucinous cystadenoma with malignant transformation [136]. Cellular pleomorphism and signet ring cell appearance

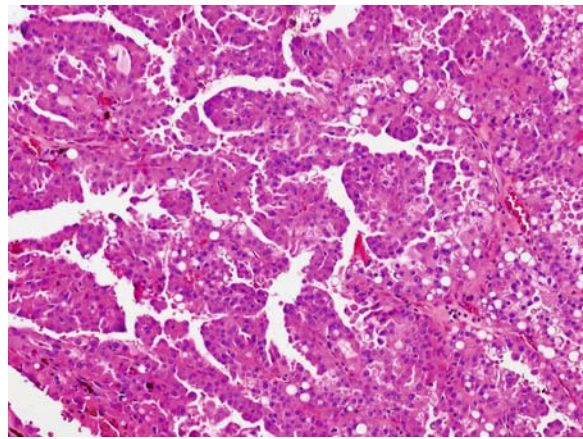


Fig. 5.25. Acinic cell carcinoma, papillary subtype: papillae are lined with intercalated duct-like cells, some containing microvesicles, others showing a hobnail/clear cell appearance

and centenarians. The parotid is involved in 92% of cases (3% bilateral), with only occasional examples in the submandibular or minor glands [62], or periparotid lymph nodes [161]. The typical clinical history is of a slowly enlarging mass (for as long as 40 years) sometimes with pain and facial nerve weakness. Most tumours are partly circumscribed, with a diameter of 10–30 mm, although some may reach 220 mm [4]. Microscopy shows one or more growth patterns – solid, microcystic, follicular and papillary-cystic. The follicular pattern resembles thyroid tissue, and any tumour in the parotid with a papillary-cystic architecture should be considered to be an AcCC, until proven otherwise. The cells in AcCC may take one of several forms – acinar (serous or blue dot), intercalated ductal (cuboidal, often lining small ducts), microvesicular, hob-nail or clear – the last is surprisingly rare, being seen in only

6% of cases [62]. Several growth patterns and cell types may be seen in any individual tumour (Figs 5.24–5.26). Dedifferentiation towards a high-grade malignancy occurs occasionally [51], and all surgical specimens of AcCC must be sampled adequately. A lymphoid infiltrate is found in about 30% of cases, but is only of clinical significance (having a good prognosis) when the tumour is a well-circumscribed nodule with a microfollicular architecture (Fig. 5.27) [133].

The most useful special stain in AcCC is PASD, which highlights cytoplasmic zymogen granules (Fig. 5.28). Immunohistochemistry is of limited value – positivity is seen with cytokeratin, amylase, CEA and in 10% S-100 protein [221]. Other myoepithelial markers are negative. It has been suggested that bone morphogenetic protein-6 (BMP-6) may be useful, but this marker is not yet widely available [92]. Electron

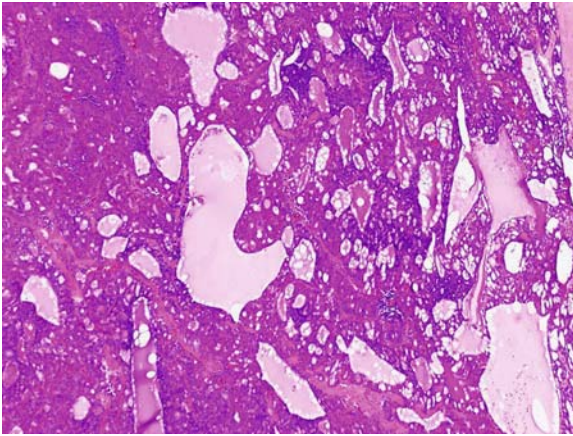


Fig. 5.26. Follicular variant of acinic cell carcinoma: the tumour is composed of follicle-like spaces of varying sizes lined with cuboidal intercalated duct-type cells

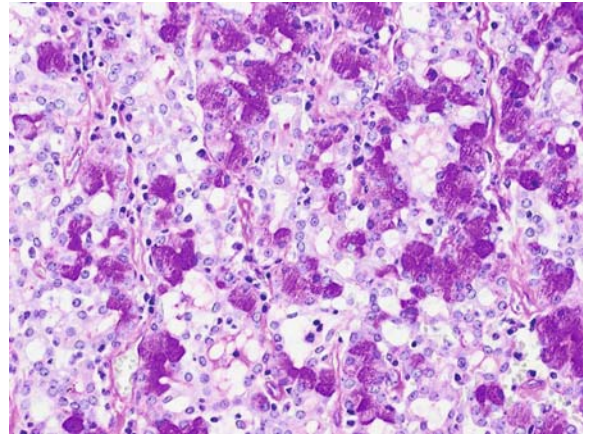


Fig. 5.28. Acinic cell carcinoma. PAS-D emphasises coarse zymogen granules in the cytoplasm of the tumour cells

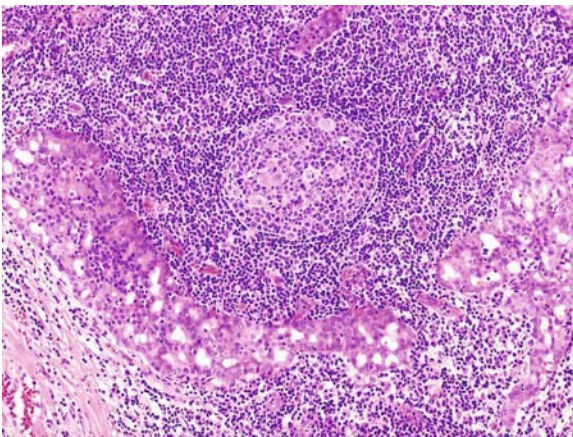


Fig. 5.27. Acinic cell carcinoma with lymphoid stroma: a characteristic microcystic appearance of this tumour subtype is seen

microscopy shows multiple, round, electron-dense cytoplasmic secretory granules [62]. The differential diagnosis depends on the subtype: serous cells resemble normal parotid acini, but with an abnormal architecture. The papillary-cystic type bears a close similarity to the controversial entity cystadenocarcinoma. A follicular pattern suggests metastatic thyroid carcinoma, but is thyroglobulin-negative. The clear cell variant must be differentiated from other neoplasms composed of clear cells, but there are always some cells with PASD-positive granules. AcCC is a genuine malignancy capable of killing, although this may take many years. Average figures for recurrence are 35% and death from disease 16% [62]. Several unsuccessful attempts have been made to predict the clinical outcome of AcCC from morphology, as even the blandest of tumours may cause death. Two studies have shown

that Ki-67 (MIB1) is an independent prognostic indicator [94, 198]. Skálová et al. found that tumours with a proliferation index <5% were cured by complete excision, whereas more than half of AcCCs with indices above this either recurred or metastasised [198]. The most effective treatment is complete surgical excision of the primary. Radiation may have a role if this is not possible.

5.9.2 Mucoepidermoid Carcinoma

ICD-O:8430/3

Mucoepidermoid carcinoma (MEC) demonstrates a wide age distribution with a mean of 45 years. Patients with tumours in the palate tend to be younger than those with tongue lesions. It is also the commonest salivary malignancy in children, and can be seen in patients as young as 4 years old [35]. There is a slight 3:2 female predominance. It can occur in either major or minor glands. MEC is “a tumour characterised by the presence of mucus-producing cells, epidermoid cells and cells of intermediate type”. The proportion of the different cell types and their architectural configuration (including cyst formation) vary between tumours and sometimes within any individual neoplasm. Mucous cells tend to be more numerous in MECs with cyst formation. Mucous cells are cuboidal, columnar or goblet-like and form solid masses or line cysts, where they may be single or multi-layered [173]. The mucin stains with PASD, Alcian blue and mucicarmine, and these are particularly useful in cases where mucous cells are few. Mucus-filled cysts may rupture and elicit an inflammatory response. Epidermoid cells usually have intercellular bridges, but it should be noted that the term *epidermoid* does not indicate squamous differentiation, but simply a squamous-like appear-

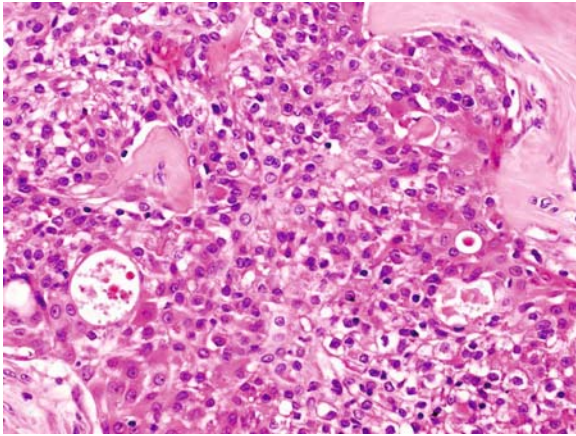


Fig. 5.29. Mucoepidermoid carcinoma: clear, intermediate and mucus-secreting cells

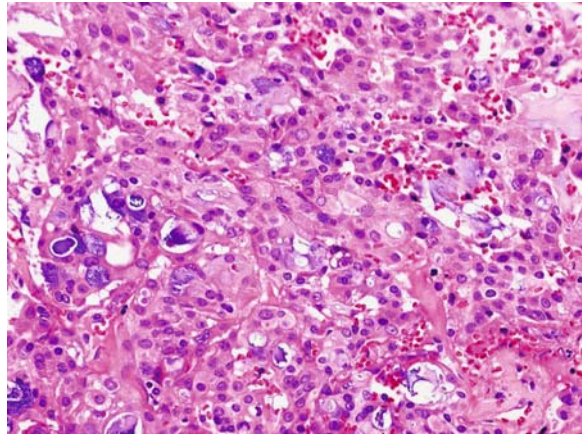


Fig. 5.31. High-grade mucoepidermoid carcinoma: “epidermoid” cells arranged in a solid pattern also show nuclear pleomorphism. Mucus-secreting cells may be scarce

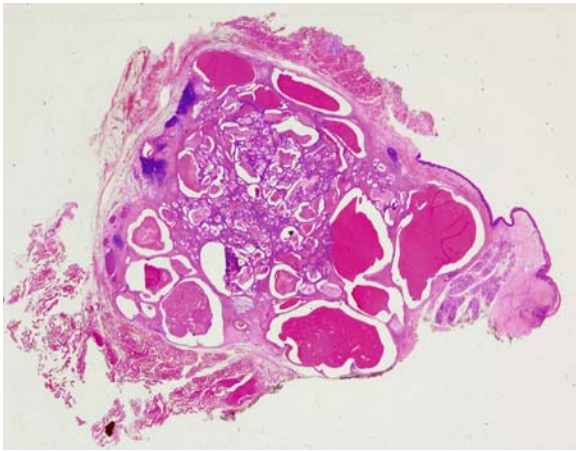


Fig. 5.30. Low-grade mucoepidermoid carcinoma: typical cystic and solid pattern

ance (Figs. 5.29–5.31). In fact, keratinisation is very rare in MEC, and indeed is much commoner as part of squamous metaplasia in pleomorphic adenoma or malignant myoepithelioma, and in metastatic squamous carcinoma from the skin or upper aerodigestive tract. Epidermoid cells may be sparse in MECs, and high molecular weight cytokeratin stains (e.g. LP34) and p63 can help identify them. Intermediate cells are small with dark-staining nuclei and they often form the stratified lining of cysts beneath the mucous cells. Clear cell change may be seen in either the squamous or intermediate cells and MEC may take the form of a clear cell carcinoma [182]. Similarly, oncocytes can be plentiful [109]. All MECs are malignant with a metastatic potential, regardless of their microscopic appearance. Nevertheless, histological features can be used to

predict outcome to some degree, and MECs should be given one of three microscopic grades, based on the extent of the cystic component, neural invasion, necrosis, cytological pleomorphism and mitotic activity. This assessment has considerable prognostic significance, with death rates due to disease of 3.3, 9.7 and 46.3% for grades 1, 2 and 3 respectively [62]. Recently, a new grading system has been proposed, but it is still under evaluation [22]. Assessment of the MIB1 proliferation index has also been shown to be of value [196].

5.9.3 Adenoid Cystic Carcinoma

ICD-O:8200/3

Adenoid cystic carcinoma (AdCC) is a malignant tumour with no particular age or sex predilection. It can occur in any gland, but most often in the submandibular or minor salivary glands, particularly the palate. However, in spite of often apparently slow growth, outcome over the long term is poor. AdCC is an extensively infiltrative tumour with characteristic perineural invasion, and this is partly responsible for the clinical presentation of late, but repeated local recurrences. Unlike other salivary gland malignancies, when AdCC metastasises, it tends to involve distant organs (lung, bone) rather than local lymph nodes [117].

Histologically, AdCC is a generally solid tumour in which the cribriform pattern is easily recognised on microscopy, but tubular and solid structures can also be present. The commonest growth patterns are:

Cribriform: this is the most characteristic microscopic feature, dominated by multiple cribriform structures, composed of epithelial and basal/myoepithelial cells. The nuclei are usually dark, hyperchromatic and angulated. Mitotic figures are easy to find and may be abun-

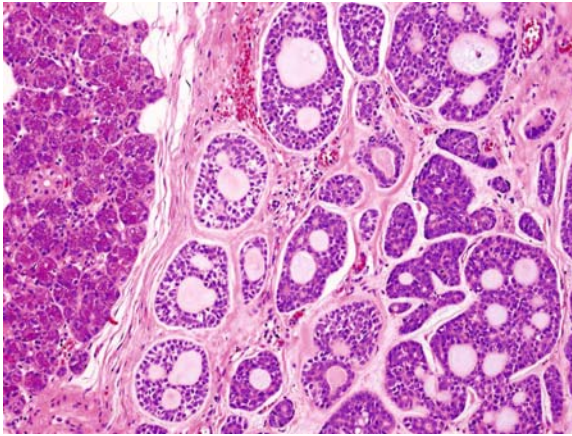


Fig. 5.32. Adenoid cystic carcinoma, cribriform variant: multiple cribriform spaces composed of basaloid cells, with hyalinised material surrounded by small hyperchromatic cells

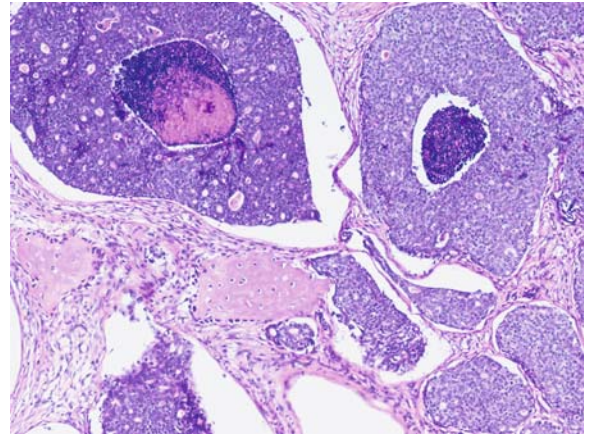


Fig. 5.34. Adenoid cystic carcinoma, solid variant. This is composed of multiple solid nodules, some displaying central comedo-like necrosis. The tumour can be seen to infiltrate bone

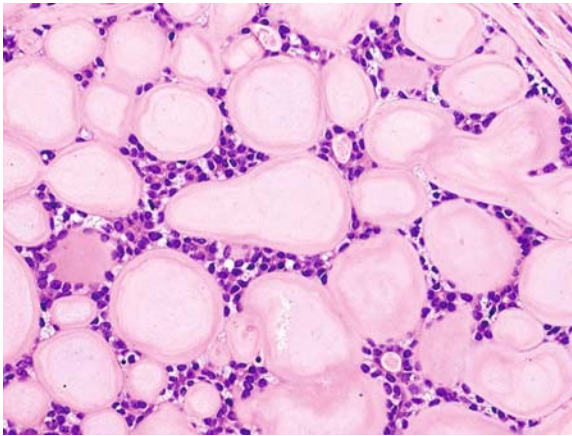


Fig. 5.33. Adenoid cystic carcinoma, cribriform variant. Diffuse hyalinisation with compression of tumour cells. Nuclear pleomorphism may be difficult to appreciate, leading to a false diagnosis of pleomorphic adenoma (Figs. 5.32, 5.33).

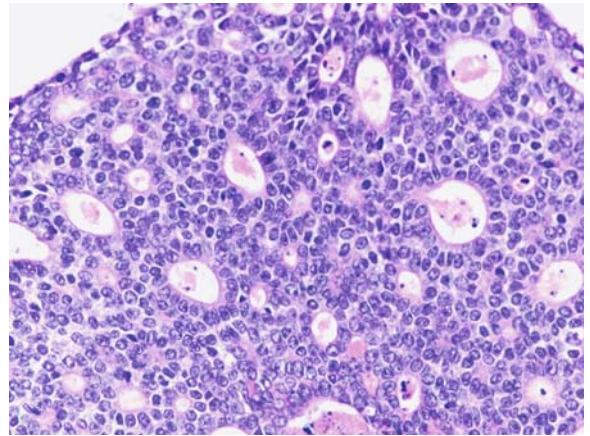


Fig. 5.35. Adenoid cystic carcinoma, solid variant. Tumour islands contain small ducts lined with a layer of epithelial cells. In the absence of characteristic cribriform structures, the latter feature is diagnostic

dant; the MIB1 proliferation index exceeds 10% [201]. The contents of the spaces can be loose and basophilic or dense and eosinophilic. Hyalinisation is common in adenoid cystic carcinoma and may be extreme. In those cases with excessive deposition of hyalinised material, the spaces are distended with loss of the cribriform pattern. Tumour cells may be sparse and bland, and thus the lesions may mimic a pleomorphic adenoma (Figs. 5.32, 5.33).

Tubular: this is composed of small tubules lined with one or two cell types, luminal and abluminal without significant cytological atypia. Because of this bland cytological appearance it may be mistaken for basal cell adenoma, except for the presence of infiltration.

Solid (basaloid): this is dominated by large solid sheets of tumour cells, sometimes with comedo-like central necrosis. Within the solid masses of tumour cells, there are small duct-like spaces surrounded by a definite layer of epithelial cells (Figs. 5.34, 5.35). This latter finding distinguishes solid variant AdCC from (relatively low-grade) basal cell adenocarcinoma and the aggressive basaloid squamous cell carcinoma, which in addition often shows intraepithelial dysplastic changes.

A rare finding in all types of AdCC is squamous metaplasia, either as single cells or with keratin pearl formation [62].

A system of three grades based on the presence of tubular, cribriform and solid pattern [171] has shown

that outcome is better in tubular ACC, while the worst prognosis is seen in solid AdCC. Nevertheless, clinical stage appears to be a better predictor than grade [210].

Another unfavourable feature of AdCC is the frequent involvement of resection margins in the surgical specimen, particularly as the result of extensive perineural infiltration. As complete excision of AdCC is difficult, patients often require postoperative radiotherapy.

A most important histological differential diagnosis is between AdCC and polymorphous low-grade adenocarcinoma (see Sect. 5.9.4).

5.9.4 Polymorphous Low-Grade Adenocarcinoma

ICD-O:8525/3

Polymorphous low-grade adenocarcinoma (PLGA) is also known as terminal duct or lobular carcinoma. It is more frequent in women, and the average age at presentation is 59 years (range 21–94) [62]. Most cases arise in intra-oral minor salivary glands, particularly the palate, with only rare examples in the parotid, sometimes developing into a pleomorphic adenoma [223]. The characteristic histological picture of PLGA is an infiltrating tumour with cytological uniformity and morphological diversity [171]. The architecture comprises a variety of patterns, including ducts, streams, and micropapillary, cribriform and solid structures (Fig. 5.36). Diffuse infiltration of tumour cells with Indian filing and concentric growth around nerves is reminiscent of lobular carcinoma of the breast (Fig. 5.37).

The cells each have single regular round, ovoid or fusiform bland nuclei, sometimes with intra-nuclear vacuoles [187] and absent or small nucleoli. Variably present are oncocytic, clear or mucous cells. Mitotic figures are scanty, and never atypical. The stroma varies from fibromyxoid to densely hyaline, but the chondroid matrix of a pleomorphic adenoma is not seen. Immunohistochemistry shows positivity with epithelial markers (cytokeratins, EMA), S-100, *bcl-2* and sometimes CEA, α SMA and vimentin [26]; MIB1 proliferation is low – mean 2.4% (range 0.2–6.4) in one study [201]. PLGA behaves as a low-grade malignancy; a literature review found a recurrence rate of 21%, regional nodal metastasis in 6.5%, distant metastasis in 1.8%, and death due to cancer in 0.9% [116]. However, after 10 years late recurrences and metastases are perhaps more common than that [63], although in another study with a long follow-up, recurrence was in large part due to incompleteness of excision – none of the 22 excised tumours recurred or caused death [159]. In a larger series of 164 PLGA, more than 95% of the patients had no evidence of disease after a long-term follow-up [26]. The recommend-

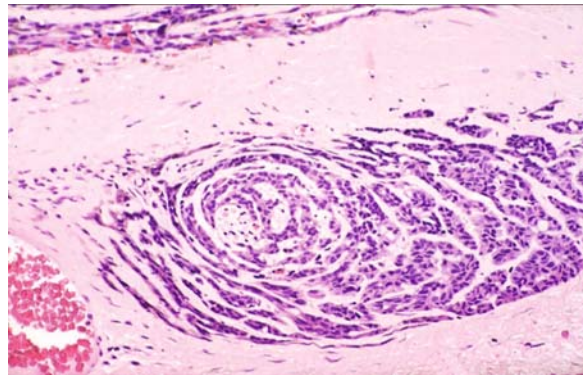


Fig. 5.36. Polymorphous low-grade adenocarcinoma. Perineural infiltration. Tumour cells show bland cytonuclear abnormality

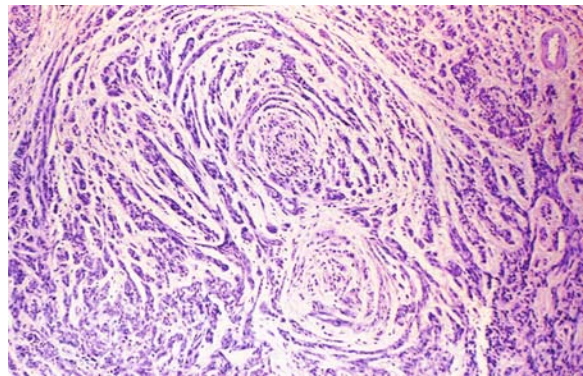


Fig. 5.37. Polymorphous low-grade adenocarcinoma. Indian filing appearance resembling lobular carcinoma of the breast

ed treatment of PLGA is wide, but conservative surgical excision, postoperative radiation and chemotherapy have little place.

The most important histopathological differential diagnosis is from the much more aggressive adenoid cystic carcinoma. Although both are diffusely infiltrating carcinomas that display morphological diversity, at a cytological level the nuclei in AdCC are seen to be hyperchromatic, angulated, pleomorphic and densely packed with more frequent mitotic figures, in contrast to the nuclei in PLGA, which are uniform with finely speckled chromatin. In addition, staining with S-100 protein is usually more diffuse and stronger in PLGA than AdCC [201, 225]. Other markers such as c-kit (CD117) are of little use in practice, as staining can be seen in AdCC and most PLGAs [59]. Much more reliable marker is the MIB1 proliferation index, which is almost always significantly lower in PLGA [201, 225]. Other differential diagnoses include pleomorphic adenoma, which in minor salivary glands can be poorly circumscribed. The presence of chondroid matrix and any circumscription fa-

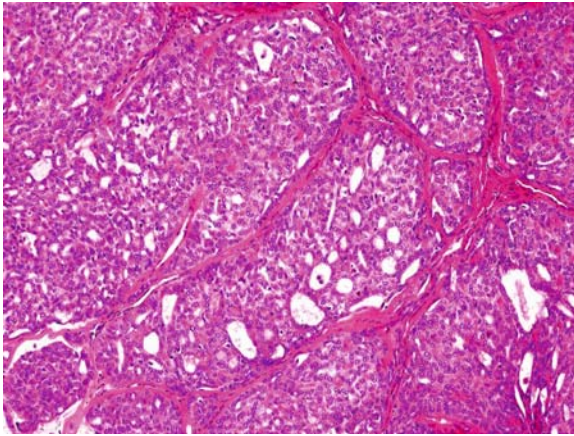


Fig. 5.38. Cribriform adenocarcinoma of the tongue (CAT). A vaguely nodular growth pattern is composed of solid nests with tubular structures

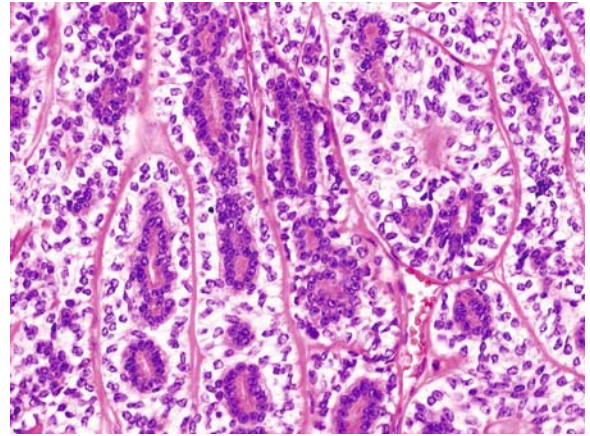


Fig. 5.39. Epithelial myoepithelial carcinoma (EMCa): characteristic biphasic appearance with an inner layer of ductal cells and outer layer of clear myoepithelial cells. Basal membrane-like material surrounds the outer cells

vours PA, but it is sometimes not possible to distinguish these tumours, particularly on a small biopsy. Papillary structures form part of the spectrum of growth patterns seen in PLGA [206], but when extensive, there is evidence that these tumours are slightly but significantly more aggressive [63, 64], although they do not seem to affect long-term survival. Genuine high-grade malignancy can occur rarely, as either a poorly differentiated PLGA or as a salivary duct carcinoma [191].

5.9.4.1 Cribriform Adenocarcinoma of the Tongue

ICD-O:8525/3

A newly described tumour [134] found so far only in the tongue, shares some histological features with PLGA, to which it is probably related. Cribriform adenocarcinoma of the tongue (CAT) usually arises in adults with a mean age of 50 years and equal sex incidence in the root of the tongue. Generally, at the time of diagnosis there are metastases in the neck lymph nodes, either unilaterally or bilaterally, but distant spread has not been described.

Microscopic examination shows lobules divided by fibrous septa, composed of areas with solid and microcystic growth patterns. In the solid areas, tumour nests often display a well-developed hyperchromatic outer layer with a perpendicular arrangement of cells. This layer is frequently detached, forming papillae or glomeruloid structures surrounded by apparent clefts. The microcystic growth pattern is composed of lobules of neoplastic cells with a cribriform and/or tubular architecture, the two patterns often intermingling. Typically, the tubules are approximately of the same size and consist of

one cell layer. Cytologically, there is one cell type; characteristically, the nuclei, which often overlap one another, are pale and vesicular with a “ground glass” quality, thus resembling those of papillary thyroid carcinoma (Fig. 5.38).

Each nucleus can contain up to three nucleoli of varying conspicuousness. Immunohistochemically, a strong or patchy reaction is seen with cytokeratins and S-100 protein. Actin, calponin and smooth muscle myosin heavy chain react with only a few areas. They are completely negative for thyroglobulin.

Patients treated with surgical excision and subsequent irradiation have a good chance of prolonged survival without recurrence or further metastatic spread [134].

5.9.5 Epithelial-Myoepithelial Carcinoma

ICD-O:8562/3

The mean age at diagnosis of epithelial-myoeplithelial carcinoma (EMCa) is 60 years (range 8–103), with a small majority in females [62]. It occurs predominantly in the parotid gland, less often in the submandibular gland, occasionally in minor salivary glands and rarely in the bronchus [234]. The microscopic appearance is characterised by small ductular lumina lined with two layers of cells (Fig. 5.39). The inner comprises cytokeratin-positive epithelial cells, and it is surrounded by an outer mantle of often clear myoepithelial cells, which express α SMA, smooth muscle myosin heavy chain and calponin. S-100 protein also stains the outer cells strongly, but is less specific and sometimes reacts with the inner layer [114] – CK 14 appears to be un-

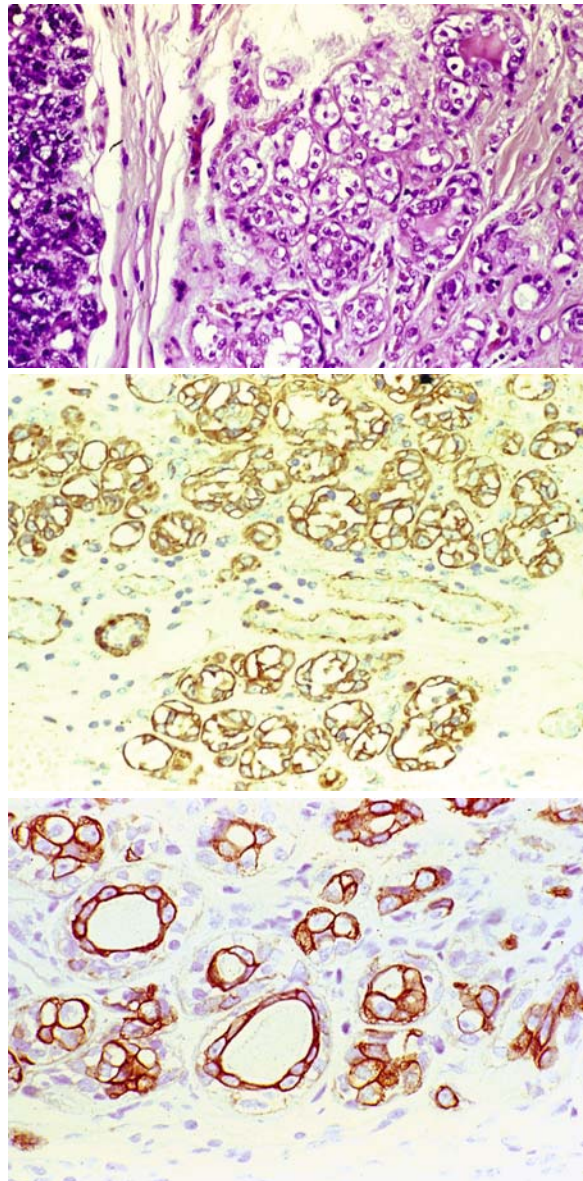
helpful. The outer cells are in turn surrounded by a rim of PAS-positive basement membrane material of variable thickness. This pattern is reproduced throughout most of the tumour, though each element may vary in prominence both between and within each lesion. Grossly, the tumours often appear to be well circumscribed, but microscopy usually reveals some invasion of surrounding structures. Cytological pleomorphism is infrequent, but mitotic figures may be numerous. The stroma is usually scanty, but on occasions it consists of plentiful hyaline basement membrane material with relatively inconspicuous bilayered ducts; the tumour can then be mistaken for a pleomorphic adenoma [186]. Other differential diagnoses encompass a wide range of salivary neoplasms, mainly those composed of clear cells, both primary and metastatic. Many salivary tumours can be diagnosed purely on H&E morphology, but clear cell lesions are an exception, and most require immunohistochemistry and sometimes electron microscopy. EMCa can occasionally dedifferentiate as a high-grade adenocarcinoma [2] or a sarcomatoid spindle cell neoplasm of myoepithelial type [186]. That they originate from intercalated ducts is supported by an unusual case of a typical EMCa in a parotid gland, which also contained multiple nodules of intercalated duct hyperplasia (Figs. 5.40–5.42) [48].

This appearance may explain why EMCa is not infrequent in hybrid tumours [31, 37]. The behaviour of EMCa is generally considered to be low grade, and in a literature review of 67 cases, recurrences were noted in 31%, cervical lymph node metastasis in 18%, distant metastasis in 7% and death due to tumour in 7% [13]. In contrast, the series of Fonseca and Soares [71] found that 50% of neoplasms recurred and 40% of patients died of cancer. The only morphological feature found to correlate with a poor prognosis was nuclear atypia in more than 20% of tumour cells. In another study DNA analysis has shown that aneuploidy is associated with an increased chance of recurrence [34].

5.9.6 Hyalinising Clear Cell Carcinoma

ICD-O:8310/3

Monomorphic clear cell carcinomas are either epithelial or myoepithelial (clear cell malignant myoepithelioma). The former, now known as hyalinising clear cell carcinoma was first described by Škorpil in Czech and German [205] and was rediscovered recently [138, 193], but was not included in the revised WHO classification [171]. It usually arises in the minor glands and is of low-grade malignancy. Microscopically, it is characterised by groups and trabeculae of polygonal glycogen-rich cells separated by dense collagen bands. At times, particularly in the deeper parts of the tumours, the cells may lose their clarity when their cytoplasm appears weakly



Figs. 5.40–5.42. Intercalated duct hyperplasia of the parotid gland. Top: Hyperplastic foci are composed of an inner layer of epithelial cells surrounded by myoepithelial cells with ample and clear cytoplasm. The former stain for CAM5.2 (lower) and the latter for smooth muscle actin (middle)

eosinophilic. Immunohistochemistry reveals positivity with epithelial markers (e.g. cytokeratin), but myoepithelial markers (e.g. S-100 protein and α SMA) are negative [138].

5.9.7 Basal Cell Adenocarcinoma

This tumour has the architecture and cytology of basal cell adenoma, but displays infiltration. Most cases arise

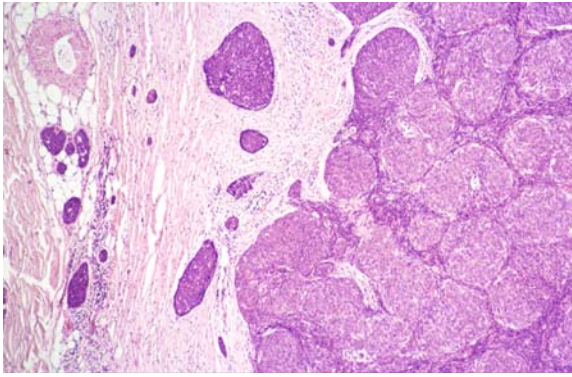


Fig. 5.43. Basal cell adenocarcinoma. In spite of the lack of significant cellular atypia, the infiltrative pattern is diagnostic of malignancy. Courtesy of Prof. J.W. Eveson, Bristol, UK

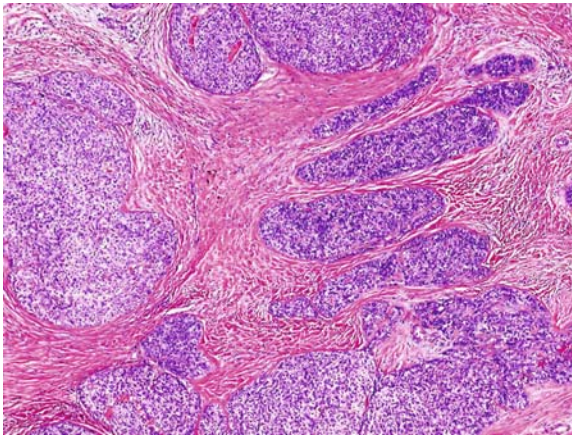


Fig. 5.44. Myoepithelial carcinoma. Multiple nodules infiltrate dense fibrous tissue

in patients over 50 years of age, and there is an equal sex incidence [16]. The usual site is the parotid gland, but they have been described in the submandibular [131, 144], sublingual [139] and minor glands [111]. They can arise *de novo*, but about 25% develop in a pre-existing basal cell adenoma [144], usually of the membranous type [16] (see Sect. 5.8.3). Microscopically, the general morphological and cytological appearances are almost identical to basal cell adenoma and likewise, four growth patterns are recognised – *solid*, *tubular*, *trabecular* and *membranous* – although these are not thought to have prognostic significance. The tumour islands contain a mixture of large, paler and small basaloid cells, with the latter usually demonstrating peripheral palisading, though this is less marked than in the benign counterpart. The large cells sometimes form eddies, and the tumour islands may also contain small tubules and foci of squamous metaplasia. The

amount of basement membrane material varies, but can be marked, especially in the membranous variant. Occasional cases show cytological pleomorphism, but generally this is absent, and mitotic figures are usually sparse. The most reliable indicator of malignancy is infiltration of the surrounding gland, and less frequently of blood vessels and nerves (Fig. 5.43) [16]. In addition, the Ki-67 proliferation index is usually higher in basal cell adenocarcinoma than its benign counterpart (>5% vs. <2.7%) [152]. More than half the carcinomas in one study expressed p53, and 3 out of 11 cases were positive for epidermal growth factor receptor (EGFR); in contrast, all the adenomas were negative [152]. The differential diagnosis of basal cell adenocarcinoma includes solid forms of adenoid cystic carcinoma (see Sect. 5.9.3), which are much more aggressive neoplasms with cytological pleomorphism and plentiful mitotic figures; these are generally associated with other growth patterns such as small luminal structures. The behaviour of most basal cell adenocarcinomas is low grade. A review found an incidence of local recurrence of 37%, cervical lymph node metastasis of 8%, distant metastases of 4% and one patient died of disseminated disease [144].

5.9.8 Myoepithelial Carcinoma (Malignant Myoepithelioma)

ICD-O:8982/3

Myoepithelial carcinoma is defined as a malignant epithelial neoplasm in which the predominant differentiation of the tumour cells is myoepithelial [171]. The average age of patients at presentation is about 55 years (range 14–86), and the sex incidence is approximately equal. Most cases arise in the parotid, but they also occur in the submandibular and minor glands [62, 168]. They may arise *de novo*, but at least 50% develop in a pre-existing pleomorphic adenoma or benign myoepithelioma [2, 54, 149, 168].

Macroscopically, malignant myoepitheliomas are unencapsulated masses usually 20–50 mm in diameter (maximum 250 mm). The microscopic architecture is often multinodular with infiltration into adjacent tissues. The nodules comprise solid and sheet-like growths of tumour cells often with plentiful myxoid or hyaline material, and sometimes displaying central necrosis (Figs. 5.44, 5.45). The range of cell types reflects that seen in benign myoepitheliomas and includes epithelioid cells (the most frequent) often arranged in trabecular or pseudo-acinar structures with cleft-like spaces. Cells with clear cytoplasm or vacuolation (resembling lipoblasts) and cells with hyaline (plasmacytoid) and spindle to stellate forms are also seen (Fig. 5.46). In most malignant myoepitheliomas one cell type predom-

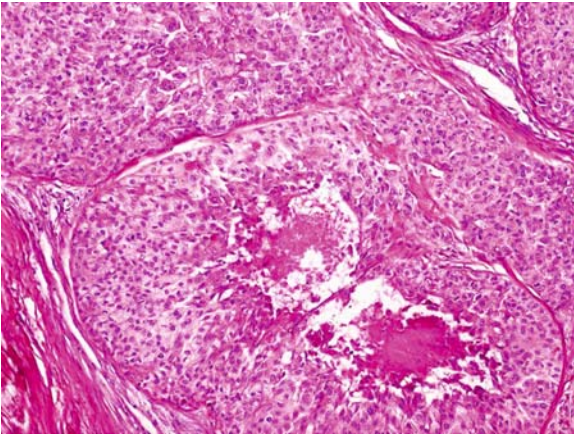


Fig. 5.45. Myoepithelial carcinoma, solid growth pattern with central necrosis in one of the nodules. This finding may mimic salivary duct carcinoma with comedo-like necrosis

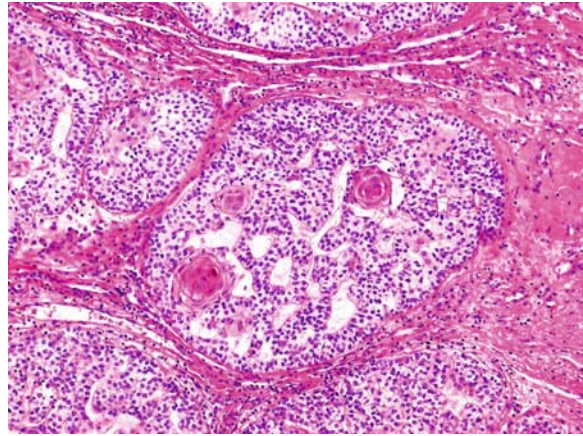


Fig. 5.47. Myoepithelial carcinoma: focal squamous metaplasia with keratin pearl formation

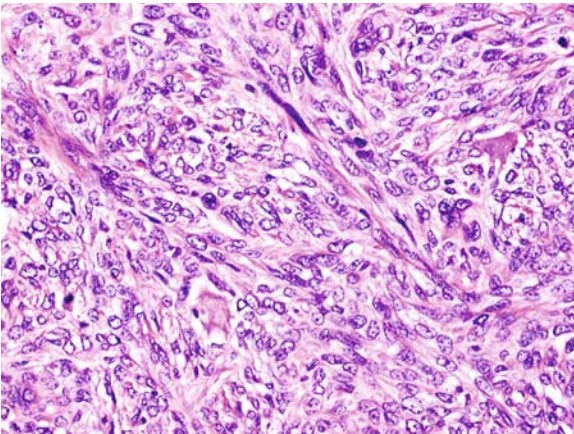


Fig. 5.46. Myoepithelial carcinoma. The spindle cell component shows nuclear pleomorphism resembling a soft tissue sarcoma. A helpful diagnostic pointer is that other types of myoepithelial cell are usually identified elsewhere

inates, but there is usually a minor component of other cell types. No true glands or lumina are seen in pure, malignant myoepitheliomas, but as with their benign counterparts, occasional small ducts in a neoplasm with otherwise typical features should not preclude the diagnosis [183]. The nuclei can vary from relatively uniform, small with finely distributed chromatin, lacking obvious nucleoli, to markedly enlarged and pleomorphic, showing chromatin clumping and large nucleoli. Mitotic figures may be plentiful (range 3 to 51 per 10 high power fields) and include atypical forms [168]. Multinucleate [33] and bizarre tumour giant cells may occasionally be present. The tumour-related matrix is generally prominent and is hyalinised or myxoid.

Special stains in tumours without any ductal differentiation show no mucicarmine-positive mucus, but plentiful glycogen is found in clear cells and the myxoid matrix is positive with Alcian Blue. Metaplastic changes are frequent and include areas showing squamous differentiation, often with keratinisation (Fig. 5.47). Perineural invasion is seen in 44% and vascular invasion in 16%. In one series, 40% of tumours were categorised as high grade and 60% as low grade [168]. All tumours show some positivity for S-100 protein, vimentin and broad-spectrum cytokeratin (e.g. AE1-AE3 or MNF116). Other cytokeratin antisera (CAM 5.2 and LP34) show some reactivity in most tumours, and about half display some expression of cytokeratin [13]. Of the more specific myoepithelial markers, approximately 75% of tumours including those composed of plasmacytoid cells, express calponin and about 50% are positive with α SMA; p63 was positive in 60% [166]. Amongst other markers, glial fibrillary acidic protein (GFAP) is positive in 31% and epithelial membrane antigen (EMA) in 20%, in addition to highlighting any true small ducts, but carcino-embryonic antigen (CEA) is usually negative. CD117 (c-kit) was positive in the few cases studied [112]. The mean MIB1 (Ki-67) index in one series was 35% (range 15–65), with any count above 10% said to be diagnostic of malignancy in a myoepithelial neoplasm [151].

Electron microscopy shows that some tumour cells contain small desmosomes, but actin filaments are few [168]. It has been shown that malignant myoepitheliomas secrete matrix-degrading proteinases, as well as proteinase inhibitors [215], and this appears to be associated with demonstrated inhibition of angiogenesis. These features indicate an anti-invasive effect, and although as yet poorly understood, this is likely to have

Table 5.3. Classification of clear cell tumours and tumour-like conditions of the salivary glands [174]

Benign	Pleomorphic adenoma Myoepithelioma Sebaceous adenoma Oncocytoma Multifocal nodular oncocytic hyperplasia (MNOH)
Malignant, primary (carcinomas not usually characterised by clear cells, but with rare clear cell variants)	Mucoepidermoid carcinoma Acinic cell carcinoma
Malignant, primary (carcinomas usually characterised by clear cells)	Epithelial-myoepithelial carcinoma Hyalinising clear cell carcinoma Clear cell malignant myoepithelioma (myoepithelial carcinoma) Sebaceous carcinoma
Malignant, metastatic	Carcinomas: especially kidney, thyroid. Also melanoma

an effect on the biological aggressiveness of any particular tumour.

The variable appearance of malignant myoepithelioma, leads to a wide differential diagnosis, including other salivary carcinomas. Nodules with central necrosis mimic the comedocarcinoma structures in salivary duct carcinoma, but there is usually more stromal material in the myoepithelial neoplasm and in addition, S-100 and/or myoepithelial markers are usually positive. The clear cell variant resembles many other salivary neoplasms composed of clear cells, benign and malignant, primary and metastatic (Table 5.3) [132, 174] (see Sect. 5.9.5).

The prognosis of malignant myoepithelioma is variable, but approximately one-third of patients die of disease, another third have residual tumour and the remaining third are disease-free [62, 168]. When metastases occur, they can be found in neck lymph nodes and at distant sites, including lungs, kidney, brain and bones. Malignant myoepitheliomas arising in ordinary pleomorphic adenomas behave in the same way as those that arise de novo [168], but it has been suggested that neoplasms developing in multiply recurrent pleomorphic adenomas may pursue a prolonged course [52]. A further suggestion is that malignant myoepitheliomas composed mainly of plasmacytoid cells may be more aggressive [53, 218]. However, Saveria and Sloman in their series of 25 cases found only a weak statistical correlation for outcome with cytological atypia (high grade), but other parameters (tumour size, site, cell type, mitotic rate, presence of a benign tumour, necrosis, perineural and vascular invasion) showed no relationship [168]. In practice with any particular case, the various histological features should be listed, and an attempt made to describe the tumour as low- or high-grade, but adding a rider that histological grade is as yet a far from proven guide to clinical behaviour. Treatment is surgical, and

no role for radio- and chemotherapy has yet been established.

5.9.9 Salivary Duct Carcinoma

ICD-O:8500/3

Salivary duct carcinoma (SDC) is probably not as uncommon as previously thought [87, 93]. Most patients are over 50 years old and there is at least a 3:1 male predominance. It arises mainly in the parotid, less often in the submandibular gland and only occasionally in the minor glands of the palate [47], buccal mucosa [162], maxilla [122] and larynx [69]. It can develop de novo or in a pre-existing pleomorphic adenoma [86, 87] or polymorphous low-grade adenocarcinoma [191]. The microscopic appearance of SDC bears a striking resemblance to ductal carcinoma of the breast, both in situ and invasive, where all of the features of the mammary equivalent can be reproduced (Fig. 5.48). Perineural and lymphovascular invasion are seen in many cases. Nuclear pleomorphism is usual, and is also apparent on FNA cytology [192]. Mitotic figures are often numerous, also reflected in a high Ki-67 proliferation index [93].

Although most cases of SDC can be diagnosed with HE alone, special stains can help in a few instances. Immunohistochemistry shows expression of epithelial markers such as cytokeratins (including subtype 7, but not 20), EMA and GCDFP-15. S-100 protein is usually negative, as are myoepithelial markers, although they may highlight subtle in situ lesions [5]. Despite the morphological similarity to breast carcinoma, staining for oestrogen and progesterone receptors is almost always negative, in contrast to that for androgen receptors (AR), where >90% of SDCs react, even in women. AR positivity appears to be specific to SDC (including when it arises in a pleomorphic adenoma), and is not seen in for example, mucoepidermoid

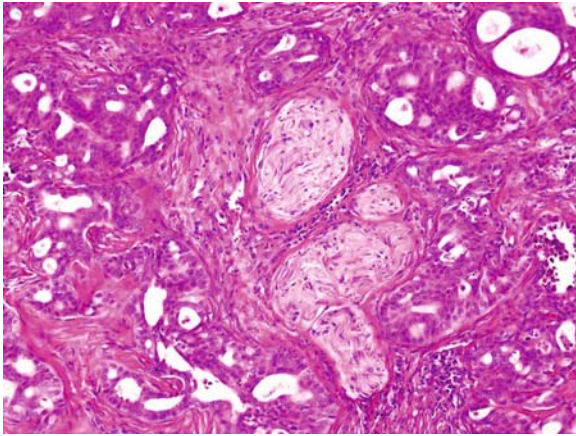


Fig. 5.48. Salivary duct carcinoma: invasive irregular ducts and cribriform structures strongly resemble ductal carcinoma of the breast

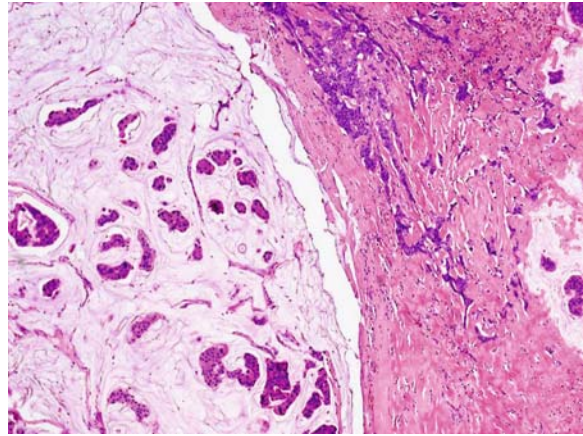


Fig. 5.49. Salivary duct carcinoma, mucin-rich variant. This is composed of a mixture of usual-type salivary duct carcinoma and lakes of mucinous adenocarcinoma

carcinoma [142]. Some studies have shown SDCs to express prostate specific antigen (PSA) or acid phosphatase [110, 120], but another failed to confirm this [185] and similarly, only 1 out of 40 cases in a Mayo Clinic series was PSA-positive [115]. More recently cases of SDC showing positive staining for HER-2/neu (*c-erbB-2*) protein on immunohistochemistry have been published [202], and the gene amplification has been demonstrated with FISH analysis [204].

Several rare morphological variants of SDC have been described, including cribriform [23], micropapillary [147], sarcomatoid [96], mucin-rich [190] and oncocytic (Figs. 5.49, 5.50) [184]. So-called low grade salivary duct carcinoma [46] is probably a separate entity (see below).

The differential diagnoses of SDC are high-grade mucoepidermoid carcinoma, oncocytic carcinoma and some metastases. The diagnosis of mucoepidermoid carcinoma requires the presence of squamous-like cells, mucus-producing cells and cells of intermediate type, and there is no expression of androgen receptors. Many salivary oncocytic carcinomas probably demonstrate other types of malignancy (including SDC) with plentiful oncocytic cells, but a true oncocytic carcinoma lacks any features of SDC and is AR-negative. At present, neither of these two differential diagnoses is clinically critical since the prognosis is similar. However, it is important to identify metastatic carcinoma, particularly from the prostate or breast. In most cases, metastases will be obvious from clinical investigation and imaging studies, but the usual immunoprofile of these tumours is different: prostatic carcinomas tend to be AR+, ER-, PSA+, CK 7+; breast carcinoma tend to be usually AR-, often ER+, PSA-, CK 7+; SDC is AR+, ER-, usually PSA-, and CK 7+.

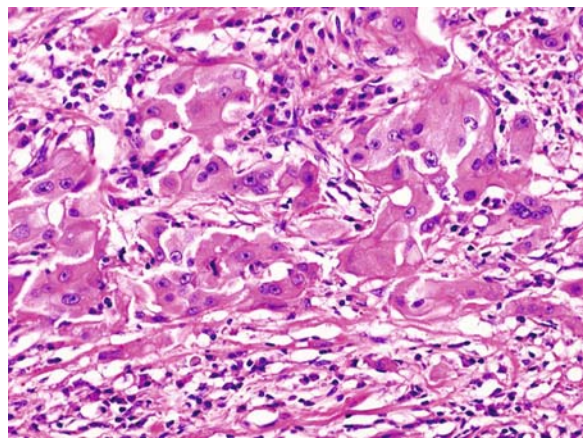


Fig. 5.50. Salivary duct carcinoma with oncocytic differentiation. The cells have ample granular cytoplasm with vesicular nuclei and prominent nucleoli. A clear distinction between oncocytic salivary duct carcinoma and true oncocytic carcinoma may not be possible, as they may not be separate entities

The prognosis for SDC is poor, and most series have shown that more than 70% of patients die of disease, usually within 3 years. Nevertheless, Grenko et al. [86] alluded to a minority (about 25–30%) who do well, but their study was unable to identify any particular features of this group. Amongst possible prognostic indicators, tumour size is probably important, with lesions <30 mm in diameter having a better prognosis [103], but nevertheless several fatal lesions of 20 mm have been reported [23, 36, 87, 185]. Determination of tumour DNA ploidy has not been found to have prognostic significance [9, 86], but it is possible that MIB1 proliferative activity might do so [93]. At present, the best hope for long-term survival appears to be complete surgical excision

with radical neck dissection followed by radiotherapy to the tumour bed and chemotherapy [36, 145]. The recent identification of androgen receptors expression in SDC raises the question as to whether anti-androgen therapy (e.g. flutamide or goserelin) might have merit [99, 142, 153]. The significance of staining for HER-2/neu (*c-erbB-2*) protein is at present uncertain [202, 204], either prognostically or for planning therapy with herceptin.

The entity “*low grade salivary duct carcinoma (low grade cribriform cystadenocarcinoma)*” has a predominantly intraductal growth pattern with low-grade cytological features [46], and its relationship to usual-type SDC is as yet uncertain. The tumour is S-100-positive and the only case studied for AR was negative [19]. The prognosis is good, and although only a few cases have been described, none of the patients has died of disease.

5.9.10 Oncocytic Carcinoma

ICD-O:8290/3

Several carcinoma types have variants composed of oncocytic cells, but only a few dozen cases of pure oncocytic carcinoma have been reported. The average age is 63 years (range 29–91), and most have occurred in the parotid [62]; some have arisen in Warthin’s tumours [222]. The diagnosis of a pure oncocytic carcinoma requires the identification of malignancy, oncocytic differentiation and lack of features of any other tumour type. It is likely that a pure oncocytic carcinoma is an aggressive tumour, as over half of the patients reported either died of disease or suffered recurrences [169].

5.9.11 Malignancy in Pleomorphic Adenoma Malignant Mixed Tumour

The histological diagnosis of pleomorphic adenoma (PA; benign mixed tumour) is not always straightforward, as benign lesions may display atypical histologic features such as capsular infiltration, hypercellularity, cellular atypia, necrosis and vascular invasion [3, 7], which cause suspected malignancy. In addition, some PAs contain genuine cytologically malignant cells, but behave in a benign fashion [21, 56]. A further paradox is the rare occurrence of histologically benign-looking PAs that metastasise [232]. Thus, the concept of malignancy in PA is much more complex than appears at first sight. This is reflected by the variable incidence for the reported frequency of malignancy in PA. In several large series [83, 125, 149, 209, 223] the average was 3.6% of all salivary gland tumours and 11.7% of malignancies;

overall, malignancy develops in 6.2% of all PAs (range in different series 1.9 to 23.3%). The incidence of malignant change increases with the length of history of the PA, from 1.5% at 5 years to 10% after 15 years. The concept of malignant mixed tumour (MMT) as a malignant tumour that contains remnants of benign mixed tumour was developed by LiVolsi and Perzin in 1977 [125]. Spiro et al. [209] agreed with this, but suggested a possible de novo origin in cases lacking a clinical history or histological evidence of a pre-existing salivary gland tumour.

The revised WHO classification of salivary gland tumours [171] discussed the topic of MMT with the title *Carcinoma in Pleomorphic Adenoma* and the sub-title *Malignant Mixed Tumour*. Three entities are recognised: carcinoma in pleomorphic adenoma, carcinosarcoma (true malignant mixed tumour) and metastasising pleomorphic adenoma [171]. There is no uniform agreement on this classification as metastasising PA does not contain histological features of malignancy and therefore it is anomalous to include it as a form of malignancy in PA. In addition, not all carcinosarcomas arise from a PA. Finally, the possibility of myoepithelial malignancy arising in a PA is not included [49].

5.9.11.1 Carcinoma Ex Pleomorphic Adenoma

ICD-O:8941/3

Two subtypes should be recognised: invasive and non-invasive carcinoma.

5.9.11.1.1 Invasive Carcinoma Ex PA

This is the commoner form, in which the malignancy involves only the epithelial component. It occurs mainly in men over 60 years old. Most cases (81.7%) involve the parotid gland, with the submandibular in 18% and the sublingual in 0.3%; the minor salivary glands, particularly in the palate, can also be affected [229]. The typical presentation is a long history of a salivary gland nodule that suddenly increases in size.

The demonstration of both a carcinoma and a PA is necessary for the diagnosis.

A history of a long-standing parotid tumour is not sufficient evidence for a pre-existing PA, whilst a previously excised PA at the site of a carcinoma is acceptable [62].

Grossly, carcinoma ex PA is often larger than a benign PA. Histological recognition of a pre-existing PA may be difficult, as it could be obscured by the carcinoma, or may only show degenerate changes such as

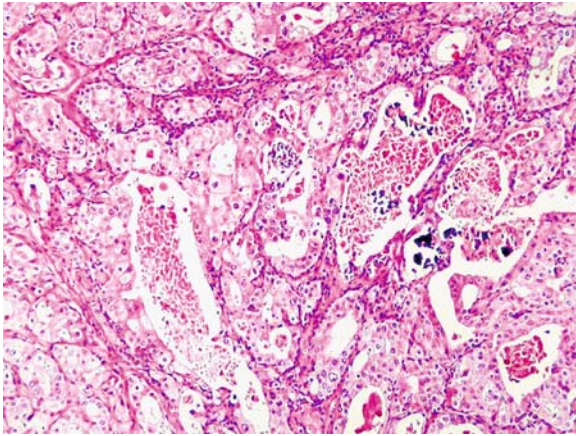


Fig. 5.51. Non-invasive carcinoma in a pleomorphic adenoma. Ducts contain cells with atypical nuclei. Focal necrosis and calcification is also present

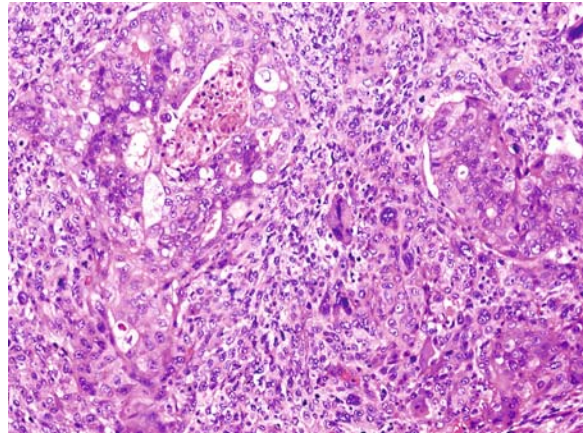


Fig. 5.52. True malignant mixed tumour/carcinosarcoma. The epithelial component is a poorly differentiated carcinoma with some features suggesting salivary duct carcinoma. The sarcomatous component is a high-grade spindle cell sarcoma, in this case, without specific differentiation

scarring, dystrophic calcification, necrosis and haemorrhage with occasional transitional changes made up of cells showing features intermediate between frank malignancy and PA [49, 124]. Although the proportion of the malignant component varies from minute foci to almost the whole lesion, recognition of frankly invasive carcinoma ex PA is usually simple. Capsular, perineural and vascular invasion are easily identified, as well as extension into neighbouring tissues [49, 62, 124].

Recent studies show adenocarcinoma not otherwise specified and salivary duct carcinoma to be the most frequent histological types [49, 87], and there is immunohistochemical and ultrastructural evidence that many carcinomas previously described as “undifferentiated” are in fact myoepithelial – indeed many myoepithelial carcinomas can be shown to have arisen in a pre-existing PA [52, 53, 151, 168]. It is not uncommon to find other concurrent differentiation, e.g. squamous, mucoepidermoid, polymorphous low-grade adenocarcinoma [125, 149, 209]. In determining the prognosis, the extent of invasion is more important than the histological type: Tortoledo et al. [223] found that none of the patients whose tumour penetrated <6 mm beyond the capsule died of disease, but that all patients with invasion of >8 mm died of disease. A more recent study found that none of the tumours that invaded <5 mm beyond the host PA progressed [124].

5.9.11.1.2 Non-Invasive Carcinoma Ex PA

In contrast to the aggressive behaviour of invasive carcinoma ex PA, tumours that contain only circumscribed areas of malignancy confined within the capsule [171] behave in a benign fashion after excision (Fig. 5.51). In one series, four patients with intracapsular (non-invasive) carcinoma all had a good clinical outcome [124]. Brandwein et al. [21] confirmed this and also noted that the same benign behaviour applies for minimally invasive carcinoma ex PA. In contrast, there is a single report of metastases developing from a non-invasive carcinoma [68]. In spite of the generally excellent behaviour, the cells in non-invasive carcinoma ex PA display overexpression and amplification of HER-2/neu protein, and thus probably represent true carcinoma in an early phase rather than just bizarre cytological changes [57]. This study also recommended the use of HER-2/neu immunohistochemistry to distinguish between PAs with atypical cells and non-invasive carcinoma ex PA [57].

5.9.11.2 Carcinosarcoma (True Malignant Mixed Tumour) Ex Pleomorphic Adenoma

ICD-O:8980/3

Only about 60 cases of carcinosarcoma (CS) true malignant mixed tumour (TMMT) have been reported to date [83, 214]. Many arise in a pre-existing PA, but they can also develop de novo. As with carcinoma in a PA,

the history will usually be that of rapid growth in a long-standing salivary nodule.

Microscopy shows a biphasic tumour composed of epithelial and mesenchymal elements. The former is generally a poorly differentiated (adeno)carcinoma, but salivary duct carcinoma is increasingly reported (Fig. 5.52) [49, 50]. The other component is usually a chondrosarcoma, but osteogenic sarcoma, fibrosarcoma, malignant fibrous histiocytoma, pleomorphic rhabdomyosarcoma and osteoclast-type giant cell neoplasms [214, 224] have also been described.

Epithelial markers are usually detected in the epithelial component, which may or may not also be expressed in the sarcomatous component. Positive staining for epithelial markers has been used as proof of the fact that CS are *carcinomas* showing divergent differentiation and as an indication of their monoclonal origin. However, keratin staining can be negative casting doubt onto the monoclonal-carcinomatous nature of the whole tumour. Molecular studies have been helpful in clarifying this issue. In analogous neoplasms in other organs such as breast, uterus and in salivary glands, molecular studies have demonstrated that carcinomatous and sarcomatous components have *similar* genetic profiles. Moreover, in a subset of CS with osteoclastic-type giant cells, Tse et al. [224] found mutation of the same allele on chromosome 17p13, which is a known mutation of salivary duct carcinoma. This indicates that carcinosarcoma are in fact carcinomas of high-grade malignancy and should be treated as such. HER-2 overexpression on immunohistochemistry is also seen in the salivary duct component of CS. The meaning of this information has still not been clarified [57].

5.9.11.3 Metastasising Pleomorphic Adenoma

ICD-O:8940/0

This tumour is histologically indistinguishable from benign PA, yet it metastasises widely to sites including lymph nodes, bone, lung and kidney, and can kill the patient [232]. Whereas the WHO revised classification lists metastasising pleomorphic adenoma (MPA) as one entity in the MMT category of [171], it differs because it remains histologically “benign” in the primary site, local recurrences, and metastatic deposits [56, 232].

It is a rare tumour with fewer than 100 reported cases so far. Despite this, MPA has a clear-cut clinicopathological profile: the reported cases shared several similarities, such as long time intervals (up to 50 years) between the primary tumour and metastases, and simultaneous, usually multiple, local recurrences and distant

metastases [232]. Although the morphology of both is almost identical, the recurrences seem to play an important role in the genesis of systemic spread. This suggests that surgical manipulation may favour vascular implantation or invasion eventually leading to metastases, but in many cases of MPA it was not possible histologically to demonstrate actual vascular permeation [56, 232].

5.9.12 Sebaceous Carcinoma

ICD-O:8410/3

Although sebaceous glands are common in the oral mucosa (Fordyce granules), sebaceous neoplasms of the salivary glands are rare. Most sebaceous carcinomas have arisen in the parotid [62], possibly from pluripotent duct cells [219]. The sex incidence is equal, and the mean age is 69 years (range 17–93). Macroscopically, they are partly encapsulated and vary in size from 6 to 85 mm across the greatest diameter. Microscopy shows invasive islands, duct-like structures and sheets of tumour cells, which may be sebaceous, squamous or basaloid; intracellular mucin may be found [12]. Sebaceous cells are present in varying numbers, and typically comprise foamy cytoplasm and a single vesicular nucleus with a prominent nucleolus. Areas of necrosis are frequent [85]. The tumour cells react with cytokeratin and EMA, but not with S-100 protein or actin [219]. The behaviour is intermediate to high-grade, and recurrences, metastases and death due to disease have all been reported. Three cases of sebaceous lymphadenocarcinoma have been described, representing malignant transformation of sebaceous lymphadenoma. One of the patients died because of the tumour [62].

5.9.13 Lymphoepithelial Carcinoma

ICD-O:8082/3

The WHO revised classification includes this tumour under undifferentiated carcinomas [171], but it is a genuine clinicopathological entity and can be considered separately.

Lymphoepithelial carcinoma is extremely rare except in Eskimos (Inuit) and in Southern China. The median age is 40 years (range 10–86), and it is slightly commoner in females [62]; familial clusters have been identified amongst patients from Greenland [1]. The parotid is involved in 80% of cases, with the rest occurring in the submandibular glands. Forty per cent of patients have lymph node metastases at the time of presentation. A few examples have been described in association with lymphoepithelial sialadenitis [121], but a much more important association is with Epstein-Barr

Table 5.4. Metastases to the parotid gland, adapted from Gnepp [82]

Location of primary	Number of tumours
Skin of head and neck	422 (53.8%)
Upper aero-digestive tract (mouth, nose, sinuses, pharynx)	63
Eye (conjunctiva, lacrimal gland)	6
Thyroid	5
Head, not otherwise specified	4
Central nervous system	4
Submandibular salivary gland	1
Lung	28
Kidney	23
Breast	19
Colorectal	7
Prostate	4
Skin, distant	3
Stomach	2
Uterus	1
Pancreas	1
Total, distant sites	88 (11.2%)
Skin, not otherwise specified	108
Unknown primary site	84

virus, and viral genomes can be detected in the malignant cells [89].

There is a marked histological similarity to undifferentiated nasopharyngeal carcinoma, which has also been linked to Epstein-Barr virus. Microscopic examination shows syncytial groups of large epithelial cells with vesicular nuclei and prominent nucleoli, intimately mixed with lymphocytes and plasma cells, sometimes with germinal centre formation. Mitotic figures are often numerous. At times, the epithelium is difficult to identify, but it can be highlighted by cytokeratin markers. The most important differential diagnosis is a metastasis from a nasopharyngeal primary, which can present as a parotid mass [231], or possibly very poorly differentiated squamous carcinoma of usual type originating in the skin or upper aerodigestive tract. The outcome is surprisingly good for such an aggressive-looking carcinoma, and the 5-year survival rate is 60%.

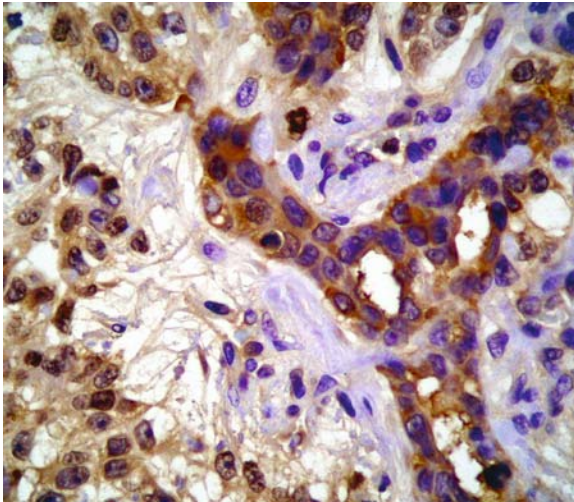
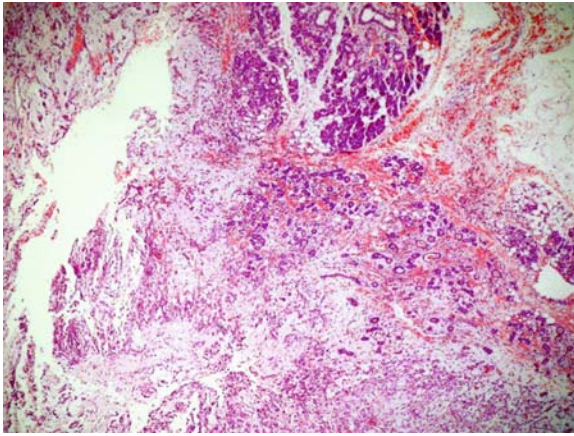
5.9.14 Small Cell Carcinoma

ICD-O:8041/3

Small cell carcinoma (SCC) is unlikely to be a single entity, as electron microscopy reveals that some neoplasms show neuroendocrine differentiation, whilst others have squamous and ductal features not apparent histologically [15, 118], and occasionally both patterns are evident in the same tumours. Some neoplasms

called small cell carcinoma may in fact be primary primitive neuroectodermal tumours [44]. They are seen more often in men, and the mean age is 56 years (range 5–86) [62]. The microscopic appearance may be similar to small cell carcinoma of the lung or Merkel cell carcinoma of the skin. Both comprise solid sheets, nests and cords of closely packed cells; the difference is in the cell size – small and dark cells in the former, slightly larger and with pale chromatin in the latter.

Immunohistochemistry shows positive staining for chromogranin, synaptophysin, neuron-specific enolase and CAM5.2, often with paranuclear dots in both types. However, immunohistochemistry for cytokeratin 20 seems to identify two subtypes of small cell carcinoma: CK 20– lung cell type and CK 20+ Merkel cell type carcinoma. A recent study by Nagao et al. [148] showed that CK 20+ small cell carcinomas of the salivary glands have a better prognosis than CK 20– cases. This suggests that staining for CK 20 should be performed in SCC as the results may have prognostic value [148]. The differential diagnosis includes metastasis from small cell carcinomas of the lung and this must be excluded before a primary small cell carcinoma can be said to be of salivary origin. Lymphomas and primary primitive neuroectodermal tumours of the salivary glands [44, 105] may be somewhat similar morphologically, and can be excluded immunohistochemically.



Figs. 5.53, 5.54. Endodermal sinus tumour of the parotid gland. Positive staining for placental alkaline phosphatase (PLAP) is essential to confirm the diagnosis. Courtesy of Dr. Isabela Wernicke [211]

5.9.15 Higher Grade Change in Carcinomas

High-grade transformation is a rare but well-established event in several primary low-grade salivary carcinomas, and usually heralds a more aggressive clinical course. Examples have been described in acinic cell [51, 95, 154, 213], adenoid cystic [32, 140], epithelial-myoepithelial [2, 73, 186], mucoepidermoid [146] and polymorphous low-grade adenocarcinoma [160, 191], as well as malignant myoepithelioma [156]. In each case, the diagnoses of high-grade change were based on histopathological criteria, especially increased mitotic and proliferation rates. Most of the transformed components were poorly differentiated adenocarcinomas, but some of those in adenoid cystic and epithe-

lial-myoepithelial carcinomas showed myoepithelial features. The processes underlying dedifferentiation of salivary neoplasms remain to be established, but previous radiotherapy may have been important in some of the AdCCs [32] and PLGAs [160]. In general, no definite factors in the progression of low-grade to high-grade carcinomas have been identified at a molecular level [208]; for example, there is conflicting evidence regarding p53 mutations, which might have been involved in a single case of transformed AdCC [32], but was not a factor in dedifferentiated acinic cell carcinomas [51, 95].

5.9.16 Metastatic Malignancies

Metastases to the major glands and the intraparotid lymph nodes constitute approximately 10% of all salivary carcinomas [82]; the exact figure varies from study to study depending on local factors such as different incidences of particular cancers. For example, Bergensen et al. [18] in Australia reported that metastases constituted 72% of all malignancies, resulting from the high incidence of skin cancer. In an AFIP series and literature review in 1991 of 785 parotid metastases [82], 64% were found to have originated from the head and neck region (including the skin), 11% from distant sites and 25% from an unknown primary. Of the distant sites, lung, kidney and breast accounted for more than four-fifths (Table 5.4); only four cases were from the prostate, but it is perhaps under-recognised [195]. Metastases to the submandibular glands are less common than to the parotids, but are more likely to be from distant sites [226].

Microscopically, metastases in the salivary glands can resemble almost any primary tumour, so that for example, mammary duct carcinoma is morphologically identical (but immunohistochemically different) to salivary duct carcinoma (see Sect. 5.9.9). Similarly, renal cell carcinoma is part of the differential diagnosis of any clear cell tumour of the salivary glands, and examples of prostate carcinoma have been mistaken for acinic cell carcinoma [195]. Immunohistochemistry is of some value, and can identify prostate and thyroid primaries and melanoma with a reasonable degree of accuracy. Unlike most primary malignant salivary tumours, renal cell carcinomas are usually negative with cytokeratin 7; in contrast, CD10 stains most kidney carcinomas, but is only positive in salivary tumours with myoepithelial differentiation. However, the possibility of metastasis is still best confirmed or excluded by imaging techniques of the kidneys.

5.10 Hybrid Carcinoma

Hybrid tumours are composed of two different types of tumour, each of which conforms to an exactly defined category of tumour. They are rare, comprising <0.1% of neoplasms in the Hamburg Salivary Tumour Registry [172]. Malignant examples demonstrate various combinations, e.g. epithelial-myoepithelial and adenoid cystic carcinomas [37].

5.11 Endodermal Sinus Tumour

ICD-O:9071/3

There are only two reports of primary endodermal sinus tumour (EST) of the parotid gland. One that recurred after chemotherapy occurred in a 2-year-old girl [227]; the other was seen in a 16-month-old girl, who is alive and well 2 years after chemotherapy [211]. The serum AFP was elevated and returned to normal levels after surgical resection of the EST. As for EST in other sites, several patterns can be recognised [211]. Diffuse positive staining for AFP and placental alkaline phosphatase (PLAP) by immunohistochemistry may be necessary to confirm the diagnosis (Figs. 5.53, 5.54) [211].

5.12 Sialoblastoma

ICD-O:8974/1

This rare tumour of the major glands arises in the perinatal period or in the first year of life [62]. It is well circumscribed, up to 150 mm in diameter and composed of numerous solid hypercellular islands of primitive basaloid cells, some with peripheral palisading, and often with small central ducts. The tumour cells have large round to ovoid vesicular nuclei and abundant eosinophilic cytoplasm, and immunohistochemistry and electron microscopy show both epithelial and myoepithelial cells [102]. Mitotic figures may be numerous, but none is atypical. Criteria for malignancy include invasion of nerves or vascular spaces, necrosis and marked cytological atypia [14]. Out of 15 reported cases, 4 had recurrences and another had metastases to regional lymph nodes.

5.13 Alterations in Gene Expression and Molecular Derangements in Salivary Gland Carcinoma

Present classifications contain at least 17 different salivary malignancies that can be broadly subdivided into carcinomas with myoepithelial differentiation and carcinomas with acinar/epithelial differentiation. Marker proteins including cell-proliferation antigens, myoepithelial proteins, matrix metalloproteinases, growth factors and their receptors, and steroid receptors have been introduced for diagnosis and prognostication of specific types of salivary gland carcinoma [171].

Despite advances, the genetic events associated with the development and progression of salivary gland neoplasia are largely unknown. There is a clear need for better understanding of such events, for defining new prognostic and diagnostic markers, and for designing targeted therapeutic interventions. The recent application of microarray technologies in the study of head and neck cancer, as well as other malignancies, has resulted in the generation of interesting new data [167, 216, 235]. Also, studies of microsatellite markers have identified losses of heterozygosity [212] and differences in chromosomal loci among various types of salivary gland carcinoma.

5.13.1 Predominantly Myoepithelial Malignancies

The commonest salivary gland malignancy expressing myoepithelial properties is the adenoid cystic carcinoma (AdCC). Abnormal gene expression of AdCC has been studied using oligonucleotide microarrays of 8,920 genes [79]. The most overexpressed genes coded for basement membrane and extracellular matrix proteins of myoepithelial differentiation, such as laminin- β 1, versican, biglycan and type IV collagen- α 1. Other overexpressed genes included transcription factors SOX-4 and the AP-2 family, and members of the Wnt/beta-catenin signalling pathway such as casein kinase 1, epsilon and frizzled-7. The most underexpressed genes included in particular those encoding for secretory proteins of acinar differentiation such as amylase, carbonic anhydrase and salivary proline-rich proteins. In AdCC, loss of heterozygosity frequently occurs in chromosome 6q23-25, correlating with prognostic parameters [212]. In addition, altered gene expression in pleomorphic adenomas has been recently studied in cDNA microarrays [78].

5.13.2 Predominantly Epithelial Malignancies

Major salivary gland carcinomas with acinar/ductal epithelial differentiation include mucoepidermoid carcinoma (MEC), acinic cell carcinoma (AcCC) and salivary duct carcinoma (SDC). Gene expression profiles have been determined in all three using Clontech's cDNA arrays including 1,176 cancer-related genes [123]. Only five such genes are overexpressed by all these carcinoma types including fibronectin (*FNI*), tissue metalloproteinase inhibitor-1 (*TIMP1*), biglycan (*BGN*), tenascin C (*HXB*), and insulin-like growth-factor binding protein-5 (*IGFBP5*). Sixteen genes, i.e. *KIAA0137/TLK1*, *VRK2*, *ADSL*, *CREBBP*, *PSM/FOLH*, *PIK3R1*, *PRKACB*, *BAG1*, *SMAD4/MADH4*, *TRAM*, *LAMA4*, *AKAP1*, *MAPK13*, *ATP5J*, *ATIC*, and *EPS15*, are underexpressed in all of them.

Average-linkage hierarchical clustering indicates genes that are significantly differently expressed among these carcinoma types. They were identified using significance analysis of microarrays (SAM). In hierarchical clustering, low-grade and high-grade MECs cluster closely together, and separate from closely clustered SDC [123]. A hierarchical clustering of SDC and ACC shows that each entity clusters together, and separates from the other entity. In SAM, 27 genes are significantly differently expressed between MEC and SDC [123]. Five genes, i.e. *MMP11*, *DAPI2*, *KIAA0324*, *FASN* and *CASPI0* are overexpressed by SDC, while eight genes, including *IL-6* and *KRT14* are overexpressed by MEC. Another 14 genes that are mainly involved in DNA modification, such as *NME4*, *NTHL1*, *RBBP4*, *HMG17* and *NDP52*, are underexpressed by MEC. Quantitative RT-PCR confirms results including overexpression of *FNI* and *TIMP1*, underexpression of *PSM/FOLH1* and *MADH4/SMAD4*, as well as the difference of expression profiles of *IL-6*, *CASPI0* and *KRT14* between SDC and MEC. Immunohistochemistry indicates distinct expression of cytokeratin 14 in MEC, with no expression in AcCC and SDC [123].

Furthermore, major differences between predominantly myoepithelial and predominantly epithelial carcinomas also exist. In MEC and AdCC, the expression of important effector molecules such as erbB-2, erbB-3, epidermal growth factor receptor and transforming growth factor- α is largely dissimilar [80].

The small number of similarly deregulated genes in these major types of salivary gland carcinoma suggests heterogenic mechanisms of tumorigenesis. This is consistent with the great histopathological diversity among carcinomas of the salivary glands [171]. Diversity is also implicated by differences in gene expression among tumour types in hierarchical clustering. The small number of genes jointly overexpressed by major

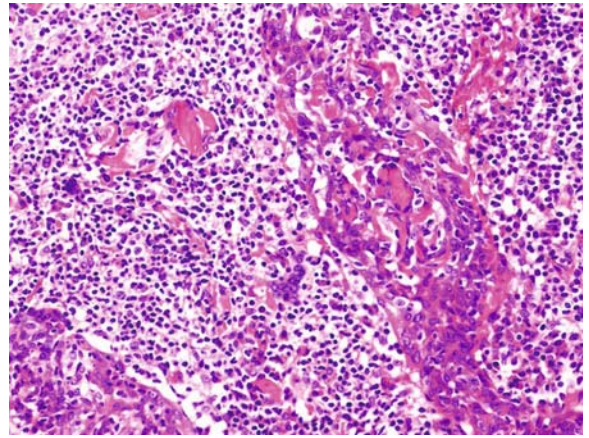


Fig. 5.55. Lymphoepithelial sialoadenitis (LESA): lymphoepithelial lesions are cohesive aggregates of epithelial cells with hyalinised basal membrane-like material infiltrated by lymphocytes

salivary gland carcinomas with epithelial differentiation relate to cell adhesion, motility and cell shape (*FNI*, *BGN*, *HXB*), cancer growth, metastasis, tumour angiogenesis and apoptosis (*TIMP-1*, *IGFBP-5*). The jointly underexpressed genes include cell-cycle proteins, proteins of signal transduction and translation, and extracellular matrix and membrane proteins. Interestingly, the jointly underexpressed *CREBBP* and *MADH4/SMAD4* are intimately involved in the TGF- β transcription pathway of growth inhibition, and *MADH4/SMAD4* has been shown to be deleted or mutated in half of pancreatic carcinomas [178]. Thus, overexpression of *TIMP1*, *PLAT* and *SFN* [38, 178], and underexpression of *MADH4/SMAD4* are shared by carcinomas of the salivary glands and the pancreas, but not with other exocrine carcinomas. In the salivary glands, coordinated loss of *SMAD4* and *CREBBP* functions could impair growth control and promote oncogenic transformation.

5.14 Benign and Malignant Lymphoid Infiltrates

5.14.1 Non-Autoimmune Lymphoid Infiltrates

These can be considered in four groups – obstructive, infective, various non-infective inflammatory processes, and associated with epithelial tumours, especially carcinomas (see Sect. 5.9).

Table 5.5. Overview of autoimmune and neoplastic salivary lymphoid proliferations, adapted from Quintana et al. [165]

Benign	LESA (lymphoepithelial sialadenitis), non-clonal
Borderline	(Histological or clonal evidence of neoplasia, but unlikely to disseminate): LESA, clonal; LESA with halos of marginal zone B-cells
Low-grade lymphoma	Potential for spread to nodes and less often, systemically: low-grade marginal zone B-cell lymphoma of mucosa-associated lymphoid tissue (MALT lymphoma) – confluent proliferation of marginal zone B-cells Low-grade marginal zone B-cell lymphoma of mucosa-associated lymphoid tissue (MALT lymphoma) with plasmacytic differentiation

5.14.2 Benign Autoimmune Lymphoid Infiltrates

The most frequent form of autoimmune sialadenitis goes under several synonyms, such as Mikulicz sialadenitis/disease, myoepithelial sialadenitis (MESA) and benign lymphoepithelial lesion, none of which is satisfactory [194]. In 1999, Harris introduced the much more accurate term, lymphoepithelial sialadenitis (LESA) [91], and this has begun to gain general acceptance, and will be used here. Sjögren's syndrome is not a pathological term, but a clinical combination of dry eyes and mouth due to autoimmune infiltrates of the lacrimal and salivary glands. It is often associated with other autoimmune or connective tissue diseases, particularly rheumatoid arthritis, but also for example scleroderma, systemic lupus erythematosus, Hashimoto's thyroiditis and chronic active hepatitis. Most patients with Sjögren's syndrome develop LESA, but not so the reverse, as up to 50% of patients with LESA do not develop the clinical features of Sjögren's syndrome [81].

Lymphoepithelial sialadenitis is considered to be an autoimmune disease [40, 77] of unknown aetiology. Several viruses have been implicated [76, 88], but they act probably only as cofactors.

About 80% of patients with LESA are female, with a mean age at presentation of 55 years (range 1 to 86). The parotids are involved in over 80% of cases (20% bilaterally), the submandibular glands in 11%, usually in combination with the parotids [40], and other sites in the head and neck in 6% [40, 81]. Tumour-like lesions of the minor glands are rare, but in contrast, subclinical focal periductal and peri-acinar lymphoplasmacytic infiltrates are frequently seen in the labial salivary glands in Sjögren's syndrome, and a semi-quantitative assessment of the amount of inflammation in a lip biopsy may be useful as part of the investigation of patients with a dry mouth [41].

In the earliest stages of LESA salivary ducts are dilated and surrounded by a lymphoid infiltrate with germinal centres. B-cells appear to concentrate around

the ducts and focally infiltrate the epithelium, unlike in many non-autoimmune chronic inflammatory infiltrates, where lymphocytic invasion of the ducts is less marked. In LESA many B-cells are of monocytoid or marginal zone type [91]. They are slightly larger than small lymphocytes of the mantle zone, and are characterised by nuclei with irregular outlines somewhat resembling centrocytes [105]. Plasma cells and T-lymphocytes are also present. In time, the ducts condense, with partial or complete loss of their lumina, to form lymphoepithelial lesions (LELs) [105, 172, 194]; these were previously inaccurately called epimyoeplithelial islands and similarly, the old usage of LEL to refer to the whole lesion should be discontinued [91]. LELs consist of cohesive aggregates of epithelium with hyalinised basal lamina material containing variable numbers of B-cells (Fig. 5.55). Myoepithelial cells are present as well, but are often relatively inconspicuous [42]. As the disease progresses the acini become atrophied and are then totally replaced by lymphoid tissue leading to clinical enlargement of the salivary glands. Monoclonality by PCR can be demonstrated in over 40% of patients with LESA [165], but this alone is probably insufficient for a diagnosis of lymphoma, and stronger evidence is required from the demonstration of monoclonality by immunohistochemistry or flow cytometry [107].

5.14.3 Malignant Lymphoma

ICD-O:9590/3

Overall, extranodal and nodal lymphomas represented 16.3% of all malignant tumours of the major salivary glands at the AFIP from 1985 to 1995 [62]. Almost all extranodal lymphomas are marginal zone B-cell lymphoma (MALT lymphomas), which is the preferred terminology of the current WHO classification of lymphomas [108].

Mucosa-associated lymphoid tissue lymphomas usually present clinically as parotid enlargement, sometimes bilateral [217]. There is often a history of Sjögren's syndrome, but not always. Cases have been reported in post-transplant patients [101]. General lymphadenopathy and bone marrow involvement are unusual in MALT lymphoma, and such a presentation favours a diagnosis of nodal lymphoma.

The histopathology of MALT lymphoma is intimately linked with that of LESA from which it develops – the risk of lymphoma in LESA has been estimated at approximately 4–7% [91]. Histological criteria alone cannot identify exactly when a clonal B-cell population emerges in LESA, and in practice the process can be considered not so much a sharp change from one (benign) entity to another (malignant) one, but rather as a spectrum of lymphoma gradually evolving from a purely inflammatory process (Table 5.5) [165]. It can be considered that MALT lymphoma begins as an antigen-driven lymphoid proliferation that progresses first to monoclonality and then, with the acquisition of secondary genetic changes, to MALT lymphoma [105].

The microscopic picture evolves with time [105]; the earliest morphologically recognisable feature of malignancy is the proliferation of marginal zone B-cells to form a distinct halo-like zone around the LELs of LESA. As the lymphoma evolves in a background of LESA marginal zones B cells expand, displace and then replace the follicles. Alternatively, they may colonise the germinal centres assuming a follicular-like architecture (pseudo-follicles) [106]. In addition, there may be foci of sclerosis, and infiltration by epithelioid histiocytes, which can form small granulomas.

Mucosa-associated lymphoid tissue lymphoma restricted to the salivary glands is a relatively indolent disease that is often curable with local treatment. Prognosis remains favourable even in the presence of other extranodal sites, including bone marrow [108].

Other primary non-MALT extranodal salivary lymphomas are rare, and are mainly T-cell neoplasms [29].

Nodal non-Hodgkin's lymphomas can involve the intra-salivary and adjacent lymph nodes, and they should be classified using the appropriate scheme [104, 108].

5.15 Other Tumours

A variety of soft tissue and other non-salivary neoplasms may rarely present as tumours of the salivary glands. These include solitary fibrous tumour, granular cell tumour, follicular dendritic cell sarcoma, inflammatory pseudotumour (inflammatory myofibroblastic

tumour), primary malignant melanoma, primitive neuroectodermal tumour (PNET) and teratoma.

5.16 Unclassified Tumours

The revised WHO classification defines this group as benign or malignant tumours that cannot be placed in any of the categories [171]. This designation may be unavoidable if only a small quantity of tissue is available for study.

References

- Albeck H, Bentzen J, Ockelmann HH, Nielsen NH, Bretlau P, Hansen HS (1993) Familial clusters of nasopharyngeal carcinoma and salivary gland carcinomas in Greenland natives. *Cancer* 72:196–200
- Alós LL, Cardesa A, Bombí JA, Mallofré C, Cuchi A, Traserri J (1996) Myoepithelial tumors of salivary glands: a clinicopathologic, immunohistochemical and flow-cytometric study. *Semin Diagn Pathol* 13:138–147
- Altini M, Coleman H, Kienkle F (1997) Intra-vascular tumour in pleomorphic adenoma – a report of four cases. *Histopathology* 31:55–59
- Angeles-Angeles A, Caballero-Mendoza E, Tapia-Rangel B, Cortés-González R, Larriva-Sahd J (1998) Adenocarcinoma gigante de células acinares de tipo quístico papilar en parótida. *Rev Invest Clin* 50:245–248
- Araújo VC de, Loduca SVL, Sobral APV, Kowalski AL, Soares F, Araújo NS de (2002) Salivary duct carcinoma: cytokeratin 14 as a marker of in situ intraductal growth. *Histopathology* 41:244–249
- Auclair P (1994) Tumor-associated lymphoid proliferation in the parotid gland: a potential diagnostic pitfall. *Oral Surg Oral Med Oral Pathol* 77:19–26
- Auclair PL, Ellis GL (1996) Atypical features in salivary gland mixed tumors: their relationship to malignant transformation. *Mod Pathol* 9:652–657
- Barbareschi M, Pecciarini L, Cangi MG, Macri E, Rizzo A, Viale G, Doglioni C (2001) p63, a p53 homologue, is a selective nuclear marker of myoepithelial cells of the human breast. *Am J Surg Pathol* 25:1054–1060
- Barnes L, Eveson JW, Reichart P, Sidransky D, (eds) (2005) WHO Classification of Tumours. Pathology and Genetics. Head and Neck Tumours. Chapter 5. Salivary glands. IARC Press Lyon
- Barnes L, Rao U, Krause J, Contis L, Schwartz A, Scalapogna P (1994) Salivary duct carcinoma. I. A clinicopathologic evaluation and DNA image analysis of 13 cases with review of the literature. *Oral Surg Oral Med Oral Pathol* 78:64–73
- Batsakis JG (1979) Tumors of the head and neck: clinical and pathological considerations, 2nd edn. Williams & Wilkins, Baltimore, p 116
- Batsakis JG (1996) Sclerosing polycystic adenosis: a newly recognized salivary gland lesion, a form of chronic sialadenitis. *Adv Anat Pathol* 3:298–304
- Batsakis JG, El-Naggar AK (1990) Sebaceous lesions of salivary glands and oral cavity. *Ann Otol Rhinol Laryngol* 99:416–418
- Batsakis JG, El-Naggar AK, Luna MA (1992) Epithelial-myoepithelial carcinoma of salivary glands. *Ann Otol Rhinol Laryngol* 101:540–542
- Batsakis JG, Frankenthaler R (1992) Embryoma (sialoblastoma) of salivary glands. *Ann Otol Rhinol Laryngol* 101:958–960

15. Batsakis JG, Luna MA (1991) Undifferentiated carcinomas of salivary glands. *Ann Otol Rhinol Laryngol* 100:82–84
16. Batsakis JG, Luna MA (1991) Basaloid salivary carcinomas. *Ann Otol Rhinol Laryngol* 100:785–787
17. Batsakis JG, Manning JT (1987) Necrotizing sialometaplasia of major salivary glands. *J Laryngol Otol* 101:962–966
18. Bergensen PJ, Kennedy PJ, Kneale KL (1987) Metastatic tumours of the parotid region. *Aust NZ J Surg* 57:23–26
19. Brandwein-Gensler M, Hille J, Wang BY, Urken M, Gordon R, Wang LJ, Simpson JR, Simpson RH, Gnepp DR (2004) Low-grade salivary duct carcinoma: description of 16 cases. *Am J Surg Pathol* 28:1040–1044
20. Brandwein MS, Huvos AG (1991) Oncocytic tumors of major salivary glands. A study of 68 cases with follow-up of 44 patients. *Am J Surg Pathol* 15:514–528
21. Brandwein M, Huvos AG, Dardick I, Thomas MG, Theise ND (1996) Noninvasive and minimally invasive carcinoma ex mixed tumor. A clinicopathologic and ploidy study of 12 patients with major salivary tumors of low malignant potential. *Oral Surg Oral Med Oral Pathol* 81:665–664
22. Brandwein MS, Ivanov K, Wallace DI, Hille JJ, Wang B, Fahmy A, Bodian C, Urken ML, Gnepp DR, Huvos A, Lumerman H, Mills SE (2001) Mucoepidermoid carcinoma: a clinicopathologic study of 80 patients with special reference to histological grading. *Am J Surg Pathol* 25:835–845
23. Brandwein MS, Jagirdar J, Patil J, Biller H, Kaneko M (1990) Salivary duct carcinoma (cribriform salivary carcinoma of excretory ducts): a clinicopathologic and immunohistochemical study of 12 cases. *Cancer* 65:2307–2314
24. Brannon RB, Fowler CB, Hartman KS (1991) Necrotizing sialometaplasia: a clinicopathologic study of sixty-nine cases and review of the literature. *Oral Surg Oral Med Oral Pathol* 72:317–325
25. Buchner A, Merrell PW, Carpenter WM, Leider AS (1991) Adenomatoid hyperplasia of minor salivary glands. *Oral Surg Oral Med Oral Pathol* 71:583–587
26. Castle JT, Thompson LDR, Frommelt RA, Wenig BM, Kessler HP (1996) Polymorphous low-grade adenocarcinoma: a clinicopathologic study of 164 cases. *Cancer* 86:207–219
27. Chan JKC, Hui PK, Ng CS, Yuen NWF, Kung ITM, Gwi E (1989) Epithelioid haemangioma (angiolympoid hyperplasia with eosinophilia) and Kimura's disease in Chinese. *Histopathology* 15:557–574
28. Chan JKC, Tang SK, Tsang WYW, Lee KC, Batsakis JG (1996) Histologic changes induced by fine-needle aspiration. *Adv Anat Pathol* 3:71–90
29. Chan JKC, Tsang WYW, Hui P-K, Ng C-S, Sin V-C, Khan SM, Siu LLP (1997) T-and T/Natural killer-cell lymphomas of the salivary gland: a clinicopathologic, immunohistochemical and molecular study of six cases. *Hum Pathol* 28:238–245
30. Chau MN, Radden BG (1989) A clinico-pathological study of 53 intra-oral pleomorphic adenomas. *Int J Oral Maxillofac Surg* 18:158–162
31. Chetty R (2000) Intercalated duct hyperplasia: possible relationship to epithelial-myoepithelial carcinoma and hybrid tumours of salivary gland. *Histopathology* 37:260–263
32. Cheuk W, Chan JK, Ngan RK (1999) Dedifferentiation in adenoid cystic carcinoma of salivary gland: an uncommon complication associated with an accelerated clinical course. *Am J Surg Pathol* 23:465–472
33. Chieng DC, Paulino AF (2002) Cytology of myoepithelial carcinoma of the salivary gland: a study of four cases. *Cancer (Cancer Cytopathol)* 96:32–36
34. Cho KJ, El-Naggar AK, Ordóñez NG, Luna MA, Austin J, Batsakis JG (1995) Epithelial-myoepithelial carcinoma of salivary glands: a clinicopathologic, DNA flow cytometric, and immunohistochemical study of Ki-67 and HER-2/neu oncogene. *Am J Clin Pathol* 103:432–437
35. Claros P, Dominte G, Claros Jr A, Castillo M, Cardesa A, Claros A (2002) Parotid gland mucoepidermoid carcinoma in a 4 year old child. *Int J Pediatr Otorhinolaryngol* 63:67–72
36. Colmenero Ruiz C, Patrón Romero M, Martín Pérez M (1993) Salivary duct carcinoma: a report of nine cases. *J Oral Maxillofac Surg* 51:641–646
37. Croitoru CM, Suarez PA, Luna MA (1999) Hybrid carcinoma of salivary glands: report of 4 cases and review of the literature. *Arch Pathol Lab Med* 123:698–702
38. Crnogorac-Jurcevic T, Efthimiou E, Nielsen T, Loader J, Teris B, Stamp G, Baron A, Scarpa A, Lemoine NR (2002) Expression profiling of microdissected pancreatic adenocarcinomas. *Oncogene* 21:4587–4594
39. Daley TD (1984) The canalicular adenoma: considerations on differential diagnosis and treatment. *J Oral Maxillofac Surg* 42:728–730
40. Daniels TE (1991) Benign lymphoepithelial lesion and Sjögren's syndrome. In: Ellis GL, Auclair PL, Gnepp DR (eds) *Surgical pathology of the salivary glands*. Saunders, Philadelphia, pp 83–106
41. Daniels TE, Fox PS (1992) Salivary and oral components of Sjögren's syndrome. *Rheum Dis Clin N Am* 18:571–589
42. Dardick I, van Nostrand P, Rippstein P, Skimming L, Hoppe D, Dairkee SH (1988) Characterization of epimyoeplithelial islands in benign lymphoepithelial lesions of major salivary gland: an immunohistochemical and ultrastructural study. *Head Neck Surg* 10:168–178
43. Dardick I, Thomas MJ, Nostrand AWP van (1989) Myoepithelioma – new concepts of histology and classification: a light and electron microscopic study. *Ultrastruct Pathol* 13:187–224
44. Deb RA, Desai SB, Amonkar PP, Aiyer PM, Borges AM (1998) Primary primitive neuroectodermal tumour of the parotid gland. *Histopathology* 33:375–378
45. Dehner LP, Valbuena L, Perez-Atayde A, Reddick RL, Askin FB, Rosai J (1984) Salivary gland anlage tumor ("congenital pleomorphic adenoma"): a clinicopathologic, immunohistochemical and ultrastructural study of nine cases. *Am J Surg Pathol* 18:25–36
46. Delgado R, Klimstra D, Albores-Saavedra J (1996) Low grade salivary duct carcinoma: a distinctive variant with a low grade histology and a predominant intraductal growth pattern. *Cancer* 78:958–967
47. Delgado R, Vuitch F, Albores-Saavedra J (1993) Salivary duct carcinoma. *Cancer* 72:1503–1512
48. Di Palma S (1994) Epithelial-myoepithelial carcinoma with co-existing multifocal intercalated duct hyperplasia of the parotid gland. *Histopathology* 25:494–496
49. Di Palma S (2003) Malignancy in pleomorphic adenoma (malignant mixed tumour) of salivary glands. Gale N, Luzar B (eds) *Proceedings in head and neck pathology*. Institute of Pathology Faculty of Medicine, University of Ljubljana, Ljubljana 4–6 September 2003, pp 92–98
50. Di Palma S (2004) Case 23, slide seminar of head and neck pathology. II. Intercontinental Congress of Pathology, Iguassu, Brazil
51. Di Palma S, Corletto V, Lavarino C, Birindelli S, Pilotti S (1999) Unilateral aneuploid dedifferentiated acinic cell carcinoma associated with bilateral low grade diploid acinic cell carcinoma of the parotid gland. *Virchows Arch* 434:361–365
52. Di Palma S, Guzzo M (1993) Malignant myoepithelioma of salivary glands: clinicopathological features of ten cases. *Virchows Arch A Pathol Anat* 423:389–396
53. Di Palma S, Guzzo M (1998) Myoepithelial carcinoma with predominance of plasmacytoid cells arising in a pleomorphic adenoma of the parotid gland. *Histopathology* 33:485
54. Di Palma S, Pilotti S, Rilke F (1991) Malignant myoepithelioma of the parotid arising in a pleomorphic adenoma. *Histopathology* 19:273–275
55. Di Palma S, Simpson RHW, Skálová A, Michal M (1999) Metaplastic (infarcted) Warthin's tumour of the parotid gland: a possible consequence of fine needle aspiration biopsy. *Histopathology* 35:432–438
56. Di Palma S, Skálová A (1999) Malignancy in pleomorphic adenoma. *Rev Esp Patol* 32:431–432

57. Di Palma S, Skalova A, Vanecsek T, Simpson RHW, Starek I, Leivo I (2005) Non invasive intracapsular carcinoma ex pleomorphic adenoma: recognition of focal carcinoma by HER-2/neu and MIB-1 immunohistochemistry. *Histopathology* 46:144–152
58. Donath K, Seifert G (1997) Sclerosing polycystic sialadenopathy. *Pathologie* 18:368–373
59. Edwards PC, Bhuiya T, Kelsch RD (2003) C-kit expression in the salivary gland neoplasms adenoid cystic carcinoma, polymorphous low-grade adenocarcinoma, and monomorphic adenoma. *Oral Surg Oral Med Oral Pathol Oral Radiol Endod* 95:686–693
60. Elliott JN, Oertel YC (1990) Lymphoepithelial cysts of the salivary glands: histologic and cytologic features. *Am J Clin Pathol* 93:39–43
61. Ellis GL (1988) “Clear cell” oncocytoma of salivary gland. *Hum Pathol* 19:862–867
62. Ellis GL, Auclair PL (1996) Malignant epithelial tumors. In: Atlas of tumor pathology, 3rd series, fascicle 17: tumors of the salivary glands. AFIP, Washington DC
63. Evans HL, Luna MA (2000) Polymorphous low-grade adenocarcinoma: a study of 40 cases with long-term follow up and evaluation of the importance of papillary areas. *Am J Surg Pathol* 24:1319–1328
64. Eveson JW (1992) Troublesome tumours 2: borderline tumours of salivary glands. *J Clin Pathol* 45:369–377
65. Eveson JW (1999) Oncocytic and squamous differentiation in salivary glands and tumors. *Rev Esp Patol* 32:433–434
66. Eveson JW, Cawson RA (1989) Infarcted (“infected”) adenolymphomas. A clinicopathological study of 20 cases. *Clin Otolaryngol* 14:205–210
67. Feind CR (1972) The head and neck. In: Haagensen CD, Feind CR, Herter FP (eds) *The lymphatics in cancer*. Saunders, Philadelphia, pp 63–64
68. Felix A, Rosa-Santos J, Mendoca ME, Torrinha F, Soares J (2002) Intracapsular carcinoma ex pleomorphic adenoma. Report of a case with unusual metastatic behaviour. *Oral Oncol* 38:107–110
69. Ferlito A, Gale N, Hvala H (1981) Laryngeal salivary duct carcinoma: a light and electron microscopic study. *J Laryngol Otol* 95:731–738
70. Ferreiro JA (1994) Immunohistochemistry of basal cell adenoma of the major salivary glands. *Histopathology* 24:539–542
71. Fonseca I, Soares J (1993) Epithelial-myoepithelial carcinoma of the salivary glands. A study of 22 cases. *Virchows Arch A Pathol Anat* 422:389–396
72. Fonseca I, Soares J (1996) Basal cell adenocarcinoma of minor salivary and seromucinous glands of the head and neck region. *Semin Diagn Pathol* 13:128–137
73. Fonseca I, Felix A, Soares J (2000) Dedifferentiation in salivary gland carcinomas. *Am J Surg Pathol* 24:469–471
74. Foschini M, Scarpellini F, Gown AM, Eusebi V (2000) Differential expression of myoepithelial markers in salivary, sweat and mammary glands. *Int J Surg Pathol* 8:29–37
75. Foucar E, Rosai J, Dorfman R (1990) Sinus histiocytosis with massive lymphadenopathy (Rosai-Dorfman disease): review of the entity. *Semin Diagn Pathol* 7:19–73
76. Fox RI, Pearson G, Vaughan JH (1986) Detection of Epstein-Barr virus-associated antigens and DNA in salivary gland biopsies from patients with Sjögren’s syndrome. *J Immunol* 137:3162–3168
77. Fox RI, Kang HI (1992) Pathogenesis of Sjögren’s syndrome. *Rheum Dis Clin N Am* 18:517–538
78. Francioso F, Carinci F, Tosi L, Scapoli L, Pezetti F, Passerella E, Evangelisti R, Pastore A, Pelucchi S, Piattelli A, Rubini C, Fioroni M, Carinci P, Volinia S (2002) Identification of differentially expressed genes in human salivary gland tumors by DNA microarrays. *Mol Cancer Ther* 1:533–538
79. Frierson HF, El-Naggar AK, Welsh JB, Sapinoso LM, Su, AI, Cheng J, Saku T, Moskaluk CA, Hampton GM (2002) Large scale molecular analysis identifies genes with altered expression in salivary adenoid cystic carcinoma. *Am J Surg Pathol* 161:1315–1323
80. Gibbons MD, Manne U, Carroll WR, Peters GE, Weiss HL, Grizzle WE (2001) Molecular differences in mucoepidermoid carcinoma and adenoid cystic carcinoma of the major salivary glands. *Laryngoscope* 111:1373–1378
81. Gleeson MJ, Cawson RA, Bennett MH (1986) Benign lymphoepithelial lesion: a less than benign disease. *Clin Otolaryngol* 11:47–51
82. Gnepp DR (1991) Metastatic disease to the major salivary glands. In: Ellis GL, Auclair PL, Gnepp DR (eds) *Surgical pathology of the salivary glands*. Saunders, Philadelphia, pp 560–569
83. Gnepp DR (1993) Malignant mixed tumors of salivary glands: a review. *Pathol Annu* 28:279–328
84. Gnepp DR (2003) Sclerosing polycystic adenosis of the salivary gland: a lesion that may be associated with dysplasia and carcinoma in situ. *Adv Anat Pathol* 10:218–222
85. Gnepp DR, Brannon R (1984) Sebaceous neoplasms of salivary gland origin: report of 21 cases. *Cancer* 53:2155–2170
86. Grenko R T, Gemryd P, Tytor M, Lundqvist PG, Boeryd B (1995) Salivary duct carcinoma. *Histopathology* 26:261–266
87. Guzzo M, Di Palma S, Grandi C, Molinari R (1997) Salivary duct carcinoma: clinical characteristics and treatment strategies. *Head Neck* 19:126–133
88. Haddad J, Deny P, Munz-Gotheil C, Ambrosini JC, Trinchet JC, Pateron D, Mal F, Callard P, Beaugrand M (1992) Lymphocytic sialadenitis of Sjögren’s syndrome associated with chronic hepatitis C virus liver disease. *Lancet* 339:321–323
89. Hamilton-Dutoit SJ, Therkildsen MH, Nielsen NH, Jensen H, Hansen JPH, Pallesen G (1991) Undifferentiated carcinoma of the salivary gland in Greenlandic Eskimos: demonstration of Epstein-Barr virus DNA by in situ nucleic acid hybridization. *Hum Pathol* 22:811–815
90. Harmse JL, Saleh HA, Odutoye T, Alsanjari NA, Mountain RE (1997) Recurrent canalicular adenoma of the minor salivary glands in the upper lip. *J Laryngol Otol* 111:985–987
91. Harris NL (1999) Lymphoid proliferations of the salivary glands. *Am J Clin Pathol* 111 [Suppl 1]:S94–S103
92. Heikinheimo AK, Laine MA, Ritvos OV-P, Voutilainen RJ, Hogan BLM, Leivo I (1999) Bone morphogenetic protein-6 is a marker of serous acinar cell differentiation in normal and neoplastic human salivary gland. *Cancer Res* 59:5815–5821
93. Hellquist HB, Karlsson MG, Nilsson C (1994) Salivary duct carcinoma – a highly aggressive salivary gland tumour with overexpression of c-erbB-2. *J Pathol* 172:35–44
94. Hellquist HB, Sundelin K, Di Bacco A, Tytor M, Manzotti M, Viale G (1997) Tumour growth fraction and apoptosis in salivary gland acinic cell carcinomas. Prognostic implications of Ki-67 and bcl-2 expression and of in situ end labelling (TUNEL). *J Pathol* 181:323–329
95. Henley JD, Geary WA, Jackson CL, Wu CD, Gnepp DR (1997) Dedifferentiated acinic cell carcinoma of the parotid gland: a distinct rarely described entity. *Hum Pathol* 28:869–873
96. Henley JD, Seo IS, Dayan D, Gnepp DR (2000). Sarcomatoid salivary duct carcinoma of the parotid gland. *Hum Pathol* 31:208–213
97. Henriksson G, Westrin KM, Carlsöö B, Silfversvärd C (1998) Recurrent primary pleomorphic adenomas of salivary gland origin: intrasurgical rupture, histopathologic features, and pseudopodia. *Cancer* 82:617–620
98. Herold J, Nicholson AG (1992) Fine needle aspiration cytology in the diagnosis of amyloid in the submandibular gland. *Br J Oral Maxillofac Surg* 30:393–394
99. Hoang MP, Callender DL, Sola-Gallego JJ, Huang Z, Sneige N, Luna MA, Batsakis JG, El-Naggar AK (2001) Molecular and biomarker analyses of salivary duct carcinomas: comparison with mammary duct carcinoma. *Int J Oncol* 19:865–871

100. Honda K, Kashima K, Yokohama S, Nakayama I (2000) Clonal analysis of the epithelial component of Warthin's tumor. *Hum Pathol* 31:1377–1380
101. Hsi ED, Singleton TP, Swinnen L, Dunphy CH, Alkan S (2000) Mucosa-associated lymphoid tissue-type lymphomas occurring in post-transplantation patients. *Am J Surg Pathol* 24:100–106
102. Hsueh C, Gonzalez-Crussi F (1992) Sialoblastoma: a case report and review of the literature on congenital epithelial tumors of salivary gland origin. *Pediatr Pathol* 12:205–214
103. Hui KK, Batsakis JG, Luna MA, MacKay B, Byers RM (1986) Salivary duct adenocarcinoma: a high grade malignancy. *J Laryngol Otol* 100:105–114
104. Isaacson PG (1996) Malignant lymphomas with a follicular growth pattern. *Histopathology* 28:487–495
105. Isaacson PG, Norton AJ (1994) Malignant lymphoma of the salivary glands. In: Isaacson PG, Norton AG (eds) *Extranodal lymphomas*. Churchill-Livingstone, Edinburgh, pp 67–83
106. Isaacson PG, Wotherspoon AC, Diss TC, Pan LX (1991) Follicular colonization in B-cell lymphoma of MALT. *Am J Surg Pathol* 15:819–828
107. Jaffe ES (2002) Lymphoid lesions of the head and neck: a model of lymphocyte homing and lymphomagenesis. *Mod Pathol* 15:255–263
108. Jaffe ES, Harris NL, Stein H, Vardiman JW (2001) *World Health Organization classification of tumours: tumours of haematopoietic and lymphoid tissues*. Springer, Berlin Heidelberg New York
109. Jahan-Parwar B, Huberman RM, Donovan D (1999) Oncocytic mucoepidermoid carcinoma of the salivary glands. *Am J Surg Pathol* 23:523–529
110. James GK, Pudek M, Berean KW, Diamandis EP, Archibald BL (1996) Salivary duct carcinoma secreting prostate-specific antigen. *Am J Clin Pathol* 106:242–247
111. Jayakrishnan A, Elmalah I, Hussain K, Odell EW (2003) Basal cell adenocarcinoma in minor salivary glands. *Histopathology* 42:610–614
112. Jeng YM, Lin CY, Hsu HC (2000) Expression of the c-kit protein is associated with certain subtypes of salivary gland carcinoma. *Cancer Lett* 154:107–111
113. Jensen JL (1991) Idiopathic diseases. In: Ellis GL, Auclair PL, Gnepp DR (eds) *Surgical pathology of the salivary glands*. Saunders, Philadelphia, pp 60–82
114. Jones H, Moshtael F, Simpson RHW (1992) Immunoreactivity of smooth muscle actin in salivary gland tumours: a comparison with S 100 protein. *J Clin Pathol* 45:938–940
115. Kay PA, Roche PC, Olsen KD, Lewis JE (2001) Salivary duct carcinoma: immunohistochemical analysis of androgen receptor, prostate markers and HER-2/neu oncoprotein in 40 cases. [Abstract]. *Mod Pathol* 14:150A
116. Kemp BL, Batsakis JG, El-Naggar AK, Kotliar SN, Luna MA (1995) Terminal duct adenocarcinomas of the parotid gland. *J Laryngol Otol* 109:466–468
117. Kokemueller H, Eckardt A, Brachvogel P, Hausamen JE (2004) Adenoid cystic carcinoma of the head and neck – a 20 years experience. *Int J Oral Maxillofac Surg* 33:25–31
118. Kraemer BB, MacKay B, Batsakis JG (1983) Small cell carcinomas of the parotid gland: a clinicopathologic study of three cases. *Cancer* 52:2115–2121
119. Kratochvil FJ (1991) Canalicular adenoma and basal cell adenoma. In: Ellis GL, Auclair PL, Gnepp DR (eds) *Surgical pathology of the salivary glands*. Saunders, Philadelphia, pp 202–224
120. Krieken JHJM van (1993) Prostate marker immunoreactivity in salivary gland neoplasms: a rare pitfall in immunohistochemistry. *Am J Surg Pathol* 17:410–414
121. Krishnamurthy S, Lanier AP, Dohan P, Lanier JF, Henle W (1988) Salivary gland cancer in Alaskan natives, 1966–1980. *Hum Pathol* 18:986–996; erratum 19:328
122. Kumar RV, Kini L, Bhargava AK, Mukherjee G, Hazarikha D, Shenoy AM, Anantha N (1993) Salivary duct carcinoma. *J Surg Oncol* 54:193–198
123. Leivo I, Jee, KJ, Heikinheimo K, Laine M, Ollila J, Nagy B, Knuutila S (2005) Characterization of gene expression in major types of salivary gland carcinoma with epithelial differentiation. *Cancer Genet Cytogenet* 156:104–113
124. Lewis JE, Olsen KD, Sebo TJ (2001) Carcinoma ex pleomorphic adenoma: pathologic analysis of 73 cases. *Hum Pathol* 32:596–604
125. LiVolsi VA, Perzin KH (1977) Malignant mixed tumor arising in salivary gland: carcinomas arising in benign mixed tumor. A clinico-pathologic study. *Cancer* 39:2209–2230
126. Li S, Baloch ZW, Tomaszewski JE, Livolsi VA (2000) Worrisome histologic alteration following fine-needle aspiration of benign parotid lesions. *Arch Pathol Lab Med* 124:87–91
127. Luna MA, Batsakis JG, Tortoledo ME, del Junco GW (1989) Carcinomas ex monomorphic adenoma of salivary glands. *J Laryngol Otol* 103:756–759
128. Luna MA, Tortoledo ME, Allen M (1987) Salivary dermal analogue tumors arising in lymph nodes. *Cancer* 59:1165–1169
129. Martinez-Madriral F, Micheau C (1989) Histology of the major salivary glands. *Am J Surg Pathol* 13:879–899
130. Maurizi M, Salvinelli F, Capelli A (1990) Monomorphic adenomas of the major salivary glands: clinicopathological study of 44 cases. *J Laryngol Otol* 104:790–796
131. McCluggage G, Sloan J, Cameron S, Hamilton P, Toner P (1995) Basal cell adenocarcinoma of the submandibular gland. *Oral Surg Oral Med Oral Pathol Oral Radiol Endod* 79:342–350
132. Michal M, Skálová A, Simpson RHW, Rychterová V, Leivo I (1996) Clear cell malignant myoepithelioma of the salivary glands. *Histopathology* 28:309–315
133. Michal M, Skálová A, Simpson RHW, Leivo I, Ryška A, Stárek I (1997) Well differentiated acinic cell carcinoma of salivary glands associated with lymphoid rich stroma: clinicopathologic and immunohistochemical study using a proliferative marker MIB1. *Hum Pathol* 28:595–600
134. Michal M, Skálová A, Simpson RHW, Raslan WF, Čuřík R, Leivo I, Mukenšnábl P (1999) Cribriform adenocarcinoma of the tongue: a hitherto unrecognized type of adenocarcinoma characteristically occurring in the tongue. *Histopathology* 35:495–501
135. Michal M, Skálová A, Hrabal P (2002) Micropapillary carcinoma of the parotid gland arising in mucinous cystadenoma. *Virchows Arch* 437:465–468
136. Michal M, Sokol L, Mukenšnábl P (1996) Salivary gland anlage tumor. A case with widespread necrosis and large cyst formation (congenital pleomorphic adenoma). *Pathology* 28:128–130
137. Mikulicz J von (1982) Über eine eigenartige symmetrische Erkrankung der Tränen- und Mundspeicheldrüsen. *Beitr Chir Festschr Theodor Billroth*, pp 610–630
138. Milchgrub S, Gnepp DR, Vuitch F, Delgado R, Albores-Saavedra J (1994) Hyalinizing clear cell carcinoma of the salivary gland. *Am J Surg Pathol* 18:74–82
139. Mima T, Shirasuna K, Kishino M, Matsuya T (1996) Basal cell adenocarcinoma of the sublingual gland: report of a case. *J Oral Maxillofac Surg* 54:1121–1123
140. Moles MA, Avila IR, Archilla AR (1999) Dedifferentiation occurring in adenoid cystic carcinoma of the tongue. *Oral Surg Oral Med Oral Pathol Oral Radiol Endod* 88:177–180
141. Moody AB, Avery CME, Harrison JD (1998) Dermoid cyst of the parotid gland. *Int J Oral Maxillofac Surg* 27:461–462
142. Moriki T, Ueta S, Takahashi T, Mitani M, Ichien M (2001) Salivary duct carcinoma: cytologic characteristics and application of androgen receptor immunostaining for diagnosis. *Cancer (Cancer Cytopathol)* 93:344–350
143. Moritani S, Kushima R, Sugihara H, Bamba M, Kobayashi TK, Hattori T (2002) Availability of CD10 immunohistochemistry as a marker of breast myoepithelial cells on paraffin sections. *Mod Pathol* 15:397–405
144. Muller S, Barnes LE (1996) Basal cell adenocarcinoma of the salivary glands: report of seven cases and review of the literature. *Cancer* 78:2471–2477

145. Murrah VA, Batsakis JG (1994) Salivary duct carcinoma. *Ann Otol Rhinol Laryngol* 103:244–247
146. Nagao T, Gaffey TA, Kay PA, Unni KK, Nascimento AG, Sebo TJ, Serizawa H, Minato H, Lewis JE (2003) Dedifferentiation in low-grade mucoepidermoid carcinoma of the parotid gland. *Hum Pathol* 34:1068–1072
147. Nagao T, Gaffey TA, Visscher DW, Kay PA, Minato H, Serizawa H (2004) Invasive micropapillary salivary duct carcinoma: a distinct histologic variant with biologic significance. *Am J Surg Pathol* 28:319–326
148. Nagao T, Gaffey TA, Olsen KD, Serizawa H, Lewis JE (2004) Small cell carcinoma of the major salivary glands. Clinicopathologic study with emphasis on cytokeratin immunoreactivity and clinical outcome. *Am J Surg Pathol* 28:762–770
149. Nagao K, Matsuzaki O, Saiga H, Sugano I, Shigematsu H, Kaneko T, Katoh T, Kitamura T (1981) Histopathologic studies on carcinoma in pleomorphic adenoma of the parotid gland. *Cancer* 48:113–121
150. Nagao T, Serizawa H, Iwaya K, Shimizu T, Sugano I, Ishida Y, Yamazaki K, Shimizu M, Itoh T, Konno A, Ebihara Y (2002) Keratocystoma of the parotid gland: a report of two cases of an unusual pathologic entity. *Mod Pathol* 15:1005–1010
151. Nagao T, Sugano I, Ishida Y, Tajima Y, Matsuzaki O, Konno A, Kondo Y, Nagao K (1998) Salivary gland malignant myoepithelioma: a clinicopathologic and immunohistochemical study of ten cases. *Cancer* 83:1292–1299
152. Nagao T, Sugano I, Ishida Y, Hasegawa M, Matsuzaki O, Konno A, Kondo Y, Nagao K (1998) Basal cell adenocarcinoma of the salivary glands; comparison with basal cell adenoma through assessment of cell proliferation, apoptosis, and expression of p53 and bcl-2. *Cancer* 82:439–447
153. Nasser SM, Faquin WC, Dayal Y (2003) Expression of androgen, estrogen, and progesterone receptor in salivary gland tumours. Frequent expression of androgen receptor in a subset of malignant salivary gland tumours. *Am J Clin Pathol* 119:801–806
154. Nunes JF, Fonseca I, Soares J (1996) Helioid inclusions in dedifferentiated acinic cell carcinoma of the parotid gland. *Ultrastruct Pathol* 20:443–449
155. Nyrop M (1994) Kimura's disease: case report and brief review of the literature. *J Laryngol Otol* 108:1005–1007
156. Ogawa I, Nishida T, Miyauchi M, Sato S, Takata T (2003) Dedifferentiated malignant myoepithelioma of the parotid gland. *Pathol Int* 53:704–709
157. Ogawa Y, Kishino M, Atsumi Y, Kimoto M, Fukuda Y, Ishida T (2003) Plasmocytoid cells in salivary-gland pleomorphic adenomas: evidence of luminal differentiation. *Virchows Arch* 443:625–634
158. Palmer TJ, Gleeson MJ, Eveson JW, Cawson RA (1990) Oncocytic adenomas and oncocytic hyperplasia of salivary glands. A clinicopathological study of 26 cases. *Histopathology* 16:487–493
159. Parrett TJ, Prasad AR, Raslan WF, Kakar S, Lewis JE (2002) Long term and life-long follow-up in polymorphous low grade adenocarcinoma (Abstract). *Mod Pathol* 15:223A
160. Pelkey TJ, Mills SE (1999) Histologic transformation of polymorphous low-grade adenocarcinoma of salivary gland. *Am J Clin Pathol* 111:785–791
161. Perzin KH, LiVolsi VA (1980) Acinic cell carcinoma arising in ectopic salivary gland tissue. *Cancer* 45:967–972
162. Pesce C, Colacino R, Buffa P (1986) Duct carcinoma of the minor salivary glands: a case report. *J Laryngol Otol* 100:611–613
163. Pieterse AS, Seymore AE (1981) Parotid cysts: an analysis of 16 cases and suggested classification. *Pathology* 13:225–234
164. Prasad AR, Saveria AT, Gown AM, Zarbo RJ (1999) The myoepithelial immunophenotype in 135 benign and malignant salivary gland tumors other than pleomorphic adenoma. *Arch Pathol Lab Med* 123:801–806
165. Quintana PG, Kapadia SB, Bahler DW, Johnson JT, Swerdlow SH (1997) Salivary gland lymphoid infiltrates associated with lymphoepithelial lesions: a clinicopathologic, immunophenotypic, and genotypic study. *Hum Pathol* 28:850–861
166. Reis-Filho JS, Simpson RHW, Fulford LG, Steppeler Y, Martins A, Schmitt FC (2004) p63 distribution in normal salivary gland and salivary gland neoplasms (abstract). *Mod Pathol* 17:231A
167. Russo G, Zegar C, Giordano A (2003) Advantages and limitations of microarray technology in human cancer. *Oncogene* 22:6497–6507
168. Saveria AT, Sloman A, Huvos AG, Klimstra DS (2000) Myoepithelial carcinoma of the salivary glands: a clinicopathologic study of 25 patients. *Am J Surg Pathol* 24:761–774
169. Scher RL, Feldman PS, Lambert PR (1991) Oncocytic malignancy of the parotid gland. *Otolaryngol Head Neck Surg* 105:868–876
170. Sciubba JJ, Brannon RB (1982) Myoepithelioma of salivary glands: report of 23 cases. *Cancer* 49:562–572
171. Seifert G (1991) World Health Organization international histological classification of tumours: histological typing of salivary gland tumours, 2nd edn. Springer, Berlin Heidelberg New York
172. Seifert G (1992) Tumour-like lesions of the salivary glands: the new WHO classification. *Pathol Res Pract* 188:836–846
173. Seifert G (1996) Mucoepidermoid carcinoma in a salivary duct cyst of the parotid gland: contribution to the development of tumours in salivary gland cysts. *Pathol Res Pract* 192:1211–1217
174. Seifert G (1996) Classification and differential diagnosis of clear and basal cell tumors of the salivary glands. *Semin Diagn Pathol* 13:95–103
175. Seifert G (1997) Primäre Speicheldrüsentumoren in Lymphknoten der Parotis: Bericht über 3 Fälle und Übersicht über die Literatur. *Pathologie* 18:141–146
176. Seifert G, Miehle A, Haubrich J, Chilla R (1986) Diseases of the salivary glands. Thieme, Stuttgart
177. Seifert G, Thomsen S, Donath K (1981) Bilateral dysgenetic polycystic parotid glands: morphological analysis and differential diagnosis of a rare disease of the salivary glands. *Virchows Arch A Pathol Anat Histol* 390:273–288
178. Servillo G, Della Fazio MA, Sassone-Corsi P (2002) Coupling cAMP signaling to transcription in the liver: pivotal role of CREB and CREM. *Exp Cell Res* 275:143–154
179. Sheldon WH (1943) So-called mixed tumors of the salivary glands. *Arch Pathol* 35:1–20
180. Shintaku M, Honda T (1997) Identification of oncocytic lesions of salivary glands by anti-mitochondrial immunohistochemistry. *Histopathology* 31:408–411
181. Simpson RHW (1994) Classification of tumours of salivary glands. *Histopathology* 24:187–191
182. Simpson RHW (1999) Clear cell tumors. *Rev Esp Patol* 32:432–433
183. Simpson RHW (2002) Myoepithelial tumours of the salivary glands. *Curr Diagn Pathol* 8:328–337
184. Simpson RHW (2004) Case 22, slide seminar head and neck pathology. II. Intercontinental Congress of Pathology, Iguassu, Brazil, 2004
185. Simpson RHW, Clarke TJ, Sarsfield PTL, Babajews AV (1991) Salivary duct adenocarcinoma. *Histopathology* 18:229–235
186. Simpson RHW, Clarke TJ, Sarsfield PTL, Gluckman PGC (1991) Epithelial-myoepithelial carcinoma of salivary glands. *J Clin Pathol* 44:419–423
187. Simpson RHW, Clarke TJ, Sarsfield PTL, Gluckman PGC, Babajews AV (1991) Polymorphous low grade adenocarcinoma of the salivary glands: a clinicopathological comparison with adenoid cystic carcinoma. *Histopathology* 19:121–129
188. Simpson RHW, Di Palma S (2003) Myoepithelial tumour of salivary glands. In: Gale N, Luzan B (eds) Proceedings in Head and Neck Pathology. Institute of Pathology Faculty of Medicine, University of Ljubljana, Ljubljana 4–6 September 2003, pp 92–98
189. Simpson RHW, Jones H, Beasley P (1995) Myoepithelioma of the salivary glands: a true entity? *Histopathology* 27:1–9
190. Simpson RHW, Prasad A, Lewis JE, Skalová A, David L (2003) Mucin-rich variant of salivary duct carcinoma: a

- clinicopathological study of four cases. *Am J Surg Pathol* 27:1070–1079
191. Simpson RHW, Reis-Filho JS, Pereira EM, Ribeiro AC, Abdulkadir A (2002) Polymorphous low grade adenocarcinoma of the salivary glands with transformation to high grade carcinoma. *Histopathology* 41:250–259
 192. Simpson RHW, Robertson NJ, Arora DS, Saunders MW (1996) Salivary duct carcinoma: a cytological and histopathological study. *Cytopathology* 7:141–144
 193. Simpson RHW, Sarsfield PTL, Clarke T, Babajews AV (1990) Clear cell carcinoma of minor salivary glands. *Histopathology* 17:433–438
 194. Simpson RHW, Sarsfield PTL (1997) Benign and malignant lymphoid lesions of the salivary glands. *Curr Diagn Pathol* 4:91–99
 195. Simpson RHW, Skálová A (1997). Metastatic carcinoma of the prostate presenting as a parotid tumour. *Histopathology* 30:70–74
 196. Skálová A, Lehtonen H, von Boguslawsky K, Leivo I (1994) Prognostic significance of cell proliferation in mucoepidermoid carcinoma of the salivary gland: clinicopathological study using MIB1 antibody in paraffin sections. *Hum Pathol* 25:929–935
 197. Skálová A, Leivo I, Michal M, Saksela E (1992) Analysis of collagen isotopes in crystalloid structures of salivary gland tumors. *Hum Pathol* 23:748–754
 198. Skálová A, Leivo I, von Boguslawsky K, Saksela E (1994) Cell proliferation correlates with prognosis in acinic cell carcinomas of salivary gland origin. Immunohistochemical study of 30 cases using the MIB1 antibody in formalin-fixed paraffin sections. *J Pathol* 173:13–21
 199. Skálová A, Leivo I, Wolf H, Fakan F (2000) Oncocytic cystadenoma of the parotid gland with tyrosine-rich crystals. *Pathol Res Pract* 196:849–851
 200. Skálová A, Michal M, Simpson RHW, Stárek I, Přádná J, Pfaltz M (2002) Sclerosing polycystic adenosis of parotid gland with dysplasia and ductal carcinoma in situ: report of three cases with immunohistochemical and ultrastructural examination. *Virchows Arch* 440:29–35
 201. Skálová A, Simpson RHW, Lehtonen H, Leivo I (1997) Assessment of proliferative activity using the MIB1 antibody helps to distinguish polymorphous low grade adenocarcinoma from adenoid cystic carcinoma of salivary glands. *Pathol Res Pract* 193:695–703
 202. Skálová A, Stárek I, Kučerová V, Szépe P, Plank L (2001) Salivary duct carcinoma – a highly aggressive salivary gland tumor with HER-2/neu oncoprotein overexpression. *Pathol Res Pract* 197:621–626
 203. Skálová A, Stárek I, Simpson RHW, Kučerová V, Dvorackova J, Čuřík R, Duskova M (2001) Spindle cell myoepithelial tumours of the parotid gland with extensive lipomatous metaplasia. *Virchows Arch* 439:762–767
 204. Skálová A, Stárek I, Vanecek T, Kucerova V, Plank L, Szepe P, Di Palma S, Leivo I (2003) Expression of HER-2/neu gene and protein in salivary duct carcinomas of parotid gland as revealed by immunofluorescence in situ hybridization and immunohistochemistry. *Histopathology* 42:1–9
 205. Škorpil F (1940) Über das Speicheldrüsenadenom. *Virchows Arch A Anat Pathol* 306:714–736
 206. Slootweg PJ (1993) Low-grade adenocarcinoma of the oral cavity: polymorphous or papillary? *J Oral Pathol Med* 22:327–330
 207. Smyth AG, Ward-Booth RP, High AS (1993) Polycystic disease of the parotid glands: two familial cases. *Br J Oral Maxillofac Surg* 31:38–40
 208. Soares J (1999) Progression to low-grade and high-grade salivary gland tumors. *Rev Esp Patol* 32:434–435
 209. Spiro RH, Huvos AG, Strong EW (1977) Malignant mixed tumor of salivary origin: a clinicopathologic study of 146 cases. *Cancer* 39:388–396
 210. Spiro RH, Huvos AG (1992) Stage means more than grade in adenoid cystic carcinoma. *Am J Surg Pathol* 164:623–628
 211. Sredni ST, da Cunha IW, de Carvalho Filho NP, Magrin J, Pinto CA, Lopes LF (2004) Endodermal sinus tumour of the parotid gland in a child. *Pediatr Dev Pathol* 7:77–80
 212. Stallmach I, Zenklusen P, Komminoth P, Schmid S, Perren A, Roos M, Jianming Z, Heitz PU, Pfaltz M (2002) Loss of heterozygosity at chromosome 6q23–25 correlates with clinical and histologic parameters in salivary gland adenoid cystic carcinoma. *Virchows Arch* 440:77–84
 213. Stanley RJ, Weiland LH, Pearson BW (1988) Dedifferentiated acinic cell (acinous) carcinoma of the parotid gland. *Otolaryngol Head Neck Surg* 98:155–161
 214. Stephen J, Batsakis JG, Luna MA, von der Heyden U, Byers RM (1986) True malignant mixed tumors (carcinosarcoma) of salivary glands. *Oral Surg Oral Med Oral Pathol* 61:597–602
 215. Sternlicht MD, Barsky SH (1997) The myoepithelial defense: a host defense against cancer. *Med Hypotheses* 48:37–46
 216. Su AI, Welsh JB, Sapinoso LM, Kern SG, Dimitrov P, Lapp H, Schultz PG, Powell SM, Moskaluk CA, Frierson HF Jr, Hampton GM (2001) Molecular classification of human carcinomas by use of gene expression signatures. *Cancer Res* 61:7388–7393
 217. Suchy BH, Wolf SR (2000) Bilateral mucosa-associated lymphoid tissue lymphoma of the parotid gland. *Arch Otolaryngol Head Neck Surg* 126:224–226
 218. Suzuki H, Inoue K, Fujioka Y, Ishikura H, Furuta Y, Fukuda S (1998) Myoepithelial carcinoma with predominance of plasmacytoid cells arising in a pleomorphic adenoma of the parotid gland. *Histopathology* 32:86–87
 219. Takata T, Ogawa I, Nikai H (1989) Sebaceous carcinoma of the parotid gland: an immunohistochemical and ultrastructural study. *Virchows Arch A Pathol Anat* 414:459–464
 220. Takahashi H, Fujita S, Okabe H, Tsuda N, Tezuka F (1991) Immunohistochemical characterization of basal cell adenomas of the salivary gland. *Pathol Res Pract* 187:145–156
 221. Takahashi H, Fujita S, Okabe H (1992) Distribution of tissue markers in acinic cell carcinomas of salivary gland. *Pathol Res Pract* 188:692–700
 222. Therkildsen MH, Christensen N, Andersen LJ, Larsen S, Katholm M (1992) Malignant Warthin's tumour: a case study. *Histopathology* 21:167–171
 223. Tortoledo ME, Luna MA, Batsakis JG (1984) Carcinomas ex pleomorphic adenoma and malignant mixed tumors: histomorphologic indexes. *Arch Otolaryngol* 110:172–186
 224. Tse LL, Finkelstein SD, Siegler RW, Barnes L (2004) Osteoclast-type giant cell neoplasm of salivary gland. A microdissection-based comparative genotyping assay and literature review. *Am J Surg Pathol* 28:953–961
 225. Vargas H, Sudilovsky D, Kaplan MJ, Regezi JA, Weidner N (1997) Mixed tumor, polymorphous low-grade adenocarcinoma and adenoid cystic carcinoma of the salivary gland: pathogenic implications and differential diagnosis by Ki-67 (MIB1), BCL2, and S-100 immunohistochemistry. *Appl Immunohistochem* 5:8–16
 226. Vessecchia G, Di Palma S, Giardini R (1995) Submandibular gland metastasis of breast carcinoma: a case report and review of the literature. *Virchows Arch* 427:349–351
 227. Viva E, Zorzi F, Annibale G, Stefani S, Baronchelli C, Bonetti MF (1992) Endodermal sinus (yolk sac) tumour of the parotid gland, a case report. *Int J Pediatr Otorhinolaryngol* 24:269–274
 228. Waldron CA (1991) Mixed tumor (pleomorphic adenoma) and myoepithelioma. In: Ellis GL, Auclair PL, Gnepp DR (eds) *Surgical pathology of the salivary glands*. Saunders, Philadelphia, pp 165–186
 229. Waldron CA, el Mofty SK, Gnepp DR (1988) Tumors of the intraoral minor salivary glands: a demographic and histologic study of 426 cases. *Oral Surg Oral Med Oral Pathol* 66:323–333
 230. Walt JD van der, Leake J (1987) Granulomatous sialadenitis of the major salivary glands. A clinicopathological study of 57 cases. *Histopathology* 11:131–144
 231. Wanamaker JR, Kraus DH, Biscotti CV, Eliachar I (1994) Undifferentiated nasopharyngeal carcinoma presenting as a parotid mass. *Head Neck* 16:589–593

232. Wenig BM, Hitchcock CL, Ellis GL, Gnepp DR (1992) Metastasizing mixed tumor of salivary glands: a clinicopathologic and flow cytometric analysis. *Am J Surg Pathol* 16:845–858
233. Werning JT (1991) Infectious and systemic diseases. In: Ellis GL, Auclair PL, Gnepp DR (eds) *Surgical pathology of the salivary glands*. Saunders, Philadelphia, pp 39–59
234. Wilson RW, Moran CA (1997) Epithelial-myoepithelial carcinoma of the lung: immunohistochemical and ultrastructural observations and review of the literature. *Hum Pathol* 28:631–635
235. Worner GC, Reis PP, Makitie AA, Sukhai MA, Arora S, Jurisica I, Wells RA, Gullane P, Irish J, Kamel-Reid S (2004) Current applications of microarrays in head and neck cancer research. *Laryngoscope* 114:241–248
236. Zarbo RJ, Prasad AR, Regezi JA, Gown AM, Saveria AT (2000) Salivary gland basal cell and canalicular adenomas: immunohistochemical demonstration of myoepithelial cell participation and morphogenetic considerations. *Arch Pathol* 124:401–405
237. Zarbo RJ, Regezi JA, Batsakis JG (1986) S-100 protein in salivary gland tumors: an immunohistochemical study of 129 cases. *Head Neck Surg* 8:268–275

Nasopharynx and Waldeyer's Ring

S. Regauer

Contents

6.1	Embryological Development of the Nasopharynx and Waldeyer's Ring	172	6.2.6.2	Papillary Adenocarcinoma of the Nasopharynx	182
6.2	Nasopharynx.	173	6.2.7	Malignant Non-Epithelial Tumours of the Nasopharynx	183
6.2.1	Anatomy and Histology	173	6.2.7.1	Chordoma	183
6.2.2	Congenital Developmental Anomalies	173	6.2.7.2	Sarcoma.	183
6.2.2.1	Nasopharyngeal Branchial Cleft Cysts	173	6.3	Waldeyer's Ring	183
6.2.2.2	Tornwaldt's Cyst.	173	6.3.1	Anatomy and Histology of Waldeyer's Ring.	183
6.2.2.3	Rathke's Cleft Cyst/Ectopic Pituitary Tissue	174	6.3.2	Congenital Anomalies of Waldeyer's Ring.	184
6.2.2.4	Craniopharyngioma	174	6.3.3	Tonsillitis.	184
6.2.2.5	Heterotopic Brain Tissue/Encephalocele	174	6.3.3.1	Bacterial Tonsillitis	184
6.2.3	Congenital Tumours	174	6.3.3.2	Viral Tonsillitis	185
6.2.3.1	Salivary Gland Anlage Tumour	175	6.3.4	Benign Tumours of Waldeyer's Ring	187
6.2.3.2	Hairy Polyp	175	6.3.4.1	Squamous Papilloma	187
6.2.3.3	Congenital Nasopharyngeal Teratoma	175	6.3.4.2	Lymphangiomatous Tonsillar Polyp	187
6.2.4	Benign Tumours and Tumour-Like Lesions	175	6.3.5	Carcinomas of Waldeyer's Ring.	187
6.2.4.1	Nasopharyngeal Angiofibroma	175	6.3.6	Malignant Lymphomas of Waldeyer's Ring	189
6.2.4.2	Respiratory Epithelial Adenomatoid Hamartoma.	178	6.3.6.1	Mantle Cell Lymphoma	189
6.2.4.3	Nasopharyngeal Inverted Papilloma	178	6.3.6.2	Extranodal Marginal Zone B-Cell Lymphoma of Mucosa-Associated Lymphoid Tissue	190
6.2.4.4	Solitary Fibrous Tumour	179	6.3.6.3	Extranodal NK/T-Cell Lymphoma, Nasal Type	190
6.2.4.5	Paraganglioma.	179	6.3.6.4	Hodgkin's Lymphoma	190
6.2.4.6	Meningioma	179	6.3.6.5	Extramedullary Plasmacytoma	190
6.2.4.7	Glandular Retention Cysts	179	6.3.7	Systemic Disease Affecting Waldeyer's Ring	190
6.2.5	Nasopharyngeal Carcinoma.	180	References	191	
6.2.5.1	Non-Keratinising Nasopharyngeal Carcinoma	180			
6.2.5.2	Keratinising Nasopharyngeal Carcinoma	182			
6.2.6	Nasopharyngeal Adenocarcinoma	182			
6.2.6.1	Salivary Gland-Type Adenocarcinoma of the Nasopharynx	182			

6.1 Embryological Development of the Nasopharynx and Waldeyer's Ring

The pharynx is divided into an upper portion, the *nasopharynx*, and a lower portion consisting of the *oropharynx* and *hypopharynx*. The nasopharynx is located above the soft palate and communicates with the nasal passages. The oropharynx extends from the soft palate and the velum palatinum to the epiglottis. The hypopharynx extends from the tip of the epiglottis to the lower margin of the cricoid cartilage. The term *Waldeyer's ring* refers to the ring of lymphoid tissues extending throughout the naso- and oropharynx and includes the palatine, pharyngeal, lingual and tubal tonsils.

The earliest embryological stage relevant for the development of the nasopharynx is around the 3rd week of gestation. The embryo has already developed all three germ layers and consists of the notochord with a notochordal lumen [134]. At the cranial end, the notochord is still fused with the ecto- and endodermal germ layers, which form the bilaminar *oropharyngeal* (or *buccopharyngeal*) *membrane*. The first process in the formation of the pharynx is the development of a *primitive mouth* (or *stomodeum*) and a *primitive pharynx* during the 4th week via rupture of the *oropharyngeal membrane*. At that time, the primitive nasal cavities and the nasopharynx are still separated from the oral cavity by the *primary palate* and the *oronasal membrane*. The oronasal membrane ruptures around week 6, bringing the nasal and oral cavity into continuity and forming the *primitive choanae*. During the posterior extension of the primary palate and development of the secondary palate, the choanae become located posteriorly and connect the newly formed nasal cavities and nasopharynx. The development of the *pituitary gland* (or *hypophysis*) begins around the middle of the 4th week with an upward proliferation of the ectodermal roof of the stomodeum, the *Rathke's pouch* (or *hypophyseal duct*), and a downgrowth from the diencephalon called the *neurohypophyseal bud*. The Rathke's pouch passes through the chondrification centres of the developing sphenoid bones. By the 5th week, both portions of the pituitary gland have come in contact and the Rathke's pouch becomes constricted at its attachment to the oronasal epithelium. The stalk degenerates and the Rathke's pouch involutes to a series of microcysts, which persist throughout adult life in the pituitary gland. Occasionally, they can be recognised macroscopically by a zone of colloid cysts. Symptomatic enlargement leads to the formation of a Rathke's cleft cyst (see Sect. 6.2.2.3). Around the same time, during the involution of the notochord, a *pharyngeal bursa* is formed temporarily at the site of early communication between the notochord and the roof of the pharynx. This ectodermally derived *pharyngeal bursa* normally obliterates during the 6th gestational week. A persistent pharynge-

al bursa in adults is located at the posterior median wall of the nasopharynx above the superior pharyngeal constrictor muscles at the lower end of the pharyngeal tonsil and is known as Tornwaldt's cyst (see Sect. 6.2.2.2). Remnants of the notochord give rise to cranial chordomas (see Sect. 6.2.7.1).

The oropharynx, mouth and larynx develop from the *pharyngeal* (or *branchial*) apparatus during the 4th and 5th weeks of gestation. The growth of the forebrain and the development of the pharyngeal/branchial apparatus produce a prominent elevation of the head with a quite distinct first and second pharyngeal arch around day 24. At the end of the 4th embryonic week, four well-defined and two rudimentary bilateral pairs of pharyngeal arches are separated by the *pharyngeal grooves*. Each arch consists of a core of embryonic mesenchyme with an artery, a cartilage rod, a nerve and a muscular component, and is covered externally by ectoderm and internally by endoderm. The ectodermally derived pharyngeal arches and grooves support the lateral walls of the primitive pharynx. The inner lining consists of endoderm with balloon-like diverticuli called *pharyngeal pouches*, which are also present in four well-defined pairs. The second pharyngeal pouch is the major contributor to the formation of the pharynx and is largely obliterated when the palatine tonsils develop around weeks 12–14 post-conception. A part of the cavity of the second pouch remains as the *intratonsillar cleft* (or *tonsillar fossa*) in the palatine tonsils (see Sect. 6.3.1). The neural crest-derived mesenchyme will form most of the skeletal (cartilage and bone) and connective tissue structure of the head and neck, but the original mesenchyme of the second arch forms the blood vessels and skeletal musculature of the pharynx. The nerve supply of the pharynx develops from the 3rd pharyngeal arch (IX glossopharyngeal nerve). The adult vascular pattern of the head and neck depends on a complex transformation of the pharyngeal apparatus with involution and obliteration of the early vessels. Incomplete involution, particularly of the first pharyngeal artery, has been postulated to be responsible for the development of nasopharyngeal angiofibromas (see Sect. 6.2.4.1). The *auditory* (*Eustachian*) *tube* is derived from the first pharyngeal arch and pouch. Incomplete regression may be responsible for the occurrence of hairy polyps (see Sect. 6.2.3.2). The tongue also begins to develop at the end of the 4th week. The oral part of the tongue is derived from the first pharyngeal arch; the posterior pharyngeal tongue develops by fusion of the ventromedial parts of the second and the third pharyngeal arch. The tissues derived from the second pharyngeal arch are gradually overgrown by the third pharyngeal arch.

The lymphoid tissues of Waldeyer's ring develop between the 14th and 18th weeks of gestation. The development of the pharyngeal tonsil begins from an anlage

consisting of longitudinal folds on the dorsal wall of the nasopharynx around the 12–14th gestational week. The development of the palatine tonsils begins with a proliferation of the endodermal epithelium of the second pharyngeal pouch down into the surrounding mesenchyme, forming the epithelium-lined crypts. In the connective tissue, mesenchymal cells of the second pharyngeal pouch form so-called *condensation centres*. The first primary follicles can be localised around week 14. The parafollicular areas develop into T-cell areas and precursors of interdigitating cells can be identified. Around week 16, the epithelium shows the first signs of cornification, and the lymphocytic infiltration of the epithelium occurs [59, 60].

6.2 Nasopharynx

6.2.1 Anatomy and Histology

The nasopharynx is bordered anteriorly by the nasal choanae and nasal cavities. The roof and posterior wall of the nasopharynx form an arch just below the base of the skull with the sphenoid sinus and the floor of the sella turcica. The postero-superior roof contains the (*naso*)*pharyngeal tonsil*. At its lower end in the posterior midline lies a blind recess known as the *pharyngeal bursa*. The lateral walls of the nasopharynx contain the pharyngeal ostia of the auditory tubes, which are surrounded by small aggregates of lymphoid tissue, the *tubal tonsil*. The cartilage of the auditory tube protrudes above the ostium and is called the *torus tubarius*, behind which the *Rosenmüller fossa* is located. The floor of the nasopharynx is formed by the soft palate and uvula. The anterior and cranial portions of the nasopharynx are lined by respiratory mucosa with ciliated columnar epithelium with goblet cells and foci of metaplastic squamous epithelium. Squamous mucosa predominates in the lower nasopharynx adjacent to the oropharynx. Small seromucinous glands and aggregates of lymphoid tissue are present in the submucosa throughout the nasopharynx as a normal finding without qualifying as “chronic inflammation”.

6.2.2 Congenital Developmental Anomalies

Congenital developmental anomalies of the nasopharynx are rare and include choanal atresias and pharyngeal stenosis. Bilateral occlusion has been reported in up to 40% of patients with choanal atresias. Bilateral atresias are typically osseous, unilateral atresias are membranous. Pharyngeal stenosis is a paediatric disorder

associated with sleep apnoea and other craniofacial anomalies [108, 137]. Far more common are congenital cysts and tumours arising from remnants of embryonic tissue.

6.2.2.1 Nasopharyngeal Branchial Cleft Cysts

Nasopharyngeal branchial cleft cysts and fistulas are located in the *lateral* nasopharyngeal wall and can extend to the base of the skull through the parapharyngeal space. They occur unilaterally or bilaterally and have a postulated second pharyngeal arch origin. Most nasopharyngeal branchial cleft cysts are clinically silent during childhood and discovery may be delayed into early adulthood, when chronic inflammation induces proliferation of the lymphoid tissues. This produces a mass resulting in respiratory difficulties and nasal obstruction. The cysts are lined with respiratory epithelium. Chronic irritation and inflammation induces squamous metaplasia. Surgical specimens of nasopharyngeal cysts removed for symptomatic disease may therefore show exclusively squamous epithelium and lymphoid hyperplasia in a fibrosed cyst wall [143, 177, 185].

6.2.2.2 Tornwaldt's Cyst

A Tornwaldt's cyst (or *pharyngeal bursitis*; named after Gustav Ludwig Tornwaldt, 1843–1910) is a dilatation of a persistent pharyngeal bursa in the *posterior median wall* of the nasopharynx above the superior pharyngeal constrictor muscles and at the lower end of the pharyngeal tonsil caudally and posteriorly to where Rathke's cleft cysts arise [128]. The cysts arise at the site of embryonic communication between the notochord and the roof of the pharynx and can be detected in up to 7% of adults at routine autopsies [86]. Tornwaldt's cysts are typically less than 1 cm in size and asymptomatic [92]. Obstruction of the bursal orifice results in a cystic dilatation. The cysts may become infected and inflamed with subsequent abscess formation. Symptomatic disease, termed *Tornwaldt's disease*, may present with nasal obstruction and nasopharyngeal drainage, dull occipital headaches, pain in the ears and neck muscles and occasionally neck muscle stiffness [130]. Tornwaldt's cysts are lined with tall, columnar, ciliated respiratory epithelium, but inflammation and infection induces squamous metaplasia and fibrosis of the walls. Tornwaldt's cyst may contain varying amounts of lymphoid tissue (Fig. 6.1). Most surgical specimens of symptomatic Tornwaldt's cysts are either devoid of an epithelial lining or lined with squamous epithelium.

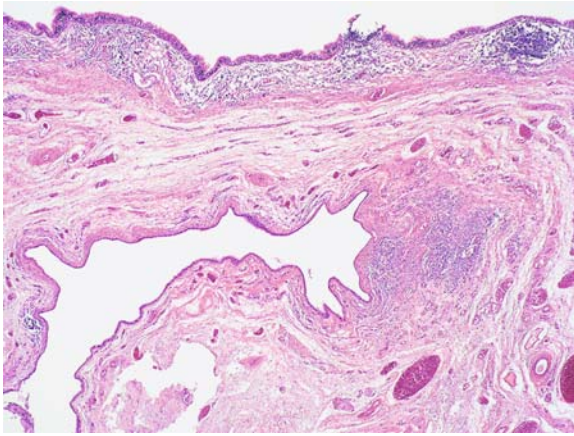


Fig. 6.1. Tornwaldt's cyst. Tornwaldt's cysts are thin-walled cysts of varying sizes located in the nasopharyngeal submucosa. The nasopharyngeal surface is covered either by squamous epithelium or respiratory epithelium. The cysts are lined by respiratory type epithelium with varying extent of squamous metaplasia. The cyst wall contains varying amounts of inflammatory cells and may be fibrosed

6.2.2.3 Rathke's Cleft Cyst/ Ectopic Pituitary Tissue

Rathke's cleft cysts (or *Rathke's cyst*; named after Martin Heinrich Rathke, 1793–1860) arise from the *Rathke's pouch* (or *hypophyseal duct*), an ectodermal remnant of the stomodeum that gives rise to the anterior lobe of the pituitary gland. The Rathke's pouch is normally obliterated to become microscopic clefts, but remnants of the Rathke's pouch are incidental findings in up to 33% of unselected autopsies. Rathke's cleft cysts can have diameters ranging from 0.3 to 4 cm [90, 192]. The thin-walled cysts are lined with respiratory epithelium with interspersed goblet cells and are filled with a clear, colloid, mucinous, viscous, turbid or haemorrhagic fluid. In cases of inflammation, metaplastic non-keratinising squamous epithelium and a mural lymphocytic infiltrate dominate [72, 90]. Rupture induces a granulomatous and xanthomatous inflammation with fibrosis, cholesterol needles and foreign body cell reaction, and even amyloid deposition. Rathke's cleft cysts are virtually never removed intact and surgical specimens typically consist of inflamed fibrous tissue. The epithelium is often elusive. Rare examples of Rathke's cleft cysts contain mural nodules of anterior pituitary tissue or concomitant pituitary adenoma. Most nasopharyngeal pituitary adenomas represent nasopharyngeal extension of intracranial pituitary adenomas. Primary nasopharyngeal pituitary adenomas are extremely rare and mostly non-functioning [110, 123]. Symptoms depend on the type of secreted hormone and the location of the adenoma. Histologically, ectopic pituitary gland tissue can display the entire spectrum with chromophobe, acidophilic and basophilic cells [29].

6.2.2.4 Craniopharyngioma

ICD-O:9350/1

All reported extracranial craniopharyngiomas (or *Rathke's pouch tumour*, *craniopharyngeal duct tumour*) were located in the nasopharynx, sella turcica and sphenoid sinus, and presented during the first two decades of life with headaches, nasal obstruction and epistaxis (for reviews see [18, 67]). Intracranial craniopharyngiomas occur classically in an adamantinomatous and papillary subtype. The majority of the extracranial nasopharyngeal craniopharyngiomas are of the adamantinomatous subtype with cords of basaloid squamous cells and foci of squamous differentiation and horn pearls embedded in fibrous stroma. Other typical secondary changes are cysts filled with brown fluid, areas of necrosis, calcifications and cholesterol crystals. Treatment is surgical and supplemented with radiotherapy in the case of incompletely resected tumours and recurrences.

6.2.2.5 Heterotopic Brain Tissue/ Encephalocele

Encephaloceles are herniations of brain through a congenital opening of the skull. Glial heterotopias with and without encephaloceles cause neonatal airway obstruction and rhinorrhoea. Heterotopic brain in a nasopharyngeal location is rare [168]. From a pathologist's perspective, encephaloceles and brain heterotopias can be distinguished only after correlation with the patient's clinical and radiological findings. Histologically, mature neuroglial tissues are embedded in fibrovascular stroma. Encephaloceles/glial heterotopias involving the nasopharynx differ from the more common nasal gliomas in that they contain ependyma, choroid plexus, retinal components and occasionally neoplastic tissue, such as an oligodendroglioma [14].

6.2.3 Congenital Tumours

Among the tumourous developmental abnormalities are hamartomas, choristomas and teratomas. A *hamartoma* is a benign tumour-like nodule composed of mature cells and tissues that normally occur in the affected part, but often with one element predominating. *Choristomas* represent a mass of histologically normal mature tissues located at a site where these tissues do not normally occur. These tumours are also called *aberrant rests* or *heterotopic tissue*. *Teratomas* are true neoplastic proliferations made up of mature or immature tissues in random organisation derived from all three germ layers.

6.2.3.1 Salivary Gland Anlage Tumour

Salivary gland anlage tumours are rare tumours of neonates that arise from minor salivary glands of the nasopharynx and are also known as *congenital pleomorphic adenoma* [13, 38, 73]. The firm, polypoid, pedunculated midline masses can reach up to 3 cm in size and cause respiratory distress and feeding problems. Salivary gland anlage tumours are multinodular and usually solid tumours. Histologically, they are characterised by an epithelial proliferation imitating embryonic salivary glands (Fig. 6.2). The epithelial proliferation can be extensive with solid squamous areas with focal keratinisation, keratinised nests, cyst and pearls. Calcification within the cysts occurs. Salivary gland anlage tumours may contain branching ductal and glandular structures, occasionally with complex intraluminal papillations. The surrounding stroma may be loose and myxoid with numerous inflammatory cells, but may also show some fibrosis. Other salivary gland anlage tumours consist predominantly of densely packed sheet and nodules of small fusiform spindle cells with occasional regular mitoses. Rare keratinised duct and cystic structures are seen in these areas. Haemorrhage and focal necrosis can be seen [125]. Immunohistochemically, all cells stain positive for salivary gland amylase. The spindle cells are immunoreactive with antibodies to vimentin, cytokeratins, EMA and smooth muscle actin, but are negative for S-100 and GFAP. The epithelial structures stain for cytokeratin and EMA. The exact classification of the salivary gland anlage tumour as a hamartoma or true (benign) neoplasm has not yet been resolved. Dehner and colleagues favour a hamartomatous origin, although the present name indicates a tumorous growth [38].

6.2.3.2 Hairy Polyp

Hairy polyps (or *dermoids*) are found in the naso- and oropharynx of neonates or young infants. About 60% of the roughly 140 reported cases arose as single, pedunculated or sessile, 0.5 to 6 cm polyps in the lateral vault of the nasopharynx near the Eustachian tube orifice and very rarely within the Eustachian tube and middle ear [17, 78, 109]. The remaining cases occurred in the tonsillar region (for tonsillar and bilateral location see Sect. 6.3.2). Hairy polyps cause respiratory distress or feeding problems. Simultaneous congenital abnormalities such as cleft palate are more common than ipsilateral branchial sinus, congenital atresia of the carotid artery, osteopetrosis and malformations of the auricle [36, 68]. Treatment is simple surgical resection. A hairy polyp is covered by keratinised or glycogenated squamous epithelium containing hair with sebaceous glands and sweat glands. The mesenchymal core consists of mature fibroadipose tissue and blood vessels with oc-

casional smooth muscle and striated muscle fibres. The stalk may contain foci or plates of hyaline cartilage [27]. Hairy polyps fulfil the definition of a choristoma, although the literature refers to hairy polyps mistakenly often as "teratoma".

6.2.3.3 Congenital Nasopharyngeal Teratoma

ICD-O:9080/1

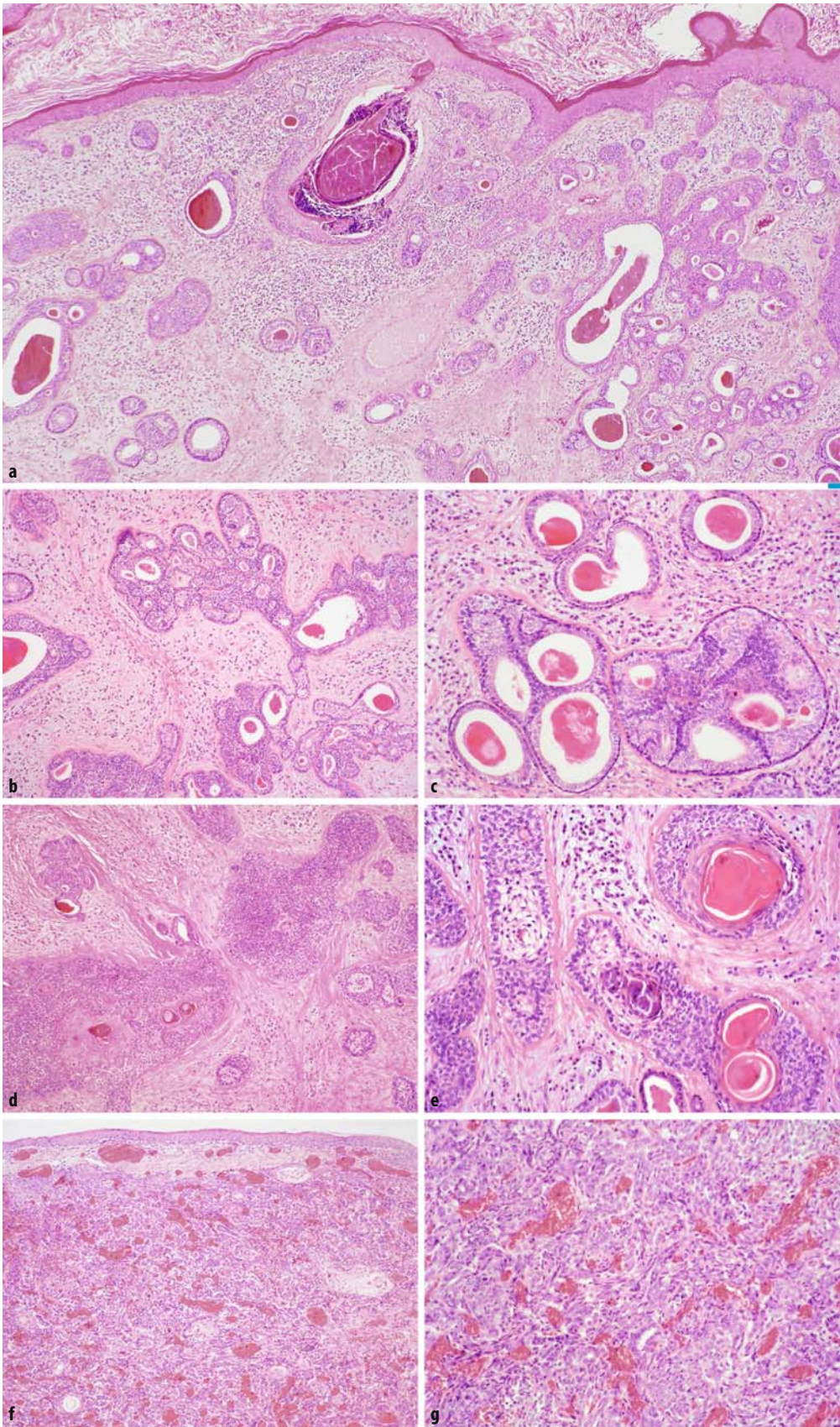
Congenital teratomas are most common in the saccrococcygeal region; less than one-third of all teratomas arise in the head and neck region. The nasopharynx is an exceptionally rare location [84, 167, 187]. Teratomas are ill-formed, lobular solid and cystic tumour masses typically diagnosed in the neonatal period with airway obstruction. Mature teratomas are completely benign and consist of mature tissues of ecto-, meso- and endodermal derivation in a more or less organised fashion. Optimal treatment is complete excision. Immature teratomas contain tissues of varying degrees of differentiation and maturation. Immature teratomas in infants have an excellent prognosis, quite in contrast to adult patients with immature teratomas.

6.2.4 Benign Tumours and Tumour-Like Lesions

6.2.4.1 Nasopharyngeal Angiofibroma

ICD-O:9160/0

Nasopharyngeal angiofibromas (or *juvenile nasopharyngeal angiofibromas*) are rare benign tumours with an incidence of 0.5% of all head and neck tumours. They occur exclusively in adolescent males and become clinically evident between 10 and 25 years of age with nose bleeds, respiratory distress, headaches or sometimes visual disturbances. Nasopharyngeal angiofibromas arise from the posterior lateral wall of the nasal cavity near the pterygo-palatine fossa at the superior margin of the foramen sphenopalatinum and extend into adjacent structures such as maxillary, sphenoid or ethmoid sinuses and the nasal cavity. The most advanced cases show intracranial extension [153, 203]. The blood supply of nasopharyngeal angiofibromas comes from the external carotid artery with the internal maxillary artery as feeding branch. In a minority of cases, the feeding vessels are the sphenopalatine artery and the ascending pharyngeal artery [75, 153]. Diagnosis of a nasopharyngeal angiofibroma is based on clinical examination and computer tomography, which shows two consistent features: 1) localisation in the posterior nasal cavity and pterygopalatine fossa, and 2) bone erosions of the



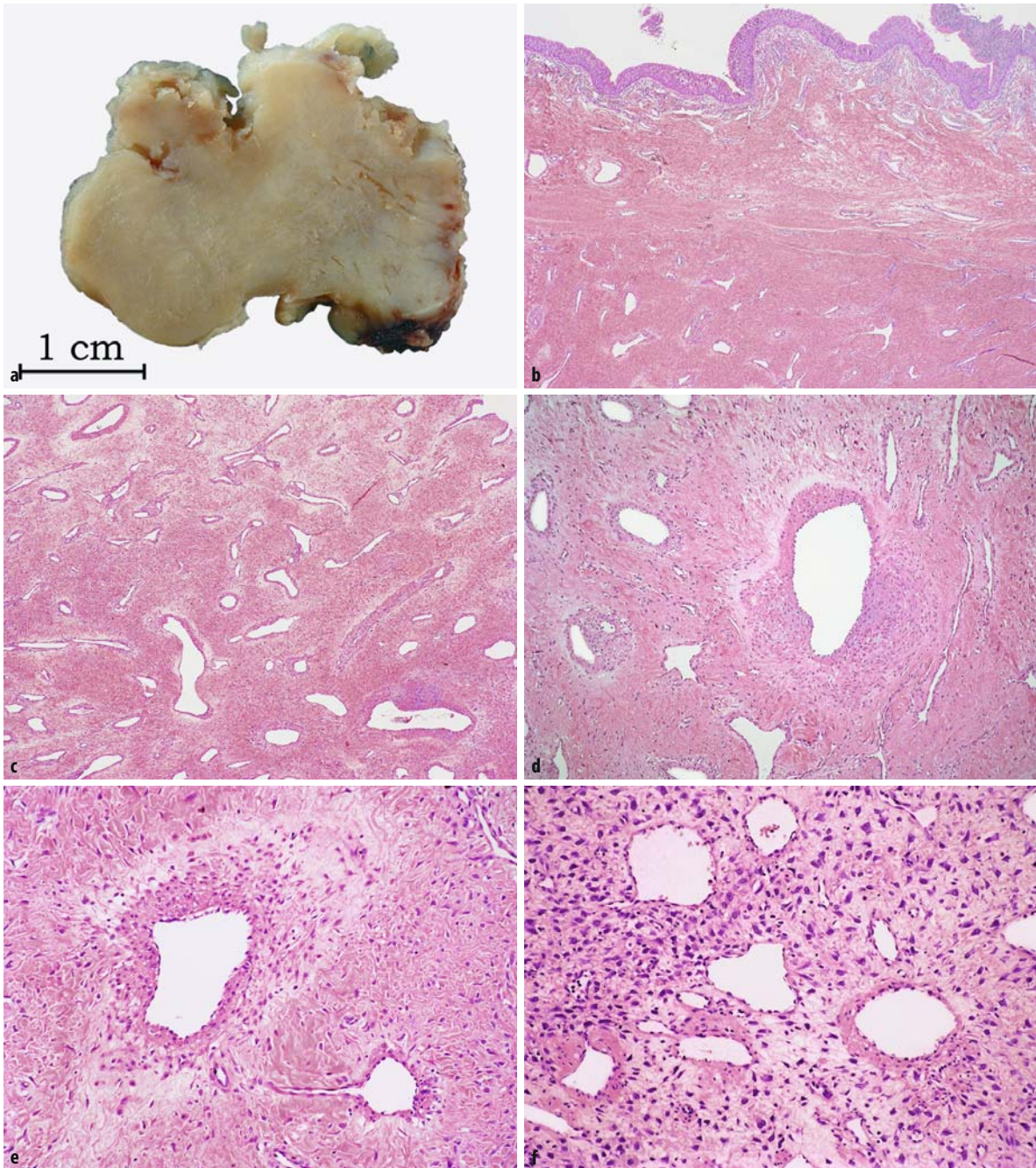


Fig. 6.3. Nasopharyngeal angiofibroma. **a–b** Nasopharyngeal angiofibromas are large, white, firm, bulging tumours covered by respiratory mucosa. **c–d** Abnormal large muscular and smaller sinusoidal vessels are embedded in a fibrous and partly sclerotic stroma.

The muscular vessels exhibit irregular muscle walls with varying thickness and arbitrary arrangement of the individual smooth muscle cells. **e–f** The stroma is either fibrous or myxoid with stellate or spindled cells

Fig. 6.2. Salivary gland anlage tumour. **a–c** Salivary gland anlage tumours have an intact surface epithelium, which may be partly keratinized. The branching epithelial proliferations show ducts filled with proteinaceous casts. The stroma is myxoid and contains numerous plasma cells and lymphocytes. **d–e** There are solid squamous areas with keratin-filled cysts and calcifications. **f–g** Other areas are dominated by proliferations of spindle cells in solid, fascicular and nested arrangement with occasional ductal and cystic elements. Haemorrhage is common

id squamous areas with keratin-filled cysts and calcifications. **f–g** Other areas are dominated by proliferations of spindle cells in solid, fascicular and nested arrangement with occasional ductal and cystic elements. Haemorrhage is common

sphenopalatine foramen with extension to the upper medial pterygoid plate [118]. Nasopharyngeal angiofibromas are unencapsulated, lobulated, firm, grey to tan tumours. Abnormal blood vessels of different sizes and irregular architecture in arbitrary arrangement are embedded in a myofibroblastic stroma. The proportions of both components can vary considerably (Fig. 6.3). The vascular component can be divided into small sinusoidal vessels and large muscular vessels with irregular and incomplete smooth muscle layers with abrupt transitions from a muscular coat to an endothelial cell lining only. Irrespective of their architecture, all vessels are lined with a continuous layer of single regular endothelial cells. The stromal component varies in amount and cellularity. The majority of stromal fibroblasts are plump and stellate, others assume an elongated spindled configuration. Mitoses are inconspicuous. The majority of stromal cells react with vimentin only, while a subpopulation is characterised by co-expression of vimentin and smooth muscle actin.

Despite the body of literature, there is still uncertainty about the aetiology of nasopharyngeal angiofibromas. They have been called haemangioma and vascular hamartoma arising from ectopic vascular tissue of the inferior turbinate. Other theories have included overgrowth of paraganglionic tissue, hyperplasia in response to allergic stimulus, fibromatosis, teratoma arising from the occipital plate, but also an androgen-dependent neoplastic process due to an imbalance of the pituitary-androgenital system [9]. A concomitant presentation of nasopharyngeal angiofibromas and the familial adenomatous polyposis syndrome has been reported in 4 out of 825 patients at the Johns Hopkins' Registry for familial colonic polyposis [47, 62]. A mutation in the APC gene, however, was not demonstrated in 9 patients with nasopharyngeal angiofibroma, and a comparative genomic hybridisation study describes a normal chromosome 5 in 3 patients with nasopharyngeal angiofibroma [70, 170]. The same study reports gains on chromosome 8 at the site of the genes for TGF- β inducible early growth response and LYN (v-yes-1 Yamaguchi sarcoma viral-related oncogene homologue), and on chromosome 6, on which the gene for the vascular endothelial growth factor is located [170]. The additional complex gains on the X chromosome and losses on the Y chromosome may explain the exclusive occurrence in male patients. The interpretation of nasopharyngeal angiofibromas as a vascular malformation has proved to be the most consistent theory over the past few decades. A recent publication proposes that nasopharyngeal angiofibromas arise from an embryological vascular remnant of the first pharyngeal arch artery, which normally regresses to a vascular plexus, giving rise to the maxillary artery [75, 153, 171]. Incomplete involution leaves behind vascular remnants in the lateral nasal wall in the area of the sphenopalatine foramen from where nasopharyngeal angiofibro-

mas originate. This theory explains the abnormal vascular structures and the complex anatomical extensions of nasopharyngeal angiofibromas. The growth stimulation during puberty and the restriction to males remain unexplained by this theory, however. Treatment of nasopharyngeal angiofibromas is surgical after embolisation, although radiation therapy and hormonal therapy have been used extensively in the past [15, 37]. Nasopharyngeal angiofibromas have no malignant potential, except for radiation-related malignant transformation.

6.2.4.2 Respiratory Epithelial Adenomatoid Hamartoma

Respiratory epithelial adenomatoid hamartoma (or *polypoid hamartomas*) typically arises within the nasal cavity and paranasal sinuses (see also Chap. 2), but has also been reported in the nasopharynx [199]. Patients are adults with an age range of 24–81 years. The polypoid exophytic hamartomas are rubbery, tan to brown and can reach up to 6 cm in size. They are lined with ciliated respiratory epithelium with mucin-secreting goblet cells. The widely spaced glandular proliferations arise from invagination of the surface epithelium. A thick eosinophilic basement membrane surrounds the glands and surface epithelium. The ample stroma may be oedematous and well-vascularised or fibrous with varying amounts of lymphocytes and inflammatory cells (Fig. 6.4). Glandular acinar proliferations may be scant and large cysts may predominate when the fibrous stroma predominates [206]. Some nasopharyngeal hamartomas include a chondro-osseous component and cysts lined with squamous epithelium. Due to overgrowth of a single mesenchymal element, respiratory epithelial adenomatoid hamartomas may resemble fibromas, lipomas or chondromas [199]. Treatment of choice is surgery. The differential diagnoses of respiratory epithelial adenomatoid hamartoma include inverted papilloma and adenocarcinoma. The presence of excess glands and the respiratory epithelium distinguish the hamartoma readily from an inverted papilloma. The lack of malignant cytological and histological features and invasion distinguishes the respiratory epithelial adenomatoid hamartoma from an adenocarcinoma.

6.2.4.3 Nasopharyngeal Inverted Papilloma

ICD-O:8121/1

Inverted papillomas (or *Schneiderian papillomas*) arising outside the sinonasal tract are extremely rare. One publication reported 15 pharyngeal inverted papillomas, 11 of which arose in the nasopharynx [183]. The pink or grey firm polyps had a convoluted surface, which cor-

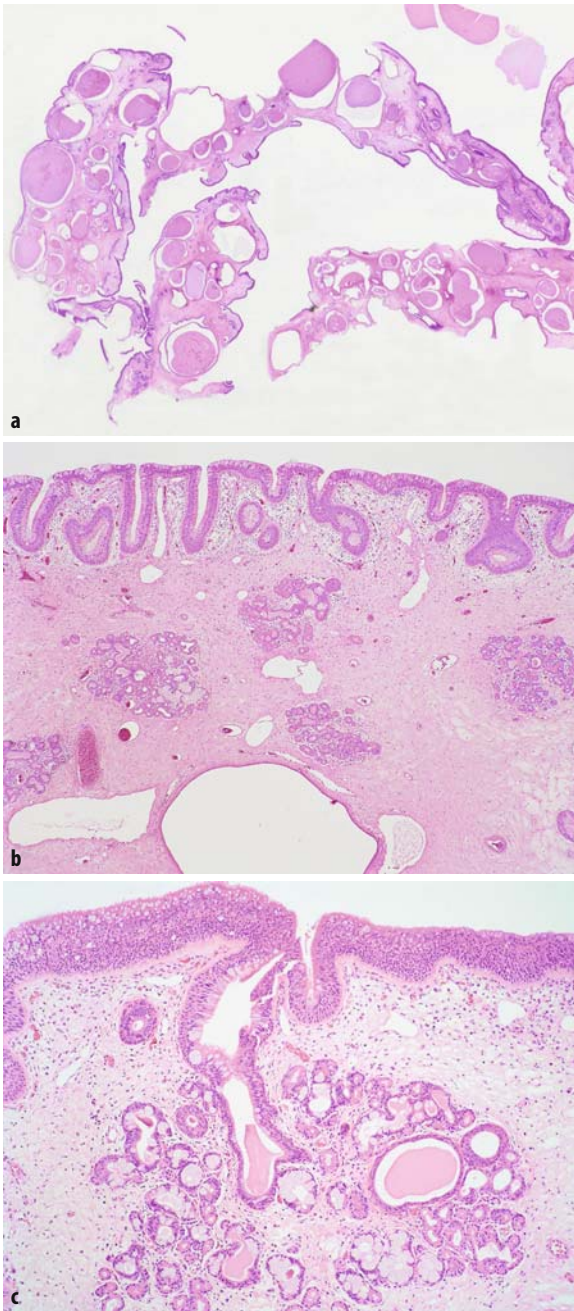


Fig. 6.4. Respiratory epithelial adenomatoid hamartoma. **a** This fragmented surgical specimen of polypoid hamartoma displays numerous fluid and mucin filled cysts. **b** The surface is lined by tall columnar respiratory epithelium and there are widely spaced acinar proliferations embedded in a fibrous stroma. **c** The acinar proliferations are in continuity with invaginations of the surface respiratory epithelium and recapitulate either seromucous glands. The basement membrane is typically thickened

responded histologically to a multilayered, transitional-type epithelium with foci of respiratory and squamous epithelium growing endophytically into the underlying loose and myxoid stroma. Nasopharyngeal inverted

papillomas have an increased potential for recurrence, which is higher in the nasopharynx than in the sinonasal location. This probably reflects the high rate of incomplete initial removal due to the unexpected nature of the lesion and the difficult nasopharyngeal anatomy. As in a sinonasal location, inverted papillomas are at risk of malignant transformation. For a detailed description of inverted papillomas, see Chap. 2.

6.2.4.4 Solitary Fibrous Tumour

ICD-O:8815/0

Solitary fibrous tumours are exceptionally rare in the upper respiratory tract. In the nasopharynx, only 4 cases have been described to date [96, 122, 201].

6.2.4.5 Paraganglioma

ICD-O:8680/1

Paraganglioma (or *chemodectoma*) arise in the head and neck region most commonly in the carotid body, glomus tympanicus and glomus jugulare. They are extremely rare in the nasopharynx with about 20 cases described (for review see [101]), but need to be considered when profuse haemorrhage and a pulsatile mass are encountered in the nasopharynx. These slowly enlarging, painless, firm, encapsulated tumours are characterised by nests (so-called *Zellballen*) of small to medium-sized pale monomorphous cells with prominent, rounded hyperchromatic nuclei and a prominent network of endothelial cell lined vascular channels (see also Chaps. 8 and 9).

6.2.4.6 Meningioma

ICD-O:9530/0

Among the rarest tumours of the nasopharynx are extracranial meningiomas [162]. In a series of 30 extracranial meningiomas, 3 were located in the nasopharynx [188]. There is only a single case report of a primary tonsillar ectopic meningioma [107]. Extracranial meningiomas show the same histological subtypes, differentiation and prognosis as intracranial meningiomas, but the syncytial (meningothelial) subtype predominates. For meningiomas at other sites in the head and neck area, see Chaps. 2, 8 and 10.

6.2.4.7 Glandular Retention Cysts

Glandular retention cysts are rather common in the oro- and nasopharynx and some may become large enough to mimic nasopharyngeal tumours. They arise from di-

lated and occluded excretory ducts of the seromucinous salivary glands of the nasopharynx. The cysts are filled with mucin and lined with a single layer of cuboidal epithelium. Varying amounts of squamous metaplasia and oncocytic metaplasia can be observed, and when extensive, the designation *oncocytic cyst* or *nasopharyngeal oncocytoma* may be most appropriate [3, 12, 136]. Retention cysts may rupture. The ensuing inflammation induced periductal fibrosis and an inflammatory infiltrate. The epithelium is destroyed and replaced by macrophages. These mucin-filled cysts are then called *mucocoeles*.

6.2.5 Nasopharyngeal Carcinoma

Classification of nasopharyngeal carcinomas has undergone several changes in the past editions of the WHO classification. The 1991 edition separates nasopharyngeal carcinoma into two subtypes, the keratinising and the non-keratinising carcinoma [176]. The non-keratinising carcinomas have been further subdivided into *undifferentiated* and *differentiated* forms. This subdivision, however, is nowadays considered optional since their distinction is of no clinical or prognostic significance. Whether basaloid-squamous carcinoma merits separate recognition or merely represents a morphologic variant of non-keratinising carcinoma has not yet been clarified [7, 138, 159, 194].

6.2.5.1 Non-Keratinising Nasopharyngeal Carcinoma

In the past, non-keratinising nasopharyngeal carcinomas have been divided into the more common *undifferentiated* nasopharyngeal carcinoma (ICD-O:8082/3), (synonymous *lymphoepithelial carcinoma*, *lymphoepithelioma of Regaud and Schmincke*, *undifferentiated carcinoma with lymphoid stroma*) and the less common *differentiated* nasopharyngeal carcinoma (ICD-O:8073/3) (or *transitional-type carcinoma*, *intermediate cell carcinoma*). The distinction between undifferentiated and differentiated carcinoma is considered unimportant for therapy and prognosis, as these two subtypes represent a spectrum of the same tumour. Nasopharyngeal carcinoma is by far the most common carcinoma in China and Taiwan, accounting for 18% of all carcinomas there, with an incidence of 10–20/100,000 [83]. Nasopharyngeal carcinomas also occur in endemic forms in Asia, Greenland, Alaska and Africa. In these high-incidence areas, 99% of nasopharyngeal carcinomas are of the non-keratinising subtype. In the western world – a low-incidence area with 0.4–1/100,000 – the non-keratinising nasopharyngeal carcinoma accounts for 75% compared with 25% for keratinising carcinoma [8, 43, 141]. Naso-

pharyngeal carcinomas show a strong male predilection. While most patients with non-keratinising nasopharyngeal carcinoma are older than 50 years in endemic areas, there is a bimodal age distribution with a peak presentation in the 2nd and 6th decades in intermediate- and low-incidence areas [8, 43, 63, 77, 175]. The causative and aetiological role of EBV is well established in invasive and in situ nasopharyngeal carcinomas, irrespective of the ethnic origin of the patient and the histological subtype [31, 158]. However, environmental factors seem to play a role, since the incidence of non-keratinising nasopharyngeal carcinoma decreases among second and third generation Chinese living in non-endemic areas [83]. Nasopharyngeal carcinomas arise in the lateral walls of the nasopharynx in the area of the Rosenmüller fossa and presenting symptoms may be nasal obstruction, epistaxis, post-nasal drip, tinnitus and cranial nerve palsy. Hearing loss and unilateral otitis media are related to auditory tube involvement. In more than 50% of patients, however, metastases to cervical lymph nodes are the presenting sign. Since most nasopharyngeal carcinomas are difficult to visualise on endoscopic examination, “blind” biopsies of the nasopharynx, base of tongue and palatine tonsils are necessary to establish a histological diagnosis of undifferentiated nasopharyngeal carcinoma. In patients presenting with lymph node metastases and clinically occult primary carcinoma, demonstration of EBV in the metastatic carcinoma may be a helpful diagnostic tool to correctly identify the primary nasopharyngeal carcinoma [26, 40, 119, 191]. Nasopharyngeal carcinomas are highly responsive to radiation therapy. The overall 5-year survival has been reported to be between 25 and 50% in the past, but the results of treatment have improved due to refinements in staging and techniques of therapy [4, 115].

Histologically, non-keratinising nasopharyngeal carcinomas lack glandular differentiation. The *undifferentiated* subtype consists of bland uniform undifferentiated cells in large cohesive nests and cords as well as smaller nests and groups of epithelial cells with numerous mitoses. They may be sharply outlined and separated from the surrounding infiltrate or permeated by a dense inflammatory infiltrate consisting of numerous lymphocytes, plasma cells and eosinophilic granulocytes. This pattern often has a distinctly non-carcinomatous and lymphoma-like appearance. The infiltrating lymphocytes are a mixture of plasma cells, B-cells and T-cells, with B-cells usually predominating. Portions of the T-cells are cytotoxic cells. A variant of undifferentiated carcinoma shows extensive acantholysis resulting in a pseudoglandular and pseudovascular pattern. The *differentiated* subtype shows cellular stratification often in a plexiform growth, reminiscent of transitional cell carcinoma of the urinary bladder (Fig. 6.5). The stroma of non-keratinising nasopharyngeal carcinoma can be fibrous, but is rarely desmoplastic. Coagulative necrosis

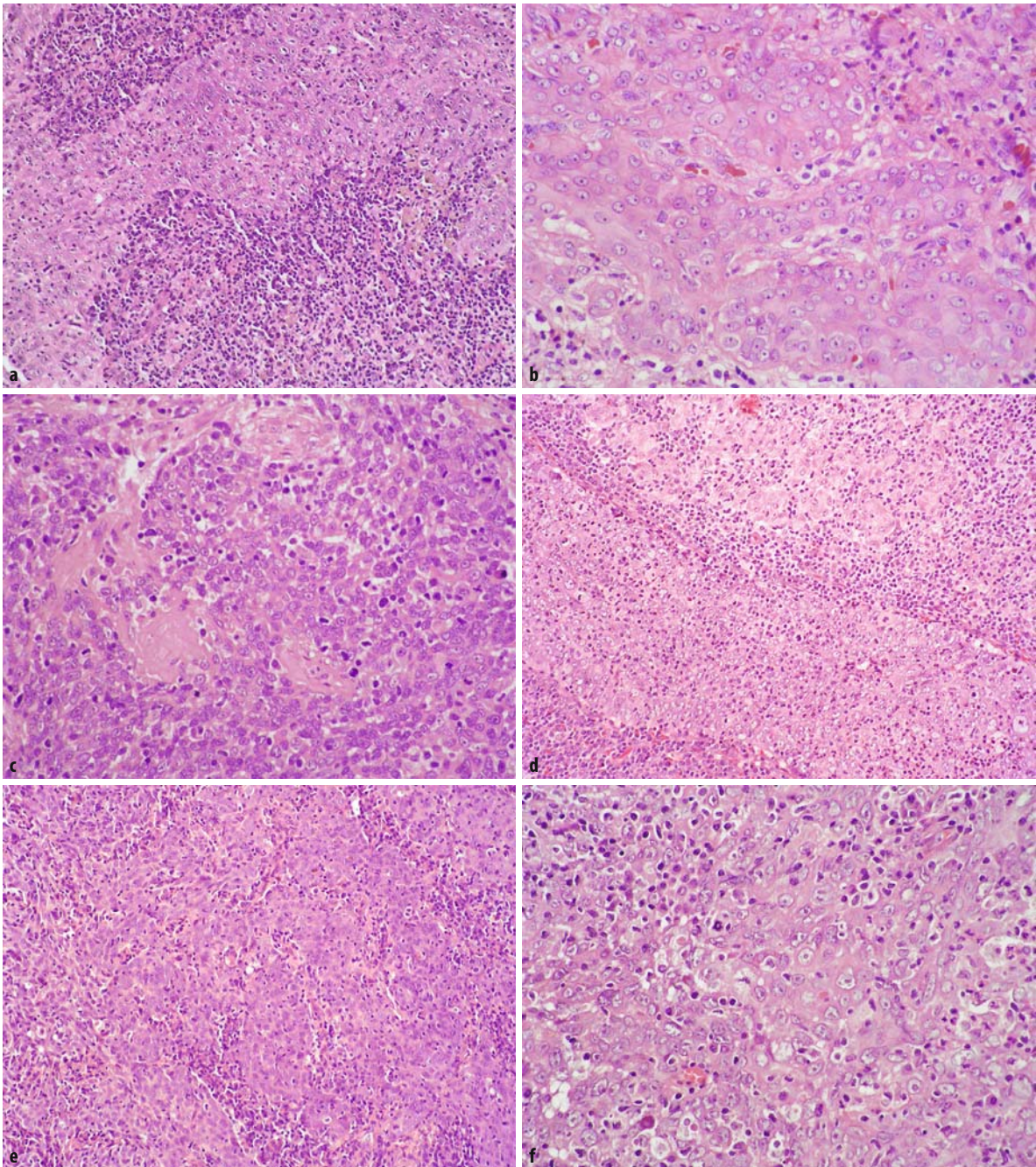


Fig. 6.5. Non-keratinizing nasopharyngeal carcinoma. **a–b** Nasopharyngeal carcinoma grows in solid sheets of large epithelial cells which are clearly demarcated by a mixed inflammatory infiltrate consisting of lymphocytes, plasma cells and histiocytes. **c** globular amyloid deposition is not uncommon. **d–e** Non-keratinizing nasopharyngeal carcinoma can be heavily infiltrated by the lymphocytes. **f** Tumour cells are large, undifferentiated, with abundant pale cytoplasm, inconspicuous cell membranes, and large nuclei with prominent nucleoli

may be present. Small amyloid globules can be found within the tumour cells or scattered among the carcinomatous stroma. Epithelioid granulomas, occasionally with caseous necrosis, have been described in nasopharyngeal carcinoma in up to 18% of cases. Some features are associated with a better prognosis of nasopharyngeal carcinoma: high density of dendritic cells, high number of infiltrating lymphocytes, and low numbers of granzyme-B positive cytotoxic cells [58, 80, 151, 208]. The most reliable and sensitive method of detection of

may be present. Small amyloid globules can be found within the tumour cells or scattered among the carcinomatous stroma. Epithelioid granulomas, occasionally with caseous necrosis, have been described in nasopharyngeal carcinoma in up to 18% of cases. Some features are associated with a better prognosis of nasopharyngeal carcinoma: high density of dendritic cells, high number of infiltrating lymphocytes, and low numbers of granzyme-B positive cytotoxic cells [58, 80, 151, 208]. The most reliable and sensitive method of detection of

may be present. Small amyloid globules can be found within the tumour cells or scattered among the carcinomatous stroma. Epithelioid granulomas, occasionally with caseous necrosis, have been described in nasopharyngeal carcinoma in up to 18% of cases. Some features are associated with a better prognosis of nasopharyngeal carcinoma: high density of dendritic cells, high number of infiltrating lymphocytes, and low numbers of granzyme-B positive cytotoxic cells [58, 80, 151, 208]. The most reliable and sensitive method of detection of

EBV in paraffin sections in routine diagnostic pathology is EBER in situ hybridisation [88, 93, 157, 196]. The main differential diagnosis of nasopharyngeal carcinoma is a non-Hodgkin's lymphoma, particularly the large cell lymphoma. The diagnosis of a nasopharyngeal carcinoma can be confirmed by positive staining with antibodies to cytokeratins, especially high molecular weight keratin.

6.2.5.2 Keratinising Nasopharyngeal Carcinoma

ICD-O:8070/3

Keratinising nasopharyngeal carcinoma (squamous cell carcinoma, SCC) occurs typically after 40 years of age and shows obvious squamous differentiation with varying amounts of keratinisation. The stroma is desmoplastic and infiltrated by variable numbers of lymphocytes, plasma cells, neutrophils and eosinophils. Poorly differentiated SCC may only contain rare horn pearls or focal areas of easily recognisable cornification. Immunohistochemical analysis with antibody to involucrin is helpful in identifying areas of abortive keratinisation [98]. EBV is almost always positive in nasopharyngeal SCC in endemic areas for nasopharyngeal carcinoma, but only a small number of cases in low incidence areas are positive for EBV. SCC shows a greater propensity for localised advanced tumour growth, but a lower rate of lymph node metastases [141, 164]. Radical surgery is not performed since radiotherapy is extremely effective. Survival and prognosis of SCC depends on tumour stage and has been reported to be better than that for non-keratinising nasopharyngeal carcinoma.

6.2.6 Nasopharyngeal Adenocarcinoma

Adenocarcinomas of the nasopharynx are extremely uncommon tumours and can be separated into carcinomas arising from the surface epithelium or from the mucoserous salivary glands. The salivary gland-type carcinomas are more common than those arising from the surface epithelium [114].

6.2.6.1 Salivary Gland-Type Adenocarcinoma of the Nasopharynx

Adenoid cystic carcinoma (ICD-O:8200/3), the most common carcinoma of the salivary type in the oral cavity and hard palate, is rare in the nasopharynx [21, 114, 181]. Adenoid cystic carcinomas of the nasopharynx are more common in Japan than in the western world. It is

an insidiously growing tumour with a predisposition for perineural spread, local recurrence and distant metastasis. Regional lymph node metastases are rare. Histologically, adenoid cystic carcinomas are classified in tubular, cribriform and solid subtypes. The tubular and cribriform subtypes are considered low-grade tumours; the solid sub-type is a high-grade tumour with a rapid, fatal course and a higher incidence of distant metastasis with a poor prognosis [114]. When compared with conventional nasopharyngeal carcinoma, adenoid cystic carcinoma has a higher incidence of cranial nerve involvement, but a lower incidence of cervical lymph node metastases.

Polymorphous low-grade adenocarcinoma of minor salivary glands (ICD-O:8525/3) (or *terminal duct carcinoma, lobular carcinoma, low-grade papillary adenocarcinoma*) is a low-grade neoplasm typically occurring in the oral cavity. It has been documented in the nasopharynx in rare cases [144, 198]. The polymorphous low-grade carcinoma has a wide diversity of histological patterns including solid areas, papillary growth, ductal differentiation, cystic spaces and an infiltrative growth pattern with perineural invasion. The main bulk of the carcinoma is found in the submucosa and the surface epithelium is often intact. In the nasopharynx, surgery or radiotherapy is the treatment of choice. Polymorphous low-grade carcinomas of salivary gland origin have a potentially aggressive biological course with metastases to cervical lymph nodes. For a detailed description of salivary gland tumours see Chap. 5.

6.2.6.2 Papillary Adenocarcinoma of the Nasopharynx

ICD-O:8260/3

Papillary adenocarcinomas of the nasopharynx are extremely uncommon, slow-growing, low-grade carcinomas without known risk factors [76, 114]. In a series of 9 patients, aged 11 to 64 years, the papillary adenocarcinomas of the nasopharynx were confined to the roof and postero-lateral walls of the nasopharynx [198]. Papillary nasopharyngeal adenocarcinomas are unencapsulated, exophytic, cauliflower-like tumours with an occasional gritty consistency due to numerous psammoma bodies. Complex papillations arise from the surface epithelium. The papillae and crowded back-to-back glands are lined with uniform, bland, tall, columnar cells with intermixed mucin-containing, PAS-positive goblet cells. Some areas show overlapping vesicular nuclei with granular cytoplasm resembling thyroid carcinomas. Stromal calcifications and psammoma bodies can be found. Vascular, lymphatic or neural invasion is uncommon. Low-grade papillary adenocarcinomas of the nasopharynx should be distinguished from the polymorphous low-

grade carcinoma of salivary gland origin because they do not metastasise.

6.2.7 Malignant Non-Epithelial Tumours of the Nasopharynx

6.2.7.1 Chordoma

ICD-O:9370/3

Chordomas are tumours arising from remnants of the notochord in the axial skeleton near its cranial and caudal ends. The cranially located chordomas comprise about one-third of all chordomas, arise earlier than the sacral chordomas, around the 3rd to the 5th decade and in children. Most chordomas in nasopharyngeal location are extensions of cranial chordomas, but they rarely arise *de novo* in the nasopharynx and paranasal sinuses [19, 34, 54]. For a more detailed description of chordoma, see Chap. 4.

6.2.7.2 Sarcoma

The most common sarcoma in the head and neck area is the rhabdomyosarcoma, specifically the embryonal rhabdomyosarcoma (ICD-O:8910/3) in children less than 5 years of age [49]. Primary nasopharyngeal rhabdomyosarcomas are rare [20, 39, 50] as are primary nasopharyngeal chondrosarcomas (ICD-O:9220/3) [54, 56]. Case reports of primary nasopharyngeal sarcomas include an osteosarcoma in an 11-year-old girl after multi-agent chemotherapy and radiation treatment of a retinoblastoma, a liposarcoma and a granulocytic sarcoma in a 37-year-old Chinese man [5, 42, 139]. The follicular dendritic cell sarcoma, a tumour of antigen-presenting cells of B-follicles of lymphoid tissues, is commonly found extranodally in the head and neck area, but rarely in the nasopharynx [10, 22, 23]. It is characterised by positivity for CD21, CD35 and CD23, as well as indolent clinical behaviour and a low risk of recurrence and metastasis [87].

6.3 Waldeyer's Ring

6.3.1 Anatomy and Histology of Waldeyer's Ring

The term *Waldeyer's ring* refers to the ring of lymphoid tissues occurring in the nasopharynx and oropharynx. The oropharynx is separated from the nasopharynx by the *oropharyngeal isthmus*, which is formed by the merging muscular pillars of the *palatoglossal* and the

palatopharyngeal muscles. In the lateral walls, at the widest points of the pharynx, lies the triangular *tonsillar fossa*, which contains the *palatine tonsil*. The tonsils of Waldeyer's ring belong to the gut-associated lympho-epithelial organs, which show a close morphological and functional correlation between lymphatic tissue of mesenchymal origin and the endodermal epithelium of the second pharyngeal pouch. The Waldeyer's ring tonsils are composed of the *paired palatine tonsils* in the tonsillar fossa, the unpaired (*naso*)*pharyngeal tonsil* in the roof of the nasopharynx, the bilateral *tubal tonsils* in the lateral walls of the nasopharynx at the entrance to the auditory tube and the *lingual tonsil* in the retrolingual region. Lymphoid aggregations close to the epiglottis are also counted as part of Waldeyer's ring.

The palatine tonsils are the largest of the tonsils and lie in the tonsillar fossa along the anterolateral border of the oropharynx between the palatoglossal and palatopharyngeal muscle arches. The lateral surface of the palatine tonsil has a fibrous capsule, but skeletal muscle fibres and islands of mostly elastic cartilage are normal findings there. The medial surface has 10–30 epithelium-lined, extensively branching and anastomosing tonsillar crypts that extend deeply into the lymphoid tissue. The surface of the palatine tonsils is lined by stratified squamous epithelium, the crypts are covered by non-keratinising stratified (“transitional-type”) epithelium with a discontinuous basement membrane and numerous intraepithelial lymphoid cells. This so-called *lymphoepithelium* represents the specialised epithelium of the tonsils and contains M-cells (resembling the intestinal membranous [M] cells of the Peyer's patches), T- and B-cells, and patchily distributed macrophages and dendritic cells [140, 152]. The surface epithelium is evenly infiltrated by T-cells and B-cells; up to 30% of the intraepithelial T-cells are $\gamma\delta$ T-cells, which are involved in antigen recognition independent of MHC restriction and prior antigen processing [66, 149]. A clustering of CD4+ T-cells with B-cells is typical within the lymphoepithelium of the crypts and in the submucosa [66]. The submucosal lymphoid tissue contains numerous primary and secondary lymph follicles with germinal centres, a mantle zone and a network of follicular dendritic cells. T-cells, interdigitating dendritic cells, plasma cells, macrophages and high-endothelial venules are found in the extrafollicular regions [140]. The palatine tonsils have no afferent lymph vessels. The rich efferent lymphatic drainage is via the retropharyngeal lymph nodes to the upper deep cervical lymph nodes.

The small unencapsulated (*naso*)*pharyngeal tonsil* with about 12–15 shallow crypts is lined with a columnar ciliated respiratory surface epithelium with numerous goblet cells, which may also be seen in the lymphoepithelial lining of the short and plump crypts [200]. The lymphoid tissue contains numerous lymph follicles with germinal centres. Minor salivary glands in the periph-

ery and within the submucosa of the pharyngeal tonsil are a normal finding. The *tubal tonsils* are poorly defined condensations of lymphoid tissue located around the auditory tube in the nasopharynx and around the *fossa of Rosenmüller*. The term *lingual tonsil* refers to the abundant non-encapsulated lymphoid tissue in the adult posterior tongue. The crypts do not appear until birth, are shallow and much less branched than in the palatine tonsil. The surface is covered by non-keratinising squamous epithelium. Adipose tissue and skeletal muscle fibres at the base of the lingual tonsil, and mucous salivary glands and lymph follicles within the lingual tonsil are integral parts of the tongue. Efferent lymphatic vessels of the posterior tongue drain into the deep cervical lymph nodes, after they pass through the pharyngeal wall in front of or behind the external carotid artery [41].

6.3.2 Congenital Anomalies of Waldeyer's Ring

Congenital anomalies include the extremely rare absence of palatine tonsils and accessory tonsils within the oral cavity [68, 155]. Slightly more common is the “hairy polyp”, a choristoma, which arises from remnants of the ectodermal and mesodermal germ layers in the palatine tonsil and nasopharynx (see also Sect. 6.2.3.2). The unilateral pedunculated hairy polyps of up to 5 cm arise mostly on the superior pole of the palatine tonsil and present with acute respiratory distress [129]. A rare bilateral presentation has been described [52]. These polyps show a mesenchymal fibrovascular core, often with adipose tissue and skeletal muscle fibres and are covered in regular skin with hair appendages. In tonsillar hairy polyps, submucosal plates of elastic cartilage of uniform thickness resembling the external ear auricular tags and auricular cartilage have been reported [78]. Hairy polyps of the tonsils have been postulated to arise from the second pharyngeal pouch [17], but due to the presence of the cartilage plates they have also been interpreted as accessory auricles with a postulated origin from the first pharyngeal arch [78].

6.3.3 Tonsillitis

The lymphoid tissues of Waldeyer's ring play a key role in initiating immune responses against inhaled and ingested pathogens. The tonsils are responsible for the recognition and processing of antigens presented to the pharynx. The size of the tonsils is directly proportional to the amount of lymphoid tissue, which increases during antigen challenge. The reactive lymphoid hyperplasia of the palatine tonsils is often simply referred to as “*tonsillitis*” and in the case of the pharyngeal tonsil as

“(hyperplastic) adenoids”. Tonsillar hypertrophy is associated with normal childhood development, mostly due to viral challenge or can be secondary to specific bacterial or viral infections. Childhood hypertrophy of the pharyngeal tonsil begins at approximately 2 years of age or during infancy and usually regresses by 8 years of age. Palatine tonsils hypertrophy at the end of the first decade, somewhat later than the pharyngeal tonsil. They regress by puberty and are atrophied in adults. The lingual tonsil enlarges at the time of puberty and regresses very little during adult life [41]. Tonsillar hypertrophy is usually symmetrical and diffuse, but can be papillary and unilateral.

The normal flora of the naso- and oropharynx includes anaerobic bacteria such as gram-positive *Actinomyces* and *Propionibacterium*, and gram-negative bacteria such as *Bacteroides*, *Fusobacterium* and *Vibrio* [202]. *Actinomyces israelii* is a common nosocomial saprophyte in the oro-/nasopharyngeal cavity. The true incidence of tonsillar manifestations of actinomyces is unknown, but has been reported to be as high as 40% [57, 120]. Occasionally, actinomyces form small sulphur granules that can be seen as small yellow dots on the tonsillar surface. Larger aggregates of actinomyces may produce a tumour-like mass [172]. The tangled masses of gram-positive branching mycelial-like bacteria lie within the crypts or are attached to the surface epithelium of normal tonsils. Tonsillectomies for hypertrophied tonsils or adenoids are one of the most common surgical procedures, but the term “tonsillitis” is still poorly defined. Surgical resection specimens may demonstrate only hyperplastic lymphoid tissue and lymph follicles with enlarged germinal centres or no pathology at all [91].

6.3.3.1 Bacterial Tonsillitis

Bacterial suppurative tonsillitis is among the most frequent paediatric infections. Group A beta-haemolytic streptococci are the most frequent cause. Other common isolates in bacterial tonsillitis are *Hemophilus influenzae*, *Streptococcus pyogenes*, *Streptococcus milleri* and *Staphylococcus aureus* [97, 202, 205]. Children with acute streptococcal tonsillitis are significantly older than children with viral tonsillitis. The treatment of choice is penicillin administration for 10 days. Prevention of acute rheumatic fever is the principal goal of treatment. Surgical specimens of acute tonsillitis are rarely encountered. The surface epithelium may be ulcerated, and the surface and crypt epithelium is infiltrated by neutrophilic granulocytes producing a cryptitis with crypt abscesses. Acute bacterial infections may advance to intraparenchymal and peritonsillar abscesses (quinsy) with a lateral extension into the parapharyngeal space, base of skull and the sheath of the carotid artery [33, 64]. Rare other bacteria

causing acute necrotising tonsillitis include *Clostridium perfringens* and *Bartonella henselae* with an unusual presentation of cat scratch disease [61, 121].

6.3.3.2 Viral Tonsillitis

The most common causes of upper respiratory tract infections and pharyngo-tonsillitis in the general population, including infants and young children, are viruses such as *influenza virus*, *Coxsackie's virus* (group A), *adenovirus*, and the ubiquitous herpes virus *Epstein-Barr virus* [205]. EBV infects epithelial cells and B-lymphocytes of Waldeyer's ring, which represent the reservoir for life-long viral persistence [104, 186]. Primary infections with EBV occur early in infancy and childhood in developing countries and are generally asymptomatic. In contrast, in developed countries, primary infection occurs in adolescents and young adults. EBV infections may cause the mostly self-limiting acute disease *infectious mononucleosis*, affecting adolescents and young adults in the western world. In Japan, however, an endemic area for EBV, acute cases of infectious mononucleosis are commonly diagnosed in children less than 4 years of age [100]. The symptoms include enlarged swollen palatine tonsils, occasionally with peritonsillar abscesses, sore throat, fever, malaise, cervical lymphadenopathy, lymphocytosis and occasional hepato-splenomegaly [133]. The diagnosis in typical cases is made clinically and/or serologically [69]. Histologically, the changes of a primary EBV infection can be dramatic [30]. The surface epithelium of the palatine tonsils is often necrotic. Follicular hyperplasia with fused or bizarre-shaped follicles and numerous tangible body macrophages and distended interfollicular areas with atypical immunoblasts, plasma cells, plasmacytoid lymphocytes and histiocytes, occasionally grouped around necrotic foci, are typical. Mitoses are numerous. Rare Reed-Sternberg-like cells with single or multiple nuclei without nucleoli may be present beneath the crypt epithelium. The often atypical immunoblasts may simulate lymphoma, but in infectious mononucleosis, they often merge with cells in the reactive follicles and paracortex (Fig. 6.6). The proliferating lymphoid cells are predominantly activated T lymphocytes with CD8-positive T-cells dominating over CD4-positive T-cells. The immunoblasts can be of B-cell or T-cell type, and are occasionally CD30-positive, but CD15-negative [1]. Infected cells are reactive for EBV nuclear antigen (EBNA) [2] and latent membrane protein (LMP) [182, 186].

The most important differential diagnosis of infectious mononucleosis, especially in older patients, is the extranodal manifestation of Hodgkin's lymphoma and non-Hodgkin's lymphoma (large cell and immunoblastic types). Immunoglobulin rearrangements and T-cell

receptor gene rearrangements are lacking in infectious mononucleosis. The differential diagnosis of ulcerating tonsillitis includes infections with *herpes virus hominis* (usually Herpes simplex virus type 1). Herpes simplex virus can produce a vesiculo-bullous pharyngitis and may involve the palatine tonsils [106, 195]. Rupture of the vesicles results in sharply circumscribed shallow ulcers infiltrated by neutrophilic granulocytes. Infected epithelial cells show the characteristic multinucleated giant cells with nuclear viral inclusion. The lymphoid infiltrate and hyperplasia of a Herpes simplex virus infection may mimic a NK/T-cell lymphoma [184]. Group A *Coxsackie's virus* also produces punched-out vesicles and is often associated with a concomitant Herpes simplex virus infection. Rare systemic autoimmune diseases, like the anti-phospholipid antibody syndrome, may cause tonsillar ulcers [79].

Chronic and recurrent tonsillitis are typically associated with *respiratory syncytial virus*, reactivation of latent *Epstein-Barr virus*, *H. influenza* and *Staphylococcus aureus* [44, 117, 204]. After episodes of recurrent tonsillitis, the palatine tonsils show extensive fibrosis at the site of the former capsule and scarring with entrapped, "pulled up" skeletal muscle fibres at the base of the tonsil and atrophic lymphoid tissue with small lymphoid follicles with atrophic germinal centres. Granulomas may be present. The crypts are distended and filled with keratinous debris, inflammatory cells and occasional aggregates of actinomyces. Retention cysts can be formed within the deep crypts of chronically irritated palatine tonsils after occlusion of the orifice. The crypt epithelium becomes keratinised. Calcification of the desquamated debris following deposition of inorganic salts may result in tonsillar calculi, so-called *tonsilloliths*. The presence of actinomyces is not associated causally with recurrent tonsillitis [57, 120].

Human immunodeficiency virus 1 (HIV-1) infects lymphocytes of lymph nodes and extranodal lymphoid tissue. Hypertrophy of the nasopharyngeal and palatine tonsils is among the earliest clinical manifestations of HIV-1 infections. Enlargement of the palatine tonsils is usually bilateral and large ulcers may lead to complete destruction of the tonsils [28]. The histological changes in HIV-induced tonsillar hypertrophy vary with stage and progression of the infection. The earliest changes include florid reactive follicular hyperplasia with irregularly shaped germinal centres with an attenuated or absent mantle cell zone. Another early change suggesting HIV infection is "follicle lysis", with permeation and disruption of germinal centres by "infiltrating" small lymphocytes creating a "moth eaten" appearance. Follicle lysis/follicular involution involves loss of tangible body macrophages as well as the mantle zone of lymph follicles. Interfollicular haemorrhage is another feature of follicular involution. Multinucleated giant cells are a typical and specific feature of HIV tonsillitis. The multinucleated gi-

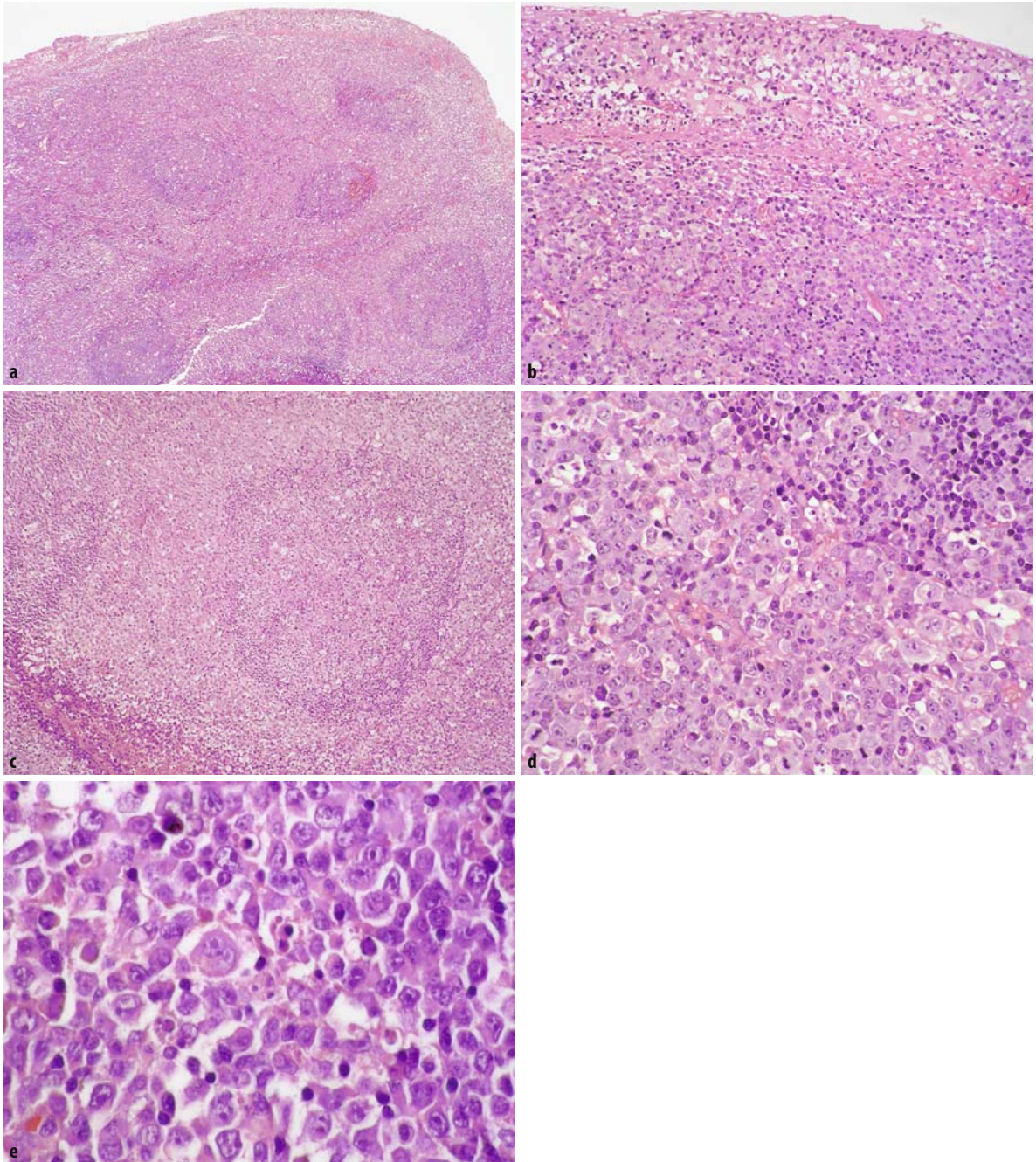


Fig. 6.6. EBV tonsillitis. **a** The hypertrophic palatine tonsil contains reactive lymph follicles which are distended by a dense interfollicular infiltrate. **b** The surface epithelium is also heavily infiltrated by numerous atypical lymphocytes, plasma cells, histio-

cytes. **c–d** The atypical large immunoblasts with prominent nucleoli show numerous mitoses and merge with the germinal centres. **e** The atypical immunoblasts may be binuclear atypical lymphoblasts

ant cells are arranged preferentially in clusters beneath the squamous surface and crypt epithelium, and are only occasionally seen in intrafollicular areas. They have a foamy cytoplasm and the nuclei are arranged at the periphery of the cells. The giant cells react with antibodies

to S-100 and CD68. Other features of chronic HIV infection are monocytoid B-cell hyperplasia, paracortical and interfollicular expansion with immunoblasts and plasma cells, often with Russell bodies, and prominent interfollicular clusters of high endothelial venules. The histolog-

ical features in patients with advanced disease are effacement of nodal architecture, loss of the normal lymphoid cell population with replacement by benign plasma cells and increased vascularity [53, 174, 197].

Acute non-bacterial tonsillitis and hypertrophy can be the first sign of a post-transplant lymphoproliferative disorder [163]. In a study of 42 paediatric transplant patients, 28% had involvement of Waldeyer's ring [147]. In immunosuppressed children in particular with rapid progressive enlargement of the tonsils lymphoma should be suspected [180].

6.3.4 Benign Tumours of Waldeyer's Ring

6.3.4.1 Squamous Papilloma

ICD-O:8121/0

Squamous papillomas represent the majority of benign tonsillar and oropharyngeal tumours [89]. They arise on the soft palate and uvula, but also on the posterior wall of the oropharynx. They have an exophytic appearance. The fibrovascular stalk is covered in a regular, stratified, non-keratinising or keratinising squamous mucosa, with occasional parakeratosis. The vast majority show no viral cell changes. Some papillomas, however, show HPV-related cell changes with the typical koilocytes with small pyknotic nuclei and a perinuclear halo, the so-called tonsillar condylomata [190]. Subtyping for HPV demonstrates typically low-risk HPV 6 and 11. For a detailed description of squamous papilloma in the oropharynx see Chap. 1.

6.3.4.2 Lymphangiomatous Tonsillar Polyp

Lymphangiomatous tonsillar polyps are benign tumours of the palatine tonsil, accounting for about 2% of all tonsillar neoplasms. They have been reported by a number of different names such as *angiomas*, *angiofibromas*, *fibrolipoma*, *polypoid tumour containing fibro-adipose tissue* and *hamartomatous tonsillar polyp* and *lymphangiectatic fibrous polyp* [105]. They are pedunculated, mostly unilateral proliferations in the upper pole of the palatine tonsils in adults and children (age range of reported cases 3–63 years, with a median age of 26 years). Clinical symptoms are dysphagia, sore throat and the sensation of “a mass in the throat”. Lymphangiomatous tonsillar polyps measure between 0.5 and 4 cm. They are covered by respiratory epithelium or glycogenated or keratinised squamous epithelium with foci of hyper- and parakeratosis. Clusters of lymphocytes are found within the

squamous epithelium (lymphocytic epitheliotropism) or in the submucosa beneath the basement membrane (Fig. 6.7). The stalk consists of dense fibrous tissue, adipose tissues or myxoid and oedematous stroma, which contains numerous small to medium-sized, endothelial-lined, lymphatic/vascular channels filled with proteinaceous fluid and lymphocytes [82]. Valves can be appreciated. Some endothelial cells stain with antibodies to factor VIII, CD31 and CD34; others are non reactive. The pathogenesis of the lymphangiomatous polyps is uncertain. They may be a hamartomatous proliferation, but they may also be the result of a chronic inflammatory hyperplasia. Especially in children, lymphangiomatous polyps and papillary lymphoid polyps may be a manifestation of a chronic tonsillitis.

6.3.5 Carcinomas of Waldeyer's Ring

ICD-O:8070/3

Carcinomas of Waldeyer's ring are typically squamous cell carcinomas (SCC) arising in the palatine tonsil and the base of the tongue. They are more common in men than in women and present during the 5th and 7th decades. Smoking, alcohol, poor hygiene, but also HPV infections, are risk factors [32, 51, 160]. Some SCC may be fungating and exophytic tumours, others present as deeply ulcerated infiltrative lesions. The majority of SCC of the palatine tonsil and base of the tongue typically grow undetected for some time as they arise from the crypt epithelium. At the time of clinical detection, extensive infiltration of the surrounding tissues and regional cervical lymph node metastases are typical. The metastases to cervical lymph nodes are often the presenting symptom of tonsillar carcinomas (Fig. 6.8). Histologically, primary carcinomas of the palatine tonsil and base of the tongue can be divided into keratinising and non-keratinising subtypes. The solid non-keratinising carcinomas predominate. Tonsillar carcinomas may show a “transitional type” differentiation resembling lymphoepithelial carcinoma and EBV positivity [111, 132]. A basaloid-squamous carcinoma of Waldeyer's ring has also been described [7, 159]. The lymph node metastases can be quite large and are often cystic with multilocular complex lumina and papillary projections [165, 166, 189]. The majority of cystic metastases are lined with a stratified epithelium with cytological atypia and numerous mitoses. Foci of keratinisation can be appreciated. The cysts mostly contain necrotic tumour cells and debris. A minority of the cystic lymph node metastases is filled with clear fluid. Fluid-filled cystic metastases are more common in carcinomas of the base of the tongue than those arising from the palatine tonsils. It has been postulated that

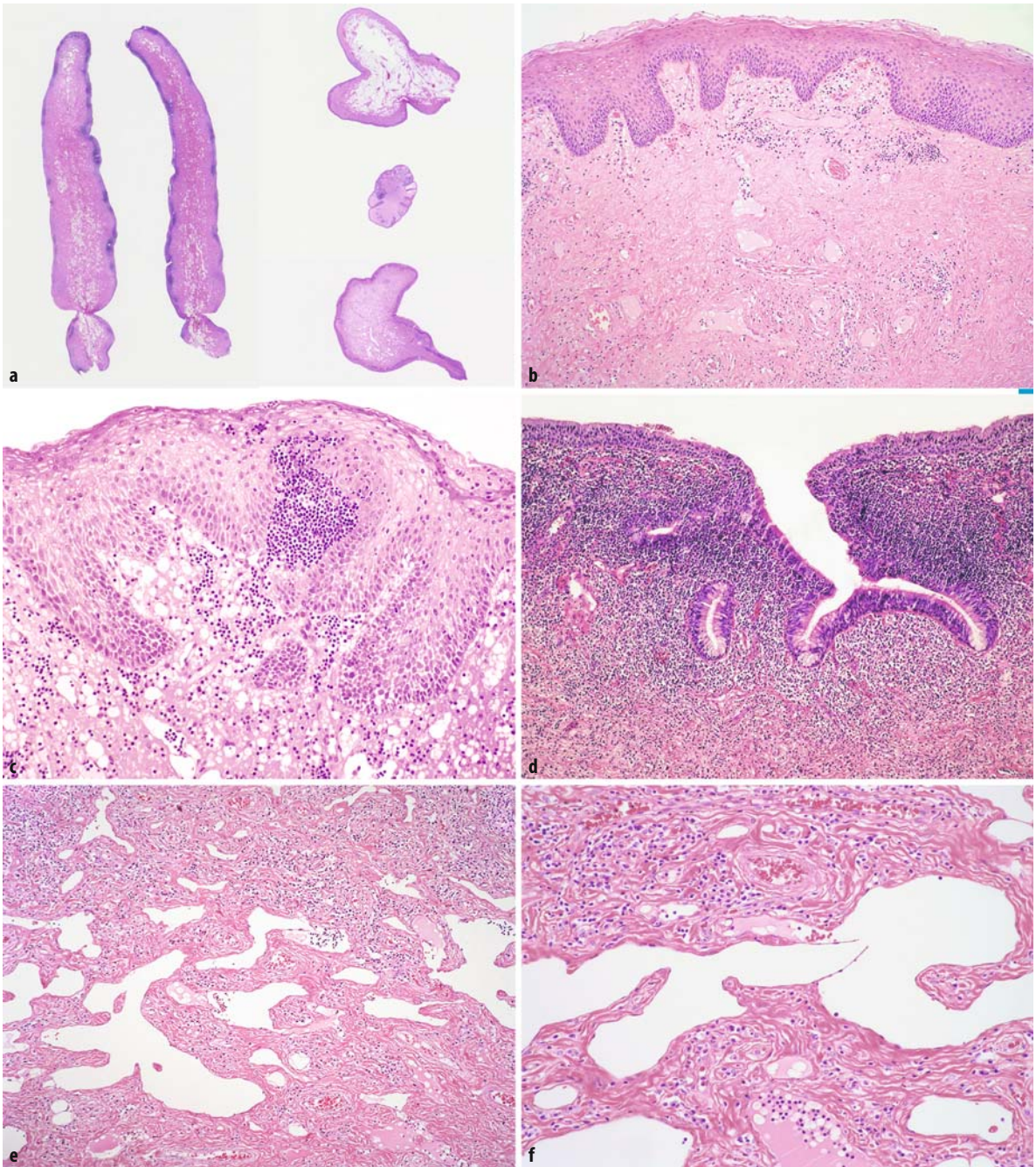


Fig. 6.7. Lymphangiomatous tonsillar polyp. **a** Lymphangiomatous polyps vary in size between several millimetres to several centimetres. The stalk may be composed of fibro-vascular stroma or adipose tissue. **b** The stroma may be fibrotic and contains numerous thin-walled vascular channels filled with proteinaceous

fluid and lymphocytes. **c-d** The surface is covered by either squamous epithelium with numerous intraepithelial lymphocytes or by respiratory epithelium with a dense lymphocytic infiltrate. **e-f** Markedly dilated lymphatic vessels accompanied by lymphocytic infiltrate

carcinomas that produce cystic metastases originate from the excretory ductal system of the submucosal minor salivary glands within the base of the tongue and the palatine tonsil [165].

A search for the primary carcinoma within the pharynx in patients with clinically occult tumours should include multiple blind biopsies of the base of the tongue and oro- and nasopharynx and/or ton-

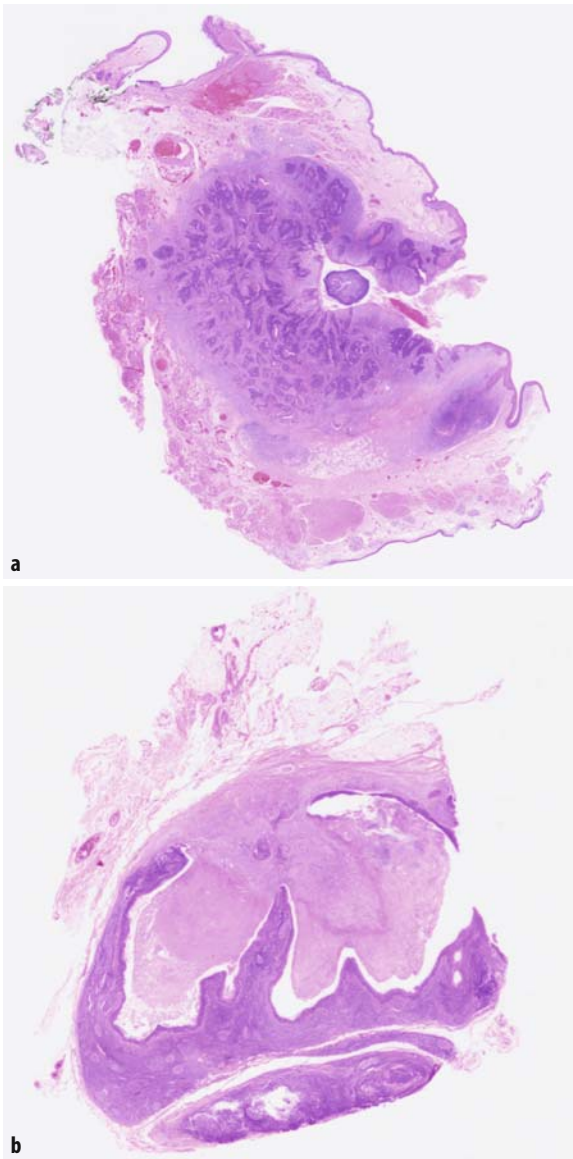


Fig. 6.8. Tonsillar carcinoma. **a** Tonsillar squamous cell carcinomas frequently arise from the crypt epithelium. The carcinoma infiltrates deeply into the surrounding structures including skeletal muscles. **b** Cystic lymph node metastasis showing complex papillations which are lined by squamous epithelium; the cyst content is necrotic debris

sillectomies. This practice has provided overwhelming evidence that isolated carcinomas in neck lymph nodes are metastases and not so-called primary “branchiogenic carcinomas” within a cervical lymph node. The evolution of in situ or invasive SCC from non-neoplastic squamous epithelium through dysplasia is viewed as the most important criterion for the histopathological diagnosis of a primary branchiogenic carcinoma. Primary cystic carcinoma arising in a

lymph node or carcinoma arising in a branchiogenic cyst is probably a hypothetical entity. Reports of a supposed branchiogenic carcinoma included an extremely well-differentiated SCC arising in the background of longstanding chronic inflammation and scarring, one carcinoma arising from pre-auricular ectodermal remnants of the first pharyngeal/branchial cleft and another report of a well-differentiated mucoepidermoid branchiogenic carcinoma [16, 154, 178]. Treatment of SCC of Waldeyer's ring is surgical resection with a neck dissection.

6.3.6 Malignant Lymphomas of Waldeyer's ring

This section gives a brief overview of lymphomas of Waldeyer's ring. For a more detailed description, including genetic characteristics of these lymphomas see the WHO classification and the revised European-American classification of lymphoid neoplasms [74, 95]. Extranodal lymphomas of Waldeyer's ring constitute about 5–10% of all lymphomas in the USA and Europe, about 15% in Hong Kong and about 10–20% in Japan. Of all lymphomas involving Waldeyer's ring, 80% are primary to this site and the tonsillar fossa is the most common location, followed by the nasopharynx and the base of the tongue. Up to 20% of patients with tonsillar lymphoma have an associated gastrointestinal involvement. Clinical presentation is that of a localised neoplasm, sore throat, dysphagias, and in cases of nasopharyngeal involvement cranial nerve, auditory and nasal symptoms. Between 85 and 90% of all non-Hodgkin's lymphomas in Waldeyer's ring are of the B-cell phenotype, the remainder are of the T-cell type, but regional differences have been reported [146, 150]. The vast majority of Waldeyer's ring lymphomas are high-grade lymphomas, with only less than 15% being of low grade [113]. The majority of AIDS-related extranodal head and neck lymphomas are aggressive B-cell lymphomas of the Burkitt type or immunoblastic diffuse large B-cell lymphomas [207].

6.3.6.1 Mantle Cell Lymphoma

ICD-O:9673/3

Mantle cell lymphoma (or *centrocytic (mantle cell) lymphoma* in the Kiel classification; *diffuse, small cleaved cell type* in the Working Formulation) constitutes about 5% of all non-Hodgkin's B-cell lymphomas. Common extranodal sites are the spleen, bone marrow, gastrointestinal tract and Waldeyer's ring, particularly the palatine tonsil.

6.3.6.2 Extranodal Marginal Zone B-Cell Lymphoma of Mucosa-Associated Lymphoid Tissue

ICD-O:9699/3

Mucosa-associated lymphoid tissue (MALT lymphomas or *immunocytoma* in the REAL classification; *small lymphocytic, lymphoplasmacytoid, diffuse small cleaved cell lymphoma* in the Working Formulation) are low-grade extranodal lymphomas that comprise about 8% of all B-cell lymphomas, typically in gastrointestinal locations. Up to 14% occur in the head and neck area, but MALT lymphomas arising in Waldeyer's ring are exceptionally rare [112, 145]. In epithelial tissues, the MALT lymphoma cells infiltrate the epithelium, forming *lymphoepithelial lesions*. In Waldeyer's ring, however, caution is advised not to over-interpret the normally occurring intraepithelial lymphocytes within the tonsillar and nasopharyngeal mucosa as lymphoma [94]. In general MALT lymphomas run an indolent course with a tendency to remain localised. They are sensitive to radiation therapy. Patients have prolonged disease-free intervals after treatment, but recurrences may involve other extranodal sites.

6.3.6.3 Extranodal NK/T-Cell Lymphoma, Nasal Type

ICD-O:9719/3

The extranodal NK/T-cell lymphoma, nasal type (or *angiocentric T-cell lymphoma* in the REAL classification; other historical names: *lethal midline granuloma, malignant midline reticulosis, angiocentric immunoproliferative lesion*) shows a predilection for the nasal cavity, nasopharynx and palate, but also occurs in skin, soft tissues, gastrointestinal tract and testis. The denominator "nasal type" indicates that the nasal cavity is the most common and prototypic site of involvement (Chap. 2). Some cases can be accompanied by secondary lymph node involvement. Rapid systemic dissemination is common, but bone marrow involvement is very rare. NK/T-cell lymphoma is more common in Asia, Mexico and South America than in Europe and North America, and shows a strong association with Epstein-Barr virus [24, 65, 99, 135, 142, 148]. The prognosis of nasal NK/T-cell lymphoma is variable despite aggressive therapy. Some patients respond well and others die with disseminated disease. The prognostic influence of the cytological differentiation is unclear.

6.3.6.4 Hodgkin's Lymphoma

ICD-O:9650/3

Although exceptionally rare in extranodal sites, primary Hodgkin's lymphoma does occur in Waldeyer's ring and nasopharynx. In a review of 659 upper respiratory tract lymphomas, 6 cases of Hodgkin's lymphoma in Waldeyer's ring were identified [35, 103]. The WHO divides Hodgkin's lymphomas into the *nodular lymphocyte predominant Hodgkin's lymphoma* and the *classical Hodgkin's lymphoma* (subdivided into lymphocyte-rich, nodular sclerosis, mixed cellularity and lymphocyte-depleted Hodgkin's lymphoma) [95]. Waldeyer's ring Hodgkin's lymphomas belong predominantly to the classical subtypes: seven primary cases of nodular lymphocyte-rich Hodgkin lymphoma were reported in two studies with a total of 27 patients [25, 179]. In another series with 16 patients with Waldeyer's ring Hodgkin's lymphoma, 50% were classified as mixed cellularity, 25% as nodular sclerosis, one case was a nodular lymphocyte predominant subtype and three were unclassified [103]. Epstein-Barr virus has been postulated to play a pathogenetic role in Hodgkin's lymphoma since it has been demonstrated in the majority of Hodgkin's lymphomas of Waldeyer's ring at a higher incidence than in nodal Hodgkin's lymphomas [81, 103]. In addition, patients often had a history of infectious mononucleosis. Therapy is local irradiation with or without chemotherapy.

6.3.6.5 Extramedullary Plasmacytoma

ICD-O:9734/3

The upper aerodigestive tract is the most common site for extra-osseous plasmacytomas, with 80% arising in the head and neck area. In a series of 299 cases, 22% arose in the nasopharynx and 7% in the tonsil [55, 102, 124]. Plasmacytomas of Waldeyer's ring proceed less often to multiple myeloma than those of other locations.

6.3.7 Systemic Disease Affecting Waldeyer's Ring

Tangier's disease (familial hypo-alpha-lipoproteinemia) is an autosomal-recessive metabolic disease with a deficiency of high-density lipoproteins and extremely low levels of plasma cholesterol [85]. The deranged fat metabolism results in storage of cholesterol esters in the reticuloendothelial system and macrophages of the pharyngeal and gastrointestinal tract mucosa, but also in smooth muscle cells, pericytes and Schwann cells of pe-

ripheral nerves. Clinically, most patients are asymptomatic, but children with Tangier's disease have enlarged, hyperplastic palatine and pharyngeal tonsils with yellow-orange or yellow-grey discoloration. Histologically, large groups and accumulations of macrophages with foamy cytoplasm can be identified in the palatine and pharyngeal tonsils [6, 48].

Amyloidosis is usually a systemic disease of multifactorial origin that may involve the head and neck area. Particularly the upper respiratory tract is commonly affected by amyloidosis with a symmetrical enlargement of the tongue. Small amounts of amyloid deposition in Waldeyer's ring have been described in plasmacytomas, nasopharyngeal carcinomas or tonsillitis. Isolated tumour-like involvement of the nasopharynx with and without immunoglobulin light chain restriction, of the entire Waldeyer's ring or the palatine tonsils without systemic disease is exceptionally rare [11, 45, 116, 156].

Involvement of the naso- and oropharynx by systemic *sarcoidosis* is well documented [127]. Unsuspected isolated sarcoidosis of the palatine and pharyngeal tonsils in the absence of systemic disease is very rare [46, 126]. Histologically, the sarcoidosis granulomas are composed of densely packed epithelioid histiocytes and macrophages without central necrosis. Differential diagnoses include recurrent tonsillitis, which may feature giant cells and even foreign body giant cell granulomas. Another differential diagnosis consists of infections with *mycobacterium tuberculosis* and formation of caseating tuberculoid granulomas. The majority of patients with pulmonary tuberculosis have nasopharyngeal involvement, but isolated nasopharyngeal tuberculosis is rare [2, 161, 193].

Metastases from primary tumours outside the head and neck area to the naso- and oropharynx are exceptionally rare, because the nasopharyngeal and palatine tonsils have no afferent lymph vessels. Consequently, most metastatic tumours in tonsils represent haematogenous deposits. Bilateral metastases to the palatine tonsils have been described for pancreatic carcinoma [131]. Other metastatic tumours to the palatine tonsil include carcinomas of the breast, lung, stomach, colon, prostate, skin and kidneys [173]. Renal cell carcinomas are known to metastasise to the nasopharynx [169].

References

1. Abbondanzo S, Sato N, Straus SE, Jaffe ES (1990) Acute infectious mononucleosis. *Am J Clin Pathol* 93:698–702
2. Aktan B, Selimoglu E, Ucuncu H, Sutbeyaz Y (2002) Primary nasopharyngeal tuberculosis in a patient with the complaint of snoring. *J Laryngol Otol* 116:301–303
3. Albers FW, Cuvelier CA, Renders MT, Cauwenberge PB (1993) Oncocytoma of the nasopharynx. *Rhinol* 31:41–43
4. Al-Sarraf M, Reddy MS (2002) Nasopharyngeal carcinoma. *Curr Treat Options Oncol* 3:21–23
5. Au WY, Kwong YL, Ho WK, Shek TW (2001) Primary granulocytic sarcoma of the nasopharynx. *Am J Hematol* 67:273–274
6. Bale P, Clifton-Bligh P, Benjamin B, Whyte H (1971) Pathology of Tangier disease. *J Clin Pathol* 24:609–616
7. Banks ER, Frierson HF Jr, Mills SE, George E, Zarbo RJ, Swanson PE (1992) Basaloid squamous cell carcinoma of the head and neck. A clinicopathologic and immunohistochemical study of 40 cases. *Am J Surg Pathol* 16:939–946
8. Batsakis JG, Solomon AR, Rice DH (1981) The pathology of head and neck tumors: carcinoma of the nasopharynx, part 11. *Head Neck Surg* 3:511–524
9. Beham A, Beham-Schmid C, Regauer S, Auböck L, Stammberger H (2000) Nasopharyngeal angiofibroma: true neoplasm or vascular malformation? *Adv Anat Pathol* 7:36–46
10. Beham-Schmid C, Beham A, Jakse R, Auböck L, Höfler G (1998) Extranodal follicular dendritic cell tumour of the nasopharynx. *Virchows Arch* 432:293–298
11. Beiser M, Messer G, Samuel J, Gross B, Shanon E (1980) Amyloidosis of Waldeyer's ring. A clinical and ultrastructural report. *Acta Otolaryngol* 89:562–569
12. Benke TT, Zitsch RP, Nashelsky MB (1995) Bilateral oncocytic cysts of the nasopharynx. *Otolaryngol Head Neck Surg* 112:321–324
13. Boccon-Gibod LA, Grangeponde MC, Boucheron S, Josset PP, Roger G, Berthier-Falissard ML (1996) Salivary gland anlage tumor of the nasopharynx: a clinicopathologic and immunohistochemical study of three cases. *Pediatr Pathol Lab Med* 16:973–983
14. Bossen EH, Hudson WR (1987) Oligodendroglioma arising in heterotopic brain tissue of the soft palate and nasopharynx. *Am J Surg Pathol* 11:571–574
15. Bremer JW, Neel HB, DeSanto LW, Jones GC (1986) Angiofibroma: treatment trends in 150 patients during 40 years. *Laryngoscope* 96:1321–1329
16. Browder JP, Wheeler MS, Henley JT, Geratz JD (1984) Mucoepidermoid carcinoma in a cervical cyst: a case of bronchogenic carcinoma? *Laryngoscope* 94:107–112
17. Burns BV, Axon PR, Pahade A (2001) 'Hairy polyp' of the pharynx in association with an ipsilateral branchial sinus: evidence that the 'hairy polyp' is a second branchial arch malformation. *J Laryngol Otol* 115:145–148
18. Byrne MN, Session DG (1990) Nasopharyngeal craniopharyngioma. Case report and literature review. *Ann Otol Rhinol Laryngol* 99:633–639
19. Campbell WM, McDonald TJ, Unni KK (1980) Nasal and paranasal presentations of chordomas. *Laryngoscope* 90:612–618
20. Canalis RF, Jenkins HA, Hemenway WG, Lincoln C (1978) Nasopharyngeal rhabdomyosarcoma. A clinical perspective. *Arch Otolaryngol* 104:122–126
21. Carrau RL, Petruzzelli G, Cass SP (1995) Adenoid cystic carcinoma of the nasopharynx. *Otolaryngol Head Neck Surg* 112:501–502
22. Chan AC, Chan KW, Chan JK, Au WY, Ho WK, Ng WM (2001) Development of follicular dendritic cell sarcoma in hyaline-vascular Castleman's disease of the nasopharynx: tracing its evolution by sequential biopsies. *Histopathology* 38:510–518
23. Chan JK, Tsang WY, Ng CS (1994) Follicular dendritic cell tumor and vascular neoplasm complicating hyaline-vascular Castleman's disease. *Am J Surg Pathol* 18:517–525

24. Chan JK, Yip TT, Tsang WY, Ng CS, Lau WH, Poon YF, Wong CC, Ma VW (1994) Detection of Epstein-Barr viral RNA in malignant lymphomas of the upper aerodigestive tract. *Am J Surg Pathol* 18:938–946
25. Chang KL, Kamel OW, Arber DA, Horyd ID, Weiss LM (1995) Pathologic features of nodular lymphocyte predominance Hodgkin's disease in extranodal sites. *Am J Surg Pathol* 19:1313–1324
26. Chao TY, Chow KC, Chang JY, Wang CC, Tsao TY, Harn HJ, Chi KH (1996) Expression of Epstein-Barr virus-encoded RNAs as a marker for metastatic undifferentiated nasopharyngeal carcinoma. *Cancer* 78:24–29
27. Chaudhry AP, Lore JM Jr, Fisher JE, Gambino AG (1978) So-called hairy polyps or teratoid tumors of the nasopharynx. *Arch Otolaryngol* 104:517–525
28. Chaudhry R, Akhtar S, Lucente FE, Kim DS (1996) Large oral ulcers leading to destruction of the tonsils in patients with AIDS. *Otolaryngol Head Neck Surg* 114:474–478
29. Chessin H, Urdaneta N, Smith H, Gilder JV (1976) Chromophobe adenoma manifesting as a nasopharyngeal mass. *Arch Otolaryngol* 102:631–633
30. Childs C, Parham DM, Berard CW (1987) Infectious mononucleosis. The spectrum of morphologic changes simulating lymphoma in lymph nodes and tonsils. *Am J Surg Pathol* 11:122–132
31. Choi P, Suen MW, Huang DP, Lo KW, Lee JC (1970) Nasopharyngeal carcinoma: genetic changes, Epstein-Barr virus infection, or both. A clinical and molecular study of 36 patients. *Cancer* 72:2873–2878
32. Civantos FJ, Goodwin WJJ (1996) Cancer of the oropharynx. In: Myers EN, Suen YJ (1996) *Cancer of the head and neck*. Saunders, Philadelphia, pp 381–380
33. Civen R, Vaisanen ML, Finegold SM (1993) Peritonsillar abscess, retropharyngeal abscess, mediastinitis, and nonclostridial anaerobic myonecrosis: a case report. *Clin Infect Dis* 16:299–303
34. Coffin C, Swanson P, Wick M, Dehner L (1993) Chordoma in childhood and adolescence. A clinicopathologic analysis of 12 cases. *Arch Pathol Lab Med* 117:927–933
35. Colby TV, Hoppe RT, Warnke RA (1981) Hodgkin's disease: a clinicopathologic study of 659 cases. *Cancer* 49:1848–1858
36. Coppit GL III, Perkins JA, Manning SC (2000) Nasopharyngeal teratomas and dermoids: a review of the literature and case series. *Int J Pediatr Otorhinolaryngol* 52:219–227
37. Cummings BJ, Blend R, Fitzpatrick P, Clark R, Harwood A, Keane T, Beale F, Garrett P, Payne D, Rider W (1984) Primary radiation therapy for juvenile nasopharyngeal angiofibroma. *Laryngoscope* 94:1599–1605
38. Dehner LP, Valbuena L, Perez-Atayde A, Reddick RL, Askin FB, Rosai J (1994) Salivary gland anlage tumor ("congenital pleomorphic adenoma"). A clinicopathologic, immunohistochemical and ultrastructural study of nine cases. *Am J Surg Pathol* 18:25–26
39. Deutsch M, Orlando SJ (1999) Re-irradiation for recurrent rhabdomyosarcoma of the nasopharynx in a child. *Oral Oncol* 35:343–345
40. Dictor M, Siven M, Tennvall J, Rambech E (1995) Determination of non-endemic nasopharyngeal carcinoma by in situ hybridization for Epstein-Barr virus EBV1 RNA: sensitivity and specificity in cervical node metastases. *Laryngoscope* 105:407–412
41. Dolen WK, Spofford B, Selner JC (1990) The hidden tonsils of Waldeyer's ring. *Ann Allergy* 65:244–248
42. Dubey SP, Sengupta SK, Vele DD (1996) Nasopharyngeal osteosarcoma as second malignant neoplasm in a post-treated unilateral retinoblastoma: report of a case and review of literature. *Int J Pediatr Otorhinolaryngol* 34:265–271
43. Easton J, Levine PH, Hyams VJ (1980) Nasopharyngeal carcinoma in the United States. A pathologic study of 177 US and 30 foreign cases. *Arch Otolaryngol* 106:88–91
44. Endo LH, Ferreira D, Montenegro MCS, Pinto GA, Altamiani A, Bortolato AE Jr, Vassallo J (2001) Detection of Epstein-Barr virus in tonsillar tissue of children and the relationship with recurrent tonsillitis. *Int J Pediatr Otorhinolaryngol* 58:9–15
45. Eriksen HE (1970) A case of primary localized amyloidosis in both tonsils. *J Laryngol Otol* 84:525–531
46. Erwin SA (1989) Unsuspected sarcoidosis of the tonsil. *Otolaryngol Head Neck Surg* 100:245–247
47. Ferouz AS, Mohr RM, Paul P (1995) Juvenile nasopharyngeal angiofibroma and familial adenomatous polyposis: an association? *Otolaryngol Head Neck Surg* 113:435–439
48. Ferrans V, Fredrickson D (1975) The pathology of Tangier disease. A light and electron microscopic study. *Am J Pathol* 78:101–158
49. Fletcher CDM, Unni KK, Mertens F (2002) World Health Organization Classification of Tumours. In: Kleihues P, Sobin LH (eds) *Pathology and genetics of tumors of soft tissue and bone*. IARC, Lyon
50. Folpe AL, McKenney JK, Bridge JA, Weiss SW (2002) Sclerosing rhabdomyosarcoma in adults: report of four cases of a hyalinizing, matrix-rich variant of rhabdomyosarcoma that may be confused with osteosarcoma, chondrosarcoma, or angiosarcoma. *Am J Surg Pathol* 26:1175–1183
51. Fouret P, Monceaux G, Temam S, Lacourreye L, Guily JLS (1997) Human papillomavirus in head and neck squamous cell carcinomas in nonsmokers. *Arch Otolaryngol Head Neck Surg* 123:513–516
52. Franco V, Florena AM, Lombardo F, Restivo S (1996) Bilateral hairy polyp of the oropharynx. *J Laryngol Otol* 110:288–290
53. Frankel S, Wenig B, Ferlito A (1997) Human immunodeficiency virus-1 infection of the lymphoid tissues of Waldeyer's ring. *Ann Otol Rhinol Laryngol* 106:611–618
54. Fu YS, Perzin KH (1974) Non-epithelial tumors of the nasal cavity, paranasal sinuses and nasopharynx: a clinicopathologic study. III. Cartilaginous tumors (chondroma, chondrosarcoma). *Cancer* 34:453–463
55. Fu YS, Perzin KH (1978) Nonepithelial tumors of the nasal cavity, paranasal sinuses and nasopharynx. A clinicopathologic study. IX. Plasmacytoma. *Cancer* 42:2399–2406
56. Gadwal SR, Fanburg-Smith JC, Gannon FH, Thompson LD (2000) Primary chondrosarcoma of the head and neck in pediatric patients: a clinicopathologic study of 14 cases with a review of the literature. *Cancer* 88:2181–2188
57. Gaffney R, Harrison M, Walsh M, Sweeney E, Cafferkey M (1993) The incidence and role of actinomycetes in recurrent acute tonsillitis. *Clin Otolaryngol* 18:268–271
58. Gallo O, Bianchi S, Giannini A, Gallina E, Libonati G, Fini-Storchi O (1991) Correlation between histopathological and biological findings in nasopharyngeal carcinoma and its prognostic significance. *Laryngoscope* 101:487–593
59. Gaudecker B von (1988) Development and functional anatomy of the human tonsilla palatina. *Acta Otolaryngol Suppl* 454:28–32
60. Gaudecker B von, Muller-Hermelink H (1982) The development of the human tonsilla palatina. *Cell Tissue Res* 224:579–600
61. Gerber JE (2001) Acute necrotizing bacterial tonsillitis with *Clostridium perfringens*. *Am J Forensic Med Pathol* 22:177–179
62. Giardiello FM, Hamilton SR, Krush AJ, Offerhaus JA, Booker SV, Petersen GM (1993) Nasopharyngeal angiofibroma in patients with familial adenomatous polyposis. *Gastroenterology* 105:1550–1552
63. Giffler RF, Gillespie JJ, Ayala AG, Newland JR (1977) Lymphoepithelioma in cervical lymph nodes of children and young adults. *Am J Surg Pathol* 1:293–302
64. Goldenberg D, Golz A, Netzer A, Flax-Goldenberg R, Joachims HZ (2001) Synergistic necrotizing cellulitis as a complication of peritonsillar abscess. *Am J Otolaryngol* 22:415–419
65. Gorp J van, Weiping L, Jacobse K, Liu YH, Li FY, Weger RA de, Li G (1994) Epstein-Barr virus in nasal T-cell lymphomas (polymorphic reticulosis/midline malignant reticulosis) in western China. *J Pathol* 173:81–87

66. Graeme-Cook F, Bhan AK, Harris NL (1993) Immunohistochemical characterization of intraepithelial and subepithelial mononuclear cells of the upper airways. *Am J Pathol* 143:1416–1422
67. Graziani N, Donnet A, Bugha TN, Dufour H, Figarella-Branger D, Grisoli F (1994) Ectopic basisphenoidal cranio-pharyngioma: case report and review of the literature. *Neurosurgery* 34:346–349
68. Grewal D, Hiranandani N, Kalgutkar J (1985) Congenital absence of the palatine tonsil associated with congenital malformation of the external ear. A congenital anomaly. *J Laryngol Otol* 99:285–288
69. Gulley ML, Amin MB, Nicholls JM, Banks PM, Ayala AG, Srigley JR, Eagan PA, Ro JY (1995) Epstein-Barr virus is detected in undifferentiated nasopharyngeal carcinoma but not in lymphoepithelioma-like carcinoma of the urinary bladder. *Hum Pathol* 26:1207–1214
70. Gürtl B, Beham A, Zechner R, Stammberger H, Höfler G (2000) Nasopharyngeal angiofibroma: an APC-gene-associated tumor? *Hum Pathol* 31:1411–1413
71. Haddad Jr J, Senders CW, Leach CS, Stool SE (1990) Congenital hairy polyp of the nasopharynx associated with cleft palate: report of two cases. *Int J Pediatr Otorhinolaryngol* 20:127–135
72. Hama S, Arita K, Nishisaka T, Fukuhara T, Tominaga A, Sugiyama K, Yoshioka H, Eguchi K, Sumida M, Heike Y, Kurisu K (2002) Changes in the epithelium of Rathke cleft cyst associated with inflammation. *J Neurosurg* 96:209–216
73. Har-El G, Zirkin H, Tovi F, Sidi J (1985) Congenital pleomorphic adenoma of the nasopharynx (report of a case). *J Otolaryngol* 99:25–36
74. Harris NL, Jaffe ES, Stein H, Banks PM, Chan JKC, Cleary ML, Delsol G, Wolf-Peeters CD, Falini B, Gatter KC, Grogan TM, Isaacson PG, Knowles DM, Mason DY, Muller-Hermelink HK, Pileri SA, Piris MA, Ralfkiaer E, Warnke RA (1994) A revised European-American classification of lymphoid neoplasms: a proposal from the International Lymphoma Study Group. *Blood* 84:1361–1392
75. Harrison DFN (1987) The natural history, pathogenesis, and treatment of juvenile angiofibroma. *Arch Otolaryngol Head Neck Surg* 113:936–942
76. Hasselt CA van, Ng NK (1991) Papillary adenocarcinoma of the nasopharynx. *J Laryngol Otol* 105:853–854
77. Hawkins E, Krischer JP, Smith BE, Hawkins HK, Finegold MJ (1990) Nasopharyngeal carcinoma in children – a retrospective review and demonstration of Epstein-Barr viral genomes in tumor cell cytoplasm. A report of the Pediatric Oncology Group. *Hum Pathol* 21:805–810
78. Heffner DK, Thompson LD, Schall DG, Anderson V (1996) Pharyngeal dermoids (“hairy polyps”) as accessory auricles. *Ann Otol Rhinol Laryngol* 105:819–824
79. Henning B, Buchner N, Kirchner J, Gillesen A (2000) Antiphospholipid antibody syndrome as the cause of clinical rapidly progressing vasculopathy. *Dtsch Med Wochenschr* 125:589–593
80. Herait P, Ganem G, Lipinski M, Carlu C, Micheau C, Schwaab G, The G, Tursz T (1987) Lymphocyte subsets in tumour of patients with undifferentiated nasopharyngeal carcinoma: presence of lymphocytes with the phenotype of activated T-cells. *Br J Cancer* 55:135–139
81. Herbst H, Niedobitek G, Kneba M (1990) High incidence of Epstein-Barr virus genomes in Hodgkin's disease. *Am J Pathol* 137:13–18
82. Hiraide F, Inouye T, Tanaka E (1985) Lymphangiectatic fibrous polyp of the palatine tonsil. A report of three cases. *J Laryngol Otol* 99:403–409
83. Hirayama T (1978) Descriptive and analytical epidemiology of nasopharyngeal cancer. Ablashi DV, De-The G, Ito ?Y (eds) *Nasopharyngeal carcinoma: etiology and control*. IARC, Lyon, pp 167–189
84. Hjertaas RJ, Morrison MD, Murray RB (1979) Teratomas of the nasopharynx. *J Otolaryngol* 8:411–416
85. Hobbs HH, Rader DJ (1999) ABC1: connecting yellow tonsils, neuropathy, and very low HDL. *J Clin Invest* 104:1015–1017
86. Hollender A (1946) The nasopharynx. A study of 140 autopsy specimens. *Laryngoscope* 56:282–304
87. Hollowood K, Pease C, Mackay AM, Fletcher CDM (1991) Sarcomatoid tumours of lymph nodes showing follicular dendritic cell differentiation. *J Pathol* 103:90–97
88. Hsiao J, Jin Y, Tsai S (1998) EBER1 in situ hybridization as an adjuvant for diagnosis of recurrent nasopharyngeal carcinoma. *Anticancer Res* 18:4585–4589
89. Hyams VJ (1978) Differential diagnosis of neoplasia of the palatine tonsil. *Clin Otolaryngol* 3:117–126
90. Ikeda H, Yoshimoto T (2002) Clinicopathological study of Rathke's cleft cysts. *Clin Neuropathol* 21:82–91
91. Ikram M, Khan MAA, Ahmed M, Siddiqui T, Mian MY (2000) The histopathology of routine tonsillectomy specimens: results of a study and review of literature. *Ear Nose Throat J* 79:880–882
92. Ikushima I, Korogi Y, Makita O, Komohara Y, Kawano H, Yamura M, Arikawa K, Takahashi M (1999) MR imaging of Tornwaldt's cysts. *AJR Am J Roentgenol* 172:1663–1665
93. Inoue H, Sato Y, Tsuchiya B, Nagai H, Takahashi H, Kameya T (2002) Expression of Epstein-Barr virus-encoded small nuclear RNA 1 in Japanese nasopharyngeal carcinoma. *Acta Otolaryngol Suppl* (547)113–117
94. Jaffe ES (2002) Lymphoid lesions of the head and neck: a model of lymphocyte homing and lymphomagenesis. *Mod Pathol* 15:255–263
95. Jaffe ES, Harris NL, H. HS, Vardiman VW (2001) Pathology and genetics of tumors of haematopoietic and lymphoid tissues. In: Kleihues P, Sobin LH (eds) *WHO Classification of Tumours*. IARC, Lyon
96. Job A, Walter N, David TM (1991) Solitary fibrous tumor of the nasopharynx. *J Laryngol Otol* 105:213–214
97. Jousimies-Somer H, Savolainen S, Makitie A, Ylikoski J (1993) Bacteriologic findings in peritonsillar abscesses in young adults. *Clin Infect Dis* 16:292–298
98. Kamino H, Huang SJ, Fu YS (1988) Keratin and involucrin immunohistochemistry of nasopharyngeal carcinoma. *Cancer* 61:1142–1148
99. Kanavaros P, Lescs MC, Briere J, Divine M, Galateau F, Joab I, Bosg J, Farcet JP, Reyes F, Gaulard P (1993) Nasal T-cell lymphoma: a clinicopathologic entity associated with peculiar phenotype and with Epstein-Barr virus. *Blood* 81:2688–2695
100. Kanegane H, Kanegane C, Yachie A, Miyawaki T, Tosato G (1997) Infectious mononucleosis as a disease of early childhood in Japan caused by primary Epstein-Barr virus infection. *Acta Paediatr Jpn* 39:166–171
101. Kanoh N, Nishimura Y, Nakamura M, Mori M, Uematsu K (1991) Primary nasopharyngeal paraganglioma: a case report. *Auris Nasus Larynx* 18:307–314
102. Kapadia SB, Desai U, Cheng VS (1982) Extramedullary plasmacytoma of the head and neck. A clinicopathologic study of 20 cases. *Medicine* 61:317–329
103. Kapadia SB, Roman LN, Kingma DW, Jaffe ES, Frizzera G (1995) Hodgkin's disease of Waldeyer's ring. Clinical and histoimmunophenotypic findings and association with Epstein-Barr virus in 16 cases. *Am J Surg Pathol* 19:1431–1439
104. Karajannis MA, Hummel M, Anagnostopoulos I, Stein H (1997) Strict lymphotropism of Epstein-Barr virus during acute infectious mononucleosis in nonimmunocompromised individuals. *Blood* 89:2856–2862
105. Kardon DE, Wenig BM, Heffner DK, Thompson LD (2000) Tonsillar lymphangiomas: a clinicopathologic series of 26 cases. *Mod Pathol* 13:1128–1133
106. Karnachow PN, Kaul WH (1988) Chronic herpetic laryngitis with oropharyngitis. *Ann Otol Rhinol Laryngol* 97:286–288
107. Kaur A, Shetty SC, Prasad D, Nirmala V (1997) Primary ectopic meningioma of the palatine tonsil – a case report. *J Laryngol Otol* 111:179–181
108. Kawashiro N, Koga K, Tsuchihashi N, Araki A (1994) Chondral atresia and congenital pharyngeal stenosis. *Acta Otolaryngol* 517:27–32

109. Kieff DA, Curtin HD, Limb CJ, Nadol JB (1998) A hairy polyp presenting as a middle ear mass in a pediatric patient. *Am J Otolaryngol* 19:228–231
110. Kikuchi K, Kowada M, Sasaki J, Sageshima M (1994) Large pituitary adenoma of the sphenoid sinus and the nasopharynx: report of a case with ultrastructural evaluations. *Surg Neurol* 42:330–334
111. Klijanienko J, Micheau C, Azli N (1989) Undifferentiated carcinoma of nasopharyngeal type of tonsil. *Arch Otolaryngol (Head Neck Surg)* 115:731–734
112. Kojima M, Tamaki Y, Nakamura S (1993) Malignant lymphoma of Waldeyer's ring. A histological and immunohistochemical study. *APMIS* 101:537–544
113. Krol ADG, Cessie SL, Snijder S, Kluin-Nelemans JC, Kluin PM, Noordijk EM (2001) Waldeyer's ring lymphomas: a clinical study from the Comprehensive Cancer Center West population based NHL registry. *Leuk Lymphoma* 42:1005–1013
114. Kuo T, Tsang NM (2001) Salivary gland type nasopharyngeal carcinoma: a histologic, immunohistochemical, and Epstein-Barr virus study of 15 cases including a psammomatous mucoepidermoid carcinoma. *Am J Surg Pathol* 25:80–86
115. Lee AW, Poon YP, Foo W, Law SC, Cheung FK, Chan DK, Tung SY, Thaw M, Ho JH. (1992) Retrospective analysis of 5037 patients with nasopharyngeal cancer treated during 1976–1985: overall survival and patterns of failure. *Int J Radiol Oncol Biol Phys* 23:261–270
116. Lim JS, Lebowitz RA, Jacobs JB (1999) Primary amyloidosis presenting as a nasopharyngeal mass. *Am J Rhinol* 13:209–212
117. Lindroos R (2000) Bacteriology of the tonsil core in recurrent tonsillitis and tonsillar hypertrophy – a short review. *Acta Otolaryngol Suppl* 543:206–208
118. Lloyd G, Howard D, Lund VJ, Savy L (2000) Imaging for juvenile angiofibroma. *J Laryngol Otol* 114:727–730
119. MacDonald MR, Freeman JL, Hui MF, Cheung RK, Warde P, Mclvor NP, Irish J, Dosch HM (1995) Role of Epstein-Barr virus in fine-needle aspirates of metastatic neck nodes in the diagnosis of nasopharyngeal carcinoma. *Head Neck* 17:487–493
120. Maher A, Bassiouny A, Bucci TJ, Moawad MK, Hendawy DS (1982) Tonsillomycosis: a myco-histopathological study. *J Laryngol Otol* 96:229–240
121. McEwan J, Basha S, Rogers S, Harkness P (2001) An unusual presentation of cat-scratch disease. *J Laryngol Otol* 115:826–828
122. Mentzel T, Bainbridge TC, Katenkamp D (1997) Solitary fibrous tumour: clinicopathological, immunohistochemical, and ultrastructural analysis of 12 cases arising in soft tissues, nasal cavity and nasopharynx, urinary bladder and prostate. *Virchows Arch* 430:445–453
123. Mey AGL van der, Krieken JHJM van, Dulken H van, Steters AP van, Vielvoje J, Hulshof JH (1989) Large pituitary adenomas with extension into the nasopharynx. Report of three cases with a review of the literature. *Ann Otol Rhinol Laryngol* 98:618–624
124. Michaels L, Hyams VJ (1979) Amyloid in localised deposits and plasmacytomas of the respiratory tract. *J Pathol* 128:29–38
125. Michal M, Sokol L, Mukensnabl P (1996) Salivary gland anlage tumor. A case with widespread necrosis and large cyst formation. *Pathology* 28:128–130
126. Miglets AW, Barton CL (1970) Sarcoid of the tonsil. *Arch Otolaryngol* 92:516–517
127. Miglets AW, Viall JH, Kataria YP (1977) Sarcoidosis of the head and neck. *Laryngoscope* 87:2038–2048
128. Miller R, Sneed W (1985) Tornwaldt's bursa. *Clin Otolaryngol* 10:21–25
129. Mitchell TE, Girling AC (1996) Hairy polyp of the tonsil. *J Laryngol Otol* 110:101–103
130. Miyahara H, Matsunaga T (1994) Tornwaldt's disease. *Acta Otolaryngol Suppl* 517:36–39
131. Moar E, Tovi F, Sacks M (1983) Carcinoma of the pancreas presenting with bilateral tonsillar metastases. *Ann Otol Rhinol Laryngol* 92:192–195
132. Möller P, Wirbel R, Hofmann W (1984) Lymphoepithelial carcinoma (Schmincke type) as a derivate of the tonsillar crypt epithelium. *Virchows Arch (Pathol Anat)* 405:85–93
133. Monem S, O'Connor P, O'Leary T (1999) Peritonsillar abscess and infectious mononucleosis: an association or a different presentation of the same condition. *Ir Med J* 92:278–280
134. Moore KL, Persaud TVN (1993) The developing human: clinically oriented embryology, 5th edn. Saunders, Philadelphia
135. Mori N, Yatabe Y, Oka K, Kinoshita T, Kobayashi T, Ono T, Asai J (1996) Expression of perforin in nasal lymphoma. Additional evidence of its natural killer cell derivation. *Am J Pathol* 149:699–705
136. Morin GV, Shank C, Burgess PA, Heffner DK (1991) Oncocytic metaplasia of the pharynx. *Otolaryngol Head Neck Surg* 105:86
137. Morrison D, Rose EL, Smith AP, Lesser TH (1992) Dyskeratosis congenita and nasopharyngeal atresia. *J Laryngol Otol* 106:996–997
138. Müller E, Beleites E (2000) The basaloid squamous cell carcinoma of the nasopharynx. *Rhinology* 38:208–211
139. Nageris B, Feinmesser M, Brama I, Feinmesser R (1991) Liposarcoma of the nasopharynx: a case report. *Ear Nose Throat J* 70:520–522
140. Nave H, Gebert A, Pabst R (2001) Morphology and immunology of the human palatine tonsil. *Anat Embryol* 204:367–373
141. Neel 3rd HB (1985) Nasopharyngeal carcinoma. Clinical presentation, diagnosis, treatment, and prognosis. *Otolaryngol Clin North Am* 18:479–490
142. Ng CS, Lo ST, Chan JK, Chan WC (1997) CD56+ putative natural killer cell lymphomas: production of cytolytic effectors and related proteins mediating tumor cell apoptosis? *Hum Pathol* 28:1276–1282
143. Nicolai P, Luzzago F, Maroldi R, Falchetti M, Antonelli A (1989) Nasopharyngeal cysts. Report of seven cases with review of the literature. *Arch Otolaryngol Head Neck Surg* 115:860–864
144. Nojog MM, Jalaludin MA, Jayalakshmi P (1998) Papillary adenocarcinoma of the nasopharynx – case report and review of the literature. *Med J Malaysia* 53:104–106
145. Norval E (1998) A mucosa-associated lymphoid tissue (MALT) type lymphoma (marginal zone B-cell lymphoma) from the palatine tonsil. *Pathology* 30:209–211
146. Norval E, Thompson I (2001) Non-Hodgkin's lymphomas of Waldeyer's ring: a clinicopathological and immunological study of 64 cases in the western Cape. *SADJ* 56:545–548
147. Nouwen J, Smets F, Rombaux P, Hamoir M, Sokal EM (2002) Acute tonsillitis as the first manifestation of post-transplant lymphoproliferative disorder. *Ann Otol Rhinol Laryngol* 111:165–168
148. Ohshima K, Suzumiya J, Shimazaki K, Kato A, Tanaka T, Kanda M, Kikuchi M (1997) Nasal T/NK cell lymphomas commonly express perforin and Fas ligand: important mediators of tissue damage. *Histopathology* 31:444–450
149. Olofsson K, Hellstrom S, Hammarstrom M (1998) The surface epithelium of recurrent infected palatine tonsils is rich in gammadelta T cells. *Clin Exp Immunol* 111:36–47
150. Ott G, Kalla J, Ott MM, Müller-Hermelink HK (1997) The Epstein-Barr virus in malignant non-Hodgkin's lymphoma of the upper aerodigestive tract. *Mol Pathol* 6:134–139
151. Oudejans JJ, Harijadi H, Kummer JA, Tan IB, Bloemena E, Middelmeier JM, Bladergroen B, Dukers DF, Vos W, Meijer CJ (2002) High numbers of granzyme B/CD8-positive tumour-infiltrating lymphocytes in nasopharyngeal carcinoma biopsies predict rapid fatal outcome in patients treated with curative intent. *J Pathol* 198:468–475
152. Papadas T, Batistatou A, Ravazoula P, Zolota V, Goumas P (2002) S-100 protein-positive dendritic cells and CD-34 positive dendritic interstitial cells in palatine tonsils. *Arch Otorhinolaryngol* 258:243–245
153. Paris J, Guelfucci B, Moulin G, Zanaret M, Triglia JM (2001) Diagnosis and treatment of juvenile nasopharyngeal angiofibroma. *Eur Arch Otorhinolaryngol* 258:120–124

154. Parks SS, Karmody CS (1992) The first branchial cleft carcinoma. *Arch Otolaryngol Head Neck Surg* 118:969–971
155. Paslin D (1980) Accessory tonsils. *Arch Dermatol* 116:720–721
156. Patel A, Pambuccian S, Maisel R (2002) Nasopharyngeal amyloidosis. *Am J Otolaryngol* 23:308–311
157. Pathmanathan R, Prasad U, Chandrika G, Sadler R, Flynn K, Raab-Traub N (1995) Undifferentiated, nonkeratinizing, and squamous cell carcinoma of the nasopharynx. Variants of Epstein-Barr virus-infected neoplasia. *Am J Pathol* 146:1355–1367
158. Pathmanathan R, Prasad U, Sadler R, Flynn K, Raab-Traub N (1995) Clonal proliferations of cells infected with Epstein-Barr virus in preinvasive lesions related to nasopharyngeal carcinoma. *N Engl J Med* 333:693–698
159. Paulino AF, Singh B, Shah JP, Huvos AG (2000) Basaloid squamous cell carcinoma of the head and neck. *Laryngoscope* 110:1479–1482
160. Paz IB, Cook N, Odom-Maryon T, Xie Y, Wilczynski SP (1997) Human papillomavirus (HPV) in head and neck cancer. An association of HPV 16 with squamous cell carcinoma of Waldeyer's tonsillar ring. *Cancer* 79:595–604
161. Percodani J, Braun F, Arrue P, Yardeni E, Murriss-Espin M, Serrano, Pessey JJ (1999) Nasopharyngeal tuberculosis. *J Laryngol Otol* 113:928–931
162. Perzin KH, Pushparaj N (1984) Nonepithelial tumors of the nasal cavity, paranasal sinuses, and nasopharynx. A clinicopathologic study. XIII: meningiomas. *Cancer* 54:1860–1869
163. Posey LA, Kerschner JE, Conley SF (1999) Posttransplantation lymphoproliferative disease in children: otolaryngologic manifestations and management. *South Med J* 92:1079–1082
164. Reddy S, Raslan W, Gooneratne S, Kathuria S, Marks J (1995) Prognostic significance of keratinization in nasopharyngeal carcinoma. *Am J Otolaryngol* 16:103–108
165. Regauer S, Beham A, Mannweiler S (2000) CK7 expression in carcinomas of the Waldeyer's ring area. *Hum Pathol* 31:1096–1101
166. Regauer S, Mannweiler S, Anderhuber W, Gottschuli A, Berghold A, Schachenreiter J, Jakse R, Beham A (1999) Cystic lymph node metastases of squamous cell carcinoma of Waldeyer's ring origin. *Br J Cancer* 1437–1442
167. Rowe LD (1980) Neonatal airway obstruction secondary to nasopharyngeal teratoma. *Otolaryngol Head Neck Surg* 88:221–226
168. Ruff T, Diaz JA (1986) Heterotopic brain in the nasopharynx. *Otolaryngol Head Neck Surg* 94:254–256
169. Sabo R, Sela M, Sabo G, Herskovitz P, Feinmesser R (2001) Metastatic hypernephroma to the head and neck: unusual case reports and review of the literature. *J Otolaryngol* 30:140–144
170. Schick B, Brunner C, Praetorius M, Plinkert PK, Urbschat S (2002) First evidence of genetic imbalances in angiofibromas. *Laryngoscope* 112:397–401
171. Schick B, Plinkert PK, Prescher A (2002) Aetiology of angiofibromas: reflection on their specific vascular component. *Laryngorhinootologie* 81:280–284
172. Scott A, Stansbie JM (1997) Actinomycosis presenting as a nasopharyngeal tumour: a case report. *J Laryngol Otol* 111:163–169
173. Sellars SL (1971) Metastatic tumours of the tonsil. *J Laryngol Otol* 85:289–292
174. Shahab I, Osborne B, Butler J (1994) Nasopharyngeal lymphoid tissue masses in patients with human immunodeficiency virus-1. *Cancer* 74:3083–3088
175. Sham J, Poon YF, Wei WI, Choy D (1990) Nasopharyngeal carcinoma in young patients. *Cancer* 65:2606–2610
176. Shanmugaratnam K, Sobin LH (1991) Histological typing of tumours of the upper respiratory tract and ear. WHO International Histological Classification of Tumours. Springer, Berlin Heidelberg New York
177. Shidara K, Uruma T, Yasuoka Y, Kamei T (1993) Two cases of nasopharyngeal branchial cyst. *J Laryngol Otol* 107:453–455
178. Shreedhar R, Tooley AH (1984) Carcinoma arising in a branchial cyst. *Br J Surg* 75:115
179. Siebert JD, Stuckey JH, Kurtin PJ, Banks PM (1995) Extranodal lymphocyte predominance Hodgkin's disease. Clinical and pathologic features. *Am J Clin Pathol* 103:485–491
180. Smitheringale A (2000) Lymphomas presenting in Waldeyer's ring. *Otolaryngology* 29:183–185
181. Sofferman RA, Heisse JWH Jr (1985) Adenoid cystic carcinoma of the nasopharynx after previous adenoid irradiation. *Laryngoscope* 95:458–461
182. Strickler J, Fedeli F, Horowitz CA, Copenhaver CM, Frizzera G (1993) Infectious mononucleosis in lymphoid tissue. Histopathology, in-situ hybridization, and differential diagnosis. *Arch Pathol Lab Med* 117:269–278
183. Sulica RL, Wenig BM, Debo RF, Sessions RB (1999) Schneiderian papillomas of the pharynx. *Ann Otol Rhinol Laryngol* 108:392–397
184. Taddasse-Heath L, Feldman J, Fahle GA, Fisher SH, Sorbara L, Raffeld M, Jaffe E (2003) Florid CD4+, CD56+ T-cell infiltrate associated with Herpes simplex infection simulating nasal NK-/T-cell lymphoma. *Mod Pathol* 16:166–172
185. Tamagawa Y, Kitamura K, Miyata M (1995) Branchial cyst of the nasopharynx: resection via the endonasal approach. *J Laryngol Otol* 109:139–141
186. Tao Q, Srivastava G, Chan AC, Chung LP, Loke SL, Ho FC (1995) Evidence for lytic infection by Epstein-Barr virus in mucosal lymphocytes instead of nasopharyngeal epithelial cells in normal individuals. *J Med Virol* 45:71–77
187. Tharrington C, Bossen E (1992) Nasopharyngeal teratomas. *Arch Pathol Lab Med* 116:165–167
188. Thompson L, Gyure K (2000) Extracranial sinonasal tract meningiomas. a clinicopathologic study of 30 cases with a review of the literature. *Am J Surg Pathol* 24:640–650
189. Thompson LDR, Heffner DK (1998) The clinical importance of cystic squamous cell carcinomas in the neck. *Cancer* 82:944–956
190. Tominaga S, Fukushima K, Nishizaki K, Watanabe S, Masuda Y, Ogura H (1996) Presence of human papillomavirus type 6 in tonsillar condylolema acuminatum and clinically normal tonsillar mucosa. *Jpn J Clin Oncol* 26:393–397
191. Tsai ST, Jin YT, Su JJ (1996) Expression of EBER1 in primary and metastatic nasopharyngeal carcinoma tissues using in situ hybridization. A correlation with WHO histologic subtypes. *Cancer* 77:231–236
192. Voelker JL, Campbell RL, Muller L (1991) Clinical, radiographic and pathological features of symptomatic Rathke's cleft cysts. *J Neurosurg* 74:535–644
193. Waldron J, Hasselt CAV, Skinner DW, Arnold M (1992) Tuberculosis of the nasopharynx: clinicopathological features. *Clin Otolaryngol* 17:57–59
194. Wan SK, Chan JK, Lau WH, Yip TT (1995) Basaloid-squamous carcinoma of the nasopharynx. An Epstein-Barr virus-associated neoplasm compared with morphologically identical tumors occurring in other sites. *Cancer* 76:1689–1693
195. Wat PJ, Strickler JG, Jeffrey L, Nordstrom MR (1994) Herpes simplex infection causing acute necrotizing tonsillitis. *Mayo Clin Proc* 69:269–271
196. Weiss LM, Movahed LA, Butler AE, Swanson SA, Frierson HFJ, Cooper PH, Colby TV, Mills SE (1989) Analysis of lymphoepithelioma and lymphoepithelioma-like carcinomas for Epstein-Barr viral genomes by in situ hybridization. *Am J Surg Pathol* 13:625–631
197. Wenig B, Thompson L, Frankel S (1996) Lymphoid changes of the nasopharyngeal and palatine tonsils that are indicative of human immunodeficiency virus infection. *Am J Surg Pathol* 20:572–587
198. Wenig BM, Harpaz N, DelBridg C (1989) Polymorphous low-grade adenocarcinoma of seromucous glands of the nasopharynx. A report of a case and a discussion of the morphologic and immunohistochemical features. *Am J Clin Pathol* 92:104–109
199. Wenig BM, Heffner DK (1995) Respiratory epithelial adenomatoid hamartomas of the sinonasal tract and nasopharynx: a clinicopathologic study of 31 cases. *Ann Otol Rhinol Laryngol* 104:639–645

200. Winther B, Innes D (1994) The human adenoid. *Arch Otolaryngol Head Neck Surg* 120:144–149
201. Witkin GB, Rosai J (1991) Solitary fibrous tumor of the upper respiratory tract. A report of six cases. *Am J Surg Pathol* 15:842–848
202. Woodruff C (1980) Nonneoplastic and inflammatory disorders of Waldeyer's ring. *Ear Nose Throat J* 59:457–465
203. Yadav SP, Singh I, Chanda R, Sachdeva OP (2002) Nasopharyngeal angiofibroma. *Otolaryngol* 31:346–350
204. Yamanaka N, Kataura A (1984) Viral infections associated with recurrent tonsillitis. *Acta Otolaryngol Suppl* 416:30–37
205. Ylikoski J, Karjalainen J (1989) Acute tonsillitis in young men: etiological agents and their differentiation. *Scand J Infect* 21:169–174
206. Zarbo R, McClatchey K (1983) Nasopharyngeal hamartoma. *Laryngoscope* 93:494–497
207. Ziegler JL, Beckstead JA, Volberding PA, Abrams DI, Levine AM, Lukes RJ, Gill PS, Burkes RL, Meyer PR, Metroka CE (1984) Non-Hodgkin's lymphoma in 90 homosexual men. Relation to generalized lymphadenopathy and the acquired immunodeficiency syndrome. *N Engl J Med* 311:565–570
208. Zong Y, Zhang C, Zhang F, Ruan JB, Chen MY, Feng KT, Yu ZF (1993) Infiltrating lymphocytes and accessory cells in nasopharyngeal carcinoma. *Jpn J Cancer Res* 84:900–905

Larynx and Hypopharynx

N. Gale · A. Cardesa · N. Zidar

Contents

7.1	Summary of Anatomy, Histology and Embryology.	198
7.2	Laryngocele, Cysts, Heterotopia.	199
7.2.1	General Considerations	199
7.2.2	Laryngocele	199
7.2.3	Saccular Cyst	199
7.2.4	Ductal Cyst.	199
7.2.5	Oncocytic Cyst.	200
7.2.6	Zenker's Hypopharyngeal Diverticle	201
7.2.7	Aberrant Thyroid Tissue	201
7.2.8	Tracheopathia Osteochondroplastica	202
7.3	Inflammatory Lesions	202
7.3.1	Acute Infections	202
7.3.1.1	Epiglottitis	202
7.3.1.2	Laryngotracheobronchitis	202
7.3.1.3	Diphtheria	202
7.3.2	Chronic Infections	202
7.3.2.1	Tuberculosis	202
7.3.2.2	Fungal Infections	203
7.3.2.3	Other Rare Infections.	203
7.3.3	Non-Infectious Inflammatory Lesions	203
7.3.3.1	Wegener's Granulomatosis.	203
7.3.3.2	Sarcoidosis	204
7.3.3.3	Rheumatoid Arthritis.	204
7.3.3.4	Relapsing Polychondritis.	205
7.3.3.5	Gout	206
7.3.3.6	Teflon Granuloma	206
7.3.3.7	Idiopathic Subglottic Laryngeal Stenosis	206
7.3.3.8	Angioneurotic Oedema.	207
7.4	Degenerative Lesions	207
7.4.1	Oculopharyngeal Muscular Dystrophy	207
7.5	Pseudotumours	207
7.5.1	Exudative Lesions of Reinke's Space	207
7.5.1.1	Reinke's Oedema	208
7.5.1.2	Vocal Cord Polyp and Nodule.	208
7.5.2	Contact Ulcer and Granuloma, Intubation Granuloma	210
7.5.3	Necrotising Sialometaplasia	211
7.5.4	Metaplastic Elastic Cartilaginous Nodules	211
7.5.5	Amyloidosis	211
7.5.6	Sinus Histiocytosis with Massive Lymphadenopathy and Other Rare Pseudotumours.	212
7.5.7	Inflammatory Myofibroblastic Tumour	213
7.6	Benign Neoplasms.	214
7.6.1	Squamous Cell Papilloma	214
7.6.2	Salivary Gland-Type Tumours.	214
7.6.2.1	Pleomorphic Adenoma	214
7.6.2.2	Oncocytoma	214
7.6.3	Haemangioma (Neonatal and Adult Types)	214
7.6.4	Paraganglioma.	215
7.6.5	Granular Cell Tumour	216
7.6.6	Chondroma.	217
7.7	Malignant Neoplasms.	217
7.7.1	Potentially Malignant (Precancerous) Lesions	217
7.7.2	Invasive Squamous Cell Carcinoma	218
7.7.2.1	Epidemiology	218
7.7.2.2	Aetiology	218
7.7.2.3	Anatomic Sites.	218
7.7.2.4	Histological Variants	219
7.7.2.5	TNM Grading	220
7.7.3	Neuroendocrine Carcinoma	220
7.7.3.1	Well-Differentiated Neuroendocrine Carcinoma (Carcinoid)	220
7.7.3.2	Moderately Differentiated Neuroendocrine Carcinoma (Atypical Carcinoid)	220
7.7.3.3	Poorly Differentiated Neuroendocrine Carcinoma (Small Cell Carcinoma)	221
7.7.4	Adenocarcinoma	222
7.7.4.1	Adenoid Cystic Carcinoma	222
7.7.4.2	Mucoepidermoid Carcinoma	222
7.7.5	Sarcomas	223
7.7.5.1	Chondrosarcoma	223
7.7.5.2	Other Sarcomas	224
7.7.6	Other Malignant Neoplasms.	224
7.7.6.1	Malignant Lymphoma	224
7.7.6.2	Extrasosseous (Extramedullary) Plasmacytoma.	224
7.7.6.3	Primary Mucosal Melanoma.	225
7.7.6.4	Metastases to the Larynx.	225
	References	226

7.1 Summary of Anatomy, Histology and Embryology

The larynx and hypopharynx are constituent parts of the upper aerodigestive tract, intimately linked together with their connective tissue elements and different epithelia. The anatomy and histology of both organs are very complex and details are available in various standard textbooks and specialised papers [103, 158, 238, 321, 322]. Only essential data will be given here.

The larynx is a hollow tube that communicates cranially with the hypopharynx. Its upper limits are the free edge of the epiglottis and the two aryepiglottic folds. The lower laryngeal part continues caudally with the trachea, and its inferior limit is the lower edge of the cricoid cartilage. The anterior border consists of the lingual surface of the epiglottis, thyrohyoid membrane, thyroid cartilage and the anterior arch of the cricoid cartilage. Posteriorly, the cricoid cartilage and area of the arytenoids limit the larynx.

The larynx is divided into supraglottic, glottic and subglottic regions, which have particular significance for the biological behaviour and staging of tumours. The supraglottic region extends from the tip of the epiglottis down to the superior edge of the true vocal cord and includes the epiglottis, aryepiglottic folds, arytenoids, the false vocal cords and ventricles. The glottis includes the vocal cords with anterior and posterior commissures. The subglottis extends below the true vocal cords to the lower border of the cricoid cartilage.

Our own experience suggests that marked variations in the distribution of different types of laryngeal epithelia related to age seem to be the rule [177]. The lingual and, variably, laryngeal side of the epiglottis and the true vocal cords are covered by the non-keratinising stratified squamous cell epithelium, the rest of the larynx is lined with the respiratory epithelium. The seromucinous glands are abundant in all compartments of the larynx except in the vocal cords, where they are essentially missing on their free edges and are sparse in the rest of the cords.

It is important to draw attention to some particularities in the laryngeal structure that considerably influence the spread of malignant tumours. The elastic cartilage of the epiglottis with numerous fenestrations for vessels, nerves and glands provides a "locus minoris resistentiae" for the progress of malignant growth from the laryngeal to the lingual side or vice versa. In the anterior commissure, where the true vocal cords meet in the anterior midline, a band of fibrous tissue (protrusions of the two vocal ligaments) with lymphatic and blood vessels is attached to the thyroid cartilage. There is no perichondrium at this point, which certainly facilitates the ingrowth of malignant tu-

mours in the thyroid cartilage. The network of capillaries is poorly developed in Reinke's space of the vocal cords and lymphatics are lacking. These specificities contribute to the development of various exudative lesions of the vocal cords and delayed metastases of glottic cancers.

Embryologically, the supraglottic part of the larynx arises from the third and the fourth branchial arches, while the glottic and subglottic portions are derived from the sixth arch. The first appearance of the respiratory tract occurs at approximately 21 days during embryogenesis as an evagination or a vertical groove of the cephalic portion of the foregut. This evagination is the precursor of the epiglottis, the earliest portion of the larynx. Its outlines appear at the 6-mm foetal stage by 30 days. The respiratory groove begins to close and with the formation of the arytenoids, the closure becomes complete [103]. The covering epithelium of the groove appears in the 3–5-mm embryo as three lines of polyhedral embryonic cells of endodermal origin. In a 30-mm foetus, by 60–70 days, the thickness of the embryonic stratified squamous epithelium increases, and the vocal cords begin to differentiate. The ciliated epithelium occurs in a 40-mm foetus on the epiglottis and laryngeal vestibule. A sharp distinction between the two epithelia appears after the foetus reaches a length of 95 mm. The larynx of a newborn is covered in the ciliated epithelium, except on the true vocal cords. In addition to this location, the stratified squamous epithelium is also present on the interarytenoid area and on the tip of the epiglottis [158].

The hypopharynx is the caudal part of the pharynx with the wide part superiorly, extending from the tip of the epiglottis to the inferior level of the cricoid cartilage, where it becomes narrow and continuously proceeds to the oesophagus. The hypopharynx is divided into three compartments: left and right pyriform sinuses, postcricoidal region, and posterior pharyngeal walls. The pyriform sinuses are medially limited by the aryepiglottic folds and laterally by the thyroid cartilage. The postcricoid area is the posterior side of the cricoid cartilage. The posterior wall is situated in front of the cervical spine. The entire hypopharynx is covered in the stratified squamous cell epithelium.

Embryologically, the pharyngeal gut or pharynx extends from the buccopharyngeal membrane to the tracheobronchial diverticulum. The hypopharynx is almost entirely of endodermal origin. In the 8th through to the 10th gestation week the pharynx, as well as the hypopharynx, is rather small and after the 10th week of gestation, remarkable growth occurs in this region [204, 252].

7.2 Laryngocele, Cysts, Heterotopia

7.2.1 General Considerations

A laryngocele is a rare congenital or acquired laryngeal lesion that appears within and around the laryngeal sacculle. Laryngeal cysts account for approximately 5% of benign laryngeal lesions [177, 265]. DeSanto presented a classification of laryngeal cysts in which the lesions were divided into ductal, saccular and thyroid cartilage foraminal cysts [80]. This classification, which is more clinically adjusted, is based on the intramucosal depth of the cyst and its location. Newman and co-workers found it difficult to apply and proposed a new one, dividing the lesions into tonsillar, epithelial (saccular and ductal) and oncocytic cysts. According to the original article, more than half of all laryngeal cysts were epithelial, one quarter tonsillar and less than 15% oncocytic [265].

7.2.2 Laryngocele

Laryngocele is defined as an excessive elongation and dilatation of the air-filled laryngeal sacculle (ventricular appendix), which communicates directly with the laryngeal lumen. According to its site, there are three types of lesions: internal, external, and mixed. An internal laryngocele extends in a superior-posterior direction, towards the area of the false vocal cord and aryepiglottic fold. An external one expands cranially and laterally to the neck through the weak zone of the thyrohyoid membrane. It presents as a lateral neck mass that varies in size depending on variations of the intralaryngeal pressure. A mixed or combined form has both internal and external components with a swelling of the neck and endolaryngeal bulging [14, 15, 53]. The combined laryngocele is the most common (44%), followed by internal (30%) and external (26%) forms [50].

A laryngocele is quite a rare lesion, occurring as congenital [60] or acquired, most frequently observed in infants and adults between 50 and 60 years. A male predominance is evident with a ratio of 7:1 [227, 287]. Most laryngoceles are unilateral. Aetiologically, the lesion occurs in persons with a congenital large sacculle and weakness of the periventricular soft tissue. In adults, various conditions involving a repeated increase in intralaryngeal pressure, such as inflicting glass-blowers, wind instrument musicians, singers, professional speakers, and patients with a chronic cough, are reported [227]. Stenosis of the sacculle neck, which functions as a valve system, may also lead to the occurrence of a laryngocele. The leading symptoms of an internal or compound lesion are hoarse-

ness, cough, dyspnoea, dysphagia, and the sensation of a foreign body.

The lesion may, however, be also asymptomatic in approximately 12% of the cases [62]. The diagnosis is established by the history, and by physical and radiological examination, especially computed tomography (CT).

Histologically, a cystic extension of the sacculle is evident and its wall tends to lose its folded surface. The laryngocele is covered by the respiratory epithelium; occasionally an oncocytic or cuboidal metaplasia is present. Focally, chronic mononuclear inflammatory cells are seen in the subepithelial stroma. Laryngocele-related complications include infection (laryngopyocele), aspiration and subsequent pneumonia [287]. There is also a relationship between laryngocele and laryngeal squamous cell carcinoma in 4.9 to 28.8% of cases [140]. The endoscopic surgical treatment of laryngocele is the method of choice [354].

7.2.3 Saccular Cyst

A saccular cyst (SC) is a mucus-filled dilatation of the laryngeal sacculle that has no communication with the laryngeal lumen [80, 161]. Most SCs are congenital in origin; some may also appear as acquired lesions caused by various inflammatory processes, traumatic events, or tumours [1, 161, 257]. SCs, which may occur at any age, are divided into anterior and lateral. The former spread medially and posteriorly, and protrude into the laryngeal lumen between the true and false vocal cord. The latter are generally larger and extend towards the false vocal cord and aryepiglottic fold. They may rarely spread through the thyrohyoid membrane [10, 80, 161, 357]. SCs may be asymptomatic, but the most common symptoms are progressive cough, dysphagia, hoarseness, dyspnoea and foreign body sensation. Diagnosis is often made by laryngoscopy combined with CT scan [69].

Histologically, SCs are lined with ciliated respiratory epithelium. An increased number of goblet cells may be present. Rarely, the cysts are partially or entirely lined by metaplastic squamous or oncocytic epithelium. Subepithelial stroma, i.e. the cyst wall, usually contains focal lymphocytic infiltrates [177].

Treatment is surgical, the decision on an endoscopic or an external approach depends on the type and size of the cyst, as well as the individual patient's condition.

7.2.4 Ductal Cyst

Ductal cysts (DCs) are the most common laryngeal cysts and comprise up to 62.5% of all laryngeal cystic lesions. The characteristic retention of mucus in the dilated collecting ducts of the intramucosal seromucinous glands

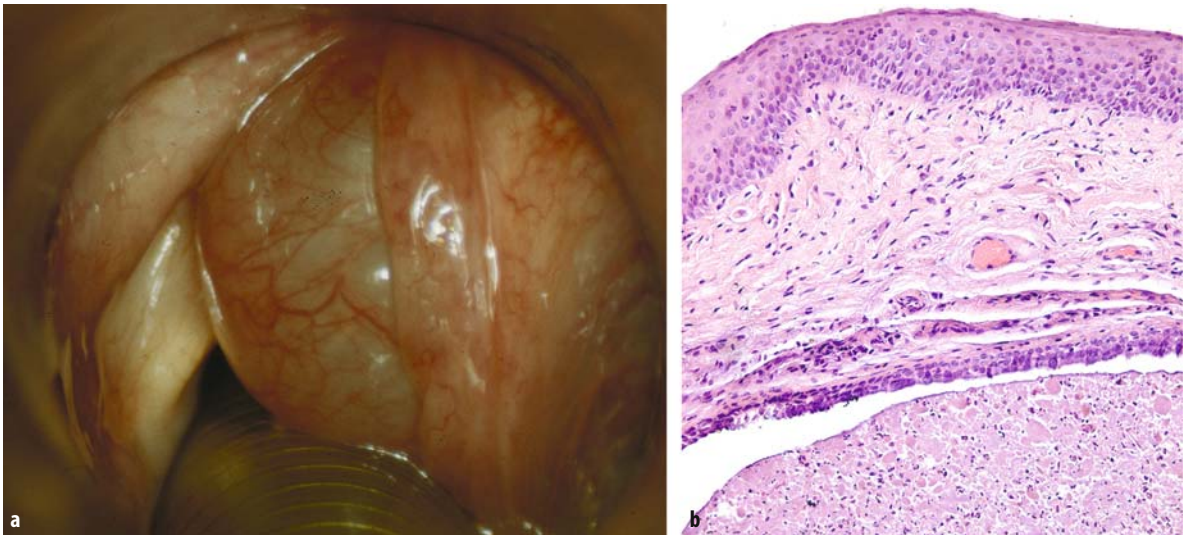


Fig. 7.1. Ductal cyst. **a** Large cyst arises from the right ventricle. **b** Ductal cyst is covered in ductal epithelium and filled with mucin

can be found anywhere in the larynx [10, 177]. DCs originate from an obstruction of the glandular ducts, caused mainly by chronic inflammation. They are mainly located on the vocal cords, ventricle of Morgagni, ventricular folds, aryepiglottic folds, and on the pharyngeal side of the epiglottis, where they tend to be larger, even up to 7.5 cm in diameter (Fig. 7.1a) [14, 177].

The origin of a so-called epidermoid cyst of the vocal cord is probably related to microtraumatic inclusion of small fragments of squamous epithelium into the subepithelial tissue or to the remnants of the vocal cord sulcus [251]. These cysts are usually smaller than other laryngeal retention cysts, measuring 1–4 mm and not exceeding 10 mm in diameter [80].

Laryngoscopically, ductal cysts are seen as a sharply delineated spherical protrusion, the overlying mucosa is smooth and stretched. Larger cysts, mainly in newborns or in small children, can obstruct breathing.

The histological picture of DCs is influenced by origin. Laryngeal retention cysts are covered in double-layered cylindrical, cuboidal or flattened ductal epithelium (Fig. 7.1b). Squamous or oncocytic metaplasia of the ductal epithelium, partial or complete, is frequently present. Classical “epidermoid” or keratinising cysts of the vocal cords are usually lined with atrophic keratinising epithelium with intraluminal stratified basophilic keratin scales. The therapy of choice for DC is surgical removal.

7.2.5 Oncocytic Cyst

Although the oncocytic lesions dominate in the parotid gland, they may appear in the minor salivary glands of

the upper aerodigestive tract, including the larynx. A whole spectrum of oncocytic laryngeal lesions has been observed, ranging from focal to diffuse oncocytic metaplasia, papillary cystic hyperplastic lesions to benign and malignant tumours (the latter occur mainly in the sinonasal and palatal region) [44]. On the other hand, it has been suggested that all these lesions, variously called oncocytic cyst (OC), oncocytic papillary cystadenoma, oncocytoma, oncocytic adenomatous hyperplasia, more likely belong to non-neoplastic rather than to true neoplastic lesions [193, 265, 291]. This opinion has been supported by the various extent of oncocytic metaplasia in the laryngeal minor salivary glands, as well as by the occasional appearance of multiple cystic lesions [84, 111, 230, 387].

Oncocytes are enlarged cells with characteristic granular eosinophilic cytoplasm, caused by an increased number of tightly packed abnormal mitochondria, and small, dense, darkly stained nuclei. The exact cause of oncocytic metaplasia remains unknown, but it is related to the process of aging and especially to disturbance of the organisation of the mitochondrial enzymes [238]. Laryngeal OCs may show focal, inconspicuous or extensive proliferation of oncocytes, mainly with unilocular or multilocular cystic formations with papillary projections, resembling the Warthin’s tumour [119].

Laryngeal OCs probably represent a separate clinicopathologic entity, showing typical age group, location and histopathologic features. They occur on the false vocal cords and ventricles in middle-aged to elderly persons with hoarseness or a cough as the leading symptoms [216, 265, 283, 304]. Clinically, OCs appear as solitary polypoid lesions in the subepithelial stroma, while

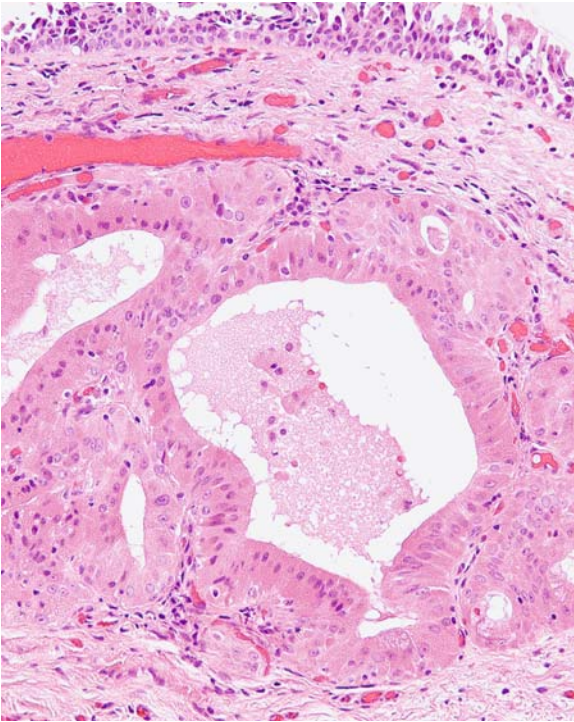


Fig. 7.2. Oncocytic cyst of the ventricular cord. Cyst is lined with oncocytic epithelium

a diffuse involvement as oncocytic cystadenomatosis is exceptional [230].

Histologically, the epithelium of an OC shows papillary proliferations or a different degree of folding of the cystic wall. The epithelium is typically double layered; the inner layer consists of columnar eosinophilic cells encircling the cystic lumina, while the outer layer is composed of small basal cells (Fig. 7.2). Complete endoscopic surgical excision is the recommended treatment, if necessary by laryngofissure [216].

7.2.6 Zenker's Hypopharyngeal Diverticle

An outpouching of the dorsal hypopharyngeal wall above the upper oesophageal sphincter is known as Zenker's diverticulum (ZD). The condition is more often seen in northern Europe, especially the UK, than elsewhere in the world [42]. The site of origin is between the thyropharyngeal and the more horizontal part of the cricopharyngeal muscle. The aetiological factors of ZD occurrence have not been explained, but an incomplete sphincter opening with an increase in hypopharyngeal pressure during swallowing has to be considered [266]. The lesion, which usually occurs in elderly persons, is now widely accepted to be of ac-

quired rather than congenital origin. The symptoms are virtually pathognomonic: dysphagia, regurgitation of undigested food, weight loss, foetor ex ore, coughing and repeated aspiration [42]. Diagnosis of the disease may be confirmed by a barium swallow. Histologically, ZD is composed of a squamous epithelium, thinned fibrous tissue of the subepithelial stroma with possible inflammatory changes. The conservative open surgical procedures provide effective results [266]. Exceedingly rarely, squamous cell carcinoma may develop in ZD [42].

7.2.7 Aberrant Thyroid Tissue

Thyroid tissue rarely appears in sites outside of its embryonic development. The subglottic area of the larynx and upper trachea are places where aberrant thyroid tissue (ATT) may be found [36], especially between the lower border of the cricoid cartilage and the upper ring of the trachea. According to different reports, intraluminal thyroid tissue occurs anywhere between the glottis and the bifurcation of the trachea, as a broad-based, smooth, rounded mass protruding from the left subglottic posterolateral wall [305, 345]. It has been pointed out that two-thirds of patients are middle-aged women from regions of endemic goitre [22, 36]. Intralaryngotracheal thyroid is a rare lesion. Only about 125 cases were described up to 1998 [327]. Waggoner divided intralaryngotracheal thyroid tissue into "false" and "true" aberrant thyroids. The former is likely to arise in the pre- or neonatal period, when the thyroid gland could grow into incompletely formed laryngotracheal cartilages that remain in continuity with the thyroid gland. The latter, the "true aberrant thyroid", develops during the foetal period as an isolated, misplaced thyroid tissue, when the thyroid gland is encroached upon and divided by the later developed laryngeal and tracheal cartilages [327, 361, 372]. The most common symptom of intralaryngeal ATT is slowly progressive dyspnoea, but it may be also asymptomatic [278].

Histologically, the thyroid follicles are usually small, regular, with a well-formed colloid lying close to the seromucinous glands in the laryngeal mucosa [238]. The overlying mucosa is commonly intact, and there may be some evidence of chronic irritation. The finding of thyroid tissue in the laryngotracheal wall raises the question as to whether or not it represents ectopic tissue appearing through a developmental defect or a well-differentiated carcinoma. The final decision must be based on an overall clinical evaluation and not only on histological findings [36, 327]. Management of ATT is often not clear-cut, but is proposed to be primarily surgical [327, 345, 372].

7.2.8 Tracheopathia Osteochondroplastica

Tracheopathia osteochondroplastica (TO) is a rare, slowly progressing lesion, characterised by the presence of cartilaginous and bony submucosal nodules projecting into the lumen of the trachea, larynx and major bronchi [148, 279, 295, 355]. Most cases are recognised at autopsy, but may be also suspected due to problems of endotracheal intubation [186].

The aetiology and pathogenesis remain uncertain. Chronic infections, chemical and mechanical irritations, metabolic disorders, ecchondrosis, exostosis and metaplasia of the elastic tissue are thought to be causal factors [279, 295, 355, 356]. TO appears predominantly in late adult life, but may be seen in childhood and early adult life [148, 295]. TO with minimal expressions may often be overlooked. Typical florid cases narrow the airways and cause a dry cough, dyspnoea, hoarseness and recurrent infections [356]. Laryngobronchoscopic examination is decisive for the diagnosis. Elevated, hard, whitish nodules bulge into the lumen with the appearance of a stalactite cave. The posterior wall of the trachea is usually spared [186, 279]. An intralaryngeal location of TO is very rare; as a rule it appears in the subglottic region [355], exceptionally around the arytenoids [279].

Histologically, submucosal nodules of cartilage and lamellar bone with marrow spaces are characteristic findings, usually in relation to the underlying cartilage. Calcifications, ossifications and fatty marrow formations may be seen within the nodules [295]. Bone morphogenetic protein-2 and transforming growth factor beta, the potent inducers of new bone formation, have been recently detected in TO immunohistochemically and may have some decisive roles in the pathogenesis [356]. Surgical treatment has been recommended only in symptomatic patients [35, 186, 250].

7.3 Inflammatory Lesions

7.3.1 Acute Infections

7.3.1.1 Epiglottitis

Acute epiglottitis (AE), or more precisely termed supraglottitis [121, 331], is a potential risk of fatal airway obstruction in previously healthy persons. In the past, AE was mainly a childhood disease caused by *Haemophilus influenzae* type B. Due to the introduction of an immunisation programme in the late 1980s, the disease has been steadily decreasing in children, but still has a high incidence in the adult population, more frequently in a form related to infections with pyogenic cocci [75,

87, 231]. The most consistently found presenting symptom is severe pain on swallowing. In children, breathing difficulties are often the predominant symptom. Other symptoms and signs are hoarseness, drooling, fever, tachycardia and toxic appearance [75, 87]. Reddish and evidently oedematous supraglottic area, including tongue and pharyngeal structures, is observed. Oedematous swelling rarely spreads to the glottic region.

Microscopic examination shows diffuse exudative inflammation with fibrin, neutrophils and erythrocytes involving supraglottic structures. An early complaint of dyspnoea may safely discriminate between patients requiring invasive airway management with intubation and conservative treatment with close observation [150].

7.3.1.2 Laryngotracheobronchitis

Laryngotracheobronchitis (LTB), also known as subglottic laryngitis, non-diphtheric croup, virus croup, spasmodic croup and fibrinous LTB, often occurs in children aged 1–3 years. Generally, LTB is of limited duration, caused by influenza, parainfluenza or other viruses. Prolonged infection by other pathogens may be also involved [170]. The onset of the disease is more gradual compared with acute epiglottitis. When fully developed, a croupy cough with inspiratory and expiratory stridor is present. Histologically, characteristic fibrinous laryngitis is observed with destruction of the respiratory epithelium. The mortality rate of the disease has remained low for many years [238, 353].

7.3.1.3 Diphtheria

Fortunately, laryngeal diphtheria is a matter of history now in the developed world. Very exceptionally, an individual case has been reported [137]. Histologically, dirty white, fibrinosuppurative membranes covering the laryngeal mucosa, accompanied by a foul smell, are characteristic of the disease [203].

7.3.2 Chronic Infections

7.3.2.1 Tuberculosis

Laryngeal tuberculosis (LT) was considered one of the most common diseases in the pre-antibiotic period, affecting the larynx in 35 to 83% of patients with pulmonary tuberculosis [268, 390]. By the 1980s, the disease had become very rare in the developed world, owing to the advent of antibiotic therapy, immunisation and improved social and economic conditions. However, since 1980, tuberculosis has again been showing a rising in-

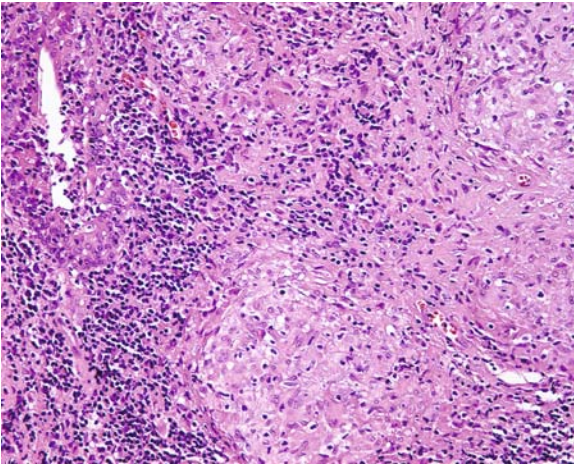


Fig. 7.3. Laryngeal tuberculosis. Granulomas are composed of epithelioid cells, Langerhans giant cells without necrosis, surrounded by mononuclear inflammatory cells

idence worldwide, including developed countries, owing to the spread of the HIV infection, poor living standards with malnutrition, the emergence of drug-resistant mycobacteria and immigration from countries where tuberculosis is still endemic [61, 78, 125, 184, 268, 311, 315]. Consequently, the World Health Organisation has declared tuberculosis to be a global emergency [258].

LT currently affects mostly males; the average age of patients is about 50, with a history of heavy drinking and smoking. The most common presenting symptom is dysphonia, followed by dysphagia, odynophagia, stridor, a cough, and haemoptysis, generally associated with more or less obvious signs of pulmonary involvement [315, 390]. The true vocal cords are most commonly affected, although the supraglottic region is also involved [311]. The majority of cases present as hypertrophic, exophytic, hyperaemic lesions, sometimes nodular or ulcerated.

Histologically, the subepithelial stroma contains caseating granulomas with a central caseous necrosis, surrounded by epithelioid macrophages, Langerhans-type giant cells and lymphocytes (Fig. 7.3). The covering epithelium may be normal, ulcerated or show pseudoepitheliomatous hyperplasia. Identification of *Mycobacterium tuberculosis* by special stainings or molecular genetic methods confirms the diagnosis of LB.

Differential diagnosis includes a large spectrum of granulomatous diseases, such as sarcoidosis, cat-scratch disease, fungal infections, Wegener's granulomatosis and tumourous lesions. Differentiation between sarcoidosis and tuberculosis is difficult. Generally, granulomas in sarcoidosis lack caseation and stainings for mycobacteria are negative. Cat-scratch disease can be ruled out by the presence of rounded or stellate gran-

ulomas containing central granular debris and neutrophils. Fungal granulomas can be confirmed by identification of the microorganism. Granulomas in Wegener's granulomatosis are not closely packed, fibrinoid necrosis of collagen is prominent and vasculitis is occasionally present.

The treatment of LT primarily consists of antituberculous treatment, while surgical procedure is reserved for cases of air compromise [390].

7.3.2.2 Fungal Infections

Fungal infections of the larynx are very rare, but may be expected to arise, though not exclusively, in immunocompromised patients. Mycotic infections tend to occur as a result of the dissemination of the fungi, especially from the bronchopulmonary foci. An important exception is laryngeal candidiasis, which usually occurs as a result of direct spread from the oral cavity [280]. Different types of mycotic infections have been reported, such as laryngeal *histoplasmosis* [302, 319], *cryptococcosis* [171, 236], *coccidioidomycosis* [41], *blastomycosis* [89, 307], *candidiasis* [280], *paracoccidioidomycosis* [317] and *aspergillosis* [272, 310]. The histological features are similar for each of these infections and range from granulomatous lesions related to histoplasma and cryptococcus, to abscess formation in blastomycosis and aspergillosis [291]. Pronounced epithelial hyperplasia with prominent ortho-parakeratosis or pseudoepitheliomatous hyperplasia in laryngeal blastomycosis, candidiasis and aspergillosis may mimic the squamous cell and verrucous cell carcinoma [272, 280, 307]. The identification of the causal agents by special silver, PAS or mucicarmine stains of the biopsy specimens and/or cultures of microorganisms are crucial for successful treatment.

7.3.2.3 Other Rare Infections

In non-European countries, the larynx is occasionally involved in rare infections, such as rhinoscleroma [7, 100, 275], leprosy [145, 342], leishmaniasis and trichinosis [238].

7.3.3 Non-Infectious Inflammatory Lesions

7.3.3.1 Wegener's Granulomatosis

Wegener's granulomatosis (WG) is a systemic disease characterised by necrotising vasculitis, formation of granulomas in the upper and lower respiratory tracts,

and glomerulonephritis. Limited forms of WG also occur, often with involvement of the respiratory tract, but without kidney involvement. The vast majority of patients have antineutrophil cytoplasmic antibodies (ANCA) in the serum with a characteristic cytoplasmic pattern (C-ANCA) [172].

The upper respiratory tract is the commonest presenting site of WG, mainly affecting the paranasal sinuses, followed by the nose, nasopharynx and larynx [82]. Local clinical symptoms and signs, such as rhinorrhoea, pain, mucosal ulcerations and hoarseness, are non-specific. They may be accompanied by systemic symptoms and signs, such as fever, weakness and weight loss [339].

Histological features include inflammation, necrotising granulomas, and vasculitis. Necrosis in WG has a patchy distribution, with serpiginous borders, and is usually basophilic, with a finely granular appearance. Granulomas tend to be loose, not closely packed as in sarcoidosis or tuberculosis [82]. Vasculitis typically involves small to medium-sized arteries and veins, with any of the following features: fibrinoid necrosis, fragmentation of the elastic lamina, acute and chronic inflammatory cells and granulomas. The lesions may undergo organisation and fibrosis.

The diagnosis of WG is based on clinical features, biopsy of the related lesions, and the cytoplasmic pattern of anti-neutrophil cytoplasmic antibodies (C-ANCA) in the serum [102]. A positive biopsy of the upper respiratory tract has a high predictive value, up to 100%, indicating few or even no false-positive results [173]. However, vasculitis is only rarely seen on biopsy. Histology often reveals non-specific features – inflammation and necrosis, with or without granuloma formation [397].

Wegener's granulomatosis should be differentiated from other forms of vasculitis, other granulomatous diseases, cocaine abuse, and from neoplasms, particularly NK/T lymphoma of the nasal type [339]. The presence of C-ANCA proves extremely helpful in differentiation from almost all the diseases mentioned [173].

Wegener's granulomatosis was almost universally fatal in the past, usually within a few months of the onset of clinically apparent renal disease. However, with modern immunosuppressive therapy, the prognosis of WG is excellent. A marked improvement is seen in 90% of patients and complete remission is achieved in 75% of patients [160]. Early detection of WG is essential to prevent fully developed disease. For WG at other sites in the head and neck, see also Chaps. 2 and 3.

7.3.3.2 Sarcoidosis

Sarcoidosis is a chronic granulomatous disease of unknown aetiology that can affect any organ system. In addition to the classic involvement of lungs, hilar and

mediastinal lymph nodes, the eyes, skin, liver, bones and nervous system may also be affected. Laryngeal involvement is usually a part of generalised disease with an incidence of 1–5% [72, 197]. However, laryngeal sarcoidosis can also appear as an isolated disease [40, 197, 263]. The supraglottic region is mostly affected, especially the epiglottis, aryepiglottic folds and arytenoids, showing oedematous, pale, diffusely enlarged mucosa with occasional nodularity, which has been considered the pathognomonic feature of laryngeal disease [29, 72, 263]. Subglottic and true vocal cord involvement is rare [40, 237, 263]. The disease is usually self-healing with an inconspicuous course including remissions and exacerbations.

Histologically, non-caseating and non-confluent granulomas are a characteristic feature. Granulomas are composed of epithelioid cells and Langerhans-type giant cells with no central necrosis. Two structures are often found in giant cells, although they are not pathognomonic for sarcoidosis: asteroid bodies are stellate crystalline inclusions, and laminated concretions, composed of calcium and proteins, known as Schaumann bodies. The sarcoid granulomas can be transformed into hyaline fibrous scars.

In histologically proven non-caseating granulomas, other laryngeal granulomatous diseases, such as infectious granulomatous diseases, granulomatous processes of unknown pathogenesis (Wegener's granulomatosis) and inhalant granulomatous processes (berylliosis, asbestosis), must be excluded [189]. No microorganisms are found in sarcoidal granulomas with some exceptions, such as cell wall-deficient forms of mycobacteria [294]. In contrast to tuberculosis and histoplasmosis, sarcoidal granulomas are non-caseating. Sarcoidosis lacks vasculitis, characteristic of Wegener's granulomatosis. Inhalant granulomatous diseases, which result in significant pulmonary fibrosis, rarely affect the laryngeal mucosa [189].

Early diagnosis and adequate treatment of laryngeal sarcoidosis is important to prevent upper airway obstruction and tracheotomy. Although the course of disease may be of long duration, spontaneous remissions usually occur. When treatment is necessary, the administration of intralesional or systemic steroids is performed [72].

7.3.3.3 Rheumatoid Arthritis

Rheumatoid arthritis (RA) is a chronic systemic, presumably autoimmune disorder, characterised by proliferative synovitis that often progresses to destruction of the articular cartilage and ankylosis of the joints. Other tissues and organs may also be affected, such as the skin, blood vessels, heart, lung, nervous system, etc.

Laryngeal involvement in RA includes arthritis of the cricoarytenoid and cricothyroid joints, and/or the formation of rheumatoid nodules in the soft tissue of the larynx [47, 95, 130].

Histologically, the acute phase of arthritis is characterised by swelling and thickening of the synovia, which is heavily infiltrated by mononuclear cells, resulting in villous hypertrophy. In the chronic phase, there is destruction of the articular cartilage and proliferation of fibrous tissue with obliteration of the joint spaces, rarely leading to bony ankylosis [47].

Rheumatoid nodules may develop in the soft tissue adjacent to the joints, or in the vocal cords. Microscopically, they consist of a central fibrinoid necrosis, surrounded by palisading macrophages, lymphocytes and plasma cells (Fig. 7.4) [95, 343].

In the acute phase symptoms and signs are usually mild, and consist of pain and voice disturbance. In the chronic phase, dyspnoea and respiratory obstruction may develop [2, 39, 95].

Arthritis and rheumatoid nodules are not pathognomonic of RA, but are also seen in patients with other autoimmune diseases, particularly systemic lupus erythematosus [241, 366].

Rheumatoid arthritis is treated by anti-inflammatory drugs and local administration of steroids by means of injection or aerosol; in rare cases, surgical therapy is needed to relieve airway obstruction [2, 27, 39, 95].

7.3.3.4 Relapsing Polychondritis

Relapsing polychondritis (RP) is a rare autoimmune disease characterised by progressive inflammation of cartilaginous structures, both elastic and hyaline, throughout the body [68, 233, 364]. The disease typically involves the ear, nose, eye, larynx and lower respiratory tract, costal cartilages, joints, cardiovascular system, renal tissue and central nervous system. The most serious consequence of RP in the larynx and trachea is destruction of the cartilaginous framework, with collapse of the airway and breathing difficulties. RP commonly affects patients between 40 and 60 years [208], and a female-to-male ratio of 3:1 was recently noted [364]. Aetiologically, there is strong indication of an autoimmune origin of RP [364], which has recently been supported by the finding of antibodies to type II collagen in two-thirds of patients [349], and linkage to the human leukocyte antigen DR4 gene and other autoimmune diseases. The onset of RP is generally sudden, with recurrent attacks of acute inflammation of the auricle. The diagnosis of RP is believed to be convincing if patients have at least three of the following involvements: bilateral auricular lesions, seronegative arthritis, nasal and ocular affections, respiratory tract

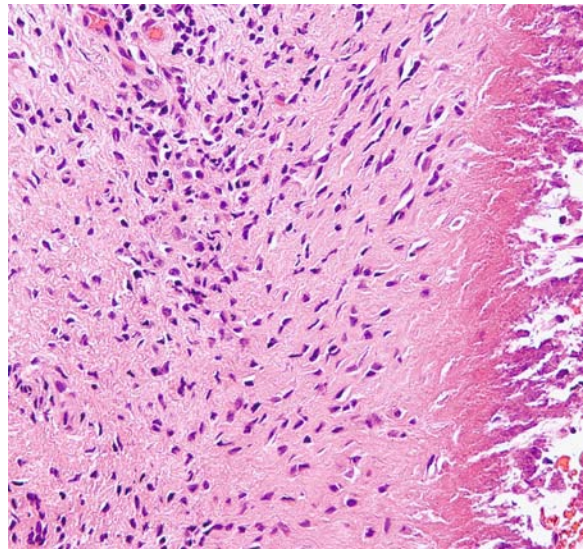


Fig. 7.4. Rheumatoid nodule of the vocal cord. Fibrinoid necrosis surrounded by palisading macrophages, lymphocytes and plasma cells

chondritis, audiovestibular damages and histological confirmation of the disease [233].

Hoarseness, coughing, dyspnoea, choking and tenderness over the laryngotracheal cartilages are symptoms of laryngeal and lower respiratory tract involvement [152]. Although airway obstruction could be localised to the glottic and subglottic area, a diffuse involvement of the respiratory tract is more common [247] and occurs in up to 50% of patients with RP [93].

Histologically, the affected cartilage shows distinct features: the cartilaginous matrix loses its basophilic staining; peri- and intracartilaginous inflammation is evident; inflammatory cells infiltrate the perichondrium and cartilage. The chondrocytes become vacuolated and necrotic, and fragmentation of cartilage is evident. With the progression of the disease, necrotic cartilage is replaced by granulation tissue and later by fibrosis. In the course of the disease, persistent inflammation can destroy the cartilaginous rings and cause luminal collapse.

Differential diagnosis includes all conditions that essentially show cartilage destruction: various infectious (tuberculosis and other bacterial, fungal, and viral infections), non-infectious diseases (sarcoidosis, Wegener's granulomatosis and other types of systemic vasculitides) and tumours (lymphoma, cartilaginous tumours).

Treatment for RP is based on systemic steroid and occasionally immunosuppressive therapy [261]. Involvement of the larynx and the lower respiratory tract is the most serious complication. The mortality rate reported

in 1972 was 50% [164], and had fallen to 10% 14 years later [239]. Early diagnosis can influence a better outcome, and survival rate appears more favourable than was previously thought [364].

7.3.3.5 Gout

Gout is a disorder of the purine metabolism typically identified by hyperuricaemia. The disease is characterised by temporary attacks of acute arthritis caused by precipitation of monosodium urate crystals within and about the joints. The course of the disease may eventually lead to deposition of urates in the joints and other soft tissues, creating tophi. The first attack of the disease is mainly monoarticular with a predilection to the first metatarsophalangeal joint. The head and neck region is rarely involved, although the classic site is the external ear. In addition, tophi may appear in the intervertebral discs, oropharynx, temporomandibular joint, and tongue. There has been limited evidence of chronic gouty involvement of the larynx, with less than 20 cases having been reported so far [365]. Acute gouty cricoarythenoid arthritis is the most common and may give rise to pain within the larynx, dysphonia, odynophagia, dysphagia or stridor. After repeated attacks, the articular cartilage is gradually destroyed leading to ankylosis of the joint. The fixed vocal cord may mimic growth of a malignant tumour [365]. Tophi of the laryngeal soft tissue are exceedingly rare [146], the involved mucosa of the vocal cords shows a granular surface [228]. The histological features of tophi are conspicuous, with large aggregates of needle-shaped urate crystals (birefringent crystalline deposits) surrounded by macrophages, foreign-type giant cells, lymphocytes and fibroblasts [146]. In more remote differential diagnostic possibilities, other lesions with deposition of various substances in the laryngeal mucosa, such as amyloid or Teflon, need to be considered.

7.3.3.6 Teflon Granuloma

Injection of Teflon paste (polytetrafluoroethylene) into the lateral thyroarytenoid muscle has been used in patients with unilateral paralysis of the vocal cord, with the aim of augmenting and medialising the paralysed hemilarynx. The increased bulk of the vocal cord could, therefore, contribute to a more complete glottic closure, prevent aspiration, and improve a poor-quality voice caused by impaired breathing. The most common cause of vocal cord paralysis is surgical trauma of the laryngeal recurrent nerve and/or malignant tumours [31, 370, 385]. In general, Teflon injection has been well tolerated, and after a short-lived inflammatory reaction, it becomes stable and walled-off by surrounding fibrosis

[31, 210]. Technical errors during injections, such as over injection or misplaced injection of Teflon may, however, cause dysphonia and airway obstruction, as well as the presence of a neck mass, resembling a neoplasm, in the case of an escape of Teflon via the cricothyroid membrane [264, 370].

Teflon granulomas (TGs) are submucosal polypoid lesions of the vocal cord. Histologically, they are composed of a foreign body giant cell reaction with extension to the underlying muscle and cartilage. Teflon is present in foreign body giant cells, and also extracellularly, as glassy crystalline deposits that are characteristically birefringent under polarised light. A dense fibrotic tissue is evident over time, while the surrounding inflammatory infiltrate is not present [385]. TG is treated by conservative surgery, although the results are unpredictable [31]. There have been no reports of cancer development in TG [385]. With the introduction of laryngeal framework surgery and medialisation laryngoplasty, fewer centres nowadays additionally advocate Teflon injection [370].

7.3.3.7 Idiopathic Subglottic Laryngeal Stenosis

Idiopathic subglottic stenosis (ISS) is a rare, slowly progressive inflammatory disease of unknown aetiology involving mainly the region of cricoid cartilage and the first tracheal ring. The pathogenesis of the disease remains hypothetical. ISS has recently been associated with various possible causes, such as gastro-oesophageal reflux, autoimmune diseases and previous infections of the respiratory tract [30, 174, 369]. Maronian and co-workers suggested that the term ISS should even be replaced by reflux-induced subglottic stenosis, if there is no other clear cause of the disease [229]. ISS has a strong female predilection [73, 132, 369]. The age of females when the symptoms start to appear ranges from 15 to 75 years (average 43.5 years) [73].

The diagnosis of disease is a matter of exclusion, and all other possible causes of a subglottic stenosis must first be ruled out. Aetiologically, subglottic stenoses are most commonly linked to endolaryngeal trauma, especially after prolonged intubation. Other diseases, including infections, laryngotracheal localisation of systemic diseases such as Wegener's granulomatosis and other collagen vascular diseases, amyloidosis and sarcoidosis, are rarely associated with laryngeal stenosis. Various benign and malignant tumours may also resemble ISS [132, 281]. ISS usually presents as dyspnoea, a cough and dysphonia [30, 73, 369].

Histological examination characteristically shows a spreading of dense fibrous tissue, extending up to the surface of the epithelium. Fibrosis is usually poorly cellular, with prominent augmentation of thick col-

lagenous fibres. Some inconspicuous chronic inflammatory infiltrate may be present around blood vessels, without evidence of vasculitis. The covering epithelium, squamous or respiratory, may be reactively hyperplastic. ISS is a chronic lifetime disease that requires multiple surgical dilatations for palliation [73]. Evaluation for laryngopharyngeal reflux disease should be performed with pharyngeal pH testing in all patients, in an attempt to clarify the aetiology of ISS [229]. More severe cases are managed with laryngotracheal resection and reconstruction [369].

7.3.3.8 Angioneurotic Oedema

Angioneurotic oedema (ANO) is a rapidly appearing, recurrent, non-pitting oedema of the subcutaneous and/or submucosal tissues causing a life-threatening condition, affecting the larynx, hypo- and oropharynx and oral cavity [144]. ANO can occur as a result of hereditary and acquired deficiencies in the immune and non-immune responses [81]. Several forms of ANO are recognised:

1. IgE-dependent, caused by pollens, foods, drugs, fungi, cold, sun and exercise;
2. Complement-mediated, hereditary and acquired with deficiency of the C1 esterase inhibitor of the complement cascade;
3. Non-immunologic, direct mast cell-releasing agents caused by different drugs and aspirin, and other non-steroidal anti-inflammatory drugs that alter the arachidonic acid metabolism;
4. Idiopathic [13].

Angioneurotic oedema, either acquired or hereditary, is characterised by sudden onset with full development within a few hours and fades over the course of 48–72 h. Gastrointestinal mucosa may also be affected, mainly in the hereditary disease, causing severe abdominal pain, nausea, vomiting and diarrhoea. Various degrees of laryngeal oedema may be present, affecting mainly the anterior surface of the epiglottis, aryepiglottic folds, base of the tongue and hypopharynx [238]. Generally, ANO resolves without harm, but laryngeal and tracheal oedema may cause asphyxiation and remains a considerable cause of death [90, 362]. The frequency of attacks in hereditary forms varies considerably from less than 1 to 25 per year. Lesions can be solitary or multiple, and primarily involve the extremities, larynx, face and bowel wall [90]. Emergency treatment is required if the process leads to respiratory distress because of laryngeal involvement.

7.4 Degenerative Lesions

7.4.1 Oculopharyngeal Muscular Dystrophy

Oculopharyngeal muscular dystrophy (OPMD) is a late-onset, dominantly inherited, slowly progressing disease, carried by a limited expansion of the triplet of GCG nucleotides in the *PABP2* gene on chromosome 14q11 [43]. Although OPMD has a world-wide distribution, its prevalence is highest in patients of French-Canadian origin [129, 155]. The onset of disease occurs in middle life, most often presenting with ptosis and a slight degree of ophthalmoplegia, followed later by dysphagia and often proximal limb weakness. The disease progresses slowly, but the dysphagia may be severe and has been reported to be a cause of death by starvation in several cases [316]. Muscle biopsy reveals various changes in muscle fibres, such as atrophy and regeneration with an increased number of myocyte nuclei and their centripetal orientation. Some findings, such as intracytoplasmic rimmed vacuoles, found by light microscopy, and intranuclear filament inclusions, seen by electron microscopy, are its pathological hallmarks [316]. Hill and co-workers provided confirmation that the detection of expanded GCG-repeated lengths in the *PABP2* gene is a reliable diagnostic test for OPMD in the English population [155]. However, their results were not in accordance with other molecular studies [43]. Simple procedures such as blepharoplasty and cricopharyngeal myotomy considerably improve the quality of life of these patients [129].

7.5 Pseudotumours

7.5.1 Exudative Lesions of Reinke's Space

The special anatomic framework of Reinke's space is considered essential for the development of a group of so-called exudative benign lesions of the vocal cords, including Reinke's oedema (RO), vocal cord polyps (VCPs) and nodules (VCNs) [177, 179, 181, 238, 308]. Each of three entities has its own clinical and morphological specificities [85], but most of them overlap. The common basic pathogenetic mechanism is blood vessel injuries with accumulation of oedematous fluid in Reinke's space [85, 308].

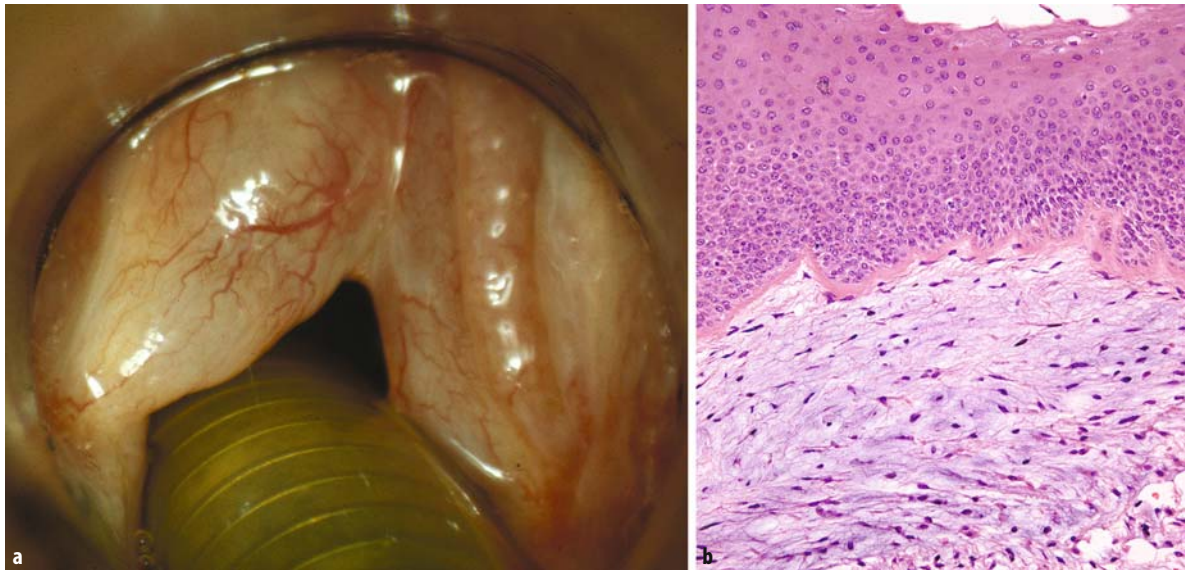


Fig. 7.5. Reinke's oedema. **a** Diffuse oedematous swelling in the entire length of both vocal cords. **b** Diffusely oedematous, blue-coloured subepithelial stroma is lined with hyperplastic squa-

mous epithelium with thickened basement membrane. Epithelium shows hyperplasia of basal and parabasal cells

7.5.1.1 Reinke's Oedema

Reinke's oedema is a chronic, diffuse, mainly bilateral, oedematous swelling of the membranous part of the vocal cords [177]. Several synonyms for RO have been used, such as polypoid vocal fold, polypoid degeneration, chronic polypoid chondritis and chronic oedematous hypertrophy [320]. The specific morphologic features of Reinke's space, such as sparse lymphatic drainage and its sharply demarcated borders, except the lateral one, contribute to the development of RO [158, 177, 179, 308, 309]. Various mechanical and chemical aetiological factors are related to the development of RO, including overuse or abuse of the voice, and cigarette smoking. The role of constitutional and hormonal disturbances such as hypothyroidism, remains uncertain [32, 177, 308, 395]. The lesion appears most commonly in women of 20–40 years of age with hoarseness as the leading symptom.

Laryngoscopically, the surface of the swollen vocal cords along their entire length is smooth, translucent and jelly-like, with a clearly visible capillary network. Incision yields a characteristic yellowish or gelatinous fluid (Fig. 7.5a) [177, 226].

Histologically, an excessive accumulation of oedema is a leading microscopic feature. Increased thickness of the walls of the teleangiectatic blood vessels, and thickening of the epithelial basement membrane complete the classical triad of morphologic changes. The sulphated glycosaminoglycans are probably responsible for the characteristic blue-coloured abundant amorphous material in the subepithelial stroma in haematoxylin and

eosin (H&E)-stained slides (Fig. 7.5b) [238]. Fragility and alterations in the walls of blood vessels, such as thin endothelium with many fenestrae and vesicles, and thickened basement membrane, revealed by electron microscopy, are considered important in the development of RO [320]. Connective tissue proliferation, especially with aging of the lesion, makes the lesion irreversible unless surgical removal is provided. Changes in the covering squamous epithelium of all three exudative lesions are expected to be only reactive (squamous cell hyperplasia, basal and parabasal cell hyperplasia) and may turn with aging and enlargement of the lesions into atrophic epithelium. Exceptionally, 12 (1.7%) patients with potentially malignant lesions (atypical hyperplasia, and LIN I and II) were found in a review of two comprehensive studies. No malignant alteration was reported within these two studies [177, 226].

In the early stage, only voice rehabilitation and avoidance of irritating factors should be attempted. However, microlaryngoscopic excision is required in the great majority of cases. Following surgery, voice therapy is often indicated [32, 177, 386].

7.5.1.2 Vocal Cord Polyp and Nodule

Vocal cord polyp (VCP) and vocal cord nodule (VCN) are fairly common benign reactive lesions, causally related to phonotrauma and vocal abuse [85, 175, 177, 181, 194, 308]. The distinction between a VCP and VCN is

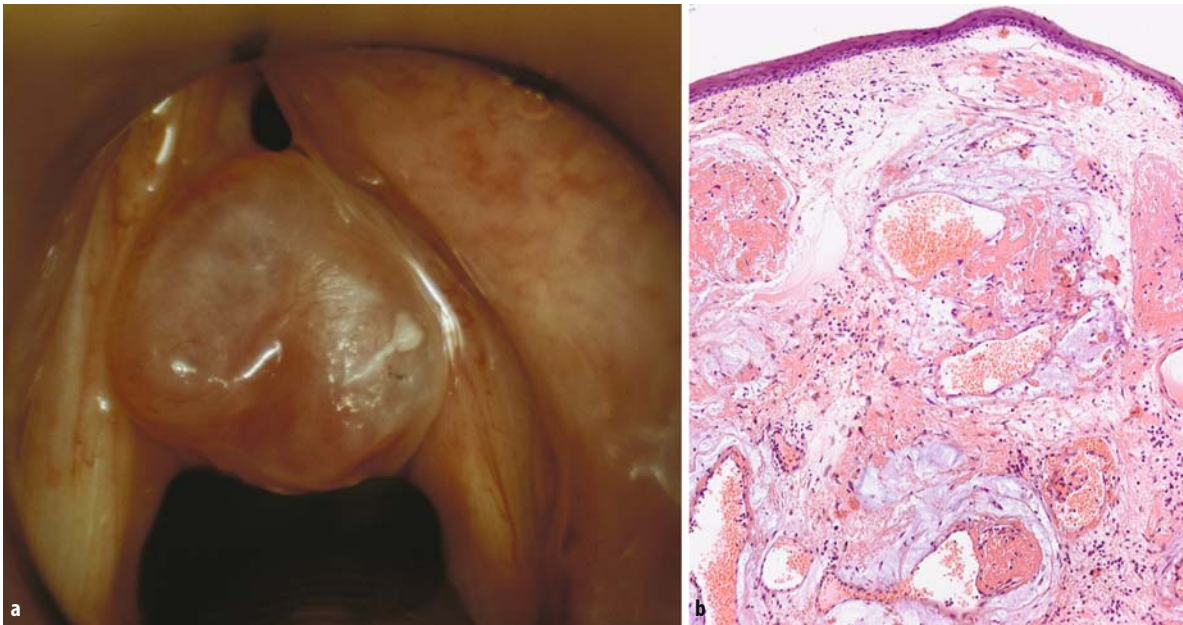


Fig. 7.6. Vocal cord polyp. **a** Huge vocal cord polyp arising from the middle third of the right vocal cord. **b** Myxomatous fibrous tissue with fibrin deposition and dilated blood vessels

probably only a matter of terminology, since both exhibit similar aetiology, pathogenesis, and to a certain degree, similar histologic characteristics.

A VCP is a pedunculated or sessile, mono- or multilobulated lesion, measuring up to 10 mm in diameter, and located between the anterior and middle thirds of the vocal cord [177]. Bilateral polyps are found in only 15% of cases [21]. They affect primarily adults between 20 and 50 years of age, although they may also occur in other age groups. Men are affected at least twice as frequently as women [177, 181, 194].

Vocal chord nodules are smaller, often bilateral, sessile, fusiform swellings of the vocal cords, positioned symmetrically, and rarely exceed 2 mm in diameter. They usually occur in children, more frequently in boys with the peak between the ages of 5 and 10 years [363]. In adults, the highest incidence of these lesions is in young to middle-aged women. VCNs are considered to be the most common benign lesions of the vocal cords [177, 386].

In addition to phonotrauma and vocal abuse, cigarette smoking, unfavourable occupational exposure, infections and endocrine dysfunction, are also considered to be possible aetiological factors of VCPs [175, 177, 181, 194, 308]. VCNs are mainly caused by chronic misuse and overuse of the voice, as well as by emotional disturbances in children, and hormonal disorders and smoking in adults [4, 177, 308].

Damage of the subepithelial blood vessels is the initial event in the evolution of a VCP or VCN. However, the morphology of the two exudative lesions depends on

the severity of the initial damage and repeated injuries [123, 138, 177, 181, 194, 308].

The gross appearance of a VCP varies from a glassy translucent gelatinous formation, to congested and purple red in teleangiectatic variants, and finally, to whitish, firm and opalescent in the predominant fibrous forms at the end stage of the lesions (Fig. 7.6a). VCNs start as a soft reddish swelling. Gradually, when the fibrous tissue proliferates, the VCNs become firmer, whitish in colour, and conical in shape.

Hoarseness is the predominant clinical symptom in both lesions. A great variety of voice changes, ranging from mild hoarseness to complete aphonia, is found, depending on the location and size of the lesions [21, 94, 177, 181, 352].

Histologically, different stages of VCP development are noted. Initially, the subepithelial stroma is diffusely oedematous with dilated vessels. After severe or repeated injuries, massive leakage of oedema, mainly fibrin as amorphous hyaline pink material, and erythrocytes, are the predominant features in the vicinity of the angiectatic vessels, which may also be thrombotic (hyaline forms of the VCP). Evidently dilated vessels, haemorrhages with consequent haemosiderosis and conspicuous ingrowths of new blood vessels create the angiectatic or vascular stage of the VCP (Fig. 7.6b). Finally, the lesions may be transformed into a fibrous variant containing an increased amount of fibrous tissue and blood vessels. Not infrequently, mixed type VCPs are seen, composed of two or more different histologic patterns [21, 123, 177, 194, 308].

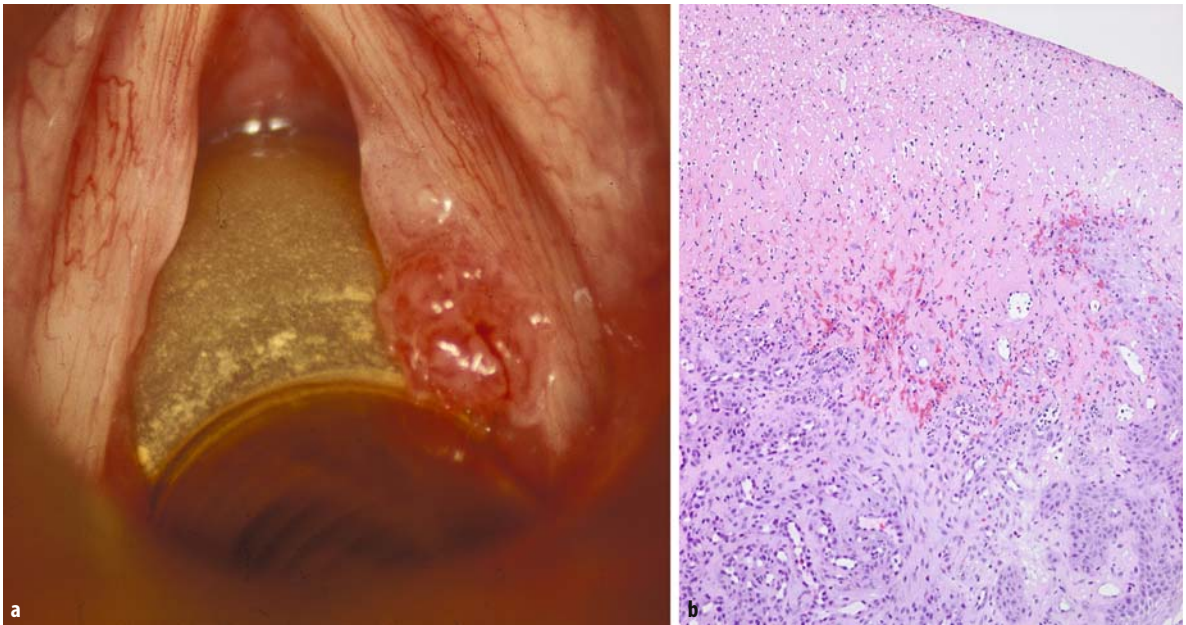


Fig. 7.7. Intubation granuloma. **a** Exophytic intubation granuloma located on the posterior third of the right vocal cord. **b** Pol-

ypoid granulation tissue is ulcerated with re-epithelialisation at the edge

Rarely, scattered atypical stromal cells, not associated with increased mitotic activity, may be found within the core of the VCP. This finding must not incorrectly lead to a diagnosis of malignancy [383].

In the initial stage, VCNs show diffusely oedematous tissue with distended capillaries and venules and tiny perivascular haemorrhages surrounded by a minimal or moderate inflammatory reaction. In time, the loose connective stroma is replaced by a mild to moderate cellular fibrous tissue changing in varying stages of evolution.

As previously mentioned, the covering squamous epithelium in both lesions shows predominantly benign reactive changes. In 4 (0.8%) patients, potentially malignant changes (atypical hyperplasia) were noted in the covering epithelium, but there were no data on malignant alteration [177, 226].

The treatment of choice for VCPs is microlaryngoscopic surgical removal. Childhood VCNs may disappear in puberty. Small incipient VCNs in adults may also vanish spontaneously or after voice rehabilitation. Surgical intervention is indicated when there is no improvement after conservative treatment.

7.5.2 Contact Ulcer and Granuloma, Intubation Granuloma

Contact ulcer (CU), granuloma (CG) and intubation granuloma (IG) are benign, inflammatory, exophytic or ulcerative lesions, usually located in the posterior third

of the glottic area. Aetiologically, the lesions arise in response to various mechanical and chemical injuries, such as voice abuse or protracted forceful coughing, acid regurgitation and intubation injuries. They display similar symptomatology and clinical appearance, and more or less identical histopathological features and prognosis [16, 28, 77, 177, 180, 374, 383, 384].

Excessive shouting or coughing cause repeated microtraumas of the thin mucosa of the vocal cord processes. They strike each other in phonatory adduction of the arytenoids, which leads to the development of ulcerative or exophytic lesions of one or both vocal cords [384]. Additionally, acid regurgitation due to hiatal hernia or gastritis may cause the same type of lesions in the posterior glottic area.

Intubation granuloma is an undesired sequel of intubation tube pressure during anaesthesia or intensive care treatment.

Intubation granulomas are more common in females, while hyperacidic granulomas and CU/CGs are predominant in males [104, 177, 180, 383].

Clinically, ulceration or exophytic lesions can be found, mono- or multilobular, frequently bilateral, measuring up to 15 mm in diameter, that range from pale grey to dark red, sometimes with an ulcerated surface (Fig. 7.7a). Hoarseness, the sensation of a foreign body, coughing, a sticking sensation, pain in the throat, and the feeling of acidity, are the prevailing symptoms in all three types of lesions.

Histologically, an ulceration of the posterior mucosa, covered by necrotic tissue and fibrin, is initially seen.

The depth of the ulcers may vary from superficial to deep lesions extending down to the perichondrium of the arytenoid cartilage. The localised necrosis of the epithelial and subepithelial tissue triggers an acute inflammatory reaction, with proliferation of granulation tissue initially infiltrated by neutrophils and later by macrophages, lymphocytes and plasma cells (Fig. 7.7b). The marginal epithelium starts to proliferate, some regenerative atypia of epithelial cells, such as plump nuclei, and increased mitoses may be present [217, 383].

An exuberant proliferation of granulation tissue forms an exophytic polypoid lesion. New vessels are characteristically arranged radially from the base to the fibrin-covered surface of the lesion. Approximately 1 week after the initial injury, connective cells and collagenous fibres become more abundant and finally the predominant elements in the granuloma, which in the end stage is entirely covered in squamous epithelium. The covering epithelium is usually considerably thickened due to hyperplasia of the prickle cell layer or, rarely, of the basal and parabasal layer [177, 180].

The basis of therapy in CU/CGs and hyperacidic granulomas is the elimination of causative factors, voice rest, voice re-education, dietary measures, prohibition of smoking and alcohol abuse, and medical therapy such as antacids, corticosteroids and vitamins [224]. IGs frequently do not require treatment due to their self-limiting nature. In refractory cases, surgical treatment is indicated, either microsurgery or CO₂ laser [28].

7.5.3 Necrotising Sialometaplasia

Necrotising sialometaplasia (NS) is a rare, benign, self-healing inflammatory lesion involving the minor salivary glands, primarily of the hard palate. The lesion is discussed in detail in Chap. 5. Here, some specificities of the extremely rare appearance of NS in the larynx are presented [373, 380, 383]. According to previous reports [373, 380], as well as our own experience, NS occurs in the larynx secondary to trauma or concomitantly with other non-neoplastic or neoplastic lesions. The pathogenesis is probably associated with ischaemia. Laryngeal NS appears in the supraglottic and subglottic regions where seromucinous glands are present as a deep ulcerative or submucosal nodular lesion. The most prominent histologic characteristics that help to distinguish the lesion from various forms of laryngeal carcinomas are: preservation of the lobular architecture of the necrotic glandular islands, the appearance of epithelial-myoeepithelial islands with smooth margins, no cellular atypia or occurrence of pathologic mitoses in the rest of the cellular part, and the retention of the lumina in preserved ductal formations. The appearance of surface pseudoepitheliomatous hyperplasia may cause additional problems in differential

diagnosis with laryngeal cancers, especially when frozen section analysis is performed. The duration of the healing process is related to the size of the lesion [380].

7.5.4 Metaplastic Elastic Cartilaginous Nodules

Metaplastic elastic cartilaginous nodules (MECN) are small (less than 1 cm) fibroelastic lesions occurring most frequently in the posterior and mid-portions of the glottis and ventricular bands. Cartilaginous nodules are composed of a peripheral rim of fibroblasts with transition into fibroelastic cartilage towards the centre [112]. Aetiologically, an association with laryngeal trauma has been suggested [277]. The development of MECN shows a smooth transition from the initial accumulation of acid mucopolysaccharides between the collagen bundles and their separation, to transition of fibroblasts to enlarged, rounded cells resembling chondrocytes. Aggregates of elastic fibres are present in the centre of the lesions [156]. Nodules are usually covered by intact mucosa.

Metaplastic elastic cartilaginous nodules are rarely clinically relevant [277]. We should be aware of their possible existence and distinction from chondroma and low-grade chondrosarcoma. Chondroma has a characteristic lobular pattern and low cellularity, which is not the case with MECN. Low-grade chondrosarcomas differ mainly from MECN in their locations, and cellular and structural atypia [277].

7.5.5 Amyloidosis

Amyloidosis is a heterogeneous group of disorders associated with extracellular deposition of an abnormal fibrillar protein with pathognomonic tinctorial properties. It may be hereditary or acquired, localised or systemic in distribution. The current classification of amyloidosis is based on the biochemical composition of its peptide subunits [131].

Laryngeal amyloidosis (LA) is rare and is mostly a localised disease. In the majority of LA cases, the amyloid is composed of immunoglobulin light chains (AL amyloid). LA may occasionally be part of systemic disease or can be associated with a tumour, such as neuroendocrine carcinoma of the larynx or medullary carcinoma of the thyroid [359].

Laryngeal amyloidosis primarily affects patients between 40 and 60 years of age, more frequently males [298]. A few cases have been reported in children [273]. All parts of the larynx can be affected [359], but in some studies the supraglottis was the most common site of involvement [159]. It can affect the larynx multifocally, and can also extend to the tracheobronchial tree. The main symptom is hoarseness, in some patients accompanied by dysphagia, dyspnoea, or haemoptysis [159].

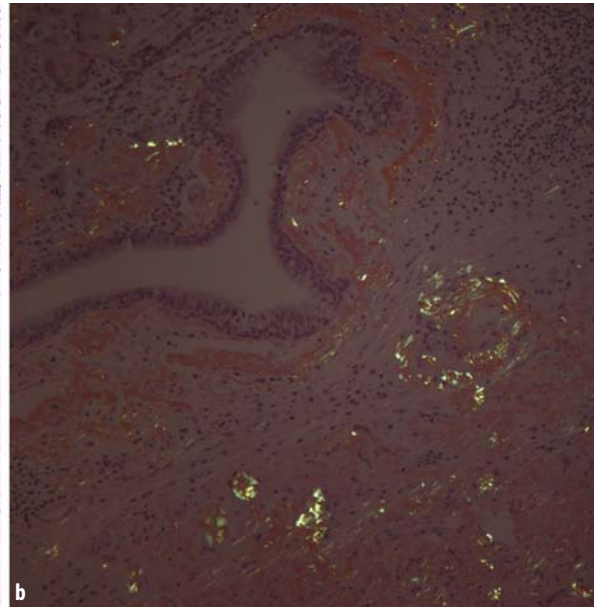
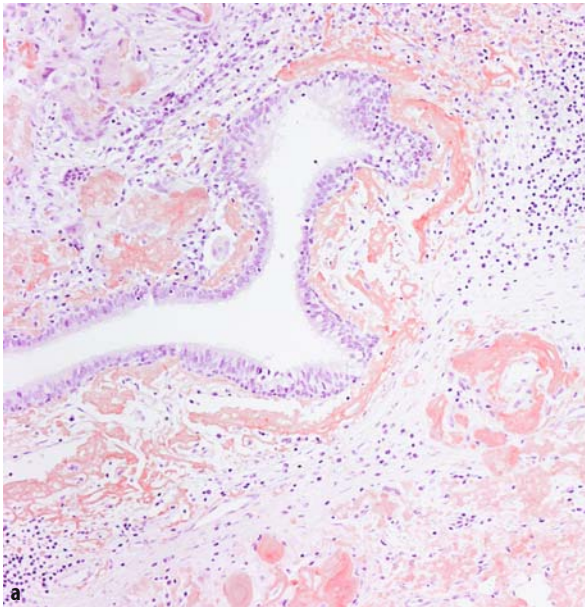


Fig. 7.8. Amyloidosis of the larynx. **a** Scattered reddish masses of amyloid are seen in the subepithelial stroma by Congo red stain-

ing. **b** The same field, green birefringence of the amyloid with polarised light

Grossly, the affected area of the larynx is swollen, sometimes polypoid, covered by an intact mucosa. On a cut surface, it is firm, pale, waxy, tan-yellow to red-grey [359]. Microscopically, H&E staining shows the deposition of an amorphous, eosinophilic, hyaline, extracellular substance in the subepithelial stroma, blood vessel walls, and along the basement membranes of seromucinous glands, with intact covering epithelium. The deposits may be discrete, or may appear as large rounded masses of variable size. They stain with Congo red and display green birefringence with polarised light; this property remains the diagnostic gold standard (Fig. 7.8). Immunohistochemical analysis must also be performed to determine the amyloid type [131].

Most patients can be successfully treated by a conserving surgical excision to preserve laryngeal function for as long as possible. In some patients, multiple procedures may be necessary, and recurrences may occur. A fatal outcome has been described in patients with progressive tracheobronchial involvement, but association with systemic amyloidosis is rare [59]. Clinical examination is advised to exclude the possibility of a systemic disease.

7.5.6 Sinus Histiocytosis with Massive Lymphadenopathy and Other Rare Pseudotumours

Sinus histiocytosis with massive lymphadenopathy (SHML), or Rosai-Dorfman disease, is an idiopathic, relatively rare benign lesion, based on a nodal and/or extranodal histiocytic proliferative disorder that usu-

ally resolves spontaneously. The most frequent clinical manifestation of the disease is cervical, bilateral and painless lymphadenopathy. However, extranodal sites may also be involved and the head and neck region is one of the most commonly affected areas [381]. Extranodal disease may be the initial or sometimes the sole manifestation of the disease. Foucar and co-workers reported that 43% of patients had at least one site of extranodal location of SHML [118]. Within the head and neck, the nasal cavity, paranasal sinuses and orbit are commonly involved. Some cases of laryngeal lesions have been reported too [5, 11, 52, 66, 118, 207]. Typically, the SHML begins insidiously and progresses to a protracted course of the active stage, and ends with spontaneous remission. SHML occasionally appears with subsequent recurrence and serious consequences, occasionally even death, if vital organs are affected. Exclusive extranodal disease is more frequent in elderly persons [51]. Laryngeal SHML usually manifests as a circumferential narrowing or polypoid mucosal lesion of a tan-white to yellow appearance. Vocal cord involvement results in impaired mobility [51].

Histologically, the laryngeal mucosa is almost diffusely infiltrated by lymphocytes, plasma cells, neutrophils and clusters of histiocytes. Histiocytes are of various sizes, with a focally vacuolated pale to pink cytoplasm, but ill-defined borders. Their nuclei are round or oval, sometimes vesicular, with well-defined central nucleoli. Lympho- and granulophagocytosis is evident in the cytoplasm of these histiocytes; the phenomenon is termed emperipolesis. Immunohistochemical-

ly, the histiocytes are strongly positive for S-100 protein and Leu-M1. No nuclear and cytoplasmic atypia is observed.

Differential diagnosis includes infectious diseases (rhinoscleroma), Wegener's granulomatosis, NK/T lymphoma of the nasal type, eosinophilic granuloma, Hodgkin's lymphoma and fibroinflammatory disorders. Rhinoscleroma is characterised by a proliferation of large macrophages (Mikulicz cells) in which *Klebsiella rhinoscleromatis* can be identified. In this disease the phenomenon of emperipolesis is not found. Histologically, in Wegener's granulomatosis the S-100 positive histiocytes are lacking, while NK/T lymphoma of the nasal type shows an infiltration of malignant lymphoid cells. Eosinophilic granuloma is histologically similar to Rosai-Dorfman disease, but differentiation is possible with the morphologic specificities of the Langerhans cells, characteristic of eosinophilic granuloma: their nuclei show lobulation, indentation or longitudinal grooving. Finally, fibroinflammatory lesions, such as aggressive fibromatosis, can be easily differentiated due to the relatively acellular appearance compared with the characteristic cellular infiltration in Rosai-Dorfman disease [381].

Some rare laryngeal lesions may clinically and pathologically mimic neoplastic growth and could be ranged in a category of pseudotumours: hamartoma [282, 314], warty dyskeratoma of the vocal cord [178], and Kimura disease of the epiglottis [58].

7.5.7 Inflammatory Myofibroblastic Tumour

ICD-O:8825/1

Inflammatory myofibroblastic tumour (IMT) is clinicopathologically a well-defined fibroinflammatory proliferative lesion with unpredictable biological behaviour. Lung, gastrointestinal and genitourinary tract systems are the commonest sites for IMT, although the lesion has been reported throughout the body [382]. It rarely affects the head and neck region, and only a few well documented IMTs have been found in the larynx and pharynx [65, 96, 167, 188, 382].

The aetiology of the lesion is unknown, but different infections with an exaggerated response to some unknown microorganism or post-traumatic events have been attributed as causal factors [9, 76, 167, 382]. Most reported laryngeal IMTs are polypoid or pedunculated lesions that occur in the true vocal cords or in the subglottic area. Hoarseness, foreign body sensation, dyspnoea and stridor are presenting symptoms. Patients with laryngeal IMTs are mainly adult males [382].

Histologically, IMT is composed of myofibroblastic spindle cells, admixed with a prominent infiltrate

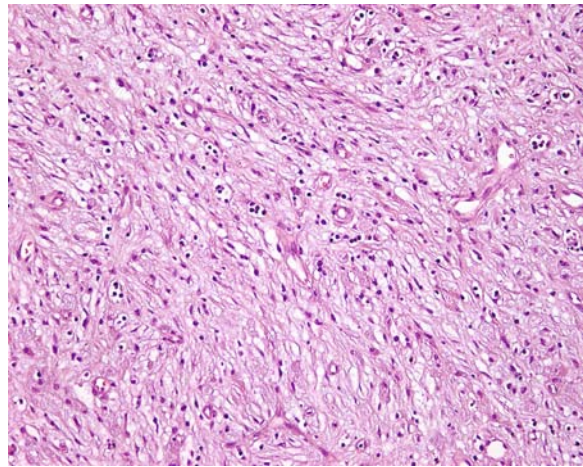


Fig. 7.9. Inflammatory myofibroblastic tumour. Lesion is composed of uniform spindle cells, intermingled with inflammatory cells

of lymphocytes, plasma cells and neutrophils. The nuclei of the spindle cells are elongated, slightly polymorphous, containing one or more small nucleoli, the cytoplasm is palely eosinophilic (Fig. 7.9). Occasional regular mitoses are seen. Inflammatory cells are unevenly distributed within the lesion.

Three basic histological patterns have been described:

1. Myxoid/vascular pattern, resembling inflammatory granulation tissue;
2. Compact spindle cell pattern with fascicular and/or storiform areas with various cellular density;
3. Hypocellular pattern, densely collagenised and reminiscent of a fibrous scar [64].

Immunohistochemistry confirms the myofibroblastic phenotype of the spindle cells, which are typically reactive to vimentin, smooth muscle actin, and muscle-specific actin [64, 382]. Additionally, ALK1 and/or p80 were reported in a cytoplasmic pattern in 40% of cases of IMT [56]. Both markers are useful indicators of a 2p23 abnormality, suggesting the neoplastic nature of positive cases of IMT. However, it must be interpreted in the context of histologic and other clinicopathologic data if used as an adjunct to differential diagnosis [56].

Radical excision of the lesions has been reported to be curative in more than 90% of extrapulmonary IMTs, including head and neck lesions [63]. Six out of seven patients with laryngeal IMTs in Wenig's series were free of disease over periods of 12 to 36 months after complete excision. In one patient, laryngectomy was required after recurrence of the disease [382]. A metastatic potential has been exceptionally noted in patients with abdominal and mediastinal IMTs. However, a fatal outcome of a patient with IMT of the paranasal sinuses has

been recently reported [124]. Aggressive behaviour supports recent observations that at least a subset of IMTs represents true neoplasms rather than reactive myofibroblastic proliferation [124, 165].

Differential diagnosis mainly includes spindle-shaped lesions, such as spindle cell carcinoma, different types of sarcomas and lesions composed of myofibroblasts and fibroblasts. The presence of cytokeratin reactivity cannot reliably distinguish between spindle cell carcinoma and IMT. In contrast, a lack of nuclear atypia and considerable mitotic activity favour a diagnosis of IMT and help to differentiate the lesion from different variants of laryngeal malignant tumours. Compared with myofibroblastic lesions, IMTs are generally larger than nodular fasciitis, tend to occur in younger age groups and are composed of longer fascicles of spindle cells in an inflammatory background rich in plasma cells [333]. In contrast, nodular fasciitis usually lacks the striking inflammatory infiltrate characteristically present in IMT. The recently described laryngeal myofibroblastoma shares many similarities with IMT, except for a lack of inflammatory infiltrate and could be considered its pure spindle cell proliferation form [218].

7.6 Benign Neoplasms

7.6.1 Squamous Cell Papilloma

ICD-O:8052/0

Squamous cell papillomas (SCPs) are the most common benign epithelial tumours of the larynx, causally related to human papillomavirus (HPV) infection. SCPs are discussed in detail in Chap. 1.

7.6.2 Salivary Gland-Type Tumours

7.6.2.1 Pleomorphic Adenoma

ICD-O:8940/0

Pleomorphic adenoma (PA) has rarely been reported in the larynx [88, 219, 323]. To date, only about 20 cases have been described. Men predominate slightly over women, and the patients' ages range from 15 to 82 years [88]. The supraglottis is by far the most common site of origin. PA, which may grow up to several centimetres in diameter, occurs as a submucosal mass without ulceration. Histologically, PA shows all the characteristics of a tumour arising in the major salivary glands (see Chap. 5). The diagnosis of laryngeal PA should be considered very carefully due to its rarity in this location and other tumours, such as chondrosarcoma, adenoid

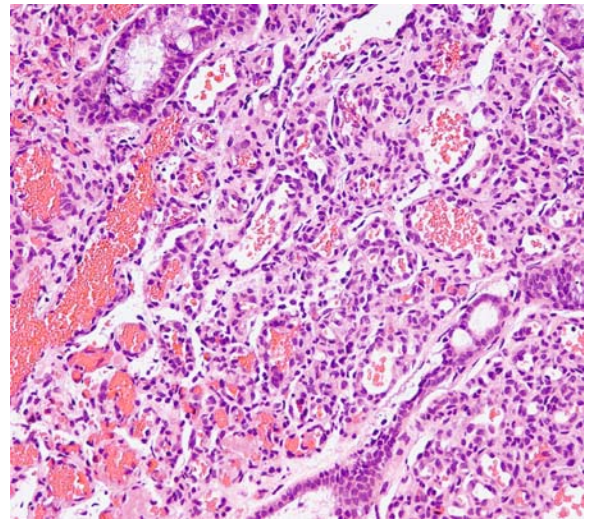


Fig. 7.10. Subglottic haemangioma. A dense proliferation of capillaries infiltrates the subepithelial stroma around ductal structures

cystic carcinoma and mucoepidermoid carcinoma, need to be excluded.

7.6.2.2 Oncocytoma

ICD-O:8290/0

As has been previously discussed in the Sect. 7.2.5, the whole spectrum of laryngeal oncocytic lesions may be considered to be ductal hyperplasia and metaplasia with a cystic character rather than true neoplasms. Solid oncocytoma of the larynx, similar to those in the major salivary glands, probably does not exist in this location.

7.6.3 Haemangioma (Neonatal and Adult Types)

ICD-O:9120/0

Laryngeal haemangiomas (LH) are uncommon lesions of vascular origin, defined as benign proliferation of the blood vessels. They are divided into two distinct clinicopathologic entities: the neonatal and adult forms.

Neonatal LH is a rare congenital malformation characteristically involving the subglottic area. Although the lesion is present at birth, symptoms become clinically evident during the first 6 months. A progressive croup-like disease with inspiratory stridor turns into biphasic stridor as the obstruction progresses. Characteristically, the symptoms are intermittent, accentuated during crying, when the vessels are filled up under increased pressure [195, 196, 290, 312, 328].

Subglottic LH appears more frequently in girls, with a ratio of 2:1 [334]. A co-existence of haemangiomas of the skin and mucosa of the oral cavity and pharynx, as well as in other organs [195, 337], may also be an important indicator of disease.

The gross appearance of the lesion ranges from a flat to polypoid, soft, compressible submucosal mass, pink-reddish to blue in colour. The lesion is usually one-sided, and is located in the posterolateral subglottic area. However, some haemangiomas are horseshoe-shaped and are present as a bilateral subglottic reddish swelling [195]. The diagnosis is based on characteristic clinical features and endoscopic appearance. Biopsy should be avoided because of an increased risk of excessive bleeding.

Laryngeal haemangiomas of adults, which are usually localised in the glottic and supraglottic region, are seen as inconspicuous, submucosal, reddish blue lesions. Common symptoms are hoarseness, dyspnoea and/or foreign body sensation [336].

Histologically, subglottic LHs are divided into capillary and cavernous forms. The majority of lesions are of the capillary type [334], consisting of the proliferating capillaries that infiltrate the surrounding submucosal structures (Fig. 7.10).

Vascular channels may be of various sizes, lined with plump endothelial cells in which some regular mitoses may be present. Vascular tissue is intertwined with fibrous tissue and infiltrated with a variable amount of inflammatory cells. Focally, depositions of haemosiderin may be found in the fibrous stroma. It is important to note that haemangiomas in infants are considerably more cellular than adult ones [48]. The cavernous form of LH is less frequent, composed of proliferation of large angiectatic vascular spaces, lined with thin, spindle-shaped endothelial cells, and filled with erythrocytes. This type of lesion is more common in adults. Immunohistochemical analysis helps to confirm endothelial cell proliferations in both forms, with positivity for CD31, CD34 and factor XIIIa antigens.

In differential diagnosis, various lesions of vascular origin, such as the vascular type of the vocal cord polyp (VCP), pyogenic granuloma, intravascular papillary endothelial hyperplasia and even angiosarcoma, must be considered. The vascular variant of VCP is usually characterised by highly angiectatic vascular spaces surrounded by massive leakage of fibrin as amorphous hyaline pink material, a feature not characteristic of capillary haemangioma. Pyogenic granuloma is diffusely infiltrated with neutrophils, which is not the case in haemangiomas, if the covering epithelium is intact. Papillary endothelial hyperplasia represents an organisation of thrombosis with papillary proliferation of the endothelial cells, which is not a striking histological feature of haemangioma. The distinction between the cellular variant of haemangioma and angiosarcoma may sometimes be problematic. However, anastomoses of the vas-

cular channels, lined with considerably pleomorphic endothelial cells with evident pathologic mitoses, certainly favour a diagnosis of angiosarcoma [48].

Subglottic LH of infants is generally a self-limited but potentially fatal lesion, causing progressive airway obstruction. Various treatment modalities have been proposed, including expectant policy, systemic steroids and interferon alfa-2a applications, CO₂ laser excision and tracheostomy, but no very promising treatments are yet available [139, 196, 328].

7.6.4 Paraganglioma

ICD-O:8680/1

Paragangliomas are rare benign tumours, originating from the anatomically dispersed neuroendocrine system (paraganglia), characterised by similar neurosecretory cells derived from the neural crest and associated with autonomic ganglia. The extra-adrenal portions of the paraganglia are divided into four groups according to their distribution and innervations: branchiomeric, intravagal, aortosympathetic and visceral autonomic. The paraganglia of the larynx are part of the branchiomeric paraganglionic system, together with the jugulotympanic, carotid body, subclavian, coronary, aorticopulmonary, pulmonary and orbital paraganglia [18].

Laryngeal paragangliomas (LP) are extremely rare, almost always benign tumours originating in the superior and inferior paired paraganglia. The former are localised in the false vocal cords, the latter in the vicinity of the cricoid cartilage [18, 255]. Patients are usually of middle age with a median age of 47 years. Surprisingly, compared with other neuroendocrine tumours, the LPs are three times more common in women. The predominant site is the supraglottic (82%), followed by the subglottic in 15% and the glottic area in 3% of cases. Signs and symptoms are mainly related to the localisation and size of the tumour [45, 289]. LPs are rarely functional, multicentric or associated with other head and neck paragangliomas.

Macroscopically, the tumour usually presents as a rounded submucosal mass with an intact covering mucosa, ranging in size from 0.5 to 6 cm [18]. The tumours are firm; on the cut surface they may be homogenous or nodular, from pink to tan and dark red in colour. Prominent vascularity of the tumour may cause abundant bleeding during biopsy.

Histologically, LPs are composed of two cell types: chief and sustentacular or supporting cells. The chief cells of epithelioid appearance are packed into round nests showing an organoid pattern, surrounded by highly vascular fibrous tissue (i.e. Zellballen; Fig. 7.11a). However, the characteristic cell nests may be squeezed and not apparent in a small biopsy specimen. The chief

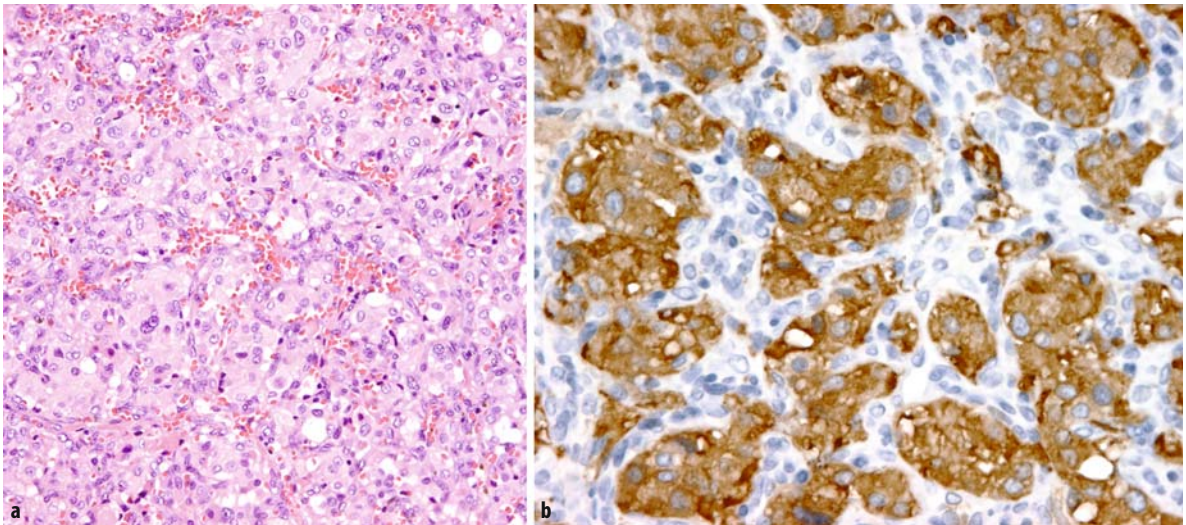


Fig. 7.11. Paraganglioma. **a** Characteristic arrangement into “Zellballen” composed of central chief and peripheral sustentac-

ular cells. **b** Chief cells stain immunohistochemically for synaptophysin

cells typically have an eosinophilic, finely granular cytoplasm and central vesicular nuclei. Cellular pleomorphism may be present and is occasionally prominent, but prognostically unimportant. Rare mitoses can be found, usually less than 2–3 per 10 high power fields. The supporting cells are usually inconspicuous, spindle-shaped, and most frequently found at the edge of the cell balls [18, 375].

Immunohistochemical findings are characteristic and decisive for the diagnosis. The chief cells are positive for neuroendocrine markers, such as chromogranin, synaptophysin and neuron-specific enolase (Fig. 7.11b).

The paragangliomas usually stain negatively for epithelial markers, such as cytokeratin, epithelial membrane antigen, carcinoembryonic antigen, and calcitonin. Sustentacular cells are positively stained with S-100 protein and glial fibrillary acid protein [18, 375].

Laryngeal paragangliomas must be primarily differentiated from typical and atypical carcinoids. The most reliable aid is positivity for both epithelial (cytokeratin, epithelial membrane antigen and carcinoembryonic antigen) and neuroendocrine markers in both types of carcinoids [107, 110]. Other, more remote differential diagnostic possibilities include malignant melanoma, renal cell carcinoma and medullary thyroid carcinoma. Melanoma can be confirmed by melan A and HMB-45 positivity. Renal cell carcinoma, in contrast to paraganglioma, does not express neuroendocrine markers. Medullary carcinoma expresses positive staining for calcitonin, amyloid and CEA [18, 106, 375].

Since paragangliomas are only exceptionally malignant, conservative surgical treatment is suggested [18, 20, 110]. There are no histological criteria that could reliably predict the biological behaviour of the lesion [18].

In a recent genetic study, it was postulated that sporadic head and neck paragangliomas have deletions at the same or closely related loci (11q13 and 11q22-23) as their family counterparts [33].

7.6.5 Granular Cell Tumour

ICD-O:9580/0

Granular cell tumour (GCT) is an uncommon benign, slowly growing lesion and about half of the cases occur in the head and neck region [201, 205, 371]. Various histogenetic origins have been attributed to GCT, but recent prevailing opinion supports a relationship to Schwann cells. The tongue and subcutaneous tissue of the head and neck are the most common sites of the tumour, while laryngeal involvement is less frequent [162, 176, 187, 205, 286, 330, 371], and comprises about 10% of all cases [205]. These tumours most commonly appear in the posterior area of the true vocal cords and half of them extend into the subglottis as a smooth, polypoid and sessile lesion [205, 286, 371]. GCT typically appears between the fourth and fifth decades and the average age for laryngeal forms is 36 years [286]. The tumour rarely occurs in children [162]. Hoarseness, stridor and dysphagia are the most common complaints.

Histologically, the tumour is poorly circumscribed and consists of clusters and sheets of rounded and polygonal cells with indistinct cellular borders and small, bland-looking and central nuclei. A mild degree of nuclear pleomorphism may be present, but mitotic activity is low. Cytoplasm of tumourous cells is abundant, characteristically coarsely granular and eosinophilic.

Cytoplasmic granula are PAS-positive and resistant to digestion. Marked desmoplasia is often present in older lesions, thereby masking the presence of granular cells. In about 50–60% of cases, the covering epithelium shows pseudoepitheliomatous hyperplasia of the overlying squamous epithelium [190]. This curious histological feature mimicking infiltrative growth of islands of squamous epithelium may lead to the lesion being mistaken for a squamous cell carcinoma. However, the co-existence of GCT and true squamous cell laryngeal carcinoma has also been reported [206].

Immunohistochemical positivity for S-100 protein, vimentin, CD-68 and neuron-specific enolase, and negativity for keratin is in accordance with the proposed theory [49, 198, 232]. It is also confirmed by electron microscopic examination; the cytoplasmic granula were found to be lysosomal structures that contain inclusions of cell membranes similar to those in Schwann cells [245].

Differential diagnosis should include benign lesions such as rhabdomyoma, paraganglioma or histiocytic proliferations. In contrast to GCT, rhabdomyoma does not show infiltrative growth, its cells are larger with well-defined cellular borders and evidence of cross-striation. Paraganglioma typically shows an organoid pattern (i.e., Zellballen) and positivity for neuroendocrine markers. Proliferation of histiocytes is usually related to inflammatory reaction. Sheets of histiocytes are characteristically intermingled with inflammatory cells not commonly found in GCT. Covering pseudoepitheliomatous hyperplasia of the GCT may lead to incorrect diagnosis of squamous cell carcinoma. An identification of the underlying granular cells may resolve this sometimes difficult diagnostic problem.

Complete surgical excision, with an attempt to preserve the normal structures, is the treatment of choice [371].

7.6.6 Chondroma

ICD-O:9220/0

Chondromas of the larynx are exceedingly uncommon, well-circumscribed, small (less than 2 cm) cartilaginous tumours that most commonly originate from the posterior lamina of the cricoid (70–78%) and thyroid cartilage (15–20%) [26, 57, 83, 209, 324, 358], and exceptionally from the epiglottis [166, 209]. They are more common in men than in women, the peak incidence rate is in the fifth decade [57]. The development of chondromas in the older population is probably related to the alteration of the ossification process, which starts in the cricoid and thyroid cartilages in the third decade, and increases with advanced years [358]. Hoarseness, dyspnoea, dysphagia are the usual complaints of patients,

but the tumours may also be asymptomatic. Computerised tomography is a method of choice for radiological evaluation [324].

Histologically, chondromas show a characteristic well-defined lobular pattern with benign looking and evenly distributed chondrocytes that lack nuclear pleomorphism and mitotic activity. The cellularity is judged to be low, when a given high power (×40) field is unlikely to contain more than 40 nuclei of chondrocytes [83, 209].

Pathologic diagnosis of laryngeal chondroma, especially from a small biopsy specimen, should be reported with due reservation. A misleading chondroma-like area may present in a well-differentiated case of a chondrosarcoma [26]. It has become apparent that many of the so-called chondromas from the past that recurred locally were actually misdiagnosed as low-grade chondrosarcomas [83]. It is obvious that the distinction between chondroma and low-grade chondrosarcoma remains a very difficult task. Increased cellularity, nuclear pleomorphism and hyperchromasia, and the appearance of clusters of malignant-looking chondrocytes in a single lacuna, are the most conspicuous histological features of chondrosarcoma. A thorough examination of the entire specimen is suggested, trying to avoid an incorrect diagnosis of a given tumour. Chondromas should also be distinguished from laryngeal chondrometaplasia, which appears as small nodules of the fibroelastic cartilage in the submucosal tissue of the glottic region [112].

Local conservative excision is preferred for treatment of laryngeal chondromas. Each recurrence of the lesion should be considered a low-grade chondrosarcoma [358].

7.7 Malignant Neoplasms

7.7.1 Potentially Malignant (Precancerous) Lesions

Potentially malignant (precancerous) lesions are histologically defined as alterations of the squamous epithelium from which invasive SCC develops more often than from other epithelial lesions [127, 177, 215]. Different grades of epithelial lesions that appear during the multistep process of carcinogenesis can easily be identified histologically. They are cumulatively called squamous intraepithelial lesions of the larynx (SILs) and represent a wide spectrum of histomorphologic changes, ranging from benign, reactive lesions, to potentially malignant (risky epithelium) and intraepithelial carcinoma. SILs are discussed in detail in Chap. 1.

7.7.2 Invasive Squamous Cell Carcinoma

ICD-O:8070/3

Squamous cell carcinoma (SCC) is by far the most common malignant tumour of the larynx and hypopharynx, accounting for about 95–96% of all malignant tumours at this location. The majority are conventional-type SCC.

7.7.2.1 Epidemiology

Squamous cell carcinoma of the larynx and hypopharynx is the second most common respiratory cancer, after lung cancer [54]. It accounts for 1.6–2% of all malignant tumours in men, and 0.2–0.4% in women [37, 293]. Its incidence is increasing in much of the world, being slightly higher in urban than in rural areas. It is also higher among blacks than whites [54, 299].

Laryngeal and hypopharyngeal SCC occur most frequently in the sixth and seventh decades of life. It rarely occurs in children and adolescents [17, 274]. It is more common in men [54, 299], with a male:female ratio of about 5:1 worldwide [253]. The male:female ratio is decreasing in some countries, reflecting a greater incidence among women. The increasing incidence of laryngeal cancer in women has been attributed to the increased incidence of smoking over the last two decades [79].

7.7.2.2 Aetiology

Cigarette smoking and alcohol consumption are the chief risk factors in laryngeal and hypopharyngeal cancer, and smoking has been shown to have the greatest effect. Epidemiological studies have shown that the relative risk of laryngeal cancer associated with cigarette smoking is approximately 10 for all subsites of the larynx and hypopharynx. The role of alcohol independent of that of tobacco is less striking, although plausible [38] and is demonstrated in some studies [329]. Smoking and drinking combined have a multiplicative rather than additive effect [222, 223, 254, 367, 393]. Avoidance of smoking and alcohol consumption could prevent about 90% of the current incidence of laryngeal cancer [101].

Some other factors, such as gastro-oesophageal reflux, diet and nutritional factors [38, 98, 120, 200, 276, 396] have also been related to an increased risk of laryngeal cancer development, particularly in patients who lack the major risk factors [12, 122].

Much attention has recently been paid to the possible role of infection with human papillomavirus (HPV) in the pathogenesis of laryngeal and hypopharyngeal

cancer, but the results are conflicting. HPV, mainly type 16, has been found in 3–85% of laryngeal cancers [213]. Moreover, HPV DNA has been detected in 12–25% of individuals with a clinically and histologically normal larynx [271, 313]. It appears, therefore, that HPV infection plays little role, if any, in laryngeal carcinogenesis [126, 177, 211, 213].

7.7.2.3 Anatomic Sites

The larynx is anatomically divided into three compartments: supraglottic, glottic and subglottic. Superiorly and posteriorly, it is continuous with the hypopharynx. Because of this anatomic proximity, the tumours of the larynx often extend to the hypopharynx, as well as vice versa, so that in large tumours, it is impossible to determine whether it originates from the larynx or hypopharynx.

There are geographic differences in the topographic distribution of the laryngeal SCC [19, 301]. In France, Spain, Italy, Finland and the Netherlands, supraglottic SCC predominates, while in the USA, Canada, UK and Sweden glottic SCC is more common. In Japan, SCC is approximately equally distributed between the two sites. The rarest localisation of laryngeal cancer is the subglottis (1–5%) [19, 318].

Determining the primary site of origin of laryngeal/hypopharyngeal cancer is important as it has a significant impact on the clinical presentation, spread, behaviour, and prognosis [117, 300]. This, however is not always possible, especially in large tumours.

The most common location of *supraglottic* SCC is the epiglottis (45–55% of supraglottic cancer; Fig. 7.12a), followed by the false vocal cords (12–33%) and the aryepiglottic folds (8–21%). The remaining cases arise from the ventricles and the arytenoids [19]. Supraglottic SCC tends to spread to oropharynx and pyriform sinus, but it rarely invades the glottis and thyroid cartilage.

The most common symptoms in supraglottic cancer are: dysphagia, change in the quality of the voice, a sensation of a foreign body in the throat, haemoptysis, and odynophagia.

Lymph node metastases are present in 30–40% of patients. The overall 5-year survival rate in supraglottic SCC is 65–75% [19, 301].

Glottic SCC arises mostly from the anterior half of the vocal cord or from the anterior commissure (Fig. 7.12b); a posterior origin is rare. Because of poor lymphatic supply, glottic SCC tends to remain localised for a long period. As SCC progresses, it invades the vocal muscle resulting in the fixed vocal cord, which is an ominous clinical sign [192]. In the late stages of the disease, it may extend to the opposite true vocal cord, to the supraglottis and subglottis; it may also extend through the thyroid cartilage and invade the soft tissue of the neck.

The most common early symptom in glottic cancer is hoarseness. Other symptoms include dysphagia, change in the quality of the voice, a sensation of a foreign body in the throat, haemoptysis and odynophagia.

The incidence of lymph node metastases in the early stages is low (0–11% for T1 and T2) and increases to 14–40% in the advanced stages. The overall 5-year survival rate is 80–85% [19, 301].

If SCC crosses the ventricles and involves the supraglottis and subglottis, it is termed *transglottic* SCC (Fig. 7.12c). Transglottic carcinoma is rare, accounting for 5% of all laryngeal SCC, and is associated with a high incidence of lymph node metastases and a poor prognosis [235].

Subglottic carcinoma is rare. The most common presenting symptoms are dyspnoea and stridor [113], often requiring an emergency tracheotomy [350]. The subglottic SCC may spread to the thyroid gland, cervical oesophagus, hypopharynx and trachea.

About 20–25% of patients have cervical lymph node metastases at presentation, but about 50% of patients have clinically undetectable metastases in the paratracheal lymph nodes. It has therefore been suggested that paratracheal and superior mediastinal nodes should be removed in patients with subglottic cancer [149]. A frequent complication in the course of the disease is a stomal recurrence, which is defined as a recurrent SCC in the mucocutaneous junction of the tracheostomy after laryngectomy [169, 392, 394]. The overall 5-year survival rate in subglottic SCC is 40–47% [19, 318].

Hypopharyngeal SCC occurs most frequently in the pyriform sinus (60–85% of hypopharyngeal SCC), and rarely in other localisations, such as the posterior pharyngeal wall (10–20%) and postcricoid area (5–15%) [151, 368].

Hypopharyngeal cancer frequently extends to the larynx.

The most frequent symptoms in hypopharyngeal SCC are odynophagia, dysphagia and a neck mass. Other symptoms include voice changes, otalgia, and constitutional symptoms [368].

The prognosis of hypopharyngeal cancer is poor. Because of the rich lymphatic supply, unrestricted area for tumour growth, and late symptoms, patients mostly present in the advanced stages. About 70% of patients have lymph node metastases at presentation. Haematogenous dissemination is rather frequent (in 20–40% of patients) [346]. The overall 5-year survival rate in hypopharyngeal SCC is 62.5% [346].

7.7.2.4 Histological Variants

Several variants of SCC occur in the larynx and hypopharynx, including verrucous carcinoma, spindle cell carcinoma, basaloid SCC, papillary SCC, lymphoepithelial carcinoma, adenoid (acantholytic) SCC and adenosquamous carcinoma, which are dealt with sepa-

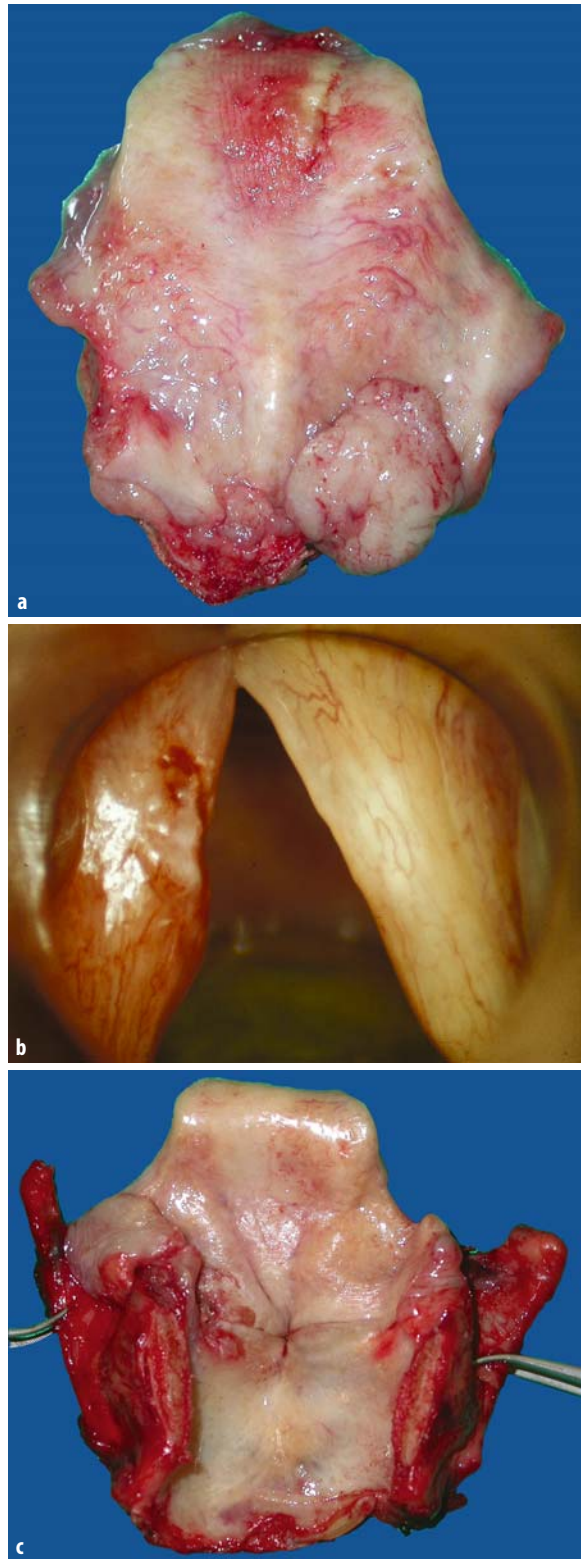


Fig. 7.12. Macroscopic appearance of the squamous cell carcinoma of the larynx. **a** Supraglottic carcinoma: an exophytic tumour at the base of the epiglottis. **b** Carcinoma of the vocal cord, endoscopic view. **c** Transglottic carcinoma crossing the ventricles, involving glottis and supraglottis

rately in Chap. 1. Their recognition is important because most of them are true clinicopathologic entities, with an important prognostic implication: basaloid SCC, adeno-squamous carcinoma and lymphoepithelial carcinoma are more aggressive than conventional SCC, while verrucous SCC and arguably, papillary SCC, have a better prognosis than conventional SCC.

7.7.2.5 TNM Grading

For the staging of laryngeal cancer, the TNM system (T – tumour, N – node, M – metastasis), established by the International Union Against Cancer (UICC) is widely used [340]. Stage remains the most significant predictor of survival. The size of the tumour and the presence of regional and distant metastases are independent predictors of survival.

An important parameter ignored in the TNM system is extracapsular spread. Several studies have shown that the presence of extracapsular spread in the lymph nodes is strongly associated with both regional recurrence and distant metastases, resulting in decreased survival [71, 116, 157, 344]. Some studies, on the contrary, have not confirmed the independent prognostic significance of extracapsular spread [225, 292].

7.7.3 Neuroendocrine Carcinoma

Neuroendocrine carcinomas (NEC) of the larynx are uncommon, accounting for less than 1% of laryngeal tumours. NEC are divided into well-differentiated NEC (WD-NEC; carcinoid), moderately differentiated NEC (MD-NEC; atypical carcinoid), and poorly differentiated NEC (PD-NEC; small cell carcinoma). MD-NEC is the most common type of NEC in the larynx, followed by PD-NEC and WD-NEC [19, 92, 106].

The putative cells of origin are the Kultschitzky-like argyrophilic cells, which have been described in the human laryngeal mucosa, and are similar or identical to the Kultschitzky cells in the bronchial mucosa [285, 288]. Other possible cells of origin are the pluripotent stem cells of the surface or glandular epithelium.

7.7.3.1 Well-Differentiated Neuroendocrine Carcinoma (Carcinoid)

ICD-O:8240/3

Well-differentiated neuroendocrine carcinoma (WD-NEC) is the least common type of laryngeal NEC. In a critical review of the world literature, El-Naggar and Batsakis found only 12 well-documented cases of laryngeal WD-NEC [91]. Since then, a few more cases have

been described in the English-language literature [67, 191, 242, 326, 341, 391].

Well-differentiated NEC occurs predominantly in males, the average age is 58 years, and the majority (83%) are located in the supraglottis [92]. They present clinically with dyspnoea, hoarseness and/or sore throat.

Grossly, laryngeal WD-NEC is typically a submucosal nodule or a polypoid lesion measuring up to 2 cm in diameter. Microscopically, like WD-NEC elsewhere in the body, they are composed of small uniform cells growing in islands, ribbons and cords, occasionally forming gland-like structures. Mucin may occasionally be present. The nuclei are round, with finely dispersed chromatin and inconspicuous nucleoli; the cytoplasm is scant, clear or eosinophilic. Mitoses are sparse or absent, and there is no necrosis or cellular pleomorphism.

Immunohistochemically, laryngeal WD-NEC expresses markers of neuroendocrine differentiation (such as chromogranin, synaptophysin, neuron-specific enolase, Leu-7), and markers of epithelial differentiation (such as cytokeratins and epithelial membrane antigen) [106]. Electron microscopy reveals dense-core neurosecretory granules [91, 106].

Differential diagnosis includes moderately differentiated NEC, paraganglioma, and adenocarcinoma, and is discussed in the next section.

The treatment of choice is complete but conservative surgical excision. Neck dissection is not indicated. Radiotherapy and chemotherapy have not proven effective [106, 248].

The prognosis is favourable, although metastases to the lymph node, liver, bones and skin have been reported in one-third of patients. Only one patient has died of the disease [91]. These data suggest the more aggressive behaviour of laryngeal WD-NEC compared with bronchial WD-NEC, but the number of patients is too small to draw any conclusions [19].

7.7.3.2 Moderately Differentiated Neuroendocrine Carcinoma (Atypical Carcinoid)

ICD-O:8249/3

It is the most frequent type of NEC in the larynx, constituting 54% of all laryngeal neuroendocrine neoplasms, with approximately 300 cases described in the literature [106, 242].

Similar to other types of NEC, MD-NEC is more common in males, with a wide age range from 20 to 83 years. The majority of patients are heavy smokers. It arises mostly in the supraglottic region. Hoarseness and dysphagia are the most common symptoms; 20–30% of patients also experience pain [19, 243]. MD-NEC is rarely associated with carcinoid syndrome [388]. Some pa-

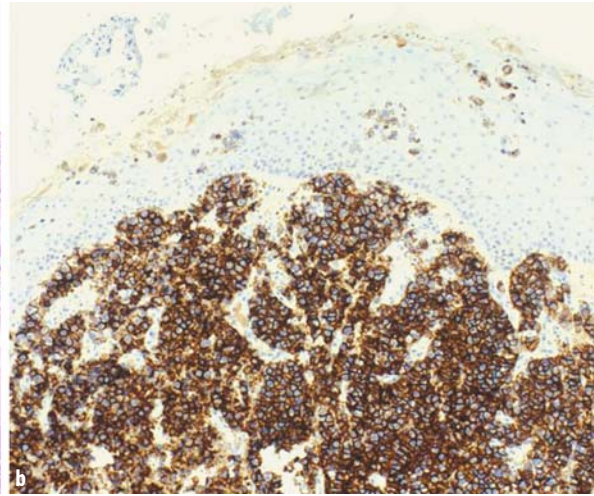
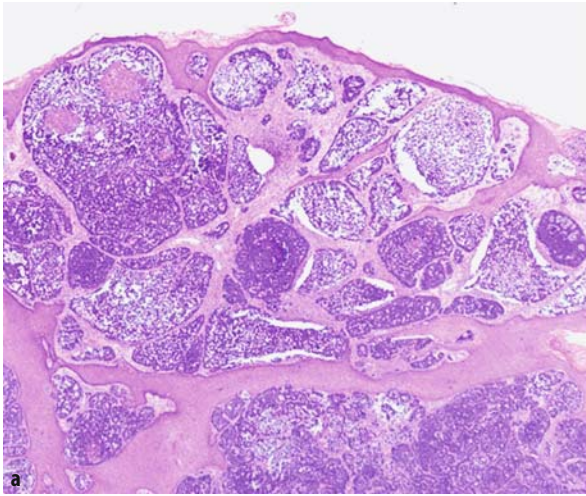


Fig. 7.13. Moderately differentiated neuroendocrine carcinoma of the larynx. **a** Islands of closely packed small cells with hyper-

chromatic nuclei beneath the surface squamous cell epithelium. **b** Immunohistochemical expression of CD56 in tumour cells

tients with MD-NEC have an elevated level of the serum calcitonin [23, 338].

Grossly, it presents as a submucosal nodule or as a polypoid lesion measuring up to 4 cm in diameter (average 1.6 cm), with or without surface ulceration.

Microscopically, the tumour grows in rounded nests, trabeculae, cords, ribbons and glandular structures; the tumour cells are round, with round nuclei and a moderate amount of cytoplasm, which is slightly eosinophilic or occasionally oncocytic. Mucin production may be present [234].

In contrast to WD-NEC, cellular pleomorphism, increased mitotic activity and necroses are frequently present in MD-NEC. Vascular and perineural invasion may be present.

Immunohistochemically, MD-NEC usually expresses synaptophysin, cytokeratin, and chromogranin; they may also express CD56, calcitonin and carcinoembryonic antigens, but rarely serotonin (Figs. 7.13) [97, 234, 242, 388].

Differential diagnosis includes paraganglioma, adenocarcinoma, other neuroendocrine carcinomas and medullary carcinoma of the thyroid gland.

The differentiation between paraganglioma and MD-NEC is important because the former usually behaves as a benign tumour, while the latter behaves as an aggressive tumour. The correct diagnosis is usually possible with the use of immunohistochemistry: MD-NEC expresses cytokeratin and carcinoembryonic antigen (CEA), while paraganglioma does not. Both tumours express markers of neuroendocrine differentiation [18, 242]. Adenocarcinoma can be distinguished from carcinoid by the absence of neuroendocrine markers. The presence of cellular pleomorphism, increased mitotic activity and necroses helps to distinguish MD-NEC from WD-NEC.

Differentiation from thyroid medullary carcinoma may be difficult, especially when dealing with cervical metastases, as tumour cells in both medullary carcinoma and MD-NEC express calcitonin by immunohistochemistry. The most important distinguishing feature is the different locations of the primary tumours. Additional useful information may be obtained by measuring the serum level of CEA, which is elevated in metastatic medullary carcinoma of the thyroid, and normal in MD-NEC [19]. The elevated serum level of calcitonin should not be considered as a reliable feature of medullary carcinoma, as it has been reported in patients with MD-NEC [92, 338].

Moderately differentiated NEC is an aggressive, potentially lethal tumour. Lymph node metastases have been reported in 43% of patients, cutaneous metastases in 22% and distant metastases in 44% of patients, mostly to the lungs, liver and bones [97, 234, 388].

Surgery is the treatment of choice. Neck dissection is also advised because of the high incidence of cervical lymph node metastases. Radiation and chemotherapy have not been effective [248]. The 5- and 10-year survival rates are 48 and 30% respectively [388].

7.7.3.3 Poorly Differentiated Neuroendocrine Carcinoma (Small Cell Carcinoma)

ICD-O:8041/3

Poorly differentiated neuroendocrine carcinoma is the least differentiated and the most aggressive type of NEC. It is rare, accounting for less than 0.5% of all laryngeal carcinomas. Approximately 160 cases have been described in the literature [106, 244].

Poorly differentiated NEC arises most often in the supraglottis, but it also occurs in other parts of the larynx. It affects men more frequently than women, mostly between 50 and 70 years of age; most patients are heavy smokers. The most common presenting symptoms are hoarseness and dysphagia, frequently associated with painless enlarged cervical lymph nodes due to metastases. It may be associated with a paraneoplastic syndrome [108, 244].

Grossly, PD-NECs are submucosal nodular or polypoid masses, frequently ulcerated and cannot be distinguished from other laryngeal carcinomas.

Microscopically, laryngeal PD-NECs are identical to their pulmonary counterparts [243]. They are composed of closely packed small cells with hyperchromatic round, oval or spindle nuclei and very scant cytoplasm. Necroses, mitoses, as well as vascular and perineural invasion are frequently present. PD-NEC can also be composed of slightly larger cells with more cytoplasm. The mucosa is often ulcerated, but there is no carcinoma in situ or significant atypia.

Immunohistochemically, the tumour cells variably express cytokeratins and neuroendocrine markers, such as synaptophysin, neuron-specific enolase, chromogranin, S-100 protein and CD56.

By electron microscopy, sparse neurosecretory granules are occasionally found, but they may be absent.

In the differential diagnosis, the possibility of a metastasis from the lung must be excluded. PD-NEC must also not be confused with the basaloid squamous carcinoma, malignant lymphoma, and malignant melanoma. Basaloid squamous carcinoma is composed of larger cells, contains areas of squamous differentiation, tends to stain for high molecular-weight cytokeratins, and is frequently associated with atypia of the overlying squamous epithelium. Malignant lymphomas characteristically express leukocyte common antigen and B- or T-cell markers, which are absent in PD-NEC. Malignant melanoma occasionally consists of small undifferentiated cells, thus resembling PD-NEC, but, in contrast to PD-NEC, it typically expresses S-100 protein, melan A and/or HMB45.

The clinical course is aggressive, characterised by early metastases to the regional lymph nodes and distant sites, especially to the lungs, bones and liver. In contrast to lung PD-NEC, laryngeal PD-NEC does not frequently metastasise to the brain.

Radiation with chemotherapy is the treatment of choice. Surgical therapy is not indicated because most patients have disseminated disease at presentation. The prognosis is poor, and the 2- and 5-year survival rates are 16 and 5% respectively [114, 135].

7.7.4 Adenocarcinoma

In spite of rather prominent salivary gland tissue in the supraglottic and subglottic larynx, laryngeal adenocarcinoma is rare, accounting for 1% of all laryngeal neoplasms [3, 25, 347]. The majority of laryngeal adenocarcinomas are of the salivary gland type. The most common types are adenoid cystic carcinoma and mucoepidermoid carcinoma. Rare examples of other types of adenocarcinoma have been also described in the larynx, such as acinic cell carcinoma [306], clear cell carcinoma [262], malignant myoepithelioma [168], epithelial-myoepithelial carcinoma [240], salivary duct carcinoma [109], etc.

The aetiology is unknown, although exposure to asbestos or lead, alcohol abuse, viral infections, ionising radiation and genetic risk factors have been implicated as possible aetiologic factors [221].

7.7.4.1 Adenoid Cystic Carcinoma

ICD-O:8200/3

In contrast to other laryngeal carcinomas, adenoid cystic carcinoma (ACC) occurs at a younger age, with no gender predominance, and is more common in the subglottis [348]. Symptoms are similar to those of other tumours in the same localisation. In addition, pain is frequently present, probably because of the tendency of ACC towards perineural invasion.

Macroscopically, the tumour usually grows as a submucosal mass, covered by normal mucosa.

The microscopic features of laryngeal ACC are the same as in other locations.

Laryngeal ACC is characterised by a slowly progressive course, with a high incidence of local recurrence, long survival and a low cure rate. ACC has a tendency towards haematogenic spread, mostly to the lungs and less frequently to the bones, liver and other organs [86, 348]. It does not usually metastasise to the regional lymph nodes.

The treatment of choice is complete surgical excision. The 5-year survival rate is 30% [221, 347].

7.7.4.2 Mucoepidermoid Carcinoma

ICD-O:8430/3

Mucoepidermoid carcinoma (MEC) occurs at all ages, even in childhood, but it usually presents in the 6th and 7th decades, predominantly in males. The majority occurs in the supraglottis, but it has also been described in the glottis and subglottis, as well as in the hypopharynx [221, 335]. The clinical picture correlates with the localisation and size of the tumour.

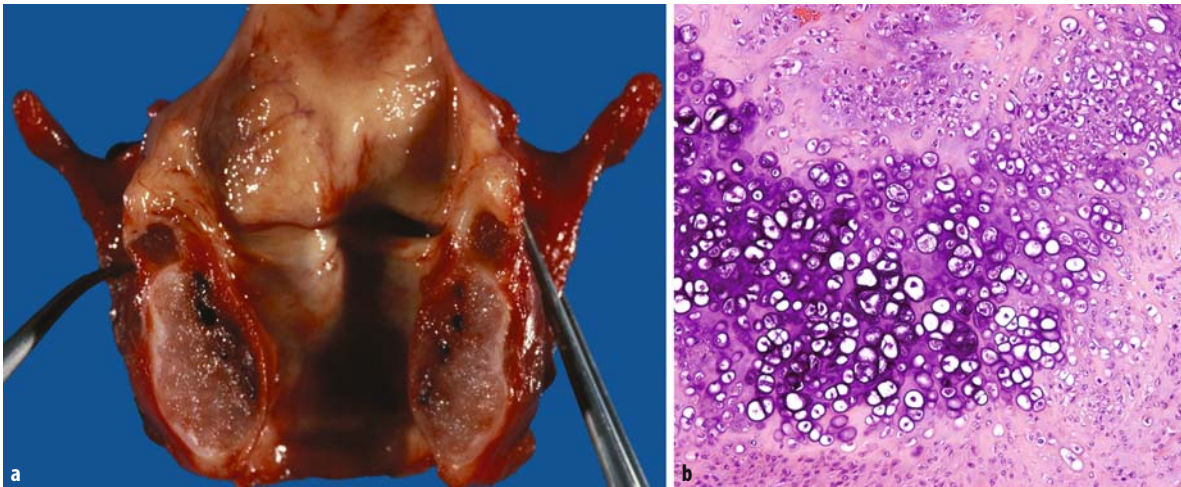


Fig. 7.14. Chondrosarcoma of the cricoid cartilage of the larynx. **a** Typical macroscopic appearance of the tumour located in the cricoid cartilage: cut section reveals a glistening, lobulated, glassy

tumour. **b** Microscopically, there is slightly increased cellularity, binucleation in the lacunar spaces, mild nuclear pleomorphism and hyperchromasia

Macroscopically, they mostly present as submucosal masses [335].

Microscopically, they are similar to MEC in other sites, and are classified as low-, intermediate-, and high-grade MEC (see Chap. 5).

The behaviour is unpredictable, and is related to the grade and stage of the disease. The best treatment is complete surgical excision. Radiotherapy has been reported to be successful in a limited number of patients [335]. Neck dissection may be necessary, as 50% of patients with MEC have metastases in the regional lymph nodes. The 5-year survival is 90–100% for low-grade MEC, and 50% for high-grade MEC [115].

7.7.5 Sarcomas

Sarcomas of the larynx are uncommon, accounting for 1–2% of all laryngeal neoplasms. Among them, chondrosarcoma is the most frequent type, comprising 75% of all laryngeal sarcomas [209].

7.7.5.1 Chondrosarcoma

ICD-O:9220/3

Chondrosarcoma (CS) is the most common non-epithelial neoplasm in the larynx. It appears that laryngeal CS behaves less aggressively than its counterpart in the rest of the body. The majority of laryngeal CS are low grade CS [209, 360].

Laryngeal CS affects men more frequently than women, mostly in the 7th decade [209]. It usually presents with hoarseness; other symptoms include dyspnoea,

dysphonia, a cough, a neck mass, airway obstruction and pain [209, 360]. The symptoms are frequently present for a long time before the diagnosis is established.

Chondrosarcoma arises predominantly in the cricoid cartilage, especially at the inner posterior plate; it can also arise in the thyroid and arytenoid cartilages. It very rarely arises in the epiglottis [209, 360].

The aetiology is unknown, although disordered ossification of the laryngeal cartilages and ischaemic changes in a chondroma have been suggested as possible predisposing risk factors [360]. Other possible risk factors include previous radiation exposure [134] and Teflon injection [147].

Grossly, CS is characteristically a lobulated, submucosal mass covered by normal mucosa; on its cut surface it is glassy, firm white or grey (Fig. 7.14a). Radiographic findings are characteristic showing coarse or stippled calcifications [360, 377]. Microscopically, laryngeal CS is indistinguishable from CS of bone origin elsewhere in the body, and is graded according to the histologic criteria proposed by Evans and co-workers [99] for CS of the bones. Low-grade CS (grade I) has slightly increased cellularity, binucleation in the lacunar spaces, slight nuclear pleomorphism, and hyperchromasia (Fig. 7.14b). High-grade CS (grade III) has remarkable cellularity, multinucleation in the lacunar spaces, nuclear pleomorphism, nuclear hyperchromasia, necrosis and mitotic activity, whereas the intermediate grade CS (grade II) has medium cellularity and less nuclear pleomorphism [128].

The vast majority of laryngeal CS are of low- or intermediate grade. High-grade CS are considered to be rare; in a large series of 111 laryngeal CS, only 6 (6%) were of a high grade [360]. Dedifferentiated (mesenchymal) CS

characterised by the presence of both well-differentiated CS and a high-grade non-cartilaginous sarcoma is even rarer [46, 128, 259, 360].

Immunohistochemically, CS expresses S-100 protein and vimentin [46].

Differential diagnosis includes chondroma and chondrometaplasia. Differentiation between low-grade CS and chondroma can be extremely difficult, and is only possible with adequate tumour sampling. Chondromas are considered to be exceedingly rare in the larynx; they are smaller than CS and less cellular, with less pleomorphism, lacking mitoses and necrosis.

The treatment of choice is conservative surgery [46, 182, 209]. Total laryngectomy should be avoided as long as possible, even in recurrent CS. Radiation therapy is generally regarded as ineffective though a few cases with a favourable response to radiation have been reported [141].

The prognosis is favourable. CS is characterised by a slowly progressive growth, with frequent recurrences (18–40%) that are related to incomplete surgical excision and/or higher tumour grade [360]. Metastases from laryngeal CS are unusual and are reported in approximately 10% of patients, most commonly to the lungs and lymph nodes [259, 360]. The 5- and 10-year survival rates are 90 and 80.9% respectively.

7.7.5.2 Other Sarcomas

Rare examples of other sarcomas have been described in the larynx and hypopharynx, such as liposarcoma [136], osteosarcoma [220, 256, 332], angiosarcoma [214], synovial sarcoma [34], malignant fibrous histiocytoma [143], Kaposi's sarcoma [246, 325], leiomyosarcoma [202, 297], etc.

The aetiology of laryngeal sarcomas is unknown, although exposure to radiation [284] has been implicated as a possible aetiological factor for osteosarcoma [332] and malignant fibrous histiocytoma [143], and infection with HIV for Kaposi's sarcoma [246, 325].

7.7.6 Other Malignant Neoplasms

The larynx may be rarely involved in disseminated systemic lymphoma or leukaemia [163]. It can also be the primary site of a haematopoietic or lymphoid neoplasm. Extramedullary plasmacytoma seems to be the most common primary lymphoid neoplasm of the larynx. Various types of non-Hodgkin's lymphoma of B-cell type and T-cell type have also been reported in the larynx, as well as rare cases of granulocytic sarcoma and mast cell sarcoma [163].

7.7.6.1 Malignant Lymphoma

Primary non-Hodgkin's lymphoma (NHL) of the larynx is rare, accounting for less than 1% of all laryngeal neoplasms [8] and approximately 1% of all primary extranodal lymphomas [389]. By definition, the bulk of the disease should occur in the larynx [389]. About 65 cases have been reported in the English-language literature [8, 55, 70, 249].

The majority of laryngeal NHL are of B-cell type, especially diffuse large B-cell lymphoma, and extranodal marginal lymphoma of the MALT type. Rare cases of T-cell NHL have been reported, such as NK/T cell lymphoma of the nasal type, and peripheral T-cell lymphoma [389]. All regions of the larynx may be involved, with the exception of the extranodal marginal lymphoma of the MALT type, which has been described in the supraglottis only [70, 199], presumably because mucosa-associated lymphoid tissue has been found mostly in the supraglottic region [199].

They present mostly at stage I or II and are limited to the larynx, with or without regional lymph node involvement. The most common symptoms are hoarseness, foreign body sensation, and airway obstruction.

The prognosis is favourable. Laryngeal NHL should be treated according to the histologic type of NHL. It usually responds well to radiation therapy. Systemic chemotherapy is indicated for recurrent or disseminated disease [8].

7.7.6.2 Extraosseous (Extramedullary) Plasmacytoma

ICD-O:9734/3

Extraosseous plasmacytoma is a clonal proliferation of plasma cells forming a tumour at an extraosseous and extramedullary site. By definition, there is no evidence of plasma cell myeloma on bone marrow examination or by radiography [142]. The malignant plasma cells express monotypic cytoplasmic immunoglobulins, and plasma cell-associated antigens, with an absence of immature B-cell antigens [142, 389].

The majority of extraosseous plasmacytomas occur in the upper respiratory tract; among them, the larynx is involved in only 6–18%. An incidence of 1–5 plasmacytomas in 1,000 laryngeal tumours has been reported [269].

Laryngeal plasmacytoma is more frequent in males, with a mean age of 60 years. The epiglottis is the most common site of involvement, followed by the vocal cords, false cords, ventricles and the subglottis [183, 269, 270, 303, 378]. It generally presents as a solitary, submucosal lesion, or as a polypoid lesion. It may occasionally involve multiple sites in the larynx [269, 303].

Histologically, the tumour consists of sheets of plasma cells that vary in differentiation from well- to poorly differentiated. They may contain Russell bodies or grape-like inclusions of retained immunoglobulin (Mott cells), which are also found in reactive plasma cells and do not help in establishing the diagnosis of plasmacytoma [142].

Well-differentiated plasmacytoma cannot be distinguished morphologically from reactive (polyclonal) proliferation of plasma cells. Therefore, the monoclonality of plasma cells must be proven, which is best achieved by demonstrating the cytoplasmic immunoglobulin heavy and/or light chain restriction. Besides immunohistochemistry, non-isotopic paraffin section in situ hybridisation is useful in the assessment of clonality for kappa or lambda light chain mRNA [389].

Poorly differentiated plasmacytoma must be differentiated from other lymphoid neoplasms and from other malignant tumours, such as malignant melanoma and carcinoma. This is achieved by appropriate immunohistochemical analysis; plasmacytoma, in contrast to lymphoma, does not express CD45 and immature B- and T-cell markers [351]. It also does not express antigens characteristic of malignant melanoma (i.e. S-100 protein, HMB-45 and melan-A), carcinoma (cytokeratins) and neuroendocrine neoplasms (i.e. synaptophysin, chromogranin).

Plasmacytoma is radiosensitive and complete eradication by radiation and/or surgery is potentially curative [183, 269, 270, 303, 378]. The prognosis is favourable, although the development of a plasma cell myeloma may occur in 15% of patients with extraosseous plasmacytoma [142].

7.7.6.3 Primary Mucosal Melanoma

ICD-O:8720/3

Primary malignant melanoma (MM) of the larynx is extremely rare; less than 60 cases have been described in the literature. They represent 3.6 to 7.4% of all mucosal melanomas of the head and neck [6, 185, 212, 379].

Primary laryngeal MM is more common in men, mostly in the 6th and 7th decades. It occurs primarily in the supraglottic region and less often in the glottic region, but it has not yet been described in the subglottis. The symptoms vary according to the site of involvement and generally occur over a short period of time [379].

Macroscopically, it may present as a polypoid, exophytic, nodular, sessile, or pedunculated lesion, with or without surface ulceration, varying in colour from black or brown, to tan-grey or white.

Microscopically, primary laryngeal MM is indistinguishable from MM of the skin and other mucous membranes. It may be composed of epithelioid cells, spindle cells, or both. Nuclear and cellular pleomorphism, nu-

clear pseudoinclusions, mitoses and necroses are usually prominent.

The diagnosis is based on histological examination, together with special stainings for melanin, such as Fontana-Masson, and immunohistochemistry.

The differential diagnosis must always include the possibility of a metastatic MM because in the larynx, metastatic MM is considerably more common than primary MM [153]. Histologic features that favour the diagnosis of primary MM are junctional activity and/or an in situ component. However, as normal melanocytes are also normally present in the subepithelial compartment, junctional changes are not required for the diagnosis of primary MM [379].

Apart from metastatic MM, the differential diagnosis includes carcinoma (especially spindle cell carcinoma), sarcoma and lymphoma. Positive staining for well-known MM markers, such as S-100 protein, HMB-45, melan-A and vimentin, and negative staining for CD45, B- and T-cell markers, as well as markers of epithelial differentiation (cytokeratins, epithelial membrane antigen) is diagnostic for MM.

The treatment of choice is complete surgical excision. The prognosis of primary laryngeal MM is poor, similar to primary mucosal malignant melanoma in general, with an average survival of less than 3.5 years [260, 379].

7.7.6.4 Metastases to the Larynx

Metastases to the larynx from distant primary tumours are uncommon, accounting for less than 0.5% of all laryngeal neoplasms. Metastases to the hypopharynx and trachea are even less common. The most common source is malignant melanoma (Fig. 7.15), followed by renal cell carcinoma. Other tumours with proven laryngeal metastases include cancer of the breast, lung, prostate, colon, stomach and ovary [24, 74, 105, 154, 267, 296]. The rare occurrence of metastases to the larynx seems to be related to the terminal location of this organ in the lymphatic and vascular circulation.

Laryngeal metastases are most commonly located in the supraglottic and subglottic regions, presumably due to their rich vascular supply [24, 133]. They can be divided into those located in the soft tissue (metastases from melanoma and renal cell carcinoma) and those located primarily in the marrow spaces of the ossified laryngeal cartilage (metastases from breast, prostate, and lung cancer).

The signs and symptoms of metastatic laryngeal tumours do not differ from those of other laryngeal tumours and vary according to the site of involvement. Haemoptysis may be present, especially in highly vascularised metastatic renal cell carcinoma.

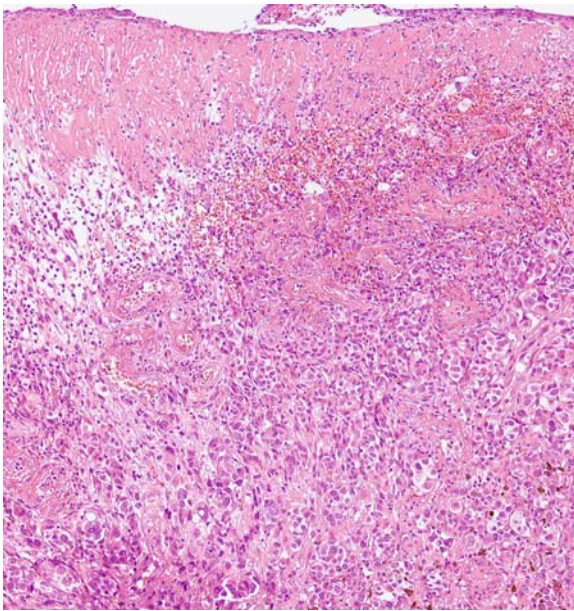


Fig. 7.15. Metastatic malignant melanoma of the larynx. An ulcerated tumour composed of large, atypical epithelioid cells with focal melanin pigment. Primary tumour was located on the left heel

The prognosis for patients with laryngeal metastases is generally poor as laryngeal involvement is usually a sign of dissemination in the terminal stage of the disease. In such patients, only palliative treatment is advised; laser endoscopic resection has been reported to be an excellent tool for relieving airway obstruction [267]. However, cases of isolated laryngeal metastases have been described, in which local excision and/or radiation therapy was associated with prolonged survival [74, 105].

References

- Abramson AL, Zielinski B (1984) Congenital laryngeal sacular cyst of the newborn. *Laryngoscope* 94:1580–1582
- Absalom AR, Watts R, Kong A (1998) Airway obstruction caused by rheumatoid cricoarytenoid arthritis. *Lancet* 351:1099–1100
- Alavi S, Namazie A, Calcaterra TC, Blackwell KE (1999) Glandular carcinoma of the larynx: the UCLA experience. *Ann Otol Rhinol Laryngol* 108:485–489
- Allen MS, Pettit JM, Sherblom JC (1991) Management of vocal nodules: a regional survey of otolaryngologists and speech-language pathologists. *J Speech Hear Res* 34:229–235
- Aluffi P, Prestinari A, Ramponi A, Castri M, Pia F (2000) Rosai-Dorfman disease of the larynx. *J Laryngol Otol* 114:565–567
- Amin HM, Petruzzelli GJ, Husain AN, Nickoloff BJ (2001) Primary malignant melanoma of the larynx. *Arch Pathol Lab Med* 125:271–273
- Amoils CP, Shindo ML (1996) Laryngotracheal manifestations of rhinoscleroma. *Ann Otol Rhinol Laryngol* 105:336–340
- Ansell S, Habermann TM, Hoyer JD, Strickler JG, Chen MG, McDonald TJ (1997) Primary laryngeal lymphoma. *Laryngoscope* 107:1502–1506
- Arber DA, Weiss LM, Chang KL (1998) Detection of Epstein-Barr virus in inflammatory pseudotumor. *Semin Diagn Pathol* 15:155–160
- Arens C, Glanz H, Kleinsasser O (1997) Clinical and morphological aspects of laryngeal cysts. *Eur Arch Otorhinolaryngol* 254:430–436
- Asrar L, Facharzt EH, Haque I (1998) Rosai-Dorfman disease: presenting as isolated extranodal involvement of larynx. *J Otolaryngol* 27:85–86
- Assimakopoulos D, Patrikakos G (2002) The role of gastroesophageal reflux in the pathogenesis of laryngeal carcinoma. *Am J Otolaryngol* 23:351–357
- Austen KF (2001) Allergies, anaphylaxis and systemic mastocytosis. In: Braunwald E, Fauci AS, Kasper DL, Hauser SL, Longo DL, Jameson JL (eds) *Harrison's principles of internal medicine*, 15th edn, McGraw Hill, New York, pp 1913–1922
- Bachman AL (1978) Benign, non-neoplastic conditions of the larynx and pharynx. *Radiol Clin North Am* 16:273–290
- Baker HL, Baker SR, McClatchey KD (1982) Manifestations and management of laryngoceles. *Head Neck Surg* 4:450–456
- Balestrieri F, Watson CB (1982) Intubation granuloma. *Otolaryngol Clin North Am* 15:567–579
- Barnes C, Sexton M, Sizeland A, Tiedemann K, Berkowitz RG, Waters K (2001) Laryngo-pharyngeal carcinoma in childhood. *Int J Pediatr Otorhinolaryngol* 61:83–86
- Barnes L (1991) Paraganglioma of the larynx. A critical review of the literature. *ORL J Otorhinolaryngol Relat Spec* 53:220–234
- Barnes L (2001) Diseases of the larynx, hypopharynx, and esophagus. In: Barnes L (ed) *Surgical pathology of the head and neck*. Dekker, New York, pp127–237
- Barnes L, Ferlito A, Wenig BM (1997) Laryngeal paragangliomas. A review and report of a single case. *J Laryngol Otol* 111:197–198
- Barnes L, Peel RL (1990) *Head and neck pathology: a text/atlas of differential diagnosis*. Igaku-Shoin, New York, pp 70–77
- Batsakis JG (1987) Laryngeal involvement by thyroid disease. *Ann Otol Rhinol Laryngol* 96:718–719
- Batsakis JG, El-Naggar AK, Luna MA (1992) Neuroendocrine tumors of the larynx. *Ann Otol Rhinol Laryngol* 101:710–714
- Batsakis JG, Luna MA, Byers RM (1985) Metastases to the larynx. *Head Neck Surg* 7:458–460
- Batsakis JG, Luna MA, El-Naggar AK (1992) Nonsquamous carcinomas of the larynx. *Ann Otol Rhinol Laryngol* 102:1024–1026
- Batsakis JG, Raymond AK (1988) Cartilage tumors of the larynx. *South Med J* 81:481–484
- Bengtsson M, Bengtsson A (1998) Cricoarytenoid arthritis – a cause of upper airway obstruction in the rheumatoid arthritis patient. *Intensive Care Med* 24:643
- Benjamin B, Croxson G (1985) Vocal cord granulomas. *Ann Otol Rhinol Laryngol* 94:538–541
- Benjamin B, Dalton C, Croxson G (1995) Laryngoscopic diagnosis of laryngeal sarcoid. *Ann Otol Rhinol Laryngol* 104:529–553
- Benjamin B, Jacobson I, Eckstein R (1997) Idiopathic subglottic stenosis: diagnosis and endoscopic laser treatment. *Ann Otol Rhinol Laryngol* 106:770–774
- Benjamin B, Robb P, Clifford A, Eckstein R (1991) Giant Teflon granuloma of the larynx. *Head Neck* 13:453–456
- Bennett S, Bishop S, Lumpkin SM (1987) Phonatory characteristics associated with bilateral diffuse polypoid degeneration. *Laryngoscope* 97:446–450
- Bikhazi PH, Messina L, Mhatre AN, Goldstein JA, Lalwani AK (2000) Molecular pathogenesis in sporadic head and neck paraganglioma. *Laryngoscope* 110:1346–1348
- Bilgic B, Mete Ö, Öztürk AS, Demiryont M, Keles N, Basaran M (2003) Synovial sarcoma: a rare tumor of the larynx. *Pathol Oncol Res* 9:242–245

35. Birzgalis AR, Farrington WT, O'Keefe L, Shaw J (1993) Localized tracheopathia osteoplastica of the subglottis. *J Laryngol Otol* 107:352–353
36. Bone RC, Biller HF, Irwin TM (1972) Intralaryngotracheal thyroid. *Ann Otol Rhinol Laryngol* 81:424–428
37. Boring CC, Squires TS, Tong T, Montgomery S (1994) Cancer statistics, 1994. *CA Cancer J Clin* 44:7–26
38. Bosetti C, Talamini R, Levi F, Negri E, Franceschi S, Airoldi L, La Vecchia C (2002) Fried foods: a risk factor for laryngeal cancer? *Br J Cancer* 87:1230–1233
39. Bossingham DH, Simpson FG (1996) Acute laryngeal obstruction in rheumatoid arthritis. *BMJ* 312:295–296
40. Bower JS, Belen JE, Weg JG, Dantzker DR (1980) Manifestations and treatment of laryngeal sarcoidosis. *Am Rev Respir Dis* 122:325–332
41. Boyle JO, Coulthard SW, Mandel RM (1991) Laryngeal involvement in disseminated coccidioidomycosis. *Arch Otolaryngol Head Neck Surg* 117:433–438
42. Bradley PJ, Kochar A, Quraishi MS (1999) Pharyngeal pouch carcinoma: real or imaginary risks? *Ann Otol Rhinol Laryngol* 108:1027–1032
43. Brais B, Bouchard JP, Xie YG, Rochefort DL, Chretien N, Tome FM, Lafreniere RG, Rommens JM, Uyama E, Nohira O, Blumen S, Korczyn AD, Heutink P, Mathieu J, Durancieu A, Codere F, Fardeau M, Rouleau GA, Korczyn AD (1998) Short GCG expansions in the PABP2 gene cause oculopharyngeal muscular dystrophy. *Nat Genet* 18:164–167
44. Brandwein M, Huvos A (1995) Laryngeal oncocyctic cystadenomas. Eight cases and a literature review. *Arch Otolaryngol Head Neck Surg* 121:1302–1305
45. Brandwein M, Levi G, Som P, Urken ML (1992) Paraganglioma of the inferior laryngeal paraganglia. A case report. *Arch Otolaryngol Head Neck Surg* 118:994–996
46. Brandwein M, Moore S, Som P, Biller H (1992) Laryngeal chondrosarcomas: a clinicopathologic study of 11 cases including two chondrosarcomas with additional malignant mesenchymal component. *Laryngoscope* 8:858–867
47. Bridger MW, Jahn AF, van Nostrand AW (1980) Laryngeal rheumatoid arthritis. *Laryngoscope* 90:296–303
48. Brodsky L, Yoshpe N, Ruben RJ (1983) Clinical-pathological correlates of congenital subglottic hemangiomas. *Ann Otol Rhinol Laryngol* 105:4–18
49. Buley ID, Gatter KC, Kelly PM, Heryet A, Millard PR (1988) Granular cell tumours revisited. An immunohistological and ultrastructural study. *Histopathology* 12:263–274
50. Canalis RF, Maxwell DS, Hemenway WG (1977) Laryngocele – an updated review. *J Otolaryngol* 6:191–199
51. Carbone A, Passannante A, Gloghini A, Devaney KO, Rinaldo A, Ferlito A (1999) Review of sinus histiocytosis with massive lymphadenopathy (Rosai-Dorfman disease) of head and neck. *Ann Otol Rhinol Laryngol* 108:1095–1104
52. Carpenter RJ III, Banks PM, McDonald TJ, Sanderson DR (1978) Sinus histiocytosis with massive lymphadenopathy (Rosai-Dorfman disease): report of a case with respiratory tract involvement. *Laryngoscope* 88:1963–1969
53. Cassano L, Lombardo P, Marchese-Ragona R, Pastore A (2000) Laryngopyocele: three new clinical cases and review of the literature. *Eur Arch Otorhinolaryngol* 257:507–511
54. Cattaruzza MS, Maisonneuve P, Boyle P (1996) Epidemiology of laryngeal cancer. *Oral Oncol Eur J Cancer* 32B:293–305
55. Cavalot AL, Preti G, Vione N, Nazionale G, Palonta F, Fadda GL (2001) Isolated primary non-Hodgkin's malignant lymphoma of the larynx. *J Laryngol Otol* 115:324–326
56. Cessna MH, Zhou H, Sanger WG, Perkins SL, Tripp S, Pickering D, Daines C, Coffin CM (2002) Expression of ALK1 and p80 in inflammatory myofibroblastic tumor and its mesenchymal mimics: a study of 135 cases. *Mod Pathol* 15:931–938
57. Chiu LD, Rasgon BM (1996) Laryngeal chondroma: a benign process with long-term clinical implications. *Ear Nose Throat J* 75:540–542; 544–549
58. Cho MS, Kim ES, Kim HJ, Yang WI (1997) Kimura's disease of the epiglottis. *Histopathology* 30:592–594
59. Chow LT, Chow WH, Shum BS (1993) Fatal massive upper respiratory tract haemorrhage: an unusual complication of localized amyloidosis of the larynx. *J Laryngol Otol* 107:51–53
60. Chu L, Gussack GS, Orr JB, Hood D (1994) Neonatal laryngoceles. A cause for airway obstruction. *Arch Otolaryngol Head Neck Surg* 120:454–458
61. Cleary KR, Batsakis JG (1995) Mycobacterial disease of the head and neck: current perspective. *Ann Otol Rhinol Laryngol* 104:830–833
62. Close LG, Merkel M, Burns DK, Deaton CW Jr, Schaefer SD (1987) Asymptomatic laryngocele: incidence and association with laryngeal cancer. *Ann Otol Rhinol Laryngol* 96:393–399
63. Coffin CM, Humphrey PA, Dehner LP (1998) Extrapulmonary inflammatory myofibroblastic tumor: a clinical and pathological survey. *Semin Diagn Pathol* 15:85–101
64. Coffin CM, Watterson J, Priest JR, Dehner LP (1995) Extrapulmonary inflammatory myofibroblastic tumor (inflammatory pseudotumor). A clinicopathologic and immunohistochemical study of 84 cases. *Am J Surg Pathol* 19:859–872
65. Corsi A, Ciofalo A, Leonardi M, Zambetti G, Bosman C (1997) Recurrent inflammatory myofibroblastic tumor of the glottis mimicking malignancy. *Am J Otolaryngol* 18:121–126
66. Courtney-Harris RG, Goddard MJ (1992) Sinus histiocytosis with massive lymphadenopathy (Rosai-Dorfman disease): a rare case of subglottic narrowing. *J Laryngol Otol* 106:61–62
67. Cuzzourt JC, Pezold JC, Dunn CW (2002) Typical carcinoid tumor of the larynx occurring with otalgia. *Ear Nose Throat* 81:40–43
68. Damiani JM, Levine HL (1979) Relapsing polychondritis: report of ten cases. *Laryngoscope* 89:929–946
69. Danish HM, Meleca RJ, Dworkin JP, Abbarah TR (1998) Laryngeal obstructing saccular cysts: a review of this disease and treatment approach emphasizing complete endoscopic carbon dioxide laser excision. *Arch Otolaryngol Head Neck Surg* 124:593–596
70. De Bree R, Mahieu HF, Ossenkoppele GJ, van der Valk P (1998) Malignant lymphoma of mucosa-associated lymphoid tissue in the larynx. *Eur Arch Otorhinolaryngol* 255:368–370
71. De Carvalho MB (1998) Quantitative analysis of the extent of extracapsular invasion and its prognostic significance: a prospective study of 170 cases of carcinoma of the larynx and hypopharynx. *Head Neck* 20:16–21
72. Dean CM, Sataloff RT, Hawkshaw MJ, Pribikin E (2002) Laryngeal sarcoidosis. *J Voice* 16:283–288
73. Dedo HH, Catten MD (2001) Idiopathic progressive subglottic stenosis: findings and treatment in 52 patients. *Ann Otol Rhinol Laryngol* 110:305–311
74. Dee SL, Eshghi M, Otto CS (2000) Laryngeal metastasis 7 years after radical nephrectomy. *Arch Pathol Lab Med* 124:1833–1834
75. Deeb ZE (1997) Acute supraglottitis in adults: early indicators of airway obstruction. *Am J Otolaryngol* 18:112–115
76. Dehner LP (2000) The enigmatic inflammatory pseudotumours: the current state of our understanding, or misunderstanding. *J Pathol* 192:277–279
77. Delahunty JE (1972) Acid laryngitis. *J Laryngol Otol* 86:335–342
78. Delap TG, Lavy JA, Alusi G, Quiney RE (1997) Tuberculosis presenting as a laryngeal tumour. *J Infect* 34:139–141
79. DeRienzo DP, Greenberg SD, Fraire AE (1991) Carcinoma of the larynx. Changing incidence in women. *Arch Otolaryngol Head Neck Surg* 117:681–684
80. DeSanto LW, Devine KD, Weiland LH (1970) Cysts of the larynx – classification. *Laryngoscope* 80:145–176
81. Deutsch ES, Zalzal GH (1991) Quincke's edema, revisited. *Arch Otolaryngol Head Neck Surg* 117:100–102
82. Devaney KO, Ferlito A, Hunter BC, Devaney SL, Rinaldo A (1998) Wegener's granulomatosis of the head and neck. *Ann Otol Rhinol Laryngol* 107:439–445

83. Devaney KO, Ferlito A, Silver CE (1995) Cartilaginous tumors of the larynx. *Ann Otol Rhinol Laryngol* 104:251–255
84. Dhingra JK, Aqel NM, McEwen J, Bleach NR (1995) Multiple oncocytic cysts of the larynx. *J Laryngol Otol* 109:1226–1228
85. Dikkers FG, Nikkels PG (1995) Benign lesions of the vocal folds: histopathology and phonotrauma. *Ann Otol Rhinol Laryngol* 104:698–703
86. Donovan DT, Conley J (1983) Adenoid cystic carcinoma of the subglottic region. *Ann Otol Rhinol Laryngol* 92:491–495
87. Dort JC, Frohlich AM, Tate RB (1994) Acute epiglottitis in adults: diagnosis and treatment in 43 patients. *J Otolaryngol* 23:281–285
88. Dubey SP, Banerjee S, Ghosh LM, Roy S (1997) Benign pleomorphic adenoma of the larynx: report of a case and review and analysis of 20 additional cases in the literature. *Ear Nose Throat J* 76:548–550; 552; 554–557
89. Dumich PS, Neel HB III (1983) Blastomycosis of the larynx. *Laryngoscope* 93:1266–1270
90. Ebo DG, Stevens WJ (2000) Hereditary angioneurotic edema: review of the literature. *Acta Clin Belg* 55:22–29
91. El-Naggar AK, Batsakis JG (1991) Carcinoid tumor of the larynx. A critical review of the literature. *ORL Otorhinolaryngol Relat Spec* 53:188–193
92. El-Naggar AK, Batsakis JG, Luna MA (1992) Neuroendocrine tumors of larynx. *Ann Otol Rhinol Laryngol* 101:710–714
93. Eng J, Sabanathan S (1991) Airway complications in relapsing polychondritis. *Ann Thorac Surg* 51:686–692
94. Epstein SS, Winston P, Friedmann I, Ormerod FC (1957) The vocal cord polyp. *J Laryngol Otol* 71:673–688
95. Erb N, Pace AV, Delamere JP, Kitas GD (2001) Dysphagia and stridor caused by laryngeal rheumatoid arthritis. *Rheumatology* 40:952–953
96. Ereno C, Lopez JI, Grande J, Santaolalla F, Bilbao FJ (2001) Inflammatory myofibroblastic tumour of the larynx. *J Laryngol Otol* 115:856–858
97. Ereno C, Lopez JI, Sanchez JM (1997) Atypical carcinoid of larynx: presentation with scalp metastases. *J Laryngol Otol* 111:89–91
98. Esteve J, Riboli E, Pequignot G, Terracini B, Merletti F, Crognani P, Ascunze N, Zubiri L, Blanchet F, Raymond L, Repetto F, Tuyns AJ (1996) Diet and cancers of the larynx and hypopharynx: the IARC multi-center study in southwestern Europe. *Cancer Causes Control* 7:240–252
99. Evans HL, Ayala AG, Romsdahl MM (1977) Prognostic factors in chondrosarcoma of bone: a clinicopathologic analysis with emphasis on histologic grading. *Cancer* 40:818–831
100. Fajardo-Dolci G, Chavolla R, Lamadrid-Bautista E, Rizo-Alvarez J (1999) Laryngeal scleroma. *J Otolaryngol* 28:229–231
101. Farchi G (1992) Estimation of the impact of cigarette smoking reduction on mortality. *Ann Ist Super Sanita* 28:147–53
102. Fauci AS (1998) The vasculitis syndromes. In: Fauci AS, Braunwald E, Isselbacher KJ, Wilson JD, Martin JB, Kasper DL, Hauser SL, Longo DL (eds) *Harrison's principles of internal medicine*, 14th edn. McGraw-Hill, New York, pp 1910–1922
103. Fechner RE, Mills SE (1997) Larynx and pharynx. In: Sternberg SS (ed) *Histology for pathologists*. Lippincott-Raven, Philadelphia, pp 391–403
104. Feder RJ, Michell MJ (1984) Hyperfunctional, hyperacidic, and intubation granulomas. *Arch Otolaryngol* 110:582–584
105. Ferlito A (1993) Secondary neoplasms. In: Ferlito A (ed) *Neoplasms of the larynx*. Churchill Livingstone, Edinburgh, pp 349–360
106. Ferlito A, Barnes L, Rinaldo A, Gnepp DR, Milroy CM (1998) A review of neuroendocrine neoplasms of the larynx: update on diagnosis and treatment. *J Laryngol Otol* 112:827–834
107. Ferlito A, Barnes L, Wenig BM (1994) Identification, classification, treatment, and prognosis of laryngeal paraganglioma. Review of the literature and eight new cases. *Ann Otol Rhinol Laryngol* 103:525–536
108. Ferlito A, Friedmann I (1993) Neuroendocrine neoplasms. In: Ferlito A (ed) *Neoplasms of the larynx*. Churchill Livingstone, Edinburgh, pp 169–205
109. Ferlito A, Gale N, Hvala A (1981) Laryngeal salivary duct carcinoma: a light and electron microscopic study. *J Laryngol Otol* 95:731–738
110. Ferlito A, Milroy CM, Wenig BM, Barnes L, Silver CE (1995) Laryngeal paraganglioma versus atypical carcinoid tumor. *Ann Otol Rhinol Laryngol* 104:78–83
111. Ferlito A, Recher G (1981) Oncocytic lesions of the larynx. *Arch Otorhinolaryngol* 232:107–115
112. Ferlito A, Recher G (1985) Chondrometaplasia of the larynx. *ORL J Otorhinolaryngol Relat Spec* 47:174–177
113. Ferlito A, Rinaldo A (2000) The pathology and management of subglottic cancer. *Eur Arch Otorhinolaryngol* 257:168–173
114. Ferlito A, Rinaldo A (2003) Small cell neuroendocrine carcinoma of the larynx: a preventable and frustrating disease with a highly aggressive lethal behavior. *ORL J Otorhinolaryngol Relat Spec* 65:131–133
115. Ferlito A, Rinaldo A, Devaney KO, Devaney SL, Milroy CM (1998) Impact of phenotype on treatment and prognosis of laryngeal malignancies. *J Laryngol Otol* 112:710–714
116. Ferlito A, Rinaldo A, Devaney KO, MacLennan K, Myers JN, Petruzzelli GJ, Shaha AR, Genden EM, Johnson JT, de Carvalho M, Myers EN (2002) Prognostic significance of microscopic and macroscopic extracapsular spread from metastatic tumor in the cervical lymph nodes. *Oral Oncol* 38:747–751
117. Ferlito A, Shaha AR, Silver CE, Rinaldo A, Mondin V (2001) Incidence and sites of distant metastases from head and neck cancer. *ORL J Otorhinolaryngol Relat Spec* 63:202–207
118. Foucar E, Rosai J, Dorfman R (1990) Sinus histiocytosis with massive lymphadenopathy (Rosai-Dorfman disease): review of the entity. *Semin Diagn Pathol* 7:19–73
119. Foulsham CK II, Snyder GG III, Carpenter RJ III (1981) Papillary cystadenoma lymphomatosum of the larynx. *Otolaryngol Head Neck Surg* 89:960–964
120. Franceschi S (2003) Fibre intake and laryngeal cancer risk. *Ann Oncol* 14:162–167
121. Frantz TD, Rasgon BM, Quesenberry CP Jr (1994) Acute epiglottitis in adults. Analysis of 129 cases. *JAMA* 272:1358–1360
122. Freije JE, Beatty TW, Campbell BH, Woodson BT, Schultz CJ, Toohill RJ (1996) Carcinoma of the larynx in patients with gastroesophageal reflux. *Am J Otolaryngol* 17:386–390
123. Frenzel H, Schmitt-Graff A, Seitz RJ (1985) An immunohistochemical and electron-microscopic study of vascular endothelial cells in vocal fold polyps. *Arch Otorhinolaryngol* 241:271–278
124. Gale N, Zidar N, Podboj J, Volavšek M, Luzar B (2003) Inflammatory myofibroblastic tumour of paranasal sinuses with fatal outcome: reactive lesion or tumour? *J Clin Pathol* 56:715–717
125. Galli J, Nardi C, Contucci AM, Cadoni G, Lauriola L, Fantoni M (2002) Atypical isolated epiglottic tuberculosis: a case report and a review of the literature. *Am J Otolaryngol* 23:237–240
126. Gallo O, Bianchi S, Giannini A, Boccuzzi S, Calzolari A, Fini-Storchi O (1994) Lack of detection of human papillomavirus (HPV) in transformed laryngeal keratoses by in situ hybridization (ISH) technique. *Acta Otolaryngol* 114:213–217
127. Gallo A, de Vicentis M, Della Rocca C, Moi R, Simonelli M, Minni A, Shaha AR (2001) Evolution of precancerous lesions: a clinicopathologic study with long-term follow-up on 259 patients. *Head Neck* 23:42–47
128. Garcia RE, Gannon FH, Thompson LDR (2002) Dedifferentiated chondrosarcoma of the larynx: a report of two cases and review of the literature. *Laryngoscope* 112:1015–1018
129. Gervais M, Dorion D (2003) Quality of life following surgical treatment of oculopharyngeal syndrome. *J Otolaryngol* 32:1–5
130. Geterud A (1991) Rheumatoid arthritis in the larynx. *Scand J Rheumatol* 20:215
131. Gillmore JD, Hawkins PN, Pepys MB (1997) Amyloidosis: a review of recent diagnostic and therapeutic developments. *Br J Haematol* 99:245–256

132. Giudice M, Piazza C, Focoli P, Toninelli C, Cavaliere S, Peretti G (2003) Idiopathic subglottic stenosis: management by endoscopic and open-neck surgery in a series of 30 patients. *Eur Arch Otorhinolaryngol* 260:235–238
133. Glanz H, Kleinsasser O (1978) Metastasen im Kehlkopf. *HNO* 26:163–167
134. Glaubiger DL, Casler JD, Garrett WL, Yuo HS, Lilis-Hearne PK (1991) Chondrosarcoma of the larynx after radiation treatment for vocal cord cancer. *Cancer* 68:1828–1831
135. Gnepp DR (1991) Small cell neuroendocrine carcinoma of the larynx: a critical review of the literature. *ORL J Otorhinolaryngol Relat Spec* 53:210–219
136. Gonzales-Lois C, Ibarrola C, Ballestin C, Martanez-Tello FJ (2002) Dedifferentiated liposarcoma of the pyriform sinus: report of a case and review of the literature. *Int J Surg Pathol* 10:75–79
137. Goutas N, Simopoulou S, Papazoglou K, Agapitos E (1994) A fatal case of diphtheria. *Pediatr Pathol* 14:391–395
138. Gray SD, Hammond E, Hanson DF (1995) Benign pathologic responses of the larynx. *Ann Otol Rhinol Laryngol* 104:13–18
139. Gregg CM, Wiatrak BJ, Koopmann CF Jr (1995) Management options for infantile subglottic hemangioma. *Am J Otolaryngol* 16:409–414
140. Gregor RT, Loftus B, Cohen P, Balm AJ, Hilgers FJ (1994) Saccular mucocele in association with laryngeal cancer. *Ann Otol Rhinol Laryngol* 103:732–736
141. Gripp S, Pape H, Scmitt G (1998) Chondrosarcoma of the larynx – the role of radiotherapy revisited – case report and review of the literature. *Cancer* 82:108–115
142. Grogan TM, Van Camp B, Kyle RA, Muller-Hermelink HK, Harris NL, Stein H, Vardiman JW (eds) *Tumours of haematopoietic and lymphoid tissues*. IARC Press, Lyon, pp 142–156
143. Guney E, Yigitbasi OG, Balkanli S, Canoz OM (2002) Post-irradiation malignant fibrous histiocytoma of the larynx: a case report. *Am J Otolaryngol* 23:293–296
144. Gunkel AR, Thurner KH, Kanonier G, Sprinzel GM, Thumfart WF (1996) Angioneurotic edema as a reaction to angiotensin-converting enzyme inhibitors. *Am J Otolaryngol* 17:87–91
145. Gupta OP, Jain RK, Tripathi PP, Gupta S (1984) Leprosy of the larynx: a clinicopathological study. *Int J Lepr Other Mycobact Dis* 52:171–175
146. Guttenplan MD, Hendrix RA, Townsend MJ, Balsara G (1991) Laryngeal manifestations of gout. *Ann Otol Rhinol Laryngol* 100:899–902
147. Hakky M, Kolbusz R, Reyes CV (1989) Chondrosarcoma of the larynx. *Ear Nose Throat* 68:60–62
148. Härmä RA, Suurkari S (1977) Tracheopathia chondro-osteoplastica. A clinical study of thirty cases. *Acta Otolaryngol* 84:118–123
149. Harrison DFN (1971) The pathology and management of subglottic cancer. *Ann Otol Rhinol Laryngol* 80:6–12
150. Hébert PC, Ducic Y, Boisvert D, Lamothe A (1998) Adult epiglottitis in a Canadian setting. *Laryngoscope* 108:64–69
151. Helliwell TR (2003) Evidence based pathology: squamous carcinoma of the hypopharynx. *J Clin Pathol* 56:81–85
152. Heman-Ackah YD, Remley KB, Goding GS Jr (1999) A new role for magnetic resonance imaging in the diagnosis of laryngeal relapsing polychondritis. *Head Neck* 21:484–489
153. Henderson LT, Robbins KT, Weitzner S (1986) Upper aerodigestive tract metastases in disseminated malignant melanoma. *Arch Otolaryngol Head Neck Surg* 112:659–663
154. Hilger AW, Prichard AJ, Jones T (1998) Adenocarcinoma of the larynx – a distant metastasis from a rectal primary. *J Laryngol Otol* 112:199–201
155. Hill ME, Creed GA, McMullan TF, Tyers AG, Hilton-Jones D, Robinson DO, Hammans SR (2001) Oculopharyngeal muscular dystrophy: phenotypic and genotypic studies in a UK population. *Brain* 124:522–526
156. Hill MJ, Taylor CL, Scott GB (1980) Chondromatous metaplasia in the human larynx. *Histopathology* 4:205–214
157. Hirabayashi H, Koshii K, Uno K, Ohgaki H, Nakasone Y, Fujisawa T, Syouno N, Hinohara T, Hirabayashi K (1991) Extracapsular spread of squamous cell carcinoma in neck lymph nodes: prognostic factor of laryngeal cancer. *Laryngoscope* 101:501–506
158. Hirano M, Sato K (1993) *Histological color atlas of the human larynx*. Singular, San Diego, pp 1–112
159. Hočevár-Boltežar I, Zidar N, Žargi M, Župevc A, Lestan B, Andoljšek D (2000) Amyloidosis of the larynx. *Wien Klin Wochenschr* 112:732–734
160. Hoffman GS, Kerr GS, Leavitt RY, Hallahan CW, Lebovics RS, Travis WD, Rottem M, Fauci AS (1992) Wegener granulomatosis: an analysis of 158 patients. *Ann Intern Med* 116:488–498
161. Holinger LD, Barnes DR, Smid LJ, Holinger PH (1978) Laryngocele and saccular cysts. *Ann Otol Rhinol Laryngol* 87:675–685
162. Holland RS, Abaza N, Balsara G, Lesser R (1998) Granular cell tumor of the larynx in a six-year-old child: case report and review of the literature. *Ear Nose Throat J* 77:652–654; 656; 658
163. Horny HP, Kaiserling E (1995) Involvement of the larynx by hemopoietic neoplasms. An investigation of autopsy cases and review of the literature. *Pathol Res Pract* 191:130–138
164. Hughes RA, Berry CL, Seifert M, Lessof MH (1972) Relapsing polychondritis. Three cases with a clinico-pathological study and literature review. *Q J Med* 41:363–380
165. Hussong JW, Brown M, Perkins SL, Dehner LP, Coffin CM (1999) Comparison of DNA ploidy, histologic, and immunohistochemical findings with clinical outcome in inflammatory myofibroblastic tumors. *Mod Pathol* 12:279–286
166. Hyams VJ, Rabuzzi DD (1970) Cartilaginous tumors of the larynx. *Laryngoscope* 80:755–767
167. Hytiroglou P, Brandwein MS, Strauchen JA, Mirante JP, Urken ML, Biller HF (1992) Inflammatory pseudotumor of the parapharyngeal space: case report and review of the literature. *Head Neck* 14:230–234
168. Ibrahim R, Bird DJ, Sieler MW (1991) Malignant myoepithelioma of the larynx with massive metastatic spread to the liver – an ultrastructural and immunocytochemical study. *Ultrastruct Pathol* 15:69–76
169. Imauchi Y, Ito K, Takasago E, Nibu KI, Sugawara M, Ichimura K (2002) Stomal recurrence after total laryngectomy for squamous cell carcinoma of the larynx. *Otolaryngol Head Neck Surg* 126:63–66
170. Inglis AF Jr (1993) Herpes simplex virus infection. A rare cause of prolonged croup. *Arch Otolaryngol Head Neck Surg* 119:551–552
171. Isaacson JE, Frable MA (1996) Cryptococcosis of the larynx. *Otolaryngol Head Neck Surg* 114:106–109
172. Jennette JC (1994) Pathogenic potential of anti-neutrophil cytoplasmic autoantibodies. *Lab Invest* 70:135–137
173. Jennings CR, Jones NS, Dugar J, Powell RJ, Lowe J (1998) Wegener's granulomatosis – a review of diagnosis and treatment in 53 subjects. *Rhinology* 36:188–191
174. Jindal JR, Milbrath MM, Shaker R, Hogan WJ, Toohill RJ (1994) Gastroesophageal reflux disease as a likely cause of "idiopathic" subglottic stenosis. *Ann Otol Rhinol* 103:186–191
175. Johns MM (2003) Update on the etiology, diagnosis, and treatment of vocal fold nodules, polyps, and cysts. *Curr Opin Otolaryngol Head Neck Surg* 11:456–461
176. Kamal SA, Othman EO (1998) Granular cell tumour of the larynx. *J Laryngol Otol* 112:83–85
177. Kambič V, Gale N (1995) Epithelial hyperplastic lesions of the larynx. Elsevier, Amsterdam, pp 1–265
178. Kambič V, Gale N, Radšelj Z (1982) Warty dyskeratoma of the vocal cord. First reported case. *Arch Otolaryngol* 108:385–387
179. Kambič V, Gale N, Radšelj Z (1989) Anatomical markers of Reinke's space and the etiopathogenesis of Reinke edema. *Laryngorhinootologie* 68:231–235
180. Kambič V, Radšelj Z (1984) Acid posterior laryngitis. Aetiology, histology, diagnosis and treatment. *J Laryngol Otol* 98:1237–1240

181. Kambič V, Radšel Z, Žargi M, Ačko M (1981) Vocal cord polyps: incidence, histology and pathogenesis. *J Laryngol Otol* 95:609–618
182. Kambič V, Žargi M, Gale N (1989) Laryngeal chondrosarcoma: is conservative surgery adequate treatment? *J Laryngol Otol* 103:970–972
183. Kamiyo T, Inagi K, Nakajima M, Motoori T, Tadokoro K, Nishiyam S (2002) A case of extramedullary plasmacytoma of the larynx. *Acta Otolaryngol Suppl* 547:104–107
184. Kandiloros DC, Nikolopoulos TP, Ferekidis EA, Tsangaroulakis A, Yiotakis JE, Davilis D, Adamopoulos GK (1997) Laryngeal tuberculosis at the end of the 20th century. *J Laryngol Otol* 111:619–621
185. Karagiannidis K, Noussios G, Sakellariou T (1998) Primary laryngeal melanoma. *J Otolaryngol* 27:104–106
186. Karlikaya C, Yuksel M, Kilicli S, Candan L (2000) Tracheobronchopathia osteochondroplastica. *Respirology* 5:377–380
187. Kawaida M, Fukuda H, Kohno N (2000) Granular cell tumors arising nearly simultaneously in the larynx and subcutaneous cervical region. *Ear Nose Throat J* 79:162–166
188. Kendall CH, Johnston MN (1998) Pseudo-malignant laryngeal nodule (inflammatory myofibroblastic tumour). *Histopathology* 32:286–287
189. Kenny TJ, Werkhaven J, Nettekville JL (2000) Sarcoidosis of the pediatric larynx. *Arch Otolaryngol Head Neck Surg* 126:536–539
190. Kershisnik M, Batsakis JG, Mackay B (1994) Granular cell tumors. *Ann Otol Rhinol Laryngol* 103:416–419
191. Kienast U, Neumann HJ, Stintz S (1997) Isolated carcinoid of the larynx – a rare neuroendocrine tumor of the upper airways. *Otorhinolaryngol Nova* 7:286–287
192. Kirchner JA, Som JL (1971) Clinical significance of fixed vocal cord. *Laryngoscope* 81:1029–1044
193. Kleidermacher P, Mastro NP, Miller FR, Jones EW, Wood BG (1995) Pathologic quiz case 2. Oncocytic cyst of the larynx. *Arch Otolaryngol Head Neck Surg* 121:1430–1431; 1433
194. Kleinsasser O (1982) Pathogenesis of vocal cord polyps. *Ann Otol Rhinol Laryngol* 91:378–381
195. Kleinsasser O (1988) Tumors of the larynx and hypopharynx. Thieme, Stuttgart
196. Kontzoglou G, Triaridis S, Noussios G, Valeri R, Nanas C (2002) Subglottic hemangioma treated with interferon alpha 2A. *Acta Otorhinolaryngol Belg* 56:83–85
197. Krespi YP, Mitrani M, Husain S, Meltzer CJ (1987) Treatment of laryngeal sarcoidosis with intralesional steroid injection. *Ann Otol Rhinol Laryngol* 96:713–715
198. Kurtin PJ, Bonin DM (1994) Immunohistochemical demonstration of the lysosome-associated glycoprotein CD68 (KP-1) in granular cell tumors and schwannomas. *Hum Pathol* 25:1172–1178
199. Kutta H, Steven P, Tillmann BN, Tsokos M, Paulsen FP (2003) Region-specific immunological response of the different laryngeal compartments: significance of larynx-associated lymphoid tissue. *Cell Tissue Res* 311:365–371
200. La Vecchia C, Negri E, D'Avanzo B, Franceschi S, Decarli A, Boyle P (1990) Dietary indicators of laryngeal cancer risk. *Cancer Res* 50:4497–4500
201. Lack EE, Worsham GF, Callihan MD, Crawford BE, Klappenbach S, Rowden G, Chun B (1980) Granular cell tumor: a clinicopathologic study of 110 patients. *J Surg Oncol* 13:301–316
202. Lan MY, Guo YC, Chu PY, Ho DM, Chang SY (2001) Pathology quiz case 2: leiomyosarcoma of the larynx. *Arch Otolaryngol Head Neck Surg* 127:1503–1505
203. Lang WS (1965) Diphtheria at the present time. *Laryngoscope* 75:1092–1102
204. Larsen WJ (1997) Human embryology, 2nd edn. Churchill Livingstone, New York, pp 347–374
205. Lassaletta L, Alonso S, Ballestin C, Martinez-Tello FJ, Alvarez-Vicent JJ (1999) Immunoreactivity in granular cell tumors of the larynx. *Auris Nasus Larynx* 26:305–310
206. Lassaletta L, Alonso S, Granell J, Ballestin C, Serrano A, Alvarez-Vicent JJ (1998) Synchronous glottic granular cell tumor and subglottic spindle cell carcinoma. *Arch Otolaryngol Head Neck Surg* 124:1031–1034
207. Leighton SE, Gallimore AP (1994) Extranodal sinus histiocytosis with massive lymphadenopathy affecting the subglottis and trachea. *Histopathology* 24:393–394
208. Lerner DM, Deeb Z (1993) Acute upper airway obstruction resulting from systemic diseases. *South Med J* 86:623–627
209. Lewis JE, Olsen KD, Inwards CY (1997) Cartilaginous tumors of the larynx: clinicopathologic review of 47 cases. *Ann Otol Rhinol Laryngol* 106:94–100
210. Lewy RB, Millet D (1978) Immediate local tissue reactions to Teflon vocal cord implants. *Laryngoscope* 88:1339–1342
211. Lie ES, Karlens F, Holm R (1996) Presence of human papillomavirus in squamous cell laryngeal carcinomas. A study of thirty-nine cases using polymerase chain reaction and in situ hybridization. *Acta Otolaryngol* 116:900–905
212. Lin SY, Hsu CY, Jan YJ (2001) Primary laryngeal melanoma. *Otolaryngol Head Neck* 125:569–570
213. Lindeberg H, Krogdahl A (1999) Laryngeal cancer and human papillomavirus: HPV is absent in the majority of laryngeal carcinomas. *Cancer Lett* 146:9–13
214. Loos BM, Wieneke JA, Thompson LDR (2001) Laryngeal angiosarcoma: clinicopathologic study of five cases with a review of the literature. *Laryngoscope* 111:1197–1202
215. Luna MA, Pineda-Daboin K (2001) Upper aerodigestive tract. In: Henson D, Albores-Saavedra J Pathology of incipient neoplasia, 3rd edn. Oxford University Press, New York, pp 57–85
216. Lundgren J, Olofsson J, Hellquist H (1982) Oncocytic lesions of the larynx. *Acta Otolaryngol* 94:335–344
217. Luzar B, Gale N, Klopčič U, Fischinger J (2000) Laryngeal granuloma: characteristics of the covering epithelium. *J Laryngol Otol* 114:264–267
218. MacGregor AR, Batsakis JG, El-Naggar AK (2003) Myofibroblastoma of the larynx: a study of two cases. *Head Neck* 25:606–611
219. MacMillan RH III, Fechner RE (1986) Pleomorphic adenoma of the larynx. *Arch Pathol Lab Med* 110:245–247
220. Madrigal FM, Godoy LM, Daboin KP, Casiraghi O, Garcia AM, Lu MA (2002) Laryngeal osteosarcoma: a clinicopathologic analysis of four cases and comparison with a carcinosarcoma. *Ann Diagn Pathol* 6:1–9
221. Mahlstedt K, Ußmüller J, Donath K (2002) Malignant sialogenic tumours of the larynx. *J Laryngol Otol* 116:119–122
222. Maier H, Dietz A, Gewelke U, Heller WD, Weidauer H (1992) Tobacco and alcohol and the risk of head and neck cancer. *Clin Invest* 70:320–327
223. Maier H, Tisch M (1997) Epidemiology of laryngeal cancer: results of the Heidelberg case-control study. *Acta Otolaryngol Suppl* 527:160–164
224. Maier W, Lohle E, Welte V (1994) Pathogenetic and therapeutic aspects of contact granuloma. *Laryngorhinotologie* 73:488–491
225. Mamelle G, Pampurik J, Luboinski B, Lancar R, Lusinchi A, Bosq J (1994) Lymph node prognostic factors in head and neck squamous cell carcinomas. *Am J Surg* 168:494–498
226. Marcotullio D, Magliulo G, Pietruni S, Suriano M (2002) Exudative laryngeal diseases of Reinke's space: a clinicohistopathological framing. *J Otolaryngol* 31:376–380
227. Marcotullio D, Paduano F, Magliulo G (1996) Laryngopycele: an atypical case. *Am J Otolaryngol* 17:345–348
228. Marion RB, Alperin JE, Maloney WH (1972) Gouty tophus of the true vocal cord. *Arch Otolaryngol* 96:161–162
229. Maronian NC, Azadeh H, Waugh P, Hillel A (2001) Association of laryngopharyngeal reflux disease and subglottic stenosis. *Ann Otol Rhinol Laryngol* 110:606–612
230. Martin-Hirsch DP, Lannigan FJ, Irani B, Batman P (1992) Oncocytic papillary cystadenomatosis of the larynx. *J Laryngol Otol* 106:656–658
231. Mayo-Smith MF, Spinale JW, Donskey CJ, Yukawa M, Li RH, Schiffman FJ (1995) Acute epiglottitis. An 18-year experience in Rhode Island. *Chest* 108:1640–1647
232. Mazur MT, Shultz JJ, Myers JL (1990) Granular cell tumor. Immunohistochemical analysis of 21 benign tumors and one malignant tumor. *Arch Pathol Lab Med* 114:692–696

233. McAdam LP, O'Hanlan MA, Bluestone R, Pearson CM (1976) Relapsing polychondritis: prospective study of 23 patients and a review of the literature. *Medicine* 55:193–215
234. McCluggage WC, Cameron CH, Arthure K, Toner PG (1997) Atypical carcinoid tumor of the larynx: an immunohistochemical, ultrastructural, and flow cytometric analysis. *Ultrastruct Pathol* 21:431–438
235. McGavran MH, Bauer WC, Ogura JH (1961) The incidence of cervical lymph node metastases from epidermoid carcinoma of the larynx and their relationship to certain characteristics of the primary tumor. A study based on the clinical and pathological findings for 96 patients treated by primary en bloc laryngectomy and radical neck dissection. *Cancer* 14:55–66
236. McGregor DK, Citron D, Shahab I (2003) Cryptococcal infection of the larynx simulating laryngeal carcinoma. *South Med J* 96:74–77
237. McLaughlin RB, Spiegel JR, Selber J, Gotsdiner DB, Sataloff RT (1999) Laryngeal sarcoidosis presenting as an isolated submucosal vocal fold mass. *J Voice* 13:240–245
238. Michaels L, Hellquist HB (2001) Ear, nose and throat histopathology, 2nd edn. Springer, London
239. Michet CJ Jr, McKenna CH, Luthra HS, O'Fallon WM (1986) Relapsing polychondritis. Survival and predictive role of early disease manifestations. *Ann Intern Med* 104:74–78
240. Mikaelian DO, Contrucci RB, Batsakis JG (1986) Epithelial-myoepithelial carcinoma of the subglottic region: a case presentation and review of the literature. *Otolaryngol Head Neck Surg* 95:104–106
241. Miller FR, Wanamaker JR, Hicks DM, Tucker HM (1994) Cricoarytenoid arthritis and ankylosing spondylitis. *Arch Otolaryngol Head Neck Surg* 120:214–216
242. Mills SE (2002) Neuroendocrine neoplasms of the head and neck with emphasis on neuroendocrine carcinomas. *Mod Pathol* 15:264–278
243. Milroy CM, Rode J, Moss E (1991) Laryngeal paragangliomas and neuroendocrine carcinomas. *Histopathology* 18:201–209
244. Mineta H, Miura K, Takebayashi S, Araki K, Ueda Y, Harada H, Misawa K (2001) Immunohistochemical analysis of small cell carcinoma of the head and neck: a report of four patients and a review of sixteen patients in the literature with ectopic hormone production. *Ann Otol Rhinol Laryngol* 110:76–82
245. Mittal KR, True LD (1988) Origin of granules in granular cell tumor. Intracellular myelin formation with autodigestion. *Arch Pathol Lab Med* 112:302–303
246. Mochloulis G, Irving RM, Grant HR, Miller RF (1996) Laryngeal Kaposi's sarcoma in patients with AIDS. *J Laryngol Otol* 110:1034–1037
247. Mohsenifar Z, Tashkin DP, Carson SA, Bellamy PE (1982) Pulmonary function in patients with relapsing polychondritis. *Chest* 81:711–717
248. Moisa II, Silver CE (1991) Treatment of neuroendocrine neoplasms of the larynx. *ORL J Otorhinolaryngol Rel Spec* 53:259–264
249. Mok JSW, Pak MW, Chan KF, Chow J, van Hasselt CA (2001) Unusual T- and T/NK- cell non-Hodgkin's lymphoma of the larynx: a diagnostic challenge for clinicians and pathologists. *Head Neck*. 23:625–628
250. Molloy AR, McMahon JN (1988) Rapid progression of tracheal stenosis associated with tracheopathia osteo-chondroplastica. *Intensive Care Med* 15:60–62
251. Monday LA, Cornut G, Bouchayer M, Roch JB (1983) Epidermoid cysts of the vocal cords. *Ann Otol Rhinol Laryngol* 92:124–127
252. Moore KL, Persaud TVN (1998) The developing human, 6th edn. Saunders, Philadelphia, pp 215–256
253. Muir C, Weiland L (1995) Upper aerodigestive tract cancers. *Cancer* 75:147–153
254. Muscat JE, Wynder EL (1992) Tobacco, alcohol, asbestos, and occupational risk factors for laryngeal cancer. *Cancer* 69:2244–2251
255. Myssiorek D, Halaas Y, Silver C (2001) Laryngeal and sinonasal paragangliomas. *Otolaryngol Clin North Am* 34:971–982
256. Myssiorek D, Patel M, Wasserman P, Rofeim O (1998) Osteosarcoma of the larynx. *Ann Otol Rhinol Laryngol* 107:70–74
257. Myssiorek D, Persky M (1989) Laser endoscopic treatment of laryngoceles and laryngeal cysts. *Otolaryngol Head Neck Surg* 100:538–541
258. Nakajima H (1993) Tuberculosis: a global emergency. *World Health Forum* 14:438
259. Nakayama M, Brandenburg JH, Hafez GR (1993) Dedifferentiated chondrosarcoma of the larynx with regional and distant metastases. *Ann Otol Rhinol Laryngol* 102:785–791
260. Nandapalan V, Roland NJ, Helliwell TR, Williams EM, Hamilton J, Jones AS (1998) Mucosal melanoma of the head and neck. *Clin Otolaryngol* 23:107–116
261. Narozny W, Stankiewicz C, Przewozny T, Bakowska A, Czuszyńska Z (2001) A case of multisymptomatic relapsing polychondritis in a 22-year-old woman. *Acta Otorhinolaryngol Belg* 55:227–233
262. Nayak DR, Balakrishnan R, Rao RV, Hazarika P (2001) Clear cell carcinoma of the larynx. *Int J Pediatr Otorhinolaryngol* 57:149–153
263. Neel HB III, McDonald TJ (1982) Laryngeal sarcoidosis: report of 13 patients. *Ann Otol Rhinol Laryngol* 91:359–362
264. Netterville JL, Coleman JR Jr, Chang S, Rainey CL, Reinisch L, Ossoff RH (1998) Lateral laryngotomy for the removal of Teflon granuloma. *Ann Otol Rhinol Laryngol* 107:735–744
265. Newman BH, Taxy JB, Laker HI (1984) Laryngeal cysts in adults: a clinicopathologic study of 20 cases. *Am J Clin Pathol* 81:715–720
266. Nguyen HC, Urquhart AC (1997) Zenker's diverticulum. *Laryngoscope* 107:1436–1440
267. Nicolai P, Puxeddu R, Cappiello J, Peretti G, Battochio S, Facchetti F, Antonelli AR (1996) Metastatic neoplasms to the larynx: report of three cases. *Laryngoscope* 106:851–855
268. Nishiike S, Irifune M, Doi K, Sawada T, Kubo T (2002) Laryngeal tuberculosis: a report of 15 cases. *Ann Otol Rhinol Laryngol* 111:916–918
269. Nosfinger YC, Mirza N, Rowan PT, Lanza D, Weinstein G (1997) Head and neck manifestations of plasma cell neoplasms. *Laryngoscope* 107:741–746
270. Nowak-Sadzikowska J, Weiss M (1998) Extramedullary plasmacytoma of the larynx. Analysis of 5 cases. *Eur J Cancer* 34:1468
271. Nunez DA, Astley SM, Lewis FA, Wells M (1994) Human papilloma viruses: a study of their prevalence in the normal larynx. *J Laryngol Otol* 108:319–320
272. Ogawa Y, Nishiyama N, Hagiwara A, Ami T, Fujita H, Yoshida T, Suzuki M (2002) A case of laryngeal aspergillosis following radiation therapy. *Auris Nasus Larynx* 29:73–76
273. O'Halloran LR, Lusk RP (1994) Amyloidosis of the larynx in a child. *Ann Otol Rhinol Laryngol* 103:590–594
274. Ohlms LA, McGill T, Healy GB (1994) Malignant laryngeal tumors in children: a 15-year experience with four patients. *Ann Otol Rhinol Laryngol* 103:686–692
275. Omeroglu A, Weisenberg E, Baim HM, Rhone DP (2001) Pathologic quiz case. Supraglottic granulomas in a young Central American Man. *Arch Pathol Lab Med* 125:157–158
276. Oreggia F, De Stefani E, Boffetta P, Brennan P, Deneo-Pellegrini H, Ronco AL (2001) Meat, fat and risk of laryngeal cancer: a case-control study in Uruguay. *Oral Oncol* 37:141–145
277. Orlandi A, Fratoni S, Hermann I, Spagnoli LG (2003) Symptomatic laryngeal nodular chondrometaplasia: a clinicopathological study. *J Clin Pathol* 56:976–977
278. Osammar JY, Bulman CH, Blewitt RW (1990) Intralaryngo-tracheal thyroid. *J Laryngol Otol* 104:733–736
279. Paaske PB, Tang E (1985) Tracheopathia osteoplastica in the larynx. *J Laryngol Otol* 99:305–310
280. Pabuçuoğlu U, Tuncer C, Sengiz S (2002) Histopathology of candidal hyperplastic lesions of the larynx. *Pathol Res Pract* 198:675–678
281. Park SS, Streitz JM Jr, Rebeiz EE, Shapshay SM (1995) Idiopathic subglottic stenosis. *Arch Otolaryngol Head Neck Surg* 121:894–897

282. Patterson HC, Dickerson GR, Pilch BZ, Bentkover SH (1981) Hamartoma of the hypopharynx. *Arch Otolaryngol* 107:767–772
283. Peeters A, Schmelzer B, Beernaert A, Fannes H (2001) Oncocytic laryngeal cysts: a case report and literature review. *Acta Otorhinolaryngol Belg* 55:71–75
284. Pelliteri PK, Ferlito A, Bradley PJ, Shaha AR, Rinaldo A (2003) Management of sarcomas of the head and neck in adults. *Oral Oncol* 39:2–12
285. Pelucchi C, Talamini R, Levi F, Bosetti C, La Vecchia C, Negri E, Parpinel M, Pesce C, Tobia-Gallelli F, Toncini C (1984) APUD cells of the larynx. *Acta Otolaryngol* 98:158–162
286. Pelucchi S, Amoroso C, Grandi E, Carinci F, Pastore A (2002) Granular cell tumour of the larynx: literature review and case report. *J Otolaryngol* 31:234–235
287. Pennings RJ, van den Hoogen FJ, Marres HA (2001) Giant laryngoceles: a cause of upper airway obstruction. *Eur Arch Otorhinolaryngol* 258:137–140
288. Pesce C, Tobia-Gallelli F, Toncini C (1984) APUD cells of the larynx. *Acta Otolaryngol* 98:158–162
289. Peterson KL, Fu YS, Calcaterra T (1997) Subglottic paraganglioma. *Head Neck* 19:54–56
290. Phipps CD, Gibson WS, Wood WE (1997) Infantile subglottic hemangioma: a review and presentation of two cases of surgical excision. *Int J Pediatr Otorhinolaryngol* 41:71–79
291. Pilch BZ (2001) Larynx and hypopharynx. In: Pilch BZ (ed) *Head and neck surgical pathology*. Lippincott Williams & Wilkins, Philadelphia, pp 230–283
292. Pinsolle J, Pinsolle V, Majoufre C, Duroux S, Demeaux H, Siberchicot F (1997) Prognostic value of histologic findings in neck dissections for squamous cell carcinoma. *Arch Otolaryngol Head Neck Surg* 123:145–148
293. Pompe-Kirn V (2002) Epidemiological features of laryngeal cancer in Slovenia. *Zdrav Vestn* 71:59–63
294. Popper HH, Winter E, Hofler G (1994) DNA of *Mycobacterium tuberculosis* in formalin-fixed, paraffin-embedded tissue in tuberculosis and sarcoidosis detected by polymerase chain reaction. *Am J Clin Pathol* 101:738–741
295. Pounder DJ, Pieterse AS (1982) Tracheopathia osteoplastica: a study of the minimal lesion. *J Pathol* 138:235–239
296. Prescher A, Schick B, Stütz A, Brors D (2002) Laryngeal prostatic cancer metastases: an underestimated route of metastases? *Laryngoscope* 112:1467–1473
297. Preti G, Palonta F, Vione N, Rosso P, Cavalot AL (2003) Leiomyosarcoma of the larynx. *Tumori* 89:321–323
298. Pribitkin E, Friedman O, O'Hara B, Cunnane MF, Levi D, Rosen M, Keane WM, Sataloff RT (2003) Amyloidosis of the upper aerodigestive tract. *Laryngoscope* 113:2095–2101
299. Rafferty MA, Fenton JE, Jones AS (2001) The history, aetiology and epidemiology of laryngeal carcinoma. *Clin Otolaryngol* 26:442–446
300. Raitiola H, Pukander J (2000) Symptoms of laryngeal carcinoma and their prognostic significance. *Acta Oncol* 39:213–216
301. Raitiola H, Pukander J, Laippala P (1999) Glottic and supraglottic laryngeal carcinoma: differences in epidemiology, clinical characteristics and prognosis. *Acta Otolaryngol* 119:847–851
302. Rajah V, Essa A (1993) Histoplasmosis of the oral cavity, oropharynx and larynx. *J Laryngol Otol* 107:58–61
303. Rakover Y, Bennett M, David R, Rosen G (2000) Isolated extramedullary plasmacytoma of the vocal fold. *J Laryngol Otol* 114:540–542
304. Ramesar K, Albizzati C (1988) Laryngeal cysts: clinical relevance of a modified working classification. *J Laryngol Otol* 102:923–925
305. Randolph J, Grunt JA, Vawter GF (1963) The medical and surgical aspects of intratracheal goiter. *N Engl J Med* 268:457–461
306. Rassaei N, Frye DA, Harter KW, Troost TR, Ozdemirli M (2003) Acinic cell carcinoma of the glottis: case report. *Am J Otolaryngol* 24:258–260
307. Reder PA, Neel HB III (1993) Blastomycosis in otolaryngology: review of a large series. *Laryngoscope* 103:53–58
308. Remacle M, Degols JC, Delos M (1996) Exudative lesions of Reinke's space. An anatomopathological correlation. *Acta Otorhinolaryngol Belg* 50:253–264
309. Remenar E, Elo J, Frint T (1984) The morphological basis for development of Reinke's oedema. *Acta Otolaryngol* 97:169–176
310. Richardson BE, Morrison VA, Gapany M (1996) Invasive aspergillosis of the larynx: case report and review of the literature. *Otolaryngol Head Neck Surg* 114:471–473
311. Richter B, Fradis M, Kohler G, Ridder GJ (2001) Epiglottic tuberculosis: differential diagnosis and treatment. Case report and review of the literature. *Ann Otol Rhinol Laryngol* 110:197–201
312. Riding K (1992) Subglottic hemangioma: a practical approach. *J Otolaryngol* 21:419–421
313. Rihkanen H, Peltomaa J, Syrjänen S (1994) Prevalence of human papillomavirus DNA in vocal cords without laryngeal papillomas. *Acta Otolaryngol* 114:348–351
314. Rinaldo A, Mannara GM, Fisher C, Ferlito A (1998) Hamartoma of the larynx: a critical review of the literature. *Ann Otol Rhinol Laryngol* 107:264–267
315. Rizzo PB, Da Mosto MC, Clari M, Scotton PG, Vaglia A, Marchiori C (2003) Laryngeal tuberculosis: an often forgotten diagnosis. *Int J Infect Dis* 7:129–131
316. Salvesen R, Brautaset NJ (1996) Oculopharyngeal muscular dystrophy in Norway. Survey of a large Norwegian family. *Acta Neurol Scand* 93:281–285
317. Sant'Anna GD, Mauri M, Arrarte JL, Camargo H Jr (1999) Laryngeal manifestations of paracoccidioidomycosis (South American blastomycosis). *Arch Otolaryngol Head Neck Surg* 125:1375–1378
318. Santoro R, Turelli M, Polli G (2000) Primary carcinoma of the subglottic larynx. *Eur Arch Otorhinolaryngol* 257:548–551
319. Sataloff RT, Wilborn A, Prestipino A, Hawkshaw M, Heuer RJ, Cohn J (1993) Histoplasmosis of the larynx. *Am J Otolaryngol* 14:199–205
320. Sato K, Hirano M, Nakashima T (1999) Electron microscopic and immunohistochemical investigation of Reinke's edema. *Ann Otol Rhinol Laryngol* 108:1068–1072
321. Sato K, Kurita S, Hirano M (1993) Location of the preepiglottic space and its relationship to the paraglottic space. *Ann Otol Rhinol Laryngol* 102:930–934
322. Sato K, Umeno T, Hirano M, Nakashima T (2002) Cricoid area of the larynx: its physiological and pathological significance. *Acta Otolaryngol* 122:882–886
323. Sawatsubashi M, Tuda K, Tokunaga O, Shin T (1997) Pleomorphic adenoma of the larynx: a case and review of the literature in Japan. *Otolaryngol Head Neck Surg* 117:415–417
324. Saydam L, Koybasi S, Kutluay L (2003) Laryngeal chondroma presenting as an external neck mass. *Eur Arch Otorhinolaryngol* 260:239–241
325. Schiff NF, Annino DJ, Woo P, Shapshay SM (1997) Kaposi's sarcoma of the larynx. *Ann Otol Rhinol Laryngol* 106:563–567
326. Schmidt U, Metz KA, Schrader M, Leder LD (1994) Well-differentiated (oncocytoid) neuroendocrine carcinoma of the larynx with multiple skin metastases – a brief report. *J Laryngol Otol* 108:272–274
327. See AC, Patel SG, Montgomery PQ, Rhys Evans PH, Fisher C (1998) Intralaryngeotracheal thyroid-ectopic thyroid or invasive carcinoma? *J Laryngol Otol* 112:673–676
328. Seikaly H, Cuyler JP (1994) Infantile subglottic hemangioma. *J Otolaryngol* 23:135–137
329. Seitz HK, Simanowski UA, Kommerell B (1988) Alcohol and cancer. *Z Gastroenterol Suppl* 3:106–119
330. Shapiro AM, Rimell FL, Kenna MA (1995) Pathologic quiz case 1. Granular cell tumor (GCT) of larynx. *Arch Otolaryngol Head Neck Surg* 121:1058; 1060–1061
331. Shapiro J, Eavey RD, Baker AS (1988) Adult supraglottitis. A prospective analysis. *JAMA* 259:563–567
332. Sheen TS, Wu CT, Heieh T, Hsu MM (1997) Postirradiation laryngeal osteosarcoma: case report and literature review. *Head Neck* 19:57–62

333. Shek AW, Wu PC, Samman N (1996) Inflammatory pseudotumour of the mouth and maxilla. *J Clin Pathol* 49:164–167
334. Shikhani AH, Jones MM, Marsh BR, Holliday MJ (1986) Infantile subglottic hemangiomas. An update. *Ann Otol Rhinol Laryngol* 95:336–347
335. Shonai T, Hareyama M, Sakata K, Oouchi A, Nagakura H, Koito K, Morita K, Satoh M, Asakura K, Kataura A, Hinoda Y (1998) Mucoepidermoid carcinoma of the larynx: a case which responded completely to radiotherapy and a review of the literature. *Jpn J Clin Oncol* 28:339–342
336. Shpitzer T, Noyek AM, Witterick I, Kassel T, Ichise M, Gullane P, Neligan P, Freeman J (1997) Noncutaneous cavernous hemangiomas of the head and neck. *Am J Otolaryngol* 18:367–374
337. Sie KC, McGill T, Healy GB (1994) Subglottic hemangioma: ten years' experience with the carbon dioxide laser. *Ann Otol Rhinol Laryngol* 103:167–172
338. Smets G, Warson F, Dehou MF, Storme G, Sacre R, Van Belle S, Somers G, Gepts W, Kloppel G (1990) Metastasizing neuroendocrine carcinoma of the larynx with calcitonin and somatostatin secretion and CEA production, resembling medullary thyroid carcinoma. *Virchows Arch* 416:539–543
339. Sneller MC (1995) Wegener's granulomatosis. *JAMA* 273:1288–1291
340. Sobin LH, Wittekind CH (2002) TNM classification of malignant tumors, 6th edn, Wiley, New York
341. Soga J, Osaka M, Yakuwa Y (2002) Laryngeal endocrinomas (carcinoids and relevant neoplasms): analysis of 278 reported cases. *J Exp Cancer Res* 21:5–13
342. Soni NK (1992) Leprosy of the larynx. *J Laryngol Otol* 106:518–520
343. Sorensen WT, Moller-Andersen K, Behrendt N (1998) Rheumatoid nodules of the larynx. *J Laryngol Otol* 112:573–574
344. Souglu Y, Erdamar B, Katircioglu OS, Karatay MC, Sunay T (2002) Extracapsular spread in ipsilateral neck and contralateral neck metastases in laryngeal cancer. *Ann Otol Rhinol Laryngol* 111:447–454
345. Soylu L, Kiroglu F, Ersoz C, Ozcan C, Aydogan B (1993) Intralaryngotracheal thyroid. *Am J Otolaryngol* 14:145–147
346. Spector JG, Sessions DG, Emami B, Simpson J, Haughey B, Harvey J, Fredrickson JM (1995) Squamous cell carcinoma of the pyriform sinuses: a nonrandomized study comparison of therapeutic modalities and long-term results. *Laryngoscope* 105:397–406
347. Spiro RH (1986) Salivary neoplasms: overview of a 35-year experience with 2807 patients. *Head Neck Surg* 8:177–184
348. Spiro RH (1997) Distant metastasis in adenoid cystic carcinoma of the salivary origin. *Am J Surg* 174:495–498
349. Spraggs PD, Tostevin PM, Howard DJ (1997) Management of laryngotracheobronchial sequelae and complications of relapsing polychondritis. *Laryngoscope* 107:936–941
350. Stell PM, Tobin KE (1975) The behaviour of cancer affecting the subglottic space. *Can J Otolaryngol* 4:612–617
351. Strickler JG, Audeh MW, Copenhaver CM, Warnke RA (1988) Immunophenotypic differences between plasmacytoma, multiple myeloma and immunoblastic lymphoma. *Cancer* 61:1782–1786
352. Strong MS, Vaughan CW (1971) Vocal cord nodules and polyps – the role of surgical treatment. *Laryngoscope* 81:911–923
353. Szpunar J, Glowacki J, Laskowski A, Miszke A (1971) Fibrinous laryngotracheobronchitis in children. *Arch Otolaryngol* 93:173–178
354. Szwarc BJ, Kashima HK (1997) Endoscopic management of a combined laryngocele. *Ann Otol Rhinol Laryngol* 106:556–559
355. Šmid L, Lavrenčak B, Žargi M (1992) Laryngo-tracheo-bronchopathia chondro-osteoplastica. *J Laryngol Otol* 106:845–848
356. Tajima K, Yamakawa M, Katagiri T, Sasaki H (1997) Immunohistochemical detection of bone morphogenetic protein-2 and transforming growth factor beta-1 in tracheopathia osteochondroplastica. *Virchows Arch* 431:359–363
357. Thabet MH, Kotob H (2001) Lateral saccular cysts of the larynx. Aetiology, diagnosis and management. *J Laryngol Otol* 115:293–297
358. Thome R, Thome DC, de la Cortina RA (2001) Long-term follow-up of cartilaginous tumors of the larynx. *Otolaryngol Head Neck Surg* 124:634–640
359. Thompson LD, Derringer GA, Wenig BM (2000) Amyloidosis of the larynx: a clinicopathologic study of 11 cases. *Mod Pathol* 13:528–535
360. Thompson LDR, Gannon FH (2002) Chondrosarcoma of the larynx. A clinicopathologic study of 111 cases with review of the literature. *Am J Surg Pathol* 26:836–851
361. Thoren L (1947) Intratracheal goitre. *Acta Chir Scand* 95:495–512
362. Tisch M, Lampl L, Groh A, Maier H (2002) Angioneurotic edemas of the upper aerodigestive tract after ACE-inhibitor treatment. *Eur Arch Otorhinolaryngol* 259:419–421
363. Toohill RJ (1975) The psychosomatic aspects of children with vocal nodules. *Arch Otolaryngol* 101:591–595
364. Trentham DE, Le CH (1998) Relapsing polychondritis. *Ann Intern Med* 129:114–122
365. Tsikoudas A, Coatesworth AP, Martin-Hirsch DP (2002) Laryngeal gout. *J Laryngol Otol* 116:140–142
366. Tsunoda K, Soda Y (1996) Hoarseness as the initial manifestation of systemic lupus erythematosus. *J Laryngol Otol* 110:478–479
367. Tuyns AJ, Estève J, Raymond L, Berrino F, Benhamou E, Blanchet F, Boffetta P, Crosignani P, del Moral A, Lehmann W, Merletti F, Péquignot G, Riboli E, Sancho-Garnier H, Terracini B, Zubiri A, Zubiri L (1988) Cancer of the larynx/hypopharynx, tobacco and alcohol: IARC international case-control study in Turin and Varese (Italy), Zaragoza and Navarra (Spain), Geneva (Switzerland) and Calvados (France). *Int J Cancer* 41:483–491
368. Uzcudun EA, Fernandez PB, Sanchez JJ, Grande AG, Retolaza IR, Baron MG, Bouzas JG (2001) Clinical features of pharyngeal cancer: a retrospective study of 258 consecutive patients. *J Laryngol Otol* 115:112–118
369. Valdez TA, Shapshay SM (2002) Idiopathic subglottic stenosis revisited. *Ann Otol Rhinol Laryngol* 111:690–695
370. Varvares MA, Montgomery WW, Hillman RE (1995) Teflon granuloma of the larynx: etiology, pathophysiology, and management. *Ann Otol Rhinol Laryngol* 104:511–515
371. Victoria LV, Hoffman HT, Robinson RA (1998) Granular cell tumour of the larynx. *J Laryngol Otol* 112:373–376
372. Waggoner LG (1958) Intralaryngeal intratracheal thyroid. *Ann Otol Rhinol Laryngol* 67:61–71
373. Walker GK, Fechner RE, Johns ME, Teja K (1982) Necrotizing sialometaplasia of the larynx secondary to atheromatous embolization. *Am J Clin Pathol* 77:221–223
374. Wani MK, Woodson GE (1999) Laryngeal contact granuloma. *Laryngoscope* 109:1589–1593
375. Wasserman PG, Savargaonkar P (2001) Paragangliomas: classification, pathology, and differential diagnosis. *Otolaryngol Clin North Am* 34:845–862
376. Waterhouse JAH (1993) Epidemiology. In: Ferlito A (ed) *Neoplasms of the larynx*. Churchill Livingstone, Edinburgh, pp 49–64
377. Weber AL, Shortleeve M, Goodman M, Montgomery W, Grillo HC (1978) Cartilaginous tumors of the larynx and trachea. *Radiol Clin North Am* 16:261–267
378. Welsh J, Westra WH, Eisele D, Hogan R, Lee DJ (1998) Solitary plasmacytoma of the epiglottis: a case report and review of the literature. *J Laryngol Otol* 112:174–176
379. Wenig BM (1995) Laryngeal mucosal malignant melanoma. A clinicopathologic, immunohistochemical, and ultrastructural study of four patients and review of the literature. *Cancer* 75:1568–1577
380. Wenig BM (1995) Necrotizing sialometaplasia of the larynx. A report of two cases and a review of the literature. *Am J Clin Pathol* 103:609–613
381. Wenig BM, Abbondanzo SL, Childers EL, Kapadia SB, Hefner DR (1993) Extranodal sinus histiocytosis with massive lymphadenopathy (Rosai-Dorfman disease) of the head and neck. *Hum Pathol* 24:483–492

382. Wenig BM, Devaney K, Bisceglia M (1995) Inflammatory myofibroblastic tumor of the larynx. A clinicopathologic study of eight cases simulating a malignant spindle cell neoplasm. *Cancer* 76:2217–2229
383. Wenig BM, Devaney K, Wenig BL (1995) Pseudoneoplastic lesions of the oropharynx and larynx simulating cancer. *Pathol Annu* 30:143–187
384. Wenig BM, Heffner DK (1990) Contact ulcers of the larynx. A reacquaintance with the pathology of an often underdiagnosed entity. *Arch Pathol Lab Med* 114:825–828
385. Wenig BM, Heffner DK, Oertel YC, Johnson FB (1990) Teflonomas of the larynx and neck. *Hum Pathol* 21:617–623
386. Werkhaven J, Ossoff RH (1991) Surgery for benign lesions of the glottis. *Otolaryngol Clin North Am* 24:1179–1199
387. Westerberg BD, Durham JS, Berean KW (1995) Multiple oncocytic laryngeal cysts presenting as acute airway obstruction. *J Otolaryngol* 24:319–321
388. Woodruff JM, Senie RT (1991) Atypical carcinoid tumor of the larynx. A critical review of the literature. *ORL* 53:194–209
389. World Health Organization Classification of Tumours (2005) Pathology and genetics of tumours of the head and neck. IARC, Lyon
390. Yench MW, Linfesty R, Blackmon A (2000) Laryngeal tuberculosis. *Am J Otolaryngol* 21:122–126
391. Yuan YG, Han DM, Yang BQ, Yu ZK (1999) Laryngeal carcinoid tumours: Report of three cases. *J Otolaryngol* 28:54–56
392. Yuen APW, Wei WI, Ho WK, Hui Y (1996) Risk factors of tracheostomal recurrence after laryngectomy for laryngeal carcinoma. *Am J Surg* 172:263–266
393. Zatonski W, Becher H, Lissowska J, Wahrendorf J (1991) Tobacco, alcohol, and diet in the etiology of laryngeal cancer: a population-based case-control study. *Cancer Causes Control* 2:3–10
394. Zbaren P, Greiner R, Kengelbacher M (1996) Stomal recurrence after laryngectomy: an analysis of risk factors. *Otolaryngol Head Neck Surg* 114:569–575
395. Zeitels SM, Hillman RE, Bunting GW, Vaughn T (1997) Reinke's edema: phonatory mechanisms and management strategies. *Ann Otol Rhinol Laryngol* 106:533–543
396. Zheng W, Blot WJ, Shu X, Gao YT, Ji BT, Ziegler RG, Fraumeni Jr (1992) Diet and other risk factors for laryngeal cancer in Shanghai, China. *Am J Epidemiol* 136:178–191
397. Zidar N, Volavšek M, Trček C, Kern I, Gale N (2000) Wegener's granulomatosis in the upper respiratory tract. *Wien Klin Wochenschr* 112:676–679

Ear and Temporal Bone

L. Michaels

Contents

8.1	Summary of Embryology, Anatomy and Histology	236	8.2.5.3	Basal Cell Carcinoma	242
8.1.1	Embryology	236	8.2.5.4	Squamous Cell Carcinoma	243
8.1.2	Anatomy	236	8.2.5.5	Melanotic Neoplasms	243
8.1.3	Histology	237	8.3	Middle Ear and Mastoid	244
8.2	External Ear and Auditory Canal	237	8.3.1	Inflammatory Lesions	244
8.2.1	Inflammatory and Metabolic Lesions	237	8.3.1.1	Acute and Chronic Otitis Media	244
8.2.1.1	Diffuse External Otitis	237	8.3.1.2	Cholesteatoma	244
8.2.1.2	Perichondritis	237	8.3.1.3	Unusual Inflammatory Lesions	247
8.2.1.3	Malignant Otitis Externa	237	8.3.2	Neoplasms and Lesions Resembling Neoplasms	247
8.2.1.4	Relapsing Polychondritis	238	8.3.2.1	Choristoma (Salivary Gland, Glial and Sebaceous Types)	247
8.2.1.5	Gout	238	8.3.2.2	Adenoma	247
8.2.1.6	Ochronosis	238	8.3.2.3	Papillary Tumours	248
8.2.2	Pseudocystic and Cystic Lesions	238	8.3.2.4	Jugulotympanic Paraganglioma	249
8.2.2.1	Idiopathic Pseudocystic Chondromalacia	238	8.3.2.5	Squamous Carcinoma	250
8.2.2.2	First Branchial Cleft Cyst	238	8.3.2.6	Meningioma	251
8.2.3	Tumour-Like Lesions	239	8.3.2.7	Rhabdomyosarcoma	251
8.2.3.1	Chondrodermatitis Nodularis Helicis	239	8.3.2.8	Metastatic Carcinoma	252
8.2.3.2	Keratosis Obturans and Cholesteatoma of External Canal	239	8.4	Inner Ear	252
8.2.3.3	Keratin Granuloma	239	8.4.1	Bony Labyrinth	252
8.2.3.4	Angiolymphoid Hyperplasia with Eosinophilia and Kimura's Disease	239	8.4.1.1	Otosclerosis	252
8.2.3.5	Accessory Tragus	240	8.4.1.2	Paget's Disease	253
8.2.3.6	Keloid	240	8.4.1.3	Osteogenesis Imperfecta	254
8.2.4	Benign Neoplasms	240	8.4.1.4	Osteopetrosis	254
8.2.4.1	Adenoma of Ceruminal Glands	240	8.4.2	Membranous Labyrinth and Cranial Nerves	254
8.2.4.2	Pleomorphic Adenoma of Ceruminal Glands	241	8.4.2.1	Viral, Bacterial and Mycotic Infections	254
8.2.4.3	Syringocystadenoma Papilliferum of Ceruminal Glands	241	8.4.2.2	Lesions of the Vestibular System	256
8.2.4.4	Bony Lesions	241	8.4.2.3	Tumours and Tumour-Like Lesions	257
8.2.5	Malignant Neoplasms	242	8.4.2.4	Presbycusis	260
8.2.5.1	Adenocarcinoma of Ceruminal Glands	242	8.4.2.5	Malformations	260
8.2.5.2	Adenoid Cystic Carcinoma of Ceruminal Glands	242	References	260	

8.1 Summary of Embryology, Anatomy and Histology

8.1.1 Embryology

The ear is not a single organ, but two, being the peripheral receptor site both for stimuli derived from sound waves and for changes in posture. The structures subserving both of those functions are developed from an invagination of the ectoderm early in embryonic life – the otocyst – to produce the epithelia of the membranous labyrinth of the inner ear. Superimposed upon, and developing slightly later, the first and second branchial arch systems provide structures that augment the hearing function. The endodermal component of the first branchial system, the branchial pouch, gives rise to the Eustachian tube and middle ear epithelia and the corresponding ectodermal outgrowth, the first branchial cleft, to the external ear epidermis. The connective tissue part of the local branchial cranial (auditory vestibular) nerve outflow from the central nervous system, both its vestibular and cochlear branches, grows to link up with the sensory epithelia lining the otocyst-derived cochlear and vestibular endolymph-containing cavities; there is recent evidence that terminal ganglion cells, e.g. spiral ganglion cells, may also be otocyst-derived. Cartilaginous, bony and muscular configurations of the ear are developed from the mesenchyme surrounding these early epithelia. The seventh cranial (facial) nerve develops in close relation to the structures of the ear for much of its course.

8.1.2 Anatomy

The anatomy of the ear may be considered by reference to its functions in hearing and balance (Fig. 8.1).

The pinna and external canal conduct sound waves in the air to the tympanic membrane, which transmits them by very delicate vibrations. The middle ear enhances this sound energy transmission by conveying vibrations from the larger area of the tympanic membrane through the ossicular chain (malleus, incus and stapes) to the much smaller area of the footplate of the stapes, which lies in the oval window of the vestibule in contact with the perilymph. In this way vibrations representing sound are conducted to the fluids of the inner ear. The air space of the middle ear cavity is magnified by the mastoid air cells, which are complex expansions into the mastoid bone. There is a connection of the middle ear space with the nasopharynx and so with the external air through the Eustachian tube, by which air pressure can be adjusted.

From the vestibular perilymph, vibrations derived from sound waves pass directly via the scala vestibuli into the spirally coiled perilymphatic spaces of the cochlea, where it forms an upper compartment ascending from the vestibule and oval window. A lower compartment, the scala tympani, descends spirally to the round window membrane, a connective tissue disc separating the perilymph compartment from the middle ear. Between the scalae vestibuli and tympani there is an endolymph-containing coiled middle compartment, the cochlear duct (scala media), which houses the senso-

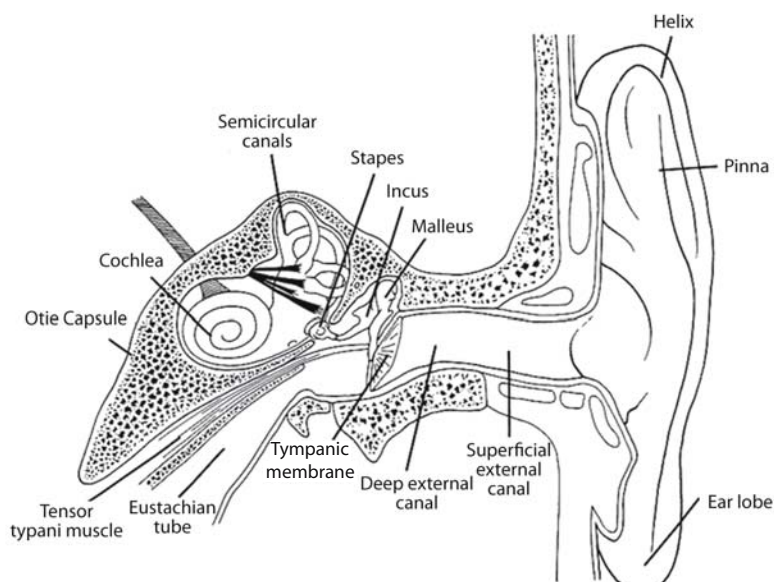


Fig. 8.1. Anatomical diagram of the ear. Reproduced from Michaels and Hellquist [68]

ry organ of sound reception, the organ of Corti. Waves of vibration are conveyed from the perilymph to the walls of the scala media, from which, through the endolymph, they affect the sensory cells of the organ of Corti.

The cochlear duct communicates with the vestibular endolymph-containing sacs through two fine canals so that the endolymphatic system of the cochlea and vestibule is continuous, like the perilymphatic one. Gravitational acceleration of the head is detected in a sensory organ arranged within endolymph-containing sacs in the vestibule (the utricle and saccule), and angular acceleration is detected within tubes emanating in three dimensions from the utricle (lateral, posterior and superior semicircular canals). The sensory cells are located as a thickened portion of epithelium, the macula, in the saccule and utricle and a raised prominence of epithelium, the crista, in expansions of each semicircular canal, the ampullae. The vestibular aqueduct contains the endolymphatic duct and sac, which constitute a blind offshoot of the endolymphatic system, probably functioning to absorb endolymph. The cochlear aqueduct is a communication between the cerebrospinal fluid in the subarachnoid space to the perilymph of the scala tympani near the round window. Cochlea, vestibule and semicircular canals are surrounded by very dense bone, the otic capsule.

The cochlear and vestibular sensory structures are supplied by a double nerve, the audiovestibular nerve or eighth cranial nerve, which enters the temporal bone through the internal auditory meatus. The facial nerve or seventh cranial nerve, enters the temporal bone through the same canal, and after a right-angled bend in the genu, where the geniculate ganglion is located, reaches the posterior wall of the middle ear, from which it passes down through the mastoid to emerge in the region of the parotid salivary gland, after which it provides motor nerve supply for the muscles of the face.

8.1.3 Histology

The ear and temporal bone are composed of many different tissues, the normal histology of which is best considered when describing the pathologic appearances of these parts.

8.2 External Ear and Auditory Canal

8.2.1 Inflammatory and Metabolic Lesions

8.2.1.1 Diffuse External Otitis

This is a common condition, most frequently associated with *Pseudomonas aeruginosa* infection, but local trauma is also an important causative factor. Histological features include acute inflammation of the dermis, together with acanthosis and hyperkeratosis of the epidermis.

8.2.1.2 Perichondritis

Perichondritis most commonly affects the pinna, where it may follow surgical trauma. As in the diffuse acute inflammation of the ear canal, *Pseudomonas aeruginosa* is the most common infecting organism. Pus accumulates between the perichondrium and cartilage of the pinna. This may interfere with the blood supply of the cartilage and so lead to its necrosis.

8.2.1.3 Malignant Otitis Externa

Malignant otitis externa was first described as a severe infection of the external auditory canal [16]. It usually (but not always [101]) affects elderly diabetics, resulting in unremitting pain, purulent discharge and invasion of cartilage, nerve, bone and adjacent soft tissue. The causative agent is usually *Pseudomonas aeruginosa*, but other organisms including fungi have been incriminated. The condition frequently goes on to ninth, tenth, eleventh and twelfth cranial nerve palsies and meningitis and death may result.

Histopathological changes in the temporal bones of two patients who had been diagnosed clinically as having malignant otitis externa and were thought to have died of this condition [123] were those of severe otitis media and osteomyelitis of the jugular foramen secondary to it. It seems likely that the manifestations of malignant otitis media are due to the spread of inflammation from the tympanic cavity and mastoid air spaces to the petrous apex through bone marrow spaces by a process of osteomyelitis [85]. In recent years several patients with AIDS have been reported to have malignant otitis externa, and in one of them the presence of acute osteomyelitis of the skull base in addition supported the concept of osteomyelitis as the pathologic basis for malignant otitis externa put forward above [121].

8.2.1.4 Relapsing Polychondritis

Relapsing polychondritis is a rare disease of unknown aetiology characterised by recurring bouts of inflammation affecting cartilaginous structures and the eye. Although the cartilage of the external ear is most frequently involved and that of the nose next in frequency, it is the inflammation with destruction of the cartilages of the respiratory tract, particularly those of the larynx, which threatens life, and in most cases where death has resulted from the condition it is from respiratory obstruction due to such cartilage damage.

The cartilage of the pinna, is recurrently acutely inflamed and this leads eventually to a cobblestone appearance resembling boxer's ear. Inflammation of the nasal septum leads to a sinking of this structure, producing a "saddle nose" appearance. Involvement of laryngeal and tracheal cartilages may lead to respiratory difficulty. Rib cartilages may be swollen and tender. Episcleritis or scleritis, iritis, conjunctivitis or keratitis may also be found in relapsing polychondritis. Heart lesions are characteristically aortic, showing signs of regurgitation. The histology of this affliction is dealt with in Chap. 7.

8.2.1.5 Gout

Gout is manifested both as an acute arthritis that is related to deposits of urates in the joint capsule, most frequently in the big toe joint, and as tophi in non-articular tissues. The external ear is one of the most frequent places for the latter and deposits may occur in the helix and antihelix. They may ulcerate, discharging a creamy white material within which needle-like crystals of sodium urate may be detected on microscopy. For histology, see Chap. 7.

8.2.1.6 Ochronosis

Ochronosis (alkaptonuria) is an inherited disease of the metabolism in which a step in tyrosine metabolism is disturbed, resulting in accumulation of homogentisic acid in a variety of places, but especially in the cartilages. The substance is colourless in the urine when first passed, but darkens to a black or brown polymer on standing. The disease is inherited as an autosomal recessive.

In the external ear there may be one or both of two manifestations: (a) dark colour of the wax; when seen in a child this may be the first manifestation of ochronosis; (b) dark colour of the aural cartilage due to the binding of the homogentisic acid to the cartilage ground substance.

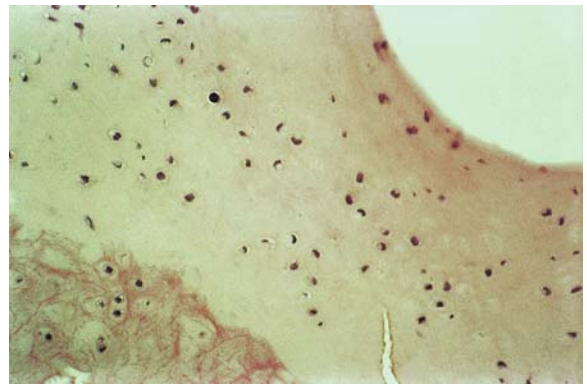


Fig. 8.2. Idiopathic pseudocystic chondromalacia of the cartilage of the auricle. Note the cystic cavity in the cartilage lined with degenerated cartilage that has lost its elastic tissue. Normal elastic tissue is present further away from the pseudocyst at the left hand corner. Reproduced from Michaels and Hellquist [68]

8.2.2 Pseudocystic and Cystic Lesions

8.2.2.1 Idiopathic Pseudocystic Chondromalacia

Idiopathic pseudocystic chondromalacia occurs mainly in young and middle-aged adults. The gross appearance is one of a localised swelling of the auricular cartilage. A cut surface shows a well-defined cavity in the cartilage, which is distended with yellowish watery fluid [42]. Microscopically, the cavity shows a lining of degenerated cartilage on one surface (Fig. 8.2); on the other surface the cartilage is normal. It seems possible that the fluid is an exudate from undamaged perichondrial vessels that cannot be absorbed by the damaged perichondrial vessels. The association of this lesion with severe atopic eczema in four children [27] suggested that minor trauma from repeated rubbing of the auricle may play a part. Small pseudocysts of the elastic cartilage of the pinna may also be seen in the vicinity of inflammatory or neoplastic lesions of that region.

8.2.2.2 First Branchial Cleft Cyst

A developmental origin from the first branchial cleft has been assumed in some fistulas, sinuses, and cysts arising in the periauricular and the parotid region and also in some fistulas arising in the neck that are located above a horizontal plane passing through the hyoid bone. The commonest of these lesions is the preauricular sinus. This usually shows a stratified squamous epithelial lining, but occasionally it may be of respiratory epithelium,

deep to which the connective tissue is chronically inflamed. There is often elastic cartilage in the deep wall of the sinus. Branchial cleft cysts are more extensively discussed in Chap. 9.

8.2.3 Tumour-Like Lesions

8.2.3.1 Chondrodermatitis Nodularis Helicis

In chondrodermatitis nodularis chronica helicis, sometimes known as Winkler's disease, a small nodule forms on the auricle, usually in the superior portion of the helix. Pain is always a prominent feature.

Histological examination of biopsies of such lesions in which the elastic cartilage underlying the skin of the auricle is particularly well-represented, shows ulceration of the skin of the auricle and complete necrosis of the tip of the underlying elastic cartilage of the auricle. In some cases a piece of extruded necrotic cartilage may be seen on the floor of the ulcer. The perichondrium of the elastic cartilage in this region shows obstructive thickening of small arteries.

The helix is one of the furthest points from the source of the arterial blood supply of the pinna. It seems likely that obstruction of small arteries of the perichondrium is the primary lesion leading to cartilage necrosis, and that the acute inflammation and epidermal ulceration are secondary to the nearby cartilage necrosis. An association between chondrodermatitis nodularis helicis and systemic sclerosis has been described [12]. In this condition obstructive changes are frequently found in small arteries.

8.2.3.2 Keratosis Obturans and Cholesteatoma of External Canal

In keratosis obturans the keratin produced by exfoliation from the skin of the tympanic membrane and external canal is retained on the epithelial surface and forms a solid plug. This enlarges and may cause circumferential erosion of the bony canal. Keratosis obturans is probably the result of a defect of the normal migratory properties of the squamous epithelium of tympanic membrane and adjacent ear canal that causes the accumulation of keratinous debris [20]. A minor degree of this process – keratosis of the tympanic membrane – in which deposits of keratin grow on the eardrum and cause tinnitus has also been found to be associated with absent or defective auditory epithelial migration [103].

A condition that has been distinguished from keratosis obturans is cholesteatoma of the external canal. In

this lesion epidermoid tissue appears to penetrate into the wall of the deep external canal causing localised osteonecrosis and bone erosion [87].

8.2.3.3 Keratin Granuloma

A granulomatous process may result in the external ear canal when keratin squames become implanted into the deeper tissues following traumatic laceration [39]. The granuloma contains foreign body-type giant cells, histiocytes, lymphocytes, plasma cells and flakes of keratin. The latter are strongly eosinophilic and birefringent in polarised light. Aural polyps frequently contain such granulomas, but the keratin is then more likely to be derived from a middle ear cholesteatoma (see below).

8.2.3.4 Angiolymphoid Hyperplasia with Eosinophilia and Kimura's Disease

Synonyms for angiolymphoid hyperplasia with eosinophilia are epithelioid haemangioma, benign angiomatous nodules of face and scalp, atypical pyogenic granuloma, and several other terms. Although this entity was first described by Kimura, "Kimura's disease" is now believed to be a different condition (see below).

Angiolymphoid hyperplasia with eosinophilia may occur anywhere in the skin, especially on the scalp and face, but there is a particular predilection for the external auricle and external auditory meatus. It is a lesion of young and middle-aged of both sexes and all races.

Grossly, there are sessile or plaque-like red or reddish-blue lesions from 2 to 10 mm in diameter, which may coalesce to form large plaques that obstruct the ear canal. On transection the lesion is seen to be present in the dermis and subcutaneous tissue. Microscopically, there is a mixture of two proliferated elements in the dermis: blood vessels and lymphoid tissue. The blood vessels are mainly capillaries lined by plump, often protruding (hobnailed) sometimes multilayered, endothelial cells (Fig. 8.3). Occasionally an artery or vein showing intimal fibrous thickening is part of the vascular component. Solid clusters of cells, which are often vacuolated, show features intermediate between endothelial cells and histiocytes are also observed [6]. The lymphoid tissue may possess germinal centres. Eosinophils (often extremely numerous), mast cells and macrophages may also be prominent.

Kimura's disease is commoner in orientals, mainly affecting young males. It is a chronic inflammatory condition of unknown aetiology. It presents as large, deep and often disfiguring, subcutaneous masses in the preauricular, parotid and submandibular regions. Often, there is enlargement of regional lymph nodes. Occasion-

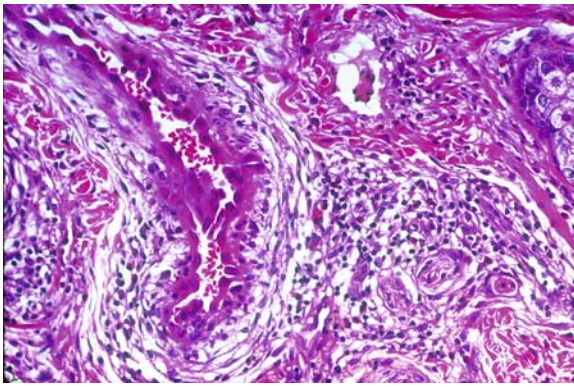


Fig. 8.3. Epithelioid haemangioma showing “hobnailed” endothelium of the capillary on the left and lymphocytic infiltration

ally, only lymph nodes are involved. There is a peripheral blood eosinophilia and raised levels of IgE.

Microscopically, the subcutaneous masses are found to be composed of lymphoid follicles surrounded by oedematous connective tissue rich in eosinophils and containing numerous thin-walled blood vessels resembling high endothelial venules [6]. Infiltration of the germinal centres with eosinophils and follicle lysis is a frequent finding, as is the presence of multinucleated cells. There is deposition of IgE on the processes of the follicular dendritic cells and there are also numerous mast cells, the latter well shown by immunostaining with IgE mAb. Plasma cells may also be prominent.

Diagnostic confusion between angiolymphoid hyperplasia with eosinophilia and Kimura's disease is likely to occur if the characteristic vascular appearances in angiolymphoid hyperplasia with eosinophilia have not been recognised and if there is very prominent lymphoid hyperplasia with follicle formation and marked tissue eosinophilia in the latter. In Kimura's disease the endothelial cells in the proliferating vessels never show an epithelioid/histiocytoid appearance, nor is there an associated large vessel with intimal thickening. In angiolymphoid hyperplasia with eosinophilia there is never lymph node enlargement or tissue deposition of IgE.

Both epithelioid haemangioma and Kimura's disease are benign entities. Recurrence is rare in the former if it is completely excised. It is more frequent in the latter, but eventually it becomes stationary. A nephrotic syndrome may rarely occur in Kimura's disease.

8.2.3.5 Accessory Tragus

Accessory tragus is a fairly common congenital malformation of the external ear. In the majority of cases it is an isolated developmental defect not associated with other abnormalities. It is, however, a consistent feature

of the oculoauriculovertebral syndrome (Goldenhar's syndrome) [49]. The lesion, which may be bilateral, is usually situated anterior to the normal tragus. Like the latter, the accessory tragus is composed of elastic cartilage with a covering of skin. In rare cases a similar structure has been found in the neck [8] or in the suprasternal region [54].

8.2.3.6 Keloid

Keloid, a common benign skin lesion, follows injury to the skin of the ear, often after piercing the earlobes for wearing an ear-ring. It is particularly frequent in black people. Grossly, there is a lobulated swelling covered in normal skin. Microscopically, the dermis is enlarged by deposits of eosinophilic, poorly cellular collagen.

8.2.4 Benign Neoplasms

External ear neoplasms derived from ceruminous glands are very uncommon. Only the adenoma can usually be categorised with certainty as being derived specifically from ceruminous glands, since its component acini display an apocrine secretory structure. Syringocystadenoma papilliferum and adenoid cystic carcinoma arising in this region can sometimes appear to be developing from ceruminous glands.

8.2.4.1 Adenoma of Ceruminous Glands

ICD-O:8420/0

Adenomas are unusual neoplasms that present with a blockage of the lateral part of the external auditory meatus, often associated with deafness and discharge. An important part of the clinical investigation of all glandular neoplasms of the ear canal is exclusion of an origin in the parotid gland.

Gross appearances are those of a superficial grey mass up to 4 cm in diameter, which is covered in skin. Microscopically this neoplasm lacks a definite capsule. It is composed of regular glands often with intraluminal projections (Fig. 8.4). The glandular epithelium is bilayered, the outer layer being myoepithelial, but this may not be obvious in all parts of the neoplasm. The glands are often arranged in groups surrounded by fibrous tissue. In some ceruminomas, acid-fast fluorescent pigment may be found in the tumour cells that is similar to that found in normal ceruminous glands [15, 125].

Adenoma of ceruminous glands is a benign neoplasm. Recurrence should not be expected if it is carefully excised.

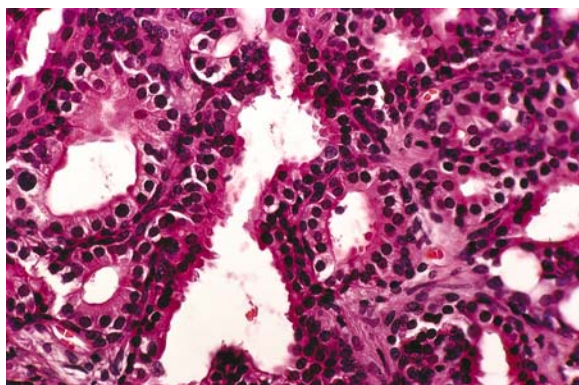


Fig. 8.4. Ceruminoma of the external canal. Note peg-like protrusions into the lumina, indicating apocrine secretion. Reproduced from Michaels and Hellquist [68]

8.2.4.2 Pleomorphic Adenoma of Ceruminal Glands

ICD-O:8940/0

A benign neoplasm of the skin with a structure similar to that of pleomorphic adenoma of salivary glands is also occasionally seen in the external auditory meatus. Cartilage, myoepithelial and adenomatous structures are features of this neoplasm.

8.2.4.3 Syringocystadenoma Papilliferum of Ceruminal Glands

ICD-O:8406/0

Syringocystadenoma papilliferum is seen in children or young adults usually on the scalp or face. Occasionally it occurs in the ear canal. The histological appearance of the neoplasm is that of an invagination from the surface epithelium forming a cyst-like structure. Projecting into the lumen are papillae lined with bilayered glandular epithelium, which may show decapitation secretion typical of apocrine (ceruminal) glands.

8.2.4.4 Bony Lesions

Because of the difficulty of classifying a solitary benign neoplasm composed of woven bone and fibrous tissue into one or other of the classical groups – monostotic fibrous dysplasia or ossifying fibroma – the designation *benign fibro-osseous lesion (fibrous dysplasia)* may be used in most circumstances without loss of accuracy. Lesions of this type are found in the temporal bone often presenting deep to the external ear [65, 80]. On other sides, this lumping is less appropriate, as discussed in Chap. 4.

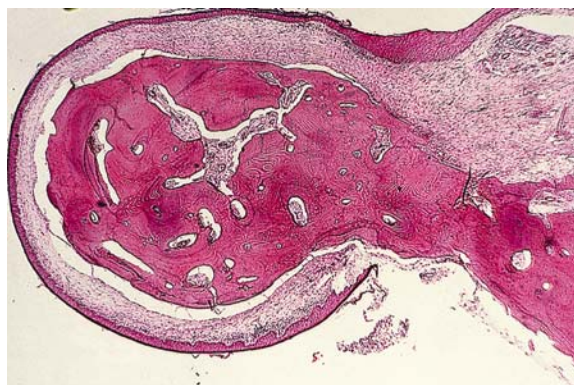

Fig. 8.5. Osteoma of the deep external canal. Reproduced from Michaels and Hellquist [68]

The main clinical features are progressive loss of hearing, conductive in most, sensorineural, which can be profound, in some and enlargement of the temporal bone with progressive bony occlusion of the external auditory meatus. Facial nerve palsy is present in some patients due to involvement of the facial nerve by the pathological process.

The gross appearance of benign fibro-osseous lesions is one of yellowish-white resilient tissue, which occasionally includes small cysts filled with an amber-coloured fluid. The transition to normal bone is sharp. Microscopically, irregular trabeculae of woven bone are embedded in a connective tissue stroma. The constriction of the ear canal may cause an epidermoid cyst lateral to the tympanic membrane, referred to in some publications as “cholesteatoma” [65].

Although fibrous dysplasia has been on rare occasions associated with malignant disease such as osteogenic sarcoma, fibrosarcoma, chondrosarcoma and giant cell tumour, the temporal bone is not one of the sites where this change has been described.

Osteoma and *exostosis* are two types of benign bony enlargement of the deeper bony portion of the external auditory canal. Osteoma is a spherical mass arising from the region of the tympanosquamous or tympanomastoid suture line by a distinct bony pedicle. Symptoms are usually those of ear canal obstruction. Microscopically, the osteoma is composed of lamellar bone and may show outer cortical and inner cancellous trabeculated areas, the latter with marrow spaces. There may be a thin layer of woven bone on the surfaces of the lamellar bone. The osteoma is covered in the normal squamous epithelium of the ear canal (Fig. 8.5).

Exostosis is a broad-based lesion, which is often bilateral and symmetrical. It is usually situated deeper in the ear canal than osteomas. In the bony portion of the normal external auditory meatus there are no adnexal structures, and the subcutaneous tissue and

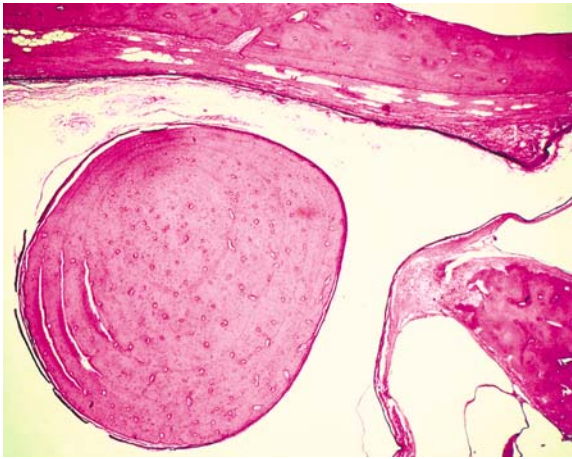


Fig. 8.6. Exostosis of the deep external canal. Note thin epidermal layer on the exostosis and canal skin and their proximity to the bone. Reproduced from Michaels and Hellquist [68]

periosteum merge to form a thin layer. The distance between the epidermal surface and underlying bone is consequently small. This explains the propensity towards exostoses of the tympanic bone to develop in this region in those who swim frequently in cold water. It seems likely that the water, after dribbling into the deep external auditory canal, exerts a cooling effect on the bone surface and stimulates it to produce new bone. Unlike osteoma (Fig. 8.5) the bone formations of exostosis are said not to possess any marrow spaces (Fig. 8.6).

Osteoma and exostosis are often associated with infection of the external canal on their tympanic membrane side and surgical removal may be required to enhance drainage as well as to relieve the conductive hearing loss.

Five cases of a benign circumscribed bony lesion of the external auditory canal distinct from exostosis and osteoma have recently been described [91]. They all showed a hard, round, unilateral, skin-covered mass occluding the superficial external auditory canal with no relationship to the cartilaginous tissue or to the bony structure surrounding that canal. Histologically, the lesion displayed an osteoma-like bone formation with sparse osteoblastic areas; mature lamellar bone was observed some cases, and also bone marrow containing adipose tissue and hematopoietic remnants. The bone showed irregular trabeculae, bordered by osteoid osteoblasts.

8.2.5 Malignant Neoplasms

8.2.5.1 Adenocarcinoma of Ceruminal Glands

ICD-O:8420/3

Adenocarcinoma of ceruminal glands is a rare neoplasm presenting in the superficial part of the external ear canal. There is always local infiltration. The neoplasm possesses a glandular structure with evidence of apocrine differentiation, but the glands show loss of a myo-epithelial layer and the cells are markedly atypical with increased mitotic activity. Recurrence is to be expected following surgical removal. Death due to involvement of local vital structures has been reported. Rare examples of low-grade adenocarcinoma of ceruminal glands have been documented.

8.2.5.2 Adenoid Cystic Carcinoma of Ceruminal Glands

ICD-O:8200/3

This malignant neoplasm has the gross and microscopic features of the corresponding major or minor salivary gland neoplasm, including its tendency to invade along nerve sheaths. Relentless though often delayed recurrence and eventual bloodstream metastasis, particularly to the lungs, are likewise features of this cancer.

8.2.5.3 Basal Cell Carcinoma

ICD-O:8090/3

The great majority of malignant epithelial neoplasms of the pinna are basal cell carcinomas, a small number only being squamous cell carcinomas. The few basal cell carcinomas that occur in the ear canal arise near the external opening. Their preference for the exposed part of the external ear is in keeping with the accepted view that sunlight is in most cases the causal factor in skin insufficiently protected by melanin pigment.

The gross appearance of basal cell carcinoma is usually one of a pearly wax-like nodule that eventually ulcerates. Twenty-five per cent of basal cell carcinomas of the pinna are of the morphea type (see below). The importance of this variety is that although the edge of the tumour tends to infiltrate subcutaneously, this cannot be recognised clinically or on gross pathological examination. The classical and most frequent form of basal cell carcinoma is composed of solid masses of cells, which are seen to be arising from the basal layers of the epidermis or the outer layers of the hair follicles. The cells are uniform with basophilic nuclei and little cy-

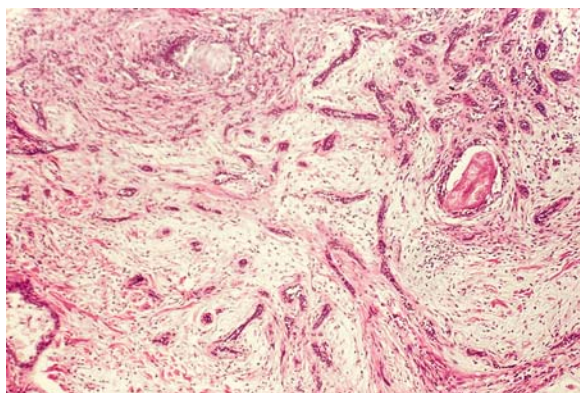


Fig. 8.7. Morphea type of basal cell carcinoma showing thin downgrowths with stroma of inflammatory connective tissue. Reproduced from Michaels and Hellquist [68]

toplasm. At the periphery of the neoplastic lobules the cells tend to be palisaded. Mitoses are frequent as are alveolar or cystic spaces. Squamous cell differentiation is also common.

The splitting up of cell groups by much hyaline fibrous tissue, so that the carcinoma appears compressed into thin strands, is referred to as the morphea type of basal cell carcinoma (Fig. 8.7). The suggestion that tumours with this histology have a worse outlook is probably related to their tendency towards insidious infiltration (see above). There is otherwise no convincing evidence of the relationship of a particular histological appearance to prognosis in basal cell carcinoma. However, when immunohistochemical assessment for Ki-67 antigen (MIB1 in paraffin sections), a proliferation-associated antigen, is performed on basal cell carcinomas, those tumours that recur have been shown to possess a higher proportion of cells positive for that antigen than those that do not [40]. The degree of tumour angiogenesis is another histologic factor that shows promise in judging the prognosis of basal cell carcinoma [107].

This is not an aggressive neoplasm and in at least 90% of cases a 3-year cure can be easily achieved by surgical excision. In a few cases repeated recurrences with deep extension to the middle ear, mastoid and even cranial cavity may, however, take place. Metastasis is rare.

8.2.5.4 Squamous Cell Carcinoma

ICD-O:8070/3

The majority of squamous cell carcinomas of the external ear arise in the pinna; a lesser number arise in the external canal.

Pinna lesions in a prominent position are identified early. A serious problem with the canal lesions is the delay in diagnosis because of the minimal symptoms that may be present. Pain, hearing loss and drainage of blood or pus are the main features in that group. A plaque-like or even polypoid mass may be felt or even seen.

Squamous carcinomas arising on the pinna grossly resemble those seen elsewhere on the skin. The appearances of the canal lesions are those of a mass, sometimes warty, occluding the lumen and invading deeply into the surrounding tissues. There may be dissolution of the tympanic membrane with invasion of the middle ear.

Squamous cell carcinoma of the external ear usually shows significant degrees of keratinisation. In the cases with a canal origin evidence of origin from canal epidermis is usually present. In cases arising deep within the ear canal there is usually a concomitant origin from middle ear epithelium and dissolution of the tympanic membrane (see below). The neoplasm may be so well differentiated that it can be confused with benign papilloma. The association of a well-differentiated squamous carcinoma with marked desmoplasia may also delay the correct diagnosis. The verrucous form of squamous cell carcinoma has been seen in the external ear [105]. Metastatic spread of squamous carcinoma of the pinna and external auditory meatus to lymph nodes is unusual. Squamous carcinoma of the external canal is an aggressive disease with a high propensity towards local recurrence. The outcome of the disease following surgical excision is related to the clinical stage at presentation; the higher the stage the worse the outcome [83].

8.2.5.5 Melanotic Neoplasms

Melanotic neoplasms are unusual in the external ear. Nevi arise mainly in the ear canal, but are rare on the auricle. Malignant melanomas, on the other hand usually arise on the auricle; origin in the external canal is extremely unusual [72]. Malignant melanoma of the external ear is a highly malignant disease. In a review of 16 patients with this condition as many as 9 cases showed invasion to Clark level IV or more [22]. It is likely that cervical and parotid gland lymph nodes will be involved when malignant melanoma of the external ear is first diagnosed [99].

8.3 Middle Ear and Mastoid

8.3.1 Inflammatory Lesions

8.3.1.1 Acute and Chronic Otitis Media

Otitis media is one of the most common of all diseases, particularly in young children. The disease is usually caused by bacterial infection, *Haemophilus influenzae* and Gram-positive cocci usually being incriminated in the acute form and Gram-negative bacilli in the chronic form. The clinical forms of the acute and chronic conditions correspond to the pathological changes, but intermediate or mixed states are frequent. Perforation of the tympanic membrane may occur at any phase of otitis media, but an effusion, accompanied by all of the other manifestations of chronic otitis media, is often present behind an intact tympanic membrane, a condition known as serous otitis media.

The appearances of the middle ear mucosa in acute otitis media may be seen in the bone chips removed at mastoidectomy. There is congestion and oedema of the mucosa of the mastoid air cells. Haemorrhage may be severe and the mucosa and air cells are filled with neutrophils. Pus destroys bone, the actual dissolution being carried out by osteoclasts. At the same time new bone formation takes place, commencing as osteoid, later becoming woven and finally lamellar. Fibrosis may also be active even in the acute stage. Acute inflammatory changes are also prominent in other parts of the middle ear. The tympanic membrane shows marked congestion, the dilated vessels distending the connective tissue layer. Pus cells fill the middle ear cavity. The acute inflammation may spread deep into the temporal bone as osteomyelitis.

The chronic form of otitis media is associated with necrosis, caused by the bacterial infection. There is, as in the acute form, marked congestion. The latter results in haemorrhage in many cases. Because of the poor lymph drainage in the middle ear old haematoma becomes converted into cholesterol granuloma, with cholesterol clefts surrounded by foreign body-type giant cells, and haemosiderin.

Associated with these changes and representing an important part of the pathological picture, is proliferative activity of middle ear tissue. The columnar epithelium of the middle ear has, in the presence of inflammation or other pathological changes in the middle ear, the remarkable property of invaginating itself to produce glands, which often develop luminal secretion. The glandular transformation of the middle ear mucosa, known as glandular metaplasia, may be seen in any part of the cleft, including the mastoid ear cells. The se-

cretion of the glands contributes to the exudate in otitis media with effusion. Fibrous tissue proliferation may also occur in combination with glandular transformation – a process which, in the advanced state, has been called “fibrocystic sclerosis” [95].

A specific form of reparative reaction following inflammation is the development of granulation tissue. In this process, the endothelium of blood vessels and fibroblasts are the newly formed cells. Mononuclear inflammatory cells usually accompany the latter. The granulation tissue is usually particularly prominent in the middle ear under the mucosa covering the promontory from which it frequently protrudes into the external canal through a perforation of the tympanic membrane, forming an aural polyp that is covered in pseudostratified columnar, ciliated respiratory or stratified squamous epithelium. Fibroblasts and collagen are abundant in the terminal phase of the reparative stage.

A normal degree of fibroblast cellularity in the fibrous reaction is seen in *adhesive otitis media*. A peculiar form of scar tissue production occurs in the middle ear, in which the collagen is poorly cellular and hyalinised. This condition, known as *tympanosclerosis*, is also characterised by deposition of calcium salts in the hyaline fibrous tissue. The bony walls of the middle ear also frequently react to the inflammatory process with a new formation of bone. This is woven in the early stages and lamellar later.

8.3.1.2 Cholesteatoma

Cholesteatoma is the presence of stratified squamous epithelium in considerable quantities in the middle ear. The common acquired form of cholesteatoma is associated with severe otitis media.

Stratified squamous epithelium in the normal foetal middle ear: small colonies of cells being epidermoid in nature as confirmed by immunohistochemistry are found near the tympanic membrane on the lateral anterior superior surface of the middle ear in every temporal bone after 15 weeks' gestation. These epidermal colonies, which are known as “epidermoid formations”, increase significantly in size with increasing age and pari passu undergo increasing epidermoid differentiation [58]. During the first postpartum year these epidermoid formations disappear. It is possible that the entry and growth of epidermoid formations in the foetal middle ear may lead to a local cellular immunity as a defence mechanism against the entry of keratinocytes into the middle ear. This could cause the eventual dissolution of all epidermoid formations. If immunity is delayed or defective epidermis could continue to grow and lead to congenital cholesteatoma.

Stratified squamous epithelium in the middle ear of a young child (congenital cholesteatoma): congenital cholesteatoma is seen, in most cases as a spherical whitish

object in the anterosuperior part of the tympanic cavity behind an intact tympanic membrane (Fig. 8.8). In some cases the lesion may fill most of the tympanic cavity. At operation the cholesteatoma is reported usually to be a cyst in the anterosuperior part of the middle ear. Bone erosion is not present when the cholesteatoma is small. In larger lesions some degree of this change is present [61] and eventually it may enlarge to involve the mastoid, cause a perforation of the tympanic membrane and even grow into the middle cranial fossa [34] so that it becomes indistinguishable from acquired cholesteatoma (see below). Indeed, it is possible that many cases of acquired cholesteatoma originated from congenital cholesteatoma.

In approximately 10% of cases the cholesteatoma is not cystic, but open and shows layers of squames and a matrix (living basal and malpighian layers of epidermis) that is plastered to the wall of the tympanic cavity [19]. The microscopic appearances of the matrix of congenital cholesteatoma are those of skin epidermis, comprising a single row of basal cells, several rows of malpighian cells and a thin granular layer. The surface of dead, keratinous squames merges with the keratinous contents of the cyst, or lamellae in the case of the open type. When the histological appearance of these cases is compared with that of acquired cholesteatoma, little difference can be seen.

Stratified squamous epithelium in the middle ear of an older child or adult, acquired cholesteatoma: typically in acquired cholesteatoma a lesion far more common than that of congenital cholesteatoma, the patient presents with a foul-smelling aural discharge and conductive hearing loss. On examination of the tympanic membrane there is, in most cases, a perforation of the superior or posterosuperior margin. The cholesteatoma appears as a pearly grey structure in the middle ear cavity. The wall of the cyst may often be seen as a thin membrane.

The cholesteatoma is usually situated in the upper posterior part of the middle ear cleft and discharges usually through a perforation of the pars flaccida of the tympanic membrane, sometimes through a perforation located at the edge of the tympanic membrane near the annulus. The cholesteatoma may extend through the aditus into the mastoid antrum and mastoid air cells. Frequently, the outline of the cholesteatomatous sac is adapted to that of normal structures such as ossicles. Chronic inflammatory changes are always present. In most cases at least one ossicle is seriously damaged, thus interrupting the continuity of the ossicular chain. The scutum, the upper part of the bony ring of the tympanic opening, is eroded in most cholesteatomas.

Under the microscope acquired cholesteatoma is usually “open” rather than “closed” or cystic. The pearly

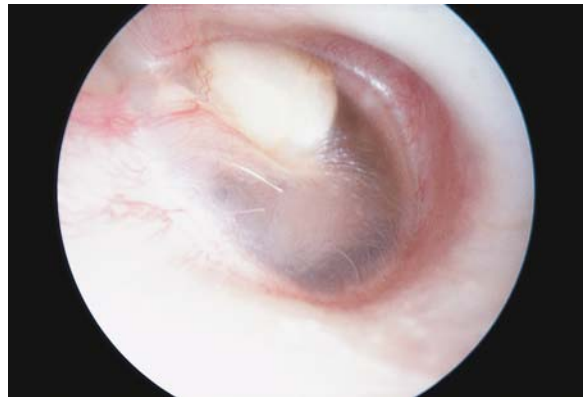


Fig. 8.8. Congenital cholesteatoma seen as a small cyst in the anterosuperior part of the middle ear. Reproduced from Michaels and Hellquist [68]

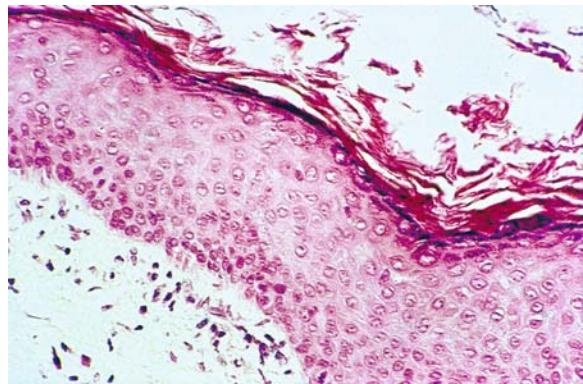


Fig. 8.9. Acquired cholesteatoma showing keratinising stratified squamous epithelium with a granular layer. Reproduced from Michaels and Hellquist [68]

material of the cholesteatoma consists of dead, fully differentiated anucleate keratin squames. This is the corneal layer of the squamous cell epithelium. As in any normal stratified epithelium there are one to three basal layers of cells above which is a prickle (malpighian or spinous) layer composed of five or six rows of cells with intercellular bridges (Fig. 8.9).

The deeper layers of the epithelium of the cholesteatoma matrix frequently show evidence of activity in the form of downgrowths into the underlying connective tissue (Fig. 8.10). Such excessive activity has been confirmed by:

1. The strong expression of cytokeratin 16, a marker for hyperproliferative keratinocytes, by cholesteatoma, but its absence in middle ear and external ear epithelium, except in the annulus region of the external tympanic membrane epithelium [13];

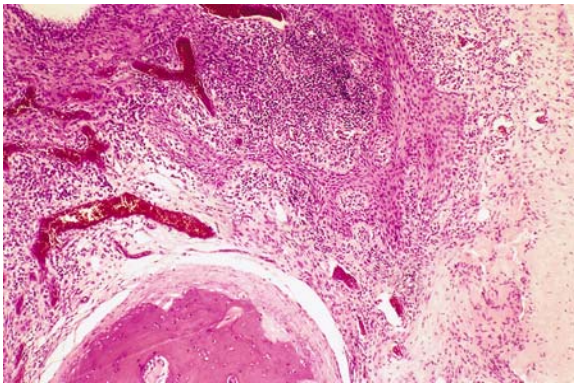


Fig. 8.10. Acquired cholesteatoma showing downgrowths from the deeper layer of cholesteatoma epithelium

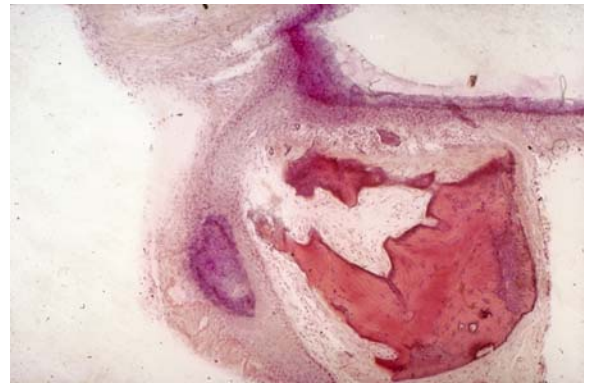


Fig. 8.11. The fundus of a retraction pocket is seen in the *top right* hand part of the illustration. Emanating from it and passing down to the *bottom centre* is a band of stratified squamous epithelium, within which is a bluish staining zone of stratum granulosum and keratin – a "mini-cholesteatoma". An ossicle lies to the right of the epidermal band. It is an eroded incus, damage to which has probably been caused by previous otitis media

2. The strong expression of MIB1, an antigen related to Ki-67, which also indicates hyperproliferative activity [113];
3. Counts of silver-stained argyrophil nucleolar organiser regions, a technique that likewise displays proliferative activity, showed significantly larger numbers of these structures in the nuclei of acquired cholesteatoma compared with those of the epidermis of the deep external auditory meatal skin [115];
4. Acquired cholesteatomatous epithelium shows an abnormally high concentration of IL-1, TGF- α , EGF-R and 4F2, all being growth factors [114] indicating greater growth and differentiating activity than is present in normal epidermis.

Congenital cholesteatoma probably arises due to the continued growth of the epidermoid formation. This structure is derived from external ear epidermis (see above). It seems likely that acquired cholesteatoma is also derived from entry of external ear canal epidermis into the middle ear. This is clearly shown in those cases of acquired cholesteatoma that follow blast injury with perforation of the tympanic membrane at the time of the injury [56]. Acquired cholesteatoma is also known to follow the retraction pocket of the tympanic membrane. This is not due to obstruction of the mouth of a retraction pocket, but rather, it seems, to the ingrowth of a band of stratified squamous epithelium from the fundus of the retraction pocket deeply into the middle ear (Fig. 8.11) [122]. A similar entry of stratified squamous epithelium from the external ear epidermis through the tympanic membrane may sometimes be observed in human temporal bone sections in cases of severe otitis media (Fig. 8.12). The placement of irritants or bacteria into the middle ear cavity of animals

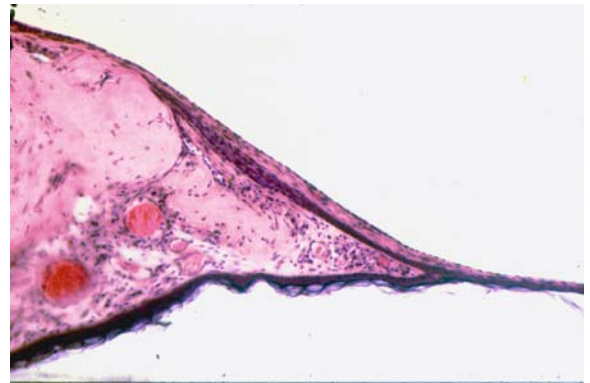

Fig. 8.12. A thin strand of stratified squamous epithelium is seen passing from the epidermis of the tympanic membrane towards the middle ear epithelium, almost touching it. To the left of this epidermal band the middle collagenous layer of the eardrum is distorted by a deposit of tymanosclerosis, composed of partially calcified hyaline collagen

has been known to provoke an otitis media that is associated with epidermal invasion through the tympanic membrane with the subsequent development of cholesteatoma. In chinchillas, destruction of the epithelium of both middle ear and lateral tympanic membrane surfaces takes place in the early stages of such an artificial acute otitis media, induced by insertion of propylene glycol into the middle ear. This is followed by re-epithelialisation with hyperplastic epidermal cells and then penetration of the thickened fibrous layer of the tympanic membrane by the epidermal cells to reach the middle ear cavity and the formation of keratinous masses in the middle ear typical of cholesteatoma [60, 127].

8.3.1.3 Unusual Inflammatory Lesions

Tuberculous otitis media is an unusual form of chronic otitis media, which is generally associated with active pulmonary tuberculosis. In the initial stages multiple perforations of the tympanic membrane develop. Granulations in the middle ear may appear pale and are often profuse. Complications, especially involvement of the facial nerve, are more frequent than in the commoner form of chronic otitis media. The diagnosis is usually made by histopathological examination of biopsy material from middle ear contents. This is often delayed because surgeons are reluctant to take biopsies from cases of chronic otitis media that seem fairly typical.

Culture of middle ear inflammatory tissue may produce tubercle bacilli. Histological examination shows tuberculoid granulation tissue composed of epithelioid cells, Langerhans giant cells and areas of caseation situated in the middle ear mucosa. There is much bone destruction. Acid-fast bacilli are found with difficulty in the granulomatous material.

8.3.2 Neoplasms and Lesions Resembling Neoplasms

8.3.2.1 Choristoma (Salivary Gland, Glial and Sebaceous Types)

A hamartoma is a focal overgrowth, in improper proportions, of tissues normally present in that part of the body. A choristoma is similar to hamartoma, except that the tissues of which it is composed are not normally present in the part of the body where it is found. Choristomas are occasionally seen in the middle ear. They are composed of one or other of three types of tissue: salivary gland, glial or sebaceous glandular tissue.

Salivary gland choristomas consist as a rule of mixed mucous and serous elements like the normal submandibular or sublingual gland, but unlike the parotid gland. The lesion typically consists of a lobulated mass of histologically normal salivary gland tissue in the middle ear attached posteriorly in the region of the oval window. Frequently, the mass is intimately associated with the facial nerve. There are usually absent or malformed ossicles [44].

Glial choristomas are composed largely of astrocytic cells with large amounts of glial fibrils, the identity of which may be confirmed by immunohistochemical staining for glial acidic fibrillary protein. When such masses are identified in biopsy material from the middle

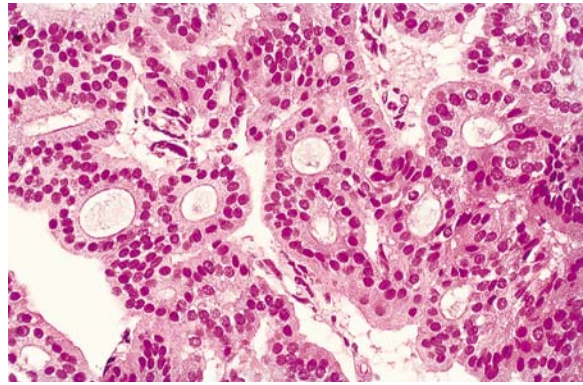


Fig. 8.13. Adenoma of the middle ear. Reproduced from Michaels and Hellquist [68]

ear a bony deficit with consequent herniation of brain tissue into the middle ear should be ruled out [53]. Three cases of heterotopic brain tissue in the middle ear associated with cholesteatoma have been reported [62]. It is possible that in all three, brain herniation occurred as a result of inflammatory damage to the tegmen tympani. Spontaneous herniations of brain (encephaloceles) may occur into the middle ear through a congenital deficiency of the tegmen or other sites [47].

A case of *sebaceous choristoma* of the middle ear has been described [82].

8.3.2.2 Adenoma

ICD-O:8140/0

Adenoma is the commonest neoplasm of the middle ear. The epithelium of the middle ear has a propensity towards gland formation in otitis media (see above) and adenoma would seem to represent a benign neoplastic transformation of the epithelium along the same lines.

The neoplasm has been described as being white, yellow, grey or reddish brown at operation and unlike paraganglioma is usually not vascular. It is usually situated in the middle ear cavity, sometimes extending into the mastoid. It seems to peel away from the walls of the surrounding middle ear with ease, although ossicles may sometimes be entrapped in the tumour mass and may even show destruction.

Adenoma is formed by closely apposed small glands with a "back to back" appearance (Fig. 8.13). In some places a solid or trabecular arrangement is present. Sheet-like, disorganised areas are seen in which the glandular pattern appears to be lost. This may be artefactual and related to the effects of trauma used in taking the biopsy specimen on the delicate structure of the cells, but the appearance may erroneously lead one to suspect malignancy. The cells are regular, cuboidal or columnar and may enclose luminal secretion. A dis-

tinct and predominant “plasmacytoid” appearance of the epithelial cells of the neoplasm may be displayed [92].

No myoepithelial layer is seen. PAS and Alcian blue stains may be positive for mucoprotein secretion in the gland lumina and in the cytoplasm of the tumour cells.

Benign glandular tumours of the middle ear were not described until 1976 [26, 45]. It was soon reported that a glandular tumour of the middle ear, otherwise apparently identical to an adenoma, was Grimelius positive and on electron microscopy, showed numerous membrane-bound granules [75]. The use of immunohistochemistry from 1987, further confirmed the presence of neuroendocrine features in some of these neoplasms [108]. In an investigation of five cases of adenoma of the middle ear by light microscopic methods, immunohistochemistry and transmission electron microscopy, the glandular areas of the tumour in each patient showed bidirectional mucinous and neuroendocrine differentiation. This was demonstrated by the presence of two cell types. Apically situated dark cells contained mucous granules; these cells were negative for neuroendocrine markers. Basally situated cells contained neuroendocrine granules; these cells were positive for neuroendocrine markers – vasoactive intestinal polypeptides or neuron-specific enolase [120].

It seems likely that there is but a single benign glandular neoplasm of the middle ear, the adenoma. Neuroendocrine as well as mucinous differentiation is frequent, perhaps universal, in these neoplasms. Contrary to what has been suggested by some authors there is no evidence that the presence of neuroendocrine differentiation reflects a more aggressive potential in adenomas, which are benign tumours.

8.3.2.3 Papillary Tumours

ICD-O:8260/0, 8260/3

Aggressive papillary tumour is characterised by a papillary, non-stratified epithelial histological pattern that shows aggressive, often invasive behaviour. Forty-six cases in which the temporal bone was affected by this neoplasm were collected from the literature in 1994 [31]. Some of these had been reported as low-grade adenocarcinoma of probable endolymphatic sac origin (see below and also Sect. 8.4.2.3) [41]. I have reviewed each of the case reports cited in these two studies together with cases reported in the literature more recently, and this has produced a total of 25 cases in which the middle ear was definitely involved in the neoplasm. Some of the literature sources reported more than one case [1, 9, 10, 21, 31–33, 35, 38, 41, 50, 86, 88, 109, 111, 118].

The 25 literature cases with this middle ear neoplasm comprised 18 females and 7 males. The age-range at time of diagnosis was between 16 and 55 years with a median age of 33 and a mean age of 34 years. In many of the cas-

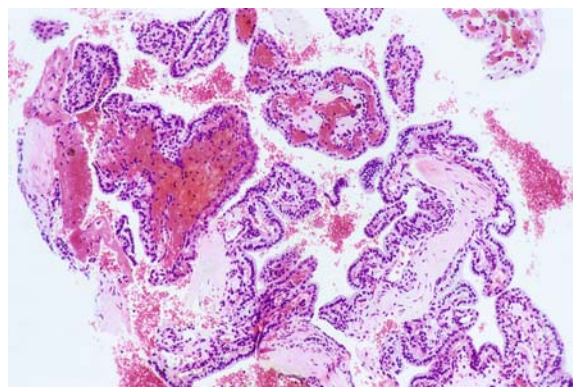


Fig. 8.14. Aggressive papillary tumour of the middle ear

es, however, the patient had already suffered symptoms subsequently ascribable to the tumour for some years when the diagnosis was made, so that the age of onset may be considerably younger than is suggested.

The tumour is found in any area of the middle ear, including the mastoid process and air cells and may fill the tympanic cavity. In all of the described cases, except three [21, 109, 118], there was extensive invasion outside the middle ear, involving the apical portion of the petrous bone in most and in a few the tumour reached the cerebellopontine angle and the cerebellum.

It has been suggested that cases of aggressive papillary middle ear tumour with widespread involvement of the temporal bone may arise from a primary papillary adenocarcinoma of the endolymphatic sac (*endolymphatic sac tumour, low-grade adenocarcinoma of probable endolymphatic sac origin*) [41]. The frequent association of papillary tumours in the middle ear with apical petrous bone neoplasia of the same type, the similarity of the histological appearances of the neoplasm in the two regions and the association of some cases of papillary tumours in both regions with von Hippel-Lindau disease would seem to favour this concept. Such an origin has not yet been confirmed by autopsy study. Indeed, in the single description of the pathological changes of aggressive papillary tumour of the middle ear in an autopsy-acquired temporal bone, widespread deposits of tumour at inner ear sites are depicted, but no mention is made of involvement of the endolymphatic sac or duct [100]. Thus, a middle ear origin for some cases of this neoplasm at least has not been definitely excluded. Whatever the site or sites of origin of this tumour, it should be recognised that papillary epithelial tumour of the middle ear is an aggressive neoplasm, in contrast to the non-papillary adenoma of the middle ear, which is quite benign [73].

In view of the association of some cases of von Hippel-Lindau disease with aggressive papillary middle ear tumours it is suggested that the clinical assessment of

each case with the latter neoplasm should include an investigation of the gene mutations of von Hippel-Lindau disease.

In most cases of this neoplasm, clinical and audiological features point to a middle ear lesion. Suspicion of a neoplasm of the middle ear is enhanced by the otoscopic features.

The middle ear cleft, including the mastoid air cells, is usually filled with the papillary tumour. Bone invasion is often seen. A papillary glandular pattern is present with complex interdigitating papillae lying loosely or infiltrating fibrous connective tissue. The papillae are lined with a single layer of low cuboidal to columnar epithelial cells with uniform nuclei, eosinophilic cytoplasm and indistinct cell borders (Fig. 8.14). Thyroid follicle-like areas may be present similar to those seen in endolymphatic sac carcinoma (see below).

Markers for cytokeratin, epithelial membrane antigen and S-100 are positive. The absence of thyroglobulin must be determined to exclude metastatic papillary carcinoma of the thyroid. Markers for CK 7, CK 20 and carcinoembryonic antigen may also be useful to exclude metastatic deposits from lung and colon.

Schneiderian papillomas (ICD-O:8121/0) are tumours of the nose and paranasal sinuses that are stated to be derived from the Schneiderian epithelium, a term used to denote the normal respiratory-type ciliated epithelium of the nose and paranasal sinuses. Three types of such papillomas are described: *inverted (endophytic)*, *exophytic (fungiform, everted)* and *oncocyctic (cylindrical cell)*. Intermediate types are said to be found among the three forms [73]. It has, however, been denied that such intermediate forms exist and it is suggested that the three types are each separate and distinct entities of the nose and paranasal sinuses [71]. Of the three histological forms only inverted papilloma is characteristically a sinonasal neoplasm. The other two types of Schneiderian-type papilloma may be seen at other sites. Low-grade squamous carcinoma in the nose may sometimes be mistaken for inverted papilloma [67].

Fourteen cases of middle ear tumours purportedly resembling Schneiderian-type papilloma have been found in the literature. Each of these cases is listed in Table 8.1; wherever possible the histological appearances are summarised in the table. In some insufficient or no histological description was given. In two cases only were the features of inverted papilloma depicted: in Case 1 the term “inverted” and in Case 2 the term “endophytic” were used to describe the neoplasm. “Inverted” or “endophytic” features comprised only a portion of the tumours in the two cases. In Case 2 [52] the term transitional cell papilloma was used. This is a term that has been frequently applied to describe everted squamous cell papilloma. In this case inverted papilloma was found in the nasal cavity and it was suggested that the papillomas may have spread from there to the mid-

dle ear by way of the Eustachian tube. In Cases 1, 4 and 10 inverted papilloma was found in the middle ear concomitantly with in situ or invasive squamous carcinoma and it seems possible that the inverted papilloma areas might have been, in reality, areas of low-grade squamous carcinoma.

I would suggest that a good case has not been made for the occurrence of inverted papilloma in the middle ear. Some of the lesions may have been papillomas of the middle ear as described above. In Case 2 an inverted papilloma could conceivably have colonised the middle ear from the nasal cavity. Further detailed descriptions of the entity are required to justify the diagnosis of such a diagnostic category in this situation.

8.3.2.4 Jugulotympanic Paraganglioma

ICD-O:8690/1

Most jugulotympanic paragangliomas arise from the paraganglion situated in the wall of the jugular bulb. These tumours have been referred to as jugular paragangliomas or glomus jugulare tumours. A minority arise from the paraganglion situated near the middle ear surface of the promontory. These tumours have been referred to as tympanic paragangliomas or glomus tympanicum tumours. The distinction between jugular and tympanic paragangliomas can easily be made in the patient by modern imaging methods by which the jugular neoplasm is identified as arising from the jugular bulb region and shows evidence of invasion of the petrous bone, while the tympanic neoplasm is confined to the middle ear.

The gross and histological appearances of the two types of neoplasm in the *middle ear* are, however, identical. Solitary jugulotympanic paragangliomas arise predominantly in females. The neoplasm has been seen at ages between 13 and 85 years with a mean age of about 50 years. Most patients present with conductive hearing loss. Pain in the ear, facial palsy, haemorrhage and tinnitus are also described as symptoms of this lesion. On examination a red vascular mass is seen either behind the intact tympanic membrane or sprouting through the latter into the external canal. Surgical approach to the mass at biopsy often results in severe bleeding.

Jugulotympanic paragangliomas may also be multicentric or coexist with tumours of other types. They may be bilateral in the same patient and coexist with carotid body paragangliomas that may be bilateral [84]. They may also coexist with adrenal gland pheochromocytomas, which can produce hypertension. A familial tendency to grow paragangliomas has been noted particularly in cases with multiple tumours of this type. In families containing patients with head

Table 8.1. Schneiderian-type or inverted papillomas of the middle ear described in the literature

Case number	Literature source	Histological description given	Possible alternative diagnosis
1	[110]	“Inverted papilloma” and high-grade carcinoma	Squamous cell carcinoma of the middle ear
2	[52]	“Transitional cell papilloma” Inverted papilloma in nose	Inverted papilloma derived from a nasal tumour
3	[93]	Entirely papillary	Papilloma of the middle ear
4	[98]	Malignant change in inverted papilloma	Squamous cell carcinoma of the middle ear
5	[124] Case 1	“Epidermoid papilloma” with “inverted” and “cylindric cell papilloma”	Papilloma of the middle ear
6	[124] Case 2	“Epidermoid papilloma” with exophytic and endophytic growth	Papilloma of middle ear
7	[124] Case 3	“Epidermoid papilloma” with features of “cylindric cell papilloma”	Papilloma of the middle ear
8	[124] Case 4	“Epidermoid papilloma” with features of “cylindric cell papilloma”	Papilloma of the middle ear
9	[124] Case 5	“Epidermoid papilloma” with features of “cylindric cell papilloma”	Papilloma of the middle ear
10	[51]	Squamous epithelium with areas of carcinoma in situ	Squamous carcinoma of the middle ear
11	[17]	Papillary with areas of squamous epithelium adjacent to respiratory epithelium	Papilloma of the middle ear
12	[90] Case 1	None	?
13	[90] Case 2		?
14	[11] Two cases	Insufficient description	?

and neck, including jugulotympanic, paragangliomas there is, unlike the solitary jugulotympanic paraganglioma, a preponderance for the male sex and inheritance is autosomal dominant, with increased penetrance with age [5]. There is evidence from molecular genetic studies that the gene underlying familial paragangliomas is located on chromosome 11q proximal to the tyrosinase gene locus [59].

The neoplasm is a reddish sprouting mass at its external canal surface. In the jugular variety the petrous temporal bone is largely replaced by red, firm material and the middle ear space is occupied by soft neoplasm as far as the tympanic membrane. The otic capsule is rarely invaded by paraganglioma. Investigation of a paraganglioma in an autopsy temporal bone by the microsliding method showed the origin of the tumour to be in the jugular bulb region and its spread through the petrous bone and middle ear to the tympanic membrane (Fig. 8.15). The histology of paraganglioma is described in Chap. 9 (Fig. 8.16) [55].

The incidence of clinically functioning paraganglioma with symptoms and signs of norepinephrine excess, particularly hypertension, is only 1–3% [97].

Jugulotympanic paraganglioma is a neoplasm of slow growth. The jugular variety infiltrates the petrous bone, but distant metastasis is rare. Radiation therapy, and in some cases surgery, offers a high rate of cure for these neoplasms and the number of patients who do badly after such therapy is very small.

8.3.2.5 Squamous Cell Carcinoma

ICD-O:8070/3

Squamous cell carcinoma is uncommon in the middle ear. It sometimes accompanies squamous cell carcinoma of the external canal or may arise solely from the middle ear epithelium. The patient always has an aural discharge and conductive hearing loss. Pain in the ear, bleeding and facial palsy are common.

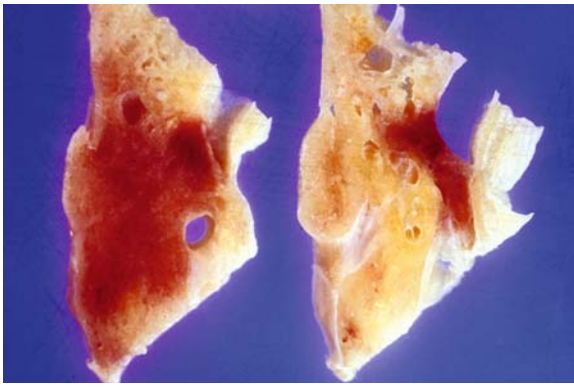


Fig. 8.15. Microsliced specimen of jugular paraganglioma removed at autopsy. Two slices of the temporal bone in the region of the neoplasm are seen. The one on the *left* shows invasion of the temporal bone by the reddish paraganglioma from its apical region as far as the tympanic membrane. The slice on the *right* is taken at a higher level and shows sparing of the cochlea and bony labyrinth by the tumour

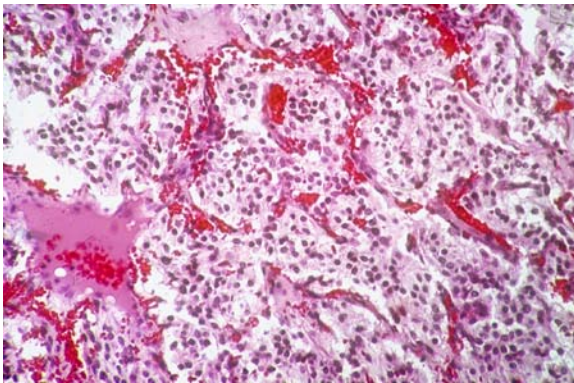


Fig. 8.16. Jugular paraganglioma. The cells form small clusters, each surrounded by a row of flattened cells, probably sustentacular cells, and separated by blood vessels

In microscopic sections the tumour may be seen arising from surface stratified squamous epithelium, itself metaplastic from the normal cubical epithelium. In certain areas an origin directly from basal layers of cubical or columnar epithelium may be seen. There is no evidence that the epidermoid formation, a cell rest that occurs normally in the middle ear during development (see above), may be a source of squamous cell carcinoma. The neoplasm is squamous cell carcinoma with variable degrees of differentiation. Atypical change and even carcinoma in situ may be seen in some parts of the middle ear epithelium adjacent to the growth. The mode of spread of the neoplasm from the middle ear epithelium has been ascertained in temporal bone autopsy sections [70] and this pattern has been confirmed by imaging in living patients. The carcinoma tends to grow into and erode the thin bony plate that separates the me-

dial wall of the middle ear, at its junction with the Eustachian tube, from the carotid canal. This bony wall is normally up to 1 mm in thickness and may be recognised radiologically. Having reached the carotid canal the growth will extend rapidly along the sympathetic nerves and the tumour is then impossible to eradicate surgically. Another important method of spread is through the bony walls of the posterior mastoid air cells to the dura of the posterior surface of the temporal bone. From there it spreads medially, enters the internal auditory meatus and may then invade the cochlea and vestibule. Spread into the lamellar bone in both of these situations is along vascular channels between bone trabeculae. A similar type of bone invasion may also occur from other parts of the middle ear surface such as in the region of the facial nerve. The special bone of the otic capsule is, on the other hand, peculiarly resistant to direct spread of growth from tumours within the middle ear, and even the round window membrane is not invaded. When invasion does occur it takes place after entry of the tumour into the internal auditory meatus and penetration of the bone by way of the filaments of the vestibular and cochlear divisions of the eighth nerve. In the later stages tumour grows extensively in the middle cranial fossa; it may also invade the condyle of the mandible. Death is usually due to direct intracranial extension. Lymph node metastasis is unusual and spread by the bloodstream even more so [70].

8.3.2.6 Meningioma

ICD-O:9530/0

Meningioma is a benign tumour that usually grows intracerebrally, but is sometimes seen involving bony structures around the brain including the middle ear. It arises from the pia-arachnoid cells of the meninges. These structures may be formed at a number of sites in the temporal bone, including the internal auditory meatus, the jugular foramen, the geniculate ganglion region and the roof of the Eustachian tube. Thus, meningiomas that arise from them may be found in a wide area within the temporal bone itself [78].

Meningioma of the middle ear affects females more than males, shows an age range of between 10 and 80 years (with a mean age of 49.6 years), with female patients presenting at an older age (mean 52.0 years) than male patients (mean, 44.8 years) [116].

The commonest temporal bone site for primary meningioma is in the middle ear cleft. In a recent study of 36 cases, most of which involved the middle ear, but a few involved adjacent structures such as the external canal or temporal bone, only 2 showed a CNS connection on radiography [116].

Patients present clinically with hearing change, otitis media, pain, and/or dizziness/vertigo.

Gross appearances are those of a granular or even gritty mass. Microscopically, the neoplasm takes the same forms as any of the well-described intracranial types of meningioma. The commonest variety seen in the middle ear is the meningotheial type, in which the tumour cells form masses of epithelioid, regular cells often disposed into whorls, which may be large or small. Fibroblastic and psammomatous varieties are also sometimes seen in the middle ear.

Histological diagnosis of meningioma may be difficult because the above features are indistinct. Under these circumstances immunocytochemistry may be of some diagnostic value. Meningiomas are negative for most markers, including cytokeratins. The majority of meningiomas, however, are positive for vimentin and epithelial membrane antigen.

Nager's review of temporal bone meningiomas indicated that only 2 out of 30 patients survived a 5-year period [78]. More recent experience of middle ear meningiomas signals a better outlook after careful local excision. In a recent study of 35 patients with follow up in which the tumour was sited mainly in the middle ear [116] surgical excision was used in all patients. Ten patients developed a recurrence from 5 months to 2 years later and 5 patients died with recurrent disease (mean, 3.5 years); the remaining 30 patients were alive ($n=25$, mean: 19.0 years) or had died ($n=5$, mean: 9.5 years) of unrelated causes without evidence of disease. Meningiomas of the middle ear behave as slow-growing neoplasms with a good overall prognosis (raw 5-year survival, 83%). Extent of surgical excision is probably the most important factor in determining outlook because recurrences develop in 28% of cases.

8.3.2.7 Rhabdomyosarcoma

ICD-O:8900/3

Rhabdomyosarcoma is seen occasionally in the middle ear of young children [126]. On rare occasions it is found in the middle ear of adults [81]. The tympanic membrane is usually eroded by the growth, which extends into the external canal. Grossly, the tumour is lobulated and dark red with a haemorrhagic cut surface. Almost all temporal bone rhabdomyosarcomas are of the embryonal type, displaying mainly spindle or round primitive skeletal muscle cells, some of which have clear cytoplasm staining positively for glycogen and others have eosinophilic areas in the cytoplasm. Cross striations are unusual in this neoplasm. Immunohistochemical markers for desmin, muscle-specific actin and antibodies against MyoD1 and myogenin confirm this diagnosis.

Rhabdomyosarcoma of the temporal bone is highly malignant and spreads extensively into the cranial cavity, externally or to the pharyngeal region. Lymph node

and bloodstream metastases frequently develop in these patients.

8.3.2.8 Metastatic Carcinoma

Metastasis of malignant neoplasms to the temporal bone including the middle ear is not uncommon. The breast is the commonest primary source of metastatic tumours, followed by lung, kidney, stomach, larynx and cutaneous malignant melanoma [43, 48]. Two distinct modes of spread may be involved in bringing the neoplasms from their primary sites to the middle ear: (a) along vascular channels in the petrous bone (these convey tumour deposits to the temporal bone from distant sites), and (b) along nerves emanating from the internal auditory meatus into the labyrinthine structures and bone. In this way, tumours reaching the meninges may spread into the temporal bone. In addition, direct spread may bring tumours into the ear from primary sites in areas adjacent to the temporal bone.

8.4 Inner Ear

8.4.1 Bony Labyrinth

8.4.1.1 Otosclerosis

Otosclerosis is a disease of the bony labyrinth, which, by involvement and fixation of the stapes footplate, leads to severe conductive hearing loss. Otosclerosis has some features of a hereditary disease, but its genetics still remain incompletely elucidated. Ultrastructural and immunohistochemical evidence for measles virus and isolation and identification of DNA and RNA sequences of that virus have been found in otosclerotic tissue [18].

Otosclerosis usually affects both ears symmetrically. The disease process is probably confined to the temporal bone. The pink swelling of otosclerosis may sometimes even be detected clinically through a particularly transparent tympanic membrane as a well-demarcated and pink focus near the promontory. A characteristic translucency of bone adjacent to the cochlea and anterior to the footplate is identified on a CT scan.

The lesion always commences in the otic capsule tissue anterior to the footplate of the stapes. In this position it does not produce symptoms. These occur when the otosclerosis invades the adjacent stapes footplate and produces fixation of that structure and thus conductive hearing loss. It later spreads widely in the otic capsule and may involve the round window ligament. Blood vessels are prominent and evenly dis-

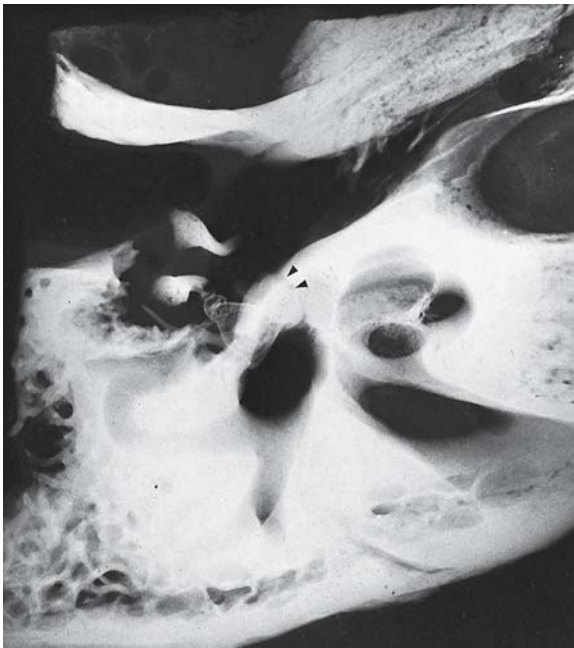


Fig. 8.17. Radiograph of microslice of autopsy temporal bone with focus of otosclerosis. The focus is an area of mottled translucency in the region of the fissula ante fenestram (arrowheads). Reproduced from Michaels and Hellquist [68]

tributed. X-rays of temporal bone specimens show the well-defined lesion as a patch of mottled translucency (Fig. 8.17).

The histological characteristic of otosclerosis is the presence of trabeculae of new bone, mostly of the woven type with marked vascularity. This contrasts with the well-developed lamellar bone under the outer periosteum, the endochondral middle layer and the endosteal layer of the otic capsule, a sharply demarcated edge between normal and otosclerotic bone being a prominent feature. In most places osteocytes are very abundant within the woven bone. The footplate of the stapes is often invaded by otosclerotic bone, and the lower end of the anterior crus of the stapes is sometimes invaded (Fig. 8.18). Otosclerotic bone sometimes reaches the endosteum of the cochlear capsule. In some cases it may lead to a fibrous reaction deep to the spiral ligament. These changes are probably the basis of the sensorineural hearing loss that is also occasionally found in cases of otosclerosis.

Stapedectomy with insertion of a prosthesis to replace the fixed stapes and so reinstate the mobility of the ossicular chain is frequently performed as a treatment for otosclerosis. If the specimen of stapes is composed of the head and crura only microscopic examination will not show the changes of otosclerosis. On the other hand, if the whole stapes is removed, as is usually the

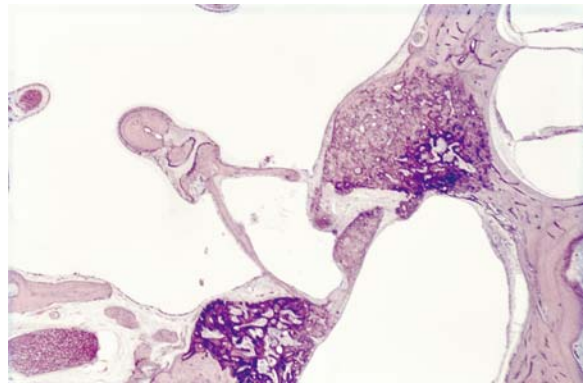


Fig. 8.18. Focus of otosclerosis involving both the anterior (upper) and posterior (lower) part of footplate of the stapes. The anterior focus has invaded onto the footplate and the anterior crus. This would have produced fixation of the stapes and its attendant conductive hearing loss. Notice that the otosclerotic foci are more darkly staining and vascular than the adjacent normal bone. Reproduced from Michaels and Hellquist [68]

case, otosclerotic bone will possibly be observed in sections of the anterior part of the footplate.

8.4.1.2 Paget's Disease

Paget's disease (osteitis deformans) is a common condition affecting particularly the skull, pelvis, vertebral column and femur in people over 40 years of age. The cause is not yet certain, but the presence in many cases of paramyxovirus-like structures seen within osteoclasts has prompted the suggestion that Paget's disease may be of viral aetiology and the measles virus and canine distemper viruses have been under scrutiny as candidates. The pathological change is one of active bone formation proceeding alongside active bone destruction. The affected bones are enlarged, porous and deformed. Microscopically, bone formation is seen in trabeculae of bone with a lining of numerous osteoblasts. A mosaic appearance is formed by the frequent successive deposition of bone, cessation of deposition resulting in thin, blue "cement lines", followed again by resumption of deposition and its cessation, and so production of further cement lines. Bone destruction is shown by the presence of numerous, large osteoclastic giant cells with Howship's lacunae. Areas of chronic inflammatory exudate intermixed with the bone are common.

In the temporal bone the petrous apex, the mastoid and the bony part of the Eustachian tube are most frequently affected [23, 79]. The periosteal part of the bony labyrinth is the first to undergo pagetoid changes and the pagetoid changes spread through the bone towards the membranous labyrinth, usually with a sharp line of

demarcation between the pagetoid area and the normal bony labyrinth.

8.4.1.3 Osteogenesis Imperfecta

Osteogenesis imperfecta is a general bone disease with a triad of clinical features: multiple fractures, blue sclerae and conductive hearing loss. There is a congenital recessive form in newborns that is often rapidly fatal and a tardive one in adults that is inherited as a mendelian dominant and is more benign. Mutations of type I collagen genes have been established as the underlying cause leading to a general disturbance in the development of collagen, hence the thin sclerae appearing blue as well as poorly formed bone tissue.

In the long bones the resorption of cartilage in the development of bone is normal, but the bony trabeculae themselves are poorly formed and the same may be seen in the temporal bone [46]. The ossicles in the tardive form are very thin and subject to fractures. The stapes footplate is also frequently fixed. The disturbance in lamellar bone formation can lead to extreme thinness, dehiscence, and non-union of the stapedia superstructure with the footplate, or thickening with fixation of the footplate. The nature of the bony tissue causing this fixation is problematical. It has been suggested that osteogenesis imperfecta can be associated with otosclerosis so that the fixation is indeed otosclerotic [28]. Otosclerosis, like osteogenesis imperfecta, may indeed be part of a general connective tissue disturbance [4].

Indeed, some cases of clinical otosclerosis may be related to mutations within the COL1A1 gene that are similar to those found in mild forms of osteogenesis imperfecta [63].

8.4.1.4 Osteopetrosis

Osteopetrosis (often known as marble bone disease) is a rare disease of bone, in which there is a failure to absorb calcified cartilage and primitive bone due to deficient activity of osteoclasts. A relatively benign form, inherited as a dominant, presents in adults, and a malignant one, inherited as a recessive, in infants and young children. The patients with the benign form often survive to old age and present prominent otological symptoms. The intermediate, endochondral portion of the otic capsule is swollen and appears as an exaggeratedly thickened form of the normal state. Globuli ossei composed of groups of calcified cartilage cells are normally present in this region, and in osteopetrosis they are greatly increased in number and are arranged into a markedly thickened zone. The periosteal bone is normal. The ossicles are of foetal shape and filled with unabsorbed, calcified cartilage. The canals for the sev-

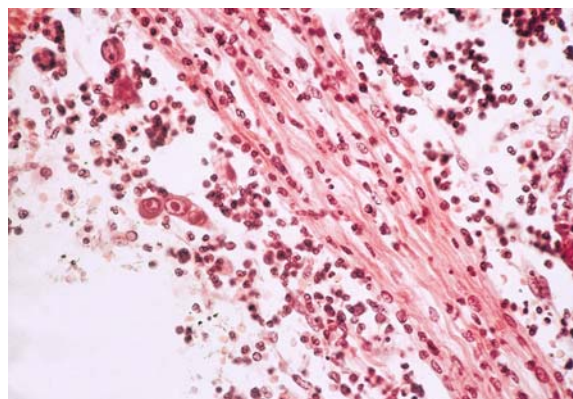


Fig. 8.19. Cytomegalovirus infection of vestibular nerve in the region of Scarpa's ganglion. The nerve is inflamed with the infiltration of neutrophils, leucocytes and plasma cells. Four enlarged cells, three to the left of centre, the fourth on the far right) with purplish inclusions, each surrounded by a pale halo, features characteristic of cytomegalovirus infection, can be identified. Autopsy findings in a patient with AIDS. Reproduced from Michaels and Hellquist [68]

enth and eighth cranial nerves are greatly narrowed by the expanded cartilaginous and bony tissue and these changes are probably responsible for the characteristic symptoms of facial palsy and hearing loss respectively [36, 74, 77].

8.4.2 Membranous Labyrinth and Cranial Nerves

8.4.2.1 Viral, Bacterial and Mycotic Infections

Cytomegaloviruses are DNA-containing members of the herpesvirus group. General infection is frequent, an intrauterine source often being incriminated. The developing human ear has been thought to be particularly susceptible to CMV infection [106] and the virus has been incriminated on clinical and virological grounds as the most common cause of congenital hearing loss [24, 25, 37, 76, 112]. In infant inner ears the endolabyrinth is mainly involved. CMV infection is commonly seen in patients with AIDS. Thirty-nine percent of patients with AIDS were found to have a hearing loss of sensorineural type [104]. In a study of the temporal bones at autopsy of 25 patients CMV infection was identified in the inner ears of 5 patients by the presence of the characteristic inclusions. The inclusions were found in the vestibular nerve in the internal canal (Fig. 8.19), in the stria and in the saccule, utricle and lateral semicircular duct [69].

It is likely, therefore, that the hearing loss in patients with AIDS is due to cochlear CMV infection.

Maternal *rubella* is an important factor in the genesis of congenital sensorineural hearing loss. The virus is an RNA one. In two cases the temporal bones showed inflammatory collections at the upper end near the junction with Reissner's membrane and adherent to it [29]. The organ of Corti was mainly normal.

In *herpes zoster auris* (Ramsay Hunt syndrome), the virus (the *DNA herpes varicella virus*) enters the inner ear along the seventh and eighth cranial nerves, presumably from nerve ganglia where it lies dormant until the immunological status of the patient deteriorates. In histopathological studies previously described there were extensive inflammatory changes mainly in those two cranial nerves serving in the transmission of the virus. Varicella zoster has also been detected in the cytoplasm and nuclei of inflammatory cells of the middle ear in two cases of the Ramsay-Hunt syndrome by an immunofluorescence method [30]. Herpes varicella-zoster viral (VZV) DNA has been identified, using the polymerase chain reaction, in archival celloidin-embedded temporal bone sections from two patients who clinically had Ramsay-Hunt syndrome (*herpes zoster oticus*) [119].

A condition possibly due to viral infection in the inner ear is that of *Bell's palsy*, which is manifested clinically as a peripheral facial paralysis. The suggestion has been made, with some virological support, that this condition is the result of infection with herpes simplex virus, type 1. There have been a very small number of reports of temporal bone studies from patients with Bell's palsy. In two cases of Bell's palsy I studied, serial sections of the temporal bones both showed the following histological findings. In the genu region there appeared to be constriction of the facial nerve by inflammatory tissue, which formed a sheath around it and encroached on its interior. The adjacent bone showed foci of resorption with abundant osteoclasts (Fig. 8.20). The geniculate ganglion was infiltrated by lymphocytes. In some places the affected facial nerve appeared severely oedematous and nerve cells were shrunken and showed an eosinophilic cytoplasm. The descending part of the facial nerve presented swelling and vacuolation of myelin sheaths with some loss of axis cylinders. These findings are compatible with geniculate ganglionitis. In one of these cases, herpes simplex viral type 1 was demonstrated in archival paraffin-embedded sections of the affected geniculate ganglion by carrying out PCR followed by electrophoresis on agarose gel [14].

Petrositis: bacterial infections of the inner ear may involve both the petrous bone itself and the labyrinthine structures within it. Bacterial infection of the petrous bone is frequently derived by extension from middle ear infection. There are four possible routes by which infection may extend from the middle ear into the petrous bone [68]:

1. Via air cells. Mastoid air cells frequently extend into the temporal bone as far as the apical region. It is

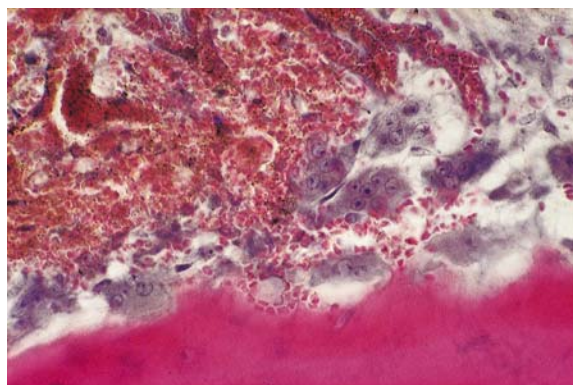


Fig. 8.20. Interface between geniculate ganglion and adjacent bone in a case of Bell's palsy, showing numerous osteoclasts with Howship's lacunae. Reproduced from Michaels and Hellquist [68]

possible, therefore, that infection to the petrous apex may extend from the middle ear by the medium of infection of air cells;

2. As direct spread of the inflammatory process by bone necrosis (osteitis);
3. By extension through the bone marrow of the petrous bone (osteomyelitis);
4. Along vessels and nerves.

In addition to inflammatory infiltration the pathological process of petrositis comprises three main changes in the bone tissue, all of which may be seen simultaneously: (a) bone necrosis, (b) bone erosion, (c) new bone formation. Petrositis is of great importance because involvement of the labyrinth, nerves, artery, veins, meninges and cerebral tissue embedded in and surrounding the petrous bone may each cause serious symptoms, and perhaps death.

Extension to the labyrinth may lead to labyrinthitis with destruction of the organs of hearing and balance. Important nerves may be damaged. The facial nerve is at risk early on. Involvement of the trigeminal ganglion and the sixth cranial nerve lead to "Gradenigo's syndrome". Extension to the jugular foramen region by the inflammatory process may cause palsy of the ninth, tenth and eleventh cranial nerves ("jugular foramen syndrome").

The wall of the internal carotid artery may become inflamed and this may lead to thrombosis of the vessel with possible cerebral complications. Similarly, the lateral sinus may become thrombosed and this and/or extension of the thrombus to the superior sagittal sinus may be associated with the somewhat arcane syndrome of otitic hydrocephalus. Spread of the infection to the immediately adjacent cranial structures will lead to meningitis and cerebral abscess.

Labyrinthitis: the source of labyrinthitis is, in many instances, otitis media, as with petrositis. Infection may

enter the labyrinth by penetrating the oval or the round window. An infected air cell may rupture into the labyrinthine system at some point of its complex periphery. Occasionally, damage to bone by the inflammation may produce a fistula between the middle ear and the labyrinth, usually in the lateral semicircular canal because this is the nearest vulnerable point to the middle ear. The latter complication takes place in most cases when a cholesteatoma is present, which has the effect of stimulating the inflammatory process.

Infection may also be conveyed from meningitis through the cochlear aqueduct and the internal auditory meatus into the labyrinth. Sensorineural hearing loss is an important sequela of acute bacterial meningitis [66].

In suppurative labyrinthitis the perilymph spaces display a usually massive exudate of neutrophils. If the process extends to the endolymphatic spaces there is concomitant destruction of membranous structures and irreparable damage to sensory epithelia.

Healing is at first by fibrosis, but later osseous repair is frequent, leading to a condition of “labyrinthitis ossificans”. In this condition the spaces of the bony labyrinth are filled in by a newer bone, which appears in striking contrast with the normal bone surrounding the bony labyrinth.

Cryptococcosis is a fungus infection that usually infects the meninges. There may be extension by the organism *Cryptococcus neoformans*, from the meninges along the internal auditory meatus and then into the cochlea via the modiolus. Such a progression was clearly present in two cases of AIDS with cryptococcal meningitis that had spread to the labyrinth [69].

8.4.2.2 Lesions of the Vestibular System

The pathology of the vestibular labyrinth has not been as well studied as that of the cochlea and other parts of the labyrinth. This is the result of the paucity of operative procedures with biopsy carried out in this area and also of the rapidity of autolysis, which takes place after death so that histological study of this area is difficult. The non-neoplastic lesions listed below are described in detail by Michaels and Hellquist [68].

Ototoxicity: many drugs damage the sensory epithelia of the inner ear. The most obvious clinical effect is when the cochlear sensory cells are involved so that hearing loss results. Part of the damage produced by aminoglycoside antibiotics such as gentamycin, however, may be to the sensory epithelium of the cristae and maculae, producing symptoms of imbalance.

Virus infection: in rubella and cytomegalovirus infection changes have been observed in the utricle and saccule (see above).

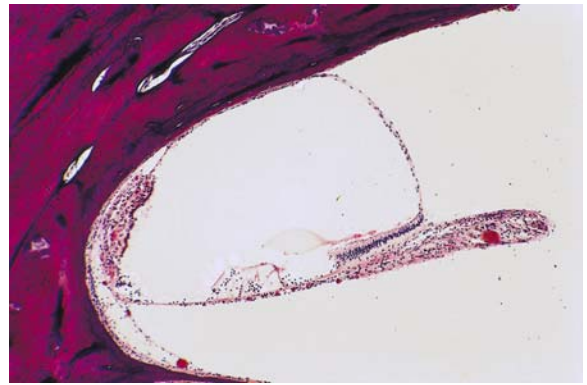


Fig. 8.21. Hydrops of scala media of the cochlea. Reissner's membrane is distended to such a degree that it touches the top of the scala vestibuli. Reproduced from Michaels and Hellquist [68]

Bacterial infection: bacterial infection may involve the vestibular system as part of labyrinthitis. In most bacterial infections, spread occurs from the middle ear via the oval window. A direct fistula resulting from the bone erosion of otitis media may take place leading into the lateral semicircular canal, particularly in the presence of cholesteatoma.

Bone diseases: Paget's disease frequently involves the bony vestibule and semicircular canals to a severe degree and as a result clinical symptoms referable to this system are likely to occur. Otosclerosis, although frequently present in relation to the bony wall of the vestibule, rarely involves the membranous structures of the vestibular system so that vestibular symptoms are rare in this condition.

Hydrops of the saccule, which sometimes extends to the utricle, is the major pathological feature of Ménière's disease and is responsible for the characteristic symptom of that disease – vertigo. The scala media of the cochlea is usually distended in Ménière's disease (Fig. 8.21), and this is the pathological basis of the hearing loss and tinnitus that are the other disturbing symptoms in attacks of the disease. Saccular hydrops may also be a manifestation of syphilitic and bacterial inflammation involving the labyrinth.

Positional vertigo is a very common condition in which vertigo is induced in the patient by alteration in the position of the head. In 1969, Schuknecht described the temporal bone findings in two cases of positional vertigo [94]. Attached to the posterior surface of the cupula of the left posterior semicircular canal in each of the cases was a basophilically stained homogeneous deposit. On the basis of these cases, Schuknecht has built up an explanation of the symptomatology of positional vertigo postulating that the calcific material derived from otoconia in a degenerated utricular macula will descend by gravity along

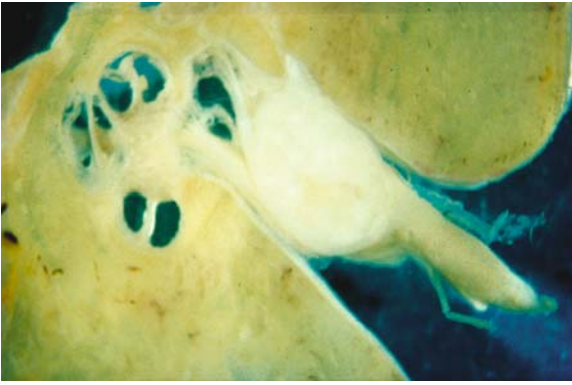


Fig. 8.22. Vestibular schwannoma in a microsliced temporal bone. The neoplasm is arising from the vestibular division of the eighth nerve and compressing the cochlear division. Note the granular deposit lining the cochlea. Reproduced from Michaels and Hellquist [68]

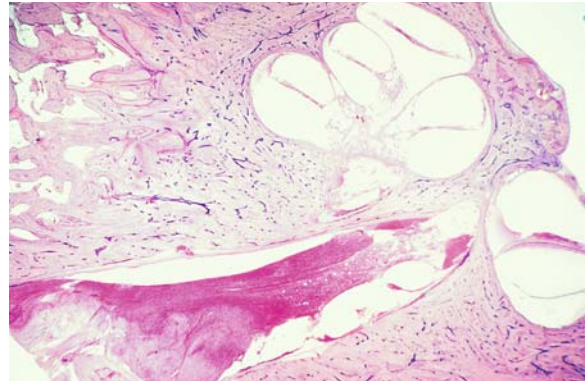


Fig. 8.23. Small vestibular schwannoma. It arises from the vestibular division of the eighth nerve in the region of the glial neurilemmal junction and causes only a small indentation of the bony wall of the internal canal. There is exudate in the vestibule, but not in the cochlea. Reproduced from Michaels and Hellquist [68]

the endolymph and form on the crista of the posterior semicircular canal, the lowest region of the labyrinthine sensory epithelium. This ingenious theory has attracted much interest and the term “cupulolithiasis” is nowadays frequently used as a synonym for positional vertigo.

8.4.2.3 Tumours and Tumour-Like Lesions

The most important neoplasm of the vestibular system is *schwannoma* (*acoustic neuroma*, ICD-O:9560/0) of the vestibular division of the eighth cranial nerve. This does not usually invade the vestibule, but may do so in cases of neurofibromatosis [2] (see below). The saccule and utricle show an exudate of proteinaceous fluid in the presence of a schwannoma of the internal auditory meatus. Another much rarer neoplasm is the low-grade adenocarcinoma of the endolymphatic sac (endolymphatic sac tumour; see below). Metastatic deposits are unusual; invasion of the vestibular system from the internal auditory meatus by way of the vestibular nerve may occur in metastatic neoplasm or in carcinoma of the middle ear (see above).

Vestibular schwannoma is stated to arise most commonly at the glial-neurilemmal junction of the eighth nerve, which is usually within the internal auditory meatus. In one study of five temporal bones with small vestibular schwannomas, the tumour arose more peripherally, however [128]. When seen at surgery or autopsy vestibular schwannoma in most cases is found to occupy a much greater part of the nerve. Usually it is the vestibular division of the nerve that is affected; in a few the cochlear division is the source of the neoplasm (Fig. 8.22). Growth takes place from origin, both centrally onto the cerebellopontine angle, and distally along the canal.

Vestibular schwannoma is usually unilateral, but may be bilateral (see below).

The neoplasm may grow slowly for years without causing symptoms and may be first diagnosed only at post-mortem where it has been found in about 1 in 220 consecutive adults [57]. Although it arises on the vestibular branch of the eighth cranial nerve, hearing loss and tinnitus are early symptoms produced by involvement of the cochlear division of the nerve; in the later stages vertigo and abnormal caloric and electronystagmographic responses develop from damage to the vestibular division itself. Surgical removal may be carried out by drilling from the external canal through the temporal bone, by craniotomy and the middle fossa approach to the internal auditory meatus, or by stereotactically guided gamma knife surgery.

The neoplasm, seen grossly, is of variable size and of round or oval shape. Small tumours either do not widen the canal at all or produce only a small indentation in the bone (Fig. 8.23). The larger tumours often have a mushroom shape with two components, the stalk – an elongated part in the canal – and an expanded part in the region of the cerebellopontine angle. The bone of the internal auditory canal is widened funnel-wise as the neoplasm grows. The tumour surface is smooth and lobulated. The cut surface is yellowish, often with areas of haemorrhage and cysts. The vestibular division of the eighth nerve may be identified on the surface of the tumour.

Acoustic neuroma has the features of a neoplasm of Schwann cells showing Antoni A and Antoni B areas. Antoni A areas display spindle cells closely packed together with palisading of nuclei. Verocay bodies, which may be present in the Antoni A areas, are whorled formations of palisaded tumour cells. The degree of cellularity of the neoplasm can be high or low. The spindle cells frequently are moderately pleomorphic, but mitotic

figures are unusual. The presence of pleomorphism does not denote a malignant tendency. Antoni B areas, probably a degenerated form of the Antoni A pattern, show a loose reticular pattern, sometimes with histiocytic proliferation. Thrombosis and necrosis may be present in some parts of the neoplasm. A mild degree of invasion of modiolus or vestibule along cochlear or vestibular nerve branches may be present even in solitary vestibular schwannomas. Granular or homogeneous fluid exudate is usually present in the perilymphatic spaces of the cochlea and vestibule. This may arise as a result of pressure by the neoplasm on veins draining the cochlea and vestibule in the internal auditory meatus. Hydrops of the endolymphatic system may occur (see above) and in larger tumours there is atrophy of spiral ganglion cells and nerve fibres in the basilar membrane.

The tumour is benign and usually grows slowly. Serious symptoms and even death may occur, however, due to damage to cerebral structures if the neoplasm grows to a large size.

Neurofibromatosis 2 (Bilateral Vestibular Schwannoma, ICD-O:9540/1): bilateral vestibular schwannoma acoustic neuroma (neurofibromatosis 2, NF2) is, unlike neurofibromatosis 1 (von Recklinghausen's disease), not associated with large numbers of cutaneous neurofibromas and cafe-au-lait spots, but the temporal bone locality of the neural tumour and its bilaterality are inherited as an autosomal dominant trait. This condition has been related to a gene localised near the centre of the long arm of chromosome 22. At autopsy of cases of neurofibromatosis 2, neural neoplasms are present in both eighth nerves and other central nerves. There are often many small schwannomas and collections of cells of neurofibromatous and meningiomatous appearance growing on cranial nerves and on the meninges in the vicinity of the vestibular schwannomas and sometimes even intermixed with them. The NF2 tumours are histologically similar to those of the single tumours except that the former have more Verocay bodies and more foci of high cellularity. The NF2 tumours are more invasive, however, tending to infiltrate the cochlea and vestibule more deeply.

As with all schwannomas, the strongest and most consistent immunohistochemical reaction is the positivity displayed when staining with a polyclonal antibody against S-100 protein is carried out. The vimentin marker is also usually positive. These findings are common to both unilateral vestibular schwannoma and the schwannomas of NF2. Glial fibrillary acidic protein and neuron-specific enolase markers are also sometimes positive; the tumours are consistently negative for CD34, a marker widely used for the diagnosis of solitary fibrous tumours, unless the vestibular schwannoma is widely degenerated [117].

An antibody against Ki67 (MIB1 in paraffin sections) has been utilised in a number of investigations to determine whether the degree of positivity with this prolifer-

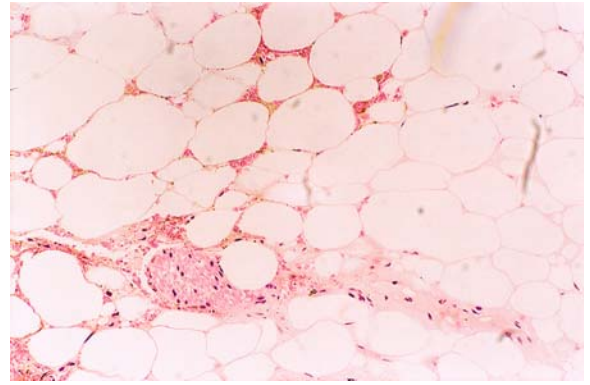


Fig. 8.24. Lipoma of the internal auditory canal. Note nerve branch passing through adipose tissue near the bottom. Reproduced from Michaels and Hellquist [68]

ation marker can be related to the clinical activity of the tumour. It has been demonstrated that tumours 18 mm or smaller in diameter have lower proliferation indices and growth rates, compared with tumours larger than 18 mm [6]. The degree of labelling with the proliferation marker is higher in cases of NF2 than in those of solitary vestibular schwannoma [2].

Meningiomas (*ICD-O:9530/0*) are usually intracranial masses. They arise from arachnoid villi, which are small protrusions of the arachnoid membranes into the venous sinuses. Arachnoid villi may be found in parts of the temporal bone, including the inner ear, and on occasion meningiomas may arise from these structures as primary neoplasms of the inner ear region. The most likely position for a primary inner ear meningioma is in the wall of the internal auditory meatus, where arachnoid villi are normally frequent. The histological appearances of a meningioma are those of a tumour with a whorled arrangement of cells: meningotheliomatous if the tumour cells appear epithelioid, psammomatous if calcification of the whorled masses is prominent and fibroblastic if the tumour cells resemble fibroblasts. Meningiomas as well as acoustic neuromas may appear in the inner ear in the NF2 syndrome. The meningioma is a slowly growing tumour of the temporal bone that has had a reputation for complete benignity. In the temporal bone, however, middle ear meningioma sometimes has a strong propensity towards local recurrence and invasion (see above).

Lipomas (ICD-O:8850/0) of the internal auditory canal and cerebellopontine angle are rare tumours that may be confused clinically with the much commoner vestibular schwannoma. On magnetic resonance using fat-suppressed T1-weighted images after gadolinium enhancement, however, this tumour displays characteristics of adipose tissue rather than those of schwannoma. There may be erosion of the walls of the internal auditory canal as with vestibular schwannoma, and lipoma may appear similar to the latter at operation. Since

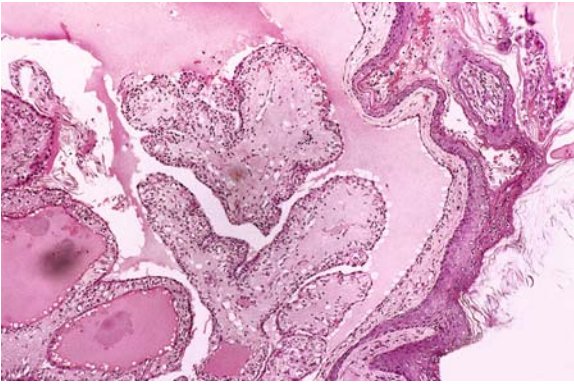


Fig. 8.25. Low-grade adenocarcinoma of probable endolymphatic sac origin showing a papillary pattern. The epidermoid epithelium on the right is probably that of the external auditory canal to which the tumour had extended. Reproduced from Michaels and Hellquist [68]

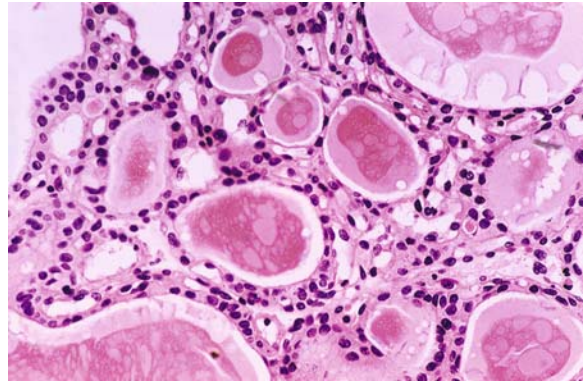


Fig. 8.26. Low-grade adenocarcinoma of probable endolymphatic sac origin showing a thyroid-like glandular pattern from another area of the tumour shown in Fig. 8.25. Reproduced from Michaels and Hellquist [68]

the seventh and eighth cranial nerves or their branches (Fig. 8.24) may pass through the lesion and their integrity be damaged by removal of the tumour it is recommended that diagnosis be made whenever the possibility of this neoplasm is suspected at operation by examination of frozen sections. If a diagnosis of lipoma is made in this way the tumour should not be resected, since its further growth does not constitute a threat to vital structures [102].

Low-grade adenocarcinoma of probable endolymphatic sac origin (endolymphatic sac tumour): there is evidence of the existence of an epithelial neoplasm of the endolymphatic system, mainly in the endolymphatic sac [35, 38, 41]. Although of bland histological appearance and of slow growth the neoplasm seems to have considerable invasive capacity and therefore the term “low-grade adenocarcinoma of probable endolymphatic sac origin” has been applied. Other terms, such as endolymphatic sac tumour and Heffner’s tumour, are also in use. Some cases have presented bilateral neoplasms of the same type and some have also been associated with von Hippel-Lindau disease [64]. The course of the tumour’s growth may extend over many years. Tinnitus or vertigo, similar or identical to the symptoms of Ménière’s disease, are present in about one-third of patients. It is presumed that early obstruction of the endolymphatic sac leads to hydrops of the endolymphatic system of the labyrinth and so to the Ménière’s symptoms. Imaging reveals a lytic temporal bone lesion, appearing to originate from the region between the internal auditory canal and sigmoid sinus (which is the approximate position of the endolymphatic sac). There is usually prominent extension into the posterior cranial cavity and invasion of the middle ear.

In most cases the tumour has a papillary-glandular appearance, the papillary proliferation being lined by a single row of low cuboidal cells. The vascular nature of the papillae in some cases has given the tumour

a histological resemblance to choroid plexus papilloma (Fig. 8.25). In some cases the tumour also shows areas of dilated glands containing secretion that has some resemblance to colloid and under these circumstances the lesion may resemble papillary adenocarcinoma of the thyroid (Fig. 8.26). Such thyroid-like areas may even dominate the histological pattern. A few cases show a clear cell predominance resembling carcinoma of the kidney. On immunohistochemistry the epithelial cells of this neoplasm contain antigens of cytokeratins. Some tumours contain glial fibrillary acidic protein. Thyroglobulin is always absent.

It seems possible that many cases of the so-called “aggressive papillary middle ear tumours” may be low-grade adenocarcinomas of the endolymphatic sac with extension of the neoplasm to the middle ear (see also Sect. 8.3.2.3) [31]. Not all of such tumours may arise in the endolymphatic sac [89].

The histological appearances of low-grade adenocarcinomas of probable endolymphatic sac origin are indeed in keeping with the normal histological structure of the endolymphatic sac, which is lined by a papillary columnar epithelial layer.

Cholesteatoma (epidermoid cyst) usually presents with symptoms relating to its involvement of the seventh and eighth cranial nerves in the cerebellopontine angle. The histological appearance is similar to that of middle ear cholesteatoma (see above). It is probably of congenital origin, but no cell rest has been discovered from which it might arise.

Cholesterol granuloma is a lesion of the petrous apex with the typical features of cholesterol granuloma as seen in the middle ear and mastoid in chronic otitis media, and has been identified in recent years with increasing frequency. At operation it appears cystic, the contents being altered blood and cholesterol clefts with a foreign body giant cell reaction.

Microscopic examination shows non-specific granulation tissue and haemosiderin deposits in its wall. It is believed to result from an inflammatory response to an obstruction of the pneumatized air cells at the apex of the temporal bone and low cuboidal epithelium; the epithelium of the air cell is sometimes identified near the cholesterol granuloma. As the process develops, bone is eroded by this expansile lesion, often involving the petrous apex, the cerebellopontine angle and the middle ear, when the lesion may be mistaken for an invading neoplasm such as the adenocarcinoma of the endolymphatic sac [3].

8.4.2.4 Presbycusis

Sensorineural hearing loss is an affliction that affects all people to a greater or lesser degree over the age of 60 years. The greatest losses are sustained in the higher frequencies, but there is a moderate degree of loss of hearing throughout the whole range of audible frequencies. It has been shown that the pathological basis of this condition is a complete degeneration of the organ of Corti and associated nerve supply at the end of the basal coil of the cochlea and moderate outer hair cell loss throughout the whole of the rest of the cochlea. An illustrated account of this condition will be found in Michaels and Hellquist [68].

8.4.2.5 Malformations

Modern methods of imaging have identified a wide range of malformations of the inner ear. In addition, there is a common form of congenital sensorineural hearing loss in which no change can be identified by CT or MRI scan. In such cases it is inferred that the loss is caused by microscopic lesions within the organ of Corti, many of which have been described. Some inner ear malformations are associated with gene mutations. An account of this subject is beyond the range of this chapter. A detailed and illustrated review will be found in Michaels and Hellquist [68].

References

- Adam W, Johnson JC Paul DJ, Clausen K, Schuller DE (1982) Primary adenocarcinoma of the middle ear. *AJNR Am J Neuroradiol* 3:674–676
- Aguiar PH, Tatagiba M, Samii M, Dankoweit-Timpe E, Osertag H (1995) The comparison between the growth fraction of bilateral vestibular schwannomas in neurofibromatosis 2 (NF2) and unilateral vestibular schwannomas using the monoclonal antibody MIB 1. *Acta Neurochir (Wien)* 134:40–45
- Amedee RG, Marks HW, Lyons GD (1987) Cholesterol granuloma of the petrous apex. *Am J Otol* 8:48–55
- Arslan M, Ricci V (1963) Histochemical investigations of otosclerosis with special regard to collagen disease. *J Laryngol Otol* 77:365–373
- Baars FM van, Cremers CW, Broek P van den, Veldman JE (1981) Familial non-chromaffinic paragangliomas (glomus tumors). Clinical and genetic aspects. *Acta Otolaryngol Stockh* 91:589–593
- Barnes L, Koss W, Nieland ML (1980) Angiolymphoid hyperplasia: a disease that may be confused with malignancy. *Head Neck Surg* 2:425–434
- Bedavanija A, Brieger J, Lehr HA, Maurer J, Mann WJ (2003) Association of proliferative activity and size in acoustic neuroma: implications for timing of surgery. *J Neurosurg* 98:807–811
- Bendet E (1999) A wattle (cervical accessory tragus). *Otolaryngol Head Neck Surg* 121:508–509
- Benecke JE, Noel FL, Carberry JN, House JW, Patterson M (1990) Adenomatous tumors of the middle ear and mastoid. *Am J Otol* 11:20–26
- Blamires TL, Friedmann I, Moffat DA (1992) Von Hippel-Lindau disease associated with an invasive choroid plexus tumour presenting as a middle ear mass. *J Laryngol Otol* 106:429–435
- Blandamura S, Marioni G, de Filippis C, Giacomelli LP, Segato P, Staffieri A. (2003) Temporal bone and sinonasal inverted papilloma: the same pathological entity? *Arch Otolaryngol Head Neck Surg* 129:553–556
- Bottomley WW, Goodfield MD (1994) Chondrodermatitis nodularis helioides occurring with systemic sclerosis – an under-reported association? *Clin Exp Dermatol* 19:219–220
- Broekaert D, Couke P, Leperque S (1992) Immunohistochemical analysis of the cytokeratin expression in middle ear cholesteatoma and related epithelial tissues. *Ann Otol Rhinol Laryngol* 101:931–938
- Burgess RC, Michaels L, Bale JF, Smith RJ (1994) Polymerase chain reaction amplification of Herpes simplex viral DNA from the geniculate ganglion of a patient with Bell's palsy. *Ann Otol Rhinol Laryngol* 103:775–779
- Cankar V, Crowley H (1964) Tumors of ceruminous glands: a clinicopathological study of seven cases. *Cancer* 17:67–75
- Chandler JR (1968) Malignant external otitis. *Laryngoscope* 78:1257–1294
- Chhetri DK, Gajjar NA, Bhuta S, Andrews JC (2001) Pathology forum. Quiz case 2. Schneiderian-type papilloma of the middle ear. *Arch Otolaryngol Head Neck Surg* 127:79; 80–82
- Chole RA, McKenna M (2001) Pathophysiology of otosclerosis. *Otol Neurotol* 22:249–257
- Cohen D (1987) Locations of primary cholesteatoma. *Am J Otol* 8:61–65
- Corbridge RJ, Michaels L, Wright A (1996) Epithelial migration in keratosis obturans. *Am J Otolaryngol* 17:411–414
- Dadas B, Alkan S, Turgut S, Basak T (2001) Primary papillary adenocarcinoma confined to the middle ear and mastoid. *Eur Arch Otorhinolaryngol* 258:93–95
- Davidsson A, Hellquist HB, Villman K, Westman G (1993) Malignant melanoma of the ear. *J Laryngol Otol* 107:798–802
- Davies DG (1968) Paget's disease of the temporal bone. A clinical and histopathological survey. *Acta Otolaryngol [Suppl] (Scand)* 242:1–47
- Davis GL (1969) Cytomegalovirus in the inner ear: case report and electron microscopic study. *Ann Otol* 78:1178–1188
- Davis LE, Johnsson L-G, Kornfeld M (1981) Cytomegalovirus labyrinthitis in an infant: morphological, virological and immunofluorescent studies. *J Neuropathol Exp Neurol* 40:9–19
- Derlacki EL, Barney PL (1976) Adenomatous tumors of the middle ear and mastoid. *Laryngoscope* 86:1123–1135
- Devlin J, Harrison CJ, Whitby DJ, David T (1990) Cartilaginous pseudocyst of the external auricle in children with atopic eczema. *Br J Dermatol* 122:699–704

28. Dieler R, Muller J, Helm (1997) Stapes surgery in osteogenesis imperfecta patients. *Eur Arch Otorhinolaryngol* 254:120–127
29. Friedmann I, Wright MI (1966) Histopathological changes in the foetal and infantile inner ear caused by maternal rubella. *Br Med J* II:20–23
30. Fujiwara Y, Yanagihara N, Kurata T (1990) Middle ear mucosa in Ramsay Hunt syndrome. *Ann Otol Rhinol Laryngol* 99:359–362
31. Gaffey MJ, Mills SE, Boyd JC (1994) Aggressive papillary tumor of middle ear/temporal bone and adnexal papillary cystadenoma. Manifestations of von Hippel-Lindau disease. *Am J Surg Pathol* 18:1254–1260
32. Gaffey MJ, Mills SE, Fechner RE, Intemann SR, Wick MR (1988) Aggressive papillary middle-ear tumor. A clinicopathologic entity distinct from middle-ear adenoma. *Am J Surg Pathol* 12:790–797
33. Goebel JA, Smith PG, Kemink JL, Graham MD (1987) Primary adenocarcinoma of the temporal bone mimicking paragangliomas: radiographic and clinical recognition. *Otolaryngol Head Neck Surg* 96:231–238
34. Grundfast KM, Ahuja GS, Parisier SC, Culver SM (1995) Delayed diagnosis and fate of congenital cholesteatoma (keratoma). *Arch Otolaryngol Head Neck Surg* 121:903–907
35. Gulya AJ, Glasscock ME, Pensak ML (1986) Primary adenocarcinoma of the temporal bone with posterior fossa extension: case report. *Laryngoscope* 96:675–677
36. Hamersma H (1970) Osteopetrosis (marble bone disease) of the temporal bone. *Laryngoscope* 80:1518–1539
37. Hanshaw JP (1976) School failure and deafness after “silent” congenital cytomegalovirus infection. *N Engl J Med* 295:468–470
38. Hassard AD, Boudreau SF, Cron CC (1984) Adenoma of the endolymphatic sac. *J Otolaryngol* 13:213–216
39. Hawke M, Jahn AF (1974) Keratin implantation granuloma in external ear canal. *Arch Otolaryngol* 100:317–318
40. Healy E, Angus B, Lawrence CM, Rees JL (1995) Prognostic value of Ki67 antigen expression in basal cell carcinomas. *Br J Dermatol* 133:737–741
41. Heffner DK (1989) Low-grade adenocarcinoma of probable endolymphatic sac origin. A clinicopathologic study of 20 cases. *Cancer* 64:2292–2302
42. Heffner DK, Hyams VJ (1986) Cystic chondromalacia (enchondral pseudocysts of the auricle). *Arch Pathol Lab Med* 110:740–743
43. Hill BA, Kohut RI (1976) Metastatic adenocarcinomas of the temporal bone. *Arch Otolaryngol* 102:568–571
44. Hinni ML, Beatty CW (1996) Salivary gland choristoma of the middle ear: report of a case and review of the literature. *Ear Nose Throat J* 75:422–424
45. Hyams VJ, Michaels L (1976) Benign adenomatous neoplasms (adenoma) of the middle ear. *Clin Otolaryngol* 1:17–26
46. Igarashi M, King AI, Schwenzfeier CW, Watanabe T, Alford BR (1980) Inner ear pathology in osteogenesis imperfecta congenita. *J Laryngol Otol* 94:697–705
47. Iurato S, Bux G, Colucci S, Davidson C, Ettorre GC, Mazzarella L, Mevoli S, Selvini C, Zallone AZ (1992) Histopathology of spontaneous brain herniations into the middle ear. *Acta Otolaryngol (Stockh)* 112:328–333
48. Jahn AF, Farkashidy J, Berman JM (1979) Metastatic tumors in the temporal bone – a pathophysiologic study. *J Otolaryngol* 8:85–95
49. Jansen T, Romiti R, Altmeyer P (2000) Accessory tragus: report of two cases and review of the literature. *Pediatr Dermatol* 17:391–394
50. Jefferson G, Whitehead R (1931) Papilliferous cystoma of petrous bone associated with hypernephroma and cystic pancreas. *Br J Surg* 19:55–62
51. Jones ME, Wackym PA, Said-Al-Naief N, Brandwein M, Shaari CM, Som PM, Zhang DY, King WA (1998) Clinical and molecular pathology of aggressive Schneiderian papilloma involving the temporal bone. *Head Neck* 20:83–88
52. Kaddour HS, Woodhead CJ (1992) Transitional papilloma of the middle ear. *J Laryngol Otol* 106:628–629
53. Kameron DB, Caparosa RJ (1982) Temporal bone encephalocele. Diagnosis and treatment. *Laryngoscope* 92:878–881
54. Kim SW, Moon SE, Kim JA (1997) Bilateral accessory tragi on the suprasternal region. *J Dermatol* 24:543–545
55. Kliewer KE, Duan-Ren W, Pasquale A, Cochrane AJ (1989) Paragangliomas: assessment of prognosis by histologic, immunohistochemical and ultrastructural techniques. *Hum Pathol* 20:29–39
56. Kronenburg J, Ben-Shoshan J, Modam M, Leventon G (1988) Blast injury and cholesteatoma. *Am J Otol* 9:127–130
57. Leonard J, Talbot M (1970) Asymptomatic acoustic neurolipoma. *Arch Otolaryngol* 91:117–124
58. Liang J, Michaels L, Wright A (2003) Immunohistochemical characterization of the epidermoid formation in the human middle ear. *Laryngoscope* 113:1007–1014
59. Mariman EC, Beersum SE van, Cremers CW, Baars FM van, Ropers HH (1993) Analysis of a second family with hereditary non-chromaffin paragangliomas locates the underlying gene at the proximal region of chromosome 11q. *Hum Genet* 91:357–361
60. Masaki M, Wright CG, Lee DH, Meyerhoff WL (1989) Experimental cholesteatoma. Epidermal ingrowth through tympanic membrane following middle ear application of propylene glycol. *Acta Otolaryngol (Stockh)* 108:113–121
61. McGill TJ, Merchant S, Healy GB, Friedman EM (1991) Congenital cholesteatoma of the middle ear in children: a clinical and histopathological report. *Laryngoscope* 101:606–613
62. McGregor DH, Cherian R, Kepes JJ, Kepes M (1994) Case reports: heterotopic brain tissue of middle ear associated with cholesteatoma. *Am J Med Sci* 308:180–183
63. McKenna MJ, Kristiansen AG, Bartley ML, Rogus JJ, Haines JL (1998) Association of COL1A1 and otosclerosis: evidence for a shared genetic etiology with mild osteogenesis imperfecta. *Am J Otol* 19:604–610
64. Megerian CA, Haynes DS, Poe DS, Choo DI, Keriakas TJ, Glasscock ME III (2002) Hearing preservation surgery for small endolymphatic sac tumors in patients with von Hippel-Lindau syndrome. *Otol Neurotol* 23:378–387
65. Megerian CA, Sofferman RA, McKenna MJ, Eavey RD, Nadol JB Jr (1995) Fibrous dysplasia of the temporal bone: ten new cases demonstrating the spectrum of otologic sequelae. *Am J Otol* 16:408–419
66. Merchant SN, Gopen Q (1996) A human temporal bone study of acute bacterial meningogenic labyrinthitis. *Am J Otol* 17:375–385
67. Michaels L (1996) Benign mucosal tumors of the nose and paranasal sinuses. *Semin Diagn Pathol* 13:113–117
68. Michaels L, Hellquist H (2001) Ear, nose and throat histopathology, 2nd edn. Springer, London
69. Michaels L, Soucek S, Liang J (1994) The ear in the acquired immunodeficiency syndrome. I. Temporal bone histopathologic study. *Am J Otol* 15:515–522
70. Michaels L, Wells M (1980) Squamous cell carcinoma of the middle ear. *Clin Otolaryngol* 5:235–248
71. Michaels L, Young M (1995) Histogenesis of papillomas of the nose and paranasal sinuses. *Arch Pathol Lab Med* 119:821–826
72. Milbrath MM, Campbell BH, Madiedo G, Janjan NA (1998) Malignant melanoma of the external auditory canal. *Am J Clin Oncol* 21:28–30
73. Mills SE, Gaffey MJ, Frierson HF Jr (2000) Tumors of the upper aerodigestive tract and ear. Atlas of tumor pathology, third series, fascicle 26
74. Milroy CM, Michaels L (1990) Temporal bone pathology of adult-type osteopetrosis. *Arch Otolaryngol Head Neck Surg* 116:79–84
75. Murphy GE, Pilch BZ, Dickersin GR, Goodman MC, Nadol JB (1980) Carcinoid tumor of the middle ear. *Am J Clin Pathol* 73:816–823
76. Myers EN, Stool S (1968) Cytomegalic inclusion disease of the inner ear. *Laryngoscope* 78:1904–1915
77. Myers EN, Stool S (1969) The temporal bone in osteopetrosis. *Arch Otolaryngol* 89:460–469
78. Nager GT (1963) Meningiomas involving the temporal bone. Thomas, Springfield

79. Nager GT (1975) Paget's disease of the temporal bone. *Ann Otol Rhinol Laryngol* 84 [Suppl] 22:3–32
80. Nager GT, Kennedy DW, Kopstein E (1982) Fibrous dysplasia: a review of the disease and its manifestations in the temporal bone. *Ann Otol Rhinol Laryngol* 91:Suppl 92
81. Nakhleh RE, Swanson PE, Dehner LP (1991) Juvenile (embryonal and alveolar) rhabdomyosarcoma of the head and neck in adults. A clinical, pathologic, and immunohistochemical study of 12 cases. *Cancer* 67:1019–1024
82. Nelson EG, Kratz RC (1993) Sebaceous choristoma of the middle ear. *Otolaryngol Head Neck Surg* 108:372–373
83. Nyrop M, Grantved A (2002) Cancer of the external auditory canal. *Arch Otolaryngol Head Neck Surg* 128:834–837
84. Ophir D (1991) Familial multicentric paragangliomas in a child. *J Laryngol Otol* 105:376–380
85. Ostfeld E, Segal M, Czernobilsky B (1982) External otitis: early histopathologic changes and pathogenic mechanism. *Laryngoscope* 91:965–970
86. Palmer JM, Coker NJ, Harper RL (1989) Papillary adenoma of the temporal bone in von Hippel-Lindau disease. *Otolaryngol Head Neck Surg* 100:64–68
87. Persaud R, Hajjoff D, Thevasagayam MS, Wareing MJ, Wright A (2004) Keratosis obturans and external ear canal cholesteatoma: how and why we should distinguish between these conditions. *Clin Otolaryngol* 29:1–5
88. Polinsky MN, Brunberg JA, McKeever PE, Sandler HM, Telian S, Ross D (1994) Aggressive papillary middle ear tumors: a report of two cases with review of the literature. *Neurosurgery* 35:493–497; discussion 497
89. Pollak A, Bohmer A, Spycher M, Fisch U (1995) Are papillary adenomas endolymphatic sac tumors? *Ann Otol Rhinol Laryngol* 104:613–619
90. Pou AM, Vrabec JT (2002) Inverting papilloma of the temporal bone. *Laryngoscope* 112:140–142
91. Ramirez-Camacho R, Vicente J, Garcia Berrocal JR, Ramon y Cajal S (1999) Fibro-osseous lesions of the external auditory canal. *Laryngoscope* 109:488–491
92. Ribe A, Fernandez PL, Ostertarg H, Claros P, Bombi JA, Palacin A, Cardesa A (1997) Middle-ear adenoma (MEA): a report of two cases, one with predominant "plasmacytoid" features. *Histopathology* 30:359–364
93. Roberts WH, Dinges DL, Hanly MG (1993) Inverted papilloma of the middle ear. *Ann Otol Rhinol Laryngol* 102:890–892
94. Schuknecht H (1969) Cupulithiasis. *Arch Otolaryngol* 90:765–778
95. Schuknecht HF (1993) Pathology of the ear, 2nd edn. Lea & Febiger, Philadelphia, pp 209–210
96. Schuller DE, Conley JJ, Goodman JH, Clausen KP, Miller WJ (1983) Primary adenocarcinoma of the middle ear. *Otolaryngol Head Neck Surg* 91:280–283
97. Schwaber MK, Glasscock ME, Jackson CG, Smith PG (1984) Diagnosis and management of catecholamine secreting glomus tumors. *Laryngoscope* 94:1008–1015
98. Seshul MJ, Eby TL, Crowe DR, Peters GE (1995) Nasal inverted papilloma with involvement of middle ear and mastoid. *Arch Otolaryngol Head Neck Surg* 121:1045–1048
99. Shah JP, Kraus DH, Dubner S, Sarkar S (1991) Patterns of regional lymph node metastases from cutaneous melanomas of the head and neck. *Am J Surg* 162:320–323
100. Siedentop KH, Jeantet C (1961) Primary adenocarcinoma of the middle ear. Report of three cases. *Ann Otol Rhinol Laryngol* 70:719–733
101. Shpitzer T, Stern Y, Cohen O, Levy R, Segal K, Feinmesser R (1993) Malignant external otitis in nondiabetic patients. *Ann Otol Rhinol Laryngol* 102:870–872
102. Singh SP, Cottingham SL, Slone W, Boesel CP, Welling DB, Yates AJ (1996) Lipomas of the internal auditory canal. *Arch Pathol Lab Med* 120:681–683
103. Soucek S, Michaels L (1993) Keratosis of the tympanic membrane and deep external canal: a defect of auditory epithelial migration. *Eur Arch Otorhinolaryngol* 250:140–142
104. Soucek S, Michaels L (1996) The ear in the acquired immunodeficiency syndrome. II. Clinical and audiological investigation. *Am J Otol* 17:35–39
105. Stafford ND, Frootko NJ (1986) Verrucous carcinoma in the external auditory canal. *Am J Otol* 7:443–445
106. Stagno S, Reynolds DW, Amos CS, Dahle AJ, McCollister FP, Mohindra I, Ermocilla R, Alford CA (1977) Auditory and visual defects resulting from symptomatic and subclinical congenital cytomegaloviral and toxoplasma infections. *Pediatrics* 59:669–678
107. Staibano S, Boscaino A, Salvatore G, Orabona P, Palombini L, De Rosa G A (1996) The prognostic significance of tumor angiogenesis in nonaggressive and aggressive basal cell carcinoma of the human skin. *Hum Pathol* 27:695–700
108. Stanley MW, Horwitz CA, Levinson RM, Sibley RK (1987) Carcinoid tumors of the middle ear. *Am J Clin Pathol* 87:592–600
109. Stendel R, Suess O, Proscenc N, Funk T, Brock M (1998) Neoplasm of endolymphatic sac origin: clinical, radiological and pathological features. *Acta Neurochir (Wien)* 140:1083–1087
110. Stone DM, Bertold RE, Ranganathan C, Wiet RJ (1987) Inverted papilloma of the middle ear and mastoid. *Otolaryngol Head Neck Surg* 97:416–418
111. Stone HE, Lipa M, Bell RD (1975) Primary adenocarcinoma of the middle ear. *Arch Otolaryngol* 101:702–705
112. Strauss M (1990) Human cytomegalovirus labyrinthitis. *Am J Otolaryngol* 11:292–298
113. Sudhoff H, Bujia J, Fisselereckhoff A, Holly A, Schufflake C, Hildmann H (1995) Expression of a cell-cycle-associated nuclear antigen (MIB1) in cholesteatoma and auditory meatal skin. *Laryngoscope* 105:1227–1231
114. Sudhoff H, Bujia J, Holly A, Kim C, Fischler-Eckhoff (1994) Functional characterization of middle ear mucosa residues in cholesteatomatous samples. *Am J Otol* 15:217–221
115. Sudhoff H, Fisseler-Eckhoff A, Stark T, Borkowski G, Luckhaupt H, Cooper J, Michaels L (1997) Argyrophilic nucleolar organizer regions in auditory meatal skin and middle ear cholesteatoma. *Clin Otolaryngol* 22:545–548
116. Thompson LD, Bouffard JP, Sandberg GD, Mena H (2003) Primary ear and temporal bone meningiomas: a clinicopathologic study of 36 cases with a review of the literature. *Mod Pathol* 16:236–245
117. Tosaka M, Hirato J, Miyagishima T, Saito N, Nakazato Y, Sasaki T (2002) Calcified vestibular schwannoma with unusual histological characteristics – positive immunoreactivity for CD-34 antigen. *Acta Neurochir (Wien)* 144:395–399
118. Tysome JR, Harcourt J, Patel MC, Sandison A, Michaels L (2006) Aggressive papillary tumour of the middle ear. *Ear, Nose and Throat Journal*, in press
119. Wackym PA (1997) Molecular temporal bone pathology. II. Ramsay Hunt syndrome (herpes zoster oticus). *Laryngoscope* 107:1165–1175
120. Wassef M, Kanavara P, Polivka M, Nemeth J, Monteil JP, Frachet B, Tran Ba Huy P (1989) Middle ear adenoma. A tumor displaying mucinous and neuroendocrine differentiation. *Am J Surg Pathol* 13:838–847
121. Weinroth SE, Schessel D, Tuazon CU (1992) Malignant otitis externa in AIDS patients: case report and review of the literature. *Ear Nose Throat J* 73:772–774
122. Wells MD, Michaels L (1983) Role of retraction pockets in cholesteatoma formation. *Clin Otolaryngol* 8:39–45
123. Wells M, Michaels L (1984) "Malignant otitis externa": a manifestation of chronic otitis media with complications? *Clin Otolaryngol* 9:131 (abstract)
124. Wenig BM (1996) Schneiderian-type mucosal papillomas of the middle ear and mastoid. *Ann Otol Rhinol Laryngol* 105:226–233
125. Wetli CV, Pardo V, Millard M, Gersdon K (1972) Tumors of ceruminous glands. *Cancer* 29:1169–1178
126. Wiatrak BJ, Pensak ML (1989) Rhabdomyosarcoma of the ear and temporal bone. *Laryngoscope* 99:1188–1192
127. Wright CG, Meyerhoff WL, Burns DK (1985) Middle ear cholesteatoma: an animal model. *Am J Otolaryngol* 6:327–341
128. Xenellis JE, Linthicum FH Jr (2003) On the myth of the glial/schwann junction (Obersteiner-Redlich zone): origin of vestibular nerve schwannomas. *Otol Neurotol* 24:1

Cysts and Unknown Primary and Secondary Tumours of the Neck, and Neck Dissection

M. A Luna · K. Pineda-Daboin

Contents

9.1	Introduction	264	9.4.4	Cervical Salivary Gland Cystic Neoplasms	273
9.2	Anatomy	264	9.4.5	Miscellaneous Lesions	273
9.2.1	Triangles of the Neck	264	9.5	Paraganglioma	273
9.2.2	Lymph Node Regions of the Neck	264	9.6	Unknown Primary and Secondary Tumours	274
9.3	Cysts of the Neck	264	9.6.1	Definition	274
9.3.1	Developmental Cysts	265	9.6.2	Clinical Features	275
9.3.1.1	Branchial Cleft Cysts, Sinuses and Fistulae	265	9.6.3	Search for the Primary Tumour	275
9.3.2	Branchiogenic Carcinoma	267	9.6.4	Common Location of the Primary Tumour	276
9.3.3	Thyroglossal Duct Cyst and Ectopic Thyroid	268	9.6.5	Histologic Type of Metastases and Immunohistochemical Features	276
9.3.4	Cervical Thymic Cyst	269	9.6.6	Differential Diagnosis	276
9.3.5	Cervical Parathyroid Cyst	270	9.6.7	Treatment and Results	278
9.3.6	Cervical Bronchogenic Cyst	270	9.7	Neck Dissection	278
9.3.7	Dermoid Cyst	271	9.7.1	Classification of Neck Dissections	278
9.3.8	Unclassified Cervical Cyst	271	9.7.2	Gross Examination of Neck Dissection Surgical Specimens	279
9.3.9	Non-Developmental Cysts	271	9.7.3	Histologic Evaluation of Neck Dissection	279
9.3.9.1	Ranula	271	References	280	
9.3.9.2	Laryngocele	271			
9.4	Cystic Neoplasms	272			
9.4.1	Cystic Hygroma and Lymphangioma	272			
9.4.2	Haemangioma	272			
9.4.3	Teratoma	272			

9.1 Introduction

The neck connects the organs of the head with those of the thorax. It contains important anatomic structures, including blood and lymphatic vessels, nerves and paranglia, muscles and vertebrae, and numerous lymph nodes, in addition to parenchymatous glands, salivary, thyroid, and parathyroid. The neck also contains organs of the upper aerodigestive tract: larynx, hypopharynx and segments of the oesophagus and trachea.

The fact that a neck mass can originate in any of the cervical structures means that a host of disorders challenges the diagnostic ability of the surgical pathologist. The differential diagnosis of a neck mass includes developmental, inflammatory, benign and malignant neoplastic lesions. The purpose of this chapter is to review the pathology and diagnosis of cervical cysts. Occult primary tumours of the neck and neck dissection also are discussed.

9.2 Anatomy

9.2.1 Triangles of the Neck

It is customary to divide the neck into two large triangles, the anterior cervical triangle and the posterior cervical triangle. The anterior triangle is bounded by the midline of the neck, the anterior border of the sternocleidomastoid muscle, and the inferior border of the mandible. The posterior triangle is bounded by the anterior margin of the trapezius muscle, the posterior border of the sternocleidomastoid muscle and the clavicle.

The anterior cervical triangle can be further subdivided into four lesser triangles (submental, submandibular, superior carotid and inferior carotid) and the posterior triangle into two (occipital and supraclavicular) the boundaries of which are described in greater detail in other sources [12].

9.2.2 Lymph Node Regions of the Neck

The cervical lymph nodes can be divided into superficial and deep nodes, and each of these groups into lateral and medial. The deep lateral nodes are distributed among several large groups:

1. The submental and submandibular group;
2. The internal jugular chain (superior, middle, and inferior);
3. The spinal accessory nerves chain;
4. The supraclavicular node chain.

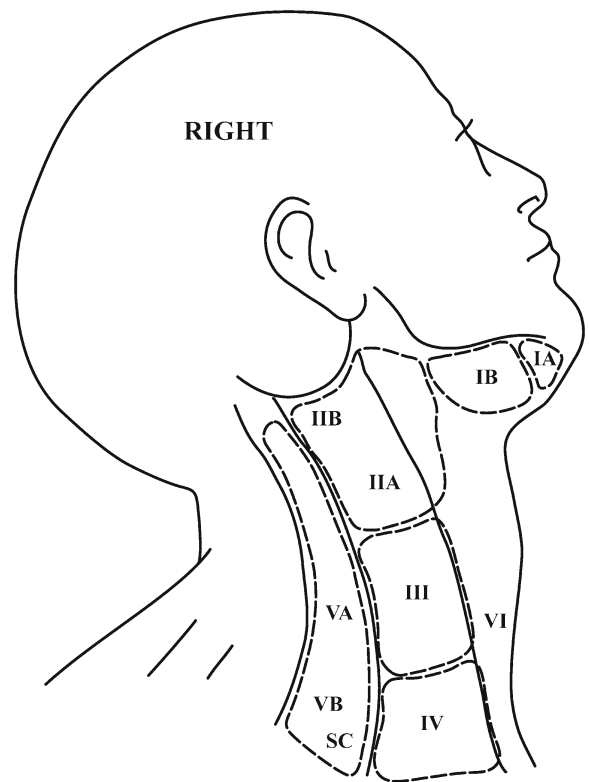


Fig. 9.1. Cervical nodes by levels and sublevels: *IA* submental, *IB* submandibular, *II* upper jugular, *IIA* jugulogastric, *IIB* supra-spinal accessory, *III* middle jugular, *IV* lower jugular, *V* Posterior cervical, *VA* spinal accessory nerve nodes, *VB* transverse cervical nodes, *SC* supraclavicular, *VI* anterior group

The deep medial cervical group consists of the prelaryngeal, prethyroidal, pretracheal and paratracheal lymph nodes. The superficial medial lymph nodes are distributed around the anterior jugular vein. The superficial lateral cervical nodes are located along the external jugular vein.

Figure 9.1 shows the system for describing the location of lymph nodes in the neck, and used the levels recommended by the Committee for Head and Neck Surgery and Oncology of the American Academy for Otolaryngology-Head and Neck Surgery [99].

9.3 Cysts of the Neck

Cysts of the neck are pathological cavities lined with epithelium. The type of epithelium varies, and the cavity may contain fluid, keratin, mucus or other products. Cervical cysts can be divided into two large groups: developmental and non-developmental. Establishing the precise nature of these cysts is important because there are considerable differences in their biological and clinical

Table 9.1. Order of frequency of cervical cystic tumours according to age (extracted from [52, 68, 70, 115]). CA carcinoma

Infants and children	Adolescents	Adults
Thyroglossal duct cyst	Thyroglossal duct cyst	Metastatic cystic ca
Branchial cleft cyst	Branchial cleft cyst	Thyroglossal duct cyst
Lymphangioma	Bronchogenic cyst	Cervical ranula
Haemangioma	Thymic cyst	Branchial cleft cyst
Teratoma and dermoid	Teratoma and dermoid	Laryngocele
Bronchogenic cyst	Metastatic thyroid ca	Parathyroid cyst
Thymic cyst		Thymic cyst
Laryngocele		
Metastatic thyroid ca		

cal behaviour [26]. Because of the frequent similarities in the morphological aspects of various cysts, a definitive diagnosis is dependent on clinical data. These include the exact location of the lesion and the age of the patient. The clinical manifestations of cysts depend largely on their size. Most cysts in the early stages are asymptomatic and are found on routine physical or radiographic examination. Rupture and drainage leads to infection, abscess, and sinus formation, which are frequently accompanied by pain and swelling. In certain instances, computed tomography scan can be of benefit in establishing the diagnosis and/or extension into adjacent structures [59]. Aspiration needle biopsy can also be useful in distinguishing between cysts and other pathoses that present a similar roentgenographic appearance [41].

In adults, an asymptomatic neck mass should be considered malignancy until proven otherwise. With the exception of thyroid nodules and salivary gland tumours, neck masses in adults have the following characteristics: 80% of the masses are neoplastic, 80% of neoplastic masses are malignant, 80% of malignancies are metastatic, and in 80%, the primary tumour is located above the level of clavicle [70]. In contrast, 90% of neck masses in children represent benign conditions. In a review of 445 children with neck masses, 55% of the masses were congenital cysts, 27% were inflammatory lesions, 11% were malignant and 7% were miscellaneous conditions [117]. Table 9.1 lists the causes of neck masses in order of the frequency with which they occur, according to the age of the patient.

9.3.1 Developmental Cysts

9.3.1.1 Branchial Cleft Cysts, Sinuses and Fistulae

Branchial apparatus anomalies are lateral cervical lesions that result from congenital developmental defects arising from the primitive branchial arches, clefts and pouches.

The branchial apparatus appears around the 4th week of gestation and gives rise to multiple structures or derivatives of the ears, face, oral cavity and neck. These structures are described in more detail in other sources [126]. Anatomically, the branchial apparatus consists of a paired series of six arches, five internal pouches and five external clefts or grooves. The external grooves are of ectodermal origin and are called branchial clefts. The internal pouches are of endodermal origin and are known as pharyngeal pouches; they are separated by their branchial plates [126]. Each branchial arch is supplied by an artery and a nerve and develops into well-defined muscles, bone and cartilage. Thus, all three germ-cell layers contribute to formation of the branchial apparatus. The arches are numbered 1–6, from cranial to caudal, and the clefts and pouches 1–5. The corresponding cleft and pouch lie immediately caudal to their numerical arch, that is, the first cleft and pouch lie between the first and second arches, the second cleft and pouch lie between the second and third arches, and so on.

A number of theories exist to explain the genesis of branchial cleft anomalies. Regauer and associates have proposed that the cysts arise from the endodermally derived second branchial pouch [95]. An alternative explanation is that the cysts develop from cystic epithelial inclusions in lymph nodes that are either of salivary gland origin or from displaced epithelium from the palatine tonsil [43]. Gollidge and Ellis recently reviewed the various theories on the histogenesis of branchial cleft cysts [43].

Papers dealing with anomalies of the branchial apparatus do not always distinguish between the terms sinus and fistula and often use them interchangeably as synonyms. A sinus is a tract that has only one opening, either cutaneous or mucosal. A fistula is a tract that has two openings, one cutaneous and one mucosal. A cyst may occur independently or in association with a sinus or fistula.

Most anomalies of the branchial apparatus of concern to the surgical pathologist present clinically as a cyst, fistula, sinus or skin tag. Fistulae, sinuses and skin tags occur in younger patients than cysts do [20]. Bran-

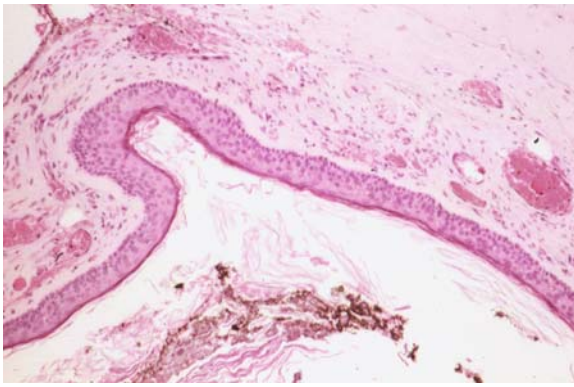


Fig. 9.2. Branchial cleft cyst. Wall lined with stratified squamous epithelium

chial cleft cysts constitute approximately 75–80% of all branchial anomalies, and fistulae and sinuses together account for 15–20% of all such malformations [1]. In some series, external fistulae, sinuses and skin tags are more common than cysts [57].

Of all branchial anomalies, 92–99% are associated with the *second branchial clefts apparatus*, probably because it is deeper and longer than the others [8]. Use of the name “branchial cyst” without further qualification generally refers to a cyst of second branchial origin. Cysts are three times more common than sinuses and fistulae in this apparatus. They typically occur along the anterior border of the sternocleidomastoid muscle from the hyoid bone to the suprasternal notch, but have infrequently been described in the midline, just as a thyroglossal duct cyst may occur laterally, as bilateral branchial cleft cysts, or even in the lateral wall of the nasopharynx [8, 85].

Branchial cleft anomalies have no gender preference. Most patients (75%) are aged 20–40 years at the time of diagnosis. Since fewer than 3% of cysts are found in patients older than 50 years, the pathologist must be careful in making this diagnosis in this age group; a metastatic cystic squamous cell carcinoma in a cervical lymph node may masquerade as a branchial cleft cyst.

On pathologic examination the cysts are unilocular, usually between 2 and 6 cm in diameter, and lined with stratified squamous epithelium (90%), respiratory epithelium (8%), or both (2%; Fig. 9.2). Lymphoid aggregates with or without reactive germinal centres beneath the lining epithelium are found in the majority of cysts (75–80%). Acute and chronic inflammation, foreign body giant-cell reaction and fibrosis are the secondary microscopic changes in the wall of the cyst. In exceptional cases, heterotopic salivary tissue may even be found in the wall of the cyst [111]. Carcinoma in situ has seldom been described in the lining of the cysts [132]. Regauer et al. have postulated that the cysts are initially lined with the endodermally derived pouch type of respiratory epithelium, which is replaced by squamous ep-

ithelium through an intermediate stage of pseudostratified transitional-type epithelium [95].

Fistulae and sinuses are more often found at birth or in early childhood than cysts. The external opening, when present, is usually located along the anterior border of the sternocleidomastoid muscle at the junction of its middle and lower thirds. The tract, if there is one, follows the carotid sheath; it crosses over the hypoglossal nerve, runs between the internal and external carotid arteries and ends at the tonsillar fossa [122].

Thymic cyst and cystic low-grade mucoepidermoid carcinoma with prominent lymphoid stroma are considerations in the differential diagnosis. The cyst's benign lining distinguishes it from metastatic cystic squamous carcinoma.

Complete surgical excision of the cyst, sinus, or fistula is indicated. In a review of 274 patients with branchial remnants treated at the Mayo Clinic, the recurrence rate was only 2.7% for patients with no history of surgery or infection, 14% in those with a history of infection and 21.2% in those who had undergone prior attempts at surgical removal [28].

Anomalies from the *first branchial arch* accounted for only 8% of all branchial cleft anomalies at the Mayo Clinic [82]. Of these, 68% were cysts, 16% sinuses and 16% fistulae. These anomalies occur predominantly in females and are found in all age groups. In general, sinuses and fistulae tend to develop in infants and children, whereas cysts are more common in older groups. Clinically, they may masquerade as parotid tumours or as otitis with ear drainage [82].

Disorders of the first branchial cleft are classified into two types [119]. Type I are those that embryologically duplicate the membrane (cutaneous) external auditory canal. Accordingly, only ectodermal components are observed under the microscope. On histologic examination they are often confused with epidermoid cysts, for they are lined solely by keratinised, stratified squamous epithelium, with no adnexal structures or cartilage. Characteristically, they are located medial, inferior or posterior to the concha and pinna. Drainage from cysts or fistulae may occur in any of these sites. The fistula tract or sinus may parallel the external auditory canal and ends in a blind cul de sac at the level of the mesotympanum.

Type II deformities are composed of both ectodermal and mesodermal elements and therefore contain, in addition to skin, cutaneous appendages and cartilage (Fig. 9.3). Patients with this defect usually present with an abscess or fistula at a point just below the angle of the mandible, through the parotid gland, toward the external auditory canal. Type II defects are therefore more intimately associated with the parotid gland than are type I defects. Sometimes an anomaly cannot be distinguished as type I or type II. In those instances, Olsen et al. suggested that the abnormality be classified only as to whether it is a cyst, sinus, or fistula [82]. Complete excision is

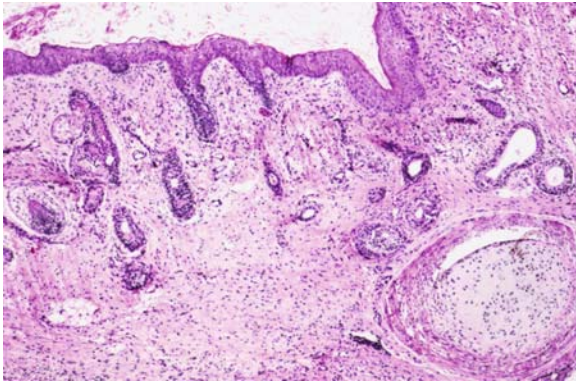


Fig. 9.3. First branchial cleft cyst, Type II. Squamous epithelium lining the cystic cavity. Note the presence of skin appendage structures and cartilage in the stroma

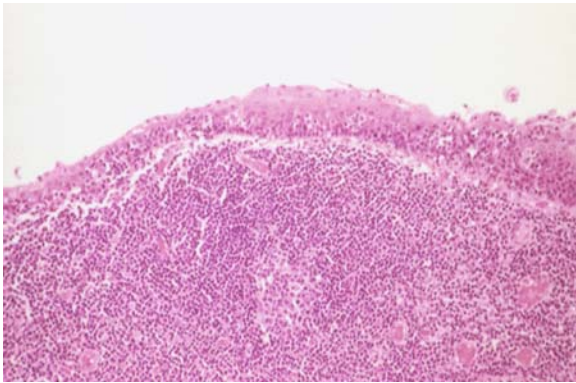


Fig. 9.4. Lymphoepithelial cyst. Note the absence of lymphoid hyperplasia

the only effective treatment. In some cases, this may necessitate a superficial parotidectomy. First branchial cleft abnormalities must be differentiated pathologically from epidermal cysts (especially type I), dermoids (especially type II), and cystic sebaceous lymphadenoma.

Anomalies from the *third and fourth branchial apparatuses* are rare and together account for fewer than 5% of all branchial cysts, sinuses and fistulae [80]. A fistula in the pyriform sinus is one of the more common manifestations of a third branchial anomaly [32]. Recurrent infections of the lower neck, including suppurative thyroiditis, and a fistulous tract into the pyriform sinus are the features of a fourth branchial cleft or pouch anomaly [80].

Third and fourth branchial sinus anomalies can be distinguished only by detailed surgical exploration. A third branchial sinus always extends from the pyriform sinus through the thyroid membrane cranial to the superior laryngeal nerve. In contrast, a fourth branchial sinus extends from the pyriform sinus caudal to the superior laryngeal nerve and exits the larynx near the cricothyroid joint [127].

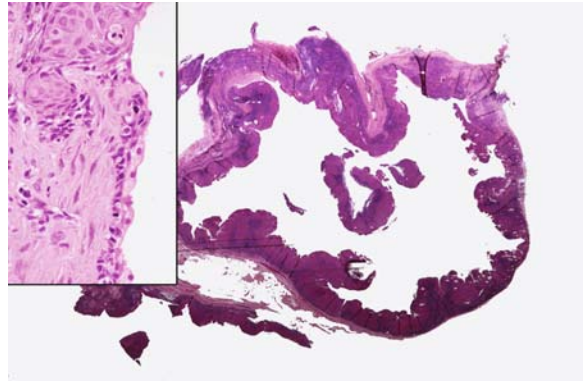


Fig. 9.5. Branchiogenic carcinoma. *Inset:* malignant squamous and respiratory epithelium lining the cystic wall

Neither the fifth nor the sixth branchial arch forms clefts or pouches in humans [126]. Branchial cleft cysts have been reported infrequently in the parotid, thyroid and parathyroid glands, floor of the mouth, tonsil, pharynx and mediastinum [17]. Many of these cysts have the microscopic features of lymphoepithelial cysts (Fig. 9.4).

9.3.2 Branchiogenic Carcinoma

Branchiogenic carcinoma or primary cervical neoplastic cysts are of interest from an historical viewpoint [69, 96]. Few of the purported examples of this entity fulfil the four criteria that Martin et al. considered necessary to establish the diagnosis, which are as follows:

1. The cervical tumour occurs along the line extending from a point just anterior to the tragus, along the anterior border of the sternocleidomastoid muscle, to the clavicle;
2. The histologic appearance must be consistent with an origin from tissue known to be present in the branchial vestigial;
3. No primary source of the carcinoma should be discovered during follow-up for at least 5 years;
4. Cancer arising in the wall of an epithelium-lined cyst situated in the lateral aspect of the neck can be demonstrated histologically (Fig. 9.5) [69].

The fulfilment of these criteria is practically impossible, and the existence of “branchiogenic carcinoma” must remain entirely hypothetical [69, 73, 96, 116]. The criteria have been criticised on the grounds that they are much too restrictive and nearly preclude a diagnosis of branchiogenic carcinoma [15, 86].

Several authors have estimated that, even accepting tentative examples of branchiogenic carcinoma, its incidence would be minuscule (0.3% of all malignant su-

praclavicular tumours) [15, 58]. There is no doubt that most, if not all of them are actually cervical node metastases with a cystic pattern. The palatine tonsil, or more generally the anatomic region of Waldeyer's ring, is notorious for producing cystic solitary metastases that resemble the usual appearance of branchial cleft cysts [69, 73, 96, 116].

All of the suspected branchiogenic carcinomas have been squamous-cell in type, and all but one have been in the region of the second branchial apparatus [15, 58, 86]. The patients have been predominantly males ranging in age from 38 to 71 years [15, 58]. Nearly all of these masses have been cystic and have resided in a lymphoid matrix, hence the presumed relationship to a branchial cyst. It should be obvious that neither cystic architecture nor association with lymphoid tissue is, in itself, an acceptable criterion for diagnosis of branchiogenic carcinoma [73, 96, 116].

An absence or presence of peripheral lymphatic sinuses and/or follicular centres in the lymphoid tissue has been used to exclude or confirm metastasis to the lymph nodes. This criterion is not valid. Branchial cleft cysts often lie within lymph nodes, and metastases can obscure the architecture of a lymph node [96, 116].

9.3.3 Thyroglossal Duct Cyst and Ectopic Thyroid

Cysts and sinuses may be found along the course of the thyroglossal duct; these cysts develop during the migration of the thyroid gland from the base of the tongue. The cysts are situated in the midline of the neck, usually below the hyoid bone. A fistula may develop from an infected cyst.

The thyroid begins to develop during the 4th week of gestation when the embryo is about 2–2.5 mm long [126]. It is an endodermal derivative composed of two small lateral anlagen and the more substantial median anlage from the foramen caecum at the base of the tongue. Because of elongated cephalad embryonic growth rather than active descent, the orthotopic pretracheal location of the thyroid is caudal to the foramen caecum [126].

Thyroglossal duct cysts (TDC) are twice as common as branchial cleft cysts. In a review of 1,534 cases in the literature, Allard observed that, at the time of presentation, 67% of patients had a cyst and 33% a fistula [5].

Approximately 90% of TDC occur in the midline of the neck, although some may occur paramedially, most often on the left. Overall, 73.8% occur below the hyoid bone, 24.1% are suprahyoid, and 2.1% are intralingual [65]. Spinelli et al. reviewed their experience with neck masses in children and noted that 17 (26%) of 154 cases were TDC, and branchial cleft cysts were less common [115].

Most patients with a TDC have no symptoms; they seek evaluation for a midline neck mass discovered incidentally by themselves or a family member. The most common manifestations are pain, a draining sinus or fistula, infection, or dysphagia. A cyst in the floor of the mouth may cause feeding problems in newborns, whereas a cyst at the base of the tongue has, in rare instances, been responsible for sudden death in infancy [106].

Thyroglossal duct cysts range in size from 0.5 to 4 cm in diameter. They can be either unilocular or multilocular and usually contain mucoid material if the cyst is not infected or mucopurulent material or pus if it is. The type of epithelium lining the cyst varies from one case to another, or even within the same surgical specimen. A columnar to stratified cuboidal epithelium with cilia is the most common type of epithelial lining, found in 50–60% of cases (Fig. 9.6). Lymphoid nodules in the wall of the cyst are found in 15–20% of cases, while they occur in 75% of branchial cleft cysts. A TDC with squamous lining and lymphoid tissue may be difficult to differentiate from a branchial cleft cyst. Immunoperoxidase staining for thyroglobulin may be of help. Ectopic thyroid tissue is identified (as collections of thyroid follicles in the soft tissues adjacent to the cyst) in 3–20% of TDCs, although these figures are related to some extent to the number of tissue slides taken for histologic examination and the extent of inflammatory and reactive changes present in the surrounding tissue.

Mucous glands were identified in 60% of the TDC studied by Sade and Rosen [102]. These authors believe the mucous glands to be part of the normal thyroglossal apparatus and not just glands found at the base of the tongue.

Thyroglossal duct remnants are treated by complete surgical excision using the Sistrunk operation [112]. This consists of a block excision of the entire thyroglossal tract to the foramen caecum, as well as removal of the central 1–2 cm of the hyoid bone. If this procedure is performed, the TDC recurrence rate is less than 5% [91]. If the central portion of the bone is not removed, the recurrence rate is as high as 50% [3, 74].

Ectopic thyroid is defined by identification of gross or microscopic thyroid tissue outside of the thyroid gland. Most commonly from the base of the tongue (lingual thyroid) to the mid-lower neck superior to the orthotopic thyroid [25]. The ectopia can be complete or more often associated with an orthotopic thyroid.

Hypothyroidism is a frequent finding in patients with lingual thyroid [105]. Batsakis and collaborators noted a clinical prevalence of lingual thyroid of 1 in 10,000 individuals, but an autopsy prevalence of 1 in 10 [10]. Ectopic thyroid is histologically composed of uniform, often small, follicles containing minimal colloid. The microfollicles are usually intercepted by the skeletal muscle of the tongue.

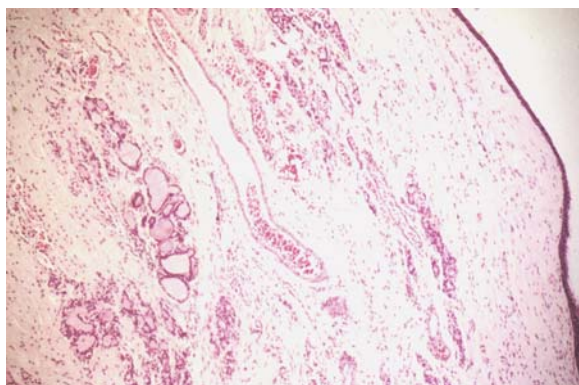


Fig. 9.6. Thyroglossal duct cyst. Thyroid follicles are present in the wall

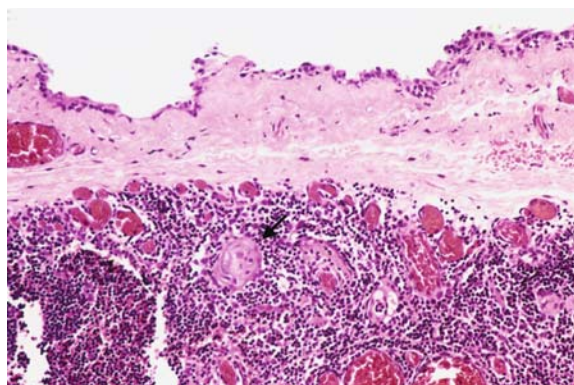


Fig. 9.7. Cervical thymic cyst. Notice Hassall's corpuscles in the wall (arrow)

Patients with presumed ectopic thyroid should undergo a preoperative thyroid scan to rule out ectopic thyroid gland, because patients with an ectopic thyroid gland have no additional normally functional tissue, and thus are rendered permanently athyroid by excision of the ectopic gland [88].

Carcinoma from the thyroglossal duct (Hürthle cell adenomas and papillary carcinomas) have been reported in less than 1% of TDC [6, 118]. Yoo et al. reviewed 115 cases of papillary carcinoma arising in TDC published in the literature [128]. These tumours are typically intracystic, and usually the thyroid gland proper is uninvolved. However, multifocal papillary carcinomas have been documented in TDC as well as in the gland [6, 118]. Most researchers agree that a) total thyroidectomy is not routinely indicated as long as there are no palpable abnormalities in the gland and no significant scintiscan findings, and b) the Sistrunk operation probably offers a reasonable chance of cure [6, 63, 118, 128].

9.3.4 Cervical Thymic Cyst

Faulty development of the third and fourth pharyngeal pouches results in abnormalities of the thymus and parathyroid glands.

Cervical thymic cysts (CTC) are morphologically identical to their mediastinal counterparts. They are found in the anterior triangle of the neck along the normal path of descent of the thymus, with or without parathyroid glands, and they have a fibrous band or a solid thymic cord connection to the pharynx or mediastinum.

The thymus develops as paired structures from the third branchial pouch in the 6th week of gestation. The endodermal primordium of the thymus has a ductal or luminal connection to the pouch that is known as the thymopharyngeal duct. Ventromedial and caudal growth of the respective anlage results in separation of the thymus from the pharynx. The fragmented rem-

nants of the solid thymopharyngeal duct are thought to be the progenitors of accessory parathyroid and thymic tissue in the neck [62]. The inferior parathyroid glands also originate from the third pouch, and their descent with the thymus explains their localisation relative to the superior parathyroids, which arise from the fourth branchial pouch. By the end of the 8th week, the lower poles of the thymic anlage approach each other, but do not fuse, at the level of the aortic arch. Failures to involute or descend of any of the thymic anlage are responsible for a variety of abnormalities, such as thymic cysts. The reader is referred to the excellent paper by Zarbo et al. for the classification of these developmental abnormalities of the thymus [130].

Cervical thymic cysts are uncommon; approximately 120 cases in children were reported through 2001 [51, 89]. Males are affected more commonly than females. According to Guba et al., 70% of CTC are on the left side of the neck, 23% on the right and the remainder in the midline [47]. They can be found anywhere from the angle of the mandible to the sternum, paralleling the sternocleidomastoid muscle and normal descent of the thymus. Sixty-seven percent occur in the first decade of life. The remainder occur in the second and third decades [51].

The cysts range between 2 and 15 cm and may be either unilocular or multilocular. The epithelial lining may be cuboidal, columnar, or stratified squamous. In some areas, the epithelium may be replaced by fibrous or granulation tissue containing cholesterol clefts and multinucleated giant cells. To qualify a cyst as a CTC, thymic tissue must be found within the cyst wall (Fig. 9.7); detection of this tissue may require numerous sections.

Cervical thymic cysts rarely have malignant potential. Recently, Moran et al. reported for the first time carcinomas arising in CTC [76]. This contrasts with mediastinal thymic cysts, in which malignancies are often seen. CTC also have not demonstrated pseudoepitheliomatous hyperplastic changes, as in some mediastinal cysts.

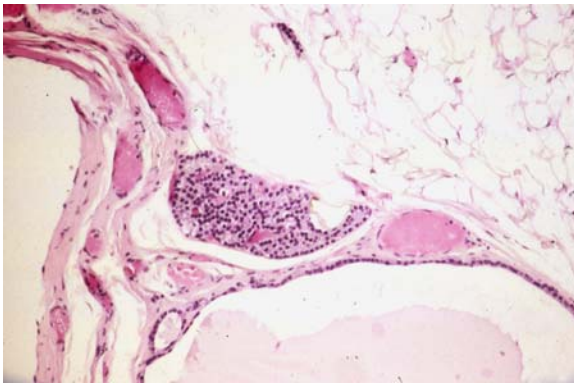


Fig. 9.8. Cervical parathyroid cyst lined with cuboidal epithelium. Parathyroid tissue is present in the wall

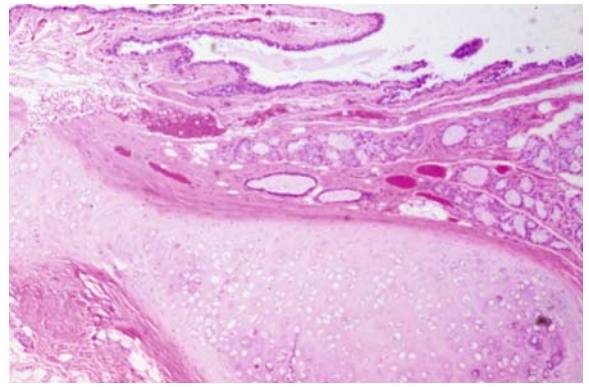


Fig. 9.9. Cervical bronchogenic cyst. Respiratory epithelium lines the cyst wall

The differential diagnosis includes the other developmental cysts of the neck, as well as rare cystic presentations of Hodgkin's disease, thymoma, and germinoma. These three neoplasms are more likely, however, to present in the anterior mediastinum. The reader is referred to the excellent paper by May for clinical features useful in differentiating these conditions [70]. Complete surgical excision is the treatment of choice.

9.3.5 Cervical Parathyroid Cyst

Cysts of the parathyroid glands, like thymic cysts, have several characteristic morphologic features, including a persistent hollow tract with the third or fourth branchial pouch. It is estimated that 5% of neck cysts or fewer are parathyroid in origin. Few parathyroid cysts have been reported in childhood, implying that most are acquired, including cystic parathyroid adenoma.

There appear to be two distinct types of parathyroid cysts: non-functioning and functioning. The former make up the majority of these cysts and are about two to three times more common in women than in men. The mean age of patients with a non-functioning cyst is 43.3 years. Functioning cysts account for 11.5 to 30% of these cysts [48]. They are more common in men by a ratio of 1.6:1 and tend to occur in sites other than the inferior parathyroid glands, from the angle of the mandible to the mediastinum [120]. The mean age of patients with functioning cysts is 51.9 years.

About 95% of these cysts occur below the inferior thyroid border, and 65% are associated with the inferior parathyroid glands. Cysts have been identified from the angle of the mandible to the mediastinum, however, and they can occur in the thyroid lobe or posteriorly [36].

Fine-needle aspiration is the principal diagnostic tool. Aspiration of clear fluid with an elevated parathy-

roid hormone level is a definite indication of a parathyroid cyst. The C-terminal/midmolecular zone of the parathyroid hormone should be assayed, because the N-terminal-specific assay is frequently associated with false-negative results [81].

Histologic studies show that a parathyroid cyst's wall is usually formed by a solitary layer of compressed cuboidal or low columnar epithelium, with either chief or oxyphilic cells present in the fibrous capsule (Fig. 9.8). Some cysts may not have any identifiable parathyroid tissue, but even in these cases a diagnosis can be established by testing the cystic fluid. Immunostaining for parathyroid hormone could be of help.

Aspiration may be curative, but persistence or recurrence of the cyst is a sign that surgical removal is in order. Functional cysts are associated with a high risk of other parathyroid gland abnormalities such as hyperplasia or adenoma [92].

9.3.6 Cervical Bronchogenic Cyst

Cervical bronchogenic cysts are uncommon congenital lesions found almost invariably in the skin or subcutaneous tissue in the vicinity of the suprasternal notch or manubrium sterni, rarely in the anterior neck or shoulder.

Bronchial cysts are derived from small buds of diverticula that separate from the foregut during formation of the tracheobronchial tree. When they occur outside the thoracic cavity, the cyst presumably arises from erratic migration of sequestered primordial cells.

They are usually discovered at or soon after birth and appear as asymptomatic nodules that slowly increase in size or as draining sinuses exuding a mucoid material. They are more common in males, in some series by a margin of 3:1 [31]. The cysts range from 0.3 to 6 cm in size. They are lined by ciliated, pseudostratified columnar epithelium (Fig. 9.9). If the cyst is infect-

ed squamous epithelium is found. The cyst wall contains smooth muscle, elastic fibres and seromucous glands. In the 30 cases studied by Fraga et al., smooth muscle was identified in 24 and seromucous glands in 16. In contrast to their intrathoracic counterparts, only 2 contained cartilage [39].

A bronchogenic cyst can be distinguished from a teratoma by a complete absence of tissues other than those that can be explained on the basis of a malformation. The lack of ciliated epithelium distinguishes a lateral cervical cyst containing gastric mucosa from a cervical bronchogenic cyst. TDC can be differentiated from a bronchogenic cyst by finding thyroid follicles; furthermore, TDC do not contain smooth muscle or cartilage.

Complete surgical excision of a bronchogenic cyst along with its sinus tract is curative. Malignancies have not been described in cervical bronchogenic cysts.

9.3.7 Dermoid Cyst

ICD-O:9084/0

The term dermoid cyst should be reserved for a cystic neoplasm that originates from the ectoderm and mesoderm; endoderm is never found in these cysts [101]. The head and neck area is a common site of occurrence for dermoid cysts, accounting for 34% of cases. These cysts are located in the skin and subcutaneous tissues [113].

The position of these dermoid cysts at the midline and along the lines of embryonic fusion of the facial processes is consistent with their origin by inclusions of ectodermal tissue along lines of closure at junctions of bone, soft tissue, and embryonic membranes [87].

Dermoid cysts in the neck account for 22% of midline or near-midline neck lesions [101]. They have been described in the upper neck, near the thyroid cartilage, and as low as the suprasternal notch. They may occur in people of almost any age. More than 50% are detected by the time a person is 6 years old, and approximately one-third are present at birth [87, 101, 113]. The distribution between the sexes is approximately equal.

Dermoid cysts range in size from a few millimetres to 12 cm in diameter. On microscopic examination they are lined by stratified squamous epithelium supported by a fibrous connective tissue wall. Ectodermal derivatives may be seen, including dermal adnexa such as hair follicles, sebaceous glands, and sweat glands.

9.3.8 Unclassified Cervical Cyst

Some cysts may be difficult to classify because of an apparent discrepancy between the anatomic site of presentation and the histologic features, indeterminate microscopic findings, loss of an intact epithelial lining, or

mixed histologic appearance. When a final determination regarding the type of cyst is not possible, the term “congenital or developmental cyst, indeterminate type” should be used [121].

9.3.9 Non-Developmental Cysts

Most of the non-developmental cysts in the head and neck region occur in the jaw bones, oral cavity or parenchyma organs, such as the thyroid gland, salivary glands and parathyroid glands. Mucoceles, ranulas, and laryngoceles are considered non-developmental cysts that may occur in the neck. Ranulas are actually pseudocysts: they lack an epithelial lining. Because they mimic true cysts histopathologically as well as clinically or radiographically, however, it is reasonable and convenient to include them in a general discussion of cystic lesions. Mucoceles are discussed in Chap. 5.

9.3.9.1 Ranula

A ranula is a special type of mucous retention cyst most commonly caused by partial obstruction of the excretory duct of the sublingual gland. Rarely, it may originate from the cervical sinus or from branchial cleft remnants. The classic or simple ranula is a true cyst lined with cuboidal, columnar or squamous epithelium and filled with mucoid material similar to that found in mucoceles. It produces a mass in the floor of the mouth to one side of the midline. Dissection of the mucus into the fascial planes of the neck results in a pseudocyst called plunging ranula. Simple ranulas are distinguished from mucoceles by their location and by the presence of an epithelial lining [11].

The plunging ranula may mimic other cystic or glandular swellings, such as dermoid and epidermoid cysts, TDC or cystic hygroma. Quick and Lowell [90] have pointed out that no specific clinical diagnostic tests are available to distinguish these lesions. Consequently, a definitive diagnosis is dependent on postoperative histopathologic evaluation of the surgical specimen.

The management of these lesions requires removal of the sublingual gland and excision of the ranula. The recurrence rate after this procedure is 0%. Excision of only the ranula was followed by a 25% recurrence rate, whereas marsupialisation results in a 36% recurrence rate [129].

9.3.9.2 Laryngocele

Laryngocele is a dilatation of Morgagni's ventricle or its appendages, which is filled with air or fluid [16, 37, 49]. For more details on this lesion, see Chap. 7.

9.4 Cystic Neoplasms

9.4.1 Cystic Hygroma and Lymphangioma

Cystic hygroma and lymphangioma represent the two ends of the spectrum of the histopathologic classification of lymphatic lesions [124]. Whether these are true neoplasms or represent malformations or hamartomas is still debated, but this issue is of no clinical consequence. These lymphatic lesions may be divided into three morphologic types: capillary (lymphangioma circumscriptum, *ICD-O:9171/0*), cavernous (lymphangioma cavernosum, *ICD-O:9172/0*), and cystic (cystic hygroma, *ICD-O:9173/0*) [34].

Lymphangiomas are relatively rare. Almost all lymphangiomas appear during the first 2 years of life, most commonly in the oral cavity, parotid gland, neck or axilla. Lymphangiomas often lie in the lateral cervical region beneath the platysma, less frequently in the anterior cervical region, and may extend into the mediastinum.

Cervical cystic hygroma (hygroma colli cysticum) is a cystic lymphangioma of the neck. It can be associated with foetal hydrops and Turner's syndrome [27]. This lesion consists microscopically of lymphatic channels of variable size and shape lined with typical endothelial cells. Focal infiltrates of lymphocytes in the stroma are common.

The main differential diagnosis of lymphangiomas of the head and neck is cavernous haemangioma. Lymphangiomas contain proteinaceous fluid and thin valves, and the surrounding tissue is usually infiltrated by lymphocytes, whereas cavernous haemangiomas are filled with red blood cells and lack valve structures.

Treatment of lymphangioma consists of surgery; staged procedures may be required for large lesions. Recurrence rates range from 15 to 80% [38].

9.4.2 Haemangioma

Haemangiomas are a heterogeneous group of vascular lesions commonly located in the head and neck. Most haemangiomas in this region are superficial; however, they may arise within skeletal muscle and involve parenchymal tissue such as salivary glands and the thyroid gland. Haemangiomas are classified by morphology into capillary, cavernous, arteriovenous, venous and epithelioid types [78]. Of these types, cavernous is the one that most often simulates a cyst. The other types more often manifest themselves as solid lesions.

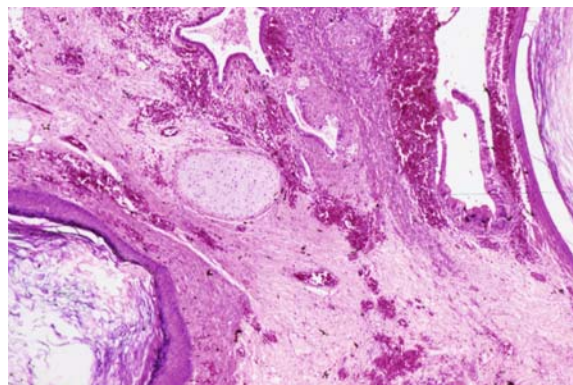


Fig. 9.10. Mature teratoma. Cysts lined with squamous and respiratory epithelium. Cartilage is present

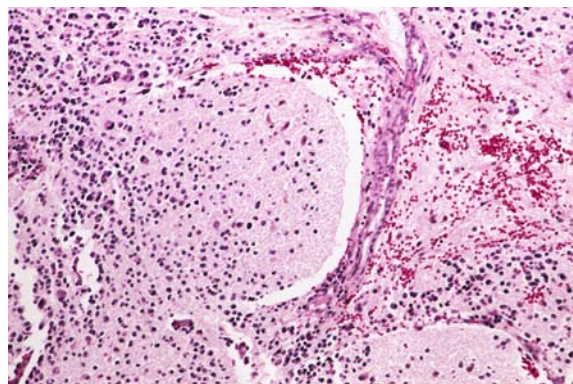


Fig. 9.11. Immature teratoma composed of primitive neuroectodermal tissue

9.4.3 Teratoma

ICD-O:9080/1

Teratomas are neoplasms composed of elements from more than one of the three germ layers (ectoderm, endoderm and mesoderm). Cervical teratomas represent only about 3% of all teratomas [9]. In the head and neck region, lesions are also found in the central nervous system, orbit, temporal fossa, oropharynx, oral cavity, nasopharynx, nasal cavity, palate and tonsil [60].

Teratomas arising in the cervical region are rare. Although they were previously divided into those arising from the thyroid gland and those arising elsewhere, this distinction has not proved to be clinically useful. The most significant clinical marker divides the tumours presenting in infancy or early childhood from those presenting after the first decade of life. The former group exhibits primarily benign clinical behaviour. However, such lesions are associated with a high mortality rate at the time of birth, generally because the airway and pulmonary function are compromised. The latter group is

composed of tumours that are usually smaller and more likely to be malignant [9, 33, 44, 50].

Various systems of classification for teratomas have been proposed. The majority of these were considered by Gonzalez-Crussi, who presented a tentative new classification system for all teratomas that does not rely on the primary site of occurrence of the tumour [44].

On gross examination, these tumours are usually cystic, but they can be solid or multiloculated. They are commonly encapsulated, lobulated masses that measure up to 15 cm in their greatest dimension [44]. On microscopic examination, the cervical teratomas are similar to those found in other anatomical regions. They may contain skin, hair, fatty tissue, central nervous tissue, cartilage, bone and components of the respiratory or digestive tract (Fig. 9.10). Areas of more immature or embryonal tissue may be present (Fig. 9.11).

It is exceedingly important to adequately sample all potentially teratomatous tumours. Specifically, solid areas with necrosis or haemorrhage should be carefully examined. It is not unusual to find, in teratomas throughout the body, small foci of malignant germ cell tumours, especially endodermal sinus tumour or choriocarcinoma. The presence of either of these two tissue types adversely affects patient prognosis. It is also important for the pathologist to recognise that the more immature foetal tissues have malignant potential [10, 33, 44, 50]. Patients with these tumours require especially close clinical follow-up.

Cervical teratomas in the neonate are almost always benign, whereas the few reported cases of cervical teratoma arising in adults were malignant [44]. To the best of our knowledge, only seven cases of congenital cervical teratoma with metastasis have been reported [50]. Resection seems to offer the best control in cases of aggressive biologic behaviour.

Most authors strongly favour the operative management of teratomas [33, 44, 50]. When malignant components are found in a teratoma, the patient may need chemotherapy and/or radiotherapy in addition to surgery.

9.4.4 Cervical Salivary Gland Cystic Neoplasms

Heterotopic normal salivary glands and salivary gland neoplasms arising in cervical lymph nodes may simulate cervical cysts [107, 131]. These are uncommon neoplasms, and the pathologist may confuse them with metastatic salivary gland tumours [23, 131]. Ectopic islands of salivary gland tissue within lymph nodes have been implicated in the pathogenesis of lymphoepithelial cysts and some neoplastic lesions by several authors [22, 108].

This type of neoplasm presents as a painless mass, often cystic, located in the periparotid region, the upper neck, or the anterior cervical triangle. Occasional-

ly, however, these tumours have been described in the lower neck [108, 131]. In the series reported by Zatchuz et al., the age of the patients ranged from 10 to 81 years, with a mean of 45 years. Females were affected more commonly than males, with a ratio of 3:1 [131].

The tumours that more often arise in ectopic salivary gland tissue in the lymph nodes and simulate cysts are Warthin's tumour and sebaceous lymphadenoma. Other rare types of salivary gland tumours that may resemble cervical cysts, are dermal analogue tumours, mucoepidermoid carcinomas and acinic cell carcinomas [67, 103]. The pathology of these lesions is discussed in Chap. 5.

Surgical excision is the treatment of choice. In sialocarcinomas, excision of the adjacent salivary gland may appear to be the appropriate treatment to define the site of the primary tumour, because malignant salivary tumours located within lymph nodes suggest metastatic disease.

9.4.5 Miscellaneous Lesions

Other tumours that may appear as cervical cysts are cystic neurogenic neoplasms and cervical thymomas. In the neck, the most common locations for neuromas with cystic degeneration are along the course of the vagus nerve or the cervical sympathetic chain [4]. Cervical thymomas are classified as being one of four types:

1. Ectopic hamartomatous thymoma,
2. Cervical thymoma,
3. Spindle epithelial tumour with thymus-like differentiation (SETTLE),
4. Carcinoma showing thymus-like differentiation (CASTLE).

Of these, the first is benign and the second can be locally aggressive. The third and fourth types are malignant [18].

Infectious processes often simulate cervical cysts. Such infections can be bacterial, fungal, parasitic, or viral [46, 104, 114]. Amyloidosis and carotid artery aneurysms have been reported to mimic cervical cystic tumours [24, 35].

9.5 Paraganglioma

ICD-O:8680/1

Paraganglioma, often referred to as chemodectoma, is a tumour derived from paraganglia, structures of neuroectodermal crest derivation that are found throughout the body. Paragangliomas are intimately associated with vascular and neural structures in the head and neck region and are most commonly classified according to their location: jugulotympanic, vagal, carotid body, and others, including laryngeal, nasal and ocular [30, 61]. In

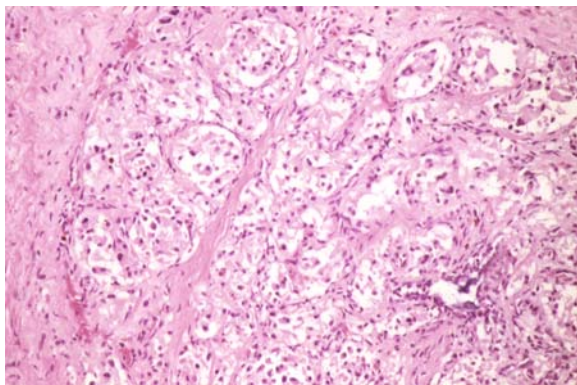


Fig. 9.12. Zellballen pattern in a carotid body tumour

this section, only neoplasms of the carotid body and intravagal paraganglia are discussed.

Carotid body paragangliomas are the most common tumours of the head and neck paraganglia, making up 60–70% of the tumours of this type [30, 61, 100]. Lack et al. found 69 paragangliomas of the head and neck in more than 600,000 operations (0.12%), and only 1 in 13,400 autopsies at Memorial Hospital in New York city [61].

The tumour, typically located in the carotid bifurcation, is typically found in individuals of either sex in the third to the eighth decades of life. It often presents as a painless, slowly enlarging mass. It is the only neoplasm that arises in that particular location. Carotid angiography is a valuable diagnostic aid. The risk of developing this tumour is higher in persons living at high altitudes than those living at sea level [100]. Carotid body paragangliomas with endocrine activity are rare. The tumour seldom undergoes malignant transformation; histologic criteria are of little prognostic value. The incidence of metastasis is estimated to be less than 10% [14, 61].

The vagal region is the third most frequent site of involvement after the carotid body and jugulotympanic region. Unlike the circumscribed carotid body, the vagal paraganglioma represents collections of microscopic nests located along the vagus nerve distal to the ganglion nodosum. Because of the variability in location of the normal vagal paraganglia, paragangliomas arising from these structures also vary in location. At the time of diagnosis, patients are usually in the fourth to fifth decade of life, and there is a female predominance [14, 30].

Patients generally report a slowly growing neck mass, and, because of the intimate relationship with the vagus nerve, cranial nerve palsies may also be present [14, 30]. Vagal paragangliomas displace the carotid vessels anteriorly, are grossly round or fusiform, and abut the base of the skull. Multiple, also bilateral, and familial occurrences of paragangliomas have been documented.

Paragangliomas have a tan, soft cut surface. Paragangliomas from all regions of the head and neck are

histologically similar. They are well circumscribed and composed of chief cells arranged in nests known as Zellballen (Fig. 9.12). The tumour cells have granular cytoplasm and round nuclei with prominent nucleoli. Nuclear pleomorphism may be present, but mitosis is rare, and necrosis is usually present only if the patient underwent preoperative embolisation or if the nests of cells are very large. Compressed sustentacular cells and a rich capillary network surround each nest. A reticulin stain highlights the Zellballen arrangement of the cells. Malignant varieties are difficult to distinguish on histologic examination, but generally they have a higher mitotic rate and more necrosis than benign tumours. Vascular invasion may be present in both benign and malignant paragangliomas.

The chief cells are positive for neuroendocrine markers such as chromogranin and synaptophysin. They are usually negative for cytokeratin, but an occasional case has been reported to be positive [55]. The sustentacular cells are positive for S-100 protein [55].

Electron microscopy studies show the tumour cells to contain neurosecretory granules. The cells have cytoplasmic processes that surround neighbouring cells, and the cytoplasm contains abundant large mitochondria and inconspicuous Golgi apparatus, smooth and rough endoplasmic reticulum.

Although histologic findings are generally quite distinctive, the differential diagnosis of paragangliomas of the head and neck may include endocrine neoplasms arising from the thyroid (medullary carcinoma) or parathyroid glands and other neuroendocrine carcinomas. Less commonly, alveolar soft part sarcoma, melanoma, granular cell tumour and metastatic renal cell carcinoma are included in the differential diagnosis [14, 30, 55, 61].

Surgery is the treatment of choice for paragangliomas. If the neoplasm is completely excised, recurrence is relatively rare; recurrence rates are 10% for carotid body tumours and 5–25% for vagal paragangliomas [14, 30, 55, 61]. Radiotherapy may be useful as a palliative method for those tumours that cannot be controlled by surgical means. Local infiltration of vagal body tumours and extension into the cranial cavity represent significant problems in disease control. The rate of metastasis in intravagal tumours is estimated at 16%, but most of these are to regional lymph nodes [14, 30].

9.6 Unknown Primary and Secondary Tumours

9.6.1 Definition

In head and neck oncology, the term “unknown primary tumour” means a primary neoplasm that has not been found in a patient with neck metastasis, even after a

Table 9.2. Location of lymph node metastasis and predominant sites of their primary tumours (extracted from [75, 99, 125]. *ENT* ear nose throat, *GI* gastrointestinal, *GU* genitourinary)

Lymph node region affected by metastasis	Predominant sites(s) of primary tumour
Sublevel IA (submental)	Anterior floor of mouth; anterior oral tongue, anterior mandibular ridge lower lip
Sublevel IB (submandibular)	Oral cavity, anterior nasal cavity, midface, submandibular gland
Sublevel IIA (upper jugular)	Waldeyer's ring, oral cavity, nasal cavity, oropharynx, supraglottis, floor of mouth, pyriform sinus
Sublevel IIB (upper jugular)	Anterior tongue, nasopharynx, tonsil
Level III (middle jugular)	Hypopharynx, base of tongue posterior pharyngeal wall, supraglottic larynx
Level IV (lower jugular)	Hypopharynx, thyroid
Sublevels VA, VB (posterior cervical) Supraclavicular	Nasopharynx, thyroid, oropharynx Lungs (40%), thyroid (22%) GI tract (12%), GU tract (8%) all ENT regions (20%)

thorough work-up. The neck metastasis may represent regional or distant primary disease.

shows the probable primary sites by region of metastasis [75, 109, 125].

9.6.2 Clinical Features

An enlarged cervical lymph node is frequently the first clinical manifestation of a neoplastic process in the head and neck. Cervical lymph node metastasis is the presenting symptom in 25% of patients with cancer of the oral cavity or pharynx, in 47% of patients with nasopharyngeal carcinoma, and in 23% of patients with thyroid carcinoma. In some instances, however, despite a thorough search, a primary tumour cannot be found [45, 64, 72, 79, 93, 123].

Patients with a high probability of a metastatic tumour in the cervical lymph nodes are men (male: female ratio 4:1) older than 40 years, who smoke and drink alcohol heavily. They usually present with a painless node larger than 2 cm along the jugular chain or the supraclavicular fossa. Various groups of lymph nodes can be affected by metastatic neoplasms, but the most frequently involved are the upper jugular (71%), the midjugular (22%), the supraclavicular (18%), and the posterior cervical nodes (12%). Approximately 14% of patients with such disease have more than one lymph node group affected by metastases and 10% have bilateral lymph node metastases [45, 123]. The lymphatic drainage of the head and neck region is highly predictable, and the location of the adenopathy may provide a clue to the location of the primary lesion. Table 9.2

9.6.3 Search for the Primary Tumour

If the search is conducted systematically, the primary cancer can be discovered in 75–90% of patients presenting with cervical adenopathy. Evaluation protocols have been outlined by several authors [66, 72]. With advances in upper aerodigestive tract examination that use flexible fibre optic endoscopes and rigid telescopes, the failure of radiographic tests to determine the location of an unknown primary has become even more apparent. This may change in the future, however, with the application of advanced radiologic techniques that allow functional assessment of tissues. Single-photon emission computed tomography (SPECT) using 2-(18-F) fluoro-2-deoxy-D-glucose was able to detect 9 out of 11 histologically proven occult primary neoplasms of the upper aerodigestive tract [77].

The success rates of the ultimate detection of occult primaries (by various authors) vary between 10 and 75% [64, 72, 79]. As might be expected, occult primary tumours are significantly less likely to be detected in patients treated with radiation [98]. Nearly 50% of primary carcinomas originally considered occult that are eventually found in patients after treatment of the cervical lymph node are located in the region of Waldeyer's ring [73, 116]. Of originally un-

Table 9.3. Frequency of histologic type of metastases from unknown primary tumours (Extracted from [64, 66, 75])

Cervical	Supraclavicular
Squamous cell carcinoma	Adenocarcinoma
Undifferentiated carcinoma	Squamous cell carcinoma
Melanoma	Undifferentiated carcinoma
Thyroid carcinoma	Thyroid carcinoma
Adenocarcinoma	Prostate carcinoma
Salivary gland carcinoma	Sarcoma

known primary tumours found below the clavicle, the largest number are in the lungs, followed by the gastrointestinal tract.

In cases in which the primary tumour is not found, the most likely explanations are that either the primary lesion is so small that it is not visible or it has regressed spontaneously. The latter consideration is speculative, since spontaneous regression cannot be proved. Although the origin of a carcinoma in the wall of a branchiogenic cyst is possible, this remains entirely hypothetical. Few observers are willing to agree that primary squamous cell carcinoma (SCC) or other types of carcinoma arise in branchiogenic cysts. The most attractive hypothesis, therefore, is that the primary neoplasm is too small to be detected.

9.6.4 Common Location of the Primary Tumour

The gross appearance of a metastasis is important only when it is present in a cystic node, because in cystic metastases, the primary tumour is most frequently located in the palatine tonsils or in Waldeyer's ring [79, 96, 116]. In other situations, the metastatic deposits may adopt a multitude of appearances, from the solid white-grey to yellow haemorrhagic deposits of renal cell carcinoma to the deeply pigmented focus of metastatic melanoma.

9.6.5 Histologic Type of Metastases and Immunohistochemical Features

Nearly any histologic type of malignancy can present as a metastasis to the cervical lymph nodes, but metastatic SCC is by far the most common tumour to do so. In cases of metastases of an unknown primary tumour to the cervical lymph nodes, 80–85% are of this histologic type (Table 9.3). Undifferentiated carcinomas, adenocarcinomas, thyroid carcinomas, melanoma, rhabdomyosarcomas and sialocarcinomas are the other neoplasms that often metastasise to cervical lymph nodes. Adenocarcinomas, undifferentiated carcinomas and thyroid carci-

nomas more commonly metastasise to the supraclavicular and scalene nodes. Most of the adenocarcinomas in the upper jugular region are metastases from lesions of the sinonasal tract or salivary glands.

The origin of a keratinising SCC, regardless of differentiation, cannot be suggested by its morphology alone. The location of the node can, however, be a clue about the location of the primary neoplasm (Table 9.2). The cyto-keratin (CK) pattern may be of some help in determining the origin of the metastasis. SCC of the upper aerodigestive tract are positive for CK 5/6, 10, 13,14,17 and 19, whereas SCC of the lung are positive for CK 5/6, 12 and 14 in 100% of cases and CK 17, 8/18 and 19 in 80% of cases. Fewer than 4% of cases are positive for CK 7 and 20 [21]. Furthermore, thyroid transcription factor 1 (TTF-1) is positive in 10 to 37% of pulmonary SCC [83].

A cystic neoplasm composed of poorly differentiated non-keratinising carcinoma recapitulating tonsillar crypt epithelium (Fig. 9.13) most likely originates in the lingual or faucial tonsil [73, 96, 116]. Metastases from the tonsil are often unicystic, whereas those from the tongue are more often multicystic [96]. Since the carcinomas are deep in the tonsils, tonsillectomy rather than biopsy is needed to demonstrate the primary neoplasm [97]. A subset of these crypt carcinomas are often positive for CK 7, especially those with basaloid features (Fig. 9.14) [94]. These two types of metastatic cystic carcinoma are often mistaken for a branchial cleft cyst or branchiogenic carcinomas by the unwary pathologist [73, 96, 116].

9.6.6 Differential Diagnosis

Cystic metastatic SCC should be distinguished from benign lesions lined with benign squamous epithelium, such as branchial cleft cysts, AIDS-related cystic lymphoid hyperplasia, benign lymphoepithelial cysts, thymic cysts and cystic cervical thymomas. In all these lesions, the bland appearance of the epithelium rules out metastatic SCC.

The most common location of metastatic adenocarcinomas in the neck is in the lower regions, and the primary neoplasms are usually located in the thyroid, lung,

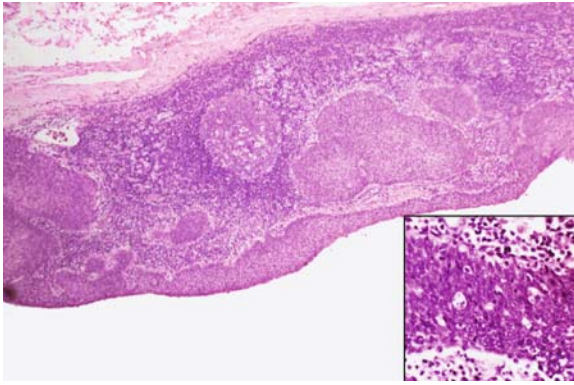


Fig. 9.13. Metastatic cystic tonsillar crypt carcinoma, resembling a branchial cleft cyst. *Inset:* high power view of non-keratinising carcinoma, human papilloma virus type 16 positive

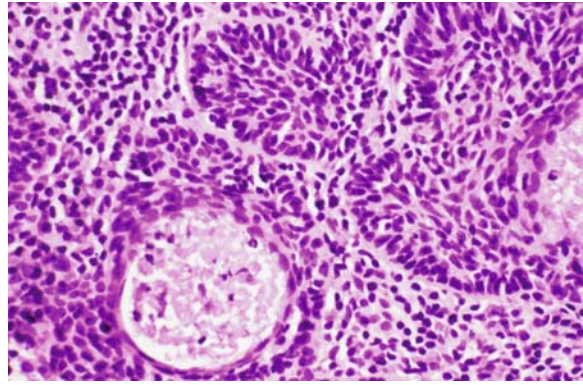


Fig. 9.14. Cyokeratin 7 positive metastatic tonsillar basaloid carcinoma in a cervical lymph node

Table 9.4. Immunohistochemical approach to metastasis of unknown primary tumour. (Extracted from references [19, 21, 29, 40, 56, 66, 83, 84, 94])

Cytokeratin-positive	
Keratinizing squamous cell carcinoma	CKs 5/6, 7 and 20
Non-keratinizing squamous carcinoma	CKs 5/6, 7 and 20 EBV, HPV 16
Adenocarcinoma	CKs 7, 20 TTF-1 Thyroglobulin Females: GCDFP-15, WT-1, CA 125 Males: PSA .Young males: AFP, HCG
Undifferentiated carcinoma	CKs 7 and 20 Synaptophysin Chromogranin EBV
Cytokeratin-negative	
Various tumours	S-100 protein HMB 45 Melan A Desmin Lymphoma markers

gastrointestinal tract, or prostate. In the upper and middle neck, on the other hand, the primary lesions are located in the sinonasal tract and salivary glands. Only in cases of thyroid carcinoma or prostate carcinoma is the origin of an adenocarcinoma apparent from the morphology of the nodal metastases. Metastatic adenocarcinomas with enteric morphology can arise in the sinonasal region; they are CK 20-positive, like their counterparts of colonic origin [21]. Thyroglobulin, calcitonin, and TTF-1 are useful markers to probe the thyroid origin of a neoplasm of unknown origin [83]. Adenocarcinoma of the prostate may present as metastasis in the left side of the neck, especially in the supraclavicular nodes. The diagnosis can be confirmed by using the prostate-specific antigen (PSA) test (Table 9.4).

The presence of oestrogen receptors and gross cystic disease fluid protein 15 (GCDFP-15) would suggest a breast origin for adenocarcinoma, but these markers are non-specific for the breast. Lung adenocarcinomas are positive for TTF-1 and B 72.3 (Table. 9.4) [83].

Benign glandular inclusions in cervical lymph nodes should not be mistaken for metastatic adenocarcinomas; heterotopic glands of salivary tissue are common in the paraparotid lymph nodes and less common in the upper cervical nodes. Acinic cell carcinomas, mucoepidermoid carcinomas, Warthin's tumour and pleomorphic adenomas have been described in cervical lymph nodes, and they should not be confused with metastatic adenocarcinomas [23, 67, 131].

Metastatic spindle cell neoplasms most likely represent sarcomatoid carcinomas, melanomas and sarcomas, especially rhabdomyosarcomas. Pankeratin, MART-1, HMB-45, S-100 protein, desmin, smooth muscle actin and myogenin are some immunostains that help to distinguish these neoplasms [29]. Primary spindle cell lesions arising in lymph nodes, such as Kaposi's sarcoma, presumed tumours of the reticulum cell lineage and benign intranodal myofibroblastomas, must be distinguished from metastatic spindle neoplasms [2, 56].

Undifferentiated malignant neoplasms in cervical lymph nodes need to be investigated with immunohistochemical studies. CK-positive malignancies with the morphology of the nasopharyngeal type of carcinomas (NPC) are usually located in the posterior neck, whereas metastasis from undifferentiated sinonasal carcinomas (SNUC) are present in the upper and mid-cervical regions. If the metastases are located in the lower neck, the lung is the most likely source. If the carcinomas in addition exhibited neuroendocrine differentiation, Merkel cell carcinoma or small cell neuroendocrine carcinoma, from either the lung or the larynx, is the best diagnosis. Merkel cell carcinomas are CK 20-positive [19] and pulmonary small cell carcinomas are CK 20-negative and TTF-1 positive in 83–100% of cases [83]. Benign nevus cells have been found in the capsules of submandibular lymph nodes. This rare finding should not lead to an erroneous diagnosis of malignancy [54].

Paccioni et al. evaluated 25 cases of occult metastasis to cervical lymph nodes for the presence of Epstein-Barr virus (EBV) by in situ hybridisation following fine-needle aspiration biopsies of the neck mass and correlated the findings with the histologic types of the surgical specimens (after locating the primary site of origin). These authors reported that EBV was expressed in 7 metastases, ultimately proving their origin from the nasopharynx, while the remaining 18 cases (not of Waldeyer's ring origin) were negative for EBV [84]. The authors indicated that detection of EBV in cervical metastases may assist in the localisation of the occult primary to Waldeyer's ring. SNUC do not express EBV [84].

The pattern of CK expression is significantly different in SNUC and NPC, which could be of diagnostic aid. Franchi et al. demonstrated that SNUC express CK 8 in 100% of cases and CK 19 and CK 7 in 50%, and are negative for CK 5/6, while NPC express CK 5/6 and CK 13 in 90% of cases and are negative for CK 7 [40].

Metastases from melanoma, rhabdomyosarcoma, and rarely from olfactory neuroblastoma should be considered with the CK-negative undifferentiated neoplasms and proper immunohistochemical markers investigated (Fig. 9.15). In CK-negative tumours, the possibility of malignant lymphoma should be considered and CD 20, CD 3 and antibodies for leukocyte common antigen should be measured [29].

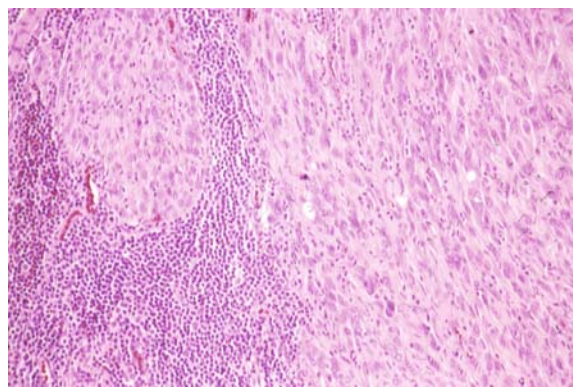


Fig. 9.15. Metastatic spindle cell melanoma in a cervical lymph node

9.6.7 Treatment and Results

Factors that affect survival in patients with metastasis from an unknown primary tumour are clinical stage of the neck, extranodal extension of metastasis and the presence of recurrent or residual disease after treatment. Surgery combined with irradiation has resulted in better local control of the disease than either therapy alone [53]. The 5-year survival results in series of patients with SCC metastatic to the neck from an unknown primary origin range from 0 to 54% [45, 64, 72, 75]. In the last series from the University of Texas M.D. Anderson Cancer Center, the 5-year actuarial survival rate was 55% [123].

9.7 Neck Dissection

9.7.1 Classification of Neck Dissections

The American Academy of Otolaryngology-Head and Neck Surgery and the American Society of Head and Neck Surgery classified neck dissection into four categories: radical, modified radical, extended and selective [99].

Neck dissection is classified primarily by the cervical lymph node groups that are removed, and secondarily on the anatomic structures that may be preserved, such as the spinal accessory nerve, the sternocleidomastoid muscle, and the internal jugular vein [71, 99].

The cervical lymph node groups are referred to using the level system as described by the Sloan-Kettering Memorial Hospital Group (Fig. 9.1). Definition of the anatomic boundaries of the different lymph node groups is beyond the scope of this chapter and can be found in other sources [99, 110].

Table 9.5. Updated classification of neck dissection (extracted from [99]). *SCM* sternocleidomastoid, *IJV* internal jugular vein, *SAN* spinal accessory nerve

Type of dissection	Lymph node levels removed	Non-lymphatic structures resected
Radical neck dissection	I, II, III, IV, V	SCM, IJV, SAN
Modified radical neck dissection	I, II, III, IV, V	Preservation of one or more of the following: SCM, IJV, SAN
Selective neck dissection	Preservation of one or more of the following: I, II, III, IV, V. Brackets are used to denote levels or sublevels removed. (e.g. SND {I, II, III})	None
Extended neck dissection	Resection of one or more or additional lymph nodes levels routinely not removed by the radical neck dissection (e.g. parapharyngeal)	Resection of one or more non-lymphatic structures routinely not removed by the radical neck dissection (e.g. carotid artery)

Radical neck dissection consists of the removal of all five lymph node regions of one side of the neck (levels I–V). This includes removal of the sternocleidomastoid muscle, the internal jugular vein, and the spinal accessory nerve. Modified radical neck dissection refers to excision of all lymph nodes routinely removed by radical neck dissection, with preservation of one or more of the non-lymphatic structures (i.e. spinal accessory nerve, internal jugular vein, and/or sternocleidomastoid muscle).

The term extended radical neck dissection refers to a neck dissection that is extended to include either lymph node groups or non-lymphatic structures that are not routinely removed in a standard radical neck dissection.

Selective neck dissection is any type of cervical lymphadenectomy in which one or more of the lymph node groups that are removed in a radical neck dissection is preserved [13, 71, 99] (Table 9.5).

9.7.2 Gross Examination of Neck Dissection Surgical Specimens

The following procedure pertains to standard radical neck dissections and needs to be modified for the other three types. When the main anatomic landmarks such as the submandibular gland and internal jugular vein are lacking in a neck dissection specimen, the surgeon must identify and label the lymph node groups. This is

especially important in selective and extended neck dissections.

After the neck dissection specimen has been oriented as it appears in vivo, its overall dimensions are measured. The lengths of the sternocleidomastoid muscle and the internal jugular vein are measured separately. The jugular vein should be opened along its entire length. Tumour involvement, including thrombosis, should be noted, described and sampled adequately. Next, the submandibular gland, the sternocleidomastoid muscle, and the internal jugular vein should be divided, and the node-containing fat separated into the five levels:

1. Sublingual and submandibular,
2. Superior jugular,
3. Middle jugular,
4. Inferior jugular,
5. Posterior.

The presence of tumour in soft tissues, submandibular gland and muscle should be described. All lymph nodes visible and palpable are carefully dissected from connective tissue with a rim of perinodal connective tissue or fat. The number of lymph nodes (by level) should be noted; if a tumour is present, the actual size of metastases in centimetres and the presence of extracapsular extension are also noted and recorded. It is generally recognised that most masses larger than 3 cm in diameter are not single nodes but are confluent nodes or tumour in soft tissues [7]. Midline nodes, if found, are considered ipsilateral nodes. The contralateral neck dissection is treated similarly. Nodes larger than 2–3 cm

are bisected along their longest axis plane and both halves submitted. Smaller lymph nodes are submitted in toto. The tissue sections of lymph nodes submitted for processing should include a capsule of lymph node, including a rim of perinodal connective tissue or fat. If a group of matted lymph nodes is present, two or three sections through the nodes are often adequate to document the extent of the tumour. Tissue sections submitted for processing include all lymph nodes (by level), the submandibular gland, the sternocleidomastoid muscle, and the internal jugular vein. If the neck dissection is of the extended type, sections of all extra lymph node groups and non-lymphatic structures that were removed should be submitted for tissue processing.

9.7.3 Histologic Evaluation of Neck Dissection

The major aim of the histologic evaluation of the status of lymph nodes in cases of carcinoma of the head and neck is to provide information required for staging disease, planning further treatment and predicting patient outcome. The histologic evaluation also documents and confirms the pathologist's own gross evaluation of the dissected specimen. More importantly, increasingly important histologic parameters, such as number, sizes and levels of positive nodes, the presence or absence of extracapsular spread, the presence of desmoplastic reaction, the presence of gross residual tumour and the presence of tumour emboli in intervening lymphatics, among others, can be assessed by a thorough histologic evaluation. These histologic findings by themselves and in combination with other histologic parameters have been increasingly identified as important prognostic factors in disease control and survival, recurrence of neck disease and distant metastasis. The five factors that are currently indicators for adjuvant postoperative therapy can be reliably provided only by histologic evaluation; they are:

1. Extranodal spread of disease,
2. Number of lymph nodes involved,
3. Number of lymph node regions involved,
4. Size of metastases,
5. Presence of desmoplastic reaction in metastatic disease [42].

References

1. Agaton-Bonilla FC, Gay-Escola C (1996) Diagnosis and treatment of branchial cleft cysts and fistulae. A retrospective study of 183 patients. *Oral Maxillofac Surg* 25:449–445
2. Aguacil-Garcia A (1992) Intranodal myofibroblastoma in a submandibular lymph node. A case report. *Am J Clin Pathol* 97:69–72
3. Al-Dousary S (1997) Current management of thyroglossal duct remnant. *J Otolaryngol* 126:259–265
4. Al-Ghandi S, Black MJ, Lafond G (1992) Extracranial head and neck schwannomas. *J Otolaryngol* 2:86–88
5. Allard RHB (1982) The thyroglossal duct cyst. *Head Neck* 1:134–136
6. Aluffi P, Pino M, Boldorin R et al. (2003). Papillary thyroid carcinoma identified after Sistrunk procedure, report of two cases and review of the literature. *Tumori* 89:207–210
7. American Joint Committee on Cancer (1997) Cancer staging manual. Lippincott, Philadelphia
8. Ayache D, Ducroz V, Roger G et al. (1997) Midline cervical cleft. *Int Pediatr Otorhinolaryngol* 40:189–193
9. Batsakis JG, El-Naggar AK, Luna MA (1995) Teratomas of the head and neck with emphasis on malignancy. *Ann Otol Rhinol Laryngol* 104:456–500
10. Batsakis JG, El Naggar AK, Luna MA (1996) Thyroid gland ectopia. *Ann Otol Rhinol Laryngol* 105:996–1000
11. Baurmash HD (2003) Mucoceles and ranulas. *J Oral Maxillofac Surg* 61:369–378
12. Bielamowicz SA, Storper BA et al. (1994) Spaces and triangles of head and neck. *Head Neck* 164:383–388
13. Byers RM (1985) Modified neck dissection: a study of 967 cases from 1970 to 1980. *Am J Surg* 150:414–421
14. Carlsen CS, Godballe C, Krogdahl AS et al. (2003). Malignant vagal paraganglioma: report of a case treated with embolization. *Auris Nasus Larynx* 30:443–446
15. Carroll W, Zappia JL, McClatchey K (1993) Branchiogenic carcinoma. *J Otolaryngol* 22:26–28
16. Cassano L, Lombardo P, Marchese-Ragona R et al. (2000). Laryngopyocele: three new cases and review of the literature. *Eur Arch Otorhinolaryngol* 257:507–511
17. Cassarino DS, Milas M, Folpe AL (2003) Bilateral intrathyroidal lymphoepithelial cyst. *Arch Pathol Lab Med* 127:251–252
18. Chan JK, Rosai J (1991) Tumors of the neck showing thymic or related brachial pouch differentiation. A unifying concept. *Hum Pathol* 22:349–367
19. Chan JKC, Suster S, Wenig B et al. (1997) Cytokeratin 20 immunoreactivity distinguishes Merkel cell (primary cutaneous neuroendocrine) carcinomas and salivary gland small cell carcinomas from small cell carcinomas of various sites. *Am J Surg Pathol* 21:226–234
20. Choi SS, Zalzal GH (1995). Branchial anomalies a review of 52 cases. *Laryngoscope* 105:909–913
21. Chu PG, Weiss LM (2002) Keratin expression in human tissue and neoplasms. *Histopathology* 40:403–439
22. Cleary K, Batsakis JG (1990) Lymphoepithelial cyst of the parotid gland region. A new face on an old lesion. *Ann Otol Rhinol Laryngol* 99:62–64
23. Croce A, Moreti H, Bianchedi M et al. (1996) Carcinoma in ectopic Warthin's tumor: a case study and review of the literature. *Acta Otorhinolaryngol Ital* 16:543–549
24. Cunningham MJ, Rueger RG, Rothfus WE (1989) Extracranial carotid aneurysm: an unusual neck mass in a young adult. *Ann Otol Rhinol Laryngol* 98:396–399
25. Damiano A, Glickman AB, Rubin JS et al. (1996) Ectopic thyroid tissue presenting as a midline neck mass. *Int J Pediatr Otorhinolaryngol* 34:141–148
26. Davenport M (1996) Lumps and swelling of the head and neck. *BMJ* 312:368–371
27. De Serres L, Sie KCY, Richardson MA (1995) Lymphatic malformations of the head and neck. A proposal for staging. *Arch Otolaryngol Head Neck Surg* 121:577–582
28. Deane SA, Telander RL (1978) Surgery for thyroglossal duct and branchial cleft anomalies. *Am J Surg* 136:348–353
29. DeYoung BR, Wick MR (2000) Immunohistochemical evaluation of metastatic carcinoma of unknown origin: an algorithmic approach. *Semin Diagn Pathol* 17:184–193
30. Diaz Manzano JA, Medina Benegas A, Osete Alaladejo JM et al. (2003) Paraganglioma of the vagus. A case report and review of the literature. *An Otorrinolaringol Ibero Am* 30:127–136
31. Dolgin SE, Groisman GM, Shah K (1995) Subcutaneous bronchogenic cysts and sinuses. *Otolaryngol Head Neck Surg* 112:763–766

32. Edmonds JL, Girod DA, Woodroof JM et al. (1997) Third branchial anomalies. Avoiding recurrences. *Arch Otolaryngol Head Neck Surg* 123:438–441
33. Elmasalme F, Giacomantonio M, Clark KD et al. (2000) Congenital cervical teratoma in neonates, case report and review. *Eur J Pediatr Surg* 10:252–257
34. Emery PJ, Baily CM, Evans JNG (1984) Cystic hygroma of the head and neck. A review of 37 cases. *J Laryngol Otol* 98:613–619
35. Endicott JN, Cohen JJ (1979) Amyloidosis presenting as a mass in the neck. *Laryngoscope* 89:1224–1228
36. Entwistle JWC, Pierce CV, Johnson DE et al. (1994) Parathyroid cyst: report of the sixth and youngest pediatric case. *J Pediatr Surg* 29:1528–1529
37. Ettema SL, Carothers DG, Hoffman HT (2003) Laryngocele resection by combined external and endoscopic laser approach. *Ann Otol Rhinol Laryngol* 112:361–364
38. Farmand M, Kuttnerberger JJ (1996) A new therapeutic concept for the treatment of cystic hygroma. *Oral Surg Oral Med Oral Pathol Oral Radiol Endod* 81:389–395
39. Fraga S, Helwig EB, Rosen SH (1971) Bronchogenic cysts in the skin and subcutaneous tissue. *Am J Clin Pathol* 56:230–238
40. Franchi A, Meroni M, Massi D et al. (2002) Sinonasal undifferentiated carcinoma, nasopharyngeal-type undifferentiated carcinoma, and keratinizing and nonkeratinizing squamous cell carcinoma express differentiated cytokeratin patterns. *Am J Surg Pathol* 25:1597–1604
41. Frierson HF (1996) Cysts of the head and neck sampled by fine-needle aspiration. *Am J Clin Pathol* 106:559–560
42. Gillies EM, Luna MA (1998) Histologic evaluation of neck dissection specimens. *Otolaryngol Clin North Am* 31:759–771
43. Golledge L, Ellis H (1994) The etiology of lateral cervical (branchial) cysts past, present theories. *Laryngol Otol* 108:653–659
44. Gonzalez-Crussi F (1982) Extraglottal teratomas. In: Atlas of tumor pathology, 2nd edn. Fascicle 18. Armed Forces Institute of Pathology, Washington DC
45. Grau C, Johansen LV, Jakobsen J et al. (2000) Cervical lymph node metastases from unknown primary tumours. Results from a national survey by Danish Society for Head and Neck Oncology. *Radiother Oncol* 55:121–129
46. Gruber B, Rippon J, Dayal VS (1988) Phaeomycotic cyst (chromoblastomycosis) of the neck. *Arch Otorhinolaryngol Head Neck Surg* 114:1031–1033
47. Guba Am, Adam AE, Jacques DA et al. (1978) Cervical presentation of thymic cysts. *Am J Surg* 130:430–436
48. Hamy A, Masson S, Heymann MF et al. (2002) Parathyroid cyst. Report of 10 cases. *Ann Chir* 127:203–207
49. Harney M, Pat IN, Walsh R et al. (2001) Laryngoceles and squamous cell carcinoma of the larynx. *J Laryngol Otol* 115:590–592
50. Heifetz SA, Cushings B, Giller R et al. (1998) Immature teratoma in children: pathologic, considerations: a report from the combined Pediatric Oncology Group/Children's Cancer Group. *Am J Surg Pathol* 22:1115–1124
51. Hendrickson M, Azarow K, Ein S et al. (1998) Congenital thymic cysts in children mostly misdiagnosed. *J Pediatr Surg* 33:821–825
52. Hsieh YY, Hsueh S, Hsueh S et al. (2003) Pathologic analysis of congenital cervical cysts in children: 20 years experience at Chang Gung Memorial Hospital. *Chang Gung Med J* 26:107–113
53. Iganej S, Kagan R, Anderson P et al. (2002) Metastatic squamous cell carcinoma of the neck from an unknown primary: management options and patterns of relapse. *Head Neck* 24:236–246
54. Jensen JL, Corell RW (1980) Nevus cells aggregates in submandibular lymph nodes. *Oral Surg Oral Med Oral Pathol* 50:552–556
55. Johnson TL, Zarbo RJ, Looyd RV et al. (1988) Paragangliomas of head and neck immunohistochemical neuroendocrine and intermediate filaments typing. *Mod Pathol* 1:216–223
56. Jones D, Amin M, Ordones NG (2001) Reticulum cell sarcoma of lymph nodes with mixed dendritic and fibroblastic features. *Mod Pathol* 14:1059–1067
57. Kenealy JF, Torsinglieri AR, Tom LW (1990) Branchial cleft anomalies: a five year retrospective study. *Trans Pa Acad Ophthalmol Otolaryngol* 42:1022–1025
58. Khali RA, Prichep R, Minkowitz S (1984) Primary bronchogenic carcinoma. *Head Neck* 11:153–156
59. Koeller KK, Alamo L, Adair CF et al. (1999) Congenital cystic masses of the neck: radiographic-pathologic correlation. *Radiographics* 19:121–146
60. Kountakis SE, Minotti AM, Maillard A et al. (1994) Teratomas of the head and neck. *Am J Otolaryngol* 15:292–296
61. Lack E, Cubilla AZ, Woodruff JM (1979) Paragangliomas of the head and neck region: a pathologic study of tumors from 73 patients. *Hum Pathol* 10:191–218
62. Langman J (1975) Pharyngeal gut. In: Lagman J (eds) Medical embryology, 3rd edn. Williams & Wilkins, Baltimore, pp 260–281
63. LaRouere MJ, Drake AF, Baker SR et al. (1987) Evaluation and management of a carcinoma arising in a thyroglossal duct cyst. *Ann J Otolaryngol* 8:351–355
64. Lefebvre JL, Coche-Dequenat B, Ton Van J et al. (1990) Cervical lymph nodes from unknown primary tumor in 190 patients. *Am J Surg* 160:443–446
65. Liu TP, Jeng KS, Yang TL et al. (1992) Thyroglossal duct cyst. An analysis of 92 cases. *Clin Med J* 49:72–75
66. Luna MA, Pfaltz M (2000) Cysts of the neck, unknown primary and neck dissection. In: Gnepp D, (ed) Diagnostic surgical pathology of the head and neck. Saunders, Philadelphia, p 671
67. Luna MA, Tortoledo ME, Allen M (1987) Salivary dermal analogue tumor arising in lymph nodes. *Cancer* 59:1165–1169
68. Maisel RH (1980) When your patient complains of a neck mass. *Geriatrics* 35:3–8
69. Martin H, Morfit HM, Ehrlich H (1950) The case for bronchogenic cancer (malignant branchioma). *Ann Surg* 132:867–887
70. May M (1978) Neck masses in children: diagnosis and treatment. *Ear Nose Throat J* 57:136–158
71. Medina JE, Houck JR (1995) Advances in neck dissection. *Arch Otolaryngol Head Neck Surg* 9:183–196
72. Mendenhall WM, Mancuso AA, Parson J T et al. (1998) Diagnostic evaluation of squamous cell carcinoma metastatic to cervical lymph nodes from unknown head and neck primary site. *Head Neck* 20:739–744
73. Micheau C, Kijanienko J, Luboinski B et al. (1990) So-called bronchogenic carcinoma is actually cystic metastasis in the neck from a tonsillar primary. *Laryngoscope* 100:878–883
74. Michelini ME, Casadio G, Franchella A (2003) Thyroglossal duct cysts: a retrospective study. *Minerva Pediatr* 55:51–54
75. Molinari R, Cantu G, Chiesa F et al. (1977) A statistical approach to detection of the primary cancer based on the site of neck lymph node metastases. *Tumori* 63:267–282
76. Moran C, Suster S, El-Naggar et al. (2004) Carcinoma arising in multilocular thymic cysts of the neck: a clinicopathological study of three cases. *Histopathology* 44:64–68
77. Mukherji SK, Drane WE, Mancuso AA et al. (1996) Occult primary tumors of the head and neck: detection with 2-[¹⁸F] fluoro-2-deoxy-d-glucose SPECT. *Radiology* 199:761–766
78. Mulliken JB, Glowacki J (1982) Hemangiomas and vascular malformations in infants and children: a classification based on endothelial characteristics. *Plastic Reconstr Surg* 69:412–420
79. Nguyen C, Shenouda G, Black MJ et al. (1994) Metastatic squamous cell carcinoma to cervical lymph nodes from unknown primary mucosal sites. *Head Neck* 16:58–63
80. Nicollas R, Ducroz NE, Garabedian EN et al. (1998) Fourth branchial pouch anomalies: a study of six cases and review of the literature. *Int J Pediatr Otorhinolaryngol* 44:5–10
81. Nozeran S, Duquenne M, Guyetan S et al. (2000) Diagnosis of parathyroid cysts: value of parathyroid hormone. *Presse Med* 29:939–941

82. Olsen KD, Maragos NE, Weiland LH (1980) First branchial cleft anomalies. *Laryngoscope* 90:423–436
83. Ordonez NG (2000) Expression of thyroid transcription in human tumors. *Adv Anat Pathol* 7:120–126
84. Paccioni D, Negro F, Valente G et al. (1994) Epstein-Barr virus by in situ hybridization in fine needle aspiration biopsy. *Diagn Mol Pathol* 3:100–105
85. Papay FA, Kalucis C, Eliachar I et al. (1994) Nasopharyngeal presentation of a second branchial cleft cyst. *Otolaryngol Head Neck Surg* 110:232–234
86. Park SS, Kamody CS (1992) The first branchial cleft carcinoma. *Arch Otolaryngol Head Neck Surg* 118:969–971
87. Peter JC, Sinclair-Smith C, de Villiers JC (1991) Midline dermal sinuses and cysts and their relationship to the central nervous system. *Eur J Pediatr Surg* 1:73–79
88. Pinczower E, Crocket DM, Atkinson JB et al. (1992) Preoperative thyroid scanning in presumed thyroglossal duct cysts. *Arch Otolaryngol Head Neck Surg* 118:985–988
89. Prasad KK, Gupta RK, Jain M et al. (2001) Cervical thymic cyst: report of a case and review of the literature. *Indian J Pathol Microbiol* 44:483–485
90. Quick CA, Lowell SH (1977) Ranula and the sublingual gland. *Arch Otolaryngol* 103:397–400
91. Radkowski D, Arnold J, Healy GB et al. (1991) Thyroglossal duct remnants. Preoperative evaluation and management. *Arch Otolaryngol Head Neck Surg* 117:1378–1381
92. Rangnekar H, Bailer WJ, Ghani A et al. (1996) Parathyroid cysts. Report of four cases and review of the literature. *Int Surg* 81:412–414
93. Redaelli de Zinis LO, Nicolai P, Piccioni LO et al. (1998) Cervical metastatic carcinoma from an unknown primary: a study on 65 patients. *Br J Cancer* 77S:28
94. Regauer S, Beham A, Mannweiler MO (2000) CK7 expression in carcinomas of the Waldeyer's ring area. *Hum Pathol* 31:1096–1101
95. Regauer S, Gogg-Kamerer, Braun H et al. (1997) Lateral neck cyst the branchial theory revisited. A critical review and clinicopathologic study of 97 cases with special emphasis on cytokeratin expression. *APMIS* 105:623–630
96. Regauer S, Manhweller S, Anderhuber A et al. (1999) Cystic lymph node metastases of squamous cell carcinoma of Waldeyer's ring. *Br J Cancer* 79:1437–1442
97. Rhigi JD, Sofferan RA (1995) Screening unilateral tonsillectomy in the unknown primary *Laryngoscope* 105:548–550
98. Richard JM, Micheau C (1997) Malignant cervical adenopathies from carcinomas of unknown origin. *Tumori* 63:249–258
99. Robbins KT, Clayman G, Levine PA et al. (2002) Neck dissection classification update. Revisions proposed by the American Head and Neck Society and the American Academy of Otolaryngology—Head and Neck Surgery. *Arch Otolaryngol Head Neck Surg* 128:751–758
100. Rodriguez-Cuevas S, Lopez-Garza J, Labastida-Almendaro S (1998) Carotid body tumors in inhabitants of altitudes higher than 2000 meters above sea level. *Head Neck* 20:374–37
101. Rosen D, Wirtschafer A, Rao VM et al. (1998) Dermoid cyst of the lateral neck, a case report and literature review. *Ear Nose Throat J* 125:129–132
102. Sade J, Rosen G (1968) Thyroglossal cysts and tracts: a histological and histochemical study. *Ann Otol Rhino Laryngol* 77:139–145
103. Saenz J, Catalina F, Fernández MJJ et al. (2003) Mucoepidermoid carcinoma arising in cervical lymph nodes. A report of three cases with FNA findings. *Acta Cytol* 47:470–474
104. Saitz EW (1981) Cervical lymphadenitis caused by atypical mycobacteria. *Pediatr Clin North Am* 28:823–839
105. Sambola-Cabrer I, Fernandez-Real JM, Ricard W (1996) Ectopic thyroid tissue presenting as a submandibular mass. *Head Neck* 18:87–90
106. Samuel M, Freeman NV, Sajwany MJ (1993) Lingual thyroglossal duct cyst presenting in infancy 28:891–893
107. Scherer K, Szeimies RM, Landthaler M (2000) Ectopic parotid tissue. An unusual differential cervical cystic tumor diagnosis. *Hautarzt* 51:865–868
108. Senger MI, Applebaum EL, Ley KD (1979) Heterotopic salivary tissue in the neck. *Laryngoscope* 80:1772–1778
109. Shah JP (1990) Patterns of cervical lymph node metastasis from squamous cell carcinoma of the upper aerodigestive tract. *Am J Surg* 160:405–409
110. Shah JP, Strang E, Spiro RH et al. (1981) Neck dissection, current status and future possibilities. *Clin Bull* 11:25–33
111. Shvero J, Hadar TA, Vidos I et al. (1986) Heterotopic salivary tissue and branchial sinuses. *Laryngol Otol* 100:243–246
112. Sistrunk WE (1920) The surgical treatment of cysts of the thyroglossal tract. *Ann Surg* 71:121–122
113. Smirniotopoulos JG, Chiechi MV (1995) Teratomas, dermoids, and epidermoids of the head and neck. *Radiographics* 15:1437–1455
114. Soylu L, Aydogan LB, Kiroglu M et al. (1995) Hydatidic cyst in the head and neck area. *Am J Otolaryngol* 16:123–125
115. Spinelli C, Ricci E, Berti P et al. (1990) Neck mass in childhood. Surgical experience of 154 cases. *Minerva Pediatr* 42:169–172
116. Thompson L, Heffner DK (1998) The clinical importance of cystic squamous cell carcinoma in the neck. *Cancer* 82:944–956
117. Torsiglier AJ Jr, Tom LW, Ross AJ et al. (1988) Pediatric neck masses: guidelines for evaluation. *Int Pediatr Otorhinolaryngol* 16:199–210
118. Tovi F, Fliss DM, Inbar-Yanai I (1988) Hürthle cell adenoma of the thyroglossal duct. *Head Neck Surg* 10:346–349
119. Triglia JM, Nicollas R, Ducroz V et al. (1998) First branchial cleft anomalies. A study of 39 cases and a review of the literature. *Arch Otolaryngol Head Neck Surg* 124:291–295
120. Turner A, Lampe FB, Cramer H (1989) Parathyroid cysts. *J Otolaryngol* 18:11–13
121. Tyson RW, Groff DB (1993) An unusual lateral neck cyst with the combined features of a bronchogenic, thyroglossal, and branchial cleft origin. *Pediatr Pathol* 13:567–572
122. Vermeire VM, Dale JJ (1991) Second branchial cleft-pouch set fistulae, sinuses and cysts in children. *Acta Otorhinolaryngol Belg* 45:437–442
123. Wang RC, Goepfert H, Barber AE et al. (1990) Unknown primary SCC metastatic to the neck. *Arch Otolaryngol Head Neck Surg* 116:1388–1393
124. Wassef M (1992) Cervicophalic hemangiomas and vascular malformations. Histological appearance and classification. *J Mal Vasc* 17:20–25
125. Werner AJ, Dunne AA, Myers JN (2003) Functional anatomy of the lymphatic drainage system of the upper aerodigestive tract and its role in metastasis of squamous cell carcinoma. *Head Neck* 25:322–332
126. Wilson DB (1979) Embryonic development of the head and neck. II. The branchial region. *Head Neck Surg* 2:59–66
127. Yang C, Cohen J, Everts E et al. (1999) Fourth branchial arch sinus: clinical presentation, diagnostic workup, and surgical treatment. *Laryngoscope* 109:442–446
128. Yoo KS, Chengazi VU, O'Mara RE (1998) Thyroglossal duct cyst with papillary carcinoma in a 11-year-old girl. *J Pediatr Surg* 33:745–746
129. Yoshimura Y, Obara S, Kondoh T et al. (1995) A comparison of three methods used for treatment of ranula. *J Oral Maxillofac Surg* 53:280–282
130. Zarbo RJ, McClatchey KD, Arcen RG et al. (1983) Thymopharyngeal duct cyst; a form of cervical thymus. *Ann Otol Rhinol Laryngol* 92:284–289
131. Zatchuz JT, Paton CA, Hyams VJ (1982) Cervical heterotopic salivary gland neoplasms: a diagnostic dilemma. *Otolaryngol Head Neck Surg* 80:178–181
132. Zimmermann CE, Domarus H von, Moubayed P (2002) Carcinoma in situ in a lateral cervical cyst. *Head Neck* 24:965–969

M.R. Canning-Van Dijk

Contents

10.1	Summary of Anatomy and Histology.	284	10.4.2.3	Granulomatous Inflammation.	295
10.1.1	Conjunctiva	284	10.4.3	Trauma	296
10.1.2	Cornea	284	10.4.4	Degeneration.	296
10.1.3	Intraocular Tissues	284	10.4.4.1	Glaucoma.	296
10.1.4	Optic Nerve	284	10.4.4.2	Cataracts	297
10.1.5	Lacrimal Glands and Lacrimal Passages	284	10.4.4.3	Phtisis Bulbi	298
10.1.6	Eyelids	284	10.4.4.4	Retinal Vascular Disease	298
10.1.7	Orbit.	285	10.4.4.5	Retinal Detachment.	298
10.2	Conjunctiva	285	10.4.4.6	Retinitis Pigmentosa	298
10.2.1	Developmental Anomalies.	285	10.4.5	Tumours and Tumour-Like Conditions	298
10.2.1.1	Dermoid, Dermolipoma and Complex Choristoma	285	10.4.5.1	Melanocytic	298
10.2.2	Cysts.	285	10.4.5.2	Lymphoid.	300
10.2.2.1	Inclusion cysts	285	10.4.5.3	Retinoblastoma and Pseudoretinoblastoma	300
10.2.3	Degeneration.	286	10.4.5.4	Glial	301
10.2.3.1	Pinguecula and Pterygium.	286	10.4.5.5	Vascular	301
10.2.4	Inflammatory Processes	286	10.4.5.6	Other Primary Tumours	301
10.2.4.1	Acute Conjunctivitis	286	10.4.5.7	Metastatic Tumours.	302
10.2.4.2	Chronic Non-Granulomatous Conjunctivitis.	287	10.5	Optic Nerve	302
10.2.4.3	Granulomatous Conjunctivitis	287	10.5.1	Papilloedema.	302
10.2.4.4	Ligneous Conjunctivitis	287	10.5.2	Optic Neuritis	302
10.2.4.5	Chlamydia Trachomatis (TRIC Agent) Infection.	287	10.5.3	Optic Atrophy	302
10.2.5	Dermatologic and Systemic Diseases	288	10.5.4	Tumours	302
10.2.5.1	Keratoconjunctivitis Sicca	288	10.5.4.1	Glioma	302
10.2.5.2	Dermatologic Diseases	288	10.5.4.2	Meningioma	302
10.2.5.3	Metabolic Diseases	288	10.6	Lacrimal Gland and Lacrimal Passages	302
10.2.6	Tumours and Tumour-Like Conditions	288	10.6.1	Inflammatory Processes	302
10.2.6.1	Epithelial	288	10.6.2	Tumours and Tumour-Like Conditions	303
10.2.6.2	Melanocytic	290	10.7	Eyelids	303
10.2.6.3	Other Neoplasms	291	10.7.1	Cysts.	303
10.3	Cornea	292	10.7.1.1	Dermoid Cyst	303
10.3.1	Keratitis and Corneal Ulcers.	292	10.7.1.2	Epidermal Cyst	303
10.3.1.1	Herpes Simplex Keratitis	292	10.7.1.3	Hydrocystoma	303
10.3.1.2	Corneal Ulceration Due to Systemic Disease	292	10.7.2	Inflammatory Processes	303
10.3.2	Keratoconus	292	10.7.2.1	Chalazion and Other Ruptured Cysts	304
10.3.3	Hereditary Corneal Dystrophies	293	10.7.2.2	Deep Granuloma Annulare	304
10.3.3.1	Epithelial Dystrophies	293	10.7.2.3	Necrobiotic Xanthogranuloma	304
10.3.3.2	Stromal Dystrophies	293	10.7.3	Amyloidosis	305
10.3.3.3	Endothelial Dystrophies	293	10.7.4	Tumours and Tumour-Like Conditions	305
10.3.4	Failed Previous Grafts	294	10.7.4.1	Xanthelasmata.	305
10.4	Intraocular Tissues	294	10.8	Orbit.	305
10.4.1	Developmental Anomalies.	294	10.8.1	Inflammatory Processes	305
10.4.1.1	Congenital Glaucoma.	294	10.8.1.1	Dysthyroid Ophthalmopathy	305
10.4.1.2	Retinopathy of Prematurity	294	10.8.1.2	Cellulitis	305
10.4.1.3	Persistent Primary Hyperplastic Vitreous	294	10.8.1.3	Pseudotumour	306
10.4.1.4	Retinal Dysplasia	294	10.8.2	Tumours and Tumour-Like Conditions	306
10.4.1.5	Aniridia.	294	10.8.2.1	Developmental Cysts	306
10.4.1.6	Congenital Rubella Syndrome.	294	10.8.2.2	Optic Nerve and Meningeal Tumours	306
10.4.2	Inflammatory Processes	295	10.8.2.3	Metastatic Tumours.	307
10.4.2.1	Acute Inflammation	295	References		307
10.4.2.2	Chronic Non-Granulomatous Inflammation	295			

10.1 Summary of Anatomy and Histology

10.1.1 Conjunctiva

The conjunctiva is a thin mucous membrane, covering most of the anterior surface of the eye and the inner surface of the eyelids. The conjunctiva is composed of two to five layers of stratified columnar epithelium containing mucin-secreting goblet cells. At the corneoscleral junction, the limbus, a gradual transition from stratified columnar to stratified squamous corneal epithelium is seen. At the palpebral margins, a relatively abrupt transition into the epidermis is present. The basal layer contains melanocytes and Langerhans cells. The conjunctival stroma is composed of fibrous connective tissue containing fibroblasts, some inflammatory cells, blood vessels, smooth muscle, nerves and lymphatic channels. In the fornices the conjunctival epithelium contains more goblet cells and the stroma can additionally contain cartilage. In the medial interpalpebral area of the eye, a nodular mass is present: the caruncle. The caruncle is covered by stratified non-keratinised squamous epithelium and the subepithelial stroma contains sebaceous glands, hair follicles and muscle fibres.

10.1.2 Cornea

The cornea is divisible into five distinctive layers: the epithelium, Bowman's layer, the stroma, Descemet's membrane and the endothelium. The non-keratinising stratified squamous epithelium consists in the centre of the cornea of five layers, increasing to nine or ten layers at the periphery. Bowman's layer is believed to represent a modified layer of the stroma. It is composed of small collagen fibrils surrounded by a mucoprotein ground substance. The stroma is avascular and consists of collagenous lamellae arranged in an almost parallel manner interspersed with flattened fibroblasts (keratocytes). Descemet's membrane is a faintly eosinophilic staining, PAS-positive, acellular structure, formed by corneal endothelial cells. The underlying endothelium is a single layer of polygonal cells.

10.1.3 Intraocular Tissues

The intra-ocular tissue is formed by the uveal tract, the retina, the lens and the vitreous gel. The uveal tract consists of highly vascularised, loosely arranged stroma, which can be found in all three parts of the tract: the iris, the ciliary body and the choroid. In the iris, in addition to the stroma, the pigment epithelium and

the smooth muscles of the musculus sphincter pupillae and musculus dilator pupillae can be found. The ciliary body consists of two parts: the pars plicata contains the ciliary processes, the pars plana serves as an attachment for the vitreous gel. In both parts, layers of ciliary muscle are present. The choroid contains nerves and a variable number of melanocytes, related to race. The retina consists of a nerve fibre layer, peripheral ganglion cells, the bipolar cell layer, the photoreceptor cells and the retinal pigment epithelium. The thickness of the retina varies in different regions. The biconvex lens is a transparent structure, the form of which is easily altered by contraction of the ciliary muscles. The shape of the lens is maintained by the elastic lens capsule. In a fixed specimen the lens is rigid, caused by coagulation of the soluble crystallins. The inner surface of the anterior lens capsule is covered with a single layer of cuboidal epithelium. A loose framework of type II collagen containing mainly water and acid mucopolysaccharides forms the vitreous gel.

10.1.4 Optic Nerve

The axons from the retinal nerve fibre layer converge at the optic disc. The axons in the nerve fibre layer of the optic disc form a bulge as they pass through the lamina cribrosa, a sieve-like plate of connective tissue formed by fibroblasts, ingrowing from the posterior part of the adjacent sclera. This bulge is larger on the nasal side. The tissue anterior to the lamina derives blood supply from the posterior ciliary arteries, and the tissue posterior to the lamina has a meningeal blood supply derived from branches of the ophthalmic and central retinal artery.

10.1.5 Lacrimal Glands and Lacrimal Passages

The pale brown and ovoid lacrimal gland is located in the upper outer orbit. The large ducts pass through the conjunctival epithelium into the superior fornix. The tear fluids drain into the canaliculi, ending in the lacrimal sac. The secretory gland is composed of lobular grouped acini, secreting solutes and glycosaminoglycans. The drainage system consists of ductules, formed by epithelial cells surrounded by myoepithelium. The canaliculi are covered with stratified epithelium, while the lacrimal sac is covered with columnar epithelium.

10.1.6 Eyelids

The eyelids are covered by an epidermis above a thin dermis with small sweat glands and pilosebaceous units.

The dermis covers the musculus orbicularis oculi, located on the anterior surface of the tarsal plate, which is composed of compact stroma. In the anterior part of the eyelids, the pilosebaceous units are much larger to form the lashes. The parts of the tarsal plates closest to the lid margins, contain the large sebaceous (Meibomian) glands. A transition from keratinised squamous epithelium of the outer eyelid into columnar epithelium of the tarsal conjunctiva is present in the transition zone. Small pilosebaceous glands (Zeis) and sweat glands (Moll) are present at the lid margins.

10.1.7 Orbit

The orbital septum and globe divide the orbit into anterior and posterior compartments. The anterior compartment consists of the lids, lacrimal apparatus and anterior soft tissues. The posterior compartment is also called the retrobulbar space. The cone of this retrobulbar space consists of the extraocular muscles and an envelope of fascia. The optic nerve is located within the intraconal space, surrounded by fibrous and fatty tissue.

10.2 Conjunctiva

Because conjunctival biopsies and excisions are very thin, they tend to fold when placed into fixative. Without causing compression artefacts, the surgeon should spread the tissue onto a piece of cardboard or filter paper and let it dry for a few seconds, before placing it into the fixative.

10.2.1 Developmental Anomalies

10.2.1.1 Dermoid, Dermolipoma and Complex Choristoma

ICD-O:9084/0

Dermoid tumours are firm or cystic masses, typically occurring at the limbus on the temporal side and are the most frequent epibulbar tumours in children [30]. They are composed of epithelial and/or connective tissue elements that become entrapped within embryonic clefts. On histological examination, the surface epithelium consists of stratified squamous epithelium, frequently containing skin appendages. The stromal component consists of collagen arranged in thick bundles; it contains blood vessels and nerve fibres. If adipose tissue is present, the lesion is called dermolipoma (Figs. 10.1, 10.2). Sometimes cartilage or lacrimal gland tissue is present, these lesions are known as complex choristoma [28, 35].

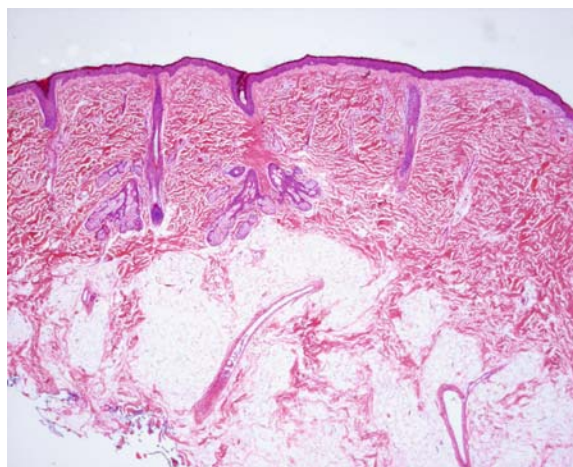


Fig. 10.1. Dermolipoma: excision of a limbal mass, consisting of collagen and adipose tissue

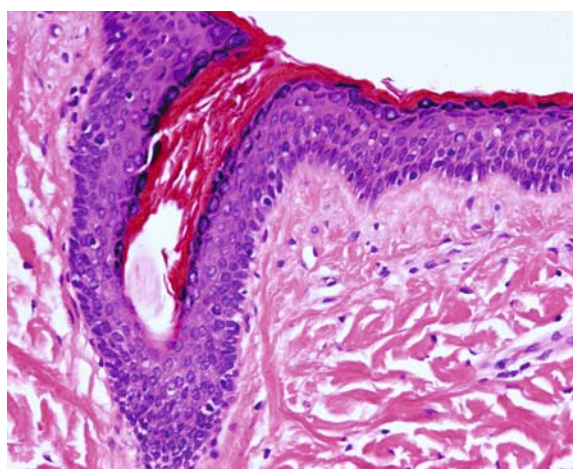


Fig. 10.2. Dermolipoma: detail of the stratified squamous epithelium containing hair follicles

Dermoids are present at birth and have little or no growth potential. The lesions can occur as isolated ocular lesions or in association with anomalies affecting other organs (Goldenhar's syndrome, mandibulofacial dysostosis and neurocutaneous syndrome) [22, 41, 46, 55, 100, 118].

10.2.2 Cysts

10.2.2.1 Inclusion Cysts

Conjunctival inclusion cysts are acquired lesions, usually arising following surgical or accidental trauma [9, 42, 83]. The cysts are lined with non-keratinising cuboidal

epithelium with apocrine changes and containing goblet cells (Fig. 10.3). In the underlying stroma, chronic inflammatory cells may be present.

10.2.3 Degeneration

10.2.3.1 Pinguecula and Pterygium

Pingueculae are raised, localised, yellowish-grey lesions that occur in the bulbar conjunctiva, close to the limbus on the nasal or temporal side of the cornea. Pterygia are similar in appearance and also develop in these areas, but involve the peripheral cornea, mostly the nasal side, as well. Pingueculae and pterygia are degenerative lesions causally related to prolonged actinic exposure. The lesions are often bilateral and occur in middle-aged and elderly patients, especially in areas with high levels of sunlight. On histologic examination both lesions are identical. The essential feature is elastotic degeneration of the collagen, resulting in a subepithelial zone of amorphous, basophilic material (Fig. 10.4). This material stains black with the Elastica van Gieson stain (Fig. 10.5). In older lesions calcification can occur. The overlying epithelium may show a wide variety of changes, but most frequently it is thin, atrophic conjunctival epithelium or acanthosis without cellular atypia. In the epithelium an actinic keratosis or even a squamous cell carcinoma may develop [110].

Since pingueculae are not progressive, they are seldom excised. Pterygia are of more clinical importance because of their extension to the cornea.

10.2.4 Inflammatory Processes

The conjunctiva is prone to inflammations with many different causes, either infectious or as a part of a non-infectious dermatologic or systemic disease. Usually these lesions do not cause diagnostic problems, but a biopsy can be useful in making the correct diagnosis [97]. In this chapter the inflammatory processes of the conjunctiva are divided into acute, chronic and granulomatous. The only lesions mentioned separately are ligneous conjunctivitis and lesions caused by Chlamydia infections.

10.2.4.1 Acute Conjunctivitis

In acute conjunctivitis there is a rapid onset of a swollen, hyperaemic conjunctiva accompanied by increased tear formation. There may be a watery (viral infections), fibrinous (bacterial infections) or mucoid (allergic reac-

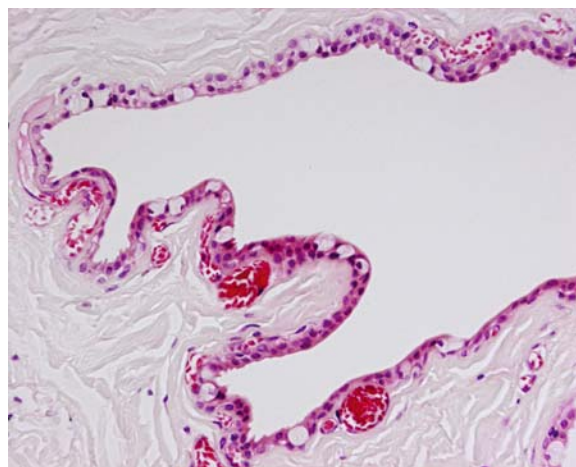


Fig. 10.3. Conjunctival inclusion cyst: a cystic space is covered with non-keratinising cuboidal epithelium, containing goblet cells

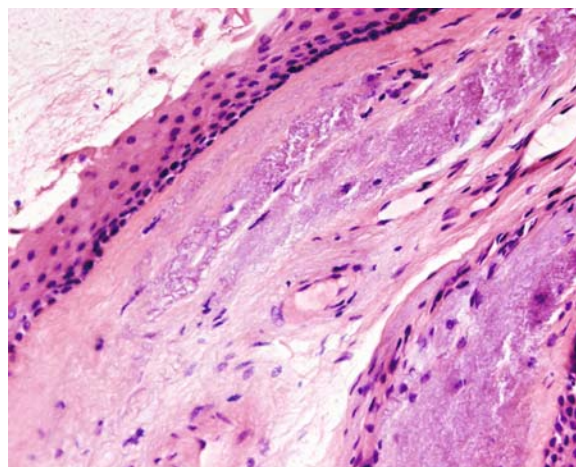


Fig. 10.4. Pinguecula: amorphous, basophilic material in the stroma represents the elastotic degenerated collagen

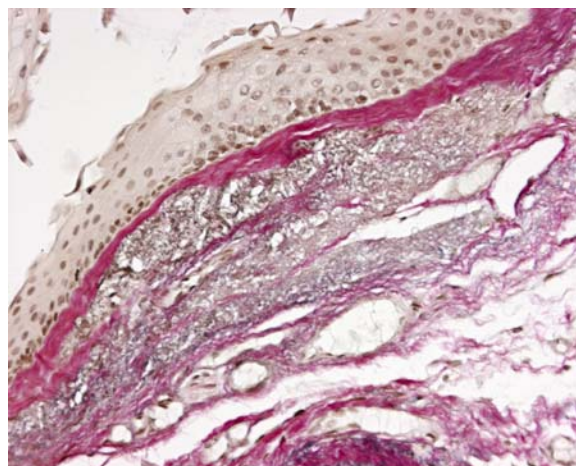


Fig. 10.5. Pinguecula: the elastotic collagen stains black in elastica staining (Elastica van Gieson stain)

tions) discharge [124]. The histological pattern depends on the cause of the inflammation. In viral infections the infiltrate consists mostly of mononuclear cells. In a bacterial infection many neutrophilic leukocytes can be seen [124]. When the cause is an allergic response, many eosinophils are usually found.

10.2.4.2 Chronic Non-Granulomatous Conjunctivitis

Chronic conjunctivitis can be caused by many infectious, immunological and toxic agents. Also, anatomic aberrations (like ectropion or proptosis) can cause inflammation. In chronic conjunctivitis the epithelium becomes hyperplastic and the goblet cells increase in number. Crypt-like epithelial infoldings can occur, forming sub-epithelial retention cysts. These cysts contain mucus in which calcification can be seen over time. The presence of perivascular infiltrate in the stroma can induce fibrous bands between the epithelium and the tarsus, which can cause surface irregularities, the so-called papillary conjunctivitis. In fact, the epithelial and stromal responses of a papillary conjunctivitis are non-specific and can also be seen in atopic conjunctivitis and, in a more extreme form in individuals wearing contact lenses (giant papillary conjunctivitis) [108, 114]. When lymph follicles are found in the superficial stroma, it is called follicular conjunctivitis. The presence of these follicles is associated with adenoviral infections [25]. It can also be seen in early chlamydial infections [37], *Borrelia burgdorferi* infections [60, 132] and in patients using topical medication. In these situations a lymphoma has to be excluded by immunohistochemistry [2, 48, 131].

With long-standing inflammation the epithelium can become atrophic, with loss of goblet cells. The epithelium can show keratinisation, resulting in a white appearance (leukoplakia). The long-standing inflammation may result in scarring of the conjunctival stroma.

10.2.4.3 Granulomatous Conjunctivitis

Granulomatous inflammation of the conjunctiva is usually associated with systemic diseases. The presence of exogenous material or parasites may cause an isolated granulomatous inflammation of the conjunctiva. In the case of a chalazion the palpebral conjunctiva may also be affected (see Sect. 10.7.2.1).

10.2.4.3.1 Infectious

Like in other anatomic sites, a caseating necrotising granulomatous infection can be caused by tuberculosis, especially in children [32, 45, 76].

10.2.4.3.2 Sarcoidosis

In sarcoidosis the granulomas are usually small and sharply demarcated [6, 39]. Serial sections can be necessary to confirm the diagnosis.

10.2.4.4 Ligneous Conjunctivitis

Ligneous conjunctivitis (chronic pseudomembranous conjunctivitis) is a rare bilateral disease, mainly occurring in young girls. It presents as a subacute inflammation of the tarsal conjunctiva, often accompanied by nasopharyngitis and vaginitis. The disease seems to be due to a defective fibrinolysin system. Microscopically, granulation tissue is present, covered with plaques of fibrinous material, later forming a hyalinised mass. After removal of the plaque, recurrence is common. It can be complicated by corneal involvement and perforation with loss of the eye may occur [15, 17, 99].

10.2.4.5 Chlamydia Trachomatis (TRIC Agent) Infection

Chlamydia trachomatis (TRIC agent: TR = trachoma, IC = inclusion conjunctivitis) is an obligate intracellular pathogen of columnar epithelial cells [79]. In hot climates it can cause trachoma, primarily affecting the conjunctiva and corneal epithelium, ultimately causing cicatrization of this tissue. Trachoma commonly affects children and is one of the world's major causes of blindness. Trachoma is spread from eye to eye by transfer of ocular discharges. In temperate climates chlamydial infection is venereal, with only mild conjunctival infection, called inclusion conjunctivitis. A third manifestation of this pathogen is ophthalmia neonatorum [75].

10.2.4.5.1 Trachoma

The clinical manifestations of trachoma vary with the severity and duration of the initial infection and also depend upon environmental factors, the patient's nutritional and immune status, the number of reinfections, and the presence or absence of secondary bacterial infection. It is usually bilateral. The course of trachoma can be divided into four stages (the McCollan classification) [68]. During the active stages of infection inclusions can be found in Giemsa-stained cells scraped from the surface of infected epithelium. More easy to recognise is a positive direct immunofluorescence for *Chlamydia trachomatis* on the scraping, it can be very helpful in making the correct diagnosis [62, 90]. The diagnosis can also be made by isolation of

the causative agent in cell cultures and the detection of chlamydial antibody in blood or tear fluid. At Stage I there is epithelial infection by *Chlamydia trachomatis*. It is characterised clinically by the formation of conjunctival follicles and diffuse punctate inflammation of the cornea. The histology is indistinguishable from that of follicular conjunctivitis caused by other agents. Lymphocytes and plasma cells infiltrate the subepithelial tissue; polymorphonuclear leukocytes infiltrate the corneal and conjunctival epithelium. At Stage II, the inflammatory reaction occupies the stroma, with the further formation of follicles. Large macrophages with phagocytised debris (Leber cells) are seen in the conjunctiva, accompanying the epithelial hyperplasia with round cell infiltration and subepithelial oedema [125]. At Stage III the follicles disappear and cicatrization occurs. The fibrosis causes inversion of the upper lid (cicatricial entropion), misdirected lashes (trichiasis) and decreased tear formation. On histologic examination, scattered lymphocytes and plasma cells can still be seen along with subepithelial scar tissue. At Stage IV, there is spontaneous arrest of the disease, which is no longer contagious. The residual entropion and trichiasis lead to continuing corneal damage. Denuding of the epithelium leaves the cornea vulnerable to infection and further opacification as a result of scarring.

10.2.4.5.2 Inclusion Conjunctivitis

The conjunctival involvement of the sexually transmitted chlamydial infection is mild and can even be asymptomatic. In adults, it presents as a subacute follicular conjunctivitis. It is accompanied by a chronic urethritis in the male and a symptomless cervicitis in the female. In newborns, it occurs with an acute mucopurulent discharge, 5 to 10 days after birth. It is accompanied by infection of the maternal vagina by the same agent. Because the extranodal lymphoid tissues are not fully developed, the conjunctivitis is more papillary than follicular. Like trachoma it can be diagnosed by Giemsa staining on conjunctival scrapings.

10.2.5 Dermatologic and Systemic Diseases

10.2.5.1 Keratoconjunctivitis Sicca

In this condition the cornea and conjunctiva are dry, causing a painful and gritty sensation. Keratoconjunctivitis sicca was described first by Sjögren in 1933 [106, 107]. It is therefore best known as one of the symptoms of Sjögren's syndrome. However, it can also be seen in other auto-immune diseases like scleroderma or rheu-

matoid arthritis. Moreover, keratoconjunctivitis sicca is the most frequent cause of eye involvement in graft-versus-host disease [20, 50, 64]. Histologically, there is atrophy of the lacrimal acinar parenchyma, accompanied by fibrosis and fatty infiltration, but with preservation of the lobular architecture. There is a focal or diffuse presence of lymphocytes and plasma cells. Sometimes lymphoepithelial lesions can be seen (See Chap. 5 for more detail.).

10.2.5.2 Dermatologic Diseases

Many skin diseases can involve the conjunctiva. Most frequently seen are bullous diseases like pemphigus [72], bullous pemphigoid, Stevens-Johnson syndrome [43], paraneoplastic pemphigus [58, 74] and less commonly, dermatitis herpetiformis [43] and linear IgA disease [4]. Other dermatologic diseases with conjunctival involvement are lupus erythematosus [40, 115, 122], familial chronic benign pemphigus (Hailey-Hailey disease) [80] and lichen planus [78, 116].

10.2.5.3 Metabolic Diseases

A conjunctival biopsy can be of diagnostic value in metabolic diseases with specific ultrastructural features, like galactosialidosis and different types of mucopolysaccharidoses [14, 121].

10.2.6 Tumours and Tumour-Like Conditions

10.2.6.1 Epithelial

Epithelial tumours of the conjunctiva can be divided into tumours of the surface epithelium (papilloma, intraepithelial neoplasia and squamous cell carcinoma) and adnexal tumours. Since the caruncle contains accessory lacrimal glands, sweat glands, hair follicles and sebaceous glands, adnexal tumours of different kinds can be found.

10.2.6.1.1 Papilloma

ICD-O:8560/0

The commonest epithelial tumours of the conjunctiva are papillomas, usually presenting as a red, papillomatous mass. These benign tumours histologically consist of a fibrovascular core, lined with conjunctival epithelium, eventually with squamous metaplasia (Figs. 10.6, 10.7). The sessile variant usually shows only

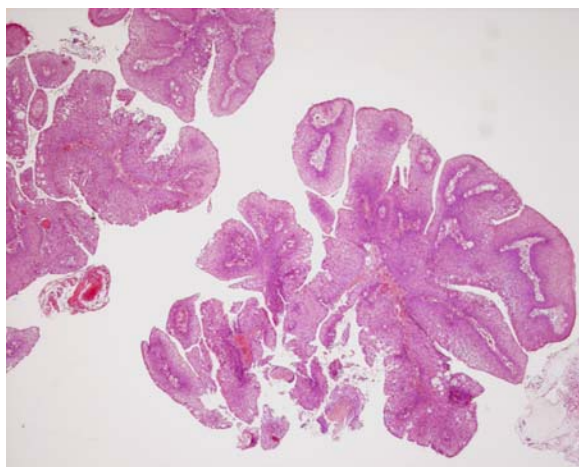


Fig. 10.6. Conjunctival papilloma: papillomatous mass consisting of a fibrovascular core covered with squamous metaplastic epithelium

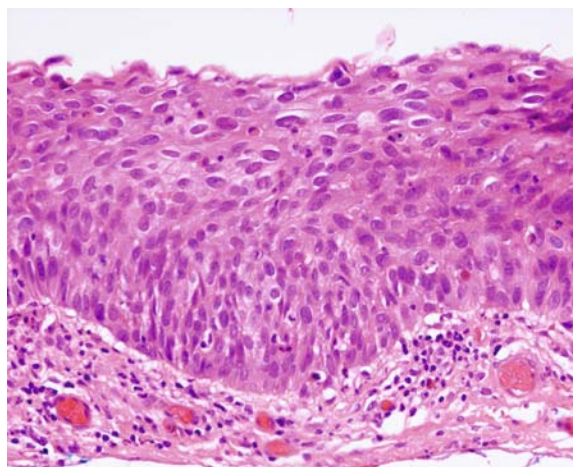


Fig. 10.8. Conjunctival intraepithelial neoplasia: the epithelium consists of atypical cells without orderly differentiation

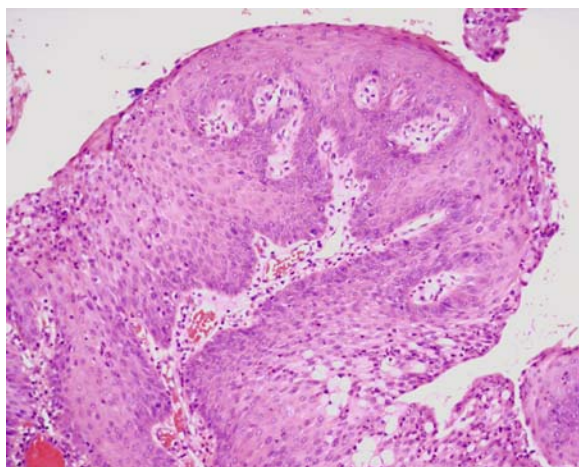


Fig. 10.7. Conjunctival papilloma: detail of the squamous metaplastic epithelium

metaplastic epithelium, without goblet cells. There is a strong association between HPV and conjunctival papillomas. HPV type 6/11 is the most common HPV type in conjunctival papilloma. The sensitivity of koilocytosis as an indicator of HPV in conjunctival papilloma is low [105]. Papillomas are more extensively discussed in Chap. 1.

10.2.6.1.2 Conjunctival Intraepithelial Neoplasia

Intraepithelial neoplasia of the conjunctiva can be caused by sun-damage (actinic keratosis) or by HPV-induced pre-malignant transformation (Bowenoid type). In both types

of dysplasia, the epithelial cells show atypia (Fig. 10.8). In actinic keratosis the epithelium is thin and the stroma shows damage of elastic tissue. In the Bowenoid type mitotic figures can be seen in the upper epithelial layers and HPV-related epithelial changes like multinucleated cells and koilocytes can be found [47, 71, 82].

10.2.6.1.3 Malignant Tumours of the Surface Epithelium

Squamous cell carcinomas are rare and usually well differentiated. After adequate therapy total cure is often achieved [13, 120]. More aggressive variants of this carcinoma, like the acantholytic or adenoid type [70] and the spindle cell type are even more rare. Mucoepidermoid carcinoma of the conjunctiva has also been reported [34, 101] (See Chaps. 1 and 5 for more details.).

10.2.6.1.4 Oncocytoma

ICD-O:8290/0

An oncocytoma (oxyphil cell adenoma, oxyphilic granular cell adenoma) is a benign tumour that can occur in the conjunctiva, the lacrimal gland and the lacrimal sac [7, 111]. It presents as an asymptomatic, slowly progressive swelling of the caruncle in older persons. The lesion consists of large epithelial cells with eosinophilic, granular cytoplasm, due to a large number of mitochondria. The cells can be arranged in cords, sheets or nests. Ductal and cystic glandular structures can be found. The malignant variant of this tumour, the oncocytic adenocarcinoma of the lacrimal system is very rare.

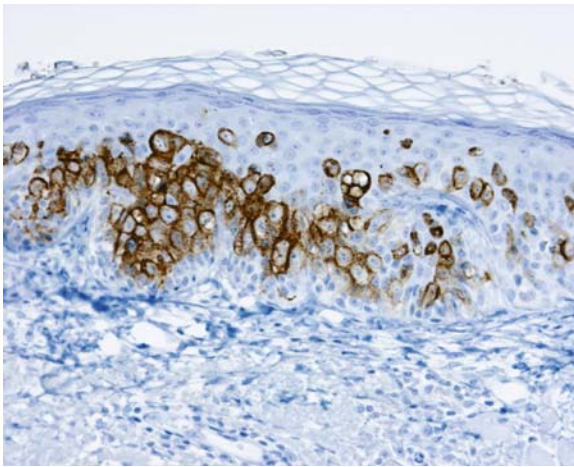


Fig. 10.09. Intraepithelial component of a sebaceous adenocarcinoma: intraepithelial pagetoid spread of tumour cells may be misinterpreted as dysplasia; positive staining for EMA can be very helpful (EMA immunostaining)

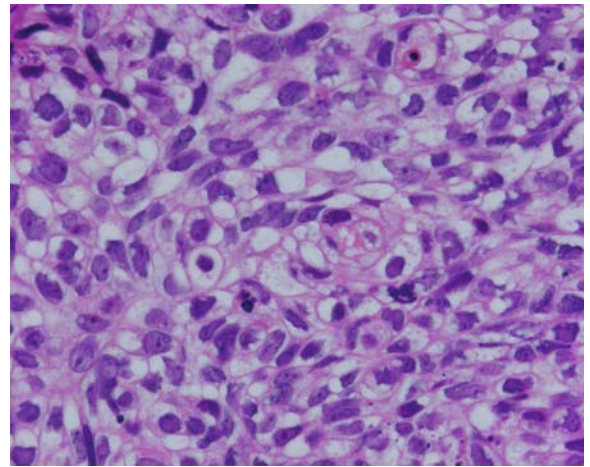


Fig. 10.11. Sebaceous adenocarcinoma: detail of the clear cells, showing sebaceous differentiation

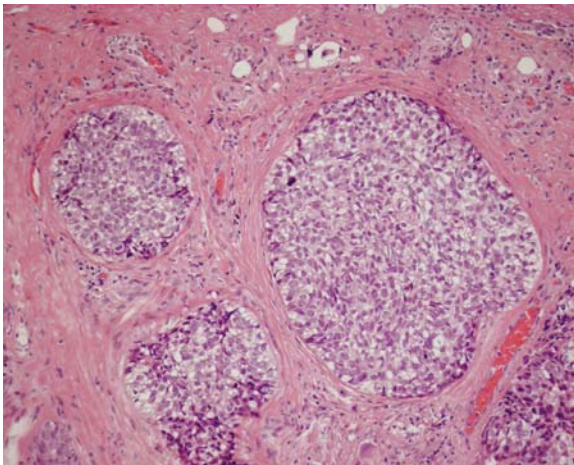


Fig. 10.10. Sebaceous adenocarcinoma: basaloid epithelial nests with a clear cell component

10.2.6.1.5 Sebaceous Adenocarcinoma

ICD-O:8410/3

This lesion is important because it can be a pitfall for both the clinician and the pathologist. The tumour presents as a solitary nodule, that can clinically be misdiagnosed as a basal cell carcinoma or even as a chalazion or blepharconjunctivitis [1, 36, 81]. Histologically, the tumour is composed of epithelial nests with varying sebaceous differentiation. The well-differentiated sebaceous carcinomas are not very hard to recognise, but the poorly differentiated ones can be easily missed. The intraepithelial pagetoid spread of tumour cells (which is frequently present) may be misinterpreted as dysplasia. Immunohistochemical stainings

like EMA and CAM 5.2 can help in differentiating this aggressive tumour from a squamous cell carcinoma (Figs. 10.09–10.11). Treatment of choice is wide excision, which can cure patients at an early stage of the lesion. However, the mortality rate from metastases is 25%, and even higher in a poorly differentiated tumour with angioinvasive growth.

10.2.6.2 Melanocytic

10.2.6.2.1 Naevus

ICD-O:8720/0

The most common melanocytic lesion of the conjunctiva is the compound naevus. Other types of naevi that can be found in the conjunctiva are intraepithelial, subepithelial, Spitz and blue naevi. Their histology is similar to melanocytic skin lesions. The naevus mostly arises in the first or second decade as a nodule in the bulbar conjunctiva. A band of melanocytes in the basal layer of the epithelium represents the intraepithelial component. These melanocytes can be melanin-containing, but can also present as clear cells. Melanocytes can also be found in the epithelium of the inclusion cysts, which are almost invariably present. These large, mucin-containing cysts are formed by incarcerated epithelial nests and can give an erroneous clinical impression of growth. The stromal component is formed by nests of mature cells with maturation to smaller cells in the deeper parts of the lesion (Fig. 10.12). Especially at a young age, a considerable variation in cell size can be seen; these active lesions are easily overdiagnosed as malignant melanomas.

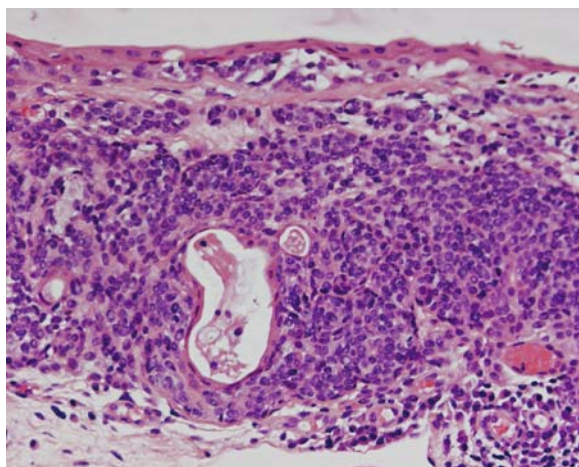


Fig. 10.12. Compound conjunctival naevus: the intraepithelial component is represented by a band of clear melanocytes in the basal layer of the epithelium. A small inclusion cyst is present, surrounded by unsuspecting naevoid cells with maturation to smaller cells in the deeper part of the lesion

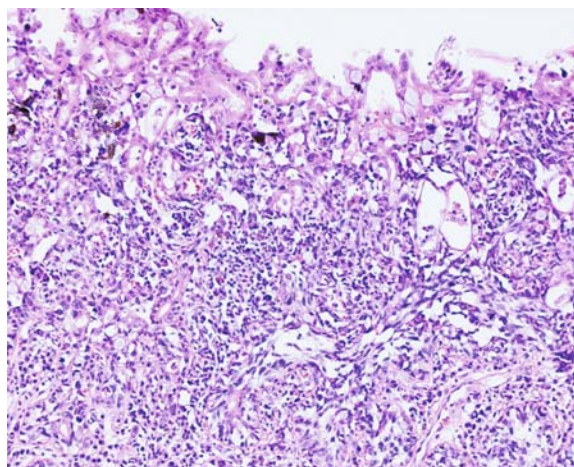


Fig. 10.14. Malignant melanoma arising from primary acquired melanosis with atypia: the conjunctival epithelium is ulcerated and the atypical cells spread into the underlying stroma

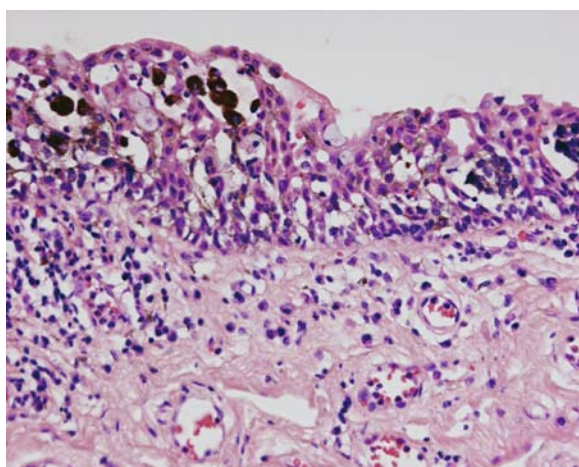


Fig. 10.13. Primary acquired melanosis with atypia: an almost continuous proliferation of atypical melanocytes is present in the conjunctival epithelium

10.2.6.2.2 Primary Acquired Melanosis

ICD-O:8741/2

Primary acquired melanosis (PAM) arises in middle-aged or elderly patients as a stippled, yellow-brown, flat pigmentation of the conjunctiva. Two subgroups of PAM can be recognised: PAM without atypia (benign acquired melanosis) and PAM with atypia. In benign acquired melanosis, there is hyperpigmentation of the basal layer, but there is only a mild increase in melanocytes. The melanocytes can be large, but show little or no cytologic atypia. Although the evolution of PAM is unpredictable, lesions without atypia have a good prognosis. PAM with atypia can disappear

spontaneously, can remain stationary or may progress to malignant melanoma. Histologically, there is an increase in atypical melanocytes in the conjunctival epithelium (Fig. 10.13). The atypia can be graded mild to severe. To exclude invasive growth, use of the immunohistochemical marker CD68 can be helpful in identifying melanin-containing cells in the stroma as macrophages.

10.2.6.2.3 Malignant Melanoma

ICD-O:8720/3

The majority of conjunctival melanomas arise within primary acquired melanosis with atypia. Development of a melanoma in a pre-existing naevus or de novo is possible, but uncommon [44, 61]. In malignant melanoma clusters of atypical melanocytes are present in the stroma (Figs. 10.14, 10.15). The melanocytes are most frequently epithelioid, but can also be spindle-shaped or bizarre. The intraepithelial component shows large, atypical melanocytes, often without ascending cells. This differs from skin melanocytic lesions, where ascending melanocytes can be very helpful in diagnosing a malignant melanoma. These cytological characteristics do not seem to influence prognosis. Depth of the tumour, however, does have prognostic value: thickness less than 1.5 mm means a low risk of metastatic disease.

10.2.6.3 Other Neoplasms

Lymphomas may involve the conjunctiva. Also, tumours from adjacent locations may extend into this site. They are discussed under their appropriate headings.

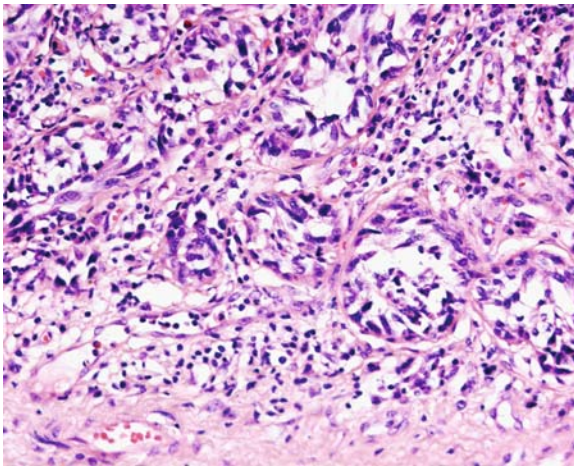


Fig. 10.15. Malignant melanoma: detail of the nested, atypical melanocytes without maturation in the stroma

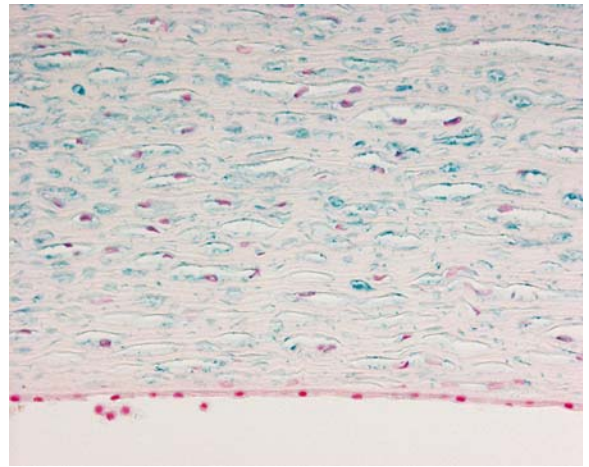


Fig. 10.16. Mucopolysaccharidosis: this cornea showed no abnormalities on H&E staining, but colloidal iron showed deposits of mucopolysaccharides very clearly

10.3 Cornea

Inflammation and ulceration of the cornea can be caused by trauma, surgery to the eye, infectious diseases and systemic diseases. The trauma can be mechanical, chemical or caused by heat or irradiation. The increasing incidence of cataract extraction has led to an increase in cases with corneal damage during the surgical procedure. Infectious keratitis can be viral, bacterial, fungal or parasitic. In chronic granulomatous keratitis, causes like leprosy, syphilis and tuberculosis should be considered. Especially in immunocompromised patients infectious causes should be excluded by additional stains like PAS, Grocott and Gram. In corneal ulcers without a clear aetiology, artificial keratitis has to be considered. Factitious injury is rare and can be either the result of mechanical trauma or the abuse of toxic eye drops [26]. Histology of factitious lesions is non-specific. An example of a systemic disease affecting the cornea is mucopolysaccharidosis (Fig. 10.16).

10.3.1 Keratitis and Corneal Ulcers

10.3.1.1 Herpes Simplex Keratitis

Type 1 herpes simplex virus is the most common cause of corneal disease. After primary infection of the lip, the virus remains latent in the sensory trigeminal ganglion. Transneuronal migration and proliferation of the virus is triggered by stress, sunlight or cold. The virus parasitises the epithelium, leading to superficial epithelial loss in a branching pattern (dendritic ulceration)

or punctate spots (punctate keratopathy). If the disease recurs, the virus may infect stromal keratocytes, causing chronic destruction with ulceration. Histologically, an early herpetic ulcer shows multinucleated epithelial cells with intranuclear viral inclusions. DNA in situ hybridisation, immunohistochemistry and PCR are modern techniques replacing the transmission electron microscopy that was used to demonstrate the herpes virus particles in earlier days [49]. In end-stage disease, epithelial changes are no longer present; there is just fibrosis with scarring. Often, Bowman's layer is focally replaced by fibrosis.

10.3.1.2 Corneal Ulceration Due to Systemic Disease

Systemic vasculitides like systemic lupus erythematosus, polyarteritis nodosa and Wegener's granulomatosis can cause peripheral corneal ulceration due to vascular occlusion by immune complex deposition in the limbal vessels [73, 85]. In rheumatoid arthritis corneal ulceration can occur due to the release of collagenases [92].

10.3.2 Keratoconus

This condition presents at puberty and has been found in association with systemic disorders like Marfan's syndrome, Down's syndrome [52, 88], neurofibromatosis, Ehlers-Danlos syndrome [56, 94, 129] and atopic dermatitis [93, 109, 119]. It can also be seen in combination with ocular disorders like aniridia, cataract and retinitis pigmentosa [11, 33, 53]. A progressive, non-inflamma-

tory, bilateral thinning of the central corneal stroma leads to severe astigmatism. Aetiology and pathogenesis are unclear. At histological examination the epithelium can be either atrophic or hyperplastic. The most striking finding is interruption of Bowman's membrane, with downgrowths of epithelium or upgrowths of corneal stroma in the breaking spot. The breaks may be narrow and the pathology is often restricted to a narrow 1–2 mm zone, sometimes serial sections are required to find the lesion. At the edge of the conus, iron can be found in the epithelium (Fleischer's ring). The axial stroma shows mucoid degeneration, the peripheral stroma is of normal appearance. In severe cases, rupture of Descemet's membrane and the endothelium can occur, resulting in an inflow of water and the appearance of cystic spaces. Keratoconus can be treated by surgery with use of stromal cornea grafts.

10.3.3 Hereditary Corneal Dystrophies

Corneal dystrophies are inherited, bilateral disorders that can be divided into epithelial, stromal and endothelial abnormalities. Routine stains for suspected corneal dystrophy must include PAS, Masson, Alcian blue, Congo red and Trichrome stains. In end-stage dystrophies a keratopathy can develop, in which all layers of the cornea are involved. Many patients with corneal dystrophies have a point mutation in a gene on chromosome 5q31 [54, 77, 113].

10.3.3.1 Epithelial Dystrophies

Epithelial corneal dystrophies are Cogan's microcystic dystrophy, Meesman's dystrophy and Reis-Buckler's ring dystrophy [123]. The epithelial dystrophies present with photophobia and/or foreign body sensation. The most common form of epithelial dystrophy is Cogan's microcystic dystrophy, affecting females of middle age. A thickened and folded basement membrane with epithelial cysts containing necrotic debris is characteristic. Bowman's membrane is not involved. In Meesman's dystrophy small layers of the basement membrane can be found between the epithelial cells. Reis-Buckler ring dystrophy is a bilateral, autosomal dominant dystrophy, not only affecting the epithelium, but also the anterior corneal stroma. The epithelium is oedematous and atrophic, Bowman's membrane is interrupted and the anterior stroma contains abnormal fibrous tissue. Histology is not specific and transmission electron microscopy, which will show electron-dense rods in the superficial stroma, is necessary to confirm the diagnosis [87].

10.3.3.2 Stromal Dystrophies

10.3.3.2.1 Granular Dystrophy

Granular dystrophy is an autosomal dominant disorder, presenting in early childhood with discrete, opaque granules in the otherwise transparent anterior corneal stroma. Histologically, non-birefringent hyaline bodies are present in the stroma. The deposits are strongly positive with Masson stain [67].

10.3.3.2.2 Lattice Dystrophy

Lattice dystrophy is an autosomal dominant disorder, clinically presenting in early childhood (type I) [66] or in the 2nd decade (type II) [95] with linear opacities. Histologically, eosinophilic deposits are found in the corneal stroma. They consist of amyloid and are strongly Congo red-positive [67, 112]. The disease is treated by keratoplasty.

The presence of amyloid in the corneal stroma can also be seen in chronic inflammatory conditions, these secondary amyloid deposits should not be confused with lattice dystrophy.

10.3.3.2.3 Avellino Dystrophy

A combined granular-lattice dystrophy with both hyaline and amyloid deposits in the corneal stroma was first described in the Italian village of Avellino [29].

10.3.3.2.4 Macular Corneal Dystrophy

Macular dystrophy presents in childhood as a bilateral process with irregular opacities between cloudy corneal stroma. It is a disease disabling vision, inherited as an autosomal recessive trait. The disease is considered to be a localised metabolic disorder with production of excessive amounts of acid mucopolysaccharide by fibroblasts [24, 67]. The disease is not associated with systemic mucopolysaccharidoses.

10.3.3.3 Endothelial Dystrophies

10.3.3.3.1 Fuchs Dystrophy

This disorder affects elderly patients and is quite common in routine histopathology. It presents clinically with bilateral diffuse cloudy and oedematous stroma. Histologically, the corneal epithelium is oedematous,

Descemet's membrane is thickened and there is reduction of the endothelial cell population. A PAS stain sometimes shows lamination of Descemet's membrane. On the posterior surface of Descemet's membrane, nodular excrescences can be seen.

10.3.4 Failed Previous Grafts

Many corneal diseases can be treated by keratoplasty. Complications are rejection, formation of a retrocorneal fibrous membrane and recurrence of the original disease.

Rejection of the graft can occur immediately after the operation or many years later. Histologically, there is vascularisation of the corneal stroma, accompanied by a lymphocytic infiltrate.

Formation of retrocorneal fibrous membranes occurs following fibroblastic metaplasia of keratocytes at the posterior edges of the host-graft junction. This complication is diminishing with advances in microsurgery.

Over a longer period of time, recurrence of the original disease is common in patients with corneal dystrophies.

10.4 Intraocular Tissues

Pathology of the intraocular tissues can be divided into developmental anomalies, inflammatory processes, trauma, degeneration and tumours.

10.4.1 Developmental Anomalies

10.4.1.1 Congenital Glaucoma

Glaucoma due to congenital malformation is rare. Associations with systemic disorders like neurofibromatosis [8, 84, 130] and Sturge-Weber syndrome [18, 19] have been described. A malformation of the trabecular meshwork (goniodysgenesis) or persistence of embryonic tissue in the chamber angle causes an outflow obstruction. The corneoscleral envelope of the infant is distensible, so that a raised intraocular pressure can produce an enlargement of the globe (buphthalmos). A hypercellular trabecular meshwork with hyaloid degeneration is the best visible histopathological finding in those specimens [133].

10.4.1.2 Retinopathy of Prematurity

In premature children requiring artificial breathing with high oxygen pressures to survive, disordered neovascularisation at the periphery of the retina can occur [91]. A white retrolental fibrous membrane can form in

the most extreme cases, causing bilateral blindness (retrolental fibroplasia). At the end stage of the disease neovascular glaucoma leads to enucleation. The distorted retina is macroscopically visible, most frequently forming a straight band behind the lens. Histology shows retinal gliosis and optic atrophy [21].

10.4.1.3 Persistent Primary Hyperplastic Vitreous

In the embryo, the lens is supported posteriorly by a mass of vascular tissue, the primary vitreous. If this primary vitreous fails to involute before birth, embryonic fibrovascular tissue persists in the anterior or posterior part of the vitreous and becomes hyperplastic. In persistent anterior primary hyperplastic vitreous, a retrolental fibrovascular mass can penetrate the posterior lens capsule and lens cortex, causing an autoimmune inflammatory response. In persistent posterior hyperplastic primary vitreous, the fibrovascular mass damages the optic disc.

10.4.1.4 Retinal Dysplasia

Failure of organisation of the layers of the retina leads to retinal dysplasia, in which nests of neuroblastic cells form rosettes within the retina. Clustering of rosettes leads to thickening of the retina, which may become detached. Retinal dysplasia is a common feature of trisomy 13, trisomy 18 and other chromosomal disorders. As an isolated entity, retinal dysplasia is very rare [65].

10.4.1.5 Aniridia

Aniridia is a rare bilateral disease. It occurs as a condition that may be inherited as an autosomal dominant disorder or as part of several systemic syndromes. In some cases of aniridia, deletion of the short arm of chromosome 11 occurs. Because this locus lies close to the gene for nephroblastoma (Wilms' tumour), the recognition of a child with sporadic aniridia should alert physicians to the increased risk of development of Wilms' tumour [10, 23]. Histology of enucleated eyes or trabeculectomy specimens shows a rudimentary iris, consisting of hypercellular stroma, often with an abnormal proliferation of pigment epithelium.

10.4.1.6 Congenital Rubella Syndrome

Maternal rubella infection during the first trimester of pregnancy can affect the development and function of the entire eye. It can manifest as a congenital cataract,

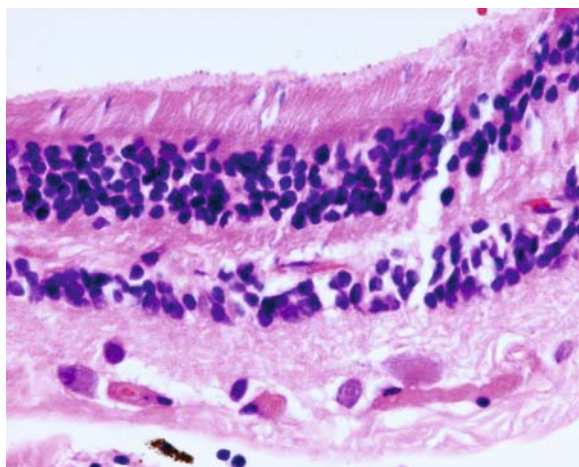


Fig. 10.17. Cytomegaloviral retinitis: large eosinophilic inclusions are present in the infected endothelial cells. In this biopsy the retina showed almost no signs of necrosis, which is uncommon in cytomegalovirus retinitis

disciform keratitis, retinopathy, microphthalmus or open-angle glaucoma [3, 51]. In societies with immunisation the condition is rare. The histologic findings in the lens are characteristic, but it should be mentioned that the features may not yet be apparent in foetal eyes after early elective termination of pregnancy [38]. The central nucleus of the lens, which is normally free of cells, shows pyknotic nuclei. There is an abrupt transition from the central nucleus into the normal peripheral cortex of the lens [128].

10.4.2 Inflammatory Processes

10.4.2.1 Acute Inflammation

Acute endophthalmitis or panophthalmitis can occur as a postoperative complication or following a trauma [12, 57]. Endocarditis or injection of contaminated material in drug addicts can be the cause of metastatic bacterial infection, especially in immunocompromised patients [89]. Not only bacterial, but also fungal and viral infections can cause acute endophthalmitis. Histology shows an extensive infiltrate of leukocytes with destruction of intraocular tissues. The pathogen can sometimes be found in Gram, PAS or Silver stains. Acute necrotising retinitis and low-grade uveitis can be seen in cytomegaloviral and herpes infection (Fig. 10.17). The characteristic eosinophilic inclusions of the cytomegalovirus can be found in the cytoplasm and nuclei of infected cells. Immunohistochemical staining with anti-cytomegalovirus can be helpful in identifying the virus. The inclusions of herpes simplex

retinitis can also be visualised with DNA in situ hybridisation.

10.4.2.2 Chronic Non-Granulomatous Inflammation

Chronic non-granulomatous inflammation of the uveal tract is a poorly understood condition. It can be divided into anterior uveitis, with risk of secondary angle closure glaucoma, and posterior uveitis with risk of degeneration of retinal pigment epithelium. The histology is non-specific, with only a few lymphocytes in the uveal tissues.

10.4.2.3 Granulomatous Inflammation

The specific granulomatous inflammations of the intra-ocular tissues can be divided into infectious and autoimmune causes. The autoimmune diseases are sarcoidosis, sympathetic ophthalmitis and lens-induced uveitis. While many of these diseases may be appropriately treated with immunosuppressive medication, the management of infectious uveitis is antimicrobial therapy. Inappropriate immunosuppressive therapy may be disastrous for patients with an infection. Chorioretinal biopsy may provide useful information for determining the diagnosis and guiding the subsequent management of patients with progressive chorioretinal lesions of unknown aetiology [69].

10.4.2.3.1 Infectious

The most important causes of infectious granulomatous inflammatory diseases of the intraocular tissues are tuberculosis and toxoplasmosis.

Tuberculosis is rare and shows caseating granulomas, in which tubercle bacilli can be found in a Ziehl-Neelsen staining.

Toxoplasmic retinochoroiditis in neonates infected in utero with *Toxoplasma gondii* can show a wide variation in the pattern of tissue destruction. The disease can be limited to a low grade uveitis and retinal lymphocytic perivasculitis. In more severely affected eyes focal, sectorial or total retinal destruction can be seen. Toxoplasma cysts can be found in the retina and optic nerve. In the most severely affected eyes the retina is necrotic and calcified [5].

10.4.2.3.2 Sarcoidosis

In patients with systemic sarcoidosis, ocular involvement can occur. Most frequently affected are the retina, the

uveal tract and the optic nerve. Histology shows sharply demarcated, non-caseating granulomas [59, 96].

10.4.2.3.3 Sympathetic Ophthalmitis

Sympathetic ophthalmitis is an uncommon, but feared complication because of its potential to blind both eyes. It can result not only from penetrating trauma or ocular surgery, but also from non-penetrating ocular procedures. Early enucleation of the traumatised eye reduces the risk of occurrence of sympathetic ophthalmitis in the non-traumatised (“sympathetic”) eye. The condition seems to be caused by a T-cell-mediated autoimmune response and can be treated with immunosuppressive therapy. Infectious causes must be ruled out before starting this therapy. Histology of the enucleated traumatised eye shows a granulomatous uveitis with a thickened choroid featuring non-caseating granulomas with a few plasma cells and eosinophils, very similar to sarcoidosis [16]. Fine melanin granules can be seen in the cytoplasm of the histiocytes. The granulomatous inflammatory reaction can spread around small nerves.

10.4.2.3.4 Lens-Induced Uveitis

Lens-induced uveitis or phacoanaphylactic endophthalmitis is a chronic endophthalmitis with a zonal granulomatous inflammation surrounding a ruptured lens. Most cases occur after trauma, surgical or non-surgical. The condition may result in vision-threatening intraocular inflammation that is poorly responsive to medical management. Leaking of lens proteins through an intact lens capsule may result in a lympho-plasmacytic anterior uveitis [102, 127]. The inflammation can be confined to the anterior aspect of the eye, but the choroid can also be involved. Surgical removal of the lens material is generally indicated shortly after the injury in an effort to save vision. Normally, small amounts of circulating lens proteins maintain a normal T-cell tolerance for lens proteins. Lens-induced uveitis develops when a breakdown occurs of this normal T-cell tolerance. Immune complexes play an important role in the tissue damage associated with the ensuing inflammation.

10.4.3 Trauma

Mechanical injury is the most frequent cause of trauma of the eye. It can be caused by many different forces, like broken glass, airguns, knives and golf balls. Chemical, toxic and radiation damage is less often seen. Traumatised eyes can be enucleated at three different moments in the time following the injury.

The first moment to make the decision for enucleation is immediately or within a day or two following the injury. The globe is ruptured, massive intraocular bleeding is present and there is evidence that repair will not restore visual function. To lower the risk of sympathetic ophthalmitis, the eye will be enucleated at an early phase. A wide range of foreign bodies can be found in these eyes. The inflammation is usually mild or absent. The most important mission for the pathologist is to confirm the irreparable damage. The lens is often absent or prolapsed through the corneal wound, a retinal tear shows the side of penetration, the vitreous is haemorrhagic, papilloedema is present and the retina can show exudative detachment (Fig. 10.18).

When attempts to repair the eye are made, mild uveitis develops. Within a period of 2–3 weeks the uveitis should diminish. If not, many ophthalmologists will make the decision to enucleate the eye to avoid the risk of sympathetic ophthalmitis. In these eyes, removed within a few weeks after the trauma, reparative changes like fibrous ingrowth of the corneal wound can be found. The blood in the vitreous will show organisation.

Traumatised eyes with residual vision and without inflammatory complications can become hypotonic and atrophic over a period of years. Secondary glaucoma can develop and the eyes are removed because of pain or for cosmetic reasons. Frequently, the secondary changes are very complicated and the primary pathology is not visible anymore. At macroscopic examination, the site of the trauma can be identified by the presence of scars, suture tracks or just by episcleral thickening. Post-traumatic glaucoma is most often caused by secondary angle closure. Furthermore, dislocation of the lens and lens-induced uveitis can be seen. The retina is usually partially or totally detached, and is thickened by reactive gliosis.

10.4.4 Degeneration

10.4.4.1 Glaucoma

The normal pressure (13–21 mmHg) in the corneoscleral envelope is maintained by a balance between the aqueous inflow and the resistance in the outflow system. The fluid is pumped into the eye by the ciliary epithelium, passes through the pupil to the chamber angle and leaves the eye via the trabecular meshwork and the canal of Schlemm to the collector canals in the sclera, draining into the episcleral venous system. Impaired outflow can cause high intraocular pressures and when the intraocular pressure is high enough to cause damage to the intraocular tissues, the term glaucoma is used. The primary cause of glaucoma can in

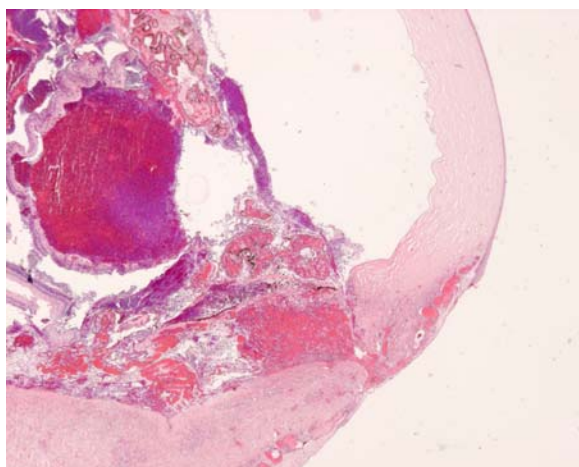


Fig. 10.18. Trauma caused by a wooden stick: this eye was enucleated 1 week after the trauma and showed scleral perforation, retinal detachment and haemorrhagic vitreous

most cases not be detected in the tissue without the complete clinical history. Depending upon the rapidity of the rise in pressure, glaucoma causes tissue damage. In a pressure rise to 80 mmHg within 1 or 2 days (acute glaucoma) severe corneal oedema, infarction of the iris, necrosis of the lens and retinal oedema occur. When the pressure rises over a longer period of time more chronic changes can be found. The cornea shows fibrovascular tissue ingrowth at the periphery. The angle is closed by a corneal endothelial downgrowth and the trabecular tissue is fused and hyalinised. The iris stroma and ciliary body become atrophic and fibrotic. The nucleus of the lens becomes sclerotic. The vitreous may be unaffected, but in cases of retinal vascular disease, the vitreous contains blood and macrophages with fibrous strands. Atrophy of the optic disc is visible by cupping and shrinkage down to the lamina cribrosa, which becomes bowed posteriorly. The choroid and retinal pigment epithelium are able to withstand high pressure and will only show atrophy and fibrosis in end-stage disease. Pathologic examination of enucleated glaucomatous eyes is often complicated by previous surgical procedures. Glaucoma can be divided into four subgroups.

10.4.4.1.1 Primary Open Angle Glaucoma

Primary open angle glaucoma occurs predominantly in the elderly and is caused by an acquired unilateral or bilateral disease of the trabecular meshwork, visible at histopathological examination by hyalinisation of the trabecular meshwork.

10.4.4.1.2 Primary Angle Closure Glaucoma

In primary angle closure glaucoma, the aqueous outflow is obstructed by apposition of the iris to the inner surface of the cornea and the trabecular meshwork. The acute form of the disease occurs unilaterally in middle-aged and elderly patients and presents with a rapid and painful rise in intraocular pressure. Both in acute and chronic angle closure glaucoma, three ageing processes seem to cause the closure of the angle: shrinkage of the eye, reduction in depth of the anterior chamber and increased size of the lens.

10.4.4.1.3 Secondary Open Angle Glaucoma

Particulate or cellular elements present in the trabecular meshwork can cause outflow obstruction. Examples are iatrogenic glaucoma (caused by silicone oil, topical steroids or viscoelastic substances used to coat lens implants), haemolytic glaucoma, lens protein glaucoma, post-traumatic glaucoma and glaucoma in association with tumours (caused by necrotic cells of malignant melanomas and retinoblastomas). The outflow system can also be blocked by melanin pigment granules released from iris stroma or pigment epithelium when the iris is traumatised or becomes atrophic.

10.4.4.1.4 Secondary Angle Closure Glaucoma

In secondary angle closure glaucoma, iridotrabecular or iridocorneal contact is present. This is most frequently caused by neovascular glaucoma, in which neovascularisation with fibrosis of the iris occurs, for example in retinopathy of prematurity. Other causes are end-stage inflammatory disease, retinal detachment, tumours or trauma.

10.4.4.2 Cataracts

Prolonged exposure to ultraviolet light seems to be an important cause of cataracts, a frequent disorder in elderly patients. An extracted lens should be fixed, embedded in paraffin wax and cut in two halves in the antero-posterior direction. Slides can be made by sectioning the cut surface. Cutting the lens before processing can cause artefacts. In cataracts of the elderly degenerated lens fibres form discrete globules and the epithelium covering the inner surface of the anterior lens capsule may extend to the posterior part of the lens. Similar observations are made in cataracts in children [104].

10.4.4.3 Phtisis Bulbi

A long period of time after a trauma or an inflammatory disease, the total eye becomes atrophic. As long as choroïdal and retinal anatomy are preserved, this is called atrophía bulbi. As soon as disorganisation of choroïdeá and retina occurs, it is called phtisis bulbi. A reactive cell proliferation dominates the histology. This proliferation can be fibroblastic (trauma of cornea, sclera, choroïdeá and iris), or glial (retinal damage). Also, proliferation of retinal pigment epithelium or ciliary body epithelium can be seen. The optic nerve is usually completely atrophic.

10.4.4.4 Retinal Vascular Disease

Loss of vision caused by ischaemic disease of the retina is common. It can be due to several different vascular disorders. Most frequently it is caused by central retinal vein occlusion, diabetes, or occlusion of a branch vein. More rare are vasculitis, retinopathy of prematurity, radiation retinopathy, central retinal artery occlusion, hypertension and disseminated intravascular coagulopathy. Occlusion of an artery causes white infarction, while occlusion of veins leads to haemorrhagic infarction. The ischaemic area can vary between focal (occlusion of branch vessels), segmental, or total (occlusion of the central retinal vein or artery). Ischaemia of the retina with damage of retinal vasculature shows leakage of red cells, followed by neovascularisation and formation of microaneurysms. In the final stage, secondary angle closure glaucoma can develop with corneal ulceration and cataract formation, resulting in a not only blind but also painful eye. The globes are often enucleated to relieve pain. At macroscopic examination an ectropion of the iris pigment epithelium, caused by the neovascular membrane on the iris surface is visible (but only if the cornea is transparent). At microscopic examination, the proliferation of endothelial cells in the retina is the most striking finding. Sometimes CD31 and GFAP staining are necessary to differentiate the vascular proliferation from reactive gliosis.

10.4.4.5 Retinal Detachment

Several degenerative conditions predispose to retinal detachment. The separation between the neural retina and the retinal pigment epithelium can be caused by traction, exudate, or by so-called rhegmatogenous detachment. Traction detachment occurs when the vitreous shows fibrosis or gliosis, following trauma or by neovascularisation. Accumulation of fluid between the layers of the retina is called exudative detachment. It can be caused by processes with excessive permeability of reti-

nal or choroïdal vessels, like inflammatory or neoplastic disorders. In rhegmatogenous detachment, passage of fluid from the vitreous cavity to the subretinal space is present. It occurs through a hole in the retina, caused by degeneration or a minor trauma. Enucleated eyes with retinal detachment usually show many signs of previous surgical intervention. The most important information for the surgeons is whether the retina survived the separation and reattachment or not and if a reason for surgical failure can be found.

10.4.4.6 Retinitis Pigmentosa

Retinitis pigmentosa presents in early life with night blindness and a progressive reduction in the visual field, starting at the periphery. Retinal architecture remains best preserved at the macula, so the patient ends up with tunnel vision. Different chromosomal abnormalities have been found in patients with retinitis pigmentosa. Microscopic examination shows retinal atrophy with proliferation of Müller cells (retinal supporting cells at the outer side of the retina) replacing the outer nuclear layer. The retinal pigment epithelium proliferates and can surround small hyalinised vessels in the retina. A marked variation in the extent of retinal degeneration can be seen in two relatives with retinitis pigmentosa [117].

10.4.5 Tumours and Tumour-Like Conditions

10.4.5.1 Melanocytic

Melanocytes in the uveal tract can give rise to both benign and malignant tumours. Racial differences may reflect themselves by variance in prominence and enlargement of melanocytes in the choroid, ciliary body and iris. It is very important for pathologists to be aware of these differences.

10.4.5.1.1 Naevus

ICD-O:8720/0

Iris naevi present as pigmented macular lesions, are very slowly progressive, and often completely static over years. When the clinical presentation is not suspicious, in most cases the lesion will not be excised. For that reason, naevi of the uveal tract are most commonly incidental findings. Histology shows a symmetrical lesion, located in the anterior part of the iris stroma, and usually composed of small spindle cells with small, uniform nuclei. Large nucleoli and especially mitotic figures indicate a suspected malignant melanoma.

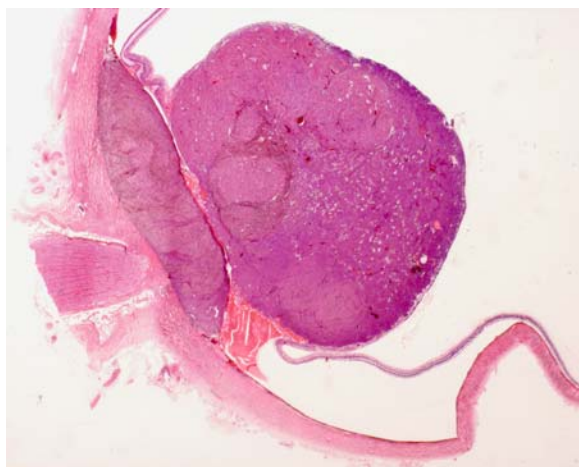

Fig. 10.19. Uveal tract melanoma arising in the choroid

In the ciliary body naevi are very rare; the histology is comparable with iris naevi: spindle-shaped cells without atypia and without mitotic figures. In the choroid, naevus cells are spindle-shaped and often heavily pigmented, nuclei are uniform, and no mitotic figures are seen. Depigmentation of the slides may be helpful in evaluating cytological details.

10.4.5.1.2 Malignant Melanoma

ICD-O:8720/3

The major part of uveal tract melanomas arise in the choroid (Fig. 10.19). Most frequently affected are white individuals in the sixth and seventh decades of life. Most melanomas are single and confined to one eye. In most cases they arise from pre-existing naevi in the choroid. Ciliary body and iris melanomas are rare. Malignant melanoma of the choroid presents with loss of vision in one eye, or with secondary closed angle glaucoma. The glaucoma is caused by detachment of the retina with lens–pupil block. Spread of the tumour into the orbita can cause proptosis. The primary clinical differential diagnosis for melanoma is choroidal metastasis. At macroscopic examination of an enucleated eye with a choroidal melanoma, it is important to locate the tumour before cutting the eye. The tumour can be located by palpation and transillumination. If possible, the main histological section should contain the centre of the pupil, the optic nerve and the centre of the tumour. Small pigmented nodules can be seen on the external surface of the sclera in case of transscleral extension of the tumour. The sample taken at this point sometimes needs section at multiple levels to demonstrate the tumour passing through the scleral canals. Microscopically, the melanomas consist of

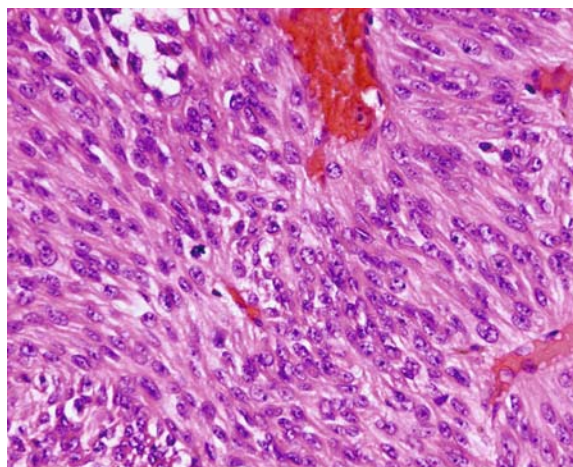


Fig. 10.20. Uveal tract melanoma: detail of closely packed spindle-shaped cells; in this area almost no pigment is present

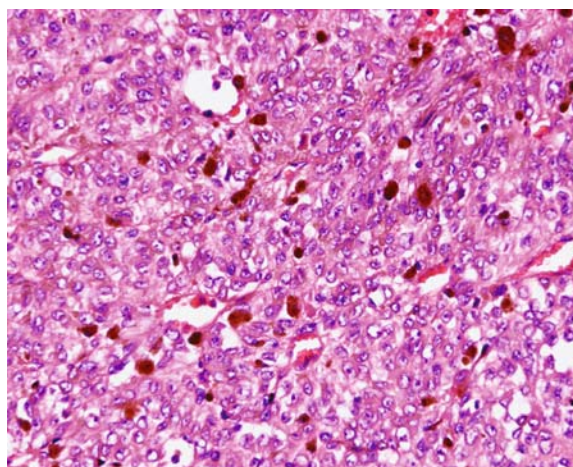


Fig. 10.21. Uveal tract melanoma: a more pigmented area

spindle-shaped cells, epithelioid cells, or a combination of both (mixed cell type). The spindle-shaped cells are closely packed elongated cells, often with pronounced nucleoli and a few mitotic figures. In epithelioid lesions, the cytoplasm is more eosinophilic and mitotic figures are easily found. Melanin pigment is usually present, but amelanotic lesions can be seen (Figs. 10.20–10.23). Positive immunohistochemistry with S-100, melan A or HMB45 confirms the diagnosis in those cases. The final report should include the origin of the tumour (choroid, ciliary body, iris), the thickness of the tumour (in mm), the cell type (spindle cell type, epithelioid cell type or mixed cell type) and extraocular growth. The 5-year survival of pure spindle tumours is 80%, while pure epithelioid tumours have a 5-year survival of 35%. The 20-year survival of both groups is only 20%.

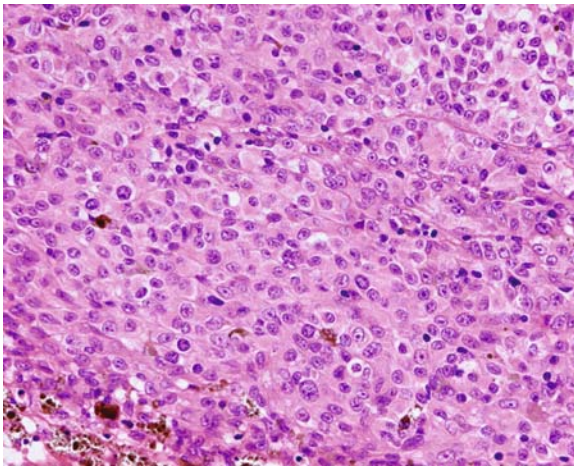


Fig. 10.22. Uveal tract melanoma: detail of an epithelioid lesion consisting of cells with a large amount of eosinophilic cytoplasm

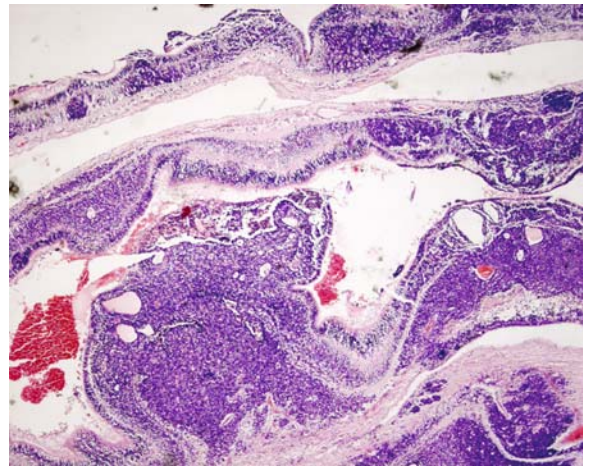


Fig. 10.24. Retinoblastoma: a detached retina with small blue round cell proliferation

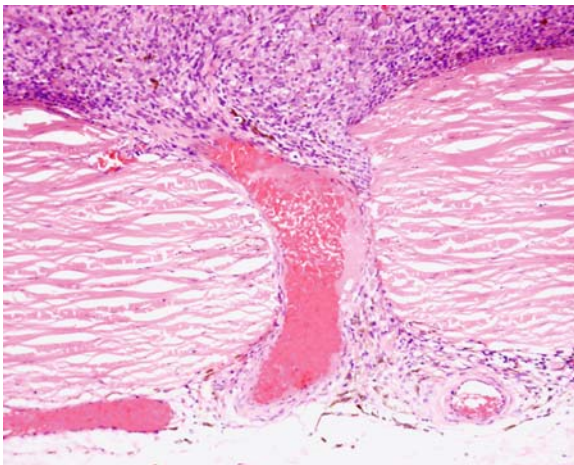


Fig. 10.23. Uveal tract melanoma: trans-scleral extension of the tumour

10.4.5.2 Lymphoid

Intraocular lymphomas are not different from those occurring elsewhere in the body. Therefore, discussion of their features lies beyond the scope of this chapter.

10.4.5.3 Retinoblastoma and Pseudoretinoblastoma

ICD-O:9510/3

Retinoblastoma is rare, but nevertheless the most common intraocular malignant tumour of childhood, clinically presenting as a white mass behind the lens, resulting in the so-called cat's eye reflex. Vision in the eye is

impaired, leading to strabismus. The tumour affects children younger than 5 years and can be unilateral or bilateral (30%). Retinoblastoma in adults is extremely rare. Lesions with the typical clinical presentation but are of other kinds are called *pseudoretinoblastoma*. They can be other tumours (astrocytic hamartomas, haemangioblastomas), congenital malformations or inflammatory conditions (especially solitary *Toxocara granuloma*). The accuracy of clinical diagnosis has been improved by radiology, ultrasonography, CT scanning and nuclear magnetic resonance, and this has brought about a considerable reduction in the number of such cases.

The retinoblastoma gene, located on chromosome 13q14 is a tumour-suppressor gene. Retinoblastoma can be inherited (bilateral tumours in the first 2 years of life) or sporadic (unilateral tumours in children aged 2–5 years). One-third of the patients with a sporadic retinoblastoma show a germline mutation and can transmit the disease to their offspring. Compared with the general population, carriers of germline mutations in the retinoblastoma gene, who survive retinoblastoma are at increased risk of early-onset second cancers, particularly sarcomas and brain tumours. External beam radiotherapy has been a standard treatment for medium and large, or vision-threatening, intraocular retinoblastoma, but it markedly increases the risk of cosmetic deformities and secondary cancer in children with germline mutations. For that reason primary systemic chemotherapy called “chemoreduction” has been employed to avoid radiotherapy and enucleation. The cure rate of retinoblastoma is more than 90% in specialised centres.

Retinoblastomas are tumours originating from pluripotent germinal retinoblasts; the tumour can grow endophytically (growing into the vitreous), exophytically (growing into the subretinal space, leading to retinal detachment) or diffusely (a rare pattern with widespread

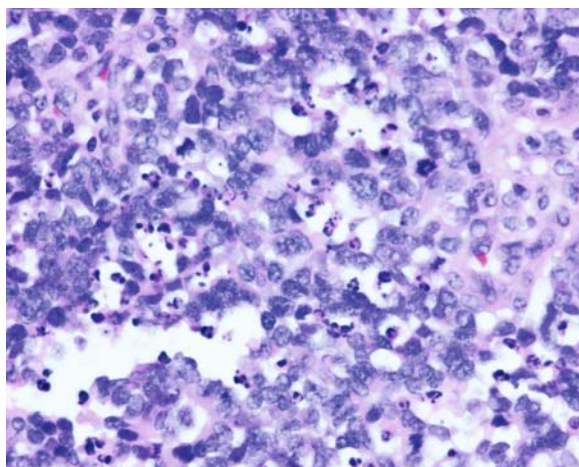


Fig. 10.25. Retinoblastoma: detail of the small blue round cells with high mitotic and apoptotic activity

nodular thickening of the retina). The diffuse growth pattern has a bad prognosis. Trans-scleral spread of retinoblastoma is uncommon. The tumour usually spreads into the meninges or parenchyma of the optic nerve. For this reason, it is important to take transverse blocks of the cut surface of the optic nerve, before cutting the enucleated eye. Microscopic examination will show a small blue round cell tumour with a high mitotic rate. The cells have ill-defined cytoplasm and inconspicuous nucleoli. Rosettes are frequently seen and apoptosis is common (Figs. 10.24, 10.25). Glial differentiation is rare. If the tumour was irradiated before enucleation, amorphous calcified structures will be present. Immunohistochemistry of retinoblastomas will show positivity for S-100, GFAP and NSE. Use of these markers can be helpful not only in identifying the tumour, but also in identifying the spread of the tumour. Choroidal invasion in particular can be hard to recognise in an H&E staining. Axonal degeneration in the optic nerve, with reactive proliferation of astrocytes has to be differentiated from real tumour spread.

10.4.5.4 Glial

From the glial tumours, only astrocytomas can be found in the retina and optic nerve. Optic pathway gliomas are frequently asymptomatic; sometimes they demonstrate rapid growth, causing considerable visual dysfunction, neurologic deficits, and endocrine disturbances. Most optic pathway gliomas are diagnosed in patients with neurofibromatosis. Children with optic pathway gliomas associated with neurofibromatosis 1 predominantly have multifocal lesions.

Benign astrocytic tumours of the retina (astrocytic hamartomas) most frequently occur in patients with tu-

berous sclerosis. Retinal astrocytic hamartoma and retinoblastoma may be very similar clinically and their differentiation in atypical cases can be difficult, even with the use of ultrasonography and computed tomography. Histologically, a well-circumscribed glial cell proliferation, sparing the outer layers of the retina will be visible.

10.4.5.5 Vascular

10.4.5.5.1 Angiomatosis Retinae

Von Hippel-Lindau disease is an autosomal dominantly inherited multi-system disorder characterised by haemangioblastic lesions of the central nervous system and visceral organs [126]. Angiomatosis retinae (retinal haemangioblastoma) is often the first observable manifestation of von Hippel-Lindau disease. Histology shows a proliferation of capillary endothelial cells and vacuolated stromal cells.

In some patients with von Hippel-Lindau disease or in the close relatives of such patients, unusual retinal vascular hamartomas other than retinal angiomas can be detected.

10.4.5.5.2 Cavernous and Capillary Haemangioma

ICD-O:9120/0

Haemangiomas of the choroid can be diagnosed clinically by fluorescein angiography. Diffuse haemangiomas with facial skin involvement can be seen in the Sturge-Weber syndrome. The treatment of these vascular lesions is radiation (external beam or radioactive plaque); for this reason pathologists do not see these lesions very often. Only when the haemangiomas lead to retinal attachment and blindness will enucleation follow. The excised globe usually shows reactive changes due to radiotherapy.

10.4.5.6 Other Primary Tumours

Tumours other than melanocytic, lymphoid, retinoblastic and vascular can be found in the intraocular structures, but they are extremely rare. In the iris leiomyoma, leiomyosarcoma, schwannoma, juvenile xanthogranuloma, rhabdomyosarcoma, inclusion cysts of the pigment epithelium, primary adenoma of the iris pigment epithelium and adenocarcinoma have been reported.

In the ciliary body leiomyomas, leiomyosarcomas, schwannomas, adenomas and medulloepitheliomas can be found, and in the choroid osteomas, adenomas and adenocarcinomas of the retinal pigment epithelium and hamar-

tomas have been described [63]. Choroidal osteomas can develop within a degenerated choroidal haemangioma or an inflammatory scar, but can also be idiopathic.

10.4.5.7 Metastatic Tumours

Metastatic tumours to the eye have a predilection for the highly vascular choroid. The metastases can be discovered in a patient known to have a malignancy, but they can also be the first presentation of the malignant disease. Histology most often shows an adenocarcinoma and the primary tumour is found in the breast or lung [86]. More rare are metastases from thyroid carcinoma, carcinoid tumours, endometrial carcinoma, haemangiosarcoma and adenocarcinoma of the intestinal tract. The lesions usually show severe necrosis due to palliative radiotherapy.

10.5 Optic Nerve

10.5.1 Papilloedema

Any condition in which the intracranial pressure is raised can cause papilloedema. The prelaminar part of the optic disc is swollen and the peripapillary photoreceptors are placed laterally. If the reason for the papilloedema is not identified, the oedema can present as a tumour. This so-called pseudotumour cerebri is treated by optic nerve fenestration to relieve the pressure in the subarachnoid space. The pathologist will receive the meninges surrounding the optic nerve, which are histologically completely normal.

10.5.2 Optic Neuritis

Optic neuritis presents as acute, unilateral and painful vision loss. It can result from inflammatory disorders, can occur as isolated inflammation, or may be part of the spectrum of multiple sclerosis. Magnetic resonance imaging is indicated to rule out compressive optic neuropathy. Spontaneous outcome of optic neuropathies is favourable. Secondary inflammatory optic neuritis (infection, vasculitis, sarcoidosis) is rare and usually presents with atypical evolution or other symptoms. Histologically, the optic nerve in multiple sclerosis will show a perivascular lymphocytic infiltrate with focal areas of demyelination and axonal atrophy at the end stage.

10.5.3 Optic Atrophy

In a normal optic disc, a large bulge of nerve fibre is formed. In enucleated glaucomatous eyes, the optic disc is obviously cupped and shrinks down to the lamina cribrosa, which becomes bowed posteriorly. Reactive fibrovascular tissue fills the cupped disc.

10.5.4 Tumours

10.5.4.1 Glioma

ICD-O:9380/3

Most glial tumours of the optic nerve are of the juvenile type. They present with slowly progressive proptosis. The juvenile tumours have a good prognosis, unlike the more rare adult types, which are invariably lethal. Bilateral optic nerve gliomas can be found in patients with neurofibromatosis. Histologically, the juvenile tumours are of the pilocytic type, while the adult tumours resemble the high-grade glioblastoma multiforme.

10.5.4.2 Meningioma

ICD-O:9530/0

Meningiomas surrounding the optic nerve can result from a primary tumour arising in the meningeal sheet of the optic nerve or can result from an intracranial meningioma spreading into the orbit. As in the intracranial compartment, meningiomas of the orbit occur most commonly in middle-aged females. The tumours present with proptosis. Optic nerve sheath meningiomas in the adult group grow slowly and have a good prognosis. Meningiomas at other sites in the head and neck are mentioned in Chaps. 2, 6 and 8.

10.6 Lacrimal Gland and Lacrimal Passages

10.6.1 Inflammatory Processes

Enlargement of the lacrimal gland is often caused by chronic inflammatory processes that can have many different causes. When chronic dacryoadenitis is associated with enlargement of the salivary glands, it is called Mikulicz syndrome. Mikulicz syndrome can be caused by many different diseases like sarcoidosis, tu-

berculosis, mumps, malignant lymphoma and syphilis. The most frequent cause of Mikulicz syndrome is Mikulicz disease; the histology is similar to that of benign lymphoepithelial lesions seen in the salivary glands. Acute and chronic dacryocystitis and canaliculitis are the result of inflammation, mostly non-specific, of the lacrimal passages. It may lead to dacryolithiasis (stones in the lacrimal sac) and to lacrimal mucocele.

10.6.2 Tumours and Tumour-Like Conditions

If a mass is found in the superolateral quadrant of the orbit, dermoid cysts and lacrimal gland masses should be considered. Fifty percent of lacrimal gland tumours are pleomorphic adenomas and the other half are malignant [27, 98, 134]. The malignant category includes predominantly adenoid cystic, carcinoma ex pleomorphic adenoma and mucoepidermoid carcinoma. The lacrimal tumours have few distinguishing imaging features, showing mostly a homogeneous character and moderate contrast enhancement. Poorly defined margins with bone destruction suggest a malignancy, but even the malignant lesions can be relatively well defined. The histology of lacrimal gland tumours is similar to that of salivary gland tumours as discussed in Chap. 5. Papillomas and squamous cell carcinomas are the benign and malignant tumours most commonly seen in the lacrimal sac. Their microscopic features are similar to those arising from the mucosa of the nose (see Chap. 2) or in the conjunctiva.

10.7 Eyelids

10.7.1 Cysts

Because of the numerous adnexal glands present in the eyelids, cysts are very common at this localisation. The cysts can be of developmental origin (dermoid cysts) or can be caused by inclusion or retention.

10.7.1.1 Dermoid Cyst

The most common type of a cyst of the eyelids in children is the dermoid cyst, a developmental cyst caused by inclusion of ectodermal rests within the lines of closure of the branchial arches. Dermoid cysts are lined with stratified squamous epithelium with small pilosebaceous units attached to the wall (Fig. 10.26). The lumen usually contains small hairs and keratin. The presence

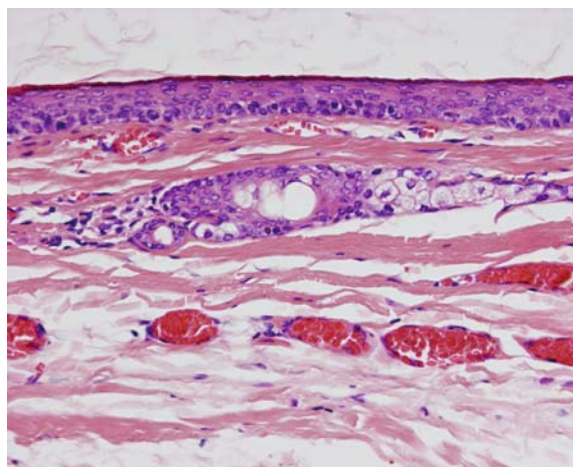


Fig. 10.26. Dermoid cyst: lined with squamous epithelium with small pilosebaceous units in the wall

of pilosebaceous units differentiates this cyst from epidermal cysts.

10.7.1.2 Epidermal cysts

Epidermal cysts (epidermoid cysts, keratinous cysts) are firm, often yellow-brown masses, diagnosed clinically as “sebaceous cysts”. However, real sebaceous cysts (steatocystomas) are very rare and most cysts will histologically show a lining with stratified squamous epithelium without pilosebaceous glands. The cysts are filled with strands of keratin. Epidermal cysts can be caused by dermal inclusion of epithelial cells after a microtrauma, but also by occlusion of a pilosebaceous unit. If an epidermal cyst ruptures, keratin will be released between the collagen bundles of the dermis, causing a granulomatous foreign body reaction.

10.7.1.3 Hidrocystoma

Cysts derived from the small sweat glands present in the eyelids present as bluish, round lesions and are clinically often misdiagnosed as haemangiomas. The term hidrocystoma is preferred, but many other names, like cysts of Moll’s glands and sudiferous cysts, can be found in the literature. The eccrine cysts are lined with cuboidal to flattened epithelium with a myoepithelial base (Fig. 10.27). Sometimes only one epithelial layer is visible, showing eosinophilic cytoplasm with snouts, characteristic of apocrine differentiation. It can be very hard to differentiate between eccrine or apocrine origins and sometimes both components can be found in the cysts.

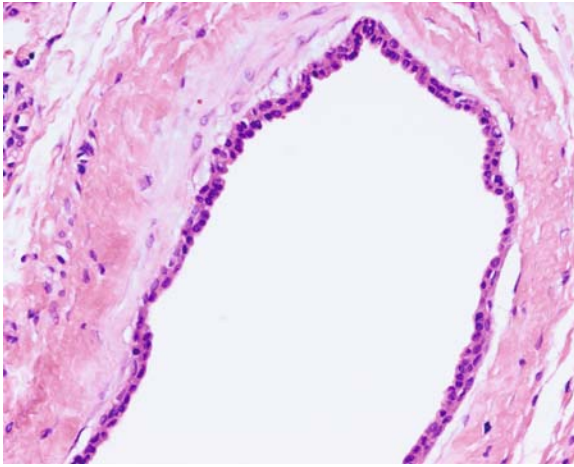


Fig. 10.27. Hidrocystoma: cystic space lined with flattened epithelium with a myoepithelial base

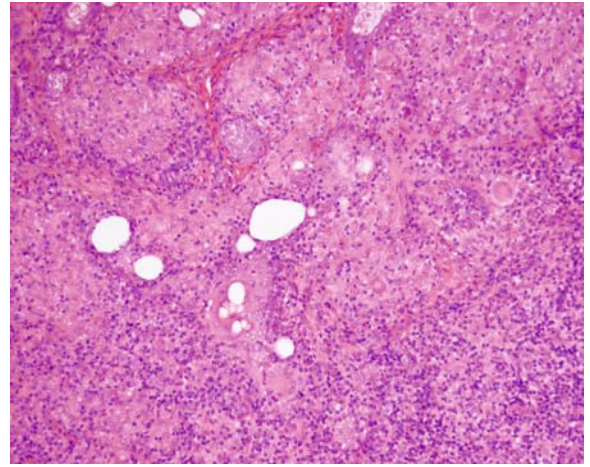


Fig. 10.28. Chalazion: optical empty spaces surrounded by histiocytes forming granulomas. The infiltrate also contains lymphocytes and neutrophils

10.7.2 Inflammatory Processes

A very common inflammatory condition of the eyelids is a chalazion. Furthermore, many inflammatory skin diseases can involve the periorbital region. Periorbital eczema may be an expression of a constitutional disease, an irritant or allergic dermatitis. Other inflammatory dermatoses that can involve the eyelids are seborrheic dermatitis, psoriasis, rosacea and dermatomyositis. Other causes of inflammation of the eyelids include bacterial, fungal and viral infections.

10.7.2.1 Chalazion and Other Ruptured Cysts

Chalazia are very common. The clinical presentation is usually very typical, with an acute swelling in the tarsal conjunctiva. In a few days the swelling becomes a firm nodule. Excision or excochleation is the treatment of choice. Because of the typical clinical presentation, many ophthalmologists will not offer the material for routine histological examination. Chalazia are caused by the obstruction of the duct of a small (Zeis) or larger (Meibomian) sebaceous gland. A small retention cyst is formed and rupture of this cyst causes the escape of fatty products into the surrounding tissues. The fatty material triggers an acute inflammatory reaction first, followed by a chronic granulomatous reaction (Fig. 10.28). In the very late stages of chalazia, fibrosis and scarring can be seen. The presence of fatty cells or even larger optical empty spaces within a granulomatous reaction is characteristic of a chalazion. The only other conditions with similar lipogranulomatous reactions are leakage of

implants (for example silicon) and dermatitis artefacta. If patients with dermatitis artefacta use oily fluids to inject, the histological picture is identical to that of a chalazion.

All other cysts (dermoid, epidermal and hidrocystomas) can rupture. The wall of the cyst is sometimes no longer identifiable. The presence of small pieces of the content of the former cyst (hair, keratin) in multinucleated giant cells proves the diagnosis of an inflamed and ruptured cyst.

10.7.2.2 Deep Granuloma Annulare

Granuloma annulare usually occurs on the dorsum of the hands and the lower arms. It is considered to be a cutaneous reaction pattern, most frequently associated with diabetes mellitus. However, in children the deep variant of granuloma annulare is a benign, relatively common dermatosis, not related to systemic disease. In granuloma annulare of childhood lesions typically occur on the extremities and resolve spontaneously over a period of several months to years. Localised facial involvement, sometimes with involvement of the eyelids, is rare. The clinical relevance is that granuloma annulare, presenting in the periocular region, may mimic other lesions. This diagnosis should be considered for any acquired papules of the periorbital area, especially if there is a history of antecedent trauma. Unnecessary surgical excision can then be avoided. Histology shows deep foci of degeneration of collagen, surrounded by histiocytes. Often there is increased dermal mucin.

10.7.2.3 Necrobiotic Xanthogranuloma

Necrobiotic xanthogranuloma is a rare chronic and often progressive disorder with a predilection for the periorbital skin. Other areas of the face, as well as the trunk and limbs, can also be involved. Lesions present as sharply demarcated violaceous, partly xanthomatous nodules and plaques. Ulceration may develop. Almost all patients with necrobiotic xanthogranuloma are diagnosed with a paraproteinaemia. Other, more rare associations are hyperlipidaemia and leukopenia. Scleritis, episcleritis and keratitis are common ophthalmic complications. The histological changes are present in the dermis and in the subcutis. Large zones of necrobiotic collagen with hyaline and sometimes mucinous changes are present in the deep dermis. These areas are surrounded by histiocytes, partly with a foamy cytoplasm. Sometimes the xanthomatous changes are only minor. Multinucleated giant cells are easily found; they can be of the Touton type, but also of the foreign body type with bizarre nuclei. In ulcerating lesions, transepidermal elimination of debris can be seen.

10.7.3 Amyloidosis

Solitary or multiple nodules of amyloid may occur both in the eyelids and in the conjunctiva. Most frequently it is a localised process, without signs of systemic amyloidosis. Histology shows amorphous, eosinophilic, Congo red-positive masses in the stroma. The walls of blood vessels often also contain amyloid.

10.7.4 Tumours and Tumour-Like Conditions

Tumours of the eyelids are very similar to tumours occurring in the conjunctiva and the skin. The most important tumours of the eyelids are basal cell carcinomas, squamous cell carcinomas and sebaceous adenocarcinomas. These tumours are discussed in Sect. 10.2.6. A tumour-like condition with a predilection for the eyelids and the surrounding skin is xanthelasma.

10.7.4.1 Xanthelasmata

Xanthelasmata are yellow papules and plaques, most frequently occurring on the eyelids and the skin surrounding the eyes. They are relatively frequent. Xanthelasmata can be a manifestation of hypercholesterolaemia, but most cases are idiopathic. Histology shows multiple foamy histiocytes in the superficial dermis (Fig. 10.29).

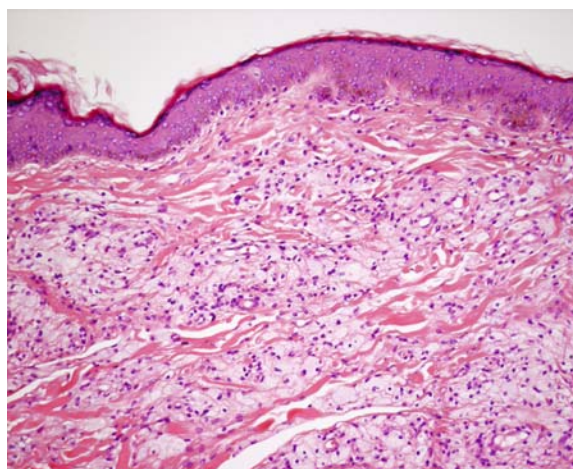


Fig. 10.29. Xanthelasmata: multiple foamy histiocytes are present in the dermis

10.8 Orbit

10.8.1 Inflammatory Processes

The most common inflammatory diseases of the orbit include Graves' disease (dysthyroid ophthalmopathy), orbital cellulitis and pseudotumours.

10.8.1.1 Dysthyroid Ophthalmopathy

The most common cause of bilateral proptosis is Graves' disease. Seventy percent of cases are bilateral and symmetrical. In cases of unilateral involvement, other diseases must be considered. Females are more frequently affected than males. The disease is characterised by symmetrical swelling of the extraocular muscles. The inferior and medial rectus muscles are most often involved. The muscle enlargement characteristically involves the body of the muscle, sparing the tendinous attachment to the globe. Histologically, the fibrous tissue of the orbit and the swollen muscles show oedema and chronic inflammation in early stages and fibrosis in end-stage disease. The degenerated muscle fibres become hyalinised.

10.8.1.2 Cellulitis

Acute bacterial infection (cellulitis) of the orbit is uncommon. It is most frequently caused by direct spread of an infection from the paranasal sinuses or eyelids. It may also be of odontogenic origin and can be one of the presenting features of retinoblastoma or other tumours. Chronic intranasal cocaine abuse can result in exten-

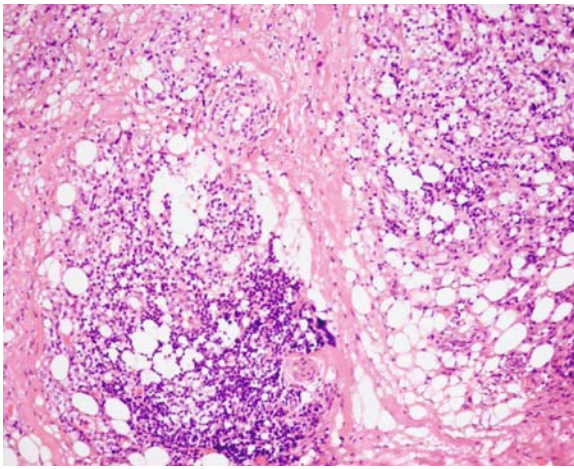


Fig. 10.30. Pseudotumour of the orbit: fibrous tissue with necrotic fat cells is infiltrated by large groups of lymphocytes. Immunohistochemistry is necessary to rule out a malignant lymphoma

sive bony destruction of the orbital walls with associated orbital cellulitis. In patients with poorly controlled diabetes, but also in immunocompromised patients, orbital cellulitis can also be caused by fungal agents, for example mucormycosis. Presenting symptoms most frequently include oedema of the upper eyelid, headache and facial pain. Sometimes it can be asymptomatic. Clinically, orbital cellulitis is of great importance, as it is a severe disease with potentially disastrous consequences. Despite antifungal or antibacterial therapy, disease can progress. It may lead to optic neuritis, optic atrophy, blindness, cavernous sinus thrombosis, intracranial abscess formation, meningitis, subdural empyema, and even death. An incision biopsy of the process can be helpful in the diagnostic work-up. Histology will show an extensive neutrophilic infiltration of the orbital fibrous tissue and fat. The causative microorganisms can often be found with PAS, Gram and silver stainings. It is important for the pathologist to look for underlying causes, like tumours.

10.8.1.3 Pseudotumour

Non-specific inflammation of orbital tissues is known as orbital pseudotumour. It tends to be unilateral and accounts for 25% of all cases of unilateral exophthalmos. Spontaneous regression can occur and a response to steroids is often seen. However, orbital pseudotumours can also be chronic and progressive. The diagnosis has to be confirmed by an incision biopsy, especially in cases in which the pseudotumour appears as a discrete mass and simulates a neoplastic lesion. Histology shows oedema of the orbital fibrous tissue

and fat in the earliest stages. This will be followed by lymphocytic infiltration and end with fibrous changes. In cases of massive infiltration by lymphocytes, immunohistochemistry is necessary to rule out malignant lymphoma (Fig. 10.30). Another disease that can mimic pseudotumours is sarcoidosis. Sarcoidosis is histologically characterised by typical granulomas, not surrounded by lymphocytes.

10.8.2 Tumours and Tumour-Like Conditions

A variety of tumours and pseudotumours can involve the orbit. Most orbital lesions are benign (65%). The percentage of malignant tumours increases with age, with 60% of malignancies in patients over 60 years of age, because of the higher incidence of lymphoma and metastatic tumours in the elderly. Orbital tumours of childhood are distinct from tumours that occur in adults. Many are congenital with early presentations. Most paediatric orbital tumours are benign (80%); developmental cysts comprise half of orbital cases, with capillary haemangioma being the second most common orbital tumour in children. The most common orbital malignancy in children is rhabdomyosarcoma. Whereas the malignant tumours may be life-threatening, both malignant and benign tumours may be vision-threatening. Almost all lymphomas, soft tissue and bone tumours may involve the orbit.

10.8.2.1 Developmental Cysts

Epithelial rests found at sutural sites within the orbit can give rise to epithelial cysts. Cysts of the surface epithelium are further divided into simple epithelial cysts (epidermal, conjunctival, respiratory and apocrine gland), and dermoid cysts (epidermal and conjunctival). Epidermal dermoid cyst (dermoid) is by far the most common orbital cystic lesion in children, accounting for over 40% of all orbital lesions of childhood. Other developmental cysts are teratomatous cysts, neural cysts (congenital cystic eye and colobomatous cyst) and those associated with brain and meningeal tissue (encephalocele and optic nerve meningocele) [103]. Developmental cysts have to be differentiated from secondary cysts, like mucocele and inflammatory cysts. Mucocele can occur in children with cystic fibrosis. Inflammatory cysts are generally due to parasitic infestations and are more common in tropical areas of the world. Furthermore, non-cystic tumourous lesions with a cystic component (like rhabdomyosarcoma and lymphangioma) can present as a cyst.

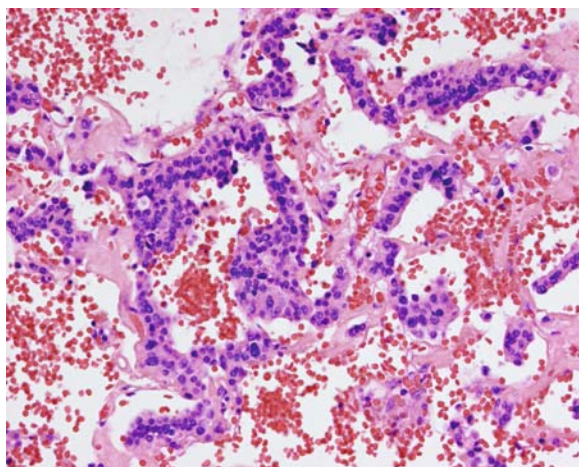


Fig. 10.31. Carcinoid metastatic to the orbit: this haemorrhagic orbital mass contained small nests of monomorphous epithelial cells. Immunohistochemistry was consistent with a carcinoid

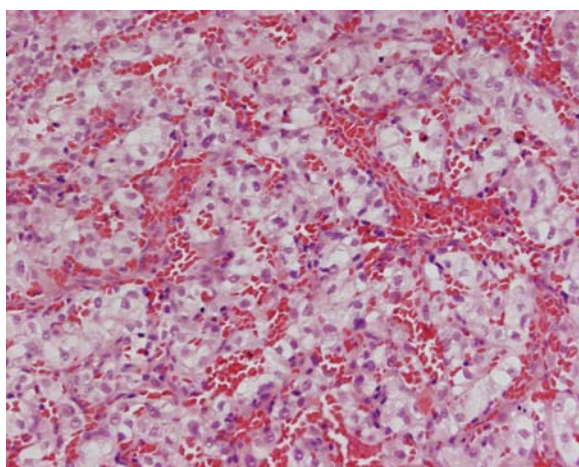


Fig. 10.32. Renal cell adenocarcinoma metastatic to the orbit: nests of clear epithelioid cells were found; immunohistochemistry showed positivity for both vimentin and cytokeratin

10.8.2.2 Optic Nerve and Meningeal Tumours

Optic nerve and meningeal tumours can spread into the orbit. Together they represent 8% of all orbital tumours.

10.8.2.3 Metastatic Tumours

The orbit is the most common location for metastases to the eye and adjacent structures in children (neuro-

blastoma), whereas the choroid is the predominant site in adults. Approximately 5% of all orbital tumour-like lesions are metastatic lesions. However, because malignancies are far more frequent in adults, most orbital metastatic lesions are found in elderly patients. The mean period of time between the onset of the primary disease and orbital manifestation is 5 years. The main primary symptoms are lid swelling, red eye, diplopia and proptosis. The most frequent primary tumour is a breast carcinoma, but many other carcinomas can metastasise to the orbit (Figs. 10.31, 10.32). Metastatic melanomas to the eye and orbit are rare and generally occur in patients with disseminated metastases during the terminal stages of the disease, with a short life expectancy.

References

1. Akpek EK, Polcharoen W, Chan R, Foster CS (1999) Ocular surface neoplasia masquerading as chronic blepharokeratoconjunctivitis. *Cornea* 18:282–288
2. Akpek EK, Polcharoen W, Ferry JA, Foster CS (1999) Conjunctival lymphoma masquerading as chronic conjunctivitis. *Ophthalmology* 106:757–760
3. Armstrong NT (1992) The ocular manifestations of congenital rubella syndrome. *Insight* 17:14–16
4. Aultbrinker EA, Starr MB, Donnenfeld ED (1988) Linear IgA disease. The ocular manifestations. *Ophthalmology* 95:340–343
5. Balayre S, Gomez K, Tribut A, Dore P, Gobert F (2003) Toxoplasma gondii and necrotizing retinitis: a case report. *J Fr Ophthalmol* 26:837–841
6. Bastiaensen LA, Verpalen MC, Pijpers PM, Sprong AC (1985) Conjunctival sarcoidosis. *Doc Ophthalmol* 59:5–9
7. Biggs SL, Font RL (1977) Oncocytic lesions of the caruncle and other ocular adnexa. *Arch Ophthalmol* 95:474–478
8. Bost M, Mouillon M, Romanet JP, Deiber M, Navoni F (1985) Congenital glaucoma and Von Recklinghausen's disease. *Pediatric* 40:207–212
9. Bourcier T, Monin C, Baudrimont M, Larricart P, Borderie V, Laroche L (2003) Conjunctival inclusion cyst following pars plana vitrectomy. *Arch Ophthalmol* 121:1067
10. Breslow NE, Norris R, Norkool PA, Kang T, Beckwith JB, Perlman EJ, Ritchey ML, Green DM, Nichols KE (2003) Characteristics and outcomes of children with the Wilms tumor-Aniridia syndrome: a report from the National Wilms Tumor Study Group. *J Clin Oncol* 21:4579–4585
11. Bruna F (1954) Association of keratoconus with retinitis pigmentosa. *Boll Ocul* 33:145–157
12. Busbee BG (2004) Advances in knowledge and treatment: an update on endophthalmitis. *Curr Opin Ophthalmol* 15:232–237
13. Cervantes G, Rodriguez AA Jr, Leal AG (2002) Squamous cell carcinoma of the conjunctiva: clinicopathological features in 287 cases. *Can J Ophthalmol* 37:14–19; discussion 19–20
14. Ceuterick C, Martin JJ (1984) Diagnostic role of skin or conjunctival biopsies in neurological disorders. An update. *J Neurol Sci* 65:179–191
15. Chai F, Coates H (2003) Otolaryngological manifestations of ligneous conjunctivitis. *Int J Pediatr Otorhinolaryngol* 67:189–194
16. Chan CC, BenEzra D, Hsu SM, Palestine AG, Nussenblatt RB (1985) Granulomas in sympathetic ophthalmia and sarcoidosis. Immunohistochemical study. *Arch Ophthalmol* 103:198–202

17. Chen S, Wishart M, Hiscott P (2000) Ligneous conjunctivitis: a local manifestation of a systemic disorder? *J AAPOS* 4:313–315
18. Cibis GW (1987) Congenital glaucoma. *J Am Optom Assoc* 58:728–733
19. Cibis GW, Tripathi RC, Tripathi BJ (1984) Glaucoma in Sturge-Weber syndrome. *Ophthalmology* 91:1061–1071
20. Claes K, Kestelyn P (2000) Ocular manifestations of graft versus host disease following bone marrow transplantation. *Bull Soc Belge Ophthalmol* 21–26
21. Cogan DG (1971) Congenital anomalies of the retina. *Birth Defects Orig Artic Ser* 7:41–51
22. Craitoiu S (1992) Goldenhar's oculoauricular dysplasia, limbic dermoid and conjunctival dermolipoma. *Oftalmologia* 36:357–361
23. Crolla JA, van Heyningen V (2002) Frequent chromosome aberrations revealed by molecular cytogenetic studies in patients with aniridia. *Am J Hum Genet* 71:1138–1149
24. Cursiefen C, Hofmann-Rummelt C, Schlotzer-Schrehardt U, Fischer DC, Kuchle M (2000) Immunophenotype classification of macular corneal dystrophy: first case report of immunophenotype I A outside of Saudi Arabia. A clinical histopathological correlation with immunohistochemistry and electron microscopy. *Klin Monatsbl Augenheilkd* 217:118–126
25. Darougar S, Pearce R, Gibson JA, McSwiggan DA (1978) Adenovirus type 21 keratoconjunctivitis. *Br J Ophthalmol* 62:836–837
26. Dart J (2003) Corneal toxicity: the epithelium and stroma in iatrogenic and factitious disease. *Eye* 17:886–892
27. De Rosa G, Zeppa P, Tranfa F, Bonavolonta G (1986) Acinic cell carcinoma arising in a lacrimal gland. First case report. *Cancer* 57:1988–1991
28. Dokonalova E, Vymazalova Z, Vymazal M, Riegrova D (1990) A complex choristoma of the conjunctiva. *Acta Univ Palacki Olomuc Fac Med* 126:227–231
29. El-Ashry MF, El-Aziz MM, Larkin DF, Clarke B, Cree IA, Hardcastle AJ, Bhattacharya SS, Ebenezer ND (2003) A clinical, histopathological, and genetic study of Avellino corneal dystrophy in British families. *Br J Ophthalmol* 87:839–842
30. Elsas FJ, Green WR (1975) Epibulbar tumors in childhood. *Am J Ophthalmol* 79:1001–1007
31. Faraj HG, Hoang-Xuan T (2001) Chronic cicatrizing conjunctivitis. *Curr Opin Ophthalmol* 12:250–257
32. Fernandes M, Vemuganti GK, Pasricha G, Bansal AK, Sangwan VS (2003) Unilateral tuberculous conjunctivitis with tarsal necrosis. *Arch Ophthalmol* 121:1475–1478
33. Freedman J, Gombos GM (1971) Bilateral macular coloboma, keratoconus, and retinitis pigmentosa. *Ann Ophthalmol* 3:664–665
34. Gamel JW, Eiferman RA, Guibor P (1984) Mucoepidermoid carcinoma of the conjunctiva. *Arch Ophthalmol* 102:730–731
35. Gayre GS, Proia AD, Dutton JJ (2002) Epibulbar osseous choristoma: case report and review of the literature. *Ophthalmic Surg Lasers* 33:410–415
36. Gloor P, Ansari I, Sinar J (1999) Sebaceous carcinoma presenting as a unilateral papillary conjunctivitis. *Am J Ophthalmol* 127:458–459
37. Haller EM, Auer-Grumbach P, Stuenzner D, Kessler HH, Pierer K, Zenz H, Muellner K (1996) Evaluation of two non-culture antigen tests and three serotests for detection of anti-chlamydial antibodies in the diagnosis of ocular chlamydial infections. *Graefes Arch Clin Exp Ophthalmol* 234:510–514
38. Hanna C (1976) Embryopathic time-table of cataract formation in congenital rubella. *J Pediatr Ophthalmol* 13:266–273
39. Hegab SM, al-Mutawa SA, Sheriff SM (1998) Sarcoidosis presenting as multilobular limbal corneal nodules. *J Pediatr Ophthalmol Strabismus* 35:323–326
40. Heiligenhaus A, Dutt JE, Foster CS (1996) Histology and immunopathology of systemic lupus erythematosus affecting the conjunctiva. *Eye* 10:425–432
41. Ho MW, Crean SJ, Sharma A, Sukhija J, Das A, Saroha V, Sukhi S, Mohan K (2003) Simultaneous occurrence of sublingual dermoid cyst and oral alimentary tract cyst in an infant: a case report and review of the literature. *Int J Paediatr Dent* 13:441–446.
42. Ho VT, Rao VM, Flanders AE (1994) Postsurgical conjunctival epithelial cysts. *AJNR Am J Neuroradiol* 15:1181–1183
43. Hochman MA, Mayers M (1997) Stevens-Johnson syndrome, epidermolysis bullosa, staphylococcal scalded skin syndrome, and dermatitis herpetiformis. *Int Ophthalmol Clin* 37:77–92
44. Jakobiec FA, Folberg R, Iwamoto T (1989) Clinicopathologic characteristics of premalignant and malignant melanocytic lesions of the conjunctiva. *Ophthalmology* 96:147–166
45. Jordaan HF, Schneider JW, Schaaf HS, Victor TS, Geiger DH, Van Helden PD, Rossouw DJ (1996) Papulonecrotic tuberculid in children. A report of eight patients. *Am J Dermatopathol* 18:172–185
46. Kallor AD, Hendricks WM, Salvitti C, Azulay RD, Heringer ML, Almeida de Faria IA (1979) Oculoauriculovertebral dysplasia (Goldenhar's syndrome). *Cutis* 24:41–42
47. Karcioğlu ZA, Issa TM (1997) Human papilloma virus in neoplastic and non-neoplastic conditions of the external eye. *Br J Ophthalmol* 81:595–598
48. Kawamoto K, Miyana Y, Toriyama S (1996) A case of bilateral MALT (mucosa-associated lymphoid tissue) type conjunctival malignant lymphoma. *Nippon Ganka Gakkai Zasshi* 100:246–252
49. Kaye SB, Baker K, Bonshek R, Maseruka H, Grinfeld E, Tullo A, Easty DL, Hart CA (2000) Human herpesviruses in the cornea. *Br J Ophthalmol* 84:563–571
50. Kerty E, Vigander K, Flage T, Brinch L (1999) Ocular findings in allogeneic stem cell transplantation without total body irradiation. *Ophthalmology* 106:1334–1338
51. Khandekar R, Al Awaidy S, Ganesh A, Bawikar S (2004) An epidemiological and clinical study of ocular manifestations of congenital rubella syndrome in Omani children. *Arch Ophthalmol* 122:541–545
52. Kim JH, Hwang JM, Kim HJ, Yu YS (2002) Characteristic ocular findings in Asian children with Down syndrome. *Eye* 16:710–714
53. Knoll A (1955) Simultaneous occurrence of degenerative retinitis pigmentosa and keratoconus. *Szemeszet* 92:165–168
54. Korvatska E, Munier FL, Djemai A, Wang MX, Frueh B, Chiou AG, Uffer S, Ballestrazzi E, Braunstein RE, Forster RK, Culbertson WW, Boman H, Zografos L, Schorderet DF (1998) Mutation hot spots in 5q31-linked corneal dystrophies. *Am J Hum Genet* 62:320–324
55. Kruk J, Kallor AD, Hendricks WM, Salvitti C, Azulay RD, Heringer ML, Almeida de Faria IA (1979) Goldenhar's syndrome: aetiopathogenesis, morphology and treatment. *Klin Oczna* 81:485–486
56. Kuming BS, Joffe L (1977) Ehlers-Danlos syndrome associated with keratoconus. A case report. *S Afr Med J* 52:403–405
57. Kunimoto DY, Tasman W, Rapuano C, Recchia F, Busbee B, Pearlman R, Belmont J, Cohen E, Vander J, Laibson P, Raber I (2004) Endophthalmitis after penetrating keratoplasty: microbiologic spectrum and susceptibility of isolates. *Am J Ophthalmol* 137:343–345
58. Lam S, Stone MS, Goeken JA, Massicotte SJ, Smith AC, Folberg R, Krachmer JH (1992) Paraneoplastic pemphigus, cicatricial conjunctivitis, and acanthosis nigricans with pachydermatoglyphy in a patient with bronchogenic squamous cell carcinoma. *Ophthalmology* 99:108–113
59. Langlois M, Evain B, Fournier E, Potier F (1986) Choroidal pseudotumoral granuloma in sarcoidosis (apropos of a case). *Bull Soc Ophthalmol Fr* 86:223–224
60. Lesser RL (1995) Ocular manifestations of Lyme disease. *Am J Med* 98:60S–62S
61. Liesegang TJ (1994) Pigmented conjunctival and scleral lesions. *Mayo Clin Proc* 69:151–161

62. Lin J, Li Y, Zhang J, Feng G, Zhang P, Zheng H, Zheng J (1999) Rapid diagnosis of chlamydial conjunctivitis in laboratory. *Yan Ke Xue Bao* 15:191–194
63. Liu CC, Kou HK, Tsai MH, Su CC, Kao ML, Chen YJ, Tsai SH (2001) Choroidal masses: a fourteen-year analysis. *Chang Gung Med J* 24:502–511
64. Livesey SJ, Holmes JA, Whittaker JA (1989) Ocular complications of bone marrow transplantation. *Eye* 3:271–276
65. Lloyd IC, Colley A, Tullo AB, Bonshek R (1993) Dominantly inherited unilateral retinal dysplasia. *Br J Ophthalmol* 77:378–380
66. Longanesi L, Cavallini GM, Iammarino A, Vaccina F, Guerra R, De Pol A (1998) Ultrastructural localization of gelsolin in lattice corneal dystrophy type I. *Ophthalmologica* 212:415–421
67. Luo Q, Wang L, Feng X, Cai R, Shen G, Deng Y, Xia R (1999) Observation of special stain and ultrastructure of lattice, granular and macular corneal dystrophy. *Zhonghua Yan Ke Za Zhi* 35:268–270
68. MacCallan A (1931) The epidemiology of trachoma. *Br J Ophthalmol* 15:369–411
69. Martin DF, Chan CC, de Smet MD, Palestine AG, Davis JL, Whitcup SM, Burnier MN Jr, Nussenblatt RB (1993) The role of chorioretinal biopsy in the management of posterior uveitis. *Ophthalmology* 100:705–714
70. Mauriello JA Jr, Abdelsalam A, McLean IW (1997) Adenoid squamous carcinoma of the conjunctiva – a clinicopathological study of 14 cases. *Br J Ophthalmol* 81:1001–1005
71. McDonnell JM, McDonnell PJ, Sun YY (1992) Human papillomavirus DNA in tissues and ocular surface swabs of patients with conjunctival epithelial neoplasia. *Invest Ophthalmol Vis Sci* 33:184–189
72. Merchant S, Weinstein M (2003) Pemphigus vulgaris: the eyes have it. *Pediatrics* 112:183–185
73. Messmer EM, Foster CS (1999) Vasculitic peripheral ulcerative keratitis. *Surv Ophthalmol* 43:379–396
74. Meyers SJ, Varley GA, Meisler DM, Camisa C, Wander AH (1992) Conjunctival involvement in paraneoplastic pemphigus. *Am J Ophthalmol* 114:621–624
75. Mohile M, Deorari AK, Satpathy G, Sharma A, Singh M (2002) Microbiological study of neonatal conjunctivitis with special reference to Chlamydia trachomatis. *Indian J Ophthalmol* 50:295–299
76. Mubarak M, Nabi B, Ladakhi GM, Sethi AS (2000) Childhood tuberculosis. I. Epidemiology, pathogenesis, clinical profile. *JK Pract* 7:12–15
77. Munier FL, Korvatska E, Djemai A, Le Paslier D, Zografos L, Pescia G, Schorderet DF (1997) Kerato-epithelin mutations in four 5q31-linked corneal dystrophies. *Nat Genet* 15:247–251
78. Neumann R, Dutt CJ, Foster CS (1993) Immunohistopathologic features and therapy of conjunctival lichen planus. *Am J Ophthalmol* 115:494–500
79. Oehme A, Muhlsholt PB, Dreesbach K (1991) Chlamydiae as pathogens – an overview of diagnostic techniques, clinical features, and therapy of human infections. *Klin Wochenschr* 69:463–473
80. Oguz O, Gokler G, Ocakoglu O, Oguz V, Demirkesen C, Aydemir EH (1997) Conjunctival involvement in familial chronic benign pemphigus (Hailey-Hailey disease). *Int J Dermatol* 36:282–285
81. O'Neal ML, Brunson A, Spadafora J (2001) Ocular sebaceous carcinoma: case report and review of the literature. *Compr Ther* 27:144–147
82. Palazzi MA, Erwenne CM, Villa LL (2000) Detection of human papillomavirus in epithelial lesions of the conjunctiva. *Sao Paulo Med J* 118:125–130
83. Panda A, Arora R, Mohan M (1987) Cystic lesions of conjunctiva. *Ann Ophthalmol* 19:60–62
84. Payne MS, Nadell JM, Lacassie Y, Tilton AH (2003) Congenital glaucoma and neurofibromatosis in a monozygotic twin: case report and review of the literature. *J Child Neurol* 18:504–508
85. Pleyer U, Bergmann L, Krause A, Hartmann C (1996) Autoimmune diseases of the peripheral cornea. Immunopathology, clinical aspects and therapy. *Klin Monatsbl Augenheilkd* 208:73–81
86. Potter De P (1998) Ocular manifestations of cancer. *Curr Opin Ophthalmol* 9:100–104
87. Pouliquen Y, Giraud JP, Savoldelli M (1978) Reis-Buckler's dystrophy. *Albrecht Von Graefes Arch Klin Exp Ophthalmol* 208:25–31
88. Rabinowitz YS (1998) Keratoconus. *Surv Ophthalmol* 42:297–319
89. Ravault MP, Trepsat C, Chatenoud F (1983) Candida albicans endophthalmitis in drug addicts: apropos of 2 cases. *Bull Soc Ophthalmol Fr* 83:1307–1308
90. Reccia R, Del Prete A, Scala A, Masciello M, Di Giovanni A, Sebastiani A (1994) Direct immunofluorescence and scraping conjunctival cytology in the study of 912 patients affected by microfollicular conjunctivitis. *Ophthalmologica* 208:295–297
91. Reedy EA (2004) The discovery of retrolental fibroplasia and the role of oxygen: a historical review, 1942–1956. *Neonatal Netw* 23:31–38
92. Riley GP, Harrall RL, Watson PG, Cawston TE, Hazleman BL (1995) Collagenase (MMP-1) and TIMP-1 in destructive corneal disease associated with rheumatoid arthritis. *Eye* 9:703–718
93. Ring CC (1958) Atopic dermatitis with cataracts; a report of three cases, one with keratoconus. *Trans Ophthalmol Soc N Z* 10:41–47
94. Robertson I (1975) Keratoconus and the Ehlers-Danlos syndrome: a new aspect of keratoconus. *Med J Aust* 1:571–573
95. Rosenberg ME, Tervo TM, Gallar J, Acosta MC, Muller LJ, Moilanen JA, Tarkkanen AH, Vesaluoma MH (2001) Corneal morphology and sensitivity in lattice dystrophy type II (familial amyloidosis, Finnish type). *Invest Ophthalmol Vis Sci* 42:634–641
96. Ryckewaert M, Zanlonghi X, Castier P, Francois P (1988) Choroidal granuloma in sarcoidosis. Discussion apropos of 2 cases. *J Fr Ophtalmol* 11:773–778
97. Sanchez-Tocino H, Saornil MA, Herreras JM, Blanco G, Calonge M, Rodriguez De La Rúa E (2001) Usefulness of conjunctival biopsy as diagnostic technique. *Arch Soc Esp Oftalmol* 76:31–36
98. Sanders TE, Ackerman LV, Zimmerman LE (1962) Epithelial tumors of the lacrimal gland. A comparison of the pathologic and clinical behavior with those of the salivary glands. *Am J Surg* 104:657–665
99. Schuster V, Seregard S (2003) Ligneous conjunctivitis. *Surv Ophthalmol* 48:369–388
100. Sehgal VN, Ramesh V, Ghorpade A (1984) Naevus sebaceous associated with ocular dermolipoma. *J Dermatol* 11:97–98
101. Seitz B, Henke V (1995) Mucoepidermoid carcinoma of the epibulbar connective tissue with diffuse intraocular epithelial invasion. *Klin Monatsbl Augenheilkd* 207:264–265
102. Sekundo W, Augustin AJ (2001) Differences in the composition of inflammatory cell infiltrate in lens-induced uveitis under therapy with allopurinol or steroids. *Eur J Ophthalmol* 11:264–268
103. Shields JA, Shields CL (2004) Orbital cysts of childhood – classification, clinical features, and management. *Surv Ophthalmol* 49:281–299
104. Shirai K, Saika S, Okada Y, Oda S, Ohnishi Y (2004) Histology and immunohistochemistry of fibrous posterior capsule opacification in an infant. *J Cataract Refract Surg* 30:523–526
105. Sjo NC, Heegaard S, Prause JU, von Buchwald C, Lindeberg H (2001) Human papillomavirus in conjunctival papilloma. *Br J Ophthalmol* 85:785–787
106. Sjoegren H (1933) Angeborenes Fehlen der Tranensekretion und der Keratoconjunctivitis sicca bei Kindern. *Klin Monatsbl Augenheilkd* 22:554–559
107. Sjoegren H (1933) Zur Kenntnis der Keratoconjunctivitis sicca (Keratitis filiformes bei hypofunktion der Tranendrusen). *Acta Ophthalmol* 2:1–151

108. Skotnitsky C, Sankaridurg PR, Sweeney DF, Holden BA (2002) General and local contact lens induced papillary conjunctivitis (CLPC). *Clin Exp Optom* 85:193–197
109. Spencer WH, Fisher JJ (1959) The association of keratoconus with atopic dermatitis. *Am J Ophthalmol* 47:332–344
110. Spraul CW, Grossniklaus HE (1996) Tumors of the cornea and conjunctiva. *Curr Opin Ophthalmol* 7:28–34
111. Spraul CW, Lang GK (1996) Oncocytoma of the conjunctiva. *Klin Monatsbl Augenheilkd* 209:176–177
112. Starck T, Kenyon KR, Hanninen LA, Beyer-Machule C, Fabian R, Gorn RA, McMullan FD, Baum J, McAdam KP (1991) Clinical and histopathologic studies of two families with lattice corneal dystrophy and familial systemic amyloidosis (Meretoja syndrome). *Ophthalmology* 98:1197–1206
113. Stewart H, Black GC, Donnai D, Bonshek RE, McCarthy J, Morgan S, Dixon MJ, Ridgway AA (1999) A mutation within exon 14 of the TGFB1 (BIGH3) gene on chromosome 5q31 causes an asymmetric, late-onset form of lattice corneal dystrophy. *Ophthalmology* 106:964–970
114. Suchecki JK, Donshik P, Ehlers WH (2003) Contact lens complications. *Ophthalmol Clin North Am* 16:471–484
115. Thorne JE, Jabs DA, Nikolskaia O, Anhalt G, Nousari HC (2002) Discoid lupus erythematosus and cicatrizing conjunctivitis: clinicopathologic study of two cases. *Ocul Immunol Inflamm* 10:287–292
116. Thorne JE, Jabs DA, Nikolskaia OV, Mimouni D, Anhalt GJ, Nousari HC (2003) Lichen planus and cicatrizing conjunctivitis: characterization of five cases. *Am J Ophthalmol* 136:239–243
117. To K, Adamian M, Dryja TP, Berson EL (2002) Histopathologic study of variation in severity of retinitis pigmentosa due to the dominant rhodopsin mutation Pro23His. *Am J Ophthalmol* 134:290–293
118. Tranos L (1954) Mandibulofacial dysostosis associated with dermolipoma of the conjunctiva. *Am J Ophthalmol* 37:354–359
119. Tuft SJ, Kemeny DM, Dart JK, Buckley RJ (1991) Clinical features of atopic keratoconjunctivitis. *Ophthalmology* 98:150–158
120. Tunc M, Char DH, Crawford B, Miller T (1999) Intraepithelial and invasive squamous cell carcinoma of the conjunctiva: analysis of 60 cases. *Br J Ophthalmol* 83:98–103
121. Usui T, Sawaguchi S, Abe H, Iwata K, Oyanagi K (1993) Conjunctival biopsy in adult form galactosialidosis. *Br J Ophthalmol* 77:165–167
122. Uy HS, Pineda R II, Shore JW, Polcharoen W, Jakobiec FA, Foster CS (1999) Hypertrophic discoid lupus erythematosus of the conjunctiva. *Am J Ophthalmol* 127:604–605
123. Waring GO III, Rodrigues MM, Laibson PR (1978) Corneal dystrophies. I. Dystrophies of the epithelium, Bowman's layer and stroma. *Surv Ophthalmol* 23:71–122
124. Weber CM, Eichenbaum JW (1997) Acute red eye. Differentiating viral conjunctivitis from other, less common causes. *Postgrad Med* 101:185–196
125. Wilhelmus KR, Robinson NM, Tredici LL, Jones DB (1986) Conjunctival cytology of adult chlamydial conjunctivitis. *Arch Ophthalmol* 104:691–693
126. Wizigmann-Voos S, Plate KH (1996) Pathology, genetics and cell biology of hemangioblastomas. *Histol Histopathol* 11:1049–1061
127. Woerd van der A (2000) Lens-induced uveitis. *Vet Ophthalmol* 3:227–234
128. Wolff SM (1972) The ocular manifestations of congenital rubella. *Trans Am Ophthalmol Soc* 70:577–614
129. Woodward EG, Morris MT (1990) Joint hypermobility in keratoconus. *Ophthalmic Physiol Opt* 10:360–362
130. Wu SX (1987) Neurofibromatosis accompanied by congenital glaucoma (report of 2 cases). *Yan Ke Xue Bao* 3:43–46
131. Yeung L, Tsao YP, Chen PY, Kuo TT, Lin KK, Lai LJ (2004) Combination of adult inclusion conjunctivitis and mucosa-associated lymphoid tissue (MALT) lymphoma in a young adult. *Cornea* 23:71–75
132. Zaidman GW (1997) The ocular manifestations of Lyme disease. *Int Ophthalmol Clin* 37:13–28
133. Zhang J (1991) Histo- and ultrahistopathology of the anterior chamber angle in congenital glaucoma. *Zhonghua Yan Ke Za Zhi* 27:151–153
134. Zhu JB, Li B, Sun XL, Li LQ, Shi JT, An YZ (2004) Clinical and pathological features of 273 cases of lacrimal epithelial tumors. *Zhonghua Yan Ke Za Zhi* 40:220–224

Subject Index

A

abscess 184
peritonsillar 184
abuse of the voice 208
accessory tragus 240
external ear 240
acinic cell carcinoma 60
sinonasal 60
Addison disease 88
adenocarcinoma 149, 150, 151, 182,
222, 242
basal cell 151
ceruminous glands 242
cribriform of the tongue 150
larynx 222
nasopharynx 182
polymorphous low-grade 149
adenoid cystic carcinoma 59, 182, 222,
242
ceruminous glands 242
larynx 222
nasopharynx 182
sinonasal 60
adenoid squamous cell carcinoma 22
adenoma 48, 137, 140, 141, 143, 144, 158,
174, 214, 240, 241, 247, 248
basal cell 141
canalicular 143
ceruminous glands 240
ceruminous glands pleomorphic 241
congenital pleomorphic 140
larynx pleomorphic 214
middle ear 247
middle ear neuroendocrine 248
middle ear plasmacytoid 248
nasopharyngeal pituitary 174
pleomorphic 48, 137
pleomorphic metastasising 158
sebaceous 144
sinonasal pituitary 48
adenomatoid hyperplasia 134
salivary glands 134
adenomatoid odontogenic tumour 112
adenosquamous carcinoma 23
differential diagnosis 23
agenesis 132
salivary glands 132
aggressive papillary tumour 248
middle ear 248
amalgam tattoo 86
ameloblastic carcinoma 119
ameloblastic fibro-dentinoma 116
ameloblastic fibro-odontoma 116

ameloblastic fibro-odontosarcoma 120
ameloblastic fibrodentinoma 120
ameloblastic fibroma 116
granular cell 116
ameloblastic fibrosarcoma 120
ameloblastoma 110, 111, 112, 119
acanthomatous 111
basaloid 111
basal cell 111
desmoplastic 111
granular cell type 111
malignant 119
metastasising 119
peripheral 112
unicystic 111
amyloidosis 43, 191, 211, 305
larynx 211
sinonasal 43
Waldeyer's ring 191
aneurysmal bone cyst 124
angiofibroma 50, 175
nasopharyngeal 50, 175
angiolympoid hyperplasia
with eosinophilia 239
external ear 239
aniridia 294
with Wilm's tumour 294
aphthae 77
herpetiform 77
major 77
minor 77
aplasia 132
salivary glands 132
aspergillosis 44, 203
invasive 44
larynx 203
sinonasal 44
astrocytic hamartoma 301
in tuberous sclerosis 301
of retina 301
atresia 132
salivary glands 132
atypical hyperplasia 10

B

B-cell lymphoma 61
sinonasal 61
basaloid squamous cell carcinoma 20
basal and parabasal cell hyperplasia 9
basal cell carcinoma 242
external ear 242
Behçet disease 78

Bell's palsy 255
blastomycosis
larynx 203
Bohn's nodules 109
botryoid odontogenic cyst 107
branchial 265
arch 265
cleft 265
cyst 265
fistula 265
pouch 265
sinus 265
branchial cleft cyst 238
first 238
branchiogenic carcinoma 267

C

calcifying cystic odontogenic tumour 118
calcifying epithelial odontogenic tumour
112
calcifying odontogenic cyst 118
candidiasis 203
larynx 203
candidosis 81, 82
chronic hyperplastic 82
carcinoma 119, 144, 146, 147, 150, 151,
152, 154, 156, 157, 158, 159, 180, 189,
252, 267, 290
acinic cell 144
adenoid cystic 147
branchiogenic 189, 267
epithelial-myoepithelial 150
ex pleomorphic adenoma 156
ex pleomorphic adenoma,
non-invasive 157
hyalinising clear cell 151
lymphoepithelial 158
middle ear metastatic 252
mucoepidermoid 146
myoepithelial 152
nasopharyngeal keratinising 180
nasopharyngeal non-keratinising 180
nasopharyngeal undifferentiated 180
oncocytic 156
primary intraosseous 119
salivary duct 154
sebaceous 158
sebaceous of conjunctiva 290
small cell 159
carcinoma in situ 11
carcinosarcoma 157
salivary gland 157

- cataract 297
 cellulitis 306
 in orbit 306
 cemento-ossifying fibroma 121
 cementoblastoma 115
 cementoma 124
 familial gigantiform 124
 ceruminoma 240
 ear canal 240
 chalazia 304
 cheilitis granulomatosa 282
 cherubism 124
 Chickenpox 73
 Chievitz's organ 72
 chlamydia trachomatis 287
 cholesteatoma 239, 244, 246, 259
 cerebellopontine angle 259
 congenital 246
 external canal 239
 middle ear 244
 cholesterol granuloma 43, 259
 maxillary sinus 43
 petrous apex 259
 chondrodermatitis nodularis helices 239
 chondroid chordoma 125
 chondromas 217
 larynx 217
 chondrosarcoma 125, 183, 223
 larynx 223
 nasopharynx 183
 chordoma 125, 183
 chondroid 125
 nasopharynx 183
 choristoma 247
 glial middle ear 247
 salivary gland middle ear 247
 sebaceous middle ear 247
 clear cell odontogenic carcinoma 120
 clear cell odontogenic tumour 120
 cocaine abuse 46
 nasal 46
 coccidioidomycosis
 larynx 203
 complex odontoma 117
 compound odontoma 117
 condyloma acuminatum 2
 conjunctivitis 286, 287, 288
 acute 286
 chronic 287
 inclusion 287, 288
 in dermatologic diseases 288
 ligneous 287
 contact ulcer 210
 glottic 210
 corneal 294
 failed graft 294
 corneal dystrophies 293
 Avellino 293
 Cogan's 293
 Fuchs 293
 granular 293
 lattice 293
 macular 293
 Meesman's 293
 Reis-Buckler's 293
 corneal ulceration 292
 in systemic disease 292
 coxsackie virus 73
 craniopharyngioma 118, 174
 nasopharynx 174
 Crohn's disease 91
 cryptococcosis 203
 larynx 203
 cylindrical cell carcinoma 52
 sinonasal 52
 cyst 42, 105, 106, 107, 108, 109, 124, 135, 173, 174, 179, 199, 200, 268, 269, 270, 271, 273, 285, 303, 306
 aneurysmal bone 124
 benign lymphoepithelial 136
 botryoid odontogenic 107
 bronchial 270
 bronchogenic 270
 calcifying odontogenic 118
 conjunctival inclusion 285
 dentigerous 106
 dermoid 271, 303
 epidermal 303
 eruption 106
 gingival 108
 glandular odontogenic 107
 glandular retention 179
 larynx ductal 199
 larynx epidermoid 200
 larynx oncocytic 200
 larynx saccular 199
 lateral periodontal 107
 lymphoepithelial 273
 nasolabial 109
 nasopalatine duct 109
 nasopharyngeal branchial 173
 nose dermoid 42
 of orbit 306
 paradental 106
 parathyroid 270
 primordial 107
 radicular 105
 Rathke's cleft 174
 residual 105
 salivary duct 135
 salivary glands 135
 sialo-odontogenic 107
 simple bone 109
 solitary bone 109
 surgical ciliated 109
 thymic 269
 thyroglossal duct 268
 Tornwaldt's 173
 traumatic bone 109
 cystadenoma 144
 mucinous 144
 oncocytic 144
 papillary 144
 cystic hygroma 272
 cystic lymphoid hyperplasia of AIDS 136
 cytomegalovirus 133, 254
 cochlear infection 254
 salivary glands 133
- D**
- dacryoadenitis 302
 dental follicle 114, 115, 117
 dental papilla 114
 dentigerous cyst 106
 dentinogenic ghost cell tumour 118
 dermatitis herpetiformis 76
 dermoid 285
 dermolipoma 285
 desmoid fibromatosis 49
 sinonasal 49
 desmoplastic ameloblastoma 111
 desmoplastic fibroma 115
 diphtheria 202
 larynx 202
 dysplasia 5, 8
- E**
- endodermal sinus tumour 161
 endolymphatic sac tumour 259
 temporal bone 259
 endophthalmitis 295
 eosinophilic angiocentric fibrosis 43
 sinonasal 43
 eosinophilic ulcer 79
 epidermoid cyst 200
 epiglottitis 202
 acute 202
 Epstein-Barr virus 133
 salivary glands 133
 Epstein's pearls 109
 epulis 90, 93
 fibrous 90
 giant cell 93
 eruption cyst 106
 erythema multiforme 77
 erythroplakia 6
 exostosis 241
 ear canal 241
- F**
- facial paralysis 255
 familial gigantiform cementoma 124
 fibro-osseous lesions 121
 fibrosarcoma 62
 sinonasal 62
 fibrous dysplasia 121
 fibrous histiocytoma 49
 sinonasal 49
 focal osseous dysplasia 124
 focal epithelial hyperplasia 2
 Fordyce granules 72
 foreign body 210
 frictional keratosis 86
- G**
- genetic alterations 161
 salivary gland tumours 161

- geographic tongue 85
giant-cell hyalin angiopathy 93
giant cell epulis 93, 124
giant cell fibroma 94
giant cell granuloma 124
 central 124
 peripheral 93, 124
gingival 91
 fibromatosis 91
 hypertrophy 91
gingival cyst 108
gingival hyperplasia 93
 inflammatory 93
gingivitis 79, 82, 92
 acute necrotising 79
 chronic marginal 92
 desquamative 82
glandular odontogenic cyst 107
glaucoma 294, 296
 neurofibromatosis 294
 Sturge-Weber syndrome 294
glial heterotopia 43
glioma 301, 302
 in neurofibromatosis 302
 nasal 43
 of optic nerve 302
 of optic pathway 301
gout 206, 238
 external ear 238
 larynx 206
granular cell ameloblastic fibroma 116
granular cell odontogenic fibroma 116
granular cell tumour 96, 216
 larynx 216
granuloma 206, 210, 211
 glottic 210
 glottic intubation 210
 vocal cord teflon 206
granulomatous infections 133
 salivary glands 133
granuloma annulare 304
Graves' disease 305
- H**
- haemangioblastoma 301
 of retina 301
haemangioma 48, 95, 214, 215, 272, 301
 of choroid 301
 sinonasal 48
 larynx 214
 subglottic 215
haemangiopericytoma 48
 sinonasal 48
hairy tongue 85
hamartoma 42, 178, 247
 middle ear 247
 nasopharynx 178
 respiratory epithelial adenomatoid 42, 178
 sinonasal 42
hand-foot-and-mouth disease 73
herpangina 74
herpes simplex 72
Hertwig sheath of 104
heterotopic brain 174
 nasopharyngeal 174
hidrocystoma 303
Hippel-Lindau disease 248
 middle ear 248
histoplasmosis 203
 larynx 203
hygroma 95, 272
 cystic 95, 272
hyperacidic granulomas 211
hyperplastic vitreous 294
hypoplasia 132
 salivary glands 132
- I**
- idiopathic pseudocystic chondromalacia 238
 pinna 238
inflammatory myofibroblastic tumour 213
 larynx 213
intercalated duct hyperplasia 151
intestinal-type adenocarcinoma 58
 sinonasal 58
intraepithelial neoplasia 289
 of conjunctiva 289
- K**
- keloid 240
 ear 240
keratinising cysts 200
keratin granuloma 239
 external ear 239
keratitis 292
 herpes simplex 292
keratoameloblastoma 111
keratoconjunctivitis sicca 288
keratoconus 292
 syndrome-associated 292
keratocyst 107
keratocystic odontogenic tumour 108
keratocystoma 137
keratosis 5
keratosis obturans 239
 ear canal 239
Kimura's disease 239
 external ear 239
Küttner tumour 133
- L**
- labyrinthitis 255
lacrimal gland 303
 tumours 303
laryngocele 199, 271
laryngotracheobronchitis 202
lateral periodontal cyst 107
Laugier Hunziker syndrome 89
leiomyoma 49
 sinonasal 49
leiomyosarcoma 63
 sinonasal 63
leishmaniasis 45, 203
 larynx 203
 nasal 45
leprosy 45, 203
 larynx 203
 nasal 45
leukoplakia 5, 6, 85
 hairy 85
lichenoid drug eruption 83
lichen planus 82
linear IgA disease 76
lipoma 258
 inner ear 258
Lipschutz bodies 72
Ljubljana grading system 9
low-grade adenocarcinoma 60
 sinonasal 60
lupus erythematosus 83
lymphadenoma 144
 sebaceous 144
lymphangioma 95, 272
lymphoepithelial carcinoma 24
 differential diagnosis 25
 larynx 24
 nasopharynx 24
 oropharynx 24
lymphoepithelial sialadenitis 163
lymphoid hyperplasia 184
 palatine tonsil 184
 pharyngeal tonsil 184
lymphoma 61, 164, 189, 190, 224
 larynx 224
 MALT 164
 sinonasal 61
 Waldeyer's ring 189
 Waldeyer's ring Hodgkin 190
 Waldeyer's ring MALT 190
 Waldeyer's ring mantel cell 189
 Waldeyer's ring NK/T-cell 190
lymph nodes 264
 cervical groups 264
- M**
- macule 86
 oral melanotic 86
Malassez rests of 104
malignant epithelial odontogenic ghost cell tumour 120
malignant fibrous histiocytoma 62
 sinonasal 62
malignant melanoma 243
 external ear 243
malignant peripheral nerve sheath tumour 63
 sinonasal 63
Marfan's syndrome 107
melanoacanthoma 87
melanoma 55, 87, 225, 291, 299
 in situ 88
 larynx 225
 of conjunctiva 291

of uveal tract 299
 sinonasal 55
 melanosis 89, 291
 of conjunctiva 291
 smoker's 89
 melanotic neuroectodermal tumour of
 infancy 126
 melanotic nevi 243
 external ear 243
 Melkersson Rosenthal syndrome 92
 Ménière's disease 256
 meningioma 50, 123, 125, 179, 251,
 258, 302
 chondroid 125
 middle ear 251
 nasopharynx 179
 sinonasal 50
 inner ear 258
 metastases 160, 225, 307
 larynx 225
 of orbit 307
 salivary glands 160
 metastatic renal cell carcinoma 61
 sinonasal 61
 metastatic tumour 191, 302
 of the eye 302
 nasopharynx 191
 Miescher's syndrome 92
 migratory stomatitis 85
 Mikulicz syndrome 302
 mucocele 43, 132, 135
 extravasation 132
 sinonasal 43
 mucocystoid carcinoma 61, 222
 larynx 222
 sinonasal 61
 mucormycosis
 sinonasal 44
 multiple endocrine neoplasia syndrome
 96
 mumps 133
 salivary glands 133
 muscular dystrophy 207
 oculopharyngeal 207
 myoepithelioma 140, 152
 malignant 152
 myospherulosis 43
 sinonasal 43
 myxoma 114

N

naevi 87
 blue 87
 intramucosal 87
 melanocytic 87
 naevus 84, 290, 298
 of conjunctiva 290
 of uveal tract 298
 oral epithelial 84
 unius lateris 84
 white sponge 84
 nasolabial cyst 109
 nasopalatine duct cyst 109

nasopharyngeal-type undifferentiated
 carcinomas 54
 sinonasal 54
 neck triangles 264
 neck dissection 278
 examination 279
 level 278
 types 279
 necrobiotic xanthogranuloma 305
 necrotising sialometaplasia 133
 larynx 211
 neurilemmoma 96
 neurinoma 96
 neuritis 302
 optic 302
 neuroendocrine carcinoma 220, 221
 larynx 220
 larynx moderately differentiated 220
 larynx poorly differentiated 221
 larynx well differentiated 220
 neurofibroma 49, 96
 sinonasal 49
 neurofibromatosis 96, 124, 258
 acoustic 258
 neuromas 96
 mucosal 96
 nevoid basal cell carcinoma syndrome 107
 NK/T cell lymphoma 61
 sinonasal 61
 nodule 208, 211
 glottic metaplastic elastic cartilaginous
 211
 vocal cord 208
 Noonan's syndrome 124

O

ochronosis 238
 external ear 238
 odonto-ameloblastoma 118
 odontogenic carcinosarcoma 121
 odontogenic epithelial hamartoma 115
 odontogenic fibroma 114, 115, 116
 granular cell 115, 116
 peripheral 115
 odontogenic ghost cell carcinoma 120
 odontogenic ghost cell tumour 120
 malignant epithelial 120
 odontogenic gingival epithelial hamar-
 toma 112
 odontogenic granular cell tumour 115
 odontogenic keratocyst 107
 odontogenic myxoma 114
 odontoma 117
 complex 117
 compound 117
 oedema 207, 208
 larynx angioneurotic 207
 vocal cord Reinke's 208
 olfactory neuroblastoma 57
 oncocytic hyperplasia 135
 oncocytic metaplasia 134, 200
 oncocyoma 143, 214, 289
 larynx 214
 of conjunctiva 289

oncocytosis 134
 ophthalmitis 296
 sarcoidosis 295
 sympathetic 296
 optic atrophy 302
 orofacial granulomatosis 92
 osseous dysplasia 123, 124
 florid 124
 focal 124
 periapical 124
 ossifying fibroma 90, 115, 121, 122, 241
 juvenile psammomatoid 122
 juvenile trabecular 122
 peripheral 90, 115
 temporal bone 241
 osteoblastoma 115
 osteogenesis imperfecta 254
 stapes 254
 osteoma 125, 241
 ear canal 241
 Gardner's syndrome 125
 osteomyelitis 104
 osteopetrosis 254
 otic 254
 osteoporotic bone marrow defect 109
 osteosarcoma 183
 nasopharynx 183
 otitis 237, 244
 malignant externa 237
 media 244
 otosclerosis 252
 bony labyrinth 252
 stapes footplate 252

P

Paget's disease 253, 256
 inner ear 256
 temporal bone 253
 panophthalmitis 295
 papillary adenocarcinoma 182
 nasopharynx 182
 papillary hyperplasia 90
 papillary squamous cell carcinoma 19
 differential diagnosis 20
 papilloedema 302
 papilloma 46, 47, 144, 178, 249, 288
 ductal 144
 exophytic 46
 middle ear schneiderian 249
 nasopharynx inverted 178
 of conjunctiva 288
 sinonasal 46
 sinonasal exophytic 46
 sinonasal inverted 46
 sinonasal oncocytic 47
 papillomatosis 3
 recurrent respiratory 3
 paracoccidioidomycosis 203
 larynx 203
 paradental cyst 106
 paraganglioma 50, 215, 249, 273
 middle ear jugulotympanic 249
 multicentric jugulotympanic 249
 sinonasal 50

- solitary jugulotympanic 249
 larynx 215
 pemphigoid 75
 cicatricial 75
 mucous membrane 75
 pemphigus 74
 paraneoplastic 75
 vegetans 74
 vulgaris 74
 periapical osseous dysplasia 124
 perichondritis 237
 pinna 237
 periostitis 104
 peripheral ameloblastoma 112
 petrositis 255
 bacterial 255
 Peutz Jeghers syndrome 89
 phonotrauma 209
 phthisis bulbi 298
 pigmentation 89, 90
 drugs associated 90
 heavy metals 90
 racial 89
 Pindborg tumour 112
 pinguecula 286
 plasmacytoma 62, 190, 224
 larynx 224
 sinonasal 62
 Waldeyer's ring 190
 polycystic dysgenetic disease 135
 polymorphous low-grade adenocarcinoma 182
 nasopharynx 182
 polyp 41, 90, 175, 184, 187, 208
 allergic sinonasal 41
 antrochoanal 41
 antroanasal 42
 atypical fibroblasts 41
 fibroepithelial 90
 immobile cilia syndrome 41
 Kartagener's syndrome 41
 mucoviscidosis 41
 nasopharynx hairy 175
 oropharynx hairy 175
 palatine tonsil hairy 184
 tonsillar lymphangiomas 187
 vocal cord 208
 postintubation granuloma 211
 presbycusis 260
 primary intraosseous carcinoma 119
 primitive neuroectodermal tumour 58
 sinonasal 58
 primordial cyst 107
 proliferative verrucous hyperplasia 6
 pseudotumour 306
 of orbit 306
 psoriasis 86
 pterygium 286
 pulse granuloma 93
 pyogenic granuloma 93
- R**
- radicular cyst 105
 ranula 132, 271
 Reinke's oedema 208
 Reinke's space 208
 Reiter disease 78
 relapsing polychondritis 205, 238
 larynx 205
 pinna 238
 residual cyst 105
 retention cyst 200
 retinal detachment 298
 retinal dysplasia 294
 retinal ischaemia 298
 retinitis pigmentosa 298
 retinoblastoma 300
 retinochoroiditis 295
 toxoplasma gondii 295
 retrolental fibroplasia 294
 rhabdomyosarcoma 63, 183, 252
 middle ear 252
 nasopharynx 183
 sinonasal 63
 rheumatoid arthritis 204
 larynx 204
 rhinitis 40
 allergic 40
 atrophic 41
 bacterial 40
 hypertrophic 41
 viral 40
 rhinoscleroma 45, 203
 larynx 203
 nasal 45
 rhinosinusitis 40
 bacterial 40
 rhinosporidiosis 44
 sinonasal 44
 rhomboid glossitis 78
 Riga-Fede disease 79
 Rubella syndrome 294
 congenital 294
 Rushton bodies 105, 108
- S**
- saccular cysts 199
 salivary duct carcinomas 60
 sinonasal 60
 salivary gland anlage tumour 140, 175
 nasopharynx 175
 salivary gland neoplasms 273
 cervical cystic 273
 sarcoidosis 45, 191, 204
 larynx 204
 sinonasal 45
 Waldeyer's ring 191
 sarcoma 183, 224
 larynx 224
 larynx granulocytic 224
 larynx mast cell 224
 nasopharynx granulocytic 183
 schwannoma 49, 96, 257
 acoustic 257
 sinonasal 49
 sclerosing polycystic sialadenopathy 136
 Serres rests of 104
 sialadenosis 133
 sialo-odontogenic cyst 107
 sialoblastoma 161
 simple bone cyst 109
 sinusitis 44
 allergic mucinous 44
 sinus histiocytosis with massive lymphadenopathy 212
 larynx 212
 Sjögren's syndrome 288
 small cell neuroendocrine carcinoma 54
 sinonasal 54
 smoker's keratosis 84
 solitary bone cyst 109
 solitary fibrous tumour 48, 179
 nasopharynx 48, 179
 sinonasal 48
 spindle cell carcinoma 16
 differential diagnosis 17, 21
 squamous cell carcinoma 13, 15, 25, 51, 96, 187, 218, 243, 250
 acantholytic 22
 adenoid 22
 alcohol 14
 basaloid 20
 conventional 13
 cystic metastasis 187
 differential diagnosis 15
 external ear 243
 glottic 218
 grading 15
 hypopharyngeal 219
 invasive front 15
 larynx aetiology 218
 larynx epidemiology 218
 metastases 25
 microinvasion 13
 micrometastasis 27
 middle ear 250
 molecular pathology 28
 nasal vestibule 51
 pseudoglandular 22
 second primary tumours 25
 sinonasal 51
 smoking 14
 spindle 16
 stromal reaction 15
 subglottic 219
 supraglottic 218
 transglottic 219
 treatment and prognosis 15
 Waldeyer's ring 187
 squamous cell hyperplasia 9
 squamous cell papilloma 2, 187, 214
 larynx 214
 malignant transformation 4
 oral cavity 2
 oropharyngeal 187
 oropharynx 2
 tonsillar 187
 nasal vestibule 46
 squamous intraepithelial lesions 4, 217
 genetic progression 12
 larynx 5, 12, 217
 oral cavity 5
 oropharynx 5

squamous odontogenic tumour 113
steroid injections 46
 nasal 46
stomatitis nicotina 84
subglottic stenosis 206
 idiopathic 206
surgical ciliated cyst 109
syringocystadenoma papilliferum 241
 ceruminal glands 241

T

Tangier's disease 190
 Waldeyer's ring 190
teratocarcinosarcoma 63
 sinonasal 63
teratoma 175, 272
 cervical 272
 nasopharynx congenital 175
thymoma 273
 cervical 273
thyroid 94, 201, 268
 ectopic 268
 ectopic lingual 94
 larynx aberrant 201
tonsillitis 184, 185
 bacterial suppurative 184
 viral 185
tori 125
tracheopathia osteochondroplastica 202
trachoma 287
 stages 287

traumatic bone cyst 109
trichinosis 203
 larynx 203
tuberculosis 45, 81, 133, 191, 202, 247
 larynx 202
 middle ear 247
 nasal 45
 salivary glands 133
 Waldeyer's ring 191
tuberous sclerosis 115
tubulopapillary carcinoma 61
 sinonasal 61
Turner's syndrome 95, 272
tympanosclerosis 244
Tzanck cells 74

U

undifferentiated carcinoma 53
 sinonasal 53
unicystic ameloblastoma 111
unknown primary tumour 274
uveitis 296
 lens-induced 296

V

varicella zoster 73
verruca vulgaris 2
verrucous carcinoma 17
 differential diagnosis 18

verrucous hyperplasia 7
vertigo 256
 positional 256
vocal cord polyp 209
voice changes 209
voice re-education 211
voice rehabilitation 208, 210
voice rest 211
von Hippel-Lindau disease 301
von Recklinghausen disease 96

W

Warthin's tumour 142
Wegener's disease 45, 80, 203
 larynx 203
 sinonasal 45

X

xanthelasmata 305
xanthoma 95
 verruciform 95

Z

Zenker's diverticulum 201
 hypopharynx 201