

Current Clinical Urology
Series Editor: Eric A. Klein

Li-Ming Su *Editor*

Atlas of Robotic Urologic Surgery

 Humana Press

CURRENT CLINICAL UROLOGY

ERIC A. KLEIN, MD, SERIES EDITOR

For further volumes:
<http://www.springer.com/series/7635>

Atlas of Robotic Urologic Surgery

Current Clinical Urology

Edited by
Li-Ming Su, M.D.

Editor

Li-Ming Su, M.D.
Department of Urology
College of Medicine
University of Florida
Gainesville, FL 32611, USA
sulm@urology.ufl.edu

ISBN 978-1-60761-025-0 e-ISBN 978-1-60761-026-7

DOI 10.1007/978-1-60761-026-7

Springer New York Dordrecht Heidelberg London

Library of Congress Control Number: 2011924669

© Springer Science+Business Media, LLC 2011

All rights reserved. This work may not be translated or copied in whole or in part without the written permission of the publisher (Humana Press, c/o Springer Science+Business Media, LLC, 233 Spring Street, New York, NY 10013, USA), except for brief excerpts in connection with reviews or scholarly analysis. Use in connection with any form of information storage and retrieval, electronic adaptation, computer software, or by similar or dissimilar methodology now known or hereafter developed is forbidden.

The use in this publication of trade names, trademarks, service marks, and similar terms, even if they are not identified as such, is not to be taken as an expression of opinion as to whether or not they are subject to proprietary rights.

While the advice and information in this book are believed to be true and accurate at the date of going to press, neither the authors nor the editors nor the publisher can accept any legal responsibility for any errors or omissions that may be made. The publisher makes no warranty, express or implied, with respect to the material contained herein.

Printed on acid-free paper

Humana Press is part of Springer Science+Business Media (www.springer.com)

To my wife Maria and kids, Sean and Reilly, who are my constant source of love, laughter and inspiration. Special thanks to Linda H. Horne without whose dedication, commitment and tireless efforts this book would not have been possible.

Preface

Few events have had as dramatic an impact on the field of urology as the introduction of robot surgery. The rapid adoption of robotics into the armamentarium of urologic surgery surpasses that of any other minimally invasive technology including shock wave lithotripsy, lasers, percutaneous surgery and laparoscopy. Most notably is the impact that robot-assisted laparoscopic radical prostatectomy has had on the practice pattern of clinically localized prostate cancer treatment in the USA as well as select centers worldwide. In only a few years, surgical practice in the USA has shifted from a predominance of open retropubic prostatectomy to robotic surgery. More recently, robotic surgery has expanded as an alternative treatment option for not only prostate cancer, but also a wide range of upper and lower urinary tract disorders.

This dramatic paradigm shift in urologic practice is a result of multiple factors, some of which relate to benefits to the operating surgeons and ultimately their patients. Robotic surgery has gained traction with urologists as it has offered the opportunity for many urologists, who have little to no experience with laparoscopy, to provide a minimally invasive surgical approach for their patients. The three-dimensional, high definition, and magnified view provided by the current robotic platform offers an unprecedented view of surgical anatomy, superior to that of open and conventional laparoscopic surgery. Along with other benefits such as motion scaling technology and articulating robotic instrumentation, surgeons are provided the opportunity of performing even more precise and meticulous surgery in a relatively bloodless operative field than ever before. Taken together, these benefits have translated in most cases into similar outcomes, but with reduced blood loss and transfusions, less pain, shorter hospital stays, and faster recovery times for patients undergoing robotic surgery as compared to traditional open surgery.

Despite the widespread adoption of robotics into urologic practice, robotic urologic procedures remain technically complex and the skill set required to perform robotic surgery differ significantly from that of traditional open surgery. Unlike open surgery where tactile feedback is often used as an intraoperative tool providing critical information, during robotic surgery, the surgeon is immersed in an environment absent of haptic feedback where operative decisions are made based instead on subtleties and nuances provided by visual cues. Visual cues such as vascularity, organ movement, distortion, and tissue adherence offer different and unique insights into the nature and behavior of organs and their interaction with surrounding structures such as blood vessels, fat, nerves and muscles. As a result, surgeons are required to think and interpret surgical dissection in a way that is unique and different from their training in open surgery.

The *Atlas of Robotic Urologic Surgery* was designed to provide a detailed, step-by-step guide to common robotic urologic procedures for the purpose of helping novice surgeons in their transition to robotic surgery and seasoned robotic surgeons to refine their surgical technique and expand their repertoire of robotic procedures. In addition, less commonly performed robotic procedures such as

those for male infertility, pelvic organ prolapse, urinary tract reconstruction, and pediatrics are included. Each chapter is written by thought leaders in robotic urologic surgery with descriptive step-by-step text, complimented by figures and intraoperative photographs detailing the nuances of each procedure. Emphasis is placed on operative setup, instrument and equipment needs, and surgical techniques for both the primary surgeon as well as the operative assistant. The use of ancillary equipment and robotic instrument and endoscope exchanges are highlighted throughout the procedural text by tables designed to aid surgeons and their teams in improving efficiency. The hope is that this atlas will provide unique insights into robotic urologic surgery and reduce the learning curve of accomplishing these increasingly popular procedures.

FL, USA

Li-Ming Su

Contents

Part I Background and Establishing a Robotics Team

- 1 **Robotics in Urology: Past, Present, and Future** 3
Pierre Mozer, Jocelyne Troccaz, and Dan Stoianovici
- 2 **Robotic Instrumentation, Personnel and Operating Room Setup** 15
Ty T. Higuchi and Matthew T. Gettman

Part II Robotic Surgery of the Lower Urinary Tract

- 3 **Transperitoneal Robot-Assisted Laparoscopic Radical Prostatectomy:
Anterior Approach** 33
Joshua M. Stern and David I. Lee
- 4 **Transperitoneal Robot-Assisted Laparoscopic Radical Prostatectomy:
Posterior Approach** 47
Ryan Turpen, Hany Atalah, and Li-Ming Su
- 5 **Extraperitoneal Robot-Assisted Laparoscopic Radical Prostatectomy** 69
Jean V. Joseph and Matthew Lux
- 6 **Robot-Assisted Laparoscopic Radical Prostatectomy:
Management of the Difficult Case** 79
Geoff Coughlin and Vipul R. Patel
- 7 **Robot-Assisted Radical Cystoprostatectomy** 91
Gerald J. Wang and Douglas S. Scherr
- 8 **Robot-Assisted Laparoscopic Sacrocolpopexy** 107
Shawn M. McGee, Mark S. Shimko, Daniel S. Elliott, and George K. Chow

Part III Robotic Surgery of the Upper Urinary Tract

9 Robot-Assisted Total and Partial Adrenalectomy	121
Manish N. Patel, Nilesh Patil, Mahendra Bhandari, Vinod Narra, Mani Menon, and Craig G. Rogers	
10 Robot-Assisted Radical and Partial Nephrectomy	133
Monish Aron, Andre Berger, and Inderbir S. Gill	
11 Robot-Assisted Radical Nephroureterectomy	143
Daniel Willis, Joseph Pugh, Sijo J. Parekattil, Hany Atalah, and Li-Ming Su	
12 Robot-Assisted Pyeloplasty	159
Raymond J. Leveillee, Jorge Bracho, Steve K. Williams, John M. Shields, and Charles R. Moore	
13 Robot-Assisted Extended Pyelolithotomy and Ureterolithotomy	173
Ashok K. Hemal and Mani Menon	
14 Robot-Assisted Ureteral Reconstruction	187
Patrick Mufarrij, Elias Hyams, and Michael Stifelman	
Part IV Miscellaneous Robotic Urologic Procedures	
15 Robotic Surgical Procedures for Male Infertility	217
Sijo J. Parekattil and Marc S. Cohen	
16 Pediatric Urologic Robotic Procedures	237
Kenneth Thomas and Craig A. Peters	
Index	267

Contributors

Monish Aron, M.D.

Center for Laparoscopic and Robotic Surgery, Department of Urology, Glickman Urological and Kidney Institute, Cleveland Clinic, Cleveland OH, USA

Hany Atalah, M.D.

Department of Urology, University of Florida College of Medicine, Gainesville, FL, USA

Andre Berger, M.D.

Center for Laparoscopic and Robotic Surgery, Department of Urology, Glickman Urological and Kidney Institute, Cleveland Clinic, Cleveland, OH, USA

Mahendra Bhandari, M.D.

Vattikuti Urology Institute, Henry Ford Hospital, Detroit, MI, USA

Jorge Bracho, M.D.

Division of Endourology and Laparoscopy, Department of Urology, University of Miami Leonard Miller School of Medicine, Miami, FL, USA

George K. Chow, M.D.

Department of Urology, Mayo Medical School and Mayo Clinic, Rochester, MN, USA

Marc S. Cohen, M.D.

Department of Urology, University of Florida College of Medicine, Gainesville, FL, USA

Geoff Coughlin, FRACS

Global Robotics Institute, Florida Hospital Celebration Health, University of Central Florida, Orlando, FL, USA

Daniel S. Elliot, M.D.

Department of Urology, Mayo Medical School and Mayo Clinic, Rochester, MN, USA

Matthew T. Gettman, M.D.

Department of Urology, Mayo Clinic, Rochester, MN, USA

Inderbir S. Gill, M.D.

Department of Urology, Cleveland Clinic, Cleveland, OH, USA

Ashok K. Hemal, M.D.

Department of Urology, Wake Forest University Health Sciences, Winston-Salem, NC, USA

Ty T. Higuchi, M.D., Ph.D.

Department of Urology, Mayo Clinic, Rochester, MN, USA

Elias Hyams, M.D.

Department of Urology, New York University Langone Medical Center, New York, NY, USA

Jean V. Joseph, M.D.

Department of Urology and Wilmot Cancer Center, University of Rochester Medical Center and Strong Memorial Hospital, Rochester, NY, USA

David I. Lee, M.D.

Department of Urology, University of Pennsylvania, School of Medicine and Penn Presbyterian Medical Center, Philadelphia, PA, USA

Raymond J. Leveillee, M.D.

Division of Endourology and Laparoscopy, Department of Urology, University of Miami Leonard Miller School of Medicine, Miami, FL, USA

Matthew Lux, M.D.

Department of Urology, University of Rochester Medical Center and Strong Memorial Hospital, Rochester, NY, USA

Shawn M. McGee, M.D.

Department of Urology, Mayo Medical School and Mayo Clinic, Rochester, MN, USA

Mani Menon, M.D.

Chairman, Vattikuti Urology Institute, Henry Ford Hospital, Detroit, MI, USA

Charles R. Moore, M.D.

Division of Endourology and Laparoscopy, Department of Urology, University of Miami Leonard Miller School of Medicine, Miami, FL, USA

Pierre Mozer, Ph.D.

Groupe Hospitalier Pitié-Salpêtrière, Department of Urology, Paris, France
and also with the Institut des Systèmes Intelligents et de Robotique,
Pierre & Marie Curie University, Paris, France, UK

Patrick Mufarrij, M.D.

Department of Urology, New York University Langone Medical Center, New York, NY, USA

Vinod Narra, M.D.

Department of Surgery, Henry Ford Hospital, Detroit, MI, USA

Sijo J. Parekattil, M.D.

Department of Urology, University of Florida College of Medicine, Gainesville, FL, USA

Manish N. Patel, M.D.

Vattikuti Urology Institute, Henry Ford Hospital, Detroit, MI, USA

Vipul R. Patel, M.D.

Florida Hospital, Celebration, FL, USA

Nilesh Patil, M.D.

Vattikuti Urology Institute, Henry Ford Hospital, Detroit, MI, USA

Craig A. Peters, M.D.

Division of Surgical Innovation, Sheikh Zayed Institute for Pediatric Surgical Innovation, Children's National Medical Center, Washington, DC, USA

Joseph Pugh, M.D.

Department of Urology, University of Florida College of Medicine, Gainesville, FL, USA

Craig G. Rogers, M.D.

Vattikuti Urology Institute, Henry Ford Hospital, Detroit, MI, USA

Douglas S. Scherr, M.D.

Department of Urology, Weill Medical College of Cornell University and New York Presbyterian Hospital, New York, NY, USA

John M. Shields, M.D.

Division of Endourology and Laparoscopy, Department of Urology, University of Miami Leonard Miller School of Medicine, Miami, FL, USA

Mark S. Shimko, M.D.

Department of Urology, Mayo Medical School and Mayo Clinic, Rochester, MN, USA

Joshua M. Stern, M.D.

Department of Urology, Penn Presbyterian Medical Center, Philadelphia, PA, USA

Michael Stifelman, M.D.

Department of Urology, New York University Langone Medical Center, New York, NY, USA

Dan Stoianovici, M.D.

Johns Hopkins University, Brady Urological Institute, Baltimore, MD, USA

Li-Ming Su, M.D.

Department of Urology, University of Florida College of Medicine, Gainesville, FL, USA

Kenneth Thomas, M.D.

Department of Urology, University of Virginia Health System, Charlottesville, VA, USA

Jocelyne Troccaz, Ph.D.

CNRS Research Director, TIMC-IMAG CNRS UJF Laboratory, Grenoble, France, UK

Ryan Turpen, M.D.

Department of Urology, University of Florida College of Medicine, Gainesville, FL, USA

Gerald J. Wang, M.D.

Department of Urology, Weill Medical College of Cornell University and New York Presbyterian Hospital, New York, NY, USA

Steve K. Williams, M.D.

Division of Endourology and Laparoscopy, Department of Urology, University of Miami Leonard Miller School of Medicine, Miami, FL, USA

Daniel Willis, M.D.

Department of Urology, University of Florida College of Medicine, Gainesville, FL, USA

Part I
Background and Establishing a Robotics Team

Chapter 1

Robotics in Urology: Past, Present, and Future

Pierre Mozer, Jocelyne Troccaz, and Dan Stoianovici

Introduction

A robot is a mechanical device controlled by a computer. Medical robots have been classified in several ways. Three types were distinguished from an operational point of view [1]: remote controlled, synergistic, and automated or semi-automated robots. In the first two types, the physician has direct real-time control of the robotic instrument either from a console or by handling the instrument itself. The best known remote system is the da Vinci[®] Surgical System (Intuitive Surgical, Inc. Sunnyvale, CA), and examples of the synergetic class are the MAKO orthopedics robot (MAKO Surgical Corp., Ft. Lauderdale, FL) or Acrobot system (The Acrobot Company, Ltd. London, UK). For the later class, the physician does not have to continuously control the motion of the robot, but rather define its task and monitor the execution. Image-guided robots are commonly operated under this mode, for example, the Innomotion robot (Innomedic, GmbH, Herxheim, Germany. Acquired by Synthes West Chester, PA in March 2008) and our AcuBot robot for computed tomography (CT)-guided interventions [2].

Robots in different categories are significantly dissimilar from the technical point of view, having

other design requirements. It is commonly the case that directly controlled robots have less precision requirements, because the motion is compensated by the physician, but have additional complexity for implementing the direct control of the physician. Image-guided robots do not normally need a surgeon console, but need to be more accurate and precise to operate without human compensation.

This chapter gives a short presentation of the achievements and developments in the field, a few key concepts of robotics and medical robotics, and several examples of these technologies commercial and under development.

Robots of the Past

The term *robot* was used for the first time in 1921, to indicate the idea of forced labor, in a Czech play written by Karel Capek (Rossom's Universal Robot) and the term *robotic* was introduced by Isaac Asimov in 1950 in his novel *Runaround*. Several years later, Asimov defined three novelistic laws of robotics (a robot cannot hurt a human being, it must obey the orders given to it by a human being, and a robot must protect its own existence without infringing the first two laws) [3]. Although the term is relatively recent, the idea of an intelligent machine dates back to Antiquity, as, in Song XVIII of the Iliad, Hephaestus, the God of Fire, builds three-legged tables fitted with casters that are able to go back and forth on their own in the palaces of the Gods.

D. Stoianovici (✉)
Johns Hopkins University, Brady Urological Institute,
JHBMC, MFL-W115, 5200 Eastern Ave., Baltimore,
MD 21224, USA
e-mail: dss@jhu.edu

The first master–slave robotic system was used to manipulate radioactive substances and was invented in 1954 by R. Goertz [4]. The first industrial robot, called Unimate, was invented by G. Deroe and J. Engelberger in 1961 and consisted of an articulated arm with hydraulic motorization used in the automobile industry [5].

Robots for medical applications have been initially derived from industrial robots. The first medical system, developed in the mid-1980s by Y. Kwok and R. Young, was a neurosurgical stereotactic guidance system integrated with a CT scanner. The first patient was operated in 1985 [6] and despite its accuracy, the system did not appear adapted to surgery due to some drawbacks, such as safety, the time needed for the setup, and its limited workspace. Medical requirements for safety and specifications related to the fields of applications rapidly led to the development of dedicated robots in the field of urology.

From a historic point of view the first systems were robots with image-guided capabilities. Davies developed a robot for prostatectomies, called Probot [7], based on an industrial Unimate Puma robot constrained within a frame for safety consideration. The robot was guided by transrectal ultrasound (TRUS) images and it was the first robotic device used to remove tissue from a patient when it underwent its first clinical trial in March of 1991.

A few years later, the URobot system was developed in Singapore by Ng et al. The robot was designed to perform a transurethral and transperineal access to the prostate for laser resection in 2001 [8] or brachytherapy [9], respectively. At Johns Hopkins University, our team has developed several needle driving systems under various x-ray based guidance modalities, and performed numerous clinical tests for urology applications [2, 10–14]. Commercially, the German company Innomedic is pursuing the development of a system for guiding needles under direct magnetic resonance imaging (MRI) guidance.

Simultaneously, some others research teams worked on the concept of remote manipulation mostly for augmenting the performance of

minimally invasive surgery [15]. The first system was named Artemis (Advanced Robotic Telemanipulator for Minimally Invasive Surgery) [16]. Computer Motion Inc. (Santa Barbara, CA) was able to develop the first robotic arm approved by the Food and Drug Administration (FDA) to hold an endoscope [17]. This system called AESOP (Automated Endoscopic System for Optimal Positioning) was a robotic arm with motorized joints controlled by the surgeon with hand and foot controls or through a speech recognition system. Early clinical use was reported [18] and the idea to use the same arm to drive surgical tools gave birth to the Zeus surgical system. This system consists of a surgeon's console and three separate robotic arms that are attached to the operating room table. The distance between the interface, by which the operator gives his instructions to the machine, and the patient can range from several meters to several thousand kilometers, opening the way to telesurgery [19]. Nevertheless, the Zeus was not FDA approved and another company, Intuitive Surgical, opened the field of robotic surgery with the da Vinci®. The da Vinci® robotic platform is a master–slave system with three or four arms allowing endowrist capabilities and a three-dimensional visualization of the surgical field. Even though several drawbacks have been echoed about its functionality and possible improvements, this system popularized the concept and instrumentation of robotic surgery in several medical fields. The first radical prostatectomy was reported in 2000 by Abbou et al. [20]. Some other applications in general surgery were explored [21], but even though the system was not purposely designed for urology, prostatectomy appears to be its best suited application.

Robots of the Present

Currently, the da Vinci® platform is the only robotic system used in common practice with more than 800 robots installed worldwide. In large majority the robots are used for robot-assisted laparoscopic radical prostatectomy

(RALP) [22]. Even if the review of published literature on RALP and open radical prostatectomy (ORP) is currently insufficient to favor one surgical technique, it seems that short-term outcomes of RALP achieve equivalence to open surgery with regard to complications and functional results [23]. Applications to bladder cancer, renal cancer, ureteropelvic junction obstruction, and pelvic prolapse have also been explored [24]. The main technical improvement since the first release of the system was the addition of a fourth robotic arm, yet other features especially with respect to improved sensory feedback could significantly improve its performance and surgeon acceptance.

A new class of robot, called synergistic [25], is under evaluation mainly for orthopedic surgery. This robot (MAKO Surgical Corp.) confines a bone cutting tool by hardware and software robotic means to a defined volume in space creating a “no-fly zone” defined by the surgeon based on preacquired images. Evaluation of the MAKO system for partial knee resurfacing is ongoing. Also for orthopedics, the Acrobot system can be used for unicompartmental knee replacement [26] or hip resurfacing surgery [27].

Robots of the Future

Current developments aim at creating robotic systems with decreased learning curves that would allow for safer and more homogeneous outcomes with less variability of surgeon performance, as well as new tools to perform more autonomous tasks in a less invasive way at lower costs. Conceptually, robotic developments are an integral part of the computer aided surgery (CAS) paradigm [28]. This integrates preoperative planning, intraoperative guidance, robotic assistance, and postoperative verification and follow-up. Augmented reality is a part of this concept including image fusion from various imaging modalities, such as preoperative CT with laparoscopic images [29]. Fusion of fluoroscopic and ultrasound images has been proposed to couple the intraoperative guidance of the

real-time ultrasound with the higher imaging capabilities of the CT [30].

Based on the CAS concepts, future systems are expected to advance in the following two directions: improvements of remote manipulation robots for surgery, developments of image-guided robots for interventions, and possibly combining the two categories.

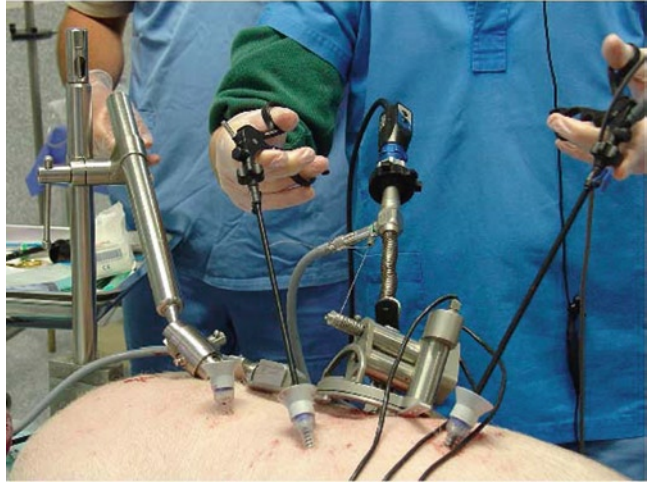
Remote Manipulation Robots

Current surgical robotic research shows a trend of size reduction compared to the da Vinci® system. For example, the NeuroArm (University of Calgary, Canada) proceeds with the development of a remotely controlled bilateral arm robot for neurosurgical operations. Part of the scope is to reduce its size to where the robot could be brought in the bore of an MRI scanner. Even though this is not yet possible, their current version is substantially smaller than the da Vinci®, and has additional features such as force feedback [31]. Another example is the VickY system [32], which is a very compact robot allowing to move a laparoscopic camera. Technical works to hold surgical tools on this platform are ongoing (Fig. 1.1).

Currently a major concern with the da Vinci® is the lack of haptic feedback. Several teams are pursuing additions to the existing system for augmenting sensory feedback [33] and with modified trocar instruments for allowing the measurement of manipulation forces [34].

A novel approach is pursuing the development of tools to be deployed in the peritoneal cavity and controlled externally with magnetic fields for reducing the number of transabdominal trocars and for increasing the range of motion and accessibility [35].

The development of natural orifice transluminal endoscopic surgery (NOTES) is potentially the next paradigm shift in minimally invasive surgery. The concept is to access to the peritoneal cavity without passing through the anterior abdominal wall. The first clinical case, performed in 2007, was a cholecystectomy in a

Fig. 1.1 VickY robot

woman via a transvaginal approach [36]. Nevertheless, NOTES procedures are performed using modified endoscopic tools with significant constraints, and new tools are necessary to allow the surgeon to better visualize and dexterously manipulate within the surgical environment. A two-armed dexterous miniature robot with stereoscopic vision capabilities is under development [37].

Direct Image-Guided Robots

Traditionally, image-guidance and navigation of instruments has been performed manually based on preacquired images with the use of spatial localizers such as optical [38] and magnetic trackers [39]. However, robots have the potential to improve the precision, accuracy, and reliability of performance in image-guidance interventions, because the tasks are done in a full digital way, from image to instrument manipulation.

Robots for interventions with needles or other slender probes or instruments can be connected to an imaging modality (CT, MRI, ultrasound, fluoroscopy, etc.). Targets and paths are defined in the image based on planning algorithms, and the robot aligns and may insert the needle accordingly. The true potential of needle delivery mechanisms relies

on their ability to operate with, be guided by, and use feedback from medical imaging equipment.

Moreover, robots can do complex movements, impossible to perform by a human to limit tissue and needle deformations during the insertion. Indeed, mechanical laws dictate that the reduction of needle insertion force diminishes tissue deformations and target deflection. Mockup experiments with a prostate brachytherapy needle correlated deflections to the speed of needle insertion and correlated with the change in axial force [40].

Decreasing the force of needle insertion has been proposed with special movements for increasing the accuracy to reaching a target. Abolhassani [41] described an interesting approach during the puncture of a prostate phantom. The deflection of the needle is estimated using online force/moment measurements at the needle base and to compensate for the needle deflection, the needle is axially rotated through 180° . Results show on a prostate phantom with an 18-Gauge beveled-tip needle that the deflection at the target was reduced by as much as 90%. Nevertheless, applying just a rotation of the needle at the rate of 50 rpm is less complex and the results were similar. Results on needle rotation were confirmed by others teams, but concerns regarding tissue damage due to the “drilling” nature of the insertion were also raised, depending on the geometry of the needle point especially with the bevel. Meltner et al. [42] showed that with a bevel point

needle, the damage to the gelatin mockup used became greater when the rotation speed increases. To avoid this effect during the needle insertion, they suggested rotating only the barrel of the needle and not its stylet with the point. Podder et al. [43] proposed a system designed to insert multiple needles simultaneously for prostate therapies. Rotation was also used for reducing insertion forces.

Image Input

Image-guided robots have stringent requirements for imager compatibility, precision, sterility, safety, as well as size and ergonomics [28]. A robot's compatibility with a medical imager refers to the capability of the robot to safely operate within the confined space of the imager while performing its clinical function, without interfering with the functionality of the imager [44].

The current research trend is to embed the robot with the imager (CT, MRI, ultrasound, fluoroscopy, etc.) for reimaging during the intervention for relocalization, treatment planning updates, and quality control. We term these procedures direct image-guided interventions (DIGI). The performance of DIGI interventions is not new, in fact the routine TRUS biopsy is done under direct guidance; however, the new term is essential for distinguishing this important class of image-guided intervention (IGI) from navigation based on preacquired imaging data.

Among all types of imagers, the MRI is the most demanding, and the development of MRI-compatible robots is a very challenging engineering task [45]. But, this also makes MRI-compatible multi-imager compatible, if care is taken for the selection of radiolucent materials for the components in immediate proximity of the imaging site [44]. Due to the strong requirements needed to build a MRI-compatible robot, the following description of many robots under development is presented with respect to their capabilities of operation leading up to those used in conjunction with MRI.

Ultrasound and CT-Compatible Robots

Professor Brian Davies of the Imperial College in London, who pioneered the robotics filed in urology with the Probot [7], has also reported the development of a simple robot that performs similar to the brachytherapy template [46]. Rotation about the axis of the needle is added in order to reduce needle deflections. The system uses two-dimensional TRUS guidance and the report describes successful preclinical testing.


In the Robarts Research Institute (London, Canada) [47] and in the Nanyang Technological University (Singapore) [48], three dimensional reconstruction from a regular two dimensional TRUS probe has been investigated by sweeping the probe about its axis. This was integrated with a robot in a system for prostate brachytherapy or biopsy. Mockup tests demonstrated a precision on the order of 1 mm and a clinical study for biopsy is ongoing in Singapore.

Our URobotics laboratory at Johns Hopkins has also developed several versions of a CT-guided robot [2]. Recently, the AcuBot robot was instrumented with a new end-effector, the revolving needle driver (RND). The RND is a fully actuated driver for needle insertion, spinning, release, and force measurement (Fig. 1.2). The driver supports the needle from its head, and provides an additional needle support guide in close proximity of the skin entry point. This is similar to holding the needle with two finger-like grippers, one from its head and one from its barrel next to the skin. The top one pushes the needle in and out, while the lower holds the guide to support the direction of the needle as close as possible to the skin. Both grippers can simultaneously release the needle automatically. Finally, the new driver is also equipped with a set of force sensors to measure the interaction of the nozzle with the patient and the force of needle insertion [49, 50].

MRI-Compatible Robots

The earliest work for MRI-guided prostate intervention robots was performed at the Brigham and

Fig. 1.2 Revolving needle driver on the AcuBot robot



Women's Hospital, Boston MA in collaboration with AIST-MITI, Japan [51]. A robotic intervention assistant was constructed for open MRI to provide a guide for needles and probes [52]. To minimize image interference from motors, the robot had to be located distally, at the top of the imager between the vertical coils of the MRI. To operate at the isocenter, long arms had to be extended, which made them flexible. The system assists the physician by positioning a needle guide for manual needle intervention. Applications included prostate biopsy and brachytherapy [53, 54].

The Institute for Medical Engineering and Biophysics (IMB), Karlsruhe, Germany reported several versions of a robotic system for breast lesion biopsy and therapy under MR guidance [55, 56]. Their last version used a cylinder for driving an end-effector axis [57], and their report gives a well-reasoned presentation of these advantages. This German institute is no longer active, but fortunately a spin-off company was created. The company (Innomedic, Germany) is developing a pneumatic robot for general CT- or MRI-guided needle procedures [58]. The robot orients the needle about the axial-sagittal planes for interventions targeting abdominal organs. However, a group from Frankfurt, Germany has

recently used the Innomotion system for targeting the prostate [59, 60]. The limitations of the robot restricted the access to the transgluteal path (prone patient with needle pointing down) for which the needle path is much deeper than normal (~14 cm reported in the cadaver experiment) [60]. A 15 Ga needle was used to prevent deflections. Manual needle insertion was performed through the guide after retracting the table from the scanner. Even though the Innomedic system is not FDA approved and its designed application range does not include the prostate, it is approved for clinical use in Europe and is a commercial DIGI robot.

TIMC laboratory in France reported a lightweight MRI-compatible robot for abdominal and thoracic percutaneous procedures [61]. This robot, named LPR (acronym for Light Puncture Robot), has an original compact (15 × 23 cm) body supported architecture, which is naturally able to follow the patient body surface respiratory movements. It is entirely made of plastic, and uses MR-compatible pneumatic actuators powered by compressed air. The needle-holder puncture part includes clamps used to grasp the needle, and a translation unit (a fast linear pneumatic actuator), which is able to perform a fast puncture in a single motion (above 9 cm/s) to

perforate the skin or organ's walls. Mockup experiments are on going to measure system accuracy in the MRI.

Our group at Johns Hopkins has also developed an MRI-compatible robot for prostate access [62]. MrBot was constructed to be multi-imager compatible, which includes compatibility with all classes of medical imaging equipment (ultrasound, x-ray, and MR-based imagers) [44]. All robotic components are constructed of non-magnetic and dielectric materials. To overcome MRI incompatibilities a new type of motor was purposely designed for the robot. This, PneuStep [63], is a pneumatic motor using optical feedback with fail safe operation, and it is the only fully MRI-compatible motor.

The robot presents six degrees of freedom (DOF), five for positioning and orienting the injector, and one for setting the depth of needle insertion. Various needle drivers can be mounted in the robot for performing various needle interventions. The first driver was developed for fully automated low-dose (seed) brachytherapy [64–67] (Fig. 1.3).

Compared with the classic template of needle guides commonly used in TRUS interventions, the robot gives additional freedom of motion for better targeting. For example, the skin entry point may be chosen ahead of time and targeting can be performed with angulations, which is impossible with the template. As such, multiple

needle insertions can be performed through the same skin entry point. Moreover, angulations also allow for reducing pubic arch interference, thus allowing for targeting otherwise inaccessible regions of the prostate.

The robot is controlled from a unit remotely located outside the imager's room, either in the control room of the imager or other proximal space. The robot is connected to the control cabinet by a bundle of hoses. This allows for all MRI-incompatible components of the system to be located outside the MRI room.

Precision tests in tissue mockups yielded a mean seed placement error of 0.72 ± 0.36 mm [66]. With different needle drivers, the MrBot applies to various automated DIGI, such as biopsy, therapy injections, and thermal or radiofrequency ablations. The system is presently in preclinical testing with cadaver and animal experiments, but tests show very promising results and clinical trials are expected soon.

Image-Augmented Remote Manipulation Robots

The combination of the two classes presented above, remote manipulation and direct image-guided robots are very likely, a highly promising

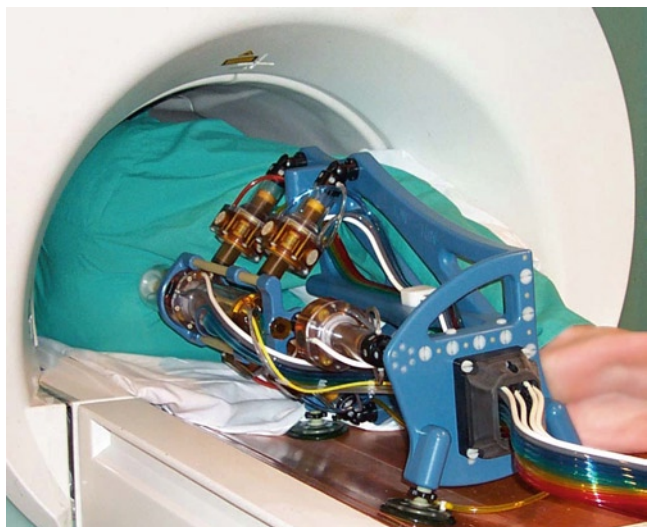

Fig. 1.3 MrBot robot for MRI guided prostate interventions

direction of future developments. Augmenting guidance from medical imagers to surgical procedures could substantially improve the way that operations are being performed, and would give a clear undisputable advantage for using robotic technologies in surgery.

The NeuroArm robot under development in Canada is a good example of these technologies [31]. Even though it may not yet operate inside the MRI scanner as planned, this may operate next to the MRI scanner and take advantage of recently acquired images to guide the surgery. This does not qualify as MRI safe and compatible, but is a “mini da Vinci” with force feedback. Image processing algorithms used in robotic surgery could also improve the localization of the surgical tools [68] and intraoperative analyses [69].

Conclusion

The most popular medical robot thus far is perhaps the da Vinci®. In only a few years since its commercial release, this technology has seen significant widespread adoption and use in operating rooms across the world. Most importantly, robotic technology such as the da Vinci® has also shown the potential of these new medical instruments and has substantially boosted confidence of the physicians in using these technologies in the operating room environment. Concerns regarding its current capabilities and possible upgrades have been echoed, especially about its lack of force feedback. Nevertheless, da Vinci® represents a significant technology breakthrough and advances will improve its performance.

It is also notable that the potential of robots lies much further ahead than the accomplishments of the da Vinci® system. The integration of imaging with robotics holds a substantial promise, because this can accomplish tasks otherwise impossible. Image-guided robots have the potential to offer a paradigm shift. The final goal of robots is to allow safer and more homogeneous outcomes with less variability of surgeon performance, as well as new tools to perform tasks based on medical transcutaneous imaging, in a less invasive way and at lower costs.

Acknowledgments The work reported from the Urology Robotics lab at Johns Hopkins has been partially supported by the National Cancer Institute (NCI) of the National Institutes of Health (NIH), the Prostate Cancer Foundation (PCF), the Patrick C. Walsh Prostate Cancer Foundation (PCW), and the Prostate Cancer Research Program of the Department of Defense (PCRP). The contents are solely the responsibility of the authors and do not necessarily represent the official views of NCI, PCF, PCW, or the PCRP.

References

1. Davies B (2000) A review of robotics in surgery. *Proc Inst Mech Eng H* 214(1):129–140
2. Stoianovici D, Cleary K, Patriciu A, Mazilu D, Stanimir A, Craciunoiu N, Watson V, Kavoussi LR (Oct 2003) AcuBot: a robot for radiological interventions. *IEEE Trans Robot Autom* 19(5):926–930, <http://urology.jhu.edu/urobotics/pub/2003-stoianovici-ieeeetra.pdf>
3. Isaac Asimov (1942) *Runaround*: in *Astounding Science Fiction*
4. Goertz RC, Thompson WM (1954) Electronically controlled manipulator. *Nucleonics* 11:46–47
5. Devol J: Programmed article transfer. USA Patent 2988237, 1954
6. Kwok YS, Hou J, Jonckheere EA, Hayati S, Hayati EA (Feb 1988) A robot with improved absolute positioning accuracy for CT guided stereotactic brain surgery. *IEEE Trans Biomed Eng* 35(2):153–160
7. Davies BL, Hibberd RD, Ng WS, Timoney AG, Wickham JE (1991) The development of a surgeon robot for prostatectomies. *Proc Inst Mech Eng H* 205(1):35–38
8. Ho G, Ng WS, Teo MY, Kwok CK, Cheng WS (Apr 2001) Experimental study of transurethral robotic laser resection of the prostate using the LaserTrode lightguide. *J Biomed Opt* 6(2):244–251
9. Ng WS, Chung VR, Vasan S, Lim P (1996) Robotic radiation seed implantation for prostatic cancer. *Proc Int Conf IEEE Eng Med Biol Soc Bridg Discipline Biomed* 1:231–233
10. Solomon SB, Patriciu A, Stoianovici DS (May 2006) Tumor ablation treatment planning coupled to robotic implementation: a feasibility study. *J Vasc Interv Radiol* 17(5):903–907, <http://urology.jhu.edu/urobotics/pub/2006-solomon-JVIR.pdf>
11. Su LM, Stoianovici D, Jarrett TW, Patriciu A, Roberts WW, Cadeddu JA, Ramakumar S, Solomon SB, Kavoussi LR (Sep 2002) Robotic percutaneous access to the kidney: comparison with standard manual access. *J Endourol* 16(7):471–475, <http://urology.jhu.edu/urobotics/pub/2002-su-jendourol.pdf>
12. Solomon SB, Patriciu A, Bohlman ME, Kavoussi LR, Stoianovici D (Oct 2002) Robotically driven interventions: a method of using CT fluoroscopy without radiation exposure to the physician. *Radiology*

- 225(1):277–282, <http://urology.jhu.edu/urobotics/pub/2002-solomon-rad.pdf>
13. Stoianovici D, Whitcomb LL, Anderson JH, Taylor RH, Kavoussi LR (1998) A modular surgical robotic system for image guided percutaneous procedures. *Lect Notes Comput Sci* 1496:404–410, <http://urology.jhu.edu/urobotics/pub/1998-stoianovici-miccai.pdf>
 14. Stoianovici D, Cadeddu JA, Demaree RD, Basile SA, Taylor RH, Whitcomb LL, Sharpe WN, Kavoussi LR (1997) An efficient needle injection technique and radiological guidance method for percutaneous procedures. *Lect Notes Comput Sci* 1205:295–298, <http://urology.jhu.edu/urobotics/pub/1997-stoianovici-miccai.pdf>
 15. Challacombe B, Kavoussi L, Patriciu A, Stoianovici D, Dasgupta P (Nov 2006) Technology insight: telemonitoring and telesurgery in urology. *Nat Clin Pract Urol* 3(11):611–617, <http://urology.jhu.edu/urobotics/pub/2006-challacombe-nature.pdf>
 16. Schurr MO, Buess G, Neisius B, Voges U (Apr 2000) Robotics and telemanipulation technologies for endoscopic surgery. A review of the ARTEMIS project. *Advanced Robotic Telemanipulator for Minimally Invasive Surgery. Surg Endosc* 14(4):375–381
 17. Unger SW, Unger HM, Bass RT (Sep 1994) AESOP robotic arm. *Surg Endosc* 8(9):1131
 18. Kavoussi LR, Moore RG, Partin AW, Bender JS, Zenilman ME, Satava RM (Jul 1994) Telerobotic assisted laparoscopic surgery: initial laboratory and clinical experience. *Urology* 44(1):15–19
 19. Marescaux J, Leroy J, Gagner M, Rubino F, Mutter D, Vix M, Butner SE, Smith MK (Sep 2001) Transatlantic robot-assisted telesurgery. *Nature* 413(6854):379–380
 20. Cadiere GB, Himpens J, Gernay O, Izizaw R, Degueldre M, Vandromme J, Capelluto E, Bruyns J (Nov 2001) Feasibility of robotic laparoscopic surgery: 146 cases. *World J Surg* 25(11):1467–1477
 21. Abbou CC, Hoznek A, Salomon L, Lobontiu A, Saint F, Cicco A, Antiphon P, Chopin D (Sep 2000) [Remote laparoscopic radical prostatectomy carried out with a robot. Report of a case]. *Prog Urol* 10(4):520–523
 22. Badani KK, Kaul S, Menon M (Nov 2007) Evolution of robotic radical prostatectomy: assessment after 2766 procedures. *Cancer* 110(9):1951–1958
 23. Rassweiler J, Hruza M, Teber D, Su LM (Apr 2006) Laparoscopic and robotic assisted radical prostatectomy—critical analysis of the results. *Eur Urol* 49(4):612–624
 24. Dasgupta P (Mar 2008) Robotics in urology. *Int J Med Robot* 4(1):1–2
 25. Troccaz J, Peshkin M, Davies B (Jun 1998) Guiding systems for computer-assisted surgery: introducing synergistic devices and discussing the different approaches. *Med Image Anal* 2(2):101–119
 26. Cobb J, Henckel J, Gomes P, Harris S, Jakopec M, Rodriguez F, Barrett A, Davies B (Feb 2006) Hands-on robotic unicompartmental knee replacement: a prospective, randomised controlled study of the acrobot system. *J Bone Joint Surg Br* 88(2):188–197
 27. Barrett AR, Davies BL, Gomes MP, Harris SJ, Henckel J, Jakopec M, Kannan V, Rodriguez y Baena FM, Cobb JP (Oct 2007) Computer-assisted hip resurfacing surgery using the acrobot navigation system. *Proc Inst Mech Eng H* 221(7):773–785
 28. Taylor RH, Stoianovici D (Oct 2003) Medical robotics in computer-integrated surgery. *IEEE Trans Robot Autom* 19(5):765–781, <http://urology.jhu.edu/urobotics/pub/2003-taylor-ieeeetra.pdf>
 29. Ukimura O, Gill IS (Apr 2008) Imaging-assisted endoscopic surgery: Cleveland clinic experience. *J Endourol* 22(4):803–810
 30. Mozer P, Conort P, Leroy A, Baumann M, Payan Y, Troccaz J, Chartier-Kastler E, Richard F (May 2007) Aid to percutaneous renal access by virtual projection of the ultrasound puncture tract onto fluoroscopic images. *J Endourol* 21(5):460–465
 31. Sutherland GR, Latour I, Greer AD (May–Jun 2008) Integrating an image-guided robot with intraoperative MRI: a review of the design and construction of neuroArm. *IEEE Eng Med Biol Mag* 27(3):59–65
 32. Long JA, Cinquin P, Troccaz J, Voros S, Berkelman P, Descotes JL, Letoublon C, Rambeaud JJ (Aug 2007) Development of miniaturized light endoscope-holder robot for laparoscopic surgery. *J Endourol* 21(8):911–914
 33. Reiley CE, Akinbiyi T, Burschka D, Chang DC, Okamura AM, Yuh DD (Jan 2008) Effects of visual force feedback on robot-assisted surgical task performance. *J Thorac Cardiovasc Surg* 135(1):196–202
 34. Zemiti N, Morel G, Ortmaier T, Bonnet N (2007) Mechatronic design of a new robot for force control in minimally invasive surgery. *IEEE ASME Trans Mech* 12(2):143–153
 35. Zeltser IS, Cadeddu JA (Jan 2008) A novel magnetic anchoring and guidance system to facilitate single trocar laparoscopic nephrectomy. *Curr Urol Rep* 9(1):62–64
 36. Marescaux J, Dallemagne B, Perretta S, Wattiez A, Mutter D, Coumaros D (Sep 2007) Surgery without scars: report of transluminal cholecystectomy in a human being. *Arch Surg* 142(9):823–826, discussion 826–827
 37. Lehman AC, Dumpert J, Wood NA, Visty AQ, Farritor SM, Oleynikov D (2008) In vivo robotics for natural orifice transgastric peritoneoscopy. *Stud Health Technol Inform* 132:236–241
 38. Bucki M, Dauliac B, Daanen V, Moalic R, Descotes J-L, Troccaz J (2005) PRONAV: A NAVIGATION SOFTWARE FOR PROSTATE BIOPSIES. *Surgetica®™2005: Sauramps Medical479–483%U* http://www-timc.imag.fr/Jocelyne.Troccaz/applis-cliniques_fichiers/ProNav-Surgetica405.pdf
 39. Xu S, Kruecker J, Guion P, Glossop N, Neeman Z, Choyke P, Singh AK, Wood BJ (2007) Closed-loop control in fused MR-TRUS image-guided prostate biopsy. *Med Image Comput Assist Interv.* 10(1):128–135. PMID:18051052
 40. Podder TK, Clark DP, Fuller D, Sherman J, Ng WS, Liao L, Rubens DJ, Strang JG, Messing EM, Zhang YD, Yu Y (2005) Effects of velocity modulation during surgical needle insertion. *Conf Proc IEEE Eng Med Biol Soc.* 6:5766–5770. PMID:17281568

41. Abolhassani N, Patel RV, Ayazi F (Jun 2007) Minimization of needle deflection in robot-assisted percutaneous therapy. *Int J Med Robot* 3(2):140–148
42. Meltser MA, Ferrier NJ, Thomadsen BR (2007) Observations on rotating needle insertions using a brachytherapy robot. *Phys Med Biol* 52(19):6027–6037
43. Podder Tk, Ng Ws, Yu Y (2007) Multi-Channel Robotic System For Prostate Brachytherapy. *Conf Proc IEEE Eng Med Biol Soc.* 1233–1236. PMID:18002186
44. Stoianovici D (Jan 2005) Multi-imager compatible actuation principles in surgical robotics. *Int J Med Robot Comput Assist Surg* 1(2):86–100, <http://urology.jhu.edu/urobotics/pub/2005-stoianovici-MRCASJ.pdf>
45. Gassert R, Yamamoto A, Chapuis D, Dovat L, Bleuler H, Burdet E (Oct 2006) Actuation methods for applications in MR environments. *Concept Magn Reson B Magn Reson Eng* 29B(4):191–209, <Go to ISI>://000241550200005
46. Davies BL, Harris SJ, Dibble E (Jun 2004) Brachytherapy--an example of a urological minimally invasive robotic procedure. *Int J Med Robot.* 1(1):88–96. PMID:17520600
47. Wei Z, Wan G, Gardi L, Mills G, Downey D, Fenster A (Mar 2004) Robot-assisted 3D-TRUS guided prostate brachytherapy: system integration and validation. *Med Phys* 31(3):539–548
48. Yu Y, Podder T, Zhang Y, Ng WS, Mistic V, Sherman J, Fu L, Fuller D, Messing E, Rubens D, Strang J, Brasacchio R (2006) Robot-assisted prostate brachytherapy. *Med Image Comput Assist Interv.* 9(1):41–49. PMID:17354872
49. Shah S, Kapoor A, Ding J, Guion P, Petrisor D, Karanian J, Pritchard W, Stoianovici D, Wood B, Cleary K (2008) Robotically Assisted Needle Driver: Evaluation of Safety Release, Force Profiles, and Needle Spin in a Swine Abdominal Model. *Int J Comput Assist Radiol Sug.* 3:173–179. <http://urobotics.urology.jhu.edu/pub/2008-shah-ijcars.pdf>
50. Petrisor D, Mozer P, Vigarou B, Cleary K, Stoianovici D (2008) Rotating Needle Driver for Robotic Interventions. *Engineering and Urology Society, 23rd Annual Meeting.* pp.22. http://engineering-urology.org/am/23EUS_2008.pdf
51. Chinzei K, Hata N, Jolesz FA, Kikinis R (2000) MR compatible surgical assist robot: system integration and preliminary feasibility study. *Med Image Comput Assist Interv MICCAI 2000* 1935:921–930
52. Chinzei K, Miller K (Jan–Feb 2001) Towards MRI guided surgical manipulator. *Med Sci Monit* 7(1):153–163
53. Koseki Y, Koyachi N, Arai T, Chinzei K (2003) Remote actuation mechanism for MR-compatible manipulator using leverage and parallelogram - workspace analysis, workspace control, and stiffness evaluation. 1:652–657 vol.651
54. Koseki Y, Kikinis R, Jolesz FA, Chinzei K (2004) Precise evaluation of positioning repeatability of MR-compatible manipulator inside MRI. *Med Image Comput Assist Interv MICCAI 2004 Pt 2 Proc* 3217:192–199
55. Kaiser WA, Fischer H, Vagner J, Selig M (Aug 2000) Robotic system for biopsy and therapy of breast lesions in a high-field whole-body magnetic resonance tomography unit. *Invest Radiol* 35(8):513–519
56. Felden A, Vagner J, Hinz A, Fischer H, Pfeleiderer SO, Reichenbach JR, Kaiser WA (2002) ROBITOM-robot for biopsy and therapy of the mamma. *Biomed Tech Berl* 47(Suppl 1 Pt 1):2–5
57. Hempel E, Fischer H, Gumb L, Hohn T, Krause H, Voges U, Breitwieser H, Gutmann B, Durke J, Bock M, Melzer A (2003) An MRI-compatible surgical robot for precise radiological interventions. *Comput Aided Surg* 8(4):180–191
58. Cleary K, Melzer A, Watson V, Kronreif G, Stoianovici D (2006) Interventional robotic systems: applications and technology state-of-the-art. *Minimal Invasiv Ther* 15(2):101–113
59. Zangos S, Eichler K, Thalhammer A, Schoepf JU, Costello P, Herzog C, Mack MG, Vogl TJ (2007) MR-guided interventions of the prostate gland. *Minim Invasiv Ther Allied Technol* 16(4):222–229
60. Zangos S, Herzog C, Eichler K, Hammerstingl R, Lukoschek A, Guthmann S, Gutmann B, Schoepf UJ, Costello P, Vogl TJ (Apr 2007) MR-compatible assistance system for puncture in a high-field system: device and feasibility of transluteal biopsies of the prostate gland. *Eur Radiol* 17(4):1118–1124
61. Bricault I, Zemiti N, Jouniaux E, Fouard C, Taillant E, Dorandeu F, Cinquin P (May–Jun 2008) Light puncture robot for CT and MRI interventions: designing a new robotic architecture to perform abdominal and thoracic punctures. *IEEE Eng Med Biol Mag* 27(3):42–50
62. Stoianovici D, Song D, Petrisor D, Ursu D, Mazilu D, Muntener M, Schar M, Patriciu A (2007) “MRI Stealth” robot for prostate interventions. *Minim Invasiv Ther Allied Technol* 16(4):241–248, <http://urology.jhu.edu/urobotics/pub/2007-stoianovici-mitat.pdf>
63. Stoianovici D, Patriciu A, Mazilu D, Petrisor D, Kavoussi L (Feb 2007) A new type of motor: pneumatic step motor. *IEEE ASME Trans Mech* 12(1):98–106, 2008 Best Paper Award of the Journal. <http://urology.jhu.edu/urobotics/pub/2007-stoianovici-tmech.pdf>
64. Muntener M, Ursu D, Patriciu A, Petrisor D, Stoianovici D (Sep 2006) Robotic prostate surgery. *Expert Rev Med Devices* 3(5):575–584, <http://urology.jhu.edu/urobotics/pub/2006-muntener-ermd.pdf>
65. Muntener M, Patriciu A, Petrisor D, Schar M, Ursu D, Song D, Stoianovici D (May 2008) Transperineal prostate intervention: robot for fully automated MR imaging – system description and proof of principle in a canine model. *Radiology* 247(2):543–549, <http://urology.jhu.edu/urobotics/pub/2008-muntener-radiology.pdf>
66. Muntener M, Patriciu A, Petrisor D, Mazilu D, Kavoussi L, Cleary K, Stoianovici D (Dec 2006)

- Magnetic resonance imaging compatible robotic system for fully automated brachytherapy seed placement. *Urology* 68(6):1313–1317, <http://urology.jhu.edu/urobotics/pub/2006-muntener-urology.pdf>
67. Patriciu A, Petrisor D, Muntener M, Mazilu D, Schar M, Stoianovici D (Aug 2007) Automatic Brachytherapy seed placement under MRI guidance. *IEEE Trans Biomed Eng* 54(8):1499–1506, <http://urology.jhu.edu/urobotics/pub/2007-patriciu-tbme.pdf>
68. Voros S, Long JA, Cinquin P (2006) Automatic localization of laparoscopic instruments for the visual servoing of an endoscopic camera holder. *Int Conf Med Image Comput Comput Assist Interv* 9(Pt 1):535–542
69. Reiley CE, Lin HC, Varadarajan B, Vagvolgyi B, Khudanpur S, Yuh DD, Hager GD (2008) Automatic recognition of surgical motions using statistical modeling for capturing variability. *Stud Health Technol Inform* 132:396–401

Chapter 2

Robotic Instrumentation, Personnel and Operating Room Setup

Ty T. Higuchi and Matthew T. Gettman

Introduction

Over the past decade the field of robotic-assisted surgery has evolved from endoscope positioning to “master-slave systems,” where the surgeons hand movements are translated to robotic instrument arms positioned inside the patient several feet away [1, 2]. The da Vinci® is currently the most commonly utilized “master-slave system” system. Since the first robotic-assisted prostatectomy in 2000 and subsequent Federal Drug Administration approval, the use of the da Vinci® in urologic surgery has increased to include the upper and lower urinary tracts and is rapidly expanding in the field of pediatric urology. Over the years four different da Vinci® models have been introduced – standard, streamlined (S), S-high definition (HD), and recently the S integrated (i) systems. This chapter will review the personnel, operating room setup and equipment for urologic surgical procedures utilizing the da Vinci®. This chapter is not designed to replace the hands-on training session provided by Intuitive Surgical, but act as a reference for any member of the surgical team.

Surgical Team

The surgical team consists of the surgeon, circulating nurse, surgical technician and surgical assistant(s). Each member must be knowledgeable in robotic-assisted surgery and communication between each of these individuals is vital for successful outcomes [3, 4]. Intuitive Surgical offers a training course for the surgical team and each member should complete the course prior to starting on the surgical team. It is also important for the surgical team to remain consistent and it is generally recommend to have a dedicated team to work through the learning curve and if possible, all robotic cases [3].

The surgeon will lead the team and should not only master driving the robot, but also become familiar with the setup, basic operation and troubleshooting the system. The circulating nurse and surgical technician are critical for operating the robot and should become experts on system startup, draping, docking, instruments, troubleshooting, exchanging instruments, and turn-over. The surgical assistant should have a similar knowledge, but will also need to understand the basics of laparoscopic surgery and be comfortable assisting with trocar placement, clipping, suction, irrigation, retraction and cutting [1, 3].

Operating Room Setup

The operating room should be able to accommodate all of the robotic components so there is a clear view of the patient from the surgeon

M.T. Gettman (✉)
Department of Urology, Mayo Clinic, Rochester,
MN 55905, USA
e-mail: gettman.matthew@mayo.edu

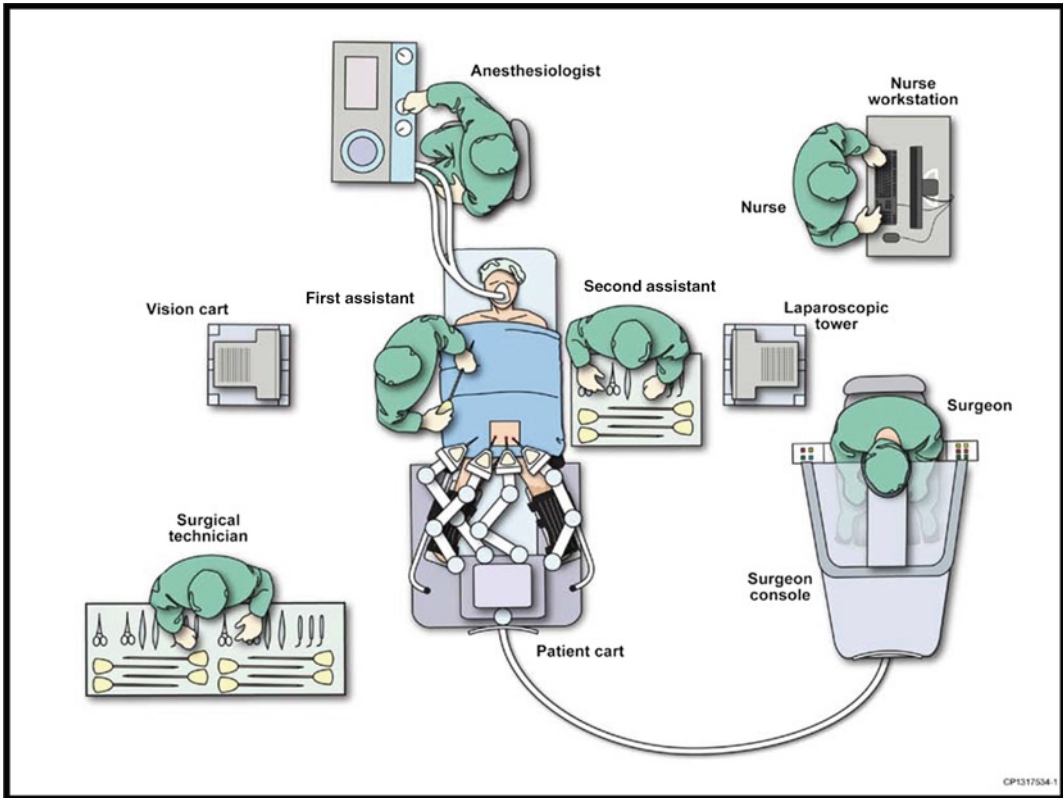


Fig. 2.1 Schematic of operating room setup and surgical team for the da Vinci®

console, tension-free cable connections between the equipment, and clear pathways for operating room personnel to move freely around the room (Fig. 2.1). In addition the room should be able to facilitate docking of the robot from several different angles depending on the type of surgery being performed.

If the operating room is a standard operating room (Fig. 2.2a) that is converted to a robotics room on operative days, there may need to be additional laparoscopic towers to hold the insufflator, insufflation tank, electro-surgical units, video system and extra monitors. In this situation, some of the equipment may also be placed on the vision cart. Ideally the operating room will be in a dedicated room designed for laparoscopic surgery with an integration system to allow DVD recording and telemedicine (Fig. 2.2b). In addition, flat panel monitors are mounted from the ceiling, CO₂ gas is piped

directly into the room for insufflation, and ceiling mounted equipment booms can house insufflators, electro-surgical units, laparoscopic camera equipment and lights sources.

Patient Positioning

For surgery of the pelvis and anterior transabdominal surgery, patients are moved directly onto an operating room table with a gel pad (Fig. 2.2) [4, 5]. The gel pad increases friction and prevents patients from sliding during the procedure. The patient is positioned in a modified lithotomy position using yellow fin stirrups (Fig. 2.3a) with thromboembolic stockings and sequential compression devices. Both arms are padded and positioned along side of the patient on arm boards. A safety strap or tape can be

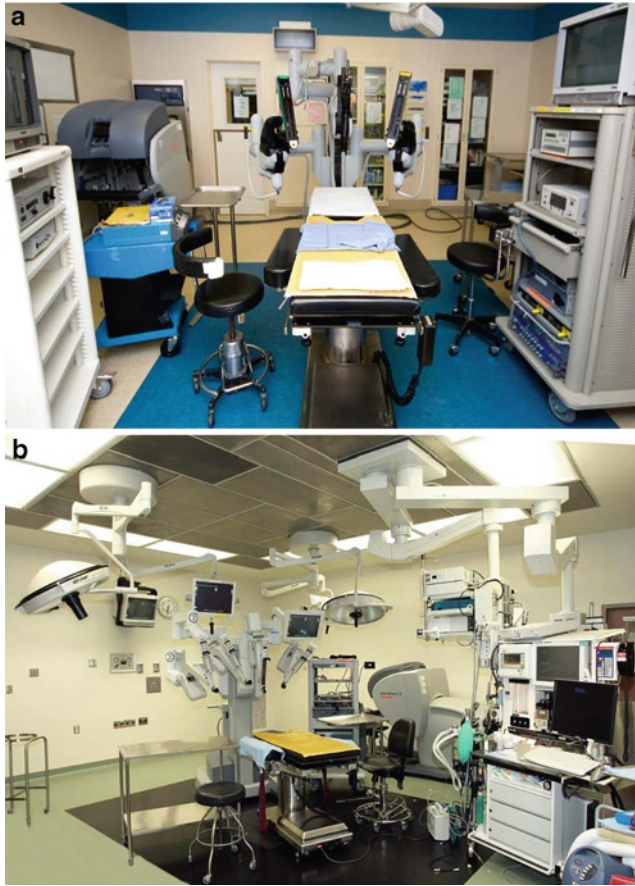


Fig. 2.2 Photograph of operating room for the da Vinci® standard (a) and S (b) systems. Standard system operating room (a) with an additional laparoscopic tower and seating for a second surgical assistant. S system operating room (b) where several telemonitors are

mounted from the ceiling and a laparoscopic tower is mounted on a ceiling boom with the electrosurgical unit, insufflator and light source. The room is also equipped with an integration system for DVD recording and telemedicine

used to secure the patient to the table and it is recommended that it not be placed across the shoulder to prevent the risk of postoperative neuropathy. An upper body Bair Hugger® (Arizant Inc., Eden Prairie, MN) is then placed above the xiphoid and insulated with a blanket. Once the patient is positioned, we secure a face shield plate (Fig. 2.4) to protect the patient's face and endotracheal tube from inadvertent damage or dislodgement during movement of the robotic endoscope. The patient is then prepped from the xiphoid to perineum to midaxillary lines and draped.

For surgery of the kidney or ureters the patient is moved onto the surgical table with a beanbag immobilizer and positioned in a 45° modified flank position for transperitoneal access or a full flank position for transperitoneal or retroperitoneal access [6] (Fig. 2.3b). The patient is positioned with the space between the costal margin and anterior superior iliac spine over the kidney rest; however the kidney rest is not typically used for these cases. Thromboembolic stockings and sequential compression devices are placed and a urethral catheter inserted. In both positions, the patient is rolled onto their side into a 45° or full

Fig. 2.3 Photographs of patients positioned in modified lithotomy for pelvic and anterior transabdominal surgery (**a**) and flank position for upper urinary tract surgery (**b**)

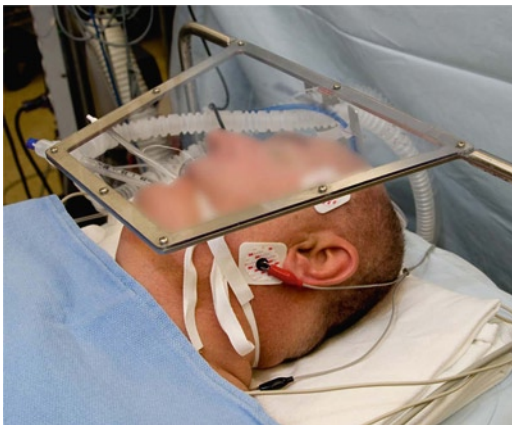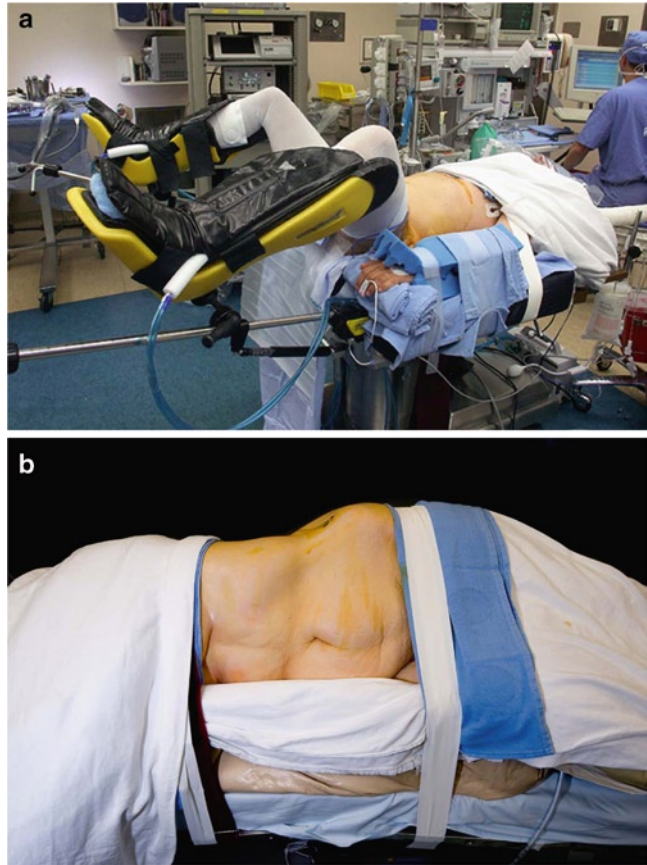


Fig. 2.4 Photograph of patient with a protective face shield plate secured to the operating room table

flank position with the surgical side up. The surgical side leg is bent slightly and padded with pillows or towels. An axillary roll is placed to prevent postoperative neuropathy and the arm is padded and secured. The upper arm is padded and secured to an arm board and the table can then be flexed. When flexing the table, the anesthesiologist should be alerted to support the head and place several pillows or towels to avoid hyperextension of the cervical spine. Safety straps or tape can be used over the hip, lower extremity and thorax to secure the patient to the bed. An upper body Bair Hugger® is placed and insulated with a blanket. The patient is prepped from the nipples to anterior superior iliac spine and midline to erector spinae.

Abdominal Access

Robotic-assisted surgery begins with abdominal access and trocar placement. Pneumoperitoneum may be established using a Veress needle or with open trocar placement by the Hasson technique [4]. We typically gain abdominal access by making a small incision and carrying the dissection down to the level of the fascia. The fascia is then elevated with tracheal hooks and the Veress needle is inserted [7]. Placement is verified with the hanging drop test and the abdomen is insufflated to 15 mmHg. A 12 mm trocar is then placed with a Visiport™ device (Ethicon Endo-Surgery, Inc., Cincinnati, OH). This will serve as the trocar for the da Vinci® endoscope, and the robotic camera arm is compatible with most 12 mm laparoscopic trocars. The camera trocar should be placed 15–18 cm from the target anatomy to allow optimal visualization of the surgical field. For obese patients, the camera trocar may need to be placed closer to target anatomy to adjust for abdominal girth. This is especially important when using the da Vinci® standard system [5].

After visual access is obtained, secondary trocars can be placed under laparoscopic vision. The robotic instrument arms are compatible with specific da Vinci® 5 or 8 mm metal trocars that can be placed using blunt or sharp obturators (Fig. 2.5). The robotic trocars need to be

inserted with the thick black band at the level of the abdominal fascia. This acts as the pivot point for the trocar and robotic instrument arm. It is recommended that the robotic trocars be placed at least 8–10 cm away from the camera to avoid instrument arm collision and facilitate intracorporeal suturing. In addition, the angle created by the robotic and camera trocars should be greater than 90° to increase instrument arm maneuverability [1, 3]. Other laparoscopic instruments may need to be available for lysis of adhesions prior to robot docking and for the first assistant to use during the procedure (Table 2.1).

The da Vinci® Surgical System

The da Vinci® is available in four different models – standard, streamlined (S), S-high definition (HD), and S integrated (i)-HD. Each system has three components: surgeon console, patient cart, and vision cart [2, 8]. There are several sterile accessories and EndoWrist® (Intuitive Surgical, Inc., Sunnyvale, CA) instrument required for each system (Table 2.1). The standard system was released in 1999 and was originally offered with one camera arm and two instrument arms. Later a third instrument arm became available

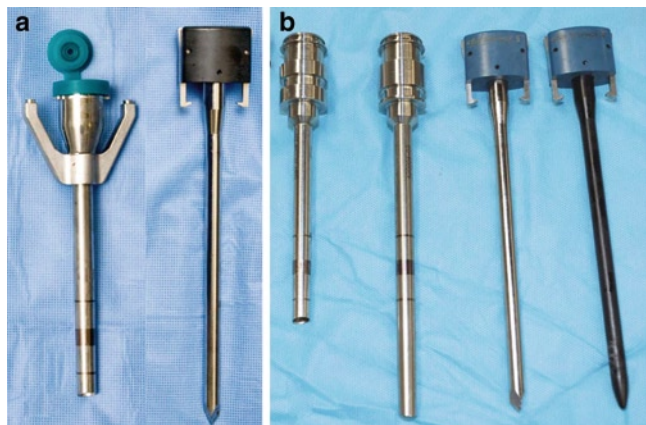

Fig. 2.5 Photograph of 8 mm trocar for the da Vinci® standard (a) and S systems (b). The trocars for the S system also have a trocar that can be connected to the insufflator. Also shown are the sharp and blunt obturators used for trocar placement

Table 2.1 Instruments for robotic-assisted surgery**Laparoscopic instruments**

Veress needle
Visiport™ (Ethicon Endo-Surgery, Cincinnati, OH)
12 mm Optiview™ (Ethicon Endo-Surgery, Cincinnati, OH)
12 mm Xcel™ (Ethicon Endo-Surgery, Cincinnati, OH)
6 mm TERNAMIAN EndoTIP™ (Karl Storz Endoscopy America, Inc., Culver City, CA)
Fascial closure device
10 mm ENDO CATCH® entrapment sac (Covidien, Mansfield, MA)
Curved endo Metzenbaum scissors
Maryland dissector
Hook cautery
Needle driver
Endoscopic clip applier
Suction irrigator
0° and 30° laparoscope lens
Camera and fiber optic cords
5 mm and 10 mm Hem-o-lok® clips (Teleflex Medical, Research Triangle Park, NC)
Hot water bath for endoscopes

Robotic instruments

da Vinci® (Intuitive Surgical, Inc., Sunnyvale, CA)
8 mm or 5 mm robotic trocars (2–3 depending on the number of instrument arms)
EndoWrist® instruments (Intuitive Surgical, Inc., Sunnyvale, CA)
Sterile drapes for camera and instrument arms, camera and telemonitor
Sterile camera mount and camera trocar mount (depending on the type of system)
Sterile trocar mount (depending on the type of system)
Sterile instrument adapter (comes attached to the drape for the S)
Sterile camera adapter

as an option on new systems or an upgrade to existing systems. In 2006 the da Vinci® S system was introduced. This system has a similar platform to the standard system, but added numerous improvements including a motorized patient cart, color coded fiber-optic connections, easier instrument exchanges, quick click trocar attachments, increased range of motion and reach of instrument arms and interactive video touch screen display. In 2007 the S system became available with an HD camera and video system. Recently, the Si-HD system was released with enhanced HD vision at 1080i, upgraded surgeon

console and dual console capability. The dual console feature connects two surgeon consoles to the same patient cart. This allows two surgeons to coordinate a surgical procedure by exchanging control over instruments arms and the endoscope. The dual console feature and HD vision can be added to existing S systems as an upgrade by the manufacturer.

Surgeon Console

The surgeon console (Figs. 2.6 and 2.7) is the driver's seat for controlling the da Vinci®. From here the surgeon views a three dimensional image of the surgical field through the stereoviewer, adjusts the system with the pod controls, and controls the instruments arms using the master controllers and foot pedals [2, 8]. The standard and S systems have similar surgeon consoles with minor differences (Fig. 2.6), while the Si surgeon console was remodeled to increase ergonomics and working space, and integrates the right and left pod control into a central touch pad that can be seen without the surgeon removing their head from the stereoviewer (Fig. 2.7).

The stereoviewer displays the real-time high-resolution three dimensional image of the surgical field and system status icons and messages. The three dimensional image is created by capturing two independent views from two 5 mm endoscopes fitted into the stereo endoscope (Fig. 2.8) and displaying them into right and left optical channels [2]. The system status icons and messages are displayed in specific locations within the stereoviewer and alert the surgeon to any changes or errors with the system. Directly adjacent to the stereoviewer are infrared sensors that activate the surgeon console and instruments when the surgeon's head is placed between them. This feature prevents unintentional movement of robotic instruments inside of the patient's body as the robotic instruments are immediately deactivated when the surgeon looks away from the stereoviewer and

Fig. 2.6 Photograph of da Vinci[®] S surgeon console (a), right (b) and left-side (c) pod controls

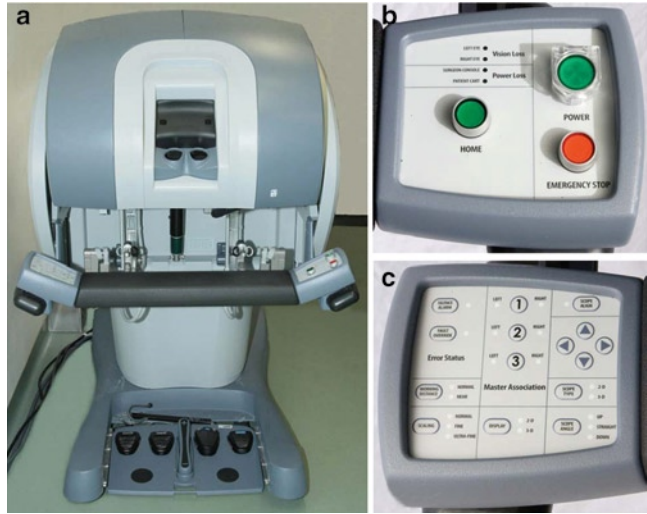

Fig. 2.7 Photograph of da Vinci[®] Si-HD surgeon console (Reproduced with permission from Intuitive Surgical, Inc © 2009)

removes his head from between the infrared sensors. Below the stereoviewer are knobs to adjust the intraocular distance, intercom volume, brightness and contrast. Some of these controls may not be equipped on every model.


The da Vinci[®] standard and S-models (Fig. 2.6) have right- and left-sided pod controls on the end of the arm rest. The right-side pod controls communicate major system errors and turn the system on and off, while the left-side pod controls are used to set the system configuration and troubleshoot system faults. On the outside edge of the left-sided pod controls are adjustment buttons for raising and lowering the height of the surgeon console. The Si-HD combines the right and left pod controls into a central touchpad on the arm rest (Fig. 2.7). In addition, the console can be adjusted in four different directions to facilitate better ergonomics and the specific settings can be stored for each surgeon.

For all of the da Vinci[®] systems, the master controllers (Fig. 2.9) are the manual manipulators the surgeon uses to control the instrument arms and endoscope. The controllers are grasped with the index finger and thumb and movements

Fig. 2.8 Photograph of da Vinci® stereo endoscope (a) showing the two individual 5 mm endoscopes (b) and camera (c) with right and left optical channels



Fig. 2.9 Photograph of master controllers from the da Vinci® S system



are translated by a computer that scales, filters and relays them to the instruments. There is no measurable delay between surgeon and robotic instrument movement and there is a filtering mechanism that eliminates physiologic tremor [8]. Total working area for the masters in the da Vinci® standard and S systems is 1 cubic foot, while the Si-HD has 1.5 times the working space. Surgeons should adjust their working space between the master controllers to a comfortable working distance using the master clutch (see below) to avoid collision between the master controllers as well as against the walls of the working space. This helps to prevent reaching or stretching with eventual arm and wrist fatigue. The Si-HD also has added a

finger clutch on each of the master controllers that can also be used to adjust the working space of each individual master controller independently. To activate the instrument arms during surgery, the surgeon must “match grips” by grasping the masters to match the position and grip of the EndoWrist® instrument tips as seen within the body. This feature prevents accidental activation of the instrument arms and inadvertent tissue damage. When toggling between two instruments and taking control of an instrument that is retracting tissue, keep the master closed to prevent dropping the tissue.

The foot switch panel (Fig. 2.10) is used in conjunction with the master controllers to drive the surgery. The clutch pedal allows the

Fig. 2.10 Photograph of foot switch panels from the da Vinci® S system with pedals for clutch, camera, focus control, accessory/bipolar, and monopolar electrocautery



surgeon to shift to the third arm or adjust the working distance between the master controllers. By quickly tapping the clutch pedal once, the designated master controller toggles between control of the current arm to the third robotic arm. Tapping the clutch pedal once again will toggle back to the default settings and control of the original robotic arm. This feature allows the surgeon to toggle control of two different robotic arms using the same master controller. Completely depressing the clutch pedal disengages the master controls from the instrument arms and the surgeon can readjust their arms to a more comfortable position in the working space. Adjusting the working space is similar to moving a computer mouse when the limits of the mouse pad are reached. We generally recommend adjusting the working space when your elbows start to lift off of the armrest, your hands are in an awkward position, or if the master controllers are colliding with the side walls or with one another. Completely depressing the camera pedal disengages the master controls from the instrument arms and instead engages the endoscope. The endoscope may then be moved or rotated to the appropriate area of interest within the body. Tapping the camera pedal on the S system activates the auxiliary visual channels in the lower third of the stereoviewer which can be connected to intraoperative monitors or ultrasound allowing for picture-in-picture view (called TilePro™, Intuitive Surgical Inc., Sunnyvale, CA). There is a focus control pedal on the standard and S systems for the endoscope labeled “+/-” in the

center of the footswitch panel. The standard system has an auxiliary pedal, while the S system has a bipolar pedal that can be connected to bipolar energy. The coagulation pedal is connected to a compatible electrosurgical unit. With the dual energy capabilities, one instrument arm can be connected to bipolar energy while the other one is connected to monopolar energy. The Si-HD system has a completely remodeled foot panel with two tiers of pedals and pedals on the side of the panel (Fig. 2.7). There are still clutch and camera pedals on the left side of the panel, while on the right side there is a cut and coagulation pedal. The pedals on the side of the panel are used to switch control between the two surgeons in dual console mode. In addition the footswitch panel on the right can be used to change the coagulation pedal to bipolar mode. This feature prevents inadvertent electrosurgical activation of the wrong instrument arm. On all of the systems, the back of the surgeon console houses the AC powerconnection, color-coded cable connections, bipolar and monopolar electrocautery inputs, and additional audio and visual connections.

Patient Cart

The patient cart for the standard (Fig. 2.11) and S (Fig. 2.12) systems house the camera and instrument arms [2, 8]. Each arm has several clutch buttons that assist with the gross movements of the arm and to insert or withdraw

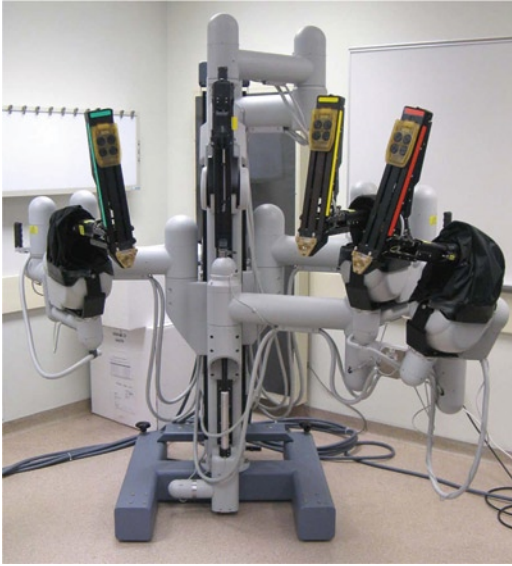

Fig. 2.11 Photograph of the da Vinci® standard patient cart with optional third instrument arm

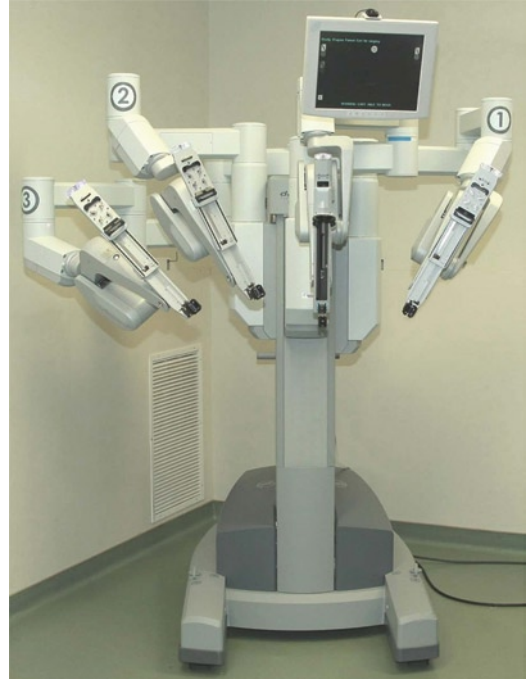


Fig. 2.13 Photograph of the da Vinci® S patient cart

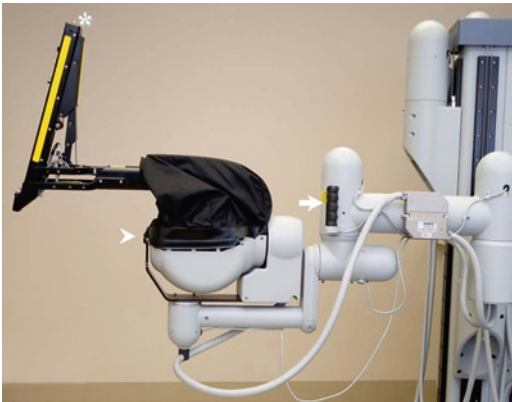

Fig. 2.12 Photograph of the da Vinci® standard instrument arm showing the port clutch joystick button (*arrow*), port clutch button (*arrowhead*) and instrument clutch button (*asterisks*) used to position the arm for draping, docking and storage



Fig. 2.14 Photograph of the da Vinci® S and HD instrument arm showing the port clutch buttons (*arrows*) and instrument clutch button with LED indicator (*asterisks*). Also seen is the trocar mount (*arrowhead*)

instruments (Figs. 2.13 and 2.14). To activate the clutch, the buttons is depressed and the arm is moved, otherwise there will be resistance encountered and the arm will return to the original position. Each arm has two port clutch buttons used for gross movements of the instrument arm and there is a specific camera or instrument clutch button located at the top of each arm to

adjust the final trajectory of the arm during docking and to insert or withdraw endoscope/instruments. Each arm requires several sterile accessories that are placed during the draping procedure (Fig. 2.15).

The standard system was originally offered with a camera arm and two instrument arms. Later an optional third instrument arm became

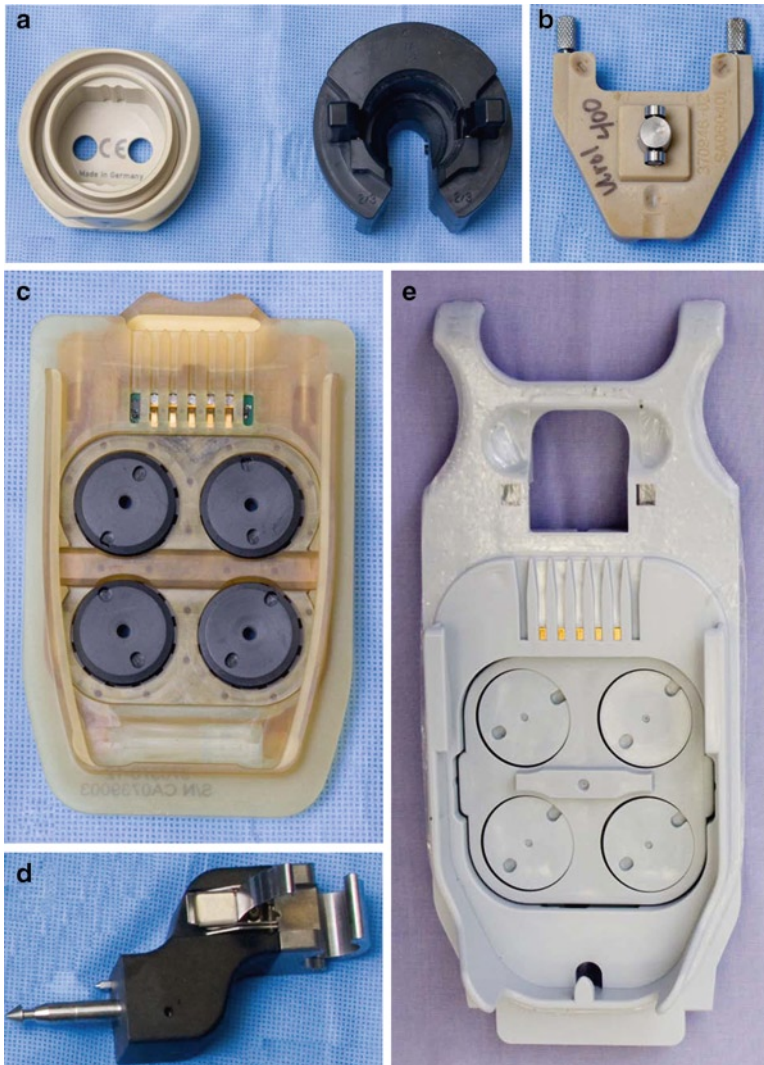


Fig. 2.15 Photographs of sterile accessories placed during the draping procedure. (a) Camera sterile adapter (left) and camera arm sterile adapter (right). Da Vinci® standard trocar mount (b), instrument arm sterile adapter

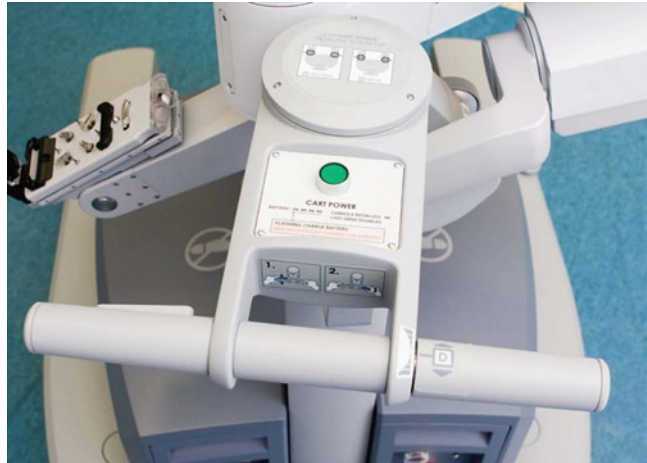(c) and camera trocar mount (d). The instrument arm sterile adapter may be reused 50 times (e). Da Vinci® S instrument arm sterile adapter can only be used one time before being discarded

available for new standard systems or could be added as an upgrade to existing systems. The third instrument arm is mounted on the same axis as the camera arm (Fig. 2.11). Therefore care must be taken when positioning the third arm so that it does not collide with the other arms or operating room table. Each arm on the standard system is color coded with the camera arm (blue) and the instrument arms (yellow, green, and red). When moving the instrument arms using the port clutch, you should use your free

hand to brace the instrument arm for better control. With the standard system, you can only use one clutch at a time to move the instrument arm. With the S and Si systems you can use the port clutch and camera/instrument clutch simultaneously to maneuver the arm into position.

Similar to the standard system, the S and Si systems have a camera arm and two instrument arms (Fig. 2.12) and are available with an optional third instrument arm. Each instrument arm is numbered. These models also added an

Fig. 2.16 Photograph of the back of the da Vinci® S patient cart showing the power switch and motor drive controls



LED light below the camera/instrument clutch and a touchscreen monitor. The LED light communicates the status of the arm to the surgical team using a preset color scheme. The touchscreen monitor is synchronized with the surgeons view and displays all of the system status icons and messages. It can be used for endoscope alignment, telestration, or to toggle between video inputs. The telestration feature can be used to draw real time images on the screen that is relayed to the stereoviewer. This feature is especially useful for training residents or fellows. The touchscreen monitor can also be mounted on the vision cart. The patient side cart of the S and Si systems also feature a motor drive (Fig. 2.16), which assists in docking the patient cart to the operating table and trocars. All cable connections are located at the back of the cart.

Vision Cart

The vision cart (Fig. 2.17) contains the light source, video processing equipment, camera focus control, and camera storage bin [2, 8]. There are also several empty storage areas that can be used for insufflators, electrosurgical units or a DVD recording device. A telemonitor may be placed on the top of the tower. The light source is a xenon fiber optic system with a lamp life of approximately 500 h.

On the standard and S systems the light source is connected to the endoscope by a sterile bifurcated cable to illuminate the right and left channels, while the Si has a single cable. On some of the standard systems two light sources and two cables were required. The lamp on the S and S-HD systems can be changed by a member from the surgical team, while the standard systems require a service visit.

The endoscope is available as a 0° and 30° lens. We typically use the 30° downward lens for most robotic procedures in the pelvis, while a variety of endoscopes (i.e., 0°, 30° upward, 30° downward) are used for interventions of the upper urinary tract depending on the particular procedure and approach. With the standard and S system, the endoscope is connected to either a high-magnification (15× magnification with 45° view) or wide-angle (10× magnification with 60° view) camera head with right and left optical channels. The HD systems only come with one camera (see below). The right and left optical channels are connected to two 3 chip camera control units (CCU) (Fig. 2.8). The input from these CCUs is integrated in the surgeon console to produce the three dimensional image. The camera head is also connected to an automatic focus control that is linked to the surgeon console. The S-HD system adds a high definition camera and CCUs to increase resolution and aspect ratio. The first generation HD system had a resolution of

Fig. 2.17 Photographs of vision cart for the da Vinci® standard (a) and S systems (b)



720p (1280 × 720) which is significantly increased from standard NTSC 720 × 480. The aspect ratio also increases to 16:9, which improves the viewing area by 20%. The system also has a digital zoom that allows the surgeon to magnify the tissue without moving the endoscope. This is done by pressing the left and right arrow keys on the left-side pod controls or depressing the camera pedal and moving the masters together or apart. The Si-HD system is equipped with increased resolution to 1080i (1920 × 1080). The patient cart for the Si-HD was remodeled to integrate the light source and camera control unit into single connections. In addition, the camera adjustments and white balance are performed using the central touch pad or telemonitor.

EndoWrist® Instruments

The EndoWrist® instruments (Fig. 2.18) carry out motions originating from the master controllers. The instruments have seven degrees of freedom with 180° of articulation and 540° of rotation

simulating a surgeon’s hand and wrist movements (Fig. 2.19). Each instrument has a fixed number of uses before becoming deactivated. The system automatically tracks the number of uses remaining on each instrument and communicates this in the stereoviewer. An instrument arm will not function if an outdated instrument is loaded [8].

EndoWrist® instruments are composed of an instrument housing with release levers, instrument shaft, wrist and a variety of instrument tips (Fig. 2.18). The da Vinci® standard instruments are 52 cm with grey housing compared to the S systems being 57 cm with blue housing. The instruments are not interchangeable between the systems. Currently, there are more than 40 EndoWrist® instruments available in 8 mm or 5 mm shaft diameters and several have been designed specifically for urologic surgery. The 8 mm instruments operate on an “angled joint” compared to the 5 mm on a “snake joint” (Fig. 2.20). The angled joint allows the tip to rotate using a shorter radius compared to the snake joint. We have consistently used the 8 mm ProGrasp™ forceps (Intuitive Surgical, Inc., Sunnyvale, CA), monopolar curved shears, large

Fig. 2.18 Photograph of an EndoWrist® instrument for the standard (a) and S (b) systems

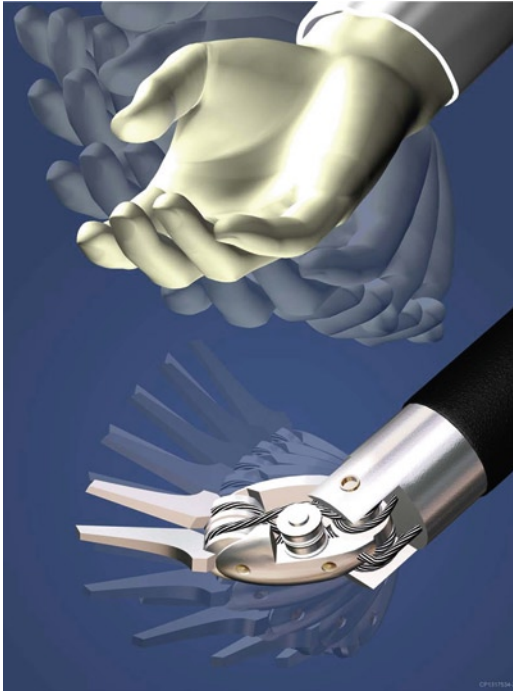


Fig. 2.19 Illustration comparing surgeon hand movements to EndoWrist® instrument

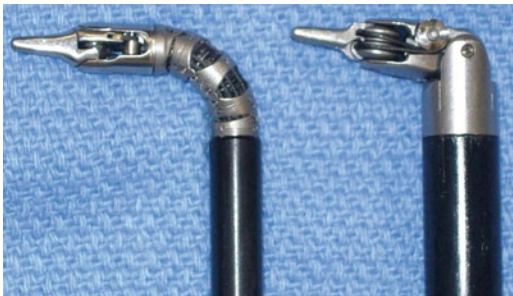

Fig. 2.20 Photograph of EndoWrist® needle drivers. On the left is a 5 mm needle driver with the “snake joint” compared to the 8 mm needle driver with an “angled joint”

needle driver, and Maryland bipolar forceps for our robotics practice.

Preparing the da Vinci® for Surgery

Preparing the operating room for robotic assisted procedures begins well before the patient enters the room. Once the equipment is positioned, the surgical team can prepare the system [8].

1. Connect system cables, optical channels, focus control, power cables and turn the system on. The system will then perform a self-test. During this time, do not attempt to manipulate the system or a fault may be triggered.
2. Position the instrument and camera arms so they have adequate room to move.
3. Initiate homing sequence.
4. Drape the patient cart arms. This takes a coordinated team effort between surgical technician and circulating nurse and uses system specific sterile drapes and accessories. Make sure the drapes are not too tight as this may decrease the range of motion of the robotic arms.
 - a. The instrument arms are draped to completely cover the arm and the sterile instrument adapter is locked into the instrument arm carriage. For the standard system the sterile trocar mount is also locked into position, while the S system has the trocar mount permanently attached and the drape is placed over the mount.
 - b. The camera arm is draped in a similar fashion. For the standard system, a sterile endoscope trocar mount and camera arm sterile adapter are also placed at this time.

The S system also requires a camera arm sterile adapter. Depending on when the S system was purchased, some use a sterile endoscope trocar mount, while others have the mount permanently attached. There are different robotic camera arm trocar mounts for each trocar manufacturer.

- c. The touchscreen monitor is draped for the S systems.
5. Drape the endoscope by connecting the camera sterile adapter to the endoscope and then taping the drape to the sterile adapter. The camera head is connected and the drape is inverted over the camera head and optical cables.
6. Connect the light source to the endoscope with the sterile light cable. Perform a black and white balance.
7. Align the endoscope and set endoscope settings (three dimensional vs. two dimensional, 0° vs. 30° up or down).
8. Set the “sweet spot” of the camera arm by aligning the trocar mount with the center of the patient cart column and extending the camera arm so there is approximately 20” between the back of the camera arm and patient cart. The S systems have a guide on the camera arm to assist with setting the sweet spot. This allows maximal range of motion of the camera and instrument arms and prevents collisions.

Patient Cart Docking

After abdominal access is obtained, the patient cart is maneuvered into position to align the patient cart tower, camera arm and target anatomy. One member of the surgical team drives the patient cart while another one guides the driver. To avoid any confusion during docking, it is recommended that the navigator use anatomic or room references versus directional cues. The surgical table should be placed in the desired position (Trendelenburg, etc.) prior to docking the patient cart.

The standard system is pushed into position and the brakes at the base of the cart are hand-tightened. The S and Si systems have a motor drive

to assist with docking, however use of the motor drive is not mandatory for the docking process (Fig. 2.16). To operate the motor drive, unlock the brakes and turn the shift switches on the base of the cart to the drive position. Engage the motor drive by holding the throttle-enable switch on the left and turning the throttle forward or backwards with the right hand. To move the cart without the motor drive assist turn the shift switches to neutral. There is no mechanical brake like the standard system and once an instrument arm is connected to a trocar, the motor drive brakes automatically to keep the cart from moving.

The camera arm is the first one connected to the patient by locking the camera trocar mount to the camera trocar. It is important to use the camera setup joint buttons to move the camera arm into position and the camera clutch to adjust the final trajectory of the arm. Exclusively using the camera clutch to move the camera arm, may limit the range of motion of the camera during surgery. The instrument arms are then attached to the robotic trocars and screwed into place using a twist-lock device when using a standard system. When using the S or Si system, snap mounted devices are used to engage the robotic trocars. Again use the port clutch for gross movements of the instrument arms and the instrument clutch for the final trajectory. When using the standard system with the third instrument arm for surgery of the pelvis, the arm comes from below the table and wraps around the patients leg. Care must be taken when docking to avoid collision, contact or pinching the patient’s arm, body, or leg.

Once all of the robotic arms are connected, the surgical team should check each of the arms for proper working distance and make sure the arms are not compressing the patient. The endoscope is inserted by placing the lens into the trocar and locking it into the camera trocar mount. The endoscope can then be advanced into the surgical field using the camera clutch button. EndoWrist® instruments are inserted by straightening the instrument wrist and placing the instrument tip into the trocar and sliding the instrument housing into the adapter. The instrument is then advanced into the surgical field using

the instrument clutch button. Each instrument should be placed into the patient under laparoscopic vision. To remove an instrument, the surgeon should straighten the instrument wrist and the assistant squeezes the release levers and pulls the instrument out. Maintaining close communication between the surgeon and assistant especially during instrument exchanges is important so as to avoid inadvertent adjustment, movement, and complete removal of an instrument that is in active use. As a safety measure, the S system features a guided tool change where a new instrument can be inserted and placed to a depth 1 mm short of the previous instrument position.

For surgery of the pelvis, the surgical team can take their positions for the procedure (Figs. 2.1 and 2.2). The surgeon sits at the console, circulating nurse at their workstation, surgical technician on the patient's left and the surgical assistant on patient's right side. When using a system with two instrument arms, a second surgical assistant or the surgical technician can assist with the procedure from the patients left side. In this instance, the second assistant uses a separately prepared Mayo stand with the instruments they need to complete the case. Using a third instrument arm can often eliminate the need for a second surgical assistant during the procedure. The cost and benefits of the third instrument arm must be weighed against the cost of a second assistant.

System Shutdown

Once robotic assisted surgery is completed, all of the instruments are removed first, followed by the endoscope. The arms are disconnected from the trocars and the patient cart is undocked from the patient. For the S and Si systems the motor drive system cannot be activated until all the instruments are removed and the camera and instrument arms are disconnected. The specimen is delivered within a specimen retrieval bag by extending one of the incisions. This incision and any 12 mm trocars made with a cutting trocar require fascial closure to prevent incisional

hernias. The 8 and 5 mm trocars generally do not require fascial closure [3, 4]. Once the surgery is completed, the sterile accessories and drapes are removed and the system is cleaned. It is not necessary to power the system off between surgical procedures.

Conclusions

Robotic-assisted urologic surgery has increased significantly over the past decade. Successful implementation of a robotics program hinges on proper operating room setup and a complete understanding of instrumentation required. In addition, a knowledgeable, well-trained and collegial surgical team is crucial for operating room dynamics and likely contributes to positive patient outcomes.

References

1. Gettman MT, Cadeddu JA (2004) Robotics in urologic surgery. In: Graham SD, Keane TE, Glenn JF (eds) Glenn's urologic surgery. Lippincott Williams & Wilkins, Philadelphia, pp 1027–1033
2. Narula VK, Melvin SM (2007) Robotic surgical systems. In: Patel VR (ed) Robotic urologic surgery. Springer-Verlag, London, pp 5–14
3. Gettman MT et al (2003) Current status of robotics in urologic laparoscopy. *Eur Urol* 43(2):106–112
4. Su LM, Smith JA Jr (2007) Laparoscopic and robotic-assisted laparoscopic radical prostatectomy and pelvic lymphadenectomy. In: Wein AJ, Kavoussi LR, Novick AC, Partin AW, Peters CA (eds) Campbell-Walsh urology. Saunders Elsevier, Philadelphia, pp 2985–3005
5. Gettman MT et al (2003) Laparoscopic radical prostatectomy: description of the extraperitoneal approach using the da Vinci robotic system. *J Urol* 170 (2 Pt 1): 416–419
6. Gettman MT et al (2004) Robotic-assisted laparoscopic partial nephrectomy: technique and initial clinical experience with DaVinci robotic system. *Urology* 64(5):914–918
7. Joyce AD, Beerlage H, Janetscheck G (2000) Urological laparoscopy for beginners. *Eur Urol* 38(3):365–373
8. Bhandari A, Hemal A, Menon M (2005) Instrumentation, sterilization, and preparation of robot. *Indian J Urol* 21(2):83–85

Part II
Robotic Surgery of the Lower Urinary Tract

Chapter 3

Transperitoneal Robot-Assisted Laparoscopic Radical Prostatectomy: Anterior Approach

Joshua M. Stern and David I. Lee

This chapter contains a video segment which can be found at the URL: <http://www.springerimages.com/Su>

Patient Selection

Patients who are candidates for open radical prostatectomy are generally also good candidates for robot-assisted laparoscopic radical prostatectomy (RALP). We do not select patients based on weight or prostate size although these patients are certainly more challenging and should be cautiously approached early in a particular surgeon's learning curve. Patients with prior abdominal surgery or prior prostate surgery can also be quite difficult; however, these are also not strict contraindications to a robotic approach.

Preoperative Preparation

Patients are typically screened preoperatively with an EKG, chest x-ray, complete blood count, chemistries, coagulation profile, and urinalysis with culture if indicated. We recommend a clear liquid diet the day before surgery and then nothing by mouth after midnight. A laxative is self administered the night before surgery. Upon arrival to the operating room, parenteral antibiotics are administered prior to skin incision. Sequential compression boots are routinely used in all patients. In patients who are at high risk for

deep venous thrombosis, a single dose of 5,000 U of subcutaneous heparin may be administered preoperatively.

Operative Setup

Selection of the operating room and subsequent organization of the equipment is critical for rapid patient setup, robot docking, and room turnover. A consistent preoperative approach and setup that involves the entire surgical team will minimize wasted time and maximize utilized operating room space. Our operating room setup is shown in Fig. 3.1. For transperitoneal robot-assisted laparoscopic radical prostatectomy (RALP), the robot must be brought in from the patient's feet and so this pathway must be unobstructed.

Our preference is to place the tableside surgical assistant on the patient's left side such that his or her dominant hand (usually right) can manipulate the suction device. The scrub nurse is on the patient's right side. We make use of a Mayo stand placed over the patient's face as an instrument stand. It should be lowered as far as the ET tube will allow and thus will protect the tube from inadvertent dislodgement from the camera movement.

Patient Positioning and Preparation

Lower extremity compression stockings are placed. After induction of general anesthesia, the legs are split 30° away from each and then

D.I. Lee (✉)

Department of Urology, University of Pennsylvania, School of Medicine and Penn Presbyterian Medical Center, 51 N. 39th St, MOB Suite 300, Philadelphia, PA 19104, USA
e-mail: david.lee@uphs.upenn.edu

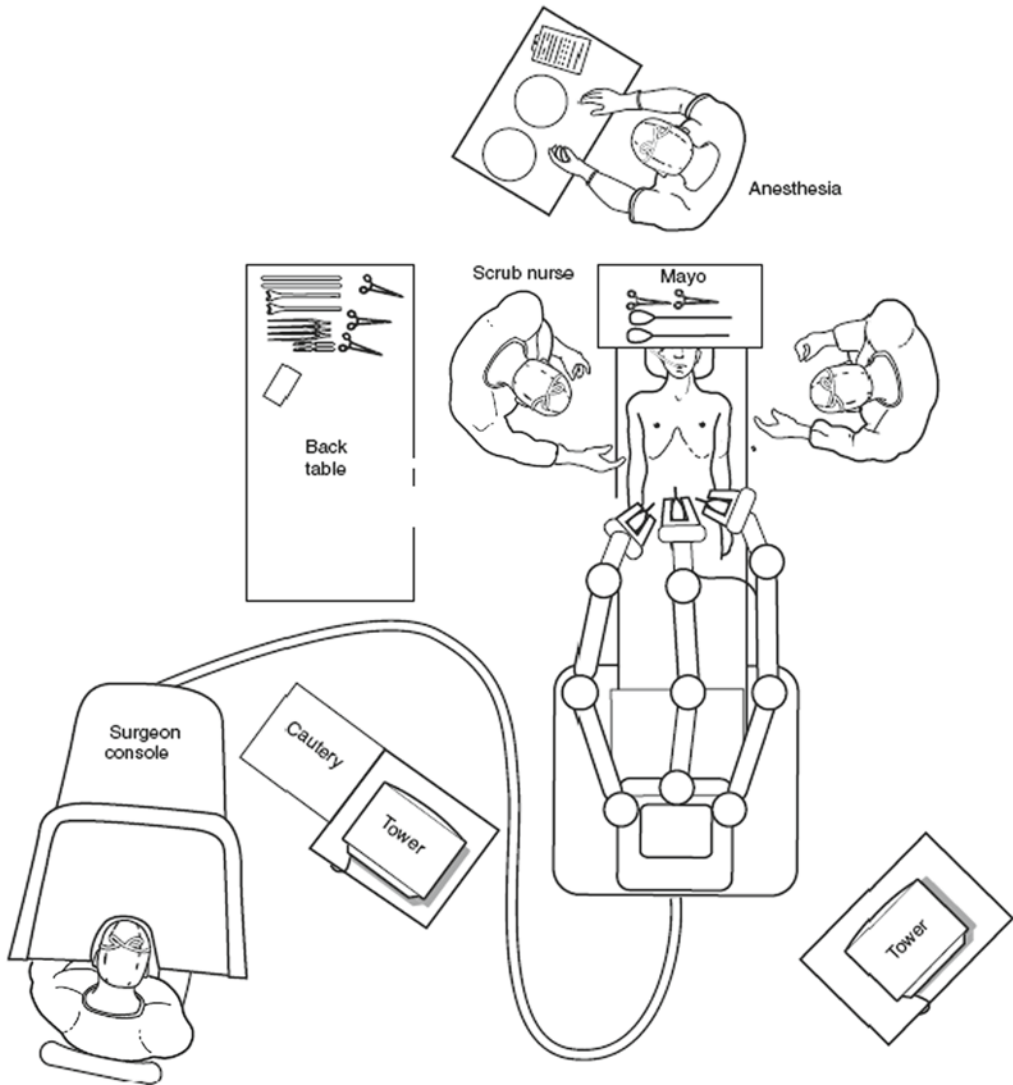


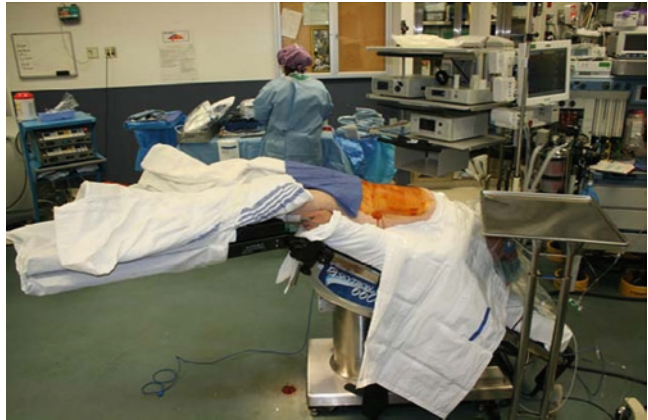Fig. 3.1 Typical operating room setup for transperitoneal robot-assisted laparoscopic radical prostatectomy (RALP). Adequate room for rolling the robot to and away from the

table is necessary. If a fourth arm is utilized, it can be placed on either side of the patient depending on surgeon preference (Reproduced by permission of Saunders, 2007 [1])

extended at the hip 30° using either split leg positioners (preferable) (Amsco Surgical, San Antonio, TX) or alternatively using stirrups (Fig. 3.2). This positioning facilitates docking of the robot. We loosely wrap each leg with a blanket and use 3-inch silk tape to secure the blanket and legs to the table. We then tuck the arms to the patient's side and remove the arm boards. The bed is then placed into a 30° Trendelenburg

position. We do not routinely use shoulder rolls or foam padding, because we feel that simply tucking the arms and lowering the legs sufficiently anchors most patients from sliding. Once the patient is prepped and draped, we place an 18 Fr urethral catheter and place it to gravity drainage. An intraoperative oral-gastric tube is placed at the outset and then removed at the completion of the procedure.

Fig. 3.2 Patient is positioned with legs on spreader bars and in the steep Trendelenburg position



Trocar Configuration

We typically use a Veress needle to obtain pneumoperitoneum; alternatively, use a Hasson approach, if desired. We place the Veress through the belly of the rectus muscle infraumbilically. Once adequate insufflation has been obtained, trocars are placed as shown in Fig. 3.3, beginning with the midline supraumbilical trocar. Insert the camera, with a 0° lens and inspect the abdomen for any adhesions or injury as a consequence of Veress needle or primary trocar placement. Meticulously place the remaining trocars under laparoscopic vision. The robot trocar sites should be no more than 18 cm from the pubis because the robotic instruments have a maximum working length of 25 cm [2].

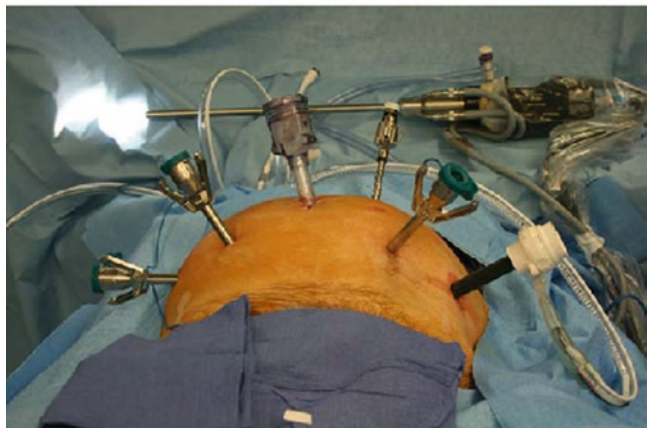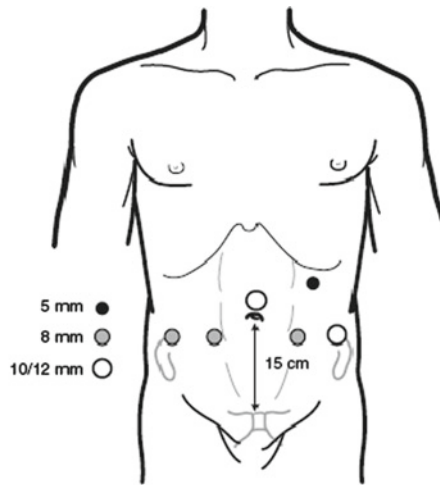
We standardly use a total of six trocars: three Intuitive 8 mm metal robotic trocars for the robotic working arms, a 5 mm and a 12 mm trocar for the tableside assistant, and one 12 mm trocar for the camera.

We feel that it is critical to precisely measure, rather than estimate by hand width, the distances for each trocar, especially in patients that are very small or large. Initially, we use a marking pen to identify the top of the pubis. We then place a 12 mm mark just above the umbilicus for the camera trocar. Once the abdomen is insufflated, a midline mark is made 14.5 cm cephalad from the pubis. Then, the robot trocar sites are triangulated such that they are 14.5 cm from the pubis and 8 cm from the lower midline mark. This ensures

sufficient working room between the arms of the robot as well as adequate reach such that the tips of the instruments will reach to the membranous urethra. Difficulty with robot arm collisions can become greatly magnified if the trocar sites are too close together. The straight line that is created by the first two robot trocars then delineates placement of the fourth arm trocar and the assistant's 12 mm trocar. These trocars are placed 8 cm lateral to the two robotic trocars. Finally, place a 5 mm trocar 8 cm on a diagonal line cephalad and lateral to the camera trocar. This trocar site can lie very close to the costal margin on smaller patients. This high position is essential, however, to provide working room for the hand of the assistant; placing this trocar too low can trap the assistant's hand between the robotic arms.

Once the trocars are placed, move the robot into position between the legs of the patient. When using a standard da Vinci® system, bring the camera and the yellow and green arms of the robot over the patient and dock them top of the trocars. The red or fourth arm should be brought in underneath the leg of the patient and docked. When using the da Vinci® S system, all arms are brought over the top of the patient and docked. The fourth arm once docked should be checked to ensure sufficient mobility such that its instrument tip can easily touch the anterior abdominal wall. This ensures that adequate upward retraction can be performed. Be sure the previously placed mayo stand does not inhibit the fourth arm's and camera arm's mobility.

Fig. 3.3 A midline, periumbilical, point 15 cm from the pubic symphysis is marked. The two medial robotic trocars are placed 14.5 cm from the pubic symphysis and 8 cm from the periumbilical mark. The two lateral trocars are placed in a straight line 8 cm lateral from the medial trocars. The camera is placed in a 12 mm trocar placed superior to the umbilicus



Instrumentation and Equipment List

Equipment

- da Vinci® S Surgical System (4-arm system; Intuitive Surgical, Inc., Sunnyvale, CA)
- EndoWrist® Maryland bipolar forceps or PK dissector (Intuitive Surgical, Inc., Sunnyvale, CA)
- EndoWrist® curved monopolar scissors (Intuitive Surgical, Inc., Sunnyvale, CA)
- EndoWrist® Spatula Electrocautery (Intuitive Surgical, Inc., Sunnyvale, CA)
- EndoWrist® ProGrasp™ forceps (Intuitive Surgical, Inc., Sunnyvale, CA)
- EndoWrist® needle drivers (2) (Intuitive Surgical, Inc., Sunnyvale, CA)

- InSite® Vision System with 0° and 30° lens (Intuitive Surgical, Inc., Sunnyvale, CA)

Trocars

- 12 mm trocars (2)
- 8 mm robotic trocars (3)
- 5 mm trocar (1)

Recommended sutures

- Vesicourethral anastomosis: 3-0 monocryl and 3-0 polyglactin double armed suture (6–7 in. each) on a SH needle tied together.
- Modified Rocco stitch: 3-0 monocryl suture on a SH needle cut to 8 in.
- Anterior bladder neck closure (if necessary): 3-0 polyglactin suture on a SH needle cut to 6 in.

Instruments used by the surgical assistant

- Laparoscopic needle driver
- Laparoscopic scissors
- Blunt tip grasper
- Suction irrigator device
- 10 mm specimen entrapment bag
- Hem-o-lok® clip applicator (Teleflex Medical, Research Triangle Park, NC)
- Small, Medium-Large, and Extra Large Hem-o-lok® clips (Teleflex Medical, Research Triangle Park, NC)
- Endo-GIA linear stapling device (US Surgical, Mansfield, MA) with a 45 mm cartridge length and 3.0 mm staple length.
- 10 mm specimen entrapment bag
- EnSeal® device 5 mm diameter, 45 cm shaft length (SurgRx®, Redwood City, CA) (optional)
- SURGICEL® hemostatic gauze (Ethicon, Inc., Cincinnati, OH)
- 18 Fr urethral catheter

Step-by-Step Technique

Step 1: Entering the space of retzius

Surgeon instrumentation			Assistant instrumentation
Right arm	Left arm	Fourth arm	• Suction-irrigator
• Curved monopolar scissors	• Maryland bipolar grasper	• ProGrasp™ forceps	
Endoscope lens: 0°			

Our lens preference is a 0° lens at the outset. Be sure to confirm that the lens setting on the robot control panel is set to “straight” rather than “angled.” The monopolar scissors (right hand) and bipolar grasper (left hand) are the primary working instruments at this stage. The ProGrasp™ forceps is used with the fourth robotic arm for grasping and retraction of tissues. The electrocautery generator settings used throughout the operation are 35 W for both monopolar and bipolar electrocautery. Once abdominal access is achieved, inspect the peritoneum for bowel adhesions and identify the internal inguinal rings, urachus, and the medial umbilical ligaments. Lyse adhesions as

is necessary. We also prefer to mobilize the sigmoid colon so that it is fairly mobile.

We prefer the anterior transperitoneal approach and thus drop the bladder to enter the space of Retzius as our initial step of the operation. Incise the peritoneum just lateral to the medial umbilical ligaments and carry the dissection laterally to the level of the vas deferens. We prefer to keep the incision just medial and anterior to the internal inguinal ring. Keep the incisions superficial so as not to injure the epigastric vessels. The assistant can use the suction device to prevent camera fogging by evacuating smoke during this dissection. Bladder irrigation via the urethral catheter can help define the limits of the bladder; however, incisions created lateral to the medial ligaments obviate the likelihood of bladder injury. Carry the incisions medially and anteriorly until they are joined at the midline at the urachus, which is then divided. We prefer to incise as cephalad as possible to avoid redundant tissue obscuring the view of the camera throughout the case. As the bladder flap is created, the whitish fibers of the transversalis fascia come into view. Follow these fibers caudally; once these thin out, follow the contour of the abdominal wall inferiorly until the pubis is seen. Clean the pubis of connective tissue. We thoroughly sweep all periprostatic fat toward the midline. This move also cleans off the endopelvic fascia. The superficial dorsal vein is usually contained within this fat; use bipolar electrocautery to seal this vessel. After the vein is divided, roll the fat away from the apical portion of the prostate toward the base. We excise the large fat bundle and send it for pathologic examination due to the possible presence of lymph nodes [3].

Step 2: Incision of the endopelvic fascia

Sharply incise the fascia laterally so that the underlying prostate and levator muscles are seen (Fig. 3.4). We prefer cold sharp incision with scissors; this prevents the “jumping” of the pelvic floor muscles that can be seen with electrocautery. Initiate this incision in the region of the prostatovesical junction and then carry it toward the apex of the prostate. This helps avoid bleeding from the vessels that are consistently present at

Fig. 3.4 The right endopelvic fascia has been opened. The levator muscle is seen to the right. This dissection is through a mostly avascular plane and can be carried proximally as far as the bladder neck (Reproduced by permission of Saunders, 2007 [1])

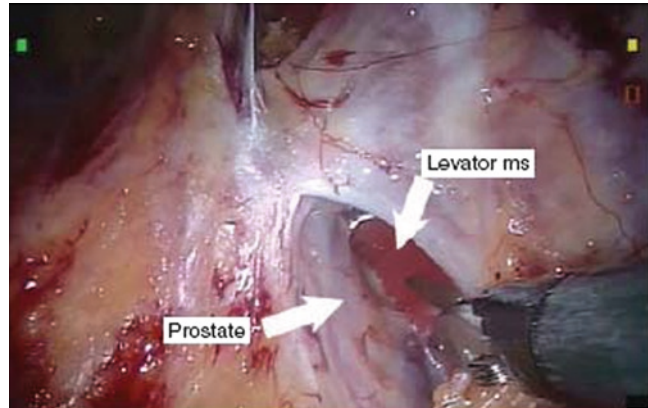
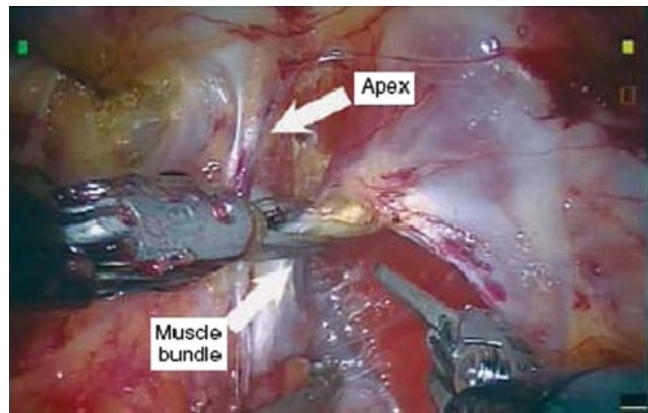


Fig. 3.5 Apical vessels traversing between the levator muscle and prostatic apex are usually cauterized with bipolar energy before division from the prostate to help minimizing bleeding (Reproduced by permission of Saunders, 2007 [1])



the prostatic apex. We prefer to create a small separation of the levator muscles from the prostate; too much separation at this point is not necessary and may lead to inadvertent injury of the neurovascular bundle (NVB). Inferolateral to apex of the prostate, a band of muscle is often present that usually encases a vein, artery, or both. Using a small amount of bipolar electrocautery to seal these vessels prior to incising this tissue close to the prostate can limit blood loss and as such preserve visibility (Fig. 3.5). To better define the dorsal venous complex (DVC), we coldly incise the puboprostatic ligaments. With the prostate apex clearly in view, thin the fascia overlying the lateral aspect of the DVC in order to better define the junction between the vein and the urethra.

Step 3: Ligation of the dorsal venous complex

Surgeon instrumentation			Assistant instrumentation
Right arm	Left arm	Fourth arm	
<ul style="list-style-type: none"> • Curved monopolar scissors • Needle driver (if suturing DVC) 	<ul style="list-style-type: none"> • Maryland bipolar grasper • Needle driver (if suturing DVC) 	<ul style="list-style-type: none"> • ProGrasp™ forceps 	<ul style="list-style-type: none"> • Suction-irrigator • Laparoscopic scissors • Endo-GIA linear stapling device (if stapling DVC)
Endoscope lens: 0°			

The DVC can be handled by one of several methods; the most common methods are suture ligation or stapling. If suturing is to be performed, a 0-Polyglactin or PDS suture on a CT-1 needle is typically used to place a figure of eight around the

DVC. We have used a figure-of-eight suture that is pexed into the pubic periosteum. This helps elevate the urethra after division of the prostatic apex which helps to visualize the urethra during the anastomosis and may be associated with recovery of urinary continence. Often, a back-bleeding suture is also placed toward the prostate base. Once tied, the DVC can be divided at this point, but many surgeons leave this intact temporarily until the urethra is approached later during the case.

We prefer to staple the DVC using the laparoscopic Endo-GIA stapler (US Surgical, Mansfield, MA) with a 45 mm cartridge length and 3.0 mm staple length. The assistant introduces the stapler into the field through the lateral 12 mm assistant trocar. From this angle, place the anvil portion of the stapler on the contralateral side so that the black lines just pass the edge of the DVC (Fig. 3.6). The console surgeon can bunch up the prostate apex to aid in the assistant's visualization of the DVC. Clamp the stapler to the locked position and fire the stapler very slowly. This provides tissue compression, which improves staple formation and hemostasis. Once divided, there should be a small line of stapled tissue left, which can be easily divided later during the apical dissection. If there is any bleeding or if the staple line separates, use a small figure-of-eight stitch with a 3-0 polyglactin suture to stop the remaining bleeding. So far, no reported incidence of staple migration or increased risk of bladder neck contracture has been reported using this technique.

Step 4: Division of the prostatovesical junction

Surgeon instrumentation			Assistant instrumentation
Right arm	Left arm	Fourth arm	• Suction-irrigator
• Monopolar electrocautery spatula	• Maryland bipolar grasper	• ProGrasp™ forceps	
Endoscope lens: 30° down			

The endoscope lens is switched to a 30° down lens to provide a more familiar downward view of the prostatovesical junction. Our preference is to utilize the monopolar electrocautery spatula in the right hand during this step as this instrument has a very atraumatic tip which can be used for gentle blunt dissection. To help visualize the bladder neck, the bedside assistant slowly pushes in and withdraws the urethral catheter. The prior removal of superficial fat from the prostate usually allows easy visualization of the catheter balloon. Lateral deviation of the urethral catheter during this “wiggle” maneuver is a clue for the presence of the median lobe. Once the location of the prostatovesical junction is firmly in mind, use small bursts of electrocautery alternating with blunt dissection to define the superficial layer of the bladder just proximal and lateral to the junction (Fig. 3.7). If this plane is developed carefully, the large superficial veins coursing from the prostate to the bladder can be lifted off the underlying structures thereby minimizing bleeding. The lateral junction between the prostate and the bladder can then be identified by a visible drop-off around the edge of the bladder. From this point, carry the

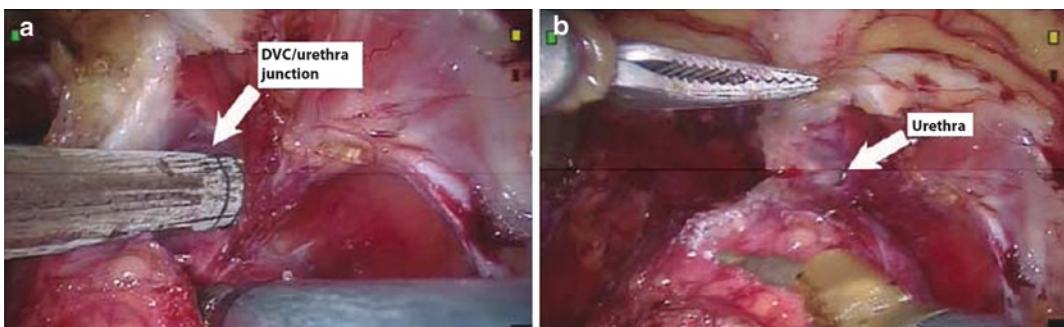


Fig. 3.6 (a), Endo-GIA linear stapler is seen across the DVC. The second black line is placed at the junction between the dorsal vein and urethra. (b), Appearance

of the transected dorsal vein after stapling showing the urethra beneath (Reproduced by permission of Saunders, 2007 [1])

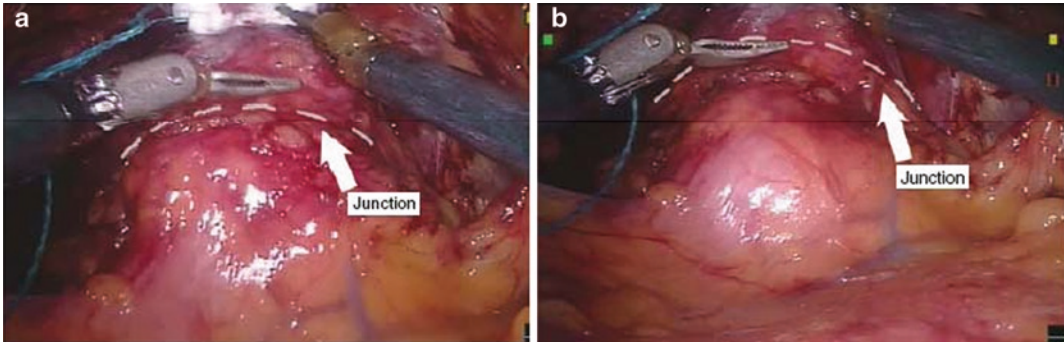


Fig. 3.7 Movement of the urethral catheter balloon (inflated to 10 mL) in (b) and out (a) greatly aids in the visual identification the prostatovesical junction. If an

eccentric movement of the catheter balloon is noted then the presence of a median lobe is likely (Reproduced by permission of Saunders, 2007 [1])

dissection from lateral to medial to thin out the attachment fibers of the bladder to the prostate. This will help separate and drop the lateral edge of the bladder from the prostate creating an increasingly defined bladder neck. This dissection essentially grooms the prostatovesical junction so that it is easily visualized. Key aspects of this dissection are the technique; short bursts of electrocautery followed by sweeping of the tissue helps to maintain excellent vision of the tissue planes. Too much electrocautery and the tissue will become charred; not enough and the tissue will bleed. The table-side assistant during this dissection is providing downward countertraction with the suction irrigator against the upward pull or lift of tissues by the console surgeon. Careful dissection usually allows excellent vision of the entire junction and the bladder neck can be spared or taken widely at the surgeon's discretion.

Enter the bladder neck medially, and deflate the balloon of the urethral catheter. Grasp the catheter through its eye with the fourth arm Prograsp™ forceps and pull the catheter anteriorly. We ensure that the catheter tip is lifted far above the pubis to provide optimal visualization of the posterior bladder neck margin. This holds the fourth arm well out of the way of the other two robot working arms minimizing arm collisions. The table-side assistant then provides tension on the urethral catheter outside the patient thereby lifting the prostate upward facilitating the posterior dissection. Once the bladder is opened,

great care must be taken to visualize the posterior bladder neck for the presence of a median lobe. Also, inspect the bladder neck to ensure that there is sufficient distance from the ureteral orifices for later suturing and any need for later bladder neck reconstruction. We do not typically use indigo carmine to identify the ureteral orifices; however, this can be a useful adjunct. Finally, completely divide the bladder neck.

Step 5: Dissection and ligation of the seminal vesicles and vas deferens

We prefer to create a fairly generous incision along the bladder neck to allow the bladder to drop well away from the prostate. Using blunt sweeping dissection along the posterior bladder neck, a whitish fibrous layer should come into view. This layer should be divided sharply to reveal a layer of fat that in turn overlies the ampulla of the vas. It is helpful at this point of the dissection to observe the general size of the prostate (Fig. 3.8). If the prostate is very large or has a significant median lobe component, then the angle at which this layer is divided is much steeper than if the prostate is small. If this is not appreciated, for example, in the case of large prostate, a portion of the prostate may easily be shaved off as one is searching for the vasa if too shallow a plane is taken.

Once one of the vasa is identified, gentle dissection should be used to enable grasping with

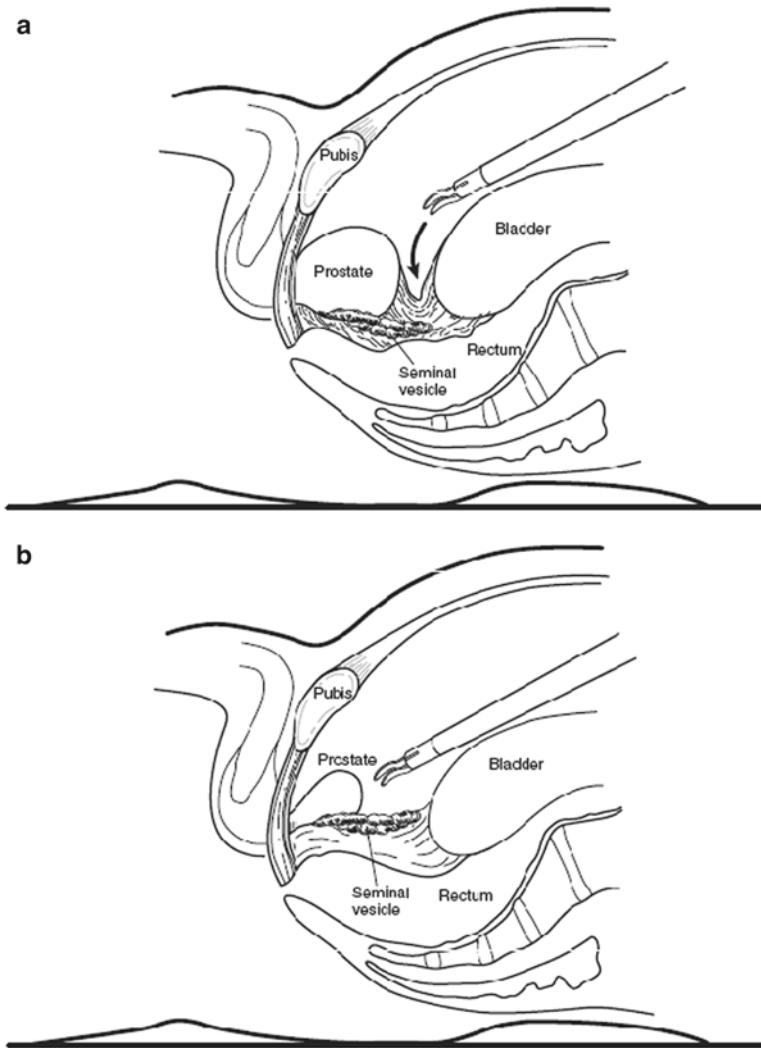


Fig. 3.8 (a) Large prostates require a much steeper plane (*arrow*) to find the ampulla of the vas. (b) Smaller prostates require a much shallower plane (Reproduced by permission of Saunders, 2007 [1])

the Prograsp™ forceps. The fourth arm is then used to lift the vas of interest upward and away from the rectum. Careful dissection should reveal a plane on top of this structure that allows easy blunt sweeping of all surrounding tissues. Lateral dissection along the vas will reveal its paired seminal vesicle (SV). The assistant's downward pressure with the suction device opens this space and significantly aids the dissection. Blunt dissection along the medial edge of the SV will allow this structure to roll up away from its bed (Fig. 3.9). Spot bipolar electrocautery or clips

can control small feeding vessels. Continuous and minor repositioning of the fourth arm can provide subtle retraction that can greatly facilitate this dissection. The use of electrocautery lateral to the SVs should be avoided to prevent thermal energy damage to the NVB [4]. One can excise a piece of vas for later use as a pledget during the anastomosis. If a pledget is not used, simply clip and transect the vas and leave them in situ. Once the vasa are divided and the SVs are rotated medially, very little lateral dissection is necessary to complete the dissection.

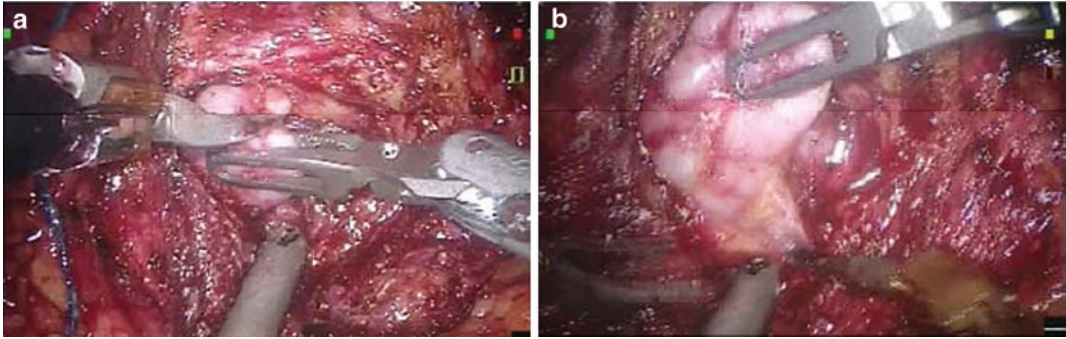


Fig. 3.9 (a) The ProGrasp instrument in the fourth arm acts as an excellent retractor especially during the course of the vas dissection. As movement of the fourth arm is performed, one must be aware to not strike the pubic arch

with the wrist of the instrument resulting in unwanted bleeding. (b) Elevation of the SV allows identification of its insertion into the prostate completing the SV dissection (Reproduced by permission of Saunders, 2007 [1])

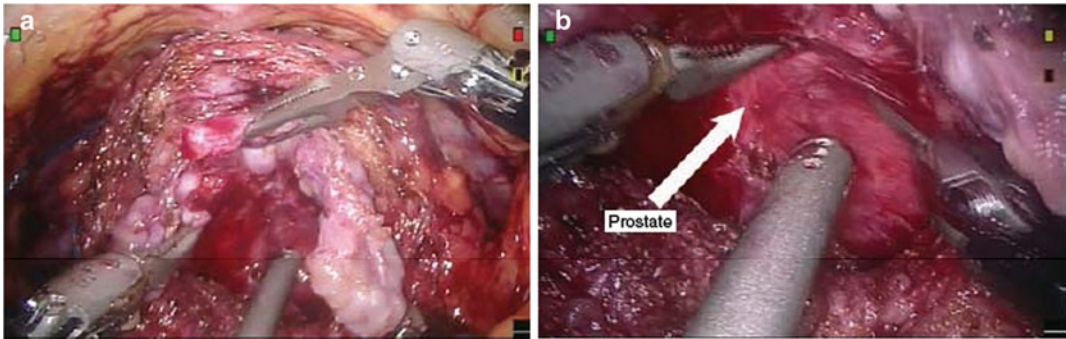


Fig. 3.10 (a) Grasping both vas stumps and retracting anteriorly helps to delineate the posterior plane on the prostate. (b) Incision directly on the curve demonstrated

is a reproducible landmark if proper anterior traction of the prostate is obtained (Reproduced by permission of Saunders, 2007 [1])

Step 6: Posterior prostate dissection

Surgeon instrumentation			Assistant instrumentation
Right arm	Left arm	Fourth arm	
• Curved monopolar scissors	• Maryland bipolar grasper	• ProGrasp™ forceps	• Suction-irrigator
Endoscope lens: 30° down			

Grasp the stumps of the vasa with the fourth arm and use them to pull the prostate upward toward the pubis and out of the pelvis toward the umbilicus. Once proper traction is obtained, note the posterior contour of the prostate which can be appreciated very nicely with the three-dimensional vision provided by the (Fig. 3.10).

Incising Denonvillier's fascia precisely at this point helps to minimize any chance of injuring the rectum or incising into the prostate. Divide the Denonvillier's fascia horizontally along the posterior surface of the prostate, and gently push down the fat overlying the rectum, away from the prostate. Definitively identify the posterior capsule of the prostate, and carry the dissection along this plane toward the apex and laterally as far as can be reached. In men with smaller prostates, the fibers of the rectourethralis can often be identified. Once the rectum has been definitively mobilized posteriorly, either excise or spare the cavernous nerves based on clinico-pathologic findings.

Step 7: Neurovascular bundle and prostatic pedicle dissection

Surgeon instrumentation			Assistant instrumentation
Right arm	Left arm	Fourth arm	
<ul style="list-style-type: none"> • Curved monopolar scissors 	<ul style="list-style-type: none"> • Maryland bipolar grasper 	<ul style="list-style-type: none"> • ProGrasp™ forceps 	<ul style="list-style-type: none"> • Suction-irrigator • Linear stapling device (for non-nerve-sparing cases) • Hem-o-lok® clip applicator (for nerve-sparing cases)
Endoscope lens: 30° down			

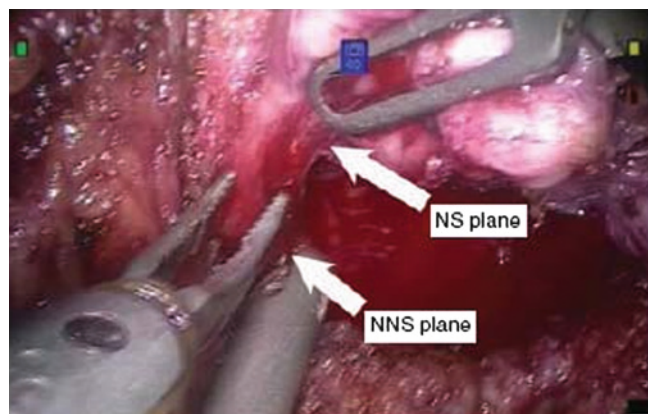
For a non-nerve-sparing procedure, the plane adjacent to the rectum can be continued laterally. This provides as large a margin as possible around the base and lateral portion of the prostate (Fig. 3.11). Use of electrocautery or even a laparoscopic stapler is acceptable and can be expedient if a non-nerve sparing procedure is planned. Wide resection can be difficult especially when approaching the apex as the NVBs must be once again divided just past the apex of the prostate. Careful use of clips or bipolar energy can be helpful. Care must be exercised to not injure the rectum in this region with careful dissection and clear visualization. In the small number of rectal injuries that we have encountered, they have been in patients in whom wide resections were performed near the apex.

For a nerve-sparing procedure, our preference is to use an interfascial technique, where the lateral prostatic fascia is entered and a small amount

of tissue is left covering the prostate capsule. We have found that by routinely stripping off most of the tissue from the capsule of the prostate, the T2 positive margins rate are slightly higher. We prefer to start this nerve sparing by performing an early anterior release of the lateral prostatic fascia beginning at the apex of the prostate. The lateral prostatic fascia is identified and incised with scissors. Sweeping of the fascia posterolaterally releases the NVB from the prostate. We continue to separate the posterolateral portion of the NVB from the prostate so that the prostatic pedicles are clearly defined and then return to the antegrade dissection for control of the pedicles. The pedicles of the prostate are secured athermally with large Hem-o-lok® clips (Teleflex Medical, Research Triangle Park, NC). Once the bulk of the pedicle has been divided, the remainder of the posterolateral plane opens up rather easily and the remaining bundle can be teased away from the prostate with very little difficulty. Small perforators are commonly encountered along this dissection and these vessels are usually allowed to bleed. These will stop spontaneously the majority of the time. If not, they can be individually clipped or suture ligated. However, electrocautery should be avoided so as to avoid damage to the nearby cavernous nerves.

Several different methods have been described to control bleeding around the pedicle, including bipolar electrocautery and sharp dissection, hemostatic clips, and placement of bulldog clamps on the pedicles with later

Fig. 3.11 Once the rectum has been dropped away from the posterior aspect of the prostate, the NVB can be either spared or resected. *Arrows* indicate the plane of dissection for a nerve-sparing (NS) and non-nerve-sparing (NNS) approach (Reproduced by permission of Saunders, 2007 [1])



oversewing [5]. Intuitively, minimizing energy discharge in the region of the pedicles seems the most prudent; this idea has been supported by experimental work in the canine model [6]. However, clinical outcomes are awaited to support the optimal method for sparing the NVB.

Step 8: Prostatic apex dissection

Once the apex is reached during the NVB dissection, the anterior urethra is dissected and exposed. If staples were used to ligate the DVC, a short burst of monopolar electrocautery expeditiously divides the tissue, allowing the underlying urethra to come into view. The remainder of the apical dissection is completed without thermal devices to avoid injury to the nerves or striated sphincter. After maximizing its length with gentle blunt dissection, the urethra is entered with scissors; the urethral catheter is withdrawn until it is just visible in the stump of the urethra. The fourth arm is then used to pull the prostate away from the pelvic floor. Gradually rocking the prostate back and forth provides exposure for division of the posterior urethra, remaining rectourethral, and posterior rhabdosphincter attachments.

Step 9: Entrapment of specimen

Surgeon instrumentation			Assistant instrumentation
Right arm	Left arm	Fourth arm	
• Curved monopolar scissors	• Maryland bipolar grasper	• ProGrasp™ forceps	• Suction-irrigator • Specimen entrapment bag
Endoscope lens: 30° down			

Once freed, the prostate is placed into an entrapment sac and left in upper abdomen until the anastomosis is complete. A careful inspection of the bed of the prostate is performed to ensure no significant bleeders are present that might need attention.

Step 10: Reconstruction of posterior rhabdosphincter

Surgeon instrumentation			Assistant instrumentation
Right arm	Left arm	Fourth arm	
• Needle driver	• Needle driver	• ProGrasp™ forceps	• Suction-Irrigator • Laparoscopic scissors • Needle driver
Endoscope lens: 30° down			

In order to reduce time to continence by restoring urethral length and posterior support, we reconstruct the posterior rhabdosphincter as described in 2006 in both open and laparoscopic RRP by Rocco [7, 8]. During radical prostatectomy the posterior prostatic musculofascial plate is transected. The Rocco maneuver serves to restore the plate's original anatomy and hence its functional support. To perform this, we use a single 3-0 monocril suture cut to 8 in. The first pass is through the cut edge of Denonvilliers' where the suture is anchored down. Next, the suture is passed through the posterior edge of the rhabdosphincter lying immediately beneath the urethra. The urethral catheter can be placed so as to be visible in the urethra at this time to ensure proper stitch placement. This is repeated in a figure-of-eight fashion, pulling gentle traction at each pass. The suture is then tied down, rejoining the musculofascial plate to continuity. One may also pass this suture into the posterior bladder neck so as to anchor the bladder neck closer to the urethra as is originally described by Rocco and colleagues. We feel that this stitch is also a significant aid to hemostasis along the prostatic bed. Smaller venous oozing will often subside after this stitch is completed.

Step 11: Vesicourethral anastomosis

For the anastomosis, we prefer to use the Van Velthoven stitch [9]. This running, double-armed suture has many benefits, including minimizing knot-tying and providing a water-tight anastomosis. We use a 3-0 monocril suture and a 3-0 polyglactin suture tied at the loose ends with a length of 6–7 in. for each arm. The needles can be a UR-6 or RB-1 but we prefer an SH needle. Once the holding knot is tied between the two arms of the suture, a very small piece of vas deferens can be placed as a pledget to bolster the posterior bladder neck.

We start the anastomosis by placing both arms of the suture outside-in at the 6 and 7 o'clock positions along the posterior bladder neck. Place the sutures in the urethra inside-out at the corresponding positions. We standardly use the monocril suture to begin the right side of the anastomosis by starting outside-in on the bladder, inside-out on the urethra, and so on, such that the suture exits at about

3 o'clock on the urethra. The left-sided polyglactin stitch is then placed until the suture is exiting the 8 o'clock position on the urethra. Then, slowly but firmly the sutures can be pulled upward so that the bladder neck can be brought into close apposition to the urethra. We pull on the stitch with one needle driver and use the other as a "pulley" that anchors the delicate urethral tissue by placing the jaws of the instrument just below the stitch. By doing this, we have found that a large amount of force can be applied to the stitch serving to bring the bladder to the urethra without tearing the urethra.

Once the bladder is visually coapted against the urethra, use the fourth arm Prograsp™ forceps to hold the 3 o'clock suture taut, to prevent slippage of the monocryl stitch. Continue to suture the left side of the anastomosis in the same manner until the suture exits inside-out on the urethra at the 11 o'clock position. The tension on the polyglactin suture will often maintain itself without aid of the fourth arm. Sew the right hand suture to the 1 o'clock position inside-out on the urethra. Pass the transition suture at 12 o'clock outside-in on the urethra and pass it inside-out on the bladder neck. Pass the catheter into the bladder. Ensure that all passes through the urethra have been sufficiently pulled taught in order to avoid a gap in the anastomosis. Tie the two sutures together across the anastomosis. We irrigate the bladder with 120 mL of saline to ensure a water tight anastomosis. If there is a small leak, a figure-of-eight stitch can be used to close the defect. We have not, in general, been leaving pelvic drains in place even with very small leaks.

Step 12: Exiting the abdomen

The assistant places the drawstring from the specimen retrieval bag into the abdomen under laparoscopic vision. The console surgeon then grasps the end of the string in the right hand needle driver and then lines up the camera trocar directly to the string. Then the camera is placed into the lateral 12 mm assistant trocar. The assistant places a laparoscopic needle driver into the camera trocar site, and removes the drawstring from the grasp of the right hand needle driver. The tail of the drawstring is clamped externally with a hemostat to prevent the drawstring from slipping back into

the abdomen. The robot is then undocked and the trocars removed under laparoscopic vision to check for any bleeding. The specimen is then removed by extending the incision of the camera trocar site. The fascia is opened with electrocautery until the specimen can be retrieved and then closed with #1 Maxon suture following extraction of the specimen. The remaining trocar sites are closed with a subcuticular stitch of 3-0 or 4-0 monocryl, and the skin reapproximated with a skin adhesive or stitches and steristrips.

Postoperative Management

Remove the orogastric tube in the operating suite. Patients are prescribed ketorolac around the clock and morphine as needed for pain. Patients are encouraged to ambulate as soon as possible, usually within 6 h of the returning to their hospital room. A clear liquid diet is instituted that is advanced to a regular diet by the patient's next meal. Discharge is planned for the morning of postoperative day one. Patients are seen back in 1 week for catheter removal.

Special Considerations

Some surgeons may utilize adjustments in trocar configuration for obese patients; however, we typically use the same configuration for even very large patients. Other patients that may also present difficulty are those with very large prostates or large median lobes, prior prostate or abdominal surgery, and those with relatively small bony pelvises. These more complex patient scenarios will be the subject of a later chapter entitled "Robot-Assisted Radical Prostatectomy: Management of the Difficult Case."

Steps to Avoid Complications

All complications related to laparoscopic surgery readily apply to robot-assisted laparoscopic radical prostatectomy (RALP). Intraoperative

complications include bleeding, injury to adjacent organs, and conversion to open surgery. Rectal injury is an ever-present danger, especially in patients with a history of preoperative androgen ablation. In cases of small rectal tears, consideration can be given to primary closure in two layers with interrupted sutures in patients who have been given a preoperative bowel preparation. Copious irrigation of the pelvis and broad-spectrum intravenous antibiotics should be instituted. Large injuries may be handled by conversion to an open procedure with primary rectal repair and consideration of a diverting ileostomy. Postoperative hematuria may be troublesome for some patients. Instruct patients to seek immediate attention for problems involving catheter obstruction related to clot retention. Late complications such as incontinence and impotence are beyond the scope of this chapter but are explained in detail in other sources.

References

1. Lee DI (2007) Robotic prostatectomy. Atlas of Laparoscopic Retroperitoneal Surgery. Bishoff J (eds.). Philadelphia: WB Saunders, 273–81
2. Pick DL, Lee DI, Skarecky DW et al (2004) Anatomic guide for port placement for daVinci robotic radical prostatectomy. *J Endourol* 18:572
3. Finley DS, Deane L, Rodriguez E et al (2007) Anatomic excision of anterior prostatic fat at radical prostatectomy: implications for pathologic upstaging. *Urology* 70:1000
4. Tewari A, Rao S, Martinez-Salamanca JI et al (2008) Cancer control and the preservation of neurovascular tissue: how to meet competing goals during robotic radical prostatectomy. *BJU Int* 101:1013
5. Ahlering TE, Eichel L, Chou D et al (2005) Feasibility study for robotic radical prostatectomy cautery-free neurovascular bundle preservation. *Urology* 65:994
6. Ong AM, Su LM, Varkarakis I et al (2004) Nerve sparing radical prostatectomy: effects of hemostatic energy sources on the recovery of cavernous nerve function in a canine model. *J Urol* 172:1318
7. Rocco B, Gregori A, Stener S et al (2007) Posterior reconstruction of the rhabdosphincter allows a rapid recovery of continence after transperitoneal video-laparoscopic radical prostatectomy. *Eur Urol* 51:996
8. Rocco F, Carmignani L, Acquati P et al (2006) Restoration of posterior aspect of rhabdosphincter shortens continence time after radical retropubic prostatectomy. *J Urol* 175:2201
9. Van Velthoven RF, Ahlering TE, Peltier A et al (2003) Technique for laparoscopic running urethrovesical anastomosis: the single knot method. *Urology* 61:699

Chapter 4

Transperitoneal Robot-Assisted Laparoscopic Radical Prostatectomy: Posterior Approach

Ryan Turpen, Hany Atalah, and Li-Ming Su

This chapter contains a video segment which can be found at the URL: <http://www.springerimages.com/Su>

Patient Selection

The indications for robot-assisted laparoscopic radical prostatectomy (RALP) are identical to that for open surgery, that is, patients with clinical stage T2 or less with no evidence of metastasis either clinically or radiographically (computed tomography and bone scan). Absolute contraindications include uncorrectable bleeding diatheses or the inability to undergo general anesthesia due to severe cardiopulmonary compromise. Patients who have received neoadjuvant hormonal therapy or who have a history of prior complex lower abdominal and pelvic surgery such as partial colectomy, inguinal mesh herniorrhaphy, or prior transurethral resection of the prostate (TURP) pose a greater technical challenge due to distortion of normal anatomy and adhesions. Morbidly obese patients pose additional challenges due to the potential respiratory compromise encountered when placing these patients in a steep Trendelenburg position as well as the relatively limited working space and limitations of trocar size and instrumentation length. Patients with large prostate volumes (e.g., >70 g) are often met with longer operative times, blood loss, and hospital stay than those with smaller glands. Salvage surgery after failure of primary treatment (e.g., radiation, brachytherapy, cryotherapy, high-intensity focused ultrasound)

has been successfully reported in properly selected patients, but should be approached with caution due to the attendant risks and complications [1, 2]. These more complex patient scenarios should be avoided in a surgeon's early experience with robot-assisted laparoscopic radical prostatectomy (RALP). However, these patient features are not by themselves absolute contraindications.

Preoperative Preparation

Bowel Preparation

One bottle of citrate of magnesium is taken the day before surgery and the patient's diet is limited to clear liquids. A Fleet Enema (C.B. Fleet Company, Inc., Lynchburg, VA) is administered the morning of surgery. A broad-spectrum antibiotic such as cefazolin is administered intravenously 30 min before surgery. Aspirin and other anticoagulants are held at least 7–10 days prior to surgery.

Informed Consent

In addition to bleeding, transfusion, and infection, patients undergoing robot-assisted laparoscopic radical prostatectomy (RALP) must be aware of the potential for conversion to open surgery. As with open surgery, patients must be counseled on the risk of impotence, incontinence, incisional hernia, and adjacent organ

L.-M. Su (✉)
Department of Urology, University of Florida
College of Medicine, 1600 SW Archer Road,
Gainesville, FL 32610-2047, USA
e-mail: sulm@urology.ufl.edu

injury (e.g., ureter, rectum, bladder, small bowel). The risks of general anesthesia must also be presented to the patient as robot-assisted laparoscopic radical prostatectomy (RALP) cannot be performed under regional anesthesia.

Obtaining a baseline assessment of the patient's preoperative urinary and sexual function are critical in guiding preoperative counseling in providing a realistic forecast of return of urinary and sexual function following surgery. Use of a validated questionnaire such as the Sexual Health Inventory for Men and International Prostate Symptom Score allow for an objective evaluation of baseline function. At our

institution, we also incorporate the Expanded Prostate Cancer Index Composite as a comprehensive validated health-related quality of life survey for all men undergoing prostatectomy.

Operative Setup

At our institution we use the da Vinci[®] Si HD Surgical System (Intuitive Surgical, Inc., Sunnyvale, CA) with a four-armed technique. As such, only one assistant is required and is placed on the patient's right side. Across from the assistant

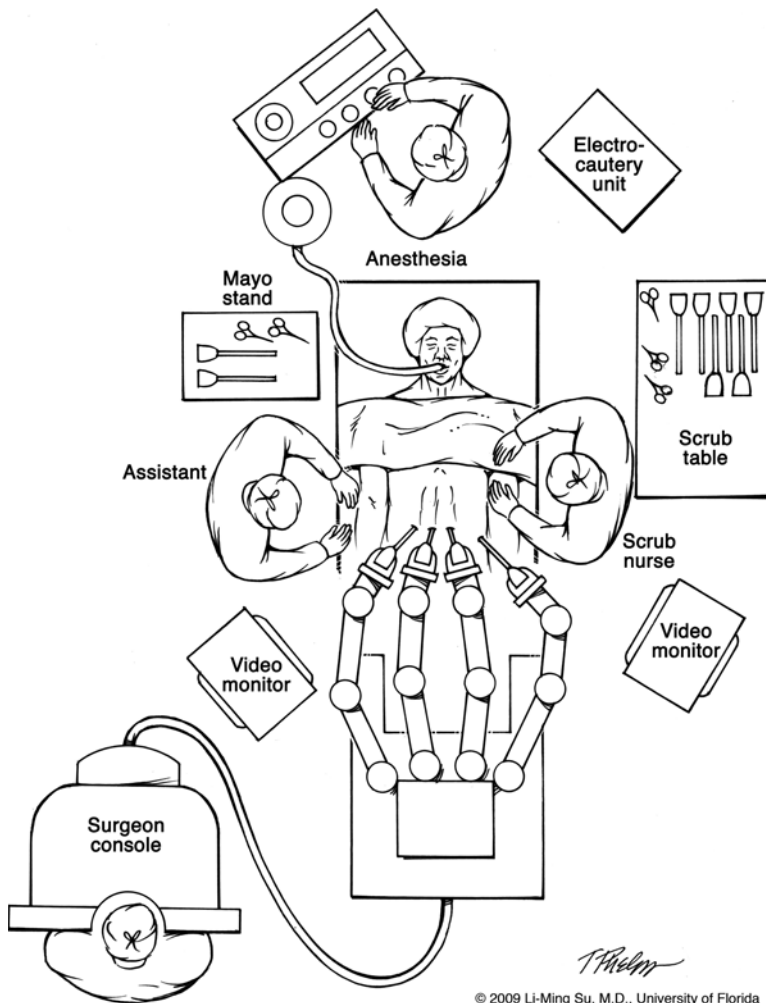


Fig. 4.1 Operating room setup for transperitoneal Robot-assisted laparoscopic radical prostatectomy (RALP) demonstrating standard configuration of operating room personnel and equipment

is the scrub technician with video monitors placed for easy viewing by each team member. A Mayo stand is placed next to the assistant for commonly used instrumentation. The patient-side surgical robotic cart is positioned between the patient's legs. The final operating room setup is as shown in Fig. 4.1. Having a large operating room, ideally dedicated solely to robotic surgery, is important as these surgeries require significant equipment that is both large as well as delicate. Moving this equipment from one operating room to another risks damage and may delay surgery.

Patient Positioning and Preparation

Having a dedicated team versed in robotic surgery helps to ensure a smooth and efficient surgery. Preoperative briefings allows for the entire

team including the surgeon, circulating nurse, scrub technician, and anesthesiologist to identify the patient and planned procedure as well as verbalize any concerns so that these may be addressed and resolved before beginning the surgery. This includes communication with the anesthesiologist, making them aware of surgical expectations and anticipated challenges such as intravenous access, fluid administration, and end-tidal carbon-dioxide monitoring especially with the patient placed in the steep Trendelenburg position.

Once in the operating room, the patient is placed in a supine position. After induction of general endotracheal anesthesia, the patient's arms are tucked to the sides using two draw-sheets and egg-crate padding (Fig. 4.2a–d). To secure the patient's arms, one draw sheet is left below the arm, while the second draw sheet is held taught against the patient's abdomen.

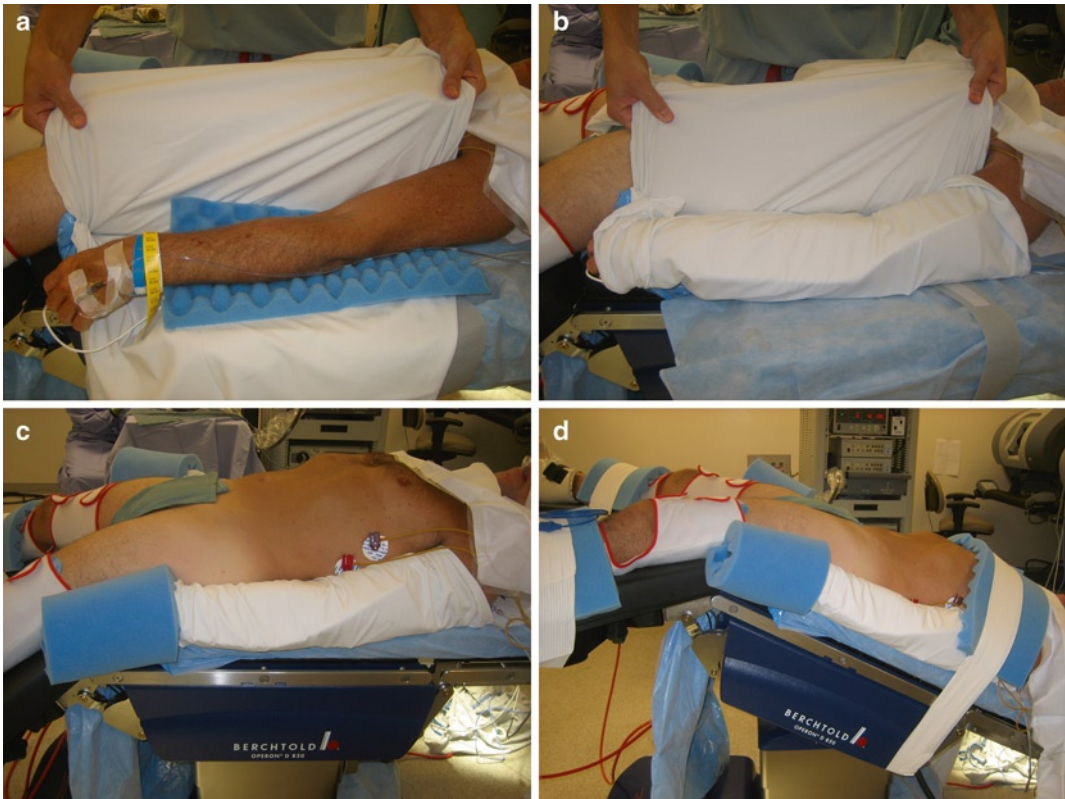


Fig. 4.2 Patient positioning including padding along the patient's arms, hands, and chest

The arm is placed on an egg-crate padding to provide additional cushion (Fig. 4.2a). The first draw sheet is then brought over the arm and tucked below the patient while using the second draw sheet to slightly lift and roll the patient to aid in tucking (Fig. 4.2b). The second draw sheet is then brought down and tucked under the patient while an assistant gently lifts the ipsilateral hip to aid in securing the second draw sheet. Alternatively, arm sleds padded with egg-crate padding may be used. Finally, the hand and wrist are protected using an additional egg-crate padding, keeping the thumb directed upward (Fig. 4.2c). The patient's legs are abducted and placed in a gently flexed position on a split leg table to allow for access to the rectum and perineum. The patient's legs are secured to the split leg supports with egg-crate padding and adhesive tape. Alternatively yellow fin stirrups may be used; however, docking of the fourth arm can at times be compromised by the relatively wide profile of the stirrups as compared to the more narrow split leg supports. Sequential compression stocking devices are placed on both legs and activated. Lastly, the patient is secured to the operating room table above the xyphoid process with egg-crate padding and heavy cloth tape. The patient is placed in steep Trendelenburg and is ready for shaving and prepping (Fig. 4.2d). An orogastric tube is inserted to decompress the stomach and a 16 Fr urethral catheter is placed under sterile conditions so that it can be accessed throughout the surgery by the bedside assistant.

The prostate biopsy pathology is again reviewed on the day of surgery to help guide the intraoperative surgical approach. By mapping the approximate site-specific locations of cancer based upon sextant biopsy findings, a surgeon can begin to formulate a tentative plan for bilateral vs. unilateral vs. incremental neurovascular bundle (NVB) preservation. If high-risk features (i.e., high-grade disease, high percent core involvement, palpable disease) are present, plans for a non-nerve-sparing approach may be prudent. A digital rectal examination is again performed with the patient now under general anesthesia as this is the best opportunity

to examine the prostate, while the patient is fully relaxed. This is the only time during the surgery that the surgeon has true tactile feedback to assess the size, shape, and abnormalities of the patient's prostate, especially along the posterolateral border adjacent to the location of the NVB.

Trocar Configuration

In total, six trocars are placed transabdominally (Fig. 4.3). The first trocar is a 12 mm trocar for the endoscope and camera and is placed 15 cm superior to the pubic symphysis and generally just below the umbilicus. Two 8 mm pararectus trocars are placed, on the left and right sides. These accommodate the second and third robotic arms. An additional 8 mm trocar is placed in the left lumbar region high above the iliac crest and accommodates the fourth arm of the robot, allowing for intraoperative retraction among other uses. For the surgical assistant, a 12 mm trocar is placed in the right lower quadrant above the anterior iliac spine at the same level as the pararectus trocars. An additional 5 mm assistant trocar is placed in the right upper quadrant at the apex of a triangle made between the assistant trocar and the right pararectus trocar.

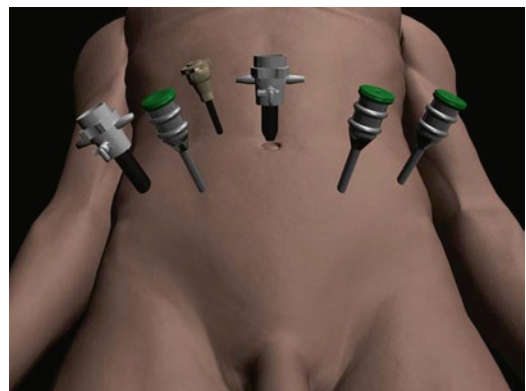

Fig. 4.3 Trocar configuration for transperitoneal Robot-assisted laparoscopic radical prostatectomy (RALP)

Instrumentation and Equipment List

Equipment

- da Vinci® Si HD Surgical System (4-arm system; Intuitive Surgical, Inc., Sunnyvale, CA)
- EndoWrist® Maryland bipolar forceps or PK dissector (Intuitive Surgical, Inc., Sunnyvale, CA)
- EndoWrist® curved monopolar scissors (Intuitive Surgical, Inc., Sunnyvale, CA)
- EndoWrist® ProGrasp™ forceps (Intuitive Surgical, Inc., Sunnyvale, CA)
- EndoWrist® needle drivers (2) (Intuitive Surgical, Inc., Sunnyvale, CA)
- InSite® Vision System with 0° and 30° lens (Intuitive Surgical, Inc., Sunnyvale, CA)

Trocars

- 12 mm trocars (2)
- 8 mm robotic trocars (3)
- 5 mm trocar (1)

Recommended sutures

- Ligation of the deep dorsal vein complex (DVC): 0 PDS suture on a CT-1 needle cut to 10 in. and 4-0 polyglactin suture on a RB1 needle cut to 6 in. (if necessary)
- Vesicourethral anastomosis: 2-0 Monocryl (ETHICON, INC. a Johnson and Johnson Company, Somerville, NJ) and CAPROSYN (Covidien, Mansfield, MA) double armed suture each cut to 8 in. on a UR-6 needle tied together.
- Modified Rocco stitch: 2-0 Monocryl suture on a UR-6 needle cut to 10 in.
- Anterior bladder neck closure (if necessary): 2-0 polyglactin suture on a UR-6 needle cut to 6 in.

Instruments used by the surgical assistant

- Laparoscopic needle driver
- Laparoscopic scissors
- Blunt tip grasper
- Suction irrigator device
- Hem-o-lok® clip applicator (Teleflex Medical, Research Triangle Park, NC)
- Small, Medium-Large and Extra Large Hem-o-lok® clips (Teleflex Medical, Research Triangle Park, NC)
- 10 mm specimen entrapment bag

- Sponge on a stick
- EnSeal® device 5 mm diameter, 45 cm shaft length (SurgRx®, Redwood City, CA) (optional)
- SURGICEL® hemostatic gauze (Ethicon, Inc., Cincinnati, OH)
- 18 Fr silicone urethral catheter
- Hemovac or Jackson-Pratt closed suction pelvic drain

Step-by-Step Technique

Step 1: Abdominal access and trocar placement

For a transperitoneal robot-assisted laparoscopic radical prostatectomy (RALP) approach, pneumoperitoneum is established using a Veress needle inserted at the base of the umbilicus. Alternatively, an open trocar placement with a Hasson technique can be used. The insufflation pressure is maintained at 15 mmHg. A 12 mm trocar is placed immediately below the umbilicus (approximately 15 cm from the pubic symphysis) under direct visualization using a visual obturator. Occasionally, this trocar is placed supraumbilical if the distance from the umbilicus and pubic symphysis is less than 15 cm. Secondary trocars, as mentioned above, are then placed under laparoscopic view. The da Vinci® robot is then positioned between the patient's legs and the four robotic arms are docked to their respective trocars.

Once intraperitoneal access and a pneumoperitoneum are established, the camera is inserted through the 12 mm umbilical trocar. The console surgeon controls camera movement by depressing the foot pedals and using brief arm movements to affect camera and instrument positioning. Stereo endoscopes with either angled (30°) or straight ahead (0°) viewing are available and interchangeable at various portions of the procedure. However, our preference is to use the 0° lens throughout the entire operation. Under direct visualization, the robotic arms are then loaded with instruments and positioned within the operative field at which point the console surgeon takes control. The Maryland scissors are placed in the second robotic arm ("right hand" of the console surgeon) while bipolar forceps are inserted into

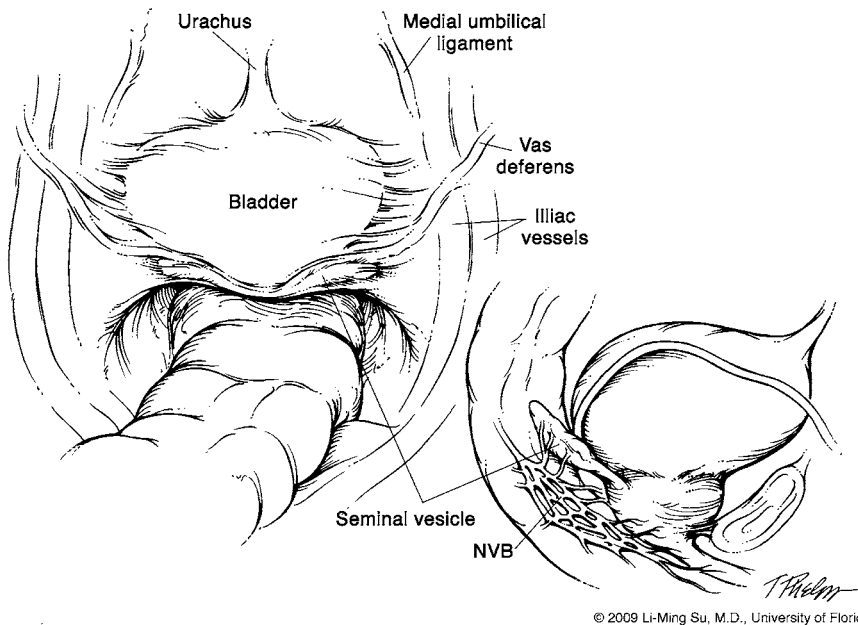
the third robotic arm (“left hand”). Finally, the fourth arm is used to control ProGrasp™ forceps (Intuitive Surgical, Inc., Sunnyvale, CA). Once the bedside assistant advances these instruments into proper position within the operative field, the robotic arms, in general, do not require any further adjustment for the remainder of the case. When instruments are exchanged, the robot will retain “memory” of the precise location of the removed instrument within the body, and therefore the new instrument will return to a few millimeters short of the last position automatically, reducing the risk for incidental injury to abdominal and pelvic structures. The electrocautery set-

tings used during the operation are 45 W for both monopolar and bipolar electrocautery.

Upon initial inspection of the operative field, the relevant landmarks include the bladder, median (urachus) and medial umbilical ligaments, vas deferens, iliac vessels, and rectum (Fig. 4.4). Frequently, adhesions are encountered within the pelvic cavity especially between the sigmoid colon and the left lateral pelvic side wall, which are released using sharp dissection. During transperitoneal-posterior approach, the initial step is retrovesical dissection of the vas deferentia and seminal vesicles (SVs) following the same principles described by the Montsouris technique [3]. After using the ProGrasp™ forceps to retract the sigmoid colon out of the pelvic cavity, the vas deferens is identified laterally coursing over the medial umbilical ligaments. The peritoneum overlying the vas deferens is incised sharply and the vas is traced medially to its coalescence with the ipsilateral SV and then divided. The contralateral vas is then dissected. Upon completing this step, the two vasa should be touching at their coalescence into the ejaculatory

Step 2: Dissection of seminal vesicles and vas deferens

Surgeon instrumentation			Assistant instrumentation
Right arm	Left arm	Fourth arm	
• Curved monopolar scissors	• Maryland bipolar grasper	• ProGrasp™ forceps	• Suction-irrigator • Hem-o-lok® clip applier
Endoscope lens: 0°			



© 2009 Li-Ming Su, M.D., University of Florida

Fig. 4.4 Anatomic landmarks within the pelvis. Upon initial inspection of pelvis, the bladder, urachus, medial umbilical ligaments, vas deferens, and iliac vessels as

well as the rectum should be identified to serve as anatomical landmarks to aid in dissection

ducts and the vasa should be freed anteriorly off of the posterior aspect of the bladder to aid in later identification of the vasa during division of the bladder neck.

Next the SVs are dissected. The assistant provides counter traction by lifting the bladder at the 12 o'clock position to improve exposure to the SVs. The posterior dissection of the SV is carried out first as very few blood vessels are encountered along this relatively avascular plane. Next, the anterior dissection of the SV is performed using gentle, blunt dissection to define and isolate the two to three vessels that often course along the anterolateral surface of the SV. Hemoclips are judiciously applied to these vessels along the lateral surface of the SV starting from the tip and traveling toward the base. These vascular packets are divided using cold scissors, and use of thermal energy is limited and avoided if possible during this dissection in efforts to avoid injury to the nearby NVB (Fig. 4.5).

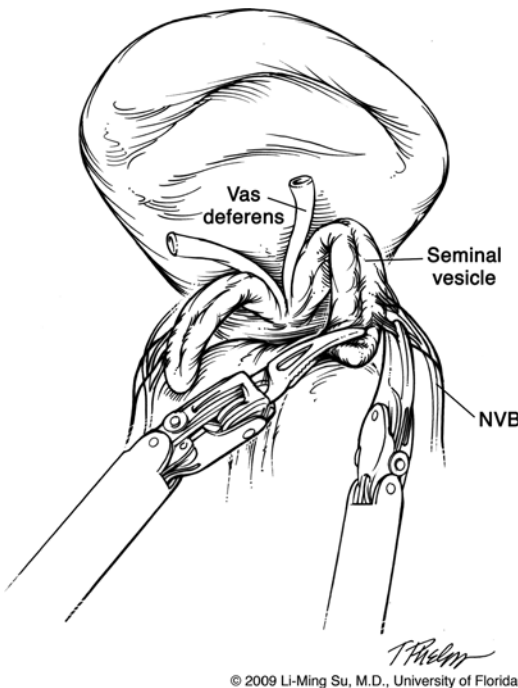


Fig. 4.5 Seminal vesicle dissection. Anterolateral dissection of the SV is performed using Hem-o-lok® clips and cold scissors. Electrocautery should be avoided if possible during this step due to the close proximity of the NVB

Step 3: Posterior dissection of the prostate

The SVs and vasa are lifted anteriorly with the ProGrasp™ forceps and a 2–3 cm horizontal incision is made through the posterior layer of Denonvillier’s fascia approximately 0.5 cm below the base of the SVs (Fig. 4.6). In patients with low-volume, nonpalpable disease, the posterior dissection plane is developed between Denonvillier’s fascia posteriorly and the prostatic fascia anteriorly to help facilitate later release of the NVB located along the posterolateral surface of the prostate. In the case of high volume or palpable disease, this posterior dissection should be carried out one layer deeper, between Denonvillier’s fascia and the prerectal fat plane, thus maintaining additional tissue coverage along the posterior aspect of the prostate. In addition, in cases of prior acute prostatitis, this prerectal fat plane is often preserved with few adhesions and may be a safer plane of dissection in these unique cases.

The assistant provides counter traction by applying gentle pressure at the 6 o’clock position using a suction-irrigator, retracting Denonvillier’s fascia and the rectum inferiorly. The surgeon elevates the posterior aspect of the prostate with the left instrument using blunt dissection with the right instrument to develop this avascular plane along the posterior aspect of the prostate. Using gentle sweeping motions, all posterior attachments are released toward the prostatic apex. Thorough and wide dissection of the rectum off of the posterior prostate is critical in order to minimize the risk of rectal injury during subsequent steps such as division of the urethra and dissection of the prostatic apex. Once again, thermal energy should be minimized especially along the medial aspect of the NVBs.

Step 4: Developing the space of retzius

The bladder is dissected from the anterior abdominal wall by dividing the urachus high above the bladder and incising the peritoneum bilaterally just lateral to the medial umbilical ligaments (Fig. 4.7). Prior to dividing the medial umbilical ligaments, the obliterated umbilical vessels must be controlled with bipolar electrocautery prior to

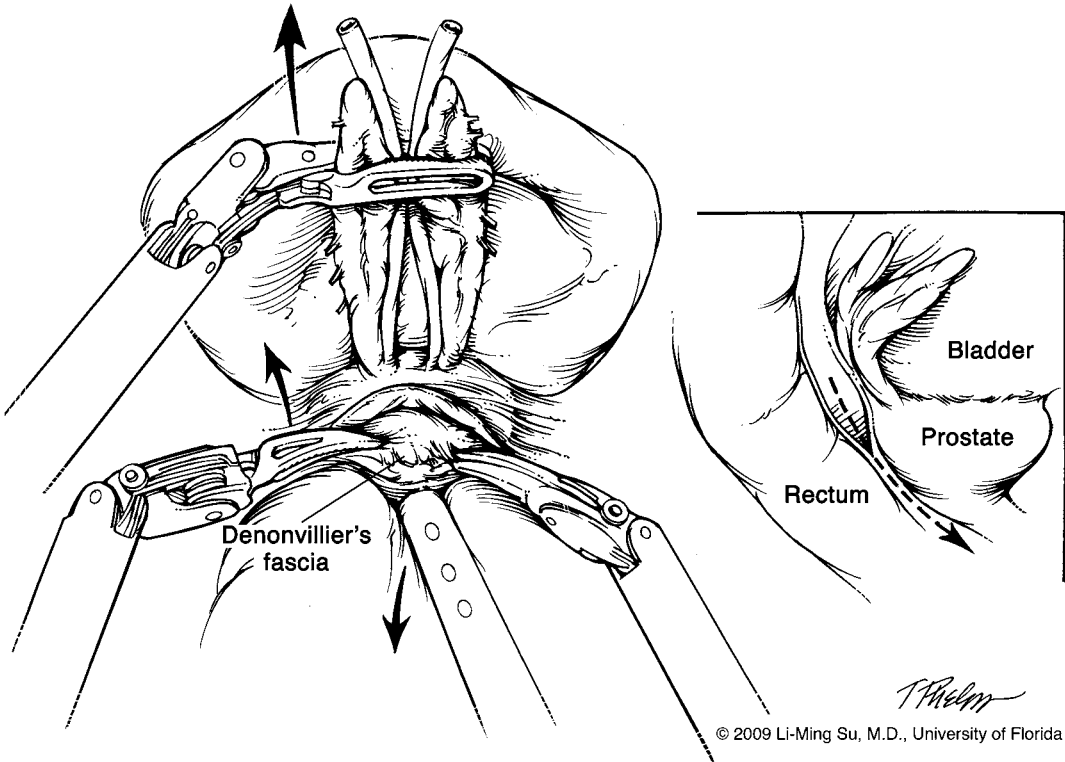


Fig. 4.6 Posterior dissection of the prostate. During the posterior dissection of the prostate, the fourth robotic arm is used to lift the SVs anteriorly. Denonvillier's fascia is

incised horizontally 0.5 cm below the base of the SVs and the dissection is carried caudally toward the prostatic apex

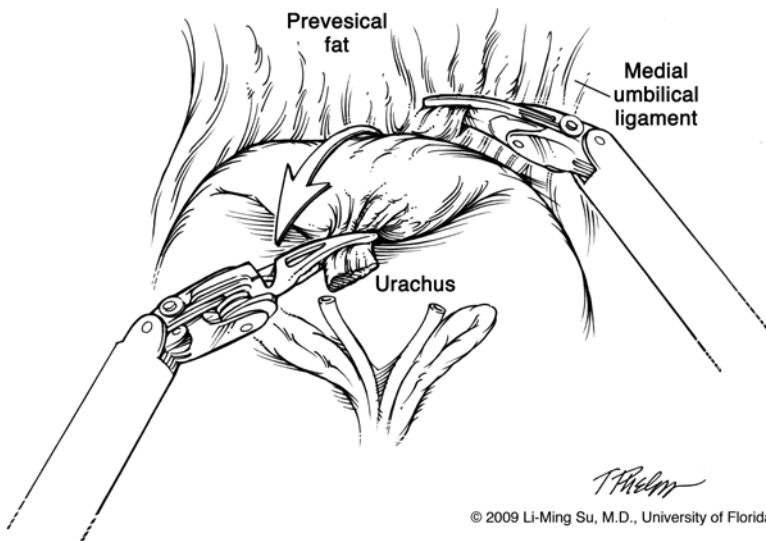


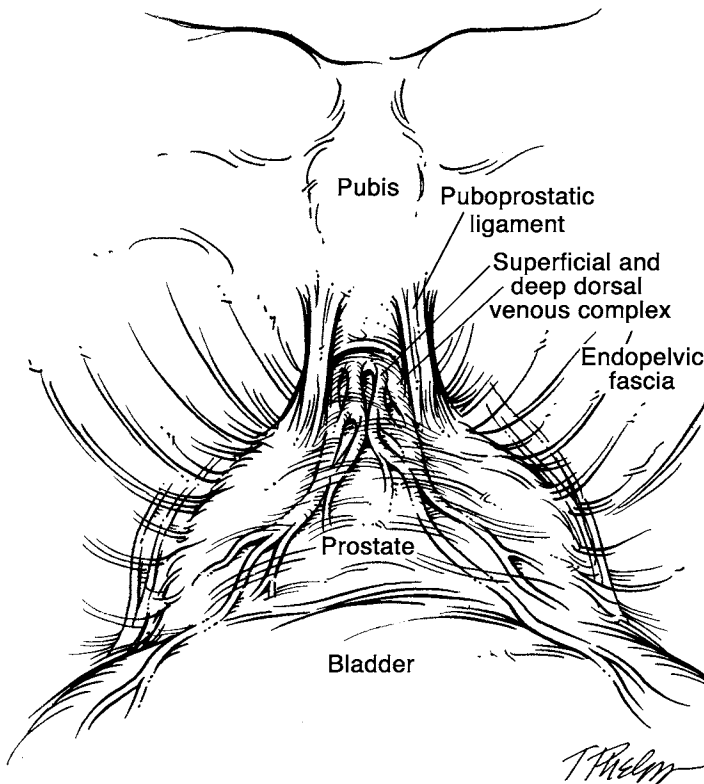
Fig. 4.7 Entering the space of retzius. The bladder is dissected from the anterior abdominal wall by dividing the urachus and medial umbilical ligaments

laterally. The presence of fatty alveolar tissue ensures the correct plane that is extended down to the pubic symphysis

division so as to avoid unwanted bleeding. The bladder is released laterally to the point where the medial umbilical ligament crosses the vas deferens cross. This ensures that the bladder is optimally mobilized from the pelvic side wall so as to reduce tension at the vesicourethral anastomosis during the later steps of the operation. The presence of fatty alveolar tissue confirms the proper plane of dissection within the space of Retzius. Applying posterior traction on the urachus, the prevesical fat is identified and bluntly dissected, exposing the pubic symphysis.

The fat overlying the anterior prostate is then removed to improve exposure of the prostate. Using mainly blunt dissection, this fat pad is dissected from a lateral to medial direction isolating the superficial DVC. These vessels travel anterior to the prostatic apex and through the anterior pro-

static fatty tissue and are coagulated with bipolar electrocautery prior to division. The fat pad is rolled off of the prostate in a cephalad direction from apex to base. The distal branches of the superficial DVC are then coagulated with bipolar electrocautery prior to division allowing for the fat pad to be removed as a single specimen. Upon removal of the anterior fat, visible landmarks include the anterior aspect of the bladder and prostate, puboprostatic ligaments, endopelvic fascia, and pubis (Fig. 4.8). Using the ProGrasp™ forceps to grasp and retract the bladder, the endopelvic fascia and puboprostatic ligaments are sharply divided exposing the levator muscle fibers attached to the lateral and apical portions of the prostate. These fibers are meticulously and bluntly dissected from the surface of the prostate exposing the prostatic apex, DVC, and urethra.



© 2009 Li-Ming Su, M.D., University of Florida

Fig. 4.8 View of the anterior prostate. The fat overlying the anterior prostate is dissected in a lateral to medial direction and removed in a single packet by rolling the tissue from the apex toward the base of the prostate.

Bipolar electrocautery is used to transect the superficial DVC. This helps to better expose the anterior prostate and bladder, puboprostatic ligaments, and endopelvic fascia

Step 5: Ligation of the deep dorsal venous complex

Surgeon instrumentation			Assistant instrumentation
Right arm	Left arm	Fourth arm	
• Needle driver	• Needle driver	• ProGrasp™ forceps	<ul style="list-style-type: none"> • Suction-irrigator • Laparoscopic scissors • Laparoscopic needle driver
Endoscope lens: 0°			

The ProGrasp™ forceps is used to bunch the deep DVC along the anterior prostatovesical junction while simultaneously applying slight cephalad traction. This provides optimal exposure of the DVC and pubis. A 0-PDS suture on a CT-1 needle is passed by the assistant to the surgeon using a laparoscopic needle driver and the DVC is suture ligated using a slip knot or figure-of-eight suture (Fig. 4.9). The needle is passed beneath the DVC and anterior to the urethra. Securing the DVC as far away from the prostatic apex as possible can help minimize iatrogenic entry into the prostatic apex during later division of the DVC. A second DVC stitch is placed distal to the first and used to suspend the DVC to the

inferior pubic symphysis. The DVC is not divided until later in the operation and immediately prior to prostatic apical dissection and division of the urethra. An additional 0-PDS suture may be placed along the anterior bladder neck to prevent venous back bleeding and to help identify the contour of the prostate for subsequent bladder neck transection.

Step 6: Anterior bladder neck transection

Surgeon instrumentation			Assistant instrumentation
Right arm	Left arm	Fourth arm	
• Curved monopolar scissors	• Maryland bipolar grasper	• ProGrasp™ forceps	<ul style="list-style-type: none"> • Suction-irrigator • Hem-o-lok® clip applicator • EnSeal® device (optional)
Endoscope lens: 0°			

The anterior bladder is divided using monopolar electrocautery. With experience, the proper plane of dissection can be visualized by simply inspecting the contour of the prostate and bladder neck [4]. Several maneuvers are used to better delineate this plane of dissection. First, visual

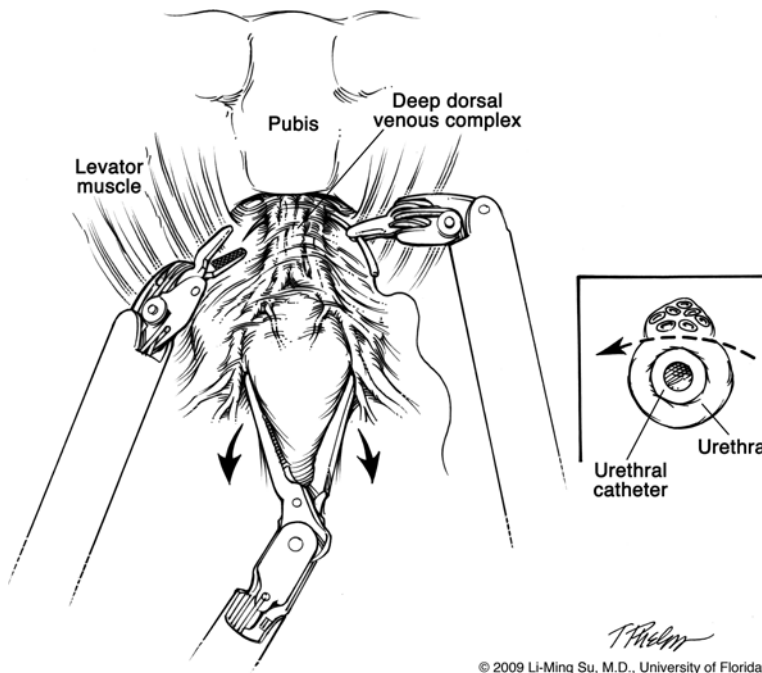


Fig. 4.9 Ligation of the deep dorsal venous complex. The DVC is secured by passing the needle below the venous complex and anterior to the urethra, ligating the DVC as distal to the apex as possible

inspection of the prevesical adipose tissue as it transitions to the bare anterior prostate gland often defines the bladder neck. Second, lifting the dome of the bladder in a cephalad direction with the ProGrasp™ forceps often reveals a “tenting” effect that defines the point at which the bladder connects to the base of the prostate. Third, performing a “bimanual pinch” by compressing the tissues of the bladder and prostate between the two robotic instruments allows the surgeon to gain a sense of where the plane lies. Using this technique and visual cues, the surgeon will note that the bladder tissue easily coapts between the two instruments while the prostate tissue remains more substantive and more “stiff.” Finally, having the bedside assistant provide traction on the urethral catheter, bringing the balloon to the bladder neck also provides a visual cue to the proper plane of dissection. Use of all four of these maneuvers is advised during one’s early experience with robot-assisted laparoscopic radical prostatectomy (RALP) so as to avoid inadvertent entry into the base of the prostate resulting in a positive bladder neck margin. When in doubt, a more proximal plane of dissection at the bladder neck is advised with later

bladder neck reconstruction, if necessary, to correct for any discrepancy between the bladder neck opening and urethra.

The anterior bladder neck is divided horizontally staying close to the midline. Carrying the dissection too laterally can result in unwanted bleeding from the lateral bladder pedicles. Once the anterior bladder neck is transected, the urethral catheter is exposed. The catheter balloon is decompressed and the catheter tip is advanced through the anterior bladder defect. The fourth arm is then used to grasp the catheter tip and provide traction by pulling superiorly toward the anterior abdominal wall. The proximal end of the catheter is cinched by the assistant at the penile meatus thus creating a “hammock” effect, suspending the prostate anteriorly. This maneuver provides improved exposure to the posterior bladder neck.

Step 7: Posterior bladder neck transection

The posterior bladder wall is inspected to identify the presence or absence of a median lobe as well as the location of the ureteral orifices (Fig. 4.10). If a median lobe is encountered,

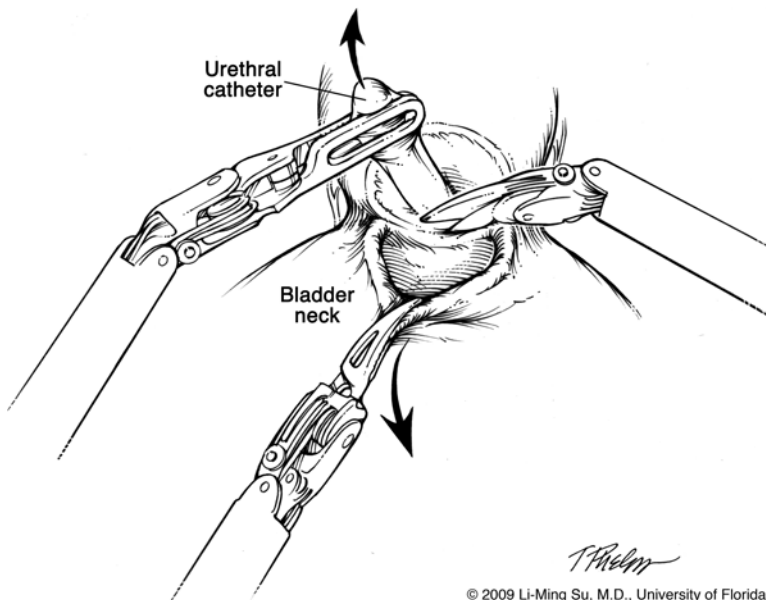


Fig. 4.10 Posterior bladder neck division. Horizontal dissection is carried out through the posterior bladder neck in a 45° downward angle to prevent entry into the prostate base and excessive thinning of the posterior bladder neck

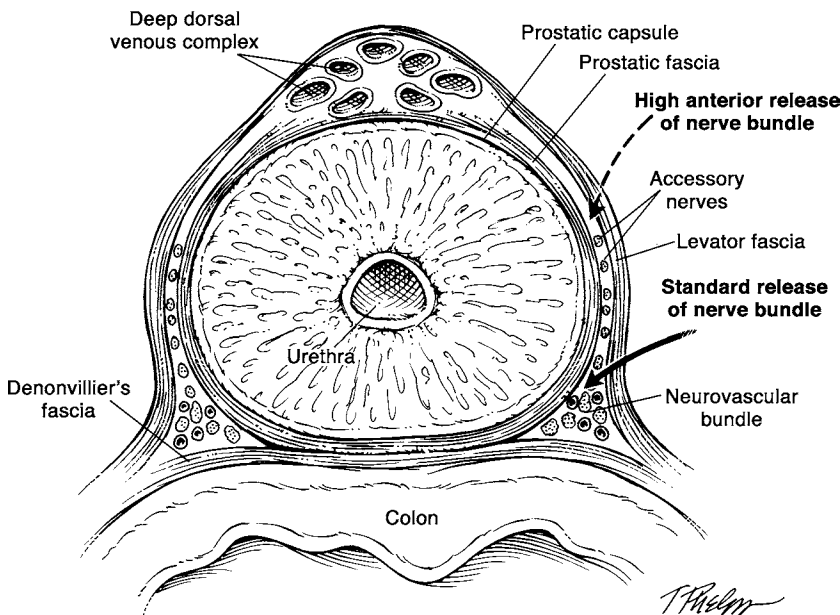
dissection of the posterior bladder neck is performed beneath the protruding median lobe by lifting the median lobe anterior with the left hand instrument or ProGrasp™ forceps. Similar to the anterior bladder neck, the posterior bladder neck is divided horizontally along the midline avoiding the lateral pedicles. Once the mucosa is incised, the posterior bladder neck is divided from the base of the prostate with monopolar electrocautery by taking an approximately 45° downward angle of dissection. This angle helps to avoid inadvertent entry into the prostate as well as excessive thinning of the posterior bladder neck. If excessive bleeding is encountered, one should be concerned about the possibility of inadvertent entry into the prostate gland. When dividing the posterior bladder neck, one should ensure that the posterior bladder wall thickness remains uniform with the anterior bladder neck thickness.

Upon entering the retrovesical space, the SVs and vas deferentia that have been previously dissected are grasped and brought through the open-

ing created between the bladder neck and prostate. This is one of the unique advantages of the transperitoneal posterior approach as since the SVs and vasa have been already dissected in previous steps, these structures are now easily identified and do not require extensive dissection especially in cases of a median lobe where visualization is compromised. The bladder pillars (i.e., remaining anterolateral attachments between the bladder and prostate base) are divided either between hemoclips or with the EnSeal® device (SurgRx®, Redwood City, CA) as the terminal branches from the DVC travel through this tissue.

Step 8: Lateral interfascial dissection of the neurovascular bundles

The NVB travels between two distinct fascial planes that surround the prostate, namely the prostatic fascia and levator fascia (Fig. 4.11). For select patients with low-risk disease (i.e., low-grade, low-volume, nonpalpable disease), a more



© 2009 Li-Ming Su, M.D., University of Florida

Fig. 4.11 Schematic cross section of the periprostatic fascial planes and NVBs. Anatomically, the NVBs run between the levator fascia and above the prostatic fascia (i.e., interfascial plane). The high anterior release of the

NVB is begun by making a higher incision of the levator fascia along the anteromedial border of the prostate as compared to a more posterolateral incision made for a standard nerve-sparing procedure

aggressive approach to NVB preservation may be taken, preserving the NVB along with a generous amount of periprostatic fascia containing accessory nerves, which have been suggested by some to improve postoperative erectile function [5]. This high anterior release of the periprostatic fascia and NVB entails a longitudinal incision of the levator fascia along the more anteromedial border of the prostate. For patients with intermediate-risk disease, a more conservative approach to NVB preservation may be taken so as to avoid an iatrogenic positive margin from dissecting too close to the surface of the prostate. In such cases, a standard release of the NVB may be chosen by incising the levator fascia along the 5 and 7 o'clock position along the posterolateral surface of the prostate.

In preparation for the lateral release of the NVBs, the base of the prostate or tip of the urethral catheter is grasped with the ProGrasp™ and retracted medially, exposing the lateral surface of the prostate. An opening in the levator fascia is made by sharp incision and carried out toward the apex and base (Fig. 4.12). The interfascial plane (i.e., between the levator and

prostatic fascia) is developed gently using blunt dissection. A groove between the NVB and prostate (i.e., the lateral NVB groove) is created by progressively developing this interfascial plane toward the posterolateral aspect of the prostate. Dissection continues in close approximation to the surface of the prostatic fascia in efforts to optimize quantitative cavernous nerve preservation. If bleeding occurs from periprostatic vessels, insufflation pressure can be temporarily increased and pressure applied to the source of bleeding with SURGICEL® hemostatic gauze. Hemostasis with electrocautery should be avoided if possible during dissection near the NVBs as these energy sources have been shown to be harmful to cavernous nerves function in both canine and human studies [6, 7]. Proximal dissection of the NVB is carried to the level of the prostatic pedicles.

Step 9: Ligation of the prostatic pedicles

The SVs and vasa are lifted anteriorly with the ProGrasp™ forceps defining the proximal extent of the prostatic pedicles located at the

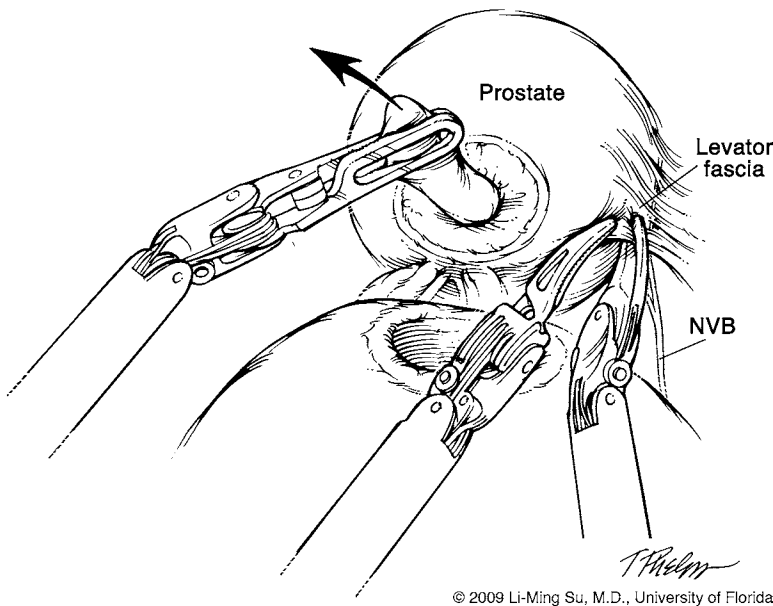


Fig. 4.12 Incising the levator fascia. Using the fourth robotic arm to provide countertraction on the prostate, the levator fascia is incised longitudinally along the

anteromedial border of the prostate to perform the high anterior release. The sharp dissection is carried out toward the apex and base, developing the lateral NVB groove

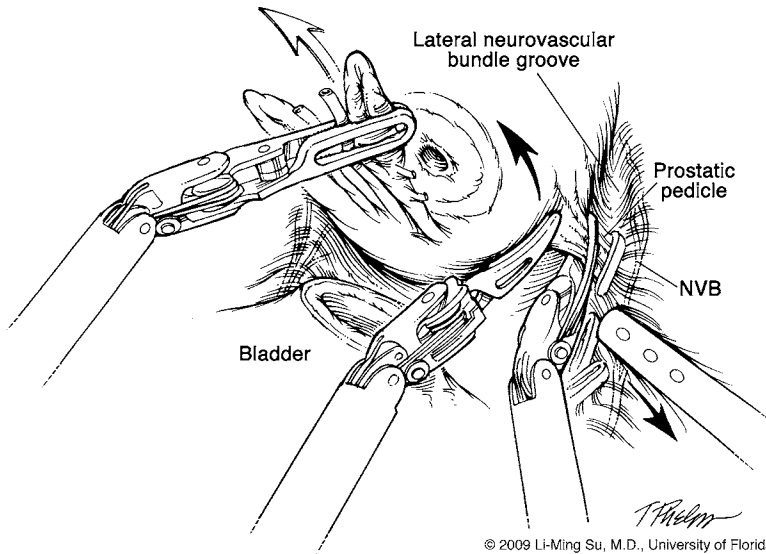


Fig. 4.13 Ligation of the prostatic pedicles. Countertraction is again provided by use of the fourth robotic arm to help display the prostatic pedicles. The previously formed lat-

eral NVB groove helps to identify the precise location of the NVB in reference to the prostatic pedicle, thus minimizing nerve injury during clip placement

5 and 7 o'clock positions. Having already accomplished the lateral release of the NVB and established the lateral NVB groove, this helps to define the distal limit of the prostatic pedicles (Fig. 4.13). The assistant provides further exposure of the pedicles by applying posterior and cephalad counter traction on the bladder neck. The surgeon creates tissue packets within the prostatic pedicles and two to three medium-large Hem-o-lok® clips are applied to control the prostatic vessels in lieu of electrocautery. Great care must be taken so as to avoid past pointing with the hemoclips resulting in entrapment of the nearby NVB.

Step 10: Antegrade neurovascular bundle preservation

After division of the prostatic pedicles, dissection is carried out toward the previously defined lateral NVB groove in an “antegrade” or “descending” manner (Fig. 4.14). As the posterior dissection between the rectum and prostate has already been completed, the medial border of the NVB is already visibly defined. Both the medial border of the NVB and lateral NVB groove serve as critical landmarks to help guide the proper

angle and direction of dissection to optimize antegrade NVB preservation. The remaining attachments between the NVBs and prostate are gently teased off of the posterolateral surface of the prostate using a combination of blunt and sharp dissection. When small vessels coursing between the NVB and prostate are encountered, small hemoclips may be used. Antegrade dissection of the NVBs is carried out as far distally toward the apex as possible. The use of electrocautery and direct manipulation of the NVB is minimized to avoid injury to the cavernous nerves. If adhesions are encountered between the NVB and prostate, slightly wider dissection may be carried out in efforts to avoid an iatrogenic positive surgical margin, especially in locations at risk for extraprostatic extension of cancer. As such, incremental preservation of cavernous nerves can often be achieved without having to sacrifice the entire NVB (i.e., wide excision of NVB).

Step 11: Division of the deep dorsal venous complex

The DVC is divided just proximal to the previously placed DVC suture. Great care must be taken to avoid inadvertent entry into the prostatic

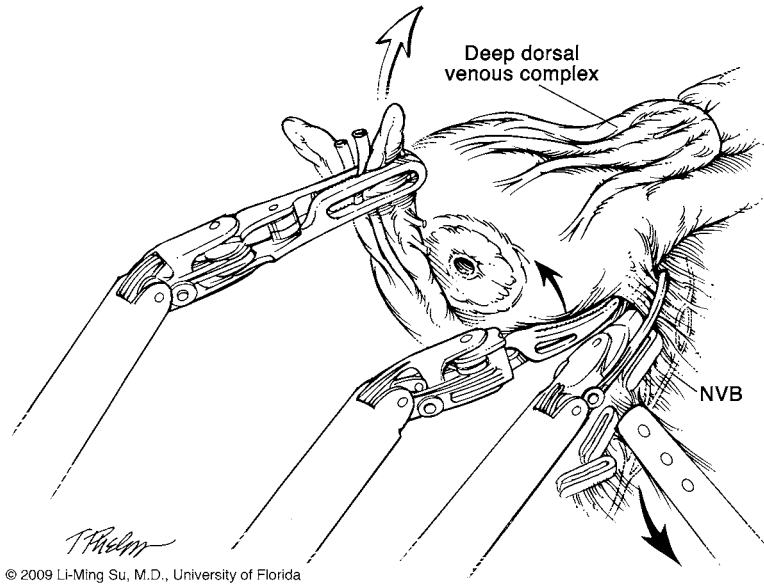


Fig. 4.14 Antegrade preservation of the neurovascular bundle. Combined blunt and sharp dissections are used to free the final prostatic attachments from the NVB as far distally toward the apex as possible

apex, resulting in an iatrogenic positive apical margin. Spot electrocautery may be required for minor arterial bleeding from the DVC. If adequate dissection of the NVBs has been accomplished in previous steps, the NVBs should be visible immediately adjacent and lateral to the DVC. Attention should be paid to avoid the use of electrocautery specifically at this location. Occasionally, additional 4-0 polyglactin DVC sutures may be required if large venous sinuses are encountered that were not adequately secured or if the original DVC suture becomes dislodged. After complete division of the DVC, a notch representing the anterior aspect of the prostatourethral junction should be visible.

Step 12: Prostatic apical dissection and division of urethra

As the distal portion of the NVBs lie in intimate association with the lateral aspect of the prostatic apex, the remaining attachments between the NVB and prostatic apex are gently and meticulously dissected free using sharp dissection without electrocautery (Fig. 4.15). The anterior urethra is divided sharply, taking care to preserve

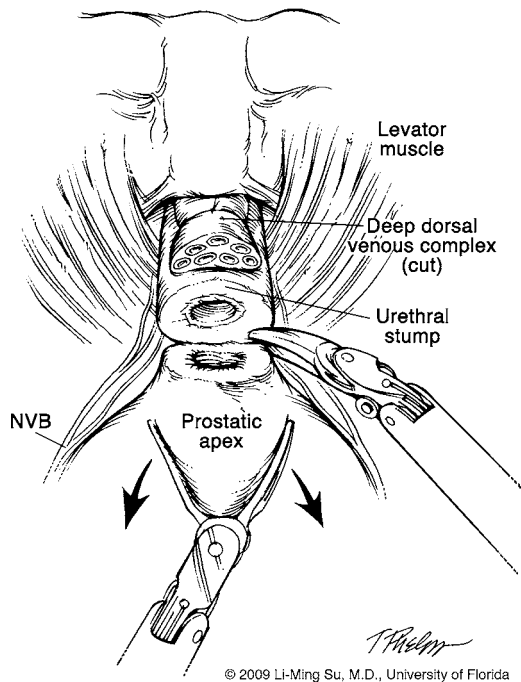


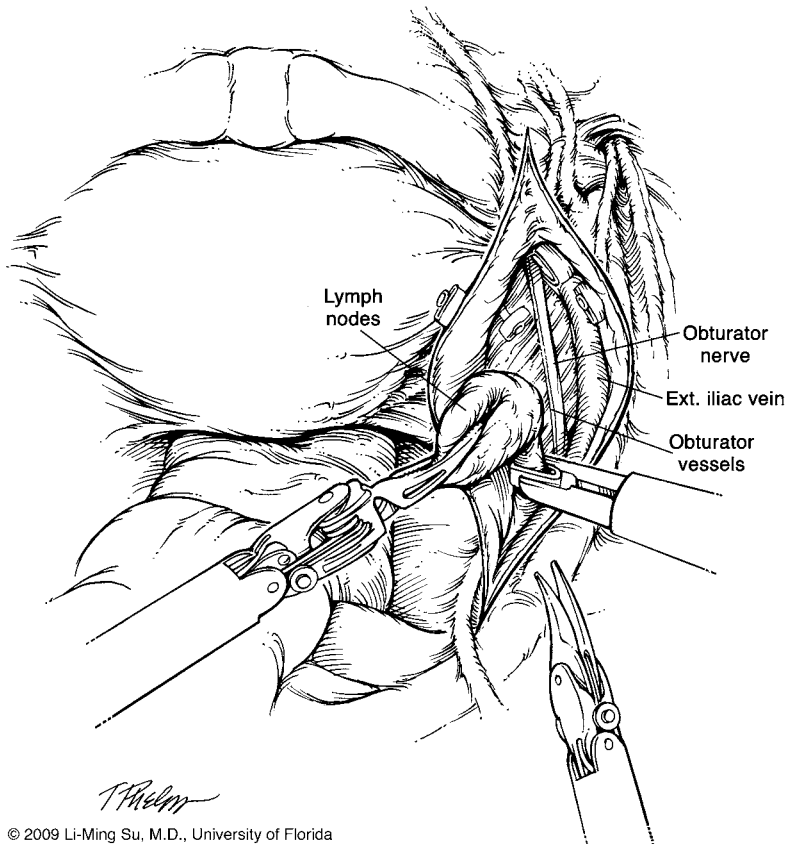
Fig. 4.15 Division of prostatic apex. After transecting the DVC, the anterior urethra is divided sharply, taking care to preserve the NVBs coursing along the posterolateral surface of the urethra. The posterior urethra is also divided sharply after carefully inspecting for the presence and contour of the posterior prostatic apex

the NVBs coursing along the posterolateral surface of the urethra. With the urethral catheter now exposed, the tip of the catheter is withdrawn by the assistant into the urethral stump. Prior to division of posterior urethra, great care must be taken to inspect the contour of the posterior prostatic apex. In some patients, the posterior prostatic apex can protrude beneath and beyond the urethra resulting in an iatrogenic positive margin if not identified and cut across. Having already completed the posterior prostatic dissection, little additional dissection is often required to free the prostate in its entirety once the posterior urethra and posterior rhabdosphincter is divided.

Step 13: Pelvic lymph node dissection

With the prostate now removed and prior to completion of the vesicourethral anastomosis, a

pelvic lymph node dissection is completed. As with an open approach, a key initial step is separation of the nodal packet from the external iliac vein. The lymph node packet is grasped, retracted medially, and a relatively avascular plane between the lymph node packet and lateral pelvic sidewall is identified and dissected using blunt dissection and spot monopolar electrocautery. Dissection is carried out proximally to the iliac bifurcation and distally to the pubis, thus defining the lateral extent of the lymph node packet. By retracting the lymph node packet medially, the precise course of the obturator nerve and vessels can be identified and protected (Fig. 4.16). After securing the distal extent of the lymph node packet with hemoclips, the packet is then retracted cranially to separate it from the obturator vessels and nerves. The proximal extent of the lymph node packet is then secured



© 2009 Li-Ming Su, M.D., University of Florida

Fig. 4.16 Pelvic lymph node dissection. Anatomic landmarks during pelvic lymph node dissection include the external iliac vein, obturator nerve pubic symphysis, and bifurcation of the iliac vessels

with hemoclips at the bifurcation of the iliac vessels. The lymph nodes can usually be removed as a single packet and are extracted in the specimen entrapment bag along with the prostate specimen. For identification purposes, a single Hem-o-lok® clip is applied to the left packet to distinguish it from the right pelvic lymph nodes.

Step 14: Laparoscopic inspection and entrapment of the prostate specimen

Surgeon instrumentation			Assistant instrumentation
Right arm	Left arm	Fourth arm	
• Curved monopolar scissors	• Maryland bipolar grasper	• ProGrasp™ forceps	• Suction-irrigator • 10 mm specimen entrapment bag
Endoscope lens: 0°			

Prior to entrapment of the specimens, the margins of the prostate are closely inspected by laparoscopic means. If a close margin is noted, excision of site-specific tissue for frozen section analysis may be performed along the bed of the prostate; however, with experience this should be a rare occurrence. The specimen along with the pelvic lymph nodes are placed in an entrapment bag and stored in the right lower quadrant of the abdomen until completion of the operation.

Step 15: Posterior support of the vesicourethral anastomosis (modified Rocco stitch)

Surgeon instrumentation			Assistant instrumentation
Right arm	Left arm	Fourth arm	
• Needle driver	• Needle driver	• ProGrasp™ forceps	• Suction-irrigator • Laparoscopic scissors • Laparoscopic needle driver • Sponge on a stick
Endoscope lens: 0°			

To help reduce tension at the vesicourethral anastomosis and provide support to the bladder neck, reapproximation of the remnant Denonvillier’s fascia, posterior detrusor, and posterior rhabdosphincter located below the urethra is performed [8]. A 2-0 monocryl suture on a UR-6 needle is passed by the assistant to the surgeon using a laparoscopic needle driver and the remnant Denonvillier’s fascia and superficial detrusor from the posterior bladder is brought together with the posterior rhabdosphincter located below the urethra using a running continuous suture (Fig. 4.17). Use of a urethral catheter and perineal pressure to visualize the urethral lumen allows for easier identification of the posterior rhabdosphincter lying just posterior to the urethra. In theory, this stitch also helps to bring the sphincteric complex into the peritoneal cavity,

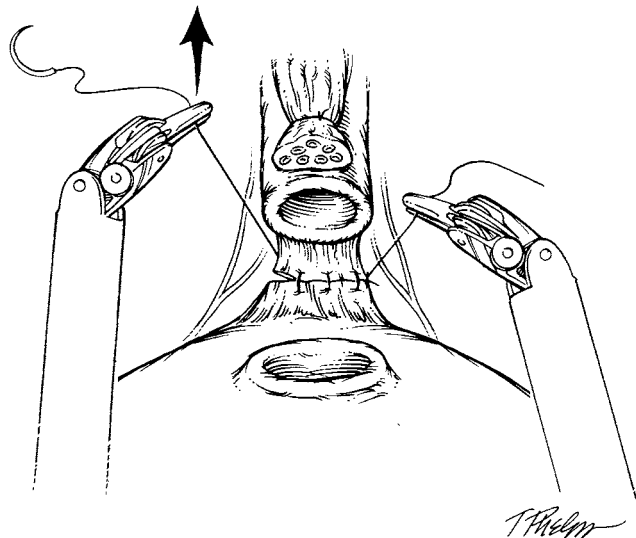


Fig. 4.17 Modified Rocco stitch. The remnant Denonvillier’s fascia and superficial detrusor from the posterior bladder is brought together with the posterior rhabdosphincter located below the urethra using a running continuous suture

restoring its natural positioning and therefore promoting earlier return of urinary continence.

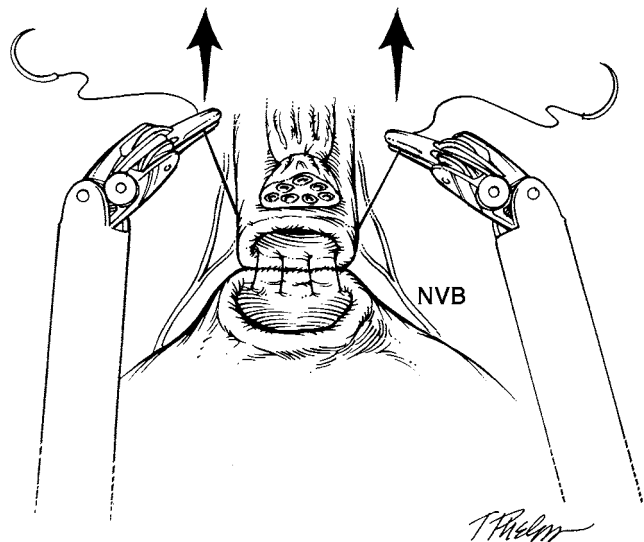
Step 16: Vesicourethral anastomosis

A critical first step in accomplishing the vesicourethral anastomosis is the establishment of secure posterior tissue approximation. The posterior anastomosis is typically the site of greatest tension. It is at risk for disruption and subsequent urinary leakage during passage of the urethral catheter if mucosa-to-mucosa approximation of the posterior anastomosis is not established. To avoid this complication, the assistant can apply pressure to the perineum using a sponge stick to better reveal the posterior urethra during placement of the posterior urethral bites. The vesicourethral anastomosis is accomplished in a running continuous fashion using 2-0 CAPROSYN™ and 2-0 MONOCRYL sutures tied together as a double armed suture (Fig. 4.18). The anastomosis is begun by starting each suture at the 5 and 7 o'clock positions, outside-in along the posterior bladder neck. Corresponding inside-out bites are taken of the urethra at the 5 and 7 o'clock positions. A urethral catheter is passed and withdrawn repeatedly to identify the urethral opening during the urethral bites of the anastomosis. Once the two sutures are run up to

the 3 and 9 o'clock position, respectively, ending inside-out on the urethral side of the anastomosis, the two ends of the sutures are lifted *anteriorly*, cinching the bladder neck down to the urethra. Great care must be taken not to lift back or in a cephalad direction as this will result in applying excessive forces on the urethral bites resulting in tearing of the urethral tissues. The anterior portion of the anastomosis is completed by running the right arm of the suture to the 12 o'clock position while tension is maintained on the left arm of the suture using the ProGrasp™ device to lift the suture anteriorly. Next, the ProGrasp™ is used to apply tension on the right suture while the left suture is used to complete the anastomosis, reversing the suture outside-in on the urethral bite to allow for the two sutures to be tied across the anastomosis.

Following completion of the anastomosis, a final 18 F urethral catheter is placed by the assistant and the balloon inflated with 20 ml of sterile water. The integrity of the anastomosis is tested by filling the bladder with approximately 120 mL of saline through the urethral catheter. Any visible leaks at the anastomosis may be repaired with additional sutures as necessary. A closed suction pelvic drain is placed exiting the left lower quadrant fourth arm 8 mm robotic trocar site and secured to the skin with 2-0 nylon suture.

Fig. 4.18 Running vesicourethral anastomosis. The vesicourethral anastomosis is accomplished in a running continuous fashion. The anastomosis is begun by starting each suture at the 5 and 7 o'clock positions, outside-in along the posterior bladder neck. Corresponding inside-out bites are taken of the urethra at the 5 and 7 o'clock positions. A urethral catheter is passed and withdrawn repeatedly to identify the urethral opening during the urethral bites of the anastomosis



Step 17: Delivery of the specimens and exiting the abdomen

The entrapment bag containing the prostate and lymph node specimens is delivered via extension of the infraumbilical incision and fascia. The fascia of the infraumbilical site is closed primarily to prevent incisional hernia with 0-PDS interrupted sutures. The 8 mm and 5 mm robotic trocars generally do not require fascial closure but are simply closed subcutaneously. The fascia of the 12 mm assistant trocar also does not generally require formal closure if a nonbladed, self dilating trocar is used.

Postoperative Management

Intravenous narcotics are provided for postoperative pain. Alternatively, ketorolac may be administered if the risk of bleeding and renal insufficiency is low. Patients are provided liquids on the day of surgery and advanced to regular diet on postoperative day 1 as tolerated. Hospital stay is in general 1–2 days. The pelvic drain is removed prior to discharge if outputs are low. However, if a urine leak is suspected, the fluid may be sent for creatinine and the drain maintained for an additional few days to a week off of suction if an anastomotic leak is confirmed. A cystogram is performed on postoperative day 7 to ensure a water tight vesicourethral anastomosis prior to removal of the urethral catheter.

Special Considerations

A large-size prostate gland and/or presence of a median lobe may dictate a more proximal incision of the bladder neck, leaving a large bladder neck opening and the ureteral orifices at close proximity to the edge of the bladder neck. Either an anterior or posterior tennis racquet closure of the bladder neck using 2-0 polyglactin suture on a UR-6 needle may be required if there is significant discrepancy between the bladder neck opening and urethra. If the ureteral orifices are

located along the immediate edge of the posterior bladder neck, a 5 and 7 o'clock figure-of-eight suture may be placed using 2-0 monocryl suture to imbricate the ureteral orifices and keep them out of harm's way prior to completion of the vesicourethral anastomosis.

On occasions, a subclinical inguinal (direct or indirect) hernia is identified during robot-assisted laparoscopic radical prostatectomy (RALP). It is the authors' opinion that these hernias be fixed if possible at the time of robot-assisted laparoscopic radical prostatectomy (RALP) so as to avoid symptoms or strangulation down the road. Our practice is to apply a polypropylene mesh to cover the hernia defect after fully reducing the hernia and tack the mesh into place using either a laparoscopic hernia stapler or 2-0 PDS suture. The mesh is then covered with either a peritoneal flap or the bladder to avoid direct contact with the bowels and minimize the chance of bowel fistulization.

In the rare event of a rectal injury, prompt identification and repair is paramount. Large defects may be identified by the assistant by transrectal digital inspection of the rectum. Smaller injuries may be missed by this maneuver and therefore insufflation of the rectum with air (through a catheter placed transrectally) in a saline-filled pelvis can identify bubbles at the site of a small rectal defect. Once identified, the edges of the defect are clearly delineated and the injury closed in multiple layers with 2-0 silk suture. An omental flap may be brought beneath the bladder to cover the repair as an additional layer and interpose between the rectum and vesicourethral anastomosis in efforts to avoid a rectovesical fistula.

Other more complex patient scenarios will be the subject of a later chapter entitled "Robot-Assisted Laparoscopic Radical Prostatectomy: Management of the Difficult Case."

Steps to Avoid Complications

For novice robotic surgeons, establishing a consistent operative schedule with at least 1–2 robot-assisted laparoscopic radical prostatectomy

(RALPs) per week can help promote consistency and standardization of surgical approach by the surgeon and surgical team alike. The use of a skilled surgical assistant knowledgeable in laparoscopic and robotic surgery and equipment is perhaps one of the most important steps to gaining consistency in technique, improving operative efficiency, and avoiding complications. Such an individual can aid in obtaining optimal and timely exposure and visualization during each step of the operation as well as troubleshoot instrumentation issues such as instrument exchanges and clashing of robotic arms at the bedside.

It is our practice to achieve meticulous hemostasis throughout all steps of the surgical dissection where the risk of electrocautery effect on the NVB is negligible. By maintaining hemostasis, tissue planes, important anatomic structures, and landmarks remain well visualized. This helps to facilitate a cleaner and more precise dissection, which in turn can lead to improved patient outcomes. When working in close proximity to the anatomic course of the NVB, electrocautery is avoided as much as is possible and instead hemoclips are applied to small arteries, while a small amount of venous bleeding is accepted. In addition to this, direct manipulation of the NVBs as well as traction is minimized in efforts to maintain the integrity of the cavernous nerves as well as optimize postoperative recovery of erectile function. In terms of optimizing postoperative incontinence, the length of the urethral stump is optimized and integrity of the surrounding supportive tissues of the urethra is maintained.

Ureteral and rectal injuries are rare events during robot-assisted laparoscopic radical prostatectomy (RALP) and by in large avoidable if proper steps are followed. Ureteral injury can occur during three steps of a transperitoneal posterior approach to robot-assisted laparoscopic radical prostatectomy (RALP). First, the ureter may be encountered during dissection of the vas deferens. Maintaining close dissection to the adventitia of the vas will help prevent inadvertent compromise to the nearby ureter traveling lateral and posterior to the vas.

Second, the ureter may be injured during completion of the vesicourethral anastomosis especially in cases of a large bladder neck opening where the ureteral orifices are in close proximity to the posterior bladder neck. In such cases, imbrication of the ureteral orifices prior to performing the anastomosis may reduce compromise to the ureters as mentioned previously. Lastly, the ureter may in theory be encountered during dissection of the pelvic lymph nodes. During dissection of the proximal extent of the lymph node packet at the iliac bifurcation, use of thermal energy should be minimized as this may compromise the ureter as it passes over the iliac vessels. Rectal injuries, in general, can be avoided by thorough and blunt dissection of the rectum and overlying Denonvillier's off of the posterior aspect of the prostate. With inadequate dissection of the rectum, the prostate remains adherent posteriorly to the rectum, making these attachments difficult to visualize and safely dissect free once the bladder neck and urethra are divided. Therefore, wide dissection of the rectum off of the entire posterior border of the prostate is strongly recommended early in the operation as is the case with the posterior approach to robot-assisted laparoscopic radical prostatectomy (RALP).

References

1. Kaouk JH, Hafron J, Goel R, Haber GP, Jones JS (2008) Robotic salvage retropubic prostatectomy after radiation/brachytherapy: initial results. *BJU Int* 102(1):93–96
2. Boris RS, Bhandari A, Krane LS, Eun D, Kaul S, Peabody JO (2009) Salvage robotic-assisted radical prostatectomy: initial results and early report of outcomes. *BJU Int* 103(7):952–956
3. Guillonnet B, Vallancien G (2000) Laparoscopic radical prostatectomy: the Montsouris experience. *J Urol* 163(2):418–422
4. Smith JA (2004) Robotically assisted laparoscopic prostatectomy: an assessment of its contemporary role in the surgical management of localized prostate cancer. *Am J Surg* 188(4A Suppl):63S–67S
5. Kaul S, Savera A, Badani K, Fumo M, Bhandari A, Menon M (2006) Functional outcomes and oncological

- efficacy of Vattikuti Institute prostatectomy with Veil of Aphrodite nerve-sparing: an analysis of 154 consecutive patients. *BJU Int* 97(3):467–472
6. Ong AM, Su LM, Varkarakis I, Inagaki T, Link RE, Bhayani SB, Patriciu A, Crain B, Walsh PC (2004) Nerve sparing radical prostatectomy: effects of hemostatic energy sources on the recovery of cavernous nerve function in a canine model. *J Urol* 172(4 Pt 1): 1318–1322
 7. Ahlering TE, Eichel L, Chou D, Skarecky DW (2005) Feasibility study for robotic radical prostatectomy cautery-free neurovascular bundle preservation. *Urology* 65(5):994–997
 8. Rocco F, Carmignani L, Acquati P, Gadda F, Dell’Orto P, Rocco B, Bozzini G, Gazzano G, Morabito A (2006) Restoration of posterior aspect of rhabdosphincter shortens continence time after radical retropubic prostatectomy. *J Urol* 175(6):2201–2206

Chapter 5

Extraperitoneal Robot-Assisted Laparoscopic Radical Prostatectomy

Jean V. Joseph and Matthew Lux

This chapter contains a video segment which can be found at the URL: <http://www.springerimages.com/Su>

Patient Selection

As in any surgery, patient selection remains the key to a successful outcome. The indications for the extraperitoneal approach are the same as those for the transperitoneal route. In patients with multiple prior abdominal surgeries, the extraperitoneal approach allows rapid access to the prostate, as it obviates the need for lysis of intraperitoneal adhesions, which can be associated with injury to the intra-abdominal organs.

The extraperitoneal space can be developed in most patients, but can be quite difficult in some. The relative contraindications in our hands include patients with a history of prior extraperitoneal surgery, particularly mesh herniorrhaphy. The inflammatory reaction caused by the mesh obliterates the extraperitoneal space, and inevitably results in multiple peritoneotomies resulting in transperitoneal insufflation, which further compress the extraperitoneal space. Patients with prior intra-abdominal surgeries who have an incision extending down to the pubic symphysis may also be best approached transperitoneally,

at least in the early phase of the learning curve. While these patients may require extensive intraperitoneal lysis of adhesions, the lack of easily recognizable planes in the scarred extraperitoneal space makes the extraperitoneal route less attractive, but feasible.

Preoperative Preparation

All patients receive a bowel preparation consisting of one bottle of magnesium citrate, doses of neomycin, metronidazole, and an enema the day before surgery. They are admitted to the hospital 2 h prior to surgery. Broad-spectrum intravenous antibiotics and 5,000 U subcutaneous heparin are administered 1 h before incision. We do not recommend routine donation of autologous blood, since our transfusion rate is insignificant.

Operative Setup

The location of the surgical console, bedside surgical cart and the assistants are as shown (Fig. 5.1).

Patient Positioning

The patient is placed supine on a split leg bed. The legs are abducted slightly and secured to the table. The arms are adducted and secured in

J.V. Joseph (✉)

Department of Urology, University of Rochester
Medical Center and Strong Memorial Hospital,
2400 South Clinton Avenue, H-150, Rochester, NY
14618, USA

and

Wilmot Cancer Center, University of Rochester Medical
Center and Strong Memorial Hospital, 2400 South
Clinton Avenue, H-150, Rochester, NY 14618, USA
e-mail: jean_joseph@urmc.rochester.edu

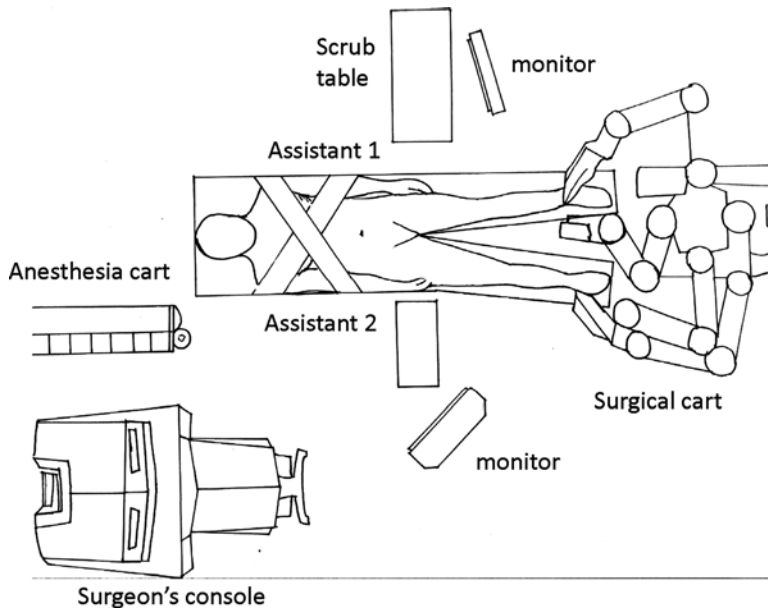


Fig. 5.1 View of the operating room set up. Patient is positioned on a split leg table (mild Trendelenburg) and secured to the table at the torso with Velcro straps

foam to avoid pressure sores or neuropraxia. Velcro straps are used and crisscrossed over gel pads on the torso to avoid movement with table tilting (Fig. 5.1). Orogastric tube and sterile urethral catheter placement are done prior to trocar insertion. Trendelenburg positioning is generally at about 10° . The robot (or surgical cart) is positioned between the patient's legs once the trocars are in place.

Trocar Configuration

Once the extraperitoneal space is developed and insufflated (see step 1 below), additional trocars are placed under laparoscopic view. A total of five trocars are used routinely, using a "W" shaped trocar configuration as shown (Fig. 5.2). With a three-armed robot we use two 8 mm da Vinci[®] trocars, placed about 10 cm caudad to the umbilicus, and from the midline. A 10 mm and a 5 mm trocar are placed laterally on either side, about 5 cm cephalad and medial to the anterior superior iliac spine. With a four-armed robot one of the assistant 5 mm trocar is replaced by the

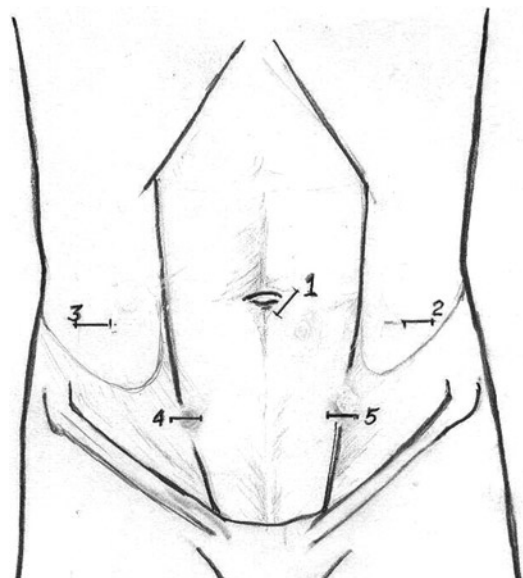


Fig. 5.2 View of trocar placement in a "W" configuration. (1) Initial access site, 10 mm camera trocar. (2) 10 mm assistant trocar. (3) 5 mm assistant trocar or 8 mm da Vinci[®] fourth arm trocar. (4) and (5) 8 mm da Vinci[®] trocars

fourth arm robotic trocar. If these assistant trocars are placed too lateral, difficulty accessing the prostate apex can be encountered, in addition to

undue pressure on the iliac vessels. Care must be taken so as to avoid injury to the epigastric vessels during placement of the secondary trocars. Our preference is to use a four-armed technique with one surgical assistant and a scrub technician at the bedside. The following technique will be based upon this operative arrangement and personnel.

Instrumentation and Equipment List

Equipment

- da Vinci® S Surgical System (4-arm system; Intuitive Surgical, Inc., Sunnyvale, CA)
- EndoWrist® Maryland bipolar forceps or (Intuitive Surgical, Inc., Sunnyvale, CA)
- EndoWrist® curved monopolar scissors (Intuitive Surgical, Inc., Sunnyvale, CA)
- EndoWrist® ProGrasp™ forceps (Intuitive Surgical, Inc., Sunnyvale, CA)
- EndoWrist® needle drivers (2) (Intuitive Surgical, Inc., Sunnyvale, CA)
- InSite® Vision System with 0° and 30° lens (Intuitive Surgical, Inc., Sunnyvale, CA)

Trocars

- 12 mm trocars (2)
- 8 mm robotic trocars (3)
- 5 mm trocar (1)

Recommended sutures

- Ligation of the deep dorsal vein complex (DVC): 2-0 polyglactin suture on SH needle cut to 9 in., and 2-0 polyglactin suture on a RB1 needle cut to 6 in. (if necessary)
- Vesicourethral anastomosis: 2 (2-0 polyglactin) sutures (9 in. each) on a RB 1 needle
- Posterior reconstruction stitch: 2-0 polyglactin suture on a RB 1 needle cut to 9 in.
- Anterior bladder neck closure (if necessary): 2-0 polyglactin suture on a RB 1 needle cut to 9 in.

Instruments used by the surgical assistant

- Laparoscopic scissors
- Blunt tip grasper
- Suction irrigator device

- Hem-o-lok® clip applier (Teleflex Medical, Research Triangle Park, NC)
- Large Hem-o-lok® clips (Teleflex Medical, Research Triangle Park, NC)
- 10 mm specimen entrapment sac
- EnSeal® device 5 mm diameter, 45 cm shaft length (SurgRx®, Redwood City, CA) (optional)
- SURGICEL® hemostatic gauze (Ethicon, Inc., Cincinnati, OH)
- 20 Fr silicone urethral catheter
- Jackson-Pratt closed suction pelvic drain

Step-by-Step Technique

Step 1: Creation of extraperitoneal space

The initial step of extraperitoneal robot-assisted laparoscopic radical prostatectomy (RALP) is creation of the extraperitoneal space. A 1-inch paraumbilical skin incision is made down to the level of the anterior rectus sheath. A 1 cm incision is made in the latter to expose the rectus muscle. The muscle fibers are pushed laterally using a clamp, exposing the posterior rectus sheath. A balloon dilator (Extra View™ Balloon, OMS-XB 2, Tyco Healthcare, Norwalk, CT) is inserted just above the posterior sheath and advanced down to the pubic symphysis in the midline, below the linea alba (Fig. 5.3). A 0° scope is placed in the balloon trocar to allow direct visualization of the space being created. Care should be taken not to overstretch or tear the epigastric or iliac vessel from overinflation. Once the space is created, the balloon dilator is replaced by a long 12 mm trocar. The retroperitoneum is insufflated up to 12–15 mm Hg. The beveled tip of the trocar is used to further create the extraperitoneal space laterally, facilitating placement of the assistant trocars as mentioned above. The loose areolar tissue is swept laterally and cephalad, bluntly pushing the peritoneum off the abdominal wall. The epigastric vessels are left attached to the anterior abdominal wall to avoid bleeding from branches entering the rectus muscle (Figs. 5.3 and 5.4).

Fig. 5.3 View of left pelvis following balloon dilation of extraperitoneal space

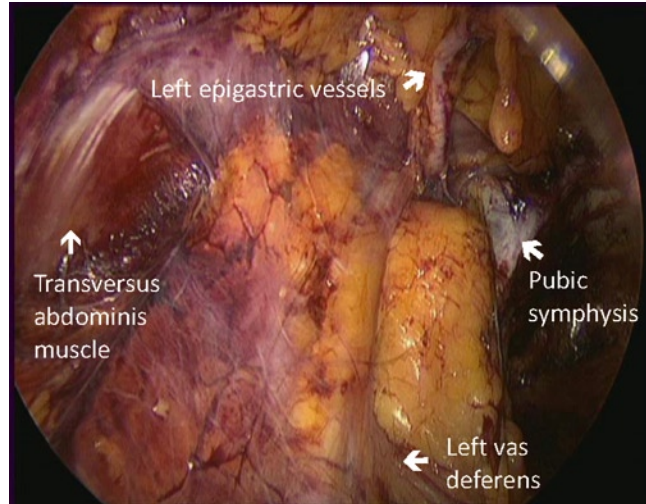
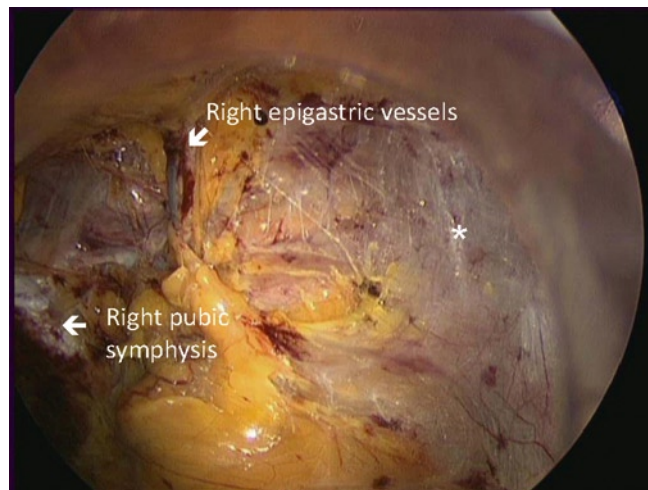


Fig. 5.4 View of right pelvis following balloon dilation of extraperitoneal space. Asterisk denotes loose alveolar connective tissue where blunt dissection is carried out in an anterior cephalad direction to push the peritoneum away and expose the transversus abdominis muscle



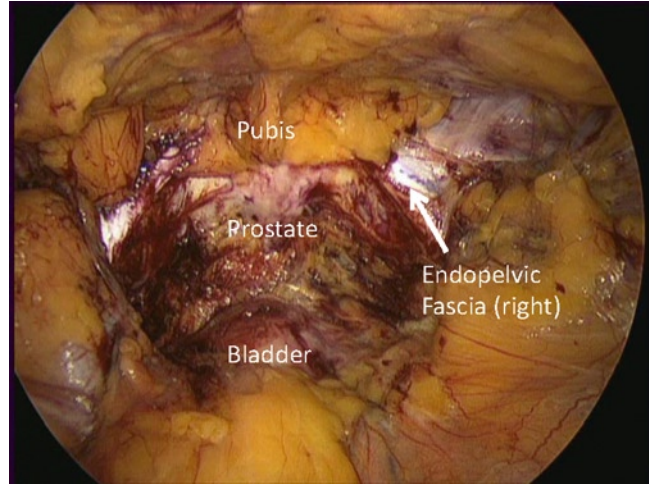
Step 2: Endopelvic fascia dissection

Surgeon instrumentation			Assistant instrumentation
Right arm	Left arm	Fourth arm	• Suction-Irrigator
• Curved monopolar scissors	• Maryland bipolar Grasper	• ProGrasp™ forceps	
Endoscope lens: 0°			

During extraperitoneal robot-assisted laparoscopic radical prostatectomy (RALP), a 0° lens is used throughout the entire operation. Monopolar and bipolar electrocautery settings are set to 90 W and 30 W, respectively. Accessing the retropubic space by the extraperitoneal

approach described above eliminates the bladder “take-down” step required during the transperitoneal approach, and allows rapid visualization and access to the prostate, endopelvic fascia, and puboprostatic ligaments (Fig. 5.5). The fatty tissue overlying the endopelvic fascia is easily swept away exposing the prostate. We routinely incise the endopelvic fascia, freeing the prostate from its lateral attachments. Accessory pudendal vessels, if present, are identified and preserved. We routinely incise the puboprostatic ligaments to allow adequate mobilization of the prostatic apex. Superficial vessels encountered are cauterized.

Fig. 5.5 Complete view of the pelvis including the pubis, prostate, bladder, and endopelvic fascia following balloon dilation of the extraperitoneal space



Step 3: Dorsal vein ligation

Surgeon instrumentation			Assistant instrumentation
Right arm	Left arm	Fourth arm	<ul style="list-style-type: none"> • Suction-Irrigator • Laparoscopic scissors • Laparoscopic needle driver
• Needle driver	• Needle driver	• ProGrasp™ Forceps	
Endoscope lens: 0°			

With medial retraction of the prostatic apex, a groove is visualized between the DVC and the anterior urethra. A 2-0 polyglactin suture on an SH needle is used to ligate the DVC. Back bleeding sutures can also be placed on the tributaries of Santorini’s plexus along the anterior aspect of the prostate.

Step 4: Bladder neck dissection

Surgeon instrumentation			Assistant instrumentation
Right arm	Left arm	Fourth arm	<ul style="list-style-type: none"> • Suction-Irrigator
• Curved monopolar scissors	• Maryland bipolar grasper	• ProGrasp™ forceps	
Endoscope lens: 0°			

With cephalad tension on the bladder, the loose areolar connective tissue crossing the bladder neck is removed allowing identification of the bladder neck (Fig. 5.6). With the magnification afforded by the da Vinci® robot, the plane between the prostate and bladder neck is easily

identified. A combination of electrocautery and blunt dissection allows separation of the bladder from the prostate. Judicious use of electrocautery is necessary to avoid excessive charring and obliteration of the tissue planes. Given the lack of tactile feedback, following the tissue planes allows an accurate anatomical dissection, without violation of the prostate capsule. Once the longitudinal urethral fibers are identified, the bladder neck is transected (Fig. 5.7). The previously placed urethral catheter is removed allowing access to the posterior bladder neck. The transection is done sharply, with no significant bleeding encountered. If a bleeding vessel is present, it can be selectively cauterized avoiding the bladder neck mucosa. The anatomical groove between the bladder and prostate is further dissected, pushing the bladder cephalad. The bladder neck dissection is completed with the identification of the longitudinal muscle fibers coursing posterior to the bladder, covering the seminal vesicles (SVs) (Fig. 5.8).

Step 5: Seminal vesicle dissection

Surgeon instrumentation			Assistant instrumentation
Right arm	Left arm	Fourth arm	<ul style="list-style-type: none"> • Suction-Irrigator • Hemoclip applier
• Curved monopolar scissors	• Maryland bipolar grasper	• ProGrasp™ forceps	
Endoscope lens: 0°			

Fig. 5.6 View of bladder neck (dashed line) following DVC ligation, with traction placed on the perivesical fat

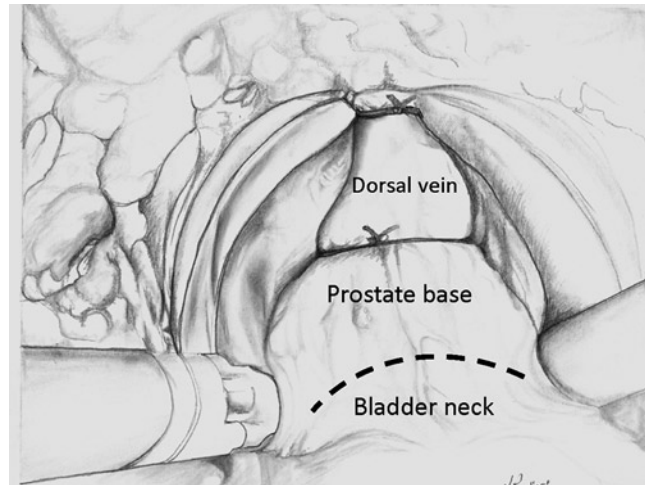


Fig. 5.7 View of circumferential dissection of bladder neck (dashed line) prior to transection

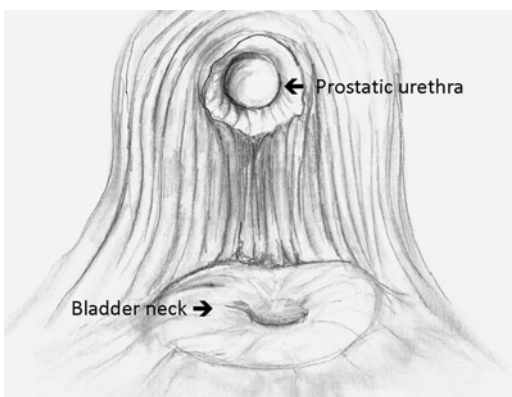
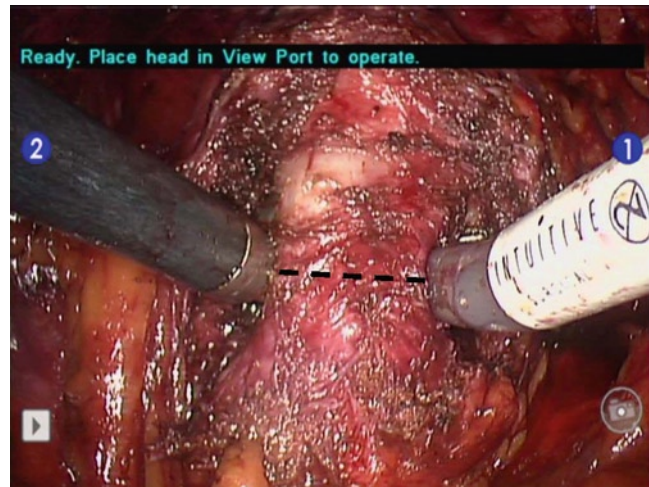


Fig. 5.8 View of bladder neck following transection

Once the longitudinal fibers are transected, the ampullae of the vasa and attached SVs are identified. These fibers need to be incised transversely in the midline allowing identification of both vasa. If a four-armed robot is used, the fourth arm ProGrasp™ forceps can be used to elevate the posterior aspect of the prostate. Once the ampullae are fully identified, the fourth arm can also be used to elevate the attached SVs. Best traction is achieved by pulling the vas toward the contralateral pubic bone. The dissection should be carried cephalad to the tip of the SVs. Dissecting in a caudal direction will inadvertently enter the posterior aspect of the prostate. It is helpful to avoid directly grasping or traumatizing the SVs, since that will alter the dissection plane. Instead, leaving the SVs attached to their

respective ampullae helps with retraction of both structures by grasping only the ampulla. With the SVs full, blood vessels indenting their walls can be selectively cauterized. The artery to the vas located between the SVs and the vas deferens is clipped en bloc. When performing a nerve-sparing procedure, electrocautery is avoided to prevent damage to the nerve plexus traveling near the tip of the SVs.

Step 6: Posterior prostate dissection

Once the SVs are completely dissected, both ampullae are retracted anteriorly exposing Denonvilliers' fascia (Fig. 5.9). The latter is incised transversely, exposing the yellow perirectal fat. The assistant uses the suction to gently retract the rectal wall in a cephalad direction. The rectal wall is pushed bluntly from the posterior aspect of the prostate all the way to the prostate apex. If the latter is not possible due to a very enlarged gland, this step can be carried out once the posterior prostate pedicles are mobilized. It is important to note that the rectal wall is being pulled anteriorly with the traction on the prostate or SVs. The caudad dissection should be carried out parallel to the posterior prostate to avoid injury to the rectal wall. A rectal bougie or an assistant's finger can be used to help delineate the rectal wall if necessary. This dissection is carried out primarily in the midline, avoiding trauma to the laterally located neurovascular bundles (NVBs).

Step 7: Neurovascular bundle dissection

The ampullae and SVs are pulled medially in the opposite direction from the side being dissected. Using the suction, the assistant can place traction on Denonvilliers' fascia posterior to the bladder, allowing better visualization of the bundles. In patients selected for nerve sparing, the prostate capsule is exposed bluntly using graspers to push off the overlying fat and periprostatic fascia. With further lateral dissection, arterial pulsations from the cavernous vessels within the NVBs are easily noted. These vessels are preserved by gently pushing them posterolaterally toward the rectum. Dissecting in a cephalad direction helps identify the main neurovascular trunks,

bifurcating in anterior branches entering the prostate, and the posteriorly located NVBs coursing toward the pelvic diaphragm and toward the corpora cavernosum.

Prior to clipping the prostatic branches, the levator fascia is incised allowing improved identification of the lateral aspects of the NVBs. As for the posterior dissection, this can be carried out bluntly with minimal bleeding encountered. Dissection in a medial direction leads to the previously dissected anterior rectal space, with the NVBs mobilized posteriorly. Clips can be selectively applied, in lieu of electrocautery, to the vascular branches of the prostatic pedicles prior to their transection (Fig. 5.10). Once the prostatic pedicles are transected, the periprostatic

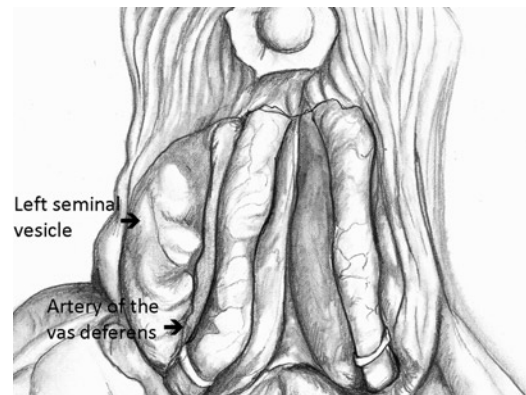


Fig. 5.9 Seminal Vesicles with clipped ampulla

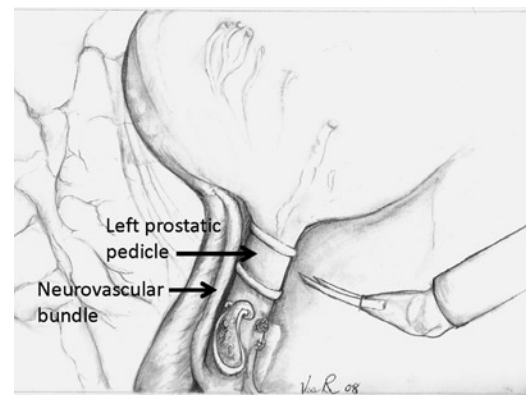


Fig. 5.10 Hem-o-lok® clips used to control the prostatic pedicle, while leaving the NVBs intact, coursing posterior to the prostate to enter the pelvic diaphragm

fascia encompassing the NVBs can be detached bluntly from the prostate, in a caudal direction all the way to the prostatic apex.

In non-nerve-sparing cases, the periprostatic fascia is incised next to levator ani. The bundles and their investing fascia are left attached to the prostate capsule, allowing for wide excision of the NVBs along with the prostate.

Step 8: Apical dissection

With the prostate retracted in a postero-cephalad direction, the DVC is transected. A urethral catheter should be inserted in the urethra to facilitate identification of the urethral stump. Electrocautery should be avoided in order not to damage the NVBs coursing lateral to the prostatic apex. The DVC can be ligated at this stage, if it was not done following the endopelvic fascia dissection as discussed earlier. Care should be taken not to enter the prostate at this point. This is best achieved by following the normal curvature of the apex, transecting the vein in a caudal direction (Fig. 5.11). A perpendicular dissection plane inevitably will enter the prostate gland. If bleeding is encountered or the previously placed DVC suture is dislodged, additional sutures are placed on the DVC, using 2-0 polyglactin suture on a RB 1 needle, to achieve hemostasis. Temporary increase in intra-abdominal pressure up to 20 mm Hg facilitates completion of the DVC transection, when profuse bleeding from venous sinuses is present.

Step 9: Urethral transection

With the urethral catheter in place, the longitudinal anterior urethral fibers can be identified. The ureter is dissected cephalad close to the prostate and transected. Urethral length should be preserved without compromising cancer control at the apex. Once the catheter is exposed, it is retracted by the assistant, facilitating visualization and transection of the posterior urethra. We prefer cutting the urethra sharply to avoid ischemic mucosal injury that can occur with the use of electrocautery (Fig. 5.11).

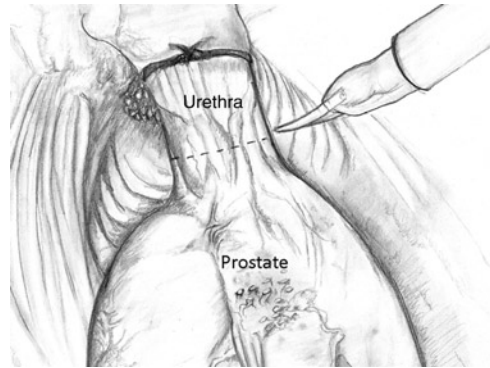


Fig. 5.11 View of prostatic apex following DVC transection, prior to urethral transection

The prostate is then retracted in an anterior and cephalad direction to allow visualization of the posterior apex. The NVB should be thoroughly dissected, pushed in a posterolateral direction prior to transecting the remaining posterior apical attachments. The prostate is placed in a 10 mm ENDO CATCH™ bag (Covidien, Mansfield, MA), which is pulled out of the pelvis and stored out of the operative field in the abdomen until the end of the operation. The prostate fossa is irrigated and inspected for hemostasis and integrity of the rectal wall. When arterial bleeding is noted from the NVB, the bleeding vessel is selectively controlled using 2-0 polyglactin suture ligatures. If a rectal injury is suspected, a finger or rectal bougie is placed to tent the rectal wall to allow a thorough examination.

Step 10: Posterior reconstruction

Surgeon instrumentation			Assistant instrumentation
Right arm	Left arm	Fourth arm	<ul style="list-style-type: none"> • Suction-Irrigator • Laparoscopic scissors • Laparoscopic needle driver
• Needle driver	• Needle driver	• ProGrasp™ forceps	
Endoscope lens: 0°			

A posterior reconstruction is routinely performed prior to completing the vesicourethral anastomosis. In one step, the posterior layer of the rhabdosphincter is sewn to Denonvilliers' fascia and the posterior aspect of the bladder. The posterior bladder tissue encompassed is the longitudinal

fibrous layer which previously covered the anterior aspect of the SVs. Two interrupted 2-0 polyglactin sutures on a RB-1 needle are used for this purpose. The insufflation pressure in the retroperitoneum is lowered to 8–10 mm Hg, while pressure is applied to the perineum to facilitate tying of these two interrupted sutures. This reconstructed layer helps bring the bladder and urethra in close proximity in preparation for the vesicourethral anastomosis.

Step 11: Vesicourethral anastomosis

The anastomosis is completed using two separate sutures (2-0 polyglactin suture on an RB 1 needle). The first suture is placed at the 5 o'clock position approximating the bladder neck and urethra using the right hand (forehand on both bladder and urethra). Urethral sutures are placed while the assistant withdraws the urethral catheter exposing the urethral mucosa. Initially, the anastomosis is carried out in a clockwise fashion to the 7 o'clock position when the needle placement is done using right hand (backhand) on the urethra, and left hand (forehand) on the bladder. This suture is tied to itself at the 11 o'clock position. The second suture is carried out in a counter clockwise direction completing the anterior wall of the anastomosis. The 5–11 o'clock locations are done using the right hand (forehand) on the bladder, and the left hand (backhand) on the urethra. The anterior most aspect of the anastomosis (1–11 o'clock) is accomplished using the right hand (backhand) on the bladder, and the left hand (backhand) on the urethra. The second suture is also tied at the 11 o'clock position. Bladder neck mucosa is encompassed into every suture to facilitate mucosal apposition. Care should be taken for the suture not to pass through the posterior bladder neck mucosa, while placing the anterior bladder sutures. Once the anastomosis is completed, a new 20 Fr urethral catheter is inserted into the bladder under direct vision, prior to cinching the second counterclockwise anastomotic suture (Fig. 5.12). When cinching this suture, it is best to pull on the urethral side

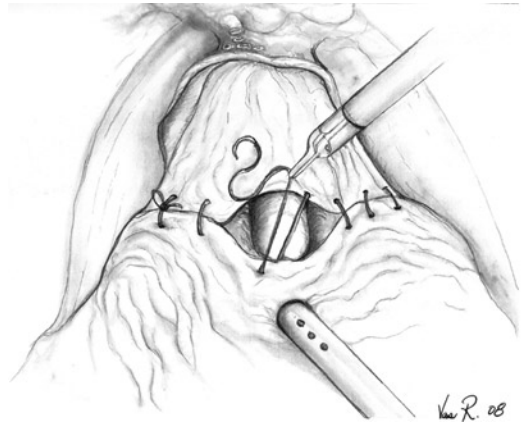


Fig. 5.12 View of the vesicourethral anastomosis. Final urethral catheter is passed into the bladder prior to cinching the anterior anastomotic suture

of the anastomosis, in a direction perpendicular to the longitudinal urethral fibers. This maneuver avoids shearing the urethral wall, while achieving water tightness of the anastomosis. The urethral catheter is irrigated verifying absence of anastomotic leakage.

Step 12: Delivery of the specimens and exiting the abdomen

The surgical cart is disconnected from the trocars and wheeled away from the patient. The specimen bag is retrieved from the midline camera trocar at the end of the procedure. A 19 Fr JP drain is placed in the retropubic space via the 10 mm lateral assistant trocar site and subsequently secured to the skin. The robotic trocars are removed under vision, verifying hemostasis from the exit sites. The anterior rectus sheath adjacent to the midline fascia is incised to allow withdrawal of the bag. The anterior rectus fascia opening is closed using absorbable sutures. All skin openings are later closed in a similar manner. With the extraperitoneal approach, no other fascial closure is necessary. In conditions where air is trapped into the peritoneal cavity, it is evacuated with a small opening in the posterior sheath and peritoneum, which is later closed.

Postoperative Management

Postoperative pain management consists of ketorolac, and morphine sulfate for breakthrough pain. We do not use ketorolac in patients with bleeding diathesis or abnormal renal function. Two additional doses of 5,000 U of subcutaneous heparin are administered postoperatively following the initial preoperative dose. Patients are ambulated and fed once they fully recover from anesthesia. They are generally discharged within 23 h of surgery. Jackson-Pratt drains are removed before discharge if the output remains low with less than 30 cc in an 8 h shift. The urethral catheter is removed in the outpatient setting 7–10 days after surgery. We perform cystograms only in patients with gross hematuria, or prolong JP drainage, to verify the integrity of the anastomosis prior to instituting a void trial.

Special Considerations

Obesity

Obesity does not pose a challenge with the extraperitoneal approach. In fact, we favor this approach in this patient population for a variety of reasons. The peritoneum serves as an excellent natural barrier keeping the bowels out of the operative field. A steep Trendelenburg position is also not necessary, which can be associated with anesthetic complications in an obese patient due to diaphragmatic splinting. Laryngeal and facial edema associated with the steep Trendelenburg position may lead to delayed extubation, and a prolonged recovery.

Large Prostate Gland

The added difficulty with a large gland may be due to difficulty associated with moving the gland within a narrow pelvis. The posterior apical dissection may be difficult due to inability to lift the prostate anteriorly to reach the posterior aspect of the prostate apex. Anterior mobility of the prostate is limited by the pubic symphysis. In such cases, the posterior dissection is best completed following dissection of the apex and transection of the urethra.

Steps to Avoid Complications

Bleeding is the most common complication encountered during the development of the extraperitoneal space. Balloon insufflation should be carried out under direct vision to avoid stretching or tearing of the epigastric or iliac vessel. The epigastric vessels give off several perforators entering the rectus muscles which can be injured during creation of the extraperitoneal space. Occasionally this may result in tearing of a branch of the epigastric artery which may necessitate clipping. Increasing the pressure in the preperitoneal space may help decrease the bleeding until an additional trocar is inserted to allow clipping of the bleeding vessel. If mild venous bleeding is encountered, which can be from perforating veins or vessels behind the pubic symphysis, it is easily controlled with preperitoneal insufflation. Overcompression of the iliac vessels, impairing flow from the lower extremities should be avoided.

Chapter 6

Robot-Assisted Laparoscopic Radical Prostatectomy: Management of the Difficult Case

Geoff Coughlin and Vipul R. Patel

This chapter contains a video segment which can be found at the URL: <http://www.springerimages.com/Su>

Robot-assisted laparoscopic radical prostatectomy (RALP) can present unique challenges to the entire operating team. Basic proficiency at this operation has been estimated to be approximately 20 cases based on satisfactory operative times [1, 2]. During this initial stage of the learning curve, the surgeon should screen potential operative candidates cautiously to minimize the technical challenges of the procedure. As experience of the surgeon and team grows, they will naturally progress to tackling more difficult scenarios. While this evolution will be different for all teams, a survey of experts performing RALP showed that difficult cases were optimally attempted after a median of 50 procedures had been performed [3].

While the difficulty of radical prostatectomy is somewhat unpredictable, certain screening criteria can help the novice robotic surgeon avoid certain challenges. During the initial learning period, we recommend excluding obese patients (BMI > 30) and patients with prior major abdominal surgery. We also advocate screening all patients with either flexible cystoscopy or transrectal ultrasound to detect and avoid patients with a median lobe, a prior transurethral resection of the prostate (TURP), or large gland size. As the experience and confidence of the surgeon and team increases such exclusions and screening will become unnecessary.

This chapter outlines some of the predictable challenging scenarios encountered during RALP and illustrates the techniques we use to overcome them. The accompanying video gives narrated examples of these scenarios.

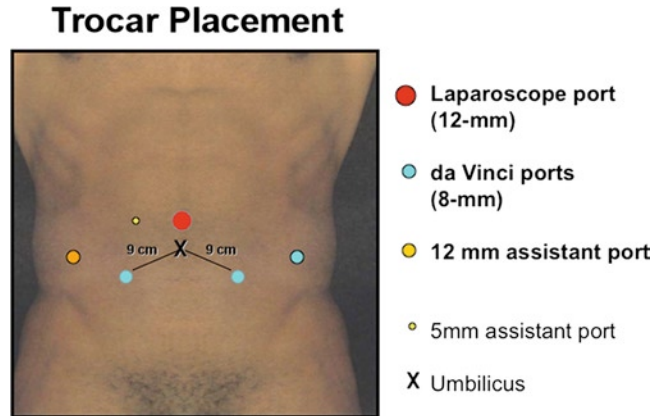
The Obese Patient

Obese (body mass index [BMI] > 30) and morbidly obese (BMI > 40) patients require special consideration from the surgical and anesthesia teams when undergoing RALP. These patients are more prone to compression nerve injuries from positioning, to venous thromboembolism, and can also be difficult to ventilate in the Trendelenburg position. From a technical view point, the large amount of intraperitoneal fat and the difficult working angles create unique operative challenges.

Careful positioning with padding of all pressure points is important. We use a modified lithotomy position securing the patient on a bean bag covered with a gel foam mattress. Extra foam padding is used at the shoulders, elbows, and hands. The patient and bean bag are also secured to the operating table with tape. We recommend using both mechanical and pharmacological deep venous thrombosis (DVT) prophylaxis in these patients due to the increased risk of thromboembolism.

Following positioning, correct trocar placement is crucial. We use a six trocar transperitoneal approach in all RALPs. Our trocar configuration is shown in Fig. 6.1. This trocar configuration has been consistent now for our last 1,500 cases.

V.R. Patel (✉)
Florida Hospital, 410 Celebration Place, Suite 302,
Celebration, FL 34747, USA
e-mail: Vipul.PatelMD@flhosp.org

Fig. 6.1 Trocar placement

We have found that this trocar configuration minimizes clashing of robotic arms and maximizes the working space for the assistant. When using this configuration on the standard da Vinci® Surgical System (Intuitive Surgical, Inc., Sunnyvale, CA), reach of the instrument deep into the pelvis may become problematic. Pressing the joint release button and advancing the trocars further into the abdominal wall will generally overcome this limitation and allow the instruments to reach their intended target. It is important not to insert the trocars lower on the abdomen to improve reach. This will often result in such an acute working angle under the pubis that dissection in the apical region becomes challenging if not impossible. The extrareach provided by the da Vinci® S system has largely overcome these issues. Particular attention should also be paid to the angle of insertion of the trocars. They must be inserted perpendicular to the anterior abdominal wall musculature to ensure proper robotic arm mobility. In morbidly obese patients, the extra-long da Vinci® robotic trocars (Intuitive Surgical Inc., Sunnyvale, CA) may be required.

Intraoperative difficulties are common with obese patients. A large amount of intraperitoneal fat is customary. Here a skilled laparoscopic assistant is essential. Either the fourth robotic arm or the assistant will be required to retract intra-abdominal fat and/or bowel for the majority of the case. For teams using a five trocar approach, use of a second assistant trocar (i.e., six trocar approach) is strongly recommended. The other common problem encountered is difficult working angles during the apical dissection and

anastomosis. This situation arises because obese patients commonly have lax abdominal walls that insufflate high like a dome. This raises the trocars high above the pubic symphysis creating vertical working angles with frequent instrument collision with the pubic symphysis especially when trying to reach the apex of the prostate (Fig. 6.2). Two adjustments can help overcome these difficulties. First, switching from a 30° down lens to the 0° lens will improve visualization of the apical region (Figs. 6.3 and 6.4). Second, to improve working angles of the instruments, the joint release button is pressed and the trocars are tucked posteriorly into the abdominal wall producing a less acute instrument angle to the pubic bone.

Despite the challenges obese patients present, RALP can be performed safely and efficiently by an experienced team. While these cases are difficult, the improved visualization and surgical access within the pelvis generally makes the robotic approach more technically feasible than open radical prostatectomy.

Prior Abdominal Surgery

While some prior abdominal procedures alter the approach to RALP little, two scenarios deserve special mention. These are patients with prior midline laparotomies and patients with prior inguinal hernia repairs. Prior midline laparotomies create unique challenges with obtaining safe and adequate access, while prior inguinal hernia repair can distort the operative anatomy.

Fig. 6.2 The lax abdominal wall in obese patients insufflate like a dome raising the height of the trocars. This creates difficult working angles when dissecting about the apex of the prostate as collision with the pubis limits access to the apex. Moving the trocars lower on the abdomen (i.e., toward the pubic bone) will worsen these angles and increase clashes with the pubic symphysis

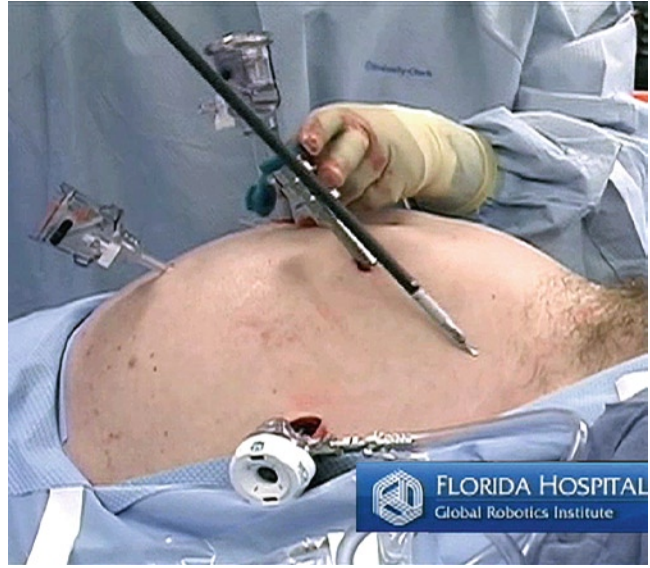

Fig. 6.3 View of the pelvis in an obese male with the 30° down lens. Note the inability to adequately visualize the apex of the prostate

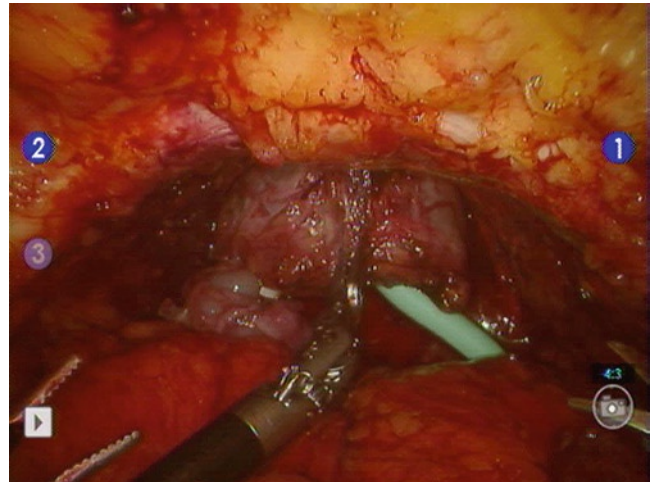
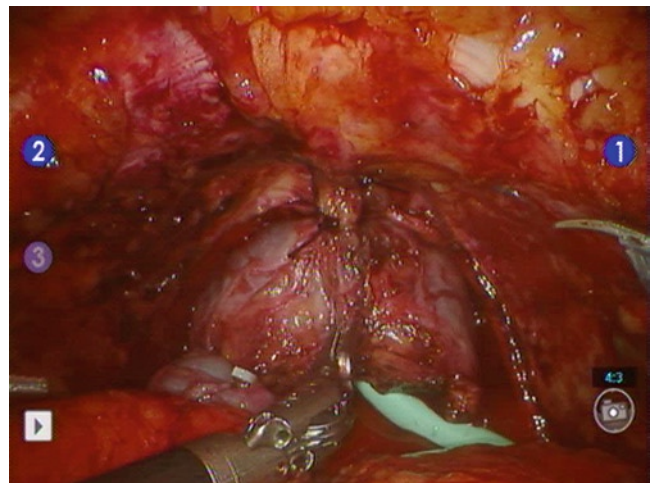


Fig. 6.4 The same patient seen in Fig. 6.3 is shown here but with a view provided by a 0° lens. Note the vastly improved visualization of the apical region beneath the pubic symphysis



Prior Midline Laparotomies

Patients with prior midline laparotomies have unpredictable amounts of adhesions. Those who have had multiple laparotomies or colectomies are often the worse affected. The major challenges are safe creation of pneumoperitoneum, safe trocar placement, and adequate access to the pelvis. In this setting, we perform an open Hasson insertion supraumbilically, entering the peritoneal cavity under direct vision. The extent of intraperitoneal adhesions is assessed either digitally or under laparoscopic view. If extensive adhesions are present, the incision is lengthened to a small minilaparotomy (2–3 in.) (Fig. 6.5). Via this incision, an open adhesiolysis is performed until at least two other trocars can be inserted in their regular position. The minilaparotomy is then closed around the camera trocar and pneumoperitoneum is established. Other trocars are placed and a laparoscopic adhesiolysis is performed to create clear entry points for all trocars. Once the robot is docked, adhesions in the lower abdomen and pelvis can be released robotically. We have found the three-dimensional vision and wristed instrumentation a significant advantage for performing adhesiolysis. We therefore only divide the minimum amount of adhesions laparoscopically to allow safe trocar placement and robot docking. Having a 5 mm laparoscope available can provide different views and working angles during the laparoscopic adhesiolysis.

Prior Inguinal Hernia Repair

Prior inguinal hernia repair either open or laparoscopic distorts the operative anatomy during RALP. Despite this, RALP can be performed safely and effectively in these patients [4]. The key is early identification of anatomical landmarks to provide spatial orientation prior to dissecting in the area of hernia repair and scarring. The mesh is often readily apparent during the initial laparoscopy (Fig. 6.6). We begin by dividing the urachus and medial umbilical ligaments. The retropubic space is entered in the midline and the posterior aspect of the pubic symphysis is identified. Dissection deep in the true pelvis is usually unaltered by hernia repairs. The superior pubic rami can be exposed and the dissection continues below this level within the pelvis to expose the endopelvic fascia bilaterally (Fig. 6.7). Hence prior to approaching the region of hernia repair/mesh, several valuable anatomical landmarks have been identified and can be used to maintain correct spatial orientation as the dissection proceeds laterally. The peritoneal incisions are then extended laterally to the medial border of the vas deferens. Using this technique in patients with prior open mesh inguinal hernia repairs, the mesh or scarring is often never encountered. If the mesh is seen, it is essential to keep the plane of dissection deep to the mesh at all times.

In patients with prior laparoscopic preperitoneal hernia repairs, the scarring is typically more

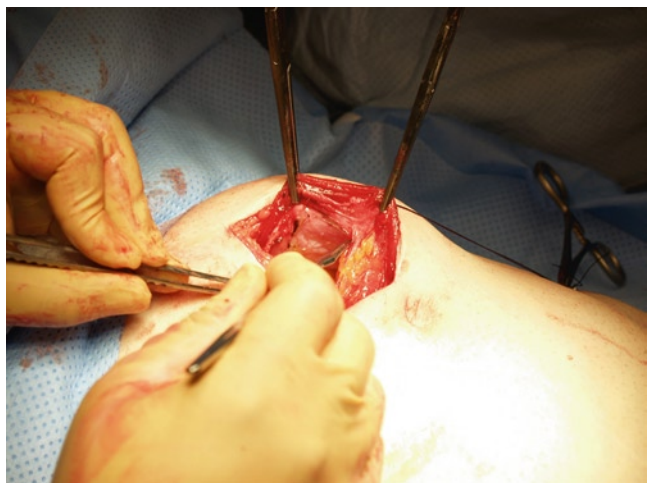

Fig. 6.5 Establishing safe access in a patient with prior midline laparotomies. A supraumbilical incision is made and adhesions are released by open surgical techniques. Once two further trocars can be inserted, the incision is closed around the camera trocars and a laparoscopic and/or robotic adhesiolysis is performed

Fig. 6.6 The mesh from a prior laparoscopic inguinal hernia repair is readily apparent on initial laparoscopy overlying the right internal inguinal ring

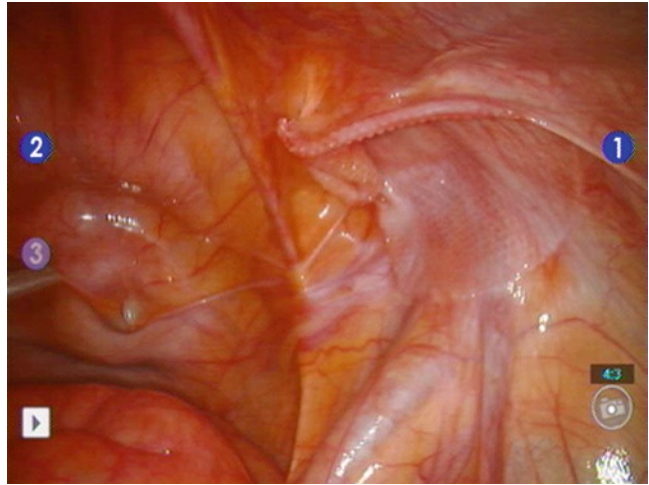
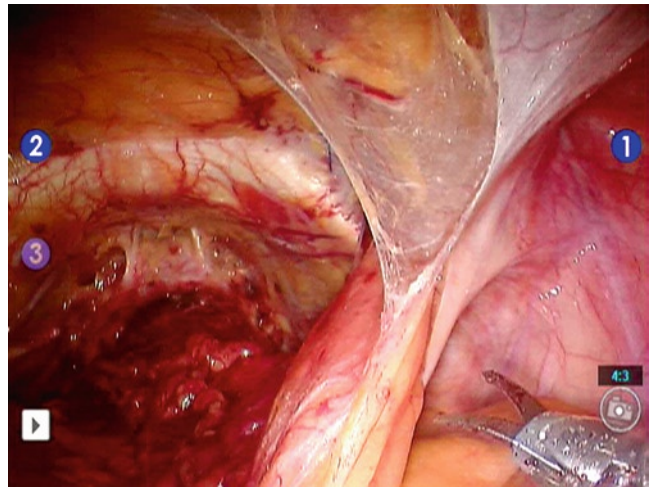


Fig. 6.7 The true pelvis has been dissected, displaying the superior pubic rami and endopelvic fascia prior to dissecting laterally toward the mesh hernia repair. This provides anatomical landmarks for reference if significant scarring is encountered laterally around the mesh



extensive. Again the same principles are followed. The midline dissection is usually less affected and the retropubic space and pelvic dissection can be approached in the midline with little difficulty. Again early exposure of anatomical landmarks in the pelvis will provide the necessary spatial orientation prior to dissecting further laterally beneath the mesh.

Accessory Pudendal Arteries

Arterial insufficiency following radical prostatectomy is a contributing factor to postoperative erectile dysfunction [5]. Accessory pudendal

arteries are diagnosed with varying frequency depending on the method of diagnosis and the size of vessel considered significant. During open retropubic prostatectomy, the incidence of large accessory pudendals is reported in 4% of cases [6]. In laparoscopic radical prostatectomy, they have been identified during 25% and 30% of cases [7, 8]. Rogers et al showed improved postoperative potency rates with preservation of these vessels [6].

Robotic technology provides several advantages for identifying and preserving these arteries. The magnified three-dimensional vision and wristed instrumentation aids in the appreciation of these vessels and the intricate dissection required to preserve them. The pneumoperitoneum

minimizes venous bleeding when releasing these vessels from the dorsal venous complex (DVC) that they are intimately associated with.

Accessory pudendal vessels may be seen either coursing across the anterolateral aspect of the bladder and prostate beneath the endopelvic fascia or emerging through the levator ani musculature laterally near the apex of the gland. They travel distally beneath the puboprostatic ligaments, alongside the DVC to pass through the pelvic floor. Typically in the region of the apex, they give off one or more branches to the prostate gland.

Upon identification of an accessory pudendal vessel, we recommend completing dissection of the endopelvic fascia on the contralateral side first. When returning to the side of the accessory pudendal vessel, the endopelvic fascia is opened sharply and the levator ani musculature is swept from the prostate. The puboprostatic ligament is divided and the lateral aspect of the DVC with adjacent accessory pudendal is exposed. The lateral pelvic fascia is then opened superficial to the accessory pudendal and a combination of sharp and blunt dissection is used to free the vessel from the prostate and subsequently the DVC (Fig. 6.8). Small branches to the prostate in the apical region can be controlled with bipolar electrocautery. Care is taken to avoid excessive handling or traction on the vessel. The artery must be released from the adjacent DVC distally enough to allow suture ligation of the complex (Fig. 6.9).

Large Prostate

Large prostates fill the narrow confines of the pelvis making maneuverability and exposure during RALP difficult. These glands frequently have a generous blood supply, further complicating the procedure. One advantage of large prostates, however, is that they do possess more obvious boundaries making the anatomical planes of dissection more distinct. It is important when performing RALP on large glands to execute each stage of the procedure precisely. Small mistakes during these cases have a tendency to produce an escalating “snow ball” effect leading ultimately to nonprogression. With experience and precision, RALP can be performed safely with good outcomes and low complication rates on large prostates [9, 10].

During RALP in patients with large prostates, we recommend early control of the DVC with suture ligation. Early control of the DVC reduces venous bleeding from large periprostatic veins throughout the case. To allow accurate ligation of the complex, it is important to completely divide the puboprostatic ligaments to allow maximum exposure of the apex of the gland.

The bladder neck dissection is often the most challenging part of the procedure with large prostates. Several techniques can assist with identification of the vesicoprostatic junction. Visual appreciation of the lateral contours of the base of the gland is helpful. Providing cranial

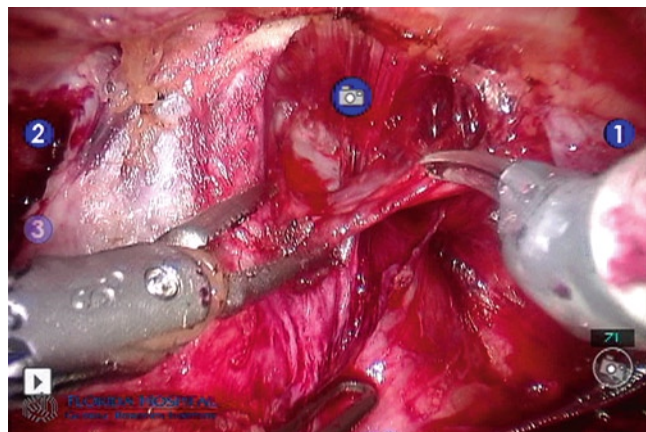
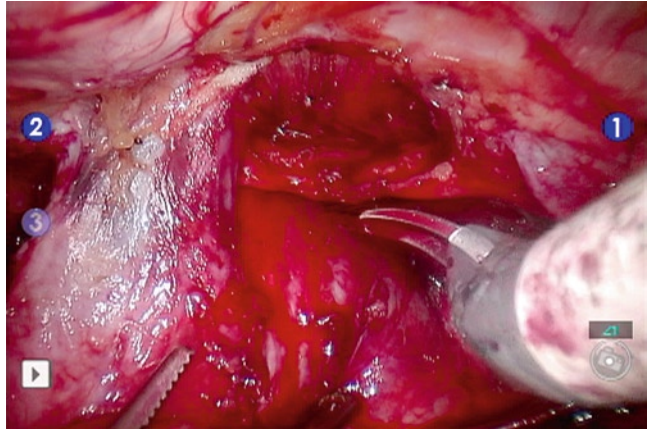


Fig. 6.8 The endopelvic fascia has been opened and the levator ani musculature released from the prostate to reveal a right-sided accessory pudendal artery

Fig. 6.9 The accessory pudendal has been released from the DVC medially to allow suture ligation of the DVC without occlusion of the accessory pudendal artery



retraction on the bladder with the fourth arm will frequently produce an inverted V of detrusor at the vesicoprostatic junction. Traction can be applied on the urethral catheter by the assistant while visualizing the position of the catheter balloon along the bladder neck. Perhaps the most helpful technique, however, is to observe where the vesical fat ceases at the vesicoprostatic junction.

The anterior bladder neck dissection should be approached in the midline following the bladder fibers down to enter the bladder lumen. One should refrain from dissecting laterally at this point as bleeding from large venous sinuses will occur. The urethral catheter is then elevated with the fourth arm to expose the posterior bladder neck. The posterior bladder neck dissection can be the most problematic step of these procedures. Quite a deep dissection is typically required to reach and indentify the seminal vesicles. Releasing some of the lateral bladder neck fibers to broaden exposure and flatten out the posterior dissection prevents working in a hole. Again if this dissection is continued too far laterally excessive bleeding will be encountered from venous sinuses. The bladder is then incised full thickness across the midline of the bladder neck. The vesicoprostatic plane is followed posteriorly. Gentle traction and movement of the bladder on the prostate base, and following the detrusor fibers helps maintain the correct plane of dissection. Once the seminal vesicles are identified, the lateral bladder attachments are clipped with large Hem-o-loks and divided. The keys to

a successful bladder neck dissection are broad exposure, maintaining a relative bloodless operative field, and correct identification of surgical planes.

Median Lobe

Presence of a median lobe requires a significantly different approach to the bladder neck dissection during RALP. During a surgeon's initial learning curve with RALP, patients with a median lobe should be avoided and identified preoperatively using either transrectal ultrasound or flexible cystoscopy. The first step for managing a middle lobe is identifying its presence. If not diagnosed preoperatively, several intraoperative signs can assist with recognizing the presence of a median lobe. Prior to beginning the bladder neck dissection, the urethral catheter balloon may be seen deviating to one side. This typically indicates the presence of a middle lobe or other complicated bladder neck anatomy (i.e., prior TURP). The next sign to look for is an elevated bladder when the urethral catheter is retracted upwards with the fourth arm after dividing the anterior bladder neck. The most definitive observation, however, is absence of the "drop off" sign. When the urethral catheter is elevated and the bladder neck is spread with the bipolar or plasma kinetic forceps, the vertical drop off of the mucosa of the posterior bladder neck should be observed in the case of normal

prostate anatomy. If the bladder is seen continuing cranially, however, a middle lobe is almost certainly present.

In this situation, the lateral bladder neck fibers should be carefully divided to increase exposure at the bladder neck and visualization within the bladder. With retraction on the anterior bladder neck, the middle lobe can be delivered out of the bladder neck and elevated with the fourth arm (Fig. 6.10). If unable to do this despite releasing the lateral bladder attachments, the bladder can be opened further with a midline anterior cystotomy to gain definitive visualization and assessment of the bladder neck anatomy.

Once the middle lobe is elevated, time is taken to ensure that the location of the ureteral orifices is confirmed with certainty. If doubt exists as to their precise location, intravenous methylene blue or indigo carmine may be administered to look for blue efflux from the ureteric jets. It is vital that the posterior bladder neck is not incised until the location of the ureteral orifices is confirmed so as to avoid inadvertent ureteral injury or compromise. With large middle lobes they can lie in close proximity to the intravesical adenoma.

The posterior dissection begins laterally releasing the corners of the bladder first. The bladder is then incised full thickness below the level of the median lobe (Fig. 6.10). The plane between the adenoma and bladder is identified and followed anteriorly. As the bladder neck is released and traction on it decreases, the ureteral orifices drift closer to the plane of dissection.

The surgeon must remain cognizant of their location throughout this portion of the dissection. Following the plane of the median lobe adenoma is useful during the initial dissection. The surgeon must be aware, however, that once under the middle lobe, the dissection will turn more posteriorly to follow the plane of the bladder. If one were to continue on the plane of the adenoma, they risk inadvertently creating a plane between it and the peripheral zone of the prostate. Zooming out for a global view of the anatomy, judging the thickness of the posterior bladder neck, moving the bladder on the base of the gland, and following the detrusor fibers all aid in identifying the correct plane. Keeping a broad dissection and a relatively bloodless field are valuable during these challenging dissections. Provided the anatomy of the prostate is followed, complications can be avoided.

Prior Transurethral Resection of the Prostate

Operating on patients who have had prior TURPs is one of the most challenging scenarios during RALP. In patients diagnosed via TURP, we wait for a minimum of 12 weeks to allow inflammation from the procedure to subside and adequate healing to occur. The normal planes of dissection about the prostate may be obliterated necessitating a greater use of shaper dissection. Again, the

Fig. 6.10 A median lobe has been identified and elevated with the fourth arm. The *yellow line* represents the level of mucosal incision to be made for the posterior bladder neck dissection. It is essential to visualize the ureteral orifices in such cases prior to making this incision

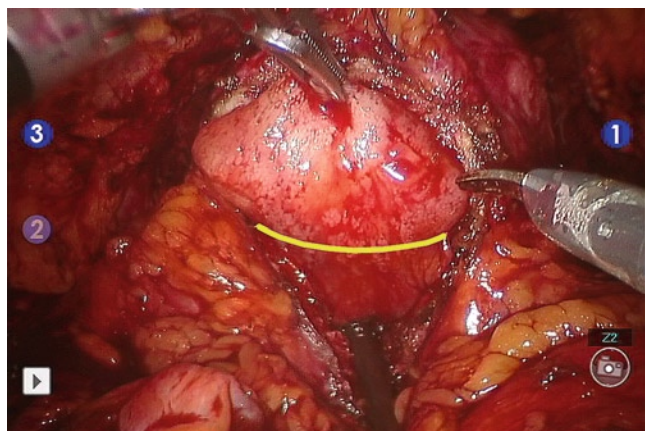


Fig. 6.11 Bladder neck dissection in a patient who has undergone a previous TURP. Reurothelialization makes identification of the posterior bladder neck difficult

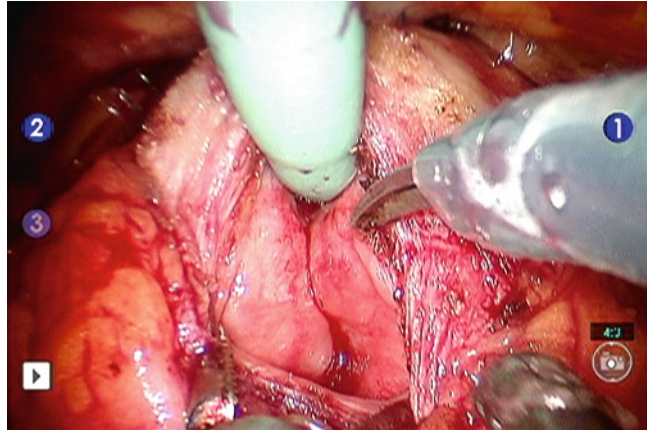
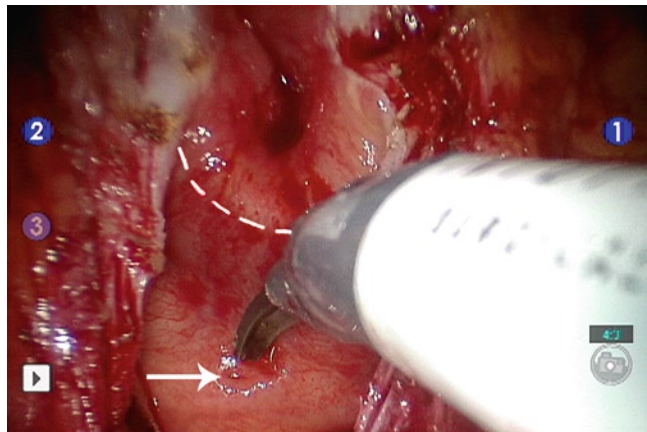


Fig. 6.12 In the same patient as Fig. 6.11, the lateral bladder neck fibers have been released improving exposure. The left ureteric orifices have been identified (*white arrow*). With improved exposure and identification of the ureteral orifices, the line of dissection for the posterior bladder neck can be determined (*white dashed line*)



most difficult step in these procedures is the bladder neck dissection.

When judging the position of the vesicoprostatic junction, the most reliable signs are cessation of vesical fat at the junction between the bladder and prostate gland and assessing the contour of the prostate. Observing the position of the urethral catheter balloon while applying traction on the catheter is a misleading sign, as the balloon will often descend into the prostatic fossa in these patients.

The anterior bladder is again approached in the midline to enter the bladder quickly and elevate the urethral catheter with the fourth robotic arm. The bladder neck anatomy can then be surveyed from within (Fig. 6.11). Identification of the posterior bladder neck is usually complicated by either reurothelialization or regrowth of adenoma. Again in these cases, identification of the ureteral

orifices is essential prior to proceeding with the posterior bladder neck incision (Fig. 6.12). Once the ureteral orifices have been identified, the posterior bladder neck is incised full thickness. The normal tissue planes are replaced by scar tissue complicating the dissection. Careful assessment of bladder thickness while dissecting posteriorly is usually the best approach. A cautious yet confident approach is required.

Bladder Neck Reconstruction

Following prostatectomy in patients with median lobes or prior TURPs, we recommend reconstructing the bladder neck prior to performing the vesicourethral anastomosis (Fig. 6.13). We have found the most useful technique to be lateral

Fig. 6.13 Intraoperative view of a large bladder neck opening prior to bladder neck reconstruction

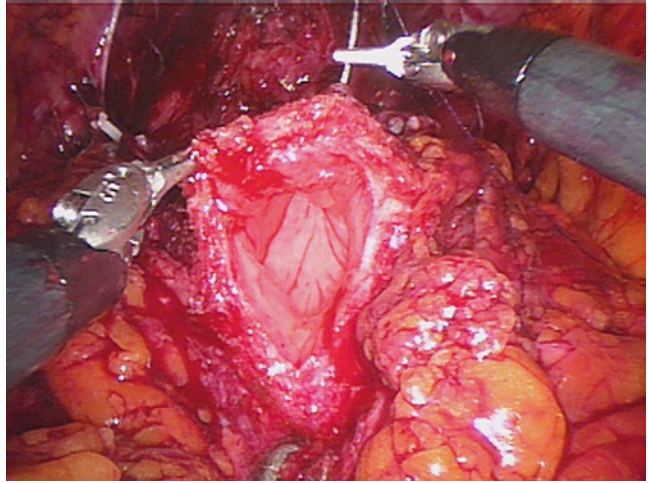
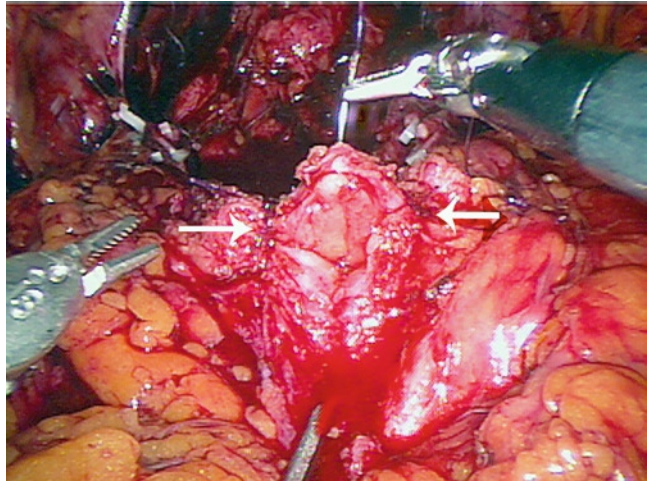


Fig. 6.14 The same bladder neck as shown in Fig. 6.13 has now been reconstructed with laterally placed figure-of-eight sutures (white arrows)



closure with figure-of-eight 3-0 monocryl sutures (Fig. 6.14). With this technique, the ureteral orifices are tucked out of the way and out of the path of the ensuing anastomosis. For larger bladder neck openings, the lateral reconstruction can be performed with a continuous suture.

scenarios are a daunting prospect for the novice robotic surgeon. With judicious case selection and a graduated stepwise exposure to operative challenges, the most difficult cases can be mastered in a safe and efficient manner.

Conclusion

Acquiring proficiency in RALP is as challenging as it is rewarding. With experience of more than 2,000 cases, we continually modify our technique as we master different subtleties in an attempt for optimal outcomes. The above difficult

References

1. Menon M, Shrivastava A, Tewari A, Sarle R, Hemal A, Peabody JO et al (2002) Laparoscopic and robot assisted radical prostatectomy: establishment of a structured program and preliminary analysis of outcomes. *J Urol* 168(3):945–9
2. Ahlering TE, Skarecky D, Lee D et al (2003) Successful transfer of open surgical skills to a laparoscopic environment using a robotic interface: Initial experience

- with laparoscopic radical prostatectomy. *J Urol* 170: 1738–1741
3. Hugh JL, Thaly R, Shah K, Patel V. (2007) The advanced learning curve in robotic prostatectomy: a multi-institutional survey: AUA abstract, presented 05/20/07
 4. Laungani RG, Kaul S, Muhletaler F et al (2007) Impact of previous inguinal hernia repair on transperitoneal robotic prostatectomy. *Can J Urol* 14(4):3635–9
 5. Mulhall JP, Slovick R, Hotaling J et al (2002) Erectile dysfunction after radical prostatectomy: hemodynamic profiles and their correlation with the recovery of erectile dysfunction. *J Urol* 167:1371–1375
 6. Rogers CG, Trock BP, Walsh PC (2004) Preservation of accessory pudendal arteries during radical retropubic prostatectomy: surgical technique and results. *Urology* 64:148–151
 7. Matin SF (2006) Recognition and preservation of accessory pudendal arteries during laparoscopic radical prostatectomy. *Urology* 67:1012–1015
 8. Secin FP, Touijer K, Mulhall J et al (2007) Anatomy and preservation of accessory pudendal arteries in laparoscopic radical prostatectomy. *Eur Urol* 51:1229–1235
 9. Zorn KC, Orvieto MA, Mikhail AA et al (2007) Effect of prostate weight on operative and postoperative outcomes of robotic-assisted laparoscopic prostatectomy. *Urology* 69(2):300–305
 10. Boczek J, Erturk E, Golijanin D et al (2007) Impact of prostate size in robot-assisted radical prostatectomy. *J EndoUrol* 21(2):184–188

Chapter 7

Robot-Assisted Radical Cystoprostatectomy

Gerald J. Wang and Douglas S. Scherr

This chapter contains a video segment which can be found at the URL: <http://www.springerimages.com/Su>

Patient Selection

Indications for robot-assisted radical cystoprostatectomy are identical to those of the open approach and the goal is surgical cure of disease. Indications include muscle-invasive bladder cancer and high-grade, non-muscle-invasive bladder cancer (CIS or T1) refractory to intravesical immunotherapy or chemotherapy. On rare occasions, palliative cystectomy is performed in patients with severe symptoms from disease as an adjunct to chemotherapy. All patients referred to our center with bladder cancer undergo an exam under anesthesia and restaging transurethral resection of bladder. There are no absolute contraindications to robotic cystoprostatectomy. However, level of difficulty must be balanced with surgeon comfort and experience, and one must always be prepared for open conversion, as oncologic efficacy and patient safety should not be compromised. Relative contraindications include history of extensive abdominal or pelvic surgery and radiation, as well as preoperative evidence of extensive local disease. We refer all patients with clinical T2 disease or higher to medical oncology in consultation for neoadjuvant platinum-based chemotherapy. In our series, 36% of patients had prior abdominal surgery, 10% had prior abdominal or pelvic

radiation, and 35% had undergone neoadjuvant platinum-based chemotherapy. Robotic cystectomy is certainly feasible in the setting of prior surgery or radiation, though again, the decision to proceed is determined primarily by surgeon experience. In cases of prior pelvic radiation, the posterior dissection can be particularly challenging and great care must be taken to avoid rectal injury. In patients with prior intra-abdominal surgery, extensive laparoscopic lysis of adhesions is sometimes needed to enable safe placement of all trocars. Robotic cystectomy is feasible in patients who have undergone neoadjuvant chemotherapy, and these patients make up approximately one-third of our current series. To date, clinical stage was $\geq T2$ in 49% of patients, and 38% of patients had extravesical disease on final pathology. Open conversion has occurred in two patients due to locally advanced disease into adjacent organs.

Patient Preparation

Prior to surgery, all patients are counseled extensively on the risks and benefits of radical cystoprostatectomy. Both the open and robotic approaches are explained, and patients are made fully aware that open conversion, while rare, is always a possibility. A great deal of time is spent explaining the different types of urinary diversions to patients and their families. Informed consent is obtained with the patient, family, and nursing staff present. For patients undergoing ileal conduit or orthotopic ileal neobladder, bowel preparation consists of 48 h of

D.S. Scherr (✉)
Department of Urology, Weill Medical College of
Cornell University and New York Presbyterian
Hospital, New York, NY, USA
e-mail: dss2001@med.cornell.edu

clear liquid diet prior to surgery, followed by one bottle of magnesium citrate (300 mL) at 3 p.m. and one tablespoon of mineral oil at bedtime on the day prior to surgery. For patients undergoing continent cutaneous diversion using right colon, bowel preparation begins with 48 h of clear liquids, followed by 1 gal of polyethylene glycol electrolyte solution (GoLYTELY®, Braintree Laboratories, Inc., Braintree, MA) on the day prior to surgery. Additionally, oral neomycin (1 g for three doses), erythromycin base (1 g for three doses), and one tablespoon of mineral oil are given the day before surgery. Rectal enema is performed the evening before and the morning of surgery.

Operative Setup

Operative setup for robot-assisted radical cystectomy will in many cases be dictated by the specific characteristics of each surgeon's operating room. In Fig. 7.1, we provide a schematic overhead view of our preferred operative setup. Because of space constraints, any number of variations of operating room setup is possible as long as a few key principles are followed. (1) We currently use the 3-arm da Vinci® Surgical System (Intuitive Surgical, Inc., Sunnyvale, CA) and therefore employ right and left assistants. We feel that at least three monitors are needed in this setting to allow for each team member to have optimum viewing of the operative steps. (2) The scrub nurse should be positioned on the side of the assistant with the 15 mm trocar, which in our case is the right-sided assistant, to facilitate exchange of clip appliers, sutures, and Endo Catch™ (Covidien, Mansfield, MA) retrieval bags. (3) The console surgeon must have easy access to the operative table to scrub into the procedure at a moment's notice.

Patient Positioning and Preparation

We place the patient in the dorsal lithotomy position using standard operative stirrups. With the table flat, we then use plastic arm sleds to

tuck the patient's arms at the side. All pressure points are protected using standard egg-crate foam padding. Sequential compression stocking devices are placed on both legs and are activated. We also routinely administer 5,000 units of subcutaneous heparin. Next, the patient is secured to the operating table using a cross-shoulder harness made by four strips of egg-crate foam padding. Each strip is 6 × 24 inches, and two strips are used on each side of the patient creating an "X" configuration across the patient's chest. The pads are secured to the operating table using cloth tape. Care must be taken not to secure the lower portion of the pads below the costal margin, as this may interfere with subsequent lateral trocar placement. Once the patient is secured to the table, the leg attachment is lowered and the patient is placed in 30° steep Trendelenburg position (Fig. 7.2). Of note, the anesthesia team places an orogastric tube to low wall suction for the duration of the case, and a foam padding is placed over the patient's face to prevent injury from the camera, particularly when the 30°-down lens is being used. A urethral catheter is placed on the operative field.

Trocar Configuration

Our standard trocar configuration for robot-assisted radical cystectomy is shown in Fig. 7.3. Insufflation of the abdominal cavity is performed using a Veress needle to 15 mmHg, which in general is maintained throughout the operation. In particularly obese patients, communication with the anesthesia team is imperative as pneumoperitoneum can result in unacceptably high inspiratory pressure necessitating a lower abdominal insufflation pressure. Once the abdomen has been insufflated, we place a 10–12 mm, bladed, disposable trocar in the periumbilical location as our camera trocar. We mark a standard laparotomy incision at the beginning of the case and use the superior 1 cm of the curvilinear, periumbilical portion of the incision for our robotic camera

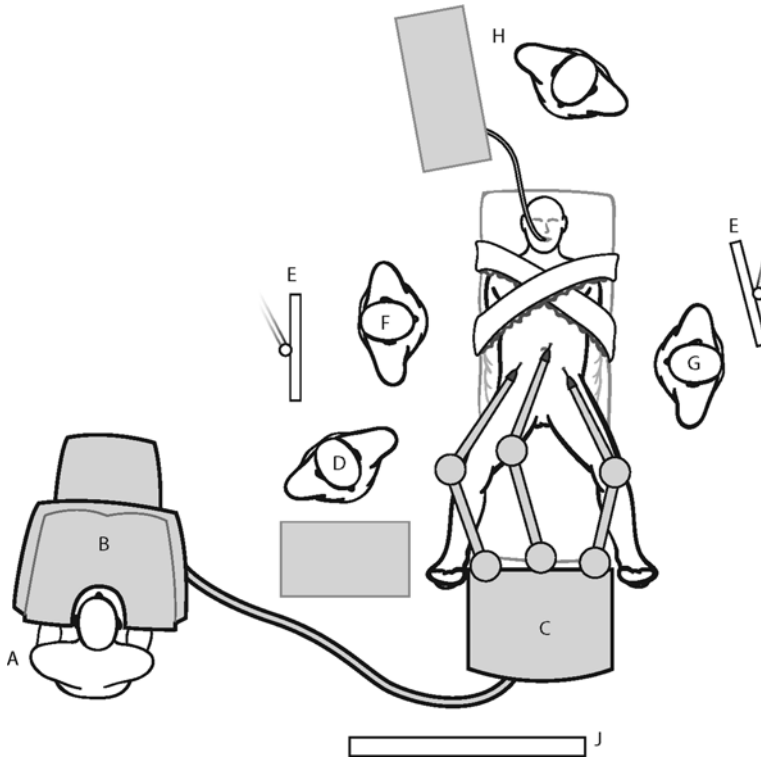


Fig. 7.1 Schematic overhead view of operative set up for robot-assisted radical cystectomy. (A) Surgeon, (B) Console, (C) da Vinci®, (D) Scrub nurse, (E, J) High-definition monitors, (F) Right assistant, (G) Left assistant, (H) Anesthesia

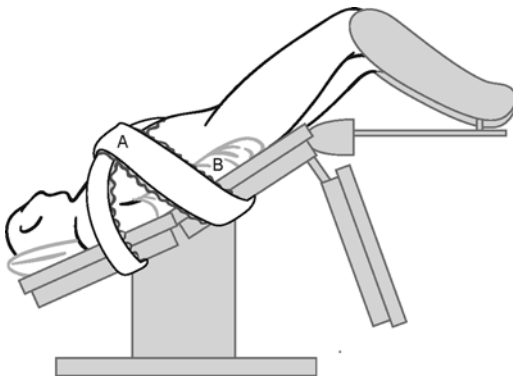


Fig. 7.2 Final patient positioning with the patient secured to the table with a cross-shoulder harness “X” configuration (A) and the arms tucked at the side with plastic arm sleds (B)

trocars. The 30°-up lens is then passed through this trocar to aid in subsequent trocar placement. With the left assistant holding the

camera, we then place our right 8 mm robotic trocar 10 cm lateral to, and 4 cm inferior to, the camera trocar. A Versaport™ Plus (Covidien, Mansfield, MA), 5–15 mm trocar is then placed as the main right assistant trocar in the midaxillary line 3 cm superior to the anterior superior iliac spine (ASIS). A Versaport™ V₂ (Covidien, Mansfield, MA) 5 mm disposable trocar, used primarily by the right-sided assistant for suction-irrigation, is then placed midway between the camera trocar and the right robotic trocar. We place our suction trocar in the same axial plane as the camera trocar, because placement of this trocar in a lower position can limit movement between the camera and right robotic arm. Because our suction is in a slightly higher position, we use the extra long suction tip adapter to reach the most dependent portions of the pelvis. At this point, the left 8 mm

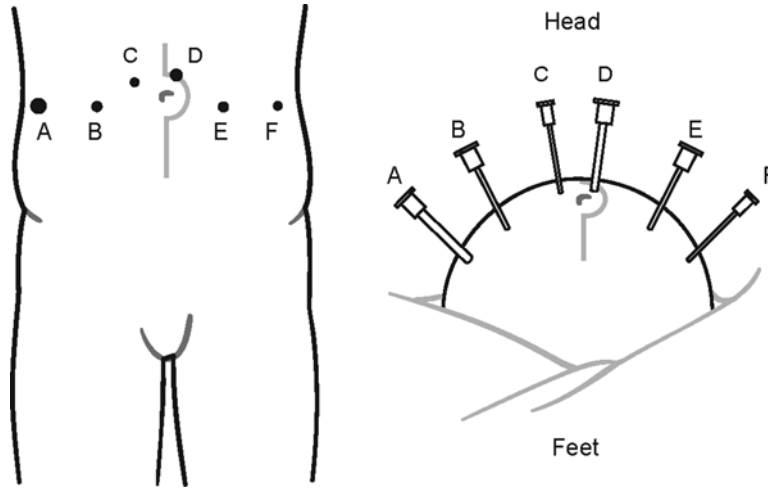


Fig. 7.3 Trocar configuration for robot-assisted radical cystectomy. Left figure demonstrates overhead view of trocar configuration and right figure demonstrates view from

the patient’s feet. (A) Main right-sided assistant trocar, (B) and (E) 8 mm robotic trocars, (C) secondary right assistant trocar, (D) camera trocar, (F) left-sided assistant trocar

robotic trocar is placed at a location that is the mirror image of the right robotic trocar. A Versaport™ V₂ 5 mm disposable trocar is then placed for the left assistant in the midaxillary line 3 cm superior to the ASIS.

Instrumentation and Equipment List

Equipment

- da Vinci® standard or S Surgical System
- PreCise™ bipolar forceps (Intuitive Surgical, Inc., Sunnyvale, CA)
- EndoWrist® curved monopolar scissors (Intuitive Surgical, Inc., Sunnyvale, CA)
- EndoWrist® needle drivers (2) (Intuitive Surgical, Inc., Sunnyvale, CA)
- InSite® Vision System with 0° and 30° lens (Intuitive Surgical, Inc., Sunnyvale, CA)

Trocars

- 5–15 mm trocar
- 10–12 mm bladed trocar
- 8-mm robotic trocars (2)
- 5-mm trocar (2)

Suture	Length	Needle	Procedure	Note
0-polyglactin tie (secured to medium-large Hem-o-lok® clip)	Full length (24 in.)		Used to tag the ureter once it is transected	Dyed and undyed
0-polyglactin	8 in.	GS-21	Ligation of dorsal venous complex (DVC)	
2-0 Biosyn (undyed)	10 in.	GU-46	Urethral-neobladder anastomosis	
2-0 Monocryl (dyed)	10 in.	UR-6	Urethral-neobladder anastomosis	Sutures are tied together to create a double-armed suture
0-Maxon	Full length	GS-21	Fascial closure of perumbilical incision	
4-0 Biosyn	Full length	P-12	Skin closure	

Recommended sutures

Instruments used by the surgical assistants

- MicroFrance® grasper (Medtronic, Inc., Minneapolis, MN)
- Laparoscopic scissors
- 10 mm LigaSure Atlas™ (Vallylab, Tyco Healthcare Group, Boulder, CO)

- 5 mm Harmonic Scalpel® (Ethicon Endo-Surgery, Cincinnati, OH)
- Hem-o-lok® clip applicator (Teleflex Medical, Research Triangle Park, NC)
- Small, Medium-Large and Extra Large Hem-o-lok® clips (Teleflex Medical, Research Triangle Park, NC)
- Endo Clip™ 10 mm multifire titanium clip applicator (Covidien, Mansfield, MA)
- 15 mm Endo Catch™ retrieval device (1) (Covidien, Mansfield, MA)
- 10 mm Endo Catch™ retrieval device (2)
- Laparoscopic needle driver
- Laparoscopic Maryland grasper
- Suction-Irrigator device
- 15Fr round Jackson-Pratt drain
- 24Fr Malecot suprapubic tube
- 20Fr urethral catheter with 5 cm³ balloon
- 7Fr single J ureteral catheter (2)
- Endo Close™ fascial closer device (Autosuture, Covidien, Mansfield, MA)

Step-By-Step Technique

Step 1: Identification and dissection of the ureter

Surgeon instrumentation		Assistant instrumentation
Right arm	Left arm	<ul style="list-style-type: none"> • Suction-irrigator • MicroFrance® grasper
<ul style="list-style-type: none"> • Curved monopolar scissors 	<ul style="list-style-type: none"> • PreCise™ bipolar forceps 	
Endoscope lens: 30° down		

Unless stated otherwise, robot-assisted radical cystectomy is performed using the 30°-down lens. For the majority of the operation, curved monopolar scissors are used in the right robotic arm and the PreCise™ bipolar forceps in the left. Electrocautery settings are 30 W for both monopolar and bipolar devices. The procedure begins by identification and dissection of the ureters. Identification of the left ureter (Figs. 7.4 and 7.5) begins with the right assistant retracting the sigmoid colon medially using a MicroFrance® grasper. The surgeon incises the posterior peritoneum overlying the external iliac artery where

the ureter is most easily identified. The ureter should not be directly grasped by the surgeon or the assistants, and effective ureteral retraction can be accomplished by placing the left robotic grasper beneath the ureter and elevating it gently. The ureter is then dissected proximally as high as possible to the level of the upper common iliac artery. Distal dissection is performed to the level of the ureteral hiatus. During distal ureteral dissection, the vas deferens and the obliterated umbilical artery are encountered, clipped, and divided.

Step 2: Development of the anterior bladder pedicle

Development of the anterior bladder pedicle, shown in Figs. 7.5 and 7.6a, b on the patient’s left side, begins with identifying the avascular plane located between the pelvic sidewall and the bladder. We begin developing this avascular plane by placing both robotic instruments in the space between the left pelvic sidewall and the bladder (Fig. 7.5). Then, using broad, horizontal sweeping movements with the robotic arms, the avascular plane is developed, as shown in Fig. 7.6a, b. The left obturator nerve and pelvic sidewall are shown here as the lateral border of the avascular plane. The suction device is retracting the bladder and left ureter medially which reveals the fibrous connective tissue of the avascular plane.

Step 3: Transection of the anterior pedicle and ureter

Surgeon instrumentation		Assistant instrumentation
Right arm	Left arm	<ul style="list-style-type: none"> • Suction-irrigator • MicroFrance® grasper • LigaSure™ device • Hem-o-lok® clip applicator
<ul style="list-style-type: none"> • Curved monopolar scissors 	<ul style="list-style-type: none"> • PreCise™ bipolar forceps 	
Endoscope lens: 30° down		

Development of the avascular plane between the left bladder and sidewall reveals the anterior bladder pedicle, shown on the patient’s left side in Fig. 7.7a, b, just lateral to the ureteral hiatus. The anterior pedicle which contains the superior vesicle artery can be secured and divided using either the LigaSure™ device or Hem-o-lok®

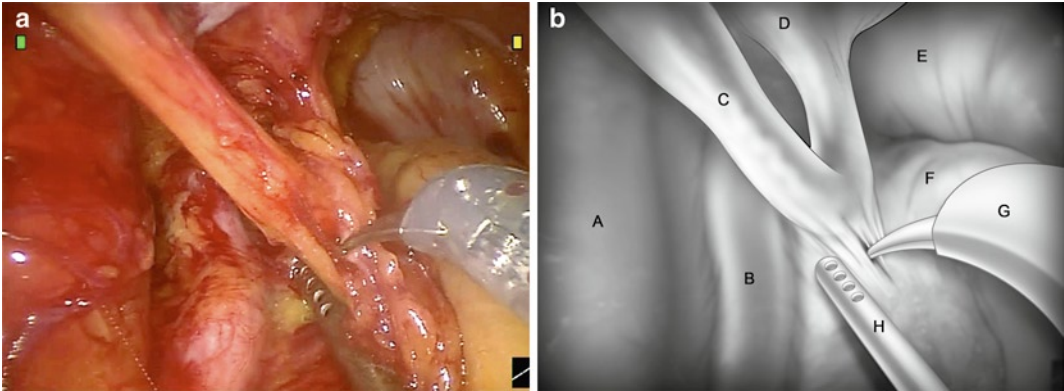


Fig. 7.4 (a, b). View of the left pelvic sidewall, iliac vessels and left ureter (foreground) being dissected toward the bladder. Pertinent anatomy includes (A) pelvic sidewall and external iliac artery, (B) hypo-

gastric artery, (C) left ureter, retracted anteriorly by left robotic arm, (D) bladder and ureteral hiatus, (E) rectum, (F) sigmoid colon, (G) right robotic arm, and (H) suction-irrigator

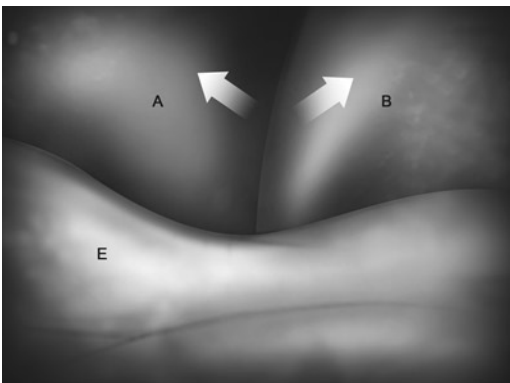


Fig. 7.5 Schematic drawing showing the early development of the avascular plane between the left side of the bladder (B) and left pelvic sidewall and iliac vessels (A). The arrows indicate the blunt horizontal sweeping motions used to develop the avascular plane. The peritoneal reflection is denoted by (E)

clips. Prior to ureteral transection at the hiatus, a large Hem-o-lok® clip is applied distally and a second large Hem-o-lok® clip, which is attached to a long 0-polyglactin suture, is applied proximally on the ureter. The suture on the ureter facilitates subsequent ureteral identification during the later steps of urinary diversion. Additionally, we recommend using dyed and undyed polyglactin sutures to enable distinction between the right and left ureters. Once the ureter is divided on the left side, the right assistant

uses a MicroFrance® grasper to pass the polyglactin tie with the left ureter to the left assistant. The left assistant then retracts the left ureter superiorly by bringing the polyglactin tie out of the left 5 mm assistant trocar. A similar dissection is carried out on the right side exposing the right anterior bladder pedicle, ureter, and pelvic sidewall.

Step 4: Development of the posterior plane

Once the anterior pedicles are divided, we incise the posterior peritoneal reflection horizontally along the cul de sac, separating the bladder from the rectum along the midline (Fig. 7.8a, b). The left assistant lifts the bladder anteriorly and the right assistant retracts the posterior peritoneal edge. Using a combination of broad, sweeping motions and electrocautery with the monopolar scissors, we develop the posterior plane between the bladder and rectum beneath the posterior leaflet of Denonvillier's fascia. This dissection is carried as distally as possible and well beyond the vasa deferentia and seminal vesicles (SVs) toward the prostatic apex.

Step 5: Identification and transection of the posterior bladder pedicles

Development of the plane between the bladder and rectum reveals the posterior bladder pedicle,

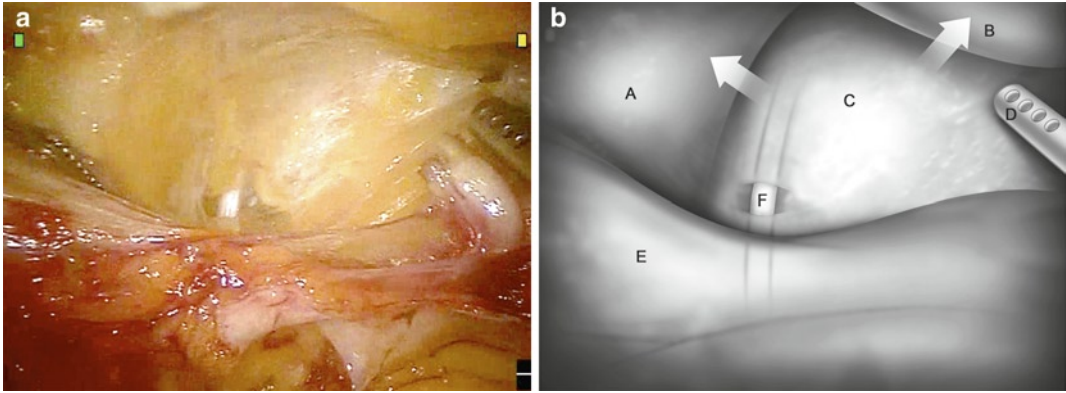


Fig. 7.6 (a, b). View of avascular plane between the left side of the bladder and pelvic sidewall with pertinent anatomy including (A) left pelvic sidewall and

external iliac vessels, (B) bladder, (C) avascular plane, (D) suction-irrigator, (E) peritoneal reflection, and (F) left obturator nerve

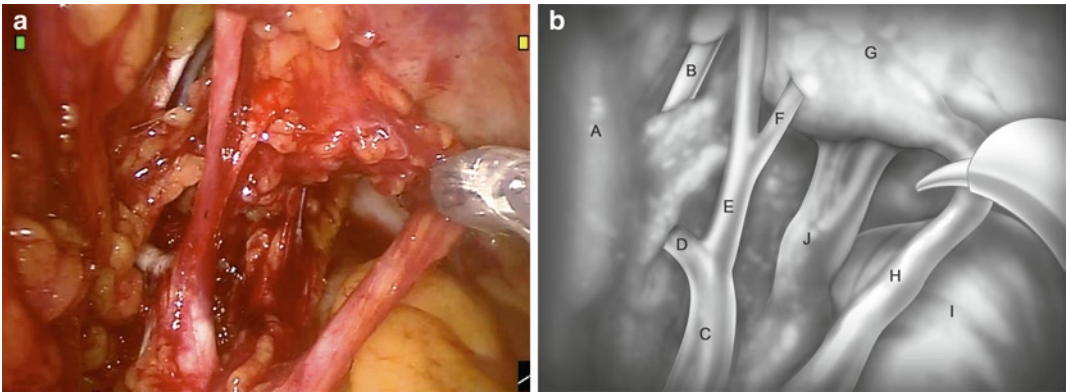


Fig. 7.7 (a, b). View of the left anterior bladder pedicle with pertinent anatomy including (A) pelvic sidewall, (B) obturator nerve, (C) hypogastric artery, (D) obturator

artery, (E) superior vesical artery, (F) branch of superior vesical artery, (G) bladder, (H) left ureter, (I) sigmoid colon, and (J) posterior bladder pedicle

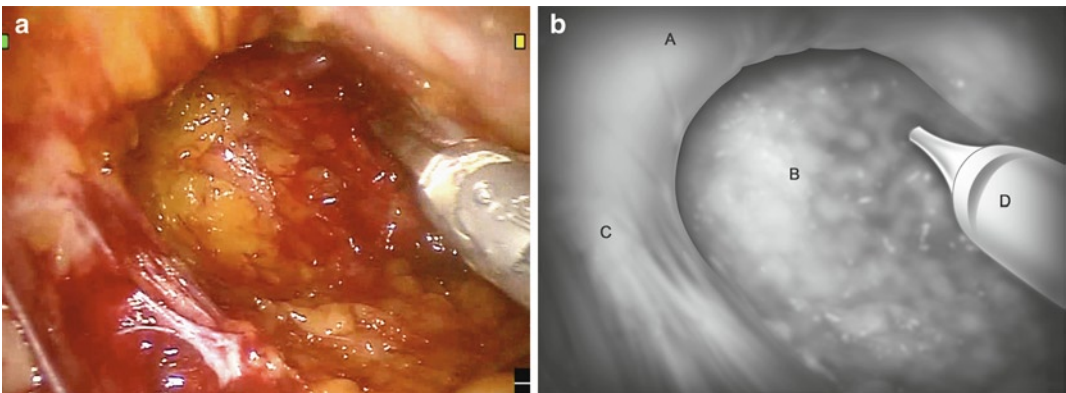


Fig. 7.8 (a, b). View of the posterior plane created between the bladder, A anteriorly and prerectal fat (B) posteriorly. The left posterior bladder pedicle (C) and right robotic arm with monopolar scissors (D) are also shown

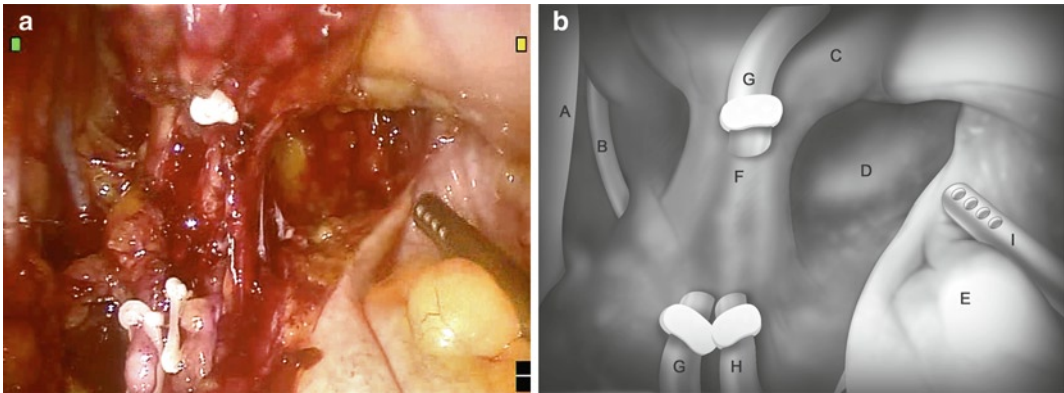


Fig. 7.9 (a, b) View of the left posterior bladder pedicle with relevant anatomy including (A) left external iliac vessel, (B) left obturator nerve, (C) bladder, (D) rectum, (E)

sigmoid colon, (F) posterior bladder pedicle, (G) superior vesicle artery (clipped and cut), (H) branch of superior vesicle artery (clipped and cut), and (I) suction-irrigator

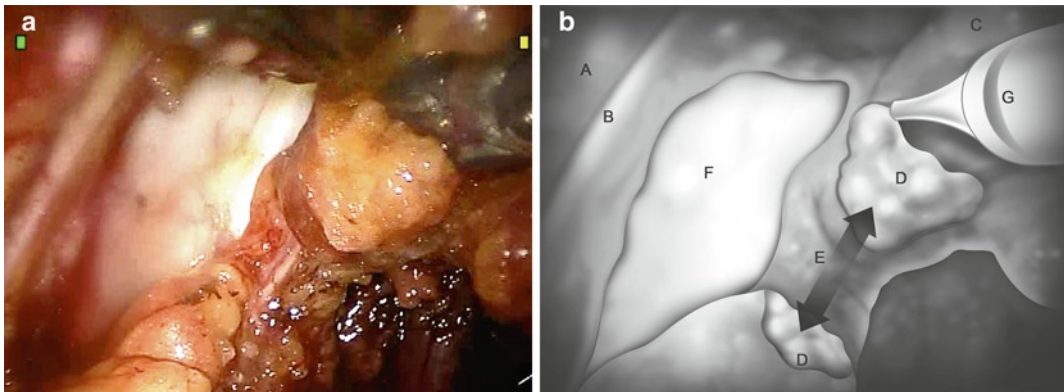


Fig. 7.10 (a, b) View of the left endopelvic fascia. Labeled structures include (A) pubic bone, (B) pectineal line, (C) bladder, (D) left posterior bladder pedicle (cut),

(E) beginning of left prostatic pedicle, (F) left endopelvic fascia, and (G) right robotic arm

shown on the patient's left side in Fig. 7.9a, b. The posterior bladder pedicle is located just distal to the previously divided anterior pedicle. Exposure of the left posterior bladder pedicle is facilitated by the right assistant providing superior and medial traction on the bladder, while the left assistant provides posterior retraction of the rectum. In a non-nerve-sparing operation, we secure and divide the posterior pedicle using the LigaSure™ device. In a nerve-sparing procedure, we use Hem-o-lok® clips to prevent thermal damage to the neurovascular bundle. Division of the posterior pedicle is complete when the endopelvic fascia is encountered.

Step 6: Exposure of the endopelvic fascia

The adipose tissue overlying the endopelvic fascia, shown on the patient's left side in Fig. 7.10a, b, is removed by the robotic instruments using blunt sweeping motions. For exposure of the endopelvic fascia, retraction by the assistants is similar to that used for identification and division of the posterior pedicles. The endopelvic fascia is sharply incised using the robotic scissors. This exposes the prostatic pedicles which are then secured and divided using the LigaSure™ device in a non-nerve-sparing operation. Alternatively, Hem-o-lok® clips can be used in a nerve-sparing procedure. To avoid injury to

the rectum, the right assistant should retract the rectum posteriorly using either the suction or MicroFrance® forceps (Medtronic, Inc., Minneapolis, MN). It is important to carry this dissection as distally as possible, because once the bladder is released from its anterior attachment, visualization of the posterior prostatic apex is quite limited.

Step 7: Anterior dissection of the bladder and prostate

Surgeon instrumentation		Assistant instrumentation
Right arm	Left arm	
Curved monopolar scissors	• Maryland bipolar grasper	<ul style="list-style-type: none"> • Suction-irrigator • Hem-o-lok® clip applier • Laparoscopic needle driver
Endoscope lens: 0°		

The 0° lens can be used at this point in the procedure to better visualize the anterior abdominal wall, the dorsal venous complex (DVC), and the urethra. Similar to the oncologic principles in open radical cystectomy, we remove the urachus with the bladder en bloc taking wide peritoneal wings (Fig. 7.11a, b). The importance of placing the camera trocar several centimeters superior to the umbilicus at the beginning of the procedure is now revealed. If the camera trocar is not placed superiorly enough, then complete excision of the urachus will be compromised, as will the proximal extent of the subsequent pelvic lymphadenectomy. The medial umbilical ligament on each

side is grasped by the contralateral assistant. Providing medial retraction, the monopolar scissors are then used to incise the anterior peritoneum which enables entrance into the space of Retzius. The peritoneum is incised widely, lateral to the medial umbilical ligaments and in an inferior direction until the pubic bone is exposed.

Step 8: Control of the dorsal venous complex, and division of the urethra

Surgeon instrumentation		Assistant instrumentation
Right arm	Left arm	
<ul style="list-style-type: none"> • Curved monopolar scissors • Needle driver 	<ul style="list-style-type: none"> • PreCise™ bipolar forceps • Needle driver 	<ul style="list-style-type: none"> • Suction-irrigator • Hem-o-lok® clip applier • Laparoscopic needle driver • 15 mm Endo Catch™ retrieval device
Endoscope lens: 0°		

After dissecting the anterior attachments of the bladder and entering the space of Retzius, the visible landmarks include the anterior bladder, prostate, puboprostatic ligaments, and pubic bone (Fig. 7.12a, b). The puboprostatic ligaments are preserved for orthotopic urinary diversion. For nonorthotopic diversion, the urethra is not preserved and therefore we divide the puboprostatic ligaments for optimal distal dissection. A 0-polyglactin suture is placed to secure the DVC. In a non-nerve-sparing cystoprostatectomy, we divide the DVC using electrocautery with the monopolar scissors. In nerve-sparing procedures, electrocautery is not

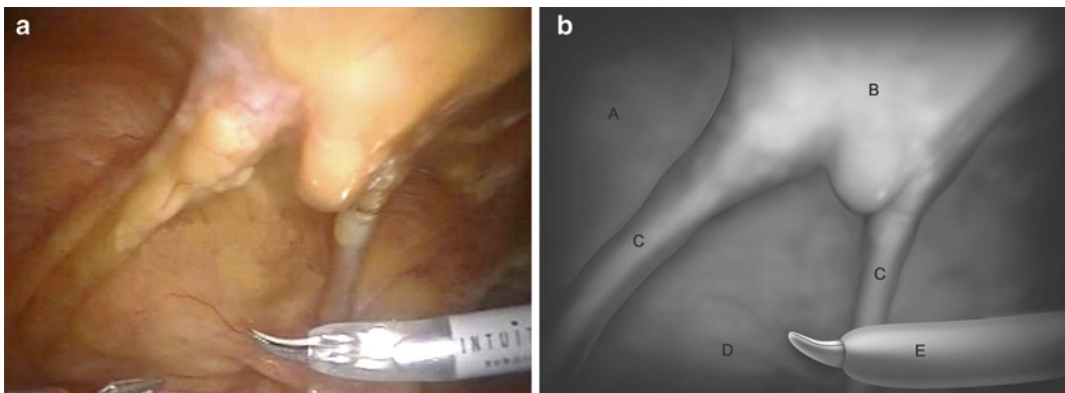


Fig. 7.11 (a, b) View of the anterior abdominal wall (A), urachus (B), bilateral medial umbilical ligaments (C), bladder (D), and right robotic monopolar scissors (E)

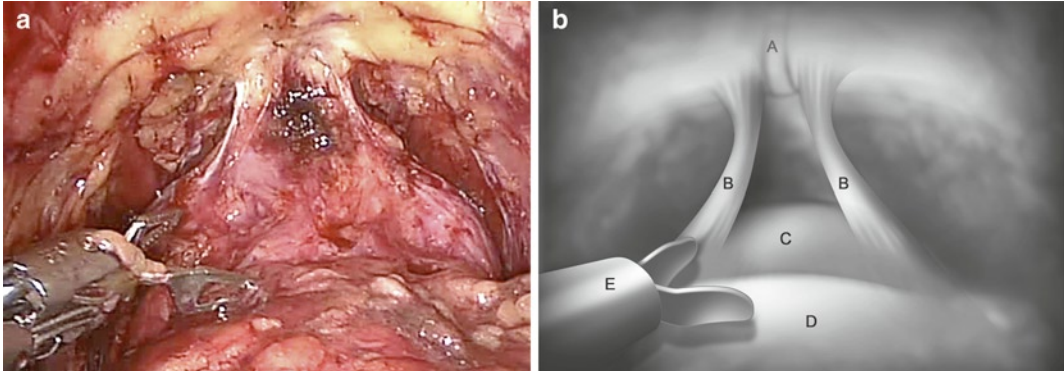


Fig. 7.12 (a, b) View of the pubic bone (A), puboprostatic ligaments (B), prostate (C), and anterior bladder (D), following release of the anterior bladder attachments

and dissection of the space of Retzius. The left robotic bipolar forceps (E) is also shown

used. The urethra is also divided without electrocautery for patients undergoing orthotopic neobladder. With either the right or left assistant providing superior traction on the bladder, the anterior one half of the urethra is divided and the urethral catheter is exposed and the catheter tip pulled in through the urethral opening. The catheter lumen is secured with a large Hem-o-lok® clip and is then divided using the laparoscopic scissors, preventing any possible spillage of tumor. The left assistant provides superior retraction on the prostate and bladder by grasping the cut end of the urethral catheter. Remaining apical attachments are divided, and the bladder, prostate, and seminal vesicles are placed in a 15 mm Endo Catch™ retrieval device.

Step 9: Pelvic lymphadenectomy

Surgeon instrumentation		Assistant instrumentation
Right arm	Left arm	<ul style="list-style-type: none"> • Suction-irrigator • MicroFrance® grasper • Hem-o-lok® clip applier • 10 mm titanium clip applier • 10 mm Endo Catch™ retrieval device
• Curved monopolar scissors	• PreCise™ bipolar forceps	
Endoscope lens: 30° down		

At this time, the 0° lens should be replaced with the 30°-down lens. We begin our pelvic lymphadenectomy by completely denuding the external iliac artery of its surrounding lymphatic tissue, shown here on the patient’s right side in

Fig. 7.13a, b. The contralateral assistant retracts the node packet medially with a MicroFrance® grasper and the packet is developed proximally. Hem-o-lok® or titanium clips are applied liberally during pelvic lymphadenectomy to help minimize the risk of a postoperative pelvic lymphocele. The borders of our pelvic lymphadenectomy are the upper-third of the common iliac artery superiorly, Cooper’s ligament inferiorly, the genitofemoral nerve laterally, and the sacral promontory medially. All presacral, hypogastric, external iliac, obturator, and common iliac lymph node packets are removed en bloc and placed in a 10 mm Endo Catch™ retrieval device. The left and right pelvic lymph node packets are placed in separate bags and can be distinguished by placing a Hem-o-lok® clip on one of the retrieval bags.

Step 10: Transposition of the left ureter

Surgeon instrumentation		Assistant instrumentation
Right arm	Left arm	<ul style="list-style-type: none"> • Suction-irrigator • Maryland dissector
• Curved monopolar scissors	• PreCise™ bipolar forceps	
Endoscope lens: 30° down		

Prior to completion of the urinary diversion, the left ureter is transposed beneath the sigmoid colon mesentery to the right side of the pelvis. The left assistant places the suction-irrigator device through the left 5 mm assistant trocar. With the

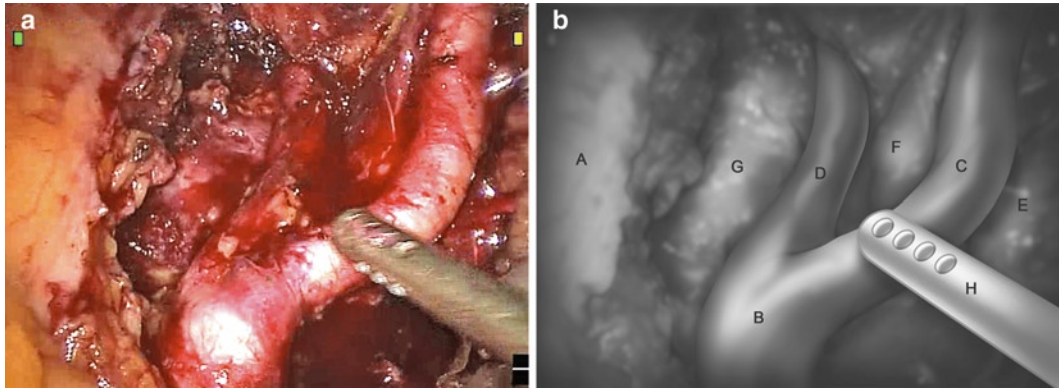


Fig. 7.13 (a, b) View of right pelvic lymph node dissection with the relevant anatomic landmarks including (A) posterior peritoneum (cut), (B) common iliac artery, (C) external

iliac artery, (D) hypogastric artery, (E) external iliac lymph node packet, (F) hypogastric lymph node packet. (G) presacral lymph node packet, and (H) suction-irrigator

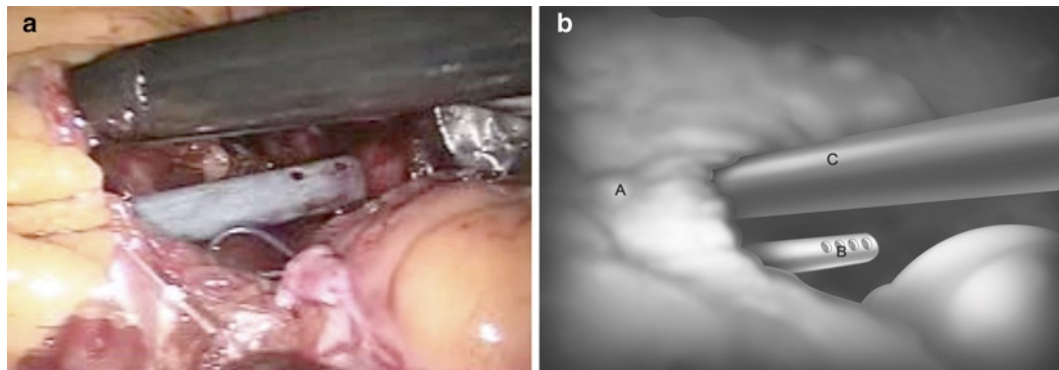


Fig. 7.14 (a, b) Preparing for transposition of the left ureter under the sigmoid colon mesentery. Labeled structures include (A) sigmoid colon, (B) suction-irrigator,

passed posterior to the sigmoid mesentery from the patient's left to right side, and (C) right robotic arm, elevating sigmoid colon

right assistant retracting the sigmoid colon with a MicroFrance® grasper, the surgeon defines a plane posterior to the sigmoid mesentery and superior to the aortic bifurcation just anterior to the great vessels. The suction device is then passed from left to right along this plane (Fig. 7.14a, b). Further dissection is often necessary on the right side of the sigmoid mesentery to identify the tip of the suction device. The right assistant then passes a laparoscopic Maryland dissector through the 5–12 mm right-sided assistant trocar and the tips of the Maryland are placed firmly into the tip of the suction-irrigator device. The right assistant then directs his instrument toward the patient's left side as the suction-irrigator device is drawn back slowly such that the tips of the Maryland

dissector can now be found posterior to the sigmoid mesentery and on the patient's left side. The 0-polyglactin tie attached to the left ureter is placed in the Maryland grasper and the left ureter is then brought behind the sigmoid mesentery to the patient's right side, as shown in Fig. 7.15a, b.

Step 11: Specimen extraction

Surgeon instrumentation		Assistant instrumentation
Right arm	Left arm	<ul style="list-style-type: none"> • Suction-irrigator • MicroFrance® grasper • 15Fr round Jackson-Pratt drain • Endo Close™ device
Curved monopolar scissors	PreCise™ bipolar forceps	
Endoscope lens: 30° down		

Before the robot is undocked, we place a 15Fr round Jackson-Pratt drain through the left 5 mm

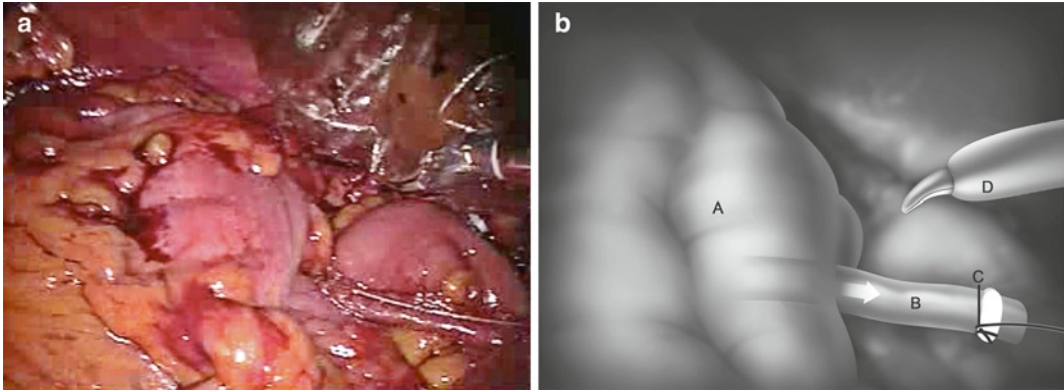


Fig. 7.15 (a, b) Final view following transposition of the left ureter underneath the sigmoid colon and mesentery. Labeled structures include (A) sigmoid colon, (B) left ureter, passed posterior to the sigmoid mesentery

and delivered to the patient’s right side, (C) Hem-o-lok® clip with 0-polyglactin tie attached to the cut end of the left ureter, and (D) right robotic arm

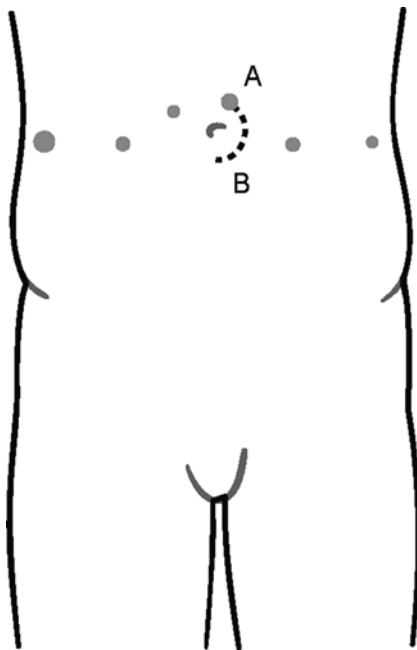


Fig. 7.16 Extraction of specimens is accomplished by extending the periumbilical camera trocar site (A) in a curvilinear fashion (dotted line) around the umbilicus. B The bladder, prostate, and bilateral pelvic lymph node specimens are removed through this incision

close the 5–15 mm right assistant trocar. After the robot has been undocked, the 1 cm periumbilical camera incision is extended inferiorly in a curvilinear fashion around the umbilicus (Fig. 7.16). Depending on the patient’s body habitus, the periumbilical incision used for specimen extraction and extracorporeal urinary diversion ranges from 5 to 7 cm. The three separate Endo Catch™ retrieval bags are removed containing the cystoprostatectomy specimen and the two separate lymph node packets. If the surgeon plans to perform a completely intracorporeal urinary diversion in female patients, the specimens can be removed via the vagina. Urinary diversions including ileal conduit, continent cutaneous diversion, and orthotopic ileal neobladder and the bilateral ureteral anastomoses are performed in the standard open fashion [1,2].

assistant trocar. For orthotopic neobladders, the drain is placed after the anastomosis has been completed robotically. Additionally, we use a 0-polyglactin tie on an Endo Close™ device to

Step 12: Urethral-neobladder anastomosis

Surgeon instrumentation		Assistant instrumentation
Right arm	Left arm	<ul style="list-style-type: none"> • Suction-irrigator • Laparoscopic needle driver • 15Fr round Jackson-Pratt drain
• Needle driver	• Needle driver	
Endoscope lens: 0° or 30° down		

For patients undergoing orthotopic neobladder, the newly created neobladder is brought down into the pelvis. We then place a urethral catheter

per urethra and into the opening created in the neobladder and the catheter balloon is inflated with 15 mL of sterile water and the catheter placed on mild traction to bring the neobladder in closer proximity to the urethra. Prior to redocking of the robot for the urethral-neobladder anastomosis, a suprapubic tube and ureteral stents are brought through a single stab wound in the right lower quadrant of the abdominal wall. This stabilizes the neobladder and facilitates the urethral-neobladder anastomosis. We then close the periumbilical anterior rectus fascia using a 0-Maxon suture in a running fashion, leaving a 1 cm opening at the superior aspect of the wound for placement of the 10–12 mm robotic camera trocar. The robot is then redocked, pneumoperitoneum is reestablished, and the urethral-neobladder anastomosis is performed as shown in Fig. 7.17.

Depending on the depth of the patient's pelvis, we use either the 30°-down or 0° lens for this portion of the procedure. We use a double-armed suture consisting of an undyed 2-0 Biosyn on a GU-46 needle cut to 10 in. which is then tied to a 10-in. segment of dyed 2-0 Monocryl on a

UR-6 needle. We begin our anastomosis at the 6 o'clock position with the dyed 2-0 Monocryl suture. This suture is placed outside to in on the neobladder, then inside to out on the urethra. After five throws have been placed in a clockwise direction, the suture will be on the inside of the neobladder and the neobladder is brought down to the urethra. The left assistant then grasps the dyed suture and places it on gentle traction to prevent the posterior anastomosis from distracting. The undyed 2-0 Biosyn suture is then placed outside to in on the urethra at the 5 o'clock position. This suture is run in a counter-clockwise direction until the undyed 2-0 Biosyn is outside the bladder at the 2 o'clock position. The right assistant is then handed the undyed suture which is placed on gentle traction. The dyed 2-0 Monocryl suture is then run in a clockwise fashion until the suture is outside the urethra at the 12 o'clock position. Both needles are then removed and the anastomosis is secured. At this time, a 15Fr round Jackson-Pratt drain is placed through the 5 mm left-sided assistant trocar. We then undock the robot and remove the camera trocar to complete our fascial closure of the

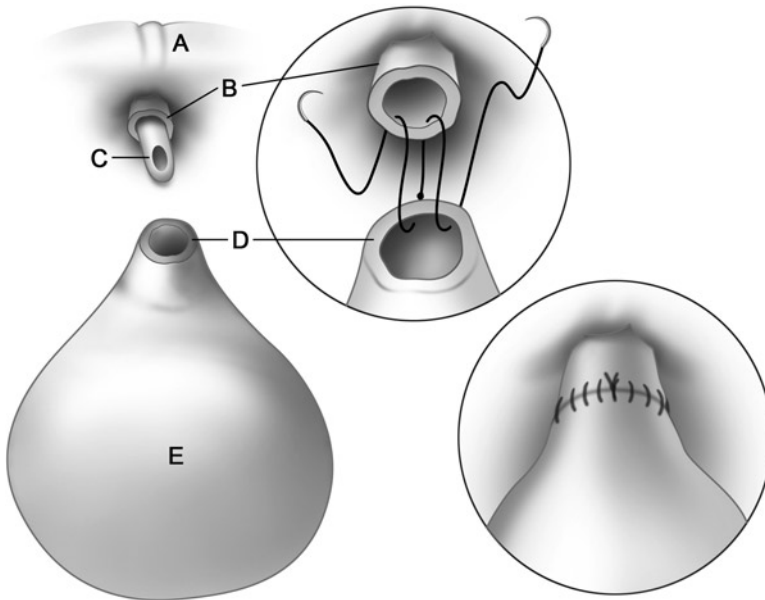


Fig. 7.17 Running vesicourethral anastomosis following creation of neobladder. Labeled structures are as follows: (A) pubic bone, (B) urethra, (C) urethral catheter,

(D) everted mucosa of neobladder, (E) neobladder. Insets show the running anastomotic suture and the completed anastomosis

periumbilical incision. All wounds are copiously irrigated with sterile water and injected with 0.25% bupivocaine. Skin closure is performed in a running subcuticular fashion using 4-0 Biosyn suture on a P-12 needle.

Postoperative Care

We use clinical pathways for routine postoperative care in our cystectomy patients, both open and robotic. Nasogastric tubes are not routinely used and bowel rest is maintained for 2–3 days postoperatively. Patients are aggressively ambulated and are closely followed by both physical and occupational therapy. If patients have not passed flatus by postoperative day 3, we then begin a promotility regimen consisting of metoclopramide 10 mg and erythromycin 125 mg intravenously every 6 h, and bisacodyl suppositories twice a day. Intravenous patient-controlled analgesia is used until patients are tolerating a liquid diet and patients routinely receive intravenous ketorolac to decrease narcotic requirement. Patients resume a regular diet after 1 day of clear liquids. Our median length of stay is 4–6 days, and we have found a decrease in our median length of stay with the use of clinical pathways.

We routinely place a self-contained suction drain at the completion of the robotic portion of the case and this is removed prior to discharge from the hospital. For ileal conduits, the stomal catheter is removed prior to discharge, and the bilateral ureteral stents are removed 2 weeks after surgery in the office. Intramuscular gentamycin and oral furosemide are administered at the time of ureteral stent removal. For continent cutaneous diversions, ureteral stents are removed prior to discharge. The stomal catheter is removed 2 weeks later in the office and patients begin a regimen of self-catheterization. If postvoid residuals are acceptable, the suprapubic tube is subsequently removed. For orthotopic diversions, ureteral stents are also removed prior to discharge. The urethral catheter is removed 2 weeks after surgery in the

office and the suprapubic tube is subsequently removed if postvoid residuals are acceptable.

Special Considerations

1. To facilitate continent cutaneous urinary diversion through a small periumbilical incision, we use the 5 mm Ethicon™ Harmonic Scalpel™ after trocar placement to mobilize the right colon from the midtransverse colon to the ileocecal valve. This enables delivery of the right colon through the small periumbilical incision during extracorporeal urinary diversion.
2. In female patients, a sponge stick is placed in the vagina at the beginning of the case. The labia majora are then sutured together using a #1 Prolene to prevent loss of subsequent pneumoperitoneum through the vagina. For most muscle-invasive bladder tumors, the anterior vaginal wall is excised en bloc with the bladder. This is done by anterior elevation of the sponge stick to define the vaginal apex which is then incised using the monopolar scissors. For anterior bladder tumors, the vagina can be spared by developing the avascular plane between the bladder and the anterior vaginal wall.
3. In female patients, prior to ureteral dissection, we divide the gonadal vessels using either Hem-o-lok® clips or the LigaSure™ device, and the ovaries and uterus are mobilized along with the bladder and are subsequently removed.

Steps to Avoid Complications

Posterior dissection should be performed beneath the posterior leaflet of Denonvillier's fascia to ensure oncologic efficacy. Also, perirectal fat must always be visible during this portion of the dissection to decrease the risk of rectal injury, particularly at the apex where most rectal injuries occur. Posterior dissection should be carried as distally as possible, because

once the bladder is released from the anterior abdominal wall, posterior visualization becomes quite limited.

The left ureter should be brought beneath the sigmoid mesentery as high as possible, preferably at the level of the aortic bifurcation or higher, to minimize kinking of the left ureter.

References

1. Rowland RG, Mitchell ME, Bihle R, Kahnoski RJ, Piser JE (1987) Indiana continent urinary reservoir. *J Urol* 137:1136–1139
2. Hautmann RE, Egghart G, Frohneberg D, Miller K (1988) The ileal neobladder. *J Urol* 139:39–42

Chapter 8

Robot-Assisted Laparoscopic Sacrocolpopexy

Shawn M. McGee, Mark S. Shimko, Daniel S. Elliott, and George K. Chow

This chapter contains a video segment which can be found at the URL: <http://www.springerimages.com/Su>

Patient Selection

The success of the sacrocolpopexy is largely due to correctly identifying the appropriate patient for the robot-assisted laparoscopic sacrocolpopexy (RALS) [1]. The diagnosis of vaginal vault prolapse is broad and includes female patients with or without a uterus presenting with a cystocele, rectocele, enterocele, or a combination of these findings. The sacrocolpopexy has traditionally been used for patients with posthysterectomy apical vaginal vault prolapse, which may include a concomitant posterior or anterior vaginal vault defect (Fig. 8.1). The female patient may be a candidate for sacrocolpopexy if she suffers from high-grade apical vaginal prolapse as classified by a standardized grading system such the Baden Walker scale or Pelvic Organ Prolapse Quantification system. In addition, as our RALS procedure has evolved, review of the patient selection has confirmed that the RALS is successful in obese females with no increase in intraoperative or postoperative complications [2].

M.S. Shimko(✉)
Department of Urology, Mayo Medical School and
Mayo Clinic, 200 First Street Southwest,
Rochester, MN 55905, USA
e-mail: Shimko.Mark@mayo.edu

Preoperative Preparation

Not unlike other robot-assisted procedures performed in the pelvis, a laxative such as magnesium citrate is typically used the evening before surgery to evacuate and decompress the bowels, improve visualization of the operative field, and minimize the risk of inadvertent bowel injury.

In addition, the patient is consented for a RALS much like a patient undergoing a robot-assisted laparoscopic prostatectomy with special attention paid to the risks of infection, bleeding, postoperative ileus, bowel injury, and conversion to an open procedure. Currently, we quote less than 1% chance for infection, hemorrhage, ileus, bowel injury and less than 8% chance of conversion to an open procedure for our RALS procedure.

Operative Setup

The robotic system and operative suite is set-up similar to the robot-assisted laparoscopic prostatectomy (Fig. 8.2). The surgeon console is in the corner of the room toward the foot of the operating table. The patient cart, when rolled in, should have its center column between the legs of the patient; with the base of the patient cart straddling the base of the operating table. The surgical assistant stands on the right side of the patient which allows access to the perineum during the procedure. The scrub nurse stands across from the assistant on the patient's left side.

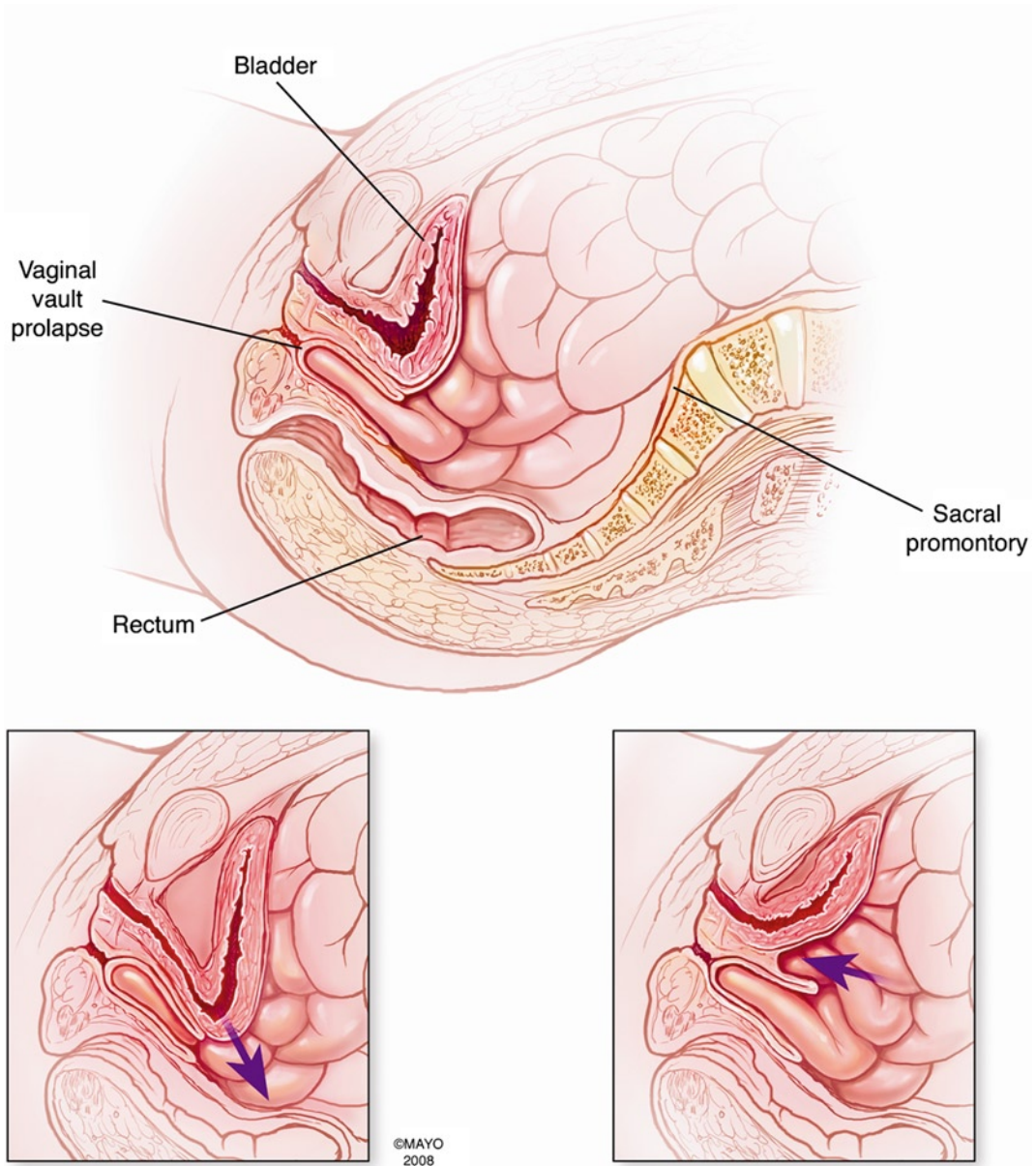


Fig. 8.1 Sagittal section of female pelvis demonstrating apical vaginal vault prolapse; anatomical variation with posterior bladder wall draping over apex of vagina

(*lower-left inset*); anatomical variation with posterior bladder wall recessed distally away from vaginal apex (*lower-right inset*)

Patient Positioning and Preparation

The patient's legs are placed in cushioned, full supporting Allen stirrups to keep the patient in dorsal lithotomy for the entire procedure and allow access to the vagina before and after the

patient cart is rolled in (Fig. 8.3). The lower extremities' pressure points are padded, specifically paying attention to the region behind the knees. The stirrups should not place the lower extremities in excessive angles to dissuade plexus injuries. The patient is placed in Trendelenburg

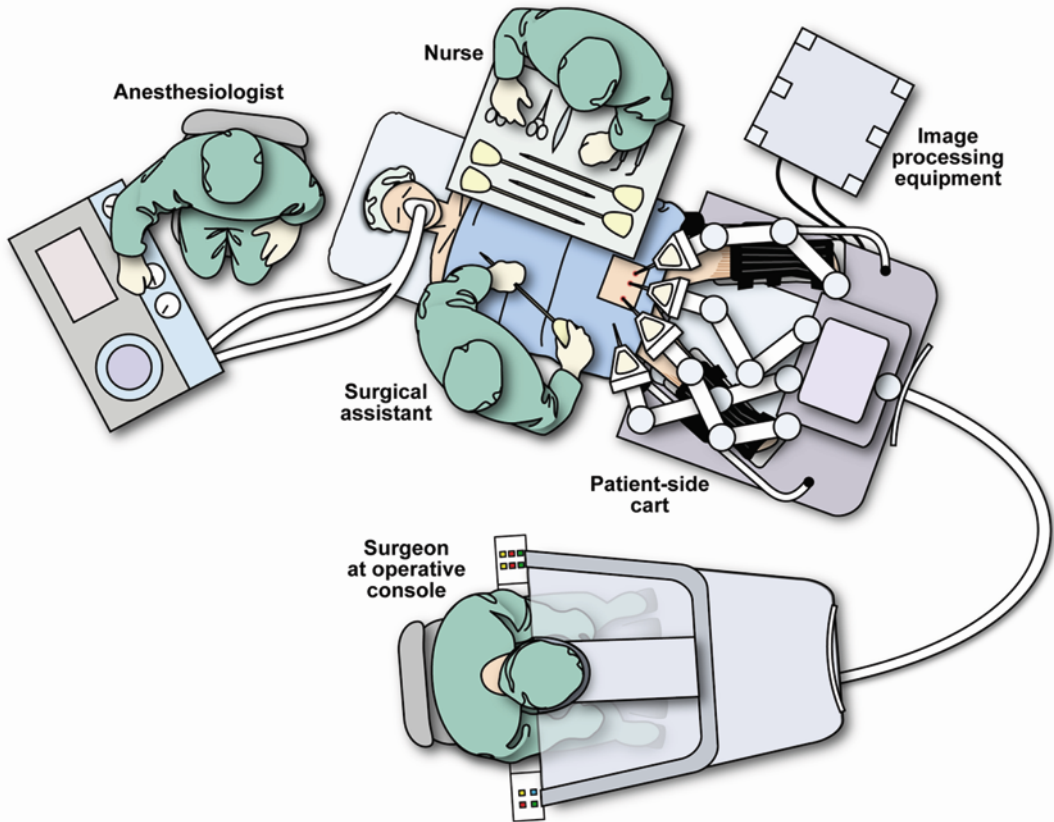


Fig. 8.2 Overhead view of operating room setup for RALS

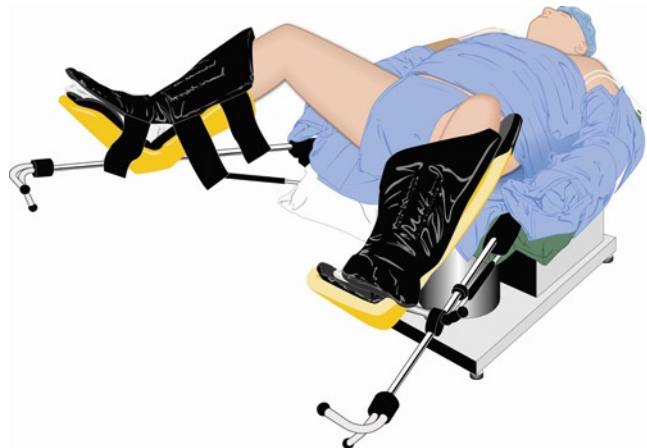

Fig. 8.3 Patient positioning on operative table with stirrups

(between 15° and 20°) after a strap is securely placed across the chest below the level of the breasts. The patient's arms are tucked beside the torso on arm-boards after padding the arm's pressure points. A nasogastric tube is placed

before the case to decompress the stomach and removed at the completion of surgery. A urethral catheter is placed into the bladder and attached to drainage which will remain until the morning of postoperative day #1. The abdomen below the

level of the breasts, pelvis, vagina, and perineum are prepped for surgery. The vagina is left exposed during draping to allow placement of the hand-held vaginal retractor during the case (explained later in the description of RALS).

Trocar Configuration

RALS is performed using the da Vinci-S[®] Surgical System (Intuitive Surgical, Inc., Sunnyvale, CA). The initial placement of the central camera trocar is based on the patient's pubic symphysis and umbilicus (Fig. 8.4). Generally the initial central camera trocar is placed 12–15 cm above the pubic symphysis but below the umbilicus. All measurements are generalized and can change based on a patient's body habitus. The placement of trocars is started by placing the 12 mm disposable camera trocar (red circle in Fig. 8.4). This is placed 12–15 cm above the pubic symphysis but staying below the umbilicus. The right and left da Vinci[®] arm reusable 8 mm trocars (blue circle) are placed 10–12 mm from the central camera trocar below the level of the camera trocar, lateral to the rectus muscles and two fingerbreadths superior to the level of the anterior superior iliac spine. The assistant 12 mm trocar (green circle) is placed two finger-breadths below the subcostal margin and lateral to the rectus muscle, one hand-breadth

(8–10 cm) away from the right robotic 8 mm instrument trocar. This trocar is approximately 10–12 cm from the central camera trocar. An optional assistant 5 mm trocar or possible third robotic arm (black circle) can be placed one hand-breadth (8–10 cm) inferior-laterally from the assistant 12 mm trocar at approximately the level of the umbilicus. This trocar is approximately 10–12 cm from the central camera trocar. The bowel retraction suture site (orange circle) is not an actual laparoscopic trocar and will be explained later in the description of RALS.

Instrumentation and Equipment List

Initially, standard laparoscopic instruments were utilized in performing the RALS to assist in taking down adhesions and dissecting the vagina from the posterior wall of the bladder. Now all of the procedure, including the dissection of the vagina is done with the da Vinci[®] robotic instrumentation. Regardless of the method used, the sacrocolpopexy depends on the correct identification of the vaginal apex and ability to retract the vagina inferiorly during dissection of the anterior vaginal plane. We utilize a specialized instrument engineered at our institution designated the hand-held vaginal retractor to visualize

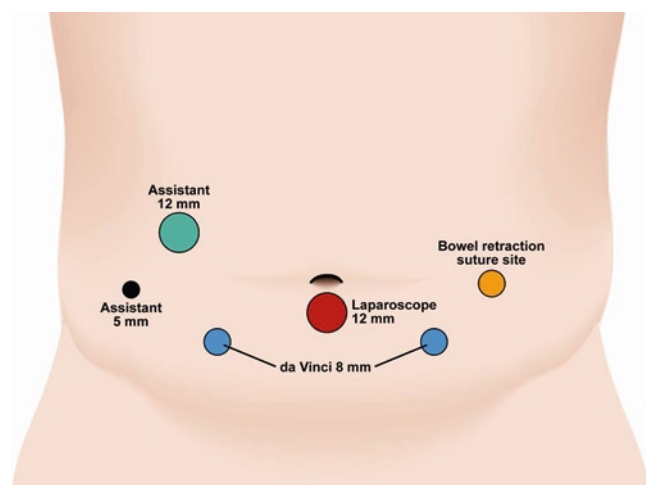


Fig. 8.4 Trocar configuration for RALS

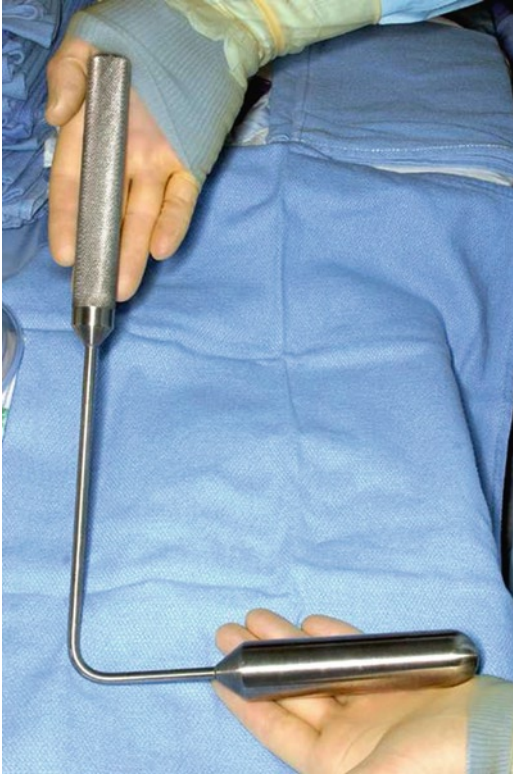

Fig. 8.5 Hand-held vaginal retractor

the plane between the vagina and bladder (Fig. 8.5). The laparoscopic and robotic instruments are listed below.

Equipment

- da Vinci® S Surgical System (Intuitive Surgical, Inc., Sunnyvale, CA)
- EndoWrist® curved monopolar scissors (Intuitive Surgical, Inc., Sunnyvale, CA)
- EndoWrist® ProGrasp™ forceps (Intuitive Surgical, Inc., Sunnyvale, CA)
- EndoWrist® needle drivers (2) (Intuitive Surgical, Inc., Sunnyvale, CA)
- InSite® Vision System with 0° and 30° lens (Intuitive Surgical, Inc., Sunnyvale, CA)

Trocars

- 12 mm trocars (2)
- 8 mm robotic trocars (2)
- 5 mm trocar (1)

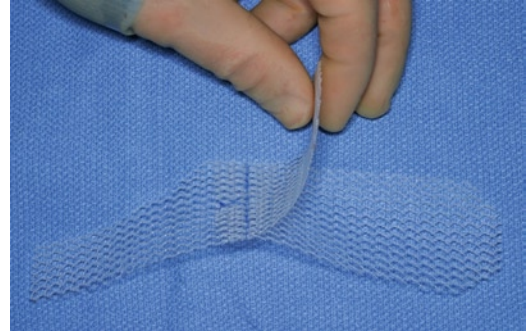

Fig. 8.6 Mesh Y-graft (polypropylene)

Recommended sutures

- Retraction stitch for sigmoid colon: 2-0 Prolene suture full length on a Keith needle
- Fixation suture for polypropylene Y-graft: 2-0 GorTex on CV-2 needle cut to 7 cm
- Y-graft mesh preparation: 2-0 monocryl
- Mesh retroperitonealization: 2-0 polyglactin on CT-1 cut to 7 cm

Instruments used by the surgical assistant

- Laparoscopic needle driver
- Laparoscopic scissors
- Maryland grasper
- Suction irrigator device
- 16 Fr silicone urethral catheter
- Polypropylene Y-graft (AMS, Minnetonka, MN) (see Fig. 8.6)

Step-by-Step Technique

RALS is performed using the da Vinci-S®, which allows three-dimensional visualization and six degrees of freedom of instrument movement to the surgeon through the modulated remote control. Docking the da Vinci® includes connecting the camera arm to the laparoscopic 12 mm trocar (red circle, Fig. 8.4), and connecting the instrument arms to the laparoscopic 8 mm trocars (blue circles, Fig. 8.4). During the entire procedure, a 30° lens in the down-ward view is placed via the camera trocar. We have started each description of our steps with an instrument index table which names the instrument used, the trocar used, and the handedness.

Step 1: Abdominal access and trocar placement

Prior to placement of the laparoscopic trocars, a 16 Fr urethral catheter is placed for the entire procedure. As noted above, the initial placement of the central camera trocar is based on the patient's pubic symphysis and umbilicus (Fig. 8.4). After abdominal insufflation using a Veress needle, we place a peri-umbilical Visiport optical trocar (Autosuture, Norwalk, CT) through a disposable 12 mm trocar under direct vision to avoid visceral or vascular injury. Generally, this initial trocar (camera) is placed 12–15 cm above the pubic symphysis but below the umbilicus. The assistant and robotic arm trocars are then placed under direct vision in the locations described above in section entitled "Trocar configuration" (Fig. 8.4).

Step 2: Vaginal retractor placement and retraction of sigmoid colon

Robotic instruments	
Right arm	Left arm
<ul style="list-style-type: none"> • Curved monopolar scissors • Large needle driver 	<ul style="list-style-type: none"> • ProGrasp™ dissector • Large needle driver
Assistant instruments	
Right hand	Left hand
<ul style="list-style-type: none"> • Hand-held vaginal retractor 	

Initially all adhesions are taken down in the abdomen and pelvis with a ProGrasp™ in the left hand and monopolar curved scissors in the right hand. Adhesion takedown should allow exposure of the vagina and sigmoid colon. To avoid tissue damage along the planes between bladder and vagina, electrocautery is used judiciously at a setting of 30–40 W. To assist in dissection, the hand-held vaginal retractor is then placed in the previously prepped vaginal canal by the assistant to expose the vaginal apex (Fig. 8.7). Prior to vaginal dissection, the sigmoid colon is reflected superior-laterally to the patient's left with a retracting suture. The site of the retraction suture is typically 8–10 cm lateral to the camera trocar at the level of the umbilicus (orange circle – Fig. 8.4). Retraction of the sigmoid is done with a 2-0 Prolene suture on a Keith needle which is introduced through the anterior abdominal wall 8–10 cm lateral to the camera trocar at the level of the umbilicus (orange circle – Fig. 8.4). Utilizing a needle driver in the right hand and a

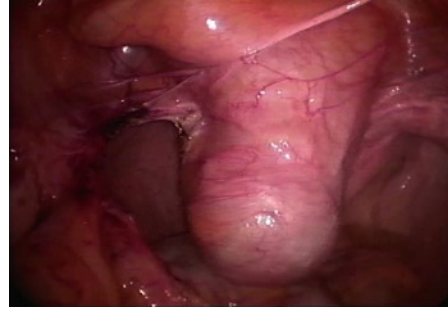


Fig. 8.7 Intraoperative view demonstrating insertion of hand-held vaginal retractor to delineate the vaginal apex

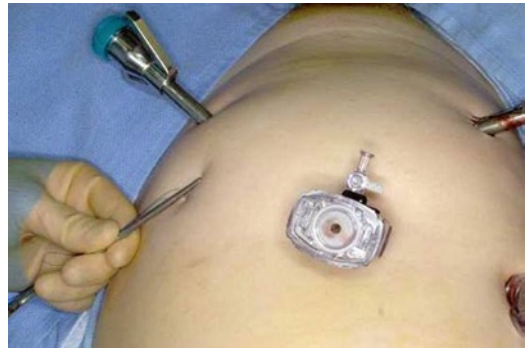

Fig. 8.8 Mosquito clamp holding retraction suture approximately one hand breadth lateral to camera trocar

ProGrasp™ in the left hand, the Prolene suture is grasped from the anterior abdominal wall and placed through the tenia of the sigmoid colon. The suture is then brought out of the abdominal wall near its entrance site. The two ends of the suture are gently retracted together with a curved mosquito outside the body to expose the sacral promontory (Fig. 8.8).

Step 3: Vaginal dissection

Robotic instruments	
Right arm	Left arm
<ul style="list-style-type: none"> • Curved monopolar scissors 	<ul style="list-style-type: none"> • ProGrasp™ dissector
Assistant instruments	
Right hand (assistant 5 mm – black circle)	Left hand (assistant 12 mm – green circle)
<ul style="list-style-type: none"> • Suction-irrigator • Hand-held vaginal retractor 	<ul style="list-style-type: none"> • Maryland grasper

Utilizing monopolar curved scissors with electrocautery in the right hand and ProGrasp™ in the left hand, the plane between the anterior vagina and posterior bladder wall is dissected

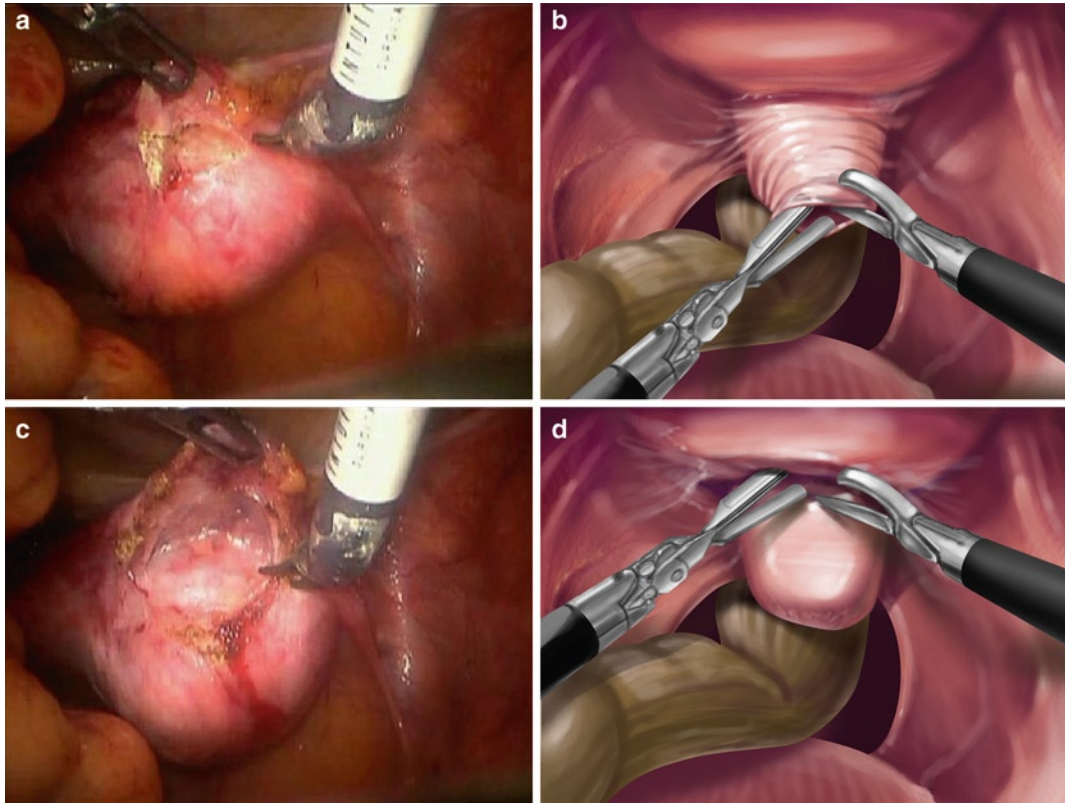


Fig. 8.9 (a,b) Bladder being dissected off of the anterior vaginal wall using the spread and cut technique. (c,d) Plane developed between bladder and anterior vagina

beginning with electrocautery to gently score the surface of the vagina. Thereafter, no electrocautery is used to dissuade devascularization of the vaginal wall. The hand-held vaginal retractor is used to deflect the vaginal apex inferiorly to allow better visualization of the plane between the vagina and bladder. It is important to note that anatomical variation exists between the anterior vaginal wall and posterior bladder wall that can make finding the correct plane difficult (please refer to the “Steps to avoid complications” section for further discussion).

Utilizing scissors with electrocautery in the right hand and ProGrasp™ in the left hand, the plane between the anterior vagina and bladder is dissected with a spread and cut technique in combination with blunt dissection. The left hand instrument should be grasping the tissue anterior to the vagina and retracting superior to allow visualization of the apex of the vagina (Fig. 8.9a–d). If the surgeon is in the right plane, this dissection

is generally bloodless. This plane between the anterior vagina and bladder wall is continued distally, as close as possible to the introitus, to maximize the support given by the Y-mesh graft. The plane between the rectum and posterior vagina generally requires less dissection and in some patients may be exposed to the level of the introitus. If dissection is needed in this plane, the same instruments and technique can be utilized as above for the anterior dissection.

Step 4: Exposing the sacral promontory and placement of GorTex sutures

Robotic instruments	
Right arm	Left arm
<ul style="list-style-type: none"> • Curved monopolar scissors • Needle driver 	<ul style="list-style-type: none"> • ProGrasp™ dissector • Needle driver
Assistant instruments	
Right hand (assistant 5 mm – black circle)	Left hand (assistant 12 mm – green circle)
<ul style="list-style-type: none"> • Suction-irrigator 	<ul style="list-style-type: none"> • Maryland grasper

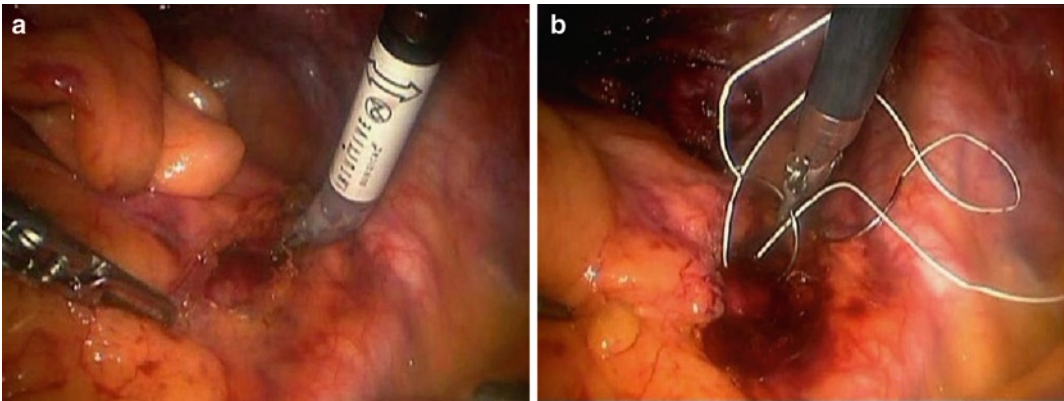


Fig. 8.10 (a) Window created in posterior peritoneum exposing the sacral promontory. (b) Placement of GorTex sutures into sacral promontory for later mesh fixation

Utilizing curved monopolar scissors in the right hand and ProGrasp™ in the left hand, the peritoneal reflection above the proximal sacrum is gently scored with electrocautery to begin the dissection. Continue the dissection through the tissues underlying the peritoneal reflection to visualize the sacral promontory (Fig. 8.10). It is important to note that severe bleeding is described by authors who have dissected and sutured mesh below the S-2 level in the transabdominal sacrocolpopexy [3]. Because of this, our technique stays proximal on the sacrum during dissection and suture placement for mesh fixation (please refer to the “Steps to avoid complications” section for further discussion).

Utilizing needle drivers in both hands, individual 2-0 GorTex sutures on a CV-2 needle approximately 7 cm in length are placed horizontally into the sacrum above the level of S2 (Fig. 8.10). The suture should be placed deep enough into the sacral promontory to sufficiently withstand moderate traction with the needle drivers. A total of three to four sutures with the needles left attached remain in the abdomen for mesh fixation. The surgical assistant typically uses a suction irrigator in the right hand (5 mm assistant trocar) and a Maryland grasper in the left hand (12 mm assistant trocar) for assistance and bowel retraction through this step.

Step 5: Suturing mesh to vagina

Robotic instruments	
Right arm	Left arm
• Needle driver	• Needle driver
Assistant instruments	
Right hand (assistant 5 mm – black circle)	Left hand (assistant 12 mm – green circle)
• Suction-irrigator	
• Hand-held vaginal retractor	

At this point in the procedure, the mesh Y-graft (polypropylene Y-graft; AMS, Minnetonka, MN) is prepared to introduce into the abdominal cavity. The anterior flap of the Y-graft is temporarily sutured back onto the tail of the Y-graft with 2-0 Monocryl suture outside the body (Fig. 8.11a). This maneuver keeps the flap from obscuring the surgeon’s view and allows easier suturing of the posterior flap to the posterior vaginal canal. The mesh Y-graft is then introduced via the 12 mm assistant trocar with the posterior flap orientated along the posterior vaginal canal. The surgical assistant replaces the hand-held vaginal retractor into the vaginal canal and deflects it superiorly to reorientate the surgeon prior to placing sutures. The surgeon then places the distal end of the posterior flap of the Y-mesh graft as close to the introitus as possible. The distal end of the Y-mesh graft’s posterior flap is then sutured as close to the introitus as possible with individual 2-0 GorTex sutures on a CV-2 needle approximately

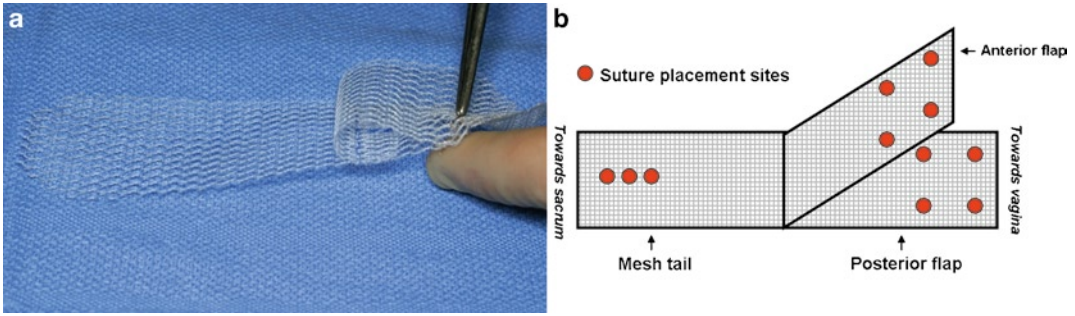


Fig. 8.11 (a) Mesh Y-graft’s anterior flap sutured back onto tail in preparation for posterior flap suturing intracorporeally. (b) Suture configuration on mesh Y-graft

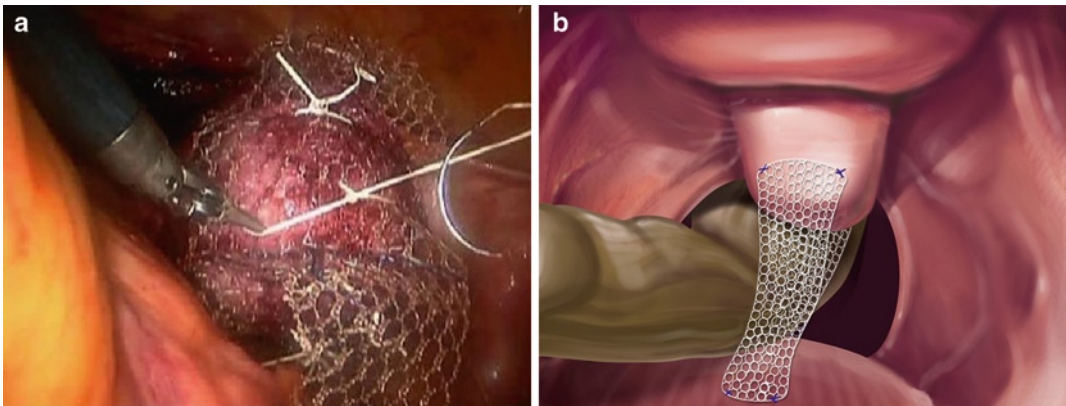


Fig. 8.12 (a) Mesh fixation to anterior vagina. (b) Schematic demonstrating completed fixation of the mesh to the anterior and posterior vagina

7 cm in length. To obtain the best support of the apex, and posterior vagina, four to six total GorTex sutures are used on the posterior flap of the Y-mesh graft. Please see Fig. 8.11b which shows the suture configuration for mesh fixation to the vagina. The temporary Monocryl suture is then cut allowing the anterior flap to be manipulated to the anterior vagina. Due to fixing the posterior flap of the Y-mesh graft first, upward traction on the anterior flap allows easier and more precise mesh fixation and better visualization. The surgeon then places the distal end of the anterior flap of the Y-mesh graft as close to the introitus as possible.

Utilizing the needle drivers on both the right and left robotic arms, the distal end of the Y-mesh graft’s anterior flap is sutured as close to the introitus as possible with individual 2-0 GorTex sutures on a CV-2 needle approximately 7 cm in

length (Fig. 8.12a, b). To obtain the best support of the apex, and anterior vagina, four to six total GorTex sutures are used on the anterior flap of the Y-mesh graft. Please see Fig. 8.11b which shows the suture configuration for mesh fixation to the vagina. All needles from the GorTex suture are removed by the assistant.

Step 6: Suturing mesh to sacrum

Robotic instruments	
Right arm	Left arm
• Needle driver	• Needle driver
Assistant instruments	
Right hand (assistant 5 mm – black circle)	Left hand (assistant 12 mm – green circle)
• Suction-irrigator	• Maryland grasper

Utilizing needle drivers in the right and left hands of the robot, the previously placed sacral sutures are used to tie the tail of the Y-mesh graft

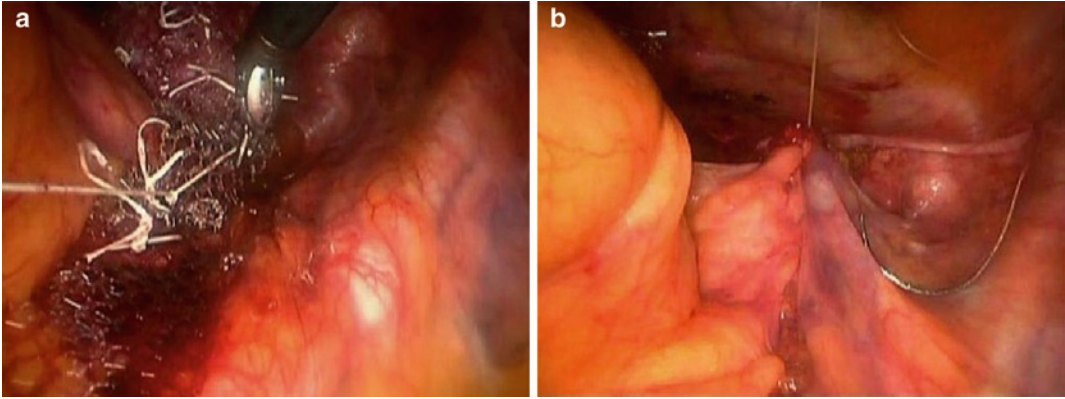


Fig. 8.13 (a) Mesh fixation to sacrum. (b) Retroperitonealization of mesh

to the sacrum (Fig. 8.13a). See Fig. 8.11b which shows the suture configuration on the tail of the Y-mesh graft. The mesh should not be under tension but should approximate the apex of the vagina into a more normal anatomical position. By using the hand-held vaginal retractor, the assistant directs the vaginal apex into the normal anatomical configuration which allows the surgeon to tie the sutures without tension. The excess stem of the Y-mesh graft is excised and removed through the assistant trocar along with the GorTex needles.

Step 7: Retroperitonealizing the mesh and exiting the abdomen

Robotic instruments	
Right arm	Left arm
• Needle driver	• Needle driver
Assistant instruments	
Right hand (assistant 5 mm – black circle)	Left hand (assistant 12 mm – green circle)
• Suction-irrigator	• Maryland grasper

Next, with the needle drivers on the robotic arms, a running 2-0 polyglactin suture on a CT-1 needle (7 cm in length) is used to reapproximate the peritoneal reflection over the Y-mesh graft which is now tied to the sacrum (Fig. 8.13b). Figure 8.14 demonstrates what the final repair should resemble anatomically. The Y-mesh graft should approximate the vagina in a more normal anatomical position, but also support the anterior and

posterior walls of the vaginal canal. After confirming hemostasis, trocar-site closure is done in the usual manner, using a trocar site closure device to close all wounds greater than 5 mm in diameter.

Postoperative Management

The hospital course for RALS is similar to robot-assisted prostatectomies in terms of pain control and advancement of diet. We routinely will use scheduled non-narcotic pain medications such as ketorolac in addition to oral narcotics for pain control. The patient's diet is advanced to a regular diet by the morning of postoperative day #1.

In addition, since the majority of our dissection is between the bladder and vagina, we closely observe for urine output volume and color and vaginal drainage/bleeding. The urethral catheter is removed prior to discharge on postoperative day #1.

Special Considerations

Increased Body Mass Index

A majority of patients undergoing sacrocolpopexy have a higher body mass index since obesity is a known risk factor in the development of

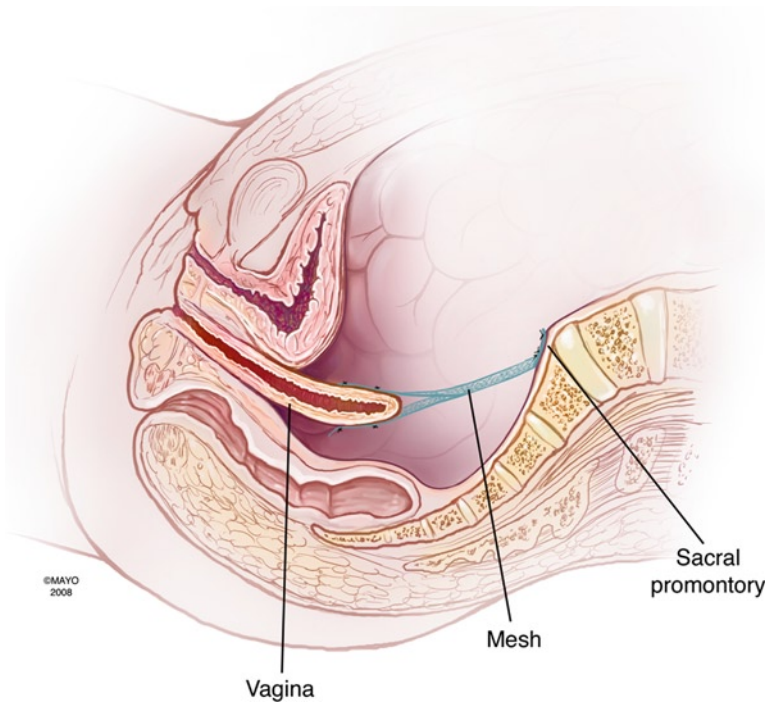


Fig. 8.14 Schematic diagram of sagittal section of female pelvis showing completed prolapse repair

pelvic organ prolapse. Despite prior studies demonstrating an increased difficulty level for laparoscopic procedures in obese patients, the patient's body mass index appears to have no effect on durability after RALS at our institution [4].

Mesh Material

Synthetic meshes are used in the majority of patients undergoing a sacrocolpopexy described in literature [5]. Current literature has reported that polypropylene mesh is superior to cadaveric fascia lata when comparing prolapse failure based on postoperative POPQ stage [6]. The author's preference is to use synthetic mesh (polypropylene) because of its initial pliability and long-term durability. Overall, the mesh erosion rate is 3.4% in a large review of the abdominal sacrocolpopexy [5]. Currently in our series of RALS we have reported two patients with mesh erosion (3.8%) [7].

Concomitant Surgical Procedures

It is the surgeon's preference to perform a culdoplasty as described by Halban, on a case-by-case basis, prior to retroperitonealizing the mesh. The need for culdoplasty is based on the depth of the cul-de-sac at the time of surgery. The vast majority of RALS at our institution, as well as those reported in the literature, are performed in conjunction with an incontinence procedure [8, 9]. Both incontinence and prolapse are due to pelvic floor dysfunction, and have similar risk factors. Concomitant urinary incontinence in females with pelvic organ prolapse is common with up to 40% of patients presenting with urinary incontinence also suffering significant genital prolapse [10]. It is the surgeon's preference to place a synthetic urethral sling at the time of sacrocolpopexy due to the ease of its placement with the patient in a dorsal lithotomy position.

Steps to Avoid Complications

Vaginal/Bladder Dissection and Anatomical Variations

In our experience, some patients with apical vaginal prolapse have a more difficult vaginal dissection due to the location of the bladder. Some patients exhibit a posterior bladder wall that drapes over the apex of vagina that inhibits the surgeon from easily finding the bloodless plane between the bladder and vagina (Fig. 8.1; lower-left inset). Some patients exhibit a posterior bladder wall that is recessed back along the anterior wall which makes the correct identification of a plane between the bladder and vagina difficult (Fig. 8.1; lower-right inset). Extra time and effort, along with using the hand-held vaginal retractor, is necessary to carefully find the correct plane and not inadvertently perforate the bladder, vagina, or rectum. Cases of inadvertent bladder or vaginal perforation during RALS at our institution were all due to the anatomical variations described in Fig. 8.1 (lower-left inset). In these two cases, the perforation was repaired and the sacrocolpopexy finished.

Intraoperative Hemorrhage

Traditionally, the mesh from the vagina was fixated at the S3 or S4 level due to the resultant normal axis of the vagina after repair. In the modern era, the sacrocolpopexy is performed with mesh fixation at the sacral promontory above S3 to dissuade hemorrhage attributed to the unrecognized presacral vessels [3]. Because of this, our technique stays proximal on the sacrum during dissection and suture placement for mesh fixation.

Acknowledgments The authors would like to thank our surgical assistants, especially Ms. Nancy Mork, for their contributions in the operative suite.

We would also like to thank the Medical Illustration and Audiovisual Departments at Mayo Clinic for their contributions.

References

1. Elliott DS, Krambeck AE, Chow GK (2006) Long-term results of robotic assisted laparoscopic sacrocolpopexy for the treatment of high grade vaginal vault prolapse. *J Urol* 176:655–659
2. Elliott DS, Frank I, DiMarco DS, Chow GK (2004) Gynecologic use of the robotically assisted laparoscopy: sacrocolpopexy for the treatment of high-grade vaginal vault prolapse. *Am J Surg* 188:52S–56S
3. Sutton GP, Addison WA, Livengood C, Hammond CB (1981) Life-threatening hemorrhage complicating sacrocolpopexy. *Am J Obstet Gynecol* 140:836–837
4. Priyanka G, Siddiqui SA, Lohse CM, McGee SM, Chow GK, Elliott DS (2008) Impact of obesity on surgical outcomes after robotic-assisted laparoscopic sacrocolpopexy. *World Congress of Endourology, Shanghai*
5. Nygaard IE, McCreery R, Brubaker L, Connolly A, Cundiff G, Weber AM, Zyczynski H (2004) Abdominal sacrocolpopexy: a comprehensive review. *Obstet Gynecol* 104:805–823
6. Culligan PJ, Blackwell L, Goldsmith LJ, Graham CA, Rogers A, Heit MH (2005) A randomized controlled trial comparing fascia lata and synthetic mesh for sacral colpopexy. *Obstet Gynecol* 106:29–37
7. McGee SM, Chow GK, Elliott DS (2008) Surgical complications of the robotically-assisted versus trans-abdominal sacrocolpopexy. *World Congress of Endourology, Shanghai*
8. Elliott DS, Siddiqui SA, Chow GK (2007) Assessment of the durability of robot-assisted laparoscopic sacrocolpopexy for treatment of vaginal vault prolapse. *J Robotic Surg* 1:163–168
9. Daneshgari F, Kefer JC, Moore C, Kaouk J (2007) Robotic abdominal sacrocolpopexy/sacrouteropexy repair of advanced female pelvic organ prolapse (POP): utilizing POP-quantification-based staging and outcomes. *BJU Int* 100:875–879
10. Seim A, Eriksen BC, Hunskaar S (1996) A study of female urinary incontinence in general practice. Demography, medical history, and clinical findings. *Scand J Urol Nephrol* 30:465–471

Part III
Robotic Surgery of the Upper Urinary Tract

Chapter 9

Robot-Assisted Total and Partial Adrenalectomy

Manish N. Patel, Nilesh Patil, Mahendra Bhandari, Vinod Narra, Mani Menon, and Craig G. Rogers

This chapter contains a video segment which can be found at the URL: <http://www.springerimages.com/Su>

Robot-Assisted Total Adrenalectomy

Patient Selection

Masses of the adrenal gland can be categorized into two main groups, benign and malignant. Benign masses can be further subcategorized into functional and nonfunctional masses. Functional masses are those that secrete hormones, normally produced by the adrenal gland such as aldosterone (Conn's Syndrome), cortisol (Cushing's syndrome), virilizing hormones, or sympathetic agents. Hormonally active tumors require extirpative treatment to avoid the long-term consequences caused by the excessive hormone production. Investigation of these tumors is performed by performing a thorough history and physical, as well as laboratory tests including serum electrolytes, 24h urinary catecholamines, and urinary free cortisol [1]. Nonfunctioning adrenal masses tend to be incidental findings during workups for other conditions. Removal of these masses is generally based on size or for suspicion of malignancy by increasing size on serial imaging [2].

A minimally invasive approach to the treatment of masses of the adrenal gland has been described by several groups [3–28]. These surgeries should

be performed by skilled minimally invasive surgeons. Size is considered a relative contraindication to this approach for a malignant mass. Local invasion into adjacent structures is considered a contraindication to a minimally invasive approach.

There are no absolute contraindications to a robotic approach except for uncorrectable bleeding disorders. Any patient who is physically able to undergo general endotracheal anesthesia can have a robotic approach. A relative contraindication to a robotic approach is extensive prior abdominal surgery.

Preoperative Evaluation and Preparation

Patients being considered for robot-assisted adrenalectomy should have preoperative abdominal radiographic imaging with a CT or MRI. All functional masses are evaluated preoperatively and treated appropriately. Patients with pheochromocytoma are placed on several weeks of alpha blockade, followed by beta blockade prior to surgery. Calcium channel blockers can also be used to help control blood pressure and hypertensive episodes. Patients with cortisol producing masses are given preoperative steroids as the contralateral adrenal is severely suppressed by excessive production of cortisol by the mass. Hormone replacement therapy is continued for a number of weeks postoperatively until the contralateral adrenal has had time to normalize. Patients with aldosterone secreting tumors

C.G. Rogers (✉)
Vattikuti Urology Institute, Henry Ford Hospital,
2799 West Grand Boulevard, Detroit,
MI 48202, USA
e-mail: crogers2@hfhs.org

receive treatment for any blood pressure issues and any deficiencies in potassium are corrected.

Preoperatively all patients have blood work done including electrolytes, a complete blood count, and coagulation tests. Any patients on anticoagulation therapy are instructed to stop at least 5 days prior to surgery. Patients can be given a bowel preparation, such as one bottle of magnesium citrate, the day before surgery. They are also instructed not to eat or drink anything after midnight the night before surgery. A first generation cephalosporin is given perioperatively about 30 min prior to skin incision.

Operative Setup

We use the da Vinci[®] Surgical System (Intuitive Surgical, Inc., Sunnyvale, CA) to perform robot-assisted adrenalectomies using a three-armed technique. The fourth robotic arm may be used but in general is not necessary. The operative setup including the position of the robot, console surgeon, bedside assistant, scrub technician, and monitors is illustrated in Fig. 9.1. The robot is docked over the shoulder of the patient at a 45° angle with the long axis of the operating table.

The surgical team includes one operating console surgeon, one bedside assistant, and a scrub technician. The operating surgeon may scrub initially to assist in patient preparation and trocar placement, and then breaks scrub prior to sitting at the robotic console. The bedside team

remains scrubbed throughout the case and assists the console surgeon during the procedure.

Patient Positioning and Preparation

General endotracheal anesthesia is used for this procedure. A urethral catheter is placed before positioning the patient. The patient is placed in the full flank position with an axillary roll. Moderate table flexion (approximately 15°) is used to increase the space for trocars with the kidney placed at the center of the table break (Fig. 9.2). The arms are padded at the elbows, wrists, and hands, and extended in front of the patient with the upper arm suspended. The lower leg is flexed, the upper leg is straight, and all lower extremity pressure points are padded. The patient is secured to the table at the chest, iliac crest, and knees with wide cloth tape and Velcro straps to ensure the patient does not move during the procedure. Tape blisters are avoided by placing egg crate foam padding or abdominal pads between the skin and the tape. All pressure points including the head, neck, axilla, arms, hip, knees, and ankles are inspected and additional padding is placed if necessary.

Trocar Configuration

The trocar configuration for left and right robot-assisted adrenalectomy is demonstrated in Figs. 9.3 and 9.11, respectively. Two 12 mm standard trocars

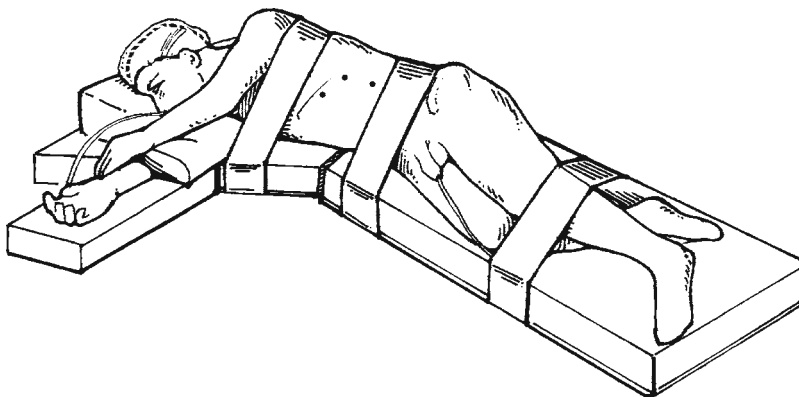


Fig. 9.1 Patient positioning for left robotic adrenalectomy

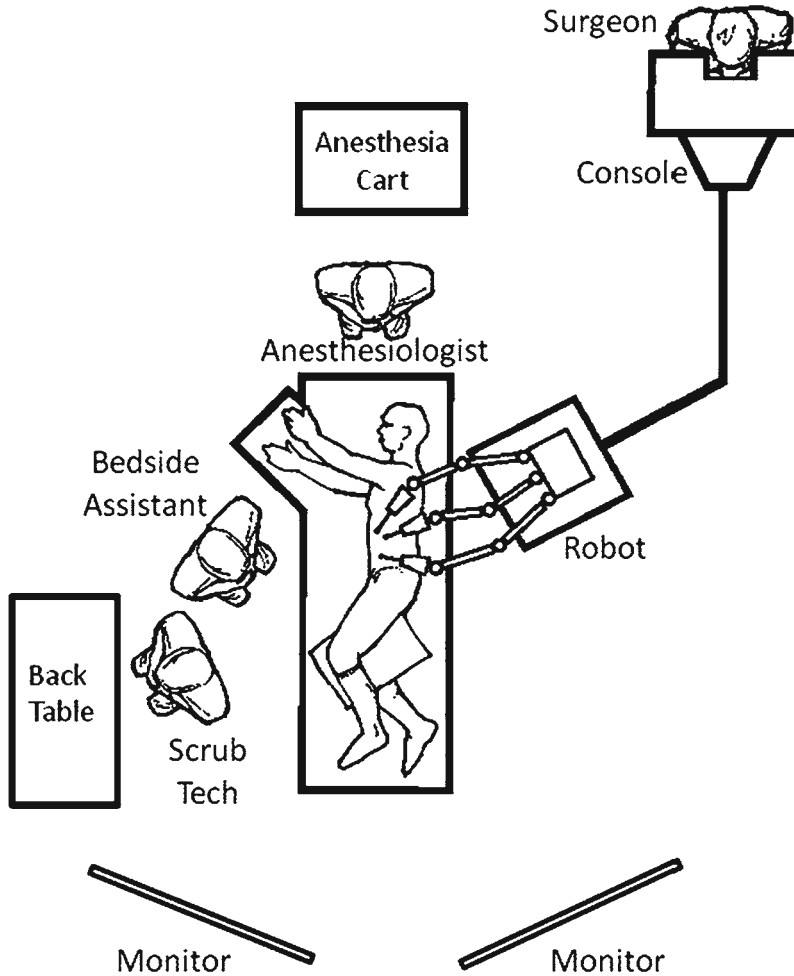


Fig. 9.2 OR setup for left robotic adrenalectomy

and two 8 mm robotic trocars are used for both techniques. An additional 5 mm trocar is used for a right-sided technique for retraction of the liver.

- InSite® Vision System with 0° and 30° lens (Intuitive Surgical, Inc., Sunnyvale, CA)

Instrumentation and Equipment List

Equipment

- da Vinci® S (4-arm system)
- EndoWrist® Maryland bipolar forceps (Intuitive Surgical, Inc., Sunnyvale, CA)
- EndoWrist® curved monopolar scissors (Intuitive Surgical, Inc., Sunnyvale, CA)
- EndoWrist® monopolar hook (Intuitive Surgical, Inc., Sunnyvale, CA)

Trocars

- 12 mm trocars (2)
- 8 mm robotic trocars (2)
- 5 mm trocar (1, for right sided technique)

Instruments used by the surgical assistant:

- Laparoscopic needle driver
- Laparoscopic scissors
- Blunt tip grasper
- 5 mm blunt tip locking grasper for liver retraction
- Suction irrigator device

- Hem-o-lok® (Teleflex Medical, Research Triangle Park, NC) or titanium clip applier
- 10 mm specimen entrapment bag
- 16 Fr urethral catheter

Surgical Anatomy

Knowledge of the surgical anatomy of the adrenal gland and the vessels associated with each gland is essential to performing a successful adrenalectomy. Each adrenal is associated with a major vessel and has a unique venous drainage. The adrenal gland receives its arterial blood supply from the branches of the inferior phrenic artery, renal artery, and aorta. This network of arteries enter the gland along its superior and medial border making the inferolateral, posterior and anterior surfaces of the gland relatively avascular.

The right adrenal gland is in close relationship with the inferior vena cava (IVC). The right adrenal vein arises from the superomedial surface of the gland and drains into the IVC. The left adrenal vein leaves the adrenal gland via the inferomedial aspect and drains into the left renal vein. It is easiest to identify the left adrenal vein along the superior border of the left renal vein and medial in location as compared to the insertion of the left gonadal vein.

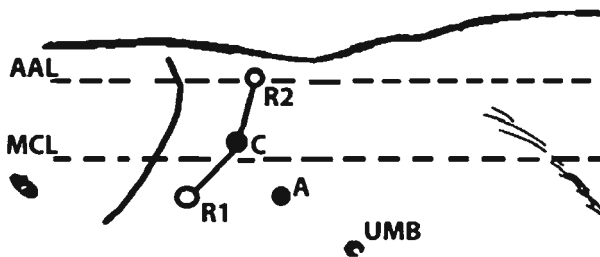
Note that under robotic visualization, the right adrenal vein runs for a few millimeters on the anterior surface of the adrenal gland before entering it. This gives enough room to doubly ligate the vein or place multiple clips. Also, there are invariably, collateral veins draining from the adrenal gland. These veins are distinguishable from the adrenal vein in being more tortuous, thin walled, and inferior than the main adrenal vein. The main adrenal vein is high up on the adrenal, has thicker walls, and is shorter.

Step-by-Step Technique

Transperitoneal Left Robot-Assisted Adrenalectomy

Step 1: Trocar placement

Abdominal insufflation is achieved using Veress needle access at the level of the umbilicus. Insufflation is initiated at 20 mm Hg but may be decreased to 12 mm Hg during the operation. A 12 mm camera trocar is placed about 5 cm below the costal margin just lateral to the midclavicular line. Two 8 mm robotic trocars are placed approximately 4–5 cm away from the camera trocar in an almost straight line. Finally, a 12 mm assistant trocar is placed between the camera trocar and the umbilicus (Fig. 9.3).



AAL – Anterior Axillary Line MCL - Midclavicular Line
C - Camera Trocar A - 12mm Assistant Trocar
R1,R2 - 8mm Robotic Trocars UMB – Umbilicus

Fig. 9.3 Trocar configuration for left robotic adrenalectomy. AAL anterior axillary line, MCL midclavicular line, C camera trocar, A 12 mm assistant trocar, R1,R2 8 mm robotic trocars, UMB, umbilicus

Step 2: Mobilization of colon and spleen

Surgeon instrumentation		Assistant instrumentation
Right arm	Left arm	
• Monopolar hook	• Maryland bipolar grasper	• Suction-Irrigator • Hem-o-lok® or titanium clip applicator • Specimen entrapment bag
Endoscope lens: 30° upward or 0°		

We use a 30° up angled or 0° camera with the Maryland bipolar forceps in the left arm and a monopolar hook in the right arm (electrocautery settings: 30 W bipolar, 30 W monopolar). The splenic flexure is mobilized along the line of Toldd. Lienophrenic, lienorenal, and lienocolic ligaments may be taken down to allow the spleen along with the descending colon to fall medially and out of the operating field (Fig. 9.4). This helps to provide optimal exposure of the left adrenal gland.

Step 3: Exposure and ligation of left adrenal vein

Gerota's fascia is incised at the level of the renal hilum and the left renal vein is identified. The left adrenal vein is identified draining from the inferomedial aspect of the gland into the superior border of the renal vein (Fig. 9.5). The left adrenal vein is isolated circumferentially using robotic instruments (Fig. 9.6). The adrenal vein should be ligated prior to manipulation of the adrenal gland, particularly in cases of pheochromocytoma in which there is potential for release of catecholamines into the systemic circulation during manipulation of the tumor resulting in

sudden hypertension. The adrenal vein is ligated using Hem-o-lok® or titanium clips placed by the assistant, robotic Hem-o-lok clips, or by suture ligation using robotic needle drivers (Fig. 9.7). The vein should have enough length to be doubly ligated.

Step 4: Dissection of upper pole renal attachments

After the adrenal vein is secured, gentle traction on the adrenal gland using the Maryland bipolar forceps and counter traction on the kidney by the assistant aids in the dissection of the gland by opening the space between the adrenal gland and the upper pole of the kidney (Fig. 9.8). Dissection is carried out along the upper pole of the kidney as this plane is generally avascular and as well achieves a wide tissue margin around the adrenal tumor. The magnification provided by the robotic camera generally allows for identification of small adrenal arteries, which can be clipped or coagulated. Collateral veins may be seen exiting the adrenal gland. These thin walled veins may be either ligated with clips or cauterized.

Step 5: Dissection of medial, lateral, and superior attachments

Careful meticulous dissection of the adrenal gland while avoiding grasping the gland directly can help minimize blood loss. The splenic artery and vein and pancreas are

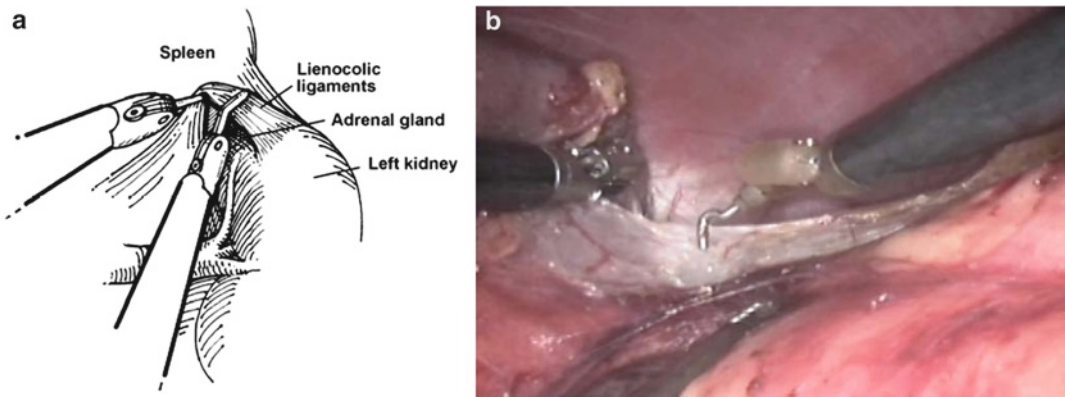


Fig. 9.4 Take down of the lienocolic ligaments (a) and lienorenal ligaments (b) to free the spleen and expose the left adrenal gland

Fig. 9.5 Exposure of left renal vein and adrenal vein

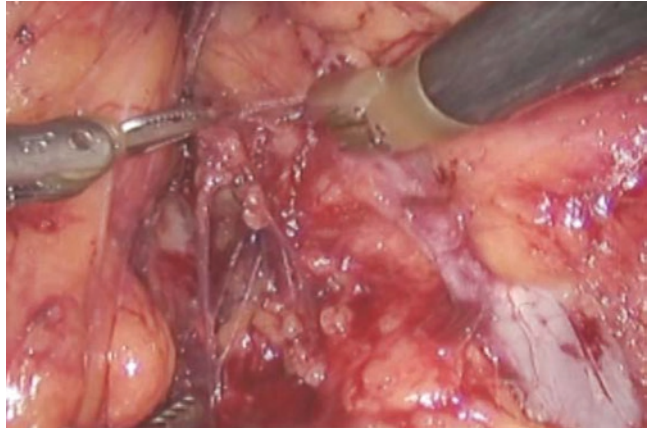


Fig. 9.6 Circumferential robotic dissection of left adrenal vein

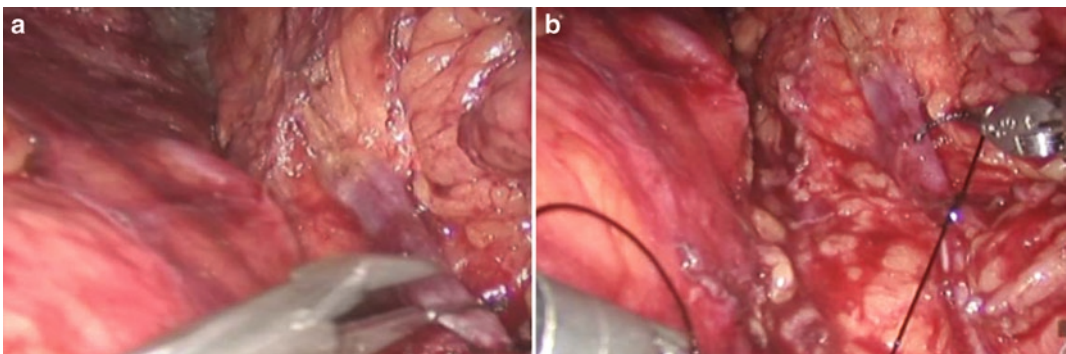
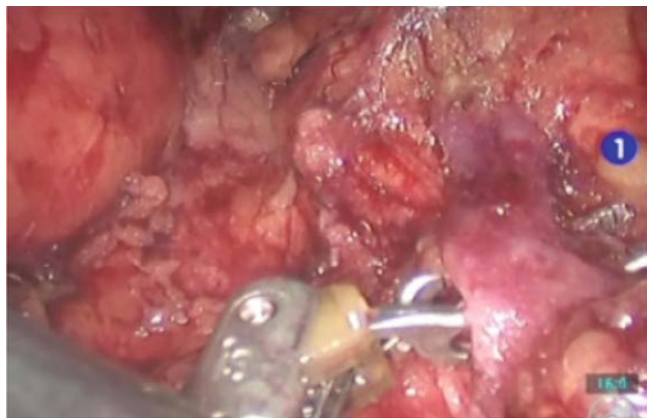


Fig. 9.7 Ligation of left adrenal vein using clips (a) or suture ligation (b)

adjacent to the anteromedial aspect of the gland. Care must be taken not to injure these structures during the dissection. Small vessels encountered during the dissection can be

controlled with clips or electrocautery to help minimize blood loss. The remaining superior and lateral attachments of the gland are dissected free (Fig. 9.9).

Fig. 9.8 Dissecting the plane between the left adrenal gland (*left*) and the upper pole of the kidney (*right*) following ligation of adrenal vein

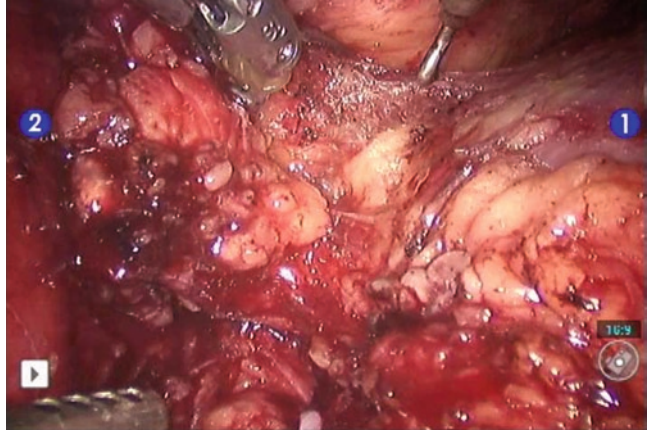
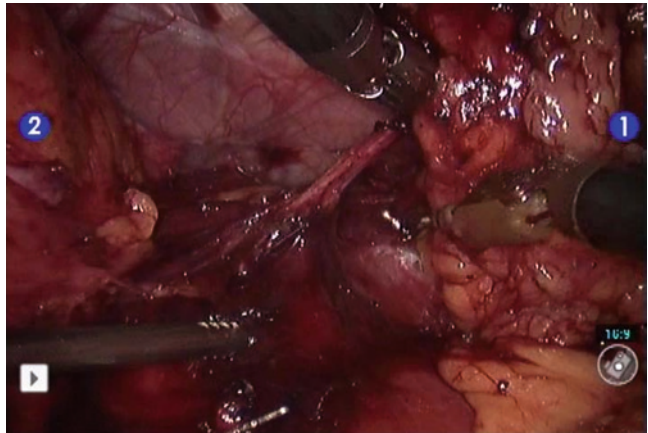


Fig. 9.9 Transecting final superior adrenal attachments to free the left adrenal gland



Step 6: Entrapment and extraction of specimen

The adrenal gland is placed in a 10 mm specimen entrapment bag (Fig. 9.10). Pneumoperitoneum is decreased to 5 mm Hg and the adrenal bed is inspected for bleeding. After adequate hemostasis is confirmed the specimen bag is removed from the 12 mm assistant trocar. Extension of this incision is performed if necessary to extract larger tumors.

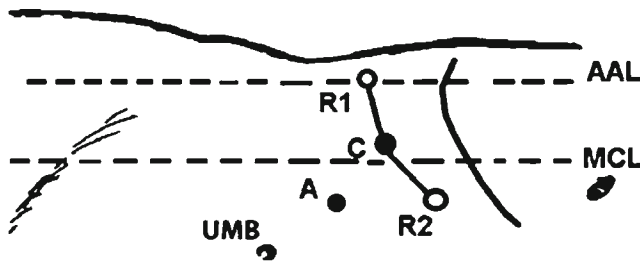
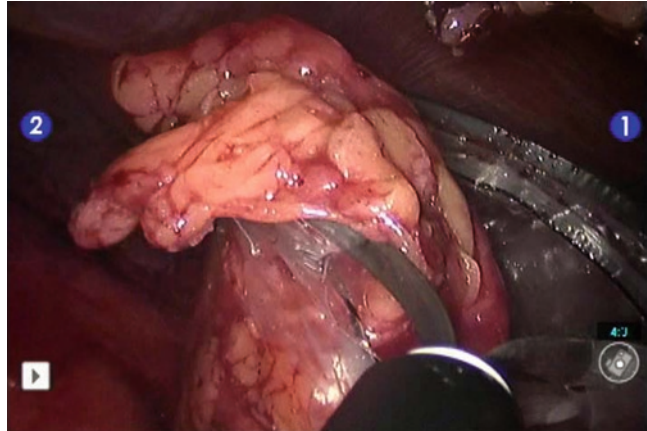
Transperitoneal Right Robot-Assisted Adrenalectomy

Step 1: Trocar placement

Trocar placement for a right robot-assisted adrenalectomy is illustrated in Fig. 9.11. A

Veress needle is introduced at the level of the umbilicus in the right lateral abdomen, just below the costal margin, and pneumoperitoneum is established to 20 mm Hg and then dropped to 12 mm Hg after placement of all trocars. A 12 mm camera trocar is placed about 5 cm below the costal margin just lateral to the midclavicular line. Two 8 mm robotic trocars are placed approximately 4–5 cm away from the camera trocar in almost a straight line. A 12 mm assistant trocar is placed between the camera trocar and the umbilicus. For liver retraction, we place a 5 mm subxiphoid trocar and pass a 5 mm locking grasper under the liver and secure it to the abdominal sidewall.

Fig. 9.10 Placement of adrenalectomy specimen into the entrapment bag



AAL – Anterior Axillary Line **MCL** - Midclavicular Line
C - Camera Trocar **A** - 12mm Assistant Trocar
R1,R2 - 8mm Robotic Trocars **UMB** – Umbilicus

Fig. 9.11 Trocar configuration for right robotic adrenalectomy. *AAL* anterior axillary line, *MCL* midclavicular line, *C* camera trocar, *A* 12 mm assistant trocar, *R1,R2* 8 mm robotic trocars, *UMB*, umbilicus

Step 2: Mobilization of liver, colon, and duodenum

Surgeon instrumentation		Assistant instrumentation
Right arm	Left arm	<ul style="list-style-type: none"> • Suction-Irrigator • Hem-o-lok® or titanium clip applicator • Liver retractor (5 mm locking grasper) • Specimen entrapment bag
• Monopolar hook	• Maryland bipolar grasper	
Endoscope lens: 30° upward or 0°		

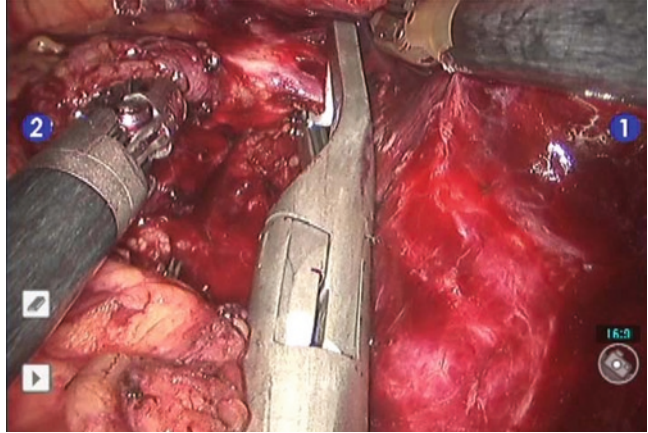
We use a 30° up angled camera while performing the operation. The console surgeon uses the Maryland bipolar forceps in the left hand and a monopolar hook in the right hand. Attachments of the liver are incised allowing for upward traction applied to the liver by the assistant with a 5 mm blunt tip liver retractor. Mobilization of the hepatic flexure of the colon and Kocherization

of the duodenum are performed to expose the IVC from the inferior aspect of the liver to the entry of the renal vein.

Step 3: Exposure and ligation of right adrenal vein

Dissection along the lateral aspect of the IVC is carried out to identify the adrenal vein. During dissection, any collateral adrenal veins which are encountered may be clipped or cauterized. Gentle lateral traction on the adrenal gland and mild medial traction on the IVC helps in dissecting between the IVC and the adrenal gland so as to identify the short right adrenal vein. The adrenal vein generally exits high up from the adrenal gland and runs for a few millimeters on its anterior

Fig. 9.12 Hem-o-lok® clip being applied to the right adrenal vein at its junction with the inferior vena cava



surface. The adrenal vein is carefully isolated circumferentially and ligated as described for the left-sided procedure (Fig. 9.12).

Step 4: Dissection of inferior, posterior, and superior attachments

Gerota's fascia is incised and the plane between the upper pole of the kidney and adrenal gland is dissected with the assistance of gentle traction on the kidney by the assistant. A small amount of fat is left on the adrenal to serve as a handle and to minimize direct manipulation of the gland. Small adrenal arteries can be clipped or coagulated as they are identified. Dissection is continued and a plane is developed between the posterior surface of the adrenal and the psoas and quadratus lumborum muscles. Finally, the superior attachments are released and the adrenal gland is placed in a 10 mm specimen entrapment bag. The pneumoperitoneum is decreased to 5 mm Hg and the adrenal bed is inspected for bleeding. After adequate hemostasis is confirmed, the specimen entrapment bag is removed through the 12 mm assistant trocar.

Robot-Assisted Partial Adrenalectomy

Patient Selection

Indications for partial adrenalectomy include bilateral and hereditary adrenal tumors as well as tumors in a solitary adrenal gland. Hereditary

adrenal pheochromocytoma is associated with syndromes such as von Hippel–Lindau disease, multiple endocrine neoplasia type 2, and neurofibromatosis type 1. The goal of partial adrenalectomy is to provide tumor control while preserving adrenocortical function. The safety and feasibility of partial adrenalectomy, particularly by endoscopic techniques, has been shown by several groups [6, 7, 10, 29, 30]. Partial adrenalectomy can provide patients with a greater hormonal reserve, thus decreasing the risk of subsequent adrenal insufficiency and Addisonian crisis as well as the morbidity of life-long adrenal steroid replacement. The safety and efficacy of robot-assisted adrenalectomy has been described [31]. However, only a few case reports of robot-assisted partial adrenalectomy have been described [32, 33].

Use of Intraoperative Imaging

An important difference in technique while performing partial versus total adrenalectomy is the use of intraoperative ultrasound. Ultrasound allows for more precise demarcation of the limits of the tumor within the adrenal gland during partial adrenalectomy much like the technique used in laparoscopic and robot-assisted partial nephrectomy. The adrenal gland gets its blood supply from multiple blood vessels and thus it may be possible to selectively remove the adrenal tumor while preserving the remaining parenchyma.

Patient Positioning and Operative Setup

Patient positioning, trocar configuration, and operative setup are similar to total adrenalectomy as described previously. Instrumentation and equipment are as described previously with the exception of intraoperative laparoscopic ultrasonography, which is used to detect the size, location, and anatomic boundaries of the tumor within the affected adrenal gland.

Surgical Technique

Surgeon instrumentation		Assistant instrumentation
Right arm	Left arm	<ul style="list-style-type: none"> • Suction-Irrigator • Hem-o-lok® or titanium clip applier • Laparoscopic ultrasound probe • Specimen entrapment bag
<ul style="list-style-type: none"> • Monopolar hook and curved scissors 	<ul style="list-style-type: none"> • Maryland bipolar grasper 	
Endoscope lens: 30° upward or 0°		

The same instrumentation and technique is used as in total adrenalectomy to gain access to the adrenal gland. Once the adrenal gland is visualized, a flexible laparoscopic ultrasound probe is inserted through the 12 mm assistant trocar and is used to locate the tumor(s) and to define anatomic margins (Fig. 9.13). Using the TilePro™

(Intuitive Surgical, Inc., Sunnyvale, CA) feature of the da Vinci® S, the console surgeon is able to display the live intraoperative ultrasound images as a picture-in-picture image on the console screen [34]. The robotic Maryland bipolar forceps and curved monopolar scissors are used to resect the adrenal mass and to free the adrenal tumor from the remaining normal adrenal gland (Fig. 9.14). The adrenal tumor is mobilized and placed in a specimen entrapment bag, which is subsequently removed through the periumbilical trocar incision.

Postoperative Care

A complete blood count and basic serum chemistries are ordered in the recovery room and 12 h postoperatively. Overnight, patients receive intravenous fluids, analgesics as necessary, prophylaxis for deep vein thrombosis with subcutaneous heparin, and antibiotic prophylaxis per hospital protocol. The morning following surgery, the urethral catheter is removed, a clear liquid diet is started, and patients are encouraged to ambulate. The most important aspect of postoperative care is management of any endocrine dysfunction. Management of these dysfunctions is beyond the scope of this text, and consultation with an endocrinologist may be warranted.

Fig. 9.13 Laparoscopic ultrasound probe is seen underneath a left adrenal tumor defining its anatomic borders prior to transecting the final adrenal attachments to free the tumor

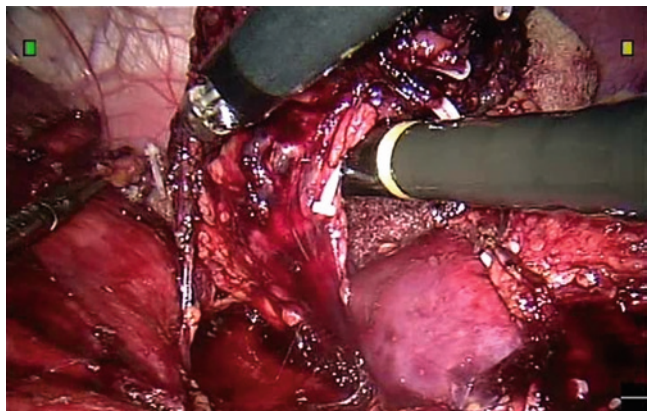
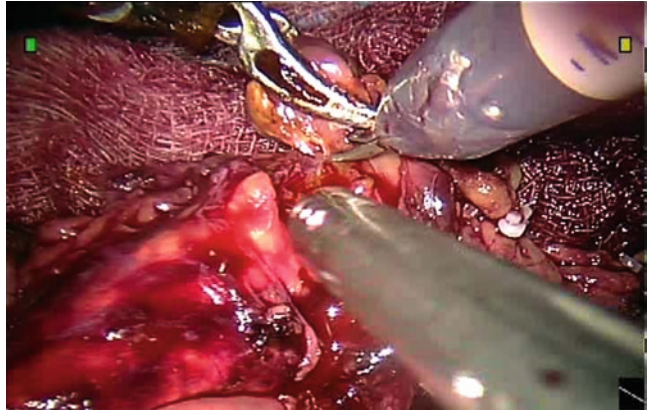


Fig. 9.14 Transecting final adrenal attachments to free an adrenal tumor during a robotic partial adrenalectomy



Steps to Avoid Complications

Potential complications associated with this procedure include vascular injury, bowel injury, liver and splenic injury. The reported rates of vascular injury are about 0.7–5.4% [35–37], but transfusion rates are as high as 10% [38]. While injury to major vessels is often noticed immediately, small vessel injury may initially go unrecognized due to the pneumoperitoneum. Manifestations of small vessel injury are not usually seen until the postoperative period when hematomas form or the patient becomes hemodynamically unstable. Bowel injury is also a known complication of minimally invasive adrenalectomy and can be severe if unnoticed. The small bowel is the most commonly injured segment with duodenal injury associated with the most serious sequelae. Thermal injuries are the most common, accounting for up to 50% of bowel injuries [39]. Use of cautery should be minimized when working near the bowel, particularly near the duodenum. Liver and splenic injuries may also occur during adrenalectomy. Capsular tears may be caused by insertion of instruments or aggressive retraction. Adequate lysis of adhesions prior to retracting can help avoid these injuries. All trocars and assistant instruments should enter under direct vision to avoid injuring any viscera.

Conclusion

Robot-assisted adrenalectomy is a feasible and safe procedure. Although adrenalectomy is an extirpative procedure without the need for intracorporeal sutured reconstruction, robotic assistance with wristed instruments and magnified three-dimensional vision can help with precise dissection of large and small vessels. Robotic assistance can facilitate dissection of vessels and adrenal tumors during total adrenalectomy and partial adrenalectomy, potentially allowing more surgeons, even those with limited laparoscopic experience, to offer their patients a minimally invasive approach to adrenalectomy.

References

1. Zeh HJ III, Udelsman R (2003) One hundred laparoscopic adrenalectomies: a single surgeon's experience. *Ann Surg Oncol* 10:1012–7
2. Gill IS (2001) The case for laparoscopic adrenalectomy. *J Urol* 166:429–36
3. Cyriac J, Weizman D, Urbach DR (2006) Laparoscopic adrenalectomy for the management of benign and malignant adrenal tumors. *Expert Rev Med Devices* 3:777–86
4. Liao CH, Chueh SC, Lai MK et al (2006) Laparoscopic adrenalectomy for potentially malignant adrenal tumors greater than 5 centimeters. *J Clin Endocrinol Metab* 91:3080–3

5. Tsuru N, Ushiyama T, Suzuki K (2005) Laparoscopic adrenalectomy for primary and secondary malignant adrenal tumors. *J Endourol* 19:702–8, discussion 708–9
6. Diner EK, Franks ME, Behari A et al (2005) Partial adrenalectomy: the National Cancer Institute experience. *Urology* 66:19–23
7. Walther MM, Herring J, Choyke PL et al (2000) Laparoscopic partial adrenalectomy in patients with hereditary forms of pheochromocytoma. *J Urol* 164:14–7
8. Henry JF, Defechereux T, Gramatica L et al (1999) Should laparoscopic approach be proposed for large and/or potentially malignant adrenal tumors? *Langenbecks Arch Surg* 384:366–9
9. Liatsikos EN, Papatthanassiou Z, Voudoukis T et al (2006) Case report: laparoscopic adrenalectomy in a patient with primary adrenal malignant melanoma. *J Endourol* 20:123–6
10. Janetschek G, Finkenstedt G, Gasser R et al (1998) Laparoscopic surgery for pheochromocytoma: adrenalectomy, partial resection, excision of paragangliomas. *J Urol* 160:330–4
11. Gagner M, Lacroix A, Bolte E (1992) Laparoscopic adrenalectomy in Cushing's syndrome and pheochromocytoma. *N Engl J Med* 327:1033
12. Guazzoni G, Cestari A, Montorsi F et al (2004) Laparoscopic treatment of adrenal diseases: 10 years on. *BJU Int* 93:221–7
13. Hazzan D, Shiloni E, Golijanin D et al (2001) Laparoscopic vs open adrenalectomy for benign adrenal neoplasm. *Surg Endosc* 15:1356–8
14. Valeri A, Borrelli A, Presenti L et al (2001) Adrenal masses in neoplastic patients: the role of laparoscopic procedure. *Surg Endosc* 15:90–3
15. Fazeli-Matin S, Gill IS, Hsu TH et al (1999) Laparoscopic renal and adrenal surgery in obese patients: comparison to open surgery. *J Urol* 162:665–9
16. Hallfeldt KK, Mussack T, Trupka A et al (2003) Laparoscopic lateral adrenalectomy versus open posterior adrenalectomy for the treatment of benign adrenal tumors. *Surg Endosc* 17:264–7
17. Jacobsen NE, Campbell JB, Hobart MG (2003) Laparoscopic versus open adrenalectomy for surgical adrenal disease. *Can J Urol* 10:1995–9
18. Kirshtein B, Yelle JD, Moloo H et al (2008) Laparoscopic adrenalectomy for adrenal malignancy: a preliminary report comparing the short-term outcomes with open adrenalectomy. *J Laparoendosc Adv Surg Tech A* 18:42–6
19. Horgan S, Vanuno D (2001) Robots in laparoscopic surgery. *J Laparoendosc Adv Surg Tech A* 11:415–9
20. Brunaud L, Bresler L, Ayav A et al (2008) Robotic-assisted adrenalectomy: what advantages compared to lateral transperitoneal laparoscopic adrenalectomy? *Am J Surg* 195:433–8
21. Brunaud L, Bresler L, Zarnegar R et al (2004) Does robotic adrenalectomy improve patient quality of life when compared to laparoscopic adrenalectomy? *World J Surg* 28:1180–5
22. Desai MM, Gill IS, Kaouk JH et al (2002) Robotic-assisted laparoscopic adrenalectomy. *Urology* 60:1104–7
23. Gill IS, Sung GT, Hsu TH et al (2000) Robotic remote laparoscopic nephrectomy and adrenalectomy: the initial experience. *J Urol* 164:2082–5
24. Krane LS, Shrivastava A, Eun D et al (2008) A four-step technique of robotic right adrenalectomy: initial experience. *BJU Int* 101:1289–92
25. Moinzadeh A, Gill IS (2004) Robotic adrenalectomy. *Urol Clin North Am* 31:753–6
26. Sung GT, Gill IS (2003) Robotic renal and adrenal surgery. *Surg Clin North Am* 83:1469–82
27. Wu JC, Wu HS, Lin MS et al (2005) Robotic-assisted laparoscopic adrenalectomy. *J Formos Med Assoc* 104:748–51
28. Young JA, Chapman WH III, Kim VB et al (2002) Robotic-assisted adrenalectomy for adrenal incidentaloma: case and review of the technique. *Surg Laparosc Endosc Percutan Tech* 12:126–30
29. Sasagawa I, Suzuki Y, Itoh K et al (2003) Posterior retroperitoneoscopic partial adrenalectomy: clinical experience in 47 procedures. *Eur Urol* 43:381–5
30. Walz MK, Peitgen K, Diesing D et al (2004) Partial versus total adrenalectomy by the posterior retroperitoneoscopic approach: early and long-term results of 325 consecutive procedures in primary adrenal neoplasias. *World J Surg* 28:1323–9
31. Winter JM, Talamini MA, Stanfield CL et al (2006) Thirty robotic adrenalectomies: a single institution's experience. *Surg Endosc* 20:119–24
32. Rogers CG, Blatt AM, Miles GE et al (2008) Concurrent robotic partial adrenalectomy and extra-adrenal pheochromocytoma resection in a pediatric patient with von Hippel-Lindau disease. *J Endourol* 22:1501–3
33. Julien JS, Ball D, Schulick R (2006) Robot-assisted cortical-sparing adrenalectomy in a patient with von hippel-lindau disease and bilateral pheochromocytomas separated by 9 years. *J Laparoendosc Adv Surg Tech A* 16:473–7
34. Rogers CG, Laungani, R., Bhandari, A., Krane, L. S., Eun, D., Patel, M. N., Boris, R., Shrivastava, A., Menon, M. (2009) Maximizing console surgeon independence during robotic renal surgery by utilizing the fourth arm and TilePro. *J Endourol* 21:115–121
35. Permpongkosol S, Link RE, Su LM et al (2007) Complications of 2, 775 urological laparoscopic procedures: 1993 to 2005. *J Urol* 177:580–5
36. Rosevear HM, Montgomery JS, Roberts WW et al (2006) Characterization and management of postoperative hemorrhage following upper retroperitoneal laparoscopic surgery. *J Urol* 176:1458–62
37. Walz MK, Alesina PF, Wenger FA et al (2006) Posterior retroperitoneoscopic adrenalectomy—results of 560 procedures in 520 patients. *Surgery* 140:943–8, discussion 948–50
38. Strebel RT, Muntener M, Sulser T (2008) Intraoperative complications of laparoscopic adrenalectomy. *World J Urol* 26:555–60
39. Bishoff JT, Allaf ME, Kirkels W et al (1999) Laparoscopic bowel injury: incidence and clinical presentation. *J Urol* 161:887–90

Chapter 10

Robot-Assisted Radical and Partial Nephrectomy

Monish Aron, Andre Berger, and Inderbir S. Gill

This chapter contains a video segment which can be found at the URL: <http://www.springerimages.com/Su>

Patient Selection

Indications for robot-assisted radical nephrectomy (RARN) are identical for that of pure laparoscopic radical nephrectomy. For RARN, tumor size cut-off depends on surgeon expertise and comfort level. Although RARN is a reasonable option for most large (e.g., >4 cm) renal tumors, we do not recommend RARN for tumors larger than 15 cm.

Indications for robot-assisted partial nephrectomy (RAPN) are identical for that of laparoscopic partial nephrectomy. Most small renal tumors including hilar and intraparenchymal tumors can be managed safely by RAPN; however, we do not perform robotic partial for lesions larger than clinical stage T1, unless there is an absolute indication. Even so, patients with preexisting renal insufficiency may be best served by undergoing an open partial nephrectomy under cold ischemia. Patients with uncorrectable bleeding diatheses, or the inability to undergo general anesthesia due to severe cardiopulmonary compromise are poor candidates for RARN and RAPN.

Preoperative Preparation

A thorough preoperative evaluation is necessary, including cardiac and medical clearance. Antiplatelet agents need to be discontinued at least a week before surgery.

With regard to a bowel preparation, one bottle of magnesium citrate taken the night before the procedures is generally sufficient. Prophylactic intravenous antibiotic (usually a first-generation cephalosporin) is administered at induction of general anesthesia. Subcutaneous heparin is started at time of induction and used perioperatively for prophylaxis against deep vein thrombosis. All patients are counseled and consented for the possibility of conversion to pure laparoscopic or open surgery in the rare event of complications or robot malfunction. In the case of RAPN, all patients are consented for the possibility of total nephrectomy.

Operative Setup

Robotic renal surgery can be accomplished using either a 3- or 4-armed robotic technique and is based largely upon surgeon preference as well as the experience and skill of the surgical team. We favor the use of the four arm robot. However, if the patient is very small, there is no space for the fourth arm and a three arm robot can be used. Operative setup for a

M. Aron (✉)
Center for Laparoscopic and Robotic Surgery,
Department of Urology, Glickman Urological and
Kidney Institute, Cleveland Clinic, Cleveland, OH, USA
and
Glickman Urological and Kidney Institute, Cleveland
Clinic, 9500 Euclid Ave, Cleveland, OH 44195, USA
e-mail: aronm@ccf.org

RARN and RAPN using a 3- and 4-armed robotic technique is as shown in Fig. 10.1a, b, respectively. A single surgical assistant and scrub technician are used, both of whom stand on the side opposite the robot. The surgeon sits at the robotic console. The scrub technician

stands at the end of the table and has the instrument table next to her/him. Two 20-in. laparoscopic flat-panel ceiling-mounted LCD monitors are positioned such that they are in direct line of sight of the first assistant and the scrub technician.

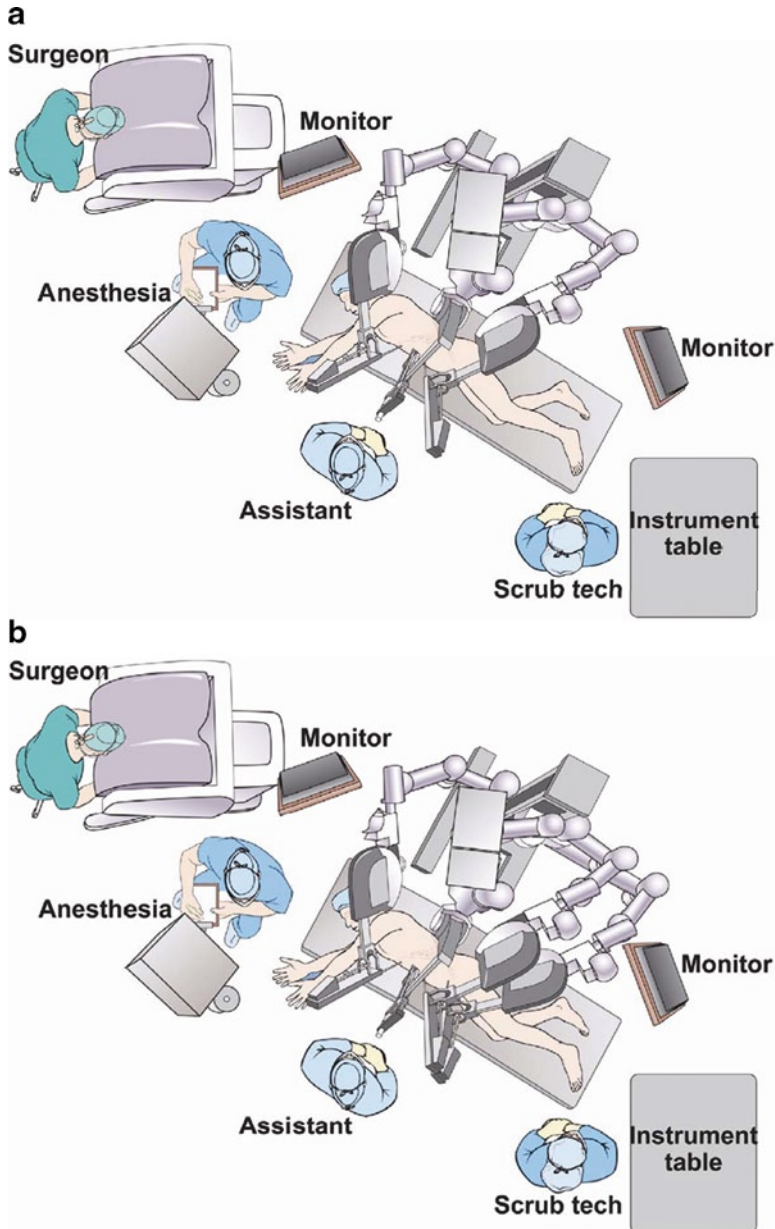


Fig. 10.1 (a) Operating room set up using a 3-armed robotic technique. (b) Operating room setup using a 4-armed robotic technique

Patient Positioning and Preparation Trocar Configuration

A 16 Fr urethral catheter is inserted into the bladder. For RAPN, initial cystoscopic placement of a 5–6 Fr open ended ureteral catheter is performed prior to positioning for the robotic procedure. The patient is then secured on the operating table in the 45° flank position, thus allowing access to the kidney. Inclining the operating table by 30–45° in the operating room provides more space on the side of the robot to accommodate the vision cart, the laparoscopic boom and monitors, and for movement of personnel. The table is placed in a gently flexed position, expanding the space along the ipsilateral flank for trocar placement. In addition, this maneuver is especially important when using a four-armed technique as it drops the height of the ipsilateral thigh and hip allowing for improved mobility when using the fourth robotic arm and avoiding collisions with the patient's thigh (Figs. 10.1b and 10.2b). All pressure points are meticulously padded. Sequential compressing stockings are applied. The patient is prepared from the nipples down to the mid-thighs, including the genitalia. A warming blanket covers the upper chest and shoulders. The patient is draped in a sterile fashion using a special laparoscopy drape. This drape has Velcro™-secured pockets along both sides to keep the various cables and leads neatly tucked away from the operative field.

Trocar configuration for a left RARN and RAPN are as shown in Fig. 10.2a, b, reflecting the setup for a three- and four-armed robotic technique, respectively. The lateral 8 mm trocar is placed just medial to the anterior superior iliac spine (ASIS) and is used for retraction using the fourth arm. The distance between the robotic trocars is usually 8–10 cm. The location of the 12 mm assistant trocar can be altered based on whether the assistant is right handed or left handed. For RAPN an additional 12 mm trocar is placed above the pubis for the Satinsky clamp. If a hybrid laparoscopic-robotic partial nephrectomy is performed, initial dissection is performed laparoscopically and the robot is docked for tumor excision and renal reconstruction. For such a hybrid procedure, the 8 mm robotic trocars are inserted through the existing 12 mm laparoscopic trocars (i.e., port-in-port technique) prior to docking the robot.

Trocar configuration for a right RARN and RAPN are as shown in Fig. 10.3a, b, reflecting the setup for a three- and four-armed robotic technique, respectively. The lateral 8 mm trocar, just medial to ASIS, is used for the fourth arm for retraction. For a right-sided technique, an additional 5 mm trocar is placed below the xyphoid for placement of a liver retractor for exposure and aiding dissection of the upper

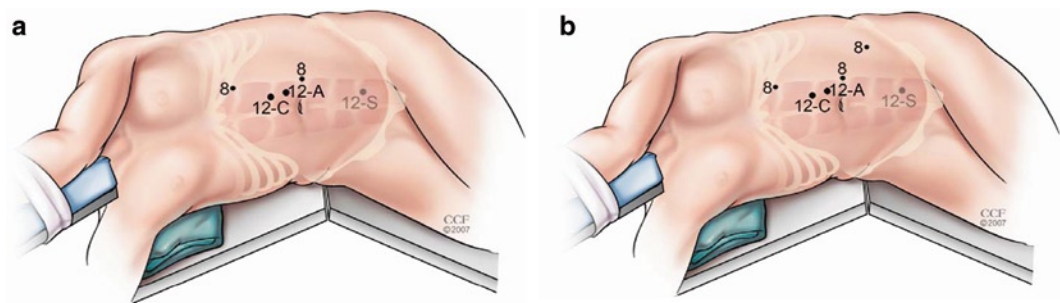


Fig. 10.2 (a) Trocar configuration for a left RARN and RAPN using a 3-armed robotic technique. Numbers indicate the size of the trocars used including two 8 mm robotic trocars, a 12 mm camera trocar (12-C), and 12 mm assistant trocar (12-A). For RAPN an additional 12 mm trocar is placed for the Satinsky clamp (12-S).

(b) Trocar configuration for a left RARN and RAPN using a 4-armed robotic technique. Numbers indicate the size of the trocars used including three 8 mm robotic trocars, a 12 mm camera trocar (12-C) and 12 mm assistant trocar (12-A). For RAPN an additional 12 mm trocar is placed for the Satinsky clamp (12-S).

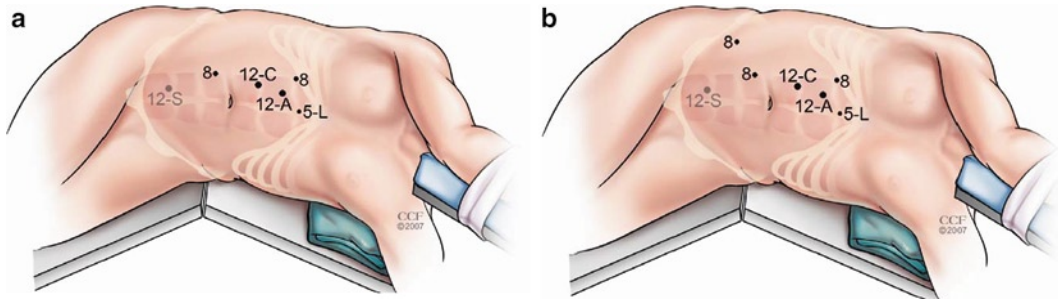


Fig. 10.3 (a) Trocar configuration for a right RARN and RAPN using a 3-armed robotic technique. Numbers indicate the size of the trocars used including two 8 mm robotic trocars, a 12 mm camera trocar (12-C), 12 mm assistant trocar (12-A), and a 5 mm liver retractor trocar (5-L). For RAPN, an additional 12 mm trocar placed for the Satinsky clamp (12-S). (b) Trocar configuration for

a right RARN and RAPN using a 4-armed robotic technique. Numbers indicate the size of the trocars used including three 8 mm robotic trocars, a 12 mm camera trocar (12-C), 12 mm assistant trocar (12-A), and a 5 mm liver retractor trocar (5-L). For RAPN an additional 12 mm trocar is placed for the Satinsky clamp (12-S)

pole of the kidney. For RAPN an additional 12 mm trocar is placed above the pubis for the Satinsky clamp. If a hybrid laparoscopic-robotic partial nephrectomy is performed the 8 mm robotic trocars are inserted through 12 mm laparoscopic trocars as mentioned previously.

Instrumentation and Equipment List

Equipment

- da Vinci® S Surgical System (4-arm system; Intuitive Surgical, Inc., Sunnyvale, CA)
- EndoWrist® Maryland bipolar forceps (Intuitive Surgical, Inc., Sunnyvale, CA)
- EndoWrist® curved monopolar scissors (Intuitive Surgical, Inc., Sunnyvale, CA)
- EndoWrist® ProGrasp™ forceps (Intuitive Surgical, Inc., Sunnyvale, CA)
- EndoWrist® monopolar hook (Intuitive Surgical, Inc., Sunnyvale, CA)
- InSite® Vision System with 30° lens (Intuitive Surgical, Inc., Sunnyvale, CA)

Trocars

- 12 mm trocars (2)
- 8 mm robotic trocars (2–3)
- 5 mm trocar (1)

Instruments used by the surgical assistant

- Laparoscopic scissors
- Blunt tip grasper
- Suction irrigator device
- Hem-o-lok® clip applicator (Teleflex Medical, Research Triangle Park, NC)
- Small, Medium-Large Hem-o-lok® clips (Teleflex Medical, Research Triangle Park, NC)
- 10 mm titanium clip applicator
- Laparoscopic stapling device
- 15 mm specimen entrapment bag
- 16 Fr silicone urethral catheter

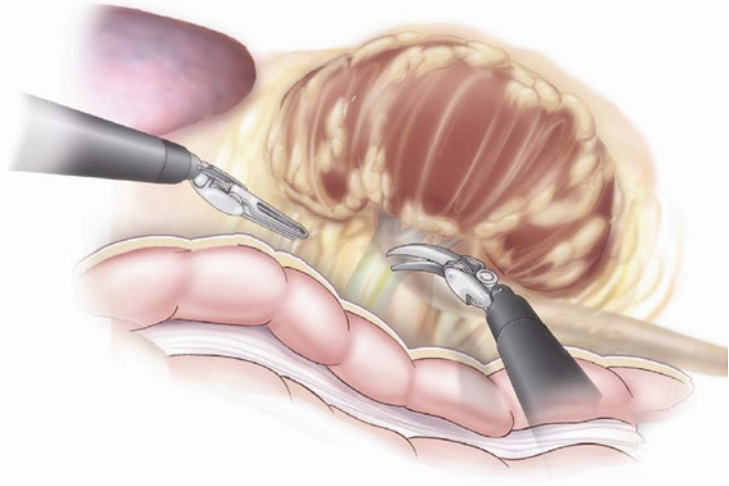
Step-by-Step Technique

Step 1: Mobilizing of the ipsilateral colon

Surgeon instrumentation			Assistant instrumentation
Right arm	Left arm	Fourth arm	
• Curved monopolar scissors or hook	• ProGrasp™ forceps	• ProGrasp™ forceps	• Suction-Irrigator • Blunt tip grasper
Endoscope lens: 30° down			

After obtaining transperitoneal access and placing the trocars as described above, the da Vinci® robot is docked to the trocars. Routinely,

Fig. 10.4 Mobilization of colon during left RARN



we use 15 mmHg insufflation pressure. Using a 30° down lens, the colon is mobilized with robotic assistance by incising along the white line of Toldt and medially reflecting the bowel to expose the kidney using ProGrasp™ and curved monopolar scissors or hook (Fig. 10.4). Monopolar (35 cut and 55 coagulation) and bipolar (70) electrocautery are the preferred energy used. On the left side, the lienorenal attachments are released allowing the spleen, tail of the pancreas, and descending colon to reflect medially, thus providing optimal exposure to the renal hilum, upper pole, and adrenal gland. The gonadal vein and ureter are identified and retracted laterally together in one packet with the surrounding fibrofatty tissue. A ProGrasp™ in the fourth arm is quite handy for this lateral retraction.

On the right side, the ascending colon and duodenum are mobilized medially and the gonadal vein is maintained medially with the inferior vena cava and not retracted laterally. A liver retractor is often necessary to lift the right lobe of the liver anteriorly and provide adequate exposure to the upper pole of the kidney and adrenal gland. Once the psoas muscle is clearly identified, this dissection proceeds cephalad toward the renal hilum. The assistant aids the dissection by keeping the field free of smoke and fluid, as well as by applying gentle traction or countertraction using laparoscopic suction device or a bowel clamp.

Step 2: Dissection and division of renal hilar vessels

Surgeon instrumentation			Assistant instrumentation
Right arm	Left arm	Fourth arm	
• Curved monopolar scissors or hook	• Maryland bipolar forceps	ProGrasp™ forceps	• Suction-Irrigator • Blunt tip grasper • Hem-o-lok® clip applicator • Titanium clip applicator • Laparoscopic stapling device
Endoscope lens: 30° down			

The fourth arm is used to retract the kidney laterally and place the renal hilum on stretch during dissection of the renal hilum. The hilar vessels are skeletonized using a bipolar Maryland in the left hand and a robotic hook in the right hand. The renal artery is controlled with two medium-large Hem-o-lok® clips and 1 metal clip on the “stay” side and 1 Hem-o-lok® clip on the “go” side, and then divided (Fig. 10.5). The renal vein is then divided with a laparoscopic stapler applied by the first assistant (Fig. 10.6).

Step 3: Dissection of remaining renal attachments

Surgeon instrumentation			Assistant instrumentation
Right arm	Left arm	Fourth arm	
• Curved monopolar scissors or hook	• Maryland bipolar forceps	ProGrasp™ forceps	• Suction-Irrigator • Blunt tip grasper • Titanium clip applicator
Endoscope lens: 30° down			

Fig. 10.5 Division of renal artery

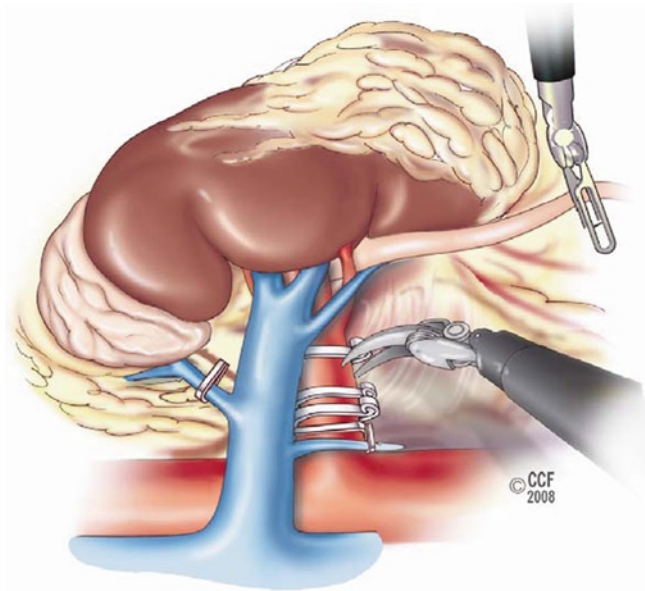
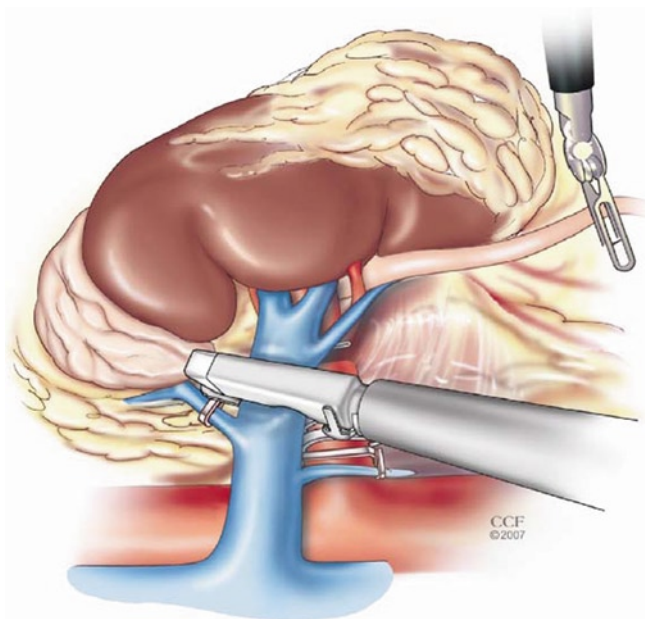


Fig. 10.6 Laparoscopic stapling device applied to renal vein by the surgical assistant



After controlling the vessels, the upper pole is mobilized and the ureter and gonadal vein (on the left side) are divided between titanium clips (Fig. 10.7). The plane of upper pole mobilization depends on whether or not the adrenal gland is being spared. The fourth arm is invaluable

for upper pole mobilization as it can provide excellent countertraction for the medial, cephalad, and lateral dissection of the upper pole. The lateral attachments of the kidney are released last, freeing the kidney specimen in its entirety.

Fig. 10.7 Mobilization of remaining renal attachments

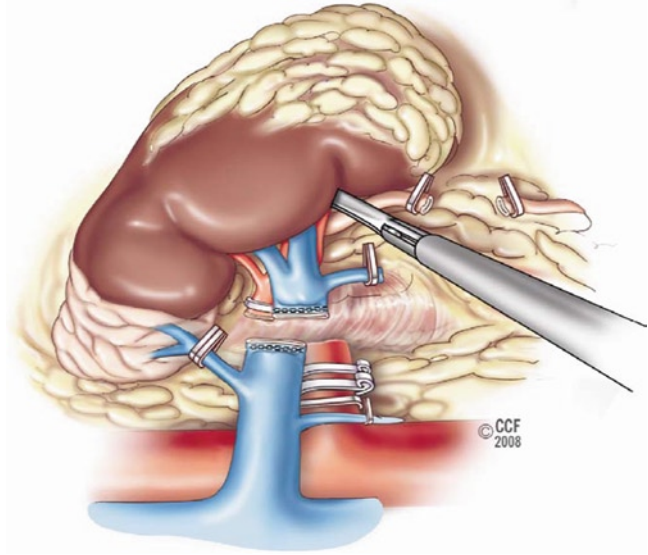
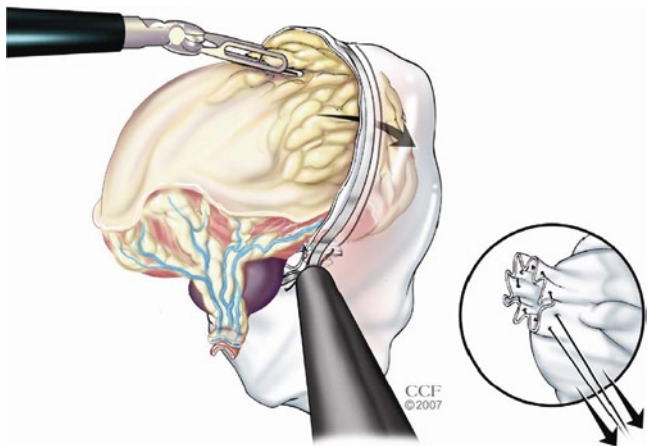


Fig. 10.8 Entrapment of specimen. Inset shows the specimen bag tie being pulled by the assistant to cinch the bag closed and completely entrap the specimen



Step 4: Entrapment of the specimen and exiting the abdomen

Surgeon instrumentation			Assistant instrumentation
Right arm	Left arm	Fourth arm	
• Curved monopolar scissors or hook	• Maryland bipolar forceps	ProGrasp™ forceps	<ul style="list-style-type: none"> • Suction-Irrigator • Blunt tip grasper • Specimen entrapment bag
Endoscope lens: 30° down			

The kidney is mobilized along with its perirenal fat and placed in a 15 mm Endo Catch™ bag

introduced into the abdomen by the assistant (Fig. 10.8). Usually, a 15 mm entrapment bag is introduced through the skin incision of the 12 mm assistant trocar. After entrapment of the specimen, the bag is cinched closed by the assistant and the specimen is extracted intact at the end of the operation through a small supra-pubic Pfannenstiel incision. The robot is undocked from the trocars and the operative site and trocar sites are inspected for bleeding under low insufflation pressure prior to exiting the abdomen.

Postoperative Management

On postoperative day 1, the urethral catheter is removed and routine labs are drawn. Patients are generally discharged on postoperative day 1 if stable. Patients are encouraged to slowly return to normal physical activities as tolerated.

Special Considerations

Obese patients. When operating on obese patients, trocars should be placed more cephalad and lateral. Extra-long robotic trocars may be required if there is a lot of body wall fat. If there is a lot of visceral fat, defatting around the tumor is cumbersome, but becomes very important to dissect the tumor and identify anatomical landmarks. If there is a large amount of visceral fat in the mesentery, an extra trocar is inserted to place a fan retractor and provide exposure.

Large tumors. Especially at upper pole, large tumors can make mobilization of the kidney challenging. A large tumor may distort normal anatomic relationships and this must be kept in mind specially when dissecting hilum and upper pole of the kidney.

Steps to Avoid Complications

Bleeding. Excessive bleeding is a rare complication during RARN. The most critical step in reducing this complication is efficient and safe control of the renal vasculature. Although dissection and transaction of the renal artery and vein is relatively straightforward for kidneys with small to middle sized tumors, large, bulky hilar tumors may distort the renal hilum posing a greater challenge during dissection of the renal vasculature. Review of preoperative imaging is critical for identifying the precise number and anatomic course of the renal arteries and veins for preoperative planning. In addition,

the presence or absence of aberrant or collateral vessels should be noted prior to surgery in efforts to anticipate these vessels during surgical dissection. During dissection of a suspected renal artery, especially for large left-sided tumors, the artery should be carefully traced from the aorta to the kidney so as to avoid accidental ligation of the nearby superior mesenteric artery.

Bowel Injury. Great care should be taken when exchanging instruments so as to avoid accidental injury to the bowels lying deep to the trocars. Movement of the stereoendoscope allowing the surgeon to directly visualize the entry of new instruments is the best way to ensure that there is no inadvertent injury to any internal organ or structure. Bowel injuries can also occur due to thermal injury. Therefore, it is critical to remain diligent when using electrocautery especially in close proximity to the bowels.

Review of the Literature

In 2000, Gill et al. performed the first series of robotic nephrectomies and adrenalectomies in the porcine model [1]. Klingler et al. confirmed the feasibility of robotic radical nephrectomy in a human cohort [2]. The largest series of total and radical nephrectomy includes 42 patients (34 with pathologically confirmed renal cell carcinoma). Mean tumor size was 5.1 cm, mean console time was 158 min, mean estimated blood loss was 223 mL, and mean hospital stay was 2–4 days [3].

Hemal et al. prospectively evaluated robotic versus laparoscopic radical nephrectomy surgery with 15 patients in each group. Operative time was longer in the robotic radical nephrectomy group. However, mean estimated blood loss, intraoperative and postoperative complications, blood transfusion rate, analgesic requirement, hospital stay, and convalescence were comparable in the two groups ($P < 0.05$). There was one conversion to open surgery in the robotic group [4].

References

1. Gill IS, Sung GT, Hsu THS, Meraney AM (2000) Robotic remote laparoscopic nephrectomy and adrenalectomy: The initial experience. *J Urol* 164:2082–2085
2. Klingler DW, Hemstreet GP, Balaji KC (2005) Feasibility of robotic radical nephrectomy—initial results of single-institution pilot study. *Urology* 65:1086–1089
3. Rogers C, Laungani R, Krane LS, Bhandari A, Bhandari M, Menon M (2008) Robotic nephrectomy for the treatment of benign and malignant disease. *BJU Int* 102:1660–1665
4. Hemal AK, Kumar A (2009) A prospective comparison of laparoscopic and robotic radical nephrectomy for T1–2N0M0 renal cell carcinoma. *World J Urol* 27:89–94

Chapter 11

Robot-Assisted Radical Nephroureterectomy

Daniel Willis, Joseph Pugh, Sijo J. Parekattil, Hany Atalah, and Li-Ming Su

This chapter contains a video segment which can be found at the URL: <http://www.springerimages.com/Su>

Patient Selection

The indications for robot-assisted radical nephroureterectomy (RARNU) are identical to that for open and laparoscopic surgery, that is, patients with radiographic (by computed tomography or intravenous pyelography) and endoscopic evidence suggestive of upper urinary tract urothelial carcinoma. A positive urine cytology may also provide supportive evidence for the presence of a high-grade urothelial carcinoma. While other therapeutic options can be applied to select upper tract urothelial tumors including endoscopic resection or laser ablation, nephroureterectomy remains the “gold standard” therapy. With equivalent oncologic outcomes to open surgery, laparoscopic [1-4] and robotic [5-8] nephroureterectomy may even be applied to high-grade, invasive, and multifocal lesions. RARNU may also be utilized in certain congenital or acquired conditions involving an atrophic or nonfunctional renal unit, particularly when associated with recurrent infection, stones, or vesicoureteral reflux. Patients with a duplicated renal collecting system and a non-functional renal moiety are also candidates for nephroureterectomy.

Absolute contraindications for RARNU include uncorrectable bleeding disorders and inability to

undergo general anesthesia due to severe cardiopulmonary compromise or other medical comorbidities. A relative contraindication for RARNU may exist for those patients with locally invasive transitional cell carcinoma with involvement of surrounding structure or lymph nodes. In this setting, an open surgical approach in addition to multimodality therapy (i.e., chemotherapy) may be prudent, but these patients appear to have poor outcomes regardless of the surgical approach [9]. Although patients with prior abdominal and pelvic surgery or morbid obesity make RARNU more challenging, these are not absolute contraindications to the procedure depending on the skill and experience of the surgeon.

Preoperative Preparation

Patients are instructed to avoid aspirin, nonsteroidal anti-inflammatories, blood thinners, or Vitamin E for 1 week prior to surgery to reduce the risk of perioperative bleeding. One bottle of magnesium citrate is taken the day before surgery and the patient’s diet is limited to clear liquids 24 hours prior to surgery. A single dose of preoperative antibiotics such as intravenous cefazolin is administered 30 min prior to skin incision.

Regarding informed consent, the risks of RARNU are similar to those of laparoscopic and open nephrectomy. These include infection, bleeding, blood transfusion, incisional hernia, and the need to convert to open surgery. Adjacent organ injury should be discussed including the

L.-M. Su (✉)
Department of Urology, University of Florida College of Medicine, 1600 SW Archer Road, 100247, Gainesville, FL 32610-2047, USA
e-mail: sulm@urology.ufl.edu

possible need for a splenectomy in left-sided lesions and liver or duodenal injury with right-sided lesions. Testicular pain appears to be an underreported side effect of renal surgery with rates as high as 30–55% [10, 11]. While the exact mechanism is unknown, it has been theorized that the testicular pain may be secondary to venous or lymphatic congestion after intraoperative ligation of the spermatic cord. In one retrospective series, the rate of testicular pain after preservation versus ligation of the gonadal vein was 3.4% versus 33%, respectively [10]. The downstream risk of renal insufficiency and failure should be discussed with patients undergoing nephroureterectomy, especially in those patients with significant comorbid medical conditions such as hypertension, diabetes, long-term nonsteroidal anti-inflammatory use, obesity, smoking and preexisting renal compromise. Finally, the possibility of local and distant tumor recurrence after nephroureterectomy should be discussed with the patient.

Operative Setup

Nephroureterectomy performed by robot-assistance creates an operative setup dilemma as a result of the large surgical field extending from the upper pole of the kidney to the deep pelvis where excision of the bladder cuff is performed. Though successful nephroureterectomy using a single docking technique has been described [8], we favor a two-docking technique to facilitate improved anatomic access and positioning, while avoiding robotic instrument collision. Our single trocar arrangement minimizes time spent on repositioning the robot cart while preserving access to the deep pelvis. Herein we will describe nephroureterectomy using a two docking technique.

At our institution we use the da Vinci® Si-HD system (Intuitive Surgical, Inc., Sunnyvale, CA) with four-arm capabilities, though we generally employ a three-armed technique during RARNU. One surgical assistant is required and is positioned on the contralateral side of the surgical specimen with a Mayo stand for commonly used instrumentation. A scrub nurse can be positioned

either on the assistant's side of the operating table or the contralateral side depending on space considerations. In the two docking RARNU, the robot is positioned differently for the nephrectomy and ureterectomy portions of the case. Figure 11.1a shows the operating setup for the nephrectomy portion of the procedure with the surgical robot cart docked posterior to the patient who is in a modified decubitus position. The robot cart is positioned at an approximately 45° angle entering from the head of the table. The robot is then redocked during the ureterectomy portion of the procedure at a 45° angle entering from the foot of the table at approximately the level of the iliac crest (Fig. 11.1b).

Patient Positioning and Preparation

The patient is initially placed in the supine position for induction of anesthesia. An orogastric or nasogastric tube and an 18 Fr Urethral catheter are placed at the beginning of the case to decompress the stomach and bladder, respectively, to facilitate safe access to the peritoneal cavity for insufflation. The abdomen is then shaved from the xyphoid process to the pubic symphysis. The patient is then positioned in a modified lateral decubitus position at a 45° angle with the operating room table. This position is maintained with a large gel roll positioned behind the back of the patient for support. As the patient is not in a full flank position, an axillary roll is generally not required to prevent brachial nerve injury. The bed is flexed to 30–40° with the break of the bed positioned at the superior margin of the iliac crest to elevate and expand the ipsilateral flank. The dependant leg is flexed to a 90° angle at the knee and is supported at the knee and ankle with gel or foam padding. Pillows are placed between the legs to support the nondependant leg which is aligned in a straight position. Sequential compression devices are applied to the lower extremities and activated.

The dependant arm is padded and placed on top of an arm board that is angled cephalad to provide sufficient working space for the robotic arms as well as surgical assistant. The two arms

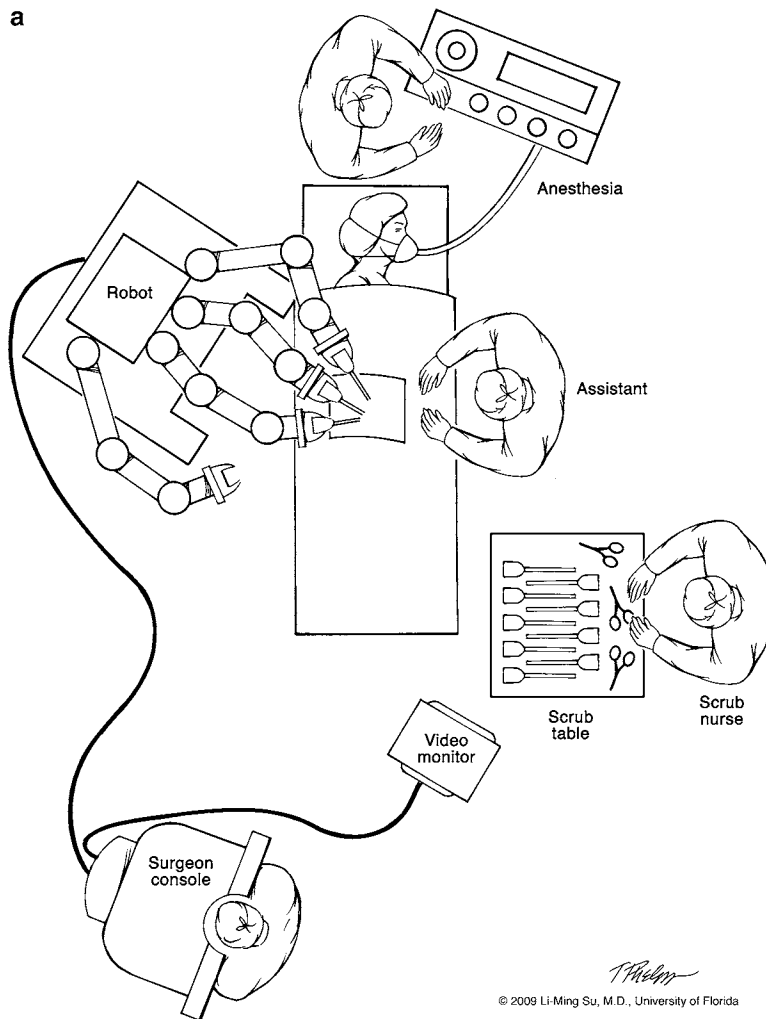


Fig. 11.1 Operating room setup. (a) The operating room setup for the nephrectomy portion of the two-docking, right transperitoneal robot-assisted nephroureterectomy including the standard configuration of the personnel and equipment. The robot cart is positioned at a 45° angle entering from the head of the table (Copyright 2009

Li-Ming Su, M.D., University of Florida) (b) Operating Room setup for the ureterectomy portion of the two-docking, right RARNU. The robotic cart has been repositioned at a 45° angle entering from the foot of the table at the level of the iliac crest (Copyright 2009 Li-Ming Su, M.D., University of Florida)

may be separated and padded in a variety of ways, but it is important that the arms be kept in a comfortable and neutral position without direct contact with the robotic arms during the operation. We routinely place three to four pillows between the dependant and nondependant arms and then secure the patient to the operative table using 2" cloth tape at the level of the upper torso and hips. Figure 11.2 illustrates proper patient positioning.

Trocar Configuration

Although we utilized a two-docking approach to RARNU, a single trocar configuration allows both the nephrectomy and ureterectomy portions of the procedure with minimal modifications as show in Figs. 11.3a and 11.3b. Trocar placement begins with a 12 mm paraumbilical trocar for the endoscope. One 8 mm robotic trocar is then placed lateral to the rectus muscle near the anterior

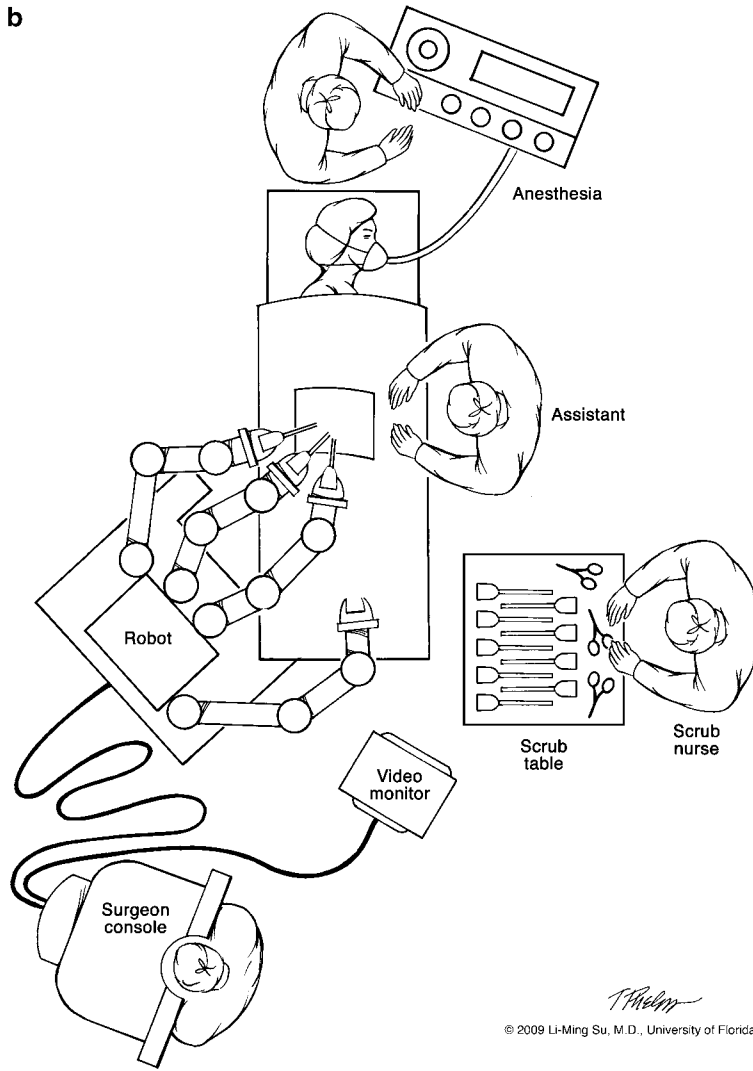
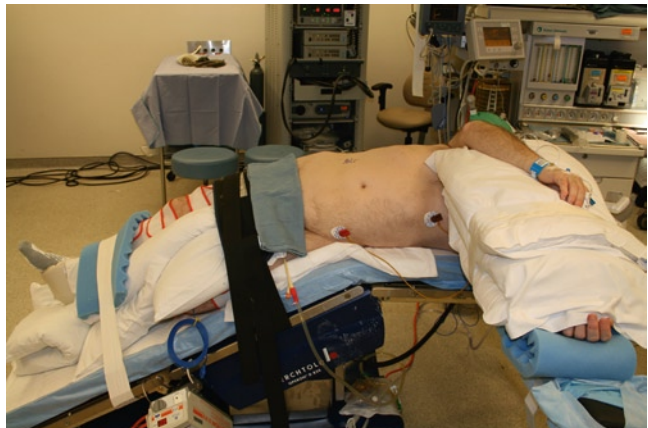

Fig.11.1 (continued)

Fig. 11.2 Patient positioning for a right RARNU. The robot cart is docked posterior to the patient



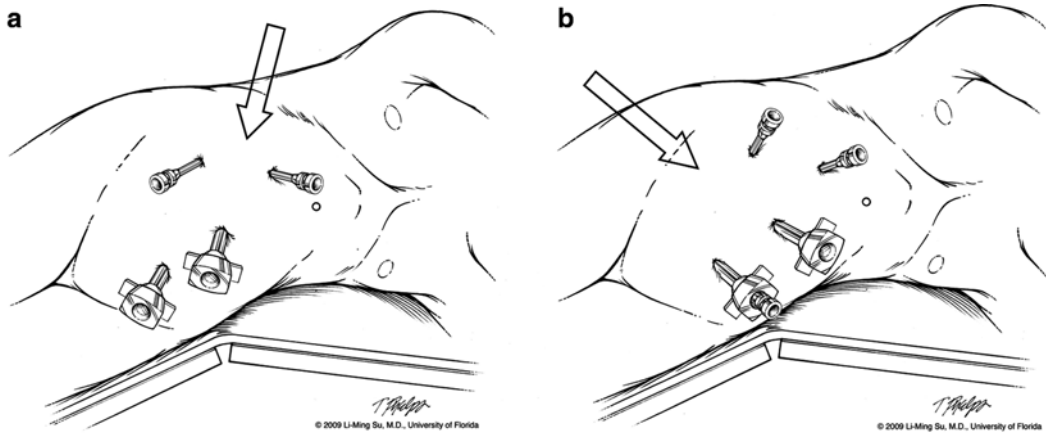


Fig. 11.3 Trocar configuration for right transperitoneal RARNU. (a) Nephrectomy portion of right RARNU. For right-sided cases, a fifth subxiphoid 5 mm trocar is placed to provide liver retraction during right-sided RARNU (depicted by the circle). The arrow depicts the orientation of the robotic (Copyright 2009 Li-Ming Su, M.D., University of Florida) (b) Trocar configuration for the ureterectomy portion of RARNU. A 8/15 mm convertible

Hybrid Cannula Trocar (Intuitive Surgical, Inc., Sunnyvale, CA) is created by inserting an 8 mm robotic trocar into the assistant 15mm outer cannula located below the umbilicus. The subcostal trocar becomes the new assistant trocar. The arrow depicts the orientation of the robotic cart entering at a 45° angle from the foot of the table (Copyright 2009 Li-Ming Su, M.D., University of Florida)

axillary line just below the level of the umbilicus. A second 8 mm robotic trocar is placed two to three finger breadths below the costal margin lateral to the rectus muscle. These trocars accommodate the left and right robotic arms for the nephrectomy portion of the operation, respectively. For the surgical assistant, a 15 mm metal robotic cannula from the 8/15 mm convertible Hybrid Cannula Trocar (Intuitive Surgical, Inc., Sunnyvale, CA) is placed in the midline midway between the umbilicus and pubis. This 15 mm trocar has a plastic reducer placed to allow for retraction, suction and irrigation by the assistant (Figs 11.4a). In obese patients with a large abdominal pannus, this trocar configuration may require a slight lateral shift toward the kidney to allow for optimal visualization and to reach to the target organ. For right-sided cases, an additional 5 mm laparoscopic trocar is placed to provide liver retraction at the subcostal margin near the xiphoid process to accommodate a 5 mm locking, atraumatic laparoscopic grasper. This should be placed cephalad and more medial with respect to the subcostal 8 mm trocar in efforts to avoid instrument clashing between the two trocars. For left-sided cases, release of the splenorenal ligament typically leads to adequate visualization of the upper pole of the

kidney without the need for an additional trocar for retraction of the spleen.

After the nephrectomy portion of the case, the robot is repositioned as previously described (Fig. 11.1b) and the ureterectomy/bladder cuff excision is performed after making two trocar adjustments. First, the 8 mm cannula of the 8/15 mm Hybrid Cannula Trocar is inserted into the 15 mm assistant trocar for the left robotic arm creating a “hybrid” trocar (Figs 11.4a and 11.4b). Second, the 8 mm subcostal trocar which previously housed the right robotic arm is sealed with the 5 mm trocar valve and becomes the new assistant trocar (Fig. 11.3b) It is important to create the “hybrid” port using the Hybrid Cannula Trocar to prevent capacitive coupling which will be discussed in greater detail later.

Instrumentation and Equipment List

Equipment

- da Vinci® Si Surgical System (Intuitive Surgical, Inc., Sunnyvale, CA)
- Endowrist® Maryland bipolar forceps or PK dissector (Intuitive Surgical, Inc., Sunnyvale, CA)

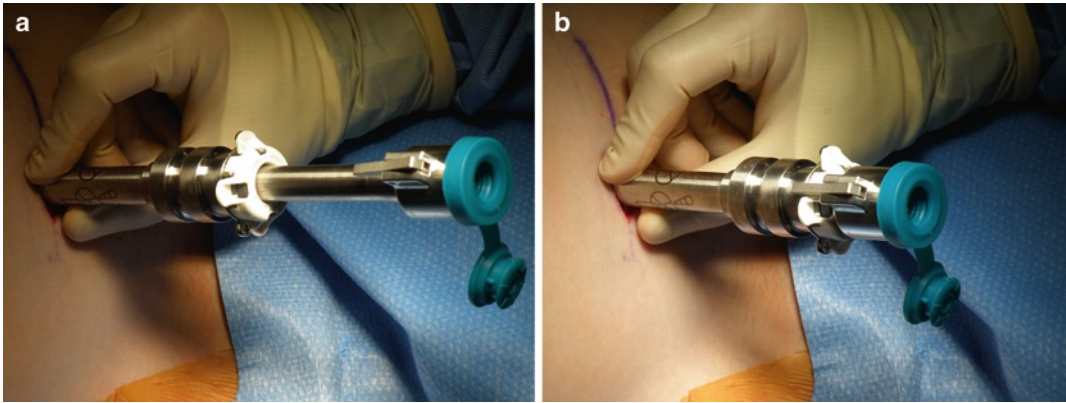


Fig. 11.4 The 8/15 mm Hybrid Cannula Trocar (Intuitive Surgical, Inc., Sunnyvale, CA) is designed to incorporate an 8 mm robotic trocar within a 15 mm outer cannula using a white plastic adapter. To assemble this trocar,

(a) an 8 mm trocar is inserted into the adapter and (b) coupled to the 15 mm outer cannula. This design helps to prevent electro-surgical injury from capacitive coupling (see Steps to Avoid Complications)

- EndoWrist® curved monopolar scissors (Intuitive Surgical, Inc., Sunnyvale, CA)
- EndoWrist® monopolar hook (Intuitive Surgical, Inc., Sunnyvale, CA)
- EndoWrist® ProGrasp™ (Intuitive Surgical, Inc., Sunnyvale, CA) – optional
- EndoWrist® needle drivers (2) (Intuitive Surgical, Inc., Sunnyvale, CA)
- InSite® Vision System with 0° and 30° lens (Intuitive Surgical, Inc., Sunnyvale, CA)

Trocars

- 12 mm trocar (1)
- 8 mm robotic trocars (2)
- 8/15 mm Hybrid Cannula Trocar (Intuitive Surgical, Inc., Sunnyvale, CA)
- 5 mm trocar (1 for right-sided RARNU technique only)

Recommended sutures

- 3-0 polyglactin suture on a SH needle cut to 10 in. for closure of bladder mucosa (1–2 sutures total)
- 2-0 polyglactin suture on a UR-6 needle cut to 10 in. for closure of the muscularis propria of the bladder (2–3 sutures total)

Instruments used by the surgical assistant

- Laparoscopic needle driver
- Laparoscopic scissors
- Blunt tip grasper

- 5 mm locking atraumatic grasper (for right-sided technique for liver retraction)
- Suction irrigator device
- Hem-o-lok® clip applicator (Teleflex Medical, Research Triangle Park, NC)
- Small and Medium-Large Hem-o-lok® clips (Teleflex Medical, Research Triangle Park, NC)
- 10 mm LigaSure Atlas™ Sealer/Divider device (Valleylab, Tyco Healthcare Group LP, Boulder, CO)
- Echelon™ 60 Endopath Stapler with white load (Ethicon, Inc., Cincinnati, OH)
- 15 mm specimen entrapment bag
- Sponge on a stick
- Surgicel® hemostatic gauze (Ethicon, Inc., Cincinnati, OH)(if necessary)
- Hemovac or Jackson Pratt closed suction pelvic drain

Step-by-Step Technique

Step 1: Abdominal access and trocar placement

To begin a transperitoneal RARNU, pneumoperitoneum is established using either a Veress needle inserted at the base of the umbilicus or with an open trocar placement using the Hasson technique. If a Veress needle is used to establish

pneumoperitoneum, the 12 mm paraumbilical trocar is placed under direct visualization using a visual obturator and a 0° laparoscope lens. Secondary trocars are then placed as previously described under direct vision and the robot is docked at a 45° angle from the head of the table. Prior to docking the robot to the trocars, the operating table is tilted maximally toward the assistant to allow for the bowels to fall medially by gravity and provide maximum exposure to the affected kidney, ureter, and bladder.

With intraperitoneal access and establishment of pneumoperitoneum, the 0° stereoscopic camera is inserted through the 12 mm paraumbilical trocar and CO₂ insufflation is maintained at 15 mmHg. For the nephrectomy portion of the operation, a 0° stereoscopic lens is generally used; however, a 30° down lens may be necessary in patients with distended bowels or intraperitoneal fat resulting in poor visualization of the kidney and renal hilum. Under direct visualization by the console surgeon, the robotic arms are loaded with instruments and are positioned within the operative field. The monopolar scissors are placed in the right robotic arm, while the bipolar forceps are inserted into the left robotic arm. Both monopolar and bipolar electrocautery are set at 45 W throughout the operation.

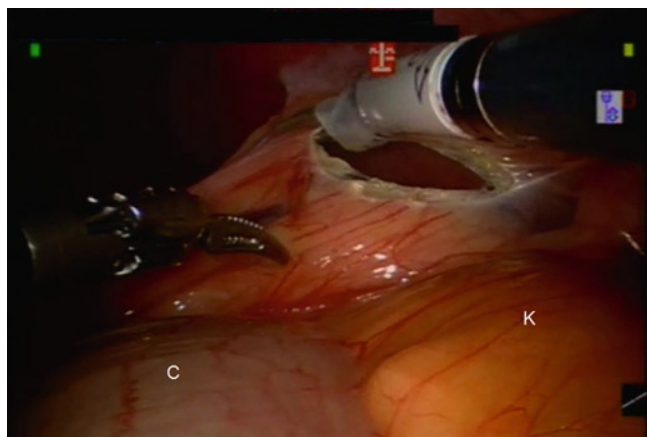
Step 2: Mobilization of colon

Surgeon instrumentation		Assistant instrumentation
Right arm	Left arm	<ul style="list-style-type: none"> • Suction-irrigator • Hem-o-lok® clip applier
• Curved monopolar scissors	• Maryland bipolar forceps	
Endoscope lens: 0°		

Frequently, adhesions are encountered within the peritoneal cavity, which are released using sharp dissection in order to gain access to the white line of Toldt. The colon is reflected medially by sharply incising along the relatively avascular white line of Toldt with limited use of electrocautery and gently sweeping the peritoneum and mesocolon medially revealing Gerota's fascia (Fig. 11.5). The assistant can facilitate this portion of the dissection by applying medial traction on the mesocolon. The colon is dissected as distally as possible into the pelvic inlet to allow for optimal mobilization of the colon and exposure of the kidney and proximal ureter.

During right-sided dissection, the line of Toldt is extended medially between the liver and transverse colon to the space of Morrison. The right coronary ligament is incised sharply and the liver retracted anteriorly and superior to expose the kidney. A 5 mm atraumatic locking grasper is placed through the subxyphoid assistant

Fig. 11.5 Incision of the white line of Toldt and mobilization of the descending colon. *C* colon, *K* left kidney



trocar for this purpose and the liver retracted anteriorly with the tip of the grasper attached to the lateral side wall forming a fixed retractor. Reflection of the hepatic flexure exposes the second portion of the duodenum, which is then Kocherized to expose the inferior vena cava. During left-sided dissection, full mobilization of the left colon requires dividing the lienorenal and phrenicocolic ligaments to allow the splenic flexure to retract medially.

Step 3: Dissection and early ligation of ureter

The tail of Gerota's fascia is entered over the lower pole of the kidney and careful dissection is used to expose the ureter and the gonadal vein. A medium-large Hem-o-lok® clip is then placed across the ureter below the index lesion(s) without transection to prevent tumor cells from caudad migration during manipulation of the kidney. A window to the psoas muscle is created under the ureter using a combination of sharp and blunt dissection. This window is utilized as a traction point to lift the inferior pole of the kidney anteriorly to facilitate dissection of the renal hilum. For right-sided dissections, the psoas window is created beneath the ureter and *above* the gonadal vein to minimize its avulsion from the inferior vena cava. During left-sided cases, the window to the psoas is created under *both* the ureter and gonadal vein, which are simultaneously retracted anteriorly.

Step 4: Dissection of renal hilum

Surgeon instrumentation		Assistant instrumentation
Right arm	Left arm	<ul style="list-style-type: none"> • Suction-irrigator • 10 mm LigaSure Atlas™ device • Echelon™ 60 Endopath stapler
<ul style="list-style-type: none"> • Curved monopolar scissors • Monopolar hook 	<ul style="list-style-type: none"> • Maryland bipolar forceps 	
Endoscope lens: 0°		

Fine dissection of perihilar tissue may be aided by use of monopolar hook electrocautery (Fig. 11.6a). Under gentle anterior retraction of the lower pole of the kidney by the assistant using the suction-irrigator device, the renal hilum is carefully and meticulously dissected, bluntly

creating small windows within the perivascular tissues parallel to the direction of the renal vessels (Fig. 11.6b). These perihilar tissues are generally avascular and can be divided using hook electrocautery or by the assistant using the LigaSure Atlas™ device. Care must be taken to identify accessory crossing renal arteries or lumbar vessels. The assistant also provides critical medial retraction of the ascending colon, vena cava, and duodenum (for right-sided dissection) and descending colon, pancreas, and spleen (for left-sided dissection) for exposure to the renal hilum. The hilum can be further exposed by first dissecting the adrenal gland off of the upper pole of the kidney (see below). Subsequently, the operating surgeon can lift the kidney anteriorly and laterally with one instrument below the lower pole and the other below the upper pole, applying a gentle stretch to the renal artery and vein (Fig. 11.7a). A 2–3 cm proximal segment of renal artery should be dissected free to allow either clipping or stapling of the renal artery based on surgeon preference, although we prefer a vascular endo-stapler for this purpose (Fig. 11.7b). Proximal dissection of the renal artery should be performed prior to the takeoff of segmental arteries for optimal and complete arterial ligation. It is important to avoid placing the endo-stapler across clips, which can result in misfiring of the stapler and unwanted bleeding. The renal vein is then similarly ligated with the endo-stapler, visualizing the tip of the stapler with respect to the great vessels in order to prevent inadvertent injury to the aorta or vena cava.

Step 5: Dissection of adrenal gland and posterolateral renal attachments

After division of the renal vasculature, the remaining superior attachments of the kidney are divided. Typically, an adrenal sparing approach is utilized unless direct adrenal extension of the tumor is radiographically or visually evident. Care must be employed during dissection of the adrenal gland as its complex arterial blood supply and short adrenal vein, particularly on the right side, may be a source of bleeding. Dissection

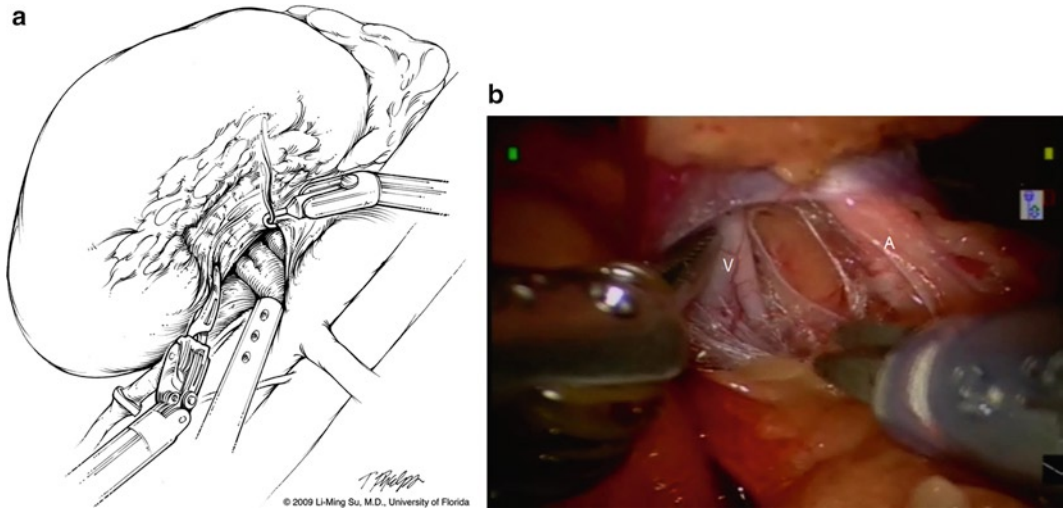


Fig. 11.6 Dissection of the renal hilum. (a) The renal hilum is carefully dissected by creating small windows within the perihilar tissues parallel to the direction of the renal vessels (right kidney shown). These perihilar

tissues can be divided using hook electrocautery (Copyright 2009 Li-Ming Su, M.D., University of Florida). (b) Dissection of the left renal hilum. V renal vein, A renal artery

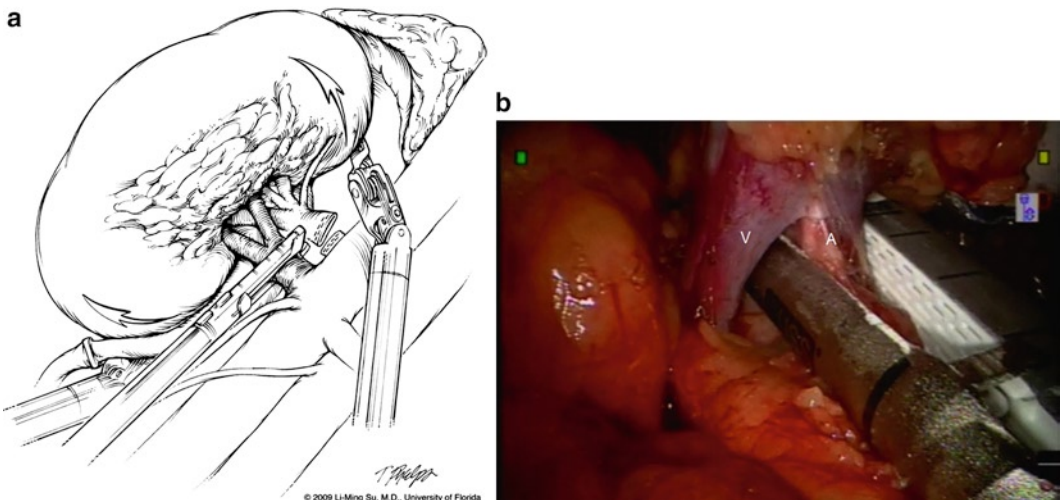


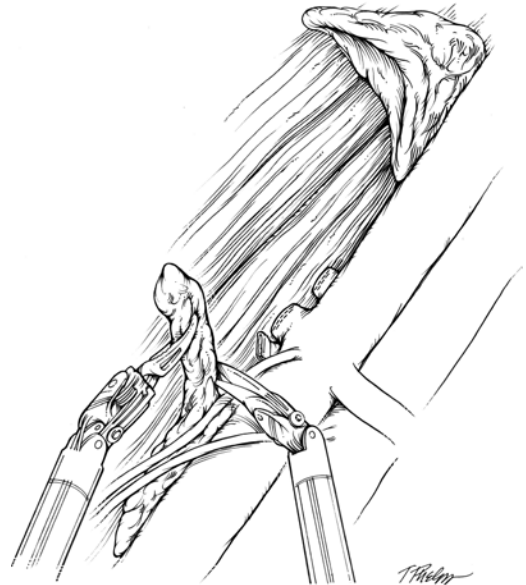
Fig. 11.7 Ligation of the renal hilum. (a) The hilum may be further exposed by first dissecting the adrenal gland off of the upper pole of the kidney (right kidney shown). Anterolateral retraction of the kidney applies gentle stretch to the renal artery

and vein which facilitates stapling and division of the renal vessels using a laparoscopic endo-stapler (Copyright 2009 Li-Ming Su, M.D., University of Florida) (b) Ligation of the left renal hilar vessels. V renal vein, A renal artery

is carried down to the upper pole parenchyma by the operating surgeon. This plane of dissection is followed superiorly and posteriorly around the upper pole until the retroperitoneum is reached. Dissection is then carried out between the upper pole of the kidney and perirenal fat including the

adrenal gland. The LigaSure Atlas™ device is a robust hemostatic device and can be used by the assistant to facilitate separation of the adrenal gland from the upper pole of the kidney. Biosealants such as Floseal™ (Baxter, IL) or hemostatic Surgicel™ gauze (Ethicon,

NC) are generally not required but may be applied to the adrenal bed if there is any concern for residual minor venous bleeding. The lateral attachments of the kidney are divided and released using the LigaSure Atlas™ in combination with blunt dissection, freeing the kidney and its surrounding perirenal fat from its attachments. The renal bed is inspected carefully for bleeding under low insufflation pressure (i.e., 10 mmHg) and meticulous hemostasis is achieved. The kidney specimen is left in the upper abdomen until final extraction of the specimen. Dissection of the ureter is carried out as distally as possible into the true pelvis prior to redocking the robotic cart to facilitate the subsequent steps of ureteral dissection.



© 2009 Li-Ming Su, M.D., University of Florida

Step 6: Regional perihilar lymphadenectomy

Robot-assisted regional perihilar lymphadenectomy can be performed during RARNU especially in patients who present with high-grade disease and/or radiographic evidence of pathologic lymph node enlargement (Fig. 11.8). The lymph node dissection is carried out primarily by blunt dissection with limited electrocautery to minimize the risk of vascular injury. The proximal and distal extents of the lymph node packets are secured with hemoclips so as to minimize lymphatic leak and a postoperative lymphocele.

Fig. 11.8 Right regional perihilar lymphadenectomy (Copyright 2009 Li-Ming Su, M.D., University of Florida)

Step 7: Dissection of distal ureter and bladder cuff

Surgeon instrumentation		Assistant instrumentation
Right arm	Left arm	<ul style="list-style-type: none"> • Suction-irrigator • 10 mm LigaSure Atlas™ device
<ul style="list-style-type: none"> • Curved monopolar scissors • Monopolar hook 	<ul style="list-style-type: none"> • Maryland bipolar forceps 	
Endoscope lens: 0 or 30° down		

The robotic instruments are removed and the arms undocked from the trocars. The robotic cart is then repositioned as previously described for the two-docking RARNU at a 45° angle from the foot of the table. The robot is then redocked using the revised trocar configuration

with an 8 mm trocar placed through the 15 mm outer cannula of the Hybrid Cannula Trocar for the left robotic arm as mentioned previously. Although the 0° lens is generally sufficient to perform the distal ureterectomy and bladder cuff dissection, a 30° down lens may be required in some patients if visualization is limited. The ureter is dissected free from the retroperitoneum and iliac vessels (Fig. 11.9). Access to the distal ureter is enhanced by dividing the vas deferens in the male patient and the suspensory/broad ligaments and round ligament of the uterus in the female patient. The ipsilateral medial umbilical ligament is also divided to allow the bladder to be mobilized medially. If needed, the superior vesical artery may be sacrificed to fully mobilize the lateral portion of the bladder for optimal exposure to the ureterovesical junction. The peritoneal layer covering the bladder and the distal ureter is then incised to reveal the splaying mucosal and muscle fibers of the bladder wall as the ureter enters the bladder at the ureterovesical junction (Figs. 11.10a, 11.10b).

Fig. 11.9 Left ureteral dissection. GV gonadal vein, U ureter (course of ureter highlighted by dashed line)

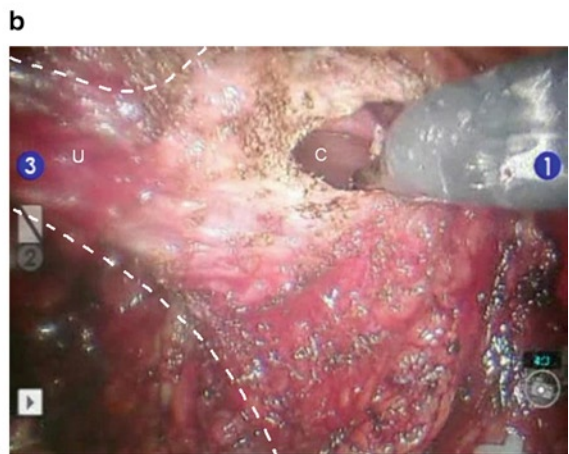
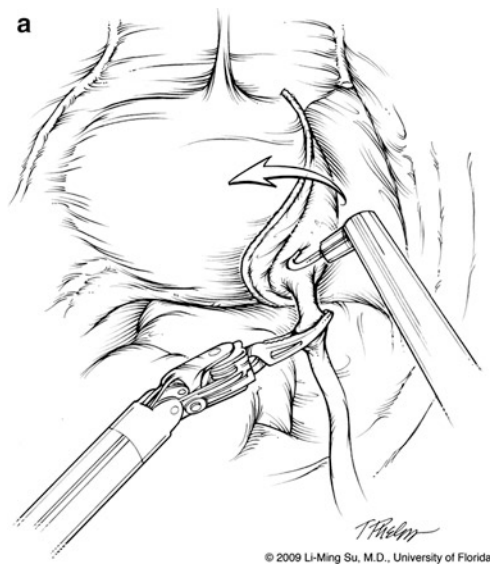
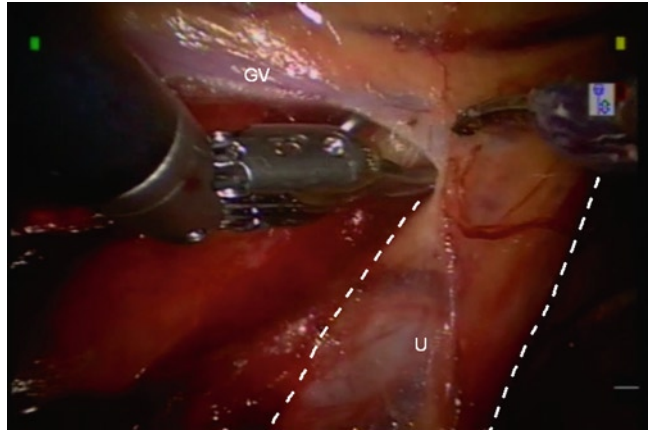


Fig. 11.10 Dissection of the bladder cuff. (a) After the bladder is mobilized and retracted medially, the peritoneal layer covering the bladder and the distal ureter (right ureter shown) is incised to reveal the splaying mucosal and muscle fibers of the bladder wall as the ureter enters

the bladder at the ureterovesical junction (Copyright 2009 Li-Ming Su, M.D., University of Florida). (b) Dissection of bladder cuff during left RARNU. U ureter (splaying of the bladder fibers at the ureterovesical junction highlighted by dashed line), C cystostomy

Step 8: Excision of bladder cuff

An extravesical approach is used to excise the bladder cuff. Complete evacuation of the bladder by the Urethral catheter is verified prior to opening the bladder at the ureterovesical junction, thus minimizing the risk of urine spillage and potential tumor seeding. The bladder is retracted medially by the assistant using the suction-irrigator

device and the monopolar scissors or hook are used to incise the detrusor muscle creating a 2 cm margin around the junction of the ureter and bladder (Figs. 11.11a, 11.11b). Once the bladder is entered, the ipsilateral ureteral orifice is visually identified and circumscribed taking care as to avoid thermal injury to the contralateral ureteral orifice. Once the bladder cuff is completely freed,

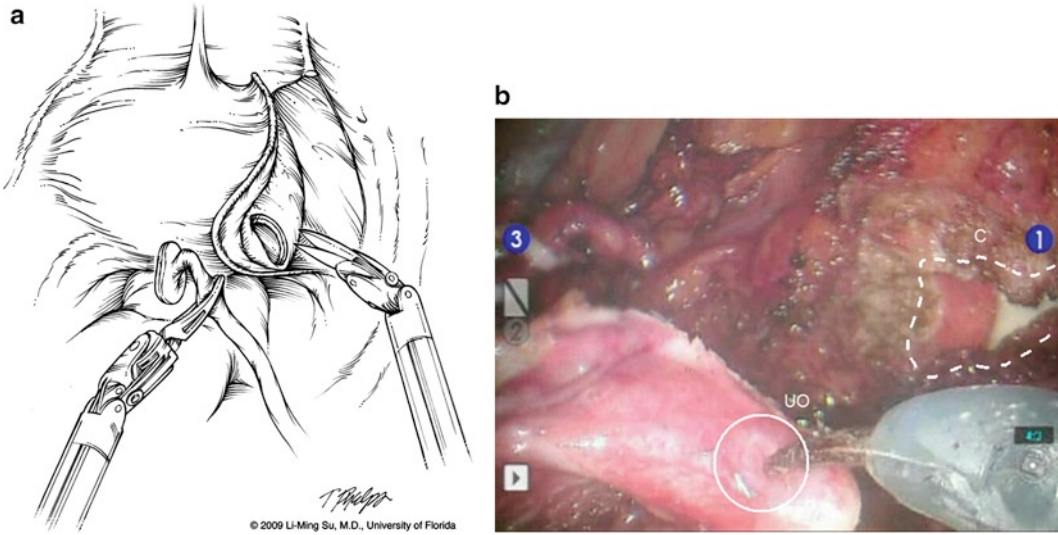


Fig. 11.11 (a) Excision of bladder cuff. with medial retraction of the bladder, the detrusor muscle is incised creating a 2 cm margin around the junction of the ureter and bladder (right ureter shown). The ipsilateral ureteral orifice is identified and circumscribed with care to avoid

thermal injury to the contralateral ureteral orifice (Copyright 2009 University of Florida) (b) After excision of the left ureter and bladder cuff, the ureteral orifice is inspected. UO ureteral orifice, C cystotomy (highlighted by dashed line)

an additional Hem-o-lok® clip may be placed across the distal ureter to prevent possible urine or tumor spillage. The specimen is then stored in the upper quadrants of the abdomen away from the surgical field.

Step 10: Regional pelvic lymphadenectomy

Surgeon instrumentation		Assistant instrumentation
Right arm	Left arm	
• Curved monopolar scissors	• Maryland bipolar forceps	• Suction-irrigator • Hem-o-lok® clip applier
Endoscope lens: 0 or 30° lens		

Step 9: Closure of cystotomy

Surgeon instrumentation		Assistant instrumentation
Right arm	Left arm	
• Needle driver	• Needle driver	• Suction-irrigator • Laparoscopic scissors • Laparoscopic needle driver
Endoscope lens: 0 or 30° down lens		

The bladder is then closed in two separate layers using 3-0 polyglactin on a SH needle on the mucosal layer and 2-0 polyglactin suture on an SH needle on the detrusor layer (Figs. 11.12a, 11.12b). After closure of the bladder is completed, the integrity of the closure it tested by the circulating nurse by filling the bladder via the Urethral catheter with approximately 100–200 ml of saline. The ureterectomy bed is inspected for bleeding under low insufflation pressure (i.e., 10 mmHg).

Regional pelvic lymphadenectomy, when indicated, can be performed adhering to the standard landmarks used during pelvic lymphadenectomy for prostate cancer (Fig. 11.13). The proximal and distal extents of the lymph node packets are secured with hemoclips so as to minimize lymphatic leak and a postoperative lymphocele.

Step 11: Entrapment and delivery of specimens and exiting the abdomen

The 8/15 mm convertible Hybrid Cannula Trocar is removed and a 15 mm specimen entrapment bag is introduced into the abdomen. The lymph node packet and surgical specimens are then placed into the entrapment bag and delivered via extension of the incision through either a low

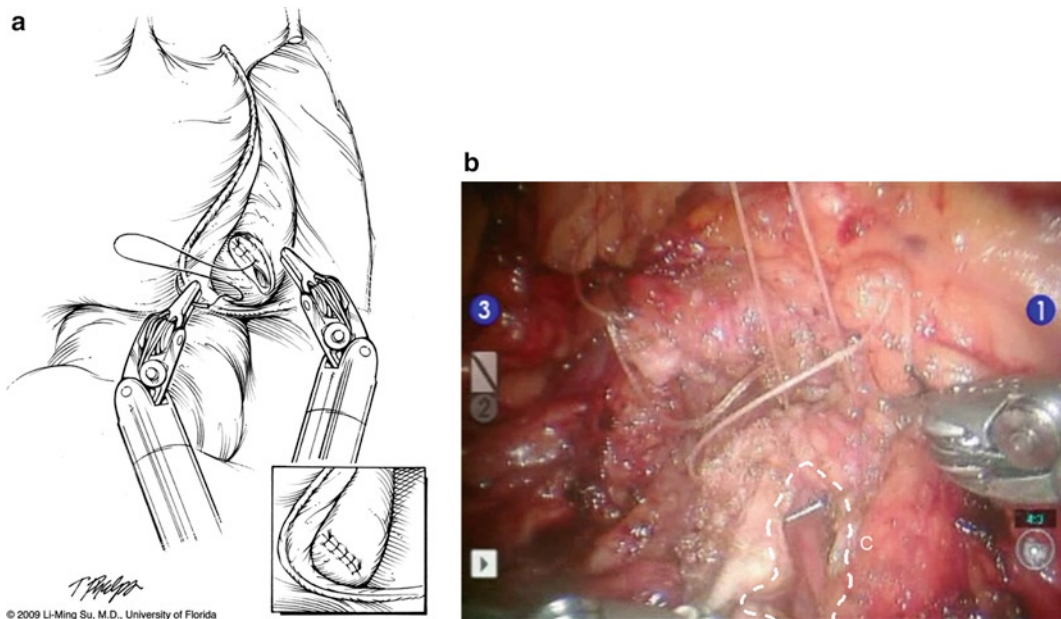


Fig. 11.12 Closure of cystostomy. (a) A two-layer repair of a right cystostomy is shown with closure of the mucosal and detrusor (see inset) layers (Copyright 2009 University

of Florida). (b) Closure of left cystostomy. C cystostomy (highlighted by dashed line)

midline or Pfannenstiel's incision (Figs. 11.14a and 11.14b). The 8 mm and 5 mm trocars do not require facial closure but are closed subcutaneously. The 12 mm trocar sites generally do not require fascial closure if a non-bladed, self-dilating trocar is used. A closed suction Hemovac or Jackson Pratt pelvic drain is left at the end of the operation, exiting the right robotic arm 8 mm trocar site.

Postoperative Management

Intravenous narcotics are provided for postoperative pain overnight and then switched to oral narcotics on postoperative day 1. Patients are provided liquids on postoperative day 1 and advanced to a regular diet as tolerated. Hospital stay is generally 2 days. The pelvic drain is removed prior to discharge if outputs are low. The urethral catheter is kept in place for 7–10 days prior to removal. A cystogram is not generally required but may be performed in patients where a urine leak is

suspected based upon intraoperative findings or high postoperative drain output.

Special Considerations

When performing RARNU in a female patient, great care must be taken during dissection of the distal ureter and bladder cuff as these structures are in close proximity to the vagina and cervix. This includes appropriate division of the round ligament of the uterus and portions of the suspensory/broad ligaments in order to obtain full exposure of the ureteral pelvic junction. During such a case, a sponge on a stick can be introduced by the assistant into the vagina to delineate its borders during distal ureterectomy and bladder cuff excision so as to avoid inadvertent injury to these structures.

In select patients with a solitary distal ureteral tumor, distal ureterectomy and ureteral reimplantation with or without psoas hitch reconstruction can be entertained. These patients

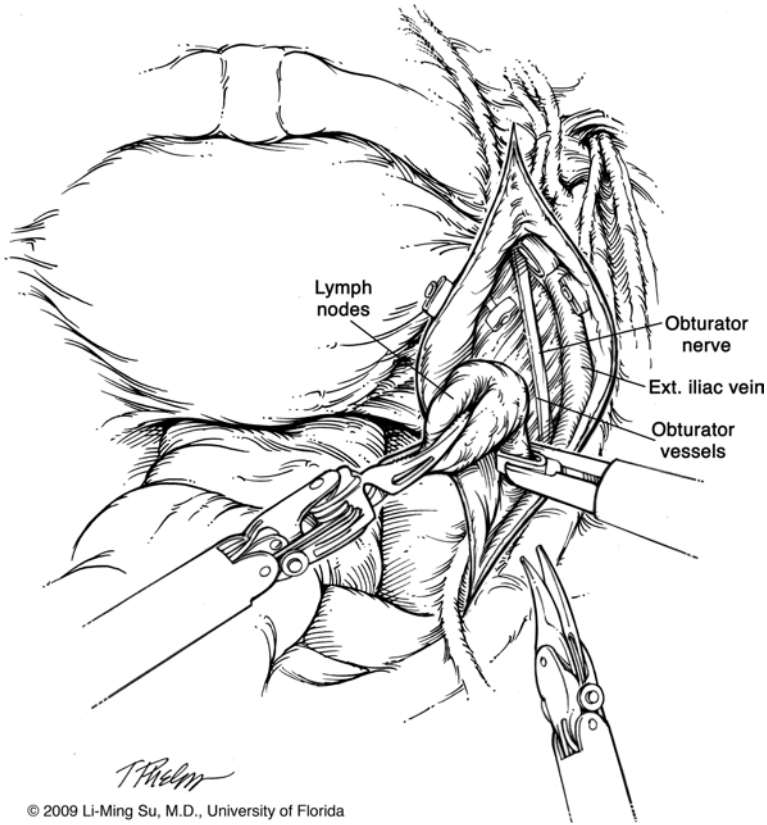


Fig. 11.13 Right ipsilateral, regional pelvic lymphadenectomy (Copyright 2009 University of Florida)

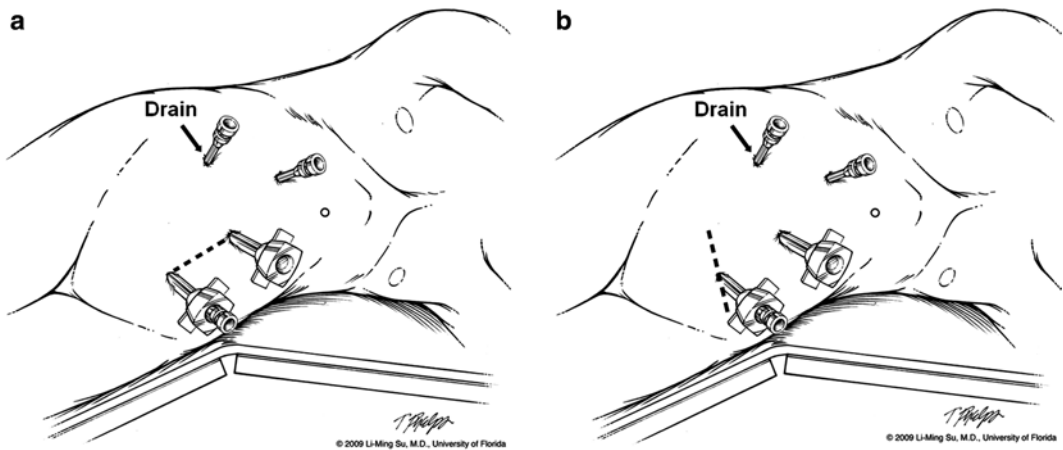


Fig. 11.14 Specimen extraction. (a) Specimen extraction with an infraumbilical incision (Copyright 2009 University of Florida). (b) Specimen extraction with a

Pfannenstiel's incision (Copyright 2009 University of Florida)

should be counseled on the relatively higher risk of ipsilateral tumor recurrence and the need for vigilant endoscopic and radiographic surveillance.

Such cases are performed in the lithotomy position similar to a robotic prostatectomy, using a standard trocar configuration as described in the

prostatectomy chapters. The affected segment of ureter is isolated between hemoclips and excised including the ipsilateral ureterovesical junction. A biopsy of the proximal ureteral stump margin is sent for frozen section analysis and the ureter reimplanted into the bladder if adequate length is available. Insufficient ureteral length necessitates a psoas hitch. For this, the entire bladder is mobilized by dividing both medial umbilical ligaments and entering into the space of Retzius. The contralateral bladder pedicle is divided allowing the bladder to be pexed to the ipsilateral psoas tendon using two interrupted 2-0 prolene sutures. The ureter is then reimplanted in a refluxing, tension-free manner into the dome of the bladder after spatulation of the ureter using interrupted 4-0 polyglactin sutures. A double pigtail ureteral stent is introduced through the assistant trocar and with the assistance of a guide wire introduced in a retrograde fashion into the ureter and renal pelvis prior to completion of the anastomosis. The ureteral stent is kept in place for 4 weeks and the urethral catheter is maintained for 7–10 days postoperatively.

Steps to Avoid Complications

RARNU is a procedure which is associated with minimal morbidity as long as appropriate anatomic landmarks are identified and precise, careful surgical technique is employed. The use of a laparoscopically trained and skilled bedside assistant is critical to the success of this operation. Judicious use of electrocautery is critically important to prevent a vascular or enteral injury.

It is important to note that the 8/15 mm convertible Hybrid Cannula Trocar used during the ureterectomy portion of the RARNU is specifically designed to minimize the risk of complications arising from capacitive coupling. Capacitive coupling is defined as transfer of current from the source of the active electrode (i.e. monopolar scissors) through intact insulation into adjacent tissues without direct contact and may occur with the use of other hybrid ports that incorporate both metal and plastic components [13].

For example, if a hybrid port is created with a metal trocar placed within an outer plastic trocar, electric current transferred to the metal trocar could not dissipate into the abdominal wall because of the outer plastic sleeve, which acts as an insulator. Instead, capacitive coupling could occur with transfer of current from the metal trocar into adjacent tissues, such as bowel, resulting in unintended injury. The 8/15 mm convertible Hybrid Cannula Trocar has been specifically designed to minimize such complications and its use is strongly advised when performing RARNU.

As previously mentioned, transection of the renal vessels is most easily accomplished using a vascular endo-stapling device. However, great care must be taken to ensure that the stapler is appropriately placed, avoiding any hemoclips in close proximity that may result in misfiring of the staples. This can lead to failure of the stapler and partial transection of the renal vessel. The bedside assistant should have a laparoscopic hemoclip immediately available following firing and removal of the vascular endo-stapler in case of bleeding at the vessel stump.

At least 11 trocar site metastases have been reported in which either no endobag was used for specimen retrieval, or the bag was torn [12]. While rare, the consequences of this complication are serious and necessitate careful manipulation of the surgical specimen to prevent spillage during handling and extraction. We recommend early entrapment of the specimen during the case. While long-term follow-up is limited, there are no reported cases to date of trocar site recurrences after RARNU.

To avoid postoperative lymphocele, during regional lymphadenectomy hemoclips should be used to secure the pedicles to all lymph nodes removed as electrocautery and thermal devices may be inferior to hemoclips in sealing lymphatic vessels.

References

1. Bariol SV, Stewart GD, McNeill SA, Tolley DA (2004) Oncological control following laparoscopic nephroureterectomy: 7-year outcome. *J Urol* 172(5):1805–1808

2. Muntener M, Nielsen ME, Romero FR, Schaeffer EM, Allaf ME, Brito FA, Pavlovich CP, Kavoussi LR, Jarrett TW (2007) Long-term oncologic outcome after laparoscopic radical nephroureterectomy for upper tract transitional cell carcinoma. *Eur Urol* 51:1639–1644
3. Capitanio U, Shariat SF, Isbarn H, Weizer A, Remzi M, Roscigno M, Kikuchi E, Raman JD, Bolenz C, Bensalah K, Koppie TM, Kassouf W, Fernandez MI, Strobel P, Wheat J, Zigeuner R, Langner C, Waldert M, Oya M, Guo CC, Ng C, Montorsi F, Wood CG, Margulis V, Karakiewicz PI (2009) Comparison of oncologic outcomes for open and laparoscopic nephroureterectomy: a multi-institutional analysis of 1249 cases. *Eur Urol* 56(1):1–9
4. Berger A, Haber GP, Kamoi K, Aron M, Desai MM, Kauok JH, Gill IS (2008) Laparoscopic radical nephroureterectomy for upper tract transitional cell carcinoma: oncological outcomes at 7 years. *J Urol* 180(3):849–854
5. Park SY, Jeong W, Ham WS, Kim WT, Tha KH (2009) Initial experience of robotic nephroureterectomy: a hybrid-port technique. *BJU Int* 104(11):1718–1721
6. Park SY, Jeong W, Choi YD, Chung BH, Hong SJ, Rha KH (2008) Yonsei experience in robotic urologic surgery-application in various urological procedures. *Yonsei Med J* 49(6):897–900
7. Eun D, Bhandari A, Boris R, Rogers C, Bhandari M, Menon M (2007) Concurrent upper and lower urinary tract robotic surgery: strategies for success. *BJU Int* 100(5):1121–1125
8. Rose K, Khan S, Godbole H, Olsburgh J, Dasgupta P (2006) Robotic assisted retroperitoneoscopic nephroureterectomy – first experience and the hybrid port technique. *Int J Clin Pract* 60(1):12–14
9. Margulis V, Shariat SF, Matin SF, Kamat AM, Zigeuner R, Kikuchi E, Lotan Y, Weizer A, Raman JD, Wood CG (2009) Outcomes of radical nephroureterectomy: a series from the Upper Tract Urothelial Carcinoma Collaboration. *Cancer* 115(6):1224–1233
10. Gjertson CK, Sundaram CP (2008) Testicular pain following laparoscopic renal surgery. *J Urol* 180(5):2040–2041
11. Kim FJ, Pinto P, Su LM, Jarrett TW, Rattner LE, Montgomery R, Kavoussi LR (2003) Ipsilateral orchialgia after laparoscopic donor nephrectomy. *J Endourol* 17(6):405–409
12. Zigeuner P, Pummer K (2008) Urothelial carcinoma of the upper urinary tract: surgical approach and prognostic factors. *Eur Urol* 53:720–731
13. Wu MP, Ou CS, Chen SL, Yen EY, Rowbothom R (2000) Complications and recommended practices for electrosurgery in laparoscopy. *Am J Surg* 179:67–73

Chapter 12

Robot-Assisted Pyeloplasty

Raymond J. Leveillee, Jorge Bracho, Steve K. Williams, John M. Shields, and Charles R. Moore

This chapter contains a video segment which can be found at the URL: <http://www.springerimages.com/Su>

Patient Selection

Patients typically present with symptomatic hydronephrosis. This may include renal colic exacerbated by fluids, pyelonephritis, or hypertension. Reconstruction is offered after an assessment of the anatomy (intravenous pyelogram, CT, or MR urography) as well as a functional assessment of the split renal function and cortical washout $t \frac{1}{2}$ as noted on diuretic nuclear renal scan (radiolabeled mercaptoacetyl glycine – MAG-3).

In patients with ureteropelvic junction obstruction (UPJO), imaging is essential to evaluate for presence of crossing vessels and to define the extent of hydroureter or hydronephrosis in relation to the renal hilar anatomy (Fig. 12.1a, b). Patients are assessed for their overall renal function, the presence of renal calculi, the level of insertion of the UPJ, the extent of pelvicaliceal dilatation, or the presence of an extrarenal or intrarenal pelvis. Various anatomic presentations may be treated with robotic pyeloplasty, such as high ureteral insertions, redundant renal pelvis or crossing vessels. The renal scan then provides a practical means for evaluating the relative success of the surgery in the postoperative setting. Any progressive decline in renal

function or recurrence of obstruction associated with the ipsilateral renal unit will be noted with sequential follow-up renal scans (Table 12.1).

Preoperative Preparation

We do not routinely utilize a bowel preparation for our patients undergoing pyeloplasty. A clear liquid diet the day prior to surgery is advised. Important considerations for the patient to be aware of is that the goal of the surgery is to improve the drainage of the affected kidney to preserve/improve renal function as well as avoid renal colic. It may be required in some instances to convert to an open operation. Blood transfusions, devascularization of the lower pole of the kidney, bowel injury, and prolonged urine leaks are extremely rare events. The informed consent should focus primarily on possible stenosis or obstruction after the surgery has been completed but may include comments outlined above.

Operative Setup

At our institution we utilize the da Vinci® S Surgical System (Intuitive Surgical, Inc., Sunnyvale, CA). Although four robotic arms are available, robotic pyeloplasty is generally performed using a three-armed technique.

R.J. Leveillee (✉)
Division of Endourology, Laparoscopy, and Minimally Invasive Surgery, Department of Urology, University of Miami School of Medicine, 1400 NW, 10th Ave., 507 Dominion Tower, Miami, FL 33136-1022, USA
e-mail: rleveill@med.miami.edu

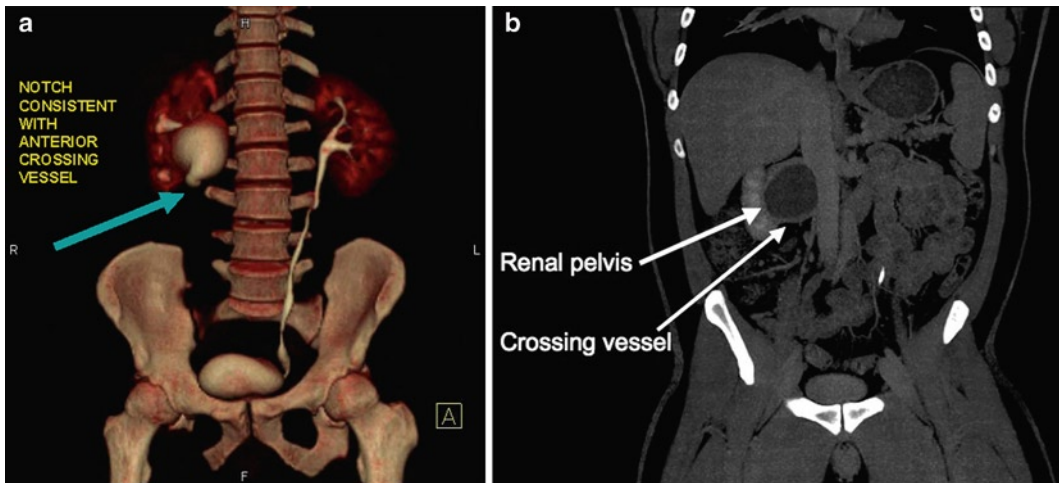


Fig. 12.1 (a) Three-dimensional reconstruction of patient with right UPJO. Note acute termination of proximal ureter with typical “notch,” seen when there is presence of

anterior crossing vessel. (b) Abdominal CAT scan. Note the area of severe hydronephrosis at the renal pelvis and the presence of anterior crossing vessel

Table 12.1 Robotic pyeloplasty in literature

Author	Number of patients	Type of repair	Operative time (min)	Anastomosis time (min)	Success (%)	Complication Rate (%)	Follow-up (months)	Stay (days)
Mendez et al.	32	Dismembered (31), Fenger (1)	300	n/a	100	3.1	10.3	1.1
Weise et al.	31	Dismembered	271	76	97	6.4	10	n/a
Gettman et al.	9	Dismembered	139	62.4	100	11.1	4.1	4.7
Siddiq et al.	26	Dismembered (23), YV (3)	245	n/a	95	13	6	2
Palese et al.	35	Dismembered	217	63	94	5.6	7.9	2.7
Bentas et al.	11	Dismembered	197	n/a	100	0	21	5.5
Palese et al.	38	Dismembered	226	64.2	94.7	10.5	12.2	2.8
Patel et al.	50	Dismembered	122	20	100	2	11.7	1.1

Only one surgical assistant is required in addition to a scrub technician, both of whom stand on the abdominal side of the patient. The vision cart is positioned so that it is easily seen by both the assistant and scrub technician. The patient side robotic cart is brought in over the patient’s ipsilateral shoulder. The final operating room setup is as shown in Fig. 12.2.

Patient Positioning and Preparation

Our technique with robotic pyeloplasty has been previously described [1] and has been modified

slightly over the years. After ureteral stent placement (see below) the patient is moved to the robotic suite and placed in a supine position on the operating table. Pneumatic compression stockings, urethral catheter, and an orogastric tube are routinely employed. Next, patients are positioned in a modified flank position with a 30° tilt and are held in place with a conformable vacuum “Bean-Bag” (Olympia, Seattle, Washington). A sub-axillary roll (gel or 1 L IV bag wrapped in a towel) is employed. The operating table is flexed gently to increase the space between the anterior-superior iliac crest and ribs. The ipsilateral (“up”) arm is supported in an Amsco “Krause” arm support that is placed above the chest to allow the arms of the robot sufficient

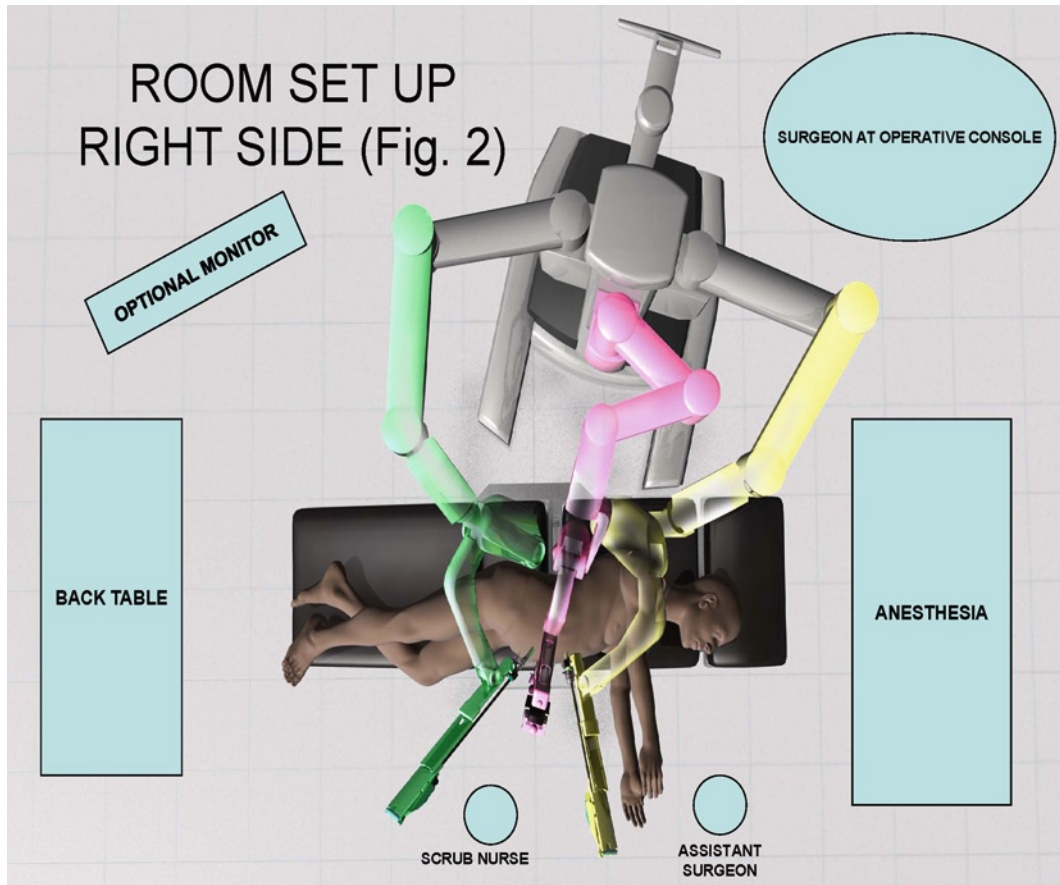


Fig. 12.2 Computer-generated graphic demonstrating operating room setup for robotic pyeloplasty. The scrub nurse and surgical assistant positions can be interchanged (Courtesy of Intuitive Surgical, Sunnyvale, CA)

space to maneuver. The contralateral (“down”) arm must lie low and angled slightly cephalad enough to allow for the midline robotic trocar and working element to be positioned without interference (Fig. 12.3a, b). The patient is secured at the arms, chest, hips, and legs with cross-table 3 in. silk tape and Velcro straps. Finally, the bed is tilted fully right and left prior to draping to ensure that the patient is adequately secured to the table.

Trocar Configuration

For the majority of patients, a 12 mm camera trocar is placed at the inferior crease of the umbilicus (Fig. 12.4). This allows for wide field of

view and is cosmetically appealing. For those with obese or redundant abdominal wall, the initial trocars can be moved laterally at the edge of the rectus muscle. Insertion of the secondary trocars is performed only after careful inspection of the abdomen for the presence of adhesions. One of the 8 mm working arm trocars is placed 8–10 cm superior to the camera trocar in the midline and the second is placed 8–10 cm lateral with a 10° inferior angle from the umbilicus (Fig. 12.5a). A 5 mm assistant trocar is placed midway and slightly lower than the umbilical and subxyphoid 8 mm robotic trocar. The final trocar configuration for a three armed robotic technique is as shown in Fig. 12.5b. When using the fourth robotic arm, an additional 8 mm robotic trocar is inserted low in the ipsilateral iliac fossa.

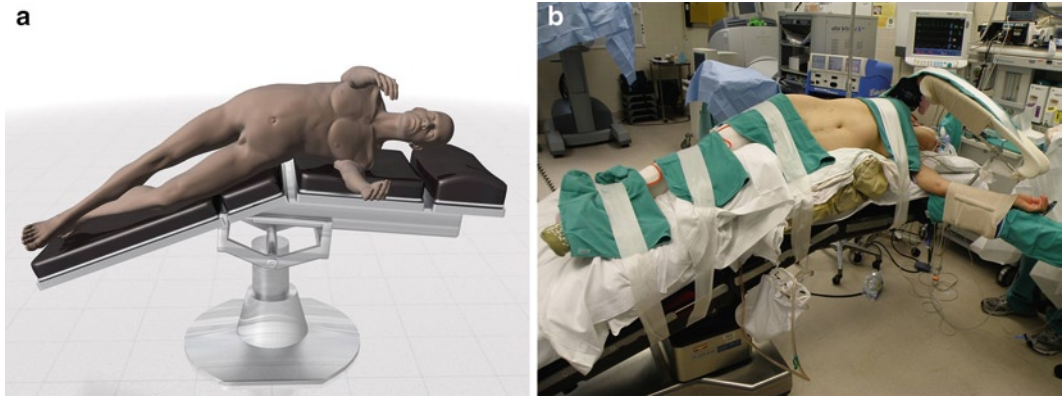


Fig. 12.3 (a) Computer-generated graphic demonstrating patient positioning for right-sided robotic pyeloplasty (Courtesy of Intuitive Surgical, Sunnyvale, CA)

(b) Photo illustrating positioning for right Pyeloplasty. Note “Bean Bag” and Krause arm hanger. Table is slightly flexed

Fig. 12.4 For the majority of patients the 12 mm camera trocar is placed at the inferior crease of the umbilicus. Picture recreates the procedure on the right side

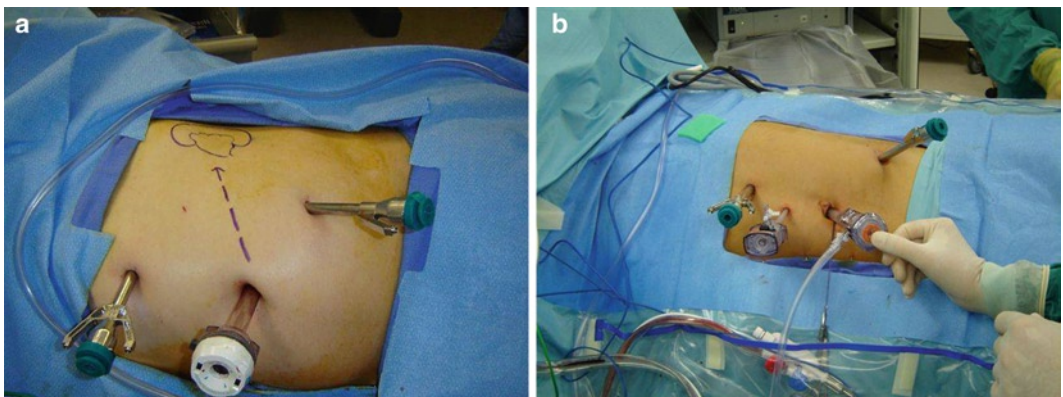
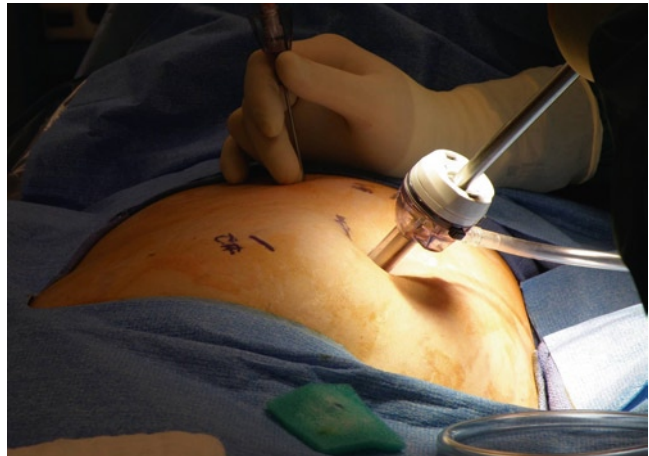

Fig. 12.5 (a) Trocar arrangement for left robotic pyeloplasty utilizing three trocars. (b) Trocar arrangement for left robotic pyeloplasty with additional 5 mm assistant trocar

Instrumentation and Equipment List

Equipment

- da Vinci® S (4-arm system)
- EndoWrist® Maryland bipolar forceps (Intuitive Surgical, Inc., Sunnyvale, CA)
- EndoWrist® curved monopolar scissors (Intuitive Surgical, Inc., Sunnyvale, CA)
- EndoWrist® Potts scissors (Intuitive Surgical, Inc., Sunnyvale, CA)
- EndoWrist® ProGrasp™ forceps (optional if using a fourth robotic arm; Intuitive Surgical, Inc., Sunnyvale, CA)
- EndoWrist® needle drivers (2) (Intuitive Surgical, Inc., Sunnyvale, CA)
- InSite® Vision System with 0° and 30° lens (Intuitive Surgical, Inc., Sunnyvale, CA)

Trocars

- 12-mm trocar (1)
- 8-mm robotic trocars (3 if using a four-armed technique)
- 5-mm trocar (1)

Recommended sutures

- 3-0 polyglactin suture on RB-1 needle cut to 6–8 in. for the ureteropelvic anastomosis
- 0 polyglactin suture for closure of the fascia
- 4-0 Monocryl suture for skin closure

Instruments used by the surgical assistant

- Laparoscopic needle driver
- Laparoscopic scissors
- Blunt tip grasper
- Suction irrigator device
- 10-mm specimen entrapment bag
- #19 round, fluted Blake closed suction drain (Ethicon, Somerville, NJ)

Robotic Pyeloplasty: Step-by-Step Technique

Basic Principles

Many of the preoperative steps are common to all robotic ureteral surgery procedures.

1. Preoperative urine culture with culture-specific antibiotics given.
2. Appropriate anatomic definition to determine the treatment options before incision. Judicious use of retrograde pyelography is to be encouraged.
3. Delicate handling of the ureter with minimal use of diathermy.
4. Sufficient mobilization without devascularization of the ureter, any associated vasculature, renal pelvis and the kidney before transection of the UPJ.
5. Clamping of the urethral catheter and forced diuresis can be a useful technique which may aid in hydrodistention (i.e., hydronephrosis) and identification of the Ureteropelvic junction obstruction (UPJO).
6. Spatulation of the ureter and fashioning a wide anastomosis to prevent restenosis.
7. Tension-free anastomosis with use of absorbable material. (Can be interrupted – our preference – or running) (2).

Step 1: Cystoscopy, retrograde pyelogram and ureteral stent placement

A retrograde pyelogram is helpful in evaluating the ureter and delineating the length of obstruction if not seen on other preoperative imaging. We prefer performing a retrograde pyelogram at the time of surgery because it also coincides with our preoperative internal double pigtail ureteral stent placement/replacement (Fig. 12.6). This is usually performed on the same day as the pyeloplasty immediately preceding it. We utilize an adjoining cystoscopy room, but a portable C-arm can be substituted with the ureteral stent placement performed in the same room as the pyeloplasty. A 6 Fr stent approximately 2 cm longer than what is usual for the patient's body habitus is chosen to prevent displacement or migration during laparoscopic manipulation of the stent. Some authors choose to place the stent in an antegrade fashion after the pyelotomy and ureteral spatulation has been performed.

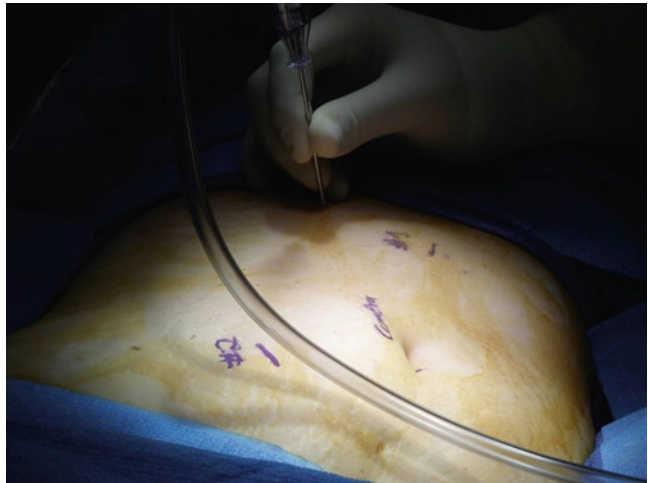
Step 2: Repositioning and abdominal access

Following completion of ureteral stent placement, the patient is repositioned in the modified decubitus position as previously mentioned and

Fig. 12.6 Prior to performance of robotic pyeloplasty, a cystoscopy and retrograde pyelogram with placement of double pig-tail stent is performed. This is usually done on the same day under the same anesthesia

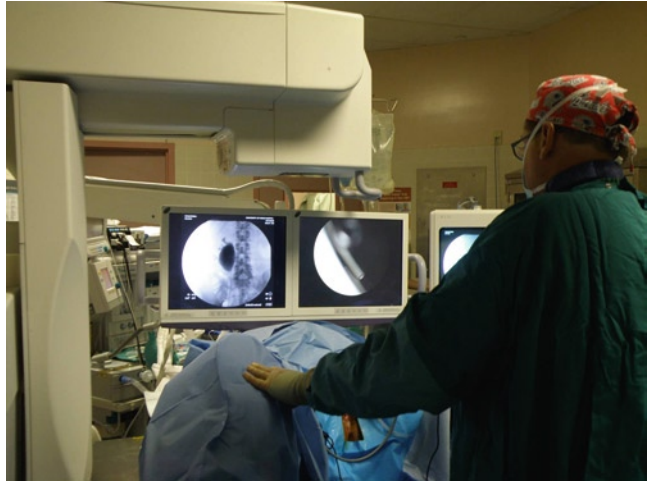

Fig. 12.7 Pneumoperitoneum is created using a Veress needle or open exposure at the umbilicus or in the ipsilateral upper quadrant. Picture recreates the procedure on the right side



reprepped and draped. Pneumoperitoneum is created using a Veress needle placed at the umbilicus or in the ipsilateral upper quadrant (Fig. 12.7). Alternatively an open Hasson trocar placement can be utilized. Trocars are then placed as described previously. The operating table is rotated maximally toward the assistant to allow the intestines to migrate medially and provide exposure of the ipsilateral kidney.

Step 3: Docking the patient side robotic cart

The patient side cart is then brought over the patient’s ipsilateral shoulder at an approximately 45° angle with the operating room table, entering from the head of the bed (Fig. 12.8a). Following

docking of the camera arm to the umbilical trocar, the two robotic arms are docked to their respective trocars, taking great care so as to optimize range of motion while at the same time avoid direct collision with the camera arm as well as the patient’s ipsilateral arm and hip (Fig. 12.8b).

Step 4: Mobilization of the ipsilateral colon and small intestines

Surgeon instrumentation			Assistant instrumentation
Right arm	Left arm	Fourth arm	
• Curved monopolar scissors	• Maryland bipolar grasper	• ProGrasp™ forceps (optional)	• Suction-irrigator • Blunt tip grasper
Endoscope lens: 30° down			

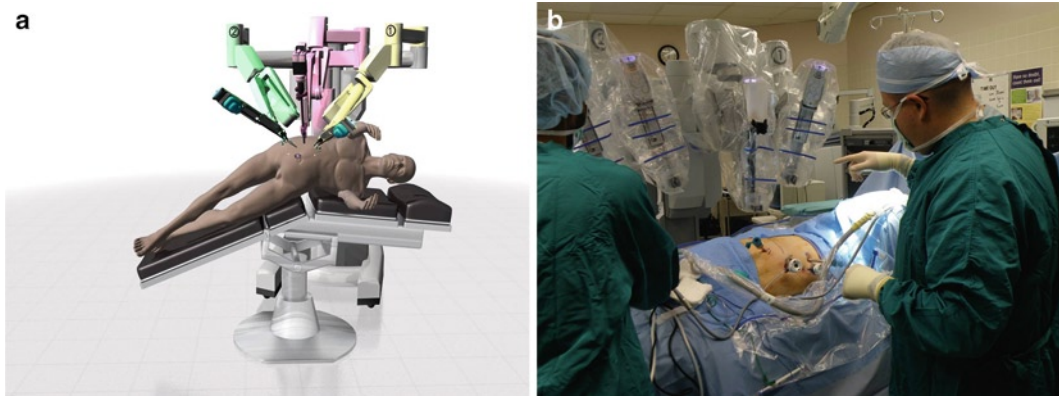
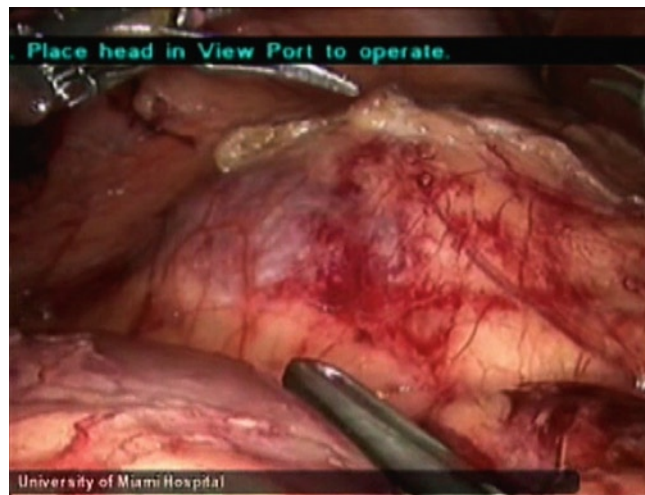

Fig. 12.8 (a) Computer-generated graphic demonstrating proper robot docking for the right side (Courtesy of Intuitive Surgical, Sunnyvale, CA) (b) Photo illustrating proper robot docking for the right kidney

Fig. 12.9 Bowel mobilization is performed, displacing the colon and duodenum medially by dividing the peritoneal attachments



In general a 30° down lens is used to perform robotic pyeloplasty; however, in some cases a 0° lens may suffice depending on the patient's body habitus. Monopolar and bipolar electrocautery settings are 30 W. Insufflation pressure is maintained at 15 mmHg throughout the operation. Prior to mobilization of the colon, the renal pelvis is distended via forced diuresis (20 mg of intravenous furosemide and copious intravenous fluids) and clamping of the urethral catheter. Bowel mobilization is performed by incising the line of Toldt and reflecting the ipsilateral colon and small bowel medially. A Kocher maneuver on the right side is rarely needed and if performed is done so without the use of electrocautery. The assistant uses a blunt

tip grasper to provide medial traction on the intestines for optimal exposure of the renal hilum (Fig. 12.9).

Step 5: Renal hilar dissection

Identification of the renal hilar vessels is useful prior to dissection of the ureter. On the right side, this involves skeletonizing the inferior vena cava and localizing the gonadal vein inferiorly and renal vein more superiorly. On the left side, this involves identification of the gonadal vein and tracing it superiorly to its origin with the left renal vein. Complete skeletonization of the renal vein and artery may or may not be necessary depending on the location of the ureteropelvic

junction. Great care must be taken to look specifically for the presence of a crossing lower pole artery and/or vein. Reference to preoperative cross-sectional imaging is important so as to avoid clipping and transecting a lower pole accessory renal artery.

Step 6: Identification and dissection of the ureteropelvic junction

The ureter is next identified coursing deep and lateral to the ipsilateral gonadal vein (Fig. 12.10). The ureter is carefully dissected avoiding direct manipulation, electrocautery or excessive stripping of periureteral fatty tissues so as to avoid devascularization. The dilated renal pelvis is

skeletonized, and the search for a high insertion of the ureter into the renal pelvis or an anterior crossing vessel is performed (Fig. 12.11). In cases of a crossing vessel(s), the vessel(s) and especially the underlying compromised ureteral segment are completely skeletonized. Often adhesions are noted between the two structures. In the absence of a crossing vessel, the entire ureteropelvic junction is skeletonized and inspected for the presence of a kink or stenosis. The decision about whether or not to perform an advancement flap (Y-V plasty) or dismembered pyeloplasty is made at this time. For a high inserting ureter, a Y-V plasty may be performed. In cases of an anterior crossing vessel, a dismembered pyeloplasty is preferred.

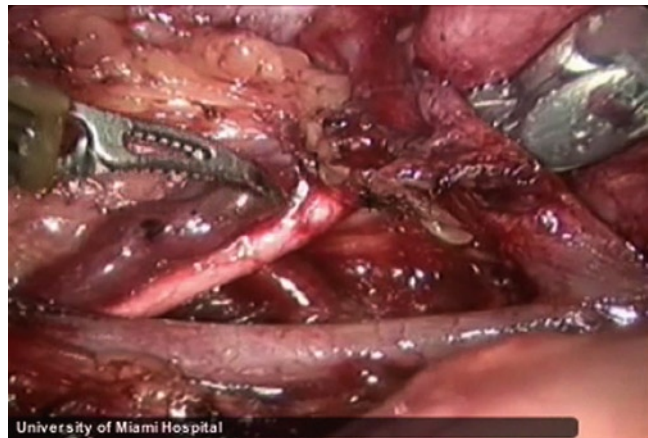


Fig. 12.10 Dissection of the ureteropelvic junction

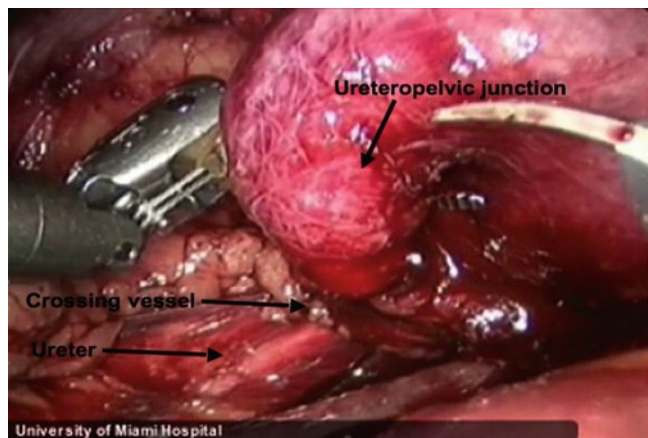


Fig. 12.11 Identification of crossing vessels and exposure of renal pelvis

Step 7: Transecting the ureteropelvic junction

The anterior portion of the UPJ is transected horizontally using cold curved monopolar scissors in order to expose the ureteral stent, taking great care not to cut the stent itself. Electrocautery is avoided to reduce the risk of devascularization. Instead, a small amount of bleeding from the ureter and pelvis is tolerated and is typically self-limited or controlled at the time of the anastomosis. The stent is then pulled out of the renal pelvis and transection of the ureter is completed (Fig. 12.12a–d). The stenotic UPJ segment is excised completely and submitted for pathologic analysis. Crossing vessels are spared (in order to preserve maximal renal perfusion and function) and the ureter and pelvis transposed anterior to the vessels.

Step 8: Reduction of a redundant renal pelvis and spatulation of the ureter

Surgeon instrumentation			Assistant instrumentation
Right arm	Left arm	Fourth arm	<ul style="list-style-type: none"> • Suction-irrigator • Blunt tip grasper
<ul style="list-style-type: none"> • Curved monopolar or Potts scissors 	<ul style="list-style-type: none"> • Maryland bipolar grasper 	<ul style="list-style-type: none"> • ProGrasp™ forceps (optional) 	
Endoscope lens: 30° down			

In cases of a large redundant renal pelvis, the pelvis can be reduced by excising a segment of the medial border (Fig. 12.13). Excessive excision of the renal pelvis should be avoided as this may compromise nearby infundibulum during later closure of the renal pelvis. The ureter is spatulated laterally for at least 2 cm using Potts scissors or curved monopolar scissors (Fig. 12.14). Fresh bleeding may be noted from the ureter, indicating the presence of healthy ureteral tissue.

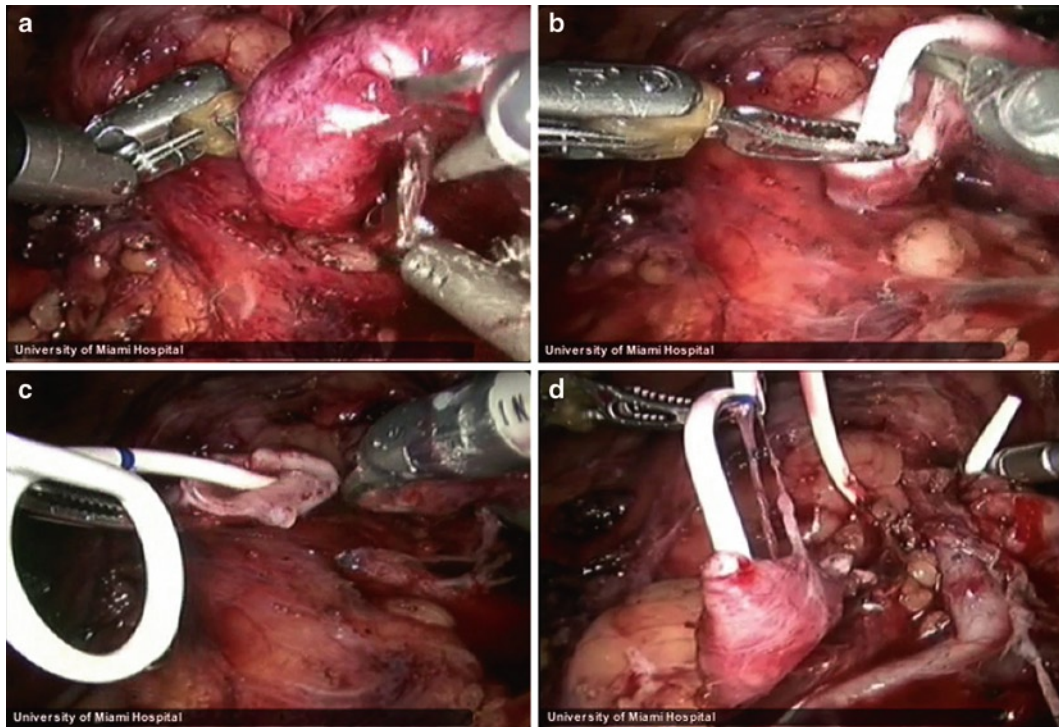


Fig. 12.12 (a) Transection of the anterior ureteropelvic junction. Note urine emanating from the incision in the dilated pelvis. (b) Exposure of the ureteral stent.

(c) Transection of the posterior ureteropelvic junction. (d) Removal of proximal portion of ureteral stent from the renal pelvis

Fig. 12.13 Reduction of the dilated renal pelvis

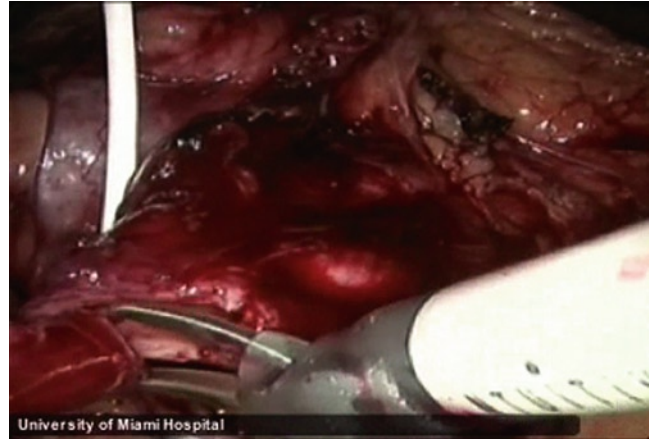
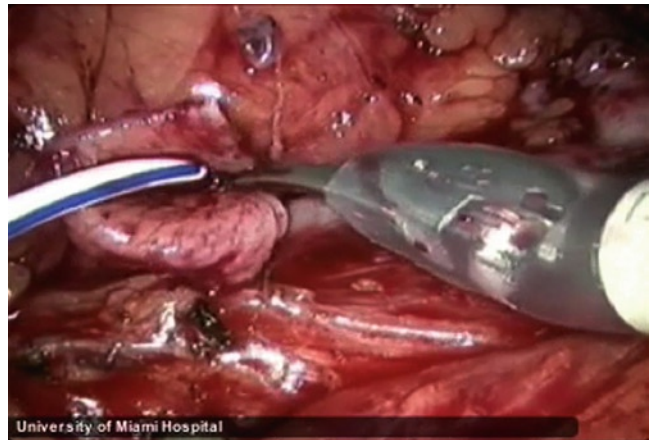


Fig. 12.14 Spatulation of the ureter



Step 9: Anastomosis of the ureter and renal pelvis

Surgeon instrumentation			Assistant instrumentation
Right arm	Left arm	Fourth arm	<ul style="list-style-type: none"> • Suction-irrigator • Laparoscopic scissors • Laparoscopic needle driver
• Needle driver	• Needle driver	• ProGrasp™ forceps	
Endoscope lens: 30° down			

The anastomosis is carried out in a dependent fashion using interrupted 3-0 polyglactin sutures on RB-1 needle to form a tension-free anastomosis. We perform the suturing in an interrupted manner to allow exact reapproximation of the ureter and renal pelvis without risk of plication. The first stitch is placed outside-in at the

fornix of the ureteral spatulation and inside-out at the most-dependent portion of the renal pelvis and tied (Fig. 12.15a–c) and is cut 1.5 cm long to use as a retractor. This suture can be passed beneath the anastomosis to better reveal the posterior aspect of the anastomosis. The second suture is placed immediately adjacent and anterior to the first suture. We close the posterior portion of the anastomosis first as visualization of the posterior border is more difficult than the anterior portion (Fig. 12.16). Once the posterior anastomosis is completed, the proximal end of the ureteral stent is replaced into the renal pelvis (Fig. 12.17a, b). Conversely, some authors may choose to perform the ureteral transection without a preplaced stent and place

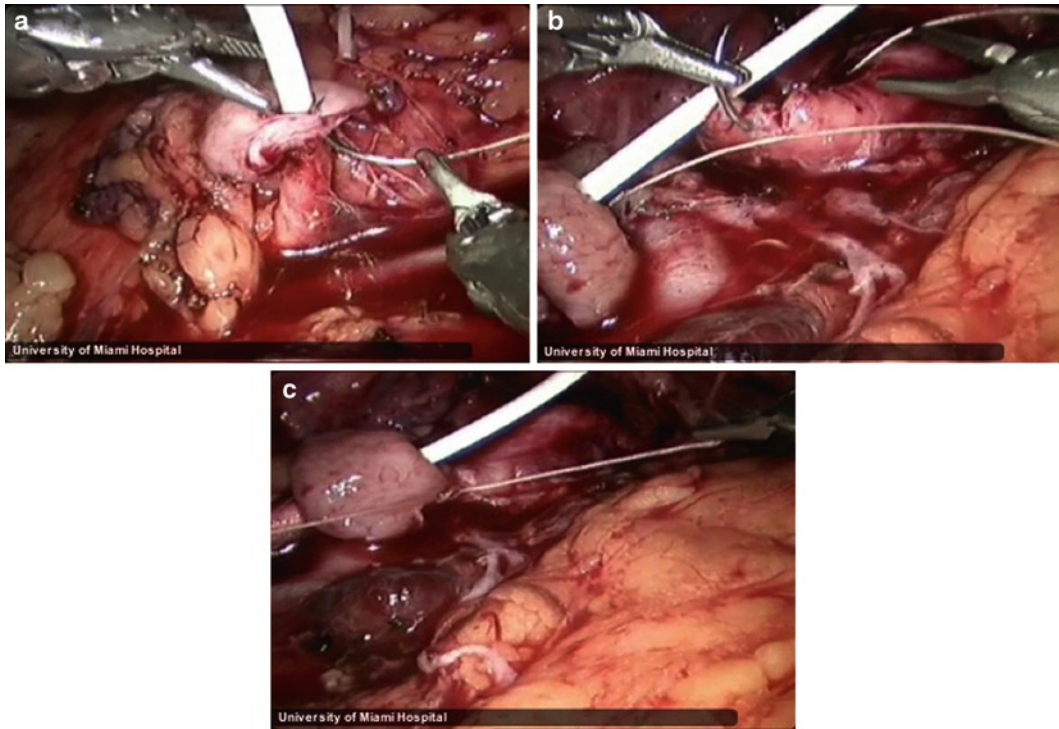
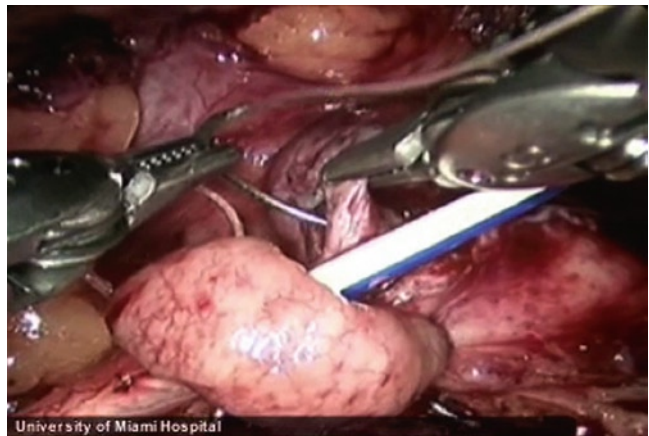


Fig. 12.15 (a) Placement of apical suture outside in on the ureter. (b) Placement of proximal suture inside out on the dependent most portion of the renal pelvis. (c) Tying the first knot and reapproximating the ureter and renal pelvis

Fig. 12.16 Placement of posterior suture



a double J stent antegrade at this point. In this case, a ureteral stent and guide wire are introduced into the abdomen through a trocar and passed down through the ureteropelvic junction and into the bladder. Finally, the anterior portion of the anastomosis is completed (Fig. 12.18). If a large opening of the renal pelvis persists,

this can be closed using a running continuous 3-0 polyglactin suture.

Step 10: Exiting the abdomen

Prior to the completion of the operation and exiting the abdomen, it is good practice to lower the

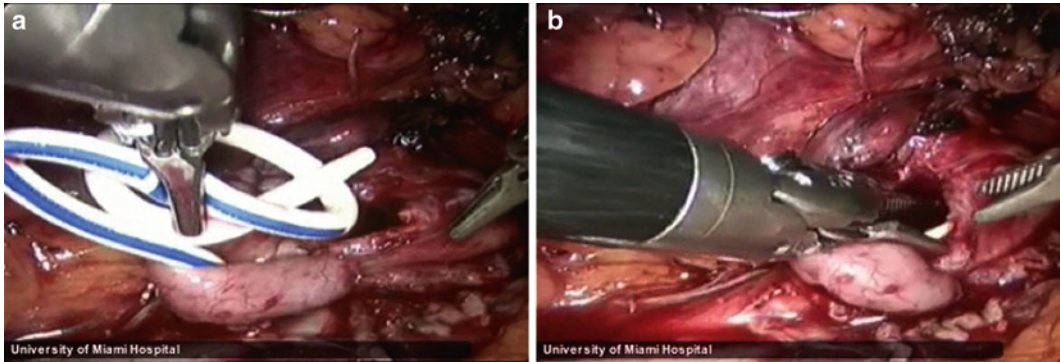
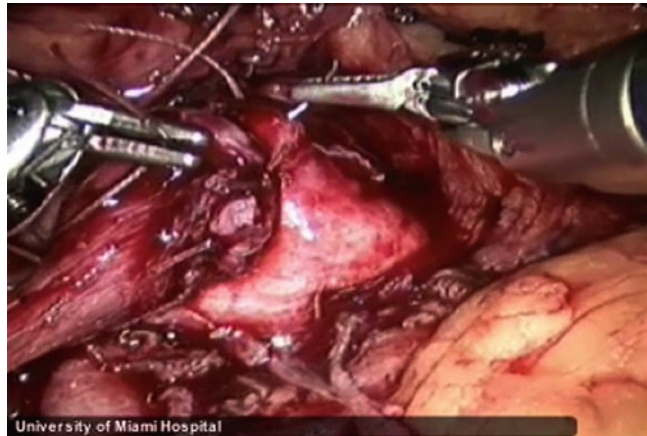


Fig. 12.17 (a) Replacing the proximal end of the ureteral stent into the renal pelvis. (b) Continuation of stent replacement

Fig. 12.18 Placement of last anastomotic stitch



intra-abdominal pressure to 6–8 mmHg CO₂ pressure to inspect for bleeding. Reapproximation of Gerota's fascia is optional and may help to prevent periureteral fibrosis. At this stage the robot is undocked, a #19 round, fluted Blake[®] closed suction drain (Ethicon, Somerville, NJ) is placed exiting the lower 8 mm robotic trocar site and the fascia of the 12 mm umbilical trocar site is closed with interrupted 0 polyglactin sutures. The skin can be reapproximated with 4-0 Monocryl and covered with Dermabond[®] (Ethicon, Somerville, NJ) or Steristrips[®]. Final healed postoperative incisions are as shown in Fig. 12.19.

Postoperative Management

Clear liquid diet is resumed the night of surgery with early ambulation. The majority of patients tolerate a regular diet the following day. The urethral catheter is usually removed on postoperative day (POD) 1, and if the drainage from the Blake drain is <100 cm³ over the next 8 h the patient is usually discharged home after drain removal. Oral narcotics are typically minimal, but we prescribe oxycodone or codeine for most, with a stool softener. There is no need for a postoperative antibiotic. We see most patients within a week (POD 7) and allow return to non-strenuous

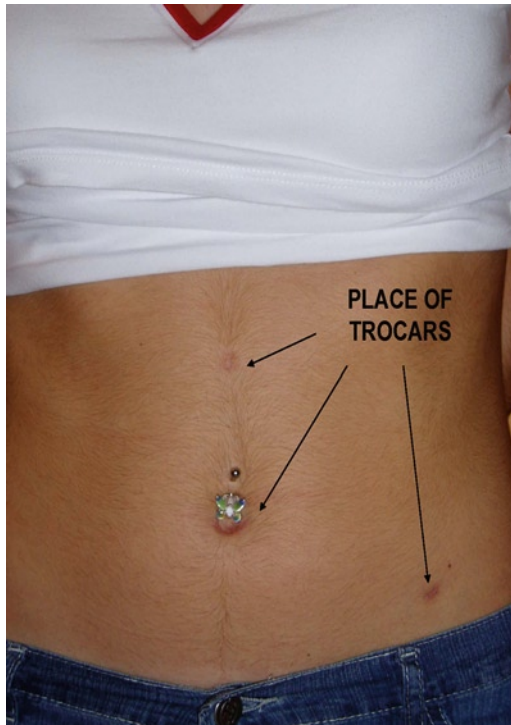


Fig. 12.19 Photo demonstrating healed postoperative incisions

activities within 2–3 weeks. The double J stent is removed via office cystoscopy at week 4–6. There is no need for retrograde pyelography. Renal scintigraphy is performed at week 10–12 (approximately 6 weeks after stent removal) and again at 6 months.

Special Considerations

Robot-assisted laparoscopic pyeloplasty poses technical considerations that may differ from a traditional laparoscopic approach. Routine steps (i.e., bowel mobilization) may be more challenging with the robot. This may be due to the robot being designed for precise movements in a small field and not gross extensive movements. Additionally, without haptic feedback the surgeon is forced to rely on visual feedback [2]. Smaller patients (pediatric, BMI < 25) result in the trocars being placed closer together with the

potential of more instrument collisions requiring adjustments of the robot arms [3]. Larger patients may need the trocar positions placed more laterally to account for the additional distance that the instruments will traverse to get to the surgical field (e.g., obese pannus). Robotic surgery requires an assistant who is familiar with laparoscopy and the clarity of the surgeon's field of vision is dependent on the assistant's ability to aid with exposure [4]. Secondary Ureteropelvic junction obstruction (UPJOs) (failed endopyelotomy or previous pyeloplasty) may be associated with an increased amount of retroperitoneal fibrosis and poorly vascularized tissues. In our experience, these have involved a previously unidentified anterior crossing vessel. These cases are quite demanding and the surgeon may want to consider reserving these cases until later in their experience [5]. Another special consideration is the treatment of concomitant stones in the kidney during the pyeloplasty. Once a small pyelotomy is made, a flexible cystoscope can be inserted via an accessory trocar and intracorporeal lithotripsy and stone basketing can be performed. If the opening in the renal pelvis is too large, sufficient distention of the renal pelvis cannot occur due to continued loss of irrigant fluid resulting in poor visualization.

Steps to Avoid Complications

Proper patient selection and careful positioning are keys to successful outcomes. Sterile urine preoperatively avoids the risk of sepsis and abscess formation. To avoid bowel complications consider open Hasson trocar placement for the initial trocar, especially for patients with a history of prior abdominal surgery and adhesions. In patients with poor renal function (i.e., differential renal function < 15%), laparoscopic nephrectomy should be considered instead of pyeloplasty if the patient is symptomatic and if clinically warranted. In addition, interrupted suture may have less potential for tying the anastomosis too tight resulting in luminal narrowing.

References

1. Siddiq FM, Leveillee RJ, Villicana P, Bird VG (2005) Computer-assisted laparoscopic pyeloplasty: University of Miami experience with the daVinci Surgical System. *J Endourol/Endourol Soc* 19(3):387–392
2. Leveillee RJ, Williams SK (2009) Role of robotics for ureteral pelvic junction obstruction and ureteral pathology. *Curr Opin Urol* 19(1):81–88
3. Gettman MT et al (2002) Anderson-Hynes dismembered pyeloplasty performed using the da Vinci robotic system. *Urology* 60(3):509–513
4. Yohannes P et al (2003) Laparoscopic Anderson-Hynes dismembered pyeloplast using the da Vinci™ robot: technical considerations. *J Endourol* 17(2): 79–83
5. Yanke BV et al (2008) Robot-assisted laparoscopic pyeloplasty: technical considerations and outcomes. *J Endourol* 22(6):1291–1295

Chapter 13

Robot-Assisted Extended Pyelolithotomy and Ureterolithotomy

Ashok K. Hemal and Mani Menon

This chapter contains a video segment which can be found at the URL: <http://www.springerimages.com/Su>

Robotic Pyelolithotomy

Patient Selection

Robotic extended pyelolithotomy (REP) is an evolving technique, the indications for which are evolving as well. The technique is ideally suited for instances when concomitant renal reconstructive procedures such as pyeloplasty and calyceal diverticulectomy are planned. That said the technique has also been used in the primary treatment of various renal and ureteral stones in patients with both normal and complex anatomy. Patients who are medically deemed candidates for traditional laparoscopy should be able to undergo robotic extended pyelolithotomy (REP). Caution should be used in patients with previous abdominal or renal surgery, including shock wave lithotripsy (SWL), as adhesions can make safe dissection problematic. This technique has been used in patients from early adolescence to late adulthood.

Robot assisted surgery has been developed for prostate, kidney, and bladder during this decade [9–13]. Recently, kidney stones ranging from 1 to 7.1 cm in size, partial to complete staghorn have been safely treated with robotic extended pyelolithotomy (REP) [1, 2]. However, true staghorn stones with secondary calculi have been associated

with chances of open conversion, residual fragments and the need for additional procedures to become stone free. Therefore we feel that robotic extended pyelolithotomy (REP) is best suited for large renal pelvis, partial staghorn, and complete staghorn stones in a hydronephrotic kidney. The chief constraints on stone size and location stem from renovascular anatomy, lack of tactile sensation and angulation of the robotic approach, yet through the use of adjunctive techniques such as intra-operative flexible nephroscopy, none of these constraints are absolute. Aberrant renal vessels, may limit pyelotomy. Even normal renal vasculature compromises the superior extent of renal pelvis dissection. In this way complex upper pole stones which involve calyces at obtuse angles to the renal axis may be problematic. Most authors prefer CT-IVP imaging and nuclear medicine renogram to precisely define stone anatomy and evaluate renal functional and provide anatomic information. Stones of any composition may be safely treated. Infectious stones such as struvite or calcium phosphate may be treated, provided sterile urine culture and appropriate antibiotic coverage (Table 13.1).

Preoperative Preparation

Urine Culture and Bowel Preparation

Patients must have documented sterile urine preoperatively, as there is considerable chance of spillage of urine into the abdomen or retroperitoneum. Perioperative antibiotics according to

A.K. Hemal (✉)

Department of Urology, and Institute of Regenerative Medicine, Robotics and Minimally Invasive Surgery, Baptist Medical Center and Wake Forest University School of Medicine, Wake Forest University Health Sciences, Winston-Salem, NC 27157-1094, USA
e-mail: ahemal@wfubmc.edu

Table 13.1 Various applications of robot-assisted procedures in treating stone disease in different locations

	Robotic procedure	Indication
Reconstructive + stone extraction	Pyeloplasty with pyelolithotomy	Ureteropelvic junction obstruction with secondary stones
	Ureteropyelostomy with pyelolithotomy	Duplex pelvicalyceal system with ureteropelvic junction obstruction in the lower moiety with secondary stone
	Ureteric reimplantation with stone extraction	Megaureter with ureteral stone
	Bladder diverticulectomy with stone	Stone in a bladder diverticulum
Primarily stone removal	Ureterolithotomy	Impacted large ureteral calculus
	Extended pyelolithotomy	Partial staghorn renal calculus
	Nephrolithotomy	Inferior calyceal calculus with narrow infundibulum and thin overlying parenchyma
Ablative	Simple nephrectomy	Non-functioning kidney with renal stone disease
	Nephroureterectomy with stone removal	Non-functioning kidney with impacted ureteric stone
	Lower pole partial nephrectomy with stone extraction	Non-functioning lower pole with inferior calyceal calculi

cultures or empiric broad spectrum agent to provide coverage for typical skin and urinary flora are given. Simple bowel preparation of clear liquids the day prior and enema or suppository the evening prior to surgery help reduce colonic distension and facilitate dissection.

Informed Consent

Informed consent should address the potential complications from both laparoscopic renal surgery and traditional stone surgery. Risks of bleeding, infection, damage to kidney or abdominal viscera, loss of kidney, and conversion to open should be discussed. Further risks including failure to eradicate all stone fragments and stone recurrence are considered.

Operative Setup

Room setup for robotic extended pyelolithotomy is similar to other robotic renal surgery. Given the limited working space of most operating rooms, we prefer to have the patient table offset towards the side of the docked robot (patient's back). The

robotic light source units and insufflators are in a common tower placed near the foot of the bed, on the side of the patient's back. This allows ample room for a patient-side assistant, scrub nurse, and instrument table on patient's abdominal side. Additionally, the robotic console is placed remotely in the same room or adjoining room. This arrangement places all surgeons, assistants, and instruments in direct access to the working surface of the patient. Additional specialized equipment such as holmium laser units or ultrasonic/hydraulic lithotripters may be brought in as needed for fragmentation of stones, if deemed necessary.

Patient Positioning and Preparation

Sequential compression stocking devices are applied to the lower extremities and activated prior to induction of general anesthesia. An orogastric tube and indwelling 16Fr urethral catheter are then inserted. For a transperitoneal approach, the patient is then placed in a modified (45°–60°) lateral decubitus position with minimal flexion of the operating table and kidney rest elevation. For a retroperitoneal approach, the patient is placed

in a full flank position. Sequential compression stocking devices are applied to the lower extremities and activated. Care is taken to ensure adequate padding of all pressure points, placement of an axillary roll and securing patient to the table. The catheter is subsequently clamped to allow gradual distension of the urinary bladder, which facilitates antegrade placement of a double pigtail ureteral stent later on in the operation, as the lower end (bladder lumen) has greater space for the stent to coil. Additionally, the reflux of fluid via the stent (seen as drops of water emanating from the holes and the end of the stent) is further reassuring regarding correct placement of the lower end of the stent in the bladder, and not in the distal ureter [3].

Trocar Configuration

We have performed robotic extended pyelolithotomy (REP) both by transperitoneal and retroperitoneal approaches, but now universally prefer a transperitoneal approach unless a compelling reason favors a retroperitoneal approach (i.e. prior extensive intraperitoneal surgery). The retroperitoneal approach, while theoretically superior in terms of reduced risk of peritoneal contamination with urine or stone fragments, remains extremely challenging technically for robotic extended pyelolithotomy (REP), as creation of retroperitoneal space and appropriate placement of trocars to provide wide excursion is cumbersome. Of note, we have found it difficult to employ a retroperitoneoscopic robotic approach in obese and short statured patients.

Transperitoneal Approach

Transperitoneal and retroperitoneal robotic pyelolithotomy were developed based on principles of laparoscopic management of stone disease [14–18]. The pneumoperitoneum is established using the Veress needle by placing it in the ipsilateral hypochondrium/iliac fossa. The rest of the trocar placements and trocar configuration is mapped out after the pneumoperitoneum is

established and is dependant upon the individuals' physical features, surgical approach (i.e. transperitoneal or retroperitoneal) as well as the surgeon's preference of stereoscopic lens [4].

If using a 0° or 30° down stereoscopic lens, a 12 mm camera trocar is placed through the lateral edge of the rectus muscle at the level of the umbilicus, while the two 8 mm robotic trocars are placed in such a manner to form a skewed wide isosceles triangle [4]. The cranial 8 mm robotic trocar is placed an inch away from the midline (ipsilaterally), between xyphoid and umbilicus (almost at the level of the renal hilum), and the second more caudal 8 mm robotic trocar is placed in the ipsilateral iliac fossa along the anterior axillary line, at least 7–8 cm away from the camera trocar, thus minimizing instrument collisions. A 12 mm assistant trocar in the midline allows for suction, retraction, passage of suture materials, specimen retrieval bag, and flexible nephroscope (Fig. 13.1). Another 5 mm assistant trocar in the midline allows for further retraction such as the liver during right sided procedures. In general, we utilize a 3-armed robotic technique; however, a fourth arm robotic trocar can be added above the pubic symphysis in a paramedian location in line with the cranial robotic trocar for the purpose of retraction and dissection.

Alternatively, when using a 30° up stereoscopic lens, the 12 mm camera trocar is placed at the level of umbilicus, laterally between the anterior axillary and mid-clavicular lines. The two 8 mm robotic trocars are placed along the para-rectus muscle, at a plane lower than the camera trocar and triangulated towards the renal pelvis [3, 4].

Retroperitoneal Approach

In this approach the patient is placed in the full lateral flank position. The bridge of the table is elevated to flatten the lumbar region. Initially tilting the table toward the anterior side allowed the peritoneum and its contents to fall forward. This maneuver helps to avoid peritoneal transgression during trocar placement. A 1–1.5 cm incision is made 2 cm above the midportion of the anterior-superior iliac crest traversing from skin down to

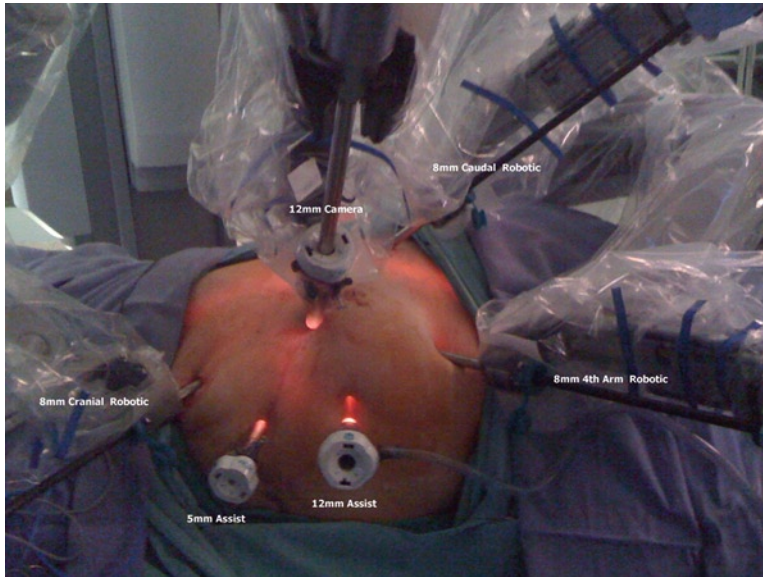


Fig. 13.1 Trocar placement for transperitoneal robotic extended pyelolithotomy. A three trocar configuration consisting of the camera trocar, cranial and caudal

robotic is the minimum recommended. Additional trocars such as a fourth arm robotic, 5 mm assist, and 12 mm assist may be placed as needed

the thoracolumbar fascia entering in to retroperitoneal space for placing the balloon to expand the space. During this step, there must be a deliberate effort made to prevent inadvertent dissection between the subcutaneous and muscular planes, as subsequently the extravasation of gas can result. At this point, this space can be developed with the help of blunt digital dissection.

A trocar mounted pre-peritoneal distension balloon (PDB 1000, US Surgical, Norwalk, CT) is introduced into the incision. With this balloon, the space is created under vision and left inflated for 5 min to ensure hemostasis. After verifying that an adequate working space has been created under laparoscopic vision, the PDB balloon is deflated and replaced with a 12 mm camera trocar. Two additional 8 mm robotic trocars are subsequently placed under vision equidistant (approximately 8–10 cm) from the camera trocar in a right angle to each other along the anterior and posterior axillary lines respectively (Fig. 13.2). A 5 mm assistant trocar is placed at the same level as the 12 mm camera trocar towards the anterior abdominal wall and equidistant from the 8 mm robotic trocar.

The robot is docked and used to further broaden the extraperitoneal space if needed.

Instrumentation and Equipment List

The robotic instruments required for the procedure include: Maryland bipolar or plasma kinetic forceps on the left hand side; and a curved monopolar scissor (hot) on the right side, interchangeable with a needle driver. However, configuration may change according to dominant hand of the surgeon. This limits the number of robotic instruments to three for improving cost effectiveness. Alternatively, two needle drivers for ease of suturing, a hook for blunt dissection of the Gil-Vernet's plane and a ProGrasp™ forceps may be used.

Equipment

- da Vinci® Standard or S Surgical System (3- or 4-arm system; Intuitive Surgical, Inc., Sunnyvale, CA)
- EndoWrist® Maryland bipolar forceps or PK dissector (Intuitive Surgical, Inc., Sunnyvale, CA)

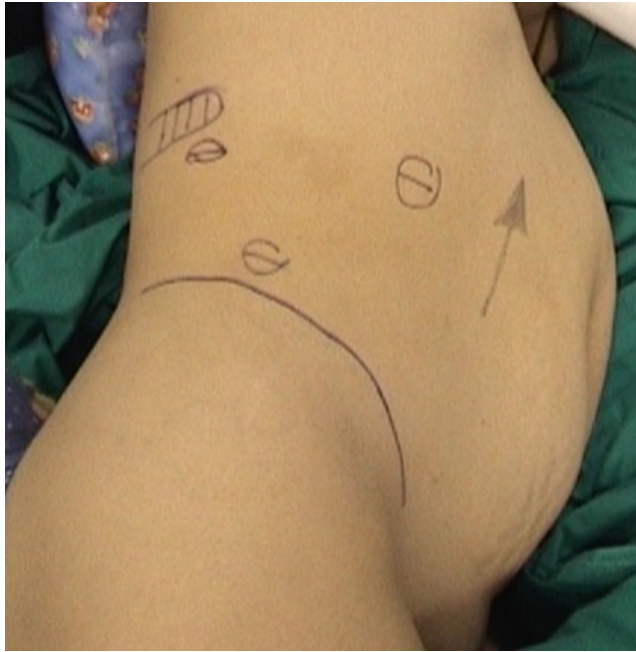

Fig. 13.2 Trocar configuration for retroperitoneal robotic pyelolithotomy. The 12 mm camera trocar is placed immediately above the iliac crest with the two more cephalad trocars representing the 8 mm

robotic trocars placed 8–10 cm away and along the anterior and posterior axillary lines. Arrow points in the direction of the patient’s head and the tip of the 12th rib is indicated

- EndoWrist® curved monopolar scissors (Intuitive Surgical, Inc., Sunnyvale, CA)
- EndoWrist® ProGrasp™ forceps (Intuitive Surgical, Inc., Sunnyvale, CA)
- EndoWrist® needle drivers (2) (Intuitive Surgical, Inc., Sunnyvale, CA)
- InSite® Vision System with 0° and 30° lens (Intuitive Surgical, Inc., Sunnyvale, CA)
- 5 mm laparoscopic lens

- 17Fr flexible cystoscope
- Nitinol stone basket or flexible stone graspers
- Preperitoneal distention balloon (PDB 1000, US Surgical, Norwalk, CT)
- 10 mm specimen entrapment bag
- 16Fr urethral catheter
- Double pigtail ureteral stent
- 10 or 15Fr Jackson-Pratt drain

Trocars

- 12 mm trocars (2)
- 8 mm robotic trocars (2)
- 5 mm trocar (1)

Recommended sutures

- 5-0 poliglecaprone on an RB-1 needle cut to 10 cm in length

Instruments used by the surgical assistant

- Laparoscopic scissors
- Blunt tip fenestrated grasper
- Suction irrigator device

Step-by-Step Technique

Step 1: Mobilization of the ipsilateral colon

Surgeon instrumentation		Assistant instrumentation
Right arm	Left arm	• Suction-irrigator
• Curved monopolar scissors	• Maryland bipolar grasper	
Endoscope lens: 0°, 30° down or 30° up depending on surgeon preference and trocar configuration		

The procedure is initiated with a Maryland bipolar forceps on the left side and a curved scissor on the right. Upon inspecting the abdominal cavity,

if adhesions exist, these should be lysed sharply with minimal electrocautery in order to avoid inadvertent bowel injury. The electrocautery settings for monopolar scissors is 50 W and for bipolar forceps is 25 W. The insufflation pressure used throughout the procedure is maintained at 14 mmHg. On the left side, a limited mobilization of the colon overlying the kidney and renal pelvis is performed by incising along the Line of Toldt. In a thin individual, sparse mesocolic fat may allow a trans-mesocolic approach, wherein a window is created in the mesocolon, overlying the renal pelvis which in such instances maybe be seen as a bulge due to the presence of the stone with a dilated renal pelvis. On the right side, an additional 5 mm liver retractor placed below the xyphoid may be required to elevate the right lobe of the liver and provide better visualization of the renal hilum and renal pelvis. The lateral peritoneal attachments of the hepatic flexure are incised to mobilize the ascending colon and duodenum providing access to the renal hilar area. Contrary to the open technique, entire mobilization of the kidney (esp. the lateral attachments) is avoided to prevent it from flopping medially and thus hampering vision.

Step 2: Dissection of ureter and renal pelvis

The next important landmark is the ureter, which is followed cranially to further identify the renal pelvis (Fig. 13.3). It is important to dissect the renal pelvis free of its surrounding peripelvic fat, which may be adherent in patients who have undergone prior shock wave lithotripsy (SWL) or percutaneous nephrolithotomy (PCNL) or have had infected stones or pyonephrosis. This dissection is important to correctly develop the Gil-Vernet's plane which allows exposure of the infundibulae of the major calyx, especially in cases of intra-renal configuration of the pelvis. Due to a transperitoneal approach, the renal vessels (renal vein in particular) are found to lie abutting the cranial edge of the renal pelvis, and tends to limit the superior extension of the pyelotomy into the superior infundibula. Correct dissection of the peripelvic fascia further facilitates mobilization of the renal pelvis free and away from the vessels. The stone identification sometimes is difficult given the presence of adhesions and inflammation, thus a gentle, careful and cautious dissection of the renal pelvis must be considered. This allows for identification and preservation of the renal vessels, especially the anterior branch of renal artery or

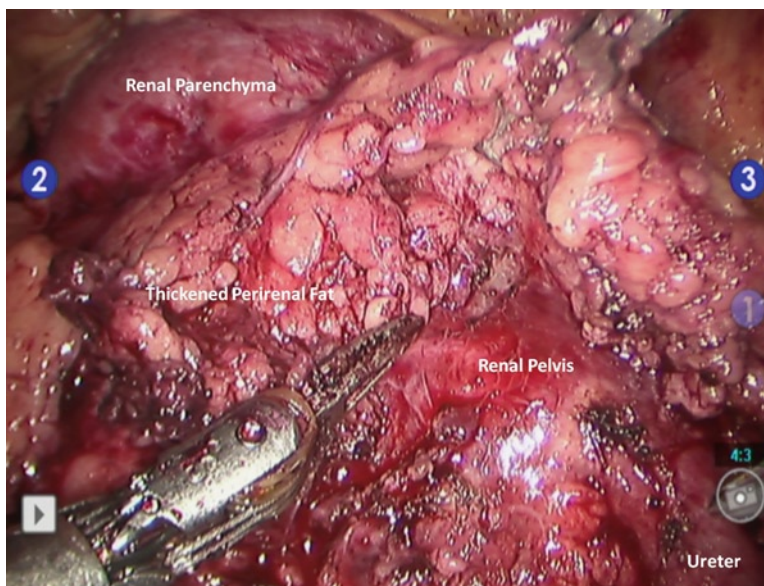


Fig. 13.3 Right transperitoneal robotic extended pyelolithotomy: exposure of the renal pelvis. The perirenal fat is notably thickened, as is common with prior inflammation and scarring associated with large renal stones and prior procedures

vein, if they are closely abutting the renal pelvis, thus preventing vascular injury at the time of pyelolithotomy. Complete skeletonization of the main renal vessels is only performed in cases where entry into the renal parenchyma is required or when contemplating an anatomic nephrolithotomy or extended pyelolithotomy.

Step 3: Pyelotomy, infundibulotomy, and removal of stones

Surgeon instrumentation		Assistant instrumentation
Right arm	Left arm	<ul style="list-style-type: none"> • Suction-irrigator • Laparoscopic fenestrated grasper
<ul style="list-style-type: none"> • Curved monopolar scissors 	<ul style="list-style-type: none"> • Maryland bipolar grasper 	
Endoscope lens: 0°, 30° down or 30° up depending on surgeon preference and trocar configuration		

Once the pelvis is adequately dissected, a V-shaped pyelotomy is performed, with or without extension into the inferior infundibulum (Fig. 13.4). However, depending upon the stone size and configuration, pyelotomy is extended into the superior or inferior infundibulum of the kidney to prevent inadvertent injury to the renal vessels. The laparoscopic assistant can also retract

the vessels superiorly using a blunt suction tip. Once an adequate pyelotomy is created, the tip of the cold scissors is utilized in dissecting the pelvic mucosa off the stone, freeing it to allow the stone to be maneuvered into a position such that its smallest diameter aligns with the pyelotomy. This allows delivering one end of the stone out first, allowing manipulation of the other end in sea-saw manner (Fig. 13.5). Secondary calyceal calculi are retrieved under vision as one has ability to move the camera into the pyelotomy incision and remove the stones using the Maryland bipolar forceps or by the assistant using a laparoscopic grasper. Stones are then placed in the paracolic gutter for later retrieval.

Step 4: Adjunctive maneuver to remove calyceal calculi

Surgeon instrumentation		Assistant instrumentation
Right arm	Left arm	<ul style="list-style-type: none"> • Suction-irrigator • Laparoscopic fenestrated grasper • 17Fr flexible cystoscope
<ul style="list-style-type: none"> • Curved monopolar scissors 	<ul style="list-style-type: none"> • Maryland bipolar grasper 	
Endoscope lens: 0°, 30° down or 30° up depending on surgeon preference and trocar configuration		<ul style="list-style-type: none"> • Nitinol stone basket or flexible graspers

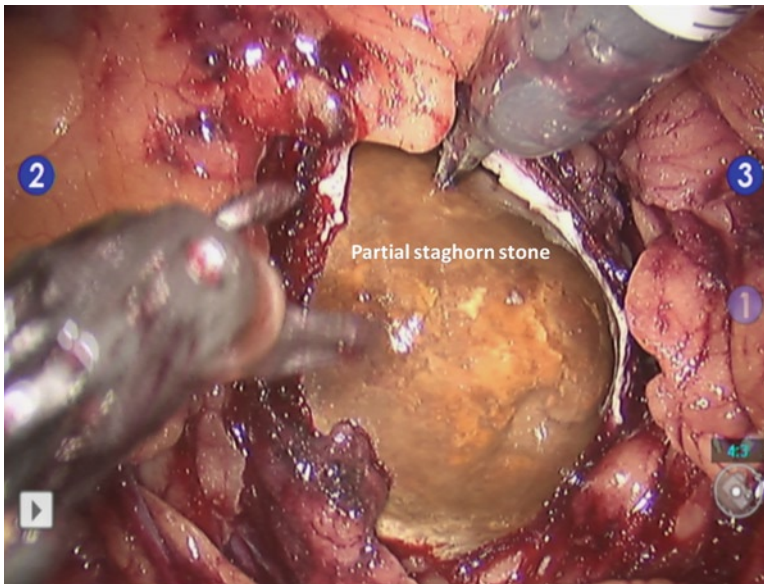


Fig. 13.4 Right transperitoneal robotic extended pyelolithotomy. Incision of renal pelvis may be extended into an infundibulum to allow branches of a staghorn to be removed

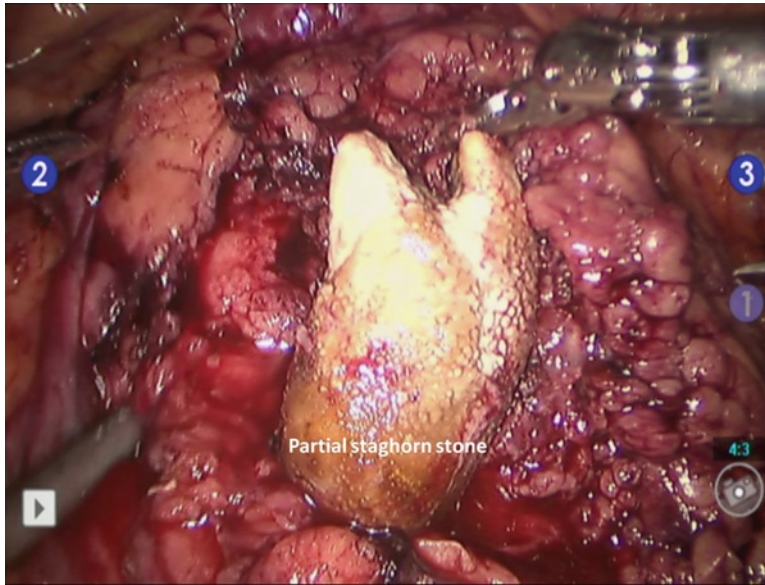


Fig. 13.5 Right transperitoneal robotic extended pyelolithotomy. The stone is grasped with robotic forceps and gently manipulated from the renal pelvis

After retrieval of the pelvic stone, attention is paid to calyceal calculi. The camera is moved close to pelvicalyceal system and some of these can be removed under direct vision. The calyces are flushed and dislodged with saline using the suction-irrigation device. Additional maneuver for extraction of calyceal calculi can be performed with a flexible cystoscope (17Fr diameter) connected to a different endoscopic vision cart. The flexible cystoscope can be introduced into the abdomen through the cranial 8 mm robotic or midline assistant 12 mm trocar. To access different calyces, pressure irrigation is required, which helps in intra-renal inspection and identification of calyceal stones. If needed, nitinol baskets or flexible graspers can be used for stone extraction. Small stone fragments may be immediately removed from the body and any larger fragments left along the paracolic gutter for later retrieval.

Step 5: Antegrade ureteral stenting

Surgeon instrumentation		Assistant instrumentation
Right arm	Left arm	
• Needle driver	• Maryland bipolar grasper	<ul style="list-style-type: none"> • Suction-irrigator • Laparoscopic fenestrated grasper • Double pigtail ureteral stent
Endoscope lens: 0°, 30° down or 30° up depending on surgeon preference and trocar configuration		

Once the stones are removed, an antegrade double pigtail ureteral stent is placed over a guide wire introduced through the 5 mm assistant laparoscopic trocar and is easily manipulated into the ureter with the robotic instruments (Fig. 13.6), which avoids cystoscopy and prior placement of the stent and then a second change in patient positioning for robotic extended pyelolithotomy (REP). With the bladder now distended, urine should be noted emanating from the proximal end of the stent once in proper position within the bladder and the guide wire is removed. The proximal end of the stent is then placed within the renal pelvis prior to closure.

Step 6: Repair of the infundibular and pyelotomy incisions

Surgeon instrumentation		Assistant instrumentation
Right arm	Left arm	
• Needle driver	• Needle driver	<ul style="list-style-type: none"> • Suction-irrigator • Laparoscopic fenestrated grasper
Endoscope lens: 0°, 30° down or 30° up depending on surgeon preference and trocar configuration		

The infundibular and pyelotomy incisions are sutured in a running fashion using 5-0 poliglecaprone on an RB-1 needle cut to 10 cm (Fig. 13.7). The peripelvic fat is also

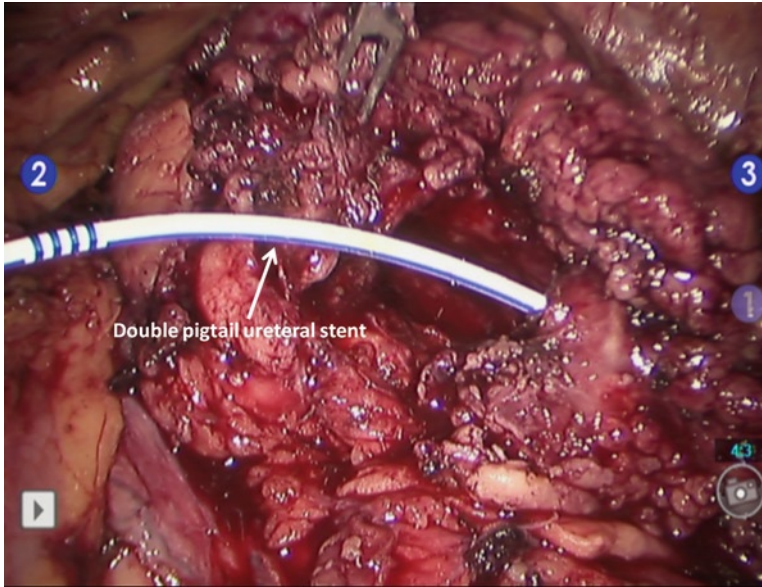


Fig. 13.6 Right transperitoneal robotic extended pyelolithotomy. A double pigtail ureteral stent is placed in an anterograde fashion over a guidewire through the assistant trocar

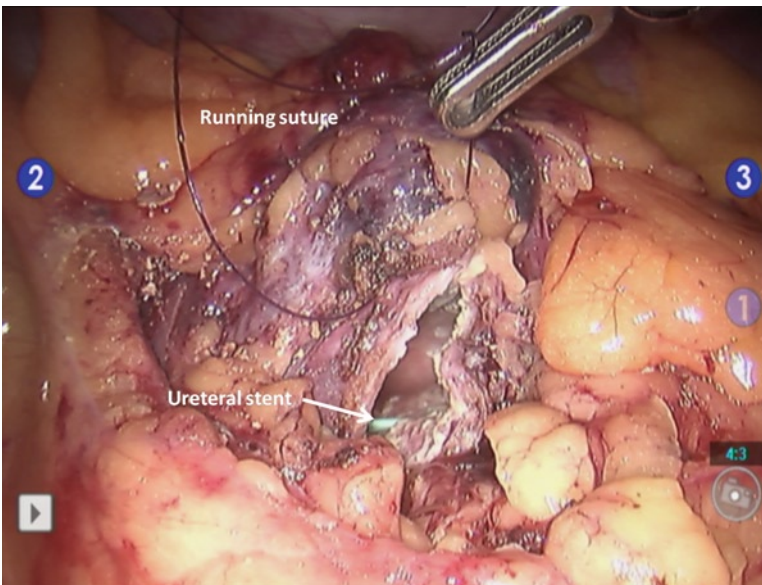


Fig. 13.7 Right transperitoneal robotic extended pyelolithotomy. The pyelotomy is closed with 5-0 suture in a running or interrupted fashion. Care is taken to avoid inclusion of the proximal stent in the suture line

approximated to isolate the repaired pyelotomy. The Gerota's fascia is approximated to close off the perinephric space from the peri-

toneal cavity. An intraperitoneal 10 or 15Fr Jackson-Pratt drain is placed through 5 mm assistant trocar.

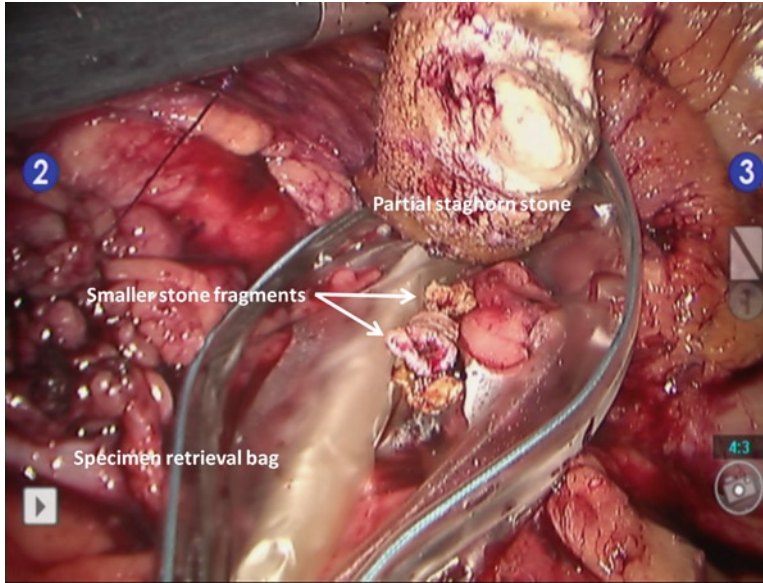


Fig. 13.8 Right transperitoneal robotic extended pyelolithotomy. All stones are moved from the paracolic gutter into the specimen retrieval bag

Step 7: Retrieval of stones from the body

Surgeon instrumentation		Assistant instrumentation
Right arm	Left arm	<ul style="list-style-type: none"> • Suction-irrigator • 10 mm specimen entrapment bag
• Needle driver	• Needle driver	
Endoscope lens: 0°, 30° down or 30° up depending on surgeon preference and trocar configuration		

The stone fragments are retrieved from the paracolic gutter using a 10 mm specimen entrapment bag inserted through the 12 mm assistant trocar (Fig. 13.8), taking caution not to risk losing fragments. The robotic instruments, camera and robot are removed and undocked and a 5 mm, 30° laparoscope lens is placed through the 5 mm assistant trocar to provide laparoscopic vision. The specimen bag is retrieved by marginally enlarging the 12 mm assistant trocar site, thus avoiding another incision to remove the bag from the peritoneal cavity. Finally the fascia along the 12 mm trocar is closed primarily and subcuticular closures are performed at all skin incision sites.

Robotic Ureterolithotomy

The operative set up and technique for robotic ureterolithotomy is similar to that used for robotic

extended pyelolithotomy (REP). Once the ureter is identified, it is traced to the site of the stone. Usually the calculus is large enough to be visually identified, appearing as a ureteral bulge. The portion of ureter containing the stone is dissected with scissors and bipolar forceps. A longitudinal ureterotomy is performed with a cold curved scissors. At this stage the stone is freed from the ureteral mucosa with the tip of the scissors or with bipolar forceps. After stone retrieval, the ureterotomy is closed with interrupted intracorporeal sutures of 5-0 poliglecaprone (Figs.13.9 and 13.10). If double pigtail ureteral stenting is planned then it is performed in an antegrade fashion as described previously. The remaining steps are the same as for robotic pyelolithotomy.

Postoperative Management

After extended pyelolithotomy (REP) and robotic ureterolithotomy, patients are initially given clear liquids and advanced to regular diet post-op day as tolerated. Pain is usually well controlled with scheduled ketorolac 15 mg IV or by mouth every 8 h for 2 days in addition to narcotics as needed for breakthrough pain. We routinely provide oral

Fig. 13.9 Preoperative abdominal X-ray demonstrating multiple radiopaque large left ureteric stones (*arrows*)

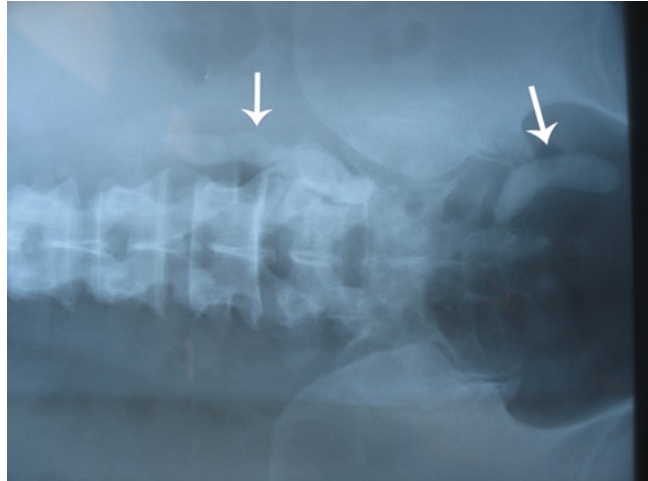
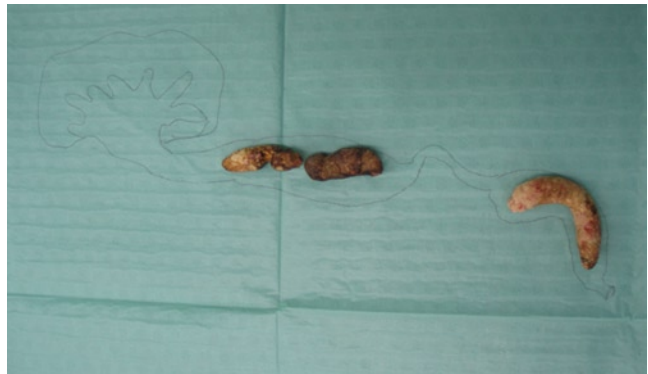

Fig. 13.10 Retrieved multiple ureteric stones by left robotic ureterolithotomy



anticholinergics as needed for stent colic. Ambulation is encouraged as soon as tolerated. The surgical drain is kept off suction, and removed when there has been less than 30 cm³ drainage in 24 h, usually on postoperative day one. The urethral catheter is removed just prior to discharge. With this regimen most patients are generally able to go home in 24–48 h.

Special Considerations

Robotic extended pyelolithotomy (REP) has been performed on patients with complex renal anatomy such as collecting system duplication, horseshoe kidney, and even crossed fused ectopia. These special cases are challenging regardless of approach and should be considered only after considerable experience with robotic surgery. More commonly, those with intra-renal pelvis are encountered and represent adequate candidates as they represent

nearly half of robotic extended pyelolithotomy (REP) patients in some series [1]. Retroperitoneal laparoscopic robotic pyelolithotomy has also been performed in select cases based on principles of retroperitoneal laparoscopy [21].

Current World Experience and Results

Presently there is insufficient data to formulate specific usage of robotics for treating stone disease primarily. The combined world experience in published literature is limited to <100 cases (Table 13.2). The earlier series laid the ground work for feasibility and safety of performing robotic extended pyelolithotomy (REP) [1]. The authors achieved a 100% clearance in cases of partial staghorn renal calculi, irrespective of the renal pelvis configuration with a mean robotic operative time of 108 min (range 60–193). None

Table 13.2 Current published world experience with robotic pyelolithotomy

	Number of patients (n)	Intra-renal pelvis configuration	Stone type		Mean stone size (cm)	Operative time (min)	Associated procedures
			Partial staghorn	Complete staghorn			
Badani et al. [1]	13	6	12	1	4.2	158	Lower polar nephrolithotomy-2
Nayyar et al. [3]	3	3	3	-	3.5	85	Secondary calculi in inferior and middle calyx-2
Lee et al. [4]	5	-	-	4		315.4	Open conversion-1 Concurrent pyeloplasty-1
Hemal et al. [19]	50	-	6	-	3.5	106	-

of the patients experienced postoperative fever or urine leak. In a later smaller series, we were able to further reduce operative time and incorporated modifications in cases that presented with an intrarenal pelvis [3]. An alternative trocar configuration was employed (with a 30° downward viewing lens) using the da Vinci®-S robot. Stone retrieval was performed using a 'home-made' endobag via the robotic camera trocar (12 mm) by providing laparoscopic vision with a 5 mm laparoscope placed through the 5 mm trocar. Lee et al. reported their experience with robotic pyelolithotomy for staghorn calculi in four children (mean age 16.6 years) with cystine staghorn calculi [4]. Of these, three were rendered stone free, while one had a 6 mm residual lower pole stone. One patient required conversion to open surgery due to inability to retrieve the stone from the pyelotomy. In our experience, a flexible cystoscope through the robotic trocar or assistant trocar can be used to extract the stones from calyces; however, it is cumbersome and a tedious maneuver and can also lead to spillage of fluid into peritoneal cavity.

Limitations of the Procedure

Robotic pyelolithotomy currently involves a transperitoneal approach in most cases, which is contrary to existing norms of treating urolithiasis. Due to this anterior approach, the renal vessels present a major limiting factor to superior

infundibulotomy. The inherent position of the patient and the robot precludes the satisfactory use of intra-op fluoroscopy to assess residual calculi. The lack of haptic feedback makes it difficult to perform a nephrolithotomy. We have performed retroperitoneoscopic robotic pyelolithotomy, but, it is not feasible to do routinely depending on the patient's body habitus and stature.

Discussion

Although endourology is the mainstay of treatment of large renal calculi, laparoscopic surgery is an acceptable minimally invasive alternative [9–18]. Meria et al. compared percutaneous nephrolithotomy (PCNL) and laparoscopic transperitoneal pyelolithotomy for pelvic stones >20 mm and found comparable results (82% vs. 88% 3 month stone-free rate) but significantly longer operative time and different postoperative morbidity [5]. While bleeding was the predominant complication in the percutaneous nephrolithotomy (PCNL) group; open conversion and urinary leakage were seen in the laparoscopic group. They concluded that though percutaneous nephrolithotomy (PCNL) remains the gold standard for most large pelvic stones, specific indications needed to be determined for each of the techniques. Transperitoneal laparoscopic pyelolithotomy was successfully utilized in children with large pelvic renal calculi with failed shock wave lithotripsy (SWL) therapy in whom a percutaneous access

failed [6]. Laparoscopic management of stone disease has been described extensively in the literature [14–18].

Robotic extended pyelolithotomy was found to be a feasible and safe technique for renal stone surgery [1]. It provided a combination of a minimally invasive technique and the surgical principles of renal parenchyma-sparing surgery [7, 8]. Clearly, pelvic bulky stones with an extra-renal pelvis configuration allowed an easier procedure; however advantages of wristed instruments and magnification allowed completion of the procedure successfully in the intra-renal pelvis configuration also. Despite the transperitoneal access, no adverse sequelae of the inevitable minimal urine spillage were reported [19]. The retroperitoneal robotic pyelolithotomy is difficult to perform routinely because of challenged anatomical configuration of trocar placement for docking the robot [21]. The procedure attempts to replicate the principles of open stone surgery in a select group of patients (i.e. bulky renal pelvic stones) without transgression of the renal parenchyma, thus obviating its associated inherent complications [3]. Robotic extended pyelolithotomy (REP) may thus serve as an additional technique, in the armamentarium of the urologist, in treating large renal calculi [19, 20]. Its renal parenchyma-sparing approach may especially prove useful in patients with bulky renal pelvic stone disease and impaired renal function/decreased renal functional reserve, allowing a minimally invasive approach, following the principles of extended pyelolithotomy.

References

1. Badani KK, Hemal AK, Fumo M, Kaul S, Shrivastava A, Rajendram AK, Yusoff NA, Sundram M, Woo S, Peabody JO, Mohamed SR, Menon M (2006) Robotic extended pyelolithotomy for treatment of renal calculi: A feasibility study. *World J Urol* 24:198–201
2. Lee RS, Passerotti CC, Cendron M, Estrada CR, Borer JG, Peters CA (2007) Early results of robot assisted laparoscopic lithotomy in adolescents. *J Urol* 177(6):2306–2309, discussion 2309–10
3. Nayyar R, Wadhwa P, Hemal AK (2007) Pure robotic extended pyelolithotomy: cosmetic replica of open surgery. *J Robotic Surg* 1:207–211
4. Hemal AK, Eun D, Tewari A, Menon M (2004) Nuances in the optimum placement of ports in pelvic and upper urinary tract surgery using the da Vinci robot. *Urol Clin North Am* 31(4):683–692
5. Meria P, Milcent S, Desgrandchamps F, Mongiat-Artus P, Duclos JM, Teillac P (2005) Management of pelvic stones larger than 20 mm: laparoscopic transperitoneal pyelolithotomy or percutaneous nephrolithotomy? *Urol Int* 75(4):322–326
6. Casale P, Grady RW, Joyner BD, Zeltser IS, Kuo RL, Mitchell ME (2004) Transperitoneal laparoscopic pyelolithotomy after failed percutaneous access in the pediatric patient. *J Urol* 172(2):680–683, discussion 683
7. Gil-Vernet J (1965) New concepts in removing renal calculi. *Urol Intl* 20:255–288
8. Fitzpatrick JM, Sleight MW, Braack A, Marberger M, Wickham JEA (1980) Intrarenal access: effects on renal function and morphology. *Br J Urol* 52:409–414
9. Menon M, Hemal AK (2004) Vattikuti Institute prostatectomy: a technique of robotic radical prostatectomy: experience in more than 1000 cases. *J Endourol* 18(7):611–619
10. Hemal AK, Abol-Enein H, Shrivastava A, Shoma AM, Ghoneim MA, Menon M (2004) Robotic radical cystectomy and urinary diversion in the management of bladder cancer. *Urol Clin North Am* 31(4):719–729
11. Hemal AK, Kolla SB, Wadhwa P (2008) Robotic reconstruction for recurrent supratriangular vesicovaginal fistulas. *J Urol* 180(3):981–985
12. Phillips CK, Taneja SS, Stifelman MD (2005) Robot-assisted laparoscopic partial nephrectomy: the NYU technique. *J Endourol* 19:441–445
13. Gettman MT, Neururer R, Bartsch G, Peschel R (2002) Anderson–Hynes dismembered pyeloplasty performed with the daVinci robotic system. *Urology* 60:509–513
14. Hemal AK, Goel A, Kumar M, Gupta NP (2001) Evaluation of laparoscopic retroperitoneal surgery in urinary stone disease. *J Endourol* 15(7):701–705
15. Ramakumar S, Segura JW (2000) Laparoscopic surgery for renal urolithiasis: pyelolithotomy, calyceal diverticulectomy, and treatment of stones in a pelvic kidney. *J Endourol* 14(10):829–832
16. Gaur DD, Trivedi S, Prabhudesai MR, Gopichand M (2002) Retroperitoneal laparoscopic pyelolithotomy for staghorn stones. *J Laparoendosc Adv Surg Tech A* 12(4):299–303
17. Yagisawa T, Ito F, Kobayashi C, Onitsuka S, Kondo T, Goto Y, Toma H (2001) Retroperitoneoscopic pyelolithotomy via a posterior approach for large impacted renal pelvic stone. *J Endourol* 15(5):525–528
18. Goel A, Hemal AK (2003) Evaluation of role of retroperitoneoscopic pyelolithotomy and its comparison

- with percutaneous nephrolithotripsy. *Int Urol Nephrol* 35(1):73–76
19. Hemal AK, Nayyar R, Gupta NP, Dorairajan LN (2010) Experience with robotic assisted laparoscopic surgery in upper tract urolithiasis. *Can J Urol* 17(4):5299–5305
 20. Badalato GM, Hemal AK, Menon M, Badani KK (2009) Current role of robot-assisted pyelolithotomy for the management of large renal calculi: a contemporary analysis. *J Endourol* 23(10):1719–1722
 21. Hemal AK (2011) Retroperitoneal Laparoscopy. *Jour Endourology*, (in press)

Chapter 14

Robot-Assisted Ureteral Reconstruction

Patrick Mufarrij, Elias Hyams, and Michael Stifelman

This chapter contains a video segment which can be found at the URL: <http://www.springerimages.com/Su>

Patient Selection

Prior to bringing a patient to the operating room, the surgeon should determine if the ureteral pathology is extrinsic or intrinsic, document the length of the involved segment, and identify any surrounding pathology. Integral to the treatment of ureteral pathology is proper imaging to illustrate the disease process and allow for accurate planning of the surgical approach. The authors advise the use of a three-phase computed tomography scan or magnetic resonance image of the abdomen and pelvis, with dedicated arterial and urographic phases. Administration of a diuretic may be beneficial to obtain optimal ureteral imaging during the delayed urographic phase. We also utilize diuretic renal scans to determine baseline function of the associated renal unit (in case nephrectomy is indicated) and to confirm obstruction in equivocal cases. When necessary, ureteroscopy with retrograde pyelography can be performed before or at the time of the reconstructive surgery to provide further anatomic

information. The indications for each procedure will be discussed in the individual procedural sections that follow.

Preoperative Preparation

All patients planned for ureteral reconstruction undergo a 2-day bowel prep, with clear liquid diet starting 48 h prior to surgery and whole bowel irrigation via an osmotically balanced polyethylene glycol solution such as GoLYTELY[®] starting the day before surgery. This is done to minimize fecal spillage should a bowel injury occur, and also optimally prepares the bowel should an intestinal segment need to be used in the reconstruction.

Patients receive an extensive informed consent regarding all possible options of ureteral reconstruction, which can include: ileal ureter, Boari flap, psoas hitch, transureteroureterostomy, ureterocalicostomy, ureteral reimplantation, nephrectomy, and autotransplant. All possible operative interventions, including open, endoscopic, laparoscopic, and robotic, are thoroughly discussed with and fully understood by the patient during the informed consent. In addition to bleeding, transfusion, and infection, patients undergoing robotic ureteral reconstruction must be aware of the potential for conversion to open surgery. The possibility of recurrence of ureteral obstruction from stricture should also be discussed, in addition to the need for long-term follow-up and the possible necessity of reoperation.

M. Stifelman (✉)
Associate Professor, NYU School of Medicine
Director, Robotic Surgery Center, NYU
Langone Medical Center Chief of Service,
Department of Urology, Tisch Hospital
Service, 150 E. 32nd Street,
New York, NY 10016, USA
e-mail: michaelstifelman@nyumc.org

Operative Setup for Robotic Ureteral Surgery

The operating room setup depends on the location of the proposed reconstruction. For mid to upper ureteral reconstructions, we place the patient in a lateral or semi-lateral decubitus position with the operative side up (Fig. 14.1). Alternatively, a lateral decubitus position with the patient in a modified low-lithotomy position can be employed if access to the bladder for ureteroscopy or antegrade stent placement is desired (Fig. 14.2). We prefer this to performing cystoscopy in the dorsolithotomy position and then re-prepping and redraping the patient for semi-lateral decubitus positioning. The robot is docked at a 90° angle to the operating table with the robot in line with the camera trocar. We have utilized both the standard and Si-HD systems with equally good results. We believe that having TilePro™, a decreased profile, a fourth robotic arm and HD make the Si the favored tool. For lower ureteral reconstructions, the patient is placed in a low-lithotomy position with steep Trendelenburg, similar to the positioning for a robotic prostatectomy. In these

cases, the robot is docked in between the patient's legs (Fig. 14.3).

In all cases, we place the scrub nurse and assistant surgeon on the same side to facilitate the passing of instruments. It is important to note that the positioning of the table and robot can be changed intraoperatively in order to access other areas of pathology throughout the urinary tract. This may require placing an additional robotic trocar and changing the position of the robotic arms. By no means is the surgeon restricted to the initial robotic setup, should a change in approach be required. Line drawings of possible operating room setups from an overhead perspective are shown in Figs. 14.4 and 14.5.

Ureterolysis and Omental Wrapping

Indications

We have performed robotic ureterolysis and omental wrapping in patients with ureteral obstruction secondary to retroperitoneal fibrosis. This procedure can be done unilaterally or

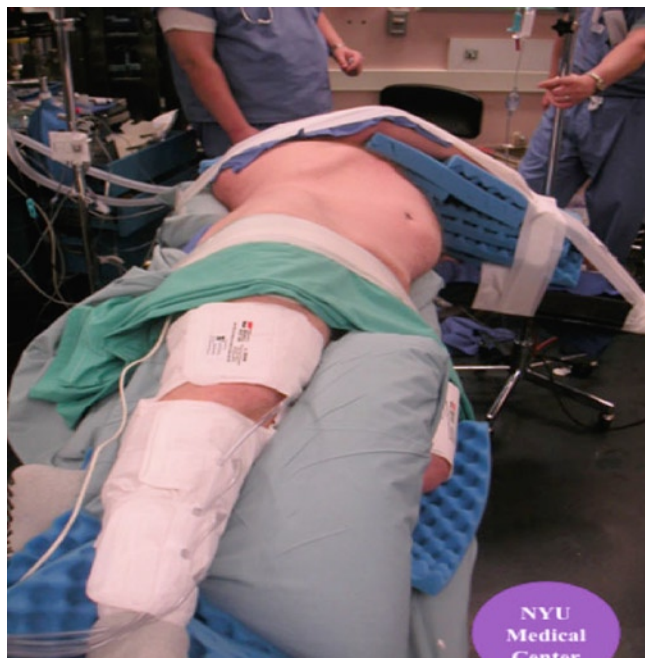

Fig. 14.1 Semi-lateral decubitus position

Fig. 14.2 Semi-lateral decubitus position with modified low-lithotomy

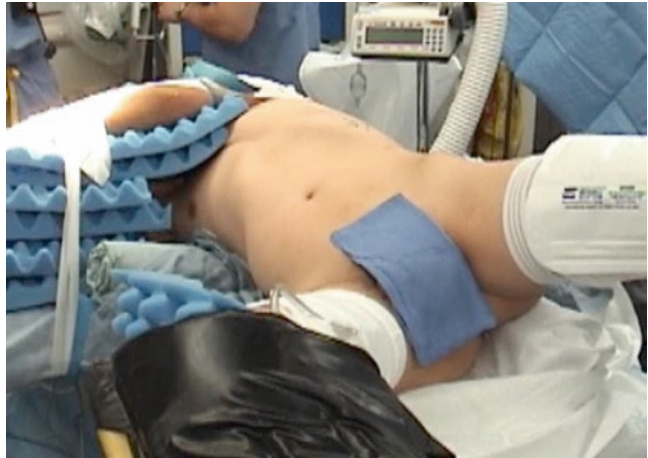
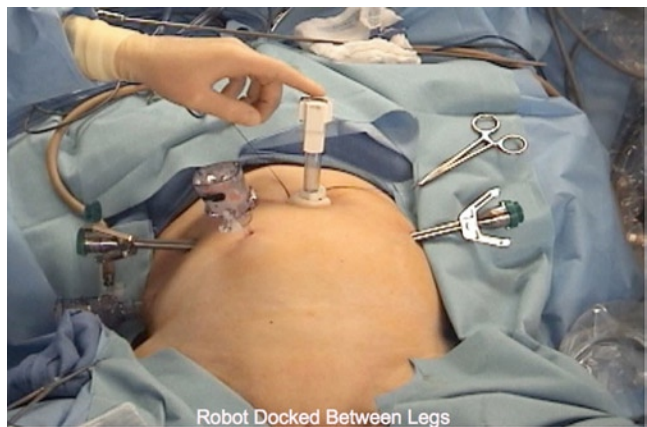
Fig. 14.3 Low lithotomy position



bilaterally as dictated based on the patient's clinical scenario.

Patient Positioning and Preparation

As most of our ureterolyses have involved the mid to upper ureter, we usually place the patient in a lateral or semi-lateral decubitus position. The patient's anterior superior iliac spine is placed directly over the flexion pivot of the operating table to allow for maximal patient flexion when desired. Two gel rolls are placed behind the patient, one at the upper back and the other at the lower back and buttocks, to help maintain a 45–60° angle. An axillary roll is placed under the patient's axilla to prevent brachial plexus injuries, and a rolled-up foam pad can be placed between the

upper shoulder and neck for support. The patient's lower arm is placed on an arm board, and egg-crate foam pads are stacked on top of it to create a place for the patient's upper arm to rest comfortably. The lower leg is flexed at the hip and knee while the upper leg is positioned straight; a pillow is placed in between the legs, and sequential compression boots are also employed for deep venous thrombosis prophylaxis. The patient is secured to the table with 3-inch silk or cloth tape. Attention is paid to ensure that all pressure points are padded. Once docked, the table is maximally rotated to allow gravitational mobilization of the bowel.

Alternatively, a lateral decubitus position with the patient in a modified low-lithotomy can be employed, as described by Wong and Leveillee [1]. In this case, the patient's legs would be placed in low-lithotomy for access to the urethra.

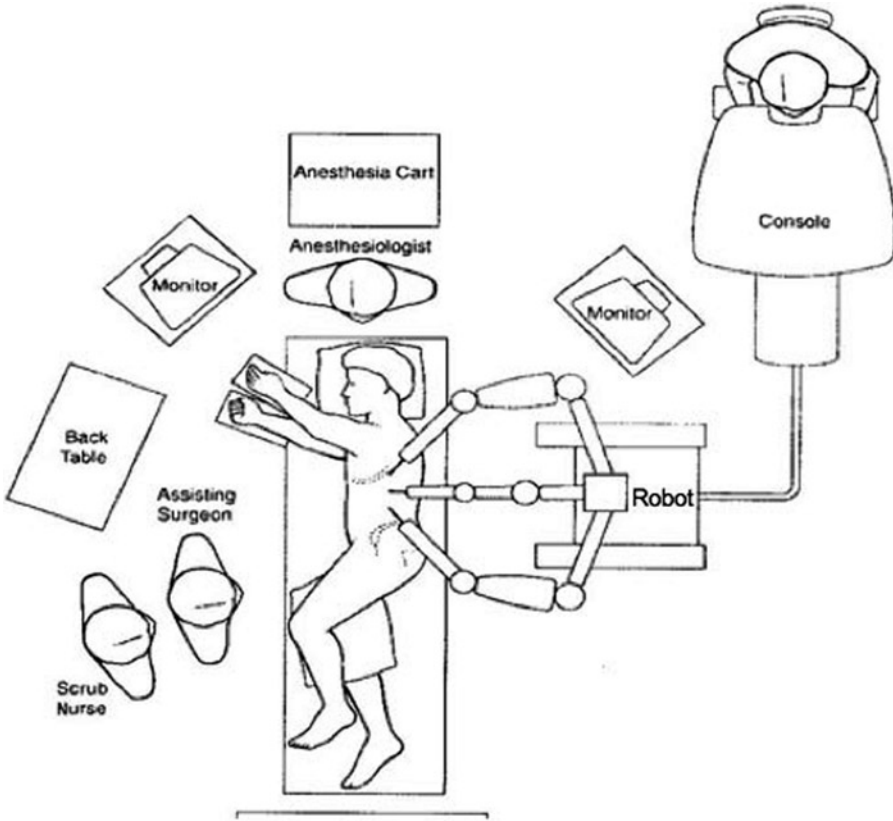


Fig. 14.4 Possible robotic ureteral reconstruction operating room setup

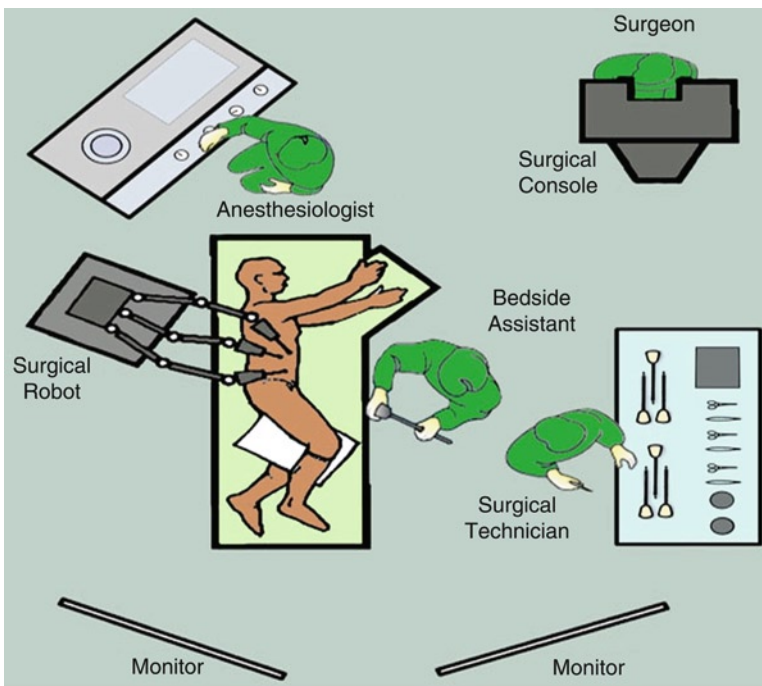


Fig. 14.5 Possible robotic ureteral reconstruction operating room setup

It is very important that time is spent positioning the legs so that the majority of the weight is supported by the feet and that adequate padding is used to prevent nerve compression. The advantage of this position is easier access to the bladder and ureter that does not require undocking the robot or changing patient position. The disadvantage is not being able to maximally flex the table to obtain increased working space along the ipsilateral flank.

In cases of bilateral disease, we believe it is necessary to undock the robot, cover or close all trocar sites, move the robot to the contralateral side and reposition the patient with the contralateral side facing up. We have done this in five patients and our average repositioning time is 20 min.

In patients who require ureterolysis of the distal ureter below the iliac vessels, requiring a ureteral reimplantation, it may be necessary to place the patient in a low-lithotomy position with steep Trendelenburg, similar to a robotic prostatectomy position. If using the modified flank low-lithotomy position, the table can be airplaned flat and robot moved beneath legs so it is in position for access to the bladder.

Trocar Configuration

When using a standard system a 12 mm origin trocar is placed directly above the umbilicus and two 8 mm trocars are positioned 2–4 cm lateral and 8–10 cm away from the origin in either direction. These three trocars create a wide “V” shaped configuration. Next, two 5 mm assistant trocars are placed on the same horizontal line as the robotic trocars and 5–8 cm medial to them. We term this the “Dice-5” trocar configuration (Fig. 14.6). When using the Si system, we utilize all four arms and one 5 mm assistant trocar. The first three arms are placed similar to the standard system but tighter, the fourth arm is in the lower quadrant 2 cm above pubic bone in the midclavicular line, and the 5 mm assistant trocar is just below the umbilicus (Fig. 14.7). With both systems, the robot is docked perpendicular to table. In terms of access, we use the Hasson technique and the Applied gel trocar (Applied Surgical, LLC, Birmingham, AL). For obese patients this template is shifted laterally to ensure there is adequate access to the diseased ureter.

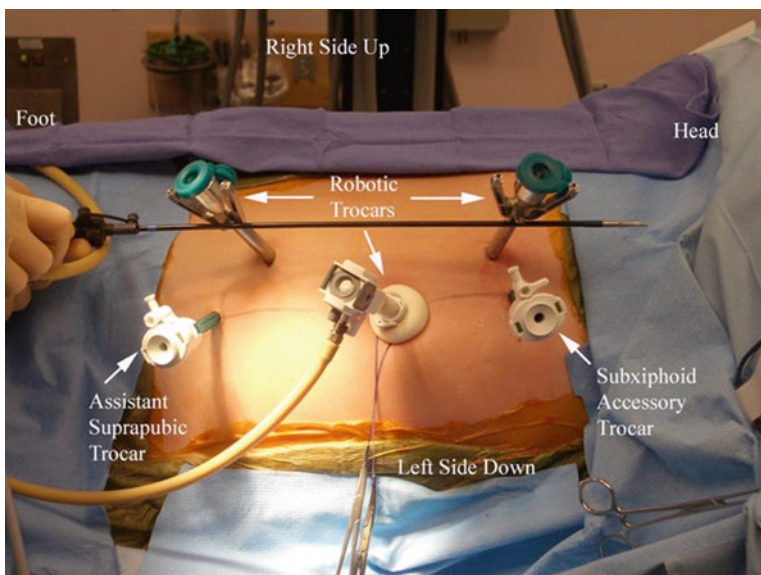
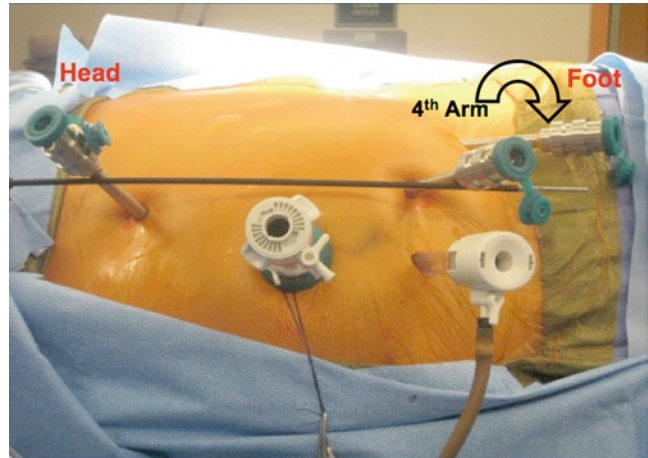


Fig. 14.6 Three-arm robotic system trocar configuration (“Dice-5”)

Fig. 14.7 Four-arm robotic system trocar configuration



Instrumentation and Equipment List

Equipment

- da Vinci® Standard or Si HD Surgical System (3- or 4-arm system; Intuitive Surgical, Inc., Sunnyvale, CA)
- EndoWrist® PK dissector (Intuitive Surgical, Inc., Sunnyvale, CA)
- EndoWrist® curved monopolar scissors (Intuitive Surgical, Inc., Sunnyvale, CA)
- EndoWrist® Cadiere forceps (Intuitive Surgical, Inc., Sunnyvale, CA)
- EndoWrist® Potts scissors (Intuitive Surgical, Inc., Sunnyvale, CA)
- EndoWrist® ProGrasp™ forceps (Intuitive Surgical, Inc., Sunnyvale, CA)
- EndoWrist® needle drivers (2) (Intuitive Surgical, Inc., Sunnyvale, CA)
- InSite® Vision System with 0° and 30° lens (Intuitive Surgical, Inc., Sunnyvale, CA)

Trocars

- 12 mm trocars (1)
- 8 mm robotic trocars (2–3)
- 5 mm trocar (2)
- Applied gel trocar (Applied Surgical, LLC, Birmingham, AL)

Instruments used by the surgical assistant

- Laparoscopic needle driver
- Laparoscopic scissors

- Blunt tip bowel grasper
- Maryland dissector
- Genzyme retractor (Snowden Pencer, Genzyme; Tucker, GA)
- Wavy grasper (Intuitive Surgical, Inc., Sunnyvale, CA)
- Laparoscopic Doppler ultrasound probe (Vascular Technology Inc. Laparoscopic Doppler System, Nashua, NH)
- 5 mm Ligasure device (for omental wrap) (Valleylab, Tyco Healthcare Group LP, Boulder, CO)
- Ethicon harmonic scalpel (for omental wrap) (Ethicon Endo-Surgery, Cincinnati, OH)
- Linear vascular stapling device (for omental wrap)
- Suction irrigator device
- Hem-o-lok® clip applicator (Teleflex Medical, Research Triangle Park, NC)
- 16 Fr silicone urethral catheter
- Hemovac or Jackson Pratt (JP) closed suction pelvic drain
- Vessiloop (Getz Bros, Chicago, IL)

Step-by-Step Technique

Step 1: Cystoscopy and ureteral stent placement

When cystoscopy, retrograde pyelography, and placement of an indwelling ureteral stent are initially performed we utilize the modified

flank low-lithotomy position. Retrograde pyelography allows confirmation of the level and length of the compressed ureter, while placing the stent is mandatory in the event of inadvertent ureteral injury and may be helpful identifying the ureter with intraoperative ultrasonography in cases of severe fibrosis and inflammation.

Step 2: Trocar placement

Trocar configuration is described in detail above for both standard and Si systems. Prior to docking, the table is maximally rotated to full flank to allow gravitational mobilization of the intestines. The robot is then brought in perpendicular to the operating table.

Step 3: Exposure of ureter

Surgeon instrumentation		Assistant instrumentation
Right arm	Left arm	
• Curved monopolar scissors	• Gyrus bipolar dissector	• Suction-irrigator • Laparoscopic Doppler ultrasound probe
Endoscope lens: 30° down		

Exposure of the entire ureter is paramount, and this is accomplished on the left by medializing the colon to the aorta from the spleen to the bladder, and, on the right, by medializing the colon and duodenum to the vena cava from the liver to the bladder (Fig. 14.8). Having the table rotated so that the patient is full flank helps with this

exposure. The console surgeon utilizes the Gyrus PK bipolar graspers (ACMI/Olympus, Southborough, MA) in the left hand and the curved robotic scissors in the right, while the side surgeon assists with a suction/irrigator. Electrocautery settings include 50 W coagulation for the monopolar curved scissors, 50 W for Maryland bipolar graspers, and VP3-40 setting for the Gyrus PK bipolar graspers. Once the entire retroperitoneum is exposed landmarks such as the gonadal vessels, iliac vessels, and lower pole of the kidney become instrumental in identifying and locating the ureter. In some cases, intraoperative laparoscopic Doppler ultrasonography can help to identify the ureter (via imaging the course of the indwelling ureteral stent) and vascular structures, which may be obscured by the dense surrounding fibrosis.

Step 4: Ureterolysis

Surgeon instrumentation		Assistant instrumentation
Right arm	Left arm	
• Potts scissors	• Gyrus bipolar dissector	• Suction-irrigator • Maryland graspers • Genzyme retractor • Wavy grasper • Hem-o-lok® clip applicator • Vessiloops
Endoscope lens: 30° down		

Once the ureter is identified, the healthy distal and proximal portions of the ureter are isolated with Vessiloops (Getz Bros, Chicago, IL), which are shortened and secured with a Hem-o-lok®

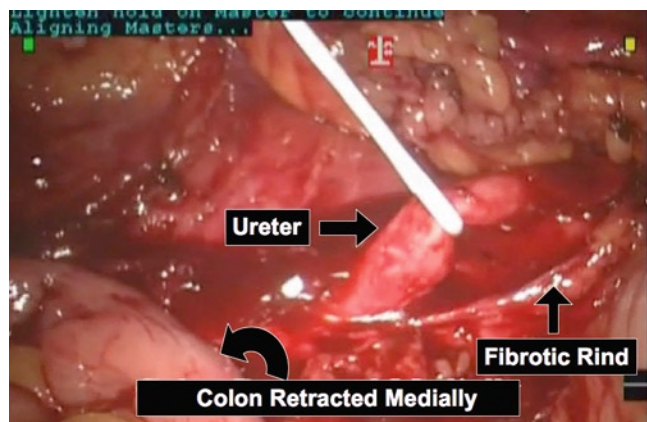


Fig. 14.8 Exposing ureter by medializing colon and using Vessiloop for retraction

Fig. 14.9 Vessiloop with Hem-o-lok® clip used to isolate and retract ureter

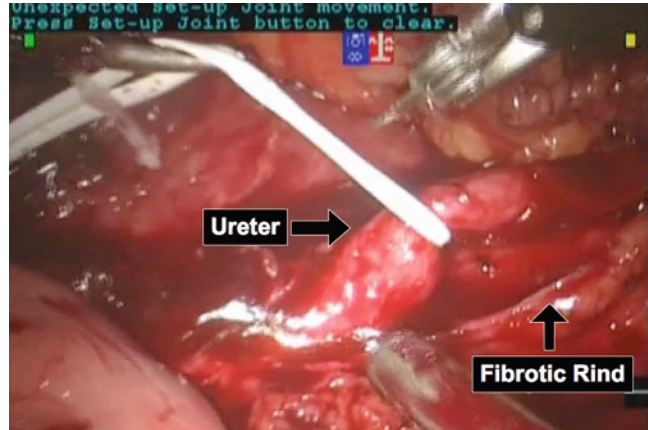
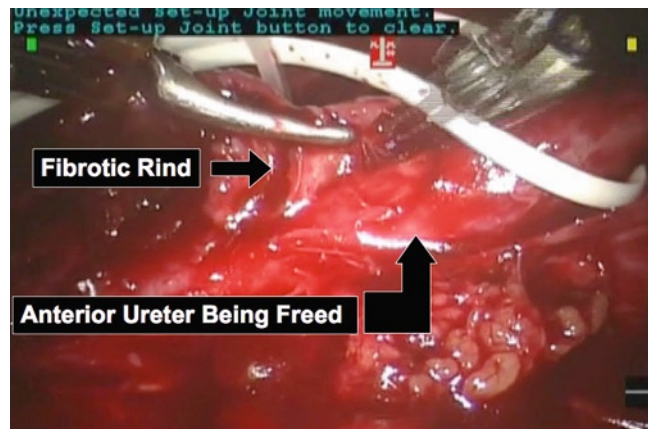


Fig. 14.10 Ureter being released from fibrosis anteriorly



clip (Fig. 14.9). To rule out the presence of lymphoma or other retroperitoneal malignancy, a frozen section of the retroperitoneal tissue is routinely sent prior to proceeding with the ureterolysis. The diseased, entrapped ureteral segment is dissected free by splitting the fibrous capsule anteriorly so that the adventitia of the ureter is visible (Fig. 14.10). For this, the console surgeon employs Gyrus PK bipolar graspers in the left hand and robotic Potts scissors in the right. The assistant uses a combination of laparoscopic Maryland graspers and the suction/irrigator to retract tissue and clear the field of blood and fluid. After identifying the anterior ureter, the remaining ureter is circumferentially released from the fibrous reaction using a combination of

blunt and sharp dissection, avoiding the use of electrocautery around the ureter (Fig. 14.11). The ureter should bluntly peel out of the fibrotic rind once the correct plane is established. The side surgeon or fourth arm creates traction by advancing the Vessiloop and placing the ureter on stretch anteriorly (Figs. 14.12 and 14.13). The robotic surgeon places counter traction with a blunt dissector, and the Potts scissors are used to sharply release any adherent tissue and to sharply sweep the ureter out of the fibrotic reaction. It is important to completely mobilize the ureter from this dense tissue and be sure that healthy ureter is identified proximally and distally. It is not uncommon for the ureter to appear ischemic or congested once lysed.

Fig. 14.11 Ureter being released circumferentially from fibrosis using sharp and blunt dissection

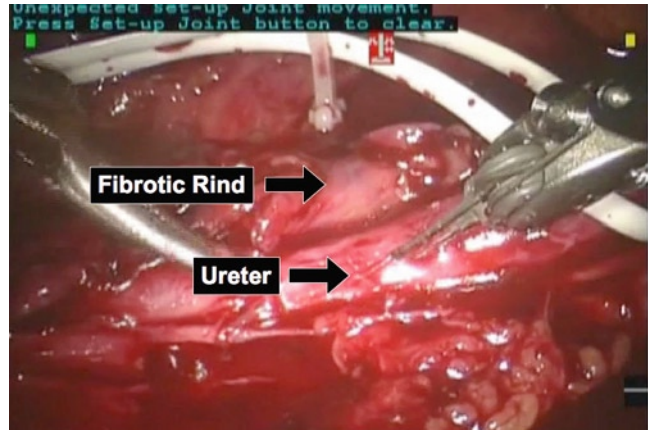


Fig. 14.12 Ureterolysis aided by traction provided on Vessiloop by side surgeon or fourth robotic arm

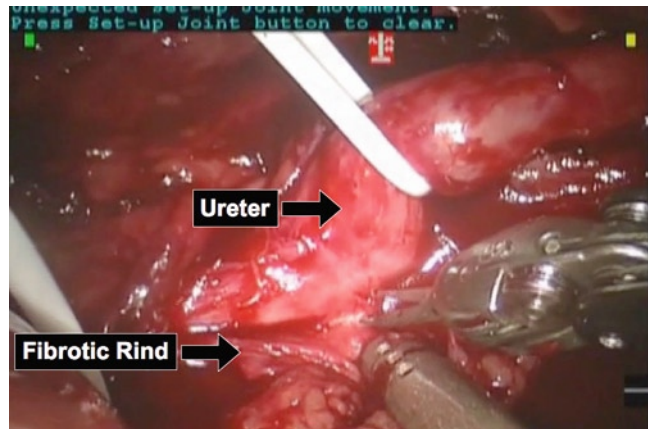
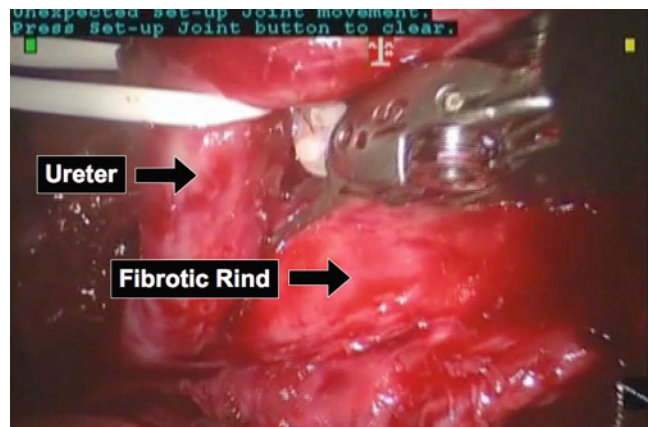


Fig. 14.13 Ureterolysis aided by traction provided on Vessiloop by side surgeon or fourth robotic arm



Step 5: Omental wrapping

Surgeon instrumentation		Assistant instrumentation
Right arm	Left arm	
• Cadiere graspers	• Gyrus bipolar dissector	<ul style="list-style-type: none"> • Suction-irrigator • Atraumatic bowel grasper • 5 mm Ligasure • Ethicon harmonic scalpel • Hem-o-lok® clip applier • Laparoscopic needle driver
Endoscope lens: 30° down		

Upon completing the robotic ureterolysis, attention is now paid to the omental wrapping. The surgeon uses Gyrus PK bipolar graspers in the left hand and ProGrasp™ forceps in the right, while the assistant uses atraumatic graspers to expose and isolate the omentum. Once the omentum is identified, the assistant employs either a 5 mm Ligasure (Valleylab, Boulder, CO) or an Ethicon harmonic scalpel to harvest the omental

pedicle. The most distal portion of the pedicle is brought underneath the ureter and tacked to the sidewall with either Hem-o-lok® clips or a 2.0 polyglactin suture (Fig. 14.14). Next, the lateral pedicle is tacked to the sidewall, allowing the entire omental flap to lay posterior to the ureter. The medial edge of the omentum, which is also medial to the ureter, is now wrapped anterior to the ureter and tacked to the sidewall (Figs. 14.15 and 14.16). At the end of the operation, a closed-suction drain is placed near the omental wrap.

Step 6: Exiting the abdomen

The operative site and omentum are examined for bleeding under low insufflation pressure, and hemostasis is achieved. The trocars are then removed under laparoscopic view. The 8 mm and 5 mm trocars generally do not require fascial

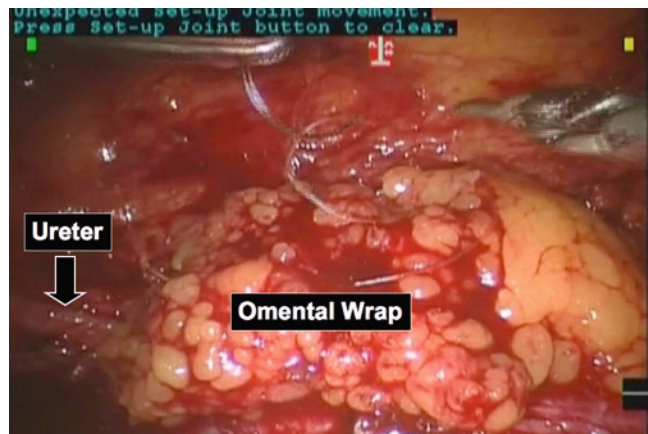

Fig. 14.14 Piece of omentum brought underneath ureter in preparation for wrapping

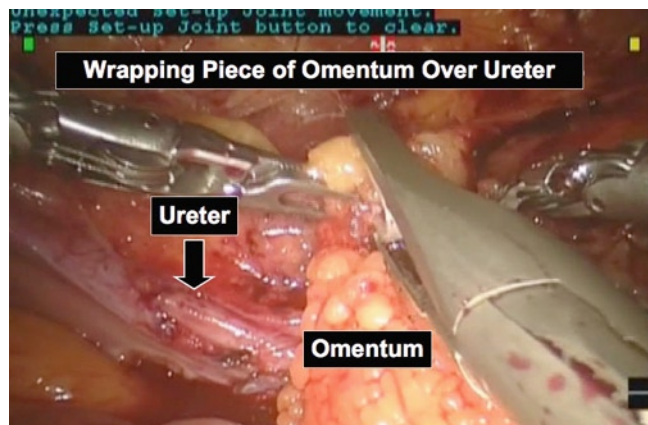
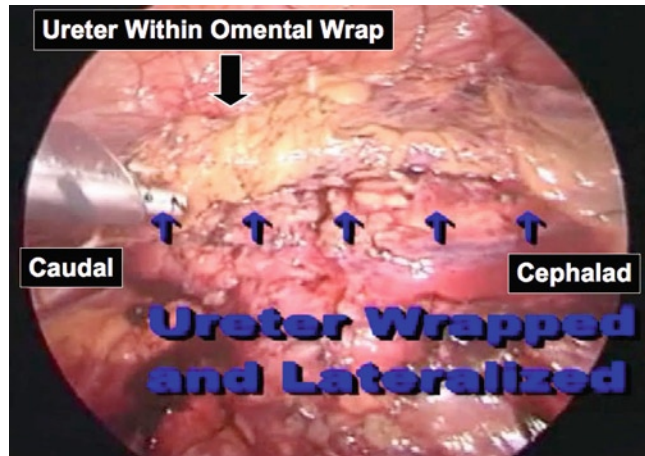


Fig. 14.15 Medial edge of omentum wrapped anterior to ureter and then tacked to side wall

Fig. 14.16 Ureter wrapped and lateralized



closure but are simply closed subcutaneously. The fascia of the 12 mm assistant trocar also does not generally require formal closure if a non-bladed, self-dilating trocar is used.

Postoperative Management

Patients typically remain in the hospital for 2–3 days. On the first postoperative day, patients begin a clear diet, aggressive ambulation, and oral pain medication. The urethral catheter is removed on postoperative day 2 for a trial of void, and 8 h later the output of the JP drain is sent for creatinine analysis to rule out a urine leak. If the JP fluid analysis is consistent with serum and not urine, the drain is removed. Once passing flatus, a soft, regular diet is offered. The patient is discharged either the second or third postoperative day. The stent is removed with a local office cystoscopy in 4–6 weeks, and appropriate imaging studies are obtained thereafter.

Special Considerations

In the case of bilateral disease, we undock the robot, reposition the patient, and then redock the robot for patients undergoing bilateral robotic ureterolysis. In the event of an intraoperative ureteral injury, we prefer immediate primary closure

as opposed to a Davis intubated ureterotomy. In addition, a closed suction drain is placed near the location of the injury to monitor for any urine leak in the postoperative period.

We routinely perform biopsies of the retroperitoneal tissue prior to ureterolysis to rule out lymphoma or other malignancies. We send the biopsies for frozen section, permanent section, and flow cytometry. If there is any question on frozen section that lymphoma may be present, we abort the procedure and wait for the results of the permanent sections before performing the ureterolysis at a later date.

Steps to Avoid Complications

Wide exposure is absolutely paramount to identify the transition of healthy to diseased ureter, as well as adjacent organs and blood vessels that may be involved in the disease process. Athermal technique, via sharp dissection, is essential to avoid potential compromise of the blood supply to the already diseased ureter, which can develop into an ischemic urine leak. The judicious use of omentum is helpful in lateralizing the ureter and protecting it from the disease process, which is usually located more medially. As in all robotic ureteral reconstructive procedures, placing surgical drains at the end of the operation is important to help identify urine leaks (via fluid analysis for creatinine)

in the postoperative period, which may alter when the urethral catheter and stent are removed.

Ureterocolicostomy

Indication

We have performed robotic ureterocolicostomy in patients with a proximal ureteral stricture and a scarred renal pelvis who have failed prior antegrade or retrograde endoscopic management, or in patients with an inaccessible intrarenal pelvis.

Patient Positioning and Preparation

We prefer the semi-lateral decubitus with modified low-lithotomy for retrograde endoscopic access to the bladder and ureter, as discussed above.

Trocar Configuration

Trocar configuration is described in detail above for both standard and Si systems. Prior to docking, the table is maximally rotated down to allow gravitational mobilization of the intestines. The robot is then brought in perpendicular to table.

Instrumentation and Equipment List

Equipment

- da Vinci® Standard or Si Surgical HD System (3- or 4-arm system; Intuitive Surgical, Inc., Sunnyvale, CA)
 - EndoWrist® PK dissector (Intuitive Surgical, Inc., Sunnyvale, CA)
 - EndoWrist® curved monopolar scissors (Intuitive Surgical, Inc., Sunnyvale, CA)
 - EndoWrist® ProGrasp™ forceps (Intuitive Surgical, Inc., Sunnyvale, CA)
 - EndoWrist® Potts scissors (Intuitive Surgical, Inc., Sunnyvale, CA)
 - EndoWrist® needle drivers (2) (Intuitive Surgical, Inc., Sunnyvale, CA)
 - InSite® Vision System with 0° and 30° lens (Intuitive Surgical, Inc., Sunnyvale, CA)
- ### **Trocars**
- 12 mm trocars (1)
 - 8 mm robotic trocars (2–3)
 - 5 mm trocar (2)
 - Applied gel trocar (Applied Surgical, LLC, Birmingham, AL)
- ### **Recommended sutures**
- 3-0 polyglactin on RB-1 or SH needle for renal parenchyma
 - 4-0 polyglactin suture on a RB-1 needle for anastomosis
- ### **Instruments used by the surgical assistant**
- Laparoscopic needle driver
 - Laparoscopic scissors
 - MicroFrance® grasper (Medtronic, Inc., Minneapolis, MN)
 - Genzyme retractor (Snowden Pencer, Genzyme; Tucker, GA)
 - Wavy grasper (Intuitive Surgical, Inc., Sunnyvale, CA)
 - Laparoscopic Doppler ultrasound probe (Vascular Technology Inc. Laparoscopic Doppler System, Nashua, NH)
 - 10 mm LigaSure™ device (Covidien, Boulder, CO)
 - Ethicon harmonic scalpel (Ethicon Endo-Surgery, Cincinnati, OH)
 - Linear vascular stapling device
 - Suction irrigator device
 - Vascular Bulldog Clamp
 - Tissuelink Device (Tissuelink Medical Inc, Dover, NH)
 - Flexible cystoscope/ureteroscope
 - 1.9 Fr tipless Nitinol basket (Boston Scientific, Natick, MA)
 - 16 Fr silicone urethral catheter
 - Hemovac or JP closed suction pelvic drain
 - Vessiloop (Getz Bros, Chicago, IL)

Step-by-Step Technique

Step 1: Cystoscopy and ureteral stent placement

Rigid cystoscopy, retrograde pyelography, and stent placement are performed at the outset of the case for the reasons outlined in the previous section. We place an open-ended ureteral stent to the level of the stricture and secure it to the urethral catheter. This allows the distal portion of the stricture to be identified by direct vision, via intraoperative ultrasound, or using retrograde pyelography.

Step 2: Trocar placement and exposure of ureter

Surgeon instrumentation		Assistant instrumentation
Right arm	Left arm	
<ul style="list-style-type: none"> • Curved monopolar scissors 	<ul style="list-style-type: none"> • Gyrus bipolar dissector • Maryland bipolar graspers 	<ul style="list-style-type: none"> • Suction-irrigator • Vessiloop • Laparoscopic Doppler ultrasound probe
Endoscope lens: 30° down		

Trocar placement and peritoneal access are performed as described for robotic ureterolysis. The ureter is exposed and isolated using a combination of sharp and blunt dissection, as has been described above. The main instruments employed by the console surgeon for this are the Maryland bipolar graspers, curved monopolar scissors, Potts scissors, and the Gyrus PK bipolar graspers. A Vessiloop (Getz Bros, Chicago, IL) is placed around the ureter to aid the side surgeon

in applying atraumatic traction on the ureter during dissection. Careful dissection is continued to free the ureter up to the area of stricture, at which point any of the above described maneuvers can be used to confirm the distal end of the stricture.

Step 3: Ureteral transection

Surgeon instrumentation		Assistant instrumentation
Right arm	Left arm	
<ul style="list-style-type: none"> • Potts scissors 	<ul style="list-style-type: none"> • Gyrus bipolar dissector • Maryland bipolar graspers 	<ul style="list-style-type: none"> • Suction-irrigator
Endoscope lens: 30° down		

The ureter is then transected just below the level of the diseased segment using Potts scissors, and the proximal end of the stent is withdrawn below the area of transection (Fig. 14.17). The healthy ureter is spatulated laterally in preparation for the anastomosis with the lower pole calyx (Fig. 14.18).

Step 4: Dissection of the renal hilum

Surgeon instrumentation		Assistant instrumentation
Right arm	Left arm	
<ul style="list-style-type: none"> • Curved monopolar scissors 	<ul style="list-style-type: none"> • Gyrus bipolar dissector • Maryland bipolar graspers 	<ul style="list-style-type: none"> • Suction-irrigator • Laparoscopic Doppler ultrasound probe
Endoscope lens: 30° down		

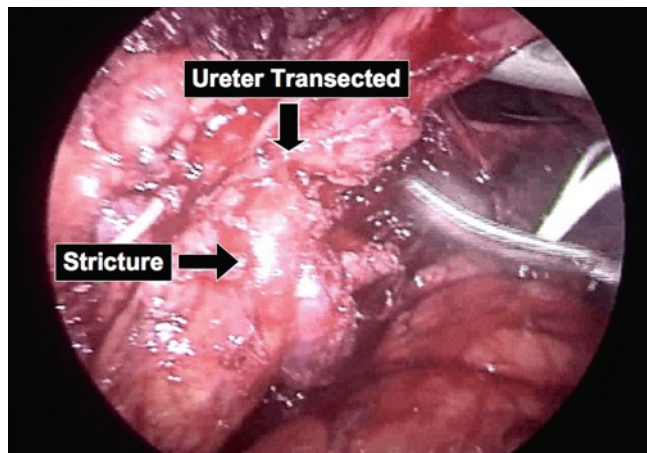


Fig. 14.17 Ureter transected below level of stricture

Fig. 14.18 Healthy ureter spatulated laterally with Potts scissors

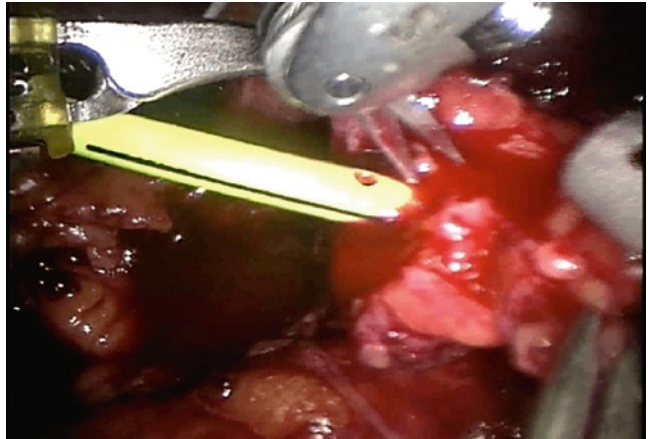
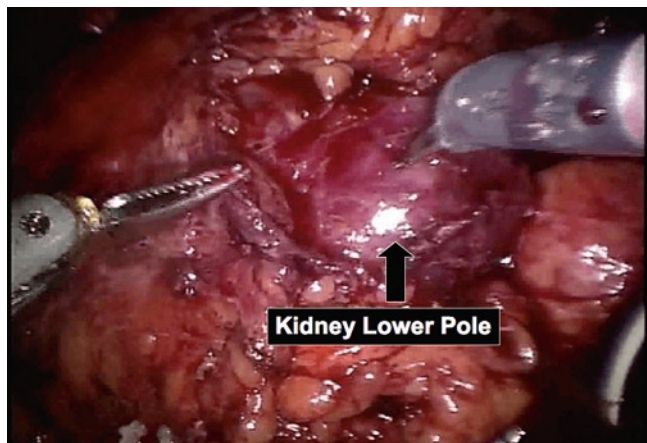


Fig. 14.19 Gerota's Fascia cleared off to expose kidney lower pole



Next, the renal hilum is isolated, and we use the same principles as standard laparoscopy to perform this step. The psoas muscle is identified, and the posterior surface of the kidney is dissected off the psoas. The kidney is then lifted anteriorly placing the renal hilum on stretch. This retraction is supplied by the assistant or the fourth arm using a ProGrasp™ forceps, allowing the console surgeon use two hands/instruments for the hilar dissection. A Doppler probe is used to identify the renal artery and vein, which is often encased in fibrotic tissue by the same process, which led to the diseased pelvis and ureter. The vessels are then dissected free from the surrounding tissue and isolated. A laparoscopic Doppler ultrasound probe is then introduced to identify the most dependent lower pole calyx.

Gerota's fascia is cleared off this segment of kidney circumferentially (Fig. 14.19). Prior to clamping the artery we ensure the patient is adequately volume resuscitated and administer 12.5 g of mannitol in an attempt to minimize reperfusion injury.

Step 5: Renal hilar control, exposure of lower pole calyx and stone extraction

Surgeon instrumentation		Assistant instrumentation
Right arm	Left arm	<ul style="list-style-type: none"> • Suction-irrigator • Laparoscopic bulldog clamps • TissueLink device • Flexiblecystoscope/ureteroscope • 1.9 Fr tipless Nitinol basket
<ul style="list-style-type: none"> • Curved monopolar scissors • Needle driver 	<ul style="list-style-type: none"> • Gyrus bipolar dissector • Maryland bipolar graspers • Needle driver 	
Endoscope lens: 30° down		

A laparoscopic vascular bulldog clamp is placed by the assistant on the renal artery and a separate one on the renal vein. The console surgeon utilizes robotic curved monopolar scissors to transect the renal lower pole to expose the calyx (Figs. 14.20 and 14.21). Vessels are suture-ligated with 3-0 polyglactin sutures on either an RB-1 needle or SH needle by the console surgeon and the renal cortex is cauterized with the TissueLink device (TissueLink Medical, Inc., Dover, NH) by the assistant, avoiding contact with the sutures or the calyceal opening. The bulldog clamp is now removed, any areas of bleeding are controlled with figure eight 3-0 polyglactin sutures, and another dose of 12.5 g of mannitol is administered. If stones are present, a flexible cystoscope or ureteroscope is introduced

by the assistant through one of the trocars and then passed through the open lower pole calyx to examine the internal collecting system of the kidney. Any encountered stones are retrieved with a 1.9 Fr tipless Nitinol basket (Boston Scientific, Natick, MA).

Step 6: Ureterocalicostomy

Surgeon instrumentation		Assistant instrumentation
Right arm	Left arm	<ul style="list-style-type: none"> • Suction-irrigator • Flexiblecystoscope/ureteroscope
• Needle driver	• Needle driver	
Endoscope lens: 30° down		

Next, the anastomosis of the spatulated proximal healthy ureter to the lower pole calyx is performed using interrupted 4-0 polyglactin sutures

Fig. 14.20 Kidney lower pole transected to expose calyx

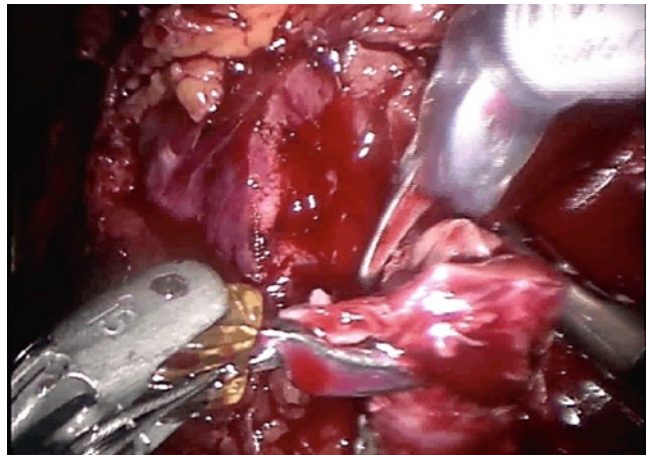


Fig. 14.21 Lower pole calyx exposed

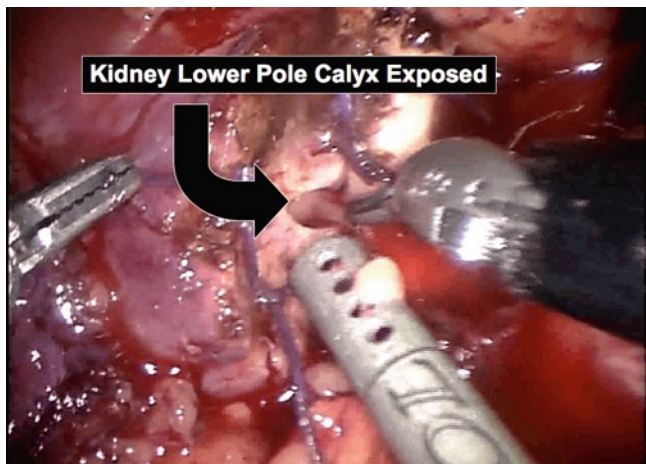


Fig. 14.22 Ureterocalycostomy anastomosis being performed

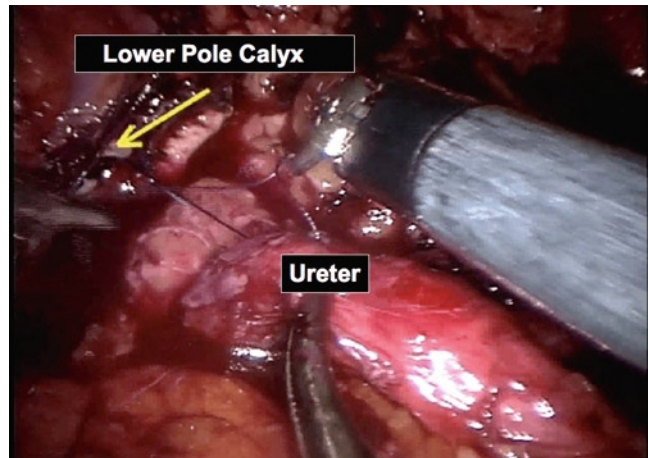
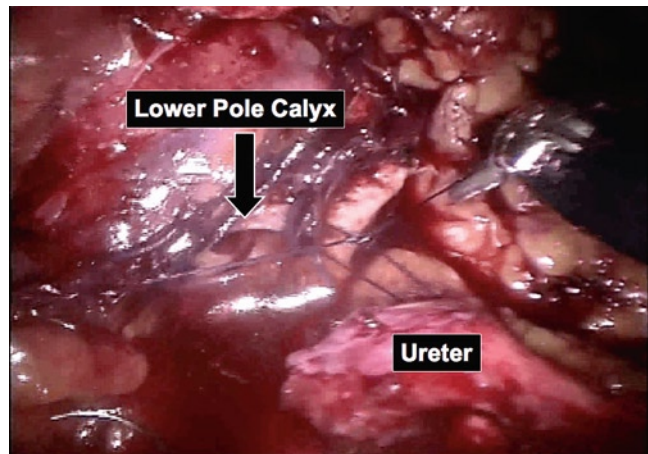


Fig. 14.23 Ureterocalycostomy anastomosis being performed



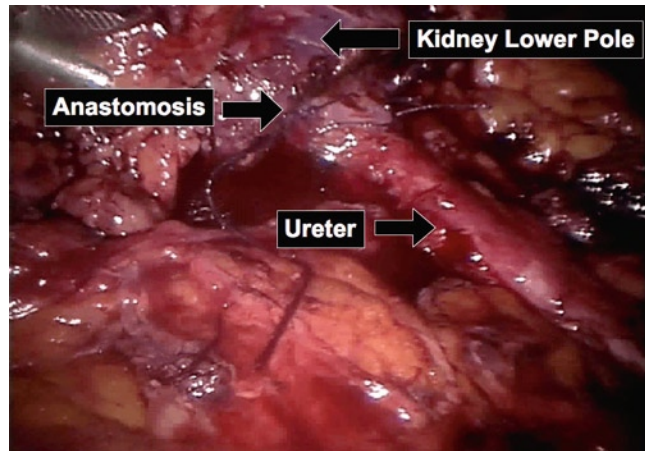
on an RB-1 needle (Figs. 14.22 and 14.23). Prior to completing the anastomosis, a wire is advanced through the open-ended stent into the pelvis. The open-ended stent that was placed cystoscopically (see above) is exchanged for a double-J stent in a retrograde fashion, under direct vision. We do not recommend antegrade stent placement since it creates significant tension on the anastomosis during the passage of the wire and stent. With the stent in position, the anastomosis is completed (Fig. 14.24). The proximal ureteral stump is suture ligated with a 2-0 polyglactin suture. We like to cover the anastomosis with either a vascularized pedicle of Gerota's fascia or omentum (see omental wrap described above). We believe this improves healing, adds blood supply, and

may protect from urine extravasation. As with all our ureteral reconstructions, a closed-suction drain is placed near the reconstruction to help detect urine leakage in the postoperative period.

Step 7: Exiting the abdomen

The operative site is examined for bleeding under low insufflation pressure and hemostasis achieved. The trocars are removed under laparoscopic view. The 8 mm and 5 mm trocars generally do not require fascial closure but are simply closed subcutaneously. The fascia of the 12 mm assistant trocar also does not generally require formal closure if a non-bladed, self-dilating trocar is used.

Fig. 14.24 Completed ureterocalycostomy anastomosis



Postoperative Management

Patients typically remain in the hospital for 2–3 days. On the first postoperative day, patients begin a clear diet, aggressive ambulation, and oral pain medication. The urethral catheter is removed on postoperative day 2 for a trial of void, and 8 h later the output of the JP drain is sent for creatinine analysis to rule out a urine leak. If the JP fluid analysis is consistent with serum and not urine, the drain is removed. Once passing flatus, a soft, regular diet is offered. The patient is discharged either the second or third postoperative day. The stent is removed with a local office cystoscopy in 4–6 weeks, and appropriate imaging studies are obtained thereafter.

Special Considerations

If ureteral length is preventing a tension-free anastomosis, there are some maneuvers that can help overcome this issue. A psoas hitch or nephropexy may be performed to allow the ureter to reach the calyx more easily and without tension. Alternatively, a renal autotransplant can be performed if salvaging the kidney is absolutely indicated. Finally, if the gap is too long to create a tension-free anastomosis and salvaging the kidney is not essential, then a simple nephrectomy should be performed rather than creating a suboptimal anastomosis that can lead to signifi-

cant morbidity and the need for further operations in the future. This highlights the need for full informed consent discussing all possible options with the patient prior to the operation.

Steps to Avoid Complications

Above all, ensuring a tension-free, secure anastomosis is paramount to the success of this operation. To that end, wide ureteral spatulation and apposition of ureteral and calyx urothelium will help prevent stricture and urine leakage from the anastomosis. Furthermore, athermal technique, via sharp dissection is essential to avoid potential compromise of the blood supply to the already diseased ureter, which can develop into an ischemic urine leak. We also support the judicious use of omentum or Gerota's fat to help protect the anastomosis, as mentioned above.

Ureteroureterostomy

Indications

We have performed this procedure in patients with mid-ureteral strictures that have been refractory to endoscopic treatments and in patients with ureteral obstruction secondary to a retrocaval ureter.

Patient Positioning and Preparation

The patient is positioned in semi-lateral decubitus or semi-lateral decubitus with modified low lithotomy to allow access to the urethra as has been previously described.

Trocar Configuration

Trocar configuration is described in detail above for both standard and Si systems. Prior to docking, the table is maximally rotated down to allow gravitational mobilization of the intestines. The robot is then brought in perpendicular to table.

Instrumentation and Equipment List

Equipment

- da Vinci® Standard or Si Surgical HD System (3- or 4-arm system; Intuitive Surgical, Inc., Sunnyvale, CA)
- EndoWrist® PK dissector (Intuitive Surgical, Inc., Sunnyvale, CA)
- EndoWrist® curved monopolar scissors (Intuitive Surgical, Inc., Sunnyvale, CA)
- EndoWrist® ProGrasp™ forceps (Intuitive Surgical, Inc., Sunnyvale, CA)
- EndoWrist® Potts scissors (Intuitive Surgical, Inc., Sunnyvale, CA)
- EndoWrist® needle drivers (2) (Intuitive Surgical, Inc., Sunnyvale, CA)
- InSite® Vision System with 0° and 30° lens (Intuitive Surgical, Inc., Sunnyvale, CA)

Trocars

- 12 mm trocars (1)
- 8 mm robotic trocars (2–3)
- 5 mm trocar (2)
- Applied gel trocar (Applied Surgical, LLC, Birmingham, AL)

Recommended sutures

- 4-0 polyglactin suture on a RB-1 needle for anastomosis

Instruments used by the surgical assistant

- Laparoscopic needle driver
- Laparoscopic scissors
- Genzyme retractor (Snowden Pencer, Genzyme; Tucker, GA)
- Wavy grasper (Intuitive Surgical, Inc., Sunnyvale, CA)
- Laparoscopic Doppler ultrasound probe (Vascular Technology Inc. Laparoscopic Doppler System, Nashua, NH)
- Suction irrigator device
- 16 Fr silicone urethral catheter
- Hemovac or JP closed suction pelvic drain

Step-by-Step Technique

Step 1: Cystoscopy and ureteral stent placement

With the patient in lateral decubitus with modified low-lithotomy position, cystoscopy and retrograde pyelography are performed to delineate the ureteral stricture or point of obstruction. An open-ended ureteral catheter is inserted to the distal level of the stricture or obstruction and then secured to an indwelling urethral catheter.

Step 2: Trocar placement and exposure of ureter

Surgeon instrumentation		Assistant instrumentation
Right arm	Left arm	<ul style="list-style-type: none"> • Suction-irrigator • Vessiloop • Laparoscopic Doppler ultrasound probe
• Curved monopolar scissors	• Gyrus bipolar dissector • Maryland bipolar graspers	
Endoscope lens: 30° down		

Trocar placement and peritoneal access are performed as have been described above. As previously described, the console surgeon reflects the colon medially, identifying and isolating the ureter using a combination of sharp and blunt dissection. If required, the previously inserted open-ended ureteral catheter may be identified using an intraoperative ultrasound probe.

Fig. 14.25 Ureter with strictured segment

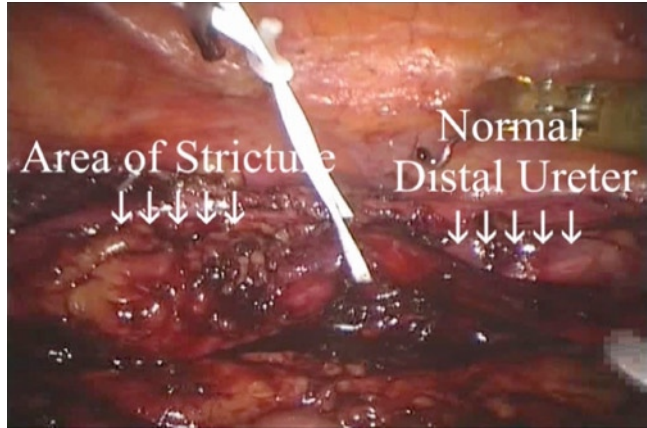
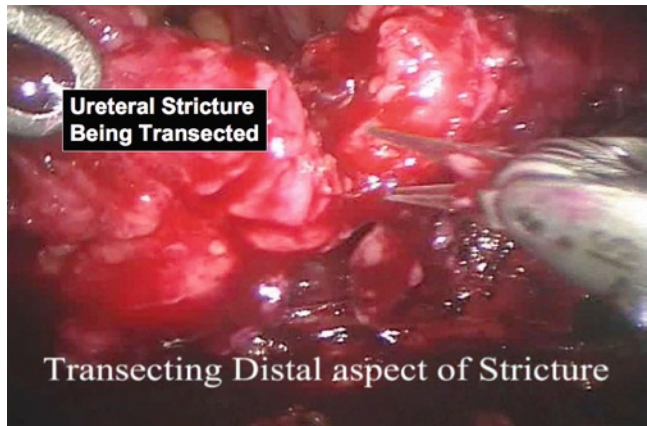


Fig. 14.26 Ureteral stricture excised with Potts scissors



Step 3: Transection of ureter and excision of diseased segment

Surgeon instrumentation		Assistant instrumentation
Right arm	Left arm	
• Potts scissors	• Gyrus bipolar dissector • Maryland bipolar graspers	• Suction-irrigator
Endoscope lens: 30° down		

In the case of a ureteral stricture, the diseased portion of the ureter is excised with Potts scissors (Figs. 14.25 and 14.26). For a retrocaval ureter, the ureter proximal and distal to the retrocaval portion can be transected, leaving the retrocaval segment in situ. Alternatively, the ureter distal to the retrocaval portion can be transected while the proximal ureter is gently retracted to bring the retrocaval portion from under the vena cava; this should only be done if the retrocaval portion can be easily negotiated

from under the vena cava. To avoid potential vascular injury, we prefer transecting the ureter twice as opposed to dissecting out the retrocaval ureteral segment. Prior to performing the anastomosis, the proximal ureter is spatulated laterally and the distal ureteral segment spatulated medially (Fig. 14.27). If there is any concern that the anastomosis will be under undue tension, the ureter can be further mobilized proximally and distally, the kidney can be mobilized inferiorly and pexed to the psoas muscle using a 2-0 nonabsorbable suture (i.e., Prolene), or a psoas hitch can be performed.

Step 4: Ureteroureterostomy

Surgeon instrumentation		Assistant instrumentation
Right arm	Left arm	
• Needle driver	• Needle driver	• Suction-irrigator
Endoscope lens: 30° down		

Fig. 14.27 Ureter being spatulated with Potts scissors

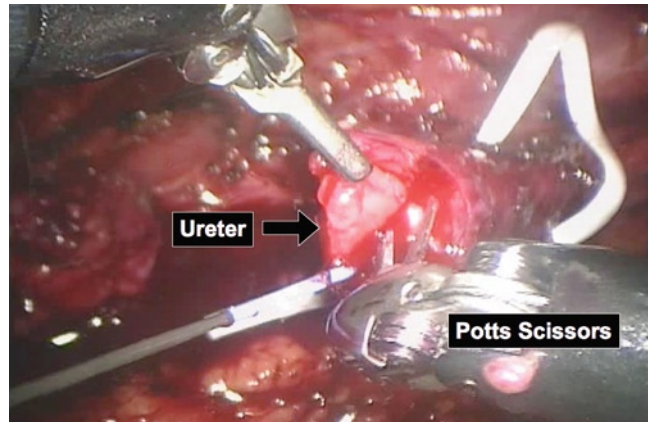
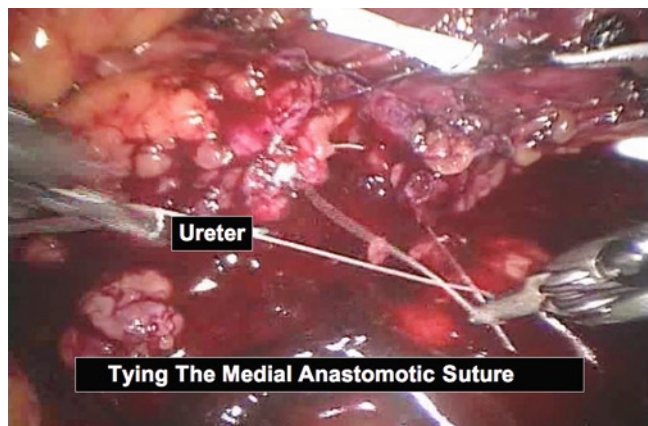

Fig. 14.28 Medial anastomotic suture being tied



Once it is confirmed that a tension-free anastomosis can be performed, we use a dyed and an undyed 4-0 polyglactin suture on a RB-1 needle. We anchor the dyed suture laterally and the undyed suture medially (Fig. 14.28). In order to perform the posterior wall anastomosis we pass the medial undyed suture underneath the ureter to rotate the ureter 180° and present the posterior wall anteriorly (Figs. 14.29 and 14.30). We run the undyed suture along the posterior wall and tie it to the dyed suture. Once the posterior wall is complete, the undyed suture is passed back underneath the ureter placing the ureter back into its anatomical position. A wire is now placed retrograde through the previously inserted (see above) 5 Fr open-ended ureteral catheter that is attached to the urethral catheter outside the urethral meatus. Over this wire, the ureteral catheter is exchanged with a double-J stent, under direct visualization. The anterior

anastomosis is then completed in a running fashion with the dyed suture, in a lateral to medial fashion (Fig. 14.31). We like to cover the anastomosis with a vascularized pedicle of omentum to provide blood supply and improve healing. As with all our ureteral reconstructions, a closed-suction drain is placed near the reconstruction to help detect urine leakage in the postoperative period.

Step 5: Exiting the abdomen

The operative site is examined for bleeding under low insufflation pressure and hemostasis achieved. The trocars are removed under laparoscopic view. The 8 mm and 5 mm trocars generally do not require fascial closure but are simply closed subcutaneously. The fascia of the 12 mm assistant trocar also does not generally require formal closure if a non-bladed, self-dilating trocar is used.

Fig. 14.29 Posterior anastomosis being performed

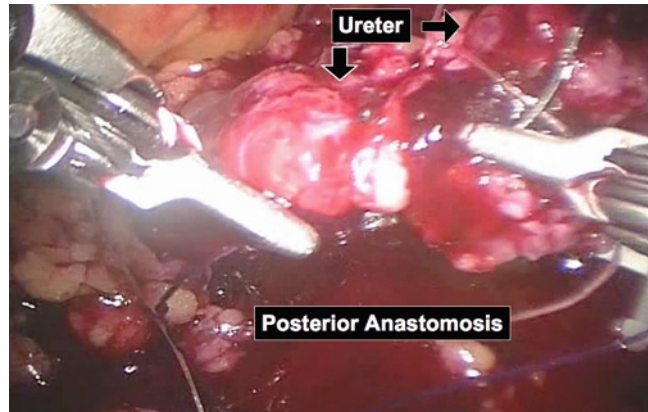


Fig. 14.30 Posterior anastomosis being performed

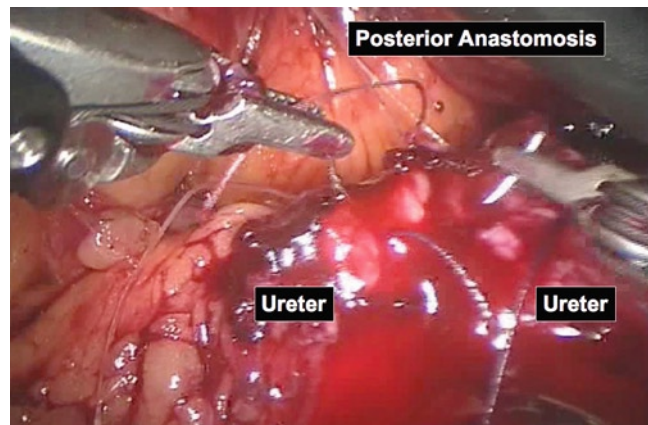
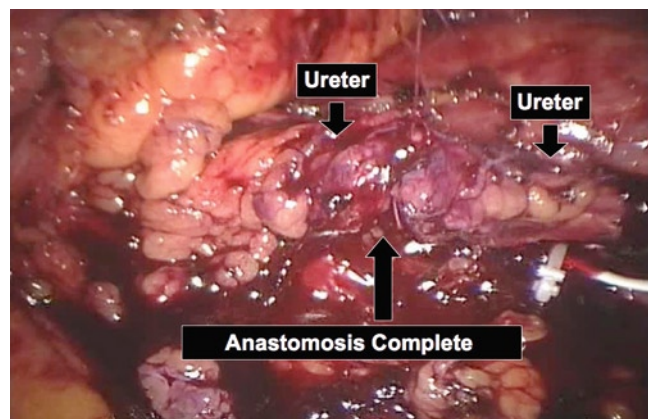


Fig. 14.31 Completed ureteroureterostomy anastomosis



Postoperative Management

Patients typically remain in the hospital for 2–3 days. On the first postoperative day, patients begin a clear diet, aggressive ambulation, and oral pain medication. The urethral catheter is

removed on postoperative day 2 for a trial of void, and 8 h later the output of the JP drain is sent for creatinine analysis to rule out a urine leak. If the JP fluid analysis is consistent with serum and not urine, the drain is removed. Once passing flatus, a soft, regular diet is offered. The

patient is discharged either the second or third postoperative day. The stent is removed with a local office cystoscopy in 4–6 weeks, and appropriate imaging studies are obtained thereafter.

Special Considerations

As discussed above, if ureteral length from either end is preventing a tension-free anastomosis, maneuvers can be employed to help overcome this issue (see above).

To preserve ureteral blood supply, it is important to minimize use of thermal energy during dissection and to preserve the periureteral adventitia. Furthermore, a “handle” of diseased ureter can be left on each end of the ureter as the ureteral ends are spatulated and the anastomosis is performed. This “handle” allows the manipulation of the ureter without having to grasp healthy tissue and risk crush injury. Once the anastomosis has been started and the reconstruction is proceeding in a controlled fashion, both ureteral “handles” can be excised and sent with the rest of the excised specimen for pathologic analysis.

For a ureteral stricture, excising the diseased portion of the ureter is critical to preventing a recurrent stricture. In cases of a distal ureteral stricture, it may be more appropriate to perform a ureteral reimplantation (see below).

Steps to Avoid Complications

Above all, ensuring a tension-free, secure anastomosis is paramount to the success of this operation. To that end, wide ureteral spatulation and apposition of ureteral urothelium will help prevent stricture and urine leakage from the anastomosis. Furthermore, athermal technique, via sharp dissection is essential to avoid potential compromise of the blood supply to the already diseased ureter, which can develop into an ischemic urine leak. We also support the judicious use of omentum to help protect the anastomosis, as mentioned above.

Ureteral Reimplantation

Indications

We have performed this procedure in patients with congenital distal ureteral strictures, iatrogenic intraoperative distal ureteral injuries, and those requiring distal segmental resection for transitional cell carcinoma (TCC).

Patient Positioning and Preparation

The patient is positioned in a dorsolithotomy position with steep Trendelenburg, similar to that of robotic prostatectomy.

Trocar Configuration

Five trocars are used as follows. A 12 mm trocar at the umbilicus, two 8 mm trocars to the left, one just lateral to the umbilicus in the midclavicular line and the other one, 2 cm superior to umbilicus in the anterior axillary line. To the right of the umbilicus we place an 8 mm trocar lateral to umbilicus in midclavicular line and a 5 mm assistant trocar above and between these 2 trocars (Fig. 14.3). The da Vinci® is then brought between the patient’s legs.

Instrumentation and Equipment List

Equipment

- da Vinci® Standard or Si Surgical HD System (3- or 4-arm system; Intuitive Surgical, Inc., Sunnyvale, CA)
- EndoWrist® PK dissector (Intuitive Surgical, Inc., Sunnyvale, CA)
- EndoWrist® curved monopolar scissors (Intuitive Surgical, Inc., Sunnyvale, CA)
- EndoWrist® ProGrasp™ forceps (Intuitive Surgical, Inc., Sunnyvale, CA)
- EndoWrist® Potts scissors (Intuitive Surgical, Inc., Sunnyvale, CA)
- EndoWrist® needle drivers (2) (Intuitive Surgical, Inc., Sunnyvale, CA)

- InSite® Vision System with 0° and 30° lens (Intuitive Surgical, Inc., Sunnyvale, CA)

Trocars

- 12 mm trocars (1)
- 8 mm robotic trocars (2)
- 5 mm trocar (2)
- Applied gel trocar (Applied Surgical, LLC, Birmingham, AL)

Recommended sutures

- 3-0 polyglactin suture on RB-1 or SH needle
- 2-0 polyglactin suture on SH needle for psoas hitch
- 4-0 Monocryl suture for anastomosis on RB-1 needle

Instruments used by the surgical assistant

- Laparoscopic needle driver
- Laparoscopic scissors
- Laparoscopic Satinsky clamp
- Genzyme retractor (Snowden Pencer, Genzyme; Tucker, GA)
- Wavy grasper (Intuitive Surgical, Inc., Sunnyvale, CA)
- Laparoscopic Doppler ultrasound probe (Vascular Technology Inc. Laparoscopic Doppler System, Nashua, NH)
- Suction irrigator device
- Hem-o-lok® clip applier (Teleflex Medical, Research Triangle Park, NC)
- 16 Fr silicone urethral catheter
- Hemovac or JP closed suction pelvic drain

Step-by-Step Technique

Step 1: Patient positioning and trocar configuration

The patient is positioned in a similar fashion to a robotic prostatectomy, in dorsolithotomy with steep Trendelenburg. Five trocars are used as described above. A 12 mm trocar at the umbilicus, two 8 mm trocars to the left, one just lateral to the umbilicus in the midclavicular line and the other one, 2 cm superior to umbilicus in the anterior axillary line. To the right of the umbilicus we place an 8 mm trocar lateral to umbilicus in midclavicular line and a 5 mm assistant trocar above and between these 2 trocars. The da Vinci® is then brought between the patient's legs.

Step 2: Exposure of ureter

Surgeon instrumentation		Assistant instrumentation
Right arm	Left arm	<ul style="list-style-type: none"> • Suction-irrigator • Vessiloop
<ul style="list-style-type: none"> • Curved monopolar scissors 	<ul style="list-style-type: none"> • Gyrus bipolar dissector • Maryland bipolar graspers 	
Endoscope lens: 30° down		

The posterior peritoneum is incised longitudinally at the level of the iliac vessels and the ureter is identified and isolated with a Vessiloop (Getz Bros, Chicago, IL). The peritoneum is then incised over the ureter until the diseased segment is identified (Fig. 14.32). In cases where

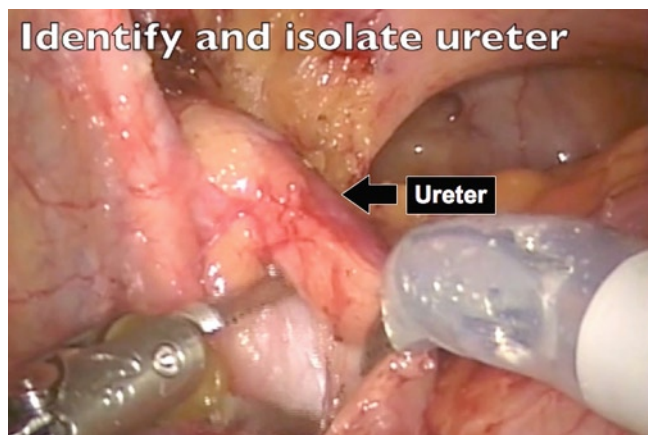
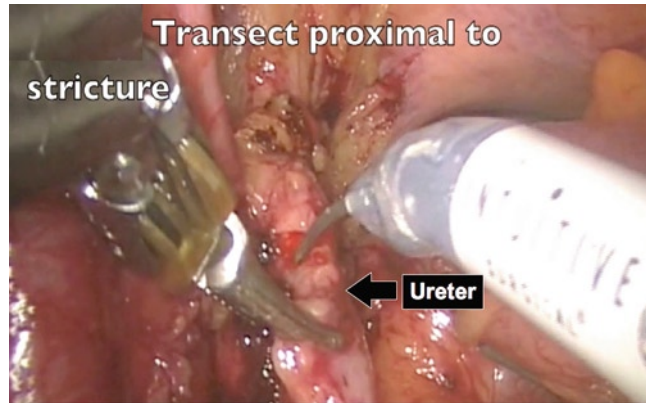


Fig. 14.32 Ureter is identified and isolated

Fig. 14.33 Transecting ureter above diseased segment



a segmental distal ureterectomy is planned, the ureter must be dissected all the way to the posterior bladder wall. In male patients not concerned with fertility, the vas deferens can be sacrificed to improve exposure. In women, the peritoneum is incised to the level of the ovary. The ovary and ovarian ligaments are retracted anteriorly allowing the ureter to be dissected posteriorly to the level of the bladder.

Step 3: Division of ureter and excision of diseased segment

Surgeon instrumentation		Assistant instrumentation
Right arm	Left arm	
<ul style="list-style-type: none"> • Curved monopolar scissors • Potts scissors • Needle driver 	<ul style="list-style-type: none"> • Gyrus bipolar dissector • Maryland bipolar graspers • Needle driver 	<ul style="list-style-type: none"> • Suction-irrigator • Vessiloop • Laparoscopic Satinsky clamp • Hem-o-lok® clip applier
Endoscope lens: 30° down		

The ureter is then transected just proximal to the diseased segment with curved monopolar scissors and spatulated using a Potts scissors (Fig. 14.33). In patients undergoing distal ureterectomy for TCC, a Hem-o-lock® clip is placed to prevent spillage and the bladder cuff is isolated with a laparoscopic Satinsky clamp and oversewn with 3-0 polyglactin suture on either an RB-1 or SH needle.

Step 4: Mobilization of bladder and psoas hitch

Surgeon instrumentation		Assistant instrumentation
Right arm	Left arm	
<ul style="list-style-type: none"> • Curved monopolar scissors • Needle driver 	<ul style="list-style-type: none"> • Gyrus bipolar dissector • Maryland bipolar graspers • Needle driver 	<ul style="list-style-type: none"> • Suction-irrigator
Endoscope lens: 30° down		

Next, the bladder is filled with 250 mL of normal saline, via the indwelling urethral catheter, and mobilized from the anterior abdominal wall, identical to the techniques used for robotic prostatectomy. The peritoneum is incised lateral to the medial umbilical ligament and the space of Retzius is entered and dissected to the pubic bone. The urachus is then transected allowing the space between the anterior abdominal wall and bladder to be developed (Fig. 14.34). Though rarely necessary, the contralateral superior bladder pedicle may be transected to increase bladder mobilization. Another technique to improve bladder mobilization is to incise the bladder horizontally and then stretch it vertically to the psoas muscle, similar to the Heineke-Mikulic technique. In all cases we perform a psoas hitch. We believe this minimizes tension at the anastomosis and keeps the path of the ureter lateral and away from bowel. We use 2-0 polyglactin suture on a SH needle to fix the posterior bladder wall

Fig. 14.34 Urachus being transected

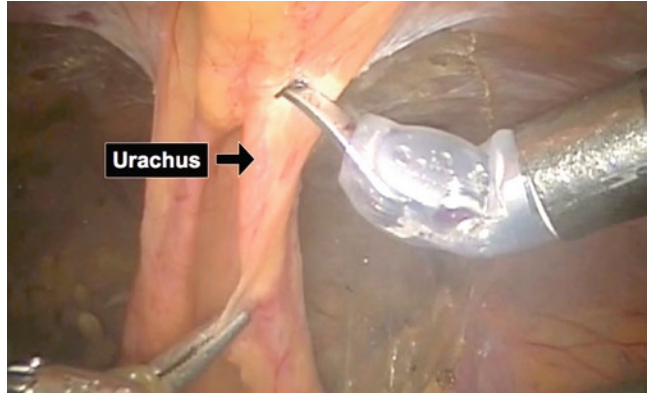
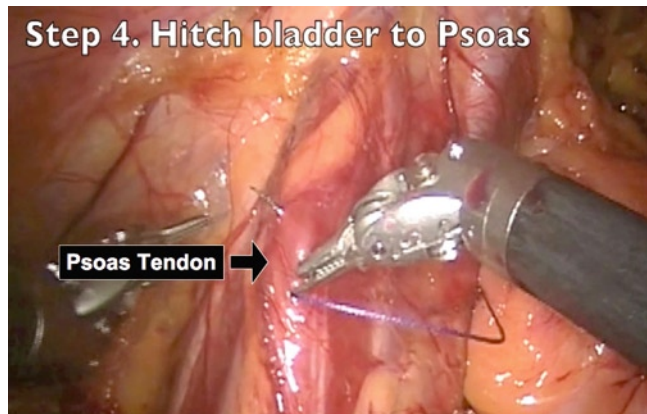


Fig. 14.35 Suture placed through psoas tendon



to the psoas muscle tendon after identifying and avoiding the genitofemoral nerve (Figs. 14.35 and 14.36).

Step 5: Creation of neocystostomy

Surgeon instrumentation		Assistant instrumentation
Right arm • Curved monopolar scissors • Potts scissors • Needle driver	Left arm • Gyrus bipolar dissector • Maryland bipolar graspers • Needle driver	• Suction-irrigator
Endoscope lens: 30° down		

Next, a small area of the bladder is isolated at the lateral dome, and a 1.5 cm incision is made into the bladder wall and mucosa using Potts scissors (the bladder remains filled to help with

this maneuver) (Fig. 14.37). With the bladder now opened and the ureter spatulated, an extra-vesical anastomosis is performed using 4-0 Monocryl sutures on an RB-1 needle in an interrupted fashion, ensuring proper mucosal apposition (Fig. 14.38 and 14.39). After completing the mucosal anastomosis, the bladder is filled with 300 mL of normal saline, and the ureteral reimplantation site is assessed to verify that there is no leakage or tension. Additional sutures can be placed as necessary. A second anastomotic layer is performed with buttressing sutures between the serosa of the bladder and the adventitia of the ureter (Fig. 14.40). A closed-suction drain can be placed near the anastomosis through the most lateral trocars on the ipsilateral side (Fig. 14.41).

Fig. 14.36 Hitching bladder to psoas tendon

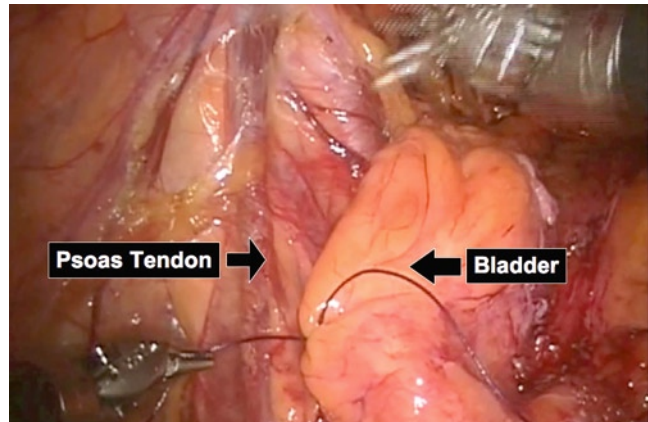


Fig. 14.37 Incision to open bladder mucosa

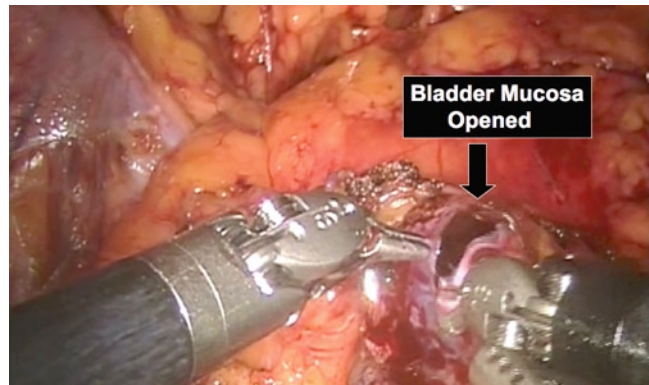
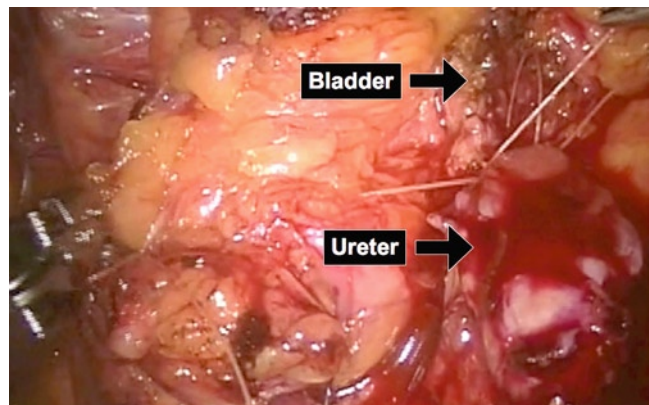


Fig. 14.38 Anastomosis between bladder and ureter



Step 6: Exiting the abdomen

The operative site is examined for bleeding under low insufflation pressure and hemostasis achieved. The trocars are removed under laparoscopic view. The 8 mm and 5 mm trocars gener-

ally do not require fascial closure but are simply closed subcutaneously. The fascia of the 12 mm assistant trocar also does not generally require formal closure if a non-bladed, self-dilating trocar is used.

Fig. 14.39 Anastomosis between bladder and ureter

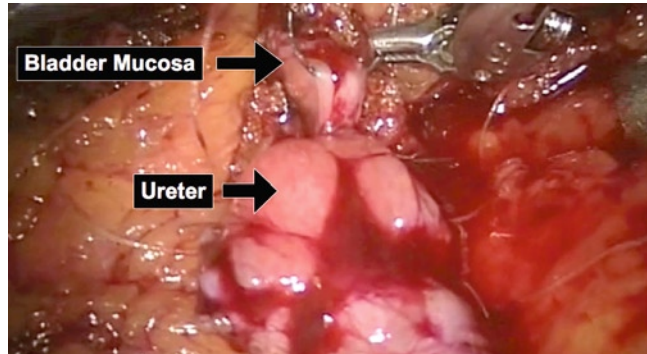


Fig. 14.40 Second closure layer of ureteral reimplantation

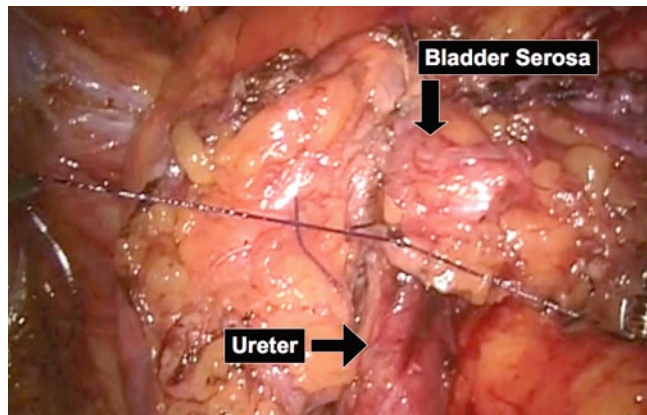
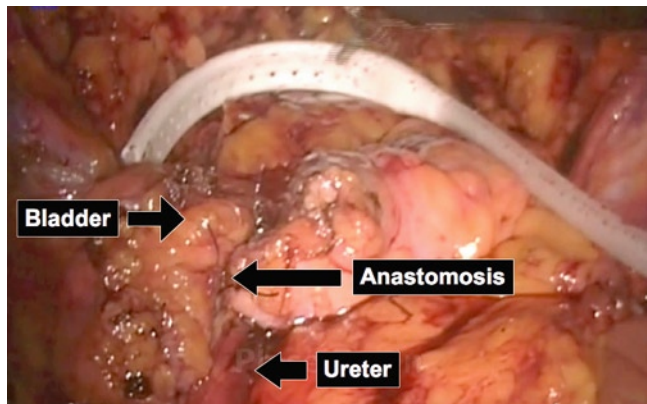


Fig. 14.41 Final anastomosis and drain placement



Step 7: Cystoscopy and ureteral stent placement

After the robot is undocked, cystoscopy is performed to pass a double-J ureteral stent into the reimplanted ureter under fluoroscopic guidance.

Postoperative Management

Patients typically remain in the hospital for 2–3 days. On the first postoperative day, patients begin a clear diet, aggressive ambulation, and oral pain medication. The JP drain is removed

on postoperative day 2 or 3, once its output has decreased to less than 30 cc per 8-h shift. The JP fluid can be sent for creatinine analysis to rule out a urine leak, prior to removal. Once passing flatus, a soft, regular diet is offered. The patient is discharged either the second or third postoperative day. The urethral catheter remains indwelling for 10–14 days and is removed in the office after a cystogram has documented no leak. The stent is removed with a local office cystoscopy in 4–6 weeks, and appropriate imaging studies are obtained thereafter.

Special Considerations

As discussed above, mobilizing the bladder to ensure a tension free anastomosis is essential to ensuring a successful reconstruction. Either a refluxing or non-refluxing anastomosis can be made into the bladder. If a non-refluxing anastomosis is desired, a longer submucosal tunnel can be made prior to reimplanting the ureter into the bladder mucosa. Non-refluxing anastomoses, however, are more technically

challenging and have increased risk of stricture formation.

Steps to Avoid Complications

As has been discussed above for the other reconstructive procedures, ensuring a tension-free, secure anastomosis is paramount to the success of this operation. To that end, wide ureteral spatulation and apposition of ureteral and bladder mucosa will help prevent stricture and urine leakage from the anastomosis. Furthermore, athermal technique, via sharp dissection is essential to avoid potential compromise of the blood supply to the already diseased distal ureter, which can develop into an ischemic urine leak. We also support the judicious use of perivesical fat to help protect the anastomosis; this can be a third layer of closure.

Reference

1. Wong C, Leveillee RJ (2002) Hand-assisted laparoscopic nephroureterectomy with cystoscopic en bloc excision of the distal ureter and bladder cuff. *J Endourol* 16:329–332

Part IV
Miscellaneous Robotic Urologic Procedures

Chapter 15

Robotic Surgical Procedures for Male Infertility

Sijo J. Parekattil and Marc S. Cohen

This chapter contains a video segment which can be found at the URL: <http://www.springerimages.com/Su>

Patient Selection

Selection for the various male infertility procedures is identical to the microsurgical arena. These patients tend to be fairly healthy, younger patients and all the procedures are performed in an outpatient setting. The robotic platform is used as an adjunct only for the microsurgical portion of the procedures once the skin incisions have been made and the tissues are exposed. Thus, body habitus and body mass index considerations are not as important as, for example, in intra-abdominal robotic applications.

Preoperative Preparation

All patients are given an antibacterial soap to bathe in the night before and the morning of the surgery. Patients are asked to shave their scrotal and pubic areas the night before the surgery. Use of any blood thinners, aspirin, or vitamin E is avoided for 5 days before surgery. A broad-spectrum antibiotic such as cefazolin is administered intravenously 30 min before surgery.

Potential complications such as bleeding and infection are discussed with the patient. Most of the microsurgical procedures require that the

patient is absolutely still for a prolonged period of time. The risks of general anesthesia are reviewed with the patient, since this is a comfortable and safe option for most patients. Intravenous sedation may be used in some cases as an alternative.

Operative Setup

At our institution we use the da Vinci® Si-HD system (Intuitive Surgical, Inc., Sunnyvale, CA) with a four-armed technique. Figure 15.1 illustrates the operative setup. The large high definition monitor at the foot of the patient allows the surgical assistant and the surgical nursing team to easily visualize the operative field and prepare instruments and suture for each step of the procedure. The robot is docked perpendicular to the operating table at the patient's side (Fig. 15.1).

Patient Positioning and Preparation

Figure 15.2 illustrates patient positioning for robotic male infertility procedures. The patient is placed in the supine position. The table is placed level (there is no Trendelenberg). The robot is brought in from the right side of the patient after skin incisions are made and the operative tissues exposed. The arms of the patient may be placed alongside (gently wrapped in the draw

S.J. Parekattil (✉)
Department of Urology, Winter Haven Hospital &
University of Florida College of Medicine,
200 Avenue F, N.E, Winter Haven,
FL 33881, USA
e-mail: sijo.parekattil@winterhavenhospital.org

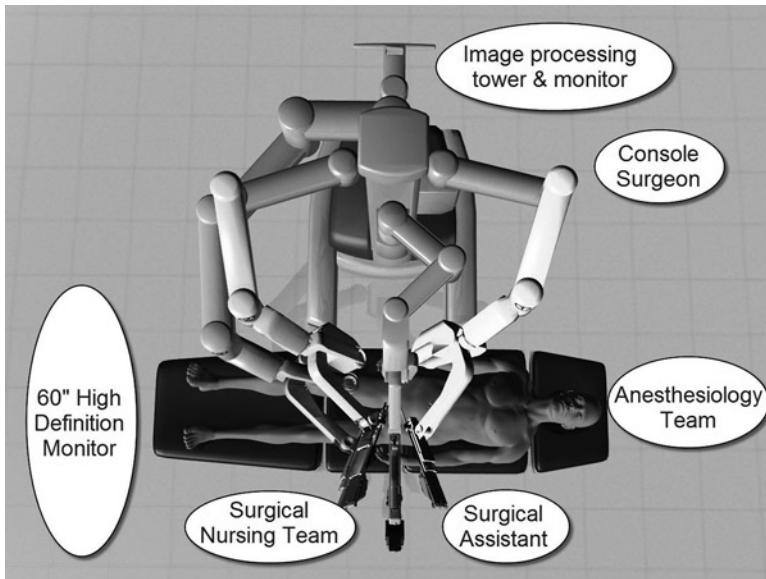


Fig. 15.1 Operative setup for male infertility robotic procedures

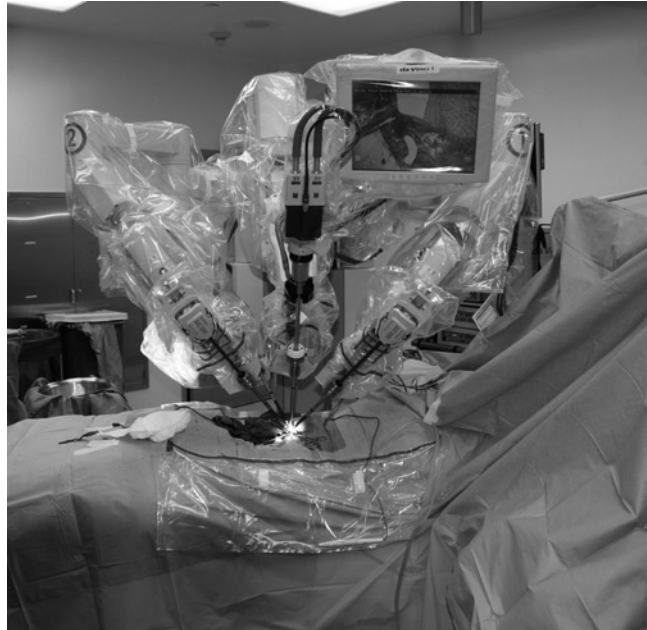


Fig. 15.2 Patient positioning for robotic male infertility procedures

sheets) or apart on arm boards with adequate padding to prevent any nerve compression injuries. Sequential compression devices are placed on the lower extremities to reduce the risk of deep venous thrombus formation. A urethral catheter

is generally not utilized, however, if the procedure lasts more than 2 h, the patient is usually straight catheterized at the end of the procedure to drain the bladder (before recovering the patient from anesthesia).

Fig. 15.3 Intraoperative trocar placement and robotic arm placement



Trocar Configuration

The robot is positioned after skin incisions are made and operative tissues are exposed. The robot is used to perform the microsurgical components of the procedure. Since this is an open case, the trocars are loaded only to allow the instruments to function and to stabilize their movements outside the patient's body. Figures 15.2 and 15.3 illustrate the trocar placement and robotic arm placement. It is important to advance the instruments at least 4–5 cm beyond the tip of the trocar when positioning the robotic arms to optimize range of motion. The fourth robotic arm may be placed lateral to the left robotic arm to minimize instrument clashes. The 0° camera lens is used to optimize the visual field during procedures.

Instrumentation and Equipment List

Equipment

- da Vinci® Si Surgical System (four arm system; Intuitive Surgical, Inc., Sunnyvale, CA)

- Endowrist® Black Diamond micro needle driver (Intuitive Surgical, Inc., Sunnyvale, CA)
- EndoWrist® Micro Potts Scissors (Intuitive Surgical, Inc., Sunnyvale, CA)
- EndoWrist® Micro bipolar forceps (Intuitive Surgical, Inc., Sunnyvale, CA)
- EndoWrist® curved monopolar scissors (Intuitive Surgical, Inc., Sunnyvale, CA)
- EndoWrist® Black Diamond micro needle driver (Intuitive Surgical, Inc., Sunnyvale, CA)
- InSite® Vision System with 0° lens (Intuitive Surgical, Inc., Sunnyvale, CA)

Trocars

- 12 mm trocar (2)
- 8 mm robotic trocars (3)

Recommended sutures

- 10-0 nylon suture on double-armed fish-hook needles for vasal mucosal lumen anastomosis
- 9-0 nylon suture on micro needles for vasal muscularis and adventitial lumen anastomosis
- 6-0 prolene suture on micro needle for vasal adventitial anastomosis and testicular tunical closure in microscopic TESE
- 3-0 silk suture ties (1.5 in. long) for vein ligation in varicocelectomy

Fig. 15.4 Distal vas deferens is grasped



- 3-0 chromic suture for dartos layer and subcutaneous skin closure
- 4-0 chromic suture for scrotal skin closure
- 4-0 monocryl suture for subinguinal skin closure

Instruments used by the surgical assistant:

- Micro Doppler Probe (Vascular Technology, Nashua, NH)
- 18-gauge angiocatheter on a 10 cm³ syringe for saline irrigation
- Weck micro sponge sticks
- Colored vessel loops for vessel identification during varicocelectomy
- Titanium or Metal small clips via automatic stapler to hold vessel loops during varicocelectomy

Step-By-Step Technique

Robot-Assisted Microsurgical Vasovasostomy

Step 1: Identifying the distal vas deferens

The proximal (testicular side) and distal (beyond vasectomy site) vas deferens around the previous vasectomy site is palpated through the scrotal skin. The distal vas just above the vasectomy site

is fixed with a towel clip through the scrotal skin (Fig. 15.4).

Step 2: Incising the scrotum over the vas deferens

A 1–2 cm vertical incision is made with a #15 blade scalpel inferiorly from the towel clip over the vas (Fig. 15.5).

Step 3: Dissection of the vas deferens

The distal and proximal vas ends are dissected free using fine electrocautery and sharp dissection. (Fig. 15.6)

Step 4: Transection of the proximal vas and examining fluid efflux

The proximal vas is carefully transected with an 11 blade scalpel and the fluid effluxing from the lumen is collected on a glass slide and examined under phase contrast microscopy to assess for the presence of any sperm (Fig. 15.7). If there is sperm found or the efflux is copious and clear or milky, then a vasovasostomy is performed on this side. If the efflux has no sperm and is thick and pasty, then a vasoepididymostomy is performed (described in the next section).

Fig. 15.5 Scrotal incision made over vas deferens

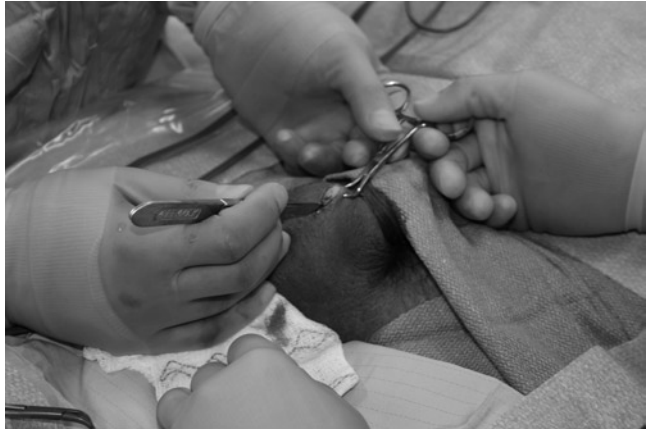

Fig. 15.6 Dissection of the vas deferens

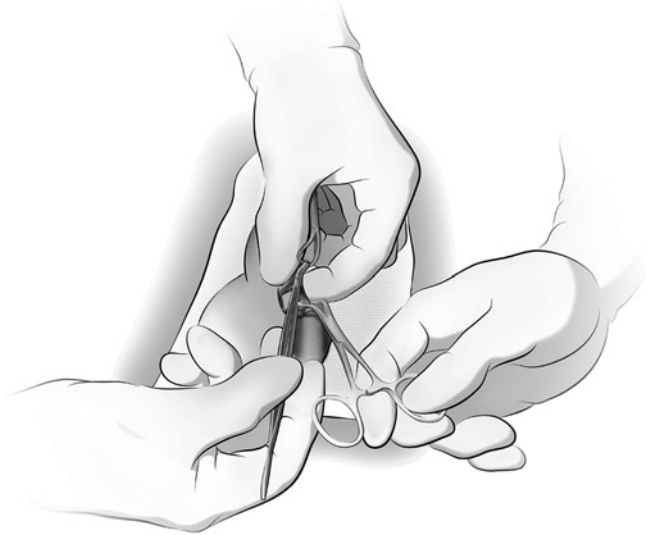
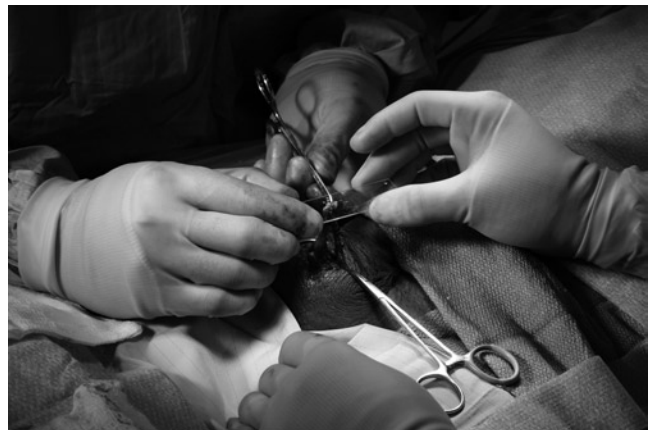
Fig. 15.7 Proximal vas is carefully transected and fluid examined



Step 5: Preparing the ends of the vasa for vasovasostomy

The distal end of the vas is also transected and the two clean ends of the vas are now approximated to each other to allow a tension-free anastomosis. Small hemostats are placed on the adventitia next to each end of the vas to avoid any direct manipulation of the vas (Fig. 15.8). The same procedure is performed on the contralateral scrotal side through the same skin incision. The robot is now positioned to perform the microsurgical vasovasostomy as described in the patient and trocar positioning sections above.

Step 6: Robot-Assisted microsurgical vasovasostomy and vasal dilation

Surgeon instrumentation			Assistant instrumentation
Right arm	Left arm	Fourth arm	
• Black diamond micro needle driver	• Black diamond micro needle driver	Micro potts scissors	• Irrigation syringe • Weck sponge sticks
Endoscope lens: 0°			

The left side vasovasostomy is performed first. The black diamond micro forceps are loaded on the right and left surgical robot arms. The 0° camera lens is loaded onto the robot camera arm. The micro Potts scissors are loaded onto the fourth robot arm. The two vas ends are placed

over a 1/4" Penrose drain. The assistant now irrigates the field with saline using a 10 cm³ syringe with an 18 gauge angiocatheter tip. Weck sponge sticks are used to dry the field. Each of the lumen of the vas is dilated with the black diamond forceps. (Fig. 15.9).

Step 7: Passing the suture to the surgeon

The assistant now passes the 9-0 nylon suture in its inner packaging to the surgical field to allow the robot console surgeon to grasp the suture (using the black diamond right hand grasper) and cut it at about 2 in. length using the micro Potts scissors (left hand fourth arm) (Fig. 15.10).

Step 8: Posterior vasal muscularis anastomosis

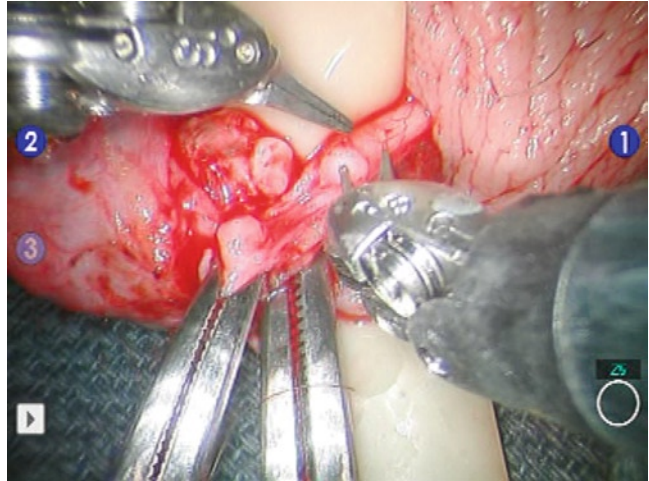
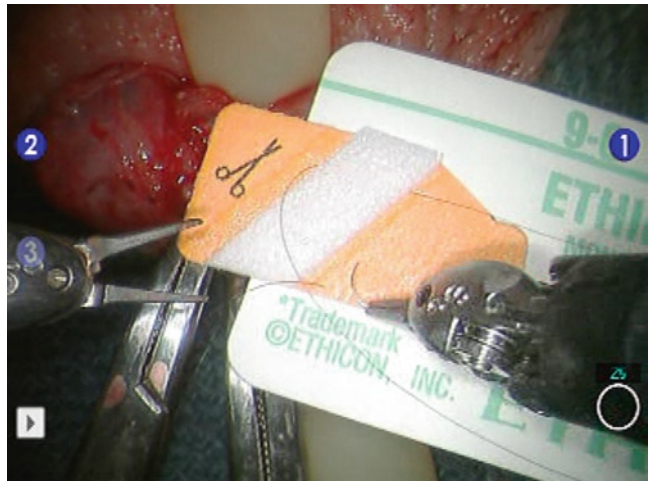
The 9-0 nylon suture is used to approximate the posterior muscularis layer of the two ends of the vas. The surgeon uses the black diamond forceps in both left and right arms as needle drivers. The fourth arm is used by toggling the surgeons left arm to use the micro Potts scissors whenever suture needs to be cut (Fig. 15.11).

Step 9: Posterior vasal mucosal lumen anastomosis

Two or three double-armed 10-0 nylon sutures are now placed to re-anastomose the posterior



Fig. 15.8 Both ends of the vas brought up to prevent any tension

Fig. 15.9 Vas lumen dilated**Fig. 15.10** Suture delivered to surgeon

mucosal lumen of the vas. The sutures are placed inside out to ensure good mucosal approximation. All sutures are placed before they are tied (Figs. 15.12 and 15.13).

Step 10: Anterior vasal mucosal lumen anastomosis

Three double-armed 10-0 nylon sutures are used to close the anterior mucosal lumen of the vas (Fig. 15.14).

Step 11: Anterior vasal muscularis anastomosis

Five to six 9-0 nylon sutures are used to approximate the muscularis layer of the vasa (Figs. 15.15 and 15.16).

Step 12: Removal of bridging scar from the vasal ends

The surgical assistant excises the bridging scar tissue between the vasal ends using fine electrocautery (Fig. 15.17).

Fig. 15.11 Posterior 9-0 nylon muscularis suture placed

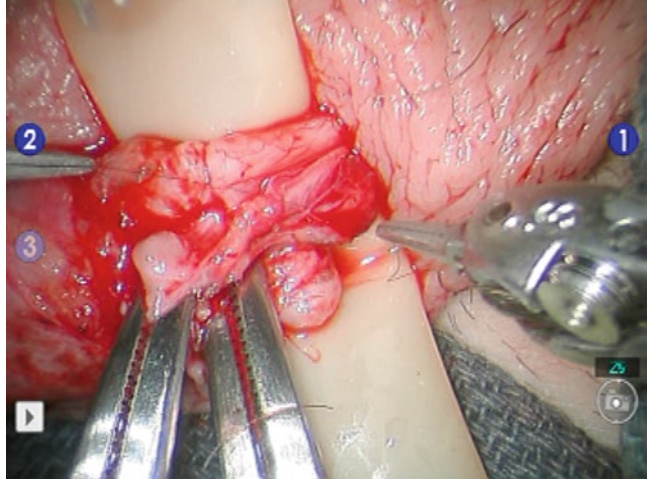


Fig. 15.12 Illustration of placement of the posterior 10-0 nylon sutures in the mucosal layer

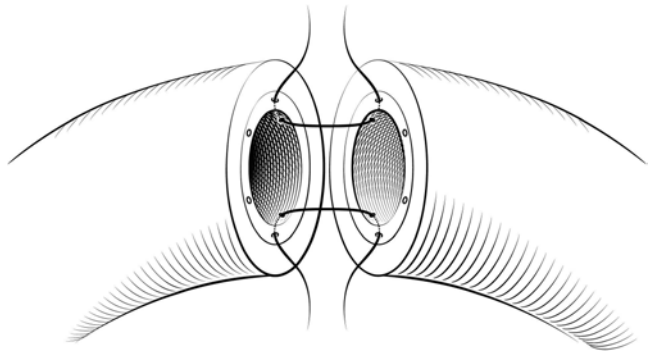


Fig. 15.13 Intraoperative image of placement of the posterior 10-0 nylon sutures in the mucosal layer

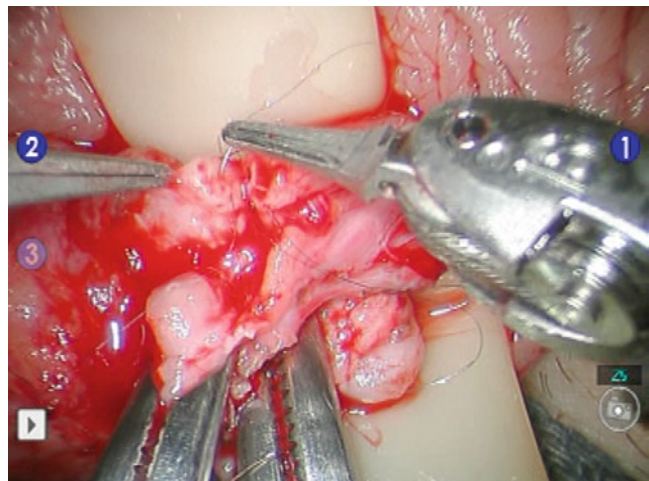


Fig. 15.14 Anterior 10-0 nylon sutures placed in mucosal lumen

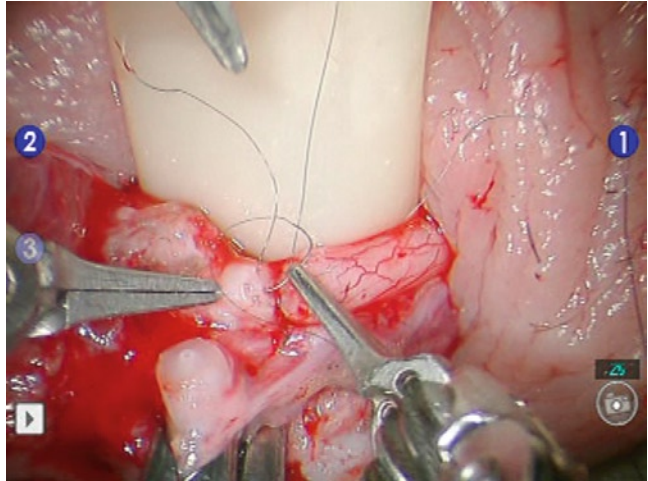


Fig. 15.15 Illustration of placement of anterior 9-0 nylon sutures in the muscularis layer

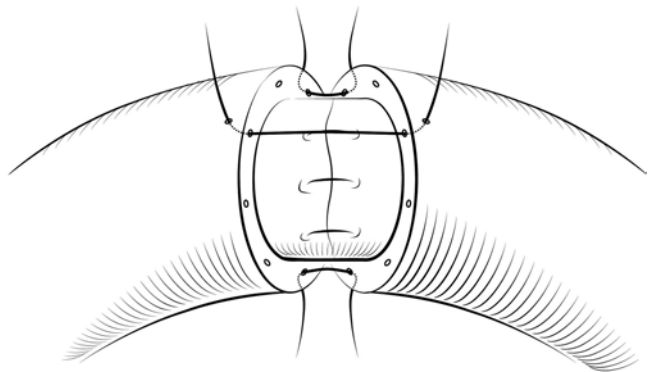


Fig. 15.16 Intraoperative image of placement of anterior 9-0 nylon sutures in the muscularis layer

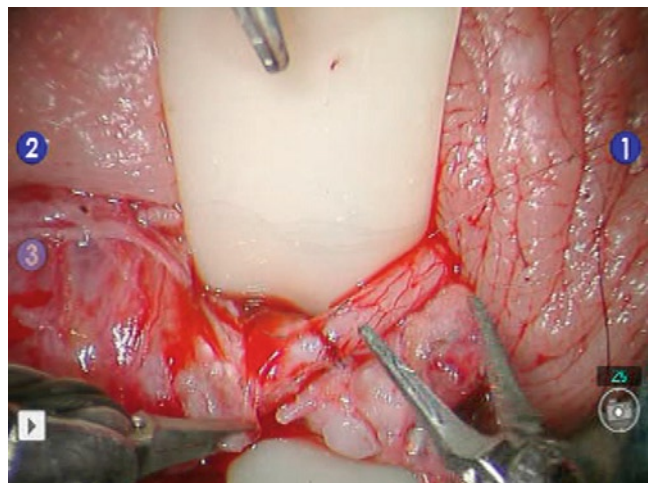


Fig. 15.17 Removal of bridging scar from the vasal ends

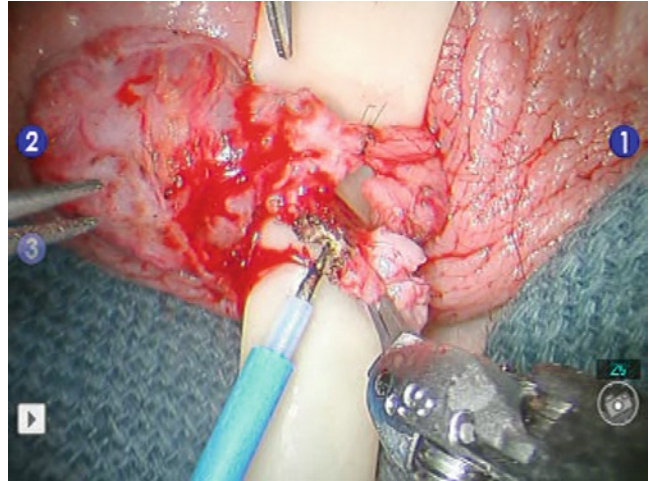
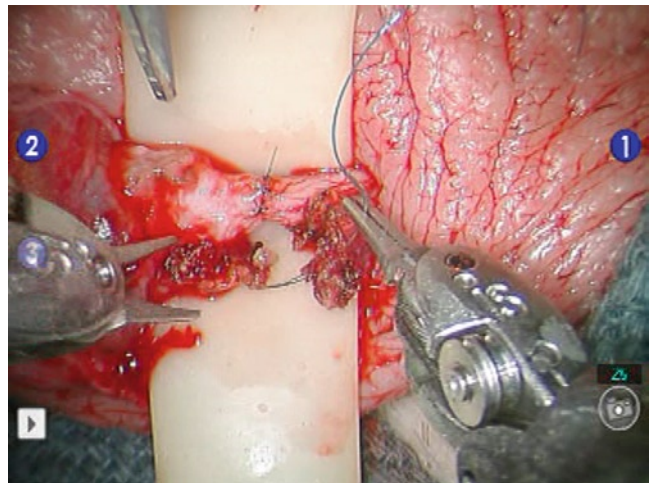


Fig. 15.18 Approximating the adventitia with a 6-0 prolene suture to relieve any tension across the anastomosis and to wrap the anastomosis



Step 13: Adventitial anastomosis

The adventitia is approximated using a 6-0 prolene suture to relieve any tension in the anastomosis and to wrap the repair site (Fig. 15.18).

Step 14: Removal of Penrose drain scaffold

The Penrose drain is gently removed from under the repair. The vas is then replaced in the scrotal cavity (Fig. 15.19).

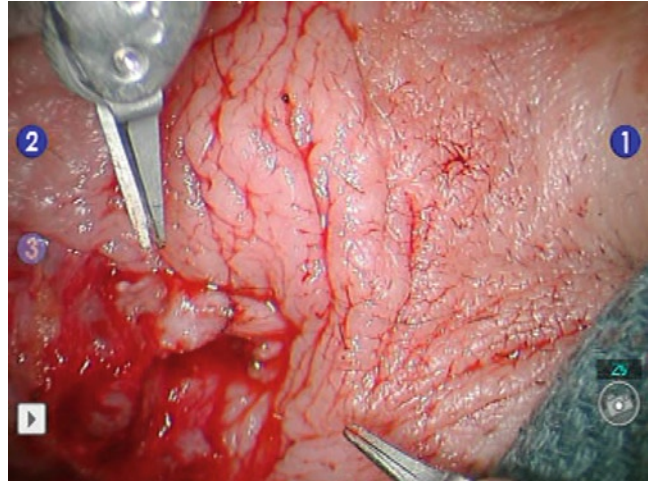
Step 15: Contralateral vasovasostomy

The same procedure is now performed on the contralateral right side by repositioning the robot away from the patient to the right scrotum. The robotic vasovasostomy is performed on the right side as previously described.

Step 16: Skin closure

The dartos layer is closed using a running 3-0 chromic suture for the scrotal skin incision. The skin is closed using a 4-0 chromic running suture.

Fig. 15.19 Removal of the Penrose drain from behind the anastomosis



Bacitracin ointment is applied to the incision and fluff dressings with an athletic support are applied. An ice pack is carefully applied to the scrotum in the recovery room.

Robot-Assisted Microsurgical Vasoepididymostomy

Step 1: Preparing the epididymis and docking of the robot

Surgeon instrumentation			Assistant instrumentation
Right arm	Left arm	Fourth arm	
• Black diamond micro needle driver	• Black diamond micro needle driver	Black diamond micro needle driver	• Irrigation syringe • Weck sponge sticks
Endoscope lens: 0°			

The first 4 steps of the robot-assisted microsurgical vasovasostomy procedure (listed above) describe the preparation of the vas for vasoepididymostomy. The robotic vasoepididymostomy procedure starts from step 4 above if there is no sperm in the fluid from the proximal vas and the fluid is thick and pasty. The scrotal incision is enlarged by another 1–2 cm inferiorly, the testicle is delivered and the tunica is incised to expose the epididymis. The adventi-

tial layer of the epididymis is incised above the level of epididymal obstruction (blue/grey zone with dilated epididymal tubules above this area). The black diamond micro forceps are used in the left and right robotic arms. An ophthalmologic micro blade is held in the fourth arm with black diamond micro forceps. The 0° camera lens is used. Two 10-0 nylon double-armed suture needles are placed longitudinally through a single epididymal tubule to expose the tubule. This tubule is then incised longitudinally using the micro blade between the two suture needles to create a lumen in the tubule (Fig. 15.20).

Step 2: Vasal adventitial to epididymal tunica anastomosis

A 6-0 prolene suture is utilized to approximate the adventitia of the epididymis to the muscularis of the vas. This prevents tension in the vas mucosa to epididymal lumen anastomosis (Fig. 15.21).

Step 3: Involution vasoepididymostomy

The two double-armed 10-0 nylon needles in the epididymal tubule are advanced through and then all four of the needle ends are brought inside out on the vas mucosal lumen to involute the epididymal tubule lumen into the vas lumen (Figs 15.22, 15.23 and 15.24).

Fig. 15.20 Incision of epididymal tubule

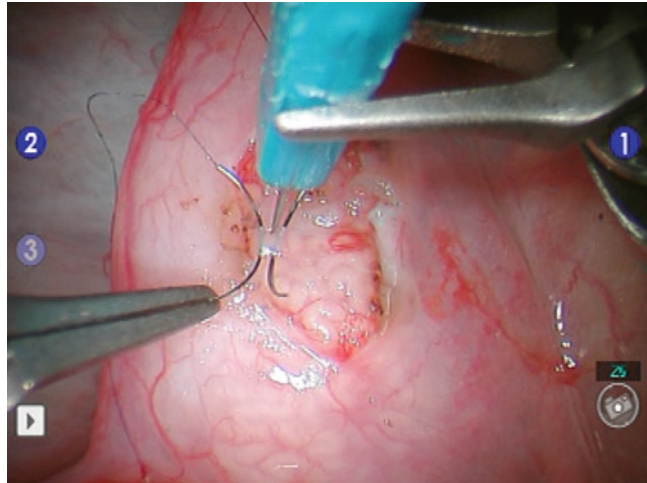
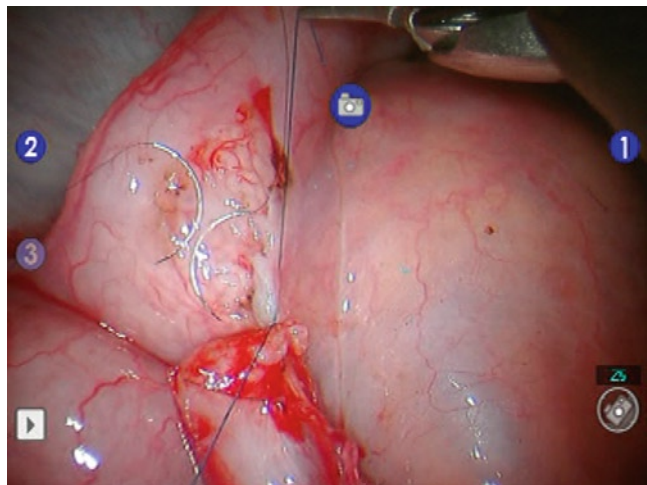


Fig. 15.21 Placement of 6-0 prolene anchor suture



Step 4: Vasal muscularis to epididymal tunica anastomosis

Five to six 9-0 nylon sutures are placed circumferentially to approximate the muscularis of the vas to the adventitia of the epididymal tubule [Figs. 15.25, 15.26 and 15.27).

Step 5: Testicular repositioning and skin closure

The testicle and anastomosis are carefully delivered back into the scrotum. The dartos layer is

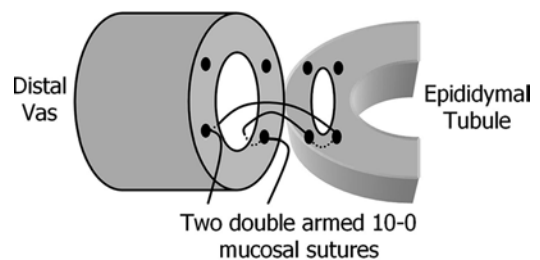


Fig. 15.22 Illustration of the placement of 10-0 double-armed nylon sutures to involute epididymal tubule into the vas mucosal lumen

Fig. 15.23 Placement of the 10-0 nylon sutures

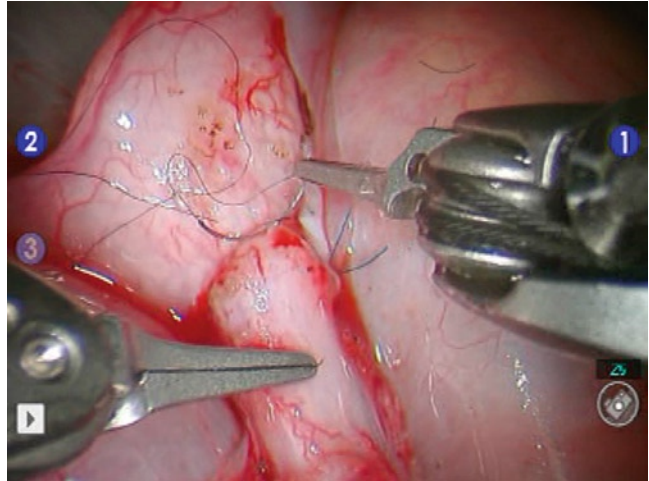


Fig. 15.24 Completion of the 10-0 nylon anastomosis

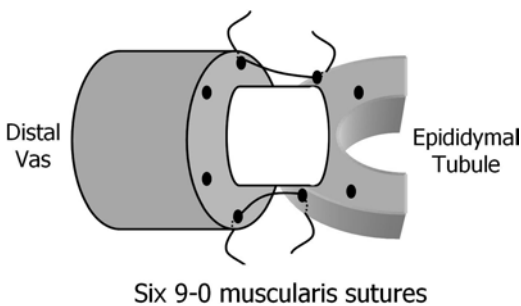
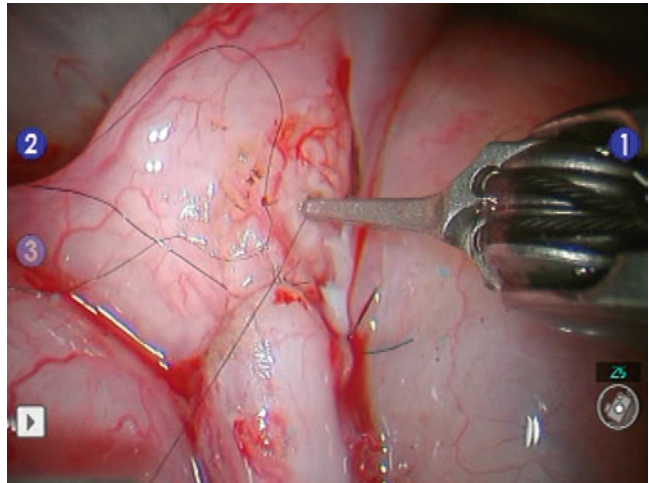


Fig. 15.25 Illustration of the circumferential placement of the 9-0 nylon vas muscularis to epididymal adventitia sutures

closed using a running 3-0 chromic suture. The skin is closed using a 4-0 chromic running suture. Bacitracin ointment is applied to the incision and fluff dressings with an athletic support are applied. An ice pack is carefully applied to the scrotum in the recovery room.

Robot-Assisted Microsurgical Varicocelectomy

Step 1: Subinguinal skin incision

A 2–3 cm subinguinal incision is made over the location of the external inguinal ring (Fig. 15.28).

Fig. 15.26 Placement of the 9-0 nylon sutures

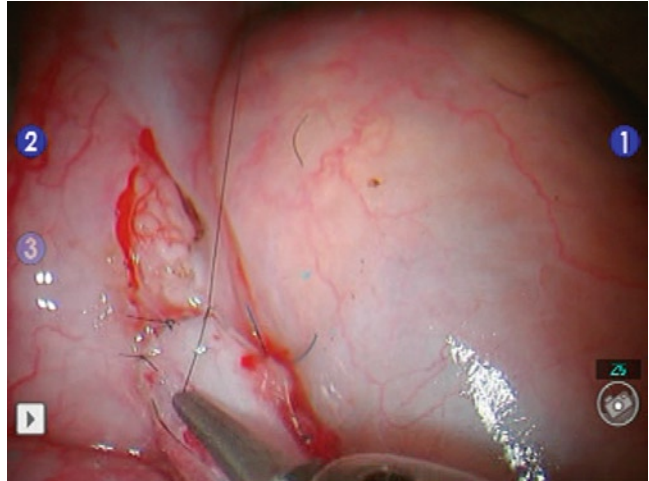
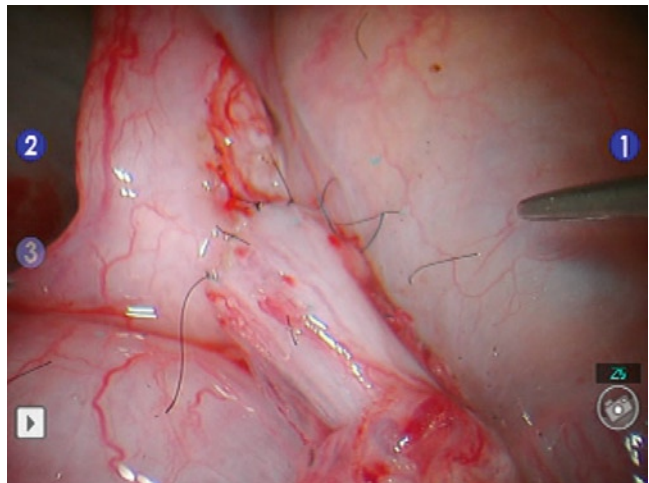


Fig. 15.27 Completion of the 9-0 nylon anastomosis



Step 2: Spermatic cord preparation, robot docking, and dissection of cremasteric muscles

Surgeon instrumentation			Assistant instrumentation
Right arm	Left arm	Fourth arm	
<ul style="list-style-type: none"> • Black diamond micro needle driver 	<ul style="list-style-type: none"> • Micro bipolar forceps 	<ul style="list-style-type: none"> • Curved monopolar scissors or micro potts scissors 	<ul style="list-style-type: none"> • Irrigation syringe • Weck sponge sticks • Micro doppler probe • Colored vessel loops • Small metal clip applicator
Endoscope lens: 0°			

The spermatic cord is carefully dissected and then raised through the skin incision. A ½” inch Penrose drain is placed under the cord to keep it elevated. A sterile tongue blade is placed through the Penrose drain under the cord to further elevate and spread the cord. The robot is positioned from the patient’s right side as described in the beginning

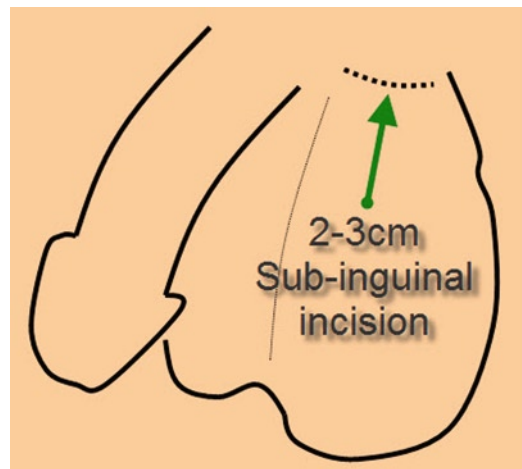


Fig. 15.28 Subinguinal skin incision

of this section. The black diamond micro forceps are used in the right robotic arm, the micro bipolar forceps in the left arm and the curved monopolar scissors in the fourth arm. For left-sided cases, a 0° camera lens is utilized, for right-sided cases, a 30° (down) lens is utilized. The cremasteric sheath of the spermatic cord is now incised to separate the cord structures (Fig. 15.29).

Step 3: Identification of testicular artery with intraoperative Doppler ultrasound

Real-time intraoperative Doppler ultrasound is utilized to localize the testicular artery and ensure that no injury occurs to this vessel (Fig. 15.30)

Step 4: Dissection and ligation of testicular veins

Enlarged veins are carefully dissected and then ligated using 3-0 silk suture ties. Doppler ultrasound verification of each vessel before it is ligated is performed to ensure that no arteries are ligated. The curved monopolar scissors or Potts scissors in the fourth arm is used to cut the vessels after being tied (Fig. 15.31).

Step 5: Optional closure of spermatic cord sheath

After all the veins are ligated, the spermatic cord sheath is now closed using a 6-0 prolene running suture. This step is optional (Fig. 15.32).

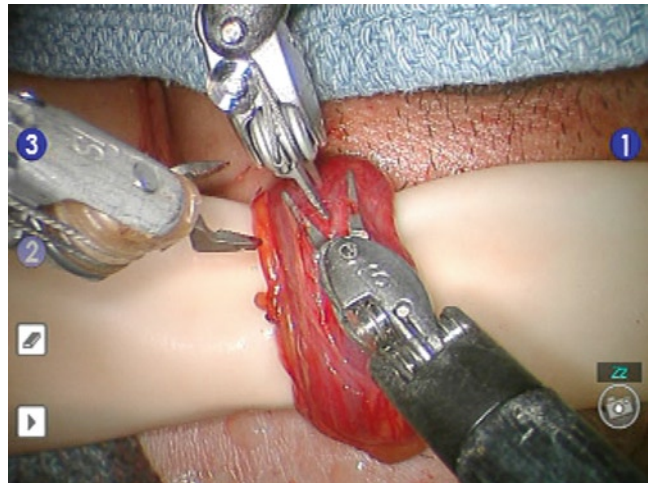


Fig. 15.29 Incision of the cremasteric sheath of the spermatic cord

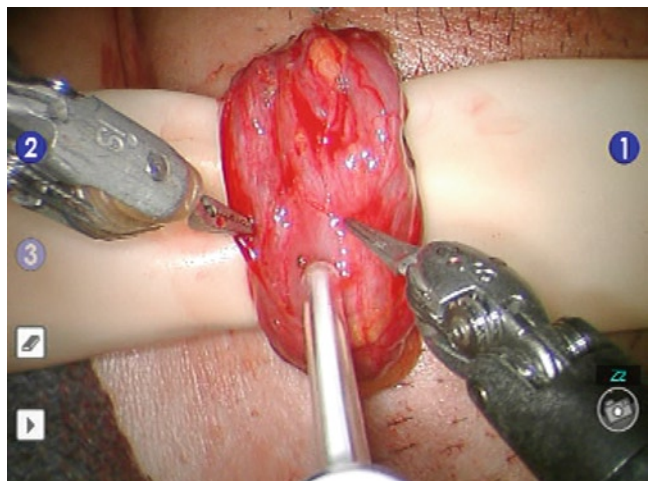

Fig. 15.30 Real-time intraoperative Doppler ultrasound of the testicular artery

Fig. 15.31 Ligation of enlarged vein in the spermatic cord

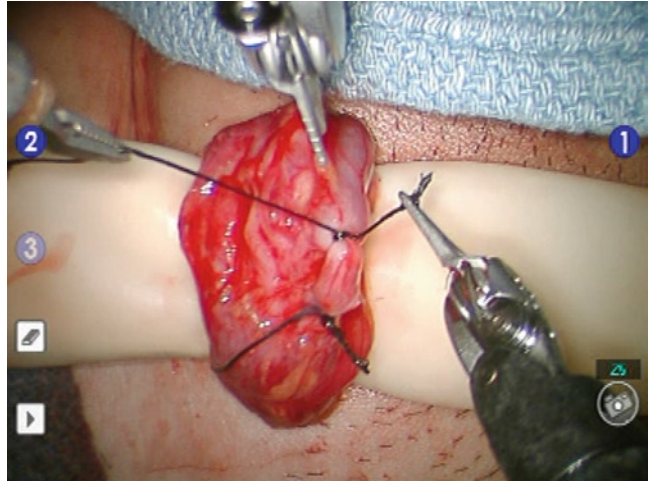
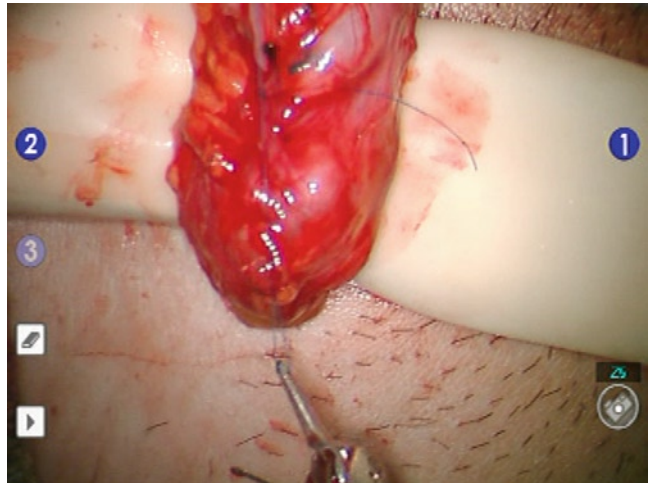

Fig. 15.32 Closure of the spermatic cord sheath



Step 6: Release of spermatic cord

The tongue blade is removed from within the Penrose. The Penrose is now carefully removed and the spermatic cord is released. The testicle is gently pulled down to retract the spermatic cord completely into the incision (Fig. 15.33).

Step 7: Skin closure

The skin incision is closed at the subcutaneous layer using a 3-0 polyglactin suture. The skin is closed using a running subcuticular 4-0 monocril suture and skin glue.

Robot-Assisted Microsurgical Testicular Sperm Extraction (TESE)

Step 1: Scrotal skin incision and robot docking

Surgeon instrumentation			Assistant instrumentation
Right arm	Left arm	Fourth arm	
• Black diamond micro needle driver	• Curved monopolar scissors	• Black diamond micro needle driver	• Irrigation syringe • Weck sponge sticks
Endoscope lens: 0°			

A vertical 4–5 cm incision is made in the scrotal skin along the median raphe (Fig. 15.34). The

Fig. 15.33 Retraction of the spermatic cord into the incision

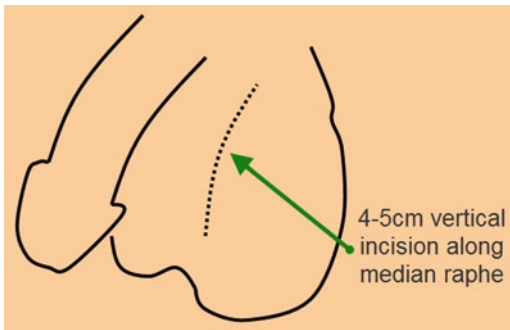
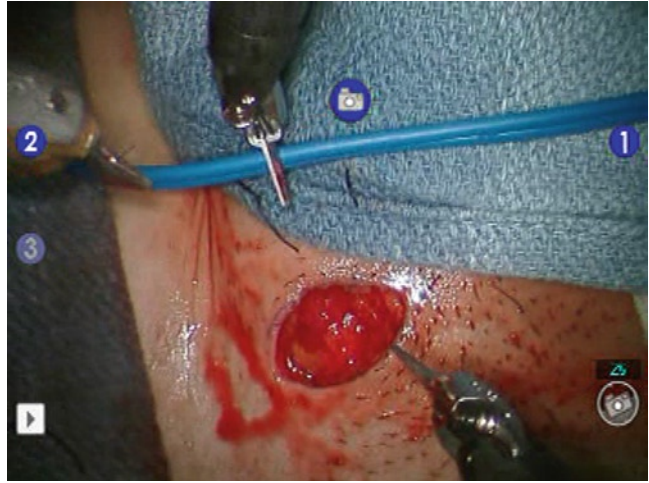

Fig. 15.34 Robotic TESE scrotal skin incision

incision is carried down to the tunica vaginalis of the scrotum and then this is incised as well to deliver the testicle. The robot is now positioned from the patient's right side as described in the beginning of this section. The black diamond micro forceps are placed in the left robotic arm. The curved monopolar scissors are placed in the right robotic arm. Another black diamond micro forceps is placed in the fourth arm of the robot.

Step 2: Tunical incision

Once the testicle is exposed, a 2–3 cm transverse incision is made in the tunica of the testicle to expose the seminiferous tubules (Figs. 15.35 and 15.36).

Step 3: Testicular exploration

The testicular lobules are carefully dissected through to find areas that appear to have larger seminiferous tubules (Fig. 15.37).

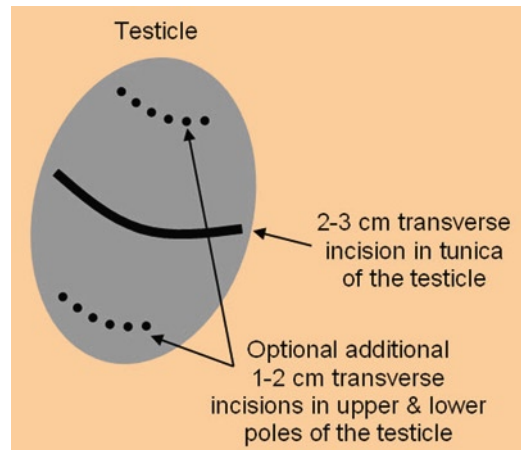


Fig. 15.35 Incisions in the testicle

Step 4: Testicular sperm extraction

These areas are sampled and the specimens are examined immediately with phase contrast microscopy. The assistance of trained embryologists in the operating room optimizes the identification and retrieval of sperm (Fig. 15.38). Sampling is performed till abundant sperm sufficient for multiple assisted reproductive technique cycles are collected. These sperm are either cryopreserved or used for fresh transfer techniques.

Step 5: Deep dissection

In cases where no sperm are readily found, the testicle is thoroughly evaluated. Dissection through the deeper lobules of the testicle is

Fig. 15.36 Incision in the tunica of the testicle

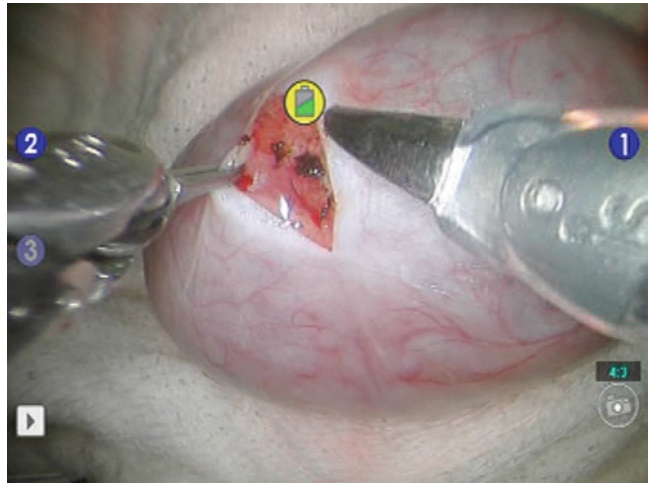
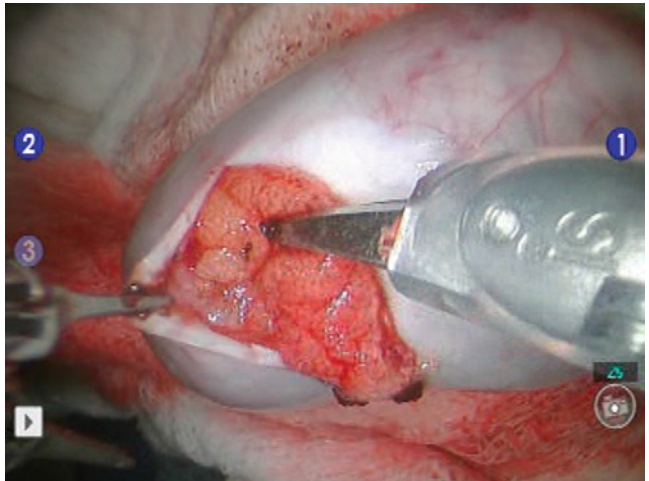


Fig. 15.37 Dissecting through the testicular lobules to identify enlarged seminiferous tubules



performed and sampling of any enlarged tubules is performed (Fig. 15.39). The additional black diamond micro forceps in the fourth robotic arm can be very helpful in deep dissection to help retract the superficial lobules out of the way as the surgeon is evaluating the deeper lobules.

Step 6: Polar dissection of the testicle

In men who have enlarged testicles, or if the upper or lower poles of the testicle cannot be reached through the mid-transverse testicular incision, an additional 1–2 cm transverse incision is made in the upper or lower pole to assess these areas (Fig. 15.40).

Step 7: Tunical and skin closure

Once adequate sperm has been retrieved or adequate sampling has been performed, the tunical incisions in the testicle are closed with 6-0 prolene running suture. The testicle is placed back into the tunica vaginalis cavity within the scrotum and this layer is closed with running 3-0 chromic suture. The dartos muscle layer of the scrotum is closed using 3-0 chromic running suture and then the scrotal skin is finally closed with 4-0 chromic running suture. Bacitracin ointment is applied to the incision and fluff dressings with an athletic support are applied. An ice pack is carefully applied to the scrotum in the recovery room.

Fig. 15.38 Sampling seminiferous tubules that appear to be enlarged

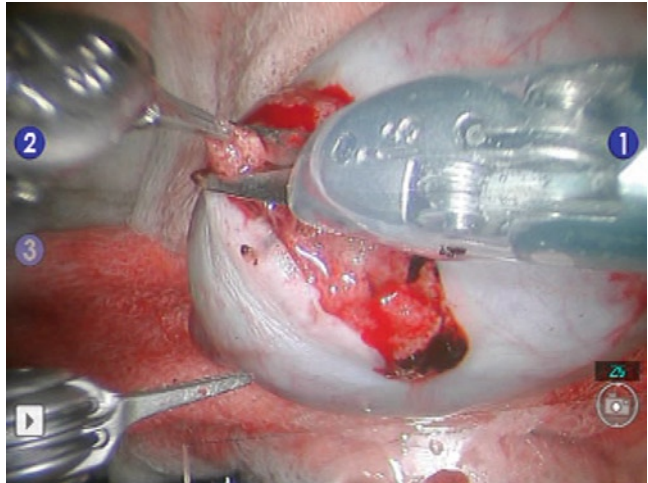
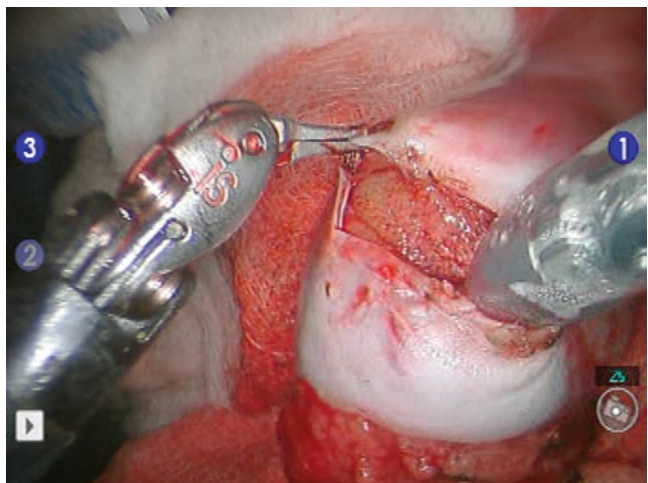


Fig. 15.39 Deeper sampling within the testicle

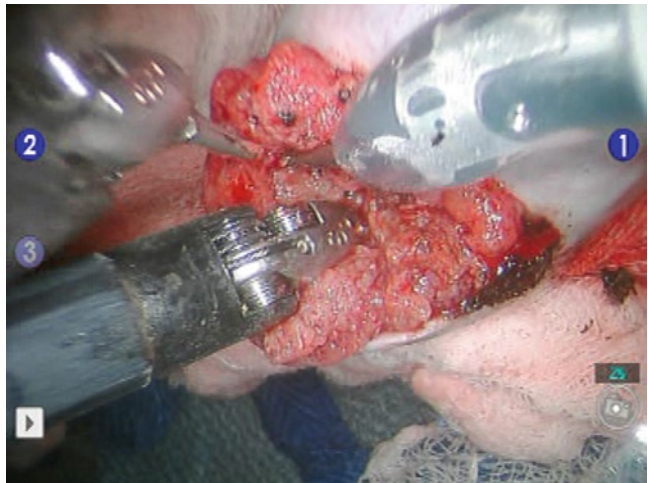

Fig. 15.40 Upper pole testicular dissection and sampling



Postoperative Management

Robotic surgical procedures for male infertility are generally performed as outpatient procedures. A scrotal support is placed prior to awaking the patient. The patient is asked to use this support for 2–3 weeks after surgery. The patient is instructed to have limited activity and have bed rest for about 1 week after surgery. No strenuous activity or heavy lifting is allowed for 4 weeks postoperatively. All patients are provided prescriptions for narcotics for a brief period and antibiotics (keflex) for a few days. Ketorolac is usually avoided to minimize the risk of scrotal hematoma development. Patients are instructed to utilize ice packs (30 min on and off) for the first week post-op to minimize the use of narcotics. In the case of vasectomy reversal, patients are instructed to refrain from masturbation or ejaculation for at least 6 weeks postoperatively.

Steps to Avoid Complications

During robot docking, care must be taken to ensure that the tip of the endoscope lens is at

least 5–10 cm away from the operative field as the heat that emanates from the light within the endoscope may potentially cause desiccation of the tissues and thermal injury to the patient. The surgical assistant must pass the sutures to the surgical field with the sutures still in the original inner packing. This allows the surgeon to remove the suture from the pack under magnified vision and reduces that risk of misplacing fine suture and needles.

Cocuzzo et al [1]. have recently shown that the systematic use of intraoperative Doppler during microsurgical varicocelectomy can significantly decrease the risk of inadvertent testicular artery injury. Thus, we routinely utilize this modality during varicocelectomy to optimize patient safety.

Reference

1. Cocuzza M, Pagani R, Coelho R, Srougi M, Hallak J (2009) The systematic use of intraoperative vascular Doppler ultrasound during microsurgical subinguinal varicocelectomy improves precise identification and preservation of testicular blood supply. *Fertility and sterility*. Mar 5

Chapter 16

Pediatric Urologic Robotic Procedures

Kenneth Thomas and Craig A. Peters

This chapter contains a video segment which can be found at the URL: <http://www.springerimages.com/Su>

Pyeloplasty

Patient Selection

With the increased use of prenatal ultrasound, most ureteropelvic junction obstructions (UPJO) are found prior to birth. Initial workup usually includes a renal ultrasound and voiding cystourethrogram (VCUG) as well as renal nuclear medicine scan, especially when significant UPJO is suspected. Prophylactic antibiotics are usually recommended at least until the above mentioned studies are done. If at any point the child develops urinary tract infections or nausea/vomiting/flank pain suspected to be related to the UPJO, then robotic pyeloplasty is offered to the parents and patient as an interventional option. Also, if on renal nuclear medicine scan, the differential kidney function is <40% or there has been a change of >10% differential, then intervention with robotic pyeloplasty is discussed. Non-resolving hydronephrosis becomes a relative indication based on parental and physician preferences.

C.A. Peters (✉)
Division of Surgical Innovation,
Sheikh Zayed Institute for Pediatric Surgical Innovation,
Children's National Medical Center
Washington, D.C. 20010
e-mail: crpeters@cnmc.org

Preoperative Preparation

Bowel Preparation

All patients are asked to have a clear liquid (apple juice, Jell-o, ginger ale, water, broth) diet for 24 h before surgery to reduce the bulk of stool in the colon. They are also given one Dulcolax® suppository (Boehringer Ingelheim Pharmaceuticals, Inc., Ridgefield, CT) for the night before. They are then NPO for at least 3 h prior to the case. Specific to infants or young children is the use of milk of magnesia (cherry flavor, refrigerated) one to two teaspoons, daily for 2 days before surgery. For 3 days prior to surgery, older children are asked to use senna liquid, one to two teaspoons up to twice daily for 3 days before surgery or ex-lax® squares (chocolate covered senna; Novartis Consumer Health, Inc., Parsippany, NJ): ½ to 1 square, repeating twice daily until cleaned out. Teenagers may use Dulcolax® tabs: 20 mg BID the day prior to surgery.

Informed Consent

All patients and family should understand that the procedure will be performed by the surgeon, not the “robot.” The da Vinci® Surgical System (Intuitive Surgical, Inc., Sunnyvale, CA) is actually a “master–slave” micromanipulator where the operator is in total control. The robot is not in any way autonomous. Some families are concerned

about this issue due to misinformation or misperceptions. The family and patient should always be made aware of the possibility of conversion to open surgery. This is emphasized to be used in cases where the ability to complete the procedure or safety are of concern. If a family is hesitant or unwilling to consent to this uncertainty, open surgery should be recommended so they know what to expect. The risks of general anesthesia must also be presented to the patient. Other risks that need to be relayed during informed consent include the realization that renal function could remain the same or even worsen after surgery. Continued flank pain, nausea, vomiting, recurrent urinary tract infections, and the possibility of reoperation also need to be discussed.

Operative Setup

At our institution we use the da Vinci® with a three-armed technique. An assistant and the scrub technician are positioned on the side of the

patient opposite the robot. Video monitors are placed for easy viewing by all team members. Overhead views of the room setup for right and left pyeloplasties are shown, respectively, in Figs. Fig. 16.1 and 16.2. We recommend having a dedicated operating room for the da Vinci® to decrease room turnover delays and possible equipment damage due to transporting the robot from one room to another.

Patient Positioning and Preparation

Initially, place the patient in lithotomy or frog-legged position for retrograde ureteral stent (if planned) and urethral catheter placement. Next, place the patient in modified flank with a 30° wedge under the ipsilateral side where the pyeloplasty will be performed with padding and tape across chest and thighs. Also, place folded towels and tape over the patient's arms but under the abdomen (Fig. 16.3). Rotate the table so that the patient's abdomen is flat while obtaining trocar access, then rotate to 60° (30° wedge plus 30°

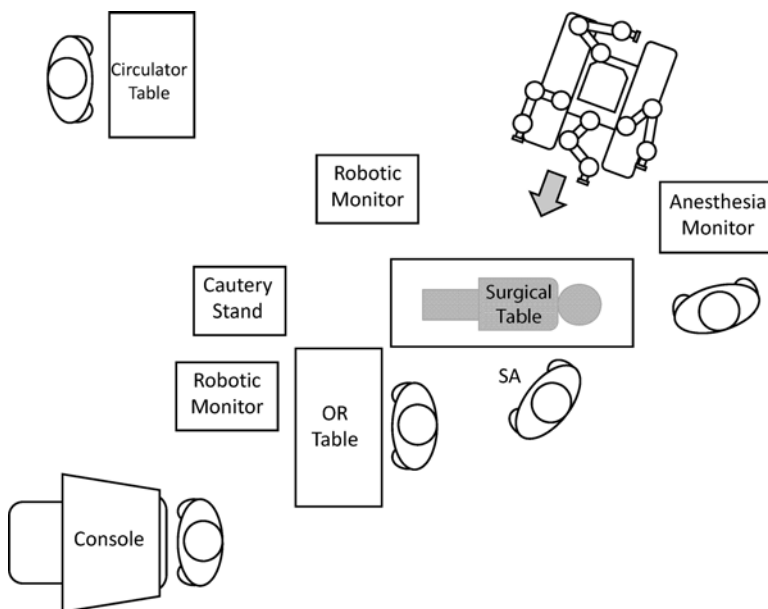


Fig. 16.1 Operating room setup for right robotic pyeloplasty demonstrating standard configuration of operating room personnel and equipment

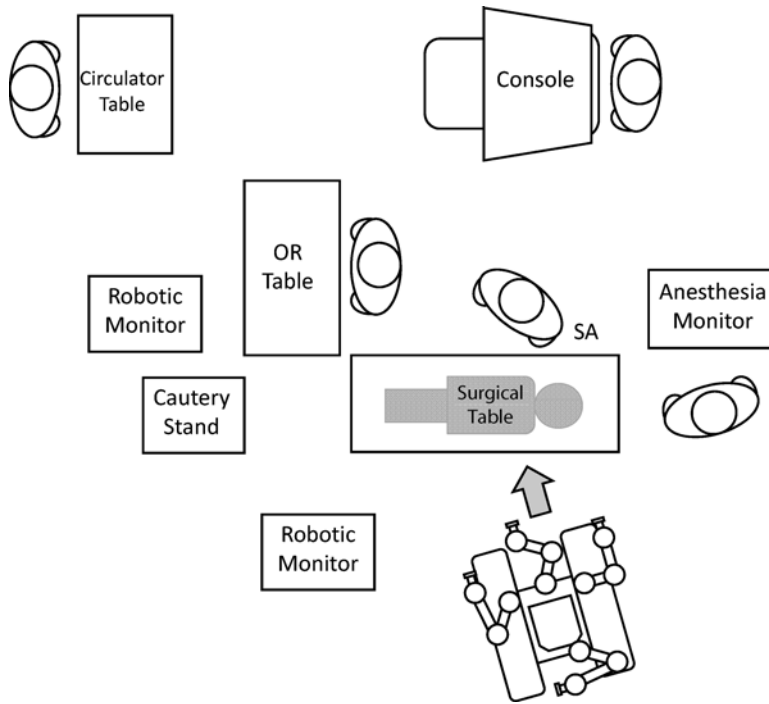


Fig. 16.2 Operating room setup for left robotic pyeloplasty demonstrating standard configuration of operating room personnel and equipment

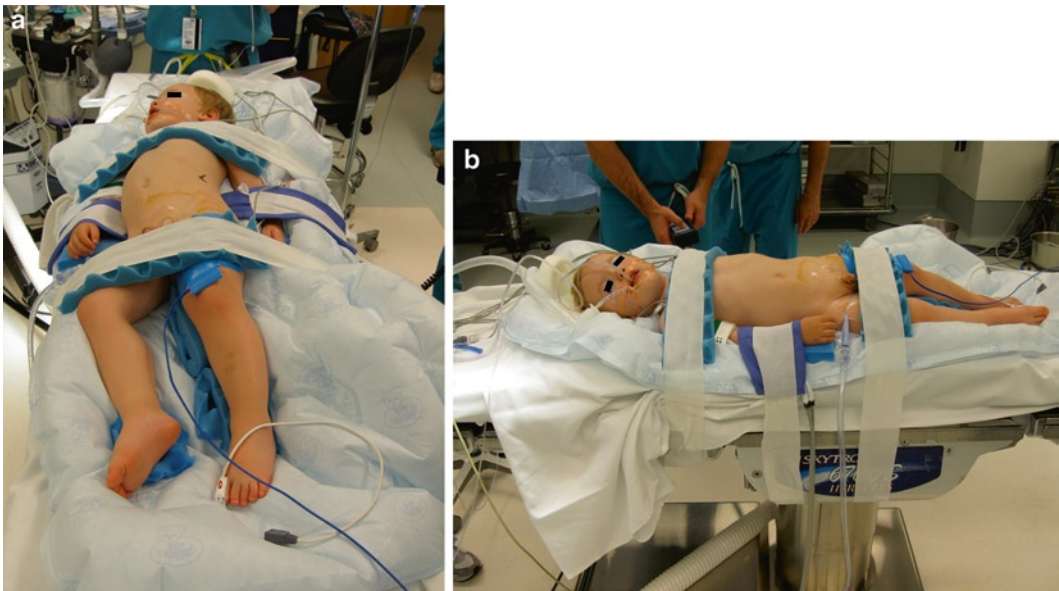


Fig. 16.3 Patient positioning shown for a left pyeloplasty. (a) Inferior view. (b) Side view

table rotation) just prior to docking the robot. The anesthesia team should place an NG or OG tube before access.

Trocar Configuration

The trocar configuration for a left versus right pyeloplasty is basically a mirror image of itself (Figs. 16.4 and 16.5). One notable difference is the possibility of needing an extra trocar for liver retraction during a right pyeloplasty, although the renal pelvis can be accessed adequately in most cases without this extra trocar. We typically use the 5 mm trocars for robotic arm access when the patient is younger than 8–10 years, otherwise the 8 mm trocars are used.

Instrumentation and Equipment List

Equipment

- da Vinci® Surgical System (3-arm system; Intuitive Surgical, Inc., Sunnyvale, CA)

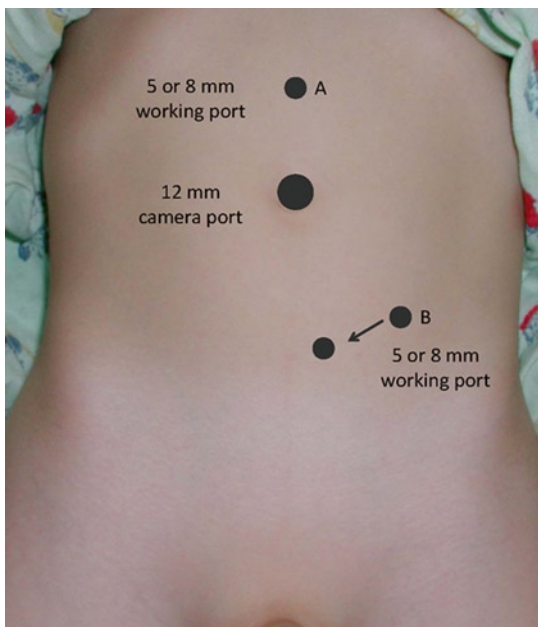
- EndoWrist® Monopolar Hook, 5 or 8 mm (Intuitive Surgical, Inc., Sunnyvale, CA)
- EndoWrist® Maryland Dissector, 5 or 8 mm (Intuitive Surgical, Inc., Sunnyvale, CA)
- EndoWrist® DeBakey Forceps, 5 or 8 mm (Intuitive Surgical, Inc., Sunnyvale, CA)
- EndoWrist® Curved Monopolar Scissors, 8 mm (Intuitive Surgical, Inc., Sunnyvale, CA)
- EndoWrist® Round Tip Scissors, 5 or 8 mm (Intuitive Surgical, Inc., Sunnyvale, CA)
- EndoWrist® Needle Driver, 5 or 8 mm (Intuitive Surgical, Inc., Sunnyvale, CA)
- InSite® Vision System with 30° lens (Intuitive Surgical, Inc., Sunnyvale, CA)

Trocars

- 12 mm trocar
- 8 mm robotic trocars (2, only if child is older than 8–10)
- 5 mm trocar (usually 2, if you need liver retraction during a right pyeloplasty then you will need 3, or a 3.5 mm cannula)

Recommended sutures:

- Preplaced fascial box stitch: 2-0 or 3-0 polyglactin suture
- Hitch stitch: 3-0 or 4-0 PDS



Working Port A is roughly half the distance between the umbilicus and the xiphoid

Working Port B is roughly 2/3 the distance between the umbilicus and the anterior superior iliac spine (ASIS), but if the area of interest is in the lower retroperitoneum or the child is small, may be adjusted medially and inferiorly

Fig. 16.4 Trocar configuration for left robotic pyeloplasty

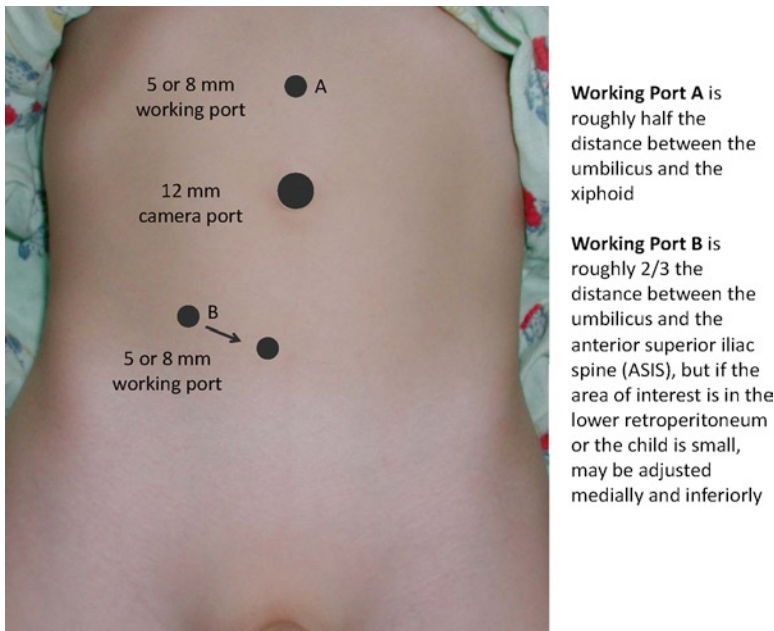


Fig. 16.5 Trocar configuration for right robotic pyeloplasty

- Pyeloplasty anastomosis: Monocryl or polyglactin suture, size depending upon age (neonate to 6 months 7–0, 6 months to 4 years 6–0, over 4 years 5–0, teenager 4–0). Length of suture approximately 12–14 cm.
- Skin Closure: 4-0 or 5-0 monocryl suture

Recommended ureteral stent:

- Ages 0–6 years: 3.7 Fr double J and 0.028 in. wire; length: age plus 2 cm
- Ages over 6: 4.6 Fr double J and 0.035 in. wire

Instruments used by the surgical assistant:

- Maryland grasper
- Suction irrigator device

Step-by-Step Technique

Step 1: Ureteral stent placement

With the patient in lithotomy or frog-legged position, perform a retrograde pyelogram and

place ureteral stent on the affected side up to the area of obstruction. Leave a string attached to the ureteral stent and tape string to inside of leg. This permits removal in clinic at a later date without cystoscopy.

Step 2: Abdominal access and trocar placement

For a left UPJO, reposition the patient in a left modified flank position as noted above; then, for trocar placement, rotate the table so the patient's abdomen is 0°. The 12 mm camera trocar is placed in the area of the umbilicus, using the Hasson open technique with 2-0 polyglactin suture on a UR-6 needle or a 3-0 polyglactin suture on a CT-2 needle bent accordingly. These are pre-placed fascial box stitches (used later for closure). Working trocars are then placed sharply under direct vision after pre-placing the fascial box stitches. Rotate the patient to approximately 60° (30° from table rotation and 30° from the wedge placed earlier) and dock the robot.

Step 3: Access to ureteropelvic junction

Surgeon instrumentation		Assistant instrumentation
Right arm	Left arm	• Suction-irrigator
• Monopolar hook tip cautery	• Maryland dissector	
Endoscope lens: 30° down		

Displace small bowel away from the surgical field and toward the midline. At this point, if the UPJO is obvious through the mesentery, then a transmesenteric approach may be followed to gain access to the ureteropelvic junction (UPJ) (Fig. 16.6). Otherwise, continue as below. Retract the colon medially and identify the white line of Toldt. Pick up the parietal peritoneum and make an incision extending from above the likely area

of the renal pedicle to the aortic bifurcation using the hook electrocautery (5 mm) or hot scissors (8 mm) (Fig. 16.7). Expose the ureter distal to the UPJ being careful not to jeopardize the segmental blood supply in the area. Also, be aware of the gonadal vessels running parallel to the ureter in this area. Dissect proximally along the ureter. As the kidney is approached, look for lower pole vessels that are common with this anomaly (Fig. 16.8). Isolate and dissect around these vessels. Do not ligate them as this could lead to segmental renal ischemia. Before excessive mobilization, determine whether the vessels appear to be contributing to the obstruction if possible. This will determine whether ureteral transposition anterior (usually) to the vessels is needed.

Fig. 16.6 Transmesenteric approach. In children, as opposed to adults, a transmesenteric approach to the kidney is reasonable and sometimes preferred. The thin colonic mesentery is seen here just above the ureteropelvic junction (UPJ)

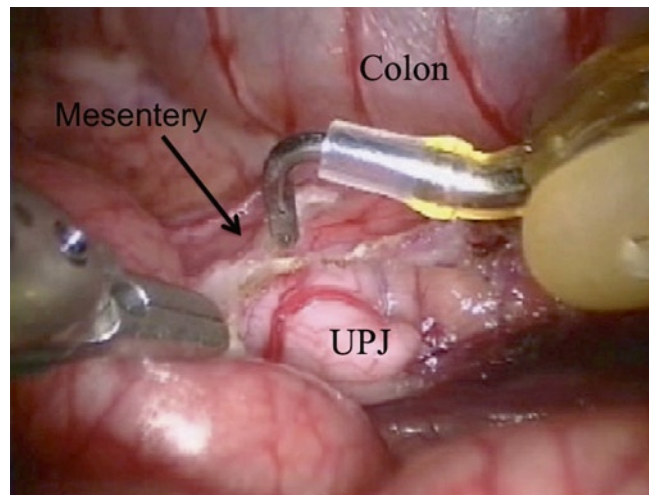


Fig. 16.7 Retraction of the colon. The colon is retracted medially and dissection is made along the white line of Toldt exposing the underlying kidney and renal pelvis

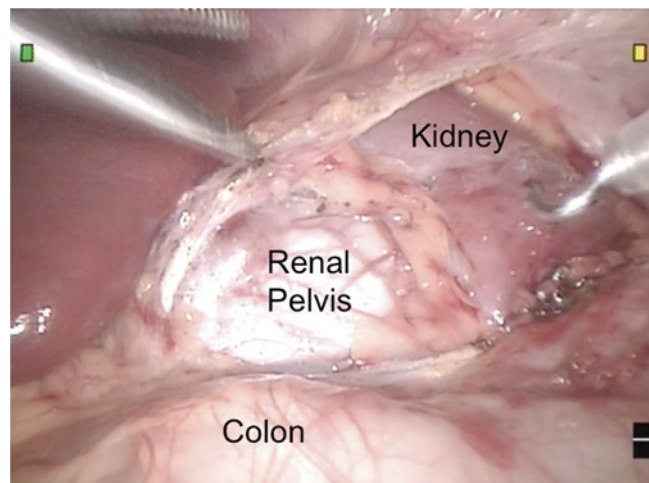


Fig. 16.8 Crossing vessels are often encountered, as shown here

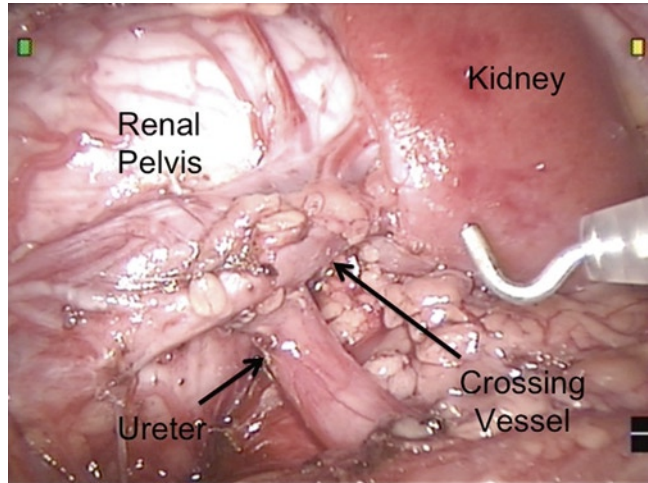
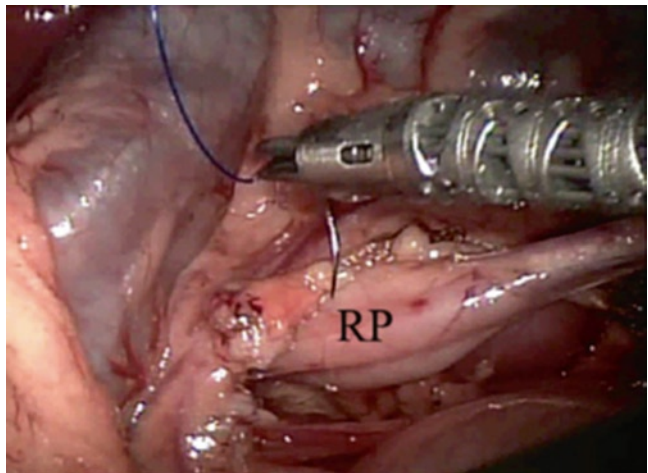


Fig. 16.9 Exposure of the renal pelvis (RP), UPJ, and proximal ureter. Obtaining excellent mobilization of the UPJ at this point in the surgery helps later on during the anastomosis



Step 4: Placement of hitch stitch

Surgeon instrumentation		Assistant instrumentation
Right arm	Left arm	• Suction-irrigator
• Needle driver	• Maryland dissector	
Endoscope lens: 30° down		

Once adequate access to the renal pelvis, UPJ, and proximal ureter is achieved (Fig. 16.9), switch the monopolar electrocautery out for a needle driver. Pass a 3-0 PDS stitch on an SH needle through the abdominal wall lateral to the kidney and just at the costal margin. Place this stitch through the anterior aspect of the renal pelvis, back out the abdominal wall, then hold in place with a hemostat. This is used as a “hitch-stitch” to elevate the renal pelvis, providing stability and lifting the operative field

out of any collection of urine or blood (Fig. 16.10). Tension is adjustable.

Step 5: Pyelotomy and ureteral spatulation

Surgeon instrumentation		Assistant instrumentation
Right arm	Left arm	• Suction-irrigator
• Round tip scissors	• Maryland dissector	
Endoscope lens: 30° down		

Place the round tip scissors in the right hand. Pyelotomy is performed with a diamond shaped incision into the renal pelvis superomedial to inferolateral below the UPJ (Fig. 16.11). Use the remaining renal pelvis on the ureter as a handle for manipulation. Perform a lateral spatulating incision of the ureter through the UPJ and

Fig. 16.10 Hitch Stitch. The hitch stitch should easily lift the renal pelvis and proximal ureter. *RP* renal pelvis

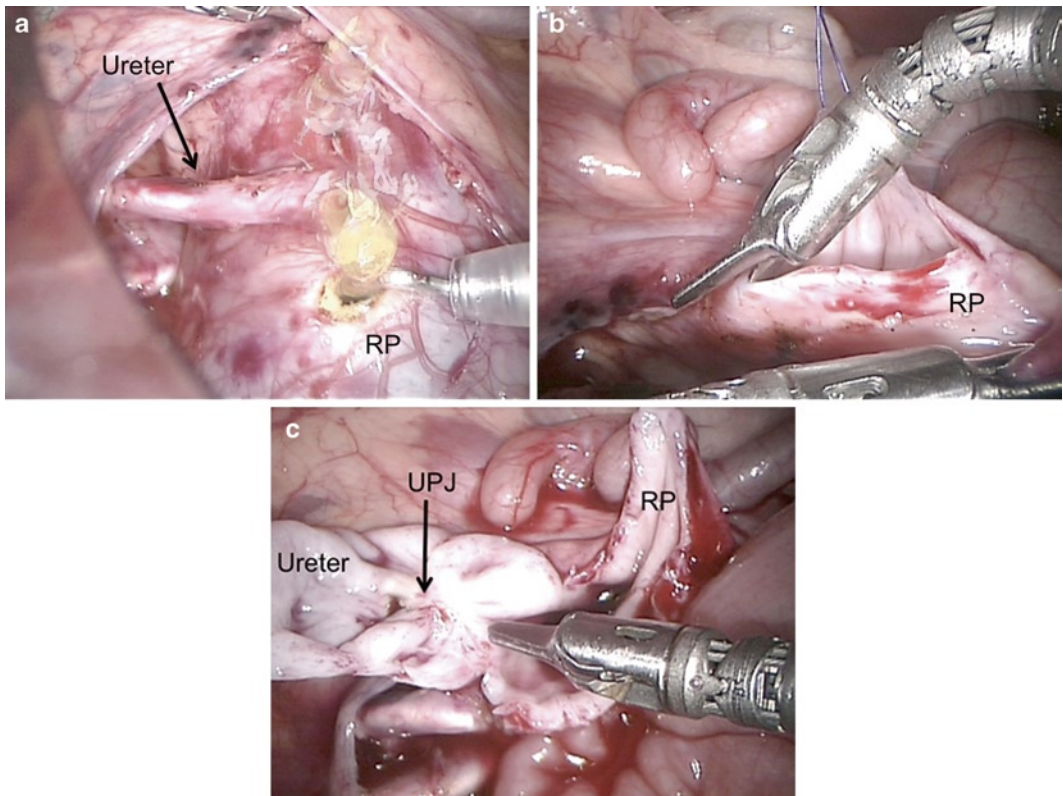
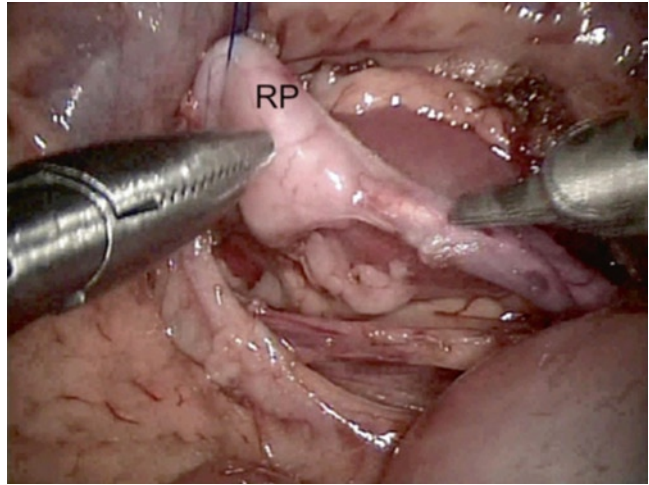


Fig. 16.11 Pyelotomy (right kidney shown). (a) The pyelotomy is begun by making a sharp incision superomedial on the renal pelvis just below the hitch stitch. *RP*

renal pelvis. (b) The incision is continued inferolaterally. (c) A tight UPJ was noted in this patient as seen here

distally to where the ureter appears normal in diameter (Fig. 16.12).

Step 6: Anastomosis of renal pelvis to the ureter

Surgeon instrumentation		Assistant instrumentation
Right arm	Left arm	
<ul style="list-style-type: none"> • Needle driver • Round tip scissors 	<ul style="list-style-type: none"> • Maryland dissector 	<ul style="list-style-type: none"> • Suction-irrigator • Laparoscopic needle driver
Endoscope lens: 30° down		

With a needle driver in the right hand, begin anastomosis of the renal pelvis to the ureter using a running Monocryl or polyglactin suture (7-0 for infants to age 6 months, 6-0 to age 2 years, 5-0 for all others; 12–14 cm in length) passed through

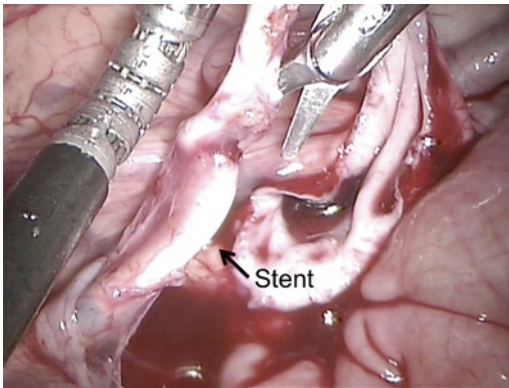


Fig. 16.12 Lateral spatulating incision of the ureter. Notice the preplaced stent seen through the wall of the ureter

one of the working trocars. The first stitch is placed in the vertex of the ureteral spatulation and the posterior side of the collecting system is usually sewn first (Fig. 16.13). This depends upon the orientation of the pelvis and the relative angle of the instruments. After completion of the first side, the ureteral stent can be positioned into the pelvis. If a stent has not been pre-placed, a stent is fed over a wire passed through the abdominal wall through a 14 or 16 G angiocatheter and down the ureter. Length should be generous to ensure bladder positioning. The redundant renal pelvis tissue is removed (Figs. 16.14, 16.15 and 16.16). The second side is anastomosed from the vertex of the ureteral spatulation upward and any extra opening of the pelvis is closed with this suture as well. A third suture may be needed if the pyelotomy is large (Figs. 16.17 and 16.18). All sutures are cut by temporarily replacing the needle driver with the round tip scissors. Needles and suture are brought in and removed through the right 5 or 8 mm robotic trocar by the assistant with the laparoscopic needle driver.

Step 7: Exiting the abdomen

The hitch stitch is cut and removed, the operative area irrigated, cleared, and inspected. The robot is undocked. Trocars are removed under direct vision, the preplaced fascial box stitches are tied, and a subcuticular Monocryl suture is used for skin closure.

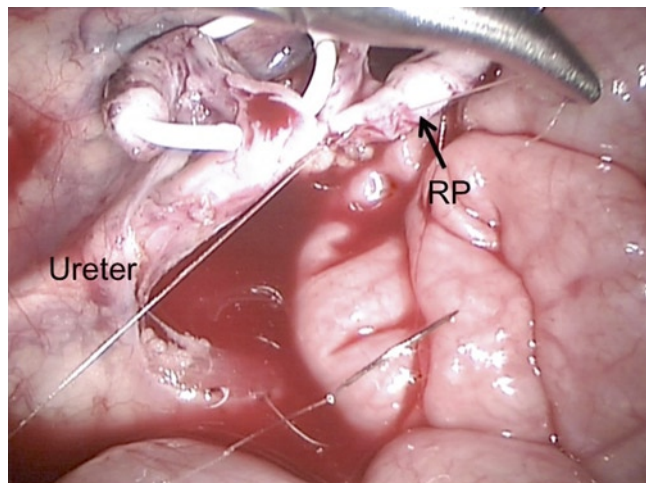


Fig. 16.13 A vertex stitch is placed to start the anastomosis. RP renal pelvis

Fig. 16.14 Posterior running stitch. The first running stitch demonstrated here is usually placed posteriorly as it eases anterior running stitch placement later

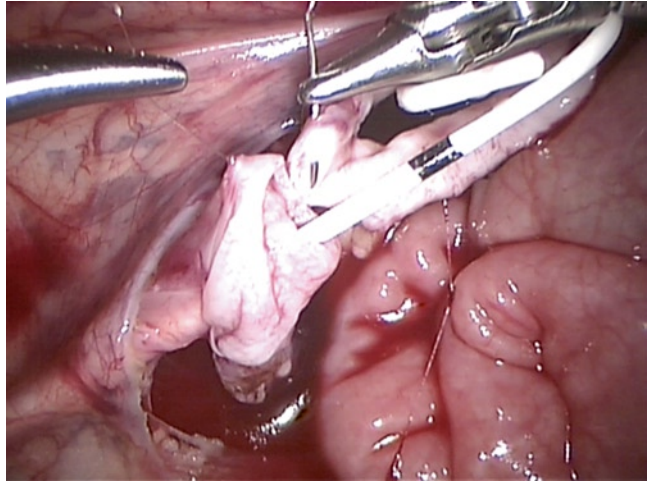


Fig. 16.15 Stent replacement. After the first running stitch is completed, the stent is replaced back into the renal pelvis

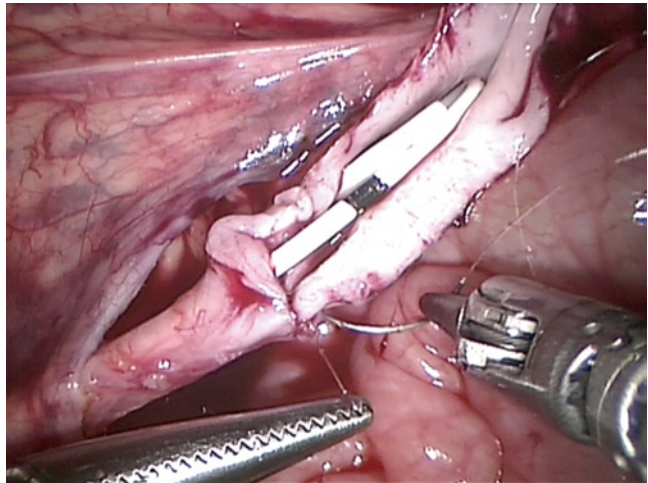


Fig. 16.16 Removal of UPJ. The UPJ is removed and sent for pathology

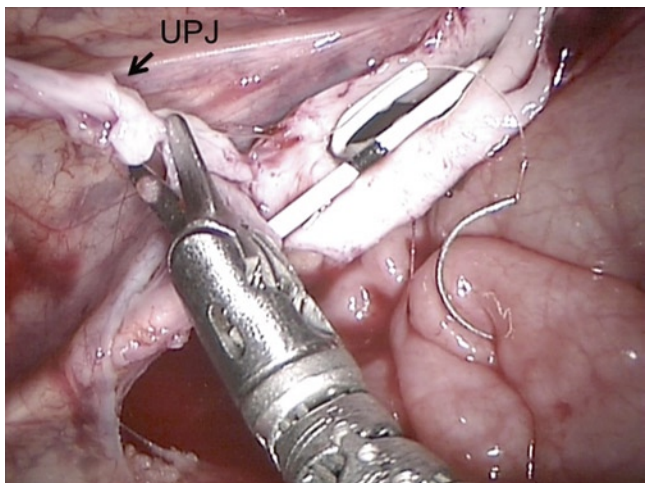


Fig. 16.17 Completion of anterior anastomosis. The anterior anastomosis is now completed. In case of a large pyelotomy, once this anastomosis is complete, the running stitch or additional sutures may be used to close the pyelotomy

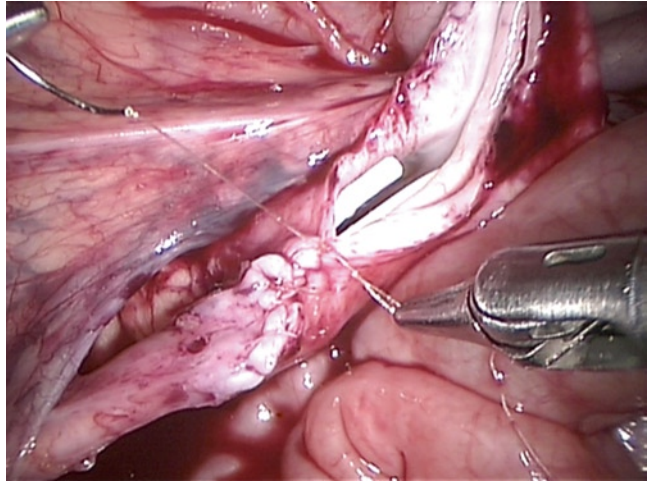
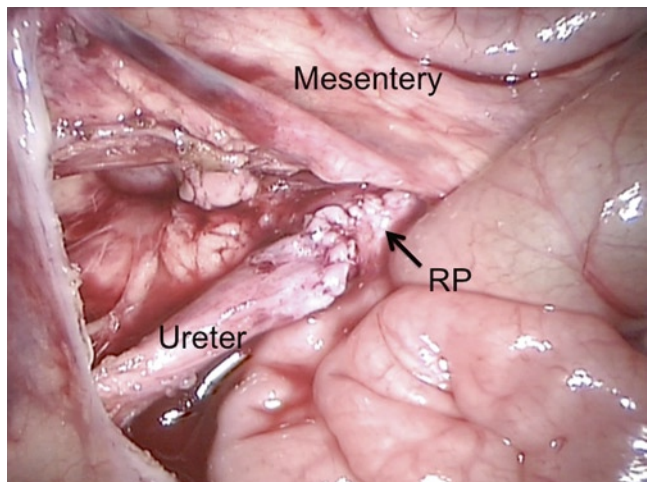


Fig. 16.18 Depiction of completed pyeloplasty. *RP* renal pelvis



Postoperative Management

Postoperatively, the patient is placed on 1.5x maintenance fluids, usually D5 ½ NS with 20 mEq potassium. He or she is started on a clear liquid diet with orders to advance as tolerated. Perioperative antibiotics (usually cefazolin 50–100 mg total over 24 h divided in three doses) are continued for 24 h. Pain control includes morphine (0.1 mg/kg IV) every 3–4 h p.r.n. pain as well as Tylenol® with codeine elixir (0.5–1 mg/kg po) every 4 h p.r.n.

pain. At our institution, we usually also place orders for oxybutynin (0.1 mg/kg po initially post-op) every 8 h p.r.n. bladder spasms as well as ondansetron (0.1 mg/kg) every 8 h p.r.n. nausea. On the morning of postoperative day 1, the oxybutynin is held and the patient's urethral catheter is removed. If a string is attached to the stent, the urethral catheter should be gently twisted to avoid dislodging the stent. Most patients are ready for discharge by the afternoon on postoperative day 1.

Special Considerations

In smaller children, transmesenteric access to the UPJ is usually readily accomplished, particularly with the aid of the “hitch-stitch.” [1] If the mesentery is thick with fat and the ureter is not easily visualized, the left colon should be reflected. For right-sided pyeloplasty, the hepatic flexure is reflected medially to expose the pelvis. In most cases, the pelvis may be exposed without using a liver retraction trocar.

Reoperative pyeloplasty follows the same steps, but may require more aggressive exposure to permit safe mobilization of the renal pelvis [2].

Steps to Avoid Complications

The major concerns specific to pyeloplasty include searching for a crossing vessel, both to avoid injury as well as recognizing its presence and determining if the ureter needs to be transposed. Patients with an intrarenal pelvis require care during mobilization of the pelvis to avoid injury to the hilar vessels. Avoid excessive mobilization of the ureter to limit devascularization and avoid excessive handling to limit edema.

Partial Nephrectomy

Patient Selection

Robotic-assisted laparoscopic partial nephrectomy in children usually involves patients who have a nonfunctioning moiety in a duplex renal system confirmed by renal nuclear medicine scan. Specific indications that would lead to discussion with the patient and parents of intervention include recurrent urinary tract infections, flank pain, or nausea/vomiting suspected to be related to the nonfunctioning moiety.

Preoperative Preparation

Bowel Preparation

All patients are asked to have a clear liquid (apple juice, Jell-o, ginger ale, water, broth) diet for 24 h before surgery to reduce the bulk of stool in the colon. They are also given one Dulcolax® suppository for the night before. They are then NPO for at least 3 h prior to the case. Specific to infants or young children is the use of milk of magnesia (cherry flavor, refrigerated) one to two teaspoons, daily for 2 days before surgery. For 3 days prior to surgery, older children are asked to use senna liquid, one to two teaspoons up to twice daily for 3 days before surgery or ex-lax® squares (chocolate covered senna): ½ to 1 square, repeating twice daily until cleaned out. Teenagers may use Dulcolax® tabs: 20 mg BID the day prior to surgery.

Informed Consent

All patients and family should understand that the procedure will be performed by the surgeon, NOT the “robot.” The da Vinci® is actually a “master–slave” micromanipulator where the operator is in total control. The robot is not in any way autonomous. Some families are concerned about this issue due to misinformation or misperceptions. The family and patient should always be made aware of the possibility of conversion to open surgery. This is emphasized to be used in cases where the ability to complete the procedure or safety are of concern. If a family is hesitant or unwilling to consent to this uncertainty, open surgery should be recommended so they know what to expect. The risks of general anesthesia must also be presented to the patient. Other risks that need to be relayed during informed consent include the possibility of continued flank pain, nausea, vomiting, recurrent urinary tracts infections, and reoperation.

Operative Setup

At our institution we use the da Vinci® with a three-armed technique. An assistant and the scrub technician are positioned on the side of the patient opposite the robot. Video monitors are placed for easy viewing by all team members. An overhead view of the room setup for right and left partial nephrectomies are shown, respectively, in Figs. 16.19 and 16.20. We recommend having a dedicated operating room for the da Vinci® system to decrease room turnover delays and possible equipment malfunction due to transporting the robot from one room to another.

Patient Positioning and Preparation

Place the patient in modified flank position with a 30° wedge under the ipsilateral side where the partial nephrectomy will be performed with padding and tape across chest and thighs. Also, place folded towels and tape over the patient's arms but under abdomen (Fig. 16.21). Rotate the table so that the patient's abdomen is flat while obtaining

trocars access, then rotate to 60° (30° wedge plus 30° table rotation) just prior to docking the robot. The anesthesia team should place an NG or OG tube prior to access.

Trocar Configuration

Trocar configurations for left and right partial nephrectomies are shown in Figs. 16.22 and 16.23. One notable difference is the possibility of needing an extra trocar for liver retraction during a right partial nephrectomy. Again, we typically use the 5 mm trocars when the patient is younger than 8–10, otherwise the 8 mm trocars are used.

Instrumentation and Equipment List

Equipment

- da Vinci® Surgical System (3-arm system; Intuitive Surgical, Inc., Sunnyvale, CA)

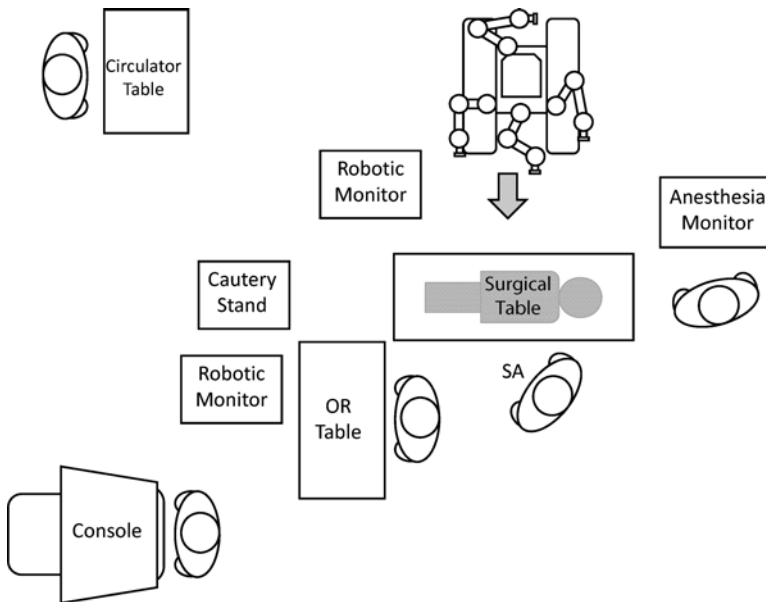


Fig. 16.19 Operating room setup for right partial nephrectomy demonstrating standard configuration of operating room personnel and equipment

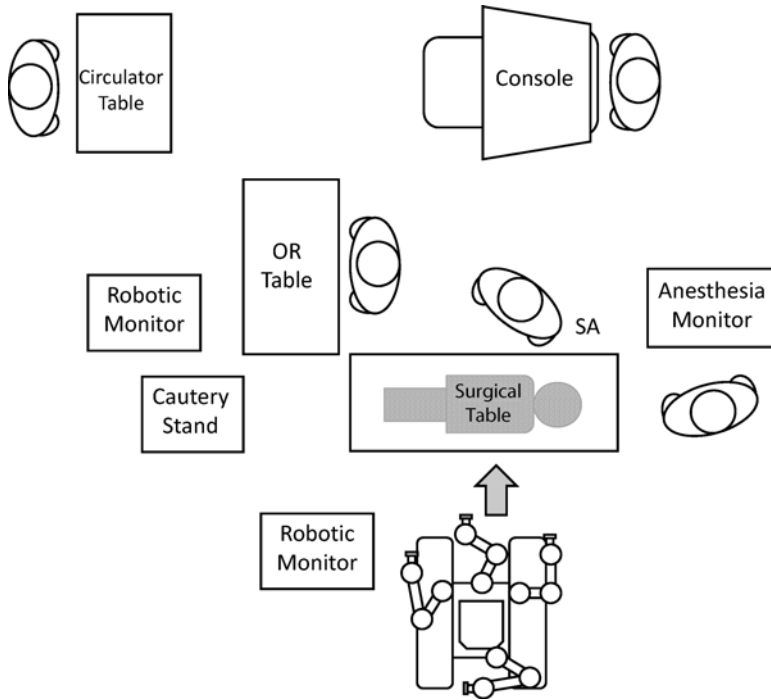


Fig. 16.20 Operating room setup for left partial nephrectomy demonstrating standard configuration of operating room personnel and equipment

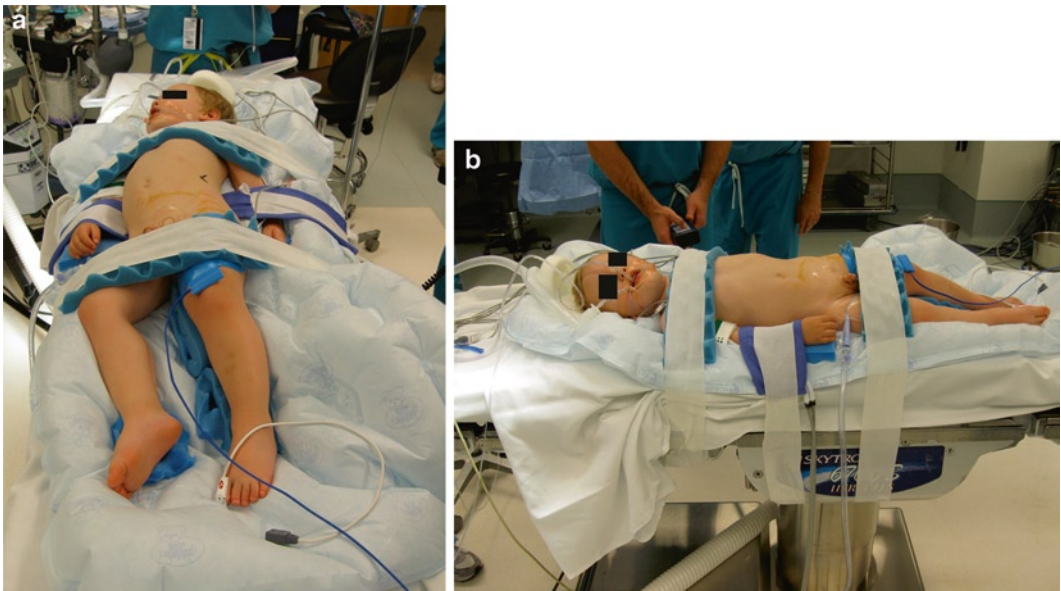
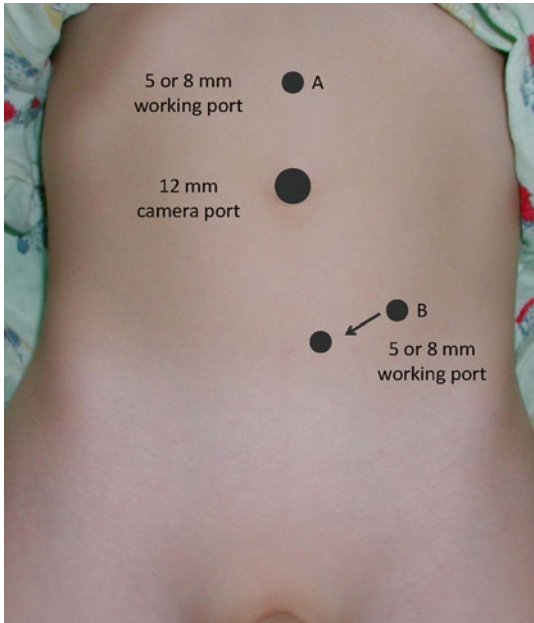


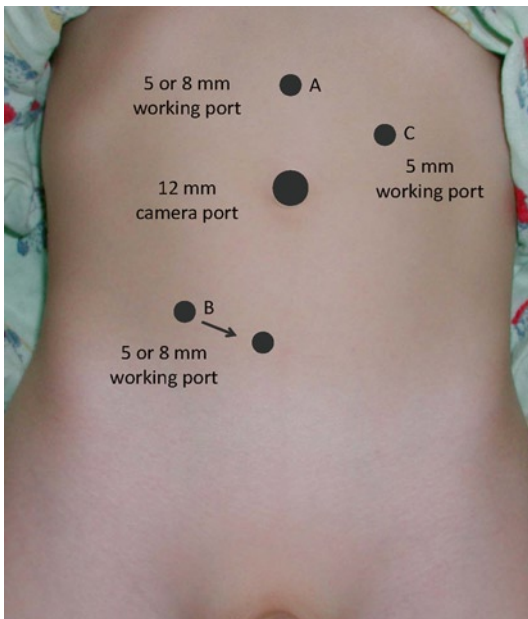
Fig. 16.21 Patient positioning shown for a left partial nephrectomy. (a) Inferior view. (b) Side view



Working Port A is roughly half the distance between the umbilicus and the xiphoid

Working Port B is roughly $\frac{2}{3}$ the distance between the umbilicus and the anterior superior iliac spine (ASIS), but if the area of interest is in the lower retroperitoneum or the child is small, may be adjusted medially and inferiorly

Fig. 16.22 Trocar configuration for left partial nephrectomy



Working Port A is roughly half the distance between the umbilicus and the xiphoid

Working Port B is roughly $\frac{2}{3}$ the distance between the umbilicus and the anterior superior iliac spine (ASIS), but if the area of interest is in the lower retroperitoneum or the child is small, may be adjusted medially and inferiorly

Working Port C is for retraction of the liver

Fig. 16.23 Trocar configuration for right partial nephrectomy

- EndoWrist® Monopolar Hook Electrocautery, 5 or 8 mm (Intuitive Surgical, Inc., Sunnyvale, CA)
- EndoWrist® Maryland Dissector, 5 or 8 mm (Intuitive Surgical, Inc., Sunnyvale, CA)
- EndoWrist® DeBakey Forceps, 5 or 8 mm (Intuitive Surgical, Inc., Sunnyvale, CA)
- EndoWrist® Curved Monopolar Scissors, 8 mm (Intuitive Surgical, Inc., Sunnyvale, CA)

- EndoWrist® Round Tip Scissors, 5 or 8 mm (Intuitive Surgical, Inc., Sunnyvale, CA)
- EndoWrist® Needle Driver, 5 or 8 mm (Intuitive Surgical, Inc., Sunnyvale, CA)
- InSite® Vision System with 30° lens (Intuitive Surgical, Inc., Sunnyvale, CA)

Trocars

- 12 mm trocar
- 8 mm robotic trocars (2, only if child is older than 8–10)
- 5 mm trocar (usually 2, if you need liver retraction during a right partial nephrectomy then you will need 3)

Recommended sutures:

- Preplaced fascial box stitch: 2-0 or 3-0 polyglactin suture
- Vessel ligation and closure of renal defect: 3-0 and/or 4-0 polyglactin suture, length 12–14 cm by age
- Skin Closure: 4-0 or 5-0 monocrlyl suture

Instruments used by the surgical assistant:

- Laparoscopic needle driver
- Laparoscopic scissors
- Maryland grasper
- Suction irrigator device
- Laparoscopic Kittner
- 5 mm titanium clip applier, medium (two are always kept in room)

Step-by-Step Technique

Step 1: Abdominal access and trocar placement

For a right partial nephrectomy, reposition the patient in a right modified flank position as noted above then, for trocar placement, rotate the table so the patient's abdomen is 0°. The 12 mm camera trocar is placed in the area of the umbilicus, using the Hasson open technique with 2-0 polyglactin suture on a UR-6 needle or a 3-0 polyglactin suture on a CT-2 needle bent accordingly. These are pre-placed fascial box stitches (used later for closure). Working trocars are then placed sharply under direct vision after pre-placing the fascial

box stitches. For right-sided operation, a fourth trocar is placed for liver retraction. This trocar is placed in the left upper quadrant to permit passing between the camera and upper working trocar without interference and to lift the liver for exposure. Either a blunt Kittner dissector or a grasping tool is passed under the liver edge, lifted and pushed against the opposite abdominal sidewall to stabilize the instrument and liver. Rotate the patient to approximately 60° (30° from table rotation and 30° from the wedge placed earlier) and dock the robot.

Step 2: Accessing the nonfunctioning moiety

Surgeon instrumentation		Assistant instrumentation
Right arm	Left arm	<ul style="list-style-type: none"> • Suction-irrigator • Laparoscopic Kittner
• Monopolar hook electrocautery	• Maryland dissector	
Endoscope lens: 30° down		

Reflect the colon away from the renal hilum and upper pole to permit full exposure of the upper aspect of the kidney (for upper pole partial) (Fig. 16.7). Expose the affected ureter at the lower pole of the kidney and separate it from the lower pole ureter carefully (Fig. 16.24). The dilated upper pole ureter is then dissected upward and under the hilar vessels with care. It must be sufficiently mobilized to permit being passed under the vessels (Fig. 16.25).

Step 3: Transection of ureter and vessels to nonfunctioning pole

Surgeon instrumentation		Assistant instrumentation
Right arm	Left arm	<ul style="list-style-type: none"> • Suction-irrigator • Laparoscopic Kittner • Laparoscopic needle driver
• Needle driver	• Maryland dissector	
• Round tip scissors		
Endoscope lens: 30° down		

Once mobilized, the ureter is ligated with polyglactin suture unless markedly dilated. If maintained somewhat distended, future dissection will be easier. The affected ureter is then transected between sutures and mobilized under the vessels and used to expose the upper pole (Fig. 16.26). This permits better identification of the upper pole vessels and subsequent control. Vessels supplying the upper pole may be clipped or ligated with silk suture (Fig. 16.27). It is

Fig. 16.24 Exposure of the upper and lower pole collecting systems. Here the lower pole (LP) and upper pole (UP) are seen as well as the renal pelvis and hilar vessels

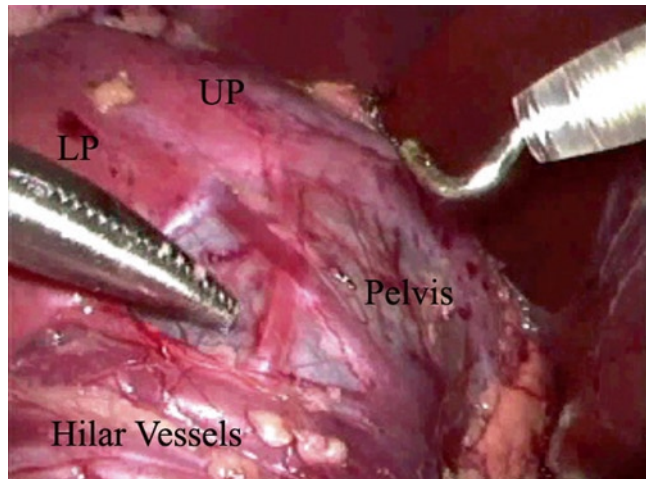


Fig. 16.25 Dissection of upper pole (UP) ureter under hilar vessels. Start this dissection distal to the hilar vessels where the upper pole ureter is obvious and work superiorly. *LP* lower pole

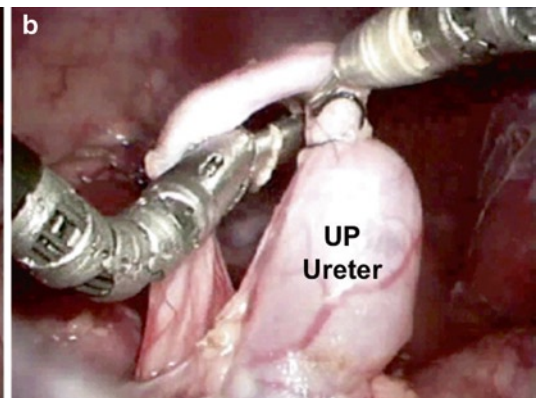
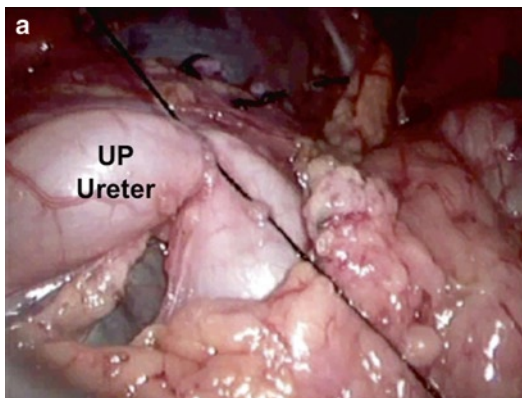
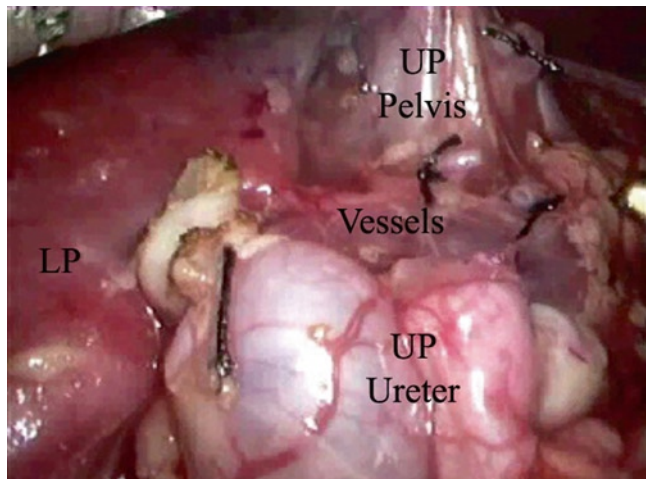


Fig. 16.26 Transection and ligation of the upper pole ureter. Keeping the upper pole ureter dilated helps with identification of the upper pole and further mobiliza-

tion and dissection. *UP* upper pole. (a) Ligation of the upper pole ureter; (b) Transection of the upper pole ureter

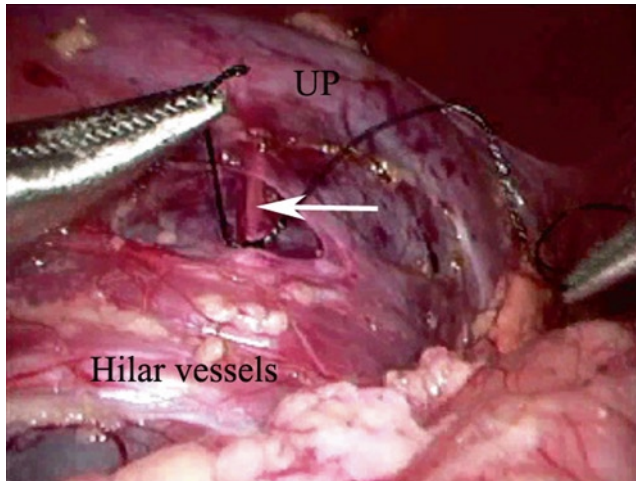


Fig. 16.27 Ligation of the upper pole vessels. The arrow denotes a small upper pole segmental vessel being ligated with silk sutures. *UP* upper pole

important to assess the effect of vessel ligation each time and make sure there are no lower pole collaterals being clipped.

Step 4: Dissection of nonfunctioning moiety

Surgeon instrumentation		Assistant instrumentation
Right arm	Left arm	
• Monopolar hook electrocautery	• Maryland dissector	• Suction-irrigator • Laparoscopic Kittner
Endoscope lens: 30° down		

Once the vessels and ureter are controlled, the affected upper pole is dissected free by establishing the plane between the upper pole collecting system and the lower pole parenchyma. This usually leaves a rim of tissue that is easily transected with electrocautery (Fig. 16.28).

Step 5: Closure of defect

Surgeon instrumentation		Assistant instrumentation
Right arm	Left arm	
• Needle driver • Round tip scissors	• Maryland dissector	• Suction-irrigator • Laparoscopic Kittner • Laparoscopic needle driver
Endoscope lens: 30° down		

Once the affected pole is removed, the defect is closed using 2-3 polyglactin mattress sutures over a bolster of local fat (Fig. 16.29). If the

lower pole collecting system is violated, it is closed and a drain is left in place, otherwise there is no drain used.

Step 6: Further dissection and removal of affected ureter

Surgeon instrumentation		Assistant instrumentation
Right arm	Left arm	
• Monopolar hook electrocautery • Needle driver • Round tip scissors	• Maryland dissector	• Suction-irrigator • Laparoscopic Kittner • Laparoscopic needle driver
Endoscope lens: 30° down		

The affected ureter is resected as low as convenient, which is usually to the iliac vessels. It is tied off with polyglactin suture if refluxing (clips are not secure), or left open if obstructed without reflux (Fig. 16.30). If refluxing and obstructed, it should be ligated as close to the bladder neck as possible. This may require re-positioning the robot.

Step 7: Exiting the abdomen

The operative area is irrigated, cleared, and inspected. The robot is undocked. Trocars are removed under direct vision. The two specimens (nonfunctioning moiety and ureter) are removed through the umbilical trocar. Preplaced fascial

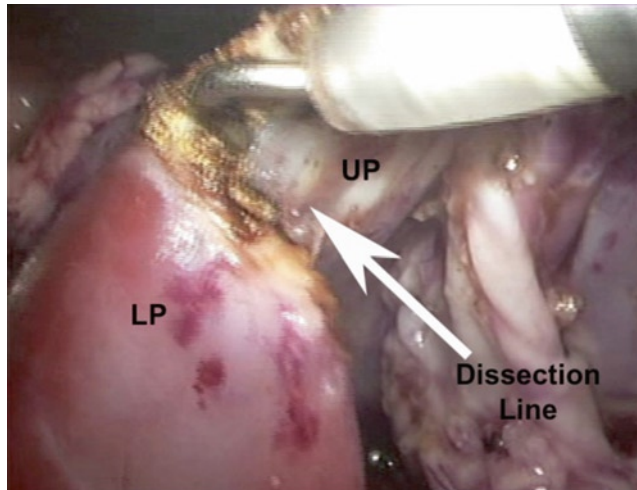


Fig. 16.28 Dissection of upper pole collecting system. Arrow indicates location of plane between the upper pole collecting system and the lower pole parenchyma. *UP* upper pole, *LP* lower pole

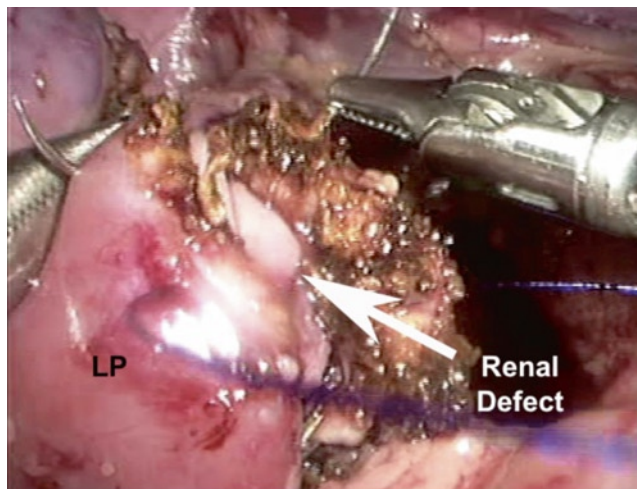


Fig. 16.29 Closure of renal defect. Arrow indicates bolster of retroperitoneal fat. *LP* lower pole

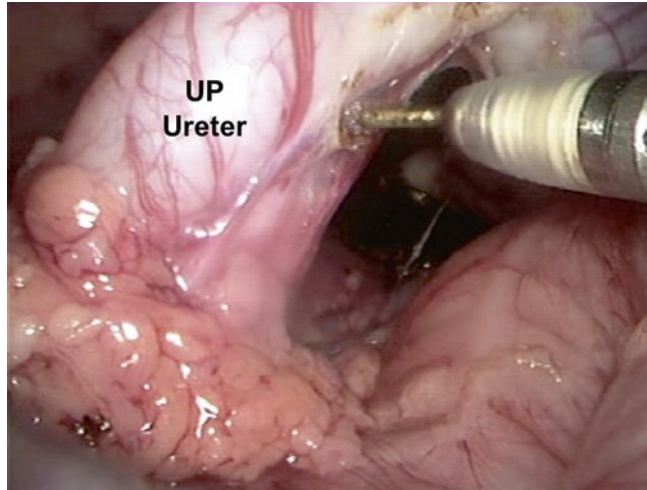
box stitches are tied, and a subcuticular Monocryl suture is used for skin closure.

Postoperative Management

Postoperatively, the patient is placed on 1.5x maintenance fluids, usually D5 ½ NS with 20 mEq potassium. He or she is started on a clear liquid diet

with orders to advance as tolerated. Perioperative antibiotics (usually cefazolin 50–100 mg total over 24 h divided in 3 doses) are continued for 24 h. Pain control includes morphine (0.1 mg/kg IV) every 3–4 h p.r.n. pain as well as Tylenol® with codeine elixir (0.5–1 mg/kg po) every 4 h p.r.n. pain. At our institution, we usually also place orders for oxybutynin (0.1 mg/kg po initially post-op) every 8 h p.r.n. bladder spasms as well as ondansetron (0.1 mg/kg) every 8 h p.r.n. nausea. The urethral catheter is

Fig. 16.30 Resection of affected ureter. Resection is performed by lifting ureter as shown here and progressively releasing attachments with hook electrocautery. UP upper pole



removed prior to leaving the operating room. If a drain is placed, it is monitored to ensure low output and is then usually removed on the morning of post-op day 1. Most patients are ready for discharge by midday on post-op day 1.

Special Considerations

Lower pole partial nephrectomy is performed in a similar manner, usually for lower pole reflux with nonfunction. The ureter is more easily controlled, but similar care must be taken to avoid upper pole vessel injury. Some authors use a ureteral catheter in the remnant pole to inject blue dye to identify collecting system leaks, but we have not found this to be necessary. The ability to efficiently close the polar defect has eliminated the occurrence of urinomata that have been reported in laparoscopic partial nephrectomy when the polar defect is not closed [3].

Handling of the distal ureter is based on practicality in terms of the extent of resection. Some authors claim it is important to remove as much as possible, but there are few data to indicate a real risk of complications with the exception of a refluxing and obstructed segment. If it is felt that entire removal of the ureter is needed, or if it is necessary to perform a contralateral anti-reflux operation, the robotic system is re-docked in the

lower position for bladder access and the dissection performed.

Steps to Avoid Complications

The most significant complication for partial nephrectomy in children with duplication anomalies is injury to the lower pole, usually through vascular injury or spasm. Great care must be taken to minimize manipulation of the hilar vessels and to carefully identify the vessels associated with the affected pole. They may be small and branched or a single vessel. Observation of the color of the remnant pole is useful to avoid inadvertent clamping of the remnant vessels. Vessels can be tied or clipped. Papaverine solution can be instilled through a long laparoscopic needle if spasm is evident.

Anti-reflux Surgery

Patient Selection

Patients with vesicoureteral reflux (VUR) initially come to our attention because of either a prenatal finding of hydronephrosis or a febrile urinary tract infection in the first few years of life.

If not already done, initial workup includes a renal ultrasound and VCUG. Prophylactic antibiotics are usually recommended at least until the above mentioned studies are done. Once the diagnosis of reflux is established, treatment options include surveillance, surveillance with prophylactic antibiotics, and anti-reflux surgery. In general, conservative measures are initially employed and if those fail (e.g., breakthrough febrile urinary tract infections on prophylactic antibiotics), anti-reflux surgery is discussed. At all interactions during the course of patient care the patient and parents are educated on the nature of reflux and treatment options so they may make educated decisions. At our institution, anti-reflux surgery is most often approached by robotic-assisted laparoscopic extravesical ureteral reimplant.

Preoperative Preparation

Bowel Preparation

All patients are asked to have a clear liquid (apple juice, Jell-o, ginger ale, water, broth) diet for 24 h before surgery to reduce the bulk of stool in the colon. They are also given one Dulcolax[®] suppository for the night before. They are then NPO for at least 3 h prior to the case. Specific to infants or young children is the use of milk of magnesia (cherry flavor, refrigerated) one to two teaspoons, daily for 2 days before surgery. For 3 days prior to surgery, older children are asked to use senna liquid, one to two teaspoons up to twice daily for 3 days before surgery or ex-lax[®] squares (chocolate covered senna): ½ to 1 square, repeating twice daily until cleaned out. Teenagers may use Dulcolax[®] tabs: 20 mg BID the day prior to surgery.

Informed Consent

All patients and family should understand that the procedure will be performed by the surgeon, NOT the “robot.” The da Vinci[®] is actually a “master–slave” micromanipulator where the operator is in total control. The robot is not in any

way autonomous. Some families are concerned about this issue due to misinformation or misperceptions. The family and patient should always be made aware of the possibility of conversion to open surgery. This is emphasized to be used in cases where the ability to complete the procedure or safety are of concern. If a family is hesitant or unwilling to consent to this uncertainty, open surgery should be recommended so they know what to expect. The risks of general anesthesia must also be presented to the patient. Other risks that need to be relayed during informed consent include the realization that renal function could remain the same or even worsen after surgery. Continued flank pain, nausea, vomiting, recurrent urinary tract infections, and the possibility of reoperation also need to be discussed.

Operative Setup

At our institution we use the da Vinci[®] with a three-armed technique. An assistant and the scrub technician are positioned on opposite sides of the table and the robot is brought in from the direction of the patient’s feet. Video monitors are placed for easy viewing by all team members. An overhead view of the room setup for ureteral reimplant is shown in Fig. 16.31. We recommend having a dedicated operating room for the da Vinci[®] to decrease room turnover delays and possible equipment damage due to transporting the robot from one room to another.

Patient Positioning and Preparation

Initially, frog leg the patient (Fig. 16.32) to prep and place urethral catheter on sterile field, place rectal tube for decompression, then adjust legs to have patient in supine position for obtaining access (Fig. 16.33). Place padding and tape across chest and lower thighs and place a blue towel and tape over arms but under abdomen. The anesthesia team should place an NG or OG tube prior to access.

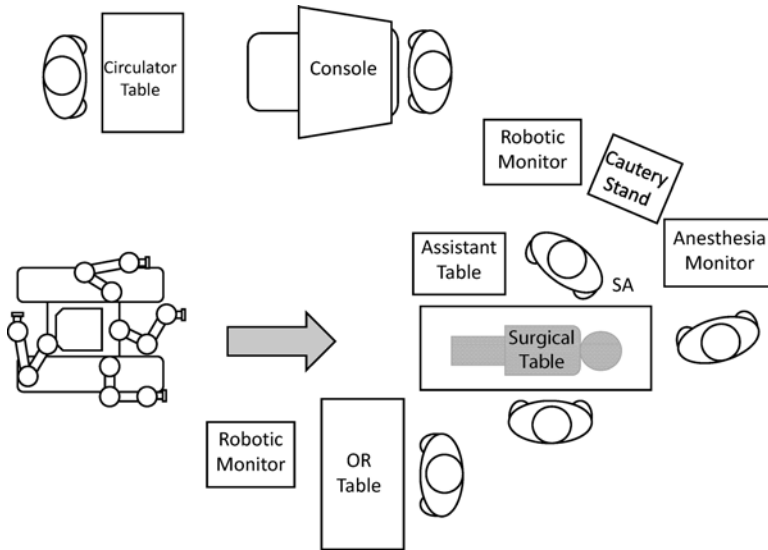


Fig. 16.31 Operating room setup for extravesical ureteral reimplant demonstrating standard configuration of operating room personnel and equipment

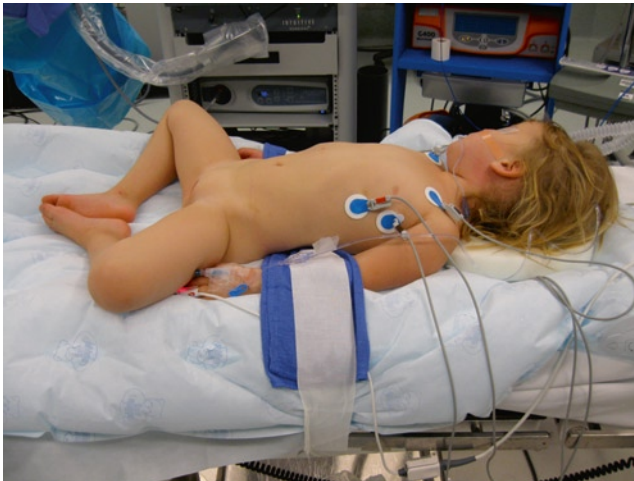

Fig. 16.32 Initial positioning for reimplant. “Frog leg” positioning helps with initial placement of urethral catheter on the sterile field in female patients

Trocar Configuration

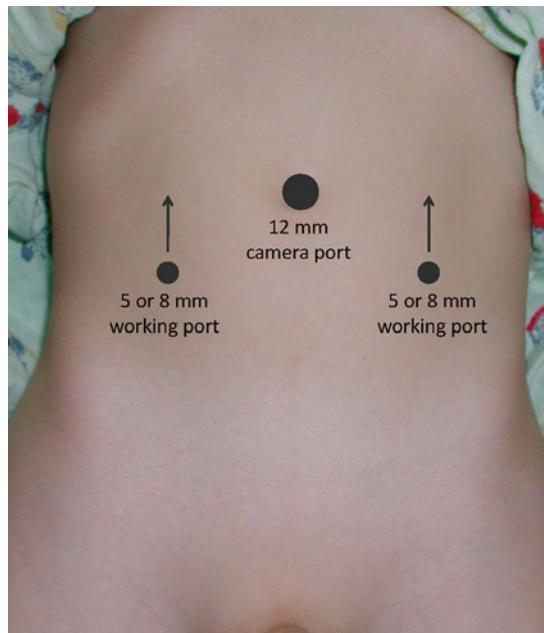
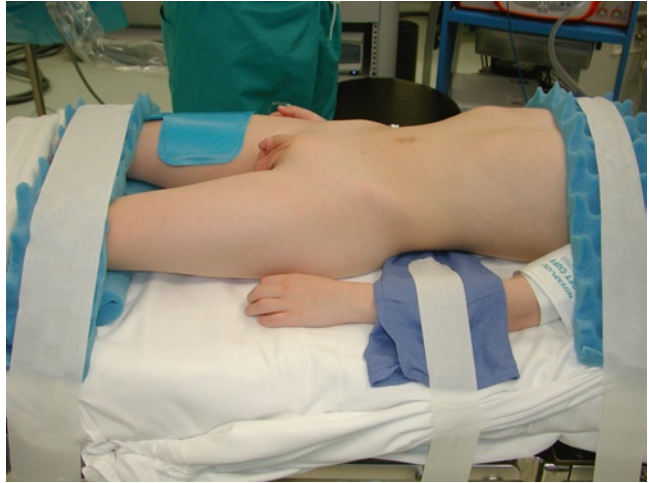Trocar configuration for an extravesical ureteral reimplant is shown in (Fig. 16.34). The 5 mm trocars are typically used when the patient is younger than 8–10, otherwise the 8 mm trocars are used. Adjust the patient to steep Trendelenburg position prior to docking robot.

Instrumentation and Equipment List

Equipment

- da Vinci® Surgical System (3-arm system; Intuitive Surgical, Inc., Sunnyvale, CA)
- EndoWrist® Monopolar Hook Electrocautery, 5 or 8 mm (Intuitive Surgical, Inc., Sunnyvale, CA)

Fig. 16.33 Final positioning for reimplant. After catheter is placed, the patient is readjusted to the supine position



Working Ports are roughly $\frac{2}{3}$ the distance between the umbilicus and the anterior superior iliac spine (ASIS). In small infants, the working ports should be moved more superiorly to prevent restrictive proximity to bladder and ureters.

Fig. 16.34 Trocar configuration for extravesical ureteral reimplant

- EndoWrist® Maryland Dissector, 5 or 8 mm (Intuitive Surgical, Inc., Sunnyvale, CA)
- EndoWrist® DeBakey Forceps, 5 or 8 mm (Intuitive Surgical, Inc., Sunnyvale, CA)
- EndoWrist® Curved Monopolar Scissors, 8 mm (Intuitive Surgical, Inc., Sunnyvale, CA)
- EndoWrist® Round Tip Scissors, 5 or 8 mm (Intuitive Surgical, Inc., Sunnyvale, CA)
- EndoWrist® Needle Driver, 5 or 8 mm (Intuitive Surgical, Inc., Sunnyvale, CA)
- InSite® Vision System with 30° lens (Intuitive Surgical, Inc., Sunnyvale, CA)

Trocars

- 12 mm trocar
- 8 mm robotic trocars (2, only if child is older than 8–10)
- 5 mm trocar (2)

Recommended sutures:

- Preplaced fascial box stitch: 2-0 or 3-0 polyglactin suture
- Hitch stitch: 3-0 or 4-0 polyglactin
- Bladder mucosal tears: 6-0 chromic, 14 cm length
- Detrusor tunnel: 4-0 polyglactin, 14 cm length
- Skin closure: 4-0 or 5-0 monocryl suture

Instruments used by the surgical assistant:

- Maryland grasper
- Suction irrigator device

Step-by-Step Technique

Step 1: Abdominal access and trocar placement

As noted above, the urethral catheter may be easily placed on the sterile field prior to adjusting the patient from frog-legged to supine position. The 12 mm camera trocar is placed in the area of the umbilicus, using the Hasson open technique with 2-0 polyglactin suture on a UR-6 needle or a 3-0 polyglactin suture on a CT-2 needle bent accordingly. These are pre-placed fascial box stitches (used later for closure). Working trocars are then placed sharply under direct vision after pre-placing the fascial box stitches. Dock the robot.

Step 2: Ureteral mobilization

Surgeon instrumentation		Assistant instrumentation
Right arm	Left arm	• Suction-irrigator
• Monopolar hook electrocautery	• Maryland dissector	
Endoscope lens: 30° down		

Access is transperitoneal to the posterior aspect of the bladder. The ureter is identified through the peritoneum, exposed by incising the peritoneum transversely lateral to the midline, posterior to bladder and anterior to uterus in girls (Fig. 16.35). The ureter is mobilized for about 5–6 cm proximal to UVJ (Fig. 16.36), staying close to the ureter without disrupting its adventitia.

A combination of blunt and electrocautery dissection is used.

Step 3: Placement of hitch stitch

Surgeon instrumentation		Assistant instrumentation
Right arm	Left arm	• Suction-irrigator
• Needle driver	• Maryland dissector	
Endoscope lens: 30° down		

Bladder wall is exposed and hitched upward by running a 3-0 or 4-0 polyglactin suture through the abdominal wall, the bladder then back through the abdominal wall, securing in place with a hemostat. Another option is to tie this suture to the posterior abdominal wall (Fig. 16.37).

Step 4: Creation of detrusor tunnel

Surgeon instrumentation		Assistant instrumentation
Right arm	Left arm	• Suction-irrigator
• Monopolar hook electrocautery	• Maryland dissector	
Endoscope lens: 30° down		

The ureteral hiatus is exposed enough to permit creation of the detrusor tunnel, but no more, to avoid unnecessary injury to perivesical nerves. A detrusor incision is made to the level of the mucosa to create a tunnel for the ureter. It is most efficient to begin at the top of the tunnel, farthest from the hiatus to permit identification of the depth of the mucosal layer and use this as a guide for the complete dissection. The bladder is partially filled with saline to provide wall tension, which facilitates dissection; this can be varied through the procedure depending upon the exposure (Fig. 16.38). Any puncture of the mucosa is closed with 6-0 chromic figure of eight stitch. Detrusor muscle flaps are elevated on each side of the incision, wide enough to wrap around the ureter (Fig. 16.39). At the hiatus, a V incision is made around the ureter; not circumferentially dissected. No advancement stitch is used.

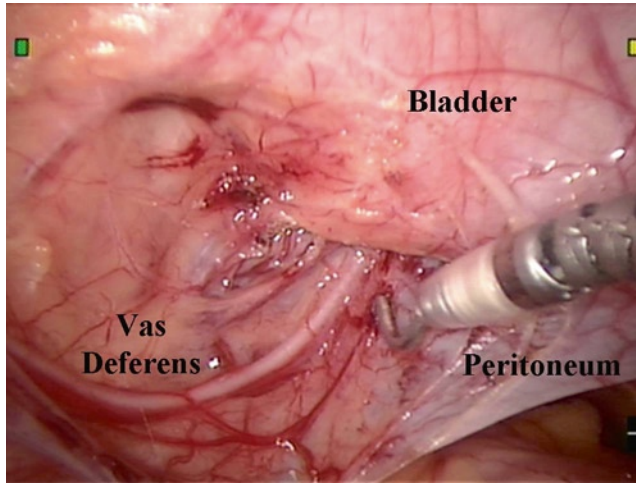


Fig. 16.35 Transperitoneal access to bladder. The peritoneum is incised just over the ureter of interest. In this picture note the peritoneum, bladder, and vas deferens

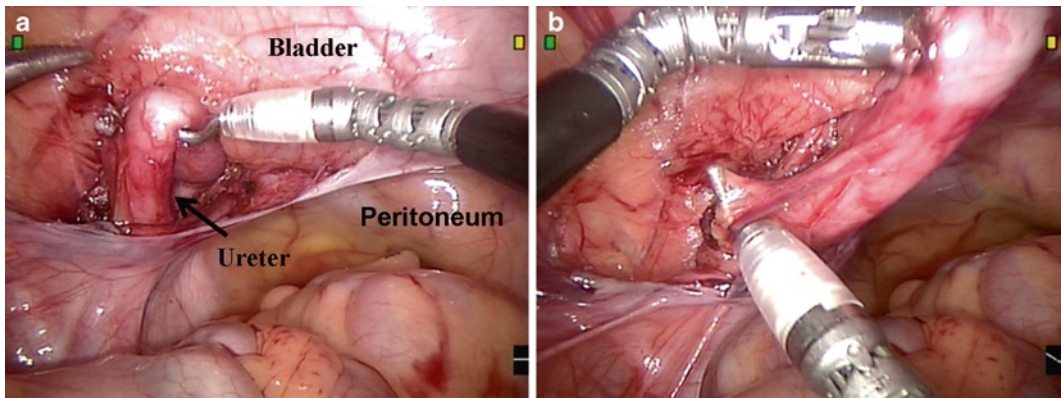


Fig. 16.36 Mobilization of ureter (a) Elevation of the ureter. (b) With the ureter elevated, lateral attachments may be cauterized away from the ureter

Step 5: Placement of ureter into tunnel

Surgeon instrumentation		Assistant instrumentation
Right arm	Left arm	<ul style="list-style-type: none"> • Suction-irrigator • Laparoscopic needle driver
<ul style="list-style-type: none"> • Needle driver • Round tip scissors 	<ul style="list-style-type: none"> • Maryland dissector 	
Endoscope lens: 30° down		

An interrupted closure of the tunnel over the ureter using 4-0 polyglactin suture (length 14 cm – three knots can be tied) is performed in one of two approaches:

- a. Distal to proximal: this necessitates passing the needle under the ureter with each stitch,

but the ureter is not in the way of suturing and the tunnel is visible for each stitch.

- b. Proximal to distal: this starts with the initial stitch that brings the ureter into the tunnel. Subsequent stitches are more easily placed, but there is limited visibility of the ureter with each stitch. The first stitch is slightly difficult to ties as the ureter is under some tension. This is best done with the ipsilateral instrument under the ureter as the knot is tied, lifting the ureter into the tunnel (Fig. 16.40).

Usually four to six stitches are placed, creating a tunnel of 2.5–3.5 cm. The robotic needle holder

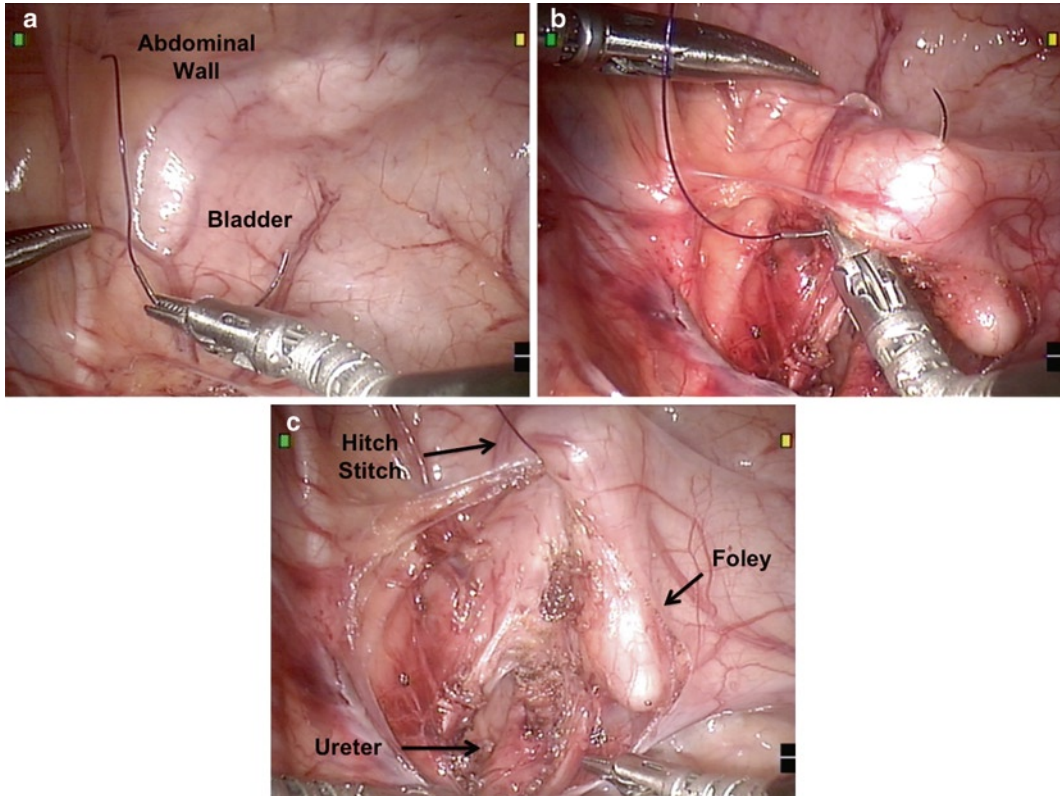


Fig. 16.37 Hitch stitch in bladder. (a) Insertion of hitch stitch. (b) Placement through the bladder just above the ureter of interest. (c) The bladder is then elevated as shown

may be used to estimate tunnel length (Figs. 16.41 and 16.42).

Step 6: Reapproximation of the peritoneum

The hitch stitch may now be removed. The peritoneum is closed with a running 4-0 polyglactin suture (Fig. 16.43).

Step 7: Exiting the abdomen

The operative area is irrigated, cleared, and inspected. The robot is undocked. Trocars are removed under direct vision, the preplaced fascial box stitches are tied, and a subcuticular Monocryl suture is used for skin closure.

Postoperative Management

Postoperatively, the patient is placed on 1.5x maintenance fluids, usually D5 ½ NS with 20 mEq

potassium. He or she is started on a clear liquid diet with orders to advance as tolerated. Perioperative antibiotics (usually cefazolin 50–100 mg total over 24 h divided in three doses) are continued for 24 h then prophylactic antibiotics are continued until at least the first follow-up clinic visit. Pain control includes morphine (0.1 mg/kg IV) every 3–4 h p.r.n. pain as well as Tylenol® with codeine elixir (0.5–1 mg/kg po) every 4 h p.r.n. pain. At our institution, we usually also place orders for ondansetron (0.1 mg/kg) every 8 h p.r.n. nausea. The urethral catheter is removed prior to leaving the operating room. Most patients are ready for discharge by midday on postoperative day 1.

Special Considerations

This method can be used for duplex ureters as long as a slightly wider dissection of the detrusor flaps is performed. This method has also been used for

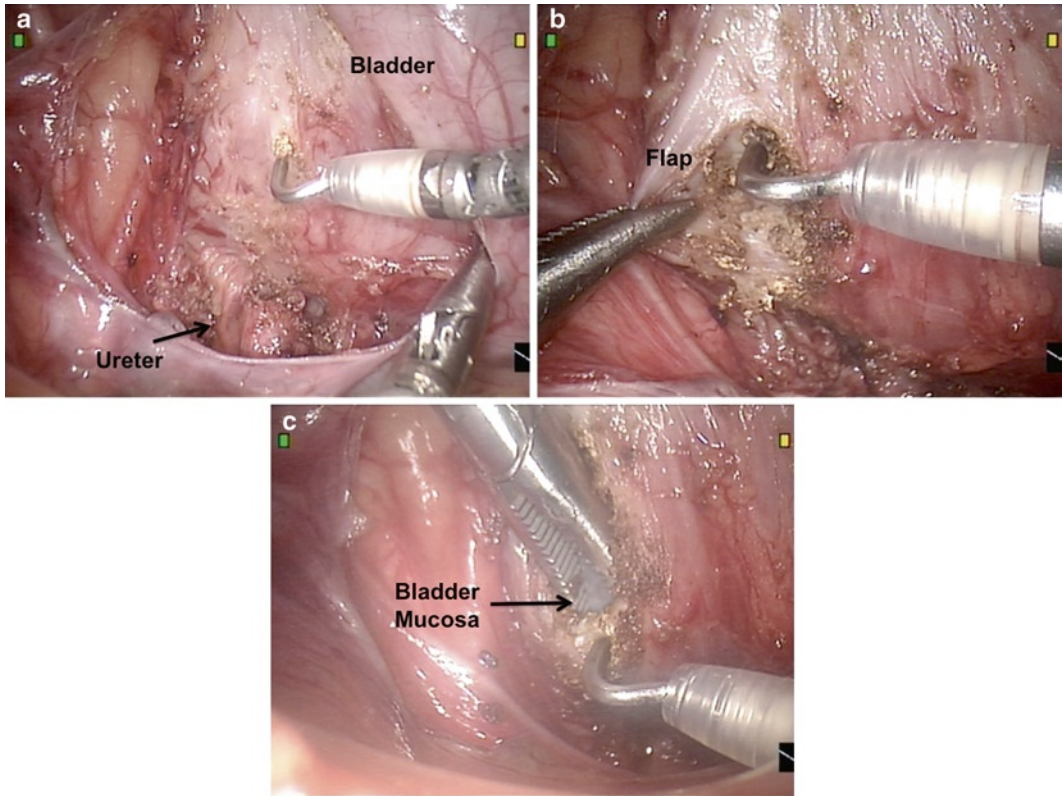


Fig. 16.38 Creation of detrusor tunnel. (a) With the bladder partially filled, an outline of the tunnel is scored. (b) The Maryland dissector is used to help manipulate the detrusor flaps as dissection is continued. (c) Here

the tunnel is almost complete. Notice the bluish hue of the mucosa. The Maryland dissector can sometimes be gently placed between the mucosa and detrusor muscle to further flap creation

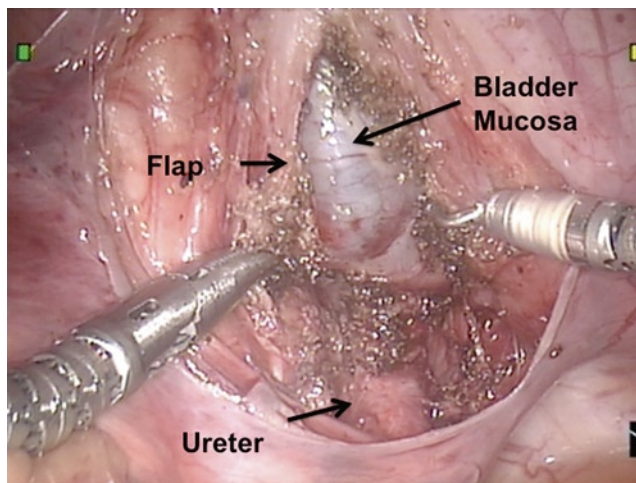


Fig. 16.39 Elevation of detrusor flaps The mucosa is gently pushed away from the detrusor muscle to augment the flaps

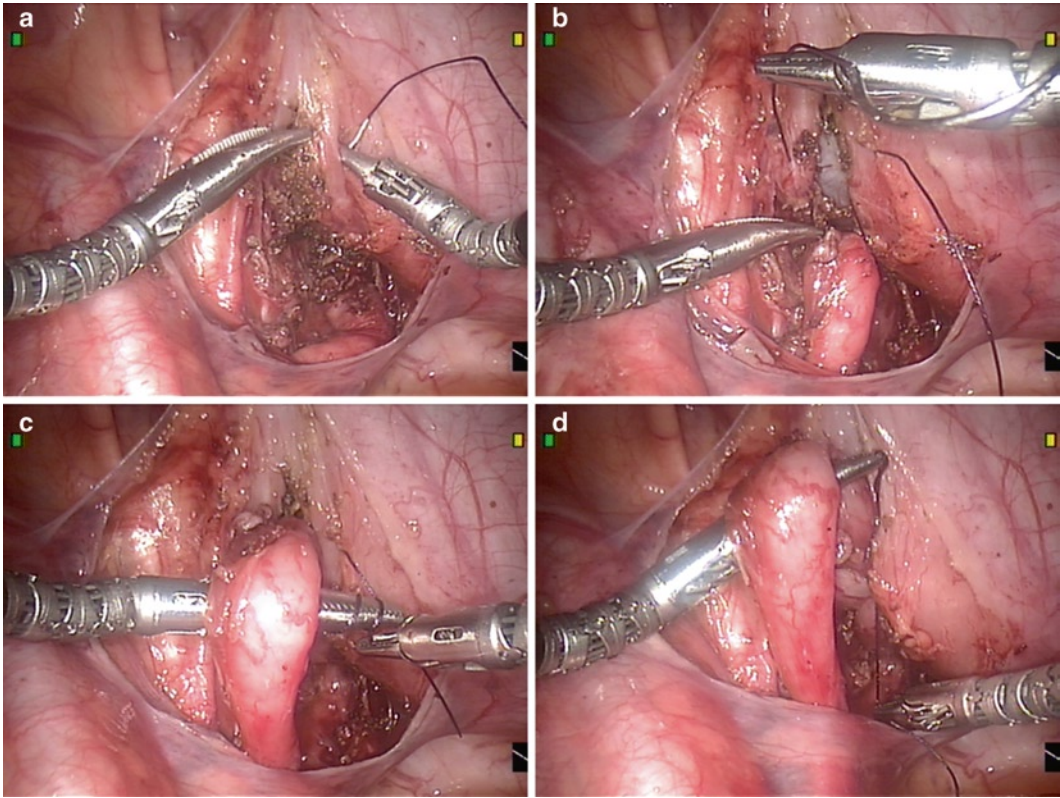


Fig. 16.40 Initiation of proximal to distal closure of tunnel. (a) Beginning of proximal to distal closure. (b) The stitch has now been placed under the ureter and through

the lateral detrusor flap. (c) One way to keep the ureter elevated while tying this stitch is to place the ipsilateral robotic arm under the ureter. (d) Completion of first stitch

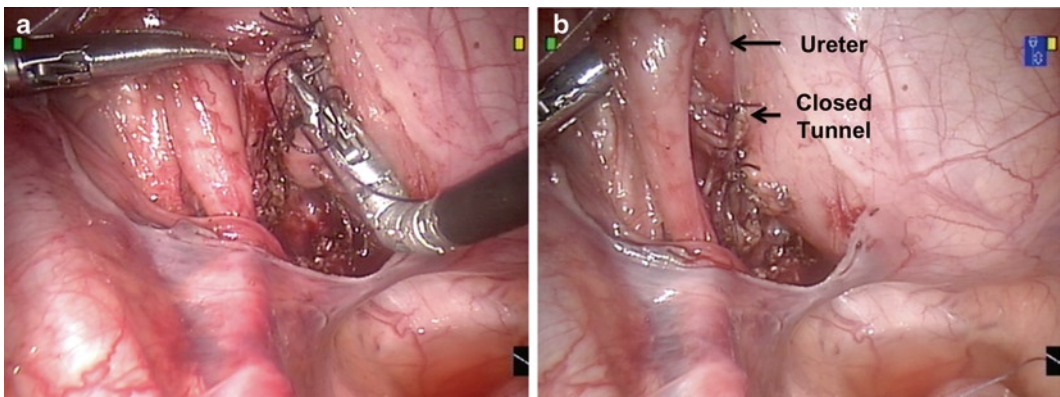


Fig. 16.41 Closure of tunnel. (a) After the most proximal stitch is placed, the other interrupted stitches used to close the tunnel fall easily in place. (b) Closure of the tunnel shown. Left arm (Maryland dissector) shown lifting up ureter

dilated ureters with both plication and excisional tapering, with resection of the obstructive distal segment. The manipulative ability is not as efficient as might be desired and the utility is uncertain.

Intravesical transtrigonal ureteral reimplantation has been performed as well as the extravesical technique, although it is more challenging and results have not been as robust [4].

Fig. 16.42 Tunnel length. The robotic needle driver may be used to approximate tunnel length

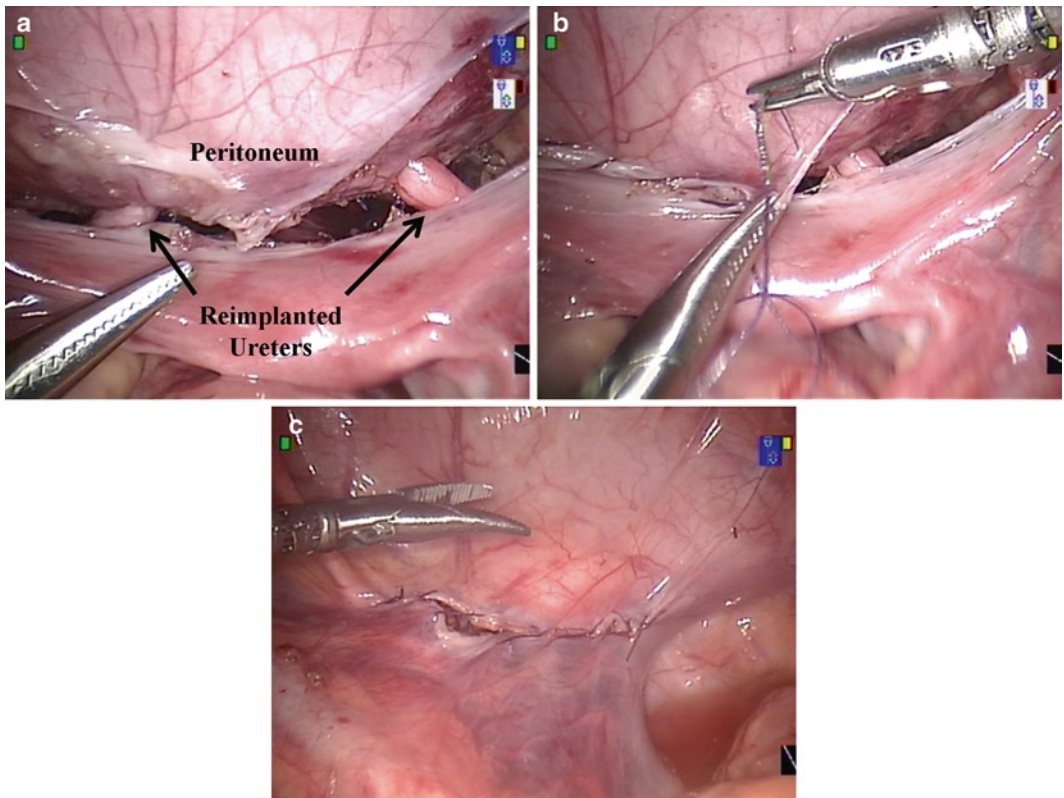
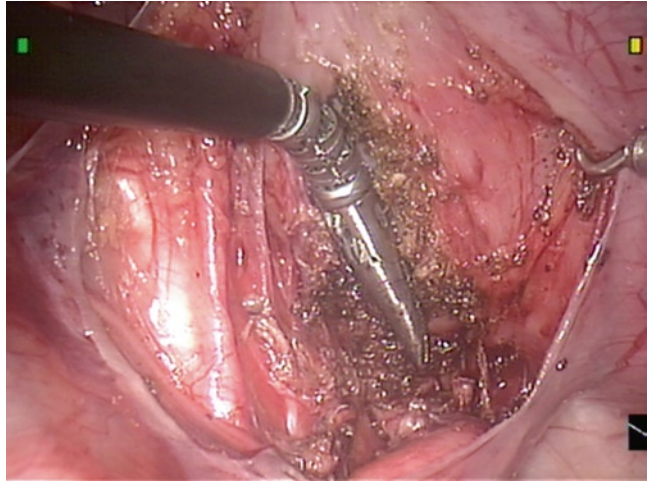


Fig. 16.43 Peritoneal closure. (a) Peritoneal defect shown on a patient with bilateral extravasical ureteral reimplants. (b) Initiation of running suture. (c) Completion of closure

Steps to Avoid Complications

Protection of the vas deferens in boys is important. The peritoneum is incised beyond the vas and the vas is retracted by sweeping the

peritoneum, rather than the vas itself. Continue to monitor the location of the vas throughout the procedure, particularly at the hiatal dissection where the vas is looping around the ureter medially [5].

No stents are left in place in most cases, but a double-J stent would be placed for a solitary kidney.

Due to the risk of postoperative urinary retention following bilateral extravesical anti-reflux surgery, attempts have been made to perform a nerve-sparing procedure [6]. While the presumed cause of retention is neural injury, this has not been proven and the local nerves are not macroscopically visible, nor associated with a marker structure as in the periprostatic nerves. The most efficient approach is to stay as close to the ureters as possible with limited extra dissection. Even so the risk is present. Our experience has been to leave the bladder catheter in overnight, and if the first voiding trial fails, to discharge the child home with a catheter to be removed in 3–5 days. The incidence of retention is lower than for open surgery, but not likely to be absent.

References

1. Lee RS, Retik AB, Borer JG, Peters CA (2006) Pediatric robot assisted laparoscopic dismembered pyeloplasty: comparison with a cohort of open surgery. *J Urol* 175:683–7, discussion 7
2. Passerotti CC, Nguyen HT, Eisner BH, Lee RS, Peters CA (2007) Laparoscopic reoperative pediatric pyeloplasty with robotic assistance. *J Endourol* 21:1137–40
3. Lee RS, Sethi AS, Passerotti CC et al (2009) Robot assisted laparoscopic partial nephrectomy: a viable and safe option in children. *J Urol* 181:823–8, discussion 8–9
4. Peters CA, Woo R (2005) Intravesical robotically assisted bilateral ureteral reimplantation. *J Endourol* 19:618–21, discussion 21–2
5. Passerotti C, Peters CA (2006) Pediatric robotic-assisted laparoscopy: a description of the principle procedures. *Sci World J* 6:2581–8
6. Casale P, Patel RP, Kolon TF (2008) Nerve sparing robotic extravesical ureteral reimplantation. *J Urol* 179:1987–9, discussion 90

Index

A

- Abdominal insufflation, 124
- AcuBot robot, 8–9
- Adrenalectomy
 - partial (*see* Partial adrenalectomy)
 - total (*see* Total adrenalectomy)
 - transperitoneal (*see* Transperitoneal adrenalectomy)
- Advanced robotic telemanipulator for minimally invasive surgery (ARTEMIS), 4
- AESOP. *See* Automated endoscopic system for optimal positioning
- Anti-reflux surgery
 - abdominal access and trocar placement, 260
 - bowel preparation, 257
 - complications, 265–266
 - detrusor tunnel creation, 260, 263
 - fascial closure, 262
 - hitch stitch placement, 260, 262
 - informed consent, 257
 - instrumentation and equipment list, 258–260
 - operative setup, 257, 258
 - patient positioning and preparation, 257–259
 - patient selection, 256–257
 - peritoneum closure, 262, 265
 - postoperative management, 262
 - special considerations, 262, 264
 - trocar configuration, 258, 259
 - ureteral mobilization, 260, 261
 - ureter placement into tunnel, 261–262, 264–265
- ARTEMIS. *See* Advanced robotic telemanipulator for minimally invasive surgery
- Automated endoscopic system for optimal positioning (AESOP), 4

C

- Conn's syndrome, 121
- Cushing's syndrome, 121
- Cystoprostatectomy, radical
 - anterior bladder pedicle development, 95
 - anterior pedicle and ureter transection, 95–96
 - bladder and prostate anterior dissection, 99
 - complications, 104–105
 - dorsal venous complex control, 99

- endopelvic fascia exposure, 98–99
- instrumentation and equipment list, 94–95
- left ureter transposition, 100–101
- operative setup, 92
- patient positioning and preparation, 92–94
- patient preparation, 91–92
- patient selection, 91
- pelvic lymphadenectomy, 100
- posterior bladder pedicles identification and transection, 96–98
- posterior plane development, 96
- postoperative care, 104
- special considerations, 104
- specimen extraction, 101–102
- sutures, 94–95
- trocar configuration, 92–94
- ureter identification and dissection, 95
- urethral-neobladder anastomosis, 102–104

D

- da Vinci® surgical system, 122, 159
 - components, 19
 - EndoWrist® instruments, 27–28
 - models, 19
 - operating room preparation, 28–29
 - patient cart
 - docking, 29–30
 - power switch and motor drive controls, 26
 - standard and S system, 23–24
 - sterile accessories, 24–26
 - remote manipulation robots, 5
 - schematics, 16
 - Si-HD system, 20
 - S system, 20
 - standard system, 19–20
 - surgeon console
 - foot switch panel, 22–23
 - master controllers, 21–22
 - Si surgeon console, 20, 21
 - standard and S systems, 20, 21
 - stereoviewer, 20–22
 - system shutdown, 30
 - vision cart, 26–27

Direct image-guided robots, 3

- AcuBot robot, 8
- image input, 7
- MRI compatible robots
 - abdominal and thoracic percutaneous procedures, 8–9
 - breast, 9
 - image-guided surgery, 9–10
 - MrBot robot, 9
 - NeuroArm robot, 10
 - prostate, 8, 9
- needle insertion, 6–7
- targets and paths, 6
- ultrasound and CT-compatible robots, 7

E

EndoWrist® instruments, 27–29

M

Male infertility robotic procedures

- complications, 236
- instrumentation and equipment list, 219–220
- operative setup, 217, 218
- patient positioning and preparation, 217–218
- patient selection, 217
- postoperative management, 236
- preoperative preparation, 217
- testicular sperm extraction
 - deep dissection, 233–235
 - pole testicular dissection, 234, 235
 - scrotal skin incision and robot docking, 232–233
 - sperm identification and retrieval, 233, 235
 - testicular exploration, 233, 234
 - tunical and skin closure, 234
 - tunical incision, 233, 234
- trocarr configuration, 219
- varicocelectomy
 - skin closure, 232
 - spermatic cord preparation, 230–231
 - spermatic cord release, 232, 233
 - spermatic cord sheath optional closure, 231, 232
 - subinguinal skin incision, 229, 230
 - testicular artery identification, 231
 - testicular veins dissection and ligation, 231, 232
- vasoepididymostomy
 - epididymal tunica anastomosis, 227, 228
 - epididymis preparation, 227, 228
 - involution vasoepididymostomy, 227–229
 - testicular repositioning and skin closure, 228–229
 - vasal muscularis, 228–230
- vasovasostomy
 - adventitial anastomosis, 226
 - anterior vasal mucosal lumen anastomosis, 223, 225
 - anterior vasal muscularis anastomosis, 223, 225
 - bridging scar removal, 223, 226
 - contralateral vasovasostomy, 226
 - distal vas deferens identification, 220

- passing the suture, 222, 223
- penrose drain scaffold removal, 226, 227
- posterior vasal mucosal lumen anastomosis, 222–224
- posterior vasal muscularis anastomosis, 222, 224
- proximal vas transection, 220–221
- scrotum incision, 220, 221
- skin closure, 226–227
- vasa ends preparation, 222
- vasal dilation, 222, 223
- vas deferens dissection, 220, 221

Medical robots

- automated endoscopic system for optimal positioning, 4
- da Vinci® robotic system, 4, 5 (*see also* da Vinci® surgical system)
- image-augmented remote manipulation robots, 9–10
- image-guided robots, 3
 - image input, 7
 - MRI-compatible robots, 7–9
 - needle insertion, 6–7
 - targets and paths, 6
 - ultrasound and CT-compatible robots, 7
- MAKO system, 5
- NOTES procedures, 5–6
- Probot, 4
- RALP, 4–5
- remote and synergistic robots, 3
- URobot, 4
- VickY system, 5, 6
- Zeus surgical system, 4

MRI compatible robots

- abdominal and thoracic percutaneous procedures, 8–9
- breast, 9
- image-guided surgery, 9–10
- MrBot robot, 9
- NeuroArm robot, 10
- prostate, 8, 9

N

Natural orifice transluminal endoscopic surgery (NOTES), 5–6

Nephrectomy

- partial (*see* Partial nephrectomy)
- radical (*see* Radical nephrectomy)

Nephroureterectomy. *See* Radical nephroureterectomy**P**

Partial adrenalectomy

- intraoperative imaging, 129
- patient positioning and operative setup, 130
- patient selection, 129
- postoperative care, 130
- potential complications, 131
- surgical technique, 130–131

Partial nephrectomy

- bleeding complication, 140
- bowel injury, 140

- instrumentation and equipment list, 136
- ipsilateral colon mobilization, 136–137
- large tumors considerations, 140
- obese patients considerations, 140
- operative setup, 133–134
- patient positioning and preparation, 135
- patient selection, 133
- pediatrics
 - abdominal access and trocar placement, 252
 - bowel preparation, 248
 - closure of defect, 254–256
 - complications, 256
 - fascial closure, 254–255
 - informed consent, 248
 - instrumentation and equipment list, 249, 251–252
 - nonfunctioning moiety access, 252, 253
 - nonfunctioning moiety dissection, 254, 255
 - operative setup, 249, 250
 - patient positioning and preparation, 249, 250
 - patient selection, 248
 - postoperative management, 255–256
 - special considerations, 256
 - transection of ureter, 252–254
 - trocar configuration, 249, 251
- postoperative management, 140
- preoperative preparation, 133
- remaining renal attachments dissection, 137–139
- renal hilar vessels, dissection and division, 137, 138
- specimen entrapment and fascial closure, 139
- trocar configuration, 135–136
- Pediatric urologic robotic surgery**
 - anti-reflux surgery**
 - abdominal access and trocar placement, 260
 - bowel preparation, 257
 - complications, 265–266
 - detrusor tunnel creation, 260, 263
 - fascial closure, 262
 - hitch stitch placement, 260, 262
 - informed consent, 257
 - instrumentation and equipment list, 258–260
 - operative setup, 257, 258
 - patient positioning and preparation, 257–259
 - patient selection, 256–257
 - peritoneum closure, 262, 265
 - postoperative management, 262
 - special considerations, 262, 264
 - trocar configuration, 258, 259
 - ureteral mobilization, 260, 261
 - ureter placement into tunnel, 261–262, 264–265
- partial nephrectomy**
 - abdominal access and trocar placement, 252
 - bowel preparation, 248
 - closure of defect, 254–256
 - complications, 256
 - fascial closure, 254–255
 - informed consent, 248
 - instrumentation and equipment list, 249, 251–252
 - nonfunctioning moiety access, 252, 253
 - nonfunctioning moiety dissection, 254, 255
 - operative setup, 249, 250
 - patient positioning and preparation, 249, 250
 - patient selection, 248
 - postoperative management, 255–256
 - special considerations, 256
 - transection of ureter, 252–254
 - trocar configuration, 249, 251
- pyeloplasty
 - abdominal access and trocar placement, 241
 - access to ureteropelvic junction, 242–243
 - bowel preparation, 237
 - complications, 248
 - fascial closure, 245
 - hitch stitch placement, 243, 244
 - informed consent, 237–238
 - instrumentation and equipment list, 240–241
 - operative setup, 238
 - patient positioning and preparation, 238–240
 - patient selection, 237
 - postoperative management, 247
 - pyelotomy and ureteral spatulation, 243–245
 - renal pelvis anastomosis, 245–247
 - special considerations, 248
 - trocar configuration, 240
 - ureteral stent placement, 241
- Probot, 4, 7
- Prostatectomy. *See* Transperitoneal robot-assisted laparoscopic radical prostatectomy
- Pyelolithotomy. *See* Robotic extended pyelolithotomy
- Pyeloplasty**
 - basic principles, 163
 - complications, 171
 - cystoscopy, retrograde pyelogram and ureteral stent placement, 163, 164
 - fascial closure, 169–171
 - instrumentation and equipment list, 163
 - ipsilateral colon and small intestines mobilization, 164–165
 - operative setup, 159–161
 - patient positioning and preparation, 160–162
 - patient selection, 159, 160
 - patient side robotic cart docking, 164, 165
 - pediatrics
 - abdominal access and trocar placement, 241
 - access to ureteropelvic junction, 242–243
 - bowel preparation, 237
 - complications, 248
 - fascial closure, 245
 - hitch stitch placement, 243, 244
 - informed consent, 237–238
 - instrumentation and equipment list, 240–241
 - operative setup, 238
 - patient positioning and preparation, 238–240
 - patient selection, 237
 - postoperative management, 247
 - pyelotomy and ureteral spatulation, 243–245
 - renal pelvis anastomosis, 245–247
 - special considerations, 248
 - trocar configuration, 240
 - ureteral stent placement, 241

Pyeloplasty (*cont.*)

- postoperative management, 170–171
- preoperative preparation, 159
- redundant renal pelvis and ureter spatulation, 167–168
- renal hilar dissection, 165–166
- repositioning and abdominal access, 163–164
- special considerations, 171
- trocar configuration, 161–162
- ureter and renal pelvis anastomosis, 168–170
- ureteropelvic junction identification and dissection, 166
- ureteropelvic junction transecting, 167

R

Radical nephrectomy

- bleeding complication, 140
- bowel injury, 140
- instrumentation and equipment list, 136
- ipsilateral colon mobilization, 136–137
- large tumors considerations, 140
- obese patients considerations, 140
- operative setup, 133–134
- patient positioning and preparation, 135
- patient selection, 133
- postoperative management, 140
- preoperative preparation, 133
- remaining renal attachments dissection, 137–139
- renal hilar vessels, dissection and division, 137, 138
- specimen entrapment and fascial closure, 139
- trocar configuration, 135–136

Radical nephroureterectomy

- abdominal access and trocar placement, 148–149
- adrenal gland dissection, 150–152
- bladder cuff excision, 153–154
- closure of cystotomy, 154, 155
- colon mobilization, 149–150
- complications, 157
- dissection and early ligation of ureter, 150
- distal ureter and bladder cuff dissection, 152–153
- entrapment and delivery of specimens, 154–156
- instrumentation and equipment list, 147–148
- operative setup, 144
- patient positioning and preparation, 144–145
- patient selection, 143
- postoperative management, 155
- preoperative preparation, 143–144
- regional pelvic lymphadenectomy, 154, 156
- regional perihilar lymphadenectomy, 152
- renal hilum dissection, 150–151
- special considerations, 155–157
- trocar configuration, 145–148

REP. *See* Robotic extended pyelolithotomy

Robot-assisted laparoscopic radical prostatectomy (RALP), 4–5

- accessory pudendal arteries, 83–84
- bladder neck reconstruction, 87–88
- extraperitoneal space
 - apical dissection, 76
 - bladder neck dissection, 73

- complications, 78
 - creation, 71–72
 - dorsal vein ligation, 73
 - endopelvic fascia dissection, 72–73
 - instruments and equipment list, 71
 - neurovascular bundle dissection, 75–76
 - operative setup, 69
 - patient positioning, 69–70
 - patient selection, 69
 - posterior prostate dissection, 75–76
 - posterior reconstruction, 76–77
 - postoperative management, 78
 - preoperative preparation, 69
 - seminal vesicle dissection, 73–75
 - special considerations, 78
 - specimen delivery and abdomen exit, 77
 - sutures list, 71
 - urethral transection, 76
 - vesicourethral anastomosis, 77
- large prostate
- bladder neck dissection, 84–85, 87
 - complication, 84, 85
- median lobe, 85–86
- obese patient
- positioning, 79
 - Vinci® robotic trocars, 80
- prior inguinal hernia repair, 82–83
- prior midline laparotomy, 82–83
- prior transurethral resection of the prostate (TURP), 86–87

Robotic extended pyelolithotomy (REP)

- current world experience, 183–184
- informed consent, 174
- instrumentation and equipment list, 176–177
- limitations, 184
- operative setup, 174
- patient positioning and preparation, 174–175
- patient selection, 173
- postoperative management, 182–183
- special considerations, 183
- step-by-step technique
 - antegrade ureteral stenting, 180, 181
 - calyceal calculi removal, 179–180
 - infundibular and pyelotomy incisions repair, 180–181
 - ipsilateral colon mobilization, 177–178
 - pyelotomy, infundibulotomy, and removal of stones, 179, 180
 - retrieval of stones, 182
 - ureter and renal pelvis dissection, 178–179
- trocar configuration
 - retroperitoneal approach, 175–177
 - transperitoneal approach, 175, 176
- urine culture and bowel preparation, 173–174

Robotic instrumentation, personnel and operating room setup

- abdominal access, 19, 20
- da Vinci® surgical system, 19–20
- DVD recording and telemedicine, 16, 17
- EndoWrist® instruments, 27–28

- operating room preparation, surgery, 28–29
- patient cart
 - docking, 29–30
 - power switch and motor drive controls, 26
 - standard and S system, 23–24
 - sterile accessories, 24–26
- patient positioning
 - face shield plate, 17, 18
 - kidney/ureters, 17–18
 - modified lithotomy position, 16–18
 - pelvis and anterior transabdominal surgery, 16–17
- schematics, 15–16
- standard operating room, 16, 17
- surgeon console
 - foot switch panel, 22–23
 - master controllers, 21–22
 - Si surgeon console, 20, 21
 - standard and S systems, 20, 21
 - stereoviewer, 20–22
- surgical team, 15
- system shutdown, 30
- vision cart, 26–27
- Robotic ureterolithotomy, 182, 183. *See also* Robotic extended pyelolithotomy

S

- Sacrocolpopexy
 - abdominal access and trocar placement, 112
 - concomitant surgical procedures, 117
 - equipment list, 110–111
 - increased body mass index, 116–117
 - instruments, 110–111
 - intraoperative hemorrhage, 118
 - mesh materials, 111
 - mesh retroperitonealization and abdomen exit, 111
 - mesh to sacrum sutures, 115–116
 - mesh to vagina sutures, 114–116
 - operative setup, 107–108
 - patient positioning and preparation, 108–110
 - patient selection, 107
 - postoperative management, 116–117
 - preoperative preparation, 107
 - sacral promontory exposure and GorTex sutures, 113–114
 - sutures, 111
 - trocar configuration, 110
 - vaginal-bladder dissection and anatomical variations, 118
 - vaginal dissection, 112–113
 - vaginal retractor placement and retraction, 112–113

T

- Testicular sperm extraction (TESE)
 - deep dissection, 233–235
 - pole testicular dissection, 234, 235
 - scrotal skin incision and robot docking, 232–233
 - sperm identification and retrieval, 233, 235
 - testicular exploration, 233, 234

- tunical and skin closure, 234
- tunical incision, 233, 234
- Total adrenalectomy
 - instrumentation and equipment list, 123–124
 - operative setup, 122
 - patient positioning and preparation, 122, 123
 - patient selection, 121
 - preoperative evaluation and preparation, 121–122
 - surgical anatomy, 124
 - transperitoneal left robot-assisted technique
 - colon and spleen mobilization, 125
 - left adrenal vein exposure and ligation, 125, 126
 - medial, lateral and superior attachments dissection, 125–127
 - specimen entrapment and extraction, 127, 128
 - trocar placement, 124
 - upper pole renal attachments dissection, 125, 127
 - transperitoneal right robot-assisted technique
 - inferior, posterior and superior attachments dissection, 129
 - liver, colon, and duodenum mobilization, 128
 - right adrenal vein exposure and ligation, 128–129
 - trocar placement, 127, 128
 - trocar configuration, 122–124
- Transperitoneal adrenalectomy
 - left robot-assisted adrenalectomy
 - colon and spleen mobilization, 125
 - left adrenal vein exposure and ligation, 125, 126
 - medial, lateral and superior attachments dissection, 125–127
 - specimen entrapment and extraction, 127, 128
 - trocar placement, 124
 - upper pole renal attachments dissection, 125, 127
 - right robot-assisted adrenalectomy
 - inferior, posterior and superior attachment dissection, 129
 - liver, colon, and duodenum mobilization, 128
 - right adrenal vein exposure and ligation, 128–129
 - trocar placement, 127, 128
- Transperitoneal robot-assisted laparoscopic radical prostatectomy
 - anterior approach
 - abdomen exit, 35
 - complications, 45–46
 - dorsal venous ligation, 38
 - endopelvic fascia incision, 37–38
 - instrumentation and equipment list, 36–37
 - neurovascular bundle and prostatic pedicle dissection, 43–44
 - operative setup, 33
 - patient positioning and preparation, 33–35
 - patient selection, 33
 - posterior prostate dissection, 42
 - posterior rhabdosphincter reconstruction, 44
 - postoperative management, 45
 - preoperative preparation, 33
 - prostatic apex dissection, 44
 - prostatovesical junction division, 39–40
 - Retzius space, 37–40
 - seminal vesicles and vas deferens, 40–42

- Transperitoneal robot-assisted laparoscopic radical prostatectomy (*cont.*)
 special considerations, 45
 specimen entrapment, 37
 trocar configuration, 35–36
 vesicourethral anastomosis, 44–45
- posterior approach
 abdomen exit and specimen delivery, 49–50
 abdominal access and trocar placement, 51–52
 antegrade neurovascular bundle preservation, 60–61
 anterior bladder neck transection, 56–57
 complications, 65–66
 deep dorsal venous complex division, 56
 deep dorsal venous complex ligation, 56–57, 60–61
 equipment list, 51
 instrumentation list, 51–53
 laparoscopic inspection and entrapment, 63–64
 neurovascular bundles interfascial dissection, 58–59
 operative setup, 48–49
 patient positioning and preparation, 49–50
 patient selection, 47
 pelvic lymph node dissection, 62–63
 posterior bladder neck transection, 57–58
 postoperative management, 65
 preoperative preparation, 47–48
 prostate posterior dissection, 53
 prostatic apical dissection and urethra division, 61–62
 prostatic pedicles ligation, 59–60
 retzius space development, 55
 seminal vesicles and vas deferentia dissection, 52–53
 special considerations, 26–27
 trocar configuration, 50
 vesicourethral anastomosis, 63–64
- Transurethral resection of the prostate (TURP), 86–87
- U**
- UPJO. *See* Ureteropelvic junction obstruction
- Ureteral reconstruction
 operative setup
 low lithotomy patient position, 189
 operating room setup, 188, 190
 semi-lateral decubitus patient position, 188–189
 patient selection, 187
 preoperative preparation, 187
 ureteral reimplantation
 bladder mobilization and psoas hitch, 210–212
 complications, 214
 cystoscopy and ureteral stent placement, 213
 division of ureter, 210
 exposure of ureter, 209–210
 fascial closure, 212
 indications, 208
 instrumentation and equipment list, 208–209
 neocystostomy creation, 211–213
 patient positioning and preparation, 208
 patient positioning and preparation, 208
 patient positioning and trocar configuration, 209
 postoperative management, 213–214
 special considerations, 214
 trocar configuration, 208
- ureterocalicostomy
 anastomosis, 201–203
 complications, 203
 cystoscopy and ureteral stent placement, 199
 fascial closure, 202
 indications, 198
 instrumentation and equipment list, 198
 patient positioning and preparation, 198
 postoperative management, 203
 renal hilar control, 200–201
 renal hilum dissection, 199–200
 special considerations, 203
 trocar configuration, 198
 trocar placement and ureter exposure, 199
 ureteral transection, 199–200
- ureterolysis and omental wrapping
 anterior ureter identification, 194
 blunt and sharp dissection, 194, 195
 complications, 197–198
 cystoscopy and ureteral stent placement, 192–193
 exposure of ureter, 193
 fascial closure, 196–197
 indications, 188–189
 instrumentation and equipment list, 192
 patient positioning and preparation, 189, 191
 postoperative management, 197
 preparation for wrapping, 196
 special considerations, 197
 traction, 194, 195
 trocar configuration, 191–192
 trocar placement, 193
 ureter isolation, 193–194
 ureter wrapping, 196–197
- ureteroureterostomy
 anastomosis, 205–207
 complications, 208
 cystoscopy and ureteral stent placement, 204
 fascial closure, 206
 indications, 203
 instrumentation and equipment list, 204
 patient positioning and preparation, 204
 postoperative management, 207–208
 special considerations, 208
 trocar configuration, 204
 trocar placement and ureter exposure, 204
 ureter transection, 205, 206
- Ureteral reimplantation
 bladder mobilization and psoas hitch, 210–212
 complications, 214
 cystoscopy and ureteral stent placement, 213
 fascial closure, 212
 indications, 208
 instrumentation and equipment list, 208–209
 neocystostomy creation, 211–213
 patient positioning and preparation, 208

- patient positioning and trocar configuration, 209
 - postoperative management, 213–214
 - special considerations, 214
 - trocar configuration, 208
 - ureter
 - division, 210
 - exposure, 209–210
 - Ureterocalicostomy
 - anastomosis, 201–203
 - complications, 203
 - cystoscopy and ureteral stent placement, 199
 - fascial closure, 202
 - indications, 198
 - instrumentation and equipment list, 198
 - patient positioning and preparation, 198
 - postoperative management, 203
 - renal hilar control, 200–201
 - renal hilum dissection, 199–200
 - special considerations, 203
 - trocar configuration, 198
 - trocar placement and ureter exposure, 199
 - ureteral transection, 199–200
 - Ureterolysis and omental wrapping, 11–13
 - anterior ureter identification, 194
 - blunt and sharp dissection, 194, 195
 - complications, 197–198
 - cystoscopy and ureteral stent placement, 192–193
 - fascial closure, 196–197
 - indications, 188–189
 - instrumentation and equipment list, 192
 - patient positioning and preparation, 189, 191
 - postoperative management, 197
 - preparation for wrapping, 196
 - special considerations, 197
 - traction, 194, 195
 - trocar
 - configuration, 191–192
 - placement, 193
 - ureter
 - exposure, 193
 - isolation, 193–194
 - wrapping, 196–197
 - Ureteropelvic junction obstruction (UPJO)
 - abdominal access and trocar placement, 241
 - patient imaging, 159
 - pyeloplasty, 163, 237
 - secondary UPJO, 171
 - three-dimensional reconstruction, 160
 - ureteropelvic junction access, 242
 - Ureteroureterostomy
 - anastomosis, 205–207
 - complications, 208
 - cystoscopy and ureteral stent placement, 204
 - fascial closure, 206
 - indications, 203
 - instrumentation and equipment list, 204
 - patient positioning and preparation, 204
 - postoperative management, 207–208
 - special considerations, 208
 - trocar configuration, 204
 - trocar placement and ureter exposure, 204
 - ureter transection, 205, 206
- V**
- Varicocelectomy
 - skin closure, 232
 - spermatic cord preparation, 230–231
 - spermatic cord release, 232, 233
 - spermatic cord sheath optional closure, 231, 232
 - subinguinal skin incision, 229, 230
 - testicular artery identification, 231
 - testicular veins dissection and ligation, 231, 232
 - Vasoepididymostomy
 - epididymal tunica anastomosis, 227, 228
 - epididymis preparation, 227, 228
 - involution vasoepididymostomy, 227–229
 - testicular repositioning and skin closure, 228–229
 - vasal muscularis, 228–230
 - Vasovasostomy
 - adventitial anastomosis, 226
 - anterior vasal mucosal lumen anastomosis, 223, 225
 - anterior vasal muscularis anastomosis, 223, 225
 - bridging scar removal, 223, 226
 - contralateral vasovasostomy, 226
 - distal vas deferens identification, 220
 - passing the suture, 222, 223
 - penrose drain scaffold removal, 226, 227
 - posterior vasal mucosal lumen anastomosis, 222–224
 - posterior vasal muscularis anastomosis, 222, 224
 - proximal vas transection, 220–221
 - scrotum incision, 220, 221
 - skin closure, 226–227
 - vasa ends preparation, 222
 - vasal dilation, 222, 223
 - vas deferens dissection, 220, 221
 - Veress needle, 35, 124, 127
 - VickY system, 5