

Michael T. Sheaff  
Deborah J. Hopster

# Post Mortem Technique Handbook

*Forewords by*  
John Sinard, Yale University  
Sir Colin Berry

**Second Edition**

 Springer

Post Mortem Technique Handbook  
Second Edition

# Post Mortem Technique Handbook

Second Edition

Michael T. Sheaff, BSc, MB BS, FRCPath  
Department of Morbid Anatomy and Histopathology,  
Royal London Hospital, Whitechapel, London, UK

Deborah J. Hopster, BSc, MBChB, MRCPath  
Department of Histopathology, Whittington Hospital, London, UK

With 128 Illustrations

With Forewords by John H. Sinard and Professor Sir Colin Berry

 Springer

Michael T. Sheaff, BSc, MB BS,  
FRCPath  
Department of Morbid Anatomy and  
Histopathology  
Royal London Hospital  
Whitechapel  
London, UK

Deborah J. Hopster, BSc, MBChB,  
MRCPath  
Department of Histopathology  
Whittington Hospital  
London, UK

British Library Cataloguing in Publication Data

Sheaff, Michael T., 1965–

Post mortem technique handbook.—2nd ed.

1. Autopsy—Handbooks, manuals, etc.

I. Title II. Hopster, D. J., 1966–  
616'.0759

ISBN 185233813X

Library of Congress Cataloging-in-Publication Data

Sheaff, Michael T., 1965–

Post mortem technique handbook/Michael T. Sheaff, Deborah J. Hopster.—2nd ed.  
p. ; cm.

Includes bibliographical references and index.

ISBN 1-85233-813-X (hc : alk. paper)

1. Autopsy—Handbooks, manuals, etc. I. Hopster, D. J., 1966– II. Title.

[DNLM: 1. Autopsy—methods—Handbooks. 2. Pathology—Handbooks.

3. Postmortem Changes—Handbooks. QZ 35 S539p 2004]

RB57.S43 2004

616.07'59—dc22

2004049160

Apart from any fair dealing for the purposes of research or private study, or criticism, or review, as permitted under the Copyright, Designs and Patents Act 1988, this publication may only be reproduced, stored or transmitted, in any form or by any means, with the prior permission in writing of the publishers, or in the case of reprographic reproduction in accordance with the terms of licences issued by the Copyright Licensing Agency. Enquiries concerning reproduction outside those terms should be sent to the publishers.

ISBN 1-85233-813-X

Springer Science+Business Media

springeronline.com

© Springer-Verlag London Limited 2005

The use of registered names, trademarks, etc., in this publication does not imply, even in the absence of a specific statement, that such names are exempt from the relevant laws and regulations and therefore free for general use.

Product liability: The publisher can give no guarantee for information about drug dosage and application thereof contained in this book. In every individual case the respective user must check its accuracy by consulting other pharmaceutical literature.

Printed in the United States of America. (BS/MV)

Printed on acid-free paper SPIN 10911587

*Once again my appreciation and love to Sue, Tim, Emma  
and my late father Peter,  
But especially mum,  
Who sadly died during the preparation of this second edition.*  
MTS

*To Andrew,  
for his love and support,  
in addition to all his help  
in writing this second edition.*  
DJH

# Foreword I

Forces are at work which may be changing the way the general public thinks about the autopsy. The past few decades have seen a consistent, almost depressing drop in autopsy rates across the world. Once considered the foundation of medical science, the autopsy has fallen into relative disfavor. As the authors of this book discuss, the overall autopsy rate in England has dropped to approximately 25%, with 22% representing coroner mandated cases and only 3% attributable to hospital/academic cases. The situation in the United States is similar, with an estimated overall autopsy rate of just under 10%, half of those attributable to hospital/academic cases. But this may be changing. At least at my own institution, autopsy rates have plateaued over the last few years, and this past year may even be showing a slow increase. As much as I would like to think this is due to internal efforts to increase the value of the autopsy, it is more likely that three relatively recent trends are altering the public's perception of this medical procedure, and that this change in perception is largely responsible for the possible reversal of the autopsy rate decline. The first is the general public's increased awareness of and involvement in their own medical care. Once available to only those select few who chose to enter the medical profession, knowledge of medical procedures, and medicine in general, is now widely available to anyone with a library card or an internet connection. Secondly, increased media focus on medical errors and/or mishaps has led to greater demands for accountability and assurances that accurate diagnoses have been made and appropriately treated. Finally, the popularity of a number of recent television series have made words like "autopsy" and "forensics" and "medical investigation" household words. The net result of these trends is a change in the public perception of post-mortem examination from a macabre procedure performed by hump-backed technicians in a dimly-lit basement to one of a modern, perhaps even high-tech medical procedure performed to answer very real and important questions. Even outside of the medical-legal environment, families simply want to know what happened, and recognize the autopsy as a way to answer many of their unanswered questions. With the world potentially poised for a resurgence

in the demand for autopsies, are pathologists ready to take on this challenge? Unfortunately, the past few decades of autopsy decline have resulted in a number of pathologists entering practice having performed fewer than forty or fifty autopsies, and as a result their knowledge of autopsy techniques is limited. This book is targeted at addressing that deficit. Nearly 50% longer than the first edition, this new edition contains updated text, many additional photographs, and a greater use of tables and lists. It is quite simply among the best detailed descriptions of post-mortem examination techniques that I have read. Comprehensive in scope, it includes both routine and specialized dissection techniques. Perfect for general study and as an ongoing reference for pathologists in training and in practice, it will undoubtedly be a valuable tool as the field of pathology faces the challenges of the future.

John H. Sinard, MD, PhD  
Director, Autopsy Pathology  
Yale-New Haven Hospital  
Associate Professor of Pathology  
Yale University School of Medicine

# Foreword II

The relentless decline in the hospital based autopsy has been documented elsewhere in detail and has been generally deplored as a loss of an important method of “quality control” at a time when the practise of Medicine is closely scrutinised. This is not the place to revisit these well-rehearsed arguments but the change itself provides a powerful justification for the production of this book.

The decrease in clinically requested autopsies in hospitals leaves a large and increasing number of Coronial autopsies to be done; many of these in circumstances of discontent with some aspect of the medical or other management of the events which ultimately lead to death. The pathologists now performing these autopsies will not have had the amount of experience that was commonplace among their predecessors; an experience of carrying out procedures which, although devised for different purposes, can provide a more complete examination of the whole body than often appears necessary in straightforward deaths in the community. In my first two years in Pathology I performed 200 autopsies; most of my contemporaries will have had a similar grounding—it would not be possible to provide this experience for staff in training now, except in some parts of the European mainland.

So there is a need to provide a written but practical account of the autopsy which will help those who may find themselves in unfamiliar territory. A “fixed” technique will not do for all cases (this is perhaps most evident in infancy and childhood) and a number of procedures are presented with this in mind. Readers will find tables of weights, dimensions and diagrams, which will help in description or illustration in reports and save searches of now unfamiliar anatomy texts. Although much has been written about the investigation of suspicious or unnatural death in recent years, it is difficult to find help with the more prosaic work and Ross’s “Post Mortem Appearances” is more than 30 years old. This text addresses questions which will present themselves to Pathologists in conventional hospital practice who have to provide clear accounts of processes and descriptions of findings for discussions with colleagues and relatives, hospital case conferences, Coroners courts or legal reports.

*Professor Sir Colin Berry*



# Acknowledgements

Many thanks again to our patient colleagues, particularly Mr Dean Jansen at the Whittington Hospital who kindly helped with photography. Grateful thanks also to all at Springer, especially Melissa Morton and Eva Senior, who encouraged us through the preparation of this second edition.

MTS  
DJH

# Contents

Foreword I by <i>John H. Sinard</i> .....	vii
Foreword II by <i>Professor Sir Colin Berry</i> .....	ix
Acknowledgements .....	xi
1. Before the Post Mortem .....	1
2. General Inspection and Initial Stages of Evisceration .....	56
3. Evisceration Techniques .....	82
4. Block Dissection .....	119
5. The Cardiovascular System .....	141
6. The Respiratory System .....	180
7. The Gastrointestinal System .....	197
8. The Genitourinary System .....	214
9. The Endocrine System .....	237
10. The Haematopoietic and Lymphoreticular Systems .....	249
11. The Musculoskeletal System .....	260
12. The Nervous System .....	282

13. After Dissection .....	319
14. Fetal, Perinatal, and Infant Autopsies .....	350
Appendix .....	420
Bibliography .....	423
Index .....	427

# 1

## Before the Post Mortem

The post mortem examination has evolved through a protean range of interest, but it remains a benchmark in the study of human disease. Originally performed for predominantly mystical or religious reasons, the post mortem evolved into a vital tool for teaching anatomy to medical students. The link with religion was so strong that during the 15th and 16th centuries papal bulls had to be issued permitting students to dissect human bodies. Although it was recognised early that such examinations could be used to document the various changes that occurred with disease, it was not until some time later that the link between post mortem findings and clinical symptoms was fully appreciated. This recognition that the appearance of the organs was based on tissue and cellular alterations was firmly established by Rokitansky as he introduced the discipline of morbid anatomy and was later expanded by Virchow when he pioneered the concept of the cellular basis of disease. These legendary figures, among others, developed the post mortem as a powerful tool in the study of human disease. During this time the use of the post mortem examination as an essential instrument in the field of forensic medicine also advanced.

Apart from these fundamental aspects, the post mortem examination, and the cause of death that it determines, is a critical element of epidemiology on which decisions regarding public health are based [1]. The post mortem examination has a continuing vital role in the basic study of disease processes, therapeutic response and complications, research, education, genetic counselling, and in audit of medical practice in addition to its elementary role in determining a cause of death.

The following are some of the many reasons for performing a post mortem examination:

- Establish a cause of death.
- Correlate with pre mortem diagnosis.
- Identify unrelated diseases.
- Confirm or dismiss genetic implications for the family.
- Audit care and treatment given.

- Characterise new disease.
- Determine the effects of treatment.
- Prevent the spread of communicable disease.
- Study pathogenesis of disease.
- Enhance research.
- Influence health policy.
- Assess medicolegal implications.
- Benefit and comfort bereaved relatives.
- Educate medical personnel and students.

In the face of all these compelling and critical motivations, the number of post mortem examinations being performed today is decreasing at an alarmingly rapid rate, particularly in the elderly, with autopsies being performed on only one in four deceased persons in the United Kingdom. Currently fewer than 10% of such examinations are performed outside the coroner system. These hospital or academic post mortems are becoming so infrequent that trainee histopathologists are being exposed to fewer and fewer cases, making it inevitable that in the near future post mortems may be performed by inexperienced operators. This also has important implications for training and examination of histopathologists. A stage may be reached soon when post-graduate examinations and qualifications may need to be altered depending on whether individuals have been able to gain the necessary autopsy experience. The situation is similar in many parts of the world, although not universal, and this has recently prompted a large amount of debate in the mainstream medical literature [2].

There are many reasons for the decline in hospital post mortem examinations. Refusal of consent based on religious or cultural attitudes is often stated as an important factor, but in reality few religions prohibit the examination per se. Attempts to avoid additional anxiety and grief to the family of the deceased are clearly well intentioned; however, in one study 88% of families felt they had benefited from knowing the cause of death and that the examination had potentially advanced medical knowledge. The families also had the reassurance that appropriate medical care had been given [3].

The increasing costs of the post mortem examination, the loss of appreciation of the post mortem both among the public and the medical community, and sometimes unreasonably sole reliance on investigative techniques for pre mortem diagnosis are probably more important factors. The risk of clinical exposure and possible malpractice lawsuits may also be contributory factors for this decline. It should be remembered, however, that the procedure continues to identify inconsistencies between clinical and post mortem diagnosis and that several studies have shown that approximately 10% of post mortems reveal findings that would have significantly changed the clinical management of the patient [3]. Furthermore, 23% of post operative deaths in the United Kingdom referred to the

National Confidential Enquiry into Perioperative Deaths (NCEPOD) in 1999 and 2000 showed major post mortem discrepancies [4–7]. Many studies have shown similar inconsistencies between pre and post mortem diagnoses. These results indicate that mortality data that have not been verified by a post mortem examination must be viewed with caution. In other words, autopsies are necessary to ensure the accuracy of death certificates. It has been stated that post mortems are as important to confirm a “known” cause of death as they are to identify an enigmatic cause.

The post mortem remains the gold standard in evaluating new treatments and diagnostic modalities and in documenting changing patterns of disease. For these reasons one could argue that now is the time to be performing more rather fewer examinations. With the advent of increasingly sophisticated pathological diagnostic techniques including numerous molecular biological procedures, valuable resources are being neglected that could extend our knowledge of even well characterised diseases. Furthermore, with the promotion of clinical governance in the United Kingdom, the autopsy is an ideal tool for assessing overall medical care, diagnosis, and treatment. From an educational standpoint, nothing can have quite the impact of fresh macropathology in stimulating an inquiring mind. It is also clear that valuable epidemiological and teaching material is being squandered when the post mortem is dismissed.

Numerous publications have appeared on the subject of the post mortem, many of the more recent of which document the role of the autopsy in a medical audit. These have been followed by several publications assessing the quality of post mortems and the subsequent post mortem reports issued. A Royal College of Pathologists (RCPath) Working Party previously developed guidelines in the United Kingdom with recommendations for the contents and issuance of post mortem reports [3], and these have been revisited recently (2002) [9]. The College of American Pathologists and the Royal College of Pathologists of Australasia have also produced guidance [9–11]. Central to all these recommendations is that implicit in the conduct of every post mortem is the certainty that future patient care will benefit. The objective of the guidelines is to provide a single standard across the relevant country and thereby increase the quality of the post mortem examination. They are intended to indicate what is acceptable practice while it is acknowledged that this may not always be exactly the same as best practice.

The Royal College of Pathologists correctly insist that there should be minimum standards (datasets) for every post mortem including a complete standard examination plus any special techniques or investigations that are required. The person performing the examination should be sufficiently experienced or suitably supervised. The recommendations specify that a summary of the findings should be provided within 5 days of the examination, with a complete report forwarded within 1 week (longer for neuropathological cases, which of course require adequate fixation of the brain

and spinal cord before slicing). The findings should be discussed at specific mortality meetings and the information stored on an appropriate IT system. The recommendations stress that it is important to confirm known disease to enhance medical and lay confidence in diagnostic methods as well as to detect discrepancies. Furthermore, in the United Kingdom special bodies have also been established to investigate perioperative, maternal, infant, and epilepsy-related deaths, as well as stillbirths, with ongoing audit, to promulgate an increase in overall standards and lead to identification of potential inadequacies, with recommended remedies that hopefully can reduce the number of future deaths and enhance patient care.

## Types of Post Mortem

In the United Kingdom just under one third of the 550,000 to 600,000 or so deaths each year will result in a post mortem. This means that in England and Wales approximately 130,000 autopsies are performed each year. These post mortems are divided into two main categories, with the majority performed at the request of the coroner. In fact, more than 90% of post mortems are “coroners,” although the coroner can certify the death without a post mortem or after holding an inquest. Approximately 37% of all deaths are referred to the coroner, and 62% of these require a post mortem examination (the physician certifies the others with the coroner’s agreement). The remainder, which comprise fewer than 10% of the overall total, are consented, hospital, or academic post mortems. The main difference between the types of examination relate to the underlying purpose of the examination. The coroner is largely interested in establishing whether death was natural or unnatural—caused by some external influence—rather than detailing the exact disease processes. The histological aspects of the examination also differ; histological examination seems to be the exception in coroners’ cases but is generally the rule with hospital post mortems, consent allowing. Implicit with the former is the question of permission (or consent) for post mortem, which is discussed more fully later in this chapter. In the United Kingdom, coroners’ post mortems are of two basic types, either standard or forensic (usually “Home Office” cases).

It has been suggested that hospital post mortems ideally should be performed on all patients who die in the hospital in order to confirm diagnoses, check the effects of treatment, identify inconsistencies, and audit the quality of the patient’s care. In practice few such examinations are requested for the reasons outlined earlier. For a post mortem to be performed outside of the coroner’s system, the death needs to be certified by an appropriate clinician caring for the patient, the circumstances surrounding the death should not dictate referral to the coroner, or referral to the coroner has been made and the coroner is satisfied that the certified cause of death is

appropriate. Occasionally a situation arises in which a death is certified by the attending physician, and the pathologist examining the case becomes concerned about an aspect of the factors surrounding the death and is prompted to speak to the coroner and procure advice. Rarely the registrar may also refer problematic cases to the coroner. Consent for a hospital post mortem is imperative, and issues surrounding this are discussed later in this chapter.

In the United Kingdom deaths are referred to the coroner from three main sources: physicians, registrars, and the police. Of the approximately 180,000 deaths that are reported annually to the coroner, about 60% come through the physician, 2% by the registrar, and the remainder mostly via the police [12]. No physician is under a statutory obligation to refer any death, but registrars of births and deaths do have a statutory obligation to refer certain categories of death to a coroner. These are contained in Statutory Instrument 1987/2088. Every physician does, however, have a statutory duty to issue a medical certificate indicating the cause of death, if known, if he or she was the attending physician of the deceased during his or her last illness. Physicians are also strongly encouraged to refer relevant deaths to the coroner directly to avoid delays and inconvenience to relatives. This has prompted the Office for National Statistics to issue guidance for physicians on these matters. This document also discusses the importance of accuracy and clarity in the filling out of the death certificate. It is also stated that, at least in England and Wales, death from AIDS or in an HIV-positive person should not normally be referred to the coroner unless there are other grounds for referral. Once consent for an examination is obtained, the hospital post mortem proceeds under the legislation of the Human Tissue Act of 1961, although currently the Human Tissue Bill is being discussed in Parliament and the Human Tissue Authority has recently been established.

## The Coronial System

The oldest record of a law officer involved in the circumstances of deaths in the United Kingdom is said to date to 1194, although it is likely that such a position probably existed several centuries earlier. Most, if not all, countries have developed similar systems, and although the particular cases that require referral to the coroner or equivalent may differ slightly between continents and countries, the general principles remain the same. Generally, if the following main points surrounding a death can be determined then referral to the coroner usually is not warranted: (1) the patient has been seen by a medical practitioner in the last 14 days, (2) the cause of death is known with a degree of certainty, and (3) those concerned with the death are satisfied that the cause was natural. Of the cases referred to the coroner



in the United Kingdom, more than 60% result in a post mortem examination taking place. (In 2001 this totalled 121,000 examinations in England and Wales).

The coronial system was introduced and has been developed as a means of assessing whether a particular death is natural or not and whether it is possible to confidently establish a cause of death. The coroner has a duty to inquire into the circumstances of death to satisfy him- or herself regarding the manner of death: natural, unnatural, criminal, suspicious, or potentially litigious. Specific details may differ between coroners and between countries, but these general principles are very similar. As mentioned earlier, the actual duty of reporting deaths to the coroner lies with the Registrar of Births and Deaths, not the physician attending the deceased before death, but in practice it is the physician who usually refers appropriate cases to avoid wasting time. It is then at the discretion of the coroner to decide if further action needs to be taken.

A list of cases requiring referral to the coroner in the United Kingdom was issued by the Office of National Statistics in its document delineating death certification in 1996. However, the coronial system has been reviewed recently in the United Kingdom and a comprehensive report issued [13]. This document examines and recommends the need for a complete reappraisal of the current death certification process (Fig. 1.1). A new Statutory Medical Adviser position is proposed, to be filled by physicians who would work alongside the coroner. The latter would perform a dedicated legal role in death investigation. A second tier of certification is recommended, with primary certification performed by fully registered physicians and secondary certification in hospital done by consultants. The outcome of the recommendations of this review is currently awaited.

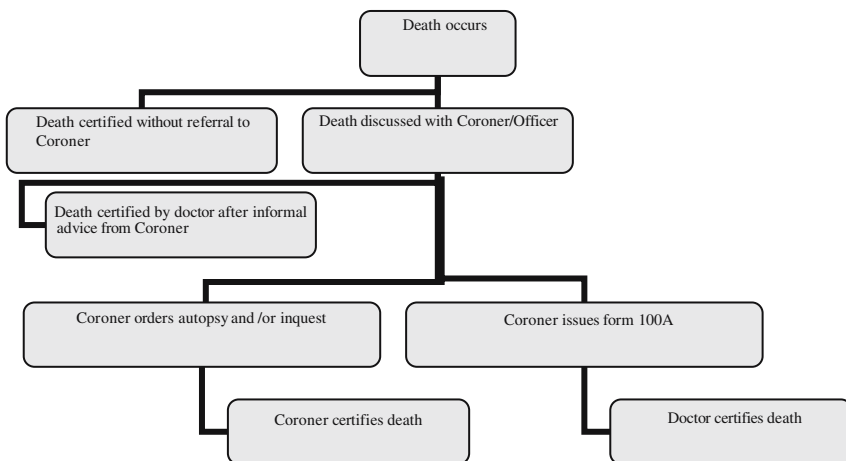


FIGURE 1.1. The current coroner's system in the United Kingdom.

In this review document recommendations are made that the following deaths should always be reported to the coroner:

- Any violent or traumatic death including traffic, workplace, post-operative, self-harm, and so forth.
- Any death in prison, military detention, police custody, or other institutions.
- Any death attributable to a certain range of communicable diseases defined by the coroner.
- Any death in which occupational disease may be relevant.
- Any death associated with lack of care, defective treatment, or an adverse reaction to medication, or unexpected deaths during medical or surgical procedures.
- Any death during pregnancy or within a year of delivery, termination, or miscarriage.
- Any death of a child on the “at risk” register or who had been cared for on behalf of social services.
- Any death in which addictive drugs may have played a role.
- Any death that a physician may not certify as being from natural causes or old age.
- Any death for which the cause is the subject of significant concern or suspicion by any interested party.
- Any death in respect of which the registrar has continuing uncertainty.

A current extensive list used by the Procurator Fiscal is also given in Appendix 1.

The majority of coroners’ post mortems are performed because a cause of death cannot be decided with certainty, often in the setting of sudden death in which there are no suspicious circumstances. In addition, the majority of those cases in which there is an unnatural cause of death, such as suicide or road traffic accidents, are fairly straightforward examinations, and are often performed by general pathologists not specifically trained in forensic medicine. In other medicolegal situations, it is at the discretion of the coroner to direct a forensic pathologist (or Home Office pathologist) to perform the examination, preferably from outside the host institution. Coroners’ autopsies that surround criminal investigations are generally performed by specially trained forensic pathologists, and the Royal College of Pathologists endorses this practice.

Unlike the ever-declining numbers of hospital post mortems, the number of coroners’ post mortems appears to be remaining steady. This will have a detrimental effect on the quantity and quality of information gained from post mortems for many reasons, not least because there is pressure not to retain tissues or perform histological examination in the vast majority of cases. A large amount of educational or research material is being overlooked or lost in this way, and this is very likely to be true of routine autopsies also in the future if the Human Tissue Bill remains so unclear about

the retention of tissues at autopsy. Several publications have previously brought attention to this, and the potential consequences and limitations of this type of system have been addressed in some detail (e.g., see [14]).

### *The Medical Examiner System*

In England, Wales, the United States, and ex-Commonwealth countries, the Anglo-Saxon legal code is generally followed, with an English common law coroner tradition and system as described previously, with developments and modernisation. The system has been extended to that of medical examiner in about 22 states in the United States and provides forensic pathology service to the police as well as investigating noncriminal deaths. Eleven states have a coroner system and 18 have a combination of the two. The situation is similar in Canada. The medical examiner, however, is a person primarily with a forensic background who establishes the manner and the cause of death but does not pursue further inquiries into the circumstances of individual deaths. It is for the medical examiner to decide if a particular death is the result of natural events or otherwise. He or she also has to decide if an autopsy is required, and if so whether he or she should perform it or whether it should be delegated to a deputy who then assigns death to a particular cause, be it natural, accident, suicide, and so forth. The medical examiner, however, has no judicial role. If there are criminal circumstances surrounding a specific case then the case needs to be referred to and discussed with the local district attorney or other legal representative.

### *The Procurator Fiscal*

In Scotland the situation is fairly similar to that in England and Wales, except that relevant deaths are not referred to local coroners, but submitted to the central Procurator Fiscal in order that he or she may carry out an inquiry and decide what further investigations are appropriate. The range of deaths reported to the Procurator Fiscal (see later) is wider than anticipated in most other European countries. Consequently, fewer coroner's type post mortems are performed in Scotland and the proportion of cases referred to the Procurator Fiscal requiring a post mortem is also lower (approximately 25%). In legal cases the Procurator Fiscal reports to the Crown Office, who decide the need for subsequent action.

A document produced by the Department of Health of the Scottish Office (CMA03402) reminds Health Boards and Trusts about the required action that should be followed, particularly after deaths in a hospital, for the Procurator Fiscal to decide what further proceedings are necessary to establish the circumstances leading to death. This document also lists which deaths should be reported to the Procurator Fiscal and in fact this list is extensive and involves 21 key points (Appendix 1). This alternative system has evolved because in Scotland, Europe, and the other European colonies

a different set of rules is followed regarding cause of death, the Code Napoleon. In Scotland the Procurator Fiscal is responsible for initiating criminal proceedings via the lord advocate and therefore is very much involved with criminality and has less concern in establishing the cause of death in nonsuspicious circumstances.

### *Other Systems*

In other European countries the policy regarding post mortem examinations is variable but most follow roughly similar principles to those described under one of the categories outlined in the preceding. Nearly all countries have a system in place for authorities to order unconsented post mortems when there are suspicious circumstances surrounding a death. In some a legal representative, the police, and/or a specific Institute of Forensic Medicine are directly involved in the decision making exercise with regard to whether or not a post mortem examination is necessary. A court order is required in some countries.

In Australia and Canada individual states or provinces investigate deaths according to state or provincial law, and both have been through substantial reforms fairly recently.

A limited list of differing mechanisms for death investigation is given in Table 1.1.

## Notification of Death or Cause of Death

In certain special situations, notification of the death or cause of death to an appropriate authority is warranted whether the post mortem is hospital or non-hospital based. Examples of such cases include those that would usually be referred to the coroner in any event, such as food poisoning, perioperative deaths, or maternal deaths. The presence of infectious diseases such as meningitis, leptospirosis, tuberculosis or various viral or parasitic diseases would not necessarily be referred to the coroner but when encountered, particularly when the diagnosis is made for the first time, should be brought to the attention of the appropriate body through the relevant channels. (For a complete list see Appendix A4 of [9]). In the first instance this will usually be the local Consultant in Communicable Disease Control.

As mentioned earlier, in the United Kingdom, deaths following a recent operative procedure (within 28 days) should be included in the National Confidential Enquiry into Perioperative Deaths (NCEPOD). This is an independent body, founded in 1988 and supported by several Royal Colleges and Associations in England and Wales, that looks at all elements of patient care and subsequent handling of events surrounding post operative deaths in these countries with subsequent reports published to increase

TABLE 1.1. Limited List of Differing Mechanisms for Death Investigation

Country	System of investigation/authority	Legislation
Australia	Coroner or medical examiner depending on state	State legislation
Canada	Coroner or medical examiner depending on province	Provincial law
England, Wales, and Northern Ireland	Coroner	Coroners Act 1988 and Coroners Rules 1984
France	Public prosecutor or judge	No legislation but provisions in article 74 of Code of Criminal Practice
Greece	Police or coroner	Ministry of Justice legislation
India	Magistrate or police	Criminal Procedure Code (Sections 174 and 176)
Ireland	Coroner	Coroners Act 1962
Italy	Public prosecutor, judge, or pretore (industrial accidents)	Governed by Code of Criminal Law Procedures, Royal decree 602 or 25/5 1931 but no specific legislation
Japan	Judge	Criminal Action Law (Acts 168 and 225)
Scotland	Procurator Fiscal	PF applies to sheriff for warrant for autopsy
South Africa	Coroner or police	Coroners Act
Spain	Judge	Mentioned in Code of Criminal Law Procedures, but no specific legislation
USA	Coroner, medical examiner or solicitor	State statutes
New Zealand	Coroner	Coroner's Act 1988

Modified from Burton and Ruttly (eds). *The hospital autopsy*, 2nd edit. Hodder Arnold, 2001.

standards at regular intervals. In the report for the period 1999–2000 it was found that post mortems were performed on 31% of referred cases. Of these, 84% were at the request of the coroner. In 23% major discrepancies were identified at autopsy that would have had an influence on pre mortem management. This is a crucial element of audit, and local discussion, including specific mortality meetings, between clinicians and all other care-workers involved in the patient's management is strongly recommended. Audit has always been an important aspect of post mortem work, but with the introduction of the concept of clinical governance the role of the post mortem in audit has been heightened (at least theoretically).

A similar inquiry into maternal deaths (NCEMD) is also ongoing. This is one of the earliest established schemes of audit investigating all aspects of care associated with deaths during pregnancy or within 42 days of child-birth. This is discussed in more detail in a recent editorial [15] and later in

this text in the section on maternal deaths in Chapter 8. The Confidential Enquiry into Stillbirth and Death in Infancy (CESDI) is also ongoing. A relatively new sentinel audit of epilepsy-related deaths has also been established.


## Consent

It is essential to establish whether consent has been given prior to any post mortem examination. In the United Kingdom the Department of Health has published a document describing a code of practice for post mortems [16] in which it emphasises the importance of the examination while stressing that respectful and sensitive communication between clinical staff and bereaved relatives is essential. In this document model consent forms are provided for adult hospital, child and perinatal hospital, and coroners' post mortem examinations (the adult consent form is presented in Fig. 1.2). This code also recommends practices for consent, retained tissues and their documentation, and disposal of tissues and also refers to the Retained Organs Commission for guidance regarding the return of previously retained organs and tissues.

When the post mortem is performed at the request of the coroner or equivalent, consent is implicit because the coroner is the person in legal possession of the body and no further consent is required from family members or next-of-kin. Indeed relatives cannot interfere with a coroner's decision if he or she considers a post mortem examination necessary. This may seem harsh but it should be remembered that a vital point of the examination is to establish whether death was due to natural causes (and to rule out any suggestion of foul play). The College of American Pathologists has also produced a consent form that is available on their website (Fig. 1.3).

With hospital post mortems, the examination should not be started before written documentation is inspected by the prosecutor. Appropriate time and sensitivity should be given to the formal request from the bereaved families, with an explanation of the reasons for, and practice involved in, the post mortem. It has been suggested that the pathologist may be in the best position to perform this role and indeed this is often the case.

Consent forms will vary somewhat depending on local requirements, although in the United Kingdom the standardised form described earlier is now used widely. This seven-page consent form is no longer just a document allowing the examination, but also includes declarations that define the extent of the examination; limits certain aspects of the examination; states whether tissue can be kept at the end of the examination and how it should be disposed of; and also authorises or prohibits retention of tissue for research, teaching, and quality assurance purposes. Permission is also obtained for taking radiographs or other images. If limitations or



## Consent to a hospital post mortem examination on an adult

Patient's surname/family name	Consultant (or other responsible health professional)
Other names (if given)	
Hospital unit number	NHS number
Date of birth	Male/female
Any other relevant details (e.g. preferred language of next-of-kin, religion)	

This form officially records what you have agreed about what will happen to your partner or relative's body and organs. We realise that this a distressing time for you but it is important that you understand what you are being asked to give your consent to. Please read the accompanying information leaflet very carefully before completing the form. A member of the hospital staff will explain the content of this form and the leaflet and try to answer any questions you may have.

The form is divided into several sections. You should read each one carefully and discuss it with the hospital staff before completing it.

**Section 1** – Agreement to a full post mortem including removal of body fluids and tissues for laboratory examination, and the taking of X-rays and other images.  
**Section 2** – Agreement to a limited post mortem.  
**Section 3** – Agreement to use of tissue and fluid samples taken during the post mortem in medical research.  
**Section 4a** – Agreement that whole organs and tissue be retained for more detailed examination after the post mortem.  
**Section 4b** – Agreement that whole organs retained after the post mortem be donated for medical research, education or audit.  
**Section 4c** – Agreement on how any remaining tissue and organs be disposed of following the post mortem.  
**Section 5** – Any other specific requests or concerns.

If you are satisfied with the information recorded, sign section 6. The member of hospital staff who has discussed the examination with you will sign section 7, and give you a copy of the complete form.

**You have the right to change your mind within a short time limit agreed with the hospital.** If you wish to ask further questions about the post mortem examination, make changes to what you have recorded on this consent form, or withdraw your consent, please telephone

(contact name and number) as soon as possible and not later than  
 (date/time). You will be given a copy of the amended form.

**Consent to a hospital post mortem examination on an adult 1**

**Copy for next-of-kin**

FIGURE 1.2. New Department of Health Consent-Declaration form. (Reprinted with permission.)

### 1. Agreement to a full post mortem examination

I agree to a post mortem examination being carried out on the body of

\_\_\_\_\_

and I am not aware that he/she objected to this or that another family member has any objections.

#### Note

During the examination, samples of body fluids and tissues may be removed for laboratory examination. Tissue samples are made into blocks and slides for examination with a microscope. Any tissue remaining from this process (residual tissue) will usually be disposed of. Blocks and slides are kept indefinitely as part of the medical record or in case they are needed in the future for further tests relating to cause of death or your partner or relative's illness. They may also be used for medical education and audit.

During the examination, photographs, X-rays or other images may be taken. They are usually kept indefinitely as part of the medical record. They may also be used for medical research, education, audit, or quality assurance, in which case information that might allow your partner or relative to be identified would be removed.

### 2. Limiting the post mortem examination

If you prefer, you may agree to a **limited** post mortem examination (with retention of tissue samples as described in section 1). This will limit the information available about the cause of death or illness, and you must discuss this with the hospital staff.

Do you wish to limit the examination? YES  NO

If yes, please say how [You may tick more than one box below]:

the head only       the chest only       the abdomen only

other (please describe) \_\_\_\_\_

I have discussed this with \_\_\_\_\_ (member of hospital staff).

FIGURE 1.2. *Continued*



**3. Agreement to donation of tissue samples for use in medical research (see information leaflet)**

If you agree, tissue and/or fluid samples taken as part of the post mortem examination (see section 1) may also be used later in ethically-approved research. This may benefit other patients in the future. Please note it is not always possible to make use of donated tissue.

**Please choose one of the following options:**

- I agree** to tissue or fluid samples already taken as part of the post mortem examination being used for medical research.
- I agree** to tissue or fluid samples already taken as part of the post mortem examination being used for medical research EXCEPT certain types of medical research, as described here:

[Redacted area]

- I object** to any tissue or fluid already taken as part of the post mortem examination being used for medical research.

**NB: No tissue may be taken primarily for use in research without completion of a specific, separate consent form for that purpose.**

**4. Consent to retention of whole organs and tissue (taken other than for blocks and slides), their uses and options for disposal**

*4a Consent to organs and tissue being retained for more detailed examination*

Only a certain amount of information can be obtained at the time of the post mortem examination. In some cases it may be necessary to retain organs and tissue for further, more detailed examination, in addition to the samples described in section 1. This may be needed to find the precise cause of death, or to give a more complete understanding of the illness. If this is necessary in your relative or partner's case, staff will explain the options and implications to you.

**Tick one of the following:**

- I agree** that any organs and tissue may be retained for further investigation, if this is necessary to understand fully the cause of death and effects of treatment.
- I agree** that any organs and tissue may be retained for further investigation EXCEPT the following:

[Redacted area]

- I object** to any organs or tissue being retained for further investigation.

FIGURE 1.2. *Continued*

**4b Donation of whole organs for medical research, education or audit**

If you agree, whole organs removed and retained after the post mortem examination may be kept for future use in ethically-approved research, medical education or audit.

**Please choose one of the following options:**

**I agree** to any whole organs which have been removed as part of the post mortem examination being kept for medical research, education or audit.

**I agree** to any whole organs which have been removed as part of the post mortem examination, EXCEPT the following:

[Redacted area]

being kept for medical research, education or audit.

**I agree** to whole organs which have been removed as part of the post mortem examination being kept for medical research, education or audit EXCEPT for certain types of medical research, education or audit as described here:

[Redacted area]

**I object** to any whole organs being kept for medical research, education or audit.

**4c Disposal of retained tissue and organs**

After further investigations are complete, what would you like to happen to any remaining tissue and organs (other than those which have been made into tissue blocks and slides for microscopic examination)?

**Please choose one of the following options:**

**Return to the body:** I should like the organs and tissue to be returned to the body. I understand that they will not be returned to their original position in the body. I understand that this may delay the funeral.

**Hospital disposal:** I should like the hospital to arrange for disposal of the organs and tissue.

**Return to self/funeral director:** I would like the organs and tissue to be returned to me/the funeral director (*please delete as appropriate*) to arrange lawful disposal. I understand that this may mean that I need to arrange a separate service after the funeral.

FIGURE 1.2. *Continued*

**5. Other requests or conditions**

Do you have any particular requests or concerns? If so, please note them here. (Hospital staff should also document here any special consents sought for this case.)

[Redacted area]

**6. Signature of next-of-kin (relative or partner)**

Name(s) [Redacted] (PLEASE PRINT)

Signature [Redacted]

Date [Redacted]

Address [Redacted]

Relationship to the deceased person: parent/ husband/wife/partner/brother/sister/other  
[Redacted] (please specify)

in the presence of

Name of witness\* [Redacted]

Signature [Redacted]

Date [Redacted]

Address [Redacted]

\*Witness may be anyone who is not a member of your family, e.g. friend, neighbour or member of hospital staff.

**Consent to a hospital post mortem examination on an adult 5**

Copy for next-of-kin

FIGURE 1.2. Continued

**7. Signature of member of staff seeking consent**

**I confirm that**

- I have explained to the person completing this form the procedures involved and the reasons for the investigations requested.
- I have explained what tissue samples, blocks and slides are.
- I have checked that no objections have been made to the removal or retention of tissues and organs as indicated.
- I have discussed any special requirements of the case, as follows:

[Redacted text]

- I have checked that all parts of the form have been completed.
- I have provided the following information leaflet(s)

[Redacted text]

- I have/have not discussed the case with an appropriate pathologist

(Please name pathologist: [Redacted] )

**Signature of doctor/nurse/other member of staff seeking consent:**

[Redacted signature line]

Date [Redacted]

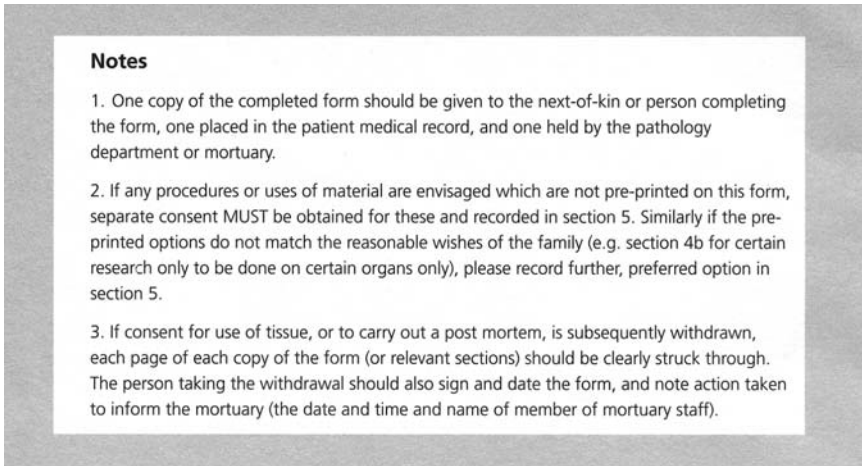
Name [Redacted]

Job title/position [Redacted]

Telephone contact number [Redacted]

Bleep [Redacted]

FIGURE 1.2. *Continued*

FIGURE 1.2. *Continued*

restrictions are required then the relevant part of the declaration/consent form should be explicit and clear. If a disfiguring procedure is considered essential to the examination then the person obtaining consent must consider getting specific permission for that procedure and documenting it on the consent form. It has become increasingly important to document clearly consent for all procedures undertaken during the examination including obtaining consent for the retention of specific organs and tissues.

Organ retention has become an extremely emotional issue in the United Kingdom since the Alder Hey and Bristol scandals and prompted the formation of the Retained Organs Commission to investigate retained material nationally. This body has produced a report discussing their findings and recommendations (2003) and this work is to be extended further with the new Human Tissue Authority and also developed in the Human Tissue Bill (being discussed in Parliament at present). It is likely that the same issues will impact on the international scene before long if they have not already done so. It is noteworthy, however, that after Alder Hey, the parents affected were more distressed that their children's organs were retained without being studied and many would have considered giving permission for retention if clear benefits had been explained to them.

It should be remembered that in many instances organ retention is essential and invaluable in establishing a specific post mortem diagnosis. Detailed examination of retained organs removed at post mortem has over the years provided unrivalled material for studying disease and audit, and led to improvements in subsequent clinical care and teaching. Much of this would not have been possible without organ and tissue retention and analysis and it appears that the current proposals for the Human Tissue Bill may have

a deleterious impact on this, not only in the post mortem field but also in routine surgical and cytological practice. Having said this, the subject is too complicated and lengthy to allow discussion of all of the philosophical points regarding benefits and problems of organ retention here. In light of the recent debates, the Royal College of Pathologists has produced an inter-

**Consent and Authorization for Autopsy**

Addressograph  
or Patient Name / Hospital Number

*The College recommends that each pathology group develop its own specific consent form tailored to applicable law, institutional policies, and local practice. This autopsy consent form is offered as a starting point. Prior to adopting a specific form, the pathology group should have the form reviewed by an attorney knowledgeable about applicable law and sensitive to local practice. The group should also have the form reviewed by appropriate individuals within any institution in which autopsies will be performed.*

\_\_\_\_\_  
Service

\_\_\_\_\_  
Attending physician

\_\_\_\_\_  
Date of death

\_\_\_\_\_  
Time of death

I, (printed name) \_\_\_\_\_, the (relationship to the deceased) \_\_\_\_\_ of the deceased, \_\_\_\_\_, being entitled by law to control the disposition of the remains, hereby request the pathologists of (name of hospital) \_\_\_\_\_ to perform an autopsy on the body of said deceased. I understand that any diagnostic information gained from the autopsy will become part of the deceased's medical record and will be subject to applicable disclosure laws.

**Retention of Organs/Tissues:**

I authorize the removal, examination, and retention of organs, tissues, prosthetic and implantable devices, and fluids as the pathologists deem proper for diagnostic, education, quality improvement and research purposes. I further agree to the eventual disposition of these materials as the pathologists of the hospital determine or as required by law. This consent does not extend to removal or use of any of these materials for transplantation or similar purposes. I understand that organs and tissues not needed for diagnostic, education, quality improvement, or research purposes will be sent to the funeral home or disposed of appropriately.

I understand that I may place limitations on both the extent of the autopsy and on the retention of organs, tissue, and devices. I understand that any limitations may compromise the diagnostic value of the autopsy and may limit the usefulness of the autopsy for education, quality improvement, or research purposes. I have been given the opportunity to ask any questions that I may have regarding the scope or purpose of the autopsy.

Limitations:  None. Permission is granted for a complete autopsy, with removal, examination, and retention of material as the pathologists deem proper for the purposes set forth above, and for disposition of such material as the pathologists or the hospital determine.

Permission is granted for an autopsy with the following limitations and conditions (specify):

\_\_\_\_\_  
\_\_\_\_\_

\_\_\_\_\_  
Signature of person authorizing the autopsy

\_\_\_\_\_  
Date

\_\_\_\_\_  
Time

\_\_\_\_\_  
Signature of person obtaining permission

\_\_\_\_\_  
Printed name of person obtaining permission

\_\_\_\_\_  
Signature of witness

\_\_\_\_\_  
Printed name of witness

Permission was obtained by telephone.

The above statements were read by the person obtaining permission to the person granting permission. The person granting permission was provided the opportunity to ask questions regarding the scope and purpose of the autopsy. The undersigned listened to the conversation with the permission of the parties and affirms that the person granting permission gave consent to the autopsy as indicated above.

\_\_\_\_\_  
Signature of Witness

\_\_\_\_\_  
Printed name of Witness

\_\_\_\_\_  
Date

\_\_\_\_\_  
Time

INSTRUCTIONS: To be valid, this document 1) must be dated, 2) must be signed by the person obtaining permission, AND 3) must be signed either by the person granting permission or the witness monitoring the phone call in which permission was given.

FIGURE 1.3. College of American Pathologists consent form. (Reprinted with permission.)

esting booklet that examines the legal and ethical issues surrounding organ retention at post mortem [17]. For those interested a list of other relevant publications is given in the Bibliography at the end of the book. Implicit in consent for post mortem is the absolute necessity for the examination to be carried out by a suitably appointed prosector. The Human Tissue Act 1961 states that the examination should not be performed by anyone other than, or in accordance with instruction of, a fully registered medical practitioner and that hospital post mortems should not be done without the permission of the person in legal possession of the body. This Act also states that tissue may be removed only by a fully registered medical practitioner. The rules governing who should be present at the post mortem for coroners' cases are stated in the Coroners' Rules (1984) [18]. These should be explained to relatives who may wish a legal representative to be present. Individuals present during hospital post mortems are not so strictly controlled but ideally all involved in the patient's care should be present, although this is not usually practicable and common sense should be used when deciding who should be allowed to attend (see Chapter 13).

Consent is required for a hospital post mortem and retention of tissues and organs for histological examination, teaching, and research. The question of who should sign the consent form is usually evident (the Human Tissue Act 1961 states a spouse or surviving relative) with a close relative such as spouse, sibling, parent, same-sex partner, or alternative next-of-kin being approached. Occasionally it may not be so straightforward and careful judgment is required. Apparently, the legal possession of the body could be granted to the occupier of the premises where the deceased actually died or where he or she currently lies, but clearly this is inappropriate when there are relatives to consult [rights of possession of human corpses is a complicated subject that recently prompted an editorial in the *Journal of Clinical Pathology* [19], to which the reader is referred for a more detailed discussion]. When it is not possible to obtain such written permission because no such relatives can be asked or when the relatives would like formally to defer responsibility to an official, then a representative from the local Health Authority, usually the chief executive, can actually sign the consent form (assuming no prior objections from the deceased are known about), although this is rare and should prompt discussion with the coroner, local legal adviser, or chair of the local Ethics Committee. All steps taken should be documented fully. If there is any hint of conflict then it is wise not to proceed with the post mortem examination.

Consent is obtained by a suitably trained person who is senior or dedicated to the role. All personnel involved in the bereavement process should be aware of the ethical and legal issues and have sufficient experience to be able to explain the reasons for the post mortem, the process of the examination, and the consequences. Information documents are usually available in United Kingdom Trusts that can be given to relatives. The Department of Health is introducing a packet that includes leaflets and a video in an

attempt to make appropriate information and support available at the time it is required. A paediatric/perinatal autopsy packet is being piloted and an adult packet is planned to follow.

If there are objections, either written or verbal, to a post mortem from either the relatives or there is knowledge of the deceased's objection prior to death then as far as possible these objections should be respected. In coroners' cases objections are obviously incongruous and the examination proceeds regardless. In hospital cases, however pressing the desire to obtain consent for a post mortem examination, the written or verbal objection of the deceased should be respected absolutely. In the case of relatives' objections in the absence of known objections from the deceased themselves, the issue is slightly more complex and difficult. Even so, it is not appropriate to consider going ahead with the examination in the face of opposition and the wishes of the relatives should still be respected.

It is vital to verify that consent has been obtained before starting the post mortem. It is particularly important in hospital cases to establish what has been consented for. Histological investigation is regularly underutilised and ideally should be included in every hospital post mortem. It is frequently necessary (and is considered good standard practice) to sample tissue for histological examination to confirm a macroscopic diagnosis. Clearly this is not possible without specific consent and therefore a potential exists for macroscopic misinterpretations to go unconfirmed, which may influence and possibly misinform public health records. This should be considered when consent is being requested, and the importance of tissue sampling and microscopic examination explained.

Unless specifically prohibited or objected to by the relatives or coroner, tissue is often retained at post mortem for these reasons, but in some cases tissue is retained for research, teaching, or therapeutic uses. Once again this procedure is governed by the Human Tissue Act of 1961 but is being reviewed in the Human Tissue Bill. Later sections on the post mortem consent form specify whether the relatives have any objection to tissue being retained and a negative response given if appropriate. On occasion there is clearly a fine line between retaining tissue for truly diagnostic purposes and reasons of personal curiosity on the part of the pathologist. In such circumstances common sense should prevail and if any doubt is present it is prudent to contact the person who signed the consent form, or simply to refrain from retaining tissue.

Organs removed for purposes of transplantation should rarely pose a problem for the pathologist because they will almost certainly have been removed prior to receipt of the body in the mortuary. One example of this type of situation in which the pathologist may be involved is the case of corneal explants. Once again, however, it is usual for an external person to come to the mortuary to remove the corneas either before or after the pathologist performs the post mortem. This person also has to be a fully registered medical practitioner (Human Tissue Act 1961).



## Mortuary Building, Clothing, and Instrument Requirements

The main influences on the design of the mortuary depend on the number of cadavers passing through the building and the number of cases that come to post mortem. Post mortems are performed either in a hospital setting or in a public mortuary, usually attached to a crematorium or coroners' court. The requirements of a particular hospital mortuary reflect the size of the hospital and the population of patients within that hospital. For example, a large geriatric hospital will require more space than a small surgical hospital. The mortuary design should not only reflect the number of deaths occurring in the hospital, but in most hospitals should also take into account the number and type of post mortems and have ample space for viewing.

Specific recommendations and requirements regarding mortuary setup are given in the Department of Health's document, "Mortuary and Post-mortem Room Health Building Note 20," originally published in 1991 [20] and revised in 2001 [21]. These recommend that there should be 4 storage spaces for every 100 hospital beds, although this of course does allow for the actual numbers of coroners' cases performed, as the bodies are often transported to the mortuary from outside the hospital. There should be 2 post mortem tables per 400 hospital beds or for every 450 deaths per year. This publication also gives recommendations and regulations for temperature control, the storage of bodies, and ventilation system within the mortuary. The building itself should be fairly inaccessible to the public and secure from wandering or disorientated passers by. It should, however, be convenient for undertakers and others who may have day-to-day business in the mortuary.

### *Facilities*

The general facilities required are fairly standard between mortuaries, but some require additional facilities (such as those for high-risk cases, to be discussed later). For most basic mortuaries, there should be adequate space and equipment for the receipt, storage, and transport of bodies; the performance of post mortems; and the viewing of bodies by relatives and friends. The layout of the building is important so that all of these necessary functions can proceed independently and simultaneously. A large area is required for the release of bodies to undertakers, usually with adequate room for the latter's vehicle to enter the building itself. It is useful if the storage refrigerators have two doors, with one side leading to the post mortem room (Fig. 1.4) and the other opening onto the general transit area so that the bodies can easily be transferred out of the mortuary (Fig. 1.5). These refrigerators should store bodies at 4°C.



FIGURE 1.4. Mortuary with access to refrigerators from one side. (Courtesy of Mr. Dean Jansen, Whittington Hospital.)



FIGURE 1.5. Body transfer area with doors on the outer aspect. (Courtesy of Mr. Dean Jansen, Whittington Hospital.)

Other facilities that need to be available are changing rooms for the pathologists and technical staff (with separate access from both post mortem room and a clean area), offices (with a desk, filing cabinets, telephone, and all of the other usual office commodities), storage for other consumables and equipment, observation areas adjacent to the post mortem room, a leisure area, and ample areas for specimen storage. The latter involves all health and safety aspects such as an extraction ventilation system for formalin and toxic fumes, keeping formalin vapour levels below the maximum recommended levels of 2 parts per million. The boundaries between clean and dirty areas should be marked adequately by signs, physical barriers, or coloured tape on the floor. A junctional zone needs to be set up between the dirty and clean areas for activities such as putting on and taking off boots and discarding soiled clothing. A waiting room for relatives, with toilet and wash area and decorated in an appropriately sensitive style, is also necessary.

The government recommendations state that the mortuary should have dedicated electrical and water supplies and extract ventilation plant, together with down-draft extraction within the dissection tables if possible. The walls and floors should have nonporous surfaces with adequate and rapid drainage for easy cleaning.

Lighting needs to be bright to allow thorough examination and optimise safety. This is particularly important over the dissection area, and additional spotlights here are often very useful. The dissection area may be over the table or in a separate area with local exhaust ventilation available, but in either case it is essential that this area is adjacent to running water. The table itself should be made of nonporous material—usually porcelain in more old-fashioned mortuaries or stainless steel in more modern ones. The recommended table height is 32 to 33 inches (81 to 84 cm). The table usually has a sponge basin at the end. As well as nearby running water, there should be adequate drainage to waste. The dissection board also needs to be impervious, and whether placed over the table or in a separate area, should be adjacent to running water, waste drainage, and have adequate space for storing instruments safely. The instruments themselves will be discussed later, but other facilities such as X-ray, video, and photography equipment as well as first aid stations should all be close at hand.

The observation area for medical staff, undergraduate students, and other relevant individuals has to be recognised as a clean area and clearly marked as such. It should be accessible via clean areas only without encroaching on dirty areas. Many mortuaries will have a protective screen between the pathologist and observers to prevent splashing into the clean area (Fig. 1.6). Once again, air should flow away from the observation area. It is wise to keep all public areas away from both the dissection room and observation area and the latter clearly marked so that wandering relatives or uninvolved staff members do not inadvertently find themselves in an unfortunate situation.



FIGURE 1.6. Dissection area adjacent to separate observation gallery (note the screen between the two). (Courtesy of Mr. Dean Jansen, Whittington Hospital.)

### *Change of Clothing*

Outside clothing needs to be completely removed and replaced with coverings for head, face, body, and feet. It is wise to wear a cap or hood to both protect the hair and to prevent long hair from obscuring the view and causing a hazardous situation. It is recommended that the eyes be protected with standardised spectacles or a visor [22], but glasses should be worn for acuity if necessary, underneath the plastic spectacles if possible. If a visor is not used, the face is covered with a surgical face mask, which protects the mouth from contamination during the examination. A surgical scrub suit consisting of shirt and trousers such as used in an operating room should be worn, with forearm protectors if the sleeves are short. A gown and plastic waterproof apron are usually worn over this suit. Recent advice from the Royal College of Pathologists recommends wearing a waterproof or water-resistant disposable gown that completely covers the arms, chest, and legs.

The feet are covered and protected by waterproof boots, often white anti-static Wellington type boots, preferably with reinforced toecaps. Gloves are worn to protect the hands, and these may well be a pair of outer latex gloves

over an inner pair of neoprene cut-resistant gloves. The gloves, apron, mask, and possibly gown are disposable and should be discarded after each post mortem procedure. The remaining clothing is laundered after use. Disposal bins, dirty linen receptacles, and boots should be available at the junction between clean changing area and dissection room so that these items are not transferred from a dirty to a clean section. It is sometimes necessary to consider wearing an all-in-one suit and a steel glove on the noncutting hand, double gloving, or using a breathing apparatus (Fig. 1.7) or a one-piece visor for high-risk cases; further details on these are discussed later.

### *Instruments*

The repertoire of instruments that may be used during the post mortem examination is extensive but those that are regularly used in the routine situation include a scalpel with a large cutting blade (such as a PM40), a smaller surgical type scalpel, a long-bladed knife such as a brain knife, blunt forceps and toothed forceps (probably of differing lengths, blunt-ended scissors (both large and small), bowel scissors, a metal ruler, weighing scales, sponge(s), saws (usually electric with a specially protected circuit but on



FIGURE 1.7. Personal respiration equipment used for high-risk cases with the potential for aerosol spread.

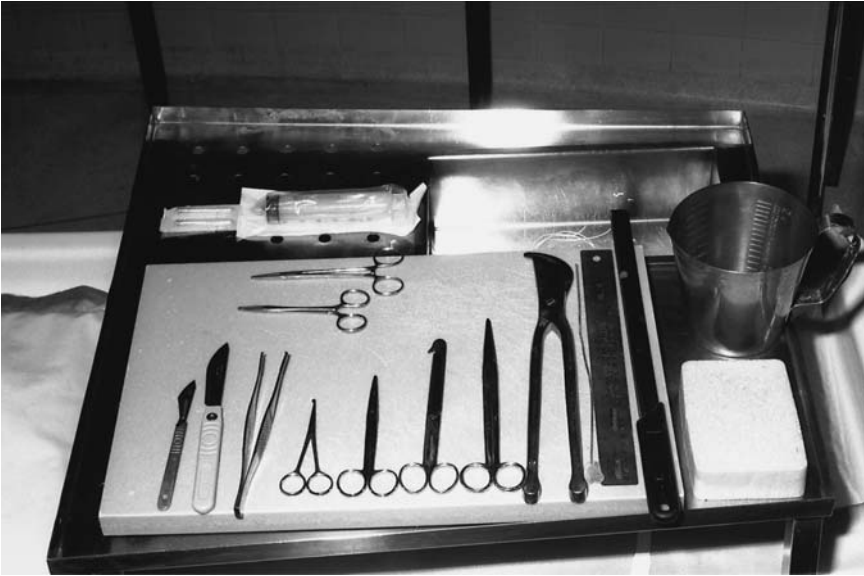

FIGURE 1.8. Routinely used instruments laid out on the dissecting board prior to post mortem examination. (Courtesy of Mr. Ivor Northey.)

occasion a handsaw), rib shearers, clamps, string, a ladle, and measuring jugs (Fig. 1.8). It is essential that all knife blades are either replaced for each examination or that knives with nondisposable blades and scissors are regularly sharpened, ideally freshly before every post mortem.

Other useful pieces of equipment include a block for support of the neck, probes, suction apparatus, a T-peg, and a mallet. Various containers should be available for collecting tissue or samples, with swabs, sterile containers, and fresh sterile scalpel blades for microbiological specimens if necessary. Hands-free dictating equipment may be useful (especially for those with poor short-term memories or those constrained by time). Large trays should be available for storing the organs during the examination and subsequent demonstration of the findings to an audience.

### *Special Cases*

Other instruments and equipment may be appropriate in other special circumstances, some of which are discussed in the following section. It is recommended that a minimum of three sets of equipment should be available in the post mortem room. This allows one set to be in use while a second set is ready for use and a third is being disinfected, cleaned, and autoclaved.

## Health and Safety

The post mortem examination and other mortuary business in general involve practices that produce potential infection risks, which can be minimised by following appropriate basic rules. Staff may be exposed to a range of other hazards in and around the mortuary, including the following:

- Infection
- Electrical
- Sharp equipment
- Manual handling
- Chemicals
- Other substances
- Foreign objects

Risk assessment is a critical exercise in identifying and potentially avoiding unnecessary encounters with these risks. This, together with raising levels of awareness and general precautions and protocol observance, have all become part of routine practice that helps to minimise risk and prevent undesired exposure.

Recent governmental publications in the United Kingdom, including *Safe working and the Prevention of Infection in the Mortuary and Post Mortem Room*, 2nd edition (2003) [23], *Safe Working and the Prevention of Infection in Clinical Laboratories* (1991) [24], and the accompanying publication entitled *Safe Working and the Prevention of Infection in Clinical Laboratories—Model Rules for Staff and Visitors* (1991) [25] have been produced to set out policies and guidelines for safe practice. These superseded the infamous Howie Report—the code of practice for the prevention of infection in clinical laboratories and post mortem rooms produced in 1978. Guidance from professional bodies is also available [9], as are recent reviews in professional journals (e.g., see [26]).

Publications are also available for consultation detailing how to handle particular infections/organisms such as transmissible spongiform encephalopathies, both from the Department of Health [27] and also specific journal articles (e.g., [28]). These recommendations cover all aspects of handling cases with known or suspected disease and provide numerous practical suggestions. It is also imperative that local rules also be implemented and adhered to at all times. Recommendations outlined in the Control of Substances Hazardous to Health Regulations [29] cover the use and handling of chemicals and other substances and these should also be observed. All of these apply to medical practitioners working in the mortuary but pertain equally to all staff involved in mortuary work, porters, and especially anatomical pathology technicians. The latter should be given responsibility appropriate to their stage of training and relevant to their qualifications.

There are different levels of responsibility for ensuring that health and safety policies are strictly adhered to, from governmental (especially the requirements of the Health and Safety at Work, etc. Act of 1974, Manual Handling Operations Regulations 1992, Management of Health and Safety at Work Regulations 1998), to national in the form of professional bodies (such as the GMC [General Medical Council] and the new APT [Anatomical Pathology Technician] body allied to the IBMS [Institute of Biomedical Science]) and unions, to local, in which the main responsibility lies with the employer. Obviously, however, the ultimate responsibility rests very much on the individual. It is crucial that personnel working in the mortuary are not complacent about or ignorant of hazards at their place of work. The risks and potential risks associated with the handling of infectious (or suspected infectious) material and with the use of hazardous substances are extremely variable, although it is hoped that strict adherence to relevant policies lowers the risk to an absolute minimum. In addition to the recommended consultative documents listed in the preceding, the Advisory Committee on Dangerous Pathogens has produced a publication on behalf of the Department of Health entitled *Categorisation of Pathogens According to Hazard and Categories of Containment*, 4th edition [30], which also makes essential reading. In this publication pathogens are grouped into categories (containment levels) depending on their likelihood of causing significant disease after exposure (see later section). A further source of relevant information is the Royal Institute of Public Health and Hygiene, which publishes a very useful handbook covering all aspects of mortuary practice and safety specifically for anatomical pathology technicians but having equal relevance to histopathologists [31] (new edition currently in press).

Further discussion of preventative measures and steps to be taken with specific high-risk post mortem situations are elaborated in the section following general mortuary practice principles. It should be emphasised, however, that following the latter will often be all that is required to prevent serious hazard exposure (with minor alterations for some specific organisms). If it is appreciated that all post mortems are potentially infectious or pose a potential noninfective risk then careful and sound working practice should prevent most unnecessary exposure.

### *Risk Assessment*

Recognised risk assessment methods can be applied to the post mortem examination. Setting up local risk assessment protocols is to be encouraged in an attempt to draw attention to the benefit of such processes. Specific risk assessment forms can be used to establish that the performance of the post mortem is acceptable. An example is given in Fig. 1.9.



**SOP for performing a risk assessment for infection before a post mortem.**

Assess the following assuming that full protective measures as prescribed in the RCPATH guidelines on autopsy practice are used

<b>1</b>	<b><u>Likelihood of exposure to the infective agent</u></b>	
	Impossible -cannot happen under any circumstance	0
	Unlikely -may happen, although not definitely	1
	Possible -could happen although it would be unusual	2
	Even chance -could happen	3
	Probable -would not be surprised if it did happen	4
	Likely -only to be expected	5
	Certain -will definitely happen	6
<b>2</b>	<b><u>Frequency of Exposure</u></b>	
	Infrequently	0.1
	Annually	0.2
	Monthly	0.3
	Weekly	0.4
	Daily	0.5
<b>3</b>	<b><u>Maximum Probable Loss.</u></b> ie What is the worst outcome of exposure	
	Death	15
	Permanent serious illness or condition including sensitisation	8
	Temporary serious illness or condition	4
	Minor illness or condition	2
	Mild ill health or effect	1
<b>4</b>	<b><u>Number of people exposed</u></b>	
	1-2	1
	3-7	2
	8-15	4
	16-50	8
	50+	12

Calculate a Hazard rating number by multiplying the scores together to arrive at one of the following

<b>Hazard Rating</b>	<b>Risk Classification</b>
0-5	Very low
6-10	Low
11-50	Medium
51-100	High
101-500	Very High
501-1000	Extreme
1000+	Unacceptable

FIGURE 1.9. Risk assessment forms that may be used prior to post mortem examination.

**RISK ASSESSMENT FOR POST MORTEMS**

This form must be filled in and signed by a consultant pathologist even if the post mortem is to be performed by a less senior pathologist.

**Number of Post Mortem Case:**

**Name of Patient:**

**Name of the consultant performing this risk assessment:**

- |           |  |              |
|-----------|--|--------------|
| <b>1</b>  | Is the post mortem a coroner's case?<br>If yes go to 4, if the post mortem is a hospital case:-  | Yes/No       |
| <b>2</b>  | Have you seen the signed consent?  | Yes/No       |
| <b>3</b>  | Has adequate clinical information been provided  | Yes/No       |
| <b>4</b>  | Is there any reason to suspect a hazard group 3 or 4 pathogen infection of the patient?<br>if the answer is yes:-  | Yes/No       |
| <b>4a</b> | If you suspect a hazard group 4 pathogen you must organise an appropriate blood test before continuing   | Done/NA      |
| <b>4b</b> | If you know of or suspect the presence of an infective agent, in particular a hazard group 3 organism you must consult the RCPATH guidelines and ensure that appropriate measures for your and others protection are taken | Done- Yes/No |
| <b>5</b>  | Conduct a risk assessment as specified on the accompanying sheets, filling in the results below  |              |

Section	<b>1</b>	<b>X</b>	<b>2</b>	<b>X</b>	<b>3</b>	<b>X</b>	<b>4</b>	<b>=</b>	<b>Total</b>
	<input type="text"/>		<input type="text"/>		<input type="text"/>		<input type="text"/>		<input type="text"/>

Equate the total to a risk classification. If this is high or above re-examine the necessity for the post mortem and examine how you can reduce the risk by the use of more appropriate protective wear and/or limiting the number of people present.

**If you answer no to questions 2 or 3, or if the risk assessment is extreme or unacceptable you must not perform an autopsy**

Signed:

FIGURE 1.9. *Continued*

## General Aspects/Rules of Mortuary Practice

The general features of safe mortuary performance are predominantly those regarding good common sense and sound basic working practices. Adequate and appropriate preparation is a key factor in any post mortem, particularly with high-risk cases. Local rules for all standard procedures should be in place, and these protocols should be followed. Many suggestions and recommendations for such procedures can be obtained from the documents mentioned earlier, but in difficult situations it may be worth considering approaching the Royal College of Pathologists or other appropriate body for advice if needed. It is important for the pathologist to be conscientious and ensure that the appropriate protocols are followed scrupulously both by him- or herself and by all the staff in the mortuary. It is also vital that the pathologist communicate to his or her colleagues, with the appropriate conviction, any concerns there may be surrounding a perceived hazard.

### *General Rules for the Post Mortem*

There is an extensive list of both documented and unwritten rules that those involved in the post mortem should follow in each and every examination. Many of these pertain to the mortuary setup and routine working practices such as excellent elementary standards of cleanliness with associated standards of hygiene before, during, and after the examination; the quality of lighting and other facilities such as waste disposal; knowledge of the appropriate disinfectants to be used in different situations; wearing the necessary clothing as described earlier; appropriate use of equipment and materials by experienced and qualified staff; and excellence of technical standards. The latter includes techniques such as good knife control, moistening the knife blade when cutting soft tissue such as brain, avoidance of splashing and squeezing with gentle manipulation of organs, and knowledge of the appropriate procedures to follow in the event of a spillage or accident. If routine procedures follow a high level of standards including appropriate attention to health and safety then risks will be minimised.

### *Accidents and First Aid*

All medical and technical staff working in the mortuary should be aware of the fundamentals of first aid including basic life support and resuscitation techniques. There should be clear instructions concerning the procedures to be followed after accidental self-injury, splashing of mucocutaneous sites, or spillage of hazardous materials. In brief, if a cut or penetrating injury (such as needle-stick injury) is sustained during the post mortem the person concerned should stop work immediately, remove his or her gloves, and wash the wound well under warm running water. The

wound is encouraged to bleed freely and is then cleaned with an appropriate antiseptic and covered with a suitable dressing. If the injury is more serious, immediate transfer to the accident and emergency department may be necessary. If the case involves a category 3 pathogen (see later) it is important to liaise with the local Occupational Health Department, as relevant boosters or gammaglobulins may be administered. All accidents and injuries should be recorded in the accident book and reported to the relevant authority. The injured person should not return to complete the post mortem but should be replaced by another operator.

Splashing accidents should also result in immediate cessation of the examination and the area affected treated with copious amounts of water. In the case of eye splashes an eye bath or eye wash bottle should be used; these should be available as components of the necessary first aid kit/box. Again, all such incidents should be recorded in the accident book and reported to the supervising pathologist.

Procedures to be followed after spillage will depend on the nature of the material spilled, but all should be set out in local codes of practice. These will, however, necessarily cover the following basic principles. All other staff in the vicinity are warned to keep at a safe distance from the hazardous source. The person supervising the situation should put on protective clothing, ventilate the area if possible, and turn off all sources of ignition if the spillage involves flammable liquids. An attempt is made to contain the spread of the spillage using mops, paper towels, or other absorbable materials. The spillage is transferred to waste buckets and moved to an appropriate safe area where it is extensively diluted with large amounts of running water before being allowed to run to waste. In certain situations special procedures may need to be employed such as neutralising acids with alkaline materials, but these should all be detailed in local codes. Finally, the contaminated area needs to be cleaned in the appropriate manner.

## Preventative Measures

It is suggested that the best way to avoid hazardous occurrences is to be aware of the likelihood of any particular risk being present and protect against that hazard if possible. In fact, there have been very few cases of documented occupational contamination in health workers and especially among those who work in mortuaries. As has been repeated earlier, sound working practice makes such an event extremely unlikely but accidents are always possible and awareness is the key to avoidance. Safety barriers can be employed, many of which have been alluded to previously and have their basis in good common sense. Additional less obvious precautionary and preventative tactics are discussed in the following paragraphs, and these can be separated into those centred around the building, the staff, and the perceived hazard.

### *The Building and Its Contents*

The physical facilities present in the autopsy room are the first fundamental aspects in the prevention of exposing unnecessary risks. The dissection area should be of adequate size and design to allow safe working and easy cleaning, including separate changing and washing areas and demonstration areas each clearly labelled to designate clean and dirty zones, often with physical barriers in between. Other facilities such as lighting, ventilation, electric supply, and drainage have been outlined earlier and are set out in Building Note 20. It is obvious that these government recommendations have been produced with safety in mind. Adequate first aid equipment should be in place with visible instructions for procedures to be followed in relevant areas. Exercising extreme care with visitors, not allowing smoking or food in the autopsy room, and posting danger of infection notices are other ways of preventing introduction of unnecessary risk into the mortuary, and in particular post mortem work.

### *Disposal of Waste*

Disposal of waste is another area in which adherence to local protocols to control segregation, containment, and disposal should minimise the potential risk of contamination. This includes effluent waste, relying on an adequate drainage system, and solid waste such as disposables, tissues, and equipment. The latter comprises waste for incineration in appropriately colour-coded containers or “sharps” placed in a sealed “sharps” container. In the United Kingdom it is recommended that different types of waste should be contained in appropriately coloured bags. Normal household waste should not be hazardous and can be put into black bags. Yellow bags are used for all routine waste to be incinerated. Waste requiring autoclaving (or equivalent) before disposal should be placed into light blue bags.

### *Transport of Specimens*

Safe transport of specimens within the mortuary, to other parts of the pathology laboratory, and to other units within and outside the hospital is essential. All containers should be appropriate for their contents, with hazard labels attached if necessary. Containers need to be sealed completely to avoid leakage and bagged as appropriate. All request forms should be filled in as completely as possible, again with an indication of any risk that may be attached to a particular specimen.

### *Cleaning Solutions*

Cleaning solutions and disinfectants are used to destroy microorganisms or at least limit their activity to safe levels, but it should be remembered that

disinfection is not synonymous with sterilisation. Several types of disinfectants are used in the mortuary, and clear indications of the appropriate usage of each and their potential hazards should be made clear to all who come into contact with them. In the United Kingdom these are governed by the COSHH [Control of Substances Hazardous to Health] regulations (2002).

The most widely used disinfectants are the soluble phenolic fluids, which should be kept in their original containers and prepared fresh each day to 1% to 2% solutions depending on the manufacturer's instructions. These are noncorrosive to metals and are not significantly inactivated by organic matter. They are useful for general purposes such as disinfecting floor surfaces, walls, drains, gullies, soiled clothing, boots, dissecting surfaces, and instruments. Phenolics are suitable for most routine work, being active against most bacteria (including tuberculosis) but ineffective against viruses. The second group of disinfectants used are the hypochlorites or chlorine-releasing agents (which include Domestos™). In contrast to the phenolics these are inactivated by organic matter and may be corrosive to metals. They are useful for disinfection of blood spillage and are active against viruses including hepatitis and human immunodeficiency virus (HIV). These also should be freshly made up in either 1% (1000 ppm available chlorine), 2.5%, or 10% dilutions, depending on their use.

The third group of disinfectants that may be used are the aldehydes. These are eye, nose, and skin irritants and special care should be taken when preparing them. There are two types in this group; glutaraldehyde and formaldehyde. The former is used as a 2% solution, is not corrosive to metals, and is recommended for decontaminating instruments in cases involving HIV or hepatitis B, but may also be useful for tuberculosis. Each has a maximum recommended exposure limit that is documented in the *Safety in Health Service Laboratories* series mentioned earlier. Formaldehyde was previously used as a 4% solution (usually a 10% solution of formalin which is a 40% solution of formaldehyde), but because the maximum exposure limit is easily reached with routine use, it is no longer recommended for routine use in the mortuary.

### *Fixatives*

Fixatives also pose a potential risk to those involved in specimen handling. Formalin, the most widely used general fixative, is a nasal, conjunctiva, and skin irritant. When formalin is used care should therefore be taken to avoid skin contact or excessive contact with toxic fumes. As stated earlier, the maximum recommended exposure level of 2ppm should be strictly observed. Gloves should be worn and eye protection used when handling formalin. When large quantities of formalin are used such as for fixing inflated lungs, the introduction of formalin should take place in a well-ventilated room, or possibly in an appropriate safety cabinet, but certainly

slicing of the lungs after such a procedure should be performed within a safety cabinet. In case of any accident or spillage of fixatives or disinfectants emergency measures should be instituted immediately as described earlier.

### *High-Risk Facilities*

In some mortuaries there will be isolation facilities for highly communicable cases, with a special room dedicated to the performance of such “high-risk” post mortems, with alterations to the routine examination practice and protective cabinets of types I and III being available as described in more detail below.

### *Personnel*

Barriers centering around the personnel working in the environment of the mortuary begin with preemployment factors such as appropriate immunisations [such as hepatitis B vaccine, tetanus, *Bacillus Calmette-Guérin* (BCG), and poliovaccine]. A strict code of personal hygiene is necessary once at work, particularly with respect to hand washing. The head of the department must be satisfied of the competence of his or her staff and ensure that staff members are suitably qualified, with strict supervision of trainee technicians and pathologists both for quality of examination and for safety considerations. Staff must not be expected to perform activities inappropriate for their level of training. As mentioned, all pathologists performing post mortems must be fully registered and technical staff must hold relevant qualifications. Anatomical pathology technicians in the United Kingdom are required to obtain the Certificate of the Royal Institute of Public Health after at least 2 years of training, with the Diploma being available after a further period of training. It is recommended that anatomical pathology technicians involved in high-risk cases hold the Diploma rather than the Certificate.

All staff must have adequate training in safe practices and must fully understand the consequences of disregarding any policies for practice. Safe technique and working environment are essential, with appropriate protective clothing and respect for the necessity for clean and dirty areas with boundaries in between. Gloves must be worn at all appropriate times, with eye protection as necessary. Particular care is needed when dealing with sharps, needles, glass, and hazardous elements such as infectious cases and chemicals. The risk of toxic exposure from inhalation, ingestion, and percutaneous inoculation or via cuts, abrasions, and the mucous membranes including the conjunctiva should all be appreciated and steps taken to avoid contamination. Knowledge and awareness of all safety principles and procedures such as those regarding spillages and cuts is essential, as discussed earlier.

## *Hazard Avoidance*

Precautions to prevent accidents and contamination may also be set up in consideration of the hazard itself. Hazardous chemicals should be handled with care and stored in appropriately safe areas, once again following the relevant guidelines. One can prevent personal injury from physical factors such as heavy objects (including bodies) or dangerous equipment by acknowledging the potential risk and pursuing practical avenues to avoid injury. The potential risk of radiation exposure also needs to be appreciated, and this is discussed in more detail later in this section. Finally (but not in order of priority), steps to avoid the risk of contamination from infective hazards, a very real potential problem, need to be undertaken.

Although all bodies coming to post mortem should be considered to be potentially infective, all pathogens are not equally dangerous and therefore in the United Kingdom these have been allocated to various categories with appropriate recommendations for containment depending on the hierarchical category. These are documented by the Advisory Committee on pathogens dangerous to health and have been separated into four categories (Table 1.2).

Hazard Group 1 includes all environmental pathogens that should pose no real threat to the individual or community.

Hazard Group 2 includes all pathogens that *usually* do not pose a threat to individuals but occasionally (hazard) is possible from such organisms. A good example of this is diarrhoeal disease, in particular *Escherichia coli* infection. With general care the risk from performing an examination on such a case should be minimal, without a need for any special containment. This bacterium, however, is highly infective, spreading via faeces, and contamination of hands with spread to the mouth is possible if the safeguards for routine examination outlined earlier are not adhered to. This includes wearing intact gloves and being thorough about hand washing.

Hazard Group 3 pathogens are more hazardous, and these organisms may cause severe human disease, may spread to the community, and may present a serious hazard to mortuary workers. However, effective treatment

TABLE 1.2. Categories of Pathogens with Their Associated Risks

Hazard group 1	An organism that is most unlikely to cause human disease.
Hazard group 2	Organism may cause human disease and might be hazard to laboratory workers but unlikely to spread to community. Laboratory exposure rarely produces infection and effective prophylaxis and/or treatment usually exists.
Hazard group 3	Organism may cause severe human disease and presents serious hazard to laboratory workers. May spread to community but there is usually effective prophylaxis and/or treatment.
Hazard group 4	Organism as 3 but has high risk of community spread and usually no effective prophylaxis or treatment is available.



and prophylaxis are usually available. Examples include *Mycobacterium tuberculosis* and HIV. It is recommended that post mortems should not be performed as a matter of routine in these circumstances, but if a post mortem is considered necessary on such patients then high-risk procedures should be followed as described below.

Hazard Group 4 pathogens are extremely dangerous and include smallpox and the viral hemorrhagic fevers. Usually no effective treatment or prophylaxis is available. Patients with these diseases are admitted to isolation wards of dedicated hospitals and post mortems should be avoided if possible. If they are absolutely essential, ultra-high-risk precautions are taken in specified units with high-security rooms and cabinets.

It is therefore apparent that all mortuaries are generally able to handle cases from categories 1 and 2. Special high-risk facilities that comply with recommended best practice standards [23] are required for category 3 cases, although it is acknowledged that it may be possible to control risk in general post mortem rooms with appropriate additional precautions [9]. Post mortems are prohibited in the presence category 4 pathogens unless performed in a specialised unit and are not discussed further.

### *Advice*

If there is any doubt about any potential risks associated with a perceived hazard the pathologist should not hesitate to try to obtain advice from other health care workers or appropriate professional body. This may include approaching the laboratory safety representative, officer, or manager; the local hospital control of infection officer and/or nurse; the local microbiologist if different from the latter; the relevant union's safety officer; the local occupational health department; the local public health department; or even the Health and Safety Commission. It is worth considering contacting the seemingly most appropriate person on this list for relevant advice when performing a post mortem on a known high-risk case even when you are comfortable that you are aware of the precautions to be taken; you may be given advice pertinent to the examination including specimen collection or antibiotic prophylaxis that you had not considered.

## Specific Rules and Recommendations for High-Risk Post Mortems

### *The Building*

With high-risk post mortems it is accepted, but should not be taken for granted, that the high general standards of routine examination practice (which are not repeated here) are performed together with supplementary precautions and practices to be discussed later. It has already been stated

that examinations on patients involving category 4 pathogens are prohibited unless performed in a recognised specialised unit where special conditions referred to in the “Memorandum on the control of viral hemorrhagic fevers” [32] can be provided. This therefore is not discussed further here except when a specific question needs to be answered. When such an examination is required, special protocols need to be followed, with the examination ideally taking place in an isolated and dedicated room within the mortuary complex. The latter may not always be possible, and in this case appropriate consideration should be given to referring the case to a unit that does have the facilities or, if necessary, exercising extreme caution during the examination. The examination should proceed under carefully controlled conditions. Demonstration of unfixed tissue should not be allowed.

### *Staff*

The Health Services Advisory Committee makes several general recommendations covering high-risk cases including advice on the qualifications of the personnel involved. Staff should usually be limited to three: the pathologist, an assistant, and a circulator. It is recommended that the assistant hold the Diploma of the Institute of Public Health and Hygiene, although only the Certificate is required for tuberculosis cases [9]. The pathologist (usually of consultant grade or equivalent) should take sole responsibility for opening, eviscerating, and examining the body. This is endorsed in the Royal College of Pathologists guidelines but the need for a circulator is arguable, and an experienced senior trainee pathologist is considered reasonable. When present the circulator should remain clean and unsoiled and that person’s role encompasses watching out for risks, preventing other members of staff from accessing the area, photography, recording, communicating, and other ancillary tasks. All staff should be up to date with their immunisation records including hepatitis B vaccine and booster, BCG, and tetanus/polio. No staff member involved should be immunocompromised or have open cuts or active dermatitis if there is a risk of blood-borne transmission. Variations to these general principles are found in the Royal College guidelines and it is accepted that training requires experience, and therefore other members of the staff may be allowed to be present during the post mortem if they stand away from the splashing zone and wear appropriate protective clothing/equipment.

### *The Setting*

There is no justification for wholesale screening of cadavers for communicable disease. It is appropriate to test post mortem if personnel are injured during the post mortem and there is suspicion of an underlying infection. In addition, pre-autopsy testing for hazard category 3 pathogens should be

considered if the purpose of the examination is to determine the cause of death. In hospital cases the next of kin should be informed, with support, and the result included in the final report. In coroners' cases the situation should be discussed with the coroner, as there are funding implications. In either situation, if the disease is relevant to the cause of death it should be recorded on the death certificate and public health records. If the diagnosis is made at post mortem then notification is warranted and relevant contacts may be sought.

It is essential that there are no disturbances during the examination and the two workers inside the dissection area should not handle sharp instruments simultaneously. If a potential problem arises, warnings should be issued by at least one member of the team and the examination stopped until the matter is cleared up. Complete dissection of particular organs may be postponed until after the tissue is fixed in formalin but this is usually not required. All soiled clothing and equipment should be disposed of or decontaminated at the end of the examination as specified by the local rules. Machines can be used that wash and disinfect contaminated instruments.

### *Clothing and Equipment*

Extra protective equipment and clothing are necessary for "danger of infection" cases, although it is equally important not to introduce further risks by employing too large a number of articles. It is reasonable to consider using the clothing outlined in the following list for all post mortems including the routine hospital case:

- Head gear (cap or hood of all-in-one suit)
- Eye protection or visor
- Face mask (visor or respirator is preferred)
- Disposable plastic apron
- Waterproof/resistant gown or all-in-one suit
- Surgical top and trousers (optional if all-in-one suit preferred)
- Disposable arm protectors
- Gloves (two pairs; latex outside with an inner neoprene cut-resistant pair)
- Boots with reinforced toecaps

The use of two sets of gloves (double gloving) clearly provides an additional benefit with regard to defence from skin wounds, although it should be remembered there is always a balance between the extra barrier offered and loss of manual dexterity and feel, therefore increasing the possibility of injury. Heavy-duty neoprene, latex, or nitrile gloves should be considered. Metal-reinforced safety gloves, usually made of stainless steel, can be used for particularly hazardous procedures.

The usual white boots can be worn for high-risk cases but reinforced toe-caps and/or dorsal steel reinforced boots are recommended. An all-in-one waterproof jumpsuit with long sleeves may be worn over the usual surgical clothing, but uncovered short-sleeved tunics are definitely not sensible in such a setting. Head covering is more important in high-risk examinations than the routine and all hair should be covered with a cap or hood (possibly as part of the one-piece suit). Face masks and plastic eye protectors or visors should be worn, although in some instances a respirator will be worn (Fig. 1.7). The latter is very important and necessary when aerosol droplets are the expected route of transmission, and so these are obligatory in cases of tuberculosis or prion disease (see later). Respirators circulate air through a filter such as charcoal, which traps particles and hence excludes transmissible aerosols from gaining entrance into the prosector's respiratory tract.

The general principles for conducting high-risk post mortems are summarised as follows:

- Consider pre mortem testing.
- Obtain all information as for a routine examination.
- Canvass specialist opinion/advice if required.
- Only appropriately experienced and immunised personnel should be involved.
- Identify risks.
- Utilise a special suite.
- Wear special clothing/equipment.
- Keep complications such as extra staff, unused equipment, or special techniques to a minimum (suggested maximum staff of three).
- Never try to catch dropped instruments.
- Avoid passing sharp instruments hand-to-hand.
- Collect histological samples in formalin (most are inactivated/killed but see the section on prion disease later).
- Use appropriate disinfectants/detergents.
- Inform all staff in contact (label body/coverings appropriately).
- Notify if necessary (first diagnosis or development of drug resistance).
- Inform undertakers and relatives of the presence of the risk and any necessary precautions.

A few of the more specialised procedures that may be considered prior to examining a high-risk case are outlined below.

### *Tuberculosis*

With the increase in incidence of tuberculosis in many countries worldwide (including the United Kingdom), awareness of the risk of exposure of pathologists to the bacterium should be heightened, and those involved in

handling bodies and performing post mortems should be on their guard to prevent spread of infection. Drug resistance is becoming a further important complication. The same does not hold true for opportunistic infections by other mycobacteria that can be handled routinely [9]. The main route of transmission is airborne by inhalation of bacteria, and this situation arises in the dissecting area during basic evisceration procedures, particularly when handling and slicing the lungs. Cutaneous spread has also been described (“prosector’s wart”). In the past, if tuberculosis was suspected it was advised that 10% formalin be introduced into the lungs via the trachea 24 hours before the examination took place (after microbiological samples had been taken). This is no longer recommended or required [9]. Care and safety considerations obviously apply to this alternative risk of using substantial quantities of hazardous chemical solutions. A high-risk suite should be used for the examination although, this is not considered essential by some with the precautions outlined earlier for all suspected cases. This will include headgear and respiratory equipment.

All unfixed tissue should be handled in a type I or III safety cabinet. One should consider leaving the lungs (and other organs if infected) intact after evisceration and fixing immersed in formalin for at least 48 hours before dissecting but this is also no longer recommended. Sputum, pus, tissue samples, and urine should be handled as little as possible to avoid splashing and aerosol formation, but if samples are required for microbiological investigation these should be obtained early during the examination. Samples may be necessary for culture confirmation, identification of drug resistance, and molecular typing. Blood probably does not usually pose a threat, as this is not the main route of infection. As few instruments as is safely possible should be used and all should be autoclaved at the end of the session. Phenolics can be used as disinfectants for tuberculosis. One must not become complacent but it is worth remembering that *Mycobacterium tuberculosis* actually has relatively low infectivity and a treated patient should no longer be infective after 2 weeks of therapy.

### *Viral Hepatitides*

As with all high-risk cases, examination of cadavers infected or suspected of being infected with one of the viral hepatitides should be performed only when considered absolutely necessary. The major hazards in this regard are the blood-borne viral diseases, namely hepatitis B, C, and delta agent. All staff must have had hepatitis B immunisation. These should be dealt with as high-risk cases in the environment described earlier. The main risk is transmission by percutaneous injury (and possibly bodily fluids), the most likely hazard being a needle-stick injury or cut. The chances of becoming infected with hepatitis B are actually quite low if the subject is “e” antigen negative, but higher (30% rather than 5%) if “e” antigen positive. There appears to be lower infectivity with hepatitis C (approximately 3% likeli-

hood of infection after a sharps injury), but it nevertheless poses a serious threat of development of cirrhosis and hepatocellular carcinoma to post mortem room workers at least partly because there is no generally available vaccine for protection.

A high-risk suite should be used if possible and the clothing described earlier worn. Hypochlorites are effective disinfectants but these are corrosive; peroxygen-based compounds are also effective and less corrosive. Formalin is suitable for fixation of tissues. The appropriate authorities should be notified of new cases and all staff coming in contact with the body should be alerted to the presence of a risk by appropriate labels and verbal instructions.

### *Human Immunodeficiency Virus*

Although the basic principles regarding post mortem examinations of high-risk cases are extremely pertinent to HIV, pathologists have been and continue to be encouraged to perform examinations on patients with AIDS. The reasons for performing an autopsy on HIV-positive patients are sixfold: (1) documentation of clinicopathological follow up, (2) description of clinical HIV pathology and epidemiology, (3) validation of trials, (4) documentation of drug efficacy and toxicity, (5) production of HIV organ banks, and (6) general education [32].

The main risks associated with performing a practical procedure on an HIV-positive individual stem from contact with blood or bodily fluids, penetrating injuries, and aerosols. Tuberculosis may also be a concern in association with underlying HIV infection. In fact HIV is less likely to be transmitted by needle-stick injury than is hepatitis B (the former estimated at 0.3%). The likelihood of infection and seriousness of the risk is related to the viral load, volume of inoculation, and susceptibility of the individual. HIV may remain viable in a cadaveric tissue for at least 20 hours, although some studies have identified the virus many days after death (up to 16; [26]). Information and recommendations for dealing with HIV during the practice of pathology are specifically detailed in a Royal College of Pathologists booklet entitled "HIV and the practice of pathology" [33]. These have now been superseded by the new full guidelines (2002) within which the measures that need to be taken are outlined. Of note is the recommendation to wear a face mask and safety glasses and if tuberculosis is suspected, a respirator. The usual change of clothing applying to high-risk cases and two or three pairs of gloves is recommended. The recommended option is a triple layer of latex-neoprene-latex. A chain mail glove should be considered when removing the skull.

Fresh tissue may be required for microbiological analysis and this should be handled carefully. Any accidents should be managed in the usual way with post exposure chemotherapy with zidovudine considered as prophylaxis. Hypochlorites and glutaraldehyde (1% solution) may be used as dis-

infectants for HIV autopsies but phenolics are preferred [26]. Again, formalin is suitable for fixation of tissues. Similar policies for warning staff handling bodies should be followed. It should be remembered, however, that it is likely that many post mortem examinations may well be performed on previously unrecognised HIV-positive patients without the elements of knowledge or suspicion of the diagnosis and therefore there is all the more reason for the utmost stringency when performing autopsy protocols and practices.

### *Prion Disease*

Examinations on patients dying with the prion-related Creutzfeldt–Jakob disease (CJD) or variants are normally performed in specialised neuropathology units, although this may not always be the case. Detailed guidance has been issued by the Department of Health [35] and the NHS Executive [36], together with a journal leader by Bell and Ironside in 1993 [28]. The specialised procedures described are also considered appropriate for autopsies on patients dying with Gerstmann–Straussler–Schneider syndrome (GSS), Kuru, those who have received hormones from human pituitary gland tissue, dura mater graft recipients, and members of familial CJD or GSS families.

The infective agent of CJD is a category 2 pathogen that is unusual in that it survives formalin fixation. The most stringent rules are followed for this reason and because there is no current treatment for these dreadful diseases. No additional personnel beyond the usual three should enter the post mortem room during the examination. A consultant (or equivalent) and diplomate APT should be involved. For the examination high-risk protective clothing is worn as described earlier, and a personal ventilation system should be utilised if possible. At the very least some form of full-face visor should be worn to spare the eyes from contamination with bone dust. Again, extra-gloving should be used, especially a steel mesh glove when removing the skull and spinal cord. As the main risk at post mortem arises from central nervous system tissue it is this part of the examination that requires particular care. If a more extensive examination is felt necessary the entire body should be kept in an open body bag with organ removal performed in a high-risk suite. In the United Kingdom funds are available for referral of such cases from the Department of Health. A large amount of wadding is placed into the body bag to soak up fluids, and it may be wise to sample tissues rather than remove organs (following the Rokitansky method of dissection described in Chapter 4). Disposable instruments should be used as much as possible. Restricted post mortems on CJD cases involving removal and examination of the neurological system alone can be performed in any mortuary, although if facilities allow it is obviously worthwhile to utilise a separate post mortem room. Removal of the brain in such cases is described fully in Chapter 12 but in brief this involves dissecting

the scalp and sawing the skull through a large polyethylene bag to contain bone dust created while using the oscillating or hand saw.

Cerebrospinal fluid is removed from the third ventricle and frozen tissue is sampled from the frontal lobes and cerebellum. The brain is suspended in a container of formalin in the routine way. All containers should be labeled appropriately. The pituitary gland should then be removed as discussed in Chapter 3. Tissue should not be used for demonstration or teaching purposes until it is decontaminated. Any tissue collected for histology should be routinely fixed in formalin before the blocks are immersed in 96% formic acid for 1 hour (although immunohistochemistry may be impossible after this).

Dedicated instruments also need to be decontaminated, which requires porous load autoclaving. Disposable instruments should be decontaminated with 2 M sodium hydroxide prior to incineration. The microtome is also disinfected with 2 M NaOH. Another possibility is autoclaving at 134°C for 18 minutes or performing six cycles at the same temperature for 3 minutes each. Blood and bodily fluids such as urine can be handled in the normal fashion. Retained tissue and slides are handled as if potentially infectious. Wax trimmings are collected and incinerated. Formalin used for fixation is absorbed with sawdust and also incinerated. At the end of the examination all disposable clothing is double bagged and sent for incineration. Surfaces are washed down with sodium hypochlorite with 20,000 ppm available chlorine or 2 M NaOH for 1 hour with repeated washings; phenolics and aldehydes are ineffective. Further details are available from the Department of Health document or, in the United Kingdom, the National CJD Surveillance Unit, Western General Hospital, Edinburgh. In the United Kingdom, this unit should also be notified of all confirmed cases.

### *Other Infectious Cases*

Other potentially hazardous infective diseases such as anthrax and leptospirosis (Weil's disease) (and previously of course smallpox) should also be considered high risk and dealt with in the way dictated by their containment level. The appropriate authorities need to be notified. It should be obvious from the preceding section that methods to prevent contamination via the mortuary follow clear logical policies including local rules. A high level of general professional standards should be pursued for all examinations so that risks are minimised and high-risk cases are essentially covered by routine practices.

## Radioactivity in the Post Mortem Room

Radiation, particularly ionising radiation, is a carcinogen and can cause injury and even death given sufficient exposure levels, although it is very



unlikely that any mortuary worker will experience any significant risk from exposure to radioactivity during routine practice. Personnel may be exposed in the mortuary when performing radiographic procedures such as X-ray studies which may be necessary in deaths associated with fractures, in perinatal and paediatric post mortems, and when performing special radiological investigations which are detailed subsequently in the specific systems chapters. In these cases safe working practices and awareness of the possible dangers should prevent significant exposure when performing radiographic techniques.

Another potential source of exposure is handling the body following death of a patient who has been treated with a radioactive substance. Diagnostic exposure of a patient while undergoing investigative radiological procedure poses no threat to either the technician or the pathologist. External beam radiotherapy used as part of a patient's treatment will similarly not pose any risk to persons coming into contact with the body after death. Rarely, however, patients will receive therapeutic radiotherapy in the form of radioactive isotopes, including implants. In such cases there is a real potential risk of significant exposure during body handling or post mortem examination.

In the United Kingdom, the recommendations are that these bodies should be clearly labelled with a red adhesive disc on the forehead, a second red disc on the shroud, and a third red disc on one foot or foot label. The ward should notify the mortuary specifically about the case. The local nuclear medicine department may be approached for advice. The local radiological safety officer should also be consulted and take responsibility for assessing the radiation hazard to staff. This officer is also responsible for discussing the situation with the pathologist if appropriate. The radiation protection adviser may also be involved in any calculations and decisions that are made.

If a post mortem examination is required it may be prudent to delay the examination until the radioactive isotope concerned has decayed to a reasonable and safe level of activity (depending on the half-life of the compound). When performing the post mortem examination, basic general principles of dealing with a potentially hazardous case as outlined earlier should be followed. This includes keeping the time of exposure of staff to the body to an absolute minimum, the involvement of suitably senior technical and medical staff, and the consideration of staff changing after various periods of time to keep exposure within safe limits. Protective clothing should be worn as for infective cases as described earlier. Long-handled scissors and forceps will allow the prosector a little more distance between him- or herself and the body but may be more difficult to control effectively. The levels of radioactivity should be monitored continually and all staff members should wear radiation film badges for personal monitoring. Any spillage should be diluted and cleaned up immediately, with all swabs and waste discarded into special, labelled containers to await decay

to bring the activity to low enough levels to allow disposal. All contaminated areas should be washed down after use with running water to dilute any residual activity and the waste allowed to run to the usual drainage for disposal.

Because different radioactive isotopes localise to particular parts of the body, an additional means of increasing safety is to deal with those organs or sites in a slightly different manner from the other organs. For example, radioactive gold localises to the serous cavities and so removal of the fluid from pleural and peritoneal cavities under closed suction drainage will remove much of the contaminated material from the body prior to evisceration. With radioactive iodine, used primarily for the treatment of thyroid tumours, the isotope (and therefore the activity) is generalised but concentrated in a few areas such as the bladder and thyroid gland. As iodine is excreted in the urine it is wise to drain off the bladder contents to the sewer via a catheter, diluting well before the examination takes place. Blood can also be drained and discarded into the sewer prior to the post mortem if it is considered necessary. Other areas of concentration include the thyroid gland, bladder, and metastatic deposits which can be removed and left in a suitable container for dissection after an appropriate delay to reduce the contact dose.

## Chemical Contaminants and Other Dangerous Foreign Material

Occasionally, foreign bodies will be encountered that have been used in medical interventions such as inferior vena caval filters in patients with deep vein thromboses and coronary artery stents. These may be expected because they were described in the clinical history, but one must remain alert to the possibility of their presence. Metal filters and stents have sharp edges that can cause scratches and puncture wounds. Rarely, short needle fragments can be found in the soft tissues and myocardium of intravenous drug abusers. However unlikely this occurrence, it should always be borne in mind when performing a post mortem on a substance abuser.

Cardiac pacemakers are another potential hazard source, particularly in cremations, as the batteries within such devices may explode when heated. For this reason pacemakers and implantable defibrillators should always be removed prior to transfer to a crematorium. In fact some coroners insist that a phrase is included on their short cause of death forms that states that no pacemaker remains in the body.

There is negligible risk of electric injury from pacemakers because their electric pulse carries only low energy. Implanted cardioverter defibrillators, however, discharge a much greater pulse to the myocardium (about 1 million times that of a pacemaker). It is therefore sensible to handle bodies containing such devices with caution and arrange for the

device to be deactivated (after consultation with the manufacturer or using a magnet).

Sharp fragments of bullet or explosive ammunition are also cited as other potential risks that ought to be considered in deaths associated with shootings. Chemical contaminants such as cyanide or organophosphate poisoning pose theoretical or real risks to post mortem staff, and special precautions should be taken when these are encountered such as chemical barrier protection and requests for specialist advice [26].

## Approach to the Post Mortem

To conclude this opening chapter, an overview of the approach the prosecutor should take when faced with a post mortem examination is outlined including the use of alternative minimally invasive techniques. The first essential factor to establish is whether or not the post mortem is a hospital or a coroner's case. This has important implications for consent and any legal consequences; it may guide the extent of the examination and may dictate the use of nonstandard methods that should be considered such as specimen collection for toxicology. The consent form should be checked and scrutinised if indeed one is required. Next, it is vital to assess all of the clinical information available and predict techniques to be used during the examination with any variations that may be necessary. This is important because certain crucial findings or procedures such as a pneumothorax or collection of "sterile" fluids can easily be overlooked, and it is often very difficult or even impossible to detect or collect these later.

Clinical information includes all hospital notes; all relevant correspondence or contact with the deceased's general practitioner; results of all investigations, both radiological and pathological (histological, cytological, haematological, biochemical, or microbiological); and all information obtained from the relatives (often by the coroner's officer). It is often useful to review any recent histo/cytopathological specimen if it has come through the department and to examine the patient's relevant radiology results as appropriate. Always contact the relevant professional for help with interpretation of any results that are not completely understood.

It is always useful to speak to any clinicians involved with the deceased person's care, and in some cases invaluable information will be gained in this way. This includes the deceased's general practitioner, junior or consultant physicians in the hospital, or midwives. These personnel will often appreciate discussing the particular case and like to feel they have some input and involvement in the bereavement and post mortem process. After all, it will often be they who have to relate and discuss the post mortem findings with the relatives. This contact enables the pathologist to invite the relevant clinicians to the post mortem demonstration, and in the case of hospital post mortems also allows the pathologist to discover what ques-

tions the clinicians would like answered by the examination. With regard to the latter, a request form filled in by the attending clinician may be considered useful to document these facts. The Royal College of Pathologists have produced a suggested format for such a form covering autopsy request and a clinical summary (Fig. 1.10). It is particularly important to contact the clinicians in cases of postoperative, perinatal, and maternal deaths to gain a sense of all of the relevant implications.

**Autopsy Request and Clinical Summary**

Consultant: \_\_\_\_\_

Ward: \_\_\_\_\_ Label \_\_\_\_\_

Date of admission: \_\_\_\_\_

Date and hour of death: \_\_\_\_\_ Coroner informed: Yes / No

Clinical diagnosis: \_\_\_\_\_

Main complaint(s) necessitating admission, and duration: \_\_\_\_\_

Relevant previous medical history: \_\_\_\_\_

Relevant clinical findings and investigations (summarise): \_\_\_\_\_

*IMPORTANT – indicate any hazard for dissection e.g. tuberculosis, hepatitis or possible AIDS.*

Previous biopsies (quote number): \_\_\_\_\_

Specific questions for the Pathologist: \_\_\_\_\_

Requesting Doctor: (CAPITALS) .....

Signed: .....

Date: .....

Figure 1.10. A recommended autopsy request form with clinical summary. (Reprinted with permission from the Royal College of Pathologists, London.)

Once the notes have been scrutinised, occasionally the pathologist may consider that referral to the coroner is warranted. Another situation that sometimes arises is the possibility of whether it would be more appropriate to refer the case to a special centre of expertise. This is particularly true with neuropathological cases, especially those involving skeletal muscle disorders or peripheral nerve problems. Other examples include perinatal deaths, deaths after organ transplantation, or deaths associated with certain infections. It may also be necessary for the post mortem examination to be carried out in a mortuary with special facilities, for example, with high-risk cases.

Prior to any incisions, additional preliminary questions about the case regarding the possibility of hazardous aspects to the practical examination must be borne in mind. These include health and safety considerations and the use of any necessary precautions that may be required. A fundamental point that should be established early is whether there is any risk to the persons performing the post mortem, particularly the possibility of infectious risk such as tuberculosis, prion disease, hepatitis B or C, or HIV as described earlier. If so, the guidelines and recommendations for the performance of such high-risk post mortems issued on behalf of the Health Services Advisory Committee and the Royal College of Pathologists are detailed in the preceding and should be followed.

In some instances it may be worth considering testing for evidence of a particular pathogen before examination, and if necessary defer the examination until after the result is known. This may occur, for instance, in deaths associated with misuse of drugs when HIV status may dictate where the post mortem should be performed or in deaths due to possible meningococcal meningitis when a positive swab result may also direct the subsequent examination procedure and may allow immediate prophylaxis to be given to close family contacts.

Photography and radiology may be appropriate to document important findings, and these are now included in the new Department of Health post mortem request form. The use of this material for educational and teaching purposes is also specifically mentioned. The GMC state that images may be used for medical purposes provided that anonymity is maintained, but this is likely to be revisited with the new Human Tissue Bill.

## Limited and Needle Post Mortem Examinations

In certain circumstances it is impossible to obtain consent for a full post mortem. Not infrequently relatives will allow almost a complete examination but do not wish tissue to be retained at the end of the procedure so that it all has to be returned prior to burial or cremation. The issues surrounding organ and tissue retention are discussed more fully in Chapter 13.

At other times the consent are more limited, allowing only a specified incision to be used or removal of only a restricted number of organs—the minimally invasive autopsy. Examples include removal of only the thoracic or abdominal organs via a single thoracic or abdominal skin incision, which can often be quite small or even laparoscopic. Sometimes relatives will not allow dissection around the head but they are content for the viscera to be examined. Any combination of these or any single site of examination may be permitted. Whatever the situation, all of these should be stated clearly on the post mortem consent form and the prosector should not disrespect the relatives' views. A further situation in which a limited post mortem is justified is when the risk of infection is great and a full examination is not believed warranted. If a limited incision site and size are agreed on it is worth attempting to remove all organs or part of organs that are accessible via that incision. Even if the relatives are determined that a full or limited post mortem should not be performed it may be appropriate to raise the possibility of a needle autopsy.

When this situation arises it is obviously essential to have a very good basic idea of anatomical areas and to give appropriate time to planning of the actual operation to be followed. It is particularly important to spend time planning and revising anatomical landmarks in the case of the needle autopsy [37]. In one study of 394 consecutive needle autopsies, meaningful pathological findings were found in 77% of cases [38], although in another study discrepancies with subsequent complete autopsy findings were found in 52% of needle autopsies [39].

The needle autopsy involves removing cores of tissue using a Tru-cut needle after making a small skin incision over the appropriate organ or area of interest. The needle with obturator retracted is inserted through the incision. Once the desired organ is reached, the obturator is advanced followed by the cannula. The needle is withdrawn and the core of tissue is removed and placed in a suitable fixative. The process can be repeated several times through the same incision. Any serous fluid that may leak out is collected and the incision is sutured to prevent further loss. Subsequent tissue processing for histology follows the usual laboratory practice. This procedure is obviously best for those conditions that affect an organ diffusely. Consent for this technique may be extremely limited by specifying the organ to be sampled with the needle, but it need not be so specific.

Recently attention has focussed on noninvasive techniques for autopsy. The concept of post mortem magnetic resonance imaging (MRI) has been suggested as a replacement for the routine autopsy. No incisions are made and the cadaver is subjected only to an MRI. Studies comparing MRI findings with subsequent conventional autopsy findings show that important disease processes are not identified [40]. This is particularly so for small anatomical lesions such a coronary artery thromboses—obviously a very common cause of death. As might be expected, pathological processes of

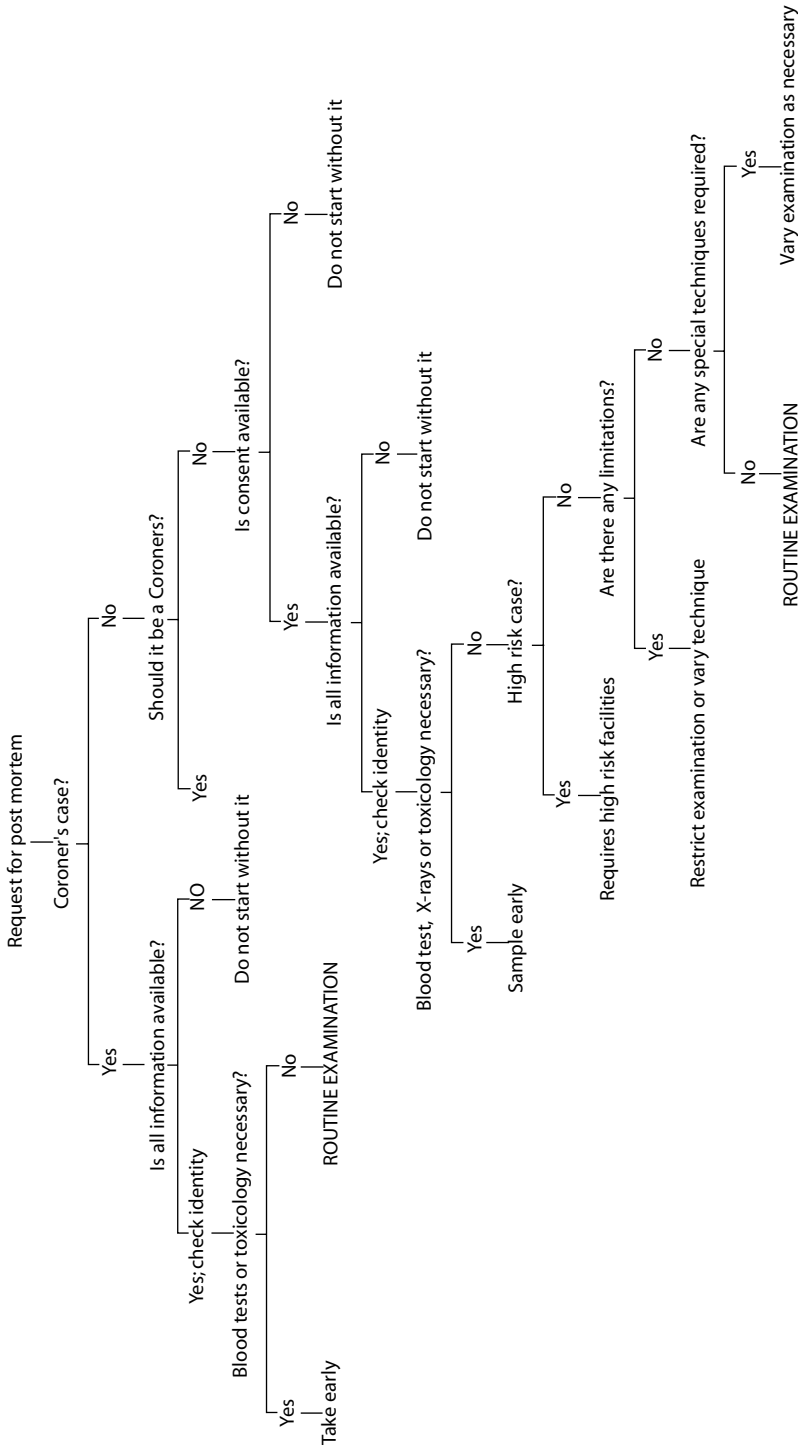


FIGURE 1.11. Algorithm for the consideration and approach to the post mortem examination.

significant size were readily identified. Experience is clearly limited at present but in the future could certainly improve. Time will tell whether this technique will gain general popularity.

## Checklist of Considerations Governing the Examination (See Also Fig. 1.11)

1. Check consent (if necessary) or coroner's request form.
2. Accumulate and assess all available clinical information.
3. If there are any doubts or points requiring clarification ask for advice from the appropriate person.
4. Identify the main points to be ascertained from the examination.
5. Assess any risks or hazards that may be present.
6. Consider any special techniques that may be necessary during the examination.
7. Check the identity of cadaver.
8. Make sure all staff have the appropriate experience.
9. All equipment and clothing should be appropriate to provide a satisfactory and safe working environment.
10. If samples are required for analysis outside the post mortem room, such as for identifying infection or toxicity, take samples early for the relevant investigation.
11. Never forget to consider air embolism or pneumothorax.
12. Follow the appropriate technique for best demonstration of findings (see the following chapters).
13. Go to the main area of interest if clinicians are present, and ask for guidance when necessary
14. Keep areas clean.
15. Use good technique.
16. Demonstrate findings clearly.
17. File a preliminary report on macroscopic findings as soon as possible.
18. File a histology and final report within 1 week (unless part of the examination is pending such as microbiology, toxicology, or neuropathology).

The scene is now set and we are ready to begin the post mortem.

## *References*

1. Dada MA, Ansari NA. The postmortem examination in diagnosis. *J Clin Pathol* 1996;49:965–966.
2. *Br Med J*. Education and debate section. 2003;327, 802–806.
3. Royal College of Pathologists. Guidelines for post mortem reports. Royal College of Pathologists, London, 1993.
4. National Confidential Enquiry into Perioperative Deaths. Extremes of age. NCEPOD, London, 1999.



5. National Confidential Enquiry into Perioperative Deaths. Then and now. NCEPOD, London, 2000.
6. National Confidential Enquiry into Perioperative deaths. Changing the way we operate. NCEPOD, London, 2001.
7. Campling EA, Devlin HB, Hoile RW, Lunn JN. The Report of the National Confidential Enquiry into Perioperative Deaths. NCEPOD, London, 1995.
8. Slavin G and members of the working party. The autopsy and audit. Royal College of Pathologists, London, 1991.
9. Royal College of Pathologists. Guidelines on autopsy practice; the report of a working group of the Royal College of Pathologists. Royal College of Pathologists, London, 2002.
10. Hutchins GM and the Autopsy Committee of the College of American pathologists. Practice guidelines for autopsy pathology: autopsy performance. *Arch Pathol Lab Med* 1994;118:19–25.
11. Hutchins GM and the Autopsy Committee of the College of American pathologists. Practice guidelines for autopsy pathology: autopsy reporting. *Arch Pathol Lab Med* 1999;123:1085–1092.
12. Office of National Statistics Newsletter, 1996.
13. Home Office. Death certification and investigation in England, Wales and Northern Ireland—The report of a fundamental review. HMSO, London, 2003.
14. Chen K. The coroner's necropsy—an epidemiological treasure trove. *J Clin Pathol* 1996;49:698–699.
15. Drife J. Maternal mortality: lessons from the confidential enquiry. *Hosp Med* 1999;60:156–157.
16. Department of Health. Families and post mortems—A code of practice. The Stationery Office, 2003.
17. Royal College of Pathologists Guidelines for the retention of tissues and organs at post-mortem examination. Royal College of Pathologists, London, 2000.
18. Kavanagh G. Coroner's rules and statutes. London: Sweet and Maxwell, 1985.
19. Hudson M. Rights of possession of human corpses. *J Clin Pathol* 1997;50:90–91.
20. Department of Health. Mortuary and post-mortem room, Health Building Note 20. HMSO, London, 1991.
21. Department of Health. HBN20 Facilities for mortuary and post-mortem room services. The Stationery Office, 2001.
22. Bull AD, Channer J, Cross SS, Start RD, Kennedy A. Should eye protection be worn when performing necropsies? *J Clin Pathol* 1991;44:782.
23. Health Services Advisory Committee. Safe working and the prevention of infection in the mortuary and post-mortem room. London: HSE Books, 2003.
24. Health Services Advisory Committee. Safe working and the prevention of infection in clinical laboratories. HMSO, London, 1991.
25. Health Services Advisory Committee. Safe working and the prevention of infection in clinical laboratories—model rules for staff and visitors. HMSO, London, 1991.
26. Burton JL. Health and safety at necropsy. *J Clin Pathol* 2003;56:254–260.
27. Department of Health. Why do mothers die? Report on Confidential Enquiries into Maternal Deaths in the United Kingdom 1994–96. HMSO, London, 1998.
28. Bell JE, Ironside JW. How to tackle a possible Creutzfeldt-Jakob disease necropsy. *J Clin Pathol* 1993;46:193–197.

29. Department of Health. Control of Substances Hazardous to Health Recommendations. The Stationery Office, London, 2002.
30. Advisory Committee on Dangerous Pathogens. Categorisation of pathogens according to hazard and categories of containment, 4th edit. London: HSE Books, 1995.
31. Royal Institute for Public Health 2004. A handbook of Anatomical Pathology Technology. RIPH, London, 2004.
32. Advisory Committee on Dangerous Pathogens. Management and control of viral haemorrhagic fevers. The Stationery Office, 1996.
33. Lucas SB. HIV and the necropsy. *J Clin Pathol* 1993;46:1071–1075.
34. Royal College of Pathologists. HIV and the practice of pathology. Royal College of Pathologists, London, 1995.
35. Advisory Committee on Dangerous Pathogens, Spongiform Encephalopathy Advisory Committee. Transmissible Spongiform Encephalopathy agents: safe working and the prevention of infection. The Stationery Office, 1998.
36. NHS Executive. Variant Creutzfeldt-jakob disease (vCJD): minimising the risk of transmission, Health Services Circular 1999/178.
37. Underwood JCE, Slater DN, Parsons MA (1983) The needle autopsy. *Br Med J* 1983;286:1632–1634.
38. Wellman KF. The needle autopsy: a retrospective evaluation of 394 consecutive cases. *Am J Clin Pathol* 1969;52:441–444.
39. West M, Chomet B. An evaluation of needle necropsies. *Am J Med Sci* 1957;234:554–560.
40. Roberts IS, Benbow EW, Bisset R, Jenkins JP, Lee SH, Reid H, Jackson A. Accuracy of magnetic resonance imaging in determining cause of sudden death in adults: comparison with conventional autopsy. *Histopathology* 2003;42:424–430.

## 2

# General Inspection and Initial Stages of Evisceration

Before using any instruments, it is vital to remember several important points, reiterated here to emphasise their importance. First, and most important, if consent is required it must be available for the prosector to inspect and it must be checked. It is crucial to determine what has been consented for and what has been excluded. This includes routine parts of the examination or limitations, special techniques, tissue retention, and histology. It is likely to become important in the future to check whether it is possible to use for teaching purposes or, especially, research, any tissue that had been removed. Second, it is always vital to verify the patient's identity [in hospital cases the name-band(s) should be checked; in other cases the relatives or a legal representative should identify the body formally]. This may be the coroner, a coroner's officer, or a representative of the police. Rarely it may be necessary to employ forensic dental examination practices or other means to try to identify an unidentified body.

All relevant information should be freely available and consulted, including a written clinical history and any results from investigations that have been undertaken (see Table 2.1). This includes radiographs and previous pathology reports. One should never feel pressured into starting a post mortem examination without reviewing all of the appropriate information and necessary reports. Recent pathology specimens may require review, especially if they are thought to have any relevance to the subsequent post mortem examination. It is useful to utilise a standard pro-forma request form for hospital post mortems indicating the reasons for the examination and specific questions to be answered, relevant medical history, and results of the significant investigations. The prosector should be dressed suitably for the nature of the examination and the appropriate instruments should be clean and in satisfactory order (as outlined in the previous chapter).

In summary, prior to the examination:

- Check consent forms.
- Check the identity of the body.

TABLE 2.1. “Minimum Dataset” for Information Presented for Deaths in the Community

---

Identifying information
Place and time of death
The precise circumstances of death
The medical history and prescribed medications
Recent hospital admissions with details of location and lead clinician
Known or suspected use of alcohol or other recreational drugs
Occupation
Phone number of the patient’s general practitioner

---

Used with permission from Royal College of Pathologists. Guidelines on Autopsy Practice: report of a working party. London, 2002.

- Read all available notes and information.
- Determine questions being asked.
- Identify any special techniques required.
- Assess risk.

## General External Inspection

It is good routine practice for the mortuary staff to record the height and weight of the cadaver, and these measurements should be made available to the prosector and included in the subsequent report. As the cadaver is approached on the dissecting table, the prosector should begin to note the external appearance, paying particular attention to the ethnicity, gender, build, state of cleanliness, skin colour, and the presence of any distinguishing features such as scars, tattoos, or malformations/deformities (Fig. 2.1). In common with the initial clinical examination of any living patient, the examiner should make a note of any cachexia, which may give a clue to an underlying malignant neoplasm; pallor, raising the possibility of anemia; redness, which could indicate carbon monoxide intoxication or suffocation; jaundice, in cases of biliary obstruction, liver parenchymal disease, or haemolysis; cyanosis; clubbing, which could suggest internal neoplasm, lung disease, inflammatory bowel disease, among others; or lymphadenopathy (reactive or neoplastic). A careful inspection of the nails and skin is then made and the abdomen palpated to identify ascites or any intraabdominal masses or organomegaly such as an enlarged spleen or liver resulting from an infective, reactive, or neoplastic process. This may be more difficult than in life but in most cases any such findings are frequently recorded in the notes. Even if these have already been documented, they should be reaffirmed at post mortem. In females palpation of the breasts is essential to avoid missing any palpable lesions (These will also be sliced at a later stage of the examination.). In males the testes could be palpated but are usually examined after removal. Any findings can quickly be noted prior to “gloving

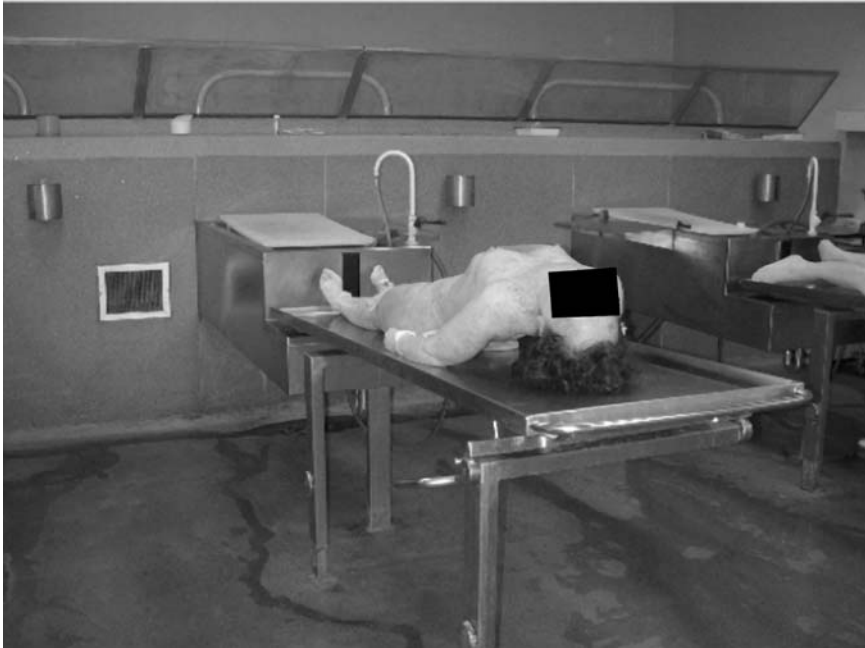

FIGURE 2.1. External examination begins as the body is approached on the dissecting table. (Courtesy of Mr. Dean Jansen, Whittington Hospital.)

up” or by a clean assistant on a printed sheet that contains a diagrammatic plan of the anterior and posterior aspects of a human body. This also acts as a memory aid when one completes the post mortem report after the examination and is used for recording organ weights (Fig. 2.2).

It is easy to neglect the anogenital area from the external examination because significant pathology is rarely situated here but this region should be examined, particularly in forensic cases, so that unexpected findings are not missed. All drains and intravascular access lines should be left in situ in order that their position within the body can be determined, with microbiological samples taken if appropriate. These should also be documented on the body plan. Other external features to be specifically examined include the presence of rigor mortis or peripheral oedema. Again, as with any clinical examination, the latter should be depressed in order to detect if the oedema is pitting and therefore likely to be hypostatic in origin. Non-pitting oedema is more usually a feature of lymphatic obstruction. Rigor mortis is caused by muscle hardening resulting from metabolic changes in myoproteins. Many factors can have an effect on the time course of this stiffening, making its use as a means of accurately establishing the time since death fairly redundant. However, a rough guide for most cases is that rigor mortis commences within 6 hours of death; it takes 6 hours to become

<p>NAME OF DECEASED : AGE :</p> <p>SCARS, TATTOOS, BED SORES, ETC.</p> <p>HEIGHT :                      WEIGHT :</p> <p>BRAIN : HEART : LIVER : SPLEEN : L. LUNG :                      R. LUNG : L. KID :                        R. KID :</p>	<p>P.M. NUMBER : DATE :</p>	<p>INTERNAL.</p> <p>SKIN.</p> <p>EYES.</p> <p>INTERNAL.</p> <p>CHEST.</p> <p>EFFUSIONS.</p> <p>PLEURAL PLAQUES</p> <p>HIATUS HERNIA</p> <p>PERICARDIUM</p> <p>LAD</p> <p>ABDOMEN.</p> <p>EFFUSIONS.</p> <p>PERFORATION - SITE</p> <p>OBSTRUCTION - CAUSE</p> <p>DIVERTICULAR DISEASE</p>	<p>WELL / POORLY NOURISHED.</p> <p>PERIPHERAL                      CENTRAL</p> <p>ARCUS SENILIS</p> <p>HAEMORRHAGIC</p> <p>FRACTURED RIBS</p> <p>RIGHT</p> <p>RIGHT</p> <p>HAEMOPERICARDIUM</p> <p>R. C.A</p> <p>DENSE</p> <p>SCATTERED</p> <p>LARGE</p> <p>MODERATE</p> <p>SMALL</p> <p>CLEAR</p> <p>ASCITIC</p> <p>PURULENT</p> <p>FACULENT</p> <p>BLOOD STAINED</p> <p>RETROPERITONEAL HAEMORRHAGE</p> <p>STERNUM</p> <p>RIGHT</p> <p>LEFT</p> <p>LEFT</p> <p>DENSE</p> <p>SCATTERED</p> <p>LEFT</p> <p>LARGE</p> <p>MODERATE</p> <p>SMALL</p> <p>STRAW</p> <p>TURBID</p> <p>PURULENT</p> <p>HAEMORRHAGIC</p> <p>CIRC.</p> <p>HAEMOPERICARDIUM</p> <p>R. C.A</p> <p>DENSE</p> <p>SCATTERED</p> <p>LARGE</p> <p>MODERATE</p> <p>SMALL</p> <p>PERFORATION - SITE</p> <p>OBSTRUCTION - CAUSE</p> <p>DIVERTICULAR DISEASE</p>
--	---------------------------------	--	--

FIGURE 2.2. Proforma for the noting of external appearances of the body prior to external examination together with a chart for internal findings and organ weights. (Reprinted with permission from Drs. S. Hill and A. O'Reilly, St. Alban's and Hemel Hempstead NHS Trust, Hemel Hempstead, UK.)

fully established and it remains for 12 hours before fading off over another 12 hours.

### *Skin*

The general appearance of the skin is noted, bearing in mind that hypostasis and post mortem lividity may significantly alter its appearance and give a misleading impression of underlying pathology. Other aspects of the skin such as colour, pallor, jaundice, needle marks, bruising (which may be perfectly innocent from intravenous line insertion but may be associated with anticoagulant use, haematological disorders, drug abuse, or liver disease), rashes (Fig. 2.3), blisters, or ulceration should all be recorded. It is also wise to consider performing a skin biopsy for any undiagnosed lesion but such biopsy specimens should, if possible, be taken from an area that will not be obvious to distraught relatives when viewing the body subsequently and thereby aggravate their grief. Occasionally reflective ultraviolet photography may be useful in demonstrating faint marks or bruises not readily visible in normal light.

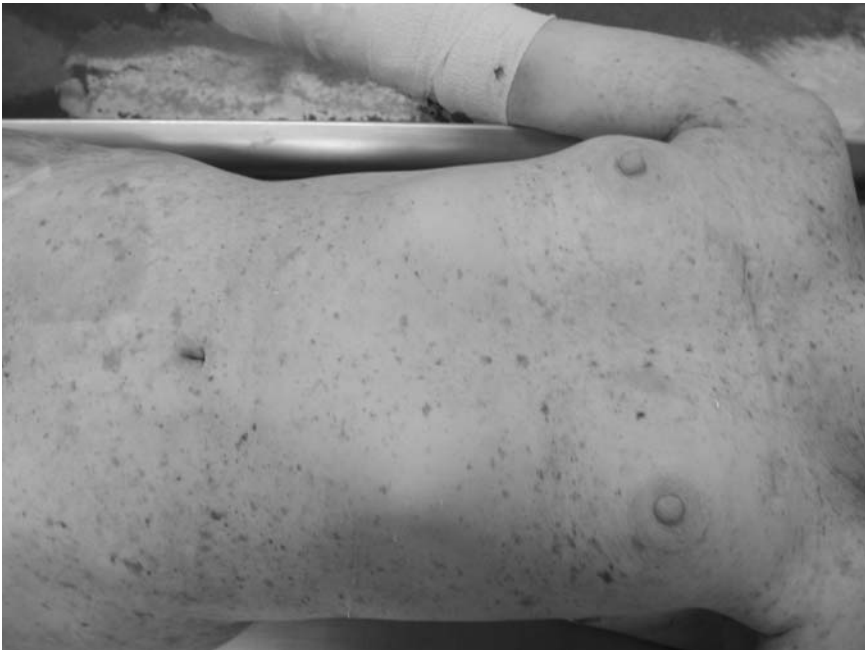

FIGURE 2.3. The skin should be inspected for many conditions, including rashes. (Courtesy of Mr. Dean Jansen, Whittington Hospital.)

## *Trauma*

In deaths associated with trauma it is essential to document all injuries, particularly those involving the soft tissues and bones. These should all be recorded on the body plan diagrams described earlier, with measurements and descriptions documented. Fractures are often obvious externally and usually can be confirmed by palpating and moving the area concerned. Some soft tissue dissection around a wound site may be appropriate to confirm the presence and extent of a fracture. Rarely it may be necessary to obtain radiographs to identify or confirm a fracture and this will also allow photographic documentary evidence of such pathology. These radiographs may have to be performed in the radiology department, however, and this obviously may produce logistical and potentially hazardous problems. In cases involving multiple injuries, such as road traffic accidents, the fractures are frequently documented in the accident and emergency department prior to death, before transfer of the patient to the mortuary. In some instances, such as cervical spine fractures, it may be useful to wait until the organs have been eviscerated before the anterior aspect of the upper vertebral column can be directly visualised and assessed clearly. When a fracture at this site is likely, or indeed possible, *an alternative approach is to inspect this region by dissecting the soft tissues of the posterior neck with the cadaver lying in a prone position on the post mortem table. This should prevent confusion caused by any apparent pathology or defect present as a result of overzealous dissection of the tissues of the antecervical vertebral area when “dropping the tongue” (see later).* This and other methods for examining the cervical vertebrae are described in Chapter 11.

## *Wounds*

Wounds also require accurate documentation, again with diagrammatic records. Occasionally it may be necessary to identify an infective organism associated with a surgical or traumatic wound. If this is required the first step is to clean the overlying and surrounding skin with alcohol, open up the wound by separating the edges, and introduce the tip of the swab into the defect formed. The swab can either be sent directly to the microbiology laboratory in the appropriate medium or container, or, alternatively, smear preparations can be made and stained in the histology/cytology laboratory. Clearly both can be performed, and as with any investigation it is always worth considering sending two samples to confirm the results.

## *Hair and Eyes*

Elementary characteristics such as hair quantity and colour are often overlooked in the external examination, but occasionally such simple observations may give an important clue in helping to identify an unidentified



corpse. Similar comments can be made regarding noting the presence of a wig. Toxicological analysis of hair may also be a useful means of documenting substance abuse or poisoning (see later). The eyes should always be inspected. Again, as in the routine clinical examination, the presence of jaundice, xanthelasma, Keiser–Fleischer rings, and arcus senilis may all indicate which internal organs need to be assessed in particular detail. Thyroid-related eye disease may be apparent and of course glass eyes should be documented in order to save possible embarrassment at a later date.

### *Mouth*

It is essential to inspect the mouth carefully and make a note of the presence of dentures. Other features that may be seen in and around the mouth include endotracheal tubes, any emissions, mass lesions, and evidence of trauma such as frenulum rupture. The latter may be an indicator of nonaccidental injury in children (and also sometimes in adults). The other external passages such as nose, ears, and genitalia also need close inspection, particularly in the setting of a perinatal post mortem. In this case their patency should be assessed by gentle probing of the orifice. In adults, identifying blood or masses emanating from one of the external orifices can sometimes be informative.

As discussed earlier, any significant features can be recorded on a preprinted plan of the body, but photographic records or video recording may also be appropriate in certain situations and may be very useful when the clinicians cannot be present at the demonstration. In these circumstances, however, one should always refer to the consent and verify that permission has been given. Another situation in which this simple method of documentation may be useful is in the training and teaching of students and postgraduate trainees. Even in this setting there is a requirement to confirm that consent has been granted.

## Preparatory Stages of Evisceration

Evisceration takes place in two stages, with a preparation stage preceding organ removal. Preparation includes the preliminary skin incisions and thoracic and abdominal wall dissections to expose the internal organs. It also involves removal of the sternum in order to gain access to the thoracic cavity to be able to examine the internal contents. We have chosen to include here the technique for dissecting the neck and releasing the neck structures, as this is common to all of the subsequent methods of evisceration. At the completion of this stage, organ removal can proceed via any one of several well-recognised methods described in Chapter 3.

The four most widely used techniques are described here, and although individual laboratories and practitioners may have their own techniques, these usually vary only slightly from one of these four major protocols. It

is noteworthy that different methods are followed in different countries, with local preference dictating the technique that is passed on to the trainees passing through a particular department. Depending on the clinical situation and personal preference, the method followed may vary—removal of either individual organs or groups of organs (organ blocks), removal of organs en masse, or dissection in situ; the relative pros and cons of each method are discussed later in this chapter. Whichever method of evisceration is preferred, the general preparation stage follows a similar routine.

Having first established a comprehensive external examination, one needs to deal with any significant findings noted during that part of the examination (such as a wound, cannula, or drain site) before the internal examination proper begins. At this stage it is also necessary to identify fistula sites if present so that they are not destroyed or distorted during organ evisceration. The course of the latter may be demonstrated by the injection of Indian ink through the external porthole and tracing the route of the dye's movement. *Alternatively, barium sulphate contrast medium can be introduced using a syringe via the same orifice and subsequent X-ray films taken.* As stated in the previous section, drains and cannulae should not be removed before their exact internal position is established, as occasionally this may have a direct bearing on the ultimate cause of death. For example, cases have been recorded in which accidental penetration of the wall of the superior vena cava has occurred during central venous line insertion, with catastrophic and fatal hemorrhagic results.

Several other less common situations may arise that need to be investigated early in the examination so that their presence is not overlooked. In certain instances, if the particular condition is not searched for and recorded specifically at the outset then it may well be impossible to reconstruct the tissue at a later stage of the examination to confirm or refute its presence. Two good examples of such situations include pneumothorax and air embolus. These obviously are very uncommon but still need to be considered in *every* case, prior to any substantial cutting. The possibility of such pathology needs to be specifically sought and excluded. An examination for a pneumothorax should be part of all post mortems, as a matter of routine; it is described in detail in the following section. Formal investigation for an air embolus applies to a more restricted number of cases and is therefore described briefly later and repeated in the section on maternal deaths in Chapter 8.

## Collection of Samples

Collection of blood and/or other tissue or fluid specimens for microbiology, toxicology, or biochemistry assessment should be performed as early as possible during the examination to keep contamination to a minimum. Samples should be transported to the appropriate laboratory with all relevant paper-

work adequately completed as soon as possible after death. In many cases this may be necessary before dissection begins. For microbiology, nasopharyngeal swabs, wound swabs, urine, or blood can be taken before the examination proper proceeds, sometimes a day earlier. It may be useful on occasion to wait for the results of such tests before deciding on any extraordinary techniques that may be required during the examination. It may also be helpful to await specific serological results, such as those that indicate human immunodeficiency virus (HIV)-positive status, because these may actually preclude a post mortem examination (at least in a routine mortuary unequipped for high-risk cases), in which situation the body should be transferred to an appropriate centre. Fluids may also be sampled for chemical or toxicological analysis prior to dissection but it should be remembered that cardiac blood may produce problems with interpretation owing to diffusion, particularly with alcohol. This usually arises if there is a delay before the examination takes place.

The following are samples that may be required at post mortem:

- Blood
- Urine
- Hair
- Vitreous humour
- Gastric contents
- Bile
- Cerebrospinal fluid
- Samples of tissue

### *Blood*

Blood can be sampled from the heart by performing a cardiac puncture with a syringe and long sterile needle, or more usually from a large femoral vessel, subclavian vessel, or, less optimally, a jugular vein. The last two peripheral vascular sites should be readily accessible and fairly easy to cannulate. Cardiac blood is rather more difficult and requires blind puncturing and aspiration through the anterior chest wall if performed before evisceration. A technique similar to that used for pericardial paracentesis can be employed by passing the needle through the fifth or sixth intercostal space anteriorly and applying gentle suction on the syringe plunger. It is difficult to contemplate when this awkward procedure for sampling blood may actually be required, but it is included here for completeness. Once the chest has been opened the situation is simplified and the heart can be visualised directly.

If blood is required for microbiological analysis it is preferable to take the sample before the examination if possible, using a sterile syringe and needle. The blood is collected into the appropriate blood culture bottles and transported in these to the microbiology department. Blood samples for

toxicology, including drugs and alcohol, should also be taken early to avoid contamination later on in the examination. It should be remembered that right atrial blood may overestimate glucose concentration because of glycogenolysis in the liver, and that samples taken for alcohol estimations may need to be collected into appropriate tubes containing antibiotic (to prevent fungal and bacterial growth) to prevent false high values. Further details of the appropriateness of blood sampling are given in Chapter 13.

### *Urine*

Urine can be obtained in a variety of ways, either before the dissection begins or after the abdomen is opened. In the first instance urine can be collected in a suitable sterile or nonsterile “universal” container for either microbiological or toxicological analysis by catheterising the urethra and bladder and draining off the bladder contents. *An alternative is to puncture the anterior abdominal wall directly, above the pubic prominence, and withdraw urine into a syringe via a sterile needle.* It is obvious that this latter method may also be performed using the same equipment once the abdomen has been opened and the bladder punctured under direct visualisation. Once the abdomen is open the dome of the bladder can be opened using forceps and scissors or a scalpel while the lower abdominal contents are held away by an assistant. A syringe is inserted through the opening in the bladder wall and urine removed and collected into a suitable container.

### *Cerebrospinal Fluid*

There are three acceptable methods for collecting cerebrospinal fluid (CSF), either by performing a routine lumbar puncture on the intact body before the examination—which will clearly require considerable assistance—or by withdrawing fluid using a needle and syringe from the central cistern or lateral ventricles, the latter after the skull has been removed. CSF aspiration from the central cistern involves passing the needle through the atlanto-occipital membrane, just below the occiput, into the cistern. Of course, CSF can be removed from the foramen magnum once the brain has been removed, but this will inevitably be contaminated with blood and possibly other fluids, so the results should be interpreted with caution.

### *Vitreous Humour*

Vitreous humour can be aspirated by puncturing the sclera with a sterile needle attached to a syringe. This is introduced laterally and volumes up to 2 to 5 ml can be removed in this way. The needle should be left in situ while the syringe is removed, the fluid collected into a container, and the syringe reconnected once filled with saline to replace the aspirated fluid. It has been shown that concentrations of electrolytes such as sodium and chloride

may be measured fairly reliably in this fluid for some time after death and that glucose concentration is approximately half that in the peripheral blood. Toxicological analysis of vitreous humour may also sometimes be possible, although with all measurements the results need to be assessed in context and the time since death may have a significant effect on the values.

### *Stomach Contents*

Gastric contents may occasionally be required for toxicological analysis, and although sampling will obviously be possible only after the peritoneum has been opened, it is discussed here with the other sampling techniques. When analysis is required the easiest way to collect the contents is to lay the unopened stomach over the edge of the dissecting board and make an incision along the greater curve, catching the contents as they spill from the gastric lumen. *Alternatively, the stomach can be opened at any site and the container introduced through the incision to collect at least some of the contents.* If it is particularly important that an accurate estimate is required of some constituent of the contents then it may be best to tie off the cardiac and pyloric ends of the stomach, transect the duodenum and oesophagus, and send the whole specimen intact with contents in situ. A similar method may be used for retaining intestinal contents. This involves tying off a short (approximately 15 cm) segment of small or large bowel, separating it from the rest of the tract, and sending it for analysis.

### *Bile*

Bile may be analysed for levels of drugs, particularly those excreted through the biliary system. Bile is obtained by passing a needle, attached to a syringe, into the lumen through the wall. Bile is aspirated and collected into a container prior to transport to the laboratory. *Alternatively, bile can be collected once the gallbladder has been removed during evisceration and bile expressed through the cystic duct or collected when the body wall is incised.* There is obviously more scope for loss of sample this way, however, and needle sampling is preferred.

### *Hair*

Samples of hair can be used to determine previous exposure to a variety of substances. This is most commonly required in cases of drug toxicity or poisoning if other samples such as blood or urine are not available (perhaps because of decomposition) or when determination of longer term low-quantity exposure is suspected. In such circumstances the presence of the substance can be confirmed and levels correlated with chronicity or toxicity.

Hair is usually sampled from the head, although hair obtained from other areas is also acceptable. It is useful and frequently necessary to include the root of the hair, and so it is better to pluck the hair rather than cut it. (This may be different for forensic examination in which cut hair is examined for substances attached to the hair.) The hair is often transported to the laboratory in foil. Analysis can determine the drugs levels, and the period of use can be established when correlated with the position of the sample along the hair.

### *Microbiology*

If microbiological examination is warranted then swabs may be used as a method of fluid/contents sampling at any of the preceding sites (meninges, intestines, and bladder). These are taken by introducing the tip of the swab into the area of interest and rapidly closing the swab stick in the holder after the swab has been inserted. If superficial wounds are present or swabs need to be taken from mucocutaneous orifices, the edges should be avoided and the swab introduced deep into the cavity after the local adjacent area is cleaned before swabbing. A similar technique can be used for producing microbiological samples from solid tissues such as the spleen. The surface of the organ should be seared using a flat-faced soldering iron or scalpel blade. The latter is heated in a flame (a Bunsen burner can be quite useful) before using. A sterile blade is then used to incise the tissue and the swab is inserted as the edges are held apart briefly. Again the swab is replaced into its sheath. With solid organs such as the kidney, spleen, or liver a portion of tissue can be removed using the same searing method and a sterile scalpel, the tissue being about the size of a small die (a cube with 1-cm sides).

## Preliminary Skin Incisions

As mentioned earlier, the preparation stage of evisceration follows a relatively standard approach irrespective of the subsequent manner of organ removal. The general principles are to cut into and reflect the skin and subcutaneous soft tissue to expose the deeper tissues. In the thorax this obviously includes removing part of the thoracic cage to allow access to the internal structures. Before any incisions are made, the top of the back should be supported from underneath by a block that is positioned between the scapulae so that the neck is extended. In doing so the following skin incisions are made easier.

### *Anterior Body Wall Incisions*

Many initial skin incisions are used in preparation (see Fig. 2.4a–d), but the most commonly used all follow similar routes with the first incision made

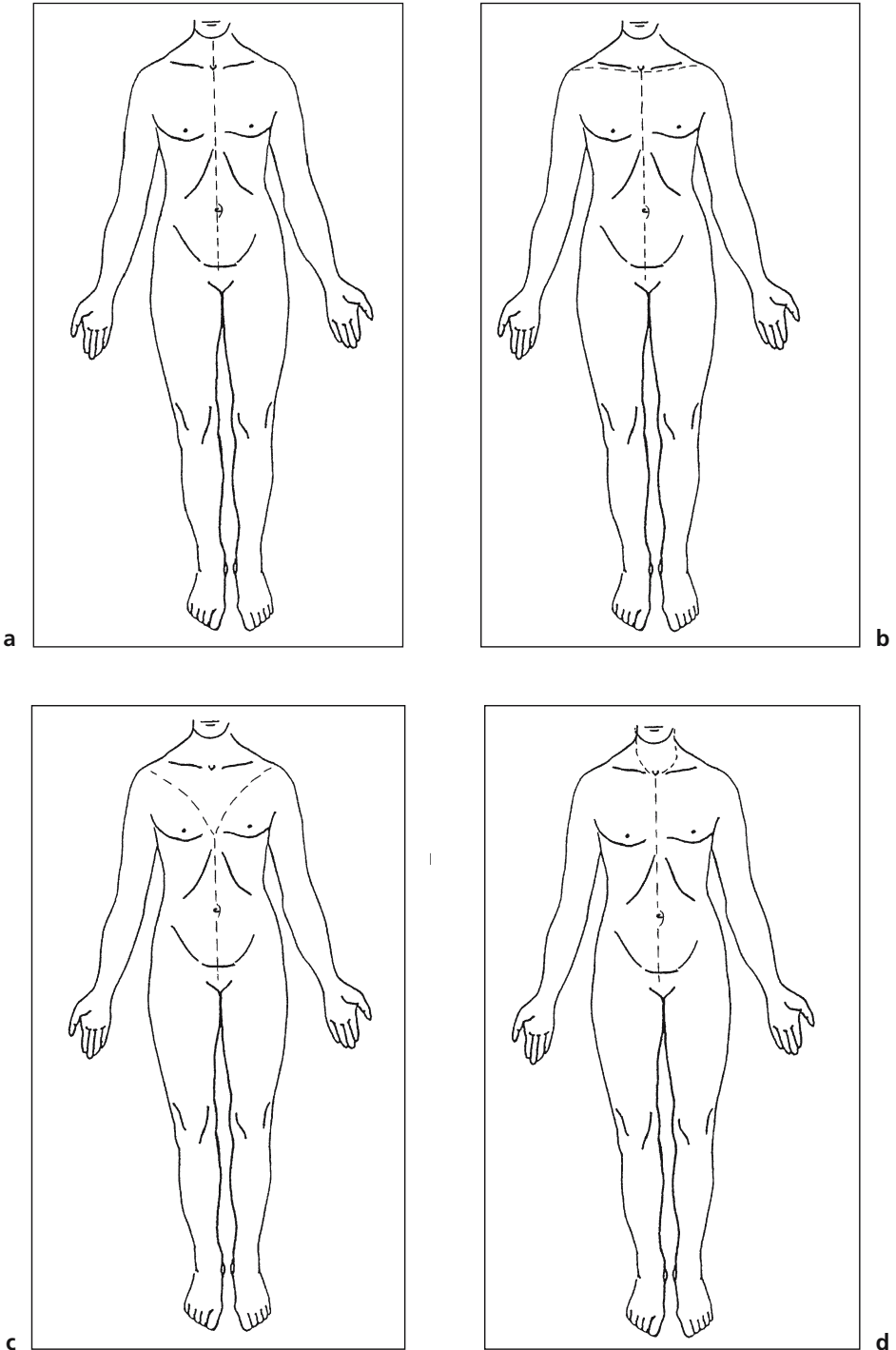


FIGURE 2.4. Skin incisions.

from the suprasternal notch inferiorly along the sternum, extending further inferiorly along the anterior abdominal wall to the pubis. Most prosectors use the PM40 for these incisions. The upper part of this incision requires substantial pressure in cutting down to the bone, but movements in the lower portion should be gentler, with care not to damage the underlying abdominal organs. The lower portion should travel down the midline, skirting just lateral to the umbilicus to end at the symphysis pubis. One should be particularly careful with the abdominal wall incision if the presence of free gas within the peritoneal cavity is suspected. This clearly needs to be confirmed or excluded before the peritoneal cavity is opened and any gas escapes unnoticed.

If intraperitoneal gas is likely to be present such as with a gastrointestinal tract perforation, a small pocket should be made in the extraperitoneal soft tissue of the anterior abdominal wall which is then filled with water. The peritoneum is punctured through the water and any gas should be demonstrated as bubbles within the water. Free abdominal gas is obviously extremely rare, and in most routine cases formal testing for this is not required. If this is not necessary, the peritoneum can now be nicked through with the scalpel and two or three fingers inserted into the abdomen. The abdominal wall skin and subcutaneous soft tissue is then lifted with this hand while a large bladed knife (PM40) or scalpel is used to make longitudinal cuts down to the pubis (some like to cut carefully between the fingers held apart). These large abdominal flaps of skin and underlying musculoadipose tissue can be loosened by slicing through the everted muscle coats but being careful not to cut too deeply and puncture the adjacent skin. With all incisions, it is wise to avoid (particularly) recent surgical scars so that they can be inspected carefully before they are damaged beyond recognition.

*Alternatively, a Y-shaped incision is made with the straight line of the Y corresponding to the xiphisternum-to-pubis incision described earlier, and the forks of the Y running superiorly across the chest, skirting the breast tissue medially and extending toward the lateral ends of the clavicles and acromium processes.*

At this stage the peritoneum can be inspected and a careful note of any masses made. All fluid should be collected whether it be ascites (associated with visceral tumours, congestive cardiac failure, or portal hypertension), peritoneal pus (indicating intraabdominal infection and/or perforation), or blood (following a ruptured vessel such as an atheromatous aneurysmal aorta). Any relevant tissue or material is removed from the peritoneum and dealt with accordingly. Any blood present is collected and its volume measured. Pus should be collected in a sterile container using either a sterile syringe or syringe and needle. *An alternative is to swab the infected peritoneal fluid or surface and transfer to the microbiology department in the sealed swab holder.* Obviously only the superficial structures are easy to inspect, but inspecting and palpating the organs may reveal a mass. Usually,



as the anterior organs are removed the deeper ones become visible and these can be inspected and palpated.

### *Neck Incisions*

The incision is continued superiorly in one of at least three ways. The first is a straight incision in front of the trachea. The second is bilateral extension of the primary incision along the anterior border of the clavicles to the skin in front of the acromium process. The third is also a bilateral incision, extending the primary incision again along the anterior border of the clavicles but moving superiorly toward the tragus along the lateral side of the neck, ending just behind the ears. If air embolus is a possibility the neck dissection should be performed particularly carefully, being alert not to injure the large neck veins. The skin and superficial subcutaneous tissues of the neck are now reflected upwards to expose the underlying structures. A useful safe and controlled method is to grasp and retract the cut border of the skin using one's fingers or nontoothed forceps and make horizontal sweeping slices with a small scalpel along the dermosubcutaneous tissue junction/plane. The latter cuts should be extremely gentle and made with limited pressure with the blade angled away from the skin surface so that penetration of the skin should not occur. Be extremely careful not to make any "buttonholes." Whichever method is chosen the soft tissue of the anterior neck should now be exposed.

### *Face*

Rarely it may be necessary to extend the superficial subcutaneous dissection superiorly, to display the underlying facial soft tissue and/or bone. This may be required when dealing with forensic type cases that involve facial damage caused by traumatic injury, or in the case of parotid gland disease. Particular care, with extreme patience, needs to be taken in pursuing the plane between dermal and subcutaneous tissue. Patient dissection should enable precision in order that the overlying skin is not punctured (the latter is impossible to satisfactorily reconstruct invisibly). Directing the scalpel blade away from the epidermal surface at all times helps to prevent such "buttonholes."

### *Demonstration of a Pneumothorax*

The skin and subcutaneous tissues are then reflected from the chest wall, being careful not to open the pleural cavity. This is done by sweeping cuts with a PM40 through the subcutaneous tissue over the chest wall, angling the blade down toward the bone of the ribs. Be careful not to puncture the intercostal soft tissue and penetrate the pleural space, as this releases air from an underlying pneumothorax and makes subsequent demonstration

impossible. When this is completed, by reflecting to the mid-axillary line, water is poured into the angle between subcutaneous tissue and the chest wall, and the intercostal tissues below the water line are pierced with a blade. This should establish whether there is an underlying pneumothorax, which may occur following trauma (a tension pneumothorax) or in patients with chronic obstructive airway disease or asthma. If present, bubbles of air will be seen rising through the water. If this sealed procedure is not followed, a pneumothorax can easily be overlooked.

*An alternative method is possible but it should be performed before any incisions are made. This involves introducing a wide-bore needle attached to a 50-ml syringe into the subcutaneous tissue over an intercostal space. The plunger should be removed previously and the syringe then filled with water. The needle is pushed slightly deeper to enter the pleural space and the water watched for the presence of any bubbles. The latter is evidence of a pneumothorax. A similar procedure is then followed on the other side. A third alternative involves post mortem chest X-ray film and assessment in a manner similar to detection of a pneumothorax in a living patient. A radiological opinion might be helpful in this case.*

### *Air Embolus*

When the possibility of a venous air embolus exists it may be worth considering obtaining a plane chest X-ray film before eviscerating in an attempt to demonstrate the pathology. The retinae should also be examined thoroughly, looking for intravascular bubbles with an ophthalmoscope (this requires corneal moistening with isotonic saline to prevent interference from corneal opaqueness). During dissection of the neck the large neck veins should be carefully exposed but not opened. It is crucial that the large neck veins are left intact before the heart is dissected in situ to avoid the confusion of air being introduced during evisceration. The abdomen is opened in the usual manner, and the abdominal contents are moved gently out of the way to inspect the inferior vena cava closely for bubbles in the lumen through its transparent wall.

The sternum is then removed by dividing the ribs, being careful not to puncture the pericardial sac. The medial dissection should be through the sternum distal to the sternoclavicular joint. The internal mammary vessels should be clamped. *An alternative is to cut a small hole in the sternum and leave the ribs intact.* The anterior pericardial sac is then opened and the external epicardial veins inspected for evidence of intraluminal bubbles. Water is then introduced into the pericardial space to fill it. Once completely covered in water, the right atrium and ventricle are incised and careful inspection is made to identify any air bubbles that escape. *Alternatively, a water-filled syringe (minus plunger) is connected to a needle, which is inserted into the right ventricle, and the syringe chamber inspected closely for the presence of bubbles.*

When the presence of an air embolus is established the vena cavae should be clamped and the thoracic and abdominal cavities flooded with water in an attempt to localise the source of the embolism if at all possible. Sometimes intracardiac gas produced by post mortem bacterial activity may produce a false air embolus appearance. To prevent error, cardiac blood and pericardial fluid should be sent for microbiological examination at the same time. *A quick alternative is to perform a pyrogallol test (Ludwig 1979). For this a 2% pyrogallol solution is freshly prepared and approximately 4 ml collected into two 10-ml syringes. Four drops of sodium hydroxide (0.5M) are introduced into the first syringe and the mixture should turn yellow. Gas is then aspirated from the right side of the heart and the needle removed and replaced with a stopper. The syringe is then shaken and the mixture should turn brown if air is present. In the absence of air the solution stays clear (indicating gas production by bacteria). The second syringe is used as a positive control by following the same procedure as earlier but including a volume of air at the same time as the sodium hydroxide is introduced. This should obviously also turn brown. The second syringe can also be used as a repeat test should the first prove unsatisfactory.*

Arterial air emboli are even more unusual and usually result from traumatic injury such as thoracic trauma involving the pulmonary veins or following air introduction during cardiopulmonary bypass. A much smaller volume of air is associated with such emboli and accordingly these are much more difficult to demonstrate. Systemic emboli may be verified by inspecting the intracranial vessels of the meninges and circle of Willis and then examining under water after clamping the internal carotid and basilar arteries if necessary.

### *Chest Wall Dissection*

Once the soft tissue has been reflected from the chest wall the breast tissue should be palpated and sliced longitudinally from the deep/internal aspect to expose any masses present. If present, several blocks of the lesion should be taken for subsequent histological assessment. Axillary lymph nodes should also be sampled in such circumstances. After this the intercostal muscles are cut so that the underlying lung can be pushed away from the parietal pleura. Superficial gentle cuts are made and if there are no pleural adhesions the lungs should lie posteriorly within the thoracic cavity as a result of gravitational effects, and slicing through the intercostal muscles should not cause any inadvertent damage to the underlying lung parenchyma.

Any loose adhesions that are present can usually be detached quite easily by blunt dissection using fingers pushed through the intercostal spaces produced after cutting through the muscles. Densely adherent fibrous bands may indicate old infection such as tuberculosis, chronic lung disease, or a pleural or underlying lung tumour. In such cases it is much more difficult

to detach firm adhesions. The principal idea in this situation is to try to find the plane between the inner aspect of the chest wall and the lining parietal pleura. This is usually possible but it may take a little time to identify the correct plane. Once this is found, by firm blunt dissection, or a limited amount of knife cutting, the parietal pleura can be worked away from the chest wall and left attached to the underlying lung. Most of the tissue can be detached in this way but it may be necessary to deal with some of the remaining tissue at a later stage when the sternum has been removed.

The next step involves reflecting the sternocleidomastoid muscles superolaterally from their inferior sternal and clavicular attachments in order to expose the large veins of the neck. It should always be remembered, however, that if the craniocervical junction is a particular area of interest, for example, in patients with rheumatoid disease or when this area needs to be removed completely for vertebral artery examination, the sternocleidomastoid muscles should be left attached to their insertions [1]. If they are not, then there will be virtually or absolutely no anchoring tissues for the head and this will become completely detached—a rather distressing situation for both pathologist and technician waiting to reconstruct the body prior to viewing by the relatives.

### *Removing the Sternum*

Using the rib cutters and beginning inferiorly, the costal cartilages are cut by sliding the lower blade of the shears beneath the cartilage close to its bony attachment to the rib and shearing through the firm tissue as cleanly as possible (in younger cadavers the cartilage is usually soft enough to cut through with a knife). Try to cut the cartilage just medial to the rib rather than the bone in to avoid exposing sharp edges. *Alternatively, the sternum can be removed by cutting through the same regions but from the second rib inferiorly to the lower costal margin.* In older cadavers the costal cartilages may be extensively calcified, making this impossible, but in this case safety can be optimised by putting a towel or the reflected skin over the potentially hazardous edges (Fig. 2.5). The sternum can now be released by grasping the lower end and lifting the sternum as horizontal cuts are made upwards toward the deep surface of the sternum to detach the adjacent anterior mediastinal soft tissue. It is important to slant the blade and direct it toward the underside of the sternum so that soft tissues such as the pericardium are not damaged. If the latter were to occur then the pericardial fluid contents may be released and lost into the pleural cavity. Knife cuts may also be necessary through the strands of tissue still attached around the costocartilagenous areas previously divided.

Using a large blade, cuts are then made through the sternoclavicular joints and the clavicles reflected. To do this the lower border of the clavicle can be traced toward the manubrial sternal edges using the PM40 and the angle between clavicle, rib, and manubrium divided. Gentle manipula-

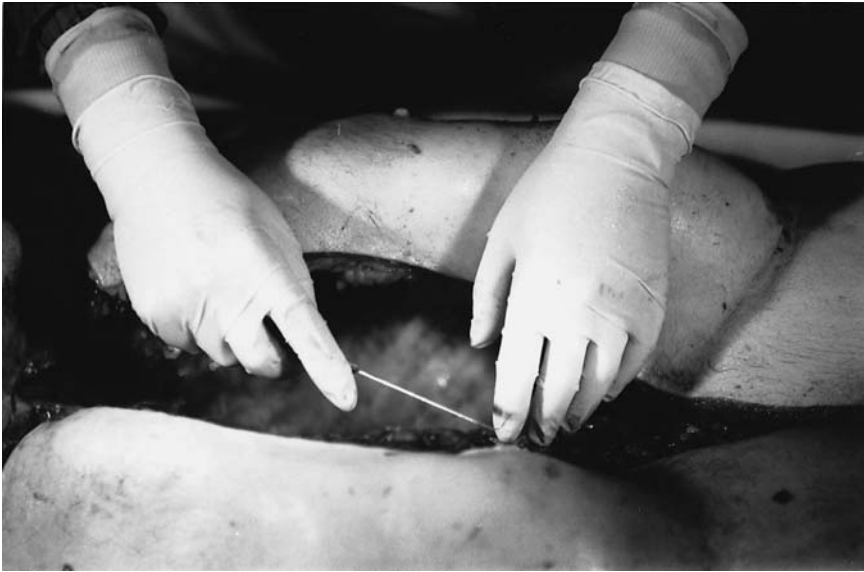

FIGURE 2.5. Protection from cut ends of ribs by skin.

tion of the lateral part of the clavicle may aid in locating the exact site of the joint. The knife is inserted into the joint and a rotary cut is made together with peripheral manipulation and a series of up-and-down strokes through the joint to disarticulate the clavicle from the sternum. The underlying vessels are inspected before the first rib is cut about 1 cm lateral to the cut made through the second rib/cartilage. Occasionally this joint can be heavily calcified and the rib shears can be utilised again.

Although this procedure often requires considerable force it should be remembered that large vascular structures lie just beneath this area and so the cuts made here should not be too deep, as these vessels can be damaged easily. In this way the large vessels situated just beneath the joints should be protected from extensive inadvertent damage caused by blind cutting which causes blood to mingle with pleural contents. The sternum can now be lifted off. It is now put to one side, as it will almost certainly not provide any useful information relevant to the remainder of the examination.

### *Mediastinal and Pleural Inspection*

The thymus may be visible at this time, particularly in younger bodies or in the presence of thymic pathology. In addition, the presence of mediastinal disease such as mediastinitis or mediastinal emphysema can be established. Once the thoracic cavities are exposed access can be gained to the pleural spaces, and any pleural fluid can be collected using a ladle and quantified

in a measuring jug. Fluid can also be collected at this stage for protein content measurement, cytological analysis, or any other type of investigation which may be required subsequently. Other material such as blood or pus can also be collected for subsequent quantitative or qualitative analysis.

### *Freeing the Oral and Neck Structures*

After the mouth is inspected thoroughly, any loose contents or dentures are removed manually. The tongue is then “brought down” by making an incision around the internal surface of the mandible from below, being careful not to cut through the salivary glands or tongue, which should be inspected at this point to check that no significant pathological lesions are present.

To perform this part of the dissection safely, a hole is first produced by the point of the blade through the muscular tissue in the midline just behind the midline symphysis of the lower jaw. The attached suprahyoid, lingual, and other muscles will thereby be divided. A finger or fingers can then be pushed through this hole behind the inner surface of the mandible and the tongue grasped and pulled through this gap. The scalpel is placed back through this same gap and the soft tissue dissected away from the posterior aspect of the internal rami of the mandible, sweeping laterally and dividing the glossal muscles as one continues back to the posterior pharynx. The parotid and submandibular glands should be examined as this dissection takes place.

The hole should now be large enough to allow the whole tongue to be pulled inferiorly through it and the stylohyoid ligaments divided. While the tongue is held further down and pulled firmly with the free hand the upper parts of the styloglossus are freed and a series of firm horizontal incisions made through the soft palate and posterior pharynx (including the tonsils) down to the fascia covering the anterior surface of the cervical vertebrae.

The first of these horizontal cuts should be made as high as possible above the uvula and oropharynx so that the carotid arteries are removed with this section of tissue. It is important to remove the carotid bifurcation in order to inspect the area and identify any atheroma, thrombus, or other significant pathology at this site. The pharynx is closely inspected at this time and any masses noted. Swabs are collected at this stage if infection is suspected and if they have not already been taken.

## Detailed Examination of the Neck

There are certain situations, such as infarcts in the posterior intracranial fossa or forensic cases dealing with neck compression or traumatic injury, in which a more careful and detailed examination of the neck structures is

essential [2]. The method of dissection varies only slightly from the method described earlier and will be directed by the type of suspected injury or disease. If compression injury is suspected care needs to be taken with dissection of the anterior structures; in traumatic spinal damage the posterior compartment is of more interest.

### *Anterior Structures*

After careful external examination of the neck and removal of the brain to allow drainage of blood from the head in order to avoid artefactual haemorrhage, attention turns to the anterior neck dissection. In fact, some advocate going further than this and suggest dividing the superior vena cava and trachea, and removing the chest organs prior to neck dissection. For the latter a bilateral, curved neck incision is recommended (as described earlier) and care is taken to avoid injuring the neck veins during dissection of the subcutaneous tissue. This tissue and the adjacent platysma muscle are inspected for evidence of bruising at this stage. The sternocleidomastoid muscles are left intact at this point and the external jugular veins examined.

Once the integrity of the external jugular veins is established, the underlying muscles are reflected in layers. First the sternal head of the sternocleidomastoid muscles is divided from the manubrium and then the more lateral clavicular head is detached. These are reflected laterally and the suprahyoid and infrahyoid muscle groups are then examined, being careful not to damage any adjacent vessels and produce a false impression of significant haemorrhage. The carotid sheath, including carotid arteries, internal jugular veins, and vagus nerve, is exposed after the omohyoid is reflected. The contained structures are gently mobilised and inspected for evidence of injury and haemorrhage. The carotid bodies can also be inspected at this point.

Further dissection of the anterior neck structures is identical to the routine method described earlier, although extra vigilance is required to identify any evidence of traumatic insult. All of the antevertebral tissues of the neck can now be separated by dividing all of the structures at the thoracic inlet, or further dissection can follow removal of these structures with the thoracic contents (as described in Chapter 3).

### *Dissection of the Anterior Neck Structures*

Once the “strap” muscles are established as free from injury, they are detached from the larynx to expose the thyroid and cricoid cartilages. The larynx is examined from the posterior aspect and the superior cornua identified by incising the pharyngeal mucosa on their posterior surface and

continuing these bilateral incisions longitudinally and inferiorly. Any undisplaced fractures should be carefully identified or excluded.

The hyoid bone itself is inspected by making a tranverse incision across the pharyngeal section of the tongue, continuing laterally through the hypoglossus. This will expose the upper surface of the bone. Once again this is carefully inspected for evidence of fracture. The contents of the carotid sheath are examined by opening the internal jugular veins from their junctions with the subclavian and brachiocephalic veins. Small scissors are used to open the vessels from below. A similar procedure is used to open the common carotids from the aortic arch on the left and the brachiocephalic artery on the right. Inspect the wall and internal surfaces for evidence of tears or thrombi.

### *Radiography of the Anterior Compartment*

A useful method for documenting fractures (especially undisplaced or partial) or airway narrowing is to take radiographs of the anterior compartment contents. X-ray films are taken either in the mortuary or after transfer to the radiology department. This will usually be necessary immediately after excision of the neck structures and before formal dissection of this region begins, although occasionally fractures may be identified during dissection that are not obvious radiologically. Several images should be taken including oblique and anteroposterior views. X-ray films can also be useful in assessing the degree of calcification present in the larynx and therefore the amount of force required for fracture (more calcification implying greater ease in fracturing).

### *Posterior Structures*

The following methods may be essential to document relevant pathology but it should be remembered that reconstruction will be time consuming and will require experience, and thus these procedures should not be undertaken lightly. Removal of the anterior compartment allows the prevertebral fascia to be inspected for evidence of traumatic injury such as the presence of crepitus. The fascia is then reflected from the underlying bone. The body is turned over and the superficial tissues (including the ligamentum nuchae) reflected from the occipital region inferiorly to the base of the neck to expose the underlying soft tissue.

### *Examination of the Cervical Spine*

Several methods can be used for examining the cervical spine, and these are described fully in Chapter 11. The methods for examining the vertebral arteries and for performing vertebral angiography are discussed here.



### *Examining the Vertebral Arteries*

The vertebral arteries can be examined and dissected in one of two principal ways. The first involves removal of the complete cervical spine as described in Chapter 11, followed by decalcification of this block before dissection. For decalcification the excised block is first fixed for 3 to 5 days in formalin, followed by 2 to 5 weeks of immersion in a 10% formic acid/formalin mixture, changing the fluid regularly. When fully decalcified the block of tissue can be serially sliced transversely at 5-mm intervals and the vertebral arteries inspected macroscopically. Any pathological lesion obviously can be sampled for histology.

*Alternatively, isolated vertebral arteries can be removed and examined away from the other cervical structures. One of the ways this can be achieved begins by identifying the vertebral arteries as they originate as the first branches of the subclavian arteries. The surrounding soft tissue and the anterior surfaces of the transverse processes are cleared away. The arteries are followed to their point of entry into the foramina in the transverse processes of the sixth cervical vertebrae. Next, the bony bars forming the anterior border of the foramina are cut away with side cutters or small shears and the route of the arteries followed superiorly. As the arteries leave C3 they run laterally to enter the foramina in the axis and then upwards to enter the foramina of the atlas. They now run medially and posteriorly, skirting the upper surface of the posterior arch before once again travelling upwards to pierce the atlanto-occipital membrane. The bone forming the posterior wall of the foramina should be chipped away in order to follow the last part of the vessels' extracranial course. The atlanto-occipital membrane is incised and the path of the vessels is followed into the skull.*

Most of the latter can of course also be performed on an excised intact cervical spine block.

### *Vertebral Angiography*

In cases of sudden collapse after head or neck injury, the possibility of subarachnoid haemorrhage following vertebral artery trauma should be entertained. If this is the case then angiography, possibly followed by excision of the cervical spine and skull base, should be considered. The subarachnoid haemorrhage should be evident after the vault of the skull has been removed.

For angiography the vertebral arteries are identified after the subclavian soft tissue has been cleared on either side of the lower cervical spine. The brain is then gently lifted to expose the underlying circle of Willis. The basilar artery is ligated by tying a suture around it (most easily by passing a suture with attached curved needle underneath it) as close to its origin from the junction of the vertebral arteries as possible. The brain is now replaced and the skull vault put back and secured with the scalp skin (a

safety pin may be necessary). The neck is slightly extended and the cervical region is revisited.

The vertebral arteries are divided close to their origins from the subclavian arteries and one of the arteries (usually the larger) is injected with approximately 5 to 10 ml of a warmed mixture containing barium sulphate, gelatin, and gum arabic for elasticity. Injection continues until the white mixture begins to appear at the cut end of the contralateral artery. This is then left to cool before radiographs are taken either in situ or after the cervical block is removed. Once again anteroposterior, lateral, and oblique views should be taken.

At this point the technique varies depending on the evisceration method chosen.

## Advantages and Disadvantages of the Different Post Mortem Examination Methods

Before the various evisceration methods are described, it is worthwhile at this point to include a few comments about the general differences between the techniques. It is also important to discuss the relative advantages and disadvantages of each method. It is hoped that in this way the benefits of knowing all of them will become apparent.

### *En Masse Dissection*

The first method to be discussed is the en masse technique, based on a method originally described by Letulle. This involves removing most, if not all, of the internal organs at one time. This method usually requires some help in certain aspects of the procedure and provides a rather bulky mass of organs for subsequent assessment and dissection. Depending on the operator, it may be one of the more rapid techniques for removing the organs from the body although the ensuing dissection is the most lengthy. It has the important advantage of leaving all organ and system attachments intact, allowing relationships between various organs to be adequately assessed. In fact this method is the best of the four for observing the pathological and anatomical relationships between structures. In certain circumstances this method is essential, if the full extent of a pathological process is to be appreciated and realised. For example, the number and sites of vessels involved by a dissecting aortic aneurysm can be fully documented only if all of the central main arteries remain in continuity with the aorta before opening. Demonstration of other pathological processes that occur around or on both sides of the diaphragm will also be best visualised with this method. Letulle's procedure is usually followed for evisceration of organs in perinatal autopsies, as the organ block is obviously not as bulky

in these cases as it is in adult cases. One of the drawbacks with this method is that large external incisions are required and a large conglomerate of organs is produced. Another is that in inexperienced hands this method can be rather time consuming.

### *The Virchow Method*

The Virchow method of evisceration is simply removal of individual organs one by one with subsequent dissection of that isolated organ. This of course is perfectly reasonable in assessing individual organ pathology and is an extremely quick and effective method if the pathological interest is in a single organ. Frequently, however, pathological abnormalities are detected in several organs and in this case relationships will often be difficult to interpret or completely destroyed.

### *En Bloc Removal*

The en bloc method of evisceration is a concession that combines the preceding two methods and is probably the most widely used in the United Kingdom. Ghon developed this method, which is relatively quick but preserves most of the important inter-organ relationships, so that inter-organ relationships and effects such as lung changes caused by cardiac disease and proximal effects of distal urinary tract obstruction can be more readily observed and demonstrated with ease. One of the benefits of this method is that as well as retaining organ relationships, flexibility within the method means that most of the examination can be performed in this standard way. However, if the detected pathology dictates an alternative approach such as cirrhosis (when varices need to be identified and the oesophagus should be transected higher than usual) or an aortic aneurysm (when the extent of vessel involvement needs to be determined and the aorta can be left intact and retained with the cardiothoracic block of tissue), minor deviations from the routine are easily accommodated. One problem with this method, however, is that if unexpected pathology is encountered (again a good example being oesophageal varices related to cirrhosis and portal hypertension) these could be destroyed and thereby neglected by transecting the lower oesophageal region. One can of course modify this method in such cases to preserve oesophageal varices by mixing the methods available. In some circumstances it may be worthwhile to eviscerate most of the organs by means of one method but also including limited aspects of another method for one particular site.

### *In Situ Dissection*

The fourth method, that of Rokitansky, is in our experience rarely performed but is included here briefly for the sake of completeness. This

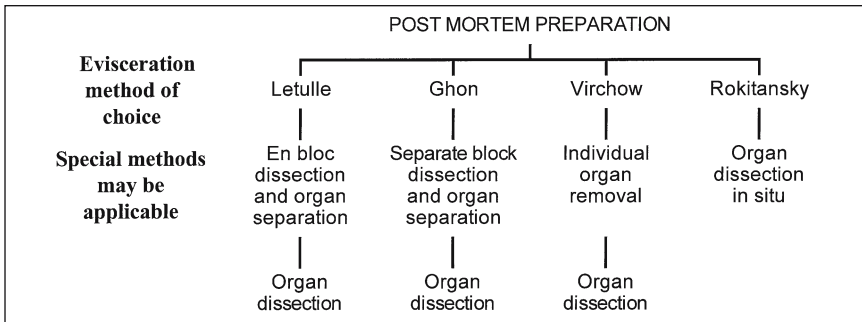


FIGURE 2.6. Schema for differing methods.

method involves dissecting the organs in situ with little actual evisceration being performed prior to dissection. It may, however, rarely be useful especially if speed is of the essence and the information gleaned from the examination is anticipated and accepted to be limited. This may be the method of choice when performing post mortems on patients with highly transmissible diseases so that tissue is not removed from the body. It therefore poses the most limited risk or threat to anyone except the prosector. In the past this method has also been described as particularly useful in post mortem examinations performed in the home!

A schema for different dissection methods is given in Fig. 2.6.

## References

1. Geddes JF, Gonzalez AG. Examination of the spinal cord in diseases of the craniocervical junction and high cervical spine. *J Clin Pathol* 1991;44:170–172.
2. Vanezis P. Post mortem techniques in the evaluation of neck injury (ACP Broad-sheet number 139). *J Clin Pathol* 1993;46:500–506.

## Further Reading

Bromilow A, Burns J. Technique for the removal of the vertebral arteries. *J Clin Pathol* 1985;38:1400–1402.

# 3

## Evisceration Techniques

The main general evisceration techniques are outlined in this chapter, but it should be remembered that alternative or improvised methods are frequently used and that special techniques are regularly required. It is hoped that all of the commonly used alternative methods are included in the present chapter together with the more routine. The specialised and less common techniques will be given in the various chapters on specific systems. In this way the majority of practices are found in this chapter to avoid extensive cross-references, allowing the more rare procedures to be described separately with organ dissection in the appropriate chapter. A degree of repetition is inevitable but this avoids the need for constant cross-referencing. The main evisceration techniques, detailed in this chapter, are the following:

- En masse (Letulle)
- En bloc (Ghon)
- Individual organs (Virchow)
- In situ (Rokitansky)

### En Masse Dissection

The most rapid technique, and probably the most convenient for the technician assisting at the post mortem, is the en masse procedure. As the intestines obscure the abdominal part of the dissection and are infrequently the source of significant or fatal disease, they are usually removed separately before the remaining organs. Of course the bowel is not neglected but once separated is examined and opened later. To do this the sigmoid colon is identified and the lateral border is lifted as scalpel strokes are made posteriorly through the mesentery to free this part of the large intestine. Mobilisation can be aided by manually grasping the outer wall of the bowel and pulling this structure anteriorly. Similar dissection proceeds proximally, detaching the descending colon, hepatic flexure (being careful of the nearby

spleen), and transverse and ascending colon, eventually elevating and freeing the caecum and appendix.

The duodeno–jejunal junction, now identified as the fourth part of the duodenum, runs anteroinferiorly just beneath the lower border of the stomach. Two ligatures or clamps are applied around the small bowel in this region approximately 3 cm apart. The bowel is divided between these ties. The cut end of the distal side is elevated with one hand while the other hand dissects away the mesentery close to the bowel wall, either with scissors or by making a series of controlled sweeping movements with a PM40. This is continued distally to the terminal ileum, lifting the subsequent part of the bowel as the preceding section is dissected. Finally the ileal and caecal dissections should meet and the majority of the bowel is free except for the most distal segment. The rectum is now identified and the luminal contents massaged back up into the sigmoid colon before one slices across the rectum about 3 cm from the anorectal junction and divides any final soft tissue attachments posteriorly. The intestinal tract can now be lifted free and removed to the sink. If this is not appropriate, as in the case of matted loops of bowel resulting from adhesions, peritonitis, or widespread intraabdominal tumour, the intestines should be removed still attached to the entire internal contents and all dissected as described in Chapter 7.

Once the bowel has been removed, it is possible to begin eviscerating the remainder of the organs either from the pelvis, proceeding superiorly, or by dissecting inferiorly from the mouth and pharynx. Letulle's method follows the former route and begins with blunt dissection of the pelvic organs and peritoneum from the surrounding bones. Starting with the lowest part of the exposed abdominal contents, the prosector's hands should pass retroperitoneally and inferiorly, forcing the pelvic structures forward. Strong fingers are needed to detach the organs forcibly from the lateral wall, extending this blunt dissection as far as possible around the rectum, bladder, and prostate gland in male subjects and in females, the internal genitalia. Once freed, this group of organs is grasped by the nondominant hand and forceful traction is exerted in an upward direction while the most inferior structures are cut across using a large PM40 knife as close to the pelvic bones as possible. Extreme care must be taken at this point with controlled knife cuts because some of this dissection inevitably will be performed under limited direct visualisation.

In male patients the dissection will proceed just distal to the prostate gland, which provides a reasonable gripping site to apply the necessary traction. In females this cut should be made through the soft tissue of the upper vaginal wall, and the cervix provides the necessary traction site here. Using the same knife, the incision is extended laterally to sever the external iliac vessels and accompanying soft tissue structures. The internal aspects of the cut ends of these vessels should be inspected as they are transacted, looking particularly for atheroma and thrombi. It is important to cut laterally

toward bone with the blade angled away from the supporting hand at all times. The dissection continues laterally on both sides around the entire interior aspect of the pelvis, freeing all soft tissue attachments (except for the spermatic cord in males), with each side eventually meeting in front of the sacrum. In male cadavers the spermatic cord on each side can be traced at this point from the inguinal canal to the scrotum by firm blunt dissection of the prepubic subcutaneous tissue and the testis retracted through the defect produced and dissected free and removed with the rest of the pelvic organs. *Alternatively, the spermatic cord can be transected and the testis removed separately later.* When completed, this group of organs is pulled free from the pelvis and the abdominal organs are then approached.

The diaphragm is dissected away from the internal surface of the body wall along its complete length. This will require inserting a hand between diaphragm and liver and spleen, being careful not to injure the latter, as the capsule is easily damaged. Again it is essential to direct the knife toward the bone at all times, cutting away from fingers to avoid unnecessary injuries. Then, beginning on the left side, the abdominal contents are freed from their posterior aspect starting with the bowel (if not already removed), left kidney, ureter, and adrenal gland. This is done by first identifying the descending colon, which is then grasped, pulled medially, and the posterior mesenteric attachments divided with cuts. The initial knife cuts free the more taut attachments of this part of the colon, which will then be partly released; blunt dissection is usually adequate for further detachment. If the bowel has been removed then a similar technique is followed, starting with the perinephric soft tissue on the right. The dissection is extended as posteriorly as possible retroperitoneally, still working toward the vertebral column at the midline and then skirting the internal body wall, to include all of the retroperitoneal structures and overlying tissue. A similar technique is used throughout, with the organs and soft tissue retracted anteromedially or pushed down and protected with one hand while the other hand uses a combination of forceful blunt dissection and knife cuts to free all of the attachments. In this way the adjacent organs are also freed as they present; the spleen, left kidney, and left adrenal gland are brought into this aggregate of organs, now lying free from the posterior body wall. The dissection is continued all the way to the midline to include the para-aortic tissue and aorta, with only abdominal wall structures remaining intact.

A similar method is used to free the organs on the right side of the abdomen including liver, right kidney, right adrenal gland, ascending colon, appendix, and caecum (if present). Beginning at the caecum, a lateral cut is made in the adjacent soft tissue and the caecum and ascending colon can be pulled medially exactly as in the case of the descending colon on the left side. A combination of blunt and sharp dissection behind the ascending colon in a fashion identical to that on the left and continuing retroperi-

toneally toward the midline should similarly free all of the anterior structures. The dissection continues behind the liver, kidney, right adrenal gland, and the more medial structures, once again moving toward the aorta.

Once the midline is reached, the aorta is freed from its posterior neighbouring structures by cutting through the retro-aortic soft tissue just in front of the vertebral column. The mesenteric root is also detached from the parietal peritoneum. The right-sided organs will now be detached to join the previously freed organs on the left. In this way the abdominal organs including the duodenum (and intestines if still attached), stomach and pancreas, together with the pelvic organs, should then all be free from their anchoring tissues, and the thoracic structures are all that remain to be addressed.

A similar principle of detaching all surrounding and posterior attachments is followed for removal of the thoracic organs, with peripheral pleural adhesions being broken or cut and the lungs retracted toward the mediastinum in turn and all organs freed from the vertebral column by appropriate blunt or sharp dissection. Once again, begin on the left side and retract the lung by dividing any posterior attachments still present. The same is done on the right.

If required it is important to look carefully at the thoracic duct at this point; otherwise it will be difficult to identify later. The thoracic duct lies to the right of the vertebral column in the midline, behind the aorta. The right lung is lifted forward and pushed to the left-hand side. The parietal pleura is incised along the upper lateral aspects of the thoracic vertebral bodies and the duct identified. This is usually most easily found about 2 to 3 cm above the diaphragm. The azygous vein can also be identified and the thoracic duct should run between it and the hemiazygos vein, behind the aorta and along the anterior border of vertebral bodies. It is recommended that a loose ligature be placed around the thoracic duct, which can aid localisation and produce leverage to allow careful dissection superiorly and inferiorly before removal.

The only structures that are now intact, and restrict removal of the viscera, are the branches of the major vessels arising from the proximal aorta and the soft tissue between the thoracic aorta, superior mediastinum, and vertebral column. The vessels can be severed using the PM40 by slicing the soft tissue structures at the thoracic inlet beneath the medial clavicular area in a lateral and posterior movement to transect these large branches. The neck cuts made previously to free the cervical structures are now extended to the thoracic inlet dissection just described. Pulling the upper thoracic/cervical tissues forward and inferiorly should free all of the posterior soft tissue attachments, and all of the visceral conglomerate should now be free. The entire aggregate can now be removed to the dissection area (often this is extremely heavy so be careful; Fig. 3.1). The method of organ separation is described in Chapter 4, and organ dissection is discussed in the relevant chapters.





FIGURE 3.1. Bulky single aggregate of organs removed en masse and transferred to the dissecting table for further dissection.

The en mass technique is summarised as follows:

- Open the body in the routine manner.
- “Drop” the tongue.
- Remove the bowel from the duodenum to the rectum.
- Dissect the pelvic structures away from pelvic wall by grasping the prostate gland or cervix.
- Transect the iliac vessels.
- Detach the diaphragm from the body wall.
- Free the left kidney, adrenal gland, and ureter.
- Continue the dissection posteriorly to the midline to release the spleen and pancreas.
- Free the liver, right kidney, adrenal gland, and ureter.
- Continue medially behind the retroperitoneal structures.
- Free the thoracic organs peripherally on the left and right.
- Identify the thoracic duct if required.
- Free the thoracic organs by posterior thoracic wall dissection.
- Dissect the few remaining vascular and soft tissue attachments.
- Remove the organ conglomerate to the board and follow the dissection outlined in Chapter 4.

## En Bloc Dissection

The second and seemingly more popular method of organ removal among physicians and technicians, at least in the United Kingdom, is the en bloc technique, which is a modification of a method originally described by Ghon. This involves extracting the organs in four separate blocks (plucks): the thoracic pluck (neck structures, heart, lungs, and mediastinum); the coeliac block (liver, stomach, spleen, pancreas, and duodenum); the intestines; and the urogenital block, leaving the neurological system to be removed as a fifth block as necessary.

The highest thoracic block is removed by reflecting the tongue, neck structures, and thoracic organs in much the same way as described in the previous chapter and section, but this time from above moving inferiorly, to include the pleura with the lungs. With the tongue and neck structures freed as discussed in the section on preparation, attention moves to the thorax. All pleural adhesions are obliterated manually or using a scalpel. Incisions will be necessary through the subclavian vessels beneath the medial ends of the clavicles on both sides to free all significant anchoring structures. At this point look for the thoracic duct, if relevant, before proceeding. The right lung is pushed across the chest toward the left and the medial pleural surface inspected. The thoracic duct is said to be found most easily by dissecting between the aorta and azygous vein in the region of the posterior thoracic wall. The parietal pleura is then incised along the upper lateral aspects of thoracic vertebrae and the duct identified about 2 to 3 cm above the diaphragm. The thoracic duct then runs between the azygous and hemiazygous veins, behind the aorta along the anterior border of vertebral bodies. It is useful to place a loose ligature around the duct to aid careful dissection up and down before removal.

Further blunt dissection may be necessary between the superior mediastinum and vertebral column, but it should now be possible to place a hand or hands around the larynx, pharynx, trachea, and oesophagus and pull anteriorly to strip the loose soft tissue connections of the posterior mediastinum and vertebral bodies. Further traction in a caudal direction should release all of the thoracic structures from the posterior thoracic wall as far down as the diaphragm.

It is important here to refrain from being too aggressive if there is any suggestion of laryngeal injury such as after strangulation or hanging. The tracheal cartilages and hyoid bone must be carefully palpated for evidence of such injury. If necessary this area should not be handled further until X-ray films of the larynx are taken, which may be especially relevant in forensic cases as described in the section on neck dissection in Chapter 2.

As the organs are pulled forward, the lower ends of the oesophagus and thoracic aorta are exposed and checked, and after the area around the

lower oesophagus is tied with a length of string or a clamp these can be cut through above the tie (or clamp). This of course assumes that there is no evidence of oesophageal varices, tumours, achalasia, and aneurysms within the inferior mediastinum. When the latter is the case it is advisable to follow either the en masse removal method described earlier or the modification detailed in later paragraphs for assessing lower oesophageal varices. The tie is important so as to retain the stomach contents within the gastric lumen. The cuts are made above the upper surface of the diaphragm (occasionally the diaphragm may also require some freeing), and at this point the thoracic pluck should be separate and easily removed to the dissecting area (Figs. 3.2. and 3.3). The inner parietal pleural surface of the chest wall should now be inspected for evidence of tumour, plaques, or other disease process.

*One commonly used alternative to this simple method of thoracic evisceration is used in cases of portal hypertension secondary to liver cirrhosis with suspected oesophageal varices. The oesophagus is tied and severed more superiorly than usual, well away from the oesophagogastric junction. This is*

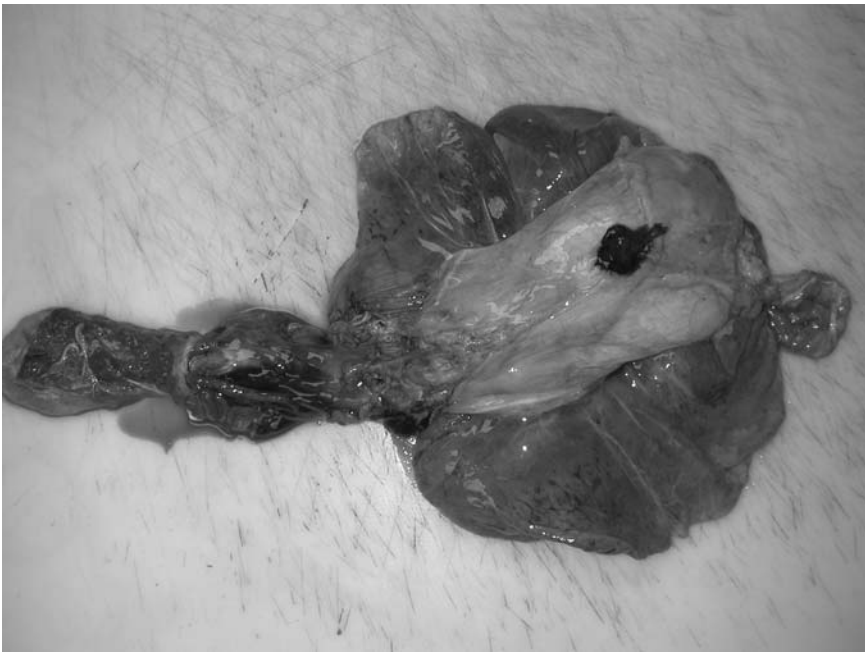

FIGURE 3.2. The thoracic pluck viewed from the front. (Courtesy of Mr. Dean Jansen, Whittington Hospital.)

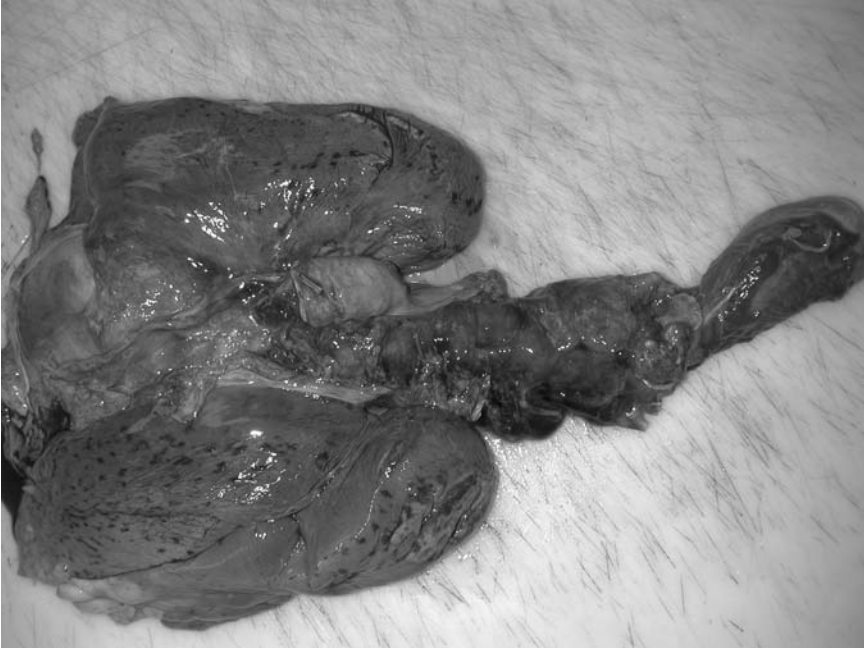

FIGURE 3.3. The thoracic pluck viewed from behind. (Courtesy of Mr. Dean Jansen, Whittington Hospital.)

*usually around the middle portion of the oesophagus, leaving the superior part with the thoracic block and retaining the inferior segment attached to the stomach. The lower oesophagus is then removed in continuity with the stomach together with the rest of the coeliac block (see later). In this way the integrity of the lower oesophagus is maintained, and it is hoped any varices present should not collapse.* The latter can be demonstrated by everting the oesophagus (turning it inside out by pushing the tied end along the oesophagus and into the gastric cardia). Everting the oesophagus may be aided by introducing long-handled forceps through the gastro-oesophageal junction lumen, clamping the tied end of the oesophagus and pulling this end back through the lower oesophagus into the gastric cavity. For optimal demonstration, the varices can be injected and the method for this is described in Chapter 7.

At this point it is useful for the novice to identify and inspect the adrenal glands prior to abdominal dissection (particularly in cadavers with a large

amount of intraabdominal adipose tissue), as they occasionally can be difficult to identify at a later stage. A brief inspection at this stage will probably be all that is required to identify or exclude significant pathology in either gland.

The next step is to identify and transect the distal duodenum close to the duodeno–jejunal junction. To do this the junction is identified by following the duodenal loop and locating a point where it begins to turn inferiorly beside the pancreas. At this site a hole about 3 cm in diameter is made in the mesentery 1 cm from the mesenteric border of the intestinal wall. Two clamps are applied or two lengths of string are tied as ligatures around the bowel wall several centimetres apart and the intestine cut between them (Fig. 3.4). Then one can either begin here or at the rectum and dissect the bowel from the mesentery using large scissors or a knife. If starting at the rectum, a hand is placed into the posterior pelvis and the rectum gripped circumferentially. Here the luminal contents are massaged back up into the upper rectum and the lower rectum is cut through with a knife or large scissors about 3 cm above the anorectal junction. It is important not to cut too inferiorly and risk penetrating the anal skin. The cut end is lifted and the mesorectum dissected.

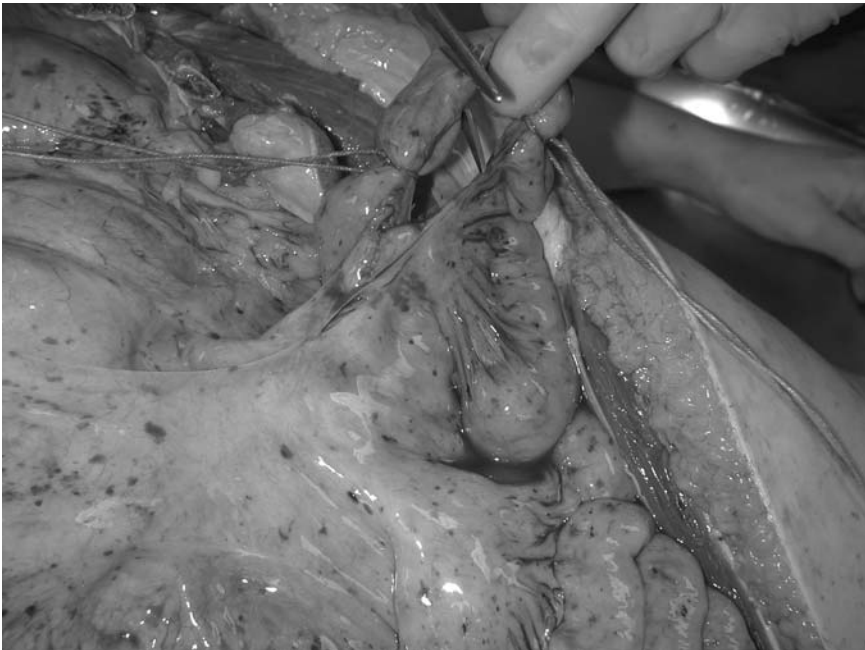


FIGURE 3.4. The duodenum is cut between two ties. (Courtesy of Mr. Dean Jansen, Whittington Hospital.)

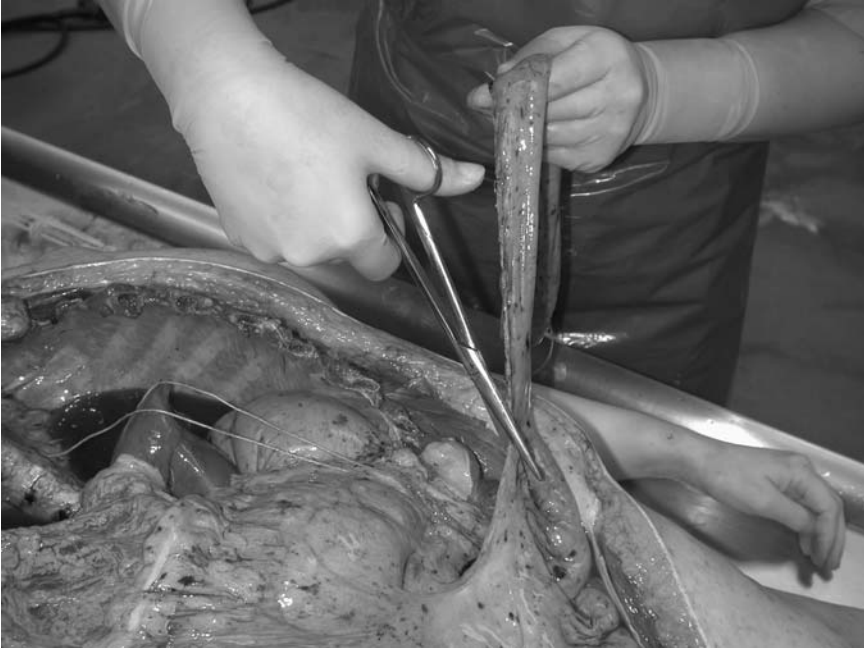

FIGURE 3.5. The mesentery is dissected from the intestine close to its wall as long as there is no significant mesenteric pathology. (Courtesy of Mr. Dean Jansen, Whittington Hospital.)

It is preferable to dissect the intestine close to its wall (Fig. 3.5), leaving the mesentery remaining in the abdomen unless significant mesenteric pathology, such as vasculopathy, is expected. Either scissors or a PM40 can be used for this procedure; with the latter a bow and string action is required, cutting close to the bowel wall extending from the rectum to various parts of the colon to appendix, terminal ileum, and proximally (or vice versa). The small and large bowels can now be lifted from the abdomen for later dissection. In most cases nothing will be lost by dissecting the bowel out in this way, but when there is any suggestion of mesenteric vascular pathology, the mesentery should be dissected at its root in to transect the mesenteric arteries and veins close to their origins or drainage routes. For this the dissection begins at the rectum as before, but as the bowel is lifted free the mesenteric base is dissected from its attachment, remaining in continuity with the small and large intestines. If this is the case it may be better to remove the intestines with the rest of the abdominal contents as described in the previous section on the en masse technique. When intestinal contents are required for analysis a segment is tied off and sent as described earlier.

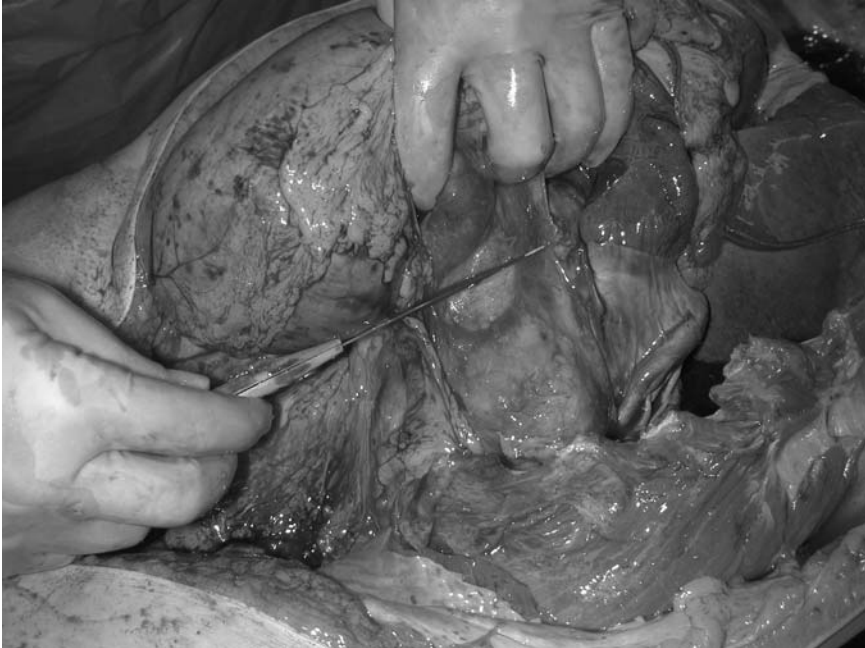

FIGURE 3.6. The abdominal organs are removed by displacing the spleen medially and dissecting the posterior soft tissue to the midline. (Courtesy of Mr. Dean Jansen, Whittington Hospital.)

Next we turn to the coeliac block, which includes the liver, biliary system, stomach, duodenum, spleen and pancreas. This group of organs is removed by carefully dissecting along a plane just anterior to the aorta and inferior to the diaphragm, cutting through the anterior aortic branches as they appear (the coeliac and mesenteric arteries). It is usual to begin on the left side of the abdomen and first free the spleen from any peripheral attachments, being careful not to damage the splenic capsule with excessive clumsiness. Then proceeding medially behind the spleen toward the vertebral column, the spleen, pancreas, and surrounding soft tissue are freed from the underlying retroperitoneal structures (Fig. 3.6). The aorta is left intact but the coeliac artery is cut close to its origin just below the liver (Fig. 3.7). *Alternatively, a short segment or ring of aorta can be taken with the coeliac block, which contains the coeliac axis.*

A similar method is followed on the right side by freeing the liver from the diaphragm superiorly and anteriorly, which will usually require cutting the posterior part of each leaf of the diaphragm and which may be aided by dissecting the falciform ligament. The liver is retracted medially and dis-

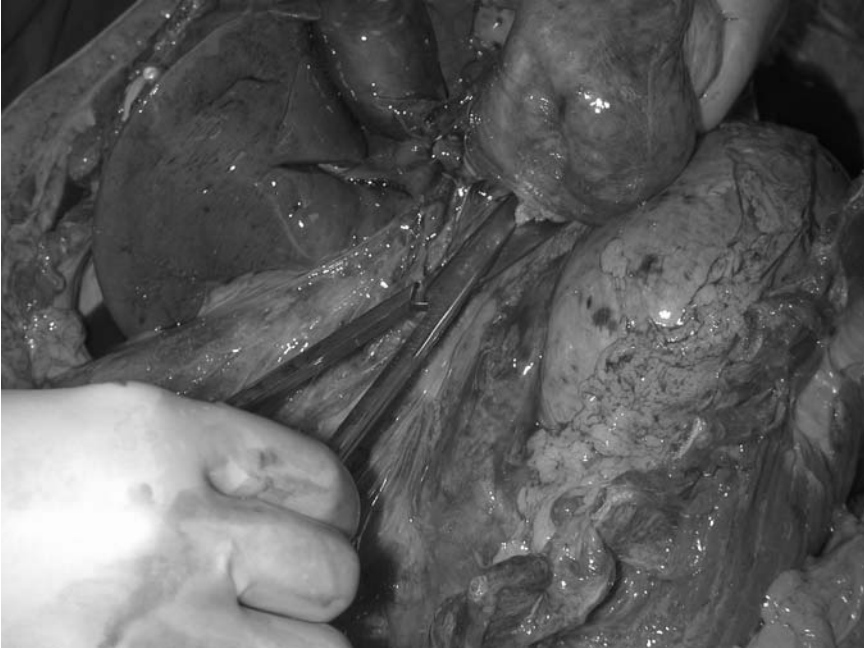

FIGURE 3.7. The coeliac block is separated by cutting through the vessels originating from the anterior aspect of the abdominal aorta. (Courtesy of Mr. Dean Jansen, Whittington Hospital.)

sected from the underlying tissues, being particularly careful not to damage the nearby right adrenal gland (Fig. 3.8). This group of organs can then be lifted free after the inferior vena cava is severed. As with the other blocks, it is important to inspect the organs for gross lesions such as tumours, ulcers, metastatic disease, or cirrhosis.

This leaves the adrenal glands, kidneys, ureters, bladder, and genital organs as the last block with the attached abdominal aorta and iliac vessels. The kidneys are inspected first by dissecting the fat around the posterolateral aspect of the kidney with a curved incision and extending the cuts medially behind the aorta. Keep a watchful eye out for benign cortical cysts while doing this because these are very common and can unexpectedly shower the prosector with cystic fluid!

Again begin on the left and free the kidney by retracting it medially while dissecting posteriorly (Fig. 3.9). Superiorly the dissection continues to include the adrenal gland with the kidney, and both are eventually freed from the underlying soft tissue. A similar method of dissection is followed



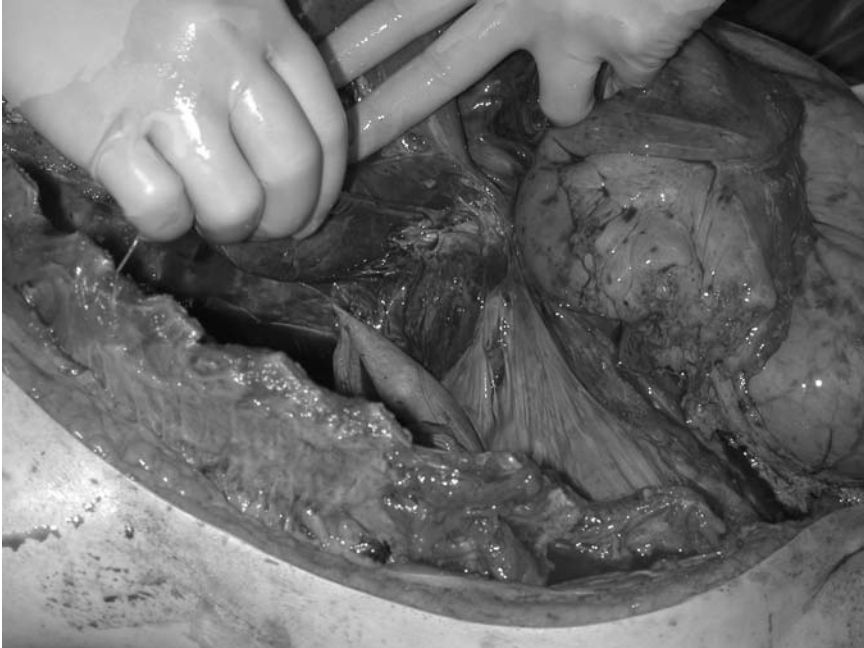

FIGURE 3.8. The liver is lifted medially and the posterior soft tissues dissected to detach the right side of the coeliac block. (Courtesy of Mr. Dean Jansen, Whittington Hospital.)

on the right, again dissecting in a medial direction behind the kidney, aiming to keep the adrenal gland with the kidney. If the dissection continues posteriorly and carefully the renal vessels will not be injured during this part of the evisceration and the soft tissue behind the ureters can also be dissected free from behind.

The ureters and surrounding vessels are located and traced to the pelvic brim, freeing the surrounding soft tissue connections. Complete the dissection of this superior group of structures from the vertebral column by retraction of the aorta and extending the blunt or scalpel dissection of the soft tissue posterior to the abdominal aorta, just anterior to the lumbar spine, down toward the lumbosacral junction. At this point the kidneys and upper abdominal aorta are freed and the lower urinary tract is still intact, but requires dissection. The idea now is to remove the pelvic organs together by dissecting around the inside of the pelvic bones and severing the large external iliac vessels. Most of this dissection can be performed with strong fingers following the line of the inner pelvic surface.

The bladder is first separated from the pubis inferiorly by blunt dissection and this dissection is continued around the urethra and prostate in males and the vagina in females and finally the rectum. Posterior soft tissue attachments are divided around the sacral promontory. By extending the retro-aortic dissection behind the common iliac vessels, the pelvic organs can now be grasped with one hand at their most inferior point and pulled up while cuts are made through the floor of the pelvis. For the routine examination the lowest point is marked by the prostate in males and the cervix and upper vagina in females. In common with the other evisceration methods, a firm grip around these structures allows an important element of leverage so that traction can be applied in a superior direction to permit a knife to pass through the urethra, vagina, and rectum, keeping the prostate and cervix intact and in continuity with the rest of the tract. The external iliac vessels are divided and any remaining soft tissue strands are dissected or pulled apart. The organs can now be removed from the body. Retaining the entire genitourinary tract complete in this way allows excellent demonstration of proximal effects of distal pathology. Dilated ureters indicate that

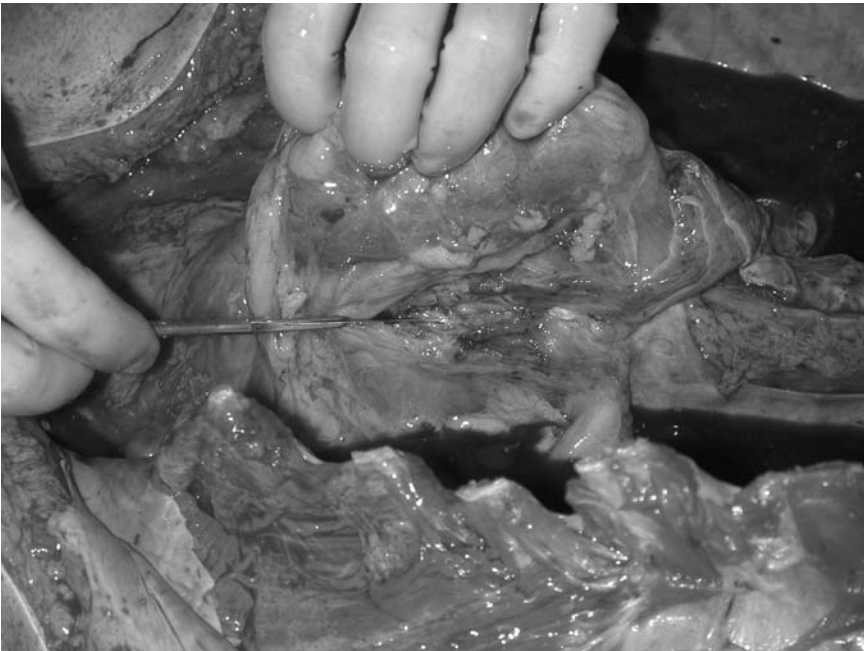

FIGURE 3.9. The left kidney is grasped and its posterior attachments divided. (Courtesy of Mr. Dean Jansen, Whittington Hospital.)

there is obstruction to urine flow in the tract beneath the dilated portion. This is commonly caused by calculi, cervical neoplasms, or benign or malignant prostatic disease obstructing the lower tract. In addition, the male urogenital tract can also be demonstrated in its entirety (if time permit) and the testes and vasa deferentia can also be included in this block. The testes are removed by retracting the spermatic cord in the inguinal canal after blunt dissection of the subcutaneous tissue of the lower abdominal wall in the pubic region using fingers. To do this, two or three fingers are forcibly introduced into the soft tissue overlying the pubic symphysis and a channel is produced from the medial part of the inguinal canal to the scrotal sac. The spermatic cord is grasped here and withdrawn toward the abdomen. Loose soft tissue attachments in the scrotum may need a little encouragement to detach by gentle scalpel cuts. Once freed the vas deferens within the spermatic cord is traced to the posterior surface of the bladder close to the seminal vesicles. These procedures are rather time consuming and rarely demonstrate significant pathological lesions relevant to the cause of death, but they may impress an examiner in an otherwise mediocre post mortem examination performance. Block dissection is again described in Chapter 4.

The standard en bloc technique is summarised as follows:

*Thoracic block*

- Perform routine dissection of the neck and bring the tongue down.
- Free pleural adhesions and identify the thoracic duct.
- Apply caudal traction on the neck structures, which should release posterior attachments.
- Identify the lower oesophagus, tie, and transect (if no significant pathology here; if pathology tie and transect higher).
- Divide the descending aorta.
- Remove the “pluck.”

*Intestinal block*

- Identify the duodeno–jejunal junction.
- Tie and cut between ties.
- Identify the upper rectum/lower sigmoid colon and free them from surrounding soft tissue.
- Cut across the upper rectum and begin cutting across the mesentery close to the bowel wall (or begin at the upper duodenal tie and proceed inferiorly).
- Free the small and large intestines.
- Remove to the sink.

*Coeliac block*

- Identify the spleen and pull medially to enable dissection posteriorly in front of left kidney to the midline.

- Free the liver and dissect the posterior peritoneal soft tissue and retroperitoneal tissue anterior to the right kidney to the midline.
- Lift the organ group and cut across the anterior aortic branches as they appear.
- Lift the block away for dissection (see Chapter 4).

#### *Urogenital block*

- Dissect behind the left kidney to release it (include the adrenal gland).
- Do the same on the right.
- Dissect the retroperitoneal soft tissue to expose ureters and trace to the bladder.
- Blunt dissect soft tissue around lower bladder.
- Grasp the lower bladder and prostate gland/cervix and cut below to release.
- Release the pelvic organs from peripheral attachments (include spermatic cords and testes if required).
- Divide the iliac vessels.
- Lift the block away for dissection (see Chapter 4).

## Individual Organ Removal (the Virchow Method)

In this technique the organs are removed one by one sequentially, isolated, and dissected immediately after removal. The majority of complete and detailed organ dissection methods are described in the relevant chapters rather than here to avoid extensive repetition. Individual organ removal is said to be the one of the most widely used techniques worldwide. As originally described, the first step was to expose the cranial cavity to assess accurately the quantity of blood in the cerebral vessels, proceeding to the spinal cord followed by thoracic, cervical, and abdominal organs, in that order. As discussed earlier, this technique is effective for normal or diffusely diseased organs, but one of the most common problems with methods such as this is destruction of structures during evisceration and the relationships between organs. Of course most adverse situations can be avoided by careful planning of the method and the utmost attention given to detail when inspecting organs in situ. The method has developed over the years and the cranial cavity is now left until last, the examination proceeding through the peritoneal, pleural, and then pericardial cavities, which are opened and inspected, with the organs removed from those areas in reverse order.

The first step is to inspect the abdominal wall. Then assess the abdominal cavity and remove any fluid and establish its amount and appearance. The abdominal organs are inspected and palpated before any dissection takes place. It is suggested that the gastrointestinal tract be checked first, including the appendix and mesenteric lymph nodes. Next assess the spleen,

liver, kidneys, and pelvic organs. The pancreas can be inspected by tearing through the omentum between the stomach and colon, opening the lesser sac.

Attention is now directed to the thorax. *If the examination is restricted to an abdominal incision only, Mallory [1] suggests that the majority of the thoracic contents can be removed from below. To do this, first the diaphragm is detached from all of its peripheral thoracic cage attachments. Next, the posterior mediastinal structures are pushed away from the vertebral column by blunt dissection with the hand. The arch of the aorta is then located and pulled inferiorly. The local structures are also pulled down and the great vessels are transected just above their origins. A firm grasp and forceful caudal traction will allow all of these structures to be released and pulled down toward the abdomen. The tissue is then cut across as high as possible.*

Routinely, however, the thoracic contents will be exposed by removing the sternum. In examining the thorax it is first necessary to inspect the pleural cavities thoroughly and collect any fluid as described previously. Next, dissect away all pleural adhesions by blunt dissection or with the knife blade. If the parietal pleura is firmly attached to the lungs it will need to be stripped with the lung as described earlier. To recap briefly, this is done by pushing the parietal pleura away from the chest wall toward the lung by finding the plane immediately outside this serosal surface at the point where the sternum has been removed and working the hand along this plane. When working in the thorax one must be careful of any sharp edges at the ends of the cut ribs. A towel can be placed over the exposed bone or the chest wall skin can be wrapped back over to cover these rough edges. Attention is turned to the anterior mediastinal soft tissue, and interstitial emphysema should be checked for. In an adult the normal thymus will be atrophic but it should be inspected at this point in case unexpected pathology is present. Now the pericardium needs to be inspected before it is opened. If a haemopericardium is present the outer surface will often appear blue before it is opened and the clotted and fluid blood can be collected through the incision described below and quantified by measuring its volume in a measuring jug. Normal pericardial fluid is straw coloured and has a volume of 5 to 50ml. The simple way to open the pericardium is to lift the middle of the anterior wall with fingertips or forceps and snip through with medium-sized scissors to create a small hole. Then this incision is continued superiorly along the right border to the root of the large vessels originating from the heart and inferolaterally toward the apex. Lifting the sac retains any contents for assessment. Blunt dissection may be required for loose adhesions, but with dense adhesions, such as after cardiac surgery, this may not be possible and the pericardium will need to be dissected later with the heart. When the pericardial sac is emptied the external form and epicardial surface of the heart can be assessed.

The heart is then removed by lifting the apex and cutting through the attached vessels in order of presentation. This will entail transecting the

inferior vena cava first, then the pulmonary veins on both sides, followed by the superior vena cava, the pulmonary artery, and lastly the aorta. If there is a suspicion of a pulmonary embolus it is important to open the pulmonary arteries first. *Obviously it is also possible to remove the heart in the manner described later for block dissection of the two previously outlined evisceration methods. In brief, this involves passing two fingers behind the aorta and main pulmonary artery just above their origins from the left and right ventricles and cutting across these with scissors. Their lumina are inspected. Next, the heart is lifted and the veins returning blood to the heart from the systemic and pulmonary circulations are cut through as close to the outer pericardial surface as possible.*

The heart is lifted free for further dissection. The exposed posterior pericardial surface can now be inspected. Clearly either a Ghon type of evisceration or preferably the en masse technique is much more appropriate if extracardiac vascular disease is suspected such as vena caval thrombi or a dissecting aortic aneurysm. In this case more information can be gained from keeping the cardiovascular system as intact as possible so that the extent of involvement of the pathological process can be established accurately. This is discussed further in the relevant sections later in this chapter.

After the left lung is freed from all of its pleural attachments it should be lifted forward out of the pleural cavity and the root held with the non-cutting hand while the dominant hand is used to cut through this hilar tissue to detach the lung through the primary bronchus, vessels, and pleura. An identical method is used to remove the right lung. If the lungs are to be inflated it is important to cut the primary bronchus toward the carina to leave a long enough stump for cannulation. If the thoracic duct requires inspection this should be done early in the examination; otherwise it becomes too difficult to identify. This may be necessary in patients with miliary tuberculosis or a chylous hydrothorax. To do this, remove the left lung as described earlier. Before the right lung is removed it is lifted forward out of pleural cavity and pushed to the left. The parietal pleura is then incised along the upper lateral aspects of the thoracic vertebrae and the duct identified. It lies to the right and posterior to the aorta and is found by dissecting between the aorta and the azygous vein, and is most easily identified 2 to 3 cm above the diaphragm. Once the azygous vein is identified the thoracic duct will be found lying between it and the hemiazygos vein, where it runs behind the aorta along the anterior border of vertebral bodies. It is often helpful to place a loose ligature around it and carefully dissect up and down before removal. If this proves too difficult it may be necessary to first identify the cisterna chyli which lies in the abdomen in the right retro-aortic and paravertebral tissue at the level of L2-3 before proceeding superiorly into the thorax. The right lung can subsequently be removed as described previously for the left. Moving to the neck, the soft tissue attachments around the lateral and posterior aspects of the upper

oesophagus and trachea are dissected to free the structures of the neck. The organs can then either be removed for separation or dissected in situ. If removed together this is very similar to the thoracic block evisceration method described earlier for the en bloc section (without the heart and lungs). If not then the posterior wall of the pharynx is cut through just next to the uvula from behind and the pharynx is inspected. The tonsils are incised and the posterior wall of the oesophagus is slit in the midline. If the mucosal surface is normal, cut through the oesophagus (dividing into two) to open the posterior wall of the trachea. The tracheal mucosa is now inspected. Longitudinal incisions can then be made in each lateral lobe of the thyroid or the thyroid can be removed prior to dissection as described later.

The parathyroid glands should now be identified, all four if possible. If pathological, identification is usually straightforward as long as one knows where to look and what the parathyroids look like. They are flattish oval structures, yellow-brown in color, and their size is variable, about 6 mm in length by 2 to 3 mm in the other dimensions. Despite variations in number, size, and site they are usually found on the posterior surface of the medial side of the lateral lobes of the thyroid, close to the oesophagus. If it proves difficult to find them first identify the inferior thyroidal artery and trace it to the thyroid gland. The inferior parathyroid gland is usually located just below the site at which the artery enters the thyroid gland, and the superior gland lies several millimetres above this area. It is the inferior gland in fact that is particularly variable, sometimes being associated with the thymus, lying embedded in the thyroid, anterior to the lower thyroid or even on its own in the soft tissue beneath. The carotid bodies can also be seen at this point immediately at or just above the bifurcation of common carotids on the medial side. They are usually about 5 mm in length.

The abdominal organs are inspected in situ and all intraabdominal fluid is collected in a manner similar to that used for the other serosal cavities. If peritonitis is found the source should be identified by palpation and inspection before dissection. Once again, if diffuse disease is present with numerous adhesions an en bloc method of evisceration with subsequent dissection is desirable, as this will often provide more information and a clearer indication of the source than the current isolating method described here. The order of removal of the abdominal contents may vary depending on the circumstances and pathology encountered, and the preferences of the prosector. Routinely the spleen is taken out first, followed by the gastrointestinal tract, liver, and pancreas, and lastly the genitourinary tract. Finally, the posterior vascular structures are dissected in situ. It is wise to remove the normal or less abnormal organs first and leave the pathological organs for a more considered approach.

Gentle manipulation of the spleen is necessary to avoid tearing its capsule. It can either be lifted forward and sliced through along its greatest diameter or lifted out of the abdomen and the hilar structures cut

through to detach the spleen and dissected once removed. If dense adhesions are present it may be necessary to remove local diaphragmatic tissue to avoid splenic damage.

The gastrointestinal tract should now be inspected from the stomach to the rectum and the mesentery examined including the integral lymph nodes. If an area of ischaemia or infarction is seen it is important to inspect the mesenteric vessels at the outset; otherwise, it may become too difficult later on. These can be dissected in situ, following the vessels either from the bowel wall proximally or from the aortic branches peripherally, as discussed in more detail in Chapter 7. As with all vessels, dissection can be performed by making transverse slices with a scalpel or by longitudinal opening with scissors. If secondary tumour deposits or abscesses are suggested from the external appearance of the liver, the portal vein should also be opened in situ.

Unless absolutely necessary it is recommended that the gastrointestinal tract be removed to a sink before it is opened. Initially the duodenum should be opened in situ by piercing the anterolateral wall with scissors at around the second to third parts. The gallbladder is squeezed to assess bile flow to and through the ampulla of Vater. The latter is easily identified by stretching the wall and looking for a small projection. Insert a probe to localise the opening and if necessary open the common bile duct and branches in situ to identify any obstructing lesion. It may also be necessary to dissect out the pancreatic duct in situ, although this can usually be done once the organs have been removed.

Once free flow of bile has been established turn to the sigmoid colon to start the removal of the intestines. Pull the colon forward in this region to be able to cut through the mesocolon. A good grip is applied to the sigmoid and, pulling medially, the mesentery is incised. Next this incision is extended inferiorly to the lowest accessible part of the rectum before turning to the more proximal areas. Take care around the splenic flexure not to damage the spleen if this has not been removed already. Detach the transverse colon from the stomach by tearing the bridging soft tissue and continue to the hepatic flexure, ascending colon, caecum, and around the appendix. Once all the large intestine is free, go back to the rectum and cut through as low as possible to remove, once again massaging all of the luminal contents back up into the sigmoid before cutting.

Virchow's method actually describes removing the large bowel and small bowel separately but there seems to be no obvious benefit in doing it this way, and we recommend leaving the ileocaecal junction intact to avoid spillage of the luminal contents. If, however, the small bowel is to be retained with the upper abdominal organs, as described later, then the large and small intestines should be removed separately.

Moving to the terminal ileum, cut through the mesentery close to the small bowel wall and progress proximally in a sequential manner until the duodenum is reached. At this stage the mesentery can be removed by dis-



secting it free from the duodenum and the intestines removed to the sink. *Alternatively, the mesentery and small bowel can be kept in continuity with the duodenum and subsequently removed with it together with the stomach and pancreas.* The latter is best done by initially separating the stomach from the liver by blunt dissection and then cutting through the diaphragm around the oesophagus to free it.

Next the hepatic hilar structures will have to be divided, and this is accomplished by stretching the hepatoduodenal ligament to demonstrate the vessels that run here, followed by cutting through these structures in the following order: hepatic artery, common bile duct, and portal vein. These are inspected as they are cut and can be traced superiorly into the porta hepatis and early hepatic branches, and inferiorly as they present.

Now grasp all of the structures anterior to the aorta and inferior vena cava and cut from below along the plane immediately in front of the aorta toward the chest. The last structure to be cut is the lower oesophagus, which may require tying first to retain the gastric contents. If oesophageal varices are suspected, however, the oesophagus should be divided higher up and the lower portion retained with the stomach as described earlier. This group of organs is very much like the coeliac pluck obtained by means of the en bloc technique (but without the liver), and a similar organ separation and dissection technique can be applied.

In brief, the stomach and intestines can be opened with scissors, the small bowel along the mesenteric side. The stomach is usually opened along the greater curve, with care to avoid any mural lesion, which should be kept as complete as possible for later dissection. The duodenum is opened with sharp scissors through its anterior wall and the incision is continued to the pylorus proximally and the distal duodenum caudally. The large bowel is opened in a similar manner along the antimesenteric border (see Chapter 7).

The liver is usually the last organ last to be removed, although if it is clearly normal it may be removed before the rest of the intraabdominal organs to provide more space for dissection of the latter. To do this, pass the left hand between the right lobe of the liver and the diaphragm and push the liver forward out of the right hypochondrium. It is suggested that a useful tip to help removal of the liver is to slice through the entire organ in a horizontal plane at this point. Blunt dissection is required to separate the gallbladder from the undersurface of the liver, possibly with additional gentle scalpel movements, and the hepatic duct cut through. Remove the gallbladder for dissection by cutting through one wall, inspecting the mucosa and contents.

Now grasp the liver by placing the thumb under the lower anterior border and insert the remaining fingers into the long incision for grip. Lift the organ and cut through the hepatoduodenal ligament under close supervision as described earlier. Next dissect off the hepatogastric ligament, inferior vena cava, falciform ligament, coronary ligament, and the soft tissue between the

liver and right kidney, being careful not to damage the right adrenal gland. Finally, elevate the right lobe and free all the attachments here, as far posteriorly as the vertebral column. The liver can now be lifted away.

The pancreas can be identified by lifting the anterior wall of the stomach and palpating the posterior soft tissue. The soft tissue around the pancreas is dissected away and the organs can be removed for assessment. The superior border of the pancreas may be identified by following the course of the splenic artery, which lies above it.

The genitourinary tract and large abdominal vessels now remain in the body. The kidneys and adrenal glands are either removed together or each kidney is shelled out of its capsule followed by subsequent removal of the adrenal glands. Once again begin on the left side. If the kidney and adrenal gland are to be removed together, the soft tissue medial to and above the left adrenal gland is cut into and a curved incision is made toward the lateral abdominal body wall. This is joined by a further curved incision extending along the lateral border of the kidney to meet at the lateral aspect of the superior cut described. The incisions should penetrate the peritoneum and perinephric fat. The left hand is introduced into the hole produced lateral to the kidney and the latter is grasped and elevated as the soft tissue dissection is continued posteromedially. The left kidney and adrenal gland can now be held free from all lateral and posterior attachments but medially the renal vessels and ureter are still attached. Depending on the presence or absence of significant ureteric pathology the ureter is divided either high, close to its pelvic junction, or more inferiorly and can be opened along its length at this point. The renal vessels are transected as close to the aorta and inferior vena cava as possible so that the renal artery and vein can be opened and inspected. An identical procedure is followed on the right-hand side. The adrenal gland on each side can now be dissected off and the perinephric fat cleared away.

*The second method involves a similar lateral curved incision on each side but then fingers are worked into the plane around the capsule, which is nicked and peeled back to expose the subcapsular surface. The kidneys are removed by peeling the capsules away medially to the hila and by cutting through the renal vessels and upper ureter. The capsules remain within the body. The adrenals are dissected free from the overlying perinephric fat.*

When the lower urinary tract is obstructed, however, with associated upper urinary tract changes, the whole tract should be removed together. This method involves the same perinephric soft tissue dissection as described earlier but the renal hilar structures are not divided. The ureters are traced in the surrounding retroperitoneal soft tissue and the latter dissected away down to pelvic brim. The pelvic organs are dissected free from the lateral pelvic wall and inferior attachments (as described in both the en bloc and en masse evisceration techniques and again later) and the genitourinary tract removed in continuity for dissection as described for the genitourinary block of the Ghon technique.

In fact the pelvic organs are most neatly and easily removed by the same method that has been described previously. This involves stripping the peritoneum from the pelvic wall with strong finger action even when the structures of the upper urinary tract have already been isolated and removed. The blunt dissection begins over the anterior bladder surface, at its lower border, and the soft tissue separation is continued laterally on both sides until the fingers meet beneath rectum. Once the posterior aspect is freed from the sacrum and local tissues the only attachments inferiorly are the lower rectum and genital openings and posteriorly the peritoneum and vessels. A cut is made through the rectum, just below the prostate or urethra and vagina after the inferior structures (prostate or cervicovaginal area) are grasped with the noncutting hand and traction is exerted in an upward direction while cutting.

The posterior attachments are now transacted with care not to injure the ureters if still attached. The spermatic cord can now be located in the inguinal canal and transected to allow removal of the pelvic organs. The testes can also be removed together with the pelvic organs by dissecting the soft tissue over the pubic bones, beneath the skin, and inserting fingers around the spermatic cord into the scrotum and pushing the testes superiorly through the incision at the same time. A limited amount of careful cutting may be required to free the testis completely. If the cord has been severed the testes can be removed on their own in this way. Organ separation and dissection will again follow the same protocol as that for the genitourinary block of the en bloc technique.

At this stage there are few remaining structures left in the body to be examined. The inferior vena cava and its branches can be opened in situ, extending the dissection to include iliac vessels and more peripheral veins if required. Similarly the aorta should be opened in situ throughout its length, including iliac vessels and main branches, although it is obviously easier to remove the thicker walled aorta intact before opening than the thinner and more delicate venous structures. Vertebral bone marrow can be assessed by sawing the bodies of the lower lumbar vertebrae parallel to the surface about 1 cm deep using either a handsaw or an electric saw. For a more detailed description of this and extensive bone marrow sampling see Chapter 10.

The Virchow (individual organ) technique is summarised as follows (organ dissection may occur at the same time):

- Inspect the abdominal contents.
- Inspect the pleural cavities.
- Open the pericardium and remove the heart.
- Remove the left and then the right lungs.
- Assess the pharynx, oesophagus, trachea, parathyroid glands, and thyroid gland.

- Remove the spleen.
- Assess biliary tract patency.
- Remove the intestines.
- Open the stomach.
- Remove the liver.
- Remove the pancreas.
- Shell out the left and right kidneys and adrenal glands.
- Trace the ureters.
- Dissect the pelvic structures.
- Inspect and open the large arteries and veins.

## In Situ Method (Rokitansky Technique)

Following this method, the thorax and abdomen are opened in the usual fashion and the cavities and organs are inspected in situ before they are dissected. The superior mediastinal structures are examined first, beginning with the thymus, then the arch of the aorta and its main branches, and finally the superior vena cava and its branches. Inspection then turns to the pleural cavities, where all fluid is collected and adhesions divided as described earlier. Now grasp and lift the right lung forward, keeping the hilum intact, and make a superficial longitudinal cut in pleura with the scalpel or PM40 along the lateral vertebral bodies at the posteromedial aspect of the right pleural cavity to expose the azygous vein and the thoracic duct. Inspect these carefully. The right lung is then lifted out of the chest and laid on the anterior chest wall. Angling it slightly with the left hand, hold the front half of the medial surface toward the prosector. After this is done, a longitudinal slice is made through all three lobes from anterior to posterior about 2 cm below the anterior border. The slice is made deeply, almost completely through the substance of the lung, to almost divide the lung into two equal halves. Further cuts are made through any focal lesions identified. The lung is then placed back into the right cavity. The left lung is lifted from the left pleural cavity and an identical procedure is followed on this side, slicing through both lobes, and the lung returned to the thoracic cavity.

The heart and pericardial cavity are inspected and opened next. The first step is to pick up the anterior pericardium with toothed forceps and cut superiorly and inferiorly after making a small hole in the sac. Any fluid or blood is obviously removed at this point for quantification. This allows the anterior border of the heart to be inspected through the hole and the heart can be lifted out of the hole by inserting a hand around the heart and pushing the pericardium aside. As the heart is lifted it is swung slightly to the right so that the right ventricle and auricle lie against the cut ends of the ribs of the right chest cage. Then the first incision is made with a PM40, cutting into the left border of the heart from the apex and continuing the dissection to the area where the left pulmonary veins drain into the left

atrium. Try to avoid cutting through the mitral valve during this incision and wait until the ventricle has been opened completely, the contents removed, and the valves palpated and assessed completely before continuing. Then the point of the knife is inserted through the valve and the incision continued to the left pulmonary veins. The endocardial surface of the left atrium and ventricle can now be examined. The incision should be made in such a way as to leave the anterior and posterior papillary muscles intact so that they can be examined without being transected. Then lift the heart again and do the same on the right side.

Insert the point of the knife through the wall at the right border of the heart at the apex and cut from the apex to a point midway between the junction of the entry points of the vena cavae into the right atrium. Hold the knife with the blade pointing outward and cut from inside to out (endocardium to epicardium). The edges of the incision are then held apart and the endocardial surface of the right atrium and ventricle should then be wiped with a sponge and examined. Next grasp the apex again with the left thumb inside the cavity of the right ventricle. Push the point of the knife through the pulmonary conus and valve to a point 3 cm above the valve where an incision is made through the anterior wall of the artery. Then the incision is continued to cut through the pulmonary artery and anterior left ventricular wall in a line toward the apex, keeping as anteriorly as possible.

The aorta now needs to be opened. To do this grasp the apical area again by holding the triangular wedge of myocardium of the anterior wall of the heart between the fingers and thumb of the left hand. Lift this tissue and rotate the heart slightly to the right while passing the knife or the blade of a large pair of scissors through the left ventricle into the aorta. As with the pulmonary artery, the point of the knife should be pushed through the anterior aortic wall above the valve and a cut made through the aorta, which will also divide the posterior part of the pulmonary outflow tract, anterior right ventricular wall, and part of the ventricular septum. *Alternatively, scissors can be used to cut through the aorta, cutting across the pulmonary valve about 1 cm above the valve ring extending into the aorta.* This latter method retains the septum intact and the valves can be inspected more easily.

Attention now turns to the abdomen. Again, all of the intraabdominal organs are examined before dissection begins and the peritoneum inspected. Once a complete gross examination has been made, dissection starts with the liver. The left hand is passed between the right lobe of the liver and the diaphragm, lifting the liver out of the right hypochondrium. Once the liver is exposed, a deep transverse cut is made across both lobes. The gallbladder is then inspected and dissected free from its hepatic attachments. Cut the cystic duct close to the common bile duct and remove the gallbladder before opening. To remove the liver lift it once again with the noncutting hand with the thumb underneath and the fingers inserted into

the previous transverse incision and expose the hepatoduodenal ligament. With gentle slicing movements, open the structures contained within the ligament; the hepatic artery, common bile duct, and portal vein. These are inspected as they are cut and can be traced superiorly and inferiorly as they present. Then cut through the inferior vena cava, the falciform ligament, the coronary ligament, and the soft tissue above the right adrenal gland. The liver should now be separate and can be inspected in isolation and moved out of the way for later examination.

The spleen is then lifted out of the left hypochondrium and rested on the rib cage on the left. A horizontal section is made through the bulk of the parenchyma from the diaphragmatic surface to the hilum. The cut surface is inspected before the hilar structures are severed and the spleen removed.

To gain access to the right kidney first lift the caecum and dissect the posterior soft tissue attachments of this and the ascending colon. Displace this section of the large intestine medially to reveal the underlying right kidney. Grasp the kidney with the noncutting hand and dissect the surrounding soft tissue laterally by making a curved incision in the perinephric fat parallel to the convex outer border. Continue the dissection posteriorly and superiorly, freeing all of the soft tissue but being careful to leave the hilar vessels, ureter, and adrenal gland intact (Fig. 3.9). Dissect the hilar soft tissue to identify the renal vessels and cut across these midway to the kidney. The ureter is untouched at this stage. Now bisect the kidney from its convexity to the hilum through calyces and pelvis and inspect the cut surface. Strip the capsule by gripping the cut edge with toothed forceps and peeling it away; examine the subcapsular surface. Open the renal pelvis with scissors by piercing the wall and cut along the ureter inferiorly down to the pelvic brim (Fig. 3.10). Make a sagittal section through the right adrenal gland and inspect the cut surface. The procedure is virtually identical for examining the left kidney and adrenal gland but in this case it is the soft tissue around the descending colon that needs to be separated in order to expose the underlying kidney and adrenal gland.

To free the pelvic organs, blunt dissection of the peripheral soft tissue is required, using strong finger movements to separate the organs from the pelvic side wall beginning in the prevesicular space and extending posterolaterally to end behind the rectum. Grasp the most inferior structures, the prostate gland or cervix and upper vagina, with the noncutting hand and apply traction in an upward direction while the PM40 sweeps across the pelvic floor with the blade dividing all of the soft tissue. The posterior soft tissue attachments between the rectum and the coccygeal bone are dissected off and the pelvic organs are lifted out onto the front of the symphysis pubis. The iliac vessels are left intact. The rectum is opened through its posterior wall and cleaned, and the mucosal surface is inspected.

Removal of the urogenital organs will vary to some extent depending on the gender of the cadaver. In males pointed scissors are used to make a hole in the anterior wall of the bladder and the incision continued into the

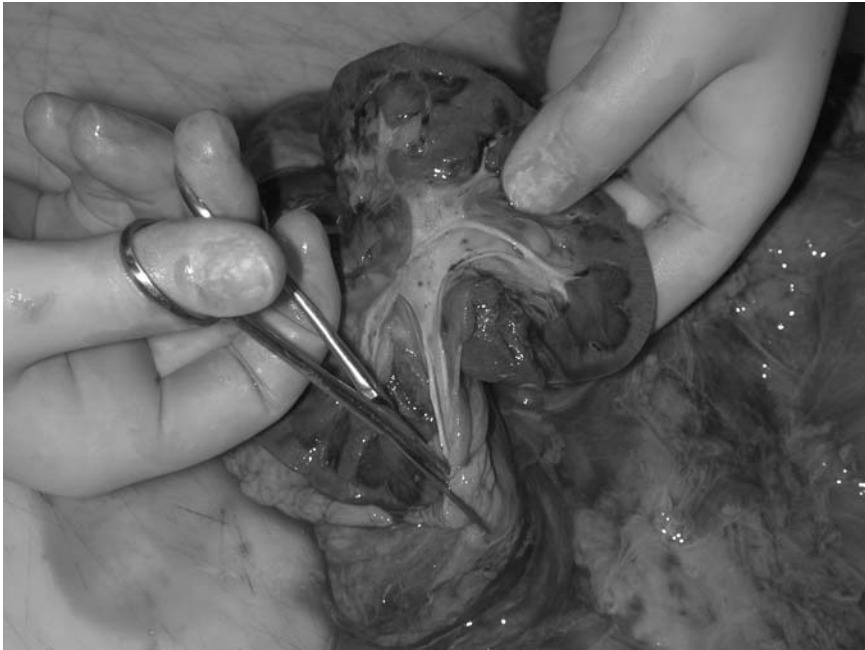

FIGURE 3.10. The ureters are opened with scissors from the renal pelvis to the bladder. (Courtesy of Mr. Dean Jansen, Whittington Hospital.)

urethra, cutting through the prostate gland. The cut surface is inspected as the cuts are made. Now examine the ureteric openings on each side from the inner aspect of the bladder and probe if necessary. The testes are withdrawn into the abdomen by blunt dissection beneath the pubic skin and Poupart's ligament. Firm manipulation with the fingertips may be necessary to free the spermatic cord and testis. Once free, both are retracted into the pelvis. Each is cut in half to demonstrate the pulp of the testis and a section is made through the epididymis.

Returning now to the posterior aspect of the pelvic block of organs, the rectum is dissected off by cutting along its anterior wall and the underlying seminal vesicles incised. If the penis needs to be removed the anterior skin incision is extended to a point about halfway along the dorsal side of the penis. The enveloping skin is dissected off by lifting each cut edge in turn followed by scalpel slices along the dermo-subcutaneous tissue junction laterally so that the dissection on each side meets in the midline at the ventral aspect. The penis is divided immediately proximal to the coronal sulcus. The corpora cavernosa with integral urethra are now forced back into the pelvis under the pubic arch and the lateral attachments divided.

In females the bladder is opened through the anterior wall via the urethra continuing the incision upwards in the midline. Again the ureteric orifices and mucosa should be inspected. The vagina and uterus can be opened by either cutting through the anterior wall again with scissors through the external cervical os or similarly through the posterior wall after removing the rectum. The former method will obviously cut through the posterior bladder wall and separate the bladder into two halves. Once the central fundal area is reached in the uterus the incisions are extended laterally on each side to the cornu. The fallopian tubes are opened longitudinally with scissors from the fimbrial end. The ovaries are sectioned longitudinally. All pelvic organs can now be removed from the body if necessary.

The remaining organs still lying within the abdominal cavity are the stomach, intestines, and pancreas. Start by opening the stomach by making a 4-cm incision in the anterior wall at the level of the pylorus with the pointed end of a pair of scissors. Examine and collect any contents as described previously. Carry this incision superiorly about 2 cm below and parallel to the lesser curve up to the cardia and esophageal junction. To examine the duodenum first dissect all attachments between the upper gastrointestinal tract and the transverse colon. Return now to the pyloric incision and continue this inferiorly through the gastroduodenal junction along the anterior wall of the duodenum as far as the beginning of the jejunum. Wash off any adherent material from the gastric and duodenal mucosa and inspect the surface closely. Localise the ampulla of Vater and probe it. Once probe patency is established, insert scissors through the opening and cut to expose the bile duct mucosal surface.

To inspect the pancreas cut through the adipose tissue attached to the stomach and lift the lower border of the stomach upwards. The transverse colon can be displaced downwards and the anterior surface of the pancreas should now be exposed. A transverse cut across the pancreas with a scalpel will demonstrate the parenchyma and it should be possible to identify the main pancreatic duct. After a small probe is placed into its lumen the duct is opened toward both the head and the tail with small scissors.

Although Rokitansky's method describes opening the intestines while they are still within the body, this will clearly be a very messy procedure in most cases and removal of the bowel to the sink before opening as described for all the other methods is highly recommended. However, for the sake of completeness the former method will be outlined here. Begin by incising the wall of the most distal part of the terminal ileum and insert the hook-ended bowel scissors. Cut with the scissors proximally along the underside at the border of the attachment of its mesentery. Continue the cutting all the way to join the anterior duodenal incision. At this point the large intestine is opened by returning to the terminal ileum and cutting distally through the ileocaecal valve into the caecum and beyond. The dissection proceeds distally by cutting through the anterior longitudinal muscle band to the previously cut end of the upper rectum. The appendix



is opened longitudinally with scissors. It is only at this stage that the stomach, intestines, and pancreas are removed from the body by cutting through all of the mesenteric attachments.

The last remaining structures to be examined are the internal body surfaces, diaphragm, vertebral column, and large posterior vessels. There is no need in most cases to remove the diaphragm and it can be inspected in situ, as can the inner surface of the body wall (including the pelvis). The vertebral column is inspected for deformities and if required a piece of lumbar vertebral bone removed with either a handsaw or electric saw for examination. For the latter the saw cuts are made parallel to the surface about 1 cm into the bulk of the vertebral bodies. Finally, all that remains to be done is to dissect, open, and inspect the inferior vena cava and its branches, the iliac veins, and the abdominal aorta with its branches.

The in situ (Rokitansky) method is summarised as follows:

- Inspect the mediastinum and pleural cavities.
- Lift the lungs anteriorly and slice each lobe.
- Open the pericardium and dissect the heart, first the left side and then the right.
- Inspect the abdominal contents.
- Slice the liver.
- Dissect the gallbladder.
- Slice the spleen.
- Slice the kidneys and adrenal glands.
- Open the bladder.
- Dissect the internal genitalia.
- Open the stomach.
- Slice the pancreas.
- Open the intestines.
- Open and inspect the large posterior vessels.

## Removal of the Brain

Removing the brain is part of every routine post mortem. In the majority of post mortems the brain is examined macroscopically for any focal pathology. In cases of known neurological disease or when unexpected lesions are detected on gross examination the brain is fixed and suspended in formalin for about 6 weeks before it is sliced and sections taken.

Standing at the top end of the table with the body supine and the head raised on a supporting block, make a skin incision through the scalp from behind one ear to the other over the vertex. This should begin about 1 cm behind one of the ear lobes, proceeding in a coronal plane to a corresponding point behind the other ear. A scalpel with a fresh sharp blade should

be used. The initial incision is made by inserting the scalpel through the skin down to bone and then turning the scalpel over with its back toward the periosteum and continuing the incision superiorly with the point of the blade travelling toward the vertex. This should part the overlying hair rather than cutting it. It is often helpful to wet the hair and brush it away before making any incisions. The skin is reflected anteriorly and posteriorly to expose the superior surface of the skull. The anterior flap should be stripped by forceful retraction of the scalp forward over the face while gentle sweeping strokes of the scalpel are made toward the calvarium, extending this to a level just above the orbits. A similar procedure is followed for the posterior flap, continuing to the occipital protuberance (Fig. 3.11).

A saw (usually of the electric oscillating type) is then used to make a series of interconnecting cuts through the skull around the periphery. Prior to sawing, the temporalis muscles on each side are cut through along the line of the subsequent saw cuts (Fig. 3.12). When using the saw it is important not to cut too deeply because the dura and leptomeninges should be removed intact with the brain if possible and not left attached to the skull. The sawing begins at the mid-temporal zone of one side with the line of the cut running anteriorly toward the forehead and then continued backwards at an angle ending just above and behind the contralateral ear.

Two further cuts begin at these end points angled backward toward the occipital protuberance, where they should meet at an angle of about  $160^\circ$ . The mallet and chisel or skull key are then used to crack the inner part of the table of the skull and this plate of skull separated. The dura is separated

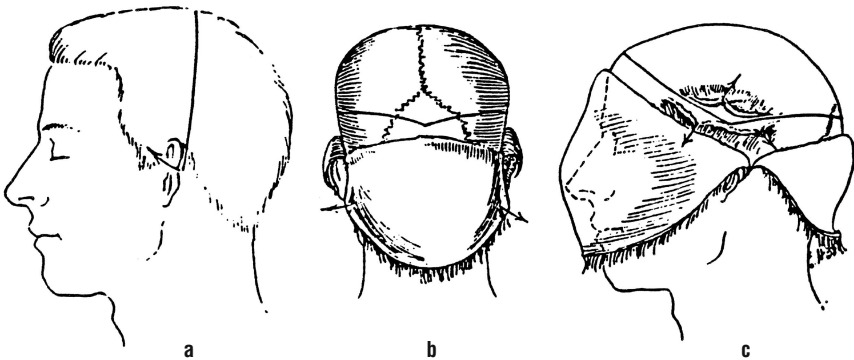


FIGURE 3.11. Diagram of the scalp and skull incisions to be made in preparation for removal of the brain. **(a)** Scalp incision from behind the left ear over the vertex to end behind the right ear. Reflection of the scalp exposes the underlying skull. **(b)** View from the posterior aspect showing the line of saw cuts converging on the occiput. **(c)** Lateral view to demonstrate lateral and anterior saw cuts. Note division of the temporalis muscles on both sides. (Modified from Mallory 1938 [1]; with permission.)

from the inner surface of the skull vault by blunt dissection with the fingers and the skull cap can then be removed (Fig. 3.13). The quality of the bone should be inspected (e.g., thickness in Paget's disease and deposits in myeloma). The sagittal sinus is inspected for any thrombosis (seen especially in postpartum patients and in those with severe dehydration). It can then be opened with scissors. At this stage the meninges should be inspected for signs of haemorrhage or infection. The latter may present as dull opacity to the meninges or as frank pus.

Once the cerebral hemispheres are exposed the dura is freed anteriorly by lifting and incising it followed by cutting the falx at its insertion into the crista galli of the ethmoid with curved scissors (with tips away from the parenchyma). The dura should then be withdrawn from the anterior to posterior direction, tearing or cutting the tiny intervening blood vessels. Let the dura hang over the occiput posteriorly, still attached. The frontal lobes should then be easily accessible and two fingers can be placed gently in front of these lobes, one on either side, between the dura and the cortex, while the brain is edged away from the base of the skull and the frontal lobes lifted. From then on it is best to perform all cuts from the anterior aspect and support the brain from behind. The olfactory nerves are easily seen

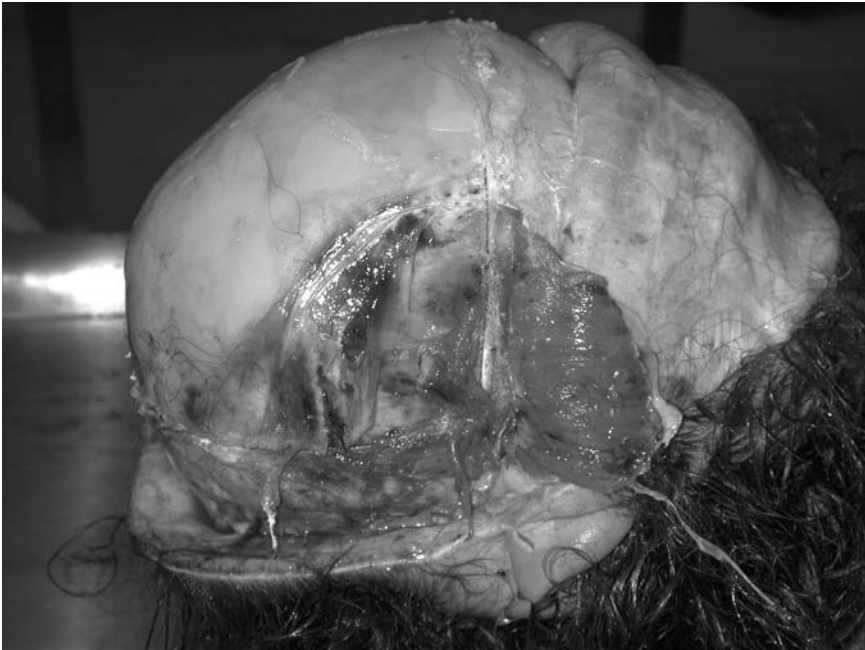


FIGURE 3.12. The scalp reflections allow the temporalis muscles to be detached for easier and safer sawing. (Courtesy of Mr. Dean Jansen, Whittington Hospital.)

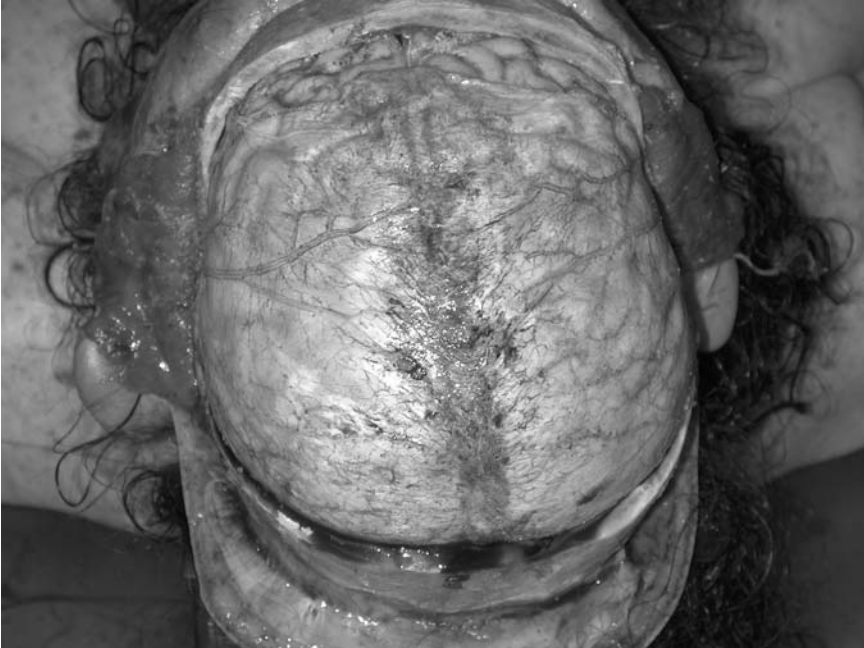

FIGURE 3.13. The skull cap is removed to expose the underlying dura. (Courtesy of Mr. Dean Jansen, Whittington Hospital.)

when the frontal lobes are retracted and these will usually come free from the cribriform plate without any need for further dissection. The optic nerves are transected as far anteriorly as possible. Working backwards, the internal carotid arteries are then sectioned, inspecting for atheroma and/or luminal thrombus, followed by the pituitary stalk and oculomotor nerves.

The dura is released along the ridge of the lesser wing of the sphenoid bone by incising with scissors from the medial to the lateral direction (extending as far laterally and posteriorly as possible). To do this, the temporal lobes are lifted and, proceeding away from the midline, the tentoria cerebelli are cut from their anterior borders, staying as close to the petrous part of the temporal bone as possible. The brain should now fall back further to expose the front of the brain stem. Working still further posteriorly, sever the cranial nerves as they come into view from around the medulla oblongata, continuing to support the weight of the brain with the noncutting hand. Finally, introduce a scalpel through the foramen magnum into the cervical spinal canal and cut across the cervical cord as it joins the brain stem in a single motion, severing the vertebral arteries at the same time. It should now be possible to deliver the brain by rotating the inferior

surface upwards with one hand while supporting the superior surface (which is now underneath) with the other. It may be necessary to cut the small amount of posterior dura that remains attached.

The base of the brain is inspected to check the vessels of the circle of Willis for atheroma and aneurysms and to check for evidence of tonsillar or temporal herniation (evidence of raised intracranial pressure). The brain is then weighed before it is suspended in formalin as soon as possible to be examined later. It should not be left on a flat surface for even a short length of time because distortion will inevitably occur and this hampers subsequent assessment. The delay in examination is deliberately intended to allow complete fixation of the brain, thus making it firmer before subsequent slicing. Slicing the fresh brain is to be avoided if there is significant (particularly microscopic) pathology because its consistency makes it difficult to handle without causing an element of distortion and mutilation. If there has been a subarachnoid haemorrhage, however, this rule does not apply. In this case the pathologist should wash off the blood around the base of the fresh brain to try and identify the source of bleeding and locate the likely aneurysm before fixation.

It is extremely important to obtain and demonstrate consent for retention of the brain should this be considered necessary. If consent is obtained then the brain should be fixed prior to slicing. For fixation, a hook (a plastic curtain hook is perfect; a paper clip will do but may well rust) or length of string is placed under the largest basal artery (nearly always the basilar). This is connected to a supporting string attached to both sides of an adequately sized container. The latter should be of sufficient volume that the brain can lie away from all of the sides and base and be surrounded by an ample amount of formalin.

After the brain is removed the pituitary fossa is inspected, covered by the diaphragma sella (Fig. 3.14). The posterior wall is formed by the sphenoid bone, which is broken forcibly with a clamp or pair of forceps. The dura is thereby detached posteriorly, and a blunt instrument or scalpel can be inserted into the fossa from the side. This should be introduced as low as possible in order that the pituitary gland can be elevated, delivered superiorly, and dissected free, hopefully complete without being crushed (Fig. 3.15). Special techniques for removing the spinal cord, eyes, and entire pituitary fossa are described in Chapter 12.

The procedure for removal of the brain is summarised as follows:

- Reflect the scalp skin and detach the temporalis muscles.
- Saw the skull peripherally on both sides to meet frontally and occipitally.
- Remove the skull cap and inspect the bone and meninges.
- Free the dural attachments and falx cerebri.
- Lift the frontal lobes and divide the cranial nerves as they appear.
- Divide the internal carotid arteries and pituitary stalk.

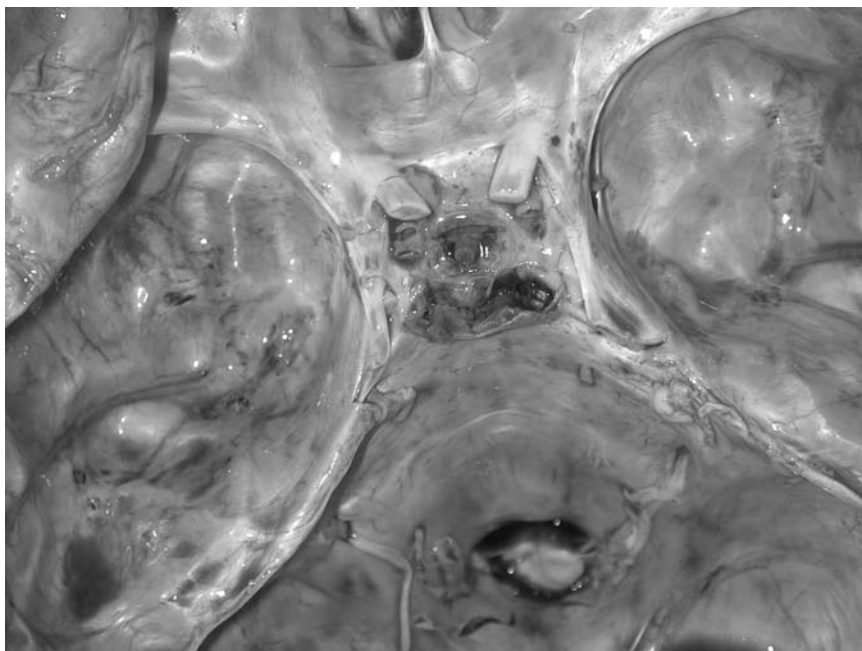


FIGURE 3.14. The pituitary fossa and surrounding structures are exposed. (Courtesy of Mr. Dean Jansen, Whittington Hospital.)

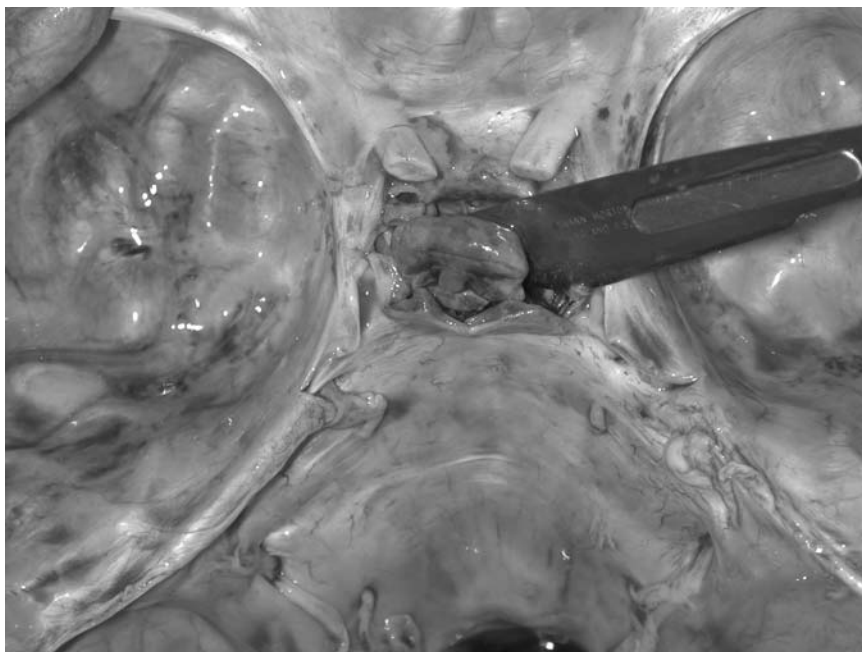


FIGURE 3.15. The pituitary gland is delivered from the pituitary fossa. (Courtesy of Mr. Dean Jansen, Whittington Hospital.)

- Dissect the dura from the sphenoid bone and tentoria cerebelli to expose the anterior brain stem.
- Insert the scalpel into the foramen magnum and divide the upper cervical spinal cord and vertebral arteries.
- Remove the brain.

## Examining the Middle Ear

It is occasionally necessary to inspect the internal ear. One example of such a situation is systemic sepsis from an unknown source. As it is difficult to identify which particular organ chapter should include this part of the dissection it is outlined here for convenience. If inspection of the middle ear is all that is required then the latter can be visualised by chipping off the overlying bone making up its roof with a chisel. To locate this area, expose the base of the skull after removal of the brain, strip the attached dura, and locate a position two thirds of the way from the calvarium to the foramen in the middle cranial fossa, just anterior to the arcuate eminence on the ridge of the petrous temporal bone and posterolateral to the foramen spinosum (Fig. 3.16). A sharp-ended chisel is placed anterior to this ridge and a sharp blow made with a mallet in an anteroposterior direction. A second chisel blow is then made lateral to this about one third of the way from the dural surface to the middle of the base of the skull. A third chisel cut is made with the chisel turned through 90° between the first two cuts. It should now be possible to remove the tegmen tympani and expose the middle ear. Pus or blood should be seen easily and a swab taken for microbiological analysis if necessary.

This is clearly suboptimal for detailed inspection, as much of the important and minute features can be lost and fragments of bone are spread across the area of inspection. A more detailed method for exposing and inspecting the middle ear involves making four saw cuts in the petrous temporal bone. For this an electric saw with a T-blade is used to make the first anteroposterior cut 1 cm medial to the squamous part of the temporal bone into the external auditory meatus. This cut should be approximately 2 cm deep. The second anteroposterior cut is made, also 2 cm deep, 1 cm lateral to the sella turcica. A third 2-cm deep cut joins these anteriorly, 1.5 cm anterior and parallel to the petrous temporal bone. The fourth and final cut is made parallel to the latter approximately 3 to 4 mm below the superior surface. A T-bar is inserted here and this plate of bone levered off to expose the middle ear.

*Alternatively, the whole internal ear can be removed for more formal study. Either a trephine needle can be used to core out the inner ear region using the landmarks described above, or a larger block of bone can be removed using an oscillating saw. This involves cutting a square of tissue, which is removed, decalcified, and sectioned for microscopic observation. Again the*

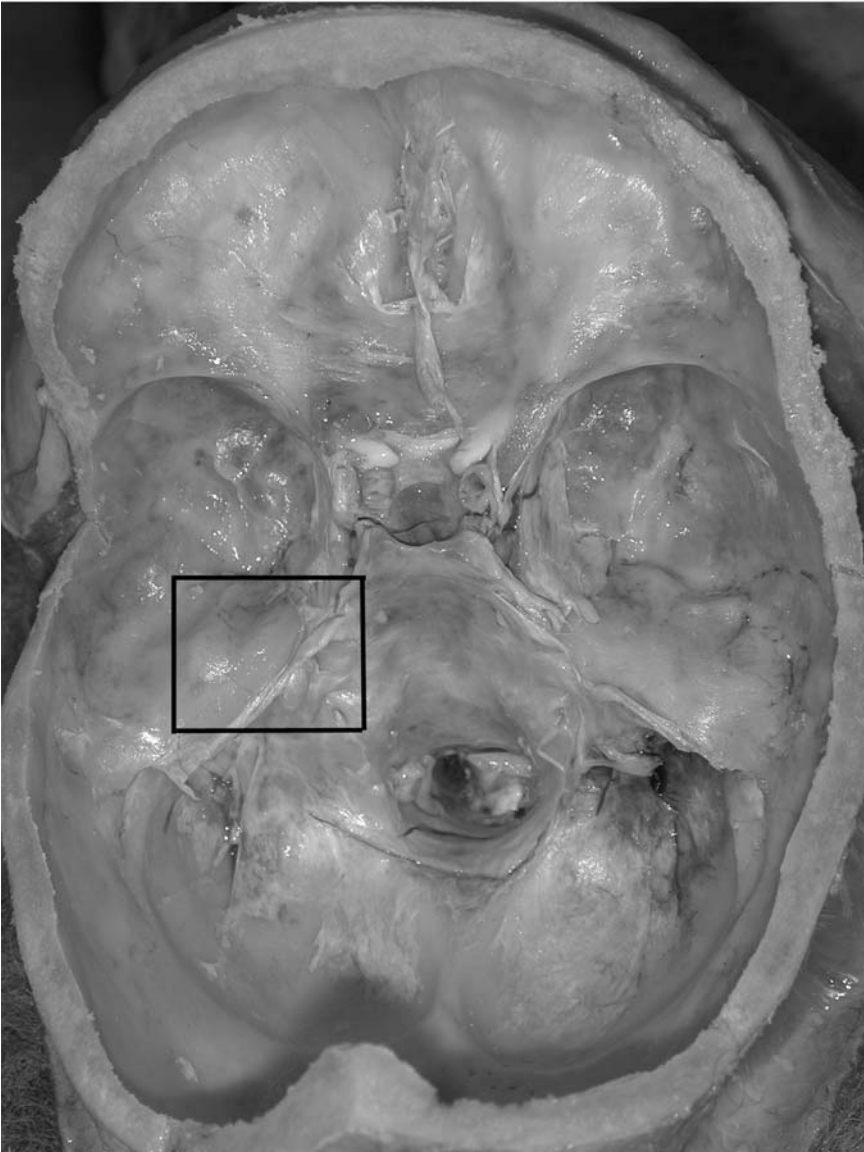

FIGURE 3.16. An indication of the area of interest for examination of the internal ear. (Courtesy of Mr. Dean Jansen, Whittington Hospital.)

*boundaries should follow the principles described earlier, with deep cuts made with the saw, one just lateral to the medial border of the orbital cavity/lateral border of the pituitary fossa, a second just behind the lesser wing of the sphenoid, a third just in front of the arcuate eminence, and the*



*last laterally to join the previous two. These cuts must be deep and reach the soft tissues behind the face and therefore obviously should be made with extreme care in order to avoid undesirable damage, which may not be reconstructable. Once the four cuts are made, this block can be lifted free by directing a long-handled scalpel into the saw cuts while lifting the bone with forceps and freeing the underlying soft tissues. Decalcification can be performed using the methods described on p. 255, followed by sectioning on a large section microtome.*

### *Reference*

1. Mallory FB. Pathological technique: a practical manual for workers in pathological histology, including directions for the performance of autopsies and microphotography. Philadelphia: WB Saunders, 1938.

# 4

## Block Dissection

This chapter will have relevance primarily to the first two evisceration methods described in Chapter 3, as Rokitansky's method involves almost entirely in situ dissection and Virchow's method separates organs during evisceration. It has been mentioned that occasionally the latter technique will have to be modified in some way to allow groups of organs to be removed in continuity and in these circumstances the dissection of these organ blocks will be identical to that described below for the en bloc evisceration method. The methods described here occasionally have to be adjusted to prevent missing important features and to optimise demonstration of the findings to an audience. This chapter focuses on the routine examination, and other less frequently used special and alternative techniques are described in the relevant organ dissection chapters.

### Whole Pluck/En Masse Method (Letulle's)

As all of the internal organs are removed together, this method evidently allows the most scope for observing and demonstrating relationships between diseased organs and systems. There are several ways by which separation can proceed, tailoring the method to best display the desired pathology either for one's own satisfaction or to allow the most advantageous demonstration. In some cases it may be appropriate to separate the organs into blocks as in Ghon's method and subsequent dissection will then follow the same route as that described below. *Alternatively, the site of interest is dissected first and the rest of the dissection may subsequently follow any of the other methods.* In most cases the intestinal tract will have been removed before the bulk of the organs, as discussed in the evisceration section. In a few instances the intestines will still be attached, however, and further dissection is described in Chapter 7. Although it may at first appear difficult to decide where to start when all of the organs are presented in this way, two well described plans are discussed in the following sections, both pursuing similar pathways through the systems.

*Method of Saphir (1958) [1]*

In this technique the retroperitoneal vessels are dissected first, followed by the adrenal glands and then the urogenital tract. The oesophagus is dissected next, before the thoracic and abdominal organs are separated and subsequently dissected in the same manner as the Ghon method described later. The mass of organs removed is laid on the dissecting table with the posterior structures facing the prosector. The inferior vena cava is identified and opened and the luminal surface inspected for thrombi. The vessel is pierced posteriorly below the liver with scissors and cuts are made superiorly and inferiorly into the iliac veins. The coeliac plexus and retroperitoneal lymph nodes are now inspected and the latter removed for histological examination if necessary.

Attention turns to the adrenal glands and their blood vessels. The anatomical sites of the adrenal glands are usually obvious, but occasionally perinephric fat will obscure these glands and often they lie extremely close to another organ (such as the liver on the right) and therefore may be inadvertently removed or cut through during retroperitoneal dissection. If they do prove difficult to find then tracing the adrenal veins should aid identification [2]. First identify the renal veins as they enter the inferior cava on the right and left renal vein on the left. The right adrenal vein drains directly into the inferior vena cava just above the right renal vein. The right spermatic or ovarian vein can also be opened. The left adrenal vein is traced and opened from the left renal vein and the left spermatic or ovarian vein is also opened. The adrenal glands can now be removed after they are dissected free from the surrounding fat.

The aorta is opened from the cut ends of the external iliac arteries on each side to the bifurcation and dissection continued up to the aortic arch. At this time the azygous vein and thoracic duct are examined if they have been removed with this conglomerate of organs but usually these will have been examined in situ during evisceration. The abdominal aorta and the thoracic descending aorta are dissected away from all surrounding soft tissues, leaving the latter attached to the arch. All lateral branches should be divided and inspected as they are cut.

Still concentrating on the posterior aspect, inspect both of the kidneys, ureters, bladder, male and female genital organs, and lower rectum. It is important to establish whether any significant pathology is likely to be found within this group of structures because this will dictate the need for more elaborate methods of removal and also whether careful individual organ dissection is appropriate. If all of the organs appear normal on examination then in fact there is little to be lost in removing at least some individually. If, however, an abnormality is identified it is best to remove the group of organs intact (as previously discussed). The latter is outlined here because it will be self evident that single organs can be separated at any point during the following if warranted. First return to the dissected

area above the right kidney from where the adrenal gland has been removed. Continue the dissection around the convex (lateral) border of the kidney to free it from the surrounding perinephric fat. This can now be gripped with the noncutting hand and lifted medially, being careful not to disrupt the ureters. A similar procedure is performed around the left kidney, taking care not to injure the nearby spleen. Attention now turns to the ureters, which are traced down to their junction with the bladder, and the surrounding soft tissues are stripped.

The bladder, genital organs, and rectum lie inferiorly. The latter should be opened and the mucosal surface inspected before it is removed by dissecting along a plane between it and the bladder or uterus anteriorly. It may be separated first and then the mucosa inspected later after it is opened. In males, the peritoneum here is now lifted to expose the seminal vesicles. It should now be apparent that the urogenital tract (of either sex) is isolated and the organs can be dissected as a unit while still in continuity or can be separated before dissection. Both methods are described in the urogenital en bloc technique section at the end of this chapter.

Next, turn to the upper part of the organ mass. Toward the upper end of the oesophagus the posterolateral parts of the lateral lobes of the thyroid will come into close proximity to the anterolateral oesophageal wall. The parathyroid glands are usually located medial to this area. After the groove between the posterolateral aspects of both thyroid lobes and the oesophagus is found, the thyroid is held by a pair of forceps while the soft tissue behind is carefully dissected with either scissors or scalpel to expose the posterior surface of the lobes. The parathyroid glands are oval, yellow-brown in colour, and about 4 to 6 mm in length. If it proves difficult to find them first identify the inferior thyroidal artery as it arises from the thyrocervical trunk (a branch of the subclavian artery) and follow it to the thyroid gland. The inferior parathyroid gland is usually located just below the site at which the artery enters the thyroid gland, and the superior gland several millimetres above this area. The glands should be collected straight into a container so that they are not inadvertently lost amidst the soft tissue cleaned away from the other organs.

The oesophagus is then dissected away from the mediastinal structures by dissecting along the plane between it and the airways anteriorly. It is transected at approximately a third of the way down, but left attached to the stomach so that it may be dissected in continuity with the latter and aid demonstration of lower oesophageal pathology (such as varices). Once this has been achieved successfully the chest organs can be separated from the abdominal contents by cutting through the inferior vena cava just above the diaphragm. It will be noted that this will not divide the lower oesophagus or aorta because these have already been dissected free from the posterior structures.

Further block dissection may now follow the procedure described below for the thoracic and coeliac blocks of the Ghon technique except that the

parathyroid glands have already been isolated, the oesophagus and stomach remain contiguous, and the length of the aorta remains intact. This is particularly suitable for optimally displaying the extent and complications of aortic aneurysms of either the saccular or dissecting type and oesophageal varices.

The sequence of dissection for the method of Saphir [1] is as follows:

- Dissect the retroperitoneal vessels.
- Identify the adrenal glands.
- Dissect the urogenital tract.
- Open the rectum.
- Identify the parathyroid glands.
- Dissect the oesophagus.
- Dissect the thoracic organs (see later).
- Dissect the coeliac organs (see later).

### *Alternative Method*

A second similar method follows a slightly different route of dissection. Again the organs will have been removed as an entire block and these are placed face down (i.e., with the posterior surface uppermost) on the dissecting table. Locate the left subclavian artery, and, using scissors, cut along its posterior wall toward the aorta. Continue the incision into the aorta and open proximally and distally to the cut ends of the external iliac arteries. Now identify the renal arteries and inspect the ostia before opening in the direction of the hila of the kidneys. The aorta is now reflected up to the arch by dividing all of the branches as they originate from the vessel.

Now open the inferior vena cava from the iliac veins to the diaphragm. Identify the right adrenal vein just above the right renal vein and open this to localise the right adrenal gland. The periadrenal soft tissue is dissected away to allow inspection and removal of the gland. A similar procedure is followed on the left by opening the left renal vein and from there the left adrenal vein to find the left adrenal gland, which can also be removed. Once the adrenal glands have been removed without injury the kidneys can also be isolated. Begin on the right by clearing away the perinephric fat to reveal the capsular surface of the kidney. To do this, the cuts made to remove the adrenal gland are continued laterally to skirt the convex outer border of the kidney, being careful not to disrupt the underlying renal parenchyma. Inferiorly the ureter must be identified before cutting through to check whether any significant abnormality is present. When all the tissue around the kidney is cleared away the kidney can be grasped with the nondominant hand while the hilar structures are divided, leaving only the ureter attached. Assuming the ureter is normal this can then be transected and the kidney removed for weighing and further dissection. An identical sequence is followed on the left, this time being careful not to damage the nearby

spleen. It is customary to leave a longer length of ureter on the left for later identification. Obviously if urinary tract pathology is significant and full demonstration is desired, the upper and lower parts of the tract should be kept in continuity and not dissected in this way. If this is the case the method of Saphir should be followed (as described earlier).

Now move down to the lower part of the organ group and locate the cut end of the urethra. The urethra and bladder can be opened in the same way in both genders; the approach differs for other pelvic structures. One blade of a pair of scissors is passed through the urethra into the bladder lumen. Cuts are made through the anterior wall in the midline (through the prostate gland in males). The incision continues to the dome, either centrally or by making curve paths toward each ureteric orifice. The mucosa is inspected. The ureterocystic junctions are now opened to allow inspection of the lower ureteric urothelium. In male subjects several tranverse slices are made through the prostate gland at this point and the parenchyma inspected. The testes are either sliced now for examination or removed by cutting through the spermatic cord for later assessment.

Again from the posterior aspect, the rectum is dissected from the more anterior organs and removed before opening. It can also be opened in situ and removed after inspecting the inner surface. In females the genital tract is examined in situ or by dissecting the organs from the bladder anteriorly for subsequent dissection. If in situ dissection is preferred the posterior wall of the uterus is cut via the external cervical os to expose the endometrial lined corporal cavity. This is usually done by passing scissors through the cervix before opening to the fundus or slicing vertically with a large-bladed knife. The fallopian tubes are also dissected with scissors, cutting from the fimbriae medially or ostia laterally. *Alternatively, a series of parallel transverse sections can be made through the wall of each fallopian tube.* The ovarian parenchyma is demonstrated by either a single section through each ovary in a coronal plane or a series of parallel slices from medial to lateral.

Return now to the mid-portion of the organ block and locate the coeliac artery. After examining for proximal vascular disease or thrombi, open the artery with scissors and continue with the incision into the hepatic artery. The proximal superior and inferior mesenteric arteries can also be examined in the same way. Identify the portal vein and open it. This is particularly important in the presence of hepatic disease.

Travelling to the upper part of the visceral pluck, the salivary glands and tonsils are inspected and sliced so that the parenchyma is demonstrated. Now the parathyroid glands are located and inspected before removing. Find the groove between the posterolateral parts of the lateral lobes of the thyroid on each side. Hold the thyroid here between the arms of a pair of forceps while the soft tissue just behind the thyroid and in front of the oesophagus is carefully dissected to expose the posterior surface of the medial side of the lateral lobes of the thyroid. If they do not present them-

selves easily, identify the inferior thyroidal artery as it arises from the thyrocervical trunk and follow it to the thyroid gland. The inferior parathyroid gland is usually located just below this as it enters the thyroid gland, the superior gland several millimetres above this area. All four glands are removed and collected into a container for subsequent assessment.

At this point the oesophagus can either be opened through its posterior wall (unless lower oesophageal pathology is suspected) or it can be dissected free from the trachea and mediastinal structures anteriorly by working around the anterior border with a combination of blunt and sharp dissection. If the oesophagus is opened first it should then be reflected from its anterior neighbours. The musculature of the diaphragmatic arches is now divided to release the lower oesophagus.

If the oesophagus is opened (as is usually the case) continue the cuts through the gastro-oesophageal junction into the cardia and fundus and along the length of the greater curvature into the duodenum. If not, continue the soft tissue dissection around the lower oesophagus, stomach, and first part of the duodenum, leaving the wall intact. Now locate the ligature or clamp placed around the duodeno-jejunal junction for removal and open the duodenum through this at the proximal end to expose the mucosa of the duodenum. Identify the ampulla of Vater (if necessary by stretching the wall) and insert a probe to examine the patency here (Fig. 4.1). Having established this, insert one blade of a pair of scissors and cut through the ampulla, continuing the cuts toward the liver to open the biliary tree.

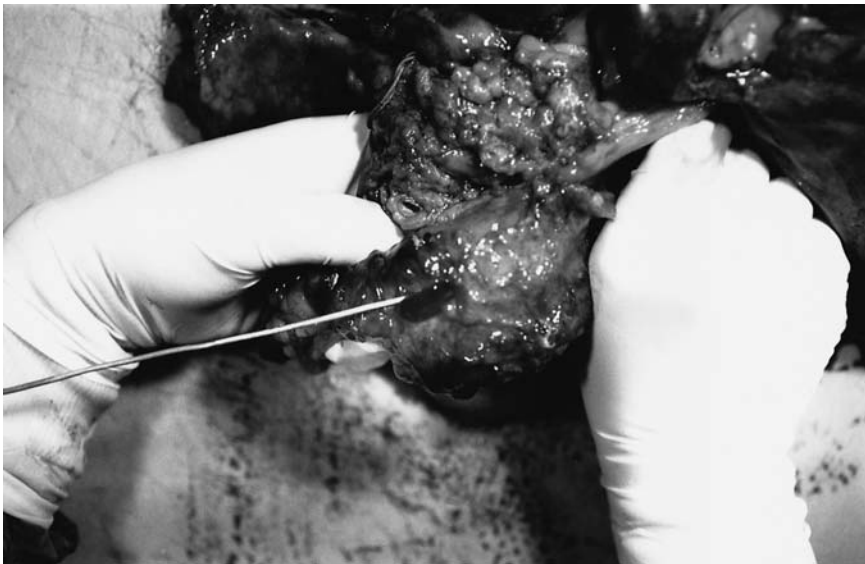

FIGURE 4.1. Patency of the ampulla of Vater can be demonstrated by placing a probe through the duodenal orifice. (Courtesy of Mr. Ivor Northey.)

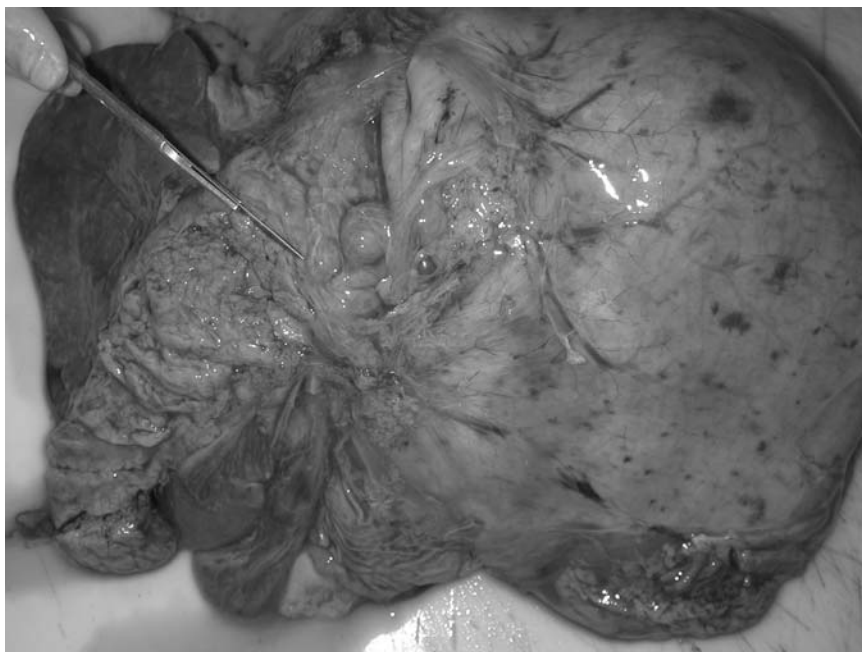


FIGURE 4.2. The pancreas can be sliced vertically and the cut surface and main pancreatic duct inspected. (Courtesy of Mr. Dean Jansen, Whittington Hospital.)

Continue further to open the gallbladder while it is still attached to the liver and open the proximal branches of the intrahepatic ducts. Inspect the mucosa and contents of the gallbladder, which can be dissected free from the liver after cutting through the cystic duct. The splenic artery and portal vein are also identified within the hepatoduodenal ligament, opened, and traced superiorly to the porta hepatis and early intrahepatic branches, and inferiorly to their tributaries or feeding vessels.

Identify the lesser sac by lifting the lower border of the stomach away from the transverse colon. These should be freed from each other by tearing through the bridging omental fat. The pancreas will be exposed in this way. The latter can be removed by dissecting around the head of the pancreas first, dividing the attachments between it and the duodenum, and extending the dissection along the borders of the pancreas toward the body and the tail. Once isolated the pancreas is removed and dissected as described in Chapter 7. The pancreas can also be examined in situ by making a transverse section across the tail, locating the main pancreatic duct, and opening this toward the ampulla with small scissors. *Alternatively, a series of parallel slices can be made from the head laterally* (Fig. 4.2). The parenchyma will also be displayed for macroscopic assessment during this procedure.



At the lateral region of the mid-portion of the organ conglomerate on the left will be found the spleen. This is grasped with the left hand and the splenic hilar vessels and soft tissue divided. The spleen can be removed. Moving across to the right side, all visceral, diaphragmatic, and nonvascular soft tissue attachments are dissected from the border of the liver which will be removed shortly. There is a deliberate intention in the subsequent part of this dissection to preserve and demonstrate any pathological relationships present between the liver and heart such as inferior vena caval disease.

Return to the arch of the aorta and continue opening the vessel proximally toward the pericardium. Cut into the pericardium and inspect and collect any contents. Open both the superior and inferior vena cavae, continuing the cuts into the right atrium. Go back to the hepatic region and inspect and cut the hepatic veins. Now the liver can be removed by dividing the few remaining soft tissue attachments. Once again revisit the heart and separate the aorta from the adjacent pulmonary artery by blunt dissection. Divide the aorta just above the aortic valve, and the aorta and arch branches can now be removed and dissected. These are opened and the luminal surfaces inspected. Make an incision in the wall of the main pulmonary artery trunk and examine closely for evidence of luminal thromboembolus. Now the heart should be lifted from the pericardial sac and the pulmonary arteries and veins cut. Remove the heart for dissection and inspect the posterior pericardium.

Once again return to the anterior neck region and continue the dissection of the soft tissue between the thyroid gland and trachea to remove the thyroid gland. This is achieved by extending the bilateral dissection performed to identify the parathyroid glands behind the thyroid medially to meet in the midline and thereby separate all of the posterior connections. Freeing the few anterior soft tissue attachments remaining after this should allow easy removal of the thyroid gland. Slightly more inferiorly the thymus is removed (if identified and not totally atrophic) by separating all of its peripheral bordering attachments. Now turn to the mediastinal structures and identify any lymph nodes and remove these. Once separated from the rest of the local structures, the larynx and trachea can be opened through the posterior (muscular/noncartilaginous) wall all the way down to the carina. *Alternatively, leave these last few structures intact to be opened in the same manner but at a later stage after the lungs have been removed.*

Before removing the lungs decide whether it is desirable to inflate one (or both) before slicing. If this is the case and only one lung needs to be inflated the left is preferable, as the main bronchus is longer and ligating the stump of this should be easier. In any case the lungs should both now be dissected free by dividing the hilar structures on each side and lifting the lungs free to be weighed and opened later.

All organs should now be isolated for subsequent remote dissection and all intervening tissues dissected away.

The alternative method is summarised as follows:

- Open the left subclavian artery.
- Open the aorta.
- Open the renal arteries.
- Dissect the aorta away from its attachments.
- Open the inferior vena cava and right adrenal vein.
- Remove the right adrenal gland.
- Do the same on the left.
- Remove the right and left kidneys.
- Open the ureters and bladder.
- Remove the rectum.
- Dissect the prostate/testes or uterus/fallopian tubes and ovaries.
- Open the coeliac artery and branches.
- Open the portal vein.
- Dissect the salivary glands and tonsils.
- Isolate the parathyroid glands.
- Remove the oesophagus.
- Open the stomach and duodenum.
- Identify and dissect the ampulla, biliary tree, and gallbladder.
- Open the splenic artery.
- Remove the pancreas and spleen.
- Dissect the aorta to the heart.
- Open the pericardium and vena cavae.
- Remove the liver.
- Examine the pulmonary artery.
- Remove the heart.
- Remove the thyroid.
- Inspect the mediastinal structures.
- Open the larynx and trachea.
- Remove the lungs.

## En Bloc Method

### *Thoracic Pluck*

It is important to start with a few clear and simple points in order to avoid problems later on. The first thing to remember is to make a preliminary examination of the heart in situ before the anatomy is disrupted and important findings potentially lost. Pulmonary emboli should be excluded before any of the other dissection continues. The parathyroid glands should be isolated early before they are lost amid the discarded tissue. If these are easily found it is important to check the kidneys carefully, as they may be hyperplastic as a result of secondary hyperparathyroidism.

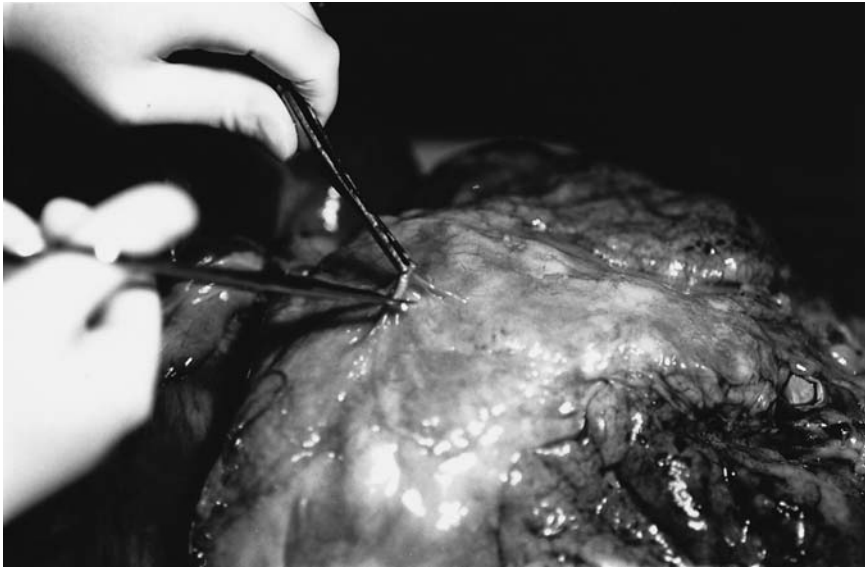

FIGURE 4.3. The pericardium is opened anteriorly by lifting the parietal layer with forceps before incising with scissors. In this way any contents within the pericardial cavity can be inspected and collected.

Start by incising the pericardium by lifting the anterior portion with toothed forceps and snipping a hole with scissors (Fig. 4.3). Any pericardial fluid is noted and collected, by syringe or ladle (depending on the quantity) before it is measured in a measuring jug. All fluid and clotted blood from a haemopericardium are similarly measured to quantify the size and severity of the loss/accumulation. Once the form and epicardial surface of the heart have been examined, the main pulmonary trunk is located and a small incision is made in its wall about 1 to 2 cm above the pulmonary valve. This primary incision is extended with scissors into each hilar area and the lumina examined for emboli. Once the presence or absence of an embolus is established, the pluck is turned over to demonstrate the posterior surface. The thoracic aorta is dissected free from its surrounding soft tissue attachments and the oesophagus is exposed.

Toward the upper end of the oesophagus, the posterolateral parts of the lateral lobes of the thyroid will come into close proximity to the anterolateral oesophageal wall. It is medial to this area that the parathyroids are usually located. After the groove between this part of the thyroid and the oesophagus is found, the thyroid is held between the arms of a pair of forceps while the soft tissue behind is carefully dissected to expose the posterior surface. The parathyroid glands are oval, yellow-brown in colour, and about 4 to 6 mm in length. If it proves difficult to find them first identify the inferior thyroidal artery as it branches from the thyrocervical trunk and

follow it to the thyroid gland. The inferior parathyroid gland is usually located just below the site at which the artery enters the thyroid gland, the superior gland several millimetres above this area. The glands should be collected straight into a container so that they are not inadvertently lost.

The thyroid gland is removed from the anterior of the trachea by continuing the dissection behind the lateral lobes, progressing in front of the trachea from both sides. Once these bilateral dissections have met in the middle, only a small amount of muscular attachment needs to be freed on the anterior aspect of the thyroid. The external surface is inspected for masses or multinodularity, and it can then be removed for later dissection.

The oesophagus is usually now opened with scissors from the lower cut margin or upper pharyngeal end (Fig. 4.4). It can also be dissected free from the other mediastinal structures (in a manner similar to that used for the aorta) for later dissection if lower oesophageal disease is present (Fig. 4.5). The pharynx should be inspected. Removing the oesophagus exposes the posterior surface of the trachea and mediastinal and hilar soft tissue with vessels and lymph nodes included. It is usual for the trachea to be opened through its posterior smooth muscular wall either at this point (Fig. 4.6), or after the lungs have been separated from the rest of the thoracic organs, by

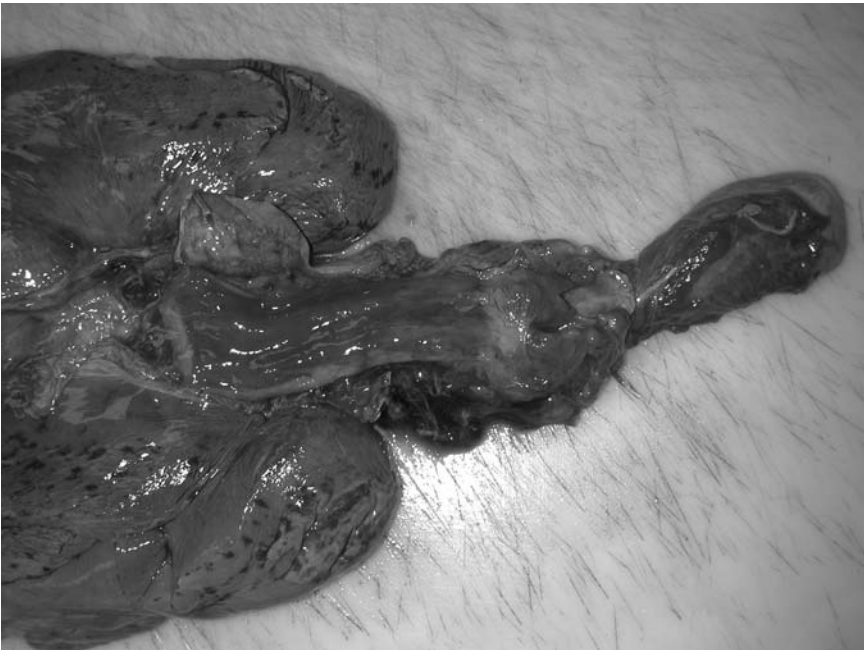

FIGURE 4.4. The oesophagus is opened through its posterior wall and the inner aspect examined. (Courtesy of Mr. Dean Jansen, Whittington Hospital.)

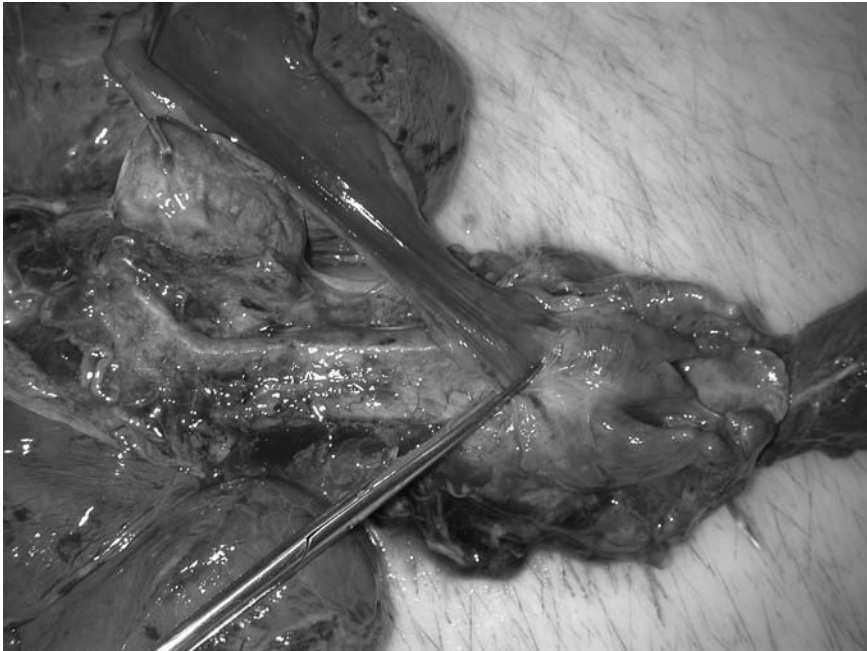

FIGURE 4.5. The oesophagus is dissected free to reveal the underlying trachea. (Courtesy of Mr. Dean Jansen, Whittington Hospital.)

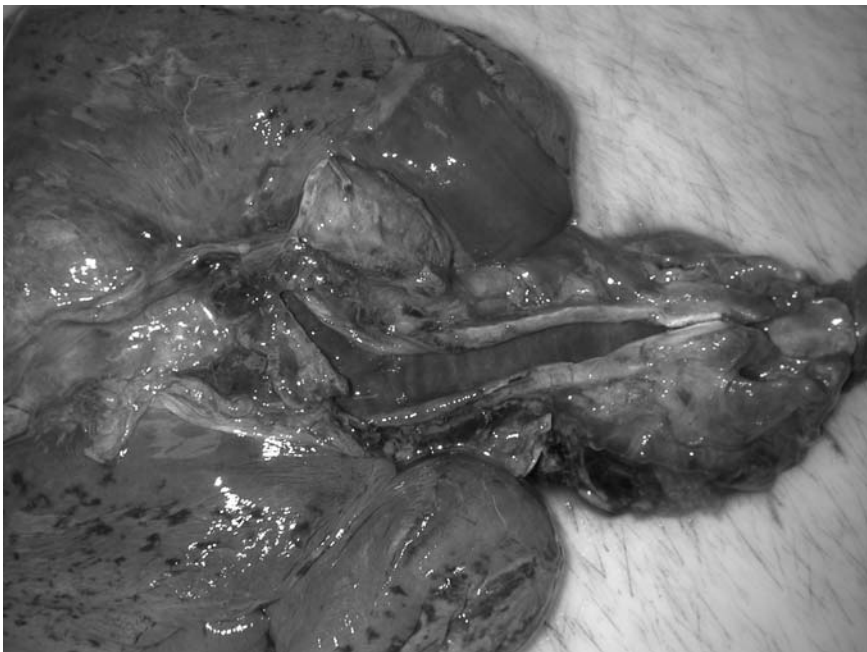

FIGURE 4.6. The trachea is opened with scissors through its posterior muscular wall. (Courtesy of Mr. Dean Jansen, Whittington Hospital.)

transecting the hilar structures on each side with either large scissors or PM40 (Fig. 4.7). Scissors are inserted into the posterior wall of the larynx after inspecting the vocal cords and surrounding structures. The laryngeal cartilage is cut through and the cut is extended along the noncartilaginous muscular posterior wall to the carina. *If a tracheo-oesophageal fistula is suspected, however, it is better to open the trachea through the anterior cartilaginous wall to avoid disrupting and possibly corrupting the site of the fistula.*

As stated previously, it is important to leave a long stump of main bronchus on the pulmonary side of this cut if the lung is to be inflated. The lungs are weighed before dissection to include the airway contents.

In most cases the heart is removed by systematically cutting through the vessels entering and leaving it, starting with the arteries and then examining and cutting through the veins. The first step is to identify the aortic root and insert a finger of the nondominant hand behind this. The finger is pushed further to get behind the pulmonary artery also. Scissors can now be guided along the superior surface of this finger and these arteries are cut through about 2cm above the valves (Fig. 4.8). The heart is now lifted by its apex and the pulmonary veins and vena cavae are sequentially cut through. *Alternatively, the apex can be lifted at the initial stage of removal of*

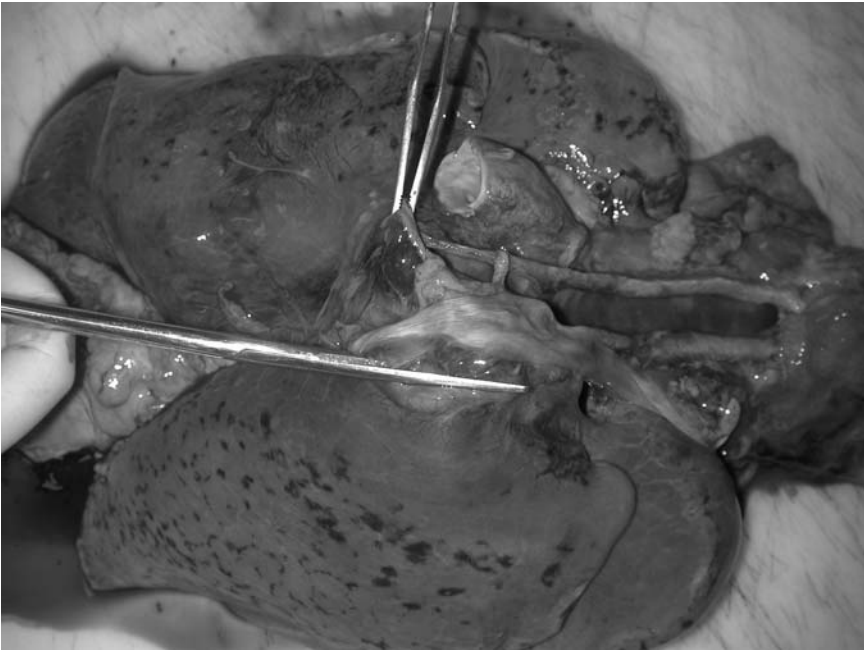


FIGURE 4.7. The lungs are separated by cutting through all of the hilar tissues with scissors or a PM40. (Courtesy of Mr. Dean Jansen, Whittington Hospital.)

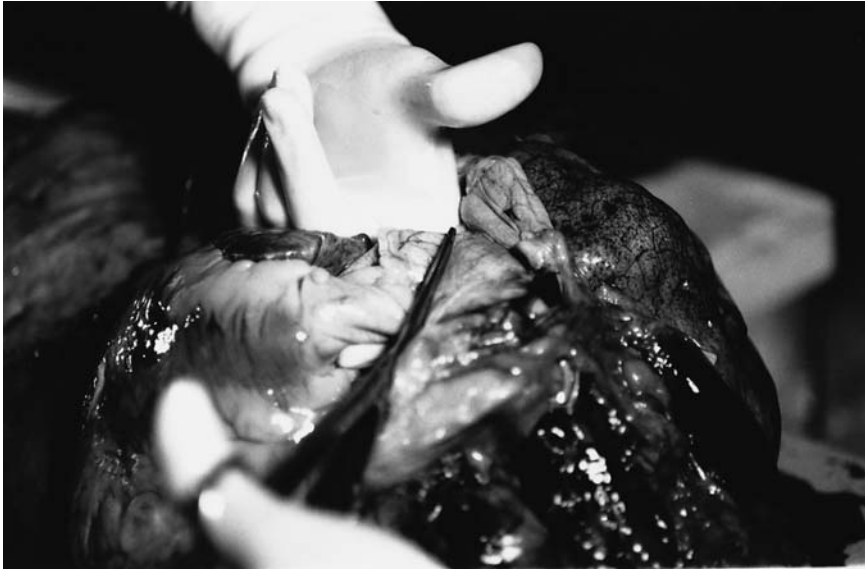

FIGURE 4.8. The roots of the great vessels are identified and a finger placed between these and the underlying structures. The vessels are transacted and any luminal contents identified and retained for demonstration. (Courtesy of Mr. Ivor Northey.)

*the heart and all of the anchoring structures cut through with a large-bladed knife. This includes all major vessels entering or leaving the heart: the inferior vena cava pulmonary veins, superior vena cava, pulmonary artery, and aorta. Either method will isolate the heart, which (in contrast to the lungs) is not weighed until after all blood within its chambers has been removed. The posterior pericardium should be inspected.*

The remaining tissue in this block can now be quickly inspected, examined, and placed to one side. Several horizontal slices are made through the tongue to assess the musculature (Fig. 4.9) and sample is taken for histology if necessary and consented. At this point the tonsils and salivary glands are incised to demonstrate their parenchyma, and these can also be dissected free and taken for histology if an abnormality is identified. The aorta is opened from behind, extending the cut with scissors proximally to the arch of the aorta. The opening includes the major arterial branches of the arch supplying the head, neck, and upper limbs. All are opened in continuity and the endothelial surface inspected, paying particular attention to the carotid bifurcation.

Individual organ dissection techniques are described in detail in the following systems chapters.

Dissection of the thoracic block is summarised as follows (the order can be changed):

- Assess important structures first.
- Incise the pericardium.
- Open the pulmonary arteries.
- Isolate the parathyroid glands.
- Remove the thyroid gland.
- Open the oesophagus.
- Open the trachea.
- Remove the lungs.
- Remove the heart.
- Examine the tongue, tonsils, pharynx, and salivary glands.
- Open the aorta and branches.

### *Coeliac Block*

This includes the stomach, duodenum, spleen, pancreas, and liver (Fig. 4.10). If oesophageal varices are present the lower oesophagus will also be included here. The order for dissecting this block is not very important, but

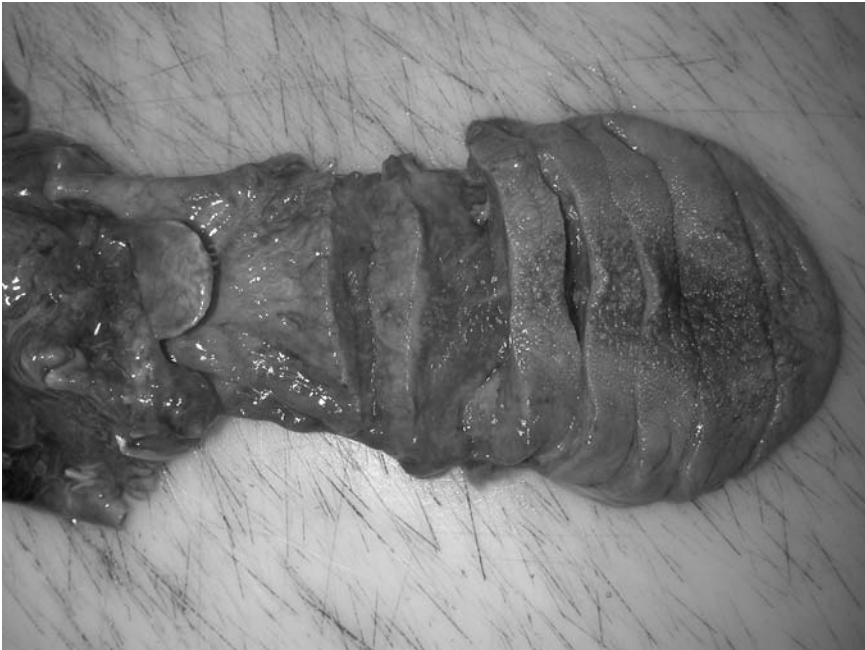

FIGURE 4.9. The tongue is sliced to inspect the musculature. (Courtesy of Mr. Dean Jansen, Whittington Hospital.)



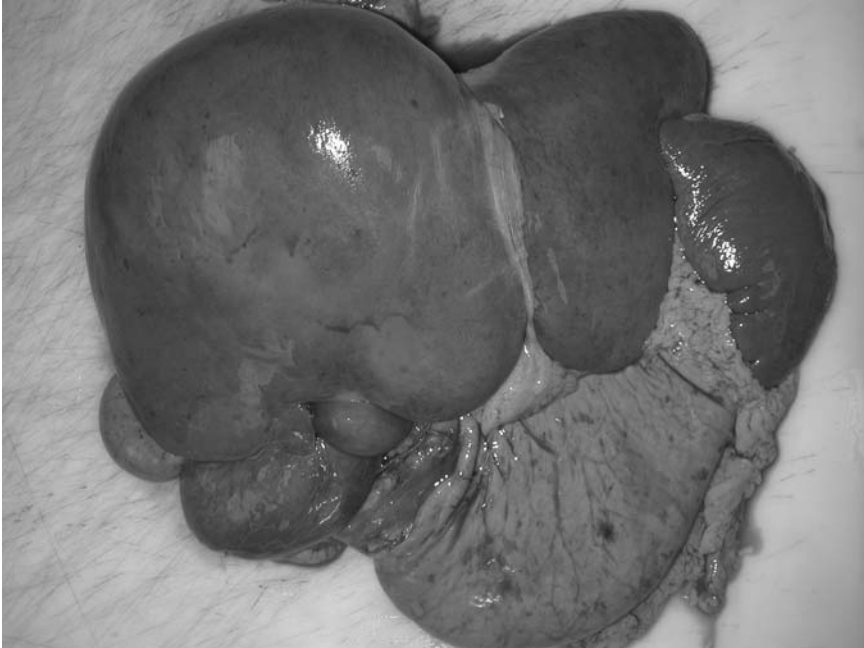

FIGURE 4.10. The coeliac block of organs ready for dissection. (Courtesy of Mr. Dean Jansen, Whittington Hospital.)

it is often useful to find the splenic artery (which runs along the superior border of the pancreas) before removing the spleen. Once this has been accomplished the spleen can be removed by grasping the outer border and cutting through the hilar structures. In cases of generalised sepsis it may be necessary to send splenic tissue for microbiological investigation as described. If this is the case, handling the spleen may be difficult because the parenchyma is often very soft and liquefied.

The next step is to examine the stomach and duodenum. The stomach is usually opened here by producing a hole in the anterior wall with pointed scissors or a scalpel about 4cm proximal to the pylorus. The lesser and greater curvatures are avoided because these are the frequent sites of pathology. Gastric contents are collected if required as previously described and the mucosa inspected. The incision is continued superiorly to the cardia and into the gastro-oesophageal junction. The dissection then proceeds distally, cutting through the anterior border of the pylorus into the duodenum, continuing to the cut end at the duodeno-jejunal junction.

It is wise at this stage to assess the patency of the biliary system by squeezing the gallbladder and checking the ampulla of Vater in the duodenum for bile flow (see Fig. 4.1). One can get a good idea about the presence of extrahepatic biliary or pancreatic pathology (caused by a stone,

stricture, or tumour) by observing a lack of bile flowing into the duodenum. If free bile flow is observed then the dissection proceeds to the porta hepatis (see later). If bile flow is not seen the careful dissection of this area is warranted in an attempt to identify the site and cause of the obstruction. Radiology may be employed for the former, and this is described in detail in Chapter 7. If there is a lesion in the head of the pancreas it may be demonstrated by making a slice through the duodenum and pancreas and inspecting the cut surface. *Alternatively, scissors can be inserted into the ampulla and the main duct opened through its anterior border, extending the cuts along both the common bile duct within the hepatoduodenal ligament (Fig. 4.11) and along the main pancreatic duct. In this way stones, strictures, or masses can be identified and documented (possibly requiring histology for confirmation). The portal vein and splenic artery are dissected in a similar manner, tracing their routes toward and away from the liver.*

If bile flows freely then the porta hepatis is inspected from its posterior aspect for any lymph nodes. After one checks for any vascular disease, the ligament can be divided. A finger is inserted behind the structures entering and leaving the liver at the porta hepatis in the hepatoduodenal ligament and superficial incisions are made transversely across the structures, being extremely careful not to cut too deeply and into the underlying finger. The

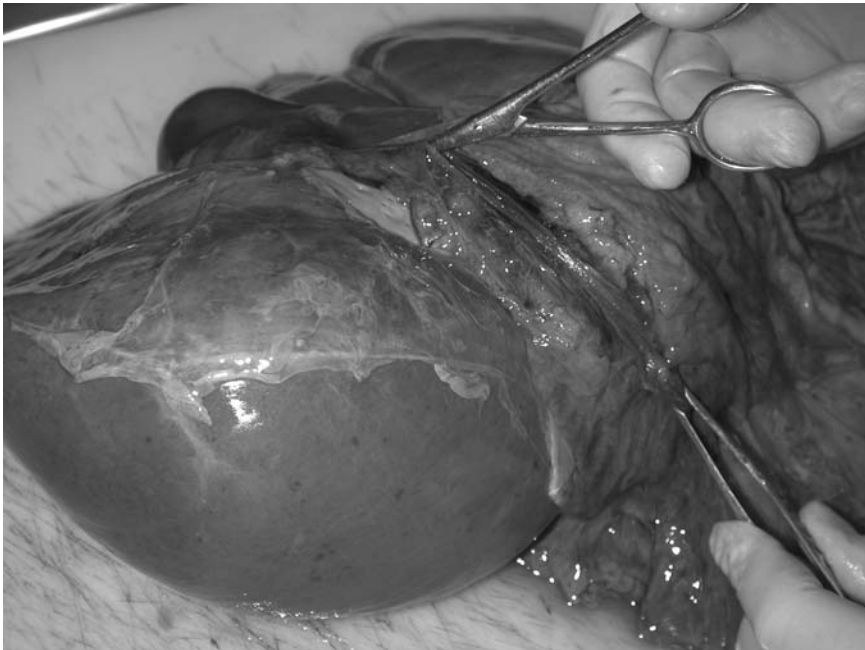

FIGURE 4.11. The common bile duct and gallbladder are opened to inspect the luminal surface. (Courtesy of Mr. Dean Jansen, Whittington Hospital.)

common bile duct, splenic artery, and portal vein are traced superiorly to the gallbladder and early intrahepatic branches. Inferiorly the portal vein, splenic artery, and their branches and tributaries are opened. Tracing the hepatic duct inferiorly to the ampulla of Vater should easily identify any calculi or masses in the head of the pancreas.

The liver can now be removed by dividing the few remaining soft tissue attachments. The gallbladder is palpated and removed by dissecting the soft tissue between it and the liver. It is opened and any calculi are removed and the contents collected if warranted. The pancreas can now be detached from this block by dissecting the attachments to the duodenum around its head. All of the organs should be weighed and dissected as detailed in Chapter 7.

Coeliac block dissection is summarised as follows:

- Inspect all organs.
- Remove the spleen.
- Open the stomach and duodenum.
- Squeeze the gallbladder to observe free flowing bile at ampulla.
- Transect the hepatoduodenal ligament.
- Isolate the liver.
- Remove the pancreas.

### *Intestinal Block*

There is little to be said here except that most pathology involving this block will be evident macroscopically during the evisceration stage and carcinomas and diverticula are usually easily demonstrated. With ischaemic changes secondary to vascular obstruction or vessel wall damage the mesentery should be removed with the bowel and the main vessels traced out as described, although thrombi are frequently difficult to demonstrate. Occasionally lesions may be small or difficult to identify externally. Dissection of the intestines is described later with the relevant special techniques.

### *Genitourinary Block*

The urogenital organs ideally will have been removed in continuity, and although organ separation of the upper tract is similar for both genders, the lower region will require slightly different approaches depending on the gender. Lay the organs on the dissection table as they are located in the body (Fig. 4.12). From the front open the inferior vena cava from its cut end just below the liver inferiorly into iliac veins. Identify the renal veins and open these to the hilum of each kidney. The right adrenal vein drains directly into the inferior vena cava and this is now opened from its orifice just above the right renal vein. The right spermatic or ovarian vein can also

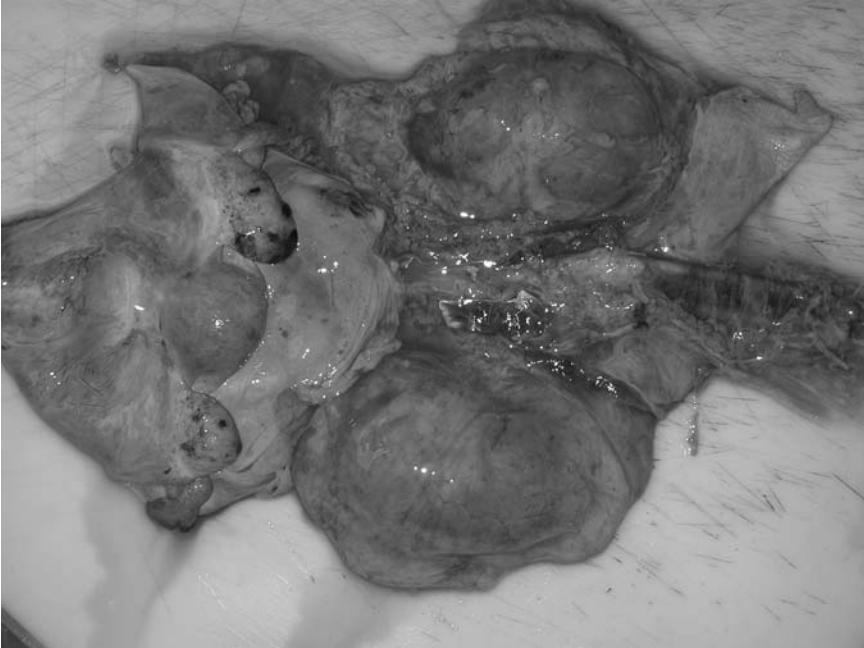

FIGURE 4.12. The female genitourinary block includes kidneys, adrenal glands, ureters, bladder, uterus, and adnexae. (Courtesy of Mr. Dean Jansen, Whittington Hospital.)

be opened. The left adrenal vein drains into the left renal vein just after it passes across the midline. This is traced and opened from the left renal vein and the left spermatic or ovarian vein are also opened if necessary. Tracing the adrenal veins simplifies localisation and identification of the adrenal glands, particularly in obese individuals. The adrenal glands can now be removed after the surrounding fat is dissected away (Fig. 4.13). The perinephric adipose tissue should now be cleared away from both of the kidneys and placed on one side.

This group of organs is now turned over and the posterior wall of the lower abdominal aorta opened along its length with scissors, continuing the dissection to severed ends of the external iliac arteries. Inspect the luminal surface and make a note of the distribution of any mural disease and any complications. The renal artery ostia are identified and the vessel opened to the renal hilum and examined. The anterior wall of the renal pelvis is incised and the urothelial surface examined. The ureters are now opened from the renal pelvis to the bladder with blunt-ended scissors, checking for any luminal lesions such as tumours or stones. The cuts are continued through the ureterocystic junctions into the bladder.

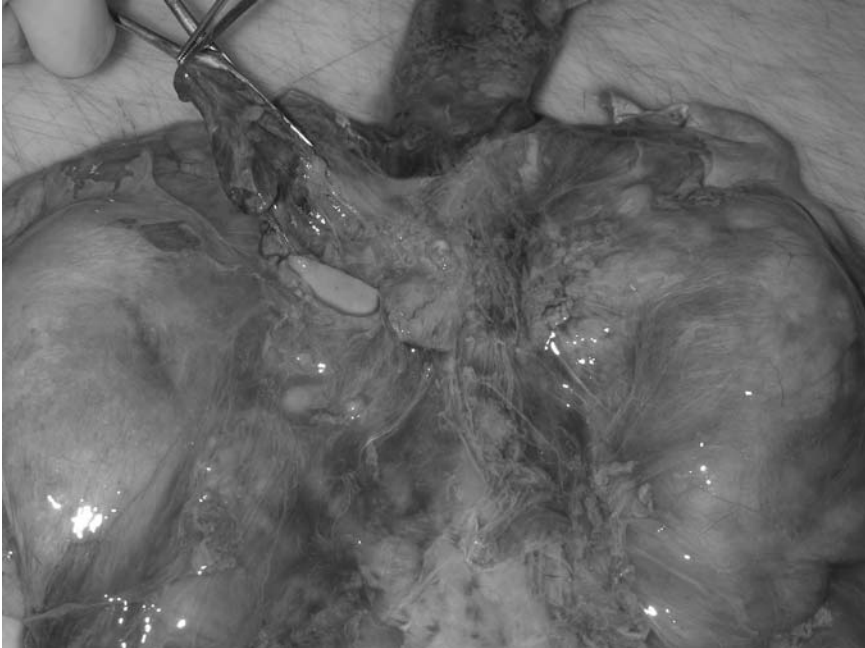

FIGURE 4.13. The adrenal gland is located and dissected free; on this occasion it shows haemorrhage typical of Waterhouse—Friedrichsen syndrome. (Courtesy of Mr. Dean Jansen, Whittington Hospital.)

The bladder can be opened now, usually through the inferior urethral orifice and cuts extended either along the midline of the anterior bladder wall or curved toward the ureteric orifices. In this way the mucosa from the renal pelvis to urethra can be inspected simultaneously. If the urinary tract is to be kept intact for demonstration purposes, a sagittal section is now made through the convex border of each kidney toward the hilum. The capsules are stripped to reveal the subcapsular surfaces and each kidney can be laid open rather like a book to demonstrate the corticomedullary parenchyma. Usually this is not required, however, and the kidneys can be removed by cutting through their hilar and ureteric attachments to be weighed and dissected as described later.

The rectum is opened posteriorly and dissected from its anterior neighbouring organs. In the male the peritoneum covering the posterior surface of bladder is now stripped away to expose the seminal vesicles. Horizontal slices should be made across these and the cut surface inspected. By careful and patient dissection it will now be possible to display the male urogenital tract complete from kidney to urethra via ureter, bladder, and prostate with the seminal vesicle, epididymis, and testes all attached, the latter by

the vas deferens dissected from the spermatic cord. As mentioned this is rather time consuming but can be very impressive during an examination. Routinely, however, the organs are all separated from one another and opened individually as described. Once the bladder is opened the prostate gland can be examined by making a series of horizontal slices through the parenchyma from the urethral aspect.

In females most of the dissection follows a similar pattern and it is only when the internal genitalia are tackled that the method differs. The bladder should be dissected from the uterus posteriorly by dividing the soft tissue between the two. The genital tract can be opened in much the same way as the urethra and bladder through the anterior wall but this is described more fully in the relevant chapter with a description of dissection of the fallopian tubes and ovaries. There is no reason why the posterior wall should not be opened, however, and if a pathological lesion is known to involve the anterior or posterior wall solely then this method may be preferable. *The uterus can also be opened in the same way through its anterior wall by cutting through the bladder if it was not dissected away previously.*

Urogenital block dissection is summarised as follows:

- Inspect all organs.
- Open the inferior vena cava.
- Open the renal and adrenal veins.
- Remove the adrenal glands.
- Open the abdominal aorta.
- Open the pelvices and trace ureters.
- Open the bladder and remove (with prostate gland and slice).
- Slice, inspect, and remove kidneys.
- Isolate the female genital organs.

## Conclusion

Although the methods described in this chapter have been described individually it will be obvious that there is considerable overlap between parts of all of the techniques and there is no reason why favourite portions of one particular method cannot be used in conjunction with different parts of another. Throughout the chapter emphasis has been placed on certain techniques that may be more applicable to particular situations and it is important here to reinforce the previous statement that knowledge of all of the methods should provide the best framework for performing any post mortem examination. It will also be clear that there is certainly scope for a degree of improvisation within any of the methods described and that any post mortem technique can be tailored to optimise the identification and demonstration of the underlying pathological processes.

At this stage all of the organs will now have been separated and individual organs can be dissected by following the methods in subsequent chapters. Of course in practice several structures such as the upper airways, upper digestive tract, and aorta will be opened during evisceration and these are not repeated later unless special techniques are applicable. In fact, some operators will dissect some of the organs as they are individualised during evisceration (e.g., the endocrine organs). This is particularly the case with the coroner's type of post mortem, in which time is often limited and establishment of a natural cause of death is the prime motive for performing the examination. The following chapters also contain details of any special techniques that may be useful.

### *References*

1. Saphir O. Autopsy diagnosis and technic, 4th edit. New York: Paul B Hoeber, 1958.
2. Shimizu M, Sakurai T, Tadaoka Y. A simple method for identifying the adrenal glands at necropsy. *J Clin Pathol* 1997;50:263–264.

# 5

## The Cardiovascular System

The routine removal of the heart and the examination of the major arteries and veins have already been described in Chapters 3 and 4. This chapter includes:

- Routine dissection of the coronary arteries
- Routine dissection of the heart
- Special techniques used in heart dissection
- Special techniques used in dissection of the vascular system

The aim is to include the vast majority of situations that are likely to be encountered by a nonspecialised pathologist.

### The Heart

Cardiac disease is very common, and is certainly the most frequent cause of death identified at post mortem. Atherosclerosis and hypertension, although responsible for the vast majority of cardiac deaths, are also commonly present when death is attributable to other causes, both cardiac and noncardiac. Coronary artery atherosclerosis, myocardial infarction, and hypertensive heart disease are therefore frequently encountered at autopsy. This means that a detailed and thorough examination of the heart is one of the most important features of any post mortem and must be performed carefully.

The technique may have to vary somewhat depending on the clinical details and expected findings; however, all require that a certain balance be maintained between obtaining as much information as possible and minimising the disruption caused to allow proper demonstration. Ultimately, the exact technique used depends largely on personal preference.

There are two basic methods of heart dissection: opening along the path of blood flow and ventricular slicing. The advantages of slicing are that any ischaemic changes are sited more precisely and therefore this technique can be useful in cases of known or suspected myocardial infarction. Its major



disadvantage, however, is that organ continuity is not maintained, and therefore opening along the path of blood flow is the more commonly used technique.

The coronary arteries may also be examined using one of two methods: transverse sectioning or longitudinal opening. If the degree and site of coronary artery disease are vital, coronary artery angiography can be performed prior to dissection (see p. 166), although this is rarely necessary and is not possible in many departments. Transverse sectioning is the preferred technique, as it allows the degree of stenosis to be assessed more accurately and is less likely to dislodge a thrombus, although longitudinal opening does retain continuity and therefore makes it easier to document exact site(s) of disease. When, as is frequently the case, the vessels are heavily calcified, examination by either method is difficult and information may be lost unless the vessels are separated and decalcified prior to examination. This is not always possible, however, as it will inevitably lead to a delay in the report.

If the slicing method is to be used, examination of the coronary arteries must be undertaken before the examination of the heart. It is also common to examine the coronary arteries first when using the opening method, but it is still possible to examine them after the heart has been opened. The advantages of the latter are that the vessels may be easier to find after opening, and that any ischaemic pathology, having already been identified, can be related to the vascular supply. The major disadvantage, however, is that the vessels will inevitably be transected during opening of the heart, and therefore information may be lost.

### *External Examination of the Heart*

The heart should be placed in the anatomical position, and its size and shape assessed. The epicardial surface must be examined for evidence of pericarditis and for any rupture or focal hyperaemia and flaccidity, which may indicate underlying infarction. Small white “soldier’s” patches are often seen, particularly anteriorly over the right ventricle, and are thought to represent either previous trauma or episodes of subclinical pericarditis.

Although tempting to do so, the heart should not be weighed at this point, as it will inevitably contain blood clot which would falsely elevate the weight obtained, leading to mistaken impressions of hypertrophy.

### *Examination of the Coronary Arteries*

Anatomy (See Fig. 5.1)

The origin of the left main coronary artery can usually be identified externally between the aorta and the left auricle. It soon divides into the left cir-

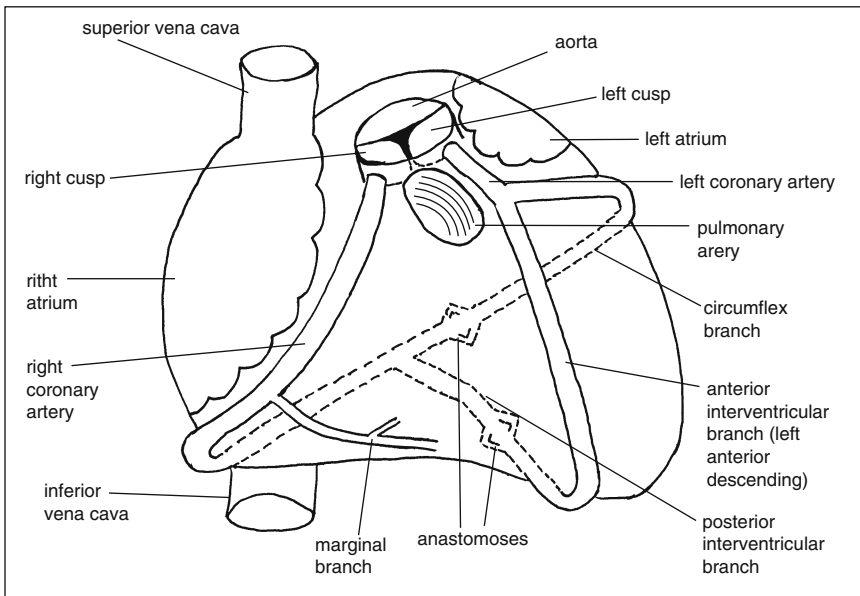


FIGURE 5.1. Diagram illustrating the “normal” course of the coronary arteries, although it is extremely variable. The most common variation is that the posterior interventricular branch comes off the left circumflex artery, in which case the left coronary artery is said to be dominant.

cumflex artery and the left anterior descending artery. The left circumflex artery runs in the atrioventricular groove between the left atrium and the left ventricle, and tends to become difficult to identify posteriorly. It is often the smallest artery and should be distinguished from the main coronary vein, as they have adjacent courses. The left anterior descending artery runs in the septal groove between the left and right ventricles, and usually becomes unidentifiable near the apex. The right coronary artery is often the largest, but paradoxically may be the most difficult to find, as it is often buried within a large amount of epicardial fat. It emerges between the right auricle and pulmonary trunk, runs posteriorly in the atrioventricular groove between the right atrium and ventricle, and then commonly turns inferiorly to run in the posterior septal groove, where it travels to the apex of the heart and supplies the posterior septal wall.

Individual variations include absence or duplication of a vessel, “tunnelling” of vessels within myocardium, differences in vessel calibre, and discrepancies between which vessel supplies the posterior septal wall. This latter variation is an important one, as this artery—the posterior descending coronary artery—indicates the “dominant” arterial supply. It is important to know whether the right or left coronary artery is “dominant,” as this

will have an important effect on the expected site of any ischaemic pathology.

### Removal of Coronary Arteries for Decalcification

If the degree of atherosclerosis needs to be assessed with particular accuracy, the vessels can be dissected from the epicardial fat and removed whole for decalcification prior to examination, although this does significantly delay the autopsy report. It is usual to remove each artery separately, in which case the artery should be divided transversely at its origin (usually keeping the left anterior descending artery in continuity with the left main trunk). If (as is often the case) the ostia are also involved by atheroma, it is desirable to remove them in continuity with the arteries, in which case a small cuff of surrounding aortic wall can be cut to remove the artery and ostia intact. The vessels must then be carefully dissected free from the surrounding fat as far distally as is possible. Each artery should then be fixed in formalin prior to decalcification, using separate containers to enable identification.

### Dissection of the Coronary Arteries

Whichever technique is to be used, the origin of the arteries must be identified and their course within the epicardium followed. This is variable, and in difficult cases it may be necessary to first identify the ostia by inspecting the aortic sinuses from above.

The vessels should be carefully examined during whichever procedure is used for any evidence of thrombus or loose atheroma which may otherwise be lost during the examination. Once complete, the extent and severity of any atheroma should be assessed, and the affected areas noted. If the arteries are sectioned transversely, an estimation of the percentage of luminal stenosis can and should be made, and may be aided by diagrammatic charts (see Fig. 5.2).

#### *Method 1: Transverse Sectioning Technique (See Figs. 5.3 and 5.4)*

A sharp scalpel blade is used to slice completely through the arteries at intervals of not more than 0.3 cm. Proximally, where atheroma and thrombus are more likely, the transections should be even closer together if possible. When heavily calcified vessels are encountered, it will be necessary to transect the vessel with a sharp pair of artery scissors.

A firm grip on the heart must be maintained while cutting through the vessels, usually by grasping the aorta, pulmonary arteries, and as much of the atria as possible with one hand, while holding the scalpel with the other. It is tempting to put a finger down the aorta to steady the heart; however, this should be avoided while transecting the proximal vessels as there is a significant risk of personal injury.

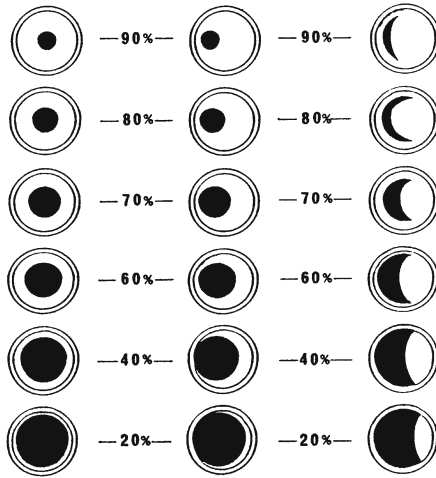


FIGURE 5.2. Diagrammatic representation of coronary artery stenosis. Outer circle is artery exterior, inner circle is elastic lamina, black area is arterial lumen, and white area is atheroma. (Reprinted with permission from Champ CS and Coghill SB. *J Clin Pathol* 1989;42(8):887–888.)

### *Method 2: Longitudinal Opening Technique (See Fig. 5.5)*

A sharp pair of artery scissors is used to open the arteries from the ostia, extending as far down their course as possible.

#### Clinical Correlation

Significant or severe disease is indicated by a stenosis of 75% or more. In the absence of occlusive thrombus, death should be ascribed to

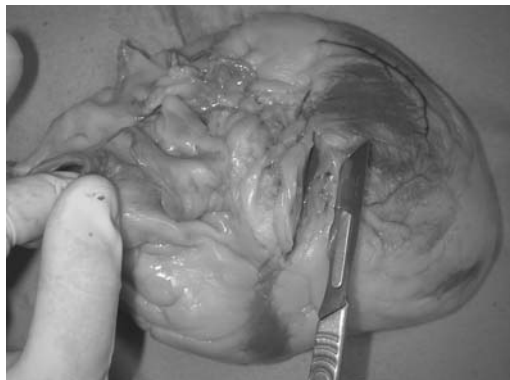


FIGURE 5.3. Opening the left anterior descending coronary artery using the transverse sectioning method. There is minimal atherosclerosis in this case. (Courtesy of Mr. Dean Jansen, Whittington Hospital.)

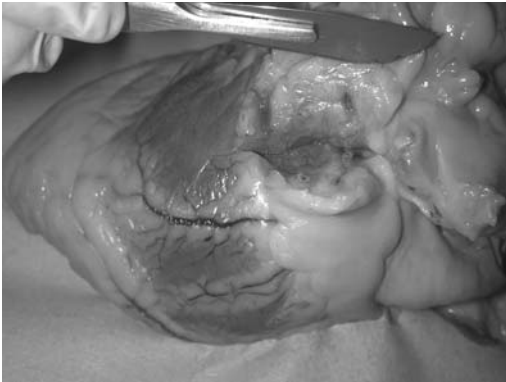

FIGURE 5.4. Opening the left circumflex artery using the transverse sectioning method. There is minimal atherosclerosis in this case. (Courtesy of Mr. Dean Jansen, Whittington Hospital.)

atherosclerosis only if the stenosis is severe [1]. If there are no other findings, severe atheroma in a single vessel is sufficient, but it is vastly preferable to see significant stenosis in more than one vessel before attributing death to atherosclerosis, as coronary artery atheroma is almost ubiquitous within any elderly population in the developed world.

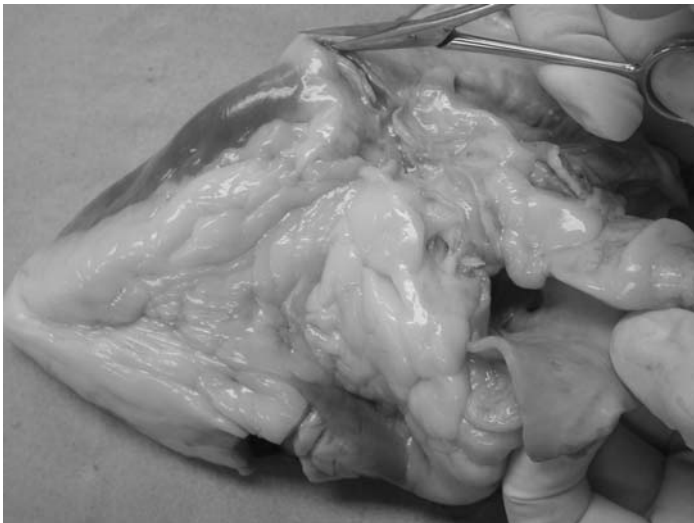

FIGURE 5.5. Opening the right coronary artery using the longitudinal opening method. There is minimal atherosclerosis in this case. (Courtesy of Mr. Dean Jansen, Whittington Hospital.)

### *Dissection of the Heart by Opening Along the Path of Blood Flow (See Fig. 5.6)*

Either scissors, a large knife, or a combination of both can be used, depending on personal preference. During opening, the valves should be examined before they are cut, and if possible the valve orifice should be measured in situ using specially designed conical measures.

#### Step 1.

Make an incomplete, transverse slice through the ventricles at a point about 3 cm from the apex, as this allows good demonstration of left ventricular myocardium. This slice should be hinged to the remaining heart by the epicardium, to retain continuity.

#### Step 2.

Separate the aorta and pulmonary trunk from their intervening connective tissue, to make the subsequent opening of the outflow tracts easier.

#### Step 3.

Open the right atrium by cutting anteriorly from the free end of the inferior vena cava to the tip of the atrial appendage. The superior vena cava is deliberately left intact to allow (if necessary) the later examination of the sinoatrial node (see p. 163).

#### Step 4.

Open the right ventricle along the free, lateral border, by cutting through the tricuspid ring and continuing the excision to the apex. It is customary to place this cut through a commissure of the tricuspid valve.

*An alternative is to open the right ventricle posteriorly as close to the septal wall as possible, which (together with an opposing anterior opening of the left ventricle) has the advantage of allowing the heart to be laid flat after opening.*

#### Step 5.

Open the pulmonary outflow tract via a cut in the anterior wall of the right ventricle which starts at the apex and continues up through the pulmonary conus, valve, and artery. It is preferable to cut through the centre of a cusp of the pulmonary valve. The cut should be kept close to the interventricular septum to leave the anterior papillary muscles intact.

*An alternative is to open the outflow tract directly by making a cut through the tricuspid valve leaflet, and extending it through the pulmonary conus, valve, and artery, but this causes more destruction to the tricuspid valve.*

#### Step 6.

Open the left atrium by making a hole in the atrial appendage and then extending it into a cut in a line parallel with and above the atrioventricu-

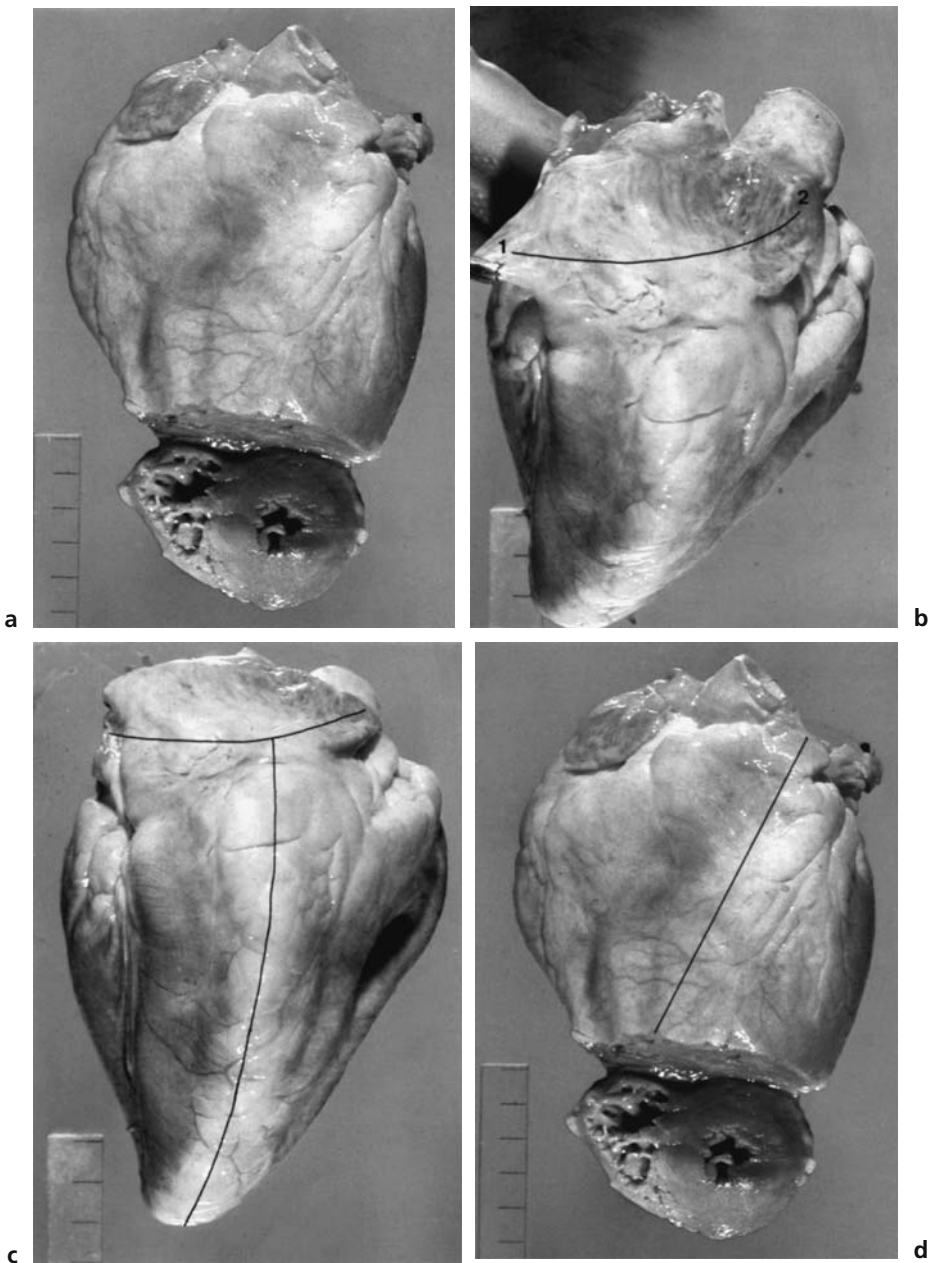


FIGURE 5.6. These photographs illustrate the necessary incisions when opening the heart along the path of flow. (Reprinted with permission from Farrer-Brown G. A colour atlas of cardiac pathology. Wolfe Medical Publications, 1982, pp. 10–13.) **(a)** Step 1: A hinged cut across the ventricles about 3 cm above the apex. **(b)** Step 3: Opening the right atrium by cutting from the inferior vena cava (1) up to the tip of the atrial appendage (2). **(c)** Step 4: Opening the right ventricle down the lateral free border, first cutting through the tricuspid valve ring. **(d)** Step 5: Opening the pulmonary outflow tract by a cut that starts at the apex, keeps close to the inter-ventricular septum, and is then extended up through the conus, valve, and artery.

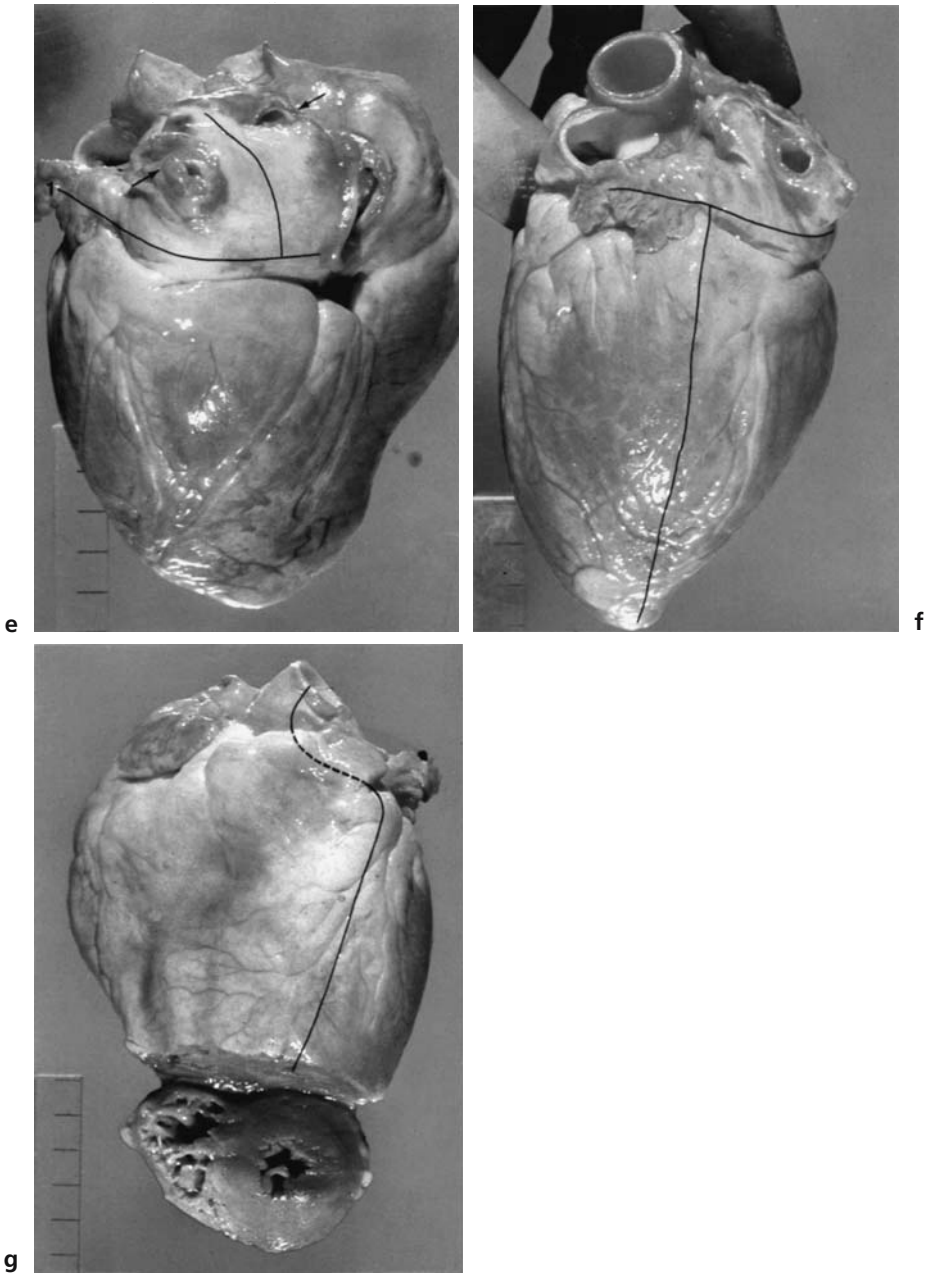


FIGURE 5.6. **(e)** Step 6: Opening the left atrium by cutting into the appendage (1) and extending the incision in a line parallel with the atrioventricular groove and then making a second cut between the pulmonary veins (*arrows*). **(f)** Step 7: Opening the left ventricle by cutting through the mitral valve ring and along the lateral free border to the apex. **(g)** Step 8: Opening the left ventricular outflow tract by cutting up the anterior wall as far as the base of the appendage and then directing the cut up into the aortic valve and aorta.



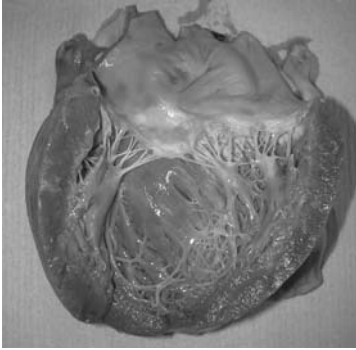


FIGURE 5.7. The left ventricle has been opened along the lateral wall. (Courtesy of Mr. Dean Jansen, Whittington Hospital.)

lar groove. Then make a second incision, at a 90° angle to the first, between the orifice of the pulmonary veins.

*An alternative is to cut across the roof of the atrium from the orifice of the right pulmonary vein to the orifice of the left and then extending into the atrial appendage, but this destroys the pulmonary veins.*

Step 7. See also Fig. 5.7.

Open the left ventricle by making a cut along the free, lateral border, through the mitral valve ring and extending to the apex. As with the tricuspid valve, it is best to place this cut through a commissure of the mitral valve.

*Alternatively, if the right ventricle has been opened posteriorly, the left ventricle can be opened along the anterior border, as close to the interventricular septum as possible, thus allowing both sides of the heart to be laid flat.*

Step 8. See also Fig. 5.8.

When the left ventricle has been opened along the lateral border, the outflow tract can be opened by cutting from the apex along the anterior

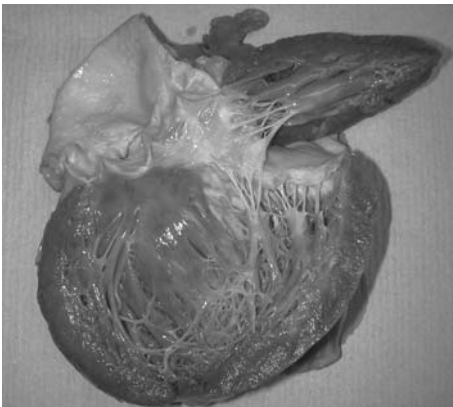


FIGURE 5.8. The outflow tract of the left ventricle has been opened along the anterior wall, producing a flap of myocardium and thus allowing the anterior mitral valve leaflet to be left intact. (Courtesy of Mr. Dean Jansen, Whittington Hospital.)

wall, as close to the septal wall as possible, and then through the aortic valve to the free end of the aorta. This method has the advantage of keeping the mitral valve intact, but usually transects the left anterior descending coronary artery. As with the pulmonary valve, the aortic valve should be cut through a valve cusp. If possible, the cut should be made through the left cusp at a point slightly to the right of centre, to avoid transection of the left coronary ostia.

*An alternative, whether the anterior or the lateral border has been opened, is to open the outflow tract directly by cutting through the mitral valve and continuing the cut through the aortic valve and aorta. This does cause more destruction to the mitral valve, but is the only option if the left ventricle has already been opened anteriorly.*

Step 9. See Fig. 5.9.

Make incomplete, transverse slices through the wall of the left ventricle from the endocardial surface. Leave epicardial tissue intact to hinge the slices together, thereby keeping the ventricle intact for demonstration purposes. The slices should be spaced about 0.5 cm apart to allow a close inspection of the myocardium.

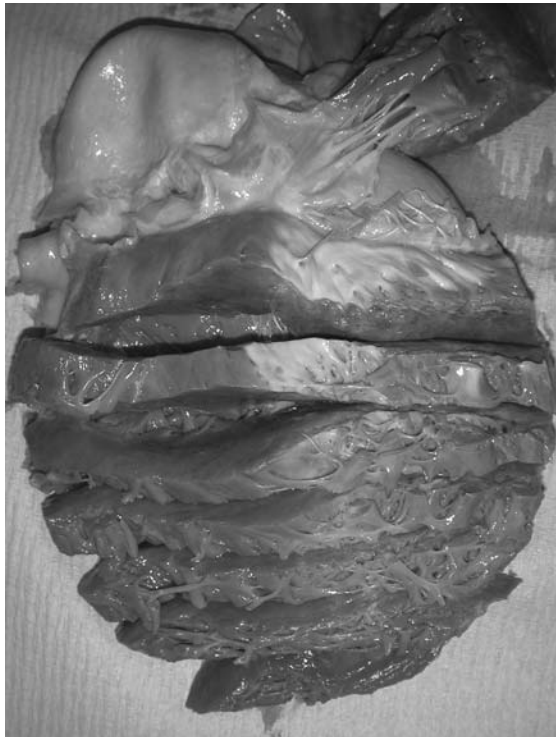

FIGURE 5.9. The wall of the left ventricle has been incompletely sliced from the endocardial surface, to allow examination of the myocardium. (Courtesy of Mr. Dean Jansen, Whittington Hospital.)

### *Dissection of the Heart by Ventricular Slicing*

#### Step 1.

With the heart in the anatomical position, slice through the heart at a point about 3 cm from the apex. This slice should be complete, separating the apex from the remainder of the heart.

#### Step 2. See Fig. 5.10.

Make further complete slices in parallel to the first slice, about 1 cm apart, until reaching a point about 1 cm below the atrioventricular valves. The ventricular slices can then be laid out in order and any focal lesions identified.

#### Step 3.

Dissect the rest of the heart by opening along the path of blood flow, as described previously; the atrioventricular valve rings are opened along their lateral border and the atria are opened and examined exactly as before.

### *Internal Examination of the Heart*

Whichever method of examination has been used, all post mortem blood clots should now be removed and the heart weighed. Obviously these figures vary with the height, weight, and age of the body, and should be adjusted accordingly. See Table 5.1. The average weight of the adult heart is 250 g in women and 300 g in men [2].

The morphology of the chambers should then be examined closely and any septal defects noted. The endocardium should be examined for evidence of fibrosis. A close search should be made for attached pre mortem thrombus, including in the atrial appendages, where thrombus is most common. The valves should be examined, including number of cusps/leaflets; fusion between cusps/leaflets; and evidence of vegetations, fibrosis, or calcification. The valve circumference can then be measured with a ruler or a length of string. Such values vary with both gender and age. Average measurements of heart valves are given in Table 5.2.

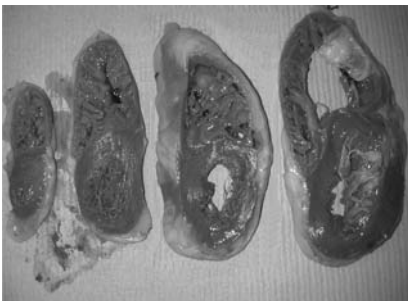


FIGURE 5.10. Slices from a heart examined using the ventricular slicing method. The remainder of the heart is examined by opening along the direction of blood flow. In this case there is marked dilatation of both ventricles, owing to congestive heart failure. (Courtesy of Mr. Dean Jansen, Whittington Hospital.)

TABLE 5.1. Male and Female Heart Weights for Different Body Weights<sup>a</sup> and Heights<sup>b</sup>

Male		Female	
Body weight (kg)	Heart (g)	Body weight (kg)	Heart (g)
40	247	30	196
50	276	40	221
60	302	50	243
70	327	60	262
80	349	70	280
90	371	80	297
100	391	90	312
110	410	100	326
120	429	110	339
130	446	120	352
140	463	130	364
150	479	140	376
Body length (cm)	Heart (g)	Body length (cm)	Heart (g)
140	264	135	219
150	283	145	236
160	302	155	254
170	321	165	272
180	340	175	290
190	359	185	307
200	378	195	325

<sup>a</sup> Adapted with permission from Kitzman DW, Scholz DG, Hagen PT, Ilstrup DM, Edwards WD. Age-related changes in normal human hearts during the first 10 decades of life. Part II (Maturity): A quantitative anatomic study of 765 specimens from subjects 20 to 99 years old. *Mayo Clin Proc* 1988;63:137–146.

<sup>b</sup> Adapted with permission from Zeek PM. Heart weight. I. The weight of the normal heart. *Arch Pathol* 1942;34:820–832.

TABLE 5.2. Average Measurements of Heart Valves

	Male	Female
Mitral valve (as a rough guide admits two fingers)	9.5 cm	8.6 cm
Tricuspid valve (as a rough guide admits three fingers)	11.5 cm	10.5 cm
Aortic valve	6.7 cm < 60 years 8.3 cm > 60 years	6.3 < 60 years 7.6 > 60 years
Pulmonary valve	6.6 cm < 60 years 7.3 cm > 60 years	6.2 < 60 years 7.1 > 60 years

Adapted with permission from Kitzman DW, Scholz DG, Hagen PT, Ilstrup DM, Edwards WD. Age-related changes in normal human hearts. Part II (Maturity): a quantitative anatomic study of 765 specimens from subjects 20–99 years old. *Mayo Clin Proc* 1988;63:137–146.

### Clinical Correlation

A significant increase in circumference is suggestive of regurgitation/incompetence and a significant decrease in circumference is suggestive of stenosis. These would always be accompanied by scarring, fusion, and calcification, however, unless there is regurgitation secondary to valve ring dilatation. If no such abnormality is seen, therefore, little importance should be placed on an abnormal measurement.

The myocardium can then be examined for areas of previous fibrosis or recent infarction. The size of any infarcted area should be measured, its extent through the wall noted (i.e., whether transmural or subendocardial), and its site noted and correlated with any arterial disease present.

### Clinical Correlation

The presence of a collateral circulation of small arteries and the multi-focal nature of the arterial lesions mean that the site of infarction does not always correlate well with the site of arterial disease.

An infarct less than about 12 hours of age will not be identifiable macroscopically or histologically. Macroscopical dye techniques have been described for the identification of such early infarcts, and are discussed in the special techniques section (p. 168) but are of somewhat dubious validity.

Between about 12 and 24 hours, infarction is identifiable as a softened area with a dusky, haemorrhagic discolouration. Between about 1 and 4 days, the changes are more obvious, with a mottled yellow/red pattern. After this time, an infarct is more homogeneous, being first yellow then increasingly white in colour.

These changes correspond to the microscopical changes seen, which are, the initial haemorrhage and infiltration of neutrophils and macrophages, the formation of granulation tissue, and the production of fibrosis.

An assessment of the possibility of ventricular hypertrophy should then be made, using one of two possible methods.

#### Method 1: Measuring Ventricular Thickness

This is the most straightforward and involves measuring the thickness of both ventricular walls at a point about 1 cm below the atrioventricular valve. This is an easy technique but not particularly sensitive, as any dilatation will mask hypertrophy. Although there is a wide variation, suggested values for the upper limits of normal are [2]:

Left ventricle	1.5 cm
Right ventricle	0.5 cm
Atrial muscle	0.3 cm

### Method 2: Fulton's Technique [3]

This is more sensitive and involves separating the left ventricle (LV) and septal wall (S) from the right ventricle (RV) and weighing them separately to obtain a ratio. The atria and atrioventricular valves must be removed and all excess fat trimmed, making it a time-consuming process. This obviously destroys the heart and is therefore best done after any demonstration is complete. Biventricular hypertrophy may produce a normal ratio; however, the heart will be greatly increased in weight. If left ventricular hypertrophy is identified, an assessment of symmetry should be made, as some diseases cause asymmetrical hypertrophy—in particular, hypertrophic obstructive cardiomyopathy, which often preferentially involves the septum and outflow tract.

Normal ratio LV + S:RV	2.3–3.3:1
Left ventricular hypertrophy	3.6:1 or LV + S > 225 g
Right ventricular hypertrophy	<2:1 or RV > 80 g

Histology should be taken if the appropriate permission has been given. Any identifiable lesion should be sampled for histology, preferably at the end of the post mortem to avoid destruction of the organ for demonstration purposes. A single block of left ventricular myocardium should be taken as part of routine histology, even if no abnormality has been identified. If coronary artery occlusion has been identified, and an early infarct suspected, the myocardium supplied by the involved artery should be extensively sampled.

## Special Techniques Used in the Dissection of the Heart

### *Examination of the Heart with Known Valvular Disease or Following Valvular Surgery*

It is important to obtain as much clinical information as possible before the examination, either from the notes or from the clinician involved. In the case of valvular disease, it is desirable to know which valves are involved and which disease process is responsible. In addition to this information, in the case of valvular surgery, it is also preferable to know the exact form of surgery undertaken, that is, valvotomy or valve replacement. Prosthetic valves may be biological or mechanical. Biological valves are either human or porcine and are less thrombogenic than mechanical valves but have a shorter life-span. Rejection does not occur as the endothelium is removed before use, leaving only paucicellular collagen over which the host's endothelium regrows. Many types of mechanical valve have been developed; however, the most common involve either a tilting disc or a ball and cage. Not only is it preferable to know the exact type of valve replacement,

but, in the case of a mechanical valve, it is also helpful to know the trade name.

### Dissection

The pericardial cavity is often obliterated by fibrous adhesions as a consequence of the surgery, but as much pericardium as is possible should be dissected free and removed, to expose the epicardial surface. A pericardial “window” may be present, which is an area without pericardium in the anterior pericardial wall following surgery. Whether valve disease is present or valve surgery has taken place, the heart should be examined using the method of opening the heart in the direction of blood flow, however, the technique requires modification to maintain the integrity of all valve rings. This can be accomplished by ending each cut just before the valve is reached, to leave the valve intact, and then making an incision in the distal chamber or vessel and continuing the cut along the normal course.

### Examination

The basic examination proceeds as usual, although particular attention must obviously be paid to the valves themselves:

- Assess the integrity of the valve ring, using probes to identify any paravalvular leaks.
- Note the presence or absence of vegetations and/or thrombi.
- Send any thrombi/vegetations for microbiological assessment as well as submitting for histology.
- Assess the size of the lumen of native or bioprosthetic valves, preferably using specially graded conical measures, although measurement of circumference using a length of string is an acceptable alternative.
- Inspect native valves for flexibility, fibrous thickening, scarring, and calcification.
- Assess bioprosthetic valve function, that is, are the cusps flexible?
- Note any commissure fusion or shortening of chordae tendinae in native or bioprosthetic valves.
- Note the presence or absence of components of a mechanical valve.
- Assess mechanical valve function: Does the tilting disk move fully into both open and closed positions? Does the caged ball fully occlude the valve ring and seat?

In addition to blocks from any areas of pathology, tissue should be taken from all native or bioprosthetic valves, with decalcification prior to processing if necessary. Such blocks should be taken through the full thickness of the valve, and include the adjacent heart wall or vessel. In atrioventricular valves, the chordae tendinae and the superior papillary muscles should also be included.

### *Microbiological Samples in Cases of Suspected Endocarditis*

Samples of any vegetations and/or endocardial thrombi should be submitted for microbiology as well as for histology. They should be removed using sterile instruments as soon as possible after the relevant chamber is opened. If endocarditis is suspected before the heart is examined, the surface of the relevant chamber can be seared with a heated blade and a sterile scalpel and forceps used to open the chamber and obtain the sample. This technique will minimise the risk of contamination, which is often a problem when culturing post mortem tissue. An opinion from a microbiologist can also be helpful in determining the significance of any growth.

### *Examination of the Heart Following Coronary Artery Bypass Grafting (CABG)*

In this situation, it is essential that both the native and grafted coronary arteries are examined before the rest of the heart. In fact, if the case is to be demonstrated, it may be more appropriate to leave the examination of the heart itself until during or after the demonstration, as inevitably some of the arteries will be disrupted. Although not feasible in all departments, coronary artery angiography may be particularly useful in these cases, and should be compared to the pre mortem angiograms. It is preferable that the source of the graft(s) is known before the post mortem is begun, as either the internal mammary artery or lengths of saphenous vein can be used. It is also easier if exact details of the number and site(s) are available. When an internal mammary (internal thoracic) artery is used for grafting, it is usually kept in continuity at its origin, although can also be used as a free graft. These arteries originate from their respective subclavian arteries and run inferiorly behind the ribs, about 1 cm lateral to the sternum. Each ends at the sixth rib space by dividing into the superior epigastric and musculophrenic arteries, and has the anterior intercostal arteries as its branches. Grafts from the internal mammary arteries (when kept in continuity with their origins) will be destroyed if the sternum is not dissected from the mediastinum with particular care. Obviously, in the case of free saphenous vein grafting, surgical incision(s) will be evident on one or both legs in the path of the vein.

#### Dissection

The pericardial cavity is often obliterated by fibrous adhesions as a consequence of the surgery, but as much pericardium as is possible should be dissected free and removed, to expose the epicardial surface. A pericardial “window” may be present, which is an area without pericardium in the anterior pericardial wall following surgery.



The grafts should then be identified; they are usually situated proximally and run along the epicardial surface rather than within the fat. They often originate from the aorta at a point just above the aortic valve, but may originate from a coronary artery itself, and are identified by the accompanying nonabsorbable surgical sutures. It is then necessary to note any twists or excessive tautness in the graft. Next, the anastomoses should be examined closely to assess their integrity. If an aortic anastomosis is present, it may be helpful to open the aorta first in order to visualise clearly the origin(s) of the graft(s). The grafted arteries should then be examined, either by transverse sectioning or longitudinal opening; the usual advantages and disadvantages of each apply. If making transverse sections, the grafted arteries must be hinged posteriorly via incomplete transection, as they lie free and would otherwise not remain in place for demonstration. The anastomoses should be left intact when sectioning transversely, but will be unavoidably disrupted when opening longitudinally. Particular attention must be paid to the patency of the anastomoses and the presence of thrombus and atherosclerosis within the grafts. Anastomoses may be "side-to-side," in which windows are made in the adjacent walls of two vessels, or "end-to-side," in which the end of one vessel is attached via a window to the wall of a second vessel.

The native arteries are examined as normal, although this can be difficult owing to the severe atherosclerosis that is invariably present and may be aided by prior decalcification as previously described (p. 144). The heart can then be examined in the usual way, paying particular attention to the distribution of any ischaemia, which should then be correlated with any arterial disease that is identified.

In addition to tissue blocks from areas of pathology, sections of myocardium distal to the graft(s) should also be taken, even if they appear normal. Sections of the graft(s) themselves should also be taken for histology, in which the degree of arterialization of venous grafts can be examined and the degree of stenosis assessed more accurately. Sections should also be taken from the anastomoses, particularly distally, as these are a common site of stenosis.

### *Examination of the Heart Following Cardiac Pacing*

Cardiac pacing wires are either epicardial or endocardial in position. Endocardial wires are used for either temporary or permanent pacing and are placed via an intravenous route, usually from the right subclavian vein. Their exact position depends on the type of electrode used and the site of any preexisting disease, but they are usually placed somewhere within the right atrium or auricle. Epicardial wires are used only for permanent pacing and require an open thoracotomy for placement. Their exact site depends on the approach of the operation as well as the site of any preexisting disease; however, they are usually found near the apex of the right or left

ventricle. Temporary pacing is via a bedside pacing box, which will not usually accompany the body to the mortuary. A permanent pacemaker is placed subcutaneously at a relatively distant site, usually anterolaterally within the subcutaneous tissues of the upper chest. As with all surgery, it is greatly preferable to know exactly which procedure has been performed prior to the post mortem examination. It is helpful to have pre mortem radiographs to assess the position of the pacing wire, but if the function of the cardiac pacing is likely to be an issue, additional post mortem radiography is essential.

### Examination

The site of the electrode, the course of the wire, and the site of the pacemaker must be noted. The presence or absence of infection must be assessed by using an aseptic technique to collect microbiological samples of possible infected tissue and swabs of any free pus found. Infection usually starts in the subcutaneous tissue pocket of a permanent pacemaker and may track a variable distance along the wire, to involve the electrode or the surrounding cardiac tissue. An epicardial wire is often fixed down by fibrous tissue, and in addition to checking continuity, it is necessary to examine any associated coronary vessels for thrombi, as they may occur in association with the local fixation.

The heart should then be examined as normal, using the method of opening along the direction of blood flow. In addition to routine histology, tissue must be taken from the site of electrode contact. This should be taken using an aseptic technique and part sent for microbiological assessment with the remainder submitted for histology.

If there is a suspicion that the permanent pacemaker device itself has malfunctioned, it should be removed and sent for expert electrical analysis. At any rate, it must be removed if the body is to be cremated, as the lithium batteries present in some pacemakers explode in heat, and can cause considerable damage to the incinerator.

### *Examination of the Heart Following Cardiac Transplantation*

Post mortem examination following transplantation is often complicated, and it is therefore essential to examine carefully the clinical notes and if possible to discuss the case with the clinicians beforehand. Long-term studies are often being conducted in the pathology departments of cardiothoracic surgery centres, and it is therefore helpful to send the entire heart to them if possible, even if the examination has already been completed. Of course, appropriate permission from the relatives, as well as from the coroner or equivalent in a medicolegal case, will need to be obtained.

### Dissection

When the heart is removed, the great vessels must be transected sufficiently distal to the heart to include all anastomotic margins.

In cardiac-only transplantation, the four anastomoses are as follows, with the recipient's proximal atria and the respective veins retained:

- Aorta distal to donor aortic valve
- Pulmonary artery distal to donor pulmonary valve
- Mid right atrium
- Mid left atrium

In a heart and lung transplant recipient, only two anastomoses are present:

- Aorta distal to the donor aortic valve
- Mid right atrium

The pericardial cavity is often obliterated by adhesions caused by the surgery. Where possible, however, the pericardium should be dissected free and removed. A pericardial “window” may be present, which is an area without pericardium in the anterior pericardial wall following surgery. The heart should then be examined as usual, with particular attention to the following:

- The integrity of the anastomoses
- The presence of previous ventricular biopsy sites on the right septal wall
- The extent and (a)symmetry of hypertrophy (an adaptive post-transplant occurrence)
- The possibility of acute rejection
- The possibility of chronic rejection
- Any evidence of mural thrombi, recent necrosis, and previous fibrosis

### Clinical Correlation

Acute rejection is indicated by a mottled brown and haemorrhagic appearance of the entire donor tissue. This is best seen within the atria, where the anastomoses of recipient and donor tissue will produce a sharp mid-atrial demarcation line if acute rejection is present. Chronic, vascular rejection is indicated by concentric intimal thickening of coronary arteries producing marked stenosis. Acute rejection is common only in the first 2 years post transplant; however, a degree of chronic rejection is inevitable in the long term.

In addition to blocks from any pathology, tissue should routinely be taken from:

- All anastomoses
- The free wall of the right ventricle
- Representative lengths of coronary arteries

- Transverse section of right septal wall
- Longitudinal section of left septal wall with the mitral valve ring, to include some of the conduction system
- The free wall of the left ventricle
- Papillary muscle

### *Examination of the Conduction System*

Examination of the conduction system is necessary only in the rare cases in which pathology within the conduction system is an isolated cardiac problem. When congenital conduction defects are suspected, it is probably better to refer the examination to a specialist cardiac pathologist, by sending the fixed heart in its entirety. In other circumstances, however, the necessary tissue blocks can be removed and sections cut, although help from a specialist may be necessary for accurate histological interpretation.

#### Preparation

It is better to fix the heart before examination of the conduction system, and ideally before any examination of the heart. As much blood should be removed from the heart as is possible, either via an apical slice or a longitudinal cut in the lateral ventricular walls, and the heart packed with cotton wool and placed in formalin. It is likely, however, that prior examination of the heart will have been necessary, in which case the method of opening along the path of blood flow should be used. If this is the case, the final incomplete slicing of the ventricles should not be done. The superior vena cava, atria, and ventricles should then be packed with cotton wool so that they retain their shape during fixation.

#### Anatomy (See Fig. 5.11)

The electrical impulse originates from the sinoatrial (SA) node, which lies in the wall of the right atrium around the sinoatrial node artery and adjacent to epicardial fat. This is situated just below the summit of the right atrium, at the junction of the superior vena cava and the crest of the right atrial appendage. The impulse then passes to the atrioventricular (AV) node via three atrial muscle bundles. The AV node lies in the right atrial wall beneath the endocardium. It is situated between the opening of the coronary sinus and the medial leaflet of the tricuspid valve. The impulse then travels from the AV node to first the penetrating and then the branching portions of the atrioventricular bundle (bundle of His). Left and right bundle branches (of His) are formed that then distribute the impulse to the ventricles. The left bundle branch consists of a number of small muscle fascicles that pass down the left side of the posterior part of the interventricular septum in a subendocardial position and then spread out into the free wall of the left ventricle. The right bundle branch is best considered as the

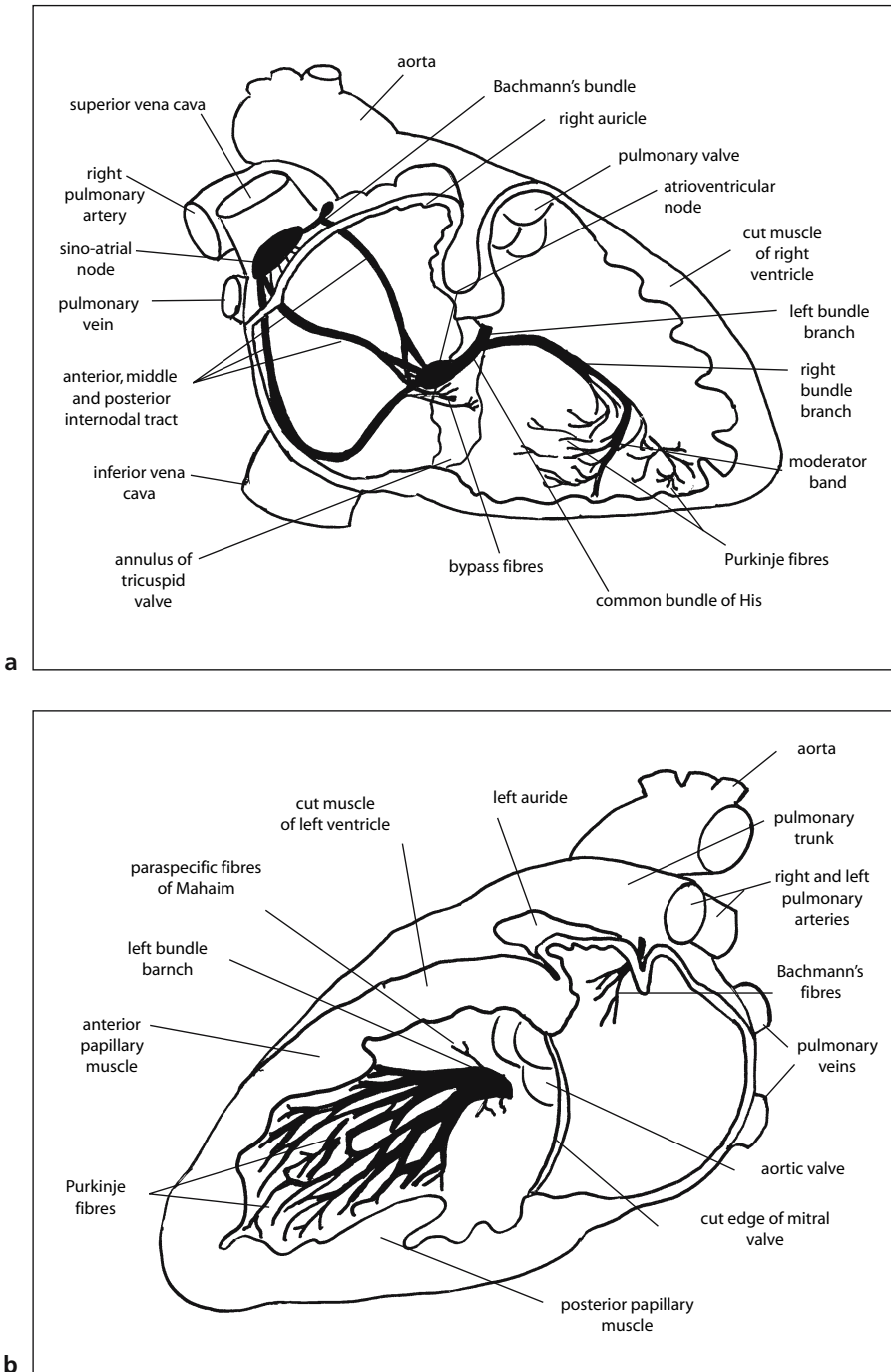


FIGURE 5.11. A diagram of the conduction system. **(a)** Septal aspect of the right atrium and ventricle. **(b)** Septal aspect of the left atrium and ventricle.

continuation of the AV bundle and originates at a point where all of the left bundle branches have divided off. It has a variable course but is usually a single, discrete muscle fascicle passing through the anterior part of the right interventricular septum, where it is known as the moderator band. It ends at the base of the anterior papillary muscle in the right ventricle, where it divides into a network of muscle bundles coursing throughout the subendocardium.

### Block Selection

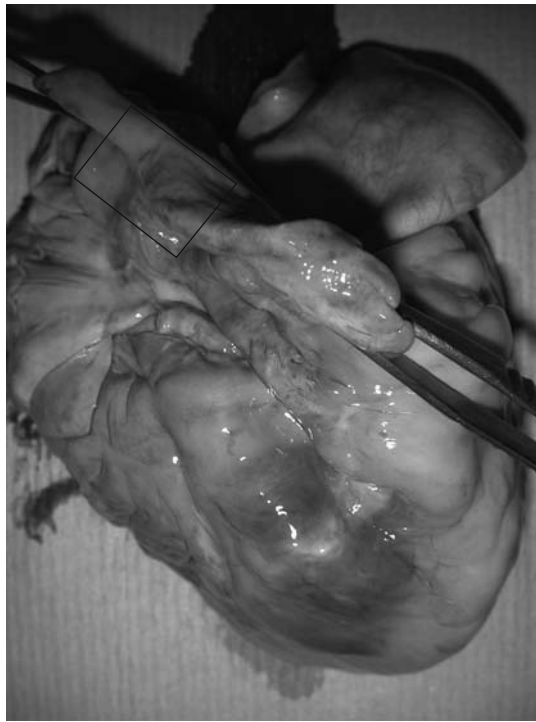Although with practice the SA node and the AV node can be identified macroscopically, the examination of the conduction system is largely a histological process, and is best undertaken by removing three tissue blocks containing the SA node, the AV node, and the AV bundles, respectively.

#### *Block 1. SA Node (See Fig. 5.12)*

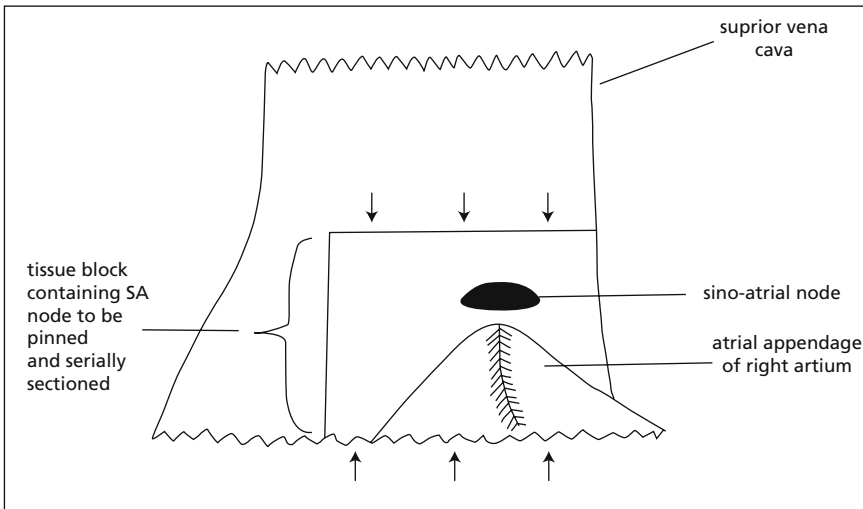
The entire sinoatrial junction should be removed, including the proximal superior vena cava and the base of the atrial appendage. This is accomplished by opening the superior vena cava posteriorly and continuing the cut into the right atrium. The relevant rectangular tissue block can then be removed using a horizontal cut across the upper atrium. This is then laid flat, using pins and a cork board if necessary, and serially sliced in a longitudinal plane. All slices should then be labelled sequentially and submitted for histology. Histologically, the node can be identified as a network of small myofibres within a dense fibrous stroma, situated about a muscular artery.

#### *Block 2. AV Node, Bundles and Proximal Bundle Branches (See Fig. 5.13)*

These are removed by displaying the opened right atrium and ventricle, and making a vertical cut through the interventricular septum at a point immediately anterior to the coronary sinus. This should extend from above the coronary sinus to about 3 cm below the tricuspid valve ring. A parallel longitudinal cut is then made at a point just behind the supraventricular crest and pulmonary outflow tract. This cut must be sufficiently anterior to include the entire membranous portion of the interventricular septum. These two vertical incisions are then joined above and below by two horizontal cuts, and the tissue block removed. This large tissue block should then be divided into two by a horizontal cut at a point just below the tricuspid valve ring, with the resulting upper block containing the AV node and bundle and the lower block containing the proximal bundle branches. The upper block should then be laid flat, again using pins and a cork board if necessary, and serially sliced in a longitudinal plane. The lower block is similarly laid flat and serially sliced in a horizontal, that is, transverse plane. All slices are sequentially labelled and either some or all submitted for




**a**

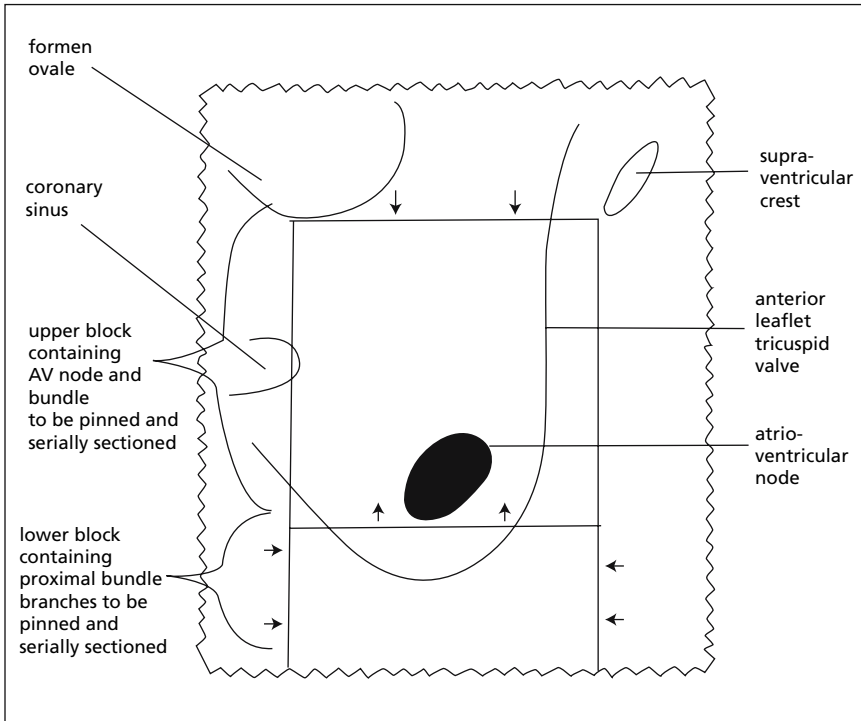


**b**

FIGURE 5.12. Selecting the tissue block containing the sinoatrial node. **(a)** This photograph shows the junction of the superior vena cava and the auricle of the right atrium. The box indicates the tissue block to be removed. (Courtesy of Mr. Dean Jansen, Whittington Hospital.) **(b)** This diagram illustrates the position of the sinoatrial node in relation to the tissue block. *Arrows* indicate the direction of serial slicing.



**a**



**b**

FIGURE 5.13. Selecting the tissue blocks containing the atrioventricular node and proximal bundle branches. **(a)** This photograph is of the opened right atrium and ventricle. The box indicates the initial tissue block to be removed. (Courtesy of Mr. Dean Jansen, Whittington Hospital.) **(b)** This diagram illustrates the position of the atrioventricular node in relation to the tissue block. *Arrows* indicate the direction of serial slicing when the initial block is divided into two.



histology, depending on the expected findings. Histologically, the AV node is identified as a loose structure composed of small muscle fibres separated by strands of fibrous tissue. Unfortunately no central artery is present to aid identification. The AV bundle branches are identified as more condensed muscle fibre bundles, also separated by fibrous tissue.

*Block 3. Distal Bundle Branches (See Fig. 5.14)*

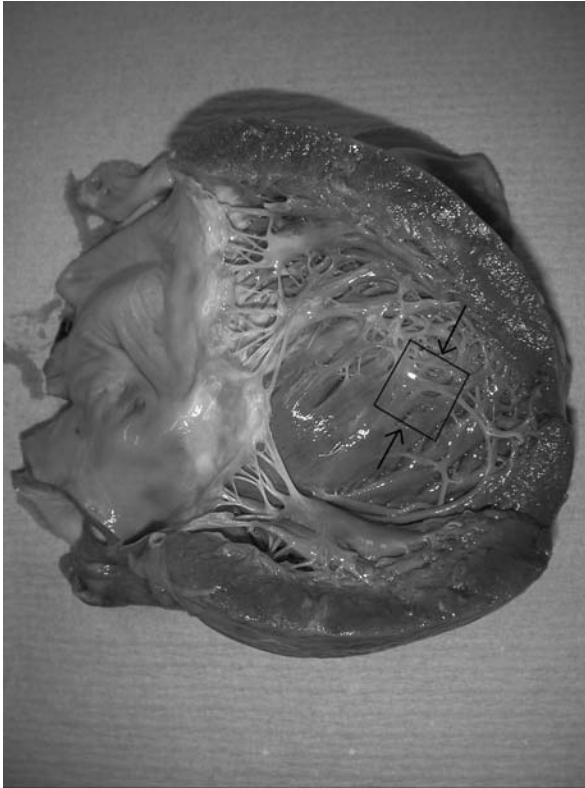
A complete examination would also include two further tissue blocks, from the left and right distal bundle branches, respectively, which should also be serially sliced horizontally and submitted for histology. These are best taken from the respective septal surface at a point about 3 cm from the apex of the heart; the anterior part of the septal wall being taken on the right side and the posterior part being taken on the left.

### *Post Mortem Coronary Angiography*

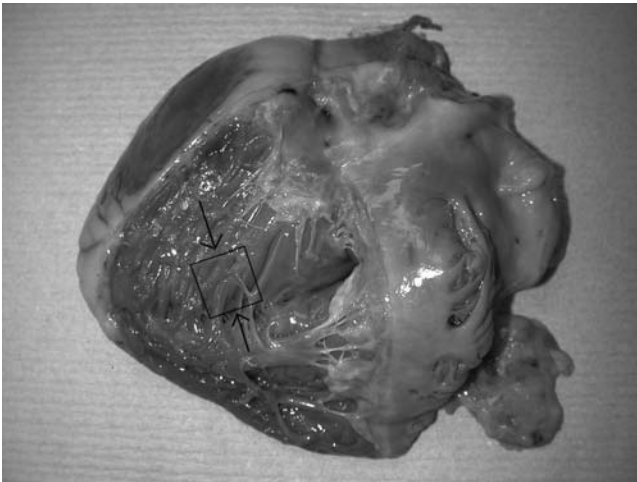
Corporal post mortem angiography is unfeasible in most departments, as few mortuaries have their own X-ray facilities. This means that either portable X-ray equipment must be used or bodies must be transferred to the radiology department. On the other hand, cardiac angiography can be extremely helpful in situations in which assessment of the degree and extent of atheroma is vital, for example, in medico-legal post operative cases, in which comparison with pre mortem angiograms is important. The mixture used is a barium sulphate suspension (0.6 g/ml). If a more permanent preparation is required, a 4% gelatin mixture can be added. This preparation is obviously solid at room temperature and needs to be warmed until liquefied before it is used. Once injected it will then cool and solidify again, producing a permanent cast within the vessel. Some people also add gum arabic (acacia) to the mixture, which increases the elasticity of the gelatin and therefore makes it flow through small vessels more easily. A 200-ml barium sulphate suspension with 15 g of gelatin and 2 or 3 g of acacia is perfect and can be stored in aliquots in a refrigerator. Radiographs of the injected heart can be obtained using any standard machine, within either the pathology or radiology departments.

#### Examination

First the aorta distal to the valve should be opened anteriorly to expose the two coronary ostia. The proximal segment of both the right coronary artery and the left main stem should be dissected free from the epicardial fat, while maintaining their continuity. The two arterial trees can then be sequentially injected. Two lengths of suture should be placed loosely around the circumference of the respective artery, a cannula (a green venflon with the needle guide removed is perfect) inserted via the ostium, and the artery tied with one of the sutures. A 10-ml syringe containing the barium mixture is



**a**



**b**

FIGURE 5.14. Selecting the tissue blocks containing the distal bundle branches. **(a)** This photograph shows the septal surface of the left side of the heart. The box indicates the tissue block to be taken when examining the left distal bundle branches. *Arrows* indicate the direction of serial slicing. (Courtesy of Mr. Dean Jansen, Whittington Hospital.) **(b)** This photograph shows the septal surface of the right side of the heart. The box indicates the tissue block to be taken when examining the right distal bundle branches. *Arrows* indicate the direction of serial slicing. (Courtesy of Mr. Dean Jansen, Whittington Hospital.)

then connected and the barium injected using firm and steady pressure until a definite increase in resistance is felt. If barium is injected beyond this point, capillaries as well as arteries will be filled, confusing the X-ray picture by producing a so-called “capillary blush.” After injection is complete, the cannula is removed and the artery tied as proximally as possible, using the second suture. X-ray films can either be taken at this point, after one arterial system is filled, or the process can be repeated with the second artery and X-ray films taken at the end of the procedure.

### *Macroscopical Dye Technique for the Identification of Early Myocardial Infarction*

The identification of early myocardial infarction is a common problem in autopsy pathology, as sudden cardiac death is often encountered in post mortems performed for medico-legal reasons. An infarct must be present for 12 to 24 hours before it is identifiable either macroscopically or microscopically. Without definitive evidence of infarction, a presumptive diagnosis must be made on the basis of the presence of occlusive thrombus and/or severe stenosis caused by atherosclerosis. Many techniques have therefore been studied in an attempt to identify infarction earlier, one of the easiest and most reproducible being macroscopical dye techniques. These all depend on particular enzymes being absent in infarcted myocardium but present in normal myocardium. Unfortunately, if the post mortem examination is carried out 12 or more hours after death (which is frequently the case), the level of enzymes present in the normal myocardium has also decreased as a result of autolysis. Consequently, none of these dye techniques are in regular use. The most well-known uses Nitro-BT dye (2,2'-di-*p*-nitrophenyl-5,5'-diphenyl-3,3'-[3,3'-dimethoxy-4,4'-biphenylene]dite-trazolium chloride). An incubation solution is made with one volume of 1 *M* Sorenson's buffer at pH 7.4, one volume of Nitro-BT at 5 mg/ml, and eight volumes of de-ionised distilled water. Slices of myocardium are washed and then placed in the incubation solution for 30 minutes at 37°C. Normal fresh myocardium turns a purple-blue colour whereas ischaemic myocardium remains unstained.

## Special Techniques Used in the Examination of the Vascular System

### *Examination of the Upper Limb Vessels*

Occasionally the clinical history and/or pre mortem investigations will make it necessary to examine the upper limb vessels. This would include situations where thromboembolic phenomena are suspected or vasculitis is a possibility. Usually only examination of either the arterial or the venous

system is required; however, there is no reason why both should not be examined at the same time using this technique.

The procedure should not be done unless absolutely necessary, as it will inevitably lead to a degree of disfigurement to a part of the body easily accessible to viewing by relatives, and once the relevant section of vessel has been reached and examined the procedure should be discontinued.

### Anatomy (See Fig. 5.15)

The axillary artery begins at the outer border of the first rib as a continuation of the subclavian artery, and in turn becomes the brachial artery at the inferior border of the teres major muscle. The brachial artery then runs anteromedially (in the anatomical position) to end at the neck of the radius in the cubital fossa, where it divides into the radial and ulnar arteries. The radial artery is the smaller of the two and runs from the mid-cubital fossa to a point just medial to the tip of the styloid process of the radius. It continues round the lateral aspect of the radius and then passes posteriorly to cross the floor of the "anatomical snuff box," where it ends by completing the deep palmar arch with the ulnar artery. The ulnar artery passes inferomedially from the mid-cubital fossa to a point anterior to the head of the ulna when it ends at the deep palmar arch.

The venous system is similar, although is more variable, particularly distally. The main veins in the forearm are the cephalic vein and the basilic vein, which have several large anastomoses, especially in the cubital fossa. The basilic vein continues in the arm, running alongside the brachial artery, and becomes the axillary vein at the inferior border of the teres major muscle. The axillary vein then ends at the outer border of the first rib by becoming the subclavian vein.

### Dissection

To examine the vessels, it is best to use a stepwise procedure, starting at the axilla. First make a cut about 15 cm in length in the skin and subcutis of the anteromedial axilla, using the subclavian vessels as guidance to the course of the vessels, and starting at the edge of the original incision used for evisceration. Having exposed the vessels in this way, use a pair of artery scissors to open the vessel in question until the end of the initial cut is reached. Then make a further cut of similar length in the skin and subcutis of the anteromedial upper arm, using the already opened vessels as a guide to the subsequent course. The vessel being examined can then be opened as before. Continue this procedure until the point of interest has been reached. It is important to proceed in this stepwise fashion for two reasons. First, it is difficult to make a single cut correctly along the entire length of the vessel's course, and thus attempting to do so increases the risk of multiple parallel cuts being necessary (and increasingly mutilatory). Second, once the vessels have become smaller it is difficult to differentiate them from

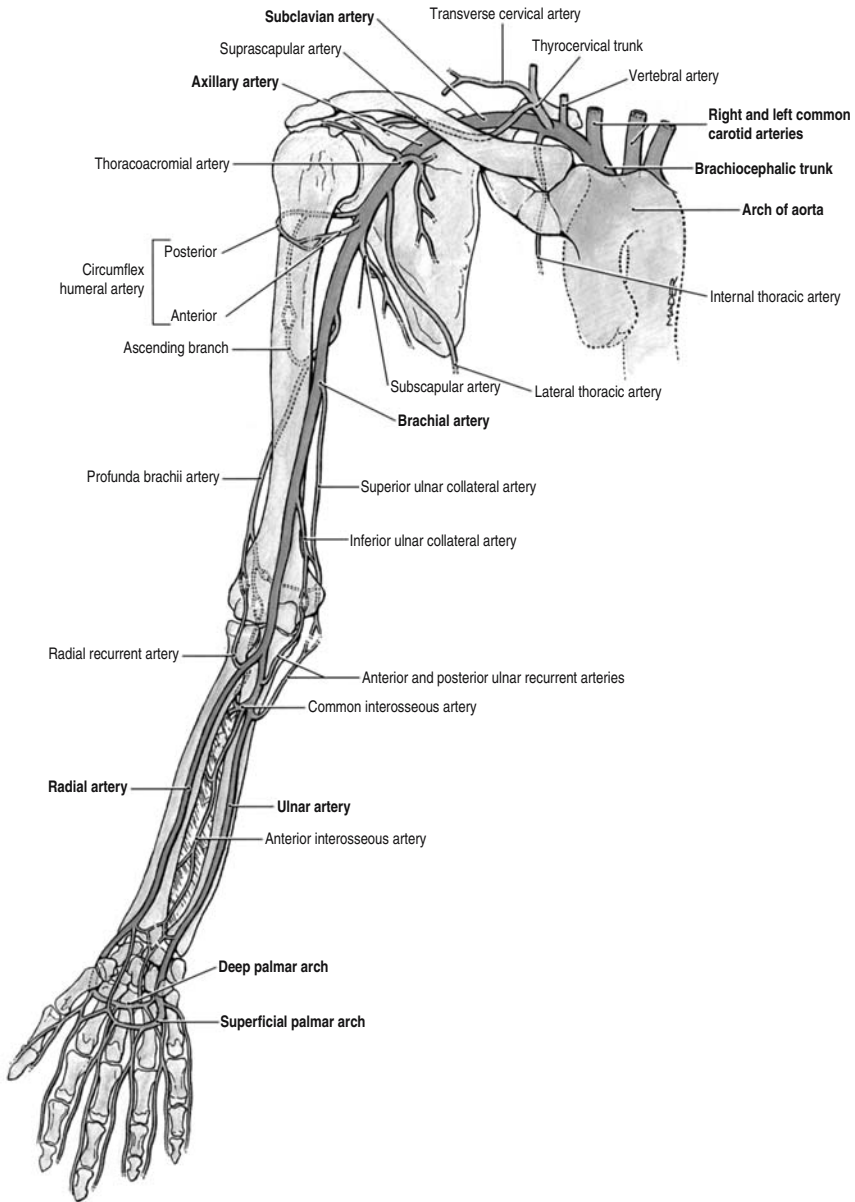


FIGURE 5.15. An anterior view of the major arteries of the upper limb. (Reprinted with permission from Agur AMR and Lee MJ. Grant's atlas of anatomy. Lippincott, Williams & Wilkins, 1999, p. 420.)

each other and from nerves, so a distal examination is extremely difficult without the preceding proximal examination to produce opened vessels for guidance.

### *Examination of the Lower Limb Vessels (Including Deep Calf Veins)*

Examination of the more proximal femoral vessels should be a routine part of every post mortem. A more complete examination of lower limb vessels is also often necessary, either of arteries in cases of known peripheral vascular disease, or of veins when searching for the source of a pulmonary embolus. In particular, the deep calf veins must always be examined if a pulmonary embolus is found at post mortem or was identified pre mortem.

#### Anatomy (See Fig. 5.16)

The external iliac artery becomes the femoral artery at the inguinal ligament and passes inferiorly in the thigh from an anterior to a posterior position. Following the origin of its major branch—the profunda femoral artery (deep femoral artery), which passes laterally and deeply—it becomes the superficial femoral artery. Just above the knee this becomes the popliteal artery, which passes inferolaterally before dividing into the anterior and posterior tibial arteries. The posterior tibial artery is the larger of the two, and begins at the lower border of the popliteus muscle. It passes inferomedially ending in the plantar arch under cover of the origin of the abductor hallucis muscle. The anterior tibial artery passes downwards anterolaterally, ending anteriorly between the two malleoli where it forms the deep plantar arch on the ventral aspect of the foot.

Proximally the venous system is similar to the arterial system, although more variable. The popliteal vein becomes the femoral vein just above the knee and this in turn becomes the iliac vein at the inguinal ligament. More distally, venous drainage consists of two anastomosing systems: a superficial network of vessels of little significance at post mortem; and a number of deep veins that are a common site of thrombus formation. In most cases of pulmonary embolism, however, the thrombus has extended from these deep calf veins, and can therefore be found in the proximal veins of the thigh. In a smaller number of cases, venous thrombi from other sites, such as pelvic or uterine veins, are the source of pulmonary emboli.

#### Dissection of Arteries and Thigh Veins

The examination of these vessels is similar to that of the upper limb (see p. 168), with the exception of the deep calf veins. As for the upper limb, examination should be carried out only if the clinical details or post mortem

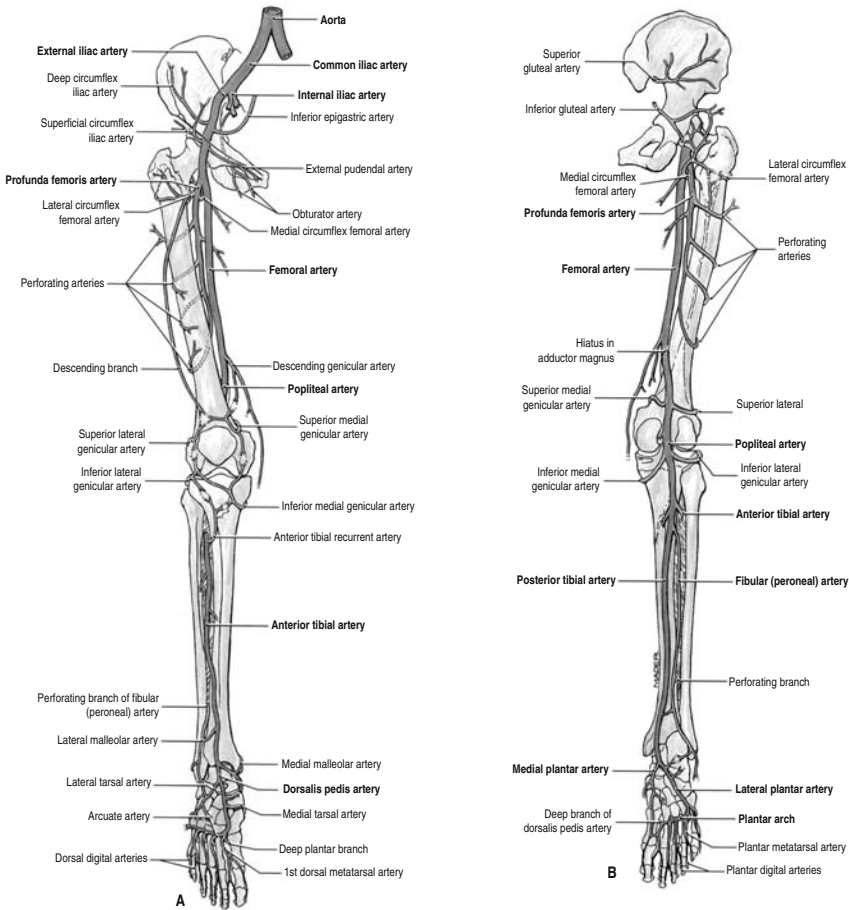


FIGURE 5.16. The major arteries of the lower limb. (a) Anterior view. (b) Posterior view. (Reprinted with permission from Agur AMR and Lee MJ. Grant's atlas of anatomy. Lippincott, Williams & Wilkins, 1999, p. 308.)

findings dictate, in order to avoid unnecessary disfigurement. A stepwise procedure is undertaken, with an initial skin and subcutis incision to expose the vessels, followed by opening of the vessels themselves. The first cut should be made anteromedially using the iliac vessels as a guide to the subsequent vessel course. This incision should start at the edge of the incision used for evisceration. Further incisions will run anteromedially down the thigh. As the dissection approaches the knee, however, it will be necessary to continue the examination from behind. This means moving the body into a prone position, and continuing the cut medially just above the knee, and

then inferiorly down the back of the calf. To avoid turning the body after evisceration, this examination could be undertaken first if it is obviously necessary from the outset, although this makes the initial incision more difficult as the iliac vessels are not visible as a guide.

### Dissection of Deep Calf Veins

The deep calf veins can be examined in situ, using a medioposterior vertical incision in the calf or even the posterior incision already used for the examination of the popliteal artery (although these two procedures are unlikely to be necessary in the same patient). It is difficult, however, to make the necessary horizontal slices through the calf muscles from the confines of a single vertical excision, and clearly numerous horizontal cuts to the skin would be inappropriate mutilation. The best method of examination, therefore, is to separate and remove the entire calf musculature. This can be accomplished by making a medioposterior incision along the length of the calf and then extending the incision laterally to pass horizontally below the knee (see Fig. 5.17). The incision should be deepened until the tibia is reached. The musculature can then be stripped from the overlying skin and underlying bone, and then removed from the body. A series of incomplete horizontal slices can then be made that will identify any thrombus within the deep veins. The sliced muscle can then be returned to the body for reconstitution.

### *Examination of the Mesenteric Vessels*

Anatomy (See Fig. 5.18a and b)

The superior mesenteric artery supplies the small intestine from the second part of the duodenum to the terminal ileum and the large intestine from the caecum to the middle of the transverse colon. It arises anteriorly from




FIGURE 5.17. The left calf from a posterior view. The lines indicate the necessary incisions when removing the muscle bulk to examine the deep calf veins. (Courtesy of Mr. Dean Jansen, Whittington Hospital.)



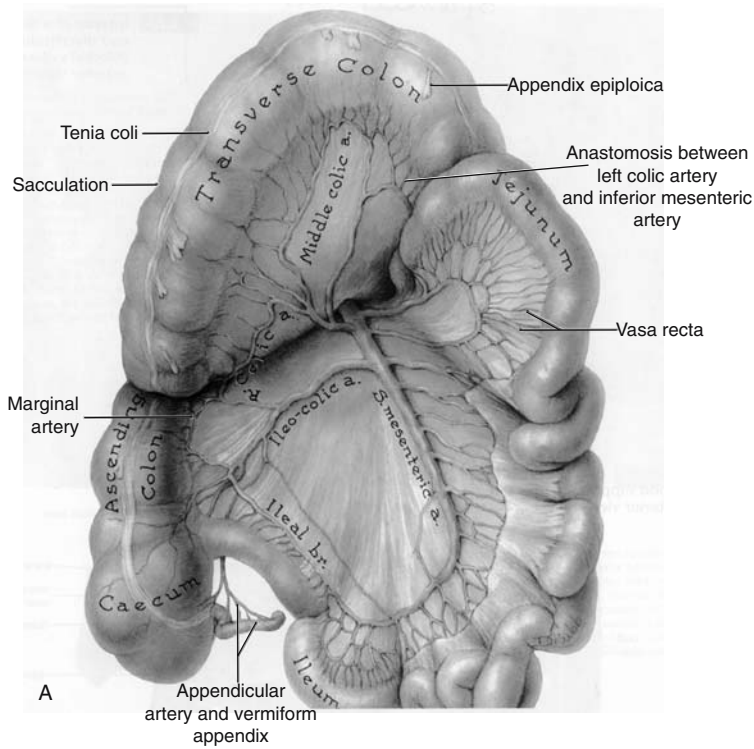


FIGURE 5.18. An anterior view of the mesenteric arteries and their major branches. **(a)** Superior mesenteric artery. **(b)** Inferior mesenteric artery. (Reprinted with permission from Agur AMR and Lee MJ. Grant's atlas of anatomy. Lippincott, Williams & Wilkins, 1999, pp. 138 and 140.)

the aorta, usually at the level of the first lumbar vertebra, about 1 cm below the coeliac trunk and posterior to the body of the pancreas and the splenic vein. It enters the small bowel mesentery after crossing the left renal vein, the uncinat process of the pancreas, and the third part of the duodenum. The artery runs along the root of the small intestinal mesentery, supplying the small intestine via vasa recta that arise from anastomosing loops or arches known as arterial arcades. The middle colic artery, the right colic artery, and the ileocolic artery are branches that supply the large intestine, anastomosing to form a marginal artery from which more vasa recta supply the bowel wall.

The inferior mesenteric artery supplies the large bowel from the middle of the transverse colon to the rectum. It arises anteriorly from the aorta, usually at the level of the third lumbar vertebra, about 4 cm above the aortic bifurcation, and crosses the left common iliac vessels. It branches into a

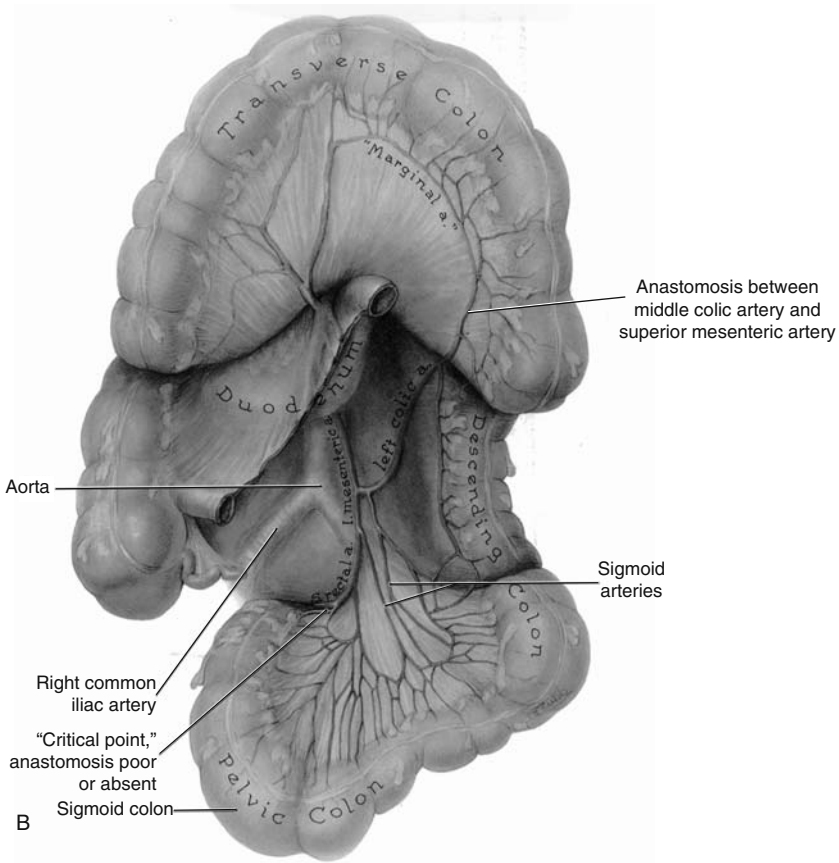


FIGURE 5.18. *Continued*

superior left colic artery and several inferior left colic arteries which again anastomose to form a marginal artery that supplies the gut wall through vasa recta. There is considerable anastomosis between the marginal arteries from the superior and inferior arteries in the transverse colon.

The venous system is similar to the arterial system, although it is more variable. The superior mesenteric vein joins the splenic vein to form the portal vein, posterior to the head of the pancreas. The inferior mesenteric vein either empties into the splenic vein, the superior mesenteric vein, or the junction between the two.

### Preparation

Examination of the mesenteric arteries and veins may be necessary in the investigation of bowel infarction or ischaemic colitis, although these may

have already been delineated pre mortem. The necessary specimens must be prepared before the bowel has been removed from the mesentery and opened. This is best achieved at the beginning of the post mortem, after the small bowel and the rectum have been tied off as usual. The entire bowel can then be removed at the root of the mesentery. Particular care must be taken with the ascending and descending colon, as there very little mesentery is present. As much pericolic fat as possible must therefore be removed with the colon, so that the vessels are not destroyed. The mid-transverse colon is then tied twice, at about a 5-cm interval, and transected between the ties. The proximal specimen contains the superior mesenteric vessels, the proximal ends being identifiable at the root of the mesentery. The distal specimen contains the inferior mesenteric vessels, the proximal ends being identifiable in the mesentery of the transverse colon.

### Radiology

Angiography should be undertaken if identification of any site of obstruction is vital. Whole body radiography is difficult in most mortuaries, as few have facilities on site, necessitating either a portable X-ray machine or transportation of the body to the radiology department. It is much easier, therefore, to prepare the appropriate specimen, as described earlier, allowing radiography of this smaller specimen in standard mortuary X-ray machines or making transport of the specimen to radiology much easier.

The vessel in question should be cannulated and injected with the contrast media. String must be used to ligate the vessel about the cannula to prevent leakage during injection. Considerable pressure is needed to move the mixture through the whole arterial system; however, pressure must be stopped once resistance is felt, to avoid spillage of the mixture into the capillaries, as this produces a "capillary blush" that makes interpretation of X-ray films difficult. A further length of string should be tied round the vessel once the cannula is removed, to keep the mixture within the vascular system.

### Dissection

Direct examination can also be undertaken from the two specimens described earlier. Small artery scissors can be used to open the vessels longitudinally along their course. Although transverse sectioning may allow a better assessment of stenosis, it is not feasible in this situation, as the large number of vessels would make demonstration difficult.

*Alternatively, if a less thorough examination is all that is required, the root of the small bowel mesentery, the transverse colon mesentery, and the sigmoid colon mesentery can be serially sliced in a plane parallel to the bowel wall. This will identify any large thrombi within vessels.*

### Clinical Correlation

Once identified, the number and site of any thrombi or thromboemboli should be noted and correlated with any area of bowel infarction or ischaemia. Such correlation is often difficult, however, as the rich anastomoses between the mesenteric vessels mean that infarction often occurs at “watershed” areas whichever vessel is occluded. These watershed areas are at the limits of arterial supply, that is, the splenic flexure, which is at the junction between the superior and inferior mesenteric arterial supply; and the rectum, which is at the junction of the inferior mesenteric supply and the hypogastric artery.

### *Examination of the Vertebral Arteries*

There are several situations in which the vertebral arteries should be examined. They are a necessary part of the investigation of cerebrovascular events and should always be examined if a cerebral infarct has been identified or is suspected clinically. They are also part of the examination of the neck following trauma, including hanging and road traffic accidents as well as suspicious deaths. In addition, they should be examined in all cases of subarachnoid haemorrhage when a berry aneurysm has not been found. They can be examined in situ or after removal and decalcification of the cervical spine. They can also be examined using angiography; however, the usual difficulties with body transportation apply if the angiography is undertaken in situ and therefore angiography after the cervical spine block has been removed is easier.

The various techniques are described within Chapter 12; see p. 305.

### *Post Mortem Angiography*

Angiography of individual organs or vessels has already been discussed in the context of several separated organs:

Heart (see p. 166)

Mesenteric arteries (see p. 176)

Vertebral artery (see p. 307)

Pulmonary arteries (see p. 189)

Renal artery (see p. 217)

Gastric arterial supply (see p. 209)

In theory, angiography of any arterial or venous system is possible at post mortem, although is rarely necessary. Angiography will allow the identification of a length of vessel obstruction, usually caused by thrombus or embolus. Areas of vasculitis will also be identifiable, particularly those of polyarteritis nodosa, which produces a characteristic segmental swelling of the arterial wall. In addition, any vessel rupture will be delineated, and is

usually secondary to trauma. Most such diseases will already have been well documented pre mortem, however, and even if they have not been clarified radiologically, can often be delineated sufficiently by the examination of distant disease (such as infarction) in the organ that the vessel is supplying. Post mortem angiography is therefore really necessary only in medico-legal cases, where the exact site or extent of vessel obstruction is in dispute. This would be particularly the case if the patient has died during an attempted angioplasty. In this situation, post mortem angiography will not only delineate the obstruction but can also isolate iatrogenically produced lesions such as arterial dissection.

As has already been discussed, whole body radiology is difficult, as either a portable X-ray machine is required or the body has to be transported to the radiology department. In contrast, angiography of a single organ or vessel allows the small X-ray machines that are often available within pathology departments to be used and produces a specimen that is easily transported between the mortuary and radiology department.

### Method

The vessel should be fully exposed and two lengths of suture placed around it to allow the vessel to be easily tied off both during and after injection. The mixture used is a barium sulphate suspension (0.6 g/ml). If a more permanent preparation is required a 4% gelatin mixture can be added. This preparation is obviously solid at room temperature and needs to be warmed until liquefied before being used. Once injected it will then cool and solidify again, producing a permanent cast within the vessel. Some people also add gum arabic (acacia) to the mixture, which increases the elasticity of the gelatin and therefore makes it flow through small vessels more easily. A 200-ml barium sulphate suspension with 15 g of gelatin and 2 or 3 g of acacia is perfect and can be stored in aliquots in a refrigerator. When injecting the mixture, a syringe and cannula should be used. The size of the syringe depends on the size of the vascular system to be filled and the size of the cannula depends on the diameter of the vessel that is being injected. For many vessels, a green "venflon" with the needle removed can be used. The mixture should be injected with a steady force until resistance is felt. String should be used to ligate the vessel about the cannula during injection, to prevent leakage. Obviously, the force needed will also depend on the size of the vascular system being filled. Injection must be stopped when resistance is felt, as this prevents the mixture from entering the capillaries, which produces a confusing "capillary blush" on the X-ray film. Once injected, the vessel should be tied off again to prevent leakage through the injection site. X-ray films can then be taken, and can be at multiple angles if necessary.

*Alternatively, if examining a single organ, the vessels can be injected with latex instead of barium, using different colours for arteries and veins. The soft tissues can then be dissolved in acid to leave vascular casts. These can be used*

*for demonstration purposes, for example, in a pathology museum, but are not appropriate for routine autopsy use.*

### *References*

1. Davies MJ. The investigation of sudden cardiac death. *Histopathology* 1999;34: 93–98.
2. Sunderman WF, Boerner F. Normal values in clinical medicine. Philadelphia: WB Saunders, 1949.
3. Fulton RM, Hutchinson EC, Jones AM. Ventricular weight in cardiac hypertrophy. *Br Heart J.* 1952;14:413–420.

# 6

## The Respiratory System

The respiratory system extends from the nares to the most distal alveolar spaces. Although in life many infections occur in the upper tract, the majority of respiratory conditions relevant to the post mortem are found in the lung. Many ultimate causes of death involve the pulmonary tree, and this makes careful investigation of the lungs especially important. Most of the major pathological findings such as tumours or infections will have been identified pre mortem or found at the time of evisceration, but it is as well to follow a routine for dissecting the airways to avoid overlooking relevant pathology. For example, it is important to examine the pleural cavities for fluid, adhesions, or pneumothorax and the pulmonary arteries for emboli at the appropriate time in every case in order that these findings are not passed over and therefore neglected. These have been discussed fully in Chapter 3 on general evisceration and are not repeated here. Obviously, flexibility of technique is also important in order to obtain as much information from the post mortem examination as possible and avoid potential problems from hazards such as tuberculosis. Flexibility also allows optimal impact at the time of demonstration. This chapter outlines:

- Routine examination and dissection of the lungs
- Special techniques used in lung dissection
- Dissection in cases of lung transplantation
- Special techniques used in dissection of the nasopharynx, sinuses, and larynx

### The Lungs

As mentioned previously, removal of the lungs for dissection is achieved by cutting through each of the main bronchial stems distal to the carina with a large pair of scissors or PM40 (see Fig. 4.7). In many cases it is not particularly important where these cuts are made, but if a proximal tumour is present, or when it is crucial to examine the lung parenchyma closely (e.g.,

with possible interstitial lung disease or in cases of pneumoconiosis) the cut should be made toward the carina, leaving as long stump of bronchus as possible. In this way the lungs can be inflated and fixed to allow the subsequent morphological assessment to be optimised. It is almost impossible to interpret collapsed lung tissue sections accurately and conditions such as emphysema or interstitial lung disease cannot always reliably be recognised from examination of unfixed, often squashed, uninflated lungs. This is also useful for distinguishing between arterioles and venules as the anatomical relationships are better preserved. In cases of suspected glue sniffing or chemical inhalation a whole lung can be removed to an airtight container and retained for analysis before the solvent evaporates.

### *External Examination*

Normally the lungs weigh 350 to 400 g each in an adult (see also Appendix), but may weigh well in excess of 1 kg in cases of severe cardiac failure or other severe acute diffuse lung pathology such as pneumonia or diffuse alveolar damage. The weights are recorded prior to dissection to obtain a quantifiable measure of the amount of intraalveolar fluid, particularly oedema. As will be recalled, there are three lobes on the right and two lobes with a lingula on the left. Each lobe is served by a main lobar bronchus, which branches into the segmental bronchi, which in turn split into bronchioles. The following descriptions are documented as if dissecting one lung, but apply to both left and right lungs equally.

### *Internal Examination*

#### Dissection of the Airways

It is conventional to open the airways with a medium to large pair of rounded scissors from the large to small airways, from medial to lateral to include all lobes and segments opening along the branches as they are encountered (Fig. 6.1). In this way it is possible to gain an impression of the parenchymal appearance and texture and to approximate the airway calibre. Very small sized lung tumours (especially small cell carcinoma) are among a limited group of malignancies in which a miniscule primary may be associated with (or even present with) widespread metastases and therefore careful inspection is warranted in such cases.

Apical disease such as old tuberculous cavities or fungal balls can also be demonstrated. A rough guide to the presence of chronic obstructive pulmonary disease (COPD) can also be made by assessing how far peripherally the airways can be opened. The further the passages can be opened the more severe the COPD. A more accurate and demonstrable way to assess COPD is to produce Gough–Wentworth slices of inflated and fixed lung as described below. The latter enhances the appearance and can be examined



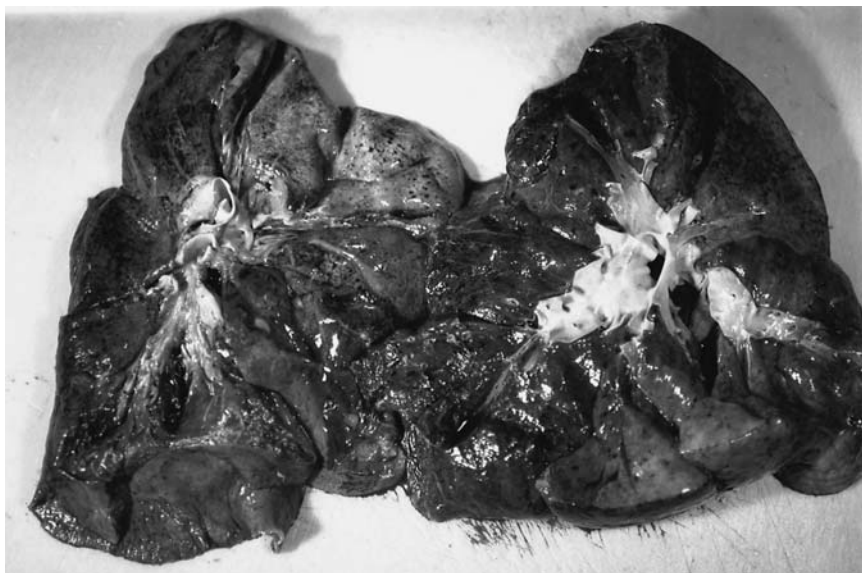

FIGURE 6.1. The pulmonary airways and arterial tree are demonstrated by tracing the systems from the hilum peripherally with medium or small scissors. It is customary to open the airways from the medial aspect and the vessels from the outer aspect. The airways are demonstrated here on the left and arteries on the right. In practice both systems are opened more distally than they appear in this photograph.

with a hand lens. Air spaces greater than 1 mm are considered emphysematous. Once the airways have been opened the parenchyma is inspected to look for fibrosis, consolidation, tumours, scars, or cavities. The parenchyma should be squeezed or massaged and any pus or fluid expressed should be noted.

#### Dissection of the Vessels

The lung is now turned over so the outer visceral pleural surface can be reexamined. The horizontal and oblique fissures are then identified and the soft tissue deep within the fissure is dissected superficially to expose the outer surface of the wall of the hilar segment of each pulmonary artery. A scissor cut at this point into the lumen will allow access to the rest of the pulmonary tree by opening the vessels in a peripheral direction, rather like the method for opening the airways (Fig. 6.1). Obviously here it is important to look for emboli and atheroma; the latter is associated with raised pulmonary pressure/pulmonary hypertension. Large emboli associated with sudden death are usually found at the evisceration stage; emboli identified when opening the smaller arteries may well have less significance. It is also possible if required to open the airways and vessels both from either the

hilar or outer aspects but there will obviously be a significant amount of cross-cutting and loss of control over the procedure.

### Slicing the Lung

Once the airways and vessels have been dissected it is useful to make a horizontal slice through each lobe with a large-bladed knife such as a brain knife in order to inspect the rest of the parenchyma. This is done on the dissecting board by laying the lung flat with the medial side down toward the board. A sponge can then be placed over the outer surface of the lobe to be cut to protect the securing hand from inadvertent injury during slicing (Fig. 6.2). It is occasionally preferable to make large horizontal slices through the whole lung rather than opening the airways and vessels as described previously. This displays any large mass lesion in the lung, such as a large bronchogenic carcinoma, well and preserves all the local relationships for demonstration.

### Histology

When blocks are required for histology, and consent is available for this, they should be taken from each lobe of each lung even if no obvious



FIGURE 6.2. The lung is sliced parallel to the dissecting board with the upper surface controlled with a sponge. (Courtesy of Mr. Dean Jansen, Whittington Hospital.)

pathology is identified. Identification of the origin of these blocks is aided by following a system of cutting particular shapes of tissue for a particular site as described in Chapter 13. The tissue blocks should be of the usual size, approximately  $3 \times 2 \times 0.4$  cm, and need to be fixed well before processing and sectioning. Extra blocks will need to be taken from any masses identified or areas of interest. Remember that it is better to retain and fix excess tissue at the time of post mortem if there is any possibility of it being relevant to the examination, as it is impossible to retrieve later. This does not of course mean that all tissue retained needs to be processed and sectioned if it turns out that it is not required. Histology is essential in cases of industrial related diseases relevant to the cause of death, especially if this has not been documented and established during life, and methods for assessing asbestos exposure are described later in this chapter. Immunohistochemical methods for differentiating pleural metastases from primary malignant mesothelioma are sometimes required and these should follow routine surgical pathological principles and are not discussed here.

### *Special Techniques*

#### Method for Opening Airways and Vasculature Avoiding Transection

A method has been described for examining the lungs that allows demonstration of both the bronchi and pulmonary arteries without potential problems caused by transection [4]. This is a modification of the method described above which opens the airways on the hilar (medial) aspect and the vessels from the outer (lateral) aspect. With the isolated lung in the palmar aspect of the hand, the visceral pleura is incised opposite the hilum in the exposed transverse (or equivalent) fissure. The vascular supply to the lower lobe can be opened with blunt ended scissors from the main pulmonary distally as described previously. Next the lingula or right middle lobe arteries are dissected similarly by cutting the visceral pleura between the upper and lower lobes (oblique fissure) on the left or between upper and middle lobes (transverse fissure) on the right. Then the lung is turned over to demonstrate the hilar side. The upper lobe arteries should then be opened from this aspect. This is intended to expose the arterial system without disrupting the airways. The next step is to open the airways to the middle, lingual, and lower lobes from the main bronchus on the medial (hilar) surface. The final stage is opening of the upper lobe airways from the hilum on both sides. It should be possible to avoid transection of the upper lobe vessels when opening the airways by advancing the scissors at an angle, underneath the arteries as the bronchi lie below the arteries in this lobe. It should be remembered, however, that local relationships between airways and vessels do show some variation and slight modifications may be necessary.

## *Inflating a Lung*

It is very useful and occasionally essential to examine the lung parenchyma in a fixed inflated state so that an accurate diagnosis and assessment of interstitial disease can be made. Three main methods are employed, all either introducing fixative via the trachea into both lungs in continuity, or fixing via the main bronchus of an isolated lung. Should this be required it should be remembered that one lung could be dissected in the usual way at post mortem while the other is retained and the following technique performed on the latter. The left lung is recommended for inflation because the left main bronchus is longer than the right and this should aid cannulation and perfusion. It is important to preserve the pleural surface in order that the fixative does not leak out during fixation. The bronchus or trachea is cannulated and this cannula is fixed firmly in place with a ligature. The lung is placed in a bath of 4% or 10% formalin or formal saline and the cannula is connected to a hose running from a container of the same fixative placed at a height from the bath. This produces a head of pressure that allows fixative to enter the airways and perfuse these distally. A pressure of about 25 to 30 cm of water is recommended, and perfusion is stopped when the pleural surface becomes smooth. Elastic recoil within the lung(s) may push some fixative out, but this is usually not a problem. The lungs are left in this state for 24 to 48 hours after which they can be washed in water and sliced using a large brain knife with the slices lying 1 to 2 cm apart in a parasagittal plane. Alternatively a meat slicer can be used to produce thinner slices. Slicing should be performed in a suitable area such as a safety cabinet to reduce the risk of exposure to formalin fumes.

### The Pump System

The second method involves a similar setup but instead of introducing the fixative by hydrostatic pressure, a constant pressure pump can be attached and this also allows recycling of formalin through the system. Slices of lung tissue can be made in a manner similar to that described earlier after 24 to 48 hours.

### Formalin Vapour Method

The third main method that has been described for inflating and fixing the lungs is to fix the lung(s) with formalin vapour. A rubber stopper is plugged into the main bronchus and this is then pierced by a needle through which the lung is inflated with formaldehyde gas at a pressure of 40 to 50 mmHg. The gas is produced by filling a large container with 40% formaldehyde solution and bubbling air through it. Once the lung is filled with gaseous fixative it again is floated on a bath of liquid fixative and covered in a soaked cloth. After 48 hours of fixation, slices can be made in the same way as

described above. In practise the previous methods are preferred because of the hazards of using formalin vapour.

#### Cases with Abundant Luminal Contents

All of these methods of lung inflation/fixation are made easier if the airways are patent and the lumina of the airways clear. If there is much pulmonary oedema or consolidation one should consider removing the bronchial material or performing the same technique as described in the previous section, but perfusing the lung with fixative via a pulmonary vessel. This also allows intraluminal material to be retained in the specimen, which may be desirable in some circumstances. There are in fact many other variations on these themes with regard to wet or dry fixation, as well as freezing, but these are not all described here.

#### Producing Lung Slices

The lung slices produced by any of the methods described can be stored in appropriate sealed containers but for permanent records barium sulphate impregnation is recommended. A slice of fixed lung is placed in a barium nitrate solution (75 g of barium nitrate dissolved in 1 litre of warm water) for 1 minute. This is then removed and placed in aqueous sodium sulphate solution (100g/l). This is repeated until tissue is opaque and greyish white, which renders the tissue opaque and allows for better visualisation. Quantitative measurements of changes such as emphysema are also easier to calculate.

#### Gough–Wentworth Slices

Lung tissue slices can also be paper mounted to produce Gough–Wentworth slices. Fixed tissue slices are washed thoroughly and then placed in a heated gelatin solution and subjected to partial vacuum until the gelatin penetrates the tissue. The slices are then incubated at 35°C for 48 hours. The gelatin is then allowed to set and is frozen overnight. Sections 400µm thick are cut with a large section microtome and refixed in 10% formalin–acetate solution. There follows another washing step and then the section is covered with a second gelatin solution which in turn is covered by a sheet of Whatman no. 1 filter paper. The whole aggregate is dried and the process is complete (Fig. 6.3).

### *Microbiology of the Lung*

It is important to sample any specimen for microbiological analysis early on in the post mortem examination although contamination either during the procedure or caused by post mortem bacterial colonisation or growth is difficult to avoid. It is suggested that all pneumonic processes identified at post mortem should prompt the prosector to consider removing lung

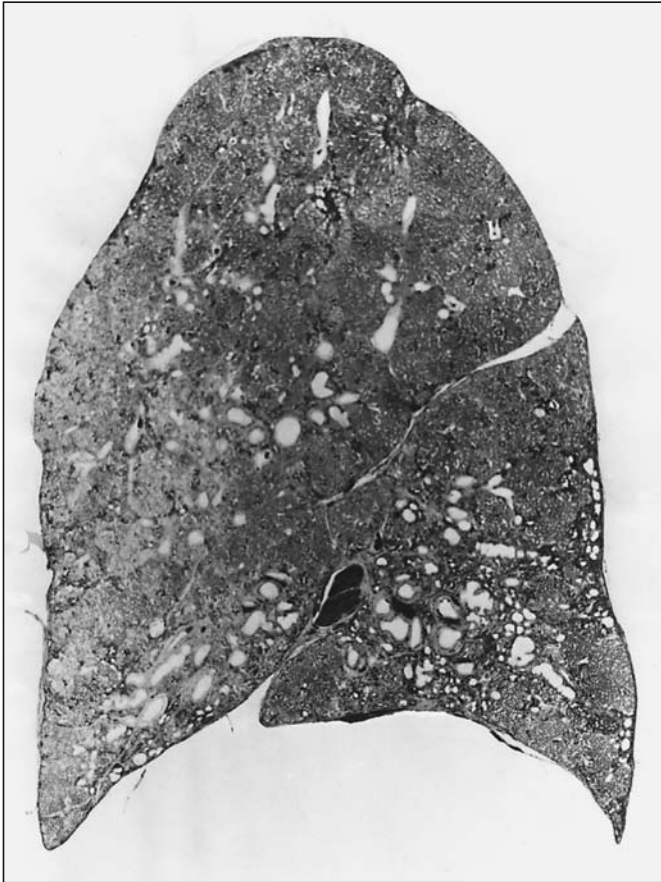


FIGURE 6.3. A paper-mounted slice of lung prepared following the Gough-Wentworth technique. This is particularly useful for demonstrating interstitial and obstructive pulmonary disease.

tissue for culture. Several methods are available, with the easiest involving removing a small wedge of peripheral lung tissue and placing it in a sterile container. There may well be contamination with such a basic method and searing the lung surface and sampling a deeper area of tissue approximately 1 to 2 cm<sup>3</sup> will potentially give more relevant results. It is possible of course to sear the surface and swab the underlying tissue and send this sealed in a sterile tube. *An alternative for pulmonary microbiology involves freezing the whole lung and producing large section imprints onto agar plates for culture* Zanen-Lim and Zanen suggest that there may be increased likelihood of sampling error with smaller pieces [6]. When tracheal specimens require investigation either a ring of tissue or a swab of secretions should be sampled. Virological samples should be collected into suitable containers.

In all cases the appropriate request forms should be completed, with details of the investigations required listed and including notification regarding any potential hazard.

### Smears and Imprints

Smears or imprints of airways tissue or fluids may also be made onto glass slides for direct microscopy after staining with appropriate stains such as Gram, periodic acid–Schiff, Grocott, and Ziehl–Neelsen, among others. Care should always be taken when handling unfixed, potentially hazardous tissue.

## *Examination of Cases of Known or Suspected Pulmonary Tuberculosis*

Whenever there is a possibility of tuberculosis, special procedures must be followed, although the scientific basis for these procedures has recently been questioned. Despite this, it is generally accepted that inflation and fixation almost entirely eliminate the risk of contamination in such cases. There are many general principles that are worth remembering when confronted with a high risk post mortem. These have been discussed in detail in the opening chapter, but a few of the important factors are repeated here. It is essential to limit the number of staff exposed to a minimum and to reduce the time of exposure to an absolute minimum. As the main risk is inhalation, the main protection for the prosector is a microfilter face mask or respiratory equipment. The area of work and equipment used should also be limited. In the case of tuberculosis it may be appropriate to fix the lungs promptly and to leave dissection to a later date (usually after several hours or days). If the risk is not apparent until during the post mortem examination then the lungs can be inflated with formol saline before dissection and left to fix in a container full of formalin fixative for the intervening period. This has been described more fully in an earlier part of this chapter. With adequate respiratory protection, however, pre-dissection filling by formalin is not considered essential and in fact is no longer recommended (RCPath guidelines 2003). The examination should be performed in a standard fashion. It was previously suggested that the thoracic block be removed as the last part of the post mortem examination so that all other systems are dealt with beforehand. It was also recommended that the rib cage be left intact until the end of the examination and Letulle's en masse method was *not* recommended.

### *Pulmonary Radiology*

It is rare for post mortem radiology to be considered necessary, but this is occasionally very useful for comparison with in vivo X-ray films. Even more

rarely is post mortem bronchography or angiography necessary, but again this can sometimes be extremely instructive. The general principles for post mortem respiratory radiology are outlined as follows:

- Cannulate the appropriate vessel or airway.
- Tie a ligature.
- Introduce warmed gelatin–barium sulphate mixture at necessary pressure.
- Cease at point of resistance.
- Take X-ray films.

Specific procedures are best carried out after fixation as outlined below.

### *Pulmonary and Bronchial Angiography and Bronchography*

These can be performed in situ, but are usually performed on organs removed from the body and are really applicable only to inflated intact lungs. The technique is rather fiddly and will require a degree of patience, care, and experience. Depending on the system to be studied either cannulate the pulmonary artery(ies), veins, bronchi, or bronchial arteries. All of the following require previous fixation in an inflated state in order to allow the medium to get access throughout the lung. The medium to be used is usually a gelatin–barium mixture but the optimal concentration of gelatin will depend on many factors and it should be tailored to each individual case.

#### **Pulmonary Arteriography**

If the lungs need to be left in situ prior to arteriography, for instance when a tumour is present, the pulmonary artery can be cannulated with a large-bore needle and barium contrast medium introduced. With isolated lungs, the main bronchus should be cannulated and the lung inflated with air under a pressure of approximately 20 mmHg. The barium–gelatin mixture is warmed to 60°C and introduced under pressure (in excess of 70 mmHg) into the main artery. After the vasculature is filled, resistance will be felt and the procedure should be stopped. It is important at this stage to keep the lung warm so that the gelatin does not set too soon.

#### **Venography**

For the venous system a similar technique can be followed but it is helpful to leave the left atrium in continuity in order to aid cannulation of the pulmonary veins.



### Bronchial Arteriogram

It is also possible to perform bronchial arteriography, either in situ or on isolated lungs. For injection in situ the axillary, common carotid, internal mammary, vertebral, and thyrocervical trunk arteries need to be ligated. The aorta also needs to be ligated just above the aortic valve. Similar gelatin-barium mixtures are introduced through the coeliac axis and stopped when the peripheral small subpleural vessels are filled. With isolated lungs the bronchial arteries are cannulated just above and behind the main bronchus. An injection pressure of approximately 150 mmHg will be required and it will also be necessary to inflate the lungs with air or carbon dioxide at the same time.

### Bronchography

Bronchograms can be produced in an essentially similar manner but in this instance contrast is introduced into the central airways and care must be taken to avoid overfilling.

### *Miscellaneous*

Further estimates of air content, blood volume, and post mortem pulmonary function studies are possible but these methods are more of historical interest and so rarely performed that the reader is referred elsewhere for these details [3]. Likewise preparation of bronchial or vascular casts and museum pieces is described in other texts.

### *Lung Transplantation*

The principles for assessment of post mortems after lung transplantation are similar to those at other sites and the aims are to establish the events leading to death, identify any features of a rejection process, identify any complications of the operative procedure or treatment, and look for evidence of the disease leading to transplantation. The examination may be complicated and the possibility of referring the case to a centre with experience and a special interest should be seriously considered. Alternatively, the undissected individual fixed organs may be referred to the specialist centre but information may be limited by the fact that inter-organ relationships and pathology may be lost. In any case it is important that a thorough examination be performed, as the findings are extremely important for educational, counselling, and audit purposes.

Before evisceration all external sutures and drains should be inspected and if tubing remains in place this should be sent for microbiological culture. During evisceration all cavitory fluids should be collected and measured and any foci of infection sampled for microbiology. It is recom-

mended that the thoracic organs be removed as a complete pluck rather than as individual organs and that this pluck should be removed and dissected last, as appropriate time and care need to be dedicated to this section.

First the neck structures can be examined in the routine manner and removed. Then the descending aorta and oesophagus are dissected and removed, leaving the larynx, trachea, lungs, and heart together. The next stage will depend on whether one or both lungs have been transplanted and which lung if only one. When dealing with combined heart and lung transplants the cardiac dissection described on p. 160 is followed and then the lung(s) are examined as described below.

As revascularisation is required in all cases, except single lung transplants on the right, and involves anastomosis of the left internal mammary artery (IMA) to the donor bronchial artery, this site needs to be assessed before evisceration of the thoracic organs. The sternum is removed with extreme care and the posterior surface inspected to note the absent left IMA. The origin of this vessel should then be identified along the left subclavian artery and its route traced to the anastomosis. The integrity of this anastomosis is checked before proceeding to the lung (and heart) dissection.

With lung lone double transplants, the heart should be separated from the lungs by dissecting the innominate veins and superior vena cava and then dividing the pulmonary veins and arteries close to the hila of the lungs. It is important to take care when separating the lungs from the trachea because there may be significant fibrosis and it is easy to damage the local structures and disrupt the tracheal suture line. The larynx and trachea are opened along the posterior wall down to the carina. Assess the tracheal or bronchial suture lines. Inflate one lung as described above. The other lung can be examined in the usual way but 1- to 2-cm thick slices are recommended. The cut surface should be examined for infection, diffuse alveolar damage, oedema, vascular lesions, or mass lesions. Samples should be taken for bacteriological/viral investigation as described previously. Blocks should also be taken for histological examination from anastomosis sites (including the left IMA and bronchial artery anastomosis) with longitudinal segments of tissue taken across the joining area, from each lobe of each lung and the pulmonary vessels (donor and recipient). Fresh frozen tissue should be kept for any future investigations that may be necessary. It is important to verify that consent has been obtained for tissue retention.

### *Other Special Techniques*

#### Pneumoconiosis

All industrial injury benefits from occupational lung disease in the United Kingdom are currently dealt with by the Medical Boarding Centre, Respiratory Diseases and the pneumoconiosis panel no longer exists. The routine

examination of the lungs of deceased workers in industries such as mining, potteries, and quarries (for which examination of the lungs was required) ceased as from 1986/7 with the abolition of the death benefit. All present cases concerning asbestos exposure and mesotheliomas are considered by the Medical Boarding Centre. Any doubts in the diagnosis are followed up by local experts. In the United States a special group within the American College of Pathologists known as the pneumoconiosis committee is involved with the pathological aspects of pneumoconiosis cases.

### Asbestos Body/Fibre Demonstration

#### *During the Examination*

There are several ways to attempt to identify asbestos at post mortem [1, 2, 5]. The easiest is to slice the lung parenchyma with a blade and to express pulmonary fluid onto several clean glass slides (Fig. 6.4). A cover slip can be placed over this wet preparation and the slide examined microscopically for ferruginous asbestos bodies. Alternatively, the exposed lung tissue can be scraped with the blade and the material applied onto a clean glass slide and examined microscopically in the same way. If asbestos bodies are seen then previous exposure is confirmed but the following methods may still be required for documentaion and quantification of the degree of morphological abnormality. If asbestos is not identified then this does not exclude previous exposure and further sampling is necessary.

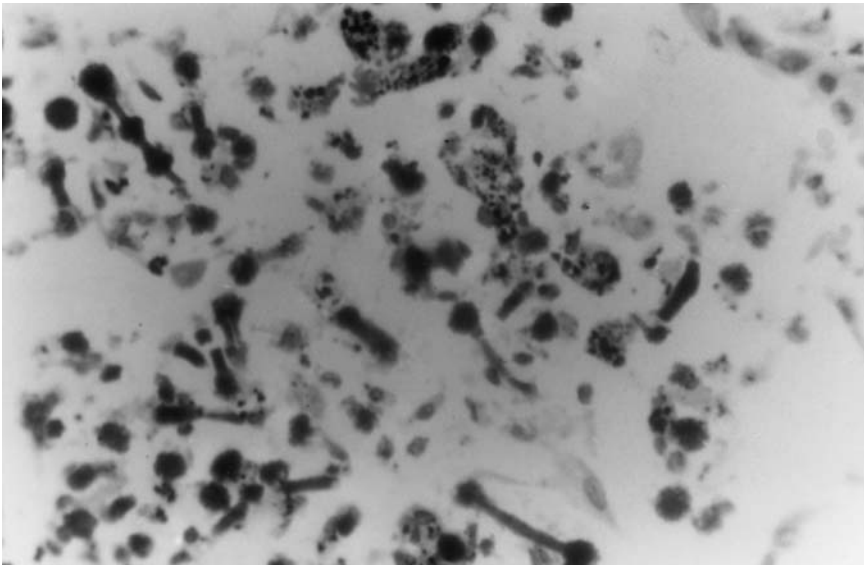


FIGURE 6.4. Asbestos (ferruginous) bodies expressed from the lung of a patient dying with a malignant mesothelioma.

### *Histological Sections*

An additional method is to examine formalin-fixed paraffin-embedded lung tissue for asbestos bodies. Asbestos bodies tend to aggregate in the same areas as carbon dust pigment. They are more easily demonstrated in thick (30µm) sections that are unstained or have a light counterstain. Because the ferruginous bodies contain ferroprotein complexes it is possible to identify this coating utilising Perl's iron stain (described in Chapter 13), and this is particularly useful if small numbers of bodies are present. The pneumoconiosis committee of the American College of Pathologists recommends examining 15 blocks of lung tissue in these cases with a minimum of 1 block per lobe, especially in subpleural and basal areas.

### *Digestion Techniques*

The next technique involves utilising the robustness of the fibres by digesting the encompassing lung tissue. This can be very useful, as not all fibres are coated in an iron-protein complex and those that are not may be invisible on routine microscopy. Digestion techniques allow these fibres to be detected and also allow quantification. For this technique standard blocks of lung tissue are taken and then weighed accurately before being exposed to sodium hypochlorite solution for digestion. The remainder of the tissue block is weighed and then dried to constant weight at 110°C to obtain a wet/dry ratio. After digestion, fat is removed by extracting with diethyl ether and the resultant suspension filtered through a Millipore membrane (0.22µm pore size). The filter is split into a sample for electron microscopy and another for phase-contrast microscopy. The latter allows measurement and counting of fibres. *Alternatively, lung tissue samples can be macerated with concentrated potassium hydroxide and the resuspended residue can be inspected directly in a Fuchs-Rosenthal counting chamber which allows the number of fibres and asbestos bodies to be counted.*

### *Electron Microscopy*

It has been shown that these light microscopic methods significantly underestimate the number of fibres that are present in a particular lung sample. If accurate quantification is required then electron microscopical analysis is necessary. Measurements are made at around ×20,000 magnification. Some of the different types of asbestos fibres can also be distinguished using X-ray diffraction analysis.

### *Environmental Lung Research Group*

In the United Kingdom it is possible to send off lung specimens (part or complete) to the Environmental Lung Research Group based at Llandough Hospital, Penarth, Wales for asbestos fibre typing and levels (as well as other fibrous minerals such as talc and silica). The findings are useful in doc-

umenting levels and therefore establishing whether occupational or just background exposure is present in any particular case. Permission will be required from the coroner and/or relatives but as the coroner should be notified of deaths associated with industrial disease, there will usually be local protocols for dealing with such cases.

### Diatom Testing in Drowning

Although this is primarily the province of forensic medicine, this tool may be of use on occasion in an attempt to establish whether a body has been immersed in water before or after death. Close cooperation and communication is needed between the mortuary and the laboratory performing the test so that appropriate samples and containers are used. The basic theory and method are briefly considered here but interpretation is not always straightforward. Whole texts have been devoted to the detail and application of this technique. The fundamental idea is to compare the diatom profile of the water in which a body has been discovered with the presence (if any) of similar diatoms in various tissues removed at post mortem.

For this method a significant sample of water is taken from the presumed drowning site and examined for diatoms. Diatoms are unicellular microscopic forms of algae covered with a wall of silica. If none are present then examination of tissue is obviously futile. Tissue samples should be taken from the lung, brain, kidney, liver, and bone marrow. Every effort should be made to avoid contamination with other tissues such as skin and gut contents, but after removing the organs, the latter are washed in a strong stream of water (tap water is said to contain much too few diatoms to cause any confusion). A decent sized block of tissue (as much as 4 cm<sup>3</sup>) should be dissected using a sterile scalpel blade, sampling from within the organ. For bone marrow the sternum is washed and cut with a saw, enabling the central marrow to be scooped out of the interior. These tissues are then sent to the laboratory for diatom analysis. This involves digestion in nitric acid, dilution centrifugation, and microscopy of the deposit produced. Identification of significant numbers of diatoms in the peripheral tissues, particularly bone marrow, indicates that death occurred after immersion in the water. The lungs should be examined first because if no diatoms are present here there will almost certainly be none in the other sites.

## Examination of the Upper Respiratory Tract

### *Nasopharynx*

Formal examination of the upper airways is often excluded from the post mortem, partly because significant pathology is infrequently found in the nose or nasopharynx and also because these are difficult areas to examine critically. Rarely a tumour arising in these areas may conceal itself but man-

ifest by metastasising widely and hence in cases where disseminated tumour is found with no obvious primary lesion, it is essential to check this location carefully. This can be done in most cases by a cursory glance from below while removing the tongue as described in Chapter 3. In others more time needs to be taken to examine this area carefully, but usually no further dissection is necessary. If further investigation is warranted then a good view of the nares and nasopharynx can be gained by chiselling off the central areas of the skull base that overly them. For an even more optimal view it may be worth considering halving the base of the skull after reflecting the skin and soft tissue further over the lower skull. A saw is then used to divide the occipital bone into two halves and then the sawing is extended anteriorly and inferiorly to separate the rest of the skull base. This is clearly potentially disfiguring and in this situation it is prudent to obtain consent from relatives before embarking on the procedure.

### *Sinuses*

The sinuses can also be inspected from above by sawing through the skull base in a manner similar to that just described. All four main groups of sinuses (frontal, ethmoidal, maxillary, and sphenoidal) can be inspected via this route. Examination of the sinuses should be performed by an experienced operator owing to the risk of seriously damaging the face of the cadaver. After removal of the brain, the skin incisions made previously are extended if necessary to allow the anterior and posterior skin flaps to be reflected as far down as possible. Next the skull base is divided in the midline by sawing with a manual or electric saw. When this division is complete, the two halves can be prised apart using a chisel or T-piece. The sinuses will be exposed and can be fully opened from the medial side. Further chiselling at the thin bone of the skull base may be required. Any pus or neoplasm needs to be removed and dealt with in the appropriate way. For infection analysis swabs should be taken and sent for microbiological study whereas tumours can be examined by sampling tissue for histology. *Alternatively one can removed the complete block of tissue using a oscillating saw and decalcifying it before sectioning and staining.* For a more rapid inspection of the sinuses, it is usually adequate to chisel away at the skull base to expose the underlying tissue and gain a limited view of the sinus cavities.

### *Larynx*

In cases in which the larynx is a major site of interest the larynx and trachea should be removed in the usual way but left intact for more detailed examination rather than opened posteriorly in the manner described previously. Examination follows the same principles as those used for dissection of a surgical laryngectomy specimen in the dissection room but obviously the margins are not of the same importance. The first stage is to cut through

the larynx by a midline posterior approach. This will expose the mucosal surface of the anterior structures. The larynx can then be cracked open by breaking the hyoid bone and thyroid cartilages by lateral pressure using both thumbs. The epiglottis and other supraglottic structures, vocal cords and glottis, and subglottis are inspected and the lesion of interest identified. Note the size, macroscopic appearance, and location of the lesion. Slice through the lesion with a scalpel and assess the depth of invasion and any infiltration of surrounding tissues. Assuming consent has been obtained, take longitudinal blocks for histological examination. The blocks may well need to be decalcified prior to sectioning (as described on p. 255). Local lymph nodes that may be involved should also be examined and, if appropriate, blocked for histology.

*If the larynx and local cartilages are very calcified it is worth considering decalcifying the whole larynx before it is examined. Following the same protocol as that described earlier, slices can be made for macroscopic and microscopic examination and any direct bony infiltration identified more easily in continuity with the lesion. It also allows full-thickness slices and blocks to be made without distortion from difficulty in slicing through hard, calcified tissues.*

Examination of the respiratory system is summarised as follows:

- Check for a pneumothorax.
- Collect pleural fluid if present.
- Check for a thromboembolus.
- Weigh and inspect the lungs.
- Dissect the airways.
- Dissect the vessels.
- Slice the lobes.
- Massage and inspect the cut surface.
- Use special techniques as necessary.

## References

1. Ashcroft T, Heppleston AG. The optical and electron microscopic determination of pulmonary asbestos fibre concentration and its relation to the human pathological reaction. *J Clin Pathol* 1973;26:224–234.
2. Gold C. Asbestos levels in human lungs. *J Clin Pathol* 1969;22:507.
3. Ludwig J. Current methods of autopsy practice, 2nd edit. Philadelphia: WB Saunders, 1979.
4. McCulloch TA, Ruttly GN. Postmortem examination of the lungs: a preservation technique for opening the bronchi and pulmonary arteries individually without transection problems. *J Clin Pathol* 1998;51:163–166.
5. Roberts GH. Asbestos bodies in lungs at necropsy. *J Clin Pathol* 1967;20:570–573.
6. Zanen-Lim OG, Zanen HC. Postmortem bacteriology of the lung by printculture of frozen tissue. *J Clin Pathol* 1980;33:474–480.

# 7

## The Gastrointestinal System

For the purposes of this chapter, the gastrointestinal system extends from the mouth to the anus and includes all local associated and integrated structures such as the salivary glands, liver, gallbladder, and pancreas. The en masse technique of dissection will obviously include all of these organs, and their separation should follow the method described in Chapter 2. Following the block removal method of evisceration, these structures will be present in all of the four main organ blocks with the submandibular salivary glands, tongue, and part of the pharynx and oesophagus in the thoracic block; the stomach, proximal small bowel, liver, gallbladder, and pancreas in the coeliac block; and the lower rectum with the pelvic organs. Of course the majority of the intestines will have been removed as a separate block. Once isolated from each other as described in the block dissection section of Chapter 2, the individual organs can be dissected as described in this chapter. Special techniques pertaining to the gastrointestinal tract are also described in the relevant sections. This chapter therefore covers:

- Routine examination of the intestines
- Special techniques used in assessment of the intestines
- Routine examination of the liver
- Special techniques used in assessment of the liver
- Examination of the transplanted liver
- Routine dissection of the pancreas
- Special techniques used in assessment of the pancreas
- Detailed examination of the oropharynx
- Detailed examination of the salivary glands
- Detailed examination of the oesophagus
- Detailed examination of the stomach
- Examination of the mesentery
- Other varied special techniques relevant to the gastrointestinal tract



## The Small and Large Intestines

### *External Examination*

In the majority of the evisceration procedures, the intestines (with or without attached mesentery) are isolated very simply, and this particular part of the post mortem dissection is usually extremely straightforward. The external surface should be inspected from jejunum to rectum during evisceration and reexamined when isolated.

### *Internal Examination*

Routinely, when no significant intestinal pathology is expected, the internal aspect is examined by opening the intestines along the antimesenteric border with bowel scissors in a sink or sluice (Fig. 7.1). One of the arms of the blades of bowel scissors has a hooked end to stop the bowel from sliding off during opening. The intestines are opened in a sink to keep the dissecting area clean and to allow easy disposal of the intestinal contents. This part of the gastrointestinal tract can be opened from the sigmoid/rectum proximally or the duodenum/jejunum distally. However, if a local mass lesion is present it is sensible to start away from any area of interest and work toward it. If a localised mass or tumour is present it should be assessed as for a routine surgical excision specimen. Slices are made through the mass to identify the cause. Diverticula may be observed. With a tumour, full-thickness slices will determine the depth of invasion and help to visualise lymph node metastases. Histological samples are taken if permission is available (see later).

### *Histology of the Intestines*

As with many other regions of the gastrointestinal tract, blocks are not routinely taken for histology because there is usually considerable autolysis of the mucosa and significant abnormality here is seldom particularly relevant to the cause of death. As with other sites (if permission is granted) it does no harm to take a random full-thickness block of tissue from the large and small bowels without necessarily processing these for histological examination. With more extensive intrainestinal pathology such as inflammatory bowel disease, microscopic assessment of the precise areas of abnormality can be documented by blocking the bowel in rolls of tissue. In this way several inches of intestine can be examined in one microscopic section and areas of dysplasia mapped out. When a tumour is present the situation is different and blocks of tumour and uninvolved bowel, together with lymph nodes, are appropriate as with any colorectal cancer received in the surgical dissection room. As described later, this is often made easier by pinning the relevant part of the bowel out on a cork board prior to fixation.



FIGURE 7.1. The intestines are opened along the antimesenteric border with appropriate bowel scissors that have a blunt hook on one blade. It is wise to perform this procedure over the sink to avoid contaminating the dissection area. (Courtesy of Mr. Ivor Northey.)

### *Special Techniques for the Intestines*

#### Collection of Intestinal Contents

Occasionally, a sample of stool is required for microbiological analysis (such as gastroenteritis/colitis caused by an organism that has not previously been isolated and documented). Early in the examination, a segment of bowel, either small or large intestine or both, approximately 5 to 6 cm in length, is removed after both ends are closed off with ties in order to contain the luminal contents. At this point either the entire specimen can be sent or the contents can be collected after one of the ties is divided and then sent in a suitable sealed sterile container.

Rarely, the whole small intestinal contents are required for chemical or microscopic analysis. This may be useful in paediatric post mortems when the possibility of an inborn error of metabolism exists. In this case the jejunum is routinely tied off at its proximal end, but a second tie is made at the ileocaecal junction. The bowel is then transected and the whole small bowel specimen sent with the contents still in place. It is also unusual for the contents of the large intestine to require analysis but this may be necessary in cases of suspected heavy metal poisoning. The caecum and distal sigmoid/rectum are the regions tied in the same way as that described earlier and transected should this be necessary.

#### Preservation of the Gastrointestinal Tract Mucosa

There is usually no particular concern over autolysis of the gastrointestinal tract mucosa, as major pathology here is rarely the sole cause of death. There are, however, instances in which preservation of small bowel mucosa is valuable (and occasionally invaluable), such as documentation of coeliac disease and its complications or other malabsorption syndromes. In the large bowel this may be required for establishing the underlying cause of a severe colitis such as inflammatory bowel disease or pseudomembranous colitis. In such cases it may be prudent to infuse formalin into the tract to counteract autolysis. The protocol for preservation of the gastrointestinal mucosa is as follows:

1. Tie the small bowel at the duodenal–jejunal junction as usual but also at the distal terminal ileum just proximal to the ileocaecal valve.
2. Cannulate a loop of small bowel.
3. Introduce formalin until the bowel is just distended (approximately 40 cm of water pressure; care must be taken with monitoring of formalin vapour/fumes to keep below the upper limit of government guidelines).
4. Leave for several hours.
5. Soak in 10% formalin for a further 24 hours.

For optimal results this technique must be employed within 6 hours of death.

#### Perfusion Fixation of Tumours

A similar method of perfusion using 10% formalin can be used to fix tumours in situ and therefore aid demonstration and subsequent dissection. The bowel should be tied distal to the tumour and formalin infused. The specimen is then placed in a bath of formalin. When the bowel is opened after approximately 24 hours, the formalin should be collected in an appropriate waste disposal area.

#### Fixation of Tumour in Bowel Already Opened

If it is obvious where the tumour lies then a method similar to that used for routine surgical intestinal cancer cases should be considered. This

involves removing the lesion and surrounding local normal bowel rather as a surgical resection specimen would be received. The segment of bowel can be opened along the border opposite the tumour (if possible) with scissors. The bowel is laid open and pinned out on a cork board which is then placed upside down in a formalin bath for fixation prior to sampling tissue for histology.

### Dissecting Microscopy

Adequate preservation will allow assessment of small bowel mucosal disease using a dissecting microscope which will give a reasonable indication of the villous architecture and morphology. Histology is clearly essential to confirm the findings microscopically.

### *Radiography of the Bowel*

When fistulae or diverticula are a significant factor in the post mortem and demonstration is desired, a technique of barium contrast radiology or India ink introduction similar to that used in the radiology department or operating theatre should be considered. Barium is generally more appropriate for larger lesions, and India ink for more localised pathology.

## The Liver

### *External Examination*

The normal liver weighs approximately 1300 to 1500 g in an adult. With significant hepatic pathology there is a large variation, however, with inflammatory, metabolic, or neoplastic processes often causing hepatomegaly, but fibrotic conditions such as cirrhosis are associated with a smaller shrunken organ. A useful clue to the presence of metastatic tumour deposition is the presence of numerous nodules within the liver manifest by a nobbly surface. The individual nodules vary in size and because they become centrally necrotic they appear umbilicated, that is, the central part of the nodule is depressed leaving the surrounding area raised above the inner crater.

### *Internal Examination*

The liver is usually one of the more elementary organs to dissect. A series of parallel vertical slices are made as close as possible (approximately 1 to 2 cm apart) from one side of the liver to the other. A large-bladed knife is essential and sweeping slices are made with a complete uninterrupted pulling motion through the full thickness of the parenchyma (Fig. 7.2). In this way the cut surface can be inspected for localised masses not apparent externally, diffuse parenchymal disease, or cysts. Some advocate sliding the liver in a horizontal manner starting with the equator of the organ (partic-



FIGURE 7.2. The liver is sliced with a “brain knife” at 1-cm intervals and the cut surface inspected. (Courtesy of Mr. Dean Jansen, Whittington Hospital.)

ularly if following Virchow’s method of evisceration). There is no real problem with this as long as the subsequent parallel slices are made at close (1 to 2 cm) distances from the primary slice, being careful to keep the non-cutting blade away from the blade. It is possible to perfusion-fix the whole organ with formalin prior to dissection but this is extremely difficult and not recommended.

### *Histology of the Liver*

It is recommended that a routine block is taken from the liver in every post mortem examination if consent allows. If histology is required but there is no focal or diffuse abnormality on the cut surface then a single subcapsular sample of the usual size (approximately  $3 \times 2 \times 0.4$  cm) is generally sufficient. With focal hepatic lesions, however, blocks of the relevant areas should be taken. With diffuse pathological processes that might require more extensive histochemical or immunohistochemical workup such as tumours, hepatitis, or cirrhosis, several blocks of tissue should be sampled and the appropriate special stains employed (see later).

## *Special Techniques for the Liver*

### Sampling Hepatic Tissue for Microbiology or Biochemistry

As described previously, if liver tissue is required for chemical or microbiological investigation then a piece of tissue is removed early in the course of the post mortem examination and when toxic, metabolic, or enzyme studies are necessary a 2-cm<sup>3</sup> sample of liver tissue is immediately frozen for subsequent analysis. The amount of iron within the liver can be formally quantified by sending a piece of liver to the chemical pathology laboratory for analysis.

Rarely, it may be important to keep larger pieces of liver tissue or even the whole organ for examination. Occasionally it is necessary to retain liver tissue for analysis of toxic substances. This may be relevant in cases of poisoning, as many toxic substances are concentrated or stored in the liver. Either the bulk of the liver or a substantial part of it should be sent to the relevant laboratory with weights recorded and the appropriate request forms completed.

### Radiography of the Liver

For hepatic angiography and cholangiography the liver needs to be removed with the diaphragm, hepaticoduodenal ligament, and inferior vena cava. Depending on which vascular compartment or biliary system is being studied, the artery, vein, or common bile duct is cannulated and a barium sulphate–gelatin mixture injected. Of course both vascular compartments can be demonstrated simultaneously by injecting India ink and a carmine–gelatin mixture into each vessel of the ligament and the result inspected microscopically. In addition, corrosion or latex casts can be made of the hepatic vessels by injecting mixtures of vinylite or neoprene latex followed by fixation in acidic formalin solution followed by hydrochloric acid digestion of the hepatic parenchyma, although extreme care is obviously required when performing such techniques which clearly produce museum-type specimens.

### Demonstration of Hepatic Iron

A useful gross stain, especially in cases of haemochromatosis, is the Perl stain. This is detailed in Chapter 13, but in brief, a thin slice of liver 3 to 4 mm deep is placed in potassium ferrocyanide (1% to 5% solution) for approximately 5 minutes and then transferred to a 2% solution of hydrochloric acid for a further 5 minutes (or a mixture of 10% hydrochloric acid and 5% aqueous potassium ferrocyanide for 10 minutes). Then the tissue slice is washed in running water for up to 12 hours. Iron is demonstrated by the tissue turning blue as a result of Perl's Prussian blue reaction (ferrous ions becoming ferric).

### Demonstration of Hepatic Amyloid

Amyloid can be demonstrated macroscopically during the examination using a technique similar to that described using Lugol's iodine in the section on the kidney in Chapter 8. Immunohistochemistry may again be helpful microscopically in determining the amyloid type.

### *Liver Transplantation*

Liver transplants are becoming more common and occasionally post mortem is required in such patients away from their specialist liver transplant unit. In such cases it is worth considering sending the cadaver or at least the whole organ to that specialist centre for investigation. It is likely that the personnel at the centre would welcome such an approach. It is often useful to at least contact the centre and speak to the clinician or the pathologist before proceeding with the post mortem to get an idea of exactly what should be looked for and how the examination should be conducted.

If the examination does proceed locally then the routine examination is followed but as with all other transplant situations, particular attention must be made to the vascular and biliary anastomoses and infective and neoplastic complications specifically searched for. It should be remembered that the organ is often cut down to an appropriate size before it is transplanted into the recipient and if this is the case a rather ragged surface will be encountered. The biliary and vascular anastomoses should be inspected and the integrity of these checked before proceeding with further dissection. The liver itself can be removed in much the usual way, although there will obviously be no attached gallbladder and the bile duct will insert directly into the duodenum/small bowel.

Extensive blocks should be taken for histology including all anastomosis sites and parenchymal areas. Special stains for opportunistic infections should be considered in every case. In addition, fresh tissue should be sent for microbiological examination including virology. If problems arise in interpretation of the histological appearances, referral to a more experienced expert should definitely be considered.

### Pancreas

The pancreas, a retroperitoneal organ with both exocrine and endocrine functions, weighs approximately 100 g in an adult. The pancreas can be opened in several ways: by cutting along the main pancreatic duct from the ampullary zone toward the tail with small scissors (or alternatively from the tail toward the head after slicing across the distal tail to localise the duct here), by making a series of parallel sagittal slices from one end to the other,

or by making one full-thickness slice in frontal plane to demonstrate the parenchyma. When a pancreatic mass is present then the abdominal contents should be removed together and subsequently dissected as detailed later.

### *Histology of the Pancreas*

A routine block from the pancreas is usually sampled from the pancreatic tail because this region contains more islets. Tumours should be sampled for histology (three blocks) together with any local tissues that are infiltrated and any involved lymph nodes.

### *Special Techniques for the Pancreas*

#### Radiography of the Pancreas

Pancreatography can be performed as part of the complete biliary and pancreatic tree (described earlier) or on the isolated pancreas. Contrast or Indian ink is introduced into the ampulla before an X-ray film is taken or the specimen sliced. The technique for performing pancreatic arteriogram is included in the angiography of the coeliac axis described later.

### *Other Special Techniques*

#### Examination of the Oropharynx

Assessment of the oropharyngeal area is obviously performed mostly during the general evisceration stages as an inspection exercise and at that time one should have a good understanding of whether this area warrants further dissection. Rarely pharyngeal tumours will be encountered. Cases with widespread metastases from an unknown primary tumour site warrant formal examination of the oropharynx to exclude origin from this region. The pharynx is inspected from below during evisceration and the oral cavity is inspected through the mouth.

#### More Detailed Examination of the Oropharynx

If further investigation is warranted then a good view of the nasopharynx can be gained by chiselling off the central areas of the skull base that overlie it. Usually this is all that will be required to exclude a nasopharyngeal lesion. A more panoramic view can be obtained by halving the base of the skull with a saw after the brain has been removed. This is achieved by dividing the occipital bone into two halves (after reflecting the skin and external soft tissue further over the lower borders of the skull). The saw strokes are made in a coronal plane. Sawing is extended anteriorly and inferiorly to separate the rest of the skull base. The two sides are manually prised



apart and the nasopharynx inspected. Any soft tissue of interest can be sampled or removed for microbiology or histological examination. Much care is clearly required in order to preserve most of the structural tissue and avoid difficulties with reconstruction.

### Detailed Examination of the Salivary Glands

The weights of the normal salivary glands are approximately as follows: parotid, 25 g; sublingual, 3 to 4 g (about almond size); and submandibular, 6 to 7 g (about walnut size). The glands will have been individualised following the instructions given in Chapter 2 and will usually require no further attention. Occasionally, however, one or all of the glands will need assessment in more depth.

### Isolating the Salivary Glands

The submandibular salivary glands are the easiest to assess, as these will have been removed with the thoracic block and lie peripheral in this tissue, making isolation from the rest of this block straightforward. The sublingual glands will require careful dissection of the soft tissue bilaterally on either side of the frenulum. The most awkward glands to isolate are the parotid glands, which require a method of dissection similar to that used for examination of the face. The latter involves retracting the skin superiorly over the face by extremely careful dissection along the soft tissue plane beneath the dermis (which is extremely shallow over the face) and above the subcutaneous tissue, exactly like the method used for demonstration and examination of facial skull fractures. The latter requires considerable finesse as the neck incision is retracted firmly by gripping with the free hand while delicate scalpel slices are made either parallel to or away from the epidermal surface with the other. As mentioned, this is rarely necessary but is more often used in forensic examinations and is especially useful for demonstrating facial fractures. Once the skin is retracted the parotid gland or glands will be visible and dissection can proceed by cutting through the adjacent surrounding soft tissues without the surgical complication of facial nerve palsy.

### Radiology of the Salivary Glands

When stones are present or a central ductal tumour is suspected or expected then radiological demonstration of this prior to dissection may be considered. A sialogram can be performed relatively easily either in situ or after removal of the individual glands once the main salivary duct is identified. A barium sulphate solution is made up and introduced via a cannula into the duct and X-ray films are taken. *Introduction of Indian ink is an alternative, followed by slicing at 2- to 3-mm intervals in order to trace the route of the duct system.*

### Assessment of Salivary Gland Tumours

Tumours are dissected in a fashion similar to that described earlier, but for histology at least three blocks should be taken from the tumour and local (cervical and related) lymph nodes assessed and blocked if necessary. With more invasive or extensive tumours obviously the dissection needs to encompass the surrounding tissues before the lesion is sliced and assessed. For routine cases blocks are not particularly relevant, but for tumours, histology may be required to type the tumour and assess nodal metastases.

### Demonstrating Oesophageal Webs and Rings

The routine method of cutting the posterior wall of the oesophagus with scissors from the pharynx down to the oesophagogastric junction will of course have to be abandoned if masses or more unusual pathology such as rings and webs are to be demonstrated adequately. Such lesions and strictures may be demonstrated radiographically but the latter needs to be considered early in the examination to avoid destruction during evisceration. The lesions can be demonstrated by tying off the proximal oesophagus and introducing a mixture of barium sulphate and 10% formalin after clamping across the upper stomach. X-ray films of the oesophagus will identify the ring or any other stricture that may be present. Achalasia can be demonstrated using the same method. Even without radiology tracheo-oesophageal fistulae can be demonstrated relatively easily. The trachea is opened anteriorly and the inner mucosal surface inspected. A probe or Indian ink is introduced into the lumen of the fistula and the track demonstrated.

### Demonstration of Oesophageal Varices

As has been stressed previously, in cases in which portal hypertension is suspected or expected, the majority of the oesophagus should be removed with the stomach in order to evert the oesophagus and identify varices that may be present and that would easily be overlooked if the lower oesophagus was transected in the routine way (and hence varices collapse). When varices are present, and the stomach and oesophagus have been everted, these can be injected by introducing a needle attached to an air hose into one of the veins and a barium sulphate-gelatin mixture injected through the same needle. This aids demonstration of any small bleeding points that may be present that would otherwise be impossible to see. Other clues found early during the post mortem examination such as ascites and an enlarged spleen may increase the suspicion of portal hypertension.

### Examination of an Infiltrative Oesophageal Mass

With more extensive oesophageal masses, more thorough and accurate assessment may be made following the mediastinal mass dissection tech-

nique outlined in Chapter 10 (see p. 257). Oesophageal tumours that infiltrate local structures are best demonstrated in this way by leaving the mediastinum intact and possibly slicing after fixation. Blocks (at least three) should be taken from any oesophageal mass in the same manner as for routine surgical cases. Lymph nodes should also be assessed and sampled if necessary.

## *Assessment of Gastric Lesions*

### Collecting Gastric Contents

Occasionally it may be necessary to retain the contents of the stomach for chemical analysis. The most rapid method for collecting these is to wash the outer surface of the stomach and move the stomach and attached tissue/organs to the border of the cutting board so that the greater curve hangs over the edge. The greater curve should be incised with care and the contents collected cleanly as they flow out. Any contents remaining can be removed by extending the initial incision along the greater curve and scooping out any solid material such as tablets with a scoop or the back of a knife. More rarely the complete stomach may be sent to the laboratory for analysis to assess any small or trace amounts of a substance that may be adherent to the gastric wall. This is easily done by tying off both the pyloric and oesophageal ends of the stomach with two ties each and then cutting between the double ties to isolate the stomach.

### Fixation of the Coeliac Block

In the standard post mortem the stomach is usually removed in continuity with the lower oesophagus and duodenum and is usually opened with large scissors along the greater curve once all of the surrounding organs have been removed. If a tumour or reasonably sized ulcer is either identified at post mortem or is suggested from the clinical history the best way to assess their extent is to take blocks for histology. If the mass is extensive and invades local structures then it may be more appropriate to fix the coeliac block or stomach, pancreas, liver, and any infiltrated tissue complete and slice through this large tissue mass either before or after fixation rather as described later for a more extensive abdominal mass. If indeed the gastric tumour is more extensive and infiltrates tissue more widely then the latter method should be used from the outset.

### Fixing the Stomach Whole

A similar approach can be followed in cases of upper gastrointestinal bleeding when the source is likely to be the stomach. Once again this needs to be considered early during the post mortem procedure before the anatomy might be destroyed by reckless or thoughtless incisions. It is also possible

to inflate the stomach prior to fixation using an apparatus similar to that used for inflating the lungs. This may be useful when special care needs to be taken with the specimen, for example, if it will become a museum piece.

### Angiography of the Stomach

Gastric angiography may sometimes be useful, particularly for demonstrating vascular malformations such as Delafiouy's anomaly, vascular ectasia, and bleeding points which would otherwise easily be missed when dissecting the stomach in the routine way (and which may extremely relevant to the cause of death). Clinical history may have revealed haematemesis and/or malaena. During evisceration an indication of upper gastrointestinal haemorrhage may be suggested by finding blood in the small bowel or altered blood in the large intestine. For angiography, first the splenic and hepatic arteries need to be tied off distally and a barium mixture similar to that described previously is injected through the coeliac artery, which is also tied. The stomach is then opened along the anterior wall and laid flat rather like a book. X-ray films are taken and the vascular component of the stomach demonstrated. Once again India ink is another possibility but this can be extremely messy and may in fact mask any potential bleeding site if it spills significantly.

### Histology of the Stomach

Routine blocks from the stomach for histology rarely reveal any significant abnormality as there will always be a degree of mucosal autolysis because of the presence of gastric juices. A single full-thickness block from the pylorus approximately  $2.5 \times 2 \times 0.4$  cm may be taken in a routine examination. In the case of tumours or ulcers, several blocks need to be taken (assuming consent has been obtained), especially from the periphery and deeper tissues. It is not unusual for the post mortem examination to reveal a gastric ulcer and a positive diagnosis of peptic ulcer disease to be made or an ulcerated neoplasm confirmed. Local lymph nodes require histological assessment also. Here again it is wise to sample generously and retain enough tissue to be confident of arriving at a definite answer; all of the tissue does not have to be processed and examined histologically, but it is impossible to go back to the cremated body and sample more tissue! When pernicious anaemia is likely, a block needs to be sampled from the body to confirm glandular atrophy and a chronic inflammatory cell infiltrate, but the latter may be difficult owing to the autodigestive effects of the gastric luminal contents on the mucosa.

### *Examination of the Mesentery*

As discussed in Chapter 2, it is very unusual for the mesentery to harbour any significant pathology relevant to the ultimate cause of death and there-

fore it is usually not kept with the intestine but separated at the evisceration stage and discarded. Sometimes, however, this structure is of interest and further examination will be required, such as in mesenteric lymphadenopathy, ischaemic bowel disease, or mesenteric vasculitis. It is also helpful to have an attached intact mesentery to perform angiography in order to demonstrate vascular malformations, especially angiodysplasia.

### Mesenteric Angiography

For mesenteric angiography it may be useful to prepare the bowel with an anti-autolytic chemical first as described earlier. Angiography will obviously need to be performed *in situ* or with this part of the gastrointestinal tract intact and will require an *en bloc* or *en masse* method of evisceration. The basic idea is to cannulate the coeliac, superior mesenteric, and inferior mesenteric arteries and to inject the barium–sulphate–gelatin mixture into these vessels with added formalin. They are perfused to a pressure of approximately 200 mmHg. This block of tissue is then separated into three parts by first dissecting the root of the superior mesenteric artery and first branch of the jejunal artery with the upper abdominal organs followed by tying the hepatic and splenic arteries with removal of the liver and spleen. The superior mesenteric artery section then consists of the intestine from the first jejunal loop to the midportion of the transverse colon. The third inferior mesenteric specimen includes the distal transverse colon and the remaining large intestine with pelvic organs if attached. X-ray films should be taken of each. *Alternatively, latex can be injected through the cannulae to make a vascular cast or India ink can be introduced to visualise the vascular tree directly.* The mesenteric vessels are then dissected starting proximally and extending as far distally as possible. As with other vessel dissections, this can be done using medium and small sized scissors and cutting along the length or by making a series of transverse cuts approximately 2 to 3 mm apart.

### *Other Special Techniques*

#### Collection of Bile

Occasionally collection of bile is required for toxicological analysis, for example, in overdose or forensic cases in which morphine or largactil poisoning is implicated. The gallbladder is dissected from the adjacent liver as described and bile is squeezed into a sterile container. *Alternatively, bile can be removed with a syringe (with or without an attached needle).* It is always wise to open the gallbladder over a strainer in order to collect any stones or sludge present. Opening involves using small sized scissors to cut along a border from the cystic duct peripherally or simply opening the gallbladder wall with a scalpel.

### Demonstration of Fat Necrosis

In the case of pancreatic inflammatory disease, the associated fat necrosis can be demonstrated by bathing a piece of the relevant tissue in (concentrated) copper acetate solution in an incubator for 24 hours (or several days at room temperature). In the presence of fat necrosis the tissue turns blue-green.

### *Examination of Widespread Intraabdominal Disease*

In the presence of peritonitis, generalised intraperitoneal tumour, or an extensive retroperitoneal mass it is essential to remove the abdominal contents en masse following either Letulle's method of evisceration or a modified Ghon approach prior to block and organ dissection. A similar situation is encountered after abdominal surgery in the case of widespread adhesions. In these situations it will often be difficult to examine the abdominal organs in the usual way, and Culora and Roche have described a method for gaining the maximum information possible after abdominal surgery [1]. With post surgical cases, it is particularly important to rule out vascular thrombosis and leaking anastomoses, especially around the hepatobiliary system, after laparoscopic surgery.

As mentioned, Letulle's en masse technique of evisceration is recommended, with dissection and clamping of cutaneous stomas, and then a retroperitoneal approach is used to dissect the abdominal organs in layers. In this way the problems of old adhesions, infection, or extensive peritoneal metastases may be dealt with. *One can of course fix the complete organ block for subsequent serial sectioning, but demonstration of anatomical relationships is often obscured by this method. It is also difficult to dissect out structures such as vessels after dissection and the organ block is rather bulky to handle.*

After evisceration the organs are placed face down on the dissecting table. The oesophagus is opened through its posterior wall or left in continuity with the stomach as described in the general evisceration chapter if lower oesophageal pathology is suspected. The oesophagus should be tied or clamped to stop gastric contents from spilling out. The thoracic organs can be dissected free and examined in the usual way. The abdominal block is now dissected from its posterior aspect. First, the aorta and vena cava are identified and opened and the lumina and main ostia examined. The kidneys, adrenals, and ureters are then identified in the usual manner and either dissected free from the block individually or left in continuity with the bladder by reflecting them over the iliac vessels. The next stage is to identify the porta hepatis and open the portal venous system. At this time the splenic vein is opened and followed to the spleen, which can then be removed for dissection. The common hepatic artery is traced and dissected

from the coeliac axis, followed by the splenic artery. Now the biliary tree can be dissected by identifying the common bile duct next to the hepatic artery.

The pancreatic duct is now opened by extending the dissection of the common bile duct and the pancreas examined. The aorta is again identified and the superior mesenteric artery opened and examined. The oesophagus, stomach, and duodenum can now be examined from behind. This leaves the bowel together with adhesions, which should be examined for perforations. If necessary water can be introduced into the bowel lumen to facilitate opening. If this is not possible then slices can be made across the bowel in a coronal plane to inspect the lumen.

At any time during this procedure the technique can be slightly altered to best demonstrate the local pathology and assess the extent of disease if surrounding tissues are involved. If a significantly large mass is identified then the preceding method should be modified so that the normal structures are dissected free, leaving the area of interest for more thorough examination. For example, if a pancreatic mass is present then the urogenital tract can be examined and removed, followed by the spleen, intestines, and pelvic organs. The pancreas and peripancreatic tissue can then be examined in isolation either by slicing across the tissue mass with a large-bladed knife, or by dissecting all of the neighbouring organs from their peripheral regions toward the main mass.

Similarly if a large renal tumour is present the uninvolved anterior gastrointestinal organs and contralateral and inferior urinary tract structures should likewise be dissected away to leave the kidney and locally involved organs for examination. Blocks should be taken from any mass and infiltrated organs as described in Chapter 13. It will be noticed that the principles of dissection here are essentially the same as those described elsewhere for both a mediastinal mass (Chapter 10) and a pelvic mass (Chapter 8) and any intraperitoneal or retroperitoneal mass can be dissected and demonstrated with confidence.

### *Dissection of Rectal Masses*

In the case of rectal lesions it is probably best to remove the pelvic organs as a group and dissect as described in the section that discusses dissection of a pelvic mass in Chapter 8 (see p. 226). With very low rectal tumours the anal skin may need to be removed with the tumour following the procedure for that of an abdominoperineal resection of a cancer in a surgical patient. The rectal part of the dissection should follow a similar method as for any pelvic mass, but to excise the relevant part of the anus, the lower part of this block should be dissected from below, preferably with the body in a lithotomy position. This allows direct vision of the anus and a neat incision of the skin and subcutaneous tissue to meet the intrapelvic dissection plane. A neat incision is necessary in order to make reconstruction as

straightforward a procedure as possible. Once removed, the block is dissected in the same manner as described for any pelvic mass.

Examination of the gastrointestinal tract is summarised as follows:

- The salivary glands and nasopharynx are examined during evisceration.
- The oesophagus is opened during block dissection/evisceration.
- The stomach and duodenum are opened during evisceration or block dissection. (Contents are collected if required.)
- The mesentery is inspected during evisceration.
- The intestines are opened in the sink.
- The rectum is removed and opened.
- The liver is removed and sliced.
- The gallbladder is opened, the contents are collected, and internal aspects are inspected.
- The pancreas is isolated and sliced.
- Special techniques are performed as required.

### *Reference*

1. Culora GA, Roche WR. Simple method for necropsy dissection of the abdominal organs after abdominal surgery. *J Clin Pathol* 1996;49:776–779.



# 8

## The Genitourinary System

The methods and details for investigation of the urogenital organs will clearly depend on the gender of the patient. As mentioned in Chapter 3, for demonstration purposes it is desirable, although rarely crucial, to keep the urological tract intact and in the male this includes the prostate, seminal vesicles, and testes. In the female the uterus, fallopian tubes, and ovaries are connected. When in continuity, the urinary tract in both sexes will include kidneys, ureters, and bladder. Removing the tract complete allows optimal demonstration of retrograde effects of more distal pathology such as the effects of an obstructing pelvic tumour (e.g., cervical carcinoma) causing bilateral hydronephrosis. After demonstration, however, the appropriate block dissection method should be followed as outlined in Chapter 3, and all of these organs will be separated and organ dissection can follow.

As mentioned previously, the autopsy in cases of maternal death necessitates a slightly different approach and this extends to a few special techniques that are described in detail in this chapter. This alteration in approach is predominantly intellectual in that it involves increased preparation and an appropriate degree of awareness before the practical procedures begin. This includes devoting time to speak to clinicians and other professionals involved in the deceased's care and finding out exactly what questions need to be answered (or attempted to be answered) by the post mortem examination. For the most part, however, the examination follows the routine course and a thorough technique, both preparatory and practical, should identify all relevant pathological features that are present in any given case. The chapter includes:

- Routine dissection of the kidneys
- Special techniques used in assessing kidney disease
- Assessment of the transplanted kidney
- Routine dissection of the generative organs
- Special techniques used in assessment of the generative organs
- The post mortem assessment of maternal death

## The Kidneys

### *External Examination of the Kidneys*

A normal adult kidney measures approximately  $11 \times 6 \times 3$  cm, although a wide range is seen depending on age, gender, and presence of disease. In men the adult kidney weighs approximately 150 g and slightly less in women. Dissection and demonstration is usually straightforward if the method described in Chapter 3 is followed. As discussed, occasionally it may be difficult to identify chronically diseased atrophic kidneys but close attention to the expected anatomical area with histology of the apparent soft tissue at that site will usually identify at least some residual parenchyma. If both are atrophic there will be a history of chronic renal failure. If one is atrophic the other may be hypertrophic. Rarely there may be congenital absence of a kidney but this is usually associated with contralateral hypertrophy. All surrounding fat should be cleared away before weighing and sometimes this can be a lengthy process, particularly with chronic parenchymal disease associated with capsular fibrosis and the presence of multiple benign cortical cysts.

### *Internal Inspection of the Kidneys*

Once the kidney is isolated, dissection is relatively simple but beware cortical cysts, which are extremely common and may lead to unexpected showers! A longitudinal, sagittal slice is made with a large-bladed knife, such as the brain knife, through the kidney from the convexity toward the hilum. This can be achieved by holding the kidney firmly, flat on the dissecting board, under a sponge anchored with the noncutting hand while the blade is drawn across the kidney in the site described (Fig. 8.1).

*Alternatively, the kidney can be grasped between the arms of a large pair of forceps with the hilar surface face down on the dissection table or board and the peripheral surface uppermost. The blade of the knife can be carefully positioned in the angle of the forceps with the blade inferior and a slice made with a downwards movement toward the hilum and dissecting board.*

This will demonstrate the parenchyma very easily and an assessment of the cortical and medullary areas and boundaries can easily be made. The slice is extended to the pelvis of the ureter so that the papillae and urothelial surfaces of the pelvices can also be inspected. The hilar vessels can be inspected at this time. Any mass or material within the kidney or pelvis can be easily recognised and sampled as appropriate. Stones should be removed and their size and quality noted. Associated findings should also be noted such as xanthogranulomatous pyelonephritis related to staghorn calculi.



FIGURE 8.1. The renal parenchyma is inspected by carefully selecting a single slice through the lateral border of each kidney from convexity toward the hilum. The subcapsular surface should be examined by stripping the capsule away at the cut surface with forceps. This is shown together in this photograph but usually will be performed with an isolated kidney, the capsule stripped after the initial longitudinal slice is made. (Courtesy of Mr. Ivor Northey.)

### Inspection of the Subcapsular Surface

Next, the capsule of the kidney should be grasped with toothed forceps where the previous incision has been made and the capsule lifted off the outer cortex and stripped back to reveal the subcapsular surface (Fig. 8.1). In a normal kidney this should be relatively smooth although persistence of fetal lobulation is a common insignificant finding. With chronic renal parenchymal disease such as chronic glomerulonephritis, various forms of nephrosclerosis, ischaemia, or infection there may be fine or coarse scars associated with capsular fibrosis and these will be seen easily and result in difficulty peeling the capsule.

Routine dissection of the kidney is summarised as follows:

- Remove the surrounding fat.
- Slice through the convexity in a sagittal direction.
- Strip the capsule.
- Inspect the cortex and medulla.
- Take blocks for histology if required.
- Perform special techniques as required.

## *Histology of the Kidneys*

Blocks for histology should be taken from areas of interest provided consent has been given. If there are no focal lesions, tissue blocks should be taken from each pole and the midzone to include cortex and medulla on each side. This may appear excessive, but all tissue retained does not necessarily need to be processed for microscopy and usually one block from each kidney will suffice. To identify which side or sample is which in retrospect, different shaped pieces can be produced for the different sides and sites (as discussed in Chapter 13). Many of the special techniques that may be necessary in characterising renal diseases histologically such as immunomethods and electron microscopy are also described in Chapter 13.

## *Special Techniques Used in the Dissection of the Kidneys*

### Examination of Kidneys Containing Tumours

Renal tumours will be visualised and demonstrated as described earlier, but if the mass is extremely large, and particularly if it invades perinephric tissue, it may be more appropriate to remove the abdominal contents en masse and dissect this block of tissue as if the case were a post operative abdominal case as described in Chapter 7 (p. 211). When dealing with renal tumours at post mortem similar principles apply as for surgical specimens in that adequate inspection of renal vein is warranted with sampling in order to identify vascular invasion which is a common feature of these tumours. Several blocks of the renal lesion (at least three) should be sampled together with any infiltrated structures or involved lymph nodes. It is recommended that the renal vein be assessed histologically in cases of renal cell carcinoma.

### Radiography of the Urinary Tract

Although in the majority of routine practice the following radiographic techniques are infrequently used it is instructive to be aware of them and sometimes they are extremely effective for demonstrating the pathology and subsequent effects. It must be considered early during the post mortem in order to avoid destroying the anatomical and pathological relationships. Both angiography and urography can give excellent results when performed either in situ or with an intact urinary tract and associated vessels.

#### *Renal Angiography*

##### *In Situ Technique*

1. Clamp the aorta in situ inferiorly at its bifurcation and superiorly just above the coeliac artery.

2. Tie off the coeliac artery and inferior mesenteric artery.
3. Cannulate the superior mesenteric artery.
4. Inject a barium sulphate–gelatin mixture at pressures similar to those described previously for the pulmonary angiography (about 70 mmHg).
5. Take appropriate X-ray films.

#### *Arteriography After Evisceration*

1. Perform evisceration using the en bloc method of organ removal.
2. Tie the nonrenal artery branches of the aorta.
3. Clamp or tie both ends of the abdominal aorta.
4. Cannulate the coeliac artery and ligate it.
5. Inject a barium sulphate mixture at an appropriate pressure.
6. Take X-ray films.

*Venography.* Venography can also be performed following an identical method but in this case it is obviously the inferior vena cava that needs to be cannulated and the corresponding veins clamped or tied off.

*Urography.* Urography is also possible post mortem but intravenous contrast is definitely not the method of choice! In this case contrast mixture similar to that described earlier should be introduced either via the bladder or pelvic part of the ureter with the opposite end tied off and pressure enough to partially distend the bladder.

#### Demonstration of Renal Amyloid

Amyloid represents a group of proteins characterised by a  $\beta$ -pleated sheet conformation that are not digestible by proteolytic enzymes. Amyloid deposition may either be systemic or localised and consist of primary or secondary forms, with a common site for the deposition of both forms being the kidney. Within the kidney the site of deposition may be within the glomerulus, interstitium, or vessels or a combination of these. A useful macroscopic clue to significant deposition of amyloid in the kidney is a glassy or waxy appearance to the cut surface of the renal parenchyma. Amyloid can be demonstrated macroscopically during the examination or microscopically on tissue sections after the post mortem. Both are described in detail in Chapter 13, but are briefly described here.

#### *Macroscopic Demonstration of Renal Amyloid*

1. Remove a slice of kidney.
2. Place the slice into Lugol's iodine for 2 to 3 minutes.
3. Wash in water.
4. Amyloid is demonstrated by the tissue turning dark brown.

#### *Microscopic Demonstration of Renal Amyloid*

For microscopy Congo red, Azarius red, or thioflavin T (with or without potassium permanganate prewashing to differentiate between primary and

secondary) or immunohistochemistry can be used to confirm the presence and type of amyloid. The latter allows accurate differentiation between primary (AL type) and secondary (AA) types of amyloid as well as confirmation of amyloid (amyloid P). With primary amyloid, kappa and lambda immunohistochemistry may also indicate which light chain is deposited. Other specific amyloid types can be characterised using specific antibodies (see Chapter 13).

### Renal Tissue Sampling for Chemical Analysis

Kidney tissue is rarely required for toxicological analysis but because most metabolites are excreted in urine they will pass through the kidney and it is logical to attempt to identify and measure the chemical here. This is particularly relevant if an overdose is suspected and a significant period of time has elapsed since death, making it difficult to interpret accurately the circulating levels of a specific compound. Sampling is easily accomplished by placing a 1-cm cube of renal tissue into a suitable container and transporting it with the appropriate form and complete clinical details to the toxicology laboratory.

### Microdissection of a Nephron/Glomerulus

Finally, and purely for information or an obsessive type of operator, it is actually possible to microdissect a nephron or glomerulus using a series of sieves and a great deal of patience. This practice is not common! For a complete description the reader is referred elsewhere [1].

## *Dissection of the Transplanted Kidney*

Transplanted kidneys are usually located within the pelvis, “plumbed into” the iliac arterial and venous vessels. As with other transplanted organs and post surgical deaths, all suture lines should be inspected before any handling or visceration begins. The kidney should be removed in continuity with its vascular connections by dissecting it free and reflecting it medially while posterior adhesions are divided. All anastomoses, either vascular or ureteric, should also be scrutinised before any are divided. The next step is to open the vessels through the sites of anastomosis to check there are no intraluminal obstructions.

### External Examination

The kidney itself should be sliced as for the routine dissection procedure and the pelvis opened and the luminal surface of the ureters inspected as they are opened. The kidney may be functioning well at the time of death and there may be no reason to suspect pathological changes in the transplanted kidney. Often, however, there will be a suggestion of pathology in the transplant kidney from the clinical history around the time of death.

Particular things to look out for are infection, rejection, and recurrence of the glomerular/other disease in the new kidney (some of which will usually require histology to confirm any macroscopic indicator). Changes in the native kidneys should also be noted. These may well be nonspecific end-stage features, with the diseased kidney in some instances being so atrophic that only a small nubbin of renal tissue remains and may require microscopy for confirmation of its true nature. With adult polycystic kidney disease the kidney are usually large and may show complications such as haemorrhage or cyst rupture.

Features of chronic renal failure/uraemia in the absence of an adequately functioning kidney should also be sought. Other changes include those associated with dialysis such as cyst formation and their complications, the formation of adenomas, or in some instances, carcinomas. A relatively recent complication is the emergence of post-transplant lymphoproliferative disorders related to stimulation of lymphoid cells by Epstein–Barr virus or occasionally other viruses. This may manifest as either lymphadenopathy or an extranodal mass which requires histology and ancillary techniques beyond the scope of this text for confident characterisation. If the prosecutor has any concerns about dealing with such cases then it is always worth discussing the case with a pathology department that specialises in renal transplantation. It may be appropriate to send either the cadaver, tissue, blocks, or sections to the centre for an opinion.

Blocks should be taken as for the routine kidney. In addition all anastomoses should be sampled and blocks should be taken from the native kidneys.

## Ureters, Bladder, and Urethra

The ureters are opened during evisceration whichever technique is followed. If significant pathology is present within or around the ureter then the protocol for removing and examining a large retroperitoneal mass should be followed as outlined later in this chapter. The bladder is also examined during evisceration. Blocks can be taken for histology from any small focal lesion. If there is more extensive bladder pathology then the method described later in this chapter is recommended. The examination of the urethra depends on the gender of the cadaver and is explained in the relevant sections that follow.

## The Female Genital Organs

### *The Uterus and Fallopian Tubes*

It is rarely necessary to remove the whole female genital tract intact but in certain circumstances it is obligatory. One such situation where this is likely

to be required is in the investigation of a maternal death. This is described in a separate section at the end of this chapter.

### External Examination

In routine cases the uterus (including cervix), ovaries, fallopian tubes, and upper vagina are usually removed together. Individual ovaries are then removed for assessment followed by the remaining structures. The non-gravid uterus measures approximately  $10 \times 6 \times 4$  cm and in an adult weighs approximately 70 g (depending on the age of the woman). Most of the posterior surface of the uterus is covered in peritoneum which should orientate the isolated organ.

### Internal Examination

The uterus is opened by a longitudinal cut from the vaginal cuff to the uterine fundus through the uterine cervix. This is easily achieved by passing a metal probe through the external cervical os to the corpus of the uterus and cutting down onto this probe with a scalpel until the endometrium is exposed. In this way the endometrium, myometrium, and cervix can all be inspected. Several further parallel cuts with the scalpel can also be made more laterally in the myometrium or cervix if these areas warrant closer scrutinisation. *Alternatively, the lower blade of a pair of scissors can be introduced into the cervix and the blades then closed to cut through the middle of the anterior wall in a direction similar to that described for the scalpel.*

The midline incisions should be extended to the uterine cornu and into the fallopian tubes. *The fallopian tube can also be opened from the fimbrial end to the cornu in the same manner or alternatively a series of transverse slice can be made along each tube from one end to the other.*

### Histology of the Uterus and Fallopian Tubes

Without obvious pathology, a routine block is taken from the uterine corpus to include endometrium and myometrium (with appropriate consent). As with mucosal/luminal tissue elsewhere in the body the endometrium may well be fairly poorly preserved. Fibroids may require sampling if present although histological assessment of these is usually not warranted unless there is macroscopic suggestion of atypia or malignancy. Any other endometrial, myometrial, or cervical lesions should also be sampled, with at least three blocks taken from any invasive tumour. In the case of the latter, infiltrated local structures and lymph nodes should also be examined histologically. Histological examination of the fallopian tube is rarely necessary but is essential to define the nature of any lesion identified macroscopically and to investigate the possibility of gestational trophoblastic



disease in an ectopic pregnancy. Usually a cross section of the abnormality will fit into one block for histological examination.

### *Ovaries*

The ovaries are bilateral amygdaloid parametrial organs measuring approximately  $3 \times 1.5 \times 1$  cm before the menopause but becoming atrophic afterwards. Together they weigh approximately 10g. A single sagittal/longitudinal section through the ovary will display the parenchyma and should identify any small lesion not visible on the external surface. A single transverse slice of each, 2 to 3 mm in width should be retained for histology.

### *Special Techniques for the Uterus and Ovaries*

#### Examination of the Cervix with In Situ or Invasive Neoplasia

With known cervical epithelial abnormalities the whole of the cervix should be retained and if necessary blocked as for a cone biopsy received in the surgical dissection. This may differ depending on local practice but usually involves amputating the cervix from the corpus and sampling the whole circumference of the cervix in four segments, each segment represented by 12–3, 3–6, 6–9, and 9–12 o'clock as per a clock face. The os should lie horizontally with the anterior cervix uppermost, that is, at the 12 o'clock position. Each quadrant is blocked separately so that the location and extent of dysplasia can be mapped out and the site of any associated invasive carcinoma documented. It may be preferable to pin the "cone" out on a cork board for fixation prior to block dissection.

*Alternatively, the cervix can be blocked by making a series of "cake slices" from 12 o'clock round the whole circumference of the cervix and blocks labelled accordingly.*

### *Assessment of Uterine, Tubal, or Ovarian Tumours*

With tumours of the female genital tract, dissection is best achieved after removing the pelvic organs together as described in the section discussing pelvic mass evisceration and dissection at the end of this chapter. Occasionally, the type of tumour will be apparent from the macroscopic appearance of the lesion, such as whether the lesion is solid or cystic, and with the latter the nature of the cyst contents. With uterine lesions the corpus can be opened in the routine way, or transverse slice made to preserve the parametrial relationships. Several blocks are necessary for histological assessment, with omental, peritoneal, or nodal deposits if present.

## The Male Genital Organs

### *Testes*

The testes develop from the embryonic urogenital ridge in the retroperitoneum and descend through the inguinal canal toward birth into the scrotum. Descent to the scrotum may be arrested at any stage and testes can end up anywhere along this path; it is as well to remember this when performing the evisceration so that undescended testes are not missed.

#### External Examination

Each testis weighs about 13 g in the adult and measures  $5 \times 3 \times 3$  cm. The size and contours of the testis should be assessed macroscopically. The presence of masses or cystic lesions should be noted and the epididymis inspected.

#### Internal Examination

Once the testes are removed, examination involves a sagittal cut through the tunica in a fashion similar to slicing the kidney. In a nondiseased testis the tubules can easily be lifted with forceps and have the appearance of brown thread. Slicing the testis in the manner described should also give a good indication of the normality or otherwise of the epididymis.

#### Histology of the Testes

For the routine case a single coronal or sagittal block of tissue suffices for processing into histological sections if required. With tumours at least three blocks should be taken (especially if the tumour is a germ cell neoplasm) in order to classify the lesion completely. Blocks of tissue from any metastatic tumour deposits must also be sampled in the usual way.

### *Special Techniques for the Testes*

#### Examination of Testicular Tumours

With testicular tumours, assessment is similar to that for the normal testis but obviously relevant lymph node groups (para-aortic and above) need to be inspected carefully and sampled for histology. If there is infiltration of the adjacent tissues and skin this also needs to be removed with the testis but of course this implies possible metastatic involvement of a different group of lymph nodes in the inguinal region and these also need to be assessed carefully. Immunohistochemical methods may be required for full characterisation of germ cell tumours.

### *Prostate Gland*

The prostate gland is examined during the routine dissection of the pelvic organs at the time of evisceration. The internal aspect is inspected as the bladder is opened and then transverse slices made through the gland. In older subjects the size and weight of the gland vary depending on the age of the individual and the presence of hyperplasia. Evidence of significant urinary outflow obstruction is usually obvious in the form of detrusor muscle hypertrophy and trabeculation. Focal lesions need to be assessed histologically if consent has been given for this. The method for handling more extensive prostatic disease should follow that outlined for a pelvic mass (see later in this chapter).

### *Other Special Techniques*

#### Collection of Urine

As removal of urine for analysis needs to be performed at an early stage of the examination, the methods for this procedure were described fully in Chapter 2 (p. 65). As there are several methods they are revisited here briefly:

1. Urine can be collected by passing a needle attached to a medium-sized syringe through the suprapubic area of the anterior abdominal wall into the bladder.
2. If a catheter is present obviously urine can be collected via this.
3. Cut the bladder dome open after evisceration of the abdominal organs with the bladder still in situ in the pelvis. The cut allows a sterile syringe to be passed into the bladder lumen and urine removed.

### *Examination of a Bladder Tumour*

If an invasive tumour of the bladder is present with extramural extension it is probably best to consider removing the pelvic organs as a whole with further dissection afterwards as described at the end of this section. In cases of urothelial malignancy it is also worth considering fixing the bladder prior to dissection to improve tissue preservation, by instilling with formalin after all of the urine has been removed via a urinary catheter. Obviously it is necessary to sample any masses adequately for histology as well as to sample the iliac lymph nodes in the case of more extensive tumours.

### *Examination of Localised Ureteric Masses*

If a ureteric stone is expected from premortem information then a urogram may be considered in order to visualise and localise the calculus before it

might be destroyed or lost during the post mortem examination (see earlier). If a urothelial tumour is present one may also consider instilling formalin through a cannula introduced via either the renal pelvis or cystoureteric junction before dissecting. The opposite end of the ureter will need to be tied off, which allows better fixation and more accurate histological assessment after fixation of what generally tend to be friable tumours.

### *Examination of More Extensive Ureteric or Periureteric Masses*

When a more extensive ureteric tumour or retroperitoneal mass is present, possibly associated with ureteric obstruction and bilateral hydronephrosis, once again it is advisable to remove the abdominal contents complete and dissect as described for a post surgical case in Chapter 7 (p. 211). Blocks of any lesions should be taken for histology, usually by removing a transverse section of the ureter.

### *Lower Urinary Tract Urography*

In addition, in either gender it may be appropriate to perform a urethrogram in order to demonstrate and localise urethral valves, strictures, or tumours. The latter can be performed simply by injecting contrast into the external urethral meatus and taking X-ray films after both ureters have been tied. If delicate valves are suspected it is better to inject the contrast or formalin fixative into the bladder and dissect against the flow of urine to preserve these strictures.

### *Examination of the Penis/Penile Urethra*

The penis is not routinely dissected but on occasion one may need to dissect or remove the urethra. For dissection of the penile urethra, two similar methods have been described. The first involves making an opening between the upper border of the symphysis pubis and skin. The corpora cavernosa are grasped with the urethra and dissected from the adjacent skin along a plane beneath the dermis and subcutaneous tissue. Evaginate these structures back into the pelvis until the glans is reached. The corpora are transected at this point and the penis (without skin) should now lie separate from the rest of the body. Open the urethra either by horizontal slices about 0.5cm apart or by using small size scissors and cutting along the urethra, rather like examining ducts elsewhere in the body. The mucosal surface should now be inspected easily.

*The second method allows for better reconstruction after the examination with fewer visible sutures. The male urethra is dissected by drawing the penis*

*out of its enclosing skin and dividing the shaft of the organ just proximal to the glans. The inferior ligamentous attachment is divided and the main anchoring ligaments to the cavernosus muscles and symphysis pubis are severed. The proximal part of the penis can now be pushed under the pelvic arch and kept in continuity with the bladder. It may occasionally be necessary to saw through the pubic bone to gain adequate access. The urethra is opened by horizontal slices or with scissors as described above.*

With the latter the penis and prostatic urethra can kept in continuity and the whole lower urinary tract can be examined this way. Should lesions be present they can be examined histologically by taking blocks of tissue, usually coronal slices, of the lesion and surrounding structures.

### *Examination of the Female Urethra*

The proximal urethra in the female will be examined when the lower border of the bladder is opened but if the full urethral surface needs to be inspected then the dissection should follow that for the female genital tract described later, including perineal skin. The urethra is opened with scissors from the external urethral orifice proximally to the bladder.

### *Examination of a "Frozen" Pelvis*

In cases in which it is advisable or important to keep all of the pelvic organs together, such as with extensive pelvic tumours in which it is vital to remove them as a whole to examine and demonstrate inter-organ relationships, a method similar to that previously described for large mediastinal or abdominal masses (or post abdominal surgery) should be employed with en bloc removal. This is achieved by skirting the inside of the pelvic bone and removing all of the soft tissue within this region as one. This is much the same as the routine method for removing the pelvic organs as a whole at the evisceration stage of the en masse or en bloc techniques as described in Chapter 3. Once the pelvis is removed the dissection technique also follows the same pattern as dissecting a large mass elsewhere. This again involves two principal methods, either by opening or dissecting the organs as they are encountered from front to back (or back to front), or by making a series of transverse slices (possibly after fixation) to obtain the best views of whole process and to establish the extent of involvement.

With the former it is usual to start at the back by opening the rectum, but obviously if this is the central area of interest it may be wise to start anteriorly with the bladder and open this in the same way as the routine dissection by passing scissors into the urethra and opening the bladder itself with cuts toward the lateral walls. Then the female genital tract needs to be dealt with. Again depending on whether the approach is from the front or back the vagina, cervix, and uterus should be opened along the anterior or posterior border by passing a probe through the external os and making

scalpel cuts as outlined earlier. Next the fallopian tubes should be opened either by transverse slices or along its length from uterine cornu to fimbriae with scissors. The ovaries are then sliced in the usual way unless a tumour is present in which case the method described earlier should be followed.

Pelvic dissection is summarised as follows:

- Remove all pelvic organs as a group (described in Chapter 3).
- Begin with the uninvolved structures anteriorly or posteriorly and open the rectum or bladder.
- Inspect the inner aspect of this.
- Cut through the anterior or posterior wall of the vagina and uterus and inspect the endometrial surface.
- Open or transect the fallopian tubes.
- Inspect the inner surface.
- Slice the ovaries.
- Inspect the cut surface.
- Open the bladder or rectum (whichever was left intact earlier).
- Inspect its mucosal surface.

*Alternatively, the whole tissue block is laid with the anterior surface down on the dissecting board. Holding the tissue steady with the free hand, make large slices through the entire block parallel to the external urethral edge from the lower border proximally. These should be at approximately 1-cm intervals until the proximal border is reached. This can be done either at the time of post mortem or after 24 to 48 hours of fixation. The tissue slices are laid out rather like the coronal slices of the cerebral hemispheres. In this way the relationships of the various organs and the extent of the pelvic mass can be demonstrated clearly. In addition it is usually straightforward to identify the site of origin of the pelvic lesion should it be so extensive that on preliminary observation it is not clear where the tumour arises. Of course it also makes sampling of tissue for histology easy since the focus of the tumour, infiltrative margins, and local structures involved by the tumour such as lymph nodes or vessels can be examined.*

## Maternal Deaths

In the United Kingdom deaths that occur during pregnancy or within 42 days of childbirth are notified to the Confidential Enquiry into Maternal Deaths. This enquiry was originally set up in the 1950s and comprises a central panel of reviewers who collate all the available information regarding all notified maternal deaths previously assessed by regional groups and who produce a report on the current situation every 3 years (see [2,3]). The report addresses all issues of care surrounding a maternal death, and if evidence of substandard care is identified, the report recommends action to

avoid future recurrence. The regional group of assessors did not originally include Pathologists but pathological input has become an essential part of the exercise since the 1970s; in fact, the 1979–81 report brought pathologists very much to the fore when it stated that an inadequately performed or incompletely recorded autopsy represented substandard care. Recently, pathologists have come into the spotlight again, having been criticised for producing deficient or even “apalling” post mortem reports when investigating maternal death [2]. The post mortem examination is clearly essential for accurate diagnosis and has a vital role in closing the audit loop. The autopsy should therefore be of a sufficiently high standard to answer the questions that are raised. The Enquiry is also interested in late deaths (up to 1 year after delivery) although these are not formally addressed in the report.

The whole subject of maternal deaths and the Confidential Enquiry has been extensively examined by Rushton and Dawson [4], and several publications and reports have been produced by the Royal College of Pathologists in the United Kingdom on precisely this subject (see [5,6]). The revised guidance on the performance of post mortem examinations produced by the Royal College of Pathologists includes a summary and practical tips on how to conduct a maternal autopsy. For a more international discussion the reader is referred to Royston and Armstrong’s edited work on preventing maternal deaths [7].

Usually maternal deaths will come under the remit of the coroner, Procurator Fiscal, or equivalent. All should be referred to the confidential enquiry. The causes of such deaths can be divided into: (1) those that are related to *direct* obstetric complications of pregnancy, labour, or the puerperium; (2) those that result from diseases that predated or occurred during that pregnancy and that were aggravated by the pregnancy, that is, *indirect* deaths; and (3) deaths that are *fortuitous*, that is, not related to or influenced by the pregnancy. In any event, the post mortem strategy needs to follow the standards previously outlined, with particular attention given to close clinicopathological communication. The case notes will be scrutinised thoroughly, seeking specialist advice in interpreting complicated data.

### *Approach to the Maternal Post Mortem*

Preparation, a meticulous attitude, and patience are the keys to a comprehensive examination. Obviously a competent examination performed by an experienced operator who is thorough about collating the clinical information, checking up on all relevant data from all available sources (including the clinicians, general practitioner and midwives involved with the patient’s care) and appraising the situation thoroughly before the actual examination takes place will pave the way for the most complete investigation and hopefully will answer all appropriate questions relating to that death. The

notes and results of all investigations should be consulted and digested. All involved health care workers should be encouraged to attend the post mortem examination.

As there are so few maternal deaths annually, serious consideration should be given to referring the examination to a pathologist with experience. In addition it is worthwhile considering discussion with a specialist obstetric pathologist, neuropathologist, or other relevant specialist as appropriate. Furthermore, if the fetus or neonate has also died the information from this examination (including placental pathology) may also have some bearing on the subsequent examination, and this information should be actively sought. If surgery was required during the time of delivery any surgical specimens taken should be examined and the findings included in the maternal death autopsy report. Fluid balance should be checked from the notes and correlated with the pathology. Identify any predisposing factors for thromboembolism; specifically search the notes for blood pressure readings and identify sources of blood loss if known.

### *Causes of Death*

The most common cause of direct maternal death is thromboembolic disease, especially pulmonary embolus. Other causes are listed in Table 8.1. Many of the conditions associated with maternal death have marked age effects, with mothers older than 40 being more than 60 times more likely to die from a pulmonary embolus than those younger than 25 years of age. It is not the place here to explore all of the causes of maternal death with

TABLE 8.1. Causes of Maternal Death

Cause	All direct deaths (1970–1990) Number of cases (%)	Direct deaths in England and Wales (1970–1972) Number of cases (%)	Direct deaths in the United Kingdom (1985–1990) Number of cases (%)
Pulmonary embolism	223 (16.1)	51 (14.9)	54 (19.7)
Pregnancy-related hypertension	221 (15.9)	43 (12.5)	53 (19.3)
Anaesthesia	141 (10.2)	37 (10.8)	10 (3.6)
Amniotic fluid embolism	91 (6.6)	14 (4.1)	20 (7.3)
Abortion	153 (11)	73 (21.3)	14 (5.5)
Ectopic pregnancy	134 (9.7)	34 (9.9)	31 (11.3)
Haemorrhage	130 (9.4)	30 (8.7)	32 (11.7)
Sepsis (outside abortion)	89 (6.4)	30 (8.7)	17 (6.2)
Ruptured uterus	51 (3.7)	11 (3.2)	8 (2.9)
Others	154 (11.1)	20 (5.8)	34 (12.4)
Total	1387 (100)	343 (100)	274 (100)

Reprinted with permission from Toner PG, Crane J (1994) [8].



detailed discussion of each but rather to highlight some of the procedures that may be employed to identify them that are rarely or never encountered in the context of a routine post mortem.

It should be remembered, however, that usually no special techniques will be required to elucidate the cause of death and the routine examination practice should adequately identify causes of death such as thromboembolic disease. A significant minority of cases, however, will necessitate methods that deviate from the norm, and if such techniques are not considered and performed for these few instances, it will be impossible to establish the cause of death. Furthermore, some of the more unusual causes of death will not be identified if certain elements of the examination (such as examining for an air embolus) are not performed consistently as this needs to be actively investigated. Therefore it is essential that the preliminary background work is done before the post mortem examination proper begins. It is crucial that the special techniques that may be required are part of the prosecutor's repertoire. Some of these, such as identifying an air embolus as mentioned earlier, need to be executed at an early stage of the examination otherwise they will be missed. This has been described in a previous chapter but it will be repeated briefly here with other methods relevant to maternal death examination.

### *Anaesthetic Deaths*

A brief note is made here about anaesthetic deaths. These include those relating to biochemical, toxicological, or oxygenation problems that may not give rise to specific gross or microscopic findings even after the most thorough examination possible. Although these are inevitably unsatisfactory and frustrating intellectually, the end result is still of some importance as the negative findings of the examination rule out other possible important pathologies.

### *External Inspection and Examination*

External examination should be thorough as with any other post mortem but particular attention should be paid to the legs, to identify evidence of deep vein thrombosis. The integrity of any scars such as a caesarean section should be scrutinized. In addition, examination of the perineum and external genitalia should not be neglected. Also before evisceration, the pregnant uterus can be fixed in situ by puncturing the uterus through anterior abdominal wall with a wide-bore needle and large-volume syringe, removing amniotic fluid and reintroducing formalin. After at least 24 hours of fixation the rest of the examination follows its routine course but the uterus is left intact. At the end of the post mortem the uterus is then carefully opened in a suitably safe area (usually in a safety cabinet due to the high levels of formalin vapours which will be present). *Alternatively, for optimal*

*tissue fixation, the fetus alone can be perfused by cannulating the umbilical vessels and instilling formalin.*

### *Evisceration and Organ Dissection*

After external assessment and before evisceration proceeds, any samples required for microbiological, biochemical, or other analysis should be taken as described in Chapter 2. In septic cases it is prudent to send blood for culture in an attempt to identify the underlying organism. When sepsis is likely, genital tract swabs and splenic swabs or tissue should also be sampled for microbiological investigation. Blood may also be required for toxicology in cases of possible poisoning or drug abuse. It may be appropriate to take blood samples for assessment of drug levels, for example with antiepileptic pharmacological agents. Viral studies are necessary if myocarditis is likely. Vitreous humor may be taken in cases associated with diabetes mellitus, renal failure or electrolyte disturbance. Hyponatraemia associated with water intoxication may also be assessed by examination of vitreous fluid. Methods for taking all of these samples have been detailed elsewhere (Chapters 2 and 13). A further blood sample from the pulmonary artery during the post mortem should be considered in patients who have died from amniotic fluid embolism. The buffy coat may reveal evidence of tell-tale fetal squames.

As mentioned, the examination itself should proceed along the usual lines but first particular attention should be paid to identifying the presence or absence of air embolism, pneumothorax, and genital tract trauma. The first two of these have been described in Chapter 2 but are repeated in full detail here as they have particular pertinence for autopsies following maternal deaths. Probably the first of these to be excluded in the order of the examination is pneumothorax. The skin over the neck and anterior chest should initially be palpated for evidence of crepitus and soft tissue emphysema, which may give a clue to an associated pneumothorax. The skin and subcutaneous tissue is then reflected from the midline or upper part of the Y-incision as described previously, always directing the blade strokes toward the bone of the chest wall, but being careful not to damage the intercostal soft tissue and puncture the parietal pleura. Dissection extends posteriorly to about the mid-axillary line and traction is then applied to the skin and underlying tissue laterally to produce an angle between chest wall and subcutaneous tissue. This area is then filled with water and the intercostal muscle incised below the water line, watching closely for air bubbles indicating an underlying pneumothorax.

Air emboli usually occur during labour or surgical intervention in delivery of the baby or products of conception after miscarriage. Air gains access to the venous circulation and travels to the right side of the heart, where it interferes with blood flow and results in rapid collapse of the cardiovascular system. During dissection of the neck, the large neck veins should be

left intact. After the abdomen is opened in the usual manner, the abdominal contents should be moved gently out of the way to inspect closely the inferior vena cava for bubbles in the lumen through its transparent wall. The sternum is then removed, being careful not to puncture the pericardial sac. The anterior pericardium is now opened and water is introduced to fill the pericardial space. Once completely covered in water, the right atrium and ventricle are incised and careful inspection is made to identify any air bubbles which escape.

Essentially the diagnosis of amniotic fluid embolism requires histology and/or examination of pulmonary artery blood for confirmation. Suggestive evidence, however, can be obtained by identifying genital tract trauma as this is the most usual origin of such emboli. Close inspection of the uterus, cervix, vagina, and adjacent soft tissue for tears or ruptures is mandatory to identify macroscopic evidence of such an occurrence. It is certainly worth considering fixing this whole group of organs complete before making this examination, if nothing is obvious during evisceration. The method(s) for removing the female genital tract are described in a separate section later in this chapter.

The rest of the examination is very much that of a routine post mortem with close inspection of the abdominal cavity, in particular looking for evidence of haemorrhage (especially with ruptured ectopic gestation). When removing and dissecting the organs, particular attention should be paid to the heart for cardiomyopathy, hypertension (in which case the ventricles should be weighed and measured separately as described in Chapter 5), or valvular disease. Congenital cardiac defects may require specialist input in their interpretation as may assessment of the conducting system.

The most important conditions to identify or exclude in the respiratory system are pulmonary emboli, gastric aspiration, and diffuse alveolar damage/adult respiratory distress syndrome (particularly in association with sepsis, diffuse intravascular coagulation, severe haemorrhage, and ventilatory support). It is essential not to mistake the pulmonary changes seen with resuscitation attempts for regurgitation associated with significant aspiration. The latter is a particular risk during anaesthesia induction for an emergency caesarean section. If thromboembolism is present in the pulmonary vasculature it is recommended that an attempt be made to identify the source with dissection of the deep veins of the legs and thighs as described previously in Chapter 5.

There are limited findings of specific note in relation to the alimentary tract in maternal deaths. Of course acute gastric dilatation, small bowel distension or ileus should be noted but the liver may be haemorrhagic in eclampsia (histology is necessary for confirmation). The kidneys should be examined macroscopically for evidence of hypertension or pyelonephritis and the lower urinary tract examined for infection or evidence of traumatic injury. The genital tract has been dealt with earlier but it is important to examine the fallopian tubes carefully for evidence of an ectopic pregnancy.

If a hysterectomy has been performed in the recent past the histological slides should be reviewed. Similarly the placenta should be examined if pertinent. Relevant findings in the neurological system in the brain include identification of subarachnoid haemorrhage (a relatively common cause of indirect mortality associated with ruptured Berry aneurysms). Removal of the spinal cord intact may be warranted, particularly if epidural or spinal anaesthesia has been used. Again, as with routine post mortems, the brain should be fixed before slicing and samples examined histologically for eclampsia.

Maternal death post mortem examination is summarised as follows:

1. Allow time and prepare adequately.
2. Collate all information and discuss with relevant parties before the autopsy.
3. Consider specialist referral or advice.
4. Perform a routine external examination, paying particular attention to legs, perineum, and scars.
5. Take necessary specimens for toxicology, biochemistry, and microbiology at this stage.
6. Examine for pneumothorax, air embolus, and pulmonary embolus early.
7. Perform a routine examination.
8. Take time, particularly over the heart (cardiomyopathy, hypertrophy, conducting system); lungs (emboli, diffuse alveolar damage, amniotic fluid embolus); genital tract (trauma, haemorrhage); uterus (rupture, ectopic pregnancy); placental site (placenta previa, haemorrhage); brain (masses, infection, or vasculopathy); bowel (perforation); and other foci of haemorrhage such as aneurysms.
9. Examine deep veins if thromboembolism is present.
10. Take histology.

### *Histology of the Maternal Post Mortem*

The histological assessment of maternal post mortems has been highlighted as a major defect by successive reports of the Confidential Enquiry. As these are likely to be coroners' cases, the coroner will usually sanction the retention and histological examination of tissues. Indeed the Royal College of Pathologists guidelines insist that all of the major organs should be sampled for histopathology, including the uterus. Adequate numbers of blocks from all organs need to be taken even if subsequently it does not become necessary to process the tissue. All tissue reserved for examination should be listed in the report. Routine blocks that will inevitably require histological examination include tissue from the heart, each lobe of lung, liver, kidneys, placental site and brain. Sections of the heart are particularly important for

myocarditis, conduction abnormalities and cardiomyopathy, the lungs for aspiration and diffuse alveolar damage. The liver is often the best organ in which to identify the microscopic changes associated with pre-/eclampsia and is essential in making a diagnosis of acute fatty liver of pregnancy. The kidneys are helpful for hypertension or diffuse intravascular coagulation. Cerebral tissue may be useful when eclampsia is likely. It should be obvious, however, that any other macroscopic abnormality should also be fully characterised histologically.

Apart from the routine haematoxylin and eosin stain, other special stains may sometimes also be extremely useful. A good example of such is the histochemical stain alcian blue-phloxine-tartrazine which will identify fetal squames, mucin, vernix, and lanugo hairs in parametrial or lung tissue sections [9]. Martius scarlet-blue (MSB) trichrome stain may be helpful in confirming microthrombi in the renal vasculature in cases with diffuse intravascular coagulation. MSB should also highlight fibrin deposits in the liver (periportal sinusoids) in pre-/eclampsia and also the hyaline membranes of diffuse alveolar damage in the lungs. Both of the above features can also be identified with immunohistochemical methods, fetal squames by cytokeratin antibodies, and antibodies to fibrinogen for fibrin deposits.

In summary, maternal autopsy histology should include (minimum = blocks of lungs, liver, kidney, heart, brain, and placental site):

- Lungs (especially for amniotic fluid embolism)
- Liver (especially for pre/eclampsia or acute fatty liver)
- Sites of trauma/surgery
- Ectopic pregnancy
- Brain (especially epilepsy and hyperemesis)
- Heart (both ventricles, conducting system)
- Special methods as appropriate

### *The Placenta*

When the placenta is available for examination in maternal death cases, it should be examined as part of the complete post mortem investigation, according to the method described in the section on the perinatal autopsy. When the placenta is still in situ it should be examined while still within the uterus, possibly after instilling formalin into the corporal cavity. Its location needs to be established and any areas of detachment or myometrial penetration documented. Placenta previa or accreta can be verified and demonstrated in this way. Blocks of tissue will be required for histology from the placental bed, uteroplacental junctional region, and membranes (plus umbilical cord if present). Once this area has been sampled the placenta can be detached and examined in the usual way (see Chapter 14).

### *Removal of Female Genital Tract Complete*

Certain post mortems will necessitate removal of the female genital tract complete. Examples of such cases include death during or following pregnancy, death following abortion or miscarriage, and more uncommon unpleasant and distasteful forensic cases. The principles involve carrying out the rest of the examination in the usual way, being careful not to disturb the pelvic structures. Then the skin and subcutaneous tissue incision performed at the beginning of the post mortem is extended from its lower pubic end inferiorly using a scalpel. It is helpful to perform this part of the procedure with the body in the lithotomy position.

The initial midline extension is then split into two as the perineum is reached and each of these cuts is carried on around the lateral perineal border. This involves cutting lateral to the vulva on each side along the groove between the perineum and inner thigh. These cuts are extended posteriorly to join again behind the anus. These superficial cuts are then made deeper into the underlying soft tissues, being careful not to damage the vagina or rectum. It may be helpful if an assistant holds the legs forward to expose the perineum to best advantage.

With the body laid in the normal position back on the table, the soft tissue covering the pubic bones is dissected away and these bones are sawed through (either with a handsaw or the electric oscillating saw) about 5 cm from the symphysis pubis. This will mean sawing through the superior pubic ramus first and then through the inferior ramus. By freeing the adjacent soft tissue, the lower portion of this special block is now released.

The next stage involves the more conventional technique of dissecting the pelvic contents away from the lateral pelvic wall. As before, a large PM40 is used to cut through the peripheral attachments, with the noncutting hand retracting the tissues in the plane of dissection. Laterally the external iliac vessels should be cut through and as the dissection becomes more anterior the bladder and urethra will be reached. Still cutting down toward the bone of the pelvic inlet, with traction on the bladder base, these structures should remain safe from inadvertent injury. It is quite easy to follow the internal rim of the pelvis in this way and not interfere with the more medial organs. Posteriorly the soft tissue is dissected anterior to the sacrum and coccyx until the inferior dissections described previously are reached. In this way the pelvic contents, parts of the pubic bones, and the perineal skin and soft tissue can be lifted up and removed together.

*An experienced dissector can actually remove this block without sawing through the pubic bones and skirting the innermost surface of these bones, but this is much more likely to result in unwanted trauma to the lower genital tract structures.* Reconstitution involves extension of the sutures around the pubis and along the midline of the perineum.

Removal of the female genital tract is summarised as follows:

- Place the body in the lithotomy position.
- Extend the pubic end of abdominal wall incision inferiorly.
- Fork the incision to skirt the perineal skin, lateral to the vulva, medial to the skin of the thigh.
- Join these branched incisions behind the anus.
- Dissect the soft tissue deep to these preliminary cuts.
- Replace the legs to the table.
- Saw through the medial parts of the pubic rami.
- Detach pelvic contents from the lateral wall in the conventional way.
- Cut through iliac vessels and posterior coccygeal attachments.
- Remove the block intact for careful examination.

### *References*

1. Ludwig J. Current methods of autopsy practice, 2nd edit. Philadelphia: WB Saunders, 1979.
2. Department of Health. Why mothers die. Report on Confidential Enquiries into Maternal Deaths in England and Wales, 1994–1996. The Stationery Office, 1998.
3. National Institute of Clinical Excellence. Why mothers die 1997–1999. Report on Confidential Enquiries into Maternal Deaths in the United Kingdom. Department of Health, London, 2001.
4. Rushton DI, Dawson IMP. The maternal autopsy. *J Clin Pathol* 1982;35:909–921.
5. Royal College of Obstetricians and Gynaecologists and The Royal College of Pathologists. Fetal and perinatal pathology. Report of a joint working party. Royal College of Obstetricians and Gynaecologists, London, 2001.
6. Royal College of Pathologists. Guidelines on autopsy practice: report of a working party of the Royal College of Pathologists. Royal College of Pathologists, London, 2002.
7. Royston E, Armstrong S (editors). Preventing maternal deaths. Geneva: WHO, 1989.
8. Toner PG, Crane J. Pathology of death in pregnancy. In: Anthony PP, MacSween RNM, editors. Recent advances in histopathology, Vol. 16. Edinburgh: Churchill Livingstone, 1994; pp. 189–211.
9. Attwood HD. Amniotic fluid embolism. In: Sommers PP, editor. *Pathology Annual*. New York: Appleton-Century-Crofts, 1972; pp. 145–172.

# 9

## The Endocrine System

For the purposes of post mortem dissection, the endocrine system is composed of the thyroid gland, the parathyroid glands, the adrenal glands, and the pituitary gland; and the removal of these glands has been discussed earlier. Although there are obviously other endocrine organs, they either form part of a diffuse endocrine system, such as in the bronchial and intestinal mucosa, or are embedded within another organ, such as the endocrine pancreas.

This chapter includes:

- Further dissection of the separated glands
- Special techniques that may be necessary
- Examination of the paraganglia

Pathology within the endocrine system is not found particularly often at autopsy, and when identified it is even less commonly related to the cause of death. Nevertheless, the examination of the endocrine system is part of any thorough post mortem examination, and does occasionally produce surprises, particularly on histological examination.

A set of scales that are accurate at small weights are an absolute necessity for the adequate assessment of endocrine glands.

### The Thyroid Gland

If an infiltrative tumour has been identified during evisceration that is causing attachment of the thyroid gland to adjacent structures, the gland should be examined in continuity with the neck organs (see p. 240). Otherwise, all attached strap muscles and connective tissue should be removed from the now separate gland, using forceps and scissors. The gland is composed of right and left lobes, joined by an isthmus (Fig. 9.1). The thyroid can now be weighed and measured, to identify and quantify any atrophy or hyperplasia:



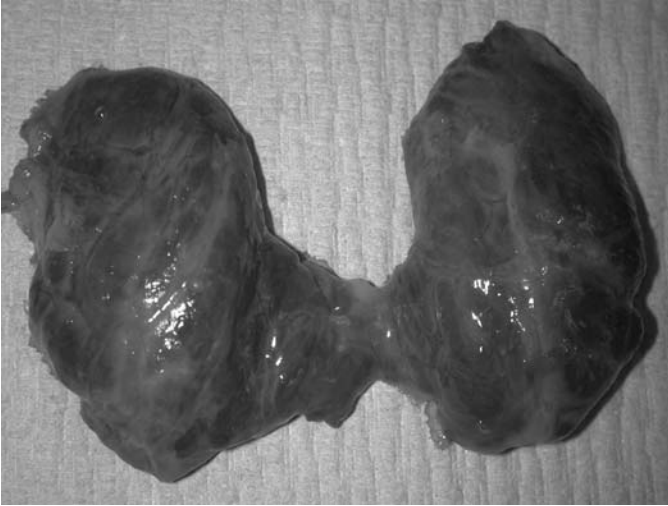

FIGURE 9.1. The normal thyroid gland, stripped of all attached muscle for weighing. (Courtesy of Mr. Dean Jansen, Whittington Hospital.)

Average weight of thyroid gland [1] 40 g (range 30–70 g)  
Average size of each lobe [1]  $6 \times 3.5 \times 2$  cm

Incomplete vertical slices can then be made from the anterior surface, about 0.5 cm apart, thus retaining continuity at the posterior surface to keep the gland intact (Fig. 9.2). The cut surfaces should then be examined.

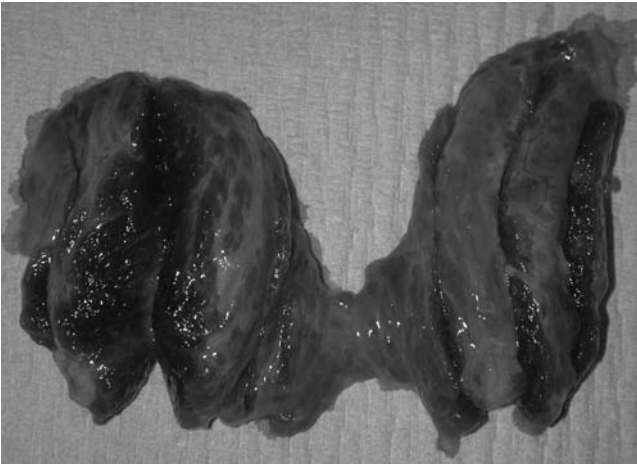

FIGURE 9.2. Dissection of the thyroid gland. Incomplete slices have been made from the anterior surface to allow examination of the parenchyma but keep the gland intact. (Courtesy of Mr. Dean Jansen, Whittington Hospital.)

Any focal lesions identified should be measured and examined, and then submitted for histology in their entirety. Standard routine histology, however, should include a single block of thyroid tissue even in the absence of obvious abnormality, providing appropriate permission has been obtained.

### Clinical Correlation

A weight that is significantly below the normal range indicates atrophy or hypoplasia. Atrophy may be due to previous thyroiditis or may be a consequence of overtreatment of hyperthyroidism. Hypoplasia is a developmental anomaly that is congenital in origin. The presence of either atrophy or hypoplasia should alert the prosector to look for other indications and associations of hypothyroidism.

A weight that is significantly above the normal range indicates hyperplasia, in the absence of a focal lesion. Such enlargement of the gland is termed a goitre, and may be caused by Grave's disease or a dietary deficiency of iodine, or it may be idiopathic. The presence of hyperplasia should alert the prosector to look for other signs of hyperthyroidism.

Focal lesions may be cystic, "colloid," or solid. "Colloid" nodules are also often multiple. Cystic lesions may either be simple cysts or may represent "colloid" or solid lesions that have undergone cystic degeneration. Solid lesions are likely to be neoplastic.

## The Parathyroid Glands

If an infiltrative tumour has been identified during evisceration that is causing attachment of the parathyroid gland(s) to adjacent structures, the glands should be examined in continuity with the neck organs (see p. 240). Otherwise, the now separate glands should be stripped of any attached fat and weighed together, using scales that are specially designed for very low weights.

Average combined weight of parathyroid glands [1] 0.12–0.18 g (0.03–0.045 g each)

Average size of each gland [1] 0.3–0.6 cm in maximum diameter

Glands of normal size should be submitted for histology if indicated by the clinical details or the post mortem findings, providing appropriate permission has been obtained. Any glands that are grossly enlarged should be cut into separate slices, examined, and submitted in their entirety for histology, providing that appropriate consent has been obtained.

### Clinical Correlation

Enlargement may be due to hyperplasia or neoplasia; the latter obviously includes both adenomas and carcinomas. It is extremely difficult to distinguish hyperplasia from an adenoma histologically, so the diagnosis often rests on the macroscopical findings. Enlargement of all glands indicates hyperplasia whereas enlargement of only one or two glands indicates an adenoma (or more rarely a carcinoma). Both hyperplasia and neoplasia usually produce hyperparathyroidism, and therefore parathyroid gland enlargement should prompt the prosector to look for other signs and associations of gland overfunction.

Parathyroid glands may also be absent or unidentifiable because of hypoplasia or as a consequence of previous surgery. Hypoparathyroidism is a largely functional disorder, however, and produces few anatomical changes that are identifiable at post mortem.

## Special Techniques

### *Examination of the Thyroid or Parathyroid Glands When an Infiltrative Tumour Is Present*

If an infiltrative carcinoma of the thyroid or parathyroid glands is expected or identified during evisceration the thyroid and parathyroid glands should be left attached to the neck organ block and examined in continuity. This allows assessment of the extent of local invasion. Whichever post mortem technique is used, the neck organs need to be removed from the thoracic organs by cutting through the lower trachea, oesophagus, and surrounding soft tissues. The thyroid gland, parathyroid glands, and attached neck structures should then be sliced from the anterior surface, at intervals of about 1 cm, using a large knife. These slices should be complete, and can then be laid out flat and examined separately. If either senile cartilaginous or tumour calcification is encountered, a hand saw or shears may be necessary to complete the slices. An extremely large thyroid or parathyroid tumour may extend to the hyoid bone, in which case it is easier to arrange the slices so that they fall either side of the bone than it is to attempt to section the bone itself. *Alternatively, the entire tissue block can be decalcified prior to sectioning.*

Relevant blocks of tumour, including the infiltrative margin, can then be taken for histology, decalcifying before processing if necessary, and providing that appropriate permission has been obtained.

This method does have the disadvantage of destroying the thyroid and parathyroid glands before they can be weighed; however, in these circumstances the weight is less important than the identification of the extent of invasion.

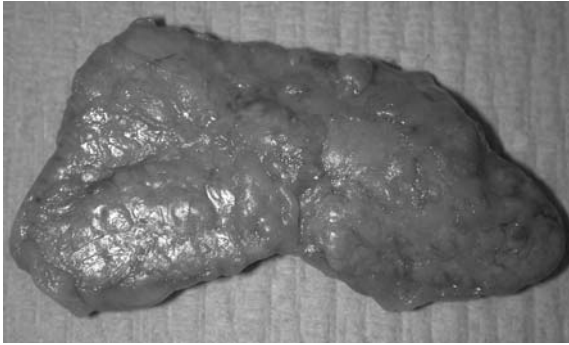

FIGURE 9.3. The normal adrenal gland, stripped of all fat for weighing. (Courtesy of Mr. Dean Jansen, Whittington Hospital.)

## The Adrenal Gland

Infiltration of the surrounding structures is extremely unusual in adrenal tumours, but if identified during evisceration this requires special dissection of the retroperitoneum (see p. 211).

When no infiltrative tumour is present, all attached fat should be painstakingly removed from the glands, using forceps and scissors, if weighing is to be accurate (see Fig. 9.3). The adrenals can then be weighed and measured, and any atrophy or hyperplasia assessed.

Average weight single stripped adrenal gland [2]	5.75 g (up to 10 g)
Average size single stripped adrenal gland [1]	4.5 × 3 × 0.5 cm

Incomplete vertical slices should now be made, about 0.5 cm apart, retaining continuity at one border to keep the gland intact (see Fig. 9.4). The cut



FIGURE 9.4. Dissection of the adrenal gland. Incomplete slices have been made from one border to allow examination of the parenchyma but keep the gland intact. (Courtesy of Mr. Dean Jansen, Whittington Hospital.)

surfaces can now be examined and any focal lesions identified. All focal lesions should be measured and examined and then appropriate blocks submitted for histology. Standard routine histology should include a block of each adrenal gland, however, even if no lesions are identified, providing the appropriate consent has been obtained.

#### Clinical Correlation

A significant reduction in gland weight indicates atrophy and is usually a consequence of systemic steroid therapy although may be caused by previous adrenalitis. It should alert the prosector to look for other indications of adrenal underfunction. A significant increase in gland weight, in the absence of a focal lesion, indicates hyperplasia and should prompt the prosector to look for signs and associations of adrenal overfunction.

Focal lesions may be caused by nodular hyperplasia or neoplasia; the latter obviously include both adenomas and carcinomas. Most such lesions are functional and should lead the prosector to look for other indications of gland overfunction. Destructive lesions such as tuberculosis and metastatic deposits also usually produce macroscopically identifiable lesions. These may be associated with underfunction of the gland and should prompt a search for the signs and associations of gland underfunction.

## Special Techniques

### *Examination of a Suspected Pheochromocytoma*

If an adrenal tumour is present, it could be a pheochromocytoma that is secreting adrenaline or noradrenaline. This can be identified at the time of post mortem using a macroscopic dye technique. To do this, a slice of tumour should be placed in a 10% solution of potassium dichromate (pH 5 to 6) for about 5 minutes. If either adrenaline or noradrenaline is present, the tissue will become dark brown. The tissue can then either be discarded or washed thoroughly before being fixed and retained.

## The Pituitary Gland

If a mass is macroscopically visible or a large tumour has been identified pre mortem, the pituitary gland should be removed in continuity with the sphenoid bone (see p. 243), to assess the extent of any local invasion. In all other situations, the pituitary will have already been removed from the sella turcica (see Fig. 9.5). The gland can then be weighed and measured, to identify and quantify any atrophy or hyperplasia.

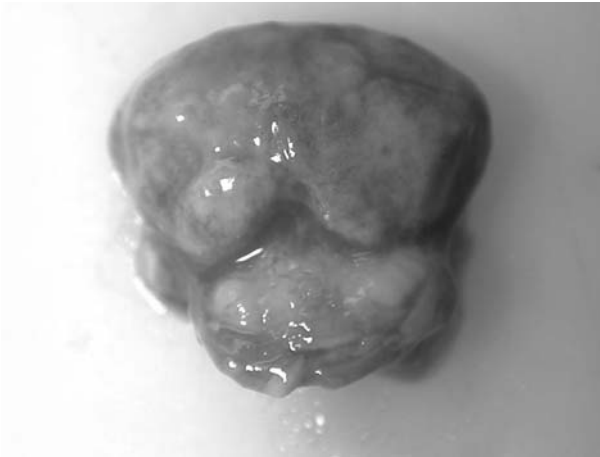


FIGURE 9.5. Photograph of the normal pituitary gland with the stalk inferiorly. (Courtesy of Mr. Dean Jansen, Whittington Hospital.)

Average weight of pituitary gland [1] 0.6 g (up to 1 g in pregnant women)  
 Average size of pituitary gland [1]  $2.1 \times 1.4 \times 0.5$  cm

The gland should then be bisected through the stalk in a sagittal plane, and the cut surfaces of the anterior and posterior lobes examined to identify any small focal lesions (see Fig. 9.6). Any focal lesion should be sampled in its entirety for histology. Apparently normal pituitary should also be submitted for histology if indicated by the clinical history or macroscopical findings, providing that the appropriate consent has been obtained.

#### Clinical Correlation

A significant reduction in gland weight indicates atrophy and should prompt the prosector to look for other signs and associations of pituitary underfunction. A significant increase in gland weight usually indicates a pituitary tumour, although more rarely it can be caused by hyperplasia.

Focal lesions are usually adenomas and can be typed histologically using immunohistochemistry for secretory hormones. Carcinomas are very rare.

## Special Techniques

### *Examination of the Pituitary Gland When a Large Tumour Is Present*

If a large pituitary gland tumour has been identified clinically or is suspected at post mortem, it is preferable to remove the entire sella turcica en

bloc rather than removing the pituitary gland in the normal way. This en bloc removal allows an accurate assessment of size and extent of invasion that is not possible from the sellar pituitary tissue alone.

The brain should be removed in the normal way, and the dura mater stripped completely from the base of the skull. An electric saw with a fan-shaped blade should then be used to remove the central portion of the base of the skull, including the sella turcica and the surrounding bone. The technique is a difficult one, and therefore should be undertaken with great care and only when necessary. The main risk is of causing fractures within the base of the skull, which may produce instability, and if they involve the orbital plate can lead to sinking of the globes and thus make reconstitution difficult. Nevertheless, providing this technique is undertaken (or at least supervised) by someone with experience in using an electrical saw (usually a technician) there will be no external evidence that this procedure has taken place.

Coronal cuts should be made about 1 cm in front of the anterior clinoid process and about 2 cm behind the posterior clinoid process, anterior to the foramen magnum. These two cuts should extend about 1 cm lateral to the sella turcica on each side. They should then be joined by two parasagittal cuts. Figure 9.7 illustrates the saw cuts that need to be made. All such cuts need to be made through the full thickness of the base of the skull, where-

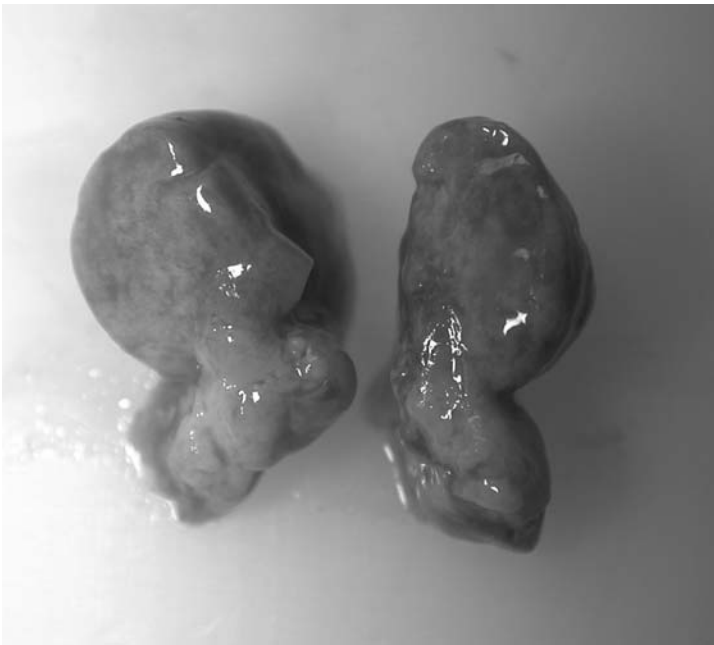

FIGURE 9.6. Photograph of the pituitary and stalk bisected in the sagittal plane and showing the cut surfaces. (Courtesy of Mr. Dean Jansen, Whittington Hospital.)

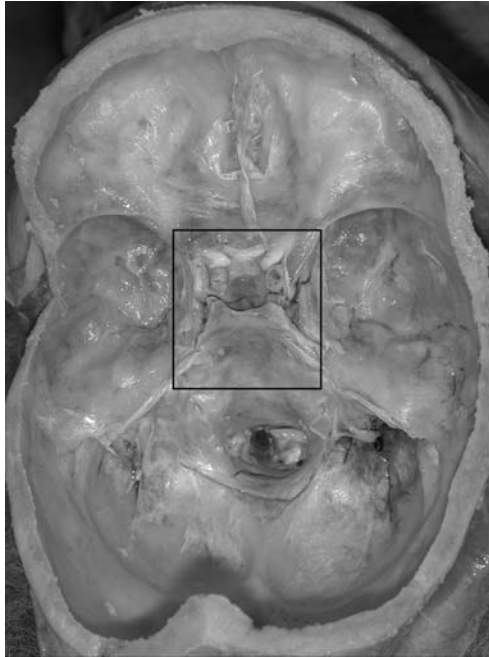


FIGURE 9.7. Photograph of the base of the skull. The box indicates the position of the saw cuts necessary to remove the sella turcica en bloc. (Courtesy of Mr. Dean Janssem Whittington Hospital.)

upon an immediate lack of resistance will be felt. The central bony section produced can then be levered to each side and a scalpel used to cut through the soft tissues of the nasopharynx. This should completely free the block of bone and allow its removal. The entire block can then be decalcified, following which it can be sectioned, examined, and appropriate tissue blocks taken for histology. The need for decalcification will inevitably lead to a delay in the report. If a histological diagnosis has not previously been made, therefore, and is needed more urgently, a small piece of the tumour can be removed (either with a biopsy needle or scalpel) and submitted for immediate histology while the residual tissue block is being decalcified.

## Other Special Techniques

### *Examination of the Paraganglion System*

#### Anatomy

The paraganglion system is composed of clusters of cells of neuroendocrine derivation secreting various bioactive amines and peptides, the most



important of which are the catecholamines. The largest paraganglion is the adrenal medulla. The extra-adrenal paraganglion system is closely associated with the autonomic nervous system and is composed of paraganglia that are very difficult to identify macroscopically unless they are enlarged by tumour. They are divided into three groups based on their anatomical distribution: branchiomic, intravagal, and aortosympathetic. The branchiomic and intravagal paraganglia are associated with the parasympathetic system and are located close to the arteries and nerves of the head and neck; the intravagal are closely associated, as the name implies, with the vagal nerve. Some of the branchial paraganglia are also chemoreceptors. The aortosympathetic paraganglia are associated with the chain of sympathetic ganglia and are therefore distributed about the abdominal aorta. Most paraganglia are named according to nearby structures, but there is a group about the aortic bifurcation at the origin of the inferior mesenteric artery called the organs of Zuckerkandl!

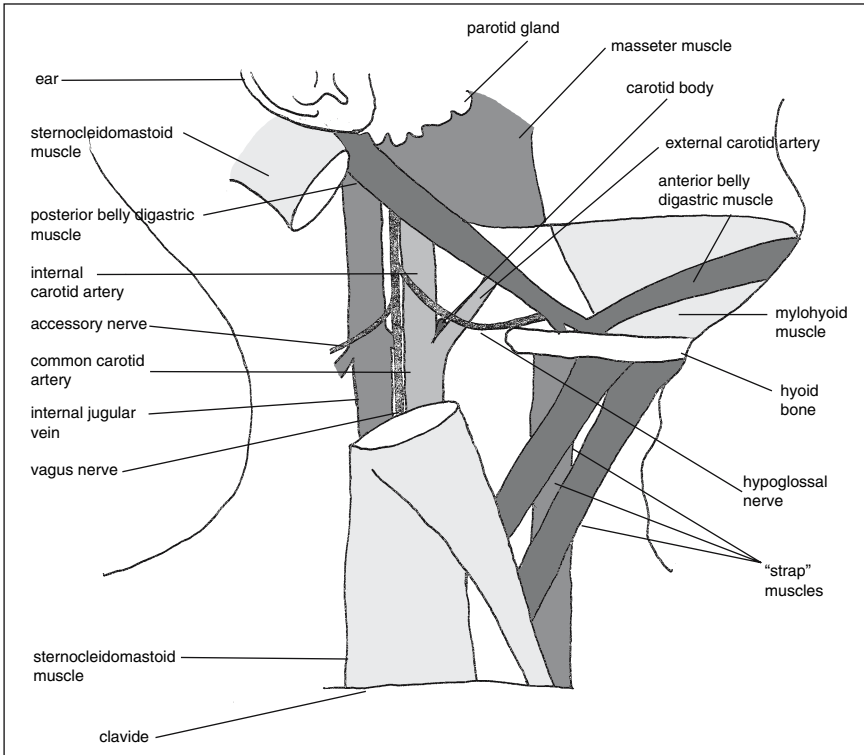


FIGURE 9.8. Diagram illustrating the position of the carotid body in relation to the surrounding structures of the neck. The lymph nodes and submandibular salivary gland have been removed.

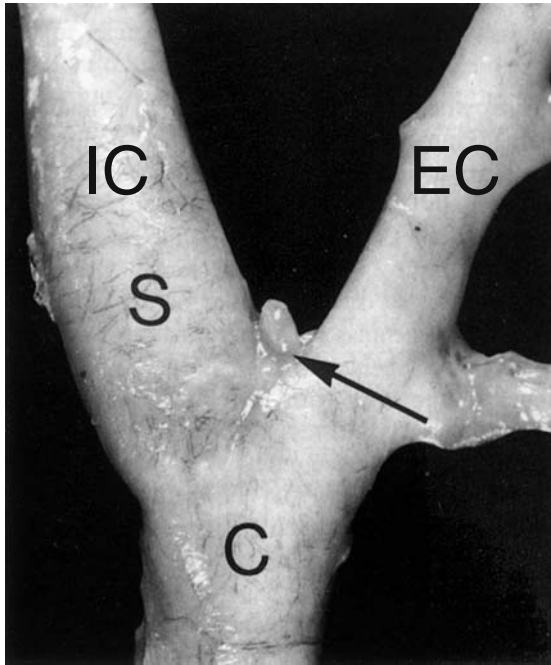


FIGURE 9.9. A normal carotid body (*arrow*) at the carotid bifurcation, after the overlying soft tissue has been carefully dissected free. C, Common carotid artery; S, carotid sinus; IC, internal carotid; EC, external carotid. (Adapted with permission from Harris P and Heath D. *The human pulmonary circulation*. Churchill Livingstone, 1986, p. 486.)

The examination of the paraganglion system is likely to be necessary only when a known primary tumour is present, in which case it will be easy to identify macroscopically, and can simply be removed, weighed, sliced, and appropriate tissue samples submitted for histology.

In certain circumstances, however, it may be necessary to examine the carotid body, for example, in cases of pulmonary hypertension. It is a very small, flattened ovoid mass of tissue attached to the outer wall of the common carotid artery, just in the curve of the bifurcation into external and internal branches. Figure 9.8 illustrates the position of the carotid body in relation to the other neck structures and Fig. 9.9 is a photograph of the carotid body. It should be dissected carefully from the soft tissue at this site, before the carotid artery has been opened. It can then be weighed and submitted for histology. A significant increase in weight suggests chronic hypoxia.

Average weight of single carotid body [2] 0.02 g (range 0.004–0.034 g)

### *References*

1. Sunderman WF, Boerner F. Normal values in clinical medicine. Philadelphia: WB Saunders, 1949.
2. Furbank RA. Conversion data, normal values, normograms and other standards. In: Simpson K, editor. Modern trends in forensic medicine. New York: Appleton-Century-Crofts, 1967; pp. 344–364.

# 10

## The Haematopoietic and Lymphoreticular Systems

For the purposes of this chapter, the haematopoietic and lymphoreticular systems are limited to the lymph nodes, thymus, spleen, bone marrow, and lymphatics. The majority of lymph node groups associated with organs are examined with that particular organ at the time of evisceration and block/organ dissection. More specialised and individual areas of the lymphoreticular system such as the Kupffer cells in the liver will obviously be examined as part of the organ system within which they lie and usually will be evident only histologically. The following are included:

- Lymph node dissection
- Special techniques applicable to lymph nodes
- Dissection of the spleen
- Special techniques applicable to the spleen
- Bone marrow examination
- Assessment of the thymus
- Dissection of the thoracic duct
- Dissection of a mediastinal mass
- The autopsy in sickle cell disease

### The Lymph Nodes

#### *External Appearance*

Superficial lymphadenopathy is likely to be noted either clinically or as part of the external examination. If present, nodes can easily be dissected early during the post mortem and fixed for later examination or collected in a sterile container and sent for microbiological examination. It is not usually necessary to weigh individual nodes and normal sizes and weights for lymph nodes are variable depending on their site. It is rarely necessary to apply special methods when removing lymph nodes and indeed all lymph nodes that may need inspection should have been assessed visually during the evisceration stages. The deeper node groups will be removed at the evis-

ceration stage and will accompany their relevant organs or neighbouring structures. Samples can be retained and processed as described for the superficial nodes.

### *Internal Appearance*

If there is evidence of lymphadenopathy the individual enlarged nodes should be sliced through and the cut surface inspected. The normal appearance of a lymph node is uniformly light grey/tan. When the node is involved by a pathological process, the appearances may be reasonably distinctive for that process. For example, metastatic tumour tends to present as firm to hard areas of often white discolouration within the node, whereas involvement by infection is usually softer and less discrete. Necrosis of course can be present with either. Current tuberculous infection may show as classical zones of caseous necrosis, whereas old tuberculosis tends to calcify.

### *Histology of Lymph Nodes*

When dealing with a lymphoma it is wise to save appropriate tissue (fresh-frozen) for any subsequent molecular studies that may be required (see Chapter 13). With most lymph nodes it is possible to bisect the node, if thought relevant for microscopy, and block one half for histology, but if extremely large a 0.3- to 0.4-cm thick sample should be examined and the remainder retained in case it is required. Special stains may be necessary to characterise nodal processes and these are also discussed in Chapter 13.

### *Special Techniques for Lymph Nodes*

#### Dissection of Nodal Disease with Perinodal Infiltration

Occasionally the pathological process involving the lymph nodes may be so extensive that it infiltrates local structures or completely replaces the node, making identification difficult. Obviously in these cases the mass of tissue should be removed as completely as possible to assess the extent of the disease process and to sample tissue for subsequent histological characterisation of the pathology.

#### Lymph Node Imprints

Dab imprints can be made at the time of post mortem if a rapid diagnosis is needed. It is important to be careful not to press too hard and obscure the cytological detail. This is preferably performed in a safety cabinet because of the potential risk of exposure to infected fresh tissue. Imprints are produced by cutting the node in half and dabbing the cut surface onto clean glass slides. Air-dried preparations can be stained with May–Grunwald–Giemsa and alcohol-fixed slides can be stained with Papanicolou and/or haematoxylin and eosin or kept for any necessary special stains

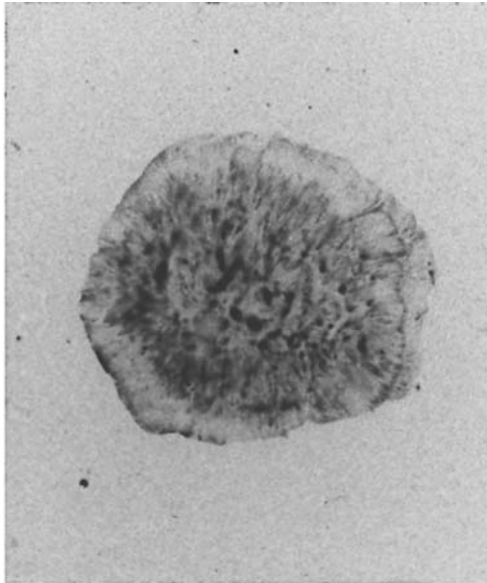


FIGURE 10.1. Dab imprint of a lymph node removed at post mortem. Pressure should be light to avoid obscuring the cellular detail and at least two slides are usually prepared, one air-dried, the other wet-fixed. (Courtesy of Mr. Ivor Northey.)

(Fig. 10.1). These may include special stains for microorganisms or immunohistochemistry. The latter may be extremely important in lymphoma diagnosis.

### Microbiology of Lymph Nodes

When infective lymphadenitis is relevant to the post mortem diagnosis it may be necessary to attempt to identify the causative organism. This then becomes the domain of the microbiologist, but the ability to differentiate confidently between contaminant and pertinent organisms may be very difficult if tissue is sampled in a less than wholly sterile manner. It is important to use new, sterile equipment and to obtain the tissue as early as possible during the examination. A small portion of the node removed in this manner should be sealed in a sterile container and transported to the microbiology department with all of the relevant clinical information included on the request form.

## The Spleen

### *External Appearance*

Whichever method is used for evisceration and block dissection, the spleen will ultimately be isolated from the other organs. A careful record of the

splenic weight is made, with a normal range of 155 to 195 g (see Appendix 2). As mentioned previously, the hilum should be inspected for splenunculi before dealing with the spleen proper. Often pathological processes will involve both. Before slicing the spleen it is important to establish whether it is necessary to send tissue for microbiological investigation, as contamination is extremely easy in the post mortem room and meaningful microbiological studies can be obscured by lack of awareness (see later).

### *Internal Examination*

The spleen should then be sliced through completely in a vertical plane using a large sharp knife. The slices should lie no more than 1 cm apart (Fig. 10.2). The slices can be laid out on the dissecting board for closer inspection (Fig. 10.3). With a normal spleen or spleen involved by tumour (particularly lymphoma), amyloid, or portal hypertension this will be easy but in cases of sepsis the spleen will often be soft and liquefied, and slicing may be impossible. In such cases the demonstration of a liquefied “bag” of splenic tissue is indicative of septicaemia and nothing is usually lost in the inability to inspect the cut surface of slices.



FIGURE 10.2. The spleen is sliced at 1-cm intervals with a large-bladed knife. (Courtesy of Mr. Dean Jansen, Whittington Hospital.)



FIGURE 10.3. The spleen is sliced at parallel intervals of no more than 1 cm apart to demonstrate the parenchyma.

A splenunculus found during an adult post mortem is irrelevant in itself, but if there are many this may be due to previous traumatic rupture and peritoneal seeding. Similar vertical slices should be made to inspect the parenchyma. Samples of the relevant areas need to be taken if there is any macroscopic evidence of splenic pathology. When the spleen appears normal a single block approximately  $3 \times 2 \times 0.3$  cm should be removed for histology, which should include the capsule on one side.

### *Special Techniques for the Spleen*

#### Microbiology of the Spleen

This investigation may be required when there is known sepsis or alternatively may be indicated following an observation noted during the post mortem examination itself, such as peritonitis. An important clue to septicaemia is the presence of a large, wrinkled, and extremely soft spleen (dif-



fluent). Slicing is often difficult and reveals a core of mushy tissue that is liquefied and runs over the capsule as an amorphous mass. If infection is suspected then it is best to obtain splenic tissue or a splenic swab prior to contamination of the spleen during slicing. The capsular surface should be seared with a very hot sterile metal implement such as the flat side of a scalpel blade and a cut made through this area using a sterile scalpel blade. A small piece of deeper splenic parenchymal tissue should then be removed and placed in a sterile container for transportation to the microbiology department. *Alternatively, a sterile swab can be inserted into the original defect and transferred to the microbiological department in a swab tube.*

Microbiological sampling of splenic tissue is summarised as follows:

- Sear the outside of the spleen.
- Separate the edges.
- Introduce the swab or remove a cube of tissue.
- Remove the swab and reintroduce into a transport tube or place the tissue into a sterile container.
- Label all specimens and tubes.
- Complete the request form with all relevant information and hazard stickers if necessary.

### Fixing the Spleen Whole

Rarely, it may be felt necessary or appropriate to keep the spleen whole for later dissection. In these cases consent must be sought before the spleen is retained. To prevent further autolysis it is possible to inject fixative through the splenic artery at moderate pressure while the splenic vein is clamped.

## Bone Marrow

Bone marrow should be examined in cases of hereditary haemoglobinopathies, haematological malignancies, lymphomas (for staging), disseminated cancers, and generalised infections. There are two main sites for examining the bone marrow. The first is to inspect a long bone such as the femur, which gives a good idea of the quantity of any expansion in haemopoietic tissue. This is fully described in Chapter 11 on p. 261 and is not repeated here. The second area for assessment is within the vertebral bodies. In adults most of the haemopoietic marrow is concentrated in the axial skeleton and it is very easy to either use the electric saw or even a handsaw to remove the anterior portions of the lumbar vertebral bodies and inspect the exposed marrow. This can be performed most easily by approaching the vertebral column from the anterior aspect after all of the organs have been eviscerated. All of the bulky paravertebral skeletal

muscle (e.g., psoas and paraspinal muscles) and soft tissue should be removed using a PM 40 to allow easier access for sawing. This also prevents the soft tissue from causing dangerous slippage of the electric or hand saw. Sawing begins along the lateral border of the vertebral bodies bilaterally and the cut is extended around the lower border of the lumbar spine just above the pelvis. A superior cut is then made with a large scalpel (PM40) through the surrounding soft tissue and through an appropriate disc/disc space. This block of tissue can now be lifted off and the undersurface examined. The tissue can be decalcified (following the method discussed later) before sampling for histological examination or a small block cut prior to decalcification.

Rarely, it may be necessary to examine bone marrow from the sternum. For this the sternum is removed in the usual way and a cut is made across the bone with a handsaw to expose the integral marrow tissue. The latter can be scooped out with a curette for fixation and microscopy.

### *Special Techniques for Bone Marrow*

#### Decalcification of Tissue for Bone Marrow Histology

When histological assessment of the bone marrow is required, it will usually be necessary to decalcify the tissue prior to preparation of the sections. This is also essential for diagnosis of any calcified lesions or bony tumours. It is first important that an adequate sample of the relevant tissue is fully fixed before any of the following methods of decalcification are started. Decalcifiers are either acids or chelators. The acids may be strong or weak but the latter is preferable, as preservation of staining characteristics is superior. One of the most commonly used techniques is immersion of the fixed tissue in formic acid (5% to 10% solution) which is then left for an appropriate length of time. With small pieces of tissue, decalcification will require only a matter of 24 to 48 hours, but larger segments of tissue will need longer periods. In the latter situation, it may be necessary to take serial X-ray films of the specimen to assess the amount of calcium still present in the tissue. Once appropriately decalcified, blocks of the usual size can be trimmed from the specimen and sections cut in the routine way. *An alternative is to embed the bone marrow in resin which can be sectioned on a special microtome without the need for decalcification.*

If the calcified tissue is not in fact appreciated until the sectioning stage then only brief surface decalcification may be necessary. The block is either bathed in 1% hydrochloric acid for 15 to 60 minutes prior to sectioning or the block is placed face down on a cotton wool pad soaked in 10% hydrochloric acid before the sections are cut. It should be remembered that with all of these methods there may well be some resultant loss of staining ability in the tissues.

## The Thymus

In the vast majority of adult post mortems the thymus will not be relevant to the cause of death and it is rarely the site of significant pathology. As it naturally atrophies with age it is either glossed over or not appreciated in the course of most examinations. The size of the thymus gland is therefore extremely dependent on age and is given in Appendix 2. Certain pathological processes may involve the thymus in adults, and in these cases the thymus should be removed complete and histology taken. The method for removing a thymic tumour follows the description given later in this chapter for any mediastinal mass. Blocks approximately  $3 \times 2 \times 0.3$  cm should be removed from a thymic tumour, including samples from the periphery/normal tissue junction, for histological assessment.

In young children and infants the thymus may be more relevant to the underlying pathological process and is usually more conspicuous. It becomes part of the routine examination. It should be weighed accurately and examined carefully both macroscopically and microscopically with at least one block taken for histology (see Chapter 14).

## Other Special Techniques

### *Dissection of the Thoracic Duct*

The thoracic duct is a structure that is conventionally ignored during the post mortem examination. It may be relevant in some settings, however, to dissect out the duct. The most likely situations include necropsies with malignancy, tuberculosis, and situations with a chylous pleural effusion. The thoracic duct is a thin-walled cord-like lymphatic vessel that originates at the cisterna chyli adjacent to the lower end of the abdominal aorta on the right side. It passes superiorly beside the aorta through the diaphragm. In the thorax it passes across the midline, medial to the main azygous vein on the left, at the level of the aortic arch/fifth thoracic vertebral body. It then runs posteriorly above the large arteries and veins passing to or returning from the left shoulder and arm and sweeps down and enters the left brachiocephalic or subclavian vein.

It is wise to identify the thoracic duct before the main thoracic evisceration takes place, as this thin-walled structure is rather difficult to assess afterwards. This is best accomplished by lifting the left lung forward and inspecting the posterior mediastinum. The intercostal arteries are transected close to the aorta in the lower part of the mediastinum. The aorta is pulled to the right to expose the retro-aortic adipose tissue and the thoracic duct is identified. This is then held with forceps while the duct is dissected off its neighbouring tissues superiorly and inferiorly, cutting across the remaining intercostal arteries. Dissection can be aided by injecting warm

5% gelatin into the duct in order to aid visualisation and provide a firm structure to grasp, although in practice this a laborious procedure that is very rarely performed. Barium sulphate can also be injected at this time if post mortem lymphangiography is considered necessary. If the thoracic duct is obviously macroscopically abnormal, tissue can be taken for microscopic investigation in as sterile a manner as possible.

### *Removal of a Mediastinal Mass*

The following technique should be followed whenever a large mediastinal mass is present, as it is important to identify the site of origin of the pathology and this may not be achievable once the individual organs have been removed. This method is also applicable to cases with mediastinitis with or without interstitial emphysema. Any of the general preparation techniques are reasonable but when the sternum is removed this should be done with particular care, as damage to substernal tissue may make further assessment difficult. With large masses it is likely that pleural extension will be present and so it is best to release the parietal pleura from the chest wall to keep it in continuity with the intrathoracic organs (described more fully in Chapter 3). Rarely, it may be necessary to cut the local sternal bone involved by the mediastinal disease with a saw and remove it with the mass in continuity.

The mediastinal structures should now be removed as a unit following either the en bloc or en masse technique as previously described. If the en masse method is used the upper structures will need to be separated from the abdominal organs by dividing all of the soft tissue just above the diaphragm exactly as described for removing the thoracic pluck of Ghon's evisceration technique. Depending on the suspected pathology and the size of the lesion it should now be possible to separate those organs that are not involved and remove them one by one following standard procedures (i.e., the Ghon or Virchow methods previously described). This will obviously be most appropriate and easiest for small tumours but less suitable for large-scale disease processes.

With larger tumours or inflammatory conditions infiltrating its neighbouring structures, there are two possible ways to best demonstrate the pathology macroscopically. The first and probably the easiest is to leave the aggregate of organs intact and make large transverse sections through the whole block of tissue with a large sharp knife, leaving about 1 to 2 cm between slices. This can be performed either on the fresh tissue or after the block of tissue has been fixed complete to be sliced later.

*Alternatively, the routine thoracic block dissection method can be followed. This is probably performed more easily from the posterior aspect for anterior mediastinal tumour and it may be easier to open all of the surrounding organs in the mediastinal block and leave the main mass for dissection after assessing these other structures.* It is important to remember that

mediastinal masses need not necessarily be neoplastic in nature and that some may actually be inflammatory, such as sclerosing mediastinitis or tuberculosis. Obviously with the latter and a risk of infection, this should be handled appropriately.

If consent has been obtained, blocks of the usual size (up to 0.3 to 0.4 cm thick) should be taken for histology in the normal logical way, with areas of tissue sampled from the main mass, the junction between mass and adjacent tissue, and all other relevant organs.

## The Post Mortem in Sickle Cell Disease and Trait

Deaths in patients with sickle cell disease and sickle trait require careful clinicopathological correlation and if the approach described in this text for a routine examination is adhered to, the cause of death should become apparent if it is ascertainable. Experience has shown, however, that pathologists encounter difficulties when assessing sickle-related deaths.

The examination should take place as soon after death as possible to avoid potential problems with interpretation of red cell morphology. Occasionally red cells sickle after death and sickled cells unsickle [1]. It is essential to obtain all clinical information, including hospital notes, radiographs, and results of all recent tests, including microbiology. The case should be discussed with the appropriate clinicians prior to the examination to obtain a clear sequence of events leading to death. The clinicians should be invited to attend the examination, or at least attend the demonstration afterwards, to discuss the findings.

If an overdose of painkilling medication is suspected then blood and urine samples should be taken early during the examination and sent for toxicological analysis. Blood and lung tissue samples should be obtained for microbiological assessment. The heart is examined particularly carefully for all causes of sudden cardiac death (in the appropriate clinical setting). Histology should be taken from all relevant organs. In particular the heart, lungs, kidneys, muscle, and bone (with marrow) should be examined histologically. Samples should be fixed in buffered formalin to reduce post mortem intravascular sickling.

The haematopoietic and lymphoreticular systems examination is summarised as follows:

- Lymph nodes are assessed during evisceration or block dissection and sliced if necessary.
- The thymus is examined during evisceration.
- The thoracic duct is identified and examined during evisceration.

- The spleen is sliced after removal.
- Bone marrow is assessed when required.
- Special techniques are employed as necessary.

### *Reference*

1. Royal College of Pathologists. Guidelines on autopsy practice, 2002.

# 11

## The Musculoskeletal System

The routine examination of the musculoskeletal system is usually limited to a careful visual examination, although in some departments the removal of the femur is also part of every post mortem. All further examination of this system, therefore, will be described within the special techniques section. None of these special techniques should be undertaken unless absolutely necessary, both because of the inevitable degree of mutilation produced and the technical time and effort required for reconstitution.

This chapter includes:

- Two methods of examining the femur
- Assessment of osteopenia
- Accessing the various parts of the skeleton
- Dealing with fractures
- Dealing with bone tumours
- Dealing with soft tissue tumours
- Dealing with joint diseases

As discussed in Chapter 2 (p. 61) post mortem radiology may be helpful in trauma cases, particularly if no pre mortem X-ray films are available. X-ray films of bones that have been removed are much easier to interpret than in vivo radiographs, and this is therefore the best technique if a single area (such as the cervical spine) is under investigation. This also has the advantage of portability. In vivo radiographs will obviously be necessary if the suspected bony injuries are more extensive; however, most mortuaries are not equipped for whole body radiography so this will require transportation to and from the radiology department or a portable X-ray machine. If sinus tracts are present and open onto the skin surface, their course can be investigated radiologically before dissection by injecting contrast media into the opening (see p. 178 for composition of media).

## Routine Examination

During the external examination, any joint swellings or deformities should be noted and related to the clinical information. The distribution of joint involvement will aid identification of the exact disease process, if it is not already documented. More specific features, such as Heberden's nodes or rheumatoid nodules, will also be helpful. Limb, vertebral, and girdle deformities can usually be identified externally, although vertebral and girdle deformities will be seen more clearly after evisceration. The possibility of a fractured femur should always be considered and is often indicated by an abnormally positioned lower limb with true leg shortening. When measuring leg length, it is important to use the same anatomical landmark—usually the anterior superior iliac spine—on each side, to avoid apparent leg shortening due to a tilted pelvis. If there is any suspicion of femoral fracture, it is essential that an open inspection or examination of the femur be undertaken. In addition, any muscle wasting should be noted, although is difficult to identify when it is bilateral unless very marked. If unilateral wasting is suspected, it should be confirmed by limb circumference measurements. Again these must be made from the same point on each side, using a landmark such as the heel or patella.

After evisceration, spinal and rib deformities are also easily visually assessed. The pelvic girdle can also be visualised, although such an examination is obviously somewhat limited. It is not possible to inspect the shoulder girdle in the same way; however, fatal injury at this site is rare and specific examination is not necessary unless directed by the clinical information.

## Common Special Techniques

### *Removal of the Femur*

The femur is usually removed to assess haematopoietic tissue and should also be removed during the investigation of fractures, surgical prostheses, and bone tumours. In addition, removal may be necessary for the assessment of undocumented degenerative joint disease. An anterior horizontal incision should be made, about 5 cm below the patella, from a medial to a lateral position. This cut is then continued upwards along the lateral aspect of the thigh, to end just above the hip joint (see Fig. 11.1).

The depth of the initial skin and subcutaneous incision is then extended, to reach the underlying femur. The skin, soft tissue, and musculature above the knee should then be reflected to expose the patella. If the knee is then flexed, the joint capsule, the medial and lateral ligaments, and the cruciate ligaments can be divided with a knife. The lower femur can then be held in one hand and the muscles separated from bone, beginning at the knee and



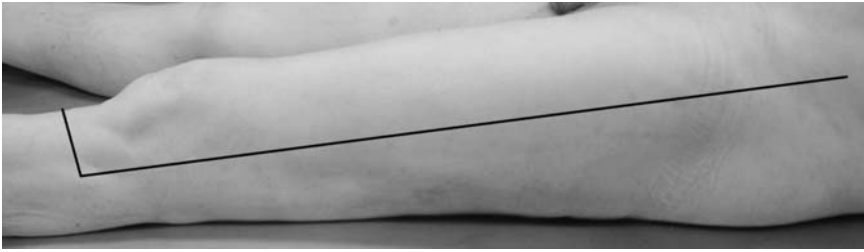


FIGURE 11.1. Photograph of the left thigh from a lateral aspect. The line indicates the necessary incision during removal of the femur. (Courtesy of Mr. Dean Jansen, Whittington Hospital.)

ending just below the hip joint. As the bone is cleared, it can be pulled laterally to aid further clearance. If the femur is then both rotated laterally and lifted, the capsule of the hip joint is exposed, and can be incised. The head of the femur can then be dislocated, using further forced rotation, and the last remaining soft tissues separated.

If a fracture is present, the femur will have to be removed in two parts: above and below the fracture site. The site itself can then be examined and X-ray films taken if necessary. Any sampling for microbiology should be undertaken as soon as the fracture is exposed. Once removed, a saw can be used to obtain histological samples if necessary. Appropriate consent is, of course, required for any such sampling. The femur can then usually be replaced.

If the femur is removed for haematological reasons, a band saw can be used to bisect the femur lengthways. The extent of active haematopoiesis, as evidenced by a red/brown marrow cavity, can then be noted; any distal activity is abnormal in an adult. Marrow can then be scraped from the marrow cavity, decalcified, and submitted for histology. Alternatively a saw can be used to obtain slivers or slices of bone and bone marrow for histological examination. The two halves of the femur can then be bound together and replaced inside the body, effecting good reconstitution.

If the femur is removed to examine surgical intervention, any surgical fixation device or prosthesis can be examined, its integrity assessed and its degree of fixation noted. Soft tissue from about the device should also be taken for microbiology, using a sterile scalpel and forceps, as soon as it is exposed. Once removed, the fixation device or prosthesis itself can also be submitted for microbiology.

If the femur is removed for the purposes of investigating a bone tumour, care must be taken when stripping the attached musculature from the femur, so that the tumour itself, together with any local invasion of soft tissue by tumour, is left intact. To this end it is probably better to leave the

bulk of the musculature attached to the femur while removing it, and to carefully dissect the uninvolved soft tissue from the femur once removed. The bone can then be divided in half using a band saw, examined, and appropriate pieces removed for histology. The plane of section will depend on the position of the tumour, but bisection lengthways is likely to be the most appropriate. Although at least part of the femur will need to be removed for histology, enough should remain to allow reconstitution by replacing what is left of the femur. If the femur is to be retained in its entirety, however, a wooden pole wrapped in cotton wool can be used as a prosthesis for reconstruction.

The ideal method of investigating joints is discussed on p. 277, however, the removal of the femur does allow some examination of both knee and hip joints. Synovial fluid can be removed via a needle and syringe from either joint before the joint capsule is incised and cartilage and/or synovium may be sampled for histology and/or microbiology.

### *Sampling the Femur for Haematological Investigation*

If the removal of the femur is not possible, owing to limited consent or technical constraints, the femur may be sampled for haematological investigation. This is worthwhile only in a child or in an adult with a known haematopoietic malignancy, as haematopoietic tissue is present only proximally in a normal adult femur, and the exact extent is extremely variable. A longitudinal incision should be made in the lateral aspect of the thigh, about 8cm in length, and at a point approximately midway between the knee and the hip. A horizontal incision is then made at both ends of this longitudinal incision, extending both anteriorly and posteriorly for about 4cm, making an H-shaped structure (see Fig. 11.2). The depth of these incisions is then extended to reach the underlying femur. A retractor, or




FIGURE 11.2. Photograph of the left thigh from a lateral aspect. The line indicates the necessary incision when sampling the femur for haematological investigation. (Courtesy of Mr. Dean Jansen, Whittington Hospital.)

another pair of hands, can then pull back the two skin and tissue flaps and expose the femur. An oscillating saw with a fan blade should then be used to remove an approximately 2 cm length of the full circumference of the femur. This can be decalcified and submitted for histology.

*Alternatively, the femur can be exposed as for its removal, described earlier. An oscillating saw can then be used to bisect the femur longitudinally, from a point just above the knee joint to a point just below the hip joint. This half of femur can then be removed using a horizontal cut through half of the bone at each end of the longitudinal cut. A length of bisected femur is now available to allow assessment of the marrow. This can be retained or replaced in the body, but no formal reconstitution is required as the other half of the femur and the joints are still in place.*

### *Assessment of Osteoporosis*

Osteopenia is defined as loss of bone density, and is the more correct term, as by definition a diagnosis of osteoporosis can be made only if this loss of density is pathological. Its identification can be vital, particularly in cases where a single fracture has led to death, as its presence indicates a pathological fracture rather than a traumatic one. In a medico-legal case, this is likely to make an inquest unnecessary, as a pathological fracture caused by osteopenia/osteoporosis is often considered a “natural” cause of death, and as such needs no further investigation. Although it is possible to use post mortem bone scanning or quantitative mechanical fractureability to assess osteopenia, this is usually used only for research purposes. The routine assessment of osteopenia at the time of post mortem is therefore usually qualitative rather than quantitative and, inevitably, somewhat subjective.

One technique follows evisceration and involves making an assessment of the residual vertebral bodies, using direct pressure with the thumb, after an anterior strip of vertebral column has been removed. This is done by first removing the psoas and paraspinal muscles, and then using an oscillating saw to bisect the vertebral column coronally. It is usually possible to complete this cut from one side of the vertebral column. The saw cut is then continued about the lower lumbar vertebra at the lower end, and a scalpel is used to cut through an appropriate cervical disc space at the upper end. The anterior half of the vertebral column can now be removed. This “thumb” assessment has been semiquantified using a grading system [1]:

- 1 = very soft
- 2 = soft
- 3 = moderate
- 4 = hard

Another technique also follows evisceration and involves taking the anterior cut end of a rib and deforming it between the finger and thumb

until it fractures. Although ribs are composed predominantly of cortical bone, and osteopenia affects primarily trabecular bone, this rib fracture-ability method appears to be both sensitive and reproducible. The result can again be graded semiquantifiably [1]:

- 1 = easy to fracture
- 2 = fairly easy to fracture
- 3 = moderately easy to fracture
- 4 = fairly difficult to fracture
- 5 = difficult to fracture
- 6 = very difficult to fracture

Bone histomorphometry can be performed on histological samples of trabecular bone taken at post mortem, usually from a vertebral body, and allows an accurate measurement of cortical bone thickness, cortical bone area, bone volume, and trabecular surface area. This requires resin embedding of the bone for histology, as the decalcification process prevents adequate identification of the osteoid seam and therefore does not allow a full assessment of any possible metabolic bone disease. Results from such ancillary investigations, however, are time consuming and obviously would not be available at the time of post mortem.

When compared against the measurement of maximum stress at failure of the femoral neck—an acceptable “gold standard” for the diagnosis of osteopenia—studies have somewhat surprisingly shown the rib deformation technique to be at least as accurate as morphometrical studies [2].

## Accessing the Skeleton

### *Accessing the Long Bones of Limbs*

Whichever long bone is to be accessed, the general principle is the same as that for the femur (described on p. 261). The skin should be incised along the lateral aspect of the limb, from just above the proximal to just below the distal joints. The incision should extend horizontally at one end, usually at the hinged joint if one is present (see Fig. 11.3 for an example). It can then be deepened to extend to the underlying bone. Starting at the end with the horizontal incision, the joint capsule and ligaments are severed. The soft tissues are then delicately reflected off the bone, pulling the bone laterally to maximise exposure. When the other end of the bone is reached, the joint capsule and ligaments can be severed and the bone removed. It can then be examined and any histological samples taken. Examination is usually best achieved by bisecting the bone longitudinally with a band saw. Decalcification of part or all of the specimen will obviously be necessary before blocks can be taken for histology. Reconstitution can be effected by bone replacement after examination and sampling, or by using an appropriate

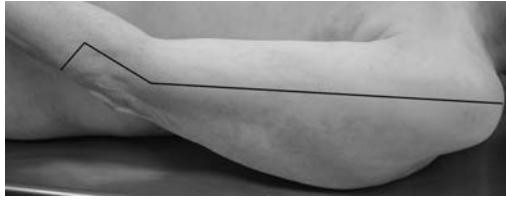

FIGURE 11.3. Photograph of the left upper arm from a lateral aspect. The lines indicate the necessary incisions when removing the humerus. (Courtesy of Mr. Dean Jansen, Whittington Hospital.)

length of wooden pole in place of the bone, if the entire bone is to be retained.

Small bones of the hands and feet are more difficult, but a single incision longitudinally over the extensor surface of the joint, with a horizontal extension at one end to produce a flap, will expose the appropriate bone (see Fig. 11.4). If the joint under the horizontal flap is then flexed, the joint capsule and ligaments will be exposed, and can be separated with a knife. The bone can then be dissected from the adjacent soft tissues until the other joint is similarly exposed. The capsule and ligaments can again be cut with a knife, and the bone removed. After examination and any histological sampling, it can be returned to the body or retained; any resultant defect is packed with cotton wool.

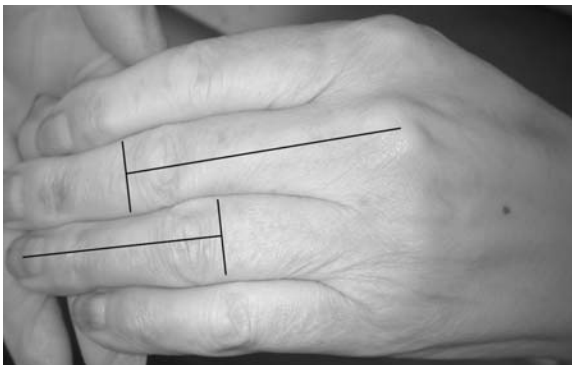


FIGURE 11.4. Photograph of the left hand from the dorsal aspect. The lines indicate the necessary incisions when removing long bones from the hand. (Courtesy of Mr. Dean Jansen, Whittington Hospital.)

## *Accessing the Vertebra*

The vertebral column can be accessed anteriorly once evisceration is complete. It is possible at this point to remove the entire vertebral column, although this is rarely necessary as removing the anterior half of the vertebral bodies is usually sufficient.

### Method 1: Removing the Anterior Half of the Vertebral Column

This is done by first removing the psoas and paraspinal muscles, and then using an oscillating saw to bisect the vertebral column coronally. It is usually possible to complete this cut from one side of the vertebral column. The saw cut is then continued about the lower lumbar vertebra at the lower end, and a scalpel is used to cut through an appropriate cervical disc space at the upper end. The anterior half of the vertebral column can now be removed. This anterior strip can then be examined and any histological samples taken, providing that appropriate consent has been obtained. It can then either be retained or returned to the body cavity.

### Method 2: Removing the Entire Vertebral Column

This is best accomplished from an anterior approach. Once the vertebral column has been exposed by removing the psoas and paraspinal muscles, the vertebral ends of the ribs must be cut through on either side, using an oscillating saw. The sacrum should then be separated from the iliac bones via an oblique saw cut on each side, again with an oscillating saw. The vertebral column must then be separated from the skull via cutting through the atlanto-occipital joints. This latter procedure requires experience and practice to get the angle right.

*Alternatively, it is much easier to separate the vertebral column from the skull by sawing through the atlas vertebra. This is therefore recommended for all cases except those in which the cervical spine is of paramount importance—as of course both the upper cervical spine and the vertebral arteries will be damaged by this procedure.*

The vertebral column can then be lifted forward from the sacrum and separated from the skin and soft tissues of the back with a short-bladed knife, such as a PM40, taking care not to damage the skin. The resulting defect can then be filled with an appropriate length of wooden pole or the vertebral column can be replaced following examination and histological sampling. Examination of the undecalcified vertebral column is best undertaken using a band saw. The plane of section can be varied depending on the lesion that is thought to be present, although sagittal bisection is often best. Samples can then be removed for histology, providing appropriate consent has been obtained, although these will require decalcification before tissue blocks can be taken.

### *Accessing the Skull*

The skull is also easily accessed, as described in Chapter 3, p. 110. Any lesions within the calvarium can obviously be examined both before and after removal. Once described, however, it is better to restrict their histological sampling to core biopsies, as in the pelvis, as the calvarium is needed for adequate reconstitution, and cannot be easily simulated. The base of the skull can be visually inspected and palpated once the brain has been removed. Removal of the middle ear and pituitary fossa may be necessary, and are described elsewhere (see pp. 116 and 243, respectively).

### *Accessing the Ribs*

Ribs are easily accessed once evisceration is complete. First, the skin and overlying musculature of the chest wall must be dissected free from the ribs, as far posteriorly as is possible. It should be possible to reach the vertebral column posteriorly, although to do so will require additional skin incisions and dissection posteriorly. To do this, a T-shaped incision should be made in the skin and subcutis of the back, with the body in the prone position (see Fig. 11.5). This is a messy procedure after evisceration and therefore best done at the start of the autopsy if possible. The skin and underlying soft tissue can then be dissected off the chest wall (as done anteriorly when preparing the body; see p. 69) until the lateral wall is reached. At this point, the anterior dissection will meet the posterior dissection, freeing the entire chest wall from its overlying skin and subcutis.

Once this skin and subcutis dissection is complete the ribs are exposed in their entirety. A knife can then be used to cut through the intercostal

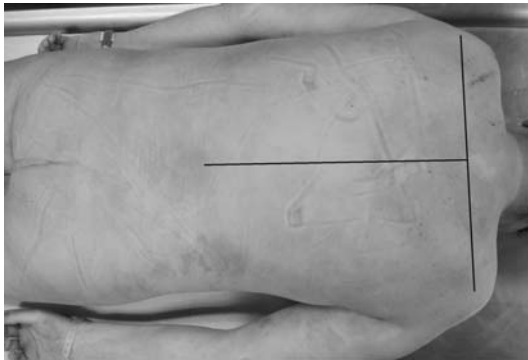


FIGURE 11.5. Photograph of a prone body. The line indicates the necessary incision when accessing the posterior ribs or scapula. Note the artefactual marks on the skin from the “block” placed under the body during evisceration. (Courtesy of Mr. Dean Jansen, Whittington Hospital.)

muscles between each rib. The ribs can then be closely examined, by a combination of visual inspection and palpation. Any rib can then be removed by cutting through its vertebral attachment with an oscillating saw. After examination and any histological sampling, it can either be retained or returned to the body cavity. Decalcification will obviously be necessary before blocks can be taken for histology.

### *Accessing the Shoulder Girdle*

With respect to the shoulder girdle, the clavicle is obviously easily accessible and can be removed for examination either during or after evisceration. It is not possible to access the scapula anteriorly, however, but the need for such examination is rare. If thorough examination is necessary, the scapula can be examined from the posterior aspect with the body in a prone position. As always, because turning the body after evisceration is such a messy procedure, this examination should be done at the beginning of the autopsy if possible. A T-shaped incision should be made in the upper back, with the “bar” of the T extending horizontally from shoulder to shoulder and the shaft of the T extending longitudinally down the centre of the back to reach the waist (see Fig. 11.5). The skin and subcutis can then be dissected free from the underlying chest wall. The musculature can then be dissected free from the underlying scapula and rib cage. The posterior surface of the scapula is now exposed. The entire scapula can then be removed by first separating the two lateral joints with a knife, and then pulling the bone posteriorly with one hand while dissecting it free from the musculature underneath it with the other hand, using a scalpel. Once examined and any histological samples taken, it can be returned to the body for reconstitution. If desired, the scapula can also be retained, and the resultant defect packed with cotton wool. Examination may require using a band saw, and obviously the tissue will have to be decalcified before blocks can be taken for histology.

### *Accessing the Pelvic Girdle*

The pelvic girdle is accessible for visual inspection and palpation once evisceration is complete. The removal of individual bones, however, is extremely difficult and can be mutilatory. For these reasons, any histological sampling is best undertaken via removal of a small area of bone with an oscillating saw or via a trephine biopsy; both of which can be multiple if necessary. It may be necessary to access the pelvis posteriorly, in which case this is best undertaken at the start of the autopsy, as turning the body is a messy procedure after evisceration. An X-shaped incision should be made in the lower back, one “arm” of the X travelling from the left lateral aspect of the waist to the posterolateral aspect of the upper right thigh and the other “arm” of the X travelling an opposing course from the right waist to the left thigh



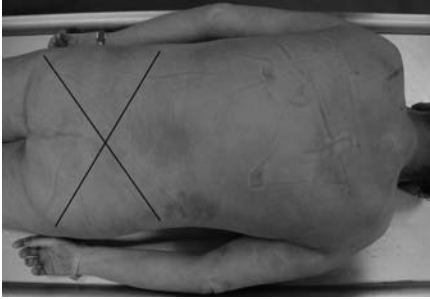


FIGURE 11.6. Photograph of a prone body. The lines indicate the necessary incisions when accessing the pelvis. Note the artefactual marks on the skin from the “block” placed under the body during evisceration. (Courtesy of Mr. Dean Jansen, Whittington Hospital.)

(see Fig. 11.6). The skin and musculature can then be dissected free from the underlying pelvic girdle to expose the bones. The massive bulk of the gluteal muscles is somewhat difficult to reflect, so another pair of hands is useful at this point. Part of a bone or trephine biopsies can then be taken as before.

## Other Special Techniques

### *Dealing with Fractures (Other than Cervical Spine)*

Relevant in vivo X-ray films, either pre or post mortem, may be sufficient for the documentation of fractures, although some fractures are not easily identified (e.g., rib fractures). Certain situations, however, will require detailed documentation of fractures; for example, cases of traumatic injury in which the circumstances are unclear. Fractures can be identified by a combination of direct vision, palpation, and stressing of the bone, preferably following either exposure or removal of the bone in question. X-ray films of a removed bone are also useful, as fractures are much more easily identified than in vivo.

All fractures must be fully documented, preferably using pictorial charts as well as a description. Examples of some of these charts are shown in Fig. 11.7. In a medico-legal case, it is of even greater importance to document such fractures well, with detailed descriptions as to length, course, and position. Photographs are also useful. Histology of fracture sites is rarely necessary; however, it may be advisable to take tissue for microbiology, if the clinical history suggests the possibility of infection. This must be done using sterile forceps and a scalpel or bone clippers, as soon as the fracture is exposed. Sampling for any purpose can only be undertaken, however, with the appropriate consent.

### Long Bones

Long bones of the limbs are accessible as described on p. 265. Although it is obviously preferable to expose the bones in this way, palpation and exam-

ination of the limb will often identify the sites of fractures. This, together with post mortem radiology, which is more accurate in the limbs than elsewhere, may make the exposure and removal of the long bone unnecessary.

### Ribs

Ribs are obviously easily accessible, as described on p. 268. In addition to visual inspection and palpation, haemorrhage within the intercostal mus-

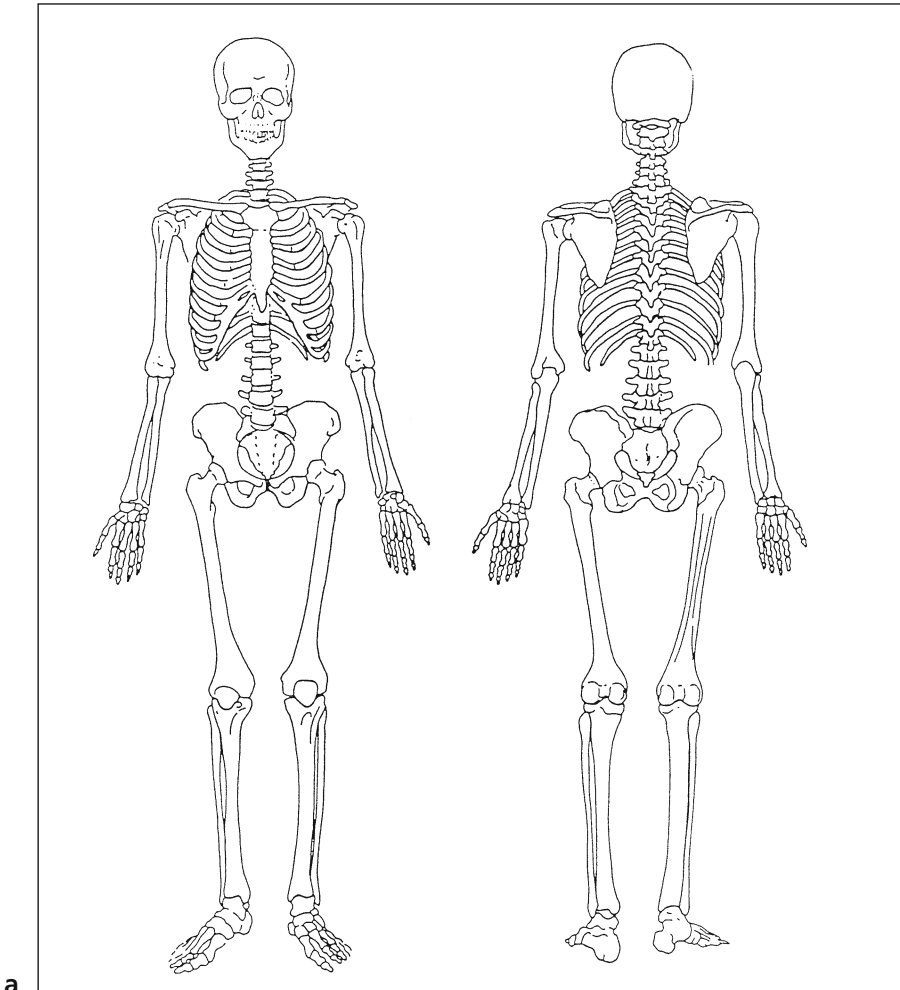


FIGURE 11.7a–e. Examples of pictorial charts used when documenting fractures. (Courtesy of the late Dr. Iain West, Department of Forensic Pathology, Guy's Hospital.)

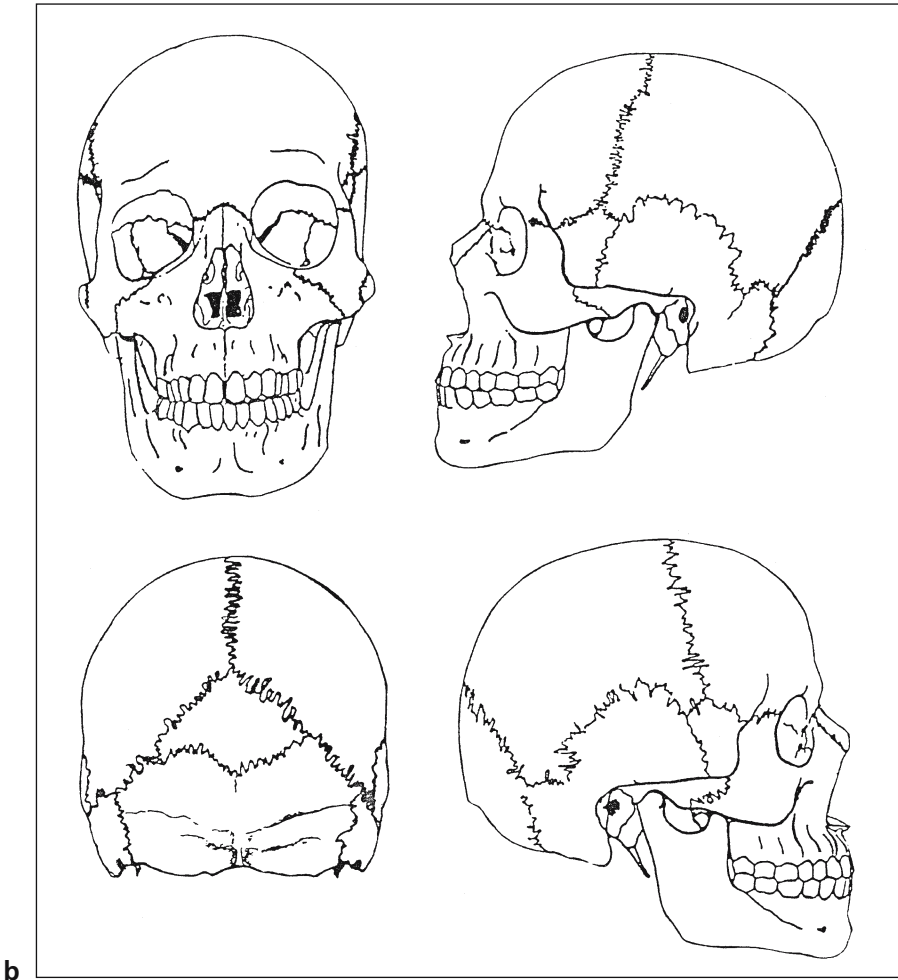
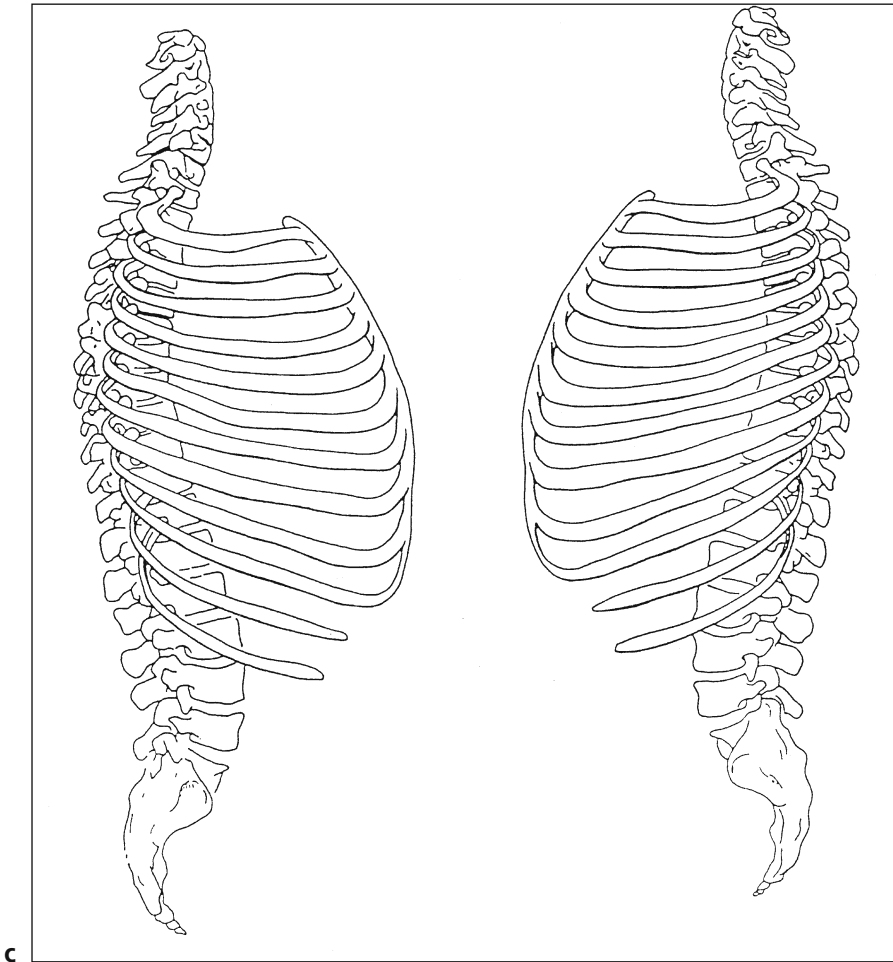


FIGURE 11.7. *Continued*

culature also points to a local fracture, and is easily seen when the muscles are being cut to separate the ribs.

#### Clinical Correlation

Resuscitation injuries, in the form of both rib and sternal fractures, are very common. The rib fractures are usually on the left and anterior, but can be bilateral. Posterior fractures, however, are rare in this context. There is usually little bleeding around the fracture sites, and this, together

FIGURE 11.7. *Continued*

with the history, allows their identification and separation from other traumatic fractures. They are most common in the elderly and are often associated with osteoporosis.

### Vertebral Column

The vertebral column is also accessible, and removal of the anterior strip of vertebral column as described on p. 267 will delineate any crush fractures. Cervical spine fractures are obviously an exception and are described separately; see p. 275.

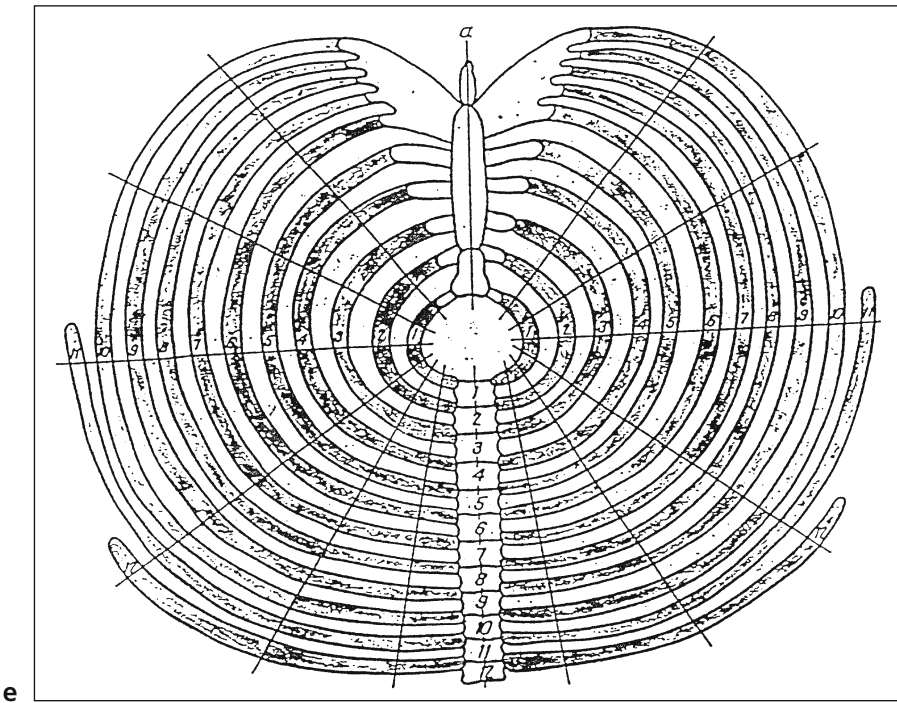
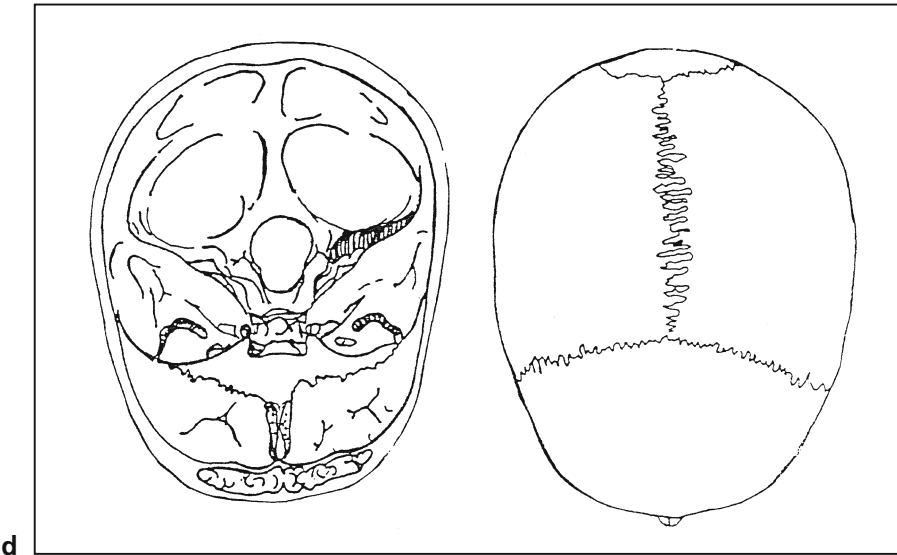


FIGURE 11.7. *Continued*

## Shoulder and Pelvic Girdles

Although difficult to remove, shoulder and pelvic girdles are accessible internally, and fractures can usually be identified by direct visual inspection, palpation, and stressing of the bones in opposing directions. Again, soft tissue haemorrhage is a useful indicator of fracture. If necessary, a posterior approach, as described on p. 269, can aid examination of the scapula and pelvis.

## Skull

Calvarium fractures are easily identified, although are best studied before removal, as post mortem fractures can occur during this process. In contrast, basal skull fractures can be extremely difficult to identify. The dura mater must be completely stripped off the base of the skull, and the skull stressed in opposing directions.

## *Examination of the Cervical Spine for Fractures*

Examination of the cervical spine, particularly the atlanto-occipital joint, is essential if a cervical fracture is suspected, for example, following a road traffic accident. This can be undertaken via an anterior or a posterior approach, in both cases following removal of the brain. It is not possible to examine the cervical spine thoroughly without removing it, at least temporarily, from the body. It is often therefore useful to keep the sternocleidomastoid muscle intact before commencing this procedure, whether via an anterior or a posterior approach. Removal of the cervical spine obviously produces great instability of the head and neck, and to some extent this can be counteracted by intact sternocleidomastoids [3]. Removal of the cervical spine can also be used to examine the vertebral arteries, in which case the block is usually retained and decalcified. The examination of the vertebral arteries is part of the examination of the neck following trauma. This would include hanging and road traffic accidents as well as suspicious deaths; the latter are usually examined by a forensic pathologist. They should also be examined in all cases of subarachnoid haemorrhage when either a berry aneurysm or an arteriovenous malformation has not been found. They can either be examined in situ or after removal and decalcification of the cervical spine. They can also be examined using angiography; however, the usual difficulties with body transportation apply if the angiography is undertaken in situ. In contrast, angiography after the cervical spine block has been removed makes any transportation of the specimen an easy process.

### Method 1: Anterior Approach

The soft tissues and musculature anterior to the cervical spine should be stripped using scalpel and forceps. With an oscillating saw one of the lower

cervical vertebral bodies should be transected. From the internal aspect of the skull, two coronal saw cuts should be made through the full thickness of the base, the anterior one just behind the posterior clinoid process and the posterior one just behind the foramen magnum. These should extend to about 2 cm on either side of the foramen magnum, and are then joined by two parasagittal cuts (see Fig. 11.8). Although difficult, with continued levering and dissection of soft tissue, it should now be possible to remove the cervical spine en bloc, whereupon X-ray films may reveal a fracture not seen in life and a combination of direct visual inspection and palpation then exposes it further for examination and, if necessary, photography. The cervical spine block can then be returned to the body for reconstruction, or the defect packed with cotton wool if it is to be retained.

#### Method 2: Posterior Approach

If the posterior approach is to be used, it is best undertaken before evisceration, as it obviously requires the body to be prone. A midline skin incision should be made, extending from the transverse scalp incision to the upper thoracic spine. The skin and soft tissues should then be dissected free using scalpel and forceps and then reflected back to expose the cervical spine. The attached musculature can then be removed and the lower cervical spine transected with an oscillating saw. Two parasagittal cuts through the occipital bone should then be made with the saw, one on either side of the midline, originating from the initial transverse cut (see Fig. 11.9). These saw cuts should then be extended within the base of the skull up to a point about 1 cm anterior to the foramen magnum on either side. These can then

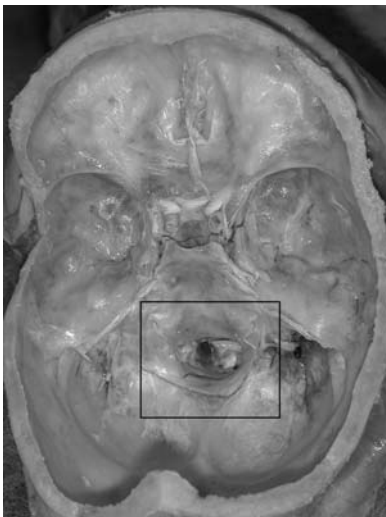
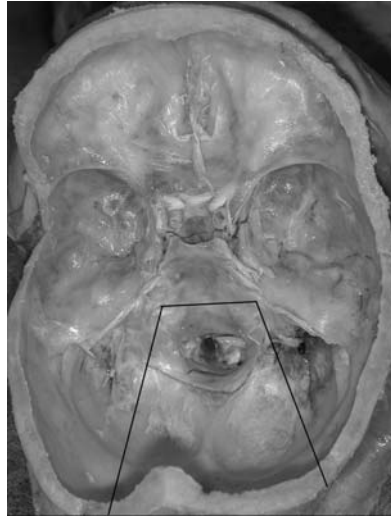


FIGURE 11.8. Photograph of the base of the skull. The lines indicate the necessary incisions when removing the cervical spine using an anterior approach. (Courtesy of Mr. Dean Jansen, Whittington Hospital.)

FIGURE 11.9. Photograph of the base of the skull. The lines indicate the necessary incisions when removing the cervical spine using a posterior approach. (Courtesy of Mr. Dean Jansen, Whittington Hospital.)



be joined by a coronal cut just behind the posterior clinoid process. The full thickness of the skull base should be sawn through in all of these cuts. It should now be possible to remove the entire block, although some leverage and further soft tissue dissection is likely to be necessary.

*Alternatively, a saw cut can be made posteriorly behind the foramen magnum, as for the anterior approach earlier, in place of the two saw cuts through the occiput. This is more difficult, however, and negates the only advantage to the posterior approach, which is otherwise more time consuming owing to the need for an extra incision and a prone body.*

The cervical spine can now be X-rayed and examined. Fractures thus identified can be further examined by a combination of direct visual inspection and palpation. Photographs can also be taken if desired. Reconstitution can be made by returning the block after examination, or by padding the resultant defect.

### *Examination of Joints*

The general principles of joint examination are the same for all joints, although the exact method will obviously depend on the site. Ideally, the entire joint should be removed, together with a part of both proximal and distal bone.

#### Limbs

Examination of the limbs is best achieved by making a longitudinal incision traversing the extensor surface of the joint in question. The incision



may need to be extended horizontally at both ends, to allow easy access to the joint capsule. The skin and soft tissues should then be dissected from the underlying joint, without incising the joint capsule itself.

Before the joint cavity is opened, synovial fluid can be removed using a needle and syringe, especially if an effusion is present. Fluid should be submitted for microbiology and cytology. A wet-prep should also be made and examined for crystals by placing two to four drops of fluid onto a clean slide using a pipette. Any fibrinous material present should always be included, as this often contains the majority of the crystals and inflammatory cells. The slide is then covered with a clean coverslip and examined microscopically under polarised light. If a permanent record is required, the edges of the coverslip can be sealed using clear nail varnish to prevent the material from drying. The entire slide should be screened at low power, to look for refractile material. Unfortunately, the presence of large numbers of red blood cells can mask the crystals and therefore produce a false-negative result. Only intracellular material is relevant; all extracellular deposits should be ignored. Considerable care must be taken to exclude false-positive artefacts such as talc crystals (from surgical gloves) which have a "Maltese cross"-like structure. Some steroids can also produce crystals; prednisolone turbutate resembles pyrophosphate and both triamcinolone heracetone and betamethasone acetate esters can resemble urate. The presence of extracellular crystals should be disregarded in the absence of clearly intracellular crystals. Urate crystals (gout) are needle-shaped and pyrophosphate crystals (pseudo-gout) are rhomboid shaped. Mixed-crystal synovitis can also occur. Hydroxyapatite crystals are too small to be identified by light microscopy. A red filter can be used to distinguish between urate and pyrophosphate for confirmation of crystal type. Both crystal types exhibit yellow-blue birefringence. To differentiate, crystals whose long axes are in the direction of the red filter (as marked on the filter itself by an arrow) must be examined. Urate crystals are yellow in this axis (negative birefringence) whereas pyrophosphate crystals are blue in this axis (positive birefringence).

The joint capsule can now be incised and the synovium and articular surfaces examined. Samples of synovium can be taken and submitted for microbiology as well as histology. This may be all that is necessary; however, if complete removal is desired a saw can be used to divide the bones above and below the joint at a point just beyond the joint capsule. This can also be done with the joint intact, if desired. A band saw can then be used to divide the joint longitudinally. The joint can then be examined and samples taken with a saw, decalcified, and submitted for histology.

At the limb girdles, it will obviously not be possible to remove the proximal bone of the joint without considerable mutilation. The joint can be examined as described earlier, however, and the distal bone removed if desired.

### Axial Skeleton

Anterior and posterior joints of the ribs can be accessed as for the removal of ribs; see p. 268. The joints of the vertebra and the sacroiliac joints can be examined by direct vision once evisceration is complete. The anterior half of the vertebral column can be removed for further examination, if necessary; see p. 267. The sacroiliac joints may also be removed with an oscillating saw, although this is rarely necessary.

### *Dealing with Bone Tumours*

The exact method of dealing with a bone tumour will obviously depend on the type of tumour suspected and the site. If histological diagnosis of a primary tumour has already been made, or if secondary tumour is suspected and the extent already assessed radiologically, further examination may not be necessary. For diagnosis of a primary bone tumour, however, removal of the bone in question will be required. If the tumour is very close to the joint, it may also be necessary to remove part of the adjoining bone. Thorough histological sampling is necessary when examining primary bone tumours and obviously may require decalcification of slices or areas of tumour obtained with a band saw before tissue blocks can be taken for histology. In addition to histological typing, it is important to assess the margins of the tumour macroscopically to identify any local invasion. Pre or post mortem X-ray films will also be helpful to identify the extent of the tumour and the involvement of adjacent structures. Appropriate consent will of course be required before any histological examination.

### Limbs

Most malignant tumours occur in the long bones of the limbs, and many are in the femur, the removal of which has already been described in detail on p. 261. During removal of the bone, great care must be taken when dissecting the soft tissue to retain in continuity any local soft tissue invaded by tumour. If marked local invasion is present, it may therefore be better to remove the bulk of the musculature with the long bone, and dissect the uninvolved muscles free once the bone has been removed. If necessary, samples from the margins can also be taken for histology, to assess the exact extent of invasion. Once removed, the bone can be bisected longitudinally with a band saw, the tumour examined and an appropriate area or slice removed for decalcification and histology.

### Axial Skeleton

When a tumour is identified within the rib cage, the relevant rib(s) should be removed, as described on p. 268. The tumour can now be examined by

bisecting the bone in an appropriate plane with a band saw, and appropriate samples taken for histology.

In the case of vertebral body tumours, it is usually sufficient to obtain the anterior strip and examine it closely for focal lesions; see p. 267. Either the whole strip should be decalcified before histological sampling, or relevant vertebral bodies decalcified and sampled; the residual strip is returned to the body cavity.

Once the scapula is removed, as described on p. 269, it can be bisected in an appropriate plane using a band saw. The tumour can then be examined, and samples taken for histology.

If a tumour is visualised within the pelvis, or its site is already known, the relevant part of the bone can be removed from the internal aspect of the pelvis using an oscillating saw. If necessary, posterior access can be obtained as described on p. 269. If no tumour is identifiable macroscopically or, although suspected, its site is not known, numerous core samples can be taken from multiple sites using a trephine. Each sample should be placed in a separate, appropriately labelled container and submitted for histology, following decalcification if necessary.

In the skull, once the tumour has been examined, histological samples should be taken via trephine biopsy to prevent unnecessary mutilation. Removal of the pituitary fossa for the investigation of a pituitary tumour has been described elsewhere (see p. 243).

### *Dealing with Soft Tissue Tumours*

These are rare tumours and, as with bone tumours, it may not be necessary to effect a complete examination of the primary site as histological diagnosis and radiological assessment is already likely to have been made. If not, a tissue biopsy can be taken for histology, via a small overlying incision, without producing mutilation. If extensive examination is necessary, the method will obviously depend on the site involved.

#### Limbs

In limbs, the muscle bulk can be removed from either or both aspects of any long bone (as for the examination of a deep vein thrombosis). This is accomplished by making a lateral incision over the muscle bulk in question, and making a horizontal extension at either one or both ends. The skin and subcutis is then carefully dissected off the underlying muscle and soft tissue. The entire muscle bulk can then be removed en bloc, cutting it free at both ends and dissecting it off the underlying bone. This can then be serially sliced and examined and appropriate blocks taken for histology. It can then be returned to the body with excellent reconstitution.

## Torso

Thoracic and abdominal wall tumours are easy to access, once evisceration is complete. Most tumours will be visible from the internal surface, and can be examined and sampled for histology. Complete removal is only possible if the tumour can be dissected free from the overlying skin and subcutis. If this is not possible, removal of the tumour would necessitate removal of the overlying skin and is therefore likely to be too mutilatory to be considered. Subcutaneous tumours overlying the rib cage will not be accessible internally, and must be reached by dissection of the overlying skin, as described on p. 268. Once the overlying skin is free, the tumour can be removed by dissecting it from the underlying rib cage. If it is not possible to dissect the skin from the underlying tumour, only sampling of the tumour for histology will be possible, as removing the overlying skin will be too mutilatory. Retroperitoneal and omental tumours are obviously accessible during evisceration and dissection, and are discussed in Chapter 7 (p. 211).

## *References*

1. Harris SC, Cotton DWK, Stephenson TJ, Howat AJ. Assessment of osteopenia at autopsy. *Med Sci Law* 1991;31:15–18.
2. Wilkinson JM, Cotton DWK, Harris SC, Patterson EA. Assessment of osteoporosis at autopsy: mechanical methods compared to radiological and histological techniques. *Med Sci Law* 1991;31:19–24.
3. Geddes JF, Gonzalez AG. Examination of the spinal cord in diseases of the craniocervical junction and high cervical spine. *J Clin Pathol* 1991;44:170–172.

# 12

## The Nervous System

The routine removal of the brain has already been described in Chapter 3 (p. 110). This chapter includes:

- Routine examination, dissection, and block selection of the brain
- Removal of the brain in a high-risk case
- Examination of the spinal cord
- Removal of the eye
- Examination of the cavernous sinus
- Examination of the vertebral arteries
- Examination of the neuromuscular system
- Examination of the autonomic nervous system

The examination of the pituitary gland is discussed in Chapter 9, p. 242. Although it is obviously impossible to include every possible eventuality, this chapter does deal with the vast majority of situations that are likely to be encountered by a nonspecialist pathologist.

### The Brain

The brain is a common site of disease, and furthermore such diseases are often responsible for death. Cerebrovascular diseases in particular, such as cerebral infarction and haemorrhage, are common causes of sudden death. In addition, degenerative brain diseases usually end in the death of the patient, even though other diseases such as bronchopneumonia often intervene. Neuropathology is a separate specialty within histopathology in many countries, which means that many general pathologists have a limited experience of detailed brain examination and therefore feel somewhat unconfident in this area. The external and internal brain examination and block selection, however, is a relatively straightforward matter, although advice from a specialist may be necessary for histological interpretation.

## *External Examination*

### Meninges and Vessels

Following removal of the brain and attached dura mater, the dura should be examined and any recent or old blood clot identified. Old subdural haematomata leave only a thin membrane that can easily be missed. The translucency and thickness of the leptomeninges should be noted and any blood clot identified and weighed. The veins within the leptomeninges should be examined for signs of congestion or evidence of an arteriovenous malformation. If there is evidence of pus formation, or meningitis has been suspected clinically, a swab should be taken. Cerebrospinal fluid (CSF) sampling will also be necessary, and should have been undertaken before the removal of the brain (see p. 325 and Figs. 13.1 and 13.2). It is then convenient to examine the arteries within the circle of Willis, looking for berry aneurysm formation and atherosclerosis. Fine dissection will be needed to examine them properly. See Fig. 12.1 for a diagram of the circle of Willis. If a blood clot is present at the base of the brain, that is, within the subarachnoid space, this should be carefully and delicately removed using forceps and water, until the source of the haemorrhage is identified. This process may take a considerable time, but should not be rushed, as it is easy to further damage the underlying vessels. It is essential to remove any blood clot before fixation, as afterwards it becomes almost impossible to remove clot without damage, as it is hardened considerably by fixation. If a subarachnoid haemorrhage is identified and neither a berry aneurysm nor an arteriovenous malformation can be found, the vertebral arteries must be examined carefully for evidence of traumatic rupture (see p. 305).

### Brain

The external surfaces of the cerebrum, cerebellum, and brain stem should then be examined for signs of increased intracranial pressure or asymmetry, indicating a space-occupying lesion. In particular, any herniation should be noted, as this indicates a downward brain shift caused by increased intracranial pressure. There are two common sites of herniation: the cerebellar tonsils at the foramen magnum and the unci (with or without the parahippocampal gyri) of the temporal lobe at the tentorium. Any apparent gyral narrowing and sulcal widening should also be noted, and may indicate atrophy. If there are signs of infection, or infection is suspected clinically, then swabs can be taken or appropriate brain tissue sampled as soon as possible, and obviously before any fixation. CSF samples will also be necessary, and should have been taken prior to the removal of the brain (see p. 325). Fresh frozen tissue may also be useful in cases of suspected neuronal storage disease or neurochemical abnormality, providing that the post mortem has taken place within 12 or so hours after death, as enzymes are

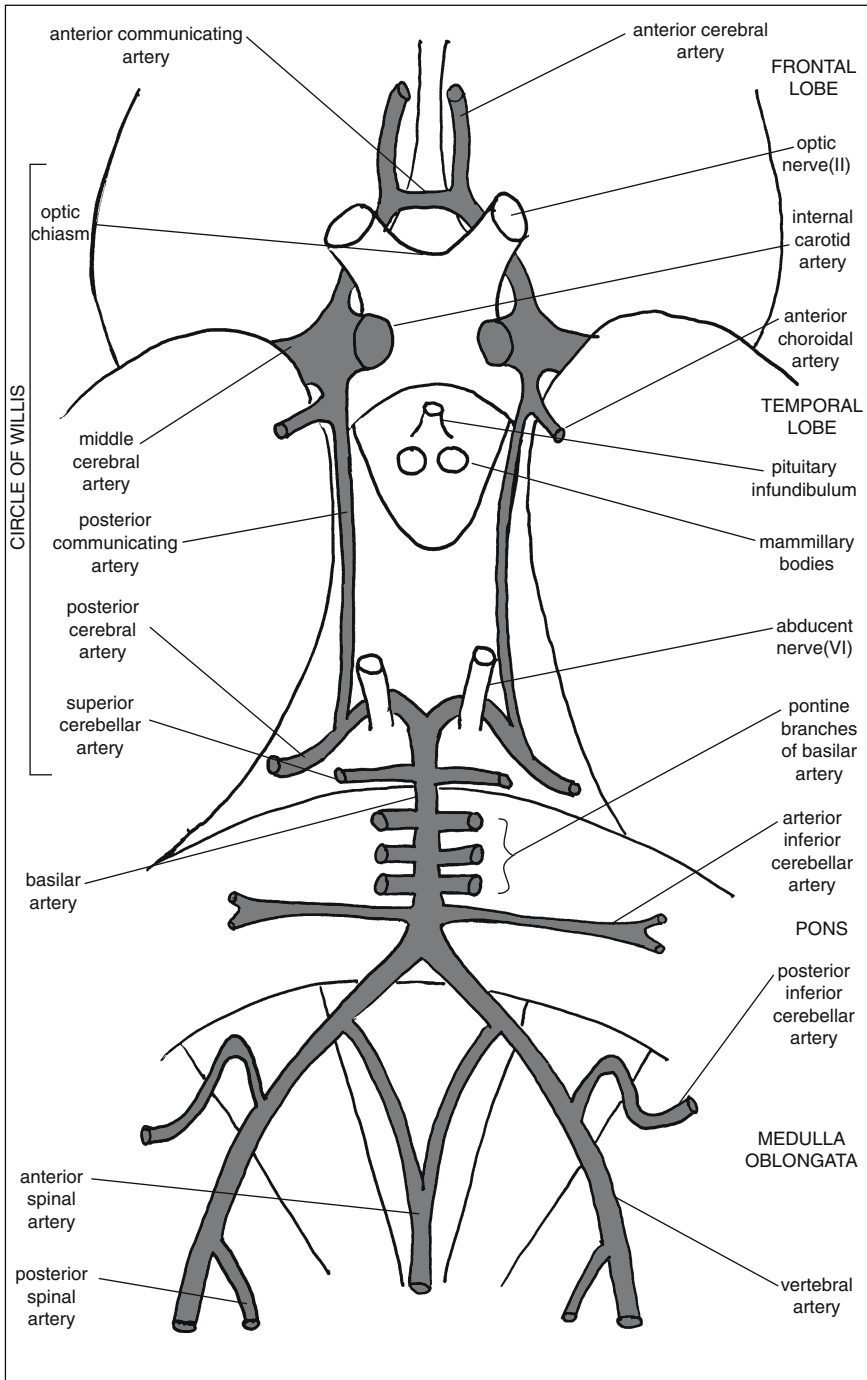


FIGURE 12.1. Diagram of the arteries at the base of the brain, together with the related structures.

too degraded to be accurately measurable after this time. Fresh frozen tissue for genetic analysis, however, can be usefully obtained for several days after death.

### *Fixation*

At this point, it is necessary to make the decision of whether or not to fix the brain prior to further examination. It is unarguably the case that fixation prior to dissection provides a far better neuropathological examination, indeed many neuropathologists would argue that fresh dissection provides no neuropathological examination at all! Against fixation is the increased time it takes to provide a report, as complete fixation takes at least 4 weeks, and particularly in post mortems performed for medico-legal reasons this degree of delay is often not permissible. In most countries the law states that in a medico-legal autopsy, tissue can be retained only if it is required to ascertain the cause of death. Thus, if the rules are adhered to strictly, the brain can be retained for fixation only if the cause of death lies within it—in which case it is even less likely that the result can wait for a month! Nevertheless, it is sometimes the case that the clinical information and an external examination, in combination with palpation, will adequately reveal the cause of death, in which case a more detailed examination will wait for fixation. In addition to permission from themselves, many coroners or their equivalents will also require the relative's permission before the brain can be retained. In a hospital case, of course, specific permission must be granted from the relatives for the brain to be retained. The use of microwave fixation considerably shortens the time taken for fixation but may affect subsequent histochemistry or immunohistochemistry performed on tissue blocks.

To fix the brain, it should be suspended upside down in a large bucket of 10% formal saline (formalin) for at least 4–6 weeks. The easiest method involves placing a paper clip or curtain hook around the basilar artery, and hanging it via a length of string tied between the two handles of the bucket. If fixation is likely to be impaired, for example by oedema, and so forth, the corpus callosum can be split to access the ventricle and thus improve the penetration of the fixative. If possible, several changes of formalin should be made, preferably after about 3 days initially and then weekly.

### *Weighing*

The brain must obviously be weighed prior to dissection. If retained for fixation, both pre and post fixation weights are desirable as there may be up to a 20% increase in weight following fixation [1]. Female brains are, on average, lighter than male brains and there is a normal, gradual reduction in weight during adult life. Although dementia is almost invariably accompanied by brain weight reduction, a diagnosis of dementia can never rely



TABLE 12.1. Table of Average Male and Female Brain Weights for Different Ages

Age (yr)	Men (g)	Women (g)
22–30	1440	1300
31–40	1440	1290
41–50	1430	1290
51–55	1410	1280
56–60	1370	1250
61–65	1370	1240
66–70	1360	1240
71–75	1350	1230
76–80	1330	1190
81–85	1310	1170
86+	1290	1140

Adapted with permission from Dekaban AS, Sadowsky D. Changes in brain weights during the span of human life: Relation of brain weights to body heights and body weights. *Ann Neurol* 1978;4:345–356.

on brain weight alone, as there is a wide normal variation. Table 12.1 lists the mean weights and normal weight ranges in male and female adults for a variety of ages.

The average weight of the adult brain is 1275 g in women and 1400 g in men.

### *Dissection*

The dissection of the brain is essentially the same, whether fixed or fresh. If fixation has been undertaken, it is useful to replace the formalin with water 24 hours prior to examination, to reduce the amount of fumes during the examination.

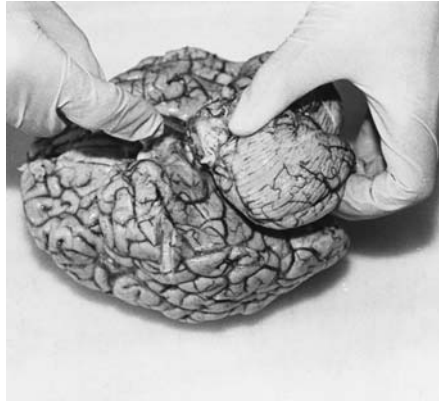
#### *Step 1.*

The cerebellum and brain stem are separated from the cerebral hemispheres (see Fig. 12.2). This is done as high as possible in the brain stem. It is also important that the cut surface is both flat and in a horizontal plane. A large scalpel should be used, ideally with a single sweeping movement.

#### *Step 2.*

The brain stem is separated from the cerebellum. This is accomplished by cutting through the cerebellar peduncles with a scalpel, approaching from the anterior aspect and as close to the brain stem as possible (see Figs. 12.3. and 12.4). If there is a tumour involving the brain stem and cerebellum or the IVth ventricle, however, it is better to leave the brain stem and cerebellum in continuity, so the lesion is kept intact.

FIGURE 12.2. This photograph illustrates the separation of the brain stem and cerebellum from the cerebrum, using a single, sweeping movement of the scalpel. (Courtesy of Dr. Andrew King and Mr. Alan Brady, Department of Neuropathology, Institute of Psychiatry, London.)



*Alternatively, the vermis can be divided posteriorly first. This allows the cerebellar peduncles to be visualised as they are cut as close to the brain stem as possible. This visualisation is often necessary to avoid damaging the cerebellar hemispheres while separation is being undertaken, particularly if the brain is swollen. The cerebellum is then removed in two halves (see Fig. 12.5).*

### *Step 3.*

The brain stem is dissected by being sliced at 5-mm intervals and laid out in order on a flat surface. It does not matter which order is used, as long as it is consistent. It is convenient to lay out as if the brain is in the anatomical position, with the anterior surfaces toward the observer, which equates

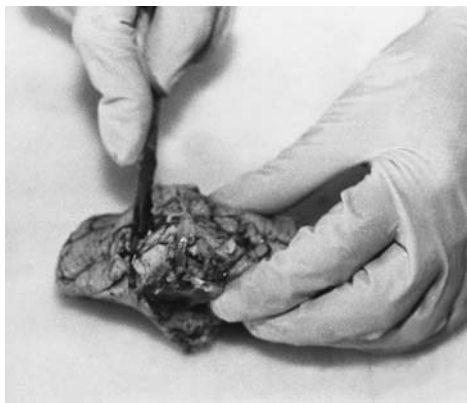

FIGURE 12.3. The brain stem is divided from the cerebellum by cutting the cerebellar peduncles as close to the brain stem as possible with a scalpel. (Courtesy of Dr. Andrew King and Mr. Alan Brady, Department of Neuropathology, Institute of Psychiatry, London.)

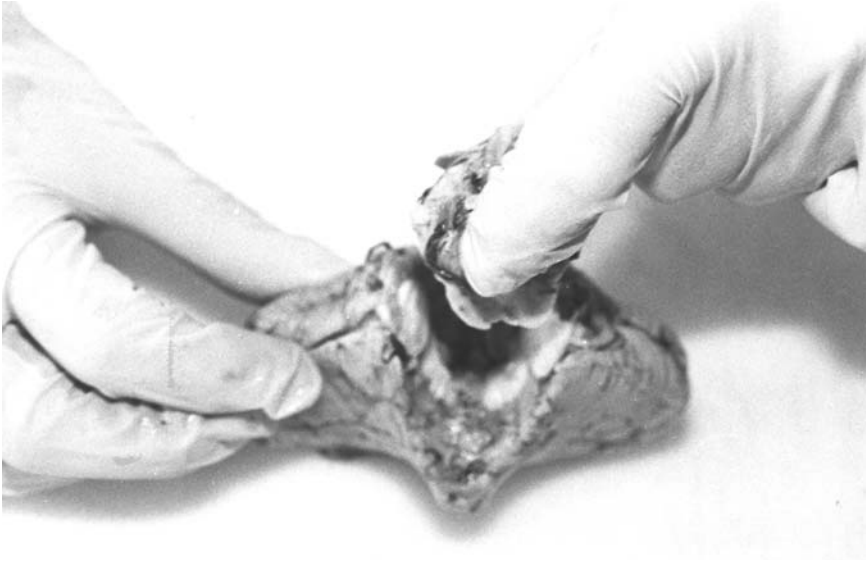


FIGURE 12.4. The brain stem and cerebellum are now separated. (Courtesy of Dr. Andrew King and Mr. Alan Brady, Department of Neuropathology, Institute of Psychiatry, London.)

to the orientation of radiological scans. One can also lay the slices out with the posterior surfaces uppermost, however, which keeps left and right orientation the same as for the prosector.

*Step 4.*

The cerebellum is dissected. This can be achieved in one of two ways: The cerebellum can be separated (if it has not already been divided) just to one side of the vermis using a long knife, thus allowing a block to be taken from

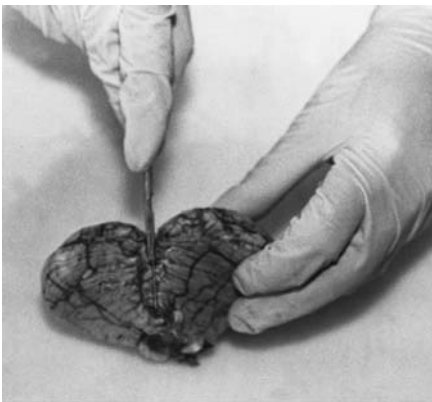

FIGURE 12.5. The cerebellar vermis is divided posteriorly to allow visualisation of the cerebellar peduncles when cutting them to separate the brain stem from the cerebellum. (Courtesy of Dr. Andrew King and Mr. Alan Brady, Department of Neuropathology, Institute of Psychiatry, London.)

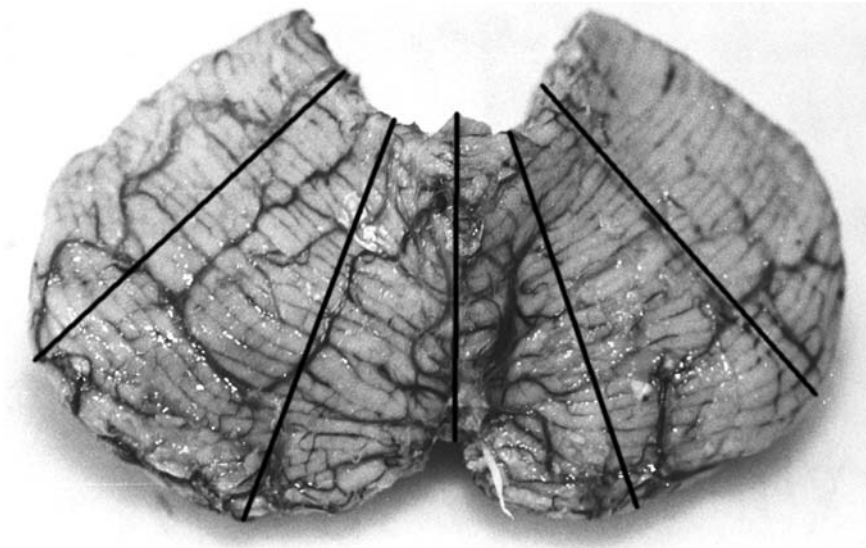


FIGURE 12.6. The lines indicate the planes of section when radially slicing the cerebellum, after it has been separated from the brain stem. (Courtesy of Dr. Andrew King and Mr. Alan Brady, Department of Neuropathology, Institute of Psychiatry, London.)

the vermis at a later stage. The two lobes can then be sliced in a “fan” shape with the middle slice going through the dentate nucleus (see Fig. 12.6).

*Alternatively, the entire cerebellum can be divided into two halves in a horizontal plane. This latter method can also be used when the brain stem is still attached (see Fig. 12.7).*

#### *Step 5.*

The midbrain block is removed. As the subsequent dissection of the cerebral hemispheres will inevitably destroy the midbrain, it is necessary to take the histology block from the midbrain at this point, providing that appropriate permission for histology has been obtained. This is achieved by taking a complete slice from the cut surface of the midbrain, using a single, sweeping movement with a scalpel (see Fig. 12.8). This block contains the substantia nigra.

#### *Step 6.*

The cerebral hemispheres are dissected. The cerebrum should be sliced in a coronal plane at 1-cm intervals. There are several ways of accomplishing this: If the brain is fresh, the cerebrum should be sliced freehand from either the frontal or occipital end, and either from the basal or the superior surface. The main aim with the fresh brain is to be as quick as possible, as the brain is so soft that it rapidly collapses. Keeping the knife wet by

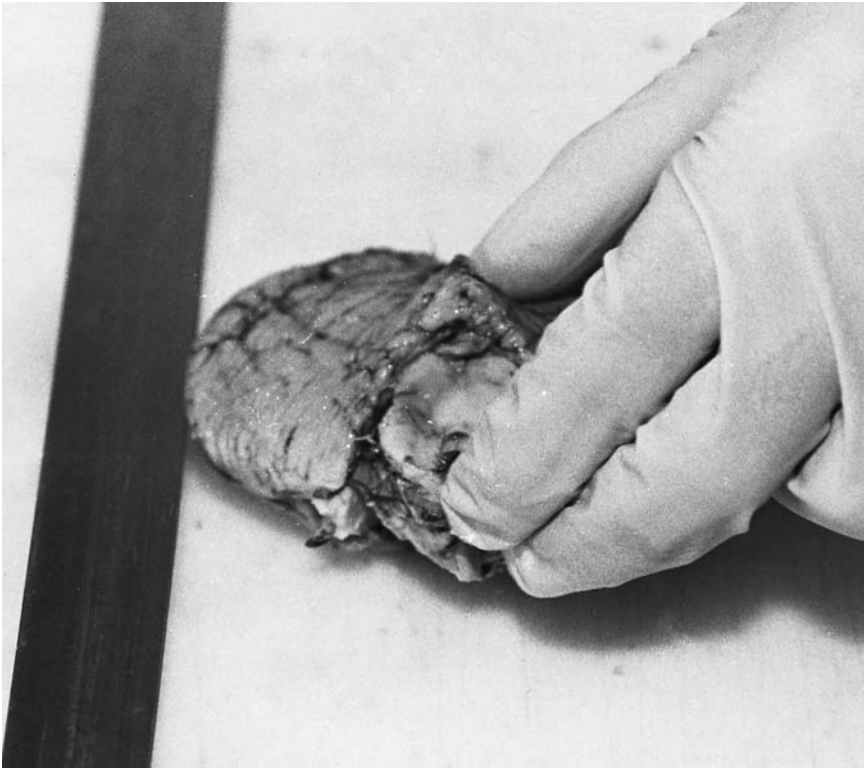


FIGURE 12.7. The cerebellum is being divided horizontally. This can be used when the brain stem has been separated or is still attached, as in this example. (Courtesy of Dr. Andrew King and Mr. Alan Brady, Department of Neuropathology, Institute of Psychiatry, London.)

running it under water between every other slice can often make slicing easier.

Although the same freehand approach can be used with the fixed brain, it is more usual to use two 1-cm thick guides (right-angled strips of plastic or metal) to allow more accurate slicing. The first slice must obviously still be done freehand, and should roughly divide the brain in half. The mammillary bodies provide a useful landmark and require the cut to be undertaken from the basal surface (see Fig. 12.9). It is important that the first slice is in an exact coronal plane, as all further slices using guides will be in the same plane, and symmetry will be lost otherwise. Thereafter, each half of the brain is sliced in turn with the flat surface laid downwards, and the right-angled guides used to keep the knife in the horizontal plane. It should be possible to cut each slice with a single sweep of a long “brain” knife, to avoid

a sawing motion and subsequent irregularities on the cut surfaces (see Fig. 12.10).

The slices should then be laid out in order on a flat surface. Again the order is immaterial as long as it is consistent and the same as that of the brain stem. It must be remembered, however, that whichever order has been used, half of the slices will require turning over before laying, as each half has been cut from opposite surfaces. By convention, most neuropathologists place the posterior surface upwards, keeping the left and right orientation of the brain the same as for the prosector. Placing the anterior surface uppermost, however, maintains the anatomical position and will equate with the orientation of any radiological scans.

*Alternatively, other planes of section may be useful in special cases. One such example is the cutting of the brain in the plane of computerised tomographic (CT) scans, for comparison with the radiology. This may be done freehand, but is often easier with the use of an angled board, as CT scans are taken at an angle of about 30° to the horizontal.*

*Another example is a single, midline sagittal section. This is particularly useful if a third or fourth ventricle lesion is expected. This is best accomplished by using a scalpel to cut through the corpus callosum, starting at the genu and then extending the cut rostrally through the midline of the brain stem and bisecting the basilar artery on the ventral surface of the pons.*

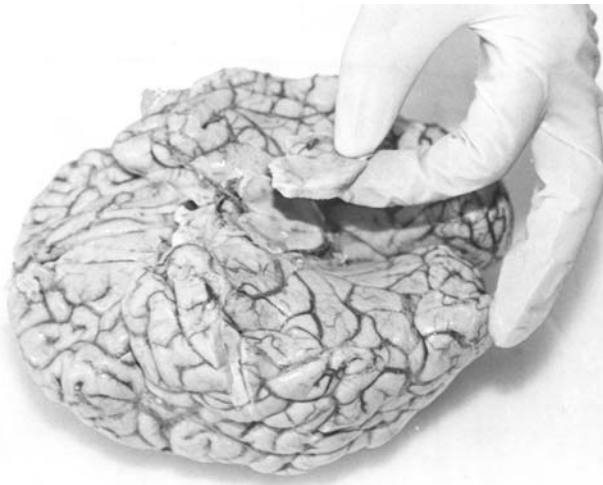

FIGURE 12.8. A slice of midbrain is being taken for histology, from the cut surface of the midbrain after the brain stem and cerebellum have been removed. (Courtesy of Dr. Andrew King and Mr. Alan Brady, Department of Neuropathology, Institute of Psychiatry, London.)

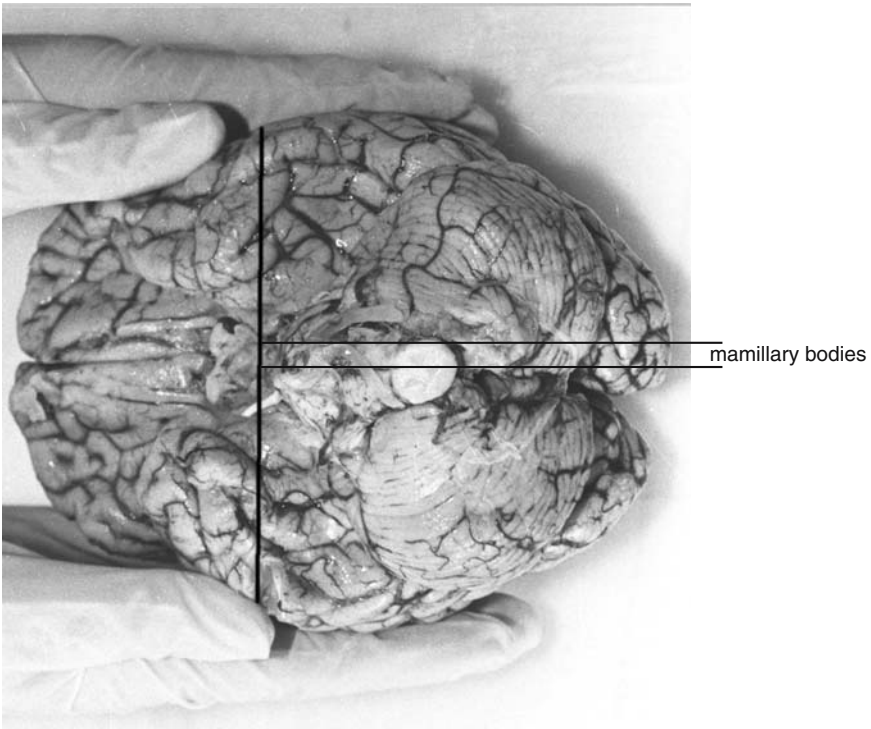


FIGURE 12.9. The dotted line indicates the position of the first slice when sectioning fixed cerebral hemispheres. It is at the level of the mamillary bodies (*arrows*) and should be symmetrical, as all subsequent slices will be in the same plane. (Courtesy of Dr. Andrew King and Mr. Alan Brady, Department of Neuropathology, Institute of Psychiatry, London.)

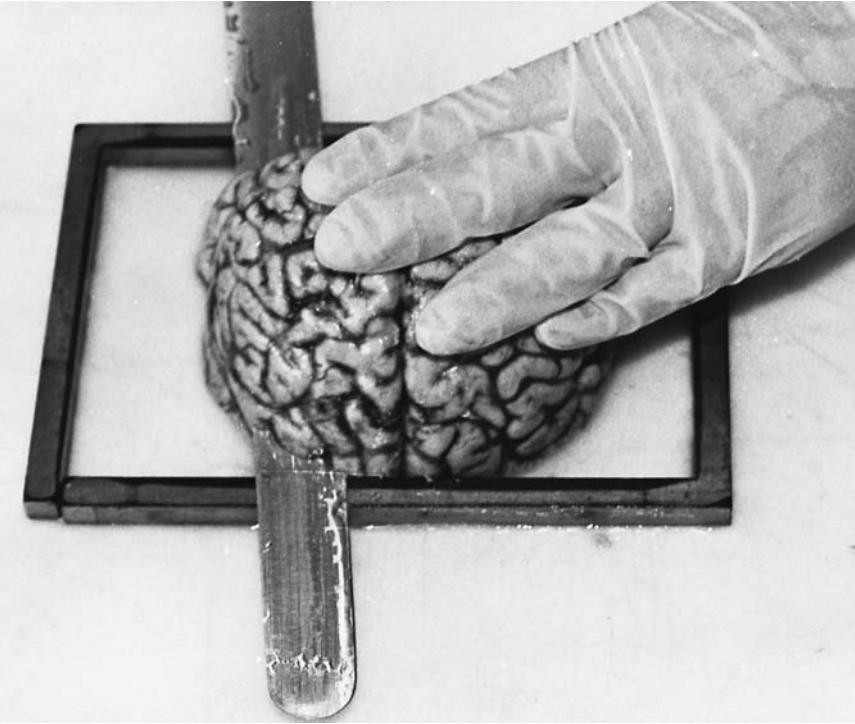
### *Internal Examination*

A careful examination of the cut slices of brain stem, cerebellum, and cerebrum must then be made, looking for focal lesions, asymmetry, and diffuse abnormality. Any lesions should be described in detail, including the exact anatomical position and size. See Fig. 12.11 for an illustration of the anatomy of the cerebral hemispheres.

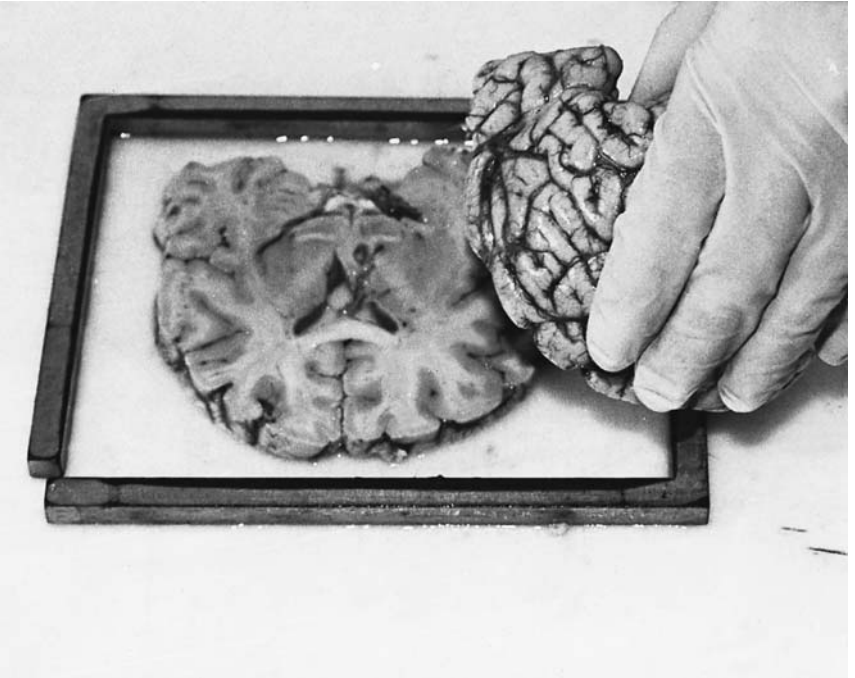
#### Clinical Correlation

Any asymmetry or brain shift indicates a large space-occupying lesion. Such focal lesions include abscesses, haemorrhage, recent infarction, and either metastatic or primary tumours. Old cerebral infarcts are cystic spaces that do not usually produce any brain shift, even when large.

*(continued on p. 296)*



a



b

FIGURE 12.10. These two photographs illustrate how the cerebrum can be serially sliced, using metal guides to ensure even, symmetrical slices. (Courtesy of Dr. Andrew King and Mr. Alan Brady, Department of Neuropathology, Institute of Psychiatry, London.)



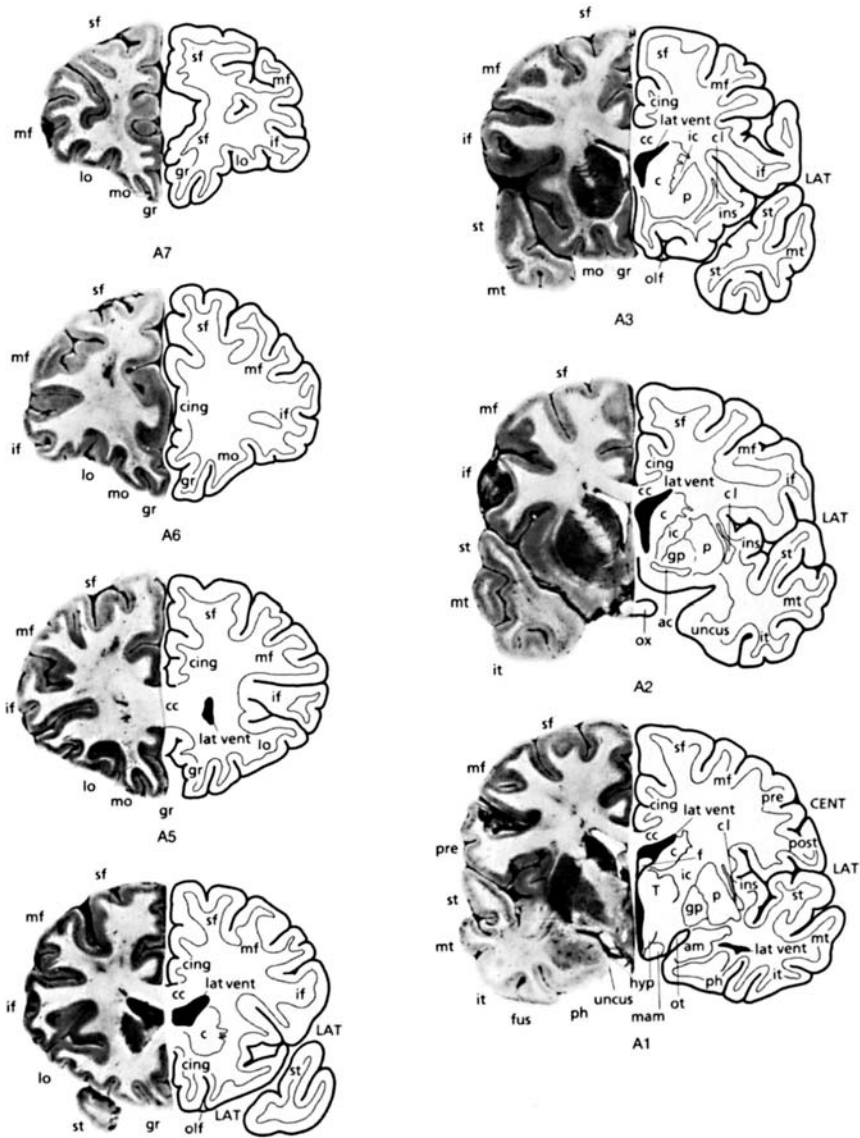


FIGURE 12.11. Coronal slices of the cerebrum with the posterior surface uppermost, illustrating the major anatomical landmarks. A1–A7 from the anterior half of the cerebrum and P1–P9 from the posterior half; both are numbered from the initial slice through the mamillary bodies. (Reprinted with permission from Esiri MM. *Oppenheimer's diagnostic neuropathology. A practical manual*, 2nd edit. Blackwell Science Ltd., 1996; pp. 16–20.)

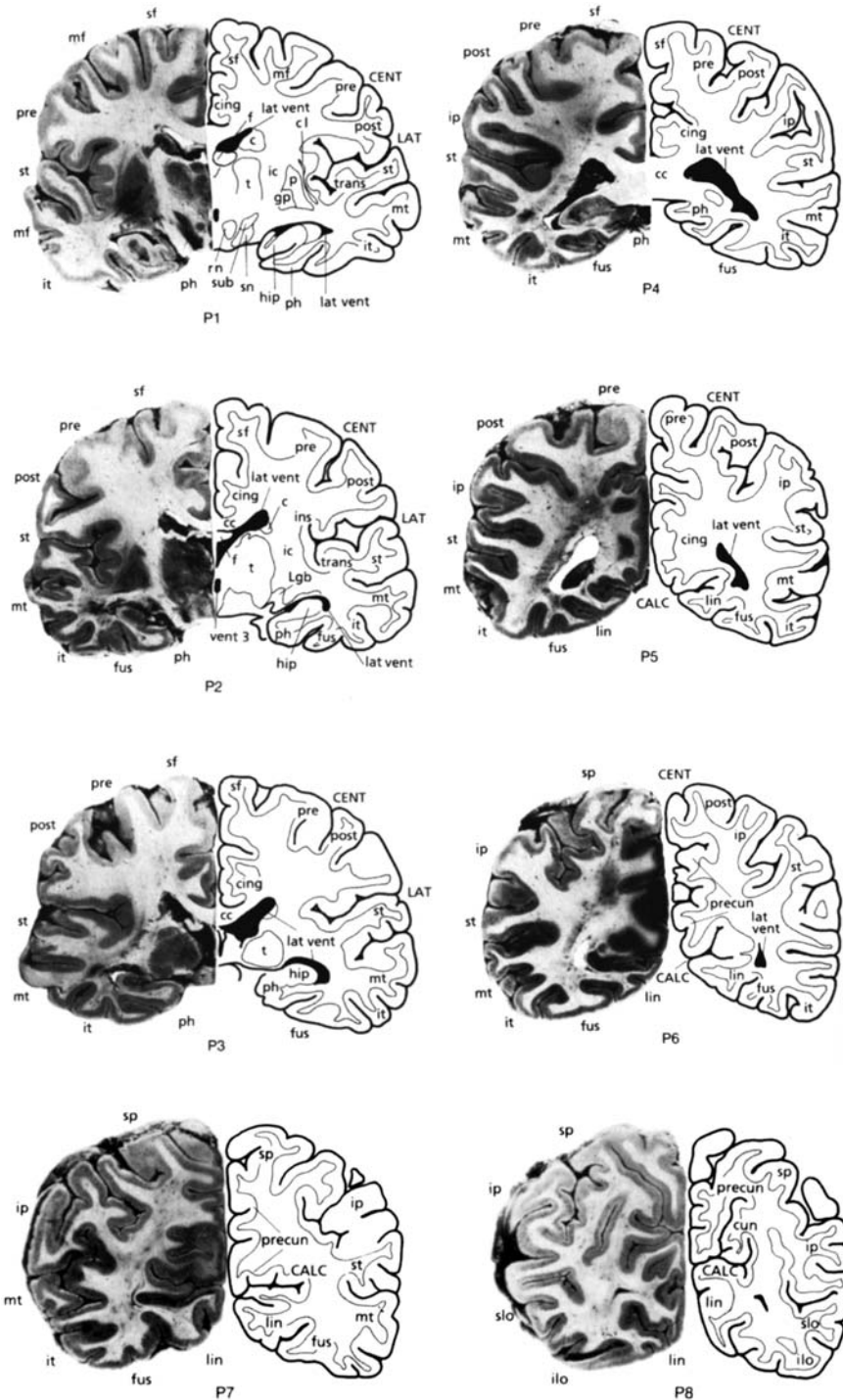
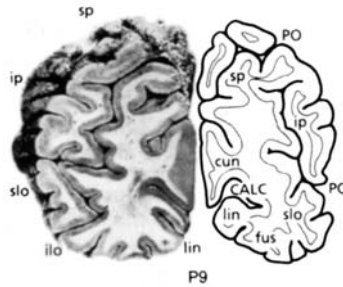


FIGURE 12.11. *Continued*



KEY			
<b>Cerebral gyri</b>		sf superior (first) frontal	<b>Central white matter</b>
ang.	angular	slo sup. lateral occipital	ac anter or commissure
cing	cingulate	sm supramarginal	cc corpus callosum
cun	cuneus	sp sup. parietal lobule	f fornix
fus	fusiform (occipito-temporal)	st sup. (first) temporal	ic internal capsule
gr	g. rectus	trans transverse (Heschl's)	
if	inferior (third) frontal		<b>Other features</b>
ilo	inf. lateral occipital	<b>Central grey matter</b>	aq aqueduct
ins	insula	am amygdaloid nucleus	CALC calcarine sulcus
ip	inf. parietal lobule	c caudate nucleus	CENT central (Rolandic) sulcus
it	inf. (third) temporal	cl claustrum	cereb cerebellum
lin	lingual	gp globus pallidus	ch pl choroid plexus
lo	lateral orbital	hip hippocampus	LAT lateral (sylvian) fissure
mf	middle (second) frontal	hyp hypothalamus	lat vent lateral ventricle
mo	medial orbital	lgb lat. geniculate body	n cranial nerve
mt	middle (second) temporal	mam mamillary body	olf olfactory tract
occ	occipital gyri	p putamen	ot optic tract
ph	parahippocampal	rn red nucleus	ox optic chiasm
post	postcentral (sensory)	sn substantia nigra	PO parieto-occipital sulcus
pre	precentral (motor)	sub subthalamic nucleus	vent 3 third ventricle
precun	precuneus	t thalamus	

FIGURE 12.11. *Continued*

Smaller focal lesions will obviously not lead to brain shift. In addition to the above causes, these may be caused by lacunar (small) infarcts, which can be associated with hypertension, and grey areas of demyelination (plaques) within the white matter. Diffuse lesions include leucoaraiosis, which is a granularity to the white matter, again associated with hypertension. Dilatation of the lateral ventricles may also be seen and can indicate atrophy, particularly if in association with gyral narrowing and sulcal widening.

Tissue blocks can then be taken for histology, and a note of these made, before returning the slices to formalin. It will usually be necessary to take large blocks for embedding in extra-large cassettes, as this allows better anatomical orientation when examining the section. To maintain orientation on the slide, one surface can be inked or nicked to allow the technical staff to always embed this surface down, thus producing slides that are all from the same surface.

If a brain is cut fresh, and unexpected pathology is identified, the slices can be laid flat in formalin and fixed prior to further examination, although it must be said that the results are vastly inferior to those obtained with pre-fixation.

Routine block selection should include one block from the following, together with any macroscopically identifiable focal lesion. The exact site and number of blocks for histology, however, will vary from cases to case, depending on the expected findings.

Superior and middle frontal gyri	Infarction (a watershed zone) and dementia (especially Alzheimer's disease)
Basal ganglia	Infarction (lacunae), movement disorders
Hippocampus and adjacent neocortex	Hypoxia, epilepsy, and dementias
Midbrain	Parkinson's disease (and Lewy body dementia)
Cerebellum	Hypoxia and toxic (i.e., drug) changes, some movement disorders

## Special Techniques

### *Removal of the Brain in a High-Risk Case*

If the case is "high-risk," that is, either a Category 3 or 4 pathogen, including a suspected prion disease, the brain can be removed in the normal way but a hand-saw must be used rather than an oscillating saw. This is because an oscillating saw produces much more bone dust than a hand saw and will therefore spread infective material further. Ventilated head-sets that blow air downwards over the face are also recommended in any high-risk cases. See Chapter 1 (p. 38), for further details on how and when to undertake "high-risk" post mortems. Known prion disease cases should be undertaken only when facilities for adequate decontamination and fixation of the brain can be undertaken. Although prion disease is technically a Category 3 pathogen, the autopsy can be undertaken as for a Category 2 pathogen, providing the brain and spinal cord are removed using the technique now described. Prion protein is not destroyed by formalin fixation and therefore remains an infective risk. Although other fixatives, such as phenol, do adequately destroy the prion protein, they also destroy all antigenic sites, making later immunohistochemistry impossible. For this reason, most departments continue to use formalin until block selection has been undertaken. Once taken, the blocks are "decontaminated" by being placed in 98% formic acid for 1 hour prior to processing. Sections can then be cut and any immunohistochemistry performed in the usual way. Before fixa-

tion, small samples should be taken from the frontal lobe and cerebellum, for frozen storage. These should not be kept permanently within the department—the high risk nature of the material requires a special licence for prolonged fresh storage—but sent as soon as possible to the appropriate facility. In the United Kingdom, this is the National Surveillance Unit in Edinburgh.

*Alternatively, the following technique for removing the brain can also be used for all “high-risk” cases, including prion disease, and has the advantage that an oscillating saw can be used [3]. The table beneath the head should be covered by an impenetrable material such as polythene, and an absorbent pad laid over the top of the sheet. The head should be on a block as normal, and should not overhang the table. Once the scalp is reflected and the muscles dissected as normal, the head should be placed in a clear polythene bag and secured with string about the neck. A hole should be made in the bag to allow the saw to enter and the hole sealed about the neck of the saw with more string. The bag should be large enough to allow movement of the saw within the bag and care must be taken to leave the air vents of the saw outside the bag. The skull can then be sawn in the usual way. Once completed, the saw can be removed and the hole resealed with string. The skull should be removed in the usual way, making further small incisions in the bag to allow entry of the T-bar and the chisel etc. The bag can then be removed with care, and contains all the bone dust. The skull cap and all instruments should be laid on the absorbent pad. The brain can then be removed in the usual way and placed into a preweighed, formalin-filled container.*

## Other Special Techniques

### *Removal of the Spinal Cord*

The spinal cord can be removed from an anterior or a posterior approach, and although usually removed separate from the brain, can be removed in continuity with the brain (from a posterior approach) if necessary. The anterior approach is perhaps the more difficult one but has the advantages of not requiring the body to be turned over (a messy procedure if evisceration has already taken place) and allowing the nerve roots and dorsal ganglia to be dissected. The posterior approach is both quicker and easier, but is best performed before the rest of the post mortem, to avoid mess. It also allows the spinal cord and brain to be removed in continuity but does not allow easy examination of the nerve roots or dorsal ganglia.

One further technique is to remove the entire vertebral column and extract the spinal cord later, following fixation. This technique saves time during the post mortem, but makes reconstitution of the body much more difficult.

### Removal of the Entire Vertebral Column

This is best accomplished from an anterior approach. Once the vertebral column has been exposed by the same technique as that of the anterior spinal cord removal (see later), the vertebral ends of the ribs must be cut through on either side, using an oscillating saw. The sacrum should then be separated from the iliac bones via an oblique saw cut on each side, again with an oscillating saw. The vertebral column must then be separated from the skull via cutting through the atlanto–occipital joints. This latter procedure requires experience and practice to get the angle right. An alternative would therefore be to saw through the atlas vertebra; however, this would damage the upper cervical cord. The vertebral column can then be lifted forward from the sacrum and separated from the skin and soft tissues of the back with a short-bladed knife, such as a PM40, taking care not to damage the skin. A length of wood such as a broom handle is then required to affect reconstitution.

### Removal of the Spinal Cord via the Anterior Approach

After evisceration is complete, scalpel and forceps should be used to clear as much soft tissue as possible from the lateral aspects of the vertebral column, taking care not to damage the nerve roots, particularly at the sacral and cervical levels. If the parietal pleura is pulled back on both sides, the nerve roots and (more laterally) the sympathetic chain will be exposed. This visibility allows dissection to be undertaken without damage to the nerves. The ribs should then be broken with a saw at their widest point, folded inwards, and covered with a cloth to prevent injury from bony spicules. A cut should then be made with an oscillating saw in the lumbar vertebrae. This cut should be made in a horizontal plane, just below the lumbar curve, and should go through the vertebral body but no further. At this point the saw will be felt to “give” whereupon the saw should be immediately withdrawn. Next the saw is used to cut through the pedicles of the vertebral bodies, starting from the horizontal cut in the lumbar region and continuing to the cervical vertebrae. This should be in a plane just anterior to the nerve roots (just anterior to the ribs in the thoracic region). A small amount of progress should be made on each side, rather than doing all of one side and then all of the other. In this way, the spinal column can be separated as the procedure is undertaken, thus allowing the correct plane of cut to be found, and preventing an incorrect plane from being continued. The angle of cut changes in different parts of the spinal column, and it is essential that the correct angle is used, both to avoid damaging the cord and to ensure complete removal of the vertebral bodies. In the lumbar region, the cut should be almost horizontal, at about 70 to 80° from the vertical. In the thoracic region it should be about 45° from the vertical. In the cervical region it should be at its steepest, at about 20 to 30° from the vertical (see Fig. 12.12). Only the bony pedicle must be cut with the saw; as soon as any “give”

is felt the saw must be withdrawn, to prevent damage to the spinal cord and dura. It is difficult to remove the upper cervical spine, as there is little room for manoeuvring the saw. It may be necessary to remove a central V-shaped wedge from the vertebral column, leaving the outer edges to be removed piecemeal using bone forceps. The vertebral column should then be completely free, and can be removed to expose the spinal cord. Bone forceps can then be used to expose the nerve roots further and remove any residual vertebral column obscuring the cord. This is a great deal easier to say than it is to do, and may take a considerable amount of time, particularly if

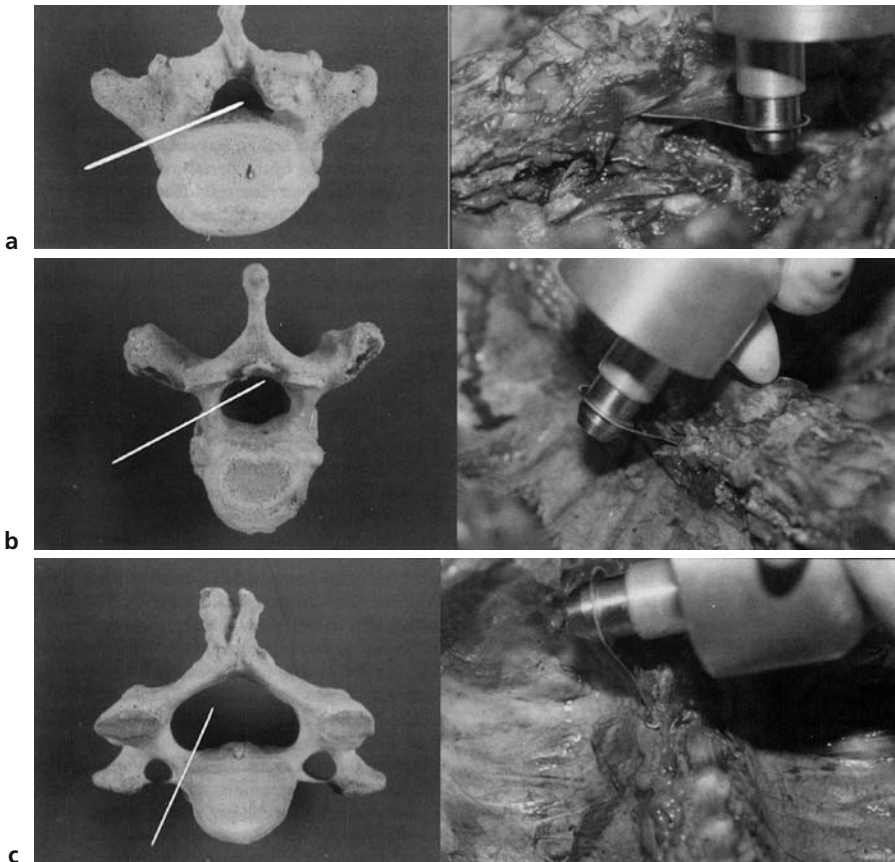


FIGURE 12.12. Removal of the spinal cord via an anterior approach, showing the angle of cut necessary **(a)** in the lumbar vertebrae; **(b)** in the thoracic vertebrae; and **(c)** in the cervical vertebrae. (Reprinted with permission from Burton J and Rutty G. *The hospital autopsy*, 2nd edit. Arnold, 2001; p. 100.)

the original saw “line” is slightly in the wrong plane. It is not usually necessary to go below L4/5, as the cord ends in the cauda equina at L2; however, if further exposure of nerve roots is required, a wedge of sacrum can be removed from the midline, and the remaining bone patiently chipped away using bone forceps, a further time-consuming procedure. Further careful dissection of soft tissue is then necessary to expose the posterior root ganglia of the lumbar and cervical regions, the latter being much more lateral than is often realised. If necessary, it is also possible to dissect out the brachial, lumbar, and sacral plexuses. Once the cord is exposed, it is best to mark certain key nerve roots with string before removal, to aid future examination, as nerve root levels are extremely tricky to identify in the separated spinal cord.

Before the cord can be removed, it is necessary to free the dura from about the foramen magnum. This is possible only from above and therefore can be undertaken only after the brain has been removed. Using toothed forceps, the dura mater of the upper cervical cord can be delicately grasped and a scalpel used to free the upper 2 to 3 cm.

The cord can now be removed with the dura intact. Using artery forceps the lumbar region should be gently gripped and the dura and nerve roots transected with a scalpel distal to the cauda equina. The caudal end of the cord can then be gently lifted, any adhesions being separated with a scalpel, and the procedure continued rostrally (see Fig. 12.13). During this procedure, the cord should be kept as straight as possible, to avoid damage produced by torsion. It may be wrapped in a length of cotton wool or similarly soft material while lifting it from the vertebral canal, to decrease the risk of damage. The spinal cord can then be fixed for later examination.

### Removal of the Spinal Cord from the Posterior Approach

With the body in the prone position, an incision is made in the midline, from the occiput to the coccyx, and forceps and scalpel used to dissect as much soft tissue as possible from the bone. It may be necessary to make horizontal cuts at the lower end of this incision, to allow the skin and subcutis to be folded back in a flap so as to leave the vertebral column exposed without hands or retractors to keep the skin incision apart. An oscillating saw can then be used to divide the exposed laminae. If necessary, for example, in a “high-risk” case, this can also be done with a hand saw. The cut should be directed forward and slightly inward and should be placed at about 2 cm from the midline on either side (see Fig. 12.14). Unlike the anterior approach, the necessary angle of cut does not change along the entire length of the vertebral column. As soon as the saw “gives” it should be withdrawn, to avoid damaging the cord. As with the anterior approach, it is preferable to do a short length on either side. This allows the vertebral column to be exposed and thus ensures that the saw is in the correct plane



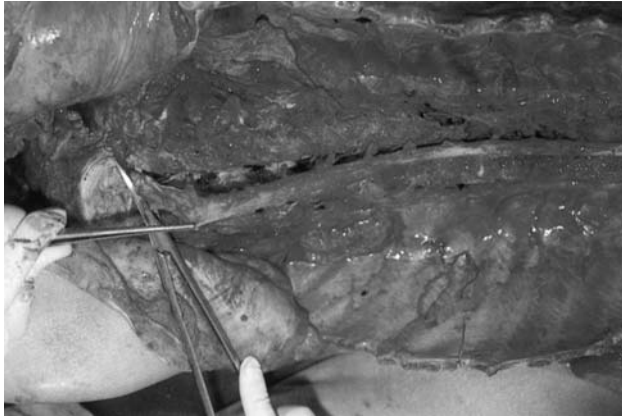


FIGURE 12.13. Removal of the spinal cord via an anterior approach, showing the spinal cord being picked up by the dura and cut through the lower nerve roots, to separate the cord inferiorly. Further cutting of the nerve roots caudally will allow the spinal cord to be freed along its entire length. (Reprinted with permission from Finkbeiner WE, Ursell PC, and Davis RL. *Autopsy pathology: A manual and atlas*. Churchill Livingstone, 2004; p. 60.)

and position. The cuts should be started inferiorly at the sacrum, where a horizontal cut should also be made to join the two vertical cuts together. When at the upper cervical region, a further horizontal cut should be made. The vertebral column can now be lifted free and the dura exposed. If the saw cuts have not been exactly in the correct plane, it may be necessary to

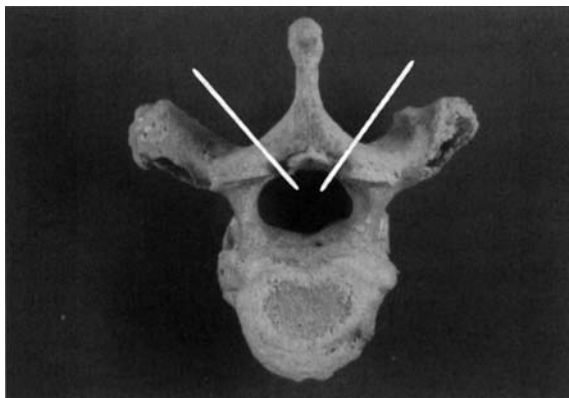


FIGURE 12.14. Removal of the spinal cord via a posterior approach, showing the angle of cut necessary. (Reprinted with permission from Burton J and Rutty G. *The hospital autopsy*, 2nd edit. Arnold, 2001; p. 101.)

chip away bone with forceps to expose the cord sufficiently to allow its removal. As before, once the cord is exposed, it is best to mark certain key nerve roots with string before removal, to aid future examination, as nerve root levels are extremely tricky to identify in the separated spinal cord.

Before the cord can be removed, it is necessary to free the dura from about the foramen magnum, in the same way as for the anterior approach. This is possible only from above and therefore can be undertaken only after the brain has been removed, unless the brain and spinal cord are being removed in continuity (see later). Using toothed forceps, the dura mater of the upper cervical cord can be delicately grasped and a scalpel used to free the upper 2 to 3 cm.

The cord can now be removed as before, with the dura intact (see Fig. 12.15). Using artery forceps the lumbar region should be gently gripped and the dura and nerve roots transected with a scalpel distal to the cauda equina. The caudal end of the cord can then be gently lifted, any adhesions being separated with a scalpel, and the procedure continued rostrally. During this procedure, the cord should be kept as straight as possible, to avoid damage produced by torsion. It may be wrapped in a length of cotton wool or similarly soft material whilst lifting it from the vertebral canal, to decrease the risk of damage. The spinal cord can then be fixed for later examination.

#### Examination of the Spinal Cord

The spinal cord should first be fixed in formalin for 4 weeks. Ideally, it should be suspended in a tall pot to prevent curling; however, if the dura is intact it is acceptable to fix in a curled position. To begin, the dura should be examined and the cord orientated by virtue of the fact that a single artery is present on the anterior surface and a complex arterial plexus is present on the posterior surface. The dura should then be opened anteriorly along its length, using small scissors, and the external surface of the spinal cord examined. The cord can then be sliced at approximately 5-mm intervals, and laid out in the same orientation as the brain stem. The slices should be made in between rather than at the level of the nerve roots, to avoid their damage. Blocks can be taken for histology, but the sites of origin must be clearly noted and marked on the specimen or cassette. Again, one surface of the block needs to be marked by inking or notching, to allow orientation of the final slide.

#### *Removal of the Brain and Spinal Cord in Continuity*

The spinal cord is freed using the posterior approach (as earlier, on p. 301). A wedge of occipital bone and the arches of the upper cervical vertebrae must then be removed. To do this, the skin incision should be extended to the coronal incision used to remove the brain, and the skin reflected. Using

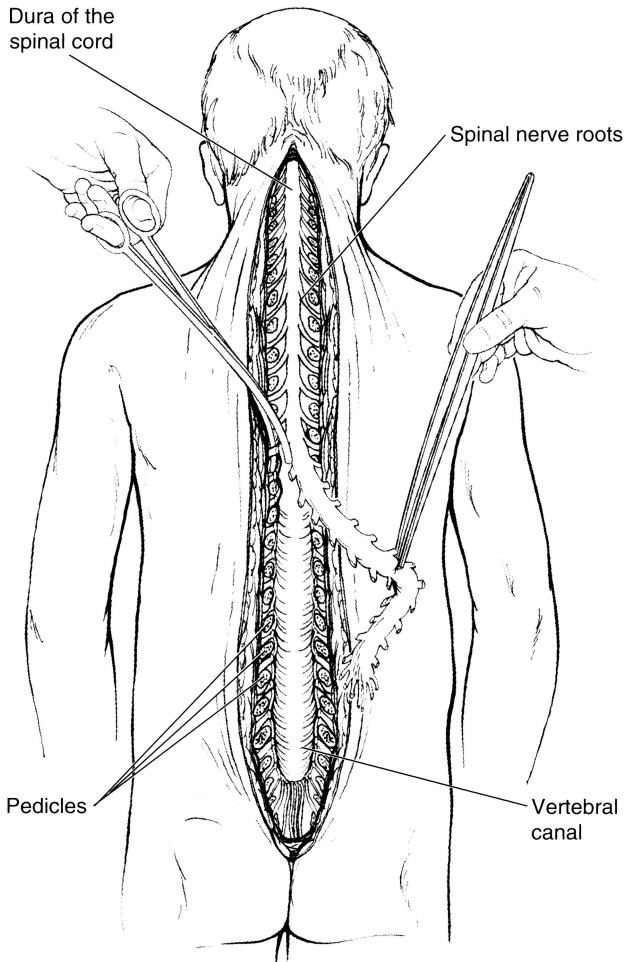


FIGURE 12.15. Removal of the spinal cord via a posterior approach, showing the spinal cord being picked up by the dura and the successive nerve roots being cut with scissors, to separate the cord along its entire length. (Reprinted with permission from Finkbeiner WE, Ursell PC, and Davis RL. *Autopsy pathology: A manual and atlas*. Churchill Livingstone, 2004; p. 62.)

a spatula, the dura should be separated from the occipital bones, via the original saw cut. Two oblique saw cuts should then be made in the occiput, from the original saw cut to the foramen magnum (see Fig. 12.16). This wedge of bone can then be removed to expose the dura covering the cerebellum. Using scalpel and forceps, the soft tissues and muscles should be dissected off the upper cervical vertebrae, exposing the laminae. An oscillating saw can then be used to cut through the laminae of the upper

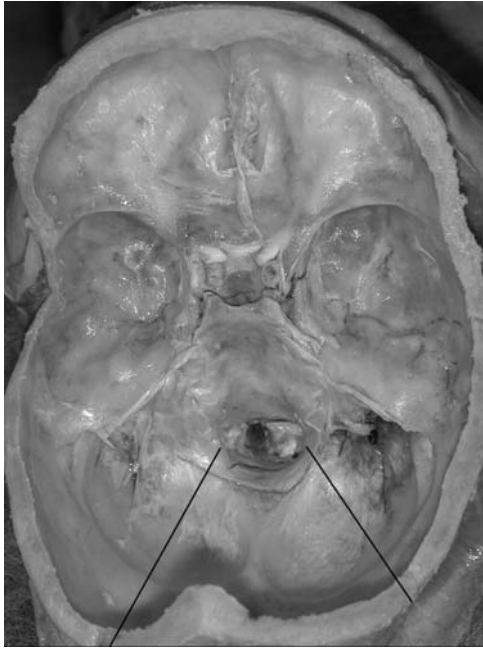

FIGURE 12.16. A photograph of the base of the skull. The lines indicate the position of the saw cuts necessary when removing the brain and cord in continuity. (Courtesy of Mr. Dean Jansen, Whittington Hospital.)

cervical vertebrae on both sides, at the same angle as before. The cord can then be freed from below, and dissection continued rostrally up to the medulla. As before, care must be taken to avoid damaging the cord by excessive torsion. With a small amount of manoeuvring and some help from a second pair of hands, the brain can be removed as normal (see p. 110) but without cutting through the medulla. The entire length of cord can then be delivered through the foramen magnum, attached to the brain.

### *Removal of the Eye*

The eye can be removed anteriorly from the palpebral fissure or, as an easier alternative, the entire contents of the orbit including the globe can be removed from a superior approach through the anterior cranial fossa. If the eye is to be used for corneal transplantation, it should be removed as soon as possible after death, using the anterior approach. The eye should then be placed in a sterile container with the cornea uppermost. The jar should be kept moist by placing the eye on a dampened piece of gauze, and the specimen placed in a refrigerator. It must then be used within 48 hours.

If a delay of more than 48 hours is unavoidable, special preservatives such as tissue culture fluid will be needed. Following removal, reconstitution can be effected by sewing the lids together with fine suture, by using a special plastic “gripper” to bring the lids together, or by inserting a false eye.

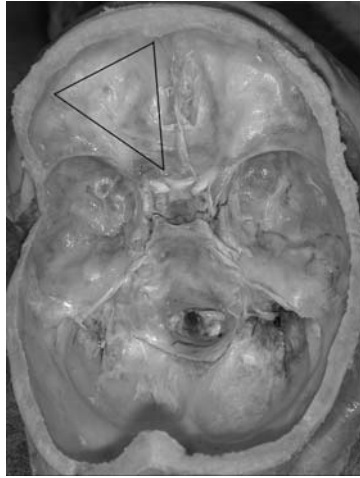
#### Anterior (External) Approach

The eyelids must first be separated using a self-retaining retractor. Using small scissors and forceps, the conjunctiva should then be separated from the sclera around the full circumference of the orbit. Using blunt dissection and traction the globe can be separated from the surrounding soft tissues. If forceps are used to retract both upper and lower conjunctiva at the medial aspect, the insertion of the medial rectus muscle is identified. A small hook can then be passed behind the muscle, and used to pull the eye laterally. A small pair of scissors should then be used to divide the muscle belly, at about 1 cm from its insertion. A similar procedure can be adopted with the other three rectus muscles, the hook being used to rotate the eye in the opposite direction, and the rectus muscle being divided 1 cm from its insertion. The eye can then be pulled forwards using artery forceps clamped about the stump of the medial rectus insertion. This allows the optic nerve to be cut with a pair of long straight scissors, taking care to transect the nerve as far posteriorly as possible. The eye can now be removed from the orbit by prolapsing the globe and dividing the superior and inferior oblique muscles. Dissection of the eye is best undertaken after fixation, and glutaraldehyde should be used for this if possible, as formal saline causes rapid opacification of the lens and vitreous humour.

#### Superior (Internal) Approach

The conjunctiva must first be divided and freed from the sclera as described for the anterior approach. Straight scissors can then be used to divide the soft tissues of the orbit from the bony wall using an anterior approach. This allows the eye to be pushed backwards into the posterior part of the orbit, where it is accessible from above. Following removal of the brain, the dura should be stripped from the base of the skull using forceps. Three cuts can then be made in the roof of the orbit, using an oscillating saw with a fan-shaped blade. The two longer cuts fan out from the origin of the optic nerve, one running parasagittally and the other running at an angle of about 45° laterally. The shorter cut joins the two longer cuts anteriorly (see Fig. 12.17). The bone flap thus produced can be removed using bone forceps, and any residual bony fragments cleared. The entire contents of the orbit are then fully exposed. The orbital tissues can be further freed from the wall of the orbit by blunt dissection, up to the level of the inferior orbital fissure. The eye can then be freed by dividing the firm connective tissue ring about the optic nerve with a scalpel. As before, dissection of the eye is best undertaken after fixation, and glutaraldehyde should be used for this if

FIGURE 12.17. A photograph of the base of the skull. The lines indicate the position of the saw cuts necessary when removing the left eye from an internal (superior) approach. (Courtesy of Mr. Dean Jansen, Whittington Hospital.)



possible, as formal saline causes rapid opacification of the lens and vitreous humour.

### *Examination of the Cavernous Sinus*

The cavernous part of the internal carotid artery should be examined whenever cerebral infarction is suspected. It runs in the cavernous sinus, which is located between the sella turcica and the body of the sphenoid bone, and extends from the superior orbital fissure anteriorly to the apex of the petrous part of the temporal bone posteriorly. See Fig. 12.18 for a diagram illustrating this anatomy.

After the pituitary gland has been removed in the usual way, the medial and superior walls of the sinus can be removed using bone forceps and soft tissue dissection, to expose the internal carotid artery (see Fig. 12.19). The artery enters the cavernous sinus posteriorly from the carotid canal and then arches anteriorly before it turns upwards and enters the subarachnoid space adjacent to the optic nerve. The ophthalmic artery originates at this point and can be exposed by removing the anterior clinoid process. The cavernous part of the internal carotid artery can be removed before examination or examined in situ, by opening longitudinally or serial transverse sectioning in either case.

### *Examination of the Vertebral Arteries*

There are several situations in which the vertebral arteries should be examined. They are a necessary part of the investigation of cerebrovascular

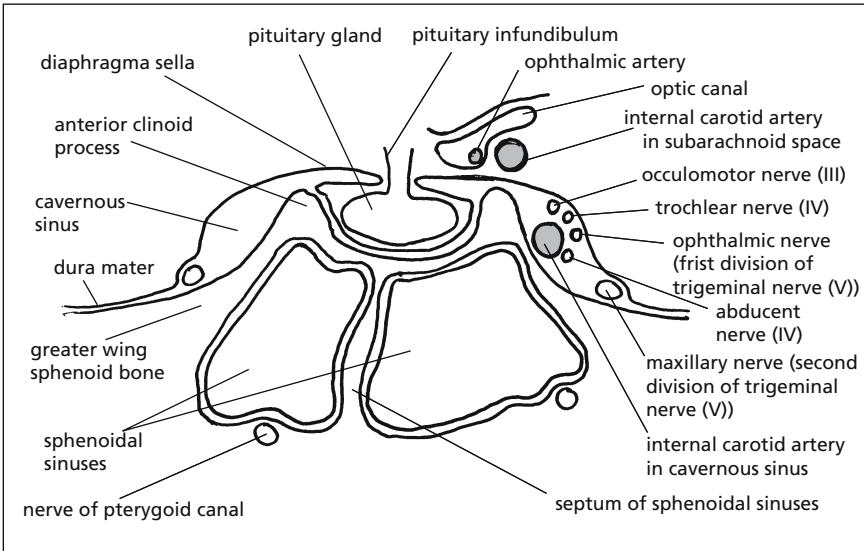


FIGURE 12.18. A coronal section through the cavernous sinus at the level of the anterior clinoid process, illustrating its contents and relationships. Note that the carotid artery (shaded) travels anteriorly in the cavernous sinus and then makes a hairpin bend so is seen again in the subarachnoid space before entering the brain.

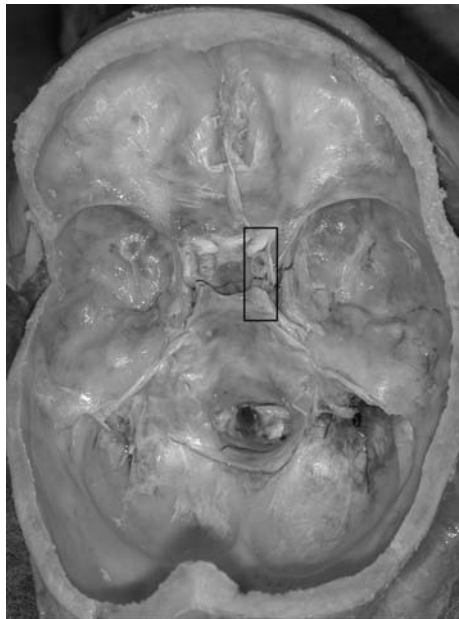


FIGURE 12.19. A photograph of the base of the skull. The lines indicate the area of bone removal necessary to expose the right cavernous sinus. (Courtesy of Mr. Dean Jansen, Whittington Hospital.)

events and should always be examined if a cerebral infarct has been identified or is suspected clinically. They are also part of the examination of the neck following trauma. This would include hanging and road traffic accidents as well as suspicious deaths, the latter usually being examined by a forensic pathologist. They should also be examined in all cases of subarachnoid haemorrhage when either a berry aneurysm or an arteriovenous malformation has not been found. They can either be examined in situ or after removal and decalcification of the cervical spine. They can also be examined using angiography; however, the usual difficulties with body transportation apply if the angiography is undertaken in situ. In contrast, angiography after the cervical spine block has been removed makes any transportation of the specimen an easy process.

#### Anatomy (See Fig. 12.20)

The vertebral artery arises as a branch of the first part of the subclavian artery. It ascends vertically between the longus colli and the scalenus anterior muscles. It then passes in front of the transverse process of C7 and through the foramina within the transverse processes of C6 to C3 before inclining laterally in the transverse foramen of the axis vertebra. It then ascends vertically again into the transverse foramen of the atlas vertebra before bending backwards at right angles and winding around the upper part of the lateral mass of the atlas. It then enters the subarachnoid space of the cerebellomedullary cistern at the level of the foramen magnum, by piercing the posterior atlanto-occipital membrane, the dura mater, and the arachnoid. The artery then runs forward on the anterolateral surface of the medulla to unite with the opposite vertebral artery at the caudal border of the pons to form the basilar artery.

#### Angiography

A Y-shaped incision from the sternum to behind the ears will be necessary for access. Angiography allows both arteries to be viewed at the same time if the basilar artery is first ligated with string. This can obviously be done once the brain is removed, but can also be achieved by temporarily displacing the brain to access the basilar artery, once the calvarium has been removed. The origins of the vertebral arteries can be identified at the subclavian artery, once the neck structures have been removed. The contrast mixture can then be injected using a 10-ml syringe and a suitable cannula, with the vessel ligated with string about the cannula to prevent leakage. The mixture will fill both arteries as the basilar artery is ligated, so once mixture is seen flowing from the origin of the other vertebral artery, the cannula can be removed and the origin of both vertebral arteries ligated to prevent spillage. Keeping the head in a slightly extended position will help the mixture fill the arteries. The mixture used is a barium sulphate suspension (0.6g/ml). If a more permanent preparation is required a 4% gelatin



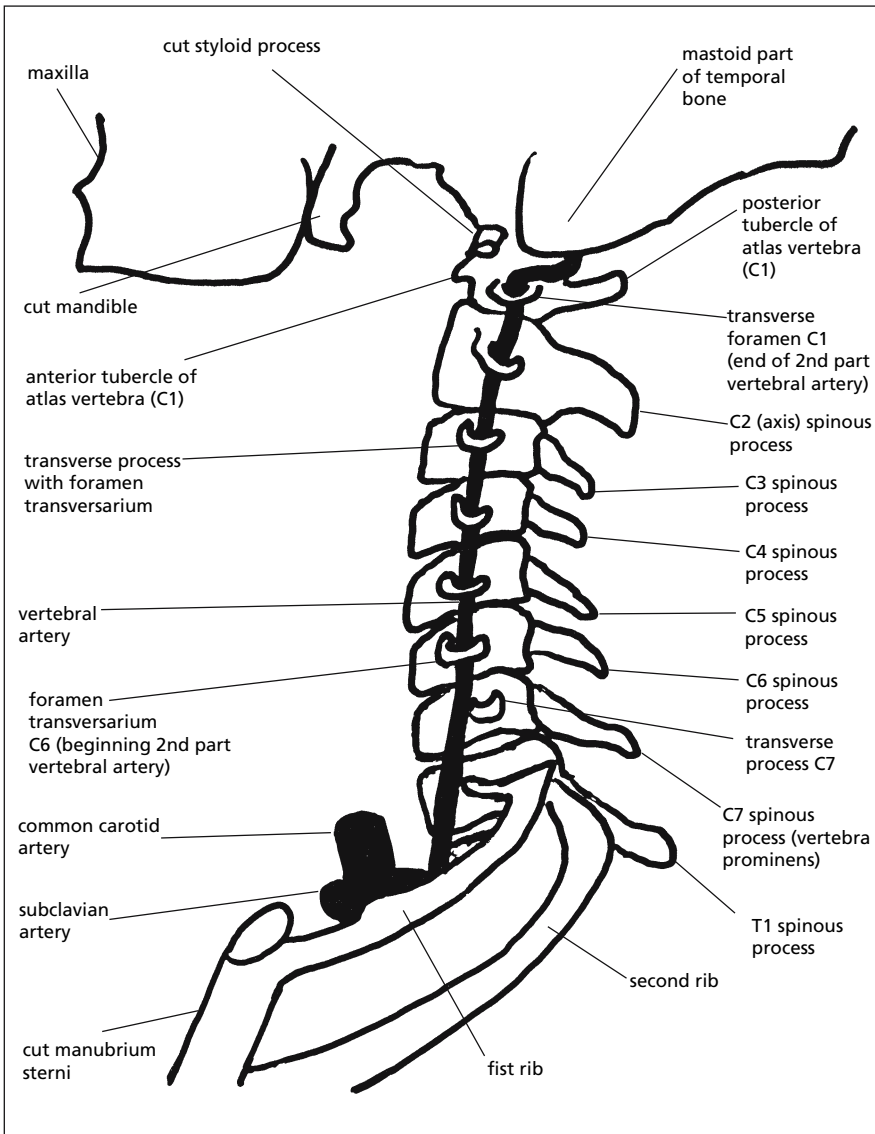


FIGURE 12.20. Diagram illustrating the course of the left vertebral artery.

mixture can be added. This preparation is obviously solid at room temperature and needs to be warmed until liquefied before being used. Once injected it will then cool and solidify again, producing a permanent cast within the vessel. Some people also add gum arabic (acacia) to the mixture, which increases the elasticity of the gelatine and therefore makes it flow

through small vessels more easily. A 200-ml barium sulphate suspension with 15 g of gelatin and 2 or 3 g of acacia is perfect and can be stored in aliquots in a refrigerator.

If whole-body radiography is available, this can now be undertaken. If not, then the cervical spine block can be removed as described below and X-ray films of the specimen obtained, giving in fact better views as the specimen can be more easily positioned.

### Removal of the Cervical Spine En Bloc

The vertebral arteries can be removed in their entirety by removing the cervical spine block. This can be achieved from either an anterior or a posterior approach. Removal of the cervical spine obviously produces great instability of the head and neck, and to some extent this can be counteracted by keeping the attachments of both sternocleidomastoid muscles intact [4].

#### *Method 1: Anterior Approach (See Fig. 11.8, p. 276)*

The soft tissues and musculature anterior to the cervical spine should be stripped using scalpel and forceps. With an oscillating saw the vertebral body of C7 or T1 should be transected. From the internal aspect of the skull, two coronal saw cuts should be made through the full thickness of the base, the anterior one just behind the posterior clinoid process and the posterior one just behind the foramen magnum. These should extend to about 2 cm either side of the foramen magnum, and are then joined by two sagittal cuts. Although difficult, with continued levering and dissection of soft tissue, it should now be possible to remove the cervical spine en bloc.

#### *Method 2: Posterior Approach (See Fig. 11.9, p. 277)*

If the posterior approach is to be used, it is best undertaken before evisceration, as it obviously requires the body to be prone. A midline skin incision should be made, extending from the transverse scalp incision to the upper thoracic spine. The skin and soft tissues should then be dissected free using scalpel and forceps and then reflected back to expose the cervical spine. The attached musculature can then be removed and the lower cervical spine transected at C7 or T1 with an oscillating saw. Two sagittal cuts through the occipital bone should then be made with the saw, one on either side of the midline, originating from the initial transverse cut. These saw cuts should then be extended within the base of the skull up to a point about 1 cm anterior to the foramen magnum on either side. These can then be joined by a coronal cut just behind the posterior clinoid process. The full thickness of the skull base should be sawn through in all of these cuts. The entire block should now be able to be removed, although some leverage and further soft tissue dissection are likely to be necessary.

*Alternatively, a saw cut can be made posteriorly behind the foramen magnum, as for the anterior approach (see above), in place of the two saw cuts through the occiput. This is more difficult, however, and negates the only advantage to the posterior approach, which is otherwise more time consuming owing to the need for an extra incision and a prone body.*

### En Bloc Examination

Once this cervical block has been removed it can be fixed in formalin and then decalcified. The disadvantage of this, however, is the considerable time that it takes to decalcify a specimen of this size, which means that the information will not be available at the time of post mortem and therefore that the cause of death may have to be delayed. The decalcified specimen should be serially sectioned transversely, at about 0.5-cm intervals, and the vertebral arteries examined closely for areas of haemorrhage, indicating trauma, or areas of thrombus or embolus that can then be correlated with any cerebral infarction.

*Alternatively, the vertebral arteries can be opened along their course, as described in the next section. This has the advantage of being much easier once decalcification has been undertaken, and is therefore less likely to produce post mortem trauma to the vessels.*

### Removal of Vertebral Arteries In Situ

With skill and a considerable amount of practice, the vertebral arteries can be removed in situ [5]. After the origin of the artery is identified, a pair of bone clippers or wire cutters can be used to break off the anterior aspects of the transverse processes of the cervical vertebral bodies. Using a probe within the artery as a guide to its course, this can be continued along the full length of the artery, although this obviously becomes extremely difficult as the artery passes backwards around the atlas. The distal vertebral artery can then be severed from above, once the brain has been removed. Continuing to work from the internal aspect of the skull, the vertebral artery can be mobilised, together with a cuff of attached dura. With patience, the vertebral artery can then be pulled through the foramen magnum and thereby removed in its entirety. Once freed, the artery can be opened longitudinally and examined closely for thromboembolus or evidence of trauma. This method has the advantage of providing information at the time of post mortem, but has the disadvantage of being difficult and therefore makes post mortem damage more likely.

### *Examination of the Neuromuscular System*

This is necessary in cases of suspected motor neurone disease, muscle disease, and peripheral neuropathy. Histological samples of muscle, periph-

eral nerve, and ganglia are needed, in addition to the spinal cord (see p. 298 for details on its removal and examination). Appropriate consent for histology will therefore be necessary. The exact muscles and nerves to be sampled will depend on the suspected disease present and its distribution, and it may be advisable to consult a neurologist or neuropathologist about this matter before undertaking the post mortem.

### Sampling Sensory Ganglia

It is necessary to use an anterior approach when removing the spinal cord, so that the nerve roots and posterior root ganglia can be exposed. These posterior root ganglia are part of the sensory nervous system and can now be sampled for histology. It may also be useful to place a small sample of posterior root ganglia in glutaraldehyde in case electron microscopy is needed. The trigeminal ganglia are also purely sensory ganglia and may need to be sampled. The trigeminal ganglion lies in Meckel's diverticulum on the superior surface of the greater wing of the sphenoid bone and can be exposed and removed by stripping the dura from the base of the skull in that region.

### Sampling Peripheral Nerves

When sampling nerves, it is best to avoid sites that are often traumatised during life, such as the median nerve at the wrist, the ulnar nerve at the elbow, and the sciatic nerve at the buttock. It is rarely necessary to examine the cranial nerves, but these can be sampled as they emerge from the base of the brain, after the brain has been removed in the normal way (see p. 110).

In the upper limb, the median, ulnar, and radial nerves are mixed motor and sensory nerves and are all easily accessible in the brachial plexus; the median and ulnar nerves lie anteriorly and the radial nerve lies posteriorly. The brachial plexus can be dissected with relative ease, once the nerve roots and the posterior root ganglia in the lower cervical and upper thoracic region have been exposed. Figure 12.21 illustrates the anatomy of the brachial plexus.

In the lower limb, the femoral nerve is also a mixed motor and sensory nerve and is easily accessible as it emerges from the psoas muscle after it has left the lumbar plexus. The medial and lateral popliteal nerves (also known as the tibial and common peroneal nerves respectively) are also mixed motor and sensory nerves and can be dissected from the popliteal fossa. The sural nerve, useful as it is almost purely sensory, can be found just beneath the skin behind the lateral malleolus.

The nerve to be sampled should be widely exposed, using a skin incision in the direction of the nerve pathway. A 3- to 4-cm length should be removed with minimal trauma, and placed slightly stretched on a card, left to

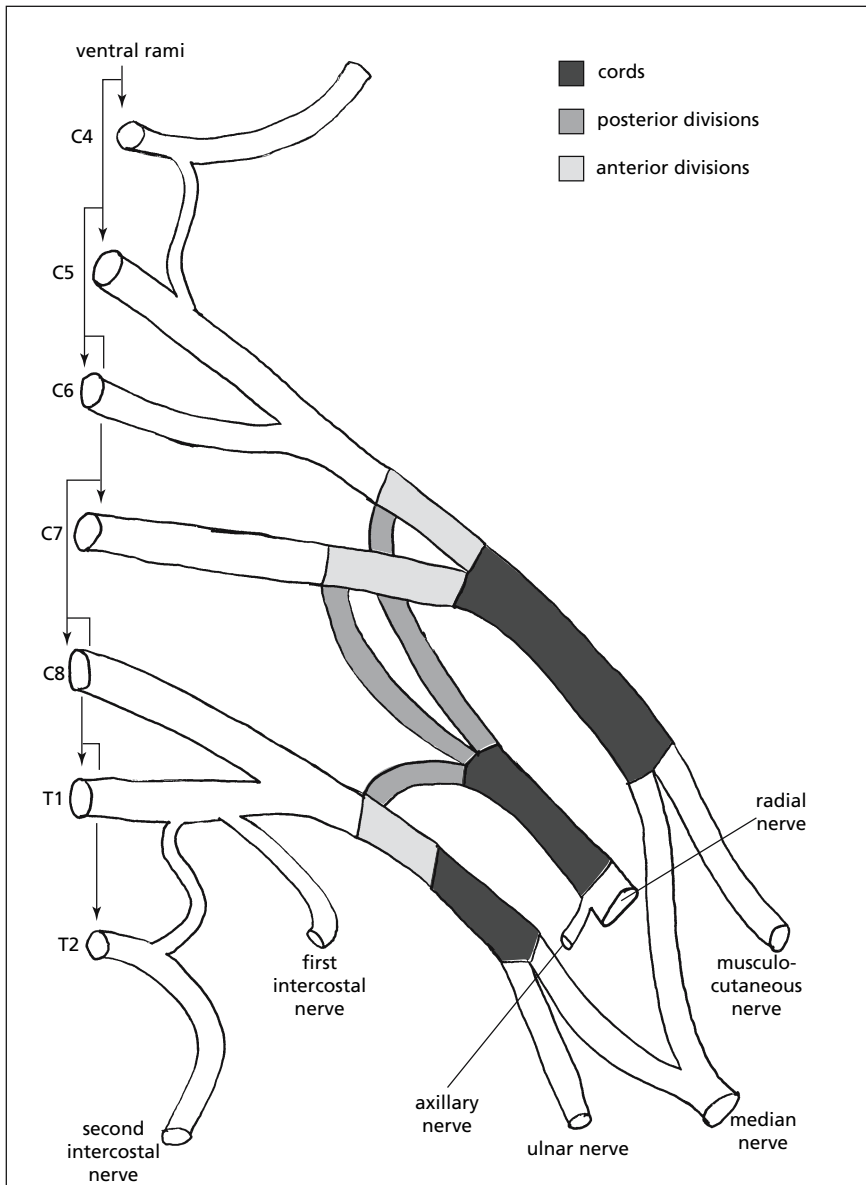


FIGURE 12.21. Diagram of the left brachial plexus.

dry for a few minutes, and then fixed on the card with the distal and proximal ends marked. A small sample should also be placed in glutaraldehyde, not only because electron microscopy may be necessary, but because semi-thin sections allow a better examination of structural detail.

### Sampling Autonomic Nerves and Ganglia

It may also be necessary to examine the autonomic nervous system, which comprises the parasympathetic system and the sympathetic nervous system, both of which are distributed throughout the central and peripheral nervous system. These nerve fibres supply the viscera via a rich network of ganglia and plexuses.

#### *Anatomy (See Fig. 12.22)*

The parasympathetic system is not separately identifiable at post mortem, using both cranial and sacral nerves for its distribution. It is best assessed by examination of the inferior vagal ganglia, which is a fairly conspicuous swelling on the vagal nerve just before it enters the skull. The vagal nerve lies in the carotid sheath, which lies beneath the sternocleidomastoid muscle and also contains the internal jugular vein and the common and internal carotid arteries.

The sympathetic system is a separate and identifiable plexus of ganglia and nerves lying in the cervical, thoracic, lumbar, and sacral regions, lateral to the posterior root ganglia. The sympathetic trunk is a chain of ganglia starting on each side just behind the vagal nerve as the superior cervical ganglion. The middle cervical ganglion lies just below on the anterior aspect of the inferior thyroid artery at about the level of the cricoid cartilage and the transverse process of C6. The inferior cervical ganglion lies below again, at a point just below where the vertebral artery enters the foramen of the transverse process of C6. It is often fused with the first thoracic (and sometimes also the second thoracic) ganglion and is then known as the stellate or cervicothoracic ganglion, which usually lies anterior to the transverse process of C7. The chain continues in the thoracic, lumbar, and sacral regions.

The sympathetic chain can be sampled by carefully peeling back the parietal pleura from the lateral aspect of the vertebral column. It is identified as a threadlike structure lateral to the dorsal root ganglia and is probably best sampled before the spinal cord is removed, as it is extremely delicate and can easily be disrupted during this process. At least some of these ganglia should be sampled for histology, again placing a small sample in glutaraldehyde for later electron microscopy.

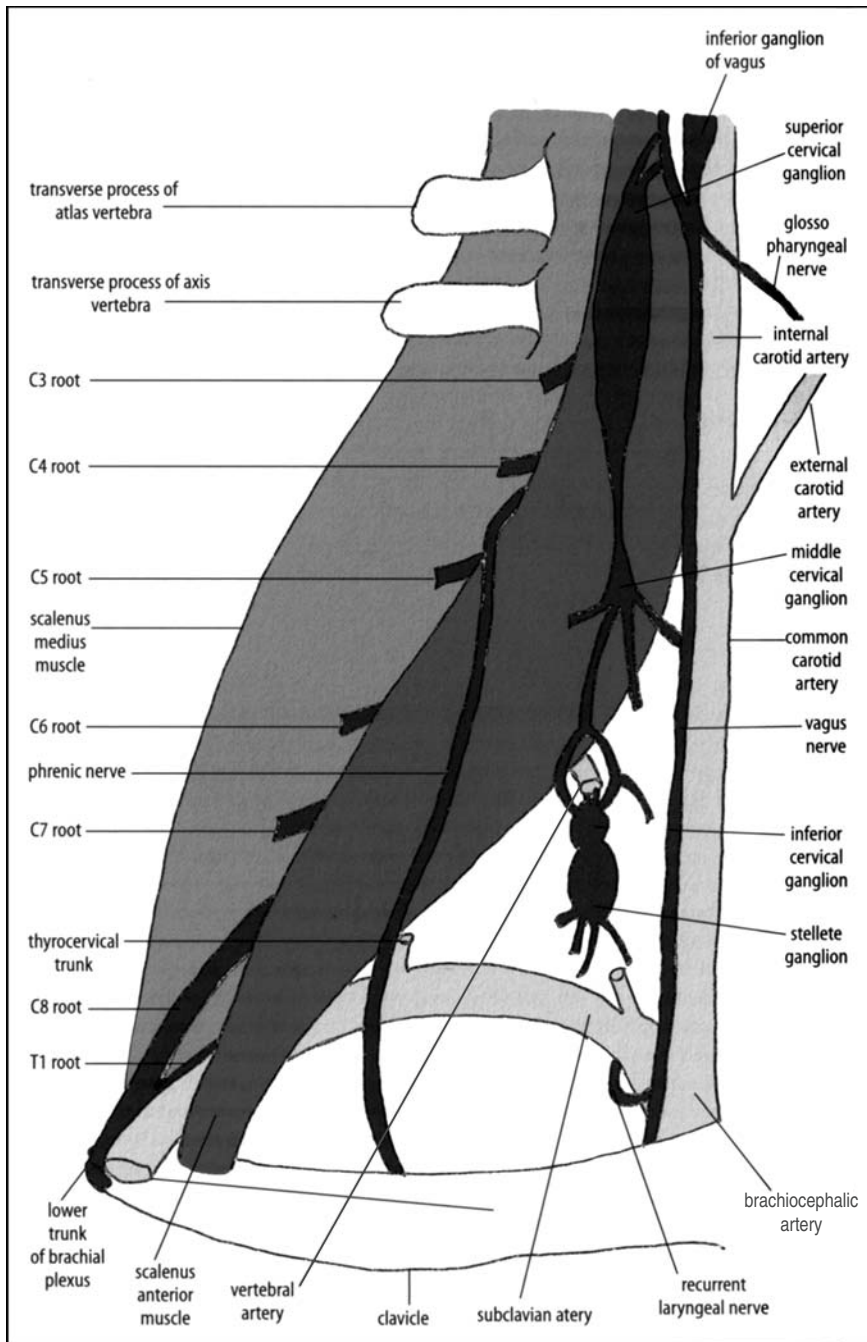


FIGURE 12.22. Diagram of a deep neck dissection, showing the relationship of the cranial nerves with the sympathetic chain.

TABLE 12.2. Table of Suggested Muscles to Be Sampled Together with the Nerve that Supplies Them

Anterior belly of digastric	5th Cranial nerve
Posterior belly of digastric	7th Cranial nerve
Sternocleidomastoid	11th Cranial nerve
Tongue	12th cranial nerve
Diaphragm	C3, C4, and C5 spinal cord segments
Deltoid	C5 and C6
Triceps	C6, C7, and C8
Flexors of forearm	C7 and C8
Interossei and lumbricals	C8 and all T, also useful for motor end-plates and muscle spindles
Quadriceps	L2, L3, and L4
Tibialis anterior	L4 and L5
Peronei	L5, S1, and S2

### Sampling Muscles

The exact muscle to be sampled again depends on the patient's disease type and distribution. Table 12.2 indicates the muscles that should ideally be sampled in every case, together with the nerve that supplies them.

Whichever muscle is sampled, it should be widely exposed, using a skin incision running in the direction of the muscle fibres. The skin flaps should then be displaced using a self-retaining retractor, exposing the muscle surface. The sample should be taken from the middle of the muscle belly. It is important that the muscle sample does not become distorted after removal. To avoid this the strip of muscle should be slightly stretched, placed on card, and left to dry for a few minutes. A piece about 3 cm long and 1.5 cm wide should be taken, taking care not to crush the middle of the sample with the forceps. A small sample should be placed in glutaraldehyde as electron microscopy may be necessary. A further sample should be taken for freezing, to allow enzyme histochemistry to be performed. This should be 0.5 cm in maximum diameter and can be rolled in starch before freezing to reduce artefacts. It is preferable to freeze in isopentane before placing in liquid nitrogen, as this also reduces artefact by freezing the tissue quickly down to the required temperature. The frozen sample should be embedded in the transverse plane to give cross sections of fibres. If more than 24 hours have elapsed since death, however, the results of enzyme histochemistry will be poor as the proteins will have denatured. The remainder of the sample should be formalin fixed and can be divided into both longitudinal and cross-sectional blocks, to increase the information obtainable.

### References

1. Schremmer CN. Gewichtsänderungen verschiedener Gewebe nach Formalin-fixierung. *Franz Z Pathol* 1967;77:299–304.



2. Saphir O. *Autopsy diagnosis and Technic*, 4<sup>th</sup> ed. New York: Hoeber-Harper, 1958.
3. Bell JE, Ironside JW. How to tackle a possible Creutzfeldt-Jacob disease necropsy. *J Clin Pathol* 1993;46:193–197.
4. Geddes JF, Gonzalez AG. Examination of the spinal cord in diseases of the cranio-cervical junction and high cervical spine. *J Clin Pathol* 1991;44:170–172.
5. Bromilow A, Burns J. Technique for removal of the vertebral arteries. *J Clin Pathol* 1985;38:1400–1402.

# 13

## After Dissection

Many of the ancillary investigations that can be performed both during and after the post mortem have been discussed as necessary in the relevant evisceration and dissection chapters. This chapter brings these and other further investigatory techniques together and discusses them in more detail, together with information about diagnoses and report writing. It includes:

- Consent issues
- Rapid diagnosis techniques at the time of post mortem
  - Frozen sections
  - Cytology
  - Macroscopical dye techniques
- Sampling for ancillary investigations
  - Microbiology
  - Biochemistry
  - Toxicology
  - Haematology
  - Criminal investigations
- Taking and reporting tissue samples for histology
- Demonstrating post mortem findings
- Determining and phrasing the cause of death
- Writing the autopsy report
- Role of the post mortem in the clinical audit
- Presenting post mortem evidence in court.

This chapter therefore aims to bring together all of the necessary information that is required to perform a post mortem, over and above the actual evisceration and dissection.

### Consent

The recent investigations in the United Kingdom into organ retention at post mortem have been discussed in Chapter 1 (see p. 18), and began with the Royal Liverpool Children's Hospital inquiry [1]. They have led to sig-

nificant changes in post mortem consent procedures, and now most countries have adopted a new and much more detailed consent form (see Fig. 1.2 for UK example). Any ancillary investigation in a hospital post mortem needs specific consent from the next of kin. Furthermore, the next of kin must also be asked whether any samples removed can be kept by the pathologist for storage or later disposal or must be returned to the body. In the latter case, this may lead to a delay in funeral arrangements, and this must also be discussed with the relatives. Further specific consent is required if such ancillary investigations are to involve a whole organ or tissue, in which case each organ concerned must be listed and consented to individually. In contrast, only one encompassing consent is needed for investigations involving only tissue or fluid samples. Separate consent is required, however, for all purposes other than diagnosis, for example, for teaching or research. In addition, of course, the use of human tissue for research would also have to be approved by the appropriate regulatory authority, for example, a research ethics committee in the United Kingdom or an institutional review board in the United States. In the United Kingdom, a new Human Tissue Bill is currently going through Parliament [2] and is intended to replace the previous Human Tissue Act of 1961 [3]. This will require written consent for diagnosis on all tissue or fluid specimens, and is likely to require separate permission for nondiagnostic usage, such as teaching or research. Although, at least in the United Kingdom, such consent is already in use for post mortem tissue, the bill as it is currently written requires any nondiagnostic usage to be specified. This may mean that retrospective research on stored tissue will no longer be possible without further consent, and this is likely to impinge on any future research that uses post mortem tissue.

In medico-legal post mortems, ancillary investigations are permitted only if they are required to establish the cause of death, and it is the duty of the pathologist to see that such investigations are completed. Specific consent is required from the coroner or equivalent, who is also responsible for setting a time limit for sample retention, in discussion with the pathologist. As for hospital cases, relatives must be consulted as to whether they would like the samples returned to the body or disposed of, although in this context they have no legal say in the conduct of the investigation itself, as it is necessary to establish the cause of death. These issues are legally enshrined in the United Kingdom under the Coroner's Rules and later Coroner's Act [4, 5]. The recent changes in hospital post mortem consent, however, have led to most coroners or equivalents requiring additional consent from the next of kin, even though this is not strictly speaking necessary in law at the present time. This consent may be sought by coroners or equivalents, or they may ask the pathologist or clinician concerned to obtain consent themselves. If ancillary investigations are desired by the pathologist or clinician, but are not necessary to identify the cause of death, then by law the coroner or equivalent can refuse consent but is unable to

give it, and therefore consent must be sought from the relatives in exactly the same way as in a hospital post mortem. There has been a recent review of the Coronial service in the United Kingdom [6] that is likely to lead to a new Coroner's Act in the next few years. It is anticipated that the service will undergo significant changes, particularly around issues of death certification, and this will inevitably have implications for medico-legal post mortem work in the future.

## Diagnostic Techniques at the Time of Post Mortem

### *Frozen Section*

On rare occasions, a microscopical diagnosis may be necessary at the time of post mortem. This may be because the autopsy is being performed for medico-legal reasons, in which case it is preferable to be able to issue a cause of death on the same day. In most cases the urgent histology is that of a tumour, often because widespread tumour is apparent and the origin is uncertain. Suspected infective conditions, however, are another situation in which immediate diagnosis may be appropriate, although obviously this is not possible on "high-risk" (Category 3 or 4 pathogen) cases, as the cutting of fresh tissue in such circumstances contravenes health and safety codes of practice [7, 8]. The need for rapid diagnosis can also apply to brain lesions, the histology of which is otherwise delayed for a considerable time as the brain is ideally fixed before dissection. In hospital cases, although there is no urgency of histological diagnosis with respect to the cause of death, it may be necessary to know of a particular infection or tumour before the post mortem can proceed further, for example, in case a particular dissection technique is required.

A tissue sample of the lesion in question should be taken and trimmed to a block approximately 5 mm<sup>2</sup> and 3 mm thick. The flattest surface should be placed uppermost on a "chock" in an appropriate medium, for example, cryo-M-bed, and the tissue "snap-frozen." It is then sectioned in a cryostat and stained, usually with haematoxylin and eosin (H&E). Such frozen sections are available in most histopathology departments and take approximately 10 minutes, although the laboratory may require some warning if delay is to be avoided. Tissue samples may also be taken for freezing if certain histochemical or immunohistochemical stains are required that cannot be performed on paraffin-embedded material, in which case approximately 5-mm<sup>2</sup> samples should be "snap-frozen" in liquid nitrogen and stored until needed. Storing fresh frozen tissue can also be useful in the investigation of metabolic or storage disorders, in which enzyme analysis is necessary for diagnosis, although in this situation the post mortem must be undertaken within 12 hours of death as enzymes rapidly denature.

### *Smear Technique for Rapid Diagnosis in Neuropathology*

Instead of a frozen section, neuropathologists often prefer to use a smear technique for the rapid diagnosis of brain or spinal cord lesions. As with frozen sections, this can be useful in both tumours and inflammatory conditions, to provide a diagnosis at the time of post mortem.

An approximately 2-mm<sup>3</sup> sample should be taken from the lesion, preferably from the centre rather than the periphery, as the latter can be difficult to interpret. This is placed at one end of a clean glass slide and squashed by one end of another glass slide held at 90° in the horizontal plane. The uppermost slide is then immediately used to spread the squashed tissue onto both slides, moving each slide along the other at 90° to each other, to cover both slides with material. Both slides should be placed immediately into fixative, without air-drying, and then stained using H&E, toluidine blue, or both, depending on personal preferences. Such smears can be difficult to interpret if the pathologist is not experienced in using this technique, however, as it produces a microscopical appearance different from any other seen in either histology or cytology, and is in common usage only in neuropathological practice.

### *Cytology*

#### Fine-Needle Aspiration

If frozen section examination is not available, or is prevented by limited consent, then fine-needle aspiration (FNA) of a tumour mass can be used for diagnosis and can be immediate if necessary. Using a needle and syringe (with a syringe holder if desired), the needle is inserted into the mass. Negative pressure is exerted on the syringe, by pulling back the plunger, and the needle moved backwards and forwards, changing the direction slightly on each occasion to ensure thorough sampling. It is also helpful if the needle and syringe are also rotated during this procedure, to “core” tissue fragments from the lesion and thus increase cell yield. The pressure on the syringe should then be released, and the needle and still attached syringe withdrawn. The needle should then be carefully removed from the syringe. If any material is present in the syringe, it should be placed on a clean glass slide and smeared using another slide placed horizontally at 90°. Air should then be drawn into the syringe and the needle reattached. The plunger should then be depressed and a drop of the contents of the needle deposited onto as many glass slides as there is material available, and smeared as before. The presence of two people is a distinct advantage at this point, so that one person can be preparing more slides while the other is staining the initial slides. The slides should be dried quickly, by waving rapidly in the air or using a hair drier, and can then be stained using a rapid Giemsa method. If more than one or two smears are available, the remaining slides should

be fixed immediately, without air-drying, some in ethanol and (if possible) some in methanol. The former can be used for later Papanicolaou or H&E staining, and the latter for any immunohistochemical staining that may be required.

#### Examination of Fluids for Cellular Content

Any fluids, including pericardial, pleural, peritoneal, and joint effusions, together with urine, can be collected at post mortem for cytological examination. This will rarely be necessary, however, as macroscopical and histological examination will best delineate the presence of tumours—the usual purpose of such cytological examination. Its main use is in the context of a post mortem limited either by consent or high risk, where a needle and syringe could be used to collect such samples when full organ examination and sampling is not possible. The samples thus collected will usually require cytospinning before either air-dried and/or fixed smears can be made and stained appropriately. Although this can be done immediately, routine processing in most cytology departments will provide slides for examination within the course of a working day.

#### Examination of Joint Fluid for Crystals

Fluid from a joint space can be collected using a needle and syringe, particularly when an effusion is present, as described in Chapter 11 on p. 277. This fluid can then be examined cytologically, primarily to identify the presence of crystals, but also to assess the cellular constituents. The colour and quantity of the fluid should be noted and the fluid placed in a sterile container. Although it will keep in a refrigerator for several days, it is best to examine it as soon as is possible. For the identification of crystals, two to four drops of fluid should be placed onto a clean slide using a pipette. Any fibrinous material present should always be included, as this often contains the majority of the crystals and inflammatory cells. The slide is then covered with a clean coverslip and examined microscopically under polarised light. If a permanent record is required, the edges of the coverslip can be sealed using clear nail varnish, to prevent the material drying. The entire slide should be screened at low power, to look for refractile material. Unfortunately, the presence of large numbers of red blood cells can mask the crystals and therefore produce a false-negative result. Considerable care must be taken to exclude false-positive artefacts such as talc crystals (from surgical gloves) which have a “Maltese cross”-like structure. Some steroids can also produce crystals; prednisolone turbutate resembles pyrophosphate and both triamcinolone heracetone and betamethasone acetate esters can resemble urate. The presence of extracellular crystals should be disregarded in the absence of clearly intracellular crystals. Urate crystals (gout) are needle shaped and pyrophosphate crystals (pseudo-gout) are rhomboid shaped. Mixed-crystal synovitis can also occur. Hydroxyapatite crystals are

too small to be identified by light microscopy. A red filter can be used to distinguish between urate and pyrophosphate for confirmation of crystal type. Both crystal types exhibit yellow-blue birefringence. To differentiate, crystals whose long axes are in the direction of the red filter (as marked on the filter itself by an arrow) must be examined. Urate crystals are yellow in this axis (negative birefringence) whereas pyrophosphate crystals are blue in this axis (positive birefringence).

#### “Touch” Imprint Preparations

In cases of suspected haematopoietic malignancies, particularly if marked lymphadenopathy is identified, diagnosis from imprint cytological preparations can be easier than from FNA, and may also be rapid if necessary. An enlarged node should be bisected along its long axis and the cut surface “dabbed” onto the centre of several clean slides, holding the opposite end of the node with a pair of forceps (see Fig. 10.1). Some of these slides should then be air-dried and stained using a rapid Giemsa method, which can either be done immediately, or sent to the cytology laboratory for routine processing. The remaining slides should be fixed in methanol, and can subsequently be used for any necessary special stains or immunocytochemistry.

### *Macroscopical Dye Techniques*

Although most of the following can be used as diagnostic tools at the time of post mortem, they may also be valuable for demonstration purposes.

#### Staining for Iron/Haemosiderin

The Perl’s reaction is used to demonstrate ferric iron and ferritin, if haemochromatosis/haemosiderosis is suspected. A slice of tissue should be placed in an equal mix of a 2% aqueous solution of potassium ferrocyanide and a 2% solution of hydrochloric acid for about 30 minutes, and then rinsed.

*Alternatively, a solution of 5% hydrochloric acid and 5% aqueous potassium ferrocyanide can be used, immersing the tissue for approximately 15 minutes, although the staining is less precise.*

Tissue containing iron will turn blue; the intensity of the colour roughly reflecting the amount of iron present. The tissue should be thoroughly washed in water before fixation (if a permanent record is required) or the tissue can simply be discarded.

#### Staining for Amyloid

If amyloidosis is suspected, a slice of tissue should be placed in a solution of Lugol’s iodine (1g of iodine, 2g of potassium iodide, 1ml of sulphuric acid, and 100ml of water) for about 5 minutes, and then rinsed. If amyloid

is present, the tissue will turn dark brown; the intensity of the colour change again corresponds approximately to the amount of amyloid present. Again, if a permanent record is required, the tissue should be thoroughly washed before fixation; otherwise the tissue can be discarded.

#### Staining for Adrenaline and Noradrenaline

Most pheochromocytomas arise in the adrenal gland and secrete either adrenaline or noradrenaline. Identifying the presence of either substance within a tumour would therefore confirm the diagnosis. To do this, a slice of tumour should be placed in a 10% solution of potassium dichromate (pH 5 to 6) for about 5 minutes, and then thoroughly rinsed. If either adrenaline or noradrenaline is present, the tissue will turn dark brown. The tissue can then either be discarded or washed thoroughly before fixation, if a permanent record is required.

#### Staining for Calcium

To demonstrate the presence of calcium deposits, place a slice of the tissue in a 2% aqueous solution of Alizarin red S for approximately 5 minutes, adjusting the pH to 4.2 using 10% ammonium hydroxide. After thorough rinsing, calcium deposits will be stained orange-red. The tissue can then be discarded or washed thoroughly before fixation.

#### Staining for Fat

A slice of the appropriate tissue should be placed in a saturated solution of Sudan black in 70% ethanol for 15 minutes, and then rinsed. The presence of lipid (with the exception of most phospholipids) is denoted by blue-black discolouration. The tissue can then be discarded or fixed after thorough washing.

#### Staining for Copper

Although this technique takes too long to be useful at the time of autopsy, it can be used for demonstration purposes. A slice of tissue should be placed in a solution of 0.1% rubeanic acid in 5 ml of absolute alcohol to which is added 10% aqueous sodium acetate. This should be left for 8 hours (or overnight) and then rinsed. The presence of copper is denoted by a green-black colouration. After demonstration, the tissue can either be fixed after thorough washing or discarded.

#### Macroscopical Dye Technique for Identification of Early Myocardial Infarction

Many techniques have been used for this purpose; the most popular technique uses nitro-BT dye (2,2'-di-*p*-nitrophenyl-5,5'-diphenyl-3,3'-[3,3'-dimethoxy-4,4'-biphenylene]dimitrazolium chloride). An incubation solution is made with one volume of 1 *M* Sorenson's buffer at pH 7.4, one



volume of nitro-BT at 5 mg/ml, and eight volumes of de-ionised distilled water. Slices of myocardium are washed and then placed in the incubation solution for 30 minutes at 37°C. Normal myocardium turns a purple-blue colour whereas ischaemic myocardium remains unstained. Unfortunately, this applies only to fresh material (within approximately 12 hours of death), as autolysed normal myocardium will no longer contain the enzymes required for the colour change. This makes interpretation extremely difficult in most cases and has led to a loss of confidence in the general technique.

## Taking Samples for Ancillary Investigations

### *Microbiological Investigation*

Obviously, any results of microbiological investigation of post mortem tissue must be interpreted with some caution, as a degree of contamination is almost impossible to avoid. Prompt refrigeration of the body, as occurs in most hospital deaths, does reduce considerably the contamination from endogenous sources. Meaningful results can also be obtained even after antibiotic therapy, particularly with the help of a microbiologist. Full information should always be included on the request form, including the fact that the tissue is post mortem in origin. Although it may seem useless to request antibiotic susceptibility in a dead patient, it is useful to monitor drug resistance and is a necessity if the suspected condition is epidemic or may require preventative treatment in others. It may also seem unnecessary to take post mortem samples if infection is well documented pre mortem (as this is likely to be much more accurate); however, there is always a potential for litigation citing inadequate treatment of a known infection, in which case pre mortem and autopsy microbiology need to be compared to confirm the source of any fatal infection.

All samples for microbiology must obviously be collected using sterile instruments and placed in sterile containers, and transport delay to the laboratory should be avoided. Samples for bacteriological and virological study should be sent in separate containers, as they are often sent to different laboratories. Different swabs are also required for virology and bacteriology. If fungal organisms, mycobacterial organisms, or atypical bacteria are suspected, this information must also be included on the request form, as they will not be identified using routine culture methods. If samples for virology are sent, the request must include the specific viruses that are suspected to be present.

### Fluid Samples

Blood for culture should be obtained in all cases of suspected infection, but particularly in cases of suspected septicaemia, including endocarditis and

meningitis. A needle and syringe should be used to obtain the specimens before evisceration has begun. Unlike other analyses, any site is satisfactory, including the heart. If difficulties in finding the vessels occur, the overlying skin and subcutis can be cut to allow direct visualisation.

If possible, any effusion fluid should also be obtained using a needle and syringe before evisceration, although pericardial fluid can be collected without contamination after the sternum has been removed. Urine should be collected using a needle and syringe as soon as possible after the abdomen is opened. Cerebrospinal fluid (CSF) is more difficult to collect from a dead body than a live one, but can be obtained from three sites. One is posteriorly from about the cauda equina, as in a live adult, and before the brain is removed. For this, the body should be flexed and a needle and syringe passed between two lumbar vertebra. When the theca is penetrated, CSF can be aspirated (no internal pressure is present to indicate when the needle is correctly positioned). Another site is the central cistern before the brain is removed, posteriorly through the atlanto–occipital membrane (see Fig. 13.1). With this technique, the needle should be passed just below the occiput and upwards until the skull is reached. The needle should then be slightly withdrawn, and readvanced until it has passed through the atlanto–occipital membrane and into the basal cistern. This technique is greatly aided by direct exposure of the atlanto–occipital membrane. The last site is the lateral ventricles, using a long needle passed through the brain, once the skull has been removed (see Fig. 13.2).

Samples of gut contents should be taken as soon as possible, preferably by tying off about a 15-cm length of bowel and removing it, then emptying its contents into a sterile container.

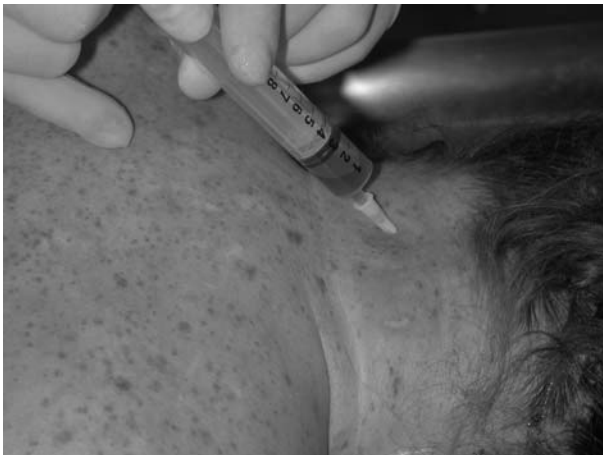

FIGURE 13.1. A needle and syringe is used to collect CSF from the central cistern by passing the needle through the atlanto–occipital membrane. (Courtesy of Mr. Dean Jansen, Whittington Hospital.)

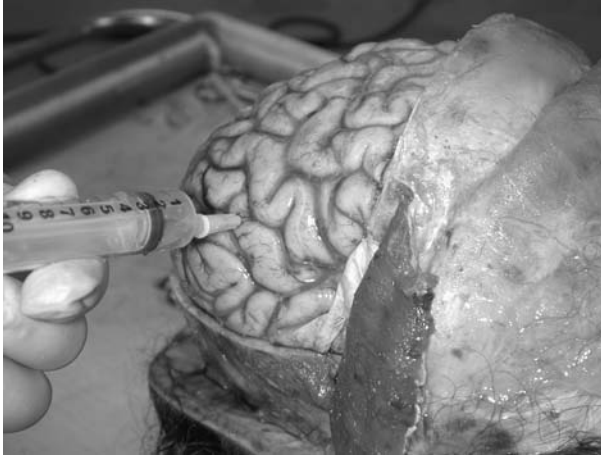

FIGURE 13.2. A long needle and syringe are used to collect CSF from the lateral ventricles, once the calvarium has been removed. (Courtesy of Mr. Dean Jansen, Whittington Hospital.)

### Tissue Samples

Any tissue specimens should also be taken as soon as possible, preferably before evisceration. An area of the organ surface should be sterilised by searing with a heated scalpel blade. A tissue sample should then be removed with scalpel and forceps, through the sterilised surface. Alternatively, a swab can be pushed through the seared surface and moved from side to side within the tissue to be sampled. If no flame source is available to sear the surface (as is usually the case because of health and safety regulations), one sterile scalpel blade should be used to make the first incision and a second scalpel blade or swab used to remove tissue from deep within the incised organ. Having said this, however, it is often the case that infected lesions are not suspected until the organ dissection stage, but it is still worth taking samples for microbiology. If possible, sterilise the surface of the organ/slice of organ, using a heated scalpel blade as before. Then use sterile scalpel and forceps to remove tissue from the centre of the organ/slice. Cardiac valve tissue should always be sent for microbiology when either diseased or prosthetic valves are present. The sample should be removed using sterile instruments as soon as possible after opening the relevant chamber. If suspected before the heart is examined, the surface of the relevant chamber can be seared with a heated blade and a sterile scalpel and forceps used to open the chamber and obtain the sample.

## *Biochemical, Toxicological, and Haematological Investigation*

Any requirements for biochemical, toxicological, or haematological analysis should be discussed with the relevant department before the post mortem is even started. In most hospital deaths, sufficient pre mortem blood samples for any required analyses are likely to already be available within the biochemistry or haematology departments. The results of any such investigations should also be discussed with the relevant professionals. Toxicology results, in particular, should be discussed with an expert, as such results often pertain to the cause of death and therefore accurate interpretation is essential.

### Blood

Blood samples should be taken before evisceration if possible. Although any blood is suitable for most biochemical and haematological investigations, peripheral blood is usually the only suitable site for toxicological analysis; the limb vessels are vastly preferable to the jugular. This is because thoracic, that is, heart blood is contaminated by post mortem diffusion of drugs from the stomach and intestine, and jugular blood is often contaminated with thoracic blood [9].

Femoral or axillary blood can be obtained using a needle and syringe, with a skin "cut-down" if necessary. *Alternatively, it can also be obtained once the thorax and abdomen are opened, by cutting the iliac or subclavian vessels; this yields greater amounts and microbiological contamination is not as important a factor. The limb should not be "milked" by running the hands proximally along the vessels course, however, as this obviously affects sample concentrations.*

If only jugular or heart blood is available for toxicology, it should be taken, but must be labelled as such. Blood from different sites should not be mixed, if insufficient in amount, but submitted separately. The container used to collect the sample is often contaminated during collection, and if so the sample should be decanted into clean specimen containers.

Most biochemical and toxicological analysis requires serum; therefore, whole blood samples should be stored in a refrigerator and sent to the laboratory as soon as possible for centrifugal separation. Two samples should be taken (or the original whole blood sample split into two), one placed into a clean glass container and the other into a clean glass or plastic container with fluoride preservative. The amount of fluoride preservative needs to be enough to reach a final concentration of at least 1.5% by weight, that is, 10mg/ml of sodium or potassium fluoride, and is necessary for toxicological analysis of alcohol, cocaine, and cyanide. If cyanide is suspected, the laboratory must obviously be warned so that the laboratory staff can be protected. If solvent abuse or an anaesthetic death is suspected, it is essen-

tial that the glass container has a foil-lined lid to prevent gas escaping (as gas can permeate rubber) and that the container is filled to the very top to prevent gas escaping into "dead" air space.

Blood for haematological investigation, including glycosylated haemoglobin and fructosamine in diabetics, should be sent in a clean glass or plastic container with anticoagulant (edetic acid (EDTA), heparin, or potassium oxalate).

### Other Fluids

Urine and bile may be useful for toxicological analysis and can be taken as soon as the abdomen is opened. Urine is helpful for the analyses of most drugs and other toxic compounds, and bile is particularly useful for chlorpromazine, morphine, and chronic heavy metal poisoning. Urine can be obtained using a needle and syringe; however, bile is too viscous to travel up a needle and should be collected with a syringe alone. If the gallbladder is surgically absent, useful quantities of bile can often be obtained from the common bile duct. As with blood, the samples should be split, with fluoride added to one half.

Stomach contents will be useful for the toxicological investigation of most ingested compounds, and should be sent complete, although if this is not possible a sample is acceptable, providing a note of the full amount is included. Small and large bowel contents may also be useful in some cases; the latter being most useful in cases of gastrointestinal poisons such as heavy metals, particularly arsenic, mercury, and lead. The laboratory may also require a sample of the stomach or gut wall to accompany these specimens.

Vitreous humour can be useful for biochemical analyses, particularly sodium, urea, and glucose levels, especially if putrefaction has begun, as it is one of the last sites to be contaminated. Samples should be taken from each eye, as slight differences in concentration may occur. A small needle and 5-ml syringe can be used to withdraw about 5 ml of fluid. The needle should enter posteriorly and be advanced to the centre of the globe, to avoid aspiration of the retina. Reconstitution of the eyeball can be effected by leaving the needle in situ, removing the syringe and (after the sample has been decanted) drawing up 5 ml of saline, reattaching the syringe to the needle, and replacing the lost vitreous with saline. Samples with and without fluoride should be sent as before.

### Tissues

Particularly if some days have passed between death and post mortem, tissue samples may be the most useful for toxicological analysis, as the compound will no longer be present in blood or urine. About 100 to 200 g of brain, fat, liver, and kidney should be placed in glass containers, together with a note of the weight of the complete organ.

Blood or splenic tissue are the best specimens for DNA analysis, and should be frozen if there is likely to be any delay before reaching the laboratory. Fluids, swabs, hair, and other organs (liver, muscle, kidney, and brain), however, are also acceptable. Blood should be sent in a plastic, anti-coagulated container. Scrapings and swabs should be dried without heat. Two grams of each tissue is sufficient.

If solvent abuse or an anaesthetic death is suspected, one lung should be removed as soon as the body has been opened and placed whole in a nylon bag which is then heat sealed. The main bronchus should be tied off with string before cutting.

If chronic heavy metal poisoning is suspected, hair or fingernail clippings may be useful (particularly for antimony, arsenic, or thallium). Hair should preferably be plucked from the roots, but if cut hair must be used, it is essential to keep the hair together and mark the proximal cut ends.

In the past, in cases of suspected drowning, blood sampling from the right and left ventricle was recommended for measurements of dilution. This is no longer in use as the results are widely variable; however, if the water involved has a particularly high concentration of fluoride, blood sampling for fluoride levels may be useful. Diatom measurements (see also p. 194) were also thought to be helpful indicators of drowning in the past, although are now thought too unreliable. They depend on the presence of microscopic alga—called diatoms—in seawater and unpolluted fresh water. Lung tissue and the involved water are collected and the type of diatoms present are compared. Diatoms have an indestructible capsule, therefore the tissue must be destroyed (by acid digestion, detergents, or enzymes) and the deposit centrifuged and examined microscopically. Problems occur because diatoms are ubiquitous and contamination is therefore very easy. The tissue for examination must not come into contact with water, the body surface or any instrument that has been in contact with the body surface.

If subcutaneous (e.g., insulin), intramuscular or intravenous drug overdose is suspected, a fresh sample of skin and subcutis from the injection site should be submitted, together with a similar sized random skin sample to act as a control, preferably from a similar site. The tissue sampling should extend along the full-thickness of the needle track.

### *Sampling for Criminal Investigation*

Cases involving sexual assault and murder will almost always be autopsied by a forensic pathologist. The necessary samples would include nail clippings for analysis of material found underneath the nails, in case the DNA of the attacker can be identified from any skin fragments and blood found. The nails should be cut close to the skin and the nails of each hand sent separately. Head and pubic hair should be combed onto brown paper and any material collected into a suitably labelled bag. Samples of pubic and head hair should also be taken and should be plucked from the roots. Plain

swabs (for DNA) and both bacteriology and virology swabs should be taken from the following sites: vulva (both around vaginal orifice and labia); mid-vagina; upper vagina; rectum; and anus (both around anal verge and inner anus). Special swabs are available for the vagina and rectum. They have a protective plastic sheath/applicator over the swab that prevents contamination as the swab is being placed at the site.

## Histology

Ideally, extensive tissue sampling for histology should be undertaken on each and every case, providing that appropriate consent has been obtained (see p. 319). In medico-legal autopsies, however, this is likely to be impossible both financially and because of limitations of consent. The need for histology to establish the cause of death is open to interpretation, however, and depends on the local coroner or equivalent. Although, if the cause of death has been identified, it may not be absolutely necessary to have histological confirmation, it can always be reasonably argued that sampling major organs for histology pertains to any cause of death. In contrast, all hospital autopsies should have finances available for histological investigation.

Tissue from all major organs, including the bone marrow, should be taken when possible. It is always a good idea to store larger amounts of fixed tissue initially, even if you later decide to take histology blocks from only some of the samples. All tissue should be retained until after the histology report has been completed, unless limited by consent. Although it is preferable to store the tissue after this time, space constraints in most mortuaries and laboratories mean that the tissue will then have to be discarded. Tissue from any medico-legal cases that are still ongoing, either because of the need for an inquest or because of further litigation, should obviously be kept until the conclusion of the case and all associated legal investigations. It is sometimes desirable to keep whole organs, either to demonstrate a lesion that would be destroyed on dissection or because of a desire for further investigation. The latter may be relevant if the dissection technique requires a period of fixation before examination, for example, the brain or an inflated lung, or if an expert opinion is required, for example, the heart in a suspected primary arrhythmia. Although such organ retention should always be undertaken if possible, it can be done only if appropriate consent has been obtained.

Tissue blocks of varying shape and size can be used to indicate exact site of origin within organs, using a personal code. For example, different shapes can be used to indicate the side of origin in bilateral organs and even to distinguish between all pulmonary lobes. Several organ samples per cassette can be used, if necessary, to reduce the number of paraffin blocks. Histology of the brain is unlikely to be useful if the brain was sliced fresh and no lesions were identified, and can therefore usually be omitted.

Most immunohistochemistry tests can be performed on paraffin-embedded material. Some lymphoid antibodies and many “new” antibodies, however, require frozen sections, and therefore fresh tissue should be “snap-frozen” and stored if such techniques are likely to be necessary. Similarly, enzyme histochemical staining requires frozen sections, and is often necessary in the investigation of muscle disorders and metabolic diseases. If electron microscopy may be necessary it is preferable to fix a separate, small sample of the tissue in question in glutaraldehyde for 2 hours, before transferring to washing buffer. Although electron microscopy can be performed on formalin-fixed tissue, and even from paraffin-embedded blocks, glutaraldehyde is the best preserver of intracellular structures.

The speed with which the histology is processed will depend on other constraints within the laboratory concerned. Although it is preferable that the histology is available early enough to allow its inclusion in the written report, this is not possible in many laboratories. In most cases, therefore, an initial macroscopic autopsy report should be sent out, followed by a separate histology report at a later date. In this situation, it is often useful to include a copy of the original macroscopical report with the histology report, to ensure that they are together within the patient’s records. Guidelines on best practice, however, suggest that histological examination should not significantly delay the report, and therefore that a final report, including histology, should be available within 1 week, except in the rare cases in which further investigation is necessary [10].

## Demonstration of Post Mortem Findings

When a hospital post mortem has been performed it is important that the findings are demonstrated to the requesting clinicians, both to convey the information and to encourage further hospital post mortem requests. In addition, post mortem findings provide good teaching material for medical students and other interested parties, such as nurses, policemen, firemen, and ambulancemen, providing that appropriate consent has been obtained. Post mortems on any high-risk cases (Category 3 or 4 pathogen) are, for obvious reasons, unsuitable for demonstration purposes, although organs of interest can be fixed and kept or photographed for later demonstration. Although performed only to establish the cause of death, demonstrations on autopsies performed for medico-legal reasons are possible, with the consent of the coroner or equivalent. It is polite to let both clinicians and students know of such a demonstration as soon as possible. For the clinicians a phone call prior to the autopsy to let them know the day and time of the examination and to discuss a mutually satisfactory demonstration time is well worth the effort. Very few hospital doctors can drop everything at a moment’s notice, and yet in many hospitals this is how clinicians are invited to a post mortem demonstration. In the case of the students, this



means putting a notice on a previously designated noticeboard, or sending an e-mail, including the time of the demonstration and the basic details of the case. Having thus obtained an audience, it is then equally important to make the demonstration as aesthetically comfortable as possible. Pathologists often forget just how unpleasant the autopsy procedure can be to those who do not participate regularly. The body should therefore be cleaned and as much reconstitution undertaken as is possible, in particular the head, which can also be covered if necessary. The pathologist and any assistants should change into clean clothes, clean aprons, and clean gloves. The organs for demonstration should be cleaned and dried as much as possible, and laid out onto an appropriate tray or board. The findings should be demonstrated clearly, avoiding splashing and dripping, and time given for answering questions. If facilities for video or photography are available, these can also be used for demonstration purposes, either to a larger audience or at a later date, providing that appropriate consent has been obtained.

## Cause of Death

In the case of a hospital post mortem, there is no legal need to provide a cause of death, particularly at the time of post mortem, as by definition a death certificate must already have been issued. Best practice guidelines [10], however, include a formal cause of death, both for purposes of statistical coding and because it is useful to the clinicians. In the United Kingdom, the clinician who filled in the death certificate can indicate on it that a hospital post mortem is to be undertaken. In these circumstances, the registrar of deaths will send a form to the clinician at a later date, asking if the cause of death at post mortem differed from the pre mortem cause of death registered. There is then an opportunity to state the revised cause of death and aid accurate epidemiological statistics.

In the case of a post mortem performed for medico-legal reasons, the cause of death is the entire reason for the examination. Although the pathologist will not usually be asked to certify the death officially, he or she will be required to give the cause of death to the coroner or equivalent, who will then register the death and decide if further investigation in the form of an inquest or other legal proceeding is appropriate. The format for the recording of the cause of death is the same in most countries, and follows the World Health Organisation (WHO) guidelines. In the United Kingdom it is the Office of National Statistics that oversees this data collection (see Fig. 13.3 for a UK specimen death certificate). It contains two parts: a Part 1 for documentation of the direct cause of death, and a Part 2 for the documentation of other serious conditions present that may have indirectly contributed to death. The first part is usually divided into three subsections, although as many more as is necessary may be added (although rarely is) by the person registering the death. These subsections are used to

Registrar to enter  
 this as a Death Entry

**MEDICAL CERTIFICATE OF CAUSE OF DEATH**

For use only by a Registered Medical Practitioner WHO HAS BEEN IN ATTENDANCE during the deceased's last illness, and to be delivered by him forthwith to the Registrar of Births and Deaths.

Name of deceased \_\_\_\_\_  
 Date of death as stated to me \_\_\_\_\_ day of \_\_\_\_\_ Age as stated to me \_\_\_\_\_  
 Place of death \_\_\_\_\_  
 Last seen alive by me \_\_\_\_\_ day of \_\_\_\_\_

- 1 The certified cause of death takes account of information obtained from post-mortem.  
 2 Information from post-mortem may be desirable but not essential.  
 3 Post-mortem not being held.  
 4 I have reported this death to the Coroner for further action. [See overleaf]
- Please ring appropriate digit(s) and letter
- a Seen after death by me.  
 b Seen after death by another medical practitioner but not by me.  
 c Not seen after death by a medical practitioner.

**CAUSE OF DEATH**  
 The condition thought to be the 'Underlying Cause of Death' should appear in the lowest selected line of (i) or (ii).

(i) Disease or condition directly leading to death:  
 (a) Disease or condition, if any, leading to (i) a) \_\_\_\_\_  
 (b) Other disease or condition, if any, leading to (i) b) \_\_\_\_\_  
 (c) Other disease or condition, if any, leading to (i) c) \_\_\_\_\_

(ii) Other significant conditions CONTRIBUTING TO THE DEATH but not related to the disease or condition causing it: \_\_\_\_\_

These particulars must be entered in death register.  
 Approximate interval between onset and death \_\_\_\_\_

The death might have been due to or contributed to by the employment followed at some time by the deceased.  Please tick where applicable

This does not mean the mode of dying, such as heart failure, asphyxia, assthenia, etc. it means the disease, injury, or complication which caused death.

I hereby certify that I was in medical attendance during the above named deceased's last illness, and that the particulars and cause of death above written are true to the best of my knowledge and belief.

Signature \_\_\_\_\_ Qualifications as registered by General Medical Council \_\_\_\_\_  
 Residence \_\_\_\_\_ Date \_\_\_\_\_

For deaths in hospital. Please give the name of the consultant responsible for the above-named as a patient. \_\_\_\_\_

Complete where applicable

**A**  
 I have reported this death to the Coroner for further action.  
 Initials of certifying medical practitioner. \_\_\_\_\_

**B**  
 I may be in a position later to give, on application by the Registrar General, additional information as to the cause of death for the purpose of more precise statistical classification.  
 Initials of certifying medical practitioner. \_\_\_\_\_

The Coroner needs to consider all cases where:  
 The death might have been due to or contributed to by a violent or unnatural cause (including an accident);  
 or the cause of death cannot be identified;  
 or the death might have been due to or contributed to by drugs, medicine, abortion or poison;  
 or there is reason to believe that the death occurred during an operation or under or prior to complete recovery from an anaesthetic or arising subsequently out of an incident during an operation or an anaesthetic;  
 or the death might have been due to or contributed to by the employment followed at some time by the deceased.

**LIST OF SOME OF THE CATEGORIES OF DEATH WHICH MAY BE OF INDUSTRIAL ORIGIN**

MALIGNANT DISEASES	Causes include:	INFECTIOUS DISEASES	Causes include:
(a) Skin	- radiation and sunlight - pitch or tar - mineral oils	(a) Anthrax	- imported bone, bone meal, hide or fur
(b) Nasal	- wood or leather work - nickel	(b) Brucellosis	- farming or veterinary
(c) Lung	- asbestos - nickel - radiation	(c) Tuberculosis	- contact at work
(d) Pleura	- asbestos	(d) Leptospirosis	- farming, sewer or underground workers
(e) Urinary Tract	- benzidine - dyestuff - chemicals in rubbers	(e) Tetanus	- farming or gardening
(f) Liver	- PVC manufacture	(f) Rabies	- animal handling
(g) Bone	- radiation	(g) Viral hepatitis	- contact at work
(h) Lymphatics and haematopoietic	- radiation - benzene	<b>BRONCHIAL ASTHMA AND PNEUMONITIS</b>	
<b>POISONING</b>		(a) Occupational asthma	- sensitising agent at work
(a) Metals	e.g. arsenics, cadmium, lead	(b) Allergic Alveolitis	farming
(b) Chemicals	e.g. chlorine, benzene	<b>PNEUMOCOONIOSIS</b>	
(c) Solvents	e.g. trichloroethylene	- mining and quarrying	- posteries
		- asbestos	

NOTE:—The Practitioner, on signing the certificate, should complete, sign and date the Notice to the Informant, which should be detached and handed to the Informant. The Practitioner should then, without delay, deliver the certificate itself to the Registrar of Births and Deaths for the sub-district in which the death occurred. Envelopes for enclosing the certificates are supplied by the Registrar.

FIGURE 13.3. (a) Specimen death certificate—front. (b) Specimen death certificate—back. (Reprinted with permission from the Office of National Statistics, London.)

indicate the precise sequence of events, in which “a” is due to “b” is due to “c.” Obviously, the exact number of subsections necessary will depend on the particular case; however, the last condition cited must be the underlying cause of death. It is not necessary to include modes of death, such as cardiac failure, and indeed these are specifically unacceptable when used alone, without qualification by at least one underlying condition. The primary pathological cause of death used for certification and statistical purposes will be the bottom condition in Part 1 (if more than one is present). The need for multiple conditions in Part 1 to be placed in sequence cannot be stressed enough—all too often the subsections are used to list in a random fashion the various lesions present, when they should be given in a causative order. When issuing a cause of death, vague terms and abbreviations must be avoided. Although old age/senility is a legally acceptable cause of death, it can be used only if the deceased was older than 70 years of age at the time of death, and should never be used if a more specific pathology is present [11]. If more than one potentially fatal pathological disease or lesion is present (as is often the case in the elderly) either the one considered by the pathologist to be the most likely cause of death should be used in Part 1 and the others listed in Part 2, or a joint cause of death should be used in Part 1, and is perfectly acceptable. There will be occasions when no cause of death is apparent at the initial post mortem examination—up to 5% of cases in some studies [12]. The first response should be to check all organs again thoroughly, especially the heart, as severe (>75%) stenosis of coronary arteries and left ventricular hypertrophy are common causes of sudden, unexpected death. Examine again, even more closely, the coronary arteries and consider the heart weight again, in relation to the height and weight of the deceased. Unfortunately, you are probably not going to be able to use Foulton’s method (see p. 154) to better assess the possibility of hypertrophy, as the possible need to examine the conduction system (see p. 161) means that you should keep the heart in continuity. Then numerous samples should be taken, if they have not already, for ancillary investigations, including histology, microbiology, and toxicology. Bronchopneumonia and myocarditis, for example, are natural causes of death that are often not identified macroscopically and drug overdose is not always suspected clinically and rarely identifiable at the time of post mortem. Any possibly relevant organs should also be retained in their entirety, providing appropriate consent can be obtained. It will have been necessary to slice the brain fresh, in search of the cause of death, but if there is any suspicion of a neuropathological lesion the slices can be kept, fixed in formalin, and sandwiched between cotton wool sheets, for later examination by a neuropathologist. Even if it appears normal, it is a good idea to keep the heart so that it also can be examined later if necessary, for example to examine the conduction system (see p. 161). The cause of death will then have to be deferred, pending the results of these further investigations. In many countries, including the United Kingdom, this will set in motion

further legal investigations, making an official “inquest” necessary. It also means that the relatives may have to wait some weeks before the body is released to them for a funeral. When all further investigations are complete, there will still be a small number of cases in which no cause of death is apparent. This is well recognised in asthmatic and epileptic individuals, who are known to have a higher risk of sudden unexplained death even when status asthmaticus and epilepticus are excluded [13–16]. In such cases, these underlying conditions can be used as the cause of death. In the other cases, death will have to be documented as unascertained, although recognition is growing of a sudden adult death syndrome, particularly in younger adults, where no specific pathological lesions can be identified [12]. The cause of death is also usually impossible to establish in bodies that are decomposed, and can be documented as unascertainable, as pathological lesions are usually unidentifiable once decomposition has occurred. In such cases, it is often acceptable to dispense with ancillary investigations (particularly histology) as they are almost certain to be unhelpful, although if any internal organ tissue remains it may be worth attempting toxicological analysis.

Obviously, in a medico-legal case, officials will need to know the pathological findings as soon as possible, and they should be telephoned, e-mailed, or faxed with a cause of death as soon as the post mortem is complete. The full report can then be issued in due course, although it is vital that the cause of death used in the written report is worded exactly as you have given it previously. The results of the autopsy cannot be given to any other interested party, however, without the consent of the coroner or equivalent. In hospital cases, the autopsy findings should be discussed as soon as possible with the requesting clinician, preferably during a post mortem demonstration, but if not possible, then over the phone or at a clinico-pathological meeting.


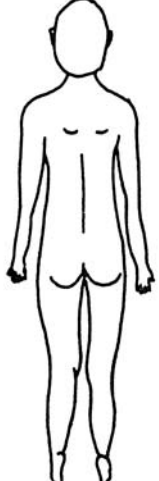
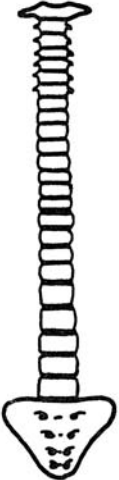

As discussed earlier, the death certificate will either have been filled in by the requesting clinician, in the case of a hospital post mortem, or will be filled in by the coroner or equivalent, in the case of a medico-legal post mortem, after all their investigations are complete. Pathologists are therefore not usually required to fill in a death certificate. There are other certificates, however, that pathologists may be asked to complete and sign. One such certificate is a cremation form. In the United Kingdom and most other countries, extra forms are required for a body to be cremated rather than buried, with the intent that any suspicious circumstances or discrepancies will be identified before all evidence is lost. This form usually has to be signed by two doctors, only one of whom should have been involved in the care of that patient. It is often the pathologist who is asked to be the second signatory, simply out of convenience, as it is often the mortuary staff who deal with this paperwork and they see the pathologists more frequently. If a post mortem has been undertaken, however, and the results are known by the doctor who fills in the first cremation form, then no second

signatory is needed, as the post mortem information is considered sufficient clarification. Another document that pathologists may be asked to fill in and sign is a “free from infection” form, which is required by most countries if a body is to be transported across country borders. It is a statement that the body is not infected by a “high-risk,” that is, Category 3 or 4 pathogen.

## Writing the Report

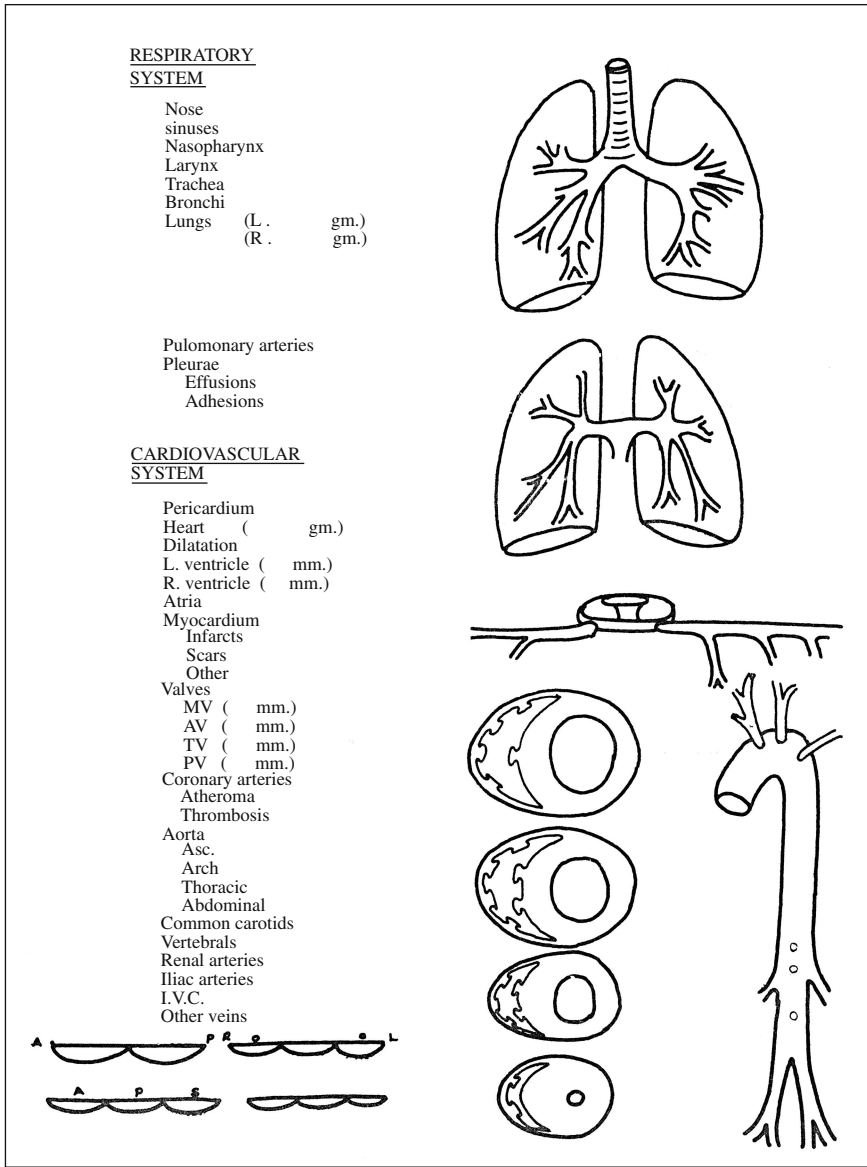
The post mortem report should be handwritten or dictated as soon as possible after the autopsy has finished. Although this is not feasible when several post mortems are being performed sequentially, it is particularly important in such circumstances to make contemporaneous notes during or at the end of each autopsy. These notes should be detailed enough to allow a report to be written without resorting to memory. An “aide-memoire” can be extremely useful, particularly if diagrams are included, and are available in most departments. See Fig. 13.4 for an example. They allow all findings to be quickly detailed, using charts, diagrams, and written notes, in addition to acting as a prompt for notation of all necessary information. More expanded diagrams, particularly for external examination, are also available and are particularly useful in cases of trauma.

The final macroscopical report can take one of two forms. The most usual format is that of a free-style essay, including the necessary headings, but leaving the writer free to use descriptions that are as short or as long as are necessary. The other format is in the form of a formal pro-forma—either on paper or computer—where brief phrases or missing words are filled in. Although the pro-forma type report is often used in departments in which a large number of medico-legal autopsies are performed, it does constrain the pathology report, and can prevent necessary expansion of particular areas of the report. The freestyle report is therefore more satisfactory, and can be written to a personal or departmental format as required. All reports should obviously include comprehensive demographic details, whichever format is used. The height and weight of the body, together with the weights of all major organs, should also be included, either within the text or as a separate list. Full descriptions are most helpful, including important negative findings. A summary of findings, in list form if desired, should also be present, together with a discussion including clinico-pathological correlation. The cause of death should be prominently displayed, particularly in medico-legal cases. Details of which, if any, samples have been taken for further investigation, including histology, should also be given. A clinical summary is a useful inclusion at the beginning of the report, and is essential in hospital cases. In cases performed for medico-legal reasons it may not always be appropriate, however, as the report is a legal document and may be used as evidence in a court of law, whereupon such a clinical

POST MORTEM EXAMINATION		P. M. No.
Name.....	Date and hour of death.....	
Age.....	Date and hour of P.M. ....	
Sex.....	Height.....	
	Weight.....	
<p><u>EXTERNAL</u></p> <p>Nutrition</p> <p>Lividity</p> <p>Rigor</p> <p>Cyanosis</p> <p>Jaundice</p> <p>Oedema</p> <p>Skin</p> <p>Hair</p> <p>Scalp</p> <p>Face</p> <p>Eyes</p> <p>Neck</p> <p>Scars</p> <p>Incisions</p> <p>Arms</p> <p>Legs</p> <p>Breasts</p>		
<p><u>HAEMOPOIETIC &amp; LYMPHORETICULAR SYSTEM</u></p> <p>Bone marrow (vertebral) (other)</p> <p>Spleen (gm.)</p> <p>Lymph nodes</p> <p>Tonsils</p>		
<p><u>MUSCULO-SKELETAL SYSTEM</u></p> <p>Bones</p> <p>Muscles</p> <p>Joints</p>		
<p>KEY: N = Normal, 4 = Present, O = Absent, N.E. = Not examined, Abnormal underline KCH 645</p>		

a

FIGURE 13.4. (a-d) Example of an “aide-memoire” for notation of post mortem findings. (Courtesy of Department of Histopathology, King’s College Hospital, London.)

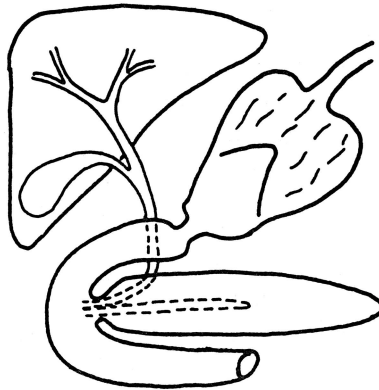


b

FIGURE 13.4. *Continued*

DIGESTIVE SYSTEM

Mouth & tongue  
Teeth  
Salivary glands  
Abdominal wall  
Liver ( gm.)

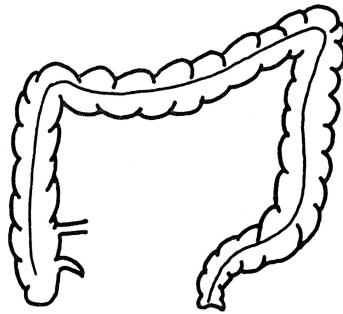


Portal vein  
Hepatic vein  
Hepatic artery  
Gall bladder  
Bile ducts  
Pancreas

Peritoneum  
Oesophagus  
Stomach

Duodenum  
Small intestine

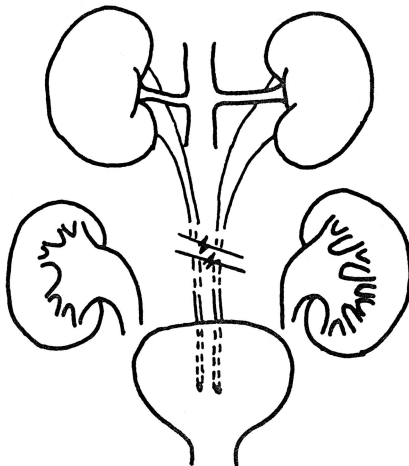
Appendix  
Large intestine



Rectum  
Anus

GENITTO-URINARY SYSTEM

Kidneys (L. gm.)  
(R. gm.)  
Capsules  
Surfaces  
Cortex ( mm.)  
Cortico-medullary definition  
Medulla  
Calyces  
Pelves  
Renal veins  
Ureters  
Bladder  
Urethra  
Prostate/uterus  
Seminal vesicles/  
Cervix  
Testes/ovaries  
Epididymis/tubes  
External genitalia



C

FIGURE 13.4. *Continued*



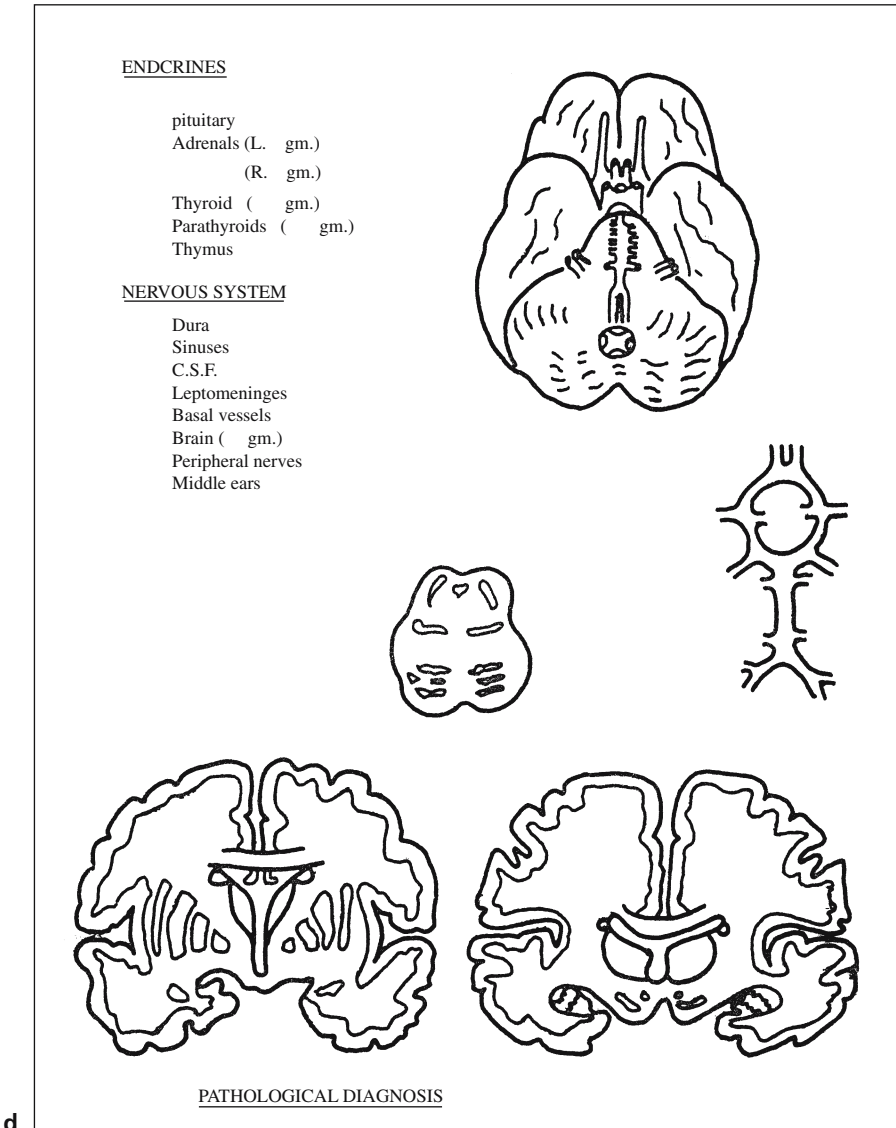


FIGURE 13.4. *Continued*

summary is likely to be viewed as hearsay. Advice on this matter should be sought from the local coroner or equivalent.

All autopsy reports should be sent out as soon as possible after the autopsy examination. Guidelines suggest that a provisional report be sent out within 5 working days and that the full report be sent out within 1 week of the availability of any ancillary investigations [10]. It is also suggested in the same guidelines that the histology result should not delay any report, and therefore that best practice would be a complete post mortem report, including histology, available within 1 week. It is often not possible, however, to obtain the results of other ancillary investigations within this time period.

The histology report can also be written in either of the two formats discussed earlier, and should also include full demographic details, thorough histological descriptions, and a conclusion. In hospital cases, copies of the report should be sent to the requesting clinician, the patient's records, and the GP, together with any other interested parties, for example, other clinicians involved in the patient's care. Although this is also desirable in medico-legal cases, permission from the coroner or equivalent is needed before reports can be sent to any other parties, and this should be discussed locally. Most are happy for reports to routinely be sent to the usual parties, although this may have to be delayed until all legal investigations are complete.

Comprehensive guidelines on post mortem reports have been issued by the Royal College of Pathologists in the United Kingdom, in consultation with the College of American Pathologists in the United States, and are reproduced in Table 13.1. Additional guidelines are available for neuropathological cases, maternal deaths, forensic examinations, and examinations in patients with sickle cell disease [10]. Guidelines are in production for many other situations, but are available only to members of the Royal College of Pathologists at the present time. It is hoped that they will be published in the near future.

## Audit

As part of clinical audit, post mortem findings should also be demonstrated, or at least discussed, at regular clinico-pathological meetings. This can be achieved via video or still photography at the time of post mortem, together with information from the results of ancillary investigations and microscopic pictures from any histological samples. As discussed in Chapter 1 (see p. 1), there are numerous studies indicating that there is still new information to be gained from post mortem examination, despite the advances in pre mortem diagnostic techniques [17–19]. Improvements in clinical care are possible only with accurate information about the disease processes present and their extent, and this is best documented at post mortem. There

TABLE 13.1. Guidelines on the Contents of Post Mortem Reports, Issued by the Royal College of Pathologists

---

Demographic details

- Autopsy sequential number
- Surname and first name
- Hospital or A&E department number
- Name of general practitioner and/or hospital consultant
- Sex, age, and date of birth
- Date of death
- Date of the autopsy
- Next of kin or person giving permission for post mortem
- Type of autopsy: Coronial or consented
- Which coronial jurisdiction
- Name of pathologist responsible for the autopsy
- Place of the autopsy, unless provided by a header on the printed report
- Persons present during the autopsy
- Details of those persons to whom the report is to be sent:
  - Coroner or Procurator Fiscal
  - General practitioner
  - Hospital consultant (including A&E department head)
  - Other relevant hospital staff (e.g. intensive therapy unit staff, anaesthetist)
- Date of the initial report and (if appropriate) date of final report

Optional demographic items include:

- Home address of patient
- Mortuary registration number
- NHS number of the patient
- Coroner's case number
- Means of identification e.g. name tag, and the name of the person who made the identification

Type of autopsy

- Complete
- Limited (with exclusions indicated)
- Specialised (e.g., suspicious/homicide, paediatric)

Clinical history

- Including source of any information, absence or difficulty in obtaining information, and any relevant clinical and laboratory investigations
- Many Coroner's or equivalent specifically do not want such a clinical history included. In this case, the information should be archived but not sent out as part of the report.

External description

- Including sex and age. Height and weight best practice in adult cases
- Ethnicity with description if uncertain
- Measurements of significant surface features, including diagrams or photographs if necessary
- Presence or absence of injuries to eyes, genitalia, and anus should be recorded.
- Radiology should be considered.

Internal examination

Comment should be made on the following. Summarising is acceptable but important negatives should be stated. Sites of recent operations and procedures must be fully explored and recorded; the state of anastomoses and suture lines must be recorded. Weights of heart, lungs, kidneys, liver, spleen, and brain should always be taken. Thyroid, parathyroid, and adrenal glands should be weighed if relevant.

TABLE 13.1. *Continued*


---

 Cardiovascular

- Pericardium including effusion
- Myocardium: atria and ventricles (size, morphology and isolated ventricular weights where indicated)
- Coronary arteries including orifices
- Valves
- Aorta (atheroma)
- Major branches of aorta (particularly in relation to sites of pathology elsewhere)
- Pulmonary arteries and veins (thrombi and emboli)
- Inferior and superior venae cavae, other major and systemic veins

## Respiratory system

- Mediastinum (including thymus if identifiable)
- Pleural cavity surfaces (visceral and parietal) and effusions
- Lung parenchyma (oedema, consolidation, tumour, infarct, etc.)
- Larynx, trachea, and bronchi

## Gastrointestinal system (including nature of contents of viscera)

- Mouth and tongue
- Salivary glands
- Pharynx
- Oesophagus
- Stomach
- Small and large bowel
- Peritoneum, omentum, and mesentery
- Liver
- Gallbladder and bile ducts
- Portal vein
- Pancreas

## Genitourinary and reproductive system

- Kidneys and renal pelvis
- Ureters
- Bladder
- Urethra (where clinically indicated)
- Male: prostate, testis, and penis
- Female: ovaries, uterus, and cervix
- Breasts

## Endocrine system

- Thyroid
- Parathyroids (where clinically indicated)
- Adrenal glands
- Pituitary gland

## Locomotor system

- Bones and joints examined as appropriate to case
- Particularly note fractures and operation sites
- Presence of osteoporosis/infection/arthritis, etc.

## Reticuloendothelial system

- Spleen
- Lymph nodes—mediastinum, hilar, paraaortic, intraabdominal, cervical, axillary, inguinal
- Bone marrow (vertebral/rib/femur/pelvis, etc.) where clinically indicated
- Thymus if identifiable

TABLE 13.1. *Continued*


---

 Central nervous system

- Skull
- Cranial cavity

Brain should be examined in all medico-legal cases but it is acceptable to not examine brain in hospital cases if no clinical indications, although best practice is still to examine in all cases

- Dura and dural sinuses
- Meninges
- Circle of Willis
- Cranial nerves
- Brain: external and following sectioning
- Spinal cord (if examined)

## Histology and other investigations

- Indicate whether histology taken and what other investigations undertaken
- Record organs retained with reference to person giving consent and a note of ultimate disposal
- Record tissues sent to third party for further investigation
- State if no material has been retained

## Summary of findings

- SNOMED coding desirable

## Clinico-pathological correlation

- Written in the light of all information available
- Observations from third parties also summarised
- Major clinical problems correlated with pathological findings and, where possible, a brief narrative of the sequence of events leading to death
- New pathological lesions indicated with explanation of how these illuminate clinical findings
- Any inconsistencies or uncertainties presented and the further necessary steps indicated
- Frank discrepancies or disagreements with clinicians noted

## Cause of death

- In standard format required by Office of National Statistics
  - If no cause of death possible then reasons must be given
  - if an operation was directly or indirectly contributory to death, this fact, together with the type and date of operation, should be given
- 

are already several independent bodies in the United Kingdom whose remit is to audit clinical care in certain circumstances, and other countries have similar institutions. These include:

- CEMACH—confidential enquiry into maternal and child health (an amalgamation of two previously separate bodies)
- NCEPOD—national confidential enquiry into patient outcome and death

All such bodies include the information gained from any post mortem examination in their enquiry and should include a pathologist in their panel. It is likely that more such bodies will be set up in the future, but until then it is still the case that deaths while a patient is under medical care should

be discussed by a multidisciplinary team that includes a pathologist, and that as many of these deaths as possible should undergo post mortem examination.

## Presentation of Post Mortem Findings in Court

The relative frequency of court appearances required of a pathologist will depend on the country as well as the caseload. Obviously only medico-legal autopsies are likely to require legal investigation. Courts may either be inquisitorial (as in a coroner's court) or adversarial (as in a Crown or criminal court). Evidence may either be requested in person or via a written statement/deposition, with a copy of the post mortem report usually serving in the latter case. The procedure for giving evidence in person varies, but will involve entering a witness box or stand and undergoing some formality to promise to tell the truth. This may take the form of an oath on a religious book or a secular declaration. If the witness then lies or knowingly conceals the truth, he or she is committing the crime of perjury, and is liable for whatever penalties. A request for the attendance of a pathologist in court is usually informal, via telephone or letter. If there is any reluctance on the part of the pathologist, however, a subpoena can be issued to ensure his or her attendance. If this is not obeyed, the pathologist is committing an offence known as "contempt of court," which is punishable by fine or even a prison sentence. Most post mortems are discussed in inquisitorial courts, apart from homicides, the autopsies of which are usually performed by a forensic pathologist. In the United Kingdom, this takes the form of a coroner's inquest in England, Wales, and Northern Ireland. In Scotland, the Procurator Fiscal operates under different rules, and the equivalent of an inquest is a fatal accident inquiry. This is much less common than an inquest, however, as its remit is more narrow (see Chapter 1, p. 8). After the evidence has been given, the relevant parties or their legal representatives are then entitled to ask the witness questions, often through the coroner or equivalent. Obviously a court appearance requires smart attire and a professional manner. Answers should be given clearly, loudly, and as succinctly as possible. Detailed explanations of pathology should be given in lay terms to ensure understanding and obviously no changes should be made from the original written report.

In the United Kingdom, there are many other official bodies that investigate certain deaths, and similar bodies exist in most other countries. Any such investigation may require evidence from the pathologist who performed the post mortem. Such bodies include:

- Civil courts investigating deaths due to possible negligence
- Health and Safety executive investigating deaths in the workplace
- Rail safety and standards boards investigating rail deaths

- Air accidents investigation branch of the Department of Transport investigating deaths in the air
- Marine accidents investigation branch of the Department of Transport investigating deaths at sea
- Internal prison inquiries investigating deaths in custody
- Police complaints authority investigating deaths in the hands of the police
- Internal hospital inquiries investigating hospital deaths
- General Medical Council during the investigation of deaths due to negligence
- Armed forces boards of inquiry investigating deaths in the armed forces
- Judicial tribunals investigating high-profile cases

## *References*

1. House of Commons. Report of the Royal Liverpool Children's Inquiry (Redfern Report). HMSO, London, 2001.
2. House of Commons. Human Tissue Bill. HMSO, London, Dec 2003.
3. House of Commons. Human Tissue Act. HMSO, London, 1961.
4. House of Commons. The Coroner's Rules. HMSO, London, 1984.
5. House of Commons. The Coroner's Act. HMSO, London, 1988.
6. Home Office. Death Certification and Investigation in England, Wales and Northern Ireland—The report of a fundamental review. HMSO, London, 2003.
7. Health Services Advisory Committee. Safeworking and the prevention of infection in the mortuary and post mortem room. HMSO, London, 2003.
8. Health Services Advisory Committee. Safeworking and the prevention of infection in clinical laboratories and similar facilities. HMSO, London, 2003.
9. Pounder DJ, Jones GR. Post mortem drug redistribution—a toxicological nightmare. *Forensic Sci Int* 1990;45:253–263.
10. The Royal College of Pathologists. Guidelines on autopsy practice. Report of a working group of The Royal College of Pathologists. RCPATH, London, Sept 2002.
11. Office of National Statistics. Guidelines issued with Medical Certificates for the Cause of Death (MCCD). HMSO, London.
12. Bowker TJ, Wood DA, Davies MJ et al. Sudden, unexpected cardiac or unexplained death in England: a national survey. *QJM* 2003;96:269–279.
13. Leestma JE, Hughes JR, Teas SS, Kalelkar MB. Sudden epilepsy deaths and the forensic pathologist. *Am J Forensic Med Pathol* 1985;6:215–218.
14. Shields LB, Hunsaker DM, Hunsaker JC 3<sup>rd</sup>, Parker JC Jr. Sudden unexpected death in epilepsy: neuropathologic findings. *Am J Forensic Med Pathol* 2002;23:307–314.
15. Morild I, Giertsen JC. Sudden death from asthma. *Forensic Sci Int* 1989; 42:142–150.
16. Robin ED, Lewiston N. Unexpected, unexplained sudden death in young asthmatic subjects. *Chest* 1989;96:790–793.
17. Perkins GD, McAuley DF, Davies S, Gao F. Discrepancies between clinical and postmortem diagnoses in critically ill patients: an observational study. *Crit Care* 2003;7:407–408.

18. Jennings CR, Bradley PJ. Are autopsies useful? Do premorbid findings predict postmortem results in head and neck cancer patients. *Ann R Coll Surg Engl* 2002;84:133–136.
19. Ooi A, Goodwin AT, Goddard M, Richie AJ. Clinical outcome versus post-mortem findings in thoracic surgery: a 10-year experience. *Eur J Cardiothorac Surg* 2003;23:878–881.



# 14

## Fetal, Perinatal, and Infant Autopsies

Although many pathologists feel less confident about performing “baby” post mortems, these are in fact comprising an increasingly high proportion of the autopsy workload. Contrary to popular belief, they are not more difficult than adult autopsies, but do require a number of extra techniques to be performed routinely. This chapter aims to cover the basic techniques required for fetal, perinatal, and infant post mortems.

The chapter is organised in much the same way as the rest of the book, and includes:

- Aspects to consider before the post mortem
- External examination
- Evisceration and block dissection
- Organ dissection in systems
- Special techniques used in perinatal and infant autopsies
- Taking samples for ancillary investigations, including histology
- Examination of the placenta
- Estimation of gestational age and growth
- Demonstration of post mortem findings
- Determining the cause of death
- Writing the report

Although it has been impossible to be fully comprehensive, the chapter covers all techniques that are likely to be necessary outside of a special paediatric pathology centre. Post mortem examinations of children older than 2 years of age do not differ greatly from adult autopsies and are not considered further.

### Introduction

The age at which a fetus becomes legally viable is defined either by the gestational age or by the body weight, and varies from country to country. In the United Kingdom, a gestational age of 24 weeks is the lower limit of legal

viability, regardless of body weight at birth. Obviously all fetuses who have shown “signs of life” are also considered legally viable, regardless of their body weight or gestation, although the survival rate of fetuses under 24 weeks is low. Although technically post mortem examinations can be conducted only on legally viable fetuses, most pathologists would perform perinatal post mortems on fetuses of a gestational age greater than about 16 weeks or a body weight greater than 400 g. Although such nonviable fetuses are actually surgical specimens and therefore written consent is not legally required, it is considered good practice to obtain consent for a post mortem in the usual way. For fetuses between 400 g and 25 g a “mini-post mortem” can be performed and below 25 g a longitudinal sectioning method can be employed. Examination of the placenta is also an essential part of the autopsy of a perinatal case. Most perinatal and neonatal autopsies are hospital cases; however, infant post mortems may be medico-legal cases if the cause of death is not known.

### *Performance of Post Mortems*

In many countries, including the United Kingdom, perinatal and paediatric pathology is a specialised branch of histopathology, requiring further formal training and often an examination before one is eligible to practise. Unfortunately, there is currently a worldwide shortfall in the number of histopathologists in general, and perinatal and paediatric pathologists in particular, although this shortage is most acute in the United Kingdom. This has led to more and more perinatal post mortems being performed by general histopathologists. A recent report into fetal and perinatal pathology in the United Kingdom [1] has reiterated the importance of perinatal and paediatric pathology as a separate discipline, but until more such pathologists can be trained, has recognised the need for uncomplicated perinatal post mortems to be performed by nonspecialised pathologists. It recommends that in each unit without a specialised pathologist one of the general pathologists act as a “lead pathologist” who is responsible for implementing appropriate protocols, attending mortality meetings, auditing quality of the post mortem service, and participating in continuing medical education on this subject. It is suggested that such “lead pathologists” should have access to at least 50 perinatal cases per year to maintain an appropriate level of expertise, which in many U.K. hospitals means that, in practice, only one general histopathologist should be performing all of the perinatal post mortem work per hospital. Post mortems on infants and young children should be performed by specialised perinatal and paediatric pathologists. If nonaccidental injury is strongly suspected, the case should be treated as a suspicious death and the post mortem examination performed by either by a perinatal and paediatric pathologist with a forensic interest or in partnership with a forensic pathologist [2].

## *Consent*

As discussed in Chapter 1 (see p. 18), the United Kingdom has recently had to deal with issues surrounding the retention of whole organs at post mortem in perinatal cases. This began with the Royal Liverpool Children's Hospital inquiry [3], and has since led to similar inquiries elsewhere in the United Kingdom [4,5]. A Retained Organs Commission was formed by the Department of Health in 2001 as a Special Health Authority within the NHS (National Health Service). Their aims are to deal sensitively and comprehensively with the organs and tissues that have already been retained and to guide future legislation to prevent similar events occurring again, in the hopes that this will restore public confidence in the post mortem system. This has led to significant changes in post mortem consent procedures, in both adult and fetal/perinatal cases. Now most countries have adopted a new and much more detailed consent form (see Fig. 14.1 for the form currently used in the United Kingdom for fetal and perinatal post mortems). Any ancillary investigation in a hospital post mortem needs specific consent from the next of kin. Furthermore, the next of kin must also be asked whether any organs or tissues removed can be kept by the pathologist for storage or later disposal or must be returned to the body. In the latter case, this may lead to a delay in funeral arrangements, and this must also be discussed with the relatives. Separate further consent is required for all purposes other than diagnosis, for example, for teaching and/or research. The next of kin can also limit both the examination and sampling by specifying which parts of the body/organs are not to be examined or used. In addition, of course, the use of human tissue for research would also have to be approved by the appropriate regulatory authority, for example, a research ethics committee in the United Kingdom or an institutional review board in the United States. In the United Kingdom, a new Human Tissue Bill is currently going through Parliament [6] and is intended to replace the previous Human Tissue Act of 1961 [7]. This will require written consent for diagnosis on all tissue or fluid specimens, and is likely to require separate permission for nondiagnostic usage, such as teaching or research. Although, at least in the United Kingdom, such consent is already in use for post mortem tissue, the bill as it is currently written requires any nondiagnostic usage to be specified. This may mean that retrospective research on stored tissue will no longer be possible without further consent, and this is likely to impinge on any future research that uses post mortem tissue.

In medico-legal post mortems, ancillary investigations are permitted only if they are required to establish the cause of death, and it is the duty of the pathologist to see that such investigations are completed. Specific consent is required from the coroner or equivalent, and they are also responsible for setting a time limit for sample retention, in discussion with the pathologist. As for hospital cases, relatives must be consulted as to whether they

**NHS**

## Consent to a hospital post mortem examination on a baby or child

Baby or child's surname/family name	Consultant (or other responsible health professional)
Other names (if given)	
Hospital unit number	NHS number
Date of birth	Male/female
Any other relevant details (e.g. preferred language of next-of-kin, religion)	

This form officially records what you have agreed about what you want to happen to your baby or child's body and organs. We realise that this is a distressing time for you but it is important that you understand what you are giving your consent to.

Please read the accompanying information leaflet very carefully before completing the form. A member of the hospital staff will explain the content of this form and the leaflet and try to answer any questions you may have.

The form is divided into several sections. You should read each one carefully and discuss it with the hospital staff before completing it.

**Section 1** – Agreement to a full post mortem including removal of body fluids and tissues for laboratory examination, and the taking of X-rays and other images.

**Section 2** – Agreement to a limited post mortem.

**Section 3** – Agreement to use of tissue samples taken during the post mortem in medical research.

**Section 4** – Agreement to genetic testing.

**Section 5a** – Agreement that whole organs and tissue be retained for more detailed examination after the post mortem.

**Section 5b** – Agreement that whole organs retained after the post mortem be donated for medical research, education or audit.

**Section 5c** – Agreement on how any remaining organs and tissue be disposed of following the post mortem.

**Section 6** – Any other specific requests or concerns.

If you are satisfied with the information recorded, sign section 7. The member of hospital staff who has discussed the examination with you will sign section 8, and give you a copy of the complete form.

**You have the right to change your mind within a short time limit agreed with the hospital.** If you wish to ask further questions about the post mortem examination, make changes to what you have recorded on this consent form, or withdraw your consent, please telephone

\_\_\_\_\_ (contact name and number) as soon as possible and not later than

\_\_\_\_\_ (date/time). You will be given a copy of the amended form.

**Consent to a hospital post mortem examination on a baby or child 1**

**Copy for next-of-kin**

FIGURE 14.1. The consent form used throughout the United Kingdom for a hospital post mortem examination on a baby or child. (Reprinted with permission from the Department of Health, London; HMSO, 2003.)

**1. Agreement to a full post mortem examination**

I am/We are the parent(s) or legal guardian(s) of [redacted] (baby/child's name, if given) and I/we agree to a post mortem examination being carried out on my/our baby/child.

**Note**  
During the examination, samples of your baby or child's body fluids and tissues may be removed for laboratory examination. Tissue samples are made into blocks and slides for examination with a microscope. Any tissue remaining after this process (residual tissue) will usually be disposed of. Blocks and slides are kept indefinitely as part of the medical record or in case they are needed in the future for further tests relating to your baby or child's cause of death or illness. They may also be used for medical education and audit.

During the examination, photographs, X-rays or other images may be taken. They are usually kept indefinitely as part of the medical record. They may also be used for medical education, audit or research, in which case information that might allow your baby or child to be identified would be removed.

**2. Limiting the post mortem examination**

*If you prefer, you may agree to a **limited** post mortem examination (with retention of tissue samples as described in section 1). This will limit the information available about the cause of death or illness, and you must discuss this with the hospital staff.*

**Do you wish to limit the examination?** YES  NO

If yes, please say how [You may tick more than one box below]:

the head only       the chest only       the abdomen only

other (please describe) [redacted]

I have discussed this with [redacted] (member of hospital staff).

*Consent to a hospital post mortem examination on a baby or child 2*

Copy for next-of-kin

FIGURE 14.1. Continued

### 3. Agreement to donation of tissue and fluid samples for use in medical research

If you agree, the tissue and/or fluid samples taken as part of the post mortem examination may also be used later in ethically-approved medical research. This may help other patients in the future.

**Please choose one of the following options:**

- I agree** to tissue or fluid samples taken as part of my baby or child's post mortem examination being used for medical research.
- I agree** to tissue or fluid samples taken as part of my baby or child's post mortem examination being used for medical research, EXCEPT for certain types of research as described here:

- I object** to any tissue or fluid already taken as part of the post mortem examination being used for medical research.

**NB: No tissue may be taken primarily for use in research without completion of a specific, separate consent form for that purpose.**

### 4. Genetic testing

In certain cases, genetic tests are important to reach a diagnosis.

- I agree** that genetic tests may be done.
- I object** to genetic tests being done.

FIGURE 14.1. *Continued*

**5. Consent to retention of whole organs and tissue (other than for blocks and slides), their uses and options for disposal**

**5a Consent to retention of organs and tissue for more detailed examination**

Only a certain amount of information can be obtained at the time of the post mortem examination, so in some cases we may wish to retain some of your baby or child's organs and tissue for further, more detailed examination. This may be needed to find your baby or child's precise cause of death, or to give a more complete understanding of the illness.

**Please choose one of the following options:**

- I agree** that any organs and tissue may be retained for further investigation, if this is necessary to understand fully my baby or child's cause of death and the effects of treatment.
- I agree** that any of my baby or child's organs and tissue may be retained for further investigation EXCEPT the following:

*(Please list organs which may NOT be retained.)*

- I object** to any of my baby or child's organs or tissue being retained for further investigation.

**5b Donation of organs for medical research, education or audit**

If you agree, whole organs retained after the post mortem examination may be kept for future use in ethically-approved research, medical education or audit.

**Please choose one of the following options:**

- I agree** to any whole organs removed as part of the post mortem examination being kept for medical research, education or audit.
- I agree** to any whole organs removed as part of the post mortem examination, EXCEPT the following:

being kept for medical research, education or audit.

FIGURE 14.1. *Continued*

**5b Donation of organs for medical research, education or audit (continued)**

**I agree** to whole organs removed as part of the post mortem examination being kept for medical research, education or audit EXCEPT for certain types of research, education or audit, as described here:

**I object** to any whole organs removed as part of the post mortem being kept for medical research, education or audit.

**5c Disposal of retained organs and tissue**

After further investigations are complete, what would you like to happen to any of your baby or child's remaining organs and tissue (other than those which have been made into tissue blocks and slides for microscopic examination)?

**Please choose one of the following options:**

**Return to the body:** I would like the organs and tissue to be returned to my baby or child's body. I understand they will not be returned to their original position in the body. I understand that this may delay the funeral.

**Hospital disposal:** I would like the hospital to arrange for disposal of the organs and tissue.

**Return to self/funeral director:** I would like my baby or child's organs and tissue to be returned to me/the funeral director (*please delete as appropriate*) to arrange lawful disposal. I understand that this may mean that I need to arrange a separate service after the funeral.

**6. Other requests or concerns**

Do you have any particular requests or concerns? If so, please note them here. (Hospital staff should also document here any special consents taken for this case.)

FIGURE 14.1. *Continued*



**7. Signature of parent(s) or other legal guardian(s)**

Name(s) \_\_\_\_\_ (PLEASE PRINT)

Signature(s) \_\_\_\_\_

Date \_\_\_\_\_

Address(es) \_\_\_\_\_

Relationship to the deceased baby or child: mother/father/other  
\_\_\_\_\_ (please specify)

in the presence of

Name of witness\* \_\_\_\_\_

Signature \_\_\_\_\_

Date \_\_\_\_\_

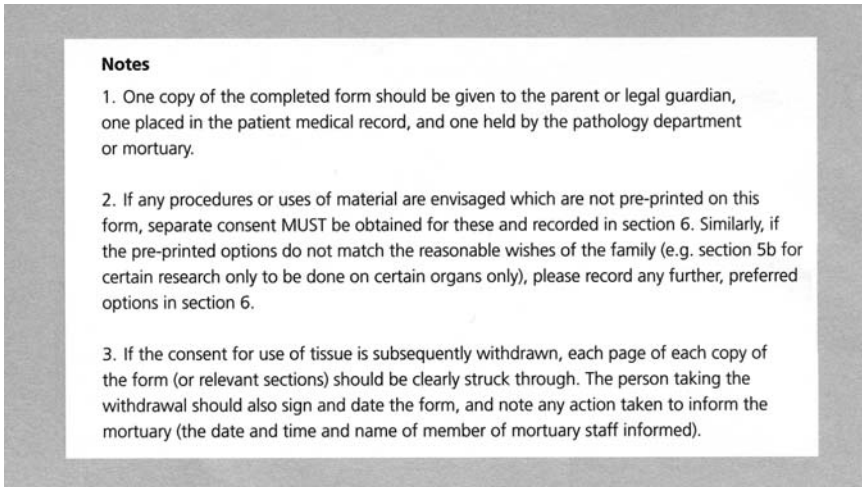
Address \_\_\_\_\_

\*Witness may be anyone who is not a member of your family, e.g. friend, neighbour, or member of hospital staff.

*Consent to a hospital post mortem examination on a baby or child 6*

**Copy for next-of-kin**

FIGURE 14.1. *Continued*

FIGURE 14.1. *Continued*

would like the samples returned to the body or disposed of, although in this context they have no legal say in the undertaking of the investigation itself, as it is necessary to establish the cause of death. These issues are legally enshrined in the United Kingdom under the Coroner's Rules and later Coroner's Act [8,9]. The recent changes in hospital post mortem consent, however, have led to most coroners or equivalents requiring additional consent from the next of kin, even though this is not strictly speaking necessary in law at the present time. This consent may be sought by coroners or equivalents, or they may ask the pathologist or clinician concerned to obtain consent themselves. If ancillary investigations are desired by the pathologist or clinician, but are not necessary to identify the cause of death, then by law the coroner or equivalent can refuse consent but is unable to give it, and therefore consent must be sought from the relatives in exactly the same way as in a hospital post mortem. There has been a recent review of the Coronial service in the United Kingdom [10] which is likely to lead to a new Coroner's Act in the next few years. It is anticipated that the service will undergo significant changes, particularly around issues of death certification, and this will inevitably have implications for medico-legal post mortem work in the future.

### *Definitions*

Embryo	1 to 8 weeks gestation
Fetus	8 weeks gestation to term
Stillbirth	Intrauterine/intrapartum fetal death after the age of legal viability, i.e., born with no "signs of life"

Perinatal	Stillbirths + neonates in first week after birth
Early neonatal	First week after birth
Neonatal	First month after birth
Post perinatal	Between 1 week and 1 year
Post neonatal	Between 28 days and 1 year
Infant	From 1 week of age to 2 years of age
Preterm	<37 weeks gestation or weight less than <2500g at birth
Term	37 to 41 weeks of gestation
Post term	>42 weeks of gestation
Small for dates	Weight at birth <10 <sup>th</sup> centile expected for gestational age
Very low birth weight	Weight at birth <1500g
Premature	Preterm, small for dates and very low birth weight
Intrauterine growth retardation	Weight/other parameters <10 <sup>th</sup> centile expected for gestational age

## Before the Post Mortem

As with all post mortems, the clinical details must be obtained wherever possible, usually from the mother’s and (if liveborn) the baby’s hospital notes. Such information should include:

- Mother’s age, parity, and ethnic origin
- Family history, including hereditary disease and multiple pregnancies
- Gestational age at birth
- Data on any relevant maternal illnesses
- Details of previous pregnancies
- Full details of the present pregnancy, including LMP (last menstrual period) and EDD (estimated date of delivery) by dates and scans
- Full details of labour and mode of delivery

In addition, if liveborn:

- Birthweight
- State of infant at birth
- Any resuscitation measures
- Neonatal course

In addition, if an infant:

- Details of any childhood illnesses and vaccinations
- Details of the death and the preceding events

In addition, if a termination of pregnancy (TOP) for fetal abnormality:

- A copy of the scan report for comparison with the post mortem findings

Although the basic autopsy varies little, there are various special investigations that may or may not be necessary, depending on the particular case. These include photography, whole body X-ray films, bacteriology, virology, metabolic studies, and chromosome analysis. At least some of these are performed in each case, and exactly which to carry out is best decided before the post mortem is started to avoid poor technique. It is best to follow standard guidelines or protocols methodically in each case, whether they be national or have been produced locally as required. In this way, all necessary data will be available for retrospective analysis and mistakes of omission will be avoided. Figure 14.2 is an algorithm of perinatal post mortem procedures.

### *Whole-Body Radiography*

This is particularly useful in the investigation of the following conditions, although in many departments it is done routinely in all cases. Two views are usually obtained, an AP (anteroposterior) and lateral.

- Chondrodysplasias
- Osteogenesis imperfecta
- Skeletal trauma
- Skeletal anomalies
- Gas—pneumothorax, necrotising enterocolitis
- Abnormal calcifications
- Estimation of gestational age via ossification centres (see p. 409)

### *Case Examples*

Some case examples follow, with lists of the appropriate special investigations. If such investigations were performed during life, however, it is not always necessary to repeat them at post mortem, although as discussed on p. 326 repeat bacteriological analysis is always useful in septic deaths to identify or confirm the origin of the sepsis.

#### Isoimmunization

- Blood for haematological examination (e.g., grouping, Coombs' test, and testing against maternal serum)

#### Nonimmunological Hydrops

- Arrange blood sample from mother for Kleihauer test
- Photography

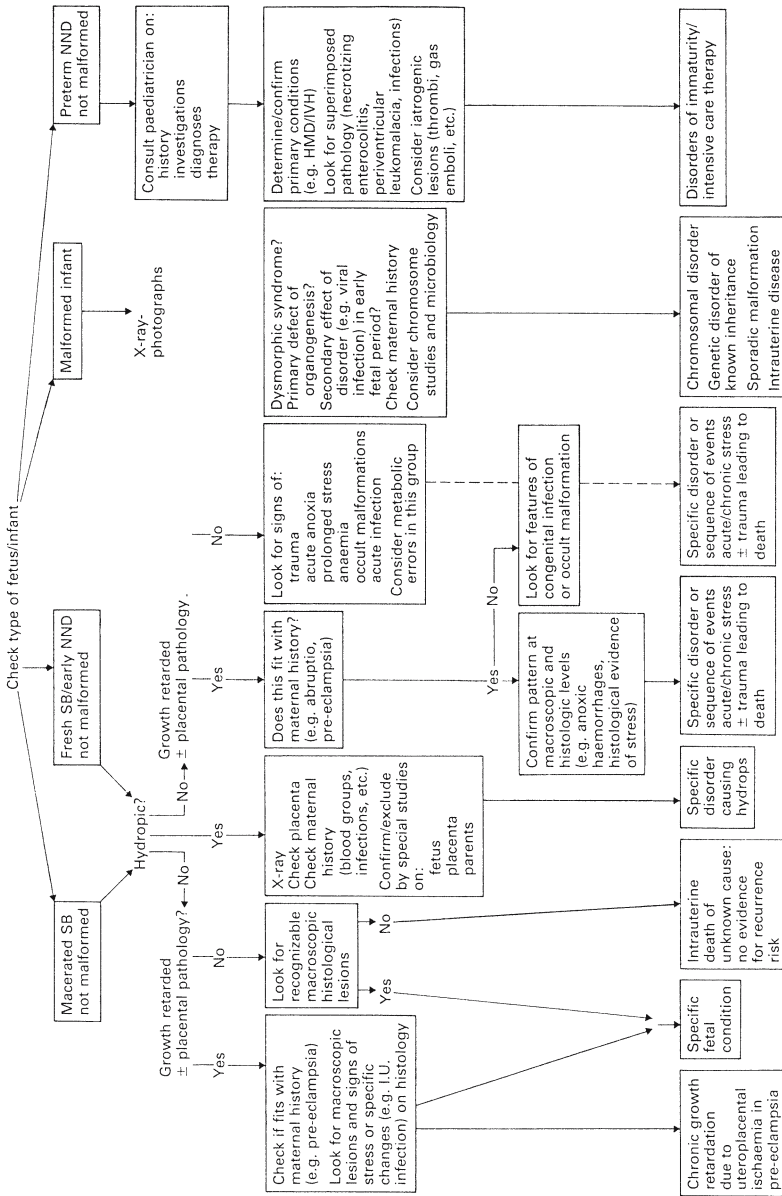


FIGURE 14.2. A representation of the perinatal post mortem as a sorting process. HMD, Hyaline membrane disease; IVH, intraventricular haemorrhage; NND, neonatal death; SB, stillbirth. (Reprinted with permission from Wigglesworth JS. Perinatal pathology. Philadelphia: WB Saunders, 1996; p. 39).

- Whole-body radiography
- Blood and bronchial/tracheal swab or lung for bacteriology
- Placenta for bacteriology
- Lung or bronchial/tracheal swab for virology
- Comprehensive histology
- Blood for haematological investigation (e.g., grouping, Coombs' test, and testing against maternal serum)
- Blood for viral serology [e.g., TORCH (toxoplasmosis–rubella–cytomegalovirus–herpes virus)] test and B19 (parvovirus)
- Tissue for cytogenetics
- Retention of liver sample frozen

#### Multiple Malformation/Dysmorphic Facies

- Photography
- Whole body X-ray films
- Tissue for cytogenetics
- Blood and tracheal/bronchial swab or lung for bacteriology
- Placenta for bacteriology

#### Skeletal Dysplasia

- Whole body X-ray films
- Photography
- Histology sample from trachea and epiphysis of a long bone
- Tissue for cytogenetics/fibroblast culture

#### Twins

- Assessment of zygosity via pattern of placentation
- If vital, assessment of zygosity via haematological investigation (e.g., blood group or DNA analysis)
- If monochorionic, assessment of possible twin to twin transfusion (by examination of vascular communications in the placenta, using barium injection into umbilical cord of donor twin if necessary)

#### Suspected Infected Baby

- Blood sample for bacteriology
- Bronchial/tracheal swab or lung sample for bacteriology and virology
- Heart and spleen samples and cerebrospinal fluid (CSF) for bacteriology and virology
- Placental sample for bacteriology if stillbirth or perinatal death

#### Stillbirth

- Assessment of interval between intrauterine death (IUD) and delivery, i.e., degree of maceration
- Infection screen (as for infected baby)

### Genetic Metabolic Disease

- Whole body X-ray films
- Tissue for cytogenetics/fibroblast culture
- Retention of urine, CSF, and plasma for biochemistry
- Blood sample for haematology (smear to assess presence of vacuolated lymphocytes)
- Comprehensive histology, including bone marrow and fat stains on frozen sections
- Samples of liver, kidney, brain, and placenta for electron microscopy
- Retention of frozen samples of skin, placenta, muscle, brain, liver, spleen, and kidney

### Preterm Infant

- Infection screen (as for infected baby)

### IUGR (Intrauterine Growth Retardation)

- Infection screen (as for infected baby)
- Tissue for cytogenetics

### SUDI (Sudden Unexpected Death in Infancy)

- Photography
- Whole body X-ray film
- Vitreous humor sample for urea/electrolytes/osmolality
- Samples of blood, CSF, intestinal contents, and bronchial/tracheal swab or lung for bacteriology
- Samples of heart, intestinal contents and lung or bronchial/tracheal swab for virology
- Immunofluorescence for RSV (respiratory syncytial virus) on a tracheal tissue block
- Refrigerate stomach contents, serum, and urine for potential toxicology
- Freeze samples of skin, liver, muscle, spleen, kidney, and brain for possible enzyme studies
- Comprehensive tissue for histology and possible electron microscopy (including fat stains on a frozen section of liver)
- Skin for tissue culture
- Blood for haematology (smear to look for toxic lymphocytes)
- Examination of middle ear for sepsis

### Fetal Anomaly Not Diagnosed Prenatally

- Photography
- X-ray film
- Tissue for cytogenetics/fibroblast culture

## Neonatal Death

- Whole body X-ray film (for diagnosis of pneumothorax)
- Infection screen (as for infected baby)

## External Examination

A careful external examination should be made to assess any external abnormality. In perinatal cases, the shape of the head, the facies, the palate, the number of digits, the external genitalia, the patency of the anus, and the continuity of the spinal column should be assessed. A probe should be passed through each nasal orifice to exclude posterior choanal atresia and into each external ear to ensure patency. The eyes should be examined for evidence of icterus and conjunctival haemorrhage.

Evidence of external trauma should also be looked for, particularly with reference to the obstetric and neonatal history. All bruises, needle punctures, forcep blade marks, surgical incisions, and so forth should be noted. Any tubes or catheters should be left in situ for later examination. It is often easiest to cut these flush with the skin. This allows later dissection to assess their siting and provides a means of resetting the site (by placing cut end flush with skin again) if they are inadvertently moved during examination.

The apparent state of nutrition and any evidence of cyanosis, pallor, jaundice, oedema, and meconium staining should be assessed. A search for petechial haemorrhages should also be made, both on the skin (particularly of the head and upper chest) and on the conjunctiva and mucous membranes of the oral cavity.

The shape of the thoracic cavity should also be assessed; a narrow cavity often indicates pulmonary hypoplasia. Interstitial emphysema should be sought in cases of neonatal death. The umbilicus should also be closely inspected.

### *Estimating the Degree of Maceration*

In the case of stillbirths, it is important to note whether the body is fresh or macerated, and if maceration is present, the degree must be assessed to aid estimation of the time interval between IUD and delivery. There is a classification system to aid the estimation of the degree of maceration, but the changes are also affected by the ambient temperature during body storage [11]:

12 hours	Skin slippage
24 hours	Skin blebs
48 hours	Skin sloughing and haemolysis of organs
5 days	Liquefied brain, overlapping of sutures, collapse of calvarium
7 days	Laxity and dislocation of joints



### *External Measurements*

The following careful measurements should be made with a ruler and a length of string, and compared to tables of normal values (see Tables 14.1 to 14.5) to aid assessment of gestational age and allow assessment of growth retardation (see p. 408).

#### Essential

- Body weight
- Crown–rump length (sitting height)
- Crown–heel length (standing height)
- Foot length
- Head circumference

#### Helpful

- Abdominal girth (at the level of the umbilicus)
- Chest circumference (at the level of the nipples)

If any abnormality is suspected, whole-body radiography and photography is advisable.

### *Case Examples*

Some examples of major syndromes and their associated external abnormalities follow, although are by no means comprehensive:

#### Oligohydramnios (from whatever cause)

- Low-set ears, a “parrot” nose, and prominent epicanthic folds
- Large, spade-like (“washer-woman’s”) hands
- Lower limbs often show distortion, hip dislocation, and talipes
- Associated internal abnormalities include renal anomalies and pulmonary hypoplasia

#### Trisomy 13

- Moderate microcephaly with a sloping forehead
- Eye defects including microphthalmos or coloboma
- Cleft lip or palate
- Often a capillary haemangioma over the forehead and localised scalp defects may be present over the parieto-occipital region
- Ears may be abnormally formed and low-set
- Frequently loose skin over the back of the neck
- Polydactyly is common and there are often simian creases and prominent heels (rocker-bottom foot)

- Common internal anomalies usually involve the central nervous system (CNS), heart, and kidneys

### Trisomy 18

- Often produces severe growth retardation
- Head characteristically has a prominent occiput and a narrow bifrontal diameter
- Ears are low-set and deformed, the palpebral fissures are small, the mouth is small, and there is micrognathia
- Hands are often clenched, with the index finger overlapping the fourth, and the hallux is often short and dorsiflexed
- A small pelvis may also be present, with limited adduction of the hip joints
- Common internal abnormalities include ventricular septal defect and both CNS and renal anomalies

### Trisomy 21

- Brachycephaly with a flatter than normal occiput and slight microcephaly
- Face is also relatively flat with a small nose, a low nasal bridge, and inner epicanthic folds
- Palpebral fissures slant upward from inner to outer canthus
- Ears are small with overfolding of an angulated upper helix
- May be excess skin on the back of the neck and the neck itself may be short
- Hands have short metacarpals and phalanges with hypoplasia of the midphalanx of the fifth finger which often also shows clinodactyly
- This short fifth finger may have a single crease and there is often a single transverse palmar crease
- May also be a wide gap between first and second toes, with a marked plantar crease
- Pelvis is usually hypoplastic with an outward flaring of the iliac wings and a shallow acetabular angle
- Most common internal abnormalities are cardiac and gastrointestinal anomalies

### Triploidy

- Variable degree of growth retardation with microphthalmia, colobomata, and low-set malformed ears
- May also be hypertelorism and micrognathia
- Syndactyly of third and fourth fingers, a single transverse palmar crease and talipes are also common
- Internal abnormalities include CNS, cardiac, and renal anomalies

TABLE 14.1. Means and standard deviations of weight and measurements of liveborn infants

Gestation (weeks)	Body weight (g)	Crown-rump (cm)	Crown-heel (cm)	Toe-heel (cm)	Brain (g)	Thymus (g)	Heart (g)	Lungs (g)	Spleen (g)	Liver (g)	Kidneys (g)	Adrenals (g)	Pancreas (g)
20	381 ±104	18.3 ±2.2	25.6 ±2.2	3.6 ±0.7	49 ±15	0.8 ±2.3	2.8 ±1.0	11.5 ±2.9	0.7 ±0.3	22.4 ±8.0	3.7 ±1.3	1.8 ±1.0	0.5 ±0.5
21	426 ±66	19.1 ±1.2	26.7 ±1.7	3.8 ±0.1	57 ±8	1 ±0.3	3.2 ±0.4	12.9 ±2.8	0.7 ±0.2	24.1 ±4.2	4.2 ±0.7	2 ±0.5	0.5
22	473 ±63	20 ±1.3	27.8 ±1.6	4 ±0.4	65 ±13	1.2 ±0.3	3.5 ±0.6	14.4 ±4.3	0.8 ±0.4	25.4 ±5.2	4.7 ±0.5	2 ±0.6	0.6 ±0.3
23	524 ±116	20.8 ±1.9	28.9 ±3.0	4.2 ±0.5	74 ±11	1.4 ±0.7	3.9 ±1.3	15.9 ±4.9	0.8 ±0.4	26.6 ±8.0	5.3 ±1.8	2.1 ±0.8	0.7 ±0.4
24	584 ±92	21.6 ±1.4	30 ±1.7	4.4 ±0.3	83 ±15	1.5 ±0.7	4.2 ±1.0	17.4 ±5.9	0.9 ±0.5	28 ±7.1	6 ±1.8	2.2 ±0.8	0.8 ±0.5
25	655 ±106	22.5 ±1.6	31.1 ±2.0	4.6 ±0.4	94 ±25	1.8 ±1.2	4.7 ±1.2	19 ±5.3	1.1 ±1.6	29.7 ±9.8	6.8 ±1.9	2.2 ±1.4	0.9 ±0.3
26	739 ±181	23.3 ±1.9	32.2 ±2.4	4.8 ±0.7	105 ±21	2 ±1.1	5.2 ±1.3	20.6 ±6.3	1.3 ±0.7	32.1 ±10.9	7.6 ±2.5	2.4 ±1.1	1 ±0.5
27	836 ±197	24.2 ±2.5	33.4 ±3.5	5 ±0.5	118 ±21	2.3 ±1.2	5.8 ±1.9	22.1 ±9.7	1.7 ±1.0	35.1 ±13.3	8.6 ±3.0	2.5 ±1.1	1.2 ±0.5
28	949 ±190	25 ±1.7	34.5 ±2.3	5.2 ±0.6	132 ±29	2.6 ±1.5	6.5 ±1.9	23.7 ±10.0	2.1 ±0.8	38.9 ±12.76	9.7 ±12.0	2.7 ±1.2	1.4 ±0.5
29	1077 ±449	25.9 ±2.8	35.6 ±4.4	5.4 ±0.8	147 ±49	3 ±1.9	7.2 ±2.7	25.3 ±12.6	2.6 ±0.9	43.5 ±15.8	10.9 ±4.4	3 ±1.2	1.5 ±1.0
30	1219 ±431	26.7 ±3.3	36.7 ±4.2	5.7 ±0.7	163 ±38	3.5 ±2.6	8.1 ±2.6	26.9 ±20.3	3.3 ±2.0	49.1 ±18.8	12.3 ±8.5	3.3 ±2.7	1.7 ±1.0
31	1375 ±281	27.6 ±3.8	37.8 ±3.1	5.9 ±0.7	180 ±34	4 ±3.4	9 ±2.8	28.5 ±13.2	4 ±1.2	55.4 ±17.3	13.7 ±5.2	3.7 ±1.3	1.8 ±0.6

32	1543	28.4	38.9	6.1	198	4.7	10.1	30.2	4.7	62.5	15.2	4.1	2
	±519	±9.5	±5.7	±1.1	±48	±3.6	±4.4	±19.0	±5.4	±30.0	±7.4	±1.7	±0.8
33	1543	28.4	38.9	6.1	198	4.7	10.1	30.2	4.7	62.5	15.2	4.1	2
	±519	±9.5	±5.7	±1.1	±48	±3.6	±4.4	±19.0	±5.4	±30.0	±7.4	±1.7	±0.8
34	1905	30.1	41.1	6.5	237	6.1	12.4	33.5	6.4	78.7	18.5	5.1	2.3
	±625	±4.3	±4.0	±0.6	±53	±3.8	±2.8	±16.5	±3.0	±30.2	±9.3	±2.2	±1.1
35	2093	30.9	42.3	6.7	257	6.9	13.7	35.2	7.2	87.4	20.1	5.6	2.5
	±309	±2.0	±2.9	±0.4	±45	±4.5	±3.6	±20.5	±5.2	±30.6	±10.9	±2.8	±0.6
36	2280	31.8	43.4	6.9	278	7.7	15	36.9	8.1	96.3	21.7	6.1	2.6
	±615	±3.9	±5.9	±1.1	±96	±5.0	±5.1	±17.5	±3.1	±33.7	±6.8	±3.1	±0.7
37	2462	32.6	44.5	7.1	298	8.4	16.4	38.7	8.8	105.1	23.3	6.6	2.8
	±821	±5.0	±7.0	±1.2	±70	±5.6	±5.7	±22.9	±6.4	±33.7	±9.9	±3.3	±0.9
38	2634	33.5	45.6	7.3	318	9	17.7	40.6	9.5	113.5	24.8	7.1	3
	±534	±3.2	±5.1	±0.8	±106	±2.8	±5.4	±17.1	±3.5	±34.7	±7.2	±2.9	±1.1
39	2789	34.3	46.7	7.5	337	9.4	19.1	42.6	10.1	121.3	26.1	7.4	3.3
	±520	±1.9	±4.4	±0.5	±91	±2.5	±2.8	±14.9	±3.5	±39.2	±4.9	±2.5	±0.5
40	2922	35.2	47.8	7.7	356	9.5	20.4	44.6	10.4	127.9	27.3	7.7	3.6
	±450	±2.8	±4.2	±0.8	±79	±5.0	±5.6	±22.7	±3.3	±35.8	±11.5	±3.0	±1.3
41	3025	36	48.9	7.9	372	9.1	21.7	46.8	10.5	133.1	28.1	7.8	3.9
	±600	±3.1	±5.4	±0.8	±65	±4.8	±10.9	±26.2	±4.5	±55.7	±12.7	±2.8	±1.5
42	3091	36.9	50	8.1	387	8.1	22.9	49.1	10.3	136.4	28.7	7.8	4.3
	±617	±2.4	±3.8	±1.1	±61	±3.8	±6.2	±14.6	±3.6	±38.9	±9.7	±3.2	±1.9

Compiled in 1988 by CJ Sung and DB Singer with 1975–1984 data from Woman and Infant’s Hospital, Providence, Rhode Island (with permission from Singer DB, Sung CJ, Wigglesworth JS. Textbook of fetal and perinatal pathology, edition 2. Editors Wigglesworth JS and Singer DB. Blackwell Scientific Publications, 1998; 28)

TABLE 14.2. Means and standard deviations of weight and measurements of stillborn infants

Gestation (weeks)	Body weight (g)	Crown-rump (cm)	Crown-heel (cm)	Toe-heel (cm)	Brain (g)	Thymus (g)	Heart (g)	Lungs (g)	Spleen (g)	Liver (g)	Kidneys (g)	Adrenals (g)	Pancreas (g)
20	313 ±139	18.0 ±2.0	24.9 ±2.3	3.3 ±0.6	41 ±24	0.4 ±0.3	2.4 ±1.0	7.1 ±3.0	0.3 ±1.0	17 ±9	2.7 ±2.9	1.3 ±0.6	0.5 ±0.1
21	353 ±125	18.9 ±4.8	26.2 ±3.6	3.5 ±0.6	48 ±18	0.5 ±0.3	2.6 ±0.9	7.9 ±3.8	0.4 ±0.6	18 ±7	3.1 ±1.3	1.4 ±0.7	0.5 ±0.4
22	398 ±117	19.8 ±9.6	27.4 ±2.5	3.8 ±0.4	55 ±15	0.6 ±0.4	2.8 ±0.9	8.7 ±3.1	0.5 ±0.4	19 ±10	3.5 ±0.8	1.4 ±0.6	0.6 ±0.5
23	450 ±118	20.6 ±2.3	28.7 ±3.3	4 ±0.5	64 ±18	0.8 ±0.5	3 ±1.4	9.5 ±5.7	0.7 ±0.5	21 ±7	4.1 ±1.7	1.5 ±0.8	0.7 ±0.3
24	510 ±179	21.5 ±3.1	29.9 ±4.3	4.2 ±0.8	74 ±25	0.9 ±0.7	3.3 ±1.8	10.5 ±5.6	0.9 ±0.7	22 ±8	4.6 ±2.4	1.5 ±0.8	0.7 ±0.3
25	581 ±178	22.3 ±4.0	31.1 ±6.5	4.4 ±0.8	85 ±31	1.1 ±0.8	3.7 ±1.3	11.6 ±4.9	1.2 ±0.4	24 ±35	5.3 ±2.4	1.6 ±0.8	0.8 ±0.7
26	663 ±227	23.2 ±4.1	32.4 ±5.3	4.7 ±0.9	98 ±37	1.4 ±1.4	4.2 ±2.2	12.9 ±8.7	1.5 ±1.1	26 ±16	6.1 ±3.6	1.7 ±0.9	0.8 ±0.7
27	758 ±227	24.1 ±2.9	33.6 ±3.2	4.9 ±1.4	112 ±37	1.7 ±1.1	4.8 ±3.6	14.4 ±9.7	1.9 ±1.0	29 ±24	7 ±3.1	1.9 ±1.5	0.9 ±0.3
28	864 ±247	24.9 ±2.2	34.9 ±5.6	5.1 ±1.2	127 ±39	2 ±2.1	5.4 ±2.6	16.1 ±7.0	2.3 ±1.1	32 ±32	7.9 ±2.5	2.1 ±1.6	1 ±0.3
29	984 ±511	25.8 ±4.1	36.1 ±5.9	5.3 ±1.2	143 ±57	2.4 ±2.6	6.2 ±2.4	18 ±13.6	2.7 ±2.0	36 ±23	9 ±4.5	2.4 ±1.2	1.1 ±1.2
30	1115 ±329	26.6 ±2.4	37.3 ±3.6	5.6 ±0.7	160 ±72	2.8 ±4.1	7 ±2.8	20.1 ±8.6	3.1 ±1.5	40 ±22	10.1 ±6.0	2.7 ±1.3	1.2 ±0.2
31	1259 ±588	27.5 ±3.0	38.6 ±2.7	5.8 ±0.7	178 ±32	3.2 ±1.9	8 ±3.1	22.5 ±10.1	3.6 ±4.0	46 ±38	11.3 ±4.1	3 ±1.8	1.4 ±1.4

32	1413	28.4	39.8	6	196	3.7	9.1	25	4.2	52	12.6	3.5	1.6
	±623	±2.8	±5.4	±0.6	±92	±2.2	±4.1	±10.7	±2.4	±32	±8.0	±1.8	±0.6
33	1578	29.2	41.1	6.2	216	4.3	10.2	27.8	4.7	58	13.9	3.9	1.8
	±254	±3.5	±3.1	±0.4	±51	±1.5	±2.0	±5.8	±2.3	±17	±3.5	±1.4	±0.8
34	1750	30.1	42.3	6.5	236	4.8	11.4	30.7	5.5	66	15.3	4.4	2
	±494	±3.5	±4.3	±0.8	±42	±5.6	±3.2	±15.2	±2.5	±22	±5.1	±1.3	±0.5
35	1930	30.9	43.5	6.7	256	5.4	12.6	33.7	5.9	74	16.7	4.9	2.3
	±865	±3.9	±5.8	±0.9	±70	±3.4	±5.3	±14.3	±6.8	±46	±7.1	±1.9	±0.7
36	2114	31.8	44.8	6.9	277	6.1	13.9	36.7	6.5	82	18.1	5.4	2.6
	±616	±4.0	±7.2	±0.8	±94	±4.1	±5.8	±16.8	±2.9	±36	±6.3	±2.4	±2.6
37	2300	32.7	46	7.2	297	6.7	15.1	39.8	7.2	91	19.4	5.8	2.9
	±647	±5.1	±7.9	±0.9	±69	±3.9	±9.9	±11.1	±6.3	±57	±9.7	±6.2	±3.1
38	2485	33.5	47.3	7.4	317	7.4	16.4	42.9	7.8	100	20.8	6.3	3.2
	±579	±2.6	±3.9	±0.8	±83	±6.1	±4.4	±15.7	±5.9	±44	±6.0	±2.1	±1.6
39	2667	34.4	48.5	7.6	337	8.1	17.5	45.8	8.5	109	22	6.7	3.5
	±596	±3.7	±4.9	±0.5	±132	±4.7	±3.9	±15.2	±4.5	±53	±5.8	±5.3	±1.9
40	2842	35.2	49.7	7.8	355	8.9	18.6	48.6	9.2	118	23.1	7	3.9
	±482	±6.4	±3.2	±0.7	±57	±4.3	±12.9	±19.4	±4.1	±49	±8.6	±2.9	±1.7
41	3006	36.1	51	8.1	373	9.6	19.5	51.1	9.9	126	24.1	7.1	4.2
	±761	±3.7	±5.4	±0.8	±141	±5.6	±4.9	±17.0	±4.5	±53	±10.5	±3.0	
42	3156	36.9	52.2	8.3	389	10.4	20.3	53.2	10.6	135	24.9	7.2	4.5
	±678	±2.0	±3.0	±0.5	±36	±5.0	±4.5	±10.1	±3.7	±54	±8.1	±2.9	±2.3

Compiled in 1988 by CJ Sung and DB Singer with 1975–1984 data from Woman and Infant’s Hospital, Providence, Rhode Island (with permission from Singer DB, Sung CJ, Wigglesworth JS. Textbook of fetal and perinatal pathology, edition 2. Editors Wigglesworth JS and Singer DB. Blackwell Scientific Publications, 1998; 29)

TABLE 14.3. Weight, Length, and Organ Weights in Fetuses from 9 to 20 Weeks of Development

Developmental Age (days)	Weight (g)	Crown-Rump Length (cm)	Heart (g)	Lungs (g)	Liver (g)	Kidneys (g)	Adrenals (g)	Brain (g)	No. of Cases
63	11	3	0.1	0.1	0.2	0.1	0.1	1.2	30
67	13	4	0.2	0.3	0.7	0.1	0.1	1.5	27
71	15	6	0.2	0.4	0.8	0.1	0.1	2.6	15
73	20	7	0.3	0.4	1.1	0.2	0.1	4.3	21
76	25	7	0.4	0.7	1.1	0.2	0.2	4.8	14
79	30	8	0.4	1.0	1.3	0.2	0.2	5.4	15
84	35	9	0.5	1.4	2.0	0.3	0.2	6.2	14
89	45	9	0.5	1.9	2.5	0.4	0.4	7.4	22
90	50	10	0.5	1.9	3.0	0.5	0.5	8.5	23
91	60	10	0.5	2.5	3.4	0.6	0.6	10	21
92	70	11	0.6	3.0	3.6	0.8	0.6	11	24
96	80	11	0.7	3.0	4.3	0.8	0.6	12	7
100	90	12	0.9	3.0	4.7	0.9	0.7	14	15
105	100	12	1.1	3.9	5.6	1.4	0.7	17	28
109	125	13	1.3	4.1	7.4	1.4	0.7	23	21
115	150	14	1.4	5.3	9.2	1.4	0.8	23	20
117	175	14	1.4	5.6	11	1.8	0.8	23	27
118	200	15	1.7	7.2	12	2.2	1.1	33	39
124	250	16	2.2	9.1	15	2.7	1.2	39	37
130	300	17	2.4	10	17	3.1	1.5	46	43
133	350	18	2.9	11	21	3.8	2.0	54	31
143	400	18	3.4	11	23	4.2	2.2	61	32

From Valdés-Dapena M, Kalousek DK, Huiff DS: Perinatal, fetal and embryonic autopsy. In Gilbert-Barness E (ed): Potter's Pathology of the Fetus and Infant. St. Louis: Mosby, 1997, pp 483-524.

TABLE 14.4. Means and Standard Deviations of Body Length and Weights of Organs of Male Infants, 1 to 12 Months

Age (mo)	Body Length (cm)	Heart (g)	Lungs, Combined (g)	Liver (g)	Pancreas (g)	Kidneys, Combined (g)	Adrenal Glands, Combined (g)	Thymus (g)	Spleen (g)	Brain (g)	No. of Cases
1	51.4 ± 3.2	23 ± 7	64 ± 21	140 ± 40	6.2 ± 3.6	34 ± 9	5.1 ± 1.7	7.8 ± 5.3	12 ± 4	460 ± 47	56
2	54.0 ± 2.9	27 ± 7	74 ± 26	100 ± 46	7.2 ± 4.4	39 ± 9	5.0 ± 1.6	9.4 ± 4.4	15 ± 5	506 ± 67	53
3	57.7 ± 2.9	30 ± 7	89 ± 23	179 ± 41	7.7 ± 3.1	45 ± 10	5.0 ± 1.3	10 ± 5	16 ± 5	567 ± 81	43
4	60.4 ± 4.1	31 ± 7	96 ± 27	195 ± 41	11 ± 5	47 ± 12	4.9 ± 2.0	10 ± 6	17 ± 5	620 ± 71	42
5	62.0 ± 3.1	35 ± 5	93 ± 18	228 ± 47	11 ± 4	54 ± 11	5.3 ± 1.9	12 ± 7	18 ± 7	746 ± 91	40
6	64.2 ± 3.9	40 ± 8	115 ± 31	259 ± 58	11 ± 5	62 ± 14	5.2 ± 2.0	10 ± 6	20 ± 7	762 ± 73	47
7	66.7 ± 5.0	43 ± 8	118 ± 33	276 ± 54	12 ± 6	69 ± 14	5.5 ± 2.1	12 ± 9	23 ± 10	767 ± 32	27
8	68.2 ± 3.4	44 ± 8	104 ± 32	285 ± 57	13 ± 7	66 ± 14	5.4 ± 2.3	10 ± 6	20 ± 7	774 ± 95	27
9	69.4 ± 4.2	45 ± 7	109 ± 33	288 ± 47	16 ± 7	67 ± 16	5.4 ± 2.0	10 ± 4	22 ± 5	820 ± 49	25
10	69.7 ± 5.9	46 ± 6	110 ± 34	300 ± 69	14 ± 6	72 ± 17	5.7 ± 2.1	9 ± 5	24 ± 11	850 ± 96	20
11	70.5 ± 4.3	48 ± 7	130 ± 31	305 ± 81	16 ± 3	76 ± 19	6.1 ± 1.8	19 ± 4	28 ± 10	875 ± 89	16
12	73.8 ± 4.1	50 ± 6	116 ± 23	325 ± 39	14 ± 6	76 ± 13	6.3 ± 2.2	12 ± 5	28 ± 7	954 ± 35	19

From Schulz DM, Giordano DA, Schulz DH: Weights of organs of fetuses and infants. Arch Pathol 1962;74:244-250.



TABLE 14.5. Means and Standard Deviations of Body Length and Weights of Organs of Female Infants, 1 to 12 Months

Age (mo)	Body Length (cm)	Heart (g)	Lungs, Combined (g)	Liver (g)	Pancreas (g)	Kidneys, Combined (g)	Adrenal Glands, Combined (g)	Thymus (g)	Spleen (g)	Brain (g)	No. of Cases
1	51.9 ± 4.5	21 ± 5	64 ± 27	139 ± 31	5.0 ± 1.8	31 ± 8	4.8 ± 1.9	6.6 ± 4.9	11 ± 4	433 ± 59	28
2	54.0 ± 3.7	26 ± 6	74 ± 23	159 ± 31	7.1 ± 2.9	36 ± 10	4.7 ± 1.4	5.8 ± 4.7	14 ± 5	490 ± 51	39
3	57.0 ± 3.7	28 ± 4	81 ± 14	183 ± 39	8.5 ± 3.2	42 ± 12	4.8 ± 1.4	9.7 ± 6.9	15 ± 5	525 ± 89	36
4	59.0 ± 3.7	30 ± 6	91 ± 24	204 ± 49	9.0 ± 3.0	50 ± 11	4.6 ± 2.1	9.0 ± 7.3	17 ± 5	595 ± 80	29
5	62.2 ± 3.3	36 ± 5	102 ± 22	227 ± 38	11 ± 3	52 ± 13	4.8 ± 2.2	13 ± 5	19 ± 5	725 ± 62	24
6	63.0 ± 3.0	37 ± 7	111 ± 30	242 ± 58	11 ± 4	58 ± 20	4.6 ± 1.6	10 ± 6	18 ± 8	730 ± 85	23
7	65.4 ± 4.2	40 ± 9	111 ± 38	272 ± 51	10 ± 3	65 ± 14	5.5 ± 2.2	10 ± 8	22 ± 8	750 ± 92	21
8	60.5 ± 4.5	41 ± 7	109 ± 35	276 ± 54	11 ± 5	60 ± 13	5.3 ± 2.3	8 ± 5	20 ± 9	770 ± 96	24
9	68.3 ± 4.7	41 ± 5	105 ± 28	288 ± 67	14 ± 5	62 ± 10	5.4 ± 1.5	9 ± 5	18 ± 6	810 ± 82	15
10	67.5 ± 4.2	43 ± 7	105 ± 21	284 ± 48	13 ± 6	66 ± 10	0.7 ± 1.7	12 ± 7	25 ± 11	830 ± 117	14
11	70.5 ± 3.1	44 ± 8	125 ± 31	292 ± 36	14 ± 7	68 ± 14	6.2 ± 2.0	15 ± 8	23 ± 9	875 ± 64	18
12	71.5 ± 4.7	49 ± 6	115 ± 34	315 ± 38	15 ± 8	72 ± 19	6.0 ± 1.4	11 ± 8	27 ± 9	886 ± 64	15

From Schulz DM, Giordano DA, Schulz DH: Weights of organs of fetuses and infants. Arch Pathol 1962;74:244-250.

### Turner's Syndrome

- Usually a small stature, a low posterior hairline, and a short neck with webbing or loose skin folds
- Anomalous ears, a narrow maxilla, a broad chest with widely spaced nipples, cubitus valgus, and lymphoedema
- Internal abnormalities include ovarian dysgenesis and renal and cardiac anomalies

### Meckel–Gruber Syndrome

- A posterior encephalocele and polydactyly
- Seen in association with renal anomalies

### Zellweger Syndrome (a Peroxisomal Disorder)

- A large fontanelle, a high forehead with shallow supraorbital ridges and a flat occiput
- Limb contractures with camptodactyly and simian creases may also be present
- Associated internal abnormalities include CNS, liver, and renal anomalies with excess iron storage

### Beckwith–Wiedemann Syndrome

- Macrosomia, with a particularly large tongue
- Many also show a small omphalocele and a particular crease pattern to the ear lobes
- Associated internal abnormalities are numerous and include renal, adrenal, and pancreatic anomalies

### Mercury Poisoning (Minamata Disease)

- Growth retardation, microcephaly, and limb deformities

### Androgenic Steroids

- Female virulization of the external genitalia

### Anticonvulsants

- Produce oral clefts and skeletal and digital anomalies
- Associated internal abnormalities include cardiac and CNS anomalies

### Warfarin

- Nasal hypoplasia and skeletal anomalies
- Internal abnormalities include optic atrophy

### Fetal Alcohol Syndrome

- Microcephaly, short palpebral fissures, and maxillary hypoplasia
- Joint anomalies
- Growth retardation

### Rubella Infection During the First Trimester

- Growth retardation
- Microcephaly, microphthalmia, and cataracts
- Also see osteolytic lesions of bone metaphyses
- Associated internal abnormalities including cardiac, CNS, and hepatosplenic anomalies

## Evisceration and Block Dissection

It is essential to have a selection of small forceps, scissors, and probes, in addition to a scalpel. A pair of scales accurate at low weights is also necessary. Although any of the methods described in Chapter 2 can be used to eviscerate a baby, the most common would be the method of Letulle, in which all organs are removed en bloc. Alternatively, the method of Ghon can be used, which removes the organs in functional “blocks” for later dissection. The former technique has the advantage of keeping continuity if malformations are suspected. Despite the much smaller scale, the actual technique is much the same as that for an adult, with the exception that some of the organ dissection is best done in situ, as anomalies are easier to identify when organs and vessels retain their continuity. In this way, the techniques used are modified using some of the methods from the evisceration and dissection techniques of Virchow and Rokitsansky.

The previous practice of fixing and keeping the whole organ blocks for later dissection is no longer acceptable and should not be done unless there are good diagnostic reasons to do so, and appropriate consent has been obtained.

### *Initial Stages of Evisceration*

Several incisions are possible; however, the best involves an inverted Y, with a central cut from below the chin to just above the umbilicus and then two branches, one down to each inguinal fossa. This allows good exposure of the umbilical arteries. A straight incision as in the adult can be used in a postnatal case, but in a perinatal case will destroy the umbilical vessels. If the body is to be viewed after autopsy, it is desirable to avoid any incision in the neck, in which case the incision can be stopped at the sternal notch and an adjoining horizontal incision made to allow removal of the neck

organs, although this is a time-consuming process from such an incision (see Fig. 14.3).

The skin and musculature should then be dissected from the thoracic cage and the upper chest and neck. This is more difficult than in the adult, as the skin is more delicate and the amount of subcutaneous tissue less. Then any pneumothorax should be identified, and is particularly likely following ventilation difficulties or the insertion of thoracic lines. The examination is performed in a similar manner to that described in the adult on p. 70. In a baby, however, it is often easier to immerse the entire body in water. An incision into the heart at the same time will also reveal any intracardiac air caused by air embolism.

*Alternatively, a needle and syringe containing sterile saline can be used. If this is inserted through the chest wall, any air will escape into the syringe and be seen as bubbles. This method has the advantage of not contaminating the chest cavity prior to any sampling for microbiology.*

Of course, a whole body X-ray film will also identify any pneumothorax. Clues may also be apparent when dissecting the skin and musculature from the chest wall, as the side of the chest with a pneumothorax can appear pale. Pneumothorax is almost invariably associated with a bulging mediastinum and interstitial emphysema.

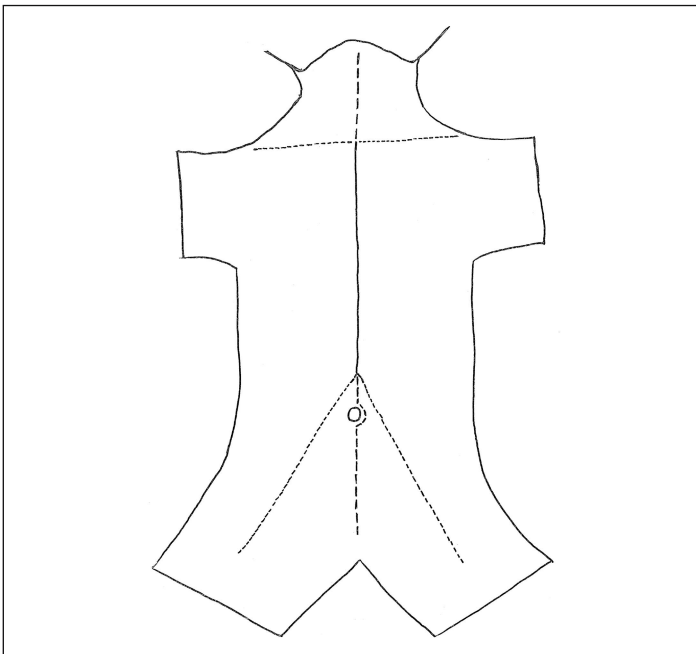


FIGURE 14.3. A diagram illustrating the possible skin incisions during evisceration.

When dissecting skin and musculature off the thoracic cage the amount of subcutaneous fat and the development of the underlying musculature should be assessed. The abdominal cavity can then be opened. If an inverted Y has been used, the umbilicus will be avoided. If not, the incision should extend around the left of the umbilicus. When dissecting the abdominal wall, the umbilical vein should be opened and examined for any evidence of thrombus or bleeding sites. The number of arteries should be noted and the arteries themselves traced to their origin in the aorta. The umbilical vessels can then be ligated and transected. The peritoneal cavity can then be examined for any evidence of ascites, haemorrhage, or meconium. From the abdomen, a finger should be placed inside to assess the level of the diaphragm, before the thorax is opened. The sternoclavicular joints should then be cut with a pair of scissors, following which the ribs can be similarly cut on both sides at the costochondral junction. The sternum and central portion of the ribs can now be removed to expose the thoracic contents. The pleural cavities should be inspected for petechial haemorrhages and fluid. Lastly, the tongue and neck organs need to be freed, again in the same way as in an adult (see p. 75). This is accomplished by freeing the tongue and the floor of the mouth by incising with a scalpel around the inside of the mandible. This incision is then extended posteriorly, to separate the hard and soft palate. The tongue can then be held with forceps, and the posterior attachments of the pharynx and neck freed with a scalpel, from above downwards. The thoracic, abdominal, and neck organs can then be closely examined and even dissected *in situ* before further evisceration.

Alternatively, some pathologists prefer to leave the tongue *in situ*, as this produces a better cosmetic result. This can be achieved by using a scalpel to transect the pharynx at a level just above the hyoid bone, incising down to the vertebral bodies below. This releases the posterior part of the tongue, the remainder of the pharynx, the epiglottis, and the upper oesophagus. The neck structures apart from the anterior tongue can then be removed as before.

The initial stages of evisceration are summarised as follows:

- Make an inverted Y incision.
- Dissect skin and musculature from the abdominal wall.
- Check for pneumothorax.
- Open and examine the abdominal cavity.
- Open the umbilical vein.
- Identify and trace umbilical arteries.
- Ligate and transect umbilical vessels.
- Assess the level of the diaphragm.
- Cut sternoclavicular joints.
- Cut ribs at costochondral junctions.
- Expose and examine the thoracic cavity.

- Free the tongue and floor of the mouth.
- Free posterior attachments of the pharynx and neck.

### *Method of Letulle (Evisceration and Dissection in a Single Block)*

The viscera can be removed in one block, in exactly the same way as in an adult (see p. 82). This has the advantage of retaining continuity in the case of any anomalies and does not have the disadvantage that it has in the adult, as the whole block is obviously still small enough to be easily handled.

Before removal, a detailed examination of the thoracic and abdominal organs should be made and any samples taken for microbiology. Most prosectors would also dissect the heart *in situ* before block removal. This dissection *in situ* allows easier identification of anomalies as continuity between the lungs, heart, and great vessels is maintained.

It is first necessary to dissect the thymus free, to allow inspection of the heart, taking care not to damage the brachiocephalic veins. The size of the thymus may help assess the length of time of an illness. It is normally bilobed and overlies most of the heart and the roots of the great vessels but may often also extend up the neck. The presence of petechial haemorrhages and surgical emphysema should also be noted. The pericardium should then be opened anteriorly. The size and shape of the heart can then be assessed, together with the major incoming and outgoing vessels, that is, superior and inferior vena cava, azygous vein, aortic root, brachiocephalic artery, left carotid artery, left subclavian artery, pulmonary trunk, and ductus venosus.

#### *In Situ Dissection of the Heart (See Fig. 14.4)*

Careful inspection of the chambers, the free walls, and the septum should be made during these cardiac incisions.

##### *Step 1.*

The superior and inferior venae cavae are connected by an incision that starts as a nick in the lateral aspect of the superior vena cava and runs down the lateral aspect of both venae cavae and the right side of the right atrium.

##### *Step 2.*

The right atrium is opened between the origins of the superior and inferior venae cavae, from the midpoint of the first incision. This cut can then be continued through the tricuspid valve and along the posterior wall of the right ventricle to end at the apex. This exposes the inflow tract of the right side of the heart. At this point it is convenient to assess the state of the foramen ovale by pressing on the left atrium, thus causing blood trapped within it to press against the septum primum and occlude the opening. A probe can then be used to touch the right side of the flap, near the normal opening. This will cause a small amount of blood to leak into the right

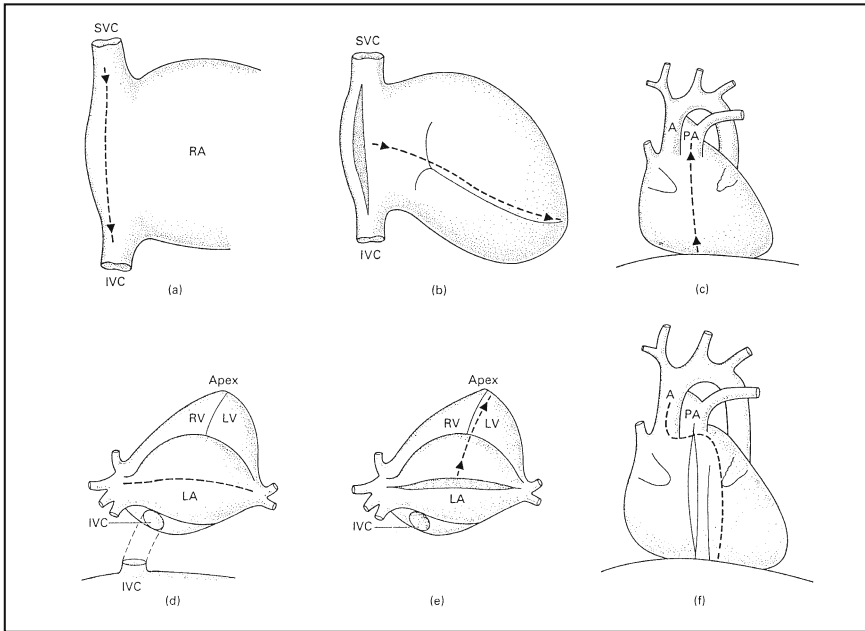


FIGURE 14.4. Opening the heart in situ. **(a)** First cut (right atrium exposed). **(b)** Second cut (right inflow tract exposed). **(c)** Third cut (right outflow tract exposed). **(d)** Fourth cut (left atrium exposed). **(e)** Fifth cut (left inflow tract exposed). **(f)** Sixth cut (left outflow tract exposed). A, Aorta; IVC, inferior vena cava; LA, left atrium; LV, left ventricle; PA, pulmonary artery; RA, right atrium; RV, right ventricle; SVC, superior vena cava. (Reprinted with permission from MacPherson TA, Valdes-Dapena M. *Textbook of fetal and perinatal pathology*, 2<sup>nd</sup> edit. Wigglesworth JS and Singer DB, eds. Blackwell Scientific Publications, 1998;96.)

ventricle and proves that the valve flap is both anatomically patent and functionally closed.

### Step 3.

The incision is continued along the anterior wall of the right ventricle and through the pulmonary outflow tract. The patency of the ductus arteriosus can then be assessed by extending the incision into the ductus or by using a probe. The pulmonary arteries can also be probed at this point.

### Step 4.

The pulmonary veins are connected by a transverse incision. Before this can be accomplished in situ, the inferior vena cava must be transected so that the heart can be turned over superiorly to expose the left inflow tract.

*Step 5.*

The left atrium is opened from between the origins of the pulmonary veins, at the midpoint of the previous incision. The cut is continued through the mitral valve and along the posterior wall of the left ventricle to the apex.

*Step 6.*

With the heart returned to its normal position the left outflow tract is opened by continuing the cut up the anterior wall of the left ventricle and through the aorta. To avoid cutting the pulmonary artery during this procedure, the aorta and pulmonary artery need to be separated first by blunt dissection. The pulmonary veins and vena cavae can then be examined with a probe.

**Block Removal**

The whole organ block can now be removed. After the tongue and neck organs have been freed, the separation of the posterior connections of the thorax with a scalpel can be continued to the diaphragm with gentle pulling forwards and downwards of the neck organs. The diaphragm is then cut posteriorly on either side, from laterally to the midline, once the leaves and the crurae have been carefully examined. The retroperitoneum is then incised vertically on each side, lateral to the kidneys, from the diaphragm to the pelvic brim. The whole organ block can then be pulled forward and downwards as before, and the posterior connections freed. To free the pelvis, it is best to place the organ block back into position. A scalpel should then be swept about the pelvic brim, transecting the urethra below the prostate in the male and including the vagina in the female. The rectum should also be transected as distally as possible. Any remaining attachments can then be severed and the whole organ block lifted free. If anomalies of the genitourinary tract are suspected, then the perineal and anal areas need to be removed en bloc (see p. 397).

**Block Dissection**

The free organ block can then be examined and dissected. This is often best achieved by laying the organ block on a damp sponge. Dissection should then be undertaken in a stepwise manner. The exact order is unimportant; the main purpose being to establish a routine in order to avoid missing any details. The aorta can be opened from posteriorly and the ostia examined. The umbilical arteries can also be examined and if an arterial catheter is in situ, the position of the tip can be noted together with any related thrombus. Sections of the umbilical vessels can also be taken for histology. The renal arteries can then be opened. The inferior vena cava should then also be opened posteriorly and the renal veins opened. The diaphragm can be dissected free to expose the adrenals and kidneys. The adrenals should then be carefully dissected from lateral to medial. This allows the identification



of the adrenal vein and any thrombus present. The adrenals can then be examined, each being about one third the size of the kidney. The aorta and inferior vena cava can then be cut at the level of the diaphragm and separated from the main organ block to expose the urogenital tract, which can then be freed from its anterior attachments to the level of the pelvis. The size and course of the ureters can be established. The size and any gross anomaly of the kidneys can also be seen. The bladder should be externally examined and the patency of the urethra assessed by squeezing the bladder to express urine through the urethra.

### Clinical Correlation

Normal ureters often appear dilated in perinates and infants, being approximately 3 to 4 mm in diameter. Gross anomaly of the kidney with anuria will cause ill-formed threadlike ureters and obstruction will obviously produce hydronephrosis and hydronephrosis. If urethral obstruction is present, the bladder wall will be thickened.

Each kidney is then bisected coronally and examined closely. The capsule of one half at least should be left intact to avoid damage to the underlying cortex. The ureters should then be opened along their length from the pelvis to the bladder. The bladder can then be opened via the urethra and the mucosa and the ureteric orifices noted. The genital organs, umbilical arteries, and urachal remnant can then be examined and the entire genitourinary tract removed from the rectum. In females, any abnormalities of the uterus, tubes, and ovaries should be noted. In males, the position of the testes should be noted and the testes removed. If they have descended into the scrotum, this can be achieved by blunt dissection under the pubic skin through the inguinal canal from above, as in the adult (see p. 84).

Any anomalies of the thyroid gland should be noted and the thyroid gland dissected free in a neonate or infant. It is not usual to dissect the thyroid gland free in small fetuses, however; most prosectors retaining its continuity for histological sampling with the larynx and oesophagus. If there is no anomaly, the heart can then be freed from the thorax and its examination completed by studying the orifices of the coronary arteries and all valves more closely. If any malformation is identified this procedure must be modified accordingly, to leave the anomaly intact for demonstration and photography. It may be easier to leave the heart and lungs attached and fix them prior to later examination, providing that appropriate consent has been obtained. The oesophagus can be opened posteriorly and any fistulae or stenosis identified. The oesophagus can then be dissected from the mid-trachea and removed with the stomach, spleen, and liver, transecting the duodenum at the junction with the jejunum and leaving the thoracic contents intact. The larynx and trachea are then similarly opened posteriorly

and closely examined with reference to atresia, fistulae, endotracheal (ET) tube trauma, mucus plugging, meconium aspiration, and aspiration of gastric contents. If a tracheo-oesophageal fistula is suspected, the trachea should be opened anteriorly rather than posteriorly and the oesophagus transected distally and left attached to the trachea. The lungs should be carefully examined externally in situ before removal and dissection. The number of pulmonary lobes on each side should be checked. Whether the lungs are aerated or not should be noted, and if liveborn the degree of aeration should be considered as to its appropriateness in relation to the history and the length of life. A rough guide to aeration is obtained from a flotation test—placing the lungs in water and seeing if they float—although in a macerated infant, bacterial contamination will produce gases that simulate aeration. Histological examination, therefore, is much more accurate. A close examination of the pleura should be made for petechial haemorrhage and interstitial emphysema. The lungs can then be removed and examined. Some prosectors prefer to dissect the lungs in situ before removal. The bronchial and pulmonary arterial trees should be opened as far as is possible with small arterial scissors. Each pulmonary lobe can then be bisected in a roughly coronal plane and the parenchyma examined for evidence of consolidation, abscess formation, haemorrhage, oedema, and focal anomalies.

It is now convenient to examine and remove the intestines. This can be achieved from anteriorly, by transecting the duodenum at the junction with the jejunum and using scissors to free the bowel distally all the way to the rectum. This is much the same way as in the adult (see p. 83), although it is not necessary to tie the gut off unless samples of gut contents are needed for microbiology. Assessment of rotation is best achieved by locating the position of the caecum and appendix and then following the small and large bowel courses proximally and distally, respectively. If the appendix lies in the right iliac fossa there is little chance of malrotation. If there is any evidence of infarction or necrotising enterocolitis, it will be necessary to examine the mesenteric vessels closely, and therefore the intestines should be removed in continuity with the abdominal organs. If malrotation is suspected the intestines should also be left in continuity and removed with the abdominal organs.

The upper abdominal block should now be dissected from behind. The splenic and portal vein should be opened. The spleen and pancreas can then be examined. The stomach and duodenum can be opened from behind along the greater curve, following the line of the previous oesophageal incision. The mucosa can then be closely inspected and the stomach contents noted. Patency of the biliary tree can be ascertained by squeezing the gallbladder. If jaundice is present or any anomaly is suspected then a very careful dissection is required to remove the extrahepatic biliary tree and the gallbladder in continuity and then serially section it for histology. The gallbladder should be opened and inspected. The liver should be freed and

placed on its diaphragmatic surface. The umbilical vein should then be opened from its severed end and the incision continued to include the portal vein and the ductus venosus.

The Letulle method is summarised as follows:

*Block removal:*

- Remove the thymus.
- Open the pericardium anteriorly.
- Examine the heart.
- Dissect the heart in situ.
- Separate the thoracic contents posteriorly.
- Cut the diaphragm bilaterally.
- Incise the retroperitoneum bilaterally.
- Separate the abdominal contents posteriorly.
- Cut around the pelvic brim.

*Block dissection:*

- Open the aorta posteriorly.
- Examine the umbilical arteries.
- Open the renal arteries.
- Open the inferior vena cava posteriorly.
- Open the renal veins.
- Dissect the adrenals free and examine.
- Separate the aorta and inferior vena cava from the block.
- Separate the kidneys and ureters anteriorly.
- Examine the size and course of the ureters.
- Examine the kidneys and bladder externally.
- Assess the patency of the urethra.
- Bisect both kidneys and open the ureters.
- Open the bladder via the urethra.
- Examine the genital organs and remove.
- Examine the thyroid and dissect free if neonate or infant.
- Free and examine the heart.
- Open the oesophagus posteriorly.
- Remove the oesophagus, stomach, spleen, and liver from the block.
- Open the larynx and trachea posteriorly and examine.
- Remove the lungs and examine.
- Remove and examine the intestines.
- Open the splenic and portal veins posteriorly.
- Examine the spleen and pancreas.
- Open the stomach and duodenum posteriorly.
- Assess the patency of biliary tree.
- Open the gallbladder and examine.
- Free the liver and open the umbilical vein.

### *The Ghon Method (Evisceration and Dissection in Organ Blocks)*

It is also possible to eviscerate in organ blocks, as has already been described in the adult (see p. 87). This has the disadvantage of a reduction in continuity, particularly of the great vessels, without the advantage that it has in the adult of making a physically large block of organs smaller and therefore easier to deal with. Before removal, a detailed examination of the thoracic and abdominal organs should be made and any samples taken for microbiology. Most prosectors would also dissect the heart in situ before block removal. This dissection in situ allows easier identification of anomalies as continuity between the lungs and the heart vessels is maintained.

It is first necessary to dissect the thymus free, to allow inspection of the heart, taking care not to damage the brachiocephalic vein. The size of the thymus may help assess the length of time of an illness. It is normally bilobed and overlies most of the heart and the roots of the great vessels but may often also extend up the neck. The presence of petechial haemorrhages and surgical emphysema should also be noted. The pericardium should then be opened anteriorly. The size and shape of the heart can then be assessed, together with the major incoming and outgoing vessels i.e. superior and inferior venae cavae, azygous vein, aortic root, brachiocephalic artery, left carotid artery, left subclavian artery, pulmonary trunk, and ductus venosus.

#### In Situ Dissection of the Heart (See Fig. 14.4)

Careful inspection of the chambers, the free walls and the septum should be made during these cardiac incisions.

##### *Step 1.*

The superior and inferior venae cavae are connected by an incision that starts as a nick in the lateral aspect of the superior vena cava and runs down the lateral aspect of both venae cavae and the right side of the right atrium.

##### *Step 2.*

The right atrium is opened between the origins of the superior and inferior venae cavae, from the mid-point of the first incision. This cut can then be continued through the tricuspid valve and along the posterior wall of the right ventricle to end at the apex. This exposes the inflow tract of the right side of the heart. At this point it is convenient to assess the state of the foramen ovale by pressing on the left atrium, thus causing blood trapped within it to press against the septum primum and occlude the opening. A probe can then be used to touch the right side of the flap, near the normal opening. This will cause a small amount of blood to leak into the right

ventricle and proves that the valve flap is both anatomically patent and functionally closed.

*Step 3.*

The incision is continued along the anterior wall of the right ventricle and through the pulmonary outflow tract. The patency of the ductus arteriosus can then be assessed by extending the incision into the ductus or by using a probe. The pulmonary arteries can also be probed at this point.

*Step 4.*

The pulmonary veins are connected by a transverse incision. Before this can be accomplished in situ, the inferior vena cava must be transected so that the heart can be turned over superiorly to expose the left inflow tract.

*Step 5.*

The left atrium is opened from between the origins of the pulmonary veins, at the mid-point of the previous incision. The cut is continued through the mitral valve and along the posterior wall of the left ventricle to the apex.

*Step 6.*

With the heart returned to its normal position the left outflow tract is opened by continuing the cut up the anterior wall of the left ventricle and through the aorta. To avoid cutting the pulmonary artery during this procedure, the aorta and pulmonary artery need to be separated first by blunt dissection. The pulmonary veins and venae cavae can then be examined with a probe.

### Intestinal Block

If the gut appears normally formed and rotated, it can be removed from the duodenal-jejunal junction to the rectum. This is achieved with a small pair of scissors, the cut being made as close to the bowel wall as possible. This is much the same way as in the adult (see p. 83), although it is not necessary to tie the gut off unless samples of gut contents are needed for microbiology. Assessment of rotation is best achieved by locating the position of the caecum and appendix and then following the small and large bowel courses proximally and distally, respectively. If the appendix lies in the right iliac fossa there is little chance of malrotation. If there is any evidence of infarction or necrotising enterocolitis, it will be necessary to examine the mesenteric vessels closely, and therefore the intestines should be removed in continuity with the abdominal organ block. If malrotation is suspected the intestines should also be left in continuity and removed with the abdominal block.

### Thoracic Block

The thoracic contents can then be removed in the same way as in the adult (see p. 87). The neck organs are gently pulled forward and downwards while a scalpel is used to free the connections posteriorly until the diaphragm is

reached. A pair of scissors can then be used to sever the thoracic contents from the abdominal organs by cutting across the aorta, lower oesophagus, and surrounding soft tissues. If any anomalies are suspected, however, the thoracic and abdominal organs should be removed en bloc using the Letulle method (see p. 82). If there is no anomaly, the heart can then be freed from the thorax and its examination completed by studying the orifices of the coronary arteries and all valves more closely. If any malformation is identified this procedure must be modified accordingly, to leave the anomaly intact for demonstration and photography. It may be easier to leave the heart and lungs attached and fix them prior to later examination, providing that appropriate consent has been obtained. Any anomalies of the thyroid gland should be noted. The thyroid can then be dissected free in neonates and infants. It is not usual to dissect the thyroid gland free in small fetuses, however; most prosectors retaining its continuity for histological sampling with the larynx and oesophagus. From behind, the oesophagus can now be opened with scissors, and the possibility of fistulae and atresia or stenosis assessed. The larynx and trachea are then similarly opened and closely examined with reference to atresia, fistulae, ET tube trauma, mucus plugging, meconium aspiration, and aspiration of gastric contents. The lungs should be carefully examined externally in situ before removal and dissection. The number of pulmonary lobes on each side should be checked. Whether the lungs are aerated or not should be noted, and if the infant was liveborn the degree of aeration should be considered as to its appropriateness in relation to the history and the length of life. A rough guide to aeration is obtained from a flotation test—placing the lungs in water and seeing if they float—although in a macerated infant, bacterial contamination will produce gases that simulate aeration. Histological examination, therefore, is much more accurate. A close examination should be made of the pleural surfaces for petechial haemorrhage and interstitial emphysema. The lungs should then be removed at the hilum and examined. Some prosectors prefer to dissect the lungs in situ before removal. The bronchial and pulmonary arterial trees should be opened as far as is possible with small artery scissors. Each pulmonary lobe can then be bisected in a roughly coronal plane and the parenchyma examined for evidence of consolidation, abscess formation, haemorrhage, oedema, and focal anomalies.

### Abdominal Block

The abdominal block, consisting of umbilical vein, liver, stomach, pancreas, and spleen, can then be removed in the same way as in the adult (see p. 91). This is achieved by separating the spleen and pancreas from the retroperitoneum, and the liver from the diaphragm, with a scalpel. Using a small pair of scissors, the mesentery is then separated from the aorta and the whole block held in one hand while scissors or a scalpel are used to remove the remaining attachments. The lower oesophagus, stomach, and duodenum can then be opened from a posterior approach, along the greater curve of the

stomach, and the stomach contents noted. The mucosa should then be closely inspected. The patency of the biliary tree can be ascertained by squeezing the gallbladder to express bile into the small bowel. If atresia or stenosis of the extrahepatic biliary tree is suspected, the entire biliary tree should be dissected intact for later serial sectioning and histology. Otherwise the gallbladder can be opened and examined. The liver should be freed and placed on its diaphragmatic surface. The umbilical vein should then be opened from its severed end and the incision continued to include the portal vein and the ductus venosus. The spleen and pancreas can then be dissected free and examined.

### Genitourinary Block

The renal tract has also been exposed, and the size and course of the ureters can be established. The size and any gross anomaly of the kidneys can also be seen. The bladder should be externally examined and the patency of the urethra assessed by squeezing the bladder to express urine through the urethra.

#### Clinical Correlation

Normal ureters often appear dilated in perinates and infants, being approximately 3 to 4 mm in diameter. Gross anomaly of the kidney with anuria will cause ill-formed threadlike ureters and obstruction will obviously produce hydronephrosis. If urethral obstruction is present, the bladder wall will be thickened.

The genitourinary tract can then be removed in continuity. It is easier to keep the adrenal glands attached at this point. This is achieved in the same way as in the adult (see p. 94). A retroperitoneal incision is made vertically on each side, lateral to the kidneys, from the diaphragm down to the pelvic brim. The kidneys, adrenals and aorta can then be pulled forward and downwards as before, and the posterior connections freed. To free the pelvis, it is best to place the organs back into position. A scalpel should then be swept about the pelvic brim, transecting the urethra below the prostate in the male and including the vagina in the female. The rectum should also be transected as distally as possible. Any remaining attachments can then be severed and the organ block lifted free. If anomalies of the genitourinary tract are suspected, then the perineal and anal areas need to be removed en bloc (see p. 397). The aorta has now been exposed and can be opened posteriorly. The umbilical arteries can be examined and if an arterial catheter is in situ, the position of the tip can be noted together with any related thrombus. Sections of the umbilical vessels may also be taken for histology. The renal arteries should then be opened. The remains of the inferior vena cava and the renal veins can then also be opened. The adrenals can then be dissected free and both the kidneys and the adrenals examined.

The adrenal gland should be approximately one third of the size and weight of the kidneys. Each kidney is then bisected coronally and examined closely. The capsule of one half at least should be left intact to avoid damage to the underlying cortex. The ureters should then be opened along their length from the pelvis to the bladder. The bladder can then be opened via the urethra and the mucosa and the ureteric orifices noted. The genital organs, umbilical arteries, and urachal remnant can then be examined. In females, any abnormalities of the uterus, tubes, and ovaries should be noted. In males, the position of the testes should be noted and the testes removed. If they lie within the scrotum, they can be removed from above through the inguinal ligament, as in an adult (see p. 84).

The Ghon method is summarised as follows:

*Before block removal:*

- Remove the thymus.
- Open the pericardium anteriorly.
- Assess the heart and vessels.
- Dissect the heart in situ.

*Abdominal block:*

- Separate the spleen and pancreas from the retroperitoneum.
- Separate the liver from the diaphragm.
- Separate the mesentery from the aorta to remove the block.
- Open the stomach and duodenum posteriorly.
- Assess patency of the biliary tract.
- Open the gallbladder and examine.
- Free the liver and open the umbilical vein.
- Free the spleen and pancreas.

*Thoracic block:*

- Free the thoracic contents posteriorly.
- Cut across the aorta and oesophagus to remove the block.
- Free the heart and examine.
- Dissect the thyroid if neonate or infant.
- Open the oesophagus posteriorly.
- Open the larynx and trachea posteriorly.
- Remove the lungs and examine.

*Genitourinary block:*

- Assess the size and course of the ureters.
- Examine the kidneys and bladder externally.
- Assess patency of the urethra.
- Incise the retroperitoneum bilaterally.
- Free the abdominal contents posteriorly.
- Cut about the pelvic brim.
- Open the aorta posteriorly.



- Open the renal arteries posteriorly.
- Open the inferior vena cava posteriorly.
- Open the renal veins posteriorly.
- Remove the adrenals and examine.
- Bisect both kidneys and open the ureters.
- Open the bladder via the urethra.
- Examine the genital organs and remove.

### *Removal of the Brain*

The removal of the “baby” brain does differ from that of the adult. First, the initial coronal skin incision should be sited well behind the ears, to cause minimal disfigurement following reconstitution in a body with little to no hair. The posterior scalp flap can then be reflected back far enough to expose the suboccipital region. Any caput formation or haemorrhage can be noted during the scalp reflection. The width of the sutures, the size of the fontanelles, and the degree of calcification should also be noted to assess any hydrocephalus present. In all stillbirths, perinatal and neonatal deaths, the suboccipital muscles can then be dissected off to reveal the occipital plates and the atlanto-occipital membrane. Any separation of the occipital plates caused by birth trauma can then be seen, and is indicated by a projecting ridge. Incision of the atlanto-occipital membrane will reveal tonsillar herniation and posterior fossa haemorrhage. A sample of CSF from the cisterna magna can then be removed if necessary, using a sterile needle. The skull can then be removed. Although it is tempting to cut along the suture lines, this will destroy the falx and the superior sagittal venous sinus. It is therefore better to cut about 0.5 cm on either side of the midline suture and the occipitoparietal sutures. This can be done using a scalpel for the initial incision and small artery scissors thereafter. The coronal suture is cut across, and the frontal bone cut on each side to form two bony flaps (see Fig. 14.5). These two bone flaps can then be reflected downwards, with the dura mater attached, to allow examination of the surface of the cerebral hemispheres. Any subdural or subarachnoid haemorrhage can be noted and the extent of the subarachnoid space assessed. If the head is held in the left hand, with the face toward the wrist and the neck between the fingers and thumb, by tilting the head laterally and anteriorly and gently reflecting the occipital lobes one at a time, the falx cerebri, tentorium, vein of Galen, and cerebellum can be examined also. The anterior end of the falx should then be divided, and the falx dissected backward and removed. The superior sagittal venous sinus can now be opened with scissors and examined for thrombus. The brain can now be removed. This is accomplished in the same way as an adult brain (see p. 110); however, it is complicated by the extreme fragility of the baby brain, particularly in a perinatal and/or macerated body. The frontal lobes should be edged away from the base of the skull and the optic nerves transected. The internal carotid arteries, the pituitary, and the

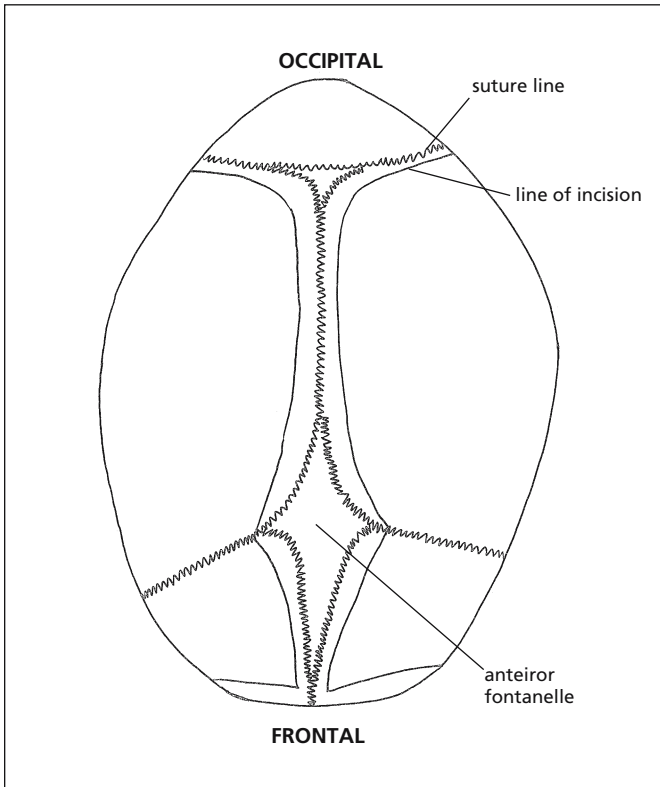


FIGURE 14.5. Diagram illustrating lines of incision (straight black lines) when opening the skull.

oculomotor nerves are then transected on both sides. The temporal lobes should now be eased away from the base of the skull and the tentoria cerebelli incised on both sides, either with scissors or a scalpel. This should be done anteriorly, as close to the petrous part of the temporal bone as possible. The brain will now separate further from the base of the skull, exposing the brain stem. The medulla oblongata, the cranial nerves, and the vertebral arteries should be cut with a scalpel, as distally as is possible. By rotating the inferior surface of the brain upwards, it should now be possible to deliver the brain. To do this without damaging a fragile brain, either the baby can be lifted by the feet with one hand (or even better, by the hand of an assistant) while the brain is removed with the other directly onto the dissecting table (see Fig. 14.6), or the brain is supported in one hand as it is dissected in the other.

Many prosectors find it easier to remove the brain under water, as this is of equal density and therefore supports the softened brain substance. It can also be removed directly into a pot of fixative, in which case a pre-brain

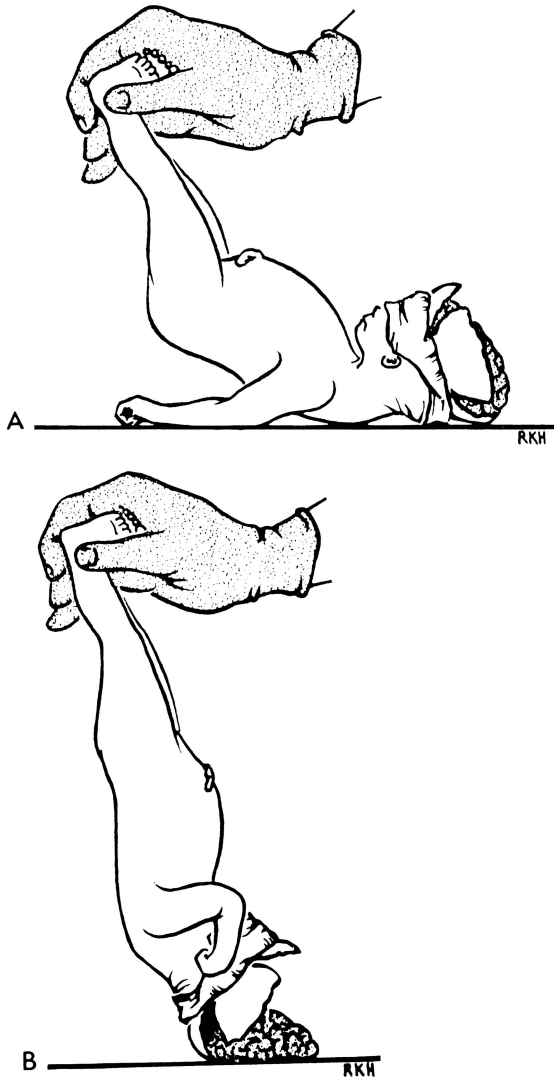


FIGURE 14.6. A method of avoiding damage when removing the fetal brain. (Reprinted with permission from Langley FA. The perinatal post mortem examination. *J Clin Pathol* 1971;24:159-169.)

weight of the pot and fixative must first be obtained, to allow weighing of the brain.

*Alternatively, some people prefer to remove each cerebral hemisphere separately by cutting through the corpus callosum and others prefer to remove both cerebral hemispheres together but without the brain stem. In both cases, the brain stem is then removed separately.*

An initial examination of the brain should then be made to assess the maturity of the gyral pattern and to identify any oedema and herniation. Further examination is best undertaken after fixation in formalin, providing that appropriate consent has been obtained. This is undertaken in the usual way by suspending the brain via a thread underneath the basilar artery, and takes anything from about a week in a fetus to 4 weeks or so in an infant. When the brain has been removed, the pituitary should be removed by cutting the posterior clinoid processes, incising the dura in front of the gland and then elevating the pituitary from the sella turcica with a scalpel. The remaining dural venous sinuses should then be incised with a scalpel and examined for thrombus. All “baby” post mortems should include examination of the middle ear by cutting the petrous temporal bone with bone forceps and lifting the roof off the middle ear. It can then be examined for the presence of pus and a swab taken if necessary. A more detailed examination may be necessary in certain circumstances, and is described on p. 395.

## Special Techniques

### *Removal of the Brain of a Macerated Baby*

Even if the brain is extremely macerated, complete examination should be undertaken, as histology can be surprisingly preserved and useful information can still be obtained. If the dura is left intact when the skull plates are cut, and carefully dissected from the skull when the bone flaps are reflected, then the entire brain can be removed while intact inside the dura.

*Alternatively, the skull plates can be reflected as usual and the fetus placed in formalin for some hours, with the head upright, before the brain is removed in the usual way. In this situation, it is desirable to have completed the evisceration or in situ dissection before the entire body is placed in fixative. Fixation of the body is obviously not very cosmetically pleasing and should therefore not be done if there is any chance that the body may be viewed after the post mortem.*

### *Removal of the Brain in a Case of Hydrocephalus or Other Cystic Congenital Anomaly*

It is difficult to remove the brain in these cases without prior fixation. Either a needle can be used to withdraw CSF from the ventricular system and replace it with formalin (usually about 50ml) or the bone flaps can be reflected as normal, and the entire body placed in a pot of fixative. Even if only 1 hour of fixation is possible prior to examination, the brain will retain its shape much better on removal, which can be undertaken in the usual way. If the entire body is to be placed in fixative, it is desirable to have com-

pleted the evisceration or in situ dissection prior to the procedure. Again, fixation of the body is obviously not very cosmetically pleasing and should therefore not be done if there is any chance that the body may be viewed after the post mortem. If contrast mixture is mixed with the formalin then X-ray films can be taken that will outline the ventricular system.

### *Removal of the Spinal Cord*

Essentially this is the same as in an adult (see p. 298), although much easier due to the size and softness of the bones. It can be accomplished from either the posterior or anterior aspect. If examination of the upper cervical cord is vital, as in the case of an Arnold–Chiari malformation, or a neural tube defect is suspected, a posterior approach should be used and the brain and cord taken out in continuity (see later).

To remove the cord from a posterior approach, a midline incision should be made dorsally, and both skin and muscle reflected. The laminae can then be incised using bone forceps and the posterior wall of the vertebral column removed. The cord and the attached dura can then be examined and removed by cutting through the nerve roots, although care is needed to prevent artefactual trauma during removal.

To remove the cord from an anterior approach, the vertebral column must first be transected at the level of the lumbosacral region. The neural arches can then be divided in sequence on each side using bone forceps. Posterior root ganglia can then be dissected free if desired. The cord can then be removed, although care is needed to prevent artefactual trauma during removal.

### *Removal of the Spinal Cord and Brain in Continuity*

This procedure is also similar to that in the adult (see p. 303), and is accomplished from a posterior approach. The midline dorsal excision from the lumbar spine (see earlier) is continued to end at the scalp incision used to expose the cranium. The skin and underlying tissue is then reflected. Two oblique cuts are made with scissors in the occiput, from the original cut to the foramen magnum. This bone flap can then be carefully removed to expose the dura over the cerebellum. The cord can then be exposed and freed as described earlier. With some manoeuvring and help from a second pair of hands, the brain can be removed as described, and the cord delivered through the foramen magnum, rather than being cut at the medulla.

### *Removal of the Spinal Cord in a Suspected Neural Tube Defect*

This is undertaken from a posterior approach. The skin is incised as usual and at the point of the defect an ellipse is removed, which completely

encircles the defect, before continuing in the midline. When the pedicles have been cut above and below the defect with bony forceps, the cord is removed in the usual way. Once the cord has been removed above and below the defect, the vertebral column above and below the defect can be transected. This allows the skin, underlying tissue, and vertebral column about the defect to be removed with the cord. This can be fixed and examined histologically after serial sectioning, providing that appropriate consent has been obtained. The resulting skin defect should be covered with a dressing.

### *Examination of the Middle and Inner Ear*

If all that is required is an assessment of the possibility of otitis media, then small bone forceps can be used to remove the roof of the temporal bone, in the same way as in the adult, to expose the middle ear cavity. Any pus can then be identified and submitted for microbiology.

If a more thorough examination of the middle and inner ear is required, however, the entire petrous bone can be removed [12]. First the brain must be removed. The coronal skin incision can then be extended to below the ear and the skin reflected forward carefully. The roof and floor of the external auditory meatus can then be divided, exposing the styloid fossa (the inner third of the external ear being composed of fibrous tissue in babies instead of bone as in adults). Scissors can then be used to open the lambdoidal suture and cuts are made in the squamous bone either side of the petrous bone. The wing thereby formed can then be grasped by toothed forceps and the petrous bone removed in its entirety by further anterior, posterior, and inferior cuts through the styloid fossa. This block can then be examined immediately, or fixed, decalcified, and examined later. The block should be divided into two; a middle ear block, containing the auditory tube, ossicles, and mastoid antrum, and an inner ear block containing the cochlea and the semicircular canals.

### *Nonaccidental Injury*

Obviously, if nonaccidental injury is the suspected cause of death, then the death is suspicious and the post mortem should be undertaken by a perinatal/paediatric pathologist with an interest in forensic pathology or jointly by a perinatal/paediatric pathologist and a forensic pathologist. Similarly, if nonaccidental injury is identified during the post mortem, then it should be stopped immediately until such pathologists have been consulted. Any sudden death of an infant or baby, however, requires a thorough post mortem including the exclusion of nonaccidental injury. First, good quality X-ray films should be taken of the whole body. If the body is

too large for the “faxitron”-type of machine, a full skeletal survey can be obtained in the radiology department. In either case, a formal report should be obtained from a radiologist. The external examination should be thorough, and include documentation, and preferably photography, of every bruise and cut present, including site, size, and colour. If hair obscures the scalp, it may be necessary to shave the head, at least over the back of the scalp, where it will be less visible. The inside of the mouth should also be closely examined, including the frenulum of the upper lip, which may show evidence of previous or recent tearing. As bruises can be present subcutaneously that are not visible on the skin surface, and conversely, as apparent bruises on the skin may not be genuine, it is necessary to expose the subcutaneous fat and muscle layers to confirm genuine bruising. In a baby or child this should include the back and front of the body and extend around all four limbs. The front of the body can be reached from the primary evisceration incision, but should be done before evisceration has taken place. The back is reached by a central incision with a horizontal bar at both ends, across the shoulders and across the buttocks. The entire circumference of the limbs are exposed from a single incision posteriorly along their length, that join the two lateral incisions at the back. Using forceps and a new scalpel blade (which should be changed several times during this procedure) the skin should be carefully dissected free from the underlying tissue, exposing the fat and identifying haematomata more clearly. Particularly on the torso, each muscle in turn should then be freed from the underlying muscles, leaving a hinge at one or other end, so that any haematomata between muscles would be visualised. After evisceration, the ribs must be closely examined for haematomata and associated fracture. This is undertaken by separating the muscles between each rib using a knife. After photographs of any haematomata have been taken, and the rest of the post mortem is complete, the layers of muscle can be laid back and the incisions sewn, to affect excellent reconstitution. It is also possible to excise the entire thoracic cage and radiograph it separately, although this makes good reconstitution difficult and should be undertaken only if absolutely necessary.

### *Examination of the Eye*

This may be necessary in cases of nonaccidental injury, to look for retinal haemorrhage, or in cases of intrauterine infection or suspected retrolental fibroplasia. It is accomplished in the same way as in the adult (see p. 305), and is most easily removed from the superior, intracranial approach. Bone forceps can be used to nibble the bone away and expose the orbit. If retinal haemorrhage is suspected, it is important that no vitreous humour is aspirated first, as this may provoke retinal detachment and therefore make accurate assessment impossible.

### *Examination of the Musculoskeletal System*

This may be necessary in cases of suspected birth injury, other causes of trauma, congenital deformity, or tumours and is undertaken in exactly the same way as in the adult (see Chapter 11).

### *Examination of the Neuromuscular System*

This would be necessary in cases of suspected neuromuscular disorders or metabolic storage disorders and again is undertaken in exactly the same way as in an adult (see p. 312).

### *Examination of the Cervical Vertebrae and Vertebral Arteries*

The cervical vertebrae can be removed en bloc as in the adult (see p. 307). It can then be fixed, decalcified and serially sectioned for histology. Alternatively, the vertebral arteries can be opened along their length, either before or after decalcification.

### *Dissection of Pelvic Organs in Continuity with Perineum and Anus*

This is necessary if any urinary tract anomaly is suspected or if the external genitalia are ambiguous. First, the symphysis pubis must be bisected with a knife. The connective tissues about the pelvic organs must then be carefully dissected, to free them anteriorly, posteriorly, and laterally.

In the male, the muscular component of the penis is separated from the overlying skin, using blunt dissection, until the end of the penis is reached. The skin of the tip is then cut at the point at which it attaches to the glans penis. The penis is then free and can be removed in continuity with the bladder, through the opened pubic arch.

In the female, the skin of the vulva is incised in a circle about the vaginal opening. Blunt dissection about the vagina allows the vagina and urethra to be removed with the pelvic organs.

To remove the anus in both sexes, the perineum is incised in a circle about the anal orifice. Blunt dissection allows the anus to be removed with the rectum when the pelvic organs are removed.

## Organ Dissection

All major organs should be accurately weighed, as they can then be compared to tables of normal values. These are produced in terms of both gestational age and body weight, for both live and stillborn babies (see



Tables 14.1 and 14.2) and for male and female infants (see Tables 14.4 and 14.5). Tables are also available for smaller fetuses (see Table 14.3), although they are less accurate. Because most techniques involve at least a degree of in situ organ dissection, much of the organ dissection has already been discussed in the section on evisceration and block dissection. This information will be repeated here, and all further dissection techniques discussed.

### *The Cardiovascular System*

If congenital heart disease is suspected, it is preferable to retain and fix the heart and lungs in continuity, for later examination by an experienced perinatal pathologist, providing that appropriate permission has been obtained. To aid later examination, formalin should be injected down the trachea using a syringe, to fix the lungs in an inflated position, before placing the organ block in formalin. If on initial inspection, the shape and size of the heart is normal, the atrial appendages are normally shaped, the great vessels arise normally, and the lungs are normally lobed, congenital heart disease is highly unlikely.

The heart is dissected along the path of blood flow, as for the adult (see Fig. 14.4). The serial slicing method of heart examination is not suitable, as it destroys continuity and does not demonstrate anomalies well. Careful inspection of the chambers, the free walls, and the septum should be made during these cardiac incisions.

#### *Step 1.*

The superior and inferior venae cavae are connected by an incision that starts as a nick in the lateral aspect of the superior vena cava and runs down the lateral aspect of both venae cavae and the right side of the right atrium.

#### *Step 2.*

The right atrium is opened between the origins of the superior and inferior venae cavae, from the midpoint of the first incision. This cut can then be continued through the tricuspid valve and along the posterior wall of the right ventricle to end at the apex. This exposes the inflow tract of the right side of the heart. At this point it is convenient to assess the state of the foramen ovale by pressing on the left atrium, thus causing blood trapped within it to press against the septum primum and occlude the opening. A probe can then be used to touch the right side of the flap, near the normal opening. This will cause a small amount of blood to leak into the right ventricle and proves that the valve flap is both anatomically patent and functionally closed.

#### *Step 3.*

The incision is continued along the anterior wall of the right ventricle and through the pulmonary outflow tract. The patency of the ductus arteriosus

can then be assessed by extending the incision into the ductus or by using a probe. The pulmonary arteries can also be probed at this point.

*Step 4.*

The pulmonary veins are connected by a transverse incision. Before this can be accomplished in situ, the inferior vena cava must be transected so that the heart can be turned over superiorly to expose the left inflow tract.

*Step 5.*

The left atrium is opened from between the origins of the pulmonary veins, at the midpoint of the previous incision. The cut is continued through the mitral valve and along the posterior wall of the left ventricle to the apex.

*Step 6.*

With the heart returned to its normal position the left outflow tract is opened by continuing the cut up the anterior wall of the left ventricle and through the aorta. To avoid cutting the pulmonary artery during this procedure, the aorta and pulmonary artery need to be separated first by blunt dissection. The pulmonary veins and venae cavae can then be examined with a probe.

Following opening, the chambers should be carefully examined and any defects or asymmetry noted. An estimation of any ventricular hypertrophy or dilatation should also be made. The ostia of the coronary arteries should be closely examined, and the proximal coronary arteries opened if there is any suggestion of anomaly. The valves should be closely inspected and any focal endocardial or myocardial lesions identified. The heart should be sampled for histology, providing appropriate permission has been obtained; the minimum sampling including a single block of right and left ventricle, papillary muscle, and septal wall.

Examination of limb vessels for the presence of thrombus may be necessary if lines have been in situ, and is accomplished in the same way as in an adult (see p. 168). Any thrombus should be sampled for both histology and microbiology.

## *The Respiratory System*

Special attention must be paid to lung lobation and the pattern and extent of any expansion with air. The lungs can be placed in water, whereupon unexpanded lungs will sink and expanded lungs will float. This 'flotation test' is not infallible, however, as postmortem bacteria can cause nonexpanded lungs to float, and previously expanded lungs can sink if infection or oedema fills alveolar air spaces. Histological examination is much more accurate.

Pulmonary hypoplasia can be diagnosed from accurate weighing [13]:

Lung weight:body weight ratio  $<0.012:1$  in gestations  $\geq 28$  weeks

Lung weight:body weight ratio  $<0.015:1$  in gestations  $<28$  weeks

One lung can be inflated with formalin in the same way as in the adult, if histological examination of alveolar architecture is likely to be required.

A close examination of the pleural surface should be made for petechial haemorrhage and interstitial emphysema. The bronchial and pulmonary arterial trees should be opened as far as is possible with small arterial scissors. Each pulmonary lobe can then be bisected in a roughly coronal plane and the parenchyma examined for evidence of consolidation, abscess formation, haemorrhage, oedema, and focal anomalies. Focal areas of collapse are seen as depressed reddish areas but pneumonia is difficult to spot macroscopically. All pulmonary lobes should be sampled for histology, providing that appropriate consent has been obtained.

If a tracheo-oesophageal fistula is suspected, the trachea should be opened anteriorly rather than posteriorly and the oesophagus transected distally and left attached to the trachea. The trachea and oesophagus should be sampled for histology, with consent, preferably at the level of the laryngeal cartilage so as to include thyroid gland in the same block.

### *The Gastrointestinal System*

Assessment of gut rotation is best achieved by locating the position of the caecum and appendix and then following the small and large bowel courses proximally and distally, respectively. If the appendix lies in the right iliac fossa there is little chance of malrotation. If there is any evidence of infarction or necrotising enterocolitis, it will be necessary to examine the mesenteric vessels closely, and therefore the intestines should be removed in continuity with the abdominal organs. If malrotation is suspected the intestines should also be left in continuity and removed with the abdominal organs. If mesenteric thromboembolus is suspected then serial sectioning of the entire small bowel mesentery is necessary.

The entire intestines should be opened and the mucosa examined. The distribution of meconium should also be assessed. The duodenum, ileum, and large bowel should be sampled for histology, providing that appropriate consent has been obtained. If extrahepatic biliary tree anomalies are suspected then serial sectioning and histology, with consent, of the entire tree will be necessary.

The liver should be weighed before being sliced in a coronal plane to allow comparison between the right and left lobes. Any colour change or focal lesions should be noted and both lobes should be sampled for histology, with consent.

The pancreas should also be sampled if possible for histology, both at the head and at the tail, as the distribution of the islets of Langerhans' changes throughout the pancreas.

### *The Genitourinary System*

Malformations of the urinary tract are common, and should be carefully assessed. Particularly in the male, they may be associated with obstructive lesions of the urinary tract and may require an extended dissection (see p. 397). Renal vein thrombosis can occur via emboli from catheterisation.

The kidneys should be weighed and sliced coronally. The cortices and medullae should be identified. The renal pelvis and calyces should also be examined. Yellow streaks of urate may be seen and prove neonatal survival. Each kidney should be sampled for histology, provided that appropriate consent has been obtained. The testes normally lie within the scrotum from 32 weeks of gestation. The gonads should be sampled for histology, with consent.

Detailed gross examination and histology of the pelvic contents will obviously be necessary if the external genitalia are ambiguous.

### *The Lymphoreticular System*

The thymus lies in the anterior mediastinum and is proportionately much larger than in adults and consequently easy to identify. It should be weighed and sampled for histology, with consent.

The spleen should also be weighed and sliced. Any focal lesions should be identified. Splenic enlargement is seen in haemolytic syndromes. The spleen should be sampled for histology, if permitted. Any lymphadenopathy should obviously be identified and sampled for histology. Routine histology should include a block of small bowel mesentery which will contain several lymph nodes.

Routine examination of bone marrow is not necessary, but if haematopoietic disturbance is suspected, marrow should be sampled for histology, if permitted. A rib is the most convenient site.

### *The Endocrine System*

Each adrenal gland should be weighed, bisected vertically, and sampled for histology, with consent. The adrenal glands are proportionately much larger in babies, being approximately one third the size of the kidneys. Adrenal haemorrhages can be seen in hypoxia and massive haemorrhage is seen in septicaemia, particularly when due to meningococcus.

The thyroid should be weighed, if it has been dissected from the laryngeal cartilage, but in fetal and perinatal cases, it is usual to leave the thyroid gland in situ. The gland should be sampled for histology, with consent, in either case. If agenesis is suspected, ectopic sites from the tongue to the base of the heart must also be excluded.

The pituitary gland should also be weighed and submitted for histology, if permitted.

## *The Nervous System*

Examination of the neuromuscular system would be necessary in rare cases of suspected neuromuscular disorders or metabolic storage disorders and is undertaken in the same way as in the adult (see p. 312).

### Examination of the Brain Following Fixation

Although it takes up to 4 weeks for the brain to fix completely, this is obviously a long time to wait for what may be vital information regarding pathology, and even cursory examination of a baby brain is difficult in the fresh state. A compromise is therefore often necessary, and if the brain is allowed to fix for about a week it will be firm enough for examination and slicing in all but the most complicated of cases. Obviously, appropriate consent must be obtained before the brain can be retained for fixation, and if not given, then the best examination possible will have to be made of the fresh brain. The examination is performed in the same way as in the adult brain (see p. 286), with particular reference to malformations, intraventricular haemorrhage, kernicterus, and periventricular leukomalacia.

#### Clinical Correlation

An external examination of the brain, with regards to gyral formation, can be used to aid an estimation of the gestational age (see Fig. 14.7).

Kernicterus occurs in the basal ganglia and nuclear areas of the hind brain and is a yellow discolouration due to increased unconjugated bilirubin. Periventricular leukomalacia is seen as areas of softening or chalky-white deposits in the white matter. Intraventricular haemorrhage usually arises from subependymal haemorrhages in the wall of the lateral ventricles.

#### Grading of germinal matrix and intraventricular haemorrhage [14]:

- Grade 0 No haemorrhage
- Grade 1 Germinal matrix haemorrhage (GMH)
- Grade 2 GMH or choroid plexus haemorrhage (CPH) with intraventricular haemorrhage (IVH) without ventricular dilatation
- Grade 3 GMH or CPH with IVH and ventricular dilatation
- Grade 4 GMH or CPH with IVH and parenchymal haemorrhage

Routine histological sampling of the brain would include the following, providing that appropriate consent has been obtained. If large blocks can be processed, many of these regions can be included together in the same block:

- Leptomeninges
- Cerebellar hemisphere including dentate nucleus
- Medulla at the level of the olives

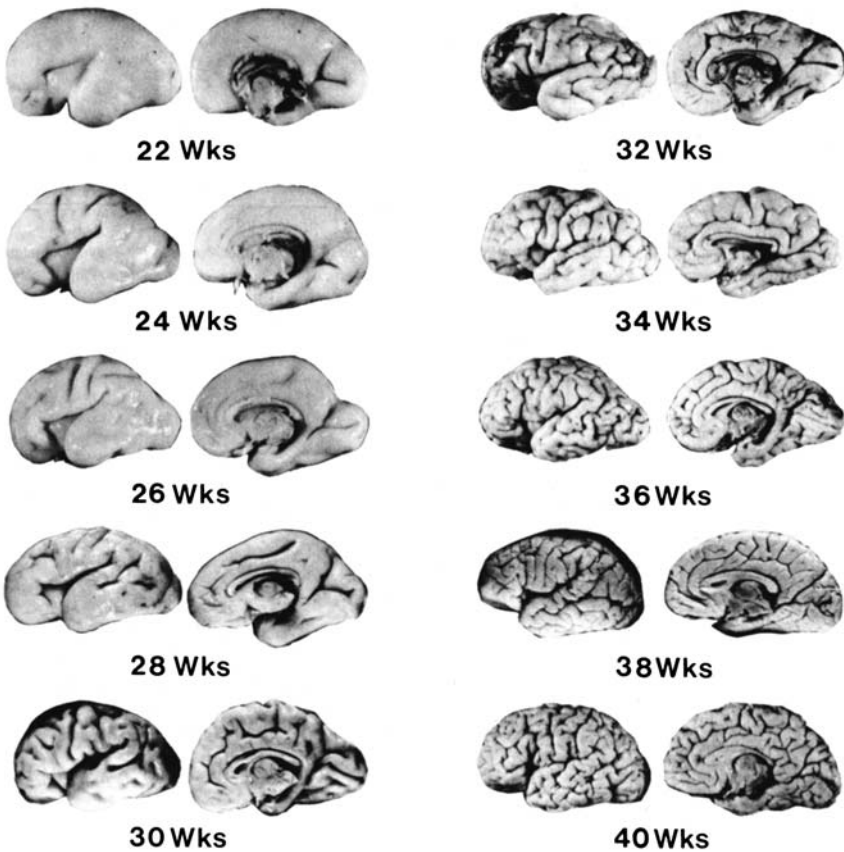


FIGURE 14.7. Photographs of the external and medial surfaces of the brain from 22 to 40 weeks of gestation at 2-week intervals. All brains have been brought to the same size. (Reprinted with permission from Dorovini-Zis K and Dolman CL. Gestational development of the brain. *Arch Pathol Lab Med* 1977;101:192–195.)

- Pons
- Midbrain through inferior colliculi
- Thalamus and hippocampus including inferior horn of lateral ventricle
- Head of caudate nucleus with lateral ventricle wall and subependymal germinal matrix
- Frontal cortex and white matter to include boundary zone between anterior and middle cerebral artery and wall of lateral ventricle
- Occipital lobe, consisting of a block at right angles to the calcarine sulcus to include the calcarine cortex
- Any other area of abnormality

### *The Musculoskeletal System*

As in the adult, specific examination is only required if abnormality is suspected, and is accomplished in the same way (see Chapter 11).

### Taking Samples for Ancillary Investigations

Much of the following information is the same as that for an adult, and has also been discussed in Chapter 13. Samples can be taken only if appropriate consent has been obtained, as discussed on p. 319.

### *Microbiology*

Samples should be taken using an aseptic technique, with sterilised forceps, scalpel blades, needles, and syringes. In addition to samples from any apparently infective lesion, the following may also be helpful:

- Heart blood
- CSF
- Bronchial/tracheal swabs
- Lung swabs or tissue samples
- Skin (if body fresh)
- Amnion (if body macerated)
- Small and large bowel contents

A basic screen includes blood, CSF and a bronchial/tracheal swab or lung sample. Other samples can be taken when necessary (see case examples on p. 361).

It is difficult to obtain sufficient blood for culture from a baby; however, a sterile syringe can be used to obtain blood from inside the heart and from the great arteries and veins available on first opening the body. If this is unsuccessful, or fails to yield sufficient blood, the surface of the heart can be seared using a heated scalpel. A swab can then be pushed into the heart at this site for bacteriology.

To obtain a tracheal or bronchial swab, open the trachea with sterile scissors and push a swab into both bronchi.

To obtain a sterile sample of CSF use a sterile syringe to perform a cisternal puncture after the atlanto–occipital membrane has been exposed.

Intestinal contents can be obtained by squeezing the contents of a short length of intestine into a sterile jar, after cutting the length free with a pair of sterile scissors. *Alternatively, a length of intestine can be opened with scissors and a swab taken or a syringe used for collection of a small sample.*

Tissue samples from any organ can be obtained, as for an adult, by searing the surface with a heated knife and using a sterile scalpel and forceps to

remove tissue. Using one scalpel blade to open the organ and a second blade to take the sample will suffice if no flame source is available in the mortuary. Although swabs are adequate for most bacteria, microorganisms that are difficult to culture, such as tuberculosis and fungi, require tissue samples and need to be specifically requested, as culture is not attempted routinely.

### *Virology*

Samples for virology can be taken in the same way as those for bacteriology, using specific virology swabs or tissue samples placed in an appropriate culture medium for transport.

### *Cytogenetics*

If less than 24 hours have elapsed since death, white blood cells from a clotted blood sample can be used for cytogenetics. Alternatively, if the body is more than 24 hours old but unmacerated, fibroblasts from a sample of skin or fascia can be used. The sample can be taken from a hidden site, such as the axilla or buttock, or from the edge of the evisceration incision, to avoid unnecessary mutilation. In a macerated baby, fibroblasts from a tendon or chondrocytes from a costochondral junction can be used successfully for cytogenetics. The former is most conveniently taken from an Achilles tendon and the latter from a rib.

### *Biochemistry*

A screening test for galactosaemia is possible from a blood sample. Lipid, carbohydrate, and mucopolysaccharide quantification and qualification can be done from frozen tissue samples of liver, spleen, kidney, heart, and skeletal muscle, although it is worthwhile taking samples only if less than 24 hours have elapsed since death. Enzyme analysis is also possible, however, from fibroblast or chondroblast culture, if the body is not fresh. Often, analysis of metabolic products is also possible from samples of urine or plasma. It is wise to consult with the biochemistry department that is going to handle the samples, to obtain information about the best samples to be taken and how they should be handled.

### *Haematology*

Haematological analysis can be performed on liquid blood obtained at post mortem. Blood should be placed in an anticoagulated bottle and special paediatric bottles should be used to reduce the sample size necessary.



### *Immunology*

Uncoagulated blood samples can be used for the measurement of immunoglobulins within 24 hours of death; however, other immunological tests require viable white blood cells and can be performed only on samples taken within about 12 hours of death.

### Histochemistry

Again, it is generally only worthwhile taking tissue samples for freezing if no more than 24 hours have elapsed since death. Skeletal muscle can be used for the assessment of fibre types and abnormalities. Pancreas and small intestine can be used for the study of polypeptide hormones. Liver can be used for the analysis of  $\alpha_1$ -antitrypsin, and large intestine and rectum can be used for the analysis of cholinesterases.

Most of these histochemical techniques, requiring fresh, frozen tissue, have now been superseded by immunohistochemistry, which can be performed on paraffin-embedded histology samples.

### *Storage*

Particularly in nonimmunological hydrops or sudden infant death, it may be worthwhile storing frozen tissue from all major organs, for future diagnosis or research, providing that appropriate consent has been obtained.

### Histology

It is often useful to make a brief further examination of organs after they have fixed, at the time of histology sampling, if retention of the organs has been permitted. The extent of histological sampling will vary, depending on both the case and the departmental workload, and requires appropriate consent to be obtained. In fetal and perinatal cases, the minimum would include tissue from major organs, as with adult post mortems, together with a block of umbilical cord if present. It is still worth taking histological samples in macerated fetuses, as valuable information can sometimes be obtained. More extensive histology would be preferable in fetal and perinatal cases, however, and is mandatory in post perinatal or sudden infant deaths, including at least one block of the following [2]:

- Epiglottis and larynx
- Trachea and oesophagus (including thyroid)
- Each lobe of lung, including one section stained by Perl's method
- Heart (including left and right ventricle, papillary muscle, and interventricular septum)

- Thymus
- Duodenum (including head of pancreas)
- Liver (including left and right lobes)
- Spleen
- Mesentery with lymph node
- Adrenal gland
- Kidney
- Gonad
- Costochondral junction of rib
- Muscle (diaphragm/pectoralis major)
- Blocks of any lesion

After post-fixation examination of the brain:

- Leptomeninges
- Cerebellar hemisphere including dentate nucleus
- Medulla at the level of the olives
- Pons
- Midbrain through inferior colliculi
- Thalamus and hippocampus including inferior horn of lateral ventricle
- Head of caudate nucleus with lateral ventricle wall and subependymal germinal matrix
- Frontal cortex and white matter to include boundary zone between anterior and middle cerebral artery and wall of lateral ventricle
- Occipital lobe, consisting of a block at right angles to the calcarine sulcus to include the calcarine cortex
- Any other area of abnormality

## The Placenta

Examination of the placenta is a vital part of any fetal or perinatal post mortem. Before examination, a sample of membranes and parenchyma can be taken using a sterile scalpel and forceps for bacteriology. This is necessary in any case of stillbirth, prematurity, or IUGR, in addition to cases in which infection is suspected. The site of cord insertion should be described and the length of cord noted. It should be examined for true knots, ruptured varices, and number of vessels. The vessels themselves should also be studied to assess the possibility of thrombus. The fetal membranes should be examined, the number of membranes assessed, and any meconium staining or discolouration (suggesting infection) noted. The size of the sac and the point of sac rupture should also be noted. The fetal vessels of the placenta itself should also be assessed for the possibility of thrombus. To aid recognition, it is helpful to know that all arterial branches cross superficial to venous branches. The maternal cotyledons should be examined closely to assess their completeness. The membranes and cord should then be

removed, and the placental disc weighed and measured. Many would also weigh the placenta with the membranes and cord intact, however, as most series of weights relate to this measurement rather than the more accurate measurement after trimming. Any blood clot received with the placenta should also be weighed. Serial slices should be made through the placental disc at approximately 1-cm intervals, one of which should go through the insertion of the cord. Any focal lesions, such as infarction, thrombosis, and haemangiomas should of course be noted and measurements made.

For histology, sections of cord, rolled up membranes, and placental parenchyma should be taken, in addition to any lesions identified macroscopically. The placental sections should include cord insertion, placental edge and membrane, and, if the cord is eccentric, an additional central block. Unless still attached to the baby, the placenta is a surgical specimen, and no separate consent is required for its macroscopical or microscopical examination.

In twin or other multiple placentae, the dividing membranes should be carefully examined to assess the number of chorionic and amniotic membranes. Monochorionic placentae indicate monozygosity whereas dichorionic placentae can occur in both homozygous and heterozygous multiple pregnancies. Any apparent anastomoses of fetal vessels should also be noted. Such twin-to-twin transfusion can also be identified more accurately using an injection of barium and gelatin into the cord of the donor twin. Histological samples should also include the rolled up dividing membrane(s) and/or the placenta at the point of the division(s).

## Estimation of Gestational Age and Growth

It is important to make as accurate an estimation of gestational age as possible, and then to use this estimation to make an assessment of intrauterine growth. Measurements of crown–rump, crown–heel, and foot lengths, together with whole body weights and organ weights are the best starting points. Milestones can also be used to assess gestational age [11]:

Fusion of palatal shelves and fingerprints	10 weeks
Differentiated external genitalia	12 weeks
Head erect and lower limbs well developed	14 weeks
Ears stand out from head	16 weeks
Vernix caseosa present and early toenail development	18 weeks
Head and body (lanugo) hair visible	20 weeks
Skin wrinkled and red	22 weeks
Fingernails present	24 weeks
Partial separation of eyelids, eyelashes present	26 weeks
Eyes open, good head of hair	28 weeks

Toenails present	30 weeks
Fingernails reach fingertips, skin smooth	32 weeks
Body plump, lanugo absent, toenails reach toetips	36 weeks
Breasts protrude, testes palpable, fingernails beyond fingertips	38 weeks

Other milestones are the radiological time of appearance of various ossification centres [15]:

Ischium, deciduous teeth rudiments	15–20 weeks
Calcaneus	25–26 weeks
Talus	27–28 weeks
Lower femoral epiphysis	36–37 weeks
Upper tibial epiphysis	38–40 weeks

An assessment of organ maturation can also be useful. The external appearances of the cerebral hemispheres (gyral formation) is little affected by growth, and is seen in Fig. 14.7 at various gestational ages. Further organ assessment is only possible histologically. In the brain, the density of the neuronal cells and the pattern of myelination can be useful. Purkinje cells in the cerebellum appear at about 28 weeks and the periventricular layer begins to disappear at about 30 weeks. In the lung, the extent of alveolar formation, the persistence of small terminal airspaces lined by cuboidal epithelium and the amount of residual parenchyma are all useful features that aid the assessment of maturity. In the kidney, the width of the glomerulogenic zone to the width of the definitive glomerular zone correlates well with gestation and culminates in the disappearance of the nephrogenic zone at about 36 weeks of gestation. The presence and quantity of extramedullary haematopoiesis in the liver and the ratio of stroma to parenchyma in the pancreas may also be useful. The thickness of the fetal skin and the development of the subcutaneous fat may also be helpful, but are obviously greatly affected by growth retardation.

Obviously, the difficulty lies with assessing parameters of maturity separately from any growth retardation that may be present, as the assessment of gestational age should be separated from the assessment of growth. Accurate dates or intrauterine scan measurements are the most accurate indication of gestational age. Clinical information may also be useful if the baby was liveborn. If available, these data should be used for the gestational age and the other parameters used to assess growth retardation. If no such data are available, however, then foot length, cerebral gyri formation and histological parameters are the least affected by growth retardation (although in severe retardation even these will be affected). After the relevant charts have been used to assess the likely gestational age, they can then be used to compare the expected size and body weight with the actual values, to assess the possibility of growth retardation. The smaller the fetus,

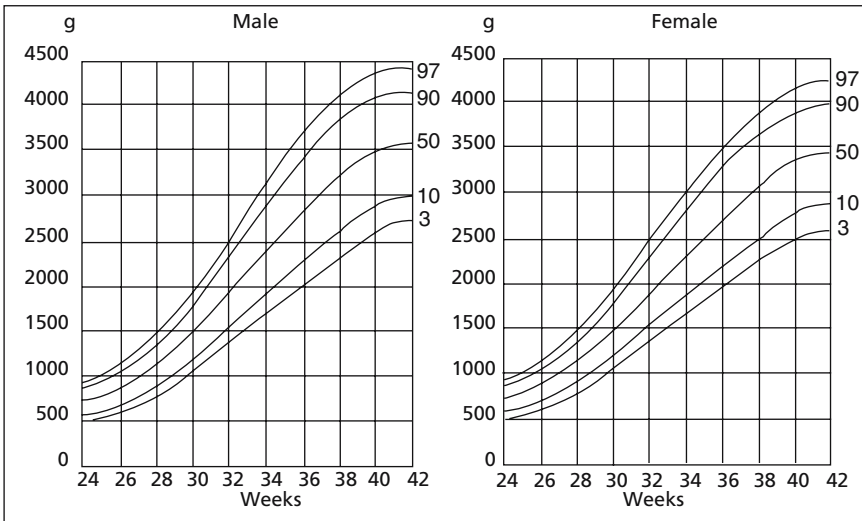


FIGURE 14.8. Birthweight centiles by gestational age for both male and female babies at 24+ weeks of gestation. (Reprinted with permission from Yudkin PL, Aboualfa M, Eyre JA, Redman CW, and Wilkinson AR. New birthweight and head circumference centiles for gestational ages 24–42 weeks. *Early Hum Dev* 1987;15(1):45–52.)

the less accurate the findings, however, charts are available for fetuses of all weights and for infants (see Tables 14.1 to 14.5). Obviously, growth retardation is significant only below a certain level, usually taken as below the 10th centile. Graphs of normal body weights for both male and female babies are shown in Fig. 14.8 at gestational ages of 24 weeks and above. Although less accurate, Fig. 14.9 shows normal fetal weights from 14 to 26 weeks gestation.

## Demonstration of Post Mortem Findings

The demonstration of an adult post mortem has already been discussed on p. 333, and all that is written there is also true for “baby” autopsies. There are also, however, additional considerations to be made in these cases. One such consideration is the size of the body. If any more than one or two people are expected to be in the audience, live video presentation is the only means of showing everything adequately to the entire audience. Even with a small audience, video presentation would allow enlargement of minute anomalies for presentation purposes. As there is, unfortunately, a higher than average litigation in “baby” deaths, maintaining video and/or

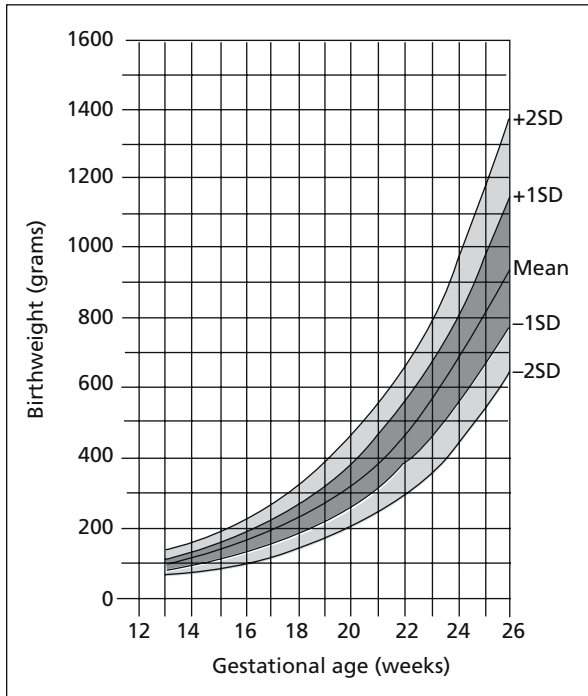


FIGURE 14.9. Birthweight means and standard deviations by gestational age in the fetus at 14 to 26 weeks gestation. (Reprinted with permission from Chambers HM, Knowles S, Staples A, Tamblyn M, and Haan EA. Anthropometric measurements in the second trimester fetus. *Early Hum Dev* 1993;33:45–59.)

photographic records would also form a useful part of the pathologist's record.

## Cause of Death/Pathological Findings

This subject has also already been discussed with regard to adult post mortems on p. 334 and all that is written there is again true of baby post mortems. There are, of course, additional considerations to be made in such cases. The vast majority of stillbirth and perinatal post mortems are hospital rather than medico-legal cases, and it is more usual to give a list of pathological lesions and important negative findings than it is to give a formal cause of death. In contrast, most infant post mortems will be on sudden, unexpected deaths or traumatic deaths, and will therefore be medico-legal examinations. In these cases, the considerations as to the cause of death are similar to those in an adult. Some of these cases will go to an

inquest or its equivalent, and will therefore require presentation in court. This does not differ in principle from adult post mortems and has also been discussed already (p. 347).

Several schemes have been proposed for the classification of perinatal deaths, some relying only on epidemiological data or clinical findings. If an autopsy has been performed, however, it is obviously going to provide the most accurate data and should be used to classify the cause of death. A simple system in common use is that of Wigglesworth [16]:

1. Normally formed macerated stillborn infants
2. Congenital malformations (stillbirths and neonatal deaths)
3. Conditions associated with immaturity (neonatal death)
4. Asphyxial conditions developing in labour (fresh stillborn or neonatal death)
5. Other specific conditions (e.g., infection)

Other classification systems are similar, but more complex, using subclassification to divide these groups up further.

In infants, there is obviously a slightly different range of causes of death. These can also be grouped/classified in a similar way:

1. Congenital malformation
2. Infection
3. Obstetrical complication
4. Cot death
5. Trauma
6. Other specific conditions, e.g., tumours

Most would agree that “cot death” should now be divided into two distinct categories: sudden infant death syndrome (SIDS) and sudden unexpected death in infancy (SUDI).

In a hospital case, the death certificate will, by definition, have already been completed by the clinician. Separate forms are available for the documentation of cause of death in both stillbirths and neonatal deaths (see Fig. 14.10a and b). As for an adult, in a medico-legal post mortem, the coroner or equivalent will fill in the death certificate based on the cause of death given by the pathologist. The same format, based on World Health Organisation (WHO) guidelines, should therefore be used to designate the cause of death. In the United Kingdom, all stillbirths and deaths in infancy are audited by the confidential enquiry into maternal and child health (CEMACH). This enquiry includes medical and nursing staff involved in fetal and infant care and has an equivalent in most other countries. Most such meetings are regional and would include the pathologist who performed the post mortem, together with the information from the post mortem report.

SB 000000

COUNTERFOIL

For use of Medical Practitioner or Midwife and complete in all cases.

Name of mother .....

Date of still-birth .....

Place of still-birth .....

Post-mortem† 1 2 3

Weight of fetus ..... grams

Duration of pregnancy ..... weeks

Death occurred before labour\*/during labour\*/not known\*

Cause of death

a

b

c

d

e

Date of certification .....

Certificate issued to (name) .....

of (address) .....

\*Strike out the words which do not apply  
†Ring appropriate digit

MEDICAL CERTIFICATE OF STILL-BIRTH

(Births and Deaths Registration Act 1953, S.1(1), as amended by the Population (Statistics) Act 1967)  
(Form prescribed by the Registration of Births, Deaths and Marriages Regulations (Amendment) (No. 2) Regulations 1985)

SB 000000

Registered at Entry No. [ ]

To be given only in respect of a child which has issued forth from its mother after the 28th week of pregnancy and which did not at any time after being completely expelled from its mother breathe or show any other signs of life.

\*I was present at the still-birth of a \*male child born \*female

\*I have examined the body of a \*male child which I am informed and believe was born \*female

on ..... day of ..... 19..... to ..... at ..... (PLACE OF BIRTH)

† { 1 The certified cause of death has been confirmed by post-mortem.  
2 Post-mortem information may be available later.  
3 Post-mortem not being held.

\*Strike out the words which do not apply.  
†Ring appropriate digit.

Weight of fetus ..... grams  
Estimated the number of weeks of pregnancy .....  
Estimated the number of weeks of delivery .....  
Date when the child died (i) before labour\* (ii) during labour\* (iii) not known\*

**CAUSE OF DEATH**

a. Main diseases or conditions in fetus .....

b. Other diseases or conditions in fetus .....

c. Main maternal diseases or conditions affecting fetus .....

d. Other maternal diseases or conditions affecting fetus .....

e. Other relevant causes .....

I hereby certify that (a) the child was not born alive, and (b) to the best of my knowledge and belief the cause of death and the estimated duration of pregnancy of the mother were as stated above.

Signature ..... Date .....

Qualification as registered by General Medical Council, or Registered No. as Registered Midwife, .....

Address .....

For stillbirths in hospital, please give the name of the consultant responsible for the care of the mother .....

FIGURE 14.10a. Specimen stillbirth death certificate (front) (a) and (back) (b) and specimen neonatal death certificate (front) (c) and (back) (d). (Reprinted with permission from the Office of National Statistics, London, HMSO.)



**NOTE TO INFORMANT**

Under Section 11(1) of the Births and Deaths Registration Act 1953, this certificate must be delivered to the Registrar of Births and Deaths by the person attending to give information of the particulars required to be registered concerning the still-birth. The persons qualified and liable to give such information include:

- (1) the mother;
- (2) the father (of a legitimate child only);
- (3) the occupier of the house in which to the knowledge of that occupier the still-birth occurred;\*
- (4) any person present at the still-birth;
- (5) any person in charge of the still-born child;
- (6) in the case of a still-born child found exposed, the person who found the child.

The still-birth is required to be registered within 42 days of its occurrence.

\*Occupier in relation to a public institution includes the governor, keeper, master, matron, superintendent, or other chief resident officer.

FIGURE 14.10b. *Continued*

MED B 120767

COUNTERFOIL

For use of Medical Practitioner, who should complete in all cases.

Name of child

Date of death

Sex

Age at death

Place of death

Place of birth

Last seen alive by me

Post-mortem/Coroner

Whether seen after death

Cause of death

- a b c d e

B. Further information offered?

Signature

Date

\*Ring appropriate digit(s) and letter.

MED B 120767

SPECIMEN

MED B 120767

BIRTHS AND DEATHS REGISTRATION ACT 1953

(Form prescribed by the Registrar of Births, Deaths and Marriages (Amendment) (No. 2) Regulations 1985)

MEDICAL CERTIFICATE OF CAUSE OF DEATH OF A LIVE-BORN CHILD DYING WITHIN THE FIRST TWENTY-EIGHT DAYS OF LIFE

For use only by a Registered Practitioner who HAS BEEN IN ATTENDANCE during the deceased's last illness, and to be returned by him to the Registrar of Births and Deaths.

Name of child, Date of death, Age at death, Sex, Place of death, Place of birth, Last seen alive by me, days of death, days (complete period of 24 hours), hours

- 1 The certified cause of death has been confirmed by post-mortem. Information from post-mortem may be available later. I have reported this death to the Coroner for further action. [See overleaf]

CAUSE OF DEATH SPECIMEN

I hereby certify that I was in medical attendance during the above named deceased's illness, and that this is the cause of death, as far as I know, from the date to the best of my knowledge and belief.

For deaths in hospital: Please give the name of the consultant responsible for the above-named as a patient.

(Form prescribed by the Registrar of Births, Deaths and Marriages Regulations 1985)

NOTICE TO INFORMANT

I hereby give notice that I have this day signed a medical certificate of cause of death of

Signature Date

This notice is to be delivered by the informant to the registrar of births and deaths for the sub-district in which the death occurred.

The certifying medical practitioner must give this notice to the person who is qualified and liable to act as informant for the registration of death (see 1a over-leaf).

DUTIES OF INFORMANT

It is the duty of the informant to register the information in this form. The informant must be registered until the medical certificate has reached the registrar.

When the death is registered the informant must be prepared to sign a statement for the registrar relating to the deceased.

- 1. The date and place of death. 2. The full name and surname. 3. The date and place of birth. 4. The names and occupations of the parents. 5. The usual address.

IF THE CHILD WAS ISSUED WITH A MEDICA CARD, THE CARD SHOULD BE DELIVERED TO THE REGISTRAR.

FIGURE 14.10c. Continued

**PERSONS QUALIFIED AND LIABLE TO ACT AS INFORMANTS**

The following persons are designated by the Births and Deaths Registration Act 1953 as qualified to give information concerning a death:—

- DEATHS IN HOUSES AND PUBLIC INSTITUTIONS**
- (1) A relative of the deceased, present at the death.
  - (2) A relative of the deceased, in attendance during the last illness.
  - (3) A relative of the deceased, residing or being in the sub-district where the death occurred.
  - (4) A person present at the death.
  - (5) The occupier\* if he knew of the happening of the death.
  - (6) Any inmate if he knew of the happening of the death.
  - (7) The person causing the disposal of the body.

**DEATHS NOT IN HOUSES OR DEAD BODIES FOUND**

- (1) Any relative of the deceased having knowledge of any of the particulars required to be registered.
- (2) Any person present at the death.
- (3) Any person who found the body.
- (4) Any person in charge of the body.
- (5) The person causing the disposal of the body.

\*"Occupier" in relation to a public institution includes the occupier, manager, superintendent, or other chief resident officer.

*Complete where applicable*

<p><b>A</b></p> <p>I have reported this death to the Coroner for further action.</p> <p>Initials of certifying medical practitioner. ....</p>	<p><b>B</b></p> <p>I may be in a position later to give, on application by the Registrar General, additional information as to the cause of death for the purpose of more precise statistical classification.</p> <p>Initials of certifying medical practitioner. ....</p>
---	--

The Coroner needs to consider all cases where:

- The death might have been due to or contributed to by a violent or unnatural cause, (including an accident);
- or the cause of death cannot be identified;
- or the death might have been due to or contributed to by drugs, medicine, abortion or poison,

or there is reason to believe that the death occurred during an operation or under or prior to complete recovery from an anaesthetic or arising subsequently out of an incident during an operation or an anaesthetic.

**NOTE:—**The Practitioner, on signing the certificate, should complete, sign and date the Notice to the Informant, which should be detached and handed to the Informant. The Practitioner should then, without delay, deliver the certificate itself to the Registrar of Births and Deaths for the sub-district in which the death occurred. Envelopes for enclosing the certificates are supplied by the Registrar.

FIGURE 14.10d. *Continued*

## Writing the Report

This has already been discussed on p. 338 in the context of adult post mortems and the general considerations made there also hold true for fetal, perinatal, and infant post mortems. There are, however, extra considerations to be made in such cases. In fetal and perinatal post mortems, the following must be included in the report, and is based on Royal College of Pathologists' guidelines [2]:

- Demographic details including mother's name, date of birth, and hospital details
- Date of autopsy
- Details of consent and any other restrictions
- Availability of clinical records at time of post mortem, including anomaly scans if relevant
- Attendance of clinician
- Clinical history
- Systematic description of external, internal, and placental examination and results of X-ray films and other ancillary investigations, including:
  - External:
    - Body weight, head circumference, crown–heel and crown–rump lengths, foot length
    - Gestation, degree of maceration (if born dead), meconium staining
    - Fontanelles, eyes, ears, nose, mouth, palate, digits, palmar creases, umbilicus, state of cord, genitalia, anus
    - Dysmorphic features, congenital malformations and deformities
    - Any other external abnormalities
  - Internal:
    - Cranial, thoracic, and abdominal cavities
    - Retention and fixation of the brain if practicable and with consent
    - Specific reference to ductus arteriosus and umbilical vessels
    - Weight of all organs to 0.1 g
    - Comment on muscle and skeleton
  - Placenta:
    - Dimensions, trimmed weight
    - Cord length, vessels, abnormalities
    - Membranes, completeness, colour, abnormalities
    - Fetal, maternal, and cut surfaces
    - Histology if permitted and other ancillary investigations as required
- Summary of major findings including:
  - Sex and apparent gestation
  - Estimated time of death (if born dead)
  - Adequacy of growth and nutrition
  - Presence/absence of congenital abnormalities
  - Major pathological lesions

- Evidence of chronic stress or disease prior to death
- Placental examination
- Mode/cause of death
- Record of photographs and any samples retained
- Record of disposal of any tissues or samples

In post neonatal deaths or sudden unexpected deaths in infancy, the report follows more closely that of an adult post mortem (see Table 13.1, p. 342), with the addition of the following:

- Name of mother
- History including pregnancy, delivery, post natal history and family history
- Head circumference, crown–heel and crown–rump lengths
- Any dysmorphism
- Weight of all organs to 0.1 g
- Measurement of thoracic and abdominal fat thickness
- Comment on ductus arteriosus and umbilicus

In all cases, it is useful to include normal weights and measurements for the age of the deceased, alongside the actual weights and measurements, to allow easy comparison. The results of all ancillary investigations, including histology, must also be included in the final post mortem report. In the ideal situation, these results should be included with the macroscopic report, but if this is not possible, the ancillary investigations can be included in a later supplementary report. Guidelines suggest a maximum of 6 weeks between death and the communication of results to parents, so a complete post mortem report should be available within this time period. It is suggested, however, that a provisional report on the macroscopical findings should be available within 48 hours [2]. It is a good idea to send a copy of the original macroscopic report with any supplementary report, as otherwise the reports tend to become separated in the records and are less easy to access at a later date.

## *References*

1. Royal College of Obstetricians and Gynaecologists and Royal College of Pathologists. Fetal and perinatal pathology. Report of a joint working party. Royal College of Obstetricians and Gynaecologists, June 2001.
2. Royal College of Pathologists. Guidelines on autopsy practice. Report of a working group of the Royal College of Pathologists. Royal College of Pathologists, September 2002.
3. House of Commons. Report of the Royal Liverpool Children's Inquiry (Redfern Report). HMSO, London, 2001.
4. Department of Health. External review of the Birmingham Children's Hospital NHS Trust. Retained organs committee report on organ retention. HMSO, London, November 2002.

5. Department of Health. Organ retention at Central Manchester and Manchester Children's University Hospitals Trust. Report of an independent investigation. HMSO, London, July 2002.
6. House of Commons. Human Tissue Bill. HMSO, London, Dec 2003.
7. House of Commons. Human Tissue Act. HMSO, London, 1961.
8. House of Commons. The Coroner's Rules. HMSO, London, 1984.
9. House of Commons. The Coroner's Act. HMSO, London, 1988.
10. Home Office. Death Certification and Investigation in England, Wales and Northern Ireland—The report of a fundamental review. HMSO, London, 2003.
11. Valdes-Dapena M, Kalousek DK, Huff DS. Perinatal, fetal and embryonic autopsy. In Gilbert-Barnes E (ed): *Potters's pathology of the fetus and infant*. St. Louis: Mosby; 1997:483–524.
12. Kelehan P, Technique for removal of the newborn middle and inner ear. In: *Perinatal pathology*. Philadelphia: WB Saunders; 1996:381–383.
13. Wigglesworth JS. Definition of pulmonary hypoplasia. In: *Perinatal pathology*. Philadelphia: WB Saunders; 1996:164–165.
14. Levene MJ, Williams JL, Fauer CL. Ultrasound of the fetal brain. In: *Clinics in developmental medicine*. Oxford: Blackwell Science; 1985:92.
15. Russel JGB. Radiological assessment of age, retardation and death. In: Barson AJ (ed). *Laboratory investigation of fetal disease*. Bristol: John Wright & Sons; 1981:3–16.
16. Wigglesworth JS. Causes and classification of fetal and perinatal death. In: Wigglesworth JS, Singer DB (eds). *Textbook of fetal and perinatal pathology*. Oxford: Blackwell Science, 1991.

# Appendix

## Appendix 1

The following is a comprehensive list of cases that should be reported to the appropriate authority and which will apply to most medicolegal systems around the world. It has been produced by the Procurator Fiscal of Scotland to ensure that the Fiscal has the opportunity to conduct an Inquiry and although extensive local practices may vary somewhat:

1. Any uncertified death.
2. Any death caused by an accident arising out of the use of a vehicle including an aircraft, a ship, or a train.
3. Any death of a person while at work.
4. Any death resulting from an accident in the course of work or arising out of industrial disease or poisoning.
5. Any death due to poisoning.
6. Any death in which the circumstances indicate that suicide may be a possibility.
7. Any death where there are indications that it occurred as a result of medical mishap, i.e.:
  - a. deaths that occur unexpectedly having regard to the clinical condition of the deceased prior to his receiving medical care;
  - b. deaths that are clinically unexplained;
  - c. deaths seemingly attributable to therapeutic or diagnostic hazard;
  - d. deaths that are apparently associated with lack of medical care;
  - e. deaths that occur during the actual administration of general or local anaesthetic; and
  - f. deaths that may be due to an anaesthetic.
8. Any death resulting from an accident.
9. Any death following an abortion or attempted abortion.
10. Any death in which the circumstances seem to indicate fault or neglect on the part of another person.
11. Any death occurring while the deceased was in legal custody as defined in section 1(4) of the 1976 Act.

12. Any death of a newborn child whose body is found.
13. Any death (not occurring in a house) where a deceased's residence is unknown.
14. Any death by drowning.
15. Any death of a child from suffocation including overlaying.
16. Any death that may be a case of sudden infant death syndrome.
17. Any death occurring as a result of food poisoning or an infectious disease.
18. Any death by burning or scalding or as a result of a fire or explosion.
19. Any death of a foster child.
20. Any other death attributable to violent, suspicious, or unexplained cause.
21. Any death in which a complaint is received from the next of kin about the medical treatment given to the deceased, and in which there is any suggestion that the medical treatment may have contributed to the death of the patient.



## Appendix 2 Quick reference Table of approximate normal and useful organ weights and cardiac dimensions

	Newborn	Puberty	Adult male	Adult female
Heart weight	23 g	150 g	300 g	250 g
Valve circumferences:				
Mitral			9.5 cm	8.6 cm
Tricuspid			11.5 cm	10.5 cm
Aortic			6.7 cm (<60 y) 8.3 cm (>60 y)	6.3 cm (<60 y) 7.6 cm (>60 y)
Pulmonary			6.6 cm (<60 y) 7.3 cm (>60 y)	6.2 cm (<60 y) 7.1 cm (>60 y)
Left ventricle thickness			Up to 1.5 cm	Up to 1.5 cm
Right ventricle			Up to 0.5 cm	Up to 0.5 cm
Atria			0.3 cm	0.3 cm
LV+septum: RV ratio			2.3–3.3:1	
Left ventricular hypertrophy			>3.6:1 or LV+S > 225 g	>3.6:1 or <V + S > 225 g
Right ventricular hypertrophy			<2.1 or RV > 80 g	<2.1 or RV > 80 g
Lungs (very variable)	50 g (together)	410 g (together)	300–400 g (each)	250–350 g (each)
Brain	380 g	1150 g	1400 g	1275 g
Liver	135 g	1400 g	1400–1550 g	1300–1450 g
Kidneys	28 g (together)	220 g (together)	150 g	140 g
Spleen	10 g	95 g	140–170 g	130–160 g
Adrenals	8 g (together)	9 g (together)	5.75–10 g (each)	5.75–10 g (each)
Pancreas	4 g	40 g	100 g (80–120 g)	90 g (70–110 g)
Uterus	3 g	8 g	—	70 g (40–125 g)
Ovaries	0.3 g (together)	5 g (together)	—	4.5–5.5 g (each)
Testes	2 g (together)	20 g (together)	13 g (each)	—
Thyroid gland	3 g	25 g	40 g (30–70 g)	40 g (30–70 g)
Thymus	13 g	35 g	usually atrophic	usually atrophic
Pituitary	0.1 g	0.6 g	0.6 g	up to 1 g during pregnancy
Stomach	8 g	80 g	150 g	140 g
Parathyroid glands	—	—	0.035–0.045 g (each) 0.12–0.18 (combined)	0.03–0.04 g (each) 0.12–0.18 (combined)
Prostate (very variable)	—	—	15–20 g	—
Carotid body	—	—	0.02 g (0.004–0.034 g)	0.02 g (0.004–0.034 g)

# Bibliography

## Bibliography and Websites

### *General Information*

College of American Pathologists: [www.cap.org](http://www.cap.org)

Department of Health, UK: [www.doh.gov.uk](http://www.doh.gov.uk)

Department of Health. Mortuary and post-mortem room, Health Building Note 20. HMSO, London, 1991.

Department of Health. HBN20 Facilities for mortuary and post-mortem room services. The Stationery Office, London, 2001.

Department of Health. Families and post mortems—A code of practice. The Stationery Office, London, 2003.

Hill RB, Anderson RE. The autopsy—medical practice and public policy, 2nd edit. Boston: Butterworths, 1988.

Home Office. Death certification and investigation in England, Wales and Northern Ireland—The report of a fundamental review. HMSO, London, 2003.

Hutchins GM and the Autopsy Committee of the College of American Pathologists. Practice guidelines for autopsy pathology: autopsy performance. *Arch Pathol Lab Med* 1994;118:19–25.

Hutchins GM and the Autopsy Committee of the College of American Pathologists. Practice guidelines for autopsy pathology: autopsy reporting. *Arch Pathol Lab Med* 1999;123:1085–1092.

National Confidential Enquiry into Perioperative deaths: [ncepod.org.uk](http://ncepod.org.uk)

National Confidential Enquiry into Perioperative Deaths. Extremes of age. NCEPOD, London, 1999.

National Confidential Enquiry into Perioperative Deaths. Then and now. NCEPOD, London, 2000.

National Confidential Enquiry into Perioperative Deaths. Changing the way we operate. NCEPOD, London, 2001.

National Sentinel Clinical Audit of Epilepsy-Related Deaths: [www.official-documents.co.uk/document/reps/nscaerd/report](http://www.official-documents.co.uk/document/reps/nscaerd/report)

National Sentinel Clinical Audit of Epilepsy-Related Deaths. Epilepsy: death in the shadows. The Stationery Office, London, 2002. [www.nhs.uk/retainedorgans](http://www.nhs.uk/retainedorgans)

Royal College of Pathologists: [www.rcpath.org](http://www.rcpath.org)

- Royal College of Pathologists. Guidelines for post mortem reports. Royal College of Pathologists, London, 1993.
- Royal College of Pathologists. HIV and the practice of pathology. Royal College of Pathologists, London, 1995.
- Royal College of Pathologists. Guidelines on autopsy practice; the report of a working group of the Royal College of Pathologists. Royal College of Pathologists, London, 2002.
- Royal College of Pathologists of Australasia: [www.rcpa.edu.au](http://www.rcpa.edu.au)
- Royal Institute of Public Health: [www.riph.org.uk](http://www.riph.org.uk)
- Royal Institute of Public Health. A handbook of Anatomical Pathology Technology. London: RIPH, 2004.
- Rutter GN (ed). Essentials of autopsy practice, vol. 1. London: Springer-Verlag, 2001.
- Slavin G and members of the working party. The autopsy and audit. Royal College of Pathologists, London, 1991.
- Stamp GWH, Wright N. Advanced histopathology. Berlin/Heidelberg/New York: Springer-Verlag, 1990.

### *Coroner's Autopsies*

- Coroners review: [www.coronersreview.org.uk](http://www.coronersreview.org.uk)
- House of Commons. The Coroner's rules. HMSO, London, 1984.
- House of Commons. The Coroner's Act. HMSO, London, 1988.
- Knight B. The coroner's autopsy, 2nd edit. Edinburgh: Churchill Livingstone, 1983.

### *Health and Safety*

- Advisory Committee on Dangerous Pathogens, Spongiform Encephalopathy Advisory Committee. Transmissible Spongiform Encephalopathy agents: safe working and the prevention of infection. The Stationery Office, London, 1998.
- Advisory Committee on Dangerous Pathogens. Categorisation of pathogens according to hazard and categories of containment, 5th edit. London: HSE Books, 1995.
- Advisory Committee on Dangerous Pathogens. Management and control of viral haemorrhagic fevers. The Stationery Office, London, 1996.
- Department of Health. Control of Substances Hazardous to Health Recommendations (COSHH). The Stationery Office, London, 2002.
- Health and Safety at work etc. Act 1974. HMSO, London.
- Health Services Advisory Committee. Safe working and the prevention of infection in the mortuary and post-mortem room. London: HSE Books, 2003.
- Health Services Advisory Committee. Safe working and the prevention of infection in clinical laboratories. HMSO, London, 1991.
- Health Services Advisory Committee. Safe working and the prevention of infection in clinical laboratories—model rules for staff and visitors. HMSO, London, 1991.

### *General Technique*

- Baker RD. Postmortem examination: specific methods and procedures. Philadelphia: WB Saunders, 1967.
- Burton J, Rutty G. The hospital autopsy, 2nd edit. London: Arnold, 2001.

- Finkbeiner WE, Ursell PC, Davis RL. Autopsy pathology. A manual and atlas. Philadelphia: Churchill Livingstone, 2004.
- Ludwig J. Autopsy practice, 3rd edit. Totowa, NJ: Humana Press, 2002.
- Mallory FB. Pathological technique: a practical manual for workers in pathological histology, including directions for the performance of autopsies and microphotography. Philadelphia: WB Saunders, 1938.
- Saphir O. Autopsy diagnosis and technic, 4th edit. New York: Paul B Hoeber, 1958.
- Saukko P, Knight B. Knight's forensic pathology, 3rd edit. London: Arnold, 2003.

### *Maternal Death Autopsy*

- Drife J. Maternal mortality: lessons from the confidential enquiry. *Hosp Med* 1999;60:156–157.
- UK Confidential Enquiry into Maternal and Child Health (CEMACH) [www.cemach.org.uk](http://www.cemach.org.uk)
- Department of Health. Why mothers die. Report on Confidential Enquiries into Maternal Deaths in England and Wales, 1994–1996. The Stationery Office, London, 1998.
- National Institute of Clinical Excellence. Why mothers die 1997–1999. Report on Confidential Enquiries into Maternal Deaths in the United Kingdom. Department of Health, London, 2001.

### *Neuropathology*

- Esiri MM. Oppenheimer's diagnostic neuropathology. A practical manual, 2nd edn. Oxford: Blackwell Science, 1996.
- Hume-Adams J, Murray MF. Atlas of post-mortem techniques in neuropathology, Cambridge: Cambridge University Press, 1982.
- Ironside JW, Bell JE. "High risk" neuropathological autopsy in AIDS and Creutzfeldt-Jakob disease: principles and practice. *Neurpathol Appl Neurobiol* 1996;22:388–393.

### *Organ Retention*

- Department of Health. Human bodies, human choices—summary of responses to the consultation report. The Stationery Office, London, 2003.
- House of Commons. Report of the Royal Liverpool Children's Inquiry (Redfern report). HMSO, London, 2001.
- House of Commons. Human Tissue Bill. HMSO, London, 2003.
- House of Commons. Human tissue act HMSO, London, 1961.
- Retained Organs Commission. Final outcome report on consultation on the use and disposal of unclaimed and unidentified human organs and tissue, The Stationery Office, London, 2003.
- Royal College of Pathologists. Guidelines for the retention of tissues and organs at post-mortem examination. Royal College of Pathologists, London, 2000.
- Royal College of Pathologists. Transitional guidelines to facilitate changes in procedures for handling "surplus" and archival material from human biological samples. Royal College of Pathologists, London, 2001.

*Fetal and Perinatal Autopsy*

UK Confidential Enquiry into Maternal and Child Health (CEMACH):  
[www.cemach.org.uk](http://www.cemach.org.uk)

Jones KL. Smith's recognisable patterns of human malformations, 5th edit. Philadelphia: WB Saunders, 1997.

Wigglesworth JS. Perinatal pathology. Major problems in pathology series, vol. 15, 2nd edit. Philadelphia: WB Saunders, 1996.

Wigglesworth JS, Singer DB. Textbook of fetal and perinatal pathology, 2nd edit. Oxford: Blackwell Science, 1998.

# Index

## A

Accidents during post mortem, 32–33

Adrenal gland, dissection, en bloc method, 136–137 en masse method, 120 individual organ method, 103 in-situ method, 107 examination, 241–242 pheochromocytoma, examination of, 242 fetal, perinatal, infant autopsy dissection en bloc method, 388 en masse method, 381–382 Adrenaline, staining for, 325

After dissection, 319–349. *See also* Post-dissection procedures

Air embolus, 71–72

Airways dissection of, 181–182 opening, vasculature, avoiding transection, 184

Alder Hey scandal, 18

Amyloid, staining for, 324–325

Anaesthetic deaths, maternal deaths, 230

Ancillary investigations, samples for, 326–333 biochemistry, 329–331 criminal investigation, 331–332 haematology, 329–331 microbiology, 326–329 toxicology, 329–331

Androgenic steroids, fetal, perinatal, infant autopsy, 375

Angiography, 177–179 coronary, 166–168 gastric, 209 mesenteric, 176 pulmonary, 189 renal, 217 vertebral, 309–311

Anterior body wall incisions, 67–70

Anticonvulsants, fetal, perinatal, infant autopsy, 375

Asbestos body/fibre demonstration, lungs, 192–194 digestion techniques, 192 electron microscopy, 192 environmental lung research group, 193–194 during examination, 192 histological sections, 192

Audit, usefulness of post mortem in, 343–347

Australia, death investigation legislation, system, 9, 10

Autonomic nerves, 315–317

Autopsies. *See also* Post mortem noninvasive techniques for, 51 number of, performed annually in England, Wales, 4 planning of, need for, 51

## B

Bacillus Calmette Guréin vaccine immunization of personnel, as safety precaution, 36

- Beckwith-Wiedemann syndrome, fetal,  
perinatal, infant autopsy,  
375
- Bile, sample collection, 60, 210, 330
- Biochemical investigation, 329–331
- Bladder,  
dissection  
en bloc method, 137–138  
en masse, alternative method,  
123  
in situ method, 107–108  
examination, 220  
tumour, 224  
fetal, perinatal, infant autopsy,  
dissection  
en bloc method, 389  
en masse method, 382
- Block dissection, 119–140. *See also*  
*under* specific organ  
evisceration, 87–97  
summary 96–97  
dissection, 127–139  
coeliac/abdominal block, 133–136  
summary, 136  
genitourinary block, 136–139  
summary, 139  
thoracic block, 127–133  
summary, 133  
fetus, perinatal, infant autopsy,  
385–390  
summary, 389–390
- Blood  
biochemical, haematological and  
toxicological investigation,  
329–330  
collection, 64  
timing of, 63  
microbiological investigation,  
326–327
- Body wall incisions, 67–70
- Bone marrow, 254–256  
decalcification for histology, 255  
sampling of femur to obtain  
specimen, 263–264  
special techniques for, 255
- Bone tumours, 279–280  
axial skeleton, 279–280  
limbs, 279
- Brachial plexus, left, diagram, 314
- Brain,  
arteries at base of, diagram, 284  
block selection, 297  
brain stem  
cerebellum, separation, 286  
dissection of, 287–288  
cerebellum, dissection of, 288–289  
cerebral hemispheres, dissection of,  
289–291  
dissection, 286–292  
dura, release of, 112–114  
external examination, 283–284  
fetal, perinatal, infant autopsy,  
390–393, 402–403  
examination, 402–403  
removal, 390–393  
in case of hydrocephalus/other  
cystic congenital abnormality,  
393–394  
in macerated baby, 393  
fixation, 285  
high-risk case, removal of brain in,  
297–298  
internal examination, 292–295  
meninges and vessels, 283, 284  
midbrain block, removal of, 289, 291  
removal, 110–116  
summary, 115–116  
scalp, reflection of, 110–111  
skull, sawing of, 111  
skull cap, removal of, 112  
special techniques, 297–298  
weighing, 114, 285–286  
weight, according to gender, age, 286
- Bristol scandal, 18
- Bronchial arteriogram, 190
- Bronchography, 190
- Building layout, importance of, 22–24
- C**
- CABG. *See* Coronary artery bypass  
grafting
- Calcium, staining for, 325
- Canada, death investigation legislation,  
system, 9, 10
- Cardiac pacing, examination following,  
158–159
- Cardiac transplantation, examination  
following, 159–161

- Cardiovascular system, 141–179. *See also under* specific organ
- cardiac pacing, examination following, 158–159
- conduction system, examination of, 161–166
- anatomy, 161–162
  - block selection, 163–167
  - preparation of specimen, 161
- coronary angiography, 166–168
- coronary artery examination, 142–146
- anatomy, 142
  - angiography, 166–168
  - dominant arterial supply, importance of, 143
  - longitudinal opening technique, 145
  - removal of, for decalcification, 144
  - transverse sectioning technique, 144–145. coronary artery bypass grafting, examination following, 157–158
- endocarditis, microbiological samples, 157
- heart
- external examination, 142
  - fetal, perinatal, infant autopsy, *in situ* dissection, 398–399
  - Fulton's techniques, 154–155
  - hypertrophy, assessment of, 154–155
  - internal examination, 152–155
  - opening along path of blood flow, 147–151
  - opening by ventricular slicing, 152
  - removal
    - en bloc method, 128, 131–132
    - en masse method, alternative method, 126
    - individual organ method, 98–99
    - in situ* method, 105–106
  - valves, average measurements of, 153
  - weight, for different heights, weights, 153
- myocardial infarction, macroscopical dye technique for identification of, 168
- pacemaker device, removal necessary, 159
- post mortem angiography, 177–179
- transplantation, cardiac, examination following, 159–161
- valves, average measurements of, 153
- valvular disease, surgery, examination following, 155–156
- vascular system examination
- lower limb vessels, 171–174
  - mesenteric vessels, 174–177
  - upper limb vessels, 168–171
  - vertebral arteries, 307–312
- Carotid body examination, 246–248
- Categories of pathogens, associated risks, 37–38
- Cause of death, 334–338
- certificate, 335
  - fetal, perinatal, infant autopsy, 412
  - certificates, 413–416
  - none apparent, consequences of, 336–337
- Cavernous sinus, examination of, 307, 308
- CEMACH, *See* confidential enquiry into maternal and child health
- Cerebrospinal fluid sampling, 65, 326–328
- Certificate of death
- adult, 335
  - neonate, 417
  - stillbirth, 413–416
- Cervical spine
- fetal, perinatal, infant autopsy, 397
  - fractures
    - anterior approach, 275–276
    - examination of, 275–277
    - posterior approach, 276–277
  - vertebral artery examination
    - en bloc examination, 312
    - en bloc removal, 311–312
      - anterior approach, 311
      - posterior approach, 311–312
- Cervix with *in situ* or invasive neoplasia, 222
- Changing patterns of disease, post mortem documentation of, 3
- Chemical contaminants, 47–48



- Chest wall dissection 72–73
- Chronic obstructive pulmonary disease, presence of, 181
- Cleaning solutions, 34–35
- Clothing worn during post mortem, 25–26
- Coeliac/abdominal block dissection, 133–136  
summary, 136
- fetal, perinatal, infant autopsy, 387–388
- fixation of, 208
- College of American Pathologists, guidelines for post mortems, 3
- Conduction system, examination of, 161–166  
anatomy, 161–162  
block selection, 163–167  
preparation of specimen, 161
- Confidential enquiry into maternal and child health (CEMACH), 412
- Consent issues, 11–21, 319–321  
fetal, perinatal, infant autopsy, 352–359
- COPD. *See* Chronic obstructive pulmonary disease
- Copper, staining for, 325
- Coronary angiography, 166–168
- Coronary artery bypass grafting, examination following, 157–158
- Coronary artery examination, 142–145  
anatomy, 142–144  
“dominant” arterial supply, importance of, 143  
longitudinal opening technique, 145  
removal of, for decalcification, 144  
transverse sectioning technique, 144–145
- Coroner. *See also* Coronial system  
duties of, 6  
medical examiner, 8  
referrals to, sources of, 5  
request of post mortem by, 4
- Coronial system, 5–9
- Court, presentation of post mortem findings before, 347–348
- Cranial nerves, sympathetic chain, relationship, diagram, 316
- Criminal investigation, sampling for, 331–332
- CSF. *See* Cerebrospinal fluid
- Cystic congenital anomaly, removal of brain, fetal, perinatal, infant autopsy, 393–394
- Cytology, 322–324  
fine-needle aspiration, 322–323  
fluids  
examination for cells, 324  
examination for crystals, 323–324  
“touch” imprint preparations, 324
- D**
- Dangerous foreign material, 47–48
- Death, cause of, 334–338  
fetal, perinatal, infant autopsy, 412
- Death certificate, adult, 335  
stillbirth, 413  
neonatal, 417
- Death, notification of, 10
- Decalcification  
coronary artery examination, 144  
vertebral artery examination, 312
- Decline in hospital post mortem examination, reasons for, 2–3
- Demonstration of post mortem findings, 333–334
- Diagnostic techniques at post mortem, 324–326
- Diatom testing in drowning, 194, 331
- Disease patterns, changes in, post mortem documentation of, 3
- Disinfectants, types of, 35
- Disposal of waste, 34
- Dissecting board, 27
- DNA analysis, best specimens for, 331
- “Dominant” coronary arterial supply, importance of, 143
- Drowning, diatom testing in, 194, 331
- Duties of coroner, 6
- Dye, macroscopical techniques, 324–326
- Dysmorphic facies, infant/fetus autopsy, 363

**E**

- Ear, examination of, 116–118  
 fetal, perinatal, infant autopsy, 395
- En bloc dissection (Ghon method),  
 87–97, 127–139. *See also under*  
 specific organ system
- choosing, 79–81
- evisceration, 87–97  
 summary 96–97
- dissection, 127–139  
 coeliac/abdominal block, 133–  
 136  
 summary, 136  
 genitourinary block, 136–139  
 summary, 139  
 thoracic block, 127–133  
 summary, 133
- fetus, perinatal, infant autopsy,  
 385–390  
 summary, 389–390
- En masse dissection (Letulle's  
 method), 79–80, 82–86. *See*  
*also under* specific organ  
 system
- choosing, 79–81
- dissection, 119–127  
 Saphir method, 119–122  
 summary, 122  
 alternative method, 122–127  
 summary, 127
- evisceration, 82–86  
 summary, 86
- fetal, perinatal, infant autopsy,  
 379–384  
 summary, 384
- Endocarditis, microbiological samples,  
 157
- Endocrine system, 237–249. *See also*  
*under* specific organ
- adrenal gland  
 dissection  
 en bloc method, 136–137  
 en masse method, 120  
 individual organ method, 103  
 in-situ method, 107  
 examination, 241–242  
 pheochromocytoma,  
 examination of, 242
- fetal, perinatal, infant autopsy  
 dissection  
 en bloc method, 388  
 en masse method, 381–382
- composition of, 237
- fetal, perinatal, infant autopsy, 403
- paraganglion system, 245–248
- parathyroid glands  
 examination, 239–241  
 infiltrative tumour, 240–241
- removal  
 en bloc method, 128–129  
 en masse, alternative method,  
 123  
 en masses, Saphir method,  
 121  
 individual organ method, 100
- pituitary gland, 242–245  
 examination, 242–245  
 large tumour, 243–245  
 removal, 114–115
- thyroid gland, 237–239  
 examination, 237–240  
 tumour, 240
- fetal, perinatal, infant autopsy  
 examination, 403  
 removal en bloc, 387  
 removal en masse, 382
- removal  
 en bloc method, 128–129  
 en masse, alternative method,  
 123–124  
 individual organ method, 100
- English common law coroner tradition,  
 8
- Environmental lung research group,  
 193–194
- Europe, death investigation legislation,  
 system, 9, 10
- Evisceration techniques, 82–118  
 choosing, 79–81  
 en bloc (Ghon's method), 87–97  
 summary, 96–97  
 en masse (Letulles's method), 82–86  
 summary, 86
- fetal, perinatal, infant autopsy  
 en bloc (Ghon's method), 385–390  
 summary, 389–390

- Evisceration techniques (*cont.*)  
 en masse (Letulle's method),  
 379–384  
 summary, 384  
 initial stages of, 376–379  
 summary, 378–379  
 individual organ removal (Virchow's  
 method), 97–105  
 summary 104–105  
 initial stages of, 67–75  
*in situ* method (Rokitansky  
 technique), 105–110  
 summary, 110
- Evolution of post mortem, 1
- Examination methods, choice of, 79–81
- External inspection, general, 57–62
- Eye,  
 examination  
 anterior (external) approach, 306  
 superior (internal) approach,  
 306–307  
 fetal, perinatal, infant autopsy, 394
- F**
- Face, preliminary incisions, 70
- Facilities for post mortem, 22–31  
 high-risk, 36
- Fallopian tubes, 220–223  
 tumours, examination of, 222
- Fat, staining for, 325
- Fat necrosis, demonstration of, 210–211
- Female genital organs, 220–223  
 removal of, complete, maternal  
 deaths, 235–236  
 summary, 236
- Femur  
 removal, 261–263  
 haematological investigation,  
 sampling femur for, 263–264
- Fetal alcohol syndrome, fetal, perinatal,  
 infant autopsy, 376
- Fetal autopsy, 350–416  
 abdominal block, 387–388  
 androgenic steroids, 375  
 anticonvulsants, 375  
 Beckwith-Wiedemann syndrome, 375  
 before the post mortem, 360–365  
 biochemistry, 405  
 brain  
 examination, 402–403  
 histology, 402–403  
 removal, 390–393  
 removal, hydrocephalus or cystic  
 congenital abnormality,  
 393–394  
 removal, macerated, 393  
 cardiovascular system, 398–399  
 cause of death/pathological findings,  
 411–417  
 cervical vertebrae, examination of,  
 397  
 consent issues, 352–359  
 cystic congenital anomaly, removal  
 of brain, 393–394  
 cytogenetics, 405  
 definitions of terms, 359–360  
 demonstration of post mortem  
 findings, 410–411  
 ear, examination of, 395  
 endocrine system, 403  
 evisceration and block dissection,  
 376–390  
 en bloc (Ghon's method), 385–390  
 summary, 389–390  
 en masse (Letulle's method),  
 379–384  
 summary, 384  
 initial stages of, 376–379  
 summary, 378–379  
 external examination, 365–376  
 external measurements, 366, 368–374  
 eye, examination of, 396  
 fetal alcohol syndrome, 376  
 fetal anomaly, not diagnosed  
 prenatally, 364–365  
 gastrointestinal system, 402  
 genetic metabolic disease, 364  
 genitourinary block, 388–390  
 genitourinary system, 388, 403  
 germinal matrix and intraventricular  
 haemorrhage, grading of, 403  
 gestational age/growth, estimation of,  
 408–411  
 Ghon method (en bloc dissection),  
 385–390  
 summary, 389–390  
 haematology, 405  
 heart, *in situ* dissection of, 379–381

- histochemistry, 406
- histology, 406–407
- hydrocephalus, removal of brain, 393–394
- immunology, 406
- infected body, suspected, 363
- inner ear, examination of, 395
- intestinal block, 386
- intrauterine growth retardation, 364
- isoimmunization, 361
- Letulle's method (en masse dissection), 379–384
  - summary, 384
- lymphoreticular system, 403
- maceration, estimating degree of, 365
- Meckel-Gruber syndrome, 375
- mercury poisoning, 375
- microbiology, 404–405
- middle ear, examination of, 395
- multiple malformation/dysmorphic facies, 363
- musculoskeletal system, 397, 404
- neonatal death, 365
- nervous system, 402–403
- neural tube defect, removal of spinal cord, 394–395
- neuromuscular system, examination of, 397
- nonaccidental injury, 395–396
- nonimmunological hydrops, 361–363
- oligohydramnios, 366
- organ dissection, 397–407
- pathological findings/cause of death, 411–416
- pelvic organ dissection, in continuity with perineum/anus, 397
- peroxisomal disorder, 375
- placenta, 407–408
  - before post mortem, 355–365
  - preterm infant, 364
- radiography, whole-body, 361
- respiratory system, 399–400
- rubella infection during first trimester, 376
- samples for ancillary investigations, 404–407
- skeletal dysplasia, 363
- spinal cord
  - brain in continuity, removal of, 394
  - removal of, 394
  - suspected neural tube defect, removal of, 394
- stillbirth, 363–364
- sudden unexpected death in infancy, 364
- thoracic/coeliac block, 386–387
- triploidy, 367–374
- trisomy 13, 366–367
- trisomy 18, 367
- trisomy 21, 367
- Turner's syndrome, 375
- twins, 363
- vertebral arteries, examination of, 397
- virology, 405
- warfarin, 375
- writing post mortem report, 412–418
- Zellweger syndrome, 375
- Fibre demonstration, lungs, 192–194
  - digestion techniques, 192
  - electron microscopy, 192
  - environmental lung research group, 193–194
  - during examination, 192
  - histological sections, 192
- Fine-needle aspiration, 322–323
- First aid, 32–33
- Fistula sites, identification of, 63
- Fixatives, 35–36
- Fluids
  - cytology
    - examination for cells, 324
    - examination for crystals, 323–324
  - samples, ancillary investigations, biochemistry, haematology, toxicology, 330
  - microbiology, 326–327
  - sampling, 63–66
- Foreign materials, dangerous, 47–48
- Forensic post mortem, 4
- Formalin vapour method, inflating lungs, 185–186
- Forms for documentation of cause of death, 335
  - fetal, perinatal, infant autopsy, 413–416

- Fractures, 270–277
  - cervical spine, 275–277
  - long bones/limbs, 270–271
  - pelvic girdle, 275
  - ribs, 271–273
  - shoulder girdle, 275
  - skull, 275
  - vertebral column, 273–275
- France, death investigation legislation, system, 10
- “Frozen” pelvis, examination of, 226–227
- Frozen sections, 321
- Fulton’s technique, heart dissection, 154–155

## G

- Gallbladder
  - dissection
    - en bloc method, 134–135
    - en masse, alternative method, 124–125
    - individual organ method, 102
    - in-situ* method, 106
  - fetal, perinatal, infant autopsy
    - dissection, en bloc method, 388
    - dissection, en masse method, 383
- Ganglia, 315–317
- Gastric contents, collecting, 208
- Gastric lesion assessment, 208–209
  - coeliac block, fixation of, 208
  - gastric contents, collecting, 208
  - stomach
    - angiography of, 209
    - histology of, 209
  - stomach whole, fixing, 208–209
- Gastrointestinal system, 197–213. *See also under* specific organ system
- Bile collection, 66, 210, 330
- Fat necrosis, demonstration of, 210–211
- Intestines
  - dissecting microscopy, 201
  - examination, 198–201
  - external examination, 198
  - fetal, perinatal, infant autopsy
    - examination, 402
    - removal en bloc method, 386

- removal en masse method, 383
- fixation of tumour in, 200–201
- gastrointestinal tract mucosa, preservation of, 200
- histology, 198–199
- internal examination, 198, 199
- intestinal contents, collection of, 199–200
- radiography of bowel, 201
- removal
  - en bloc method, 89–91
  - en masse method, 82–83
  - individual organ method, 101
  - in-situ* method, 109–110
  - special techniques for, 199–201

## Liver

- examination, 201–204
  - external examination, 201
  - hepatic amyloid, demonstration of, 204
  - hepatic iron, demonstration of, 203
  - hepatic tissue, sampling for microbiology/biochemistry/toxicology, 203
  - histology, 202
  - internal examination, 201–202
  - radiography of, 203
  - special techniques, 203–204
  - transplantation, 204
- fetal, perinatal, infant autopsy
  - examination, 402
  - removal
    - en bloc method, 387
    - en masse method, 383–384
- removal
  - en-bloc method, 135–136
  - en-masse, alternative method, 125–126
  - individual organ method, 102
  - in-situ* method, 107
- Mesentery, 209–210
- Oesophageal mass, infiltrative, examination of, 207–208
- Oesophageal varices, demonstration of, 207
- Oesophageal webs/rings, demonstrating, 206

- Oesophagus
  - dissection
    - en bloc method, 129–130
    - en masse, alternative method, 124
    - en masse, Saphir method, 121
  - fetal, perinatal, infant autopsy dissection
    - en bloc method, 387
    - en masse method, 382
- Orpharynx, 205–206
- Pancreas,
  - dissection/removal,
    - en bloc method, 135
    - en masse, alternative method, 125
    - individual organ method, 103
    - in situ* method, 109
  - examination, 204–205
  - fetal, perinatal, infant autopsy dissection/removal
    - en bloc method, 388
    - en masse method, 383
  - examination, 402
  - histology, 205
- Rectal masses, 212
- Salivary glands
  - examination, 206
  - isolating, 206
  - radiology, 206
  - tumours, 206
- Stomach
  - angiography of, 209
  - histology of, 209
  - collection of contents, 66, 208, 330
  - dissection
    - en bloc method, 134
    - en masse, alternative method, 124
    - individual organ method, 102
    - in situ* method, 109
  - fetal, perinatal, infant autopsy
    - en bloc method, 387–388
    - en masse method, 383
  - whole, fixing, 208–209
- Genetic metabolic disease, fetal, perinatal, infant autopsy, 364
- Genitourinary block
  - dissection, 136–139
    - summary, 139
  - fetal, perinatal, infant autopsy, 388–389
- Genitourinary system
  - Bladder,
    - dissection
      - en bloc method, 137–138
      - en masse, alternative method, 123
      - in situ* method, 107–108
    - examination, 220
    - tumour, 224
  - fetal, perinatal, infant autopsy, dissection
    - en bloc method, 389
    - en masse method, 382
- Fallopian tubes, 220–223
  - tumours, examination of, 222
- Female genital tract, removal complete, 235–236
- “Frozen” pelvis, examination of, 226–227
- Kidneys,
  - angiography, 217–218
  - examination, 215–220
  - external examination, 215
  - fetal, perinatal, infant autopsy examination, 403
  - removal
    - en bloc method, 388–389
    - en masse method, 382
  - histology of, 217
  - internal examination, 215–216
  - nephron/glomerulus,
    - microdissection of, 219
  - removal
    - en bloc method, 136–138
    - en masse method
      - Saphir method, 120–121
      - alternative method, 122–123
    - individual organ method, 103
    - in situ* method, 107
  - renal amyloid, 218–219
  - renal tissue sampling, toxicology, 219
  - special techniques, 217–219

- Genitourinary system (*cont.*)  
 transplantation, 219–220  
 tumours, 217
- Maternal deaths, 227–236  
 anaesthetic deaths, 230  
 approach to, 228–229  
 cause of death, 229–230  
 evisceration and organ dissection,  
 231–233  
 removal of genital tract  
 complete, 235–236  
 summary, 236  
 external examination, 230–231  
 histology, 233–234  
 summary, 234  
 placenta, 234
- Ovary, 222  
 tumours, 222
- Testes, 223  
 external examination, 223  
 fetal, perinatal, infant autopsy  
 en bloc method, 389  
 en masse method, 382  
 histology, 223  
 internal examination, 223  
 removal  
 en bloc method, 96  
 en masse method, 84  
 individual organ method, 104  
 in situ method, 108  
 special techniques, 223  
 tumours, 223
- Ureter,  
 dissection, 137  
 examination, 220  
 localized mass, examination of,  
 224–225  
 fetal, perinatal, infant autopsy  
 dissection  
 en bloc method, 388–389  
 en masse method, 382
- Urethra,  
 female, examination of, 226  
 penile, examination of, 225–226
- Urinary tract, radiography of, 217
- Urine collection, 65, 224, 326–327,  
 330
- Urography, 218
- Uterus, 220–223  
 external examination, 221  
 fetal, perinatal, infant autopsy  
 examination, 403  
 removal of pelvic contents in  
 continuity with perineum and  
 anus, 397  
 histology, 221–222  
 internal examination, 221  
 special techniques for, 222  
 tumours, 222
- Venography, 218
- Gestational age/growth, estimation of,  
 fetal, perinatal, infant autopsy,  
 408–411
- Ghon method,  
 choosing, 79–81  
 evisceration, 87–97  
 summary, 96–97  
 dissection, 127–139  
 coeliac/abdominal block, 133–136  
 summary, 136  
 genitourinary block, 136–139  
 summary, 139  
 thoracic block, 127–133  
 summary, 133  
 fetal, perinatal, infant autopsy,  
 385–390  
 summary, 389–390
- Glomerulus, microdissection of, 219
- Gough-Wentworth slices, lungs, 186
- Greece, death investigation legislation,  
 system, 10
- Guidelines for post mortem report,  
 Royal College of Pathologists,  
 344–346  
 fetal, perinatal, infant autopsy,  
 414–417
- H**
- Haematological investigation, 329–331
- Haematopoietic system. *See*  
 Lymphoreticular system
- Haemosiderin, staining for, 324
- Hair  
 inspection of, 61–62  
 samples, 66–67, 331–332
- Hazard avoidance in post mortem,  
 37–38
- Heart, 141–155  
 cardiac pacing, examination  
 following, 158–159

- conduction system, examination of, 161–166
    - anatomy, 161–162
    - block selection, 163–167
    - preparation of specimen, 161
  - coronary angiography, 166–168
  - coronary artery bypass grafting, examination following, 157–158
  - coronary artery examination, 142–146
    - anatomy, 142
    - angiography, 166–168
    - dominant arterial supply, importance of, 143
    - longitudinal opening technique, 145
    - removal of, for decalcification, 144
    - transverse sectioning technique, 144–145
  - endocarditis, microbiological samples, 157
  - external examination, 142
  - fetal, perinatal, infant autopsy, in-situ dissection, 398–399
  - Fulton's technique, 154–155
  - hypertrophy, assessment of, 154–155
  - internal examination, 152–155
  - myocardial infarction, macroscopical dye technique for identification of, 168
  - opening along path of blood flow, 147–151
  - opening by ventricular slicing, 152
  - removal
    - en bloc method, 128, 131–132
    - en masse method, alternative method, 126
    - individual organ method, 98–99
    - in-situ method, 105–106
  - transplantation, cardiac, examination following, 159–161
  - valves, average measurements of, 153
  - valvular disease or valve surgery, examination following, 155–156
  - weight, for different heights, weights, 153
  - Hepatic amyloid, demonstration of, 204
  - Hepatic iron, demonstration of, 203
  - Hepatic tissue, sampling for microbiology/biochemistry/toxicology, 203
  - Hepatitis B vaccine immunization of personnel, as safety precaution, 36
  - High-risk facilities, 36
  - High-risk post mortems, 38–45
    - building, 38–39
    - clothing and equipment, 40–41
    - drug resistance, 42
    - human immunodeficiency virus, 43–44
    - prion disease, 44–45
    - setting, 39–40
    - staff, 39
    - tuberculosis, 41–42
    - viral hepatitis, 42–43
  - Histology, 332–333
  - Histology report, formats, 343
  - Histopathologists, worldwide shortfall of, 351
  - Hospital post mortem, 4
  - Howie Report, publications superceding, 28
  - Human Tissue Act of 1961, replacement of by Human Tissue Bill. *See* Human Tissue Bill
  - Human Tissue Bill, 7, 18–21, 320, 352
  - Hydrocephalus, removal of brain, fetal, perinatal, infant autopsy, 393–394
  - Hydrops, nonimmunological, fetal, perinatal, infant autopsy, 361–363
- I**
- Immunization of personnel, as safety precaution, 36
  - In situ* dissection (Rokitansky's method), 105–110
    - choosing, 79–81
    - fetal, perinatal, infant autopsy heart, 379–381
    - summary, 110
  - India, death investigation legislation, system, 10



- Individual organ removal (Virchow's method), 97–105  
 choosing, 79–81  
 summary, 104–105
- Infant autopsy. *See* Fetal autopsy
- abdominal block, 387–388  
 androgenic steroids, 375  
 anticonvulsants, 375  
 Beckwith-Wiedemann syndrome, 375  
 before the post mortem, 360–365  
 biochemistry, 405  
 brain  
   examination of, 402–403  
   histology, 402–404  
   removal of, 390–393  
   removal, hydrocephalus or cystic congenital abnormality, 393–394  
   removal, macerated, 393  
 cardiovascular system, 398–399  
 cause of death/pathological findings, 411–414  
 cervical vertebrae, examination of, 397  
 consent issues, 352–359  
 cystic congenital anomaly, removal of brain, 393–394  
 cytogenetics, 405  
 definitions of terms, 359–368  
 demonstration of post mortem findings, 410–411  
 ear, examination of, 395  
 endocrine system, 403  
 evisceration and block dissection, 376–390  
   en bloc (Ghon's method), 385–390  
     summary, 389–390  
   en masse (Letulle's method), 379–384  
     summary, 384  
   initial stages of, 376–379  
     summary, 378–379  
 external examination, 365–376  
 external measurements, 366, 368–374  
 eye, examination of, 396  
 fetal alcohol syndrome, 376  
 fetal anomaly, not diagnosed prenatally, 364–365  
 gastrointestinal system, 402  
 genetic metabolic disease, 364  
 genitourinary block, 388–390  
 genitourinary system, 388, 403  
 germinal matrix and intraventricular haemorrhage, grading of, 402  
 gestational age/growth, estimation of, 408–411  
 Ghon method (en bloc dissection), 385–390  
   summarised, 389–390  
 haematology, 405  
 heart, *in situ* dissection of, 379–381  
 histochemistry, 406  
 histology, 406–407  
 hydrocephalus, removal of brain, 393–394  
 immunology, 406  
 infected body, suspected, 363  
 inner ear, examination of, 395  
 intestinal block, 386  
 intrauterine growth retardation, 364  
 isoimmunization, 361  
 Letulle's method (en masse dissection), 379–384  
   summarized, 384  
 lymphoreticular system, 403  
 maceration, estimating degree of, 365  
 Meckel-Gruber syndrome, 375  
 mercury poisoning, 375  
 microbiology, 404–405  
 middle ear, examination of, 395  
 multiple malformation/dysmorphic facies, 363  
 musculoskeletal system, 397, 406  
 neonatal death, 365  
 nervous system, 402–403  
 neural tube defect, removal of spinal cord, 394–395  
 neuromuscular system, examination of, 397  
 nonaccidental injury, 395–396  
 nonimmunological hydrops, 361–363  
 oligohydramnios, 366  
 organ dissection, 397–407  
 pathological findings/cause of death, 411–413  
 pelvic organ dissection, in continuity with perineum/anus, 397  
 peroxisomal disorder, 375

- placenta, 407–408  
 before post mortem, 355–365  
 preterm infant, 364  
 radiography, whole-body, 361  
 respiratory system, 399–400  
 rubella infection during first trimester, 376  
 samples for ancillary investigations, 404–407  
 skeletal dysplasia, 363  
 spinal cord  
   brain in continuity, removal of, 394  
   removal of, 394  
   suspected neural tube defect, removal of, 394  
 stillbirth, 363–364  
 sudden unexpected death in infancy, 364  
 thoracic/coeliac block, 386–387  
 triploidy, 367–374  
 trisomy 13, 366–367  
 trisomy 18, 367  
 trisomy 21, 367  
 Turner's syndrome, 375  
 twins, 363  
 vertebral arteries, examination of, 397  
 virology, 405  
 warfarin, 375  
 writing post mortem report, 412–418  
 Zellweger syndrome, 375
- Infant death, sudden. *See* Sudden unexpected death in infancy
- Infected body, suspected, fetal, perinatal, infant autopsy, 363
- Inflating lungs, 185–186  
 with abundant luminal contents, 186  
 formalin vapour method, 185–186  
 pump system, 185  
 Inner ear, examination of, fetal, perinatal, infant autopsy, 395
- Instruments for post mortem, 26–27
- Intestinal block  
 dissection, 136, 198  
 fetal, perinatal, infant autopsy, 386
- Intestinal contents, collection of, 199–200
- Intestines  
 dissecting microscopy, 201  
 examination, 198–201  
 external examination, 198  
 fetal, perinatal, infant autopsy examination, 402  
   removal en bloc method, 386  
   removal en masse method, 383  
 fixation of tumour in, 200–201  
 gastrointestinal tract mucosa, preservation of, 200  
 histology, 198–199  
 internal examination, 198, 199  
 intestinal contents, collection of, 199–200  
 radiography of bowel, 201  
 removal  
   en bloc method, 89–91  
   en masse method, 82–83  
   individual organ method, 101  
   *in-situ* method, 109–110  
   special techniques for, 199–201
- Intraabdominal  
 disease, widespread examination of, 211–212
- Investigation of deaths, official bodies, 347–348
- Ireland, death investigation legislation, system, 10
- Iron/haemosiderin, staining for, 324
- Isoimmunization, fetal, perinatal, infant autopsy, 361
- Italy, death investigation legislation, system, 10
- J**
- Japan, death investigation legislation, system, 10
- Joint examination, 277–278  
 axial skeleton, 279  
 fluid, for crystals, 278, 323–324  
 limbs, 277–278
- K**
- Kidneys,  
 angiography, 217–218  
 examination, 215–220  
 external examination, 215  
 fetal, perinatal, infant autopsy

Kidneys (*cont.*)

- examination, 403
- removal
  - en bloc method, 388–389
  - en masse method, 382
- histology of, 217
- internal examination, 215–216
- nephron/glomerulus, microdissection of, 219
- removal
  - en bloc method, 136–138
  - en masse method
    - Saphir method, 120–121
    - alternative method, 122–123
  - individual organ method, 103
  - in situ method, 107
- renal amyloid, 218–219
- renal tissue sampling, toxicology, 219
- special techniques, 217–219
- transplantation, 219–220
  - tumours, 217
- urinary tract, radiography of, 217
- urography, 218
- venography, 218

**L**

- Large intestine, 198–201. *See also*
  - Intestines
- Larynx, 195–196
- Legal age of fetal viability, 350–351
- Legislation delineating death
  - investigation procedures,
  - country by country listing, 10
- Letulle's method
  - choosing, 79–81
  - dissection, 119–127
    - Saphir method, 119–122
    - summary, 122
  - alternative method, 122–127
    - summary, 127
  - evisceration, 82–86
    - summary, 86
  - fetal, perinatal, infant autopsy, 379–384
    - summary, 384
- Limbs/long bones
  - accessing, 265–266
  - bone tumours, 279

- fractures, 270–271
- soft tissue tumours, 280
- Limited post mortem examination, 50–53

## Liver

- examination, 201–204
  - external examination, 201
  - hepatic amyloid, demonstration of, 204
  - hepatic iron, demonstration of, 203
  - hepatic tissue, sampling for
    - microbiology/biochemistry/toxicology, 203
  - histology, 202
  - internal examination, 201–202
  - radiography of, 203
  - special techniques, 203–204
  - transplantation, 204
- fetal, perinatal, infant autopsy
  - examination, 402
  - removal
    - en bloc method, 387
    - en masse method, 383–384
- removal
  - en-bloc method, 135–136
  - en-masse, alternative method, 125–126
  - individual organ method, 102
  - in-situ* method, 107
- Lower limb vessels, examination, 171–173
- Longitudinal opening technique, coronary artery, 145
- Lungs
  - examination, 180–194
    - airways
      - dissection of, 181–182
      - opening, vasculature, avoiding transection, 184
    - arteriography, 189
    - asbestos body/fibre demonstration, 192–194
    - bronchial arteriogram, 190
    - bronchography, 190
    - chronic obstructive pulmonary disease, presence of, 181
    - drowning, diatom testing in, 194, 331
    - external examination, 181

- high risk post mortem, lung
  - examination, 188
- histology, 183–184
- internal examination, 181–184
- microbiology 188
- pneumoconiosis, 191–192
- radiology, 188–189
- slicing, 183
- special techniques, 184–194
- transplantation, 190–191
- tuberculosis, 188
- venography, 189
- vessels, dissection of, 182–183
- fetal, perinatal, infant autopsy
  - examination, 399–400
  - removal
    - en bloc method, 387
    - en masse method, 383
- removal
  - en bloc method, 129, 131
  - en masse, alternative method, 126
  - individual organ method, 99
  - in situ* method, 105
- Lymph nodes, 249–251
  - external examination, 249–250
  - fetal, perinatal, infant autopsy, 403
  - histology, 250
  - imprints, 250–251
  - internal examination, 250
  - microbiology of, 251
  - nodal disease with perinodal
    - infiltration, 250
  - special techniques for, 250–251
- Lymphoreticular system, 249–260
  - Bone marrow, 254–256
    - decalcification for histology, 255
    - sampling of femur to obtain
      - specimen, 263–264
    - special techniques for, 255
- Lymph nodes, 249–251
  - external examination, 249–250
  - fetal, perinatal, infant autopsy, 403
  - histology, 250
  - imprints, 250–251
  - internal examination, 250
  - microbiology of, 251
  - nodal disease with perinodal
    - infiltration, 250
  - special techniques, 250–251
- Mediastinal mass, removal, 257–258
- Sickle cell disease and trait,
  - examination in, 258–259
- Special techniques, 256–258
  - Spleen, 251–254
    - external examination, 251–252
    - fetal, perinatal, infant autopsy,
      - removal
        - en bloc method, 388
        - en masse method, 383
    - fixing spleen whole, 254
    - internal examination, 252–253
    - microbiology, 254
    - removal
      - en bloc method, 134
      - en masse, alternative method,
        - 126
      - individual organ method,
        - 100–101
      - in situ* method, 107
      - special techniques, 253–254
  - Thoracic duct dissection, 256–257
  - Thymus
    - examination, 256
    - fetal, perinatal, infant autopsy
      - examination, 403
      - removal, en bloc method, 385
      - removal en masse method,
        - 379

## M

- Macroscopical dye identification,
  - myocardial infarction, 168,
    - 325–326
- Male genital organs, 223–224
  - penile urethra, examination of,
    - 225–226
  - penis, examination of, 225–226
  - prostate gland, 224
  - testes, 223
    - external examination, 223
    - histology, 223
    - internal examination, 223
    - special techniques, 223
    - tumours, 223
- Maternal deaths, 227–236
  - anaesthetic deaths, 230
  - approach to, 228–229
  - cause of death, 229–230

- Maternal deaths (*cont.*)  
 evisceration and organ dissection, 231–233  
 removal of genital tract complete, 235–236  
 summary, 236  
 external examination, 230–231  
 histology, 233–234  
 summary, 234  
 placenta, 234
- Meckel-Gruber syndrome, fetal, perinatal, infant autopsy, 375
- Mediastinal inspection, 74–75
- Mediastinal mass removal, 257–258
- Medical examiner system, 8
- Mercury poisoning, fetal, perinatal, infant autopsy, 375
- Mesenteric vessels, examination, 174–177
- Mesentery examination, 209–210  
 angiography, 176, 210
- Method of Ghon. *See* Ghon's method
- Method of Letulle. *See* Letulle's method
- Method of Saphir, 120–122
- Microbiological investigation, 67, 326–328  
 blood, 326–327  
 brain, 283  
 cerebrospinal fluid, 327  
 fetal, perinatal, infant autopsy, 404–405  
 fluid, 326–327  
 intestinal contents, 199  
 liver, 203  
 lung, 188  
 lymph node, 281  
 spleen, 253–254  
 synovium, 278  
 tissues, 328  
 valve of heart, in endocarditis, 157
- Middle ear examination, 116–118  
 fetal, perinatal, infant autopsy, 395
- Minamata disease. *See* Mercury poisoning
- Mortuary, hazards of, 28
- Mortuary building, 22–31
- Mortuary practice rules, 32–33
- Mouth, inspection of, 62
- Multiple malformation/dysmorphic facies, fetal, perinatal, infant autopsy, 363
- Muscles, sampling, 317
- Musculoskeletal system, 260–281  
 accessing the skeleton  
 limbs/long bones, 265–266  
 ribs, 268–269  
 shoulder girdle, 269  
 skull, 268  
 pelvic girdle, 269–270  
 vertebrae, 267  
 bone tumours, 279–280  
 axial skeleton, 279–280  
 limbs, 279  
 cervical spine fractures  
 anterior approach, 275–276  
 examination, 275–277  
 posterior approach, 276–277  
 femur  
 removal, 261–263  
 haematological investigation, sampling femur for, 263–264  
 fetal, perinatal, infant autopsy, 397, 404  
 fractures, 270–277  
 cervical spine, 275–277  
 long bones/limbs, 270–271  
 pelvic girdle, 275  
 ribs, 271–273  
 shoulder girdle, 275  
 skull, 275  
 vertebral column, 273–275  
 joint examination, 277–278  
 axial skeleton, 279  
 fluid, for crystals, 278, 323–324  
 limbs/long bones, 277–278  
 limbs/long bones  
 accessing, 265–266  
 fractures, 270–271  
 osteoporosis, assessment of, 264–265  
 pelvic girdle  
 accessing, 269–270  
 fractures, 275  
 ribs  
 accessing, 268–269  
 assessing osteoporosis, 264–265  
 fractures, 271–272  
 routine examination, 261

- shoulder girdle,
  - accessing, 269
  - fractures, 275
- skeleton, accessing, 265–270
- skull, 275
  - accessing, 268
  - fractures, 275
- soft tissue tumours, 280–281
  - limbs, 280
  - torso, 281
- synovial fluid, sampling for
  - microbiology/cytology, 278
- vertebral column
  - accessing, 267
  - assessing osteoporosis, 264
  - fractures, 273–274
  - removing anterior half of, 267
  - removing entire, 267
- Myocardial infarction, macroscopical
  - dye identification, 168, 325–326
- N**
- Nasopharynx, 194–195
- National Confidential Enquiry into Patient Outcome and Death, 9–10, 346
- NCEPOD. *See* National Confidential Enquiry into Patient Outcome and Death
- Neck examination, 75–79
  - anterior compartment, radiography of, 77
  - anterior structures, 76
    - dissection of, 76–77
  - cervical spine,
    - en bloc examination, 312
    - en bloc removal, 311–312
    - fractures, examination of, 77
  - posterior structures, 77
  - vertebral angiography, 78–79, 309
  - vertebral arteries, examining, 78, 309–312
- Neck incisions, 70
- Needle post mortem examination, 50–53
- Nephron, microdissection of, 219
- Nervous system, 282–316
  - angiography, 309–311
  - autonomic nerves/ganglia, 315–317
  - brachial plexus, left, diagram, 314
  - brain,
    - arteries at base of, diagram, 284
    - block selection, 297
    - brain stem
      - cerebellum, separation, 286
      - dissection of, 287–288
    - cerebellum, dissection of, 288–289
    - cerebral hemispheres, dissection of, 289–291
    - dissection, 286–292
    - dura, release of, 112–114
    - external examination, 283–284
    - fetal, perinatal, infant autopsy, 390–393, 402–403
      - examination, 402–403
      - removal, 390–393
        - in case of
          - hydrocephalus/other cystic congenital abnormality, 393–394
          - in macerated baby, 393
      - fixation, 285
      - high-risk case, removal of brain in, 297–298
      - internal examination, 292–295
      - meninges and vessels, 283, 284
      - midbrain block, removal of, 289, 291
      - removal, 110–116
        - summary, 115–116
      - scalp, reflection of, 110–111
      - skull, sawing of, 111
      - skull cap, removal of, 112
      - special techniques, 297–298
      - weighing, 114, 285–286
      - weight, according to gender, age, 286
    - cavernous sinus, examination of, 307, 308
    - cervical spine en bloc examination, 312
      - en bloc removal, 311–312
      - examination for fractures, 275–277
    - cranial nerves, sympathetic chain, relationship, diagram, 316
    - eye removal, 305–307
      - anterior (external) approach, 306

- Nervous system (*cont.*)  
 superior (internal) approach, 306–307  
 muscles, sampling, 317  
 neuromuscular system, 312–317  
 autonomic nerves and ganglia, sampling, 315–317  
 muscles, sampling, 317  
 peripheral nerves, sampling, 313–315  
 sensory ganglia, sampling, 313  
 spinal cord  
 brain, removal of in continuity, 303–305  
 examination of, 303  
 fetal, perinatal, infant autopsy, 394  
 removal of, 298–304  
 anterior approach, 299–301  
 entire vertebral column, 299  
 posterior approach, 301–303  
 vertebral arteries, 177, 307–312  
 anatomy, 309  
 angiography, 309–311  
 removal  
 en bloc method, 311–312  
 anterior approach, 276, 311  
 examination, 312  
 posterior approach, 277, 311–312  
 in situ method, 312  
 vertebral column/vertebrae  
 accessing, 267  
 assessing osteoporosis, 264  
 fractures, 273–274  
 removal  
 anterior half, 267  
 entire, 267
- Neural tube defect, removal of spinal cord, infant/fetus autopsy, 394–395
- Neuromuscular system  
 autonomic nerves and ganglia, sampling, 315–317  
 fetal, perinatal, infant autopsy, 397  
 muscles, sampling, 317  
 peripheral nerves, sampling, 313–315  
 sensory ganglia, sampling, 313
- Neuropathology, smear technique for diagnosis, 322
- New Zealand, death investigation legislation, system, 10
- Next of kin, consent from, 320
- Nonaccidental injury, fetal, perinatal, infant autopsy, 395–396
- Nonimmunological hydrops, fetal, perinatal, infant autopsy, 361–363
- Noninvasive techniques for autopsy, 51
- Noradrenaline, staining for, 325
- Northern Ireland, death investigation legislation, system, 10
- Notification of death/cause of death, mechanisms for, 9–11
- O**
- Oesophageal mass, infiltrative, examination of, 207–208
- Oesophageal varices, demonstration of, 207
- Oesophageal webs/rings, demonstrating, 206
- Oesophagus  
 dissection  
 en bloc method, 129–130  
 en masse, alternative method, 124  
 en masse, Saphir method, 121  
 fetal, perinatal, infant autopsy  
 dissection  
 en bloc method, 387  
 en masse method, 382
- Oligohydramnios, infant/fetus autopsy, 366
- Opening along the path of blood flow, heart dissection, 147–150
- Oral structures, freeing, 75
- Organ retention, 18–21
- Oropharynx, examination, 205–206
- Osteoporosis, assessment of, 264–265
- Ovary, 222  
 “frozen pelvis” examination of, 226–227  
 tumours, assessment of, 222
- P**
- Pacemaker device, removal necessary, 159
- Paediatricautopsy. *See* Fetal autopsy

- Pancreas  
 dissection/removal,  
   en bloc method, 135  
   en masse, alternative method, 125  
   individual organ method, 103  
   *in situ* method, 109  
 examination, 204–205  
 fetal, perinatal, infant autopsy  
   dissection/removal  
     en bloc method, 388  
     en masse method, 383  
   examination, 402  
   histology, 205  
 Paraganglion system, 245–248  
   anatomy, 245–248  
   carotid body examination, 246–248  
 Parathyroid glands,  
   examination, 239–241  
   infiltrative tumour, 240–241  
 removal  
   en bloc method, 128–129  
   en masse, alternative method, 123  
   en masse, Saphir method, 121  
   individual organ method, 100  
 Pathogens, categories of, 37–38  
 Pathologists, registration of, 36  
 Pelvic dissection,  
   fetal, perinatal, infant autopsy,  
     dissection in continuity with  
     perineum and anus, 397  
   “frozen” pelvis, 227  
   removal of female genital tract  
     complete, 235–236  
 Pelvic girdle  
   accessing, 269–270  
   fractures, 275  
 Pelvis, “frozen,” examination of,  
   226–227  
 Penile urethra, examination of, 225–226  
 Penis, examination of, 225–226  
 Performer of post mortem, 7  
 Perinatal autopsy *See* fetal autopsy  
 Perinatal pathologists, worldwide  
   shortfall of, 351  
 Periureteric masses, examination, 225  
 Peroxisomal disorder, fetal, perinatal,  
   infant autopsy, 375  
 Personnel protection, 36  
 Pituitary gland,  
   examination, 242–245  
   large tumour, 243–245  
   removal, 114–115  
 Placenta  
   fetal, perinatal, infant autopsy,  
     407–408  
   maternal deaths, 234  
 Pleural fluid collection, 74–75  
 Pleural inspection, 74–75  
 Pneumoconiosis, 191–192  
 Pneumothorax, demonstration of,  
   70–71  
 Poliovaccine immunization of  
   personnel, as safety  
   precaution, 36  
 Post mortem  
   accidents, 32–33  
   prevention of, 33  
   after dissection, 319–349  
   anthrax, 45  
   approach to, 48–50  
   before the post mortem, 1–54  
   block dissection, 119–140  
   building/contents of, 34  
   cardiovascular system, 141–179  
   checklist of considerations governing  
     examination, 53  
   chemical contaminants, 47–48  
   cleaning solutions, 34–35  
   clothing for, 25–26  
   consent, 11–21, 319–321  
   coronial system, 5–9  
     medical examiner system, 8  
     procurator fiscal, 8–9  
   disposal of waste, 34  
   endocrine system, 237–249  
   evisceration  
     initial stages of, 56–81  
     techniques, 82–118  
   examination methods, compared,  
     79–81  
   facilities, 22–25  
   fetal autopsy, 350–416  
   first aid, 32–33  
   fixatives, 35–36  
   gastrointestinal system, 197–213  
   general inspection, 56–81  
   general rules for, 32  
   genitourinary system, 214–236  
   haematopoietic system, 249–260  
   hazards, avoidance of, 37–38



- Post mortem (*cont.*)
- health issues, 28–31
    - risk assessment, 29–31
  - high-risk, 36, 38–45
  - human immunodeficiency virus, 43–44
  - infant autopsy, 350–416
  - instruments, 26–27
  - leptospirosis, 45
  - limited examinations, 50–53
  - lymphoreticular system, 249–260
  - mortuary building, 22–25
  - musculoskeletal system, 260–281
  - needle examination, 50–53
  - nervous system, 282–316
  - notification of death/cause of death, 9–11
  - perinatal autopsy, 350–416
  - personnel, protection of, 36
  - preparation for, 1–55
  - prion disease, 44–45
  - radioactivity, 45–47
  - respiratory system, 180–196
  - safety, 28–31
    - risk assessment, 29–31
  - smallpox, 45
  - specimen transport, 34
  - tuberculosis, 41–42
  - viral hepatitis, 42–43
  - waste disposal, 34
- Post mortem report fetal, perinatal,
- infant autopsy,
    - guidelines, 414–414
    - writing, 417–418
  - guidelines, 343–346
  - timing of, 338, 343
  - writing, 338–346
- Post-dissection procedures, 319–349
- adrenaline, staining for, 325
  - amyloid, staining for, 324–325
  - audit, 343–347
  - biochemistry, 329–331
    - blood, 329–330
    - other fluids, 330
  - blood, 63–64, 326–327, 329–330
  - calcium, staining for, 325
  - cause of death, 334–338
  - consent, 11–21, 319–321
  - copper, staining for, 325
  - court, presentation of post mortem findings in, 347–348
  - criminal investigation, sampling for, 330–331
  - cytology, 322–324
    - fine-needle aspiration, 322–323
    - fluids, examination for cells, 324
    - joint fluid, examination for
      - crystals, 323–324
      - “touch” imprint preparations, 324
  - death certificate, completion of, 337–338
    - fetal, perinatal, infant, 413–416
  - demonstration of post mortem findings, 333–334
    - diagnostic techniques at post mortem, 321–326
  - DNA analysis, best specimens for, 331
  - fat, staining for, 325
  - fluids, sampling, 326–327, 330
  - frozen section, 321
  - haematology, 329–331
  - haemosiderin, staining for, 324
  - histology, 332–333
  - histology report, formats, 343
  - Human Tissue Bill, replacement of Human Tissue Act of 1961, 320
  - investigation of deaths, official bodies, 347–348
  - iron, staining for, 324
  - macroscopical dye techniques, 324–326
  - microbiology, 326–328
    - blood, 326
    - cerebrospinal fluid, 327
    - other fluid samples, 326–328
    - tissue samples, 328
  - myocardial infarction, macroscopical dye identification, 325–326
  - neuropathology, smear technique for diagnosis, 322
  - next of kin, consent from, 320
  - no cause of death apparent,
    - consequences of, 336–337
  - noradrenaline, staining for, 325
  - post mortem report
    - fetal, perinatal, infant autopsy,

- guidelines, 417–418
    - writing, 417–418
  - guidelines, 343–346
  - timing of, 338, 343
  - writing, 338–346
  - research
    - separate consent required for, 320
    - use for, approval by regulatory authority, 320
  - Royal College of Pathologists, post mortem report guidelines, 344–346
  - fetal, perinatal, infant autopsy, 417–418
  - samples for ancillary investigations, 326–333
  - teaching, separate consent required for, 320
  - tissue sampling, 328, 330–331
  - toxicology, 329–331
    - blood, 330
    - other fluids, 330
    - tissue samples, 330
  - World Health Organization
    - guidelines, recording cause of death, format for, 330
  - Preparation for post mortem, 1–55
  - Preparatory stages of evisceration, 62–63
  - Presentation of post mortem findings
    - in court, 347–348
  - Prevention of accidents, 33
  - Procurator Fiscal, referral of deaths to
    - in Scotland, 8–9
  - Prostate gland, 224
  - Publications superceding Howie Report, 28
  - Pulmonary arteriography, 189
  - Pulmonary radiology, 188–189
  - Pulmonary tuberculosis, 188
- R**
- Radioactivity in post mortem room, 45–47
  - Radiography, fetal, perinatal, infant autopsy, 361
  - Reasons for post mortem, 1–2
  - Rectal masses, dissection of, 212
  - Referrals to coroner, sources of, 5
  - Renal amyloid, demonstration, 218
  - Renal angiography, 217
  - Renal transplant, examination, 219–220
  - Renal tissue sampling, for toxicology, 219
  - Report, post mortem
    - fetal, perinatal, infant autopsy,
      - guidelines, 417–418
      - writing, 417–418
    - guidelines, 343–346
    - timing of, 338, 343
    - writing, 338–346
  - Reporting of death to coroner, types of deaths reported, 7
  - Research
    - separate consent required for, 320
    - tissue retention for, 21. *See also* Human Tissue Bill
    - use for, approval by regulatory authority, 320
  - Respiration equipment, for personal use, in high-risk cases, 26
  - Respiratory system, 180–196
    - extent of, 180
    - fetal, perinatal, infant autopsy, 399–400
    - larynx, 195–196
    - lungs, 180–194
      - examination, 180–194
        - airways
          - dissection of, 181–182
          - opening, vasculature, avoiding transection, 184
        - arteriography, 189
        - asbestos body/fibre
          - demonstration, 192–194
        - bronchial arteriogram, 190
        - bronchography, 190
        - chronic obstructive pulmonary disease, presence of, 181
        - drowning, diatom testing in, 194, 331
        - external examination, 181
        - high risk post mortem, lung examination, 188
        - histology, 183–184
        - inflating, 185–186
        - internal examination, 181–184
        - microbiology of, 188

- Respiratory system (*cont.*)
- pneumoconiosis, 191–192
  - radiology, 188–189
  - slicing, 183
  - special techniques, 184–194
  - transplantation, 190–191
  - tuberculosis, 188
  - venography, 189
  - vessels, dissection of, 182–183
- fetal, perinatal, infant autopsy
- examination, 399–400
  - removal
    - en bloc method, 387
    - en masse method, 383
  - removal
    - en bloc method, 129, 131
    - en masse, alternative method, 126
    - individual organ method, 99
    - in situ* method, 105
  - nasopharynx, 194–195
  - sinuses, 195
  - summary, 196
  - upper respiratory tract, 194–196
    - larynx, 195–196
    - nasopharynx, 194–195
    - sinuses, 195
- Retained Organs Commission, 18
- Retention of tissue, 7, 18–21. *See also* Human Tissue Bill
- Ribs
- accessing, 268–269
  - assessing osteoporosis in, 264–265
  - fractures, 271–272
- Risk assessment methods, 29–31
- Rokitansky (*in situ*) dissection method, 105–110
- choosing, 79–81
  - heart, fetal, perinatal, infant autopsy, 379–381
  - summary, 110
- Royal College of Pathologists, post mortem report guidelines, 3, 344–346
- fetal, perinatal, infant autopsy, 417–418
- Rubella infection during first trimester, fetal, perinatal, infant autopsy, 376
- Rules of mortuary practice, 32–33
- S**
- Safety issues, 28–31
- Salivary glands
- examination, 206
  - isolating, 206
  - radiology, 206
  - tumours, 206
- Samples, for ancillary investigation, 64–67, 326–333
- biochemistry, 329–331
  - bile samples, 66, 210, 330
  - blood samples, 64–65, 326–327, 329–330
  - cerebrospinal fluid samples, 65, 326–328
  - collection, 63–67
  - haematology, 329–331
  - hair samples, 66–67, 331–332
  - intestinal contents, 199–200
  - microbiology, 67, 326–328. *See also* Microbiological investigation
  - stomach contents, 66, 208, 330
  - summary of, 64
  - tissues, 328, 330–332
  - toxicology, 329–331
  - urine samples, 65, 326–327, 330
  - vitreous humour samples, 65–66, 330
- Saphir method. *See* Method of Saphir
- Scotland
- death investigation legislation, system, 10
  - Procurator Fiscal, referral of deaths to, 8–9
- Shoulder girdle
- accessing, 269
  - fractures, 275
- Sickle cell disease/trait, 258–259
- Skeletal dysplasia, fetal, perinatal, infant autopsy, 363
- Skeleton, accessing, 265–270
- Skin incisions, 67–75
- anterior body wall incisions, 67–70
  - scalp, removing the brain, 110–111
  - face, 70
  - fetal, perinatal, infant autopsy, 376–377

- femur
    - removal, 261–263
    - sampling for haematological investigation, 263–264
  - limbs, accessing, 265–266
    - neck, 70
  - pelvic girdle, accessing, 269–270
  - ribs, accessing, 268–269
  - shoulder girdle, accessing, 269
  - spinal cord, accessing, posterior approach, 301–303
  - Skin inspection, 60
  - Skull, 275
    - accessing, 268
    - fractures, 275
    - sawing, 111
  - Skull cap, removal of, 112
  - Small intestines, 198–201. *See also* Intestines
  - Smear technique for diagnosis, neuropathology, 322
  - Soft tissue tumours, 280–281
    - limbs, 280
    - torso, 281
  - South Africa, death investigation
    - legislation, system, 10
  - Spain, death investigation legislation, system, 10
  - Specimen transport, 34
  - Spinal cord
    - brain, removal of in continuity, 303–305
    - examination, 303
    - fetal, perinatal, infant autopsy, 394
    - removal, 298–304
      - anterior approach, 299–301
      - entire vertebral column, 299
      - posterior approach, 301–303
  - Spleen, 251–254
    - external examination, 251–252
    - fetal, perinatal, infant autopsy, removal
      - en bloc method, 388
      - en masse method, 383
    - fixing spleen whole, 254
    - internal examination, 252–253
    - microbiology, 254
    - removal
      - en bloc method, 134
      - en masse, alternative method, 126
      - individual organ method, 100–101
      - in situ* method, 107
      - special techniques for, 253–254
  - Staining
    - for adrenaline, 325
    - for amyloid, 324–325
    - for calcium, 325
    - for copper, 325
    - for early myocardial infarction, 325
    - for fat, 325
    - for haemosiderin, 324
    - for iron, 324
    - for noradrenaline, 325
  - Sternum, removing, 73–74
  - Stomach
    - angiography of, 209
    - histology of, 209
    - collection of contents, 66, 208, 330
    - dissection
      - en bloc method, 134
      - en masse, alternative method, 124
      - individual organ method, 102
      - in situ* method, 109
    - fetal, perinatal, infant autopsy
      - en bloc method, 387–388
      - en masse method, 383
    - whole, fixing, 208–209
  - Stomach contents sampling, 66, 208, 330
  - Sudden unexpected death in infancy, 364, 406–407
  - Synovial fluid, submitted for microbiology/cytology, 278
- T**
- Teaching
    - separate consent required for, 320
    - tissue retention for, 21. *See also* Human Tissue Bill
  - Technical staff, qualifications of, 36
  - Testes, 223
    - external examination, 223
    - fetal, perinatal, infant autopsy
      - en bloc method, 389
      - en masse method, 382
    - histology, 223
    - internal examination, 223

- Testes (*cont.*)  
 removal  
   en bloc method, 96  
   en masse method, 84  
   individual organ method, 104  
   in situ method, 108  
   special techniques, 223  
   tumours, 223
- Tetanus vaccine immunization of  
 personnel, as safety  
 precaution, 36
- Therapeutic uses, tissue retention for,  
 21. *See also* Human Tissue  
 Bill
- Thoracic block/pluck, 127–133  
 fetal, perinatal, infant autopsy,  
 386–387
- Thoracic duct dissection, 256–257
- Thymus  
 examination, 256  
 fetal, perinatal, infant autopsy  
 examination, 403  
 removal, en bloc method, 385  
 removal en masse method, 379
- Thyroid  
 examination, 237–240  
   when tumour present, 240  
 fetal, perinatal, infant autopsy  
 examination, 403  
 removal en bloc, 387  
 removal en masse, 382  
 removal  
   en bloc method, 128–129  
   en masse, alternative method,  
   123–124  
   individual organ method, 100
- Timing of post mortem report, 343
- Tissue retention, 7, 18–21. *See also*  
 Human Tissue Bill
- Torso, soft tissue tumours, 281
- “Touch” imprint preparations, in  
 cytological investigation, 324
- Toxicological analysis, 329–331  
 blood, 329–330  
 other fluids, 330  
 tissuesamples, 330–331
- Transplantation. *See also under* specific  
 organ  
 organs removed for purpose of, 21
- Transport of specimens, 34
- Transverse sectioning technique,  
 coronary artery, 144–145
- Trauma  
 dealing with fractures, 270–277  
 general external inspection, 61
- Triploidy, fetal, perinatal, infant  
 autopsy, 367–374
- Trisomy 13, fetal, perinatal, infant  
 autopsy, 366–367
- Trisomy 18, fetal, perinatal, infant  
 autopsy, 367
- Trisomy 21, fetal, perinatal, infant  
 autopsy, 367
- Tuberculosis, pulmonary, 188
- Turner syndrome, fetal, perinatal,  
 infant autopsy, 375
- Twins, fetal, perinatal, infant autopsy,  
 363
- Types of deaths reported to coroner, 7
- Types of post mortem, 4–5
- U**
- United Kingdom, death investigation  
 legislation, system, 10
- United States, death investigation  
 legislation, system, 10
- Upper limb vessels, examination,  
 168–171
- Upper respiratory tract, 194–196  
 larynx, 195–196  
 nasopharynx, 194–195  
 sinuses, 195
- Ureter,  
 dissection, 137  
 examination, 220  
   localized mass, examination of,  
   224–225  
 fetal, perinatal, infant autopsy  
 dissection  
   en bloc method, 388–389  
   en masse method, 382
- Urethra,  
 female, examination of, 226  
   removal of female genital tract  
   complete, 235–236  
 penile, examination of, 225–226
- Urine  
 collection, 65, 224, 326–327, 330

- Urogenital organs, composition of, 214
- Urography, lower urinary tract, 225
- Uterus, 220–223
  - external examination, 221
  - fetal, perinatal, infant autopsy examination, 403
  - removal of pelvic contents in continuity with perineum and anus, 397
  - histology, 221–222
  - internal examination, 221
  - removal of female genital tract complete, 235–236
  - special techniques for, 222
  - tumours, 222
- V**
- Vaccination of personnel, as safety precaution, 36
- Valves of heart
  - average measurements of, 153
  - endocarditis, microbiological samples, 157
  - examination of heart following valve disease or surgery, 155–156
- Vascular system examination, 168–179
  - lower limb vessels, 171–173
    - anatomy, 171, 172
    - dissection
      - arteries and thigh veins, 171–172
      - deep calf veins, 172–173
  - mesenteric vessels, 174–177
    - anatomy, 174–176
    - dissection, 176–177
    - preparation of specimen, 176
    - radiology, 176
  - post mortem angiography, 177–179
  - upper limb vessels, 168–171
    - anatomy, 169, 170
    - dissection, 169–171
  - vertebral arteries, 177, 307–312
    - anatomy, 309
    - angiography, 309–311
    - removal
      - en bloc method, 311–312
      - anterior approach, 276, 311
      - examination, 312
      - posterior approach, 277, 311–312
      - in situ method, 312
- posterior approach, 277, 311–312
- in situ method, 312
- Venography, lungs, 189
- Ventricular slicing method, heart dissection, 152
- Vertebra,
  - accessing, 267
  - assessment of osteoporosis, 264
  - fractures, 273–274
  - removal
    - anterior half, 267
    - entire, 267
- Vertebral arteries, 177, 307–312
  - anatomy, 309
  - angiography, 309–311
  - removal
    - en bloc method, 311–313
    - anterior approach, 276, 311
    - examination, 312
    - posterior approach, 277, 311–312
    - in situ method, 312
- Vertebral column
  - accessing, 267
  - assessing osteoporosis, 264
  - fractures, 273–274
  - removal
    - anterior half, 267
    - entire, 267
- Virchow (individual organ) method, 97–105
  - choosing, 79–81
  - summary 104–105
- Vitreous humour samples, 65–66, 330
- W**
- Wales, death investigation legislation, system, 10
- Warfarin, fetal, perinatal, infant autopsy, 375
- Waste disposal, 34
- WHO. *See* World Health Organization
- Whole pluck/en masse dissection method, 119–127. *See also* Letulle's method
  - choosing, 79–81
- World Health Organization guidelines, recording cause of death, format for, 334

Wounds, general external inspection, 61

Writing post mortem report

fetal, perinatal, infant autopsy,

guidelines, 417–418

writing, 417–418

guidelines, 343–346,

timing of, 338, 343

writing, 338–346

**Z**

Zellweger syndrome, fetal, perinatal,

infant autopsy, 375