

Daniel P. Geisler
Deborah S. Keller
Eric M. Haas
Editors

Operative Techniques in Single Incision Laparoscopic Colorectal Surgery

EXTRAS ONLINE

 Springer

Operative Techniques in Single Incision Laparoscopic Colorectal Surgery

Daniel P. Geisler • Deborah S. Keller • Eric M. Haas
Editors

Operative Techniques in Single Incision Laparoscopic Colorectal Surgery

 Springer

Editors

Daniel P. Geisler
Division of Colorectal Surgery
Department of Surgery
Houston Methodist Hospital
Houston, TX, USA

Deborah S. Keller
Division of Colorectal Surgery
Department of Surgery
Baylor University Medical Center
Dallas, TX, USA

Eric M. Haas
Division of Colorectal Surgery
Department of Surgery
Houston Methodist Hospital
Houston, TX, USA

Videos to this book can be accessed at <http://link.springer.com/book/10.1007/978-3-319-63204-9>

ISBN 978-3-319-63202-5 ISBN 978-3-319-63204-9 (eBook)
DOI 10.1007/978-3-319-63204-9

Library of Congress Control Number: 2017955078

© Springer International Publishing AG 2018

This work is subject to copyright. All rights are reserved by the Publisher, whether the whole or part of the material is concerned, specifically the rights of translation, reprinting, reuse of illustrations, recitation, broadcasting, reproduction on microfilms or in any other physical way, and transmission or information storage and retrieval, electronic adaptation, computer software, or by similar or dissimilar methodology now known or hereafter developed.

The use of general descriptive names, registered names, trademarks, service marks, etc. in this publication does not imply, even in the absence of a specific statement, that such names are exempt from the relevant protective laws and regulations and therefore free for general use.

The publisher, the authors and the editors are safe to assume that the advice and information in this book are believed to be true and accurate at the date of publication. Neither the publisher nor the authors or the editors give a warranty, express or implied, with respect to the material contained herein or for any errors or omissions that may have been made. The publisher remains neutral with regard to jurisdictional claims in published maps and institutional affiliations.

Printed on acid-free paper

This Springer imprint is published by Springer Nature
The registered company is Springer International Publishing AG
The registered company address is: Gewerbestrasse 11, 6330 Cham, Switzerland

Foreword

Laparoscopic surgery has revolutionized the field of colorectal surgery. Since its introduction over 25 years ago, the patient benefits and financial value continue to develop. Despite the undeniable benefits, growth of laparoscopy has been slow. After the landmark Clinical Outcomes of Surgical Therapy (COST) trial demonstrated the oncological equivalence of laparoscopic to open colectomy in 2004, we expected the rates of laparoscopic colectomy to rise exponentially in the United States. However, since the trial, rates of laparoscopy for all colorectal disease have only risen to about two-thirds of eligible patients, with an estimated 50% application in colon cancer and 10% in rectal cancer cases.

So why aren't more surgeons practicing laparoscopic colorectal surgery? The largest barrier to widespread utilization is education. Laparoscopic cases are technically demanding, and there is a significant learning curve and time investment for mastering the technology. For established surgeons, this creates a dilemma of taking the time out of practice to learn a new skill. For new graduates, laparoscopy is not adequately covered in surgical training, so dedication is needed to practice, and support is required to ascend the learning curve. However, the benefits for patients are worth the effort.

We can also increase the number of minimally invasive options available. This is where reduced and single port laparoscopic surgery come in. Single incision laparoscopic surgery – a hybrid of natural orifice transluminal endoscopic surgery (NOTES) and conventional laparoscopic surgery – has advanced the field of minimally invasive surgery, improving patient cosmesis, reducing postoperative pain, and further reducing length of stay compared to multiport laparoscopy. With all new technologies, there are technical challenges and a distinct learning curve. However, with experience and proper instruction, single incision laparoscopic surgery can be an integral part of your practice.

This text provides the education needed to learn this advanced minimally invasive technique. The book is designed in two sections. The first section presents the basics of perioperative care, room setup and patient positioning, available platforms with technical and ergonomic considerations, port placement, and dissection techniques. The second section details common colorectal procedures, with step-by-step conduct of the operation, pictures and video accompanying each procedure, and tips and tricks from masters of the technology. We feel this book will be a valuable tool for all minimally invasive surgeons, from novices of the technique to experienced surgeons looking to develop their skills further. Single incision laparoscopic surgery has been a huge impact in our practices, and we know with this tool, you and your practice can also reap the benefits.

Enjoy,
Debby, Eric, and Dan

Contents

1	Enhanced Recovery Pathways in Colorectal Surgery	1
	Justin T. Brady, Yuxiang Wen, and Conor P. Delaney	
2	Patient Selection and General Patient Considerations	9
	Jason Bingham and Scott R. Steele	
3	Room Setup, Equipment, and Patient Positioning	19
	Nicole E. Sharp and Harry T. Papaconstantinou	
4	Considerations for Port Placement by Procedure, Incision Techniques, and Specimen Extraction	25
	Deborah S. Keller	
5	Technical Considerations, Available Platforms, and Ergonomics	29
	Deborah S. Keller	
6	Dissection Approaches	35
	Jamie Murphy	
7	High and Low Inferior Mesenteric Artery Ligation	43
	Christopher F. McNicoll and Ovunc Bardakcioglu	
8	Mobilization of the Hepatic Flexure	51
	Jaime E. Sanchez	
9	Approaches to Splenic Flexure Mobilization	55
	Matthew Albert and Marc Dakermantji	
10	Total Mesorectal Excision	63
	Chi Chung Foo and Wai Lun Law	
11	Intraoperative Conversions in Minimally Invasive Colorectal Surgery	71
	Matthew Skancke and Vincent Obias	
12	SILS Right Hemicolectomy	77
	Deborah S. Keller	
13	Reduced Port Sigmoid and Left Colectomy	83
	Deborah S. Keller	
14	Single-Incision Total Abdominal Colectomy	87
	Deborah S. Keller and Daniel P. Geisler	
15	Single-Incision Restorative Proctocolectomy with Ileal Pouch-Anal Anastomosis	91
	Gilles Manceau and Yves Panis	
16	SILS +1 Low Anterior Resection Versus Straight SILS	95
	Deborah S. Keller	

17	Single-Incision Rectopexy (With and Without Resection)	101
	Samuel Eisenstein and Sonia Ramamoorthy	
18	Single-Incision Laparoscopic Ileostomy and Colostomy Creation	105
	Deborah S. Keller and Daniel P. Geisler	
19	Laparoscopic Ileostomy Reversal	109
	Deborah S. Keller	
20	Transanal Minimally Invasive Surgery for Local Excision	111
	Matthew R. Wilson, Sam Atallah, and George J. Nassif Jr	
Index	117

Contributors

Matthew Albert, MD, FACS, FASCRS Department of Colorectal Surgery, Center for Colon & Rectal Surgery, Florida Hospital, Orlando, FL, USA

Sam Atallah, MD, FACS, FASCRS Department of Colon & Rectal Surgery, Florida Hospital, Winter Park, FL, USA

Ovunc Bardakcioglu, MD, FACS, FASCRS Division of Colon and Rectal Surgery, Department of Surgery, University of Nevada, Las Vegas School of Medicine, Las Vegas, NV, USA

Jason Bingham, MD Department of Surgery, Madigan Army Medical Center, Tacoma, WA, USA

Justin T. Brady, MD Department of Surgery, University Hospitals Cleveland Medical Center, Cleveland, OH, USA

Conor P. Delaney, MD, PhD Digestive Disease and Surgery Institute, Cleveland Clinic, Cleveland, OH, USA

Marc Dakermadjji, MD Department of Colorectal Surgery, Center for Colon & Rectal Surgery, Florida Hospital, Orlando, FL, USA

Arielle DuBose, MD Center for Colon & Rectal Surgery, Florida Hospital, Orlando, FL, USA

Samuel Eisenstein, MD Moores Cancer Center, UC San Diego, La Jolla, CA, USA

Chi Chung Foo, MBBS, FRCSEd Department of Surgery, Queen Mary Hospital, University of Hong Kong, Hong Kong, China

Daniel P. Geisler, MD Division of Colorectal Surgery, Department of Surgery, Houston Methodist Hospital, Houston, TX, USA

Eric M. Haas, MD Division of Colorectal Surgery, Department of Surgery, Houston Methodist Hospital, Houston, TX, USA

Deobrah S. Keller, MS, MD Division of Colorectal Surgery, Department of Surgery, Baylor University Medical Center, Dallas, TX, USA

Wai Lun Law, MBBS, MS, FACS, FRCSEd, FASCRS(Hon.) Department of Surgery, Queen Mary Hospital, University of Hong Kong, Hong Kong, China

Gilles Manceau, MD, PhD Department of Colorectal Surgery, Pôle des Maladies de l'Appareil Digestif (PMAD), Beaujon Hospital, Assistance Publique-Hôpitaux de Paris (AP-HP), University Denis Diderot (Paris VII), Clichy, France

Christopher F. McNicoll, MD, MPH, MS Department of Surgery, University of Nevada, Las Vegas School of Medicine, Las Vegas, NV, USA

Jamie Murphy, BChir(Cantab.) PhD FRCS(Eng.) Academic Surgical Unit - Imperial College, London, UK

George J. Nassif Jr, DO, FACS Department of Colon & Rectal Surgery, Florida Hospital, Winter Park, FL, USA

Vincent Obias, MD, MS Division of Colon and Rectal Surgery, Department of Surgery, The George Washington University School of Medicine, Washington, DC, USA

Yves Panis, MD, PhD Department of Colorectal Surgery, Pôle des Maladies de l'Appareil Digestif (PMAD), Beaujon Hospital, Assistance Publique-Hôpitaux de Paris (AP-HP), University Denis Diderot (Paris VII), Clichy, France

Harry T. Papaconstantinou, MD, FACS, FASCRS Department of Surgery, Section of Colorectal Surgery, Texas A&M Health Science Center College of Medicine, Baylor Scott & White Healthcare, Scott & White Memorial Hospital and Clinic, Temple, TX, USA

Sonia Ramamoorthy, MD Moores Cancer Center, UC San Diego, La Jolla, CA, USA

Jaime E. Sanchez, MD, MSPH Division of Colon & Rectal Surgery, Morsani College of Medicine, University of South Florida, Tampa, FL, USA

Nicole E. Sharp, MD General Surgery Resident PGY-5, Baylor Scott & White, Healthcare, Scott & White Memorial Hospital and Clinic, Temple, TX, USA

Matthew Skancke, MD Department of Surgery, George Washington University, Washington, DC, USA

Scott R. Steele, MD, FACS, FASCRS Division of Colorectal Surgery, University Hospitals Case Medical Center, Case Western Reserve University, Cleveland, OH, USA

Yuxiang Wen, BM Department of Surgery, University Hospitals Cleveland Medical Center, Cleveland, OH, USA

Matthew R. Wilson, MD, FACS Department of Colon & Rectal Surgery, Florida Hospital, Winter Park, FL, USA

Enhanced Recovery Pathways in Colorectal Surgery

1

Justin T. Brady, Yuxiang Wen, and Conor P. Delaney

Introduction and Background

There are many components to successful outcomes in major surgery. Beyond sound technical skills, a growing focus has been placed on identifying factors that delay patient recovery. The development of fast-track or enhanced recovery after surgery (ERAS) began in the 1990s in Denmark, when Henrik Kehlet described protocols to expedite postoperative recovery [1, 2]. He subsequently reported these pathways for colorectal surgery in 1999, and our group started using and studying these pathways later that year [3]. Since then, there has been increasing adoption of ERAS and continued research to accelerated patient recovery leading to decreased hospitalization length of stay, improved healthcare utilization, and improved patient outcomes. In this chapter, we detail the development and components of enhanced recovery pathways in three sections: preoperative, intraoperative, and postoperative care (Table 1.1).

Preoperative

Patient Education and Expectations

Enhanced recovery begins with patient education and management of patient expectations. In addition to the normal stress and anxiety that come with undergoing major colorectal surgery, the thought of going home as soon as 24–48 h after surgery can be difficult for patients, if their preoperative

expectations indicated a significantly longer hospital stay. Prior to ERP, stoma education was typically performed following the procedure at many centers – although at this institution, we have provided preoperative ostomy care for many years before we started using ERAS. With the addition of preoperative stoma education, the number of days needed for a patient to achieve independent stoma care and prevent delayed discharge has decreased dramatically [4, 5]. This is also an important component of managing postoperative hydration and dehydration, and starting the education of patients into perioperative fluid management.

Selective Bowel Preparation with Oral Antibiotics

The role of preoperative bowel preparation in ERPs continues to be debated in the literature. Mechanical bowel preparation (MBP) has been used for decades in elective colorectal surgery with the proposed advantages of decreasing intraluminal stool burden, which is felt to contribute to easier bowel handling, but was initially thought to reduce wound infection rates. Previous study has shown that patients undergoing MBP have statistically significant weight loss, exercise tolerance, and electrolyte changes; however, it is not clear if these have significant clinical effects on patient recovery after surgery [6]. The most recent Cochrane review in 2011 reported no significant difference in anastomotic leak or wound infection between patients who did or did not receive MBP [7].

What many surgeons discussing the use or avoidance of MBP had not appreciated was the evidence for oral antibiotics improving outcomes when used in conjunction with MBP. A recent meta-analysis evaluating the use of MBP with oral antibiotics for patients undergoing colorectal surgery showed a significant reduction in surgical site infections compared to patients who had MBP without antibiotics or no MBP at all [8]. This clearly tips the balance in favor of oral

J.T. Brady, MD • Y. Wen, BM
Department of Surgery, University Hospitals Cleveland Medical
Center, Cleveland, OH, USA

C.P. Delaney, MD, PhD (✉)
Digestive Disease and Surgery Institute, Cleveland Clinic,
Cleveland, OH, USA
e-mail: DELANEC@ccf.org

Table 1.1 Components of enhanced recovery pathways

Preoperative	Intraoperative	Postoperative
Patient education and expectations	Maintenance of normothermia	Multimodal analgesia
Selective bowel preparation with oral antibiotics	Laparoscopy when possible	Early feeding
Intravenous antibiotics	Avoid nasogastric tubes and drains	Early removal of urinary catheter
Preoperative nutrition	Goal-directed fluid therapy	Incentive spirometry
Alvimopan (selective use)	Adequate anesthesia	Ambulation
Multimodal analgesia	Multimodal analgesia	Discharge criteria
Venous thromboembolism prophylaxis		

MBP, and in addition provides the favorable bowel handling at the time of surgery. Thus, the standard practice of the authors is mandatory MBP with oral antibiotics for patients undergoing colorectal resection. This is especially important in those who would have a diverting ileostomy, as randomized trials in Europe have clearly shown worse outcomes without MBP. Additionally, MBP is obviously important for those with planned intraoperative colonoscopy.

Preoperative Intravenous Antibiotics

In addition to evidence supporting the use of oral antibiotics with MBP, the use of prophylactic intravenous antibiotics for surgical site infection (SSI) prophylaxis is widely adopted. The Surgical Care Improvement Project (SCIP) guidelines were a catalyst for appropriate antibiotic selection and dosing protocols in colorectal surgery [9]. Literature has shown that the incidence of SSI in colorectal surgery patients decreases from 40% to 10% with the use of intravenous antibiotics [10]. Additional studies have shown that optimal timing for antibiotic infusion is within 60 min and ideally 30 min of incision time [11, 12]. SSI prevention is of particular importance to ERP because SSI is associated with significant patient morbidity and additionally increased length of stay [10].

Preoperative Nutrition

There has been a gradual change in the previous dogma of fasting after midnight prior to surgery. Both the European and American anesthesia societies now recommend fasting from clear liquids at least 2 h prior to surgery and solid foods 6 h prior to surgery [13, 14]. As part of an effort to diminish surgical stress, with the knowledge that clear liquids are safe to drink up to 2 h prior to surgery, multiple studies have been conducted on preoperative carbohydrate loading. Current data have shown that patients who consume a carbohydrate-

rich beverage have decreased protein losses and improved insulin sensitivity [15, 16]. Current literature evaluating clinical outcome such as patient thirst, postoperative nausea and vomiting, hunger and length of stay is limited and further studies are needed of the colorectal surgery population to demonstrate a clinical benefit [15, 17–19].

Alvimopan

Postoperative ileus (POI) has a significant impact on postoperative nausea, vomiting, and delayed hospital discharge following colorectal surgery, affecting up to 25% of patients [20, 21]. Alvimopan (Entereg, Merck& Co., Kenilworth, NJ) is an orally administered, peripherally acting mu-opioid antagonist that has been shown to accelerate time to recovery of bowel function, decrease postoperative nausea and vomiting, and decrease length of stay for patients undergoing open bowel resection with primary anastomosis [21–25]. Studies have shown conflicting results for POI and overall length of stay reduction in patients undergoing laparoscopic resection [26, 27]. For this reason, the authors only use alvimopan for open resections without ostomy or for those laparoscopic patients at high risk of conversion to an open procedure. Alvimopan is given between 5 h and 30 min prior to surgery and twice daily after surgery until return of bowel function or for a maximum of 15 doses.

Multimodal Analgesia

Pain control in the surgical patient has usually been part of postoperative care but with ERPs, there has been interest in preoperative nonopioid medications to improve postoperative pain. GABA agonists, pregabalin and gabapentin, have both anxiolytic and analgesic properties. Meta-analyses of both pregabalin and gabapentin given preoperatively have shown decreased postoperative pain within 24 h after surgery and decreased opioid consumption [28, 29]. Patients did report increased drowsiness and visual disturbances compared to controls, and also had significantly lower rates of vomiting. Evidence-based guidelines on the dosage and duration of administration are still pending in abdominal surgery.

Venous Thromboembolism Prophylaxis

Deep vein thrombosis (DVT) and pulmonary embolus (PE) are important patient safety priorities. Up to 40% of colorectal surgery patients will develop DVT and 5% develop PE if not given prophylactic treatment [30]. Current guidelines recommend that patients at moderate risk for DVT or PE

receive low molecular weight heparin (LMWH) or low-dose unfractionated heparin (LDUH) if they are at low risk for bleeding or sequential compression devices if they are at high risk for bleeding [31, 32]. With the use of chemoprophylaxis, the incidence of DVT and PE in the colorectal surgery population is approximately 2% [33].

Intraoperative

Maintenance of Normothermia

Patients in the operating room are at significant risk of hypothermia, especially in colorectal cases, which require additional time for proper patient positioning, foley catheter placement, and skin preparation. Hypothermia is associated with an increased risk of blood loss and transfusion requirement [34]. The effect of perioperative hypothermia on wound infections needs further study, although it appears not unreasonable to maintain normothermia in the perioperative period [35–37].

Laparoscopy When Possible

Since the first laparoscopic colon resection in 1991, the adoption of laparoscopic surgery has increased to over 40% of colorectal procedures [38, 39]. Due to the known benefits of accelerated return of bowel function by 2–3 days and decreased length of hospital stay by 1–3 days, laparoscopy is encouraged when feasible [40–43]. Patients benefit from smaller incisions, less pain, fewer complications, and a diminished stress response [44, 45]. Long-term results have shown laparoscopy to be safe and feasible in oncological resections, as well [46–49].

Avoiding Nasogastric Tubes and Drains

Intraoperative use of nasogastric (NG) decompression helps to improve visualization and access to the abdominal compartment, especially in laparoscopic surgery. Over 20 years of data have shown that routine continuation of NG tube for more than 24 h after surgery, however, is associated with an increased time to return of bowel function and resumption of an oral diet, and more frequent respiratory complications [50, 51]. In addition, routine NG tube use beyond 24 h does not reduce pulmonary complications or decrease the incidence of anastomotic leak [50, 51]. Empirically, NG tubes hinder early patient mobilization after surgery. For this reason, removal of the NG tube prior to reversal of anesthesia is a basic component of ERPs, consistent with known meta-analysis data existing since the 1980s.

Peritoneal drains have been used in colorectal surgery to allow for detection of anastomotic leak and prevent accumulation of fluid thought to be a source of infection. Multiple studies have shown that the use of drains for peritoneal fluid does not reduce mortality, increase surgical site infection rates, and provide early detection of anastomotic leak at best very rarely [52, 53]. Similar to NG tubes, peritoneal drains are a barrier to early patient mobilization. The authors avoid use of peritoneal drainage except for extensive pelvic dissections in selected rectal resections or multivisceral resections.

Goal-Directed Fluid Therapy

There is continued debate regarding optimal intraoperative and postoperative fluid management in colorectal surgery. Earlier literature compared liberal versus restrictive fluid management strategies. Liberal fluid management reported avoiding complications of hypovolemia such as organ dysfunction, postoperative nausea and vomiting, and increased length of stay but with increased bowel edema and risk of pulmonary complications [54, 55]. A more restrictive fluid management strategy can be associated with an accelerated time to tolerating a diet and decreased pulmonary complications, but with increased cardiac and renal complications; however, the data remain inconclusive [56, 57]. Current research is focused on goal-directed fluid therapy (GDFT) using esophageal doppler or noninvasive cardiac output monitoring. GDFT is associated with decreased overall fluid administration compared to a liberal fluid management approach but benefits remain elusive [55, 58, 59]. Future research is needed.

Anesthesia and Multimodal Analgesia

Beyond fluid management, there are little data on the anesthesia protocols as part of ERPs. There must be a balance between adequate anesthesia to allow for pneumoperitoneum in laparoscopic procedures and abdominal wall retraction in open procedures but at the same time avoiding overly deep sedation that will prolong time to mobilization.

Multimodal analgesia is an important component of ERPs and there have been many studies evaluating the types of medications and delivery method to accelerate patient recovery. Initial studies of epidural analgesia prior to ERP suggested improved pain scores and faster return of bowel function, but only if the epidural was opioid-free [60, 61]. However, with the implementation of ERPs, epidural analgesia was not found to offer superior recovery than that seen with patient-controlled analgesia (PCA) [62]. More recent evidence has shown that epidural anesthesia slows down

recovery after laparoscopic colorectal resections without adding obvious benefits, and is not recommended as part of an ERP [63]. The transversus abdominis plane (TAP) block has been evaluated as an adjunct intraoperative technique for abdominal wall analgesia. The injection of local anesthetic has been shown to improve postoperative pain scores throughout the patient's hospitalization [64, 65]. The effects of this analgesic technique on overall narcotic usage and length of stay are unclear [65, 66]. Given the documented analgesic benefits, the development of longer acting local analgesics may show greater promise for this technique in the future, and is another area ready for research. At the current time there is as yet no evidence to support the use of liposomal bupivacaine over standard bupivacaine alone.

Postoperative

Multimodal Analgesia

Optimal pain control postoperatively plays an important role in accelerated patient recovery and patient satisfaction. Despite the known side effect profile, opioid medications are commonly used for many patients. Patient-controlled analgesia (PCA) provides patients with the opportunity to titrate the amount of pain medication needed. Evidence shows that PCA users have better pain control and satisfaction scores compared to "as needed" dosing but with overall greater opioid consumption [67]. We transition patients from PCA to oral opioid medications as needed on postoperative day 1. Due to the known side effects of opioid, including nausea, vomiting, and decreased bowel motility that can contribute to ileus, additional opioid-sparing analgesics are given in scheduled doses to minimize narcotic usage.

Nonsteroidal anti-inflammatory drugs (NSAIDs) are commonly used in combination with opioid medications to improve postoperative analgesia. They have been shown to reduce opioid consumption in surgical patients and provide superior pain control compared to patients receiving opioid alone in randomized controlled trials [68, 69]. They can be given both intravenously and orally. In addition to known risks of bleeding due to antiplatelet activity and risk of kidney injury, there has been recent concern about increased risk of anastomotic leak with NSAID use. One large retrospective analysis showed an increased risk of anastomotic leak, but only in the nonelective colorectal surgery population (OR 1.70, $P = 0.01$), while the other study did not show an increased risk of anastomotic leak but did show an increased incidence of sepsis (OR = 1.47, $P = 0.03$) [70, 71]. NSAIDs have clear benefits for ERP, but they must be weighed against potential risk of complications. Based on our evaluation of the literature and clinical outcomes, we have used them consistently for the last 15 years.

In contrast to NSAIDs, acetaminophen is a central-acting analgesic without the risks of antiplatelet activity, gastrointestinal or kidney injury, or limitations in patients with a cardiac history. Dosing is limited to 4000 mg daily due to risk of hepatotoxicity. Cochrane analysis demonstrated that acetaminophen alone can significantly reduce postoperative pain and the need for additional analgesia in postoperative patients [72]. Two other studies showed that combination of acetaminophen with ibuprofen or oxycodone provided superior pain relief than ibuprofen or oxycodone alone [73, 74]. Multimodal pain relief is a cornerstone of accelerated patient recovery following colorectal surgery. We use acetaminophen routinely, starting intravenous, and transitioning to oral as soon as the patient tolerates PO, even on the day of surgery.

Early Feeding

Due to the physiological ileus following surgery, the same dogma that leads to routine NG tube decompression also dictated delayed patient feeding until resolution of ileus. Just as surgeons questioned the role of routine NG tube decompression, they also evaluated the safety and benefits of early feeding after colorectal surgery. Studies show that early enteral nutrition, defined as feeding within 24 h, is not associated with increased risks of pneumonia, ileus, anastomotic dehiscence or mortality [75, 76]. Overall patients tolerate early feeding well with similar rates of postoperative vomiting, and NG tube reinsertion [76].

Some patients, and surgeons, may be hesitant to resume oral feedings early after surgery, which can hinder return of bowel function. This leads to trailing sham feedings with chewing gum, thought to stimulate the cephalic phase of digestion. Multiple studies have evaluated the effects of chewing gum with overall positive results [77]. It is unclear if chewing gum decreases overall length of stay, but most evidence suggests that use of chewing gum is safe and associated with a faster time to passage of flatus and stool by approximately 1 day [78, 79]. It is not clearly defined whether this is a sorbitol-related benefit, or one related to cephalic stimulation of the GI tract.

Early Removal of Urinary Catheter

Urinary catheters are standard practice during colorectal surgery, as they help monitor urinary output, decompress the bladder for improved visualization intraoperatively, and manage urinary retention postoperatively. Indwelling urinary catheters are also a potential source of infection, and continuation of a urinary catheter beyond postoperative day 2 is associated with increased risk of urinary tract infection (UTI) [80]. For patients undergoing colon resection, catheter removal on post-

operative day 1 is a standard practice in ERP, as it is associated with low rates of UTI and comparable rates of urinary retention compared to removal after postoperative day 1 [81]. Patients undergoing rectal resection are thought to be at higher risk for urinary retention due to extensive pelvic dissection and nerve disruption. One randomized controlled trial reported urinary retention in 25% of patients who had their catheter removed on postoperative day 1 and an incidence of UTI at 42% in patients whose urinary catheter was removed on postoperative day 5 [82]. The practice of the authors is to remove the urinary catheter on postoperative day 1 or 2, depending on the frailty of the patient and their ability to ambulate.

Incentive Spirometry

In addition to urinary complications, preventing pulmonary complications are important to accelerating patient recovery. While there is consensus on the importance of preoperative pulmonary optimization, the data on postoperative pulmonary optimization are lacking. Incentive spirometers are standard in our practice; however, meta-analysis of low quality studies has not shown them to be superior to deep breathing exercises or chest physiotherapy [83, 84]. Incentive spirometers, however, are inexpensive, simple devices that can give patients and surgeons a noninvasive method to monitor pulmonary changes. There is no risk to their use, and the potential clinical benefits to patients validate their use, even without evidence-based guidelines.

Ambulation

Early mobilization is known to have many benefits for patient recovery. Many parts of ERPs, such as early removal of urinary catheters, early remove of NG tubes, early discontinuation of intravenous fluids, and PCA pain medications, facilitate ambulation the day after surgery or earlier. Literature has shown that failure to ambulate is a strong predictor of a patient to fail the ERP [85].

Discharge Criteria

Finally, it is important to standardize discharge criteria, to assure all care team members have a common plan, patient expectations are managed, and subjective opinions are minimized in decision-making. For many years, we have used the criteria of feeling and looking well with normal vital signs, adequate oral pain relief, adequate tolerance of diet and liquids (we aim for 1000 ml), and adequate home support. Those with an ileostomy also are observed and educated, and we make sure output is less than 1000 ml daily, with adequate

fluid intake. Home support is something that can be considered preoperatively depending on the patient's home situation, and their frailty. Those who come from more than 4 h drive, or another state are also often observed an extra day in hospital, or stay a night near the hospital in a guest house.

Conclusion

Since Kehlet et al. first proposed the concept of fast-track or ERAS, there has been growing interest in improving and safely accelerating postoperative recovery. Much research has been done to identify the different variables of patient recovery that can be improved. It is clear that while great progress has been made, there is still considerable opportunity for improvement. About 25–30% of our laparoscopic colectomies are discharged on the day after surgery, usually without need for opioids, with low readmission and complication rates. As enhanced recovery pathways continue to be refined, we hope to be able to expand such accelerated recovery to more patients.

References

1. Kehlet H. Multimodal approach to control postoperative pathophysiology and rehabilitation. *Br J Anaesth* [Internet]. 1997;78(5):606–17. Available from: <http://www.ncbi.nlm.nih.gov/pubmed/9175983>.
2. Ljungqvist O. ERAS--enhanced recovery after surgery: moving evidence-based perioperative care to practice. *JPEN J Parenter Enter Nutr* [Internet]. 2014;38(5):559–66. Available from: <http://www.ncbi.nlm.nih.gov/pubmed/24567343>.
3. Kehlet H, Mogensen T. Hospital stay of 2 days after open sigmoidectomy with a multimodal rehabilitation programme. *Br J Surg* [Internet]. 1999;86(2):227–30. Available from: <http://www.ncbi.nlm.nih.gov/pubmed/10100792>.
4. Bryan S, Dukes S. The enhanced recovery Programme for stoma patients: an audit. *Br J Nurs* [Internet]. 2010;19(13):831–4. Available from: <http://www.ncbi.nlm.nih.gov/pubmed/20606612>.
5. Younis J, Salerno G, Fanto D, Hadjipavlou M, Chellar D, Trickett JP. Focused preoperative patient stoma education, prior to ileostomy formation after anterior resection, contributes to a reduction in delayed discharge within the enhanced recovery programme. *Int J Color Dis* [Internet]. 2012;27(1):43–7. Available from: <http://www.ncbi.nlm.nih.gov/pubmed/21660418>.
6. Holte K, Nielsen KG, Madsen JL, Kehlet H. Physiologic effects of bowel preparation. *Dis Colon Rectum* [Internet]. 2004;47(8):1397–402. Available from: <http://www.ncbi.nlm.nih.gov/pubmed/15484356>.
7. Guenaga KF, Matos D, Wille-Jorgensen P. Mechanical bowel preparation for elective colorectal surgery. *Cochrane Database Syst Rev* [Internet]. 2011;7(9):CD001544. Available from: <http://www.ncbi.nlm.nih.gov/pubmed/21901677>.
8. Kiran RP, Murray AC, Chiuzan C, Estrada D, Forde K. Combined preoperative mechanical bowel preparation with oral antibiotics significantly reduces surgical site infection, anastomotic leak, and ileus after colorectal surgery. *Ann Surg* [Internet]. 2015;262(3):415–6. Available from: <http://www.ncbi.nlm.nih.gov/pubmed/26258310>.

9. Graft B, Major O, Rate IM, Medicare P, Patients O. ACE Demonstration Quality Monitoring Program Frequency of Reporting and Applicable Surgical Procedures Revised February 3, 2011 Exhibit 2–8 (continued) ACE Demonstration Quality Monitoring Program Frequency of Reporting and Applicable Surgical Procedures. 2011.
10. Nelson RL, Gladman E, Barbateskovic M. Antimicrobial prophylaxis for colorectal surgery. *Cochrane Database Syst Rev* [Internet]. 2014;5:CD001181. Available from: <http://www.ncbi.nlm.nih.gov/pubmed/24817514>.
11. Hawn MT, Richman JS, Vick CC, Deierhoi RJ, Graham LA, Henderson WG, et al. Timing of surgical antibiotic prophylaxis and the risk of surgical site infection. *JAMA Surg* [Internet]. 2013;148(7):649–57. Available from: <http://www.ncbi.nlm.nih.gov/pubmed/23552769>.
12. Steinberg JP, Braun BI, Hellinger WC, Kusek L, Bozikis MR, Bush AJ, et al. Timing of antimicrobial prophylaxis and the risk of surgical site infections: results from the trial to reduce antimicrobial prophylaxis errors. *Ann Surg* [Internet]. 2009;250(1):10–6. Available from: <http://www.ncbi.nlm.nih.gov/pubmed/19561486>.
13. American Society of Anesthesiologists C. Practice guidelines for preoperative fasting and the use of pharmacologic agents to reduce the risk of pulmonary aspiration: application to healthy patients undergoing elective procedures: an updated report by the American Society of Anesthesiologists Com. *Anesthesiology* [Internet]. 2011;114(3):495–511. Available from: <http://www.ncbi.nlm.nih.gov/pubmed/21307770>
14. Smith I, Kranke P, Murat I, Smith A, O’Sullivan G, Soreide E, et al. Perioperative fasting in adults and children: guidelines from the European Society of Anaesthesiology. *Eur J Anaesthesiol* [Internet]. 2011;28(8):556–69. Available from: <http://www.ncbi.nlm.nih.gov/pubmed/21712716>.
15. Jones C, Badger SA, Hannon R. The role of carbohydrate drinks in pre-operative nutrition for elective colorectal surgery. *Ann R Coll Surg Engl* [Internet]. 2011;93(7):504–7. Available from: <http://www.ncbi.nlm.nih.gov/pubmed/22004631>.
16. Svanfeldt M, Thorell A, Hausel J, Soop M, Rooyackers O, Nygren J, et al. Randomized clinical trial of the effect of preoperative oral carbohydrate treatment on postoperative whole-body protein and glucose kinetics. *Br J Surg* [Internet]. 2007;94(11):1342–50. Available from: <http://www.ncbi.nlm.nih.gov/pubmed/17902094>.
17. Noblett SE, Watson DS, Huang H, Davison B, Hainsworth PJ, Horgan AF. Pre-operative oral carbohydrate loading in colorectal surgery: a randomized controlled trial. *Color Dis* [Internet]. 2006;8(7):563–9. Available from: <http://www.ncbi.nlm.nih.gov/pubmed/16919107>.
18. Sada F, Krasniqi A, Hamza A, Gecaj-Gashi A, Bica J, Kavaja F. A randomized trial of preoperative oral carbohydrates in abdominal surgery. *BMC Anesth* [Internet]. 2014;14:93. Available from: <http://www.ncbi.nlm.nih.gov/pubmed/25364300>.
19. Smith MD, McCall J, Plank L, Herbison GP, Soop M, Nygren J. Preoperative carbohydrate treatment for enhancing recovery after elective surgery. *Cochrane Database Syst Rev* [Internet]. 2014;8:CD009161. Available from: <http://www.ncbi.nlm.nih.gov/pubmed/25121931>
20. Asgeirsson T, El-Badawi KI, Mahmood A, Barletta J, Luchtefeld M, Senagore AJ. Postoperative ileus: it costs more than you expect. *J Am Coll Surg* [Internet]. 2010;210(2):228–31. Available from: <http://www.ncbi.nlm.nih.gov/pubmed/20113944>.
21. Delaney CP, Wolff BG, Viscusi ER, Senagore AJ, Fort JG, Du W, et al. Alvimopan, for postoperative ileus following bowel resection: a pooled analysis of phase III studies. *Ann Surg* [Internet]. 2007;245(3):355–63. Available from: <http://www.ncbi.nlm.nih.gov/pubmed/17435541>.
22. Delaney CP, Craver C, Gibbons MM, Rachfal AW, VandePol CJ, Cook SF, et al. Evaluation of clinical outcomes with alvimopan in clinical practice: a national matched-cohort study in patients undergoing bowel resection. *Ann Surg* [Internet]. 2012;255(4):731–8. Available from: <http://www.ncbi.nlm.nih.gov/pubmed/22388106>.
23. Delaney CP, Weese JL, Hyman NH, Bauer J, Techner L, Gabriel K, et al. Phase III trial of alvimopan, a novel, peripherally acting, mu opioid antagonist, for postoperative ileus after major abdominal surgery. *Dis Colon Rectum* [Internet]. 2005;48(6):1114–25. Available from: <http://www.ncbi.nlm.nih.gov/pubmed/15906123>.
24. Viscusi ER, Goldstein S, Witkowski T, Andonakakis A, Jan R, Gabriel K, et al. Alvimopan, a peripherally acting mu-opioid receptor antagonist, compared with placebo in postoperative ileus after major abdominal surgery: results of a randomized, double-blind, controlled study. *Surg Endosc* [Internet]. 2006;20(1):64–70. Available from: <http://www.ncbi.nlm.nih.gov/pubmed/16333556>.
25. Wolff BG, Michelassi F, Gerkin TM, Techner L, Gabriel K, Du W, et al. Alvimopan, a novel, peripherally acting mu opioid antagonist: results of a multicenter, randomized, double-blind, placebo-controlled, phase III trial of major abdominal surgery and postoperative ileus. *Ann Surg* [Internet]. 2004;240(4):725–8. Available from: <http://www.ncbi.nlm.nih.gov/pubmed/15383800>.
26. Obokhare ID, Champagne B, Stein SL, Krpata D, Delaney CP. The effect of alvimopan on recovery after laparoscopic segmental colectomy. *Dis Colon Rectum* [Internet]. 2011;54(6):743–6. Available from: <http://www.ncbi.nlm.nih.gov/pubmed/21552060>.
27. Barletta JF, Asgeirsson T, El-Badawi KI, Senagore AJ. Introduction of alvimopan into an enhanced recovery protocol for colectomy offers benefit in open but not laparoscopic colectomy. *J Laparoendosc Adv Surg Tech A* [Internet]. 2011;21(10):887–91. Available from: <http://www.ncbi.nlm.nih.gov/pubmed/21939354>.
28. Ho KY, Gan TJ, Habib AS. Gabapentin and postoperative pain—a systematic review of randomized controlled trials. *Pain* [Internet]. 2006;126(1–3):91–101. Available from: <http://www.ncbi.nlm.nih.gov/pubmed/16846695>.
29. Zhang J, Ho KY, Wang Y. Efficacy of pregabalin in acute postoperative pain: a meta-analysis. *Br J Anaesth* [Internet]. 2011;106(4):454–62. Available from: <http://www.ncbi.nlm.nih.gov/pubmed/21357616>.
30. Bergqvist D. Venous thromboembolism: a review of risk and prevention in colorectal surgery patients. *Dis Colon Rectum* [Internet]. 2006;49(10):1620–8. Available from: <http://www.ncbi.nlm.nih.gov/pubmed/17019655>
31. Gould MK, Garcia DA, Wren SM, Karanicolas PJ, Arcelus JJ, Heit JA, et al. Prevention of VTE in nonorthopedic surgical patients: antithrombotic therapy and prevention of thrombosis, 9th ed: American College of Chest Physicians Evidence-Based Clinical Practice Guidelines. *Chest* [Internet]. 2012;141(2 Suppl):e227S–77S. Available from: <http://www.ncbi.nlm.nih.gov/pubmed/22315263>.
32. Guyatt GH, Akl EA, Crowther M, Gutterman DD, Schunemann HJ, American College of Chest Physicians Antithrombotic T, et al. Executive summary: antithrombotic therapy and prevention of thrombosis, 9th ed: American College of Chest Physicians Evidence-Based Clinical Practice Guidelines. *Chest* [Internet]. 2012;141(2 Suppl):7S–47S. Available from: <http://www.ncbi.nlm.nih.gov/pubmed/22315257>.
33. Colorectal Writing Group for Surgical C, Outcomes Assessment Program-Comparative Effectiveness Research Translation Network C, Nelson DW, Simianu V V, Bastawrous AL, Billingham RP, et al. Thromboembolic complications and prophylaxis patterns in colorectal surgery. *JAMA Surg* [Internet]. 2015;150(8):712–20. Available from: <http://www.ncbi.nlm.nih.gov/pubmed/26060977>.
34. Rajagopalan S, Mascha E, Na J, Sessler DI. The effects of mild perioperative hypothermia on blood loss and transfusion requirement. *Anesthesiology* [Internet]. 2008;108(1):71–7. Available from: <http://www.ncbi.nlm.nih.gov/pubmed/18156884>.

35. Barone JE, Tucker JB, Cecere J, Yoon MY, Reinhard E, Blabey RG Jr, et al. Hypothermia does not result in more complications after colon surgery. *Am Surg* [Internet]. 1999;65(4):356–9. Available from: <http://www.ncbi.nlm.nih.gov/pubmed/10190363>.
36. Kurz A, Sessler DI, Lenhardt R. Perioperative normothermia to reduce the incidence of surgical-wound infection and shorten hospitalization. Study of wound infection and temperature group. *N Engl J Med* [Internet]. 1996;334(19):1209–15. Available from: <http://www.ncbi.nlm.nih.gov/pubmed/8606715>.
37. Lehtinen SJ, Onicescu G, Kuhn KM, Cole DJ, Esnaola NF. Normothermia to prevent surgical site infections after gastrointestinal surgery: holy grail or false idol? *Ann Surg* [Internet]. 2010;252(4):696–704. Available from: <http://www.ncbi.nlm.nih.gov/pubmed/20881777>.
38. Fox J, Gross CP, Longo W, Reddy V. Laparoscopic colectomy for the treatment of cancer has been widely adopted in the United States. *Dis Colon Rectum* [Internet]. 2012;55(5):501–8. Available from: <http://www.ncbi.nlm.nih.gov/pubmed/22513427>.
39. Jacobs M, Verdeja JC, Goldstein HS. Minimally invasive colon resection (laparoscopic colectomy). *Surg Laparosc Endosc* [Internet]. 1991;1(3):144–50. Available from: <http://www.ncbi.nlm.nih.gov/pubmed/1688289>.
40. Delaney CP, Chang E, Senagore AJ, Broder M. Clinical outcomes and resource utilization associated with laparoscopic and open colectomy using a large national database. *Ann Surg* [Internet]. 2008;247(5):819–24. Available from: <http://www.ncbi.nlm.nih.gov/pubmed/18438119>.
41. Delaney CP, Marcello PW, Sonoda T, Wise P, Bauer J, Techner L. Gastrointestinal recovery after laparoscopic colectomy: results of a prospective, observational, multicenter study. *Surg Endosc* [Internet]. 2010;24(3):653–61. Available from: <http://www.ncbi.nlm.nih.gov/pubmed/19688390>.
42. Guillou PJ, Quirke P, Thorpe H, Walker J, Jayne DG, Smith AM, et al. Short-term endpoints of conventional versus laparoscopic-assisted surgery in patients with colorectal cancer (MRC CLASICC trial): multicentre, randomised controlled trial. *Lancet* [Internet]. 2005;365(9472):1718–26. Available from: <http://www.ncbi.nlm.nih.gov/pubmed/15894098>.
43. Veldkamp R, Kuhry E, Hop WC, Jeekel J, Kazemier G, Bonjer HJ, et al. Laparoscopic surgery versus open surgery for colon cancer: short-term outcomes of a randomised trial. *Lancet Oncol* [Internet]. 2005;6(7):477–84. Available from: <http://www.ncbi.nlm.nih.gov/pubmed/15992696>.
44. Madbouly KM, Senagore AJ, Delaney CP. Endogenous morphine levels after laparoscopic versus open colectomy. *Br J Surg* [Internet]. 2010;97(5):759–64. Available from: <http://www.ncbi.nlm.nih.gov/pubmed/20309893>.
45. Yoshida S, Ohta J, Yamasaki K, Kamei H, Harada Y, Yahara T, et al. Effect of surgical stress on endogenous morphine and cytokine levels in the plasma after laparoscopic or open cholecystectomy. *Surg Endosc* [Internet]. 2000;14(2):137–40. Available from: <http://www.ncbi.nlm.nih.gov/pubmed/10656946>.
46. Stevenson AR, Solomon MJ, Lumley JW, Hewett P, Clouston AD, GebSKI VJ, et al. Effect of laparoscopic-assisted resection vs open resection on pathological outcomes in rectal cancer: the ALaCaRT randomized clinical trial. *JAMA* [Internet]. 2015;314(13):1356–63. Available from: <http://www.ncbi.nlm.nih.gov/pubmed/26441180>.
47. Fleshman J, Branda M, Sargent DJ, Boller AM, George V, Abbas M, et al. Effect of laparoscopic-assisted resection vs open resection of stage II or III rectal cancer on pathologic outcomes: the ACOSOG Z6051 randomized clinical trial. *JAMA* [Internet]. 2015;314(13):1346–55. Available from: <http://www.ncbi.nlm.nih.gov/pubmed/26441179>.
48. Bonjer HJ, Deijen CL, Haglind E, Group CIS. A randomized trial of laparoscopic versus open surgery for rectal cancer. *N Engl J Med* [Internet]. 2015;373(2):194. Available from: <http://www.ncbi.nlm.nih.gov/pubmed/26154803>.
49. Theophilus M, Platell C, Spilsbury K. Long-term survival following laparoscopic and open colectomy for colon cancer: a meta-analysis of randomized controlled trials. *Color Dis* [Internet]. 2014;16(3):O75–81. Available from: <http://www.ncbi.nlm.nih.gov/pubmed/24206016>.
50. Cheatham ML, Chapman WC, Key SP, Sawyers JL. A meta-analysis of selective versus routine nasogastric decompression after elective laparotomy. *Ann Surg* [Internet]. 1995;221(5):468–9. Available from: <http://www.ncbi.nlm.nih.gov/pubmed/7748028>.
51. Nelson R, Edwards S, Tse B. Prophylactic nasogastric decompression after abdominal surgery. *Cochrane Database Syst Rev* [Internet]. 2007;18(3):CD004929. Available from: <http://www.ncbi.nlm.nih.gov/pubmed/17636780>.
52. Karliczek A, Jesus EC, Matos D, Castro AA, Atallah AN, Wiggers T. Drainage or nondrainage in elective colorectal anastomosis: a systematic review and meta-analysis. *Color Dis* [Internet]. 2006;8(4):259–65. Available from: <http://www.ncbi.nlm.nih.gov/pubmed/16630227>.
53. Petrowsky H, Demartines N, Rousson V, Clavien PA. Evidence-based value of prophylactic drainage in gastrointestinal surgery: a systematic review and meta-analyses. *Ann Surg* [Internet]. 2004;240(6):1074–5. Available from: <http://www.ncbi.nlm.nih.gov/pubmed/15570212>.
54. Mythen MG, Webb AR. Perioperative plasma volume expansion reduces the incidence of gut mucosal hypoperfusion during cardiac surgery. *Arch Surg* [Internet]. 1995;130(4):423–9. Available from: <http://www.ncbi.nlm.nih.gov/pubmed/7535996>.
55. Senagore AJ, Emery T, Luchtfefeld M, Kim D, Dujovny N, Hoedema R. Fluid management for laparoscopic colectomy: a prospective, randomized assessment of goal-directed administration of balanced salt solution or hetastarch coupled with an enhanced recovery program. *Dis Colon Rectum* [Internet]. 2009;52(12):1935–40. Available from: <http://www.ncbi.nlm.nih.gov/pubmed/19934912>.
56. Abraham-Nordling M, Hjerm F, Pollack J, Prytz M, Borg T, Kressner U. Randomized clinical trial of fluid restriction in colorectal surgery. *Br J Surg* [Internet]. 2012;99(2):186–91. Available from: <http://www.ncbi.nlm.nih.gov/pubmed/21948211>.
57. Boland MR, Noorani A, Varty K, Coffey JC, Agha R, Walsh SR. Perioperative fluid restriction in major abdominal surgery: systematic review and meta-analysis of randomized, clinical trials. *World J Surg* [Internet]. 2013;37(6):1193–202. Available from: <http://www.ncbi.nlm.nih.gov/pubmed/23463399>.
58. Waldron NH, Miller TE, Thacker JK, Manchester AK, White WD, Nardiello J, et al. A prospective comparison of a noninvasive cardiac output monitor versus esophageal Doppler monitor for goal-directed fluid therapy in colorectal surgery patients. *Anesth Analg* [Internet]. 2014;118(5):966–75. Available from: <http://www.ncbi.nlm.nih.gov/pubmed/24681660>.
59. Yates DR, Davies SJ, Milner HE, Wilson RJ. Crystalloid or colloid for goal-directed fluid therapy in colorectal surgery. *Br J Anaesth* [Internet]. 2014;112(2):281–9. Available from: <http://www.ncbi.nlm.nih.gov/pubmed/24056586>.
60. Jorgensen H, Wetterslev J, Moenicke S, Dahl JB. Epidural local anaesthetics versus opioid-based analgesic regimens on postoperative gastrointestinal paralysis, PONV and pain after abdominal surgery. *Cochrane Database Syst Rev* [Internet]. 2000;(4):CD001893. Available from: <http://www.ncbi.nlm.nih.gov/pubmed/11034732>.
61. Senagore AJ, Delaney CP, Mekhail N, Dugan A, Fazio VW. Randomized clinical trial comparing epidural anaesthesia and patient-controlled analgesia after laparoscopic segmental colectomy. *Br J Surg* [Internet]. 2003;90(10):1195–9. Available from: <http://www.ncbi.nlm.nih.gov/pubmed/14515286>.
62. Zutshi M, Delaney CP, Senagore AJ, Mekhail N, Lewis B, Connor JT, et al. Randomized controlled trial comparing the controlled

- rehabilitation with early ambulation and diet pathway versus the controlled rehabilitation with early ambulation and diet with pre-emptive epidural anesthesia/analgesia after laparotomy and intestinal re. *Am J Surg* [Internet]. 2005;189(3):268–72. Available from: <http://www.ncbi.nlm.nih.gov/pubmed/15792748>.
63. Hübner M, Blanc C, Roulin D, Winiker M, Gander S, Demartines N. Randomized clinical trial on epidural versus patient-controlled analgesia for laparoscopic colorectal surgery within an enhanced recovery pathway. *Ann Surg* [Internet]. 2015;261(4):648–53. Available from: <http://www.ncbi.nlm.nih.gov/pubmed/25119117>.
 64. McDonnell JG, O'Donnell B, Curley G, Heffernan A, Power C, Laffey JG. The analgesic efficacy of transversus abdominis plane block after abdominal surgery: a prospective randomized controlled trial. *Anesth Analg* [Internet]. 2007;104(1):193–7. Available from: <http://www.ncbi.nlm.nih.gov/pubmed/17179269>.
 65. Keller DS, Ermlich BO, Schiltz N, Champagne BJ, Reynolds HL Jr, Stein SL, et al. The effect of transversus abdominis plane blocks on postoperative pain in laparoscopic colorectal surgery: a prospective, randomized, double-blind trial. *Dis Colon Rectum* [Internet]. 2014;57(11):1290–7. Available from: <http://www.ncbi.nlm.nih.gov/pubmed/25285696>.
 66. Favuzza J, Brady K, Delaney CP. Transversus abdominis plane blocks and enhanced recovery pathways: making the 23-h hospital stay a realistic goal after laparoscopic colorectal surgery. *Surg Endosc* [Internet]. 2013;27(7):2481–6. Available from: <http://www.ncbi.nlm.nih.gov/pubmed/23355160>.
 67. Hudcova J, McNicol E, Quah C, Lau J, Carr DB. Patient controlled opioid analgesia versus conventional opioid analgesia for postoperative pain. *Cochrane Database Syst Rev* [Internet]. 2006; Oct 18 (4):CD003348. Available from: <http://www.ncbi.nlm.nih.gov/pubmed/17054167>.
 68. Chen JY, Ko TL, Wen YR, Wu SC, Chou YH, Yien HW, et al. Opioid-sparing effects of ketorolac and its correlation with the recovery of postoperative bowel function in colorectal surgery patients: a prospective randomized double-blinded study. *Clin J Pain* [Internet]. 2009;25(6):485–9. Available from: <http://www.ncbi.nlm.nih.gov/pubmed/19542795>.
 69. Schlachta CM, Burpee SE, Fernandez C, Chan B, Mamazza J, Poulin EC. Optimizing recovery after laparoscopic colon surgery (ORAL-CS): effect of intravenous ketorolac on length of hospital stay. *Surg Endosc* [Internet]. 2007;21(12):2212–9. Available from: <http://www.ncbi.nlm.nih.gov/pubmed/17440782>.
 70. Hakkarainen TW, Steele SR, Bastaworous A, Dellinger EP, Farrokhi E, Farjah F, et al. Nonsteroidal anti-inflammatory drugs and the risk for anastomotic failure: a report from Washington State's surgical care and outcomes assessment program (SCOAP). *JAMA Surg* [Internet]. 2015;150(3):223–8. Available from: <http://www.ncbi.nlm.nih.gov/pubmed/25607250>.
 71. Paulasir S, Kaoutzanis C, Welch KB, Vandewarker JF, Krapohl G, Lampman RM, et al. Nonsteroidal anti-inflammatory drugs: do they increase the risk of anastomotic leaks following colorectal operations? *Dis Colon Rectum* [Internet]. 2015;58(9):870–7. Available from: <http://www.ncbi.nlm.nih.gov/pubmed/26252849>.
 72. Toms L, McQuay HJ, Derry S, Moore RA. Single dose oral paracetamol (acetaminophen) for postoperative pain in adults. *Cochrane Database Syst Rev* [Internet]. 2008; Oct 8; (4):CD004602. Available from: <http://www.ncbi.nlm.nih.gov/pubmed/18843665>.
 73. Gaskell H, Derry S, Moore RA, McQuay HJ. Single dose oral oxycodone and oxycodone plus paracetamol (acetaminophen) for acute postoperative pain in adults. *Cochrane Database Syst Rev* [Internet]. 2009; Jul 8; (3):CD002763. Available from: <http://www.ncbi.nlm.nih.gov/pubmed/19588335>.
 74. Ong CK, Seymour RA, Lirk P, Merry AF. Combining paracetamol (acetaminophen) with nonsteroidal antiinflammatory drugs: a qualitative systematic review of analgesic efficacy for acute postoperative pain. *Anesth Analg* [Internet]. 2010;110(4):1170–9. Available from: <http://www.ncbi.nlm.nih.gov/pubmed/20142348>.
 75. Lewis SJ, Andersen HK, Thomas S. Early enteral nutrition within 24 h of intestinal surgery versus later commencement of feeding: a systematic review and meta-analysis. *J Gastrointest Surg* [Internet]. 2009;13(3):569–75. Available from: <http://www.ncbi.nlm.nih.gov/pubmed/18629592>.
 76. Zhuang CL, Ye XZ, Zhang CJ, Dong QT, Chen BC, Yu Z. Early versus traditional postoperative oral feeding in patients undergoing elective colorectal surgery: a meta-analysis of randomized clinical trials. *Dig Surg* [Internet]. 2013;30(3):225–32. Available from: <http://www.ncbi.nlm.nih.gov/pubmed/23838894>.
 77. Asao T, Kuwano H, Nakamura J, Morinaga N, Hirayama I, Ide M. Gum chewing enhances early recovery from postoperative ileus after laparoscopic colectomy. *J Am Coll Surg* [Internet]. 2002;195(1):30–2. Available from: <http://www.ncbi.nlm.nih.gov/pubmed/12113542>.
 78. Chan MK, Law WL. Use of chewing gum in reducing postoperative ileus after elective colorectal resection: a systematic review. *Dis Colon Rectum* [Internet]. 2007;50(12):2149–57. Available from: <http://www.ncbi.nlm.nih.gov/pubmed/17710495>.
 79. Keller D, Stein SL. Facilitating return of bowel function after colorectal surgery: alvimopan and gum chewing. *Clin Colon Rectal Surg* [Internet]. 2013;26(3):186–90. Available from: <http://www.ncbi.nlm.nih.gov/pubmed/24436673>.
 80. Wald HL, Ma A, Bratzler DW, Kramer AM. Indwelling urinary catheter use in the postoperative period: analysis of the national surgical infection prevention project data. *Arch Surg* [Internet]. 2008;143(6):551–7. Available from: <http://www.ncbi.nlm.nih.gov/pubmed/18559747>.
 81. Hendren S. Urinary catheter management. *Clin Colon Rectal Surg* [Internet]. 2013;26(3):178–81. Available from: <http://www.ncbi.nlm.nih.gov/pubmed/24436671>.
 82. Benoist S, Panis Y, Denet C, Mauvais F, Mariani P, Valleur P. Optimal duration of urinary drainage after rectal resection: a randomized controlled trial. *Surgery* [Internet]. 1999;125(2):135–41. Available from: <http://www.ncbi.nlm.nih.gov/pubmed/10026745>.
 83. do Nascimento Junior P, Modolo NS, Andrade S, Guimaraes MM, Braz LG, El Dib R. Incentive spirometry for prevention of postoperative pulmonary complications in upper abdominal surgery. *Cochrane Database Syst Rev* [Internet]. 2014;2:CD006058. Available from: <http://www.ncbi.nlm.nih.gov/pubmed/24510642>.
 84. Lawrence VA, Cornell JE, Smetana GW, American College of P. Strategies to reduce postoperative pulmonary complications after noncardiothoracic surgery: systematic review for the American College of Physicians. *Ann Intern Med* [Internet]. 2006;144(8):596–608. Available from: <http://www.ncbi.nlm.nih.gov/pubmed/16618957>.
 85. Smart NJ, White P, Allison AS, Ockrim JB, Kennedy RH, Francis NK. Deviation and failure of enhanced recovery after surgery following laparoscopic colorectal surgery: early prediction model. *Color Dis* [Internet]. 2012;14(10):e727–34. Available from: <http://www.ncbi.nlm.nih.gov/pubmed/22594524>.

Jason Bingham and Scott R. Steele

Tips and Tricks

- Available data supports the safety and feasibility of SILS across diverse patient populations when performed by surgeons with appropriate experience and expertise.
- Early on in one's SILS experience, it is wise to first select patients with no prior abdominal operations, with low BMI, as well as avoid its use in patients with bulky tumors or a history of inflammatory disease.
- A surgeon must be honest with himself/herself regarding his or her own ability and experience when deciding a candidate for single-incision laparoscopy.
- Do not sacrifice doing the correct operation in favor of a particular approach.
- Special populations like those with inflammatory bowel disease and obese patients present issues beyond the operating room that you need to be prepared to evaluate and treat.
- Straightforward laparoscopic cases in the morbidly obese patients and those with inflammatory disease present technical challenges; the single-incision approach may exacerbate the technical challenges, but with operator experience these cases can be safely and successfully completed.
- The principles of proper operative technique apply to SILS similar to any other operative approach.

Electronic Supplementary Material: The online version of this chapter (doi:[10.1007/978-3-319-63204-9_2](https://doi.org/10.1007/978-3-319-63204-9_2)) contains supplementary material, which is available to authorized users.

J. Bingham, MD (✉)
Department of Surgery, Madigan Army Medical Center,
Building 9040A Fitzsimmons Drive, Tacoma, WA 98431, USA
e-mail: jrbingham@gmail.com

S.R. Steele, MD, FACS, FASCRS
Division of Colorectal Surgery, University Hospitals Case Medical
Center, Case Western Reserve University,
11100 Euclid Avenue, Cleveland, OH 44106, USA
e-mail: scott.steele@UHhospitals.org

Introduction

The advantages of laparoscopic surgery over an open approach are now well accepted. Surgeons and patients alike have benefited from the decreased morbidity, faster recovery, decreased pain, and shorter hospital stays offered through minimally invasive approaches. Importantly, the COST and CLASICC I and II trials have demonstrated the oncologic equivalence of laparoscopic resection compared to open resection with regard to colorectal malignancy [1, 2]. Single-incision laparoscopic surgery (SILS) appears to be the next natural step toward ever more minimally invasive approaches in the ultimate quest for “scarless surgery.”

Although high-level evidence demonstrating superiority of SILS over traditional multi-port laparoscopy does not currently exist, there are many theoretical benefits. Advocates have suggested potential benefits to include less pain, faster return of bowel function, lower hernia rate, fewer infectious complications, and decreased inflammatory response [3]. Critics of the approach express concerns over increased operative times, higher complication rates, oncologic inferiority, and a high cost with a lack of any tangible patient benefit. Regardless, assuming equivalence (even if it is proven that no additional benefit is gained by SILS over traditional laparoscopy with regard to patient outcomes), it remains an appealing option as it offers the improved cosmesis by limiting the number of abdominal wall incisions needed. Of course, any perceived benefit gained from a single-incision approach must be weighed against the safety, feasibility, and efficacy of such an approach. For proponents of this approach, there have been numerous reports in recent years demonstrating the safety and feasibility of the SILS approach when performed by well-trained and experienced surgeons, even when applied to complex procedures. Opponents note that “experience” and “expertise” are vaguely defined, and embarking on this technique with lesser training and in suboptimal patients will lead to higher rates of untoward outcomes.

Proper exposure, triangulation of instrumentation, and traction/countertraction are fundamental tenets of laparoscopic surgery, and these do not change with single-incision over multi-port laparoscopy. Achieving these tenets is clearly more challenging with SILS over traditional laparoscopy as the manipulation of straight instruments parallel to the operating camera through a small single incision can significantly decrease the surgeon's range of motion. The addition of curvilinear instruments attempts to overcome this, although also relies on a learning curve to master their use. In addition, SILS may be particularly challenging in colorectal procedures, which often require operating in multiple quadrants. Given these added challenges, proper patient selection is clearly paramount to the successful application of SILS. Despite these inherent difficulties, becoming facile in the technique provides another tool in the surgeon's armamentarium that may provide certain patients benefits and improved outcomes.

General Considerations

Patient Selection

Proper patient selection depends first on the surgeon's own personal confidence, competence, and experience—not only with the SILS approach but also with the specific operation being performed. Certainly, as the complexity of the procedure increases, so do the challenges associated with single-incision surgery. In fact, the challenges may be amplified with a single-incision approach given its unique technical characteristics mentioned above. The surgeon must be honest with himself or herself regarding their own ability and experience when deciding who is a candidate for SILS.

Perhaps one of the most important factors is the existing laparoscopic skill set of the surgeon. It has been suggested that among surgeons who have mastered traditional multi-port laparoscopy, the SILS learning curve may actually be quite minimal, generally less than 40 cases [4, 5]. However, the data with regard to the SILS learning curve are not nearly as robust as that of traditional laparoscopy, and to date there is simply too little known to make any formal credentialing suggestions. What is clear is that a strong laparoscopic skill set is a prerequisite for any surgeon who is considering adding the SILS technique to his or her surgical toolkit.

Patient factors also play an important role in deciding who is appropriate for this approach. An ileocecectomy or right hemicolectomy in a thin patient with no prior surgeries is clearly more straightforward than a total proctocolectomy with pouch reconstruction in an obese patient with ulcerative colitis and multiple prior abdominal operations. Bulky tumors, low rectal lesions, inflammatory disease, presence of fistulae, obesity, and prior abdominal operations all add to the complexity of the procedure and should be considered

carefully and cautiously when determining the appropriate surgical approach.

In general, it is prudent for the surgeon to select patients with low BMIs, without prior abdominal surgeries, and with either benign disease or small manageable tumors early in his or her experience with the SILS approach. Avoiding patients with previous surgeries is both due to the time-consuming lysis of adhesion in the face of what may already be a longer operation due to technique itself, as well as the potential higher risk of an enterotomy. Once he or she gains more experience in the SILS, there is mounting evidence that the technique can be safely performed across a wide variety of disease processes and patient populations [6–16] (Table 2.1).

It also is important to remember that this technology is still in its relatively early stages. As such, the bulk of the data currently available is retrospective or prospectively collected cohorts in which surgeons control the population, and is no doubt the subject of significant selection bias—as the majority of included patients had low BMI, no bulky malignancy, and no inflammatory disease, and the operations were performed by surgeons who were very experienced in the technique.

Indications

While SILS uses only one incision in the abdominal wall and the entire procedure is performed through this opening and traditional laparoscopy uses multiple ports, the basic tenets of minimally invasive surgery remain the same: adequate exposure, tension and counter-tension, triangulation, and safe tissue handling. Major differences may include the use of instruments and devices tailored for in-line viewing, differences in ergonomics, and relative propensity for instruments to cross with SILS. However, it is important to again point out that all types of colorectal operations have been performed safely and effectively through a SILS procedure, from a stoma to a total proctocolectomy and ileal pouch-anal anastomosis [8, 11, 12]. While opponents may claim SILS is a “gimmick” or marketing maneuver, the reality is that SILS has become the preferred approach for many surgeons.

Preoperative Planning

Regardless of the operative approach used, every patient should undergo a thorough history and physical examination, along with a generalized risk stratification to determine the potential for morbidity and mortality (Table 2.2). In addition, patients undergoing a major abdominal operation should, in general, have a complete blood count, chemistry panel and carcinoembryonic antigen [(CEA) in cases of malignancy]. Additional radiological and endoscopic examinations will allow for appropriate localization of the disease and staging

Table 2.1 Trials demonstrating feasibility of SILS approach

Series	Studydesign	Number of patients	Included inflammatory disease?	MeanBMI(kg/m ²)	Conversion multi-port laparoscopy (%)	Conversion open (%)	Mean operative time (Min)	Length of stay (days)	Morbidity (%)	Mortality (%)
Champagne et al.	Prospective Case Control	165	Yes	27	11	2.4	135	4.3	26.1	0.6
Geisler et al.	Prospective Case Series	102	Yes	26	17.6	1	99	5.9	38	1
Miller et al.	Prospective Case Series	31	Yes	26.5	3.2	9.6	164	5.7	22.6	0
Moftah et al.	Prospective Case Series	33	Yes	21.3	0	15	120	6	39	0
Olson et al.	Retrospective Case Control	20	Yes	24.8	0	10	218	7.9	40	0
Rieger et al.	Prospective Case Series	7	No	24.3	0	0	89	5.4	0	0
Rijcken et al.	Retrospective Case Control	20	Yes	21.5	0	5	137.4	9	20	0
Rizzuto et al.	Prospective Case Series	488	Yes	29	0.6	0.2	103	5	0.6	0
Ross et al.	Prospective Case Series	39	Yes	25.6	7.7	5.1	120	4.4	7.7	0
Vestweber et al.	Prospective Case Series	329	Yes	26.3	3.4	6.1	154	8	18.3	0.3

Table 2.2 Revised cardiac risk index

<i>Risk factors</i>	
1. High-risk type of surgery (intraoperative, intrathoracic, or suprainguinal vascular procedures)	
2. Ischemic heart disease	
3. Congestive heart failure	
4. History of cerebrovascular disease	
5. Insulin therapy for diabetes	
6. Preoperative serum creatinine >2.0 mg/dl	
<i>Risk classification</i> (1 point is assigned to each risk factor present)	<i>Rates of major cardiac complications^a</i>
Class I (0 points)	0.5%
Class II (1 point)	1.3%
Class III (2 points)	3.6%
Class IV (\geq 3 points)	9.1%

Adapted from Lee [47]

^aMajor cardiac complications include myocardial infarction, pulmonary edema, ventricular fibrillation or primary cardiac arrest, and complete heart block

for cases of malignancy. Surgeons should make a special point of ensuring prior tattooing with India ink or clips has been performed, as reliance on descriptive reports with regard to tumor location is fraught with potential for error. While still controversial, the authors prefer a mechanical bowel preparation with oral antibiotics for all colorectal resections. Intravenous antibiotics should be given perioperatively for all patients in conjunction with appropriate Surgical Care Improvement Project (SCIP) guidelines. Intraoperatively, it is important to ensure appropriate blood glucose control, normothermia, and that supplemental oxygen therapy is given [13].

Considerations in Select Populations

Ultimately, all patients eligible for laparoscopy may be considered potential candidates for SILS in the right hands. While there may be no definitive contraindications for SILS, the surgeon should carefully consider each patient and procedure individually when deciding the appropriate surgical approach. Three patient populations pose particular challenges and deserve special consideration: the obese, those with inflammatory disease, and colorectal cancer patients.

SILS and Obesity

It is well understood that obesity, particularly visceral obesity, significantly increases the complexity of any laparoscopic

procedure (Fig. 2.1). While the effect of obesity on outcomes following traditional laparoscopy is still an area of active investigation, evidence clearly supports that traditional multi-port laparoscopy is safe and feasible in obese patients, with outcomes similar to those of non-obese patients, especially when compared to open surgery [14–23].

SILS is undeniably more technically challenging than traditional multi-port laparoscopy in this population, amplifying the effect of obesity on the difficulty of the procedure. The presence of high amounts of visceral fat makes the identification of the correct surgical plane more difficult and impedes proper surgical exposure (Fig. 2.2). Therefore, it is not surprising that much of current literature demonstrating the feasibility of SILS has centered on non-obese patients [3, 7–10]. It is revealing that in two separate systematic reviews of single-incision laparoscopic colectomy, the mean BMIs of patients included in the literature were found to be 25.5 and 25.8 kg/m², respectively [24, 25].

Nevertheless, there have been some published data on short-term outcomes of obese patients undergoing single-incision laparoscopic colectomy. Regrettably, these studies are all based on small patient numbers and the data are somewhat conflicting. In some, visceral obesity has been associated with longer operative times, increased blood loss, and was a primary factor leading to conversion to an open procedure [26, 27]. Contrarily, others have found no difference in conversion rate, operative time, estimated blood loss, time to return of bowel function, length of stay, or reoperation and readmission rates between multi-port and single-port approaches in obese patients [15, 28]. This contrast more likely highlights the variations in surgeon experience and expertise with this approach.

Key points to consider are adhering to the simple principles of all minimally invasive surgery: proper exposure, appropriate definition of anatomy, apposite tissue handling, and technically sound operative steps. One of the initial major issues encountered is the lack of domain when establishing a pneumoperitoneum with any minimally invasive approach that often occurs in the obese patient (Fig. 2.3). Positioning the omentum in the upper abdomen, rotating the operating table to the extremes to facilitate gravity effects on the bowel, and “flipping” the mesentery of the small bowel to allow it stay in place are tricks to help ensure adequate exposure (Fig. 2.4).

While obesity is associated with increased technical challenges, it is clear that SILS can be safely applied in this patient population by experienced surgeons. However, the current data are significantly limited and further high-level studies must be done to more definitively demonstrate its feasibility in the obese population before more generalized recommendations can be made.

Fig. 2.1 Obese patients may amplify challenges in the application of minimally invasive approaches

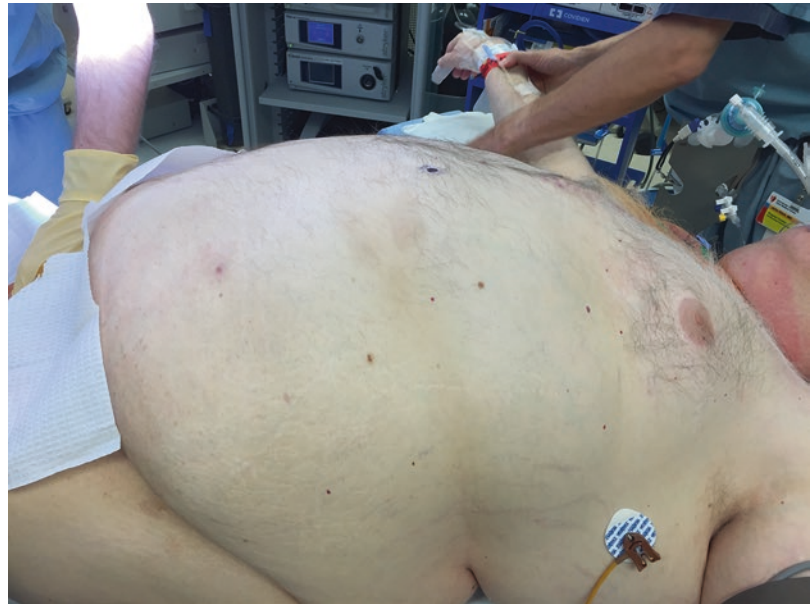

Fig. 2.2 Sigmoid colon with a large amount of visceral fat. The *straight line* marks location of the inferior mesenteric artery and the *circle* identifies the sacral promontory

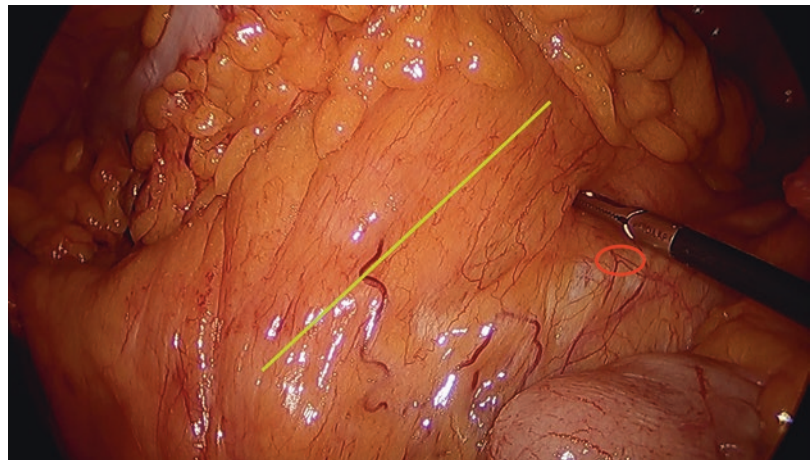


Fig. 2.3 Loss of domain due to obesity

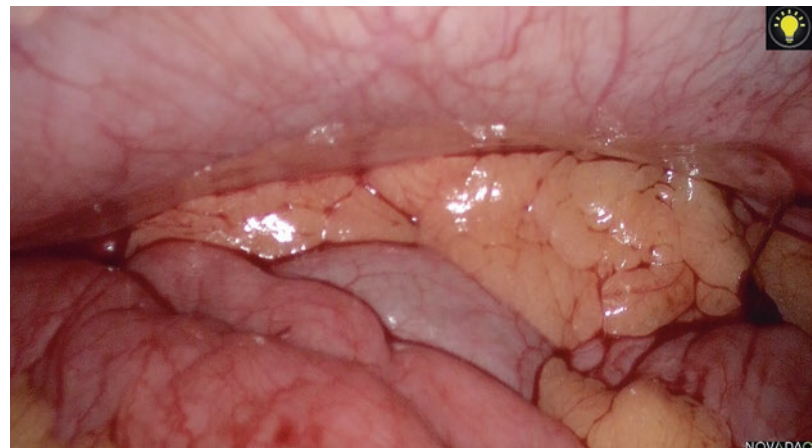

Fig. 2.4 Ileocolic pedicle in a 400 lb patient with a right colon cancer. Note the bare areas that represent relatively avascular planes of dissection around the pedicle are able to be visualized

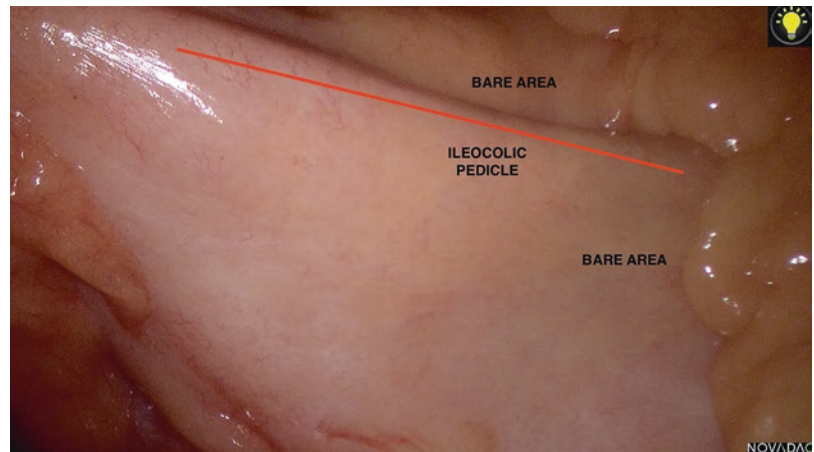
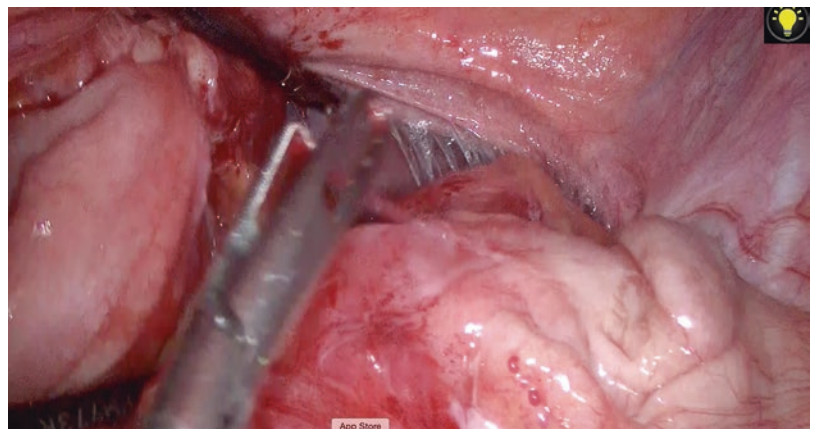


Fig. 2.5 Intra-abdominal adhesions in a patient with Crohn's disease



SILS and Inflammatory Disease

Another challenging patient population to consider in the practical application of SILS is the patient with inflammatory disease—notably Crohn's disease, ulcerative colitis, and diverticulitis. Significant inflammation, scarring, distorted planes, fistulae, abscesses, and infectious complications all contribute to making the application of minimally invasive techniques distinctly challenging in these patients (Fig. 2.5).

One must also consider the fact that general benefits of reduced narcotic requirement and shorter length of stay in hospital with minimally invasive techniques may not be as pronounced in patients with inflammatory bowel disease (IBD) [29, 30]. Thus, it is less likely SILS will offer any additional benefit over traditional laparoscopy with regard to those issues. Still, SILS has the potential of preserving the benefits standard laparoscopy does offer, while minimizing the extent of incisions with the resultant improved cosmesis. This may be best appreciated in the young IBD patient, in whom surgical scars can have a significant psychological impact. The senior author feels the ideal SILS candidate is a

young patient with inflammatory bowel disease who may require an ileocecectomy, where the majority of the operation is limited to one or two abdominal quadrants. In addition, it is important to remember that inflammatory bowel disease encompasses a spectrum of phenotypical manifestations, and those with phlegmonous or fistulizing disease present much different challenges than those with fibrostenotic manifestations.

Although well-designed, large, multicenter studies demonstrate the feasibility of SILS when performed by experienced laparoscopic surgeons [12], only a minority of patients included in the series had underlying IBD. Nevertheless, several smaller series have shown that SILS can be safely applied to IBD patients with similar outcomes to traditional laparoscopy, with no difference in operative time, conversion to open surgery, complications, or short-term clinical outcomes, even in complex and recurrent disease [6, 13, 14, 31]. In addition, in patients with isolated disease, when the inflammatory component of IBD can be safely mobilized, the remainder of the operation can be safely performed extracorporeally with relatively normal bowel (Figs. 2.6a, b).

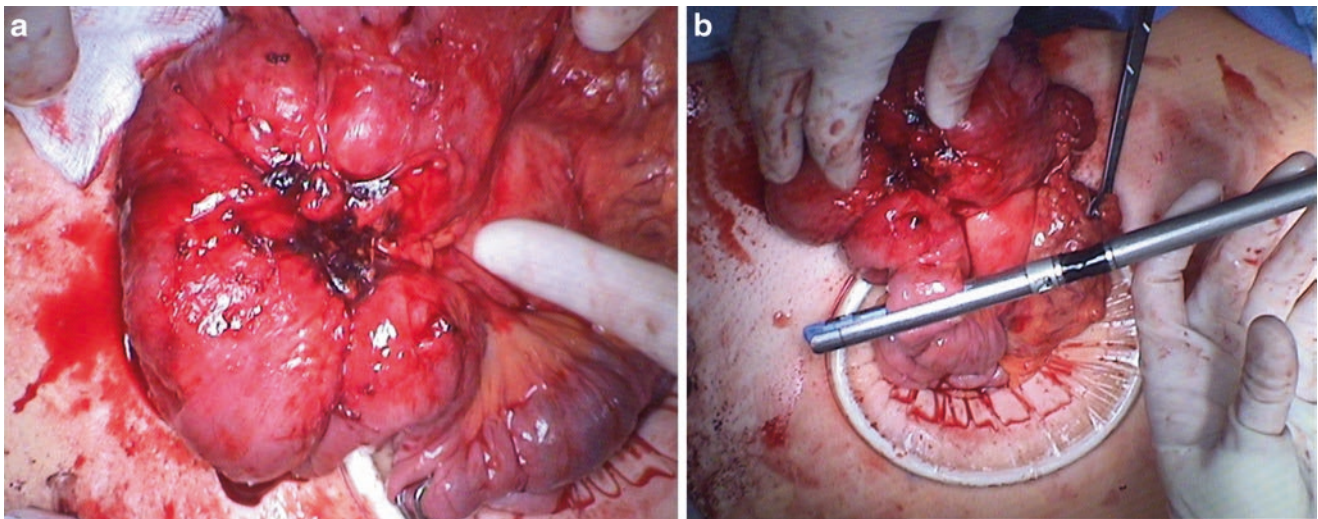


Fig. 2.6 (a) Extracorporealized segment with mesenteric abscess in a patient with IBD. (b) Extracorporealized resection of diseased segment in a patient with IBD

Diverticular Disease

As with IBD patients, those with complicated diverticular disease also pose a unique and daunting challenge to the surgeon. Patients are often systemically ill, have had prior procedures, and may not tolerate a prolonged operation. Moreover, inflammation, scarring, and presence of an abscess make minimally invasive approaches challenging. Two large retrospective series have indicated that SILS sigmoidectomy can be effective for treatment of diverticular disease, even in the setting of contained perforation and prior operations [15, 16]. Operative times, conversion to open surgery, anastomotic leak, and hernia rates were found to be similar to that of traditional laparoscopy. While not mandatory, use of ureteral stents—especially lighted stents—may facilitate identification of the left ureter in patients with an associated abscess, large amounts of inflammation or if early in one’s experience (See Video 2.1).

SILS and Malignancy

As mentioned above, the COST and CLASICC Trials have proven the oncologic equivalence of multi-port laparoscopic resection to open resection for colorectal malignancy. The laparoscopic approach has since been enthusiastically applied. The same oncologic equivalence will need to be proven for the SILS approach before it can be widely accepted and applied in the resection of colorectal cancer. However, ensuring the appropriate operation that follows traditional oncological principles is performed regardless of the

approach (SILS vs. multi-port vs. open) should lead to the same oncological results when SILS is performed.

A number of feasibility studies have been published regarding SILS colectomy for colorectal tumors—more for colon and less for rectal cancer. Not surprisingly, selection bias is again witnessed in the data available to date. The majority of data are heavily skewed regarding the type of procedure being performed, with most focusing on the right hemicolectomy [3, 26, 32–41]. Large case series have supported the use of SILS for right-sided malignancy, reporting similar operative times, conversion rates, mortality/morbidity, and most importantly, oncologic adequacy as demonstrated by specimen quality and lymph node retrieval when compared to multi-port laparoscopy [42, 43] (Table 2.3).

There is no question that procedures for left-sided and rectal malignancy are technically more challenging than right-sided lesions. The multi-quadrant mobilization, intracorporeal anastomosis, and generally more complicated exposures required with left-sided lesions make application of SILS approaches increasingly challenging. Not unexpectedly then, the data for single-incision resection of left-sided and rectal malignancies are much more limited. Early reports of SILS for rectal cancer were somewhat concerning with longer operative times, high stoma rates, and less than adequate mesorectal excision [44]. A few small, randomized trials have been performed comparing outcomes of single-incision resection for colon cancer to traditional laparoscopy [45, 46]. Importantly, these studies included left-sided colon and rectal tumors. Although small in size, these randomized trials show equivalence in operative outcomes and oncologic adequacy compared to multi-port laparoscopy.

Table 2.3 Trials demonstrating feasibility of SILS for colon cancer resection

Series	Study design	Number of patients	Conversion multi-port laparoscopy	Conversion open	Operative time (Min)	Blood loss (ml)	Lymph nodes removed	Length of stay (days)	Morbidity	Mortality
Waters et al.	Retrospective Case Series	100	2%	4%	105	105	18	4	13%	1%
Chew et al.	Retrospective Case Series	144	3	9	170	80	21	5.7	4.9%	0%

Conclusions

The overarching theme in the currently available SILS literature is that SILS is safe in select patients when performed by surgeons proficient in the technique. What is not clear is what constitutes a “select patient,” and surgeon experience may be the major factor. Much of the data is retrospective, contains bias, and represents sound clinical judgment with regard to patient and case selection by experienced surgeons. There is a need for large-scale randomized controlled trials before non-inferiority, let alone superiority, to traditional laparoscopy can be definitively demonstrated. Nevertheless, the available data does seem to support the safety and feasibility of SILS across diverse patient populations in the appropriate hands.

Early on in one’s experience, it may be prudent for a surgeon to first select patients without prior abdominal operations, low BMI, small tumors, and noninflammatory disease, as these factors undoubtedly affect the complexity of the surgery. The type of surgical procedure is also important to consider early in a surgeon’s experience. One should first select procedures that they have substantial experience and familiarity with that are relatively straightforward, such as right hemicolectomy or ileocecectomy. However, as more experience is gained with the SILS approach it can be safely performed on essentially any patient who is eligible for the more traditional minimally invasive approaches.

Ultimately the surgeon must perform an honest appraisal of their experience, abilities and comfort with a given procedure, evaluate the patient in front of them, and choose an approach that is best suited for each individual case. Above all, the surgeon should not sacrifice doing the correct operation in favor of a particular surgical approach.

References

- Clinical Outcomes of Surgical Therapy Study Group, Nelson H, Sargent DJ, Wieand HS, Fleshman J, Anvari M, Stryker SJ, Beart RW Jr, Hellinger M, Flanagan R Jr, Peters W, Ota D. A comparison of laparoscopically assisted and open colectomy for colon cancer. *N Engl J Med* [Internet]. 2004 [cited 2014 May 8];350(20):2050–9. Available from: <http://www.ncbi.nlm.nih.gov/pubmed/15141043>.
- Green BL, Marshall HC, Collinson F, Quirke P, Guillou P, Jayne DG, et al. Long-term follow-up of the Medical Research Council CLASICC trial of conventional versus laparoscopically assisted resection in colorectal cancer. *Br J Surg* [Internet]. 2013 [cited 2014 Mar 22];100(1):75–82. Available from: <http://www.ncbi.nlm.nih.gov/pubmed/23132548>.
- Bucher P, Pugin F, Morel P. Single port access laparoscopic right hemicolectomy. *Int J Colorectal Dis* [Internet]. 2008 [cited 2015 Sep 14];23(10):1013–6. Available from: <http://www.ncbi.nlm.nih.gov/pubmed/18607608>.
- Haas EM, Nieto J, Ragupathi M, et al. Critical appraisal of learning curve for single incision laparoscopic right colectomy. *Surg Endosc* 2013;27:4499–503.
- Hopping JR, Bardakcioglu O. Single-port laparoscopic right hemicolectomy: the learning curve. *JLS* [Internet] 2013;17(2):194–7. Available from: <http://www.pubmedcentral.nih.gov/articlerender.fcgi?artid=3771784&tool=pmcentrez&rendertype=abstract>.
- Rijcken E, Mennigen R, Argyris I, Senninger N, Bruewer M. Single-incision laparoscopic surgery for ileocolic resection in Crohn’s disease. *Dis Colon Rectum* [Internet]. 2012 [cited 2015 Sep 12];55(2):140–6. Available from: <http://www.ncbi.nlm.nih.gov/pubmed/22228156>.
- Geisler D, Garrett T. Single incision laparoscopic colorectal surgery: a single surgeon experience of 102 consecutive cases. *Tech Coloproctol* [Internet]. 2011 [cited 2015 Sep 16];15(4):397–401. Available from: <http://www.ncbi.nlm.nih.gov/pubmed/21887555>.
- Miller S, Causey MW, Damle A, Maykel J, Steele S. Single-incision laparoscopic colectomy: training the next generation. *Surg Endosc* [Internet]. 2013 [cited 2015 Sep 16];27(5):1784–90. Available from: <http://www.ncbi.nlm.nih.gov/pubmed/23389059>.
- Remzi FH, Kirat HT, Geisler DP. Laparoscopic single-port colectomy for sigmoid cancer. *Tech Coloproctol* [Internet]. 2010 [cited 2015 Sep 16];14(3):253–5. Available from: <http://www.ncbi.nlm.nih.gov/pubmed/19953288>.
- Rieger NA, Lam FF. Single-incision laparoscopically assisted colectomy using standard laparoscopic instrumentation. *Surg Endosc* [Internet]. 2010 [cited 2015 Sep 16];24(4):888–90. Available from: <http://www.ncbi.nlm.nih.gov/pubmed/19760335>.
- Ross H, Steele S, Whiteford M, Lee S, Albert M, Mutch M, et al. Early multi-institution experience with single-incision laparoscopic colectomy. *Dis Colon Rectum* [Internet]. 2011 [cited 2015 Sep 16];54(2):187–92. Available from: <http://www.ncbi.nlm.nih.gov/pubmed/21228667>.
- Champagne BJ, Papaconstantinou HT, Parmar SS, Nagle DA, Young-Fadok TM, Lee EC, et al. Single-incision versus standard multiport laparoscopic colectomy: a multicenter, case-controlled comparison. *Ann Surg* [Internet]. 2012 [cited 2015 Sep 11];255(1):66–9. Available from: <http://www.ncbi.nlm.nih.gov/pubmed/22104563>.
- Moftah M, Nazour F, Cunningham M, Cahill RA. Single port laparoscopic surgery for patients with complex and recurrent Crohn’s disease. *J Crohn’s Colitis* [Internet]. European Crohn’s and Colitis Organisation. 2014;8(9):1055–61. Available from: <http://dx.doi.org/10.1016/j.crohns.2014.02.003>.
- Olson CH, Bedros N, Hakiman H, Araghizadeh FY. Single-site laparoscopic surgery for inflammatory bowel disease. *JLS* [Internet].

- 2014 [cited 2015 Sep 12];18(2):258–64. Available from: <http://www.pubmedcentral.nih.gov/articlerender.fcgi?artid=4035637&tool=pmcentrez&rendertype=abstract>.
15. Rizzuto A, Lacamera U, Ulrich F, Sacco R. Single incision laparoscopic resection for diverticulitis. *Int J Surg* [Internet]. Elsevier Ltd; 2015;19:11–4. Available from: <http://dx.doi.org/10.1016/j.ijso.2015.05.012>.
 16. Vestweber B, Vestweber K-H, Paul C, Rink AD. Single-port laparoscopic resection for diverticular disease: experiences with more than 300 consecutive patients. *Surg Endosc* [Internet]. 2015;30:50. Available from: <http://link.springer.com/10.1007/s00464-015-4160-7>.
 17. Nguyen HML, Causey MW, Steele SR, Maykel JA. Single-port laparoscopic diverting sigmoid colectomy. *Dis Colon Rectum* [Internet]. 2011 [cited 2015 Sep 25];54(12):1585–8. Available from: <http://www.ncbi.nlm.nih.gov/pubmed/22067189>.
 18. Qadan M, Akça O, Mahid SS, Hornung CA, Polk HC. Perioperative supplemental oxygen therapy and surgical site infection: a meta-analysis of randomized controlled trials. *Arch Surg* [Internet]. 2009 [cited 2015 Sep 25];144(4):359–66. discussion 366–7. Available from: <http://www.ncbi.nlm.nih.gov/pubmed/19380650>.
 19. Makino T, Trencheva K, Shukla PJ, et al. The influence of obesity on short- and long-term outcomes after laparoscopic surgery for colon cancer: a case-matched study of 152 patients. *Surgery* 2014;156:661–8.
 20. Cai Y, Zhou Y, Li Z, et al. Surgical outcome of laparoscopic colectomy for colorectal cancer in obese patients: a comparative study with open colectomy. *Oncol Lett* 2013;6:1057–62.
 21. Poulsen M, Ovesen H. Is laparoscopic colorectal cancer surgery in obese patients associated with an increased risk? Short-term results from a single center study of 425 patients. *J Gastrointest Surg* 2012;16:1554–8.
 22. Krane M. K., Allaix M. E., Zoccali M., et al. Does morbid obesity change outcomes after laparoscopic surgery for inflammatory bowel disease? review of 626 consecutive cases. *Journal of the American College of Surgeons*. 2013;216(5):986–996.
 23. Hardiman K, Chang ET, Diggs BS, et al. - Laparoscopic colectomy reduces morbidity and mortality in obese patients. *Surg Endosc*. 2013;27:2907–10.
 24. Fung AKY, Aly EH. Systematic review of single-incision laparoscopic colonic surgery. *Br J Surg*. 2012;99:1353–64.
 25. Makino T, Milsom JW, Lee SW. Feasibility and safety of single-incision laparoscopic colectomy: a systematic review. *Ann Surg* [Internet]. 2012 [cited 2015 Sep 16];255(4):667–76. Available from: <http://www.ncbi.nlm.nih.gov/pubmed/22258065>.
 26. Chen WT-L, Chang S-C, Chiang H-C, Lo W-Y, Jeng L-B, Wu C, et al. Single-incision laparoscopic versus conventional laparoscopic right hemicolectomy: a comparison of short-term surgical results. *Surg Endosc* [Internet]. 2011 [cited 2014 May 25];25(6):1887–92. Available from: <http://www.ncbi.nlm.nih.gov/pubmed/21359907>.
 27. Keller DS, Ibarra S, Flores-Gonzalez JR, Ponte OM, Madhoun N, Pickron TB, et al. Outcomes for singleincision laparoscopic colectomy surgery in obese patients: A case-matched study. *Surg Endosc*. 2016;30:739–44.
 28. Aytac E, Turina M, Gorgun E, Stocchi L, Remzi FH, Costedio MM. Single-port laparoscopic colorectal resections in obese patients are as safe and effective as conventional laparoscopy. *Surg Endosc* [Internet]. 2014 [cited 2015 Sep 16];28(10):2884–9. Available from: <http://www.ncbi.nlm.nih.gov/pubmed/24853841>.
 29. Milsom JW, Hammerhofer KA, Böhm B, Marcello P, Elson P, Fazio VW. Prospective, randomized trial comparing laparoscopic vs. conventional surgery for refractory ileocolic Crohn's disease. *Dis Colon Rectum* [Internet]. 2001 [cited 2015 Sep 11];44(1):1–8. discussion 8–9. Available from: <http://www.ncbi.nlm.nih.gov/pubmed/11805557>.
 30. Maartense S, Dunker MS, Slors JFM, Cuesta MA, Pierik EGJM, Gouma DJ, et al. Laparoscopic-assisted versus open ileocolic resection for Crohn's disease: a randomized trial. *Ann Surg* [Internet]. 2006 [cited 2015 Aug 25];243(2):143–9. discussion 150–3. Available from: <http://www.pubmedcentral.nih.gov/articlerender.fcgi?artid=1448907&tool=pmcentrez&rendertype=abstract>.
 31. Gash KJ, Goede AC, Kaldowski B, Vestweber B, Dixon AR. Single incision laparoscopic (SILS) restorative proctocolectomy with ileal pouch-anal anastomosis. *Surg Endosc* [Internet]. 2011 [cited 2015 Sep 12];25(12):3877–80. Available from: <http://www.ncbi.nlm.nih.gov/pubmed/21761270>.
 32. Boni L, Dionigi G, Cassinotti E, Di Giuseppe M, Diurni M, Rausei S, et al. Single incision laparoscopic right colectomy. *Surg Endosc* [Internet]. 2010 [cited 2015 Sep 14];24(12):3233–6. Available from: <http://www.ncbi.nlm.nih.gov/pubmed/20464415>.
 33. Keshava A, Mackenzie S, Al-Kubati W. Single-port laparoscopic right colonic resection. *ANZ J Surg* [Internet]. 2010 [cited 2015 Sep 14];80(1–2):30–2. Available from: <http://www.ncbi.nlm.nih.gov/pubmed/20575877>.
 34. O'Connor DJ, Feinberg E, Jang J, Vemulapalli P, Camacho D. Single-incision laparoscopic-assisted right colon resection for cancer. *JSLs* [Internet]. 2010 [cited 2015 Sep 14];14(4):558–60. Available from: <http://www.pubmedcentral.nih.gov/articlerender.fcgi?artid=3083049&tool=pmcentrez&rendertype=abstract>.
 35. Ramos-Valadez DI, Patel CB, Ragupathi M, Bartley Pickron T, Haas EM. Single-incision laparoscopic right hemicolectomy: safety and feasibility in a series of consecutive cases. *Surg Endosc* [Internet]. 2010 [cited 2015 Sep 14];24(10):2613–6. Available from: <http://www.ncbi.nlm.nih.gov/pubmed/20364353>.
 36. Adair J, Gromski MA, Lim RB, Nagle D. Single-incision laparoscopic right colectomy: experience with 17 consecutive cases and comparison with multiport laparoscopic right colectomy. *Dis Colon Rectum* [Internet]. 2010 [cited 2015 Sep 14];53(11):1549–54. Available from: <http://www.ncbi.nlm.nih.gov/pubmed/20940605>.
 37. Lim YK, Ng KH, Eu KW. Single site laparoscopic right hemicolectomy: an oncological feasible option. *World J Surg Oncol* [Internet]. 2010 [cited 2015 Sep 14];8:79. Available from: <http://www.pubmedcentral.nih.gov/articlerender.fcgi?artid=2945348&tool=pmcentrez&rendertype=abstract>.
 38. Pietrasanta D, Romano N, Prosperi V, Lorenzetti L, Basili G, Goletti O. Single-incision laparoscopic right colectomy for cancer: a single-centre preliminary experience. *Updates Surg* [Internet]. 2010 [cited 2015 Sep 14];62(2):111–5. Available from: <http://www.ncbi.nlm.nih.gov/pubmed/20872107>.
 39. Waters JA, Guzman MJ, Fajardo AD, Selzer DJ, Wiebke EA, Robb BW, et al. Single-port laparoscopic right hemicolectomy: a safe alternative to conventional laparoscopy. *Dis Colon Rectum* [Internet]. 2010 [cited 2015 Sep 14];53(11):1467–72. Available from: <http://www.ncbi.nlm.nih.gov/pubmed/20940593>.
 40. Wong MTC, Ng KH, Ho KS, Eu KW. Single-incision laparoscopic surgery for right hemicolectomy: our initial experience with 10 cases. *Tech Coloproctol* [Internet]. 2010 [cited 2015 Sep 14];14(3):225–8. Available from: <http://www.ncbi.nlm.nih.gov/pubmed/20589521>.
 41. Papaconstantinou HT, Sharp N, Thomas JS. Single-incision laparoscopic right colectomy: a case-matched comparison with standard laparoscopic and hand-assisted laparoscopic techniques. *J Am Coll Surg* [Internet]. 2011 [cited 2015 Sep 14];213(1):72–80 ; discussion 80–2. Available from: <http://www.ncbi.nlm.nih.gov/pubmed/21420878>.
 42. Waters JA, Rapp BM, Guzman MJ, Jester AL, Selzer DJ, Robb BW, et al. Single-port laparoscopic right hemicolectomy: the first 100 resections. *Dis Colon Rectum* [Internet]. 2012 [cited 2015 Sep 14];55(2):134–9. Available from: <http://www.ncbi.nlm.nih.gov/pubmed/22228155>.
 43. Chew M-H, Chang M-H, Tan W-S, Wong MT-C, Tang C-L. Conventional laparoscopic versus single-incision laparoscopic right hemicolectomy: a case cohort comparison of short-term outcomes in 144 consecutive cases. *Surg Endosc* [Internet]. 2013

- [cited 2015 Sep 14];27(2):471–7. Available from: <http://www.ncbi.nlm.nih.gov/pubmed/22806522>.
44. Bulut O, Nielsen CB, Jespersen N. Single-port access laparoscopic surgery for rectal cancer: initial experience with 10 cases. *Dis Colon Rectum* [Internet]. 2011 [cited 2015 Sep 14];54(7):803–9. Available from: <http://www.ncbi.nlm.nih.gov/pubmed/21654246>.
 45. Huscher CG, Mingoli A, Sgarzini G, Mereu A, Binda B, Brachini G, et al. Standard laparoscopic versus single-incision laparoscopic colectomy for cancer: early results of a randomized prospective study. *Am J Surg* [Internet]. 2012 [cited 2015 Sep 14];204(1):115–20. Available from: <http://www.ncbi.nlm.nih.gov/pubmed/22178484>.
 46. Poon JTC, Cheung C-W, Fan JKM, Lo OSH, Law W-L. Single-incision versus conventional laparoscopic colectomy for colonic neoplasm: a randomized, controlled trial. *Surg Endosc* [Internet]. 2012 [cited 2015 Sep 14];26(10):2729–34. Available from: <http://www.ncbi.nlm.nih.gov/pubmed/22538676>.
 47. Lee TH, et al. Derivation and prospective validation of a simple index for prediction of cardiac risk of major noncardiac surgery. *Circulation*. 1999;100(10):1043–9.

Nicole E. Sharp and Harry T. Papaconstantinou

Tips and Tricks

- Sizable laparoscopic operative suites with high-definition monitors suspended from the ceiling, a boom, and carbon dioxide piping enhance the ergonomics of the room
- Consolidation of equipment onto a boom helps minimize equipment and cord clutter and allows unencumbered mobility of the surgical team
- A flexible tipped camera is ideal to position the surgical assistant's hands and the camera's light cord away from the surgeon
- Low lithotomy or split leg positioning allows free access and movement of the surgeon around the patient to accommodate a specific quadrant of surgical focus
- Clashing of instruments can be avoided by the use of low profile ports, staggering of ports, and use of variable length instruments/scope
- Utilize techniques of inverse triangulation

Introduction

The laparoscopic approach to colectomy has gained significant acceptance for the management of benign and malignant colorectal diseases [1–18]. Laparoscopic colectomy has distinct advantages over the open approach, including shorter hospital stay, reduced postoperative pain, decreased wound

complications, and better cosmesis [1–19]. Innovation in minimally invasive surgical techniques has resulted in the introduction of single-incision laparoscopic surgery (SILS) to further enhance outcomes of conventional laparoscopy. This platform uses a single incision for both multiport access and specimen extraction, reducing the number of incisions, pain, and cosmesis further [20–41]. However, the use of laparoscopic instruments in close proximity, or co-linear instrument management, hinders ergonomics and creates technical challenges for visualization, dissection, triangulation, and retraction. This focused area of activity, where all surgical equipment and instrumentation work through a single multiport access incision, increases the technical challenges of the procedure. Therefore, room setup, equipment, and patient positioning are extremely important for the successful completion of a SILS colectomy.

This chapter describes our experience and successful performance of SILS colectomy at our institution. It is certainly recognized that there are alternative equipment and approaches that may be equally or more suitable for individual surgeons [35]. We welcome those performing these procedures to augment and revise these suggestions to fit individual practices and hospital resources. Furthermore, it is important to remember that optimal choices will change with time, surgeon experience, the patient characteristics, and the availability of newer technology and equipment.

Room Setup

The ideal operating room setup should be efficient and organized for the entire surgical team to enhance workflow and ensure success in SIL operations. The room must be of sufficient size to hold the necessary equipment and to position the patient to allow for unencumbered movement of the surgical team. If operating room design allows, the ideal placement of insufflation, digital recording technology, high-resolution printer, and generators should be placed on a single boom to

N.E. Sharp, MD
General Surgery Resident PGY-5, Baylor Scott & White
Healthcare, Scott & White Memorial Hospital and Clinic,
2401 S. 31st Street, Temple, TX 76508, USA
e-mail: nsharp@sw.org

H.T. Papaconstantinou, MD, FACS, FASCRS (✉)
Department of Surgery, Section of Colorectal Surgery, Texas A&M
Health Science Center College of Medicine, Baylor Scott & White
Healthcare, Scott & White Memorial Hospital and Clinic,
2401 S. 31st Street, Temple, TX 76508, USA
e-mail: hpapaconstantinou@sw.org

enhance mobility and allow for free access and movement around the patient [1]. A unified location of equipment also allows for consolidation of cord clutter. Cords should be directed off the head of the bed to avoid entanglement when movement is necessary. Carbon dioxide piping into the room is ideal; however, if individual tanks must be used then spare tanks need to be present in the room to avoid tank change delays [1]. Monitor size and location are important, and must be visible to both the surgeon and camera driver. Ceiling mounted monitors allow for easy monitor adjustment when operations require surgeon movement around the operating room table. For SIL colorectal operations, this is frequently the case as the operations require focus on multiple quadrants of the abdomen. The surgeon will typically be positioned on the opposite side of the table as the surgical specimen or abdominal quadrant of operative activity. Due to the confined three-dimensional working footprint required in performing SIL colorectal operations, the surgeon and camera driver are frequently in each other's space. At times, the surgeon or camera driver may choose to stand between the patient's legs to move the camera shaft away from the operative instruments to allow adequate space to facilitate unencumbered instrument movement. Ideally, the camera driver should be positioned opposite the surgeon; however, for right colectomy and splenic flexure mobilization, the surgeon and assistant are located on the same side. The surgical technician and instrument table are typically positioned on the patient's right side at the foot of the bed. Most commonly, the primary monitor is placed at the hip of the patient on the same side as the colectomy (e.g., left hemicolectomy has monitor on the left side of patient with surgeon positioned on right side of patient). The secondary monitor is placed on the opposite side at the shoulder level primarily for the assistant's use or for the surgeon's use if standing between the patient's legs [2].

Figure 3.1a, b- Ideal room setup for most laparoscopic colorectal procedures. The room setup should allow for the unencumbered movement of the surgeon and assistant along the golden pathway to enhance both ergonomics and time efficiency.

Equipment

The equipment needs for SILS colorectal operations are similar to equipment needs for any standard laparoscopic procedures. There are a few notable exceptions, and these equipment needs are directly related to co-linear instrument management and the visualization challenges with the camera on the same axis as the instruments. There are multiple options for laparoscopic stapling devices and SILS access platforms, which may be left up the surgeon discretion. The single-site multiport concept of SILS colorectal surgery may hinder ergonomics and create technical challenges for effec-

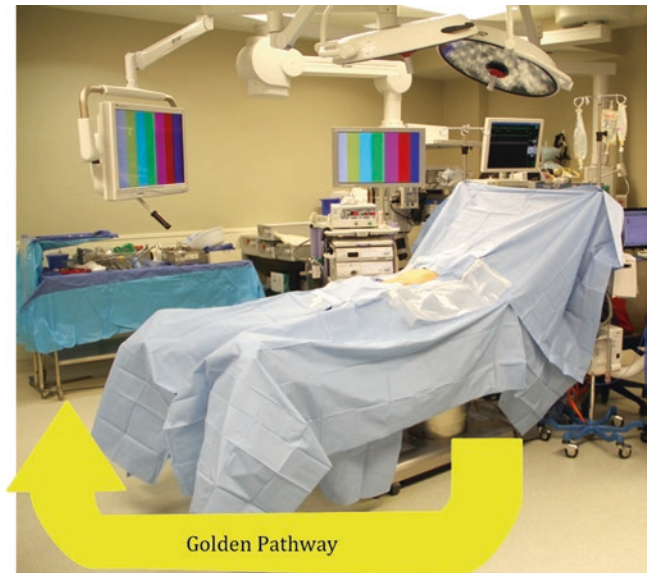

Fig. 3.1 Ideal room setup for laparoscopic colorectal procedures. The unobstructed movement of the surgeon and assistant around the patient's body is aided by maintaining the golden pathway illustrated below

tive visualization, dissection, triangulation, and retraction. It has been our experience that successful completion of SILS colorectal operations is dependent upon availability and use of a few standardized surgical tools that can help the surgeon overcome the challenges associated with co-linear instrument management in a confined space. In this section, we will focus on what we feel are necessary equipment and instruments for SIL colorectal surgery.

The challenge with visualization in SILS is the on-axis view obtained when using a single incision as the site for multiport access of the camera and instruments (Fig. 3.2a–c). Use of reverse triangulation and a bariatric length camera can improve visualization (Fig. 3.2b). Camera options also exist that can help overcome this obstacle and provide a side view of instruments, which include a flexible tip, or rigid 30 or 45 degree 5 or 10 mm camera, with possible addition of a right angle adaptor (shaft size of the camera will depend on the multiport SIL platform used) (Fig. 3.2d). In our experience, we prefer a high-definition flexible tip, 5 mm camera (ENDOYE, Olympus Medical Center Valley, PA) as it allows precise adjustment of the camera angle to obtain an optimal view, adequate space to reduce collision between instruments, and avoids crowding of the surgeons hands and the camera driver (Fig. 3.3a–c). Depending on the access device utilized, use of a 5 mm camera frees up a 10 mm port for a stapling device. Rigid 30° or 45° cameras can be effective, but we suggest using a bariatric length camera (45 cm) as it places the camera driver's hands a distance away from the surgeon's hands to further avoid external collision. If a rigid scope is preferred

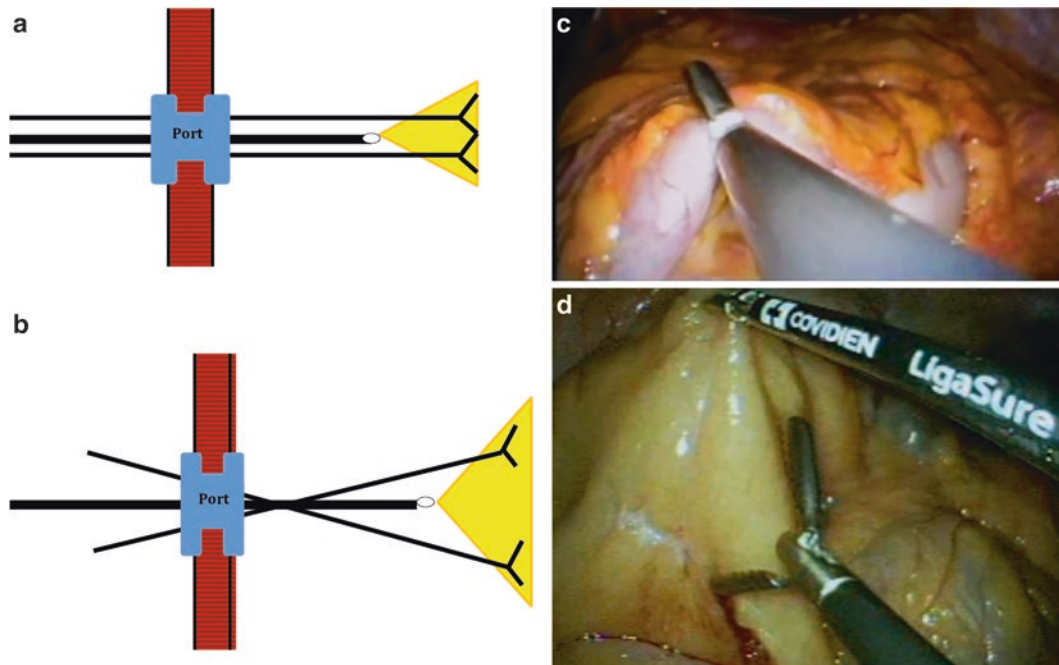


Fig. 3.2 Camera options. (a) 0° standard length camera using traditional laparoscopic triangulation techniques. Note that clashing and crowding are inevitable. Visualization is minimized by on-axis view and collinear instrument management. (b) 0° bariatric length scope using techniques of reverse triangulation maximize visualization while

decreasing crowding of the instruments and camera at port level and in the body. (c) Intraoperative on-axis view showing poor visualization (d). Intraoperative view with a flex tip camera showing side view with enhanced visualization

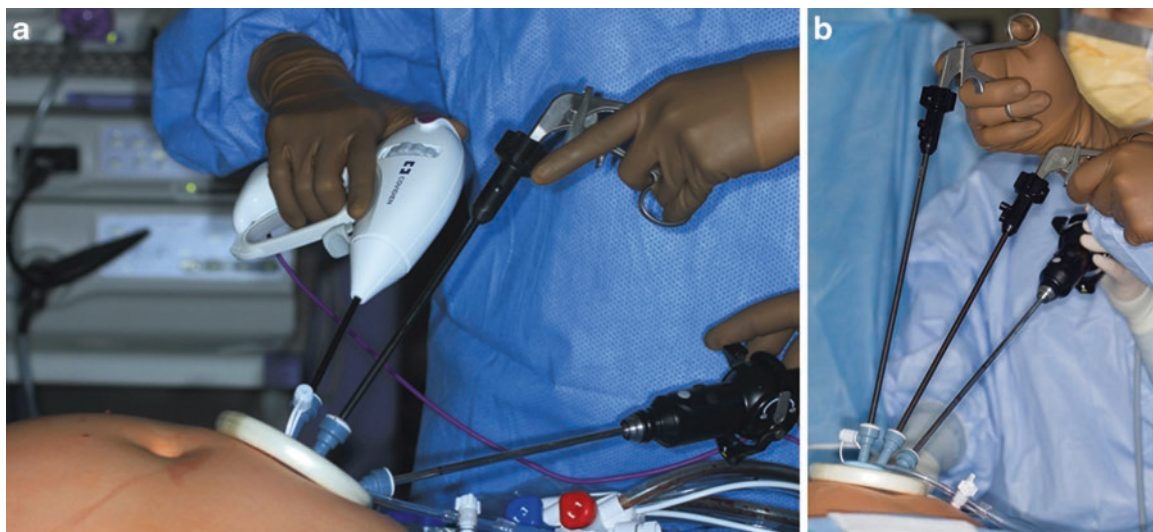


Fig. 3.3 Use of a flexible tip camera positions the assistant's hands further from the surgeon's working ports to decrease collision and crowding. Instruments can be rotated 90° to further enhance the work-

ing room between the surgeon's hands (b). Bariatric length camera further positions the assistant's hands away from the surgeon to maximize working room for the surgeon

or all that is available, we recommend cameras with in-line light cords to avoid hindrance. If a camera that requires insertion of the light cord into the shaft is utilized, a right angle adapter is advantageous to create a lower profile [35]. Camera optics are illustrated in Fig. 3.2.

Crowding or clashing of instruments and hands around the port site can be frustrating occurrence with SIL surgery. There are some basic steps that can be taken to minimize clashing which starts with the use of low-profile trocars and staggering of the heights of the trocars to minimize crowding (Fig. 3.4).

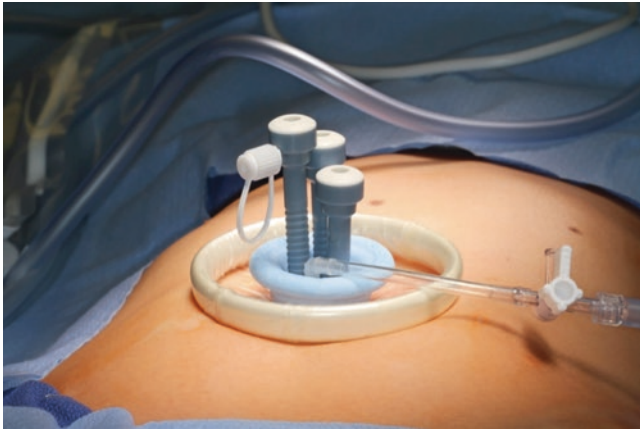

Fig. 3.4 Low-profile trocars can be staggered in height to maximize ergonomics of any single-incision laparoscopic procedure. We routinely use the SILS™ (Covidien, Norwalk, CT) multiple access port with three 5 mm trocars staggered in height inside of a medium-sized Alexis wound retractor® (Applied Medical, Rancho Santa Margarita, CA)

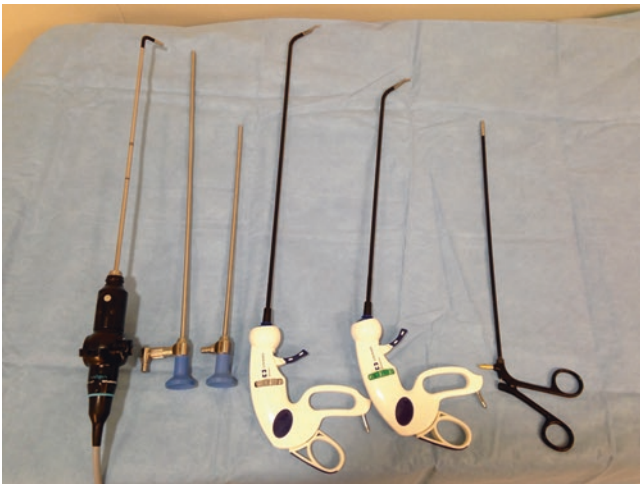

Fig. 3.5 Laparoscopic instruments (a) Flexible tip camera with 90° flexion demonstrated (Olympus Surgical, Orangeburg, NY) (b) 30° bariatric length camera (Stryker® Kalamazoo, MI) (c) 30° standard length camera (Stryker® Kalamazoo, MI) (d) Bariatric length articulating shears (Covidien, Norwalk, CT) (e) Standard length articulating dissector (Covidien, Norwalk, CT) (f) Standard length atraumatic bowel grasper (Mock Medical, Terril, IA)

The surgeon can avoid hand collisions with the camera by inverting the handles of the instruments to 90° or 180° to increase operative space (Fig. 3.3a). Bariatric length atraumatic bowel graspers (45 cm shafts versus conventional 34 cm shafts) may be particularly useful to minimize external collisions and for dissection of flexure regions (Fig. 3.5) [37, 38]. Additional triangulation can be obtained by the use of a single-bariatric length grasper in the nondominant hand and further allow more space externally between the surgeon's right and left hand [39]. However, necessity of extra-long instruments can often be avoided by simple reinsertion of the

instruments and camera into different port locations (if a fixed one piece platform is used) or rotation of the port device (if a two-piece access port device is used) to gain proximity to the dissection area [37, 40].

Laparoscopic surgery emphasizes the use of triangulation, which results from insertion of the camera and working ports through separate incisions to allow optimal visualization and traction. Initial SILS experience can result in technical difficulties with instruments working in line with the camera due to lack of range of motion and triangulation creating a chopstick or sword fighting effect [37]. Advocates of SILS have introduced a technique of inverse triangulation where instruments are crossed upon insertion resulting in the working ends of the two instruments not encountering each other but resulting in improved traction and ultimately visualization (Fig. 3.2) [37]. Other dissection techniques that can be utilized during SILS include avoidance of left to right traction in favor of up and down or in and out traction and countertraction.

Articulating instruments have been developed as an alternative to the use of standard laparoscopic instruments [37–39]. The use of two articulating instruments was originally adapted to enhance triangulation. Articulating instruments often sacrifice the transmission of constant force, ability to maintain retraction, and tactile feedback [37]. Reliance on these instruments also adds additional financial cost to the case. Furthermore, use of two articulating instruments can be technically challenging. This can be overcome by the use of one articulating instrument with one straight instrument. We have not found that articulating instruments add value to SILS colectomy or successfully overcome some ergonomic and technical challenges.

Use of extracorporeal sutures and magnetic retraction has also been described to enhance triangulation [19, 37]. This has been reported to be useful in patients with a narrow pelvic cavity requiring a total mesorectal excision or in women with a uterus obstructing the pelvic view [37, 41]. Specialized retractors such as the 10-mm Endo Retract (Covidien, Mansfield, MA, USA) or the Snowden-Pencer® laparoscopic articulating retractors (CareFusion, Waukegan, IL) can be useful to gain additional exposure [14]. Transrectal placement of an assistant's digit, stapler or a colonoscope can also assist in visualization, tension, and dissection in the pelvis [37].

There are several options for vessel sealing devices such as the Harmonic scalpel (Ethicon Endo-Surgery, Cincinnati, OH, USA), Enseal (Ethicon Endo-Surgery, Cincinnati, OH, USA), or Ligasure™ (Covidien, Mansfield, MA, USA), which all work well in a SILS procedure and can largely be left up to surgeon preference. In our experience, we have used all three and found there is no difference in outcome or quality of vessel sealing if the instruments are used correctly and as indicated. We do prefer the Enseal or Ligasure as

these instruments can be used as graspers and for blunt dissection when needed. In addition, these multiuse instruments eliminate the need to remove and reinsert different instruments, which can effectively improve efficiency and reduce operative time.

Depending on the chosen access device, a wound protector may be incorporated into the port (GelPort, Applied Medical, Rancho Santa Margarita, CA, USA). If using another platform, then a wound protector, such as the Alexis wound protector (Applied Medical, Rancho Santa Margarita, CA, USA), should be utilized to protect the wound during specimen extraction and extracorporeal anastomosis when applicable. We routinely use this type of retractor and find it very useful to maintain small access incisions and effectively extract the specimen. When using the wound protector, assure you do not dial down on the abdominal wall too tightly or necrosis could occur.

Patient Positioning

Patients are initially placed supine on the operating table for induction of general anesthesia. We routinely insert an orogastric tube and Foley catheter for all laparoscopic colorectal procedures. Positioning of the patient's perineum is important to allow for access to the anus for stapling when necessary [4].

Arms should be tucked whenever possible. If one arm must be out on an arm board due to body habitus or need for anesthesia IV access, the arm ipsilateral to the colonic pathology should be chosen to allow enough room for the assistant to stand beside the surgeon, if needed [4].

Optimal patient positioning can minimize the lack of triangulation. Care should be taken to ensure the patient is secured to the operating table, as exposure can be greatly improved with the use of steep Trendelenburg and rotation of the patient away from the operative location to utilize gravity to facilitate countertraction [14]. A standard process to secure the patient should be developed for your surgical team and may include a combination of vacuum bean bags [20]. Velcro straps and tape can be effective. We suggest you perform a trial of extreme positioning before prepping and draping the patient as this will allow the surgical team to test the patient's stability on the bed and alleviate any fears that the patient will fall from the table during the operation.

We routinely utilize split leg positioning for all colorectal procedures. We feel this position allows for the surgeon to stand between the patient's legs to assist in dissection which is especially useful for total colectomies or splenic flexure mobilization [4]. Furthermore, it keeps the hips and legs in neutral position and avoids obstructive movement when the surgeon and camera driver are working in the upper abdomen. Common alternative positions described for laparo-

scopic colectomy include supine and lithotomy [4, 7]. Care should be taken to meticulously pad and protect the patient once positioned to decrease the risk of positional injuries. If rotation of the table is utilized, the patient should be flattened whenever possible to decrease the risk of thromboembolism.

Conclusion

This chapter points out intraoperative techniques to improve the ergonomics and success of SILS colectomy. Expertise in laparoscopy is necessary to complete these procedures. Techniques to avoid clashing and crowding are necessary to minimize difficulty with SILS. Use of specific equipment and laparoscopic techniques that aid in the success of the procedure includes the use of inverse triangulation and rotation of the instruments in the surgeon's hands. Use of the operating room setup, positioning, and equipment described should facilitate the surgeon's success with SILS colectomy.

Acknowledgment Special thanks to our diagram artist Dr. John Hendricks.

References

1. Delaney CP, Neary PC, Heriot AG, Senagore AJ. Instrumentation and setup. In: Brown B, Seto J, editors. *Operative techniques in laparoscopic colorectal surgery*. Philadelphia: Lippincott Williams & Wilkins; 2007. p. 21–34.
2. Delaney CP, Neary PC, Heriot AG, Senagore AJ. Key operative steps. In: Brown B, Seto J, editors. *Operative techniques in laparoscopic colorectal surgery*. Philadelphia: Lippincott Williams & Wilkins; 2007. p. 37–58.
3. Guller U, Jain N, Hervey S, et al. Laparoscopic vs open colectomy: outcomes comparison based on large nationwide databases. *Arch Surg*. 2003;138:1179–86.
4. Clinical Outcomes of Surgical Therapy Study Group. A comparison of laparoscopically assisted and open colectomy for colon cancer. *N Engl J Med*. 2004;350:2050–9.
5. Delaney CP, Kiran RP, Senagore AJ, et al. Case-matched comparison of clinical and financial outcome after laparoscopic or open colorectal surgery. *Ann Surg*. 2003;238:67–72.
6. Becattini C, Robdelli F, Vedovati MC, et al. Incidence of risk factors for venous thromboembolism after laparoscopic surgery for colorectal cancer. *Haematologica*. 2015;100(1):e35–8.
7. Lacy AM, Garcia-Valdecasas JC, Pique JM, et al. Short-term outcome analysis of a randomized study comparing laparoscopic vs open colectomy for colon cancer. *Surg Endosc*. 1995;9:1101–5.
8. Lacy AM, Garcia-Valdecasas JC, Delgado S, et al. Laparoscopy-assisted colectomy versus open colectomy for treatment of nonmetastatic colon cancer: a randomized trial. *Lancet*. 2002;359:2224–9.
9. Kaiser AM, Kang JC, Chan LS, Vukasin P, Beart RW Jr. Laparoscopic-assisted vs open colectomy for colon cancer: a prospective randomized trial. *J Laparoendosc Adv Surg Tech A*. 2004;14:329–34.
10. Guillou PJ, Quirke P, Thorpe H, et al. MRC CLASICC trial group. Short-term endpoints of conventional versus laparoscopy-assisted surgery in patients with colorectal cancer (MRC

- CLASICC trial): multicentre, randomised controlled trial. *Lancet*. 2005;365:1718–26.
11. Gao F, Cao YF, Chen LS. Meta-analysis of short-term outcomes after laparoscopic resection for rectal cancer. *Int J Color Dis*. 2006;21:652–6.
 12. Fleshman J, Sargent DJ, Green E, et al. Clinical outcomes of surgical therapy study group. Laparoscopic collection for cancer is not inferior to open surgery based on 5-year data from the COST study group trial. *Ann Surg*. 2007;246:655–62.
 13. Bonjer HJ, Hop WC, Nelson H, et al. Transatlantic Laparoscopically assisted vs open colectomy trial study group. Laparoscopically assisted vs open colectomy for colon cancer: a meta-analysis. *Arch Surg*. 2007;142:298–303.
 14. Jayne DG, Guilou PJ, Thorpe H, et al. UK MRC CLASICC trial group. Randomized trial of laparoscopic-assisted resection of colorectal carcinoma: 3-year results of the UK MRC CLASICC trial group. *J Clin Oncol*. 2007;25:3061–8.
 15. Veldkamp R, Kuhry E, Hop WC, et al. Colon Cancer laparoscopic or open resection study group (COLOR). Laparoscopic surgery versus open surgery for colon cancer: short-term outcomes of a randomized trial. *Lancet Oncol*. 2005;6:477–82.
 16. Delaney CP, Chang E, Senagore AJ, Broder M. Clinical outcomes and resource utilization associated with laparoscopic and open colectomy using a large national database. *Ann Surg*. 2008;247:819–24.
 17. Delaney CP, Marcello PW, Sonoda T, Wise P, Bauer J, Techner L. Gastrointestinal recovery after laparoscopic colectomy: results of a prospective, observational, multicenter study. *Surg Endosc*. 2010;24:653–61.
 18. Jayne DG, Thorpe HC, Copeland J, Quirke P, Brown JM, Guillo PJ. Five-year follow-up of the Medical Research Council CLASICC trial of laparoscopically assisted versus open surgery for colorectal cancer. *Br J Surg*. 2010;97:1638–45.
 19. Delaney CP, Brady K, Woconish D, Parmar SP, Champagne BJ. Towards optimizing perioperative colorectal care: outcomes for 1,000 consecutive laparoscopic colon procedures using enhanced recovery pathways. *Am J Surg*. 2012;203:353–5.
 20. Keller DS, Haas EM. Single-incision laparoscopic colon and rectal surgery. *Clin Colon Rectal Surg*. 2015;28:135–9.
 21. Vasilakis V, Clark CE, Liasis L, Papaconstantinou HT. Noncosmetic benefits of single-incision laparoscopic sigmoid colectomy for diverticular disease: a case-matched comparison with multiport laparoscopic technique. *J Surg Res*. 2013;180:201–7.
 22. Poon JT, Cheung CW, Fan JK, Lo OS, Law WL. Single-incision versus conventional laparoscopic colectomy for colonic neoplasm: a randomized, controlled trial. *Surg Endosc*. 2012;26:2729–34.
 23. Chambers WM, Bicsak M, Lamparelli M, Dixon AR. Single-incision laparoscopic surgery (SILS) in complex colorectal surgery: a technique offering potential and not just Cosmesis. *Color Dis*. 2011;13:393–8.
 24. Bulut O, Nielsen CB, Jespersen N. Single-port access laparoscopic surgery for rectal cancer: initial experience with 10 cases. *Dis Colon Rectum*. 2011;54:803–9.
 25. Makino T, Milsom JW, Lee SW. Single-incision laparoscopic surgeries for colorectal disease: early experiences of a novel surgical method. *Minim Invasive Surg*. 2012;2012:783074. doi:10.1155/2012/783074.
 26. Rieger NH, Lam FF. Single-incision laparoscopically assisted colectomy using standard laparoscopic instrumentation. *Surg Endosc*. 2010;24:888–90.
 27. Makino T, Milsom JW, Lee SW. Feasibility and safety of single-incision laparoscopic colectomy- a systematic review. *Ann Surg*. 2012;255:667–76.
 28. Livraghi L, Berselli M, Bianchi V, Latham L, Farassino L, Coccoza E. Glovetechnique in single-port access laparoscopic surgery: results of an initial experience. *Minim Invasive Surg*. 2012;2012:415430. doi:10.1155/2012/415430. Epub 2012 Apr 5
 29. Ishida H, Okada N, Ishibashi K, Ohsawa T, Kumamoto K, Haga N. Single-incision laparoscopic-assisted surgery for colon cancer via a periumbilical approach using a surgical glove: initial experience with 9 cases. *Int J Surg*. 2011;9:150–4.
 30. Morelli L, Guadagni S, Caprili G, Candio G, Boggi U, Mosca F. Robotic right colectomy using the da Vinci single-site ® platform: case report. *Int J Med Robotics Comput Assist Surg*. 2013;9:158–61.
 31. Balaphas A, Hagen ME, Buchs NC, Pugin F, Volonte F, Inan I, Morel P. Robotically assisted laparoscopic single site surgery: a transdisciplinary review. *Int J Med Robot*. 2013;9:1–11.
 32. Lim SW, Kim HR, Kim YJ. Single incision laparoscopic colectomy for colorectal cancer: comparison with conventional laparoscopic colectomy. *Ann Surg Treat Res*. 2014;87:131–8.
 33. Papaconstantinou HT, Sharp N, Thomas JS. Single-incision laparoscopic right colectomy: a case-matched comparison with standard laparoscopic and hand-assisted laparoscopic techniques. *J Am Coll Surg*. 2011;213:72–80.
 34. Vestweber B, Galetin T, Lammerting K, et al. Single-incision laparoscopic surgery: outcomes from 224 colonic resections performed at a single center using SILS. *Surg Endosc*. 2013;27:434–42.
 35. Fung AK, Aly EH. Systematic review of single-incision laparoscopic colonic surgery. *Br J Surg*. 2012;99:1353–64.
 36. Ramos-Valdez DI, Patel CB, Ragupathi M, Bokhari MB, Pickron TB, Haas EM. Single-incision laparoscopic colectomy: outcomes of an emerging minimally invasive technique. *Int J Color Dis*. 2011;26:761–7.
 37. Kim SJ, Choi BJ, Lee SC. Overview of single-port laparoscopic surgery for colorectal cancers: past, present, and the future. *World J Gastroenterol*. 2014;20:997–1004.
 38. Romanelli JR, Earle B. Single-port laparoscopic surgery: an overview. *Surg Endosc*. 2009;23:1419–27.
 39. Marks JH, Montenegro GA, Shields MG, Frenkel JL, Marks GJ. Single-port laparoscopic colorectal surgery shows equivalent or better outcomes to standard laparoscopic surgery: results of a 190-patient, 7-criterion case-match study. *Surg Endosc*. 2015;29:1492–9.
 40. Chew MH, Wong MT, Lim BY, Ng KH, Eu KW. Evaluation of current devices in single-incision laparoscopic colorectal surgery: a preliminary experience in 32 consecutive cases. *World J Surg*. 2011;35:873–80.
 41. Uematsu D, Akiyama G, Magishi A, Nakamura J, Hotta K. Single-access laparoscopy left and right hemicolectomy combined with extracorporeal magnetic retraction. *Dis Colon Rectum*. 2010;53:944–8.

Considerations for Port Placement by Procedure, Incision Techniques, and Specimen Extraction

Deborah S. Keller

Introduction

Here we present technical considerations for incisions and port placement for various procedures. In addition to considering the positioning and incision, the editors want the surgeon to consider the 1–2–3 concept of SILS for the camera (1), grasper (2), and instruments (3). With this, visualization with the camera is the most important concept; the camera should be introduced, focused on the pathology, and not be moved. Then, the grasper should be positioned for optimal retraction and not moved while maintaining appropriate counter traction. Finally, the instrument is introduced, which should be constantly moving to progress while the grasper and camera are held still.

Positioning

Proper patient positioning is a critical step in surgical preparation. Proper positioning is necessary for optimal exposure of the surgical field and protecting the patient from iatrogenic injury and stress during surgery. We follow these general guidelines for all cases:

1. After intubation, prep the abdomen, laying towels over the xiphoid and pubis, and then perform an ultrasound-guided TAP infiltration. After the TAP infiltration, re-prep and drape.

Electronic Supplementary Material: The online version of this chapter (doi:[10.1007/978-3-319-63204-9_4](https://doi.org/10.1007/978-3-319-63204-9_4)) contains supplementary material, which is available to authorized users.

D.S. Keller, MS, MD (✉)
Division of Colorectal Surgery, Department of Surgery,
Baylor University Medical Center, Dallas, TX, USA
e-mail: debby_keller@hotmail.com

2. For right-sided resections, position supine. For all other procedures, position in modified lithotomy or split-leg table to facilitate endoscopy and intraluminal stapling.
3. To pad the arms, use an eggcrate sheet placed partly under the trunk to cradle the arms. Then, wrap the sheet over the arm and eggcrate, tucking it underneath the mattress.
 - (a) Assure the eggcrate extends from the elbow to the hand to protect the pressure points.
 - (b) If using lithotomy, use an additional 1/2 sheet of the eggcrate between the hand and Allen stirrups to prevent contact between the hand and the joint of the stirrups.
4. Place an upper body forced warm air wrap below the nipple level. Then, wrap 3" silk tape three times around to secure the patient.
 - (a) Pull the tape up, and then place it over the chest wall to assure it is not wrapped too tightly.
 - (b) When wrapping the tape around the bed, place behind the table base to help hold the arms in place, and avoid patent slippage when in Trendelenburg.
5. Place four towels on the abdomen to square off the surgical site; place wide if you anticipate adding lateral trocar sites.
6. Lay an Ioban drape over the surgical site.
 - (a) Pull the Ioban straight up, and then walk it across using your fingers to assure it lays on the abdomen without bubbles or wrinkles.
7. Place down sheet backwards, pulling the "head" over the legs and the "legs" up to anesthesia; cut the drape with a scissor to separate the legs, and then place the sterile leg covers over the down sheet.
8. Clamp sheet together on each side above the level of the stirrup.
9. Hand off laparoscopic wires, insufflation tubing, and energy sources, keeping the cord lengths on the field short; try to arrange the room so that all cords are directed in the same quadrant.

10. Place the Bovie and laparoscopic defogger toward the patient's head, securing to the drape.
11. All other cords are tucked into the pocket, exiting below the Velcro, and a clamp is placed below the cords.

Incisions

For right-sided, transverse, small bowel resections and total abdominal colectomies without a stoma, the single port is placed through a 2.5 cm incision at the umbilicus. For left-sided and rectal resections, the single port is placed through a 4 cm Pfannenstiel incision with one additional 5 mm port for the camera at the umbilicus (SILS +1 technique). Alternatively, the incision can be placed at the umbilicus for left-sided resections.

Umbilical Incision

1. 2.5 cm skin incision just below the umbilicus.
2. Open using back of 15-blade scalpel.
3. Transverse incision down to the fascia.
4. Release of umbilical stalk.
5. Release local intra-abdominal adhesions.
6. Place single-port sleeve or SILS port.
7. Insert trocars into GelPOINT cap (not necessary if using the SILS port).
8. Place one port just inside each of the three points of the triangle logo on the cap.
9. Bisect two ports with a 10 mm trocar for the camera.
10. Secure the cap on the sleeve.
11. Orient the insufflation port toward the patient's head, and attach the insufflation tubing to this port, leaving the switch port-free to vent smoke, as needed, during the procedure.
12. Instruments – two laparoscopic graspers, one energy source, 30° laparoscopic camera with a right-angle adaptor, or articulating tip laparoscopic camera.

Umbilical Placement

The umbilical port placement is the most versatile site, ideal for ileocolic, right, transverse, and total abdominal colectomy procedures, as well as small bowel resections. The key to this technique is amputating the umbilicus from the umbilical stalk, allowing full exposure.

Mark a 2.5 cm vertical incision site – 1 cm in the umbilicus and 1.5 cm below the umbilicus. Then, elevate the skin on each side of the mark, and incise the skin with the back of a 15-blade scalpel. Deepen the incision down through the dermis and subcutaneous tissue with cautery.

Insert Army-Navy or Double-Ended retractors for exposure. Palpate the umbilical stalk in the superior portion of the incision, and incise through the stalk to open the incision and expose the umbilical ring. Grasp on each side of the umbilical ring, and sharply open the fascia vertically to a length approximately 4 cm.

If using the Applied GelPOINT device, insert the ring and dial the ring down to fit against the abdominal wall. Insert a lap sponge into the abdomen and place the cap on the GelPOINT. If using the Medtronic SILS port, insert the lap sponge, and then insert the port. Insufflate the abdomen, insert the 30-degree laparoscopic camera, and survey the abdominal cavity.

Single Incision +1 (SILS +1)

1. 4 cm incision two fingerbreadths above the pubis through the skin for the Pfannenstiel incision.
2. Center the incision with the umbilicus, ensuring 2 cm on each side.
3. Dissect down to the fascia with electrocautery.
4. Incise the fascia with slight superior curvature at the lateral ends.
5. Create subfascial flaps.
6. Enter into the abdomen high in the midline.
7. Place SILS or SILS Port.
8. Insert trocars into GelPOINT cap (not necessary if using the SILS Port):
 - (a) Place one port just inside each of the three points of the triangle logo on the cap.
 - (b) Bisect two ports with a 10 mm trocar.
 - (c) Secure the cap on the sleeve.
9. Instruments – two laparoscopic graspers, one energy source, and 30° laparoscopic camera with a right-angle adaptor.
10. Under direct visualization, make a stab incision at the superior portion of the umbilical, and place a 5 mm port for the camera.

SILS +1 Incision

The SILS +1 incision combines a Pfannenstiel incision with an addition single port at the umbilicus, allowing an expanded field of view and exposure to the splenic flexure while reducing instrument fighting and external clashing. It is used for left-sided resections, such as sigmoid resection, left hemicolectomy, anterior resections, and rectal resections.

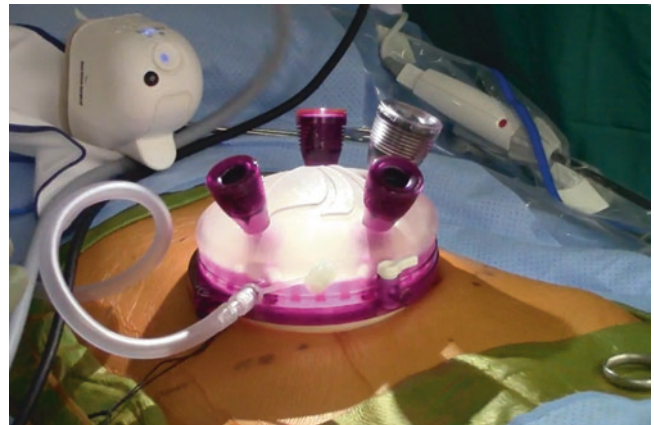
The patient's mons pubis is palpated and a mark is made 2 cm cephalad. The midline is confirmed, and a 4 cm mark is made to guide the incision. The skin is incised sharply with a 15-blade scalpel, and then the incision is deepened through

the dermis and subcutaneous tissue with cautery. Insert Army-Navy or Double-Ended retractors to expose horizontally as the incision is deepened to the rectus fascia. The fascia is incised horizontally, with an upward extension at the lateral edges so as not to enter the inguinal canal. The retractors are then replaced vertically for exposure as the flaps are developed. The upper fascial edge is grasped with two Kocher clamps, and an upper flap is developed several centimeters cephalad. Using a combination of blunt and cautery dissection, the muscle is released from the fascia. Care is taken to control any bleeding from perforating vessels. The lower flap is then developed in the same fashion. The underlying peritoneum is grasped at the midline and elevated and then sharply opened to permit a finger. The peritoneum is safely opened vertically over the operator's finger for a length of approximately 4 cm. There are currently two commercially available platforms available for use in the United States: the Applied GelPOINT and the Medtronic SILS Port. If using the Applied GelPOINT device, insert the ring and dial the ring down to fit against the abdominal wall. Insert a lap sponge into the abdomen, and place the cap on the GelPOINT. If using the Medtronic SILS port, insert the lap sponge, and then insert the port. Insufflate the abdomen, and insert the 30-degree laparoscopic camera. Using the 15-blade scalpel, a stab incision is made in the umbilicus. Under direct vision, a bladeless 5 mm port is placed toward the pelvis. The camera is switched to the umbilical port, and the abdomen is surveyed.

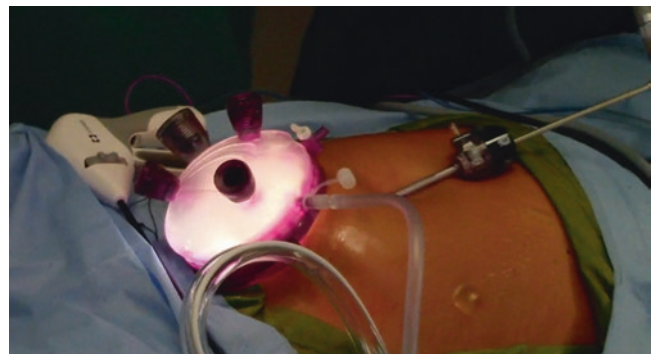Stoma Site

1. 2 cm skin disk incised at pre-marked stoma location.
2. Longitudinal incision made in the anterior rectus sheath to expose the rectus muscle.
3. Cruciate incision.
4. Rectus muscle spread to expose the peritoneum.
5. Peritoneum opened.
6. Place single-port sleeve or SILS Port.
7. Insert trocars into GelPOINT cap (not necessary if using the SILS Port).
8. Place one port just inside each of the three points of the triangle logo on the cap.
9. Bisect two ports with a 10 mm trocar for the camera.
10. Secure the cap on the sleeve.
11. Orient the insufflation port toward the patient's head, and attach the insufflation tubing to this port, leaving the switch port-free to vent smoke, as needed, during the procedure.
12. Instruments – two laparoscopic graspers, one energy source, and 30° laparoscopic camera with a right-angle adaptor.

A circular 2 cm incision is made with a 15-blade scalpel or cut setting of the electrocautery at the site of the predetermined stoma. The skin disk is excised, leaving the subcutaneous fat in place. The 2 cm disk should be approximately the size of a nickel. Insert Army-navy or Double-ended retractors to expose as the incision is deepened. A longitudinal incision is made in the anterior rectus sheath, exposing the rectus muscle. At the midpoint of the incision, 1 cm lateral extensions are made to "cruciate" the fascial incision. The rectus muscles are split and separated using a Kelly hemostat. The retractors are replaced deeper to aid exposure. The peritoneum is held with two hemostats and incised. Digital exam is performed to assure entry into the abdominal cavity. If using the Applied GelPOINT device, insert the ring and dial the ring down to fit against the abdominal wall. Insert a lap sponge into the abdomen and place the cap on the GelPOINT. If using the Medtronic SILS Port, insert the lap sponge, and then insert the port. Insufflate the abdomen, insert the 30-degree laparoscopic camera, and survey the abdominal cavity.



SILS placement at the umbilicus



SILS + 1 Configuration

Deborah S. Keller

Tips and Tricks

- Using a flexible tip laparoscopic camera or a right-angle adaptor on a standard laparoscopic camera will help reduce external collisions between the assistant and the operator.
- An experienced camera driver is helpful for SILS as the flexible tip camera has its own learning curve.
- Bariatric length instruments may reduce clashing between the surgeon's hands and the assistant's camera.
- Be patient – SILS has additional ergonomic demands and requires an additional learning curve compared to multiport laparoscopy. With time and experience, the platform is feasible.
- There are multiple commercial platforms available for SILS; the surgeon can choose a platform based on patient profile, disease variables, and surgeon preferences.
- If a commercial SILS platform is not available, the surgeon can fashion a port with a sterile surgical glove and standard laparoscopic ports.

Introduction

Single-incision laparoscopic surgery is known by many names – SILS, single-incision laparoscopic colectomy (SILC), single port access (SPA), laparoendoscopic single-site surgery (LESS), and natural orifice transluminal endoscopic surgery (NOTES). The platform was developed to advance multiport laparoscopic surgery in the direction of natural orifice transluminal endoscopic surgery (NOTES), a platform that garnered widespread attention but remains experimental in humans [1, 2].

D.S. Keller, MS, MD (✉)
Division of Colorectal Surgery, Department of Surgery,
Baylor University Medical Center, Dallas, TX, USA
e-mail: debby_keller@hotmail.com

The first report of SILS was in 1999, when a successful cholecystectomy was performed; the first colorectal application was in 2008 by Remzi and Bucher [3–5]. Since the initial cases, evidence has mounted and shown SILS is safe and feasible for both benign and malignant colorectal disease, with outcomes comparable to conventional laparoscopic surgery [6–13]. Unique benefits have also emerged for SILS, including reduced trauma from the lower number of incisions required for surgery, reduced perioperative pain, lower rates of port site-related complications, and improved cosmesis and patient satisfaction [13–18]. There is also the ability to easily convert to standard multiport laparoscopic surgery if additional ports are needed, maintaining an MIS approach [17].

Ergonomic Challenges

Despite the supporting evidence, the SILS platform has technical and ergonomic challenges that may limit extensive implementation. The benefit of this work is to understand these challenges and how to overcome them for successful application of SILS in practice. As with all new technology, obstacles can be overcome with experience and technical tricks. Overcoming these challenges requires additional time, costs, and development of skills distinct from multiport laparoscopy, especially in early cases [19–23]. With the single port, there is less overall freedom of movement, and the proximity of the instruments and the operative team is closer to each other during the operation than for conventional laparoscopy [17]. This can result in “crowding” of the instruments and the camera at the port site and external clashing of instruments and the operators [20]. Also, having the trocars at a fixed position in close proximity can lead to parallel alignment of instruments, restricting freedom of hand movements and adding internal technical difficulties. Further, there is a loss of the triangulation principle we are taught with conventional laparoscopic surgery and with the



Fig. 5.1 Olympus EndoEYE® Flex 3D Scope (Available online at <http://medical.olympusamerica.com/products/laparoscopes/endoeye-flex-3d>)

working arms and camera around the surgical target. SILS has the straight instruments working in parallel, leading to a “sword-fighting” effect between the working ports and the camera [24–26]. Several tools can help overcome these obstacles. The first is simply case experience. With case experience, the surgeon can become adept to internal crossing of instruments to help adapt to the parallel alignment of the instruments. The surgeons can also learn to stagger the instruments into the access device and switch hands to avoid clashing instruments.

In addition to experience, specialized equipment can give an advantage with SILS. A flexible laparoscopic camera, such as the EndoEYE™ (Olympus Medical, Center Valley, Pennsylvania, USA), which has an articulating 100° tip, increases the space between the operator and assistant and can view the pathology in all directions from any fixed angle (Fig. 5.1). This can reduce external collisions and eliminate the clashing of parallel instruments and the need to move the camera externally or exchange from straight to angled scope tips during the procedure to maintain a head-on directional view. If a flexible tip camera is not available, a right-angle light cord adapter with an inline camera head will work in the same fashion to enhance the ergonomics during SILS cases (Fig. 5.2). A posterior cable connection is also recommended to allow rotation of the camera without interfering with the instruments, further reducing external conflicts. An experienced assistant and camera driver are helpful for SILS, as the flexible tip camera has its own learning curve, and tricks, such as drawing the camera back toward the port can help to decrease conflict and optimize visualization, improve with experience.

Curved laparoscopic instruments were introduced specifically to address the internal sword fighting with SILS cases. While they may avoid internal clashing, there are



Visualization
Stryker Right Angle Adaptor
and 1288 Inline Camera Head

Fig. 5.2 Example of laparoscopic camera with right-angle adaptor (From Stryker. Available online at: http://www.stryker.com/en-us/GSDAMRetirement/index.htmstellent/groups/public/documents/web_content/126633.pdf)

increased external collisions, and they cannot be passed through conventional trocars; thus, we do not recommend these tools. Articulating instruments, with a flexible tip that rotates 360° around the axis of the instrument, have been recommended to increase freedom of motion and overcome the lack of triangulation with straight instruments in SILS [27–29]. However, there is a loss of rigidity and tactile feedback with these tools that adds further technical difficulty to the case; thus, the editors do not recommend them for SILS. We feel standard, straight laparoscopic instruments with the tricks aforementioned are the most effective for SILS. The straight instruments offer rigidity and tactile feedback and can transmit applied force evenly for the operator. Instruments are generally 5 mm in width and available in standard (34–35 cm) and bariatric/extra-long (44–45 cm) shaft lengths. The extra-long/bariatric length instruments may be helpful to stagger the port lengths and diminish external clashing between the surgeon’s hand and assistant’s camera.

Given the ergonomic challenges and higher technical difficulty with SILS compared with conventional laparoscopy, an additional learning curve is needed for proficiency [20, 21, 23, 30]. Studies have evaluated this learning curve in specific procedures for recommendations on how many cases are needed to ascend it. For a right hemicolectomy, a surgeon with advanced laparoscopic skills can reach baseline operative times and complication rates in ten cases [31]. Analysis of outcomes and operative time for a surgeon trained in advanced laparoscopic techniques found they are optimized following 40 SILS right colectomies [32]. Comparing the learning curve for SILS head to head to conventional multiport laparoscopy using a moving average of operative time and cumulative sum (CUSUM) analysis for right hemicolectomy, Park et al. found the learning phase of SILS was completed after 31 cases, while only 25 cases were needed for multiport laparoscopy; the CUSUM analysis demonstrated to reach a steady state of complication-free performance; ten SILS cases were needed compared to two multiport cases

[33]. Using a similar moving multidimensional analysis risk adjusted to evaluate low anterior resections for sigmoid colon cancer, Kim et al. found the cases required for proficiency (including operative time, hospital length of stay, and oncologic outcomes) with SILS were approximately 61–65 [34]. While these reports assess the learning curve in experienced laparoscopic surgeons, recent studies have shown SILS is safe and feasible in surgical training, with residents able to safely perform SILS colorectal resections with appropriate supervision [35].

Available Platforms

For SILS, there are several commercially produced platforms that are commonly used for access, as well as a home-made glove port that has been described. The most common ports are the GelPOINT® platform (Applied Medical, Rancho Santa Margarita, California, USA), the SILS™ Port (Covidien, Mansfield, Massachusetts, USA), and the TriPort or QuadPort (Olympus Medical, Center Valley, Pennsylvania, USA). The platforms all have the ability to introduce three or more working channels for instruments and a laparoscopic camera through a single port and single incision. The commercially available access devices are packaged with all essential trocars and parts and are compatible with all currently available laparoscopic instruments. Each platform has been proven effective for SILS, with individual benefits and drawbacks, so surgeon preference and availability can govern the access used.

With the GelPOINT® (Applied Medical, Rancho Santa Margarita, California, USA), Applied uses the successful same wound protector and cap design for SILS as for hand-assisted laparoscopic surgery (GelPort®) and transanal surgery (GelPOINT Path®) (Fig. 5.3). The sleeve is inserted into the abdominal cavity through a single fascial incision (usually ~ 4 cm) and then rolled down to create a secure seal. The desired trocars (5–12 mm) are introduced into the GelSeal® cap in a triangular fashion, and the cap is secured to the sleeve. Benefits of this port are that trocars can be repositioned or exchanged without affecting pneumoperitoneum and there is a smoke evacuator side port, which can aid visualization. In addition, the port has a low internal profile, and the sleeve is flexible, which helps to adapt to the patient's specific body habitus and abdominal wall size. Plus, the wound protector helps facilitate specimen extraction and offers protection from tumor seeding in malignant cases [36, 37]. Drawbacks of this port are the larger, dome-shaped external profile on the abdominal wall and that it may lose pneumoperitoneum with extreme torque and allow trocars to slip [24, 25].

The SILS™ Port (Covidien, Mansfield, Massachusetts, USA) is constructed from pliable elastomeric foam that is



Fig. 5.3 Applied GelPOINT® Port (From http://www.appliedmedical.com/Products/GelPoint_Overview.aspx)

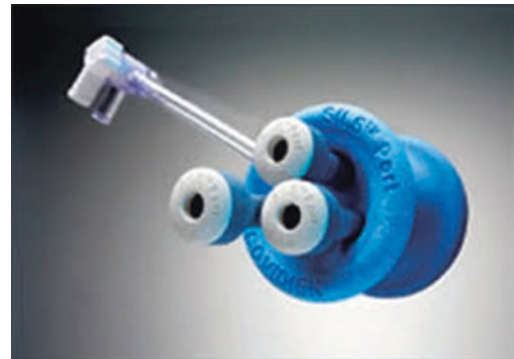

Fig. 5.4 Covidien SILS® Port (From <http://www.medtronic.com/covidien/products/trocar-access/sils-port>)

inserted through a single 2–4 cm skin and fascial incision (Fig. 5.4). Benefits of this port are that it creates a seal with the skin to maintain pneumoperitoneum and allows the surgeon to interchange 5 mm and 12 mm ports with ease and readily remove and reinsert the port as needed. The drawbacks are that the port is limited to three trocars for the instrument and camera and there is no wound protector for specimen extraction, necessitating port removal and a separate wound protector inserted for specimen extraction. The port's length is also fixed, which makes it prone to dislodgement if the fascial incision is too large and less ideal in obese or patients with a thick abdominal wall [24, 25].

The TriPort, TriPort15, and QuadPort (Olympus Medical, Center Valley, Pennsylvania, USA) are similar to the GelPOINT®, with three or four instrument channels, respectively, but a lower external profile (Fig. 5.5). The port is introduced through a single incision using the introducer from the kit with the distal ring attached. The distal ring and excess protector sleeve are then removed, the ring

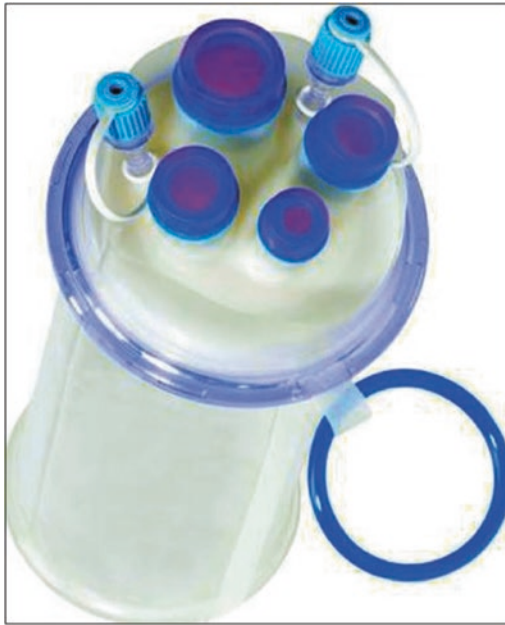

Fig. 5.5 Olympus QuadPort® (From <http://medical.olympusamerica.com/products/quadport-wa58030q>)

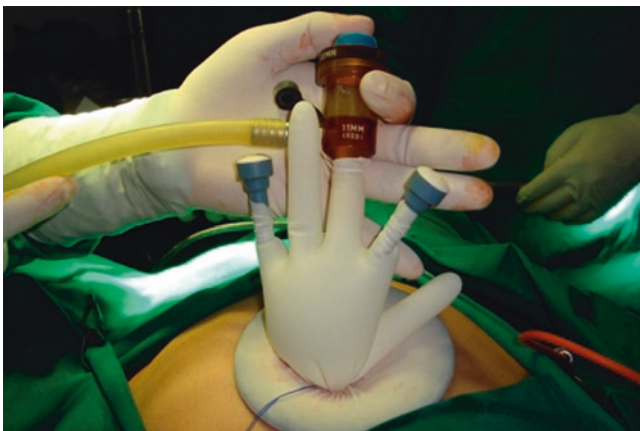

Fig. 5.6 Glove port (From Indian J Surg. 2011 Apr; 73(2): 142–145)

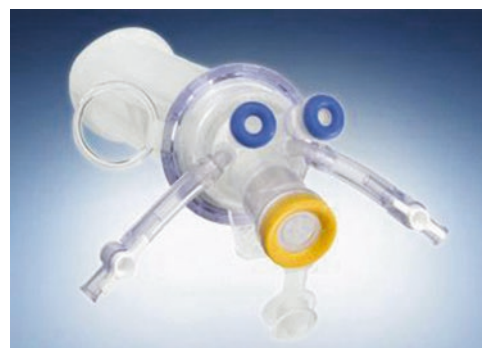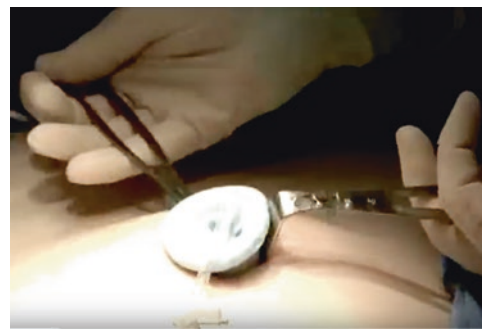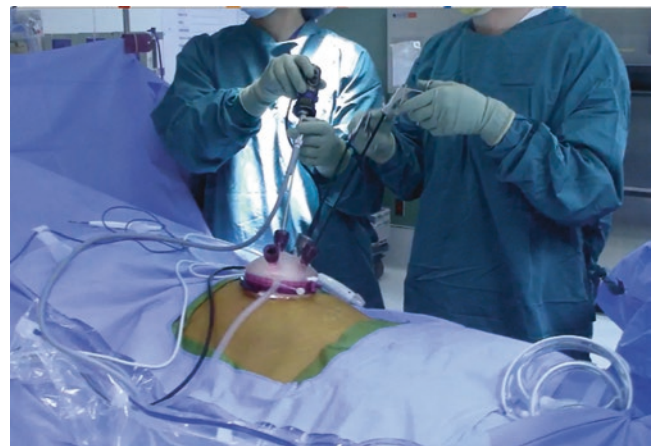is tightened to the abdominal wall, and insufflation commences. Drawbacks to these ports are that the assembly, insertion, and extracorporealization of specimens are reported more difficult than other platforms and the gel is reportedly prone to damage and leaks [24, 25]. Thus, they are not commonly used as the GelPOINT and SILS ports.

If a commercially available SILS port is not available, the surgeon can construct a glove port (Fig. 5.6). Reports have described a sterile, non-latex size 6 glove secured to a small wound protector, with the glove's fingers used for instruments and camera access as a cost-effective alternative to commercially available access platforms [38–41]. In addition to the cost advantage and simplicity of this port, the flexible finger extensions reduce the external trocar conflict

routinely experienced during SILS. Drawbacks are a poor seal, with loss of pneumoperitoneum, and lack of rigidity provided from the finger ports [12, 38–41].

Conclusions

Single-incision laparoscopic colorectal surgery is safe and feasible for a wide variety of procedures, with added potential benefits of improved cosmesis, perioperative pain, and quality of life. There are multiple ports available for access, as well as ergonomic and technical challenges, which can be overcome with experience and special tips and tricks. These pearls help ascension up the learning curve, to facilitate safe training and implementation of SILS into practice.



References

- Atallah S, Martin-Perez B, Keller D, Burke J, Hunter L. Natural-orifice transluminal endoscopic surgery. *Br J Surg*. 2015;102:e73–92.
- Cianchi F, Staderini F, Badii B. Single-incision laparoscopic colorectal surgery for cancer: state of art. *World J Gastroenterol*. 2014;20:6073–80.
- Piskun G, Rajpal S. Transumbilical laparoscopic cholecystectomy utilizes no incisions outside the umbilicus. *J Laparoendosc Adv Surg Tech A*. 1999;9:361–4.
- Remzi FH, Kirat HT, Kaouk JH, Geisler DP. Single-port laparoscopy in colorectal surgery. *Color Dis*. 2008;10:823–6.
- Bucher P, Pugin F, Morel P. Single port access laparoscopic right hemicolectomy. *Int J Color Dis*. 2008;23:1013–6.
- Law WL, Fan JK, Poon JT. Single-incision laparoscopic colectomy: early experience. *Dis Colon Rectum*. 2010;53:284–8.
- Papaconstantinou HT, Sharp N, Thomas JS. Single-incision laparoscopic right colectomy: a case-matched comparison with standard laparoscopic and hand-assisted laparoscopic techniques. *J Am Coll Surg*. 2011;213:72–80. discussion 80
- Chen WT, Chang SC, Chiang HC, et al. Single-incision laparoscopic versus conventional laparoscopic right hemicolectomy: a comparison of short-term surgical results. *Surg Endosc*. 2011;25:1887–92.
- Champagne BJ, Papaconstantinou HT, Parmar SS, et al. Single-incision versus standard multiport laparoscopic colectomy: a multicenter, case-controlled comparison. *Ann Surg*. 2012;255:66–9.
- Huscher CG, Mingoli A, Sgarzini G, et al. Standard laparoscopic versus single-incision laparoscopic colectomy for cancer: early results of a randomized prospective study. *Am J Surg*. 2012;204:115–20.
- Makino T, Milsom JW, Lee SW. Feasibility and safety of single-incision laparoscopic colectomy: a systematic review. *Ann Surg*. 2012;255:667–76.
- Moftah M, Nazour F, Cunningham M, Cahill RA. Single port laparoscopic surgery for patients with complex and recurrent Crohn's disease. *J Crohns Colitis*. 2014 Sep;8(9):1055–61. doi:10.1016/j.crohns.2014.02.003. Epub 2014 Feb 28. PMID: 24589026.
- Vasilakis V, Clark CE, Liass L, Papaconstantinou HT. Noncosmetic benefits of single-incision laparoscopic sigmoid colectomy for diverticular disease: a case-matched comparison with multiport laparoscopic technique. *J Surg Res*. 2013 Apr;180(2):201–7. doi:10.1016/j.jss.2012.04.063. Epub 2012 May 16.
- Poon JT, Cheung CW, Fan JK, Lo OS, Law WL. Single-incision versus conventional laparoscopic colectomy for colonic neoplasm: a randomized, controlled trial. *Surg Endosc*. 2012;26:2729–34.
- Chambers WM, Bicsak M, Lamparelli M, Dixon AR. Single-incision laparoscopic surgery (SILS) in complex colorectal surgery: a technique offering potential and not just cosmesis. *Color Dis*. 2011;13:393–8.
- Bulut O, Nielsen CB, Jespersen N. Single-port access laparoscopic surgery for rectal cancer: initial experience with 10 cases. *Dis Colon Rectum*. 2011;54:803–9.
- Far SS, Miraj S. Single-incision laparoscopy surgery: a systematic review. *Electron Physician*. 2016;8:3088–95.
- Hamabe A, Takemasa I, Hata T, Mizushima T, Doki Y, Mori M. Patient body image and satisfaction with surgical wound appearance after reduced port surgery for colorectal diseases. *World J Surg*. 2016;40:1748–54.
- Merchant AM, Cook MW, White BC, Davis SS, Sweeney JF, Lin E. Transumbilical Gelport access technique for performing single incision laparoscopic surgery (SILS). *J Gastrointest Surg*. 2009;13:159–62.
- Gaujoux S, Bretagnol F, Ferron M, Panis Y. Single-incision laparoscopic colonic surgery. *Color Dis*. 2011;13:1066–71.
- Champagne BJ, Lee EC, Leblanc F, Stein SL, Delaney CP. Single-incision vs straight laparoscopic segmental colectomy: a case-controlled study. *Dis Colon Rectum*. 2011;54:183–6.
- Park JS, Choi GS, Park SY, Kim HJ, Ryuk JP. Randomized clinical trial of robot-assisted versus standard laparoscopic right colectomy. *Br J Surg*. 2012;99:1219–26.
- Pucher PH, Sodergren MH, Singh P, Darzi A, Parakseva P. Have we learned from lessons of the past? A systematic review of training for single incision laparoscopic surgery. *Surg Endosc*. 2013 May;27(5):1478–84. doi:10.1007/s00464-012-2632-6. Epub 2012 Oct 17.
- Keller DS, Haas EM. Single-incision laparoscopic colon and rectal surgery. *Clin Colon Rectal Surg*. 2015;28:135–9.
- Keller DS, Flores-Gonzalez JR, Ibarra S, Haas EM. Review of 500 single incision laparoscopic colorectal surgery cases – lessons learned. *World J Gastroenterol*. 2016;22:659–67.
- Madhoun N, Keller DS, Haas EM. Review of single incision laparoscopic surgery in colorectal surgery. *World J Gastroenterol*. 2015;21:10824–9.
- Rao PP, Rao PP, Bhagwat S. Single-incision laparoscopic surgery – current status and controversies. *J Minim Access Surg*. 2011;7:6–16.
- Saber AA, El-Ghazaly TH. Single-incision transumbilical laparoscopic right hemicolectomy using SILS port. *Am Surg*. 2011;77:252–3.
- Trakarnsanga A, Akaraviputh T, Wathanaoran P, Phalanusitthepha C, Methasate A, Chinswangwattanakul V. Single-incision laparoscopic colectomy without using special articulating instruments: an initial experience. *World J Surg Oncol*. 2011;9:162.
- Kim SJ, Ryu GO, Choi BJ, et al. The short-term outcomes of conventional and single-port laparoscopic surgery for colorectal cancer. *Ann Surg*. 2011;254:933–40.
- Hopping JR, Bardakcioglu O. Single-port laparoscopic right hemicolectomy: the learning curve. *JLS*. 2013;17:194–7.
- Kirk KA, Boone BA, Evans L, Evans S, Bartlett DL, Holtzman MP. Analysis of outcomes for single-incision laparoscopic surgery (SILS) right colectomy reveals a minimal learning curve. *Surg Endosc*. 2015;29:1356–62.
- Park Y, Yong YG, Yun SH, et al. Learning curves for single incision and conventional laparoscopic right hemicolectomy: a multidimensional analysis. *Ann Surg Treat Res*. 2015;88:269–75.
- Kim CW, Kim WR, Kim HY, et al. Learning curve for single-incision laparoscopic anterior resection for sigmoid colon cancer. *J Am Coll Surg*. 2015;221:397–403.
- Tokuoka M, Ide Y, Hirose H, et al. Resident training in single-incision laparoscopic colectomy. *Mol Clin Oncol*. 2015;3:1221–8.
- Horiuchi T, Tanishima H, Tamagawa K, et al. Randomized, controlled investigation of the anti-infective properties of the Alexis retractor/protector of incision sites. *J Trauma*. 2007;62:212–5.
- Reid K, Pockney P, Draganic B, Smith SR. Barrier wound protection decreases surgical site infection in open elective colorectal surgery: a randomized clinical trial. *Dis Colon Rectum*. 2010;53:1374–80.
- Day W, Lau P. Novel “glove” access port for single port surgery in right hemicolectomy: a pilot study. *Surg Laparosc Endosc Percutan Tech*. 2011;21:e145–7.
- Livraghi L, Berselli M, Bianchi V, Latham L, Farassino L, Cocozza E. Glove technique in single-port access laparoscopic surgery: results of an initial experience. *Minim Invasive Surg*. 2012;2012:415430.
- Rodicio Miravalles JL, Rodriguez Garcia JJ, Llaneza Folgueras A, Aviles Garcia P, Gonzalez Gonzalez JJ. Single port laparoscopic colostomy using the glove technique. *Medicina (B Aires)*. 2014;74:201–4.
- Sirikurnpiboon S. Single-access laparoscopic rectal cancer surgery using the glove technique. *Asian J Endosc Surg*. 2014;7:206–13.

Jamie Murphy

Tips and Tricks

- The vertical midline incision is the most versatile, giving excellent surgical exposure for all dissection strategies, and is easily converted to a midline laparotomy if necessary; however, it does have the greatest risk of incisional hernia.
 - The author's preferred approach is lateral-to-medial dissection, as it replicates open surgery with views of the 'normal' operative planes; there are minimal requirements to layer the small bowel out of the surgical field, little to no input required from the assistant, simpler retraction, and better operative views due to the lack of dissection between mesocolic and retroperitoneal attachments.
 - In all but the thinnest patients, high ligation of the middle colic vessels is difficult to perform by a pure SILS technique due to the difficulty of gaining adequate retraction of the transverse mesocolon. Consequently, a 5 mm left iliac fossa port can be placed to facilitate the procedure.
 - Rectal dissection is the most challenging aspect of SILS colorectal surgery. If the operating surgeon intends to place a pelvic drain after rectal excision, then a 5 mm port in the left iliac fossa should be placed early – this will expedite the dissection and later serve as the skin incision through which the drain is placed.
 - During the rectal dissection, the temptation is for the surgeon to fully straighten the rectum during retraction, but it is more advantageous if a slight 'bowstring' is allowed, as it allows the plane between the rectum and anterior structures to be seen more easily.
- In complex cases where a phlegmon is present, such as Crohn's ileocolic or sigmoid disease, begin by fully mobilising the proximal and distal bowel using a lateral-to-medial approach, and then work cautiously to meet the dissection plane created above the mass and thus protecting any nearby ureters, vessels or nerves from the phlegmon. It is unwise to approach large phlegmons using a medial-to-lateral SILS approach due to the inability to retract a large mass.

Single-Port Incision and Access Device

The choice of incision through which to place the single-port access device is discussed in detail elsewhere (Chap. 4). It is, however, of significance with respect to dissection approaches and thus will be briefly discussed here. Broadly speaking there are four options available to the operating surgeon, which are vertical midline, transverse, intended stoma site and less commonly a Pfannenstiel incision. The vertical midline incision is by far the most versatile, giving excellent surgical exposure for all dissection strategies, easily converted to a midline laparotomy if necessary and strongly advised for the novice single-incision surgeon; however, it does have the greatest risk of incisional hernia. Transverse incisions are generally placed over the intended extraction site for the bowel and therefore have specific limitations. While a left muscle-splitting trans-rectus incision will usually be adequate for a right hemicolectomy in a thin or elderly patient, the corresponding right-sided incision will not always permit an oncological sigmoid or rectal resection due to the lateral nature of the incision. Placement of the access device at an intended stoma site works best when an ileostomy is to be constructed, as this generally grants good access to the left colon, with variable utility for the transverse colon or rectal dissection and acceptable access to the right colon when a total colectomy is being performed. In general, the placement of the single-incision

J. Murphy, BChir(Cantab.) PhD FRCS(Eng.) (✉)
Academic Surgical Unit - Imperial College, 10th Floor QEQM
Building, Praed St., London W2 1NY, UK
e-mail: jamie.murphy@doctors.net.uk

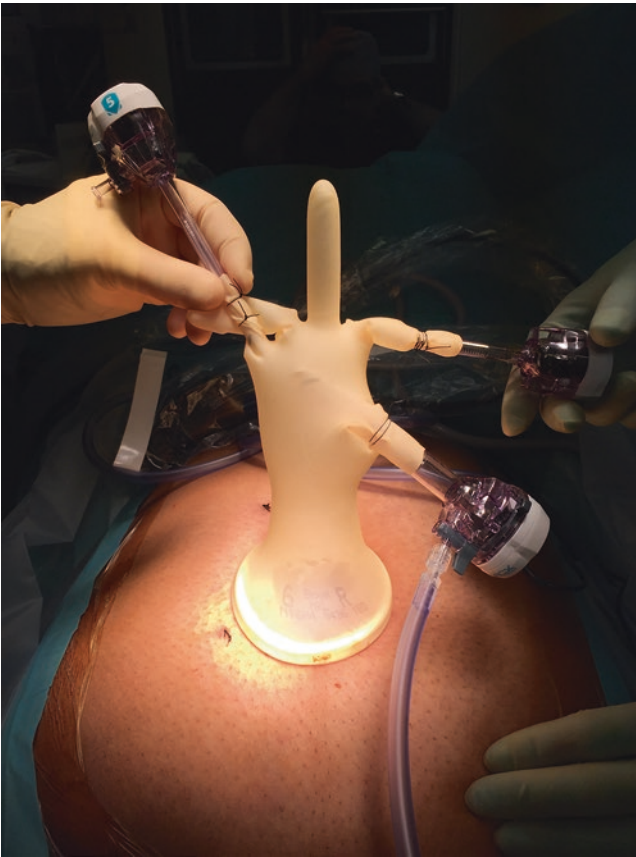

Fig. 6.1 'Glove-port' access device formed by use of conventional wound retractor, size 6 glove with three fingertips cut off and standard laparoscopic ports secured with non-absorbable suture ties

laparoscopic surgery (SILS) port via an intended colostomy site is less helpful and may only be of use when constructing a loop or end colostomy, unless the patient is elderly with a lax abdominal wall and colonic parietal attachments. A Pfannenstiel incision is really only of use when mobilising the sigmoid colon in a thin patient, as views of the transverse colon and flexures are limited due to the inferior nature of this incision.

The choice of access platform is usually an issue of personal preference. Experienced SILS surgeons may find the inexpensive 'glove-port' technique reduces instrument and camera clashes, increases surgical flexibility when performing colonic resections and decreases expenditure (Fig. 6.1); however, a more rigid conventional platform is usually necessary when performing rectal dissection. It must be remembered that more exaggerated retraction is required by the surgeon's non-dominant hand in SILS surgery as compared with conventional multiport laparoscopy. Furthermore, the retraction point may have to be more distant than is commonplace in conventional laparoscopic surgery to give the surgeon a view that is not obstructed by the instrument in their non-dominant hand.

Position, Anatomy and Body Habitus

The majority of commercially available access devices have no more than five ports, and it is often the case that the assistant will be unable to retract effectively for the operating surgeon due to ergonomics or limitations of the access device. Consequently, the surgeon has to use gravity as their 'third hand', which may necessitate more severe patient positioning than usual, with steep head-down/head-up and lateral tilt. As such, the patient may need to be more securely strapped to the table with shoulder and side supports, rather than the isolated use of a gel mat. The preferred patient position for specific points of colorectal mobilisation will be discussed later.

There are a number of anatomical considerations that may limit the progress of a single-port case. The most obvious is the presence of adhesions from prior surgery. Adhesions may be managed more easily by SILS as compared with multiport laparoscopy. The SILS port is placed by mini-laparotomy at which point 'open' adhesiolysis can be performed. This permits the creation of a working space more quickly and readily identifies whether laparotomy will be necessary or not. Generally, all colonic resections that are suitable for laparoscopy can be undertaken by SILS, assuming they are performed by an appropriately trained surgeon. The same, however, is not true for rectal dissection. In particular, a significantly raised sacral promontory may prevent rectal mobilisation due to straight instruments rocking on the promontory, a problem that will not easily be overcome even when curved or angled instruments are employed.

Patient habitus is an obvious problem that affects all laparoscopic procedures. When beginning a SILS practice, it is wise to only embark upon this technique if one anticipates a case could be completed relatively easily if it were performed by conventional laparoscopy. When the surgeon becomes more confident and attempts all laparoscopic procedures using SILS, it can be a surprise how infrequently additional ports are required. While the author has on occasion successfully completed SILS left colon or sigmoid resections for patients with a BMI > 50 patient, safety is paramount. This should never be compromised for the sake of placing extra laparoscopic ports or conversion to laparotomy.

Medial Versus Lateral Approach

While there are many ways to safely perform SILS colonic mobilisation, the author's preferred approach is lateral-to-medial dissection. The benefits this offers the surgeon are replication of open surgery with views of the 'normal' operative planes; minimal requirement to layer

the small bowel out of the surgical field, which can be challenging with SILS procedures in obese patients; little to no input required from the assistant, who is likely to lack experience with SILS ergonomics or camera holding; and simpler retraction and better operative views due to the lack of dissection between mesocolic and retroperitoneal attachments. Nevertheless, a medial-to-lateral approach is popular in the USA, the UK and Europe. For the purposes of this chapter, both lateral-to-medial and medial-to-lateral dissection techniques will be discussed, and as in the real world, a mixture of these approaches is often necessary to complete technically challenging SILS procedures.

Mobilizing the Right Colon

Lateral Approach

The operating table is placed in the head-down position with a left lateral tilt, and the surgeon stands at the left side of the patient. A lateral-to-medial dissection is commenced by retracting the appendix into the left upper quadrant with the left hand and using a combination of energy device dissection and gently sweeping from lateral to medial to free the colon, caecum and terminal ileum from their parietal attachments (Fig. 6.2). As a surgeon becomes more confident, he/she will find scissor dissection leads to more accurate separation of surgical planes. Only the lateral aspect of the duodenum is exposed and mobilised from the right colon at this point. Thereafter, the dissection is continued to the corner of the parietal peritoneum where the hepatic flexure is encountered.

The patient is then placed in the head-up position and continued left lateral tilt, with the appendices epiploicae of

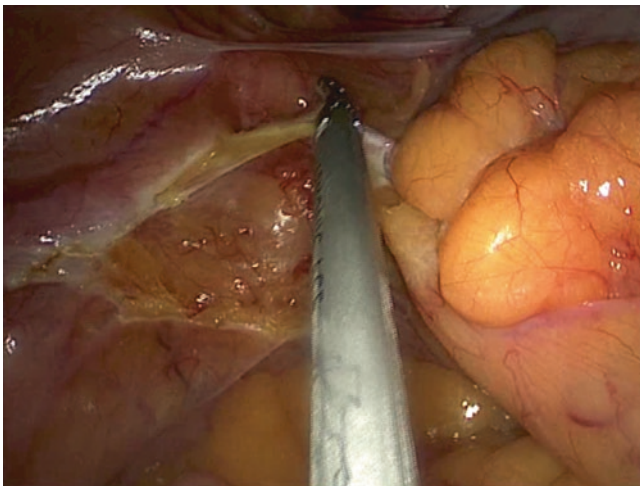


Fig. 6.2 Lateral-to-medial dissection of the caecum from the parietal peritoneum with an ultrasonic dissection device

the proximal transverse colon grasped close to the bowel by the left hand of the surgeon. The colon is then deflected downward in the direction of the right iliac fossa. An energy device is used to free the supracolic-parietal attachments of the proximal transverse colon and hepatic flexure to meet the previously developed plane. The use of diathermy scissors is discouraged at this point due to the relatively large vessels that will be encountered in this area. When the peritoneal attachments have been released, progressive retraction of the right colon towards the left iliac fossa is undertaken. This allows a plane to be developed between the retroperitoneal structures and the colon, over the anterior surface of the duodenum, by a combination of gentle sweeping movements and diathermy scissors dissection until the colon is fully mobilised.

Medial Approach

The patient is positioned in the same way as described above. The small bowel is placed in the left upper quadrant, and the ileocolic pedicle is identified following suspension of the ileocolic fat pad or meso-appendix by the left hand of the surgeon towards the abdominal wall. An energy device is then used in the surgeon's right hand to open the peritoneum underneath but parallel to the ileocolic vessels, up to the level of the superior mesenteric vein. After this is performed, the embryonic surgical plane can be seen and developed by blunt dissection towards the hepatic flexure. This plane is anterior to the duodenum, and this structure must be freed from the mesocolic fat prior to vessel division, or inadvertent duodenal injuries may occur (Fig. 6.3). The duodenum is best freed by downward blunt dissection. The lateral dissection under the

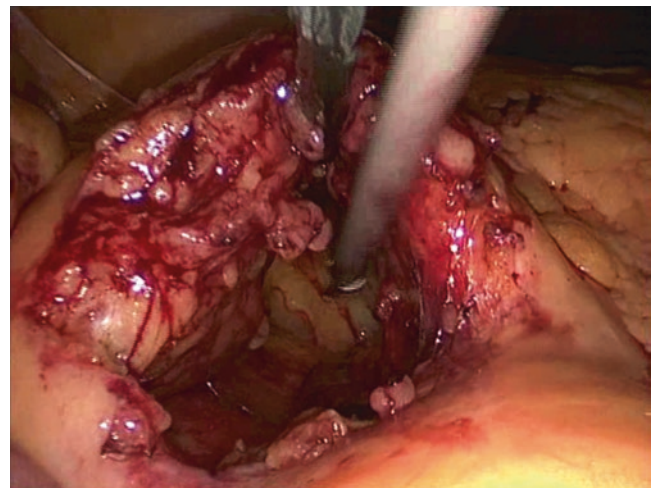


Fig. 6.3 Medial-to-lateral dissection of the right colon. Supra-duodenal tunnel created to mobilise the ileocolic vessels, which are suspended over the laparoscopic retractors. The duodenum can be seen within the tunnel on the right

colon is continued in a blunt manner in the same embryonic plane, as this will allow the operating surgeon to remain immediately above Toldt's fascia and thus protect the ureter. The remaining lateral attachments of the colon and the terminal ileum are released as previously discussed.

Mobilization of the Sigmoid Colon, Left Colon and Splenic Flexure

Lateral Approach

For this portion of the procedure, the operating room table is placed in the head-down position with right lateral tilt, and the surgeon stands on the right side of the patient. It is often easiest to free the sigmoid initially by utilising diathermy scissors rather than use an energy device, first by releasing any peritoneal attachments caused by diverticular disease or that are congenital in nature, before mobilising the sigmoid colon from Toldt's fascia, leaving the white line with the patient (Fig. 6.4). The surgeon's left hand should retract the colon towards the right side of the abdomen by sequentially holding appendices epiploicae along the colon while the right hand performs the dissection. The use of diathermy scissors is more precise and avoids any fusing of the embryonic planes that can occur with the use of energy devices. The ureter will be exposed during this dissection at the pelvic brim and easily identified during careful dissection, as is the case in open surgery. This mesocolic plane is then continued in order to mobilise the left colon until the point immediately distal to the splenic flexure.

The patient is then placed in a head-up position with continued right-sided tilt. The lateral aspect of the splenic flexure is then mobilised, with the surgeon's left hand grasping

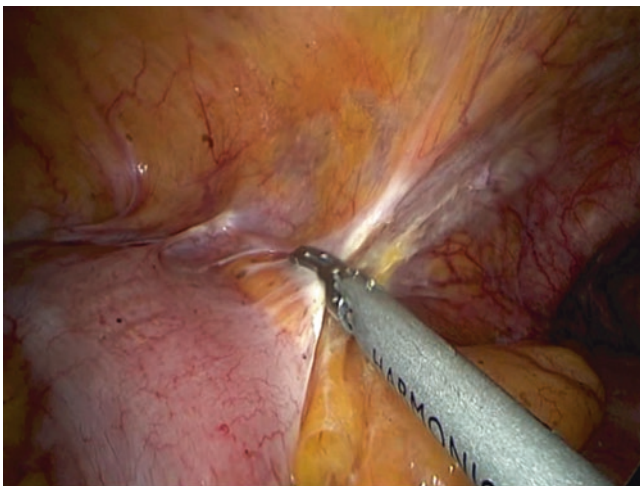


Fig. 6.4 Lateral-to-medial dissection of the descending colon from the parietal peritoneum with an ultrasonic dissection device

appendices epiploicae and retracting the flexure downward in the direction of the right iliac fossa. When this is performed to the maximum extent possible, mobilisation of the proximal aspect of the flexure is then undertaken. The surgeon's left hand retracts the left lateral remnants of the omentum upward to the abdominal wall and towards the patient's head, while an energy device is used to separate the hepatic flexure first from the omentum and then the parietal attachments of the colon. This part of the procedure can sometimes be challenging due to difficult retraction; however, gentle sweeping will reveal the operative planes and allow safe dissection. The splenic flexure is sequentially mobilised in a careful fashion from the pancreas to complete the dissection.

Medial Approach

Patient positioning is the same as for a lateral approach. The small bowel is placed in the right upper quadrant, and the inferior mesenteric artery pedicle is identified. This is best achieved by the left hand of the surgeon retracting the sigmoid mesocolon superiorly towards the abdominal wall, in order that the junction of the mesocolic and retroperitoneal fat can be identified. This peritoneum is opened from the top of the rectum to the inferior mesenteric artery with an energy device. The embryonic plane will then usually be easily identifiable, and the mesocolon can be freed from the retroperitoneum by a combination of upward and downward blunt dissection. Unlike a right colonic mobilisation, it is imperative that the ureter is identified prior to vessel division in a medial approach to the left colon. If this is difficult and the gonadal vessels are encountered, then the ureter can be found by dissecting deeper and medial to these structures until ureteric vermuculation is convincingly demonstrated. The blunt dissection should be continued out as far as possible past the gonadal vessels and to the level of, but not into, the holy rectal plane. Thereafter, the inferior mesenteric artery should be ligated and divided.

In order for the splenic flexure to be taken down and the proximal left colon fully mobilised, the blunt dissection immediately above Toldt's fascia must continue in the manner described above. The retraction on the colon is repositioned, so the surgeon's left hand is holding a more proximal part of the mesocolon, thereby placing the inferior mesenteric vein under tension from where it emerges from behind the duodenum. Ultimately, it will not be possible to continue the blunt dissection unless the inferior mesenteric vein is taken, after which the distal transected edge should be retracted upward in the left hand of the surgeon towards the abdominal wall. This will give better visualisation so that blunt dissection can be performed over the front of the pancreas and towards the gastrocolic and splenocolic ligaments.

Great care must be taken at this point so as to not injure the pancreas causing unnecessary bleeding or postoperative pancreatitis. Once this dissection is complete, the remaining lateral attachments are taken down as previously described.

Mobilization of the Transverse Colon

Transverse colonic mobilisation is a frequent concern of non-expert laparoscopists and can prove difficult for even the most experienced of minimally invasive surgeons. The preferred approach used for this dissection very much depends upon the disease process – if the middle colic artery is to be taken high in the setting of a flexure or transverse colon cancer, then, a medial-to-lateral approach is favoured. This can be very challenging when undertaken by a pure SILS technique. In the setting of benign disease, a less radical transverse mesocolic dissection is necessary. Therefore, it is the author's practice not to utilise a medial-to-lateral dissection when faced with benign pathology of the transverse colon, instead preferring a simpler lateral-to-medial dissection. Of note, the hepatic and splenic flexures will invariably have been taken down prior to this dissection.

Lateral Approach

The patient is placed in the head-up position with right-sided lateral tilt, which allows gravity to displace the small bowel into the lower abdomen and for the transverse colon to be naturally distracted downward. The surgeon stands on the right side of the patient. The greater omentum is reflected over the transverse colon onto the stomach, and the surgeon's left hand retracts the omentum upward to the abdominal wall and towards the head of the patient. This dissection usually begins immediately lateral to the falciform ligament and heads laterally to the splenic flexure. An energy device is used to release the omentum from the colon, thereby allowing the surgeon to enter the lesser sac. Once this is achieved, the retractor in the surgeon's left hand should be placed in the lesser sac in order to suspend the stomach and omentum, which will dramatically expedite the omental dissection (Fig. 6.5). After this is complete, a mesocolic window is made, and the dissection is again performed by allowing the colon to drop and placing the surgeon's left-handed retractor through this defect from above. This suspends the mesocolon to allow easy identification of the omental colonic interface and rapid transection with an energy device.

The patient is then placed in left lateral tilt with continued use of the head-up position, and the surgeon stands on the right side of the patient. The omentum is taken off the proximal transverse colon in the same fashion; however, transection of the mesocolon is slightly more difficult as the layers

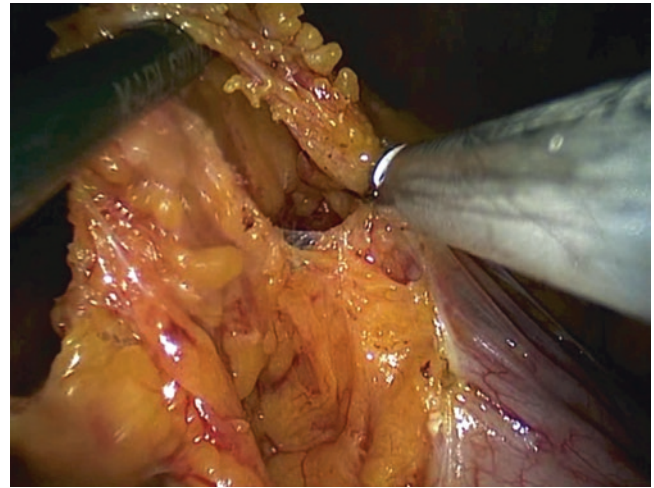


Fig. 6.5 Entry into the lesser sac by lateral-to-medial dissection. The left retractor is tenting up the omentum so that the transverse colon is suspended in a manner that allows these structures to be easily separated by ultrasonic dissection

separating the mesocolon and lesser sac often fuse at this point. Despite this issue, the dissection should be able to be continued in the same manner with relative ease.

Medial Approach

There is no doubt that in all but the thinnest patients, high ligation of the middle colic vessels is difficult to perform by a pure SILS technique due to the difficulty of gaining adequate retraction of the transverse mesocolon. Consequently, it is the author's belief that a pragmatic approach should be taken and a 5 mm left iliac fossa port placed if this proves to be difficult.

The surgeon stands between the legs of the patient, and the transverse mesocolon is exposed by lifting the colon up towards the abdominal wall and the surgeon placing the retractor in their left hand at a position halfway down the mesocolon. This will generate the necessary traction to fully expose the interface between the base of the transverse mesocolon and the retroperitoneum. The origin of the middle colic vessels will be evident in thin individuals; however, for those who are obese, a careful dissection will be necessary in the middle of the transverse mesocolon at the point it connects with the retroperitoneum. After these vessels are identified and isolated by blunt dissection, they are ligated (Fig. 6.6), but it is imperative this is not flushed with the pancreas. If there is a technical difficulty with sealing these vessels, they may retract out of site and generate significant bleeding that requires a laparotomy to control.

Following division of the middle colic vessels, the mesocolon continues to be retracted upward. Blunt dissection is used to develop the embryonic plane over the pancreas and

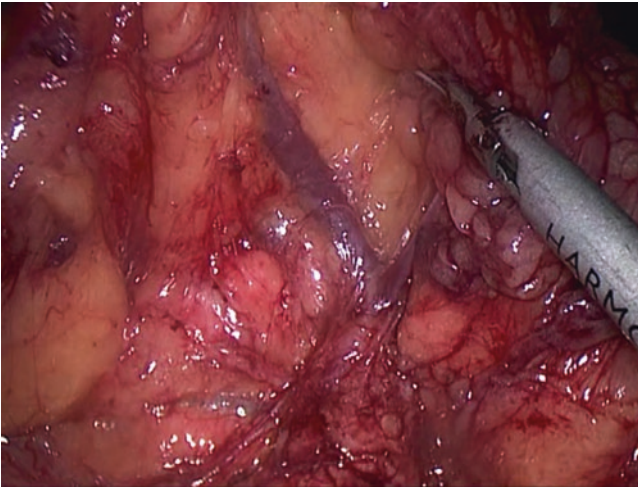


Fig. 6.6 Medial-to-lateral approach to expose the middle colic vessels at the junction of the mesocolon with the pancreas

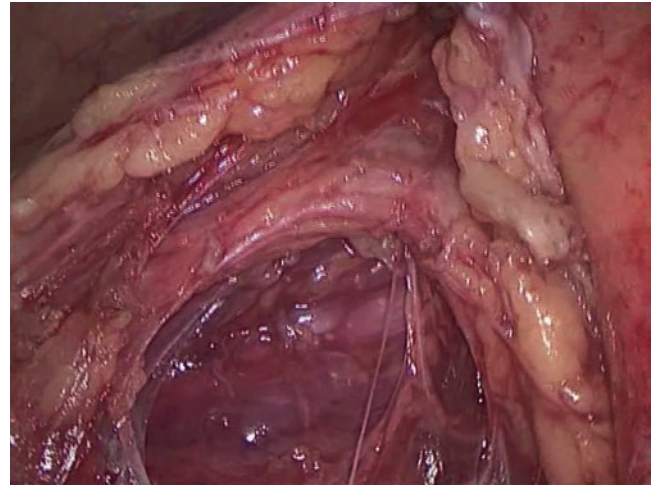


Fig. 6.7 Medial-to-lateral approach under inferior mesenteric artery to mobilise the proximal rectum

duodenum until the lesser sac is entered, at which point the stomach will become visible. In so doing, the right colic vessels may also be identified and may need to be ligated if they have not already been dealt with. Having fully mobilised the transverse mesocolon from the retroperitoneum, the omentum will need to be removed from the transverse colon as previously described.

Mobilization of the Rectum

Rectal dissection is by far the most challenging aspect of SILS colorectal surgery. It is the author's view again to be pragmatic when undertaking these procedures, and if the operating surgeon intends to place a pelvic drain after rectal excision, then a 5 mm port in the left iliac fossa should be placed early. This will expedite the dissection and will later serve as the skin incision through which the drain is placed.

The patient is placed head down with slight left lateral tilt. It is easiest to perform the initial dissection prior to transection of the inferior mesenteric artery, which acts to 'retract' the rectum (Fig. 6.7), and if the mobilised sigmoid colon is interfering with the dissection, absorbable tacks can be used to temporarily fix the appendices epiploicae of the sigmoid to the lateral abdominal wall. The surgeon stands on the right of the patient using their right hand to distract the rectosigmoid superiorly and towards the left lateral abdominal wall. The holy plane is entered using diathermy scissors in the left hand of the surgeon, first dissecting the posterior and then right lateral aspect of the rectum to the approximate level of Waldeyer's fascia in a thin patient (Fig. 6.8). Very gentle upward blunt dissection in the TME plane may expedite the dissection.

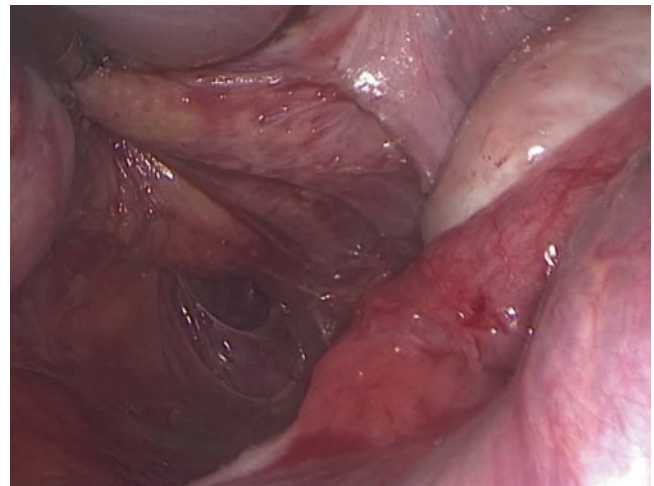


Fig. 6.8 Right-sided posterior-lateral TME dissection in female patient

The patient is then placed in slight right lateral tilt, and the surgeon stands on the left of the patient, using their left hand to deflect the rectum upward and towards the right lateral abdominal wall. The right hand then dissects the posterior and lateral aspects of the TME plane to meet the prior right-sided dissection again to approximately the level of Waldeyer's fascia. At this point, the inferior mesenteric artery will have to be divided to facilitate further dissection, and after this is done, it is wise to proceed as distally as is possible or necessary. Thereafter, the lateral mobilisation is completed in the standard fashion with the retraction for each side performed as outlined above.

The anterior dissection then has to be undertaken either in front or behind of Denonvilliers' fascia depending on whether this is a malignant anterior pathology or not, respec-

tively. Patient and surgeon positioning remains the same for anterior rectal dissection. At this point, however, the surgeon retracts the rectum superiorly out of the pelvis, while the assistant retracts the anterior parietal or peritoneum and then the prostate/vagina to provide countertraction. Suspension of the uterus with a transabdominal suture and / or the use of a vaginal retractor are invaluable in the female patient. Although the temptation is for the surgeon to fully straighten the rectum during retraction, it is more advantageous if a slight 'bowstring' is allowed as this will allow the plane between the rectum and anterior structures to be seen more easily. Wherever possible, diathermy scissors should be used as a precise dissection again to allow for better surgical plane visualisation.

Vessel Skeletalization and Ligation

The decision that the operating surgeon needs to make for taking the ileocolic and right colic vessels during right hemicolectomy is whether these need to be taken high for oncological or technical reasons. If the answer is no, then a fully mobilised right colon may easily be delivered through a periumbilical SILS port and the vessels taken extra corporeally, which will expedite the procedure.

If the answer is yes, then essentially the ileocolic, right, middle, left and inferior mesenteric vessels are all exposed in the same way as for conventional laparoscopy. The vascular pedicle is elevated to place the vessels of interest under tension with the left hand, thereby facilitating their identification in a fatty mesocolon. The right hand dissects the peritoneum overlying the vessels onto their adventitia. The next step is to create a space behind the vessels for them to be transected. The view of this part of the procedure is greatly improved by a 30-degree laparoscopic camera. This must be done carefully in a blunt manner with instruments, such as Maryland Dissecting Forceps or a right-angled dissector. The energy device may also be used to create this space if it has a blunt rounded tip, but blind division of the tissue behind vessels is strongly discouraged as there will be insufficient visualisation to safely permit this during a SILS procedure.

The means by which the vessels are secured is often a matter of personal choice and all of the options available during multiport laparoscopy can be employed. That being said, it can be cumbersome to apply a vascular stapler through the SILS port. The author's preference is to apply three clips to the vessel, slightly relax the tension on the vascular pedicle and use an ultrasonic energy device to securely seal and cut between clips two and three, thereby leaving two present on the patient side of the vessel division.

Difficult Cases

Clearly the disease process that is being dealt with has a significant impact on the technical difficulty of the case. Broadly speaking, polyp cancers and small colonic tumours may be mobilised using simple dissection techniques and are the ideal cases for surgeons who are beginning to establish SILS within their practice. The difficulty, however, comes with inflammatory masses that typically will affect either the right (e.g. Crohn's disease) or sigmoid (e.g. diverticular phlegmon) colon. This is also the case with open surgery, and the approaches used during laparotomy should be replicated as faithfully as possible when using SILS. It is clearly unwise to attempt mobilisation of the inflammatory mass or phlegmon as the first part of the procedure.

In the case of a Crohn's ileocolic phlegmon that is encroaching upon the anterior or lateral parietal peritoneum, it is wisest to begin by fully mobilising the hepatic flexure and distal ascending colon downward using a lateral-to-medial approach described above. While it is preferable not to expose the duodenum in Crohn's disease given the risk of fistulation from the anastomosis in the future, this will be necessary in extensive phlegmonous disease to protect the duodenum from inadvertent injury. Thereafter, the terminal ileum and any un-diseased caecum should be mobilised in the same fashion with the objective of meeting the dissection plane created above the mass and thus isolating the ureter from the phlegmon. With this achieved, the mass can then be dissected from the anterior and lateral parietal peritoneum. It can be unwise to approach large phlegmons using a medial-to-lateral SILS approach due to the inability to retract a large mass, which may also draw the ileocolic vessels or duodenum into unexpected positions.

A similar approach is taken when tackling a sigmoid phlegmon: first mobilising the left colon in a lateral-to-medial approach to find the correct surgical plane and then connecting this with a proximal rectal dissection to isolate the ureter before tackling the mass itself. In this case, it may be useful to perform the proximal rectal dissection and identify the ureter using a medial-to-lateral approach, coming under the inferior mesenteric artery and bluntly dissecting over the ureter and gonadal vessels as previously described. The majority of such procedures will be amenable to completion using SILS; however, the presence of extensive fibrotic adhesions to the lateral parietal peritoneum from repeated episodes of inflammation and resolution is a caveat to this statement. When this is encountered, little progress can be made, and in general the problem is not solved by conversion to multiport laparoscopy, with laparotomy and finger fracture often necessary.

The problem of posteriorly encroaching benign disease that abuts the retroperitoneal structures is a different entity,

with the primary concern being injury to a ureter or the duodenum. It is possible to complete a number of these procedures by SILS using the techniques described above, with liberal use of ureteric catheterisation advisable, although even fluorescent stents may not be of assistance if the surgical planes are fibrotic. The welfare of the patient must be the surgeon's constant first concern, and if there is any doubt regarding the safety of continuing by single-port techniques, it is wise to convert to laparotomy as multiport laparoscopy will add no benefit over SILS in this setting.

Conclusion

The dissection approaches outlined in this chapter highlight multiple strategies to successfully complete SILS colorectal surgery. Medial-to-lateral approaches are likely

to be the techniques most easily employed by senior surgeons embarking upon a SILS practice, as they will be extremely comfortable with the operative views this strategy generates. Similarly, surgeon educators who teach residents SILS are likely to find mimicking open surgical procedures results in the fastest uptake by their surgical trainees, since this does not require residents to become comfortable with new dissection approaches and views. In contrast, those surgeons who currently undertake medial-to-lateral conventional laparoscopy may prefer to replicate their multiport laparoscopic technique in SILS procedures as discussed in this chapter. While a surgeon's preference may result in them using only one of these approaches in isolation to complete straightforward cases, the ability to utilise all of the approaches described in this chapter will be necessary in order to complete technically difficult SILS procedures.

High and Low Inferior Mesenteric Artery Ligation

7

Christopher F. McNicoll and Ovunc Bardakcioglu

Steps of the Procedure

1. Positioning and single-incision port placement in the right mid-abdomen for the left colon and rectum resection.
2. Lift sigmoid colon anteriorly to provide tension to the rectosigmoid mesentery.
3. Score the peritoneum, and then use blunt dissection to gain access to the presacral space in a medial to lateral approach.
4. Dissect laterally and posteriorly along the presacral fascia on the right side of the rectum.
5. Dissect medially and posteriorly along the presacral fascia toward the left side of the rectum.
6. Dissect superiorly to separate the retroperitoneum from the sigmoid mesentery, preserving Toldt's fascia.
7. Identify the left ureter and avoid the iliac vessels within the lateral presacral space.
8. Score peritoneum proximal and distal to the inferior mesenteric artery, and dissect until origin of the left colic artery is seen.
9. Optional: Selective lymph node dissection surrounding the root of the inferior mesenteric artery.
10. Ligation of the inferior mesenteric artery (IMA):
 - (a) High ligation: Ligate IMA 1–2 centimeters beyond the origin at the aorta using either clips, a bipolar vessel sealer, harmonic scalpel, or a stapler.
 - (b) Low ligation: Ligate IMA distal to the origin of the left colic artery using either clips, a bipolar vessel sealer, harmonic scalpel, or a stapler.
11. Proceed with colorectal resection and anastomosis creation following the vessel ligation.

Tips and Tricks

- Increased anastomotic and functional complications can occur with high ligation of the inferior mesenteric artery.
- Limit manipulation of the tumor during oncologic case.
- High ligation may be necessary to avoid tension on a colorectal anastomosis but will result in decreased blood flow to the colorectal anastomosis.
- Avoid iatrogenic injury to ureter and iliac vessels in the retroperitoneum and lateral presacral space.
- Identify the inferior mesenteric artery and vein, left colic artery, sigmoidal arteries, and superior rectal artery prior to ligation.
- Assess perfusion to the anastomosis prior to ending the operation, and revise as needed.

Introduction

The inferior mesenteric artery supplies the descending colon, sigmoid colon, and rectum, and the competent surgeon must decide whether a high or low ligation should be performed before proceeding with its ligation. The decision requires technical, anatomic, and oncologic reasoning to inform the surgeon and will depend on the location and extent of disease that requires resection. Resection for colorectal cancer typically dictates the more extensive high ligation, while surgery for benign conditions typically permits a low ligation. There are risks inherent to a high ligation of the inferior mesenteric artery, including injury to autonomic nerves with resultant genitourinary and anorectal dysfunction, inadvertent ureter

C.F. McNicoll, MD, MPH, MS (✉)
Department of Surgery, University of Nevada, Las Vegas School of Medicine, 1701 West Charleston Blvd., Suite 400, Las Vegas, NV 89102, USA
e-mail: christopher.mcnicoll@unlv.edu

O. Bardakcioglu, MD, FACS, FASCRS
Division of Colon and Rectal Surgery, Department of Surgery, University of Nevada, Las Vegas School of Medicine, 1701 West Charleston Blvd., Suite 400, Las Vegas, NV 89102, USA
e-mail: ovunc.bardakcioglu@unlv.edu

injury, and decreased blood flow leading to anastomotic dehiscence. However, benefits of a high ligation include increased mobilization for anastomosis creation and a greater yield of lymph nodes within the larger resection. A low ligation occurs distal to the branching of the left colic artery and has the benefit of retaining a greater blood supply to the remaining colon. However, a low ligation makes the anastomosis from the descending colon to the remnant rectum or anal canal more difficult. Undue tension placed upon the anastomosis from a low ligation will increase the risk of anastomotic leak and failure. In single-incision laparoscopic colorectal surgery (SILS), as in traditional open or multiple port laparoscopic colorectal surgery, the completion of high or low ligation of the inferior mesenteric artery is based on multiple factors. The operative techniques, and the basis for choosing these techniques, are reviewed here.

Anatomy

Before the surgeon considers ligating the inferior mesenteric artery, it is worth reviewing the consequences that this procedure poses to the blood supply and nervous system. The inferior mesenteric artery (IMA) branches from the abdominal aorta near the third lumbar vertebra and supplies the descending colon, sigmoid colon, and upper rectum with oxygenated blood [1, 28]. The inferior mesenteric vein (IMV) courses in the vicinity of the IMA, receiving the left colic vein, sigmoid veins, and superior rectal vein, and drains into the splenic vein.

The left colic artery arises first from the IMA, and it bifurcates into an ascending and descending branch. Ligation of the left colic artery will leave any remaining left colon and proximal anastomoses, reliant on the superior mesenteric artery (SMA) for collateral flow. A watershed area exists between the SMA and the IMA at the splenic flexure of the colon, known as Griffiths' point [2]. The marginal artery of Drummond and the arc of Riolan provide the named anastomoses between the SMA and IMA, via the middle colic and left colic arteries [3–5, 25]. Given the greater length of colon dependent on collateral flow, an anastomosis between the sigmoid colon and rectum is more susceptible to ischemia than a descending colon anastomosis.

Sigmoidal branches arise from the IMA following the origin of the left colic artery. The IMA then becomes the superior rectal artery after it crosses the left common iliac artery and forms anastomoses with the middle rectal and inferior rectal arteries. These anastomoses generally provide adequate blood supply for the distal colorectal anastomosis following colorectal resection [6].

Preganglionic sympathetic fibers arise from the lumbar splanchnic nerves originating from L1 to L3 and synapse at the inferior mesenteric plexus on the anterior surface of the

aorta at the origin of the IMA. Postganglionic sympathetic fibers course along with the IMA, distributed to the descending colon, sigmoid colon, and superior rectum. The parasympathetic fibers arise from the pelvic splanchnic nerves, originating from S2 to S4, and travel with the postganglionic sympathetic fibers. The pelvic parasympathetic fibers assist with defecation, urination, and sexual activity.

Oncologic Surgical Resection: High Ligation

The staging, treatment, and prognosis of colorectal cancer are dependent upon the specific location of the tumor and the involvement of regional lymph nodes. Surgeons have long known about ligating the IMA at the aorta as a way to remove as many potentially metastatic lymph nodes as possible [53–56]. Nevertheless, the option to ligate the IMA above or below the left colic artery branch must be made for each patient within the context of current recommendations for the best oncologic outcome. Though not unique to single-incision laparoscopic colorectal surgery, a review of the literature discussing the benefits of high and low ligation of the IMA is provided here.

There are a group of lymph nodes surrounding the root of the inferior mesenteric artery, known as principal or apical nodes, which portend a worse prognosis when colon cancer has spread to them [7, 49]. Alici et al. noted that of six colorectal cancer patients found to have positive apical lymph nodes at resection, two had no other non-apical-positive lymph nodes, and only one was alive at 23 months [8]. The possibility of lymph node metastasis, including “skip” metastasis to more distal lymph node groups and beyond, encourages the high ligation of the IMA in oncologic cases. Chin et al. further showed that the greatest benefit of high ligation could be found in patients with T4 lesions [34]. By removing these nodes via a high ligation of the IMA, a more accurate pathologic staging can be performed, which potentially changes the patient's further treatment and outcome [7, 9].

However, there have been multiple studies showing no significant difference in mortality between the high and low ligation technique for colorectal cancer patients [10, 11, 47, 49, 51, 52]. Systematic reviews in 2008 and 2012 confirmed these findings [12, 13]. Low ligation with more extensive apical lymphadenectomy has been supported previously, and a 2013 study found similar outcomes in elderly patients with sigmoid and rectal cancer treated with high ligation versus low ligation with lymphadenectomy at the root of the mesentery [14].

Therefore, the level of IMA ligation and lymph node dissection is still a decision that the surgeon makes for each patient. Single-incision laparoscopic surgery also permits

the colorectal surgeon to perform a high IMA ligation with adequate lymph node yield, and it has been shown to be safe [35, 37–46]. In one study of patients requiring a high anterior resection for either malignant or benign disease, the lymph node yield was actually higher in SILS when compared to standard laparoscopic surgery [36].

The surgeon must also understand the limitations of the oncologic benefits presented in the literature regarding the high ligation, low ligation, or low ligation with extensive lymphadenectomy of the apical nodes. An inherent problem with describing the success of the high ligation technique is the staging migration phenomenon [15]. As a larger lymphadenectomy yielding more positive lymph nodes is performed, the patient will potentially be upstaged with the larger lymphadenectomy. This may have no effect on that individual patient's prognosis, but will improve the survival time for stage 2 patients by moving this particular group of patients into the stage 3 group.

Finally, the level of IMA ligation is an important tool for colorectal cancer treatment, but other factors also determine the patient's ultimate outcome. When treating a patient with colorectal cancer, the entire care team employs several techniques beyond surgical resection of the affected bowel. Neoadjuvant therapy, adjuvant therapy, and total mesenteric excision will also change the prognosis of patients with colorectal cancer, complicating the effect of the high or low ligation. The incidence of complications, discussed below, also is affected by the use of adjuvant and neoadjuvant therapies.

Complications of Ligation

The potential oncologic benefit of a high ligation must be carefully deliberated while minding the increased risk of complications such as anastomotic leak, bowel dysfunction, and genitourinary dysfunction when compared to low ligation [12]. The level of IMA ligation is one of several factors that can influence postoperative complications in colon cancer patients and must be considered in combination with the effects of neoadjuvant and adjuvant radiation and chemotherapy. Individual patient factors, such as atherosclerosis of the mesenteric vessels, may also predispose certain individuals to postoperative complications. Postoperative healing mechanisms in patients with colon cancer and poor nutrition are also reduced when compared with patients with benign disease. Furthermore, intraoperative factors such as tension, blood loss, blood transfusion, steroid use, long operative time, and contamination of the operative field can increase the risk of anastomotic leakage [64]. The development of new tools such as fluorescence angiography may lead to improved technique in IMA ligation, with fewer incidence of complications related to inadequate perfusion.

Several studies have quantified the complications associated with high ligation of the IMA, while showing no significant benefit in mortality in colorectal cancer patients [10, 26]. In 1992, Corder et al. found no significant difference in anastomotic leak rate, tumor recurrence, or death between rectal cancer patients who underwent a high ligation and a low ligation of the ascending left colic artery [16]. A meta-analysis in 2012 found no statistically significant difference in anastomotic leak in patients treated with a low IMA ligation versus high ligation for diverticular disease [22]. However, a randomized trial of patients that underwent an open left hemicolectomy for complicated diverticular disease found a significantly higher rate of clinical and radiological anastomotic dehiscence in patients that had a high IMA ligation compared to a low ligation [23]. Sarli et al. compared colon cancer patients that underwent laparoscopic left hemicolectomy with patients who underwent the same surgery for diverticulitis or polyposis [17, 18]. The cancer patients had a high ligation of the IMA and suffered significantly higher rates of diarrhea and anorectal dysfunction within the first 6 months following surgery compared to the patients who underwent a low IMA ligation for benign disease. However, a randomized controlled trial of 100 rectal cancer patients treated with anterior resection in Japan found no significant difference in defecatory function or anastomotic leak at 3 months and 1 year between the high and low ligation groups [19]. The HIGHFLOW trial is currently underway to further define the oncologic benefits and surgical complications of a high IMA ligation versus a low ligation in laparoscopic anterior rectal resection with total mesorectal excision [20].

Blood flow to the remaining colon following ligation has been shown to decrease incrementally with more proximal ligations, which can lead to proximal bowel necrosis and anastomotic leak [27, 48, 50]. Intraoperative fluorescence angiography appears to be a feasible and useful tool to reduce anastomotic leaks, and further research is needed to determine if this technology will reduce the anastomotic complication rates sustained by both high and low ligation of the IMA [21, 32].

Finally, the colorectal surgeon must be aware of the potential for nerve injury when dissecting in the vicinity of the IMA. High ligation of the IMA for oncologic purposes will involve removal of the apical lymph nodes and surrounding mesentery at the origin of the IMA. Extensive dissection can disrupt the sympathetic and parasympathetic nerve fibers and potentially cause bowel, bladder, and sexual dysfunction. Nevertheless, cadaver studies have postulated that the safest ligation level to avoid damaging the nerves running parallel to the IMA is actually at its origin [30, 31]. Diligent dissection will likely not prevent all nerve injuries, and subsequent temporary dysfunction is usually unavoidable.

Operative Techniques

1. Positioning and single-incision port placement in right mid-abdomen for left colon and rectum resection.

Single-incision laparoscopic sigmoid and rectal resections have been previously reported, and we review the best operative techniques regarding the ligation of the IMA here [35–46, 57, 58]. The laparoscopic resection of the rectum and left colon begins the same regardless of the planned level of IMA ligation. The patient is placed supine on the operating room table, and laparoscopic monitors are positioned for ease of view during the case. Lithotomy position is encouraged if the use of an end-to-end circular anastomotic stapler or an intraoperative colonoscopy is planned. Following induction of anesthesia and sterile preparation, the surgeon will stand on the right side of the patient with the assistant standing on the left.

A 3 cm incision is made in the right mid-abdomen for placement of the single-incision port for sigmoid and rectal resections, which will facilitate ligation of the IMA [33]. If a proctocolectomy or subtotal colectomy is planned, the single-incision port may be placed periumbilically for improved access to the right colon or at the planned site of diverting stoma creation [59, 60] (Fig. 7.1). Standard open technique is used to gain access to the abdominal cavity. If not part of the platform, a wound protector is placed to reduce surgical site infection and port site metastasis, though the evidence for use in laparoscopic surgery is mixed [61–63, 65–67]. The abdomen is insufflated with carbon dioxide, and the laparoscope and instruments are inserted. A 5 mm laparoscope with 30° rotation provides ample vision. When performing SILS, it is helpful to use

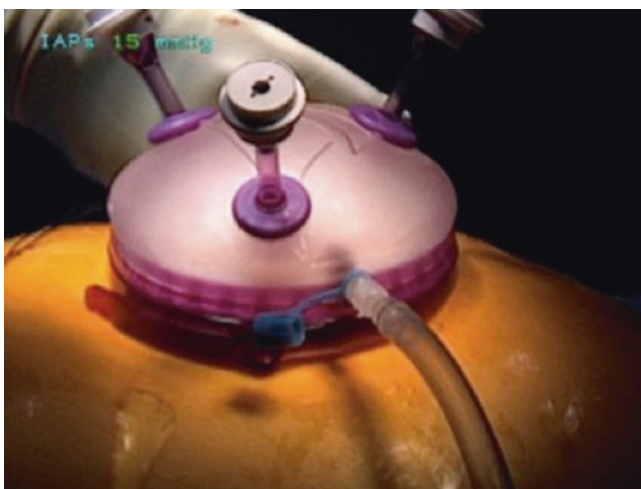


Fig. 7.1 Single-incision port insertion

instruments of varying lengths to avoid interference between the surgeon's hands. The patient can then be placed in Trendelenburg position.

2. Lift sigmoid colon anteriorly to provide tension to the rectosigmoid mesentery.

A bowel grasper lifts the sigmoid colon anteriorly, providing tension to the rectosigmoid mesentery. One or more “hanging stitches” of 2-0 silk suture can be placed intracorporeally to elevate the sigmoid colon to the left lateral anterior abdominal wall.

3. Score the peritoneum, and then use blunt dissection to gain access to the presacral space in a medial to lateral approach.

The peritoneal reflection is scored medially. A blunt dissecting instrument and a bowel grasper are used to bluntly dissect through the areolar tissue to reach the superior presacral space (Fig. 7.2). The presacral space contains the ureter and iliac vessels laterally, so care is taken to avoid inadvertent injury to those structures.

4. Dissect laterally and posteriorly along the presacral fascia on the right side of the rectum.

Dissect laterally along the retroperitoneal fascia of the right side of the rectum using an energy source or a blunt dissecting instrument (Fig. 7.3).

5. Dissect medially and posteriorly along the presacral fascia toward the left side of the rectum.

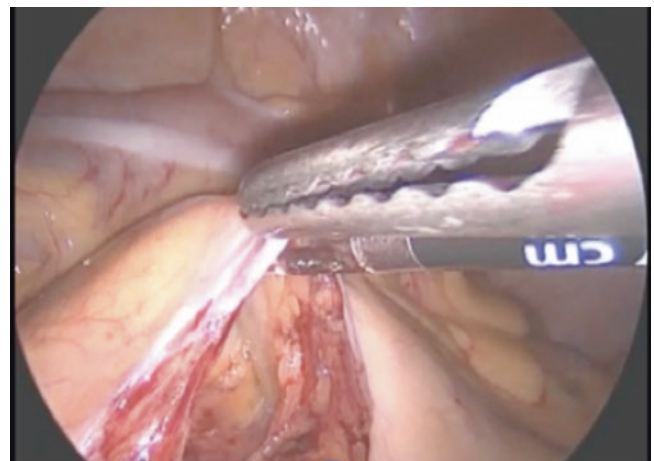


Fig. 7.2 Blunt dissection to reach the presacral space

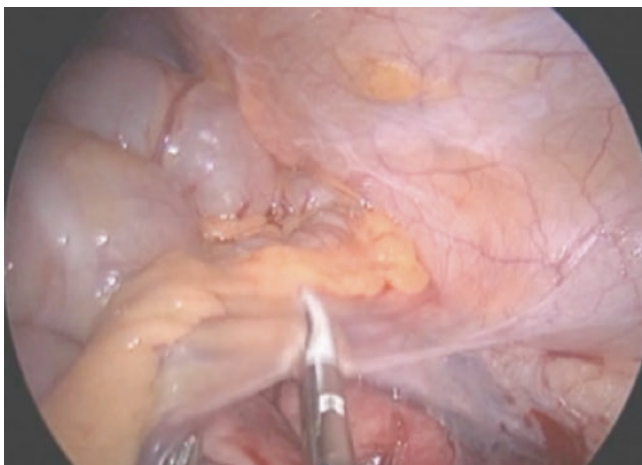


Fig. 7.3 Lateral dissection along the retroperitoneal fascia of the right side of the rectum

Dissect medially and posteriorly toward the left side of the rectum to create more space.

6. Dissect superiorly to separate the retroperitoneum from the sigmoid mesentery, preserving Toldt's fascia.

Further dissection superiorly along the presacral space will separate the retroperitoneum from the sigmoid colon mesentery. This dissection should follow the embryologic planes preserving Toldt's fascia.

7. Identify the left ureter and avoid the iliac vessels within the lateral presacral space.

At this point, the left ureter lies within the dissection field. Take care to identify the left ureter at this point to prevent accidental ligation (Fig. 7.4).

8. Score the peritoneum proximal and distal to the IMA, and dissect until origin of the left colic artery is seen.

The peritoneum proximal and distal to the inferior mesenteric artery is then scored, and dissection continues until the inferior mesenteric artery and left colic artery are seen. Triangulation is used with blunt instruments, sweeping the retroperitoneum down and opening up the plane.

9. Optional: Selective lymph node dissection surrounding the root of the inferior mesenteric artery.

At this time, a selective lymph node dissection surrounding the IMA root at the aorta can be completed if the surgeon so desires. The surgeon must identify and avoid injuring the inferior mesenteric plexus at this point.

10. Ligation of the inferior mesenteric artery (IMA).

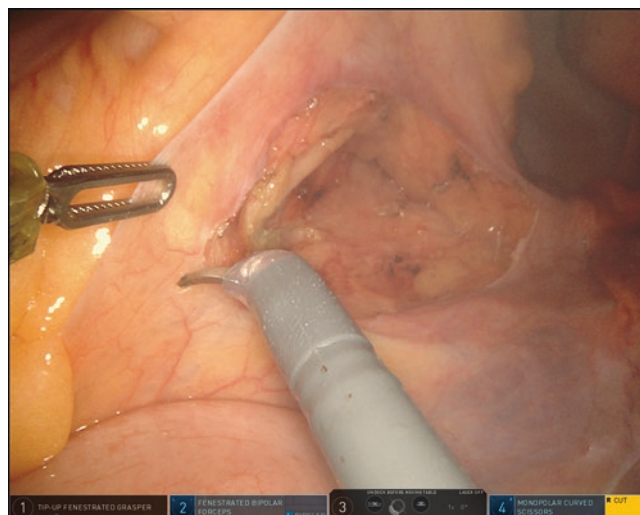


Fig. 7.4 Identify the left ureter to avoid injury

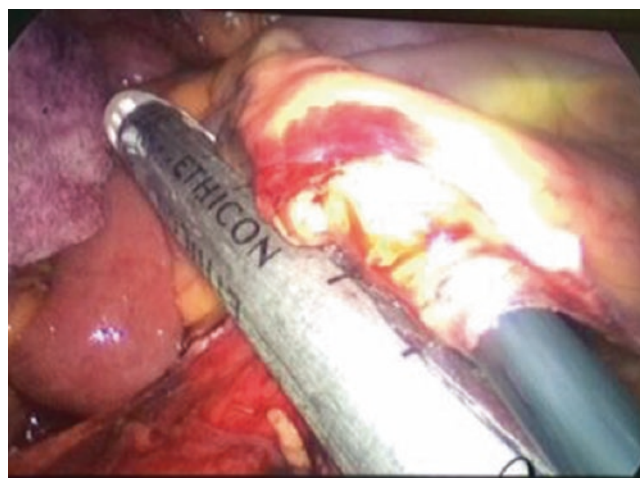


Fig. 7.5 High IMA ligation

The IMA is then ligated using a laparoscopic energy device, vessel sealer, or clip, either above or below the branching of the left colic artery [24]. For high ligation, we recommend ligating the IMA within 2 cm of its origin to the aorta. The IMV is ligated in a similar manner near the inferior margin of the pancreas. For low ligation, ligate the IMA distal to the origin of the left colic artery using either clips, a bipolar vessel sealer, harmonic scalpel, or a stapler. The apical lymph node tissue is not taken, but blood flow to the left colic artery is maintained (Fig. 7.5).

The surgeon may choose to ligate and divide the IMA at another location that is distal to the left colic artery branch (Fig. 7.6). Some authors have even differentiated the ligations that preserve the origin of the left colic artery by coining the terms “mid” and “low” ligation based on distance from the edge of the colon [21]. If additional length is not required in creating the anastomosis and if the surgery is for a benign disease when lymph node collection is

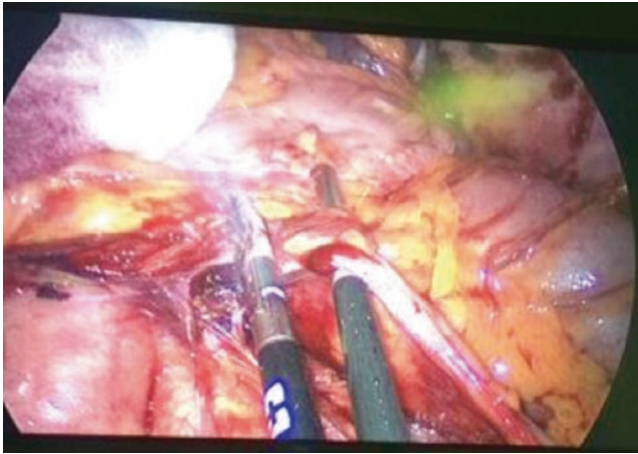


Fig. 7.6 Low IMA ligation, distal to the left colic artery

irrelevant, then the lower ligations can preserve essential blood flow to the anastomosis. One option for the low ligation is at the level of the superior rectal artery, leaving some sigmoidal arteries intact. This is a useful modification for a proctectomy for benign disease. Splenic flexure mobilization may be needed to gain enough proximal length to create the anastomosis without tension. A more proximal IMA ligation may still be warranted for this technical reason if after mobilization more length is still required [29].

11. Proceed with colorectal resection and anastomosis creation following the vessel ligation.

Summary

Inferior mesenteric artery ligation can occur flush to the aorta, proximal to the left colic artery, or at several locations distal to the branching of the left colic artery. In single-incision laparoscopic surgery, as in traditional open or laparoscopic surgery, the decision surrounding the level of IMA ligation is informed by operative indication, technical limitations, and anatomic considerations. Though a high IMA ligation is generally performed in oncologic cases, the research demonstrating its overall mortality benefit is mixed when compared to low ligation. A randomized, controlled trial is ongoing to examine patient outcomes following a high IMA ligation versus a low ligation in low anterior resections. The use of a high IMA ligation can remove undue tension on the anastomosis, and a high IMA ligation might be therefore useful in surgical resections for benign pathology. The competent surgeon needs to understand the additional risks of a high IMA ligation and the proper operative techniques to minimize the inadvertent injury of vascular, urinary, and nervous system structures. Maintaining adequate perfusion to

the anastomosis is key to prevent postoperative complications, and the development and use of new perfusion imaging technology may prove beneficial.

References

1. Keighley MRB, Williams NS, Church JM, Pahlman L, Scholefield JH, Scott NA. Anatomy and physiology investigations. In: Keighley MRB, Williams NS, Church JM, Pahlman L, Scholefield JH, Scott NA, editors. *Surgery of the anus, rectum, and colon*. 3rd ed. London: Elsevier; 2008. p. 1–45.
2. Griffiths JD. Surgical anatomy of the blood supply of the distal colon. *Ann R Coll Surg Engl*. 1956;19(4):241–56.
3. Drummond H. Some points relating to the surgical anatomy of the arterial supply of the large intestine. *Proc R Soc Med*. 1914;7(Surg Sect):185–93.
4. Gourley EJ, Gering SA. The meandering mesenteric artery: a historic review and surgical implications. *Dis Colon Rectum*. 2005;48(5):996–1000.
5. Steward JA, Rankin FW. Blood supply of the large intestine: its surgical considerations. *Arch Surg*. 1933;26(5):843–91.
6. Morgan CN, Griffiths JD. High ligation of the inferior mesenteric artery during operations for carcinoma of the distal colon and rectum. *Surg Gynecol Obstet*. 1959;108(6):641–50.
7. Kim JC, Lee KH, Yu CS, Kim HC, Kim JR, Chang HM. The clinicopathological significance of inferior mesenteric lymph node metastasis in colorectal cancer. *Eur J Surg Oncol*. 2004;30(3):271–9.
8. Alici A, Kement M, Gezen C, Akin T, Vural S, Okkabaz N, et al. Apical lymph nodes at the root of the inferior mesenteric artery in distal colorectal cancer: an analysis of the risk of tumor involvement and the impact of high ligation on anastomotic integrity. *Tech Coloproctol*. 2010;14(1):1–8.
9. Kanemitsu Y, Hirai T, Komori K, Kato T. Survival benefit of high ligation of the inferior mesenteric artery in sigmoid colon or rectal cancer surgery. *Br J Surg*. 2006;93(5):609–15.
10. Hida J, Okuno K. High ligation of the inferior mesenteric artery in rectal cancer surgery. *Surg Today*. 2013;43(1):8–19.
11. Surtees P, Ritchie JK, Phillips RKS. High versus low ligation of the inferior mesenteric artery in rectal cancer. *Br J Surg*. 1990;77(6):618–21.
12. Lange MM, Buunen M, van de Velde CJ, Lange JF. Level of arterial ligation in rectal cancer surgery: low tie preferred over high tie. A review *Dis Colon Rectum*. 2008;51(7):1139–45.
13. Cirocchi R, Trastulli S, Farinella E, Desiderio J, Vettoretto N, Parisi A, et al. High tie versus low tie of the inferior mesenteric artery in colorectal cancer: a RCT is needed. *Surg Oncol*. 2012;21(3):e111–23.
14. Polistena A, Cavallaro G, D'Ermo G, Paliotta A, Crocetti D, Rosato L, et al. Clinical and surgical aspects of high and low ligation of inferior mesenteric artery in laparoscopic resection for advanced colorectal cancer in elderly patients. *Minerva Chir*. 2013;68(3):281–8.
15. Slanetz CA Jr, Grimson R. Effect of high and intermediate ligation on survival and recurrence rates following curative resection of colorectal cancer. *Dis Colon Rectum*. 1997;40(10):1205–18.
16. Corder AP, Karanjia ND, Williams JD, Heald RJ. Flush aortic tie versus selective preservation of the ascending left colic artery in low anterior resection for rectal carcinoma. *Br J Surg*. 1992;79(7):680–2.
17. Sarli L, Pavlidis C, Cinieri FG, Regina G, Sansebastiano G, Veronesi L, et al. Prospective comparison of laparoscopic left hemicolectomy for colon cancer with laparoscopic left hemicolectomy for benign colorectal disease. *World J Surg*. 2006;30(3):446–52.

18. Sarli L, Cinieri FG, Pavlidis C, Regina G, Sansebastiano G, Veronesi L, et al. Anorectal function problems after left hemicolectomy. *J Laparoendosc Adv Surg Tech A*. 2006;16(6):565–71.
19. Matsuda K, Hotta T, Takifuji K, Yokoyama S, Oku Y, Watanabe T, et al. Randomized clinical trial of defaecatory function after anterior resection for rectal cancer with high versus low ligation of the inferior mesenteric artery. *Br J Surg*. 2015;102(5):501–8.
20. Mari G, Maggioni D, Costanzi A, Miranda A, Rigamonti L, Crippa J, et al. High or low inferior mesenteric artery ligation in laparoscopic low anterior resection: study protocol for a randomized controlled trial (HIGHFLOW trial). *Trials*. 2015;16:21.
21. Jafari MD, Wexner SD, Martz JE, McLemore EC, Margolin DA, Sherwinter DA, et al. Perfusion assessment in laparoscopic left-sided/anterior resection (PILLAR II): a multi-institutional study. *J Am Coll Surg*. 2015;220(1):82–92.
22. Cirocchi R, Trastulli S, Farinella E, Desiderio J, Listorti C, Parisi A, et al. Is inferior mesenteric artery ligation during sigmoid colectomy for diverticular disease associated with increased anastomotic leakage? A meta-analysis of randomized and non-randomized clinical trials. *Color Dis*. 2012;14(9):e521–9.
23. Tocchi A, Mazzoni G, Fornasari V, Miccini M, Daddi G, Tagliacozzo S. Preservation of the inferior mesenteric artery in colorectal resection for complicated diverticular disease. *Am J Surg*. 2001;182(2):162–7.
24. Janjua AZ, Moran BJ. Rectal Cancer. In: Phillips RKS, Clark S, editors. *Colorectal surgery: a companion to specialist surgical practice*. 5th ed. London: Elsevier; 2014. p. 69–81.
25. Fisher DF Jr, Fry WJ. Collateral mesenteric circulation. *Surg Gynecol Obstet*. 1987;164(5):487–92.
26. Candela G, Di Libero L, Varriale S, Manetta F, Giordano M, Maschio A, et al. Effects of high and low ligation on survival in patients operated for colorectal cancer. *Chir Ital*. 2008;60(1):75–81.
27. Dworkin MJ, Allen-Mersh TG. Effect of inferior mesenteric artery ligation on blood flow in the marginal artery-dependent sigmoid colon. *J Am Coll Surg*. 1996;183(4):357–60.
28. Panagouli E, Lolis E, Venieratos D. A morphometric study concerning the branching points of the main arteries in humans: relationships and correlations. *Ann Anat*. 2011;193(2):86–99.
29. Bonnet S, Berger A, Hentati N, Abid B, Chevallier JM, Wind P, et al. High tie versus low tie vascular ligation of the inferior mesenteric artery in colorectal cancer surgery: impact on the gain in colon length and implications on the feasibility of anastomoses. *Dis Colon Rectum*. 2012;55(5):515–21.
30. Nano M, Dal Corso H, Ferronato M, Solej M, Hornung JP, Dei PM. Ligation of the inferior mesenteric artery in surgery of rectal cancer: anatomical considerations. *Dig Surg*. 2004;21(2):123–6. discussion 126–7
31. Yang XF, Li GX, Luo GH, Zhong SZ, Ding ZH. New insights into autonomic nerve preservation in high ligation of the inferior mesenteric artery in laparoscopic surgery for colorectal cancer. *Asian Pac J Cancer Prev*. 2014;15(6):2533–9.
32. Bae SU, Min BS, Kim NK. Robotic low ligation of the inferior mesenteric artery for rectal cancer using the firefly technique. *Yonsei Med J*. 2015;56(4):1028–35.
33. Papaconstantinou HT, Thomas JS. Single-incision laparoscopic colectomy for cancer: assessment of oncologic resection and short-term outcomes in a case- matched comparison with standard laparoscopy. *Surgery*. 2011;150(4):820–7.
34. Chin CC, Yeh CY, Tang R, Changchien CR, Huang WS, Wang JY. The oncologic benefit of high ligation of the inferior mesenteric artery in the surgical treatment of rectal or sigmoid colon cancer. *Int J Color Dis*. 2008;23(8):783–8.
35. Kawamata F, Homma S, Minagawa N, Kawamura H, Takahashi N, Taketomi A. Comparison of single-incision plus one additional port laparoscopy-assisted anterior resection with conventional laparoscopy-assisted anterior resection for rectal cancer. *World J Surg*. 2014;38(10):2716–23.
36. Osborne AJ, Lim J, Gash KJ, Chaudhary B, Dixon AR. Comparison of single-incision laparoscopic high anterior resection with standard laparoscopic high anterior resection. *Color Dis*. 2013;15(3):329–33.
37. Bracale U, Lazzara F, Merola G, Andreuccetti J, Barone M, Pignata G. Single access laparoscopic left hemicolectomy with or without inferior mesenteric artery preservation: our preliminary experience. *Minerva Chir*. 2013;68(3):315–20.
38. Sirikurnpiboon S. Single-access laparoscopic rectal cancer surgery using the glove technique. *Asian J Endosc Surg*. 2014;7(3):206–13.
39. Haas EM, Nieto J, Ragupathi M, Martinez T. Single-incision laparoscopic sigmoid resection: a technical video of a standardized approach. *Dis Colon Rectum*. 2012;55(11):1179–82.
40. Uematsu D, Akiyama G, Narita M, Magishi A. Single-access laparoscopic low anterior resection with vertical suspension of the rectum. *Dis Colon Rectum*. 2011;54(5):632–7.
41. Bae SU, Baek SJ, Min BS, Baik SH, Kim NK, Hur H. Reduced-port laparoscopic surgery for a tumor-specific mesorectal excision in patients with colorectal cancer: initial experience with 20 consecutive cases. *Ann Coloproctol*. 2015;31(1):16–22.
42. Hamzaoglu I, Karahasanoglu T, Baca B, Karatas A, Aytac E, Kahya AS. Single-port laparoscopic sphincter-saving mesorectal excision for rectal cancer: report of the first 4 human cases. *Arch Surg*. 2011;146(1):75–81.
43. Bulut O, Nielsen CB, Jespersen N. Single-port access laparoscopic surgery for rectal cancer: initial experience with 10 cases. *Dis Colon Rectum*. 2011;54(7):803–9.
44. Hua-Feng P, Zhi-Wei J, Gang W, Xin-Xin L, Feng-Tao L. A novel approach for the resection of low rectal cancer. *Surg Laparosc Endosc Percutan Tech*. 2012;22(6):537–41.
45. Hirano Y, Hattori M, Douden K, Shimizu S, Sato Y, Maeda K, et al. Single-incision plus one port laparoscopic anterior resection for rectal cancer as a reduced port surgery. *Scand J Surg*. 2012;101(4):283–6.
46. Sirikurnpiboon S, Jivapaisarnpong P. Single-access laparoscopic rectal surgery is technically feasible. *Minim Invasive Surg*. 2013;2013:1–6.
47. Grinnell RS. Results of ligation of inferior mesenteric artery at the aorta in resections of carcinoma of the descending and sigmoid colon and rectum. *Surg Gynecol Obstet*. 1965;120:1031–6.
48. Tsujinaka S, Kawamura YJ, Tan KY, Mizokami K, Sasaki J, Maeda T, et al. Proximal bowel necrosis after high ligation of the inferior mesenteric artery in colorectal surgery. *Scand J Surg*. 2012;101(1):21–5.
49. Adachi Y, Inomata M, Miyazaki N, Sato K, Shiraishi N, Kitano S. Distribution of lymph node metastasis and level of inferior mesenteric artery ligation in colorectal cancer. *J Clin Gastroenterol*. 1998;26(3):179–82.
50. Fasth S, Hultén L, Hellberg R, Marston A, Nordgren S, Schiöler R. Blood pressure changes in the marginal artery of the colon following occlusion of the inferior mesenteric artery. *Ann Chir Gynaecol*. 1978;67(4):161–4.
51. Pezim ME, Nicholls RJ. Survival after high or low ligation of the inferior mesenteric artery during curative surgery for rectal cancer. *Ann Surg*. 1984;200(6):729–33.
52. Uehara K, Yamamoto S, Fujita S, Akasu T, Moriya Y. Impact of upward lymph node dissection on survival rates in advanced lower rectal carcinoma. *Dig Surg*. 2007;24(5):375–81.
53. Moynihan BGA. The surgical treatment of cancer of the sigmoid flexure and rectum. *Surg Gynecol Obstet*. 1908;6:463–6.
54. Grinnell RS, Hiatt RB. Ligation of the inferior mesenteric artery at the aorta in resections for carcinoma of the sigmoid and rectum. *Surg Gynecol Obstet*. 1952;94(5):526–34.

55. Grinnell RS. Results of ligation of inferior mesenteric artery at the aorta in resections of carcinoma of the descending and sigmoid colon and rectum. *Surg Gynecol Obstet.* 1965;120:1031–6.
56. Gabriel WB, Dukes C, Bussey HJ. Lymphatic spread in cancer of the rectum. *Br J Surg.* 1935;23:395–413.
57. Takemasa I, Sekimoto M, Ikeda M, Mizushima T, Yamamoto H, Doki Y. Video. Transumbilical single-incision laparoscopic surgery for sigmoid colon cancer. *Surg Endosc.* 2010;24(9):2321.
58. Bucher P, Pugin F, Morel P. Single-port access laparoscopic radical left colectomy in humans. *Dis Colon Rectum.* 2009;52(10):1797–801.
59. Hirano Y, Hattori M, Sato Y, Maeda K, Douden K, Hashizume Y. Concurrent single-incision laparoscopic right hemicolectomy and sigmoidectomy for synchronous carcinoma: report of a case. *Indian J Surg.* 2013;75(Suppl 1):293–5.
60. Geisler DP, Condon ET, Remzi FH. Single incision laparoscopic total proctocolectomy with ileopouch anal anastomosis. *Color Dis.* 2010;12(9):941–3.
61. Seow-Choen F, Wan WH, Tan KY. The use of a wound protector to prevent port site recurrence may not be totally logical. *Color Dis.* 2009;11(2):123–5.
62. Curet MJ. Port site metastases. *Am J Surg.* 2004;187(6):705–12.
63. Zanghì A, Cavallaro A, Piccolo G, Fisichella R, Di Vita M, Spartà D, et al. Dissemination metastasis after laparoscopic colorectal surgery versus conventional open surgery for colorectal cancer: a meta-analysis. *Eur Rev Med Pharmacol Sci.* 2013;17(9):1174–84.
64. McDermott FD, Heeney A, Kelly ME, Steele RJ, Carlson GL, Winter DC. Systematic review of preoperative, intraoperative and postoperative risk factors for colorectal anastomotic leaks. *Br J Surg.* 2015;102(5):462–79.
65. Reid K, Pockney P, Draganic B, Smith SR. Barrier wound protection decreases surgical site infection in open elective colorectal surgery: a randomized clinical trial. *Dis Colon Rectum.* 2010;53(10):1374–80.
66. Kercher KW, Nguyen TH, Harold KL, Poplin ME, Matthews BD, Sing RF, et al. Plastic wound protectors do not affect wound infection rates following laparoscopic-assisted colectomy. *Surg Endosc.* 2004;18(1):148–51.
67. Mihaljevic AL, Müller TC, Kehl V, Friess H, Kleeff J. Wound edge protectors in open abdominal surgery to reduce surgical site infections: a systematic review and meta-analysis. *PLoS One.* 2015 Mar 27;10(3):e0121187.

Jaime E. Sanchez

Steps of the Procedure

After ligation of the ileocolic pedicle and medial to lateral mobilization of the right colon:

1. Open lesser sac at the midpoint of the stomach.
2. Continue dissection laterally by transecting the omentum toward the right abdominal wall.
3. Dissect the hepatic flexure from any attachments to the liver, gallbladder, and/or retroperitoneum.
4. Continue peritoneal dissection caudally along the abdominal wall at the lateral peritoneal reflection of the right colon.
5. Retract the hepatic flexure and transverse colon caudally, and bluntly dissect any remaining attachments of the mesocolon to the Gerota's fascia and retroperitoneum.

Tips and Tricks

- If dissection is difficult or retraction is inadequate, convert from single-incision surgery to port reduction surgery by addition of one port at a time.
- Internal crossing of instruments is essential at times and should be embraced, to provide external freedom for the operator, especially when significant retraction is required.
- Patients with increased visceral obesity have more difficult hepatic flexure resections and are more likely to require conversion to traditional multiport surgery.

J.E. Sanchez, MD, MSPH (✉)
Division of Colon & Rectal Surgery, Morsani College of Medicine,
University of South Florida, Tampa, FL, USA
e-mail: jasanche@health.usf.edu

Anatomic Considerations

General Anatomy

The hepatic flexure must be mobilized either to be included in the resection specimen (i.e., right hemicolectomy, extended right hemicolectomy, or total colectomy) or to provide enough laxity for a tension-free anastomosis (i.e., left hemicolectomy, extended left hemicolectomy, ileocecectomy). The hepatic flexure spans the junction of the right or ascending colon and the transverse colon. It also represents the transition of the colon from a retroperitoneal to an intraperitoneal structure. It lies inferior to the right lobe of the liver and anterior to the lower pole of the right kidney. It may also, therefore, be in close proximity to the duodenum and gallbladder (Fig. 8.1). Previous operations or inflammation in this area may lead to significant adhesions affecting dissection, such as with cholecystitis or prior cholecystectomy.

Ligamentous Anatomy

The hepatic flexure is surrounded by supporting ligaments and tissues. Laterally, its peritoneal lining joins the right abdominal wall, creating the white line of Toldt that extends alongside the right colon. Its mesentery is continuous with the transverse mesocolon, which becomes the floor of the lesser sac. The hepatoduodenal ligament may extend laterally to become the hepatocolic ligament, a suspensory ligament of the hepatic flexure. The omentum on the right is often adherent to the retroperitoneum and can be challenging to dissect free laparoscopically.

Rarely, the hepatic flexure and transverse colon can be interposed between the liver and diaphragm creating an asymptomatic Chilaiditi's sign, the appearance of pneumoperitoneum, usually found incidentally on plain radiographs. First described in 1910, this occurs in only 0.028–0.25% of

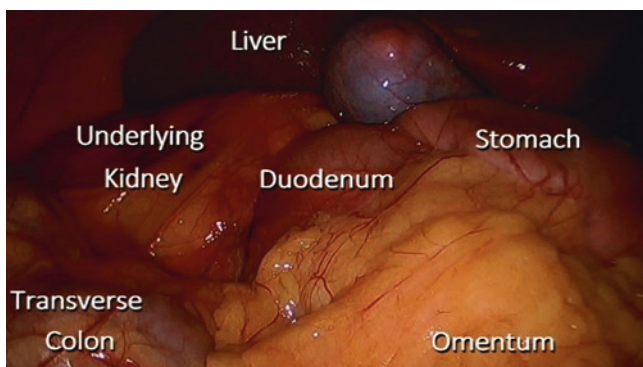


Fig. 8.1 Intraoperative view of the hepatic flexure

the general population [1–4]. Chilaiditi's interposition occurs due to laxity or absence of the suspensory ligaments of the transverse colon. This may also be associated with a concurrent laxity of the falciform ligament. Chilaiditi's syndrome occurs more commonly with a redundant or dilated colon (i.e., chronic constipation, aerophagia), liver atrophy, paresis of the hemidiaphragm, or increased intra-abdominal domain (i.e., ascites, multiple pregnancies, obesity) [5, 6]. It is also found in increased rate in those with a mental disability or schizophrenia [7]. While usually asymptomatic, Chilaiditi's interposition may make mobilization of the hepatic flexure more difficult, such as with a high splenic flexure.

Vascular Anatomy

Understanding the vascular anatomy and variations is important for safe dissection of the hepatic flexure, especially when performing an oncologic resection where high ligation of the supplying arteries is necessary. Vascular anatomy of the right and transverse colon is traditionally divided into branches of the superior mesenteric artery (SMA): ileocolic, right colic, and middle colic arteries. The primary vascular supply to the hepatic flexure is via the right colic artery and the right branch of the middle colic artery; however these are both highly variable in location and course. A true right colic artery branching from the SMA occurs only 10.7–38% of the time [8–11]. Most commonly, the dominant right colic vessel arises as a branch of the ileocolic artery and next most commonly as a branch of the middle colic artery.

The middle colic artery is more constant, occurring in >95% of individuals [8]. However, its division into right and left branches is highly variable and ranges from 3 mm to 70 mm from the origin of the middle colic at the SMA [8]. In up to 40% of individuals, it does not branch at all and arises as a branch of the inferior mesenteric artery or a dorsal pancreatic artery [12].

Technical Considerations

Port Placement

In general, we recommend periumbilical midline placement of the single-incision port for operations involving the hepatic flexure. This provides the most amenable angles for mobilization. If a stoma is being created as a part of the operation, we will typically use this as our access site. Right lower quadrant placement of the port, commonly used when an ileostomy will be created, yields the most difficult dissection angles. However, the operation can still be successfully performed safely from this location. A left-sided abdominal port may also be used, such as with a colostomy reversal, in which the hepatic flexure must be mobilized for a tension-free anastomosis or if a completion colectomy is being performed.

Skin incisions can be kept very small and are limited only by specimen size or space needed to perform an extracorporeal anastomosis. Dissection may be performed through fascial incisions of approximately 2–3 cm which easily allows introduction of a small single-incision port and instruments. Incisions that are too large may cause difficulty in seating of the port, leaking of insufflation, and are typically unnecessary when larger than the specimen. If the incision is found to be too small, the fascial defect can be enlarged while keeping the skin incision small as it will usually stretch much more than the fascia.

Optimize External Working Space

Several techniques can be employed to optimize external working space and minimize instrument collisions. The use of a 90° light cord adapter, differing length instruments (i.e., bariatric instruments), and instruments with reticulating handles will allow the surgeons hands to be offset from each other and from the camera operator. It is also important to understand that the angles required to optimize exposure of the hepatic flexure from a single entry site will differ significantly from the traditional laparoscopic approach and may be counterintuitive in some instances. Internal crossing of instruments is essential at times and should be embraced, to provide external freedom of movement for the operator, especially when significant retraction is required. However, both the surgeon and assistant should understand that there will inevitably be collisions that will require some problem solving to overcome.

Optimize Internal Working Space

Internal working space can be limited by the inline nature of instruments and camera or due to patient factors. The use of both an angled laparoscope (either fixed 30° or flexible tip)

and internal crossing of instruments helps to overcome the limitations of the single-incision technique. Dissections which are difficult due to close proximity of the target anatomy to the incision, either due to limited abdominal domain or port location, as is often encountered when opening the lesser sac from a midline site, can be overcome by upward traction on the port. This creates several centimeters of additional working space by lifting away the abdominal wall.

Patient selection is also an important consideration for successful mobilization of the hepatic flexure through a single-incision approach. Patients with increased visceral obesity are more likely to require conversion to traditional multiport surgery [13]. Most use BMI as an indicator of patient obesity; however visceral body fat is more accurately estimated by the ratio of visceral fat area to body surface area than BMI [14]. While calculating this for every patient is likely not necessary, the degree of visceral obesity can be visually estimated from a patient's preoperative CT scan.

It is important to remember that regardless of the reason, if dissection and mobilization of the flexure are found to be unsafe, unduly difficult, or retraction inadequate, an additional trocar may be added while maintaining a reduced port strategy. Placement of a 5 mm trocar, or even a 2 mm grasper, at a site away from the midline incision site such as the right lower quadrant, can be useful for retracting either the omentum or colon to provide appropriate angles for difficult hepatic flexure mobilizations. In most cases the operation can be completed without requiring full conversion to traditional laparoscopic or open approaches.

Expanded Steps of the Procedure

1. Opening the Lesser Sac

Prior to hepatic flexure mobilization, confirm adequate medial to lateral mobilization of the right colon and ligation of the ileocolic pedicle. Next enter the lesser sac at the midpoint of the stomach. Retract the stomach cephalad and anteriorly to enter the lesser sac via transection of the gastrocolic omentum. Take care during this step to avoid trauma to the stomach or injury to the gastroepiploic vessels. This technique will keep omentum with the colon and the resected specimen. Alternatively, the omentum may be excluded from the specimen by retracting it cephalad entering the lesser sac adjacent to the transverse colon. Confirm entry to into the lesser sac by visualization of the posterior aspect of the stomach and communication with prior medial to lateral dissection.

2. Dissection Toward the Right Abdominal Wall

From the point of entrance into the lesser sac, continue the transection of the gastrocolic omentum laterally to the

right abdominal wall. This will include dividing any attachments from the hepatic flexure to the liver, falciform ligament, or gallbladder. This step will vary in difficulty depending on patient anatomy and prior liver or gallbladder operations. The operative plane becomes ill defined as you move laterally from the lesser sac, and disorientation may occur. To maintain the proper plane, use gentle blunt dissection to separate the mesocolon from the overlying omentum prior to transection of the omentum. This will help avoid inadvertent dissection into the mesocolon or retroperitoneum. Great care must also be taken to avoid injury to the underlying duodenum and pancreas including inadvertent thermal spread from the electro-surgical instrument.

3. Dissection along the lateral peritoneal reflection

After separation of the hepatic flexure from the structures of the upper abdomen, the dissection plane will extend to the lateral peritoneal reflection of the right colon and be contiguous with the prior medial to lateral dissection below.

4. Continue peritoneal dissection caudally along abdominal wall at the lateral peritoneal reflection of the right colon

Continue this dissection caudally along the abdominal wall with a combination of both gentle blunt dissection and transection with an electro-surgical device until the hepatic flexure can be easily medialized and displaced caudally. In most cases the hepatic flexure mobilization is a part of right colon resection, and therefore dissection of the white line of Toldt should be continued caudally until the entire ascending colon and terminal ileum can be medialized.

5. Retract the hepatic flexure and transverse colon caudally, and bluntly dissect any remaining attachments of the mesocolon to the Gerota's fascia and retroperitoneum

While retracting the hepatic flexure caudally and medially away from the abdominal wall, transect the lateral peritoneal attachments. If the colon is not fully mobilized, identify and dissect any remaining attachments of the mesocolon to the Gerota's fascia and/or the retroperitoneum.

References

1. Chilaiditi D. Zur Frage der Hepatoptose und Ptose im allgemeinen im Anschluss an drei Fälle von temporärer, partieller Leberverlagerung. *Fortschr Geb Röntgenstr Nuklearmed Ergänzungsband*. 1910-1911;16:173-208.
2. Torgersen J. Suprahepatic interposition of the colon and volvulus of the cecum. *Am J Roentgenol Radium Ther*. 1951;66(5):747-51.
3. Behlke FM. Hepatodiaphragmatic interposition in children. *Am J Roentgenol Radium Ther*. 1964;91:669-73.

4. Kolju KJ. Roentgen diagnosis of hepatodiaphragmatic interposition of the large intestine. *Am J Roentgenol Radium Ther.* 1938;39:928–36.
5. Risaliti A, De Anna D, Terrosu G, Uzzau A, Carcoforo P, Bresadola F. Chilaiditi's syndrome as a surgical and nonsurgical problem. *Surg Gynecol Obstet.* 1993;176(1):55–8.
6. Flores N, Ingar C, Sánchez J, Fernandez J, Lazarte C, Medina M, et al. The Chilaiditi syndrome and associated volvulus of the transverse colon [in Spanish]. *Rev Gastroenterol Peru.* 2005;25(3):279–84.
7. Lekkas CN, Lentino W. Symptom-producing interposition of the colon. Clinical syndrome in mentally deficient adults. *JAMA.* 1978;240(8):747–50.
8. Garcia-Ruiz A, Milsom JW, Ludwig KA, Marchesa P. Right colonic arterial anatomy: implications for laparoscopic surgery. *Dis Colon Rectum.* 1996;39(8):906–11.
9. Peters RW, Barrels TL. Minimally invasive colectomy: are the potential benefits realized? *Dis Colon Rectum.* 1993;36(8):751–6.
10. VanDamme JP, Bonte J. *Vascular anatomy in abdominal surgery.* Germany: Thieme Medical Publishers; 1990.
11. Michels NA. *Blood supply and anatomy of the upper abdominal organs.* Philadelphia: Lippincott; 1955.
12. Yada H, Sawai K, Taniguichi H, Hoshima M, Katoh M, Takahashi T. Analysis of vascular anatomy and lymph node metastases warrants radical segmental bowel resection for colon cancer. *World J Surg.* 1997;21(1):109–15.
13. Chen WT, Chang SC, Chiang HC, Lo WY, Jeng LB, Wu C, et al. Single-incision laparoscopic versus conventional laparoscopic right hemicolectomy: a comparison of short-term surgical results. *Surg Endosc.* 2011;25(6):1887–92.
14. Seki Y, Ojue M, Sekimoto M, Takiguchi S, Takemasa I, Ikeda M, et al. Evaluation of the technical difficulty performing laparoscopic resection of a rectosigmoid carcinoma: visceral fat reflects technical difficulty more accurately than body mass index. *Surg Endosc.* 2007;21(6):929–34.

Matthew Albert and Marc Dakermadjji

Steps of the Operation

1. Port placement through the umbilicus (or stoma site) with an optional additional 5 mm supraumbilical port
2. Exploration and mobilization of the omentum and small bowel (right side down, moderate Trendelenburg)
3. Medial to lateral dissection (right side down, moderate Trendelenburg)
4. The lateral component (position is right side down, moderate Trendelenburg)
5. Supramesocolic approach (right side down, moderate Trendelenburg)

Tips and Tricks

- Optimal exposure of the left mesocolon is ensured by appropriate patient positioning at the beginning of the operation. This will also serve to prevent the patient from slipping during extreme steep table positions.
- When beginning the dissection below the inferior mesenteric vein after dividing the mesoduodenal ligament, caution must be taken to avoid going into the retroperitoneum where the left gonadal vein, ureter and even left renal vein quickly become exposed and are vulnerable to injury. Even in obese patients, the mesocolon here is much thinner than at the other major vascular pedicles. In thinner patients, a lymphatic running parallel with the aorta is frequently present with an incision made just above.

- Rarely a meandering mesenteric artery is encountered and one must be familiar with this anatomic variant to avoid injury and to minimize ischemia to the left colon.
- To avoid injury to the pancreas, it is critical to identify where Toldt's fascia runs behind it as a stopping point for the inferior dissection. The dissection is then continued just above the pancreas to divide the origin of the transverse colon and enter the lesser sac.
- Incising the transverse mesocolon from the base of the pancreas can be challenging for surgeons early in their learning curve. The lesser sac can often be more easily entered along the distal pancreas where gastropancreatic attachments are less common. Even if the lesser sac is not completely entered, it will greatly facilitate identification of the correct plane once the lesser sac is entered through the gastrocolic ligament and the "bruise" along the pancreas is visualized.

Introduction

Oncologic resection of the splenic flexure has never been clearly standardized, as cancers of the splenic flexure are less common than in the rest of the colon [1]. In addition, many surgeons have traditionally favored extended right colectomy for tumors of the distal transverse colon in order to avoid the more difficult mobilization of the flexure. While tumors of the descending colon can be performed with left colectomy, a proper oncologic resection of the splenic flexure respecting anatomic boundaries can be performed with an adequate lymphadenectomy. This entails dissection at the origin of the left colon mesentery, division of the inferior mesenteric vein at the base of the pancreas, division of the left branch of the middle colic artery, division of the left colic artery from the inferior mesenteric artery dividing the transverse mesocolon at the base of the pancreas, and removing the omentum en bloc along the left gastroepiploic arcade. In addition, the sigmoid colon should be mobilized to the

M. Albert, MD, FACS, FASCRS (✉) • M. Dakermadjji, MD
Department of Colorectal Surgery, Center for Colon & Rectal
Surgery, Florida Hospital, 2501 Orange Ave, Suite 240,
Orlando, FL 32804, USA
e-mail: matthew.albert.md@flhosp.org;
marc.dakermadjji@flhosp.org

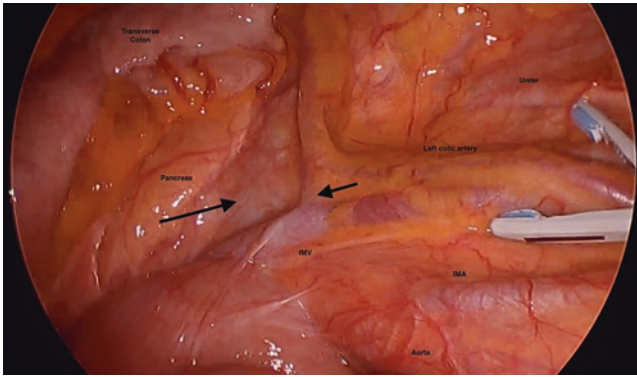


Fig. 9.1 Deconstructing the splenic flexure requires knowledge of the mesocolic vasculature as well as the critical retroperitoneal structures including the left renal vein (*large arrow*). The *small arrow* shows the left colic vein draining into the IMV. Division of the IMV should be below this

mesosigmoid fossa in order to straighten the colon for extraction and enable anastomosis of the mid transverse colon to the mid descending colon. Even less commonly the splenic flexure is resected for ischemic colitis and/or accompanying strictures (Fig. 9.1).

More frequently, splenic flexure mobilization is required to provide a tension-free anastomosis with an adequate distal blood supply for surgeries of the left colon and rectum. While applying traditional oncologic principles for left-sided colonic cancer surgery, one must consider patients' body habitus, disease status, comorbidities, as well as functional outcomes following low anterior resection. The sigmoid colon is commonly a poor conduit, especially when narrowed and thickened with diverticular disease. Furthermore, adequate colonic mobilization to permit reconstruction with a colonic J pouch should be strongly considered and may necessitate more length. Lastly, one must reflect on the need for temporary fecal diversion with loop ileostomy in high-risk patients undergoing a low pelvic anastomosis, especially in the setting of neoadjuvant chemoradiation and how it may influence port placement.

To accomplish the above, complete splenic flexure mobilization to the middle colic trunk with high ligation of the inferior mesenteric artery below the takeoff of the left colic artery and the division of the inferior mesenteric vein at the base of the pancreas provides maximal colonic length and appears mandatory. However, opponents often cite routine splenic flexure mobilization as timely, usually unnecessary, and potentially detrimental to distal colonic perfusion. In our experience, for the most reproducible, standardized resection, we recommend routine splenic flexure mobilization for all patients via a medial to lateral approach beginning at the mesoduodenal ligament. This can be achieved in a multiport fashion, as well as with reduced-port surgery safely and efficiently.

Single-Port Locations

Single-port colonic surgery has been well described in fair numbers with varying non-standardized techniques and port location. For left colonic surgery, single-port devices have been utilized at the umbilicus, in a suprapubic position (Pfannenstiel incision), and in the right lower quadrant. In patients undergoing primary splenic flexure resection, the most suitable port locations are in the umbilicus with midline extension of the incision above and below as necessary for extraction. Port placement here will allow easy access to even the apex of the flexure with adequate length while still allowing access to the left lower quadrant for mobilization of the sigmoid colon. Stapling the rectosigmoid perfectly from this location may be challenging from this angle; the editors recommend using a posterior-to-anterior or anterior-to-posterior approach when placing the stapler through this site to facilitate.

More flexibility is permitted with port placement when the splenic flexure is mobilized in preparation for left colon resection accompanied by high or low pelvic anastomosis.

The benefits of utilizing a Pfannenstiel port placement are multiple, as both stapling of the rectosigmoid colon and specimen extraction can be accomplished. Additionally, cosmesis is optimal here and postoperative incisional hernia risk is extremely low. Port placement in the right lower quadrant through a muscle splitting incision is desirable for those patients undergoing low anterior resection, especially those with preoperative chemoradiotherapy where a diverting stoma is advised. Single-port proctectomy can be performed, with equivalent results in the hands of experts; however, this remains demanding. Extraction through any single-port site can prove challenging in patients with a bulky tumor or mesocolon, and/or a thick abdominal wall, but can be facilitated by a wound protector included in many commercially available ports. In our experience, enlarging the fascial opening to facilitate extraction is superior to avoid specimen fracture or mesenteric avulsion. Intracorporeal stapling of the proximal or distal colon will nearly always simplify extraction.

Medial, Lateral, and Supramesocolic Approaches

Throughout the last two decades, techniques and improvements in laparoscopic colon surgery have continuously evolved. Multiple approaches to the splenic flexure have been described and evaluated with the nomenclature reflecting where one initiates the dissection. As in open colon surgery, early attempts at laparoscopic colonic surgery were generally performed with a lateral to medial approach. This can be initiated anywhere along the mesosigmoid recess, sigmoid colon or descending colon (Fig. 9.2). The colon is

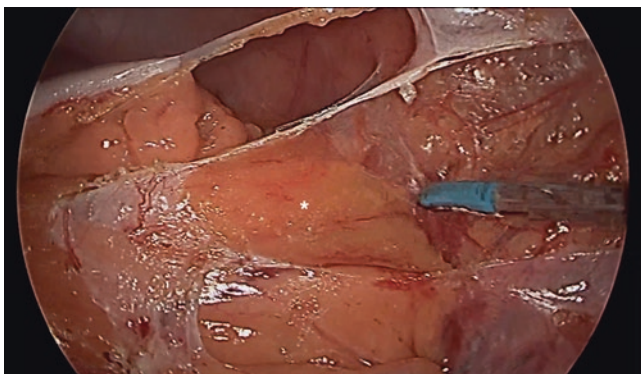


Fig. 9.2 With the lateral to medial approach, the dissection can be initiated anywhere along the *white line* of Toldt along the sigmoid or descending colon. The * is on the sigmoid mesocolon

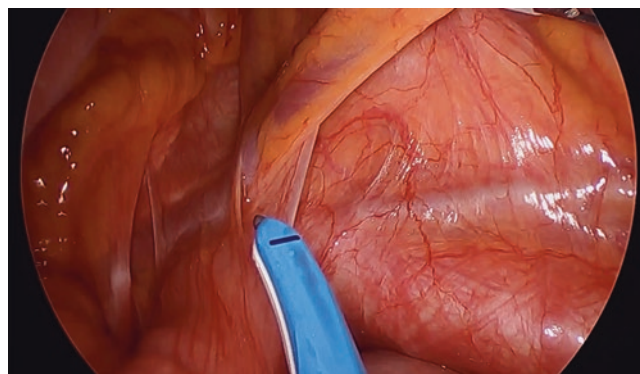


Fig. 9.3 After adequate patient positioning, the inferior mesenteric vein is easily identified

gently retracted medially, an incision made along the lateral peritoneal attachments and the mesocolon mobilized off the retroperitoneum maintaining the integrity of Toldt's fascia. Caution must be taken to find the appropriate plane laterally and not mobilize too deep, posterior to the kidney. Although the most intuitive approach, the lateral approach is challenging in that it requires the surgeon to continuously look over the colon, the splenic flexure can be difficult to turn especially when high, and the critical retroperitoneal structures are not easily identified until later in the dissection.

The medial approach to left colon mobilization, however, begins along the midline at the root of the mesocolic attachments and is traditionally started with a peritoneal incision over the mesosigmoid colon beneath the trunk of the inferior mesenteric artery and toward the sacral promontory. In our experience, the left mesocolic origin can also be targeted at the ligament of Treitz just below the inferior mesenteric vein, which has been mentioned as the inferior approach. Either location allows easy access to the retroperitoneum, early high ligation of the major colonic vascular pedicles, and prompt identification of the left ureter and gonadal vessels, while keeping the colon suspended by its lateral attachments. The inferior approach has become increasingly common for those proponents of routine splenic flexure mobilization. The constancy of the inferior mesenteric vein as it courses by the ligament of Treitz enables immediate clear identification of the initial point of dissection (Fig. 9.3). Inferior mesenteric vein division at the base of the pancreas permits maximal colonic length. This approach permits division of the base of the transverse mesocolon at its origin along the pancreas, entry into the lesser sac, and division of the splenorenal ligaments posteriorly assuring complete mobilization of the splenic flexure.

Lastly, with the supramesocolic approach the dissection begins with entry into the lesser sac, adjacent to the gastroepiploic arcade, leaving the omentum attached to the colon, or along the colon wall which will leave the omentum on the

stomach. Gastropancreatic adhesions when present are lysed to expose the entire retroperitoneum. The omentum is divided toward the splenic flexure and lateral abdominal wall. As the lesser sac is opened, the surgeon can clearly denote the plane of dissection between the gastrocolic ligament and epiploic fat which becomes less distinguishable as you approach the flexure and splenocolic attachments. The pancreas is identified, and the origin of the transverse colon is incised along the inferior edge of pancreas down to Toldt's fascia. The distal transverse mesocolon and left colon are then slowly swept inferiorly off the retroperitoneum.

In practice, routine splenic flexure mobilization may require utilizing all three approaches: first the inferior (medial) approach, next the lateral approach to divide the lateral peritoneal attachments, and finally the supramesocolic approach to completely release the flexure. Performing splenic flexure mobilization in this stepwise, methodical approach allows adequate oncologic resections and identification of all critical anatomy, thus minimizing complications.

Patient Positioning

Prior to placing the patient on the bed, the controls should be interrogated to confirm all functions are working. The patient is placed in the modified Lloyd-Davies position using Allen stirrups, preferably on one of many commercially available nonslip pads. An additional strap is placed across the chest to secure the patient from slipping during steep bed movements. It is critical that the legs are abducted and placed parallel with the torso in order to prevent working collisions while operating through the lower abdominal ports. The arms are padded and tucked, gel rolls or specialized shoulder padding are placed, and Bair Hugger (3M, St Paul, MN, USA) or other warming device is utilized. The patient must be placed low enough on the bed to access the anal canal for stapler placement.

Both the operating surgeon and assistant stand on the right side of the table, while the camera assistant may be positioned between the legs. The laparoscopic monitors are positioned opposite the operating surgeon over the left shoulder of the patient and can be easily transferred down toward the left leg as the dissection moves near the pelvis. An angled 30° or 45° camera is strongly recommended, while a flexible tip camera can bring great benefit to an assistant surgeon, helping to avoid internal and external collisions.

Port Placement (Position Is Supine)

The initial setup for splenic flexure mobilization includes a 3–4 cm midline incision to accommodate a single-port device. An incision placed through the umbilicus provides good cosmesis and allows flexibility in approach, stapling, and extraction. Alternatively a stoma incision in the right lower quadrant at a pre-marked ileostomy site can be used as well as a Pfannenstiel incision. An additional 5 mm port can be placed suprapubically for either a camera or retraction and can be the site of a pelvic drain if desired.

Exploration and Mobilization of the Omentum and Small Bowel (Position Is Right Side Down, Moderate Trendelenburg)

Complete abdominal exploration is performed carefully inspecting for evidence of extracolonic disease. The patient is placed in moderate Trendelenburg position and in steep, right-sided tilt to allow the small bowel contents to be completely displaced to the right side of the abdomen. The omentum is reflected superiorly and pushed over the transverse colon. The ligament of Treitz and bordering inferior mesenteric vein (IMV) along the paraduodenal recess are identified (Fig. 9.3). The mesoduodenal ligament running from the left

lateral border of the duodenum to the left colon mesentery is divided to adequately expose the IMV and root of the mesentery (Fig. 9.4).

Medial to Lateral Dissection (Position Is Right Side Down, Moderate Trendelenburg)

With the inferior mesenteric vein grasped and placed on tension toward the abdominal wall, a transverse incision is created at the base of the mesentery from just below the IMV following the contour of the left colic artery as it joins the inferior mesenteric artery (IMA) (Fig. 9.5a, b). The correct plane between the mesocolon and retroperitoneum is easily identified and medial to lateral dissection is performed on top of Gerota's and Toldt's fascia up to the inferior edge of the pancreas. It is important to dissect as far laterally as possible under the colon to the abdominal sidewall and underneath the splenic flexure (Fig. 9.6a, b). A laparoscopic grasper is initially used to hold up the edge of the mesocolon, however, the dissection progresses laterally by continuously moving the instrument further under the mesocolon hand over hand, providing counter traction by lifting the mesocolon and sweeping downward with the right hand.

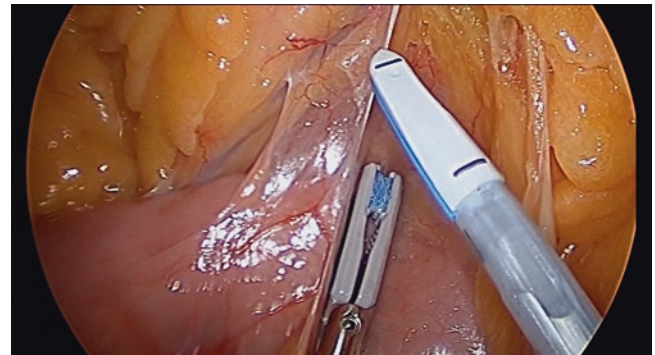


Fig. 9.4 To start the dissection, the mesoduodenal ligament is divided

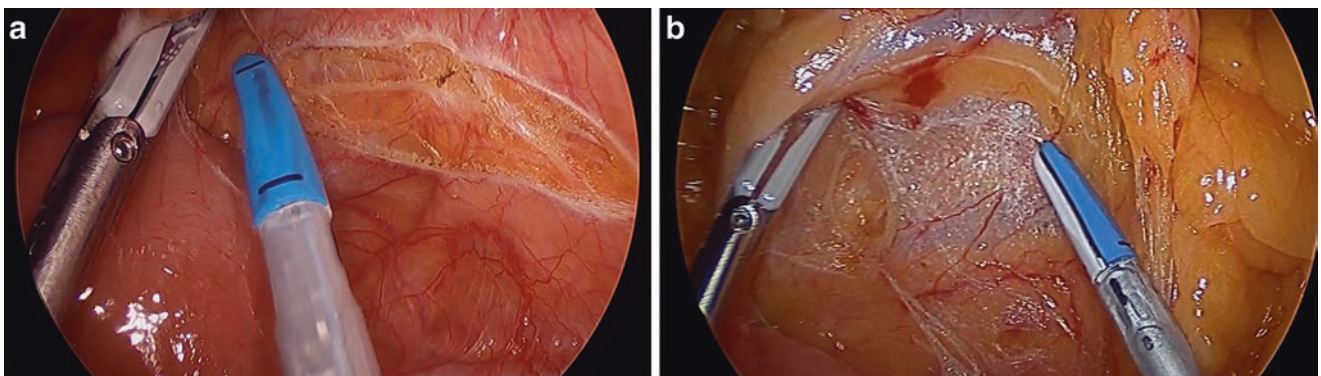


Fig. 9.5 (a, b) The initial transverse incision is made just under the inferior mesenteric vein and continued under the left colic artery

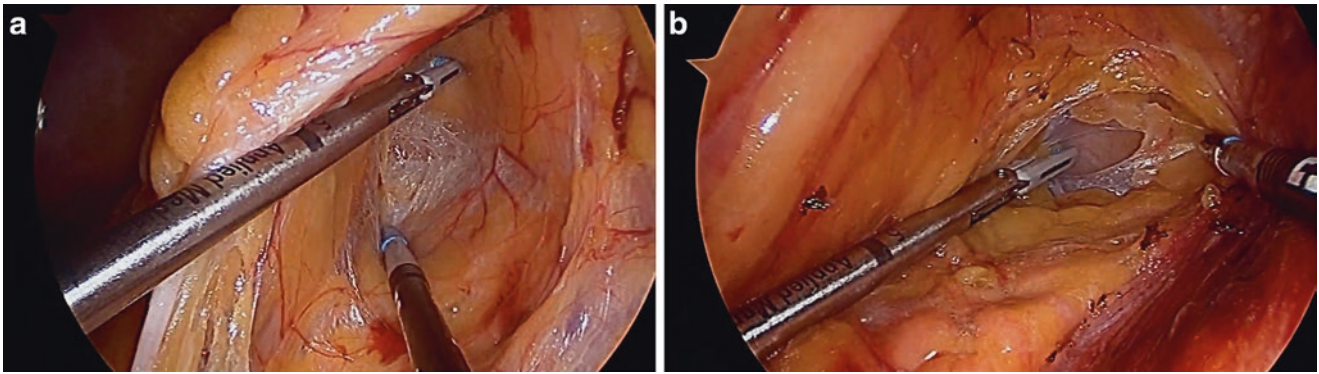


Fig. 9.6 (a, b) Medial to lateral dissection is performed mobilizing the mesocolon off of Toldt's and Gerota's fascia out toward the splenic flexure

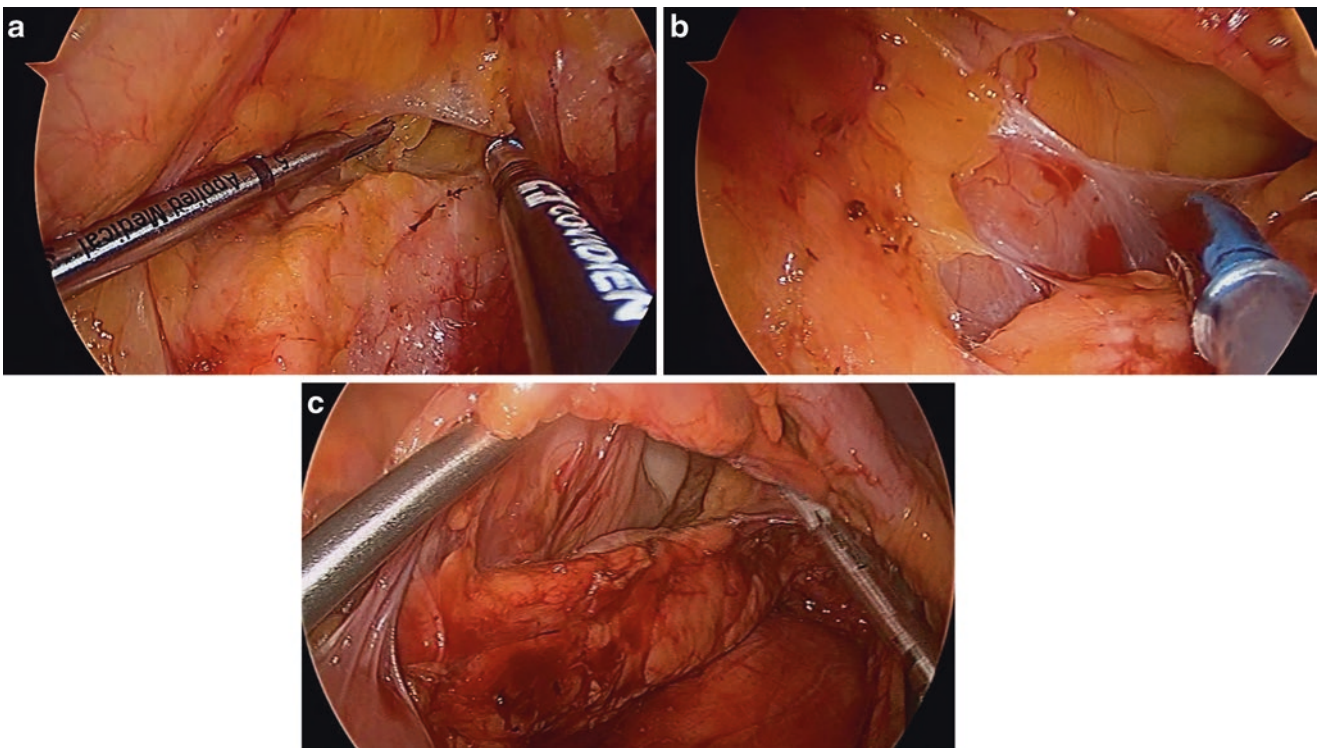


Fig. 9.7 (a–c) Posterior dissection is stopped when the pancreas is reached and a new incision is placed at the root of the transverse mesocolon at the base of the pancreas and the lesser sac entered

Following the dissection superiorly along Toldt's fascia will lead the dissection posterior to the pancreas, quickly exposing the splenic vein first and then the artery. At this point, cease the posterior dissection and move the dissection above the pancreas, making an incision above the pancreas at the root of the transverse mesocolon. The mesocolon is slowly divided and the lesser sac can be entered. Following lesser sac entry, the rest of the transverse colon mesentery is divided laterally toward the tail of the pancreas (Fig. 9.7a–c).

The inferior mesenteric vein is isolated at the base of the pancreas below the left colic vein, and is divided between clips or with an energy device (Fig. 9.8). Rarely, a meandering mesenteric artery (of Moskowitz) (Fig. 9.9) may be present running through the triangle formed by the IMV, left colic artery and the inferior edge of the pancreas. Knowledge and preservation of this anatomic variant is critical to maintaining perfusion of the left colon.

The initial peritoneal incision is continued inferiorly over the origin of the inferior mesenteric artery, along the origin

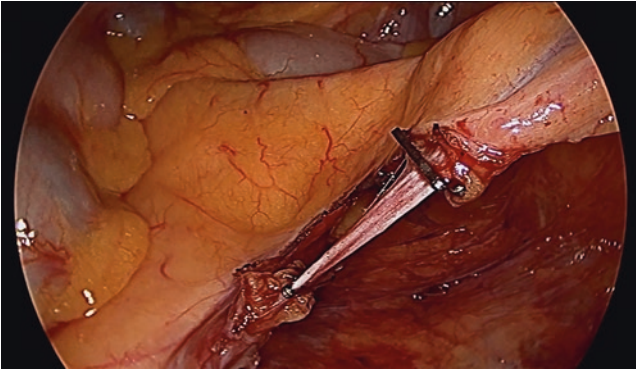


Fig. 9.8 The inferior mesenteric vein is isolated and divided at the base of the pancreas below the left colic vein. This can be performed with an energy device or between clips

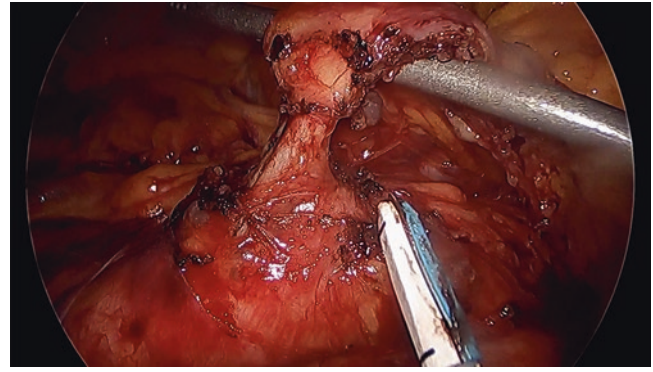


Fig. 9.10 After incising the peritoneum overlying the mesosigmoid, an instrument can be placed immediately behind the takeoff of the inferior mesenteric artery to expose it for division

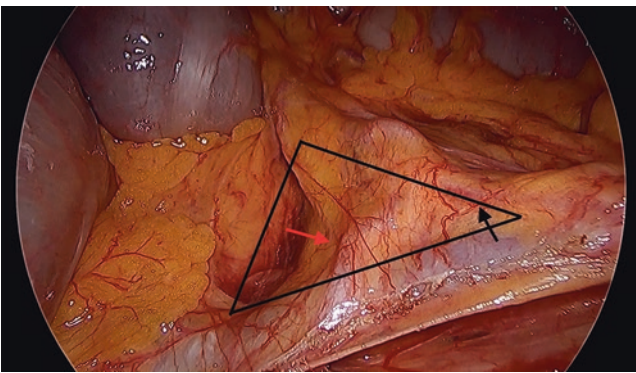


Fig. 9.9 A meandering mesenteric artery (of Moskowitz) may be present running through the *triangle* formed by the IMV, left colic artery and the inferior edge of the pancreas

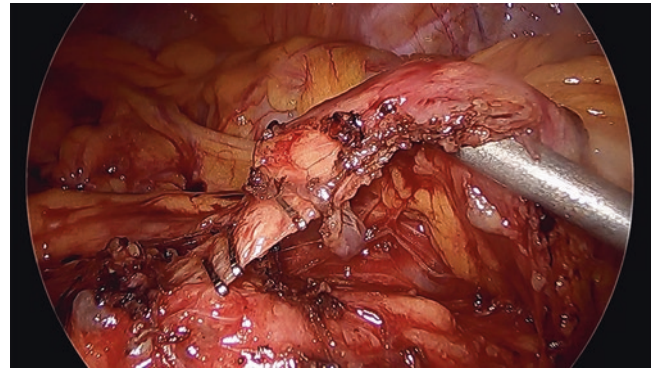


Fig. 9.11 The inferior mesenteric artery is divided between clips

of the mesosigmoid and mesorectum toward the pelvic inlet (Fig. 9.11). From a medial to lateral approach, the mesocolon is mobilized off the retroperitoneum under the superior rectal artery and vein, identifying the hypogastric nerves, left ureter, and the left gonadal vessels while working toward the lateral sidewall. At this point, the instrument in the right hand can be placed below and behind the superior rectal artery (Fig. 9.10), exposing the origin of the inferior mesenteric artery (IMA) proximal to the left colic branch for division with an energy device and clips (Fig. 9.11). The left colic artery is also divided at this time to facilitate extraction. In addition, the left colic artery is the site of division during oncologic resection of the splenic flexure (Fig. 9.12a–c).

The Lateral Component (Position Is Right Side Down, Moderate Trendelenburg)

With the sigmoid colon pulled medially using an atraumatic bowel grasper in the left hand, the peritoneal attachments in the mesosigmoid fossa can be incised over the “bruise” cre-

ated from the previous retroperitoneal dissection, and the two planes are joined (Fig. 9.13). With an instrument under the mesocolon to providing traction, the white line of Toldt can be incised to the splenic flexure along the lateral edge of the descending colon (Fig. 9.14). When the initial medial dissection is performed adequately and the pancreas is dropped posteriorly, the lateral dissection can be extended easily onto the transverse colon.

Supramesocolic Approach (Position Is Right Side Down, Moderate Trendelenburg)

A third instrument to improve triangulation is beneficial during the omental dissection simply to retract the transverse colon toward the pelvis. This can be accomplished with an accessory port or through a single-port platform, which will accommodate an additional trocar. With the operating surgeon facing cephalad, the greater omentum is retracted over the transverse mesocolon and grasped near the attachments of epiploic fat and transverse mesocolon. With an energy device in the right hand, the omentum is divided and the

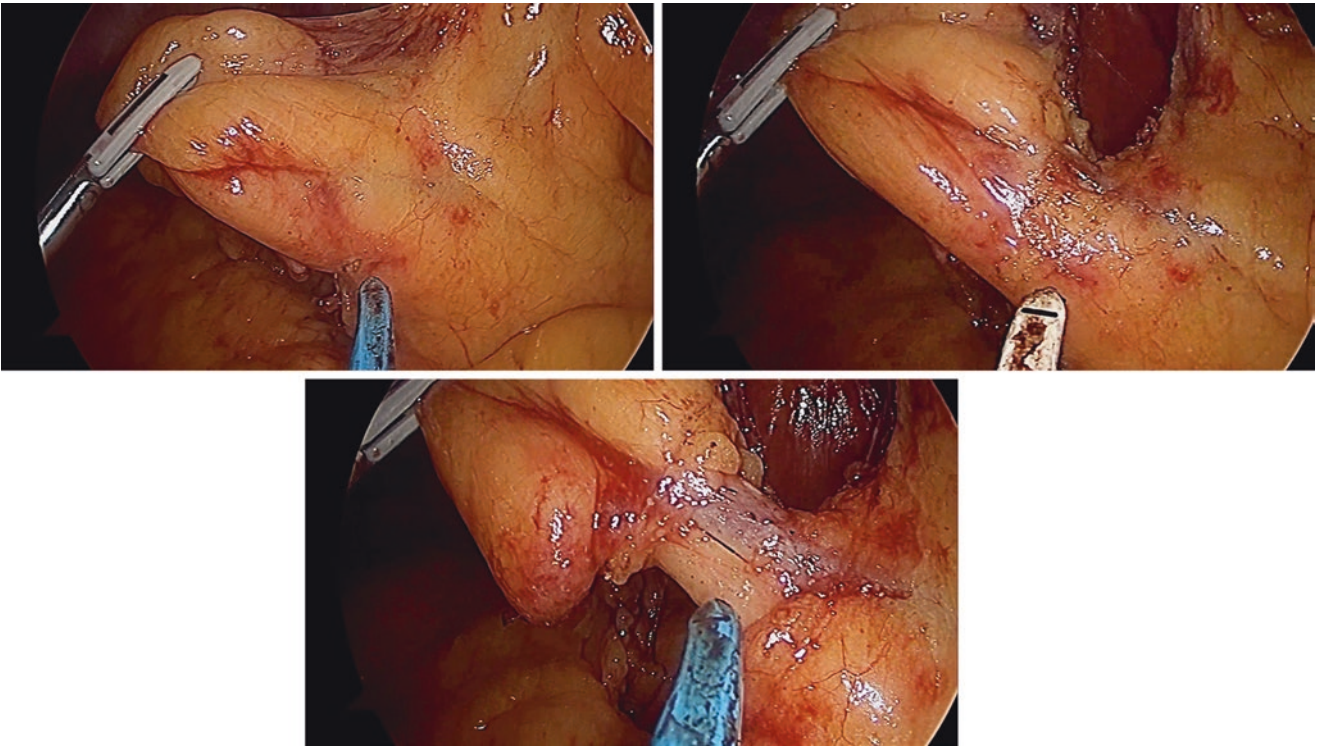


Fig. 9.12 Intracorporeal mesenteric division of the left colic artery from the inferior mesenteric artery facilitates colonic extraction of the left colon for low pelvic anastomosis and is also required for formal splenic flexure resection. The left colic artery and vein are isolated and

divided at their origin with the inferior mesenteric artery. The remaining mesentery is divided toward the descending colon dividing the marginal arcade before reaching the colon wall

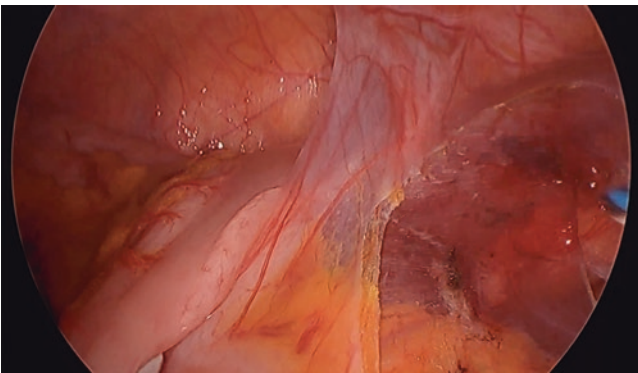


Fig. 9.13 The lateral approach is started by incising the peritoneum adjacent to the mesosigmoid recess and joining the previously dissected plane

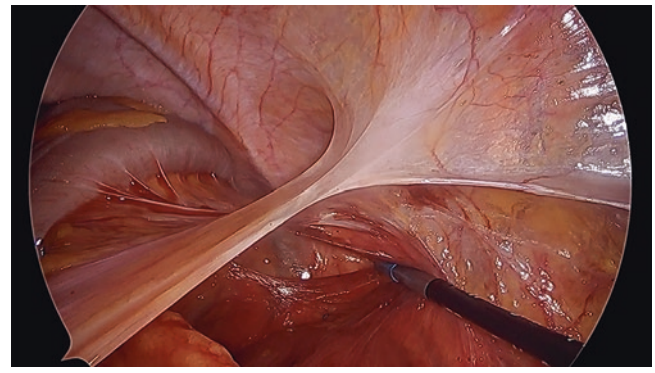


Fig. 9.14 The white line of Toldt can be incised to the splenic flexure along the lateral edge of the descending colon

lesser sac entered. Once lesser sac entry is established, the left hand instrument can be placed inside the lesser sac underneath the omentum to more easily retract (Fig. 9.15a, b). Following division of the omentum to communicate with the lateral plane previously dissected, the mesocolic plane at

the inferior edge of the pancreas is identified and incised, again communicating with the previously established retroperitoneal plane. The final splenocolic ligaments are divided, completely releasing the splenic flexure up to the middle colic pedicle (Fig. 9.16). Alternatively, the lesser sac can be

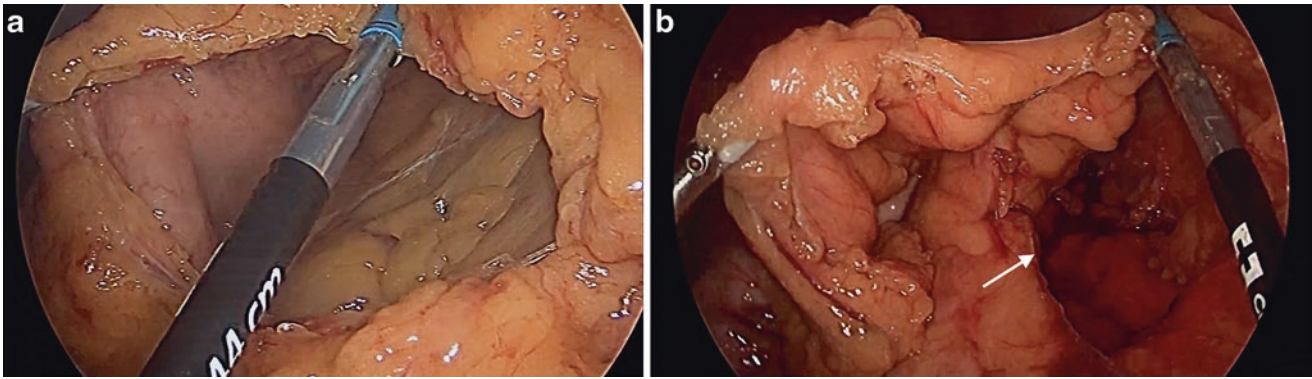


Fig. 9.15 (a, b) The stomach is elevated and the lesser sac is entered with an energy device (a) The omentum is then divided along the gastroepiploic arcade toward the spleen to communicate with the lateral dissection, completely freeing the splenic flexure. (b) The stomach is

seen in the lesser sac (*), arrow showing the inferior edge of pancreas after dividing the transverse mesocolon along the base. The energy device is dividing the final splenicocolic attachments

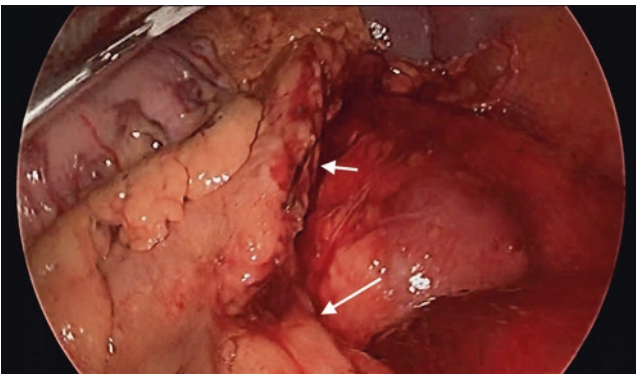


Fig. 9.16 After the deconstruction of the splenic flexure along embryologic planes, the entire colon should be released up to the middle colic vessels. *Large arrow* shows the cut edge of transverse colon, and *short arrow* the inferior edge of the pancreas

more quickly entered adjacent to the gastroepiploic arcade, which will detach the omentum and transverse colon together from the stomach. Care must be taken when performing this

approach so attachments to the omentum at the angle of the splenic flexure are not tethering the descending colon and hindering its mobilization into the pelvis.

Conclusions

Laparoscopic reduced-port splenic flexure mobilization requires a thorough understanding of the left mesocolon and its association with the solid organs of the left upper quadrant. A standardized technique, utilizing a mixture of laparoscopic approaches, is the key to full mobilization and a tension-free anastomosis.

Reference

1. Steffen C, Bokey EL, Chapuis PH. Carcinoma of the splenic flexure. *Dis Colon Rectum*. 1987;30:872–4.

Chi Chung Foo and Wai Lun Law

Steps of the Operation

1. Access into peritoneal cavity
2. Mobilization of the left colon
3. Ligation of the inferior mesenteric vessels
4. Taking down the splenic flexure
5. Rectal mobilization
6. Rectal transection
7. Delivery of specimen and intracorporeal anastomosis

Tips and Tricks

- Careful patient selection and preoperative evaluation is key for SILS.
 - Proper patient positioning can harness the effect of gravity to your advantage
 - The cross-hand technique could overcome the “chopstick effect” in SILS.
 - It is useful to hold the mesentery far away from the field of dissection to minimize instrument clashing.
 - Without the counter-traction by an assistant, make full use of gravity and position the patient to your advantage.
 - The authors find that the lateral to medial approach results in more instruments clashing, as retracting the bowel toward a medial direction will unavoidably bring instruments in close proximity.
- Tenting up the flopping mesentery during medial to lateral dissection could be helped by a laparoscopic fan retractor or a DeBakey forceps with wide opened jaws.
 - Splenic flexure mobilization in SILS is preferably achieved by the medial approach. Proximal ligation of the inferior mesenteric vein, lateral to the duodenojejunal junction, facilitates this.
 - The use of transabdominal sutures to retract the sigmoid colon has been described by Brunner [1] (Fig. 10.1).
 - Uematsu described a vertical suspension system. A detachable bowel clamp is applied to the sigmoid colon and traction is provided by an extracorporeal magnet. To vertically lift up the rectum, instead of transabdominal sutures, a custom-made suspension bar, threaded with suture inside, is used [2].
 - Leroy has described using flexible sigmoidoscopy to position the sigmoid colon and extracorporeal magnet to counter-tract colon with an intraluminally placed anvil [3].
 - Rectal mobilization is performed while observing the same total mesorectal excision principle as in the open and multiport laparoscopy approach.

Introduction

In 1982, RJ Heald published and advocated the technique of total mesorectal excision (TME) for the surgical treatment of rectal cancer. The technique emphasized sharp dissection between the visceral mesorectal fascia and parietal pelvic fascia, that is, the “Holy Plane” with the preservation of the autonomic nerves [4]. This technique has dramatically decreased the local recurrence and has become the gold standard of rectal cancer surgery [5]. In the recent two to three decades, the minimally invasive surgery approach opened a new page in colorectal surgery. Comparative studies and randomized trials have demonstrated favorable clinical outcomes for laparoscopic resections while achieving similar oncologic results as the open approach for colorectal cancers [6–9]. Some of the

Electronic Supplementary Material: The online version of this chapter (doi:10.1007/978-3-319-63204-9_10) contains supplementary material, which is available to authorized users.

C.C. Foo, MBBS, FRCSEd • W.L. Law, MBBS, MS, FACS, FRCSEd, FASCRS(Hon.) (✉)
 Department of Surgery, Queen Mary Hospital, University of Hong Kong, 12 Pokfulam Road, Hong Kong, China
 e-mail: lawwl@hku.hk

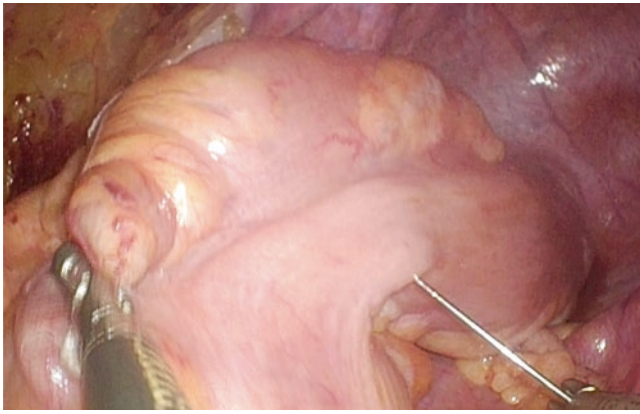


Fig. 10.1 Applying transabdominal sutures for retraction of the sigmoid colon

advantages of the laparoscopic approach include faster postoperative recovery, reduced wound pain and shorter hospital stay. In the case of rectal cancers, especially low rectal cancers, there were initially concerns regarding its safety and the relatively high conversion rate [10]. Fortunately, subsequent studies were able to show minimally invasive rectal cancer surgery, in particular laparoscopic TME, to be an oncologically safe approach even for distal rectal cancers [11–13]. Laparoscopic TME has now become a standard surgical treatment for mid to low rectal cancers.

Further development in minimally invasive colorectal surgery aims to reduce the number and length of the incisions as well as to explore the possibility of natural orifice surgery. While significant enthusiasm on natural orifice transluminal endoscopic surgery (NOTES) began a decade ago, wide application of NOTES is still limited by many issues. However, single-incision laparoscopic surgery has been developed to reduce the number of abdominal incisions. The use of the umbilicus as in single incision laparoscopic surgery is also regarded as one form of natural orifice surgery.

Despite the complexity of colorectal surgery, which includes multi-quadrant dissection, division of sizable vessels, and restoration of bowel continuity, the first single-incision laparoscopy (SILS) right hemicolectomy was published in 2008 [14, 15]. This technique was later shown to have certain advantages like less postoperative pain and faster recovery compared to conventional multiport laparoscopy [16–18]. But when SILS was applied to surgery that involves the rectum, the anatomical confines from a narrow bony pelvis, the lack of multidirectional retraction of the rectum, and the inevitable clashing of instruments and camera render this procedure rather intimidating. Given these additional hurdles, whether one would be able to observe the same principle of meticulous dissection under direct vision as proposed by Heald was questionable. Indeed, SILS TME should be reserved for a select group of patients and be performed by surgeons who are highly skilled in SILS technique. In this chapter, we will discuss the technical aspect of SILS TME and some of the tricks to overcome the technical challenges.

Preoperative Evaluation

Patients with mid or low rectal cancers are indicated for TME. Preoperative workup is equivalent to that of the open or laparoscopic approach. Preoperative anesthetic assessment is crucial for patients with medical comorbidities. Bedside digital examination serves as an informative tool prior to sophisticated investigations. Tumor location, with special consideration to its relationship with the sphincter complex, mobility of the tumor, and anal tone could be ascertained. Colonoscopic evaluation and histological confirmation is essential. Endoscopic tattooing of small rectal cancers is rarely of any value as these mid to low rectal cancers could be felt digitally. Staging is performed by imaging studies including contrast-enhanced computed-tomography of the abdomen and magnetic resonance imaging (MRI) of the pelvis. Endorectal ultrasound can be performed for early disease (T1/T2). T3 tumors, mesorectal lymph node involvement, and threatened circumferential radial margin are common indications for neoadjuvant treatment. A multidisciplinary meeting with expertise from oncologist and radiologist is recommended in this regard. The optimal time interval between neoadjuvant treatment and surgery is still controversial and we would perform the operation at least 8 weeks after completion of radiation [19].

Patient Selection

Patient selection criteria for SILS are similar but more stringent than multiport laparoscopy (MLS). Basically, patients with favorable body habitus and tumor characteristics are preferred. Morbidly obese patients, although not an absolute contraindication, will definitely increase the difficulty of pelvic dissection and the chance of conversion [18, 20, 21]. Cardiorespiratory comorbidities or uncorrected coagulopathy would render the patient less suitable for either MLS or SILS, and should be approached with caution. Large and locally advanced lesions are not suitable for SILS. With a larger lesion, the difficulty will increase and there is a need to make a bigger incision to retrieve the specimen, which partly defeats the purpose of SILS [22]. Locally advanced tumor with infiltration to surrounding structures, for example, prostate, should definitely be avoided.

Patient Preparation

Although the use of mechanical bowel preparation is controversial [23–25], it is preferred in TME to avoid the presence of stool distal to the diverting stoma. It also facilitates the use of intraoperative colonoscopy if there is a need to look for a synchronous tumor. While we do not use oral antibiotics before the operation, intravenous antibiotic prophylaxis with a second-

generation cephalosporin is given on induction of anesthesia. Urethral catheterization should always be performed. Deep vein thrombosis prophylaxis is achieved by intermittent pneumatic calf compression and low molecular weight heparin.

Patient Positioning

Patient is placed in the modified lithotomy position in which the hips are abducted and slightly extended and the knees flexed. The arms should be tucked and body strapped to the table to prevent sliding from the operating table. Pressure areas should be carefully padded. The lower part of the sacrum should be sitting at the distal edge of the table.

Equipment

There are multiple SILS access devices in the market as well as different versions of innovative self-adapted method incorporating existing MLS instruments. Specialized SILS devices include the TriPort™ Access System (Olympus, Japan), SILS™ Port (Covidien, USA), X-Cone (Karl Storz, Germany), OCTO™ Port (Dalim, Korea), and GelPOINT Advanced Access Platform (Applied Medical, USA). These devices usually house three to four 5–12 mm ports in them. They are designed to prevent air-leak, minimize clashing of the smaller ports, allow maximal instrument range of motion and maximize the already compromised triangulation of instruments. These are crucial to a successful SILS procedure. Some examples of self-adapted method include the glove-wound protector technique [26, 27], inserting multiple trocars via a single incision [1, 28], and the technique of inserting conventional trocars through a Gelport (Applied Medical, USA) [29]. These methods, though innovative, are less robust in terms of preventing air-leak and instruments clashing and should be largely replaced by specialized device in technically demanding operations like TME.

In order to overcome coaxial alignment of the laparoscope and instruments, deflectable laparoscopes have been designed. With current technology, some of these scopes have a diameter of 5 mm. Deflectable Tip EndoEYE™ (Olympus, Japan) and the IdealEyes™ HD Articulating Laparoscope (Stryker, USA) are examples of deflectable laparoscope. More so, deflectable laparoscopes providing three-dimensional view have emerged in the market.

Articulating or curved laparoscopic instruments have been designed to tackle the loss of triangulation in SILS. Studies, however, failed to show that the use of articulating instruments result in better performance or a shorter learning curve in SILS [30, 31].

The authors' preference has been a straight 10 mm 30° laparoscope with high-definition camera and straight laparoscopic instruments. The issue of coaxial alignment can partly be addressed by manipulating the orientation of the light

cable. The majority of laparoscopic surgeons are familiar with straight laparoscopic instruments and the feasibility of its use in SILS is well documented in the literature [22, 32–34]. While the use of articulating instruments requires psychometric adaptation, the transition from MLS to SILS would probably be smoother if surgeons operate with instruments they are accustomed to.

Current Evidence for SILS TME

Hamzaoglu et al. published the first case series on SILS sphincter-saving surgery for rectal cancer [35]. The series involved two partial mesorectal excisions and two TME. Subsequently, there were other series showing SILS TME to be a feasible procedure with oncological clearance comparable to MLS [27, 36, 37]. Nevertheless, SILS TME was not a very popular procedure and this could be partly reflected by the lack of large volume series in the literature. Studies have demonstrated favorable postoperative outcome in terms of faster recovery and less postoperative pain in SILS but many of these included only colectomies and high anterior resections; cases of low rectal cancer were excluded [38–40]. SILS rectal resection was associated with a longer operation time with significant higher chance of multiport conversion [41]. The conversion rates to MLS and laparotomy were 30% and 3%, respectively, in a systematic review by Maggiori et al. [42]. Apart from higher conversion rate, more cartridges may be required to transect the low rectum [35]. Under such circumstances, some devised the technique of using one additional port, the reduced port technique, for that purpose [43].

Transanal Total Mesorectal Excision

While the current evidence in the literature highlighted some of the technical issues behind SILS TME, a feasible solution emerged over the horizon. Whiteford performed the first transanal rectal mobilization on cadavers [44]. The first clinical case was later performed by the team of Sylla and Lacy [45]. This is a novel technique that involves rectal dissection with a bottom-to-up approach. The initial results demonstrated feasibility and safety in terms of oncological clearance [46]. The potential advantages of such technique include precise determination of the distal margin and better visualization of the low rectum. The distal rectum would be divided upfront, obviating the need to transect with stapler in the pelvis.

The technique described by the pioneers achieved sigmoid colon mobilization and division of vascular pedicles by MLS. The rectal dissection is performed using a transanal platform, which resembles a SILS platform (Fig. 10.2). The rectal lumen is closed distal to the tumor. After dividing the rectum circumferentially, the rectum is mobilized, following the same avascular plane used in the conventional technique, only from the opposite direction (Fig. 10.3).

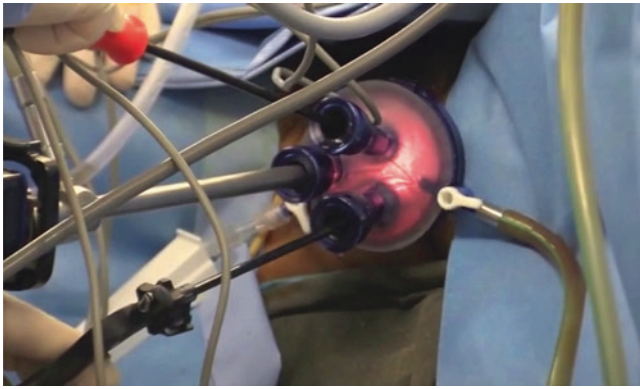


Fig. 10.2 Transanal access platform

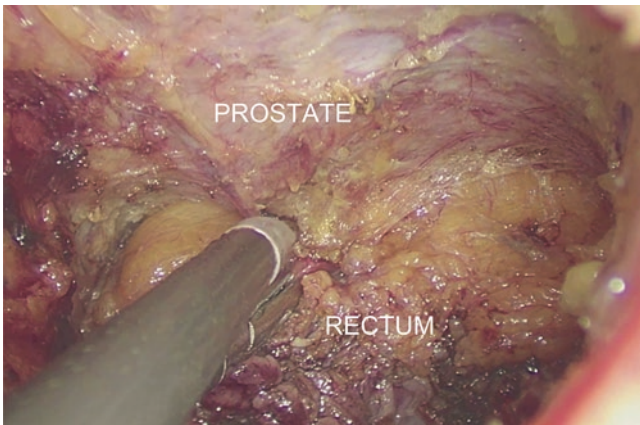


Fig. 10.3 Transanal rectal dissection

Tuech was first to report SILS combined with transanal rectal resection in a female patient [47]. Subsequently, Gaujoux and Dumont published similar case series with four male patients in the latter series [48, 49]. The initial results were encouraging. Choi reported a case series of 22 patients; the median operating time was 260 min and the complication rate was 4.5% (Clavien-Dindo Grade III or above) [50]. The conversion rate was 0%. However, hand-sewn coloanal anastomosis was fashioned almost exclusively in the initial reports. Stapled colorectal anastomosis was reported by Velthuis and Chen [51, 52]. In our opinion, we prefer to perform stapled colorectal anastomosis if possible. This is to avoid unnecessary morbidities from an ultra-low anastomosis. Hand-sewn coloanal anastomosis should be reserved for those with ultra-low rectal tumors, which mandates intersphincteric dissection.

Transanal TME may ultimately address the technical limitations of SILS TME. This combined approach allows the surgeon to follow the same oncological principles with low conversion rate while operating on patients with low rectal cancers.

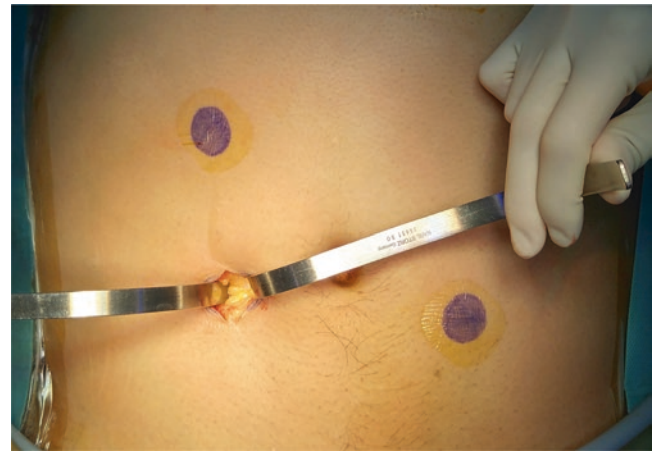

Fig. 10.4 Incision over intended ileostomy site for entry into peritoneal cavity

Expanded Steps of the Operation

The principles of SILS TME are the same as per open and laparoscopic. The operation is divided into the following steps.

Access into Peritoneal Cavity

A 3–4 cm longitudinal transumbilical skin incision is made. The incision is deepened through subcutaneous fat. Fascia and peritoneum is incised and the peritoneal cavity is entered. In order to retrieve the specimen, the fascia defect is lengthened to at least 4 cm eventually in most cases [22, 53, 54]. Struggling with a tiny 2 cm wound is therefore not advisable. A SILS device is inserted and followed by carbon dioxide insufflation at a pressure of 12 mmHg. When a diversion stoma is planned, there is an option to use the stoma site for SILS access (Fig. 10.4).

Mobilization of Left Colon (Video Clip #10.1)

Diagnostic laparoscopy is performed to detect any ascites or distant metastasis that signifies disseminated disease and surgical strategy may require to be changed. The patient is placed at the left side up and head down position. Small bowel is placed at the right side of the peritoneal cavity. The authors routinely use the medial to lateral approach for mobilization of the left colon. The sigmoid mesentery is retracted towards the left. With the use of monopolar diathermy or energy devices, the peritoneum is incised at the base of the mesentery. With proper tension applied to the mesentery, pneumodissection takes place once the peritoneum is incised. This aids in the identification of the natural

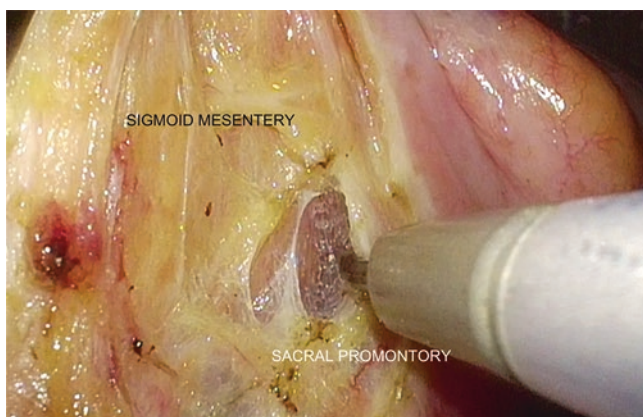


Fig. 10.5 Identification of avascular plane between sigmoid mesentery and retroperitoneum

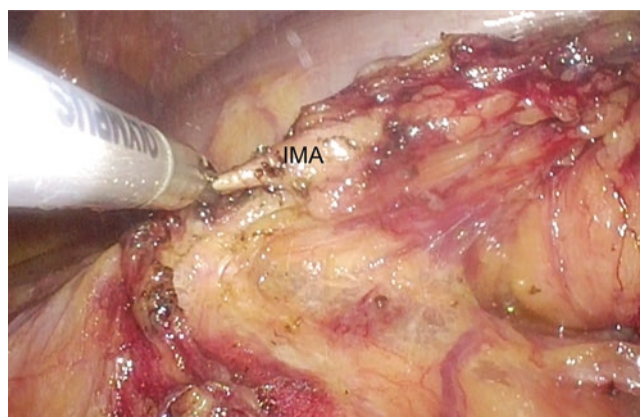


Fig. 10.7 Sealing and division of IMA with bipolar energy device

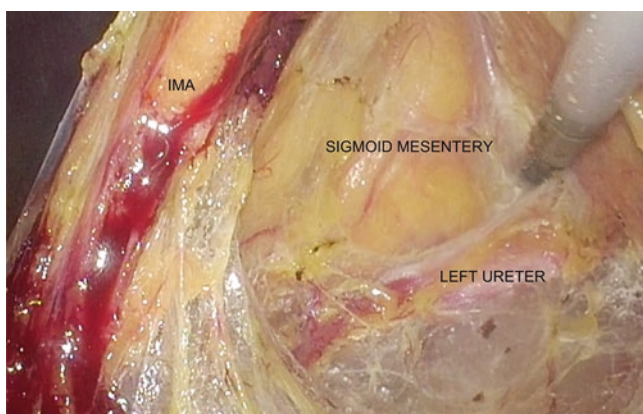


Fig. 10.6 Identification of the left ureter and inferior mesenteric artery (IMA)

avascular plane behind the mesentery (Fig. 10.5). The avascular plane is followed and further developed. This should be a rather bloodless step and bleeding usually signifies incorrect dissection plane. Retroperitoneal structures, that is, the left ureter and left gonadal vessels are identified and safeguarded (Fig. 10.6).

Ligation of the Inferior Mesenteric Vessels (Video Clip #10.2)

The tubular structure that is seen taut at the base of the mesentery is the inferior mesenteric artery. It is skeletonized, ligated, and divided (Fig. 10.7). The inferior mesenteric vein is identified as the next taut tubular structure after division of the artery. It is traced proximally to the lower border of pancreas. The duodenojejunal junction serves as an important landmark for such purpose, and the vein should be just lateral to it (Fig. 10.8). The vein is ligated and divided.

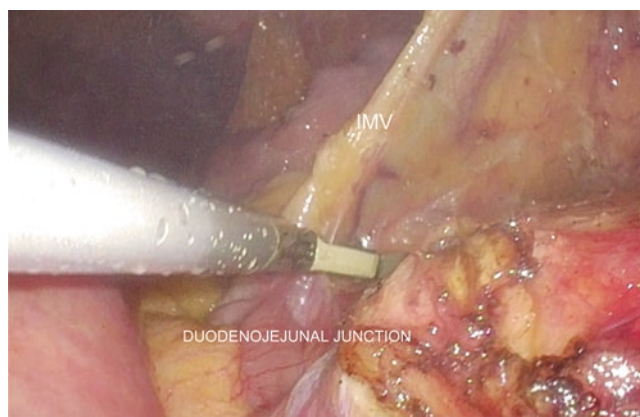


Fig. 10.8 Identification of inferior mesenteric vein (IMV)

Taking down the Splenic Flexure

In order to avoid anastomosing with irradiated bowel and to minimize tension, the splenic flexure should preferably be mobilized in TME. At this juncture, it is useful to further develop the avascular plane behind the mesentery in a cephalic and lateral direction. When the cephalic dissection is performed in the correct plane, the pancreas is seen closely related to the posterior aspect of the mesentery. It should be sharply dissected from the mesentery. Once this is achieved, the lesser sac is entered. This could be seen as mobilization of the splenic flexure via the medial approach. The sigmoid colon is retracted towards the medial direction and the lateral peritoneal attachment is then sharply divided (Video Clip #10.3). The line of division extends toward the flexure. Forceful medial traction on the omentum should be avoided to prevent splenic laceration, which, no matter how minor it is, jeopardizes the SILS procedure and increases the chance of conversion. Rather, the greater omentum should be retracted upwards and let gravity performs the countertraction to the colon. It is useful to place the patient at a

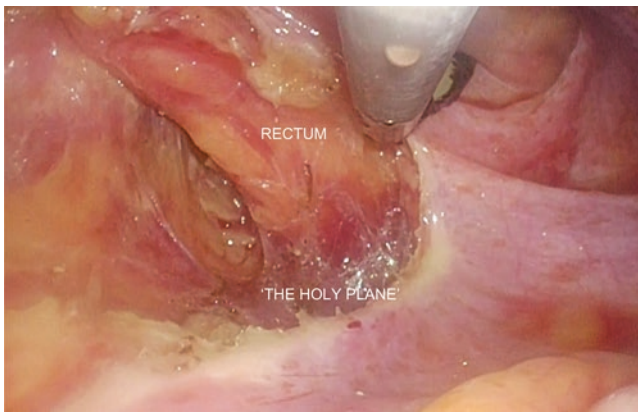


Fig. 10.9 “The Holy Plane” of dissection between the mesorectal fascia propria and the presacral fascia

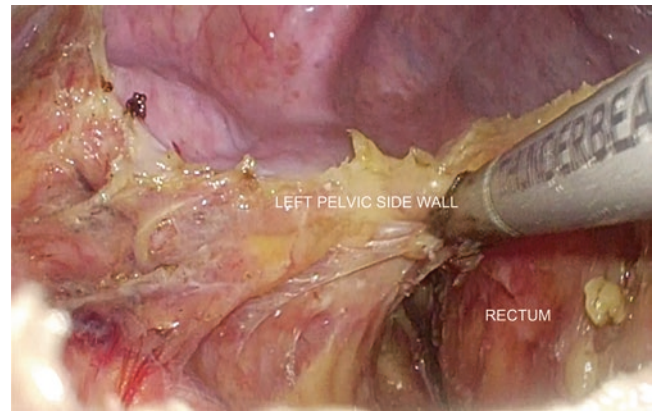


Fig. 10.11 Mobilization of rectum from the left pelvic side wall

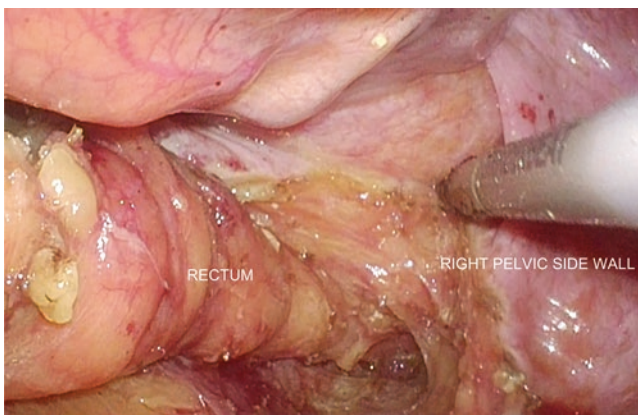


Fig. 10.10 Mobilization of rectum from the right pelvic side wall

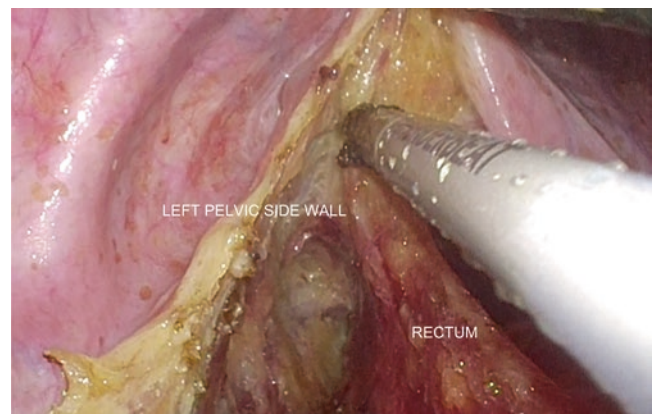


Fig. 10.12 Anterior dissection of rectum

slightly head-up position to increase the effect of gravity. The colo-omental attachment is then divided sharply. This is performed in both directions: from the left colon toward the flexure and from the transverse colon toward the flexure. Given the previous medial dissection, the splenic flexure should now be fully mobilized after taking down the lateral and colo-omental attachment.

Rectal Mobilization (Video Clip #10.4)

Rectal mobilization commences by following the avascular plane posterior to the sigmoid mesentery. Patient is placed at a steep Trendelenburg position. For female patients, transabdominal sutures could be used to sling the uterus. The sigmoid colon is retracted in the cephalic and anterior direction. The loose areolar tissue between the mesorectum and the presacral fascia is sharply divided and care should be taken not to fragment the mesorectum (Fig. 10.9). As mentioned above, bleeding usually signifies incorrect dissection plane. The avascular plane is followed on both sides laterally to a

certain extent (Figs. 10.10 and 10.11). When the lateral plane is not readily identifiable, it would be useful to perform anterior dissection at this junction (Fig. 10.12). The rectum should be retracted toward the cephalic and posterior direction. The peritoneum overlying the rectovesical pouch in male or Pouch of Douglas in female is incised. The avascular plane behind the seminal vesicles or vagina should be readily identifiable. Dissection is performed down to the pelvic floor. The Denonvillier’s fascia in male could be included in the specimen for anterior tumors. With the anterior and posterior dissection plane well defined, the remaining lateral dissection is carried out. Care is taken to avoid damaging the hypogastric plexus posterior to the rectum, pelvic plexus at the lateral sidewall, and peri-prostatic plexus anteriorly.

Rectal Transection (Video Clip #10.5)

Intracorporeal rectal transection is performed using an articulating laparoscopic linear stapler, for example, EchelonFlex™ Endopath® stapler (Ethicon, USA) and EndoGIA™ with Tri-

Staple™ stapler (Covidien, USA). Traction is applied to the rectum toward proximal and posterior directions. Rather than passing the stapler over the right side of rectum, as it is usually performed in the MLS case, it should be passed anterior to the rectum. The stapler then articulates to its full in order to clamp the rectum antero-posteriorly. Digital examination is performed to confirm adequate distal margin before clamping. The rectum is transected well below the tumor, preferably at least 2 cm. The rectum stump is irrigated with Betadine® solution (USA).

Delivery of Specimen and Intracorporeal Anastomosis (Video Clip #10.6)

The specimen is delivered through the single-incision wound with protection. The bowel is transected proximally at the descending colon. The marginal artery of Drummond has to be preserved up to the transection end. An anvil is tied at the bowel end and placed back into the peritoneal cavity. Pneumoperitoneum is reestablished. A circular stapler, for example, DST Series™ EEA™ 28 mm (Autosuture, Covidien, USA) or CDH29A (Ethicon, USA), is passed transanally and an intracorporeal colorectal anastomosis is performed. The anastomosis is examined endoscopically for bleeding. The doughnut from the stapler is checked for completeness. Air-leak test could be performed. Loop ileostomy could be fashioned. Wound is closed in layers after infiltration with local anesthetic.

Conclusion

In SILS rectal cancer surgery, the same principle as originally proposed for open approach and later adopted for laparoscopic is followed. Increased technical difficulty mandates careful patient selection and surgeon training. Certain techniques help to address the inherent limitations of SILS. Transanal rectal dissection may be the ultimate solution.

Reference

- Brunner W, Schirnhofner J, Waldstein-Wartenberg N, Frass R, Weiss H. Single incision laparoscopic sigmoid colon resections without visible scar: a novel technique. *Color Dis.* 2010;12(1):66–70.
- Uematsu D, Akiyama G, Magishi A, Nakamura J, Hotta K. Single-access laparoscopic left and right hemicolectomy combined with extracorporeal magnetic retraction. *Dis Colon Rectum.* 2010;53(6):944–8.
- Leroy J, Cahill RA, Asakuma M, Dallemagne B, Marescaux J. Single-access laparoscopic sigmoidectomy as definitive surgical management of prior diverticulitis in a human patient. *Arch Surg.* 2009;144(2):173–9;discussion 9.
- Heald RJ, Husband EM, Ryall RD. The mesorectum in rectal cancer surgery--the clue to pelvic recurrence? *Br J Surg.* 1982;69(10):613–6.
- Heald RJ, Moran BJ, Ryall RD, Sexton R, MacFarlane JK. Rectal cancer: the Basingstoke experience of total mesorectal excision, 1978-1997. *Arch Surg.* 1998;133(8):894–9.
- Law WL, Lee YM, Choi HK, Seto CL, Ho JW. Impact of laparoscopic resection for colorectal cancer on operative outcomes and survival. *Ann Surg.* 2007;245(1):1–7.
- Laurent C, Leblanc F, Wutrich P, Scheffler M, Rullier E. Laparoscopic versus open surgery for rectal cancer: long-term oncologic results. *Ann Surg.* 2009;250(1):54–61.
- Clinical Outcomes of Surgical Therapy Study Group, Nelson H, Sargent DJ, Wieand HS, Fleshman J, Anvari M, Stryker SJ, Beart RW Jr, Hellinger M, Flanagan R Jr, Peters W, Ota D. A comparison of laparoscopically assisted and open colectomy for colon cancer. *N Engl J Med.* 2004;350(20):2050–9.
- Lacy AM, Delgado S, Castells A, Prins HA, Arroyo V, Ibarzabal A, et al. The long-term results of a randomized clinical trial of laparoscopy-assisted versus open surgery for colon cancer. *Ann Surg.* 2008;248(1):1–7.
- Guillou PJ, Quirke P, Thorpe H, Walker J, Jayne DG, Smith AM, et al. Short-term endpoints of conventional versus laparoscopic-assisted surgery in patients with colorectal cancer (MRC CLASICC trial): multicentre, randomised controlled trial. *Lancet (London, England).* 2005;365(9472):1718–26.
- Kang SB, Park JW, Jeong SY, Nam BH, Choi HS, Kim DW, et al. Open versus laparoscopic surgery for mid or low rectal cancer after neoadjuvant chemoradiotherapy (COREAN trial): short-term outcomes of an open-label randomised controlled trial. *Lancet Oncol.* 2010;11(7):637–45.
- Lujan J, Valero G, Hernandez Q, Sanchez A, Frutos MD, Parrilla P. Randomized clinical trial comparing laparoscopic and open surgery in patients with rectal cancer. *Br J Surg.* 2009;96(9):982–9.
- van der Pas MH, Haglind E, Cuesta MA, Furst A, Lacy AM, Hop WC, et al. Laparoscopic versus open surgery for rectal cancer (COLOR II): short-term outcomes of a randomised, phase 3 trial. *Lancet Oncol.* 2013;14(3):210–8.
- Remzi FH, Kirat HT, Kaouk JH, Geisler DP. Single-port laparoscopy in colorectal surgery. *Color Dis.* 2008;10(8):823–6.
- Bucher P, Pugin F, Morel P. Single port access laparoscopic right hemicolectomy. *Int J Color Dis.* 2008;23(10):1013–6.
- Bulut O, Aslak KK, Rosenstock S. Technique and short-term outcomes of single-port surgery for rectal cancer: a feasibility study of 25 patients. *Scandinavian J Surg SJS (Official Organ for the Finnish Surgical Society and the Scandinavian Surgical Society).* 2014;103(1):26–33.
- Champagne BJ, Papaconstantinou HT, Parmar SS, Nagle DA, Young-Fadok TM, Lee EC, et al. Single-incision versus standard multiport laparoscopic colectomy: a multicenter, case-controlled comparison. *Ann Surg.* 2012;255(1):66–9.
- Poon JT, Cheung CW, Fan JK, Lo OS, Law WL. Single-incision versus conventional laparoscopic colectomy for colonic neoplasm: a randomized, controlled trial. *Surg Endosc.* 2012;26(10):2729–34.
- de Campos-Lobato LF, Geisler DP, da Luz MA, Stocchi L, Dietz D, Kalady MF. Neoadjuvant therapy for rectal cancer: the impact of longer interval between chemoradiation and surgery. *J Gastrointest Surg.* 2011;15(3):444–50.
- Gaujoux S, Bretagnol F, Ferron M, Panis Y. Single-incision laparoscopic colonic surgery. *Color Dis.* 2011;13(9):1066–71.
- Ramos-Valadez DI, Patel CB, Ragupathi M, Bartley Pickron T, Haas EM. Single-incision laparoscopic right hemicolectomy: safety and feasibility in a series of consecutive cases. *Surg Endosc.* 2010;24(10):2613–6.
- Leblanc F, Champagne BJ, Augestad KM, Stein SL, Marderstein E, Reynolds HL, et al. Single incision laparoscopic colectomy: techni-

- cal aspects, feasibility, and expected benefits. *Diagn Therapeutic Endosc.* 2010;2010:913216.
23. Slim K, Vicaut E, Launay-Savary MV, Contant C, Chipponi J. Updated systematic review and meta-analysis of randomized clinical trials on the role of mechanical bowel preparation before colorectal surgery. *Ann Surg.* 2009;249(2):203–9.
 24. Jung B, Pahlman L, Nystrom PO, Nilsson E. Multicentre randomized clinical trial of mechanical bowel preparation in elective colonic resection. *Br J Surg.* 2007;94(6):689–95.
 25. Contant CM, Hop WC, van't Sant HP, Oostvogel HJ, Smeets HJ, Stassen LP, et al. Mechanical bowel preparation for elective colorectal surgery: a multicentre randomised trial. *Lancet (London, England).* 2007;370(9605):2112–7.
 26. Livraghi L, Berselli M, Bianchi V, Latham L, Farassino L, Coccozza E. Glove technique in single-port access laparoscopic surgery: results of an initial experience. *Minim Invasive Surg.* 2012;2012:415430.
 27. Sirikurnpiboon S. Single-access laparoscopic rectal cancer surgery using the glove technique. *Asian J Endosc Surg.* 2014;7(3):206–13.
 28. Rieger NA, Lam FF. Single-incision laparoscopically assisted colectomy using standard laparoscopic instrumentation. *Surg Endosc.* 2010;24(4):888–90.
 29. Merchant AM, Cook MW, White BC, Davis SS, Sweeney JF, Lin E. Transumbilical Gelpport access technique for performing single incision laparoscopic surgery (SILS). *J Gastrointest Surg.* 2009;13(1):159–62.
 30. Santos BF, Reif TJ, Soper NJ, Hungness ES. Effect of training and instrument type on performance in single-incision laparoscopy: results of a randomized comparison using a surgical simulator. *Surg Endosc.* 2011;25(12):3798–804.
 31. Martinec DV, Gatta P, Zheng B, Denk PM, Swanstrom LL. The trade-off between flexibility and maneuverability: task performance with articulating laparoscopic instruments. *Surg Endosc.* 2009;23(12):2697–701.
 32. Gaujoux S, Maggiori L, Bretagnol F, Ferron M, Panis Y. Safety, feasibility, and short-term outcomes of single port access colorectal surgery: a single institutional case-matched study. *J Gastrointest Surg.* 2012;16(3):629–34.
 33. Velthuis S, van den Boezem PB, Lips DJ, Prins HA, Cuesta MA, Sietses C. Comparison of short-term surgical outcomes after single-incision laparoscopic versus multiport laparoscopic right colectomy: a two-center, prospective case-controlled study of 100 patients. *Dig Surg.* 2012;29(6):477–83.
 34. Ragupathi M, Nieto J, Haas EM. Pearls and pitfalls in SILS colectomy. *Surg Laparosc Endosc Percutan Tech.* 2012;22(3):183–8.
 35. Hamzaoglu I, Karahasanoglu T, Baca B, Karatas A, Aytac E, Kahya AS. Single-port laparoscopic sphincter-saving mesorectal excision for rectal cancer: report of the first 4 human cases. *Arch Surg.* 2011;146(1):75–81.
 36. Uematsu D, Akiyama G, Narita M, Magishi A. Single-access laparoscopic low anterior resection with vertical suspension of the rectum. *Dis Colon Rectum.* 2011;54(5):632–7.
 37. Bulut O, Nielsen CB. Single-incision laparoscopic low anterior resection for rectal cancer. *Int J Color Dis.* 2010;25(10):1261–3.
 38. Huscher CG, Mingoli A, Sgarzini G, Mereu A, Binda B, Brachini G, et al. Standard laparoscopic versus single-incision laparoscopic colectomy for cancer: early results of a randomized prospective study. *Am J Surg.* 2012;204(1):115–20.
 39. Kim SJ, Ryu GO, Choi BJ, Kim JG, Lee SC, et al. The short-term outcomes of conventional and single-port laparoscopic surgery for colorectal cancer. *Ann Surg.* 2011;254(6):933–40.
 40. Vestweber B, Galetin T, Lammerting K, Paul C, Giehl J, Straub E, et al. Single-incision laparoscopic surgery: outcomes from 224 colonic resections performed at a single center using SILS. *Surg Endosc.* 2013;27(2):434–42.
 41. Lim SW, Kim HR, Kim YJ. Single incision laparoscopic colectomy for colorectal cancer: comparison with conventional laparoscopic colectomy. *Ann Surg Treat Res.* 2014;87(3):131–8.
 42. Maggiori L, Gaujoux S, Tribillon E, Bretagnol F, Panis Y. Single-incision laparoscopy for colorectal resection: a systematic review and meta-analysis of more than a thousand procedures. *Color Dis.* 2012;14(10):e643–54.
 43. Hirano Y, Hattori M, Douden K, Shimizu S, Sato Y, Maeda K, et al. Single-incision plus one port laparoscopic anterior resection for rectal cancer as a reduced port surgery. *Scandinavian J Surg SJS (Official Organ for the Finnish Surgical Society and the Scandinavian Surgical Society).* 2012;101(4):283–6.
 44. Whiteford MH, Denk PM, Swanstrom LL. Feasibility of radical sigmoid colectomy performed as natural orifice transluminal endoscopic surgery (NOTES) using transanal endoscopic microsurgery. *Surg Endosc.* 2007;21(10):1870–4.
 45. Sylla P, Rattner DW, Delgado S, Lacy AM. NOTES transanal rectal cancer resection using transanal endoscopic microsurgery and laparoscopic assistance. *Surg Endosc.* 2010;24(5):1205–10.
 46. de Lacy AM, Rattner DW, Adelsdorfer C, Tasende MM, Fernandez M, Delgado S, et al. Transanal natural orifice transluminal endoscopic surgery (NOTES) rectal resection: “down-to-up” total mesorectal excision (TME)—short-term outcomes in the first 20 cases. *Surg Endosc.* 2013;27(9):3165–72.
 47. Tuech JJ, Bridoux V, Kianifard B, Schwarz L, Tsilivlidis B, Huet E, et al. Natural orifice total mesorectal excision using transanal port and laparoscopic assistance. *Eur J Surg Oncol.* 2011;37(4):334–5.
 48. Gaujoux S, Bretagnol F, Au J, Ferron M, Panis Y. Single port access proctectomy with total mesorectal excision and intersphincteric resection with a primary transanal approach. *Color Dis.* 2011;13(9):e305–7.
 49. Dumont F, Goere D, Honore C, Elias D. Transanal endoscopic total mesorectal excision combined with single-port laparoscopy. *Dis Colon Rectum.* 2012;55(9):996–1001.
 50. Choi BJ, Lee SC, Kang WK. Single-port laparoscopic total mesorectal excision with transanal resection (transabdominal transanal resection) for low rectal cancer: initial experience with 22 cases. *Int J Surg.* 2013;11(9):858–63.
 51. Velthuis S, van den Boezem PB, van der Peet DL, Cuesta MA, Sietses C. Feasibility study of transanal total mesorectal excision. *Br J Surg.* 2013;100(6):828–31; discussion 31.
 52. Chen WH, Kang L, Luo SL, Zhang XW, Huang Y, Liu ZH, et al. Transanal total mesorectal excision assisted by single-port laparoscopic surgery for low rectal cancer. *Tech Coloproctol.* 2015;19(9):527–34.
 53. Law WL, Fan JK, Poon JT. Single-incision laparoscopic colectomy: early experience. *Dis Colon Rectum.* 2010;53(3):284–8.
 54. Yang TX, Chua TC. Single-incision laparoscopic colectomy versus conventional multiport laparoscopic colectomy: a meta-analysis of comparative studies. *Int J Color Dis.* 2013;28(1):89–101.

Matthew Skancke and Vincent Obias

Tips and Tricks

- Failure to progress is the most common indication for conversion from single-incision laparoscopy to multi-port, hand assist, or laparotomy.
- Early conversion can save patients a prolonged and potentially dangerous operation while still affording some benefits of a minimally invasive approach.
- Preoperative preparation can be very beneficial in mitigating intraoperative complications and even potentially preventing injuries that may have warranted conversion.

Camera Disciple

1. Angled and flexible endoscopy scopes with multiple degrees of freedom.
2. Do not excessively zoom in on hemorrhage which can cause lens splatter.
3. Avoid excessive irrigation that can cause a volume effect and can splatter lens.
4. Right angle light cords are essential to minimize extracorporeal collision.

Electronic Supplementary Material: The online version of this chapter (doi:[10.1007/978-3-319-63204-9_11](https://doi.org/10.1007/978-3-319-63204-9_11)) contains supplementary material, which is available to authorized users.

M. SkanckeMD

Department of Surgery, The George Washington University School of Medicine, Washington, DC, USA

V. Obias, MD, MS (✉)

Division of Colon and Rectal Surgery, Department of Surgery, The George Washington University School of Medicine, Washington, DC, USA

e-mail: vobias@mfa.gwu.edu

Dissection and Anastomosis

1. Move slower in high-risk areas.
 - (a) Especially important for newer operators still in learning curve
2. Curved instruments can help improve triangulation.
3. Avoid excessive manipulation of inflamed bowel.
 - (a) Especially following stapled anastomosis as this can cause unexpected dehiscence
4. Green load stapler is the most efficacious for the irradiated rectum.
5. Evaluate the splenic flexure for pancolitis patients.
 - (a) Anecdotal evidence places this portion of the colon at risk for perforation.

Hemorrhage

1. Identify vascular structures and hemorrhage without changing retraction.
2. Avoid excessive suction or large caliber suction devices which will remove insufflation.
3. Local control with simple device or tissue buys time to regain composure.
 - (a) Convert to multi-port or laparotomy around device.
4. Mechanical devices provide safer hemorrhage control vs. energy devices.
 - (a) Endoloop (Fig. 11.1), clip applier, thrombotic agents, lap pad, and pelvic tacks.
 - (b) Can temporarily clip proximal and distal to bleeding vessel to gain local control.
5. Bipolar energy safe and effective (Fig. 11.2) especially at the sacral venous plexus.
6. Upsize port to allow passage of vascular clamp or laparoscopic Satinsky clamp.
 - (a) Visualization of bleed with ability for primary repair

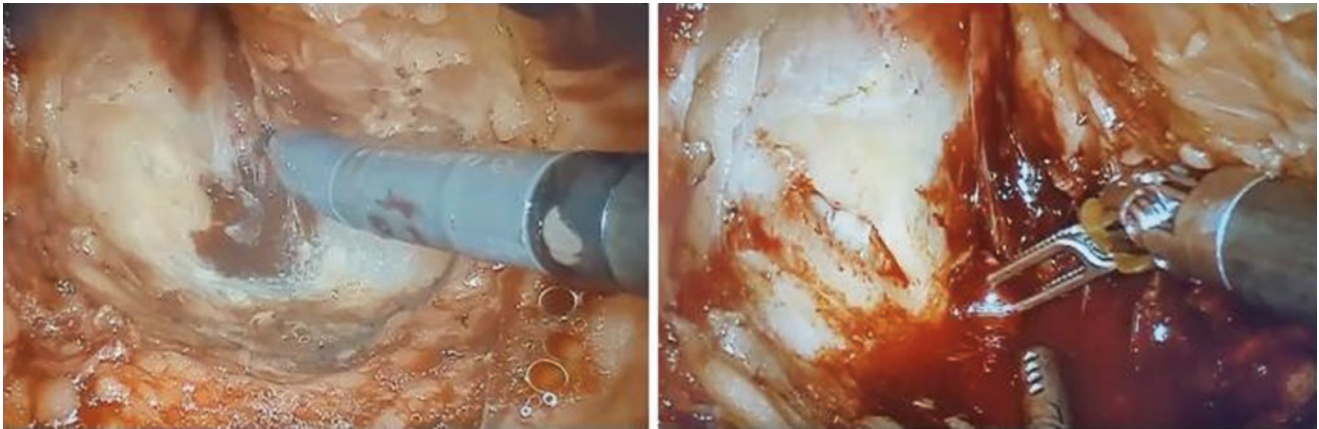


Fig. 11.1 Inferior mesenteric artery bleed during a sigmoid colectomy that is controlled using a vessel loop. First, direct vascular control is obtained without change visualization; second, the vessel loop is passed

intracorporeally and vascular control is reestablished; and, finally, the vessel loop is tightened and hemostasis is achieved

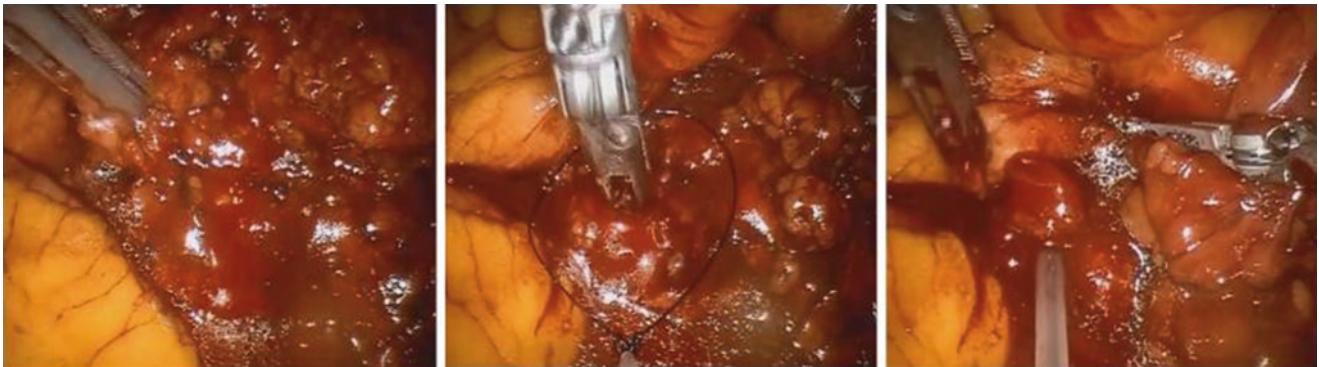


Fig. 11.2 Violation of the sacral venous plexus during a proctectomy for cancer, hemostasis achieved using bipolar cautery, and adequate suction

Introduction

In colon and rectal surgery, the overall intraoperative conversion rates is reported between 2% and 30% [1–6] depending on the pathology, planned procedure, and date of publication. Recently published meta-analysis data suggests that the conversion rate of single-incision laparoscopic surgery (SILS) to laparotomy is as low as 0.9%, while conversion to multi-port laparoscopy surgery (MPLS) is 13.3% [7]. Though the individual reasons for conversion to multi-port, hand-assisted laparoscopic surgery (HALS) or laparotomy will vary, they generally revolve around patient safety directly through iatrogenic injury and indirectly through failure to progress in the dissection. Patient selection, an efficient operating suite, and a mentally prepared operator are the best tools for maximizing the rate of successful SILS.

Intraoperative Conversions

There are numerous intraoperative complications that might force an operator to consider conversion to multi-port, hand assist, or laparotomy. This section will provide pearls for mitigating possible complications before and after they have occurred [8–10]. In the particular case of hemorrhage or other complications that might alter patient hemodynamics, it is advisable to communicate pertinent information to the anesthesiologist early and often so they may better tailor their resuscitation.

Preoperative Checklist

With SILS or any other operative approach, set up your operating room to help you succeed. Operating room setup is addressed before the patient enters the room. Ensure that the

correct sized instruments, clip applicator, harmonic, stapler, suction catheter, and camera, are available and that the correct length, bariatric vs. normal, instruments are available. Regardless of the perceived complexity, ensure the tools needed in case of conversion are available in the room.

Placing the Mayo stand at the base of the bed can facilitate simple instrument swapping without the surgeon needing to avert their eyes from the screen. This orientation allows electrical devices and grounding cords to be gathered in a single location at the base of the bed preventing cumbersome nests or cords that can potentially entangle the surgical staff.

Having multiple sizes and angles for the camera is suggested for SILS, including a flexible endoscopy tip capable of multiple degrees of freedom. A right-angle light cord is especially useful for SILS as it mitigates external collisions. Finally, ensuring that the camera and light cord have sufficient laxity to traverse all available laparoscopic entry points will facilitate ease of conversion to MPLS [8, 9].

Abdominal Entry

Single-incision laparoscopy and robotics have the distinct advantage over multi-port laparoscopy in that a modest continuous incision is used for placement of the operating port. This allows abdominal entry under direct vision through a generous skin incision. When SILS must be converted to MPLS, additional ports can be placed under direct vision or palpation. Similarly if conversion to HALS or laparotomy is necessary, the incision can be extended to facilitate the existing single-incision port.

Pneumoperitoneum

Early laparoscopy utilized oxygen as a medium of insufflation; however, this practice was abandoned with the realization that electrical devices in a high oxygen environment were prone to explosions. Carbon dioxide (CO₂) insufflation proved more stable with the added benefit that healthy patients can easily metabolize CO₂. Insufflation pressure can be modulated based on desired visibility and patient hemodynamics, and if the patient is unable to tolerate pneumoperitoneum, the operator should consider converting to laparotomy or aborting the procedure for further preoperative optimization.

Interesting complications of pneumoperitoneum revolve around inadequate metabolism of CO₂ and extra-abdominal accumulation of CO₂. Capnotherax is a phenomenon caused by insufflation of the thorax with CO₂, directly (thoracoscopy) or indirectly through microscopic (physiologic) or macroscopic (hiatal hernia, iatrogenic diaphragm injury) defects in the diaphragm, and can ultimately create tension

physiology and hemodynamic instability [11]. Physiologically, animal testing has shown that the hemodynamic compromise stems from increased thoracic pressure causing decreased venous return and a hyperdynamic state from hypercarbia [12]. The increased cardiac output from hypercarbia is unable to overcome the decreased preload and cardiovascular collapse ensues. Intraoperatively, this can be confirmed by visualizing the hemidiaphragms being displaced caudally in addition to decreased breath sounds. Management of the clinically significant capnotherax—a drop in systolic pressure between 15 and 35 mmHg, increased airway pressures, PaCO₂ greater than 50 mmHg, or SpO₂ less than 95%—requires immediate surgical evacuation by means of thoracic vent and evacuation of pneumoperitoneum [11, 13–15]. Following hemodynamic stabilization, insufflation can be attempted, but subsequent failure should be treated with conversion to open surgery. Conversely, capnotherax without hemodynamic compromise can be managed with observation and usually resolves shortly into the postoperative period [15, 16].

Failure to Progress

Drawing from the conclusions of the CLASSIC trial, the higher rate of conversion (16–34%) in early MPLS was due to excessive tumor fixity, uncertainty of tumor clearance or anatomy, surgeon experience, and obesity [5, 17]. These five factors converge on a single concept, a failure to progress the dissection in a safe manner. Studies have shown that while minimally invasive surgery (MIS) is superior to open surgery, there are diminishing returns in patient outcomes as operative time surpasses 180 min. Specifically, delay in discharge and increased infectious cardiopulmonary and cerebrovascular complications become comparable [18, 19]. Thankfully, it does not seem that overall mortality, incidence of intraoperative complications, or rate of reoperation is significantly impacted by prolonged operative time [19]. In fact, cases that begin with MIS and end with open surgery still enjoy a fraction of the benefits of the MIS approach especially when conversion is performed earlier [20]. Furthermore, conversion for non-metastatic disease was associated with a similar rate of positive surgical margins, a slightly improved nodal yield, and a shorter hospital stay with similar 30-day mortality compared to open colectomy [21].

The causes of failure in progression can be extrapolated from the conclusions in the CLASSIC trial: inflammation, unclear or obstructive anatomy, and operator experience. With the rising prevalence of obesity in America (BMI >25) [22], analyzing the effects of BMI on surgical outcomes has been popular. The visceral adiposity and larger abdominal wall as well as the caudal migration of the umbilicus have added complexity to all MIS procedures. Multiple studies have

shown direct links to complications related to obesity including superficial, deep, and organ space infections, longer operative times, and incisional hernia formation [1, 23, 24] as well as conversion from MIS to laparotomy [18, 25, 26]. While robotic surgery seems to be more insulated from obesity compared to laparoscopy [1, 26], it still suffers from infectious and hernia complications as BMI increases [18, 25] and is still thwarted by dense adhesions as much as laparoscopy [1].

Advanced tumors, prior radiation, and pathology resulting from inflammatory conditions like diverticulitis and inflammatory bowel disease add technical challenges, with increased anatomic fixity [2, 3]. However, multiple large meta-analyses have shown no difference in margin clearance or overall short-term mortality with SILS compared to MPLS [27]. Tumor size and adhesions from prior surgery seemed to have the same general effect on SILS and MPLS in their conversion rates to laparotomy; however, tumor size and adhesions do not have a significant impact on conversion from SILS to MPLS [27]. Left-sided SILS was reported more demanding compared to right-sided SILS with longer operative times due in part to difficulty in mobilizing the splenic flexure [28]. Pertaining to the rectum, successful total mesorectal excision was achievable with equal operative times and complication rates in SILS vs. MPLS; however, as tumors drifted toward the anal verge, the necessity of additional ports increased to maintain low complication rates [29, 30].

SILS for diverticular disease has reported conversion rates between 4% and 7%; new data suggests a possibly even lower conversion threshold of less than 1% for elective resection in high-volume centers [26, 28, 31, 32]. Data is not as robust for Crohn's, but as expected for complex inflammatory bowel disease, SILS is feasible but has a higher conversion rate, between 5% and 15% [33–35]. At the current time, a large dataset on SILS for chronic ulcerative colitis is lacking, but smaller series do not report appreciable conversions rates for total abdominal colectomy and restorative proctocolectomy with ileal pouch-anal anastomosis [36–38].

Hand-Assisted Laparoscopic Surgery (HALS)

HALS can help conversion from SILS while maintaining MIS benefits. HALS, first released in the mid-1990s, utilizes a minilaparotomy incision (3–6 cm) with a self-sealing retractor port which allows the surgeon to use their hand intracorporeally without sacrificing insufflation. Over the past two decades, HALS has gained popularity secondary to its decreased operative times compared to strict laparoscopy, restoration of direct tactile sensation, and non-inferiority of oncologic outcomes [39, 40]. It also boasts the benefits of laparoscopy with reduced blood loss, decreased postoperative pain, earlier return of bowel function, and shorter hospital stay [41, 42]. HALS is a very effective tool to aid the less

experienced laparoscopist through their learning curve with strict laparoscopy as well as being a step between SILS, MPLS, and laparotomy. Conveniently, for most laparoscopic colectomy procedures, a minilaparotomy incision is required for specimen extraction, extracorporeal anastomosis, or stoma maturation allowing utilization of the hand-assist port without an additional incision. The following are pearls related to HALS [8, 43]:

1. Placement along the path of a potential midline laparotomy.
 - (a) Anticipate 6–8 cm fascial defect.
 - (b) Can use prior laparotomy scar if available.
 - (i) Primary fascial closure with Z-plasty for subcutaneous tissue
2. Do not mature a stoma through an existing hand port.
3. Darker gloves help decrease glare.

Conclusions

As minimally invasive surgery continues to evolve, the complexity of cases increases and the learning curve takes more time to achieve expertise. The surgical hindgut is also a challenging environment to work in given the anatomic constraints of the pelvis and the rate of obesity in today's society. These factors lead to situations where intraoperative conversion can be a prudent decision for optimal patient outcomes. Intraoperative conversion should not be viewed as failure, especially when performed early in the face of insurmountable surgical obstacles as postoperative outcomes still show some benefits of the initial SILS approach and avoiding unexpected complications associated with failure to progress.

Acknowledgment Disclosure statements:

Dr. Skancke has no conflicts of interest or financial ties to disclose. Dr. Obias is a consultant for Intuitive Surgical, Inc.

References

1. Juo Y, Agarwal S, Luka S, et al. Single-incision robotic colectomy (SIRC) case series: initial experience at a single center. *Surg Endosc*. 2015;29:1976–81.
2. Turrado-Rodriguez V, Soler E, Bollo J, et al. Are there differences between right and left colectomies when performed by laparoscopy? *Surg Endosc*. 2015;3:1413–8.
3. Jadlovec C, Mannion E, Thielman M, et al. Evolution of techniques in performance of minimally invasive colectomies. *Dis Col Rectum*. 2014;57:1090–7.
4. Beck D, Roberts P, Saclarides T, et al. *The ASCRS textbook of colon and Rectal surgery: second edition*. New York: Springer; 2011. p. 598.
5. Guillou P, Quirke P, Thorpe H. Short-term endpoints of conventional versus laparoscopic-assisted surgery in patients with

- colorectal cancer (MRC CLASSIC trial): multicentre, randomised controlled trial. *Lancet*. 2005;365:1–9.
6. Bonjer HJ, Deijen CL, Abis GA, et al. A randomized trial of laparoscopic versus open surgery for rectal cancer. *N Engl J Med*. 2015;373:1324–32.
 7. Hirano Y, Hattori M, Douden K, et al. Single-incision laparoscopy surgery for colorectal cancer. *World J Gastrointest Surg*. 2016;8:95–100.
 8. Scott C. The SAGES manual. The Society of American Gastrointestinal and Endoscopic Surgeons. 2006;2:46–58.
 9. Ragupathi M, Nieto J, Haas E. Pearls and pitfalls in SILS colectomy. *Surg Laparosc Endosc Percutan Tech*. 2012;22:183–8.
 10. Kim BS, Kim KH, Yoo ES, et al. Hybrid technique using a Satinsky clamp for right-sided Transperitoneal hand-assisted laparoscopic donor nephrectomy: comparison with left-sided standard hand-assisted laparoscopic technique. *Urology*. 2014;84:1529–34.
 11. Hawasli A, Boutt A. Spontaneous resolution of massive laparoscopy-associated pneumothorax: the case of the bulging diaphragm and review of the literature. *J Laparoendosc Adv Surg Tech A*. 2002;12:77–82.
 12. Reinius H, Borges JB, Freden F. Real-time ventilation and perfusion distributions by electrical impedance tomography during one-lung ventilation with capnotherax. *Acta Anaesthesiol Scand*. 2015;59:354–68.
 13. Peded CJ, Prys-Roberts C. Capnotherax: implications for the anaesthetist. *Anaesthesia*. 1993;48:664–6.
 14. Prystowsky JB, Jericho BG, Epstein HM. Spontaneous bilateral pneumothorax -- complication of laparoscopic cholecystectomy. *Surgery*. 1993;114:988–92.
 15. Asakawa M. Anesthesia for Endoscopy. *Vet Clin North Am Small Anim Pract*. 2016;46:31–44.
 16. Msezane LP, Zorn KC, Gofrit ON, et al. Case report: conservative management of a large capnotherax following laparoscopic renal surgery. *J Endourol*. 2007;21:1445–7.
 17. Gervaz P, Pikarsky A, Utech M, et al. Converted laparoscopic colorectal surgery. *Surg Endosc*. 2001;15:827–32.
 18. Bailey M, Davenport D. Longer operative time: deterioration of clinical outcomes of laparoscopic colectomy versus open colectomy. *Dis Colon Rectum*. 2014;57:616–22.
 19. Scheer A, Guillaume M. Laparoscopic colon surgery: does operative time matter? *Dis Colon Rectum*. 2009;52:1746–52.
 20. Caputo D, Caricato M, La Vaccara V, et al. Conversion in minimally invasive colorectal surgery: the effect of timing on short term outcome. *Int J Surg*. 2014;12:805–9.
 21. Yerokun BA, Adam MA, Sun Z, et al. Does conversion in laparoscopic colectomy portend an inferior oncologic outcome? results from 104,400 patients. *J Gastrointest Surg*. 2016;20:1–7.
 22. Ogden CL, Carrol MD, Kit BK, et al. Prevalence of childhood and adult obesity in the United States, 2011–2012. *JAMA*. 2014;311:806–14.
 23. Hrabe J, Sherman S. The effect of BMI on outcomes in proctectomy. *Dis Colon Rectum*. 2014;54:608–15.
 24. Weiss HG, Brunner W, Biebl MO, et al. Wound complications in 1145 consecutive transumbilical single-incision laparoscopic procedures. *Ann Surg*. 2014;259:89–95.
 25. Bhamra AR, Wafa AM, Ferraro J, Collins SD, Mullard AJ, Vandewarker JF, Krapohl G, Byrn JC, Cleary RK. Comparison of risk factors for unplanned conversion from laparoscopic and robotic to open colorectal surgery using the michigan surgical quality collaborative (MSQC) database. *J Gastrointest Surg*. 2016;1–8.
 26. Diana M, Dhumane P, Cahill RA, et al. Minimal invasive single-site surgery in colorectal procedures: current state of the art. *J Minim Access Surg*. 2011;7:52–60.
 27. Podda M, Saba A, Porru F, et al. Systematic review with meta-analysis of studies comparing single-incision laparoscopic colectomy and multiport laparoscopic colectomy. *Surg Endosc*. 2016;23:1–24.
 28. Ross H, Steele S, Whiteford M, et al. Early multi-institution experience with single-incision laparoscopic colectomy. *Dis Colon Rectum*. 2011;54:187–92.
 29. Jung KU, Yun SH, Cho YB, et al. Single incision and reduced port laparoscopy low anterior resection for rectal cancer: initial experience in 96 cases. *ANZ J Surg*. 2014;18:1–5.
 30. Tei M, Wakasugi M, Akamatsu H. Comparison of short-term surgical results of single-port and multi-port laparoscopic rectal resection for rectal cancer. *Am J Surg*. 2015;210:309–14.
 31. Rizzuto A, Lacamera U, Zittel FU, et al. Single incision laparoscopic resection for diverticulitis. *Int J Surg*. 2016;19:11–4.
 32. Vestwever B, Galetin T, Lammerting K, et al. Single-incision laparoscopic surgery: outcomes from 224 colonic resections performed at a single center using SILS. *Surg Endosc*. 2013;27:434–42.
 33. Moftah M, Nazour F, Cunningham M, et al. Single port laparoscopic surgery for patients with complex and recurrent Crohn's disease. *J Crohns Colitis*. 2014;8:1055–61.
 34. Rijcken E, Mennigen R, Arygris I, et al. Single-incision laparoscopic surgery for ileocolic resection in Crohn's disease. *Dis Colon Rectum*. 2012;55:150–6.
 35. Holder J, Mariscovetere P, Holubar S. Minimally invasive surgery for inflammatory bowel disease. *Inflamm Bowel Dis*. 2015;21:1443–58.
 36. Gash KJ, Goede AC, Kaldowski B, et al. Single incision laparoscopic (SILS) restorative proctocolectomy with ileal pouch-anal anastomosis. *Surg Endosc*. 2011;25:3877–80.
 37. Fichera A, Zoccali M, Felice C, et al. Total abdominal colectomy for refractory ulcerative colitis. Surgical treatment in evolution. *J Gastrointest Surg*. 2011;15:1909–16.
 38. Fichera A, Zoccali M. Single-incision laparoscopic total abdominal colectomy for refractory ulcerative colitis. *Surg Endosc*. 2012;26:862–8.
 39. Cuschieri A, Shapiro S. Extracorporeal pneumoperitoneum access bubble for endoscopic surgery. *Am J Surg*. 1995;170:391–4.
 40. Marcello P, Fleshman J. Hand-assisted laparoscopic vs. laparoscopic colorectal surgery: a multicenter, prospective, randomized trial. *Dis Colon Rectum*. 2008;51:818–28.
 41. Sheng QS, Lin JJ. Comparison of hand-assisted laparoscopy with open total colectomy for slow transit constipation: a retrospective study. *J Dig Dis*. 2014;15:419–24.
 42. Chung CC, Kei Ng DC. Hand-Assistend laparoscopic versus open right colectomy. *Ann Surg*. 2007;246:728–33.
 43. Stifelman M, Patel R. HALS devices and operating room set-up: pearls and pitfalls. *J Endourol*. 2004;18:315–8.

Deborah S. Keller

Steps of the Procedure

1. Insert SILS port at the umbilicus (supine)
2. Expose the mesentery of right and transverse colon (bare area) (right side elevated, slight Trendelenburg)
 - Position omentum over transverse colon
 - Deliver SB to the left of the midline
 - Expose Duodenum
3. Identify and isolate the ileocolic pedicle, (right side elevated, slight Trendelenburg)
4. Open a peritoneal window above and below the pedicle and divide it (right side elevated, reverse Trendelenburg)
5. Develop the retroperitoneal plane (right side elevated, slight Trendelenburg)
6. Expose and divide R branch of middle colic artery (Right side elevated, steep Trendelenburg)
7. Retroperitoneal takedown of the hepatic flexure (right side elevated, steep Trendelenburg)
8. Enter the lesser sac (right side elevated, steep Trendelenburg)
9. Release the ileocolic attachments (inferior to superior), enter previous retroperitoneal dissection plane (right side elevated, steep Trendelenburg)
10. Takedown the right lateral sidewall (right side elevated, moderate Trendelenburg)
11. Divide the terminal ileum and exteriorize the right colon (supine)
12. Extracorporeal division of the colon and ileocolic anastomosis (supine)
13. Return the colon to abdomen, reinsufflation, and final examination (supine)
14. Close ports/incisions (supine)

Tips and Tricks

- In obese patients or those with redundant, floppy bowel, utilize the 4th port (available on the Applied GelPOINT platform) for retraction by the assistant.
- In obese patients, start the retroperitoneal dissection above the pedicle. Identify the thin, peritoneal plane overlaying the duodenum; elevate and dissect into this plane as the starting point.
- The omentum is often heavy and difficult to keep out of the working space; to passively hold the omentum out of the operative field and keep the transverse colon elevated, position a lap sponge between the liver and ribs.
- The ileocolic pedicle can be divided early, after making the initial mesenteric window, or later, after performing the retroperitoneal dissection. Doing the ligation early allows more mobility on the mesentery when performing the retroperitoneal dissection, while doing the ligation later allows for the pedicle to be used as retraction to facilitate the retroperitoneal dissection. We divide the pedicle based on the particular anatomy of the case. Once you reach the limits of the dissection, then divide the pedicle and open up the planes further.
- For malignant disease, the ileocolic pedicle is divided close to its takeoff from the superior mesenteric artery, ensuring the lymph node basin is removed with the specimen. Careful hemostasis is essential, as once the pedicle is high ligated, it often retracts and is difficult to control. For benign disease, the pedicle can be taken more distal; if bleeding is encountered in this case, the stump of the pedicle can be readily grasped for hemostatic maneuvers, such as endoloop placement.
- When extracorporealizing the colon for the anastomosis, if the colon does not reach, there are three options: (1) perform additional dissection of the retroperitoneal attachments; (2) extend the incision cranially by a few centimeters; (3) perform an intracorporeal anastomosis.
- Placing a marking stitch at proximal small bowel staple line can help maintain alignment of the mesentery when

D.S. Keller, MS, MD (✉)

Division of Colorectal Surgery, Department of Surgery, Baylor University Medical Center, Dallas, TX, USA
 e-mail: debby_keller@hotmail.com

extracorporealizing the bowel for the anastomosis. Alternatively, with thorough mobilization, the entire small bowel and right colon can be extracorporealized through a small incision, aligned, and divided extracorporeally.

- When performing the anastomosis, the small bowel is more mobile than the colon; therefore, place the stapler into the colon limb first, assure proper position, then bring the small bowel to the stapler.
- Replace the colon in its normal, anatomical position to avoid internal hernias.

Expanded Operative Procedure

Setup and Positioning

The patient is positioned supine on the operative table with both arms tucked. The surgeon stands on the patient's left side, with the assistant initially on the patient's right side. After entry into the abdomen and starting the laparoscopic portion of the operation, the assistant moves to the patient's left side, cephalad to the surgeon. The main laparoscopic monitor is placed on the patient's right side, at eye level to the surgeon. The assistant serves as the camera holder, providing exposure for the surgeon.

1. *Insert the single port device at the umbilicus (position is supine)*

Cut a hole in the ioband drape to expose the skin around the umbilicus. Make a 2.5 cm vertical incision site from the center of the umbilicus with a 15-blade scalpel. Deepen the incision down through the dermis and subcutaneous tissue with cautery. Insert Army-Navy or double-ended retractors for exposure. Palpate the umbilical stalk in the superior portion of the incision, and incise through the stalk to open the incision and expose the umbilical ring. Grasp on each side of the umbilical ring and sharply open the fascia vertically to a length approximately 4 cm. Insert the ring of the GelPOINT device and dial the ring down to fit against the abdominal wall. Insert a lap sponge into the abdomen and place the cap on the GelPOINT. If using the SILS port, insert the lap sponge, and then insert the port. Insufflate the abdomen, insert the 30° laparoscopic camera, and survey the abdominal cavity.

2. *Expose mesentery of right and transverse colon/bare area (position is right side elevated, slight Trendelenburg)*

Using two atraumatic graspers, grasp the edge of the omentum and place the omentum over transverse colon on each side of the falciform ligament, spanning from the level of the hepatic flexure to the splenic flexure. This will expose

the bare area of the right and transverse colon mesentery. Deliver the small bowel out of the pelvis and place it entirely to the left of the midline. Then, expose the bare area of the right and transverse colon mesentery. Identify the duodenum covered by a thin veil of peritoneum above the ileocolic pedicle or at the base of the transverse colon mesentery

3. *Identify and isolate ileocolic pedicle (position is right side elevated, slight Trendelenburg)*

Use a bowel grasper to elevate and retract the medial wall of the cecum inferolaterally and expose the “bow string” leading to the pedicle. The surgeon may have to grasp onto the mesentery by the cecum to have enough room to hold the mesentery on tension and expose the pedicle. With the plane inferior to the ileocolic pedicle developed, incise the peritoneum and make a window above the ileocolic pedicle (Fig. 12.1). Assure the window easily permits a grasper to pass through. Hold the window open, and if desired, the pedicle can be divided at this point; alternatively, and if performing a complete mesocolic excision with high vascular ligation, the pedicle can be divided after developing the plane more completely (Fig. 12.2). It is our preference to divide the pedicle with stapler. If using a stapler, do not skeletonize the pedicle – the fatty tissue around the pedicle will aid in the stapler grasping and sealing the tissue. Grasp by the pedicle before firing the stapler to maintain control of the stump; the stump will retract after the stapler is fired, so this allows examining and controlling any bleeding points on the divided pedicle stump. Ensure hemostasis before letting go of the distal pedicle stump. Alternative methods to divide the ileocolic pedicle include endoclips or an endoloop and sharp division or a thermal energy device. If using any of these tools to divide the pedicle, do skeletonize the pedicle for precise division and control. After dividing the pedicle, replace the small bowel to the left of the midline to expose the right pelvic inlet and cecum.

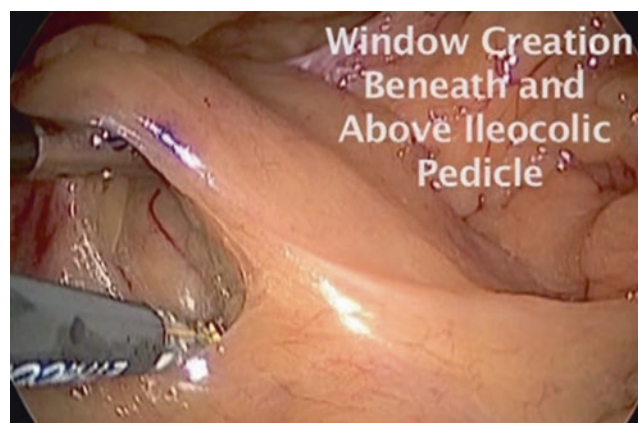

Fig. 12.1 Open a peritoneal window above and below the Ileocolic pedicle

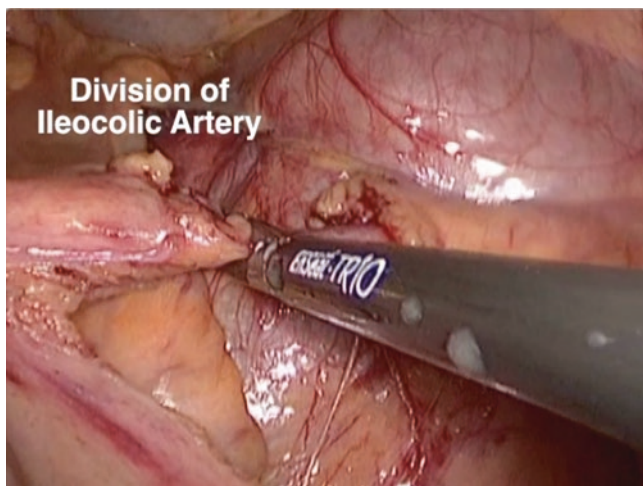


Fig. 12.2 Divide the Ileocolic artery

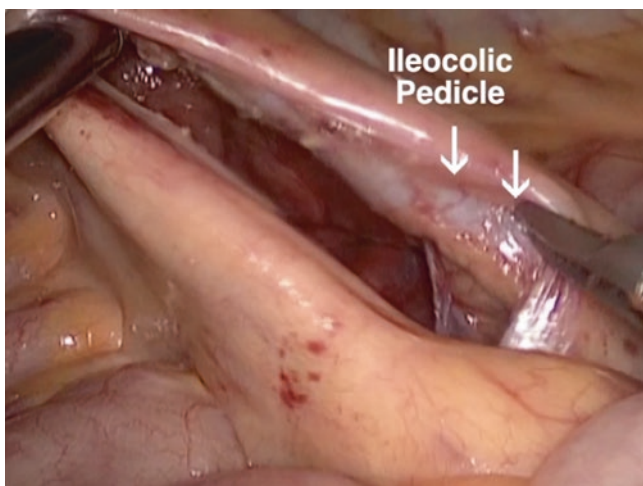


Fig. 12.3 Develop the retroperitoneal plane under the pedicle

4. *Open window below the pedicle (position is right side elevated, reverse Trendelenburg)*

Once the ileocolic pedicle is clearly identified, create a small window inferior to pedicle.

The window can be created bluntly or sharply, but avoid deep incisions or heat to protect the retroperitoneal structures. After creating the window, allow the pneumoperitoneum to open and aid in developing the retroperitoneal plane. With the window made, use the triangulation technique to develop the retroperitoneal plane (Fig. 12.3). With the left hand, place the grasper deep in the mesenteric rent and maintain firm upward traction to form the apex of the triangle. With the right hand, sweep the tissue down to delineate the retroperitoneal dissection plane.

Continue developing the retroperitoneal plane through the triangulation technique under the ascending colon and up to the hepatic flexure, moving the left hand deeper, and brushing the retroperitoneum down laterally. Identify the duodenum and carefully sweep it down toward the retroperitoneum. Identify the right branch of the middle colic artery coursing above the duodenum on the right lateral wall of the dissection plane. Continue the dissection following the lateral border of the duodenum superiorly toward the liver.

5. *Develop the retroperitoneal plane (position is right side elevated, slight Trendelenburg)*

With the freedom from dividing the ileocolic pedicle, continue the dissection of the retroperitoneal plane. The borders of retroperitoneal dissection are Gerota's fascia (deep), the lateral plane of duodenum (medial), the transverse colon (superior), and the right colon (laterally).

6. *Expose and divide the right branch of middle colic artery (position is right side elevated, steep Trendelenburg)*

During the retroperitoneal dissection, complete further dissection around the right branch of the middle colic artery and divide it (Fig. 12.4). Our choice is to use an energy source for ligation. Take care to ensure the duodenum is down and away from the field when performing the ligation. Alternatively, with an umbilical extraction site, the right branch of the middle colic vessel can be ligated extracorporeally.

7. *Incise attachments to perform a retroperitoneal takedown of the hepatic flexure (position is right side elevated, steep Trendelenburg)*

At this point, if using the GelPOINT port, use 4th port for retraction to lift under the mesentery. Continue the retroperitoneal dissection deep to the transverse colon by dividing the gastrocolic ligament. The dissection will free the attachments of the colon to the liver superiorly and expose the gallbladder and liver. Then dissect medially toward falciform ligament and laterally toward the hepatic flexure (Fig. 12.5).

8. *Enter the lesser Sac (position is right side elevated, steep Trendelenburg)*

Drop the mesentery down, and move on top of mesentery to divide the omentum from the transverse colon in a medial to lateral fashion. Incise the avascular plane between the transverse colon and the omentum using an energy source, and enter into the retroperitoneal dissection plane that was just developed. Further divide the attachments between the

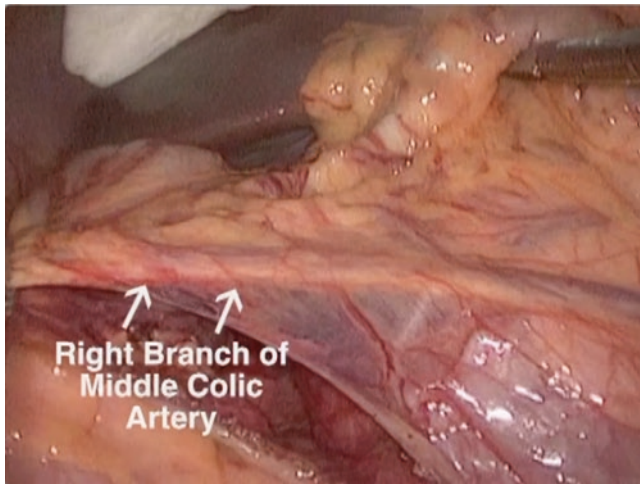


Fig. 12.4 Identify and divide the Right branch of the Middle Colic artery

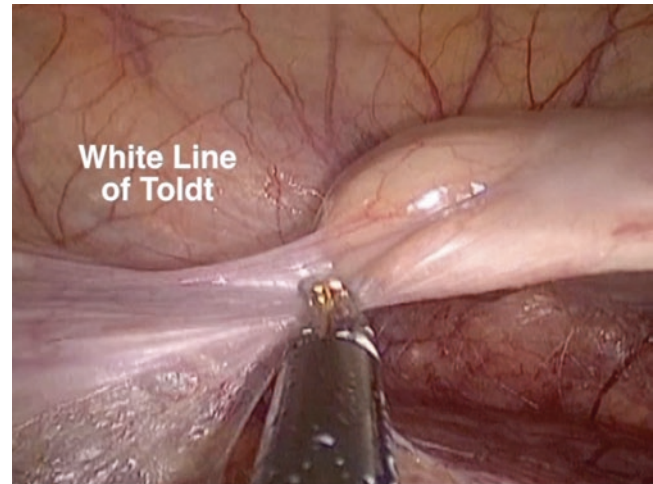


Fig. 12.6 Takedown the right lateral sidewall

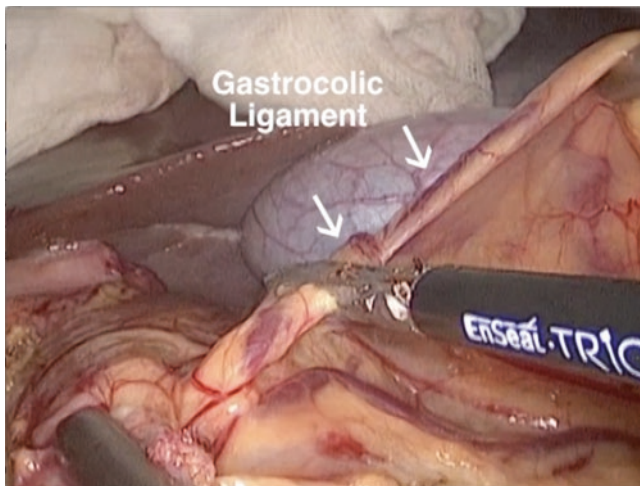


Fig. 12.5 Retroperitoneal takedown of the hepatic flexure

transverse colon, omentum, and falciform ligament to free the plane medially and laterally toward the hepatic flexure.

9. *Release ileocolic attachments (position is right side elevated, steep Trendelenburg)*

Using the left hand, grasp the base of the cecum and retract superior and medially to expose the remaining ileocolic attachments. Takedown these attachments in an inferior to superior approach. Carry the dissection medially past midline and laterally toward the hepatic flexure. Continue this dissection until entering the previous retroperitoneal dissection plane.

10. *Takedown the right lateral sidewall (position is right side elevated, moderate Trendelenburg)*

With the left hand, retract the cecum medially on firm tension and incise Toldt's fascia sharply close to the colon wall up toward the hepatic flexure to complete the hepatic flexure takedown. Roll the colon medially with the left hand and free the final attachments of the hepatic flexure to join the prior dissection plane (Fig. 12.6). Review the extent of the dissection to ensure the bowel can reach tension free for extracorporealization.

11. *Divide the terminal ileum and exteriorize the right colon (position is supine)*

Locate appropriate site on the terminal ileum the resection site. Sharply divide and ligate the small bowel mesentery with an energy device or a stapler. Ensure hemostasis in the mesentery. Divide the small bowel using a stapler. Grasp the staple line with a locking bowel grasper and remove the cap of the GelPOINT platform or the SILS port. If using a SILS port, insert an Alexis wound retractor for the extracorporealization. A Vicryl suture can be placed in the divided small bowel, left long and clamped externally to help extracorporealize and align the small bowel for the anastomosis.

12. *Extracorporeal division of the colon and ileocolic anastomosis (position is supine)*

Using a Babcock clamp, grasp the staple line of the colon and feed through the port. Release the laparoscopic grasper and extracorporealize the right colon by using gentle pressure on the anti-mesenteric surface of the colon. If needed, a lap sponge can be used to help maintain alignment of mesentery when extracorporealizing the bowel. Identify the site of transection on the ascending or transverse colon. Clear the mesentery from the proposed tran-

section site to assure no mesentery will be included in the stapler and anastomosis. Align the small bowel and colon, making a colotomy and enterotomy on the anti-mesenteric surfaces just above the proposed site of the stapling. Then, insert the laparoscopic stapler with a blue load. Place the stapler into the colon limb first, and assure proper position, then bring the small bowel to the contralateral limb of the stapler and close. After assuring proper positioning, fire the stapler. Two firings are generally used, assuring they are aligned and checking the newly created staple line for hemostasis. Then, staple across the new ileocolic anastomosis to finish the anastomosis. Assure the bowel is not rolled on the mesenteric side and no mesentery is captured in the firing. Check the patency of the anastomosis. Remove the specimen, stapler, and all dirty instruments from the operative field, and the operating team changes their outer gloves.

13. *Return colon to abdomen, reinsufflation, final examination (position is supine)*

The anastomosis is gently replaced into the abdomen. The port is replaced, the abdomen is reinsufflated, and a final check is performed to assure the anastomosis, bowel, and omentum are returned to their anatomic positions and the anastomosis is hemostatic. If placed in the abdomen, the lap sponge is removed. The port is removed and the air released.

14. *Close ports/incisions (position is supine)*

The fascia is closed with Number 1 PDS running from both ends of the incision to the midpoint and tied. The subcutaneous tissue is vigorously irrigated. The umbilical stump is reapproximated with a 3-0 Vicryl suture. The skin is closed with 4-0 monocryl. Dermabond is used to cover the incision.

Deborah S. Keller

Procedure Steps

1. Insert port-4 cm Pfannenstiel incision for SILS port and optional 5 mm umbilical incision for trocar (recommended)
2. Position omentum over the transverse colon and deliver SB out of the pelvis to the right of the midline (L side elevated, Trendelenburg)
3. Tent rectosigmoid anterolateral to expose the mesentery by the sacral promontory (L side elevated, Trendelenburg)
4. Incise the peritoneum at the pelvic brim (L side elevated, Trendelenburg)
5. Develop the retroperitoneal plane deep to the Superior Rectal Artery to the lateral sidewall (L side elevated, Trendelenburg)
6. Vascular isolation (L side elevated, Trendelenburg)
 - (a) If malignant disease, isolate the Left Colic Artery from its origin at the I Inferior Mesenteric Artery
 - (b) If benign disease, make a window around the Superior Rectal Artery at the desired point of transection in the mesentery
7. Vascular division (L side elevated, Trendelenburg)
 - (a) For malignant disease, divide the base of the Inferior Mesenteric Artery below the takeoff of the Left Colic Artery
 - (b) For benign disease, divide the Superior Rectal Artery in the open, mesenteric window
8. Divide white line of Toldt, lateral to medial dissection from the descending/sigmoid colon to the splenic flexure (L side elevated, Slight Trendelenburg)
9. Splenic flexure takedown (L side elevated, Slight Reverse Trendelenburg)
10. Mobilize rectosigmoid junction depending on distal extent of disease, divide bowel and mesentery (L side elevated, Trendelenburg)
11. Exteriorize and resect specimen, prepare for anastomosis (Supine)
12. Intracorporeal anastomosis (Steep Trendelenburg)
13. Close Pfannenstiel and umbilical incisions (Supine)

Tips and Tricks

- This exact procedure can be done through a single incision port at the Pfannenstiel or at the umbilicus. We advise the use an additional 5 mm port at the umbilicus for the operative camera to effectively widen the visual field. This approach has been labeled the “SILS + 1 technique”. The procedure steps are otherwise identical.
- After tenting the rectosigmoid, if the sacral promontory is not visible, as can occur in the obese or patients with a floppy sigmoid, grasp the mesentery closer to the pelvic brim, and flop the sigmoid over closer to the retractor, taking care not to avulse the mesentery
- When difficult to get the small bowel out of the pelvis, position in steeper Trendelenburg and incise the ileocolic attachments in an inferior to superior direction to move the cecum out of the pelvis. If small bowel is still in view, have an assistant gently grasp the terminal ileum in a superolateral direction after releasing the attachments
- Use caution in thin patients, when incising the peritoneum over the pelvic brim, as the Left Iliac Vein and gonadal vessels, para-aortic autonomic nerves, and left ureter may be attached to the tissue due to absence of the sacral fat

Electronic Supplementary Material: The online version of this chapter (doi:[10.1007/978-3-319-63204-9_13](https://doi.org/10.1007/978-3-319-63204-9_13)) contains supplementary material, which is available to authorized users.

D.S. Keller, MS, MD (✉)
Division of Colorectal Surgery, Department of Surgery, Baylor University Medical Center, Dallas, TX, USA
e-mail: debby_keller@hotmail.com

pad. While the anatomy may be more visible, use excessive caution when entering the plane

- To confirm you have entered the correct plane after incising over the pelvic brim, there should be instantaneous pneumodissection of the alveolar tissue
- We prefer use of an endoscopic stapler to divide the pedicle, as the same stapler will be used to transect the distal bowel. It is surgeons preference and alternate sources are appropriate, such as energy devices, clips and endoloops
- Identifying the Left Colic Artery and exposing the peritoneal plane can be difficult, especially in the obese. The small bowel can be retracted by an assistant to the right of the midline to expose the Left Colic Artery. The Left Colic Artery is usually visible in the mesentery, and following the pulsation of the vessel can lead to the proper location. The surgeon can then tent the mesentery to identify the pulsation of the Left Colic Artery and find the ideal entry spot between the aorta and Left Colic Artery. After incising the window, the surgeon lifts up underneath the window to expose the retroperitoneum.
- Incise the pelvic peritoneum along the upper and mid rectum on the right and left sides beyond the proposed level of transection to assure the bowel is mobile and the rectum is straight when performing the anastomosis. Use caution when dissecting beyond the mid-rectum to avoid unnecessary bleeding from the lateral stalks or nerve injury
- The intersigmoidal fossa is an area where the ureter is frequently injured, as the ureter and gonadal vessels are frequently drawn into this region. To release, use the retractor in your left hand to hook underneath the mesentery, flattening the fold, then incise the peritoneum close to the colon
- When possible, for both malignant and benign disease, carry the anastomosis onto the upper rectum to remove the high pressure zone of the sigmoid
- When stapling, assure the bowel lies flat in the stapler and is not bunched up at the jaw. Use two loads of the stapler, if needed, to assure the bowel lies flat than to force and bunch the bowel into the jaws of the stapler.
- If the specimen is too bulky to extract through the port, do not force it as the mesentery can be avulsed and in malignant disease, the tumor can be disrupted. The most common limiting factor is the skin, and by just incising a few additional millimeters on each side of the retractor, the specimen is usually easily released. Aim for the anvil spike to come out just posterior to staple line. In cases where the anastomosis needs to be revisited, this will position the staple line to be most anterior and within view and reach of the surgeon
- The transverse staple line will often extend beyond the margins of the circular stapler, like “dog-ears”, and can

serve as a weak point for anastomotic leaks. Caution against trying to incorporate both ends into the circular stapler, as this can be too much tissue for a secure anastomosis. Methods to address this include angling the spike so one side is incorporated in the circular staple line, leaving one long dog-ear. A single, interrupted 3-0 Vicryl suture can be placed through the anastomosis on both sides of the dog-ear for additional security.

Expanded Steps of the Operation

1. *Insert port-4 cm Pfannenstiel incision and recommended optional 5 mm umbilical port (SILS + 1 Incision) or Umbilical Port insertion-modified lithotomy*

The patient's mons pubis is palpated and a mark is made 2 cm proximal. The midline is confirmed, and a 4 cm mark is made to guide the incision. The skin is incised sharply with a 15-blade scalpel, and then the incision is deepened through the dermis and subcutaneous tissue with cautery. Insert Army-navy or Double-ended retractors to exposure horizontally as the incision is deepened to the rectus fascia. The fascia is incised horizontally, with an upward extension at the lateral edges so as not to enter the inguinal canal. The retractors are then replaced vertically for exposure as the fascial flaps are developed. The upper fascial edge is grasped with two Kocher clamps and an upper flap is developed several centimeters cephalad. The dissection is achieved using a combination of blunt and cautery dissection; the muscle is released from the fascia. Care is taken to control any bleeding from perforating vessels. The lower flap is then developed in the same fashion. The underlying peritoneum is grasped at the midline, elevated, then carefully opened to permit a finger. The peritoneum is safely opened vertically over the operator's finger for a length of approximately 4 cm–6 cm. Insert the single access port. Insufflate the abdomen and insert the 30-degree laparoscopic camera. Using the 15-blade scalpel, a stab incision is made in the umbilicus. Under direct vision, a bladeless 5 mm port is placed towards the pelvis. The camera is switched to the umbilical port and the abdomen is surveyed.

2. *Position omentum over the transverse colon and deliver SB out of the pelvis to the right of the midline (L side elevated, Slight Trendelenburg)*

Using two atraumatic graspers, grasp the edge of the omentum and place the omentum over transverse colon on each side of the falciform ligament. This step may take longer if pre-existing adhesions are encountered. Deliver the small bowel out of the pelvis and place it entirely to the right of the midline after assuming a Trendelenburg position.

3. *Tent rectosigmoid anterolateral to expose the mesentery by the sacral promontory-(L side elevated, Slight Trendelenburg)*

Using an atraumatic grasper, grasp and elevate the colon in the rectosigmoid area in an anterolateral direction, placing the peritoneum running towards the Inferior Mesenteric Artery on tension.

4. *Incise the peritoneum at the pelvic brim-(L side elevated, Slight Trendelenburg)*

Make a superficial rent in the peritoneum at the pelvic brim with the energy source or scissors, insert a grasper into the peritoneal defect and retract upwards underneath the Superior Rectal artery. Then, use the triangulation technique, working hand over hand to sweep down the retroperitoneum and develop the plane beneath the mesentery

5. *Develop the retroperitoneal plane under the Superior Rectal Artery to the lateral sidewall (L side elevated, Slight Trendelenburg)*

Using the triangulation technique, the dissection is continued under the Superior Rectal Artery towards the left lateral sidewall. Care is taken to identify and protect the ureter and Gonadal vessel laterally. The dissection is continued to the lateral sidewall, inferiorly to the level of upper rectum, and superior to the level of the origin of the Superior Rectal Artery.

6. *Vascular isolation-(L side elevated, Slight Trendelenburg)*

This step will differ if performing the operation for benign versus malignant disease. For both, identify and isolate the inferior margin of the Superior Rectal Artery. If malignant disease, a high ligation of the Inferior Mesenteric Artery is performed, where it is divided proximal to the takeoff of the Left Colic Artery and close to its origin, to ensure a full lymphadenectomy is achieved along the base of the Inferior Mesenteric Artery. Here, we identify and isolate the Left Colic Artery from its origin at the Inferior Mesenteric Artery and incise the peritoneum inferior to the Left Colic Artery, creating a window to the retroperitoneum. The plane is opened, assuring Gerota's fascia is down and preserved. Open this plane laterally towards the left colon and continue inferiorly towards the Inferior Mesenteric Artery pedicle until meeting the previous retroperitoneal dissection plane from below the pedicle. If benign disease, make a window around the Superior Rectal Artery at the desired point of transection in the mesentery.

7. *Vascular Division-(L side elevated, Trendelenburg)*

For malignant disease, isolate and divide the Inferior Mesenteric Artery below the takeoff of the Left Colic Artery. The retroperitoneal planes above and below the pedicle should connect. Tenting the mesentery up will create the "Eagle Sign", where the Inferior Mesenteric Artery pedicle serves as the base of the eagle, the Left Colic Artery as the upper wing, and the Superior Rectal Artery as the lower wing. With the mesentery up and the Eagle Sign exposed, assure the ureter is again identified and protected. Then, divide the Inferior Mesenteric Artery/base of the Eagle using a vascular load on the stapler.

For benign disease, open window above Superior Rectal Artery to isolate the vessel. Drop the Superior Rectal Artery to expose its take off from the Inferior Mesenteric Artery pedicle and release tension. Clear any further retroperitoneal attachments and introduce the stapler or appropriate energy device, assuring the ureter is again visualized and away. Then divide the Superior Rectal Artery in the open, mesenteric window.

8. *Divide white line of Toldt, lateral to medial dissection from descending/sigmoid colon to the splenic flexure (L side elevated, Slight Trendelenburg)*

Start at the area just proximal to the intersigmoidal fossa and incise proximally, staying close to the colon, using an energy source. The left hand retracts the colon on tension to expose the proper plane. Continue to develop the plane to enter the retroperitoneal window that has already been established.

9. *Splenic flexure takedown (L side elevated, Slight Trendelenburg)*

Carry the dissection laterally around the sigmoid flexure, staying close to the colon, to takedown the flexure in a lateral to medial approach. Dynamically change your left hand as the dissection moves proximally to assure the splenic flexure of the colon is held on tension in an inferior and medial direction without tearing the splenic capsule. The dissection is carried to the point of the lesser sac.

10. *Mobilize rectosigmoid junction, divide bowel and mesentery (L side elevated, Steep Trendelenburg)*

Begin along the right lateral rectosigmoid reflection and release the peritoneum to the level of previous dissection. The left hand retracts the rectosigmoid in a lateral, superior fashion, tenting the peritoneum along the right lateral rectosigmoid

reflection. Incise this peritoneum into the pelvis, carrying down the dissection past the point on the upper rectum where the tenae coalesce for benign disease or several centimeters past the point of adequate margins from the tumor in the case of malignant disease. Then, retract the rectosigmoid medial and superior, taking down the intersigmoidal crease, carrying the dissection down to the same level as taken on the right side, and freeing the rectosigmoid from attachments. Choose the appropriate level of transection, divide the mesentery from the area, assuring the rectal tube is cleared. For malignant disease, assure the transection point is at least 5 cm distal to the mass and the mesentery is cleared. For benign disease, assure the transection is at the upper rectum, where the tenae have coalesced, and the upper rectum lies at the sacral promontory, released from any lateral attachments. Staple across the upper rectum using a blue load, assuring the bowel lies flat. After transection, the bowel is oriented in correct anatomical position in preparation for extraction. The staple line is grasped, the cap is removed from the single port device, and the transected bowel is fed out.

11. *Exteriorize and resect specimen, prepare for anastomosis (Supine)*

The specimen is exteriorized, assuring the stapled vascular pedicle is part of the specimen. The descending colon mesentery is cleared from the bowel around the proposed resection site. The bowel is divided at the proposed level, a purse string is placed, and the anvil of a size 29 circular stapler is introduced and secured. The bowel is returned to the abdomen. The specimen is examined for adequacy of margins off the operative field, when indicated.

12. *Intracorporeal anastomosis (Steep Trendelenburg)*

Return the colon to the abdomen, replacing the port, and re-insufflating the abdomen. Assure the orientation of the colon is not twisted by following the cut edge of the mesentery back to the retroperitoneum. Once the orientation is checked, ensure the resected limb with the anvil falls into the pelvis without tension, ensuring adequacy of reach is then determined by placing the colon into the pelvis. Under laparoscopic guidance, insert the size 29 circular stapler transanally into the rectum and carefully advance it up to the apex of the rectal stump. Open the spike on the stapler, aiming for the spike to protrude through just posterior the staple line. Avoid going directly through the staple line, as this can cause the staple line to unzip. Guide the anvil onto the spike, confirming a proper join. The stapler is closed and fired. The anastomosis is tested by grasping and occluding the colon around the level of the sacral promontory and filling the pelvis with irrigating fluid. The rectum is distended with air under water, using a proctoscope or bulb syringe to assess for bubbling. The stapler 'donuts' are then examined for completeness.

13. *Close Pfannenstiel and Umbilical incision (Supine)*

Close the peritoneum with a running 2-0 Vicryl suture. Identify fascia-grasp with Kocher clamps if needed-and close with two running #1 PDS sutures, starting at each corner and meeting in the middle. Close the skin with a running 4-0 Monocryl suture. If an umbilical port was used, close the port site with a single 4-0 Monocryl subcuticular suture.

Deborah S. Keller and Daniel P. Geisler

Procedure Steps

1. Insert port –
 - (a) Umbilical
 - (b) Stoma site - if predetermined to create a stoma
2. Position omentum over the transverse colon and deliver SB out of the pelvis to the left of the midline (R side elevated, Trendelenburg). Transect ileocolic vessels and check for origin of right colic vessels.
3. Laparoscopic mobilization of right colon and terminal ileum.
4. Laparoscopic mobilization of transverse colon and take-down of splenic flexure.
5. Division of middle colic vessels.
6. Laparoscopic mobilization of left colon.
7. Mobilization and division of upper rectum, mesorectum, and descending colonic mesentery.
8. Tent rectosigmoid anterolateral to expose the mesentery by the sacral promontory (L side elevated, Trendelenburg).
9. Incise the peritoneum at the pelvic brim (L side elevated, Trendelenburg).
10. Develop the retroperitoneal plane deep to the SRA to the lateral sidewall (L side elevated, Trendelenburg).
11. Vascular isolation and division (L side elevated, Trendelenburg).
12. Exteriorize and resect specimen, prepare for anastomosis (supine).
13. Intracorporeal anastomosis (steep Trendelenburg).
14. Close incision (supine).
15. Mature right iliac fossa trephine stoma (supine) – optional.

Tips and Tricks

- The port is placed at pre-marked right lower quadrant site if a stoma is anticipated.
- Port placed at umbilicus if no stoma is anticipated of if specimen is too large for extraction via the stoma site.
- Dissection is begun on the right side to facilitate the performance and efficiency of the operation.
- The key part of the operation is finding the free, cut edge of the mesentery, which facilitates transection of the middle colic vessels.
- The camera is always placed through the apical port.
- a 1, 2, 3 approach to prioritizing instruments improves efficiency. #1 is the camera and is always given precedence. #2 is the atraumatic grasper and does not move for #3, the heat source.

Expanded Steps of the Operation

1. Insert port

The port will be placed at the umbilicus unless a stoma is pretermind. For umbilical port placement, cut a hole in the Ioban drape to expose the skin around the umbilicus. Make a 2.5 cm vertical incision site from the center of the umbilicus with a 15-blade scalpel. Deepen the incision down through the dermis and subcutaneous tissue with cautery. Insert Army-Navy or double-ended retractors for exposure. Palpate the umbilical stalk in the superior portion of the incision, and incise through the stalk to open the incision and expose the umbilical ring. Grasp on each side of the umbilical ring and sharply open the fascia vertically to a length approximately

D.S. Keller, MS, MD
Division of Colorectal Surgery, Department of Surgery, Baylor University Medical Center, Dallas, TX, USA
e-mail: debby_keller@hotmail.com

D.P. Geisler, MD (✉)
Division of Colorectal Surgery, Department of Surgery, Houston Methodist Hospital, Houston, TX, USA
e-mail: DGeisler@svhs.org

4 cm. Insert the ring of the GelPOINT device and dial the ring down to fit against the abdominal wall. Insert a lap sponge into the abdomen and place the cap on the GelPOINT. If using the SILS port, insert the lap sponge, and then insert the port. Insufflate the abdomen, insert the 30° laparoscopic camera, and survey the abdominal cavity.

If placing at the stoma site, remove a 2cm circular skin disk at the marked site. Dissect down the the fascia, leaving the fatty abdominal wall tissue in place. Deepen the incision down through the subcutaneous tissue with cautery. Insert Army-Navy or double-ended retractors for exposure. Grasp the rectus fascia, and open it 2cm longitudinally. Using a Kelly clamp, spread the muscle to expose the peritoneum. Grasp this with another Kelly clamp and open sharply with Metzenbaum scissors. Once safe entry is verified, open the incision to a length approximately 4 cm. Insert the ring of the GelPOINT device and dial the ring down to fit against the abdominal wall. Insert a lap sponge into the abdomen and place the cap on the GelPOINT. If using the SILS port, insert the lap sponge, and then insert the port. Insufflate the abdomen, insert the 30° laparoscopic camera, and survey the abdominal cavity.

2. *Position omentum over the transverse colon and deliver SB out of the pelvis to the left of the midline (L side elevated, slight Trendelenburg)*

Using two atraumatic graspers, grasp the edge of the omentum and place the omentum over transverse colon on each side of the falciform ligament. This step may take longer if pre-existing adhesions are encountered. Deliver the small bowel out of the pelvis and place it entirely to the left of the midline after assuming a Trendelenburg position.

3. *Tent rectosigmoid anterolateral to expose the mesentery by the sacral promontory (L side elevated, slight Trendelenburg)*

Using an atraumatic grasper, grasp and elevate the colon in the rectosigmoid area in an anterolateral direction, placing the peritoneum running toward the IMA on tension.

4. *Incise the peritoneum at the pelvic brim (L side elevated, slight Trendelenburg)*

Make a superficial rent in the peritoneum at the pelvic brim with the energy source or scissors, insert a grasper into the peritoneal defect, and retract upward underneath the superior rectal artery (SRA). Then, use the triangulation technique, working hand over hand to sweep down the retroperitoneum and develop the plane beneath the mesentery

5. *Develop the retroperitoneal plane under the SRA to the lateral sidewall (L side elevated, slight Trendelenburg)*

Using the triangulation technique, the dissection is continued under the SRA toward the left lateral sidewall. Care is taken to identify and protect the ureter and Gonadal vessel laterally. The dissection is continued to the lateral sidewall, inferiorly to the level of upper rectum, and superior to the level of the origin of the SRA.

6. *Vascular isolation (L side elevated, slight Trendelenburg)*

This step will differ if performing the operation for benign versus malignant disease. For both, identify and isolate the inferior margin of the SRA. If malignant disease, a high ligation of the inferior mesenteric artery (IMA) is performed, where it is divided proximal to the takeoff of the left colic artery (LCA) and close to its origin, to ensure a full lymphadenectomy is achieved along the base of the IMA. Here, we identify and isolate the LCA from its origin at the IMA and incise the peritoneum inferior to the LCA, creating a window to the retroperitoneum. The plane is opened, assuring Gerota's fascia is down and preserved. Open this plane laterally toward the left colon and continue inferiorly toward the IMA pedicle until meeting the previous retroperitoneal dissection plane from below the pedicle. If benign disease, make a window around the SRA at the desired point of transection in the mesentery.

7. *Vascular division (L side elevated, Trendelenburg)*

For malignant disease, isolate and divide the IMA below the takeoff of the LCA. The retroperitoneal planes above and below the pedicle should connect. Tenting the mesentery up will create the "Eagle Sign," where the IMA pedicle serves as the base of the eagle, the LCA as the upper wing, and the SRA as the lower wing. With the mesentery up and the Eagle Sign exposed, assure the ureter is again identified and protected. Then, divide the IMA/ base of the Eagle using a vascular load on the stapler.

For benign disease, open window above SRA to isolate the vessel. Drop the SRA to expose its takeoff from the IMA pedicle and release tension. Clear any further retroperitoneal attachments and introduce the stapler or appropriate energy device, assuring the ureter is again visualized and away. Then divide the SRA in the open, mesenteric window.

8. *Divide white line of Toldt, lateral to medial dissection from descending/sigmoid colon to the splenic flexure (L side elevated, slight Trendelenburg)*

Start at the area just proximal to the intersigmoidal fossa and incise proximally, staying close to the colon, using an energy source. The left hand retracts the colon on tension to expose the proper plane. Continue to develop the plane to enter the retroperitoneal window that has already been established.

9. Splenic flexure takedown (L side elevated, slight Trendelenburg)

Carry the dissection laterally around the sigmoid flexure, staying close to the colon, to takedown the flexure in a lateral to medial approach. Dynamically change your left hand as the dissection moves proximally to assure the splenic flexure of the colon is held on tension in an inferior and medial direction without tearing the splenic capsule. The dissection is carried to the point of the lesser sac.

10. Mobilize rectosigmoid junction, divide bowel and mesentery (L side elevated, steep Trendelenburg)

Begin along the right lateral rectosigmoid reflection and release the peritoneum to the level of previous dissection. The left hand retracts the rectosigmoid in a lateral, superior fashion, tenting the peritoneum along the right lateral rectosigmoid reflection. Incise this peritoneum into the pelvis, carrying down the dissection past the point on the upper rectum where the tenae coalesce for benign disease or several centimeters past the point of adequate margins from the tumor in the case of malignant disease. Then, retract the rectosigmoid medial and superior, taking down the intersigmoidal crease, carrying the dissection down to the same level as taken on the right side, and freeing the rectosigmoid from attachments. Choose the appropriate level of transection, and divide the mesentery from the area, assuring the rectal tube is cleared. For malignant disease, assure the transection point is at least 5 cm distal to the mass and the mesentery is cleared. For benign disease, assure the transection is at the upper rectum, where the tenae have coalesced, and the upper rectum lies at the sacral promontory, released from any lateral attachments. Staple across the upper rectum using a blue load, assuring the bowel lies flat. After transection, the bowel is oriented in correct anatomical position in preparation for extraction. The staple line is grasped, the cap is removed from the single-port device, and the transected bowel is fed out.

11. *Exteriorize and resect specimen, prepare for anastomosis (supine)*

The specimen is exteriorized, assuring the stapled vascular pedicle is part of the specimen (Fig. 14.1). The descending colon mesentery is cleared from the bowel around the proposed resection site. The bowel is divided at the proposed level, a purse string is placed, and the anvil of a size 29 circular stapler is introduced and secured. The bowel is returned to the abdomen.

12. *Intracorporeal anastomosis (steep Trendelenburg)*

Return the colon to the abdomen, replacing the port, and re-insufflating the abdomen. Assure the orientation of the colon is not twisted by following the cut edge of the mesentery back to the retroperitoneum. Once the orientation is checked, ensure the resected limb with the anvil falls into the pelvis without tension, ensuring adequacy of reach is then determined by placing the colon into the pelvis. Under laparoscopic guidance, insert the size 29 circular stapler transanally into the rectum and carefully advance it up to the apex of the rectal stump. Open the spike on the stapler, aiming for the spike to protrude through just posterior the staple line. Avoid going directly through the staple line, as this can cause the staple line to unzip. Guide the anvil onto the spike, confirming a proper join. The stapler is closed and fired. The anastomosis is tested by grasping and occluding the colon around the level of the sacral promontory and filling the pelvis with irrigating fluid. The rectum is distended with air under water, using a proctoscope or bulb syringe to assess for bubbling. The stapler “donuts” are then examined for completeness.

13. Close umbilical incision (supine)

Identify fascia – grasp with Kocher clamps if needed – and close with two running #1 PDS sutures, starting at each

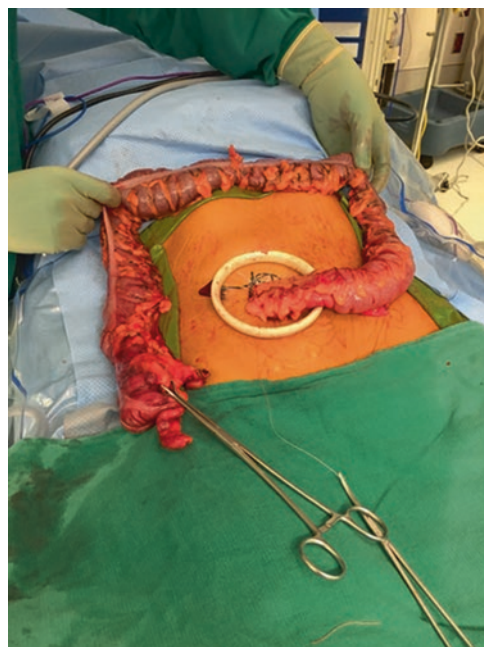


Fig. 14.1 Total colon specimen extraction through the umbilical port

corner and meeting in the middle. Close the skin with a running 4-0 Monocryl subcuticular suture.

14. Mature stoma (optional)

If performed, the proper location and orientation on the terminal ileum are marked after completing the anastomosis. Distinct proximal and distal sutures are placed to aid in

orientation, and a locking bowel grasper is placed on the loop to be matured. Pneumoperitoneum is released, the port removed, and the loop exteriorized with the aid of a Babcock clamp. Proper orientation is confirmed. A length of ileum approximately 4 cm is freed. The anterior wall is opened, and the distal end is secured flush to the dermis using three 3-0 chromic sutures. The proximal end is matured in the Brooke fashion using 3-0 chromic sutures, and a stoma appliance is placed.

Single-Incision Restorative Proctocolectomy with Ileal Pouch-Anal Anastomosis

15

Gilles Manceau and Yves Panis

Introduction

Ileoanal anastomosis after proctocolectomy was first described in 1947 by Ravitch and Sabiston [1]. Although this procedure spared patients from having a definitive stoma, the ileum was brought through the anal sphincter to the anal skin with a hand-sewn end-to-end anastomosis, which was associated with unacceptable stool frequency. In order to improve functional results and quality of life, in 1978, Parks and Nicholls [2] reported an alternative procedure with an ileal reservoir. It combined a Kock continent ileostomy and the removal of all remaining mucosa of the rectum below the peritoneal reflection. Their ileal pouch reservoir with an “S” configuration was then anastomosed to the dentate line using a perianal suturing technique. Subsequently, many improvements and modifications have been made. Currently, ileal pouch-anal anastomosis with a J configuration is considered the surgical technique of choice. It produced good long-term functional outcomes, with six semi-formed bowel movements per day and minimal incontinence.

The two major indications for proctocolectomy with ileoanal pouch construction are ulcerative colitis refractory to medical therapy and familial adenomatous polyposis. For these two pathologies, the surgical approach must be laparoscopy. Indeed, laparoscopic ileal pouch-anal procedures for ulcerative colitis offer improved short- and long-term advantages compared with an open approach, with faster recovery of bowel function, shorter length of hospital stay, and a reduced rate of small-bowel obstruction and incisional hernia [3]. Furthermore, for women of childbearing age with a desire for pregnancy, laparoscopy is the preferred

surgical approach, as it is associated with a reduction in adhesion formation and a decreased risk of postoperative tubular infertility [4, 5]. Single-incision laparoscopic surgery may be the next evolution of the conventional laparoscopic approach by further reducing surgical trauma. To date, only six studies and one case-report reported promising results of single-incision restorative proctocolectomy with ileal pouch-anal anastomosis in adults, with a total of 51 patients [6–12].

In this chapter, we will describe the different steps of our routine surgical technique for restorative proctocolectomy with ileal pouch-anal anastomosis performed by single-port laparoscopy.

Steps of the Procedure

1. Single-port placement (supine)
2. Splenic flexure takedown (left side elevated, reverse Trendelenburg)
3. Left hemicolectomy (left side elevated, steep Trendelenburg)
4. Proctectomy (left side elevated, steep Trendelenburg)
5. Right hemicolectomy (left side down, Trendelenburg)
6. Hepatic flexure takedown (left side down, reverse Trendelenburg)
7. Specimen extraction and J-pouch creation (supine)
8. Return of the small bowel to the abdomen and assuring the pouch reaches (steep Trendelenburg)
9. Anastomosis (steep Trendelenburg)
10. Creation of a diverting loop ileostomy (position is supine)

Tips and Tricks

- If performing a 3-stage procedure, the modification is that a subtotal colectomy is performed with an end ileostomy at the site of the single access port, and the pouch is created at a later stage.

G. Manceau, MD, PhD • Y. Panis, MD, PhD (✉)
Department of Colorectal Surgery, Pôle des Maladies de l'Appareil Digestif (PMAD), Beaujon Hospital, Assistance Publique-Hôpitaux de Paris (AP-HP), University Denis Diderot (Paris VII), 100 boulevard du Général Leclerc, 92110 Clichy, France
e-mail: yves.panis@aphp.fr

- Briefly, the single access port was placed in the right lower quadrant at the site of the previous marked ileostomy. Dissection of soft tissues, colorectal mesentery, serosal preparation, and vascular division were achieved with the use of an energy device. The colon specimen was removed through the wound protector at the access site, and ligation of the main ileocolic artery was performed extracorporeally. Then, both sigmoid (above the rectosigmoid junction) and ileum (close to the ileocecal junction) were divided extracorporeally (with stapler). An end ileostomy is matured in the right iliac fossa, and the stapled rectosigmoid stump returned to the abdomen or alternatively matured as a sigmoidostomy in the same orifice
- Once the left colon is fully mobilized and the rectum transected, we suggest bringing them over the small intestine, and passing the small bowel under the colon to the left paracolic gutter. Indeed, if this maneuver is not performed, the mesentery can cause an obstacle for the specimen extraction
- The ileocolic pedicle should be divided extracorporeally. Indeed, this pedicle prevents the ileal mesentery from twisting during specimen extraction
- During division of the mesenteric root, we recommend placing the patient in a steep Trendelenburg position with right side up. The entire small bowel then falls into the left upper quadrant, which facilitates dissection and visualization of the duodenum
- If it is expected to place a suction drain in the pelvis at the end of the procedure, an additional 5 mm port can be inserted in the left iliac fossa and later used as the drain site. This port can be used to help the surgeon during mobilization of the splenic flexure and to retract the anterior peritoneal reflection during pelvic dissection. The laparoscope can also be introduced through this port to improve visualization and to avoid conflict and collisions between the operative instruments and the camera

Expanded Steps of the Procedure

1. *Single-port placement* (position is placed supine, modified lithotomy)

No bowel preparation is needed prior to surgery. After general anesthesia induction, patient is placed supine in the modified lithotomy position. The body must be well positioned and attached to the table to prevent any patient slippage or nerve injury during the procedure, which requires exaggerated Trendelenburg and lateral positioning. Decompression is accomplished with an orogastric tube and a Foley catheter.

The single-incision laparoscopic platform may be introduced through a periumbilical incision. But, as we usually perform a diverting lateral ileostomy at the end of the procedure (2-stage ileal pouch-anal anastomosis), the peritoneal cavity is entered under direct visualization through a 3 cm skin incision in the right lower quadrant, at the planned stoma site, which has been marked preoperatively. Many different devices can be used: the SILS port (Covidien, Norwalk, CT, USA), the GelPOINT access platform (Applied Medical, Rancho Santa Margarita, CA, USA), the GelPort access platform (Applied Medical), the TriPort system (Advanced Surgical Concepts, Wicklow, Ireland), the Quadport access system (Olympus America, Center Valley, PA, USA), the Single Site Laparoscopy (SSL) Access systems (Ethicon Endo-Surgery Inc., Cincinnati, OH, USA), the Spider surgical system (Transenterix, Durham, NC), the R-port System (Advanced Surgical Concepts), and the Uni-X Single-Port Access Laparoscopic System (Pnavel Systems, Morganville, New Jersey, USA). We routinely use the Octoport (Landanger), with a 5 or 10 mm 0 degree straight laparoscope and conventional straight endoscopic graspers. With this single port, 4 ports can be used at the same time but most of the time, we only use three: one for the camera, and two for right and left hands. Sometimes, the fourth port is used if really needed for exposure, but because of too little space, we prefer not to use it. The abdomen is then insufflated with CO₂ to a pressure of 12 mmHg.

2. *Splenic flexure takedown* (position is left side elevated, reverse Trendelenburg)

As proctocolectomy with ileal pouch-anal anastomosis requires both a fine dissection and ligation of vascular pedicles, we perform this procedure with an energy device (the author's preferred energy source is the Thunderbeat, Olympus Medical Systems Corp, Tokyo, Japan). In benign disease, total colectomy is performed with a lateral-to-medial approach. We believe that this type of dissection is essential in order to prevent any urinary or sexual dysfunction after injury of the preaortic hypogastric nerves or pelvic plexuses.

The first step involves mobilization of the splenic flexure. The monitor is placed on the left side of the patient. The operating surgeon is on the right side of the patient with the camera operator on his side. The patient is placed in a reverse Trendelenburg position and is tilted right side down. Separation of the omentum from the transverse colon is started next to the round ligament, on the right of midline. After entering the lesser sac, the dissection is continued medially from right to left toward the splenic flexure. If splenic flexure seems difficult to take down, dissection can be continued laterally from the proximal descending colon.

3. *Left hemicolectomy* (position is left side elevated, steep Trendelenburg)

Once the omentum is freed and the splenic flexure fully mobilized, the patient is placed in steep Trendelenburg position. The left colon is dissected in a lateral-to-medial fashion. The lateral colonic attachments of the sigmoid colon and descending colon are divided with section of the Toldt's fascia, until clear identification of the left ureter. Then, the left colic pedicle is identified, isolated, sealed, and cut close to the colon, or at least 5 cm from the aorta, in order to abolish all risk of nerve injury, as in any benign disease. Division of the left mesocolon and sigmoid arteries is continued in a caudal manner away from the aorta and toward the pelvis, with a close mesocolic division.

4. *Proctectomy* (position is left side elevated, steep Trendelenburg)

In order to minimize the risk of pelvic nerve injury, proctectomy is performed deliberately in a non-oncologic plane, leaving a portion of the mesorectum posteriorly. Thus we do not enter the presacral space. We call this plane a "bad mesorectal excision." We preserve both pararectal fossa and the pouch of Douglas. In a recent randomized study including 59 patients, this type of dissection took longer compared with dissection in the total mesorectal excision plane [13]. However, it was associated with a significantly lower rate of severe complications, a lower readmission rate and a better short-term quality of life.

The rectum is completely mobilized down to the pelvic floor, with even a small opening of the intersphincteric space, in order to have a remaining rectal cuff as small as possible. The extent of pelvic dissection needs to be well appreciated by a digital rectal exam. The distal rectum is transected at the pelvic floor, no more than 2 cm from the anorectal ring, using a 60 mm endoscopic linear stapler (The authors prefer to use the Echelon Flex, Ethicon Endo-Surgery). Particular attention should be paid in women to assure the posterior wall of the vagina is protected and out of harm's way.

5. *Right hemicolectomy* (position is left side down, Trendelenburg)

The patient is tilted left side down and placed in Trendelenburg. The surgeon is situated between the legs. The camera operator remains on the right side of the patient. The right colon is fully mobilized with a lateral approach, as was done for the left colon. The mesocolon of the cecum and ascending colon is dissected until the inferior vena cava and

the inferior duodenal flexure are identified. The right ureter needs to be identified and protected.

6. *Hepatic flexure takedown* (position is left side down, reverse Trendelenburg)

Then, the patient is placed in a reverse Trendelenburg position. Separation of the omentum from the transverse colon edge is finished from the left to the right and the hepatic flexure is fully mobilized with visualization of the pancreatic head. The middle colic artery followed by the different branches of the right colic vessels are identified, isolated and ligated close to the colon. The dissection continues with division of the right mesocolon toward the cecum.

7. *Specimen extraction and J-pouch creation* (position is supine)

The abdomen is then deinsufflated. By first grasping the staple line from the proctectomy, the entire colon and rectum are pulled out and extracted through the single-port device with the wound protector. The small bowel should be placed to the left of midline. The last ileal loop is divided with a linear cutting stapler. The ileocolic pedicle is identified and divided extracorporeally. This pedicle is easily identifiable by following the duodenum and the cut edge of the mesentery. An 18 cm ileal J-pouch is then created in usual fashion, with two to three firings of a 90 mm linear cutting stapler and the anvil of the circular stapler inserted into the apex of the pouch.

8. *Return of the small bowel to the abdomen and assuring the pouch reaches* (position is reverse Trendelenburg)

After reintegration of the small bowel into the abdominal cavity, the mesenteric root is divided up to the duodenum and the ligament of Treitz, in order the pouch the reach the anus. In case of excess tension, an additional Kocher maneuver with dissection of the lateral peritoneal attachments of the duodenum can be performed. During this step, the operating surgeon is placed between the legs.

9. *Anastomosis* (position is Trendelenburg)

The patient is then returned to Trendelenburg. The operating surgeon and camera operator move to the patient's right side, with the monitor between the legs. Before creation of the anastomosis, the operating surgeon must ensure that the pouch and the mesentery are well positioned, without twisting. Then, a double-stapled ileal pouch-anal anastomosis is performed with a 28–31 mm head diameter endoluminal-stapling device through the anus.

10. Creation of a diverting loop ileostomy (position is supine)

A loop diverting ileostomy is routinely created and exteriorized at the site of the single-port device, with a productive orifice positioned on top of the ileostomy, to prevent postoperative ileus.

Conclusions

Restorative proctocolectomy with ileal pouch-anal anastomosis is the most complicated procedure in colorectal surgery. It is a technically complex intervention that requires dissection in all quadrants of the abdomen. Single-port laparoscopy should be reserved for surgeons with a good surgical experience and advanced skills in laparoscopy. However, each step of this procedure, taken separately, is feasible with adequate experience. Tips and tricks can be employed to avoid conversion to multiport or open surgery. Further comparative studies are needed to determine if single-port laparoscopy offers short- or long-term benefits in comparison with conventional laparoscopy in this situation.

Conflicts of Interest and Source of Funding None for both authors.

No funding has been received for this work.

Acknowledgement: None

References

- Ravitch MM, Sabiston DC Jr. Anal ileostomy with preservation of the sphincter; a proposed operation in patients requiring total colectomy for benign lesions. *Surg Gynecol Obstet.* 1947;84(6):1095–9.
- Parks AG, Nicholls RJ. Proctocolectomy without ileostomy for ulcerative colitis. *Br Med J.* 1978;2(6130):85–8.
- Maggiori L, Panis Y. Surgical management of IBD—from an open to a laparoscopic approach. *Nat Rev Gastroenterol Hepatol.* 2013;10(5):297–306. doi:10.1038/nrgastro.2013.30.
- Oresland T, Bemelman WA, Sampietro GM, Spinelli A, Windsor A, Ferrante M, et al. European evidence based consensus on surgery for ulcerative colitis. *J Crohns Colitis.* 2015;9(1):4–25. doi:10.1016/j.crohns.2014.08.012.
- Beyer-Berjot L, Maggiori L, Birnbaum D, Lefevre JH, Berdah S, Panis Y. A total laparoscopic approach reduces the infertility rate after ileal pouch-anal anastomosis: a 2-center study. *Ann Surg.* 2013;258(2):275–82. doi:10.1097/SLA.0b013e3182813741.
- Gash KJ, Goede AC, Kaldowski B, Vestweber B, Dixon AR. Single incision laparoscopic (SILS) restorative proctocolectomy with ileal pouch-anal anastomosis. *Surg Endosc.* 2011;25(12):3877–80. doi:10.1007/s00464-011-1814-y.
- Geisler DP, Condon ET, Remzi FH. Single incision laparoscopic total proctocolectomy with ileopouch anal anastomosis. *Color Dis.* 2010;12(9):941–3. doi:10.1111/j.1463-1318.2009.02115.x.
- Olson CH, Bedros N, Hakiman H, Araghizadeh FY. Single-site laparoscopic surgery for inflammatory bowel disease. *JLS.* 2014;18(2):258–64. doi:10.4293/108680813X13753907292872.
- Chambers WM, Bicsak M, Lamparelli M, Dixon AR. Single-incision laparoscopic surgery (SILS) in complex colorectal surgery: a technique offering potential and not just cosmesis. *Color Dis.* 2011;13(4):393–8. doi:10.1111/j.1463-1318.2009.02158.x.
- Geisler DP, Kirat HT, Remzi FH. Single-port laparoscopic total proctocolectomy with ileal pouch-anal anastomosis: initial operative experience. *Surg Endosc.* 2011;25(7):2175–8. doi:10.1007/s00464-010-1518-8.
- Vestweber B, Galetin T, Lammerting K, Paul C, Giehl J, Straub E, et al. Single-incision laparoscopic surgery: outcomes from 224 colonic resections performed at a single center using SILS. *Surg Endosc.* 2013;27(2):434–42. doi:10.1007/s00464-012-2454-6.
- Costedio MM, Aytac E, Gorgun E, Kiran RP, Remzi FH. Reduced port versus conventional laparoscopic total proctocolectomy and ileal J pouch-anal anastomosis. *Surg Endosc.* 2012;26(12):3495–9. doi:10.1007/s00464-012-2372-7.
- Bartels SA, Gardenbroek TJ, Aarts M, Ponsioen CY, Tanis PJ, Buskens CJ, et al. Short-term morbidity and quality of life from a randomized clinical trial of close rectal dissection and total mesorectal excision in ileal pouch-anal anastomosis. *Br J Surg.* 2015;102(3):281–7. doi:10.1002/bjs.9701.

Deobrah S. Keller

In our experience, a low anterior resection is the ideal procedure for a reduced port laparoscopic approach, where one additional 5 mm umbilical port is used in addition to the single incision port, to overcome technical and ergonomic challenges. Per surgeon preference, the single port can be used alone – at the umbilicus or the Pfannenstiel site – without the additional port, but we present the “SILS +1” approach for a low anterior resection.

Steps of the Procedure

1. Insert ports: 4 cm Pfannenstiel or stoma site and 5 mm umbilical port.
2. Position omentum over transverse colon and deliver small bowel to right of the midline.
3. Incise peritoneum deep to the IMV and develop retroperitoneal plane.
4. High ligation of IMV.
5. Isolate superior wing of the eagle sign.
6. Complete splenic flexure takedown.
7. Deliver small bowel out of pelvis.
8. Medial to lateral dissection over sacral promontory below the SRA.
9. Develop the (inferior wing of the eagle sign).
10. Connect dissection planes to expose IMA base.
11. Ligation of IMA and 2nd ligation of L colic.
12. Lateral to medial dissection of the sigmoid
13. Pelvic dissection and TME.
14. Divide rectum and extracorporealize specimen.
15. Perform anastomosis.
16. +/- mature loop ileostomy.

Tips and Tricks

- Isolate the IMV for ligation at a proximal location where the left colic artery runs laterally and separate; preservation of this artery is essential for collateral flow to the splenic flexure.
- When performing the splenic flexure takedown, if you follow the white line of Toldt superiorly, you will dissect out the lateral border of the kidney and ultimately the spleen – stay close to the colon.
- After dividing the IMA pedicle, the left colic artery is ligated close to its origin from the IMA for full mobility of the colon.
- When performing the deep pelvic dissection, have the assistant keep stable traction on the anterior surface of the rectosigmoid junction, aimed to the right under quadrant (when dissecting the left side) or left upper quadrant (when dissecting to right side).
- If using a camera with a flexible tip, the assistant is often best utilized on the left side of the patient.
- Typically grasp your pathology 1–2 cm further away for SILS than you would with multiport laparoscopy; that helps avoid instrument crowding.

Expanded Steps of the Operation

Setup and Positioning

The patient is positioned in modified lithotomy position in Allen or Yellowfin stirrups or on a split-leg bed with both arms tucked. A digital rectal exam and rigid proctoscopy are performed with minimal air insufflation. The surgeon stands on the patient’s right side, with the assistant initially on the

Electronic Supplementary Material: The online version of this chapter (doi:[10.1007/978-3-319-63204-9_16](https://doi.org/10.1007/978-3-319-63204-9_16)) contains supplementary material, which is available to authorized users.

D.S. Keller, MS, MD (✉)
Division of Colorectal Surgery, Department of Surgery, Baylor University Medical Center, Dallas, TX, USA
e-mail: debby_keller@hotmail.com

patient's left side. After entry into the abdomen and starting the laparoscopic portion of the operation, the assistant moves to the patient's right side, cephalad to the surgeon. The main laparoscopic monitor is placed on the patient's right side, at eye level to the surgeon. The assistant serves as the camera holder, providing exposure for the surgeon. If using a flexible tip camera, the assistant can remain on the patient's left side. The challenges of operating a camera from the opposite side of the table is one of the many challenges that a flexible tip camera helps conquer with its ease of use.

1. *Insert the single port device through a Pfannenstiel incision or at the stoma site and 5 mm umbilical port (position is supine).*

If using a Pfannenstiel incision, the patient's mons pubis is palpated and a mark is made 2 cm cephalad. The midline is confirmed, and a 4 cm mark is made to guide the incision. The skin is incised sharply with a 15-blade scalpel, and then the incision is deepened through the dermis and subcutaneous tissue with cautery. Insert army-navy or double-ended retractors to exposure horizontally as the incision is deepened to the rectus fascia. The fascia is incised horizontally, with an upward extension at the lateral edges. The retractors are then replaced vertically for exposure as the flaps are developed. The upper flap is developed first. The linea alba is grasped and elevated, and using a combination of blunt and cautery dissection, the muscle is released from the fascia. Digital palpation is used to confirm extensive release. The lower flap is then developed in the same fashion. The underlying peritoneum is grasped and elevated and then sharply opened to permit a finger. The peritoneum is safely opened vertically over the operator's finger for a length of approximately 4 cm. If using the applied GelPOINT device, insert the ring and dial the ring down to fit against the abdominal wall. If the surgeon prefers to use a lap sponge, insert the lap sponge into the abdomen now and place the cap on the GelPOINT. If using the Medtronic SILS port, insert the lap sponge, and then insert the port. The surgeon must make certain that this sponge is removed at the end of the case. Insufflate the abdomen and insert the 30-degree laparoscopic or flexible tip camera. Using the 15-blade scalpel, a stab incision is made in the umbilicus. Under direct vision, a bladeless 5 mm port is placed toward the pelvis. The camera is switched to the umbilical port and the abdomen is surveyed.

If a diverting ileostomy is planned, use the pre-marked stoma site to insert the port. A circular 2 cm incision is made with a 15-blade scalpel or cut setting of the electrocautery at the site of the predetermined stoma in the right lower quadrant. The skin disk is excised, leaving the subcutaneous fat in place. The 2 cm disk should be approximately the size of a nickel. Insert army-navy or double-ended retractors to exposure as the incision is deepened. A longitudinal incision is made in the anterior rectus sheath, exposing the rectus

muscle. The rectus muscles are split and separated using a Kelly hemostat. The retractors are replaced deeper to aid exposure. The peritoneum is held with two hemostats and sharply incised with care to underlying bowel. Digital exam is performed to assure entry into the abdominal cavity. If using the applied GelPOINT device, insert the ring and dial the ring down to fit against the abdominal wall. If the surgeon prefers to use a lap sponge, insert the lap sponge into the abdomen now and place the cap on the GelPOINT. If using the Medtronic SILS port, insert the lap sponge, and then insert the port. The surgeon must make certain that this sponge is removed at the end of the case. Insufflate the abdomen, insert the 30-degree laparoscopic or flexible tip camera, and survey the abdominal cavity.

Conversely, the single port platform can be placed through the umbilicus as described elsewhere.

2. *After thorough exploration of the abdomen, position omentum over the transverse colon and deliver the small bowel to the right of the midline.*

Using two atraumatic graspers, grasp the edge of the omentum and place the omentum over transverse colon on each side of the falciform ligament. The small bowel is delivered out of the pelvis and swept entirely to the right of the midline, exposing the ligament of Treitz (Fig. 16.1).

3. *Incise the peritoneum deep to the IMV and develop retroperitoneal plane (position is left side elevated, slight Trendelenburg).*

The inferior mesenteric vein and left colic artery are seen running lateral and parallel along the base of the descending colon mesentery. Using an atraumatic grasper, grasp and elevate

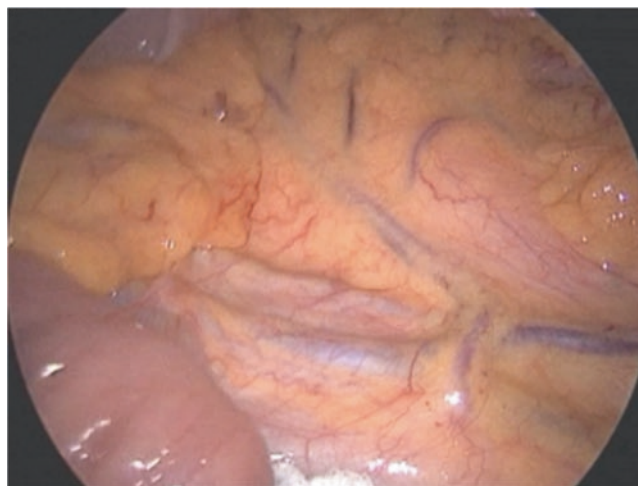


Fig. 16.1 Intraoperative view of the Ligament of Treitz, Inferior Mesenteric Vein, and Left Colic Artery for the splenic dissection portion of the operation

the IMV, tenting the peritoneum beneath it. Make a superficial incision in the peritoneum under the IMV and insert the grasper into the peritoneal defect. Then, use the triangulation technique, working hand over hand to sweep down the retroperitoneum and develop the plane beneath the mesentery. The dissection is continued superiorly, to the level of the splenic vein and pancreas, and laterally toward the splenic flexure (Fig. 16.2).

4. *High ligation of IMV (position is left side elevated, slight reverse Trendelenburg).*

The IMV is isolated and circumferentially dissected free of its peritoneal covering. Then, a high ligation is performed using an energy source (Fig. 16.3).

5. *Isolate the superior wing of the eagle sign.*

After secure ligation is completed, the left colic artery can be appreciated as a direct extension from the inferior mesenteric

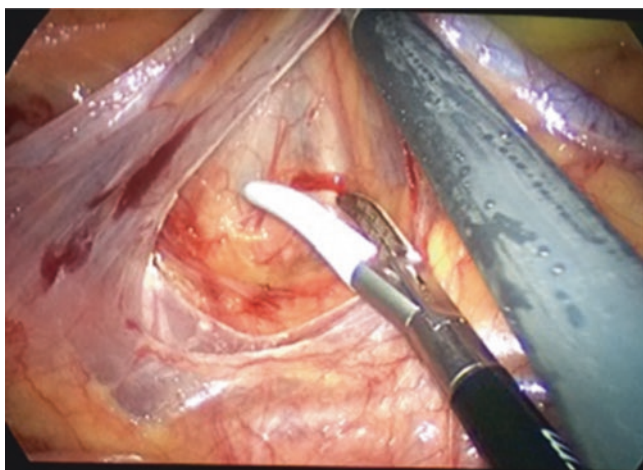


Fig. 16.2 Incise peritoneum under the Inferior Mesenteric vein and develop the retroperitoneal plane

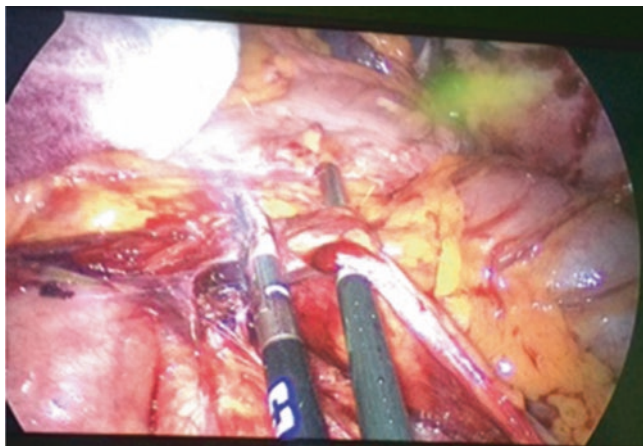


Fig. 16.3 High ligation of the Inferior Mesenteric Vein

artery pedicle running in the peritoneum proximally toward the splenic flexure. In this configuration, we use an eagle sign to describe the anatomy. The inferior mesenteric pedicle is the body of the eagle, with the peritoneum under the left colic artery as the superior wing, and the peritoneum under the superior rectal artery as the inferior wing (Fig. 16.4). The left colic artery is lifted and any remaining retroperitoneal attachments are swept down, isolating the superior wing of the eagle.

6. *Complete splenic flexure takedown.*

The descending colon is grasped or bluntly manipulated with an atraumatic grasper and retracted toward the midline and inferiorly, exposing the attachments of the colon to the lateral sidewall. The white line of Toldt is incised, and the dissection continues proximally, staying close to the colon, to the splenic flexure (Fig. 16.5). The previous retroperitoneal dissection plane will be met. The colon is retracted medially

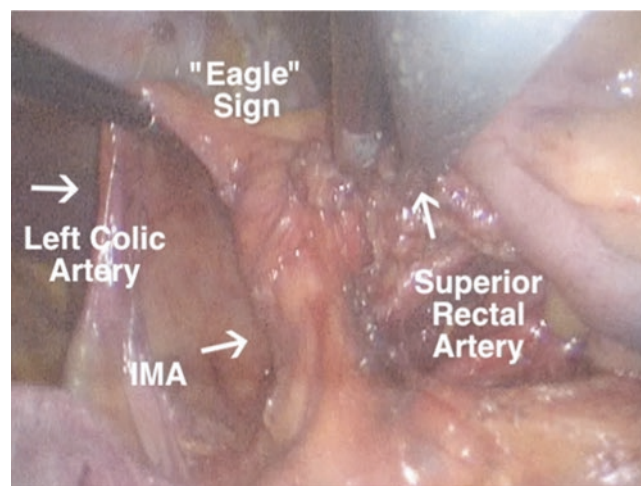


Fig. 16.4 “Eagle Sign” of the Inferior Mesenteric Artery, with the Superior Rectal artery running in the inferior wing, and the Left Colic artery running in the superior wing

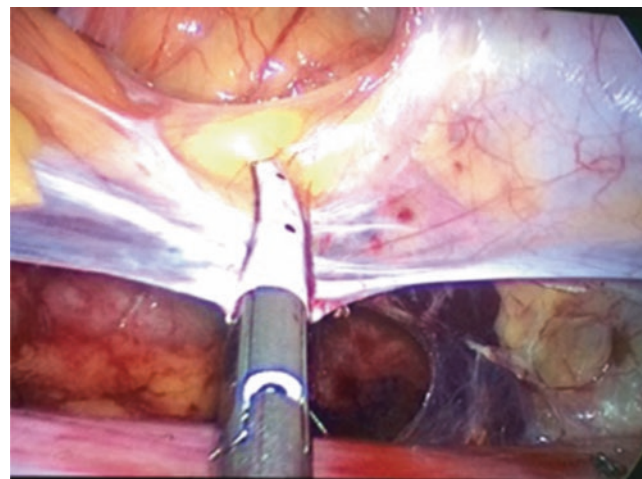


Fig. 16.5 Lateral to medial dissection

and inferiorly, and the splenicocolic ligament is divided, taking care not to avulse the splenic capsule. The omentum is suspended, and the gastrocolic ligament is divided close to the transverse colon, entering into the lesser sac. The omentum is detached from the transverse colon, moving medially to laterally to complete the splenic flexure takedown. During the detachment, stay close to the colon and assure the stomach is identified and away from the dissection. The transverse and descending colon should be fully mobilized. Alternatively, the lesser sac can be opened medially just inferior to the greater curvature of the stomach. Dissection can then be carried down in a medial to lateral fashion. Early in ones' learning curve, this step can be performed first to assure minimizing the size of a midline incision if conversion was needed.

7. *Deliver the small bowel out of the pelvis (position is left side elevated, steep Trendelenburg).*

At this point, deliver the small bowel out of the pelvis and position to the right of the midline. A lap sponge can help hold the small bowel in place if needed.

8. *Medial to lateral dissection over the sacral promontory below the superior rectal artery.*

Gently retract the sigmoid colon cephalad out of the pelvis, and identify the rectum as it dives in the pelvis over the pelvic brim. Grasp and tent the sigmoid colon mesentery toward the anterior abdominal wall, visualizing the IMA pedicle as it comes off the aorta and travels toward the colon, with the superior rectal artery traveling toward the pelvis. Make a superficial incision in the peritoneum at the base of the pedicle along the pelvic brim and underneath the SRA (Fig. 16.6).

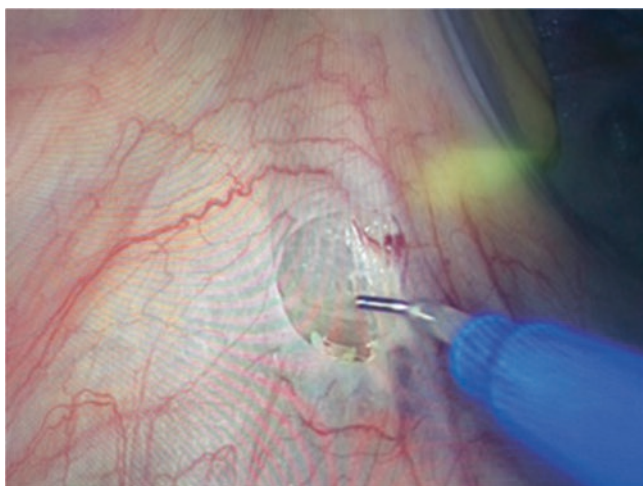


Fig. 16.6 Medial to lateral dissection over the sacral promontory below the Superior Rectal artery to develop the inferior wing of the eagle sign

Insert the grasper into the peritoneal defect and use the triangulation technique, working hand over hand to sweep down the retroperitoneum and retroperitoneal structures, and elevate the SRA and mesentery. Care is taken to sweep the preaortic hypogastric nerve plexus dorsally to protect it. The dissection is continued laterally toward the sidewall and under the descending colon toward the splenic flexure. Take care to identify and protect the left ureter and gonadal vessels.

9. *Identify the inferior wing of the eagle sign.*

The mesentery with the superior rectal artery as the inferior wing is freed, isolating the inferior wing of the eagle sign.

10. *Connect dissection planes to expose the IMA base.*

The inferior and superior wings are now freed and can be lifted freely from the underlying retroperitoneum. A grasper can be passed posterior to the inferior mesenteric pedicle, connecting the sub- and supra-IMA planes. The ureter is identified again as it courses proximally to assure it is down and away from the dissection field.

11. *Ligation of the IMA and 2nd ligation of the left colic artery.*

The IMA pedicle is isolated, and a laparoscopic stapler with a vascular/ white load is placed across the IMA (and IMV concurrently if this is feasible) (Fig. 16.7). Alternatively, a heat source can be used to divide vessels up to 7 mm in diameter if there is minimal or no calcification of the vessel. The stapler is closed and the ureter again is checked to assure it is away and protected. Both tips of the stapler are assured to be free and clearly visible, and the stapler is fired. Before the stapler is opened, both ends of the pedicle are grasped, to

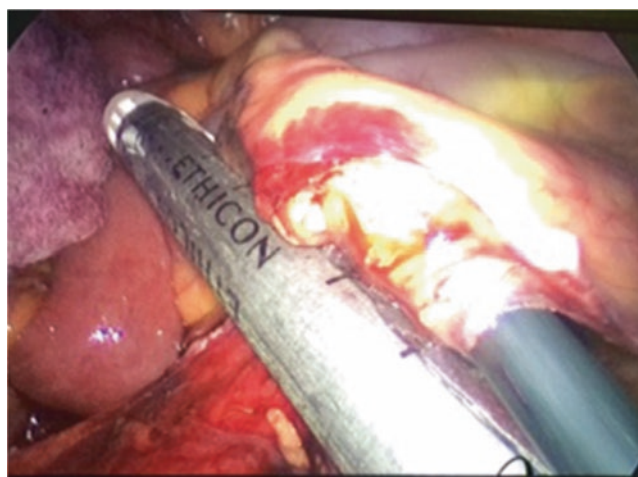


Fig. 16.7 Ligation of the IMA

assist with control in case of bleeding. The stapler is fired, dividing the pedicle. Following transection, the peritoneum is grasped, and an energy source is used to divide the left colic artery close to its origin from the IMA.

12. *Lateral to medial dissection of the sigmoid (position is left side elevated, steep Trendelenburg).*

An atraumatic grasper is used in the left hand to retract the lateral aspect of the sigmoid colon medially, tenting the lateral attachments to the sidewall under tension. Staying close to the colon, the left-lateral attachments of the upper rectum and sigmoid colon are dissected free using an energy source, and the sigmoid and descending colon are completely mobilized. The lateral attachments are brushed laterally. The prior retroperitoneal dissection plane should be encountered. Another grasper from the assistant may be required to retract the descending colon inferiorly and medially to give proper tension. Care should be taken again to identify and to avoid any injury to the gonadal vessels and the ureter.

13. *Pelvic dissection and TME.*

An atraumatic bowel grasper is used to elevate the mobilized rectosigmoid colon out of the pelvis and away from the retroperitoneum and sacral promontory, allowing entry into the presacral space. The posterior aspect of the mesorectum is identified, and the mesorectal plane is sharply developed, lifting the posterior rectal envelope from the sacrum. Making an incision in the envelope at the level of the presacral space allows pneumodissection to assist. Take care to preserve the hypogastric nerves anterior to the sacrum as they pass into the pelvis. Dissection continues down the presacral space in this avascular plane toward the pelvic floor. After the posterior dissection, a lateral dissection is commenced on the right side of the rectum. This is facilitated by retraction of the rectosigmoid colon in the direction of the splenic flexure. The peritoneum is divided down to the level of the seminal vesicles or rectovaginal septum. The dissection is continued from the free edge of the right lateral peritoneal dissection anteriorly (Fig. 16.8). The anterior dissection requires careful identification of the seminal vesicles in men and the vagina in women. An atraumatic bowel grasper is used to retract the peritoneum anterior to the rectum forward. In women, the dissection starts with identification of the peritoneum over the pouch of Douglas and incising 1–2 cm anterior after retracting the uterus anteriorly and rectum posteriorly. In men, the line of division of the peritoneum can be identified by retracting the bladder anteriorly and the rectum posteriorly and entering the plane 1–2 cm anterior to the fold. The dissection is continued posterior to Denonvilliers' fascia, separating the pelvic organs from the anterior wall of the mesorectum and continues downward. The

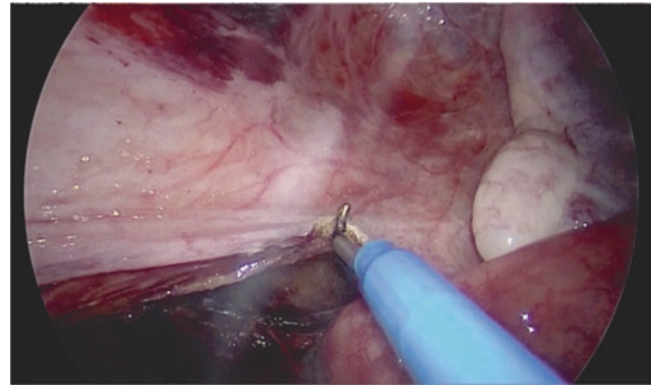


Fig. 16.8 Rectal dissection, at the free edge of the peritoneum on the right

lateral dissection is then repeated on the left side with retraction of the proximal colon in the direction of the right upper quadrant. After the lateral dissection, further progress can be made posteriorly, and the rectal dissection continues along the back of the mesorectum to the muscular tube below the inferior extent of the mesorectum to the level of the levators.

14. *Divide the rectum and extracorporealize the specimen.*

The distal resection line can be identified again by performing proctoscopy, if needed. A plane is dissected between the posterior wall of the rectum and the anterior portions of the mesorectum. At the specified point of resection, the mesorectum is divided sharply, starting on the right side, and cleared from the rectal tube. The rectum is divided from the right side using one or two applications of an endoscopic stapler with a blue load. Alternatively, an anterior-posterior approach or a posterior-anterior approach may be utilized when needed. Transect perpendicular to the rectum with the stapler, ensuring the pathology is contained in the specimen with proper margin. Grasp the transected bowel and extracorporealize the transected end to the IMA pedicle.

15. *Perform the anastomosis.*

The stapled end is removed, the pathology and proper margins above the pathology are checked, and the proposed site for resection is determined. The mesentery is serially clamped and ligated from the proposed resection site. A purse-string device is placed at the site of resection, and a clamp is placed distally. Then, the bowel is divided with a scalpel between the purse-string device and the clamp, and the specimen is handed off the table. The anvil to the intraluminal stapler is introduced into the colon and secured. The mesentery is cleared sharply from the area to be incorporated in the anastomosis. If desired, the vascular supply to the anastomosis can be evaluated at this point. We utilized the

PINPOINT system for this confirmation (Novadaq Technologies, Inc., Toronto, Ontario, Canada). The prepared proximal end is then returned to the abdomen, the abdomen is reinsufflated, and the anastomosis is performed under direct visualization. The colonic conduit is evaluated to ensure it is straight and untwisted and falls freely into the pelvis without tension. The assistant moves between the patient's legs and introduces the transanal portion of the intraluminal stapler. With guidance from the operator for direction, the assistant advances the central spike to emerge either through the staple line of the rectum or just posterior to it (Fig. 16.9). The anvil is engaged onto the spike, and the stapler is closed to approximate the two components of the anastomosis. Before the stapler is fired, care is taken to ensure that no other structures or tissue are caught in between. After firing, the stapler is removed, and the stapler donuts are checked to confirm a complete anastomosis. A bowel clamp is placed proximal to the anastomosis, and the integrity is evaluated by performing an air leak test after filling the pelvis with saline. Assess the need for diversion. If placed, the lap sponge is removed, hemostasis is ensured, the bowels are replaced in their normal anatomic location, and the omentum is replaced. Pneumoperitoneum is released, the port is removed, and the fascia and skin are closed.

16. +/- mature loop ileostomy.

If performed, the proper location and orientation on the terminal ileum are marked after completing the anastomosis.

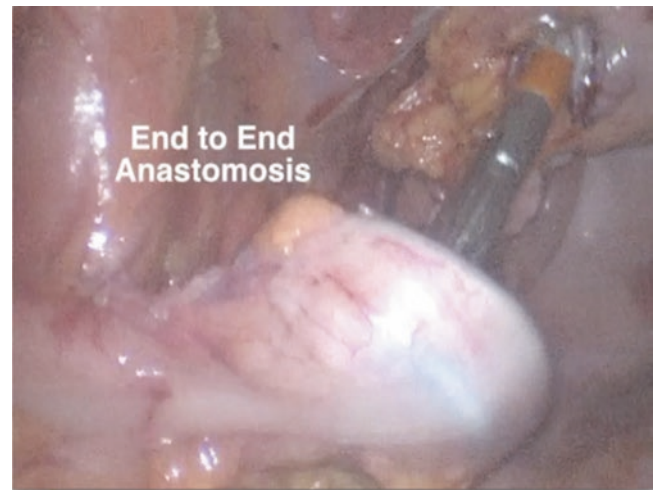

Fig. 16.9 An end to end stapled anastomosis is performed

Distinct proximal and distal sutures are placed to aid in orientation, and a locking bowel grasper is placed on the loop to be matured. Pneumoperitoneum is released, the port removed, and the loop exteriorized with the aid of a Babcock clamp. Proper orientation is confirmed. A length of ileum approximately 4 cm is freed. The anterior wall is opened, and the distal end is secured flush to the dermis using three 3-0 chromic sutures. The proximal end is matured in the Brooke fashion using 3-0 chromic sutures, and a stoma appliance is placed.

Samuel Eisenstein and Sonia Ramamoorthy

Steps of the Operation

1. Positioning and equipment setup.
 2. Single-incision platform is placed and accessing the abdomen with a 2.5–3 cm vertical transumbilical incision.
 3. Dissection is begun at the level of the superior rectal artery and a window is made posteriorly, the left ureter is identified.
 4. If a resection is to be performed, the rectum is separated off of the sigmoid colon using a linear stapler.
 5. Dissection is carried down through the mesorectal plane anteriorly and posteriorly to the level of the levators.
 6. If a resection is to be performed, the distal end of the colon is measured, exteriorized, and transected through the single-incision port.
 7. A purse-string suture is placed and the end-to-end anastomosis (EEA) anvil placed into the distal colon and the bowel returned into the abdomen.
 8. EEA is performed.
 9. Rectopexy is performed by suturing the lateral stalks to the sacral periosteum at the level of the sacral promontory.
 10. Abdominal wound is closed.
- We recommend using a robotic platform if at all possible to facilitate low pelvic dissection as well as ease of rectopexy.
 - The dissection must be carried down to the level of the levators or the recurrence rate significantly increases. The posterior mesorectal plane is the simplest place from which to approach.
 - If a resection is to be performed, ensure that there is minimal tension on the anastomosis while also minimizing redundancy. It is safer to err on the side of slight redundancy to minimize the risk of anastomotic leak. We recommend testing the length intracorporeally and marking the point at which the anastomosis will be made.
 - The anastomosis should be made prior to the rectopexy to ensure the EEA will not disrupt the sutures.
 - Rectopexy should be performed by taking generous bites of the lateral stalks and suturing to the periosteum of the sacral promontory using nonabsorbable sutures.
 - We recommend using 2-0 Prolene and placing 3 interrupted sutures on each side, starting on the left side, which is usually more difficult.
 - When suturing the rectopexy, if you encounter presacral bleeding, do not remove the suture, and tie it down to compress the bleeding vessel.
 - Rectopexy can be very difficult to hand-sew intracorporeally using the single-incision approach. To facilitate ease of the rectopexy, we recommend the use of a robotic or other articulating surgical platform. If this is not an option, consider tying the knots extracorporeally and using a knot-pushing device or consider absorbable tacks.

Tips and Tricks

- For optimal cosmetic results the vertical transumbilical incision hides well in the umbilicus. The fascia can be undermined to further accommodate space with minimal external scarring.

S. Eisenstein, MD • S. Ramamoorthy, MD (✉)
Moore's Cancer Center, UC San Diego,
3855 Health Sciences Drive #0987, La Jolla,
CA 92093-0987, USA
e-mail: seisenstein@ucsd.edu; sramamoorthy@ucsd.edu

Considerations for the Procedure

When accessing the abdomen for a single-incision rectopexy, it is important to be familiar with the tenets of the surgery in advance. The goals of a rectopexy include carrying

your dissection to the level of the pelvic floor and suturing the rectum up to the level of the sacral promontory. Access will need to allow exposure to the sigmoid colon as well as the rectum and pelvic floor. Our preferred approach is through a vertical transumbilical incision, which allows the surgeon to be an appropriate distance away from the rectum so they can obtain the best angle for the posterior dissection and still manage to triangulate their instruments by crossing them over themselves.

Additionally consideration should be given to whether a resection will be necessary to minimize any redundancy in the sigmoid colon and subsequently minimize the risk of recurrence and postoperative constipation. If so, then an extraction site will be necessary and the platform used should accommodate the extraction.

1. Positioning and equipment setup

The SILS approach is technically challenging, so it is important to ensure the proper equipment is available and the patient is appropriately positioned. We position the patient in a modified lithotomy position to allow access to the anus. Here it is key to keep the legs down and out of the way of your surgical equipment. A Foley catheter is placed and the patient is prepped and draped in standard sterile fashion. The patient should be positioned in steep Trendelenburg with a slight elevation of their left side. We recommend, if available, the use of a robotic surgical platform such as the Intuitive DaVinci Si or Xi (Intuitive Surgical, Sunnyvale, CA). Robotic platforms allow for the articulation of the ends of the instruments, which can facilitate the rectopexy. They also allow for greater access to the low pelvis to ensure the dissection is carried down to the levators.

If a robotic approach is used, the robot is docked by placing the robotic trocars through the single-incision platform's trocars. We recommend using an atraumatic grasper in the left hand and either a hook cautery or hot shears in the right. The camera should be angled at 30° and should enter through the inferior port, and the assistant will have access through the more cephalad port. During the case, it will be necessary to use needle drivers, a linear GIA stapler (if a resection is to be performed), and potentially a bipolar vessel sealing device.

If the surgery is to be performed laparoscopically, we recommend having a bowel grasper and either a harmonic scalpel or bipolar vessel sealing device available as well as a 30° scope. Again a linear stapler will be necessary for the resection and needle drivers, a laparoscopic suturing device, or a tacking device will be necessary for the rectopexy.

2. Single-incision platform is placed (position is steep Trendelenburg, left side slightly raised)

Access can be made through a small Pfannenstiel incision; however, from this distance, it can be very difficult to completely visualize the posterior dissection when the rectum courses anteriorly close to the pelvic floor. We measure a 2.5–3 cm incision through the umbilicus. Usually this carries the incision just outside the recess of the umbilicus in all but the thinnest of patients. Often times the abdomen can be accessed by placing a clamp through a small physiologic umbilical hernia and safely dividing the fascia on the clamp. The fascia is usually undermined another centimeter beyond the skin edges and the single-incision platform is placed.

Our preferred platform is the GelPOINT access platform (Applied Medical, Rancho Santa Margarita, CA). This platform consists of a wound protector device and a cap through which ports can be placed in the surgeon's desired location and which rotates on axis to allow access to the entire abdomen. We separate the ports to the periphery and use 2 10 mm ports and a 15 mm port triangulated for laparoscopic procedures and add a 10 mm port in a square configuration for robotic procedures. This port also allows us to exteriorize the sigmoid colon and remove the specimen in the case of a resection.

3. Dissection is begun at the level of the superior rectal artery and a window is made posteriorly, the left ureter is identified

Dissection should begin posteriorly at the level of the superior hemorrhoidal vessels. During this portion of the dissection, it is important to identify the left ureter as it courses lateral to the mesentery. It is crucial that the ureter be identified before transecting the mesentery if a resection is to be performed. Posteriorly the hypogastric plexus should be preserved as well. Dissection should be carried down into the posterior mesorectal plane which can be identified as loose, areolar tissue.

4. If a resection is to be performed, the rectum is separated off of the sigmoid colon using a linear stapler

In cases where a resection is to be performed, it is far simpler to perform the distal transection prior to carrying your dissection down to the pelvic floor. This is achieved by identifying the rectosigmoid junction, where the tenia begin to splay and the epiploic appendages end, and carrying your mesenteric dissection to the wall of the rectum just distal this level using a bipolar vessel sealer or harmonic scalpel.

This is defatted and separated with a liner stapler. The rectum is no longer tethered to the sigmoid colon and can be manipulated with significantly less tension. It may be necessary to transect the superior hemorrhoidal vessels to perform this maneuver. This can be done without any concern of devascularizing the rectum.

5. Dissection is carried down through the mesorectal plane anteriorly and posteriorly to the level of the levators

During this posterior dissection it may become necessary to regularly cross your instruments to achieve optimal triangulation. The grasper should be pushing the rectum anteriorly as well as side to side while your energy device cleanly separates the areolar, avascular tissue posteriorly. The blood supply to the remaining rectum will be coming through the lateral stalks, and these should be avoided to both help preserve the blood supply and provide tissue to which to perform the rectopexy. In the distal pelvis it is important to remember that the rectum courses anteriorly and visualization may need to be altered to accommodate this. Dissection should be carried down to the level of the levators to minimize the risk of recurrence. Once the posterior dissection is complete anterior dissection should also be performed. This should also be done down to the level of the levators to achieve optimal mobility.

6. If a resection is to be performed, the distal end of the colon is measured, exteriorized, and transected through the single-incision port

At this point in the surgery, if a resection is to be performed, attention should be turned toward the sigmoid colon. It is unlikely that the redundant colon will need to be mobilized extensively but any lateral attachments that may hinder a successful anastomosis should be freed. We recommend at this point identifying your proximal transection point intracorporeally by pulling up on the rectum with one instrument and applying gentle downward traction on the sigmoid colon with the other. Where the two meet, without any redundancy, but also without any tension should be the anastomotic site. We recommend marking this intracorporeally with an energy device so that when the bowel is exteriorized this site is easily identifiable. If there is any doubt, err on the side of extra redundancy as too much tension could increase the risk of anastomotic leak.

Once the sigmoid colon is marked it can be exteriorized through a wound protector. If this procedure is being done robotically it will be necessary to remove the robotic instruments and trocars from the patient and temporarily undock. This portion of the procedure is usually fairly brief and can be done without moving the robot to expedite the redocking

process. The mesentery can be taken to the level of the bowel wall at your previously measured site.

7. A purse-string suture is placed and the EEA anvil placed into the distal colon and the bowel returned into the abdomen

We then place a distal purse string and EEA anvil into the distal end of the bowel. We recommend using the largest anvil which will fit to minimize stenosis of the anastomosis. Rarely is it necessary to place an anvil smaller than 29 mm.

8. EEA is performed

The bowel is then returned into the abdomen and the anastomosis is performed with the EEA stapler which is passed transanally. This may be facilitated by a laparoscopic anvil grasping device. Once the anastomosis is complete we routinely perform a flexible sigmoidoscopy to evaluate the quality of the anastomosis, ensure there is no bleeding, and an airleak test is done with the anastomosis under water. This should be done by occluding the colon about 8–10 cm upstream of the anastomosis with a bowel grasper to prevent the entire colon filling with air. The air is suctioned out and attention is turned to the rectopexy. The anastomosis should be created prior to the rectopexy to prevent trauma to the rectopexy and disrupting the sutures when the EEA stapler is passed.

9. Rectopexy is performed by suturing the lateral stalks to the sacral periosteum at the level of the sacral promontory

The rectopexy is perhaps the most difficult portion of the procedure and because of this there are several options for this approach. Regardless of how you approach this portion of the surgery the key is to affix the lateral stalks of the rectum to the periosteum of the sacral promontory in multiple loci. We recommend 3 nonabsorbable sutures in each side. We use a 2-0 Prolene suture and start on the left side progressing lateral to medial. The right side of the rectum is often easier to visualize and therefore should be simpler to suture in place once the rectum is fixed on the contralateral side.

With SILS, our approach had been to use the needle drivers and throw stitches from the lateral stalks to the sacral periosteum and tie them intracorporeally. This is still an option, but knot tying via this platform can be quite difficult. This is why we have incorporated the surgical robot into this procedure. The wristed instruments are able to articulate and enable intracorporeal knot tying without adding significant difficulty.

If you are unable to employ the surgical robot for your surgery there are still several options. Perhaps the simplest is by throwing the stitch intracorporeally, leaving the suture

very long and tying it extracorporeally while using a knot-pusher to tighten your suture. Another technique that has been described is using the laparoscopic tacking device to tack the lateral stalks to the periosteum. This can be done with either absorbable or permanent tacks. The last option employs a laparoscopic suturing device such as the Endostitch (Covidien, Sunnyvale, CA) or the Suture Assistant (Ethicon, Somerville, NJ). These devices can be quite difficult to use and it may be difficult to pass the needles through the periosteum as they are not curved, but with some familiarity a surgeon can become quite facile with these devices.

It is important, when suturing the lateral stalks to the sacrum to minimize bleeding during this portion of the surgery. Presacral veins can bleed extensively when punctured and bleeding can often be difficult to control. Often these veins can be visualized at the level of the sacral promontory and thus should be carefully avoided when throwing your

sutures. If, during the passage of your suture, bleeding is identified, it is important that you do not panic and remove the stitch. Often this bleeding can be controlled by carefully tying down the suture, effectively ligating the vessel. If this alone is not effective manual pressure for several minutes can often achieve hemostasis.

10. Abdominal wound is closed

Once the rectopexy is completed, the intra-abdominal portion of the surgery is complete. The pelvis can be irrigated and the single-incision trocar can be removed. It is often easiest to close the fascia with a series of interrupted figure-of-8 sutures and the skin can be closed with an interrupted subcuticular suture. This is achieved most effectively by starting in the deepest portion of the umbilicus and working outward.

Deborah S. Keller and Daniel P. Geisler

Procedure Steps

1. Insert single-port device at the predetermined trephine stoma site.
2. Insufflation and laparoscopic assessment of the abdomen.
3. The small bowel and omentum are moved toward left upper quadrant (for an ileostomy) or right upper quadrant (for a colostomy).
4. Run the bowel proximally and distally for a suitable limb; ensure the ideal location and proper orientation.
5. Optional division of lateral attachments.
6. Assessment of reach of bowel (for tension-free stoma).
7. Deliver the bowel through the trephine and maturation of stoma.

Tips and Tricks

- Preoperative site marking by an enterostomal therapist helps assure the best functional location for the patient's stoma. If not available, mark the patient in a sitting position, assuring the mark is in the fat mound away from skin fold and where the patient preferably wears their waistband.
- Marking multiple quadrants is also helpful, as the patient's characteristics and intra-abdominal pathology may change your original surgical plan.
- For a loop ileostomy, it may advantageous to mark the proximal and distal position of the ileum with superficial sutures to assure proper orientation when delivered for

maturation. The author's preference is to use two different types of suture with the whole team aware of the pattern – “blue to the sky (PDS), brown to the ground (chromic).”

- Assessment of adequate reach is best done by almost completely desufflating the abdomen, so that a normal distance to the abdominal wall can be measured; however, when the abdomen is insufflated, if the bowel reaches the abdominal wall at the port site without tension, reach is likely adequate.
- For an ileostomy, pull a length of at least 5 cm out to facilitate Brooking the stoma.
- Prior to extraction, attention should be given that there is no twist of the bowel and that no small bowel lies laterally to the stoma.
- For a diverting colostomy, appropriate dissection and mobilization of the sigmoid colon and proximal transverse colon are needed, as the colon is not quite as mobile as the terminal ileum.
- A distal sigmoid colostomy is preferred over a proximal transverse colostomy due to its bulkiness, risk of prolapse, and difficulty managing the appliance; it is often ideal in the super morbidly obese patient, as its upper abdomen is often easier to bring the bowel through the abdominal wall.
- To avoid complication with the stoma, assure adequate mobilization to allow for a tension-free stoma, assure no undue twist of the bowel, and assure that, once the stoma is matured, there is no likelihood for volvulization around the stoma.

Electronic Supplementary Material: The online version of this chapter (doi:[10.1007/978-3-319-63204-9_18](https://doi.org/10.1007/978-3-319-63204-9_18)) contains supplementary material, which is available to authorized users.

D.S. Keller, MS MD (✉)
Division of Colorectal Surgery, Department of Surgery,
Baylor University Medical Center, Dallas, TX, USA
e-mail: debby_keller@hotmail.com

D.P. Geisler, MD
Division of Colorectal Surgery, Department of Surgery,
Houston Methodist Hospital, Houston, TX, USA

Expanded Steps of the Operation

1. *Positioning and Insert port at predetermined trephine stoma site (supine position)*

The patient is supine with arms tucked. For stoma creation alone, the patient's legs do not need to be in lithotomy

position; if the stoma is placed for the protection of an anastomosis as part of another procedure and the patient is already in lithotomy, maintain the lithotomy position. For an ileostomy, the primary monitor is placed on the right side of the patient at the level of the hip. The operating nurses instrument table is placed between the patient's legs. There should be sufficient space to allow the operator to move from either side of the patient to between the patient's legs if necessary. For an ileostomy, the primary operating surgeon stands on the left side of the patient with the assistant standing on the patient's right, and moving to the left side, caudad to the surgeon once ports have been inserted. For a colostomy, the placement of the operator, assistant, and monitors are similar to an ileostomy, but reversed – of the primary monitor is on the left side of the patient at the level of the hip and the operator stands on the right side of the patient with the assistant standing on the patient's left, then moving to the right side, caudad to the surgeon once ports have been inserted.

A circular skin incision is made with a 15-blade scalpel or cut setting of the electrocautery at the site of the predetermined stoma. For an ileostomy, the skin disk should be approximately 2 cm or the size of a nickel. For a colostomy, the skin disk should be approximately the size of a quarter and permit 2 fingers into the peritoneal cavity. The skin disk is excised, leaving the subcutaneous fat in place. Insert Army-Navy or double-ended retractors to exposure as the incision is deepened. A longitudinal incision made in the anterior rectus sheath, exposing the rectus muscle. The rectus muscles are split and separated using a Kelly hemostat. The retractors are replaced deeper to aid exposure. The peritoneum is held with two hemostats and incised. Digital exam is performed to assure entry into the abdominal cavity. If using the Applied GelPOINT device, insert the ring and dial the ring down to fit against the abdominal wall. Insert a lap sponge into the abdomen and place the cap on the GelPOINT. If using the Medtronic SILS port, insert the lap sponge, then insert the port.

2. Insufflation and laparoscopic assessment of the abdomen

Insufflate the abdomen, insert the 30° laparoscopic camera or flexible tip camera, and survey the abdominal cavity. Be prepared to decide on the right type and location for diversion based on pathology seen during the assessment. For this reason, marking multiple sites for the possible stoma is useful.

3. *The small bowel and omentum are moved toward left upper quadrant (for an ileostomy) or right upper quadrant (for a colostomy) (Trendelenburg)*

The patient is rotated with the right side up and left side down (ileostomy) or left side up and right side down

(colostomy), with approximately 15–20° tilt to move the small bowel over to the contralateral side of the abdomen. The patient is then placed into the Trendelenburg position to allow gravitational migration of the small bowel away from the operative field. The greater omentum is reflected over the transverse colon so that it comes to lie on the stomach.

4. *Run the bowel proximally and distally for the ideal location and to assure proper orientation (Right side elevated (ileostomy), Trendelenburg)*

For an ileostomy, the small bowel is run proximally and distally, to confirm the cecum and colon proximally and to identify the ideal location for the stoma. If necessary, for a colostomy, a length of colon can be run to assure proper orientation. Two atraumatic graspers are held approximately 10 cm apart, and the bowel is elevated toward the abdominal wall, then run in a hand-over-hand approach and to assure proper orientation and location in relation to the pathology and ileocecal valve. Marking sutures can be placed laparoscopically to help maintain position.

5. *Run the bowel proximally and distally for a suitable limb; ensure the ideal location and proper orientation*

Using an atraumatic grasper, lift the proposed loop to the right (ileostomy) or left (colostomy) lower quadrant port site assuring no tension. Assessment of adequate reach is best done by almost completely desufflating the abdomen, so that a normal distance to the abdominal wall can be measured; however, when the abdomen is insufflated, if the bowel reaches the abdominal wall at the port site without tension, reach is likely adequate.

6. *Optional division of lateral attachments (Right side elevated [Ileostomy] or Left side elevated [Colostomy], Trendelenburg)*

The lateral attachments of the cecum and terminal ileum (for an ileostomy) or sigmoid and descending colon (colostomy) can be taken down for greater mobility. The terminal ileum or sigmoid, as appropriate, is grasped by the surgeon using atraumatic bowel graspers and freedom is checked toward the midline and up to the abdominal wall. The colon is grasped and retracted medially, and the lateral attachments along the white line of Toldt are divided with an energy source.

7. *Assessment of reach of bowel (for tension-free stoma)*

Recheck mobility, by assuring the terminal ileum (ileostomy) or sigmoid (colostomy) can reach the anterior abdominal

wall. The proposed stoma site is grasped by an atraumatic bowel grasper and brought up to the abdominal wall.

8. *Deliver the bowel through trephine and maturation of the stoma (supine)*

The cap of the single-port device is removed and the terminal ileum is delivered using the internal grasper and a Babcock externally to assist. Care is taken not to twist or change the orientation of the terminal ileum or colon as it is extracted; marking suture aid in confirming the proximal and distal sites. For an ileostomy, a length of at least 5 cm is externalized to facilitate Brooking the stoma. For a colos-

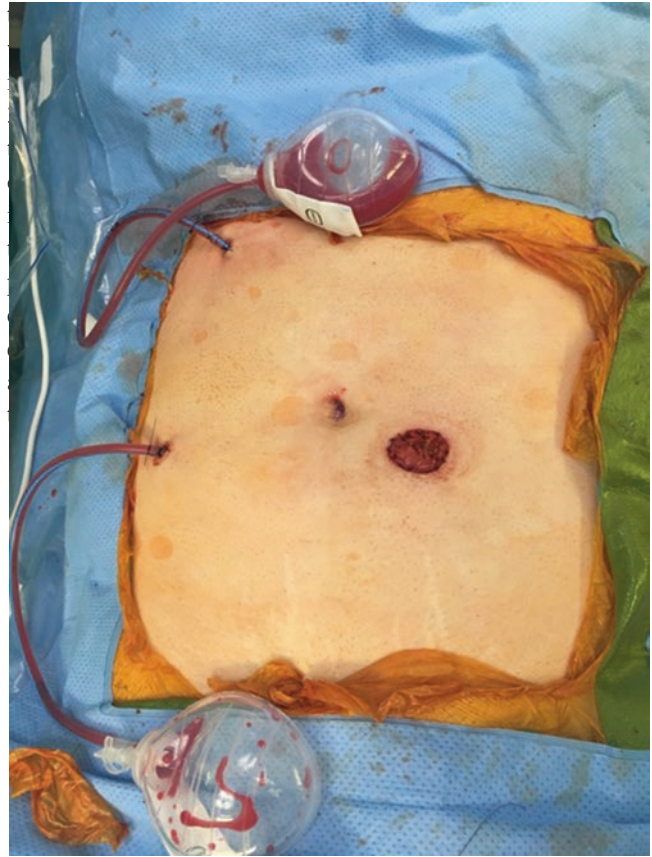


Fig. 18.1 Completed SILS Colostomy

Deborah S. Keller

Steps of the Procedure

1. Close stoma with 2-0 PDS figure-of-eight stitch.
2. Port placement: 5 mm Optiview left hypochondriac region and 5 mm port at umbilicus.
3. Identification of the afferent and efferent limbs and dissection of the hernia sac from the stoma tunnel.
4. Circumstomal incision and dissection to free matured stoma.
5. Divide mesentery and create a side-to-side stapled end anastomosis.
6. Return small bowel to the abdomen and close fascia.
7. Reinsufflate and insert laparoscopic to ensure proper orientation of the bowel and closure of the stoma site.
8. Purse-string closure of the stoma site, closure of port sites.

Tips and Tricks

- An ileostomy closure is an ideal operation for reduced port surgery; using two 5 mm ports to identify the afferent and efferent limbs and free the small bowel from the hernia sac around the stoma site will make the extra-abdominal dissection much easier.
- Use a portable ultrasound machine to identify the lateral edge of the rectus abdominis muscle; this will ensure the Optiview trocar is inserted as laterally as possible while still passing through the muscle.
- A double firing is done with the stapler to ensure a large, wide anastomosis.

Electronic Supplementary Material: The online version of this chapter (doi:10.1007/978-3-319-63204-9_19) contains supplementary material, which is available to authorized users.

D.S. Keller, MS, MD (✉)
 Division of Colorectal Surgery, Department of Surgery, Baylor University Medical Center, Dallas, TX, USA
 e-mail: debby_keller@hotmail.com

1. *Close stoma with 2-0 PDS figure-of-eight stitch (position is supine)*

After induction of general anesthesia, the stoma appliance is removed and the stoma orifice is closed with a single 2-0 PDS figure-of-eight stitch to avoid spillage. A portable ultrasound may be used to identify the lateral edge of the rectus muscle on the patient's left side; the edge is marked to ensure optimal port placement. The patient is then prepped and draped in the usual sterile fashion, and a folded Raytec sponge is placed over the sutured stoma orifice, then an Ioban is placed over the abdomen.

2. *Port placement: 5 mm Optiview left hypochondriac region and 5 mm port at umbilicus (position is supine)*

Laparoscopic access is gained with a 5 mm Optiview trocar in the left upper quadrant. The abdomen is insufflated through the Optiview trocar. Then, under direct visualization, a second trocar is placed in the umbilicus or the left iliac fossa for the camera. An additional working port can be placed in the umbilicus or the left iliac fossa

3. *Identification of the afferent and efferent limbs and dissection of the hernia sac from the stoma tunnel (position is right side elevated, reverse Trendelenburg)*

An atraumatic bowel grasper is used to run the bowel and identify the afferent and efferent limbs, assuring they are free. Scissors or an energy device is then used to sharply release the hernia sac from the ileum at the stoma tunnel. Once circumferentially freed internally, the laparoscopic instrument and camera are removed, and the pneumoperitoneum is released.

4. *Circumstomal incision and dissection to free matured stoma (position is supine)*

5. *Divide mesentery and create a side-to-side stapled end anastomosis (position is supine)*

At the proposed site of the anastomosis, the mesentery is divided, either by serially clamping, cutting, and ligating or with an energy source. Once the mesentery is cleared from the bowel, the 2 limbs are approximated in the proposed anastomotic position, and enterotomies are made on the antimesenteric surface 1–2 cm proximal to the proposed site of the end of the anastomosis. The endoscopic or linear stapler is introduced into the enterotomies and is closed. Before firing, check to assure the mesenteric side is down and the bowel lies flat in the stapler without bunching or abutting the jaw. The stapler is fired; the staple line is checked for hemostasis. A second fire is performed in the same line to create a wide anastomosis. Hemostasis is checked again. Then the side-to-side anastomosis is closed across. Before firing the stapler across the end anastomosis, assure the bowel lies flat, the corners are not rolled in, and no mesentery is incorporated. The lumen is checked for patency.

6. *Return small bowel to the abdomen and close fascia (position is supine)*

The new side-to-side end anastomosis is gently returned to the abdomen. Then, the fascia is closed with #1 PDS figure-of-eight sutures. Manually check to ensure no fascial defects.

7. *Reinsufflate and insert laparoscope to ensure proper orientation of the bowel and closure of the stoma site (position is supine)*

After the fascia is closed, the abdomen is reinsufflated and the laparoscopic camera is reinserted. Final laparoscopic exploration is performed to ensure an intact repair and no twisting of the bowel. The trocars were removed and pneumoperitoneum is released.

8. *Purse-string closure of the stoma site, closure of port sites (position is supine)*

A 3-0 Vicryl suture is used to run a purse string in the dermis to loosely reapproximate the stoma site; this allows the area to heal by secondary intention and reduce the risk of superficial site infection. Trocar site(s) is closed with 4-0 Monocryl and Dermabond.

Matthew R. Wilson, Sam Atallah, and George J. Nassif Jr

Steps to the TAMIS procedure for the local excision of rectal neoplasms

1. Proper patient selection with appropriate rectal lesions for TAMIS.
2. Patient positioning in high lithotomy position under general anesthesia.
3. Access the distal rectum with transanal multichannel port and establishment of pneumorectum.
4. Mark out appropriate resection margin of target lesion.
5. Excision of lesion beginning with distal margin and performing submucosal or full-thickness excision.
6. Closure of rectal defect.

Technical Tips and Tricks

- General endotracheal anesthesia with paralysis is essential for TAMIS.
- Positioning and setup – Prior to insertion of the TAMIS port, we recommend gentle dilation of the anal canal to facilitate proper fitting of the port. The proximal extent of the port must be placed superior to the anorectal ring.
- ALWAYS mark desired resection margins and begin the resection at distal margin, dissecting proximally. If dissection begins proximally, delivering the specimen distally will collapse the rectal lumen and obscure view.
- Distal lesions – For lesions in the upper anal canal the resection may begin distally as in a standard transanal

excision. Once the distal margin is defined and the resection is begun, the TAMIS port can then be placed to finish the resection and closure.

- Billowing – Standard unidirectional insufflation cannot adapt to changes in intra-abdominal pressure. This results in intermittent collapse of the rectal lumen – termed billowing. This can be overcome by employing high-flow, pressure-sensing insufflation. Currently the AirSeal® iFS (SurgiQuest, Millford, CT) is the only such insufflator commercially available.
- If pressure-sensing insufflation is unavailable, we recommend setting pressure between 13 and 20 mmHg and employing short bursts of suction when necessary. These two techniques can help minimize billowing.
- Smoke evacuation – One of the challenges when performing TAMIS is the accumulation of smoke in the rectal lumen when using electrocautery. Several techniques can be utilized to overcome this challenge. Continuous smoke evacuation insufflation is commercially available. Alternatively, one may set a standard laparoscopic suction irrigator to low continuous suction during cautery with good success (Video 20.1).
- Triangulation of operating instruments – As with any laparoscopic procedure, proper orientation of the working instruments is an essential part of facilitating ease of the operation. This proves challenging with all access ports are introduced through the rectum. We have found that using an angled laparoscope to be most effective for use in TAMIS. Alternatively, one may use a flexible tipped endoscope to accomplish the same task.
- Additionally, an advantage of TAMIS over TEM is the ability to interchange instruments quickly between the three working ports.
- Control of bleeding – During TAMIS, one may encounter bleeding from submucosal or mesorectal blood vessels. In this event, do not bury a monopolar instrument tip into the vessel to cauterize. Rather, grab the bleeding vessel with a laparoscopic instrument and apply more precise cautery.

Electronic Supplementary Material: The online version of this chapter (doi:10.1007/978-3-319-63204-9_20) contains supplementary material, which is available to authorized users.

M.R. Wilson, MD, FACS • S. Atallah, MD, FACS, FASCRS (✉)
G.J. Nassif Jr, DO, FACS
Department of Colon & Rectal Surgery, Florida Hospital,
242 Loch Lomond Dr., Winter Park, FL 32792, USA
e-mail: atallah@post.harvard.edu

This will control bleeding more quickly and avoid potential injury to adjacent structures (Video 20.2).

- Specimen extraction – Prior to completing excision, grasp the specimen with your instrument and plan to immediately extract through the TAMIS port. If the specimen resection is completed without proper grasping, the insufflation may cause the specimen to travel proximally in the rectum, making extraction difficult.

Expanded Steps of the Procedure

1. *Proper patient selection with appropriate rectal lesions for TAMIS*

Transanal Minimally Invasive Surgery (TAMIS) is a technique first developed in 2009 by Drs. Atallah, Larach, and Albert for local excision of well-selected rectal neoplasia [1]. TAMIS represents an ingenious advance to the technique of Transanal Endoscopic Microsurgery (TEM) initially described by Buess in 1983 [2–7]. The indications for TAMIS are the same as for TEM [8]. They include resection of benign rectal neoplasms and, for curative-intent surgery, well-selected T1 cancers, with histologically favorable features, where the risk of nodal metastasis is low [9]. The indication for TAMIS may also be broadened to include local excision of cT0 lesions in patients with locally advanced rectal cancer after neoadjuvant therapy for the purpose of confirming mural cPR (ypT0) [10–12]. This can be considered a valid option since the risk of occult node positivity for ypT0 lesions is predictably low, at 3–6% [13–15]. Additionally, TAMIS may be used in patients deemed medically unfit for radical excision.

TAMIS should not be considered as an alternative to standard oncologic resection for locally advanced tumors. The lesion should not occupy more than 40% of the luminal diameter. While TAMIS has been successfully performed in the lower, mid, and upper rectum, it is perhaps best suited for mid and lower rectal lesions, providing a less morbid alternative to anterior resection or APR in well-selected patients.

Preoperative Workup

All patients who have been selected to undergo TAMIS excision must have also undergone colonoscopy to assess for synchronous lesions and to obtain a biopsy of the rectal lesion. For malignant, early-stage tumors of the rectum, endorectal ultrasound is performed to determine preoperative T and N stage. Pelvic 3-Tesla (3T) MRI is a valid alternative. Currently, only patients with histologically favorable, early-stage malignancy (uTis or uT1uN0M0 cancer) are con-

sidered candidates for TAMIS. More advanced lesions require standard resection (APR vs. LAR) except in patients who are not medically fit to undergo major surgery. CEA level and CT body imaging is also performed to assess for tumor metastasis. Patients with stage IV disease or locally advanced lesions are not candidates for TAMIS unless the objective is palliation.

Operating Room

Patient preparation includes full mechanical bowel prep, flexible sigmoidoscopy prep, or enema prep according to surgeon preference. American College of Surgeons SCIP protocols are followed for administration of parenteral antibiotics.

2. *Patient positioning in high lithotomy position under general anesthesia*

Patients should be positioned dorsal lithotomy in candy-cane stirrups. This is preferred, regardless of the position of the lesion in the rectal wall. The operating room should be fitted with standard laparoscopic equipment, including light source, video monitor, and CO₂ insufflator. Our preferred instruments are a combination suction irrigation/ slightly angled needle tip or hooked tip monopolar and Maryland grasper. General anesthesia with muscle paralysis is preferred to avoid collapse of the rectal wall which often occurs with diaphragmatic excursion.

3. *Access the distal rectum with transanal multichannel port and establishment of pneumorectum*

Either a single-incision laparoscopy surgery port (SILS Port, Covidien) or a GelPOINT Path™ port (Applied Medical, Rancho Santa Margarita, CA, USA) is deployed into the anal canal with lubricant and gentle maneuvering. These ports are seated with the inner lip just above the anorectal ring. Once in place, three cannulas allow access to the rectum so that TAMIS can be performed (Fig. 20.1). Using a standard laparoscopic tower, pneumorectum with high-flow cycled CO₂ is established with the pressure maximum set to 18 mmHg. This is achieved via an insufflation-dedicated cannula.

The current TAMIS platforms allow use of both 5 and 10 mm devices. Once the port is placed, standard laparoscopic instruments, including graspers, thermal energy devices, and needle drives, can be used to perform the procedure. A 5 mm 30° or 45° angled camera lens or flexible tip camera is inserted, and triangulation of the instrument facilitates the surgical dissection.

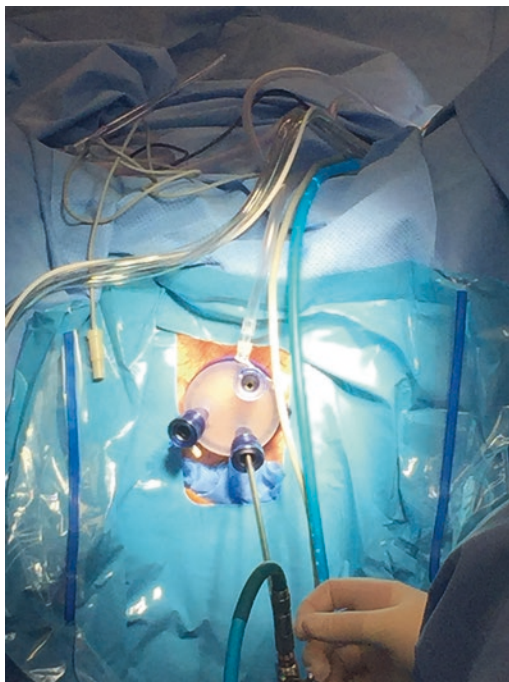

Fig. 20.1 The transanal placement of a TAMIS port is shown; this platform provides three 10 mm cannulas and insufflation is established using standard laparoscopic insufflators, or a wave-less trocar system (not shown)

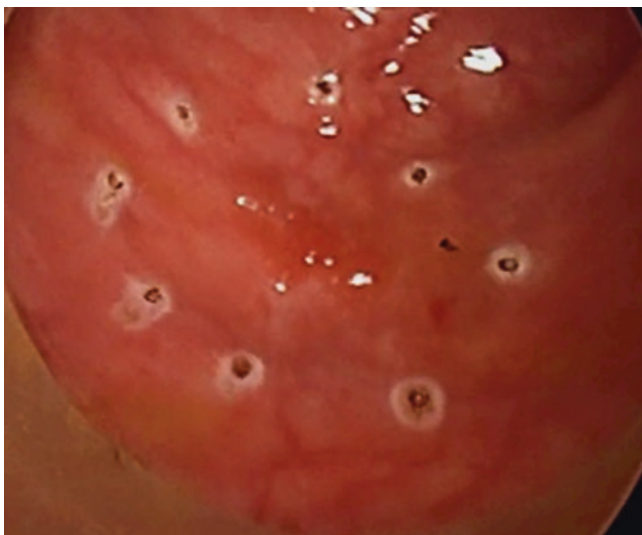

Fig. 20.2 Electrocautery has been used to delineate the excision border circumferentially. This is typically the first operative step for TAMIS

4. Mark out appropriate resection margin of target lesion

Resection using TAMIS is typically performed by demarcating the perimeter of the lesion, providing an appropriate margin (Fig. 20.2). This is done using electrocautery. This step is key to assure not only adequate margins but to keep from excess dissection.

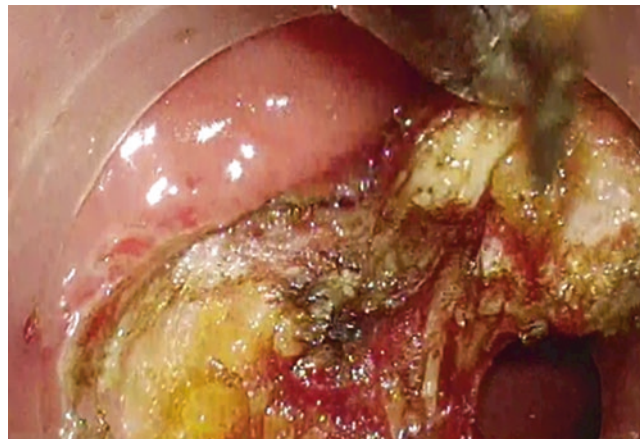


Fig. 20.3 The process of TAMIS for local excision allows complete excision of the rectal wall with adjacent adipose tissue (a part of the mesorectum)

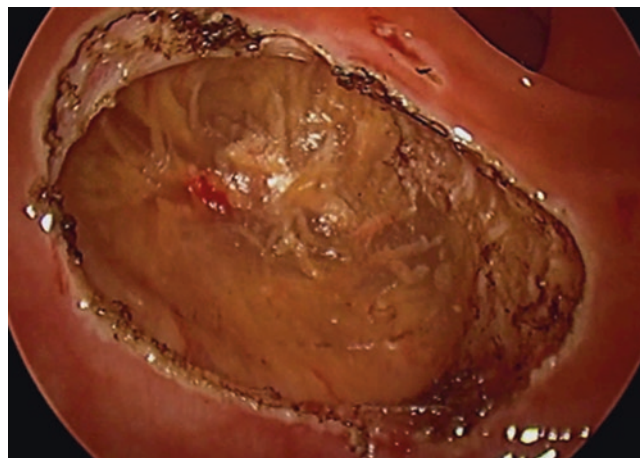


Fig. 20.4 View of rectal wall defect after full-thickness TAMIS local excision

5. Excision of lesion beginning with distal margin and performing submucosal or full-thickness resection

The specimen may be tented gently using a grasper and electrocautery on a spatula tip or needle tip allows for full-thickness excision. We recommend beginning with the distal margin and dissecting proximally in order to avoid obscuring the view during dissection (Fig. 20.3). Importantly, the CO₂ insufflation provides a natural “pneumo-dissection,” thereby augmenting the ease and clarity of local excision using TAMIS. Using this approach, TAMIS permits for margin-negative full-thickness local excision and allows for a portion of the mesorectum to be removed en bloc with the specimen in the majority of cases (Fig. 20.4). Once the excision has been completed, it can be retrieved by removing the SILS port, or by simply removing the lid of the GelPOINT path platform. Depending on surgeon discretion, the specimen may be sent to pathology intraoperatively, so that clear margins can be established.

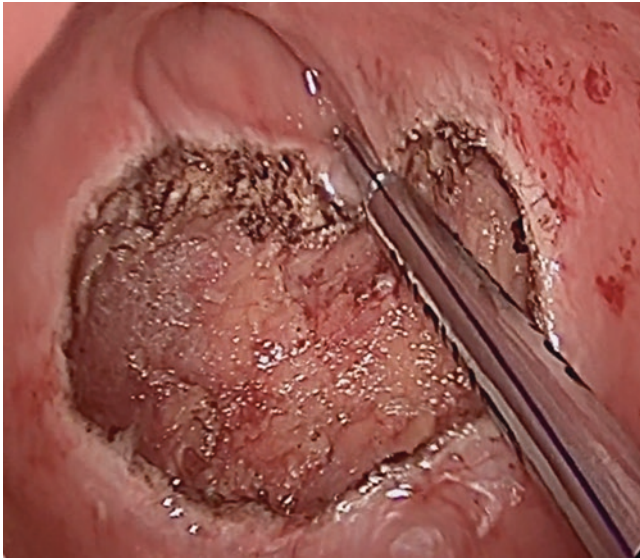


Fig. 20.5 The rectal neoplasm has been excised and an automated 5 mm suturing device is utilized to re-approximate the rectal wall and close the excision defect

6. Closure of rectal defect

Next, the TAMIS platform is reintroduced and suturing of the rectal wall defect is performed, typically with absorbable suture. Securing knots intraluminally is done with the help of a standard knot pusher or metal split shots. Alternatively, automated suturing devices such as the EndoStitch (Covidien) or RD 180 (LSI Solutions) can be used to perform endoluminal suturing. When coupled with Lapra-TY (Ethicon) or 5 mm TK (LSI Solutions), the suture can be secured without intraluminal knot tying (Fig. 20.5). Generally, it is preferred to close the rectal wall defects after excision and this should be done transversely to prevent luminal narrowing. After completion of suturing, we often rinse the surgical site with a Betadine-containing fluid for additional antimicrobial effect (Fig. 20.6).

Postoperative Care

One advantage to transanal resection using TAMIS is that post-op pain is minimal. Patients are typically discharged the day of surgery or can be observed for 23 h depending on surgeon preference. Postoperative antibiotics may be administered for patients with previous radiation therapy. There are no dietary restrictions. Follow-up is at 2 and 6 weeks. Rigid proctoscopy is performed as part of the clinical exam to assess healing. Patients with malignant lesions who underwent a satisfactory TAMIS excision are followed according to National Comprehensive Cancer Network guidelines depending on final pathology. For patients with excised specimens which reveal more advanced disease or histologically unfavorable features, standard oncologic resection is recommended (Video 20.3).

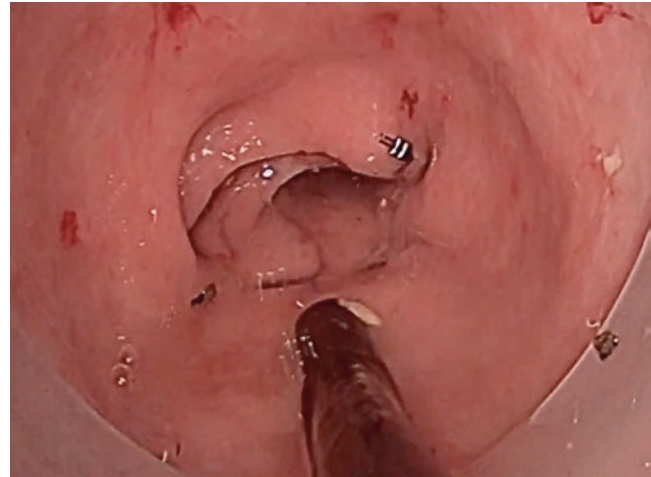


Fig. 20.6 Closure after TAMIS local excision is shown demonstrating complete re-approximation of the rectal wall, lumen patency is assessed and the an irrigation with sterile saline or water is used

References

1. Atallah S, Larach S, Albert M. Transanal minimally invasive surgery: a giant leap forward. *Surg Endosc.* 2010;24(9):2200–5. Epub 21 Feb 2010
2. Buess G, Theiss R, Gunther M, Hutterer F, Pichlmaier H. Transanal endoscopic microsurgery. *Leber Magen Darm.* 1985;15(6):271–9.
3. Buess G, Kipfmüller K, Ibalá R, Heintz A, Hack D, Braunstein S, Gabbert H, Junginger T. Clinical results of transanal endoscopic microsurgery. *Surg Endosc.* 1988;2(4):245–50.
4. Buess G, Mentges B, Manncke K, Starlinger M, Becker HD. Technique and results of transanal endoscopic microsurgery in early rectal cancer. *Am J Surg.* 1992;163(1):63–70.
5. Saclarides TJ, Smith L, Ko ST, Orkin B, Buess G. Transanal endoscopic microsurgery. *Dis Colon Rectum.* 1992;35(12):1183–91.
6. Lev-Chelouche D, Margel D, Goldman G, Rabau MJ. Transanal endoscopic microsurgery: experience with 75 rectal neoplasms. *Dis Colon Rectum.* 2000;43(5):662–7.
7. Cataldo PA. Transanal endoscopic microsurgery. *Surg Clin North Am.* 2006;86(4):915–25.
8. Qi Y, Stoddard D, Monson JR. Indications and techniques of transanal endoscopic microsurgery (TEMs). *J Gastrointest Surg.* 2011;15(8):1306–8.
9. Nascimbeni R, Burgart LJ, Nivatvongs S, Larson DR. Risk of lymph node metastasis in T1 carcinoma of the colon and rectum. *Dis Colon Rectum.* 2002;45(2):200–6.
10. Garcia-Aguilar J, Shi Q, Thomas CR Jr, Chan E, Cataldo P, Marcet J, Medich D, Pigazzi A, Oommen S, Posner MC. A phase II trial of neoadjuvant chemoradiation and local excision for T2N0 rectal cancer: preliminary results of the ACOSOG Z6041 trial. *Ann Surg Oncol.* 2012;19(2):384–91.
11. Kundel Y, Brenner R, Purim O, Peled N, Idelevich E, Fenig E, Sulkes A, Brenner B. (2010) Is local excision after complete pathological response to neoadjuvant chemoradiation for rectal cancer an acceptable treatment option? *Dis Colon Rectum.* 2010;53(12):1624–31.
12. Kim CJ, Yeatman TJ, Coppola D, Trotti A, Williams B, Barthel JS, Dinwoodie W, Karl RC, Marcet J. Local excision of T2 and T3 rectal cancers after downstaging chemoradiation. *Ann Surg.* 2001;234(3):352–8. discussion 358–9.

13. Bedrosian I, Rodriguez-Bigas MA, Feig B, Hunt KK, Ellis L, Curley SA, Vauthey JN, Delclos M, Crane C, Janjan N, Skibber JM. (2004) Predicting the node-negative mesorectum after preoperative chemoradiation for locally advanced rectal carcinoma. *J Gastrointest Surg.* 2004;8(1):56–62.
14. Bujko K, Nowacki MP, Nasierowska-Guttmejer A, Kepka L, Winkler-Spytkowska B, Suwiński R, Oledzki J, Stryczyńska G, Wiczorek A, Serkies K, Rogowska D, Tokar P. Prediction of mesorectal nodal metastases after chemoradiation for rectal cancer: results of a randomised trial: implication for subsequent local excision. *Radiother Oncol.* 2005;76(3):234–40.
15. Yeo SG, Kim DY, Kim TH, Chang HJ, Oh JH, Park W, Choi DH, Nam H, Kim JS, Cho MJ, Kim JH, Park JH, Kang MK, Koom WS, Kim JS, Nam TK, Chie EK, Kim JS, Lee KJ. Pathologic complete response of primary tumor following preoperative chemoradiotherapy for locally advanced rectal cancer: long-term outcomes and prognostic significance of pathologic nodal status (KROG 09-01). *Ann Surg.* 2010;252(6):998–1004.

Index

- A**
Alvimopan, 2
- C**
Colorectal cancer
 apical lymph nodes, 44
 IMA ligation, 45
 resection, 43
 staging, treatment and prognosis, 44
Commercial platforms
 applied GelPOINT® Port, 31
 benefits and drawbacks, 31
 Covidien SILS® Port, 31
 GelSeal® cap, 31
 Glove port, 32
 Olympus QuadPort®, 31, 32
 SILS™ Port, 31
 TriPort/QuadPort, 31
Cumulative sum (CUSUM) analysis, 30
- D**
Dissection strategies, 37–38
 anatomical considerations, 36
 Crohn's ileocolic phlegmon, 41
 ergonomics/limitations, 36
 laparoscopic procedures, 36
 medial vs. lateral approach, 36–37
 polyp cancers and small colonic tumours, 41
 rectum mobilization, 40, 41
 right colon mobilization (*see* Right colon mobilization)
 sigmoid phlegmon, 41
 single-port access device, 35, 36
 transverse colonic mobilization, 39, 40
- E**
Eagle Sign, 85
Enhanced recovery after surgery (ERAS), 1, 5
Enhanced recovery pathway, colorectal surgery
 accelerated patient recovery, 1, 4
 alvimopan, 2
 ambulation, 5
 anesthesia and multimodal analgesia, 3, 4
 bowel preparation, antibiotics, 1–2
 discharge criteria, 5
 fast-track development, 1
 feeding, 4
 GDFT, 3
 incentive spirometry, 5
 laparoscopy, 3
 multimodal analgesia, 2, 4
 NG tubes, 3, 4
 normothermia, 3
 nutrition, 2
 patient education and expectations, 1
 peritoneal drains, 3
 preoperative intravenous antibiotics, 2
 urinary catheters, 4–5
 venous thromboembolism prophylaxis, 2–3
ERAS. *See* Enhanced recovery after surgery (ERAS)
Ergonomic challenges
 curved laparoscopic instruments, 30
 experience and technical tricks, 29
 extra-long/bariatric length instruments, 30
 instruments and operative team, 29
 laparoscopic camera with right-angle adaptor, 30
 Olympus EndoEYE® Flex 3D Scope, 30
 operative time and CUSUM analysis, 30
 surgeons, 30
 “sword-fighting” effect, 30
Extended right hemicolectomy, 51
- G**
GDFT. *See* Goal-directed fluid therapy (GDFT)
GelPort®, 31
Glove-port, 31, 32, 36
Goal-directed fluid therapy (GDFT), 3
- H**
Hand-assisted laparoscopic surgery (HALS), 72, 74
Hepatic flexure
 abdominal wall dissection, 53
 anatomy, 51
 Gerota's fascia and retroperitoneum, 53
 lateral peritoneal reflection, 53
 lesser sacs, 53
 ligamentous anatomy, 51–52
 optimize external working space, 52
 optimize internal working space, 52, 53
 peritoneal dissection, 53
 port placement, 52
 vascular anatomy, 52
High ligation IMA
 colorectal cancer patients, 44
 complications, 45
 iliac vessels, 47
 lymph nodes, 44
 medial to lateral approach, 46

- High ligation IMA (*cont.*)
 oncologic benefits, limitations, 45
 patient's outcome, 45
 positioning and single-incision port placement, 46
 presacral fascia, 46
 rectosigmoid mesentery, 46
 selective lymph node dissection, 47
 surgeons, 44
 Toldt's fascia, 47
 vessel ligation, 48
- I**
- IBD. *See* Inflammatory bowel disease (IBD)
- Ileal pouch-anal anastomosis, 91–94
- Ileoanal anastomosis
 hepatic flexure takedown, 93
 J configuration, 91
 left hemicolectomy, 93
 loop ileostomy, 94
 procedure, 91
 proctectomy, 93
 proctocolectomy, 91
 right hemicolectomy, 93
 single-port placement, 92
 small bowel syndrome, 93
 specimen extraction and J-pouch creation, 93
 splenic flexure takedown, 92
- Ileocolic resection, 52
- Ileostomy, 109–110
- Incisionless surgery. *See* Single-incision laparoscopic colorectal surgery (SILS)
- Inferior mesenteric artery (IMA)
 anatomy, 44
 description, 43
 high ligation (*see* High ligation IMA)
 risks, 43
- Inferior mesenteric artery ligation, 85
- Inflammatory bowel disease (IBD), 14, 15
- Intracorporeal anastomosis, 86, 89
- Intraoperative conversions
 abdominal entry, 73
 adhesions, 74
 bleeding, 71
 camera disciple, 71
 CLASSIC trial, 73
 dissection and anastomosis, 71
 diverticular disease, 74
 HALS, 74
 hemorrhage, 71
 meta-analysis, 72
 multi-port, hand assist, and laparotomy, 72
 operating room setup, 72
 pneumoperitoneum, 73
 tumors, radiation, and pathology, 74
 visualization, 71, 72
- L**
- Laparoendoscopic single-site surgery (LESS), 29
- Laparoscopic rectopexy. *See* Rectopexy
- Lateral-to-medial dissection, 36–39
- Left hemicolectomy/sigmoid resection
 anastomosis, 86
 descending/sigmoid colon, medial dissection, 85
 intracorporeal anastomosis, 86
 omentum over transverse colon, 84
 peritoneum at pelvic brim, 85
 pfannenstiel and umbilical incision, 86
 port insertion, 84
 rectosigmoid anterolateral, 85
 rectosigmoid junction, 85, 86
 splenic flexure, 85
 superior rectal artery, 85
 vascular division, 85
 vascular isolation, 85
- LESS. *See* Laparoendoscopic single-site surgery (LESS)
- Low ligation
 anastomotic leak and failure, 44
 colorectal cancer patients, 44
 HIGHFLOW trial, 45
 surgeons, 45
- M**
- Medial-to-lateral dissection, 37, 39
- Multi-port laparoscopy surgery (MPLS), 72–74
- N**
- Nasogastric (NG) tubes, 3, 4
- Natural orifice transluminal endoscopic surgery (NOTES), 29, 64
- NG tubes. *See* Nasogastric (NG) tubes
- Nonsteroidal anti-inflammatory drugs (NSAIDs), 4
- Normothermia, 3
- NOTES. *See* Natural orifice transluminal endoscopic surgery (NOTES)
- P**
- Patient selection
 antibiotics, 12
 colon cancer resection, 16
 COST and CLASICC I and II trials, 9
 curvilinear instruments, 10
 diverticular disease, 15
 feasibility, 11
 IBD, 14, 15
 indications, 10
 inflammatory disease, 14, 15
 laparoscopic skill, 10
 laparoscopic surgery, 16
 low BMIs, 10
 malignancy, 15
 minimally invasive surgery (MIS), 9–16
 multi-port laparoscopy, 9
 obesity, 12, 13
 patient factors, 10
 personal confidence, competence, and experience, 10
 preoperative planning, 10–12
 revised cardiac risk index, 12
 safety and feasibility, 16
- Port placement
 positioning, 25, 26
 SILS +1 incision, 26, 27
 stoma site, 27
 umbilical incision, 26
 umbilical placement, 26
- Purse-string closure, stoma, 110

R

Rectal cancer, 44, 45

Rectopexy

- abdominal wound, 104
- description, 101
- dissection, superior rectal artery, 102
- distal purse string and EEA anvil, 103
- EEA stapler, 103
- linear stapler, sigmoid colon, 102
- positioning and equipment setup, 102
- posterior dissection, levators, 103
- sacral periosteum and promontory, 103, 104
- sigmoid colon, single-incision port, 103
- single-incision platform, 102

Rectum mobilization

- Denonvilliers' fascia, 40
- medial-to-lateral approach, 40
- posterior-lateral TME dissection, 40
- SILS colorectal surgery, 40
- Waldeyer's fascia, 40

Reduced port laparoscopy, ileostomy, 109

Restorative proctocolectomy, 91, 94

Right colon mobilization

- lateral approach, 37
- medial approach, 37, 38

Right hemicolectomy, 51

- abdomen, re-insufflation and final examination, 81
- anastomosis, 77, 78
- close ports/incisions, 81
- colotomy and enterotomy, 81
- hepatic flexure, 79
- identification and isolation, ileocolic pedicle, 78
- ileocolic anastomosis, 80, 81
- ileocolic attachments, 80
- ileocolic pedicle, 77
- lesser sac, 79
- middle colic artery, 79
- procedure, 77
- retroperitoneal plane, 79
- single port device, umbilicus, 78
- terminal ileum, 80
- Toldt's fascia, 80
- transverse colon mesentery, 78
- window, 79

Robotic rectopexy. *See* Rectopexy

Robotic single-incision surgery

- rectopexy, 102

S

Sigmoid colon cancer, 43, 44, 46

Sigmoid, left colon and splenic flexure mobilization

- lateral approach, 38
- medial approach, 38, 39

SILS. *See* Single-incision laparoscopic colorectal surgery (SILS)

SILS +1 technique, 84

SILS +1 low anterior resection vs. straight SILS, 95–100

SILS Port, 26, 27, 31, 32, 36, 41, 42, 46, 77, 78, 80, 83, 88, 92, 96, 106, 112, 113

Single port access (SPA), 29

Single-incision laparoscopic colectomy. *See* Single-incision laparoscopic colorectal surgery (SILS)

Single-incision laparoscopic colorectal surgery (SILS)

- advantages, 19
- anastomosis, 89
- benefits, 29

close umbilical incision, 89

cholecystectomy, 29 (*see also* Commercial platforms)

equipment

- articulating instruments, 22
- camera options, 20
- crowding/clashing, instruments, 21
- extracorporeal sutures and magnetic retraction, 22
- technical difficulties, 22
- triangulation, 22
- vessel sealing devices, 22
- visualization challenges, 20
- wound protector, 23 (*see also* Ergonomic challenges)

intracorporeal anastomosis, 89

intraoperative conversions, 71–72

mature stoma, 90

multiport access and specimen extraction, 19

omentum over transverse colon, 88

patient positioning, 23

peritoneum at pelvic brim, 88

port insertion, 87

rectopexy, 101–104

rectosigmoid junction mobilization, 89

retroperitoneal plane, 88

room set up, 19, 20

sacral promontory, 88

splenic flexure, 88, 89

types, 29

vascular division, 88

vascular isolation, 88

Single-port laparoscopy, 91, 94

SPA. *See* Single port access (SPA)

Splenic flexure mobilization

detrimental to distal colonic perfusion, 56

gastropancreatic adhesions, 57

lateral to medial approach, 56, 57

mesocolic vasculature, 56

patient positioning

- laparoscopic monitors, 58
- lateral component, 60, 61
- Lloyd-Davis position, 57
- medial to lateral dissection, 58–61
- omentum and small bowel, 57, 58
- port placement, 58
- supramesocolic approach, 60–62

single-port colonic surgery, 56

surgeons, 55

tension-free anastomosis, 56

Stoma, incisionless surgery

colostomy, 106

ileostomy, 105–107

T

TAMIS. *See* Transanal minimally invasive surgery (TAMIS)

TME. *See* Total mesorectal excision (TME)

Total colectomy, 51

Total mesorectal excision (TME)

- access, peritoneal cavity, 66
- advantages, laparoscopic approach, 64
- complexity, colorectal surgery, 64
- description, 63
- equipment, 65
- inferior mesenteric vessels, 67
- MLS and laparotomy, 65
- mobilization of left colon, 66–67
- patient positioning, 65

Total mesorectal excision (TME) (*cont.*)
 patient preparation, 64–65
 patient selection, 64
 preoperative evaluation, 64
 rectal mobilization, 68
 rectal transection, 68–69
 SILS sphincter-saving surgery, 65
 specimen and intracorporeal anastomosis, 69
 splenic flexure, 67, 68
 transanal, 65, 66
Transanal minimally invasive surgery (TAMIS)
 billowing, 111
 bleeding, 111
 distal margin and full-thickness
 excision, 113
 distal rectum, 112
 electrocautery, 113

 patient positioning, general anesthesia, 112
 patient selection, 112
 pneumorectum, 112
 positioning and setup, 111
 procedure, 111
 rectal defect, 114
 smoke evacuation, 111
 specimen extraction, 112
Transverse colonic mobilization
 lateral approach, 39, 40
 medial approach, 39, 40
 medial-to-lateral dissection, 39
 non-expert laparoscopists, 39

V

Vessel skeletalisation, 41