

Bikas Bhattacharyya

Step by Step[®] Laser in Ophthalmology

JAYPEE



With Photo CD-ROM

www.Ebook777.com

Step by Step[®] Laser in Ophthalmology



System requirement:

- Windows XP or above
- Power DVD player (Software)
- Windows media player 10.0 version or above (Software)

Accompanying Photo CD ROM is playable only in Computer and not in DVD player.

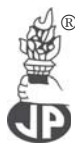Kindly wait for few seconds for Photo CD to autorun. If it does not autorun then please do the following:

- Click on my computer
- Click the **drive labelled JAYPEE** and after opening the drive, kindly double click the file **Jaypee**

Step by Step[®] **Laser in Ophthalmology**

Bikas Bhattacharyya

MBBS (Hons) MS (Ophthal) DO
Former AIOS Research Fellow
LV Prasad Eye Institute, Hyderabad
Andhra Pradesh, India
Consultant Eye and Laser Surgeon
Apollo Gleneagles Hospitals, Kolkata
Apollo Heart Centre, Gariahat, Kolkata
SN Pandit Hospital, Kolkata
Wockhardt Medical Centre
Kolkata, West Bengal, India



JAYPEE BROTHERS MEDICAL PUBLISHERS (P) LTD

New Delhi • Ahmedabad • Bengaluru • Chennai • Hyderabad • Kochi
Kolkata • Lucknow • Mumbai • Nagpur • St Louis (USA)

Published by

Jitendar P Vij

Jaypee Brothers Medical Publishers (P) Ltd

Corporate Office

4838/24 Ansari Road, Daryaganj, **New Delhi** - 110002, India, Phone: +91-11-43574357

Registered Office

B-3 EMCA House, 23/23B Ansari Road, Daryaganj, **New Delhi** - 110 002, India

Phones: +91-11-23272143, +91-11-23272703, +91-11-23282021

+91-11-23245672, Rel: +91-11-32558559, Fax: +91-11-23276490, +91-11-23245683

e-mail: jaypee@jaypeebrothers.com, Website: www.jaypeebrothers.com

Branches

- 2/B, Akruiti Society, Jodhpur Gam Road Satellite
Ahmedabad 380 015, Phones: +91-79-26926233, Rel: +91-79-32988717
Fax: +91-79-26927094, e-mail: ahmedabad@jaypeebrothers.com
- 202 Batavia Chambers, 8 Kumara Krupa Road, Kumara Park East
Bengaluru 560 001, Phones: +91-80-22285971, +91-80-22382956, 91-80-22372664
Rel: +91-80-32714073, Fax: +91-80-22281761 e-mail: bangalore@jaypeebrothers.com
- 282 IIIrd Floor, Khaleel Shirazi Estate, Fountain Plaza, Pantheon Road
Chennai 600 008, Phones: +91-44-28193265, +91-44-28194897, Rel: +91-44-32972089
Fax: +91-44-28193231 e-mail: chennai@jaypeebrothers.com
- 4-2-1067/1-3, 1st Floor, Balaji Building, Ramkote Cross Road,
Hyderabad 500 095, Phones: +91-40-66610020, +91-40-24758498
Rel: +91-40-32940929, Fax: +91-40-24758499 e-mail: hyderabad@jaypeebrothers.com
- No. 41/3098, B & B1, Kuruvi Building, St. Vincent Road
Kochi 682 018, Kerala, Phones: +91-484-4036109, +91-484-2395739
+91-484-2395740 e-mail: kochi@jaypeebrothers.com
- 1-A Indian Mirror Street, Wellington Square
Kolkata 700 013, Phones: +91-33-22651926, +91-33-22276404
+91-33-22276415, Rel: +91-33-32901926, Fax: +91-33-22656075
e-mail: kolkata@jaypeebrothers.com
- Lekhraj Market III, B-2, Sector-4, Faizabad Road, Indira Nagar
Lucknow 226 016 Phones: +91-522-3040553, +91-522-3040554
e-mail: lucknow@jaypeebrothers.com
- 106 Amit Industrial Estate, 61 Dr SS Rao Road, Near MGM Hospital, Parel
Mumbai 400 012, Phones: +91-22-24124863, +91-22-24104532,
Rel: +91-22-32926896, Fax: +91-22-24160828
e-mail: mumbai@jaypeebrothers.com
- "KAMALPUSHPA" 38, Reshimbag, Opp. Mohota Science College, Umred Road
Nagpur 440 009 (MS), Phone: Rel: +91-712-3245220, Fax: +91-712-2704275
e-mail: nagpur@jaypeebrothers.com

USA Office

1745, Pheasant Run Drive, Maryland Heights (Missouri), MO 63043, USA

Ph: 001-636-6279734

e-mail: jaypee@jaypeebrothers.com, anjulav@jaypeebrothers.com

Step by Step® Laser in Ophthalmology

©2009, Jaypee Brothers Medical Publishers

All rights reserved. No part of this publication and photo CD-ROM should be reproduced, stored in a retrieval system, or transmitted in any form or by any means: electronic, mechanical, photocopying, recording, or otherwise, without the prior written permission of the author and the publisher.

This book has been published in good faith that the material provided by author is original. Every effort is made to ensure accuracy of material, but the publisher, printer and author will not be held responsible for any inadvertent error(s). In case of any dispute, all legal matters are to be settled under Delhi jurisdiction only.

First Edition: **2009**

ISBN 978-81-8448-607-0

Typeset at JPBMP typesetting unit

Printed at



*Dedicated
To
Mount Hood and Oregon State*

PREFACE

The advent of Lasers in Ophthalmology has given the Ophthalmologists a greater additional therapeutic choice. The younger generation of Ophthalmologists should explore and master laser procedures.

In my book *Step by Step Laser in Ophthalmology*, I have tried to simplify the different common Laser procedures in a step-by-step fashion.

The book is divided into 4 (four) sections and each section is supplemented by drawings and color photographs. Every attempt is made to make this book precise and ready reckoner particularly for the beginners. Critical to the success of this book are the relevant illustrations (schematic drawings and color photographs).

Section one deals with the laser application of the retina and choroids. After giving brief practical considerations on laser application, I have gone onto the various laser surgery techniques on the retina and choroids. Section two deals with the laser application in glaucoma and on iris. Section three deals with the laser application on lens and pupillary area. Section four deals with the laser application on the vitreous.

I hope that my humble efforts should prove successful in helping the beginners in laser. However, certain inaccuracies may arise for which I apologize sincerely.

Any suggestions and comments on the book would be greatly appreciated.

Bikas Bhattacharyya

E-mail: drbhattacha_bikas@yahoo.co.in

ACKNOWLEDGEMENTS

Encouraging personal communications from Dr TP Das and Dr George Link Spaeth on my book "Clinical Applications: YAG Laser (Ophthalmology)" greatly inspired me to author a comprehensive book on common laser applications in step-by-step format.

Next, I would like to thank Shri Jitendar P Vij (Chairman and Managing Director) of Jaypee Brothers Medical Publishers (P) Ltd, New Delhi for his confidence in my humble efforts and publishing my third book.

Critical to the success of this book are the figures and tables reprinted with permission from Jaypee Brothers Medical Publishers from their publications. I sincerely thank them for their support.

I would especially like to thank Mrs Jamie Nguyen of Ocular Instruments, Bellevue, USA for providing me with the images and specifications of their contact laser lenses for reprint.

I would also like to thank Mr Tim Warrell of Volk Optical Inc Mentor, USA for providing me with the images and specifications of their contact laser lenses for reprint.

I would specially like to thank Mr Anup Bhowmick for some schematic diagrams he had so carefully drawn.

I would also like to thank my colleagues at SN Pandit Hospital for their continued encouragement.

Finally, I would like to thank my wife Sujaya, son Vinit and daughter Barnali for all the patience and support they have given me.

CONTENTS

Section One: Laser Surgery of the Retina and Choroid

1. Practical Considerations—Laser Application	3
2. Panretinal Photocoagulation (PRP) in Diabetic Retinopathy	21
3. Photocoagulation (Focal/Grid) in Diabetic Maculopathy	35
4. Photodynamic Therapy (PDT)	45
5. Transpupillary Thermotherapy (TTT)	53
6. Photocoagulation in Peripheral Retinal Degenerations and Tears	59
7. Photocoagulation in Peripheral Chorioretinal Tumors	67
I. Angiomas Retinae	68
II. Retinoblastoma	72
III. Malignant Melanoma	76
8. Photocoagulation in Retinal Venous Occlusion	81
9. Photocoagulation in Miscellaneous Retinal Diseases	89
I. Retinal Vasculitis	90
II. Central Serous Choroidopathy	94
III. Retinopathy of Prematurity	97

Section Two: Laser Surgery in Glaucoma and on Iris

10. Argon Laser Trabeculoplasty (ALT)	107
11. Selective Laser Trabeculoplasty (SLT)	115
12. Argon Laser Iridotomy	123
13. Nd: YAG Laser Iridotomy	129
14. Laser Peripheral Iridoplasty(LPI)/ Gonioplasty	137
15. Argon Laser Pupiloplasty/Photomydriasis	143

16. Nd:YAG Photomydriasis/Iridohyaloid Synechialysis	149
17. Nd: YAG Coreoplasty	153
18. Nd: YAG Persistent Hyperplastic Pupillary Membranectomy	159
19. Nd: YAG Anterior Hyaloidectomy and Cyclophotocoagulation	165

Section Three: Laser Surgery on Lens and in Pupillary Area

20. Nd: YAG Posterior Capsulotomy	173
21. Nd: YAG Sweeping	195
22. Nd: YAG Corticolysis	199
23. Nd: YAG Membranectomy	203
24. Miscellaneous Anterior Segment Applications	207

Section Four: Laser Surgery on Vitreous

25. Nd: YAG Anterior Segment Vitreolysis	217
26. Nd: YAG Posterior Segment Vitreolysis	223
<i>Index</i>	231



Section One

**Laser Surgery of the
Retina and Choroid**

CHAPTER 1

Practical Considerations— Laser Application

Laser (an abbreviation for Light Amplification by Stimulated Emission of Radiation) is the equipment capable of emitting a powerful, highly monochromatic and coherent beam of electromagnetic radiation. Monochromatic electromagnetic radiation is meant for single frequency or single wavelength and eliminates chromatic aberration. Coherent beam means all photons produced are in phase with each other with limited divergence.

Laser Tissue Interactions

Laser interaction with various tissues of the eye may be classified into following categories (Fig. 1.1).

Photocoagulation

In photocoagulation temperature of treated tissue is increased from 37°C to at least 50°C, resulting in denaturation of tissue protein and coagulation at the absorbent tissue site. This results from conversion of light energy to heat energy.

The monochromatic light from laser is absorbed by melanin, xanthophyll present in the macula and hemoglobin.

Melanin pigment universally absorbs light spectrum between 400 and 700 nm whereas, xanthophyll and hemoglobin pigments are selective absorber. Melanin pigment is the principal absorber of light in photocoagulation of trabecular meshwork and co-absorber of light in retinal pigment epithelium (melanosomes) and choroids (melanocytes). The longer the wavelength, the deeper the chorioretinal burns. Hence, Argon laser (514.5 nm) and frequency-doubled Nd: YAG (532 nm) laser are absorbed at the level of the retinal pigment epithelium (RPE) and choriocapillaries whereas, Krypton red (647 nm) and diode laser (810 nm)

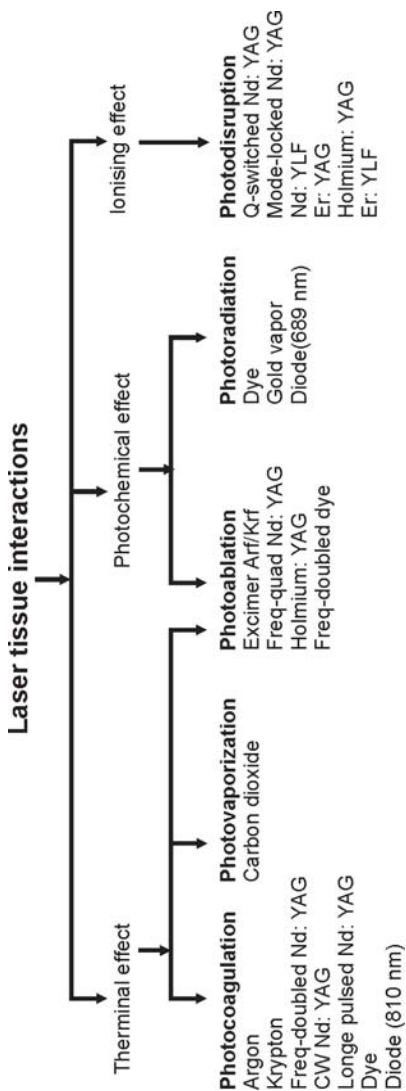


Fig.1.1: Various laser tissue interactions and the type of laser involved

produce deeper lesion in the choroids. The appearance (ophthalmoscopic) of optimum/threshold retinal burn in argon laser and freq-doubled Nd: YAG laser (green/KTP) will be the same and quite different from the krypton red and diode laser photocoagulation burn. So, similar appearing krypton red and diode laser retinal photocoagulation burn will be markedly of higher threshold and will cause more extensive choroidal damage and pain as compared with argon laser and freq-doubled Nd: YAG laser burn.

Xanthophyll pigment is present in the inner and outer plexiform layers of retina of the macular area. They absorb blue light maximally and green light poorly. Hence, in macular photocoagulation blue light (blue-green argon laser) will cause unwanted inner retinal damage. Therefore, argon green laser (514.5 nm) and freq-doubled Nd: YAG laser (532 nm-green/KTP) are preferred over argon blue-green laser in macular photocoagulation.

Hemoglobin absorbs blue, green and yellow light considerably and red light poorly. The shorter wavelength yellow lights are more easily absorbed. The red and near infrared wavelength lights are totally unabsorbed by the hemoglobin.

Lasers Commonly Used in Photocoagulation

CW green Argon laser (514.5 nm)

- It is absorbed selectively at the retinal pigment epithelium (RPE), hemoglobin pigments, choriocapillaries, layer of rods and cones and at the outer and inner nuclear layers.
- It is readily absorbed by the melanin granules.
- It coagulates from choriocapillaries to inner nuclear layer of the retina.

- It is suitable for photocoagulation of retinal pigment epithelium (RPE), choroids and blood vessels.

Freq-doubled Nd: YAG laser (532 nm)

- It produces a pea-green beam.
- It is often termed as “green Nd: YAG laser” or “KTP laser”.
- It is more highly absorbed by hemoglobin (Hb) and the melanin present in retinal pigment epithelium (RPE) and trabecular meshwork than the argon laser beam. It coagulates from choriocapillaries to outer nuclear layer of the retina.
- It is small and portable like diode laser.
- It is a solid state and diode pumped CW laser.
- The aiming beam is usually diode laser (635 nm, max.1mW)
- It causes photocoagulation with least energy transmission and shows considerable safety in macular treatment. Hence, it is fast gaining major market share of posterior segment photocoagulator.

Krypton red laser (647 nm)

- The melanin granules also readily absorb it.
- It is not absorbed by the hemoglobin (Hb) and xanthophylls pigments present in the macular area. Hence, it is particularly suitable for macular photocoagulation and coagulation of subretinal neovascular membrane
- It coagulates deeper into the retinal pigment epithelium (RPE) and choroids. It has insignificant photocoagulation effect on the vascular system of the retina. It is less absorbed and more highly transmitted through retinal pigment epithelium (RPE) . So, it is able to produce

more extensive and deep coagulation of choriocapillaries and choroids.

Diode laser (810 nm)

- It is the most important semiconductor laser [GaAlAs (720-890 nm) GaAs (810 nm)]
- Direct photocoagulation of microaneurysm is difficult because it is poorly absorbed by hemoglobin.
- However, it is as effective as argon, freq-doubled Nd: YAG laser in reducing macular edema.
- It offers increased patient comfort due to absence of bright flash of light.
- However, due to deeper penetration in to the choroids, it may be painful if the intensity of retinal coagulation is not properly titrated /reduced.
- It is a low cost, portable, small, high powered and versatile laser.

Lasers with blue wavelength light should not be used for photocoagulation in following situations;

1. In the macular area – **Xanthophyll pigments** absorb blue light maximally and green light poorly. Hence, in macular photocoagulation blue light (blue-green argon laser) will cause unwanted inner retinal damage
2. In older patients – The ageing lens absorbs blue light much more than other light wavelengths. The shorter wavelength blue lights are also more scattered by aged crystalline lenses.

Influence of Opacities in the Ocular Media Upon Laser Parameter (Power)

Any opacity in the ocular media such as corneal edema, corneal haziness, flare and cells in the anterior chamber, lental opacity and vitreous opacity reduces energy level of

Table 1.1: Various chorioretinal coagulations (Grades 1/light to 4/heavy)

Grade 1/Light	Barely visible blanching of retinal pigment epithelium (RPE)
Grade 2/Mild	Hazy, faint white retinal coagulation
Grade 3/Moderate	Opaque, dirty white retinal coagulation
Grade 4/Heavy	Dense white, chalky retinal coagulation

the laser beam striking the retinal surface by reflection, scattering or absorption of the laser beam. Hence, the optimum power level should be arrived at by gradually increasing the power to cause optimum coagulation burn (Figs 1.2 and 1.3) for that procedure.

Gradation of Photocoagulation Lesions

Visible photocoagulation intensity of chorioretinal tissues except retinal vessels can be graded from grade 1/light to grade 4/heavy (Table 1.1, Figs 1.2 and 1.3). Similarly visible photocoagulation of retinal vessels can be graded from grade I to grade IV (Fig. 1.4).

The grading is clinically very significant to ascertain the end point /optimum intensity of photocoagulation indicated for a specific retinal lesion, e.g., Grade 1/light chorioretinal coagulation is optimum intensity of photocoagulation in focal/grid laser in diabetic maculopathy whereas, Grade 3/moderate chorioretinal coagulation is optimum intensity of photocoagulation in scatter/Panretinal photocoagulation (PRP), retinal breaks and abnormal blood vessels.

Focusing of Laser Beam

All the lasers except xenon-arc emit monochromatic rays. So, energy of these lasers except xenon-arc can be focused to a fine point without significant chromatic aberration.

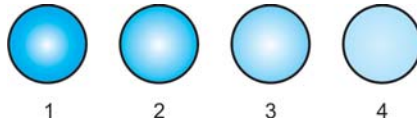


Fig. 1.2: Schematic drawing of various chorioretinal coagulations (Grades 1/light to 4/heavy)

1 = Grade 1/Light, 2= Grade 2/Mild, 3 = Grade 3/Moderate and 4 = Grade 4/Heavy

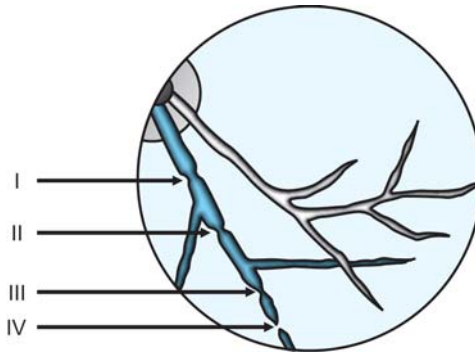


Fig. 1.3: Schematic drawing of various vascular coagulations (Grades I to IV)

- I = Minimal visible constriction of the vessel,
- II = Total constriction and spasm of the vessel,
- III = Total constriction of the vessel along with coagulations of the surrounding tissue and
- IV = Total constriction, charring of the vessel, coagulations of the surrounding tissue

The properly focused laser beam in an eye without any opacity in the refracting mediums should be circular with clearcut margin (Fig. 1.4A). An oval beam with a blurred outline indicates incorrect focusing (Fig. 1.4B).

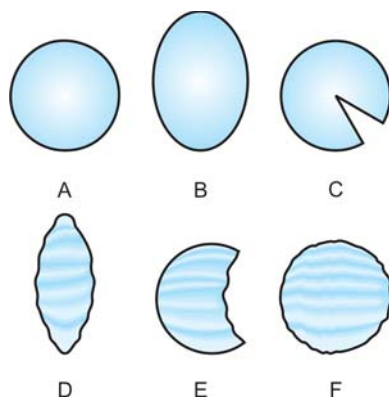


Fig. 1.4: Focusing of laser beam

- A = Properly focused laser beam without any opacity in the refracting mediums,
 B = Oval beam with a blurred outline -incorrect focusing,
 C = Large wedge shaped deficit-cortical cataracts,
 D = Elongated and irregular outline-astigmatism,
 E = Large irregular deficit-vitreous opacity and
 F = Round hazy focus and irregular outline –diffuse haziness of ocular media.

However, opacities in the ocular refracting mediums will not only block a certain percentage of laser beam energy to reach retina but also superimpose a shadow on the round laser focus. The round focused beam may take the shape of following distorted images (Figs 1.4C to F):

- Small or large wedge shaped deficit-cortical cataracts (Fig. 1.4C)
- Elongated and irregular outline-astigmatism (Fig. 1.4D)
- Large irregular deficit-vitreous opacity (Fig. 1.4E)
- Round hazy focus and irregular outline – diffuse haziness of ocular media (Fig.1.4F)

So, the circular target beam should be critically examined before proceeding to laser procedure.

Nd: YAG laser (1064 nm) emission rays are *invisible* since 1064 nm is at infrared end of the light spectrum. Single or multiple Helium-Neon/He-Ne (632.8 nm) visible red beams are usually employed for aiming of Nd: YAG laser (1064 nm). Diode red (670 nm) may be also employed as aiming beam in Nd: YAG lasers (1064 nm).

Laser Parameters

- Power = Number of "photons" emitted each second and is expressed in watts (W).
- Exposure time = The duration in second (sec.) the "photons" are emitted in each burn from the laser.
- Spot size = The diameter of the focused laser beam and is expressed in micron (μm). Spot size is usually fixed for treatment of a particular lesion. However, the energy (Power \times Exposure time) parameters must be decreased or increased, with the decrease or increase in the spot size parameter. The spot size when focused on the retina depends on; 1) Laser Spot Magnification Factor (LSMF) of the laser lens, 2) Spot size selected in the Slit-lamp and 3) Refraction of the eye under treatment.
- Energy = Number of "photons" emitted during an exposure of any duration and is expressed in joules (J).
So, **Energy (Joules) = Power (Watt) \times Exposure time (Second).**

Energy calculation

1. 1 watt is equal to 1 Joule of energy derived in 1 sec. exposure.
2. 0.5 sec exposure with 2 watt power parameter = 1 joule coagulative energy.
3. 0.5 sec exposure with 1 watt power parameter = 0.5 joule coagulative energy.

Post Photocoagulation Advice

The following restrictions are advisable to continue for a period of 3 weeks postlaser. The aim is to reduce/ control the venous pressure rise in the eyes, head and neck region.

- Avoid sneezing, cough and constipation and control with medication.
- Do not lift heavy objects.
- Avoid heavy exercise and yoga.
- Avoid sudden jerky movements of the head.
- Only paracetamol can be taken orally as pain killer.
- During sleep level of head should be above the level of heart.
- Avoid medications containing ephedrine and epinephrine.

It is ideal to supply post photocoagulation advice in a printed format.

Photovaporization

In photovaporization, laser irradiation higher than photocoagulation threshold is applied to the target tissue. As a result, the tissue temperature can reach the boiling point of water and sudden fast expansion of water vapor will cause tissue disruption, i.e. photovaporization. Photovaporization, i.e. cutting is usually accompanied by photocoagulation, i.e. cautery (or hemostasis).

Photoablation

In photoablation, temperature rise does not take place in the shorter wavelengths of the ultraviolet spectrum. At the site of impact, the tissue simply disappears without any charring and temperature rise. Surface of the target tissue can be precisely removed, layer-by-layer, in photoablation. Photoablation with 193 nm argon fluoride (ArF) excimer

laser produces superior predictable tissue ablation than longer wavelength (248 nm) krypton fluoride (KrF) excimer laser in lasik /lasek.

Photoradiation

Hematoporphyrin derivative is selectively taken up and retained by metabolically active tumor tissue. In photoradiation, this photosensitized tissue is exposed to 630 nm red lights from a dye laser, producing cytotoxic singlet oxygen and tissue destruction. Similarly, Verteporfin preferentially accumulates in choroidal neovascular membrane (CNV). In photodynamic therapy the choroidal neovascular membrane is subjected to laser emission from diode (689 nm) with resultant occlusion and thrombosis of the neovascular tissue.

Photodisruption

In photodisruption, temperature of treated localized microscopic area of tissue is increased from 37°C to 15000°C. On optical breakdown at the desired site, electrons are stripped from the atoms of target tissue resulting in development of plasma field and bubble. This leads to hydrodynamic and acoustic shock wave, which mechanically tears the tissue microscopically.

Laser delivery

Laser can be delivered through 3 types of approach;

1. Slit-lamp Biomicroscope:
 - The most common and popular delivery system.
 - Laser parameters viz.; power, exposure time and spot size can be changed.
2. Laser Indirect Ophthalmoscope (LIO):
 - Argon green and diode lasers are delivered through a fiberoptic cable.

- Ideal for photocoagulation of peripheral retinal breaks and degenerations.
- Ideal for PRP/scatter photocoagulation of extreme retinal periphery in eyes with rubeosis iridis, PDR, post-CRVO, retinopathy of prematurity (ROP) etc.
- Ideal for photocoagulation in children under general anesthesia.
- Ideal for photocoagulation in eyes with **small pupil, intraocular gas and lental opacities**.
- Unsuitable for focal and or grid laser of macula.
- Spot size is altered by the dioptric strength of the hand held condensing lens and moving a lever on the headset.
- Spot size is also altered by the refractive status of the eye. The spot size in a hypermetropic eye is smaller than in an emmetropic eye whereas, the spot size in a myopic eye is larger than in an emmetropic eye.
- In LIO,

$$\text{Retinal spot size} = \frac{\text{Power of condensing aspheric lens} \times \text{Image plane spot size}}{60}$$

3. Intraoperative Laser Endoscope:

- Argon green and diode lasers are delivered through Laser Endoscope **during vitrectomy**.
- Ideal for photocoagulation of retinal surface neovascularization (NVE), peripheral retinal breaks and degenerations after retina is attached by internal fluid-air exchange after vitrectomy.
- Since, detached retina cannot be treated, prior sub-retinal fluid (SRF) removal is essential before application of laser.
- Ideal for photocoagulation of giant retinal tear.

Indications for infiltration anesthesia

1. Uncooperative patient
2. Presence of significant ocular movement, e.g. nystagmus
3. Presence of significant ocular pain
4. Photocoagulation near the macular center

Pascal (Pattern Scan Laser) photocoagulator is recently developed by OptiMedica corporation, USA, which is a significant improvement in laser delivery systems. Pascal photocoagulator incorporates semi-automated, multiple pattern, short pulse, multiple shot, painless and precise laser burns in a very short duration in a predetermined sequence with *Freq. doubled YAG (532 nm) laser*.

Pascal photocoagulator can be used in all the retinal diseases (Proliferative and nonproliferative diabetic retinopathy, diabetic maculopathy, branch and central retinal vein occlusion, retinal tears and peripheral retinal degenerations, choroidal neovascular membrane, retinal telangiectasia, retinopathy of prematurity, etc.) treated with conventional single spot lasers (Argon, Freq. doubled YAG, Krypton, etc.).

Advantages of pascal photocoagulator over conventional single spot lasers

- Pulse duration is very short (10-20 msec) compared to conventional single spot lasers (100-200 msec). Hence, Pascal causes less collateral damage to the eye with similar effective regression of new vessels.
- The size of the retinal burn remains relatively stable after Pascal photocoagulation due to low intensity. In conventional single spot photocoagulation the laser spot burn enlarges with time. Hence, Pascal laser burns are less destructive than conventional single spot laser spot burns.

- Pascal is as efficient as conventional single spot photocoagulators.
- The gradation of retinal burns are the same but can be titrated more easily.
- Pascal allows the laser surgeon to apply different patterns of treatment with variable retinal grades of coagulation. Since the eyeball is spherical in shape semicircular pattern is better suited for photocoagulation of retinal periphery and standard square pattern is ideal for retinal midperiphery. Circular pattern is suitable for treating retinal holes/breaks.
- Pascal allows the laser surgeon to adjust the individual spot size, adjust the distance between the spots perfectly and the pattern of the spots with much more precision than is possible with a conventional single spot photocoagulator.
- Pascal allows the laser surgeon to place multiple spots in one depression of the foot pedal.
- Pascal allows the laser surgeon to complete PRP in a regular pattern, more quickly and usually in one day. Short treatment duration leads to improved patient cooperation and fixation.
- Pascal allows the laser surgeon to place burns in distant retinal periphery in a regular pattern in PRP, peripheral retinal degenerations and retinopathy of prematurity.
- Pascal allows the laser surgeon to place burns in macular grid laser more accurately in a regular pattern compared to conventional single spot lasers.
- Increase in macular edema following confluence of retinal burns is extremely low compared to conventional single spot photocoagulator.
- Since the distance between the spots is perfectly spaced, accidental confluence/overlapping of laser spots is not

possible. Hence, patient's field of vision is much better after Pascal photocoagulation than conventional single spot photocoagulation.

- Single-spot mode for conventional photocoagulation is also available.
- Using the Pascal Method, physicians can deliver up to 56 spots in approximately 0.6 seconds.
- Patients experience less pain than with traditional, single-spot laser photocoagulation.
- Reduced treatment duration.

Disadvantages of Pascal photocoagulator

- The spot size available is restricted (only 100, 200 and 400 μm). Spot sizes of 150, 300 and more than 400 μm are not possible.
- Inability to design the laser patterns at the surgeon's convenience.
- Pascal photocoagulator produces some noise when activated.
- Pascal photocoagulator emits green wavelength, which is difficult to penetrate through media opacities, e.g. cataract, retinal and vitreous hemorrhages.
- Pattern burn with Pascal photocoagulator in retinal periphery is often difficult and always use lower intensity by titration in retinal periphery to avoid intense burn.

Precise, pre-determined settings

- Square arrays (2×2 , 3×3 , 4×4 , 5×5) for proliferative diabetic retinopathy
- Triple arcs for retinal tears, lattice degeneration and proliferative diabetic retinopathy
- Modified macular grid for diffuse diabetic macular edema

- Single-spot mode for conventional photocoagulation
OptiMedica holds the exclusive license to the Pascal Photocoagulator technology, which was originally developed at Stanford University. Since its worldwide market introduction in 2006, Pascal photocoagulation procedures have been performed on tens of thousands of patients worldwide.

BIBLIOGRAPHY

1. Al-Hussainy S, Dodson PM, Gibson JM. Pain response and follow-up of patients undergoing panretinal laser photocoagulation with reduced exposure times. *Eye* 2007;1-4.
2. Bhattacharyya B. *Clinical Applications: YAG Laser (Ophthalmology)*. New Delhi: Jaypee Brothers Medical Publishers (P) Ltd, 2005:9-19.
3. David B. Karlin (ed). *Lasers in Ophthalmic Surgery*: Blackwell Science Inc. 1995:
4. Gholam A. Peyman, Donald R. Sanders, Morton F. Goldberg (eds). *Principles and Practice of Ophthalmology (1st Indian Ed.)*. Philadelphia: WB Saunders company, 1987:1098-1118.
5. Gorisch W, Boergen KP. Heat-induced contraction of blood vessels. *Lasers Surg Med* 1982;2:1.
6. Jain A, Blumenkranz MS, Paulus Y, et al. Effect of pulse duration on size and character of the lesion in retinal photocoagulation. *Arch Ophthalmol* 2008;126:78-85.
7. L'esperance FA Jr. *Ophthalmic Lasers*. (3rd edn.). St. Louis: CVMosby Co. 1989:96-112.
8. Mainster MA. Ophthalmic applications of infrared lasers—thermal considerations. *Invest Ophthalmol Vis Sci* 1979; 18:414.
9. Mainster MA, White TJ, Allen RG. Spectral dependence of retinal damage produced by intense light sources. *J Opt Soc Am* 1970;60:848.
10. Steven M Bloom, Alexander J Brucker (eds). *Laser Surgery of the Posterior Segment (2nd ed)*. Philadelphia: Lippincott-Raven, 1997.

*Panretinal
Photocoagulation
(PRP) in Diabetic
Retinopathy*

Diabetic Retinopathy Study (DRS) established the efficacy of Panretinal (PRP) or scatter photocoagulation to ameliorate the natural history of diabetic retinopathy and reduce the rate of loss of visual acuity. Panretinal (PRP) or scatter photocoagulation is universally accepted as the gold standard for laser treatment of diabetic retinopathy and retinal venous occlusion.

Panretinal photocoagulation (PRP) is done in systemically stable patient, i.e. only when the blood sugar and serum lipid level are well controlled.

Indications

Diabetic Retinopathy Study (DRS) recommendations (**High-risk characteristics**);

- Moderate or severe *NVD (at least 1/4th -1/3rd disc areas in extent).
 - Mild NVD, if associated with preretinal or vitreous hemorrhage.
 - **NVE (at least ½ disc areas in extent), if associated with preretinal or vitreous hemorrhage.
- Other accepted indications;
- Rubeosis of iris and or anterior chamber angle (irrespective of presence or absence of high-risk characteristics).
 - Eye with features of extensive retinal ischaemia, i.e. retinal hemorrhages, capillary non-perfusion and soft exudates.
 - Patients with severe proliferative diabetic retinopathy (PDR) in other eye.

*NVD (New Vessels Disc)= New vessels on the optic disc or within 1 disc diameter (DD) of the margin of the optic disc margin or in the vitreous cavity anterior to this area.

**NVE (New Vessels Elsewhere)= New vessels in other areas of retina or in the vitreous cavity anterior to other areas of retina.

- In one eye where both eyes are approaching high-risk proliferative stage.
- High-risk proliferative stage.
- In pregnancy or after renal transplantation in patients with severe pre-proliferative diabetic retinopathy (PPDR) or proliferative diabetic retinopathy (PDR) even without *high-risk* characteristic

Contraindications

- Eyes with mild to moderate non-proliferative diabetic retinopathy (NPDR).
- Relative contraindication—If proliferative diabetic retinopathy (PDR) coexists with clinically significant macular edema (CSME), either focal or grid laser treatment of CSME is done first followed by PRP 4-6 weeks later.

General Steps

1. Explain the procedure.
2. Signing informed consent.
3. Mydriasis—Maximum pupillary dilation with Tropicamide (1%) and Phenylephrine (5%) starting 2 hour prelaser.
4. Anesthesia—1 drop topical Proparacaine Hcl (0.5%) few minutes prior to photocoagulation. Peribulbar inj Lignocaine Hcl in nystagmus and uncooperative patient.
5. Antiglaucoma medication—1% Apraclonidine or 0.15-0.2% Brimonidine tartrate eye drop-1 drop one hour before laser session effectively prevents postlaser pressure spike also.
6. Comfortable sitting on revolving stool.
7. Steady fixation—Apply head strap and adjust fixation target.

Table 2.1: Specifications of laser lenses used in PRP (Courtesy Ocular instruments, Bellevue, WA, USA and Volk Optical Inc. Mentor, OH, USA)

<i>Lens</i>	<i>Image magnification</i>	<i>Laser spot magnification factor (LSMF)</i>	<i>Field of view</i>
Goldmann 3-mirror	0.93×	1.08×	140°
Mainster Widefield	0.68×	1.5×	118-127°
Mainster PRP 165	0.51×	1.96×	165-180°
Volk Quadraspheric	0.51×	1.97×	120-144°
Volk Super Quad 160	0.50×	2.00×	160-165°

8. Insert appropriate Laser contact lens (Table 2.1 and Figs 2.1A to E)—Goldmann 3-mirror. It is available with argon/diode bonded antireflective coating for PRP or scatter photocoagulation with argon green (514.5 nm), ***diode (810) or krypton (647 nm) laser. As an alternative, Mainster standard lens for PRP of posterior pole and Volk quadraspheric lens for midperiphery treatment may be conveniently used. However, Goldmann 3-mirror/ Mainster PRP 165/Volk Super Quad 160 (Table 2.1 and Figs 2.1A to E) is suitable for PRP of more peripheral area. Goldmann 3-mirror produces a virtual erect image whereas; others produce a real inverted image. The peripheral area of each mirror is used for more anterior treatment. Alternatively, the patient may be asked to look away from the mirror for more anterior treatment. Similarly, the patient may be asked to look towards the mirror for more posterior treatment.

***Diode or Krypton laser is preferred when vitreous hemorrhage or lental changes prevents adequate retinal visualization.



Fig. 2.1: (A) Goldmann 3-mirror, (B) Mainster Widefield, (C) Mainster PRP 165, (D) Volk Quadraspheric, (E) Volk Super Quad 160 (Images courtesy ocular instruments, Bellevue, WA, USA and Volk optical Inc. Mentor, OH, USA)

9. Room illumination-darkened/semi darkened.
10. Adjust Slit-lamp beam- PRP can be done through three types of delivery system viz; 1. Via slit-lamp, 2. Intraoperative endophotocoagulation and 3. Via binocular indirect ophthalmoscope. Slit-lamp magnification should be lower for PRP in more peripheral areas whereas, higher magnification should be used in focal/grid laser for diabetic maculopathy.

PRP/Scatter Photocoagulation Technique Proper (Fig. 2.2)

- a. PRP is usually divided over 3 sessions with 1-2 week(s) interval between the sessions.
- b. The Diabetic Retinopathy Study (DRS) protocol recommended 800-1600 burns in PRP. However, 1800-2200 burns are often reported.
- c. Location of PRP burns—It extends from 500 μm nasal to the optic disc margin, 2DD (3000 μm) temporal to, above

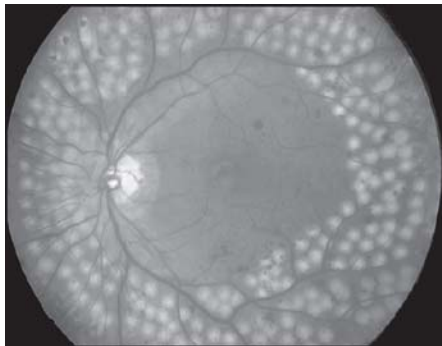


Fig. 2.2: PRP Laser (For color version see Plate 1)

(Courtesy: Ashok Garg, JT Iin, JorgeLAlío, Azad R, Jerome Jean Bovet, Bojan Bajic and Cyres K Mehta (Eds.): Natarajan S et al In: Ophthalmic lasers for Posterior Segment Diseases, page 478, 2008, with permission from Jaypee Brothers Medical Publishers Pvt. Ltd. New Delhi)

and below the macular center, just within the vascular arcade and extending peripherally to or beyond the equator (Fig. 2.3).

1. Session -1 (area 1 in Fig. 2.4)

Parameters:

- Spot size—100-200 μm
- Exposure—0.05-0.2sec.
- Power—100-400 mW (intensity-grade 3/moderate)
- Pattern—Close, non-overlapping, 1 to 1½ spot size width apart, interrupted burns to cover retinal area 1 shown in Figure 2.4.
- New vessels elsewhere (NVE), with the exception of new vessels disc (NVD) are treated focally with confluent burns.

2. Session -2 (area 2 in Fig. 2.4)

The inferior sector (area 2 in Fig. 2.4) should be treated preferably earlier than the superior sector (area 3 in Fig. 2.4). If vitreous or preretinal hemorrhage occurs, it

Fig. 2.3: Location of PRP (Schematic drawing)




Fig. 2.4: PRP/scatter laser – 3 sessions — sequence of application (Schematic drawing)

tends to gravitate inferiorly and the laser surgeon is still able to perform PRP in the superior sector.

Parameters:

- Spot size—300-500 μm
- Exposure—0.1-0.2sec.
- Power—400-800 mW (intensity-grade3/moderate)
- Pattern—Close, non overlapping, 1 spot size width apart, interrupted, burns to cover retinal area 2 shown in Figure 2.4.

3. Session -3(area 3 in Fig. 2.4)

Parameters

- Spot size—300-500 μm
- Exposure—0.1-0.2sec.
- Power—400-800 mW (intensity-grade 3/moderate)
- Pattern—Close, non overlapping, 1 spot size width apart, interrupted, burns to cover retinal area 3 shown in Figure 2.4.

- Early Treatment Diabetic Retinopathy Study (ETDRS) protocol advocated scatter photocoagulation/PRP to be done as an alternative to focal treatment within 2DD of the macular center and whenever focal treatment would produce a scar of >2DD in extent.
- Burns along location of ciliary nerves are usually painful.
- During PRP, vitreous hemorrhage may occur from new vessels and is immediately stopped by pressing on the eye with the contact laser lens.
- Patients, who have cataract and requires PRP, should have PRP prior to cataract extraction if the ocular media are sufficiently clear to permit photocoagulation. If the ocular media are not sufficiently clear to allow photocoagulation, early cataract extraction is followed by retinal examination and PRP.
- Overlapping or superimposition of photocoagulation burns should be avoided. Photocoagulation over major retinal vessels, vortex veins, retinal hemorrhages and chorioretinal scars should be avoided. Also, photocoagulation within the papillomacular bundle should be avoided
- Krypton red or diode laser is preferred over argon laser, when vitreous hemorrhage or lental opacity obscures adequate retinal visibility. However, due to deeper retinal penetration longer wavelength, Krypton red or Diode laser PRP may be more painful.

Postlaser Advice

1. Topical Cycloplegic, e.g. Cyclopentolate HCl (1%)-3 times daily × at least 3 days after each session.

2. Topical steroid- 3-4 times daily × at least 3 days after each session.
3. Tablet acetazolamide (250 mg)—If IOP spike is observed in treated eye.
4. Issue printed generalized post-photocoagulation advice (p.13 Chapter 1)-To be strictly followed for 4-6 weeks after final PRP session.

Postlaser Follow up

- 1st follow up—3 or 4 weeks after 3rd or final PRP session.
- 2nd follow up—3 or 4 weeks interval.
- 3rd follow up—3 or 4 weeks interval.
- Subsequent follow-ups—3 months interval.

Complications

1. Worsening of pain-It is common with longer wavelength diode and krypton red laser due to thermal damage to the branches of posterior ciliary nerve.
2. Transient aggravation of macular edema leading to decreased visual acuity.
3. Raised IOP—It occurs due to either choroidal effusion (angle-closure glaucoma) or temporary reduction in outflow facility in an otherwise open angle. IOP spike reaches peak within 1hour postlaser and returns to normal level within 1week. Raised IOP is controlled with oral acetazolamide and topical Timolol Maleate. 1% Apraclonidine or 0.15-0.2% Brimonidine tartrate eye drop-1 drop one hour before laser session and just after the procedure effectively prevents postlaser pressure spike also.
4. Uveitis.
5. Delayed dark adaptation.
6. Peripheral visual field constriction.

7. Vitreous hemorrhage from new vessels
8. Angle-closure glaucoma—*It occurs due to choroidal effusion particularly if PRP is done extensively in one session.*
9. Choroidal effusion.
10. Exudative retinal detachment.
11. Progression of tractional retinal detachment.
12. Choroidal detachment.

Regression of new vessels (NVD and NVE) 3 weeks after PRP is a good prognostic indicator of effective PRP and correlates with long-term visual prognosis.

Indications for Follow up Treatment

1. Persistent NVD
2. Recurrence of new vessels after complete or partial regression
3. Aggravation of new vessels
4. New areas of new vessels
5. New vitreous hemorrhage.

Guidelines for follow up treatment after initial PRP

Early Treatment Diabetic Retinopathy Study (ETDRS) recommends consideration of following six (6) factors;

1. Change in new vessels since the last photocoagulation treatment.
2. Appearance of new vessels (Caliber, degree of network formation, extent of accompanying fibrous tissue).
3. Frequency and extent of vitreous hemorrhage since the last photocoagulation treatment.
4. Status of vitreous detachment.
5. Extent of photocoagulation scars.
6. Extent of tractional retinal detachment and fibrous proliferation.

Additional photocoagulation strategy

1. Placement of burns
 - In areas between initial treatment spots/scars.
 - Anterior to the initial treatment spots/scars (using Goldmann 3- mirror lens or Laser indirect ophthalmoscope (LIO).
 - In posterior pole of retina spare the area within 500 μm from the center of the macula.
2. Preferential treatment sites
 - Quadrants with **active new vessels.
 - Areas skipped in PRP.
 - Posterior pole and areas temporal to the center of the macula.

**New vessels appear active that are suggested by 1. formation of tight networks, 2. paucity of accompanying fibrous tissue and 3. substantial increase in extent in comparison to at the time of initial treatment.

BIBLIOGRAPHY

1. Diabetic Retinopathy Study Research Group: Indications for photocoagulation treatment of diabetic retinopathy. Diabetic Retinopathy Study report No. 14. Int Ophthalmol Clin 1987;27:239-53.
2. Doft BH, Blankenship G. Retinopathy risk factor regression after laser pan-retinal photocoagulation for proliferative diabetic retinopathy. Ophthalmology 1984;91:1453-57.
3. Early Treatment Diabetic Retinopathy Study Research Group: Techniques for scatter and local photocoagulation treatment of diabetic retinopathy: The Early Treatment Diabetic Retinopathy Study report No. 3. Int Ophthalmol Clin 1987;27:254-64.
4. Early Treatment Diabetic Retinopathy Study Research Group; Early photocoagulation for diabetic retinopathy. The

- Early Treatment Diabetic Retinopathy Study report No.9: Ophthalmology 1991;98(Suppl);766-85.
5. Steven M. Bloom, Alexander J Brucker(eds). Laser Surgery of the Posterior Segment (2nd ed). Philadelphia: Lippincott-Raven 1997.
 6. The Diabetic Retinopathy Study Research Group: Four risk factors for severe visual loss in diabetic retinopathy; The third report from the Diabetic Retinopathy Study. Arch Ophthalmol 1979;97:654-55.
 7. The Diabetic Retinopathy Study Research Group: Photo-coagulation treatment of proliferative diabetic retinopathy: Clinical application of Diabetic Retinopathy Study (DRS) findings, DRS report No.8. Ophthalmology 1981;88; 583-600.
 8. Wolbarsht ML, Landers MB III. The rationale of photo-coagulation therapy for proliferative diabetic retinopathy: A review and a model. Ophthalmic Surg 1980;11:235-45.

*Photocoagulation
(Focal/Grid) in
Diabetic Maculopathy*

Introduction

Early Treatment Diabetic Retinopathy Study (ETDRS) protocol defines clinically significant macular edema (CSME) as presence of any of these lesions;

1. Retinal thickening at or within 500 μm of the macular center.
2. Hard exudates at or within 500 μm of the macular center.
3. An area or areas of retinal thickening at least 1 disc area in size, at least part of which is within 1 DD (disc diameter) of the macular center.

Green light is absorbed well by both the melanin and hemoglobin pigments. Xanthophyll pigment of the macular area absorbs blue light well and green light poorly. Hence, in macular photocoagulation blue light (blue-green argon laser) will cause unwanted inner retinal damage. Hence, argon green laser (514.5 nm) and freq-doubled Nd: YAG laser (green/KTP-532 nm) are preferred over argon blue-green laser in macular photocoagulation.

Treatment of CSME should be ideally guided by Findus Flurescein Angiography (FFA), which detects leaking microaneurysm, areas of capillary leakage and areas of capillary non-perfusion and OCT.

Role of FFA

- Accurate localization of the foveal center.
- Detects area of retinal ischaemia/capillary non-perfusion without retinal thickening.
- Detects area of retinal leakage without retinal thickening.

Role of OCT

- Differentiates between leakage and retinal edema.
- Assesses retinal thickness quantitatively.
- Assessments of laser treatment during follow up.

Laser photocoagulation of CSME may be focal laser / grid laser or a combination of focal laser and grid laser (modified grid laser).

Indications

Early Treatment Diabetic Retinopathy Study (ETDRS) protocol recommends following lesions as treatable;

Focal laser

1. Focal leakage or discrete points of retinal hyperfluorescence, ≥ 500 microns (μm) from the macular center, causing hard exudates and or retinal thickening.
2. Focal leaks, 300-500 microns (μm) away from the macular center, responsible for hard exudates and or retinal thickening.

Grid laser

1. Previously untreated areas of diffuse leakage within the retina
2. Previously untreated retinal avascular zone excluding normal Foveal Avascular Zone (FAZ).

General Steps

1. Explain the procedure—Clearly explain that the idea of focal / grid laser is not to restore the lost vision. The aim is to stall further visual loss.
2. Signing informed consent.
3. Mydriasis—Maximum pupillary dilation with Tropicamide (1%) and Phenylephrine (5%) starting 2 hour prelaser.
4. Anesthesia—1 drop topical Proparacaine HCl (0.5%) few minutes prior to photocoagulation. Peribulbar inj Lignocaine Hcl in nystagmus and uncooperative patient.

5. Comfortable sitting on revolving stool.
6. Steady fixation—Apply head strap and adjust fixation target.
7. Insert appropriate Laser contact lens (Table 3.1 and Figs 3.1A to E)—Central mirror of Goldmann 3-mirror. It is available with argon/diode bonded antireflective coating for focal or grid photocoagulation with argon green (514.5 nm) laser. As an alternative, Mainster standard/Mainster High Magnification/Ocular PDT 1.6X/Volk Area Centralis lens may be conveniently used (Table 3.1 and Figs 3.1A to E).
8. Room illumination—Darkened/semi darkened.
9. Adjust slit-lamp beam

Focal Photocoagulation Technique Proper

- Directly treat all the focal fluorescein leaks including microaneurysm(s) and intra retinal microvascular

Table 3.1: Specifications of laser lenses used in macular photocoagulation (courtesy Ocular Instruments, Bellevue, WA, USA and Volk Optical Inc. Mentor, OH, USA)

<i>Lens</i>	<i>Image magnification</i>	<i>Laser spot magnification factor (LSMF)</i>	<i>Field of view</i>
Goldmann 3-mirror	0.93×	1.08×	140°
Mainster standard	0.96×	1.05×	90-121°
*Mainster high Magnification	1.25×	0.8×	75-88°
**Ocular PDT 1.6X	0.63×	1.6×	120-133°
Volk area centralis	1.06×	0.94×	70-84°

* Very high magnification facilitates visualization of subtle vascular malformations that are usually only apparent angiographically.

** Ideal for photocoagulation of larger macular area with relatively high resolution and offers optimal image contrast.



Figs 3.1A to E: (A) Goldmann 3-mirror, (B) Mainster standard, (C) Mainster high magnification, (D) Ocular PDT 1.6x, (E) Volk area centralis (Image courtesy ocular instruments, Bellevue, WA, USA and Volk Optical Inc. Mentor, OH, USA)

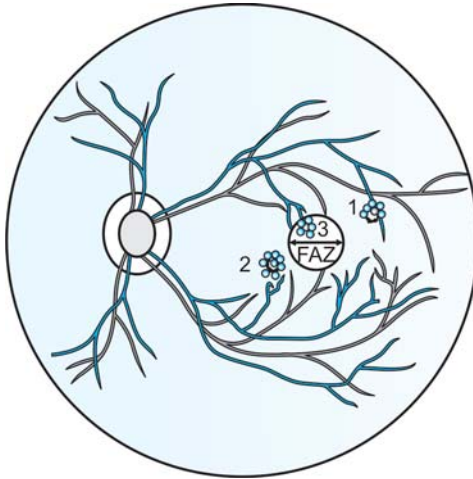


Fig. 3.2: Schematic drawing showing focal laser in diabetic maculopathy. 1 and 2- Focal laser of IRMAs, 3-Focal laser of microaneurysm

abnormalities (IRMAs) as shown in Figure 3.2 (1 and 2 in Fig. 3.2).

- Location of focal burns- 500 μm away from the macular center, 500 μm temporal to the optic disc margin and within 3000 μm (2DD) from the macular center, i.e. from arcade to arcade (Fig. 3.3).
- Focal lesion, e.g. leaking microaneurysm(s) within 300-500 micron (μm) of the macular center may also be treated (3 in Fig. 3.2).

Parameters:

- Spot size-50-100 μm
- Exposure-0.1sec.
- Power- 100-400 mW (intensity-grade 3)
- End point-Whitening or darkening of the microaneurysm(s) is sufficient to obliterate the microaneurysm(s) and intra-retinal microvascular abnormalities (IRMAs).

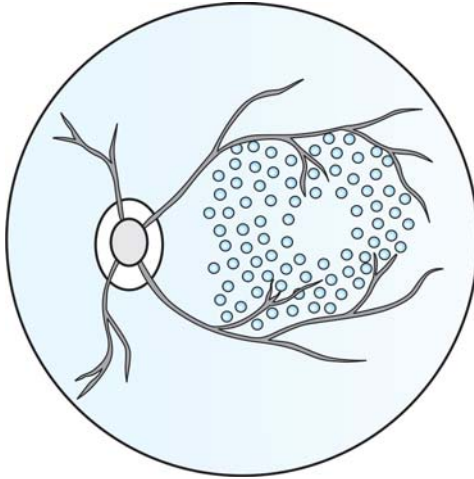


Fig. 3.3: Schematic drawing showing grid laser pattern in diabetic maculopathy

- At the end of the laser session carefully examine all the treated microaneurysm(s). Inadequately treated microaneurysm(s) after appearing dark will again turn red. These microaneurysm(s) are treated additionally.

Grid Photocoagulation Technique Proper

- All areas of thickened retina showing diffuse fluorescein leakage and or capillary non-perfusion are treated.
- Avascular zones other than FAZ are also treated.
- Location of grid burns—It extends from arcade to arcade. Area within 500 micron (μm) of the macular center and area within 500 μm of the optic disc margin are excluded. Grid laser is usually placed on papillomacular bundle (Figs 3.3 and Fig. 3.4).

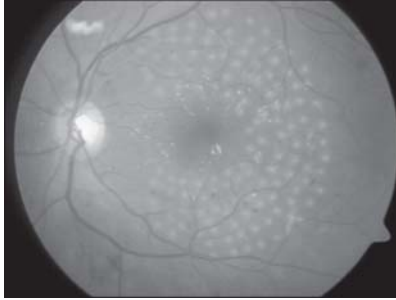


Fig. 3.4: Grid laser photocoagulation (few hours after the procedure)
(For color version see Plate 1)

(Courtesy: Ashok Garg, JT Lin, Jorge L Alio, Azad R, Jerome Jean Bovet, Bojan Bajic and Cyres K Mehta (Eds.): Tewari HK, Mondal S, Venkatesh P and Garg S. Pal in: Lasers in Diabetic Retinopathy, page 516, 2008, with permission from Jaypee Brothers Medical Publishers Pvt. Ltd. New Delhi)

Parameters

- Spot size—50-200 μm
- Exposure—0.1 sec.
- Power—ower of light intensity is applied to tickle the RPE cells and stimulate the retino-choroidal pump to enhance the absorption of exudative fluids. Start with lower power setting (50-100 mW) and gradually increase (increment of 10-20 mW) to achieve light burn intensity.
- No of burns- on an average 100-200 burns are required depending on the spot size. The laser spots are placed 1 spot size width apart. Direct treatment of micro-aneurysm(s) is avoided. Overlapping of burns particularly over papillomacular bundle should be avoided.

Modified Grid Photocoagulation Technique Proper

- The area of the papillomacular bundle is spared.
- Direct focal photocoagulation of leaking micro-aneurysm(s) is added.

Special Precautions

- *Accurate localization of the foveal center to avoid burns close to fovea i.e.; within 300 micron (μm) of the foveal center.* In presence of severe edema it is very difficult and confusing to identify the foveal center. In those situations, FFA is very helpful.
- *Intense burn is avoided* by starting the initial burns with lower power setting (50-100 mW) and gradually increasing (increment of 10-20 mW) to achieve optimal light intensity burns. The power setting should also be adjusted according to degree of retinal edema. Less edematous retinal area requires less power in comparison to more edematous area to obtain equivalent light intensity photocoagulation.

Postlaser Advice

1. Topical Cycloplegic, e.g., Cyclopentolate HCl (1%)-3 times daily \times at least 3 days after each session.
2. Topical steroid- 3-4 times daily \times at least 3 days after each session.
3. Tablet Acetazolamide (250 mg)—If IOP spike is observed in treated eye.
4. Issue printed generalized postphotocoagulation advice (p. 13 Chapter 1)—To be strictly followed for 4-6 weeks after final PRP session.

Postlaser Follow up

1st follow up – 4 weeks after the Focal/Grid laser session.
 2nd follow up – 3/4 months after the Focal/Grid laser session

- Repeat DFFA is done in 2nd follow up
- Retreatment is done if required for any persistent focal/diffuse leakage. Focal lesion, e.g., leaking microaneurysm(s) within 300-500 micron(μm) of the macular center

may be treated on follow up examination if macular edema still persists and acuity of vision is $<6/12$ with good perifoveal capillary network, using 50 micron(μm) spot size and 0.05 second exposure duration.

Complications

1. Accidental foveal burn/damage
2. Aggravation of macular edema
3. Secondary choroidal neovascularization (CNV). CNV results from rupture of Bruch's membrane following exposure to smaller spot size and higher laser energy.
4. Mild impairment of color vision perception.
5. Paracentral scotoma.
6. Impairment of contrast sensitivity.

BIBLIOGRAPHY

1. Early Treatment Diabetic Retinopathy Study report No. 1: Photocoagulation of diabetic macular edema. Arch Ophthalmol 1985;103:1796-1806.
2. Early Treatment Diabetic Retinopathy Study Research Group. Treatment techniques and clinical guidelines for photocoagulation of diabetic macular edema: Early Treatment Diabetic Retinopathy Study report No. 2. Ophthalmology 1987;84:761-74
3. Lee CM, Olk RJ. Modified grid laser photocoagulation for diffuse macular edema: Long term visual results. Ophthalmology 1991;98:1594-1602.
4. Olk RJ. Modified grid argon blue green photocoagulation for diffuse diabetic macular edema. Ophthalmology 1986; 93:938-50.
5. Steven M. Bloom, Alexander J Brucker (eds). Laser Surgery of the Posterior Segment (2nd ed). Philadelphia: Lippincott-Raven, 1997.
6. The Early Treatment Diabetic Retinopathy Study Research Group. ETDRS report no.4. Photocoagulation for diabetic macular edema. Int Ophthalmol Clin 1987;27:265-72.

*Photodynamic
Therapy (PDT)*

Introduction

*Subfoveal choroidal neovascularization (CNV) seen in wet or exudative Age-related Macular Degeneration (AMD) is best treated by Photodynamic Therapy (PDT) or Ocular Photodynamic Therapy (OPT) with verteporfin before the institution of anti-VEGF (Vascular Endothelial Growth Factor) therapies.

Indications

1. Classic subfoveal CNV in Wet AMD
2. Idiopathic CNV
3. High myopia
4. Traumatic rupture of choroids
5. Ocular histoplasmosis syndrome
6. Angiod streaks
7. Drusen of the optic nerve

The size of the lesion should be $\leq 5400 \mu\text{m}$ (microns) in its greatest linear dimension.

Contraindications

Ocular

1. Dry AMD
2. Size of the lesion $\geq 5400 \mu\text{m}$ (microns) in its greatest linear dimension.

*Subfoveal choroidal neovascularization (CNV)—Those are located at the center of the fovea.

*Juxtafoveal choroidal neovascularization (CNV)-CNV in which either 1) the posterior edge of the neovascularization is between 1 and 199 μm from the center of the FAZ or 2) neovascularization located between 200 and 2500 μm from the center of the FAZ is associated with hemorrhage and/blocked fluorescence extending within 200 μm from the center of the FAZ.

*Extrafoveal choroidal neovascularization (CNV)-CNV with angiographically evident choroidal neovascularization located between 200 and 2500 μm from the center of the FAZ.

Systemic

1. Known hypersensitivity to verteporfin
2. Patients suffering from porphyria
3. Patients suffering from severe hepatic disorder
4. Relative contraindications
 - Uncontrolled hypertension
 - Unstable cardiac disorder.

Mode of Action

Verteporfin (Visudyne) is lipophilic (binds with LDL in the blood) and preferentially accumulates in the capillary endothelial cells of neovascular membrane. The accumulated dye absorbs specific wavelength (689 nm) of rays from laser emission. The light activated verteporfin converts normal oxygen to 'singlet oxygen'. The highly energized 'singlet oxygen' and reactive free radicals destroy the endothelial cells of the CNV leading to occlusion of the neovascular membrane without collateral damage to the overlying photoreceptors.

Dose Calculation and Preparation of the Dye

The dose calculation is based on the Body Surface Area (BSA) of the patient, which is obtained from a standard nomogram entering height and weight of the patient.

Dose (in ml.) = $3 \times \text{BSA (in m}^2\text{)}$

Concentration of the drug is 2 mg/ml. A single vial contains 15 mg of the black-green powder, which is** reconstituted with 7 ml. of distilled water. After reconstitution the vial is gently shaken to fully dissolve the powder 5% Dextrose is added to the dose in ml. to form the final volume of 30 ml.

**The reconstituted vial must be used within 4 hours and kept away from exposure to strong light.

So, Dose in ml (A) + 5% Dextrose (B ml) = 30 ml.

The dye is infused through Y tubing (Fig. 4.1). One small limb is connected to a syringe filled up with final 30 ml of verteporfin. The other small limb is connected to a syringe filled up with 10 ml 5% Dextrose. A micro pore filter (1.2 μ) is incorporated in the main limb to block impurities and particulate matters. The main limb of the Y is connected to the Venflon catheter, which is inserted into the antecubital vein in the forearm of the patient (Fig. 4.1).

General Steps

1. Explain the procedure.
2. Signing informed consent.
3. Mydriasis—Maximum pupillary dilation with Tropicamide (1%) and Phenylephrine (5%) starting 2 hour prelaser.

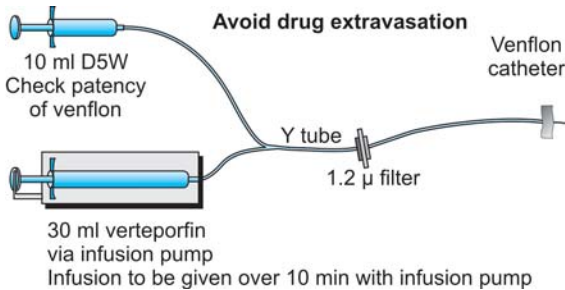


Fig. 4.1: Drug preparation: Reconstitution and infusion (of Verteporfin and infusion set)

(*Courtesy:* Ashok Garg, J T lin, JorgeLAlio, Azad R, Jerome Jean Bovet, Bojan Bajic and Cyres K Mehta (Eds.): Talwar Dinesh In: Photodynamic Therapy, page 545, 2008, with permission from Jaypee Brothers Medical Publishers Pvt. Ltd. New Delhi)

4. Anesthesia–1drop topical Proparacaine Hcl (0.5%) few minutes prior to photocoagulation. Peribulbar inj Lignocaine HCl in nystagmus and uncooperative patient.
5. Now, the patient is seated on the revolving stool facing the slit-lamp

Step II: Infusion of the Verteporfin

- The patency of the IV infusion channel is checked by infusing 5% Dextrose from smaller 10 ml syringe
- The dye is infused intravenously (IV) through the antecubital vein in forearm over a period of 10 minutes at a rate of 3 ml/minute.
- The IV infusion channel is infused with remaining 5% Dextrose from the 10 ml. Syringe to wash out residual verteporfin.
- A latent period of 5 minutes exists between end of the dye infusion and application of laser to allow maximal accumulation of verteporfin in the endothelial cells of CNV.
- Steady fixation–Apply head strap and adjust fixation target.
- Insert appropriate Laser contact lens-laser lenses used in diabetic maculopathy (see chapter 3).
- Room illumination-Darkened /semi darkened
- Adjust slit-lamp beam and parameters.
- The lesion is properly focused.

Step III: Photodynamic Therapy Technique Proper

Fifteen minutes after commencement of verteporfin infusion, i.e. 5 minutes after conclusion of dye infusion, the CNV is illuminated with light from diode laser (689 nm).

Parameters

- Spot size-500 μm
- Size of the beam—The perfectly circular beam should cover the lesion entirely and is adjusted to extend 500 μm beyond the margin of the CNV membrane. So, size of the beam = 1000 μm + Greatest linear dimension of the lesion.
- Exposure time-83 seconds
- Intensity- 600 mW/cm^2
- Total laser Energy-50J/ cm^2
- Dose of the Dye-6 mg/m^2
- Unlike thermal laser (photocoagulation), *visible retinal changes are not seen during laser application in PDT.*
- In bilateral cases, the other eye may be treated immediately after PDT of the first eye within five (5) minutes.
- **Special precaution:** There should not be any extravasations of blood after removal of the IV cannula. This is ensured by application of sufficient pressure over the injection site for sufficient period of time. If extravasations occur, cover the site completely and exposure to sunlight till absorption of the subcutaneous haematoma to be avoided.

Retreatment: PDT is repeated every 3 months interval for indefinite period. However, *in ocular histoplasmosis syndrome and high myopia repeat treatment may not be required and visual improvement occurs whereas, in other indications PDT***only slows the rate of visual loss.*

Postlaser Advice

Special precautions are advised following PDT to avoid phototoxicity;

***Monthly VEGF therapy with intravitreal Ranibizumab (Lucentis) actually improves visual acuity in wet AMD.

1. Photosensitivity usually persists for few days.
2. The patient is advised to cover whole body from head to feet during his/her return trip to home to avoid any exposure to sunlight. *Necessary clothing requirement (cap/hat, socks, gloves, full sleeve shirt, trousers etc.) was issued priorly during appointment schedule.*
3. The verteporfin manufacturer provides special photo-protective sunglasses.
4. The patient is advised strictly to stay indoors for 5 days. Only exposure to low watt fluorescent lamp is allowed at home.
5. The patient is also advised strictly to avoid application of hair dye.
6. The patient is allowed to watch TV.

Complications

1. Injection site adverse reactions
2. Transient photosensitivity reactions
3. Infusion related back pain during infusion—It typically resolves as soon as the patient stands up.

BIBLIOGRAPHY

1. Arnold JJ,Blinder KJ,Bressler NM, et al. Treatment of age-related macular degeneration with photodynamic therapy (TAP) study group; verteporfin in photodynamic therapy (VIP) study group. Acute severe visual acuity decrease after photodynamic therapy with verteporfin; case reports from randomized clinical trials-TAP and VIP report no.3, Am J Ophthalmol 2004;137(4):683-96.
2. Blinder KJ, Blumenkranz MS, Bressler NM, et al. Verteporfin therapy of subfoveal choroidal neovascularization in pathologic myopia: 2- year results of randomized clinical trials-VIP report no.3, Am J Ophthalmol 2003;110:667-73.

3. Blumenkranz MS, Bressler NM, Bressler SB, et al. Treatment of age-related macular degeneration with photodynamic therapy (TAP) study group; verteporfin therapy for subfoveal choroidal neovascularization in age-related macular degeneration: 3-year results of an open-label extension of 2 randomized clinical trials-TAP report no. 5. *Arch Ophthalmol* 2002;120(10):1307-14.
4. Bressler NM. Treatment of age-related macular degeneration with photodynamic therapy (TAP) study group; photodynamic therapy of subfoveal choroidal neovascularization in age-related macular degeneration with verteporfin: 2-year results of 2 randomized clinical trials-TAP report no. 2. *Arch Ophthalmol* 2001;119(2):198-207.
5. Saperstein DA, Rosenfeld PJ, Bressler NM, et al. Photodynamic therapy of subfoveal choroidal neovascularization with verteporfin in the ocular histoplasmosis syndrome: one-year results of an uncontrolled, prospective case series. *Ophthalmology* 2002;109:1499-1505.

*Transpupillary
Thermotherapy (TTT)*

Introduction

Transpupillary ThermoTherapy (TTT) is an alternative to Photodynamic Therapy (PDT) for treatment of subfoveal choroidal neovascular membrane (CNV) secondary to wet AMD. TTT alone is effective for only small tumors (up to 4 mm in basal diameter and 2 mm in thickness).

Indications

1. Occult subfoveal choroidal neovascular membrane (CNV) in Wet AMD
2. Occult juxtafoveal choroidal neovascular membrane (CNV) in Wet AMD
3. *Retinoblastoma
4. Choroidal hemangioma
5. Choroidal melanoma.

Contraindication

1. Dry AMD
2. Choroidal neovascular membrane (CNV) within 200 μm of the optic disc.
3. Subfoveal choroidal neovascular membrane (CNV) with good visual acuity.

Mode of Action

Intralesional marginal hyperthermia (max. 10°C) occurs (Table 5.1) following exposure to large spot size, low irradiance over longer period of time from diode laser

*TTT is effective for relatively small tumors (up to 4 mm in basal diameter and 2mm in thickness) without vitreous and or subretinal seeding. Larger retinoblastomas are initially managed by chemotherapy, followed by tumor consolidation with TTT (Chemothermotherapy)

(810 nm-Infrared). This probably causes endothelial thrombosis and occlusion of the neovascular membrane, through release of free radicals, without collateral damage to the overlying photoreceptors.

Timing of Laser

Transpupillary ThermoTherapy (TTT) is done within 72 hours post recent FFA.

General Steps

1. Explain the procedure.
2. Signing informed consent.
3. Mydriasis—Pupillary dilation with Tropicamide (1%) and Phenylephrine (5%) starting 2 hour prelaser.
4. Anesthesia—1 drop topical Proparacaine HCl (0.5%) few minutes prior to photocoagulation. Peribulbar inj Lignocaine HCl in nystagmus and uncooperative patient.
5. Now, the patient is seated on the revolving stool facing the slit-lamp
6. Steady fixation—Apply head strap and adjust fixation target.
7. Insert appropriate Laser contact lens—Goldmann 3-mirror/VOLK quadraspheric lens. They are available with argon/diode bonded antireflective coating
8. Room illumination—Darkened/semi darkened
9. Adjust slit-lamp beam and parameters- The lesion is properly focused. *The laser focusing beam should be circular and overlaps equally the slit-lamp beam on either side.*

Transpupillary Thermo Therapy (TTT) Technique Proper

The CNV is illuminated with light from diode laser (810 nm). The perfectly circular beam should cover the lesion entirely.

Parameters

- **Spot size-0.8 mm/1.2 mm/2 mm/3 mm
- Exposure time-60 seconds (fixed)
- Power-200- 600 mW. It is titrated by placing a test burn in nasal retina. *Absence of reaction or minimal reaction at the level of the RPE indicates optimum power requirement.* The power also depends on the spot size. Smaller spot size requires less power. Indian eyes being more pigmented (contains more melanin pigments) require less power in comparison to European /Caucasian eyes.

Table 5.1 :Distinguishing features between PDT and TTT

Features	PDT	TTT
Laser and Wavelength (nm)	Diode, 689	Diode, 810
Laser tissue interaction	Photoradiation	Photothermal
Indications	Classic Subfoveal CNV	1. Occult subfoveal and Juxtafoveal CNV 2. Retinoblastoma 3. Choroidal hemangioma 4. Choroidal melanoma
Temperature rise— (Intralesional)	2°C	10° C
Exposure duration	83 sec.	60 sec
Post laser restrictions	Special restrictions to avoid phototoxicity	Nil
Side effects	Inj. site extra-vasations, back pain etc.	Nil
Tolerance	Not so well-tolerated	Well-tolerated
Treatment cost	Expensive	Inexpensive

**Spot size is variable and depends on size of the lesion.

Follow up Schedule

- 1st – 6 weeks post TTT.
 - FFA is a must in 1st follow up.
 - Retreatment may be considered.
- 2nd –12 weeks post TTT.

Postlaser Advice

Unlike PDT, special precautions are not advised following TTT (Table 5.1).

BIBLIOGRAPHY

1. Kumar A, Prakash G, Singh RP. Transpupillary thermotherapy in idiopathic subfoveal choroidal neovascularization. *Acta Ophthalmol Scand.* 2004;82:205-208.
2. Macular photocoagulation study group. Subfoveal neovascular lesion in ARMD.Guidelines for evaluation and treatment in the macular photocoagulation study . *Arch Ophthalmol.* 1991;109:1242.
3. Mainster MA, Reichel E. Transpupillary thermotherapy for age-related macular degeneration: Long-pulse photocoagulation,apoptosis,and heat shock proteins.*Ophthalmic Surg Lasers* 2000;31:359-73.
4. Nagpal M, Nagpal K, Sharma S, Puri J, Nagpal PN. Transpupillary thermotherapy for the treatment of choroidal neovascularization secondary to age-related macular degeneration in Indian eyes.*Indian J Ophthalmol* 2003; 51:243-50.
5. Newsom RSB,McAlister JC,Saeed M,McHugh JDA. Transpupillary thermotherapy for the treatment of choroidal neovascularization. *Br J Ophthalmol* 2001; 85(2):173-8.
6. Reichel E, Berrosal Am, et al. Transpupillary thermotherapy of occult subfoveal choroidal neovascularization in patients with age-related macular degeneration.*Ophthalmology* 1999;106(10):1908-14.

7. Shields CL, Shields JA, DePotter P, Khetrpal S. Transpupillary ThermoTherapy in management of choroidal melanoma. *Ophthalmology* 1996;116:1509-11.
8. Shields CL, Shields JA, Cater J, et al . Transpupillary thermo-therapy for choroidal melanoma. Tumour control and visual results in 100 consecutive cases. *Ophthalmology* 1998; 105:581-90.
9. Subramaniam ML, Reichel E. Current indications of transpupillary thermotherapy for treatment of posterior segment disease. *Current Opin Ophthalmol* 2003;14:155-58.
10. Verma L, Tewari HK, et al. Transpupillary thermotherapy in subfoveal choroidal neovascular membrane secondary to age-related macular degeneration. *Indian J Ophthalmol* 2004;52:35-40.

*Photocoagulation in
Peripheral Retinal
Degenerations
and Tears*

PERIPHERAL RETINAL DEGENERATIONS

Peripheral retinal degenerations include lattice degeneration, paving stone degeneration and pigmentary degeneration etc.

Indications

1. History of retinal detachment in fellow eye
2. Morphological progression of peripheral retinal degeneration
3. Appearance of subjective symptoms like lightning flashes
4. Aphakic eye.

Contraindications

1. Asymptomatic lattice degeneration without a) hole and b) history of retinal detachment in fellow eye
2. Presence of even a shallow retinal detachment around the peripheral retinal degeneration.

General Steps

1. Explain the procedure.
2. Signing informed consent.
3. Mydriasis—Maximum pupillary dilation with Tropicamide (1%) and Phenylephrine (10%) starting 2 hour prelaser.
4. Anesthesia—1 drop topical Proparacaine HCl (0.5%) few minutes prior to photocoagulation. Peribulbar inj Lignocaine HCl in nystagmus and uncooperative patient.
5. Comfortable sitting on revolving stool.
6. Steady fixation—Apply head strap and adjust fixation target.

7. Insert appropriate Laser contact lens—Goldmann 3-mirror. It is available with argon/diode bonded antireflective coating for photocoagulation.
8. Room illumination—Darkened/semi darkened.
9. Adjust slit-lamp beam.

Photocoagulation Technique Proper

1. Parameters
 - Spot size—500-800 μm
 - Exposure—0.1-0.2 sec.
 - Power—*400-600 mW
 - Pattern—Usually solitary, linear, single row and interrupted (interval = $\frac{1}{2}$ of spot size)
2. The photocoagulation burns should be placed at least 1 DD (Disc diameter) i.e. 1500 μm away from the border of the peripheral retinal degeneration (Fig. 6.1A).
3. Initially, most **anterior margins are photocoagulated.
4. If the degeneration is extensive or considerable vitreous traction is present, initial single row of coagulation may be reinforced by double row of linear, interrupted coagulation (Fig. 6.1B).

Postlaser Advice

1. Cycloplegic, e.g. Cyclopentolate Hcl (1%)-3 times daily \times 7-10 days.
2. Topical steroid- 3-4 times daily \times 7-10 days.

Complications

1. Retinal detachment
2. Choroidal rupture
3. Vitreous hemorrhage

*More peripherally located degenerations are treated with higher power.

**Anterior most retinal periphery is more difficult to visualize and the patient may cooperate better during the earlier stage of laser session.

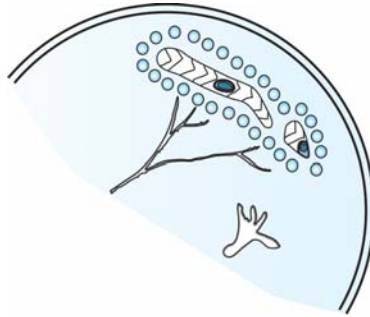


Fig.6.1A: Schematic drawing—Photocoagulation of peripheral retinal (lattice) degeneration (linear, single row, interrupted and interval = $\frac{1}{2}$ of spot size) in superotemporal periphery. Note 2 retinal holes within the lattice

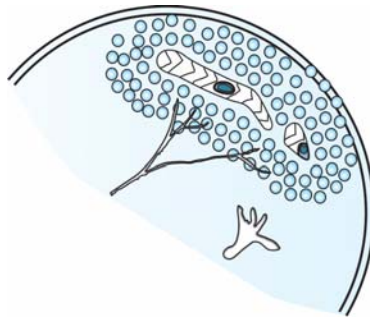


Fig.6.1B: Schematic drawing—Initial single row of coagulation is reinforced by double row of linear, interrupted laser coagulations

Follow-up

1 week → 3 weeks → 3-6 months

RETINAL BREAKS

Retinal breaks include atrophic retinal holes (without operculum), retinal holes with free floating or attached operculum and retinal tears.

Indications

1. History of retinal detachment in fellow eye.
2. Very shallow retinal detachment with little subretinal fluid (SRF).
3. Presence of vitreous traction on the margin of break or operculum.
4. Presence of vitreous or preretinal hemorrhage with a break.
5. Persistent symptomatic (Lightning flashes, shower of black spots etc.) retinal break.

Contraindications

1. Asymptomatic inferior break with pigmented margins.
2. Absence of history of retinal detachment in fellow eye.

General Steps

1. Explain the procedure.
2. Signing informed consent.
3. Mydriasis—Maximum pupillary dilation with Tropicamide (1%) and Phenylephrine (10%) starting 2 hour prelaser.
4. Anesthesia—1 drop topical Proparacaine HCl (0.5%) few minutes prior to photocoagulation. Peribulbar inj Lignocaine HCl in nystagmus and uncooperative patient.
5. Comfortable sitting on revolving stool.
6. Steady fixation—Apply head strap and adjust fixation target.
7. Insert appropriate Laser contact lens—Goldmann 3-mirror. It is available with argon/diode bonded antireflective coating for photocoagulation.
8. Room illumination—Darkened/semi darkened.
9. Adjust slit-lamp beam.

Photocoagulation Technique Proper

Parameters

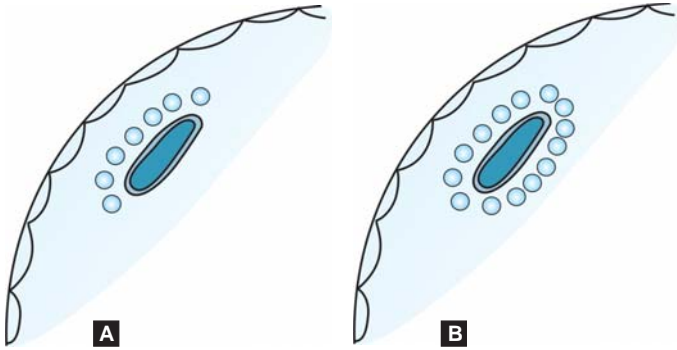
- Spot size—500-1000 μm
- Exposure—0.2-0.5 sec.
- Power—*400-600 mW
- Pattern—Usually solitary, linear, single row and interrupted (interval = $\frac{1}{4}$ of spot size) burns to surround the anterior, posterior and lateral margins of the break.
 - Initially, most** anterior margin of the break is photocoagulated (Fig. 6.2A) followed by photocoagulation of easily visible posterior margin (Fig. 6.2B)
 - In presence of considerable vitreous traction, initial single row of coagulation must be reinforced by single or double row of linear, interrupted coagulation on all margins (Fig. 6.3).
 - *The laser beam should avoid the pathway of vitreous attachment to the operculum.*
 - *The operculum of horseshoe tear should not be photocoagulated.*

Postlaser Advice

1. Cycloplegic, e.g. Cyclopentolate HCl (1%)-3 times daily \times 7-10 days.
2. Topical steroid- 3-4 times daily \times 7-10 days.

*Preretinal hemorrhage or pigment clumps present near the break or operculum absorbs more laser energy. So, in those situations less power is required.

**Anterior most retinal periphery is more difficult to visualize and the patient may cooperate better during the earlier stage of laser session.



Figs 6.2A and B: (A) Initially, most anterior margin of the break is photocoagulated (single row of linear, interrupted and interval = $\frac{1}{4}$ th of spot size coagulations); (B) Next, posterior of the break is photocoagulated (single row of linear, interrupted and interval = $\frac{1}{4}$ th of spot size coagulations)

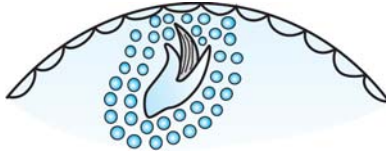


Fig.6.3: Initial single row of coagulation must be reinforced by single or double row of linear, interrupted coagulation on all margins in presence of considerable vitreous traction. The laser beam should avoid the pathway of vitreous attachment to the operculum. The operculum of horseshoe tear should not be photocoagulated

Complications

1. Extension of retinal break
2. Retinal detachment
3. Choroidal rupture
4. Vitreous hemorrhage.

Postlaser Follow-up

1 week → 3 weeks → 3-6 months

BIBLIOGRAPHY

1. American Academy of Ophthalmology. Management of posterior vitreous detachment, retinal breaks and lattice degeneration. Preferred Practice Pattern. San Francisco, CA: American Academy of Ophthalmology 1998. (I).
2. Gholam A. Peyman, Donald R. Sanders, Morton F. Goldberg (eds). Principles and Practice of Ophthalmology (1st Indian Ed.). Philadelphia: W.B. Saunders Company, 1987: 1118.
3. L'esperance FA Jr. Ophthalmic Lasers. (3rd edn.). St. Louis: CVMosby Co. 1989:291-301.

CHAPTER 7

*Photocoagulation
in Peripheral
Chorioretinal Tumors*

ANGIOMATOSIS RETINAE

Introduction

Retinal angiomas continue to enlarge and give rise to complications.

Indications

Retinal angiomas should be *photocoagulated as soon as they are detected*, otherwise they will continue to enlarge with consequent complications.

Contraindications

General Steps

- Explain the procedure-
 - Several sessions are required to obliterate a retinal angioma.
 - Visual acuity may deteriorate transiently following photocoagulation due to serous exudation in adjacent retina and hemorrhage around the tumor.
- Signing informed consent.
- Mydriasis—Maximum pupillary dilation with Tropicamide (1%) and Phenylephrine Hcl(5%) starting 2 hour prelaser.
- Anesthesia—1drop topical Proparacaine Hcl (0.5%) few minutes prior to photocoagulation. Peribulbar inj Lignocaine Hcl in nystagmus and uncooperative patient.
- Comfortable sitting on revolving stool.
- Steady fixation—Apply head strap and adjust fixation target.
- Insert appropriate Laser contact lens—Goldmann 3-mirror. It is available with argon/diode bonded antireflective coating for photocoagulation.
- Room illumination—Darkened/semi darkened.
- Adjust slit-lamp beam.

Photocoagulation Technique Proper

It involves a series of carefully planned laser sessions usually at an interval of 4-6 weeks to achieve total obliteration of the tumor mass.

1. *1st session:* Double row of punctate, linear, contiguous burns in areas of normal retina encompassing the angioma (Fig. 7.1). The idea is to prevent post laser extensive serous retinal detachment.

Parameters:

- Spot size—500 μm
- Exposure—0.2sec.
- Power—200 mW

2. *2nd session:*

- a. If the feeder and draining vessels are not too large, they are photocoagulated directly along with the tumor. The arteries (feeder) are treated first followed by the veins (draining) using following parameters (Figs 7.2A and B):

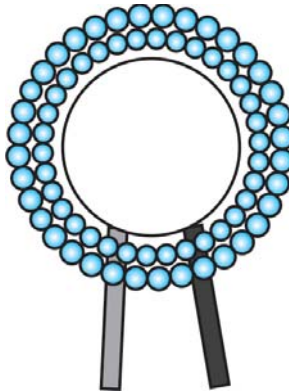
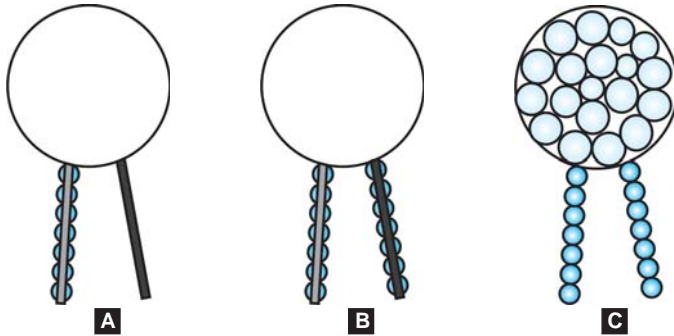


Fig. 7.1: Double row of punctate, linear, contiguous burns in areas of normal retina encompassing the angioma



Figs 7.2A to C: (A) If the feeder and draining vessels are not too large, they are photocoagulated directly along with the tumor. The arteries (feeder) are treated first; (B) Followed by the draining veins; (C) When flow of blood to the angioma is visibly decreased, the retinal angioma is photocoagulated directly

- Spot size—*500 μm
- Exposure—0.2-0.5 sec.
- Power—150-250 mW

When flow of blood to the angioma is visibly decreased, the retinal angioma is photocoagulated directly with the following laser parameters:

- Spot size—500-1000 μm
- Exposure— ≥ 0.5 sec.
- Power—**250-350 mW
- Pattern—contiguous, directly on the angioma (Fig. 7.2C)

b. If the tumor is either small or decreases in size following direct treatment, following parameters are employed:

- Spot size—500 μm

*The spot size should be at least 50% larger than the feeder vessels.

**Power should be sufficient enough to produce visible shrinkage of the tumor mass during the laser session.

- Exposure—0.5 sec.
 - Power—250-350 mW
 - Pattern—contiguous, directly on the angioma (Fig. 7.3)
 - The tumor mass is treated directly with contiguous burns of smaller spot size to occlude the blood vessels within the tumor mass.
- c. If the tumor is large and the feeder and draining vessels are too large, the tumor is directly photo-coagulated with the following parameters ;
- Spot size—500-1000 μm
 - Exposure— ≥ 0.5 sec.
 - Power—250-350 mW
 - Pattern—contiguous, directly on the angioma (Fig. 7.4).

Postlaser Advice

1. Cycloplegic, e.g. Cyclopentolate HCl (1%)-3 times daily $\times \geq 21$ days.
2. Topical steroid- 4-6 times daily $\times \geq 21$ days.

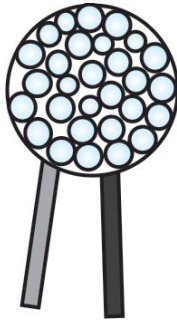

Fig. 7.3: If the tumor is either small or decreases in size following direct treatment (as in Fig.7.2C) → The tumor mass is treated directly with contiguous burns of smaller spot size to occlude the blood vessels within the tumor mass

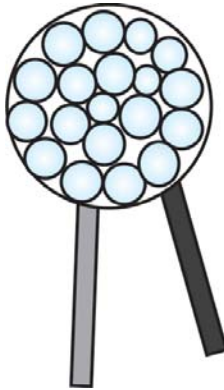


Fig.7.4: If the tumor is large and the feeder and draining vessels are too large → The tumor is directly photocoagulated

Complications

1. Extensive hemorrhage from the tumor mass- devastating and potentially sight threatening
2. Serous detachment of adjacent retina-usual
3. Hemorrhages around the angioma-usual

Postlaser Follow-up

1 week → 2 weeks → 3weeks → 4weeks

Each laser session is at an interval of 4-6 weeks to allow time for healing of serous detachment and hemorrhages around the angioma.

RETINOBLASTOMA

Introduction

Photocoagulation of retinoblastoma should be preferably done with xenon coagulator. However, xenon coagulators are actually rare to find nowadays.

Indications

1. Retinoblastoma is primarily treated with photocoagulation if only following criteria's are fulfilled;
 - Retinoblastoma is isolated from the optic disc.
 - Retinoblastoma is located at least 2DD from the foveola.
 - Retinoblastoma is confined to neurosensory retina without vitreous seeding.
 - Located in the posterior pole upto 4DD posterior to the equator.
 - Retinoblastoma is entirely visually accessible for photocoagulation through indirect ophthalmoscope.
 - Considered in less affected eye in bilateral cases.
2. As a supplementary treatment following initial cryotherapy or radiotherapy.

Contraindications

1. Lesions anterior to the equator-Easily treated by cryoretinopexy
2. Lesions where above criteria's are lacking.
Advent of TTT has replaced photocoagulation as the modality of treating retinoblastoma (see chapter 5).

General Steps

1. Explain the procedure to parents –Multiple session is required.
2. Signing informed consent.
3. Maximal Mydriasis—Pupillary dilation with Tropicamide (1%) and Phenylephrine (2.5%) starting 2 hour prelaser.
4. Anesthesia—*Local anesthesia/sedation/general anesthesia* .1drop topical Proparacaine HCl (0.5%) few minutes prior to photocoagulation. *Anesthetist should be physically present to monitor the vital signs.*

5. Insert lid speculum.
6. Room illumination—Darkened/semi darkened
7. Photocoagulation system—Argon laser is delivered through Binocular Indirect Ophthalmoscope (LIO).+20 D and ***+28 D lens are used.
8. All people present in the procedure room should wear laser safety goggles.

Photocoagulation Technique Proper

It involves a series of carefully planned laser sessions usually at an interval of 2 weeks to achieve total obliteration of the tumor mass.

1st session: Single row of linear, contiguous, non-overlapping Argon laser burns in areas of normal retina around the periphery of the retinoblastoma (Fig.7.5). The idea is to obliterate the blood supply to the tumor mass.




Fig. 7.5: Single row of linear, contiguous, non-overlapping Argon laser burns in areas of normal retina around the periphery of the Retinoblastoma to obliterate the blood supply to the tumor mass

***+28 D lens is used for wider view of the retinal periphery.

Parameters:

- Spot size—200 μm
- Exposure—0.5 sec.
- Power—300-600 mW
- Intensity—grade 4
- Pattern- contiguous, non-overlapping

2nd session: Direct treatment of the tumor mass.

Parameters:

- Spot size—200mm
- Exposure—0.5 sec.
- ****Power—300-600 mW
- Intensity—grade 4
- Pattern—contiguous, directly on the retinoblastoma (Fig. 7.6)

Complications

1. Hemorrhage from the tumor mass
2. Seeding of the tumor cells in the vitreous

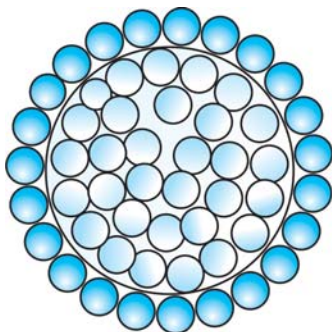


Fig.7.6: Direct treatment of the tumor mass

****Higher power should be avoided to prevent explosion of the tumor mass with attendant complication of seeding of the tumor cells in the vitreous.

3. Serous retinal detachment
4. Preretinal; fibrosis.

Post Laser Follow-up

Each laser session is at an interval of 2 weeks.

MALIGNANT MELANOMA

Introduction

Photocoagulation of malignant melanoma should be preferably done with xenon coagulator. However, xenon coagulators are actually rare to find nowadays. *However, photocoagulation has a limited role in the management of choroidal malignant melanoma. In addition, exudative retinal detachment interferes with the photocoagulation.*

Indications

1. Small malignant melanoma is primarily treated with photocoagulation if only following criteria's are fulfilled;
 - Malignant melanoma is isolated from the optic disc by atleast 2DD and outside the vascular arcade.
 - Located in the posterior pole posterior to the equator.
 - Malignant melanoma is entirely visually accessible for photocoagulation through indirect ophthalmoscope.
 - Malignant melanoma is < 6 DD in lateral extension.
 - Malignant melanoma < 2DD (3mm) in height.
 - Absence of exudative retinal detachment.
2. As a preparatory treatment before surgical resection of eye wall.

Contraindications

1. Lesions anterior to the equator.
2. Small lesions where above criteria's are lacking.

3. Large malignant melanoma.
4. Amelanotic tumors.

General Steps

1. Explain the procedure—Several sessions are required to obliterate a malignant melanoma.
2. Signing informed consent.
3. Mydriasis—Maximum pupillary dilation with Tropicamide (1%) and Phenylephrine Hcl(5%) starting 2 hour prelasers.
4. Anesthesia—1 drop topical Proparacaine Hcl (0.5%) few minutes prior to photocoagulation. Peribulbar inj Lignocaine Hcl in nystagmus and uncooperative patient.
5. Comfortable sitting on revolving stool.
6. Steady fixation—Apply head strap and adjust fixation target.
7. Insert appropriate Laser contact lens—Goldmann 3-mirror .It is available with argon/diode bonded antireflective coating for photocoagulation.
8. Room illumination—Darkened/semi darkened.
9. Adjust Slit—lamp beam.

Photocoagulation Technique Proper

It involves a series of carefully planned laser sessions usually at an interval if 3-4 weeks to achieve total obliteration of the tumor mass.

1st session: Double row of contiguous burns in areas of normal retina 360° encompassing the tumor (Fig. 7.7). The idea is to occlude the choroidal feeding vessels and preventing spread of retinal detachment . Parameters ;

- Spot size—500-1000 µm
- Exposure—0.2-0.5 sec.

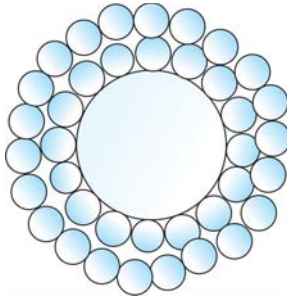


Fig. 7.7: Double row of contiguous burns in areas of normal retina 360° encompassing the tumor. The idea is to occlude the choroidal feeding vessels.

- Power—500-1250 mW
- Intensity—grade 4
3-4 weeks time is allowed to develop hyperpigmented scar at the photocoagulation site.

2nd and 3rd session: The hyperpigmented scar site is treated twice at interval of 3-4 weeks utilizing the same parameters.

4th session: The peripheral tumor mass is photocoagulated with single/double row of contiguous laser burns in centripetal fashion (Fig.7.8) utilizing the same parameters.

5th session: The central mass of the malignant melanoma is treated utilizing the same parameters.

Postlaser Advice

1. Topical Cycloplegic, e.g. Cyclopentolate Hcl (1%)-3 times daily.
2. Topical steroid—4-6 times daily.

Complications

1. Retinal break → Rhegmatogenous retinal detachment
2. Vitreous hemorrhage

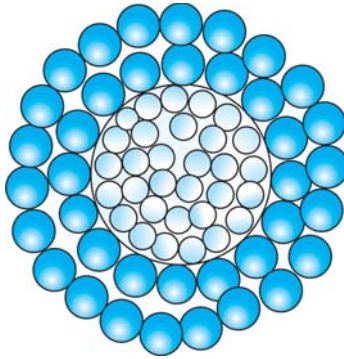


Fig.7.8: The peripheral tumor mass is photocoagulated with single/double row of contiguous laser burns in centripetal fashion

3. Macular edema
4. Seeding of the tumor cells in the vitreous.

BIBLIOGRAPHY

1. Gholam A Peyman, Donald R Sanders Morton F Goldberg (eds). Principles and Practice of Ophthalmology (1st Indian Ed.). Philadelphia:W.B.Saunders Company. 1987:1116-18
2. Goldberg MF,Koenig S. Argon laser treatment of von Hippel-Lindau retinal angiomas:I.Clinical and angiographic findings. Arch Ophthalmol 1974;92:121.
3. Höpping W: Photocoagulation in the treatment of retinoblastoma.In Current Diagnosis and Management of Chorioretinal Diseases. FA.L'esperance, Jr (ed). St. Louis: CVMosby Co. 1977:540-43.
4. L'esperance FA Jr. Ophthalmic Lasers.(3rd edn.). St. Louis: CVMosby Co. 1989:425-451.
5. Riaskoff S: Some aspects of photocoagulation treatment of intra-ocular vascular tumors and malignant melanoma of the choroids.Doc Ophthalmol 1977;42:303.

6. Shields JA. The expanding role of laser photocoagulation for intraocular tumors. The 1993 H. Christian Zweng Memorial Lecture. *Retina* 1994;14:310-22.
7. Shields JA, Shields CL, Donoso LA. Management of posterior uveal melanoma. *Surv Ophthalmol* 1991;36:161-95.
8. Vogel MH. Treatment of malignant choroidal melanomas with photocoagulation. *Am J Ophthalmol* 1972;74:1.

*Photocoagulation
in Retinal Venous
Occlusion*

In central retinal vein occlusion (CRVO), the site of occlusion is posterior to cribriform plate whereas, in branch retinal vein occlusion (BRVO), the site of occlusion is anterior to cribriform plate and usually at the arteriovenous (AV) crossings. Hence, *Vasculitis should be suspected, when the site of occlusion in branch retinal vein occlusion (BRVO) is not at the arteriovenous (AV) crossings.*

Photocoagulation in BRVO

In BRVO, the collaterals develop within the retina between normal retina and retinal areas affected by the BRVO. In BRVO, *3 months time is allowed for spontaneous recovery and development of collaterals, before considering the laser option. Retinal hemorrhages should also be sufficiently absorbed before contemplating on the laser procedure.*

Timing of Laser

In BRVO, photocoagulation performed at least 3 months after the attack. However, it should be performed within 18 months of onset.

Indication

1. Grid Laser—Persistent macular edema responsible for $\leq 6/12$ (or $20/40$) vision with intact perifoveal capillary network, in BRVO of at least 3 months duration.
2. Scatter/PRP—Retinal neovascularisation (NVE and or NVD), in BRVO of at least 3 months duration.

Contraindication

1. Macular nonperfusion, i.e. ischemia demonstrated fluorescein angiographically.
2. Reduced visual acuity due to RPE changes demonstrated fluorescein angiographically

Technique proper- GRID LASER-IN BRVO

Parameters

- Exposure time—0.1 sec.
- Spot size—100-200 μm
- Intensity of burn-mild, 1 burn/spot size width apart
- Location and pattern—Same as for grid laser in diabetic maculopathy (see grid laser in Chapter-3)
 - The grid laser may extend upto the border of the FAZ i.e.; 500 μm from the macular center and from arcade to arcade.
 - Laser burns are applied over areas of capillary leak.
 - It may be done over areas of papillomacular bundle.
 - Photocoagulation should be avoided over areas of retinal hemorrhages, unless diode or krypton laser is used.

Technique Proper- Scatter/PRP-In BRVO

It may be done either in combination with grid laser or alone for treatment of retinal neovascularisation (NVE and or NVD). *In BRVO, the new vessels are found usually at the junction of the normal and ischemic retina.*

Parameters

Exposure time—0.1 sec.

Spot size—200-500 μm

Intensity of burn-moderate, 1 burn/spot size width apart

Location and pattern of scatter-Same as for scatter/PRP in diabetic retinopathy (see scatter laser in Chapter-2). *However, the scatter burns are applied only on the sector/segment of retina affected by capillary nonperfusion in BRVO (Figs 8.1 and 8.2).*

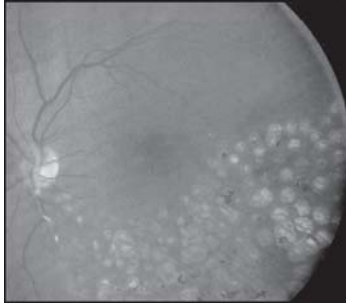


Fig. 8.1: Lasered BRVO (For color version see Plate 1)

(Courtesy: Ashok garg, J T lin, Jorge L Alio, Azad R, Jerome Jean Bovet, Bojan Bajic and Cyres K Mehta (Eds.): Natarajan S et all In: Ophthalmic Lasers for Posterior Segment Diseases, page 482, 2008, with permission from Jaypee Brothers Medical Publishers Pvt. Ltd. New Delhi)

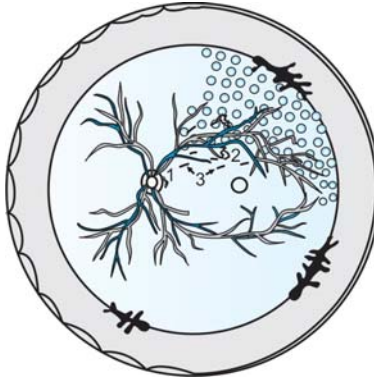


Fig. 8.2: Superotemporal BRVO-Sector Scatter/PRP
(Schematic drawing)

1 = NVD, 2 = NVE and 3 = Hard exudates/absorbed hemorrhage

- The scatter burns are typically placed 2DD (3000 μm) away from the macular center (see scatter laser in Chapter 2).

- Photocoagulation should be avoided over areas of retinal hemorrhages unless longer wavelength krypton red or diode (810 nm) laser is used

Follow up schedule—Every 4 months

1st follow up-4 months postlaser

- FFA is a must in 1st follow up
- If macular edema persists along with diminished visual acuity. additional grid photocoagulation may be considered.
- If neovascularization persists or aggravates additional scatter laser may be considered.

2nd follow up-8 months post laser.

Photocoagulation in CRVO

In CRVO, the collaterals develop on the optic disc between the retinal and choroidal circulation. In ischemic CRVO, new vessels usually develop on the iris (NVI) and angle of the anterior chamber/trabecular meshwork (NVA).

Timing of laser

CRVO patients should be examined at monthly interval during immediate 6-month post CRVO period. Routine undilated slit-lamp examination and gonioscopy is a must to detect early new vessels iris (NVI) and angle of the anterior chamber/trabecular meshwork (NVA) in monthly check ups.

Indication

1. Prompt/immediate PRP Laser—(a) In ischemic CRVO with rubeosis iridis (NVI) and or NVA. (b) In ischemic CRVO with NVE and or NVD.

2. Prophylactic PRP Laser—In CRVO when close follow up is not possible.

Macular grid laser has got no role even in CRVO with macular edema. Only PRP is done in CRVO when indicated.

High-risk characteristics in CRVO

- 1 month of symptoms
- Visual Acuity <6/60 (or 20/200)
- Angiographically extensive areas of capillary non-perfusion.

Technique Proper- PRP/Scatter Laser-In CRVO

Parameters

Exposure time—0.1-0.5 sec.

Spot size—500-1000 μm

Intensity of burn-moderate, $\frac{1}{2}$ -1 burn/spot size width apart

No. of burn—1200-2000

Location and pattern—Same as for scatter /PRP laser in diabetic retinopathy using ETDRS protocol (see PRP laser in Chapter 2)

- Presence of extensive areas of unresolved hemorrhage may prevent full laser application in all quadrants.
- Photocoagulation should be avoided over areas of retinal hemorrhages, unless diode or krypton laser is used.

Follow up schedule

Every month till regression of new vessels

1st follow up-1 month postlaser

- *Undilated Slit-lamp examination and gonioscopy is a must to detect regression of new vessels (NVI and NVA).*

After regression of new vessels the follow up is carried out at 3 months interval.

Indications for retreatment

1. Persistent NVI and NVA.
2. Aggravation of NVI and NVA.

BIBLIOGRAPHY

1. Branch vein occlusion Study Group: Argon laser photocoagulation for macular edema in branch vein occlusion. *Am J Ophthalmol* 1984;98:27.
2. Branch vein occlusion Study Group: Argon laser photocoagulation for macular edema in branch vein occlusion. *Am J Ophthalmol* 1985;99:219.
3. Branch vein occlusion Study Group: Argon laser photocoagulation for prevention of neovascularization and vitreous hemorrhage in branch vein occlusion.; A randomized clinical trial. *Arch Ophthalmol* 1986;104:34-41.
4. Das Arup, Framback DA. Retinal branch vein occlusion :In *Medical and Surgical Retina*. St.Louis : CVMosby:374-381.
5. David B.Karlin (ed). *Lasers in Ophthalmic Surgery*. Blackwell Science Inc.1995.
6. Steven M. Bloom,Alexander J.Brucker(eds). *Laser Surgery of the Posterior Segment* (2nd ed). Philadelphia:Lippincott-Raven,1997.
7. The Central Retinal Vein Occlusion Group. A randomized clinical trial of early panretinal photocoagulation for ischemic central vein occlusion. The central vein occlusion study group N report. *Ophthalmology* 1995;102:1434-44.
8. The Central Vein Occlusion Study Group M report. Evaluation of grid pattern photocoagulation for macular edema in central vein occlusion. *Ophthalmology* 1995; 102(10): 1425-33.

*Photocoagulation
in Miscellaneous
Retinal Diseases*

RETINAL VASCULITIS

Introduction

Eales' disease is inflammatory retinal vasculitis of idiopathic origin, clinically characterized by phlebitis, peripheral retinal nonperfusion and peripheral neovascularization, mainly seen in young adult male and presents with recurrent vitreous hemorrhage. Now it was termed as "Retinal Perivasculitis" since both the arteries and veins could be involved

Proliferative retinopathy in Eales' disease can be efficiently treated by photocoagulation based on the same principle used in Branch retinal venous occlusion (BRVO). However, the phlebitis in Eales' disease differs from BRVO on certain points:

- Vasculitis should be suspected, when the site of occlusion in branch retinal vein occlusion (BRVO) is not at the arteriovenous (AV) crossings.
- Usually BRVO is present in more than one site.
- Disc neovascularization is (NVD) more commonly seen. However, NVE is more common than NVD in Eales' disease and is usually located at the junction between perfused and nonperfused retina.
- The development of new vessels (NVE and NVD) is often accelerated, requiring early prompt intervention with intensive photocoagulation.

Indications

1. Eales' disease—Mainly indicated for ischemic and proliferative stages (Stage II and III).
2. Other causes of retinal vasculitis:
 - Pars planitis
 - Sarcoidosis

- CMV retinitis
- Behcet's disease.

Contraindication

1. Presence of active inflammation, i.e. phlebitis.
2. Stage I and IV of Eales' disease.

Timing of Laser

Photocoagulation is done in Eales' disease/retinal vasculitis only after the inflammation subsides or is brought under control by oral steroid.

In Eales' disease/retinal vasculitis photocoagulation can be delivered through Slit-lamp biomicroscope/ Bino-cular indirect ophthalmoscope/Endolaser.

General Steps

1. Explain the procedure.
2. Signing informed consent.
3. Mydriasis—Pupillary dilation with Tropicamide (1%) and Phenylephrine (5%) starting 2 hour prelaser.
4. Anesthesia—1drop topical Proparacaine Hcl (0.5%) few minutes prior to photocoagulation. Peribulbar inj Lignocaine HCl in nystagmus and uncooperative patient.
5. Now, the patient is seated on the revolving stool facing the Slit-lamp
6. Steady fixation—Apply head strap and adjust fixation target.
7. Insert appropriate Laser contact lens—Goldmann 3-mirror/VOLK quadraspheric lens. They are available with argon/diode bonded antireflective coating Room illumination-Darkened/semi darkened
8. Adjust Slit-lamp beam and parameters—The lesion is properly focused.

Photocoagulation Technique Proper

Technique of “Anchoring photocoagulation” is employed to eliminate or lessen complications.

Photocoagulation of new vessels around posterior pole:

1. Session-1- Anchoring the retina to the choroids.

Parameters

- Spot size—200-300 μm
 - Intensity-Moderate to strong
 - Placement-Focal burns around the neovascular tissue along temporal arcade are used. All neovascular extensions are similarly covered with focal photocoagulation burns.
 - Additional sector PRP may be done prophylactically, if vitreous hemorrhage is anticipated.
2. Session-2—It is undertaken after 3 weeks when photocoagulation scars are well formed, i.e. anchoring the retina to the choroids.
 - PRP is done in more than 1 sitting to cause peripheral retinal ablation using mild to moderate intensity burn. Following PRP regression of new vessels occurs.
 - In situations where PRP is not possible due to presence of vitreous hemorrhage or florid new vessels, peripheral cryoretinopexy would help in regression of new vessels.

Photocoagulation of peripheral new vessels:

1. Session-1—Anchoring the retina to the underlying choroids.

Parameters

- Spot size—200-300 μm
- Intensity—Moderate to strong
- Placement—Focal burns surrounding the neovascular tissue are used. Anchoring photocoagulation is extended along the draining venules. This

is done to prevent retinal breaks to develop when shrinking vascularised mass is pulled up into the vitreous.

- Usually, crimping of new vessels is performed prior to photocoagulation to lessen the chances of hemorrhage.
 - Additional sector PRP may be done anterior to the neovascular tissue.
 - In sector PRP the laser burns should extend 1500 μm anterior and posterior to the new vessels. It should also extend 1 clock hour on either side of the lesion.
2. Session-2—It is undertaken after 3 weeks when photocoagulation scars are well formed.
- *PRP is done in more than 1 sitting to cause peripheral retinal ablation using mild to moderate intensity burn. Following PRP regression of new vessels occurs.

Postlaser Advice

Systemic steroids are advised for few days.

Follow up Schedule

1st – 4 weeks postlaser

- FFA and meticulous fundus examination is a must in 1st follow up.
- Retreatment may be considered.

2nd – Every 4 weeks post 1st follow up.

Complications

- Vitreous hemorrhage
- Preretinal hemorrhage.

*However, indiscriminate PRP has no role in the treatment of peripheral neovascularization secondary to retinal vasculitis.

- Macular distortion
- Retinal break
- Rhegmatogenous retinal detachment.

CENTRAL SEROUS CHOROIDOPATHY (CSC)

Introduction

Central serous choroidopathy is:

- **Formerly known as central serous retinopathy (CSR).**
- Noninflammatory in nature
- Unknown etiology in origin.
- Affects usually young adult males.
- Characterized by serous macular detachment. Defect(s) in the RPE allows choroidal fluid to leak into the sub-retinal space.
- Occasionally associated with RPE detachment, sub-retinal yellow punctate precipitates and RPE changes.
- FFA shows $1 \geq$ points of progressive hyperfluorescence identifying the location of leakage(s) through the RPE into the subretinal space.

Indications

1. Persistent CSC of > 4-6 months duration.
2. Recurrent CSC with visual acuity < 6/12.
3. Chronic CSC.
4. Occupational need of the patient requires prompt recovery of vision.
5. Well-defined leaks > 500 μm away from the foveal center with a visual acuity of < 6/12.

Contraindication

Leak(s) within 500 μm from the foveal center.

Central serous choroidopathy spontaneously resolves in upto 90% cases within 1-6 months after onset. Hence,

laser therapy is not recommended primarily. Only reassurance and observation upto 4-6 months for spontaneously resolution is the recommended protocol. ****Systemic steroids are not advised.**

General Steps

1. Explain the procedure.
2. Signing informed consent.
3. Mydriasis—Pupillary dilation with Tropicamide (1%) and Phenylephrine (5%) starting 2 hour prelaser.
4. Anesthesia—1 drop topical Proparacaine HCl (0.5%) few minutes prior to photocoagulation. Peribulbar inj Lignocaine HCl in nystagmus and uncooperative patient.
5. Now, the patient is seated on the revolving stool facing the Slit-lamp.
6. Steady fixation—Apply head strap and adjust fixation target.
7. Insert appropriate Laser contact lens—Goldmann 3-mirror/Mainster standard lens. They are available with argon/diode bonded antireflective coating Room illumination-Darkened/semi darkened
8. Adjust Slit-lamp beam and parameters—The lesion is properly focused.

Photocoagulation Technique Proper

The pinpoint leak(s) is focally treated.

Parameters

- Spot size- ***100-200 μm

**There is no known medical treatment for CSC.

***Smaller spot size with higher power should be avoided to prevent break in Bruch's membrane with subsequent CNV membrane formation.

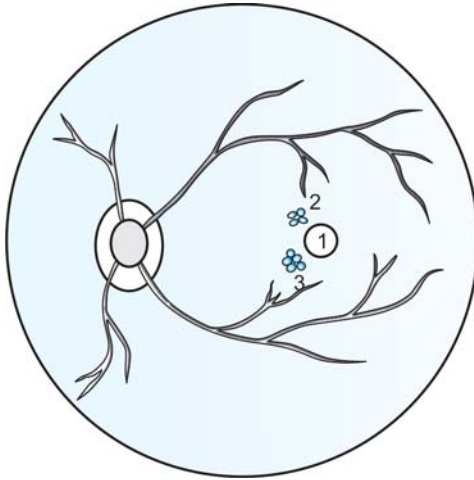


Fig. 9.1: Focal laser of 2 pinpoint leaks > 500 μm away from the foveal center in CSC (Schematic drawing)

1 = FAZ (500 μm in diameter), 2 and 3 = Confluent 4- 5 laser spots

- Exposure duration—0.1 sec
- Power—100-200 mW
- Intensity—Grade 2
- Pattern—3-5 confluent burns (Fig. 9.1).

Follow up Schedule

- 1st – 2 weeks postlaser
 – OCT may be considered.
- 2nd– Every 2 weeks post 1st follow up.

Complications

- Development of CNV membrane
- Accidental foveal damage
- Scotoma

RETINOPATHY OF PREMATURETY(ROP) RETROLENTAL FIBROPLASIA

Introduction

ROP is characterized by proliferation of abnormal vessels in premature infant's peripheral retina. Blinding sequelae of ROP can be prevented only by timely intervention in infants at high-risk for progression. The intervention includes proper and complete ablation of the avascular retina by either cryoretinopexy or photocoagulation of all affected retinal quadrants.

International Classification of ROP 1984 (modified in 1987)

The international classification of Retinopathy of Prematurity(ICROP) is based on:

1. Stages of vascular proliferation (Table 9.1)
2. Location of the disease (Table 9.2 and Fig. 9.2)
3. Extent of the disease

It is counted in clock hours (contiguous/cumulative).

Plus disease refers to presence of tortuous dilated vessels in zone I and iris.

Rush disease (Fulminant variety) refers to presence of plus disease (tortuous dilated vessels in zone I) along with

Table 9.1: ROP- Stages of vascular proliferation (ICROP)

<i>Stage</i>	<i>Characteristics</i>
1	Demarcation line
2	Ridge
3	Ridge with fibrovascular proliferation
4	Subtotal retinal detachment
	a. Extrafoveal
	b. Foveal
5	Total retinal detachment

Table 9.2: ROP- Location of the disease (ICROP)

Zone	
I	A circle surrounding the optic disc that extends to twice the distance from the optic disc to the fovea.
II	Area anterior to Zone I, extending nasally upto ora serrata but not reaching temporal ora serrata.
III	Area remaining- temporal crescent of anterior retina.

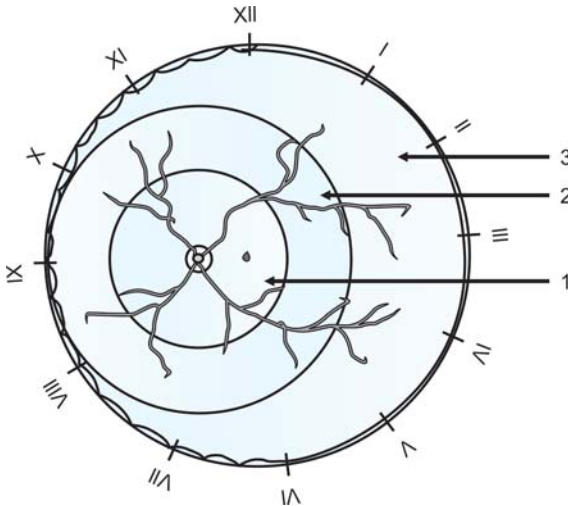


Fig.9.2: ROP- Location of the disease (ICROP).

1 = Zone I, 2 = Zone II and 3 = Zone III

iris neovascularization, shallow AC and small non-dilating pupil.

Indications

Threshold ROP (Stage 3, Zone 1 or 2, Extent 5 contiguous or 8 cumulative).

Timing of Laser

Within 24 to 48 hours of diagnosis

General Steps

1. Explain the procedure to parents.
2. Signing informed consent.
3. Maximal Mydriasis—Pupillary dilation with Tropicamide (1%) and Phenylephrine (2.5%) starting 2 hour prelaser.
4. Anesthesia—*Local anesthetic/sedation*. 1 drop topical Proparacaine HCl (0.5%) few minutes prior to photocoagulation. *Neonatologist/anesthetist should be physically present to monitor the vital signs.*
5. Insert sterilized lid speculum (pediatric).
6. Room illumination—Darkened/semi darkened
7. Photocoagulation system—Diode laser (810 nm) is delivered through Binocular Indirect Ophthalmoscope (BIO). +20 D and ****+28 D lens are used.
8. All people present in the procedure room should wear laser safety goggles.

Photocoagulation Technique Proper

Parameters

The parameters are carefully titrated to achieve desired intensity of laser burn. It should be remembered that posterior retina requires more energy.

- Spot size—100 μm
- Exposure duration—0.3 sec
- Power—300 mW
- Intensity—Grade 2

****+28 D lens is used for wider view of the retinal periphery.

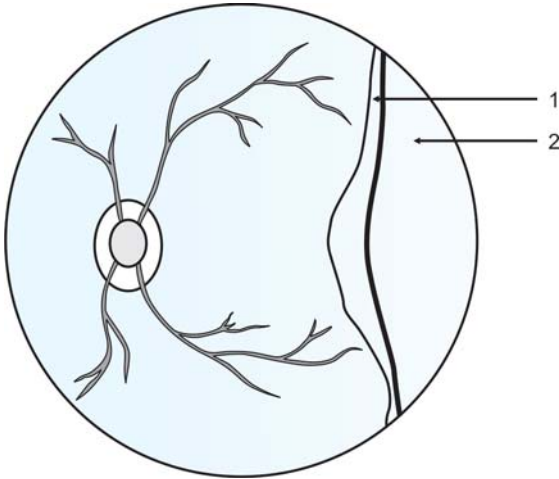


Fig. 9.3: ROP in temporal retinal periphery (Schematic drawing)
1 = Mesenchymal ridge, 2 = Avascular area

- Pattern—Nearly confluent or $\frac{1}{2}$ burn width apart. Photocoagulate the entire avascular area anterior to the mesenchymal ridge upto the ora serrata (Figs 9.3 and 9.4). *Photocoagulation over and posterior to the mesenchymal ridge should be avoided.*
 - Start with the most posterior avascular zone and adjacent to the most severe pathological area.
 - Usually, temporal area is treated at first.
 - Initially treat as many areas possible without indentation and minimal rotation of the eyeball. Subsequently, treat residual areas with indentation (using sterilized pediatric scleral depressor /Johnson ear buds/ wire vectis) and rotation of the eyeball.

Follow up Schedule

1st – 1week-post laser

- Look for skipped areas

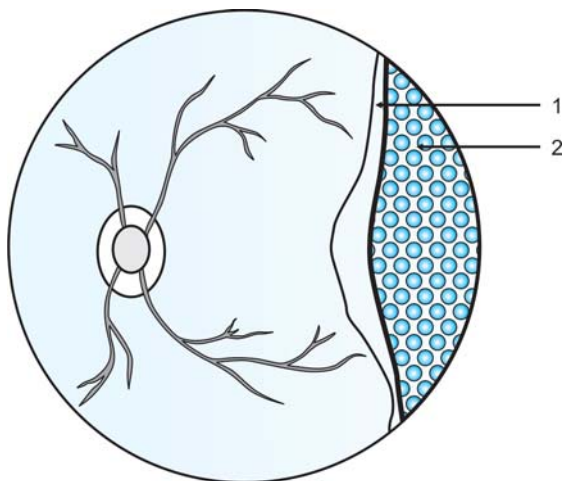


Fig. 9.4: Photocoagulation in ROP (Schematic drawing), 1= Mesenchymal ridge, 2= Avascular area treated with diode laser burns

- Look for signs of regression
 - o Flattening of mesenchymal ridge
 - o Disappearance of mesenchymal ridge
- 2nd – 2weeks-post laser
- Look for signs of regression (*visible within 2 weeks post laser*)
 - Retreatment may be considered in the absence of signs of regression
 - Treat skipped areas
- Every 2-4 weeks interval post regression of ROP.

Complications

- Hyphema
- Iris burn
- Retinal detachment

- Accidental burn over and posterior to the mesenchymal ridge
- Corneal haziness—More common with the Argon laser
- Systemic complications—Apnea, bradycardia, arrhythmia and seizure.

BIBLIOGRAPHY

1. Annesley WH, Jr, Tasman, WS, LeWin DP, Tomer TS. Retrospective evaluation of photocoagulation for idiopathic central serous chorioretinopathy. *Mod Probl Ophthalmol* 1974;12:234.
2. Azad RV, Chandra P. Retinopathy of prematurity screening and management. *J Indian Medical Assoc* 2003;101(100): 593-6.
3. Azad RV, Sethi A, Kumar H. Management outcome in pre-threshold retinopathy of prematurity. *J of Ped Ophthalmol Strabismus* 2003;40(6):330-34.
4. Committee for the classification of Retinopathy of Prematurity: An international classification of Retinopathy of Prematurity. *Arch Ophthalmol* 1984;102:1130-34.
5. Das TP, Biswas J, Kumar A, et al. Eale's Disease. *Ind J Ophthalmol* 1994;42:3.
6. Das TP, Namperumalsamy P. Combined photocoagulation and cryotherapy in treatment of Eale's retinopathy. *Proc All Ind Ophthalmol Soc* 1987;45:108.
7. Early treatment of Retinopathy of Prematurity cooperative group: Revised indication for treatment of retinopathy of prematurity; results of the early treatment for retinopathy of prematurity randomized trial. *Arch Ophthalmol* 2003; 121:1684-96.
8. Greite J-H, Birngruber R. Low intensity argon laser coagulation in central serous retinopathy (CSR). *Ophthalmologica* 1975;171:214.
9. Gholam A. Peyman, Donald R. Sanders, Morton F. Goldberg (eds). *Principles and Practice of OPHTHALMOLOGY* (1st Indian Ed.). Philadelphia:WB Saunders Company, 1987:1116-17.

10. Hurley BR, McNamara JA, Fineman MS, et al. Laser treatment for retinopathy of prematurity. Evolution of treatment technique over 15 years: *Retina* 2006;26 (7 suppl.): S16-17
11. ICROP committee for classification of late stages of ROP. An international classification of Retinopathy of Prematurity II; the classification of Retinal detachment. *Arch Ophthalmol* 1987;105:906-12.
12. Kalsi R, Patnaik B. The developing features of phlebitis retinae (A vertical study). *Ind J Ophthalmol* 1979;27:87.
13. L'esperance FA Jr. *Ophthalmic Lasers*. (3rd edn.). St. Louis: CVMosby Co. 1989;492-501.
14. Patnaik B, Kalsi R. Understanding and management of Eale's Disease. *Acta XXV concillium Ophthalmologicum* 1987:2200.
15. Samy CN, Garoudas ES. Laser photocoagulation treatment of central serous chorioretinopathy. *Int Ophthalmol Clin* 1994; 34(3):109-19.
16. Watzke RC, Burton TC, Woolson Rf. Direct and indirect laser photocoagulation of central serous choroidopathy. *Am J Ophthalmol* 1979;66:914-18.



Section Two

**Laser Surgery
in Glaucoma
and on Iris**

CHAPTER 10

Argon Laser Trabeculoplasty (ALT)

Introduction

Application of continuous wave Argon Laser either bichromatic* blue-green (454.4–528.7 nm) or monochromatic green (514.5 nm) non penetrating coagulative burns to the trabecular meshwork (TM) results in improved aqueous outflow.

Mode of Action

Improvement of aqueous outflow is quite complex and yet not fully understood. Laser thermal energy is absorbed by pigmented trabecular meshwork. Possibly this causes increased space in intertrabecular space due to shrinkage of collagen fibrils of trabecular lamellae and leads to increased aqueous outflow through the trabecular meshwork. Shrinkage of collagen fibrils also tightens the trabecular meshwork ring and opens up drainage pores. Rodrigues et al suggested that fibrosis induced at the laser site also results in inward bowing of the trabecular meshwork and further opening of Schlemm's canal. Macrophages migrate into the treated area and engulf extracellular matrix (ECM). Laser induced removal of trabecular cells further stimulate formation of ECM with altered composition to improve aqueous outflow.

Indications

1. Primary open angle glaucoma (POAG):
 - Inadequately controlled with maximal medical therapy
 - With poor patient compliance
 - As a prior choice to filtration surgery
 - Patient unfit for filtration surgery

*The laser surgeon may suffer from subtle change in color vision on long-term exposure to argon blue light.

2. Majority of secondary open angle glaucoma:
 - Pigmentary glaucoma
 - Pseudoexfoliation syndrome
 - Juvenile glaucoma
 - Angle recession glaucoma.

Contraindications

1. **Narrow angle
2. Poor visibility due to corneal opacity or hazy media
3. Congenital glaucoma
4. Inflammatory glaucoma
5. Neovascular glaucoma
6. Aphakic glaucoma with vitreous in AC
7. Failed previous 360 degree ALT/***Diode laser Trabeculoplasty.

General Steps

1. Explain the procedure.
2. Signing informed consent.

**ALT/SLT is possible if the trabecular meshwork is visible clearly and atleast 180° of the angle is open. However, narrow angle can be deepened by either of the following procedure alone or in combination performed ideally 1-2 days prior to ALT/SLT.

- Nd: YAG/Argon laser iridotomy (Chapters 12 and 13)
- Argon laser peripheral iridoplasty/Gonioplasty (Chapter 14)

***Diode laser (810 nm) trabeculoplasty offers the same therapeutic effect as ALT. The procedure and steps are essentially similar. However, it causes less disruption of the blood-aqueous barrier, less PAS formation and less post-laser pain. The diode laser parameters are-

1. Power: 800-1200 mW
 - a. Exposure: 0.1 sec. Or 0.2 sec.
 - b. Spot size: 75-100 micron. However the spot size can be reduced by Pollack lens (65%), Ritch lens (70%) and Ocular magna view lens (77%).
 - c. End point of optimal effect: Blanching or tissue whitening. *Bubble formation does not occur with diode laser.*

3. Miosis-1 drop Pilocarpine nitrate (2%) at 15 min. interval starting 2 hour prior to ALT.
4. Antiglaucoma medication-
 - 1 drop Brimonidine tartrate(0.15-0.2%) or Apraclonidine (1%) 1 hour prior to ALT.
 - Tab. Acetazolamide (250 mg) ½ hour before ALT.
5. Anaesthesia:
 - 1 drop topical Proparacaine HCl (0.5%) few minutes prior to ALT.
 - Peribulbar inj Lignocaine HCl in nystagmus and uncooperative patient.
6. Comfortable sitting on revolving stool.
7. Steady fixation—Apply head strap and adjust fixation target.
8. Insert appropriate Laser contact lens—(see Table 11.1)- Following lenses are suitable for ALT due to incorporation of either argon/diode bonded antireflective coating or YAG bonded enhanced antireflective coating.
 - Ritch trabeculoplasty laser lens
 - Goldman 3-mirror laser lens
 - Latina SLT gonio laser lens
 - Ocular magna view gonio laser lens
 - Pollack iridotomy gonio laser lens(bigger button is for iridotomy and the smaller button is for SLT, ALT).
9. Room illumination—Darkened/semidarkened.
10. Adjust Slit-lamp beam.

ALT Technique Proper

1. Parameters: Energy: 400-1200 mW, exposure-0.1 second and spot size-50 μ (micron).
2. No.of laser burns: Single session schedule-100 burns over entire 360 degree. Double session schedule-50 burns over 180 degree in two sessions at 4 weeks interval.

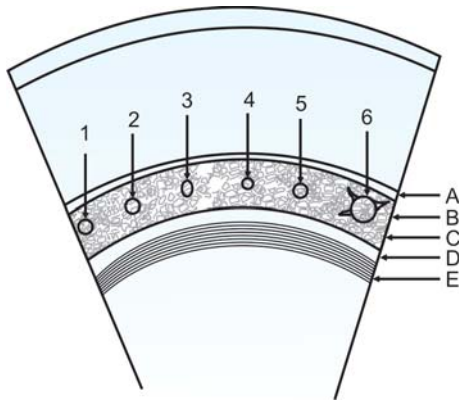


Fig.10.1: Schematic drawing illustrating ALT laser 50 μ burns and significance

- 1 and 2= Blanching or tissue whitening with no bubble formation \rightarrow Ideal,
- 3 = The aiming beam is ill focused \rightarrow the laser focus is oval with blurred edge \rightarrow unacceptable,
- 4 = Minimal or small bubble formation \rightarrow Acceptable,
- 5 = Slight discoloration \rightarrow Acceptable and
- 6 = Large bubble formation \rightarrow Indicates too high power setting \rightarrow Unacceptable,

(Schematic landmarks: A = Schwalbe's Line, B = Nonpigmented trabecular meshwork, C = Pigmented trabecular meshwork, D = Scleral Spur and E= Ciliary Band).

- 3. End point of optimal energy effect: *Blanching or tissue whitening with minimal or no bubble formation* (Fig. 10.1). Large bubble formation indicates energy level is too high (Fig. 10.1). If the tissue reaction is inadequate, increase the energy / power by 200 mW until optimal end point is achieved by least power.
- 4. Site of focus: At the junction of the anterior nonpigmented and posterior pigmented trabecular meshwork (Fig. 11.2). If properly focused the laser focus will be perfectly round with a clear outline. If the aiming laser

beam is not perpendicular to the laser lens surface, the spot will be oval with blurred edge.

5. Initially, the mirror is placed at 12 o'clock to view the inferior angle.
6. The laser burns are spaced 150 micron apart, i.e. at an interval of 3 burns width.

Postlaser Advice

1. Control of IOP rise: Acute elevation of IOP (>10 mm of Hg) occurs in 10.15 % of patients within 2 hours post-laser. 1 drop Brimonidine tartrate (0.15-0.2%) or Apraclonidine (1%) is topically applied immediately after ALT.
2. Pre-ALT all antiglaucoma medications to be continued \times 3 weeks.
3. Control of inflammation: Topical steroid 4 times daily \times 7 days only.

Complications

1. Worsening of POAG
2. Transient corneal burn
3. Iritis
4. Peripheral anterior synechiae (PAS): Posteriorly placed burns result in PAS formation and early post-laser IOP spikes.
5. Hyphaema/trabecular hemorrhage: It is stopped by increasing pressure on the eyeball with the gonioscopic lens.

BIBLIOGRAPHY

1. Bhattacharyya B. Clinical Applications: YAG Laser (Ophthalmology). New Delhi: Jaypee Brothers Medical Publishers (P)Ltd, 2005:24-26,67-71.

2. Epstein DL, et al. Nd: YAG laser trabeculopuncture in open angle glaucoma. *Ophthalmology* 1985; 92: 931.
3. Hager H. Besondere mikrochirurgische Eingriffe, 11, Teil Erste Erfahrungen mit dem Argon-Laser-Gerat 800, *Klin Monatsbl Augenheilkd* 1973; 162: 437.
4. Johnstone MA. Laser trabeculoplasty technique: current approaches. *Ophthalmic Laser Ther* 1985; 1:59.
5. Krasnov MM. Laser-puncture of the anterior chamber angle in glaucoma. *Vestn Oftalmol* 1972; 3: 27-31.
6. Krasnov MM. Laser-puncture of the anterior chamber angle in glaucoma. *Am J Ophthalmol* 1973; 75: 674.
7. McHugh D, Marshall J, Ffytche TJ, et al. Diode laser trabeculo-plasty (DLT) for primary open-angle glaucoma and ocular hypertension. *Br J Ophthalmol* 1990; 74: 743.
8. Moriarty AP, McHugh JD, Ffytche TJ, et al. Long-term follow-up of diode laser trabeculoplasty for primary open-angle glaucoma and ocular hypertension. *Ophthalmology* 1993; 100: 1614.
9. Moriarty AP, McHugh JD, Spalton DJ. Comparison of the anterior chamber inflammatory response to diode and argon laser trabeculoplasty using a laser flare meter. *Ophthalmology* 1993; 100: 1263.
10. Rodrigues MM, Spaeth GL, Donohoo P. Electron-microscopy of argon laser therapy in phakic open-angle glaucoma. *Ophthalmology* 1982; 89: 198.
11. Rouhiainen H, Leino M, Terasvirta M. The effect of some treatment variables on long-term results of argon laser trabeculoplasty. *Ophthalmologica* 1995; 209: 21.
12. Rouhiainen H, Terasvirta M. The laser power needed for optimum results in argon laser trabeculoplasty. *Acta Ophthalmol (Copenh)* 1986; 64: 254.
13. Schwartz LW, Spaeth GL, Traverso C, et al. Variation of techniques on the results of argon laser trabeculoplasty. *Ophthalmology* 1983; 90: 781.
14. Thomas JV, Simmons RJ, Bilcher CD III. Argon laser trabeculoplasty in the presurgical glaucoma patient. *Ophthalmology* 1982; 89: 187.

15. Threlkeld AB, Hertzmark E, Sturm RT, et al. Comparative study of the efficacy of argon laser trabeculoplasty for exfoliation and primary open-angle glaucoma. *J Glaucoma* 1996;5:311.
16. Weinreb RN, Ruderman J, Juster R, et al. Influence of the number of laser burns administered on the early results of argon laser trabeculoplasty. *Am J Ophthalmol* 1983;95:287.
17. Wise JB, Witter SL. Argon Laser therapy for open-angle glaucoma: A pilot study. *Arch Ophthalmol* 1979; 97: 319.
18. Worthen DM, Wickham MG. Argon laser trabeculotomy, *Trans Am Acad Ophthalmol Otolaryngol* 1974; 78: 371.

CHAPTER 11

Selective Laser Trabeculoplasty (SLT)

Introduction

“Selective Laser Trabeculoplasty” (or Selective Laser Trabeculotherapy) is performed with a Q-switched frequency doubled Nd:YAG laser (532 nm). It has replaced argon laser trabeculoplasty (ALT) due to lack of damage to the trabecular meshwork (Table 11.2).

Mode of Action

1. It selectively targets the melanin granules within the cells of the pigmented trabecular meshwork (TM). Disruption of the melanin granules cause cell death termed as “selective photothermolysis”.
2. There is no structural or photocoagulative damage to the trabecular meshwork (TM).
3. Eliminates scarring (seen in ALT) which is responsible for reduced aqueous outflow.

Indications

1. Primary open angle glaucoma (POAG):
 - Inadequately controlled with maximal medical therapy
 - With poor patient compliance
 - As a choice prior to filtration surgery
 - Patient unfit for filtration surgery
2. Majority of secondary open angle glaucoma:
 - Pigmentary glaucoma
 - Pseudoexfoliation syndrome
 - Juvenile glaucoma
 - Angle recession glaucoma
3. Failed previous argon laser trabeculoplasty (ALT)

Contraindications

1. Narrow angle
2. Poor visibility due to corneal opacity or hazy media

3. Congenital glaucoma
4. Inflammatory glaucoma
5. Neovascular glaucoma
6. Aphakic glaucoma with vitreous in AC.

General Steps

1. Explain the procedure.
2. Signing informed consent.
3. Miosis-1 drop Pilocarpine nitrate (2%) at 15 min. interval starting 2 hour prior to SLT.
4. Antiglaucoma medication:
 - 1 drop Brimonidine tartrate(0.15-0.2%) or Apraclonidine (1%) 1 hour prior to SLT.
 - Tablet Acetazolamide (250 mg) ½ hour before SLT.
5. Anaesthesia:
 - 1 drop topical Proparacaine HCl (0.5%) few minutes prior to SLT.
 - Peribulbar inj Lignocaine HCl in nystagmus and uncooperative patient.
6. Comfortable sitting on revolving stool.
7. Steady fixation—Apply head strap and adjust fixation target.
8. Insert appropriate Laser contact lens (Table 11.1 and Figs 11.1A to E). Following lenses are particularly suitable for SLT due to incorporation of YAG bonded enhanced antireflective coating.
 - Latina SLT gonio laser lens
 - Ocular magna view gonio laser lens
 - Pollack iridotomy gonio laser lens(bigger button is for iridotomy and the smaller button is for SLT, ALT).
 However, in addition to the above lenses Ritch Trabeculoplasty and Goldman 3-Mirror laser lenses are suitable for argon laser trabeculoplasty (ALT).

Table 11.1: Specifications of laser lenses used in ALT/SLT (courtesy Ocular instruments, Bellevue, WA, USA)

<i>Laser Lens</i>	<i>Image magnification</i>	<i>Laser spot magnification factor (LSMF)</i>	<i>Field of view</i>	<i>Indication</i>
Latina SLT gonio	1.0×	1.0×	130°	SLT, ALT
Ocular magna view gonio	1.3×	0.77×	160°	SLT, ALT
Ritch Trabeculoplasty	1.4×	0.70×	80°	Only ALT
Goldman 3-Mirror	0.93×	1.08×	140°	Only ALT
Pollack iridotomy gonio laser lens	1.5×	0.65×	160°	SLT, ALT



Figs11.1A to E: (A) Latina SLT gonio; (B) Ocular magna view gonio; (C) Ritch Trabeculoplasty; (D) Goldman 3-Mirror; (E) Pollack iridotomy gonio laser lens
(Images courtesy Ocular instruments, Bellevue, WA, USA)

9. Room illumination-Darkened/semidarkened.
10. Adjust Slit-lamp beam.

SLT Technique Proper

1. *Parameters:*
 Energy—0.6 -1 mJ per pulse (to avoid bubble formation)
 Pulse duration—3 nanosecond (ns) and
 Spot size—400 μm .
2. *No. of laser burns:* 50 single short pulses (3ns) spread over 180 degree of the trabecular meshwork (inferior / nasal quadrant).
3. *End point of optimal energy effect:* There is no end point like *blanching or tissue whitening or bubble formation as seen in ALT* (see Fig.10.1 and Table 11.2).
4. *Site of focus:* The shots cover entire height of trabecular meshwork(Fig.11.2 and Table 11.2).

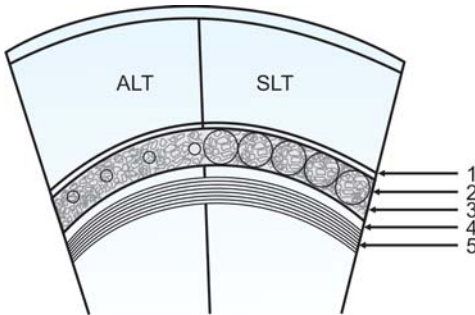


Fig. 11.2: Laser trabeculoplasty

1 = Schwalbe's Line, 2 = Nonpigmented trabecular meshwork, 3 = Pigmented trabecular meshwork, 4 = Scleral Spur and 5 = Ciliary Band. Left: Argon Laser Trabeculoplasty-50 μm laser spots at the junction of the pigmented and nonpigmented trabecular meshwork, 150 μm apart; Right: Selective Laser Trabeculoplasty-400 μm confluent laser spots covering entire height of the trabecular meshwork

Table 11.2: Comparison between ALT and SLT

Procedure	ALT	SLT
Type of laser	Argon	Freq.doubled Nd:YAG
Energy	500-1000 mW	0.6-1 mJ
Spot size	50 μ m	400 μ m
No. of laser shots	50/100	50
Pulse duration/ exposure	0.1sec.	3 ns
End point	Blanching, minimal or no bubble formation	No blanching, no bubble formation
Site of focus	At junction of pigmented and nonpigmented TM	Entire height of TM
Tissue damage	Structural and photocoagulative damage results in crater and scarring	No damage to TM
Contact laser lenses	Goldmann 3- Mirror/1-Mirror, Ritch lens	Latina SLT gonio laser lens, Pollack iridotomy gonio laser lens and Ocular magna view gonio laser lens
Repeat ALT/SLT	Ineffective	Potentially repeatable several times

- Initially, the mirror is placed at 12 o'clock to view the inferior angle.
- The laser burns are placed confluent (without overlapping).

Postlaser Advice

- Control of IOP rise:* Acute elevation of IOP (>10 mm of Hg) occurs in 10-15 % of patients within 2 hours postlaser. 1 drop Brimonidine tartrate(0.15-0.2%) or Apraclonidine (1%) is topically applied immediately post-SLT.

2. Pre-SLT all antiglaucoma medications to be continued × 3 weeks.
3. *Control of inflammation*: Topical steroid 4 times daily × 7 days only.
4. *IOP check 1 and 3 hour postlaser*.
Repeat SLT in remaining 180° of the trabecular meshwork (TM) may be undertaken after reassessment.

Complications

1. Anterior chamber inflammation is observed universally in all cases.
2. Occasional negligible pain, redness and discomfort.
3. Postlaser IOP spike.

BIBLIOGRAPHY

1. Bhattacharyya B. Clinical Applications:YAG Laser (Ophthalmology). New Delhi: Jaypee Brothers Medical Publishers (P)Ltd,2005:24-26,67-71.
2. Damli KF, Shah KC,Rock WJ, et al. Selective laser trabeculoplasty v argon laser trabeculoplasty: a prospective randomized clinical trial. Br J Ophthalmol 1999;83:718.
3. Epstein DL, et al. Nd: YAG laser trabeculopuncture in open angle glaucoma. Ophthalmology 1985; 92: 931.
4. Johnstone MA. Laser trabeculoplasty technique: current approaches. Ophthalmic Laser Ther 1985;1:59.
5. Latina MA,Tumbocon JA. Selective laser trabeculoplasty : a new treatment option for open angle glaucoma. Curr Opin Ophthalmol 2002;13:94.
6. Ocular Surg News 2000; 1:34.
7. Ocular Surg News 2000; 6:33.
8. Ritch R. Nd: YAG laser treatment for medically unresponsive attacks of angle-closure glaucoma. Am J Ophthalmol 1966; 62: 507-509.

9. Robin AL, Pollack IP. Q-switched neodymium: YAG laser angle surgery in open-angle glaucoma. *Arch Ophthalmol* 1985;103:793.
10. Schrems W, Belcher CDIII, Tomlinson CD. Thermal-mode neodymium:YAG laser trabeculoplasty in open-angle glaucoma. *Ophthalmic Laser Ther* 1986;1:93.

CHAPTER 12

Argon Laser Iridotomy

Introduction

Continuous wave (CW) or * pulsed Argon laser may be used to create an iridotomy. *However, Q-switched Nd:YAG laser has replaced it.*

Indications

1. Prophylactic iridotomy in fellow eye with history of acute congestive primary angle closure glaucoma (PACG) in other eye.
2. Pupillary block in aphakic and pseudophakic eyes.
3. Completion of an incomplete surgical iridectomy with retained posterior pigment epithelial layer.
4. Iris bombé due to seclusio pupillae.
5. Combined mechanism (open and narrow) glaucoma.
6. Pupillary block glaucoma including subluxated lens.
7. Malignant glaucoma.
8. Acute angle closure glaucoma-after termination of attack by medical therapy.
9. Chronic angle closure glaucoma with pupilliary block.
10. Positive darkroom provocative test in eyes with narrow occludable angle.
11. Nanophthalmos.

Contraindications

Absolute

1. Occluded angle (more than 60°)
2. Chronic inflammation.
3. Hazy anterior chamber.

*Pulsed argon laser is superior to continuous wave (CW) argon laser since it achieves iridotomy with more energy and less disruption, distortion of surrounding iris tissue. The parameters applied with pulsed argon laser are 20-25W, 50 micron, 0.2 sec. and 300 pulses/sec. The number of laser shots varies depending on the iris tissue.

Relative

1. Flat anterior chamber
2. Corneal opacities or edema.
3. Patients with rubeosis iridis.

General Steps

1. Explain the procedure.
2. Signing informed consent.
3. Miosis-1 drop Pilocarpine nitrate (2%) at 15 min. interval starting 2 hour prior to argon laser iridotomy.
4. Antiglaucoma medication:
 - 1 drop Brimonidine tartrate(0.15-0.2%) or Apraclonidine (1%) 1 hour prior to ALT.
 - Tab Acetazolamide (250 mg) ½ hour before argon laser iridotomy.
5. Improvement of corneal clarity—Topical Glycerol (if available) or Sodium chloride (5%) eye drop may be used 1 drop every 15 min. starting 1 hour prelaser.
6. Anaesthesia:
 - 1drop topical Proparacaine HCl (0.5%) few minutes prior to ALT.
 - Peribulbar inj Lignocaine HCl in nystagmus and uncooperative patient.
7. Comfortable sitting on revolving stool.
8. Steady fixation—Apply head strap and adjust fixation target.*The patient should be asked to look temporally or nasally during the laser procedure to avoid macular damage.*
9. Insert appropriate Laser contact lens—Abraham iridectomy or Pollack iridotomy/gonio laser lens is used. They are available with argon/diode/YAG bonded antireflective coating for Argon laser iridotomy. Abraham lens has a +66 diopter planoconvex peripheral button over a routine contact lens and increases

the laser power by a factor of 2.5. Pollack lens has two buttons. The larger button is for iridotomy and the smaller one is for gonioscopy and confirmation of opening of angle post-iridotomy with minimal re-focusing of the Slit-lamp.

10. Room illumination—Darkened/semidarkened.
11. Adjust Slit-lamp beam.

Iridotomy Technique Proper

1. *“Hump” technique*: Initially a “hump” is created on the iris with contraction burn of 500 μm spot size, 200-400 mW energy and 0.5-second exposure. The hump is penetrated full thickness with 50 μm , 700-1200 mW and 0.1/0.2 second burns.
2. *“Drumhead” technique*: Initially stretch burns are placed circularly around the site of iridotomy with 200 μm , 200 mW and 0.2 sec. Parameters to create taughtness of the central area (Fig. 12.1) like “drumhead”. The central

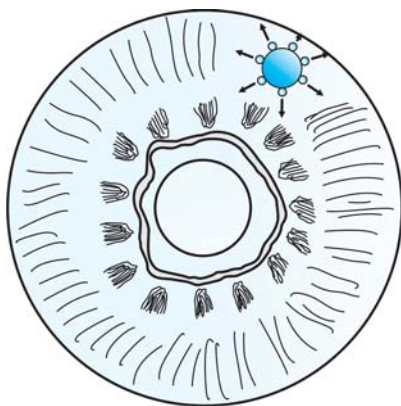


Fig. 12.1: Drum head technique

area is penetrated with 50 micron, 700-1200 mW and 0.1/0.2 second burns.

3. *Direct penetration technique:* Direct penetrating burns are most commonly used (50 micron spot size, 700-1200 mW power and 0.1/0.2 second exposure).
4. The laser beam should be directed away from the macula.
5. End point of iridotomy—It is confirmed by **red reflex through the hole on retroillumination and visible anterior lens capsule.**
6. Optimal site of iridotomy:
 - Usually superonasal quadrant is preferred. Only in aphakic patient with silicone oil, the iridotomy should be done inferiorly.
 - Between 10 O' clock and 2 O' clock and will be covered by the upper eyelid.
 - Avoid 12 O' clock area since gas bubble may collect here and interfere with the laser procedure.
 - About 2/3rd of the distance between pupillary margin and iris periphery.
 - **Iris crypts of Fuch or thin iris** are easier to perforate. In the absence of iris crypts, **wide area between radially arranged white collagen strands or pigmented freckle on the iris** might be attempted. The freckle absorbs more lasers.

Postlaser Advice

Same as Nd: YAG iridotomy (chapter 13)

Follow-up Schedule

Same as Nd: YAG iridotomy (chapter 13)

Complications

Same as Nd: YAG iridotomy (chapter 13)

BIBLIOGRAPHY

1. Abraham RK. Procedure for outpatient argon laser iridectomies for angle-closure glaucoma. *Int Ophthalmol Clin* 1976;16:1.
2. Abraham RK. Protocol for single-session argon laser iridectomy for angle-closure glaucoma. *Int Ophthalmol Clin* 1981;21:145.
3. Abraham RK, Miller GL. Outpatient argon laser iridectomy for angle closure glaucoma: a two-year study. *Trans Am Acad Ophthalmol Otolaryngol* 1975;79:OP529.
4. Anderson DR, Forster RK, Lewis ML. Laser iridectomy for aphakic pupillary block. *Arch Ophthalmol* 1975;93:343.
5. Bhattacharyya B. *Clinical Applications: YAG Laser (Ophthalmology)*. New Delhi: Jaypee Brothers Medical Publishers (P)Ltd, 2005:55-66.
6. Harrad RA, Stannard KP, Shilling JS. Argon laser iridectomy. *Br J Ophthalmol* 1985;69:368.
7. Hoskins HD, Migliazzo CV. Laser iridectomy –a technique for blue irises. *Ophthalmic Surg* 1984;15:488.
7. Khuri CH. Argon laser iridectomies. *Am J Ophthalmol* 1973;76:490.
8. L'esperance FA Jr, James WA Jr. Argon laser photocoagulation of iris abnormalities. *Trans Am Acad Ophthalmol Otolaryngol* 1975;79:OP321.
9. Pollack IP. Use of argon laser energy to produce iridotomies. *Trans Am Ophthalmol Soc* 1979;77:674.
10. Pollack IP, Patz A. Argon laser iridectomy : an experimental and clinical study. *Ophthalmic Surg* 1976;7:22.
11. Ritch R. Argon laser treatment for medically unresponsive attacks of angle-closure glaucoma. *Am J Ophthalmol* 1982; 94:197.
12. Schirmer KE. Argon laser surgery of the iris ,optimized by contact lenses. *Arch ophthalmol* 1983;101:1130.

CHAPTER 13

Nd: YAG Laser Iridotomy

Introduction

Since its commercial availability Nd: YAG laser iridotomy has replaced Argon laser due to its superior efficacy, reliability and faster perforation.

Indications

Same as Argon laser iridotomy (chapter 12).

Contraindications

Same as Argon laser iridotomy (chapter 12).

General Steps

1. Explain the procedure.
2. Obtain informed consent.
3. *Miosis*: Pupillary constriction by intense pretreatment with miotic like pilocarpine nitrate 2% topically 1 drop every fifteen minutes beginning two hours before the procedure causes maximum stretching and thinning of iris.
4. Antiglaucoma medication:
 - a. Pupillary miosis with pilocarpine nitrate 2% causes also reduction in intraocular pressure (IOP).
 - b. 1% Apraclonidine or 0.15-0.2% Brimonidine tartrate eye drop-1 drop one hour before laser session effectively prevents postlaser pressure spike also.
 - c. In glaucomatous eyes additionally carbonic anhydrase inhibitors (Acetazolamide 250 mg) one or two tablets should be given orally thirty minutes before the procedure.
5. Improvement of corneal clarity:
 - a. Topical glycerol, if available is used.
 - b. Sodium chloride 5% eye drop may be alternatively used topically to reduce corneal edema -1 drop every

fifteen minutes beginning one hour before the procedure.

6. *Anesthesia*: Topical lignocaine 4% or preferably proparacaine HCl 0.5% eye drop is used before insertion of contact lens.
7. Comfortable positioning of patient.
8. *Steady fixation*: Obtained by—
 - a. Use of head strap.
 - b. Adjusting fixation light.
9. *Insertion of contact lens*: Commonly Abraham contact Lens is used. It has a +66 diopter peripheral button over a routine contact lens. Pollack iridotomy gonio laser lens (see Fig.11.1E) may also be used.
10. *Illumination of laser room*: Darkened/semi darkened
11. Adjust/focus Slit-lamp beam.

Iridotomy Technique Proper

- Usually, 3-8 mJ per shot from Q-switched Nd: YAG laser and one to three shots are sufficient to complete the procedure.
- *A full thickness opening in iris in one shot is the optimal target.* Often up to four shots are needed to achieve perforation of iris.
- Axis of the focusing beam should coincide with the axis of the contact lens.
- Conditions/situations where use of contact lens is avoided higher energy is required and more central iridotomy is to be made.
- If the anterior chamber depth is nil, the pulse energy should not exceed 10-12 mJ.
- *Burst mode is not preferred* since hole in iris may occur before completion of burst leading to damage of anterior lens capsule.

- Optimal site of iridotomy (Fig. 13.1).
 - a. Between 10 o' clock and 2 o' clock.
 - b. *Avoid 12 o' clock site*—here gas bubble may obstruct the site of the opening.
 - c. Will be covered by the upper eyelid.
 - d. About three-fourth of the distance between pupillary margin and iris periphery.
 - e. Avoid arcus senilis —The opacity interferes with clear focus and transmits less laser energy.
 - f. Avoid visible iris vessels.
- Usually laser shots are aimed at peripheral iris onto iris crypts or area of thin stroma
- Try either of the following if an iridotomy opening is too small:
 - a. Create additional Nd: YAG iridotomy at a separate site.
 - b. Enlarge the initial small opening in iris with Argon laser. The margin of the small opening is treated with Argon laser. Do not fire laser shots at strands bridging across the opening to avoid any damage to the anterior lens capsule. The parameters are:
 - Spot size—50 μm .
 - Exposure time—0.2-0.5 sec.
 - Power—800-1000 mW.

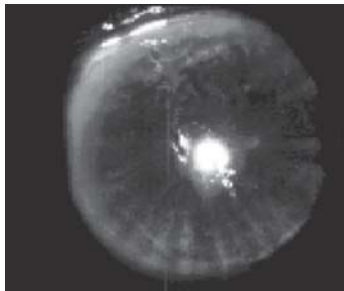


Fig. 13.1: Nd: YAG iridotomy (*For color version see Plate 1*)

Nd: YAG laser iridotomy is usually very small. *Nd: YAG laser should never be used to enlarge a small iridotomy opening to avoid injury to anterior lens capsule.*

- If an initial laser session to make a full thickness opening in the iris fails, particularly in a thick brown iris opt for either of the two following choices:
 - a. Wait for improved visibility, clearly notice the attempted site and apply laser shots at the initial site.
 - b. Choose separate site and perform iridotomy with higher energy setting.
- *Endpoint in perforation of iris (Nd: YAG Iridotomy):*
 - a. Sudden outpouring of melanotic pigments from posterior chamber to anterior chamber.
 - b. Sudden deepening of anterior chamber.
 - c. Sudden shower of pigments in pupillary area.

In Nd: YAG laser iridotomy at the end usually the red reflex and the anterior lens capsular surface may not be seen which is usual after argon laser iridotomy.
- Often higher energy is required to achieve full thickness opening in aphakic and pseudophakic eyes due to corneal edema and inflammatory conditions of iris. In those cases at least three iridotomies should be done to ensure:
 - a. Full relief from aqueous entrapment, because aqueous is often entrapped at various localized sectors.
 - b. Increased chance of at least one opening remaining patent.
- In cases where anterior chamber is very shallow and anterior chamber IOL is present try to achieve first iridotomy very close to the haptic of the ACIOL, where iris is usually a little bit away from the corneal surface.
- In Rubeosis iridis laser iridotomy can be successfully accomplished in two steps.

Step-I: Argon Laser Pretreatment for Nd:YAG laser iridotomy. It is done in following forms.

- **Drumhead pattern** (see chapter 12 and Fig. 12.1)—apply 6 to 8 stretching burns on iris surface 1 mm from the perforation site in a circle. The iris tissue is drawn centrifugally from the perforation site. The central proposed perforation site becomes taut like a “drum-head”. Stretch burns are avoided inside iris crypts because it may shrink and lessen the area of iridotomy available. The parameters are:
Power—200 mW
Exposure time—0.2 sec
Spot size—200 μm .
- **Lamellar thinning/flattening:** Apply few (5-20) Argon laser penetration burns on the perforation site on iris surface to flatten the iris and to prevent or reduce subsequent fluffing up on Nd: YAG laser treatment. The parameters are:
Power—1000 mW
Exposure time—0.02-0.05 sec
Spot size—50 μm .

Step-II: Perforation of remaining thickness of iris is achieved with 3-6 mJ pulse of Nd: YAG laser shot.

Postlaser Advice

- **Miosis:** Pilocarpine nitrate eye drop (2%)-1 drop thrice daily (8 hourly) for 7 days **in phakic eyes** to keep the iris stretched.
- **Cycloplegia and mydriasis:** Cyclopentolate (1%) or Tropicamide (1%) eye drop is used 3 or 4 times daily **in aphakic and pseudophakic pupillary block glaucoma cases. In phakic eyes mydriatics are not advised for initial 6 weeks period.**

- *Control of inflammation:* Topical Prednisolone acetate (1%) eye drop four times daily \times 2-3 weeks.
- *Control of glaucoma:* Intraocular pressure (IOP) should be monitored and in aphakic and pseudophakic eyes the antiglaucoma medications may be even continued for three weeks. Medications for control of elevated (IOP) are discussed in details in postoperative advice following Nd: YAG capsulotomy (see Chapter 20).

Complications and Management

- Uveitis
- *Pigment dispersion:* Usually transient and clears quickly.
- *Hemorrhage:* At the onset of hemorrhage discontinue the procedure and *apply pressure on the eyeball with the contact lens*. This maneuver will invariably stop the bleeding. After one hour examine the patient and if media clears try iridotomy at a separate site. If the media remains too cloudy to focus properly postpone the laser iridotomy procedure to next day
- Elevated intraocular pressure—1% Apraclonidine or 0.15-0.2% Brimonidine tartrate topical application immediately after the procedure prevents the spike in IOP.
- Damage to lens and anterior capsule of lens
- corneal burn
- Blurred vision—Transient and recovers quickly.
- Closure of initially patent iridotomy
- Failure to make full thickness iridotomy
- Diplopia—Rarely occurs if the upper eyelid does not cover iridotomy site.

Follow-up Schedule

The following protocol is suggested:

1st follow up—next day or day after tomorrow.

2nd follow up—one week postlaser.

3rd follow up—three weeks postlaser.

4th follow up—six weeks postlaser.

In follow up visits the patency of iridotomy should be checked and gonioscopy should be performed.

BIBLIOGRAPHY

1. Bhattacharyya B. Clinical Applications: YAG Laser (Ophthalmology). New Delhi: Jaypee Brothers Medical Publishers (P)Ltd, 2005:55-66.
2. Francis A. L'esperance, Jr. Ophthalmic Lasers. (3 edn). St. Louis: CV Mosby Co. 1989:812.
3. Frankhauser F, et al. Clinical studies on the efficiency of high power laser radiation upon some structures of the anterior segment of the eye. *Int Ophthalmol* 1981; 3: 129-39.
4. Hodes BL, Bentivegna JF, Weyer NJ, Hyphaema complicating laser iridotomy. *Arch Ophthalmol* 1982; 100: 924.
5. Klapper RM. Q-switched neodymium: YAG laser iridotomy. *Ophthalmology* 1984; 91: 1017-21.
6. Latina MA, Puliafito CA, Steinert RF, Epstein DL. Experimental iridotomy with the Q-switched neodymium: YAG laser. *Arch Ophthalmol* 1984; 102:1211-13.
7. Moster MR, et al. Laser iridectomy: a controlled study comparing argon and neodymium: YAG. *Ophthalmology* 1986; 93: 20.
8. Robin AL, Pollack IP. Comparison of neodymium: YAG and argon laser iridectomies. *Ophthalmology* 1984; 91: 1011-16.
9. Robin AL, Pollack IP. Q-switched neodymium: YAG laser iridotomy in patients whom argon laser fails. *Arch Ophthalmol* 1986; 104:531-35.
10. Schwartz L. Laser iridectomy. In Schwartz L, Spaeth G, Brown G, Laser therapy of the Anterior segment: A practical approach. Thorofare, NJ: Charles Slack Inc. 1984: 29-58.

CHAPTER 14

*Laser Peripheral
Iridoplasty (LPI)/
Gonioplasty*

It is a procedure to deepen the angle of the anterior chamber by placement of *cw-argon laser burns in the peripheral iris to stretch tissue between angle and site of burn.

Indications

1. Medically uncontrolled angle closure glaucoma
2. To facilitate ALT/SLT in shallow anterior chamber or narrow angle
3. To open an appositional closed angle
4. To facilitate laser goniophotocoagulation or laser iridotomy
5. Nanophthalmos
6. Plateau iris syndrome.

Contraindications

1. Flat anterior chamber
2. Extensive corneal oedema or opacity
3. Angle closure associated with extensive PAS.

General Steps

1. Explain the procedure.
2. Signing informed consent.
3. Miosis-1 drop Pilocarpine nitrate (2%) at 15 min. interval starting 2 hour prior to laser.
4. Antiglaucoma medication:
 - 1 drop Brimonidine tartrate(0.15-0.2%) or Apraclonidine (1%) 1 hour prior to laser.
 - Tab Acetazolamide (250 mg) ½ hour before laser.
5. Anaesthesia:
 - 1 drop topical Proparacaine Hcl (0.5%) few minutes prior to laser.

*Diode laser (810 nm) may also be used in gonioplasty.

- Peribulbar inj Lignocaine HCl in nystagmus and uncooperative patient.
6. Comfortable sitting on revolving stool.
 7. Steady fixation—Apply head strap and adjust fixation target. The patient is asked to look at the direction of the aiming beam even if a thin crescent of the beam encroaches upon the limbus and sclera.
 8. Insert appropriate Laser contact lens—Gonioscopic laser lenses are not suitable for LPI/gonioplasty due to following reasons:
 - Accidental damage to the trabecular meshwork (TM) and scleral spur may occur.
 - The laser strikes the iris tangentially to inflict diffuse burn and less stromal contraction.

The laser shots are applied directly to the iris periphery through the central area of laser lens (thus, avoiding the gonioscopy mirror).

9. Room illumination-Darkened/semidarkened.
10. Adjust Slit-lamp beam.

LPI Technique Proper

1. *Parameters: Energy:* 200-500 mW, exposure-0.2-0.5 second and spot size-200-500 μm . The parameters and no. of burns vary considerably. The energy and exposure is increased if contraction fails to occur. They are decreased on release of pigment or bubble formation. Darker irides require less power.
2. *No. of laser burns:* Single session schedule—8-12 burns to iris periphery in each quadrant. In a single session 180° (degree) is usually treated.
3. The **contraction effect is visible immediately by deepening of the anterior chamber**. Deepening will fail to occur in presence of PAS at that site.

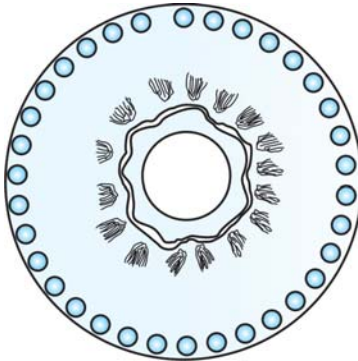


Fig. 14.1: Schematic representation of laser burns in LPI

4. *Site of focus:* The laser beam is **focused directly on the most visible iris periphery** through the flat surface of the laser contact lens. **Presence of arcus senilis is ignored** (Fig. 14.1).

Postlaser Advice

1. Topical steroid \times 3-5 days.
2. Topical antiglaucoma medication \times 7 days.

Complications

1. Transient IOP rise
2. Corneal burn
3. Pupillary distortion
4. Iris atrophy.

BIBLIOGRAPHY

1. Kimbrough RL, et al. Angle-closure glaucoma in nanophthalmos. Arch Ophthalmol 1979; 88:572.
2. Lai JS, Tham CC, Chua JK, et al. Efficacy and safety of inferior 180 degrees goniosynechialysis followed by diode laser

- peripheral iridoplasty in the treatment of chronic angle-closure glaucoma. *J Glaucoma* 2000;9:388.
3. Lai JS, Tham CC, Chua JK, et al. Immediate diode laser peripheral iridoplasty as treatment of acute attack of primary angle closure glaucoma: a preliminary study. *J Glaucoma* 2001;10:89.
 4. Lai JS, Tham CC, Chua JK, et al. Laser peripheral iridoplasty as initial treatment of acute attack of primary angle-closure: a long-term follow-up study. *J Glaucoma* 2002;11:484.
 5. Lam DS, Lai JS, Tham CC, et al. Argon laser peripheral iridoplasty versus conventional systemic medical therapy in treatment of acute primary angle-closure glaucoma: a prospective, randomized, controlled trial. *Ophthalmology* 2002;109:1591.
 6. Ritch R. Argon laser treatment for medically unresponsive attacks of angle-closure glaucoma. *Am J Ophthalmol* 1982;94:197.

CHAPTER 15

Argon Laser Pupilloplasty/ Photomydriasis

Pupilloplasty is the technique to alter the shape/size/location of an eccentric or irregular pupil. **Photomydriasis** is a variation of pupilloplasty used to enlarge a miotic pupil.

Indications

1. Miotic rigid pupil resistant to pharmacological dilation particularly in aphakia and healed uveitis.
2. Pupillary block glaucoma in aphakia or pseudophakia, as an alternative to laser iridotomy in cloudy cornea.
3. Patients on chronic miotic therapy.
4. To facilitate examination and treatment of posterior segment diseases.

Contraindications

1. Failure in improvement of visual acuity and visual field following a trial of pharmacological dilation.
2. Edematous cornea.
3. Active uveitis.

General Steps

1. Explain the procedure.
2. Signing informed consent.
3. Mydriasis (maximal)—1 drop tropicamide (1%)and Phenylephrine (10%) at 15 min interval starting 2 hour prior to laser.
4. Antiglaucoma medication—1 drop Brimonidine tartrate (0.15-0.2%) or Apraclonidine (1%) 1 hour prior to laser. Tab Acetazolamide (250 mg) ½ hour before laser.
5. Anaesthesia—1drop topical Proparacaine HCl (0.5%) few minutes prior to laser. Peribulbar inj Lignocaine HCl in nystagmus and uncooperative patient.
6. Comfortable sitting on revolving stool.

7. Steady fixation—Apply head strap and adjust fixation target. The patient is **asked to look temporally or nasally during laser procedure.**
8. Room illumination—Darkened/semidarkened.
9. Adjust Slit-lamp beam.

Photomydriasis Technique Proper

1. Initial placement of 360° contiguous, concentric, small contraction *argon laser burns (200 μm , 0.2 sec exposure and 200-400 mW power) just adjacent to the pupillary margin (Figs 15.1 and 15.2). Usually this is followed by immediate retraction of iris tissue.

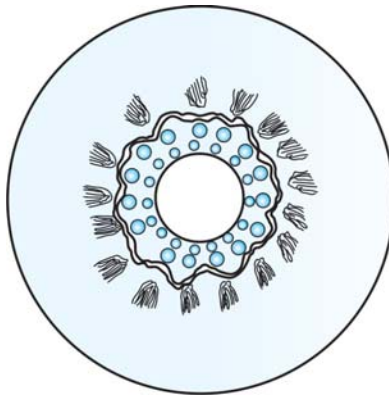


Fig.15.1: Photomydriasis (to enlarge a miotic pupil)- Placement of 360° contiguous, concentric, small contraction argon/diode laser burns (200 μm) just adjacent to the pupillary margin is followed by placement of larger argon laser burns (500 μm) concentrically just outside the initial laser shots in single row

*Diode laser (810 nm) may also be used in photomydriasis.Nd:YAG laser is used only in coreoplasty (see chapter 17)

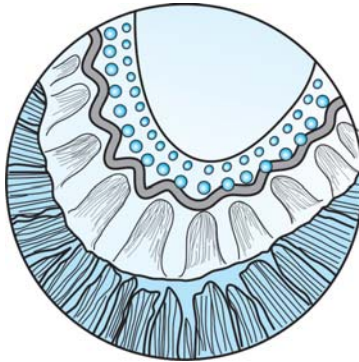


Fig.15.2: Pupilloplasty (to alter the shape of an eccentric pupil) - Placement of 360° contiguous, concentric, small contraction argon/diode laser burns (200 μm) just adjacent to the pupillary margin is followed by placement of larger argon laser burns (500 μm) concentrically just outside the initial laser shots in single row

2. Placement of larger argon laser burns (500 μm , 0.2-0.5 sec exposure and 400-500 mW power) concentrically just outside the initial laser shots in single or double row (Figs 15.1 and 15.2)
3. Alternatively, radially placed argon laser burns utilizing similar parameters overlying the sphincter pupillae may be tried.

Postlaser Advice

1. Topical steroids \times 7 days.
2. Control of IOP spike.
3. Discontinue miotics for few days.

Complications

1. Transient IOP rise
2. Iris atrophy
3. Transient iritis

BIBLIOGRAPHY

1. Cleasby GW. Photocoagulation coreoplasty. Arch Ophthalmol. 1970;83:145.
2. James WA, et al. Argon laser photomydriasis. Am J Ophthalmol. 1976;81:62
3. L'esperance FA Jr, James WA Jr, et al. Argon laser photocoagulation of iris abnormalities. Trans Am Acad Ophthalmol Otolaryngol. 1975;79:321
4. Patti JC, Cinotti AA. Iris photocoagulation therapy of aphakic pupillary block. Arch Ophthalmol. 1975;93:347.
5. Ritch R. Argon laser treatment for medically unresponsive attacks of angle-closure glaucoma. Am J Ophthalmol 1982; 94:197.
6. Steven M. Bloom and Alexander J. Brucker .Laser surgery of the posterior segment. Philadelphia: Lippincott-Raven. 1997:73.
7. Theodossiadis GP. Pupilloplasty in aphakic and pseudophakic pupillary block glaucoma. Trans Ophthalmol Soc UK. 1985;104(Pt 2):137.
8. Thomas JV. Pupilloplasty and photomydriasis. In Belcher CD III, Thomas JV, and Simmons RJ (Editors): Photocoagulation in glaucoma and anterior segment disease. Baltimore: Williams and Wilkins 1984:150-57

*Nd: YAG
Photomydriasis/
Iridohyaloid
Synechialysis*

Introduction

Frequently aphakic eyes with posterior segment or retinal pathology have rigid pupil resistant to dilation by pharmacological means. These eyes require detailed examination of retinal periphery for proper clinical diagnosis and management.

Indications

- Aphakic eyes with rigid pupil, resistant to dilation by mydriatics.
- Aphakia (ICCE) with iridohyaloid synechiae.
- Aphakic eyes on miotic therapy for long.
- Failure of Argon laser photomydriasis.

Contraindications

- Eyes with active uveitis.
- Eyes with uncontrolled glaucoma.

General Steps

1. *Explain the procedure:* During explanation of the procedure, additionally permanent nature of the laser photomydriasis and requirement of multiple session is informed.
2. Signing informed consent.
3. *Antiglaucoma medication:* 1 drop Apraclonidine (1%) or Brimonidine tartrate (0.15-0.2%) eye drop one hour before the procedure is usually sufficient.
4. *Mydriasis:* Tropicamide (1%) eye drop applied topically 2 hours before the laser application.
5. Anesthesia.
6. Comfortable sitting of patient.
7. Steady fixation.

8. *Contact lens*: It is greatly facilitated by the use of contact lenses like Abraham contact lens (with +66D central magnified button)
9. *Laser room illumination*: Darkened/semi darkened.
10. Adjustment of slit lamp

Technique Proper

It involves two stages:

- a. *Stage 1*: Nd: YAG laser radial iridotomy:
 - It is performed to unite peripheral iridectomy (PI), if present, with the pupillary margin.
 - Usually 4-6 mJ energy per pulse is required.
 - Initial laser shots are placed at a site adjacent to the peripheral iridectomy to enlarge it. Subsequent shots are towards the pupillary margin (Fig. 16.1) to complete the radial iridotomy (as in the case of coreoplasty in see Chapter 17, Figs 17.1A to D).

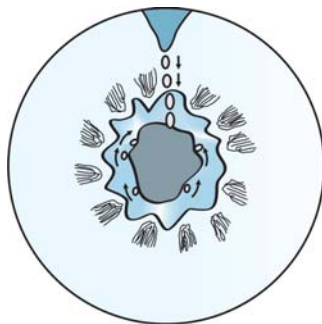


Fig.16.1: Schematic drawing-Initial laser shots are placed at a site adjacent to the peripheral iridectomy at 12 o' clock to enlarge it. Subsequent shots are towards the pupillary margin (vertical arrows show the direction) to complete the radial iridotomy. Lasers shots are applied at the junction of pupil and hyaloid interface after slight anterior defocusing. The procedure is carried out all around the pupillohyaloid interface (arrows show the direction)

- b. *Stage 2: Nd: YAG iridohyaloid synechialysis:*
- It is usually done *at least three days after* initial Nd: YAG radial iridotomy session.
 - 1-1.5 mJ energy per pulse from Q-switched Nd: YAG laser is sufficient.
 - Lasers shots are applied at the junction of pupil and hyaloid interface after slight anterior defocusing. The procedure is carried out all around the pupillohyaloid interface.

Postlaser Advice

1. *Mydriasis:* 1% Tropicamide eye drop three/four times daily X at least 7 days.
2. *Control of Inflammation:* 1% Prednisolone acetate eye drop four to six times daily × at least 7 days.
3. *Control of raised IOP:* Topical Antiglaucoma medications × 3 -7 days.

Complications

- Pigment dispersion
- Microhemorrhage.

BIBLIOGRAPHY

1. Bhattacharyya B. Clinical Applications: YAG Laser (Ophthalmology). New Delhi: Jaypee Brothers Medical Publishers (P)Ltd, 2005:99-100.
2. Kumar H, Honavar SG. Nd: YAG laser procedures for posterior segment visualization in rigid aphakic pupil. *Annals of Ophthalmology* 1996;28(5): 331-35.
3. Thomas JV. Pupilloplasty and photomydriasis. In Belcher CDIII, Thomas JV, Simmons RJ (Eds): *Photocoagulation in Glaucoma and Anterior Segment Diseases*, Baltimore: Williams and Wilkins, 1984;150-157.
4. Wise JB. Iris sphincterotomy, iridotomy and synechiotomy by linear incision with argon laser. *Ophthalmology* 1985; 92:641-45.

CHAPTER 17

Nd: YAG Coreoplasty

Introduction

Coreoplasty is the procedure of centering of ectopic pupil by altering shape or enlargement of pupil. Nd: YAG laser is preferred over Argon laser for coreoplasty due to its greater efficiency.

Indications

- Enlargement of pupil for improved vision.
- Greater view of retina for detailed examination particularly indirect ophthalmoscopy and management of retinal pathology.
- Optical iridectomy to improve vision in eyes with corneal opacity.
- Optical iridectomy to improve vision in eyes with decentered IOL.

Prelaser Examination Schedule/Protocol

Presence of bleeding or clotting disorders increases risk for perioperative hyphema. So, necessary laboratory investigations should preferably be carried out to rule out such anomalies. Slit lamp biomicroscopy is essential to detect presence of any abnormal/visible blood vessel on iris surface and to plan area of coreoplasty

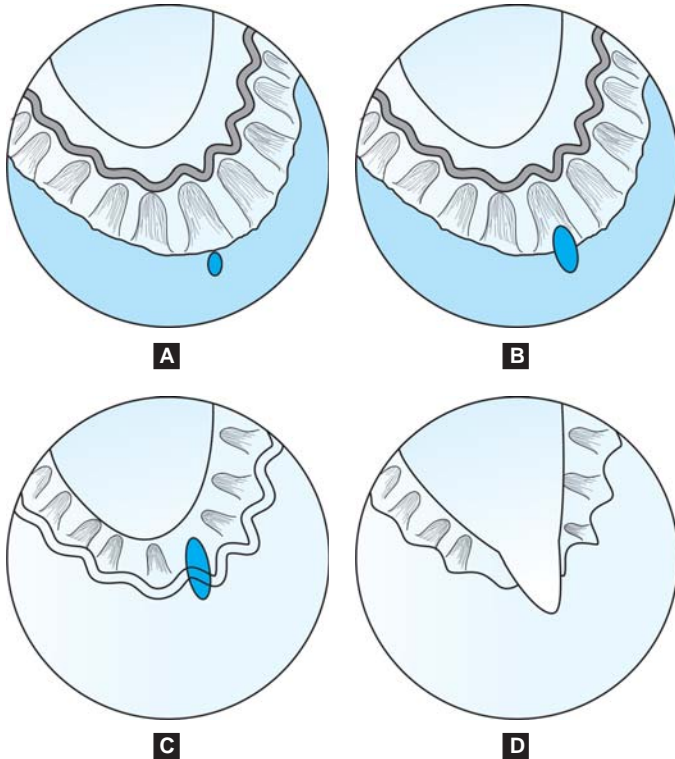
General Steps

1. Explain the procedure
2. Signing informed consent
3. *Antiglaucoma medication*: 1 drop Apraclonidine (1%) or Brimonidine tartrate (0.15-0.2%) eye drop one hour before the procedure is sufficient.
4. *Mydriasis*: Mydriasis may be required only in eyes with corneal leucoma, i.e. for optical iridectomy.

5. *Anesthesia*: Usually not required unless contact lens is applied.
6. Comfortable sitting of patient.
7. Steady fixation.
8. *Contact lens*: Usually not required.
9. Laser room illumination-Darkened/semi darkened.
10. Adjustment of slit lamp.

Coreoplasty Technique Proper

- Preparatory Argon laser coagulation (spot size 50 mm, duration 0.02-0.05 sec, power 1000 mW) is done only in presence of visible blood vessels on the iris surface at the proposed area of Nd: YAG coreoplasty to prevent hyphema.
- On an average 8-9 mJ energy is required per shot from Q-switched Nd:YAG laser. Number of shots depends upon the thickness of iris stroma and sphincter.
- *Sphincter is the toughest area to cut with Nd: YAG laser.*
- *Collarette is most prone to hemorrhage due to presence of minor arterial circle of iris.* So, if the procedure is being started from pupillary margin, occurrence of hyphema and heavy pigment dispersion will prevent the completion of procedure in one session.
- So, the procedure is started in the peripheral part of iris stroma by making full thickness hole in the iris (see Fig. 17.1A).
- Successive cuts in the iris are made towards the collarette and iris sphincter (see Figs 17.1B and C).
- The collarette, sphincter and pupillary margin is cut towards the end to delay the occurrence of hemorrhage as far as possible so that the coreoplasty procedure may be completed in one session (see Fig. 17.1D).



Figs 17.1A to D: Technique for Nd-YAG laser coreoplasty (schematic). (A) The procedure is started in the peripheral iris stroma; (B) and (C) Successive cuts in the iris are made towards the collarette and iris sphincter; (D) The collarette, sphincter and pupillary margin is cut towards the end to delay the occurrence of hemorrhage as far as possible so that the coreoplasty procedure may be completed in one session

- If hemorrhage starts and continues without clotting, it should be stopped by pressing on the eyeball by either contact laser lens or digital pressure through closed eyelids.

Postoperative Advice

The principles are:

- a. *Reduction of elevated IOP:* Timolol maleate 0.5% eye drop twice daily \times 7 days.
- b. *Reduction of inflammation:* Prednisolone acetate 1% eye drop four times daily \times 10-14 days.
- c. Cycloplegia-is usually not advised.

Follow up Schedule

The standard protocol of follow up as advised in cases of Nd: YAG laser posterior capsulotomy is also followed here (see Chapter 20).

Complications

- a. Transient rise of intraocular pressure
- b. Hyphema
- c. Pigment dispersion
- d. Cataract formation.

BIBLIOGRAPHY

1. Bhattacharyya B. Clinical Applications: YAG Laser (Ophthalmology). New Delhi: Jaypee Brothers Medical Publishers (P)Ltd,2005:80-83.
2. Cleeseby CW. Photocoagulation coreoplasty. Arch Ophthalmol 1970;83:145.
3. Francis A. L'esperance, Jr. Ophthalmic Lasers. (3rd edn). St. Louis: C.V. Mosby Co. 1989:635-8.
4. Steinert RF. Puliafito CA. The Nd-YAG Laser in Ophthalmology: Principles and Clinical Applications of Photo-disruption. Philadelphia: W B Saunders Co. 1985:108-11.

*Nd: YAG Persistent
Hyperplastic
Pupillary
Membranectomy*

Introduction

Total persistence of fetal pupillary membrane (see Fig. 18.1) is very rare and is usually associated with other congenital ocular anomalies, particularly microphthalmos. Persistent pupillary membranes usually do not give rise to impairment of vision particularly in ambient light.

Indications

- Dimness of vision in bright light
- Dimness of vision for near reading.

Prelaser Examination Schedule

- *Visual acuity*: Recorded in both bright light and ambient light for distance. Near vision is also recorded.

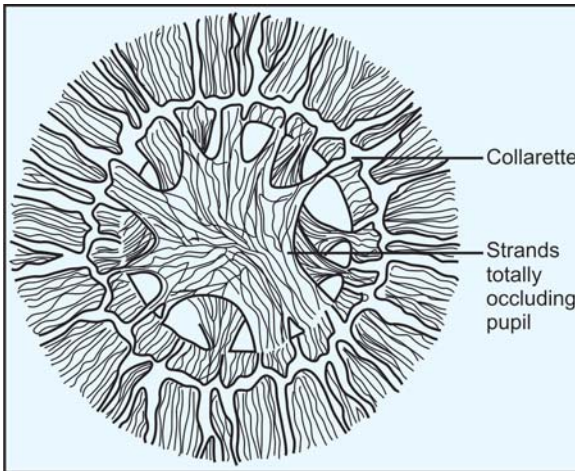


Fig. 18.1: Schematic drawing of total persistent hyperplastic pupillary membrane

- *Slit lamp biomicroscopy:* It is essential to carefully draw and plan the strands to be cut to achieve clear visual axis.

General Steps

1. *Explain the procedure:* The patient has to be informed that the procedure often requires multiple sittings.
2. Obtain informed consent.
3. *Antiglaucoma medication:* 1% Apraclonidine or 0.15-0.2% Brimonidine tartrate eye drop-1 drop one hour before laser session effectively prevents postlaser pressure spike also.
4. *Mydriasis:* The pupil should be dilated to its maximum extent (with Tropicamide 1% and Phenylephrine HCl 5% eye drops).
5. *Anesthesia:* Topical Lignocaine 4% or preferably Proparacaine HCl 0.5% eye drop is used before insertion of contact lens.
6. Comfortable positioning of patient.
7. *Steady fixation:* Obtained by:
 - a. Use of head strap.
 - b. Adjusting fixation light.
8. *Insertion of contact lens:* Commonly Abraham capsulotomy lens with central magnified +66 diopter button/Peyman G.capsulotomy lens is necessary to obtain a magnified view of pupillary membrane strands and a precise focusing of laser beam.
9. *Illumination of laser room:* Darkened/semi darkened
10. Adjust/focus laser beam.

Technique Proper

- Usually 1 to 1.5 mJ per pulse is sufficient to achieve complete section of strands at the junction with iris collarette.

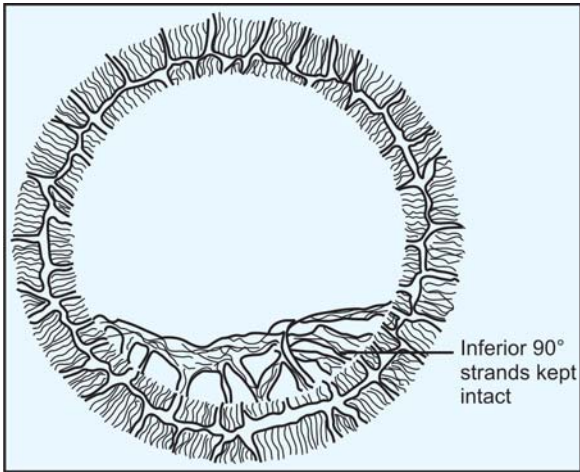


Fig. 18.2: Schematic drawing after section of strands by Nd: YAG laser

- Keeping inferior 90° strands of attachment is essential to prevent the entire pupillary membrane floating freely in the anterior chamber and consequent complications such as secondary glaucoma, visual disturbance and decompensation of cornea (see Fig. 18.2).
- Section of strands of the membrane in the upper/superior 270° at the iris strands junction is planned in the following way:
 - Start at the planned inferior most strand chosen at either nasal or temporal side to prevent reduced visualization due to pigment dispersion and microhemorrhages.
 - Proceed alternately on nasal and temporal sides moving upwards towards 12 o' clock area.
- Two or three sessions at intervals of 1 or 2 days may be required to complete the procedure due to either heavy

pigment dispersion or minute hemorrhages giving rise to poor visibility of structures.

Postoperative Advice

The medications used are similar to post Nd: YAG posterior capsulotomy for a duration of three to seven days. *Mydriasis/miosis is not required.*

Complications

- Pigment dispersion
- Microhemorrhages
- Secondary glaucoma.

BIBLIOGRAPHY

1. Bhattacharyya B. Clinical Applications: YAG Laser (Ophthalmology). New Delhi: Jaypee Brothers Medical Publishers (P)Ltd, 2005:84-87.
2. Kumar A, Kumar H, Dada T. Lasers in Ophthalmology: A Practical Guide. New Delhi: Jaypee Brothers Medical Publishers (P) Ltd. 2000:82-3.
3. Kumar H, Sakhuja N, Sachdev MS. Hyperplastic pupillary membrane and laser therapy. Ophthalmic surgery 1994; 25(3):189-90.
4. Mader TH, Wergeland FL, Chismire KJ. Enlarged pupillary membranes. J Paeditr Ophthalmol 1988;25:735.
5. Merin S, Crawford JS, Cardarelli J. Hyperplastic persistent pupillary membrane. Am J Ophthalmol 1971;72:717-19.

*Nd: YAG Anterior
Hyaloidectomy and
Cyclophotocoagulation*

ANTERIOR HYALOIDECTOMY

Anterior hyaloidectomy (or anterior hyaloid vitreolysis) is the photodisruption of anterior hyaloid face by Q-switched Nd: YAG laser in malignant glaucoma. The diagnosis of malignant glaucoma should be seriously considered when aphakic and pseudophakic acute angle-closure glaucoma do not respond to either surgical iridectomy or laser iridotomy.

Indications

- Aphakic (ciliovitreal block) malignant glaucoma.
- Pseudophakic malignant glaucoma.
- Phakic malignant glaucoma particularly following trabeculectomy.

General Steps

1. *Explain the procedure.*
2. *Obtain informed consent.*
3. *Antiglaucoma medication:*
 - a. 1% Apraclonidine or 0.15-0.2% Brimonidine tartrate eye drop-1 drop one hour before laser session effectively prevents postlaser pressure spike also.
 - b. Additionally carbonic anhydrase inhibitors (Acetazolamide -250 mg) one or two tablets should be given orally thirty minutes before the procedure.
4. *Improvement of corneal clarity:*
 - a. Topical glycerol, if available is used.
 - b. Sodium chloride 5% eye drop may be alternatively used topically to reduce corneal edema -1 drop every fifteen minutes beginning one hour before the procedure.
5. *Anesthesia:* Topical lignocaine 4% or preferably proparacaine HCl 0.5% eye drop is used before insertion of contact lens.

6. *Comfortable positioning of patient.*
7. *Steady fixation:* Obtained by-
 - a. Use of head strap.
 - b. Adjusting fixation light.
8. *Insertion of contact lens:* Commonly Abraham contact capsulotomy/iridotomy Lens is used. It has a +66 diopter central/peripheral button over a routine contact lens. Pollack iridotomy gonio laser lens may also be used.
9. *Illumination of laser room:* Darkened/semi darkened
10. *Adjust/focus Slit lamp beam.*

Anterior Hyaloidectomy Technique Proper

- Energy level-1-2 mJ.
- This procedure should be undertaken only by very experienced laser surgeon.
- Extreme care must be taken while focusing.
- It is safer to disrupt the anterior hyaloid face by posterior defocusing. The optical breakdown propagates anteriorly and breaks the optical interface of anterior hyaloid. First focusing on the anterior hyaloid face (1 and 3 in Fig. 19.1) and then pushing the joystick minimally away from the laser surgeon achieve this (2 in Fig. 19.1).
- In aphakic and pseudophakic cases the anterior hyaloidectomy is done through the pupil or the iridectomy (site 1 and 3 in Fig. 19.1).
- In phakic cases photodisruption of anterior hyaloid face is preferably done through iridectomy peripheral to equator of lens to avoid injury to lens (site 1 in Fig. 19.1).

Cyclophotocoagulation

Cyclophotocoagulation i.e. laser destruction of ciliary body is an alternative popular modality of treatment of refractory

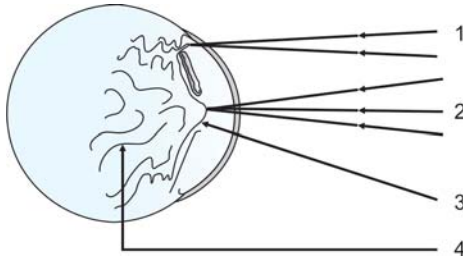


Fig.19.1: Photodisruption of anterior hyaloid face through the pupil or iridectomy by posterior defocusing

- 1 = Focusing on the anterior hyaloid face through the iridectomy
 2 = Posterior defocusing on the anterior hyaloid face through the pupil,
 3 = Focusing on the anterior hyaloid face through the pupil and
 4 = Aqueous trapped within the vitreous humour

glaucoma. Cyclophotocoagulation can be done through following methods:

- Transpupillary cyclophotocoagulation
- Endo cyclophotocoagulation
- Transcleral cyclophotocoagulation-It is the most popular method.

Indications

1. Failed shunt and filtration procedures
2. Aphakic glaucoma
3. Neovascular glaucoma
4. Intractable glaucoma refractory to medical and surgical therapy
5. Glaucoma secondary to epithelial ingrowth

Contraindications

- Active uveitis
- Thin sclera

Cyclophotocoagulation is delivered through either non contact or contact method.

Contact method

- Nd:YAG laser (free running/CW mode) with sapphire contact probe is usually used.
- Anesthesia-Topical + Retrobulbar
- Topical 5% Phenylephrine to reduce congestion
- Lid speculum is applied
- No. of laser burns- 30 to 32 (evenly placed) laser burns are delivered obliquely .
- Extent of laser burns-270° to 360° (8 burns/quadrant / session).
- Location- 1 to 3 mm posterior to the limbus in the region of the ciliary body (3 o' clock and 9 o' clock locations are avoided).
- Energy-4 to 6 J/pulse

Non contact method

- Nd:YAG laser (free running/CW mode) is usually used.
- Anesthesia-Topical + Retrobulbar
- Topical 5% Phenylephrine to reduce congestion
- Lid speculum is applied
- No. of laser burns- 30 to 32(evenly placed) laser burns are delivered obliquely .
- Extent of laser burns-270° to 360° (8 burns/quadrant / session).
- Location- 1 to 3 mm posterior to the limbus , maximally defocussed.
- Energy-4 to 8 J/pulse

Complications

1. Pain
2. Uveitis

3. Hypotony
4. Scleral thinning
5. Hyphema
6. Phthisis bulbi

BIBLIOGRAPHY

1. Bhattacharyya B. Clinical Applications: YAG Laser (Ophthalmology). New Delhi: Jaypee Brothers Medical Publishers (P)Ltd,2005:72-3.
2. Brown RH, et al. Neodymium: YAG vitreous surgery for aphakic and pseudophakic malignant glaucoma. Arch Ophthalmol 1986;104: 1464.
3. Epstein DL, Steinert RF, Puliafito CA. Neodymium-YAG laser therapy to the anterior hyaloid in aphakic malignant (ciliovitreal block) glaucoma. Am J Ophthalmol 1984;98: 137-43.
4. Shaffer RN, Hoskins HD Jr. Ciliary block (Malignant) glaucoma. Ophthalmology 1978;85:215.
5. Shaffer RN. The role of vitreous detachment in aphakic and malignant glaucoma. Trans Am Acad Ophthalmol Otolaryngol 1954;58:217-31.
6. Simmons RJ. Malignant glaucoma. Br J Ophthalmol 1972; 56:263.
7. Simmons RJ. The vitreous in glaucoma. Trans Ophthalmol Soc UK 1975;95:422.
8. Starita RJ, Klapper RM. Neodymium: YAG photodisruption of the anterior hyaloid face in aphakic flat chamber: a diagnostic and therapeutic tool. In Neodymium: YAG laser microsurgery. Int Ophthalmol Clin 1985;25:119.
9. Beckman H, Sgar HS. Neodymium laser cyclophoto-coagulation. Arch Ophthalmol 1973;90:27.
10. Frankhauser F, et al. Transscleral cyclocoagulation using a neodymium:YAG laser. Ophthalmic Surg 1986;17:94.

The image features a medical illustration of a human eye, viewed from the front. The eye is rendered in a light blue and grey color scheme. A large, semi-transparent blue circle is overlaid on the lower half of the eye, partially obscuring the iris and pupil. The background consists of horizontal light blue stripes. The text 'Section Three' is positioned at the top right, and 'Laser Surgery on Lens and in Pupillary Area' is centered within the blue circle.

Section Three

**Laser Surgery
on Lens and in
Pupillary Area**

*Nd: YAG Posterior
Capsulotomy*

Introduction

Nd: YAG capsulotomy (Fig. 20.5) is the most successful and frequent indication of YAG laser application. It has replaced surgical dissection by Zeigler's knife of posterior capsule as a much safer alternative.

Indications

- Posterior capsular opacification (PCO) causing reduced visual acuity and or excessive glare (Fig. 20.1).
- Posterior capsular opacification (PCO) with inadequate or very small YAG capsulotomy opening (Fig. 20.2).
- Capsular distension following retention of residual viscoelastic material between posterior surface of intraocular lens (IOL) and transparent posterior capsule (In Capsulorhexis)—Clinically suspected by myopic error of refraction in postoperative follow up (Fig. 20.3).
- Re-opacification (post Nd: YAG capsulotomy) (Fig. 20.4).

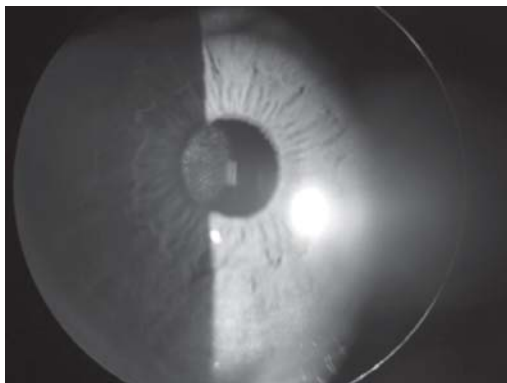


Fig. 20.1: Posterior capsular opacification in a posterior chamber IOL implanted eye (*For color version see Plate 1*)

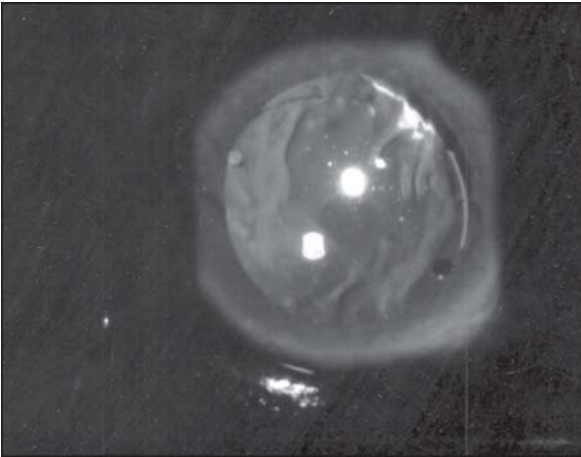


Fig. 20.2: Inadequate post Nd:YAG posterior capsulotomy opening seen in retroillumination (magnification 10x)
(For color version see Plate 1)

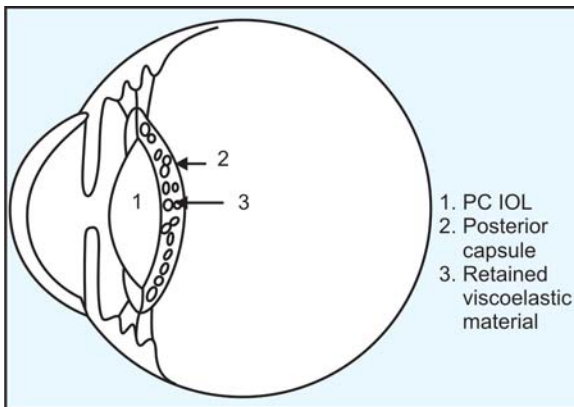


Fig. 20.3: Schematic drawing- Capsular distension due to retention of viscoelastic material between IOL and posterior capsule

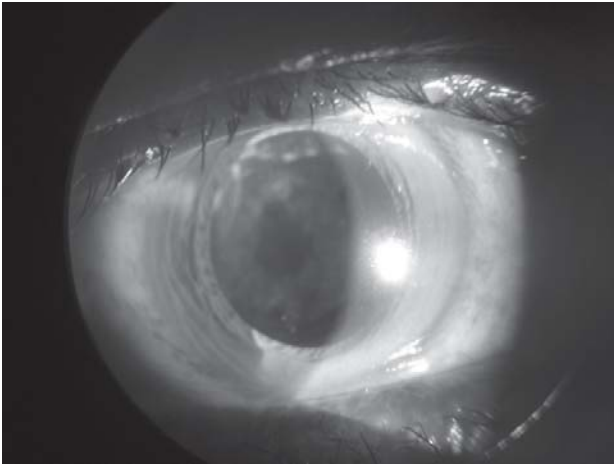


Fig. 20.4: Re-opacification (post Nd: YAG capsulotomy)
(For color version see Plate 2)

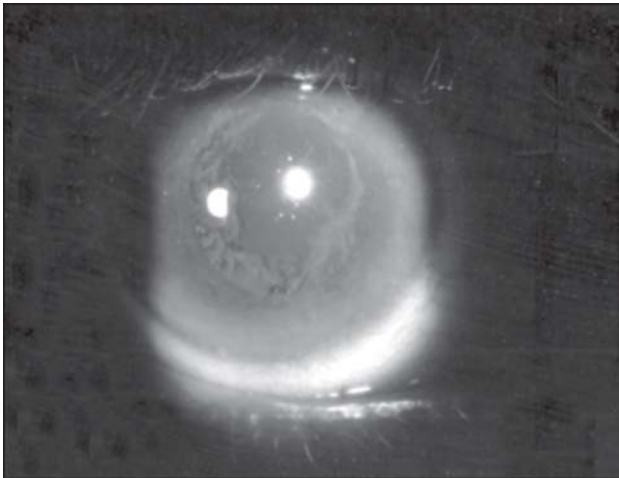


Fig. 20.5: Post Nd:YAG posterior capsulotomy seen in retroillumination. "Elschnig's Pearls" are visible peripheral to capsulotomy window [magnification 10x] (For color version see Plate 2)

Contraindications

A. Absolute

- a. Corneal leucoma/macular opacity.
- b. Corneal surface disorders.
- c. Corneal edema.

In above mentioned situations it is very difficult to visualise the target properly and if Nd: YAG capsulotomy is carried out results in unreliable optical breakdown.

- d. Inability to fixate eye steadily.
- e. Uncooperative or unwilling patients.

B. Relative

- a. Glass Intraocular Lens-Optics of glass IOLs are very prone to fracture.
- b. Diagnosed Cystoid Macular Edema (CME).
- c. Suspected Cystoid Macular Edema (CME).
- d. Eyes with very active inflammation.
- e. High risk group of patients for rhegmatogenous retinal detachment:
 - Patients with previous history of rhegmatogenous retinal detachment (RRD).
 - Treated prophylactically.
 - Myopia.
 - Having peripheral retinal degenerations, silent holes, etc.

In the above situations, minimum possible laser energy per pulse and least number of laser shots should be fired to create a capsular window/opening adequate for visualisation of peripheral retina.

Timing of Capsulotomy

The procedure of Nd: YAG posterior capsulotomy may be undertaken as early as three weeks after initial surgery.

However, it is advisable to perform later in patients with diabetic retinopathy.

Prelaser Examination Schedule/Protocol

A complete ophthalmic history, general medical history and thorough ophthalmological examination as detailed below (see Table 20.1) should be undertaken, to explain the predicted visual acuity (VA) and exclude the presence of cystoid macular edema (CME), if anticipated to avoid unnecessary Nd: YAG posterior capsulotomy and dissatisfied patient.

General Steps (see Fig. 20.6)

Explain the Procedure

- The patient is detailed about purpose of the procedure, duration, painless nature and importance of maintenance of steady fixation.
- He may hear small clicking noise produced by the acoustic waves generated.

Informed Consent

Antiglaucoma Medication

- Timolol maleate (0.5%) or Brimonidine tartrate (0.15 or 0.2%) or Apraclonidine (1%) eyedrop. — One drop one hour before laser procedure in nonglaucomatous eyes to counter the immediate postoperative intraocular pressure (IOP) spike.
- Carbonic Anhydrase inhibitors (Acetazolamide 250 mg)- One (1) tablet should be orally given additionally in glaucomatous eyes 30 minutes before the procedure.

Pupillary Dilation (Mydriasis)

- Usually not required by an experienced laser surgeon.

Table 20.1: Prelaser assessment of PCO

- A. *Recording of visual acuity (VA)*-both uncorrected and best corrected (BCVA).
- B. *Direct ophthalmoscopy*
 - i. Distant direct ophthalmoscopy helps to clearly assess the extent of posterior capsular opacification (PCO) against red glow from retina.
 - ii. Correlation of visibility of retinal details with the extent of posterior capsular opacification (PCO), is the single most reliable technique for assessment of posterior capsular opacification (PCO).
- C. *Slit-lamp biomicroscopy*
 - i. Extent of posterior capsular opacification (PCO) with both oblique and retroillumination. Retroillumination is particularly helpful in evaluation of surface characteristic of the opacified posterior capsule.
 - ii. Direction of tension lines and schematic drawing of the same.
 - iii. Distance between posterior surface of the intraocular lens (IOL) and opacified posterior capsule.
- D. *Red Reflex Evaluation*
 - Direct ophthalmoscope
 - Retinoscope
 - Slit-lamp biomicroscope—retroillumination
 - Indirect ophthalmoscope
- E. *Macular Function/Macroanatomy*
 - Slit-Lamp Biomicroscope
 - i. Hruby lens view
 - ii. 90D lens view
 - iii. Central contact lens of 3-mirror gonio lens view
 - Laser interferometer
 - Potential acuity meter (PAM)
- F. *Exclusion of CME*
 - FFA- done in suspected cases of cystoid macular edema (CME)
 - OCT- It is the most reliable and convincing confirmatory diagnostic test for cystoid macular edema (CME).

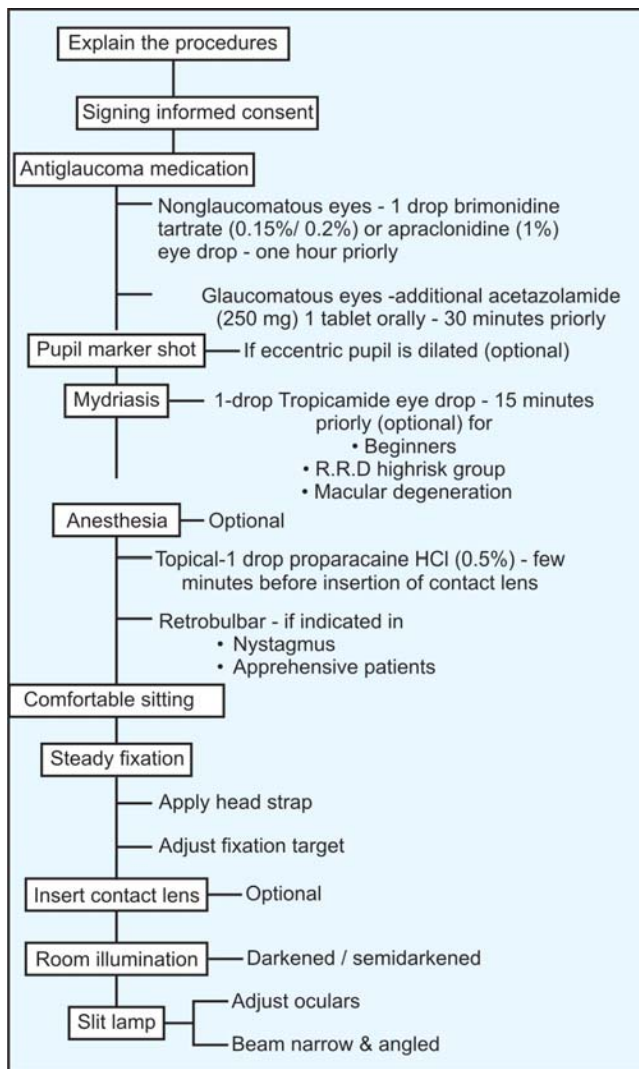


Fig. 20.6: Steps in capsulotomy

- Beginners like to dilate all pupils.
- Dilation if required should be done by a weak mydriatic like a single drop of 10% phenylephrine. A drop of 1% Tropicamide may be added if dilation is inadequate.
- In many aphakic and pseudophakic eyes the pupillary opening is eccentric. So, after dilation of pupil it becomes difficult to identify where the centre of the pupil is located. Hence, pupillary dilation is usually not advocated.

Anesthesia—Usually not Required

- Topical (Lignocaine 4% or preferably Proparacaine HCl 0.5%)-used only when insertion of contact lens is indicated.
- Retrobulbar—Lignocaine 2% may be necessary rarely in
 - Extremely apprehensive patients.
 - Patients with nystagmus to steady the fixation of the eyeball.

Comfortable Sitting of Patient

Steady Fixation

Obtained by

- Use of head strap to counter patients tendency to pull back his/her head during the procedure.
- Suitably adjusting illuminated target.

Contact Lens

Used only in following situations.

- Uncooperative patient
- Small pupil.

Contact lens serves the following purposes.

- Stabilises the eye.
- Facilitates accurate focusing
- Improves laser optics

- Increases convergence angle from 16° to 24° .
- Reduces area of laser at posterior capsule to $14\ \mu$ from $21\ \mu$.
- Increases laser beam diameter at both cornea and retina.

Illumination of Room

The laser room should be darkened/semi-darkened to improve surgeon's visualisation of the target and consequent accurate focusing of laser beam.

Slit-lamp Beam

It should be narrow and obliquely angled. This helps in minimising miosis and acts as an indicator for size of the pupil in ambient light situation. Oculars of the slit-lamp should be adjusted prior to laser session. The slit lamp beam and the aiming beam of the He-Ne/Diode laser are adjusted to become parafoveal in order to obtain maximum benefit.

Capsulotomy Technique Proper

- Usually 1.5 to 2 mJ per pulse from Q-switched Nd: YAG laser is sufficient to open posterior capsule.
- Start at low energy and gradually increase if necessary. The energy setting per pulse may be increased in recalcitrant thick posterior capsules.
- Use the lowest level of energy per pulse that will create a window in the posterior capsule.
- 5-10 shots may be sufficient to create an adequate and optimum opening in the posterior capsule by an experienced laser surgeon.
- Capsulotomy size is determined by size of the pupil in ambient light conditions (approx. 4-5 mm). Larger posterior capsulotomy may be indicated in the following situations:
 - Patients requiring visualisation of retinal periphery
 - Patients suffering from macular degeneration.

- Capsulotomy is preferably started in an existing area of separation between posterior capsule and IOL.
- Usually once the capsulotomy has begun, further areas of separation develops easily.
- The shots are placed across the tension lines to achieve maximum opening per pulse.
- If pupil is to be dilated it is safer to fire a marker shot priorly at the centre of the pupil particularly in case of eccentric pupil.
- Pulse mode is preferred and *burst mode should be avoided* to avoid damage to the intraocular lens (IOL pitting).
- *Method of focusing to avoid IOL pitting*
 - *Posterior defocusing*: In pseudophakic eyes to avoid IOL pitting intentionally focus posterior to posterior capsule (posterior defocusing) to cause optical breakdown in the anterior vitreous. The shock wave radiates forward and ruptures the posterior capsule instead of uniform anterior vitreous face whose breakdown threshold is higher than an optical interface like the posterior capsule. This is conveniently done by posterior defocus setting in the YAG laser.
 - *Anterior defocusing*: Similarly in aphakic eyes anterior defocus setting in the YAG laser is required to avoid opening of anterior hyaloid / vitreous face.
- *Pattern of capsulotomy opening*
 - *Cruciate opening*: It is the usual choice. The first shot is made superiorly in the location of some fine tension lines at 12 o' clock and progressing towards 6 o' clock (Fig. 20.7). Then progress laterally from central edges of initial vertical opening towards 3 o' clock and 9 o' clock to complete the cruciate opening (Fig. 20.8). Residual posterior capsular flaps if present in pupillary area should be directly fired with laser

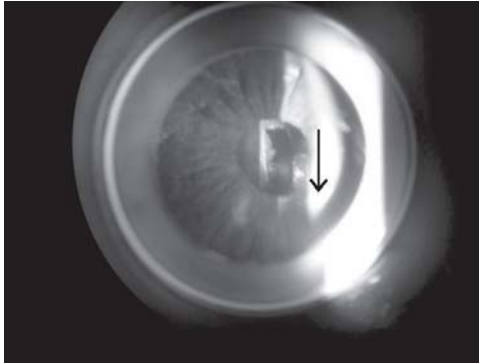


Fig. 20.7: Initial capsulotomy from 12 o' clock and progressing towards 6 o' clock (*For color version see Plate 2*)

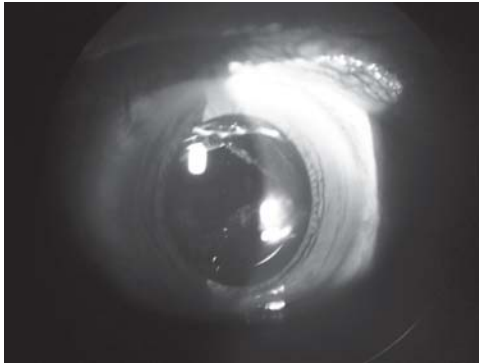


Fig. 20.8: Complete cruciate capsulotomy opening (*For color version see Plate 2*)

shots to cut them so that they retract and fall back towards periphery. Avoid creating large fragments because they may come in contact with corneal endothelium or angle of the anterior chamber. This will cause corneal decompensation later on. The aim is to make flaps based peripherally and inferiorly.

Table 20.2: Revised technique for Nd:YAG posterior capsulotomy

1. Stay within circle described by positioning holes.
2. Start at 12 o' clock and cut to 6 o' clock position (using 2.3-2.5 mJ).
3. Start at cut edge at 10 o' clock and cut horizontally to surgeon's left.
4. Start at cut edge at 2 o' clock and cut horizontally to surgeon's right.
5. Start at cut edge at 8 o' clock and cut horizontally to surgeon's left.
6. Start at cut edge at 4 o' clock and cut horizontally to surgeon's right.
7. Focus directly on—not behind—any residual flap to scroll them posteriorly and amputate, if necessary.

(Courtesy: Ashok Garg, J T Lin, Jorge L Alio, Azad R, Jerome Jean Bovet, Bojan Bajic and Cyres K Mehta (Eds.): I. Howard Fine in: YAG Laser Posterior Capsulotomy, page 76, 2008, with permission from Jaypee Brothers Medical Publishers Pvt. Ltd, New Delhi)

- *Christmas tree pattern opening*: This type of opening is preferred when there is increased tendency to intraocular lens pitting (IOL pitting) or damage due to presence of minimum gap or no gap between posterior surface of intraocular lens and opacified posterior capsule. Here laser shots are fired nasally and temporally from 12 o' clock towards 5 o' clock and 7 o' clock rather than progressing towards 6 o' clock. This strategy helps in avoiding central/optical zone of the IOL to suffer from pitting. The capsulotomy opening looks like a "christmas tree" with the base located inferiorly (see Figs 20.9A to H and 20.10).
- *Revised Hexagonal Capsulotomy technique (Table 20.2) of I. Howard Fine (Oregon, USA)*:

The technique of I Howard Fine achieves a symmetrical hexagonal (Fig. 20.11) posterior capsulotomy with posteriorly

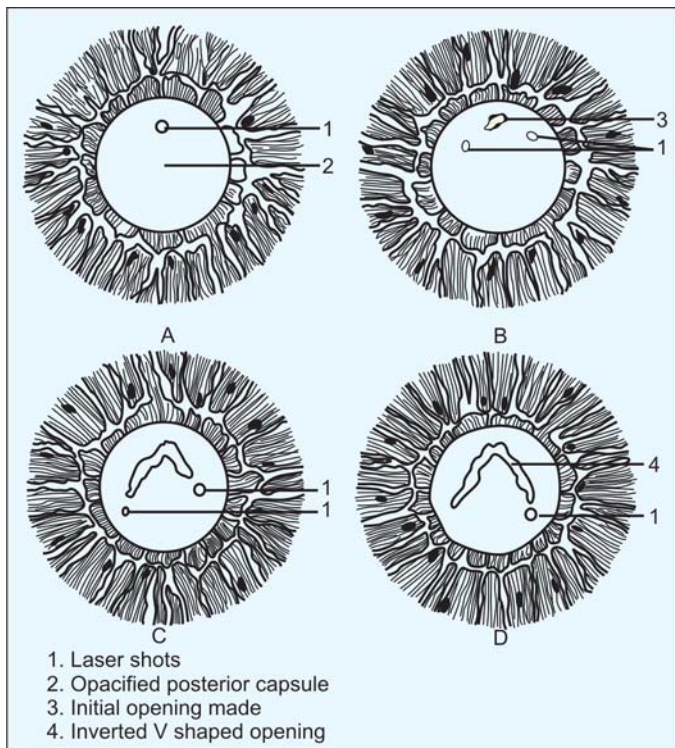
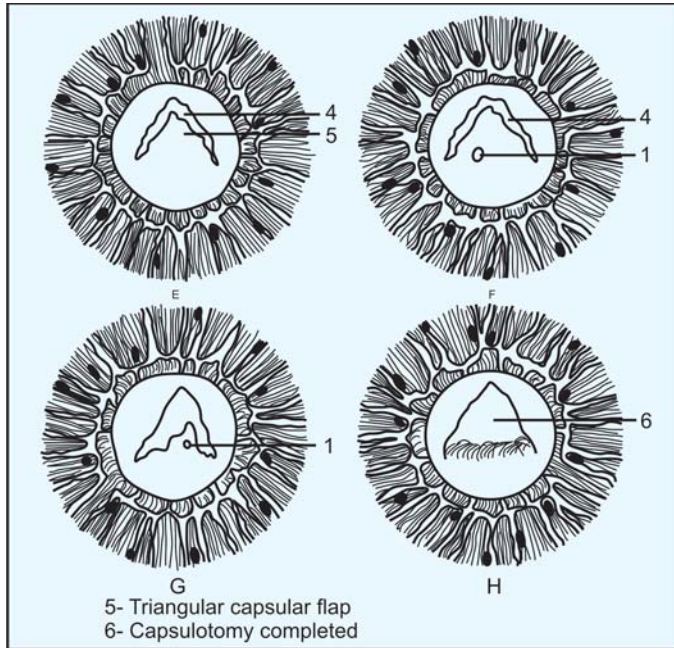


Fig. 20.9A to D: An Artist's impression of step by step posterior capsulotomy in christmas tree pattern

scrolled stable flaps and an adequate opening for visualization of extreme retinal periphery. Application of slightly higher energy additionally pushes the capsular margin slightly posteriorly and separates it from the optic (Fig. 20.11).



Figs 20.9E to H: (Continued). An Artist's impression of step by step posterior capsulotomy in christmas tree pattern

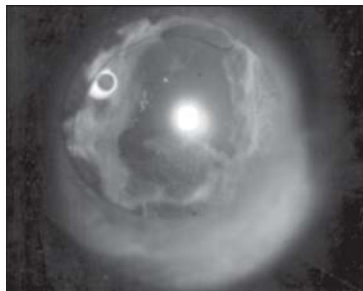


Fig. 20.10: Nd: YAG posterior capsulotomy done in a "christmas tree" pattern. An inverted V-shaped capsular opening and a triangular capsular flap is visible (For color version see Plate 2)

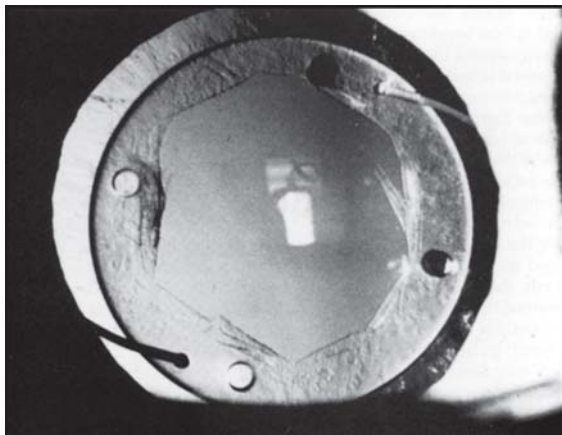


Fig. 20.11: Residual flaps are scrolled and rolled posteriorly out of the way

(Courtesy: Ashok Garg, J T Lin, Jorge L Alio, Azad R, Jerome Jean Bovet, Bojan Bajic and Cyres K Mehta (Eds.): I. Howard Fine in: YAG Laser Posterior Capsulotomy, page 76, 2008, with permission from Jaypee Brothers Medical Publishers Pvt. Ltd, New Delhi)

Postoperative Advice

The principles of postoperative advice are:

Reduction/control of elevated intraocular pressure

Rise of intraocular pressure is common hours after Nd:YAG laser posterior capsulotomy.

1. Usual medication:

Nonselective β -adrenergic antagonist such as Timolol maleate (0.5%) eye drop or α -2 adrenergic agonists such as Apraclonidine HCl (1%) and Brimonidine tartrate (0.15-0.2%) eye drop-1 drop applied topically immediate post laser is usually sufficient to counter the postlaser intraocular pressure spike and is advised to continue

for a period of at least one week. Timolol maleate 1 drop twice daily (12 hourly) and Apraclonidine HCl/ Brimonidine tartrate 1 drop thrice daily (8 hourly).

Contraindications for β -adrenergic antagonist:

- a. Known drug allergy
- b. Bronchial asthma
- c. Chronic obstructive pulmonary airway disease
- d. Heart block
- e. Congestive cardiac failure

Contraindications for α -2 adrenergic agonists:

- a. Known drug allergy
 - b. Concurrent use of MAO inhibitors
 - c. Patients with impaired renal or liver function
 - d. Patients with coronary insufficiency, recent myocardial infarction, Raynaud's disease, Thromboangitis obliterans and orthostatic hypotension.
2. Medication in situations where α -adrenergic antagonists and α -2 adrenergic agonists are contraindicated:
- a. Cholinomimetic such as Pilocarpine nitrate 2% eye drop—1 drop 3 times (8 hourly) daily for at least one week.
Or
 - b. Topical Carbonic Anhydrase Inhibitors (CAI) such as
Dorzolamide HCl 2%, Brinzolamide HCl 1% or Acetazolamide 5%-1 drop 3 times (8 hourly) daily for at least one week.
3. In pre-existing glaucomatous eyes: The antiglaucoma medications which he is using should be supplemented or reinforced by oral carbonic anhydrase inhibitors or osmotic agent at the end of the procedure and repeated after four hours.

Reduction of inflammation

Prednisolone acetate 1% or Dexamethasone 0.1% eye drop - 1 drop applied immediately after the procedure and continued in the daily dosage of 4 times (6 hourly) and tapered over two to three weeks depending on the degree of cellular reaction.

Cycloplegia

Cycloplegics such as Tropicamide 1% or Cyclopentolate HCl 1% Eye drops are *usually not required*.

Follow-up Schedule

In our country the following protocol of follow up is feasible or advisable.

- 1st follow up visit – Next day or day after tomorrow.
- 2nd follow up visit – One/two weeks.
- 3rd follow up visit – Four/six weeks.

Complications

Common complications

Transient Elevation of Intraocular Pressure (IOP)

- It is the commonest complication.
- Intraocular pressure starts rising soon after the procedure, reaches peak after three hours.
- In most treated eyes intraocular pressure returns to normal level within one week.

Cystoid Macular Edema (CME)

- The incidence varies from 0.04 to 2.3% in different studies.
- Disruption of anterior hyaloid face during the procedure may increase the likelihood of development of cystoid macular edema (CME).

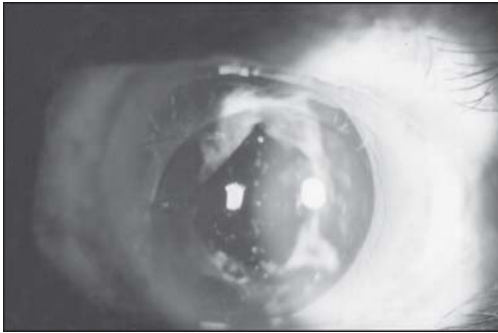

Fig. 20.12: Visually insignificant IOL pitting seen in the central area of the PCIOL (Post Nd: YAG capsulotomy) (For color version see Plate 2)

IOL Marking/Pitting

- Usually it is visually insignificant (Fig. 20.12).
- The incidence decreases as the laser surgeon gains experience. It may be avoided by taking following steps:
 - a. Use of lower energy level.
 - b. Use of single pulse mode.
 - c. Accurate focusing and posterior defocusing.
 - d. Use of contact lens.

Acute Glaucoma

- It may occur in aphakic eyes without patent iridectomy.
- The mechanism is vitreous herniation through the capsulotomy opening, resulting in acute elevation of IOP from pupillary block.

Anterior hyaloid face rupture

This may predispose to cystoid macular edema (CME) development.

Rhegmatogenous retinal detachment

- Incidence of rhegmatogenous retinal detachment after Nd: YAG capsulotomy varies between 0.1 and 3.6%.

- According to Winslow et al and Leff et al, the most frequent time interval between Nd:YAG laser capsulotomy and onset of rhegmatogenous retinal detachment is 5 to 7 months.
- Rickman-Barger et al and Dardenne et al reported that the peak incidence of rhegmatogenous retinal detachment is between 4 and 6 months after the Nd: YAG laser capsulotomy.
- However, rhegmatogenous retinal detachment can occur as early as one month after laser procedure.
- It is noted that approximately one third of cases of retinal detachment following Nd: YAG laser capsulotomy had pre-existing risk factors. The risk factors are:
 - a. *Axial myopia*: Axial length more than 25 mm is the most important risk factor confirmed by various investigators (Gills, Dardenne et al and Rickman-Barger et al).
 - b. History of lattice degeneration.
 - c. History of rhegmatogenous retinal detachment in fellow eye.

Periodic meticulous fundus examination particularly of peripheral area by indirect ophthalmoscope is a must for at least one year if Nd: YAG capsulotomy is carried out in a patient, with above mentioned pre-existing risk factors.

Less Common Complications (Very rare)

- Iritis
- Hyphaema
- Ciliochoroidal effusion
- Macular hole
- Peripheral retinal hemorrhage
- Late enlargement of capsulotomy opening
- *IOL dislocation*: It is rarely seen in Silicon lenses.

- *Endophthalmitis*: Endophthalmitis may rarely set in after Nd:YAG capsulotomy due to release of previously sequestered propionibacterium acnes into the vitreous.
- *Re-opacification of the capsulotomy opening*: It is caused by hyperproliferation of lens epithelial cells around the capsulotomy opening. This leads to narrowing of the opening. It is managed by repeat Nd:YAG capsulotomy.

BIBLIOGRAPHY

1. Alpar JJ. Experiences with the neodymium: YAG laser: interruption of anterior hyaloid membrane of the vitreous and cystoid macular edema. *Ophthalmic Surg* 1986; 17:157-65.
2. Aron-Rosa D, Aron JJ, Cohn HC. Use of a pulsed picosecond Nd:YAG laser in 6664 cases. *Am Intraocular Implant Soc J* 1984; 10:35-39.
3. Bhattacharyya B. *Clinical Applications:YAG Laser (Ophthalmology)*. New Delhi:Jaypee Brothers Medical Publishers (P)Ltd,2005:28-54.
4. Blachansky P, Newsome D. Bilateral macular holes after Nd: YAG posterior capsulotomy. *Am J Ophthalmol* 1988; 105:417-18.
5. Carlson AW, Koch DD. Endophthalmitis following Nd: YAG laser posterior capsulotomy. *Ophthalmic Surg* 1988;19: 168-70.
6. Channell MM, Beckman H. Intraocular pressure changes after neodymium -YAG laser posterior capsulotomy. *Arch Ophthalmol* 1984; 102:1024-26.
7. Coonan P. Fung WE, Webster RG, et al. The incidence of retinal detachment following extracapsular cataract extraction. A ten-year study. *Ophthalmology* 1985;92: 1096-01.
8. Dardenne MU, Gerten GJ, et al. Retrospective study of retinal detachment following neodymium- YAG laser posterior capsulotomy. *J Cataract Refract Surg* 1989; 15:676-80.

9. Fallor MK, Hoft HR. Intraocular lens damage associated with posterior capsulotomy: A comparison of intraocular lens design and four different Nd: YAG laser instruments. *Am Intraocular Implant Soc J* 1985;11:564-67.
10. Flicker LA, Steele ADM. Complications of Nd: YAG laser posterior capsulotomy. *Trans Ophthalmol Soc UK* 1985; 104:529-32.
11. Leff SR, Welch JC, Tasman W. Rhegmatogenous retinal detachment after YAG laser posterior capsulotomy. *Ophthalmology* 1987; 94:1222-25.
12. Meisler DM, Zacov ZW, et al. Endophthalmitis associated with sequestered intraocular propionibacterium acnes. *Am J Ophthalmol* 1987; 104:428-29.
13. Roger JE, Mcpherson BM, Govan AA. Posterior capsule opacification after Neodymium YAG laser capsulotomy. *J Cataract Refract Surg* 1995; 21:351-52.
14. Ruderman JM, Mitchell PG, Kraft M. Pupillary block following Nd: YAG capsulotomy. *Ophthalmic Surg* 1983; 14:418-19.
15. Schaeffer AR, Ryll DL, O'Donnell FE. Ciliochoroidal effusions after neodymium-YAG posterior capsulotomy. Association with pre-existing glaucoma and uveitis. *J Cataract Refract Surg* 1989; 15:567-68.
16. Solomon KD, Legler UFC, Kostick AMP. Capsular opacification after cataract surgery. *Current Opin Ophthalmol* 1992; 3: 46-51.
17. Tasaka W, Kimura W, Kimura T, et al. Rate of reduction of anterior capsular opening following cataract surgery with removal of lens epithelial cells. *Jpn J Ophthalmol* 1997; 51: 953-56.
18. Terry AC, Stark WJ, et al. Neodymium-YAG laser for posterior capsulotomy. *Am J Ophthalmol* 1983; 96:716-20.
19. Winslow RL, Taylor BC. Retinal complications following YAG laser capsulotomy. *Ophthalmology* 1985; 92:785-89.

CHAPTER 21

Nd: YAG Sweeping

Introduction

The procedure to remove precipitates and/or pigments from the surface of the intraocular lens (IOL) is called Nd: YAG sweeping.

Etiology

- Uveitis with iridolenticular synechiae formation
- Uveitis without synechiae formation
- Peroperative excess iris touch
- Blunt trauma.

Contraindication

Active uveitis

General Steps

1. Explain the procedure
2. Signing informed consent
3. *Antiglaucoma medication*: 1 drop Apraclonidine (1%) or Brimonidine tartrate (0.15-0.2%) eye drop one hour before the procedure is sufficient.
4. *Mydriasis*: Pupil should be middilated with a single drop of Tropicamide (1%) eye drop applied topically fifteen minutes before the laser application.
5. *Anesthesia*: Usually not required unless contact lens is applied.
6. Comfortable sitting of patient.
7. Steady fixation.
8. *Contact lens*: Usually not required.
9. *Laser room illumination*: Darkened/semi darkened.
10. Adjustment of slit lamp.

Nd: YAG Sweeping Technique Proper

- Usually 0.5 to 1.5 mJ of energy per pulse is sufficient.
- Usually 5-20 shots are sufficient to get rid of deposits or pigments from the surface of intraocular lens (IOL) from a Q-switched Nd: YAG laser.
- The laser beam is at first focused at the deposits/precipitates/pigments and then slightly defocused anteriorly in the aqueous by slightly pulling back the joystick of the slit lamp delivery system of the Nd: YAG laser (Fig. 21.1).
- The laser shots are fired in this way to dislodge the deposits/precipitates/pigments from the surface of the intraocular lens (IOL) by producing an acoustic shock wave in the anterior chamber (Fig. 21.1) to prevent damage to the IOL.

Postlaser Advice

Nd: YAG laser sweeping causes minimal postlaser intraocular pressure spike and minimal postlaser inflammation.

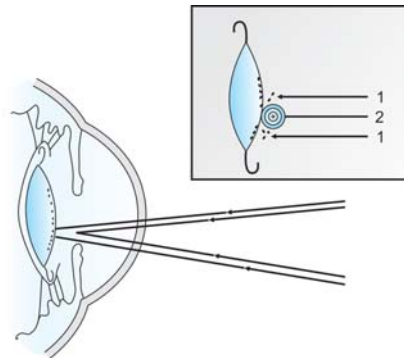


Fig. 21.1: Nd:YAG Sweeping- Laser defocused anteriorly. Inset showing deposits/precipitates/pigments (1) are dislodged by an acoustic shock wave (2) developed in the anterior chamber

- *Control of raised IOP:* Timanol maleate (0.5%)-One drop twice daily for 3-7 days.
- *Reduction of inflammation:* 0.1% Dexamethasone phosphate or 1% Prednisolone acetate eye drop-1 drop 4 times daily for 3-7 days.

BIBLIOGRAPHY

1. Francis A, L'esperance, Jr. Ophthalmic Lasers (3rd Edn), St. Louis: CV Mosby 1989:841.
2. Kumar H, Honaver SG, Vajpayee RB. Nd: YAG laser sweeping of the anterior surface of an IOL—a new observation. *Ophthal Surg* 1994;25:409-10.
3. Vajpayee RB, Kumar H. YAG sweeping—a new entity. In Kumar A, Kumar H (Eds), *Ophthalmic Lasers: Current Concepts*. New Delhi: Neelkanth graphics. 1993:61.

CHAPTER 22

Nd: YAG Corticolysis

Introduction

Nd: YAG laser treatment to accelerate the process of absorption of residual cortical matter after extracapsular extraction with or without implantation of intraocular lens (IOL) is called corticolysis.

General Steps

(As stated in chapter 21 of Nd: YAG laser sweeping)

1. Explain the procedure
2. Signing informed consent
3. *Antiglaucoma medication*: 1 drop Apraclonidine (1%) or Brimonidine tartrate (0.15-0.2%) eye drop one hour before the procedure is sufficient.
4. *Mydriasis*: Pupil should be middilated with a single drop of Tropicamide (1%) eye drop applied topically fifteen minutes before the laser application.
5. *Anesthesia*: Usually not required unless contact lens is applied.
6. Comfortable sitting of patient.
7. Steady fixation.
8. *Contact lens*: Usually not required.
9. *Laser room illumination*: Darkened/semi darkened.
10. Adjustment of slit lamp

Corticolysis Technique Proper

- Usually 4 to 5 mJ of energy per pulse from a Q-switched Nd: YAG laser is adequate.
- Pulse mode is preferred over burst mode.
- Q-switched Nd: YAG laser is focused posterior to intraocular lens (IOL) and within the substance of retained cortical matter.
- The aim is not to disrupt the posterior capsule.

- Laser shots are fired several times and the cortical matter becomes “milky” after application of few shots.

Post laser advice

The same as that advised after Nd:YAG posterior capsulotomy (see Chapter 20) although elevation of IOP and inflammatory reactions may be more pronounced than with Nd: YAG posterior capsulotomy. The absorption of residual cortical matter is usually completed within one week.

BIBLIOGRAPHY

1. Bhattacharyya B. Clinical Applications: YAG Laser (Ophthalmology). New Delhi: Jaypee Brothers Medical Publishers (P)Ltd, 2005:78-9.
2. Ficker LA, Steele AD. Complications of Nd: YAG laser posterior capsulotomy. Trans Ophthalmol Soc UK 1985; 104:529.
3. Francis A. L'esperance, Jr. Ophthalmic Lasers. (3rd edn), St. Louis: CV Mosby 1989;848.
4. Steinert RF, Puliafito CA. The Nd-YAG Laser in Ophthalmology: Principles and Clinical Applications of Photo-disruption. Philadelphia: WB Saunders Co. 1985 : 93.

CHAPTER 23

Nd: YAG Membranectomy

Introduction

Thick nonelastic pupillary membrane in front of the intraocular lens causes significant reduction of vision often restricted to perception of light and projection of rays. It is a very *important to assess thickness, density and type of membrane by slit-lamp biomicroscopy.

Indications

- Inflammatory pupillary membrane after extracapsular extraction of lens with or without posterior chamber intraocular lens particularly in diabetic patients and patients with residual cortical matter.
- Patients with above indication and poor risk for further surgical procedure.

General Steps

1. *Explain the procedure:* May require multiple session.
2. Signing informed consent
3. *Antiglaucoma medication:* 1 drop Apraclonidine (1%) or Brimonidine tartrate (0.15-0.2%) eye drop one hour before the procedure is sufficient.
4. *Mydriasis:* Tropicamide (1%) eye drop applied topically starting 2 hours before the laser application.
5. *Anesthesia:* Usually contact lens is applied.
6. Comfortable sitting of patient.
7. Steady fixation.
8. *Contact lens:* Usually required.
9. *Laser room illumination:* Darkened/semi darkened.
10. Adjustment of slit lamp

*In case of very dense and thick membrane Nd: YAG laser application may be avoided due to chances of phacoanaphylactic uveitis due to escape of entrapped protein from large Elschnig's pearls.

Membranectomy Technique Proper

- Membranectomy requires high energy per pulse ranging from 4.5 to 11 mJ due to increased thickness and lack of elasticity property of the membranes.
- The energy per pulse is gradually increased until the thick membrane begins to disrupt.
- Frequently more than 100 shots are required to achieve a visually significant opening in the pupillary area from a Q-switched Nd: YAG laser.
- The pupillary opening is created by “Chipping away technique” at the edge of the membrane bit by bit. The membrane detaches from pupillary margin and allows it to dilate. Residual membrane may remain attached to one side without causing any visual disturbance.

Postlaser Advice

This is the same as that advised after Nd: YAG capsulotomy (see chapter 20) but for a prolonged duration. This is due to the fact that post-laser elevation of intraocular pressure and inflammation may be more pronounced than with Nd: YAG laser capsulotomy.

Complications

All complications are directly proportional to the energy level and number of pulses applied.

- Uveitis: It may occur from liberation of residual cortex.
- Elevated IOP: It is largely due to block of trabecular outflow by cellular debris.
- Phacoanaphylactic uveitis.

BIBLIOGRAPHY

1. Frankhauser F, Roussel P, Steffen J, et al. Clinical studies on the efficiency of high power laser radiation upon some

structures of the anterior segment of the eye. *Int Ophthalmol* 1981;3:129-39.

2. Jagger J, Dhillon BJ. Neodymium: YAG treatment of complications following cataract extraction with intraocular lens implantation. *Eur J Impl Refract Surg* 1986;4:224.
3. Kwasniewska S, et al. Advantages, limitations of photo-disruptive laser in microsurgery in the anterior segment lasers. *Ophthalmol* 1987;1:155.
4. Steinert RF. Puliafito CA. *The Nd: YAG laser in ophthalmology: Principles and clinical applications of photo-disruption*. Philadelphia: WB Saunders Co. 1985;91.

CHAPTER 24

*Miscellaneous
Anterior Segment
Applications*

Introduction

Laser is clinically applied in various other infrequent situations for its therapeutic efficacy. The clinical experience of the surgeon will help him to plan and modify the steps according to his judicious requirement and judgment.

Retained Anterior Capsular Remnants

Rarely, a large portion of anterior capsular membrane may remain undetected during initial surgical procedure. Occasionally small or large visually disturbing anterior capsular remnant may be seen after can-opener type of anterior capsulotomy.

Indications and Techniques

1. Visually disturbing anterior capsular tag.
 - *Site of focus:* The tag is directly focused to cut with photodisruptive forces of Q-switched Nd: YAG laser.
 - *Energy:* 2-4 mJ.
2. Anterior capsular tag adherent to corneal endothelium leading to keratopathy.
 - *Site of focus:* The Q-switched Nd: YAG laser beam is focused directly on the tag as close as possible to the cornea without causing corneal burn.
 - *Energy:* 1-3 mJ.
3. Retained large anterior capsular membrane in front of IOL detected postoperatively.
 - *Site of focus:* The retained anterior capsule is cut by a series of laser shots starting from the superiormost position proceeding towards the inferior location. The anterior capsular membrane is not cut completely to float freely in the anterior chamber causing further complications such as corneal endothelial touch, blockage of trabecular meshwork etc. It is allowed to

remain attached at one point inferiorly. Few shots are fired in the anterior chamber to create pressure wave. This acoustic pressure wave curls up the capsule upon itself.

- *Energy:* 2-4 mJ.

Repositioning of PCIOL

When iris capture in a PCIOL is not associated with iridocapsular synechiae the PCIOL maybe pushed back into its own position by the pressure wave generated by Nd:YAG laser (Q-switched). When iris capture is associated with iridocapsular synechiae the repositioning of PCIOL is facilitated by successful synechialysis.

Before the patient is subjected to Q-switched Nd:YAG laser the following conservative approaches must be tried which often secures the desired result.

- The patient is laid on a supine position.
- Hyperosmotic agents are given orally to shrink volume of vitreous.
- Pupil is constricted with frequent instillation of 2% pilocarpine nitrate eye drop.
- Pressure on the eyeball by an earbud near the region of ciliary sulcus.

If the PCIOL is not repositioned by the above conservative procedures, then Nd: YAG laser therapy is indicated.

Technique

- *Site of focus:* Just inside the margin of the optic of PCIOL
- *Energy:* 4-6 mJ per pulse. Usually one to two shots are sufficient to push the PCIOL back into its position.
- *Focusing of beam:* The laser beam should be anteriorly defocused, i.e. after focusing on the anterior surface of PCIOL, the joystick is pulled back slightly. Care must be

to avoid focusing on or too close to the IOL. This will help in avoiding inadvertent damage to the implant.

Drainage of Conjunctival Cyst

Indication

Cosmetic.

Technique

- *Site of focus:* Lower part of the cyst.
- *Energy:* 1-2 mJ per pulse.
- *Focusing of beam:* Focus directly on the external wall of the cyst. Puncture of the *cyst wall will lead to drainage of fluid content of cyst and subsequent collapse.

Reopening of Blocked Filtering Site/Bleb

Indication

Obstruction of filtering site with visible nonpigmented tissue or membrane.

Technique

- *Site of focus:* Blocking tissue at filtering site.
- *Energy:* 5-9 mJ per pulse (Q-switched Nd:YAG laser).
- *Focusing of beam:* Transcamerally through a suitable gonioscopy lens.

Laser Suture Lysis

This is done usually after trabeculectomy and is effective within 1 week of filtration surgery. The objective is to release a tightly sutured scleral flap to allow easier drainage of aqueous from anterior chamber to the subconjunctival space.

*Recurrence of the cyst may occur.

Table 24.1: Comparison of different suture lysis laser lenses (specifications courtesy Ocular instruments, Bellevue, WA, USA)

<i>Lens</i>	<i>Image magnification</i>	<i>Laser spot magnification</i>	<i>Advantage</i>
Ocular Hoskins Nylon Suture	1.2×	0.83×	The Flange holds the eyelid out of the way.
Ocular Mandelkorn Suture Lysis	1.32×	0.76×	Large contact diameter helps in complete visualization of the surgical Site.
Ocular Ritch Nylon Suture	1×	1×	Cone shaped lens with the flange provides eyelid retraction

Indications

1. Tightly sutured scleral flap in filtration surgery.
2. Tight microsurgical sutures e.g. 8-0/9-0/10-0 Virgin Silk/Nylon to decrease post-operative astigmatism.

The procedure is facilitated by:

- Prior topical instillation of 5% Phenylephrine HCl.
- Compressing the conjunctiva with the edge of a contact lens, if used.
- The suture lysis can be done through special contact laser lenses (Table 24.1) which provides a clear view of the sutures.

Technique

- Usually *argon/diode laser is used.

*Nd:YAG laser (1064 nm) can also be used to cut sutures (burst mode, 4-6 pulses/burst and 8-16 mJ/pulse).

- Multiple sutures should not be cut in one session.
- *Parameters:* Spot size 50 μm , Power 500-1000 mW and exposure 0.1 to 0.2 sec.
- Usually application of 1-2 laser burn is sufficient to sever a suture.

Complications

- Over filtration \rightarrow Shallow anterior chamber.
- Conjunctival perforation \rightarrow Wound/Bleb leak.

Goniophotocoagulation

New vessels in the angle of the anterior chamber can be directly treated with laser.

Indications

- New vessels in the angle of the anterior chamber.
- Discrete blood vessels in the angle of the anterior chamber.

Technique

- Usually argon laser is used.
- *Parameters:* Spot size 100 μm , Power 200-800 mW and exposure 0.1 to 0.2 sec.
- Anesthesia-usually Topical.
- Contact Laser lens-Goldmann/ Ritch Trabeculoplasty/ Latina SLT/Ocular Magna view gonio lens
- Miosis-To help in visualization of angle of the anterior chamber.

Corneal Neovascularization-laser Application

Corneal neovascularization may occur after injury, keratitis, cataract surgery and keratoplasty.

Indications

1. Before keratoplasty to prevent graft rejection.
2. After keratoplasty to prevent graft rejection.
3. To prevent development of *lipid keratopathy (deposition of lipids in the stroma).

Technique

- Prior Fluorescein angiography is essential;
 - To identify the new vessels.
 - To distinguish between arteries and veins.
- Explain the procedure-Several sessions may be required at intervals of 1 week .
- Usually argon laser is used.
- *Parameters:* Spot size 50-100 μm , Power 200-800 mW and exposure 0.1 to 0.2 sec
- Anesthesia-usually Topical.
- Contact Laser lens-Abraham/Wise/Peyman iridotomy/ Pollack iridotomy gonio lens.
- *Miosis*-To prevent accidental retinal burn.
- Initially, main arteries peripheral to limbus are occluded followed by the main veins just inside the limbus. This procedure expands and darkens the blood column trapped within the cornea that in turn increases laser absorption.
- Applying laser burns centripetally occludes the larger veins.
- End point of laser treatment-The entire length of occluded vessel contains stationary columns of coagulated blood.
- The patient is examined after 1 hour to confirm occlusion of vessels. The reopened vessels are retreated in the same manner.

*The lipid plaques take many months to absorb.

Complications

1. Transient corneal hemorrhage-during laser session
2. Recurrence of corneal neovascularization
3. Inflammation- common- treated with topical steroids/ NSAID
4. Inadvertent injury to the iris

BIBLIOGRAPHY

1. Bhattacharyya B. Clinical Applications: YAG Laser (Ophthalmology). New Delhi: Jaypee Brothers Medical Publishers (P) Ltd, 2005:101-5.
2. Cohn HC, Aron-Rosa D. Reopening blocked trabeculectomy sites with the YAG laser. *Am J Ophthalmol* 1983;95:293-294.
3. Francis A. L'esperance, Jr. *Ophthalmic Lasers*. (3rd edn). St. Louis: CV Mosby Co. 1989:872.
4. Kumar A, Kumar H, Dada T. *Lasers in Ophthalmology: A Practical Guide*, New Delhi, Jaypee Brothers Medical Publishers (P) Ltd., 2000:85.
5. Mekler-Lupolover Y. Iris-capture phenomenon dank YAG-laser gelost. *Klin Monatsbl Augenheilkd* 1987;190:381.
6. Praeger DL. The opening of closed filtering blebs using the neodymium-YAG laser. *Ophthalmology* 1984;91:373-377.
7. Steinert RF, Puliafito CA. *The Nd-YAG Laser in Ophthalmology: Principles and Clinical Applications of Photodisruption*, Philadelphia: W.B. Saunders Co. 1985;124,129-30.
8. Steven M Bloom, Alexander J Brucker. *laser surgery of the posterior segment*, Philadelphia: Lippincott-Raven. 1997:72.



Section **Four**

**Laser Surgery
on Vitreous**

CHAPTER 25

*Nd: YAG
Anterior Segment
Vitreolysis*

- *Optical coherence topography (OCT)*: It is very useful in establishing diagnosis of cystoid macular edema.

General Steps

1. *Explanation of the procedure*: This procedure requires multiple sittings.
2. Informed consent.
3. *Miosis/mydriasis*: The dilation or constriction of the pupil depends on the location of the vitreous strand.
 - Miosis of pupil by pilocarpine nitrate 2% eye drop-1 drop every 15 minutes topically beginning two hours before the laser session induces stretching of vitreous strand passing through miotic pupil. It helps in laser treatment by facilitating identification of the vitreous strand and subsequent release of tension after lysis of the strand.
 - Mydriasis of pupil is occasionally required to properly visualize and facilitate lysis of vitreous strand behind iris, i.e. in the posterior chamber.
4. Antiglaucoma medication.
5. Anesthesia.
6. Comfortable positioning.
7. Steady fixation.
8. *Illumination of room*: Darkened.
9. *Gonio lens insertion*: Different types of gonioscopy lenses are discussed in chapter 10 and 11(see Table 11.1).
10. Adjustment of slit lamp.

Anterior Segment Vitreolysis Technique Proper

The most common anterior segment vitreous strand configurations to the corneoscleral wound are as follows:

1. A narrow discrete vitreous strand.

2. A broad sheet of vitreous without incarceration of iris at the wound.
3. A medium to broadsheet of vitreous band with either tenting upwards of iris due to adhesion or incarceration of iris to the cataract wound along with the vitreous band.

The vitreous strand/band can be lysed/transected with Nd: YAG laser (Q-switched) in four areas or zones, which are discussed in details below.

At the cataract wound

Advantages

- a. Here the vitreous strand is often most discrete and thinnest. It is always desirable to cut the strand at thinnest point.
- b. This site is most reliable landmark for anterior vitreolysis.
- c. Rate of successful vitreolysis is very high at this site. It may be achieved with three to five well-focused laser shots.
- d. Anterior vitreolysis is often facilitated by Abraham contact lens (with peripheral button), which extends view well into the angle of anterior chamber.

Disadvantages

- a. Visualization of corneoscleral wound and laser vitreolysis at this site is possible only through gonioscopy lens.
- b. Higher energy (6-12 mJ) is required for anterior vitreolysis through gonioscopy lens.
- c. Use of gonioscopy lens involves extra expertise and manipulation by the laser surgeon.

Near the limbus

Advantages

- a. Usually contact/gonioscopy lens is not required
- b. Lower energy setting (4-8 mJ)

Disadvantages

- Pigment dispersion may be more causing poor visibility.
- Damage to the iris below and cornea above may occur due to poor visibility leading to poor focusing.
- It is successful, if the cornea is clear at the limbus and vitreous band is not adherent to iris.

*In the collarette region of Iris**Advantage*

Vitreolysis at this site is particularly successful when vitreous is adherent to iris surface at this area and pulls it upward like a tent.

Disadvantage

Damage to the adjacent iris tissue is very common.

At the pupil

Anterior vitreolysis at this site is usually not recommended due to the following reasons:

- At this site vitreous traction force is very poorly defined.
- Here vitreous strand is present in the form of very wide band. Numerous shots (usually 50 to 70), even more than 100 are required to cut a large wide band.
- Anterior vitreolysis at this site is rarely successful.
- Pigment dispersion and microhemorrhages may cause poor visibility.

Successful anterior vitreolysis is often confirmed by the following observations:

- Change in the shape of deformed pupil
- Iridodonesis.

Postlaser Advice

- Anti-inflammatory: Prednisolone acetate 1% eye drop 4 times daily may be required up to 2-3 months.

- b. Antiglaucoma: Usually required for 1-2 weeks.
- c. Mydriatic/Miotic: *Usually not required.*
- d. Systemic Indomethacin: Oral indomethacin 25-50 mg three times daily or 75 mg sustained release capsule twice daily after meal should be continued for a period of 2-3 months until improvement of vision occurs.
- e. Systemic drugs to reduce Gastric irritation by Indomethacin

BIBLIOGRAPHY

1. Bhattacharyya B. Clinical Applications: YAG Laser (Ophthalmology). New Delhi: Jaypee Brothers Medical Publishers (P) Ltd, 2005:93-8.
2. Gass JDM, Norton EWD, Cystoid macular edema and papilledema following cataract extraction. Arch Ophthalmol 1966;76:646-61.
3. Iliff CE. Treatment of vitreous-tug syndrome. Am J Ophthalmol 1966;62:856-59.
4. Irvine SR. A newly defined vitreous syndrome following cataract surgery. Am J Ophthalmol 1953;36:599-619.
5. Katzen LE, Fleischman JA, Trokel S. Yag laser treatment of cystoid macular edema. Am J Ophthalmol 1983;95:589-92.
6. Steinert RF, Puliafito CA. The Nd-YAG Laser in Ophthalmology: Principles and Clinical Applications of Photo-disruption, Philadelphia: WB Saunders Co. 1985;115-23.

*Nd: YAG
Posterior Segment
Vitreolysis*

Introduction

Application of Nd: YAG (both Q-switched and mode locked) in the posterior segment of eye for transection of vitreous membrane and or band is technically much more difficult and riskier than its application in the pupillary plane or anterior segment.

This procedure is also referred to as “YAG Photo-transection”.

Indications

It is a noninvasive procedure for:

- Section of elastic vitreous traction band and or membrane to release traction on the retina.
- Section of optically disturbing elastic or fragile vitreous band and or membrane.
- Section of vitreoretinal bands along the pathway of intraocular foreign body.
- Section of vitreous traction band attached to operculum of a retinal tear (Figs 26.1A and B).

Contraindication

Extensively vascularized membrane particularly in proliferative diabetic retinopathy.

Prelaser Examination Schedule

A detailed ophthalmic history, general medical history (diabetes mellitus, hypertension) and a meticulous ophthalmic examination are a must before contemplating posterior vitreolysis.

- Visual acuity—both corrected and uncorrected.
- Indirect ophthalmoscopy
- Slit lamp biomicroscopy—with Goldmann 3-mirror contact lens and the contact lens through which the



Fig. 26.1A and B: YAG Phototransection of traction band attached to operculum of a retinal tear (A) Vitreous traction band attached to the operculum of a horse shoe retinal tear, (B) Apex of the operculum with attached Vitreous traction band is cut using Q-switched Nd:YAG laser. The attached retinal area surrounding the tear should also be photocoagulated (2/3 rows of linear, interrupted and interval = $\frac{1}{4}$ th of spot size coagulations)

procedure is to be performed. Carefully evaluate and examine the target membrane and or band.

- Fundus fluorescein angiography (FFA)—It is helpful to exclude vascularization of band or membrane.

Criteria for Selection of Site

- It should preferably be farthest from both retina and posterior capsule of lens (in phakic eyes) or IOL (in pseudophakic eyes).
- YAG laser posterior vitreolysis should be avoided over an area from macula to optic disc, if the band or membrane lies close to retinal surface.
- YAG laser posterior vitreolysis is risky if the membrane or band is located just behind the posterior capsule of lens (in phakic eyes) or implant (in pseudophakic eyes). Cataractous change or implant damage may occur.
- It is safer to select a site over a previously photocoagulated area.

General Steps

1. *Explain the procedure:* Several laser sessions may be required to achieve vitreolysis.
2. Informed consent.
3. *Maximum mydriasis:* Pupil should be well dilated with Tropicamide (1%) and Phenylephrine HCl (5%) eye drop starting one hour before the procedure.
4. Anesthesia
 - a. Topical anesthesia with Proparacaine HCl (0.5%) a few minutes before insertion of contact lens.
 - b. Additionally retrobulbar anesthesia may be required in uncooperative patients and patients with nystagmus.
5. Comfortable sitting.
6. Steady fixation by:
 - a. Head strap
 - b. Illuminated target
7. *Contact lens insertion:* Various contact laser lenses are available for YAG laser application in different locations in the posterior segment of the eye (see Table 26.1). Flat fundus contact lenses, which diminish the angle of

Table 26.1: Choice of YAG laser lenses according to site in vitreous (specifications courtesy Ocular instruments, Bellevue, WA, USA)

<i>Laser lens</i>	<i>Image magnification</i>	<i>Laser spot factor magnification</i>	<i>Site of focus</i>
Peyman Widefield 12.5mm	1.40×	0.71×	Anterior vitreous
Peyman Widefield 18mm	1.41×	0.71×	Midvitreous
Peyman Widefield 25mm	1.36×	0.74×	Posterior vitreous

beam divergence, should be avoided to avoid retinal injury.

8. *Room illumination:* Darkened.

Nd: YAG Laser Posterior Vitreolysis Technique Proper

- Start with 1-3 mJ per pulse energy.
- Gradually increase the energy level until the cutting of band is achieved.
- Single pulse mode is preferred.
- The procedure is usually a lengthy one.
- *Focus:* Focusing is much more difficult in posterior segment application than in anterior segment applications. The focusing task is made more difficult due to peripheral location of target issue. Optical aberrations due to natural lens or implant also make focusing task difficult. So clinical experience and focusing skills of the laser surgeon are vital factors for hazard free posterior segment application.
- Vascularized membrane or band should be thoroughly pretreated to cause thrombosis of the vessels before Nd: YAG laser posterior vitreolysis.

Complications

1. *Retinal and choroidal hemorrhage:* These are the most common complication and may occur due to multiple factors:
 - a. Poor focusing
 - b. Use of suprathreshold energy level close to retina
 - c. Section of epiretinal membrane or band within 4 mm from retinal surface.
 - d. Optical aberrations derived from nuclear sclerosis of natural lens or implant.

Retinal and choroidal hemorrhage is caused by the acoustic and shock waves generated by optical breakdown very close to retinal surface. Usually choroidal and retinal hemorrhages clear within four weeks. If during laser procedure choroidal hemorrhage is detected, pressure on the globe by the laser contact lens will stop it spontaneously.

2. Retinal hole formation and retinal detachment.
3. *Cataract formation (in phakic eyes)*: The suggested laser focus behind the posterior capsule to avoid this complication is 4 mm.
4. Implant damage (in Pseudophakic eyes).
5. *Vitreous hemorrhage*: Posterior vitreolysis of an untreated vascularised membrane or band causes vitreous hemorrhage.
6. Vitritis.

BIBLIOGRAPHY

1. Berglin L, et al. A new technique of treating rhegmatogenous retinal detachment using the Q-switched Nd:YAG laser. *Ophthalmic Surg* 1987;18:890-92.
2. Bhattacharyya B. *Clinical Applications: YAG Laser (Ophthalmology)*. New Delhi: Jaypee Brothers Medical Publishers (P) Ltd, 2005: 26-7, 106-10.
3. Bonner RF, Meyers SM, Gaasterland DE. Threshold for retinal damage associated with the use of a highpower neodymium YAG lasers in the vitreous. *Am J Ophthalmol* 1983;96: 153-59.
4. Frankhauser F, Kwasniewska S, Van der Zypen E. Vitreolysis with the Q-switched laser. *Arch Ophthalmol* 1985;103:1166.
5. Frankhauser F, Kwasniewska S. Neodymium: Yttrium-Aluminium-Garnet laser. In Francis A. L'esperance, Jr. (Ed.) *Ophthalmic Lasers*. St. Louis : The CV Mosby Co. 1989; 858-66.

6. Frankhauser F. The Q-switched laser: Principles and clinical results. In Trokel S (Ed.). YAG laser Ophthalmic Microsurgery. Norwalk, CT: Appleton-Century-Crofts, 1983, pp 128-31.
7. Gibbons WB, Allen RG. Retinal damage from supra-threshold Q-switched laser exposure. Health Phys 1978; 35:461-69.
8. Jampol LM, Goldberg MF, Jednock N. Retinal damage from a Q-switched YAG laser. Am J Ophthalmol 1983;96:326-29.
9. Puliafito CA, Wasson PJ, Steinert RF, et al. Nd-YAG laser surgery on experimental vitreous membranes. Arch Ophthalmol 1984;102:843-47.
10. Tassignon MJ, et al. Vitreo-retinal membranes treated with the Q-switched Nd: YAG laser. Lasers Ophthalmol 1987;1:205.

INDEX

A

- Angiomatosis retinae 68
 - complications 72
 - contraindications 68
 - indications 68
 - postlaser advice 71
 - technique 69
- Anterior hyaloidectomy 166
 - general steps 166
 - indications 166
 - technique 167
- Anterior segment applications 207
 - corneal neovascularization-laser application 212
 - complications 214
 - indications 213
 - technique 213
 - drainage of conjunctival cyst 210
 - indication 210
 - technique 210
 - goniophotocoagulation 212
 - indication 212
 - technique 212
 - laser suture lysis 210
 - complications 212
 - indications 211
 - technique 211
 - reopening of blocked filtering site/bleb 210
 - indication 210
 - technique 210
 - repositioning of PCIOL 209
 - technique 209
 - retained anterior capsular remnants 208
 - indication 208
 - techniques 208
- Anterior segment vitreolysis 217
 - general steps 219
 - indications 218
 - postlaser advice 221
 - prelaser examination protocol 218
 - technique 219
- Argon laser 107, 123, 143
 - iridotomy 123
 - complications 127
 - contraindications 124
 - follow-up schedule 127
 - general steps 125
 - indications 124
 - postlaser advice 127
 - technique 126
 - trabeculoplasty 107
 - complications 112
 - contraindications 109
 - general steps 109
 - indications 108
 - mode of action 108
 - postlaser advice 112
 - technique 110
- pupilloplasty 143
 - complications 146
 - contraindications 144
 - general steps 144
 - indications 144
 - postlaser advice 146
 - technique 145

C

- Central serous chorioidopathy 94
 - complications 96
 - contraindication 94
 - general steps 95
 - indications 94
 - technique 95

- Cyclophotocoagulation 167
 - complications 169
 - contraindications 164
 - contact method 169
 - non-contact method 169
 - indications 168

I

- Infiltration anesthesia 16

L

- Laser parameters 12
- Laser peripheral iridoplasty 137
 - complications 140
 - contraindications 138
 - general steps 138
 - indications 138
 - postlaser advice 140
 - technique 139
- Laser tissue interactions 4
 - focusing of laser beam 9
 - gradation of photocoagulation lesions 9
 - influence of opacities in ocular media 8
 - lasers in photocoagulation 6
 - diode laser 8
 - freq-doubled Nd: YAG laser 7
 - krypton red laser 7
 - photocoagulation 4

M

- Malignant melanoma 76
 - complications 78

- contraindications 76
- general steps 77
- indications 76
- postlaser advice 78
- technique 77

N

- Nd: YAG 129, 149, 153, 159, 173, 195, 199, 203
- coreoplasty 153
 - complications 157
 - follow-up schedule 157
 - general steps 154
 - indications 154
 - postoperative advice 157
 - prelaser examination schedule 154
 - technique 155
- corticolysis 199
 - general steps 200
 - postlaser advice 201
 - technique 200
- iridotomy 129
 - complications 134
 - contraindications 130
 - follow-up schedule 134
 - general steps 130
 - indications 130
 - management 134
 - postlaser advice 134
 - technique 131
- membranectomy 203
 - complications 205
 - general steps 204
 - indications 204
 - postlaser advice 205
 - technique 205
- persistent hyperplastic pupillary membranectomy 159
 - complications 163
 - general steps 161

- indications 160
 - postoperative advice 163
 - prelaser examination
 - schedule 160
 - photomydriasis 149
 - complications 152
 - contraindications 150
 - general steps 150
 - indications 150
 - postlaser advice 152
 - technique 151
 - posterior capsulotomy 173
 - complications 190
 - contraindications 177
 - follow-up schedule 190
 - general steps 178
 - indications 174
 - postoperative advice 188
 - technique 182
 - timing of capsulotomy 177
 - sweeping 195
 - contraindication 196
 - etiology 196
 - general steps 196
 - postlaser advice 197
 - technique 167
- P**
- Panretinal photocoagulation in
 - diabetic retinopathy 21
 - complications 30
 - contraindications 23
 - general steps 23
 - indications 22
 - postlaser advice 29
 - postlaser follow-up 30
 - technique 26
 - Pascal photocoagulation 16
 - Peripheral retinal degenerations 60
 - complications 61
 - contraindications 60
 - follow-up 62
 - general steps 60
 - indications 60
 - postlaser advice 61
 - technique 61
 - Photoablation 13
 - Photocoagulation 35, 82, 85
 - in BRVO 82
 - contraindication 82
 - indication 82
 - technique 83
 - timing of laser 82
 - in CRVO 85
 - follow-up schedule 86
 - indication 85
 - technique 86
 - timing of laser 85
 - in diabetic maculopathy 35
 - complications 44
 - general steps 37
 - indications 37
 - postlaser advice 43
 - postlaser follow-up 43
 - technique 38
 - Photodisruption 14
 - Photodynamic therapy 45
 - complications 51
 - contraindications 46
 - ocular 46
 - systemic 47
 - dose calculation 47
 - general steps 48
 - indications 46
 - infusion of the verteporfin 49
 - mode of action 47
 - postlaser advice 50
 - preparation of the dye 47
 - technique 49
 - Photoradiation 14
 - Photovaporization 13
 - Post photocoagulation advice 13

234 LASER IN OPHTHALMOLOGY

- Posterior segment vitreolysis 223
 complications 227
 contraindication 224
 criteria for selection of site 225
 general steps 226
 indications 224
 postlaser follow-up 72
 prelaser examination
 schedule 224
- R**
- Retinal breaks 62
 complications 65
 contraindications 63
 general steps 63
 indications 63
 postlaser advice 64
 postlaser follow-up 66
- Retinal vasculitis 90
 complications 93
 contraindication 91
 follow-up schedule 93
 general steps 91
 indications 90
 postlaser advice 93
 technique 92
 timing of laser 91
- Retinoblastoma 72
 complications 75
 contraindications 73
 general steps 73
 indications 73
 postlaser follow-up 76
 technique 74
- Retinopathy of prematurity 97
 complications 101
 follow-up schedule 100
 general steps 99
 indications 98
 retrolental fibroplasia 97
 technique 99
 timing of laser 99
- S**
- Selective laser trabeculoplasty 115
 complications 121
 contraindications 116
 general steps 117
 indications 116
 mode of action 116
 postlaser advice 120
 technique 119
- T**
- Transpupillary thermotherapy 53
 contraindication 54
 follow-up schedule 57
 general steps 55
 indications 54
 mode of action 54
 postlaser advice 57
 technique 55
 timing of laser 55
- X**
- Xanthophyll pigment 6