THE CLINICAL ANATOMY
AND MANAGEMENT
OF BACK PAIN SERIES

VOLUME 2:
Clinical Anatomy and Management of THORACIC SPINE PAIN

Edited by

L G F Giles K P Singer

PHYSIOTHERAPY/CHIROPRACTIC

CLINICAL ANATOMY AND MANAGEMENT OF BACK PAIN SERIES

SERIES EDITORS

L G F Giles MSc DC(C) PhD

Director, National Unit for Multidisciplinary Studies of Spinal Pain, North Queensland Clinical School, The University of Queensland, Brisbane, Queensland, Australia

K P Singer PT MSc PhD

Associate Professor, Director, Centre for Musculoskeletal Studies, University Department of Surgery, The University of Western Australia, Royal Perth Hospital, Perth, Western Australia, Australia

Honorary Research Fellow, Departments of Imaging Services, Neuropathology, and Bioengineering, Royal Perth Hospital, Perth, Western Australia, Australia

Clinical Anatomy and Management of Thoracic Spine Pain

Thoracic spine pain is multifaceted and it demands the sharing of ideas and knowledge to improve the management offered to patients. This text highlights the value of a team approach to appreciating the complexity of thoracic spine pain and a range of treatment approaches. Contemporary contributions from anatomy, pathology, chiropractic, osteopathy and physiotherapy are presented. Each section, written by experienced clinical and basic science experts, provides a summary of pertinent material which will lead to an improved understanding of the causes of thoracic spine pain. The book highlights a common approach to mechanical treatment which may be provided by chiropractic, osteopathy and physiotherapy practitioners.

The text has been organized into four sections so that the information required by the reader can be easily accessed:

- Section 1: introduces the reasoning behind the text
- Section 2: the clinical anatomy, pathology and biomechanics of the thoracic spine
- Section 3: diagnosis of thoracic spine pain
- Section 4: management of thoracic spine pain

Essential reading for all students of mechanical therapy, *Clinical Anatomy and Management of Thoracic Spine Pain* will also prove invaluable to clinicians who seek a comprehensive review of thoracic spine pain.

Titles in the series:

① Clinical Anatomy and Management of Low Back Pain
② Clinical Anatomy and Management of Thoracic Spine Pain
③ Clinical Anatomy and Management of Cervical Spine Pain

The Clinical Anatomy and Management of Back Pain Series

This series of three books brings together a truly multidisciplinary approach to the management of mechanical spinal pain. Each volume provides a thorough review and analysis of clinically relevant information on the basic sciences leading to diagnosis and treatment of mechanical spinal disorders. The books are aimed at both undergraduate and postgraduate students of chiropractic, medicine, osteopathy and physiotherapy, as well as all clinicians who seek a comprehensive review of mechanical spinal pain.

BUTTERWORTH
HEINEMANN

http://www.bh.com

ISBN 0-7506-4789-2

9 780750 647892

Clinical Anatomy and Management of Thoracic Spine Pain

THE CLINICAL ANATOMY AND MANAGEMENT OF THORACIC SPINE PAIN

L. G. F. Giles MSc, DC(C), PhD
Director
National Unit for Multidisciplinary Studies of Spinal Pain, North Queensland Clinical School,
The University of Queensland, Brisbane 4810, Queensland, Australia
Honorary Clinical Scientist
Townsville General Hospital, Townsville, Queensland, Australia

and

K. P. Singer PT, MSc, PhD
Associate Professor
Director
Centre for Musculoskeletal Studies, University Department of Surgery,
The University of Western Australia, Royal Perth Hospital, Perth, Western Australia
Honorary Research Fellow
Departments of Imaging Services, Neuropathology, and Bioengineering,
Royal Perth Hospital, Perth, Western Australia

BUTTERWORTH
HEINEMANN

OXFORD AUCKLAND BOSTON JOHANNESBURG MELBOURNE NEW DELHI

Butterworth-Heinemann
Linacre House, Jordan Hill, Oxford OX2 8DP
225 Wildwood Avenue, Woburn, MA 01801-2041
A division of Reed Educational and Professional Publishing Ltd

A member of the Reed Elsevier plc group

First published 2000

British Library Cataloguing in Publication Data
Giles, L. G. F.
Clinical anatomy and management of thoracic spine pain
1. Spine - Diseases 2. Backache - Treatment 3. Thoracic vertebrae - Diseases
I. Title II. Singer, K. P. (Kevin P.)
617.5'64

Library of Congress Cataloguing in Publication Data
The clinical anatomy and management of thoracic spine pain/[edited by] L.G.F. Giles and K.P. Singer.
p. cm.
Includes bibliographical references and index.
ISBN 0 7506 4789 2
1. Thoracic vertebrae - Pathophysiology. 2. Backache. 3. Spine - Diseases - Treatment. I. Giles, L. G. F. Singer, K. P. (Kevin P.)
[DNLM: 1. Thoracic Vertebrae - physiopathology. 2. Back Pain - diagnosis. 3. Back Pain - therapy. 4. Thoracic Vertebrae - anatomy and histology. WE 725 C641]
RD533.C56 99-056627
617.5'64-dc21

ISBN 0 7506 4789 2

Composition by Genesis Typesetting, Laser Quay, Rochester, Kent
Printed and bound in Great Britain by The Bath Press, Avon

Contents

List of contributors vii
Foreword ix
Preface xi
Acknowledgement xiii

Section I Introduction 1

1 Introduction: the enigma of the thoracic spine 3
K. P. Singer and S. J. Edmondston

Section II Anatomy, Pathology and Biomechanics 15

2 Anatomy of the thoracic spine 17
K. P. Singer and S. Goh

3 Ligaments of the human vertebral column 34
R. V. Putz and M. Müller-Gerbl

4 Biomechanics of the thoracic spine and ribcage 45
I. A. F. Stokes

5 Pathology of the thoracic spine 63
K. P. Singer

6 Developmental anomalies of the thoracic region 83
J. Saada, S. Song and W. H. Breidahl

7 Pathoanatomical characteristics of the thoracolumbar junctional region 100
K. P. Singer and A. Malmivaara

8 Thoracic neural anatomy 114
G. J. Groen and R. J. Stolker

Section III Diagnosis of Thoracic Spine Pain 143

9 Diagnosis of thoracic pain syndromes 145
J. H. Bland

10 Cervicothoracic and thoracolumbar spinal pain syndromes 157
J.-Y. Maigne

11 The thoracic spine and the 'tired neck syndrome' 171
H. F. Farfan

12 Radiology of the thoracic spine 177
I.W. McCall

Section IV Management of Thoracic Spine Pain 203

13 Medical and invasive management of thoracic spinal pain 205
R. J. Stolker and G. J. Groen

14 Surgical treatment of diseases and trauma of the thoracic spine 223
G. F. Findlay and S. Eisenstein

15 Chiropractic management of thoracic spine pain of mechanical origin 244
D. J. Lawrence and B. Bakkum

16 Osteopathic management of thoracic spine pain 257
T. McClune, C. Walker and K. Burton

17 Physiotherapy management of thoracic spine pain 268
D. G. Lee

18 Diagnosis of thoracic spine pain and contraindications to spinal mobilization and manipulation 283
L. G. F. Giles

Index 299

Contributors

B. Bakkum DC, PhD
National College of Chiropractic, Lombard, IL 60148, USA

J. H. Bland MD
Professor of Medicine - Rheumatology, Emeritus University of Vermont College of Medicine, Rheumatology and Clinical Immunology Unit, Given Medical Building, Room D-302, Burlington, Vermont 05405, USA

W. H. Breidahl BSc, MB BS, FRACR
Consultant Radiologist, Department of Imaging Services, Royal Perth Hospital, Perth, Western Australia

K. Burton PhD, DO, MErgS
Spinal Research Unit, University of Huddersfield, 30 Queen Street, Huddersfield HD1 3DH, UK

S. Edmondston PhD, MT, PT
Centre for Musculoskeletal Studies, University Department of Surgery, The University of Western Australia, Royal Perth Hospital, Perth 6000, Western Australia

S. Eisenstein PhD, FRCS
Consultant Orthopaedic Surgeon, Centre for Spinal Studies, Robert Jones and Agnes Hunt Hospital, Gobowen, Oswestry, Shropshire, UK

H. F. Farfan MD
(deceased)

G. F. Findlay BSc, MB, ChB, FRCS
Consultant Neurosurgeon, Walton Centre for Neurology and Neurosurgery, NHS Trust, Lower Lane, Fazakerley, Liverpool, UK

L. G. F. Giles MSc, DC(C), PhD
Director, Spinal Pain Unit, Townsville General Hospital, Townsville 4810, Queensland, Australia

S. Goh BSC(Hons), PT
Centre for Musculoskeletal Studies, University Department of Surgery, The University of Western Australia, Royal Perth Hospital, Perth 6000, Western Australia

G. J. Groen MD, PhD
Associate Professor, Centre for Perioperative Medicine, Anesthesiology and Pain Clinic, University Medical Centre Utrecht, P.O. Box 85500, 3508 GA Utrecht, The Netherlands

D. J. Lawrence DC
National College of Chiropractic, Lombard, IL 60148, USA

D. Lee MT, PT
Delta Orthopaedic Physiotherapy Clinic, #302-8425 120th Street, Delta, BC, V4C 6R2, Canada

J.-Y. Maigne MD
Hotel-Dieu Hospital, Rehabilitation Department, Place Notre Dame, 75004 Paris, France

A. Malmivaara MD, PhD
Finnish Institute of Occupational Health, Department of Occupational Medicine, Topeliuksenkatu 41 A, 00250 Helsinki, Finland

I. McCall FRCR
Consultant Radiologist, Department of Radiology, The Robert Jones and Agnes Hunt Orthopaedic Institute, Oswestry, UK

T. McClune DO
Spinal Research Unit, University of Huddersfield, 30 Queen Street, Huddersfield HD1 3DH, UK

M. Müller-Gerbl PhD
Ludwig-Maximmilians-Universität München, Anatomische Anstalt, Pettenkoferstr. 11, D-80336 München, Germany

R. Putz MD, PhD
Ludwig-Maximmilians-Universität München, Anatomische Anstalt, Pettenkoferstr. 11, D-80336 München, Germany

J. Saada FRCR
Consultant Radiologist, Norfolk Hospital, Norwich, UK

K. P. Singer PhD, PT
Centre for Musculoskeletal Studies, University Department of Surgery, The University of Western Australia, Royal Perth Hospital, Perth 6000, Western Australia

S. Song BSc (Hons), MB BS, FRACR
MRI Unit, Department of Imaging Services, Royal Perth Hospital, Perth, Western Australia 6000

I. A. F. Stokes PhD
Department of Orthopaedics and Rehabilitation, University of Vermont, Burlington, VT 05405, USA

R. J. Stolker MD, PhD
Department of Anesthesiology, Catharina Hospital, 5602 ZA Eindhoven, The Netherlands

C. Walker BSc (Hons), BSc (Ost)
Spinal Research Unit, University of Huddersfield, 30 Queen Street, Huddersfield HD1 3DH, UK

Foreword

Having been personally and heavily involved for nearly 25 years in clinical and laboratory studies of the spine, having attended numerous conferences and meetings concerned with back pain, and having read a multitude of publications dealing with the vertebral column, the perception that I gained early after taking up my interest in the spine, was that compared with the lumbar and cervical spine the thoracic spine has received much less attention. My perception has continued to be sustained over that many years. My own explanation for the reasons why the thoracic spine has not attracted the same level of clinical and laboratory investigation as the cervical and lumbar regions is that the thoracic region is less often the source of complaints of back pain, that the presence of the ribs imposes substantially different biomechanical influences and there seems to be less pathology in that region of the spine.

Taking account of this relative lack of past interest in the thoracic spine and the refreshing and thorough approach displayed by Dr Giles and Professor Singer to other regions of the spine already covered in this three-volume series, I have looked forward with particularly keen anticipation to their offering on the thoracic spine. I am not disappointed as they have assembled an excellent international team from diverse but relevant disciplines to address normal and pathological structure and function in addition to the diagnosis and management of pain involving the thoracic region. The team and their editors are to be congratulated for having assembled a comprehensive but readable account of existing knowledge, for having achieved substantial uniformity of style, and for having raised a range of new concepts. The resulting book presents a valuable source of information for professionals involved in the investigation and clinical management of back pain, as well as providing basic scientists with a rich source of existing knowledge as well as providing a substantial stimulus for new lines of investigation.

I am grateful to have this opportunity to be able to express my personal gratitude to the authors and editors for filling an important niche in the spinal literature and I confidently predict that anyone who has an interest in back pain and its causes will reach a similar conclusion.

Professor Barrie Vernon-Roberts MD, PhD
Director, Institute of Medical and Veterinary Science
Adelaide, November 1999

Preface

Our intention in compiling this new text series is to provide an international perspective on the rational approach to managing mechanical spinal pain. We present a comprehensive review and analysis of clinically relevant information from the basic sciences leading to diagnosis and treatment of mechanical spinal disorders.

This volume highlights the value of a team approach in appreciating the complexity of thoracic spine pain and a range of treatment approaches. Thoracic spine pain poses a special challenge to the clinician, who must appreciate the variety of syndromes and referral patterns which can mimic disorders at distant sites. Contemporary contributions from the fields of anatomy, pathology, biomechanics, neuroanatomy, clinical medicine, pain control, radiology, orthopaedics, neurosurgery, chiropractic, osteopathy and physiotherapy are all presented in this volume. Each section, written by experienced academic clinicians, provides a summary of pertinent material that will lead to an improved understanding of the causes of thoracic spine pain, emphasizing primarily mechanical sources. Management approaches are outlined, based on routine assessment techniques and supported by clinical reasoning strategies. This text does not attempt to endorse a single therapy, but rather to highlight the common approach to mechanical treatment that may be provided by medical, surgical, chiropractic, osteopathy and physiotherapy practitioners. Newer invasive pain control strategies are also outlined to inform clinicians of such options for the management of chronic thoracic pain.

Our goal is to present this information in a manner which will benefit both the undergraduate and postgraduate student of mechanical therapy, as well as all clinicians who seek a comprehensive review of thoracic spine pain. In the belief that quality illustrations facilitate the message, careful selection of material and detailed captions have been prepared to complement the text. An important second objective is to encourage greater communication between the clinical schools interested in this subject, through which a stronger scientific basis for evaluation and management of thoracic spine pain will emerge.

The text is organized so that it can be approached in several ways, according to the needs of the reader. Section I introduces the reasoning behind this text, describing the enigma of thoracic spine pain, the known epidemiology of the problem, and its many complexities for the clinician. Section II presents the clinical anatomy, pathology and biomechanics of the thoracic region and contains special chapters on the adjoining cervicothoracic and thoracolumbar junctional regions. This section also presents a very detailed overview of thoracic neuroanatomy to provide a basis for understanding the diagnostic challenge awaiting the clinician.

The clinician who wishes a quick overview of clinical assessment concepts should consult Section III, Diagnosis of Thoracic Spine Pain. This includes diagnostic imaging procedures and medical and surgical approaches to thoracic spine pain, and separate chapters on the assessment and management strategies provided by chiropractors, osteopaths and physiotherapists. A special chapter by the late Harry F. Farfan MD describes his reminder to clinicians to examine the whole person when assessing thoracic pain.

Section IV presents a multidisciplinary approach to the management of thoracic spine pain, and concludes with a comprehensive chapter summarizing the diagnosis of thoracic spine pain and the highly relevant issue of contraindications to spinal mobilization and manipulation.

Our general approach to both the clinical and scientific aspects of thoracic spinal pain is to provide a contemporary review of the literature and to present logical examples of clinical reasoning behind several disciplines of mechanical therapy. Despite the need to validate theories of mechanical intervention and to show long-term efficacy of these therapies, this text also sets out our challenge, as clinician-scientists, to promote communication between all interested parties. Spine pain, and in particular thoracic spine pain, is multi-faceted, and it demands the sharing of ideas and knowledge to improve the management offered to our patients.

K. P. Singer
L. G. F. Giles

Acknowledgements

My sincere thanks to all authors for their original chapter contributions on the least well-known region of the human spine. In particular I record my indebtedness to Mrs Aurelie Farfan, for kindly granting permission to incorporate into this text previously unpublished work by her late husband, Dr Harry Farfan, MD, on the association between thoracic spine pain and upper limb and neck disorders.

The support of colleagues at Royal Perth Hospital, Queen Elizabeth II Medical Centre and the Department of Anatomy and Human Biology, The University of Western Australia, for access to departmental resources, is noted with appreciation. In particular, I thank my academic colleagues and postgraduate research students for their enthusiasm and support over many years on studies related to the human thoracic spine.

To Zoë Youd and Caroline Makepeace, editors and their project team at Butterworth-Heinemann, Oxford, for their humour and wise counsel in seeing this project through to completion.

Many investigations reported in this text have been supported in part by grants from the Royal Australasian College of Radiologists, the National Health and Medical Research Council of Australia, and the Medical Research Committee of the Lotteries Commission of Western Australia.

I express my heartfelt thanks to my wife Barby and our girls, Helen and Rachel, for their patience during the extended periods of retreat 'working on the book'.

This volume is dedicated to my mother, Shirley Margaret Singer [1923 - 1999] for her example of lived faith and encouragement. May she rest in peace with the Lord.

KPS

Section I

Introduction

1

Introduction: the enigma of the thoracic spine

K. P. Singer and S. J. Edmondston

The thoracic spine may be viewed as an enigma within the vertebral column. This region accounts for the smallest proportion of published studies on the spine as a whole, in contrast to the attention paid to the neighbouring cervical and lumbar regions. Surgery performed on the thoracic spine relates to deformity correction, disc herniation, metastatic disease, traumatic instability and occasionally stenosis, but, in every case, the thoracic incidence is less than for the adjacent regions. Yet, as emphasized by many contributors to this volume, the thoracic region can often be linked to symptoms and disorders that may manifest elsewhere in the body. These conditions that may implicate the thoracic spine are many and varied (Table 1.1), and have the potential to confuse the clinician. It is timely, therefore, to direct attention to the thoracic spine and encourage clinicians to appreciate better the diagnostic puzzle this region offers. It is hoped that this book will prompt the reader to reconsider the fundamental process of diagnosis and the application of effective management strategies, where available, to non-operative musculoskeletal thoracic spine pain.

Table 1.1 *Common pathologies that may implicate the thoracic spine*

- Post-thoracotomy surgery
- Intercostal neuralgia
- Dorsal compartment syndrome
- Segmental radiation of pain, e.g. T4 syndrome
- Myogenic pain
- Visceral and abdominal referred pain
- Rib syndromes
- Osteoporosis
- Fracture
- Vertebral collapse
- Prolapsed intervertebral disc

Adapted from Broadhurst (1987), Grieve (1994).

Thus the objective of this text is to provide an overview to the anatomy, biomechanics, pathology, diagnosis and anomalies of the thoracic spine; a careful presentation of thoracic spine neurology provides an important background to the diagnosis of common conditions which affect this region. A review of the radiological, medical and surgical perspectives on the thoracic spine follows before management strategies for musculoskeletal disorders from three disciplines of mechanical therapy are outlined. The text concludes with a review of the diagnostic process and a summary of the contra-indications to mechanical therapy of the thoracic spine.

By way of introduction to the thoracic spine, three case studies from the literature are presented to highlight the diagnostic challenge of disorders of the thoracic spine (Fig. 1.1).

Case 1:

A 21-year-old male professional Australian rules football player presented 24 hours post-competition, with pain located posteriorly in the right shoulder and centrally within the glenohumeral joint (Fig. 1.1A). Pain was reported following a collision, but the exact injury mechanism was unclear. The pain progressively increased over a 24-hour period, and was exacerbated with movement of the shoulder joint. The initial provisional diagnosis was suggestive of a partial rotator cuff tear. On further assessment, full range of shoulder girdle motion was achieved; however, the patient described nonspecific discomfort on active abduction and flexion movements. Shoulder instability tests were negative. A positive shoulder impingement test was recorded, with pain reproduced in the early range of internal rotation. Manual muscle tests for subscapularis and supraspinatis were pain inhibited. Motion and palpation of the cervical spine were considered to be within normal limits. Significantly, accessory motion of the second rib, at the angle of the rib, in a postero-anterior direction, was moderately restricted and palpation was reported to be extremely painful by the patient. The first rib was considered to be normally mobile and pain free.

Oscillatory mobilizations (Maitland, 1986) in a postero-anterior direction on the second rib, at the angle of the rib, immediately produced full-range pain-free internal rotation. Subsequent reviews of this athlete over 1 week confirmed complete resolution of his symptoms and return to sport (Boyle, 1999).

Case 2:

A 44-year-old woman with a 7-year history of incapacitating epigastric abdominal pain, which had been linked to chronic pancreatitis, is described by Whitcomb *et al.* (1995) (Fig. 1.1B). The patient was reviewed prior to a 95% pancreatectomy for pain control. Previously, comprehensive radiographic, pharmacological, endoscopic and surgical investigations had been performed in an attempt to identify and treat the patient's pain. Her presenting symptoms included constant epigastric pain radiating to the back, which was relieved by forward leaning. The pain was unaffected by dietary intake, but was accompanied by nausea and worsened after vomiting. A history of repeated painful episodes following normal household activities was reported. Previous history implicated abdominal dysfunction and appeared to direct the nature of subsequent interventions, which had included a pancreaticojejunostomy, treatment with pancreatic enzymes, narcotics, histamine-2 receptor blockers, proton pump inhibitors, antidepressants, non-steroidal anti-inflammatory drugs, metoclopramide, cisapride and other medications. The control of this patient's pain was inadequate despite the implantation of a continuous intrathecal morphine infusion pump. She underwent coeliac plexus nerve blocks, each of which resulted in improvement in her pain for 1–3 weeks. The pain diminished when sitting and leaning forward; however, sitting erect caused immediate sharp pain, which was relieved by bending forward again. Physical examination of the patient's back revealed left erector spinae muscle spasm and tenderness in the T7–T8 paraspinal area radiating around the patient's left side toward the epigastrium. Suspicion of thoracic disc protrusion was confirmed by CT myelogram, which demonstrated a T7–T8 osseous disc protrusion into the vertebral canal displacing the spinal cord. Following microsurgical thoracic discectomy, the symptoms progressively resolved, with the patient becoming pain free within several weeks. This case of a herniated thoracic disc mimicking painful chronic pancreatitis, although probably very rare, emphasizes the importance of a thorough history and careful physical examination.

Case 3:

A 49-year-old woman presented with acute low back pain which radiated into the left buttock, lateral aspect of the leg and down to the left foot (Lyu *et al.*, 1999). Following MRI studies, a bulging disc and posterior vertebral osteophyte were revealed at the T11–T12 segment of the thoracolumbar junction (TLJ). Surgical removal of the osteophyte and disc herniation reduced the back pain and radicular symptoms, confirmed at the 3-year follow-up. This pattern of involvement of pain syndromes arising from the TLJ has been reported previously by Maigne (1980). TLJ syndrome may be linked to pain referral patterns involving the iliac crest, buttock, greater trochanter, lateral thigh and inguinal regions (Fig. 1.1C). Anatomical descriptions of the distant course and distribution of the lateral branches of the dorsal ramus from the last thoracic and upper lumbar segments have been summarized by Maigne (1996). Physiological confirmation of the distant referral of symptoms from the upper lumbar zygapophysial joints in normal volunteers has also been reported by McCall *et al.* (1979), following injection of physiological saline into these joints. In the clinical series reported by Maigne (1980), he described patients who rarely complained of pain at the TLJ; rather their symptoms were characteristically referred to the buttock, lateral thigh or groin. Occasionally, in the latter case, symptoms may be considered to relate to pelvic or gynaecological disorders. Treatment consisting primarily of manual therapy, and in some cases injection of anaesthetic agents, directed at the thoracolumbar junction segments would relieve these symptoms (Maigne, 1996). The case described by Lyu *et al.* (1999) confirms the need for an index of suspicion when assessing back pain and for including the thoracic region in the assessment.

These three clinical presentations highlight the diverse and at times obscure nature of thoracic musculoskeletal disorders, which may lead the clinician to consider inappropriate diagnoses and

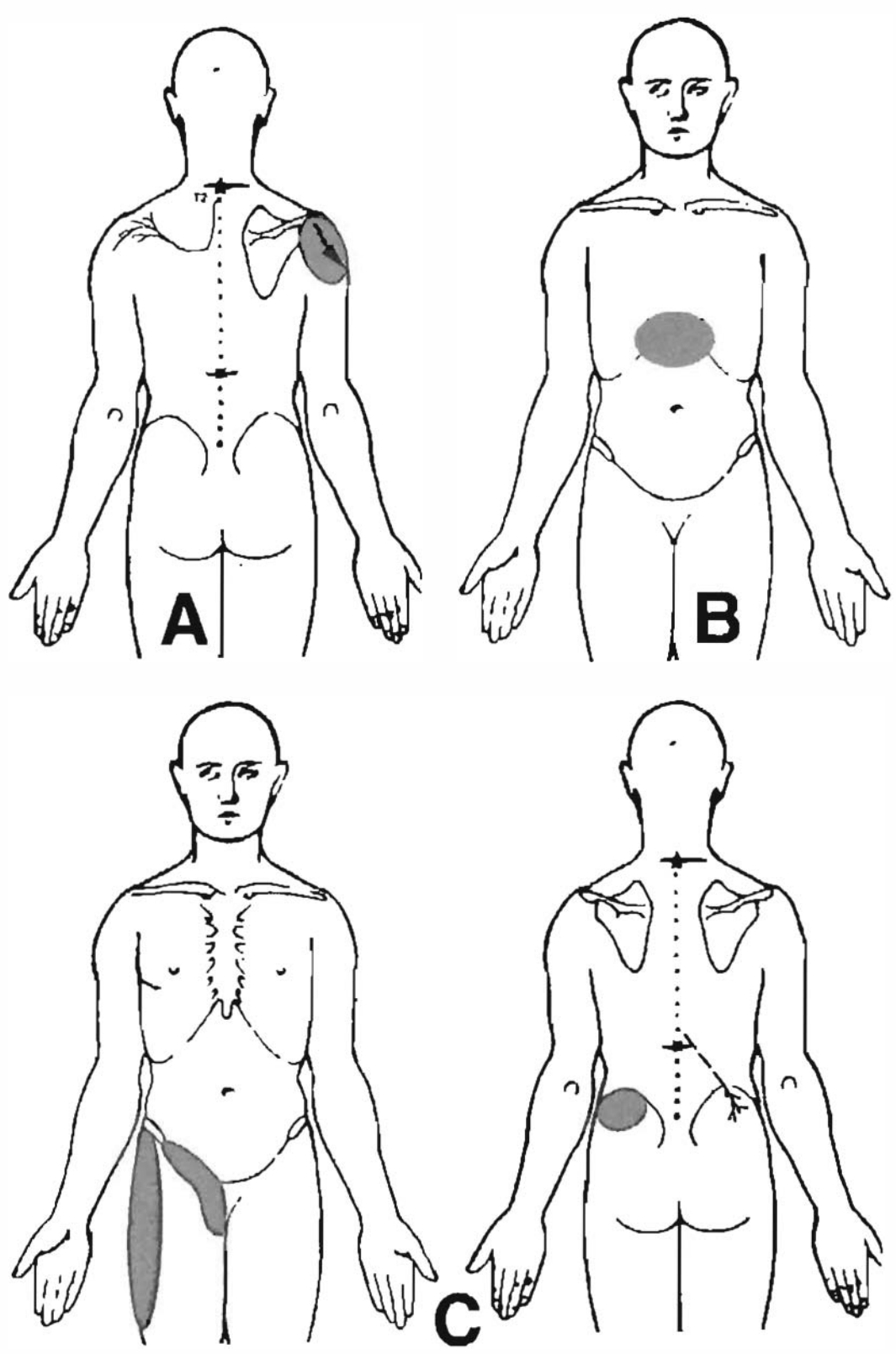

Fig. 1.1 Three cases highlight different features of the thoracic spine which require careful consideration during the differential diagnosis of thoracic pain syndromes. (A) Schematic representation of the passage of the second thoracic dorsal rami, according to Maigne *et al.* (1991), which becomes cutaneous over the lateral shoulder region. Shaded area represents location of symptoms for this case, which included pain described within the shoulder joint, relieved by mobilization of the second costotransverse joint. (B) A 7-year history of severe epigastric pain, represented by shaded area, and attributed to pancreatitis, was believed responsible for a 44-year-old woman's disabling history involving multiple interventions. A physical examination and imaging of her T7–T8 disc space identified a herniated thoracic disc and osteophyte deforming the spinal cord. Microsurgical discectomy resulted in resolution of her symptoms. (C) Pain referred to the gluteal, greater trochanter regions and occasionally mimicking a lumbosacral radiculopathy may, according to Maigne (1980), correspond to irritability, injury or disease of the thoracolumbar transitional segments.

treatments. Vigilance and care during assessment of the thoracic spine and transitional junctions is required to ensure that the most specific management is selected. Failure to do so can contribute to the frustration, disability and despair which Errico *et al.* (1997) describe for many patients with thoracic pain syndromes.

Epidemiology of thoracic pain

The limited epidemiological data in relation to thoracic pain support the view that the thoracic spine is less commonly implicated in clinical pain syndromes than the cervical and lumbar regions. In the chronic pain clinic environment, the percentage of patients with thoracic disorders is relatively small (2–3%) (cf. Chapter 13). From a questionnaire survey by Linton *et al.* (1998), an annual prevalence of spinal pain in the general population of 66% was calculated. Only 15% of those with symptoms reported their pain to be located in the thoracic spine, in comparison to 56% and 44% for the lumbar and cervical regions respectively. In a survey of factory workers, Occhipiniti *et al.* (1993) described a prevalence of thoracic pain of 5%, which did not show any association with age. In contrast, the prevalence of cervical and lumbar pain was 24% and 33% respectively, and increased with age in both cases. Despite the lower prevalence, the degree of disability resulting from thoracic pain disorders was similar to that of the other regions (Occhipiniti *et al.*, 1993). This supports the view that, although mechanical thoracic spine pain is less common, it can be as disabling as lumbar or cervical pain (Edmondston and Singer, 1997).

Occupational and recreational activities may influence the development of thoracic spine pain. Over a 14-week army training programme, Milgrom *et al.* (1993) observed the incidence of exertional thoracic pain (8%) to be similar to that of the lumbar spine (10%). In a similar group of recreational sportsmen, the prevalence of lumbar spine pain or stiffness was 47%, compared to 15% in the thoracic spine (Van der Linden and Fahrer, 1988). In the same group, the prevalence of chest pain or discomfort was 15%.

Occupations that require sustained sitting may predispose to thoracic spine pain. Anderson *et al.* (1992) described a prevalence of thoracic pain in bus drivers of 28%, in contrast to 10% in non-drivers. However, in both groups the prevalence of cervical and lumbar pain was considerably higher. The implication is that occupational and recreational activities may predispose the thoracic spine to postural pain or mechanical dysfunction; however, this region appears relatively protected in relation to the more sagittally mobile cervical and lumbar regions. A sample of studies examining the incidence and prevalence of thoracic pain is presented in Table 1.2. Given the difficulty in establishing the precise aetiology of back pain from self-reported population surveys, it is quite probable that the thoracic region is under-represented in the reported incidence of spinal pain syndromes.

Table 1.2 *A summary of selected surveys reporting the occurrence of musculoskeletal complaints reported for the thoracic region according to clinic type or specific populations*

Author	*Year*	*Discipline/Survey*	*Incidence**	*Prevalence**
Anderson	1992	Meta analysis		28
Bechgaard	1981	Chest clinic	13	
Burton	1981	Osteopathic clinic	13	
Hinkley and Drysdale	1995	Osteopathic clinic	14	
Linton *et al.*	1998	Population based survey	15	
Milgrom *et al.*	1993	Military clinic	8	
Occhipiniti *et al.*	1993	Occupational pain survey		5
Pedersen	1994	Chiropractic clinic	7	
Stolker *et al.*	1993	Chronic pain clinic	2	
Troussier *et al.*	1994	School children		34
Waskiewicz	1996	Stevedore workers	26	
Welch *et al.*	1995	Chiropractic clinic	3	

* per cent.

Thoracic kyphosis and pain

The thoracic kyphosis is the primary curve of the vertebral column,
development. In standing postures, the line of gravity passes ventral to the vertebral bodies, with the attendant axial load acting to increase the thoracic curve. These bending forces are resisted by the passive constraint of the posterior ligaments and the contraction of the deep one-joint muscles and thoracic parts of the long extensors (Asmussen, 1960; White *et al.*, 1977; Macintosh and Bogduk, 1991; Moore, 1997). Contrary to clinical theory, the thoracic curvature in relaxed standing is relatively unaffected by passive muscle length or trunk muscle strength (Klausen, 1965; Toppenberg and Bullock, 1986). Electromyographic activity in the erector spinae and abdominal muscles is very low or absent in relaxed standing (Asmussen, 1960). Influences on the magnitude of the thoracic curvature include the age of the individual (Stagnara *et al.*, 1982; Singer *et al.*, 1990), the position of the line of gravity (Pearsall and Reid, 1992), the morphology of the vertebral body, and disc shape (Manns *et al.*, 1996). Postmortem studies have found that the resting form of the thoracic column changes little following the removal of ribcage and supporting musculature (Singer *et al.*, 1994), which confirms the role of vertebral bodies, discs and ligamentous structures in forming and maintaining the essential thoracic kyphosis.

The long held assumption of a relationship between spinal posture and the development of pain syndromes is now being challenged. Attempts to define the 'normal' thoracic kyphosis have demonstrated considerable variation in the asymptomatic population (Beck and Killus, 1973; Raine and Twomey, 1997), suggesting that individual differences in thoracic curvature reflect variations in the human phenotype rather than deviation from a 'normal' form (Stagnara *et al.*, 1982). Even in older women with severe thoracic hyperkyphosis secondary to osteoporosis, the prevalence and severity of back pain may be no greater than in women without such marked structural change (Ettinger *et al.*, 1994). However, mobility, activities of daily living and respiratory function are more likely to be impaired in individuals with spinal deformities and to contribute to morbidity (Cook *et al.*, 1993).

An accentuated thoracic curvature will influence patterns of load bearing and spinal movement. In addition, the greater stiffness of the thoracic spine may induce long-term compensatory changes in patterns of motion in the lumbar and cervical regions and in the shoulder girdle (Culham and Peat, 1993; Jull, 1998). It is the mechanical consequences of the changes in thoracic posture that are likely to be important in the development of spinal pain.

Patterns of thoracic spine and chest wall pain

While pain from serious visceral and spinal metastatic disease can refer symptoms to parts of the spine, it is also true that pain arising from thoracic joints can simulate visceral disease.

The sensory innervation of the thoracic spine and chest wall is via the terminal cutaneous branches of the dorsal and ventral rami of the spinal nerves. In the thoracic region, the dermatomes surround the chest wall, each dermatome being displaced caudally in relation to its corresponding spinal level. The caudal displacement of the dorsal ramus is more pronounced than that of the ventral ramus, creating a step within each dermatome (Rickenbacher *et al.*, 1985). Neurogenic pain may be due to infection (e.g. herpes zoster) or to mechanical compression of the thoracic spinal nerves by osteophyte or disc protrusion (see Figs 5.6, 5.16). Nerve compression can produce sensory disturbances in the affected dermatome, such as pain, para/dysaesthesia and/or numbness. Pain which is perceived as localized, superficial burning or stinging, is provoked by non-noxious mechanical stimuli or emotional stress, and which may not be influenced by rest or analgesics, is typical of neurogenic disorders (Hansson and Kinnman, 1996; Gifford and Butler, 1997). Mechanisms which may explain neuropathic thoracic pain include increased activity in the primary sensory neurones (e.g. ectopic impulses or ephaptic transmission) or altered activity in the central nervous system, such as disinhibition or spontaneous activity of spinal nociceptive neurones (Hansson and Kinnman, 1996).

Pain related to disorders of deep somatic structures may also be referred to the chest wall or abdomen. Somatic referred pain is generally located close to the segment of origin, with some overlap between segments. Inter-individual variation in pain referral patterns is great, and the segmental pattern is not always sequential. Unfortunately, the site of referred pain is of little value in establishing the tissue of origin. Considerable overlap exists between pain distributions associated with stimulation of interspinous structures and deep thoracic musculature, and those described following stimulation of the thoracic zygapophysial joints (Kellgren, 1939; Feinstein, 1954; McCall *et al.*, 1979; Dreyfuss *et al.*, 1994). Pain from lower cervical discs and zygapophysial joints has also been shown to refer to the upper thoracic spine (Cloward, 1959; Dwyer *et al.*, 1990). The mechanism of somatic referred pain is thought to be convergence of somatic nociceptive afferent input, from different peripheral sites, on a common pool of spinal cord neurones. Pain is perceived in all or any of the regions which have input to the common neurone pool (Bogduk, 1997). Somatic referred pain may be sharp and severe in some acute conditions, but is commonly perceived as a deep ache which is diffuse and hard to localize.

Visceral referred pain

Abdominal and thoracic visceral organs may refer pain to the thoracic spine, chest wall and shoulder. Visceral referred pain is due to convergence of visceral nociceptive afferent fibres on dorsal horn neurones, which also receive afferent input from musculoskeletal structures. Organs referring pain to the thoracic region include the heart, stomach, gallbladder and kidneys (Grieve, 1981; Quast and Goldflies, 1989). Referred visceral pain may vary in nature and location; however, typical patterns of referral are summarized in Table 1.3. Compression of the sympathetic trunk by costovertebral joint osteophytes can affect abdominal visceral function, as well as produce symptoms and autonomic disturbances in the thorax and limbs (Nathan, 1987; Lipschitz *et al.*, 1988).

Table 1.3 *Symptoms that may suggest non-mechanical thoracic pain or serious musculoskeletal pathology, alerting the clinician to seek an urgent medical or surgical referral*

- Pain: severe, constant, worse at night, difficulty getting to sleep
- Medication: need for high intake of analgesics or use of narcotic analgesics
- Trauma associated with severe pain
- Severe pain following a trivial event (suggesting vertebral collapse)
- Constitutional symptoms: weight loss, poor appetite, unexplained fever, poor general health
- History of previous treatment for cancer
- Shortness of breath or chest pain during exertion
- Bowel or bladder function disturbance
- Sensory changes numbness or paraesthesiae in legs or feet
- Paraesthesiae or numbness of the chest wall
- Lower limb weakness or gait disturbance

A potential source of confusion in making a diagnosis is that pain of musculoskeletal origin may mimic abdominal or thoracic visceral pain. Up to 13% of chest pain in a medical setting can be referred from the thoracic spine or ribcage, making this the third most common source of chest pain (behind coronary artery disease and angina pectoris) (Bechgaard, 1981). Features of the clinical examination that may assist the differential diagnosis of chest pain have been described by Arroyo *et al.* (1992). Mid-thoracic disc herniation may produce chronic abdominal pain, and the pain of low thoracic disc herniation may simulate renal or ureteric disorders (Grieve, 1994; Whitcomb *et al.*, 1995). Pain behaviour may not always be indicative of the source of the symptoms; Grieve (1994) describes a series of examples where pain from non-musculoskeletal sources is influenced by posture and activity. Careful history taking, physical examination and radiological evaluation are essential in determining the correct diagnosis.

Non-mechanical causes of thoracic pain

Pain in the thoracic spine and chest wall may be due to serious pathology of musculoskeletal structures, such as tumours, infection or fracture. Most primary spinal tumours occur in the first half of life, and affect the lumbar spine and sacrum slightly more frequently than the thoracic spine (Weinstein and McLain, 1992). Cases of osteoid osteoma in the thoracic vertebrae, simulating mechanical pain, have been described (Hurtgen *et al.*, 1996). Although primary spinal tumours are rare, the thoracic spine is the most common site for metastases, particularly from primary malignancies of the lung, breast and prostate (Chade, 1976). The T4-T11 vertebral bodies are most commonly affected, possibly due to their proximity to the site of the primary tumour (Onimus *et al.*, 1986). Pain and neurological impairment are the principal manifestations of spinal metastases, with 80% of the tumours producing spinal cord compression in the thoracic region (MacNab and McCullough, 1990) (see Fig. 5.11).

Traumatic fractures of the thoracic spine occur most commonly in the low thoracic segments (see Fig. 5.14), with compression fractures of the vertebral bodies accounting for the majority of these (Rehn, 1968). These vertebrae are predisposed to injury due to the relative stiffness of the thoracic spine compared to the greater mobility of the lumbar and cervical regions (Singer *et al.*, 1989; Boyle *et al.*, 1998). The change from a kyphotic to a lordotic curve, as well as changes in vertebral body and zygapophysial joint morphology, may further predispose the transitional segments to fracture (Kostuik *et al.*, 1991). The majority of traumatic fractures are the consequence of combined compression and flexion loading. The thoracic kyphosis predisposes the transfer of compressive force into a flexion force that exceeds the loading threshold of the vertebral body. External factors, such as a fall onto the buttocks, an object falling onto the back or a motor vehicle impact, place the spine in flexion when exposed to a compressive force. The diagnosis of traumatic vertebral fracture is based on the history and radiological evaluation.

Fragility fractures associated with spinal osteoporosis represent an inability of the vertebral bodies to tolerate the loads associated with normal functional activities. The mid- and low thoracic vertebrae are common sites for osteoporotic vertebral fracture (Hedlund *et al.*, 1989). One-third of such fractures are related to a fall, while 20% are associated with controlled activities such as lifting, bending or reaching (Myers *et al.*, 1996). In individuals with low spinal bone mass, these activities may subject the thoracic vertebrae to loads up to three times higher than their estimated strength (Myers and Wilson, 1997). Not all thoracic vertebral deformities in the elderly are the consequence of a specific fracture event, and many fractures may be identified incidentally on spinal radiographs (Grey *et al.*, 1996). Progressive wedging of the thoracic vertebral bodies is an inevitable feature of the ageing spine, but tends to be greater, and associated with mid- and posterior vertebral height loss, in individuals with a low bone mass (Evans *et al.*, 1993; Osman-Hamid *et al.*, 1994). It is important to consider osteoporosis-related fragility fractures in the differential diagnosis of acute thoracic pain, particularly in women over the age of 50 years.

Thoracic intervertebral disc prolapse

Despite the low surgical incidence of thoracic disc prolapse, anatomical abnormalities of the intervertebral disc are common in the asymptomatic population. These may include disc bulge, anular tears, or disc herniation with associated spinal cord compression, in up to 29% of cases (Wood *et al.*, 1995). Thoracic disc herniations requiring surgical management are uncommon, and account for less than 2% of all operations performed on herniated discs (Rothman and Simeone, 1992). The T8-T11 segments are the most common sites for thoracic disc herniation, while these injuries are uncommon in the upper thoracic levels (Arce and Dohrmann, 1985; Stillerman *et al.*, 1998). Thoracic disc herniations are directly associated with significant trauma in about one-third of cases (Stillerman *et al.*, 1998). Central or radiating pain is a feature in a majority of patients with thoracic disc herniation, and usually precedes neurological impairment. Evidence of spinal cord compression may include motor impairment, hyper-reflexia and spasticity, sensory disturbances, gait disturbances and bladder dysfunction (Benson and Byrnes, 1975; Stillerman *et al.*, 1998).

Clinical syndromes of the thoracic spine

A specific anatomical diagnosis for mechanical thoracic pain is difficult in many cases, but a clinical diagnosis can be based on information derived from the history and all aspects of the physical and radiological examination. When serious pathology has been excluded (Table 1.3), the symptoms may be related to any of the thoracic articular structures (disc, zygapophysial joint or rib articulations) as well as to vascular or neural structures. There are relatively few epidemiological data on the nature and prevalence of common patterns of thoracic musculoskeletal dysfunction. Some of this literature is represented in Table 1.2 to provide an overview of the range of reported studies according to different survey groups and clinical environments.

Upper thoracic pain may be generated from the underlying joint structures and associated muscles, or it may be referred from the cervical spine. Sustained sitting postures and joint loading may produce upper thoracic spine pain due to activation of joint nociceptors and to increased levels of muscle metabolites associated with elevated activity of the cervicothoracic muscles (Harms-Ringdahl *et al.*, 1983; Simons and Mense, 1998). Pain may be referred to the tip of the acromion or scapular region via the cutaneous branches of the upper thoracic dorsal rami (Maigne *et al.*, 1991). Movement restriction in the upper thoracic spine may be secondary to pain or due to adaptive shortening of connective tissue or muscle. Normal cervical spine movement requires normal mobility of the upper and mid-thoracic motion segments (see Chapter 11). Cervical spine pain and movement restriction associated with disc degeneration or protrusion may impair the flow of movement between the cervical and upper thoracic spines, resulting in a progressive upper thoracic dysfunction.

Movement dysfunction of the upper two ribs is a common presentation. The rib articulations may produce local pain, or refer pain to the suprascapular fossa or shoulder (Bogduk and Valencia, 1994). The scalenii muscles, which insert onto these ribs, can become tight due to habitual postures or recurrent hyperactivity. The first and possibly second rib may become fixed in a cephalad position, which can restrict end-range cervical movement, particularly rotation. This situation can be associated with compromise of neurovascular structures of the thoracic inlet as they travel between the first rib and clavicle. The symptoms may include referred pain or paraesthesia (medial arm, shoulder, forearm or hand), heaviness or weakness. Vascular symptoms might include coldness, blanching of the elevated hand and swelling of the dependent hand.

Direct trauma to the thoracic spine or ribcage may be associated with a fall, sporting injury or motor vehicle accident. All may result in a varying degree of pain and movement loss, depending on the nature and severity of the impact. Although not well documented, patients with cervical whiplash injuries may also present with pain, abnormal tenderness and movement restriction in the upper and mid-thoracic regions (Carrothers, 1994; Giglia-Smith *et al.*, 1997). Non-traumatic presentations in the thoracic spine may include acute joint 'locking' and progressive movement dysfunction (McKenzie, 1990). The pathomechanics of the acute locked joint have not been described for the thoracic spine, but may be extrapolated from descriptions of acute locking of lumbar zygapophysial joints (Bogduk and Jull, 1985; Giles, 1997). Pain onset can be associated with a sudden movement, or following a sustained position while sleeping. The symptoms are commonly unilateral, and include sharp pain that may radiate around the chest wall or directly to the anterior chest. Movements towards the painful side are limited by pain, including respiratory movements where the rib articulations are involved.

Mid-thoracic hypomobility disorders are the most common thoracic presentation (Maigne, 1996). The symptoms are often insidious, and are usually present for some time before treatment is sought. The predilection for symptoms to focus about the mid-thoracic spine may be due to the high loading and movement demands on these segments due to mechanical forces (see Chapter 11, Fig. 11.2) and the higher incidence of thoracic disc degeneration in this region (Singer, 1997). The symptoms may vary from a constant dull ache to feelings of cramp or intense local fatigue. Increased discomfort is often experienced with sustained sitting and at the extremes of range during movement. Difficulty in getting comfortable at night, and morning stiffness, are two features commonly associated with these mid-thoracic disorders. The primary movement restriction is that of rotation and, to a lesser extent, extension, while flexion is usually unaffected. Both the symptoms and movement restriction are unilateral in most cases.

Although the thoracolumbar junction is a common site for vertebral fracture, non-traumatic mechanical disorders involving the low thoracic segments are uncommon relative to those in the upper and middle thoracic regions. Symptoms may be present locally or referred to the iliac crest, upper buttock or abdominal wall (McCall *et al.*, 1979; Maigne, 1996) (Fig. 1.1C). Movement restrictions are more common in the sagittal and frontal planes, particularly extension and lateral flexion. Articulations of the first and lower two ribs must be considered as a source of some of the symptoms, due to the higher prevalence of degenerative disease compared to the more cranial rib joints (Malmivaara, 1987; Nathan, 1987) (see Fig. 5.1). Local tenderness at the lateral margin of the costotransverse joint is usually indicative of rib joint involvement (Raney, 1966). Particular care is required in the treatment of the low thoracic vertebral segments with rotation manipulative techniques due to the morphology of zygapophysial joints in this region, which strongly restrain torsional loading (Singer and Giles, 1990).

Red flags for diagnosis

Features of the patient's symptoms that may suggest non-mechanical thoracic pain or serious musculoskeletal pathology are summarized in Table 1.3. The clinician must determine the seriousness of the condition and refer the patient to an appropriate medical agent for management. These issues are described in the clinical management chapters and detailed in Chapter 18, which describes the contraindications to mechanical therapy of the thoracic spine.

Diagnosis and management of thoracic pain

Appropriate management of thoracic spine pain disorders is dependent on a careful review of the history, from which a suitable physical examination plan can be developed. The key elements of the patient's history, which enable an appropriately structured physical examination to be performed, are summarized in Chapters 9 and 18. The past and current medical history, together with current radiological imaging, are important in helping to exclude visceral disorders and serious musculoskeletal pathology as the cause of the symptoms. The extent of the physical examination must be consistent with the patient's age and general condition, and the severity and irritability of the symptoms. Failure to account for this may lead to unnecessary discomfort and possible exacerbation of the presenting problem.

Structures producing thoracic pain are often deep and difficult to palpate directly. Each thoracic vertebra is involved in at least six articulations which may become symptomatic. The thoracic zygapophysial joints are deep to the thoracic semispinalis and multifidus, and the costovertebral joints are completely inaccessible in their location ventral to the transverse process. Establishing the specific tissue or structure that is the source of the patient's symptoms may not always be possible. However, through a careful evaluation of the response to movement tests, muscle length tests, joint motion and soft tissue palpation and neurological examination, a hypothesis may be developed as to the source and mechanism of the symptoms.

Management of mechanical thoracic spine disorders is based on the presenting symptoms and the physical examination findings. Mobilization and manipulation may be extremely effective techniques for restoring thoracic spinal or rib joint mobility, and a variety of methods have been described (Grieve, 1991; Bergmann *et al.*, 1993; Lee, 1994; Maigne, 1996; Hartman, 1997) and expanded in Chapters 15, 16 and 17. Manipulation may achieve a more rapid restoration of pain-free movement, and is considered by some practitioners to be superior to mobilization for the treatment of thoracic spine hypomobility (Murtagh and Kenna, 1997). Retaining the often dramatic improvement in thoracic mobility following mobilization or manipulation requires appropriate prescription of exercises and advice in relation to posture and activity. Long-standing thoracic dysfunction may result in changes in muscle length or altered patterns of muscle activity which will be more difficult to ameliorate (White and Sahrmann, 1994). Key faults in muscle function contributing to the patient's disorder must be identified in order to provide a realistic and effective rehabilitation programme.

Summary

The enigma of the thoracic spine has been exposed. The following chapters will seek to elaborate the peculiar structural anatomy and pathology of the thoracic region. Biomechanics of the thoracic spine and thorax are discussed by Stokes in Chapter 4 as a basis for considering the age-related functional changes to this region. Thoracic neuroanatomy is elegantly detailed in Chapter 8 by Groen and Stolker, who also report invasive pain management treatments for chronic thoracic pain (Chapter 13). The special clinical syndromes of the cervicothoracic and thoracolumbar transitional junctions are presented by Maigne in Chapter 10. Clinical diagnosis and radiological imaging procedures, orthopaedic and neurosurgical considerations of the thoracic spine, medical, chiropractic, osteopathic and physiotherapeutic approaches to the management of musculoskeletal thoracic pain are also outlined in this text.

Some overlap and repetition is to be expected throughout, given the wide variety of material encompassed and the varied backgrounds of the contributors. The reader may be challenged at times to reconcile views expressed within these chapters. In turn, it is hoped that this will prompt debate and discussion within and between disciplines. Despite the considerable growth in knowledge about the human spine in health and disease states, there is still much to investigate and learn.

The major goal of this text is to re-introduce the reader to the thoracic spine. Long relegated to a lesser role within the human axial skeleton, because its near neighbours have appeared to suffer more, it is helpful to examine again this central spinal region. The sophistication of its neurology (Chapter 8) and its tendency to cast symptoms some distance from their origin may lead the incautious clinician to overlook thoracic structures when forming a diagnosis (Fig. 1.1). A careful differential diagnosis, excluding serious pathology from the region, coupled with a high index of suspicion, permits the identification of mechanical disorders which are amenable to manual therapy.

In the absence of indications for such therapy, and/or the presence of 'red flags' (Table 1.3), the clinician must consider promptly the need for referral to medical or surgical physicians for subsequent management. The criteria to follow for such referral are elaborated in Chapter 18.

The contributors to this volume have provided a comprehensive overview of their subjects, from which it is hoped that the reader will be informed and their clinical acumen developed - to the benefit of their clients. The thoracic region will remain an enigma only to those who choose to overlook the possibility of its involvement in common mechanical disorders of the spine.

References

Anderson, R., Meeker, W.C., Wieick, B.E. *et al.* (1992) A meta-analysis of clinical trials of spinal manipulation. *J.M.P.T.* **15:** 181-194.

Arce, C.A., Dohrmann, G.J. (1985) Herniated thoracic disks. *Neurol. Clin.* **3:** 383-392.

Arroyo, J.F., Jolliet, P., Junod, A.F. (1992) Costovertebral joint dysfunction: another misdiagnosed cause of atypical chest pain. *Post. Med. J.* **68:** 655-659.

Asmussen, E. (1960) The weight-carrying function of the human spine. *Acta Orthop. Scand.* **29:** 276-290.

Bechgaard, P. (1981) Segmental thoracic pain in patients admitted to a medical department and a coronary unit. *Acta Med. Scand.* **644(Suppl.):** 87-89.

Beck, A., Killus, J. (1973) Normal posture of the spine determined by mathematical and statistical methods. *Aerospace Med.* **44:** 1277-1281.

Benson, M.K., Byrnes, D.P. (1975) The clinical syndromes and surgical treatment of thoracic intervertebral disc prolapse. *J. Bone Joint Surg.* **57B:** 471-477.

Bergmann, T.F., Peterson, D.H., Lawrence, D.J. (1993) *Chiropractic Technique: Principles and Procedures.* New York: Churchill-Livingstone Inc.

Bogduk, N. (1997) *Clinical Anatomy of the Lumbar Spine and Sacrum.* Melbourne: Churchill Livingstone.

Bogduk, N., Jull, G. (1985) The theoretical pathology of acute locked back: A basis for manipulative therapy. *Man. Med.* **1:** 78-82.

Bogduk, N. and Valencia, F. (1994) Innervation and pain patterns of the thoracic spine. In: *Physical Therapy of the Cervical and Thoracic Spine*, 2nd edn (Grant, R., ed.). Melbourne: Churchill Livingstone, pp. 77-88.

Boyle, J.W.W. (1999) Is the pain and dysfunction of shoulder impingement lesion really second rib syndrome in disguise? Two case studies. *Man. Ther.* **4:** 44-47.

Boyle, J.W.W., Milne, N., Singer, K.P. (1998) Clinical anatomy of the cervicothoracic junction. In: *Clinical Anatomy and Management of Cervical Spine Pain* (Giles, L.G.F., Singer, K.P., eds). Oxford: Butterworth-Heinemann, pp. 40-52.

Broadhurst, N.A. (1987) The thoracic spine and its pain syndromes. *Aust. Fam. Physician* **16:** 738-746.

Burton, A.K. (1981) Back pain in osteopathic practice. *Rheumatol. Rehabil.* **20:** 239-246.

Carrothers, C. (1994) The effect of whiplash injury on the thoracic spine. *Physio. Can.* **46:** S143.

Chade, H.O. (1976) Metastatic tumours of the spine. In: *Spinal Tumors* (Vinken, P.J., Bruyn, G.W., eds). Amsterdam: North Holland Publishers, pp. 415-433.

Cloward, R.B. (1959) Cervical diskography. *Ann. Surg.* **150:** 1052-1064.

Cook, D.J., Guyatt, G.H., Adachi, J.D. *et al.* (1993) Quality of life issues in women with vertebral fractures due to osteoporosis. *Arthritis Rheum.* **36:** 750-756.

Culham, E., Peat, M. (1993) Spinal and shoulder complex posture. II. Thoracic alignment and shoulder complex position in normal and osteoporotic women. *Clin. Rehabil.* **8:** 25-35.

Dreyfuss, P., Tibiletti, C., Dreyer, S. *et al.* (1994) Thoracic zygapophyseal joint pain: A review and description of an intra-articular block technique. *Pain Digest* **4:** 46-54.

Dwyer, A., Aprill, C., Bogduk, N. (1990) Cervical zygapophyseal joint pain patterns. I: A study in normal volunteers. *Spine* **15:** 453-457.

Edmondston, S.J., Singer, K.P. (1997) The thoracic spine: anatomical and biomechanical considerations for manual therapy. *Man. Ther.* **2:** 132-143.

Errico, T.J., Stecker, S., Kostuik, J.P. (1997) Thoracic pain syndromes. In: *The Adult Spine: Principles and Practice* (Frymoyer, J.W., ed.). Philadelphia: Lippincott-Raven, pp. 1623-1638.

Ettinger, B., Black, D.M., Palermo, L. *et al.* (1994) Kyphosis in older women and its relationship to back pain, disability and osteopenia: The study of osteoporotic fractures. *Osteop. Int.* **4:** 55-60.

Evans, S.F., Nicholson, M.J., Haddaway, M.J. *et al.* (1993) Vertebral morphometry in women aged 50-81 years. *Bone Min.* **21:** 29-40.

Feinstein B., Langton, J.B.K., Jameson, R.M. (1954) Experiments on referred pain arising from deep somatic tissues. *J. Bone Joint Surg.* **36A:** 981-997.

Gifford, L.S., Butler, D.S. (1997) The integration of pain sciences into clinical practice. *J. Hand Ther.* **10:** 86-95.

Giglia-Smith, L., Coll, F., McKenzie, A. *et al.* (1997) Is thoracic spine tenderness significant in chronic cervical pain? In: *Proceedings MPAA 10th Biennial Conference,* Melbourne, Australia, pp. 56-57.

Giles, L.G.F. (1997) Zygapophysial (facet) joints. In: *Clinical Anatomy and Management of Low Back Pain* (Giles, L.G.F., Singer, K.P., eds). Oxford: Butterworth-Heinemann, pp. 72-96.

Grey, C., Young, R., Bearcroft, P.W. *et al.* (1996) Vertebral deformity in the thoracic spine in post-menopausal women: value of lumbar spine bone density. *Br. J. Radiol.* **69:** 137-142.

Grieve, G.P. (1981) *Common Vertebral Joint Problems.* Edinburgh: Churchill Livingstone.

Grieve, G.P. (1991) *Mobilisation of the Spine*, 5th edn. Edinburgh: Churchill Livingstone.

Grieve, G.P. (1994) Thoracic musculoskeletal problems. In: *Grieve's Modern Manual Therapy* (Boyling, J.D., Palastanga, N., eds). Edinburgh: Churchill Livingstone, pp. 401-428.

Hansson, P., Kinnman, E. (1996) Unmasking mechanisms of peripheral neuropathic pain in a clinical perspective. *Pain Rev.* **3:** 272-292.

Harms-Ringdahl, K., Brodin, H., Eklund, L. *et al.* (1983) Discomfort and pain from loaded passive joint structures. *Scand. J. Rehab. Med.* **15:** 205-211.

Hartman, L.S. (1997) *Handbook of Osteopathic Technique,* 5th edn. London: Chapman and Hall.

Hedlund, L.R., Gallagher, J.C., Meeger, C. *et al.* (1989) Change in vertebral shape in spinal osteoporosis. *Calcif. Tiss. Int.* **44:** 168-172.

Hinkley, H.J., Drysdale, I.P. (1995) Audit of 1000 patients attending the clinic of the British College of Naturopathy and Osteopathy. *Br. Osteopath. J.* **16:** 17-22.

Hurtgen, K.L., Buehler, M., Santolin, S.M. (1996) Osteoid osteoma of the vertebral body with extension across the intervertebral disc. *J.M.P.T.* **19:** 118-123.

Jull, G. (1998) Physiotherapy management of neck pain of mechanical origin. In: *Clinical Anatomy and Management of Cervical Spine Pain* (Giles, L.G.F., Singer, K.P., eds). Oxford: Butterworth-Heinemann, pp. 168-191.

Kellgren, J. (1939) On the distribution of pain arising from deep somatic structures with charts of segmental pain areas. *Clin. Sci.* **4:** 35-46.

Klausen, K. (1965) The form and function of the loaded human spine. *Acta Physiol. Scand.* **65:** 176-190.

Kostuik, J.P., Huler, R.J., Esses, S.I. *et al.* (1991) Thoracolumbar spine fracture. In: *The Adult Spine* (Frymoyer, J.W., ed.). New York: Raven Press.

Lee, D. (1994) *Manual Therapy for the Thorax.* Delta: DOPC.

Linton, S.J., Hellsing, A.-L., Hallden, K. (1998) A population-based study of spinal pain among 35-45-year-old individuals. *Spine* **23:** 1457-1463.

Lipschitz, M., Bernstein-Lipschitz, L., Nathan, H. (1988) Thoracic sympathetic trunk compression by osteophytes associated with arthritis of the costovertebral joint. *Acta Anat.* **132:** 48-54.

Lyu, R.-K., Chang, H.-S., Tang, L.-M., Chen, S.-T. (1999) Thoracic disc herniation mimicking acute lumbar disc disease. *Spine* **24:** 416-418.

Macintosh, J.E., Bogduk, N. (1991) The attachments of the lumbar erector spinae. *Spine* **16:** 783-792.

MacNab, I., McCullough, J.A. (1990) *Backache*, 2nd edn. Baltimore: Williams and Wilkins.

Maigne, J.-Y., Maigne, R., Guerin-Surville, H. (1991) Upper thoracic dorsal rami: anatomic study of their medial cutaneous branches. *Surg. Radiol. Anat.* **13:** 109-112.

Maigne, R. (1980) Low back pain of thoracolumbar origin. *Arch. Phys. Med. Rehabil.* **61:** 389-395.

Maigne, R. (1996) *Diagnosis and Treatment of Pain of Vertebral Origin.* Baltimore: Williams and Wilkins.

Maitland, G.D. (1986) *Vertebral Manipulation.* Oxford, Butterworths.

Malmivaara, A., Videman, T., Kuosma, E. *et al.* (1987) Facet joint orientation, facet and costovertebral joint osteoarthrosis, disc degeneration, vertebral body osteophytosis and Schmorl's nodes in the thoracolumbar junctional region of cadaveric spines. *Spine* **12:** 458-463.

Manns, R.A., Haddaway, M.J., McCall, I.W. *et al.* (1996) The relative contribution of disc and vertebral morphometry to the angle of kyphosis in asymptomatic subjects. *Clin. Radiol.* **51:** 258-262.

McCall, I.W., Park, W.M., O'Brien, J.P. (1979) Induced pain referral from posterior lumbar elements in normal subjects. *Spine* **4:** 441-446.

McKenzie, R.A. (1990) *The Cervical and Thoracic Spine: Mechanical Diagnosis and Therapy.* Waikanae: Spinal Publications.

Milgrom, C., Finestone, A., Lev, B. *et al.* (1993) Over-exertional lumbar and thoracic back pain among recruits: a prospective study of risk factors and treatment regimens. *J. Spinal Disord.* **6:** 187-193.

Moore, K.L. (1997) Muscles and ligaments of the back. In: *Clinical Anatomy and Management of Low Back Pain*, Vol. 1 (Giles, L.G.F., Singer, K.P., eds). Oxford: Butterworth-Heinemann, pp. 156-164.

Murtagh, J.E., Kenna, C.J. (1997) *Back Pain and Spinal Manipulation*, 2nd edn. Oxford: Butterworth-Heinemann.

Myers, E.R., Wilson, S.E. (1997) Biomechanics of osteoporosis and vertebral fracture. *Spine* **22:** 25S-31S.

Myers, E.R., Wilson, S.E., Greenspan, S.L. (1996) Vertebral fractures in the elderly occur with falling and bending. *J. Bone Min. Res.* **11(Suppl.):** 355S.

Nathan, H. (1987) Osteophytes of the spine compressing the sympathetic trunk and splanchnic nerves in the thorax. *Spine* **12:** 527-532.

Occhipiniti, E., Colombini, D., Grieco, A. (1993) Study of distribution and characteristics of spinal disorders using a validated questionnaire in a group of male subjects not exposed to occupational spinal risk factors. *Spine* **18:** 1150-1159.

Onimus, M., Schraub, S., Bartin, D., Bosset, J.P., Guidet, M. (1986) Surgical treatment of vertebral metastases. *Spine* **11:** 883-891.

Osman-Hamid, A., Bassiouni, H., Koutri, R. *et al.* (1994) Aging of the thoracic spine: distinction between wedging in osteoarthritis and fracture in osteoporosis - a cross-sectional and longitudinal study. *Bone* **15:** 437-442.

Pearsall, D.J., Reid, J.G. (1992) Line gravity relative to upright vertebral posture. *Clin. Biomech.* **7:** 80-86.

Pedersen, P. (1994) A survey of chiropractic practice in Europe. *Eur. J. Chiropr.* **42:** 3-28.

Quast, M.S., Goldflies, M.L. (1989) A new differential diagnosis for musculoskeletal posterior thoracic wall pain. A case report. *Orthop Rev.* **18:** 461-465.

Raine, S., Twomey, L.T. (1997) Head and shoulder posture variations in 160 asymptomatic women and men. *Arch. Phys. Med. Rehabil.* **78:** 1215-1223.

Raney, F.L. (1966) Costovertebral-costotransverse joint complex as the source of local or referred pain. *J.B.J.S.* **48A:** 1451.

Rehn, J. (1968) Die Knöcheren Verletzungen der Wirbelsäule, Bedentung der Erstbefundes für die Spätere Begutachtung. *Die Wirbelsäule in Forschung und Praxis* **40:** 131-138.

Rickenbacher, J., Landolt, A.M., Theiler, K. (1985) *Applied Anatomy of the Back.* Berlin: Springer-Verlag.

Rothman, R.H., Simeone, F.A. (1992) *The Spine*, 3rd edn. Philadelphia: W.B. Saunders.

Simons, D.G., Mense, S. (1998) Understanding and measurement of muscle tone as related to clinical muscle pain. *Pain* **75:** 1-17.

Singer, K.P. (1997) Pathomechanics of the aging thoracic spine. In: *Advances in Chiropractic* (Lawrence, D., ed.). St Louis: Mosby, pp. 129-153.

Singer, K.P., Giles, L.G.F. (1990) Manual therapy considerations at the thoracolumbar junction: An anatomical and functional perspective. *J.M.P.T.* **13:** 83-88.

Singer, K.P., Willén, J., Breidahl, P.D. *et al.* (1989) The influence of zygapophyseal joint orientation on spinal injuries at the thoracolumbar junction. *Surg. Radiol. Anat.* **11:** 233-239.

Singer, K.P., Jones, T.J., Breidahl, P.D. (1990) A comparison of radiographic and computer-assisted measurements of thoracic and thoracolumbar sagittal curvature. *Skel. Radiol.* **19:** 21-26.

Singer, K.P., Edmondston, S.J., Day, R.E. *et al.* (1994) Computer-assisted curvature assessment and Cobb angle determination of the thoracic kyphosis: An in-vivo and in-vitro comparison. *Spine* **19:** 1381-1384.

Stagnara, P., Mauroy, J., de Dran, G. *et al.* (1982) Reciprocal angulation of vertebral bodies in a sagittal plane: Approach to references for the evaluation of kyphosis and lordosis. *Spine* **7:** 335-342.

Stillerman, C.B., Chen, T.C., Couldwell, W.T., Zhang, W., Weiss, M.H. (1998) Experience in the surgical management of 82 symptomatic herniated thoracic discs and review of literature. *J. Neurosurg.* **88:** 623-633.

Stolker, R.J., Vervest, A.C.M., Groen, G.J. (1993) Percutaneous facet denervation in chronic thoracic spinal pain. *Acta Neurochirurg.* **122:** 82-90.

Toppenberg, R.M., Bullock, M.I. (1986) The interrelationship of spinal curves, pelvic tilt and muscle lengths in the adolescent female. *Aust. J. Physio.* **32:** 6-12.

Troussier, B., Davoine, P., de Gaudemaris, R., Fauconnier, J., Phelip, X. (1994) Back pain in school children. A study among 1178 pupils. *Scand. J. Rehabil. Med.* 26: 143-146.

Van der Linden, S.M., Fahrer, H. (1988) Occurrence of spinal pain syndromes in a group of apparently healthy and physically fit sportsmen (orienteers). *Scand. J. Rheumatol.* 17: 475-481.

Waskiewicz, J. (1996) The effect of heavy work on the musculoskeletal system of dockers. *Bull. Inst. Marit. Trop. Med. Gdynia* 47: 25-32.

Weinstein, J.N., McLain, R.F. (1992) Tumours of the spine. In: *The Spine*, 3rd edn (Rothman, R.H., Simeone, F.A., eds). Philadelphia: W.B. Saunders.

Welch, M., Fletcher, P., Piper, C. (1995) A statistical package for clinic audit analysis: a pilot study at the European School of Osteopathy. *Br. Osteopath. J.* **15:** 21-27.

Whitcomb, D.C., Martin, S.P., Schoen, R.E., Jho, H. (1995) Chronic abdominal pain caused by thoracic disc herniation. *Am. J. Gastroenterol.* **90:** 835-837.

White, A.A., Panjabi, M.M., Thomas, C.L. (1977) The clinical biomechanics of kyphotic deformities. *Clin. Orthop. Rel. Res.* **128:** 9-25.

White, S.G., Sahrmann, S.A. (1994) A movement system balance approach to management of musculoskeletal pain. In: *Physical Therapy for the Cervical and Thoracic Spine*, 2nd edn (Grant, R., ed.). Edinburgh: Churchill Livingstone, pp. 339-358.

Wood, K.B., Garvey, T.A., Gundry, C. *et al.* (1995) Magnetic resonance imaging of the thoracic spine. Evaluation of asymptomatic individuals. *J. Bone Joint Surg.* **77A:** 1631-1638.

Section

II

Anatomy, Pathology and Biomechanics

2

Anatomy of the thoracic spine

K. P. Singer and S. Goh

This chapter reviews the structural anatomy of the thoracic spine and thorax. Historically the thoracic region of the human spine has been largely overlooked, with the greatest attention focused on the adjacent regions, which have occupied clinicians' time and attention. The thoracic spine has a markedly different mechanical role within the vertebral column, designed for stability while accommodating a limited mobility. This central region of the human spine, in concert with the trunk musculature, provides a supporting role to sustain all postures and facilitate motion, be it during gait or more dynamic activities like throwing (Fig. 2.1).

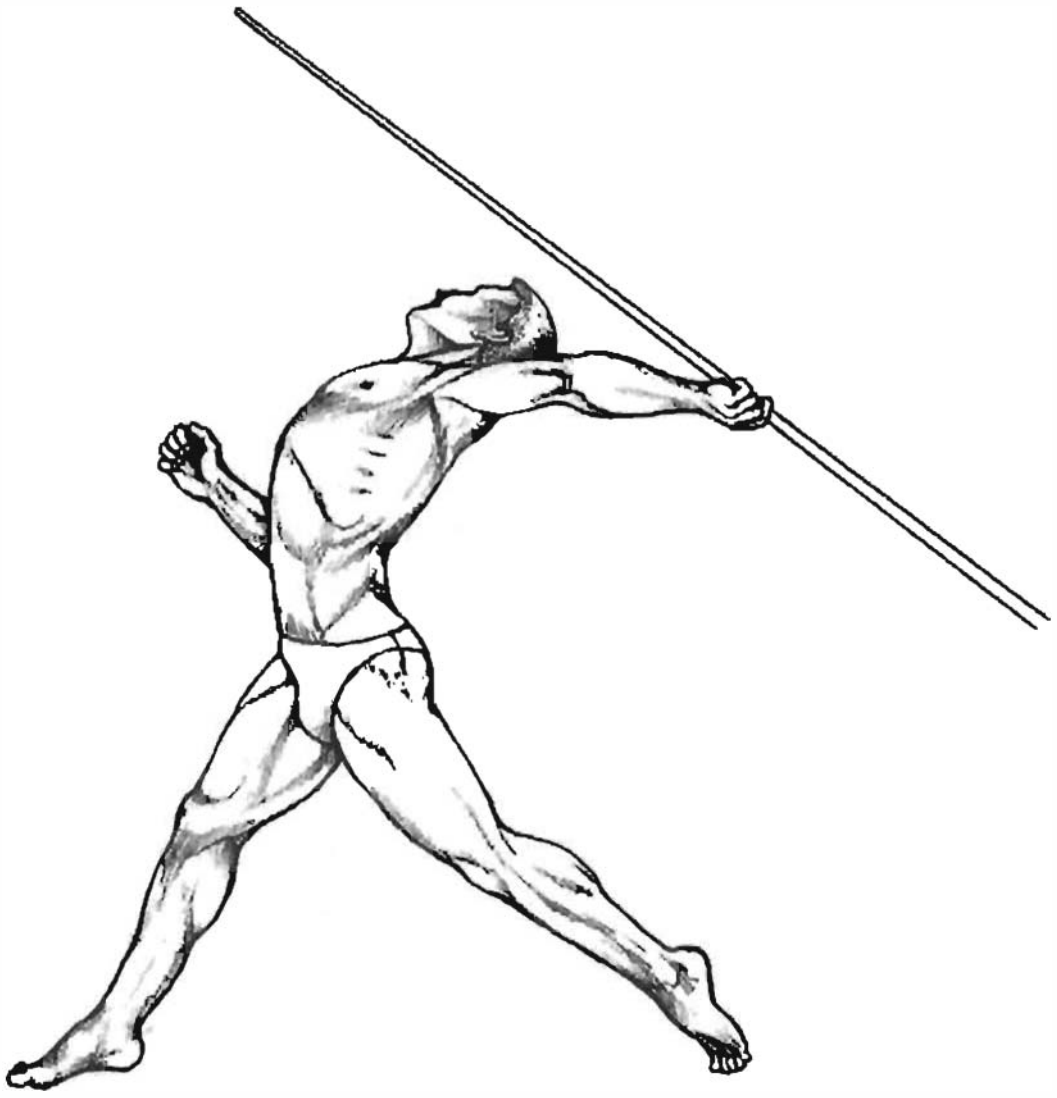

Fig. 2.1 The function of the thoracic spine may be illustrated by the dynamic action of the javelin thrower, who unleashes powerful axial torque, initiated by the lower limbs and transmitted through the thorax, into the throwing arm and implement (redrawn from Singer, 1989a).

The natural history of the vertebral column is best depicted by alterations in spinal posture, with an accentuated thoracic kyphosis being the most noticeable change, particularly in women after menopause. Here, the progressive kyphotic deformity occurs in response to an imbalance between bone resorption and formation, which can alter the mechanical loading of the mid-thoracic region and often leads to fractures and wedging of vertebral bodies (Fig. 2.2).

Thoracic vertebral anatomy

Development of the thoracic spine

Scant attention has been given to studies of the development of the thoracic region, despite its frequent involvement in the spinal deformities of kyphosis and scoliosis (Lord *et al.*, 1995). Some morphometric studies, particularly relating to longitudinal growth patterns of vertebral body and disc height (Brandner, 1970) and thoracic pedicle diameters (Zindrick *et al.*, 1986), have been recorded, where these parameters have been of value in radiological prediction of vertebral pathologies and selection of pedicle screw size for posterior instrumentation respectively. A mapping survey of 12 thoracic spines was performed by Panjabi *et al.* (1991) to provide reference ranges for many size and angle elements of this region of the spine. Similarly, Ebraheim *et al.* (1997) reviewed the thoracic zygapophysial joints in adult spines from the perspective of surgical instrumentation fixation. However, it is clear that this emphasis has been on skeletally mature

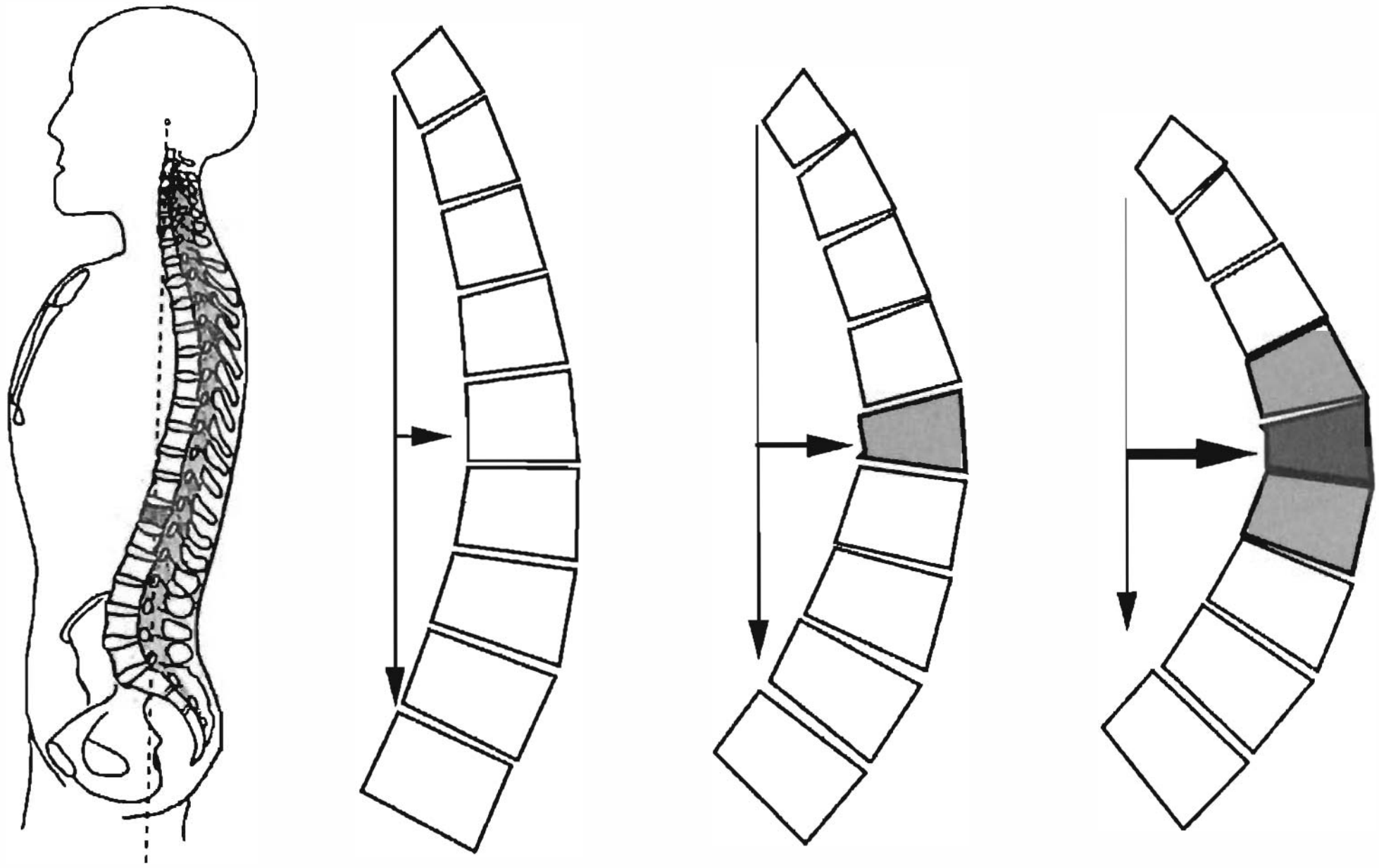

Fig. 2.2 Schematic depiction of changes in adult thoracic posture with advancing years. The thoracic kyphosis becomes more accentuated through increased loading on the vertebral elements, which is a function of the anterior displacement of the load moment. The biomechanical disadvantage is highlighted through the increased distance from the vertical line to the apical vertebra (adapted from Singer, 1997).

thoracic vertebrae, from a surgical perspective, with little work reporting earlier stages of development.

The foetal ossification pattern for the thoracic vertebrae (depicted in Fig. 2.3A) shows the vertebral centra, which appear first in the lowest thoracic segments before involving adjacent cranial and caudal levels (Noback and Robertson, 1951). In contrast, the posterior arches ossify first at the cervicothoracic junction, where they also close in the midline before this trend migrates caudally (Lord *et al.*, 1995). These sequences of ossification have been considered by Bagnall *et al.* (1977) to reflect functional stresses applied to the vertebral column *in utero*, to the developing thoracic and cervical regions. Evidence of closure of the neurocentral junction (Fig. 2.3B) was identified at 7 years of age by Lord *et al.* (1995), proceeding in a caudal direction from the upper thoracic region (Bagnall *et al.*, 1977). The delayed closure of the lower thoracic segments may reflect the need to accommodate the cranial migration of the lumbar enlargement of the spinal cord. Studies using magnetic resonance imaging (MRI) to determine the closure of the neurocentral junction has shown this to occur by 16 years of age in both males and females (Yamazaki *et al.*, 1998). In contrast, the vertebral body ring apophyses typically unite by 10 years of age (Louis, 1983). The vertebral canal, large in proportion to the juvenile vertebral body (Fig. 2.3B), appears to achieve adult proportions by 7 years of age (Lord *et al.*, 1995).

The pre-term foetal zygapophysial joints maintain a relatively near vertical and coronal plane orientation throughout the thoracic region (Huson, 1967; Lutz, 1967; Reichmann, 1971; Med, 1977) (Fig. 2.3C, D). The adult form for these joints involves a slight medial shift in coronal alignment, which ensures that the axis for transverse plane rotation is anterior to the vertebral body (Davis, 1959) (Fig. 2.3C). The main departures from this pattern occur at the cervicothoracic junction (Boyle *et al.*, 1998) and the thoracolumbar junction (TLJ), where considerable variation in zygapophysial joint configuration occurs (Davis, 1955; Veleanu, 1972; Singer *et al.*, 1989a) (see Chapter 7, Fig. 7.1).

The normal human vertebral column has 24 presacral vertebrae: seven cervical, 12 thoracic and five lumbar (Terry and Trotter, 1953). In the spine, the number of thoracic vertebrae, defined by paired rib-bearing elements, may vary from 11 to 13. This inconsistency may lead to incorrect surgical planning if not recognized and adjustments made to match the radiographic anatomy to the site of pathology (Wigh, 1980). Fifteen thoracic vertebrae with paired ribs were identified in two siblings by Melhem and Fahl (1985), confirming the variability of this region. In a large skeletal collection, 7% showed variation in

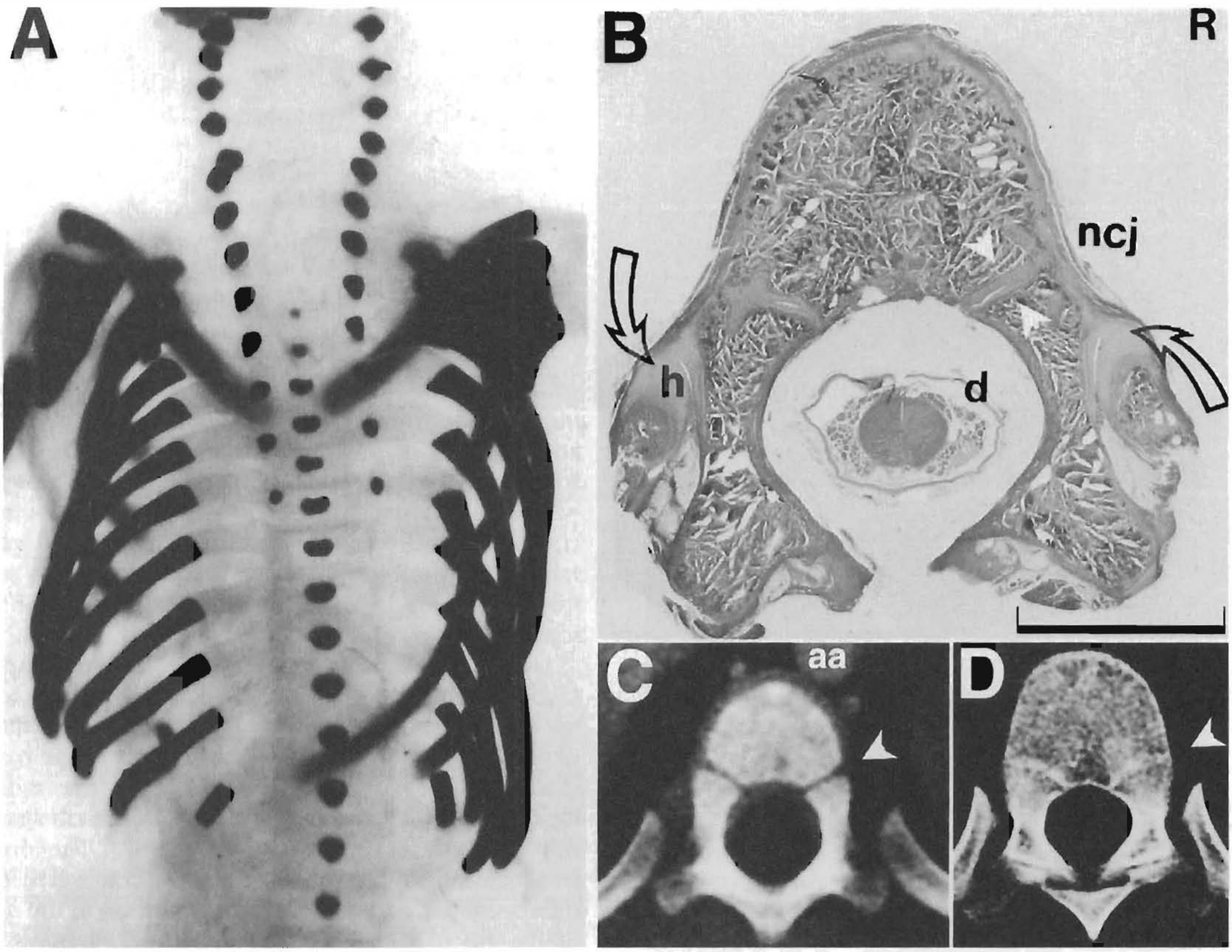

Fig. 2.3 (A) Photograph of a cleared foetus, stained with Alizarin Red, to highlight ossification centres within the axial and appendicular skeleton. The vertebral centra are shown clearly in almost all thoracic segments, with the most developed stage at the thoracolumbar junction. In contrast, the posterior arches show greatest development throughout the cervical and upper thoracic region. (B) A photomicrograph of a 200-μm thick horizontal plane section through the T12 vertebral body of a 2-year-old specimen illustrates the neurocentral junction (ncj), which demarcates the vertebral centrum from the ossification centres of the paired vertebral arches. Note the relatively large vertebral canal present at this stage of skeletal development. Thickened articular cartilage (curved arrows) line the rib heads (h). (C) Axial CT image, demonstrating the radiographic presentation of the costovertebral joints and neurocentral junction (arrow head), as shown at 3 years of age. (D) By 13 years of age, the neurocentral junction is recognized only as a line of higher intensity (Alizarin specimen kindly prepared by Mr H. Baggot, Department of Anatomy and Human Biology, the University of Western Australia).

thoracic number or configuration (Schultz, 1961). Confusion can occur when the transitional segments, at the cervicothoracic and thoracolumbar junctions, demonstrate characteristics of the adjoining region. It is worth noting that where one transitional anomaly is found, other spinal variants will often be located elsewhere in the skeleton (Schmorl and Junghanns, 1971), and these occasionally have clinical significance (Fig. 2.4). Although a feature in a small proportion of the population (approximately 1%) (Singer and Breidahl, 1990), rudimentary cervical and lumbar ribs and un-united ossification centres of the transitional segments are examples of normal variants which may be seen in medical imaging (Fig. 2.4) (Gladstone and Wakeley, 1932; Foley and Whitehouse, 1969).

The thoracic vertebrae consist of two components - a body ventrally and an arch dorsally (Terry and Trotter, 1953). The body of the vertebra functions primarily, but not exclusively, to support the weight of the trunk due to the anterior concavity of the thoracic kyphosis (Fig. 2.2). The vertebral body is deeper dorsally than ventrally, and is slightly concave on its cranial and caudal end-plate surfaces. The arch of the vertebra, with the body, encloses the vertebral foramen and serves to protect the spinal cord and the roots of the spinal nerves. Some axial load may be borne by the posterior elements through contact between the inferior articular processes and the laminae. The mid-thoracic vertebral segments in the adult conform to the typical configuration, consisting of a relatively small vertebral canal (Fig. 2.5A), and superior costal facets on the root of the pedicle and inferior margin of the vertebral body, respectively. The spinous processes are elongated and directed postero-inferiorly. The vertebral body consists of slightly concave end-plates, thickened in regions approximating the attachment of the anulus fibrosus, and a thin cortical shell. Cancellous bone networks, aligned primarily to sustain axial compressive loads (Fig. 2.5B), act as host for a rich vascular network throughout the vertebral body and communication with the basi-vertebral plexus in the epidural space (refer also to Chapter 8).

The muscular control for the thoracic region incorporates the long trunk extensors (Rab, 1979), and the thorax provides attachment for the pelvic trunk side-flexors and for the trapezius muscles, which act to regulate pelvic and scapular motions respectively. The role of the trunk muscles in maintaining posture and co-ordination of motion is summarized by Moore (1997) in the first volume of this series.

Ligamentous support for the thoracic spine involves an interplay of the costovertebral joint capsular ligaments, which provide strong discal attachment for the ribs via the intra-articular bands (Lohse *et al.*, 1985) (Fig. 2.6), and the radiate ligaments, which embrace the head of the rib against the demi-facets (Burguet *et al.*, 1987). The costotransverse ligament and lateral costotransverse ligaments combine to provide strong fixation of the neck of the rib to the transverse process. Zygapophysial joint capsular ligaments are less developed laterally to allow for the axial motion of these joints (see Fig. 2.3B). In contrast, medially, the ligamentum flavum is well developed. A detailed discussion of the specialized function of thoracic spinal ligaments is presented in Chapter 3 (see Fig. 3.9).

As an indication of the increasing load carried from head to sacrum, the thoracic vertebrae show a progressive caudal increase in size. This trend is reported from early anthropological studies (Lanier,

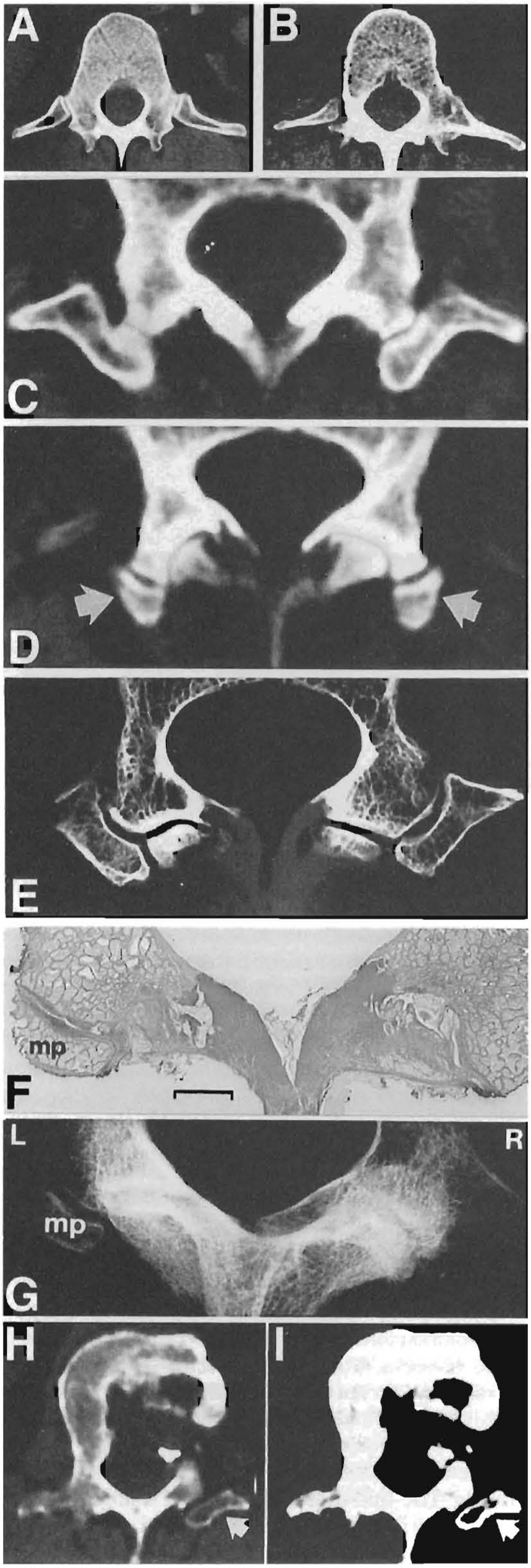

Fig. 2.4 Costal element variations are common at the cervicothoracic and thoracolumbar junctions. Rib length may be anomalously short at T12 (A) or lumbar ribs may arise variously from the L1 vertebral transverse processes (B). Mammillary process ossification centres that have not united with their host are also found (C–I), and are best identified by CT. Histologic examination of one case (F) showed the presence of articular cartilage separating the mammillary process from the superior articular process. In rare cases, the ununited ossification centre may be confused with a fracture of the transverse process, with bone window CT images highlighting the even corticated margins of the ossicle (adapted with permission from Singer and Breidahl, 1990).

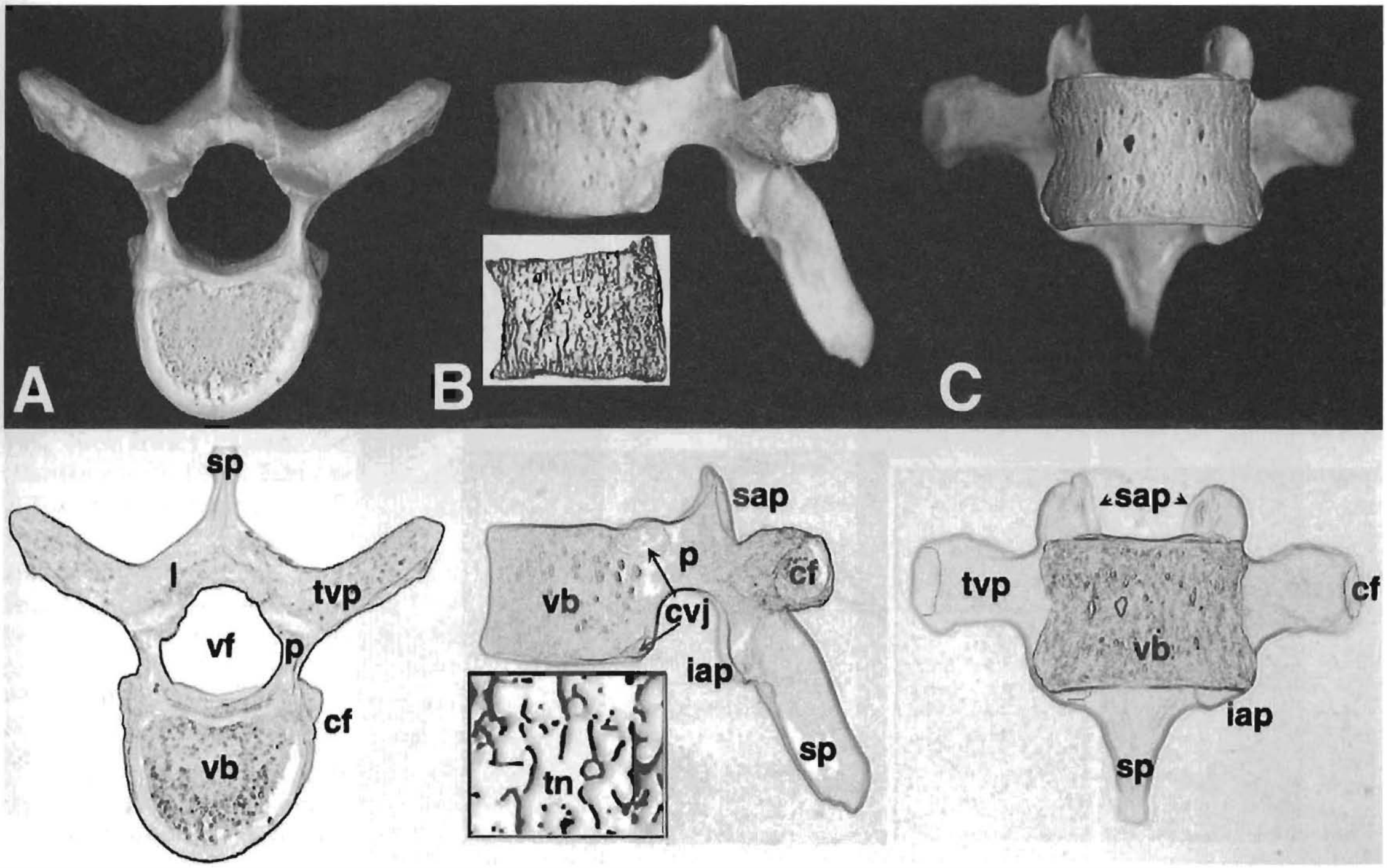

Fig. 2.5 The typical mid-thoracic vertebral segments are depicted in axial (A), lateral (B) and frontal (C) projections. The transverse processes are long and slender, providing a costal notch for articulation with the tubercle of the rib and paired demi-facets for the costovertebral joints. The zygapophysial joints are aligned in a coronal direction, and the spinous process is directed posteriorly and inferiorly. The vertebral body is crescent-shaped and attached to the posterior elements via thickened pedicles. The para-sagittal bone section at (B) highlights the complex trabecular architecture within the vertebral body, consisting of primarily horizontal and vertical elements. Abbreviations: cf, costal facet; cvj, costovertebral joint; iap, inferior articular process; l, lamina; sap, superior articular process; sp, spinous process; tn, trabecular network; tvp, transverse process; vb, vertebral body; vf, vertebral foramen. For a detailed inspection of all thoracic segments, refer to Fig. 2.7.

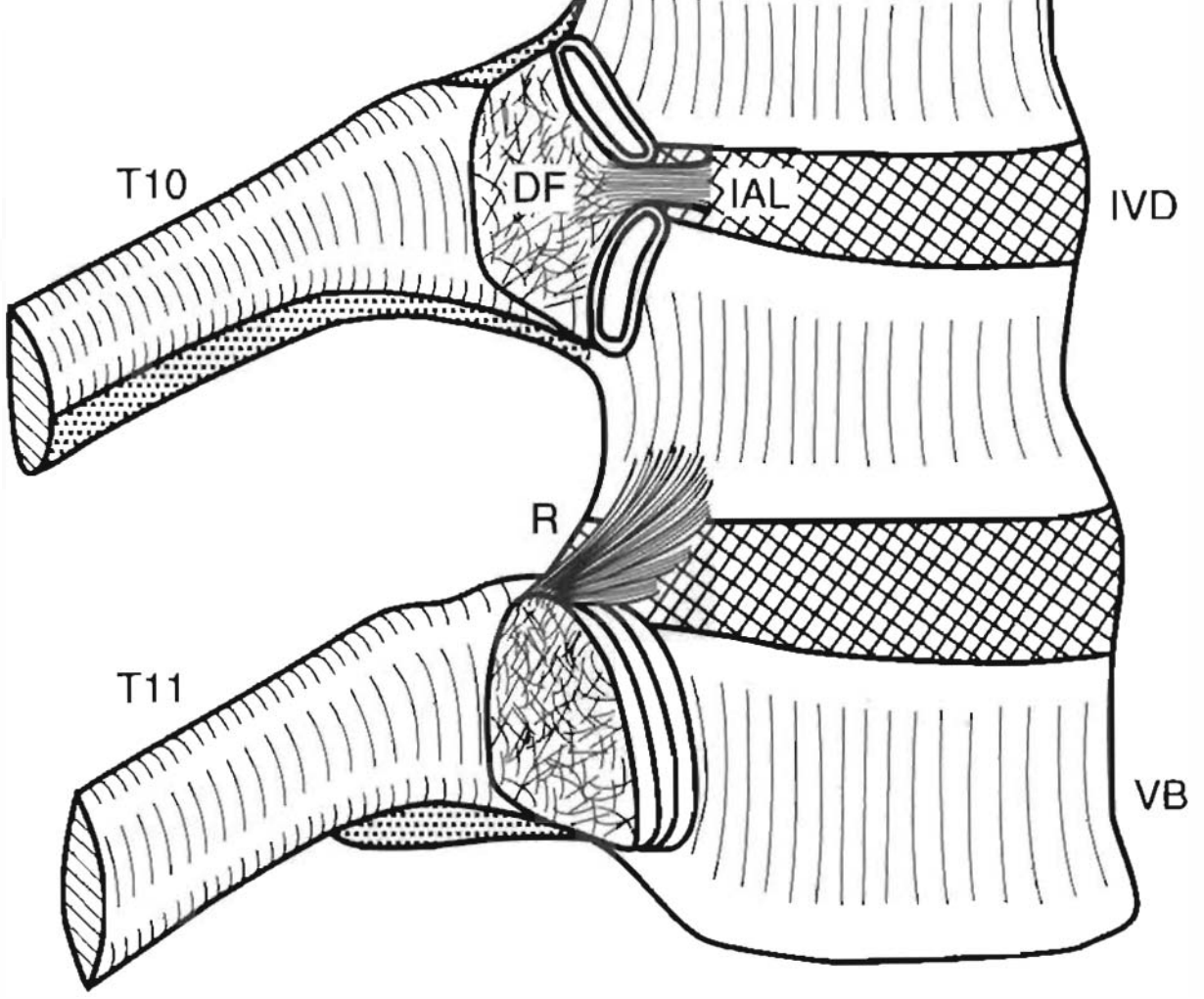

Fig. 2.6 Schematic representation of the capsular ligaments of the lower thoracic costovertebral joints to illustrate differences between typical and atypical joint morphology. The rib heads are 'cut-away' to show the articular surfaces. At T10 the intra-articular ligament is depicted attaching to the intervertebral disc, dividing the superior and inferior demi-facets. In contrast, the T11 (and T12) costovertebral joints comprise a single articular facet arising from the root of the pedicle, attached by the radiate ligament which fans the joints' superior, anterior and inferior aspects. Abbreviations: DF, demi-facets; IAL, intra-articular ligament; IVD, intervertebral disc; R, superior aspect of radiate ligament (adapted from Tan, 1993).

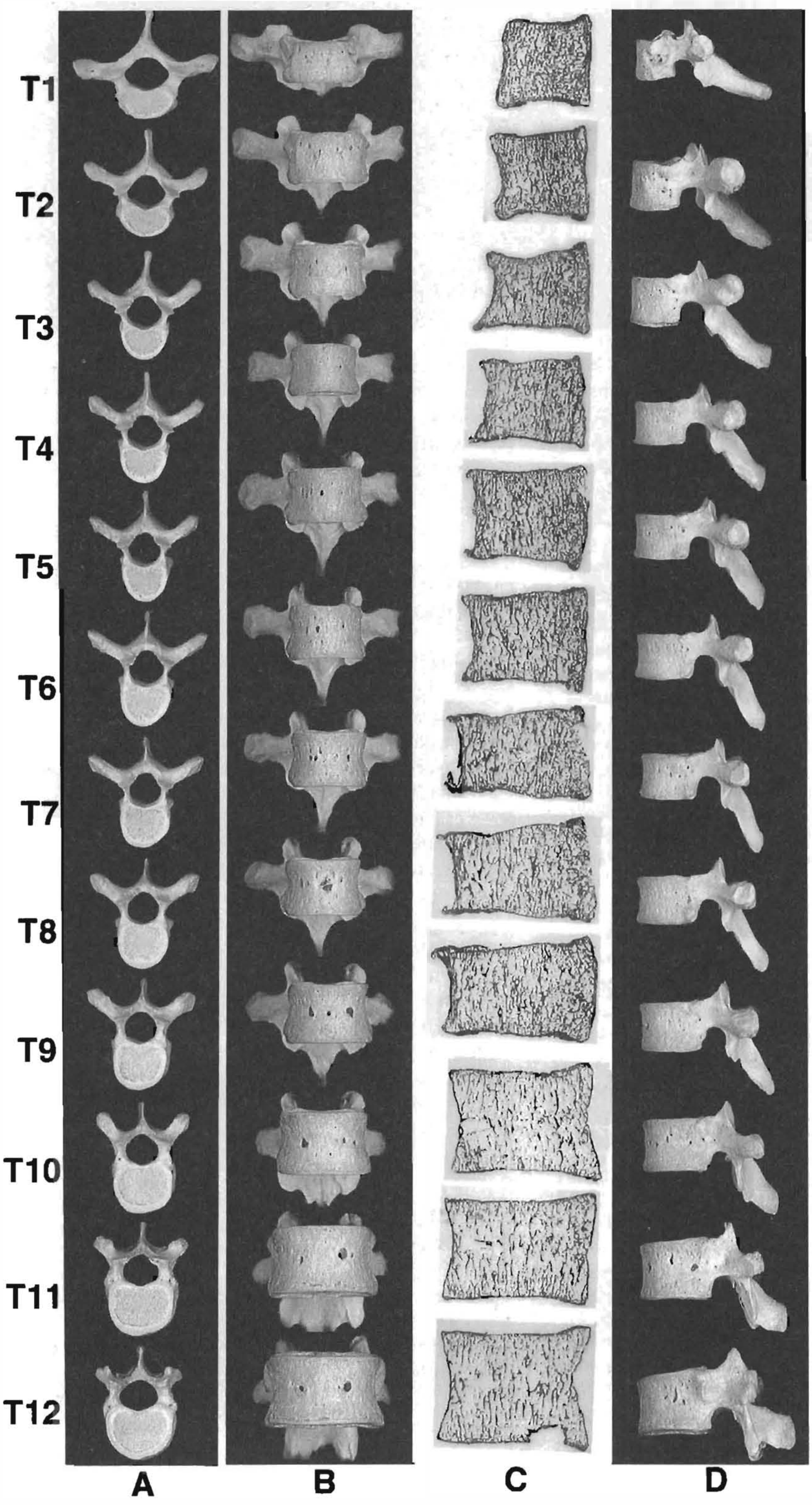

Fig. 2.7 Composite photograph of isolated thoracic vertebrae to highlight the segmental changes from T1 to T12 in size and structure. (A) In the axial view, change in transverse process orientation, size of the vertebral foramen and shape of the vertebral body are demonstrated. (B) The frontal perspective depicts the caudal change in costal facet angle on the transverse processes, the progressive increase in vertebral body height and reduction in transverse process length. Para-sagittal bone sections, surface stained by the Von Kossa method, emphasize the primarily vertical alignment of trabecular elements, the relatively thin vertebral end-plate and cortex bone. In addition, caudal reduction in bone element density / bone volume are apparent. (C) A posteriorly located Schmorl's node is seen on the inferior end-plate of T12 and marginal osteophytes, projecting from the anterior end-plates of T7–T9, are shown. (D) The lateral view shows the change in spinous process angle and length, increase in vertebral body size and relatively larger pedicles in the upper and lower regions of the thoracic spine, compared with the middle segments.

1939) and in contemporary examinations of thoracic vertebrae (Edmondston *et al.*, 1994a). The uniform caudal increase in thoracic vertebral body and disc dimensions is consistent with the cumulative load each segment carries (Fig. 2.7). The mechanical characteristics of the thoracic vertebral bodies follow this progressive trend, with a caudal increase in failure strength and bone density to accommodate the increasing body load (Singer *et al.*, 1995).

As a result of the thicker posterior dimension and loads which are anterior to the line of gravity, thoracic vertebrae demonstrate a wedge-shaped configuration, particularly the mid-thoracic segments and, to a lesser extent, the T11 and T12 vertebrae (Davies *et al.*, 1989; Edmondston *et al.*, 1994b) (Fig. 2.7) (see Chapter 5, Fig. 5.6). From cross-sectional radiographical surveys, the vertebral bodies and discs are generally thicker in males, and the anterior vertebral dimensions demonstrate a slight decline in height due to changes possibly related to an alternation in axial loading patterns with age.

Each thoracic vertebra is distinguished by costal facets on the sides of the body and, in all but the last two or three segments, by articular facets on the transverse processes, articulating respectively with the heads and tubercles of the ribs. The laminae are short, thick, broad and overlap each other like roof-tiles from above downwards (Williams and Warwick, 1980). The typical spinous process slants back and downwards, overlapping between T5 and T8 and being less oblique above and below this level. Projecting upwards at the junction of the laminae and pedicles are the superior articulating processes, facing backwards, upwards and laterally. The inferior processes project downwards from the laminae and face forwards, slightly medially and upwards. Fig. 2.7 depicts all thoracic segments from different perspectives to highlight the progressive nature of changes in morphology. Additionally, the detailed cancellous bone network within the vertebral body is highlighted from sagittal surface stained bone specimens, sectioned medial to the pedicle (Fig. 2.7C); these also depict the progressive change in cross-section of the thoracic vertebral bodies from small square-shaped elements to larger rectangular vertebral bodies.

The articular processes (zygapophyses) of adjoining thoracic vertebrae form synovial joints, which permit a limited degree of movement, primarily facilitating axial rotation (refer to Chapter 4 for a detailed discussion on segmental biomechanics). The primary axis of rotation for the mid-thoracic segments is located close to the anterior region of the thoracic intervertebral disc (Davis, 1959).

The lower thoracic zygapophysial joints provide specialized features which are characteristic of this region. The first is the greater development of the mammillary processes, which originate as extensions off the superior articular processes (Kaplan, 1945). The mammillary processes provide attachment for the multifidus muscle as it traverses medially to attach onto the spinous processes of the segments above. The direction of the mammillary process ensures that it deepens the recess into which the inferior articular process articulates. This is represented by Fig. 2.8B, D, E.

Consistent with most synovial joints, small intra-articular synovial folds (IASFs) may be found within the thoracic zygapophysial and costal joints (Meyer, 1972; Ley, 1975; Singer *et al.*, 1990a). In the zygapophysial joints, the IASFs originate medially, from tissue adjacent to the ligamentum flavum, and extend varying distances into the medial joint cavity (Fig. 2.9). It appears that these folds, comprised of fibrous or fibro-fatty tissue, fill spaces within the joint. It is speculated that these small protrusions may become trapped between the articular surfaces and stimulate painful reflex muscle spasm (Kos and Wolf, 1972).

Variations in thoracic vertebral morphology

Individuals may show transitional anatomical variants at both the cervicothoracic (Boyle *et al.*, 1996) and thoracolumbar junctional regions (Singer *et al.*, 1989a), and these features are discussed in more detail in Chapter 7. Typically, these anomalies involve the articular processes, costal elements and, occasionally, the vertebral bodies due to disruption to the primary and secondary ossification centres (Fig. 2.3). To illustrate a common variant found at the TLJ, the side-to-side variations in zygapophysial joint morphology (articular tropism) are depicted in Fig. 2.10. Differences in the symmetry of the zygapophysial joints are very common at the TLJ, where 40% of cases show a 10° variation between right and left sides (Singer, 1989a; Singer *et al.*, 1989a). This observation is consistent with several reports examining the variation in orientation of these transitional vertebrae (Whitney, 1926; Med, 1972; Malmivaara *et al.*, 1987).

Anatomy of the thoracic intervertebral discs

In the human vertebral column, disc height accounts for approximately 20–33% of the total length of the spinal column (White and Panjabi, 1990). The thoracic intervertebral discs, being narrower than those in the cervical and lumbar regions, contribute approximately one-sixth of the length of the thoracic column (Fig. 2.11) (Oliver and Middleditch, 1991). The ratio of disc to vertebral body height is 1:5 (Kapandji, 1977). Thus the motion between vertebral segments in the

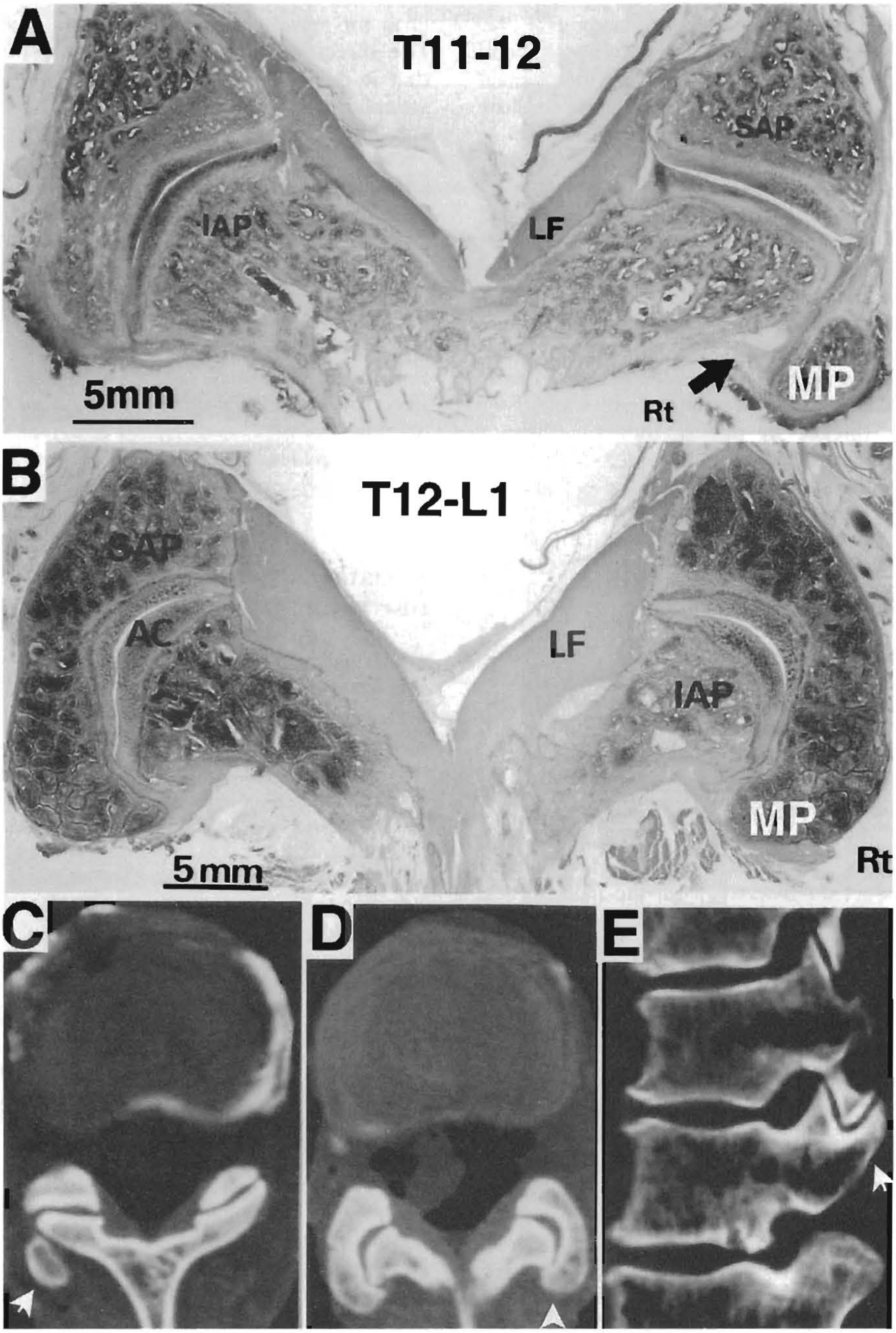

Fig. 2.8 Thoracolumbar mortice joint configurations represented by 100-μm thick horizontal histological sections at T11-T12 (A) and T12-L1 (B). The mammillary processes act to contain the inferior articular processes either unilaterally, in the case of articular asymmetry, or bilaterally. Axial CT images of thoracic spine (C) and thoracolumbar junction (D) segments further highlight this normally occurring development of the mammillary processes (arrows). A para-sagittal CT image in a cadaver spine (E) depicts the projecting mammillary process extending behind the inferior articular process at T11-T12, forming a cup-like joint, which would act to impede further extension. Abbreviations: AC, articular cartilage; IAP, inferior articular processes; LF, ligamentum flavum; MP, mammillary processes. (Histomicrographs reproduced from Singer, 1994).

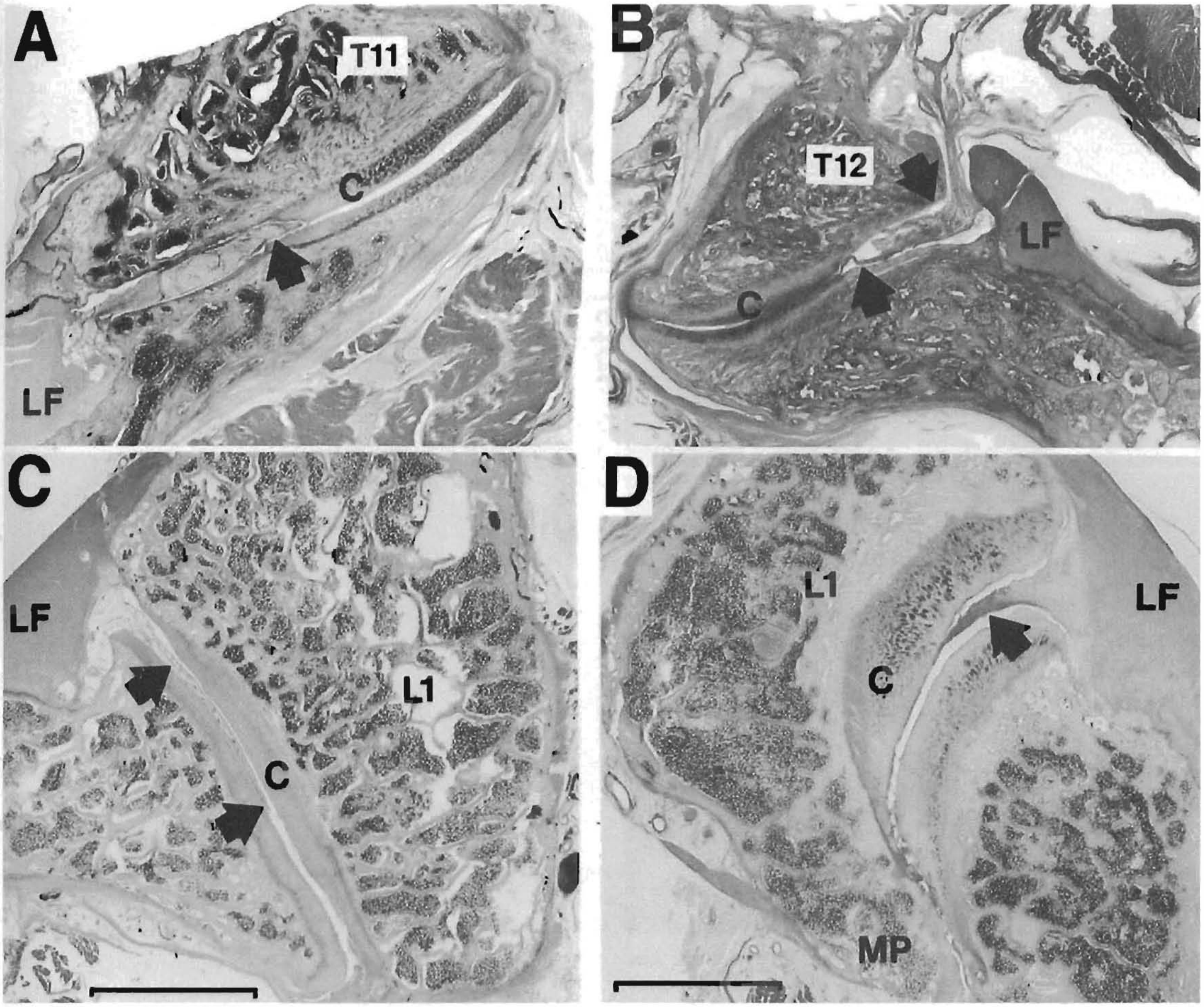

Fig. 2.9 Intra-articular synovial folds (IASFs) demonstrated within 100-μm thick horizontal histologic sections from thoracolumbar zygapophysial joints. These IASFs originate medially from tissue adjacent to the ligamentum flavum, and extend varying distances into the medial joint cavity (arrows). Comprised typically of fibrous or adipo-fibrous tissue, these folds act to fill spaces within the joint and may become trapped between the articular surfaces. They present in various forms from fatty tissue (A, C) to fibrous inclusions (B, D). Abbreviations: c, cartilage; LF, ligamentum flavum; MP, mammillary process. Scale marker = 5 mm (adapted and reprinted with permission from Singer *et al.*, 1990a).

thoracic region is slight, and is reduced further as a function of age (Peacock, 1952). The outer anulus (Fig. 2.11E) is attached into the vertebral end-plates via Sharpey's fibres, with the most superficial layers extending beyond the end-plate into the periosteum of the outer vertebral body itself. The intra-articular radiate ligament of the head of the rib also attaches onto the anulus fibrosus (Fig. 2.6).

Anterior disc height varies from approximately 4 mm at T1-T2, with a gradual decrease towards T4-T5, and increasing again caudally to about 6 mm at T11-T12 (Figs. 2.12-2.13). According to Pooni *et al.* (1986), the anterior height is least at the T4-T5 level. This view is supported from a large-scale survey of post-mortem thoracic spines (Fig. 2.12). Relative to the anterior dimensions, the thoracic discs are generally thicker posteriorly, particularly in the mid-thoracic region. Disc height dimensions are least in the upper thoracic segments, which may contribute to the relative stiffness of these segments (Gregerson and Lucas, 1967). A progressive increase in motion is recorded within the lowest segments, which are less impeded by the constraint of the thoracic cage and where the disc height is proportionally greater (White and Panjabi, 1990). As with the vertebral bodies, thoracic discs demonstrate an anteriorly-wedged configuration from T1-T2 to T8-T9, a trend most evident in the mid-thoracic region (Figs 2.12 and 2.13).

The thoracic discs vary from an elliptical shape in the upper segments to a rounded triangle in the

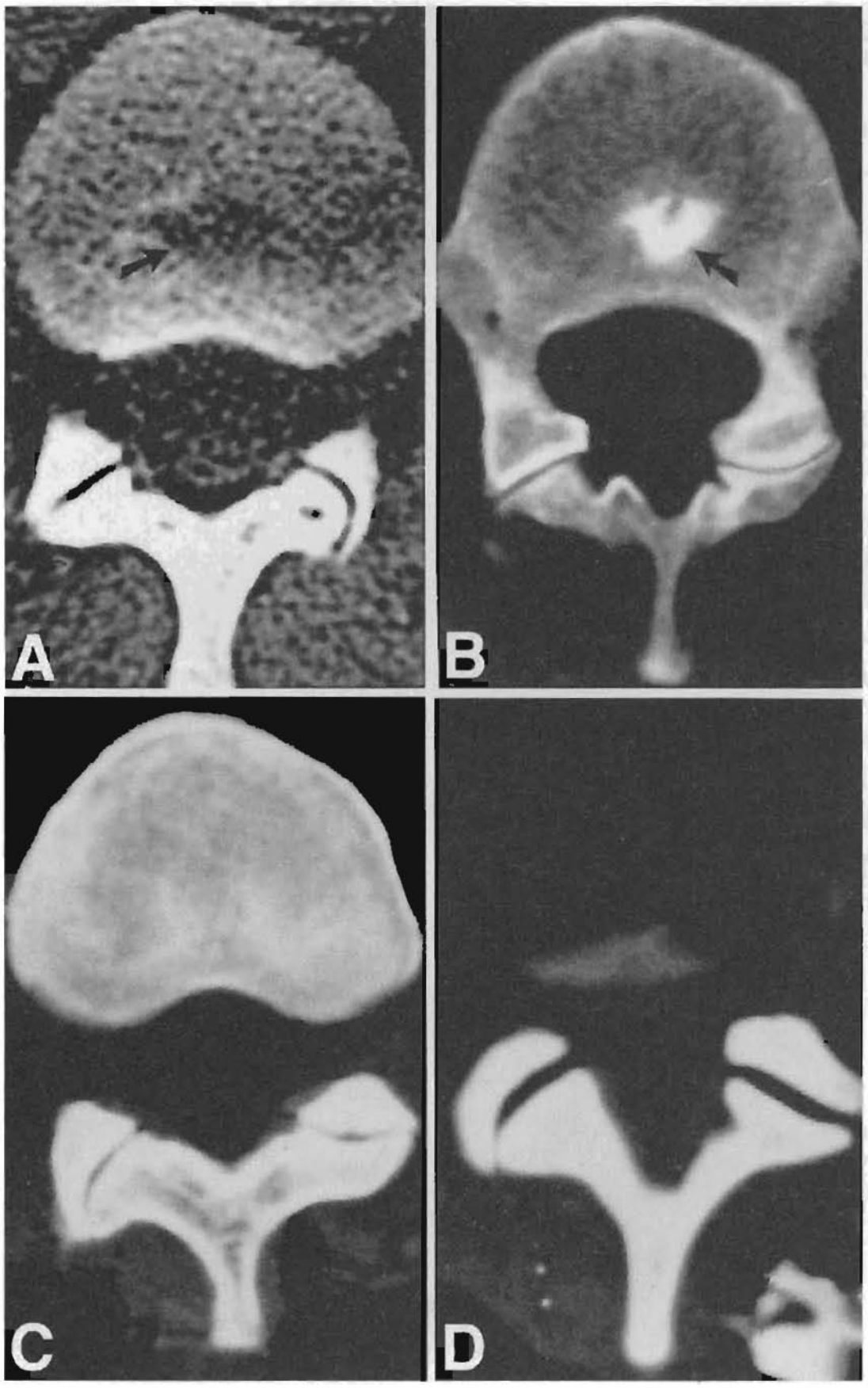

Fig. 2.10 There are multiple variations in the shape and configuration of the zygapophysial joints at the thoracolumbar transitional junction. The most varied level is T11-T12, which may show a thoracic joint on one side and a lumbar configuration on the other (A, B, C). Occasionally, where such anomalies are found at one transitional segment, others may be found elsewhere in the same spine. The T11-T12 axial CT image of a 37-year-old male (C) revealing articular tropism also highlights a similar pattern of asymmetry at L4-L5 (arrows show end-plate irregularities or bony sclerosis).

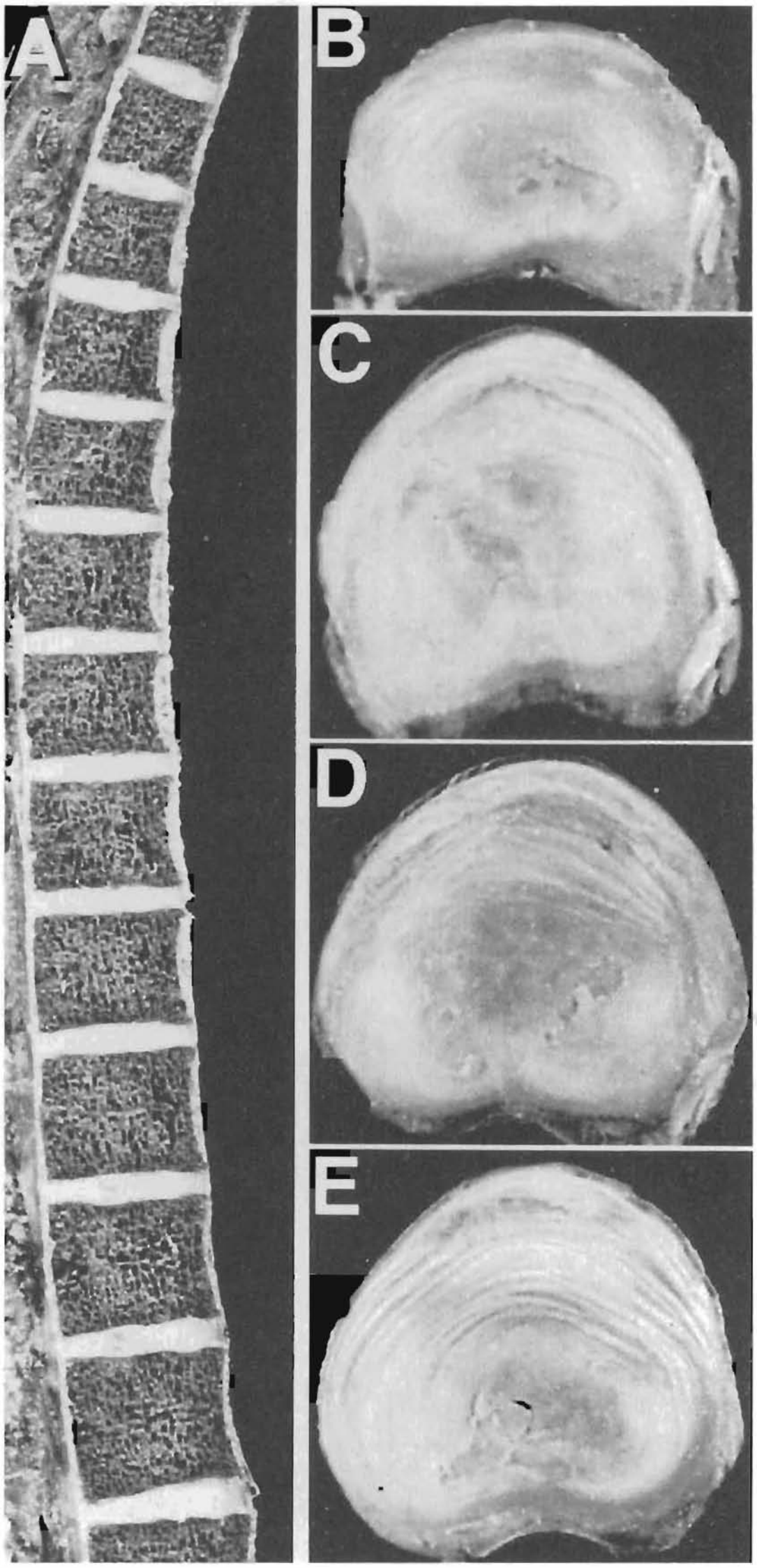

Fig. 2.11 A sagittal section of a 26-year-old normal thoracic spine at post-mortem is depicted (A) to highlight the relatively small vertical height of the thoracic discs and the physiological kyphosis, which is preserved even after hemisection. The shape of the thoracic discs vary from flattened ellipses in the upper segments (B) to rounded triangles within the middle region (C) and, finally, larger, circular discs towards the lowest thoracic levels (D, E). The anulus fibrosus layers are clearly depicted (E) against the nuclear region which, in these examples, is slightly discoloured.

middle segments, and on to a larger elliptical shape which is flattened posteriorly in the lower thoracic spine (Fig. 2.11B-E). Discs within the mid-thoracic region have the most circular cross-section of all discs within the vertebral column (Pooni *et al.*, 1986). There is a linear increase in cross-sectional area from the upper to lower thoracic regions (Pooni *et al.*, 1986; Edmondston *et al.*, 1994c; Singer *et al.*, 1995). A larger disc height tends to decrease stiffness, while a greater cross-sectional area tends to increase it. Based on descriptions of the lumbar intervertebral disc, the arrangement of the anular fibres and their attachment to the cartilage end-plates allows for great strength between vertebral bodies, while at the same time increasing resistance to torsion (Vernon-Roberts, 1992). Thus, in the thoracic spine, due to the relatively low vertical height of the vertebral bodies, their principal role is for axial loading and support for limited spinal mobility (White and Panjabi, 1990). The

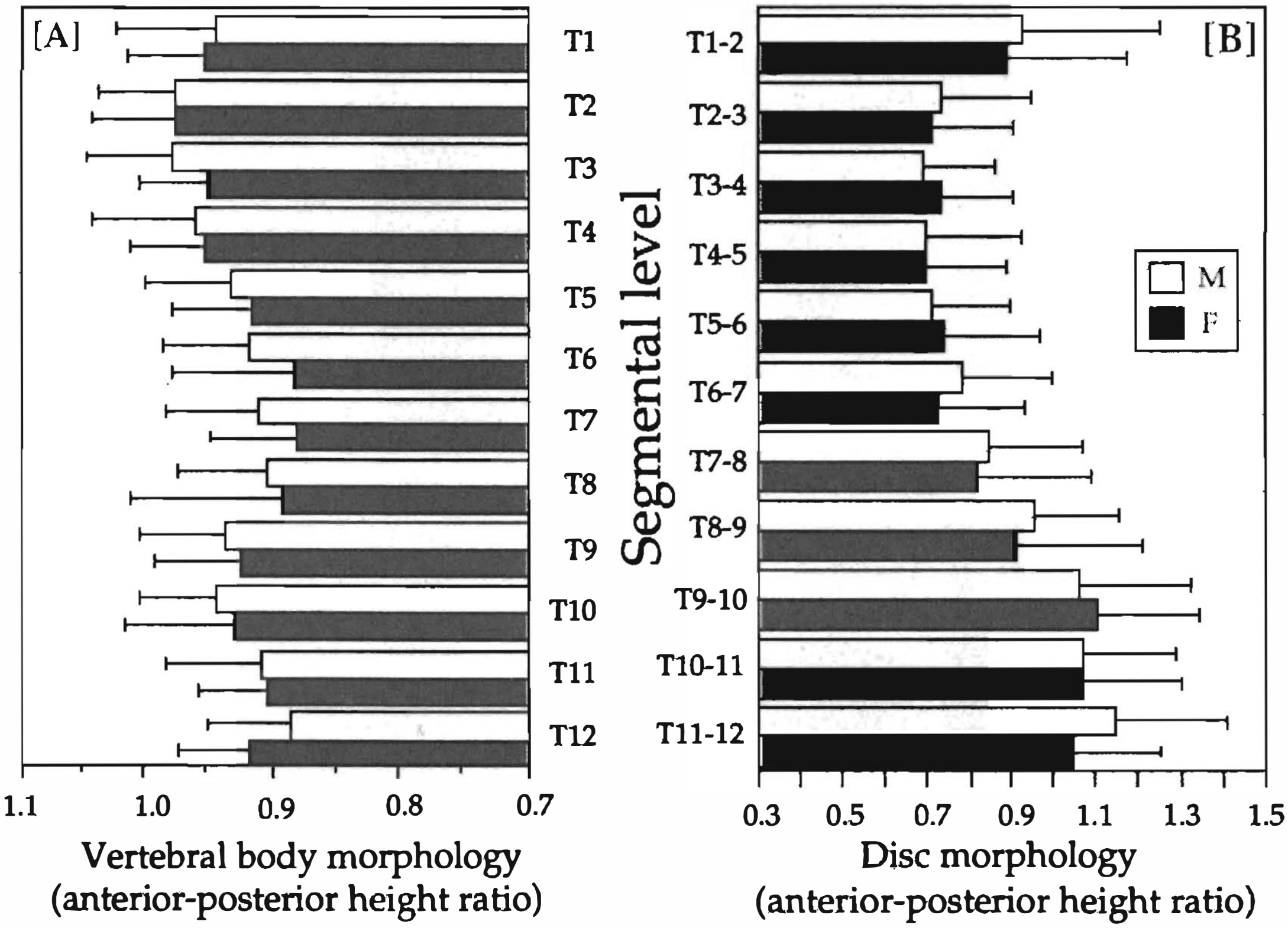

Fig. 2.12 Segmental trends in vertebral body (A) and intervertebral disc morphology (B) are represented as anterior–posterior height ratios. In both, the mid-thoracic segments show the greatest reduction in anterior height, particularly in females. These data are from a post-mortem radiological series of 93 cases.

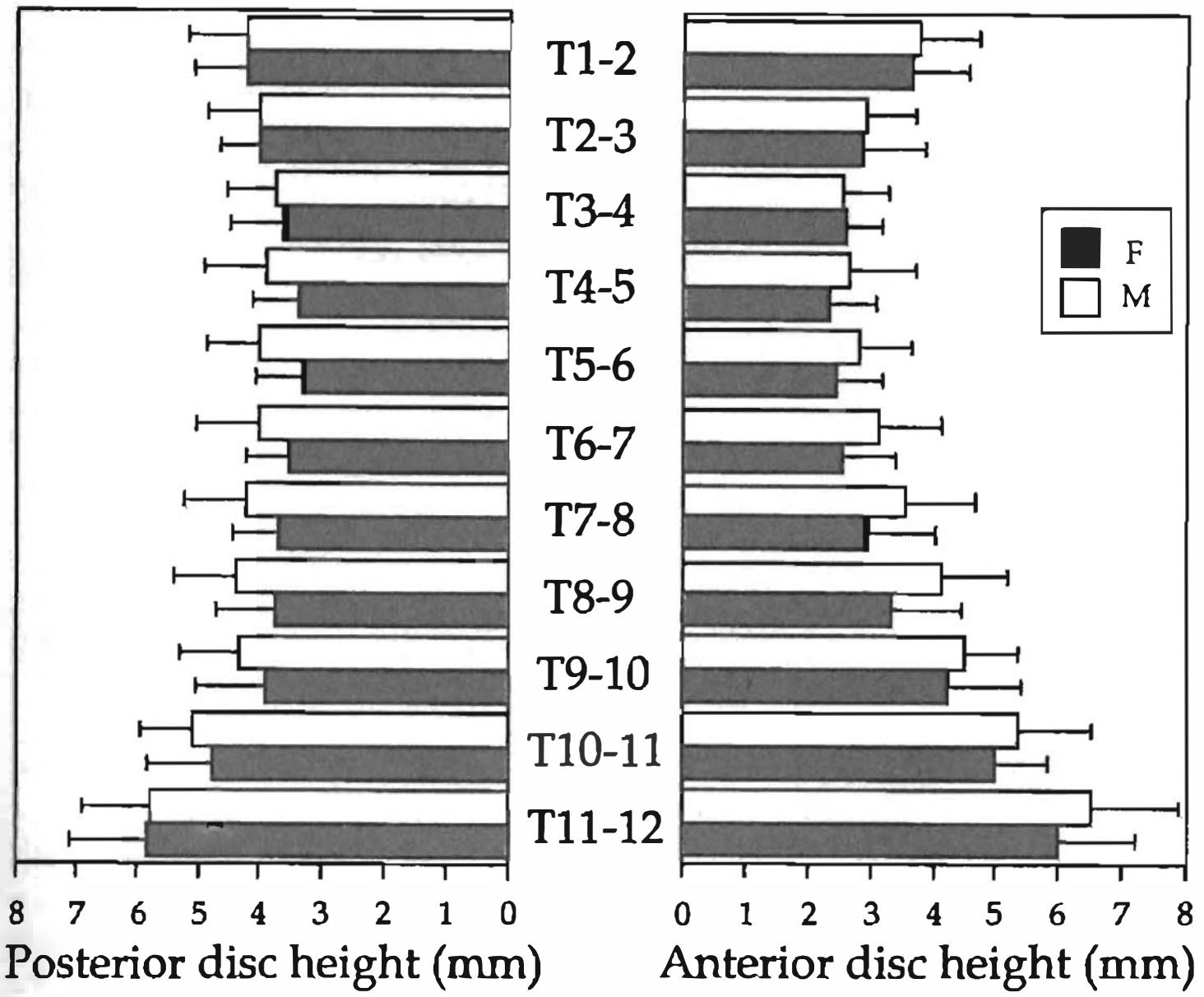

Fig. 2.13 Segmental trends in anterior and posterior disc dimensions depicting reductions in mid-thoracic height recorded from 93 post-mortem radiographs.

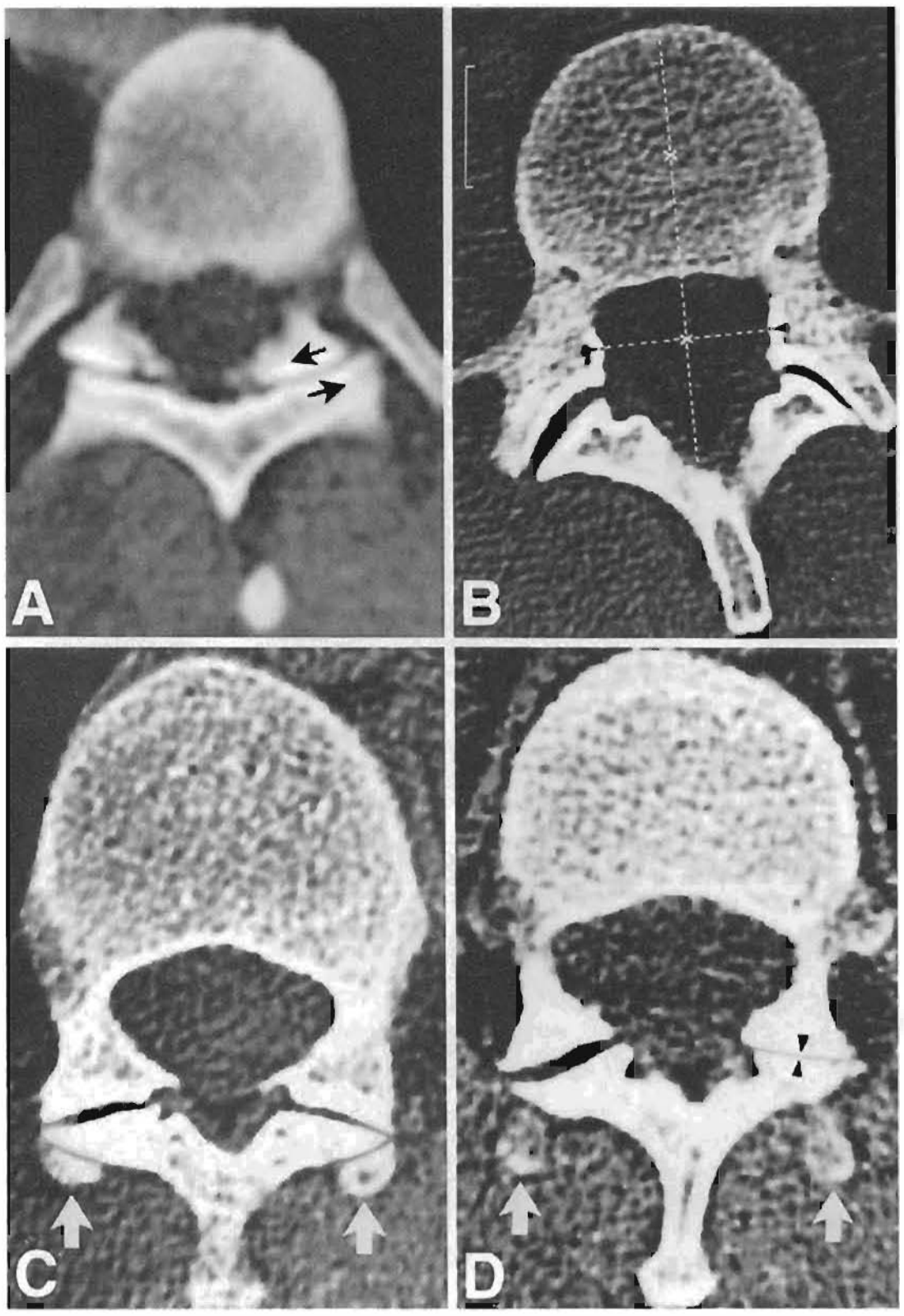

Fig. 2.14 Axial plane motion is facilitated by the typical coronal orientation of the vertebral segments above the thoracolumbar transition (A) with the presumed axis of rotation close to the vertebral body. The sagittal change in direction of the zygapophysial joints results in a marked reduction in rotation due to compression of the joint surfaces (B). The presence of mammillary processes (arrows) and their proximity to the zygapophysial joints may further restrict segmental motion (C, D) (adapted with permission from Singer *et al.*, 1989b).

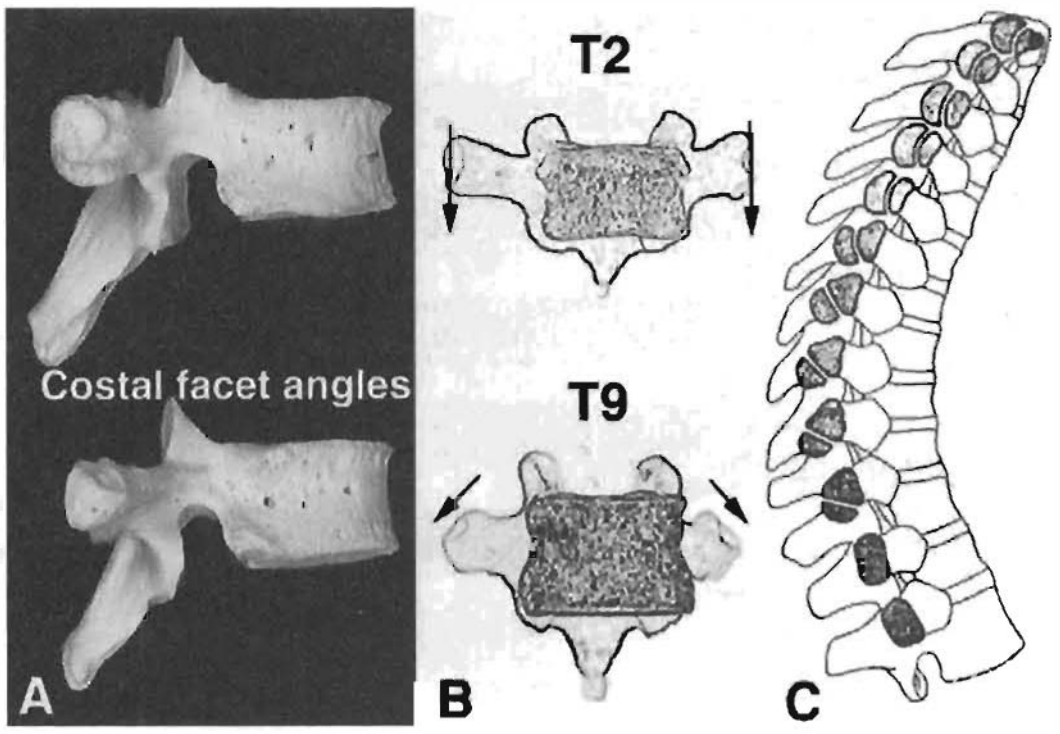

Fig. 2.15 Thoracic costal facets change in direction from superior to inferior, to accommodate greater loading from upper limb and thorax. At T2 the facets face laterally and vertically (A), whereas at T9 they adopt a cranial orientation (B) to accommodate the costotransverse joint onto a thickened and more substantial transverse process. The progressive change in configuration from T1 to T10 is depicted schematically (C) (adapted from Meyer, 1972).



Fig. 2.16 The upper three thoracic ribs (A) reveal a broad flat profile
provide attachment for muscles spanning the cervical spine. Each rib typically has a head, H, neck, N, and tubercle, T, with a cup-shaped depression at the anterior end for the articulation with the sternum. The lowest three ribs (B) are longer and more slender, again providing for attachment of muscles spanning the lumbar spine. The last two or three ribs, sometimes referred to as floating ribs, may articulate only with the vertebral body and lack a tubercle for a costotransverse articulation.

mid-thoracic segments achieve the greatest amplitude for axial rotation (Gregerson and Lucas, 1967), as depicted in Fig. 2.14A. In contrast, the vertebral morphology at the TLJ acts to impede rotation due to the configuration of the zygapophysial joints (Markolf, 1972; Singer, 1989b; Singer *et al.*, 1989b) (Fig. 2.14B–D). Overall, sagittal and frontal plane motion is relatively small compared with the cervical and lumbar spine regions (White and Panjabi, 1990).

Thoracic cage and ribs

The costovertebral and costotransverse joints have '. . . the added disadvantage, that while most of the other joints have periods of rest after periods of activity, the rib joints, unless they become ankylosed from disease, never rest entirely so long as life exists' (Goldthwait, 1940: 568). The thoracic ribs provide protection for the cardiopulmonary and visceral

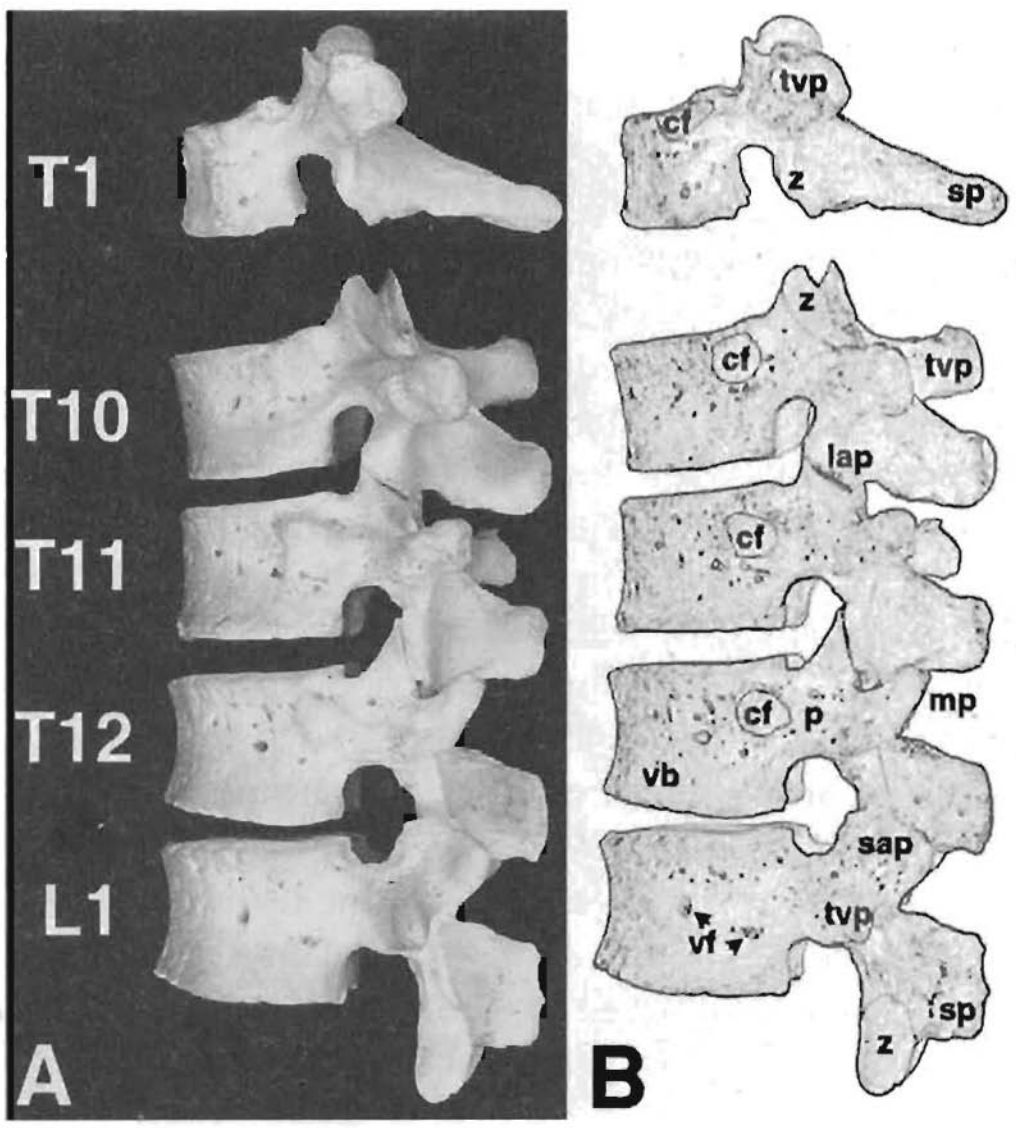

Fig. 2.17 The first and last two or three thoracic vertebral bodies contain a single costal facet on the root of the pedicle for articulation with the rib head. Occasionally, the tenth may follow the normal pattern, with a demi-facet shared with the ninth thoracic vertebra. In this figure, T1, T10, T11 and T12 show isolated costal facets. The progressive change in zygapophysial joint orientation is shown occurring at T10–T11, T11–T12 and T12–L1. Abbreviations: cf, costal facet; iap, inferior articular process; p, pedicle; sap, superior articular process; sp, spinous process; tvp, transverse process; vb, vertebral body; vf, vertebral foramen; z, zygapophysial joint.

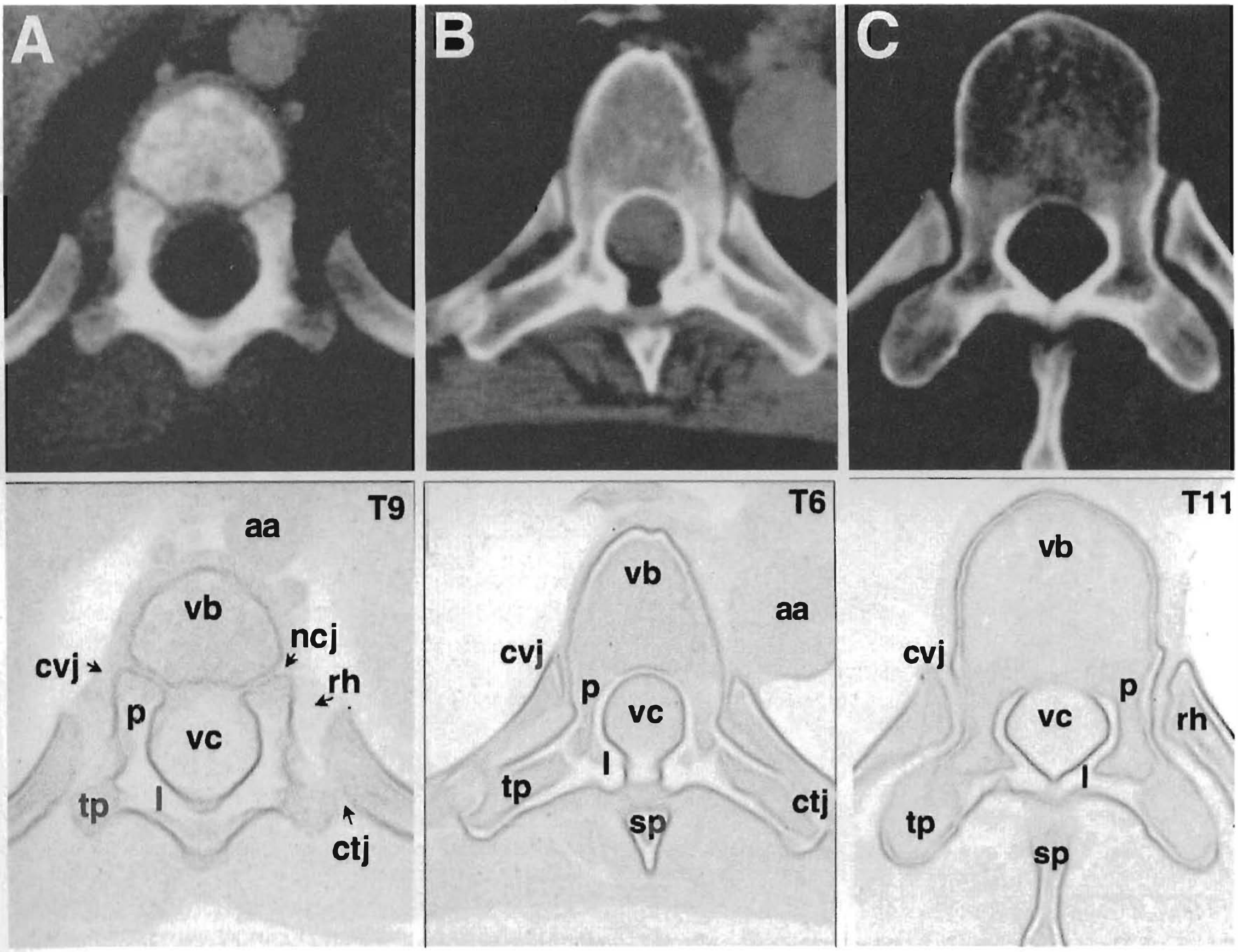

Fig. 2.18 Axial CT images depicting the paired costovertebral and costotransverse joints at T9 in a 3-year-old (A) and an adult (B). The larger costovertebral joints are depicted at T11 (C), where the transverse processes are shorter and angled in a more posterior direction. Abbreviations: aa, abdominal aorta; ctj, costotransverse joint; cvj, costovertebral joint; ncj, neurocentral junction; l, lamina; p, pedicle; sp, spinous process; vb, vertebral body; vc, vertebral canal.

contents of the upper abdomen. This bony cavity is designed to accommodate the demands of respiration through specialized costotransverse and costovertebral joints posteriorly, and costosternal articulations anteriorly. The movements of the thorax associated with the dynamics of respiration are reviewed in detail by Kapandji (1977), Andriacchi et al. (1974) and Harris and Holmes (1996).

The lower ribs, through their articulations with the transverse processes, act to convey upper limb and thorax load onto the axial skeleton. This change in angle of the costotransverse joints, depicted in Fig. 2.15B, C, is described by Meyer (1972).

The upper and lower ribs (Fig. 2.16) provide attachment locations for large muscles spanning the cervical and lumbar regions of the spine respectively. In this way, strong tension forces are applied to the thoracic region, which help explain the reactive changes at these rib articulations (see Fig. 5.1).

The T1 and T10-T12 costovertebral joints are specialized insofar as a single costal facet is located on the root of the pedicles (Fig. 2.17). Occasionally the tenth thoracic vertebral body provides a shared costal facet with the ninth, although variations have been reported (Shimaguchi, 1974).

The typical rib articulations for the middle and lower segments are represented by axial CT images in Fig. 2.18.

The rib articulations with the thoracic vertebral column, like most synovial joints, contain small IASFs comprised of fibro-fatty tissue, which act to take up any voids between articulating surfaces (Singer *et al.*, 1990a) (Fig. 2.19). These IASFs have been comprehensively mapped for the thoracic rib joints by Meyer (1972), and at the thoracolumbar junction by Tan (1993). Based on immunohistochemical studies of lumbar zygapophysial joint IASFs by Giles and Harvey (1987), it is reasonable to conclude that these small inclusions could be innervated and produce painful entrapment of both rib and thoracic zygapophysial joints (Kos and Wolf, 1972).

The human thorax comprises the thoracic vertebral column and the rib articulations with the sternum. This complex arrangement of vertebrae, ribs and cartilage provides a flexible yet stable cavity for the cardiorespiratory system and main vessels. The sternum consists of the larger manubrium and a more slender, at times multi-segmented, body. Demi-facets are located on the lateral aspect of the manubrium and body to accommodate the attachment of the

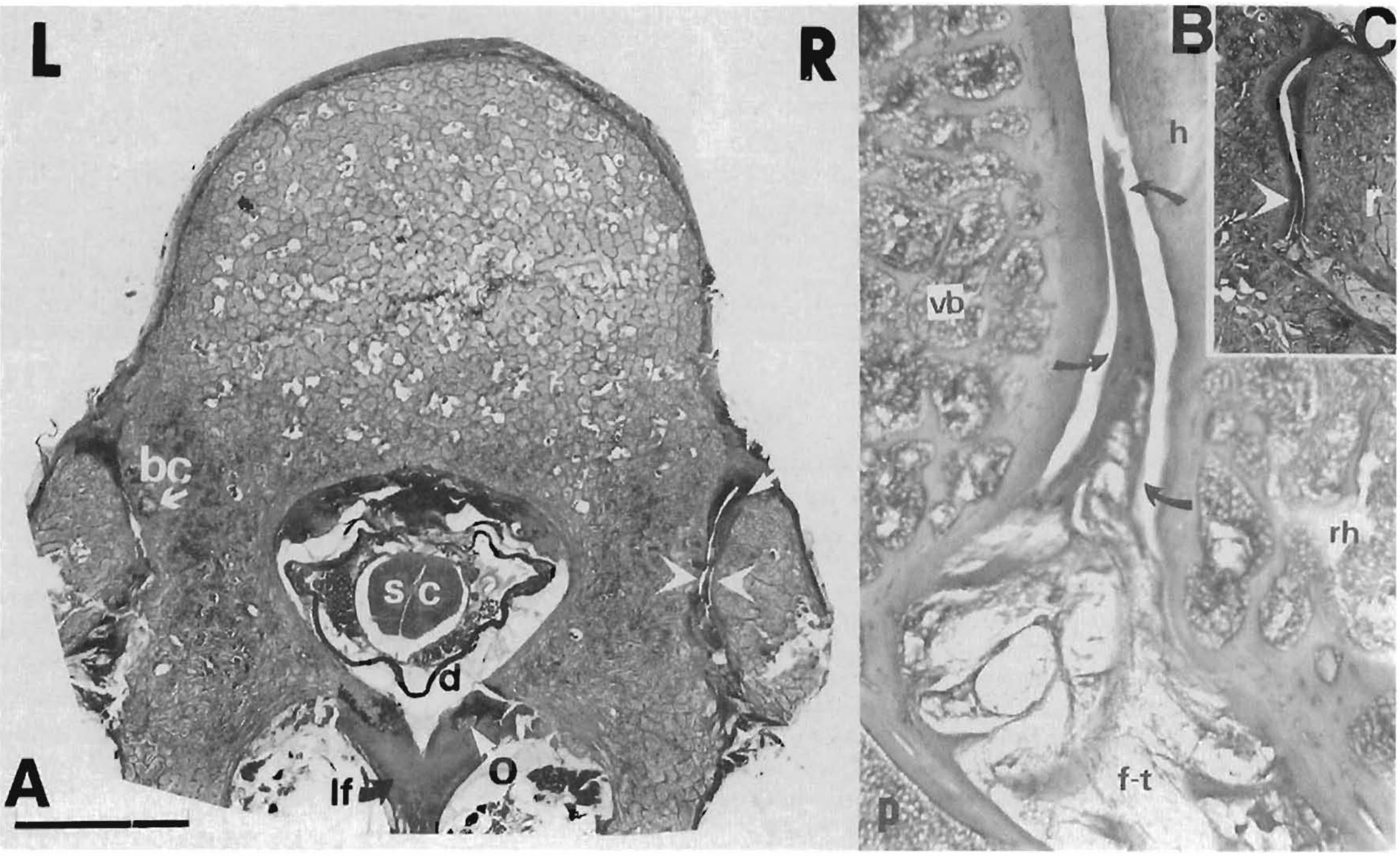

Fig. 2.19 The paired costovertebral joints, represented at T12 (A), frequently show the presence of IASFs, which originate between the pedicle and the rib head and penetrate anteriorly into the joint space (arrows). A thickened fibrous IASP is depicted in (B), originating from a fibro-fatty network. The inset (C) highlights the length of this IASP, extending approximately one-third the length of the joint. Abbreviations: bc, histological appearance of a bone cyst; d, dura; ff, fibro-fatty; lf, ligamentum flavum; o, ossification within the ligamentum flavum; rh, rib head; sc, spinal cord; vb, vertebral body.

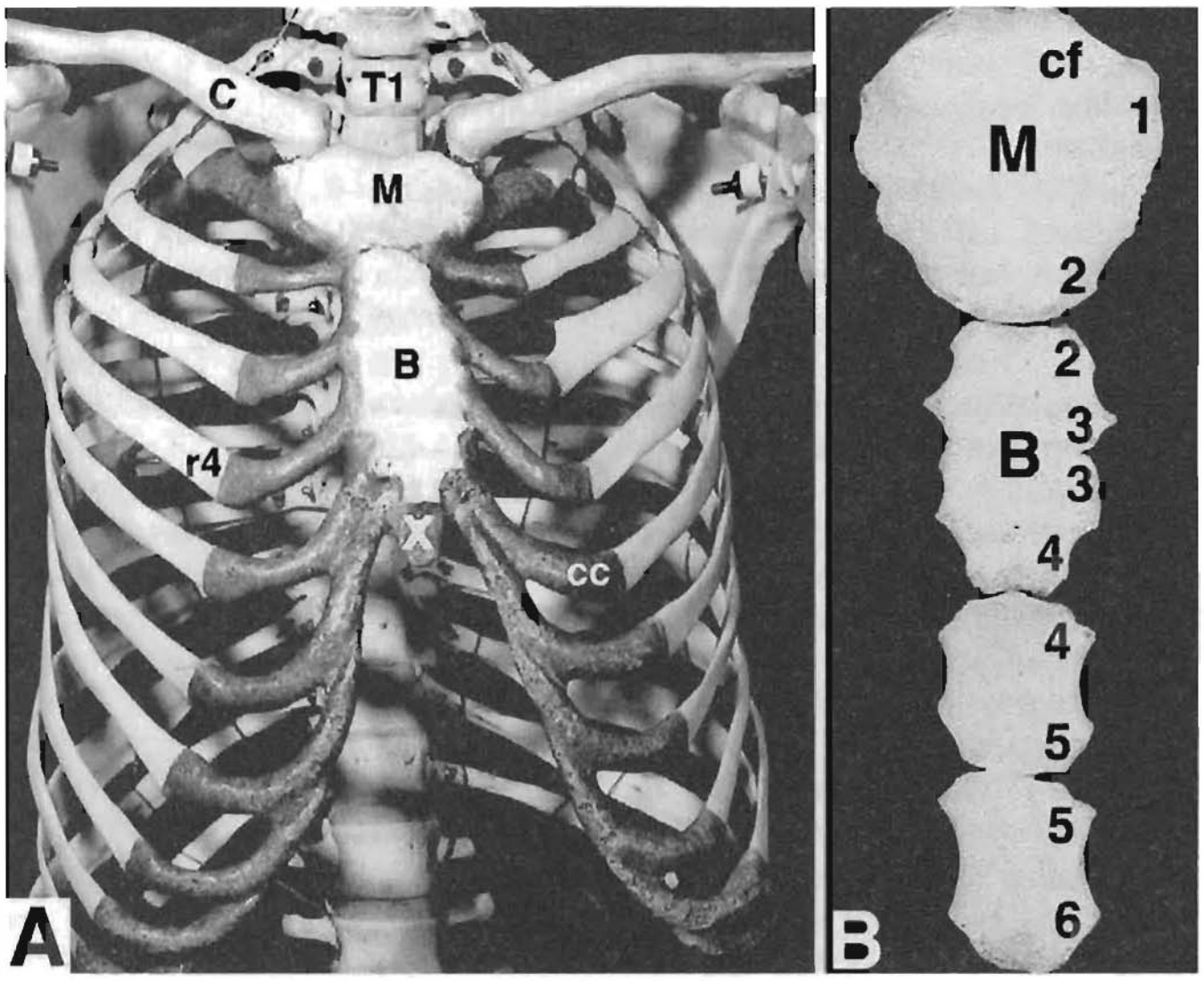

Fig. 2.20 The sternum of the human thorax is comprised of the larger manubrium and the more slender body (B). Demi-facets, shown in the left photograph, are located on the lateral aspect of the manubrium and body to accommodate the attachment of the clavicle and the first six ribs (1-6) via the costal cartilages. The xiphisternum, depicted in (A), articulates with the inferior aspect of the body. Abbreviations: c, clavicle; cc, costal cartilage; M, manubrium; r4, fourth rib; T1, first thoracic vertebral body; x, xiphoid process of sternum.

clavicle and the upper six or seven ribs via the costal cartilages. The xiphisternum articulates with the inferior aspect of the body of the manubrium (Fig. 2.20). The costal cartilages provide a flexible link from the end of the rib to the sternum, and contribute important mobility to the ribcage. For the last two and occasionally three lowest ribs, the costal cartilage terminates within the muscles of the abdominal wall.

Physiological kyphosis

The physiological S-shaped sagittal curve of the human vertebral column is well-adapted for maintenance of upright posture and efficient transmission of compressive forces. In the thoracic spine, the apex of the kyphotic curve, or the region of greatest curvature, typically lies between T6 and T8 (Singer *et al.*, 1990b; Korovessis *et al.*, 1998), the result of mechanical loads imposed on the anterior aspect of the vertebral bodies (Fig. 2.2). The cumulative effects of these loads may result in age-related progression of the thoracic sagittal curve, a process that is accentuated in individuals with osteoporosis (Sartoris, 1996). Numerous factors contribute to the kyphosis, with the shape of the vertebral bodies being the major contributor (White and Panjabi, 1990). Recent *in vivo* (Manns *et al.*, 1996) and *ex vivo* studies (Goh *et al.*, 1999) have described the contribution of the thoracic discs in determining the geometry of the kyphotic curve. Other factors include reduced muscle tone, occupational and habitual posture, and osteopenia.

The normal range of the thoracic sagittal curve generally lies between 20° and 40°, though these values are age and gender specific (Fon *et al.*, 1980; Singer *et al.*, 1990b). Progression of kyphosis across the life span is most developed in females, and is attributed to reduced physical activity and muscle tone and, in older females, the effect of the breasts (Milne and Lauder, 1974).

Summary

In this first section of the text, the anatomy of the thoracic vertebral column has been presented to highlight the regional differences of vertebrae and ribs as a preliminary to discussing the detailed ligamentous anatomy (Chapter 3) and functional biomechanics of the thoracic spine and thorax (Chapter 4).

References

Andriacchi, T., Schultz, A., Belytschko, T., Galante, J. (1974) A model for studies of mechanical interactions between the human spine and ribcage. *J. Biomech.* **7:** 497-507.

Bagnall, K.M., Harris, P.F., Jones, P.R.M. (1977) A radiographic study of the human fetal spine. 2. The sequence of development of ossification centres in the vertebral column. *J. Anat.* **124:** 791-798.

Boyle, J.W.W., Milne, N., Singer, K.P. (1998) Clinical anatomy of the cervicothoracic junction. In: *Clinical Anatomy and Management of Cervical Spine Pain* (Giles, L.G.F., Singer, K.P., eds). Oxford: Butterworth-Heinemann, pp. 40-52.

Brandner, M. (1970) Normal values of the vertebral body and intervertebral disc index during growth. *Radiology* **110:** 618-627.

Burguet, J.L., Sick, H., Wackenheim, A. (1987) CT-anatomic correlations of the normal capsulo-ligamentous bands of the extrinsic joints of the thoracic spine. *Surg. Radiol. Anat.* **9:** 217-223.

Davies, K.M., Recker, R.R., Heaney, R.P. (1989) Normal vertebral dimensions and normal variation in serial measurements of vertebrae. *J. Bone Min. Res.* **4:** 341-349.

Davis, P.R. (1955) The thoraco-lumbar mortice joint. *J. Anat.* **89:** 370-377.

Davis, P.R. (1959) The medial inclination of the human thoracic intervertebral articular facets. *J. Anat.* **93:** 68-74.

Edmondston, S.J., Breidahl, W.H., Singer, K.P. *et al.* (1994a) Segmental trends in cancellous bone structure in the thoracolumbar spine: Histological and radiological comparisons. *Aust. Radiol.* **38:** 19-24.

Edmondston, S.J., Singer, K.P., Price, R.I. *et al.* (1994b) The relationship between bone mineral density, vertebral body shape and spinal curvature in the elderly thoracolumbar spine: An in vitro study. *Br. J. Radiol.* **67:** 969-975.

Edmonston, S., Singer, K.P., Day, R.E., Breidahl, P.D., Price, R.I. (1994c) *In vitro* relationships between vertebral body density, size and compressive strength in the elderly thorocolumbar spine. *Clinical Biomechanics* **9:** 180-186.

Ebraheim, N.A., Xu, R., Ahmad, M. *et al.* (1997) The quantitative anatomy of the thoracic facet and the posterior projection of its inferior facet. *Spine* **22:** 1811-1817.

Foley, W.J., Whitehouse, W.M. (1969) Supernumerary thoracic ribs. *Radiology* **93:** 1333-1334.

Fon, G., Pitt, M., Thies, A. (1980) Thoracic kyphosis: Range in normal subjects. *A.J.R.* **134:** 979-983.

Goh, S., Price, R.I. Leedman, P.J., Singer, K.P. (1999) The relative influence of vertebral body and intervertebral disk shape on thoracic kyphosis. *Clinical Biomechanics* **14:** 439-448.

Giles, L.G.F., Harvey, A. (1987) Immunohistochemical demonstration of nociceptors in the capsule and synovial folds of human zygapophyseal joints. *Br. J. Rheumatol.* **26:** 362-364.

Gladstone, R.J., Wakeley, C.P.G. (1932) Cervical ribs and rudimentary first thoracic ribs considered from the clinical and etiological standpoints. *J. Anat.* **66:** 334-370.

Gregersen, G.G., Lucas, D.B. (1967) An in vivo study of the axial rotation of the human thoracolumbar spine. *J. Bone Joint Surg.* **49A:** 247-262.

Harris, J.D., Holmes, T.G. (1996) Rib cage and thoracic spine. *Phys. Med. Rehab. Clin. N. Am.* **7:** 761-771.

Huson, A. (1967) Les articulations intervertébrales chez les foetus humain. *Comptes Rendus des Association d'Anatomists* **138:** 676-683.

Kapandji, I. (1977) *The Trunk and Vertebral Column*, 2nd edn. Edinburgh: Churchill Livingstone.

Korovessis, P., Stamatakis, M.V., Baikousis, A.G. (1998) Reciprocal angulation of vertebral bodies in the sagittal plane in an asymptomatic Greek population. *Spine* **23:** 700-705.

Lanier, R.R. (1939) The presacral vertebrae of American white and Negro males. *Am. J. Phys. Anthro* **3:** 341-420.

Ley, F. (1975) Contribution a l'étude des cavités articulaires interapophysaires vertébrales thoraciques. *Arch. d'Anat. d'Histol. et d'Embryol.* **57:** 61-114.

Lohse, C., Hyde, D., Benson, D. (1985) Comparative development of the thoracic intervertebral discs and intra-articular ligaments in the human, monkey, mouse and cat. *Acta Anat.* **122:** 220-228.

Lord, M.J., Ogden, J.A., Ganey, T.M. (1995) Postnatal development of the thoracic spine. *Spine* **20:** 1692-1698.

Louis, R. (1983) *Surgery of the Spine*. Berlin: Springer-Verlag, pp. 10, 50.

Lutz, G. (1967) Die Entwicklung der kleinen Wirbelgelenke. *Z. Orthop. Grenzgebiete* **104:** 19-28.

Kaplan, E. (1945) The surgical and anatomic significance of the mammillary tubercle of the last thoracic vertebra. *Surgery* **17:** 78-92.

Kos, J., Wolf, J. (1972) Les menisques intervertebraux et leur role possible dans les blocages vertebraux. *Annals de Medecine Physique* **15:** 203-218.

Malmivaara, A., Videman, T., Kuosma, E., Troup, J.D.G. (1987) Facet joint orientation, facet and costovertebral joint osteoarthritis, disc degeneration, vertebral body osteophytosis and Schmorl's nodes in the thoracolumbar junctional region of cadaveric spines. *Spine* **12:** 458-463.

Manns, R.A., Haddaway, M.J., McCall, I.W. *et al.* (1996) The relative contribution of disc and vertebral morphometry to the angle of kyphosis in asymptomatic subjects. *Clin. Radiol.* **51:** 258-262.

Markolf, K. (1972) Deformation of the thoracolumbar intervertebral joints in response to external loads. A biomechanical study using autopsy material. *J. Bone Joint Surg.* **54:** 511.

Melham, R.E., Fahl, M. (1995) Fifteen dorsal vertebrae and rib pairs in two siblings. *Paed. Radiol.* **15:** 61-62.

Med, M. (1972) Articulations of the thoracic vertebrae and their variability. *Folia Morph.* **20:** 212-215.

Med, M. (1977) Prenatal development of thoracic intervertebral articulations. *Folia Morph.* **25:** 175-177.

Meyer, P.R. (1972) Contribution a' l'étude des cavités articulaires costo-vertébrales. *Arch. d'Anat. d'Histol. et d'Embryol.* **55:** 283-360

Milne, J.S., Lauder, I.J. (1974) Age effects in kyphosis and lordosis in adults. *Ann. Hum. Biol.* **1:** 327-337.

Moore, K.L. (1997) Muscles and ligaments of the back. In: *Clinical Anatomy and Management of Low Back Pain*, Vol 1 (Giles, L.G.F., Singer, K.P., eds). Oxford: Butterworth-Heinemann, pp. 156-164.

Noback, C., Robertson, G. (1951) Sequences of appearance of ossification centres in the human skeleton during the first five prenatal months. *Am. J. Anat.* **89:** 1-28.

Oliver, J., Middleditch, A. (1991) *Functional Anatomy of the Spine*. Oxford: Butterworth-Heinemann.

Panjabi, M.M., Takata, K., Goel, V. *et al.* (1991) Thoracic human vertebrae. Quantitative three-dimensional anatomy. *Spine* **16:** 888-901.

Peacock, A. (1952) Observations on the postnatal structure of the intervertebral disc in man. *J. Anat.* **86:** 162-179.

Pooni, J.S., Hukins, D.W.L., Harris, P.F. *et al.* (1986) Comparison of the structure of human intervertebral discs in the cervical, thoracic and lumbar regions of the spine. *Surg. Radiol. Anat.* **8:** 175-182.

Rab, G. (1979) Muscle forces in the posterior thoracic spine. *Clin. Orthop. Rel. Res.* **139:** 28-32.

Reichmann, S. (1971) The postnatal development of form and orientation of the lumbar intervertebral joint surfaces. *Z. Anat. Entwicklung* **133:** 102-123.

Sartoris, D. (1996) *Osteoporosis: Diagnosis and Treatment.* New York: Marcel Dekker.

Schmorl, G., Junghanns, H. (1971) *The Human Spine in Health and Disease*, 2nd edn. New York: Grune and Stratton.

Schultz, A.H. (1961) Vertebral column and thorax. In: *Primatologia* (Hofer, H., Schultz, A.H., Stark, D. eds). Basle: Karger, pp. 1-66.

Shimaguchi, S. (1974) Tenth rib is floating (in Japanese). *Anat. Anz.* **135:** 72-82.

Singer, K.P. (1989a) *Variation at the Human Thoracolumbar Transitional Junction with particular reference to the Posterior Elements.* PhD thesis. The Department of Anatomy and Human Biology, The University of Western Australia.

Singer, K.P. (1989b) The thoracolumbar mortice joint. Radiological and histological observations. *Clin. Biomech.* **4:** 137-143.

Singer, K.P. (1994) Anatomy and biomechanics of the thoracolumbar junction. In: *Grieve's Modern Manual Therapy.* (Boyling, J.D. and Palastanga, N. eds). Edinburgh: Churchill-Livingstone, pp. 85-97.

Singer, K.P. (1997) Pathomechanics of the aging thoracic spine. In: *Advances in Chiropractic* (Lawrence, D., ed.). St Louis: Mosby, pp. 129-153.

Singer, K.P., Breidahl, P.D. (1990) Accessory ossification centres at the thoracolumbar junction. *Surg. Radiol. Anat.* **12:** 53-58.

Singer, K.P., Breidahl, P.D., Day, R.E. (1989a) Posterior element variation at the thoracolumbar transition. A morphometric study using computed tomography. *Clin. Biomech.* **4:** 80-86.

Singer, K.P., Day, R.E., Breidahl, P.D. (1989b) In vivo axial rotation at the thoracolumbar junction: an investigation using low dose CT in healthy male volunteers. *Clin. Biomech.* **4:** 145-150.

Singer, K.P., Giles, L.G.F., Day, R.E. (1990a) Intra-articular synovial folds of the thoracolumbar junction zygapophyseal joints. *Anat. Rec.* **226:** 147-152.

Singer, K.P., Jones, T.J., Breidahl, P.D. (1990b) A comparison of radiographic and computer-assisted measurements of thoracic and thoracolumbar sagittal curvature. *Skel. Radiol.* **19:** 21-26.

Singer, K.P., Edmondston, S.J., Day, R.E., *et al.* (1995) Prediction of compressive strength of isolated lumbar and thoracic vertebral bodies: Relationships to age, geometry, bone density and spinal curvature. *Bone.* **17:** 167-174.

Strauss, E.D., Kahanovitz, N. & Ghelman, B. (1983) Congenital abscence of the thoracic pedicle: A case report. *Spine* **8:** 48-49.

Tan, B-K. (1993) Histomorphometry of the lower thoracic costovertebral joints; normal and pathological anatomy. Unpublished Honours thesis, Curtin University, Perth, WA.

Terry, R. & Trotter, M. (1953) Osteology. In: Schaeffer, J.P. (ed) *Morris's Human Anatomy.* McGraw-Hill, New York.

Veleanu, C.m Grünn, U., Diaconescu, M. *et al.* (1972) Structural peculiarities of the thoracic spine. Their functional significance. *Acta Anat.* **82:** 97-107.

Vernon-Roberts, B. (1992) Age-related and degenerative pathology of the intervertebral discs and apophyseal joints. In: Jayson, M.I.V. (edO *The lumbar spine and back pain.* Churchill-Livingstone, Edinburgh.

White III, A.A. & Panjabi, M.M. (1990) *Clinical biomechanics of the spine.* (2nd ed.). Philadelphia: J.B. Lippincott.

Whitney, C. (1926) Asymnmnetry of vertebral articular processes and facets. *Am. J. Phys. Anthrop.* **9:** 451-455.

Wigh, R.E. (1980) Classification of the human vertebral column: phylogenic departures and junctional anomalies. *Med. Radiogr. Photogr.* **56:** 2-11.

Williams, P. & Warwick, R. (1980) *Gray's Anatomy.* 36th edn. Churchill, London.

Yamazaki, A., Mason, D.E. & Caro, P.A. (1998) Age of closure of the neurocentral cartilage in the thoracic spine. *J. Pediatr. Orthop.* **18:** 168-172.

Zindrick, M., Wiltse, L., Doornik, A., *et al.* (1986) Analysis of the morphometric characteristics of the thoracic and lumbar pedicles. *Spine* **12:** 160-166.

3

Ligaments of the human vertebral column

R. V. Putz and M. Müller-Gerbl

The ligaments of the vertebral column can be divided into two groups. The inelastic anterior longitudinal ligament, consisting only of collagen fibres, and the segmental chain of the elastic ligamentum flavum comprise one group. The other group contains many ligaments running in directions oblique or perpendicular to the long axis of the column: the posterior longitudinal ligament, the interspinous ligament, the so-called 'transverse ligaments', which reinforce the joint capsule, and the fibrous lamellae of the anulus fibrosus. The supraspinous ligament, attached to the spinous processes, is in fact the middle band of the thoracolumbar fascia, the fibres of which are arranged in the lozenge-shaped pattern of an elevator gate.

In the lumbar region in particular, these ligaments interact as a kind of ligamentous gear system which determines the co-ordination of various movements. In the thoracic region, control is supplemented by the attachments between vertebrae and ribs. The motion segments of the cervical region are rather different, since the powerful muscular cloak makes any marked differentiation of the ligaments unnecessary.

The kinematics of the motion segments of the vertebral column in its entirety depend largely on the zygapophysial joints, the geometrical form of which shows great regional differentiation. In the lumbar region they are not only responsible for taking up shearing forces, but also play a part in limiting rotation. Those of the thoracic vertebrae, where their function is solely to counter ventrally directed shearing forces, are simplest in form. The zygapophysial joints of the cervical region are more heterogeneously shaped. Their lateral ridges are again directed somewhat dorsally, which is an expression of the part they play in limiting rotation.

Introduction

The term 'motion segment' (*bewegungssegment*) was coined by Junghanns, 1977 to describe the space between two contiguous vertebrae, together with their ligaments, the intervertebral disc and the paired zygapophysial joints. Whereas there is already an extensive literature on the discs (Weinstein and Wiesel, 1990), and the zygapophysial joints are being increasingly investigated because of their clinical importance (Putz, 1981, 1985; Bogduk and Twomey, 1987; Müller-Gerbl, 1992), very little attention has been paid to the ligaments of the vertebral column themselves (Panjabi *et al.*, 1982; Lang, 1984; Behrsin and Briggs, 1988; Myklebust *et al.*, 1988; Putz, 1992). This is reflected in their description as it appears in many textbooks, where they receive only scant formal treatment, often without account being taken of their internal structure and therefore necessarily without presenting a relevant interpretation of their function. The morphological basis of innervation, however, has been investigated during recent years (Loeweneck, 1966; Bogduk, 1983; Groen *et al.*, 1990; Jiang *et al.*, 1995) (see Chapter 8).

In the following section the individual parts of the intervertebral ligamentous apparatus are systematically described and, on this basis, an attempt is made to analyse their function. The anulus fibrosus is in a peculiar position, since it is an integral part of the intervertebral disc, but also plays an important role as a component of the entire ligamentous apparatus.

Ligaments of the vertebral bodies and intervertebral discs

Anterior longitudinal ligament

Among the ligaments, which are pally of collagen II and are therefore virtually inextensible, the anterior longitudinal ligament (ALL) is the only structure that consists of more or less parallel orientated fibres running the whole length of the vertebral column, binding the anterior (and sometimes also the lateral) surfaces of the vertebral bodies together (Figs 3.1-3.3). Investigations reported by Stofft (1966) have made it quite clear that the fibres of the ALL are anchored directly in the cortical bone at the edges of the vertebrae, and are also closely interwoven with the anterior and lateral surfaces of the vertebral bodies. The ligament begins at the anterior ridge of the foramen magnum, crosses the anterior arch of the atlas, and is relatively thick in the cervical region. It becomes somewhat narrower in the thoracic column, and then reaches its thickest and widest form in the lumbar region and at the transition to the sacrum.

The superficial layer of the ALL runs from vertebra to vertebra, its fibres crossing at an angle of about 20°. The deeper fibres follow quite a different course, being attached to the anulus fibrosus and crossing each other at an angle of over 80° (Stofft, 1966). These morphological results are confirmed by the functional investigations of Neumann *et al.* (1994), who showed that the highest peak tensile strength is to be found in the outer portion of the ligament. The ALL has the greatest tensile strength of all the vertebral ligaments (Myklebust *et al.*, 1988).

The importance of the superficial layer of the ALL, as a ventral sheet of inelastic parallel fibres, is obvious when taking into account the loading to which the vertebral column is constantly subjected during flexion - a stress which, at the level of each individual segment, becomes converted into straightforward pressure or tension. In the lordotic regions of the column, this ligament acts as an inelastic stay and prevents overextension (Hayashi *et al.*, 1977). In this way it makes it possible for the discs - at least under physiological conditions - to distribute the static and dynamic pressure equally over the surfaces of adjacent vertebral bodies. The ALL is, however, unable to offer effective resistance to ventrally-directed shearing forces, as exemplified in cases of spondylolisthesis. Such resistance is mostly supplied by the zygapophysial joints.

The fibres of the deep layer, which cross each other at a widely obtuse angle to enter the outer regions of the anulus fibrosus, do almost nothing to limit extension but are most efficient in preventing excessive rotational movements. This mechanism will be discussed in greater detail when the anuli themselves are described.

Posterior longitudinal ligament

The posterior longitudinal ligament (PLL), which originates from the inside of the anterior border of the foramen magnum, is also divided into two layers (Figs 3.1-3.4). The superficial layer is usually lost at the fourth lumbar vertebra, and is finally continued as a narrow bundle to reach the anterior wall of the sacral canal. The superficial layer is a strong wide band, whereas the deep layer is arranged segmentally. Near the intervertebral discs the two layers become virtually united to join the outer zone of each anulus fibrosus. The PLL stretches over the somewhat concave posterior surfaces of the vertebrae, thereby enclosing a shallow space, which contains the basivertebral veins and the plexus that they supply (Fig. 3.5).

Between the atlanto-occipital and atlanto-axial joints, the superficial layer of the PLL is represented by the membrana tectoria and the deep layer becomes integrated with the cruciate ligament of the atlas. In the remaining part of the thoracic column, the superficial layer reaches a width of about 2 cm where it blends with the deep layer opposite the discs and sends fibres into the anulus fibrosus. In the thoracic and upper lumbar regions, the two layers are more clearly distinguishable. The fibres of the deep layer are as much to be regarded as coming from above as passing downward and forward at each segment into the postero-lateral perimeter of the anulus fibrosus. The descending fibres also reach the marginal rings and blend with the periosteum of the pedicles (Fig. 3.4).

On account of its structure, the PLL is certainly to be regarded as the segmental derivative of single bands. Because it binds the anulus fibrosus firmly together and stretches over the posterior surfaces of the vertebral bodies, this ligament represents a kind of stay for the individual vertebra, preventing extreme ventral flexion (Pasold, 1994). The oblique course of the deep fibres also ensures that they can, especially during dynamic loading, slowly take up the stresses and strains. As with the deep layer of the ALL, the deep part of this ligament also extends the functions of the anulus fibrosus within the ligamentous system.

A shallow pocket, occupied only by loose connective tissue and a venous plexus, develops behind the extension of the lateral fibres of the PLL into the anulus fibrosus. At the edge of the band, medial protrusions of the disc can be carried laterally into

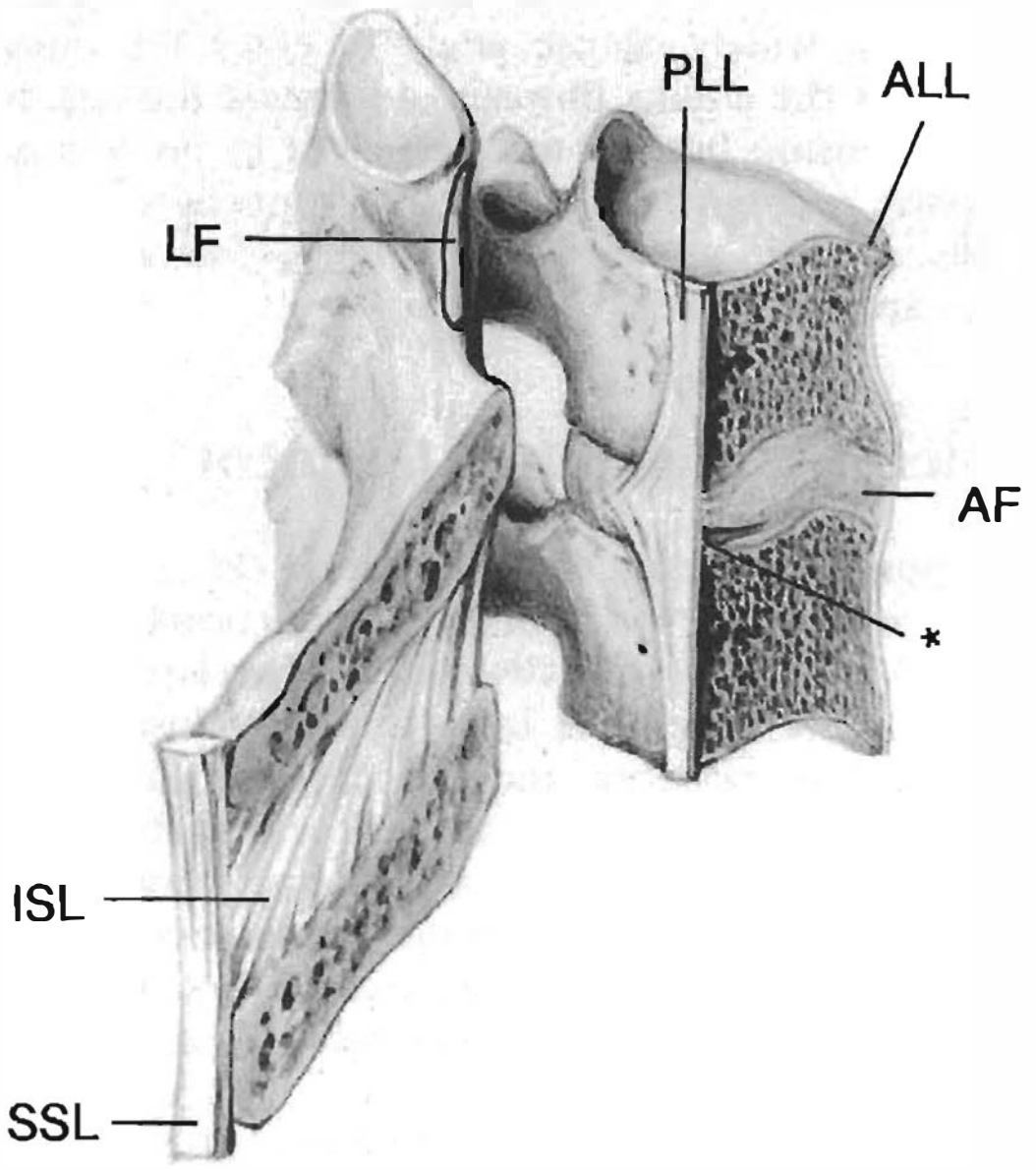

Fig. 3.1 Cervical intervertebral segment. Abbreviations: ALL, anterior longitudinal ligament; AF, anulus fibrosus; ISL, interspinous ligament; LF, ligamentum flavum (attachment zone); PLL, posterior longitudinal ligament; SSL, supraspinous ligament; *, cleft in the dorsal part of the anulus fibrosus (see text).

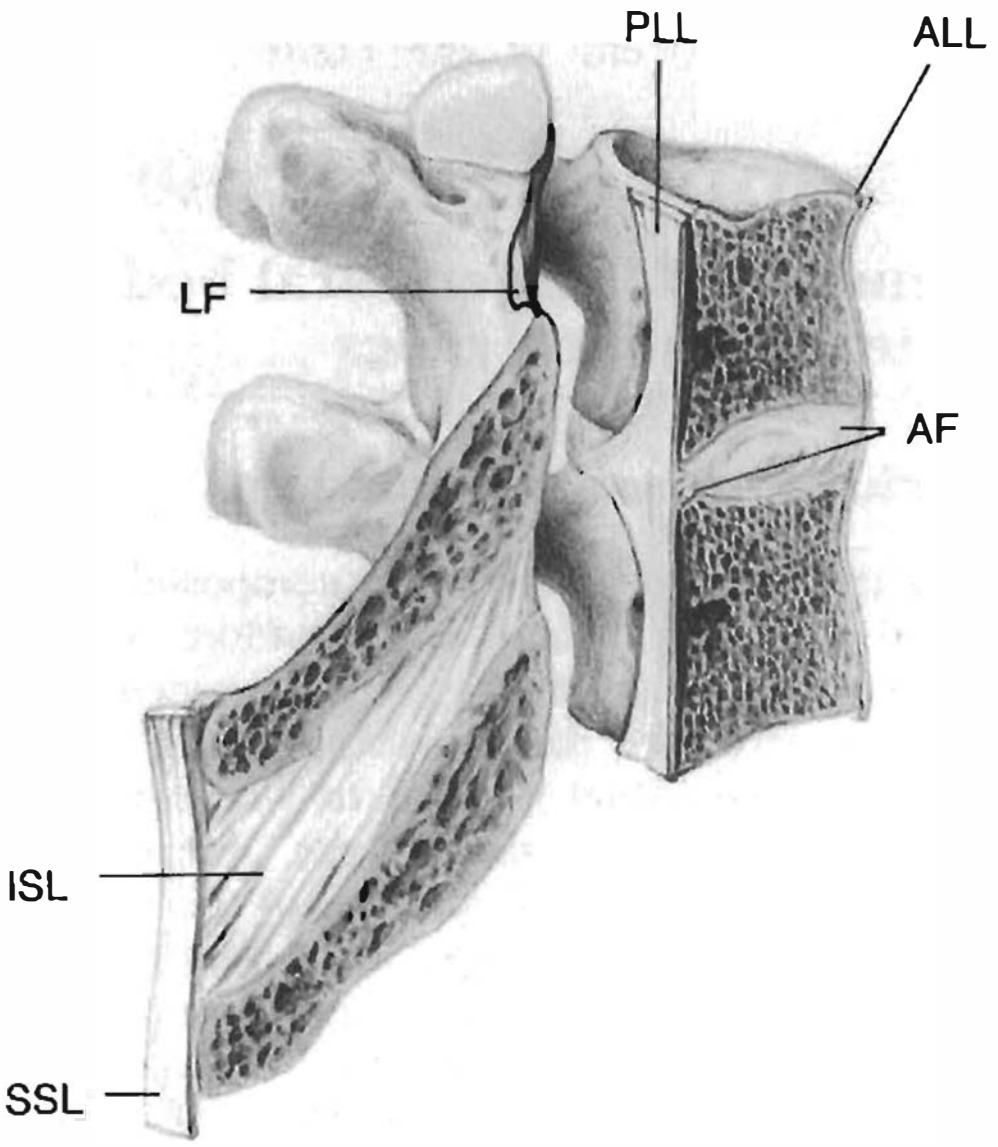

Fig. 3.2 Thoracic intervertebral segment. Abbreviations: ALL, anterior longitudinal ligament; AF, anulus fibrosus; ISL, interspinous ligament; LF, ligamentum flavum (attachment zone); PLL, posterior longitudinal ligament; SSL, supraspinous ligament.

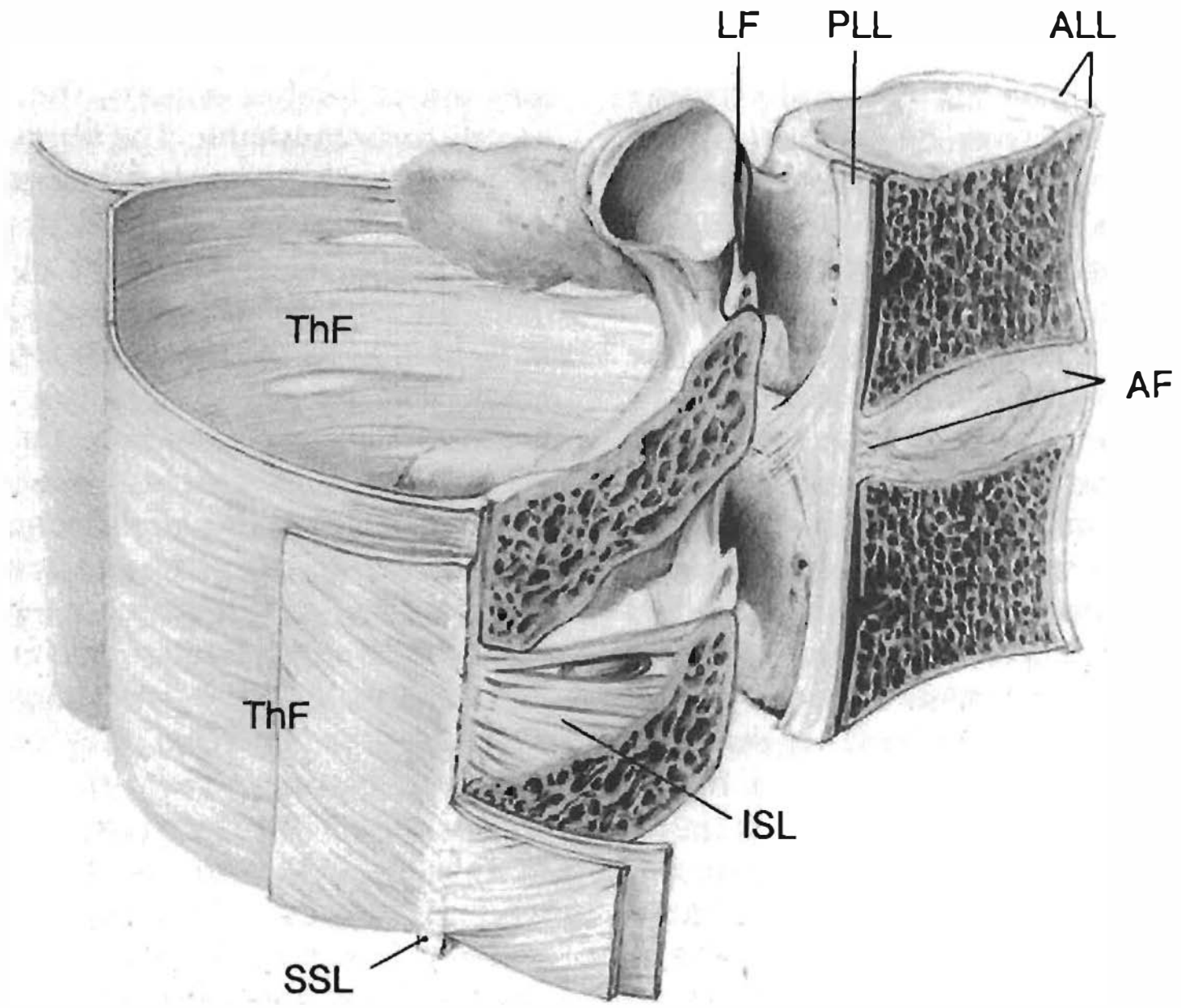

Fig. 3.3 Lumbar intervertebral segment. Abbreviations: ALL, anterior longitudinal ligament; AF, anulus fibrosus; ISL, interspinous ligament; LF, ligamentum flavum (attachment zone); PLL, posterior longitudinal ligament; SSL, supraspinous ligament; ThF, thoracolumbar fascia.

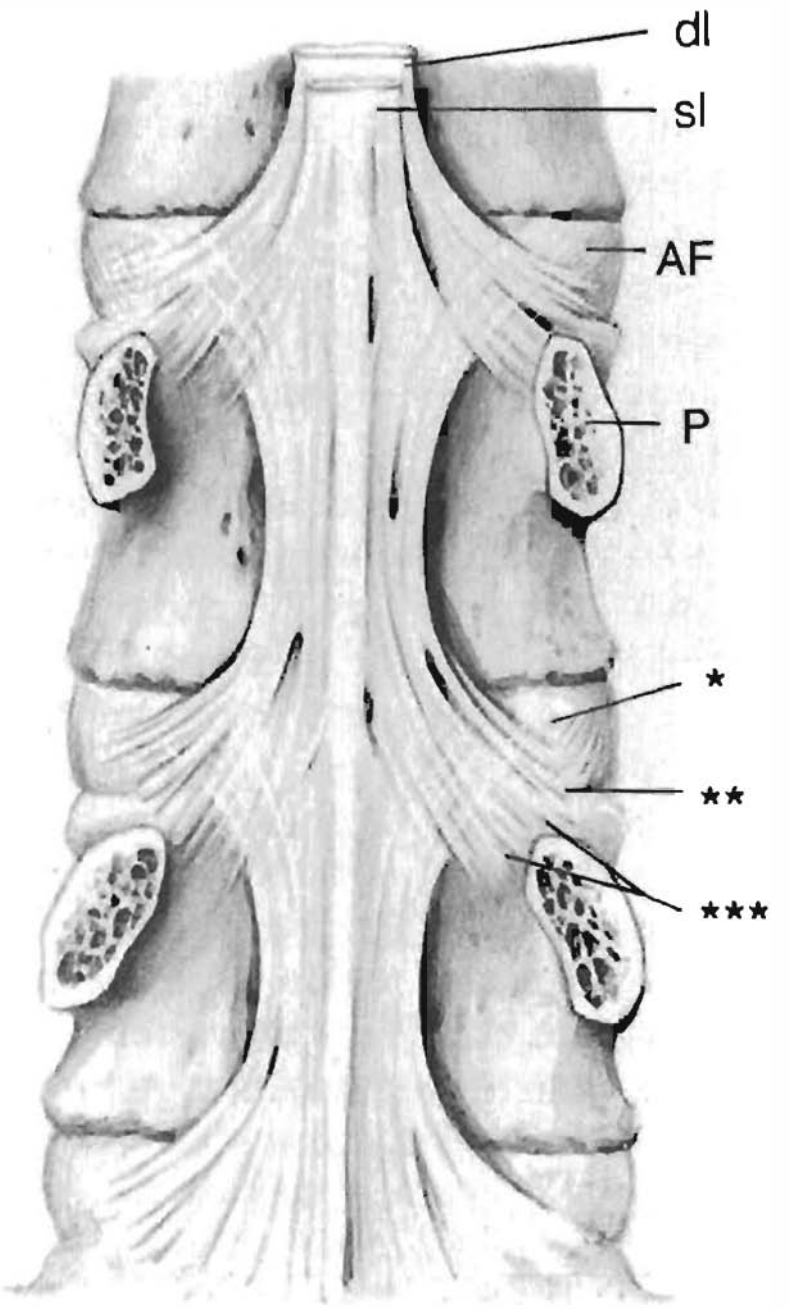

Fig. 3.4 Posterior longitudinal ligament. Abbreviations: AF, anulus fibrosus; dl, deep layer; P, pedicle (transected); sl, superficial layer; *, attachment to the anulus fibrosus; **, attachment to the marginal ring of the vertebral body; ***, attachment to the periosteum of the pedicle.

these. The outer edge of the deep layer of the PLL is continued as a thin membrane (Hofmann's ligament) which reaches the anterior borders of the segmental intervertebral foramina. This membrane, together with the PLL itself, forms a limit to the lateral extension of the anterior part of the internal vertebral venous plexus but is not connected to the dura mater (Wiltse *et al.*, 1993). A close fixation of the spinal dura mater to the PLL exists around the circumference of the foramen magnum, but there is a looser connection between these two structures in the cervical vertebral canal, which may possibly have a mechanical relevance in limiting flexion in the cervical spine (Lüdinghausen, 1967).

Below the fourth lumbar vertebra the superficial layer of the PLL is reduced to a narrow bundle, which crosses the border between the first and second sacral segments and disappears into the anterior wall of the sacral canal.

Unlike the ALL, the PLL contains elastic as well as collagen fibres (Nakagawa *et al.*, 1994) and Myklebust *et al.* (1988) have shown that the strength of this ligament in different regions of the vertebral column is not as great as that of the ALL.

Anulus fibrosus

The anulus fibrosus (Figs 3.1-3.3) is in general understood to be an integral component of the

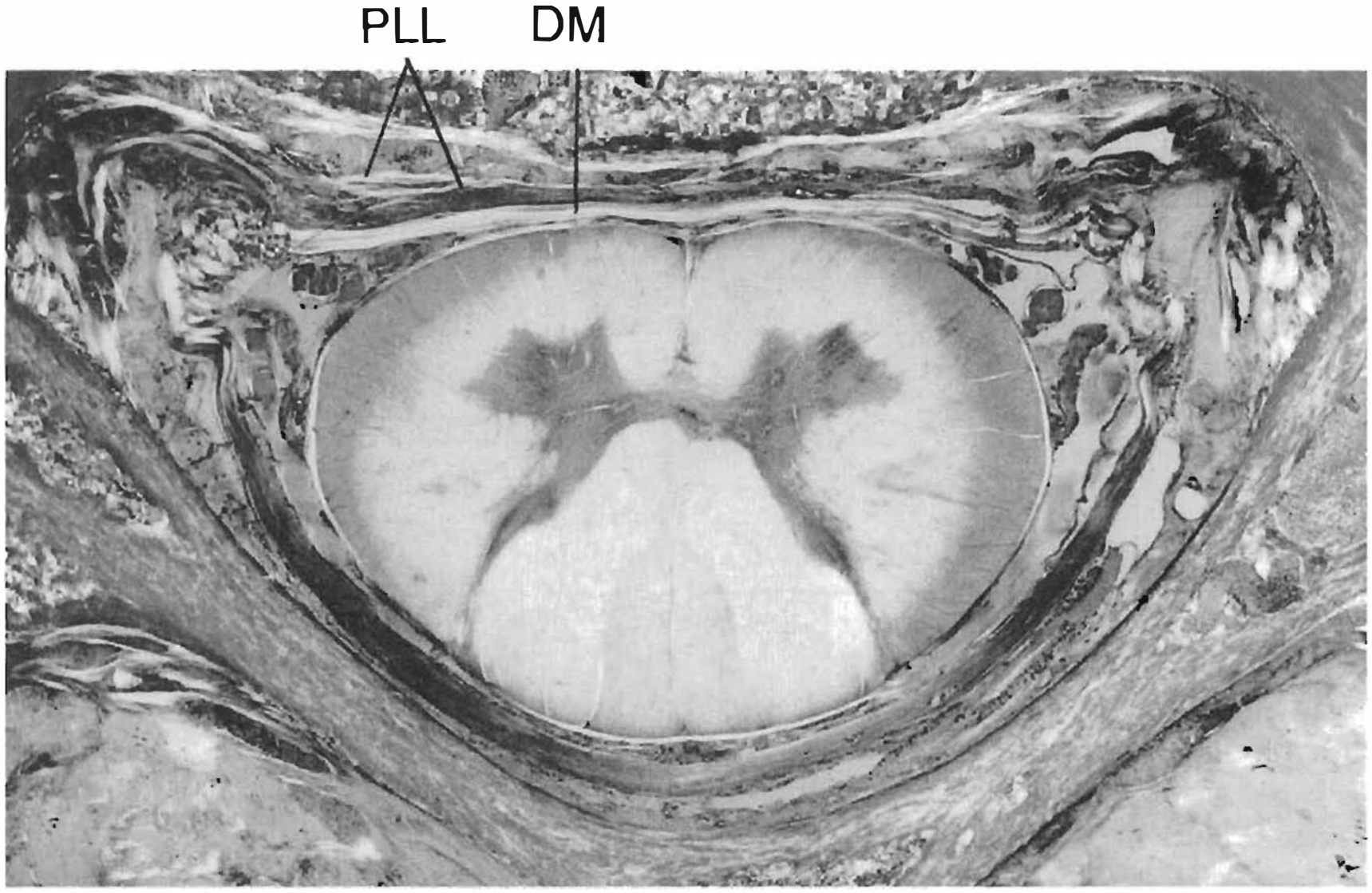

Fig. 3.5 Surrounding structures of the cervical vertebral canal, transverse section, polarized microscopy. Abbreviations: DM, dura mater; PLL, posterior longitudinal ligament.

intervertebral disc and, as such, to contribute to the function of the disc as a pressure cushion. This must be especially related to dynamic pressure, since pressure on the nucleus pulposus can only be taken up by an effective fibrous ring. It also follows that, because of the characteristic arrangement of its fibres, the anulus fibrosus (AF) plays an important part in controlling the kinematics within the individual intervertebral segments.

In the cervical region, the AF has a special part to play. It is during the first 10 years of life that lateral tears appear, leading outwards from the so-called uncovertebral clefts (Töndury and Theiler, 1990). They progress forward through the dorsal circumference of the disc towards the middle, and eventually become complete diagonal fissures.

In the thoracic and lumbar columns the fibres of the AF are packed together in 11-13 parallel lamellae, which cross one another at angles varying between 12° and 90°. Occasional chondrocytes lie scattered among the fibre bundles.

It follows from this distribution of the material that the main function of the AF is to take up tensile stresses within the disc. It is, however, striking that its thickness and division into layers varies greatly in different parts of the vertebral column.

In the thoracic region, the AF exists as essentially circular rings of equal thickness at all parts of their circumference. This changes abruptly with the orientation of the zygapophysial joints between the twelfth thoracic and the first lumbar vertebrae. From then onwards the discs are significantly thicker anteriorly than posteriorly. This does not simply refer to the absolute measurements, but is also reflected in the number of fibrous lamellae (Lorenz, 1995).

These changes in the segmental morphology of the discs indicate a direct relationship with segmental activity, and must be regarded as a functional adaptation. According to the theory expounded by Pauwel (1965) of causal histogenesis, it must follow from the regional variations in the structure of the zygapophysial joints that limitations in rotational movements at the lumbar column lead to relatively increased stress on the anterior part of the AF (Kubein-Meesenburg *et al.*, 1990; Nägerl *et al.*, 1992; Putz, 1993).

Ligaments of the vertebral arch

The ligamentum flavum

The ligamentum flavum (LF) is the strongest elastic ligament in the human body. It consists of elastin and elaunin fibres embedded in a covering of collagen fibres (Yahia *et al.*, 1990), and its proteoglycan content increases with age (Okada *et al.*, 1993). It connects the upper and lower edges of the vertebral arches of adjacent vertebrae, where its attachments are mostly delineated by sharp bony ridges (Figs 3.6 and 3.7). Although the LF contains a special regulatory system for controlling interstitial calcification (Maruta *et al.*, 1993), its areas of origin in the thoracic and thoracolumbar transitional regions are heavily calcified (Hijioka *et al.*, 1994) and show extensive ossification even in young people (Figs 3.6 and 3.7) (Herzog, 1949; Putz, 1981). Should these bony spurs, particularly in the thoracolumbar region, extend laterally into the intervertebral foramina, neurological problems may arise (see Figs 5.5 and 5.6).

In the cervical region the LF is relatively thin, and both its thickness and lateral extension increase as the column descends. In the lumbar region it even covers the capsule of the zygapophysial joint and forms the posterior wall of the lateral recess and the intervertebral foramina (Figs 3.6 and 3.7).

In the lower lumbar region of the column, and particularly at the fifth lumbar vertebra, the bony origin of the LF can bulge into the vertebral canal and produce a spinal stenosis. In most cases the distance between neighbouring vertebral arches is reduced, either with or without actual hypertrophy of the LF.

There are conflicting reports on the tensile strength of the LF. Chazal *et al.* (1985) attributed great tensile strength to this ligament, but Myklebust *et al.* (1988) reported relatively variable findings. In any case, depending upon its origin, the LF possesses significant tension, which can make the wound edges close quickly during surgical operations.

Rather surprisingly, Ashton *et al.* (1992) found that the LF does not contain a substantial number of sensory or autonomic nerve fibres. This supports the hypothesis that these ligaments act only as a passive

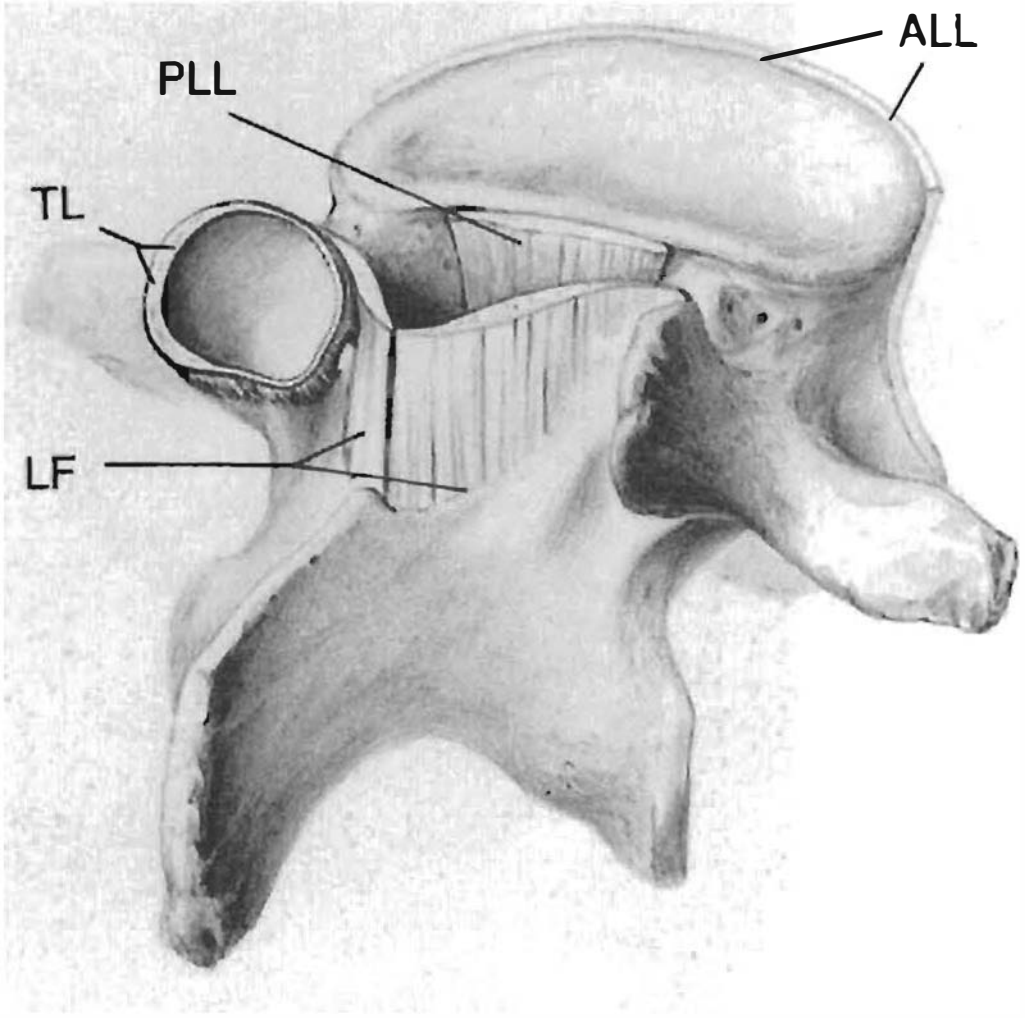

Fig. 3.6 Ligamentum flavum (LF) and the so-called 'transverse ligaments' (TL).

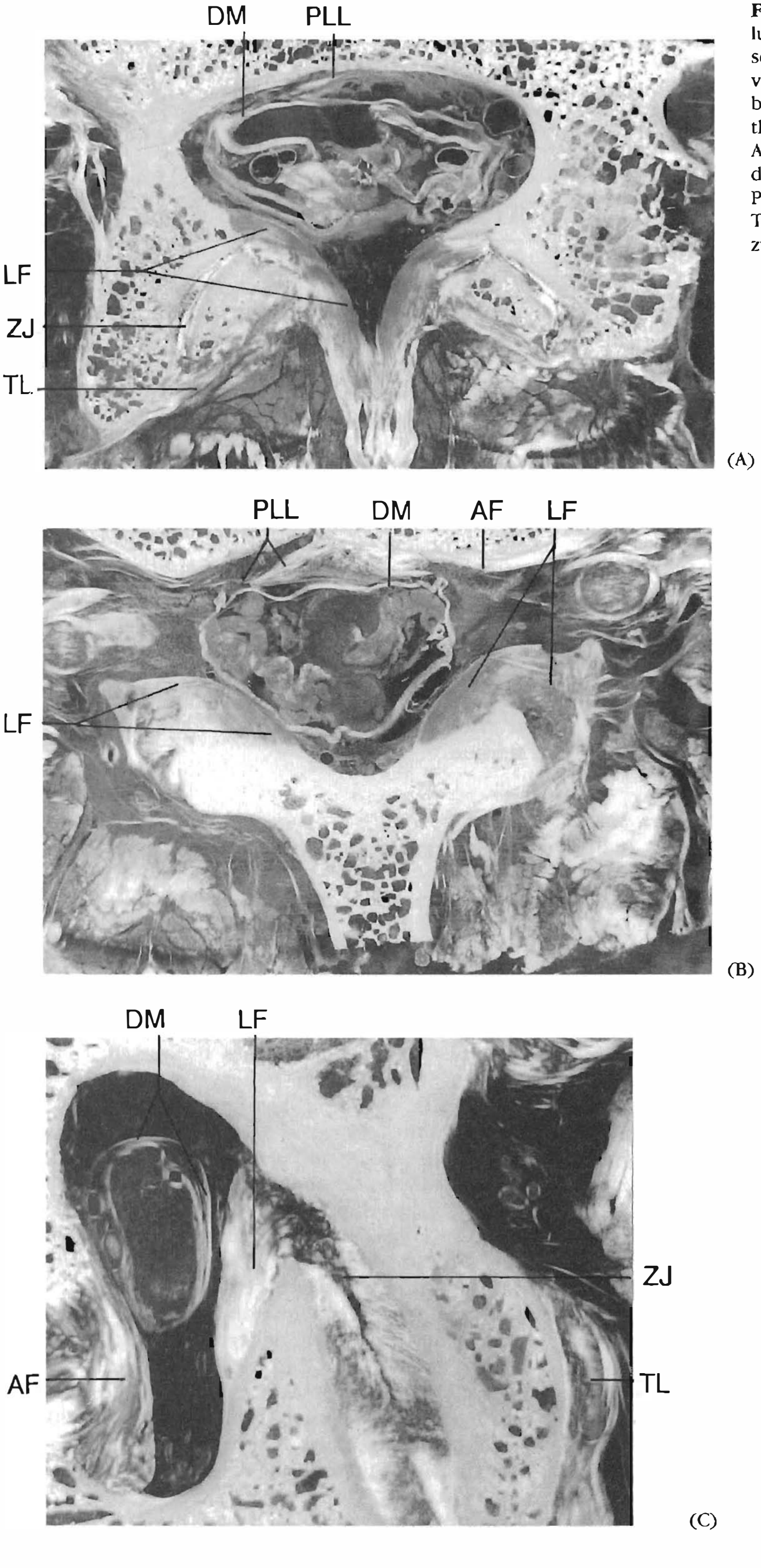

Fig. 3.7 Surrounding structures of the lumbar vertebral canal. (A) Transverse section through the pedicles. (B) Transverse section through the intervertebral foramina. (C) Sagittal section through the intervertebral foramen. Abbreviations: AF, anulus fibrosus; DM, dura mater; LF, ligamentum flavum; PLL, posterior longitudinal ligament; TL, so-called 'transverse ligament'; ZJ, zygapophysial joint.

elastic tension system, especially during extreme ventral flexion of the vertebral column.

Interspinous ligament

The interspinous ligament (ISL) shows interesting regional differences (Figs 3.1-3.3). In the cervical region its fibre bundles are arranged like slates on a roof and are fairly thin. Its strength increases in the thoracic region, but the arrangement remains the same. From the first lumbar interspinal space it radically alters its direction, passing from the lower edge of each cranial vertebra downwards and ventrally to reach the anterior region of the upper edge and lower circumference of the zygapophysial joint (Heylings, 1978; Prestar, 1982; Prestar *et al.*, 1983). In the lumbar column in particular, the ISL consists of massive (inextensible) collagen fibres, as has been confirmed by the work of Aspden *et al.* (1987).

The consequent oblique course of the ISL, relative to the long axis of the vertebral column, suggests that these ligaments are an integral part of the ligamentous gear system. They can be brought under tension in both dorsal and ventral flexion, and thus control the entire range of movement.

The supraspinous ligament and thoracolumbar fascia

Although described in most textbooks as a single band, the supraspinous ligament (SSL) is, in the authors' opinion, only one of the intermediate bands of the thoracolumbar fascia (ThF) which binds the spinous processes together (Figs 3.1-3.3). This fascia, which because of its dense fibrous structure could better be described as the thoracolumbar aponeurosis, consists of two closely interwoven layers, the fibres of which cross each other rather like the struts of an elevator gate. This allows the required excursion of the spinous processes during ventral flexion.

On the other hand, it can be shown that the ThF is closely bound up with the ISL in the intersegmental regions, and the latter can be regarded as its ventral extension. The superficial layer of the ThF (the true aponeurosis) and the deep layer of the fascia that extends from the costal processes are built up together with the vertebral arches to form an osteofibrous tube for the deep muscles of the back. This reaches cranially as far as the middle of the thoracic region. The relative increase in volume of these muscles during contraction produces tension in both parts of the fascia, and therefore leads to an increase in pressure within the osteofibrous tube. This brings about a firm rigidity, which contributes to adequate segmental control of the movements of the lumbar vertebrae upon one another (Putz, 1989, 1992, 1993). Caudal to the level of the fourth lumbar vertebra, tension in the superficial layer is transmitted to the contralateral side (Vleeming *et al.*, 1995). Both the SSL and the ThF consist of strong collagenous fibres, which accounts for the great strength of these ligaments (Myklebust *et al.*, 1988).

Transverse ligaments

This unfamiliar term is used to describe the tough transverse strengthening fibres of the capsule of the zygapophysial joints of the lumbar column (Putz, 1985, 1992, 1993). In contrast to other regions of the vertebral column, thick bundles of collagen fibres which are laid down against the fibrous membranes of the joint capsules and embrace the borders of the inferior articular processes are found here (Figs 3.3, 3.6 and 3.10C). A functional interpretation is indicated here; namely, that these ligaments also contribute to the lumbar motion segment (Putz, 1985, 1992, 1993). In the course of parallel displacement of the articular processes with ventral or lateral flexion, the separation of their points of attachment produces increasing tension, and the transverse ligaments act as shock-absorbers to these movements. In a similar fashion they play a part in limiting rotation, and restrict the separation of the joint surfaces under tension.

Ligamentous attachments to the pelvis

The iliolumbar ligaments

The iliolumbar ligaments (ILL) connect the costal processes of the fifth lumbar vertebra with the posterior superior iliac spines and the adjacent part of the iliac crest on either side (Fig. 3.8). The ontogenetic development of these ligaments is interesting. In the foetus and neonate they consist mostly of smooth muscle and are orientated together with the quadratus lumborum (Boebel, 1962). With advancing age they become increasingly replaced by collagen fibres, but remain attached to the fascia of the quadratus lumborum.

Many different opinions exist with regard to their function. The authors' investigations have shown that they come particularly under tension during ventral flexion and rotation (Paul, 1989), a finding supported by Yamamoto *et al.* (1990), and are much less strained during lateral flexion. The investigations did not confirm the opinion often put forward in the literature, that these ligaments exert a static function by transmitting the weight of the trunk from the fifth lumbar vertebra to the pelvis.

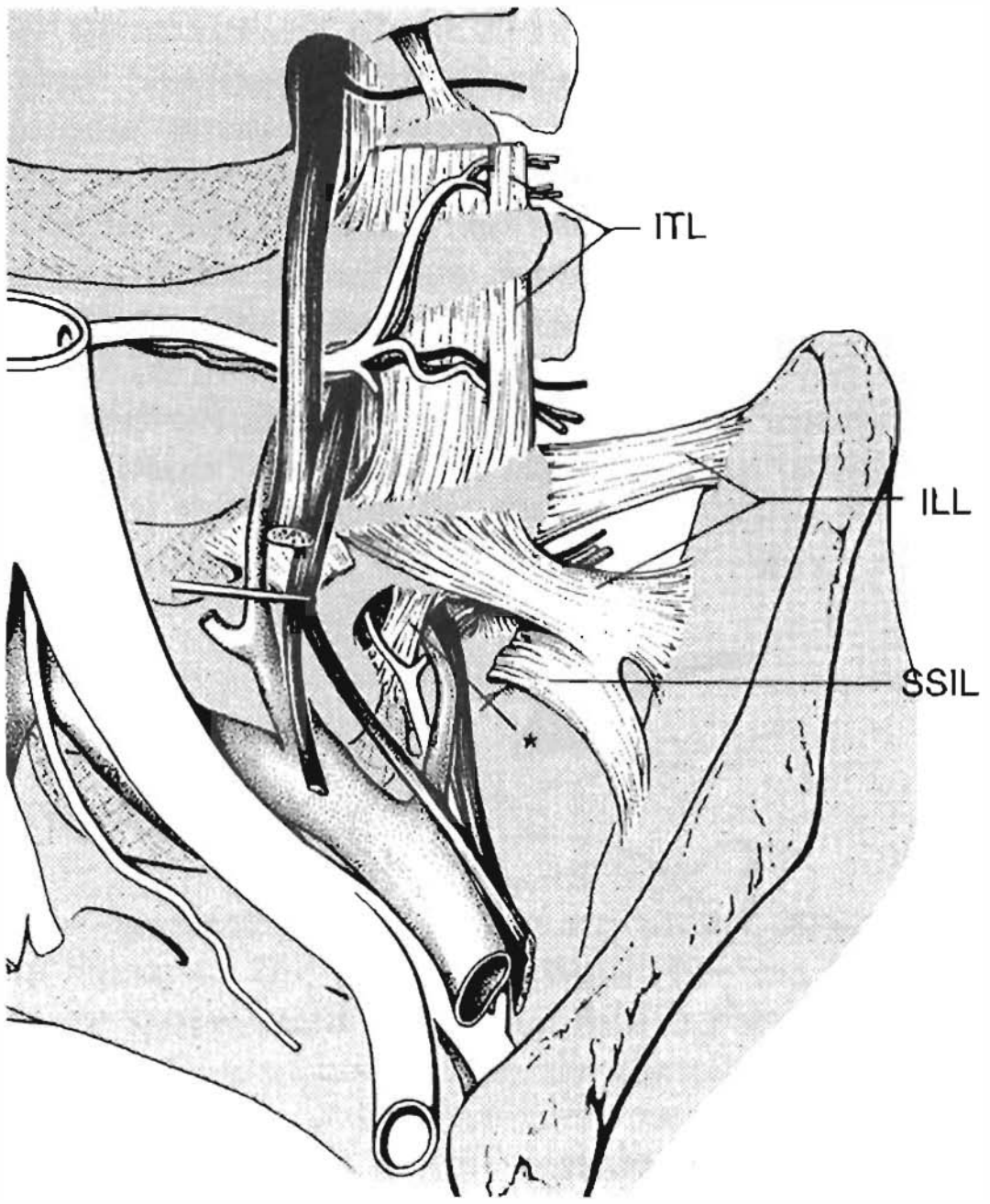

Fig. 3.8 Ligaments of the lumbosacral region. Abbreviations: ILL, iliolumbar ligament; ITL, intertransverse ligament; SSIL, superior sacroiliac ligament; *, connective tissue in the intervertebral foramen

Sacrospinous and sacrotuberous ligaments

Although it is impossible to go into detail here, it should be clearly stated that the extremely firm attachment of the sacrum to both lateral borders of the coccyx is a very important factor in ensuring the firm connection of the caudal end of the vertebral column to the pelvis. It guarantees the position of the sacrum, particularly under dynamic conditions, and influences the whole mechanism of the vertebral column.

Costovertebral attachments

The particular structure of the intervertebral discs and the arrangement of the zygapophysial joints in the thoracic region can only be understood on examining the integral attachment of the ribs to the thoracic column more closely (Fig. 3.9). Every costal head from the second to the tenth rib is attached to the segmental disc and the adjacent vertebral bodies by the radiate ligament and the intra-articular ligament of the head of the rib. The radiate ligament of the head of the rib forms a true fan-like sheath around the head, which may be regarded as an anatomical adaptation to the rotary turning movements of these structures. The space between the (so-called intraf

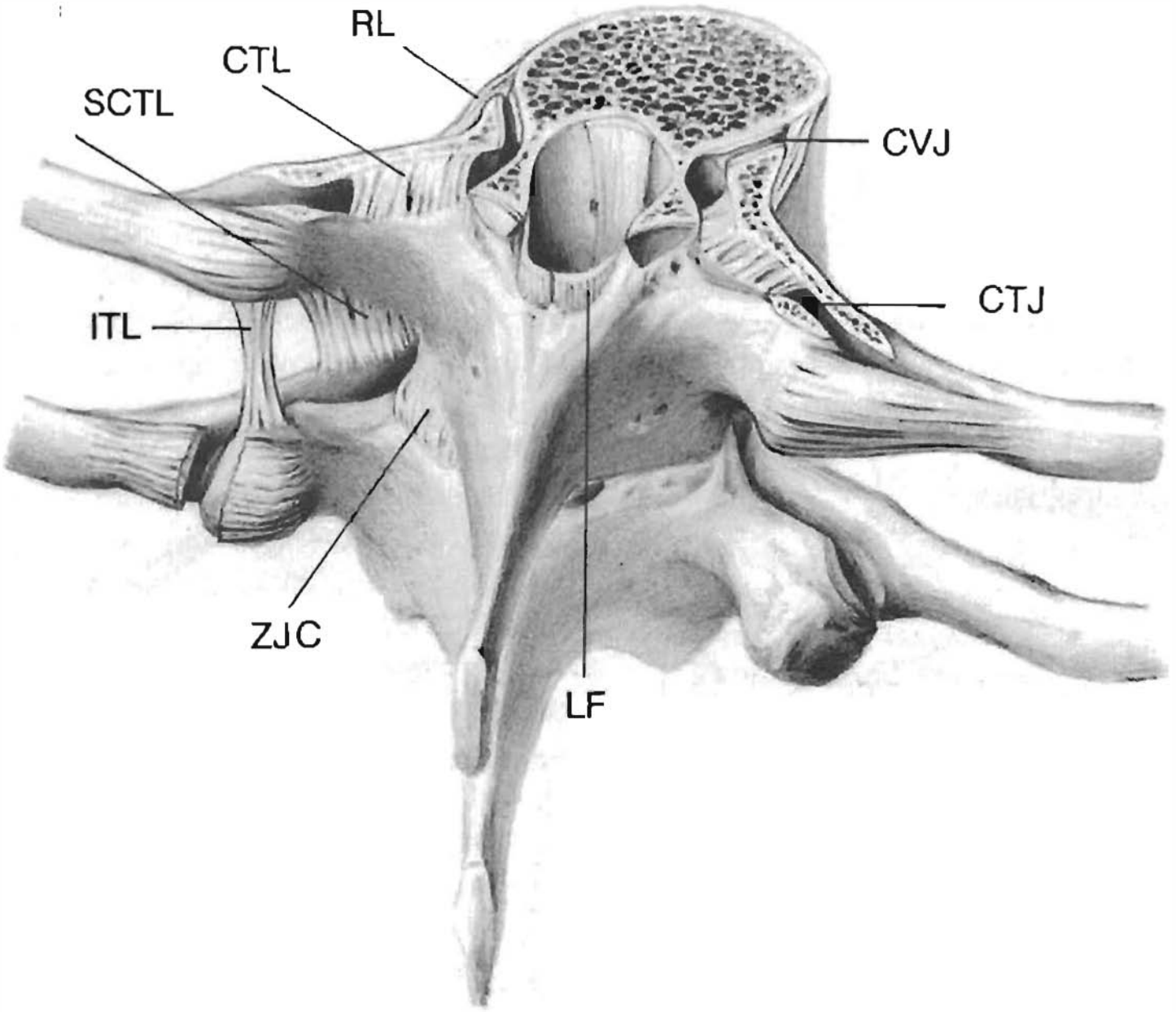

Fig. 3.9 Ligamentous attachment of the ribs to the vertebral column. Abbreviations: CVJ, costovertebral joint; CTJ, costotransverse joint; CTL, costotransverse ligament; ITL, intertransverse ligament; ZJC, joint capsule; LF, ligamentum flavum; RL, radial (or radiate) ligament; SCTL, superior costotransverse ligament.

neck of the rib and the transverse process of the same segmental vertebra contains the costotransverse ligament, the fibres of which run in a markedly sagittal direction. The superior costotransverse ligament runs from the upper edge of the neck of the rib to the lower edge of the immediately cranial transverse process.

It follows from the arrangement of the costotransverse bands and the relationship of their long lever arms to the rotation centre in the transverse plane that a very high moment is built up in these ligaments. This is sufficient slowly and efficiently to limit rotational displacement in the thoracic column so that there is no great stress on the outer zone of the zygapophysial joint, which could result in displacement of the rotation centroid. The authors regard this as a definitive mechanism for ensuring that the form and arrangement of the thoracic zygapophysial joints, which is laid down in foetal life and differs from their relationship in the cervical and lumbar regions, shall be preserved throughout life.

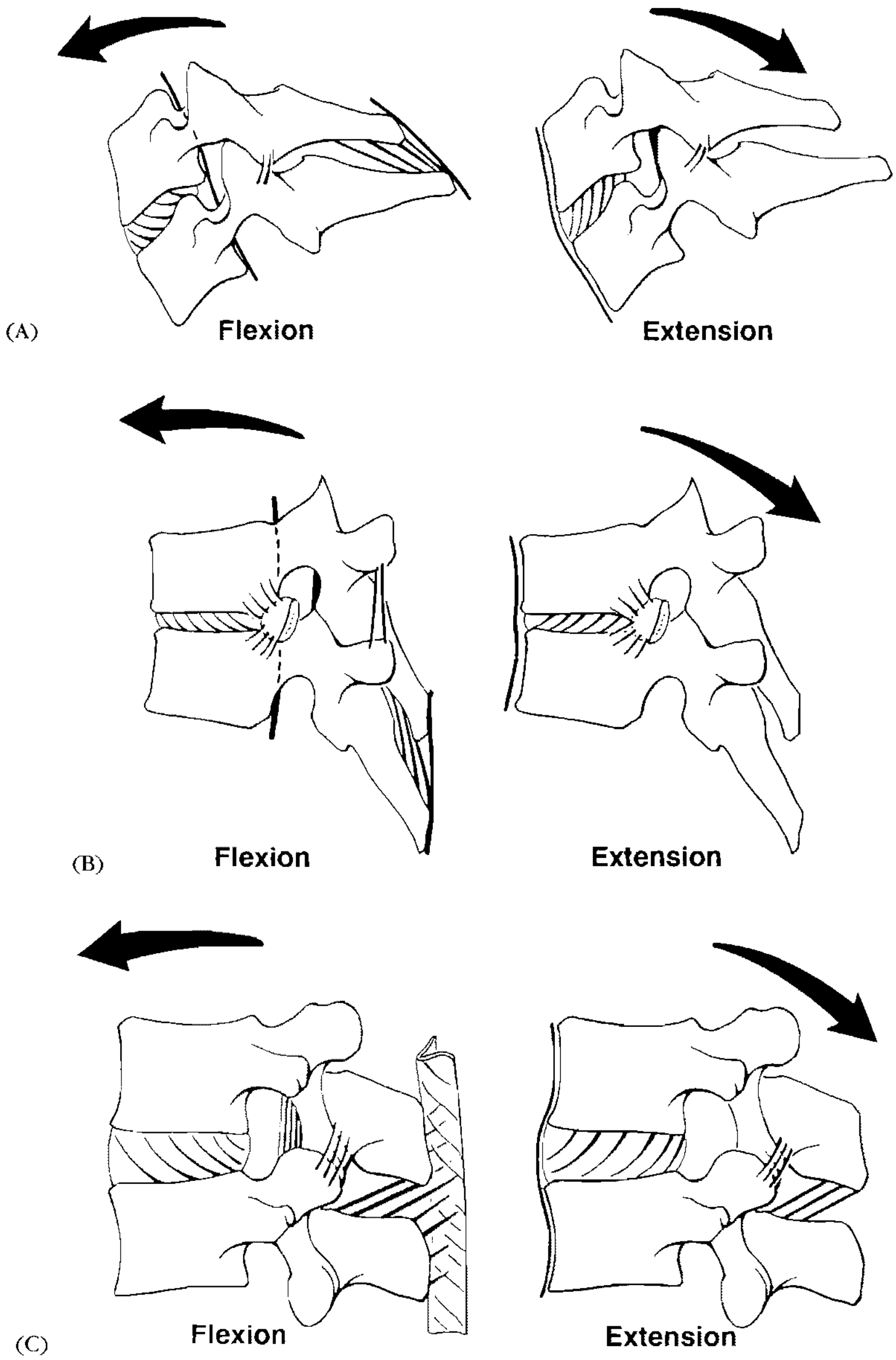

Fig. 3.10 Kinematics of the intervertebral segments in different vertebral regions. In each case, only those ligaments that play a part in the limitation of movement are shown. (A) Cervical spine. (B) Thoracic spine. (C) Lumbar spine.

The interaction of the ligaments in the regional motion segments

Cervical column

In general, the ligaments in the cervical region are all rather weak and show little structural differentiation (Figs 3.1 and 3.10A). This is undoubtedly connected with the fact that the kinematic management of the cervical column is sufficiently initiated and controlled by the massive musculature of the neck.

Thoracic column

The ligaments of this region are similar in structure to those of the cervical column but are certainly more stoutly built (Figs 3.2 and 3.10B). They are principally concerned with the limitation of ventral flexion, whereas the management of the rotation and lateral flexion in this region depends on interaction with the costovertebral attachments. To a certain degree these exert a protective effect, so that only limited structural adaptation of the ligamentous apparatus of the thoracic motion segments is necessary.

Lumbar column

The relationships in the lumbar motion segments are entirely different (Figs 3.3 and 3.10C). Here, the forces have to act on the vertebral column directly, and they can work only through short lever arms. As mentioned above, this leads, by means of causal histogenesis, to an adaptive reorganization of the lateral parts of the lumbar zygapophysial joints in the sagittal plane. In this way these joints are able to interact with the anulus fibrosus to limit rotation, and at the same time to take up ventrally directed shearing forces (Putz, 1981, 1985, 1993; Müller-Gerbl, 1992). With the exception of the ALL and the LF, the obliquely directed ligaments work together during ventral and dorsal flexion like a gear system (Putz, 1989, 1992, 1993; Kubein-Meesenburg *et al.*, 1990; Nägerl *et al.*, 1992), guaranteeing a close connection of the adjacent vertebrae during the whole range of movement as well as an equal load distribution over the vertebral end-plates and the zygapophysial joints. However, it should be noted that the predisposition for the functional efficiency is founded in the pre-tension based on the internal pressure of the vertebral disc, and on the prevention of shear stresses by the zygapophysial joints.

Summary

The functional role of all parts of the ligamentous apparatus of the vertebral column, including the anulus fibrosus, is clearly in providing guiding structures for the precise control of motion in each single intervertebral segment. The comparison of the different regions leads to the conclusion that morphology and arrangement of the ligaments should be interpreted as the result of an effective adaptation process during evolution (Putz and Müller-Gerbl, 1996).

Acknowledgement

The authors would like to express their thanks to Erika Mayr, Sybille Friedl and Dr Nikolai Sokolow for technical assistance, to Horst Russ for preparing the illustrations and to Dr Francis Steel for translating the manuscript.

References

Ashton, I.K., Ashton, B.A., Gibson, S.J. *et al.* (1992) Morphological basis for back pain: the demonstration of nerve fibres and neuropeptides in the lumbar zygapophysial joint capsules but not in ligamentum flavum. *J. Orthop. Res.* **10:** 72–78.

Aspden, R.M., Bornstein, N.H., Hukins, D.W.L. (1987) Collagen organisation in the interspinous ligament and its relationship to tissue function. *J. Anat.* **155:** 141–151.

Behrsin, J.F., Briggs, C.A. (1988) Ligaments of the lumbar spine: a review. *Surg. Radiol. Anat.* **10:** 211–219.

Boebel, R. (1962) Anatomische Untersuchungen am Lig. iliolumbale. *Z. Orthop.* **95:** 131–139.

Bogduk, N. (1983) The innervation of the spine. *Spine* **8:** 286–293.

Bogduk, N., Twomey, L.T. (1987) *Clinical Anatomy of the Lumbar Spine*. Melbourne: Churchill Livingstone

Chazal, J., Tanguy, A., Bourges, M. *et al.* (1985) Biomechanical properties of spinal ligaments and a histological study of the supraspinal ligament in traction. *J. Biomech.* **18:** 167–176.

Groen, G.J., Baljet, B., Drukker, J. (1990) Nerves and nerve plexuses of the human vertebral column. *Am. J. Anat.* **188:** 282–296.

Hayashi, K., Takeshi, Y., Takahide, K. *et al.* (1977) The anterior and the posterior longitudinal ligaments of the lower cervical spine. *J. Anat.* **124:** 633–636.

Herzog, W. (1949) Zur Morphologie und Pathologie des Ligamentum flavum. *Frankf. Z. Pathol.* **61:** 250–267.

Heylings, D.J.A. (1978) Supraspinous and interspinous ligaments of the human lumbar spine. *J. Anat.* **125:** 127–131.

Hijioka, A., Suzuki, K., Nakamura, T. *et al.* (1994) Light and electron microscopy of hydroxyapatite depositions in the ligamentum flavum. *Spine* **19**: 2626–2631.

Jiang, H., Russell, G., Raso, J. *et al.* (1995) The nature and distribution of the innervation of human supraspinal and interspinal ligaments. *Spine* **20:** 869–876.

Junghanns, H. (1977) *Nomenclatura Columnae Vertebralis. Die Wirbelsäule in Forschung und Praxis. Bd. 75.* Stuttgart: Hippokrates.

Kubein-Meesenburg, D., Nägerl, H., Klamt, B. *et al.* (1990) Elements of a general theory of joints. 4. Coupled joints as simple gear systems. *Ann. Anat.* **172:** 309-321.

Lang, J. (1984) Morphologie und funktionelle Anatomie der Lendenwirbelsäule und des benachbarten Nervensystems. In: *Neuroorthopädie*, Bd 2 (Hohmann, D., Kügelgen, B., Liebig, K., Schirmer M., eds). Berlin: Springer.

Loeweneck, H. (1966) *Über die sensible Innervation der Articulationes Intervertebrales.* Thesis, Munich University.

Lorenz, Th. K. (1995) *Kollagene Faserarchitektur der Anheftungszone der Disci intervertebrales in der unteren Lendenwirbelsäule.* Thesis, Munich University.

Lüdinghausen, M.v. (1967) Die Bänder und das Fettgewebe des menschlichen Epiduralraumes. *Anat. Anz.*, **121:** 294-312.

Maruta, K., Ichimura, K., Matsui, H. *et al.* (1993) Calcification inhibitors in human ligamentum flavum. *J. Orthop. Res.* **11:** 92-103.

Müller-Gerbl, M. (1992) Die Rolle der Wirbelgelenke für die Kinematik der Bewegungssegmente. *Ann. Anat.* **174:** 48-53.

Myklebust, J.B., Pintar, F., Yoganandan, N. *et al.* (1988) Tensile strength of spinal ligaments. *Spine,* **13**: 526-531.

Nägerl, H., Kubein-Meesenburg, D., Fanghänel, J. (1992) Elements of a general theory of joints. 7. Mechanical structures of relative motion of adjacent vertebrae. *Ann. Anat.* **174:** 66-75.

Nakagawa, H., Mikawa, Y., Watanabe, R. (1994) Elastin in the human posterior longitudinal ligament and spinal dura mater. *Spine* **19:** 2164-2169.

Neumann, P., Keller, T., Ekström, L. *et al.* (1994) Structural properties of the anterior longitudinal ligament. *Spine* **18:** 637-645.

Okada, A., Harata, S., Takeda, Y. *et al.* (1993) Age-related changes in proteoglycans of human ligamentum flavum. *Spine* **18:** 2261-2266.

Panjabi, M.M., Goel, V.K., Takata, K. (1982) Physiologic strains in the lumbar spinal ligaments. *Spine* **7:** 192-203.

Pasold, R. (1994) *Zur Wertigkeit des Ligamentum Longitudinale Posterius unter dem Blickwinkel der Traumatologie der Wirbelsäule.* Thesis, Munich University.

Paul, H.-J. (1989) *Experimentelle Untersuchunmg zur Funktion des Lig. Iliolumbale.* Thesis, Freiburg University.

Prestar, F.J. (1982) Morphologie und Funktion der Ligamenta interspinalia und des Ligamentum supraspinale der Lendenwirbelsäule. *Morphol. Med.* **2:** 53-58.

Prestar, F.J., Frick, H., Putz, R. (1983) Bandverbindungen der Dornfortsätze der Wirbelsäule. *Anat. Anz.* **159:** 259-268.

Putz, R. (1981) *Funktionelle Anatomie der Wirbelgelenke. Normale und Pathologische Anatomie*, Bd 43. Stuttgart: Thieme.

Putz, R. (1985) The functional morphology of the superior articular processes of the lumbar vertebrae. *J. Anat.* **143:** 181-187.

Putz, R. (1989) Functional morphology of the lower lumbar spine. *J. Man. Med.* **4:** 2-6.

Putz, R. (1992) The detailed functional anatomy of the ligaments of the vertebral column. *Ann. Anat.* **174:** 40-47.

Putz, R. (1993) Functional anatomy of the lumbar spine. In: *Advances in Idiopathic Low Back Pain* (Ernst, E., Jayson, M.I.V., Pope, M.H., Porter R.W., eds). Vienna: Blackwell-MZV, pp. 2-8.

Putz, R., Müller-Gerbl, M. (1996) The vertebral column - failure or success of the evolution. *Clin. Anat.* **9:** 205-212.

Stofft, E. (1966) *Die Funktionellen Strukturen des Ligamentum Longitudinale Anterius.* Thesis, Mainz University.

Töndury, G., Theiler, K. (1990) Entwicklungsgeschichte und Fehlbildungen der Wirbelsäule. *Die Wirbelsäule in Forschung und Praxis* **98**. Stuttgart: Hippokrates.

Vleeming, A., Pool-Goudzward, A.L., Stoeckart, R. *et al.* (1995) The posterior layer of the thoracolumbar fascia. *Spine* **20:** 753-758.

Weinstein, J.N., Wiesel, S.W. (1990) *The Lumbar Spine.* Philadelphia: W.B. Saunders.

Wiltse, L.L., Fonseca, A.S., Amster, J. *et al.* (1993) Relationship of the dura, Hofmann's ligament, Batson's plexus, and a fibrovascular membrane lying on the posterior surface of the vertebral bodies and attaching to the deep layer of the posterior longitudinal ligament. *Spine* **18:** 1030-1043.

Yahia, L.-H., Garzon, S., Strykowski, H. *et al.* (1990) Ultrastructure of the human interspinous ligament and ligamentum flavum. *Spine* **15:** 262-268.

Yamamoto, I., Panjabi, M.M., Oxland, T.R. *et al.* (1990) The role of the iliolumbar ligament in the lumbosacral junction. *Spine* **15:** 1138-1141.

4

Biomechanics of the thoracic spine and ribcage

I. A. F. Stokes

Introduction: Special characteristics of the thoracic spine

This chapter surveys the biomechanics of the thoracic spine, especially the relationship between forces and movements in the spine, and the relationship between forces and injury. These principles can be used to gain a better understanding of the spine from the point of view of painful and degenerative conditions, spinal growth and the development of deformities, and the causes of injury to the spine, as well as principles used in both conservative and surgical treatment. In describing the relationship between forces and motion, and between forces and tissue damage, properties of the spine must be described in mechanical terms. The spine can be considered as a mechanical system having certain geometrical properties and certain tissue material properties. Together, these characteristics determine its structural properties. In addition, the spine functions under the control of a complex neuromuscular system, consisting of muscles, sensory feedback and various reflex and central controllers.

The thoracic spine has some unique characteristics that distinguish it from the cervical and lumbar spine regions. Morphologically, it is a region that is predominantly kyphotic. The ribs attach to the thoracic vertebrae, and the form of the zygapophysial joints is such that they lie predominantly in a coronal plane orientation. These morphological factors have implications for the biomechanical function. For instance, the range of motion for flexion is less in the thoracic region than in other regions, whereas axial rotation is greater than in the lumbar region and almost as great as in the cervical region (White and Panjabi, 1978).

Although painful degenerative conditions are more common in the cervical and lumbar regions, problems of spinal deformity (especially scoliosis and exaggerated kyphosis) are common in the thoracic region. In their study, Malmivaara *et al.* (1987) found an association between zygapophysial joint morphology and degenerative changes, and noted this especially at the thoracolumbar transitional levels. At T10-T11, there was anterior degeneration in the form of disc degeneration, vertebral body osteophytosis, and Schmorl's nodes. At T12-L1, zygapophysial and costovertebral joint degeneration was dominant (posterior joint degeneration), and at T11-T12, disc degeneration, vertebral body osteophytosis, Schmorl's nodes, and zygapophysial joint and costovertebral joint degeneration all occurred (anterior and posterior degeneration).

Osteoporotic fractures are most common in thoracic vertebrae (Singer *et al.*, 1995). Traumatic injuries occur at all levels of the spine, but the pattern of injuries differs. Compression and burst injuries from large vertical accelerations and decelerations are particularly common in the thoracolumbar and thoracic regions. Therefore, the biomechanics of the thoracic region is important in a number of clinical and surgical problems.

Growth and development of the thoracic spine and ribcage

Size and shape of vertebrae

During growth, vertebral shape changes substantially. Growth of the neural arch occurs very rapidly during embryonic development and up to the age of 2-3 years, by which time the diameter of the neural canal has reached almost adult proportions (Simril and Thurston, 1955; Tulsi, 1971), whereas the vertebral bodies continue to grow (Dickson and Deacon, 1987). Since the dimensions of the neural canal develop at such a young age, factors such as diet and health status in the perinatal period can influence spinal growth and subsequent health (Clark *et al.*, 1986; Porter and Pavitt, 1987). The space available for the relatively large spinal cord inside the spinal canal is most limited in the mid-thoracic region. The control of growth is complex, with genetic, vascular, hormonal and biomechanical factors all playing a role.

Growth of the height of the vertebral bodies occurs in the cartilaginous region below the endplates and circumferential growth results from appositional bone formation (Dickson and Deacon, 1987). Additionally, there are growth centres in the neural arch. Following a cross-sectional study of vertebral body dimensions from X-rays of children aged 10-16 years, Schultz *et al.* (1984) concluded that most of the growth during this period consisted of similar proportional increases in the length of the spine as well as in the antero-posterior and lateral dimensions of the vertebrae. However, girls developed a more slender spine than did boys (i.e. smaller vertebrae compared with spinal length).

Adult vertebral body external dimensions have been reported in detail by Panjabi *et al.* (1991), who digitized a number of landmarks on 144 thoracic vertebrae taken from 12 adult cadavers, confirming that there are three distinct morphological regions of the thoracic spine: transitional cervicothoracic and thoracolumbar regions and an intermediate zone (T3-T9), which was considered important because of the presence of the combination of narrow spinal canal and critical vascular supply. The zygapophysial joint morphology also changes in these regions (Panjabi *et al.*, 1993). The zygapophysial joint morphology was thought by Oxland *et al.* (1992) to influence the mechanical behaviour. They tested thoracolumbar vertebral pairs and found that the range of extension at T11-T12 was half that at T12-L1, whereas the range of axial rotation was about twice as much at T11-T12. In part, these differences may be due to wide variations recorded for the location of the transition and also the complex morphology of the zygapophysial joints at this junctional region (Singer, 1989; Singer *et al.*, 1989a, 1989b).

Thoracic vertebral dimensions have also been catalogued with a view to obtaining a database of 'normal' dimensions from which deviations are indicative of osteoporotic fractures (Davies *et al.*, 1989; Smith-Bindman *et al.*, 1991).

Spine shape and posture

The overall spinal shape and curvatures depend on the vertebral body and disc dimensions. Measurement of the development of the spinal curvatures is complicated by the very large variability in overall spinal shape (Beck and Killius, 1973; Stagnara *et al.*, 1982; Propst-Proctor and Bleck, 1983; Singer *et al.*, 1990), and measurement difficulties may be, in part, attributable to postural changes. However, based on measurements of the back surface profile, Willner and Johnson (1983) found that the spine generally reached minimum curvature early in the adolescent growth spurt. This finding may have consequences for the stability of growth and the development of spinal deformities. Since scoliosis deformity is usually detected by examining the symmetry of the rib cage posteriorly, it is important to know the normal bounds of symmetry. Burwell *et al.* (1983) measured 636 children and found that up to 8 mm of rib hump asymmetry was 'normal'. In those with asymmetrical back shape, a more prominent right side of the thoracic region was 10 times more common than a prominent left side. These findings parallel those of Vercauteren *et al.* (1982) and Carr *et al.* (1991).

In older subjects, Fon *et al.* (1980) found that the degree of kyphosis increased with age and that the rate of increase was higher in females than in males. Gelb *et al.* (1995) made radiographic measurements of 100 adult volunteers over the age of 40 years to determine the sagittal contours of the spine. The majority of asymptomatic individuals were able to maintain their sagittal alignment despite advancing age. Loss of distal lumbar lordosis was most responsible for sagittal imbalance in those individuals who did not maintain sagittal spinal alignment.

According to Wing *et al.* (1992), there are diurnal changes in the profile shape and range of motion of the back. They reported overnight increase in stature averaging 20 mm, 40% of which, in the thoracic spine, was associated with a flattening of the kyphosis and compatible with disc height increases without commensurate changes in the intervertebral discs. Hamstring muscle length influences the spinal posture, according to Gajdosik *et al.* (1994), who found that short hamstrings were associated with decreased flexion range of motion of the pelvic and lumbar angles and increased flexion range of motion of the thoracic angle.

Ribs

The ribs develop by growth in the costochondral cartilages anteriorly, and in a posterior growth region close to the vertebral bodies. Appositional bone formation within the ribs appears to continue throughout adult life. Early in life, the transverse plane dimensions of the ribcage become less circular in cross-section (more elliptical), with an antero-posterior to lateral ratio changing from about 0.8:1 to 0.6:1 by the age of 3 years (Openshaw *et al.*, 1984).

Normal motion of the thoracic spine and intervertebral joints

Basic principles

Motion of the spine, or motion of vertebrae, can be considered as a combination of translations and rotations relative to a co-ordinate system. Similarly, forces (which produce translation) and torques (which produce rotations) can be considered to have components along and around the same set of axes. Since translations and rotations are fundamentally different, motion of the spine is considered to have six degrees of freedom (three translations and three rotations), and the force system acting on the spine has the same six degrees of freedom (Fig. 4.1).

Co-ordinate systems

A cartesian co-ordinate system is uniquely defined by the position of its origin and the direction of at least two of the three axes (the third axis, by definition, is perpendicular to the other two). Since the spine is flexible and moves, the definition of an axis system is not simple. Depending on the point of view, axes might be defined by reference to landmarks on an individual vertebra, by reference to the end vertebrae of the spine or a defined region of it, or by reference to the position of the person's entire body (Fig. 4.2). The choice of axis system can be very important, since most measurements (of forces and of displacements) will be different depending the location of the origin of axes, the directions
local, spinal or global reference is used.

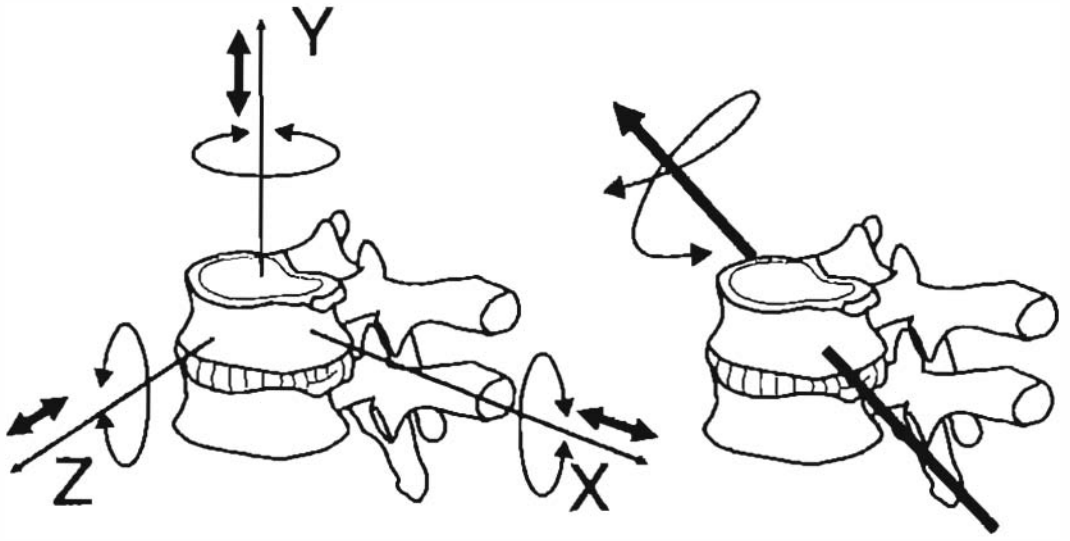

(a) 3 TRANSLATIONS and 3 ROTATIONS

(b) INSTANTANEOUS HELICAL AXIS

Fig. 4.1 A thoracic motion segment, consisting of two vertebrae and the structures (disc and ligaments) that connect them together, has six degrees of freedom. These produce six distinct components of motion (three translations and three rotations). Alternatively, the six components of motion can be expressed as motion along and around a helical axis (adapted from White and Panjabi, 1990).

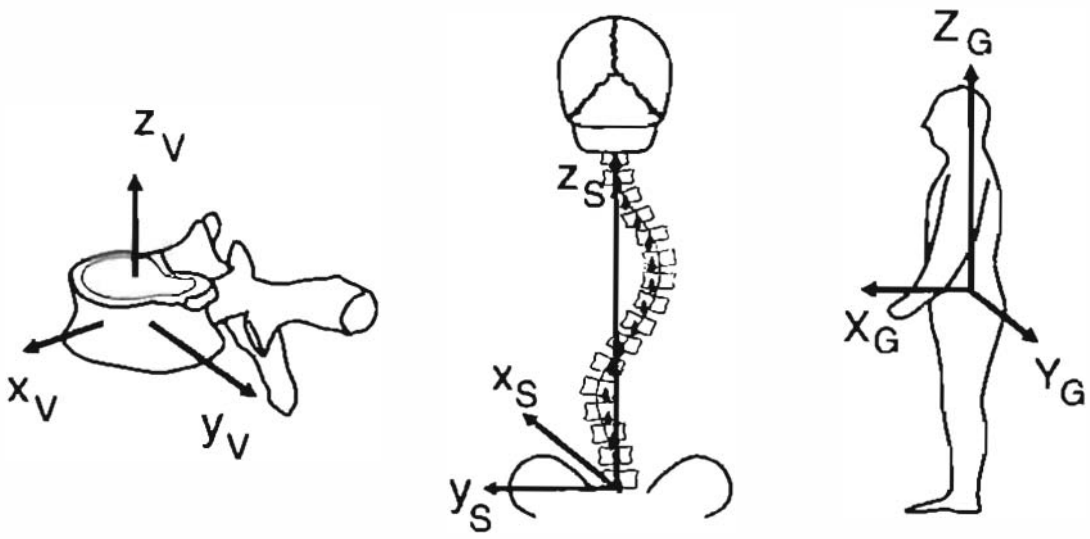

(a) Local (vertebra)

(b) Spinal (spine)

(c) Global (body)

Fig. 4.2 Axis systems: (A) vertebral, (B) spinal (spine with scoliosis), and (C) global (body) systems. The axis system that is used in any clinical measurements, such as from plane radiographs or CT sections, should always be defined and specified.

The spinal motion segment

In order to simplify consideration of its biomechanics, the spine is often broken down into mechanical units called motion segments. Each motion segment consists of two vertebrae and all of the soft tissue structures (disc, ligaments, joint capsules, etc.) which link these two vertebrae together.

The mechanical properties of the motion segment are a function of its physical dimensions and proportions, and the tissue material properties. Much of the information about mechanical function of the spine necessarily comes from studies of cadaveric material in the laboratory. Here, the behaviour can be documented accurately, but without confidence that the testing conditions are indeed physiological. On the other hand, *in vivo* studies permit measurements of motion, but it is extremely difficult to estimate the forces acting on the spine *in vivo*. Therefore, results of laboratory testing of spinal specimens must be interpreted with caution. Most investigations of properties of motion segments have been performed with aged specimens, which may be weakened by degeneration, osteoporosis, etc. Anatomical specimens may undergo post-mortem changes, in addition to dehydration and other changes in frozen storage and during testing. The *in vivo* condition includes ambient loads, especially compressive forces, which disappear at the time of post-mortem and on removal of the specimen from the body.

Stress and strain relationships of tissues

Deformation of tissue in response to applied load is usually displayed by means of a stress–strain graph (Fig. 4.3). Stress is a standardized measure of applied load in a particular direction (load divided by area of specimen), and strain is a standardized measure of the

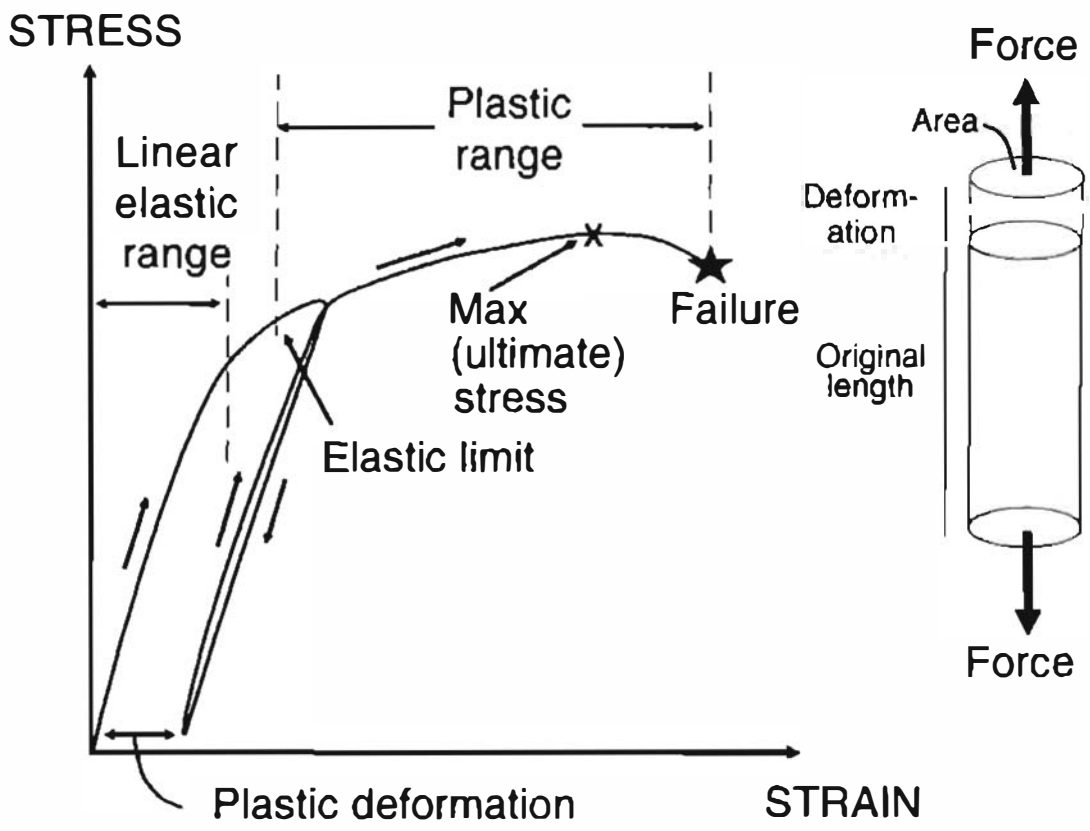

Fig. 4.3 Stress-strain graph of a typical material. A sample was loaded past its elastic limit, unloaded to demonstrate plastic deformation, and then loaded again to failure. Stress and strain are standardized measures of load and deformation. Representation of load and deformation as stress and strain permit comparison between tissue samples of different sizes.

deformation in a specified direction (elongation divided by original length for direct strain, and shear deformation divided by specimen thickness for shear strain).

Because of the complex behaviour of biological tissues, several special terms must be defined in order to describe their response. In a stress-strain curve, several tissue characteristics are displayed and can be quantified. The elastic range is the range of deformation from which complete recovery is possible after unloading. Biological tissues often have an initial region of laxity, then an approximately linear elastic range, followed by a non-linear elastic range. When the elastic limit is reached, plastic deformation may occur. After unloading a specimen that has been taken into the plastic range, a permanent, plastic deformation remains. Failure occurs when the ultimate or maximum stress is passed. These properties are illustrated in Fig. 4.3.

Time-dependent properties are a function of the history of loading. These are illustrated in Fig. 4.4, which also shows how materials with time-dependent properties can be conveniently visualized and represented by equivalent structures consisting of springs and dashpots.

The behaviour of ligaments, vertebrae, discs, etc., both acutely and over time, during normal *in vivo* function, trauma, or treatment situations, is a complex interaction between the tissue material properties, together with the sizes and shapes of these structures. In the same way as tissue properties can be displayed by a stress-strain graph, a load-deformation graph (Fig. 4.5) is used to display structural properties.

(a) Viscoelasticity

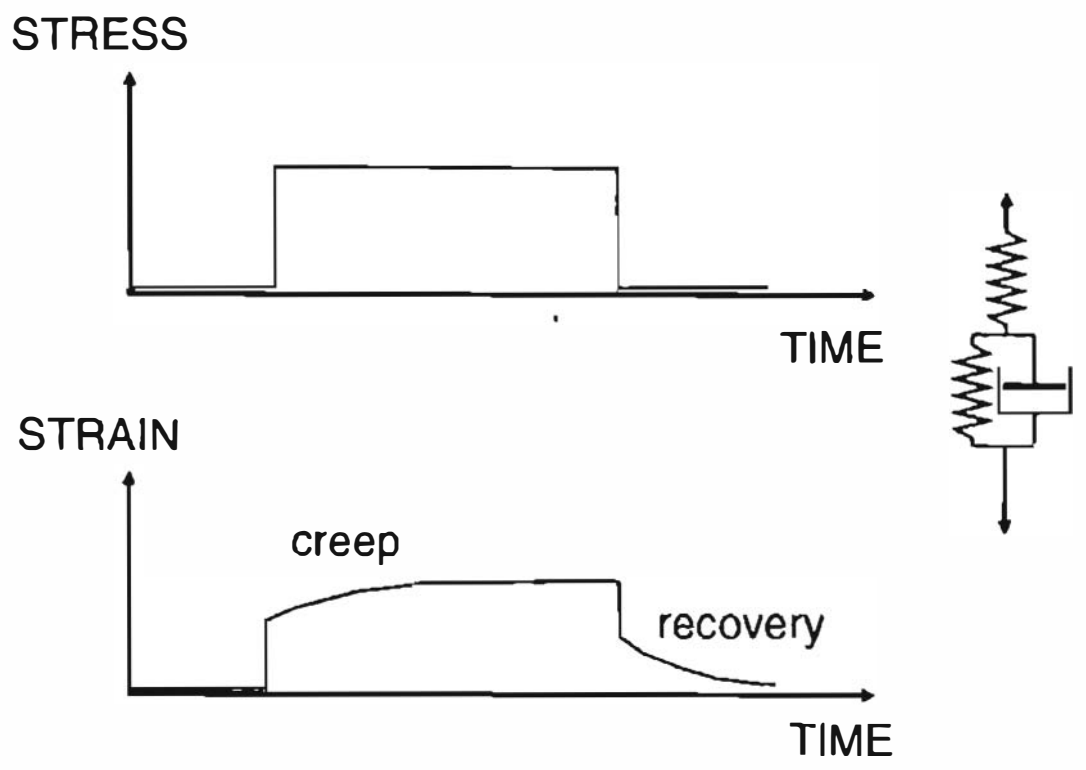

(b) Load Rate Dependent

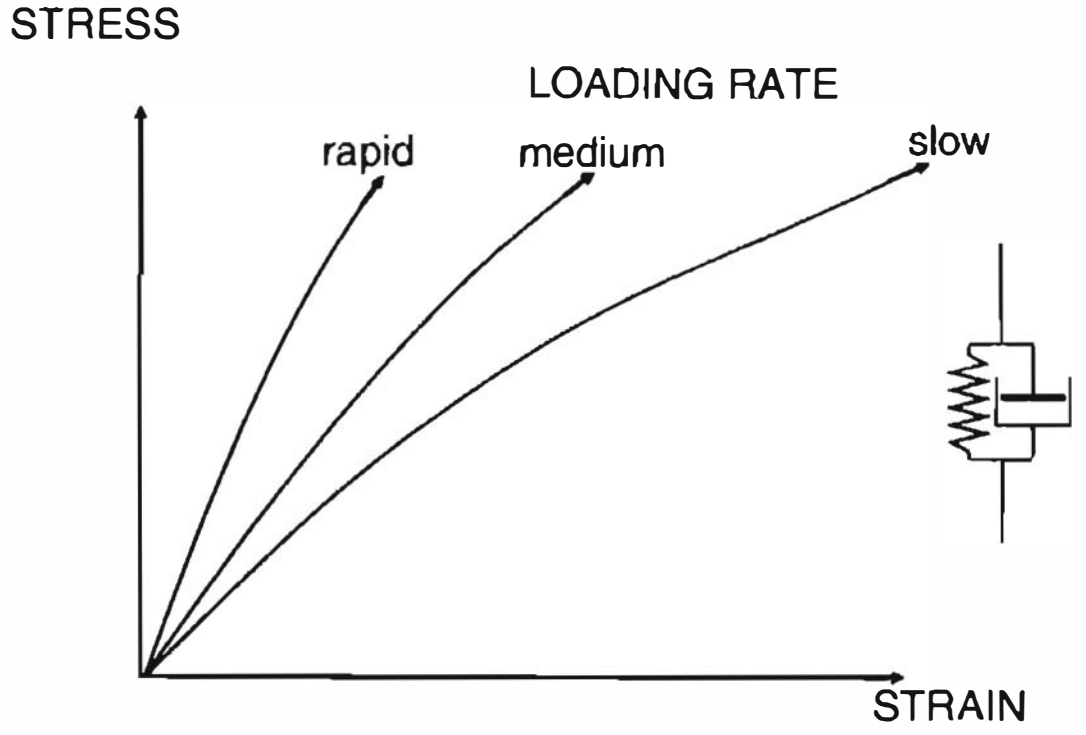

(c) Hysteresis



Fig. 4.4 Three types of material behaviour illustrated by stress and strain response and by equivalent spring and damper systems. (A) Viscoelastic behaviour: a step load produces a gradual increase in deformation and unloading initiates a slow recovery process. (B) Load-rate dependent behaviour. (C) Hysteresis: unloading path different from loading path, and energy is absorbed in each load-unload cycle.

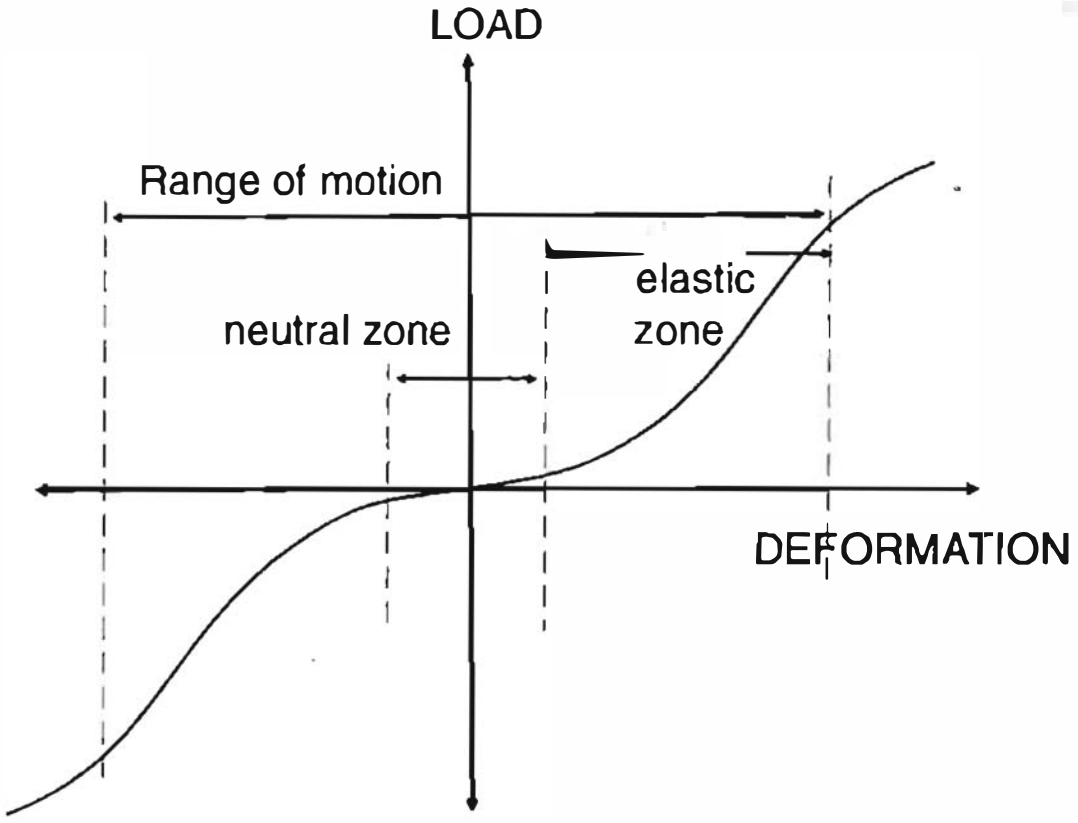

Fig. 4.5 Idealized load-deformation behaviour of a motion segment for loading along one axis, and the corresponding deformation. Motion segments display non-linear behaviour, which has been characterized by Panjabi *et al.* (1989) as having an initial region of minimal stiffness ('neutral zone'), followed by an 'elastic zone'.

Coupled motion

The relative motion of adjacent vertebrae seldom occurs in a single direction, or even in a single plane. As described above, there are six degrees of freedom, but these normally occur in combination with each other. In general, application of a single force or torque does not produce a single corresponding translation or rotation. In fact, usually, application of a single force or torque produces all six translations and rotations in varying amounts. The tendency of certain degrees of freedom to be associated with each other (especially axial rotation and lateral bending) has been referred to as 'coupling', and was reported in the earlier part of this century by Lovett (1905) who studied the cadaver spine and thorax and compared it with his observations of living subjects.

This complex mechanical behaviour is difficult to visualize. One helpful concept is the instantaneous helical axis of rotation. Here, for any instantaneous increment of motion, one vertebra can be considered as rotating about, and translating along, an axis of rotation which is fixed relative to the other vertebra. If the axis of force application is not the same as the axis of the resulting intervertebral motion, then coupling is present. If motion is planar, then the point where the axis of rotation cuts this plane is the centre of rotation. The instantaneous axis of rotation is not fixed and depends on the configuration of the applied forces and torques, as well as the position of the motion segment within its range of motion. Not only is the centre of rotation variable, but it is also difficult to measure accurately. Motion in the thoracic spine is not strongly constrained, and there is a large scatter in reported measurements of the location of the centre of rotation. The dispersion of the results is probably partly real, and partly the result of errors in measurement, because the calculation of an axis of rotation is very sensitive to measurement errors.

The deformation experienced by any tissue or structure depends on how far it is from the axis of rotation. Thus, physical constraints dictate that the axis of rotation usually passes through the intervertebral disc, minimizing the magnitude of strains within the disc structure.

In vitro properties of motion segments

An idealized load-deformation graph (Fig. 4.5) demonstrates experimentally determined characteristics of the motion segment. Load-deformation graphs for spinal motion segments show a non-linear relationship between load and deformation. Typically, there is a region of large deformation for small positive and negative loads, which has been called the 'neutral zone' (Panjabi *et al.*, 1989). This region can be considered as a region of laxity, where minimal force is required to produce displacements from the resting position. The 'elastic zone' is a region in which there is a more linear relationship between additional force and motion, and the vertebrae return essentially to their unloaded positions on removal of applied loads. Together, the 'neutral zone' and 'elastic zone' constitute the functional range of motion.

At a greater range of deformation, there is a region of increasing stiffness beyond which damage may occur. Although these characteristics of the motion segment can be defined for cadaveric spinal specimens, these properties are presently unable to be determined in living subjects.

Determination of the mechanical behaviour of a spinal motion segment

Most of our knowledge of the mechanical behaviour of motion segments comes from mechanical tests of anatomical specimens, as a result of practical constraints, despite some evidence that laboratory testing may yield results not truly representative of the *in vivo* behaviour. In particular, Keller *et al.* (1990) compared the *in vivo* and post-mortem behaviour of pig motion segments, and found them to be more compliant and able to be deformed at a faster rate *in vivo*. They concluded that predictions of the mechanical response of the spine based on *in vitro* tests may be unreliable. Janevic *et al.* (1991) found that large compressive preloads decrease lumbar motion segment flexibility *in vitro* for rotational degrees of freedom, which may explain some of the difference between *in vivo* and *in vitro* behaviour. A typical motion segment test consists of a stiffness or a flexibility test. In the stiffness method, controlled displacements (translations and rotations) are applied to the specimen, and the required forces are recorded with a load cell. In flexibility methods, the inverse is performed - a controlled load (direct force, for force couple) is applied to the specimen and the resulting displacements (translations and rotations) are recorded. In either case, the results can be drawn as a series of load-deformation graphs, and then summarized by the main features of the graph - slope or stiffness, non-linearity, point of failure, etc. (Fig. 4.5).

If it is assumed that there are linear relationships between applied forces and resulting motion, then a 6 × 6 matrix of numerical values can be used to describe the behaviour of one vertebra relative to its fixed adjacent neighbour. This relationship can be expressed in the form of either a stiffness or flexibility matrix. Each column of the stiffness matrix gives the forces and moments required to produce a unit deformation (relative displacement or rotation) and, conversely, the columns of the flexibility matrix give the motions associated with a unit of applied force or moment. Terms on the diagonal of the matrix are the principal flexibilities or stiffnesses, whereas the off-diagonal terms correspond to coupled behaviour. Panjabi *et al.* (1976) experimentally determined the value of the flexibility matrix for thoracic segments, and also derived the corresponding stiffness matrix. Gardner-Morse *et al.* (1990) showed how these values could be expressed quite accurately by an equivalent beam representation. Panjabi *et al.* (1976) noted that, especially in the sagittal plane, the behaviour was not identical for positive and negative (forwards and backwards) acting forces and torques, and they reported the behaviour in the form of a linear relationship in each direction. In fact, the relationship is not truly linear. Also, axial 'preloading' of a motion segment increases its stiffness (Janevic *et al.*, 1991). Goodwin *et al.* (1994) found that compression and distraction forces increased the torsional stiffness of thoracic segments, whereas only compression forces were found significantly to increase the stiffness of lumbar segments.

Finite element modelling of motion segments and of the spine

Finite element modelling offers an alternative to experimental measurement of motion segment properties. In this technique, the geometry of a complex structure is broken down into a mesh of regularly shaped elements (Fig. 4.6), and the material properties of each element are specified. The mechanical behaviour of the whole structure can be described in terms of local element tissue stresses and strains and *vice versa*. Finite element modelling can be used to investigate geometrical scaling effects of the dimensions of the lumbar spine. Goel and Gilbertson (1995) consider that finite element modelling has become a tool comparable to experimental approaches for investigating clinical problems of the thoracolumbar spine.

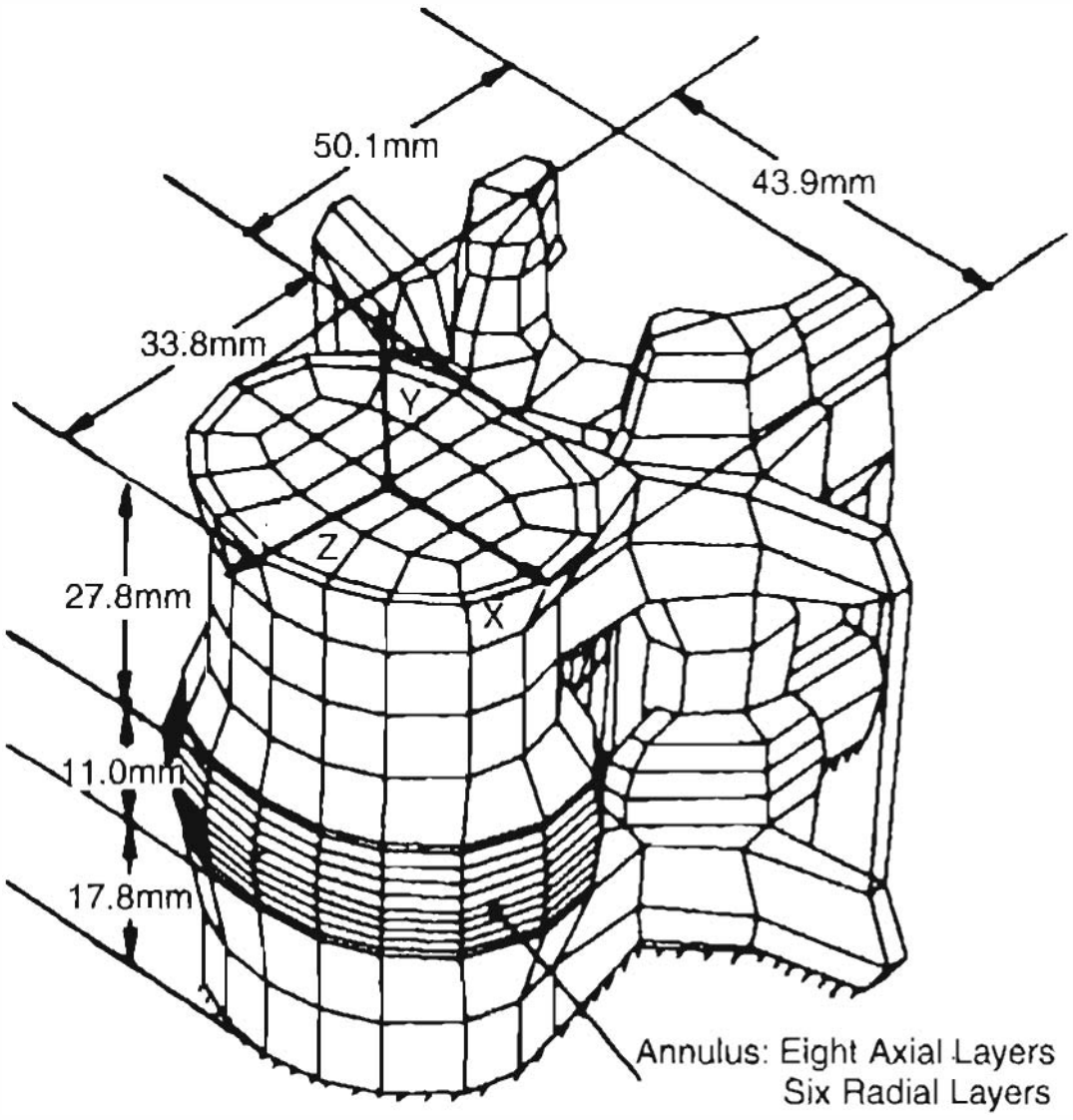

Fig. 4.6 Finite element model of a lumbar spinal motion segment. The vertebrae, discs and ligaments are represented by cuboid elements, each with specified material properties. The mechanical behaviour of the entire structure can be computed using the finite element analysis technique (reproduced with permission from Goel *et al.*, 1995).

Contribution of the spinal ligaments

The ligaments of the spine are tensile members that prevent excessive motion. They are also suspected of having a proprioceptive role. Based on the magnitude of the deformation of ligaments during spinal motion, Jiang *et al.* (1994) found that the superior costotransverse ligament appeared to be the most likely to provide sensory information which would be helpful to spinal stabilization.

Panjabi *et al.* (1981) conducted a study in which ligaments of thoracic motion segments were subjected to progressive cutting, either in a posterior to anterior sequence or an anterior to posterior sequence. They measured the motion resulting from an anterior or posteriorly directed force applied to the centre of the upper vertebra. This study confirmed the tensile importance of the ligaments, as cutting of the tissues in tension caused a rapid 50-100% increase in the amount of motion.

Maiman and Yoganandan (1990) catalogued the failure characteristics of spinal ligaments of 41 spines from all the thoracic levels. They showed a progressive increase in strength towards the lower anatomical levels. Mykebust *et al.* (1988) tested the six major ligaments from the T3–T4 level and found that they had very different failure mechanisms, which they attributed to differing composition and structure. However, all six of the ligaments failed at around 6 mm of extension, the greatest extension being 10 mm for the ligamentum flavum.

Contribution of the intervertebral disc to flexibility and strength

The intervertebral disc has a special mechanical role in transmitting large compressive forces, while also providing flexibility for rotations about all three axes. In compression loading, large pressures are generated in the nucleus pulposus, and these pressures are contained by tensile stresses in the anulus. Compression stiffness is relatively high initially, about 1 mm deflection per thousand Newtons (N) of compressive force, and it increases at greater forces. Disc compression is accompanied by a similar amount of bulging (increase in disc radius). Combined flexion, compression and shear loading of thoracic and lumbar motion segments produced an observed posterior displacement of the nucleus (Krag *et al.*, 1987). Part of the ability of the nucleus to sustain high pressures results from the large swelling pressure of this tissue. At equilibrium, the externally applied loads, which tend to expel fluid, are balanced by the electrostatic forces tending to pull more water into the disc. Although removal of the nucleus has little effect on compressive properties, it has a greater effect on motion in other planes (Panjabi *et al.*, 1984). Deformation results in a flow of fluid within the disc, as well as fluid content changes (volumetric changes). These are especially apparent as diurnal changes in disc height. Whether these fluid changes augment the nutrition of intervertebral discs by a 'pumping' mechanism is unclear (Urban *et al.*, 1982; Holm and Nachemson, 1983). The pathways for nutrition into the disc (which is avascular) include the end-plates and the disc periphery. Rates of diffusion of nutrients and metabolites by these pathways differ as a function of their molecular weight (Urban *et al.*, 1982).

Intervertebral discs can be subjected to quite large rotations in the sagittal plane without damage, whereas axial rotation permits the smallest range before damage occurs. Thus, twisting has been considered as a common source of injuries to intervertebral discs, especially of repetitive small injuries leading to disc degeneration in later life.

Contribution of the vertebral bodies to flexibility and strength

Vertebral bodies deform under compressive loading, and the end-plates become more concave under the influence of intradiscal pressure (Brinckmann *et al.*, 1983). The central deformation of the end-plate has a magnitude similar to the amount of bulging of the disc. Microscopic damage to the trabeculae (Hanssen and Roos, 1981), as well as herniation of the disc through the end-plate (Schmorl's node), may result from excessive axial compression load.

The strength of an individual vertebra depends on its shape and internal structure, as well as the material properties of its bony tissue. In osteoporosis, there is a loss of bone mineral density (BMD) and of vertebral strength. Thoracic vertebrae at all levels are affected by osteoporotic fractures, which usually involve compression of the vertebral body and can lead to the characteristic hyperkyphotic appearance of elderly, osteoporotic people, especially women. By careful comparisons of shape of the thoracic and lumbar vertebrae of 52 non-osteoporotic women and 195 post-menopausal women, Eastell *et al.* (1991) concluded that over 20% of the post-menopausal women had vertebral fractures, with an average of two per person. This represents a major health concern in the ageing population. Although both exercise and diet are important, it is difficult to delay and impossible to prevent bone mineral loss in both men and women. Measurements using dual photon absorptiometry have shown that in women measurable bone loss from the spine begins at skeletal maturity and proceeds at the rate of about 1% per year both before and after menopause (Riggs *et al.*, 1986).

Singer *et al.* (1995) point out that osteoporotic fractures are most common in the mid-thoracic spine. They studied 366 cadaver vertebrae from T1 to L5. Compressive strength correlated ($r = 0.86$) with BMD measured by dual energy absorptiometry, and with vertebral trabecular density (Hounsfield number) multiplied by cross-sectional area ($r = 0.83$) throughout the thoracic and lumbar regions. McCubbrey *et al.* (1995) found that static and fatigue characteristics depended on the density of bone in different regions. Anterior vertebral body density was most predictive of the static properties, while posterior regions were more predictive of the fatigue properties. It has long been recognized that mineralization of bone leads to greater strength, and this can be assessed radiologically as the degree of absorption of the X-ray beam (the lightness of the bone image). Therefore, it appeared that the strength of a bone should be quantifiable by the radiodensity. X-ray absorptiometry gives estimates of the bone mineral content (BMC in g/mm^2) from which the BMD can be derived by normalizing for the bone thickness. Unfortunately, the size of a patient's bone can seldom be assessed accurately. As an alternative, computed tomography (CT) gives the distribution of radiodensity within a specified slice image. Bone is a tissue with a complex internal architecture, so BMD is not the sole determinant of the behaviour of individual bones; the internal architecture should ideally be taken into account too.

Maintaining the strength of vertebrae depends on adequate diet and physical activity. Snow-Harter *et al.* (1990) found that muscle strength is an independent predictor of BMD in young women, accounting for 15-20% of the total variance in bone density in the femoral neck and in the spine, apparently because of an interaction between physical fitness, muscle strength and vertebral bone integrity.

There has been much interest recently in the mechanical behaviour of bone in osteoporosis, and also in the effects of microgravity (during space travel). Maintenance of bone mass and bone strength apparently requires adequate exercise and diet. Bone responds to mechanical loading, and appears to be more sensitive to a few cycles of high load than to a lower sustained or frequently applied load (Rubin and Lanyon, 1987).

Loss of strength of the vertebral bodies can also occur as a result of pathological changes. McGowan *et al.* (1993) simulated metastatic lesions in an animal thoracic vertebral model by removing varying amounts of the cancellous bone. The normalized strength of thoracic vertebrae with trabecular defects was linearly related to the reduction in cross-sectional area, indicating that the strength reduction due to lytic defects within the centrum of thoracic vertebrae is proportional to the cross-sectional area of bone resorbed.

Contribution of the posterior elements to flexibility and strength

Depending on their orientation, which varies along the length of the spine, zygapophysial joints can contribute to resisting compressive loading, shear loading and torsion loading (Fig. 4.7). However, probably because of flexibility in the neural arch, neither removal nor fusion of the zygapophysial joint has a dramatic effect on the flexibility of motion segments. White and Panjabi (1971) found that removal of the zygapophysial joints in the thoracic spine leads to increased extension motion and lateral bending, but little change in the amount of axial rotation. Conversely, in the lumbar spine, according to Stokes (1988), the greatest effect of zygapophysial joint removal is on the torsion behaviour. Overall, it appears that the intervertebral disc is the most crucial structure for the mechanical integrity of the motion segment, but posterior structures help to guide the motion segment and to protect the disc from injury. Singer *et al.* (1989b) used CT imaging to investigate 44 spinal injured patients, and found more congruent 'mortice' joints at the segmental level of injury, suggesting that an abrupt transition of zygapophysial joint inclination predisposes to injuries at the thoracolumbar junction.

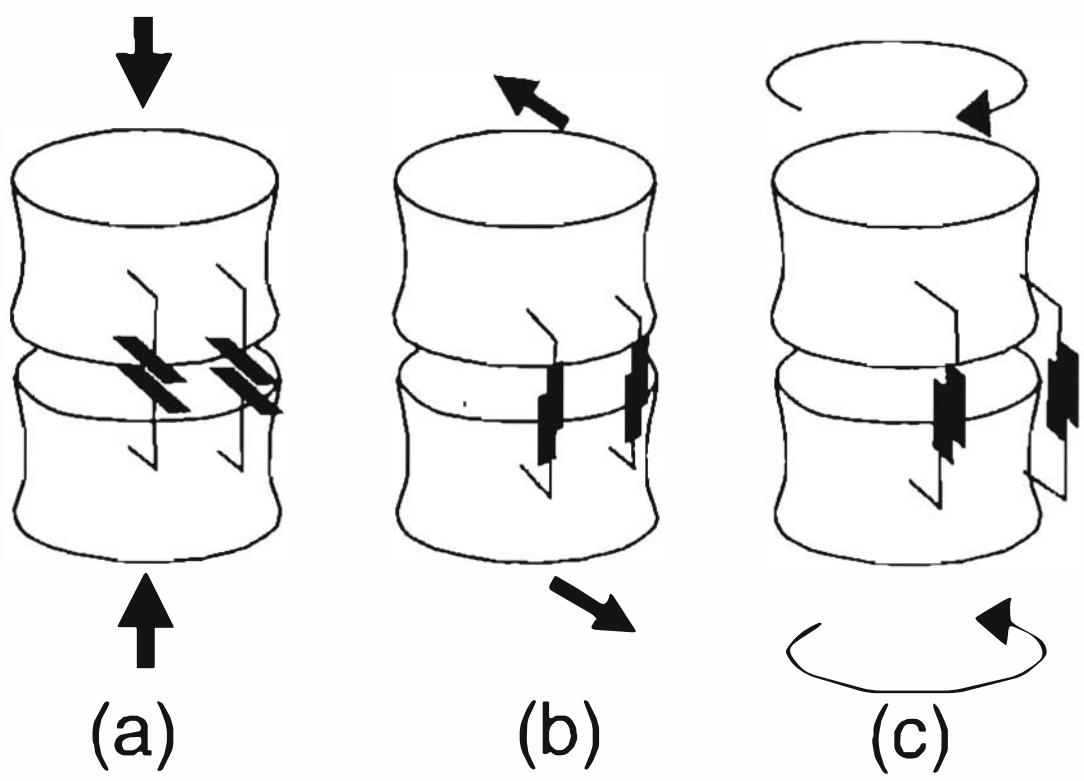

Fig. 4.7 Orientation of zygapophysial joints which would provide resistance to (A) compression, (B) forward shear and (C) axial rotation.

In vivo behaviour of the thoracic spine

The *in vivo* behaviour of the thoracic spine is difficult to study directly. Surface curvature measurements give an impression of the motion in the sagittal plane, but are probably unreliable for other planes (Hart and Rose, 1986). Gregersen and Lucas (1967) inserted pins into several spinous processes of seven subjects to measure thoracic spinal motion during the performance of maximal motion and during walking. The range of motion for axial rotation was found to be 9° between L1 and L5, and as much as 10° at the thoracolumbar junction (T12-L1). This value is very high compared with *in vitro* measurements, and is suspected of being attributed to the diversity of transitional anatomy (Singer *et al.*, 1989a), in addition to the problems noted by the authors with slippage of recording instruments affixed to the sacrum (Gregersen and Lucas, 1967). In the thoracic region there was approximately 6° of motion per level. During walking, only a small part of this range of motion was employed. There was up to 2° of axial rotation per motion segment in the region T4-10. The greatest motion (about 2°) occurred in the mid-thoracic region at T6-T7. Lovett (1905) described a coupling of lateral bending and axial rotation by examining both living subjects and anatomical specimens, and it was found that the degree of coupling was dependent on the extent of flexion or extension of the spine. Similar findings were obtained by Arkin (1950) using radiographic examination of living subjects. White (1971) examined coupling relationships in thoracic spinal motion segments and compared them with vertebral alignments in scoliosis deformities. He concluded that the pattern of interaction between lateral bending and axial rotation resulted in a different pattern to that seen in scoliosis.

Thoracic spine and ribcage interactions and respiration

Motion of the thoracic spine is connected to that of the ribcage by the costovertebral joints. The ribs articulate with the transverse processes, as well as with the vertebral bodies of the corresponding vertebra and that immediately cephalad. Motion of the ribs has been described as consisting of both 'pump-handle' and 'bucket-handle' motion. Although not well-defined, these terms imply rotations about the horizontal (mediolateral axis) and an axis joining the ends of the ribs respectively. The bucket-handle motion implies that the sternum remains fixed relative to the thoracic spine, so the only possible motion is about the axis joining the two ends of the ribs. In reality, the motion during respiration seems to be more closely aligned with an axis passing through the costotransverse and costovertebral joints posteriorly (Jordanogiou, 1969; Saumarez, 1986; Wilson *et al.*, 1987). Detailed geometrical study of the ribs and costovertebral articulations has also defined the possible movements (Minotti and Lexcellent, 1991).

The complex interactions in chest wall mechanics during breathing are difficult to explain in terms of muscular recruitment. Apparently, both the internal and external intercostal musculature, as well as the diaphragm and abdominal musculature, are involved (De Troyer *et al.*, 1983; Saumarez, 1986). A novel approach to deducing functions of intercostal muscles was employed by Loring and Woodbridge (1991), who used finite element modelling techniques to predict the effects of different patterns of muscle recruitment. One conclusion was that the internal and external intercostal muscles could be inspiratory or expiratory, depending to some extent on the distribution of their activation at differing segmental levels of the chest wall.

In vivo loading of the spine: moments of lifted objects and muscles and biomechanical models

The spine is loaded by a combination of externally applied forces, bodyweight forces and forces due to the muscles which cross the motion segments. Because the moment arms of the muscles around the spine are usually small compared with those of lifted weights and bodyweight contributions, the forces in muscles are correspondingly high. Fig. 4.8 illustrates a case in which compressive load on the spine reaches half of a tonne, which is comparable with the ultimate compressive strength of the spine. For any position of the body, and for given external loading, the internal forces acting on the spine can be estimated by considering the equilibrium between internal and external forces and torques around the spine. The weight being lifted, together with the weight of body segments above the particular level of the spine being considered, produce moments about the spine. The magnitude of each moment is the product of the force multiplied by its distance from the spine. These moments must be countered by muscles and ligaments. The analysis of this equilibrium condition is done with the help of a biomechanical model (Andersson and Winters, 1990).

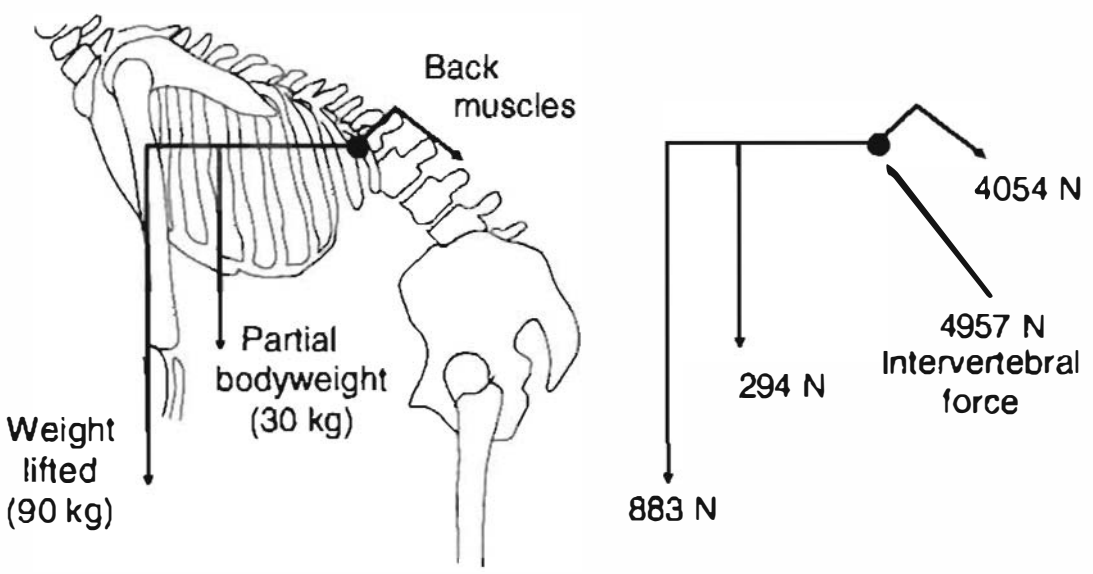

Fig. 4.8 Simple model of lifting mechanics at the thoracolumbar junction, for a heavy lift. Deep muscles of the back provide extension moments to counteract flexion moments of the weight of the head, arms and trunk, and of the lifted weight. Because of the relatively short moment arm of the dorsal muscles, the forces developed by these muscles must be higher than the lifted loads. Consequently, the spinal loading is also high (adapted from Morris and Bresler, 1961).

Estimating the muscle forces in the trunk is difficult. Electromyography (EMG) is used to estimate these forces, although the EMG-to-force conversion is always approximate. Alternatively, biomechanical models are used to calculate muscle forces by considering the balance between external loads, bodyweight loads, and the muscle forces required to maintain equilibrium. However, this calculation does not produce a unique solution, since there are many combinations of synergistic and antagonistic muscle forces that can satisfy this balance. To obtain a solution, we must make assumptions about which muscles are active, and which control strategies are used to activate them.

The exact pattern of co-activation of muscles must be found either experimentally by EMG, or by assuming rules that govern muscle recruitment. In the case of lifting tasks, abdominal muscles are recruited, and these create an intra-abdominal pressure. In heavy exertions, thoracic pressurization also occurs. At one time these pressures were thought to augment the extension moments about the spine and to help to reduce compressive loading on the spine. This effect is now considered to be negligible.

Understanding the complex patterns of muscular co-contractions is difficult. In simple, sagittal-plane lifting tasks, it appears that both muscular contraction levels and compressive loading on the spine are minimized. For tasks involving moments out of the sagittal plane, EMG studies often show a greater degree of muscle co-activation than is required by the

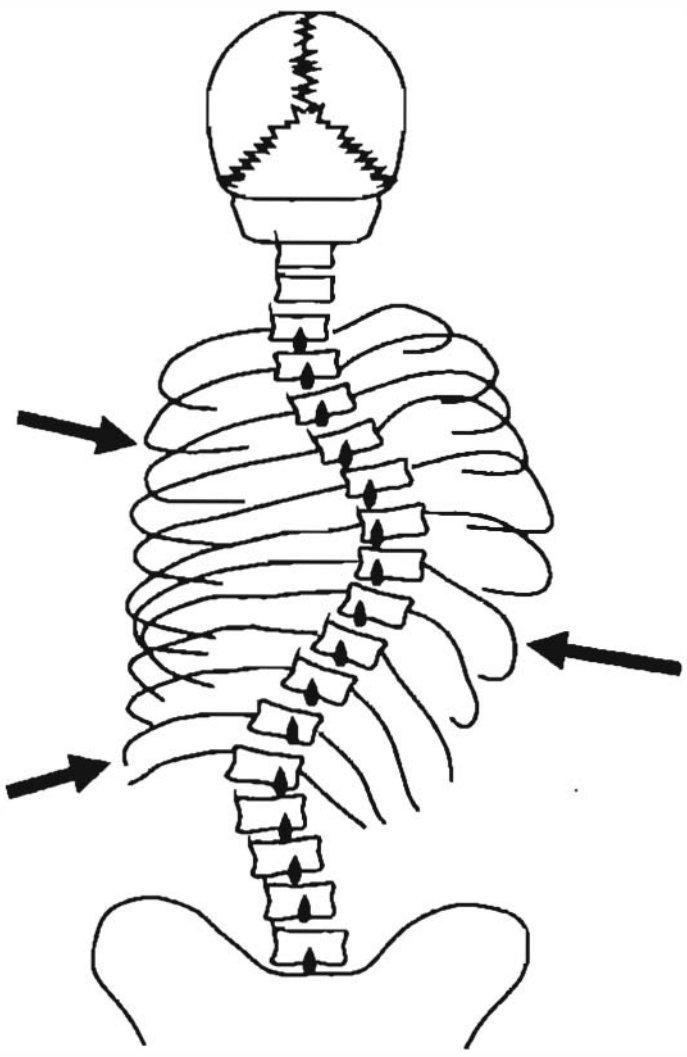

Fig. 4.9 The system of three forces applied by a brace to a spine with scoliosis deformity.

simple constraints of equilibrium. It is suspected that the additional co-activation of antagonistic muscles is part of a mechanism to stiffen the spine against perturbations, and thus make it more mechanically stable (Andersson and Winters, 1990; Gardner-Morse *et al.*, 1995).

Another complicating factor in biomechanical models of the trunk is the contribution of ligamentous structures. These passive structures only contribute to the forces acting on the spine when they are in a tightened position. In lifting tasks performed with a flexed spine, the erector spinae muscles are electrically silent, and the ligaments provide a major force contribution. However, the whole question of whether it is better to lift with the spine in a lordotic, kyphotic or neutral position is unresolved (Dolan *et al.*, 1988). As indicated in Fig. 4.8, the forces on the spine are kept to a minimum in a lifting task by keeping the lifted weight at the shortest possible horizontal distance from the spine.

Spinal stability and instability

The term spinal instability encompasses a wide range of concepts, and few of these have been well defined. According to Ashton-Miller and Schultz (1991), spinal instability has been used variously to imply hypermobility as a result of ligamentous or other injuries, unpredictability of painful symptoms, and abnormal relationships between coupled motion of the spine, as well as unpredictability of motion itself, including a tendency towards large deformations in response to small changes in the applied loads. The last of these is the classic mechanical definition of instability, such as occurs in a slender column subjected to compressive loading. Since the spine consists of a column of vertebrae linked by relatively flexible articulations, this structure is probably at risk for buckling during complex lifting tasks. Unless the tension in all of the musculature is carefully balanced, there could be a tendency for large deformations at individual articulations. These ideas have been investigated by Bergmark (1989), Crisco and Panjabi (1991) and Gardner-Morse *et al.* (1995). These works suggest a role for the muscles that cross several segments, as well as the shorter muscles (e.g. multifidus). Almost all of the possible definitions of spinal instability are very difficult to demonstrate *in vivo*. If instability occurs, it is probably transient and unlikely to be recorded on an X-ray film. Therefore, of all the possible manifestations of spinal instability, hypermobility is probably the only one that can be documented with confidence. However, it is probable that all of the other forms of instability listed above could be real phenomena, and might be the causes of injuries and acute onset thoracic spine pain.

Trauma

Thoracic spinal injuries

All of the components of the motion segment contribute to its flexibility and may contribute to the ultimate strength, depending on the failure mechanism. This depends on the direction of loading. Most classifications of thoracic spinal injuries rely on the supposed forces producing the injury (Holdsworth, 1970; Ferguson and Allen, 1984). White and Panjabi (1978) introduced the idea of the 'major injury vector' (MIV) to classify the causes of injuries according to the predominant direction of loading during an injury. Thoracic spinal injuries can be produced by predominantly compressive load, by excessive rotation about any of the three principal axes, or by varying combinations of forces and displacements. Axial compression injuries occur most commonly near the thoracolumbar junction (Holdsworth, 1970). Denis (1984) used the 'three column' concept to describe the consequences of acute spinal trauma. The three columns consist of the anterior column (vertebral body), the middle column (posterior part of the vertebra and anulus) and the posterior column (posterior elements and neural arch). Denis (1984) reclassified spinal fractures based on the extent and type of injury to these three columns, and proposed that the degree of spinal stability after injury depends on their integrity. Panjabi *et al.* (1995a) measured intervertebral motion of anatomical specimens after simulated injuries. They considered that the findings supported the three-column theory of thoracolumbar fractures, and they emphasized the role of the middle column as the primary determinant of mechanical stability of this region of the spine.

Disc injuries, including disc herniations, are relatively rare in the thoracic spine (see Chapter 5). Brown *et al* (1992) retrospectively reviewed 55 patients with 72 thoracic disc herniations. They did not state the causes, but implied that the onset was usually traumatic. The treatment programmes given to these patients were evaluated, and 15 of the 55 patients (27%) eventually required surgery. They felt that thoracic disc herniations, similar to cervical and lumbar disc herniations, do not always lead to major neurological compromise, so a less aggressive surgical approach can therefore be considered appropriate.

The spinal column protects the spinal cord, and injury can compromise the cord. Panjabi *et al.* (1995b) investigated canal encroachment by bone fragments during thoracolumbar burst fractures in a model using cadaveric specimens. They measured the amount of canal encroachment during an experimental high speed trauma (burst fractures of T11–L1), and compared it with that measured on post-trauma radiographic images. The dynamic canal encroachment was 33%, compared with residual static canal encroachment equal to 18% of the canal diameter. These findings imply that the canal encroachment is greater while an injury is occurring than that seen on post-trauma radiographs or CT scans. This may explain the frequently poor correlation between the canal encroachment measured radiographically and the neurological deficit.

Injuries to the ribcage

The passive flexibility of the chest wall is also of interest in understanding injuries to the skeletal components and visceral contents. Both impact trauma and blast trauma are of concern. Most studies of the ribcage have been done analytically, supported by experimental measurements of flexibility of the ribs and of the costosternal and costovertebral articulations (Schultz *et al.*, 1974). Models intended primarily for studying deformations of the spine and ribcage in scoliosis have been reported (Stokes and Laible, 1990; Wynarsky and Schultz, 1991; Stokes and Gardner-Morse, 1993). Other models have been developed for impact simulations, such as motor vehicle accidents and ejections from military aircraft. Because of the complexity of the behaviour of the thorax, most of these models involve simplifications that make them suitable for a relatively narrow range of applications.

Treatment of thoracic spinal injuries

The major biomechanical concern in the treatment of acute spinal injuries is usually the maintenance of stability (mechanical support and restriction of motion) in order to prevent further injury and to facilitate bony healing. This can be provided externally by bracing or internally by surgical constructs. The biomechanical requirement for stability may conflict with the need to decompress the spinal canal surgically by removing parts of the posterior elements.

New developments are underway in the field of instrumentation for surgical treatment of thoracic and thoracolumbar spinal injuries. Instrumentation is required to provide acute strength, fatigue strength and control of spinal motion after implantation. Flexibility requirements for spinal instrumentation are not well defined. Apart from the need to prevent both excessive elastic deformation and catastrophic buckling, there is concern about whether excessive rigidity can produce 'stress shielding' of the bone. Although this is observed to a small extent, it is probably unimportant compared to the more rapid graft incorporation made possible by less flexible instrumentation. Craven *et al.* (1994) studied strength and BMD in two differing diameter rods in a dog spine fusion model, and found both to be effective. Spinal instrumentation is required to correct deformity as well as to stabilize the spine; thus the traditional approach of using distraction rods requires that these should span two to three vertebrae above and below the injured region to provide adequate stiffness. However, recent developments in spinal instrumentation, especially with pedicle screws, provide options which can be applied more precisely to the injured region. The size of the thoracic pedicle places restrictions on the intrapedicular screws that can be used safely. Breaching of the cortical shell places the nerve root at risk of iatrogenic damage. Similarly, breaching of the anterior vertebral body as a result of excessive pedicle screw length can injure the great vessels. Advanced technology systems that use a combination of preoperative imaging and intra-operative monitoring are being developed to assist in the accurate sizing and placement of pedicle screws. These screws remain attractive, despite their inherent risks, because of their mechanical advantages.

Biomechanics of painful conditions of the spine

There is much disagreement about the role of biomechanical factors in the aetiology of low back pain. Some painful episodes apparently result from a single acute overload event, whereas others may result from a progressive weakening and degeneration of tissues from repetitive loading. Herreby *et al.* (1995) conducted a 25-year prospective cohort study, and showed that back pain in 14- and 16-year-olds is a strong risk factor for pain in adulthood. In radiographs of the 16-year-olds there was a 12% prevalence of radiological abnormalities, including 7% prevalence of Scheuermann's disease in the T5-T10 region, but these radiographic abnormalities were apparently not risk factors for back pain in children or subsequently in adulthood.

Treatment

Triano (1992) reviewed studies on the biomechanical effect of spinal manipulation and pointed to difficulties in establishing the scientific basis of this form of therapy because little is known about manual treatment methods or about the disorders to which they are directed. There are several putative physical effects of manual therapy: disruption of fibrous adhesions; release of capsular folds; and relaxation of muscle spasm (Giles, 1997). Triano (1992) emphasizes that it is difficult to obtain objective confirmation of the existence of these conditions in any patient, or of the relief of these conditions by therapy.

The common factor for all manual methods is that they apply an external load to the spine and its surrounding tissues. Herzog *et al.* (1993) used a thin, flexible pressure mat to measure forces exerted during spinal manipulative therapy by experienced spinal manipulators. They applied a preload followed by a thrusting force on a specific part of the spine in a well-defined direction. During such manoeuvres they recorded average peak forces of 399 ± 119 N applied to the thoracic region. Using an accelerometer, they also detected the occurrence of a 'cavitation' phenomenon, and this event occurred when the force of manipulation reached an average of 346 N. Lee *et al.* (1995) created a finite element model of the spine, ribcage and pelvic responses to simulate a specific lumbar manipulative force in relaxed subjects. Simulation of manipulation with postero-anterior force application of 100 N in the lumbar spine produced intervertebral translations of up to 1 mm at the location of force application, and also remote from it (into the thoracic spine).

Thoracic spinal deformities

Simple mechanical consideration of the structural stability of the spine suggests that spinal deformities should be common. Clearly, there are excellent controls over the growth and development of the spine in most individuals, except when muscular weakness prevents this. The apparently spontaneous development of scoliosis and abnormal kyphosis is difficult to explain (Robin, 1990). Spinal growth and development are important factors in the progression of spinal deformities (Bjerkreim and Hassan, 1982; Weinstein and Ponseti, 1983), but it is not clear whether abnormal growth initiates the deformity (Stokes and Laible, 1990). Growth and maturation are apparently disturbed in idiopathic scoliosis. However, there are few indications as to why idiopathic scoliosis is more common in girls, except that their vertebrae might be slightly more slender (Skogland and Miller, 1981; Schultz *et al.*, 1984), and there are differences in the development of the sagittal spinal curvatures (Willner and Johnson, 1983) and in the timing of growth and maturation (Drummond and Rogala, 1980). It may be that a set of subtle mechanical factors, including abnormal growth, joint laxity and sagittal spinal curvature, and neurologic factors may all play a part (Nachemson and Sahlstrand, 1977).

Biomechanical factors in the aetiology and progression of scoliosis

The exact biomechanical mechanisms responsible for scoliosis deformities, especially the transverse plane rotations of the vertebrae, are not fully understood. A number of biomechanical factors have been invoked including intervertebral motion 'coupling' (Arkin, 1950), posterior tethering during spinal growth (Somerville, 1952) and instability due to the presence of a lordosis in the thoracic spine (Dickson *et al.*, 1984).

Coupling

Although it has been noticed that both lateral bending of the spine and scoliotic deformities show transverse plane rotation, these 'coupling' relationships between lateral bending and axial rotation between adjacent vertebrae are quite dissimilar (White and Panjabi, 1971). Therefore, it seems unlikely that the complex pattern of deformity that develops in scoliosis, with maximal vertebral rotation at the curve apex, is controlled by the same mechanical principles that govern the coupling of lateral bending and axial rotation during normal kinematic motions of the spine. A second implication of this finding is that when a scoliosis is corrected by bracing or other treatment, a correction in one plane will not necessarily produce comparable correction of other components of the deformity, at least not as a result of the normal physiological coupling of spinal motions.

Tethering and reduced sagittal curvature

Another mechanical principle which has been invoked to explain the vertebral rotation is 'tethering' by posterior structures of the spine (Somerville, 1952; Dickson *et al.*, 1984; Jarvis *et al.*, 1988). There are several parts to this theory. Tethering is thought to prevent flexion of the spine and maintain a lordotic shape, which then has a greater tendency to instability. Secondly, the tether is thought to maintain a straighter alignment of the posterior elements than of the vertebral bodies, thus rotating the vertebrae in the curve. Reduced spinal sagittal plane curvature has been noted in the regions of spines with scoliosis (Dickson *et al.*, 1984), although it is uncertain exactly which features are primary and which secondary (causative and consequential). The early teen years correspond to the most flat sagittal plane curvature of the spine (Willner and Johnson, 1983), so this may be a risk factor for idiopathic scoliosis. However, an analysis of the known flexibility characteristics of the thoracic spine failed to explain how these mechanisms might generate the clinically observed patterns of deformity seen in scoliosis (Stokes and Gardner-Morse, 1991).

Proprioception and balance

There is a suspicion that people who develop idiopathic scoliosis have an abnormality of the neuromuscular control of spinal posture (Herman, 1983). There have been several studies of these patients indicating some subtle asymmetry or abnormality of the proprioceptive postural balance, vestibular and even brainstem function. However, unfortunately none of these findings have yet been found to have diagnostic or prognostic power.

Pathomechanics of progressive curvature

As a general rule, an idiopathic scoliosis of greater than 20° Cobb is liable to progress if substantial growth potential remains (Lonstein and Carlson, 1984). A curve of 40° or greater is liable to progression (albeit at a much slower rate) beyond skeletal maturity (Bjerkreim and Hassan, 1982; Weinstein and Ponseti, 1983).

It is widely believed that the progression of scoliosis is controlled to a large extent by mechanical factors, especially the 'Hueter–Volkmann law' as described by Arkin (1949) and Roaf (1963). According to this theory, a vicious circle develops in which increased compression on the concave side of the curve decelerates growth while reduced compression on the convex side accelerates it. Roaf (1963) developed a rationale for the placement of staples on the vertebral bodies for treatment of scoliosis with varying degrees of kyphosis and lordosis. Scoles *et al.* (1991) considered that the progression of Scheuermann's hyperkyphosis is also mechanically modulated, based on histological comparisons of the vertebral end-plates with the growth plates from tibial plateaux with Blount's disease. However, there are several unanswered questions about the scientific basis for this theory of scoliosis progression. For instance, the normal spinal curvatures (kyphosis and lordosis) in the sagittal plane are of similar magnitude to the curvature of scoliosis which is at risk to progress. Why do the normal kyphosis and lordosis not progress into hyperkyphosis and hyperlordosis? Also, the relationship between loading and growth rate is probably not simple. Diaphyseal bone (as opposed to growth cartilage) can respond differently to mechanical compression. A child with a mal-union of a long bone will gradually remodel and straighten the diaphysis by a process through which tissue on the concave (compression) side experiences apposition of bone, whereas the tension side experiences resorption. Conversely, the alignment of teeth can be altered by means of orthodontic braces in such a way that compressed bone resorbs while bone on the opposite side of the tooth socket (the tension side) advances.

From a mechanical point of view, the difference in the force transmission between the convex and concave sides of an angular deformity must increase as the angulation of the deformity increases, and this may produce an effective threshold when rapid progression is to be expected. Development of the rotational deformity in the spine complicates this process further. The growth plates of long bones are also responsive to torsional loads (Arkin and Katz, 1956; Moreland, 1980), but the origin of such forces in the spine during scoliosis progression is not clear. Perdriolle *et al.* (1993) examined the shapes of vertebrae from individuals with scoliosis, and proposed that wedging deformation of vertebrae occurs preferentially on the concave side. They considered that this deformation was mechanically mediated, and part of a progression process of spinal 'torsion'. Asher and Cook (1995) studied a cross-sectional database of 181 patients using stereoradiography in order to test this hypothesis. They reported that for all common idiopathic scoliosis deformities, including compensatory curves, evolution occurs as a combination of lateral displacement of the apical vertebrae together with a rotation in a clockwise arc for right apex deformities and a counter-clockwise arc for left apex deformities.

Mechanical factors in the treatment of spinal deformities

In both conservative and surgical treatment of spinal deformities, forces are applied to the spine. In the case of surgery, the desired forces can usually be applied more directly. In the same way as the motion segment has six degrees of freedom, there are, in general, six distinct components to any deformity of the spine, and forces can be applied to correct each of these components. Thus, the mechanical treatment of spinal deformities can involve horizontal forces in the frontal or sagittal planes, distraction forces, lateral bending or flexion-extension moments, or moments in the transverse plane. In practice, precise control over the applied forces is difficult to achieve. However, both brace treatment and surgical treatments are evolving in an attempt to address the three-dimensional nature of most spinal deformities.

Non-surgical treatment of thoracic spinal deformities

Exercises and physical therapy

Although apparently based on the sound logic of selective strengthening of muscles and improvement of the trunk neuromuscular control apparatus, exercise therapy has been used mostly in the management of non-progressive scoliosis. White and Panjabi (1990) consider that the trunk muscles have little mechanical advantage from the perspective of curve correction in cases of marked deformity. Stone *et al.* (1979) studied 42 patients with 5-20° curves (by Cobb angle measurement) who performed trunk mobilizing and strengthening exercises, and compared them with 59 matched retrospective controls who did not. There was minimal change in scoliosis in both groups, reflecting the difficulty of studying progression of the deformity in a population of patients with a small proportion of 'progressors'. Recently, Weiss (1992) has claimed considerable success in preventing progression of scoliosis with a structured programme of exercises directed at muscle strengthening. Overall, very few clinicians feel that they can rely on exercise alone to prevent progression, and there is little scientific evidence of their value as an adjunct to other conservative treatment.

Braces

Brace treatment usually employs the principle of three-point application of forces. The middle force is directed at the region of maximal deformity, while equilibrium is provided by two additional forces at the extremes of the deformity (Fig. 4.9). The present trend in bracing for scoliosis is to attempt to control both sagittal curvature and frontal plane curvature at the same time.

The success of brace treatment is lessened by larger scoliosis curve magnitude (Montgomery and Willner, 1989), but the reasons why this treatment is not always successful remain unclear. The changes in spinal shape with brace wearing are complex. Willner (1984) found that the Boston brace produces simultaneous reduction of both scoliosis and lordosis curvature in the lumbar region, but reduced scoliosis alone in the thoracic region. Changes in skeletal configuration (spine and ribcage) of 31 patients with right thoracic scoliosis were recorded by Labelle *et al.* (1992), using stereoradiography. They found that both the coronal and sagittal plane curvatures were reduced, leaving the plane of maximum curvature virtually unchanged. There was no significant improvement in vertebral rotation, but the ribs on the right (convex) side became more angled downwards.

Braces apply forces directly to the trunk, but they may also encourage patients to recruit their own muscles in a beneficial way (passive and active theories of brace function). However, muscular activity within a Boston brace was monitored by Wynarsky and Schultz (1989), who found little evidence that this second (active) mechanism is significant. Wynarsky and Schultz (1991) used a biomechanical model of the spine and ribcage to determine the locations and magnitudes of the passive brace forces, and the trunk muscle groups and their corresponding contraction intensity magnitudes that would optimally correct the scoliosis deformity of the spine. They inferred, based on a comparison of model results with long-term clinical results, that even under optimal conditions it is unlikely that a scoliosis can be fully corrected either by passive brace forces or by active muscle contractions.

Electrical stimulation of trunk muscles

Electrical stimulation of muscles for correction of scoliosis (Axelgaard *et al.*, 1983) is not effective in preventing scoliosis progression (Durham *et al.*, 1990; Nachemson and Peterson, 1995). Despite this lack of clinical success, modelling studies (Schultz *et al.*, 1981) suggest that many of the trunk muscles are well placed to provide correction forces. It is still not clear what biomechanical or other principles underlie successful conservative treatment of scoliosis. The brace or the electrical stimulation might apply forces which then modify bony growth and development. Alternatively, the chronic stimulation of muscles might change the resting length or tension of these muscles, thus preventing progression. Initially, the treatment appeared promising and was used only at night. Recently, the idea of night-time brace treatment has also become popular (Price *et al.*, 1990). Night treatment raises the fundamental question about how a spinal deformity responds to force application. Although the activity of bone cells has diurnal variations, it seems that providing a stimulus during the night hours is sufficient to produce the desired response in the case of orthodontic bracing. Unanswered questions remain about the underlying bone and muscle biology.

Surgical treatment of thoracic spinal deformities

A severe scoliosis can be prevented from progressing further by surgical fusion of the affected part of the spine. This also produces a loss of spinal motion, and there may be a loss of respiratory function. However, these consequences may be less severe than if surgery were not undertaken. There has been a rapid development in recent years in the complexity of surgical instrumentation and the number of options available to surgeons. New options include anterior instrumentation, sublaminar or spinous process wiring, curved rods which are rotated during surgery (Cotrel-Dubousset instrumentation), and a proliferation of possibilities provided by pedicle screw fixation to vertebrae. These developments in instrumentation design provide new possibilities for the application of complex combination of forces to the spine as well as providing increased rigidity of the final construct and, consequently, a more rapid postoperative recovery, often without the need for postoperative bracing.

Spinal surgeons now face complex surgical planning decisions as a result of these developments in the complexity of spinal instrumentation systems, and the information available to help them make decisions is extensive. Mechanical studies in the laboratory provide information on strength and flexibility of constructs applied to animal or human cadaver spines. Animal experiments have been used to gain insight into the fate of both the instrumentation and the spinal fusion *in vivo*. In principle, if the mechanical properties of both the spine and the instrumentation were understood completely, then biomechanical models could predict the outcome of surgery. There have been a number of attempts to develop such models (e.g. Schultz and Hirsch, 1974; Stokes and Gardner-Morse, 1993) but they have not been sufficiently accurate to justify their use in individualized surgical planning.

After the completion of surgery, the process of graft incorporation begins. More rigid fixation promotes more rapid fusion, but there has been some concern that extremely rigid fixation techniques would also produce 'stress shielding' of bone, resulting in osteopenia. This was found in dogs (McAfee *et al.*, 1991) but not in goats (Johnston *et al.*, 1990), and it does not appear to be significant in humans. Laboratory testing of a spinal construct (consisting of a test instrumentation applied to a standardized spinal specimen) demands a laboratory test which is representative of *in vivo* conditions. Without standardization, comparisons between instrumentation systems and surgical options are difficult to interpret (Ashman *et al.*, 1988; Panjabi, 1988).

In the paediatric spine, the question of graft placement is especially important in the presence of continuing growth. The tethering effect of a posterior fusion can produce continuing development of deformity of the vertebral column around the axis of the instrumentation, and this is known as the 'crankshaft phenomenon' (Shufflebarger and Clark, 1991).

Surgical instrumentation gives surgeons considerable control over the part of the spine on which they operate, but much less control over the unfused regions. This has manifested itself as the problem of 'balance' or 'decompensation' associated with modern rigid segmental instrumentation techniques. Preoperative lateral bending radiographs have been recommended as a way to assess the regional flexibility of the spine and its probable response to a long fusion.

Conclusions

The spine is a complex, flexible structure, which is difficult to understand biomechanically. Each motion segment has six degrees of freedom which interact with each other, and this complexity, combined with the inherent curvatures of the spine and the complex anatomy of the muscles and ligaments, produces biomechanical behaviour which is difficult to predict. However, it seems that if the underlying biology that relates mechanical factors to biological responses were better understood, then new possibilities would emerge for effective treatments.

References

Andersson, G.B.J., Winters, J.M. (1990) Role of muscle in postural tasks: Spinal loading and postural stability. *Multiple Muscle Systems. Biomechanics and Movement Organization*. New York: Springer-Verlag, Ch. 3.

Arkin, A.M. (1949) The mechanism of the structural changes in scoliosis. *J. Bone Joint Surg.* **31A:** 519-528.

Arkin, A.M. (1950) The mechanism of rotation in combination with lateral deviation in the normal spine. *J. Bone Joint Surg.* **32:** 180-188.

Arkin, A.M., Katz, J.F. (1956) The effects of pressure on epiphyseal growth. The mechanism of plasticity of growing bone. *J. Bone Joint Surg.* **38A:** 1056-1076.

Asher, M.A., Cook, L.T. (1995) The transverse plane evolution of the most common adolescent idiopathic scoliosis deformities. A cross-sectional study of 181 patients. *Spine* **20:** 1386-1391.

Ashman, R.B., Birch, J.G., Bone, L.B. *et al.* (1988) Mechanical testing of spinal instrumentation. *Clin. Orthop.* **227:** 113-125.

Ashton-Miller, J.A., Schultz, A.B. (1991) Spine instability and segmental hypermobility biomechanics: A call for the definition and standard use of terms. *Sem. Spine Surg.* **3:** 136-148.

Axelgaard, L., Nordwall, K., Brown, J.C. (1983) Correction of spinal curvatures by transcutaneous electrical muscle stimulation. *Spine* **8:** 463-481.

Beck, A., Killus, J. (1973) Normal posture of spine determined by mathematical and statistical methods. *Aerospace Med.* **44:** 1277-1281.

Bergmark, A. (1989) Stability of the lumbar spine. A study in mechanical engineering. *Acta Orthop. Scand.* **230 (Suppl.).**

Bjerkreim, I., Hassan, I. (1982) Progression in untreated idiopathic scoliosis after end of growth. *Acta Orthop. Scand.* **53:** 897-900.

Brinckmann, P., Frobin, W., Hierhoizer, E. *et al.* (1983) Deformation of the vertebral endplate under axial loading of the spine. *Spine* **8:** 851-856.

Brown, C.W., Deffer, P.A. Jr, Mmakjian, J. *et al.* (1992) The natural history of thoracic disc herniation. *Spine* **17 (Suppl.):** S97-102.

Burwell, R.G., James, N.J., Johnson, F. *et al.* (1983) Standardized trunk asymmetry scores; A study of back contour in healthy school children. *J. Bone Joint Surg.* **65B:** 452-463.

Carr, A.J., Jefferson, R.J., Turner-Smith, A.R. *et al.* (1991) An analysis of normal back shape measured by ISIS scanning. *Spine* **16:** 656-659.

Clark, G.A., Hall, N.R., Armelagos, G.J. *et al.* (1986) Poor growth prior to early childhood: decreased health and life-span in the adult. *Am. J. Phys. Anthropol.* **70:** 145-160.

Craven, T.G., Carson, W.L., Asher, M.A. *et al.* (1994) The effects of implant stiffness on the bypassed bone mineral density and facet fusion stiffness of the canine spine. *Spine* **19:** 1664-1673.

Crisco, J.J. III, Panjabi, M.M. (1991) The intersegmental and multisegmental muscles of the lumbar spine. A biomechanical model comparing lateral stabilizing potential. *Spine* **16:** 793-799.

Davies, K.M., Recker, R.R., Heaney, R.P. (1989) Normal vertebral dimensions and normal variation in serial measurements of vertebrae. *J. Bone Min. Res.* **4:** 341-349.

Denis, F. (1984) Spinal instability as defined by the three-column spine concept. *Clin. Orthop.* **189:** 65-76.

De Troyer, A., Kelly, S., Zin, W.A. (1983) Mechanical action of the intercostal muscles on the ribs. *Science* **220:** 87-88.

Dickson, R.A., Deacon, P. (1987) Annotation. Spinal growth. *J. Bone Joint Surg.* **69B:** 690-692.

Dickson, R.A., Lawton, J.O., Archer, L.K. *et al.* (1984) The pathogenesis of idiopathic scoliosis. Biplanar spinal asymmetry. *J. Bone Joint Surg.* **66B:** 8-15.

Dolan, P., Adams, M.A., Hutton, W.C. (1988) Commonly adopted postures and their effect on the lumbar spine. *Spine* **13:** 197-201.

Drummond, D.S., Rogala, E.J. (1980) Growth and maturation of adolescents with idiopathic scoliosis. *Spine* **5:** 507-511.

Durham, J.W., Moskowitz, K., Whitney, J. (1990) Surface electrical stimulation versus brace in treatment of idiopathic scoliosis. *Spine* **15:** 888-892.

Eastell, R., Cedel, S.L., Wahner, H.W. *et al.* (1991) Classification of vertebral fractures. *J. Bone Min. Res.* **6(3):** 207-215.

Ferguson, R.L., Alien, B.L. (1984) A mechanistic classification of thoracolumbar spine fracture. *Clin. Orthop.* **189:** 77-88.

Fon, G.T., Pitt, M.J., Thies, A.C. Jr (1980) Thoracic kyphosis: range in normal subjects. *A.J.R.* **134:** 979-983.

Gajdosik, R.L., Albert, C.R., Mitman, J.J. (1994) Influence of hamstring length on the standing position and flexion range of motion of the pelvic angle, lumbar angle, and thoracic angle. *J. Orthop. Sports. Phys. Ther.* **20:** 213-219.

Gardner-Morse, M.G., Laible, J.P., Stokes, I.A.F. (1990) Incorporation of spinal flexibility measurements into finite element analysis. *J Biomech. Eng.* **112:** 481-483.

Gardner-Morse, M., Stokes, I.A.F., Laible, J.P. (1995) Role of muscles in lumbar spine stability in maximum extension efforts. *J. Orthop. Res.* **13:** 802-808.

Gelb, D.E., Lenke, L.G., Bridwell, K.H. *et al.* (1995) An analysis of sagittal spinal alignment in 100 asymptomatic middle and older aged volunteers. *Spine* **20:** 1351-1358.

Giles, L.G.F. (1997) Zygapophysial (facet) joints. In: *Clinical Anatomy and Management of Low Back Pain* (Giles, L.G.F., Singer, K.P., eds). Oxford: Butterworth-Heinemann.

Goel, V.K., Gilbertson, L.G. (1995) Applications of the finite element method to thoracolumbar spinal research - past, present, and future. *Spine* **20:** 1719-1727.

Goel, V.K., Monroe, B.T., Gilbertson, L.G. *et al.* (1995) Interlaminar shear stresses and laminae separation in a disc. Finite element analysis of the L3-L4 motion segment subjected to axial compressive loads. *Spine* **20:** 689-698.

Goodwin, R.R., James, K.S., Daniels, A.U. *et al.* (1994) Distraction and compression loads enhance spine torsional stiffness. *J. Biomech.* **27:**1049-1057.

Gregersen, G.G., Lucas, D.B. (1967) An in vivo study of the axial rotation of the human thoracolumbar spine. *J. Bone Joint Surg.* **49:** 247-262.

Hanssen, T., Roos, B. (1981) Microcalluses of the trabeculae in lumbar vertebrae and their relation to the bone mineral content. *Spine* **6:** 375-380.

Hart, D.L., Rose, S.J. (1986) Reliability of a noninvasive method for measuring the lumbar curve. *J. Orthop. Sports Phys. Ther.* **8:** 180-184.

Herman, R., Mixon, J, Fisher, A. *et al.* (1985) Idiopathic scoliosis and the central nervous system: a motor control problem. *Spine* **10:** 1-14.

Herreby, M., Neergaard, K., Hesselsoe, G. *et al.* (1995) Are radiologic changes in the thoracic and lumbar spine of adolescents risk factors for low back pain in adults? *Spine* **20:** 2298-2302.

Herzog, W., Conway, P.J., Kawchuk, G.N. *et al.* (1993) Forces exerted during spinal manipulative therapy. *Spine* **18:** 1206-1212.

Holdsworth, F. (1970) Fractures, dislocations and fracture dislocations of the spine. *J. Bone Joint Surg.* **52A:** 1534-1551.

Holm, S., Nachemson, A. (1983) Variations in the nutrition of the canine intervertebral disc induced by motion. *Spine* **8:** 866-874.

Janevic, J., Ashton-Miller, J.A., Schultz, A.B. (1991) Large compressive preloads decrease lumbar motion segment flexibility. *J. Orthop. Res.* **9:** 228-236.

Jarvis, J.G., Ashman, R.B., Johnston, C.E. *et al.* (1988) The posterior tether in scoliosis. *Clin. Orthop.* **227:** 126-134.

Jiang, H., Raso, J.V., Moreau, M.J. *et al.* (1994) Quantitative morphology of the lateral ligaments of the spine. Assessment of their importance in maintaining lateral stability. *Spine* **19:** 2676-2682.

Johnston, C.E. II, Ashman, R.B., Baird, A.M. *et al.* (1990) Effect of spinal construct stiffness on early fusion mass incorporation. Experimental study. *Spine* **15:** 908-912.

Jordanogiou, J. (1969) Rib movement in health, kyphoscoliosis, and ankylosing spondylitis. *Thorax* **24:** 407-414.

Keller, T.S., Holm, S.H., Hansson, T.H. *et al.* (1990) Volvo Award in experimental studies. The dependence of intervertebral disc mechanical properties on physiologic conditions. *Spine* **15:** 751-761.

Krag, M.H., Seroussi, R.E., Wilder, D.G. *et al.* (1987) Internal displacement distribution from in vitro loading of human thoracic and lumbar spinal motion segments: experimental results and theoretical predictions. *Spine* **12:** 1001-1007.

Labelle, H., Dansereau, J., Bellefleur, Q. *et al.* (1992) 3-D study of the immediate effect of the Boston brace on the scoliotic lumbar spine (in French). *Ann. Chirurgie* **46:** 814-820.

Lee, M., Kelly, D.W., Steven, G.P. (1995) A model of the spine, ribcage and pelvic responses to a specific lumbar manipulative force in relaxed subjects. *J. Biomech.* **28:** 1403-1408.

Lonstein, J.E., Carlson, J.M. (1984) The prediction of curve progression in untreated idiopathic scoliosis during growth. *J. Bone Joint Surg.* **66A:** 1061-1071.

Loring, S.H., Woodbridge, J.A. (1991) Intercostal muscle action inferred from finite-element analysis. *J. Appl. Physiol.* **70:** 2712-2718.

Lovett, R.W. (1905) The mechanism of the normal spine and its relation to scoliosis. *Boston Med. Surg. J.* **153:** 349-358

Maiman D.J., Yoganandan N. (1990) Biomechanics of cervical spine trauma. *Clin. Neurosurg.* **37:** 543-570.

Malmivaara, A., Videman, T., Kuosma, E. *et al.* (1987) Facet joint orientation, facet and costovertebral joint osteoarthrosis, disc degeneration, vertebral body osteophytosis, and Schmorl's nodes in the thoracolumbar junctional region of cadaveric spines. *Spine* **12:** 458-463.

McAfee, P.C., Farey, I.D., Sutterlin, C.E. *et al* (1991) The effect of spinal implant rigidity on vertebral bone density. *Spine* **16:** S190-S197.

McCubbrey, D.A., Cody, D.D., Peterson, E.L. *et al.* (1995) Static and fatigue failure properties of thoracic and lumbar vertebral bodies and their relation to regional density. *J. Biomech.* **28:** 891-899.

McGowan, D.I.P., Hipp, J.A., Takeuchi, T. *et al.* (1993) Strength reductions from trabecular destruction within thoracic vertebrae. *J. Spinal Dis.* **6:** 130-136.

Minotti, P., Lexcellent, C. (1991) Geometric and kinematic modelling of a human costal slice. *J. Biomech.* **24:** 213-221.

Montgomery, F., Willner, S. (1989) Prognosis of brace-treated scoliosis. Comparison of the Boston and Milwaukee methods in 244 girls. *Acta Orthop. Scand.* **60:** 383-385.

Moreland, M.S. (1980) Morphological effects of torsion applied to growing bone. An *in vivo* study in rabbits. *J. Bone Joint Surg. (Br)* **62B:** 230-237.

Morris, J.M., Lucas, D.B., Bresler, M.S. (1961) The role of the trunk in stability of the spine. *J. Bone Joint Surg.* **43A:** 327-351.

Myklebust, J.B., Pintar, F., Yoganandan, N. *et al.* (1988) Tensile strength of spinal ligaments. *Spine* **13:** 526-531.

Nachemson, A.L., Peterson, L.E. (1995) Effectiveness of treatment with a brace in girls who have adolescent idiopathic scoliosis. A prospective, controlled study based on data from the Brace Study of the Scoliosis Research Society. *J. Bone Joint Surg.* **77:** 815-822.

Nachemson, A., Sahlstrand, T. (1977) Etiologic factors in adolescent idiopathic scoliosis. *Spine* **2:** 176-184.

Openshaw, P., Edwards, S., Helms, P. (1984) Changes in rib cage geometry during childhood. *Thorax* **39:** 624-627.

Oxland, T.R., Lin, R.M., Panjabi, M.M. (1992) Three-dimensional mechanical properties of the thoracolumbar junction. *J. Orthop. Res.* **10:** 573-580.

Panjabi, M.M. (1988) Biomechanical evaluation of spinal fixation devices: 1. Conceptual framework. *Spine* **13:** 1129-1134.

Panjabi, M.M., Brand, R.M., White, A.A. (1976) Three-dimensional flexibility and stiffness properties of the human thoracic spine. *J. Biomech.* **9:** 185-192.

Panjabi, M.M., Hausfield, J.N., White, A.A. (1981) A biomechanical study of the ligamentous stability of the thoracic spine in man. *Acta Orthop. Scand.* **52:** 315-326.

Panjabi, M.M., Krag, M.H., Chung, T.Q. (1984) Effects of disc injury on mechanical behaviour of the human spine. *Spine* **9:** 707-713.

Panjabi, M., Abumi, K., Duranceau, J. *et al.* (1989) Spinal stability and intersegmental muscle forces. A biomechanical model. *Spine* **14:** 194-200.

Panjabi, M.M., Takata, K., Goel, V.J. (1991) Thoracic human vertebrae: quantitative three-dimensional anatomy. *Spine* **16:** 888-901.

Panjabi, M.M., Oxland, T., Takata, K. *et al.* (1993) Articular facets of the human spine. Quantitative three-dimensional anatomy. *Spine* **18:** 1298-1310.

Panjabi, M.M., Oxland, T.R., Kifune, M. *et al.* (1995a) Validity of the three-column theory of thoracolumbar fractures. A biomechanic investigation. *Spine* **20:** 1122-1127.

Panjabi, M.M., Kifune, M., Wen, L. *et al.* (1995b) Dynamic canal encroachment during thoracolumbar burst fractures. *J. Spinal Dis.* **8:** 39-48.

Perdriolle, R., Becchetti, S., Vidal, J. *et al.* (1993) Mechanical process and growth cartilages. Essential factors in the progression of scoliosis. *Spine* **18:** 343-349.

Porter, R.W. and Pavitt, D. (1987) The vertebral canal: I. Nutrition and Development. *Spine* **12:** 901-906.

Price, C.T., Scott, D.S., Reed, F.E. *et al.* (1990) Night-time bracing for adolescent idiopathic scoliosis with the Charleston bending brace. Preliminary report. *Spine* **15:** 1294-1299.

Propst-Proctor, S.L., Bleck, E.E. (1983) Radiographic determination of lordosis and kyphosis in normal and scoliotic children. *J. Pediatr. Orthop.* **3:** 344-346.

Riggs, B.L., Wahner, H.W., Melton, W. *et al.* (1986) Rates of bone loss in the appendicular and axial skeletons of women. Evidence of substantial vertebral bone loss before menopause. *J. Clin. Invest.* **5:** 1487-1491.

Roaf, R. (1963) The treatment of progressive scoliosis by unilateral growth-arrest. *J. Bone Joint Surg.* **45:** 637-651.

Robin, G.C. (1990) *The Aetiology of Scoliosis. A Review of a Century of Research.* Boca Raton: CRC Press.

Rubin, C.T., Lanyon, L.E. (1987) Osteoregulatory nature of mechanical stimuli: Function as a determinant for adaptive remodelling in bone. *J. Ortho. Res.* **5:** 300-310.

Saumarez, R.C. (1986) An analysis of possible movements of human upper rib cage. *J. Appl. Physiol.* **60:** 678-689.

Schultz, A.B., Benson, D.R., Hirsch, C. (1974) Force-deformation properties of human costo-sternal and costovertebral articulations. *J. Biomech.* **7:** 311-318.

Schultz, A., Haderspeck, K., Takashima, S. (1981) Correction of scoliosis by muscle stimulation. Biomechanical analyses. *Spine* **6:** 468-476.

Schultz, A.B., Kirsch, C. (1974) Mechanical analysis of techniques for improved correction of idiopathic scoliosis. *Clin. Ortho. Rel., Res.* **100:** 66-73.

Schultz, A.B., Sörenson S.-E., Andersson, G.B.J. (1984) Measurement of spine morphology in children, ages 10-16. *Spine* **9:** 70-73.

Scoles, P.V., Latimer, B.M., DiGiovanni, B.F. *et al.* (1991) Vertebral alterations in Scheuermann's kyphosis. *Spine* **16:** 509-515.

Shufflebarger, H.L. and Clark, C.E. (1991) Prevention of the crankshaft phenomenon. *Spine* **16:** S409-S411.

Simril, W.A., Thurston, D. (1955) The normal interpediculate space in the spines of infants and children. *Radiology* **64:** 340-347

Singer, K.P. (1989) The thoracolumbar mortice joint. Radiological and histological observations. *Clin. Biomech.* **4:** 137-143.

Singer, K.P., Breidahl, P.D. and Day, R.E. (1989a) Posterior element variation at the thoracolumbar transition. A morphometric study using computed tomography. *Clin. Biomech.* **4:** 80-86.

Singer, K.P., Day, R.E., Breidahl, P.D. (1989b) In vivo axial rotation at the thoracolumbar junction: an investigation using low dose CT in healthy male volunteers. *Clin. Biomech.* **4:** 145-150.

Singer, K.P., Edmondston, S.J., Day, R. *et al.* (1995) Prediction of thoracic and lumbar vertebral body compressive strength; correlations with bone mineral density and vertebral region. *Bone* **17:** 167-174.

Singer, K.P., Jones, T.J., Briedahl, P.D. (1990) A comparison of radiographic and computer-assisted measurement of thoracic and thoracolumbar sagittal curvature. *Skel. Rad.* **19:** 21-26.

Skogland, L.B., Miller, J.A.A. (1981) The length and proportions of the thoracolumbar spine in children with idiopathic scoliosis. *Acta Orthop. Scand.* **52:** 177-185.

Smith-Bindman, R., Cummings, S.R., Steiger, P. *et al.* (1991) A comparison of morphometric definitions of vertebral fracture. *J. Bone Min. Res.* **6:** 25-34.

Snow-Harter, C., Bouxsein, M., Lewis, B. *et al.* (1990) Muscle strength as a predictor of bone mineral density in young women. *J. Bone Min. Res.* **5:** 589-595.

Somerville, E.W. (1952) Rotational lordosis: The development of the single curve. *J. Bone Joint Surg.* **34:** 421-427.

Stagnara, P., Demauroy, W., Dran, G. *et al.* (1982) Reciprocal angulation of vertebral bodies in a sagittal plane: Approach to references for the evaluation of kyphosis and lordosis. *Spine* **7:** 335-342.

Stokes, I.A.F. (1988) Mechanical function of facet joints in the lumbar spine. *Clin. Biomech.* **3:** 101-105.

Stokes, I.A.F., Gardner-Morse, M. (1991) Analysis of the interaction between spinal lateral deviation and axial rotation in scoliosis. *J. Biomech.* **24:** 753-759.

Stokes, I.A.F., Gardner-Morse, M. (1993) Three-dimensional simulation of Harrington distraction instrumentation for surgical correction of scoliosis. *Spine* **18:** 2457-2464.

Stokes, I.A.F., Laible, J.P. (1990) Three-dimensional osseo-ligamentous model of the thorax representing initiation of scoliosis by asymmetric growth. *J. Biomech.* **23:** 589-595

Stone, B., Beekman, C., Hall, V. *et al.* (1979) The effect of an exercise program on change in curve in adolescents with minimal idiopathic scoliosis. A preliminary study. *Phys. Ther.* **59:** 759-763.

Triano, J.J. (1992) Studies on the biomechanical effect of a spinal adjustment. *J.M.P.T.* **15:** 71-75.

Tulsi, R.S. (1971) Growth of the human vertebral column. An osteological study. *Acta Anat.* **79:** 570-580.

Urban, J.P.G., Holm, S., Maroudas, A. *et al.* (1982) Nutrition of the intervertebral disc. Effect of fluid flow on solute transport. *Clin. Orthop.* **170:** 296-302.

Vercauteren, M., van Beneden, M., Verplaetse, R. *et al.* (1982) Trunk asymmetries in a Belgian school population. *Spine* **7:** 555-562.

Weinstein, S.L., Ponseti, I.V. (1983) Curve progression in idiopathic scoliosis. *J. Bone Joint Surg.* **65:** 447-455.

Weiss, H.R. (1992) Influence of an inpatient exercise program on scoliotic curve. *Ital. J. Orthop. Traumatol.* **18:** 395-406.

White, A.A. (1971) Kinematics of the normal spine as related to scoliosis. *J. Biomech.* **4:** 405-411.

White, A.A., Panjabi, M.M. (1971) The significance of the vertebral posterior elements for the mechanics of the thoracic spine. *Clin. Orthop.* **81:** 2-14.

White, A.A., Panjabi, M.M. (1978) *Clinical Biomechanics of the Spine*. Philadelphia: Lippincott Co., pp. 122-184.

White, A.A., Panjabi, M.M. (1990) *Clinical Biomechanics of the Spine*, 2nd edn. Philadelphia: Lippincott Co., p. 145.

Willner, S. (1984) Effect of the Boston thoracic brace on the frontal and sagittal curves of the spine. *Acta Orthop. Scand.* **55:** 457-460.

Willner, S., Johnson, B. (1983) Thoracic kyphosis and lumbar lordosis during the growth period in children. *Acta Pediatr. Scand.* **72:** 873-878.

Wilson, T.A., Rehde, R.K., Krayer, S. *et al.* (1987) Geometry and respiratory displacement of human ribs. *J. Appl. Physiol.* **62:** 1872-1877.

Wing, P., Tsang, I., Gagnon, F. (1992) Diurnal changes in the profile shape and range of motion of the back. *Spine* **17:** 761-766.

Wynarsky, G.T., Schultz, A.B. (1989) Trunk muscle activities in braced scoliosis patients. *Spine* **14:** 1283-1286.

Wynarsky, G.T., Schultz, A.B. (1991) Optimization of skeletal configuration: Studies of scoliosis correction biomechanics. *J. Biomech.* **24:** 721-732.

5

Pathology of the thoracic spine

K. P. Singer

The purpose of this chapter is to highlight structural and visceral pathologies that involve the thoracic spine, as a background to the assessment and management of conditions affecting the thorax.

There are relatively few reports that document patterns of thoracic spine pathology, compared with the published literature on the lumbar and cervical regions. When the thoracic degenerative pathologies are viewed collectively (Fig. 5.1), they show a trend which implicates the middle and lower regions, with the lowest prevalence (apart from costovertebral joint degeneration) in the upper thoracic segments.

Patterns of pathological changes in the thoracic spine

The major pathological conditions have been classified into those of an inflammatory, degenerative, metabolic, infective or metastatic aetiology, those involving anomalies of spinal curvature or which are secondary to trauma, and those with a medical (visceral) basis. The references provide the interested reader with an introduction to both the historical and contemporary literature. Table 5.1 provides a summary of the major conditions that are reviewed in this chapter.

Inflammatory rheumatic conditions

Ankylosing spondylitis

Ankylosing spondylitis (AS) is an inflammatory disorder associated with the HLA-B27 antigen, which occurs in 90–95% of patients with AS (Bullough and Boachie-Adjei, 1988). It involves synovial and cartilaginous joints, as well as sites of tendon and ligamentous attachment, and predominantly affects young Caucasian men with onset commonly between late adolescence and 35 years of age. There is a familial and racial bias in the reported prevalence due to the variable frequency of HLA-B27 in different

Table 5.1 *General pathology classification for conditions directly involving or referring symptoms to the thoracic spine*

Inflammatory/rheumatic
- Ankylosing spondylosis
- Diffuse idiopathic skeletal hyperostosis

Degenerative
- Costovertebral and zygapophysial joint osteoarthrosis
- Degenerative disc disease, osteophytosis and ossification
- Schmorl's nodes and end-plate lesions
- Scheuermann's disease

Metabolic
- Osteoporosis and osteoporotic fracture

Infective
- Osteomyelitis

Tumours
- Metastatic
- Benign

Spinal curvature anomalies
- Scoliosis
- Kyphosis

Trauma
- Thoracic spinal trauma
- Transitional junction trauma
- Thoracic disc prolapse

Medical
- Visceral dysfunction

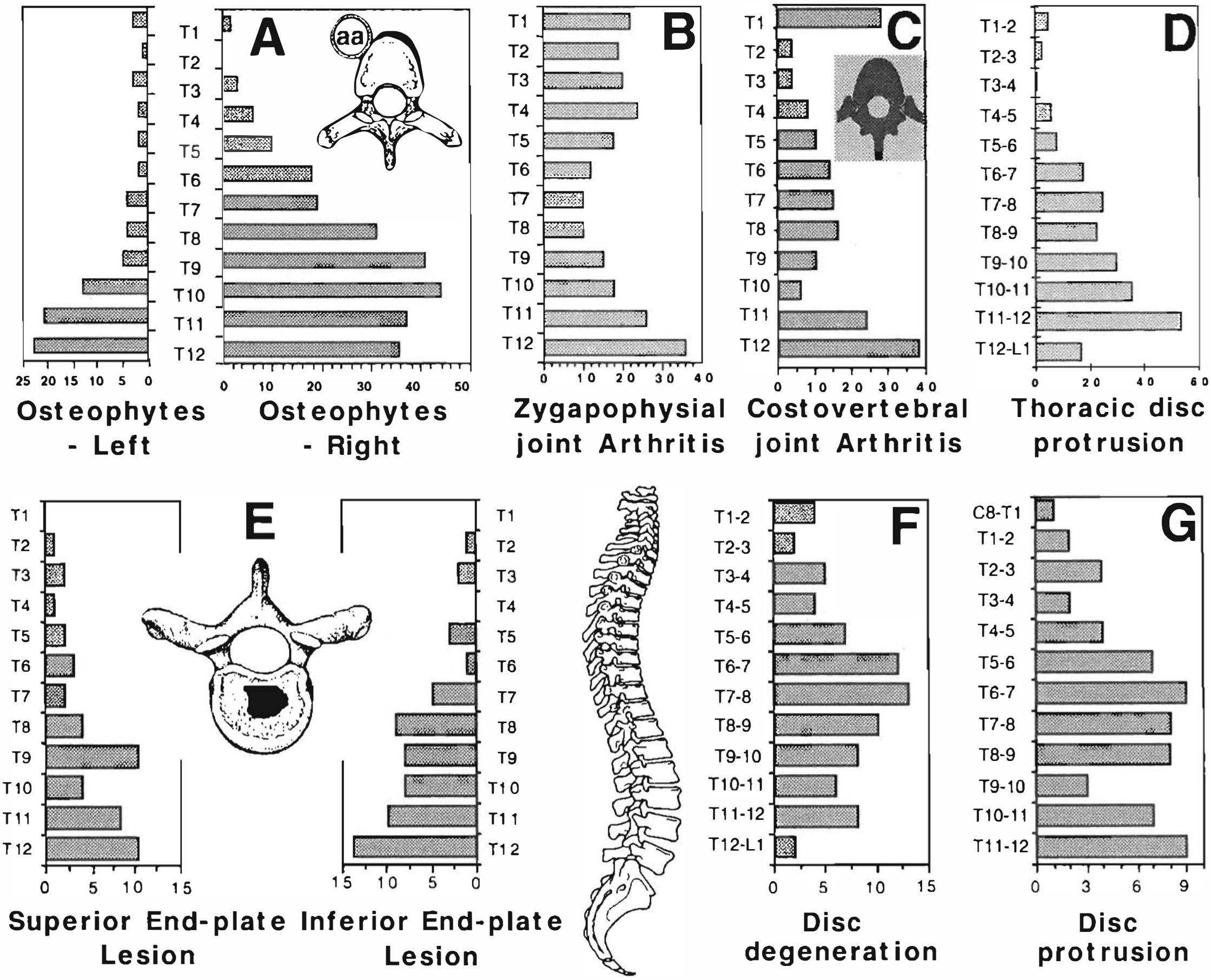

Fig. 5.1 A composite representation of reported pathological changes to the joints and intervertebral discs of the thoracic spine. (A) From studies by Nathan (1962), vertebral body osteophytes are shown to increase in size in a caudal direction and to occur predominantly on the right side of the vertebral body, due to the presence of the descending abdominal aorta (aa). (B) From a large osteological survey by Shore (1935), the upper and lower zygapophysial joints of the thoracic region demonstrated greatest evidence of osteoarthritic changes, which increased in extent towards the thoracolumbar junction. (C) Degenerative changes of the costovertebral joints are most prevalent at the first and last two thoracic vertebrae, a consequence of large muscle actions exerted on these ribs (Nathan *et al.*, 1964). (D) The surgical prevalence of thoracic disc herniation indicates an increasing incidence towards the last mobile segment above the thoracolumbar transitional junction (Singer, 1997). (E) Vertebral body end-plate lesions, inclusive of Schmorl's nodes, are shown to occur predominantly in the lower thoracic segments, and are most prevalent in the inferior vertebral end-plate (Crawford, 1994). (F) The most severe disc degeneration has been identified in the middle thoracic segments from radiological surveys (Lawrence, 1977). (G) In slight contrast to the surgical prevalence (D), the identification of small thoracic disc protrusions at post-mortem revealed an increasing caudal trend for the mid-thoracic segments (Crawford, 1994); note the different pattern at post-mortem compared with the surgical summary (D). Consistent with surgical reports, few disc protrusions were identified in the highest segments (D and G).

populations; however, the exact aetiology remains obscure (Tribus *et al.*, 1998). The prevalence given ranges from 0.1-1.5% of the population, varying according to the nature of the assessment (Resnick and Niwayama, 1995a).

Typically, patients present initially with bilateral sacroiliitis, lumbar stiffness and thoracolumbar junction (TLJ) back pain. Trunk muscle atrophy, a recognized feature of patients with AS, may contribute to a tendency to an increased thoracic kyphosis. Owing to involvement of the costal joints and costochondral junction, patients may find deep inspiration painful, resulting in limited thoracic expansion. The disease process typically involves: joint erosions, sclerosis of subchondral bone, widening of the joint spaces, and proliferation of bony

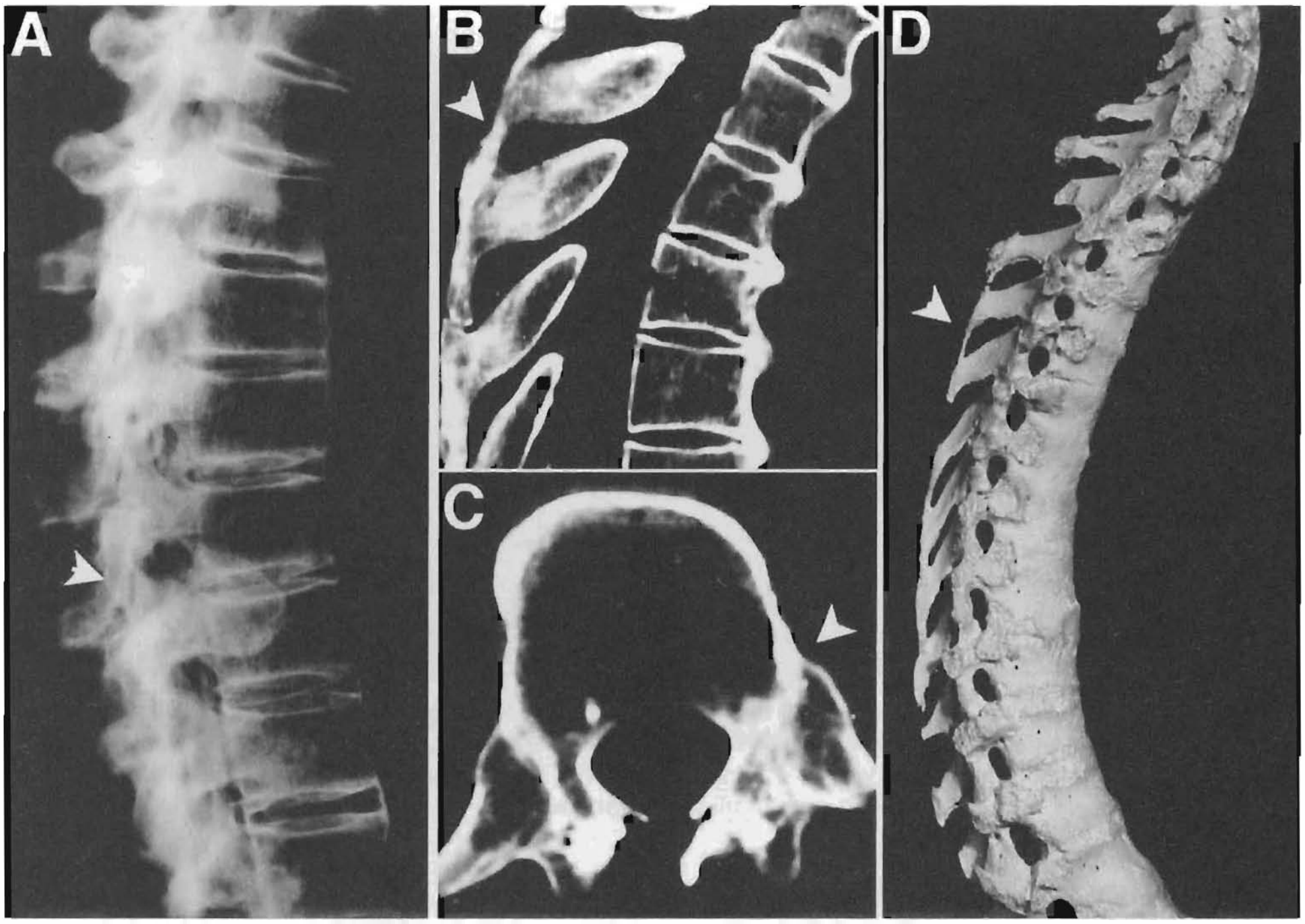

Fig. 5.2 Ossification of spinal ligaments is contrasted in (A), which shows a thoracic spine with thin lucent lines continuing across the face of the intervertebral discs. The zygapophysial joint space is still seen in this projection. Flowing ossification of the interspinous ligament and bridging osteophytes are depicted in (B), which is characteristic of diffuse idiopathic skeletal hyperostosis (DISH). Complete rib head ossification, in this case with ankylosing spondylitis, is shown at (C), with a completely ankylosed spinal column depicted at (D).

changes leading to eventual ankylosis (Resnick and Niwayama, 1995a) (Fig. 5.2D).

Ossification of the outer layers of the anulus fibrosus produces syndesmophytes, which extend across the surface of the intervertebral disc (IVD) and eventually bridge the disc space (Fig. 5.2A). In this manner they may be distinguished from spinal osteophytes, which project several millimetres from the discovertebral junction. Ankylosis of the zygapophysial, costovertebral and costotransverse joints follows, resulting in an immobile, fused spine, as depicted in Fig. 5.2C, D. Posterior interspinous and supraspinous ligament ossification is also a feature (Fig. 5.2B–D). The natural history of the disease is of a slow benign progression without remission (Vernon-Roberts, 1994). In 20% of this population the disease progresses to the point of marked disability, particularly when hip joint involvement develops.

Concurrent with this disease may be vertebral osteoporosis, which increases the susceptibility to spinal fracture (Ralston *et al.*, 1990; Tico *et al.*, 1998). When fractures are present, the vertebral end-plates may deform to give the radiographic appearance of ballooned discs.

Diffuse idiopathic skeletal hyperostosis

Ankylosing hyperostosis of the spine or DISH results in ossification of spinal ligaments without marked disc disease. Typically this condition affects older men, being uncommon in those younger than 40 years, and does not usually result in severe disability (Weinfeld *et al.*, 1997). The pathology of DISH also can involve bone spur formation (enthesophytes) within periarticular ligaments of other large joints. This extraspinal disease may produce more disability than the spinal form of DISH. Common extraspinal sites are the posterior heel, the superior pole of the patella, the ischeal tuberosities, olecranon processes, glenohumeral and hip joints (Sutro *et al.*, 1956). Occasionally a bony mass may be palpable within the substance of tendons at their insertion (Utsinger, 1985).

This condition may be largely asymptomatic; however, when symptoms are present they commonly consist of spinal stiffness, particularly in the morning, and thoracic back pain; with spinal tenderness reported to be present in 90% of a series by Utsinger (1985). Loss of spinal mobility, and occasionally thoracic cage motion, can be a feature (Resnick and Niwayama, 1976).

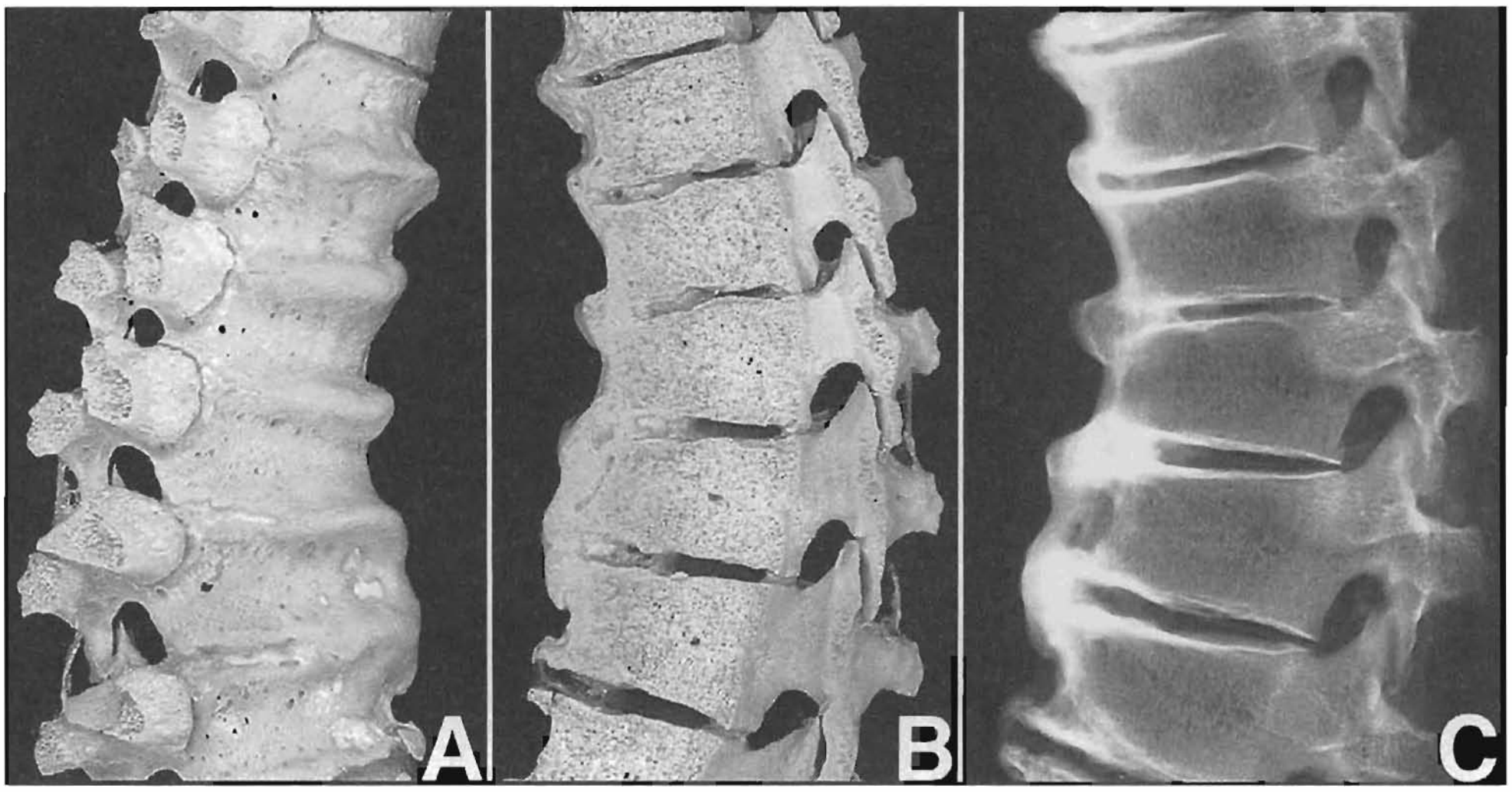

Fig. 5.3 Marked osteophytic development is shown in this case with diffuse idiopathic skeletal hyperostosis (DISH). From the anterior aspect (A), extensive flowing bridge osteophytes are seen spanning five adjacent levels; this is confirmed by inspection of the median sagittal view (B), which shows the extent of the thickened cortical nature of the osteophytes. The internal disc height is preserved and the kyphotic angulation contributed to by vertebral body wedging (C).

The principal features consist of flowing osteophytes along the course of the anterior longitudinal ligament involving at least four adjacent vertebrae (Fig. 5.3; see also Fig. 12.15), intact disc spaces and vertebral end-plates, and the absence of sacroiliac or zygapophysial joint sclerosis or ankylosis. According to early surveys by Resnick and Niwayama (1995b), radiographic evidence of DISH may be found in 12% of the population. In the majority of these cases, the thoracic spine is involved (Malone *et al.*, 1998), particularly on the right side of the T5-T12 vertebral bodies (Resnick and Niwayama, 1976). There are few published large-scale studies of the prevalence of DISH; however, a recent investigation of 2364 patients by Weinfeld *et al.* (1997) identified 25% of males and 15% of females over the age of 50 years with radiographic features of this disease.

The co-existence of multiple pathologies with DISH was a feature of the post-mortem investigation by Vernon-Roberts *et al.* (1974). In their study, they identified osteoporosis, Schmorl's nodes and lateral projection of disc tissues to be associated with their DISH cases. The thickened syndesmophytes (Fig. 5.5D) acted to bridge the disc space and maintain disc height, in contrast to other forms of spinal degenerative conditions.

Degenerative conditions

In this section, degenerative conditions that have principally a thoracic manifestation are presented.

Costovertebral and zygapophysial joint degeneration

Costovertebral and zygapophysial joint degeneration is most frequent in the upper and lower thoracic segments (Shore, 1935; Nathan *et al.*, 1964; Tan, 1993) (Fig. 5.1B, C; see also Fig.12.8). The upper and lower thoracic segments behave mechanically as 'stiffer' segments compared with the middle vertebral levels which, in comparison, show a correspondingly higher frequency of discal disease (Resnick, 1985) (Fig. 5.1F). The load transmission across the transitional junctions, which lie on the inflexion points between the physiological kyphosis and the cervical and lumbar lordoses, may act to increase bony reactive changes within the costovertebral and zygapophysial joints. The major trunk and upper limb muscle groups (Moore, 1997), which attach to the first and last thoracic ribs respectively, transmit strong muscle exertion forces across these transitional vertebral segments.

Degenerative changes in the first, mid-thoracic and lowest two rib articulations were a feature of the survey by Nathan *et al.* (1964) (Fig. 5.1C). The development of osteophytes and eventual bony fusion of the costovertebral and costotransverse joints in aged thoracic vertebral columns was a finding frequently reported by Schmorl and Junghanns (1971) in their extensive survey of spinal pathology.

Shore (1935) reported the highest incidence of zygapophysial joint degeneration in the upper and lower thoracic segments (Fig. 5.1C), and speculated that this related to the influence of the line of gravity and the transfer of loads from posterior to anterior elements. Pal and Routal (1986, 1987) have developed this theory to account for the increase in size and angulation of the pedicles at the cervicothoracic and thoracolumbar junctions (see Fig. 2.7).

The cervicothoracic and thoracolumbar junctions represent sites of interplay of forces between very mobile and relatively immobile regions of the spine; as a consequence, the patterns of degenerative change are found to be accentuated at these locations. In the cervicothoracic junction, Boyle *et al.* (1998a, 1998b) found that IVD and end-plate changes were more evident, and osteophytic formation more pronounced, in the mobile segments immediately above the transition. It was considered that the upper thoracic region and thoracic cage acted to impede inter-segmental motion and thus 'protect' these levels from marked degeneration. This observation for osteophytic formation was consistent with the skeletal survey by Nathan (1962) (Fig. 5.1A).

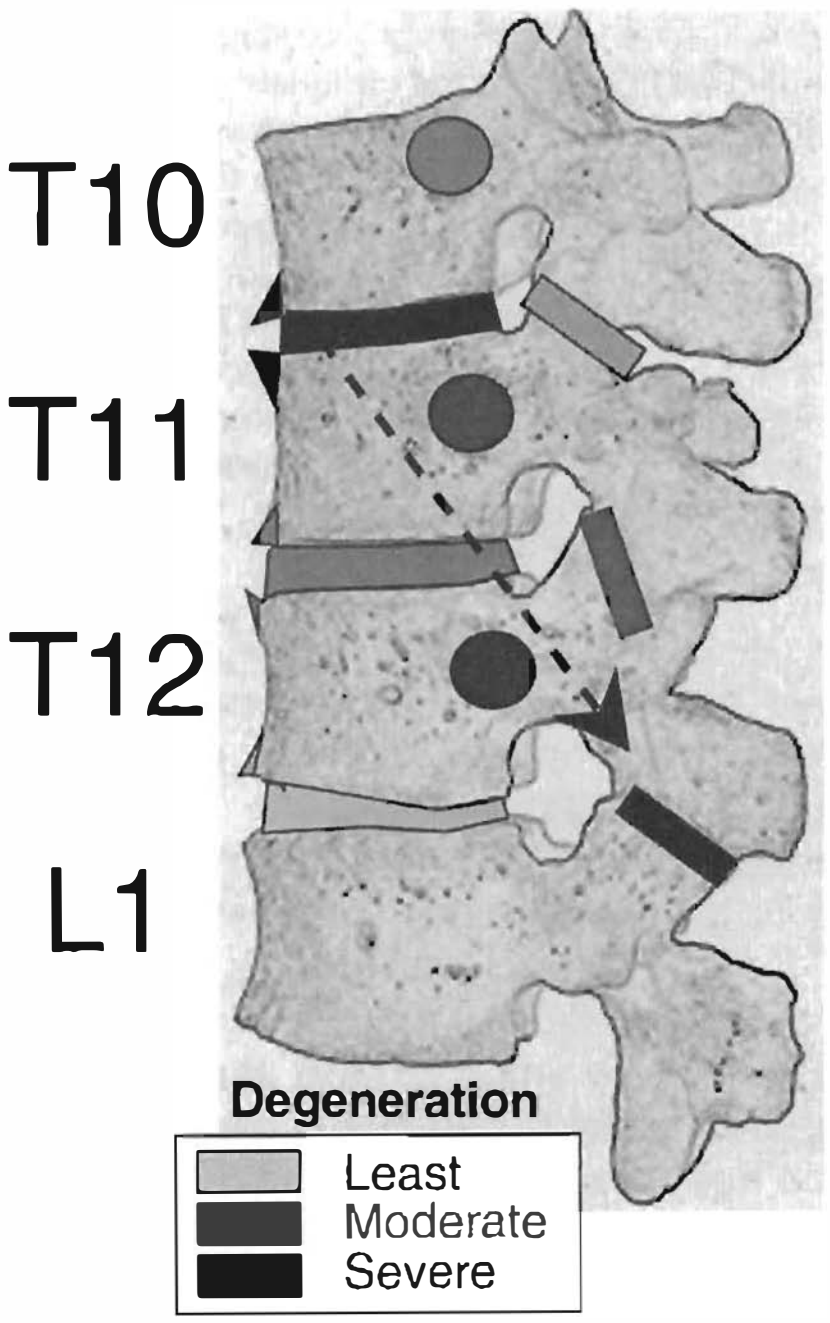

Fig. 5.4 A schematic depiction of the transition (arrow) in degeneration from anterior elements at T10, to a posterior element pattern of degeneration at T12–L1. Vertebral body osteophytes and disc degeneration were more prevalent in the T10–T11 and T11–T12 levels, in contrast with costovertebral joint reactive changes which were greatest at T12. Disc degeneration was least at T12–L1, where the zygapophysial joints acted to constrain
Malmivaara *et al.*, 1987a).

At the thoracolumbar junction, Malmivaara *et al.* (1987a) demonstrated that particular pathologies tended to be concentrated at each segment. The T10–T11 segment was characterized by disc degeneration, vertebral body osteophytosis and Schmorl's nodes; the T11–T12 segment tended to show both anterior and posterior degeneration, involving zygapophysial and costovertebral joints; while the T12–L1 joint was characterized primarily by posterior joint degeneration (Fig. 5.4). A comparison of zygapophysial joint orientation with degenerative findings suggested that the posterior elements play a significant role in resisting torsional loads, and asymmetry in the zygapophysial joint orientation tended to result in degenerative changes occurring mostly on the sagittal facing facet (Malmivaara, 1987).

Degenerative disc disease and osteophytosis

Thoracic disc degeneration

Literature describing the incidence of disc degeneration throughout the vertebral column concentrates predominantly on the lumbar spine (Kramer, 1981). The epidemiological review performed by Lawrence (1977), who assessed spinal disc degeneration using radiological criteria, indicated that the mid-thoracic discs showed a marked degree of reactive end-plate changes and marginal osteophyte formation (Fig. 5.5A). From recent post-mortem reviews, mild to severely degenerated discs were seen predominantly within the mid-thoracic segments, peaking between T6–T7, and were particularly prevalent in males (Singer, 1997) (Fig. 5.1F). This may be related to the greater magnitude of axial plane segmental motion in the mid-thoracic spine, which was evidenced in an *in vivo* study by Gregersen and Lucas (1967). Investigation into the effects of torsion on lumbar IVDs by Farfan *et al.* (1970) demonstrated that 2° of rotation strain introduced a deleterious response in the anulus fibrosus. A torsion-induced strain response, relating to axial plane motion in the order of 6° for the mid-thoracic segments (Gregersen and Lucas 1967), may be the stimulus for the degenerative response seen in the mid-thoracic segments.

The pattern of age-related decline in anterior disc height in men typifies the disc ageing process associated with senile kyphosis, as described by Schmorl and Junghanns (1971). In the absence of any marked reductions in bone density, the deformation of mid-thoracic discs in males appears to accentuate the kyphotic curve. Hence in older males without significant spinal osteopenia it is speculated that the cumulative effects of compressive loading and torsional stresses result in degeneration of the anterior anulus and the subsequent decrease in anterior disc height (Schmorl and Junghanns, 1971; Resnick, 1985; Goh *et al.*, 1999). In older females, however, mechan-

torsio

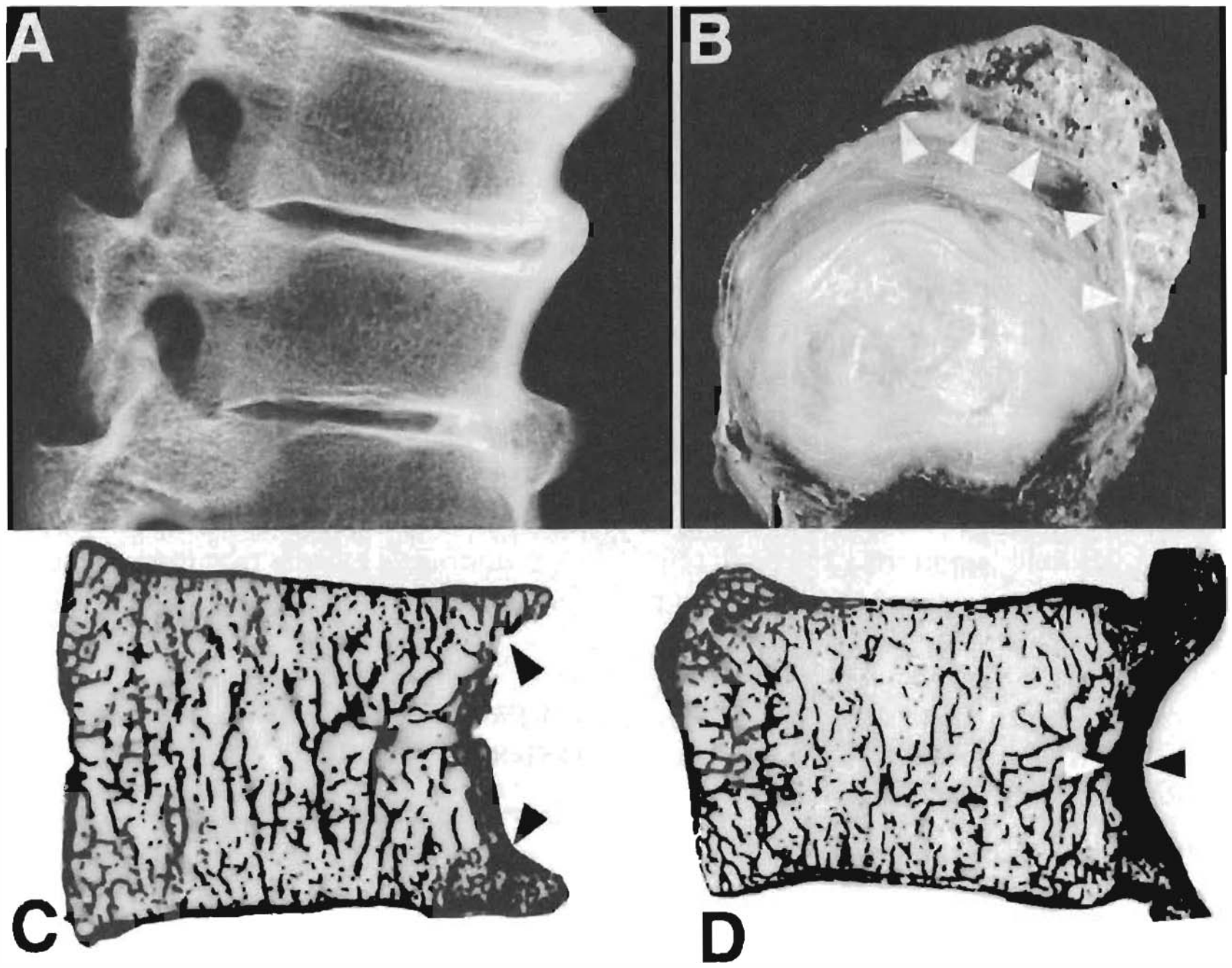

Fig. 5.5 (A) Radiographic presentations of thoracic vertebral osteophytes are shown to highlight three stages of development. In the cranial segment, two horizontal beaks are seen projecting horizontally from the vertebral end-plate margin. At the next caudal level, the osteophytes have fused to form a bony bar and, at the lowest level, a solid fusion across a wider aspect of the disc is demonstrated. (B) A horizontal section at the disc level of T12 depicts a large osteophyte on the right side of the vertebral body with a clearly demarcated line (arrow heads) defining the intervertebral disc and bony outgrowth. The flattened left side of the vertebral body defines the position for the descending thoracic aorta, which acts to inhibit osteophyte formation. Despite the bony proliferation, the disc appears well preserved. (C) This shows the horizontal bony projections at both vertebral end-plates (arrows) extending beyond the anterior cortex of the vertebral body. (D) In contrast, this shows extensive osteophyte formation with a thickened anterior cortex (arrow heads). The extent of the thickened anterior cortex is contrasted sharply by the different trabecular bone volume between these two cases (C and D); a potential problem for conventional bone density assessment, which

ical loading through the anterior aspect of the kyphotic curve is more likely to influence the vertebral bodies, causing the anterior wedge deformity commonly associated with vertebral osteoporosis. Mechanically, the middle vertebral segments are disposed to greater axial compressive and bending moments, due to their location within the apex of the thoracic kyphosis (Singer *et al.*, 1995) (see Fig. 2.2).

Disc calcification (see Fig. 12.4) has been reported by Melnick and Silverman (1963) to peak within the mid-thoracic levels, which supports the notion of the mechanical loading stress imposed on these segments, and within the apex of the thoracic kyphosis. Compared to adjacent regions, mobility of the thoracic spine is limited by the ribcage (Shea *et al.*, 1996) and relatively low height of the IVDs (Kapandji, 1977; Reuben *et al.*, 1979). Despite this, most thoracic segments are capable of greater axial plane rotation, resulting from the generally more coronally orientated zygapophysial joints (Gregerson and Lucas, 1967).

After compiling the findings from 16 authors, Nathan (1962) suggested osteophyte formation followed by IVD degeneration was an attempt to redistribute force more uniformly across the vertebral end-plates. In his study of 346 skeletal spinal columns, Nathan (1962) reported a higher incidence of vertebral body osteophytes around the tenth thoracic vertebra, with the lowest at the first and second thoracic vertebrae (Fig. 5.1A). Between thoracic levels T1 and T11, the osteophytes were predominantly on the inferior vertebral body end-plate border; they were found mainly in the middle of the vertebral borders at T1-T5 and on the right side from T5-T12. The left-sided anterior osteophytes increased in the lower thoracic vertebrae until the asymmetry disappeared in the lumbar region, a finding which Nathan (1962) attributed to the position of the descending abdominal aorta (Fig. 5.5B). The highest incidence of anteriorly fused vertebrae was seen in the lower thoracic vertebrae (Nathan, 1962).

A survey of 90 post-mortem thoracic spinal radiographs showed osteophytes to occur with a peak incidence between T6 and T8 (Singer, 1997), consistent with the observations of Nathan (1962).

In thoracolumbar disc degeneration, some degree of peripheral margin osteophyte formation of the vertebral body is frequently seen (Lawrence, 1977; Vernon-Roberts, 1992). This pattern of excess bone formation is commonly referred to as spondylosis deformans (Resnick, 1985), and is seen in approximately 60% of women and 80% of men (Schmorl and Junghanns, 1971). The degree of intervertebral space narrowing and subsequent tilting of the vertebral bodies, resulting from disc degeneration, determines the extent and the type of marginal osteophytes (Malmivaara *et al.*, 1987a) (Fig. 5.4C, D).

Ossification within spinal ligaments

Ossification in the caudal attachments of the ligamentum flavum has been reported from surveys of thoracic skeletal vertebral columns by Davis (1955), Nathan (1959) and Maigne *et al.* (1992) (Fig. 5.6). These authors noted an increased caudal frequency of bony spicules, peaking in the lowest thoracic vertebrae (Fig. 5.6C, D). Bony spurs were identified in the majority of samples, which confirms that this is a normal feature of the region. They did not seem to be age specific, appearing from the third decade of life. Maigne *et al.* (1992) determined that the size and frequency of these processes projecting into the ligamentum flavum acted to regulate the segmental response to torsion stress. Where the zygapophysial joints were orientated to allow rotation, the processes were more developed, particularly at the

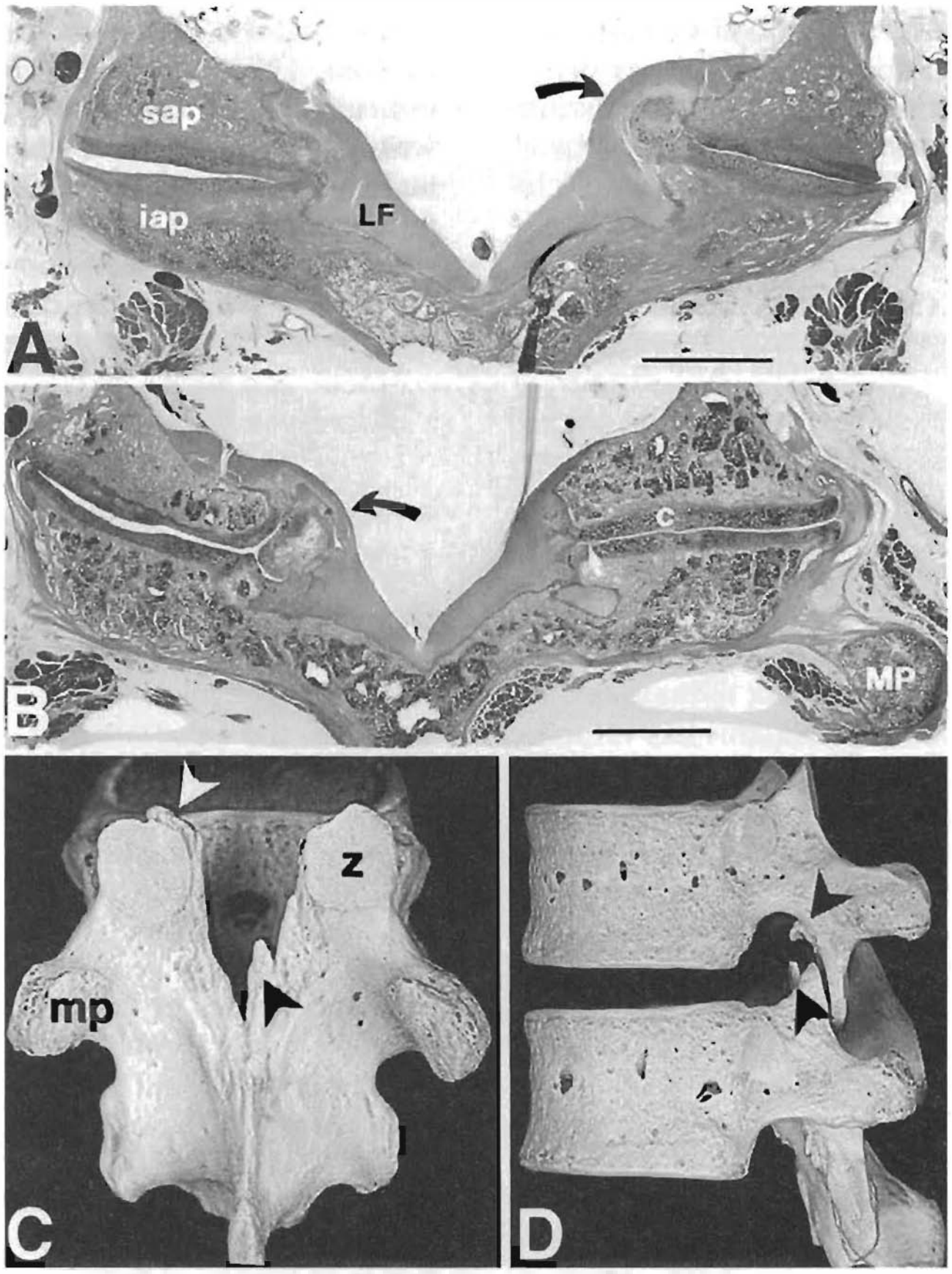

Fig. 5.6 Ossification within the ligamentum flavum (LF) (curved arrows) is shown in two 100-μm thick histological sections from the T11-T12 level of different individuals (A and B). In both, there is an expansion of the ligamentum flavum towards the vertebral canal which, in some cases, contributes to central stenosis. From macerated vertebrae at the thoracolumbar junction (T11 and 12), these projections of bone (arrows) are seen from the posterior (C) and lateral projections (D), to indicate their direction and position within the vertebral canal. Abbreviations: c, cartilage; iap, inferior articular process; mp, mammillary process; sap, superior articular process; z, zygapophysial joint facet.

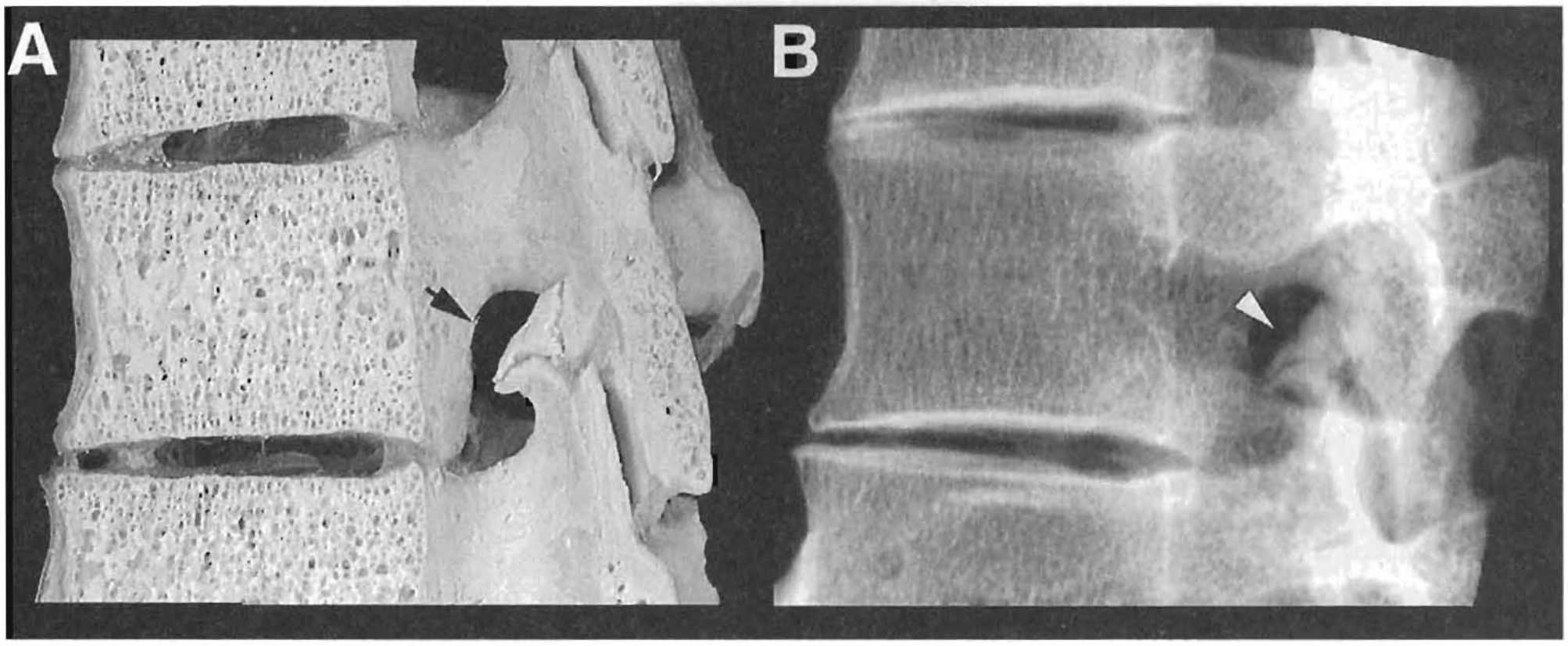

Fig. 5.7 Bony spicules are shown projecting from the laminae of adjacent vertebral levels (T5-T6) (arrows) in a macerated thoracic specimen. Marked occlusion of the intervertebral canal is shown in both the bony and radiographic views (A and B).

thoracolumbar junction (Fig. 5.6D). Occasionally these spicules may take other projections, as depicted in Fig. 5.7, where bony outgrowth extends into the intravertebral foramen.

Scheuermann's disease

Scheuermann's disease (SD) is a common problem that affects the adolescent spine. Major signs include end-plate irregularity and Schmorl's nodes, four or more wedged vertebral bodies (resulting in accentuated thoracic kyphosis), and osteophytic overgrowths (see Fig. 12.10).

Although the incidence varies widely according to reports in the literature, Scheuermann's disease is found in approximately 10% of the population, with males and females affected equally (Bradford *et al.*, 1987). A strong genetic link is evident in the aetiology of Scheuermann's disease; however, this has yet to be conclusively defined.

Histological studies reported by Ascani and La Rosa (1994) indicated pathological areas of growth cartilage within vertebral end-plates, which these authors attribute to a disorder of endochondral ossification. The increased vertebral wedging has been related to growth disturbance and mechanical loading, together producing the deformity. Age of onset is typically before puberty, and a key diagnostic feature is the inability of the individual to correct the thoracic deformity. Shortening of the hamstring and pectoral muscles is a common presenting feature. There are compensatory increases in the lumbar and cervical lordoses. Functional tests of the back extensor muscles have shown reduced strength in patients with SD compared with controls (Murray *et al.*, 1993).

Pain is a common feature of SD, often localized to the apex of the thoracic kyphosis, the interscapular region and the cervicothoracic junction (Ascani and La Rosa, 1994). According to these authors, in older individuals pain may be reported more as backache, with a distribution which implicates the thoracolumbar junction segments (T11-T12), and symptoms tend to decline as ossification occurs.

From a careful follow-up study by Murray *et al.* (1993) involving 61 patients, the natural history of the disease was reported as benign, despite the cosmetic and structural disturbances which produce a progressive hyperkyphosis.

Schmorl's nodes and end-plate lesions

Previous literature investigating the incidence of Schmorl's nodes in cadaveric or skeletal spines has been confined to thoracic segments between T8 and the TLJ. The reported incidence ranges between 38% and 79%, the large variation reflecting differences in sample size, age, gender and racial characteristics of the study sample, and geographical distribution between these studies.

Schmorl's nodes were found by Schmorl and Junghanns (1971) in 38% of cadaveric spines, with the highest incidence in males. Hilton *et al.* (1976), who used spines containing T9-T12 vertebral bodies, found the greatest incidence of Schmorl's nodes were located within the T10-T11 and T11-T12 segments. They also noted an occurrence of end-plate lesions in 38 of 50 cadaveric spine segments (T10-L5), with equal incidence above and below 50 years of age. The same authors report a 60% incidence of Schmorl's nodes in spines under the age of 20 years, with the youngest being 13 years of age. Malmivaara *et al.* (1987a) encountered Schmorl's nodes in 29 of 37 male cadaveric specimens (T10-L1) aged from 21-69 years. In contrast to the frequency of Schmorl's nodes demonstrable at autopsy, Malmivaara *et al.* (1987b) reported a limited value of plain radiography in identifying Schmorl's nodes in the thoracolumbar region. In their series of 24 cadaveric spines (T10–L1), only 35% of Schmorl's nodes, identified on direct bony observation, were evident with plain radiography (Malmivaara *et al.*, 1987b).

In one study, 64 out of 90 post-mortem thoracic radiographs had evidence of Schmorl's nodes (Singer, 1997). Both male and female cases displayed Schmorl's nodes throughout the thoracic spine, with an increasing cranio-caudal trend (Fig. 5.1E). This finding agrees with the results of Scoles *et al.* (1991), who described the distribution of Schmorl's nodes in normal skeletons and those with Scheuermann's kyphosis from a series of 1384 skeletal thoracolumbar spinal columns (T5–L5). Studies by Hilton *et al.* (1976), Malmivaara *et al.* (1987b) and Yasuma *et al.* (1988) noted higher frequencies of Schmorl's nodes on the inferior vertebral end-plates (upper border of the disc). Fig. 5.8 depicts the typical location and presence of multiple Schmorl's nodes in the lower thoracic segments, consistent with Scheuermann's disease.

Several authors have suggested that Schmorl's nodes appear most frequently in an area of end-plate weakness, possibly resulting from an incomplete resorption of the notochord (Begg, 1954; Schmorl and Junghanns, 1971; Hilton *et al.*, 1976; Resnick and Niwayama, 1978) (Fig. 5.8A, C, D).

Schmorl's nodes have been reported to occur during the late teens, with lesions as frequent in the young as in the older individual (Schmorl and Junghanns, 1971; Hilton *et al.*, 1976; Chandraraj *et al.*, 1998). It was suggested by Vernon-Roberts and Pirie (1977) that Schmorl's nodes develop at an early age, with only a relatively small percentage forming in adult life. Their examination of cadaveric lumbar spines indicated that vertebral end-plates having Schmorl's nodes tended to exhibit more advanced degenerative changes at an earlier age.

Heithoff *et al.* (1994) described patients with thoracolumbar Scheuermann's disease who had associated degenerative disc disease, suggesting that this was a manifestation of an intrinsic defect in the cartilagenous end-plate, resulting in inadequate nutrition and structural weakness and consequent early disc degeneration.

End-plate disruption is proposed to eventuate only if the end-plate itself is abnormal or the vertebral body subchondral bone is weakened (Schmorl and Junghanns, 1971). It has been proposed that congenital deficiency of the cartilage end-plate at the site of

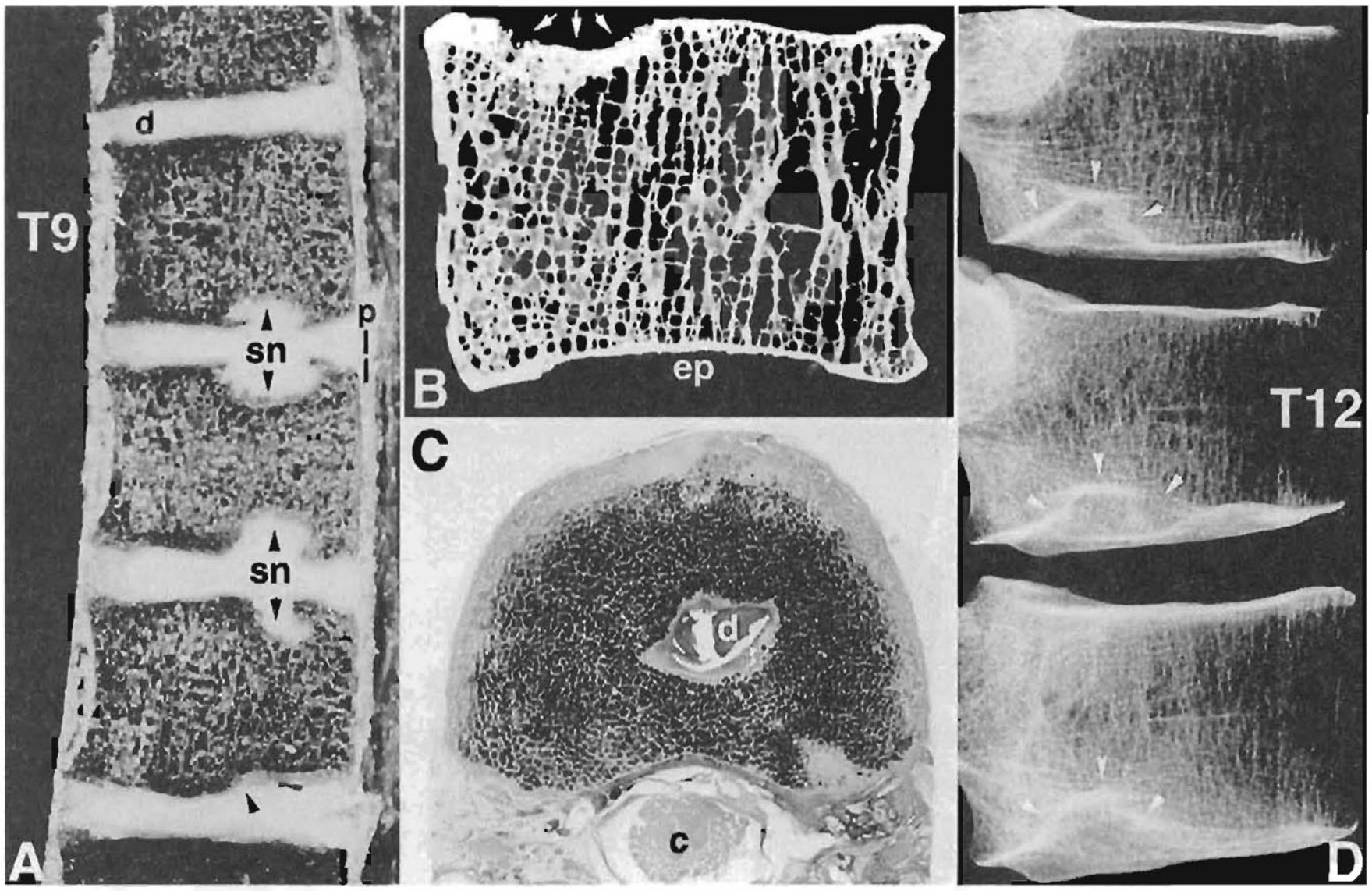

Fig. 5.8 Thoracic intravertebral protrusions, or Schmorl's nodes, are depicted from several views to highlight their location and extent. The tendency is for Schmorl's nodes to occupy a position immediately posterior to the middle of the vertebral body (A). They may project cranially and or caudally through the vertebral end-plate (arrows). End-plate irregularities are most common in the lower thoracic spine, as represented by the inferior end-plate of T11 (arrow). A depression on the superior end-plate of a 2-mm thick bone section from T11 is shown at (B), with slight inferior thickening of the end-plate compared with the regular thin end-plate. A central Schmorl's node at T12 (C), in a 100-μm thick horizontal histological section, shows disc material surrounded by sclerotic bony margins. Multiple Schmorl's nodes are shown at the thoracolumbar junction (D), all approximately in the same location and affecting the inferior vertebral end-plate, a characteristic of Scheuermann's disease. Abbreviations: c, spinal cord; d, disc; ep, end-plate; pll, posterior longitudinal ligament; sn, Schmorl's nodes.

the remnant notochord or scarring of degenerated blood vessels supplying the juvenile disc reduces the end-plate thickness, thereby increasing susceptibility to nuclear extrusion (Begg, 1954; Schmorl and Junghanns, 1971; Resnick and Niwayama, 1978).

Metabolic conditions

Osteoporosis and osteoporotic fracture

Osteoporosis is disease that can be characterized by decreased bone mass and micro-architectural deterioration of bone, which may lead to bone fragility and, subsequently, to an increase in rate of fracture (Editorial, 1993). Although resorption of bone follows the normal process of ageing, it may be induced through disordered metabolism of bone (Kanis, 1996) and is accelerated following menopause in women. The concern by health economists regarding the full impact of this disease in Western societies is mounting, given the rapidly increasing proportion of older individuals who will require various forms of management of this 'silent' disease. More recently, osteoporosis in men has become recognized as having a potentially significant bearing on health care costs (Seeman, 1995).

The epidemiology of osteoporosis is well known, whereby the risk factors of age, gender and racial contributors to bone loss and corresponding fracture risk increase exponentially with age. For the thoracic spine, one in four women over the age of 60 years will show at least one vertebral body fracture on radiographic examination, while the incidence increases to 100% in women over the age of 80 years (Melton, 1995) (see Fig. 12.17).

Evaluation is typically through bone density assessment, in which reference ranges for hip and lumbar spine bone mineral content and density are compared against the patient's values. Fracture risk, based on the known association between bone density and bone strength (Biggemann *et al.*, 1991; Singer *et al.*, 1995), can predict, in part, the relative likelihood of injury to the individual. Other factors, such as lifestyle, occupation, diet, smoking, premature onset of menopause, level of exercise, vitamin D deficiency and environmental factors, need to be taken into account to predict the true risk of fracture.

The mid-thoracic segments are the most vulnerable to osteoporotic collapse or progressive wedge deformity due to the mechanical disadvantage of these segments situated within the apex of the thoracic kyphosis (Edmondston *et al.*, 1997) (Fig. 5.9A; see also Fig. 2.2). The second peak for thoracic osteoporotic fracture is at the thoracolumbar junc-

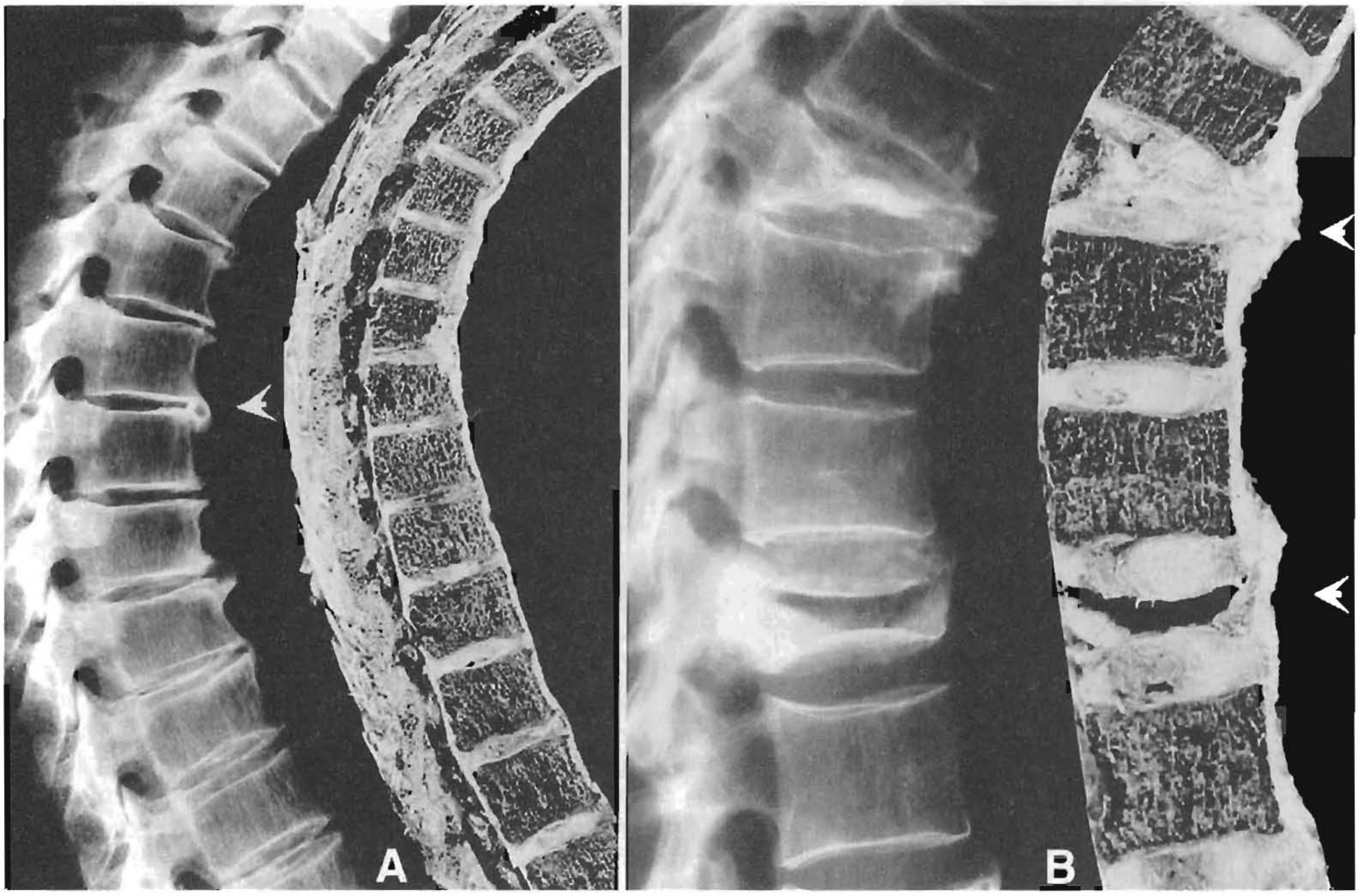

Fig. 5.9 Contrasting appearances of osteoporotic deformity and fractures of the thoracic spine are shown. (A) A progressive accentuated thoracic kyphosis is shown with bridging osteophytes depicted at multiple levels. (B) Vertebral body collapse is shown to highlight severe traumatic deformity. A marked focal wedge fracture is seen at the cranial level and a compression type of fracture at the lower level, with gas evident on the radiograph.

tion (De Smet *et al.*, 1988), where more rapid flexion and axial compression of the thoracic spine is believed to induce a pivot moment situated at this junction. These more dynamic loads may be sufficient to cause marked collapse fractures under compression (Fig. 5.9B).

Infective conditions

Osteomyelitis

Although relatively rare in Western countries, spinal infections are a potentially disabling condition. According to Bullough and Boachie-Adjei (1988), spinal osteomyelitis comprises less than 1% of such cases in the skeleton. It is seen in individuals of various ages with the lumbar spine implicated more commonly than the thoracic region. Predisposing factors are urinary infections, diabetes and drug abuse. The presenting symptoms depend upon the virulence of the infective agent, but may include back pain, radiculopathy and general systemic signs of infection. Left untreated, spinal deformity and severe neural compromise may develop. Progressive destruction of the vertebral bodies can lead to collapse, resultant deformity and death (see Fig. 12.16).

Tumours – metastatic and benign

Thoracic spine tumours

From the extensive study by Torma (1957), the thoracic spine was identified as having an involvement in 147 of 174 histologically confirmed cases of spinal metastases. This high predilection for the thoracic region is supported by other authors (Kakulas *et al.*, 1978; Henson and Urich, 1982). Of the patients studied by Torma (1957), tenderness of the spinous process on percussion was present in one-third but, surprisingly, severe pain and muscle spasm was a feature in only one-fifth of the sample.

The principal sources of origin for spinal metastases have been reported by Walter (1948), in diminishing order of frequency, as: breast, prostate, lungs, kidneys, thyroid, oesophagus, skin and uterus. This pattern is confirmed in more recent studies (Klekamp and Samii, 1998). The most common age at presentation is the late 40s to early 50s (Torma, 1957). The gender association with spinal metastases varies widely in the literature according to the clinical cohorts being studied, and, apart from gender-specific metastatic disease, there are no marked differences (Henson and Urich, 1982).

The typical clinical syndromes associated with spinal metastases involve back pain, weakness, disturbance of sensation and sphincter dysfunction. Back pain may suggest a radicular syndrome in which one or more nerve roots are involved.

Of critical clinical concern is the need for suspicion when dealing with a patient who has a history of malignancy. Such patients presenting with a new onset of spinal pain, or who describe pain at night, must be assumed to have spinal metastases until proven otherwise (Perrin and McBroom, 1992).

From careful examination of 14 cases, the localization of tumour deposit was reported by Kakulas *et al.* (1978) to occur within the vertebral bodies in 13, the pedicles in 10 and the lamina in five cases (Fig. 5.10). This general pattern was confirmed in a large series reported by Chade (1976), the only change being a larger proportion with involvement of the vertebral arch.

Metastatic spread of the tumour may also include the ribs, which may lead to pathological fractures (Fig. 5.11A; see also Fig. 12.19). A survey of 106 patients by Klekamp and Samii (1998) confirmed that the highest proportion of metastases (86%) were found within the vertebral body (Fig. 5.11B).

The mechanical effect of vertebral body collapse (as depicted at T8 in Fig. 5.11B, C) often produces an accentuated kyphotic deformity which can result in acute paraplegia due to occlusion of the vertebral canal (Kakulas *et al.*, 1978).

The radiographic evaluation of spinal tumours and surgical management is described in Chapters 12 and 14 respectively.

An acute onset scoliosis, particularly in a younger person, may indicate an osteoid osteoma or osteoblastoma (Myles and MacRae, 1988).

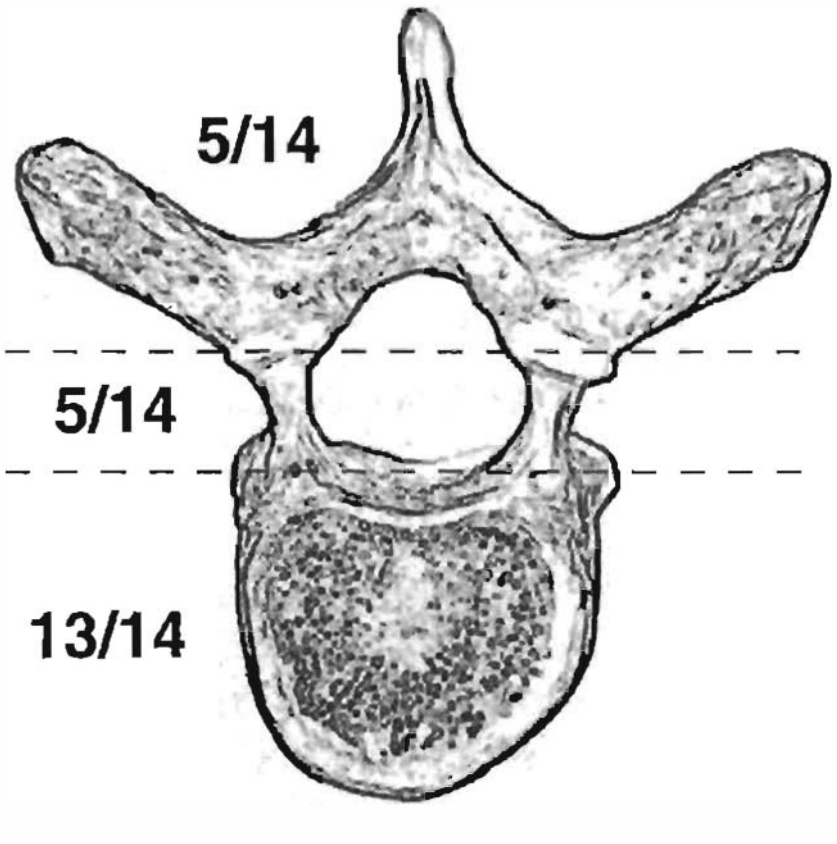

Fig. 5.10 The majority of spinal metastases are located within the vertebral body, followed by the pedicles and, finally, the posterior elements.

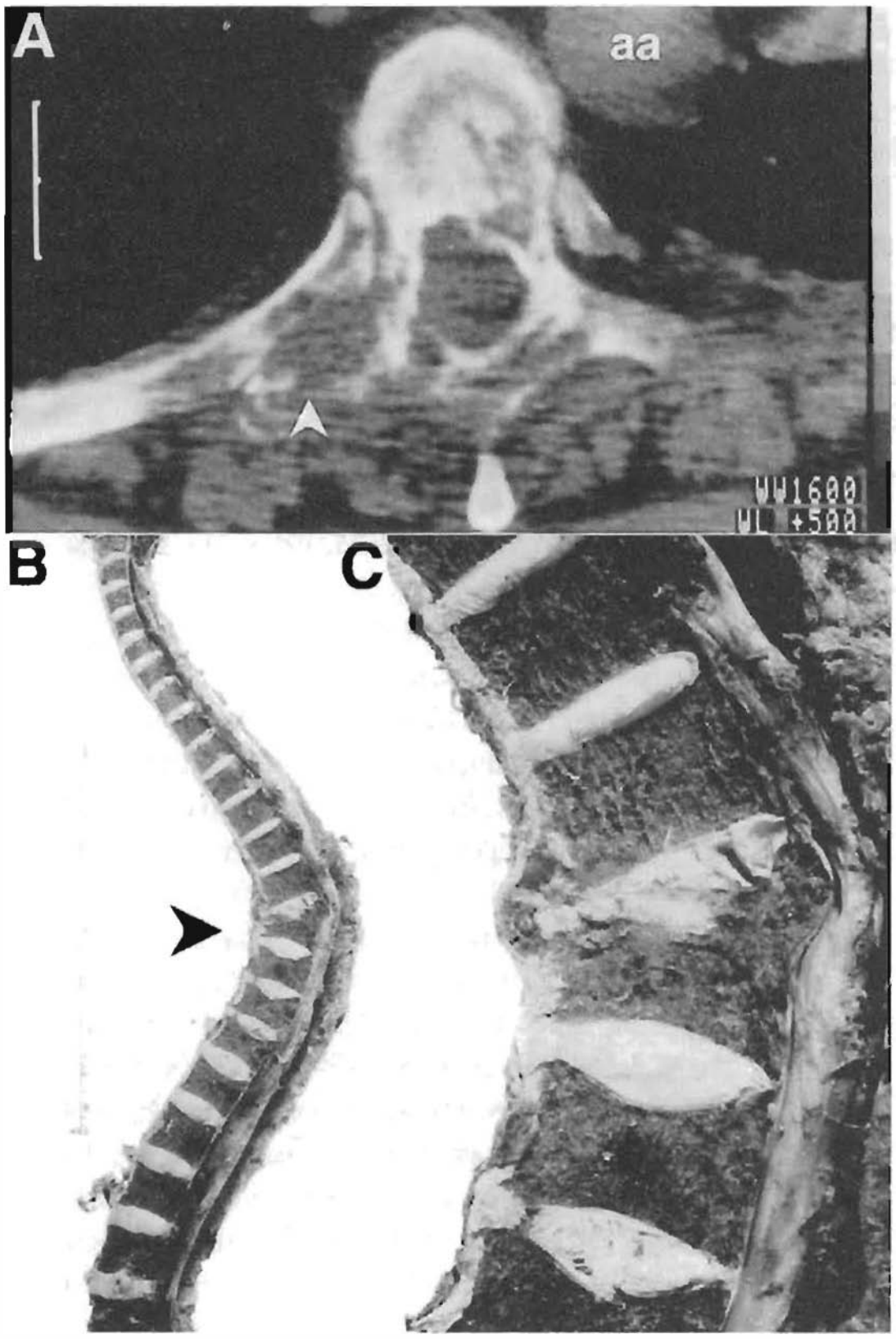

Fig. 5.11 (A) Thoracic spinal metastatic disease is illustrated by a mid-vertebral body axial CT slice at T9 showing widespread destruction of the right transverse process (arrow head) and laminae in a 45-year-old male. Patchy destruction of the vertebral body and right rib head, neck and angle is also evident. The abdominal aorta (aa) is depicted adjacent to the left side of the vertebral body. The spinous process shown is from the cranial vertebral level. (B) Anterior compression at T8 is depicted in this 53-year-old patient, with multiple myeloma, who sustained complete paraplegia at the fracture site. (C) A higher magnification of the case depicted in (B) highlights the retropulsion of the posterior vertebral body into the spinal cord.

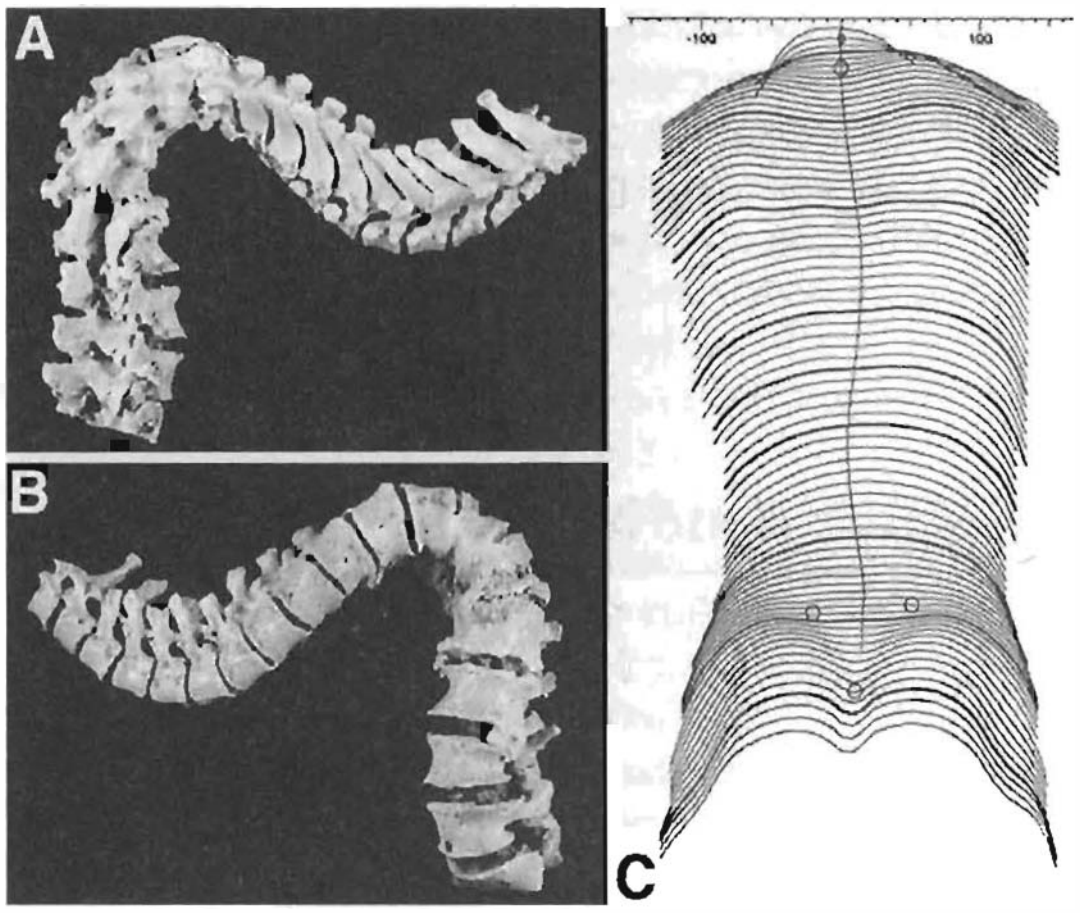

Fig. 5.12 Macerated spine showing severe kyphoscoliosis and marked osteophytic fusion across several segments within the region of the thoracolumbar transition, depicted from posterior (A) and anterior (B) aspects. A surface contour image of a mild scoliosis in a 13-year-old female, showing the typical rib hump appearance on the right aspect of the thoracic cage, is shown in (C).

Spinal curvature anomalies

Scoliosis

Idiopathic scoliosis involves a lateral curvature of the spine which is introduced through a disturbance in the longitudinal growth of the spine, particularly during the rapid growth period of early adolescence. A less common form, congenital scoliosis, occurs through defects in the formation or segmentation of the vertebral column. These vertebral anomalies include hemivertebrae, wedge vertebrae, and unilateral bar formations (McMaster, 1994). The patient with congenital scoliosis may also have abnormalities of other systems. The progression of congenital scoliosis depends upon the location of the vertebral anomaly, its type, the extent of growth imbalance it introduces to the spinal column, and the age of the individual at the time of diagnosis (Fig. 5.12A–C; see also Fig.12.18).

Idiopathic scoliosis may occur from early in the growth of the child through to the adolescent years, with surprisingly little known about the aetiology of this skeletal disorder (Weinstein, 1994). The prevalence of adolescent idiopathic scoliosis is approximately 2–3% of children between 10 and 16 years of age. In the curvature range greater than 30°, there is an overwhelming female predominance (10:1).

There are four main curve patterns that have been identified; thoracic, lumbar, thoracolumbar and double major curves. Each of these curvature patterns has its own characteristics and predictable end-point (Weinstein, 1994). Management of this disorder is based on the skeletal maturity of the patient at the time of assessment in relation to projected curve progression and its association with mechanical compromise, disability, back pain and, possibly, respiratory complications. The key concerns are skeletal immaturity, coupled with curves of larger magnitude. It is now accepted that curves continue to progress through the life span (Ascani *et al.*, 1986). The surgical indications and management of scoliosis are outlined in Chapter 14.

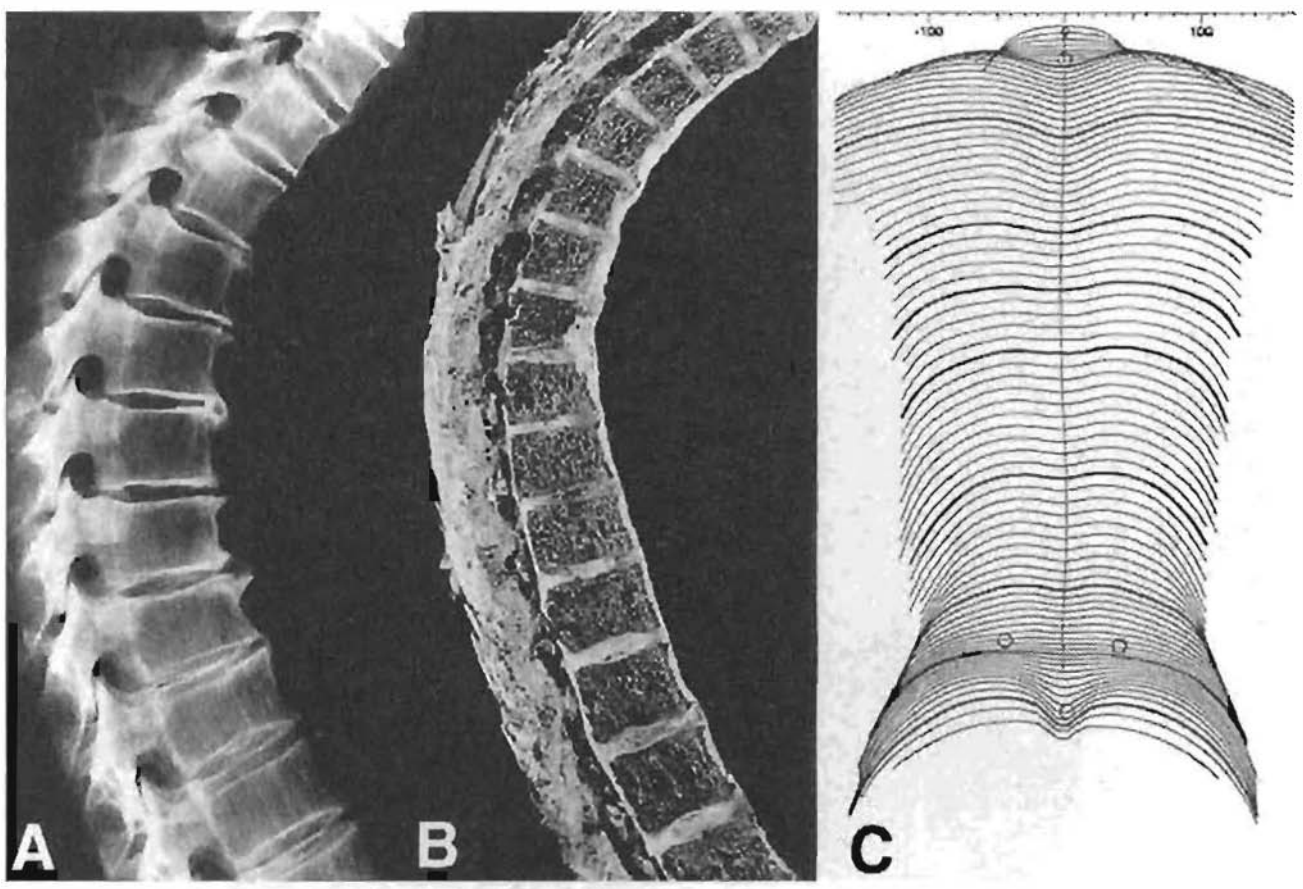

Fig. 5.13 Advanced senile kyphosis depicted radiographically (A) and macroscopically at post-mortem (B) in a 78-year-old male. Anterior disc wedging contributes to the accentuated curvature. Osteophyte formations are seen at multiple levels in the mid-thoracic region. A back shape contour map of a young adult with a normal thoracic kyphosis (C) demonstrates this non-invasive system for assessing spinal curvature (FORMETRIC, Jenoptik, GmbH).

Kyphosis

The normal range for thoracic kyphosis across the age span has been reported by Fon *et al.* (1980) and Singer *et al.* (1990). A progressive increase in kyphotic angulation occurs; this becomes more marked in women after the sixth decade, whereas in males the kyphos is less susceptible to change.

Alteration in the mechanics of the thoracic spine secondary to an increased kyphosis can have clinical implications in terms of respiratory function compromise, pain and long-term deformity.

Pathological disorders associated with the thoracic spine include adolescent kyphosis, Scheuermann's disease and the 'straight back syndrome' (Twigg *et al.*, 1967) (Fig. 5.13).

Trauma

Thoracic spinal trauma

The most common mechanism of fracture of the thoracic region involves flexion and axial loads (Meyer, 1992), attributed usually to falls or motor vehicle injuries (Daffner, 1990). Rapid loading in flexion can induce traumatic vertebral end-plate ruptures or Schmorl's nodes. In a recent post-mortem study by Fahey *et al.* (1998) of 70 spinal trauma cases, most acute Schmorl's nodes were identified in spines from individuals aged between 11 and 30 years. The male to female ratio was 9:1, and Schmorl's nodes were predominantly confined to the T8-L1 segments. Of clinical interest was the absence of radiological detection of these acute Schmorl's node injuries; this is understandable when one considers that a difference of some 40% in bone density is required for radiological identification.

The co-existence of other pathologies of the thoracic spine, particularly DISH and AS, can complicate the management of patients with spinal fracture (Bernini *et al.*, 1981).

Transitional junction trauma

The transitional junctions are also susceptible to trauma, given the marked change in segmental dynamics from regions of relative mobility to the stiffer region of the thoracic cage. In 2461 spinal fractures reported by Rehn (1968), 54% occurred between T11 and L2, followed by 20% involving the middle thoracic region (Fig. 5.14). The most commonly reported injury at the thoracolumbar junction is a wedge compression fracture (Harkönen *et al.*, 1979; Willén *et al.*, 1990). While the cervicothoracic junction is not affected by trauma to the same extent, the injuries can be severe when forces are localized to these segments (Evans, 1991) (Fig. 5.15). In the series reported by An *et al.* (1994), trauma cases reflected either vertebral compression fractures or fracture-dislocation. These authors refer to the difficulty in diagnosing injury in this region and recommend computed tomography (CT) and magnetic resonance imaging (MRI) to complement special radiographic techniques. Fractures of the first rib can be missed on standard radiographic views (Christensen and Dietz, 1980), and often require special positioning of the patient, such as the 'swimmers projection' (Boyle *et al.*, 1998a).

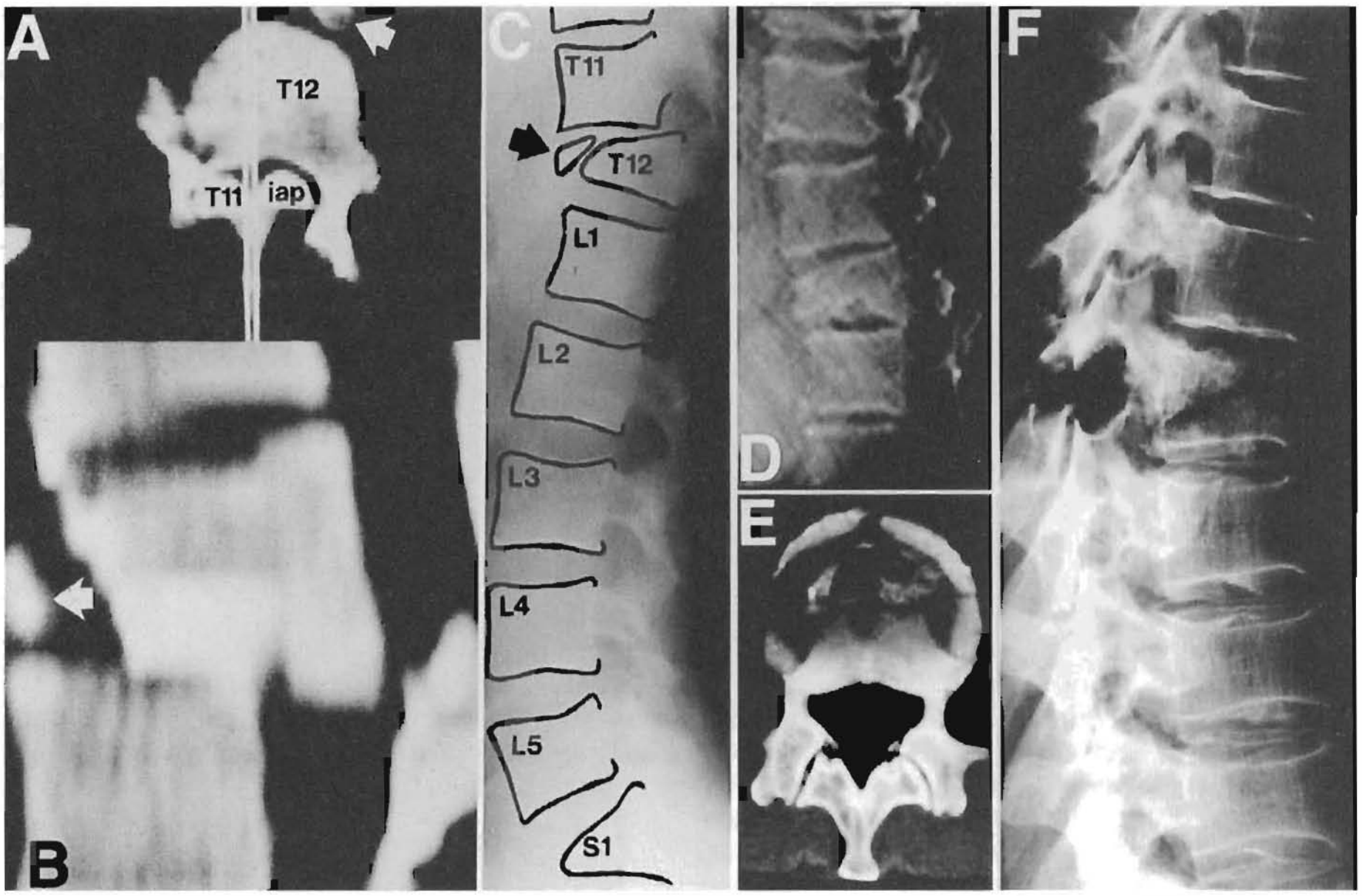

Fig. 5.14 Thoracic spine injury is depicted in this composite image showing a fracture-dislocation at T11-T12, with marked occlusion of the vertebral canal (A, B). A wedge compression fracture of the T12 vertebral body, which has resulted in an anteriorly displaced bony fragment (arrow), is depicted in (C). A burst compression fracture of the T12 vertebral body (D) is seen in association with marked disruption of the T12-L1 disc (E). Severe complete transection of the thoracic spine is shown in (F) from a post-mortem case, with complete disruption of posterior and anterior elements; the fracture extends through the vertebral body. (Fig. 5.14A is used with permission of the publisher from Singer *et al.*, 1989a).

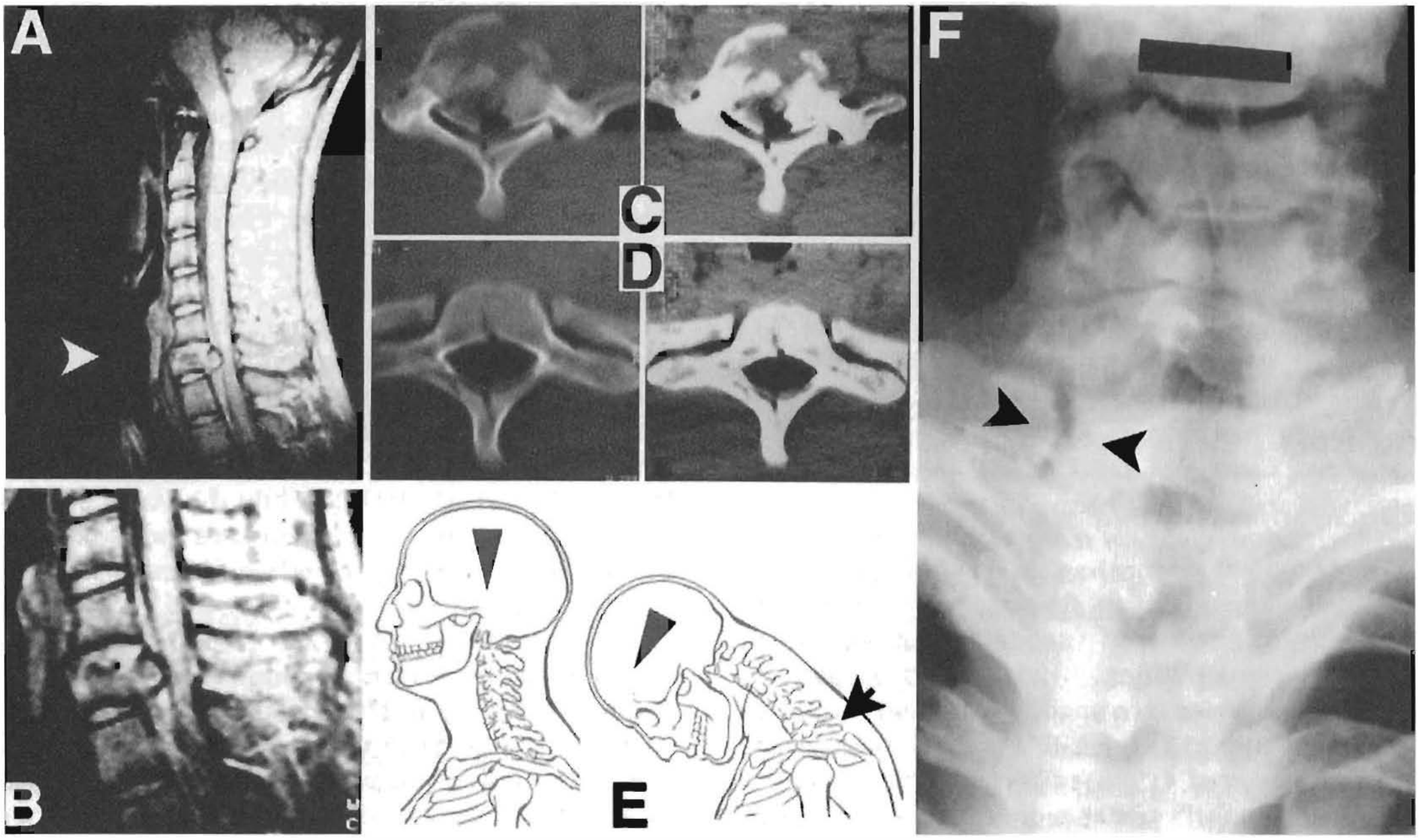

Fig. 5.15 Traumatic injury at the cervicothoracic junction is represented by a vertebral compression injury at C7 (A, B), with a large retropulsed bone fragment extending into the spinal canal at this level (C) and producing disruption of the laminae (D), a result of axial compression forces (E). Often trauma at the cervicothoracic junction is a result of compression and extreme flexion (E). Given the overlapping shadows from the first ribs and sternum, several views and the 'swimmer's projection' are required to demonstrate any fractures adequately.

In the thoracolumbar transitional region, Singer *et al.* (1989a) described a patient series in which those with an abrupt change in the zygapophysial joint orientation tended to sustain localized severe trauma/dislocation (Fig. 5.14A; see also Fig. 12.11), in contrast to those with a more gradual change.

Given the comparable stiffness of the thoracic region, trauma that is sufficient to disrupt the vertebral elements is usually associated with injury to the spinal cord (Bolestra and Bohlman, 1992).

Rib fractures

Fractures of the ribs may occur through repetitive overload resulting in stress fractures (Lord *et al.*, 1996), direct trauma to the thoracic cage, metabolic disease (particularly osteoporosis or related calcium metabolism disorders) or metastatic disease processes. Plain radiography and bone scans are typically employed to screen for the presence of fractures if suspected.

Thoracic disc prolapse

Despite its relative rarity, this entity was first described over 150 years ago by Key (1838). Thoracic disc injury and prolapse relatively rarely present as a clinical problem, with surgical management being required in approximately 2% of all intervertebral disc prolapses (Brügger, 1977; Russell, 1989). In contrast, the macroscopic inspection of 368 cadaveric spines by Andrae (1929) revealed 56 (15%) with IVD protrusion, with the largest proportion of these occurring in the thoracic spine. Andrae (1929) noted that many of the prolapses were small and flat in appearance, an observation confirmed by Schmorl and Junghanns (1971).

A macroscopic review of 49 thoracic vertebral columns, in which the discs were sectioned transversely, showed 34 cases with small disc protrusions beyond the line of the posterior anulus (Fig. 5.16). Most segmental levels were involved, with two main peaks located at the mid-thoracic and lowest thoracic segments (Fig. 5.1G; see also Fig. 12.5).

According to Carson *et al.* (1971), the clinical incidence of thoracic disc prolapse is estimated at one in a million cases. The incidence according to segmental level has been extensively reported in the surgical literature. From a review of seven clinical studies involving 221 cases of surgically confirmed thoracic prolapse, the level within the thoracic spine that showed most frequent protrusion was the T11-T12 disc (Fig. 5.1D). This may be attributed to the relatively greater disc height and volume at this region, coupled with localization of torsional forces which can occur immediately above the level of TLJ transition (Singer *et al.*, 1997). Indeed, Markolf (1972) proposed that the eleventh and twelfth thoracic vertebrae represented a site of structural weakness for stresses in the vertebral column, due to the reduced constraint of the ribcage and the change in zygapophysial joint morphology which facilitated rotation above the transitional levels and impeded it below. Although thoracic disc prolapse is rare in the upper third of the thoracic spine, the T1-T2 disc is the most commonly affected (Morgan and Abood, 1998), usually involving individuals in the fourth to sixth decades of life (Russell, 1989).

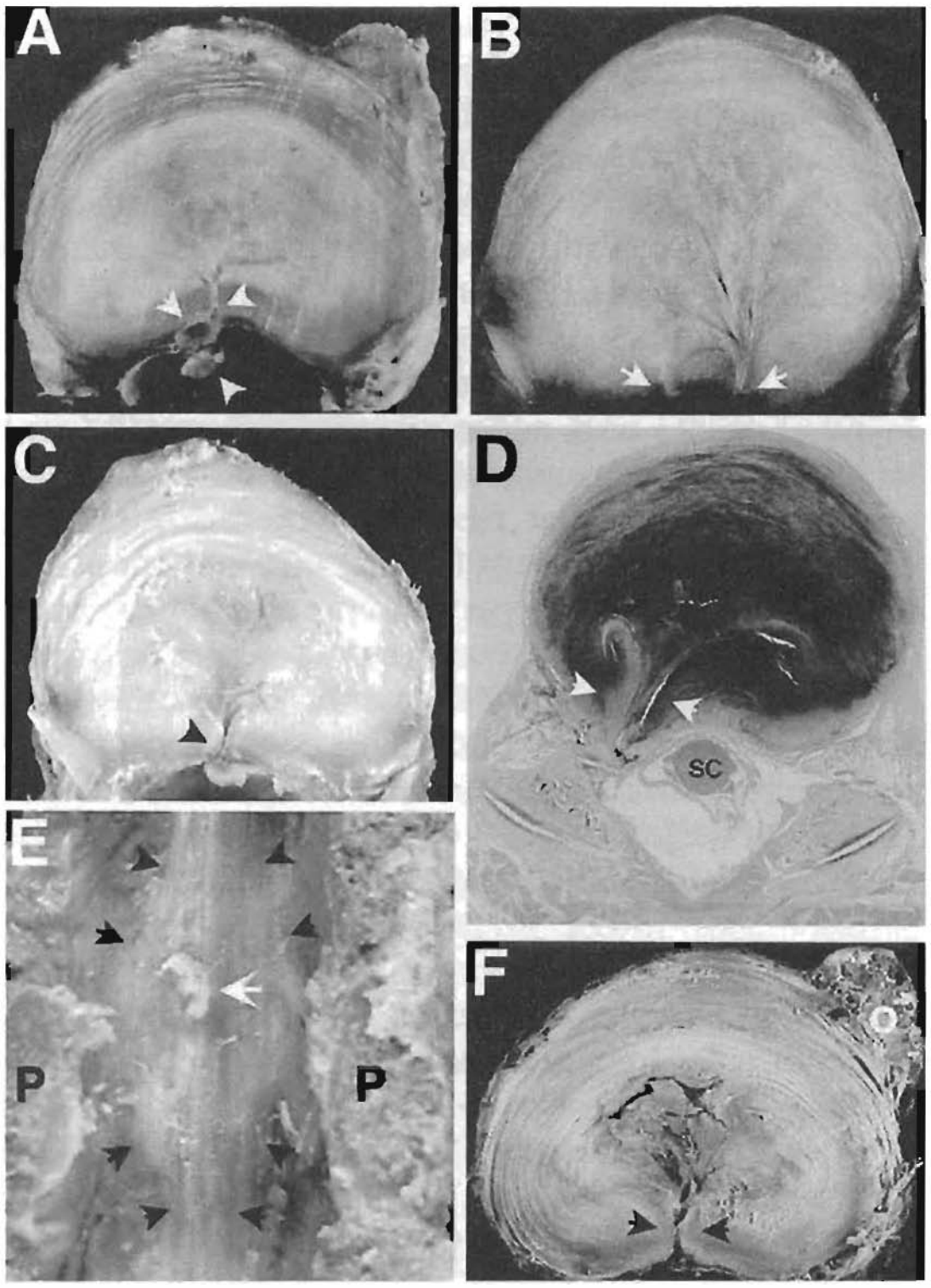

Fig. 5.16 Intervertebral disc prolapse is shown for several thoracic segments, all from the lower levels. The feature common to many is a midline posterior anulus fissure, which extends into the nuclear region of the disc (A, B, C, E, F). A 100-μm thick horizontal histological section (D) depicts a postero-lateral prolapse through the disc at T10-T11. The typical feature of these small herniations (F) is a focal appearance (white arrow) through the mid-substance of the posterior longitudinal ligament, outlined by several black arrow heads. If no herniation through the PLL occurs, there may be an encapsulated nodule of the prolapsed material contained behind this ligament (A) (arrows). Abbreviations: o, osteophyte; P, pedicles; sc, spinal cord.

With the advent of CT and MRI, the incidence of reported disc protrusion has been considerably higher. For example, post-myelography CT scanning has revealed asymptomatic thoracic disc prolapses at a rate of 11-13% (Awwad *et al.*, 1991). Additionally, a recent MRI survey of asymptomatic volunteers by Wood *et al.* (1995) found that over 30% of the sample demonstrated such lesions, with many more showing evidence of associated disc and end-plate lesions.

The development of symptoms may be progressive, with the definitive investigation usually a late feature of the process. In his report, Russell (1989) described 38 of 67 cases with a gradual onset of symptoms, 13 of sudden onset and 16 of intermittent onset but progressively worsening. Less than 50% of patients describe a history of trauma, although this may be more common in younger males (Russell, 1989). Females and males are affected equally, and while any thoracic segment may be involved, disc prolapse occurs most frequently in the middle to lower levels (Fig. 5.1D). While the range of symptoms can be diverse, many patients present with poorly defined thoracic back pain and non-specific lower limb pain (Arce and Dohrmann, 1985). Band-like chest wall pain is also a common complaint.

Posterior thoracic pain and radicular pain tend to be associated with lateral disc herniations, which may be mistaken for visceral disease (Whitcomb *et al.*, 1995). Sensory and lower limb motor disturbances are common. According to Arce and Dohrmann (1985), a high proportion of patients have some symptoms of cord compression. Bladder or bowel problems may occur in the late stage of this condition (Le Roux *et al.*, 1993), as can paralysis. Love and Schorn (1965) reported 36 of 61 patients with motor weakness, the majority reporting difficulty with gait.

The physical findings associated with thoracic disc prolapse are as varied as the history of complaints. The extent of neurological compromise is related closely to the size, composition and location of the disc prolapse, as well as to the spinal canal size at the level of the lesion. A four-tiered classification proposed by Burkus and Denis (1993) helps to differentiate the type and presentation of the thoracic disc prolapse patient, from those without radiculopathy to cases with progressively more severe motor, reflex and sensory disturbances.

The diagnosis is often unclear given the non-specific and deceptive symptoms, presentation and clinical findings. As with many cases of back pain, caution must be exercised when relying on imaging for the diagnosis of disc prolapse, and clinical correlation must be sought. A multitude of neurological disorders must be considered in the assessment of putative thoracic disc prolapse. Multiple sclerosis and amyotrophic lateral sclerosis, spinal cord tumour, infarction and transverse myelitis should all be considered (Stahlman and Hanley, 1997). Table 5.2 presents a review of many non-mechanical sources of thoracic referred pain, such as angina pectoris, pleuritis, intercostal neuritis, herpes zoster (shingles), oesophagitis, appendicitis, cholecystitis, peptic ulceration and costochondritis, all of which can be incorrectly diagnosed. Carcinoma of the breast, lung, pancreas or kidney must also be considered, as well as metastatic lesions to the ribs (Malone *et al.*, 1998). Ultimately, the time course and intensity of the patient's symptoms, the physical evaluation findings and the results of imaging are important when determining the management strategy. Unfortunately the patient often presents after an extended period of time, and most suffer some degree of myelopathy; as a consequence, the majority of diagnosed thoracic disc prolapses are therefore surgical problems. Surgical considerations are outlined by Findlay and Eisenstein in Chapter 14.

Table 5.2 *Thoracic pain referred from visceral pathologies*

Pain source	*Presenting symptoms*	*Referral pattern*
Cardiac	Crushing substernal pain Shortness of breath, pain increased with exertion Left shoulder, medial arm and jaw pain	Left pectoral region and shoulder
Aortic aneurysm	Unremitting pain, patient distressed Unchanged by position Distal pulses diminished/absent	Upper anterior chest
Pericarditis	Chest pain, worse with cough or forced respiration Common with fever	Region of upper trapezius
Oesophagus	Reflux, burning sensation Dysphagia	Sternum/back pain
Cholecystitis	Nausea and vomiting Distress, uncomfortable	T8-T9 segments, epigastrium
Renal disease	Marked distress	Low thoracic, costovertebral angle
Post-herpetic neuralgia	Neuralgic pain, rash	Unilateral segmental distribution
Intercostal neuralgia	Point tenderness	Burning pain in thorax or abdomen

(Adapted from Lillegard, 1996 and Errico *et al.*, 1997.)

Causes of referred thoracic spinal pain

Thoracic and chest wall pain may be referred from pathology of the viscera. The reciprocal situation may also arise, with profound consequences if the diagnosis is presumed or overlooked (Whitcomb *et al.*, 1995). The diagnosis of referred pain of somatic origin, to or away from the thoracic region, is reviewed by Maigne in Chapter 10, where variations in the cutaneous nerve distributions arising from the cervicothoracic and thoracolumbar junctions are presented.

Recognition that referred pain can arise from viscera is important, as is acknowledgement that the pain location may not correspond with the source of the pathology and that the nature or behaviour of the pain (e.g. dull, sharp, constant or intermittent) can guide in formulating a provisional diagnosis. The astute clinician, vigilant for any unusual patient presentation, should consider carefully the possibility of a visceral component to thoracic spinal pain. Equally, the physician should acknowledge the high percentage of patients who present with retrosternal pain arising not from the myocardium but from the thoracic cage (Wise, 1994).

As indicated earlier, there are many visceral pathologies that can refer to the thoracic spinal region. These pain syndromes include, but are not limited to, the following: cardiac system, pericardium, aorta, oesophagous, pleurae, bronchii and pulmonary system, stomach, liver and gallbladder, pancreas, kidney and adrenal glands, intestine, appendix and reproductive organs. Conversely, it is important to recognize that a considerable proportion of thoracic musculoskeletal pain syndromes can display features that suggest cardiac, pulmonary or abdominal origins (Oille, 1937; Raney, 1966; Hamberg and Lindahl, 1981; Fam, 1987; Grieve, 1994a; Arroyo *et al.*, 1992). Visceral afferents converge on the same projection neurones as somatic afferents within the dorsal horn; thus the pain source may be inappropriately represented cortically. The principal segmental levels responsible for visceral and abdominal innervation are presented in Chapter 9 (Table 9.3). A summary of the principal sources of thoracic pain referred from visceral and abdominal pathologies is provided in Table 5.2.

Neuralgic pain affecting the thoracic spine may also arise from shingles (post-herpetic neuralgia) or intercostal neuromas following fractured ribs, thoracotomy or radical mastectomy. The reader is referred to the summaries by Grieve (1994a, 1994b) on this subject for an expanded discussion.

Summary

Thoracic spinal pain may comprise a larger proportion of musculoskeletal complaints than is commonly believed. This chapter has highlighted various pathologies that may directly or indirectly be responsible for thoracic pain syndromes. The differential diagnosis of thoracic mechanical pain requires careful consideration of these possibilities to avoid the consequences to both clinician and client of a misdiagnosis. Through careful screening, the clinician also will determine conditions where medical or surgical referral and management would be recommended. Key differential diagnosis issues are outlined in Chapters 9 and 18 to help distinguish patterns of visceral pain from that of somatic origin.

The clinician must recognize situations where manipulation of the thoracic spine would be contraindicated, or conditions which predispose the patient to significant risks if treated by manipulation.

Given the increasing aged population and the prevalence of spinal degenerative conditions, it must be emphasized that patients presenting with any ankylosis and advanced degenerative condition of the spinal column are vulnerable to stress concentration at points of force application. A careful history and appropriate imaging, where indicated (see Chapter 12), will complement the assessment and often assist in determining the appropriateness of mechanical therapy.

References

An, H.S., Vaccaro, A., Cotler, J.M. *et al.* (1994) Spinal disorders at the cervicothoracic junction. *Spine* **19:** 2557-2564.

Andrae, R. (1929) Über Knorpelknötchen am hinteren Ende der Wirbelbandscheiben im Bereich des Spinalkanals. *Beitrage Z Pathol Anat.* **82:** 464-474.

Arce, C.A., Dohrmann, G.J. (1985) Thoracic disc herniation. *Surg. Neurol.* **23:** 356-361.

Arroyo, J.F., Jolliet, P., Junod, A.F. (1992) Costovertebral joint dysfunction: another misdiagnosed cause of atypical chest pain. *Postgrad. Med. J.* **68:** 655-659.

Ascani, E., Bartolozzi, P., Logroscino, C.A. *et al.* (1986) Natural history of untreated idiopathic scoliosis after skeletal maturity. *Spine* **11:** 784-789.

Ascani, E., La Rosa, G. (1994) Scheuermann's kyphosis. In: *The Pediatric Spine: Principles and Practice* (Weinstein, S.L., ed.). New York: Raven Press Ltd, pp. 557-584.

Awwad, E.E., Martin, D.S., Sundaram, R.D. (1991) Synovial cyst of the mid-thoracic spine. *Am. J. Neuroradiol.* **12:** 562-563.

Begg, A.C. (1954) Nuclear herniations of the intervertebral disc. *J. Bone Joint Surg.* **36B:** 180-193.

Bernini, P.M., Floman, Y., Marvel, J.P. *et al.* (1981) Multiple thoracic spine fractures complicating ankylosing hyperostosis of the spine. *J. Trauma* **21:** 811-814.

Biggemann, M., Hilweg, D., Seidel, S. *et al.* (1991) Risk of vertebral insufficiency fractures in relation to compressive strength predicted by quantitative computed tomography. *Euro. J. Radiol.* **13:** 6-10.

Bolestra, M.J., Bohlman, H.H. (1992) Injuries of the thoracic spine. In: *Spinal Cord Trauma* (Frankel, H.L., ed.). Amsterdam: Elsevier Science, pp. 75-87.

Boyle, J.W.W., Milne, N., Singer, K.P. (1998a) Clinical anatomy of the cervicothoracic junction. In: *Clinical Anatomy and Management of Cervical Spine Pain* (Giles, L.G.F, Singer, K.P., eds). Oxford: Butterworth-Heinemann, pp. 40-52.

Boyle, J.J.W., Singer, K.P., Milne, N. (1998b) Pathoanatomy of the intervertebral discs at the cervicothoracic junction. *Man. Ther.* **3:** 72-77.

Bradford, D.S., Loustein, J.E., Moe, J.H., Ogilivie, J.W., Winter, R.B. (1987) *Moe's Textbook of Skoliosis and other Spinal Deformities*. 2nd edn. Philadelphia: W.B. Saunders.

Brügger, A. (1977) *Die Erkrankungen des Bewegungsapparates und Seines nervensystems*. Stuttgart: Fischer.

Bullough, P.G., Boachie-Adjei, O. (1988) *Atlas of Spinal Disorders*. Philadelphia: Lippincott.

Burkus, J.K., Denis, F. (1993) Thoracic disc disease. In: *Operative Orthopaedics* (Chapman, M.W., ed.). Philadelphia: Lippincott, pp. 2726-2727.

Carson, J., Gumpert, J., Jefferson, A. (1971) Diagnosis and treatment of thoracic intervertebral disc protrusions. *J. Neurol. Neurosurg. Psych.* **34:** 68-77.

Chade, H.O. (1976) Metastatic tumours of the spine. In: *Handbook of Neurology* (Vinken, P.J., Bruyn, G.W., eds). Amsterdam: North Holland Publishers, pp. 415-433.

Chandraraj, S., Briggs, C.A., Opeskin, K. (1998) Disc herniations in the young and end-plate vascularity. *Clin. Anat.* **11:** 171-176.

Christensen, E.E., Dietz, G.W. (1980) Injuries of the first costovertebral articulation. *Radiology* **134:** 41-43.

Consensus Development Conference (1991) Diagnosis, prophylaxis, and treatment of osteoporosis. *Am. J. Med.* **90:** 107.

Crawford, R. (1994) *Normal and Degenerative Anatomy of the Thoracic Intervertebral Discs: Age and Gender Relationships*. Honours Thesis, Curtin University, Perth.

Daffner, R.H. (1990) Thoracic and lumbar vertebral trauma. *Orthop. Clin. N. Am.* **21:** 463-482.

Davis, P.R. (1955) The thoraco-lumbar mortice joint. *J. Anat.* **89:** 370-377.

De Smet, A.A., Robinson, R.G., Johnson, B.E. *et al.* (1988) Spinal compression fractures in osteoporotic women: patterns and relationship to hyperkyphosis. *Radiology* **166:** 497-500.

Editorial (1993) Consensus on osteoporosis. Diagnosis, prophylaxis and treatment of osteoporosis. *Am. J. Med.* **94:** 646-650.

Edmondston, S.J., Singer, K., Day, R. *et al* (1997) Ex-vivo estimation of thoracolumbar vertebral body compressive strength: The relative contributions of bone densitometry and vertebral morphometry. *Osteo. Int.* **7:** 142-148.

Errico, T.J., Stecker, S., Kostuik, J.P. (1997) Thoracic pain syndromes. In: *The Adult Spine: Principles and Practice* (Frymoyer, J.W., ed.). Philadelphia: Lippincott-Raven, pp. 1623-1638.

Evans, D.K. (1991) Dislocations at the cervicothoracic junction. *J. Bone Joint Surg.* **65B:** 124-127.

Fahey, V., Opeskin, K., Silberstein, M. *et al.* (1998) The pathogenesis of Schmorl's nodes in relation to acute trauma. An autopsy study. *Spine* **23:** 2272-2275.

Fam, A.G. (1987) Chest wall pain: If not cardiac disease, then what? *J. Musculoskel. Med.* **4:** 65-74.

Farfan, H.F., Cossette, J.W., Robertson, G.H. *et al* (1970) The effects of torsion on the lumbar intervertebral joints: the role of torsion in the production of disc degeneration. *J. Bone Joint Surg.* **52A:** 468-497.

Fon, G., Pitt, M., Thies, A. (1980) Thoracic kyphosis: Range in normal subjects. *A.J.R.* **134:** 979-983.

Goh, S., Price, R.I., Leedman, P.J. *et al.* (1999) The relative influence of thoracic vertebral and disc morphometry on thoracic kyphosis. *Clin. Biomech.* **13** (in press).

Gregersen, G., Lucas, D. (1967) An in vivo study of the axial rotation of the human thoraco-lumbar spine. *J. Bone Joint Surg.* **49A:** 247-262.

Grieve, G.P. (1994a) The autonomous nervous system in vertebral pain syndromes. In: *Grieve's Modern Manual Therapy* (Boyling, J.D., Palastanga, N., eds). Edinburgh: Churchill Livingstone, pp. 293-308.

Grieve, G.P. (1994b) Referred pain and other clinical features. In: *Grieve's Modern Manual Therapy* (Boyling, J.D., Palastanga, N., eds). Edinburgh: Churchill Livingstone, pp. 271-292.

Hamberg, J., Lindahl, O. (1981) Angina pectoris symptoms caused by thoracic spine disorders. Clinical examination and treatment. *Acta Med. Scand.* **644(Suppl.):** 84-86.

Harkönen, M., Kataja, M., Keski-Nisula, T. *et al.* (1979) Injuries of the thoracolumbar junction. *Arch. Orthop. Traum. Surg.* **94:** 35-41.

Heithoff, K.B., Gundry, C.R., Burton, C.V. *et al.* (1994) Juvenile discogenic disease. *Spine* **19:** 335-340.

Henson, R.A., Urich, H. (1982) Involvement of the vertebral column and spinal cord. In: *Cancer and the Nervous System: The Neurological Manifestations of Systemic Malignant Disease*. Oxford: Blackwell Scientific Publications, pp. 120-154.

Hilton, R., Ball, J., Benn, R. (1976) Vertebral end-plate lesions (Schmorl's nodes) in the dorsolumbar spine. *Ann. Rheum. Dis.* **35:** 127-132.

Kakulas, B.A., Harper, C.G., Shibasaki, K. *et al.* (1978) Vertebral metastases and spinal cord compression. *Clin. Exp. Neurol.* **15:** 98-113.

Kanis, J.A. (1996) *Textbook of Osteoporosis*. Oxford: Blackwell Science.

Kapandji, I. (1977) *The Trunk and Vertebral Column*, 2nd edn. Edinburgh: Churchill Livingstone.

Key, C. (1838) On paraplegia depending on disease of the ligaments of the spine. *Guy's Hosp. Rep.* **3:** 17-34.

Klekamp, J., Samii, H. (1998) Surgical results for spinal metastases. *Acta Neurochir.* **140:** 957-967.

Kramer, J. (1981) *Intervertebral Disk Diseases. Causes, Diagnosis, Treatment and Prophylaxis*. Stuttgart: Georg Thieme Verlag.

Lawrence, J.S. (1977) *Rheumatism in Populations*. London: William Heinemann Medical Books.

Le Roux, P.D., Haglund, M.M., Basil Harris, A. (1993) Thoracic disc disease: experience with the transpedicular approach in twenty consecutive patients. *Neurosurg.* **33:** 58-66.

Lillegard, W. (1996) Medical causes of pain in the thoracic region. In: *The Thoracic Spine and Ribcage* (Flynn, T.W., ed.). Boston: Butterworth-Heinemann, pp. 107-120.

Lord, M.J., Ha, K.I., Song, K.S. (1996) Stress fractures of the ribs in golfers. *Am. J. Sports. Med.* **24:** 118-122.

Love, J., Schorn, V. (1965) Thoracic-disk protrusions. *J. Am. Med. Assoc.* **191:** 91-95.

Maigne, J.Y., Ayral, X., Guèrin-Surville, H. (1992) Frequency and size of ossifications in the caudal attachments of the ligamentum flavum of the thoracic spine. Role of rotatory strains in their development. *Surg. Radiol. Anat.* **14:** 119-124.

Malmivaara, A. (1987) Disc degeneration in the thoracolumbar junctional region. Evaluation by radiography and discography in autopsy. *Acta Radiol.* **28**: 755-760.

Malmivaara, A., Videman, T., Kuosma, E. *et al.* (1987a) Facet joint orientation, facet and costovertebral joint osteoarthrosis, disc degeneration, vertebral body osteophytosis and Schmorl's nodes in the thoracolumbar junctional region of cadaveric spines. *Spine* **12:** 458-463.

Malmivaara, A., Videman, T., Kuosma, E. *et al.* (1987b) Plain radiographic, discographic, and direct observations of Schmorl's nodes in the thoracolumbar junctional region of the cadaveric spine. *Spine* **12:** 453-457.

Malone, D.G., Caruso, J.R., Baldwin, N.G. (1998) Degenerative and non-infectious inflammatory diseases. In: *Thoracic Spine* (Benzel, E.C., Stillerman, C.B., eds). St Louis: Quality Medical Publishing, pp. 597-606.

Markolf, K.L. (1972) Deformation of the thoracolumbar intervertebral joints in response to external loads. *J. Bone Joint Surg.* **54A:** 511-533.

McMaster, M.J. (1994) Congenital scoliosis. In: *The Pediatric Spine: Principles and Practice* (Weinstein, S.L., ed.). New York: Raven Press.

Melnick, J.C., Silverman F. (1963) Intervertebral disc calcification in childhood. *Radiology* **80:** 399-402.

Melton, J.L. (1995) Epidemiology of fractures. In: *Osteoporosis: Etiology, Diagnosis, and Management*, 2nd edn (Riggs, L.B., Melton. J.L., eds). Philadelphia: Lippincott-Raven, pp. 225-247.

Meyer, S. (1992) Thoracic spine trauma. *Sem. Roentgenol.* **27:** 254-261.

Moore, K. L. (1997) Muscles and ligaments of the back. In: *Clinical Anatomy and Management of Low Back Pain* (Giles, L.G.F., Singer, K.P., eds). Oxford: Butterworth-Heinemann, pp. 156-164.

Morgan, H., Abood, C. (1998) Disc herniation at T1-2. Report of four cases and literature review. *J. Neurosurg.* **88:** 148-150.

Murray, P.M., Weinstein, S.L., Spratt, K.F. (1993) The natural history and long-term follow-up of Scheuermann's kyphosis. *J. Bone Joint Surg.* **75A:** 236-248.

Myles, S.T., MacRae, M.E. (1988) Benign osteoblastoma of the spine in childhood. *J. Neurosurg.* **68:** 884-888.

Nathan, H. (1959) The para-articular processes of the thoracic vertebrae. *Anat. Rec.* **133:** 605-618.

Nathan, H. (1962) Osteophytes of the vertebral column. An anatomical study of their development according to age, race and sex, with considerations as to their etiology and significance. *J. Bone Joint Surg.* **44A:** 243-268.

Nathan, H., Weinberg, H., Robin, G.C. *et al.* (1964) The costovertebral joints: Anatomico-clinical observations in arthritis. *Arth. Rheumatol.* **7:** 228-240.

Oille, J.A. (1937) Differential diagnosis of pain in the chest. *Can. Med. Assoc. J.* **37:** 209.

Pal, G., Routal, R. (1986) A study of weight transmission through the cervical and upper thoracic regions of the vertebral column in man. *J. Anat.* **148:** 245-261.

Pal, G., Routal, R. (1987) Transmission of weight through the lower thoracic and lumbar regions of the vertebral column in man. *J. Anat.* **152:** 93-105.

Perrin, R.G., McBroom, R.J. (1992) Thoracic spine tumors. *Clin. Neurosurg.* **38:** 353-372.

Ralston, S.H., Urquhart, G.D.K., Brzeski, M. *et al.* (1990) Prevalence of vertebral compression fractures due to osteoporosis in ankylosing spondylitis. *Br. Med. J.* **300:** 563-565.

Raney, F.L. (1966) Costovertebral-costotransverse joint complex as the source of local or referred pain. *J. Bone Joint Surg.* **48A:** 1451.

Rehn, J. (1968) Die knöcheren Verletzungen der Wirbelsäule, Bedeutung des Erstbefundes für die spätere Begutachtung. *Wirbel. Forsch. Praxis* **40:** 131-138.

Resnick, D. (1985) Degenerative diseases of the vertebral column. *Radiology* **156:** 3-14.

Resnick, D., Niwayama, G. (1976) Radiographic and pathologic features of spinal involvement in diffuse idiopathic skeletal hyperostosis (DISH). *Radiology* **119:** 559-563.

Resnick, D., Niwayama, G. (1978) Intravertebral disk herniations: cartilaginous (Schmorl's) nodes. *Radiology* **126:** 57-65.

Resnick, D., Niwayama, G. (1995a) Ankylosing spondylitis. In: *Diagnosis of Bone and Joint Disorders*, 2nd edn (Resnick, D., ed.). Philadelphia: W.B. Saunders, pp. 1008-1074.

Resnick, D., Niwayama, G. (1995b) Diffuse idiopathic skeletal hyperostosis (DISH): Ankylosing hyperostosis of Forestier and Rotes-Querol. In: *Diagnosis of Bone and Joint Disorders*, 2nd edn (Resnick, D., ed.). Philadelphia: W.B. Saunders, pp. 1463-1508.

Reuben, J., Brown, R., Nash, C. *et al.* (1979) In vivo effects of axial loading on healthy, adolescent spines. *Clin. Orthop. Rel. Res.* **139:** 17-27.

Russell, T. (1989) Thoracic intervertebral disc protrusion: experience of 76 cases and review of the literature. *Br. J. Neurosurg.* **3:** 153-160.

Schmorl, G., Junghanns, H. (1971) *The Human Spine in Health and Disease*, 2nd edn. New York: Grunne and Stratton, pp. 10, 50.

Scoles, P.V., Latimer, B.M., DiGiovanni, B.F., Vargo, E., Bauza, S., Jellema, L.M. (1991) Vertebral alterations in Scheuermann's kyphosis. *Spine* **16:** 509-515.

Seeman, E. (1995) The dilemma of osteoporosis in men. *Am. J. Med.* **98(Suppl 2A):** 76-88.

Shea, K.G., Schlegel, J.D., Kent, N.B. *et al.* (1996) Contribution of the rib cage to thoracic spine stability. In: *Abstracts of the International Society for the Study of the Lumbar Spine*. Vermont: Burlington, p. 150.

Shore, L. (1935) On osteo-arthritis in the dorsal intervertebral joints. A study in morbid anatomy. *Br. J. Surg.* **22:** 833-849.

Singer, K.P. (1997) Pathomechanics of the aging thoracic spine. In: *Advances in Chiropractic* (Lawrence, D., ed.). St Louis: Mosby, pp. 129-153.

Singer, K.P., Edmondston, S.J., Day, R.E. *et al.* (1995) Prediction of compressive strength of isolated lumbar and thoracic vertebral bodies: Relationships to age, geometry, bone density and spinal curvature. *Bone* **17:** 167-174.

Singer, K.P., Jones, T.J., Breidahl, P.D. (1990) A comparison of radiographic and computer-assisted measurements of thoracic and thoracolumbar sagittal curvature. *Skel. Radiol.* **19:** 21-26.

Singer, K.P., Willen, J., Briedahl, P.D. *et al.* (1989a) Radiologic study of the influence of zygapophyseal joint orientation on spinal injuries at the thoracolumbar junction. *Surg. Radiol. Anat.* **11:** 233-239.

Stahlman, G.C., Hanley, E.N. (1997) Thoracic disk disease. *Orthopaedics* **5:** 185-191.

Sutro, C.J., Ehrlich, D.E., Witten, M. (1956) Generalized juxta-articular ossification of ligaments of the vertebral column and the ligaments and tendinous tissues of the extremities (also known as Bechterew's disease, osteophytosis and spondylosis deformans). *Bull. Hosp. Jt. Dis. Orthop. Inst.* **17:** 343-357.

Tan, B.K. (1993) *Histomorphometry of the Lower Thoracic Costovertebral Joints: Normal and Pathological Anatomy.* Honours thesis, Curtin University, Perth.

Tico, N., Ramon, S., Garcia-Ortun, F. *et al.* (1998) Traumatic spinal cord injury complicating ankylosing spondylitis. *Spinal Cord* **36:** 349-352.

Torma, T. (1957) Malignant tumours of the spine and the spinal extradural space. A study based on 250 histologically verified cases. *Acta Chur. Scand.* **225 (Suppl.)**.

Tribus, C.B. (1998) Scheuermann's kyphosis in adolescents and adults: diagnosis and management. *J. Am. Acad. Orthop. Surg.* **6:** 36-43.

Twigg, H.L., de Leon, A.C., Perloff, J.K. *et al.* (1967) The straight-back syndrome: Radiographic manifestations. *Radiology* **88:** 274-277.

Utsinger, P. (1985) Diffuse idiopathic skeletal hyperostosis. *Clin. Rheum. Dis.* **11:** 325-351.

Vernon-Roberts, B., Pirie, C.J. (1977) Degenerative changes in the intervertebral discs of the lumbar spine and their sequelae. *Rheum. Rehabil.* **16:** 13-21.

Vernon-Roberts, B. (1992) Age-related and degenerative pathology of the intervertebral discs and apophyseal joints. In: *The Lumbar Spine and Back Pain*, 4th edn (Jayson, M.I.V., ed.). Edinburgh: Churchill Livingstone, pp. 17-42.

Vernon-Roberts, B. (1994) Ankylosing spondylitis: pathology. In: *Rheumatology* (Klippel, J.H., Dieppe, P.A., eds). St Louis: Mosby, pp. 28.1-28.6.

Vernon-Roberts, B., Pirie, C.J., Trenwith, V. (1974) Pathology of the dorsal spine in ankylosing hyperostosis. *Ann. Rheum. Dis.* **33:** 281-288.

Walter, H.E. (1948) *Krebsmetastasen.* Basel: Schwabe.

Weinfeld, R.M., Olson, P.N., Maki, D.D. *et al.* (1997) The prevalence of diffuse idiopathic skeletal hyperostosis (DISH) in two large American Midwest metropolitan hospital populations. *Skel. Radiol.* **26:** 222-225.

Weinstein, S.L. (1994) Adolescent idiopathic scoliosis. Prevalence and natural history. In: *The Pediatric Spine* (Weinstein, S.L., ed.). New York: Raven Press, pp. 463-478.

Whitcomb, D.C., Martin, S.P., Schoen, R.E., Jho, H. (1995) Chronic abdominal pain caused by thoracic disc herniation. *Am. J. Gastroenterol* **90:** 835-837.

Willén, J., Anderson, J., Tomooka, K., Singer, K. (1990) The natural history of burst fractures in the thoracolumbar spine (T12 and L1). *J. Spinal Dis.* **3:** 39-46.

Wise, C.M. (1994) Chest wall syndromes. *Curr. Opin. Rheumatol.* **6:** 197-202.

Wood, K.B., Garvey, T.A., Gundry, C. *et al.* (1995) Magnetic resonance imaging of the thoracic spine. Evaluation of asymptomatic individuals. *J. Bone Joint Surg.* **77A:** 1631-1638.

Yasuma, T., Saito, S., Kihara, K. (1988) Schmorl's nodes. Correlation of X-ray and histological findings in postmortem specimens. *Acta Pathol. Jap.* **38:** 723-733.

6

Developmental anomalies of the thoracic region

J. Saada, S. Song and W. H. Breidahl

Development of the thoracic spine

Before reaching its final condition, the skeletal axis passes through three preliminary stages; mesenchymal, cartilaginous and bony (Verbout, 1985; Williams *et al.*, 1989). First its framework is determined by the notochord (a central cellular rod extending along the long axis of the embryo), which has developed by the seventeenth day of gestation. Mesenchymal tissue adjacent to the notochord is induced to segmentalize and form paired segments called somites. A total of 42–44 somites are formed, each producing a skin, muscle and bone component (Parke, 1975). Cells from the bone form a component of the somite, called a sclerotome, and migrate and multiply around the notochord. Each sclerotome divides in the axial plane, with each division fusing with a sclerotomic division arising from a different, rostral or caudal, neighbouring sclerotome. This results in the formation of a mesenchymal vertebral column. The site of sclerotomal division corresponds to the site of development of the intervertebral disc. Further migration of the sclerotogenous cells dorsally ventro-laterally results in the formation of the primitive vertebral arches and the costal elements.

Development of the mesenchymal vertebral column is followed by the development of the cartilage (chondrification) and bony (ossification) vertebral columns at 6 and 9 weeks respectively, completing the three-stage process.

Each vertebra has six centres of chondrification (Fig. 6.1); two costal, two neural arch, and two central (which form most of the vertebral body). Note that the two central chondrification centres fuse in the sagittal plane. The portions of the notochord incorporated within the body undergo atrophy and disappear; while those that lie within the intervertebral discs enlarge and persist as the nucleus pulposus.

Ossification of the vertebrae involves both primary and secondary ossification centres. Each vertebra is derived from three primary centres, one for the body and two for the vertebral arch (Fig. 6.1). During the ninth week of embryonic life, the vertebral body chondrification centre undergoes anterior and posterior resorption by penetrating vessels and is transformed into ossification centres. For a brief period, the ossification centre for the body demonstrates a dorsal and ventral component that is separated by a plate of cartilage (in the coronal plane). These later fuse to form a single large centre, which is separated from the disc spaces by two thick cartilaginous plates.

Vertebral arch ossification becomes evident in the second embryonic month, first in the atlas and then progressing caudally (Parke, 1975). Ossification of the vertebral bodies is usually advanced by 16 weeks, starting initially in the lower thoracic vertebrae and progressing both cranially and caudally (Bagnall *et al.*, 1977). At birth, the ossification centres have reached the anterior and posterior borders of the vertebral body and further growth occurs from the cartilaginous plate along its interface with the ossification centre. In the infant the thoracic vertebral body has an ovoid shape, gradually changing to a rectangular shape between the first to the second year of life. Between the sixth to the ninth year of life, normal, ring-like cartilaginous ridges are formed around the periphery of the end-plates and assume a wedge-like configuration, thus producing a slanted marginal defect when unossified (Kohler and Zimmer, 1993). These ring apophyses form secondary ossification centres around the twelfth year of life, and may be seen as sclerotic ridges around the superior and inferior end-plates on radiographs (Fig. 6.2). Fusion of

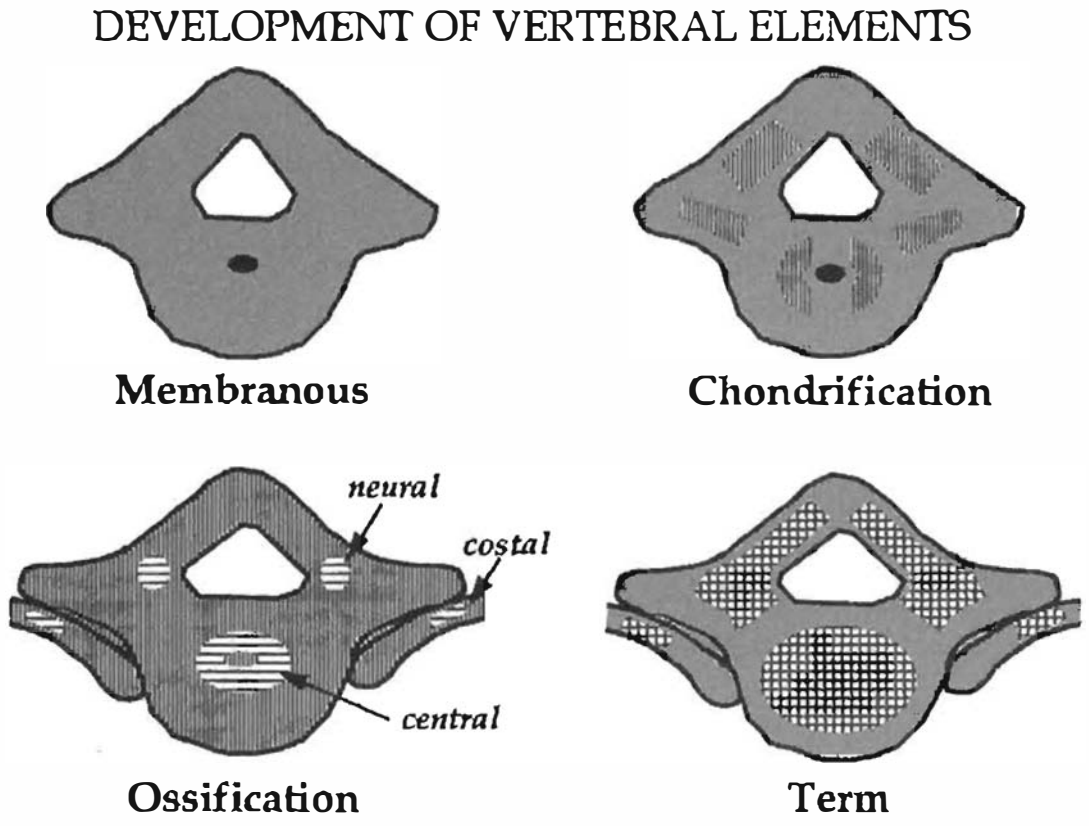

Fig. 6.1 The development of a typical thoracic vertebra from the membranous embryonal stage to that at term, passing through the chondrification and ossification stages sequentially. (Redrawn from Parke, 1975.)

these ossified cartilaginous ridges begins around the fourteenth year of life, and is usually completed by the twenty-fifth year. This structure firmly anchors the anulus to the body and, when ossified, receives the Sharpey's fibres.

Further secondary ossification centres also appear at the transverse and spinous processes around the sixteenth year of life, and fuse at approximately the twenty-fifth year. However, secondary ossification centres may remain unfused at these sites and are referred to as accessory ossification centres (Singer and Breidahl, 1990). Usually innocuous, unfused accessory ossification centres have occasional clinical significance when fractures are suspected. Where radiographic demonstration is adequate, these normal anatomical variants can generally be differentiated from recent trauma by their rounded cortical margins (Fig. 6.3).

Within the first year of life and during subsequent years a deep cleft-like indentation can be observed along the anterior vertebral body corresponding to the traversing vessels, and this may persist into adult life.

The thoracic spine in the adult

The height and width of the thoracic vertebral bodies increase in the cranio-caudal direction (Williams *et al.*, 1989). The intervertebral disc height is approximately 5 mm throughout the thoracic spine. The vertebral bodies and the intervertebral discs are gently wedged (< 2 mm) anteriorly, giving rise to the physiological kyphosis of the thoracic spine. However, the kyphosis may increase in late adult life due to a combination of loss of disc height and further

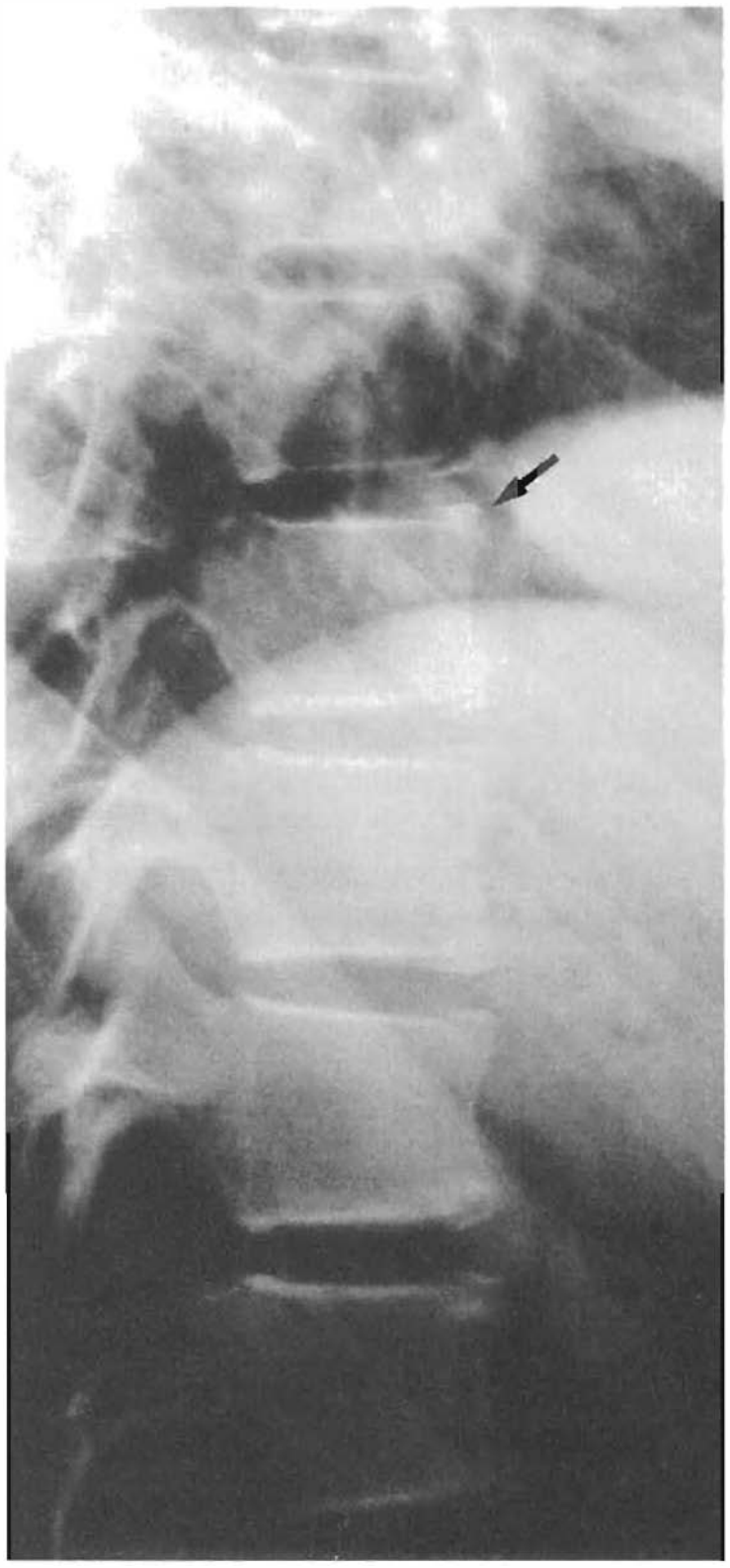

Fig. 6.2 Anterior step deformities caused by ring apophyses with triangular to discoid ossification centres (arrows).

Fig. 6.3 Rudimentary ossification centres of the transverse processes at the thoracolumbar junction. Rounded, corticated joint margins distinguish these centres from fractures (arrows).

anterior wedging of the thoracic vertebral bodies secondary to osteoporosis. Posteriorly the thoracic vertebra has a straight or slightly concave margin, with the posterior indentation for the vascular foramen of the basivertebral veins being found at the mid-level of the thoracic vertebral body.

The pedicles constitute the narrowest portion of the vertebral arches and consist of a central spongiosa, which is relatively thin and has a surrounding thick cortex. The interpedicular distance between the medial margins of the pedicles constitutes the width of the spinal canal, and this increases caudally. The first, eleventh and twelfth ribs each articulate with their corresponding vertebral bodies. All the others articulate with two adjacent vertebral bodies, with the larger articulating surface at the upper lateral margin of the corresponding vertebral body and the smaller articulating surface at the lower margin of the vertebral body immediately above. The first to the tenth ribs also articulate near the root of the transverse process of the vertebra.

Normal radiographs of the thoracic spine

In the lateral view, radiological visualization of the cervicothoracic junction is compromised by superimposed soft tissues of the shoulder. This can be improved by using the 'swimmers' view. However, a wedge-shaped upper thoracic vertebra can be mimicked by the superimposed glenoid fossa, rib or other overlapping bony structures, and care must be taken in interpreting the radiographs of this region (Keates, 1996) (Fig. 6.4).

In the mid- and lower thoracic spine improved visualization of the vertebral bodies can be achieved by taking the radiograph whilst the patient takes rapid shallow breaths, which gives rise to a tomographic effect with blurring of the overlapping ribs and pulmonary structures. This is particularly useful in the context of trauma and the assessment of metastatic disease.

In the antero-posterior (AP) view of the upper thoracic spine, superimposition of the superior border of the sternum may mimic a fracture (Fig. 6.5). The cortical structures of the pedicles project as round-to-ovoid rings over the upper portion of the vertebral bodies. As previously described, the superior and inferior articular processes of the pars form the zygapophysial joints, with the joint surfaces being almost vertically orientated, and in the lateral projection they are superimposed on each other and are further obscured by overlying ribs and lung tissue. They can be best visualized by rotating the body 20° either anteriorly or posteriorly from the lateral projection.

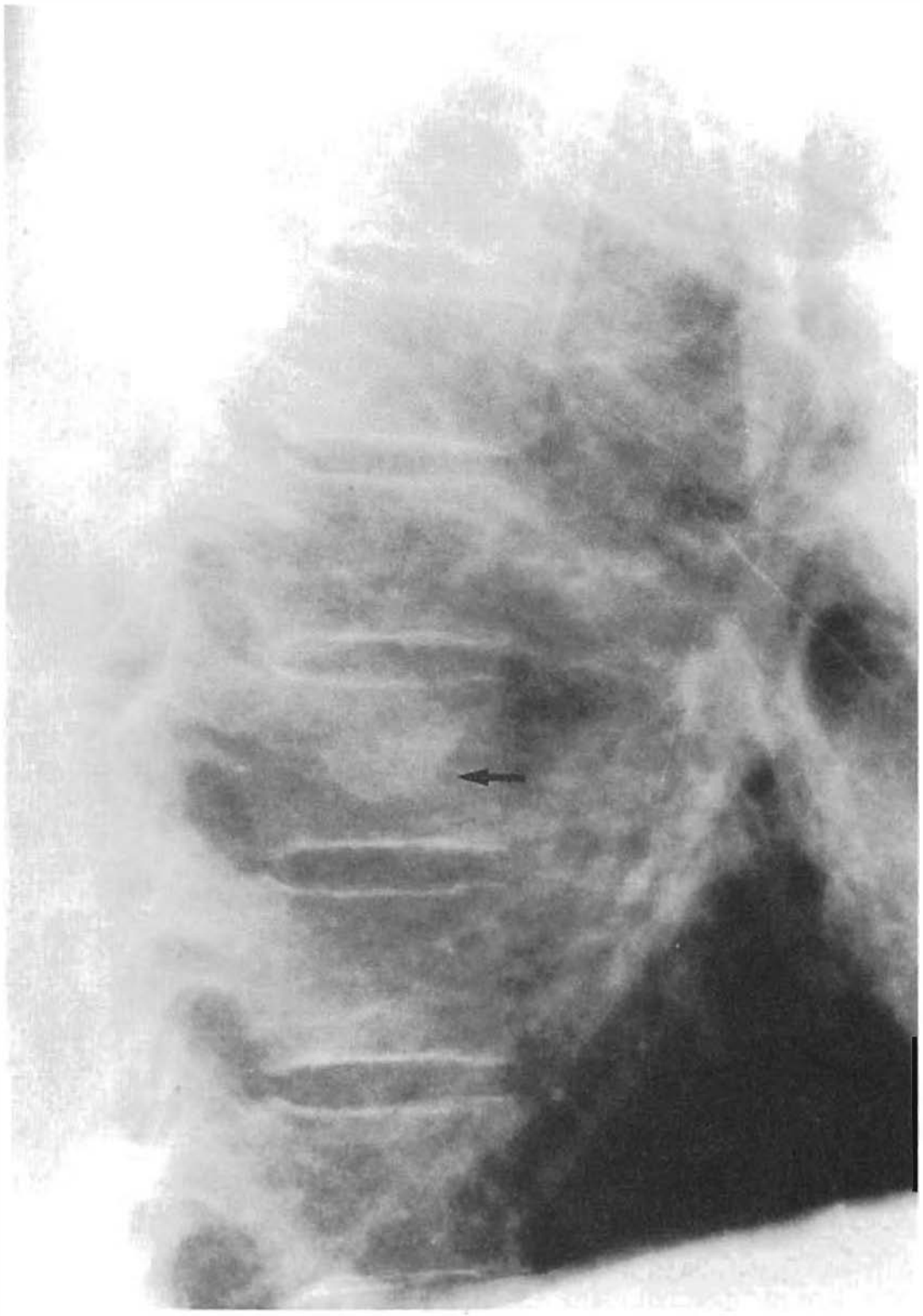

Fig. 6.4 The inferior angle of the scapula is superimposed on T7, mimicking a sclerotic lesion of the vertebral body (arrow).

In the AP projection, only the costotransverse joints at T9-T10 are seen without superimposed interfering structures. The transverse processes are hardly seen in the AP projection due to interfering summations effects, and the spinous processes are barely discernible in the lateral projection due to relative overexposure of the film.

The row of the spinous processes is easily recognized in the AP view, with the spinous processes of T10, T11 and T12 seen projecting almost straight posteriorly. Because of their caudal orientation, the remaining spinous processes are seen extending below the inferior vertebral margins and intervertebral disc space, with their tips being projected over the inferior subjacent vertebra.

Developmental anomalies

Abnormalities of the vertebral body

Any deviation from the normal developmental pathway of the vertebrae can result in deformity. The processes of mesenchymal segmentation or fusion,

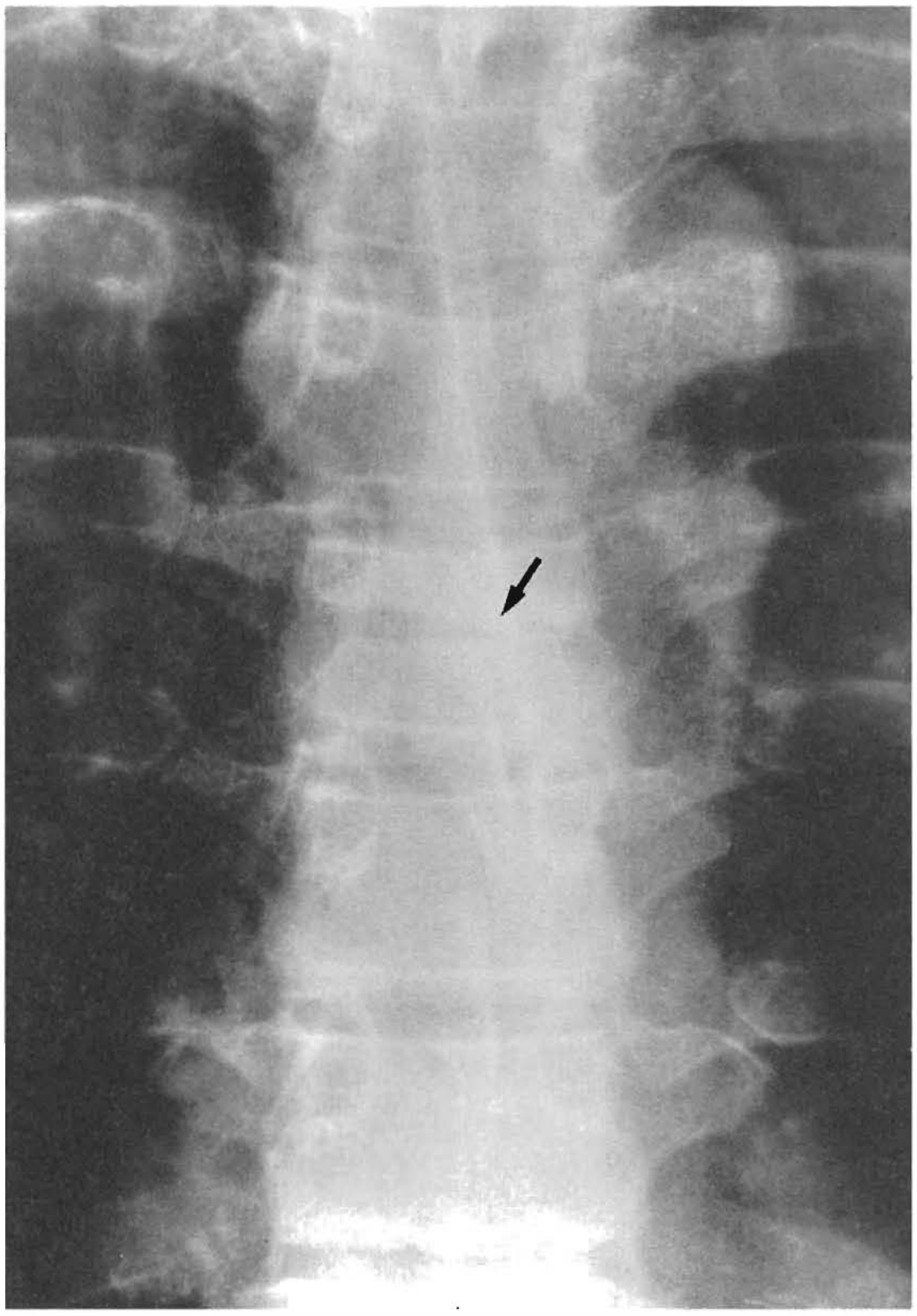

Fig. 6.5 The radiographic projection of the sternal angle over the thoracic spine produces a transverse radiolucent zone mimicking a fracture (arrow).

chondrification and ossification can be used to explain the wide spectrum of developmental abnormalities (Ozonoff, 1995; Kumar *et al.*, 1988). The underlying cause for many of these disorders remains obscure, and may involve defects at more than one of the three developmental stages. Some entities are associated with widespread abnormality; for example, vertebral body abnormalities may be associated with congenital anomalies of the genito-urinary, gastrointestinal and central nervous systems, the so-called VATER (vertebral defects, imperforate anus, tracheo-oesophageal fistula and radial and renal dysplasia) association (Beals and Rolfe, 1989).

Disorders of mesenchymal segmentation or fusion are considered to result in agenesis of the vertebral body, hemi-metameric segment displacement and block vertebrae (Kohler and Zimmer, 1993). The complete absence of a vertebra (agenesis) results from failure of sclerotomal development, although it can also result from failure of ossification centres of the body to appear, particularly when the posterior elements are unaffected. The anomaly may be multi-segmental.

Block vertebra (bony union of one or more vertebral elements) results from incomplete segmentation during the formation of the mesenchymal column. The fusion may be partial or complete (Fig. 6.6).

In complete block vertebra (where there is fusion of the anterior and posterior elements), the height of the fused bodies equals the sum of the height of the involved bodies and the intervertebral discs between them, with a waist at the level of the intervertebral disc between the fused segments. The neural foramina of the block vertebra are ovoid and narrowed. In partial fusion, four types are recognized (Kohler and Zimmer, 1993): fusion of the anterior third of the vertebral body; fusion of the posterior third of the vertebral body; fusion of the entire vertebral body; and fusion involving the posterior arch and pedicles. Another pre-cartilaginous stage abnormality is the hemi-metameric segmental deformity, whereby the left and right halves of the mesenchymal vertebral column fuse (often irregularly) across a skipped segment rather than with each other, with resultant scoliosis and ribcage deformity (Fig. 6.7). Since the left and right halves of the vertebral body arise from different chondral centres, failure of chondrification of one half will result in the development of a hemivertebra. Hemivertebrae have a wedge-shaped configuration, with the apex of the wedge being in the midline (Fig. 6.8). They are associated with rib anomalies and a scoliosis that is often present at birth.

Failure of ossification, which normally occurs from a dorsal and ventral vascular invagination of the mature chondral centre, probably accounts for the development of coronal cleft vertebrae, ventral and dorsal hemivertebrae. A kyphotic deformity is seen at the site of the dorsal hemivertebra (Fig. 6.9). Ventral hemivertebrae are extremely rare. Hypoplastic vertebrae may also result from disorders at this stage, particularly in the presence of both ventral and dorsal embryonal vascular insufficiency.

Coronal clefts result from failure of fusion of the anterior and posterior ossification centres, which remain separated by a cartilage plate and represent a delay in normal vertebral maturation (Fielden and Russel, 1970). In most cases, the clefts disappear by 6 months after birth. Coronal clefts are usually seen in premature infants. Radiographically, a coronal cleft is recognized as a radiolucent vertical band seen behind the mid-portion of the vertebral body in the lateral view.

A total sagittal cleft is rare, and is generally incompatible with life (Kohler and Zimmer, 1993). Partial ventral and dorsal clefts are more frequent. In all of these cleft formations, a persistent notochord divides the vertebral bodies into two halves. Each vertebral half decreases in height towards the unfused centre, giving the vertebra the appearance of a horizontally orientated cone in the coronal

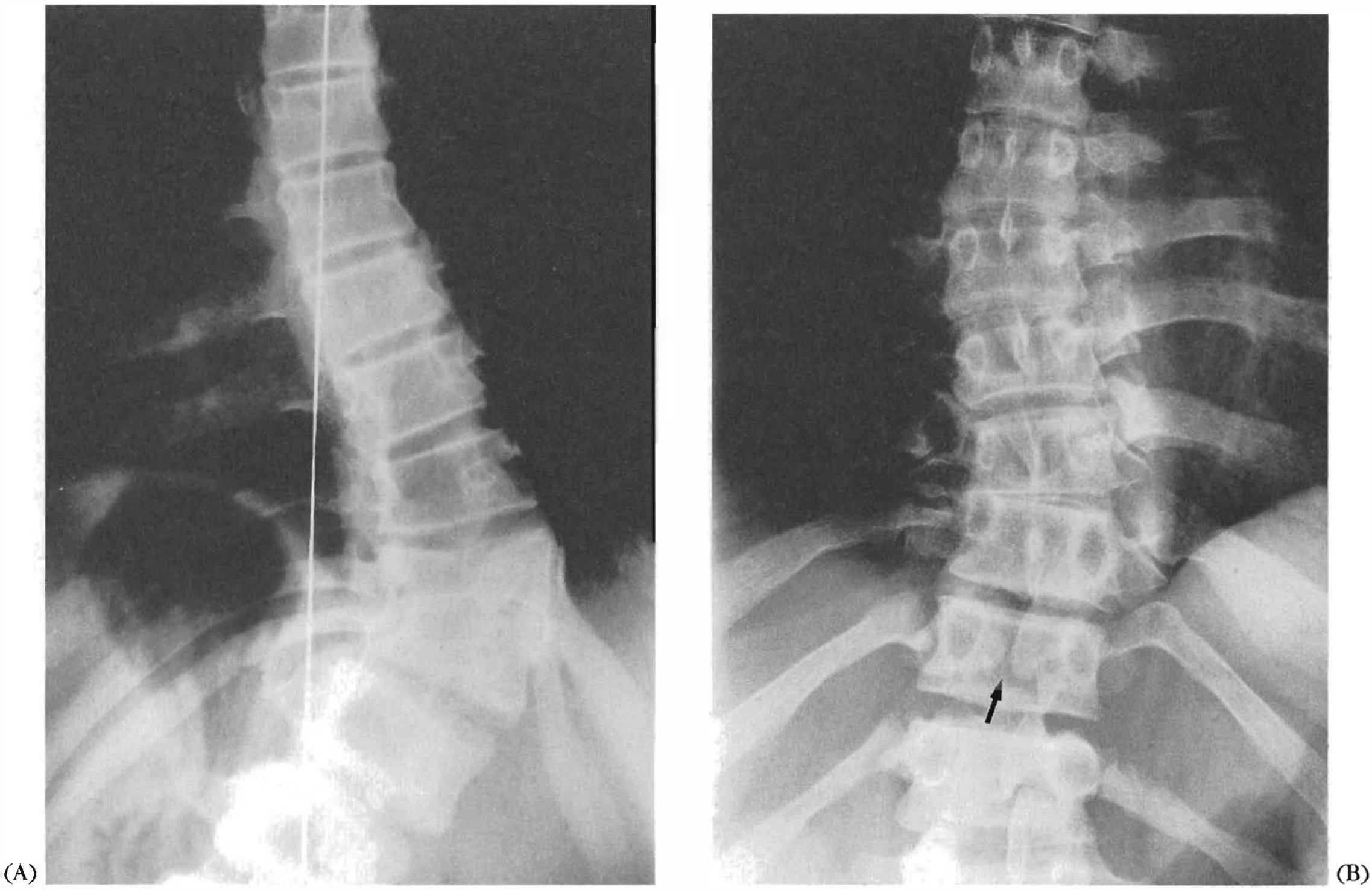

Fig. 6.6 Two patients with thoracic scoliosis. (A) Complex complete fusion of the body of T11 and T12 involving anterior and posterior vertebral elements. T11 has a 'butterfly' configuration. (B) Partial fusion of the body of T9 and T10. Note the failure of fusion of the vertebral arch of T11 (arrow).

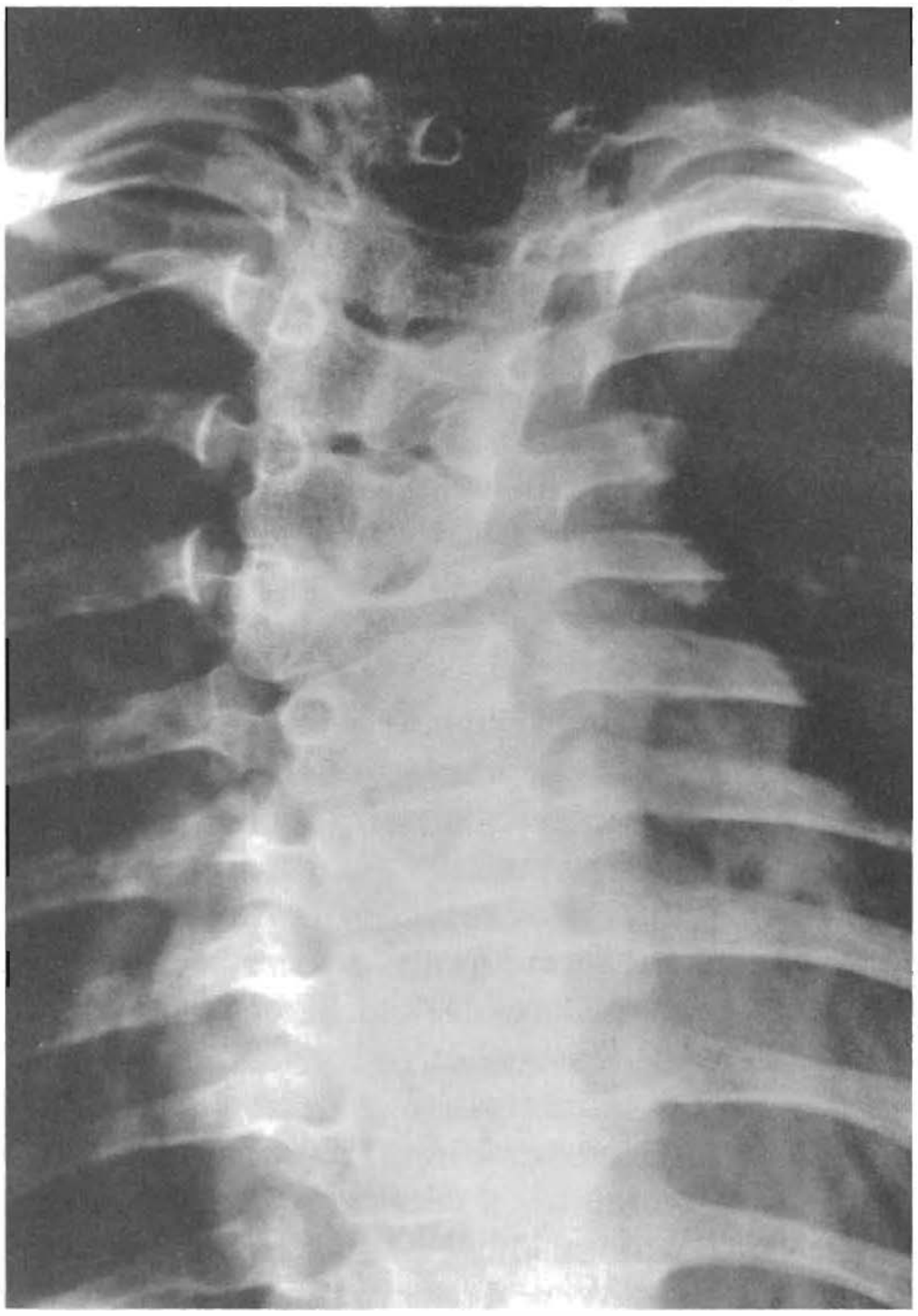

Fig. 6.7 Right hemivertebra involving T5, resulting in a scoliosis concave to the left.

Fig. 6.8 Metameric hemivertebrae at the cervicothoracic junction; the right hemivertebra at T1 is isolated in the axial plane from the corresponding left T1 hemivertebra, which is fused with the T2 vertebral body.

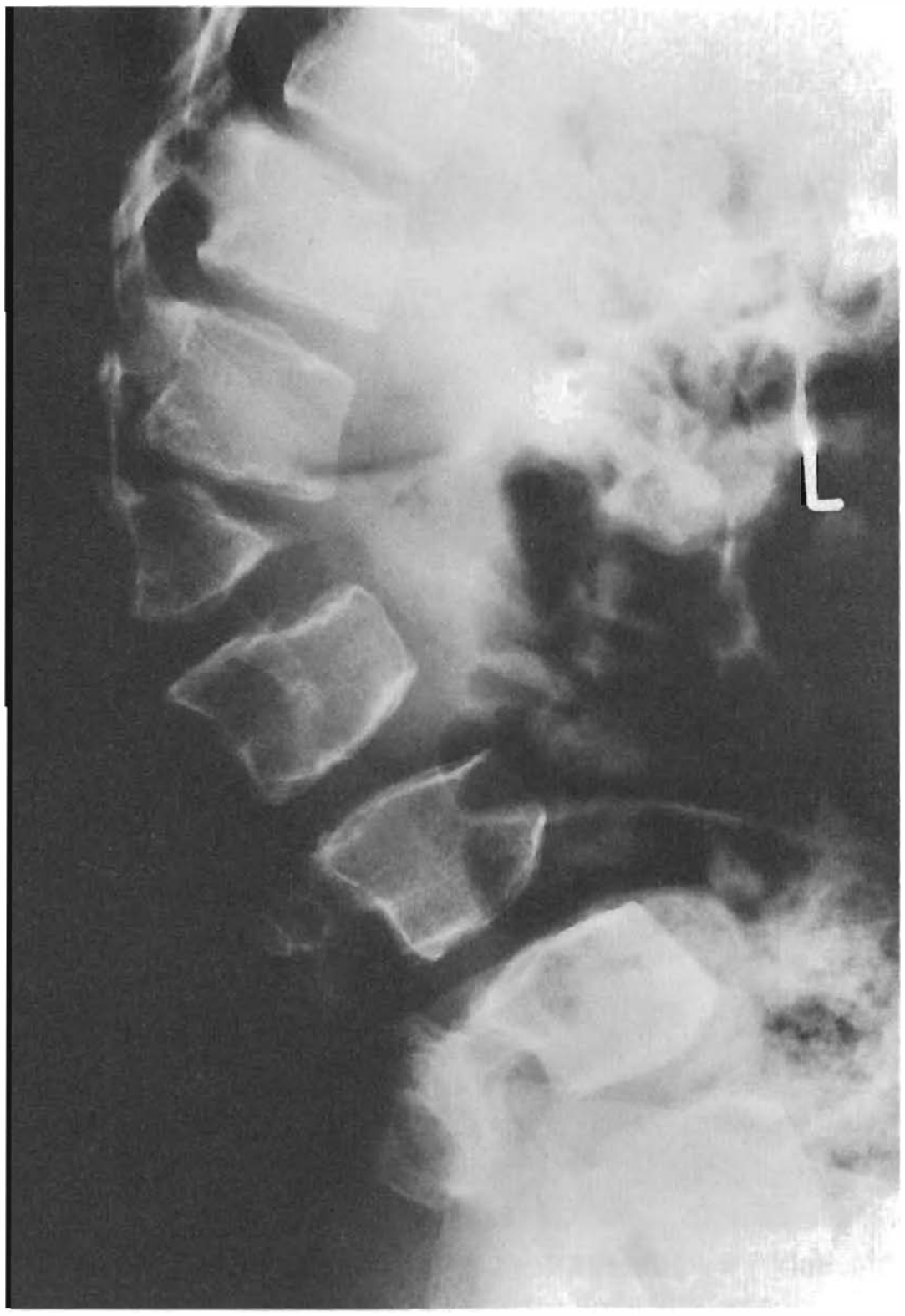

Fig. 6.9 Dorsal hemivertebra involving T12 in a patient with Morquio's disease. Note the presence of 'central beaks' along the anterior borders of the thoracolumbar junction.

projection; hence, it is generally referred to as a butterfly vertebra (Kumar *et al.*, 1988) (Fig. 6.10). The involved vertebral body is widened, and the bodies above and below the butterfly vertebra adapt to the altered intervertebral discs on either side by showing concavities along the adjacent end-plates. Some bone bridging may occur across the defect. Anterior spina bifida, with or without anterior meningoceles, may be associated. Butterfly vertebrae usually occur in the thoracic or lumbar segments.

Abnormalities of the vertebral arch

Abnormalities of development of the mesenchymal, chondral and osseous axial skeleton will also involve the vertebral arch, as is the case with the vertebral body. Failure of fusion of the spinous processes at the lumbosacral junction is not uncommon; less commonly, they may remain
and Pryde, 1956).

Congenital absence of a thoracic pedicle is a rare anomaly (Lederman and Kaufman, 1986). Associated findings include:

1. Contralateral pedicle sclerosis and hypertrophy - enlargement or 'hypertrophy' of the contralateral pedicle at the level of a pedicle deficiency is a common finding, as is associated cortical thickening and sclerosis.
2. Retropedicular hypoplasia - an associated feature of hypoplasia and aplastic pedicles is retropedicular hypoplasia of a portion of the neural arch, usually of the superior articular process.
3. Spinous process tilt - tilt of the spinous process of the affected vertebra is a common finding in neural arch deficiency, and may reflect rotational instability at the defective level. The tilt is usually towards the affected side.
4. Rib and transverse process anomaly - the ribs adjacent to a deficient thoracic pedicle articulate anomalously with a slightly expanded posterior vertebral margin, anterior to the

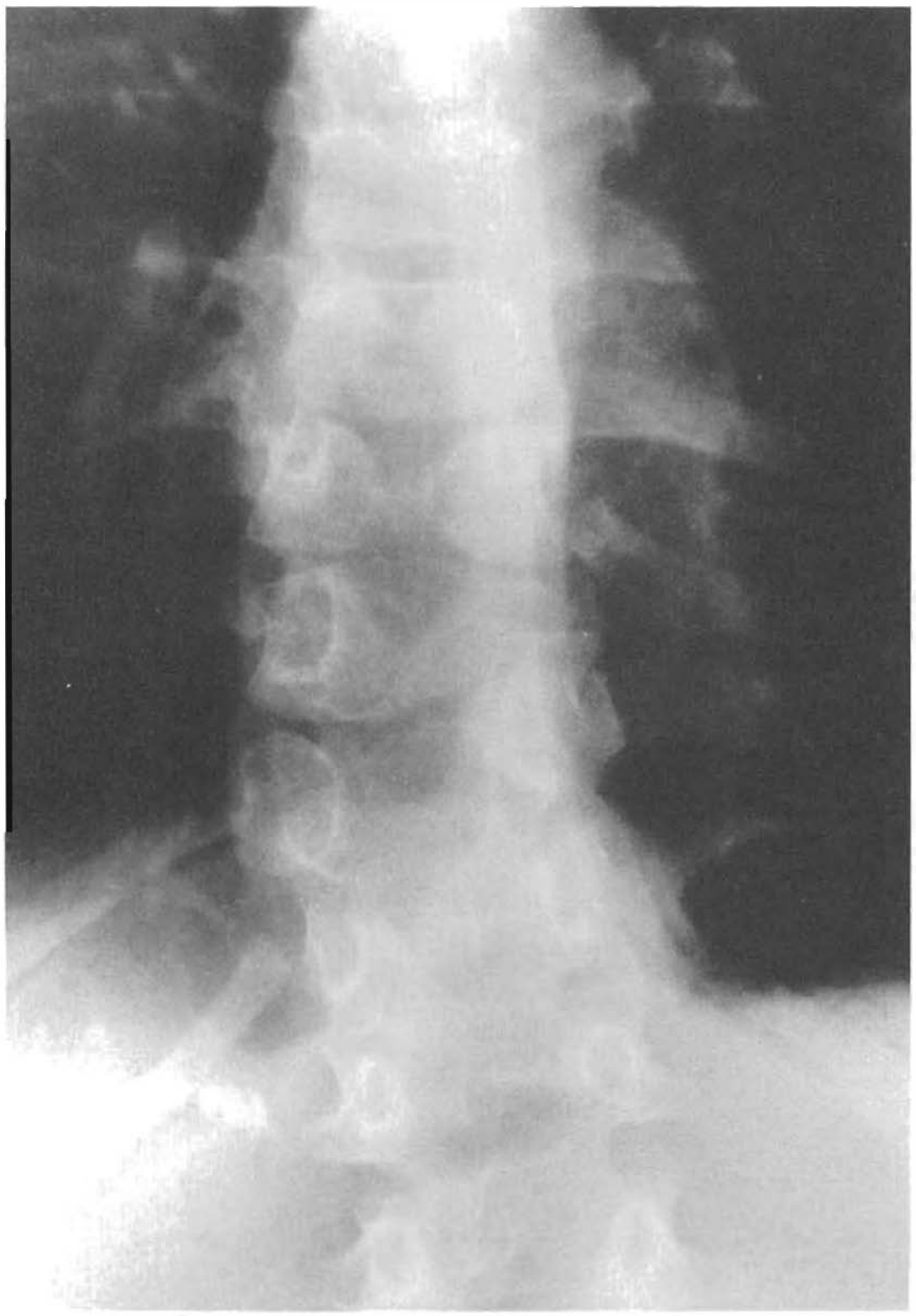

Fig. 6.10 Butterfly vertebrae involving T9.

normal placement; the associated rib head and transverse process may be absent.

5. Enlarged spinal canal capacity - this is accompanied by an increase in epidural fat on the side of the deficiency.

Failure of segmentation leads to linkage and fusion of adjacent laminae and pedicles, termed congenital vertebral bars (MacEwen *et al.*, 1968). These are frequently unilateral and have a restrictive effect on the ipsilateral spinal growth. Laminar fusions may be cartilaginous and difficult to detect on plain radiographs.

Spinal dysraphism represents a failure of midline fusion of mesenchymal, neural and bony structures. This term refers to a large spectrum of disorders encompassing at least 14 distinct entities (Byrd *et al.*, 1991) not including the commonly encountered cleft in the spinal processes or non-united laminae of L5 or S1, which are considered to be normal variants. The vertebral manifestations consist of incomplete fusion of the neural arch, typically with absence of the spinous processes and laminae. A variable degree of protrusion of spinal contents can occur through the neural arch cleft, which may be open or closed depending on the integrity of skin covering of the defect. Associated segmental abnormalities such as hemivertebrae, butterfly vertebrae and block vertebrae are not uncommon.

Diastematomyelia, a form of spinal dysraphism that commonly involves the thoracic spine, appears in an early embryonic stage and is associated with vertebral clefts and neuropathy in the lower limbs and sphincter disturbance (Byrd *et al.*, 1991). If a bony septum divides the cord, diastematomyelia can be detected on plain films (Fig. 6.11). Diastematomyelia is characterized pathologically by sagittal clefting of the spinal cord or filum terminale. The cleft is located between T9 and S1 in 85% of cases. A thoracic location is seen in 20% of cases, and a combined thoracolumbar lesion occurs in 15-20%. The spinal cord is typically split into two halves by a fibrous, bony or osteocartilaginous septum (Fig. 6.12). The cleft typically extends completely through the cord, and the cord is usually split locally with a single cord above and below the cleft. The two hemicords are somewhat asymmetric, and each hemicord contains a central canal and one set of dorsal and ventral horns and nerve roots. Half of the hemicords have a single dural

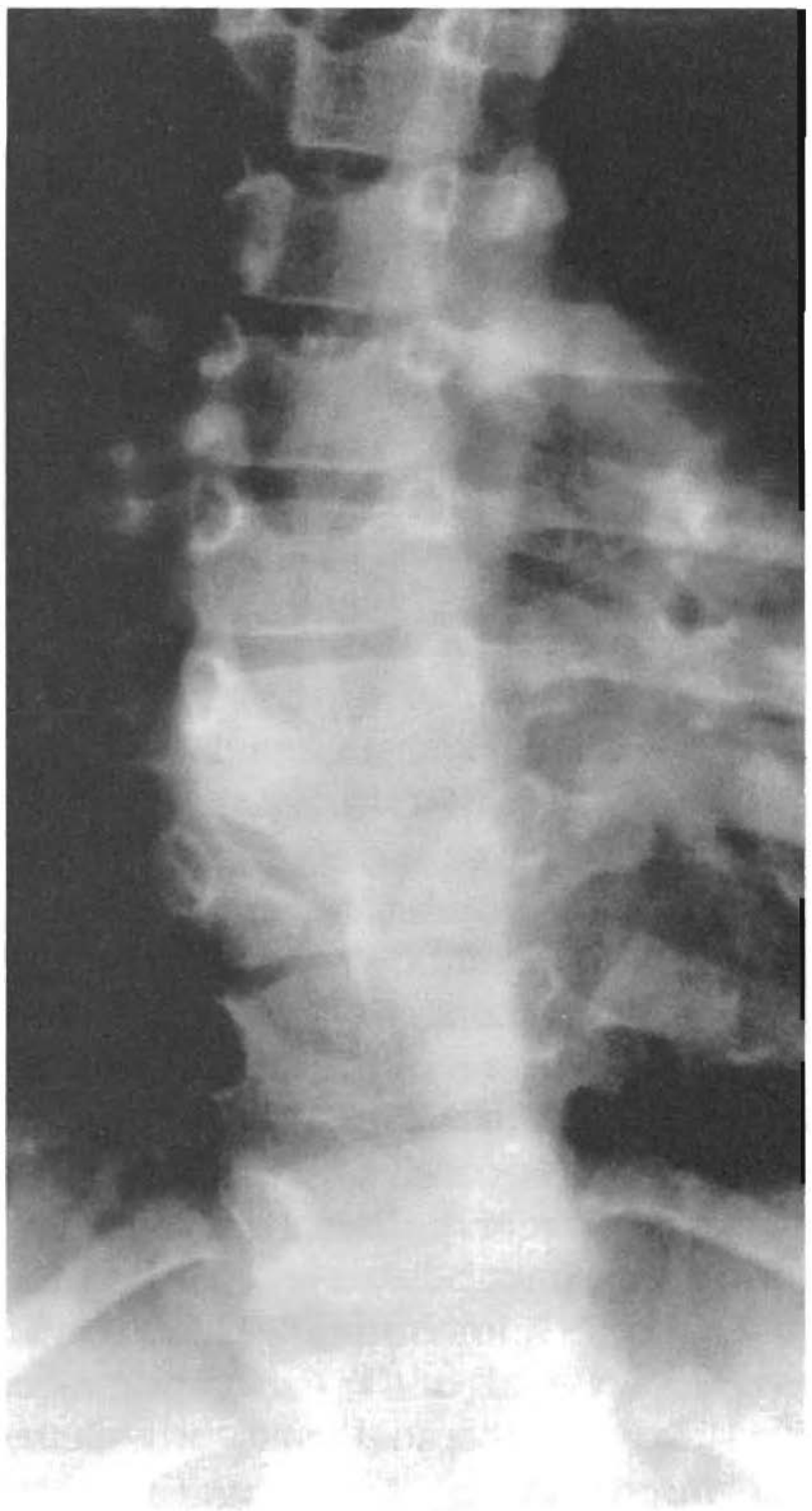

Fig. 6.11 Radiological findings in diastematomyelia. The interpedicular distance is increased from T7 to T11. The body of T8 is deformed in a fashion consistent with bilateral hemivertebrae or notochordal remnant.

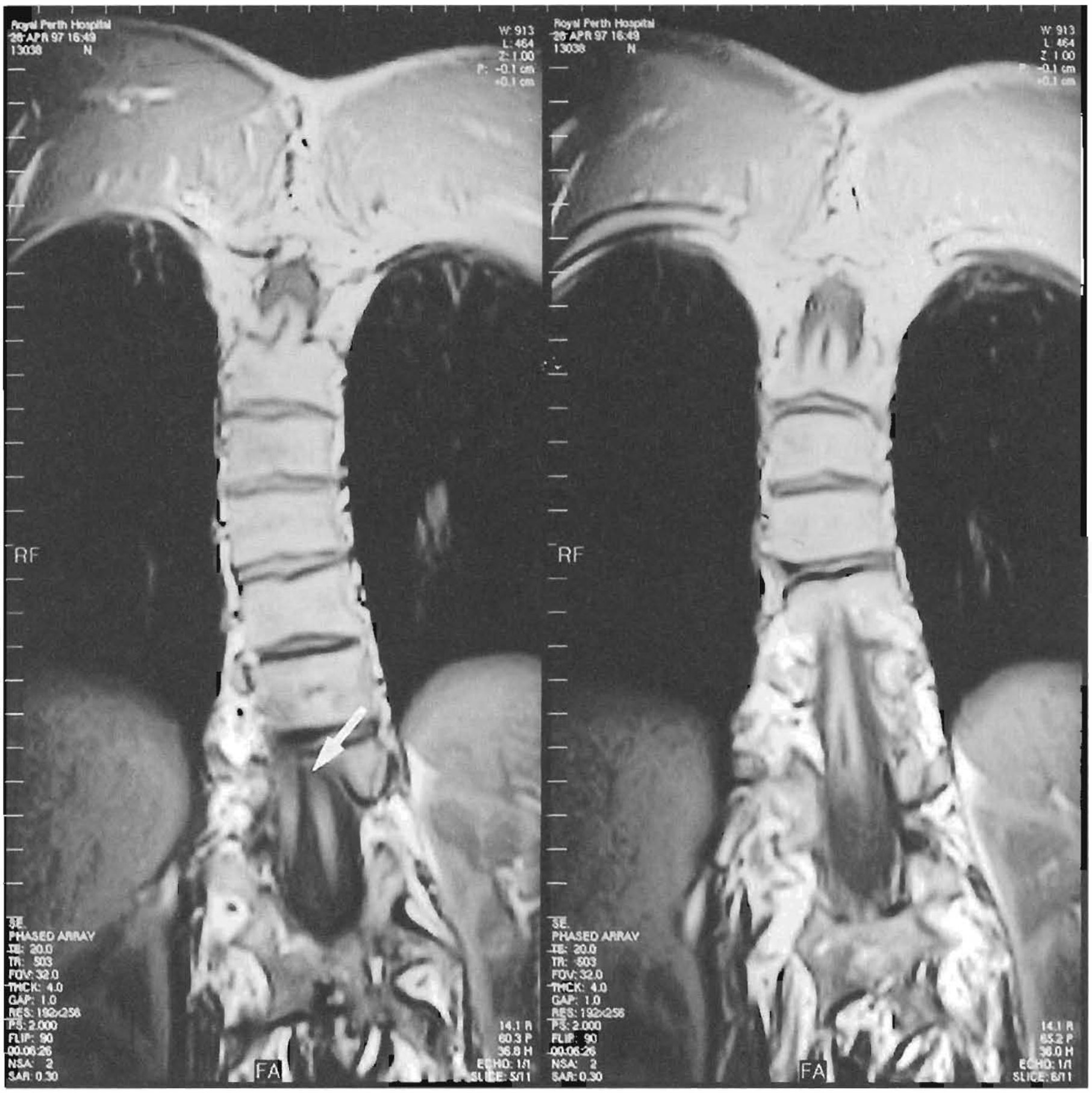

Fig. 6.12 Coronal magnetic resonance section through the thoracic spine in a patient with diastematomyelia with a 'split' cord at the upper thoracic and thoracolumbar regions (arrows).

tube, and the other 50% are enclosed in separate dural sacs (Byrd *et al.*, 1991).

Plain films and computed tomography (CT) scans nearly always show an abnormal osseous spine. The hemicords and subarachnoid spaces are well seen at myelography, CT myelography or magnetic resonance (MR) scanning. At least 85% of patients with diastematomyelia have vertebral body anomalies, including hemivertebrae, block or butterfly vertebrae and narrowed intervertebral discs. Intersegmental laminae fusion with spina bifida may also be present. An osseous spur is seen in about 50% of cases. The spur may traverse part or all of the canal and be central or eccentric. The spinal canal is also widened with increased interpedicular distance. Cutaneous stigmata overlie the spine in 50–75%, with hair patches, naevi and lipomas being common. Fifty per cent of patients with diastematomyelia are symptomatic, particularly patients with tethering of the spinal cord, presenting with motor and sensory defects of the lower limbs, bladder and bowel dysfunction, and club foot and scoliosis (Byrd *et al.*, 1991).

Alignment

Scoliosis

Scoliosis is defined as the presence of one or more lateral-rotary curvatures of the spine, and is described in relation to the convexity of the curve. It is considered non-structural if it corrects on bending toward the convexity, and structural if it is relatively rigid.

Scoliosis can be divided into idiopathic, congenital, neuromuscular and other groups (Young, 1996). Idiopathic scoliosis (Fig. 6.13) accounts for approximately 70% of cases. It usually occurs as a thoracic or thoracolumbar curve convex to the right and a lumbar curve convex to the left. It is currently

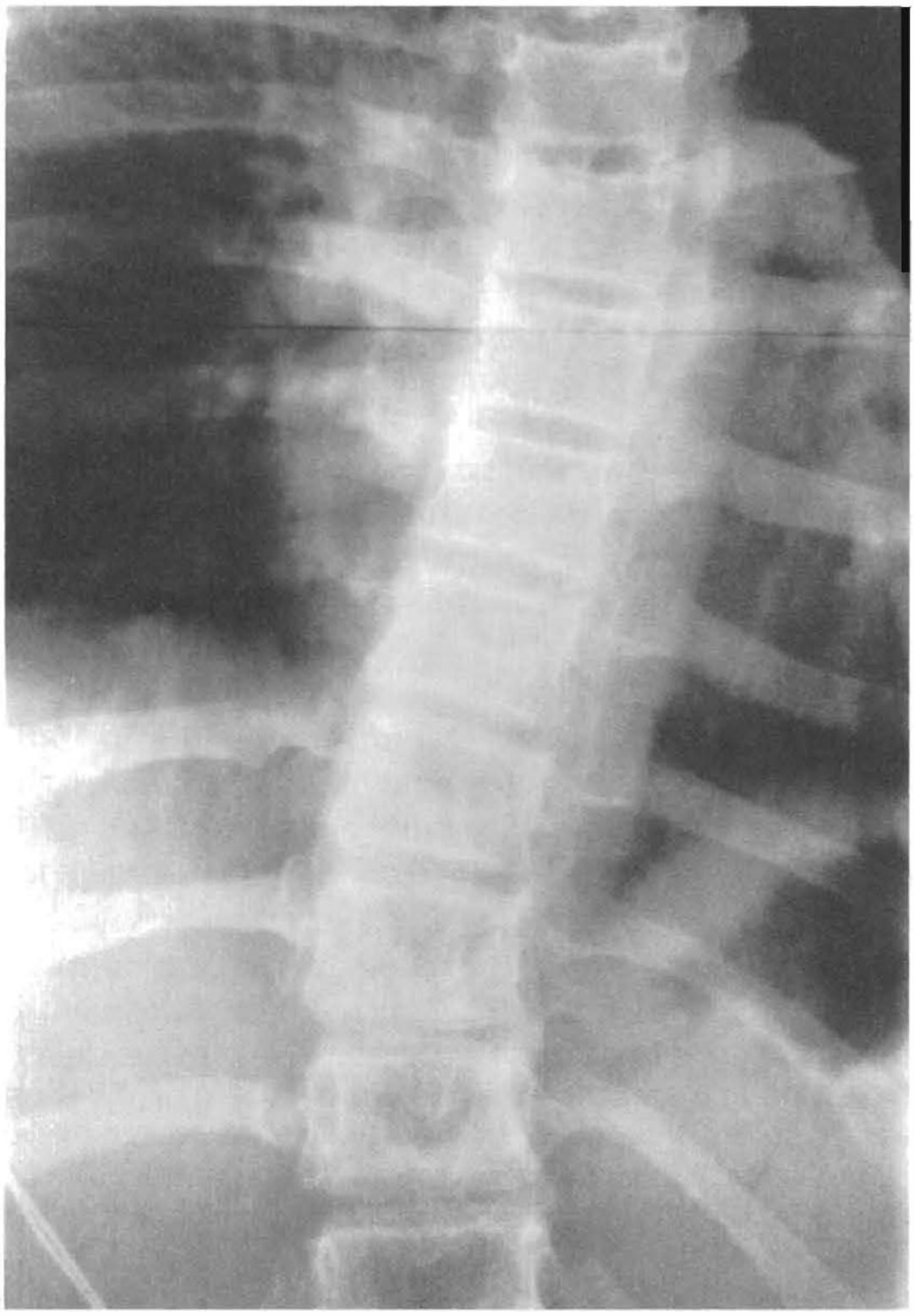

Fig. 6.13 Idiopathic scoliosis; thoracic curve concave to the left and lumbar curve concave to the right.

considered to be transmitted as an autosomal dominant trait, with females being affected eight times more frequently than males. The prevalence of significant idiopathic scoliosis (Cobb angle > 10°) in children aged 6–8 years and 12–14 years is 0.1% to 1.2% respectively (Stirling *et al.*, 1996). Congenital scoliosis may be vertebral, for example in the presence of a hemivertebra or fused vertebral bodies (see Fig. 6.6), or extravertebral, for example in the presence of developmental rib fusion.

Neuromuscular scoliosis may result from poliomyelitis, cerebral palsy, muscular dystrophy and other myopathies. Other causes of scoliosis include skeletal manifestations of neurofibromatosis, the skeletal dysplasias, Scheuermann's disease and rheumatoid arthritis, trauma, and following irradiation treatment.

Radiographic examination for scoliosis includes erect and recumbent films of the entire spine from the cervical level to the sacrum, including both iliac crests and a lateral thoracolumbar spine. Left and right bending films can also be obtained to determine the degree of correction that can be achieved.

Measurement of the scoliosis is usually done by the Cobb technique (Fig. 6.14) (Cobb, 1948). In this technique, the upper limit of the curve is defined by a line tangential to the upper margin of the most superior body tilting towards the centre of the curvature; the lower limit is defined by a line related to the lower margin of the most inferior body. One angle subtended between these lines (or perpendiculars constructed to them) measures the angle of scoliosis. Differences of 5–10° between examinations can arise from inter-observer differences and slight differences in positioning of the patient whilst the radiograph is being obtained.

Operative and non-operative therapies are currently used to treat scoliosis. Spinal fusion is the main operative treatment. Cases of unilateral bar, hemivertebrae and wedge vertebrae show progressive rotation regardless of the type of treatment; however, progression of the curvature component can be limited by spinal arthrodesis (Lopez-Sosa *et al.*, 1995). Rotation of the spine is atypical in block vertebrae. Evaluation of skeletal maturity is important in the management of scoliosis, since progression of most mild to moderate scoliosis usually ceases after the secondary ossification centres of the iliac crest are completely fused to the parent bone.

Scheuermann's disease

This poorly defined clinical entity is characterized by an accentuated thoracic kyphosis with migration of its kyphotic apex into the thoracic spine or further caudally. The kyphosis remains smoothly rounded, and may be associated with a scoliotic deformity. Most affected persons are between 13 and 17 years old. In its classical form it is associated with a spinal deformity in the adolescent, which is considered to have multifactorial aetiology. A probable genetic defect of the vertebral end-plates or discs, resulting in inadequate nutrition and structural weakness, thought to produce nuclear prolapses (Schmorl's nodes) with subsequent uneven growth and marginal defects and a ventral shift of the load on the vertebral body (Begg, 1954). This retards growth locally, resulting in wedging and kyphosis. The integrity of the supportive posterior elements (zygapophysial joints) only serves to accentuate the kyphosis and they do not compensate for the loss of ventral spinal height. Progressive kyphosis accentuates the pathological loading on the ventral aspect of the spine, which results in a vicious cycle of overstretching of the dorsal spinal muscles resulting in muscular insufficiency, and further postural deterioration (Kohler and Zimmer, 1993). This condition evolves when the spine is overloaded during growth, before the vertebral ring apophyses fuse with the vertebral bodies. A cardinal finding of Scheuermann's disease is that Schmorl's nodes are found more anteriorly, in contrast to otherwise normal vertebrae, where they are characteristically located posteriorly (Fig. 6.15). The cartilaginous protrusion causes a confined

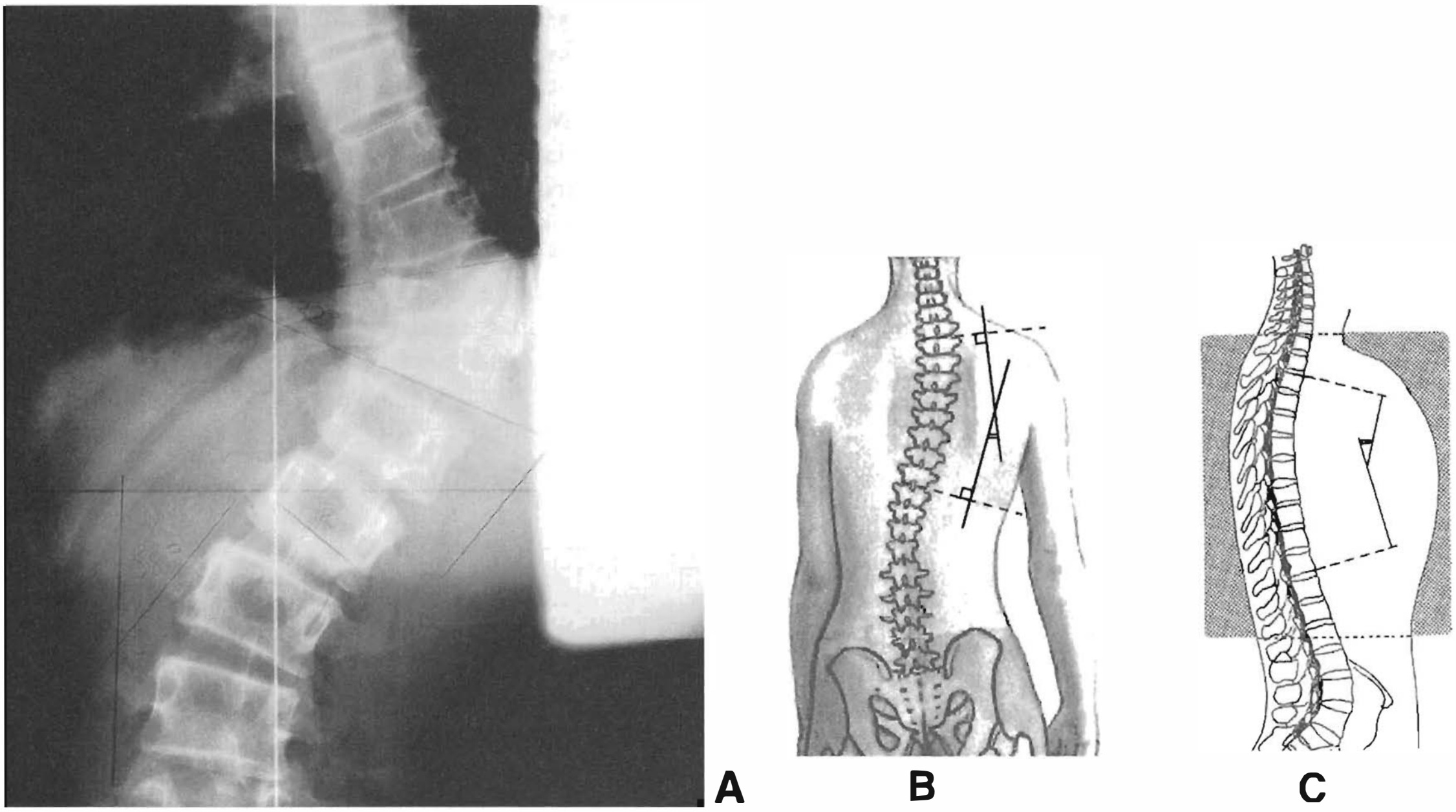

Fig. 6.14 Cobb technique: the upper limit of the curve is defined by a line tangential to the upper border of the most cephalad body tilting towards the centre of the radius of curvature; the lower limit is defined by a similar line related to the lower border of the most caudal body (A). The angle subtended between these lines measures the angle of scoliosis (B). The same technique may be used to define the thoracic kyphosis with intersection of the lines subtended from perpendiculars off the apical and distal vertebral end-plates (C).

Fig. 6.15 Scheuermann's disease: three contiguous level involvement at the thoracolumbar junction with loss of disc volume, anteriorly located Schmorl's nodes, end-plate sclerosis and minimal wedge deformity of T12.

sclerotic reaction in the adjacent vertebral spongiosa and leads to a loss of disc volume, resulting in a decreased width of the intervertebral disc space. Protrusion into the posterior margin, with extension into the intervertebral foramen or spinal canal, can lead to marginal avulsion. The affected end-plates become undulated, irregular and sclerotic. The kyphotic deformity causes increased weight bearing anteriorly, leading to irregular and coarse vertebral ring apophyses. The apophyseal fragments can appear dense. If the vertebral ring epiphysis disappears completely, the anterior margin exhibits a slanted or step-like deformity. The vertebral bodies assume a wedge configuration with the apex pointing anteriorly.

To be a manifestation of Scheuermann's disease, the vertebral deformities and anterior disc space narrowing should involve at least three but not more than five vertebral segments. The kyphosis is not an obligatory finding, and is seen in 12-63% of cases (Kohler and Zimmer, 1993). The anterior vertebral margins appear indistinct, and the sagittal diameter of a vertebra affected by Scheuermann's disease is characteristically increased whilst longitudinal vertebral growth is arrested.

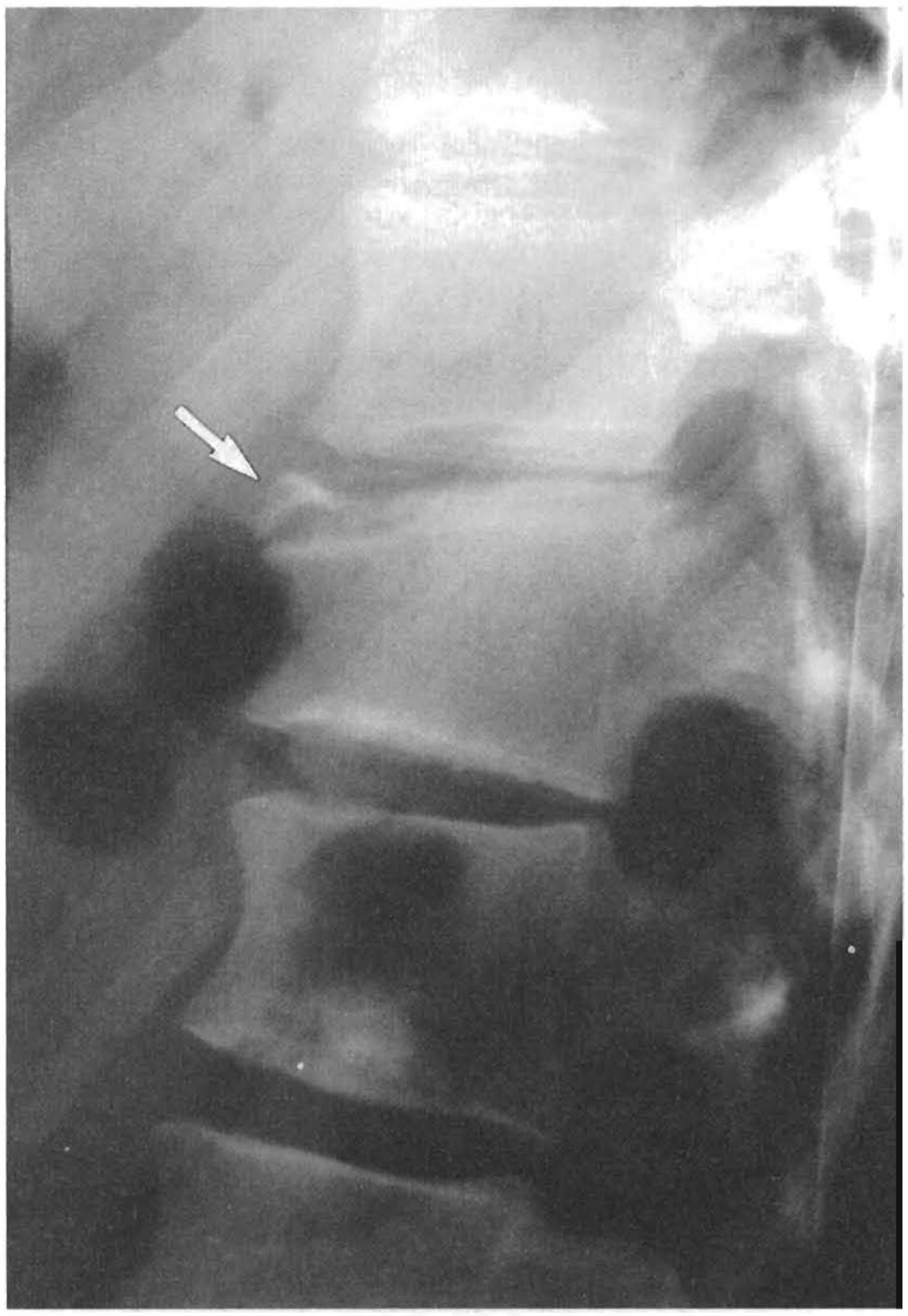

Fig. 6.16 Limbus vertebra; note the radiolucent defect at the antero-superior border of T12 (arrow).

The true prevalence of this disorder is difficult to determine due to marked variation in symptomatology and diagnostic criteria. Radiologically, irregularities of vertebral growth zones are identified with a prevalence of 4-5% and may even exceed 30% (Kohler and Zimmer, 1993). A frequency of 4-6% was found in a study on military personnel (Dameron and Gulledge, 1953). In a more recent study by Wood and colleagues (1995), 38% of all asymptomatic subjects were shown to have Scheuermann's end-plate changes or kyphosis on MR imaging. These findings emphasize the importance of obtaining full clinical correlation prior to initiating therapy for patients with radiological abnormalities.

Limbus vertebrae

A limbus vertebra represents a distinct type of disc herniation in which there is intra-osseous penetration of disc material at the junction of the end-plate with the bony rim of a vertebral body. An oblique radiolucent defect is seen coursing toward the outer surface of the vertebral body and this separates a small segment of the bone (Fig. 6.16).

Inherited abnormalities of vertebral body achondroplasia

Classic achondroplasia is the most common nonlethal skeletal dysplasia, and displays autosomal dominant inheritance (Taybi and Lachman, 1996). There is a generalized defect in enchondral bone formation, thus growth failure occurs at the neurocentral synchondrosis. Clinical manifestations include limb shortening, affecting proximal portions more than distal (rhizomelic micromelia), and thoracolumbar kyphosis in childhood with an exaggerated lumbar lordosis in adults. Spinal stenosis may result in compression of the lower brainstem, spinal cord, cauda equina or nerve roots.

Vertebral bodies are flattened and appear bullet-shaped in infancy and early childhood (Bethem *et al.*, 1981). The pedicles throughout the spine are thick and approximately one-half their normal length, so that the spinal canal is narrowed in its sagittal as well as its transverse dimensions. The vertebral bodies are concave on their dorsal surface, diminished in height, and often demonstrate anterior wedging (see Fig. 6.17). The ribs are shortened and the antero-posterior diameter of the chest is decreased. The anterior ends of the ribs may be flared.

Spondyloepiphyseal dysplasia congenita

The usual pattern of inheritance is autosomal dominant; however, this rare condition exhibits considerable genetic heterogeneity (Taybi and Lachman, 1996). There is decreased vertical height of vertebral bodies which, in infancy, may assume a pear shape

Fig. 6.17 Achondroplasia - note the spinal canal stenosis.

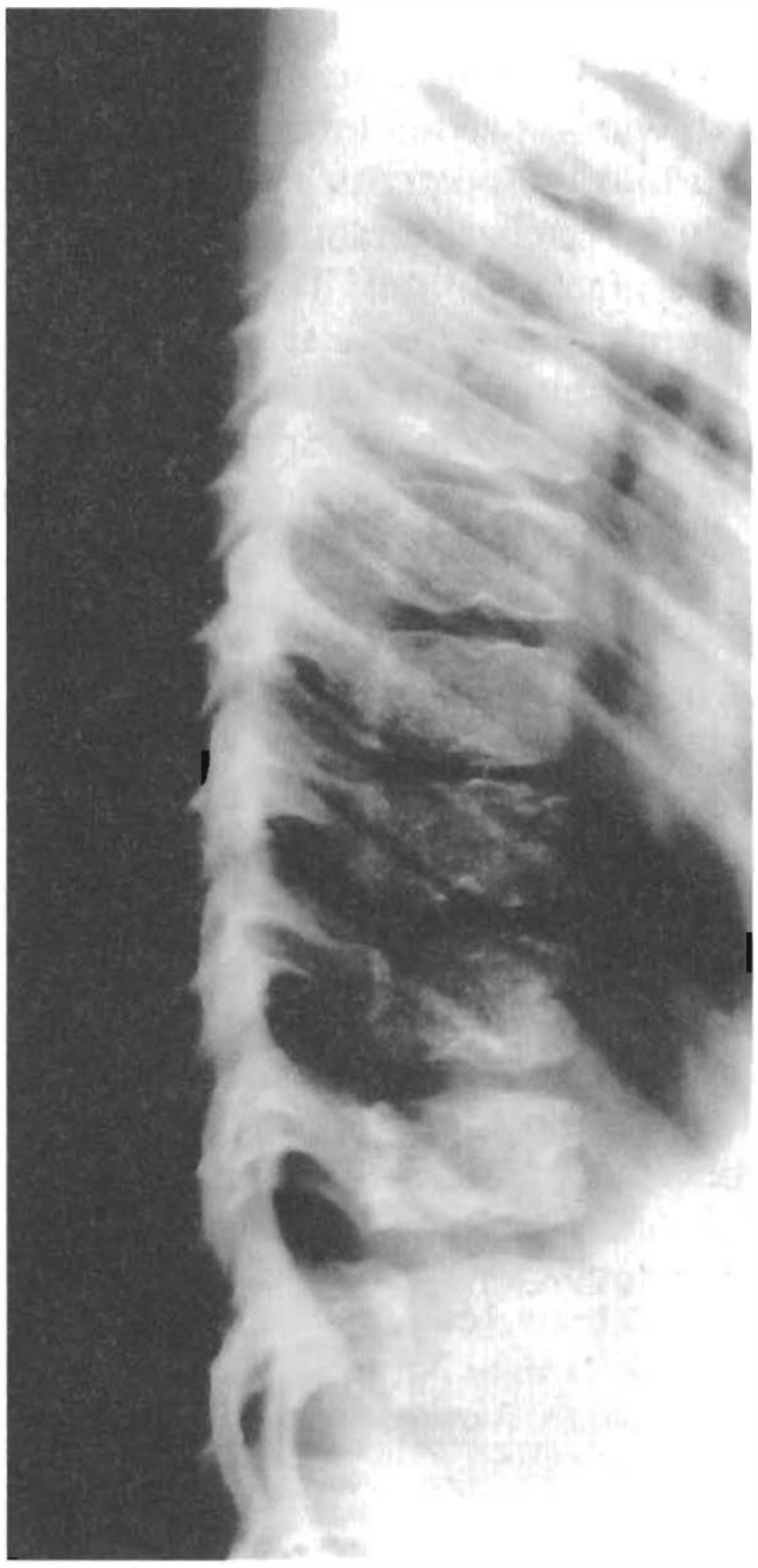

Fig. 6.18 Spondyloepiphyseal dysplasia with disc space narrowing and end-plate irregularities.

related to lack of development of the posterior aspects of vertebral bodies. In childhood, anterior wedging, and generalized flattening of the vertebral bodies occurs, with the appearance of kyphoscoliosis. The adolescent commonly has delayed development of the ring apophysis. The vertebral end-plates are commonly irregular, with disc intrusions resembling Schmorl's nodes (Fig. 6.18). There may be sclerosis of the vertebral body end-plates. The long tubular bones have delayed epiphyseal ossification with irregular epiphyses and variable metaphyseal irregularity and flaring. The femoral head often ossifies from multiple centres.

X-linked spondyloepiphyseal dysplasia tarda

Due to its predominantly X-linked mode of inheritance this condition only occurs in male subjects, and generally becomes evident between 5 and 10 years of age, although autosomal dominant and autosomal recessive forms occur (Taybi and Lachman, 1996). The characteristic radiographic changes consist of a 'hump'- shaped area of dense bone on the central and posterior portions of the vertebral body end-plates, and consequently the disc spaces appear narrow posteriorly and wide anteriorly (Langer, 1964). Degenerative changes in the spine develop early in adulthood (Poker *et al.*, 1965). Affected individuals may have thoracic disc herniation.

Mucopolysaccharidoses (MPS)

This term encompasses a group of inherited disorders of connective tissue metabolism with similar clinical and radiological findings. The common radiological findings have been designated 'dysostosis multiplex' (McAlister and Heiman, 1995). In the spine there is defective development of the antero-superior portion of the vertebral bodies at the thoracolumbar junction, resulting in hook-shaped vertebrae and kyphosis. The vertebral bodies are oval, diminished in height or flattened.

MPS-I (Hurler's syndrome) autosomal recessive is the best known of the group, and its dysostotic features occur, to varying degrees, in the other disorders (Maroteaux and Lamy, 1965) (Fig. 6.19). Death usually occurs in the first decade from cardiorespiratory causes.

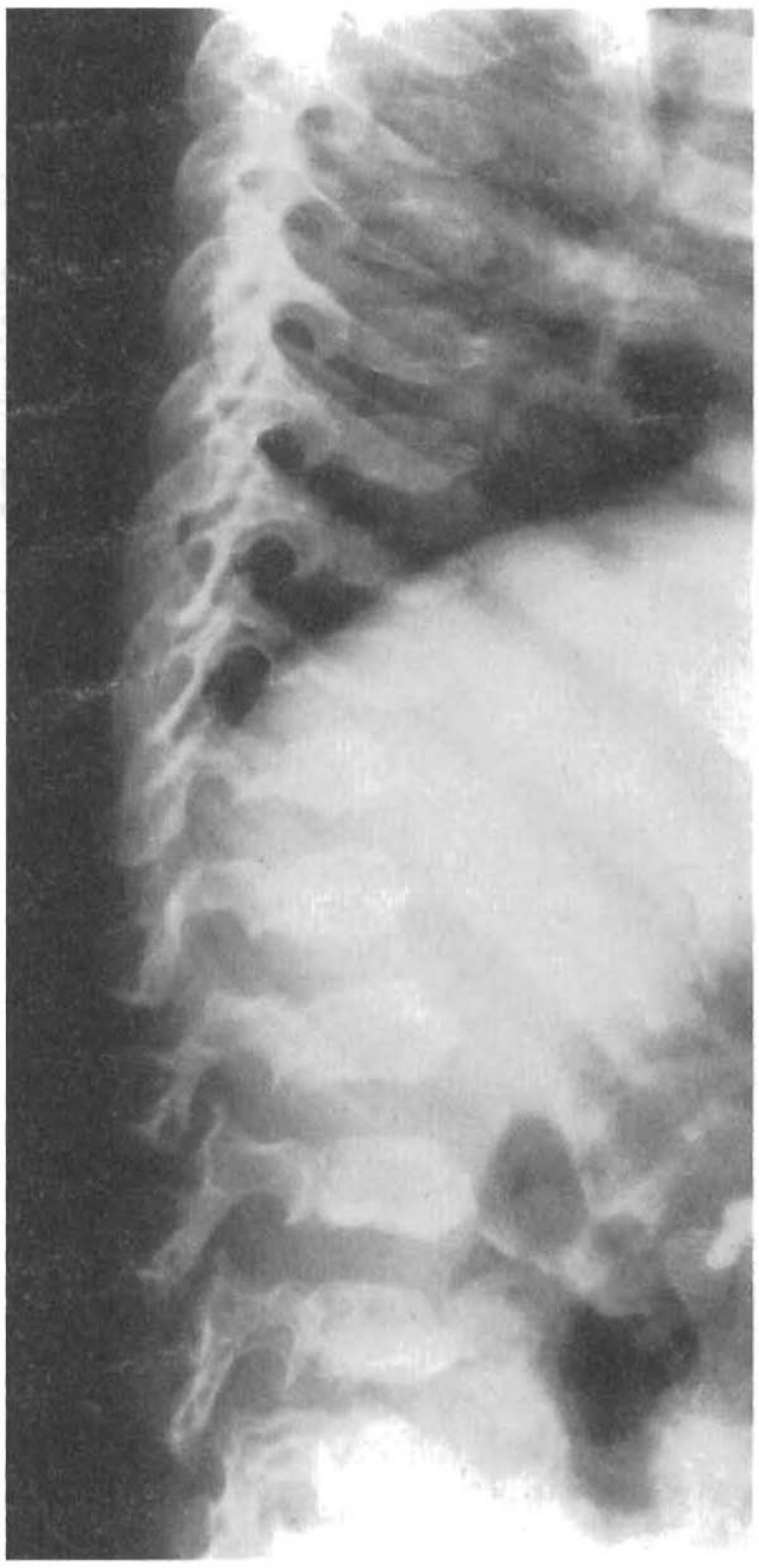

Fig. 6.19 Hurler's syndrome: a mild thoracolumbar kyphosis is present; the vertebral bodies are rounded with 'inferior beaking' of some vertebral bodies. Note the gibbus deformity at the thoracolumbar junction. (Similar but less severe changes are seen in Hunter's syndrome).

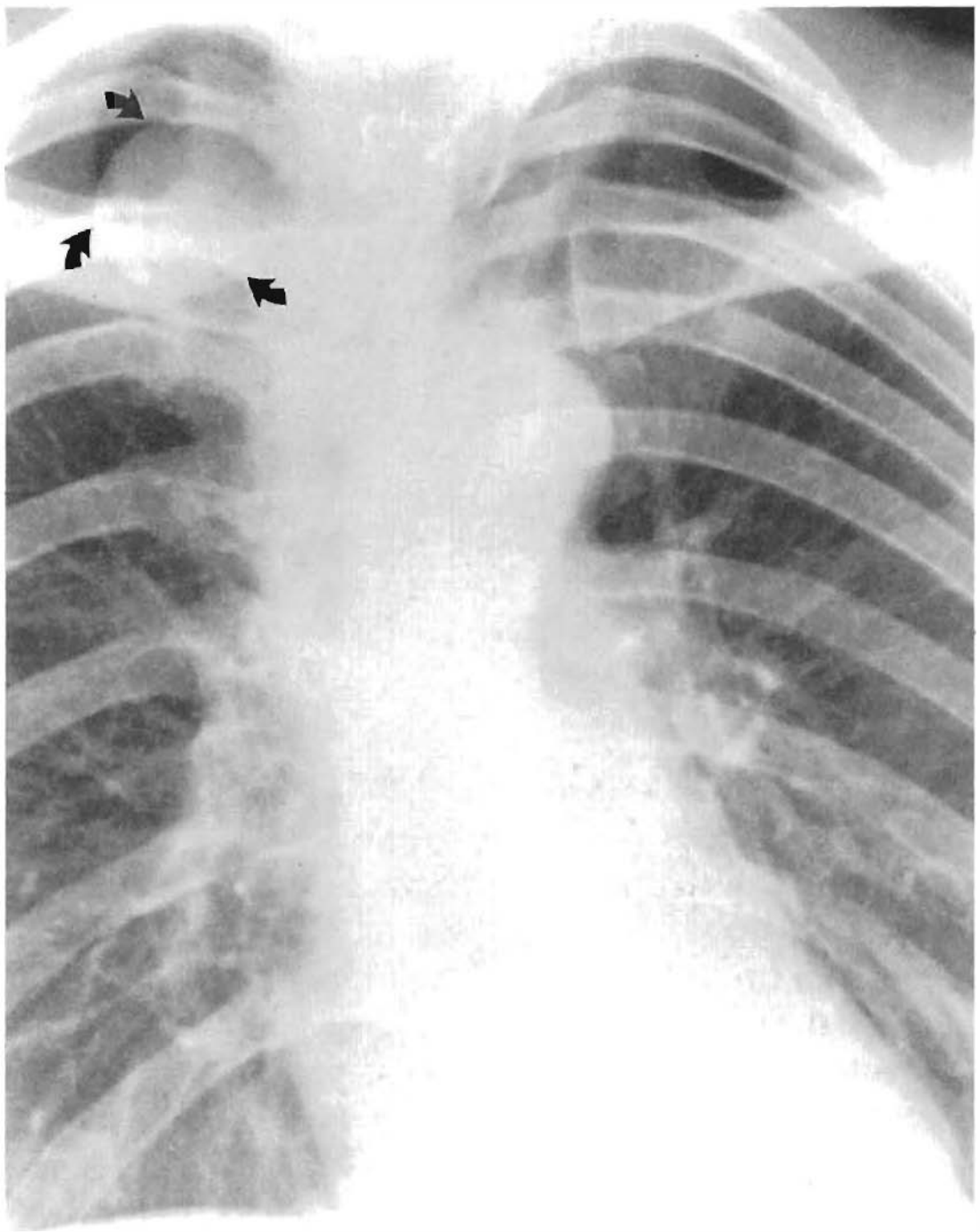

Fig. 6.20 Patient presenting with a progressive scoliosis. Note the lateral thoracic paravertebral mass (neurofibroma or thoracic meningocele) (arrow), which strongly supports the clinical diagnosis of neurofibromatosis.

MPS-II (Hunter's syndrome) is distinguished from the other MPS disorders by its X-linked recessive inheritance. The clinical and radiological features tend to be less severe than MPS-I, and the progression is slower. In mild forms, survival into middle age or beyond is not infrequent.

MPS-IV (Morquio's and related syndromes) is characterized by the appearance, in early infancy, of vertebral bodies that are rounded with a small anterior beak. With subsequent growth a central tongue appears protruding from the anterior surface of the vertebral bodies. In adulthood, the vertebrae are flat and irregular (Langer and Carey, 1966) (Fig. 6.20). Spinal instability may lead to upper spinal cord damage during neck manipulation with or without anaesthesia.

Neurofibromatosis

This is a relatively common inherited condition, with an estimated frequency of 1 in 3000 births (Taybi and Lachman, 1996). Approximately 50% of cases are the result of spontaneous mutations. There are characteristic cutaneous manifestations, including cutaneous neurofibromas and café-au-lait spots, and 60% of patients with neurofibromatosis will have some spinal abnormality. Scoliosis is the most common spinal manifestation. It may mimic idiopathic scoliosis, or may appear as a sharply angulated short segment scoliosis that commonly affects the mid- or lower thoracic spine (Yaghmai, 1986). An angular scoliosis involving less than six vertebral bodies and that is not due to an underlying segmentation anomaly is virtually diagnostic of neurofibromatosis. Rotation and lateral subluxation of vertebral bodies may be severe.

The majority of meningoceles (cerebrospinal fluid-filled herniation of the meninges) occur in patients with neurofibromatosis. They appear as paravertebral masses protruding laterally from enlarged neural foramina, and may be difficult to distinguish from neurofibromas (Fig. 6.20). The presence of a scoliosis with the convex region directed towards the mass is a feature that favours the diagnosis of a meningocele.

Other spinal abnormalities associated with neurofibromatosis include:

- Scalloping of the posterior aspect of vertebral bodies
- Foraminal enlargement
- Pedicle erosion
- Scalloped or twisted, ribbon-like ribs.

Marfan's syndrome

This is an autosomal dominant inherited disorder of connective tissue that affects the eye, skeleton and cardiovascular system (Magid *et al.*, 1990). The exact nature of the connective tissue defect remains unknown. Individuals are characteristically tall and thin with limbs disproportionately elongated in relation to the trunk. The estimated prevalence is 4-6 per 100 000.

Scoliosis or kyphoscoliosis, Schmorl's nodes, straight back and spondylolisthesis may be seen. Scoliosis occurs in 40-60% of patients with Marfan's syndrome (Sponsellars *et al.*, 1995) (Fig. 6.21). It may appear similar to idiopathic scoliosis, but usually begins earlier than the idiopathic form and lacks the female predominance of the idiopathic type. Dural ectasia may result in posterior scalloping of vertebral bodies. Osteoporosis of the spine is frequently seen, particularly in females.

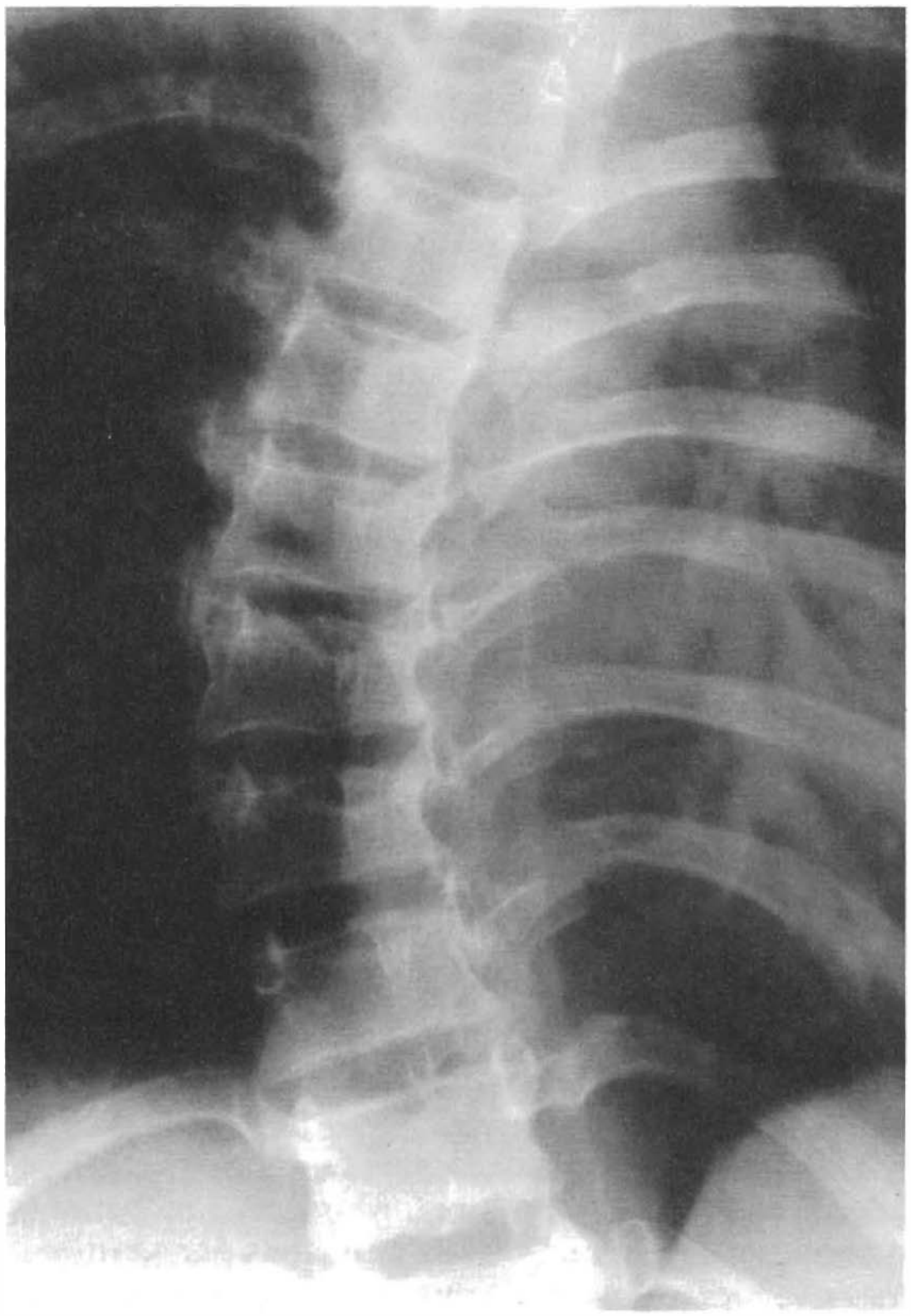

Fig. 6.21 Thoracic scoliosis in a patient with Marfan's syndrome.

Ehlers–Danlos syndrome

This is another usually autosomal dominant inherited group of disorders of connective tissue that are characterized by hyperelasticity and fragility of the skin, hyperlaxity of joints and a bleeding diathesis. Nine distinct categories of the disorder have been identified (Byers, 1994). A kyphoscoliosis is frequently present at the thoracolumbar junction. Posterior scalloping of vertebral bodies may also be seen.

Osteopetrosis

The term 'osteopetrosis' encompasses four inherited entities with defective osteoclastic resorption of bone resulting in increased bone density. The underlying pathophysiology is complex (Felix *et al.*, 1996). The two more common forms are the autosomal recessive lethal type and the autosomal dominant type.

Autosomal recessive lethal type

The obliteration of the marrow cavity by abnormal bone leads to anaemia and thrombocytopenia, and predisposes to recurrent infections and early patient demise. There is generalized osteosclerosis, with failure of differentiation between the cortex and medullary cavity. Vertebral bodies tend to be uniformly radiodense with a prominent anterior vascular notch.

Autosomal dominant type

This is also called Albers-Schönberg's disease. Affected persons may be relatively asymptomatic. The radiographic findings are similar to, but less severe, than those in the autosomal recessive form of the disease. The vertebral end-plates become accentuated, especially with advancing age (Fig. 6.22).

Osteogenesis imperfecta

This is an inherited disorder of connective tissue characterized by the abnormal synthesis or quality of fibrillar collagen (Lachman *et al.*, 1992). The four major clinical criteria are:

1. Osteoporosis with abnormal fragility of the skeleton
2. Blue sclerae

Fig. 6.22 Osteopetrosis in a child, showing marked sclerosis of the vertebral end-plates with relative sparing of the central zones (accentuation of the anterior vascular notches) resulting in a 'hamburger' appearance of the vertebral bodies. Note the presence of the healing rib fracture; a common complication of osteopetrosis.

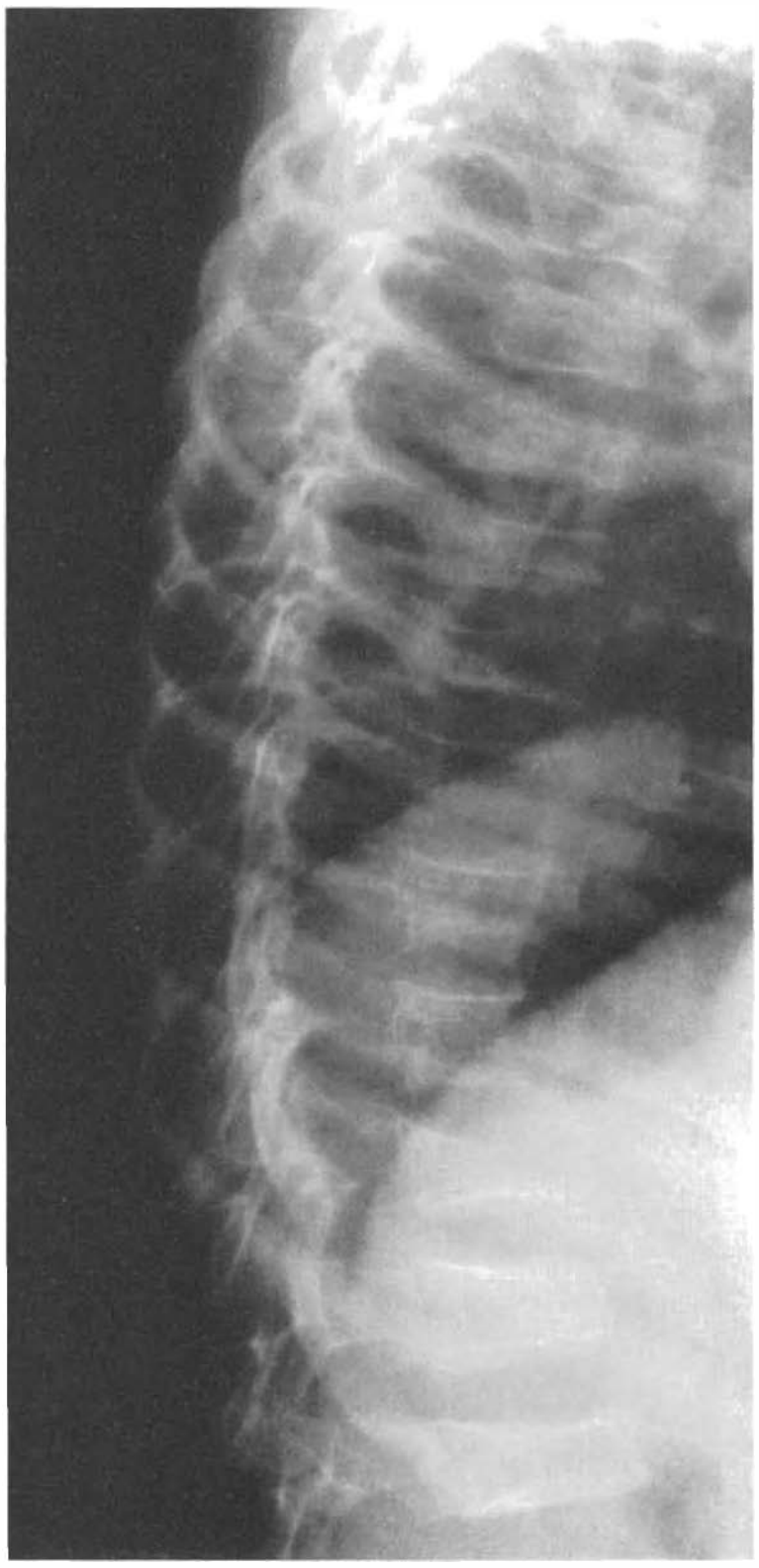

Fig. 6.23 Osteogenesis imperfecta tarda with marked osteoporosis and multiple compression deformities of the vertebral bodies.

3. Dentinogenesis imperfecta (abnormal dentition with blue or brown teeth)
4. Premature otosclerosis.

The presence of two of these abnormalities confirms the diagnosis. Four sub-groups have been defined, ranging from severe neonatal fractures with death in the perinatal period to normal life expectancy. In those who survive infancy, the frequency of fractures peaks in childhood and decreases in adolescence. The most characteristic radiographic finding is a decrease in osseous density. Vertebral bodies may become either biconcave or wedge-shaped anteriorly (Fig. 6.23). Severe kyphoscoliosis may occur. The radiographic findings may be similar in idiopathic juvenile osteoporosis and Cushing's syndrome.

Homocystinuria

The term 'homocystinuria' encompasses a group of disorders characterized by inborn defects in methionine metabolism. The most common syndrome is inherited on an autosomal recessive basis, and affects the eye, skeleton, central nervous system and vascular structures.

Skeletal changes include scoliosis, kyphoscoliosis, joint laxity and contractures. Chest wall deformities may occur gradually during childhood (MacCarthy and Carey, 1968). The vertebral bodies have an increased antero-posterior diameter, and may be biconcave in shape (Fig. 6.24). There is generalized osteoporosis, and compression fractures are frequent. Posterior scalloping of the vertebral bodies and degenerative disc disease have also been described.

Alkaptonuria

This is a rare, usually autosomal recessive inherited metabolic disorder that results in the accumulation of homogentisic acid. Abnormal pigmentation of the ears or sclerae may be seen. Intervertebral disc calcification is the most characteristic abnormality of

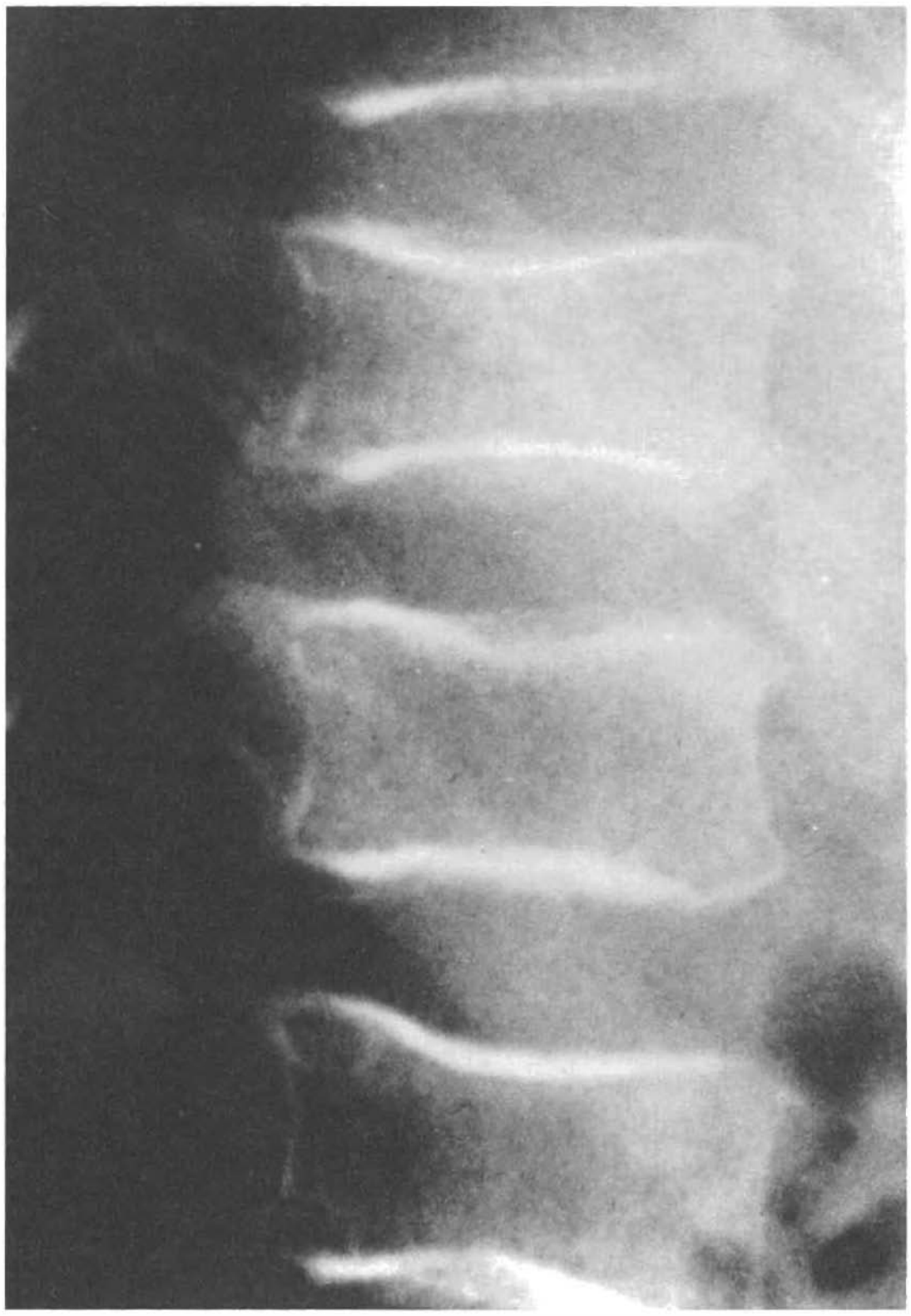

Fig. 6.24 Marked osteoporosis and moderate loss of vertebral body height in a patient with homocysteinuria.

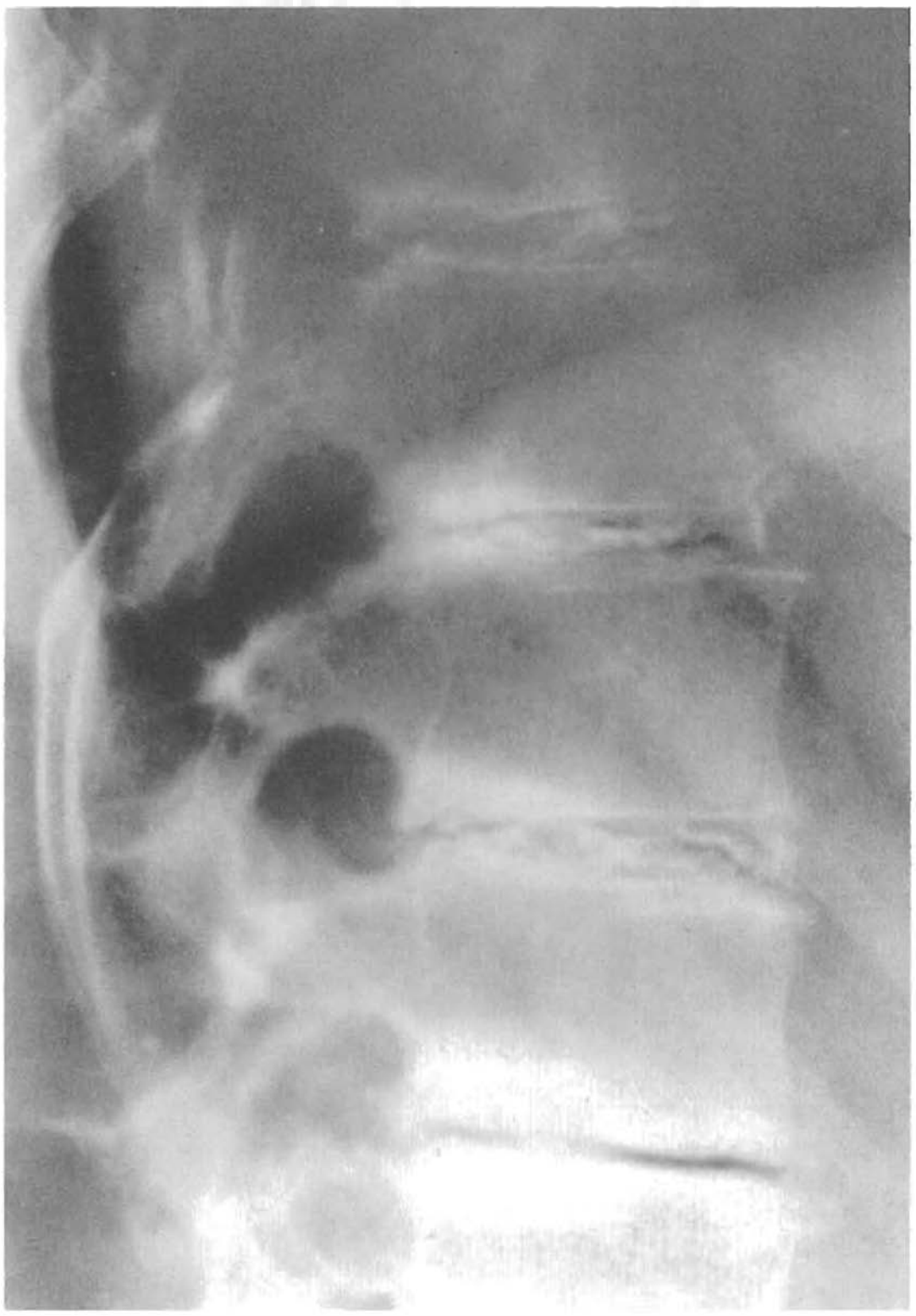

Fig. 6.25 Patient with alkaptonuria and marked degenerative thoracolumbar disc degenerative changes characterized by anular calcification, loss of disc volume, vacuum phenomenon and disc ossification.

the spine (Justesen and Anderson, 1984) (Fig. 6.25). The calcium deposits are found predominantly in the inner fibres of the anulus fibrosus. Narrowing of the intervertebral disc space and vacuum phenomena are also suggestive of this diagnosis. Progressive ossification of the discs may be seen, with formation of marginal intervertebral bridges and obliteration of the disc space, which may give the appearance of a bamboo spine and lead to the erroneous diagnosis of ankylosing spondylitis. Osteoporosis of the vertebral bodies is present, and in long-standing disease there is progressive kyphosis.

Summary

An understanding of the development of the normal thoracic spine assists the recognition and evaluation of spinal disorders. A wide range of vertebral abnormalities, including defects of segmentation and fusion, has been considered in the context of the thoracic region of the vertebral column. The causes and characteristics of congenital and acquired abnormalities of spinal curvatures have also been discussed. Identification of anomalies aids the clinician in the choice of mechanical therapy and, more importantly, prompts the appropriate referral of the patient where necessary.

References

Bagnall, K., Harris, P., Jones, P.R.M. (1977) A radiographic study of the human fetal spine. 2. The sequence of development of ossification centres in the vertebral column. *J. Anat.* **124:** 791-798.

Beals, R.K., Rolfe, B. (1989) VATER association, a unifying concept of multiple anomalies. *J. Bone Joint Surg.* **71A:** 948

Begg, A.C. (1954) Nuclear herniations of the intervertebral disc: Their radiological manifestations and significance. *J. Bone Joint Surg.* **36B:** 180-193.

Bethem, D., Winter, R., Lutter, L. *et al.* (1981) Spinal disorders of dwarfism. Review of the literature and report of eighty cases. *J. Bone Joint Surg.* **63A:** 1412-1425.

Byers, P.H. (1994) Ehlers-Danlos syndrome: recent advances and current understanding of the clinical and genetic heterogeneity. *J. Invest. Dermatol.* **103:** 47s-52s.

Byrd, S.E., Darling, C., McLone, D.G. (1991) Developmental disorders of the paediatric spine. *Radiol. Clin. North Am.* **29:** 711-752.

Cobb, J.R. (1948) Outline in the study of scoliosis. Instructional course lectures. *Am. Acad. Orthop. Surg.* **5:** 261-265.

Dameron, T.E., Gulledge, W.H. (1953) Adolescent kyphosis. *USAF Med J.* **4:** 871.

Felix, R., Hofstetter, W., Ceechini, M.G. (1966) Recent developments in the understanding of the pathophysiology of osteopetrosis. *Euro. J. Endocrinol.* **134:** 143-156.

Fielden, P., Russel, J.G.B. (1970) Coronally cleft vertebrae. *Radiology* **21:** 327-328.

Justesen, P., Anderson, P.E. Jr (1984) Radiologic manifestations in alcaptonuria. *Skel. Radiol.* **11:** 204.

Keates, T.E. (1996) *Atlas of Normal Roentgen Variants that may Simulate Disease*, 6th edn. St Louis: Mosby Year Book, p. 239.

Kohler, A., Zimmer, E.A. (1993) *Borderlands of Normal and Early Pathological Findings in Skeletal Radiography*, 4th edn. New York: Thieme Medical, p. 504.

Kumar, R., Guinto, F.C., Madewell, J.E. *et al.* (1988) The vertebral body: radiographic configurations in various congenital and acquired disorders. *Radiographics* **8:** 455-485.

Lachman, R.S., Tiller, G.E., Graham, J.M. Jr *et al.* (1992) Collagen, genes and the skeletal dysplasias on the edge of a new era: a review and update. *Euro J. Radiol.* **14:** 1-10.

Langer, L.O. Jr (1964) Spondyloepiphyseal dysplasia tarda: Hereditary chondrodysplasia with characteristic vertebral configuration in the adult. *Radiology* **82:** 833-839.

Langer, L.O. Jr, Carey, L.S. (1966) The roentgenographic features of the KS mucopolysaccharidoses of Morquio (Morquio-Brailsford disease) *A.J.R.* **97:** 1-20.

Lederman, I.M., Kaufman, R.A. (1986) Congenital absence and hypoplasia of pedicles in the thoracic spine. *Skel. Radiol.* **15:** 219-223.

Lopez-Sosa, F., Guille, J.T., Bowen, J.R. (1995) Rotation of the spine in congenital scoliosis. *J. Paed. Orthopaed.* **15:** 528-534.

McAlister, W.H., Heiman, T.E. (1995) Osteochondrodysplasias, dysostoses, chromosomal aberrations, mucopolysaccharidoses and mucolipidoses. In: *Diagnosis of Bone and Joint Disorders*, 3rd edn (Resnick, D., ed.). Philadelphia: W.B. Saunders, p. 4163.

MacCarthy, J.M.T., Carey, M.C. (1968) Bone changes in homocystinura. *Clin. Radiol.* **19:** 128.

MacEwen, G.D., Conway, J.J., Millet, W.T. (1968) Congenital scoliosis with a unilateral bar. *Radiology* **90:** 711.

Magid, D., Pyeritz, R., Fishman, E.K. (1990) Musculoskeletal manifestations of the Marfan's syndrome: Radiologic features. *A.J.R.* **155:** 99-104.

Maroteaux, P., Lamy, M. (1965) Hurler's disease, Morquio's disease, and related mucopolysaccharidoses. *J. Pediatr.* **67:** 616-620.

Ozonoff, M.B. (1995) Spinal anomalies and curvatures. In: *Diagnosis of Bone and Joint Disorders*, 3rd edn (Resnick, D., ed.). Philadelphia: W.B. Saunders, pp. 4245-4268.

Parke, W.W. (1975)The applied anatomy of the spine. In: *The Spine*, Vol. 1 (Rothman, R.H., Simeone, F.A., eds). Philadelphia: W.B. Saunders, pp. 1-24.

Poker, N., Finby, N., Archibald, R.M. (1965) Spondyloepiphyseal dysplasia tarda: Four cases in childhood and adolescence, and some considerations regarding platyspondyly. *Radiology* **85:** 474.

Singer, K.P., Breidhal, P.D. (1990) Accessory ossification centres at the thoracolumbar junction. *Surg. Radiol. Anat.* **12:** 53-58.

Sponsellars, P.D., Hobbs, W., Riley, L. *et al.* (1995) The thoracolumbar spine in Marfan syndrome. *J. Bone Joint Surg.* **77A:** 867-876.

Stirling, A.J., Howel, D., Millner, P.A. *et al.* (1996) Late onset idiopathic scoliosis in children six to fourteen years old. A cross-sectional prevalence study. *J. Bone Joint Surg.* **78:** 1330-1336.

Sutow, W.W., Pryde, A.W. (1956) Incidence of spina bifida occulta in relation to age. *Am. J. Dis. Child.* **91:** 211.

Taybi, H., Lachman, R.S. (1996) *Radiology of Syndromes, Metabolic Disorders, and Skeletal Dysplasias*, 4th edn. St Louis: Mosby Year Book.

Verbout, A.J. (1985) The development of the vertebral column. *Adv. Anat. Embryol. Cell. Biol.* **90:** 1-118.

Williams, P.L., Warwick, R., Dyson, M. *et al.* (1989) Development of the skeletal system. *Gray's Anatomy*, 39th edn. Edinburgh: Churchill Livingstone, p. 159.

Wood K.B., Garvey T.A., Gundry, C. *et al.* (1995) Magnetic resonance imaging of the thoracic spine. Evaluation of asymptomatic individuals. *J. Bone Joint Surg.* **77A:** 1631-1638.

Yaghmai, I. (1986) Spinal changes in neurofibromatosis. *Radiographics* **6:** 1-285.

Young, L.W. (1996) In: *Radiology Diagnosis - Imaging - Intervention*, Vol. 5 (Tavares, C. Ferrucci, A. eds). Philadelphia: Lippincott-Raven, pp. 1-20.

7

Pathoanatomical characteristics of the thoracolumbar junctional region

K. P. Singer and A. Malmivaara

The transitional regions of the spine are well known as sites of anatomical variations and of clinical significance (Schmorl and Junghanns, 1971), given that the junctional segments link together regions of different mobility and, as a result, can focus mechanical strains imposed upon the spine. In this chapter pathoanatomical changes in the thoracolumbar junctional region of the spine are presented, along with a summary of anatomical and mechanical features of this important transitional junction.

The thoracolumbar junctional (TLJ) region is a transitional zone between T10 and L1, recognized clinically as the site for more than half of all thoracic and lumbar fractures (Rehn, 1968; Levine and Edwards, 1987). In this region the zygapophysial joint orientation may change abruptly and the stabilizing effect of the thoracic cage is reduced. Both the clinical and biomechanical literature describe the vulnerability of this region to torsional and compressive forces. Peak values have been recorded during lumbar disc pressure measurements involving both forward bending and twisting of the body (Nachemson, 1960). These motions can be focused at the TLJ through the effect of the stiffened thoracic cage and the differences between lumbar and thoracic regions in terms of sagittal and transverse plane mobilities (Singer *et al.*, 1989b).

The TLJ region, where zygapophysial joint orientation changes from nearly coronal in the thoracic spine to nearly sagittal in the lumbar spine, provides an opportunity to study the relations between zygapophysial orientation and pathoanatomical changes. The different anatomical characteristics at each intervertebral level in the TLJ region also provide an opportunity to study the associations between pathoanatomical changes both at the same intervertebral level and between different intervertebral levels.

Development

An early signal to the stabilizing role of the human TLJ appears in the sequence of ossification of the vertebral centra. Reports by Noback and Roberston (1951), Bagnall *et al.* (1977) and Birkner (1978) indicate that the first sites of ossification are consistently located in the lower two thoracic and first lumbar vertebral bodies, before a progressive cranial and caudal pattern of ossification commences in the adjacent vertebrae. Similarly, by about 2 years of postnatal life the vertebral ring apophyses from T10 to L1 appear to ossify first (Louis, 1983). These predictable ossification patterns have prompted Bagnall *et al.* (1977) to suggest that the use of trunk musculature and associated foetal movement act to stimulate early skeletal development of the TLJ elements in response to these early mechanical stresses being applied to the vertebral column. Anatomically, the thoracolumbar transitional zone also marks an increase in the size of the vertebral bodies and intervertebral discs (Cyriax, 1929; Davis, 1980; Berry *et al.*, 1987), associated with a larger vertebral canal to accommodate the lumbar enlargement of the spinal cord and conus (Gonon *et al.*, 1975; Louis, 1983).

The thoracolumbar transitional junction

The TLJ is typically depicted in anatomical texts as showing an abrupt change in the orientation of the zygapophysial joints of the last thoracic vertebrae. This 'distinguishing feature' (Pick, 1890) is defined by inferior articular processes which 'turn to face laterally' (Testut and Latarjet, 1948; Sobotta and Uhlenhuth, 1957; Hamilton, 1976; Williams and Warwick, 1980); a notion that is perpetuated in clinical sources (Hoppenfeld, 1977; Gehweiler *et al.*, 1980; Parke, 1982). To gain an understanding of the variations of this transitional region, the early anthropological, anatomical and radiological literature must be reviewed.

Different configurations for the TLJ, in terms of cranial and caudal segmental location of the transition, have been widely reported (Humphry, 1858; Struthers, 1875; Hasebe, 1913; Schertlein, 1928; Kühne, 1932; Stewart, 1932; Lanier, 1939; Terry and Trotter, 1953; Allbrook, 1955), as have asymmetry of the TLJ zygapophysial joints (Barclay-Smith, 1911; Whitney, 1926; Shore, 1930), and a specialized mortice-like arrangement of the TLJ zygapophysial joints in which the superior articular processes embrace those from the vertebra above (Topinard, 1877; Le Double, 1912; Davis, 1955) (Fig. 7.1). These variations in TLJ location and morphology were reported to be so common that the American anthropologist, Wingate Todd (1922), thought it impractical to attempt any systematic framework for differentiating between thoracic and lumbar regions.

A comprehensive radiological survey of the T10-L2 segments was undertaken using computed tomography (CT) archives from over 600 patient examinations, complemented with histology performed on 75 cadaveric TLJs (Singer, 1989a). From this work, the notion of a gradual transition representing the normal anatomy of the TLJ was outlined (Singer *et al.*, 1989a) (Fig. 7.2). This progressive change from T10-11 to T12-L1 appeared in 70% of cases at the TLJ,

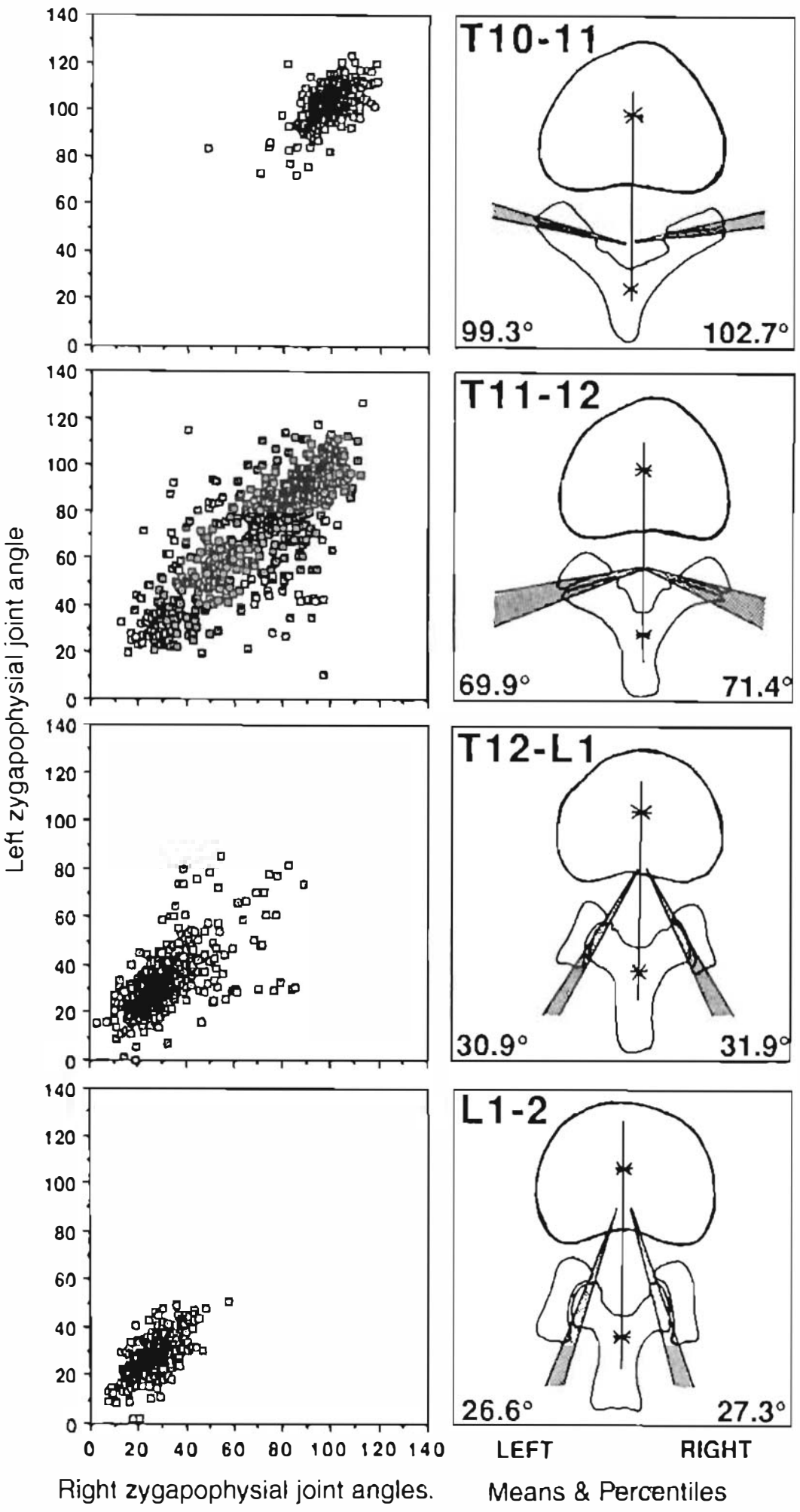

Fig. 7.1 Scattergrams depicting the dispersion of right and left zygapophysial joint angles for the T10-T11, T11-T12, T12-L1 and L1-L2 segmental levels. The relative consistency of coronal and sagittal joint orientations, at T10-T11 and L1-L2 respectively, is emphasized in the tight cluster of data points. The marked variation at T11-T12 and T12-L1 is evidenced in the scatter about the diagonal, which indicates both the diversity in level of the transition and also the extent of asymmetry or tropism between joint pairs. The classification of an abrupt transition was based on an angulation difference between adjacent paired joints of > 120°. In contrast, the gradual pattern depicts an intermediate segment interposed between the more coronally and sagittally orientated levels. Right and left joint angles were calculated by plotting a line of best fit through the joint margins in relation to the sagittal midline. (Used with permission from Singer *et al.*, 1989a.)

supporting the observations by Struthers (1875), who described the TLJ zygapophysial joints at T11-T12 as adopting an intermediate orientation between the sagittal and coronal planes of adjacent segments. In contrast, the textbook description of an abrupt transition, as defined in these studies (Fig. 7.2), applied to less than a third of the population examined. The progressive form of transition may be an adaptation to minimize stress concentration between these mobile segments of this transitional region.

Thoracolumbar curvature

Of the physiological curvatures of the column, the lordotic curves of the cervical and lumbar regions permit greater mobility than the longer thoracic kyphotic curve (Kapandji, 1977). The thoracic region, with its anterior concavity, affords protection to the thoracic and upper abdominal viscera, and tension on the spinal cord is reduced due to the attendant ribcage, which impedes thoracic flexion (Humphry, 1858).

Changes in the thoracolumbar curvature appear to vary widely in response to different physiological postures (Strasser, 1913) and to increasing age (Singer *et al.*, 1990c). These curve characteristics are also influenced by spinal fractures and resulting deformity (Willén *et al.*, 1990). In the normal orthograde posture, the location of the line of gravity in relation to the vertebral column appears to be consistently located through the transitional regions (Humphry, 1858; Braune and Fischer, 1889; Åkerblom, 1948; Nathan, 1962; Anderson, 1982). Despite changes in the magnitude of the curves from one region to another, they appear to compensate each other in order to maintain a 'balance' in relation to the line of gravity (Steindler, 1955). This reciprocal change in curvature of the thoracic kyphosis and lumbar lordosis produces an inflexion point which is located commonly between T11 and L1 (Stagnara *et al.*, 1982; Singer *et al.*, 1990c).

The strategy of locating an inflexion point at an area of mechanical and morphological transition may afford protection in the form of reduced localized bending stress, at least for sagittal plane motion. This contrasts with the curve apices which sustain the greatest deflection under static loading and clinically, at least for the mid-thoracic region, an increased risk of vertebral fractures (Kazarian, 1978; Lampmann *et al.*, 1984). However, if the bending moment is applied suddenly, the thoracic column tends to 'pivot' over the mechanically 'stiffened' thoracolumbar junctional region, usually resulting in fracture (Levine and Edwards, 1987). This fracture pattern may produce a retropulsed burst fragment which can be displaced into the spinal canal resulting in cord compression; if it occurs in combination with torsion, a fracture dislocation may result (Fig. 7.1).

In considering the functional significance of the TLJ inflexion point, the dynamic role of the vertebral column as a whole must be examined. During static axial loading, the TLJ shows little rotational deformity in the horizontal plane, compared to adjacent thoracic and lumbar regions (Kazarian, 1972). This mechanical characteristic appears to reflect the increased stability of this region during loaded postures. The morphology of the thoracolumbar mortice joint appears to contribute to the resistance against torsional stress of the TLJ segments (Markolf, 1972; Singer *et al.*, 1989b). Any explanation that seeks to account for the localized incidence of vertebral body compression fractures at the TLJ (Rehn, 1968) must consider not only the anatomical and aetiological factors contributing to the problem, but also other factors such as the biomechanical capacities of the mobile segments and the change in curvature at the TLJ.

Load-bearing by the thoracolumbar junction mobile segments

Weight transmission down the axial skeleton in the erect posture is believed to be primarily through the vertebral bodies and intervertebral discs, which progressively increase in size from C1 to L5 (Pooni *et al.*, 1986). However, the zygapophysial joints also contribute to axial weight-bearing (El-Bohy *et al.*, 1989) depending on their relationship to the line of gravity. At the TLJ, the upper lumbar vertebral bodies demonstrate a relatively marked increase in cross-sectional dimension compared with the thoracic vertebrae (Gonon *et al.*, 1975; Davis, 1980; Berry *et al.*, 1987). Vertebral trabecular density appears to show greater mean density values for the lower thoracic compared with upper lumbar vertebral levels, while the product of mid-vertebral body cross-sectional area and the associated vertebral trabecular density are similar for each vertebrae from T10 to L1 (Singer and Breidahl, 1990b). This finding may suggest that, at the TLJ, a relatively equal axial weight-bearing load may be accommodated by each vertebra despite a caudal increase in the physical dimension of the lumbar vertebrae.

The tendency for the anterior aspect of each vertebral body to demonstrate a significantly higher trabecular density measure (Singer and Breidahl, 1990b) may be accounted for by the greater flexion loading sustained by the low thoracic and upper lumbar vertebrae. The consistent finding of anterior vertebral osteophytes, demonstrated frequently in the concavity of the thoracic region, has been clearly shown by Shore (1935) and Nathan (1962) to represent an important weight-bearing mechanism for the vertebral column.

Axial load-sharing between anterior and posterior elements

In an anatomical study attempting to quantify the proportion of weight-bearing shared between the vertebral mobile segments, Pal and Routal (1987) suggested that the vertebrae intersecting the line of gravity would undergo the highest axial loading. Nachemson (1960) and Pal and Routal (1987) have, in general, tended to discount the posterior elements as less significant contributors to direct transmission of axial loads. However, the work of Yang and King (1984) has shown that lumbar zygapophysial joints can contribute up to 47% of axial load bearing. This relationship depends on the distance of each vertebra from the line of gravity. Similarly, the marked increase in pedicle cross-sectional area at the TLJ (Zindrick *et al.*, 1986; Berry *et al.*, 1987), appears purposefully designed to facilitate the transmission of load between the anterior and posterior elements relative to changes in posture.

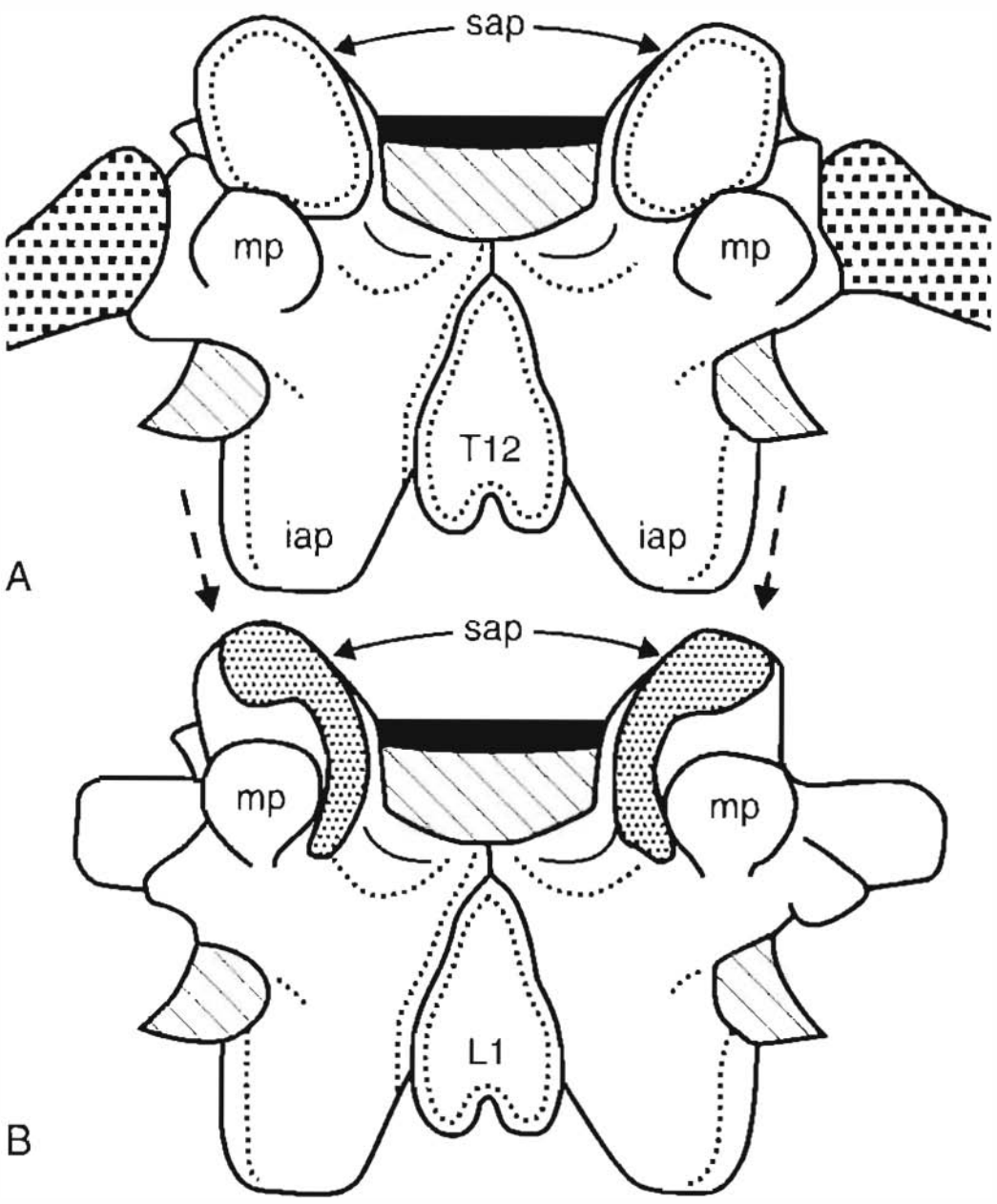

Fig. 7.2 Schematic illustration depicting the thoracolumbar junction mortice joint, formed through the interlocking inferior articular processes of the cranial vertebra (A) and the enclosing superior articular processes of the segment below (B). (Modified from Singer *et al.*, 1989c.)

As each synovial joint is designed to sustain some load transmission across the articular surfaces (Radin, 1976), the TLJ zygapophysial joints were studied to consider their potential for axial load transmission. This feature was evident from coronal CT scans of the TLJ zygapophysial joints, which demonstrated the medial taper and enclosure offered by these joints (Singer, 1989b). At the level of the mortice joint and above, the inferior articular processes would appear to abut against the lamina in axially loaded postures and in end-range spinal extension (Grieve, 1981), forming a deepened socket (Fig. 7.2).

Zygapophysial joint tropism

Differences between left and right sides in zygapophysial joint planes (tropism) is another common feature at the TLJ (Fig. 7.3). In this instance, tropism greater than 20° between joint planes showed a two-fold higher frequency in males (Singer, 1989a). Tropism at one transitional level may indicate other spinal variants elsewhere in the vertebral column. The rationales proposed to account for tropism are many and varied. Debate exists between authors who advance either a genetic or functional rationale, or both. For example, performance of manipulative tasks using the dominant upper extremity was the reason suggested by Whitney (1926) for TLJ zygapophysial joint asymmetry. Odgers (1933) was of the belief that the multifidus muscle influenced the development of lumbar zygapophysial joint sagittalization and would account for the variety of articular plane orientations between joint pairs; a view upheld by Lutz (1967) and Pfeil (1971). In the model proposed by Putz (1976, 1985), lateral mechanical shear stresses on the articular surfaces were considered to be responsible for shaping the zygapophysial joints.

The investigations by Huson (1967), Cihak (1981), Reichmann (1971), Hadley (1976) and Med (1980), who studied zygapophysial joint orientation during early development of the vertebral column, have almost invariably recorded that the orientation of all joints lies close to the coronal plane *in utero*. However, *in utero* variation in the development of the zygapophysial joints has also been reported; some individuals showing the ultimate adult form and configuration of the lumbar zygapophysial joints (Reichmann, 1971).

Zygapophysial joint tropism occurs most frequently at T11–T12 (Malmivaara *et al.*, 1987a; Singer *et al.*, 1989a), an area which has been described by Veleanu *et al.* (1972) as the 'headquarters' for the TLJ. The highly variable orientations in the zygapophysial joints present at this level may indicate an intermediate stage in the evolution of this transitional

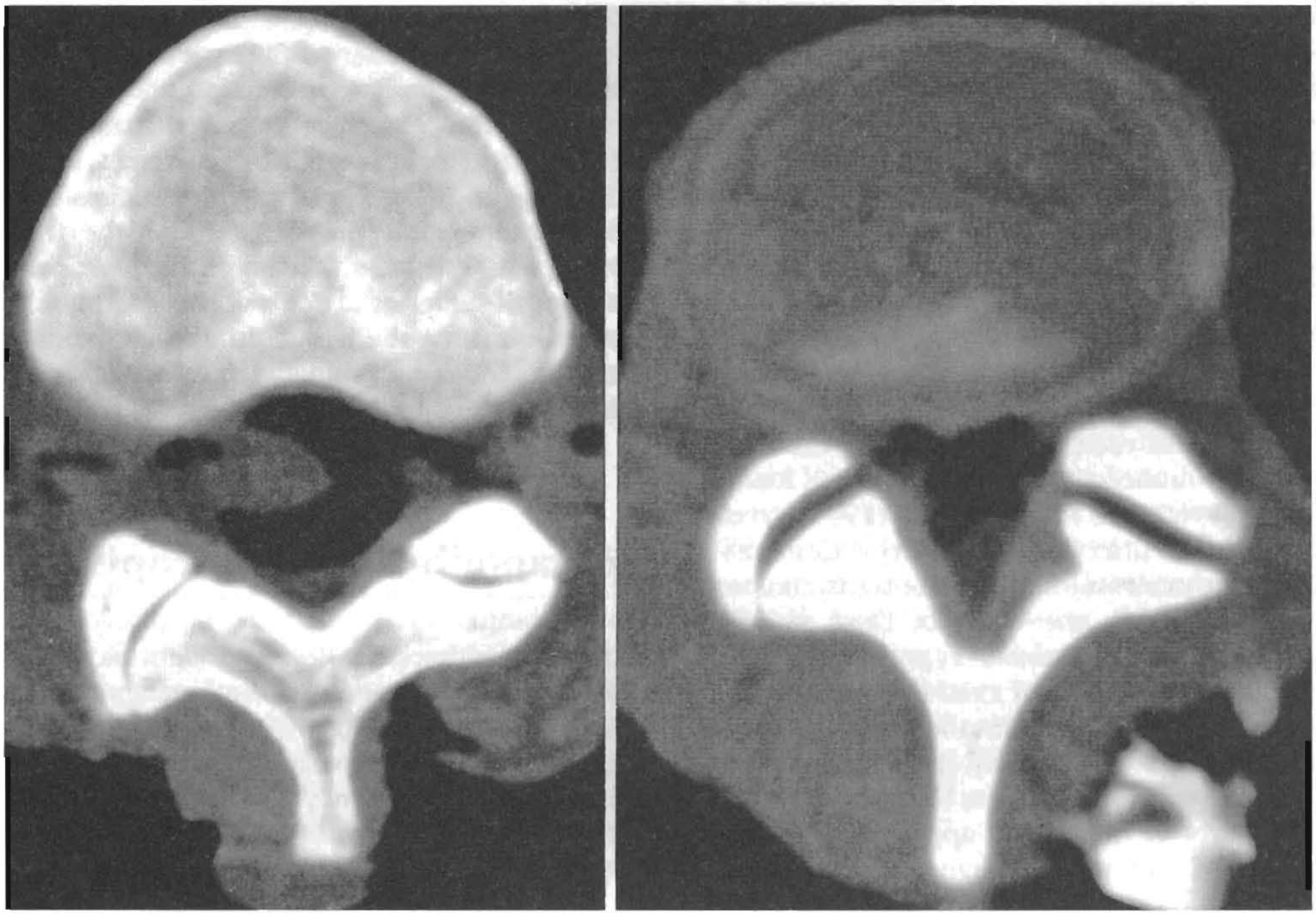

Fig. 7.3 Axial plane CT slice through the superior end-plate at T11-T12 and L4-L5 in a 60-year-old male. Marked articular tropism between the right and left articular planes is represented at both segmental levels, and reflects a tendency for multiple variations to be present within the same individual.

region. The gradual type of transition, which was found in the majority of cases, is the most developed form for this region (Singer *et al.*, 1989a).

Mortice joints

Early descriptions of inter-locking zygapophysial joints (Hildebrandt, 1816; Humphry, 1858), and the TLJ 'mortaise' joint coined by Topinard (1877) and others (Le Double, 1912; Davis, 1955), have been extensively reported. Davis (1955, 1961) suggested that the 'mortice' effect could be gauged according to development of the mammillary processes and their projection behind the inferior articular processes. This morphological feature was examined radiographically, with the use of CT, and histologically, to provide a quantitative description of the relationship of the mammillary processes to TLJ zygapophysial joint orientation (Fig. 7.4). The most common segmental level demonstrating mortice joints was T11-T12, followed by T12-L1 (Davis, 1955; Malmivaara *et al.*, 1987a; Singer, 1989b).

Of interest was the presence of unilateral mortice joints, defined previously by Malmivaara *et al.* (1987a), and their association with zygapophysial joint tropism. It was evident from the CT studies (Singer *et al.*, 1990a) that unilateral mortice joints frequently showed the presence of a mammillary process on the side of the coronally orientated joint, which appeared to form a posterior buttress for the adjacent inferior articular process. This feature was also evident in the CT scans of some subjects who were positioned in unilateral trunk rotation, whereby separation of the joint appeared to be arrested by the mammillary process (Singer *et al.*, 1989b).

According to the comparative studies reported by Vallois (1920) and Kaplan (1945), the mammillary processes are most evident at the TLJ in those primates who achieve an orthograde position during ambulation. Speculation by both writers suggests that these processes develop in response to the activity of multifidus which, from electromyographic studies performed by Donisch and Basmajian (1972), appears to function primarily as a stabilizer of adjacent vertebral segments during axial rotation. This finding might suggest that the multifidus acts more as an antagonist to rotation at the TLJ, and thereby reinforces the morphological role of the zygapophysial joints in preventing torsion. The laminar fibres of multifidus, which attach

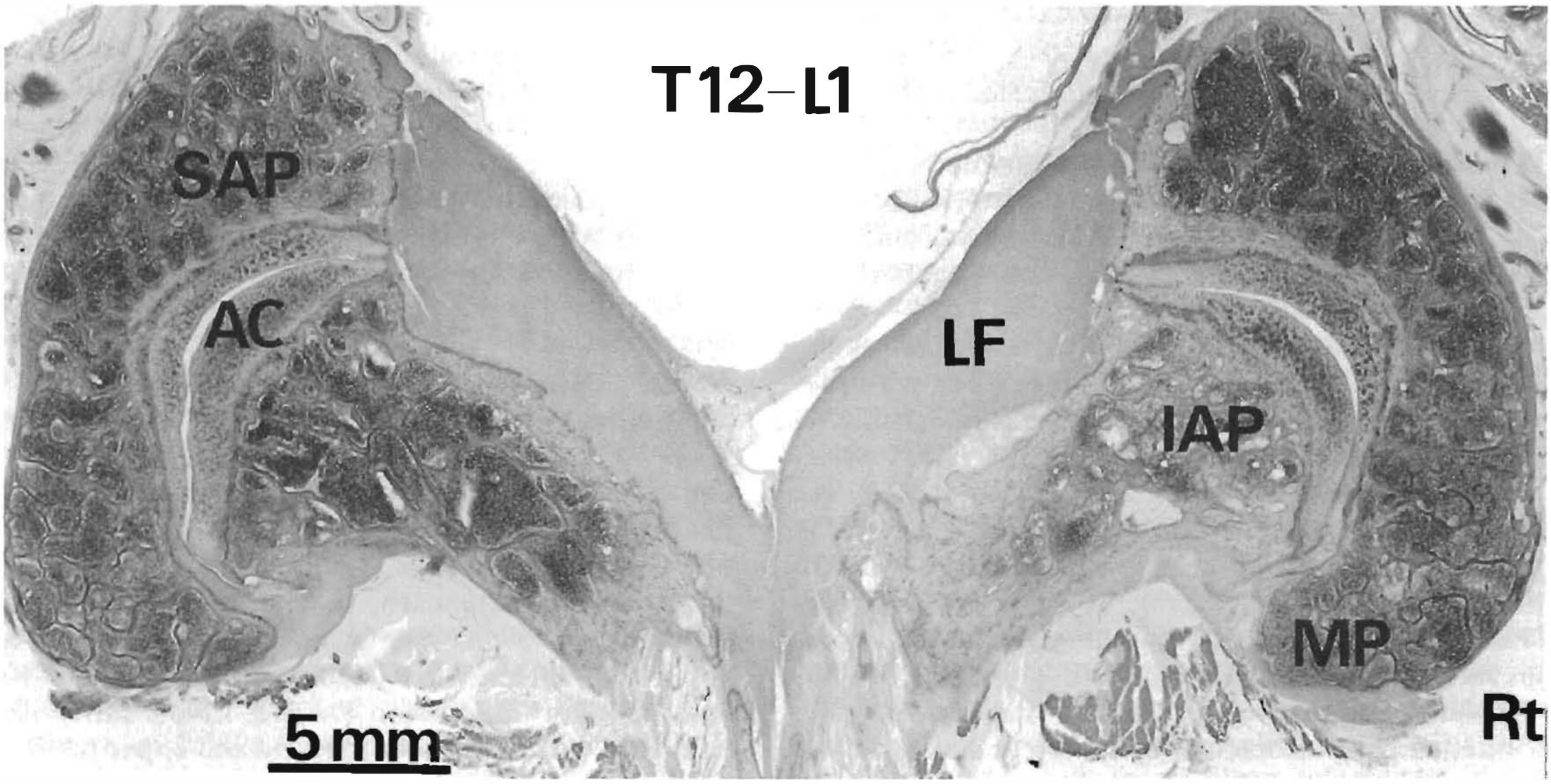

Fig. 7.4 A photomicrograph of a 150-μm thick transverse section cut in the plane of the superior vertebral end-plate at T12-L1 to illustrate a Type I mortice joint formed by the mammillary processes embracing the inferior articular process. The articular cartilage appears normal. Abbreviations: AC, articular cartilage; IAP, inferior articular process; LF, ligamentum flavum; MP, mammillary processes.

to the mammillary processes immediately below, would tend to act closer to the axial plane, whereas the fibres passing superiorly to the spinous process of the cranial segments might function as a 'brake' to flexion coupled with rotation. This may further ensure that the joints remain relatively approximated, as a strategy to reduce segmental mobility.

Accessory ossification centres at the thoracolumbar junction

The development of the TLJ zygapophysial joints is often associated with the appearance of vertebral process variants (Hayek, 1932; Heise, 1933). Accessory ossification centres appearing adjacent to the spinous, transverse and mammillary accessory processes are a relatively rare finding, occurring in approximately 1-2% of the populations studied by Pech and Haughton (1985) and Singer and Breidahl (1990a). Rudimentary costal elements are more frequently observed, and appear to be more common, in men than women (Schertlein, 1928). The clinical significance of these variations is their possible confusion with fractures at the TLJ (Keats, 1979; Singer and Breidahl, 1990a) and their contribution to miscalculations of vertebral levels during surgical staging (Wigh, 1979, 1980).

Intra-articular synovial folds

Histologically, intra-articular synovial folds have been demonstrated consistently in the TLJ zygapophysial joints (Singer *et al.*, 1990b). This finding complements similar observations reported on zygapophysial joints of the lumbosacral junction (Giles, 1987), lumbar (Töndury, 1940; Dörr, 1958; Kirkaldy-Willis, 1984), thoracic (Ley, 1975) and cervical regions (Töndury, 1940; Bland, 1987; Giles and Barker, 1998). According to Töndury (1972), these intra-articular synovial folds act as displaceable space-fillers, which deform to accommodate incongruities between the articular surfaces during normal joint excursions. The relative change in orientation of the TLJ zygapophysial joints may also account for differences in the morphology of these inclusions as seen at the mid-joint level. Fibro-adipose folds were noted more in coronally orientated joints, which appeared suited to the marked translatory movements performed by these joints. In contrast, fibrous folds tended to predominate in the more sagittally orientated joints (Singer *et al.*, 1990b), occasionally showing histological evidence of fibrosis at their tips to suggest that these folds may become tractioned or compressed. The mechanical situations favouring this occurrence may include sudden torsional forces or compression due to joint approximation during flexion or extension postures.

Biomechanics of the thoracolumbar junction

Limitation to regional spinal and segmental mobility occurs by virtue of the shape of the vertebral bodies, the thickness of the intervertebral discs, and the relative orientation of the zygapophysial joints (Fick, 1911; Pearcy, 1986).

In the thoracic region, the almost vertical alignment of the zygapophysial joints, together with the costovertebral joints and the splinting effect of the ribs, precludes any marked tendency towards flexion. Similarly, thoracic extension and rotation are limited due to the constraint afforded by the posteriorly projecting lamina and approximation of spinous processes. The stabilizing role of the thoracic cage is lessened in the lower thoracic segments due to the greater mobility afforded by the floating ribs.

Several *in vitro* investigations have been performed on the thoracolumbar vertebral column to determine the mobility of these segments (White, 1969; Kazarian, 1972; Markolf, 1972). In general, the influence of variation in transition patterns has been largely overlooked. However, the consistent finding from these studies has been the limitation in segmental mobility due to the specialized morphology of the zygapophysial joints. Kazarian (1972) has drawn attention to the idiosyncratic motion behaviour of the lower thoracic vertebral elements, particularly when loaded axially;
sized the torsional resistance afforded by the TLJ segments. An *in vivo* study was performed by Gregersen and Lucas (1967) to examine segmental mobility patterns throughout the thoracolumbar spine, but this investigation did not attempt any special examination of the TLJ region.

Axial rotation at the thoracolumbar junction

The change of zygapophysial joint orientation at the TLJ has been interpreted by anatomists and clinicians as signifying an abrupt change in the mobility of these joints, particularly in the horizontal plane (Humphry, 1858; Levine and Edwards, 1987). It is interesting to note that White and Panjabi (1978) base mobility information for T12-L1 on extrapolations from adjacent lower thoracic and upper lumbar segments. The different regional orientations of the TLJ zygapophysial joints permit mainly rotation in the thoracic segments and sagittal movement in the lumbar region (Davis, 1959; Gregerson and Lucas, 1967; Evans, 1982). For example, the upper lumbar joints, through approximation of the articular surfaces, also restrict mobility, particularly extreme extension (Davis, 1955) or flexion (Kummer, 1981);

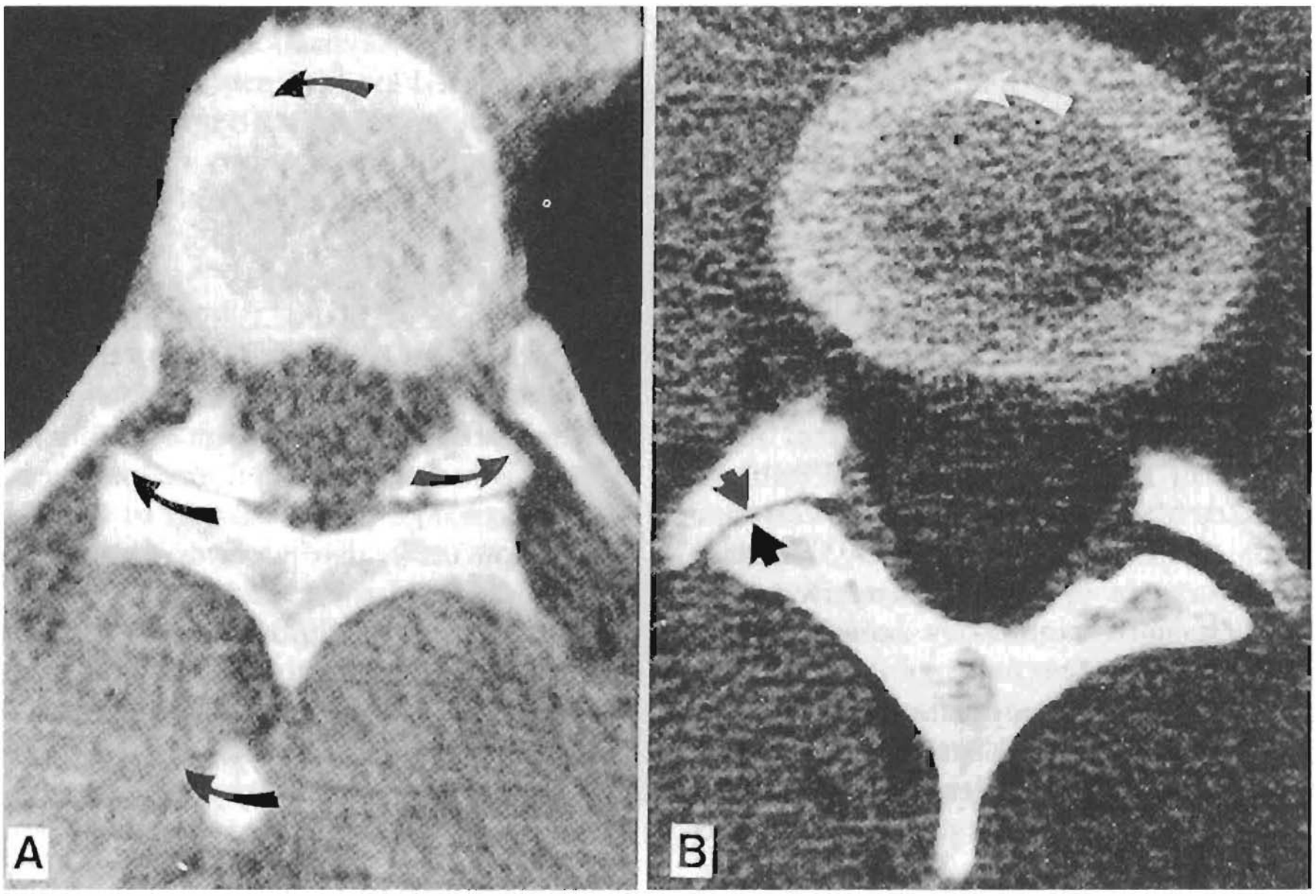

Fig. 7.5 (A) A CT slice taken through the superior end-plate of T10-T11 with the subject in comfortable end range right trunk rotation, to illustrate the extent of axial translation of the zygapophysial joints. The spinous process of the cranial segment confirms the axial displacement induced through the subject's rotated posture. (B) The same subject scanned through the superior end-plate at L4-L5, showing the relative approximation and separation of zygapophysial joints produced through a sustained right trunk rotation position. (Reproduced with permission from Singer, 1994.)

indeed, the posterior elements of the upper lumbar segments are positioned to afford stability in the plane of the intervertebral disc (Farfan, 1983) and appear to minimize excessive torsional forces (Stokes, 1988).

Low-dose CT was used by Singer *et al.* (1989b) to examine subjects who were scanned in a trunk rotated posture to consider the potential for segmental motion at the TLJ. This study consistently demonstrated ipsilateral compression and contralateral separation of the sagittally directed articular surfaces, whereas coronally directed joints tended to show translatory displacement of the articular zygapophysial joints, as depicted in Fig. 7.5 (Singer *et al.*, 1989b). Similarly, those subjects possessing a mortice type of joint demonstrated little motion relative to adjacent segments.

Other anatomical, developmental and degenerative mechanisms would appear to increase this resistance to torsion, for instance the ingrowth into the ligamentum flavum by laminar spicules (Davis, 1955; Allbrook, 1957; Maigne *et al.*, 1992) and, in some instances, ossification of the ligamentum flavum (Kudo *et al.*, 1983). The orientation of the laminar fibres of multifidus muscle may also serve to increase the axial 'stiffness' of the TLJ (Donisch and Basmajian, 1972).

The notion that axial plane rotation is restricted in the upper lumbar region, due to predominantly sagittal orientation of the zygapophysial joints, is not new. Hildebrandt (1816), and numerous commentators over the ensuing decades, have dismissed lumbar inter-segmental rotation as minimal (Humphry, 1858; Lewin *et al.*, 1962; Kummer, 1981; Farfan, 1983; Putz, 1985). Actual rotation is said to be produced through displacement of adjacent vertebrae which induces lateral shear forces within the intervertebral disc (Gregersen and Lucas, 1967), flexibility of the neural arch (Farfan, 1983; Stokes, 1988) and, to a lesser extent, by compliance of the articular surfaces (Lewin *et al.*, 1962).

At the TLJ, a 'close-packed' joint position may be achieved when the thoracolumbar column is extended, as a result of the medial taper of the zygapophysial joints (Singer, 1989b) and the mortice-like disposition of the articular surfaces and the mammillary processes (Topinard, 1877). This approximation would, to coin Davis' (1955) description, act to 'lock' the TLJ segments (Fig. 7.3).

Biomechanics of spinal injuries at the TLJ

The TLJ has been the focus for many clinical and surgical reports, due to the high frequency of serious spinal trauma located within the lower thoracic and upper lumbar mobile segments (Rehn, 1968; Rostad *et al.*, 1969; Schmorl and Junghanns, 1971; Denis, 1983; Larson, 1986). In this context, the transition has been classically regarded as mechanically disposed to trauma; being less capable of attenuating axial and torsional stresses at a point of marked anatomical and mechanical change (Humphry, 1858; Macalister, 1889). The localization of injury to the TLJ has been attributed to the difference in mobility between the thoracic and lumbar regions, given the tendency, during rapid hyperflexion, for the 'stiff' thoracic segments to act as a long lever, which pivots over the lumbar spine (Jefferson, 1927; Levine *et al.*, 1988). The majority of traumatic injuries at the TLJ involve the vertebral bodies, usually producing a compression or burst fracture (Rehn, 1968; Denis, 1983; Lindahl *et al.*, 1983; Willén *et al.*, 1990).

However, descriptions of TLJ injuries do not appear to have considered the influence that transitional variations of the zygapophysial joints might play in the mechanism of injury and the type of trauma sustained. As predicted, an abrupt transition pattern at the TLJ tended to localize trauma to these segments, particularly when rotation was a known contributor to the injury mechanism (Singer *et al.*, 1989c) (Fig. 7.6).

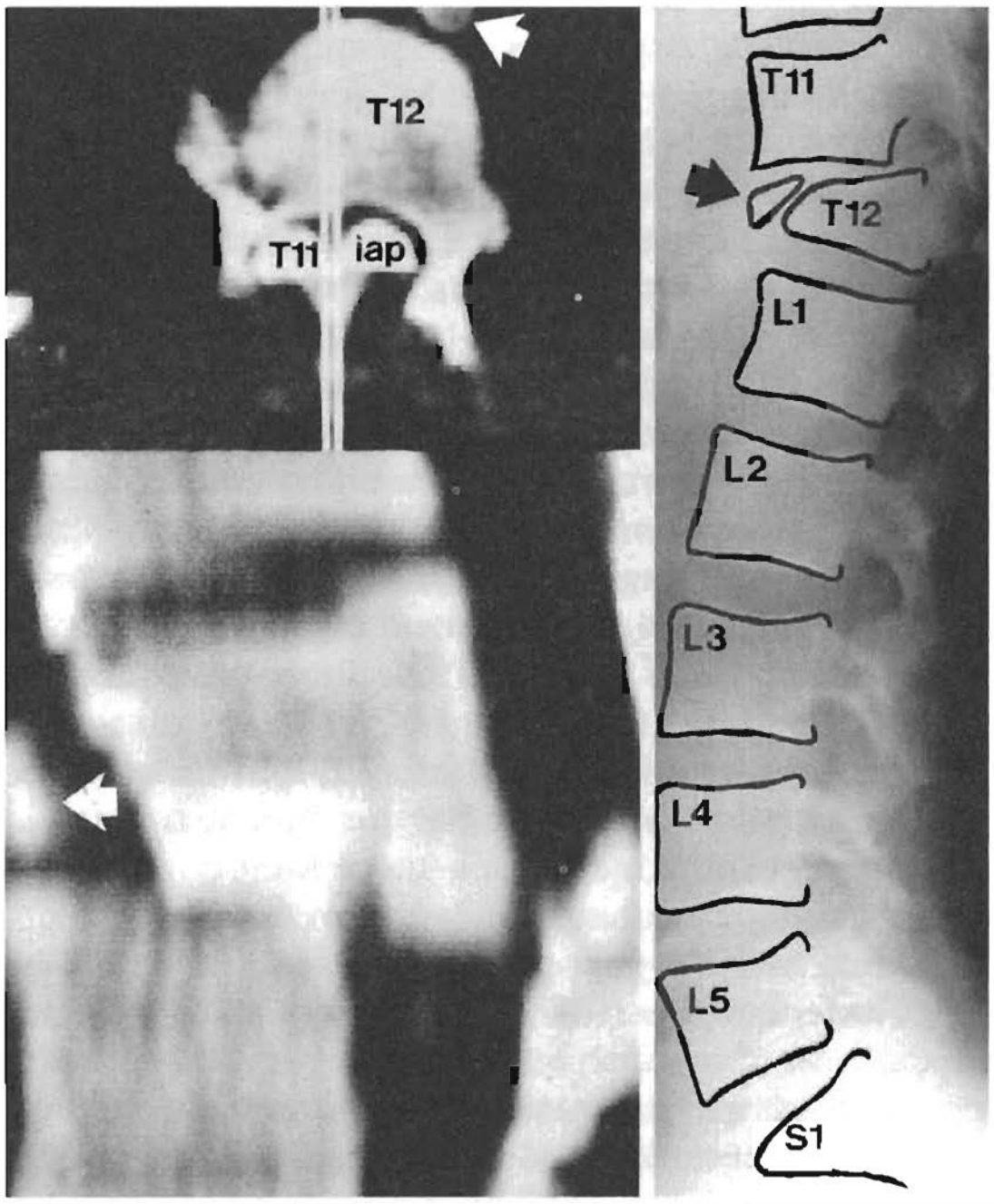

Fig. 7.6 An illustration of the severity of trauma at the thoracolumbar junction, evidenced in a fracture dislocation at T11–T12. Complete occlusion of the vertebral canal is evident through the anterior shear translation of the proximal segments. A flexion/torsional force might be presumed to have effected the injury, producing the wedge compression fracture and fragmentation of the twelfth vertebral body.

Pathoanatomical changes at the thoracolumbar junction

Osteoarthritic changes in zygapophysial and costovertebral joints occur most commonly at T11-T12-L1; vertebrae which suffer the peak incidence of traumatic fractures in the thoracolumbar spine. Variation in zygapophysial joint orientation and asymmetry at T11-T12-L1 levels exceed that encountered in any other part of the thoracolumbar spine. The incidence of zygapophysial joint osteoarthritis is greater in the joints orientated more sagitally at T11-T12, where the variation in the zygapophysial angle is the greatest (Malmivaara *et al.*, 1987a; Singer et al., 1989a). However, zygapophysial joint osteoarthritis is most frequent at T12-L1, where the zygapophysial orientation is typically more sagittal. Spondylosis, disc degeneration and Schmorl's nodes are most frequently encountered within T10-T11-T12 vertebrae.

These findings suggest that all forms of 'anterior column degeneration', involving spondylosis, disc degeneration and Schmorl's nodes, may be promoted through the reduced resistance to torsion at T10-T11-T12 (Markolf, 1972). Major or minor trauma causing axial compressional and tensile forces, coupled with torsion, may lead to anular ruptures and may cause disc bulging or strain at the anular insertions leading to spondylophyte formation. Schmorl's nodes can be produced in cases with compression trauma, any weakness of the end-plate being a predisposing factor (Schmorl, 1927; Malmivaara *et al.*, 1987a, 1989).

The relationship between zygapophysial joint orientation and osteoarthritis suggests that repeated torsional trauma or strain may well have a major role in the development of zygapophysial joint osteoarthritis in the sagittally orientated zygapophysial joints. This model of torsional strain and its consequences on the anulus of the intervertebral disc, and the restraint to torsion by posterior joints, has been developed by Farfan *et al.* (1972). However, the findings in the thoracolumbar junctional region do not support the concept of a 'three joint complex' in which the pathoanatomical changes develop concurrently in the zygapophysial joints and in the discs. The independence of the anterior and posterior changes at the same intervertebral level may stem partly from the unequal distribution of mechanical stresses, especially torsional ones, which are dissipated through the TLJ region.

The pathoanatomical findings suggest different mechanisms in the origin of spondylosis and disc degeneration. Spondylosis at the margins of the vertebral body may be an enthesopathy at the insertion of the outer layers of anulus fibrosus. Disc degeneration may stem from the inner layers of the anulus or from damage to the epiphyseal plate.

The findings showing concurrence of pathoanatomical changes at different levels of the thoracolumbar junctional region (Fig. 7.7) suggest that factors such as prolonged immobilization, excessive loads on the spine, constitutional weakness or metabolic causes may predispose to overall degeneration in the thoracolumbar junctional region in addition to factors operating at a single level, e.g. trauma. The intervertebral disc is the largest avascular structure in the body, receiving a blood supply only to its most peripheral regions (Williams and Warwick, 1980), and disturbances in the nutritional metabolism of the discs could cause degeneration at affected spinal levels. Those factors that predispose to overall segmental joint degeneration probably have less influence on zygapophysial and costovertebral joint osteoarthritis than on disc degeneration and spondylosis.

Veleanu *et al.* (1972) indicated that similar patterns of osteoarthritis are demonstrated in the lower thoracic zygapophysial and upper lumbar joint regions, due to these elements sustaining similar stresses. Lewin (1964) suggested that the thoracolumbar mortice joint morphology might predispose to the early development of osteoarthritis. This

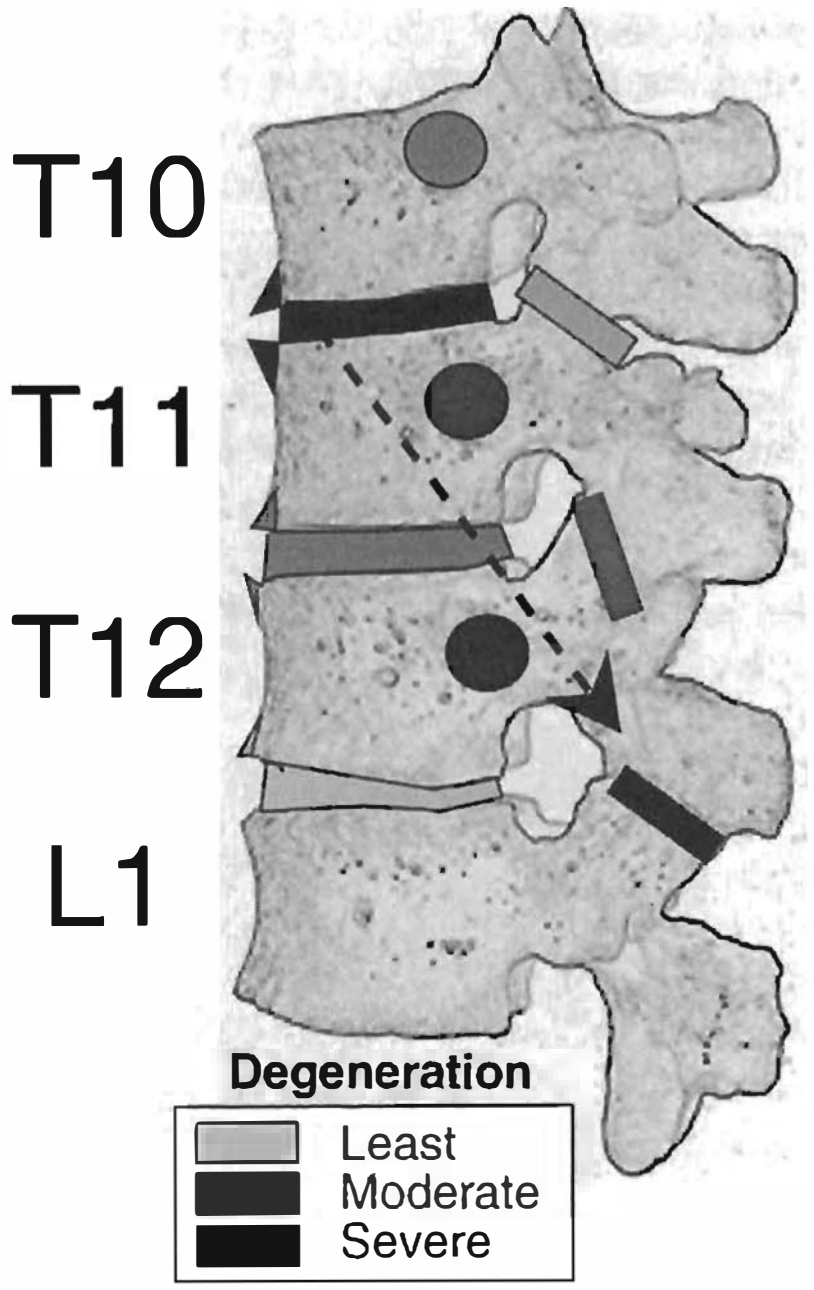

Fig. 7.7 A cranial-to-caudal shift in relationships between spondylosis, disc degeneration, costovertebral and zygapophysial joint osteoarthrosis at the thoracolumbar junction. These patterns of degeneration may reflect the different segmental responses to torsional strain within the disc and posterior joints and, additionally, the forces applied to the lowest ribs from trunk muscles. (Redrawn from Malmivaara, 1989.)

observation was confirmed for the TLJ by Malmivaara et al. (1987a) in an investigation of macerated vertebrae. However, histological examination of hyaline articular cartilage by Singer *et al.* (1990a) was unable to confirm an association between articular cartilage degeneration and tropism. Indeed, zygapophysial joint tropism and the presence of well-developed mammillary processes and mortice joints appeared to act in a protective way (Figs 7.3, 7.4).

Davis (1955) suggested that the mortice joint morphology might act as an 'axis' for flexion forces, resulting in localized TLJ vertebral compression fractures. This theory may also relate to the high frequency of vertebral end-plate lesions (Schmorl's nodes) in this region (Resnick and Niwayama, 1978; Hilton, 1980) (Fig. 7.8). In the absence of marked torsional forces, usually producing fracture/dislocation trauma, the vertebrae appear to be more susceptible to intravertebral disc herniation through the end-plates. According to Malmivaara *et al.* (1987b), this pattern of end-plate injury appears most commonly in the lower thoracic vertebrae.

Fig. 7.8 Lateral radiograph from a 33-year-old male, showing multiple Schmorl's nodes through the inferior end-plates of T11, T12 and L1 at the thoracolumbar junction. Bony laminar 'spicules' are noted projecting inferiorly in the region of the ligamentum flavum at all levels.

The lower thoracic and upper lumbar vertebrae have been associated with a marked incidence of osteoarthritis of the zygapophysial and costovertebral joints (Shore, 1935; Nathan *et al.*, 1964). Studies concentrating on pathologies involving the vertebral bodies and intervertebral discs of the TLJ (Malmivaara *et al.*, 1987a; Malmivaara, 1987a, 1987b, 1989) have helped to describe the pathoanatomic relationships between Schmorl's nodes, costovertebral joint osteoarthritis, vertebral body osteophytosis and intervertebral disc degeneration (Fig. 7.5). The thesis expounded by Malmivaara and co-workers supports the view that patterns of TLJ degeneration are closely linked to the transitional characteristics of the anterior and posterior elements, and their respective capabilities for resisting torsional and compressive forces applied to this region.

Clinical anatomy of the thoracolumbar junction

In a number of cases, transitional variations in zygapophysial joint orientation appeared at both thoracolumbar and lumbosacral junctions (Singer, 1989a). The observation of multiple anomalies present at several transitional junctions has been documented previously by Kühne (1932), Schmorl and Junghanns (1971), MacGibbon and Farfan (1979) and Wigh (1980). This tendency has several implications for the clinical assessment and management of patients with spinal pathology. Schwerdtner (1986) found that patients with structural variations at the lumbosacral junction tended to show poor responses to manipulative therapy and recommended conservative management in these cases. Similarly, Wigh (1979) noted that surgical patients with thoracolumbar and/or lumbosacral transitional variations were more likely to have inappropriate surgery. Wigh (1980) suggested that part of the difficulty in diagnosing the symptomatic level appeared to stem from the incorrect identification of accessory ossification centres and vestigial ribs (Singer and Breidahl, 1990a).

Some clinical features and syndromes appear to be specific to the TLJ. For example, investigations reported by McCall *et al.* (1979) and Maigne (1980, 1981) have suggested that irritation to the lateral branches of the dorsal rami from the low thoracic and upper lumbar segments at the TLJ may be confused with low back pain syndromes, as these nerves become cutaneous over the buttocks and the region of the greater trochanter. A discussion on clinical pain syndromes related to the TLJ is presented in Chapter 10.

Markolf (1972) has suggested, on biomechanical grounds, that the first segment above the transitional level with coronally orientated zygapophysial joints would be more susceptible to torsional stress. This speculation could not be confirmed within the context of a preliminary study of TLJ spinal injuries (Singer *et al.*, 1989c). However, there is evidence that thoracic disc herniations appear more frequently in the lower thoracic segments compared with the middle and upper thoracic region (Chin *et al.*, 1987; Ryan *et al.*, 1988). According to Bury and Powell (1989), the incidence of thoracic discal herniation is approximately 4%. However, the relationship between level of lesion and the TLJ transition may not be coincidental; mechanical aetiologies are often implicated in the production of symptoms (Russell, 1989).

Intra-articular synovial folds were demonstrated in the superior and inferior joint 'spaces' of the TLJ zygapophysial joints and, less frequently, at the middle third of the joint (Singer *et al.*, 1990b). Investigations by Giles and Harvey (1987) and Grönblad and Virri (1997) have clearly indicated the presence of free nerve endings in the substance of similar synovial folds within lower lumbar zygapophysial joints; therefore it may be assumed that compression or traction of these structures could produce pain. The specific morphology of the TLJ zygapophysial joints appear to dictate the type and location of intra-articular synovial folds (Singer *et al.*, 1990b). Therefore, forceful mobilization techniques that compress or apply torsion to these joints may be provocative.

From the foregoing discussion, it would appear that conservative treatment of painful disorders arising from the TLJ may be more appropriate than some of the recommended mechanical therapies (Grieve, 1981; Singer and Giles, 1990). The clinical impression advanced by Lewit (1986) that the TLJ is designed for rotation appears to contradict the anatomical and biomechanical studies reported on this region (Singer, 1989b; Singer *et al.*, 1989b).

Summary

A review of the anatomy of the TLJ reveals that, in a majority of the individuals studied, the posterior elements of the TLJ exhibit anatomical features consistent with reducing stress through an area of considerable morphological and functional variation, principally through a gradual transition in the orientation of the zygapophysial joints. This finding challenges the notion that the TLJ is necessarily a 'weak point' of the vertebral column.

It was evident that the conventional description of an abrupt transition produced a more demarcated pattern of segmental rotation and that this transition type was associated with a higher proportion of severe spinal injuries.

The TLJ represents the most variable of the vertebral transitional regions in terms of zygapophysial joint orientation, tropism and segmental level of transition. The mortice arrangement at the T11-T12 and T12-L1 zygapophysial joints appears to limit rotation and extension. Examination procedures and any mobilizing interventions should consider these factors for the effective management of patients with mechanical dysfunction at the thoracolumbar transition.

References

Åkerblom, B. (1948) *Standing and Sitting Posture: With Special Reference to the Construction of Chairs.* Bokhandeln: A.-B. Nordiska.

Allbrook, D. (1955) The East African vertebral column. *Am. J. Physiol. Anthropol.* **13:** 489-511.

Allbrook, D. (1957) Movements of the lumbar spinal column. *J. Bone Joint Surg.* **39B:** 339-345.

Anderson, J. (1982) The thoracolumbar spine. *Clin. Rheum. Dis.* **8:** 631-653.

Bagnall, K., Harris, P., Jones, P. (1977) A radiographic study of the human fetal spine. 2. The sequence of development of ossification centres in the vertebral column. *J. Anat.* **124:** 791-798.

Barclay-Smith, E. (1911) Multiple anomalies in a vertebral column. *J. Anat.* **45:** 144-171.

Berry, J., Moran, J., Berg. W. *et al.* (1987) A morphometric study of human lumbar and selected thoracic vertebrae. *Spine* **12:** 362-367.

Birkner, R. (1978) *Normal Radiologic Patterns and Variances of the Human Skeleton.* Baltimore: Urban and Schwarzenberg.

Bland, J. (1987) *Disorders of the Cervical Spine.* Philadelphia: W.B. Saunders.

Braune, W., Fischer, O. (1889) *Über den Schwerpunkt des Menschlichen Köpers mit Rücksicht auf die Ausrüstung des Deutschen Infansteristen.* Cited in Åkerblom, B. (1948).

Bury, R., Powell, T. (1989) Prolapsed thoracic intervertebral disc: The importance of CT assisted myelography. *Clin. Radiol.* **40:** 416-421.

Chin, L., Black, K., Hoff, J. (1987) Multiple thoracic disc herniations: case report. *J. Neurosurg.* **66:** 290-292.

Cihak, R. (1981) Die Morphologie und Entwicklung der Wirbelbogengelenke. *Die Wirbelsäule in Forschung und Praxis* **87:** 13-28.

Cyriax, E. (1929) On certain absolute and relative measurements of human vertebrae. *J. Anat.* **54:** 305-308.

Davis, P.R. (1955) The thoraco-lumbar mortice joint. *J. Anat.* **89:** 370-377.

Davis, P.R. (1959) The medial inclination of the human thoracic intervertebral articular facets. *J. Anat.* **93:** 68-74.

Davis, P.R. (1961) The thoraco-lumbar mortice joint in West Africans. *J. Anat.* **95:** 589-593.

Davis, P.R. (1980) Engineering aspects of the spine. In: *Mechanical Aspects of the Spine.* London: Mech. Eng. Pub. Ltd., pp. 33-36.

Denis, F. (1983) The three column spine and its significance in the classification of acute thoracolumbar spinal injuries. *Spine* **8:** 817-831.

Donisch, E., Basmajian, J. (1972) Electromyography of deep muscles in man. *Am. J. Anat.* **133:** 25-36.

Dörr, W. (1958) Über die Anatomie der Wirbelgelenke. *Archiv für Orthopädische und Unfallchirurgie* **50:** 222-243

El-Bohy, A., Yang, K.-H., King, A. (1989) Experimental verification of zygapophysial load transmission by direct measurement of zygapophysial lamina contact. *J. Biomech.* **22:** 931-941.

Evans, D. (1982) Biomechanics of spinal injuries. In: *Biomechanics of Musculoskeletal Injury* (Gonza, E., Harrington, I., eds). Baltimore: Williams and Wilkins, pp. 163-224

Farfan, H. (1983) Biomechanics of the lumbar spine. In: *Managing Low Back Pain* (Kirkaldy-Willis, W., ed.). New York: Churchill Livingstone, pp. 9-21.

Fick, R. (1911) *Spezielle Gelenke und Muskelmechanik. Handbuch der Anatomie und Mechanik der Gelenke.* Jena: Gustav Verlag Fischer.

Gehweiler, J., Osborne, R., Becker, R. (1980) *The Radiology of Vertebral Trauma.* Philadelphia: W.B. Saunders.

Giles, L.G.F. (1987) Lumbo-sacral zygapophysial joint tropism and its effect on hyaline cartilage. *Clin. Biomech.* **2:** 2-6.

Giles, L.G.F., Baker, P.G. (1998) Introduction. In: *Clinical Anatomy and Management of Cervical Spine Pain* (Giles, L.G.F., Singer, K.P., eds) Oxford: Butterworth-Heinemann.

Giles, L.G.F., Harvey, A. (1987) Immunohistochemical demonstration of nociceptors in the capsule and synovial folds of human zygapophysial joints. *Br. J. Rheumatol.* **26:** 362-364.

Gonon, G., Rousson, B., Fischer, L. *et al.* (1975) Donnes metriques concernant l'arc posterieur au niveau du rachis dorso-lombarire de D8 à L5. *Association des Anatomistes Comptes Rendus* **58:** 867-875

Gregersen, G.G., Lucas, D. (1967) An in vivo study of the axial rotation of the human thoraco-lumbar spine. *J. Bone Joint Surg.* **49A:** 247-262.

Grieve, G. (1981) *Common Vertebral Joint Problems.* Edinburgh: Churchill Livingstone, p. 14.

Grönblad M., Virri, J. (1997) Nerves, neuropeptides and inflammation in spinal tissues: mechanisms of back pain. In: *Clinical Anatomy and Management of Low Back Pain* (Giles, L.G.F., Singer, K.P., eds). Oxford: Butterworth-Heinemann.

Hadley, L. (1976) *Anatomico-roentgenographic Studies of the Spine.* Illinois: CC Thomas.

Hamilton, W. (1976) *Textbook of Human Anatomy*, 2nd edn. London: Macmillan.

Hasebe, K. (1913) Die Wirbelsäule der Japaner. *Zeitschrift für Morphologie Jahrbuch* **43:** 449-476.

Hayek, H. (1932) Über lendenrippen. *Fortschritte auf dem Gebiete der Rontgenstrählen und der Nuklearmedizin* **45:** 582-592.

Heise, H. (1933) Über anomalien der lendenwirbelsäule. *Deutsche Zeitschrift für Chirurgie* **227:** 349-367.

Hildebrandt, G. (1816) *Handbuch der Anatomie.* Cited in: Humphry, G. (1858).

Hilton, R. (1980) Systematic studies of spinal mobility and Schmorl's nodes. In: *The Lumbar Spine and Back Pain* (Jayson, M., ed.). Bath: Pitman, pp. 115-134.

Hoppenfeld, S. (1977) *Orthopaedic Neurology: A Diagnostic Guide to Neurologic Levels.* Philadelphia: Lippincott.

Humphry, G. (1858) *A Treatise on the Human Skeleton.* London: Macmillan, pp. 169-171.

Huson, A. (1967) Les articulations intervertébrales chez les foetus humain. *Comptes Rendus des Association D'Anatomists* **138:** 676-683.

Jefferson, G. (1927) Discussion on spinal injuries. *Proc. R. Soc. Med.* **20:** 625-637.

Kapandji, I. (1977) *The Physiology of the Joints, Vol. 3: The Trunk and Vertebral Column*, 2nd edn. Edinburgh: Churchill, pp. 16-17.

Kaplan, E. (1945) The surgical and anatomic significance of the mammillary tubercle of the last thoracic vertebra. *Surgery* **17:** 78-92.

Kazarian, L. (1972) Dynamic response characteristics of the human vertebral column. *Acta Orthop. Scand.* (Suppl 146).

Kazarian, L. (1978) Identification and classification of vertebral fractures following emergency capsule egress from military aircraft. *Aviat. Space Environ. Med.* **49:** 150-157.

Keats, T. (1979) *An Atlas of Normal Roentgen Variants that Simulate Disease*, 2nd edn. Chicago: Year Book Medical Publishers.

Kirkaldy-Willis, W. (1984) The relationship of structural pathology to the nerve root. *Spine* **9:** 49-52.

Kudo, S., Ono, M., Russell, W. (1983) Ossification of thoracic ligamenta flava. *AJR.* **141:** 117-121.

Kühne, K. (1932) Die Vererbung der Variationen der menschlichen. *Wirbelsäule Zeitschrift für Morphologie Anthropologie* **30:** 1-221.

Kummer, B. (1981) Biomechanik der Wirbelgelenke. *Die Wirbelsäule in Forschung und Praxis* **87:** 29-34.

Lampmann, L., Duursmar, S., Ruys, J. (1984) *CT Densiometry on Osteoporosis.* Boston: Martinus Nijhoff.

Lanier, R. (1939) The presacral vertebrae of American white and Negro males. *Am. J. Phys. Anthropol.* **3:** 341-420.

Larson, S. (1986) The thoracolumbar junction. In: *The Unstable Spine* (Dunsker, S.B., Schmidek, H., Frymoyer, J. *et al.*, eds). Orlando: Grune and Stratton, pp. 127-152.

Le Double, A.-F. (1912) *Traite des Variations de la Colonne Vertébrale de l'Homme.* Paris: Vignot-Freres.

Levine, A., Edwards, C. (1987) Lumbar spine trauma. In: *The Lumbar Spine* (Camins, E., O'Leary, P., eds). New York: Raven Press, pp. 183-212.

Levine, A., Bosse, M., Edwards, C. (1988) Bilateral zygapophysial dislocations in the thoracolumbar spine. *Spine* **13:** 630-640.

Lewin, T. (1964) Osteoarthritis in lumbar synovial joints. *Acta Orthop. Scand.* (Suppl 73).

Lewin, T., Moffett, B., Viidik, A. (1962) The morphology of the lumbar synovial intervertebral joints. *Acta Morph. Neerl. Scand.* **4:** 299-319.

Lewit, K. (1986) Muscular pattern in thoraco-lumbar lesions. *Man. Med.* **2:** 105-107.

Ley, F. (1975) Contribution a l'étude des cavités articulaires interapophysaires vertébrales thoraciques. *Archives d'Anatomie d'Histologie et d'Embryologie* **57:** 61-114.

Lindahl, S., Willén, J., Nordwall, A. *et al.* (1983) The 'crush-cleavage' fracture. A 'new' thoracolumbar unstable fracture. *Spine* **8:** 181-186.

Louis, R. (1983) *Surgery of the Spine.* Berlin: Springer-Verlag, p. 10.

Lutz, G. (1967) Die Entwicklung der kleinen Wirbelgelenke. *Zeitschrift für Orthopädie und ihre Grenzgebiete* **104:** 19-28.

Macalister, A. (1889) *A Textbook on Human Anatomy.* London: Griffin, p. 129.

MacGibbon, B., Farfan, H. (1979) A radiologic survey of various configurations of the lumbar spine. *Spine* **4:** 258-266.

McCall, I., Park, W., O'Brien, J. (1979) Induced pain referral from posterior lumbar elements in normal subjects. *Spine* **4:** 441-446.

Maigne, R. (1980) Low back pain of thoracolumbar origin. *Arch. Phys. Med. Rehabil.* **61:** 389-395.

Maigne, R. (1981) The thoracolumbar junction syndrome. Low back pain, pseudo-visceral pain, pseudo-hip pain and pseudo-pubalgia. *Semaine des Hopitaux de Paris* **57:** 545-554.

Maigne, J.-Y., Ayral, X., Guérin-Surville, H. (1992) Frequency and size of ossifications in the caudal attachments of the ligamentum flavum of the thoracic spine. Role of rotatory strains in their development. *Surg. Radiol. Anat.* **14:** 119-124.

Malmivaara, A. (1987a) *Thoracolumbar Junctional Region of the Spine. An Anatomical, Pathological and Radiological Study.* Helsinki: University of Helsinki, Academic dissertation.

Malmivaara, A. (1987b) Disc degeneration in the thoracolumbar junctional region. Evaluation by radiography and discography in autopsy. *Acta Radiol.* **28:** 755-760.

Malmivaara, A. (1989) Pathoanatomical changes in the thoracolumbar junctional region of the spine. *Ann. Med.* **21:** 367-368.

Malmivaara, A., Videman, T., Kuosma, E. *et al.* (1987a) Zygapophysial joint orientation, zygapophysial and costovertebral joint osteoarthrosis, disc degeneration, vertebral body osteophytosis and Schmorl's nodes in the thoracolumbar junctional region of cadaveric spines. *Spine* **12:** 458-463.

Malmivaara, A., Videman, T., Kuosma, E. *et al.* (1987b). Plain radiographic, discographic, and direct observations of Schmorl's nodes in the thoracolumbar junctional region of the cadaveric spine. *Spine* **12:** 453-457.

Markolf, K. (1972) Deformation of the thoracolumbar intervertebral joints in response to external loads. *J. Bone Joint Surg.* **54A:** 511-533.

Med, M. (1980) Prenatal development of intervertebral articulation in man and its association with ventrodorsal curvature of the spine. *Folia Morph.* **28:** 264-267.

Nachemson, A. (1960) Lumbar intradiscal pressure. *Acta Orthop. Scand.* (Suppl. 43).

Nathan, H. (1962) Osteophytes of the vertebral column. An anatomical study of their development according to age, race and sex: with considerations as to their etiology and significance. *J. Bone Joint Surg.* **44A:** 243-268.

Nathan, H., Weinberg, H., Robin, G. *et al.* (1964) The costovertebral joints: anatomico-clinical observations in arthritis. *Arthritis Rheum.* **7:** 228-240.

Noback, C., Roberston, G. (1951) Sequences of appearance of ossification centres in the human skeleton during the first five prenatal months. *Am. J. Anat.* **89:** 1-28.

Odgers, P. (1933) The lumbar and lumbo-sacral diarthrodial joints. *J. Anat.* **67:** 301-317.

Pal, G., Routal, R. (1987) Transmission of weight through the lower thoracic and lumbar regions of the vertebral column in man. *J. Anat.* **152:** 93-105.

Parke, W. (1982) Applied anatomy of the spine. In: *The Spine* (Rothman, R., Simeone, F., eds). Philadelphia: W.B. Saunders.

Pearcy, M. (1986) Measurement of back and spinal mobility. *Clin. Biomech.* **1:** 44-51

Pech, R., Haughton, V. (1985) CT appearance of unfused ossicles in the lumbar spine. *Am. J. Neuroradiol.* **6:** 629-631.

Pfeil, E. (1971) Stellungsvarianten der Gelenkfortsätze am Lendenkreuzbein-Übergang. *Zentralblatt für Chirurgie* **93:** 10-17.

Pick, T. (1890) *Gray's Anatomy: Descriptive and Surgical.* London: Longmans.

Pooni, J., Hukins, D., Harris, P. *et al.* (1986) Comparison of the structure of human intervertebral discs in the cervical, thoracic and lumbar regions of the spine. *Surg. Radiol. Anat.* **8:** 175-182.

Putz, R. (1976) Beitrag zur Morphologie und Rotationsmechanik der kleinen Gelenke der Lendenwirbelsäule. *Zeitschrift für Orthopädie* **114:** 902-912.

Putz, R. (1985) The functional morphology of the superior articular processes of the lumbar vertebrae. *J. Anat.* **143:** 181-187.

Radin, E. (1976) Aetiology of osteoarthrosis. *Clin. Rheum. Dis.* **2:** 509-522.

Rehn, J. (1968) Die knöcheren Verletzungen der Wirbelsäule Bedeutung des Erstbefundes für die spätere Begutachtung. *Die Wirbelsäule in Forschung und Praxis* **40:** 131-138

Reichmann, S. (1971) The postnatal development of form and orientation of the lumbar intervertebral joint surfaces. *Zeitschrift für Anatomie Entwicklungsgeschichte* **133:** 102-123.

Resnick, D., Niwayama, G. (1978) Intravertebral disk herniations: cartilaginous Schmorl's nodes. *Radiol.* **126:** 57-65.

Rostad, H., Solheim, K., Siewers, P. *et al.* (1969) Fracture of the spine. *Acta Orthop. Scand.* **40:** 664-665.

Russell T (1989) Thoracic intervertebral disc protrusion: experience of 76 cases and review of the literature. *Br. J. Neurosurg.* **3:** 153-160.

Ryan, R., Lally, J., Kozic, Z. (1988) Asymptomatic calcified herniated thoracic disks: CT recognition. *Am. J. Neuroradiol.* **9:** 363-366.

Schertlein, A. (1928) Über die haufigsten anomalien an der Brustlendenwirbelsäulengrenze. *Fortschritte auf dem Gebiete der Rontgenstrählen und der Nuklearmedizin* **38:** 478-488.

Schmorl, G. (1927) Ober Knorpeikntchen an den Wirbelbandscheiben. *Fortschr. Geb. Röntgenstr.* **38:** 265-279.

Schmorl, G., Junghanns, H. (1971) *The Human Spine in Health and Disease*, 2nd American edn. New York: Grune and Stratton, pp. 55-60.

Schwerdtner, H. (1986) Lumbosakrale übergangsanomalien als rezidivursache bei Chirotherapeutischen behandlungstechniken. *Man. Med.* **24:** 11-15.

Shore, L. (1930) Abnormalities of the vertebral column in a series of skeletons of Bantu natives of South Africa. *J. Anat.* **64:** 206-238.

Shore, L. (1935) On osteo-arthritis in the dorsal intervertebral joints. A study in morbid anatomy. *Br. J. Surg.* **22:** 833-849.

Singer, K.P. (1989a) *Variations at the Human Thoracolumbar Transitional Junction with Reference to the Posterior Elements.* PhD thesis. The University of Western Australia.

Singer, K.P. (1989b) The thoracolumbar mortice joint. Radiological and histological observations. *Clin. Biomech.* **4:** 137-143.

Singer, K.P. (1994) Anatomy and biomechanics of the thoracolumbar junction. In: *Grieve's Modern Manual Therapy* (Boyling, J.D., Palastanga, N., eds). Edinburgh: Churchill Livingstone, pp. 85-97.

Singer, K.P., Breidahl, P. (1990a) Accessory ossification centres at the thoracolumbar junction. *Surg. Radiol. Anat.* **12:** 53-58.

Singer, K.P., Breidahl, P. (1990b) Vertebral body trabecular density at the thoracolumbar junction using quantitative computed tomography. A post-mortem study. *Acta Radiol.* **31:** 37-40.

Singer, K.P., Giles, L.G.F. (1990) Manual therapy considerations at the thoracolumbar junction: An anatomical and functional perspective. *J.M.P.T.* **13:** 83-88.

Singer, K.P., Breidahl, P., Day, R. (1989a) Posterior element variation at the thoracolumbar transition. A morphometric study using computed tomography. *Clin. Biomech.* **4:** 80-86.

Singer, K.P., Day, R., Breidahl, P. (1989b) In vivo axial rotation at the thoracolumbar junction: an investigation using low dose CT in healthy male volunteers. *Clin. Biomech.* **4:** 145-150.

Singer, K.P., Willén, J., Breidahl, P. *et al.* (1989c) A radiologic study of the influence of zygapophysial joint orientation on spinal injuries at the thoracolumbar junction. *Surg. Radiol. Anat.* **11:** 233-239.

Singer, K.P., Giles, L.G.F., Day, R. (1990a) Influence of zyagapophyseal joint orientation on hyaline cartilage at the thoracolumbar junction. *J.M.P.T.* **13:** 207-214.

Singer, K.P., Giles, L.G.F., Day, R. (1990b) Intra-articular synovial folds of the thoracolumbar junction zygapophysial joints. *Anat. Rec.* **226:** 147-152.

Singer, K.P., Jones, T., Breidahl, P. (1990c) A comparison of radiographic and computer-assisted measurements of thoracic and thoracolumbar sagittal curvature. *Skel. Radiol.* **19:** 21-26.

Sobotta, J., Uhlenhuth. L. (1957) *Atlas of Descriptive Anatomy*, 7th English edn. New York: Hafner, p. 24.

Stagnara, P., Mauroy. J., de Dran, G. *et al.* (1982) Reciprocal angulation of vertebral bodies in a sagittal plane: Approach to references for the evaluation of kyphosis and lordosis. *Spine* **7:** 335-342.

Steindler, A. (1955) *Kinesiology of the Human Body: Under Normal and Pathological Conditions*. Illinois: CC Thomas.

Stewart, T. (1932) The vertebral column of the Eskimo. *Am. J. Phys. Anthropol.* **16:** 51-62.

Stokes, I.A.F. (1988) Mechanical function of zygapophysial joints in the lumbar spine. *Clin. Biomech.* **3:** 101-105

Strasser, H. (1913) *Die Rumpfhaultungen. Lehrbuch der Muskel und Gelenkmechanik.* Berlin: Springer, pp. 244-320.

Struthers, J. (1875) On variations of the vertebrae and ribs in man. *J Anat. Physiol.* **9:** 17-96.

Terry, R., Trotter, M. (1953) Osteology. In: *Morris' Human Anatomy* (Schaeffer, J.P., ed.). New York: McGraw-Hill, p. 102.

Testut, L., Latarjet, A. (1948) *Traité d'Anatomie Humaine*, Vol. 1, 9th edn. Paris: Dion, p. 6.

Todd, W. (1922) Numerical significance in the thoracolumbar vertebrae of the mammalia. *Anat. Rec.* **24:** 261-286.

Töndury, G. (1940) Beitrag zur Kentniss der Kleinen Wirbelgelenke. *Zeitschrift für Anatomie Entwicklungsgeschichte* **110:** 568-575.

Töndury, G. (1972) Anatomie functionelle des petites articulations de rachis. *Annal. Med. Physique* **15:** 173-191.

Topinard, P. (1877) Des anomalies de nombre de la colonne vertebrale chez l'homme. *Revue D'Anthropol.* **6:** 577-649.

Vallois, H. (1920) La signification des apophyses mammillaires et accessories des vertébres lombaires. *Comptes Rendus Societie de Biologie* **83:** 113-115.

Veleanu, C., Grün, U., Diaconescu, M. *et al.* (1972) Structural peculiarities of the thoracic spine; their functional significance. *Acta Anat.* **82:** 97-107.

White, A. (1969) Analysis of the mechanics of the thoracic spine in man. *Acta Orthop. Scand.* (Suppl. 127).

White, A., Panjabi, M. (1978) Basic kinematics of the spine. *Spine* **3:** 12-29.

Whitney, C. (1926) Asymmetry of vertebral articular processes and facets. *Am. J. Phys. Anthropol.* **9:** 451-455.

Wigh, R. (1979) Phylogeny and the herniated disc. *South. Med. J.* **72:** 1138-1143.

Wigh, R. (1980) The thoracolumbar and lumbosacral transitional junctions. *Spine* **5:** 215-222.

Willén, J., Anderson, J., Tomooka, K. *et al.* (1990) The natural history of burst fractures in the thoracolumbar spine T12 and L1. *J. Spinal Dis.* **3:** 39-46.

Williams, P., Warwick, R. (1980) Osteology. *Gray's Anatomy*, 36th edn. London: Churchill, pp. 277, 284.

Yang, K., King, A. (1984) Mechanism of zygapophysial load transmission as a hypothesis for low back pain. *Spine* **9:** 557-565.

Zindrick, M., Wiltse, L., Doornik, A. *et al.* (1986) Analysis of the morphometric characteristics of the thoracic and lumbar pedicles. *Spine* **12:** 160-166.

8

Thoracic neural anatomy

G. J. Groen and R. J. Stolker

The thoracic region is almost uniformly depicted as the most segmentally organized area of the human body. This implies that a systematic description of the thoracic spinal nerves and their branches may not seem so difficult. However, because of regional differences in adjacent structures and internal organs (e.g. ribs and costovertebral joints, heart, lungs, oesophagus, in addition to upper abdominal organs), not only the topography of the nerves but also the functional implication of thoracic pain is variable. It should be emphasized that pain in the thoracic area may arise from structures related to the thoracic spine (discs, spinal dura, nerve roots, costovertebral joints, myofascial structures, zygapophysial joints) (Dreyfuss *et al.*, 1994), but never forget that internal organs may also refer pain to the thoracic region. Even chronic abdominal pain related to thoracic disc herniation has been reported (Whitcomb *et al.*, 1995). Furthermore, as cardiopulmonary surgery is performed with increasing frequency, iatrogenic sources of thoracic pain secondary to operative procedures, varying from breast surgery to thoracotomies, must not be overlooked. Post-thoracotomy pain, in particular, is a vexing problem (Kirvelä and Antila, 1992). After cancer operations, an incidence of up to 11% of chronic post-thoracotomy pain has been reported (Keller *et al.*, 1994), more commonly following chest-wall resection and pleurectomy. A number of these thoracotomy procedures, such as large vessel intervention on the aorta, may even lead to disabilities in the function of the thoracic spine (paraparesis/paraplegia). As an increasing number of patients are subjected to this so-called 'aortic-cross clamping' procedure (Gelman, 1995), in which the arterial blood supply of the thoracic spinal cord is at risk, the arterial blood supply will be dealt with briefly. Even therapeutic procedures for spinal pain, such as the percutaneous partial posterior rhizotomy, have been reported to lead to functional disturbances of the thoracic spinal cord, when performed using incorrect technique (Koning *et al.*, 1991).

The major (macroscopic) scheme of branching of thoracic spinal nerves is as follows (Fig. 8.1). The spinal nerve is formed by the united dorsal and ventral roots, just lateral to the dorsal root ganglion (DRG). It generally bifurcates into a larger ventral ramus, i.e. the intercostal nerve, and a smaller dorsal ramus for the supply of the dorsal structures (e.g. zygapophysial joints, intrinsic back muscles and overlying skin). The intercostal nerve gives off lateral and cutaneous branches supplying, respectively, the lateral and anterior wall of the thorax and the abdomen. The intercostal nerves are located in the area bounded by the internal and innermost intercostal muscles, while those supplying the abdominal wall run in an analogous layer between the transversus abdominis and the internal oblique muscles. For further details, the reader is referred to standard textbooks.

Just lateral to the DRG the spinal nerve is connected to the sympathetic trunk by communicating rami. This scheme can be extended, particularly in relation to the innervation of the thoracic spine, and this will be described in further sections.

The thoracic spinal cord and topographical relations

Unlike the lumbar spine, in the thoracic area protrusions of intervertebral discs (see Fig. 5.16), which

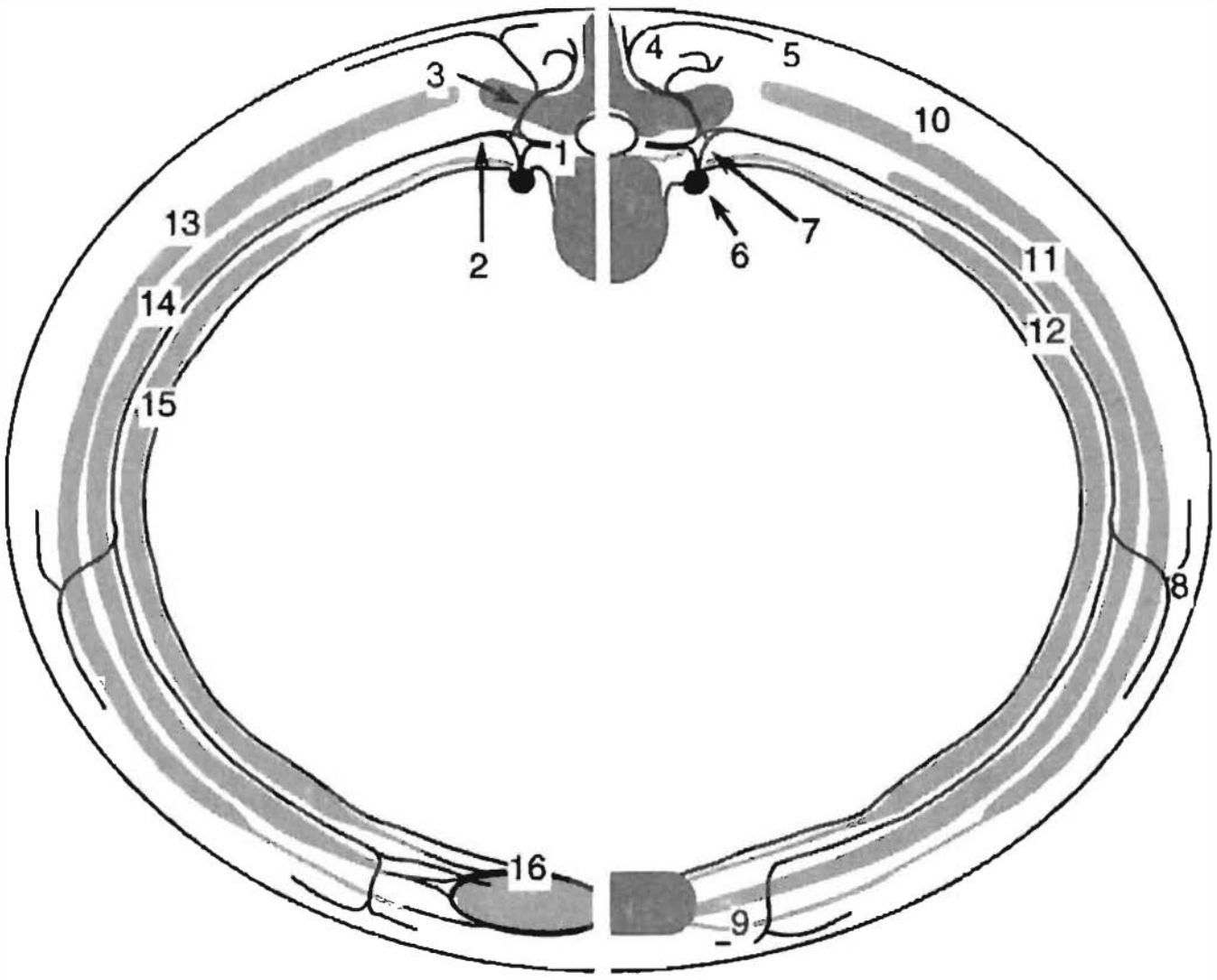

Fig. 8.1 Schematic drawing of position and branches of thoracic spinal nerves in the back, thorax wall (right side of figure) and abdominal wall (left side of figure). 1, spinal nerve; 2, ventral ramus of spinal nerve (intercostal nerve); 3, dorsal ramus of spinal nerve; 4, medial branch of dorsal ramus; 5, lateral branch of dorsal ramus; 6, sympathetic trunk; 7, communicating rami; 8, lateral branch of intercostal nerve; 9, anterior cutaneous branch of intercostal nerve; 10, 11 and 12, external, internal and innermost intercostal muscles; 13 and 14, external and internal oblique muscles; 15, transversus abdominis; 16, rectus abdominis.

are infrequent (Skubic and Kostuik, 1991; Russell, 1992), generally do not lead to radicular symptoms. It should be noted that the main component of the thoracic vertebral canal is formed by the spinal cord. In the vertebral canal the spinal cord is bounded, from deep to superficial, by the subarachnoidal space bounded by the pia-arachnoid membrane, the spinal dura, the epidural space containing the internal vertebral venous plexuses and fatty tissue, by the dorsal aspects of vertebral bodies and intervertebral discs, the posterior longitudinal ligament (PLL), and dorsally by the ligamenta flava and the laminae of the vertebral arches. The intervertebral foramina and the superior and inferior articular processes articulating in the zygapophysial joints ('facet joints') occupy the lateral border of the spinal canal.

In the cervical and thoracic areas in particular, pathological processes originating from or related to the surrounding tissues will affect spinal cord function if they protrude far enough into the vertebral canal. These extramedullary (or extra-axial) pathological processes impinging upon the spinal cord will cause 'disturbances', i.e. loss of function, of the main ascending and/or descending tracts instead of the radicular signs and symptoms that occur more commonly in the lumbar region. Topographical and somatotopical relations determine the type of functional loss below the level of the lesion.

The location of the major tracts is as follows (see also Fig. 8.2):

- The pain-conducting spinothalamic tract lies in the antero-lateral part of the white substance, and is generally described as the antero-lateral system (ALS) including its deep ascending fibres to the mesencephalon. Fibres derived from sacral segments ascend superficially; those from lumbar and thoracic levels more deeply.
- Proprioceptive information is mainly relayed via the so-called dorsal column-medial lemniscus (DCML), also referred to as the funiculus dorsalis-lemniscus medialis (FDLM) system, which is localized in the dorsal column. This system also shows a marked somatotopic organization; sacral fibres ascend medially, lumbar and thoracic fibres more laterally.
- The descending (lateral) corticospinal tract is located in the lateral funiculus, and projects mainly to alpha and gamma motoneurons of the lumbar intumescence. Fibres directed to sacral levels descend more superficially (i.e. laterally), fibres to lumbar and (a minority) to thoracic levels descend more medially.

Although the spinal cord contains more ascending and descending systems, the majority of symptoms are related to these three systems only, and will be described briefly.

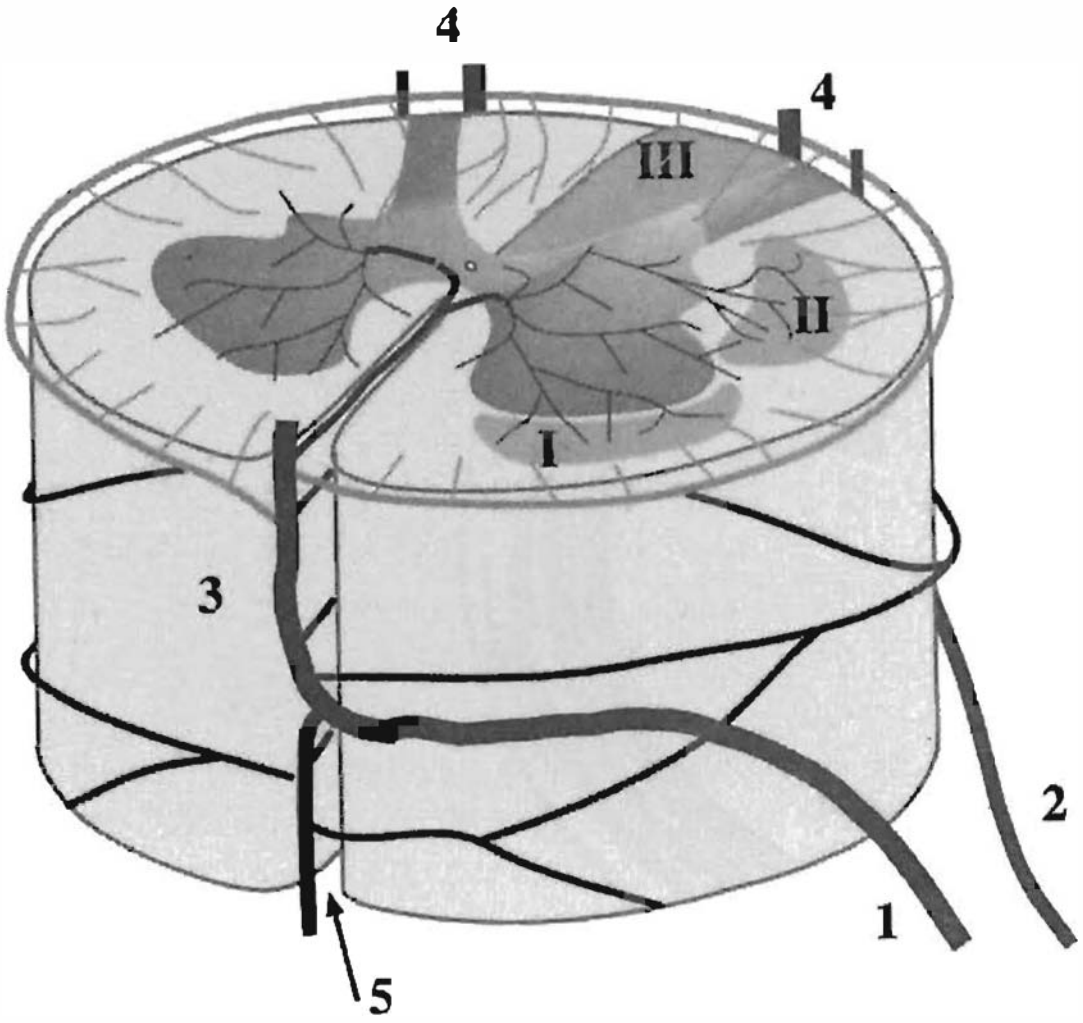

Fig. 8.2 Diagram of arterial blood supply of the spinal cord showing vascular territories and anastomosing circular arterial ring between the anterior and posterior spinal arteries. 1, anterior radicular artery; 2, posterior radicular artery; 3, anterior spinal artery supplying the central area; 4, posterior (postero-lateral) spinal arteries; 5, anterior median fissure; I, antero-lateral system (ALS or 'spinothalamic tract'); II, corticospinal tract; III, funiculus dorsalis-lemniscus medialis system (FDLM).

Symptoms caused by pathological processes

Anterior compression of the cord

As a consequence of the above, extra-axial pathological processes originating from the dorsal side of the vertebral bodies or intervertebral discs will finally, when compressing the anterior part of the spinal cord, lead to functional loss, i.e. loss of pain and temperature sensitivity in dermatomes below the level of the lesion; first in the sacral area, followed by lumbar and thoracic levels. This is, however, not the complete story, as the first structures impinged upon are the PLL and the ventral spinal dura. Both structures have a rich innervation (see below) so, in the case of irritative lesions, referred pain may be a first symptom and appear prior to the onset of spinal cord compression symptoms.

Posterior compression of the cord

Although seldom reported, extra-axial pathology compressing the spinal cord dorsally will lead to a loss of FDLM functions below the level of the lesion. However, pain symptoms are rare, as the dorsal dura is poorly supplied by nerve fibres (see below).

Lateral compression of the cord

Laterally originating pathological processes, although very rare, may first lead to muscle weakness, hypertonia and reflex disturbances (i.e. hyperreflexia and pathological reflexes) below the level of the lesion, caused by compression of the corticospinal tract. However, spinal roots and dural sleeves are often involved as well leading to related symptoms, including radicular pain and paraesthesia. At the level of the lesion, reflexes may be diminished or absent.

Intramedullary lesions

Finally, spinal cord lesions can also arise from within the spinal cord (intramedullary or intra-axial lesions), with similar symptomatology. Although differentiation between intra- and extramedullary spinal cord lesions is difficult without modern imaging technology such as high resolution magnetic resonance (MR) imaging, the symptoms themselves might give a clue about the origin of the lesion. For instance, as discussed above, pain is more common in extramedullary lesions, while intramedullary lesions may be painless for lack of nociceptors within the spinal cord. However, in traumatic lesions of the spinal cord and spinal tumours, painful sensations are frequent and troublesome sequelae of paraplegia and quadriplegia (see below). Furthermore, central lesions in the spinal cord will first affect the deep ascending/ descending fibres, and thus may lead to a sparing of superficially located fibres (e.g. the so-called sacral sparing, characteristic of thoracic syringomyelia). In addition, bladder function is affected earlier in intra-axial than in extra-axial disease (Rowland, 1991). Finally, although there is a high correlation between the level of spinal cord tumours in the thoracic region and the dermatomal level of sensory disturbance, it is important that further MR imaging is performed sufficiently cranially to indicate the limits of the compression (Hirabayashi *et al.*, 1995).

Spinal cord injury pain

Following spinal cord injury, a large number of patients experience pain. Reported incidences range from 47-96% (Yezierski, 1996). Although trauma-related pain from musculoskeletal, capsular, dural, radicular or visceral origin is to be expected, damage of the spinal cord itself may also be a source of pain. One of the most disabling syndromes after spinal cord injury is central dysaesthetic pain, defined as the presence of pain caudal to the site of injury for any period of at least 4 weeks post-injury, and usually starting within the first year (Davidoff *et al.*, 1987). The prevalence of dysaesthetic pain is reported to be highest in patients with incomplete spinal cord injuries, in comparison to patients with complete spinal cord injury, although some controversy exists (Yezierski, 1996).

Although understanding of the background of this centrally-originating pain resulting directly from lesions of the spinal cord is far from complete, recent findings, partly based on experimental animal models of spinal injury, have led to the following hypothesis on the cascade of post-injury reactions in the spinal cord (Yezierski, 1996). Mechanical trauma and local ischaemia result in neuronal cell loss and a number of neuronal changes occur, including axonal damage, axonal sprouting, changes in receptive field and neuronal excitability, changes in receptor up and down regulation, and reactive growth of glial cells. Loss of spinal nociceptive neurones may create an imbalance in spinal and supraspinal sensory function between somatosensory and somatonociceptive input (Beric, 1993). Combined with a loss of segmental and/or supraspinal and propriospinal inhibitory influences, spinal neurons may become hyperactive and are thus held responsible for producing paraesthetic and/or dysaesthetic sensations referred to the affected dermatome (Yezierski, 1996). In this respect, major emphasis is given to the loss of local GABA-ergic neurons, the decreased influence of descending monoaminergic pathways from the brainstem and the changes in activity of the endogenous opioid and cholecystokinin (CCK) peptide systems (Xu *et al.*, 1994). Thus, the loss of local inhibitory control within the injured spinal cord, executed by local circuit inhibitory GABA-ergic neurons, contributes to the increased responsiveness of dorsal horn neurons and to the onset of painful reactions to non-noxious stimuli, i.e. allodynia. Similar mechanisms are also thought to appear in deafferentation pain. Future lines of research are mainly focused on these areas (for a more extensive review, see Yezierski, 1996).

Arterial blood supply to the spinal cord

The spinal cord is supplied by branches of segmental arteries, which enter the vertebral canal via the vertebral foramina and run as anterior and posterior radicular arteries along the nerve roots to the spinal cord, where they divide into ascending and descending branches, which communicate in a longitudinal direction. Thus, one anterior spinal artery is formed ventrally, and two postero-lateral arteries dorsally. All arteries are interconnected with each other via horizontal anastomoses (the so-called vasocorona).

The anterior spinal artery gives off horizontal penetrating branches into the anterior median fissure, which bifurcate and supply both anterior horns and adjacent antero-lateral white matter (including the spinothalamic and major part of the corticospinal projections) (see Fig. 8.2). The remainder, including the FDLM, are supplied via perforating branches from the circular arterial ring. At nearly all levels anterior and posterior radicular arteries are present, although their pattern is not symmetrical; generally, left arteries predominate. Whilst the number of posterior radicular arteries exceeds that of the anterior ones (ratio 3.7:1, Jellinger, 1966), their diameter is generally smaller - the posterior radicular arteries are no larger than 600 μm (Piscol, 1972). Furthermore, large anterior radicular arteries are more or less concentrated around the lower cervical (C5-C8) and thoracolumbar (T9-L2) spinal cord segments.

The functional implication of this is that the spinal cord can be divided into areas with a rich and poor blood supply, with transitional zones. The upper cervical and lower lumbosacral segments in particular should be regarded as 'water-shed' areas with a meagre supply (Piscol, 1972), and consequently these areas are at risk in situations such as hypovolaemic shock. Alternatively, richly supplied areas are at risk if the major supplying artery is damaged by trauma or during surgery. Symptoms related to anterior spinal artery damage can be deduced from Fig. 8.2: bilateral loss of pain and temperature sensitivity below the level of the lesion, spastic paraplegia, bilateral flaccid paralysis and reflex loss at the level of the lesion, and bladder/bowel dysfunction; without loss of proprioception or tactile discrimination.

Arterial blood supply to the thoracic spinal cord

The arterial blood supply to the thoracic spinal cord is mainly attributed to larger radicular arteries (diameter ≥400 μm) (Piscol, 1972) at the mid- and lower thoracic level, which originate from spinal branches of intercostal arteries. The largest radicular artery (diameter up to 1.2 mm) is the a. radicularis magna (artery of Adamkiewicz). This anterior radicular artery originates in the majority of cases (> 80%) from the lower intercostal and upper lumbar arteries on the left side (T9-L2) (Piscol, 1972).

Thoracolumbar spinal cord damage may result particularly from aortic cross-clamping procedures. Postoperative paraplegia caused by prolonged ischaemia (long cross-clamp times, particularly those above 30-45 minutes), resection of the artery of Adamkiewicz or spinal cord reperfusion-effects by oxygen-derived free radicals has been reported in up to 40% of cases (Gelman, 1995). Since spinal cord perfusion pressure is equal to mean arterial pressure minus mean venous pressure or cerebral spinal fluid (CSF) pressure (depending on which of the two is higher), draining of CSF has been advocated in order to lower the CSF pressure and allow more blood flow (Gelman, 1995). However, great controversy exists as experimental and human studies often do not produce the same results.

Furthermore, therapeutic procedures for spinal pain, such as percutaneous partial posterior rhizotomy, have been reported to lead to functional disturbances of the thoracic spinal cord (Koning *et al.*, 1991). Koning and colleagues attributed the ischaemic lesions of the spinal cord to a 'local steal phenomenon' induced by percutaneous partial posterior rhizotomy; however, in the current authors' opinion they are caused by a technically incorrect procedure. As the psychological implications of negative comments on these procedures must not be underestimated, an objective discussion is appropriate.

Koning and colleagues state that heat application leads to local hyperaemia and vasodilatation (Koning *et al.*, 1991). However, to be effective, the spinal arteries should be of considerable calibre. In the mentioned T4-T6 levels, the number of spinal arteries generally is low and their diameter is small (Piscol, 1972), so a real 'steal phenomenon' seems unlikely. Furthermore, a local vasodilatation may increase the demands of the related artery from the supplying vessel, thus leading to an *increase* in flow distal to the artery, rather than a decrease. Moreover, even supposing such a local steal of blood occurs, both spinal cord arteries (anterior and posterior) would reallocate their blood. This would lead to a typical hypoperfusion syndrome in the border zone of their vascular territories (Bartsch, 1972) in which the symptoms would include, primarily, a lesion of the crossing spinothalamic nerve fibres, from *both* sides. Therefore, the unilateral symptoms described in both patients studied cannot be explained by hypoperfusion. Furthermore, the lesions of the spinal cord were reported to be one spinal cord segment lower than the level of rhizotomy. This is incorrect as, topographically, the affected segments of the spinal cord are located precisely at the level of the rhizotomies. Finally, a traumatic lesion of the local vasculature was reported as unlikely, since the lesion would then occur ipsilaterally and at the same level as the rhizotomy. This is difficult to understand. Ipsilateral lesions of radicular arteries may either result in hypoperfusion in both the anterior and posterior spinal arteries leading to a bilateral hypoperfusion syndrome (Bartsch, 1972) or, in the very improbable case of a major anterior radicular artery, an anterior spinal artery syndrome, also with bilateral symmetrical symptoms.

It is therefore advocated that a high thoracic percutaneous partial posterior rhizotomy should not be performed following a latero-dorsal approach, but by a straight dorsal approach through a drill hole made by a Kirschner wire, as described by Stolker *et al.* (1994a, 1994b).

Neural terminology

A central position in the innervation of the spine is taken by sympathetic structures such as the sympathetic trunk and the rami communicantes, i.e. the neural connections between spinal nerves and sympathetic trunk (Groen, 1986; Groen *et al.*, 1987, 1988, 1990). They are not only topographically related to the spine, but also serve as a neural pathway for vasomotor and viscero- and somatosensory nerve fibres. Although the term 'sympathetic-afferent' is still used in various reports it should be abandoned as, by definition, the sympathetic system is a motor (efferent) system. It would be better to describe these fibres as 'viscero-afferent' or 'viscerosensory' using sympathetic pathways.

Direct connections of the sympathetic trunk to internal organs or prevertebral ganglia are defined as splanchnic nerves. In the thoracic region large splanchnic nerves can be identified, known as the greater, lesser and least splanchnic nerves, which contain pre- and postganglionic sympathetic and sensory nerve fibres supplying the upper abdominal organs (Kuntz, 1953; Mitchell, 1953; Pick, 1970). Other visceral branches are directed towards the heart, lungs, aorta and oesophagus and are named accordingly (Hovelacque, 1927). Pick (1970) observed a large number of thoracic splanchnic nerves forming regular plexuses, without specifying their target. Muscular, articular and vascular branches of the thoracic sympathetic trunk are described by Mitchell (1953) in general terms and, in the monkey, in much more detail by Stilwell (1956). In earlier studies (Groen *et al.*, 1987, 1990) segmental connections of these thoracic splanchnic nerves have been determined, including nerve fibres to the costovertebral joints and anterior longitudinal ligament (ALL). Although by definition these types of branches should be named 'splanchnic', they will be described below as direct branches of the sympathetic trunk.

The sympathetic outflow originates in the intermedio-lateral and medial column of the thoracic and upper lumbar spinal cord (C8-L2). These myelinated preganglionic fibres (diameter 1.5-4 μm) emerge from the spinal cord through the ventral roots, join the spinal nerves at their proximal start and soon leave, in white rami communicantes, to join either the adjacent sympathetic ganglia or their intermediate segments. After synapsing on the principal ganglionic cells, the unmyelinated axons of these ganglionic neurons (generally described as postganglionic fibres) may return to the spinal nerve in grey rami communicantes, usually joining the spinal nerve just proximal to the white ramus, to be distributed to their target organs via the ventral and dorsal spinal rami. Furthermore, the postganglionic nerve fibres may leave the sympathetic trunk as medially directed splanchnic branches mainly to the

viscera, or as the above-mentioned direct branches towards the spine. Related to this thoracolumbar sympathetic outflow, it is usual to find white and grey communicating rami between the levels of C8 and L2, whilst only grey rami are present above and below that area. However, fusion of white and grey rami may occur, particularly
rami may contain myelinated somato-efferent (motor) and somato-afferent (sensory) nerve fibres (Mitchell, 1953; Pick, 1957, 1970; Groen *et al*., 1987, 1990; Williams *et al*., 1995). Since they are often mixed in the thoracic area, white and grey rami will not be distinguished in the following description but will be dealt with as 'rami communicantes'.

Thoracic spinal innervation

Much of the systematic innervation of the human spine has been extrapolated from the comprehensive description of that in the monkey by Stilwell (1956). He stated that it is obvious that only spinal structures that are innervated can act as a source of pain. As the ligamentum flavum (Ashton *et al*., 1992; Ahmed *et al*., 1993a) and the internal venous plexus are not known to be innervated, all other structures in the spine may be considered as a potential source of pain. Free nerve endings have been demonstrated in the capsules of zygapophysial joints (Pedersen *et al*., 1956; Stilwell, 1956; Hirsch *et al*., 1963; Jackson *et al*., 1966; Giles *et al*., 1986; Yamashita *et al*., 1990), and in the ALL, PLL and the anulus fibrosus (Roofe, 1940; Stilwell, 1956; Hirsch *et al*., 1963; Jackson *et al*., 1966; Yoshizawa *et al*., 1980; Groen *et al*., 1990).

Recently many papers have appeared on the immunohistochemical identification of spine-related nerve fibres, all concerned with the detection of neuropeptides. Not only is there still debate on the significance and function of these peptides but also on their presence or absence in spinal tissues, as a number of these peptides are difficult to identify because of methodological difficulties. Therefore, the presence (but not the absence) of neuropeptides used as markers for nociceptive function is conclusive (Coppes *et al*., 1997).

Currently, substance P-immunoreactive nerve fibres (SP-IR), known to participate in the sensory transmission or modulation of neural (nociceptive) impulses (Liesi *et al*., 1983; Grönblad *et al*., 1991a), have been identified in the dura (Edvinsson *et al*., 1983; Ahmed *et al*., 1993b; Segikuchi *et al*., 1996; Kumar *et al*., 1996), the zygapophysial joints (Giles and Harvey, 1987; El-Bohy *et al*., 1988; Grönblad *et al*., 1991b; Ashton *et al*., 1992; Beaman *et al*., 1993), the PLL (Korkala *et al*., 1985; Kumar *et al*., 1996) and the intervertebral disc (Konttinen *et al*., 1990; Coppes *et al*., 1990, 1997; Ahmed *et al*., 1991, 1993b; Ashton *et al*., 1994). Other markers have also been applied in identifying functional types of nerves, e.g. calcitonin gene-related peptide (CGRP)-IR nerve fibres have been found in the PLL (Korkala *et al*., 1985; Imai *et al*., 1995; Kumar *et al*., 1996), spinal dura (Segikuchi *et al*., 1996; Kumar *et al*., 1996) and intervertebral discs (Konttinen *et al*., 1990; Ahmed *et al*., 1991; Ashton *et al*., 1994), whilst vasoactive-intestinal polypeptide (VIP)-IR nerve fibres have been identified in bone marrow, periosteum, spinal dura and intervertebral discs (Konttinen *et al*., 1990; Ahmed *et al*., 1993b), and tyrosine hydroxylase (TH)-IR nerve fibres in blood vessel walls in bone periosteum, discs, spinal dura, spinal ligaments (Ahmed *et al*., 1993b), and also in the PLL as vessel-independent nerve fibres (Imai *et al*., 1995, 1997; Nakamura *et al*., 1996).

The innervation of the spine is complex. To build a complete picture of all connections, not only regional studies (most of which have been performed in the lumbar region) but also macroscopic and microscopic findings should be amalgamated. Much work has been done by dissection, with or without the aid of an operating microscope, intravital methylene blue, myeline (Stilwell, 1956; Hirsch *et al*., 1963) or silver staining (Pedersen *et al*., 1956; Grönblad *et al*., 1991b). However, none of these techniques may provide full evidence, as not all nervous tissue is stained exclusively. These objections can be overcome by applying a general neural marker staining method, such as whole-mount enzymehistochemistry for acetylcholinesterase (AChE) (Jackson *et al*., 1966; Baljet and Drukker, 1975; Baker *et al*., 1986; Tago *et al*., 1986; Groen, 1986; Kojima *et al*., 1990a, 1990b; Bleys *et al*., 1994, 1996a) or immunohistochemical detection of the protein gene product (PGP) 9.5 (Thompson *et al*., 1983; Bleys *et al*., 1996b). Particularly when the specimens are relatively small, as in experimental animals or human foetuses, unique overall views can be obtained from the origin of nerve fibres up to their plexiform ending in target organs (Groen, 1986; Groen *et al*., 1990; Kojima *et al*., 1990a, 1990b). It should be emphasized that AChE activity is *not* an indication for a cholinergic nature of neurons; noradrenergic nervous elements, for example, are also stained. Consequently, somato-efferent, pre- and postganglionic sympathetic and somato- and viscero-afferent nerve fibres are made visible.

As the pattern of connections within the peripheral autonomic nervous system does not change significantly between the foetal period and the adult stage (Kuntz, 1953; Pick, 1970), and many findings in the adult coincide with those obtained in human foetuses (Pedersen *et al*., 1956; Jackson *et al*., 1966; Groen *et al*., 1987), a comparison between the foetal and adult stage in this respect is valid. Thus basic connectivity of neural patterns is more or less determined early in life, although relative dimensions will be altered in ageing.

Considering an anatomical classification system for spinal pain, Steindler and Luck (1938) and, more recently, Bogduk (1983) distinguish between ventral and dorsal compartments, which are divided by a virtual frontal plane through the dorsal wall of the intervertebral foramen. The ventral compartment contains the vertebral bodies, discs, ALL and PLL, ventral dura and prevertebral muscles; in the thoracic area, the costovertebral joints; and in the cervical area, the uncovertebral joints (Groen, 1991). The dorsal compartment contains the zygapophysial joints, the dorsal part of the dura and intrinsic back muscles and ligaments, and, in the thoracic area, the costotransverse joints as well. This anatomical classification may seem somewhat artificial, but the major differences are due to the source of innervation. Ventral compartment structures are directly supplied by nerve fibres topographically and functionally related to the sympathetic trunk and rami communicantes from both sides, whilst dorsal compartment structures are supplied via ipsilateral dorsal rami of the spinal nerves. The only dorsal compartment structure that does not seem to fit into this scheme is the dorsal spinal dura, since it is supplied via the ventral spinal dura and has a bilateral nerve supply. Furthermore, the extent of overlap of innervation is different; ventral compartment structures may be bisegmentally or multisegmentally innervated, whilst dorsal compartment structures are bisegmentally or monosegmentally innervated. This has implications for referral pain patterns. Moreover, they differ in therapeutic approach (see Chapter 13).

Innervation of the ventral compartment

Costovertebral joints

Medio-ventral to the thoracic sympathetic trunks, regularly built networks of interlacing bundles of nerve fibres are found in the capsules and radiate ligaments of the costovertebral joints. Contributions to these costovertebral joint nerve plexuses are derived directly from small branches of the sympathetic trunks, and from paravascular nerves and perivascular nerve plexuses of intercostal arteries (Groen *et al.*, 1987) (Fig. 8.3). The costovertebral joint nerve plexuses are continuous with the nerve plexus of the ALL and are easily differentiated from it, as the prevertebral ligamentous nerve plexus is predominantly longitudinally orientated. These observations coincide with the findings in the monkey (Stilwell, 1956), where the existence of a paravertebral autonomic nerve plexus is formed by communications between the spinal and sympathetic trunk ganglia, with branches to adjacent spinal structures.

The contributions to the costovertebral joint nerve plexuses originate in adjacent parts of the sympathetic trunk in a regular segmentally organized manner, generally from the neighbouring sympathetic segment and the segment cranial to it (Stilwell, 1956; Larnicol *et al.*, 1982; Groen *et al.*, 1987). Thus it seems that the costovertebral joint nerve plexus is always supplied by at least two segmental levels, and that there is overlap in innervation. This is not surprising, in analogy to the dermatomal pattern characterized by overlap of neighbouring dermatomes. A similar bisegmental pattern is also found in the zygapophysial joint innervation, derived from the

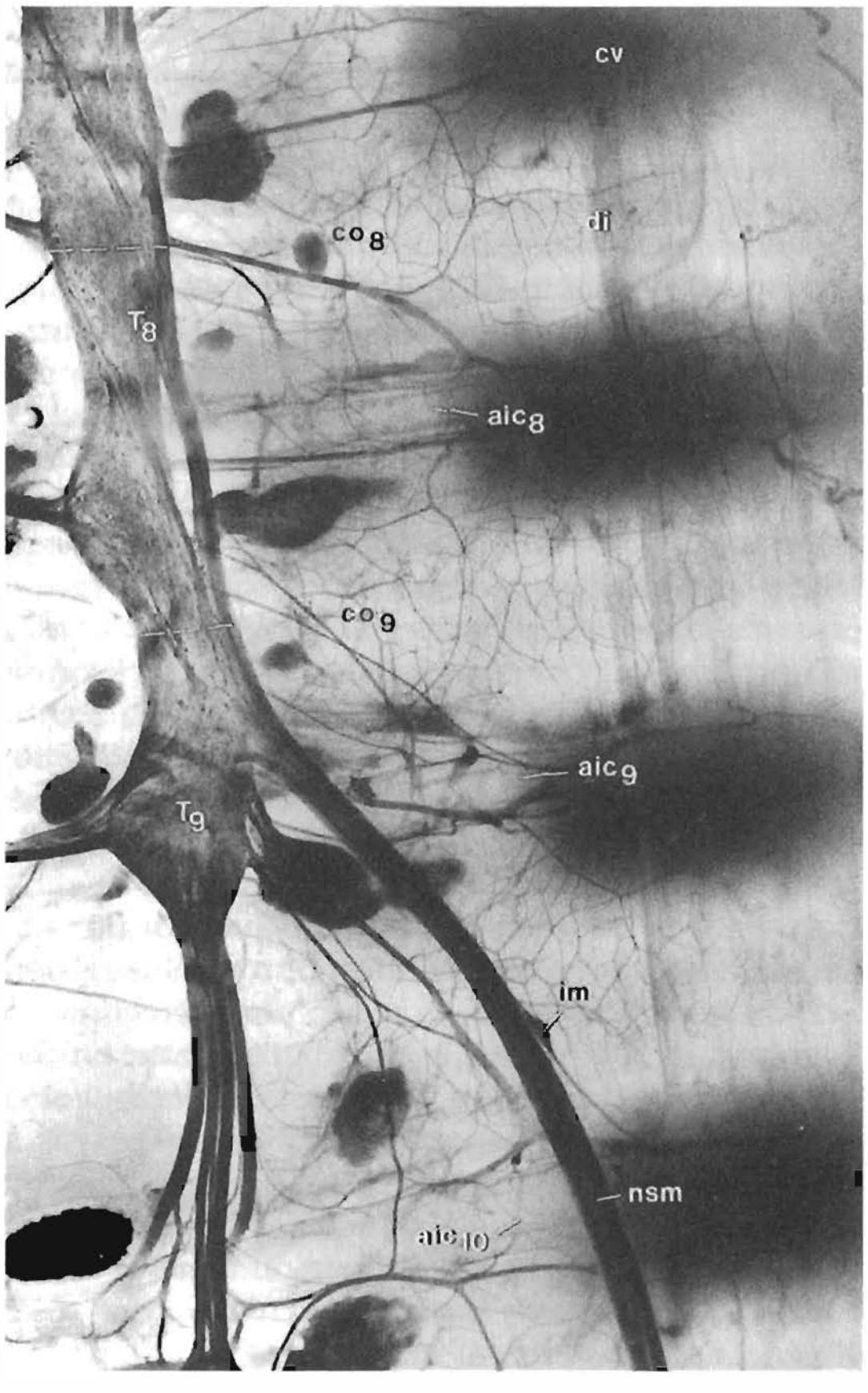

Fig. 8.3 Ventro-lateral view of right mid-thoracic sympathetic trunk. Costovertebral joint nerve plexuses, e.g. visible at location marked co_8, co_9 (head of rib 8, 9), are formed by direct branches of various calibre from the sympathetic trunk, with connections to perivascular nerve plexuses of intercostal arteries. The nerve plexus is continuous with nerves in the ALL (vertical shadow at the right side of the figure). Abbreviations: aic_{10}, 10th intercostal artery; cv, vertebral body; di, intervertebral disc; im, intermediate ganglion; nsm, major splanchnic nerve; T_8,T_9, sympathetic segment related to spinal cord segment T8-T9 (see Groen *et al.* 1987). Human foetus, 22 weeks, AChE whole mount staining (×15).

adjacent segment and the one cranial to it (Pedersen *et al.*, 1956; Stilwell, 1956; Lewin *et al.*, 1962; Bogduk, 1982; Bogduk *et al.*, 1982; Auteroche, 1983; Stolker *et al.*, 1994c; Chua and Bogduk, 1995).

Although in early human foetal material encapsulated and complex non-encapsulated endings have not yet developed, as they appear after the sixth or seventh month of development (Malinsky, 1959), type I and type II mechanoceptors and type IV nociceptor endings have been found (Vrettos and Wyke, 1974; Wyke, 1975) in the capsule of costovertebral joints in the cat. Electrophysiological experiments suggest that afferent discharges from these mechanoceptors contribute to a reflex regulation of postural and respiratory muscle activity of paraspinal and intercostal muscles (Vrettos and Wyke, 1974; Wyke, 1975). This would mean that the sympathetic trunk, in this respect, would serve as a pathway for somato-sensory nerve fibres. However, since small to minute ganglia in the costovertebral joint nerve plexuses have been described (Groen *et al.*, 1987), and recent reports have appeared on the sympathetic capsular nerve supply of other joints (Ashton *et al.*, 1992), this does not exclude an efferent sympathetic mechanism.

Despite the distinct supply of costovertebral joints described above, these joints are seldom reported as a source of thoracic pain (Pascual *et al.*, 1992).

Anterior longitudinal ligament

Throughout the entire spine, vertebral bodies and intervertebral discs are surrounded by a continuous network of interlacing nerve fibres (Groen *et al.*, 1990). Ventrally this network comprises the nerve plexus of the ALL, present from the cervical to the lumbar level, and dorsally it comprises the nerve plexus of the PLL, continuous from the cervical to the lumbosacral region. At the level of the intervertebral foramina, the anterior and posterior nerve plexuses are connected to each other by medio-ventral and medio-dorsal branches of rami communicantes, which corroborates the findings of Stilwell (1956) in the monkey. Thus the lateral border of the intervertebral disc is supplied by nerve fibres originating from the plexiform arrangement of branches from rami communicantes just ventral to the spinal nerve (Figs 8.4 and 8.5). However, according to Taylor and Twomey (1979) and Bogduk *et al.* (1981), the lateral region of (lumbar) intervertebral discs is innervated



Fig. 8.4 Cranio-dorsal view of the 9th thoracic vertebral body (cvT$_9$), after removal of the vertebral arches by cutting the pedicle. Out of a ramus communicans branches arise, e.g. directed to the PLL nerve plexus as sinuvertebral nerves (arrows) and to the radicular branch of an intercostal artery (open arrows). Abbreviations: drg, dorsal root ganglion; pll, PLL nerve plexus; rc, ramus communicans; tsg, sympathetic trunk ganglion. Human foetus, 16 weeks, AChE whole mount staining (×9.5). From Groen *et al.* (1990), with permission.

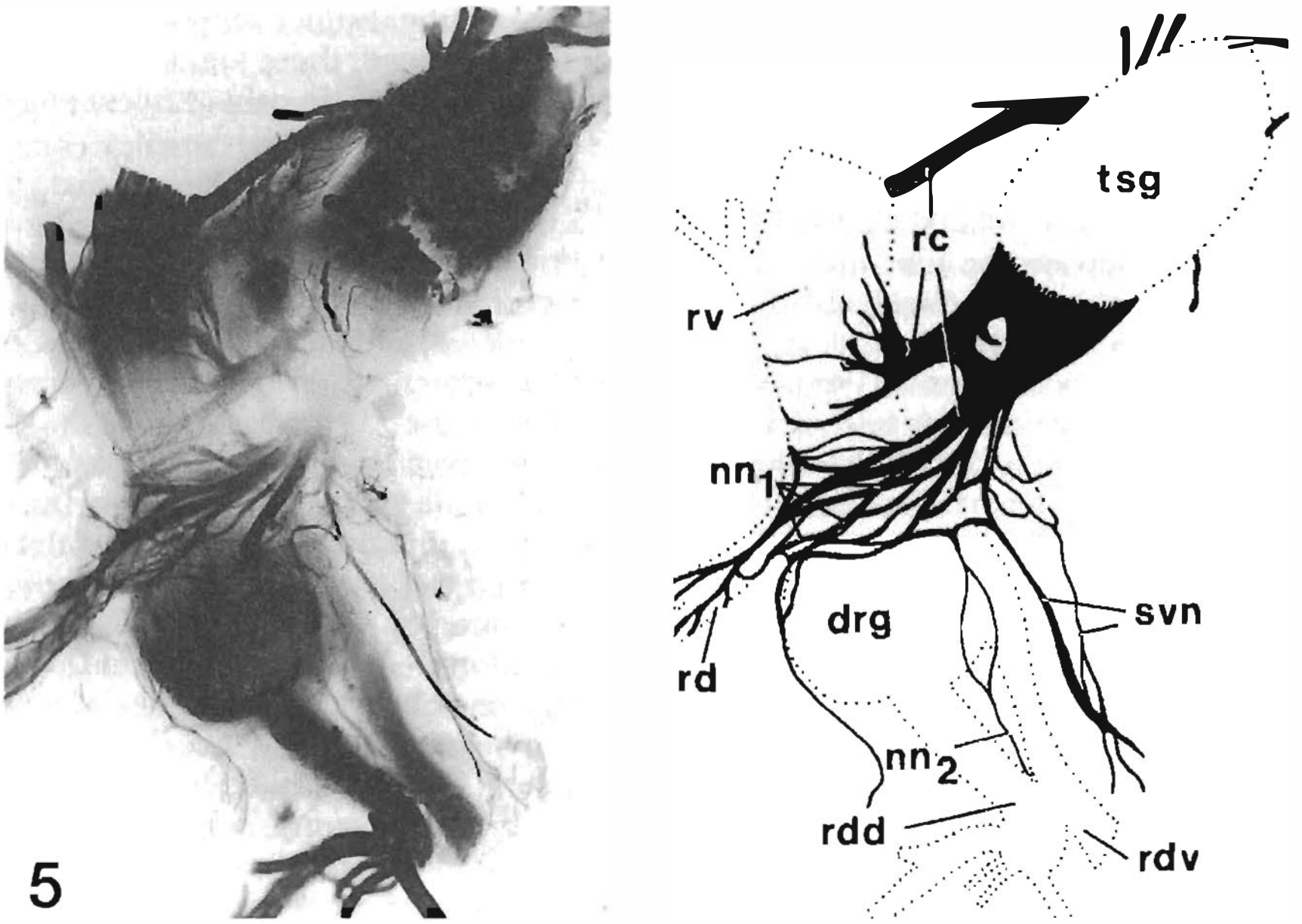

Fig. 8.5 Cranial view of the plexiform arrangement of branches of rami communicantes, at the level of the 2nd thoracic spinal nerve, showing a sympathetic trunk ganglion, the dorsal root ganglion with the dorsal and ventral roots, and the ventral and dorsal ramus of the spinal nerve. The medial ramus communicans gives off branches, which bypass the spinal nerve and dorsal root ganglion and join the dorsal ramus of the spinal nerve and separate branches, i.e. sinuvertebral nerves, to the PLL. Abbreviations: drg, dorsal root ganglion; rc, rami communicantes; rd, dorsal ramus of the spinal nerve; rdd, dorsal root; rdv, ventral root; nn_1, dorsal ramus of the spinal nerve; svn, sinuvertebral nerves; tsg, sympathetic trunk ganglion; rv, ventral ramus of the spinal nerve. Human foetus, 16 weeks, AChE whole mount staining (×25). From Groen *et al.* (1990), with permission.

by direct short branches arising from the ventral rami of lumbar spinal nerves.

At the thoracic level the ALL nerve plexus receives bilateral contributions from medio-ventral small branches of the sympathetic trunk, anterior branches of rami communicantes and perivascular nerve plexuses of intercostal arteries (Figs 8.6 and 8.7). The former two sources are consistent with the data obtained by Stilwell (1956) in the monkey and Bogduk *et al.* (1981) in the lumbar region in humans. Branches of the nerve plexuses of the costovertebral joints run transversely and obliquely towards the nerve plexus of the ALL overlying the two adjacent vertebral bodies and vanish into this nerve plexus (Figs 8.6 and 8.7) (Groen *et al.*, 1987). Further contributions, although relatively rare, derive from interconnections between the left and right thoracic sympathetic trunks (Groen *et al.*, 1990).

The ALL is densely innervated throughout its entire length. The bundles of nerve fibres in the ligament are connected to each other and form a regularly arranged longitudinal nerve plexus (Figs 8.6 and 8.7), which is consistent with the findings of Stilwell (1956) in the monkey and Jackson *et al.* (1966) in the lumbar region in humans. This arrangement is more evident at the level of the intervertebral discs than at the level of the vertebral bodies, where many transverse connections give the plexus a denser configuration (Fig. 8.7). Bundles of fibres entering the nerve plexus at the level of the vertebral body dichotomize repeatedly. Transverse nerve fibres are continuous with similar bundles from the contralateral side, whilst ascending and descending nerve fibres continue into similar bundles from the adjacent levels above and below the level of entry (Figs 8.6 and 8.7). Further branches from the ALL nerve plexus penetrate the vertebral bodies along radially arranged blood vessels and are given off towards the outer zone of the anulus fibrosus (Ferlic, 1963; Rabischong *et al.*, 1978; Yoshizawa *et al.*, 1980; Lang, 1985; Windsor *et al.*, 1985; Groen *et al.*, 1990).

Thus the ALL nerve plexus overlying one vertebral body is formed by branches from both sympathetic trunks, mainly originating from the neighbouring thoracic sympathetic trunk segment, and from branches of the costovertebral joint nerve plexuses arising from the sub- and superior sympathetic trunk segments (Groen *et al.*, 1987). The ALL nerve plexus at the level of the intervertebral disc is supplied by the two adjacent thoracic sympathetic trunk segments, the costovertebral joint nerve plexus and, partly, from

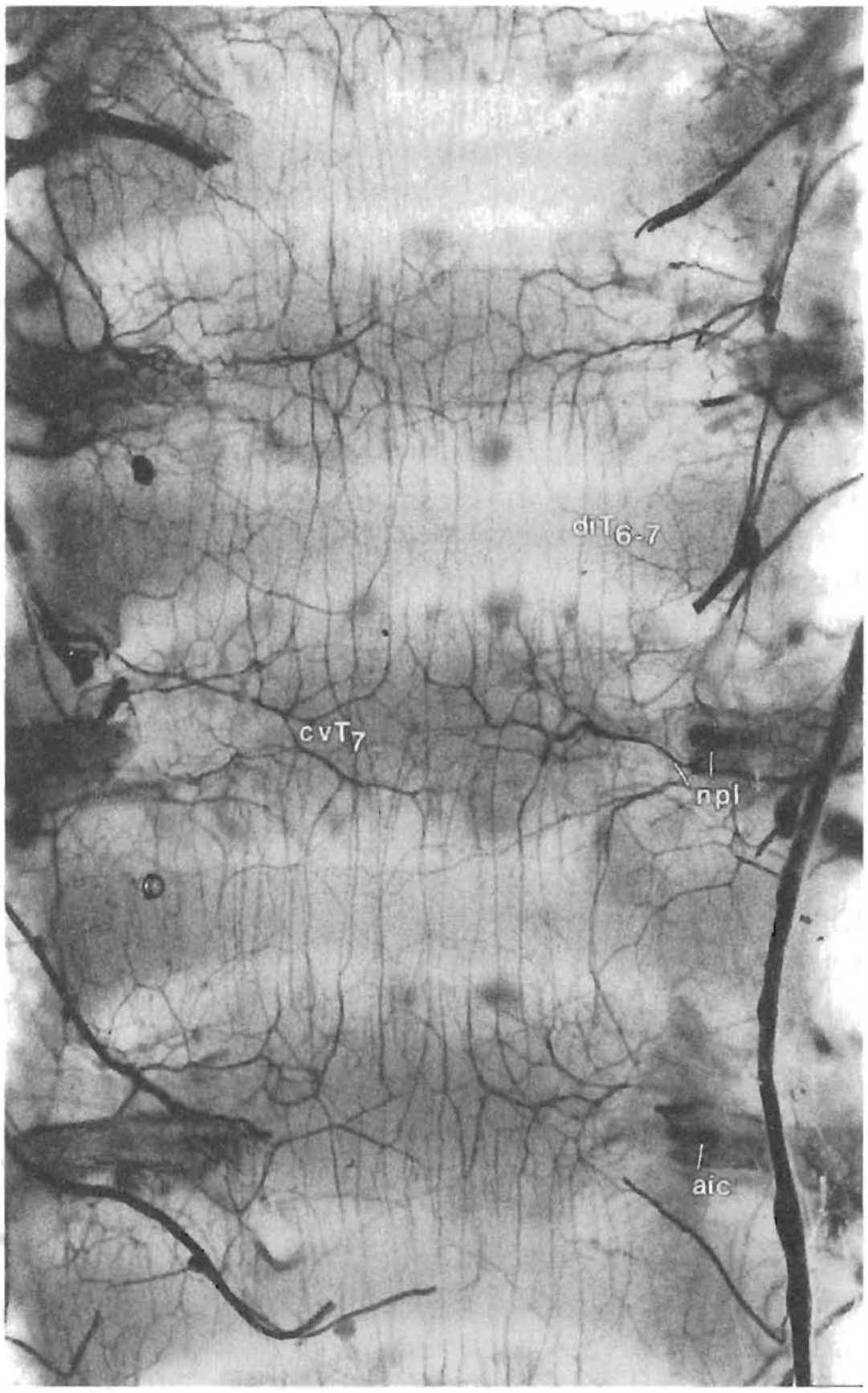

Fig. 8.6 Detailed ventral view of the mid-thoracic (T_{6-8}) ALL nerve plexus. At the level of the vertebral body, indicated by a dark area with a clear cranial and caudal border zone, bundles of nerve fibres derived from the sympathetic trunks (not visible) and perivascular nerve plexuses run medially and divide in ascending, descending and transverse branches. Further branches run longitudinally and continue into similar branches of adjacent lower and upper levels, in front of the intervertebral discs (indicated by a grey zone). Abbreviations: aic, intercostal artery; cvT_7, T7 vertebral body; diT_{6-7}, T6-T7 intervertebral disc; npl, perivascular nerve plexuses. Human foetus, 16 weeks, AChE whole mount staining (×24).

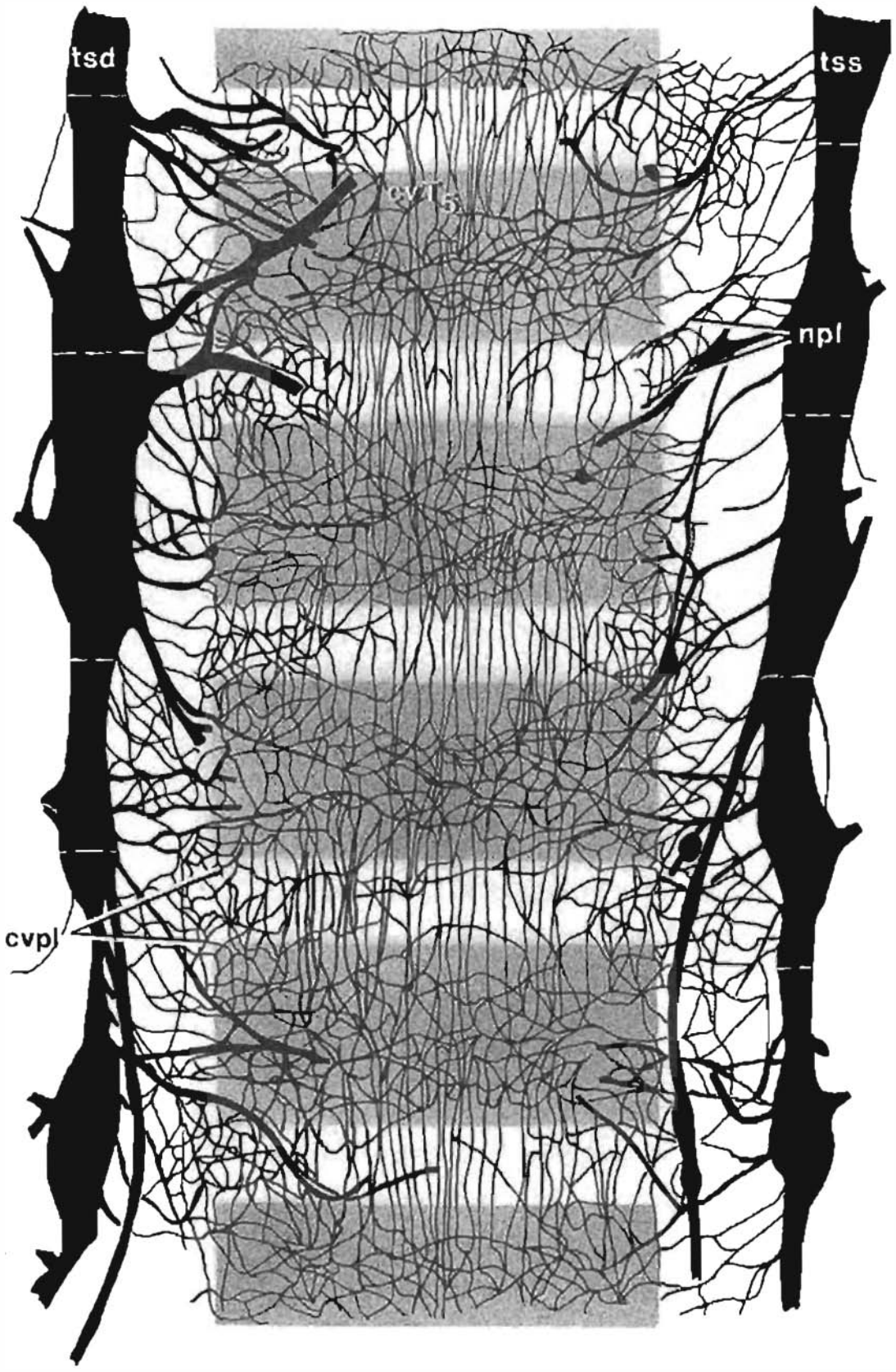

Fig. 8.7 Tracing of the mid-thoracic (T_{5-8}) ALL nerve plexus with the left and right sympathetic trunks. The nerve plexus receives, mainly at the level of the vertebral bodies, contributions from the sympathetic trunks, perivascular nerve plexuses and costovertebral joint nerve plexuses. The grey blocks indicate the position of the vertebral bodies. The white lines in the sympathetic trunks indicate the thoracic sympathetic segments (see Groen *et al.*, 1987). Abbreviations: cvT_5, T5 vertebral body; cvpl, costovertebral joint nerve plexuses; npl, perivascular nerve plexuses; tsd, right sympathetic trunks; tss, left sympathetic trunks. From Groen *et al.* (1990), with permission.

the nerve plexus overlying the adjacent vertebral bodies (Groen *et al.*, 1990). This segmental overlap corresponds with the observations in animals (Stilwell, 1956; Forsythe and Ghoshal, 1984) and in humans (Cloward, 1960; Edgar and Ghadially, 1976; Bogduk *et al.*, 1981), and has implications for referral pain patterns related to the ALL (see below).

Recent retrograde tracer studies performed in rats, on the anterior part of lumbar intervertebral discs (Morinaga *et al.*, 1996), also support a multisegmental innervation, in which the already described ventral 'sympathetic' ALL nerve plexus conceivably could be the neural pathway. However, in their study of a considerable number of animals DRGs showed no staining of transported tracer and, especially at the level of the injected intervertebral disc, the adjacent DRGs remained negative (Morinaga *et al.*, 1996). Although this could be related to technical errors, not unusual in tracer studies, another explanation could be that organization of lumbar anterior disc innervation is different from that on other levels. Furthermore, it is not clear from their report if the ALL innervation was investigated as well. Local labelling of neurons in the sympathetic trunk as found in our preliminary tracer study (Groen *et al.*, 1990) was not described, but may have divulged additional explanatory information. In a second study by this group, the importance of the presence of referred pain in dermatomal areas other than those related to the causative disc was emphasized (Takahashi *et al.*, 1996). Whilst this could explain why patients with a degenerative disc in the lower lumbar segments occasionally complain of groin pain (L1–L2 dermatome), it is tempting to say that the described hypothetical neural mechanisms (Takahashi *et al.*, 1996) may not be restricted to the lower lumbar area, since there are no major differences in organization patterns between the cervical, thoracic and lumbar areas (Groen *et al.*, 1990).

Origin and extensions of sinuvertebral nerves

In the following survey it will become clear that the remainder of the ventral compartment is supplied by nerve fibres related to the junction of the sympathetic trunk and spinal nerves, i.e. the rami communicantes, and that the dorsal compartment nerves partly originate in these rami. Since the rami communicantes and spinal nerve are connected in a plexiform manner, it is obvious that branches originating in this meshwork may seem to originate in the spinal nerve and/or rami communicantes. Those branches that re-enter the intervertebral foramina towards structures inside the spinal canal, such as the PLL and spinal dura, are generally known as the recurrent meningeal or sinuvertebral nerves (Von Luschka, 1850). Ever since they were first described (Von Luschka, 1850) there has been much debate about their origin; is it in the sympathetic trunk and/or in the spinal nerve? The sinuvertebral nerves have been reported to originate from both the spinal nerve and the sympathetic trunk or its rami communicantes (Von Luschka, 1850; Hovelacque, 1925; Kaplan, 1947; Wiberg, 1949; Pedersen *et al.*, 1956; Stilwell, 1956; Cloward, 1960; Murphey, 1968; Bogduk *et al.*, 1981), or to originate exclusively from the spinal nerve (Spurling and Bradford, 1939; Roofe, 1940; Bridge, 1959; Wyke, 1970, 1987; Brown, 1977). Pedersen *et al.* (1956), in the lumbosacral region, described that in only a few cases do the sinuvertebral nerves arise from rami communicantes, while Bridge (1959), in the thoracolumbar region, has observed many sympathetic fibres passing through the intervertebral foramina independently of the sinuvertebral nerve. According to Wiberg (1949) and Pedersen *et al.* (1956) a sympathetic contribution is not always present in the lumbosacral region, while Kimmel (1961) describes a sympathetic and spinal nerve contribution only after the stage of 47 mm (9 weeks), with an exclusively sympathetic contribution prior to this stage. Groen and colleagues' work has revealed that a maximum of five (at least one large and several small) sinuvertebral nerves in one intervertebral foramen originate from one, sometimes two, rami communicantes close to the connection with the spinal nerve, just distal to the DRG and directly ventral to it (Figs 8.4 and 8.5) (Groen *et al.*, 1990).

In the current authors' opinion, the above-mentioned differences in findings are caused by differences in methodology – i.e. mainly gross dissection without a specific nerve stain and reconstructions based upon microscopic sections by which plexiform arrangements of small bundles of nerve fibres are difficult to recover (Wiberg, 1949; Stilwell, 1956; Bogduk *et al.*, 1981). Moreover, in gross dissection the complicated origin of the sinuvertebral nerves hinders the establishment of the identity of these nerves (Stilwell, 1956). Also, the origin of the sinuvertebral nerves in the rami communicantes, close to the spinal nerve, interferes with a reliable identification in gross dissection. In many dissections, after removal of the dorsal part of the vertebral column and its contents the dorsal and spinal roots are retracted postero-laterally in order to expose their anterior aspects (Von Luschka, 1850; Wiberg, 1949; Pedersen *et al.*, 1956). Consequently, the sinuvertebral nerves seem to continue into the spinal nerve, which gives the impression that the spinal nerve is the origin of these nerves.

It is time to end this debate. In view of the knowledge now obtained about the type of nerve fibres found in the PLL and spinal dura, the debate seems only to be a semantic, academic discussion. Sinuvertebral nerves do contain postganglionic sympathetic as well as somato- and viscero-sensory nerve fibres that follow sympathetic pathways (Imai *et al.*, 1997). Only in denervation studies (Nakamura *et al.*, 1996) is it important to know the exact location of the denervation.

At the same location at which the sinuvertebral nerves originate, the rami communicantes give off branches to the dorsal ramus of the spinal nerve (Figs 8.4, 8.5). The latter fibres pass the spinal nerve and the DRG both cranially and caudally. Some of these plexiform bundles of nerve fibres accompany the sinuvertebral nerves for a short distance and then turn dorsally towards the dorsal ramus of the spinal nerve (Fig. 8.5). This corroborates the findings of Stilwell (1956) in the monkey, and Dass (1952) and Kikkawa *et al.* (1978) in humans. Finally, further branches are given off towards the radicular branch of an intercostal artery (Figs 8.4, 8.5), important for intraradicular blood flow (Parke and Watanabe, 1985; Yabuki and Kikuchi, 1995).

Although only one sinuvertebral nerve at each intervertebral foramen is described in many reports (Von Luschka, 1850; Hovelacque, 1925; Spurling and Bradford, 1939; Roofe, 1940; Lazorthes *et al.*, 1947; Wyke, 1970, 1987; Bogduk *et al.*, 1981), it is now well proven that there is more than one nerve at each level, varying from 'several' (Pedersen *et al.*, 1956), 'minimally two' (Stilwell, 1956), 'two to four' (Kimmel, 1961) and 'up to six' (Edgar and Nundy, 1966) to 'one or two large and one to four small' (Groen *et al.*, 1990). The sinuvertebral nerves are said to be absent in other mammals, such as the dog and cat, according to Forsythe and Ghoshal (1984). However, as they used gross dissection and since observations in other mammals such as the rat, by means of the AChE whole mount staining (Kojima *et al.*, 1990a, 1990b), clearly showed the presence of these nerves, the assumption of Forsythe and Ghoshal (1984) should be abandoned.

What is the destination of the sinuvertebral nerves? It is well established that the sinuvertebral nerves ramify and form a nerve plexus in the PLL and contribute to a nerve plexus in the ventral spinal dura (Pedersen *et al.*, 1956; Hirsch *et al.*, 1963; Edgar and Ghadially, 1976; Groen *et al.*, 1990). However, descriptions of branching patterns and segmental extensions - important for referral pain patterns - vary. As the larger sinuvertebral nerves run parallel to the ventral rami of the spinal branches of the segmental arteries, which are directed towards the ossification centres of the vertebral bodies, many have an ascending and/or descending direction (Fig. 8.8) and thus are connected with corresponding nerves from the neighbouring segments (Groen *et al.*, 1990). Sinuvertebral nerves may also bifurcate or run transversely towards the other side (Figs 8.8, 8.9). In many reports, generally on the lumbar region, preferential branching patterns or regional patterns have been described (Von Luschka, 1850; Spurling and Bradford, 1939; Roofe, 1940; Lazorthes *et al.*, 1947; Wiberg, 1949; Pedersen *et al.*, 1956; Stilwell, 1956; Bridge, 1959; Cloward, 1960; Kimmel, 1961; Edgar and Nundy, 1966; Wyke, 1970, 1987; Brown, 1977; Bogduk *et al.*, 1981).

Although many of the observations may seem to be contradictory, differences appear to be related to inter- and intra-individual variability. In the study by Groen and colleagues (1990), all types of branches of sinuvertebral nerves were found: short and long ascending, short and long descending, bifurcating and transverse or oblique crossing branches, including some intermediate forms. The larger sinuvertebral nerves generally show a short ascending or descending course to the respective superior level, or a bifurcation into an ascending and descending nerve to the next adjacent level. Some sinuvertebral nerves may be even longer and reach the next level above (Groen *et al.*, 1990), with consequent implications for segmental innervation patterns (see below).

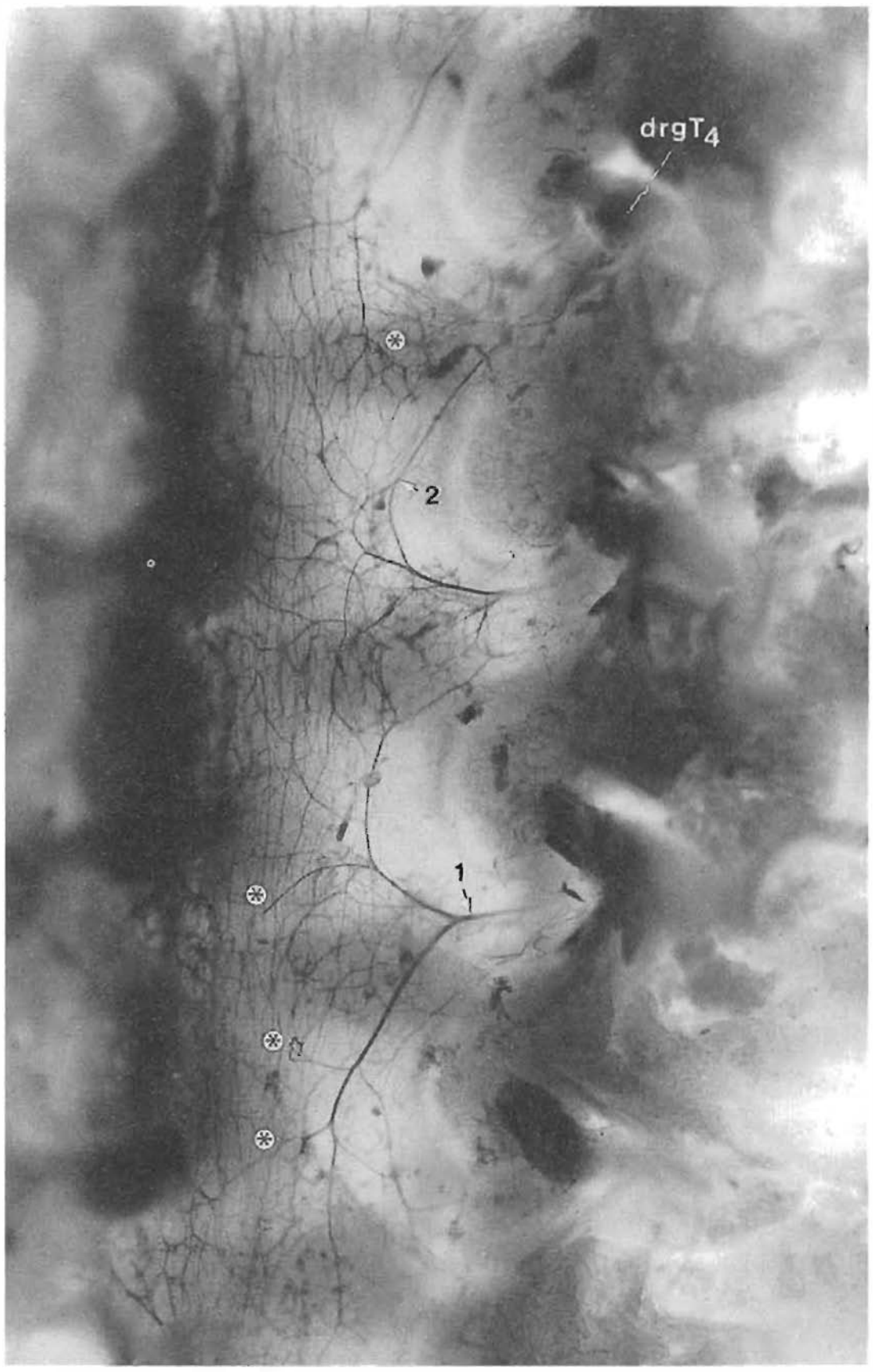

Fig. 8.8 Dorso-lateral view of the mid-thoracic (T_{4-7}) PLL nerve plexus after removal of the pedicles and the spinal cord. The ventral spinal dura was removed by cutting its contributing nerves (*). Large and small sinuvertebral nerves enter the PLL nerve plexus. A bifurcating large sinuvertebral nerve (1) is shown, as well as an ascending sinuvertebral nerve at the level of T_5 which continues into a large descending sinuvertebral nerve from T_4 (2). Abbreviation: drgT_4, dorsal root ganglion. Human foetus, 22 weeks, AChE whole mount staining (×12).

Posterior longitudinal ligament

In the intervertebral foramen the larger sinuvertebral nerves, with some parallel branches, pass the DRG ventrally. After entering the vertebral canal, they ramify several times and give off branches that connect with similar branches from the other side and from adjacent levels above and below the level of entry of the sinuvertebral nerves (Fig. 8.8). The smaller sinuvertebral nerves ramify extensively into slender bundles of nerve fibres and do not have a preferential direction. Thus a PLL nerve plexus is formed parallel to the outlines of the PLL, which is more irregular than the ALL nerve plexus (Jackson *et al.*, 1966; Groen *et al.*, 1990; Kojima *et al.*, 1990a,

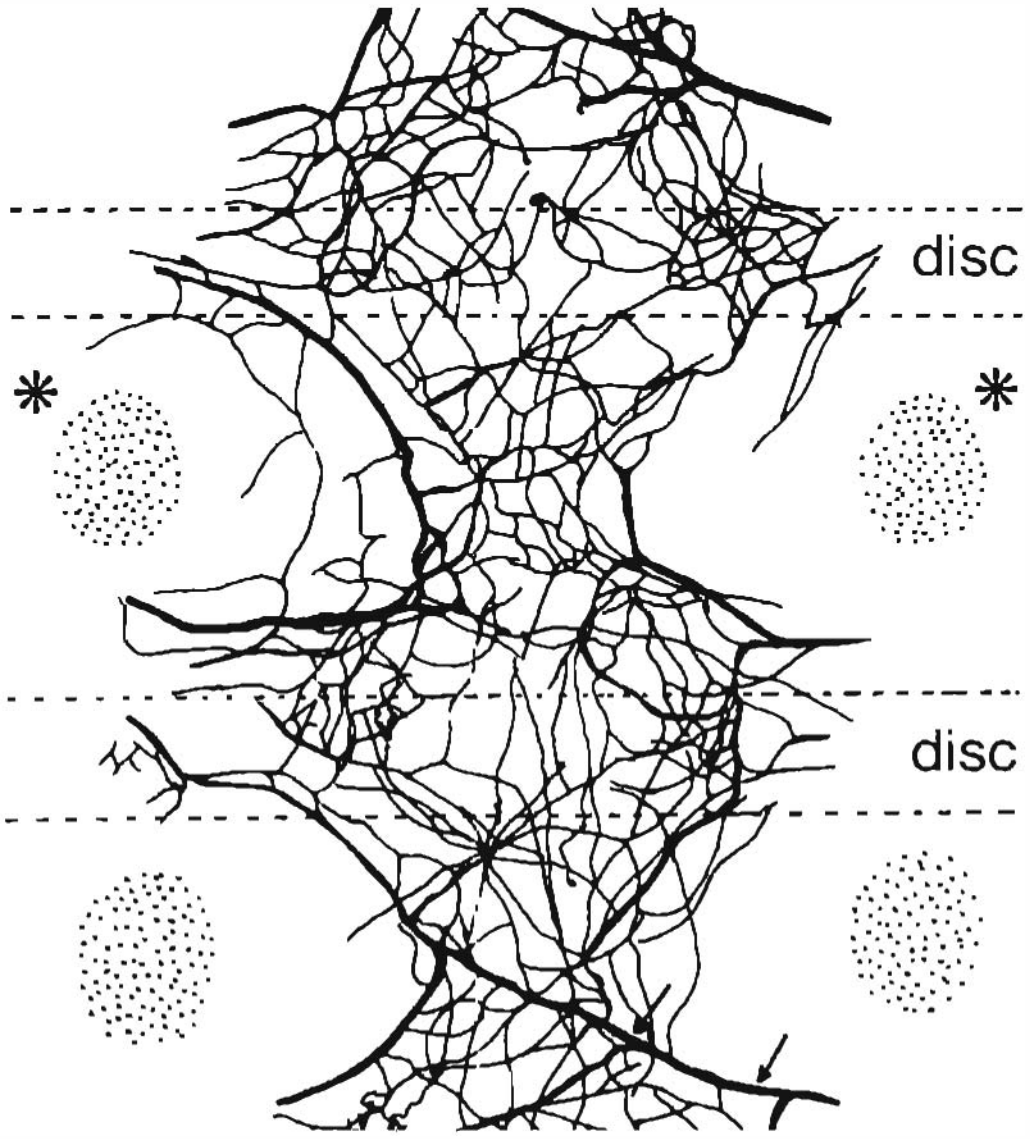

Fig. 8.9 Tracing of the PLL nerve plexus showing large and small sinuvertebral nerves entering the vertebral canal at the level of the intervertebral discs (indicated by broken lines). The PLL nerve plexus has a more irregular arrangement compared to the ALL nerve plexus. One large sinuvertebral nerve (arrows) crosses obliquely to the other side. The cut pedicles of the vertebral arches are indicated by asterisks.

1990b; Imai *et al.*, 1995; Nakamura *et al.*, 1996). The nerve plexus is wider at the level of the intervertebral discs (Fig. 8.9) than at the level of the vertebral body. It has been stated that the PLL has a rich nerve supply in comparison to the less developed innervation of the ALL (Grönblad *et al.*, 1991a); however, Groen and colleagues' findings indicate that there is no major difference in innervation density between the ALL and PLL (Groen *et al.*, 1990), although only computerized, quantitative analysis can provide a definitive answer (Bleys *et al.*, 1996a).

Immunohistochemical studies in the rat lumbar PLL have revealed a superficial, bundled network with larger and small nerve fibres extending upward and downward in the PLL, and a deeper, dispersing network consisting of thin varicose nerve fibres confined to the intervertebral region (Kojima *et al.*, 1990a, 1990b; Imai *et al.*, 1995, 1997). It was reported that, at least in the rat, the deeper network is mainly formed by nerve fibres which enter the spinal canal independently from the sinuvertebral nerves (Imai *et al.*, 1995). These nerve fibres probably correspond with the smaller sinuvertebral nerves as described earlier in human foetuses (Groen *et al.*, 1990).

In their elegant AChE study of rats, Nakamura *et al.* (1996) provided evidence for bilateral and multisegmentally organized innervation of the posterior portion of lumbar intervertebral discs and PLL. They found a profound degeneration of nerve plexuses in the dorsal aspect of lumbar intervertebral discs and PLL, following bilateral resection of the adjacent sympathetic trunks. Although their work was performed in rats, and they did not provide insight into the origin of rats' sinuvertebral nerves, they support the idea that disc and PLL innervating nerve fibres bypass sympathetic pathways, as stated earlier (Groen *et al.*, 1990; Stolker *et al.*, 1994d). However, a direct interpretation of all their findings must be handled with care for, since they described 'a deep nerve network' related to the posterior intervertebral disc and 'a superficial network' related to the PLL, the deep network could still be related to the PLL, which is attached to the intervertebral disc precisely at this location (Prestar and Putz, 1982). Further observations of a deep nervous network in the PLL were described in the rat (Kojima *et al.*, 1990a, 1990b; Imai *et al.*, 1995, 1997) and the rabbit (Cavanaugh *et al.*, 1995). Moreover, after the sympathetic trunk resection, their figures still show the presence of larger ascending and descending nerve fibres parallel to the margins of the PLL, resembling the large sinuvertebral nerves described earlier (Groen *et al.*, 1990). Finally, their semi-quantitative measurements were only confined to the transverse nerve fibres in the deep network.

The findings by Cavanaugh *et al.* (1995) also fit well with the above-mentioned description of the PLL nerve plexuses in humans (Groen *et al.*, 1990). In their silver impregnation study in lumbar discs in the rabbit, an extensive distribution of fine nerve fibres (1–3 µm) and some encapsulated endings were found in the superficial parts of the anulus fibrosus and adjacent PLL attachments. At the regions where the ALL and PLL are in contact with the anulus fibrosus, a larger population of nerve fibres was observed. The PLL showed a dense superficial network of large, branching nerve bundles (4–8 µm in diameter), with small diameter (1–2 µm) nerve fibres in deeper layers of the ligament (Cavanaugh *et al.*, 1995).

The many cranio-caudal and transverse connections between the nerves, found at every level of the spine and not only the thoracic area (Groen *et al.*, 1990), provide an explanation for the observed pain patterns after mechanical stimulation of the PLL during operations under local anaesthesia (Wiberg, 1949; Cloward, 1960; Murphey, 1968) and for referred pain patterns seemingly outside the normal referral areas (Takahashi *et al.*, 1996). As stated by Edgar and Ghadially (1976), it is evident that this ligament might be responsible for much of what is called discogenic pain, since it is anatomically the first structure outside the anulus fibrosus impinged upon by a disc protrusion.

Many studies have identified nerve fibres in the outer zone of the anulus fibrosus (Pedersen *et al.*, 1956; Rabischong *et al.*, 1978; Yoshizawa *et al.*, 1980; Bogduk *et al.*, 1981; Windsor *et al.*, 1985; Konttinen *et al.*, 1990; Coppes *et al.*, 1990, 1997; Ahmed *et al.*, 1991, 1993b; Grönblad *et al.*, 1991a; Ashton *et al.*, 1994; Cavanaugh *et al.*, 1995; Nakamura *et al.*, 1996). A definite nociceptive role for these nerve fibres has been described as uncertain, as Korkala *et al.* (1985) could not find substance P-immunoreactivity in the intervertebral discs. More recently, at least in the lumbar spine, more indications for primary discogenic pain have been found (Konttinen *et al.*, 1990; Coppes *et al.*, 1990, 1997; Ashton *et al.*, 1994; Kaäpa *et al.*, 1994). In contrast, according to Cyriax (1945, 1978), the dura mater should be a more important structure in this respect, although this is questioned by Kumar *et al.* (1996), whilst Weinstein *et al.* (1988a, 1988b) and Grönblad *et al.* (1991a) emphasize the role of the DRG.

It can be concluded that, in the thoracic area – and other regions of the spine show the same pattern (Groen, 1986; Groen *et al.*, 1990) – the PLL receives a bilateral nerve supply with many craniocaudal connections. Consequently, in concordance with the findings of Stilwell (1956) in the monkey, the PLL nerve plexus overlying one vertebral body predominantly receives contributions from two spinal segments by the adjacent sinuvertebral nerves from both sides. In the case of a long ascending or descending sinuvertebral nerve, more spinal segments are involved, but never more than two cranial or two caudal to the level of entry. In general, the PLL nerve plexus overlying one intervertebral disc receives bilateral contributions from three spinal segments, via the neighbouring, superior and inferior sinuvertebral nerves. Again here, in the presence of a long ascending or descending sinuvertebral nerve, more spinal segments are involved (Groen *et al.*, 1990, 1991, 1992; Stolker *et al.*, 1994d). Furthermore, the current authors have not found a basis for Wyke's claim (1970) that intersegmental connections between the nerves supplying contiguous segments are absent in the thoracic region, since overlapping innervation areas were demonstrated at every level of the spine (Groen *et al.*, 1990). As has already been depicted by Stilwell (1956), such an overlap of innervation could conceivably play a part in the difficulty of accurate localization of pain arising from the PLL or caused by any structure that impinges upon the ligaments.

Finally, one to three branches arise from the primary branches of the larger sinuvertebral nerves and run dorsally towards the ventral spinal dura mater as spiralling nerves (Fig. 8.10). Another supply to the ventral spinal dura is provided by small spiralling nerves originating from the PLL nerve plexus (Fig. 8.10), which cross the epidural region in accordance with the results of Edgar and Ghadially (1976). The PLL nerve plexus gives off further branches to the blood vessels of the vertebral bodies, epidural blood vessels and the outer layers of the anulus fibrosus (Pedersen *et al.*, 1956; Stilwell, 1956; Groen *et al.*, 1990).

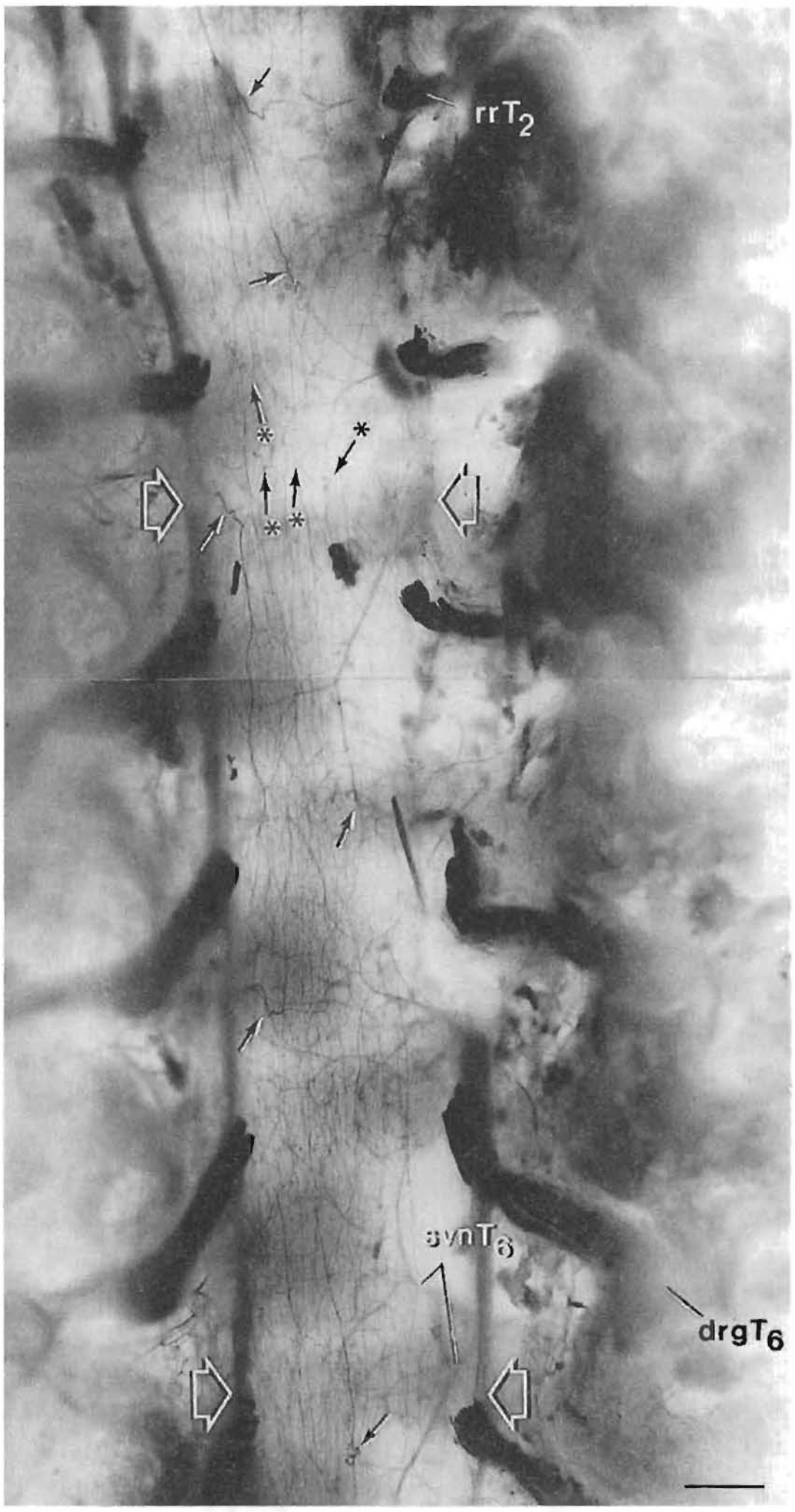

Fig. 8.10 Dorsal view of the upper thoracic (T_{2-7}) vertebral canal after complete laminectomy by cutting the pedicles of the vertebral arches and removal of the spinal cord by cutting the ventral and dorsal roots. The ventral spinal dura, of which the lateral, cut, margins are visible as dark lines (open arrows), shows a dense longitudinal nerve plexus in sharp focus. Its contributing nerves are derived from primary branches of sinuvertebral nerves, which lie deeper and somewhat out of focus, as dorsally directed spiralling nerves (arrows) and from the PLL nerve plexus itself (arrows plus asterisks). Abbreviations: drgT_6, dorsal root ganglion; rrT_2,ventral and dorsal roots; svnT_6, sinuvertebral nerves. Human foetus, 22 weeks, AChE whole mount staining (×9)

Spinal dura

It is generally agreed that the spinal dura is supplied by the sinuvertebral nerves or its primary branches and that this nerve supply is more or less confined to the ventral spinal dura (Hovelacque, 1925; Kaplan, 1947; Lazorthes *et al.*, 1947; Pedersen *et al.*, 1956; Stilwell, 1956; Kimmel, 1961; Edgar and Nundy, 1966; Edgar and Ghadially, 1976; Brown, 1977; Groen *et al.*, 1988; Segikuchi *et al.*, 1996). Dorsal recurrent nerves directed to the dorsal spinal dura were observed by Stilwell (1956) and Kimmel (1961) and were mentioned by Edgar and Ghadially (1976). However, in a study by Groen *et al.* (1988) these nerves could not be identified, although these structures could have been missed by the dissectional approach.

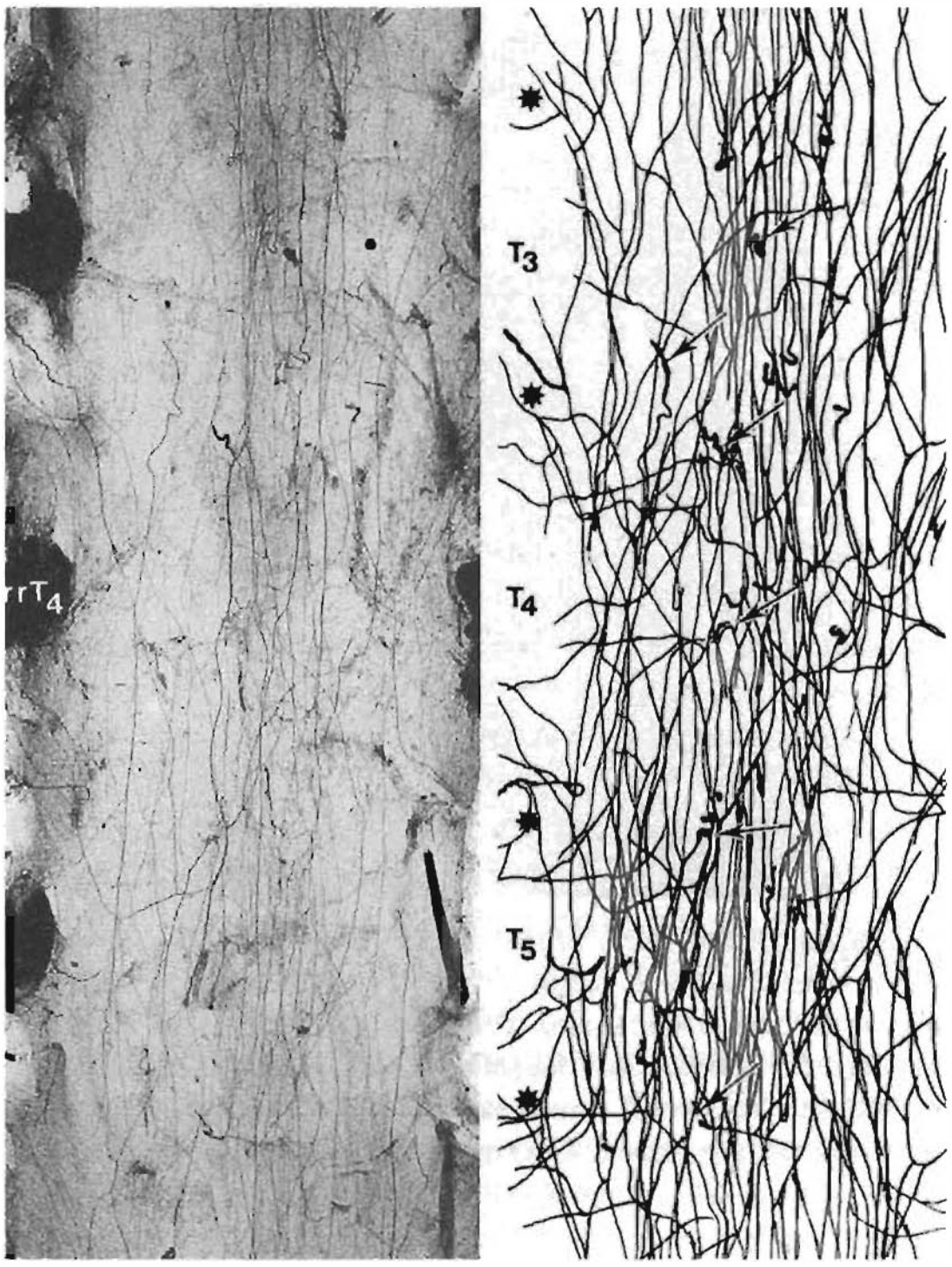

Fig. 8.11 Dorsal view of the upper thoracic (T_{2-6}) ventral spinal dura, with dural sleeves surrounding the roots (rr) of the spinal nerves. Spiralling nerves, which have been cut during the removal of the dura, are visible at all levels, indicating their connections with the sinuvertebral nerves and the PLL nerve plexus (arrows in right figure). The ventral spinal dura nerve plexus is primarily longitudinally arranged with many interconnections between the nerves. The nerves in the 'intersleeval' parts of the dura pass to the dorsal spinal dura. The right figure shows a tracing of this ventral spinal dura nerve plexus. The 'intersleeval' parts of the dura are indicated by asterisks. Human foetus, 22 weeks, AChE whole mount staining (×13).

Further input in the ventral dural nerve plexus comes from spiralling branches from the PLL nerve plexus (Edgar and Ghadially, 1976; Groen *et al.*, 1988, 1990) and by connections with the perivascular nerve plexus of radicular arteries at the dural sleeves (Fig. 8.13B). The spiralling appearance of the supplying nerves seems to provide an adequate adjustment for the well-known displacement of the spinal dura during flexion-extension movements (Lang, 1985; Tencer *et al.*, 1985). These nerves have also been observed in the adult spine (Groen, unpublished observation). The 'anterior dural ligaments', described by Lang (1985) and Tencer *et al.* (1985) as connections between the ventral spinal dura and the PLL, may serve as 'conductive' tissue for the supplying nerves.

In the ventral spinal dura the supplying nerves bifurcate in ascending and descending branches of various lengths (Figs 8.10, 8.11, 8.12), which ramify extensively in a mainly longitudinal direction, although transverse branches also exist (Groen *et al.*, 1988). The nerve fibres may run along dural blood vessels, but a large number run independently from blood vessels (Fig. 8.13A, C) with many interconnections in the dural nervous network. Connections with similar dural nerves are not restricted to the thoracic levels, but are present throughout the whole length of the dura (Groen *et al.*, 1988). This corresponds with the findings of Kimmel (1961), Edgar and Nundy (1966) and Jackson *et al.* (1966).

The dorsal spinal dura has a meagre nerve supply to the lateral quarters, whilst the medial half is devoid of nerves (Fig. 8.13D, E). This explains why no pain is elicited on piercing the dorsal medial spinal dura in procedures such as lumbar puncture (Cyriax, 1945, 1978). The dorsal dural nerves are derived from the ventral dural nerve plexus at the intersleeval parts, and do not form an evident nervous network (Fig. 8.13D). Furthermore, some branches supply the dural sleeves.

The dural nerves have been described as sensory (nociceptive) (Kimmel, 1961; Edgar and Nundy, 1966; Edgar and Ghadially, 1976; Wyke, 1987), which is consistent with both their small size and the presence of free nerve endings (Jackson *et al.*, 1966), and with the recent demonstration of substance P-immunoreactive fibres in the spinal dura (Edvinsson *et al.*, 1983; Segikuchi *et al.*, 1996). Another portion of the dural nerves is considered to be vasomotor (sympathetic) (Pedersen *et al.*, 1956; Stilwell *et al.*, 1956; Ahmed *et al.*, 1993b). However, a vasosensory role can not be excluded (Norregaard and Moskowitz, 1985; Groen *et al.*, 1988).

Thus, although Bridge (1959) was not able to detect any dural nerves in the spinal dura of the cat, dog and humans, it is an undeniable fact that the spinal dura is innervated in humans (Kimmel, 1961; Edgar and Nundy, 1966; Jackson *et al.*, 1966; Cuatico *et al.*, 1988; Groen *et al.*, 1988) (as represented in

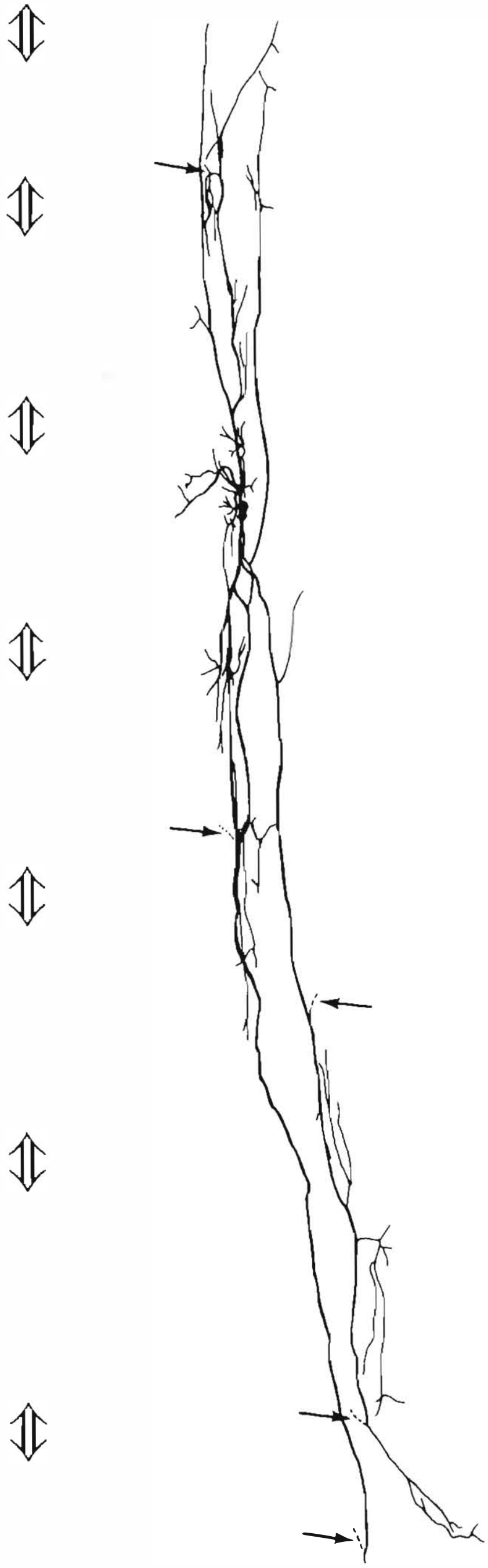

Fig. 8.12 Drawing of a major dural nerve showing its primarily cranio-caudal oriented branching pattern. The levels of the spinal roots as they pass the dural sleeves (open double arrows) are considered as segments. At various levels (indicated by broken lines, see arrows) connections with adjacent dural nerves exist. The cranial extension of this dural nerve reaches up to two and a half segments, the caudal extension up to four segments.

Fig. 8.13E) and in the rat (Ahmed *et al.*, 1993b; Segikuchi et al., 1996). Very recently, however, an intriguing study appeared in which, at least in the rat, the functional significance of spinal dural nerves in the pathogenesis of spinal pain was questioned (Kumar *et al.*, 1996). In primarily the ventral parts of the cervical and lumbar spinal dura in rats they found relatively few CGRP and SP-IR nerve fibres and mast cells (identified by serotonin), compared to a rich neural network and an abundant mast cell population in the cranial dura. However, a rich CGRP-positive network was identified in the PLL and the so-called 'peridural membrane'. Furthermore, in the spinal dura, nerve fibres associated with blood vessels were not observed. Their assumptions are based upon a supposed parallel in pathophysiology between the vascular headache as described by Moskowitz (1984), in which dural CGRP and SP-IR trigeminovascular nerve fibres and degranulation of mast cells play a central role, and the spinal dura-related pain. It was concluded that the spinal dura is relatively insensitive and may not be implicated in the pathogenesis of spinal pain (Kumar *et al.*, 1996). The clinical entity of distinct dural referred pain as caused by meningitis was, strangely enough, not discussed. Although the existence of spinal dural innervation *per se* was not denied they emphasized the relative lack of CGRP and SP-IR nerve fibres, which is in contrast to the findings of Segikuchi *et al.* (1996), who did find CGRP and SP-IR nerve fibres in the rat spinal dura, and the observations by Ahmed *et al.* (1993b) concerning the rat, Stilwell (1956) concerning the monkey and Kimmel (1961), Edgar and Nundy (1966) and Groen *et al.* (1988) concerning humans. As described earlier, Groen and colleagues found irrefutable evidence in human foetuses for spinal dural innervation at all levels by identifying a large network of AChE-positive nerve fibres in the ventral dura, both perivascular and not associated with blood vessels (Groen *et al.*, 1988). The differences described could therefore be related to interspecies variety and perhaps to regional differences, since the thoracic area was not described by Kumar *et al.* (1996).

Furthermore, AChE staining for peripheral nerves is to be considered as a general neural marker with an almost complete overlap in nerve staining with the immunohistochemical staining for PGP 9.5 (Tago *et al.*, 1986; Bleys *et al.*, 1994; Matthijssen *et al.*, 1994). Therefore, since the CGRP and SP-IR nerve fibres should be regarded as a sub-population, a lot of the spinal dura nerve fibres should still be regarded as sensory or sympathetic (Ahmed *et al.*, 1993b). Unfortunately, the perivascular dural nerve fibres identified by the current authors (see Fig. 8.13C), which probably contain CGRP-IR nerve fibres, were not reported in the study of Kumar *et al.* (1996). This could again be related to interspecies variation. However, their conclusion that the pattern of spinal dura innervation was similar to that of the PLL nerve

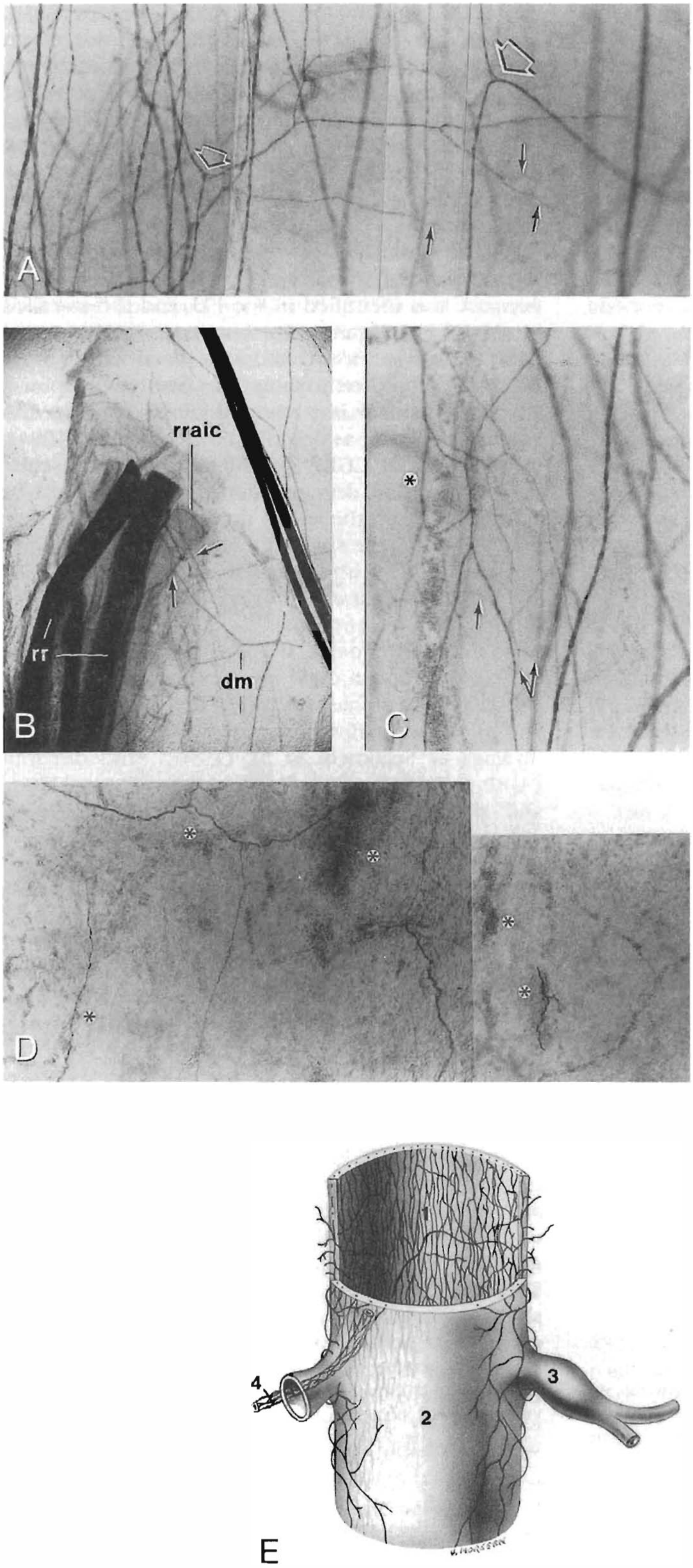

Fig. 8.13 Details of spinal dura nerve plexus. (A) Montage of photographs with different optimal focus showing a detailed view of the ventral spinal dura nerve plexus. At various levels, adjacent dural nerves are interconnected with each other (open arrows). The dural nerves branch extensively before dividing into terminal branches (small arrows). The size of the branches varies between 1 and 10 μm. Human foetus, 22 weeks, AChE whole mount staining (×81). (B) Detailed view of the roots of a thoracic spinal nerve (T$_{10}$). Small branches (arrows) of the perivascular nerve plexus of the accompanying radicular artery are connected to the ventral spinal dura nerve plexus, medial to it. Abbreviations: rr, dorsal and ventral roots; rraic, radicular artery; dm, ventral spinal dura nerve plexus. Human foetus, 20 weeks, AChE whole mount staining (×27). (C) Detailed view of dural nerves, perivascular (*) as well as independent from blood vessels. Note the very small (1-μm diameter) terminal nerve fibres (arrows). Human foetus, 20 weeks, AChE whole mount staining (×96). (D) Detailed view of the lateral quarter of the dorsal dura, showing a scarcity of dural nerves, partly running along blood vessels (*). Human foetus, 17 weeks, AChE whole mount staining (×79). (E) Schematic dorsal view of the spinal dural nerves, in which the spinal dura is represented as a cylinder with dural sleeves. The rich ventral spinal dura nerve plexus is partly supplied by branches from the perivascular nerve plexus of radicular arteries, and gives off some branches to the lateral parts of the dorsal dura. The middle two quarters of the dorsal dura are devoid of nerve fibres. 1, ventral spinal dura nerve plexus; 2, lateral parts of the dorsal dura; 3, dural sleeves; 4, perivascular nerve plexus of radicular arteries.

plexuses is erroneous (Figs 8.9–8.13), as is their statement that the spinal dura was not dissected from the PLL completely (Kumar *et al.*, 1996). An alternative explanation for these different findings could be their description of CGRP and SP-IR nerve fibres in the so-called 'peridural membrane'. This structure has been described in humans (Wiltse *et al.*, 1993), and it may parallel the posterior vertebral periosteum. Its significance in rats needs further verification, for detailed descriptions of the 'peridural membrane' have not yet appeared in new editions of standard rat anatomy textbooks (Greene, 1963; Hebel and Stromberg, 1976).

Segmental innervation patterns

As a result of the longitudinal orientation of the dural nerves, which may ascend and/or descend up to four segments cranial or caudal to the level of entry in the dural plexus (Fig. 8.12), a justifiable conclusion is that dural nerves may spread over up to nine segments and that a great amount of overlap exists between adjacent dural nerves (Groen *et al.*, 1988, 1991; Stolker *et al.*, 1994d). This has already been partly described by Edgar and Nundy (1966), although their reported segmental expansion of dural nerves did not exceed three segments (one to two caudal, one cranial).

Based upon the expansion and overlap of the dural nerves it could be postulated, in parallel with the study of Gillette *et al.* (1993) in the cat, in which a neurophysiological convergence on wide dynamic range neurons in the posterior horn was observed, that there is a convergence of multilevel dural innervation on restricted spinal segments (Groen *et al.*, 1988, 1991; Stolker *et al.*, 1994d) as depicted in Fig. 8.14. As a consequence, irritation of the spinal dura at one particular level (for instance T9), which has led to nociceptive stimulation, may have entered

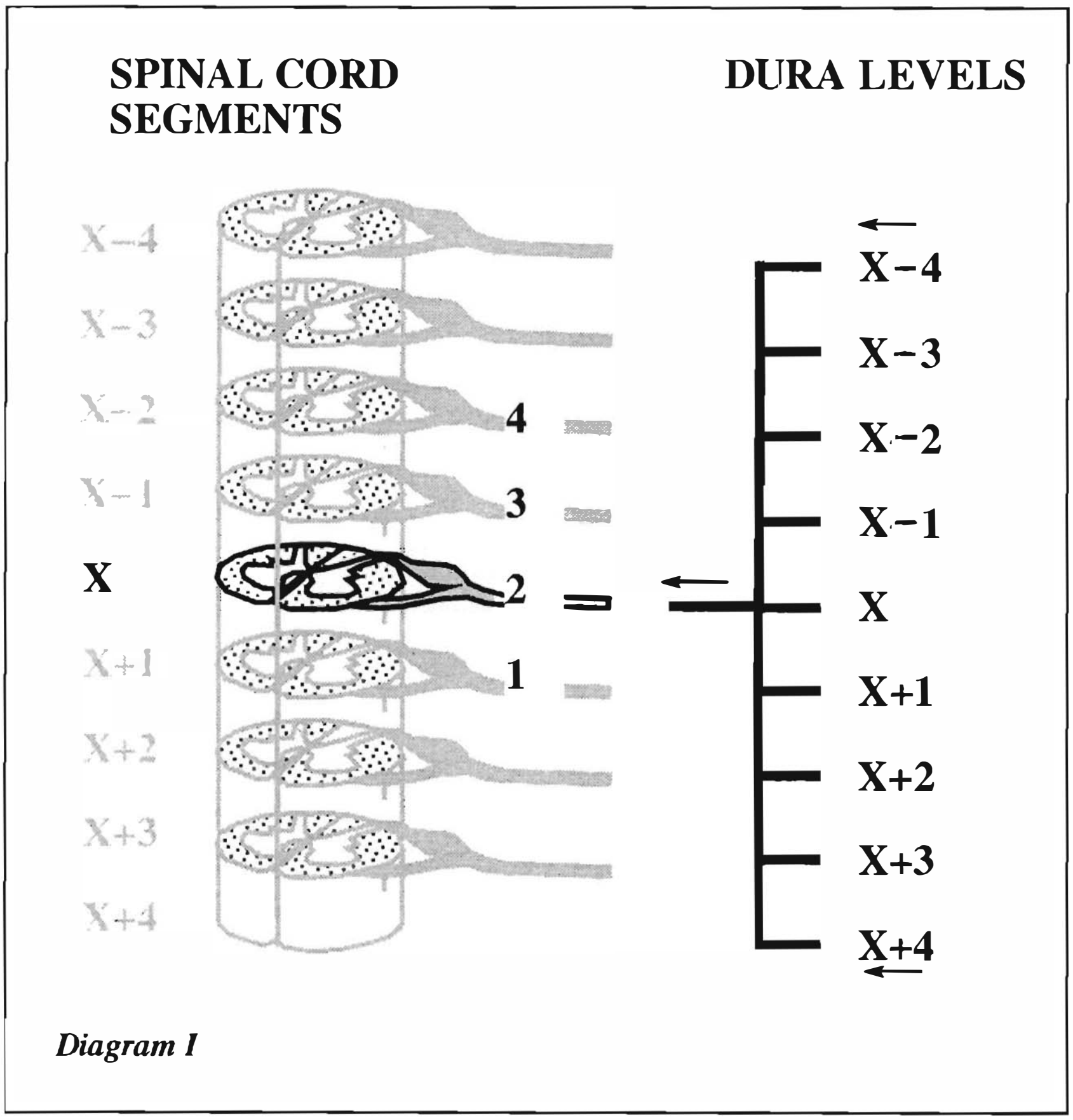

Fig. 8.14 Diagram of hypothetical convergence of multilevel dural innervation on restricted spinal segments, based upon the expansion of spinal dural nerves (maximally nine segments) and overlap of neighbouring dural nerves. Adjacent spinal cord segments receive comparable convergence, e.g. on segment (X – 1) neural input from spinal dural levels (X – 5)–(X + 3) may converge. (After Groen, 1986; Groen *et al.*, 1988.)

the spinal cord at many levels (up to about nine; in this case T5-L1). Furthermore, as referral of pain to dermatomes is restricted to dermatomes of spinal segments in which the nociceptive input arrives, it implies that monolevel dural irritation may lead to referred pain in skin areas distant from the original site (Fig. 8.15). The clinical entity of this type of dural pain has been recognized by Cyriax (1978), although it was described erroneously as 'extrasegmentally referred dural pain', which is in fact a contradiction because referred pain is always a segmental process! In view of the knowledge now obtained, the term 'multisegmentally referred dural pain' is preferred. This divergence of monolevel dural innervation to multiple segments of the spinal cord may be a common clinical feature; for example, in cervical intervertebral disc herniation patients generally also complain of pain in the interscapular region.

It will be evident that such processes of convergence and divergence could conceivably play a role in referred pain mechanisms related to the nerve supply of the ALL, PLL, vertebral bodies and intervertebral discs. In these cases segmental innervation patterns are also important, as schematized in Fig. 8.16. Furthermore, segmental referral of pain originating in the viscera and projecting into the thoracic spinal cord segments should always be considered by the clinical investigator (Fig. 8.17). Although visceral pain is generally referred to well-known segmental areas, atypical projection of pain may appear (Hansen and Schliack, 1962). For example, heart ischaemia leads to angina referred to the left ventral thorax and left arm (dermatomes C8-T7), but the pain may sometimes be projected to the dorsal side of the thorax, comparable with pancreas-related referred pain (Hansen and Schliack, 1962; Lang and Wachsmuth, 1982). Finally, as will be described in more detail below, zygapophysial joints have a bisegmental innervation; the capsule of a particular zygapophysial joint is supplied by branches of the dorsal ramus of the upper segment and one more cephalad level (Stolker *et al.*, 1994c; Chua and Bogduk, 1995).

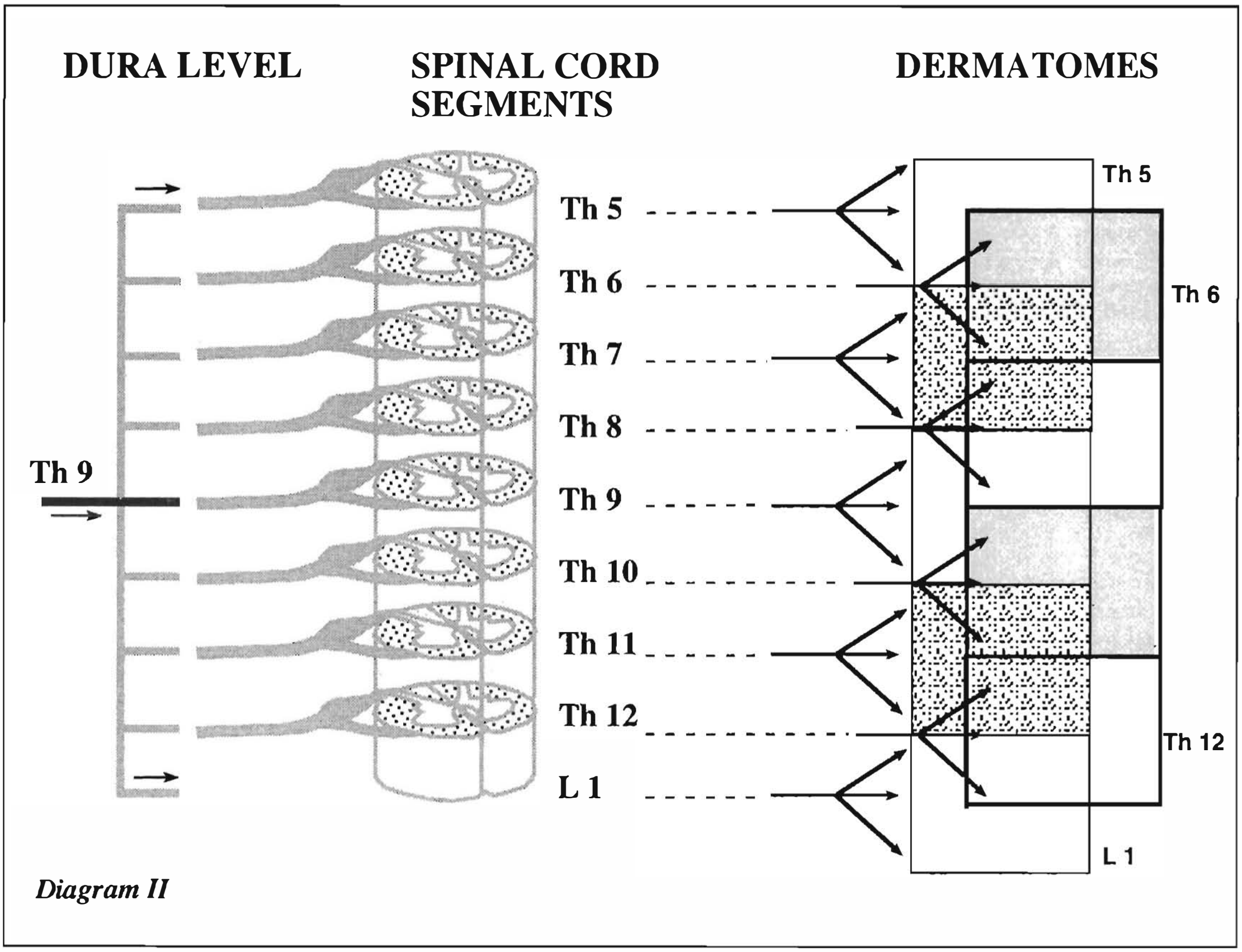

Fig. 8.15 Diagram of hypothetical divergence of monolevel spinal dural innervation to multiple spinal cord segments (up to nine) and related overlapping dermatomes, depicted for spinal ventral dura at level T_9 (after Groen, 1986; Groen *et al.*, 1988.)

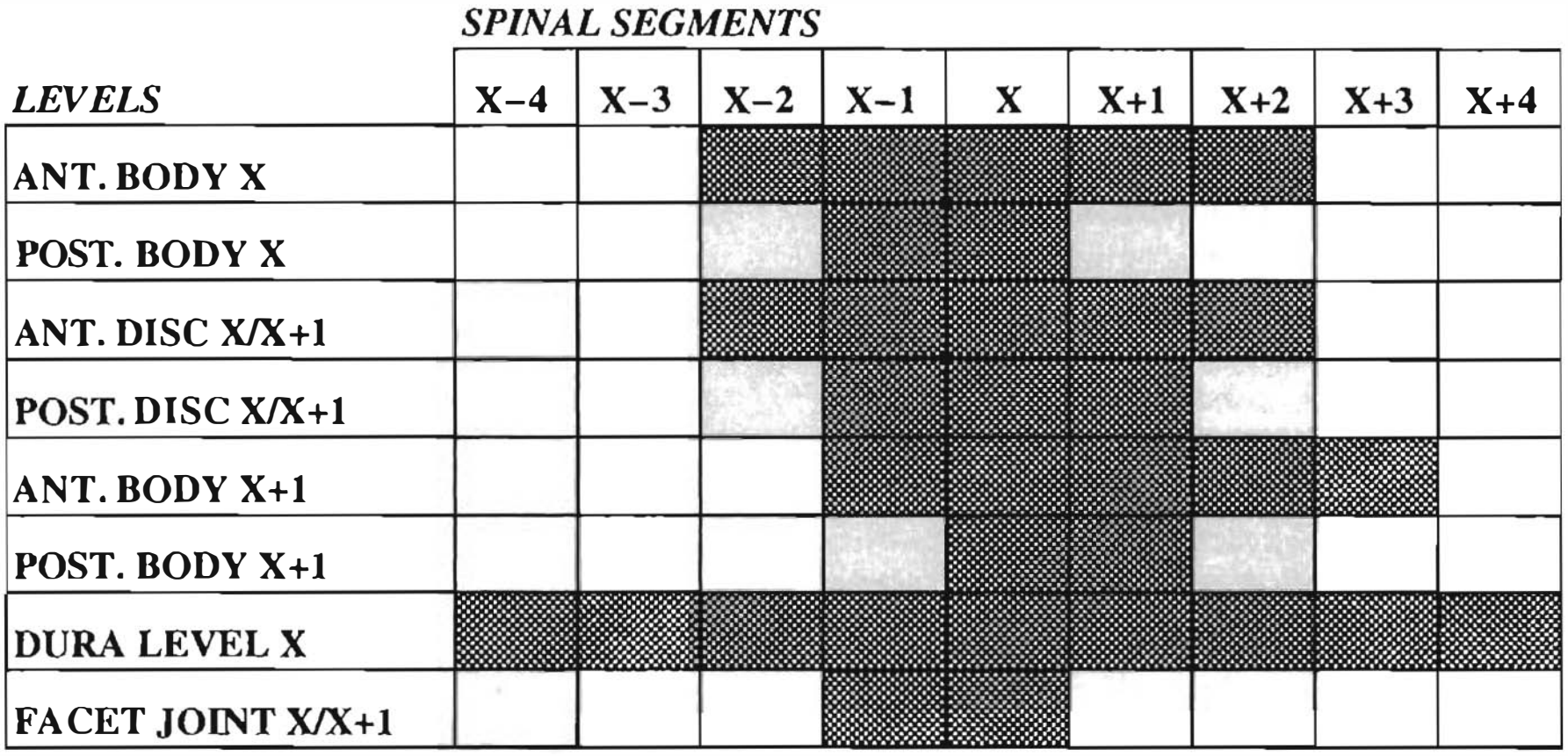

LEVELS	X−4	X−3	X−2	X−1	X	X+1	X+2	X+3	X+4
ANT. BODY X			▓	▓	▓	▓	▓		
POST. BODY X			░	▓	▓	░			
ANT. DISC X/X+1			▓	▓	▓	▓	▓		
POST. DISC X/X+1			░	▓	▓	▓	░		
ANT. BODY X+1				▓	▓	▓	▓	▓	
POST. BODY X+1				░	▓	▓	░		
DURA LEVEL X	▓	▓	▓	▓	▓	▓	▓	▓	▓
FACET JOINT X/X+1				▓	▓				

░ ***levels if long sinuvertebral nerves are present***

Fig. 8.16 Diagram of segmental innervation of a motion segment (after Groen *et al.*, 1990; Groen, 1991). This hypothetical scheme is based upon the ramification patterns of supplying nerves and upon subsequent overlap in innervation, comparable to that in dermatomes. It shows the relation between a particular spinal structure and the original level of innervation by spinal cord segments. In this way it is possible to depict the nerve supply of the intervertebral disc, vertebral bodies, dura mater and zygapophysial joints at a specific level (X)-(X + 1). Thus, for example, the posterior body of T_5 is supplied by the spinal cord segments $T_{4,5}$ (T_{3-6} in the case of long sinuvertebral nerves - light shaded rectangles), and the dura at level T_5 by the spinal cord segments T_{1-9}. This diagram implies that pain referred by spinal cord segments (X) and (X + 1) may have its origin in different structures on different levels. The innervation levels of the ALL and PLL are included in the anterior and posterior vertebral body respectively.

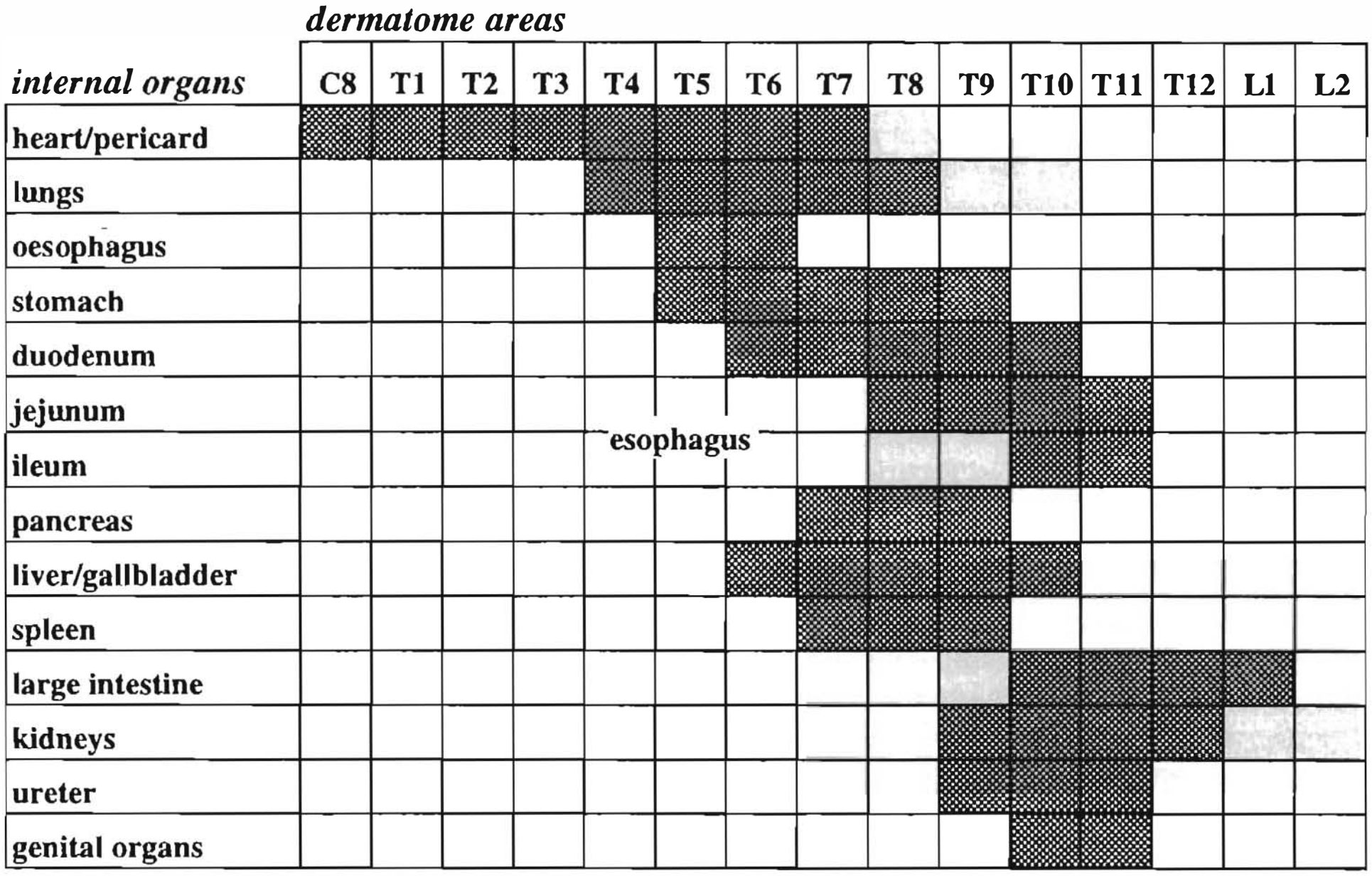

internal organs	C8	T1	T2	T3	T4	T5	T6	T7	T8	T9	T10	T11	T12	L1	L2
heart/pericard	▓	▓	▓	▓	▓	▓	▓	▓	░						
lungs					▓	▓	▓	▓	▓	░	░				
oesophagus						▓	▓								
stomach						▓	▓	▓	▓	▓					
duodenum							▓	▓	▓	▓	▓				
jejunum									▓	▓	▓	▓			
ileum									░	░	▓	▓			
pancreas								▓	▓	▓					
liver/gallbladder							▓	▓	▓	▓	▓				
spleen								▓	▓	▓					
large intestine										░	▓	▓	▓	▓	
kidneys										▓	▓	▓	▓	░	░
ureter										▓	▓	▓			
genital organs											▓	▓			

Fig. 8.17 Diagram of thoracic dermatomal areas sharing the same segmental innervation with internal organs. The light shaded rectangles display infrequent referral areas. Diseases in the internal organs may lead to referred pain in the related dermatomes. In bilateral organs (lungs, kidneys, genital organs) referral of pain generally is to the side of the body ipsilateral to the organ disease. Diseases of duodenum, ileum, liver, gallbladder and ascending colon generally refer to the right side of the body, while those of heart, stomach, jejunum, pancreas, spleen, descending colon and sigmoid generally refer to the left side of the body. (After Hansen and Schliack, 1962.)

On the one hand, this bilateral nerve supply to ventral compartment structures implies that right-sided sources of pain may project to the left side and *vice versa*; on the other hand, the multi-segmentally organized innervation may lead to referral of pain to distant areas seemingly not related to the segment where the source of pain is localized (Fig. 8.14). It may seem that the localization of pain is not a major determinant for a clinical diagnosis; however, peripheral blockades of nerves may be of help to determine the origin of pain (Stolker *et al.*, 1994d; see also Chapter 13).

Innervation of the dorsal compartment

The dorsal compartment is supplied by the medial and lateral branches of the dorsal rami. In an earlier study (Stolker *et al.*, 1994c) it was shown that the dorsal ramus originates directly lateral to the DRG, generally perpendicularly to the long axis of the spinal nerve (Fig. 8.18). However, in a recent report (Chua and Bogduk, 1995) the proximal trajectory of the dorsal ramus of the thoracic spinal nerve was depicted graphically as being more lateral than dorsal. Rami communicantes connect the sympathetic trunk with the spinal nerve (Fig. 8.18). As described earlier in this chapter, branches from the rami communicantes pass above and below the spinal nerve and DRG to join the dorsal ramus (Figs 8.4 and 8.5), which confirms the findings of Dass (1952) and Kikkawa *et al.* (1978) in humans, and of Stilwell (1956) in the monkey. This is the analogous pathway for sympathetic vasoregulatory nerve fibres of the capsule of the thoracic zygapophysial joints, as described for lumbar zygapophysial joints (Grönblad *et al.*, 1991b; Ahmed *et al.*, 1993a). Thus blockades of the dorsal rami will block not only sensory nerves, but also these sympathetic nerve fibres.

The dorsal ramus is separated from the ventral ramus (i.e. the intercostal nerve) by the anterior part of the superior costotransverse ligament (Fig. 8.18). In the thoracic region, the dorsal ramus is to be considered as a short (3-15 mm, mean 5 mm) common trunk which bifurcates immediately dorsal to the superior costotransverse ligament into a medial and a lateral branch (Fig. 8.18) (Stolker *et al.*, 1994c). Sometimes a third, intermediate branch is found. The medial branches supply the adjacent intrinsic muscles of the back, the zygapophysial joints and, in the upper thoracic region, the skin; the lateral branches supply intrinsic muscles, costotransverse joints (Vrettos and Wyke, 1974) and, in the lower thoracic region, the skin.

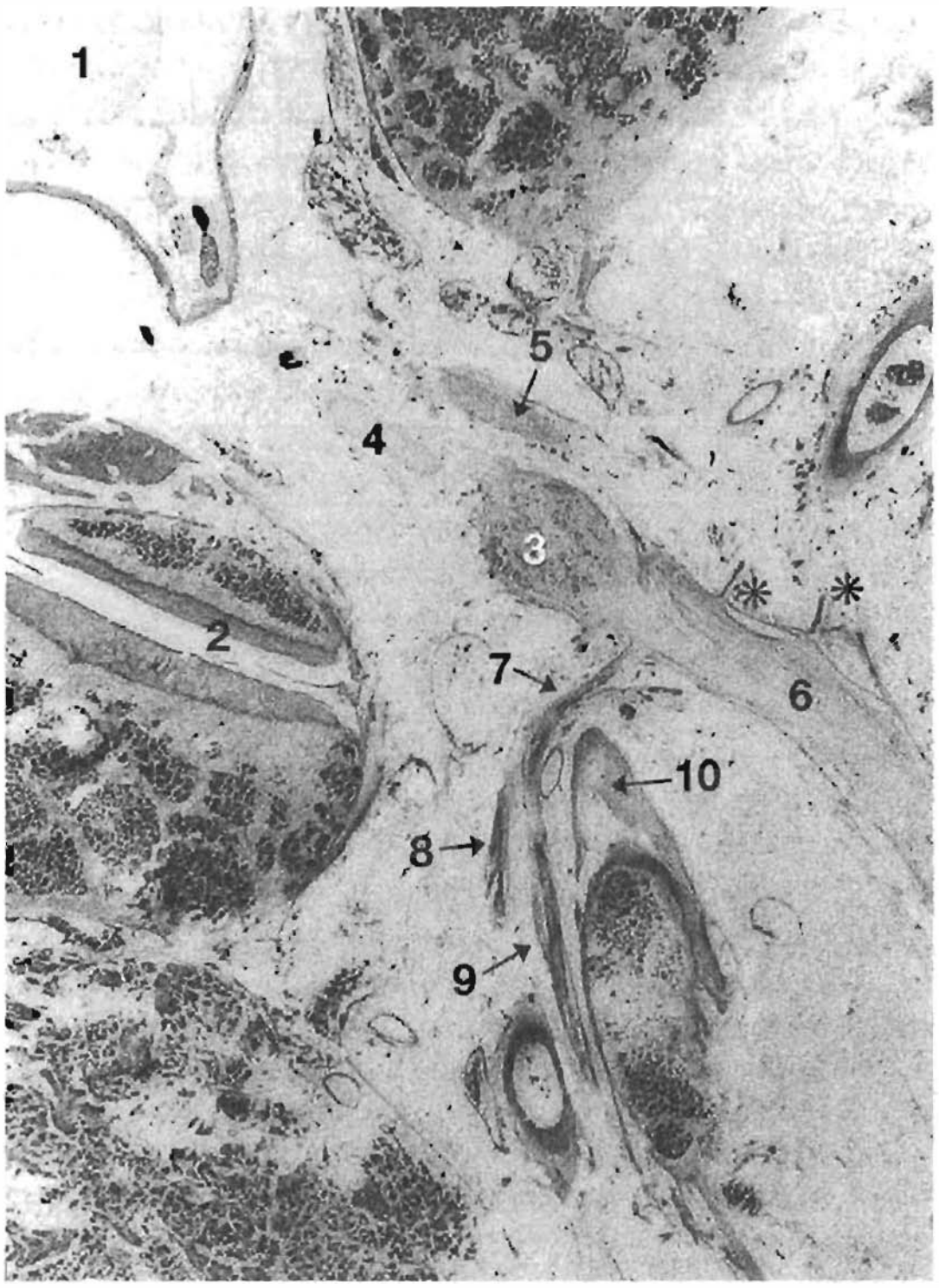

Fig. 8.18 Transverse cryomicrotome section at the level of the intervertebral foramen T_{4-5}, bounded by the posterolateral part of vertebral body T_4 (anteriorly) and the zygapophysial joint T_{4-5} (posteriorly) showing thoracic spinal nerve T_4 and its branches. Undecalcified specimen, superior view. The zygapophysial joint T_{4-5} clearly shows a synovial fold in the articular cavity, between the superior articular process (anteriorly) and the inferior articular process (posteriorly). After its origin in the spinal nerve, the dorsal ramus runs dorsal, crosses antero-medial to the superior costotransverse ligament and bifurcates into a medial branch and a lateral branch, the latter running posterior to the rib. 1, spinal cord; 2, zygapophysial joint T_{4-5}; 3, dorsal root ganglion; 4, dorsal root; 5, ventral root; 6, ventral ramus spinal nerve T_4 (i.e. intercostal nerve T_4); 7, dorsal ramus; 8, medial branch of the dorsal ramus; 9, lateral branch of the dorsal ramus; 10, superior costotransverse ligament; *, rami communicantes. Female, 96 years of age, AChE staining (×6).

Thoracic zygapophysial joint

In an analogy to the innervation of cervical and lumbar zygapophysial joints (Pedersen *et al.*, 1956; Stilwell, 1956; Lewin *et al.*, 1962; Bogduk, 1982; Bogduk *et al.*, 1982; Auteroche, 1983), the thoracic zygapophysial joints receive a bisegmental innervation from the medial branches of the dorsal ramus of the upper segment and one more cephalad level (Stolker *et al.*, 1994c; Chua and Bogduk, 1995). Thus zygapophysial joints T5 and T6, for example, are supplied by T4 and T5 spinal nerves. This is not surprising in view of the analogy in innervation patterns of the cervical, thoracic and lumbar spines as described earlier (Groen *et al.*, 1987, 1988, 1990). However, no consensus is present concerning detailed information on the topography of supplying nerves. While Chua and Bogduk (1995) report 'that the thoracic medial branches are not that close to the zygapophysial joint, as they swing laterally to circumvent the multifidus', this is in contradiction to the findings of Lazorthes (1972), Maigne *et al.* (1991) and Stolker *et al.* (1994c). Furthermore, Fig. 8.18 clearly shows the close relationship between the dorsal ramus, its medial branch and the lateral zygapophysial joint capsule. It should be emphasized that, beside the supply by the ascending and descending branches of the thoracic medial branches of dorsal rami, the zygapophysial joint capsule is further supplied by proximal nerve branches derived from the short dorsal ramus itself or from the proximal part of the medial branch (Stilwell, 1956; Lazorthes, 1972; Maigne *et al.*, 1991; Stolker *et al.*, 1994c). As this proximal innervation cannot be reached by percutaneous facet (zygapophysial) denervation (PFD) procedures, a thoracic PFD will not lead to a complete denervation of the zygapophysial joint (Stolker *et al.*, 1993, 1994e; see also Chapter 13).

Although few if any studies have been performed on thoracic zygapophysial joint capsule innervation, the current authors believe that the results of earlier studies on zygapophysial joints in other regions of the spine can be extrapolated to the thoracic region without any hesitation, since there are no major differences in innervation patterns between the various parts of the spine (Groen *et al.*, 1990). Most of the knowledge is extrapolated from the work of Stilwell (1956) in the monkey. Also, synovial folds are present in the thoracic zygapophysial joints (Fig. 8.18) and these probably contain, in analogy to the lumbar region (Giles *et al.*, 1986; Giles and Taylor, 1987), small myelinated nerves that may elucidate pain if pinched between the opposed articular facets (Giles and Taylor, 1982) - although in the thoracic region the mobility of these joints is relatively restricted. Furthermore, in the lumbar zygapophysial joint capsules fine nerve fibres and free nerve endings (Yamashita *et al.*, 1996) and substance P-immunoreactive fibres were found in humans (Giles and Harvey, 1987; Grönblad *et al.*, 1991b) and in the rat (Ahmed *et al.*, 1993a).

Dreyfuss *et al.* (1994) proved that thoracic zygapophysial joints are a potential source of thoracic pain, although the existence of a facet syndrome *per se* has been disputed (Jackson, 1992). Dreyfuss *et al.* (1994) determined referral pain patterns after provocative intra-articular injections with contrast medium in the T3-T10 thoracic zygapophysial joints. According to Dreyfuss and colleagues, intracapsular injection leads to a distension of the joint capsule, which may activate local nociceptors and cause local and distal (referred) pain. However, in about one quarter of the volunteers the provocation did not result in pain, despite capsular distension. Perhaps mechanical (i.e. capsular distension) stimulation was insufficient for nociceptor stimulation. Another explanation could be that chemical stimulation, e.g. by hypertonic saline, is the primary stimulating factor of these nociceptors. Not surprisingly, a substantial overlap in the referral patterns of the thoracic zygapophysial joints was found, whilst the most intense pain was felt within the core referral zone at or approximately one segment below the provoked joint (Dreyfuss *et al.*, 1994). Joint referred pain did not occur superiorly for more than one-half the vertical height of the vertebral segment, while no joint evoked pain more than two and a half segments inferiorly to the joint injected (Dreyfuss *et al.*, 1994).

For a quick reference, relations between the location of the spinous processes and the level of the related zygapophysial joints were described by Lang and Wachsmuth (1982). Spinous processes T1-T3 and T11-T12 are located approximately at the level of the zygapophysial joint of the adjoining level and the one below (e.g. spinous process T3 relates to the T3-T4 joint level). Spinous processes T4-T10 are located approximately halfway between the adjoining zygapophysial joint and the joint below (e.g. spinous process T7 lies halfway between zygapophysial joint T7-T8 and T8-T9).

Cutaneous branches of dorsal rami

Generally, two different patterns of cutaneous innervation are discerned in the thoracic area (Hovelacque, 1927; Stilwell, 1956; Braus, 1960; Lazorthes, 1972; Maigne *et al.*, 1991; Stolker *et al.*, 1994c; Chua and Bogduk, 1995). In the upper thoracic region, cutaneous extensions of medial branches curve around the multifidus to become subcutaneous near the spinous processes; in the lower thoracic region, the skin is supplied by the lateral branches of the dorsal rami (see Fig. 8.1). Although 'upper thoracic' may vary from T1-T6(7) and 'lower thoracic' from T7(8)-T11 according to most authors, different descriptions have been published (see Chua and Bogduk, 1995). For the levels T11 and T12, a topography more or less analogous to that described for the lumbar region (Bogduk *et al.*, 1982) is agreed upon. Furthermore, according to Hansen and Schliack (1962) and Lang and Wachsmuth (1982), the oblique caudal orientation of the dorsal spinal rami causes a caudal replacement of the dorsal dermatomes. Thus the orientation of the dermatomes at the back is as follows in relation to the tip of the spinous process: dermatomes T1-T7 are located one level caudal to the corresponding spinous process (e.g. dermatome T5 is next to spinous process T6); dermatomes T8-T12 are located approximately two levels caudal to the corresponding spinous process.

Encapsulated endings in spine-related ligaments

Encapsulated endings of various types - Pacini-form and Ruffini-form (or type II and type I respectively, according to Freeman and Wyke, 1967) - have been described in the ALL and PLL, although very few in number in humans (Malinsky, 1959; Jackson *et al.*, 1966; Yoshizawa, 1980; Coppes *et al.*, 1997) and in the rabbit (Cavanaugh *et al.*, 1995). Their primary location was at the transient tissue between the ligaments and anulus fibrosus, not deeper. However, Roberts *et al.* (1995) observed mechanoceptors in the outer lamellae of the anulus fibrosus, particularly Golgi tendon organs (type III according to Freeman and Wyke, 1967). If they become sensitized, for example by an inflammatory process, they may excite muscle activity or even spasm at lower than normal levels of stimulation (Roberts *et al.*, 1995), which would cause myogenic pain.

Encapsulated endings have also been found in other spine-related ligaments, such as the supraspinal and interspinal ligaments (Yahia *et al.*, 1988; Jiang *et al.*, 1995), next to thin single nerve fibres (Yahia *et al.*, 1988). Pacinian corpuscles have been identified near blood vessels, equally spread throughout the ligament, and Ruffini corpuscles more peripherally, near collagen bundles. Although highly unlikely, since their assumption is primarily based upon a symmetrical distribution pattern of the corpuscles and blood vessels, Jiang *et* al. (1995) have suggested a vascular function for the Pacinian corpuscles (such as sympathetic afferent endings initiating vasomotor reflexes). Most authors, however, attribute a mechanoceptive role related to movement velocity and range in the spine to the Pacinian corpuscles. Ruffinian corpuscles are described as slow adaptive end organs, sensitive to motion, especially stretch, and providing awareness of joint position and movement (Freeman and Wyke, 1967). They are common in joints where static position sense is necessary for the control of posture and, as such, are part of a neurological feedback mechanism responsible for protection and especially stability of the spine. Finally, mechanosensitive units have also been demonstrated in zygapophysial joint capsules (Yamashita *et al.*, 1990).

Summary

In conclusion, it can be summarized that the thoracic spine and its related structures are all innervated by nerve fibres which have a (partly) sympathetic pathway, although this scheme may be extended to other regions as well (Groen *et al.*, 1987, 1988, 1990).

Sympathetic postganglionic nerve fibres have been found in the PLL (Imai *et al.*, 1995, 1997; Nakamura *et al.*, 1996), spinal dura (Kumar *et al.*, 1996) and predominantly in blood vessel walls of disc and bone tissue, spinal dura mater and spinal ligaments (Ahmed *et al.*, 1993b), suggesting primarily a role in vasoregulation. The nerves are not exclusively sympathetic, as stated earlier (Groen *et al.*, 1990). Certainly the nerve plexuses contain nociceptive (Liesi *et al.*, 1983; Korkala *et al.*, 1985; Coppes *et al.*, 1990; Konttinen *et al.*, 1990; Ashton *et al.*, 1994) and proprioceptive nerve fibres (Jackson *et al.*, 1966; Cavanaugh *et al.*, 1995; Coppes *et al.*, 1997), and nerve fibres for the regulation of local bone metabolism (Ahmed *et al.*, 1993b), which partly follow the sympathetic pathway. However, this implies an intriguing area of sympathetic involvement in the pathophysiology of chronic spinal pain, although such pain is generally regarded as mediated by sensory neurons (Sekiguchi *et al.*, 1996). Active participation of sympathetic nerves in nociceptive mechanisms has been observed at the level of A-delta nociceptors (Roberts and Elardo, 1985) and of the DRG in rats (Jänig, 1990; Weinstein, 1991; McLachlan *et al.*, 1993).

Another, perhaps even more important, category of nerve fibres in the spinal nerve plexuses could be that of the so-called sensory-motor nerve fibres (Maggi, 1991; Burnstock, 1993), in which sensory stimulation leads to a peripheral 'motor' (efferent) activity. This has been known for years as the so-called 'axon-reflex', in which antidromic impulses in sensory nerve collaterals result in a vasodilatation of skin vessels (Lewis, 1927). Since the discovery of the pharmacological properties of the sensory neurotoxine capsaicin, many studies have focused on the 'motor' effects of sensory neuron stimulation (Maggi, 1991), especially with the contemporary increased interest in the action of all kinds of neuropeptides in the peripheral nervous system. The efferent function of capsaicin-sensitive afferent fibres is produced by release of neurotransmitters SP, CGRP and ATP from their peripheral endings (Burnstock, 1993). These substances act on target cells to produce several biological actions, e.g. changes in smooth muscle cell contractility, vasodilatation, increase of vascular permeability, mast cell degranulation and a variety of effects on leukocytes and fibroblasts, a process collectively known as 'neurogenic inflammation' (Maggi and Meli, 1988). Increased activity of sensory and sympathetic nerves was reported by Palmgren *et al.* (1996), who found small nerve terminals in lumbar disc herniations - both sensory SP endings and sympathetic endings. Finally, there is also evidence that 'the local release of sensory neurotransmitters plays a long-term 'trophic' role in the maintenance of tissue integrity and repair in response to injury (Williams *et al.*, 1995).

Speculatively, this would open a range of therapeutic options, since pharmaceutical or mechanical interaction with these nerve plexuses would not only

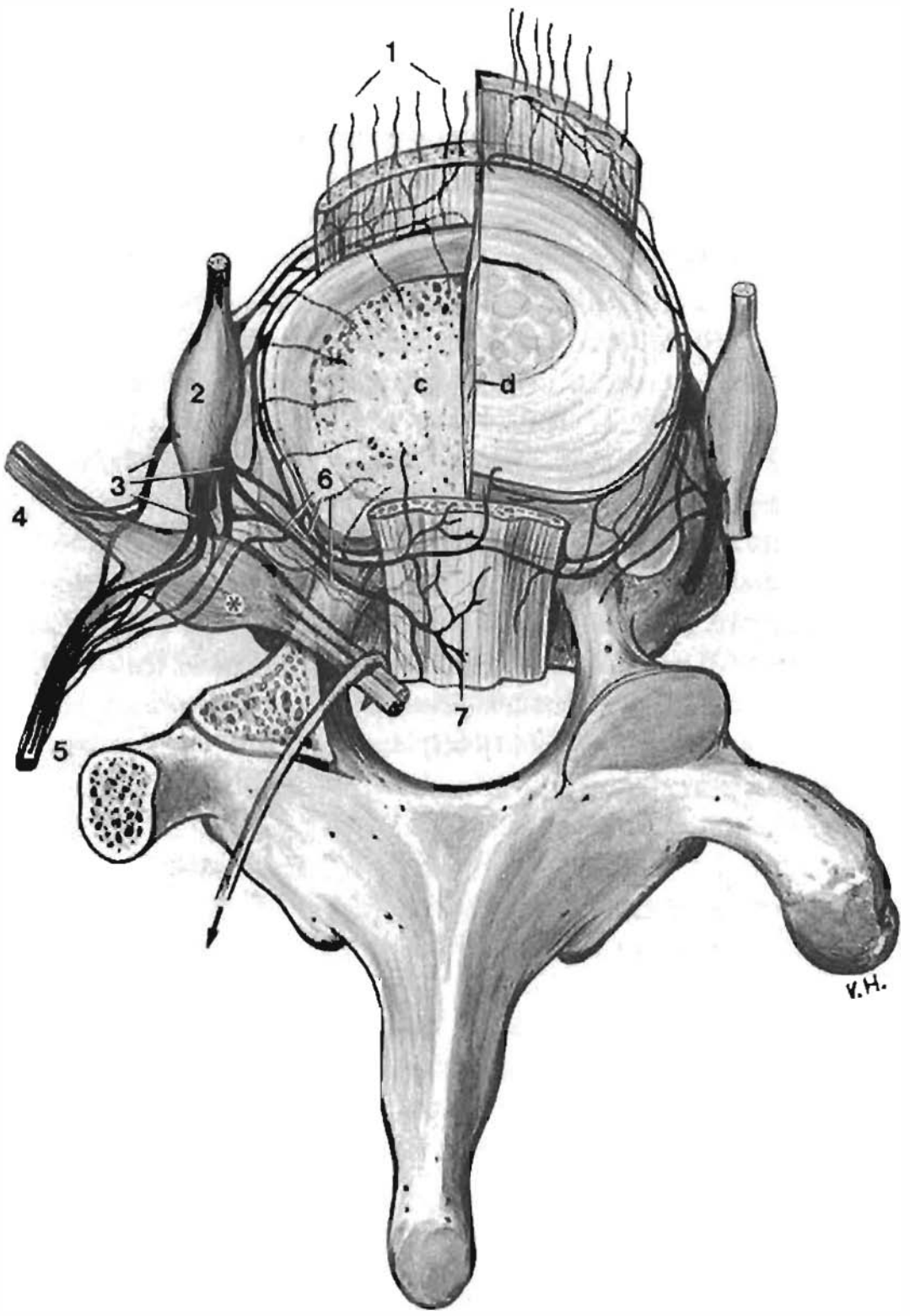

Fig. 8.19 Schematic drawing of the nerve supply of the thoracic ventral compartment at the level of the vertebral body (c) and intervertebral disc (d). The ventral and dorsal roots of the spinal nerve are retracted dorsally (arrow). Bundles of nerve fibres originating from rami communicantes pass cranial and caudal to the spinal nerve and the dorsal root ganglion (*) towards the dorsal ramus of the spinal nerve. Large and small sinuvertebral nerves derive from the rami communicantes. 1, ALL nerve plexus; 2, sympathetic trunk; 3, rami communicantes; 4, ventral ramus of the spinal nerve; 5, ramus of the spinal nerve; 6, sinuvertebral nerves; 7, PLL nerve plexus. From Groen *et al.* (1990), with permission.

have an effect on nociceptive pathways, but would also interfere with the 'neurogenic inflammatory' side of the process.

It is clear that ventral compartment structures receive a multisegmental and bilateral nerve supply from nerve fibres topographically and functionally related to the sympathetic trunk and rami communicantes (summarized in Fig. 8.19): first, the costovertebral joints, ALL, adjacent intervertebral discs and periosteum of vertebral bodies, via direct branches from the sympathetic trunk or perivascular nerve plexuses of intercostal arteries; and secondly, the PLL, adjacent intervertebral disc and periosteum, and spinal dura via the sinuvertebral nerves which have their origin in rami communicantes. Dorsal compartment structures receive a bisegmental and unilateral nerve supply via dorsal rami of the spinal nerves, which contain nerve fibres derived from rami communicantes that join this ramus after crossing the ventral ramus.

The substantial overlap in the innervation of the spine implies that pain projection and patterns are not specific and are therefore insufficient alone for diagnosis (Wyke, 1987; Groen *et al.*, 1988, 1990; Gillette *et al.*, 1993; Stolker *et al.*, 1994d). Furthermore, some authors consider all signs and symptoms in spinal pain to be rather non-specific (Jackson *et al.*, 1988; Moran *et al.*, 1988; Revel *et al.*, 1992). Therefore, in the diagnostic phase segmental blocks may be of value as an adjuvant diagnostic procedure to distinguish the different syndromes (Steindler and Luck, 1938; Mooney and Robertson, 1976; Bogduk and Marsland, 1988; Laros, 1991; Stolker *et al.*, 1993, 1994a, 1994d; see also Chapter 13). It is important to realize that a multisegmental, bilateral innervation pattern may, in some cases, demand multilevel bilateral blockades.

Finally, it should be emphasized that thoracic pain may also be referred from thoracic and upper abdominal viscera (Whitcomb *et al.*, 1995), not only related to inflammatory processes or cancer but also caused by metastatic tumours which have developed in vertebral bodies. Other possible causes of thoracic spinal pain (for instance, degenerative) are discussed elsewhere (Grieve, 1981; Bonica and Sola, 1990; see also Chapter 5).

References

Ahmed, M., Bjurholm, A., Kreicberg, A. *et al.* (1991) SP- and CGRP-immunoreactive nerve fibers in the rat lumbar spine. *Neuro-Orthoped.* **12:** 19-28.

Ahmed, M., Bjurholm, A., Kreicberg, A. *et al.* (1993a) Sensory and autonomic innervation of the facet joint in the rat lumbar spine. *Spine* **18:** 2121-2126.

Ahmed, M., Bjurholm, A., Kreicberg, A. *et al.* (1993b) Neuropeptide Y, tyrosine hydroxylase and vasoactive intestinal polypeptide-immunoreactive nerve fibers in the vertebral bodies, dura mater and spinal ligaments of the rat lumbar spine. *Spine* **18:** 268-273.

Ashton, I.K., Ashton, B.A., Gibson, S.J. *et al.* (1992) Morphological basis for back pain: the demonstration of nerve fibers and neuropeptides in the lumbar facet joint capsule but not in the ligamentum flavum. *J. Orthop. Res.* **10:** 72-78.

Ashton, I.K., Roberts, S., Jaffray, D.C. *et al.* (1994) Neuropeptides in the human intervertebral disc. *J. Orthop. Res.* **12:** 186-192.

Auteroche, P. (1983) Innervation of the zygapophyseal joints in the lumbar spine. *Anat. Clin.* **5:** 17-28.

Baker, D.G., McDonald, D.M., Basbaum, C.B. *et al.* (1986) The architecture of nerves and ganglia of the ferret trachea as revealed by acetylcholinesterase histochemistry. *J. Comp. Neurol.* **246:** 513-526.

Baljet, B., Drukker, J. (1975) An acetylcholinesterase method for in toto staining of peripheral nerves. *Stain Technol.* **50:** 31-36.

Bartsch, W. (1972) Die Pathogenese und Klinik der spinalen Durchblütungsstörungen. In: *Handbuch der Neurochirurgie, 7. Bd, II. Teil, Wirbelsaüle und Rückenmark II* (Olivecrona, H., Tönnis, W., Krenkel, W., eds). Berlin, Heidelberg, New York: Springer, p. 607.

Beaman, D.N., Graziano, G.P., Glover, R.A. *et al.* (1993) Substance P innervation of lumbar spine facet joints. *Spine* **18:** 1044-1049.

Beric, A. (1993) Central pain: new syndromes and their evaluation. *Muscle Nerve* **16:** 1017-1024.

Bleys, R.L., Groen, G.J., Matthijssen, M.A.H. (1994) A method for identifying peripheral connections of perivascular nerves based on sensitive acetylcholinesterase staining via perfusion. *J. Histochem. Cytochem.* **42:** 223-230.

Bleys, R.L., Groen, G.J., Hommersom, R.F. (1996a) Neural connections in and around the cavernous sinus in rat, with special reference to cerebrovascular innervation. *J. Comp. Neurol.* **369:** 277-291.

Bleys, R.L., Cowen, T.C., Groen, G.J. *et al.* (1996b) Perivascular nerves of the human basal cerebral arteries. I. Topographical distribution. *J. Cerebr. Blood Flow Metab.* **16:** 1034-1047.

Bogduk, N. (1982) The clinical anatomy of the cervical dorsal rami. *Spine* **7:** 319-330.

Bogduk, N. (1983) The innervation of the lumbar spine. *Spine* **8:** 286-293.

Bogduk, N., Marsland, A. (1988) The cervical zygapophyseal joints as a source of neck pain. *Spine* **13:** 610-617.

Bogduk, N., Tynan, W., Wilson, A.S. (1981) The nerve supply to the human intervertebral discs. *J. Anat.* **132:** 39-56.

Bogduk, N., Wilson, A.S., Tynan, W. (1982) The human dorsal rami. *J. Anat.* **134:** 383-397.

Bonica, J.J., Sola, A.E. (1990) Chest pain caused by other disorders. In: *The Management of Pain*, 2nd edn (Bonica, J.J., Loeser, J.D., Chapman, C.R. *et al.*, eds). Philadelphia: Lea and Febiger, pp. 1114-1145.

Braus, H. (1960) *Anatomie des Menschen I. Band 3*, 2nd edn. Berlin: Springer, pp. 41-113.

Bridge, C.J. (1959) Innervation of spinal meninges and epidural structures. *Anat. Rec.* **133:** 553-561.

Brown, F.W. (1977) Management of discogenic pain using epidural and intrathecal steroids. *Clin. Orthop.* **129:** 72-78.

Burnstock, G. (1993) Changing face of autonomic and sensory nerves in the circulation. In: *Vascular Innervation and Receptor Mechanisms: New Perspectives* (Edvinsson, L., Uddman, R., eds). Oxford: Academic Press, pp. 1-22.

Cavanaugh, J.M., Kallikuri, S., Özaktay, A.C. (1995) Innervation of the rabbit lumbar intervertebral disc and posterior longitudinal ligament. *Spine* **20:** 2080-2085.

Chua, W.H., Bogduk, N. (1995) The surgical anatomy of thoracic facet denervation. *Acta Neurochir. (Wien)* **136:** 140-144.

Cloward, R.B. (1960) The clinical significance of the sinuvertebral nerve of the cervical spine in relation to the cervical disk syndrome. *J. Neurol. Neurosurg. Psychiatr.* **23:** 321-326.

Coppes, M.H., Marani, E., Thomeer, R.T. *et al.* (1990) Innervation of anulus fibrosus in low back pain. *Lancet* **ii:** 189-190.

Coppes, M.H., Marani, E., Thomeer, R.T. *et al.* (1997) Innervation of 'painful' lumbar discs. *Spine* **22:** 2342-2349.

Cuatico, W., Parker, J.C., Pappert, E. *et al.* (1988) An anatomical and clinical investigation of spinal meningeal nerves. *Acta Neurochir. (Wien)* **90:** 139-143.

Cyriax, J. (1945) Lumbago - mechanism of dural pain. *Lancet* **ii:** 427-429.

Cyriax, J. (1978) Dural pain. *Lancet* **i:** 919-921.

Dass, R. (1952) Sympathetic components of the dorsal primary divisions of human spinal nerves. *Anat. Rec.* **113:** 493-501.

Davidoff, G., Roth, E., Guarracini, M. (1987) Function limiting dysaesthetic pain syndrome among traumatic SCI patients: a cross-sectional study. *Pain* **29:** 39-48.

Dreyfuss, P., Tibiletti, C., Dreyer, S.J. (1994) Thoracic zygapophyseal joint pain patterns. *Spine* **19:** 807-811.

Edgar, M.A., Ghadially, J.A. (1976) Innervation of the lumbar spine. *Clin. Orthop.* **115:** 35-41.

Edgar, M.A., Nundy, S. (1966) Innervation of the spinal dura mater. *J. Neurol. Neurosurg. Psychiatr.* **29:** 530-534.

Edvinsson, L., Rosendal-Helgesen, S., Uddman, R. (1983) Substance P: Localization, concentration and release in cerebral arteries, choroid plexus and dura mater. *Cell Tissue Res.* **234:** 1-7.

El-Bohy, A., Cavanaugh, J.M., Getchell, M.L. *et al.* (1988) Localization of substance P and neurofilament immunoreactive fibers in the lumbar facet joint capsule and supraspinous ligament of the rabbit. *Brain Res.* **460:** 379-382.

Ferlic, D.C. (1963) The nerve supply of the cervical intervertebral disc in man. *Bull. John Hopkins Hosp.* **113:** 247-251.

Forsythe, W.B., Ghoshal, N.G. (1984) Innervation of the canine thoracolumbar vertebral column. *Anat. Rec.* **208:** 57-63.

Freeman, M.A.R., Wyke, B. (1967) The innervation of the knee joint: an anatomical and histological study in the cat. *J. Anat.* **101:** 505-532.

Gelman, S. (1995) The pathophysiology of aortic cross-clamping (AoX) and unclamping. *Anaesthesiology* **82:** 1026-1060.

Giles, L.G.F., Harvey, A.R. (1987) Immunohistochemical demonstration of nociceptors in the capsule and synovial folds of human zygapophyseal joints. *Br. J. Rheumatol.* **26:** 362-364.

Giles, L.G.F., Taylor, J.R. (1982) Intra-articular synovial protrusions in the lower lumbar apophyseal joints. *Bull. Hosp. Joint Dis.* **42:** 248-255.

Giles, L.G.F., Taylor, J.R. (1987) Innervation of lumbar zygapophyseal joint synovial folds. *Acta Orthop. Scand.* **58:** 43-46.

Giles, L.G.F., Taylor, J.R., Cockson, A. (1986) Human zygapophyseal joint synovial folds. *Acta Anat.* **126:** 110-114.

Gillette, R.G., Kramis, R.C., Roberts, W.J. (1993) Characterization of spinal somatosensory neurons having receptive fields in lumbar tissues of cats. *Pain* **54:** 85-98.

Greene, E.C. (1963) *Anatomy of the Rat.* New York: Hafner.

Grieve, G.P. (1981) *Common Vertebral Joint Problems.* Edinburgh: Churchill Livingstone, pp. 36-53, 129-138.

Groen, G.J. (1986) *Contributions to the Anatomy of the Peripheral Nervous System.* Thesis, Rhodopi, Amsterdam.

Groen, G.J. (1991) De innervatie van de wervelkolom bij de mens. *Ned. Tijdschr. Man. Ther.* **10:** 48-60.

Groen, G.J., Baljet, B., Boekelaar, A.B. *et al.* (1987) Branches of the thoracic sympathetic trunk in the human fetus. *Anat. Embryol.* **176:** 401-411.

Groen, G.J., Baljet, B., Drukker, J. (1988) The innervation of the spinal dura mater: anatomy and clinical implications. *Acta Neurochir. (Wien)* **92:** 39-46.

Groen, G.J., Baljet, B., Drukker, J. (1990) Nerves and nerve plexuses of the human vertebral column. *Am. J. Anat.* **188:** 282-296.

Groen, G.J., Stolker, R.J., Vervest, A.C.M. (1992) Anatomische Grundlagen destruktiver Eingriffe. *Der Schmerz* **6:** S5.

Grönblad, M., Weinstein, J.N., Santavirta, S. (1991a) Immunohistochemical observations on spinal tissue innervation. A review of hypothetical mechanisms of back pain. *Acta Orthop. Scand.* **62:** 614-622.

Grönblad, M., Korkala, O., Konttinen, Y.T. *et al.* (1991b) Silver impregnation and immunohistochemical study of nerves in lumbar facet joint plical tissue. *Spine* **16:** 34-38.

Hansen, K., Schliack, H. (1962) *Segmentale Innervation. Ihre Bedeutung für Klinik und Praxis*, 2nd edn. Stuttgart: Thieme.

Hebel, R., Stromberg, M.W. (1976) *Anatomy of the Laboratory Rat.* Baltimore: Williams & Wilkins.

Hirabayashi, S., Kumano, K., Ohnishi, I. *et al.* (1995) Relationship between the anatomic and dermatomal levels of spinal cord tumors in the thoracic region. *J. Spinal Disord.* **8:** 93-102.

Hirsch, C., Ingelmark, B.E., Miller, M. (1963) The anatomical basis for low back pain. Studies on the presence of sensory nerve endings and ligamentous capsular and intervertebral disc structures in the human lumbar spine. *Acta Orthop. Scand.* **33:** 1-17.

Hovelacque, A. (1925) Le nerf sinu-vertébral. *Ann. Anat. Pathol.* **2:** 435-443.

Hovelacque, A. (1927) *Anatomie des Nerves Craniens et Rachidiens et du Système Grand Sympathique chez l'Homme.* Paris: Doin.

Imai, S., Hukuda, S., Maeda, T. (1995) Dually innervating nociceptive netwoks in the rat lumbar posterior longitudinal ligaments. *Spine* **20:** 2086-2092.

Imai, S., Konttinen, Y.T., Tokunaga, Y. *et al.* (1997) Tyrosine hydroxylase-immunoreactive fibres in rat posterior longitudinal ligament. *J. Auton. Nerv. Syst.* **63:** 51-60.

International Anatomical Nomenclature Committee (1983) *Nomina Anatomica*, 5th edn. Baltimore: Williams & Wilkins.

Jackson, R.P. (1992) The facet syndrome. Myth or reality? *Clin. Orthop.* **279:** 110-121.

Jackson, H.C., Winkelmann, R.K., Bickel, W.H. (1966) Nerve endings in the human lumbar spinal column and related structures. *J. Bone Joint Surg.* **48A:** 1272-1281.

Jackson, R.P., Jacobs, R.R., Montesano, P.X. (1988) Facet joint injection in low-back pain. *Spine* **13:** 966-971.

Jänig, W. (1990) The sympathetic nervous system in pain: physiology and pathophysiology. In: *Pain and the Sympathetic Nervous System* (Stanton-Hicks, M., ed.). Boston: Kluwer Academic Publishers, pp. 17-89.

Jellinger, K. (1966) Experimentelle Untersuchungen zur Frage der arteriellen Versorgungsgebiete des Rückenmarks. *Acta Neuropathol. (Berlin)* **6:** 200-207.

Jiang, H., Russell, G., Raso, J. *et al.* (1995) The nature and distribution of the innervation of human supraspinal and interspinal ligaments. *Spine* **20:** 869-876.

Kaäpa, E., Grönblad, M., Holm, S. *et al.* (1994) Neural elements in the normal and experimentallly injured porcine intervertebral disk. *Eur. Spine J.* **3:** 137-142.

Kaplan, E.B. (1947) Recurrent meningeal branch of the spinal nerves. *Bull. Hosp. Joint Dis.* **8:** 108-109.

Keller, S.M., Carp, N.Z., Levy, M.N. *et al.* (1994) Chronic post-thoracotomy pain. *J. Cardiovasc. Surg. (Torino)* **35:** 161-164.

Kikkawa, F., Fujikara, K., Taniya, S. *et al.* (1978) Über die Kommunikation zwischen den Rami communicantes des Sympathicus und den Rami posteriores der Lendennerven. *Anat. Anz.* **143:** 301-310.

Kimmel, D.L. (1961) Innervation of spinal dura mater and dura mater of the posterior cranial fossa. *Neurology* **11:** 800-809.

Kirvelä, O., Antila, H. (1992) Thoracic paravertebral block in chronic postoperative pain. *Region. Anesth.* **17:** 348-350.

Kojima, Y., Maeda, T., Arai, R. *et al.* (1990a) Nerve supply to the posterior longitudinal ligament and the intervertebral disc of the rat vertebral column as studied by acetylcholinesterase histochemistry. I. Distribution in the lumbar region. *J. Anat.* **169:** 237-246.

Kojima, Y., Maeda, T., Arai, R. *et al.* (1990b) Nerve supply to the posterior longitudinal ligament and the intervertebral disc of the rat vertebral column as studied by acetylcholinesterase histochemistry. II. Regional differences in the distribution of the nerve fibers and their origins. *J. Anat.* **169:** 247-255.

Koning, H.M., Koster, H.G., Niemeijer, R.P.E. (1991) Ischaemic cord lesion following percutaneous radiofrequency spinal rhizotomy. *Pain* **45:** 161-166.

Konttinen, Y.T., Grönblad, M., Antti-Polka, M.D. *et al.* (1990) Neuro-immunohistochemical analysis of peridiscal nociceptive neural elements. *Spine* **15:** 383-386.

Korkala, O., Grönblad, M., Liesi, P. *et al.* (1985) Immunohistochemical demonstration of nociceptors in the ligamentous structures of the lumbar spine. *Spine* **10:** 156-157.

Kumar, R., Berger, R.J., Dunsker, S.B. *et al.* (1996) Innervation of the spinal dura. Myth or reality? *Spine* **21:** 18-26.

Kuntz, A. (1953) *The Autonomic Nervous System*, 4th edn. Philadelphia: Lea and Febiger.

Lang, J. (1985) Anatomie der BWS und des benachbarten Nervensystems. In: *Neuroorthopädie 3. Brustwirbelsäulen-erkrankungen, Engpaßsyndrome, Chemonukleolyse, Evozierte Potentiale* (Hohmann, D., Kügeln, B., Liebig, K. *et al.*, eds). Berlin, Heidelberg, New York, Tokyo: Springer, pp. 14-73.

Lang, J., Wachsmuth, W. (1982) In: *Praktische Anatomie, Teil 7, Band 2: Rücken* (Rickenbacher, J., Landolt, A.M., Theiler, K. *et al.*, eds). Berlin, Heidelberg, New York: Springer, pp. 156-166.

Larnicol, N., Rose, D., Marlot, D. *et al.* (1982) Spinal localization of the intercostal motoneurons innervating the upper thoracic spaces. *Neurosci. Lett.* **31:** 11-16.

Laros, G.S. (1991) Differential diagnosis of low back pain. In: *Contemporary Conservative Care for Spinal Disorders* (Mayer, T.G., Mooney, V., Gatchel, R.J., eds). Philadelphia: Lea and Febiger, pp. 122-130.

Lazorthes, G. (1972) Les branches postérieures des nerves rachidiens et le plan articulaire vertébral postérieur. *Ann. Med. Phys.* **15:** 192-202.

Lazorthes, G., Poulhes, J., Espagno, J. (1947) Étude sur les nerfs sinuvertebraux lombaires. Le nerf de Roofe existe-t-il? *CR Assoc. Anat.* **34:** 317-320.

Lewin, T., Moffett, B., Viidik, A. (1962) The morphology of the lumbar synovial intervertebral joints. *Acta Morphol. Neerl-Scand.* **4:** 299-319.

Lewis, J. (1927) *The Blood Vessels in the Human Skin and Their Responses.* London: Shaw & Sons.

Liesi, P., Grönblad, M., Korkala, O. *et al.* (1983) Substance P: a neuropeptide involved in low back pain? *Lancet* **i:** 1328-1329

Maggi, C.A. (1991) The pharmacology of the efferent function of sensory nerves. *J Auton. Pharmacol.* **11:** 173-208.

Maggi, C.A., Meli, A. (1988) The sensory-efferent function of capsaicin-sensitive sensory nerves. *Gen. Pharmacol.* **19:** 1-43

Maigne, J.-Y., Maigne, R., Guérin-Surville, H. (1991) Upper thoracic dorsal rami: anatomic study of their medial cutaneous branches. *Surg. Radiol. Anat.* **13:** 109-112.

Malinsky, J. (1959) The ontogenic development of nerve terminations in the intervertebral discs of man. *Acta Anat.* **38:** 96-113.

Matthijssen, M.A.H., Hofstee, M.W.A., Thunnissen, I.E. *et al.* (1994) Comparison of AChE and PGP 9.5 in cerebrovascular nerves of the rat. *J. Anat.* **185:** 707.

McLachlan, E.M., Jänig, W., Devor, M. *et al.* (1993) Peripheral nerve injury triggers noradrenergic sprouting within dorsal root ganglia. *Nature* **363:** 543-546.

Mitchell, G.A.G. (1953) *Anatomy of the Autonomic Nervous System.* Edinburgh: Livingstone.

Mooney, V., Robertson, J. (1976) The facet syndrome. *Clin. Orthop.* **115:** 149-156.

Moran, R., O'Connell, D., Walsh, M.G. (1988) The diagnostic value of facet joint injections. *Spine* **13:** 1407-1410.

Morinaga, T., Takahashi, K., Yamagata, M. *et al.* (1996) Sensory innervation to the anterior portion of lumbar intervertebral disc. *Spine* **21:** 1848-1851.

Moskowitz, M.A. (1984) The neurobiology of vascular head pain. *Ann. Neurol.* **16:** 167-168.

Murphey, F. (1968) Sources and patterns of pain and disc disease. *Clin. Neurosurg.* **15:** 343-351.

Nakamura, S., Takahashi, K., Takahashi, Y. *et al.* (1996) Origin of nerves supplying the posterior portion of lumbar intervertebral discs in rats. *Spine* **21:** 917-924.

Norregaard, T.V., Moskowitz, M.A. (1985) Substance P and the sensory innervation of intracranial and extracranial feline cephalic arteries. Implications for vascular pain mechanisms in man. *Brain* **108:** 517-533.

Palmgren, T., Grönblad, M., Virri, J. *et al.* (1996) Immunohistochemical demonstration of sensory and autonomic nerve terminals in herniated lumbar disc tissue. *Spine* **21:** 1301-1306.

Parke, W.W., Watanabe, R. (1985) The intrinsic vasculature of the lumbosacral spinal nerve roots. *Spine* **10:** 508-515

Pascual, E., Castellano, J.A., Lopez, E. (1992) Costovertebral joint changes in ankylosing spondylitis with thoracic pain. *Br. J. Rheumatol.* **31:** 413-415.

Pedersen, H.E., Blunck, C.F.J., Gardner, E. (1956) The anatomy of lumbosacral posterior rami and meningeal branches of spinal nerves (sinuvertebral nerves) *J. Bone Joint Surg.* **38A:** 377-391.

Pick, J. (1957) The identification of sympathetic segments. *Ann. Surg.* **145:** 355-364.

Pick, J. (1970) *The Autonomic Nervous System. Morphological, Comparative, Clinical and Surgical Aspects.* Philadelphia: Lippincott.

Piscol, K. (1972) *Die Blutversorgung des Rückenmarkes und ihre klinische Relevanz. Schriftenreihe der Neurologie, Band 8.* Berlin, Heidelberg, New York: Springer, pp. 21-57

Prestar, F.J., Putz, R. (1982) Das Ligamentum longitudinale posterius - Morphologie und Funktion. *Morphol. Med.* **2:** 181-189.

Rabischong, P., Louis, R., Vignaud, J. *et al.* (1978) The intervertebral disc. *Anat. Clin.* **1:** 55-64.

Revel, M.E., Listrat, V.M., Chevalier, X.J. *et al.* (1992) Facet joint block for low back pain: Identifying predictors of a good response. *Arch. Phys. Med. Rehabil.* **73:** 824-828.

Roberts, W.J., Elardo, S.M. (1985) Sympathetic activation of A-delta nociceptors. *Somatosens. Res.* **3:** 33-44.

Roberts, S., Eisenstein, S.M., Menage, J. *et al.* (1995) Mechanoreceptors in intervertebral discs. Morphology, distribution, and neuropeptides. *Spine* **20:** 2645-2651.

Roofe, P.G. (1940) Innervation of annulus fibrosus and posterior longitudinal ligament. *Arch. Neurol. Psychiatr.* **44:** 100-103.

Rowland, L.P. (1991) Clinical syndromes of the spinal cord and brain stem. In: *Principles of Neural Science* (Kandel, E.R., Schwartz, J.H., Jessell, T.M., eds). New York, Amsterdam, London, Tokyo: Elsevier, pp. 711-730.

Russell, T. (1992) Thoracic intervertebral disc protrusion. In: *Surgery of the Spine. A Combined Orthopedic and Neurosurgical Approach,* Vol. 2 (Findlay, G., Owen, R., eds). London, Edinburgh, Boston: Blackwell Scientific, pp. 813-820.

Sekiguchi, Y., Konnai, Y., Kikuchi, S. *et al.* (1996) An anatomic study of neuropeptide immunoreactivities in the lumbar dura mater after lumbar sympathectomy. *Spine* **21:** 925-930.

Skubic, J.W., Kostuik, J.P. (1991) Thoracic pain syndromes and thoracic herniation. In: *The Adult Spine,* Vol. 2 (Frymoyer, J.W., ed.). New York: Raven Press, pp. 1441-1461.

Spurling, T.G., Bradford, F.K. (1939) Neurological aspects of herniated nucleus pulposus at the fourth and fifth lumbar interspaces. *J.A.M.A.* **113:** 2019-2022.

Steindler, A., Luck, J.V. (1938) Differential diagnosis of pain low in the back. Allocation of the source of pain by the procaine hydrochloride method. *J.A.M.A.* **110:** 106-113.

Stilwell, D.L. (1956) The nerve supply of the vertebral column and its associated structures in the monkey. *Anat. Rec.* **125:** 139-169.

Stolker, R.J., Vervest, A.C.M., Groen, G.J. (1993) Percutaneous facet denervation in chronic thoracic spinal pain. *Acta Neurochir. (Wien)* **122:** 82-90.

Stolker, R.J., Vervest, A.C.M., Groen, G.J. (1994a) The treatment of chronic thoracic segmental pain by radiofrequency percutaneous partial rhizotomy. *J. Neurosurg.* **80:** 986-992

Stolker, R.J., Vervest, A.C.M., Ramos, L.M.P., Groen, G.J. (1994b) Electrode positioning in thoracic percutaneous partial rhizotomy: an anatomical study. *Pain* **57:** 241-251.

Stolker, R.J., Vervest, A.C.M., Groen, G.J. *et al.* (1994c) On the innervation of the dorsal compartment of the thoracic spine. In: *Pain Management by Radiofrequency Procedures in the Cervical and Thoracic Spine: A Clinical and Anatomical Study.* Thesis, Utrecht, pp. 133-144.

Stolker, R.J., Vervest, A.C.M., Groen, G.J. (1994d) The management of chronic spinal pain by blockades: a review. *Pain* **58:** 1-20.

Stolker, R.J., Vervest, A.C.M., Groen G.J. (1994e) Parameters in electrode positioning in thoracic percutaneous facet denervation: an anatomical study. *Acta Neurochir. (Wien)* **128:** 32-39.

Tago, H., Kimura, H., Maeda, T. (1986) Visualization of detailed acetylcholinesterase fiber and neuron staining in rat brain by a sensitive histochemical procedure. *J. Histochem. Cytochem.* **34:** 1431-1438.

Takahashi, Y., Morinaga, T., Nakamura, S.-I. *et al.* (1996) Neural connection between the ventral portion of the lumbar intervertebral disc and the groin skin. *J. Neurosurg.* **85:** 323-328.

Taylor, J.R., Twomey, L.T. (1979) Innervation of lumbar intervertebral discs. *Med. J. Aust.* **2:** 701-702.

Tencer, A.F., Allen, B.L., Ferguson, R.L. (1985) A biomechanical study of the thoracolumbar spine fractures with bone in the canal. Part III. Mechanical properties of the dura and its tethering ligaments. *Spine* **10:** 741-747.

Thompson, R.J., Doran, J.F., Jackson, P. *et al.* (1983) PGP 9.5 - a new marker for vertebrate neurons and neuroendocrine cells. *Brain Res.* **278:** 224-228.

Von Luschka, H. (1850) *Die Nerven des Menschlichen Wirbelkanales.* Tübingen: H. Laupp.

Vrettos, X.C., Wyke, B.D. (1974) Articular reflexogenic systems in the costovertebral joints. *J. Bone Joint Surg.* **56B:** 382.

Weinstein, J.N. (1991) Anatomy and neurophysiologic mechanisms of spinal pain. In: *The Adult Spine. Principles and Practice* (Frymoyer, J.W., ed.). New York: Raven Press, pp. 593-610.

Weinstein, J.N., Claverie, W., Gibson, S. (1988a) The pain of discography. *Spine* **13:** 1344-1348.

Weinstein, J.N., Pope, M., Schmidt, R., Seroussi, R. (1988b) Neuropharmacologic effects of vibration on the dorsal root ganglion. An animal model. *Spine* **13:** 521-525.

Whitcomb, D.C., Martin, S.P., Schoen, R.E., Jho, H.D. (1995) Chronic abdominal pain caused by thoracic disc herniation. *Am. J. Gastroenterol.* **90:** 835-837.

Wiberg, G. (1949) Back pain in relation to the nerve supply of the intervertebral disc. *Acta Orthop. Scand.* **19:** 211-221.

Williams, P.L., Bannister, L.H., Berry, M.M. *et al.* (eds) (1995) *Gray's Anatomy.* New York, Edinburgh: Churchill Livingstone, p. 1311.

Wiltse, L.L., Fonseca, A.S., Amster, J. *et al.* (1993) Relationship of the dura, Hofmann's ligaments, Batson's plexus, and a fibrovascular membrane lying on the posterior surface of the vertebral bodies and attaching to the deep layer of the posterior longitudinal ligament. An anatomical, radiologic, and clinical study. *Spine* **18:** 1030-1043.

Windsor, M., Inglis, A., Bogduk, N. (1985) The innervation of the cervical intervertebral discs. *J. Anat.* **142:** 218-219.

Wyke, B.D. (1970) The neurological basis of thoracic spinal pain. *Rheumatol. Phys. Med.* **10:** 346-367.

Wyke, B.D. (1975) Morphological and functional features of the innervation of costovertebral joints. *Folia Morph.* **23:** 296-305.

Wyke, B.D. (1987) The neurology of back pain. In: *The Lumbar Spine and Back Pain* (Jayson, M.I.V., ed.). Edinburgh: Churchill Livingstone, pp. 56-99.

Xu, X.-J., Hao, J.-X., Seiger, Å. *et al.* (1994) Chronic pain-related behaviours in spinally injured rats: evidence for functional alterations of the endogenous cholecystokinin and opioid systems. *Pain* **56:** 271-277.

Yabuki, S., Kikuchi, S. (1995) Nerve root infiltration and sympathetic block. An experimental study of intraradicular blood flow. *Spine* **20:** 901-906.

Yahia, L.H., Newman, N., Rivard, C.H. (1988) Neurohistology of lumbar spinal ligaments. *Acta Orthop. Scand.* **59:** 508-512

Yamashita, T., Cavanaugh, J.M., El-Bohy, A.A. *et al.* (1990) Mechanosensitive afferent units in the lumbar facet joint. *J. Bone Joint Surg.* **72A:** 865-870.

Yamashita, T., Minaki, Y., Özaktay, A.C., Cavanaugh, J.M., King, A.I. (1996) A morphological study of the fibrous capsule of the human lumbar facet joint. *Spine* **21:** 538-543.

Yezierski, R.P. (1996) Pain following spinal cord injury: the clinical problem and experimental studies. *Pain* **68:** 185-194.

Yoshizawa, H., O'Brien, J.P., Smith, W.T., Trumper M. (1980) The neuropathology of intervertebral discs removed for low-back pain. *J. Neurosurg.* **51:** 172-177.

Section

III

Diagnosis of Thoracic Spine Pain

9

Diagnosis of thoracic pain syndromes

J. H. Bland

A perusal of the literature on clinical syndromes of the thoracic spine suggests that this area is far less commonly affected by diseases and disorders that affect the cervical and lumbar regions of the spine. Such is far from true. There are many conditions, particularly associated with osteoarthritis and some of which are relatively uncommon, that may manifest unique and frequently puzzling syndromes. For example, the author has seen a case of neurogenic claudication with positionally dependent weakness resulting from a thoracic disc herniation, which was successfully treated surgically.

The thoracic spine is relatively more stable than the lumbar or cervical spines because of the ribcage and the configuration of thoracic vertebrae. Even so, when osteoarthritis affects the thoracic spine, leading to neural compression, it can be far more serious because of the relative vulnerability to compression of the thoracic spinal cord.

Back pain has been with us from time immemorial. However it is only in the past few decades that various thoracic disease entities causing back pain have been differentiated. As with other body regions, the history and physical examination are relied upon for diagnosis of a disease state more than any other diagnostic contributions. Historical elicitation and physical examination remain supreme for diagnosis. The manifestations of disease that arise in the thoracic spine are protean and relate to pain and loss of function. Therefore, though it is important to understand the physiology and anatomy of this region, it is equally important to comprehend significant historical data and physical signs. For instance, observation of the surface of the thoracic spine, particularly the skin, provides helpful information. Pigmented spots (café au lait), pedunculated polyps, rash, localized blisters (herpes zoster), hairy patches and birthmarks may all be diagnostic. Subcutaneous lipomas are common and may be well-circumscribed, diffuse over the back, or even present as an enlargement of the buttock, suggesting probable neurological involvement.

Contrary to usual considerations of thoracic disorders, the spectrum of pathology is wide and varied. Table 9.1 lists diagnoses made over the course of a 25-year period in which the author had a special interest in clinical thoracic spine syndromes (Table 9.1).

Clinical examination of the thoracic spine

Disc lesions account for a high proportion of thoracic pain syndromes. Clinically the thoracic spine is handily divisible into three sections: the first consists of T1 and T2, and is examined with the cervical spine because the nerve roots serve the upper limbs; next is T3-T6, where displacements are extremely unusual; followed by T6-T12, where they are relatively frequent. Reduction is easy; however, relapse is commonplace. Both posterior and anterior thoracic pain may stem from the disc lesion.

The dura mater

As at other spinal levels, the mechanism of pain is usually dural. A protrusion may compress the dura mater centrally, giving rise to unilateral extrasegmentally referred pain. A T6-level protrusion can cause pain up to the base of the neck and down to the waist. A protrusion at T12 can refer pain up to T6 and down to the sacrum.

Table 9.1 *The wide and varied spectrum of thoracic pathology, representing diagnoses made over the course of a 25-year period in which the author had a special interest in clinical thoracic spine syndromes*

1. Thoracic intervertebral disc prolapse: calcified and non-calcified, calcification confined to the nucleus pulposus in children and adults.
2. Thoracic osteoarthritis.
3. Scoliosis and kyphoscoliosis – especially during rapid growth spurt, progression of curvature and concomitant osteoarthritis.
4. Scheuermann's disease – 32 cases observed, commonly in adolescents, but even in middle age associated with osteoarthritis.
5. Referred pain from cervical osteoarthritis to the thoracic spine area.
6. Osteoarthritis affecting intervertebral discs, costotransverse and costovertebral joints.
7. Metabolic bone diseases: osteoporosis (with and without demonstrable fracture), osteomalacia, Paget's disease.
8. Postural disorders, mainly in young women.
9. Altered spinal biomechanics secondary to pregnancy.
10. Primary and secondary tumours involving the thoracic spine: tumours of the spinal cord and nerve roots, neoplasms of the chest wall and pleura.
11. Ankylosing spondylitis and rheumatoid arthritis.
12. Vertebral osteomyelitis and disc space infections in both children and adults.
13. Bornholm disease (epidemic pleurodynia – named for the island of Bornholm in the Baltic Sea).
14. Intercostal neuralgia, with unknown specific aetiology – perhaps shingles.
15. Post-nephrectomy syndromes, entrapment of 12th thoracic intercostal nerve in the scar tissue.
16. Avulsion fracture of spinous processes, clay shoveler's fracture.
17. Serratus anterior nerve palsy.
18. Intrinsic spinal cord disease: focal arachnoiditis in the thoracic spinal cord; arachnoid cyst; radiation necrosis of the spinal cord.
19. Diabetic peripheral neuropathy.
20. Visceral disease in the chest and abdomen: coronary artery disease; pleurisy; hiatus hernia; renal disease; penetrating peptic ulcer; biliary disorders; pancreatitis.
21. Aortic aneurysm with thoracic vertebral involvement.
22. Post-herpetic neuralgia.
23. After rib fracture, 'slipping rib' syndrome and allied mechanical disorders; Teitze's syndrome; avulsion of lower costal chondral junction.
24. Sub-scapular bursitis.

The nerve root

A postero-lateral displacement of the disc may produce root pain referred anteriorly. At T1 and T2 (both rare occurrences), symptoms may be felt in the arm; root pain at lower levels causes pain to be experienced at the side or front of the trunk. A low cervical disc lesion is usually the cause of pain felt at the upper thoracic level and in the arm. Below the sixth thoracic dermatome, a syndrome may arise from a thoracic disc lesion. At that level, diagnosis is often difficult due to the dilemma of balancing signs of visceral disease against those that might be confirmation of a joint disorder.

The onset of a thoracic spine disc displacement is variable, from abrupt to a gradually appearing posterior thoracic backache. In postero-lateral displacement unilateral pain will be noted to the front of the chest or the abdomen, presenting diagnostic difficulties. Compression of T11 or T12 roots causes discomfort in the iliac fossa, sometimes radiating to the testicles. Coughing may initiate sharp pain, but a deep breath tends to hurt more. Symptoms suggesting pleurisy or intercostal nerve or muscular abnormality are also exaggerated by deep breathing, helping to rule out cardiac pain. True joint signs are uncommon and neurological signs, strangely enough, are conspicuous by their absence. There are no clinical tests for conduction, i.e. weakness, or mobility of nerve roots, and analgesia is rarely noted. As at any other level, pain from protruding discs is a function of posture and the physical activities undertaken by the patient.

It is important to know whether the extremities are equal in length. Any discrepancy should be equalized by placing appropriate sized heel blocks beneath the shortened extremity, if the shortening is actual and not relative. At this point, the general posture should be noted from the front, sides and back of the patient. Are the shoulders level and is the pelvis horizontal? With thoracic muscle spasm there may be a list to one side, with loss of normal contours of the thoracic spine. An increased lumbar lordosis will have an effect on the biomechanics of the thoracic spine. When the lateral spinal curve (scoliosis) is structural, the direction of the cavity and convexity should be noted. The degree of compensation or decompensation can be determined by dropping a plumb-line from the spinous process of C7, the vertebrae prominens. With compensation, the string should fall in the midline of the nates. In true disc herniation, when the herniation is lateral to the nerve root the patient tilts away from the lesion, and when the disc protrusion lies medial to the nerve root the patient will lean towards the side of the lesion.

A gibbus observed in the thoracic spine is an important observation – it could be related to infection (tuberculosis), fracture or a congenital bony anomaly of the spine. In an elderly female patient with thoracic spine pain, a kyphotic deformity may indicate compression fractures secondary to osteoporosis. In a young patient, excessive rounding may be related to ankylosing spondylitis or a decrease in the growth of the spine in Scheuermann's disease during adolescent years. It is also important to observe movement of the chest cage during respiration. With normally relatively little movement between the thoracic vertebral bodies (a physiologic state), disease in the thoracic spine may limit excursion of the chest cage when rotated and malaligned vertebral bodies and their attached ribs no longer move synchronously - for example, in ankylosing spondylitis.

Gait

The gait pattern can be very important in determining whether or not disease originates in the spine or the lower extremities. Gait observation discloses gross weakness or atrophy of the muscles that can affect normal gait. Gait may be divided into two phases; stance, during which time the foot is in contact with the ground, and swing phase, when the opposite foot is in contact with the ground. Familiarity with normal gait patterns allows observation of pathologic gaits as a source of important clinical signs.

Range of motion

Young patients have spines that are more flexible than those of advancing age, due in part to greater elasticity of soft tissues connecting the vertebral bodies in the young individual. Does motion cause pain? The cervical spine, of course, has the greatest range of motion of all spinal areas, a clinical estimate being that the cervical spine moves about 600 times an hour, the lumbar spine far less, and the thoracic spine least. The ranges of motion to be determined are flexion and extension, right and left lateral flexion or tilt, and rotation to the right and to the left. As osteoarthritis progresses in discs and zygapophysial joints, so does the corresponding decrease in normal motion. Care must be taken to examine all six motions carefully, making observations, of course, of the cervical and lumbar spine during examination of the thoracic spine. Measurement of chest expansion is a mandatory clinical observation.

Palpation

The examiner should palpate (feel) for muscle spasm while the patient is seated, standing, and during testing of motion. If a suspected malingerer does not flex the lumbar spine while erect, the patient should be asked to kneel on the padded seat of a chair facing the back rest. The muscles usually relax and soften dramatically, disclosing the malingering manoeuvre. In this case the lumbar spine may even round out with ease. Are the thoracic paravertebral muscles extraordinarily firm and tender? Do they bulge as muscle spasm increases? Are they more prominent on one side than on the other? Are there any localized masses?

The spinous processes are readily palpated and are not covered by muscle or thick connective tissues. Tender spinous processes indicate disease, including fracture, infection and tumour. The iliac crest and sacrum should be palpated. The tops of the iliac crest are normally aligned with the upper level of the fourth lumbar vertebral body. Soft tissue palpation is also important. Abdominal muscles as well as any palpable intra-abdominal organs, liver and spleen, should be examined. The inguinal region should be examined for hernia. The anterior abdominal muscles contract normally when the upper (T6-T9) and lower (T10-L1) muscle fibres have normal innervation. If the abdominal muscles are weak in the presence of strong hip flexors, hyperextension of the lumbar spine results when the patient tries to elevate the lower extremities or to sit from a supine position.

Dura mater signs

Neck flexion to its greatest degree stretches the dura mater at both cervical and thoracic levels. Pain on neck flexion is hence common to a defect at either level. If other neck movements - extension, lateral flexion and right/left rotation - are full and pain free, the thoracic zygapophysial joints are probably normal. Scapular approximation, i.e. throwing the shoulders back as far as possible and bringing the scapulae together, pulls on the thoracic extent of the dura mater via the first and second thoracic nerves; thus pain can be elicited from a central or lateral thoracic disc lesion. Pain from stretching the first thoracic root (with the arm extended toward the ceiling and then flexed to touch the upper thoracic spine in the midline) involves the T1 or T2 roots; this is a great rarity and is only occasionally accompanied by neurological signs. If weakness is present, however, the possibility of serious diseases exists.

Joint signs

Articular signs are best sought by a series of active movements, largely passive in their diagnostic significance because of the effect of body weight. Extension of the spine should be tested first, followed by the two side flexions. Bilateral limitation in the young patient indicates serious disease, but in the elderly may be attributable to no more than normal loss of mobility. Next, the entire spine should be rotated maximally, first to the right and then to the left. Lastly, flexion of the thoracic spine should be performed. Disc displacement usually causes asymmetrical pain or limitation on two, three or four movements. The movement most likely to cause pain in a disc lesion is the extreme of passive rotation, achieved by holding the patient's knees between the examiner's to fix the pelvis. In a minor disc protrusion, this may be the only painful movement.

Resisted movements

The right and left lateral flexion, extension and flexion and both rotations are all performed with the examiner providing resistance to each movement. Abnormal muscle contractions may produce the following symptoms:

- Pectoral muscles - pain on resisted adduction felt anteriorly on the chest
- Intercostal muscles - pain on breathing or taking a deep breath
- Latissimus dorsi - pain on resisted adduction felt in the back of the chest
- Inferior posterior serratus (rare) - pain on resisted rotation
- Rectus abdominus - pain on resisted flexion
- Oblique abdominal muscles - pain on resisted rotation.

Lesions of muscle do not radiate pain from the posterior thoracic spine to the anterior or *vice versa*. Such distribution is sufficient on its own to acquit the muscles.

Cautionary notes

A finding of painful and limited lateral flexion away from the painful side with both rotations free from pain always creates suspicion of serious lesions. Rotation is the movement most likely to be painful with a disc lesion; therefore, if rotary range is full and painless with another movement hurting, the examiner must be forewarned by this discrepancy. Neoplasm or neuroma are possibilities.

Joint capsular lesions show a capsular pattern that is best described as equal and grossly severe limitation of movement in every direction. Such suggests tuberculosis (rare nowadays), cancer or ankylosing spondylitis.

Spinal cord symptoms and signs

Because of the clearly increased risk and relative narrowness of the bony thoracic spinal canal, spinal cord lesions must be ruled out as contributing to the clinical picture. Occasionally the only symptom of compromise of spinal cord function is the perception of a 'pins and needles' sensation in both lower legs on neck flexion. This is not a particularly ominous sign.

Abdominal reflexes are obtained by lightly and rapidly stroking the upper (T7-T9), middle (T9-T11) and lower (T11-T12) abdominal wall with a pointed instrument obliquely from the midline outward. Care should be taken not to scratch the skin. The response is a contraction of the abdominal muscles of that segment. Note that bilateral absence of reflexes may be congenital, and hence is of less significance than a lack of response on one side. Abdominal reflexes should be investigated especially
and suspected Parkinsonism. Overactive patellar and Achilles reflexes are regarded as evidence of dysfunction of extrapyramidal pathways from the precentral

Table 9.2 *Differential diagnostic signs and symptoms in thoracic pain syndromes*

1. Visceral disorders are not influenced by thoracic movements.
2. Osteoporosis in older patients is painless unless pathological wedging has occurred; such may cause symptoms lasting up to 3 months.
3. Fracture of a rib causes localized pain lasting 6 weeks at most; symptoms from fracture of a vertebra cease at the end of 3 months.
4. Osteitis deformans, aortic aneurysm, tuberculous bone infection and metastatic malignant disease result in pain arising from diseased bone.
5. Ankylosing spondylitis produces pain that is variable, intermittent, continues for years irrespective of what the patient does; ache is often worse on waking; lumbar spine becomes rigid before thoracic joints stiffen; a flat lumbar spine is associated with upper thoracic kyphosis in ankylosing spondylitis.
6. A neuroma in tissues on one side of the patient's spine painfully limits lateral flexion *away* from that side; the reverse of the expected finding with a disc lesion. A spreading patch of cutaneous analgesia should arouse suspicion; initial symptoms may be confined to the posterior thoracic area.
7. Adult osteochondrosis is painless but limits extension in particular.
8. Neuritis of the spinal accessory, long thoracic or suprascapular nerve produces constant unilateral scapular pain for an estimated 3 weeks.
9. Pain from early thrombosis of the aorta is occasionally perceived in the lower thoracic spine area.
10. The diaphragm embryologically is derived from C3, C4 and C5 myotomes and sclerotomes, with the pain normally confined to the C4 dermatome. Pain arising from that part of the pleura not in contact with the diaphragm is perceived in the chest. A Pancoast's tumour will invade the chest wall. In epidemic myalgia, the pain is bilateral and accompanied by fever.
11. In the initial stage, neuralgic amyotrophy causes bilateral upper thoracic pain; later symptoms spread down one or both arms.
12. Embryologically the anatomical cardiac components are mainly derived from the first, second and third thoracic dermatome-myotome-sclerotome segments.

motor cortex through subcortical centres of the spinal cord. The Babinski reflex consists of dorsiflexion of the big toe and fanning of the other toes, reflecting impaired function of the pyramidal tract in the spinal cord. The reflex is carried out by stroking the outer border of the sole and crossing the plantar surface. Often the sole is so ticklish that the other reflexes must be relied upon. Their mode of response is the same, but the technique differs. The Chaddock reflex is elicited by stroking around the lateral malleolus, the Oppenheim reflex by firmly pressing the anterior tibial surface on descending towards the foot, and the Gordon reflex results from squeezing the calf muscles. The Gonda reflex is an upward movement of the big toe elicited by pressing one of the other toes downward and releasing it with a snap (the fourth toe is most effective). Complete functional interruption of the spinal cord is characterized by an extremely active flexor defence reflex giving rise to a most vigorous flexion of both legs and simultaneous evacuation of bowel and bladder, known as the Mass reflex.

A guide to the differential diagnosis of thoracic spine pain is provided in Table 9.2.

Radiologic assessment

With the continuing development and refinement of new radiological techniques, especially computerized tomography (CT), myelography and magnetic resonance (MR) scans, elucidation study of thoracic pain syndromes beyond plain radiographic images has become commonplace. Plain films of the thoracic spine have a very important initial role for diagnosis, decision-making and follow-up; however, MR and CT scans and myelography, as well as electrodiagnostic studies, are essential in more complicated circumstances.

The advent of newer methods of radiographic imaging does not change the need for careful clinical and diagnostic patient evaluation. Close co-operation between the radiologist, the neuroradiologist and the clinician is essential for accurate and cost-effective patient care.

It is important to emphasize the maximum application of clinical skills to the thoracic pain syndrome, and the integration of all aspects of radiography into clinical practice, research and education. Radiology is a tool to be used intelligently in conjunction with other methods. The radiologist must always be supplied with all pertinent clinical information, preferably through personal consultation, to assist with the optimal selection from the broad spectrum of modern diagnostic options. Clinicians should also personally read the patient's plain films and, wherever possible, review with the radiologists the far more complex but highly educational CT and MR scans.

Radiological study of the thoracic spine contributes to precise diagnosis and ongoing assessment of disease progress, identifying healing as well as the failure of therapy. Radiological studies also further the understanding of thoracic spine biomechanics and pathology. Radiographic study of other structures often allows more precise interpretation of radiographs of the thoracic spine. It is sound practice to remember that the diagnosis of cervical osteoarthritis is essentially a radiological one. On radiographs of middle-aged and elderly people these signs are the rule and not the exception; they are perhaps a more reliable sign of middle age than grey hair! Eighty per cent of normal (control) subjects have thoracic osteoarthritis. It seems logical for aetiological purposes to study the 20% of men over 50 years of age who do not have thoracic osteoarthritis.

Clearly the great majority of patients with radiological osteoarthritis are asymptomatic. A significant number have intermittent episodes of stiff neck; a small proportion have transient neurological signs indicating minor lesions of the nerve roots or long tracts of the spinal cord. Bothersome but clinically unimportant paraesthesias and hyperaesthesias may occur in the hands and feet of some patients. A very few patients develop more or less disabling syndromes secondary to nerve root or cord damage.

Clinical embryological issues

It is occasionally useful to know from which somite certain viscera are derived. The dermatome, myotome and sclerotome cells migrate during the embryonic period of segmentation, and often have clinical usefulness (see Chapter 6). Table 9.3 lists the approximate segmental derivations of viscera from T2-S5.

Table 9.3 *Segmental derivations of viscera from T2-S5*

Viscera	*Segmental spinal level*
Lungs	T2-T5
Oesophagus	T4-T5
Stomach and duodenum	T6-T8
Liver and gallbladder	T7-T8, right
Pancreas	T8, left
Small intestine	T9-T10
Appendix and ascending colon	T10-L1
Epididymis	T10
Ovary, testes, adrenal glands	T10-T12, L1
Bladder fundus, kidney, uterine fundus	T11-L1
Colonic flexure	L2-L3
Sigmoid colon, rectum, cervix	S2-S5
Neck of bladder, prostate, urethra	S2-S5

The thoracic spine and the autonomic nervous system

The autonomic nervous system has an intimate relationship with various parts of the thoracic spine. In the upper portion it passes across the necks of the ribs. It is in close contact with the rib heads and the costovertebral

portion the more anterior aspects of the vertebral bodies are contacted. The splanchnic nerves run a steep and oblique course over the lower thoracic vertebrae. Gloobe and Nathan (1971) described the distortion, attenuation and fibrosis of the sympathetic trunk (cord and ganglia) that occurs with lumbar syndesmophytes and osteophytes, and found that such changes were less marked at the T12-L1 level. Distribution of branches to the anterior longitudinal ligament and the anterior aspect of the intervertebral discs were reported. Comparable morphological studies of the sympathetic nervous system in the thorax have not been reported, but considering such diseases as ankylosing spondylitis and thoracic spine osteoarthritis (both discs and zygapophysial joints), they could suggest an explanation for some of the puzzling features of autonomic concomitance of pain in these disorders. Sympathetic dysfunction and even blocking or inhibition can reasonably be expected as sequelae to irritation and compression. Such is an uncertain field for morphological and neurophysiological research, but currently these are the clinical implications.

Specific disorders of the thoracic spine

Paget's disease

Paget's disease is characterized by gross hyperfunction of osteoclasts, which manifests as compensatory hyperactivity of osteoblasts resulting in an affected bone characterized by a patchwork appearance of bone resorption and deposition. The normal osteoblast/osteoclast relationship is grossly disturbed (Bullough and Shenoba, 1988) (Fig. 9.1). The disease may affect one or multiple bones, and clearly involves the spine. Radiographic evaluation discloses increased width and loss of height of affected vertebrae, enlargement of the pedicles, and bone masses that may project beyond the vertebral body. Bone scans demonstrate increased uptake in affected bones. Computerized tomography scans reveal vertebral changes with narrowing of the spinal canal and the lateral recesses where the nerve roots exit. Sometimes spinal lesions may involve the spinal cord or result in cauda equina compression. Such compression often occurs in the thoracic rather than the cervical or lumbar spine. In patients with progressive spinal cord signs, a decompressive laminectomy is usually effective. The procedure may be difficult because of excessive bleeding from the thickened, enormously vascularized bone. Some patients may have cord compression resulting not from the Paget's disease itself, but from sarcomatous degeneration of involved bone. Cord compression from associated epidural haematoma has also been described (Lee *et al.*, 1988).

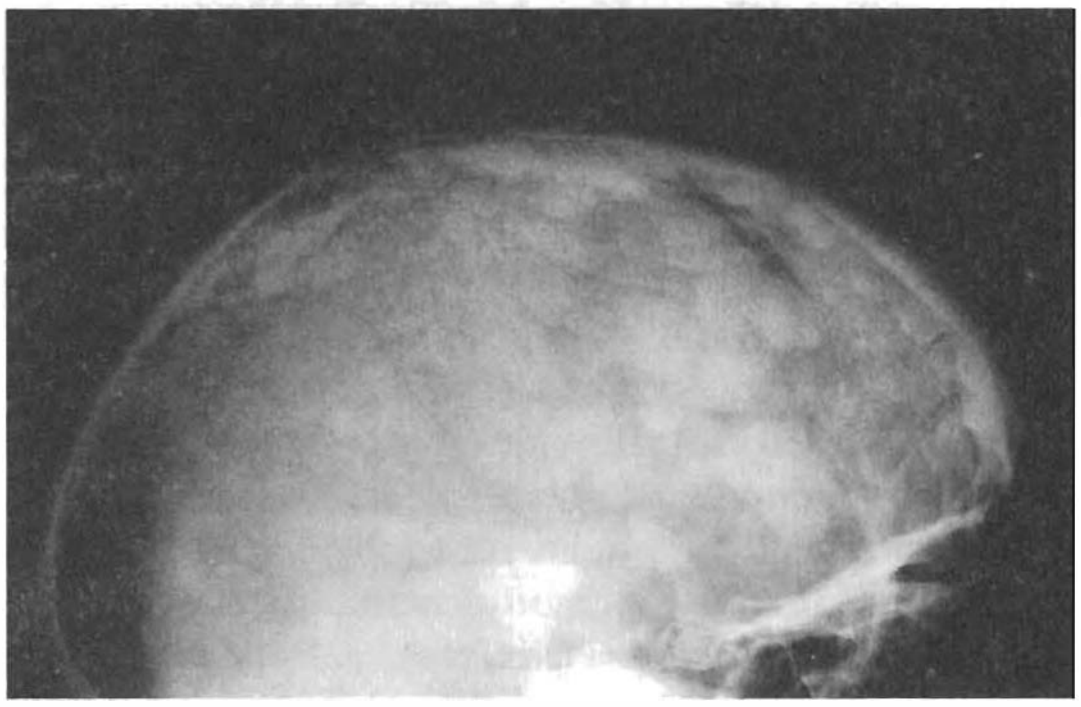

Fig. 9.1 Paget's disease of the skull. Note the mottled appearance of the bone, reflecting the pathologic osteoblast/osteoclast synthetic resorption disparity at a cellular level. The disease may affect the thoracic spine, with similar tissue consequences and clinical reflections.

Rheumatoid arthritis

Rheumatoid arthritis primarily involves the cervical spine, particularly and intensively at the C1-C2 level. It is mentioned here although it is rather unusual to have rheumatoid involvement in the thoracic spine that is of clinical significance. Thoracic involvement in ankylosing spondylitis does occur almost universally, but rheumatoid spondylitis occurs only in a few individuals (Heywood and Meyers, 1986). In such patients the disease presents with local pain, and pathologic findings including vertebral collapse, subluxation and zygapophysial joint granulations. Radiologically there is evidence of erosion of the endplates and the zygapophysial joints. Although neurological changes are seen when the disease involves the lumbar spine, none have been reported from thoracic involvement. Rheumatoid arthritis occasionally requires differentiation from thoracic spine osteoarthritis or disc space infection.

DISH syndrome

The prime characteristic of DISH syndrome (diffuse idiopathic skeletal hyperostosis or Forestier's disease) is calcification of the anterior longitudinal ligament, as well as all related, anatomically similar ligaments. Some patients have gross ankylosis of the spinal

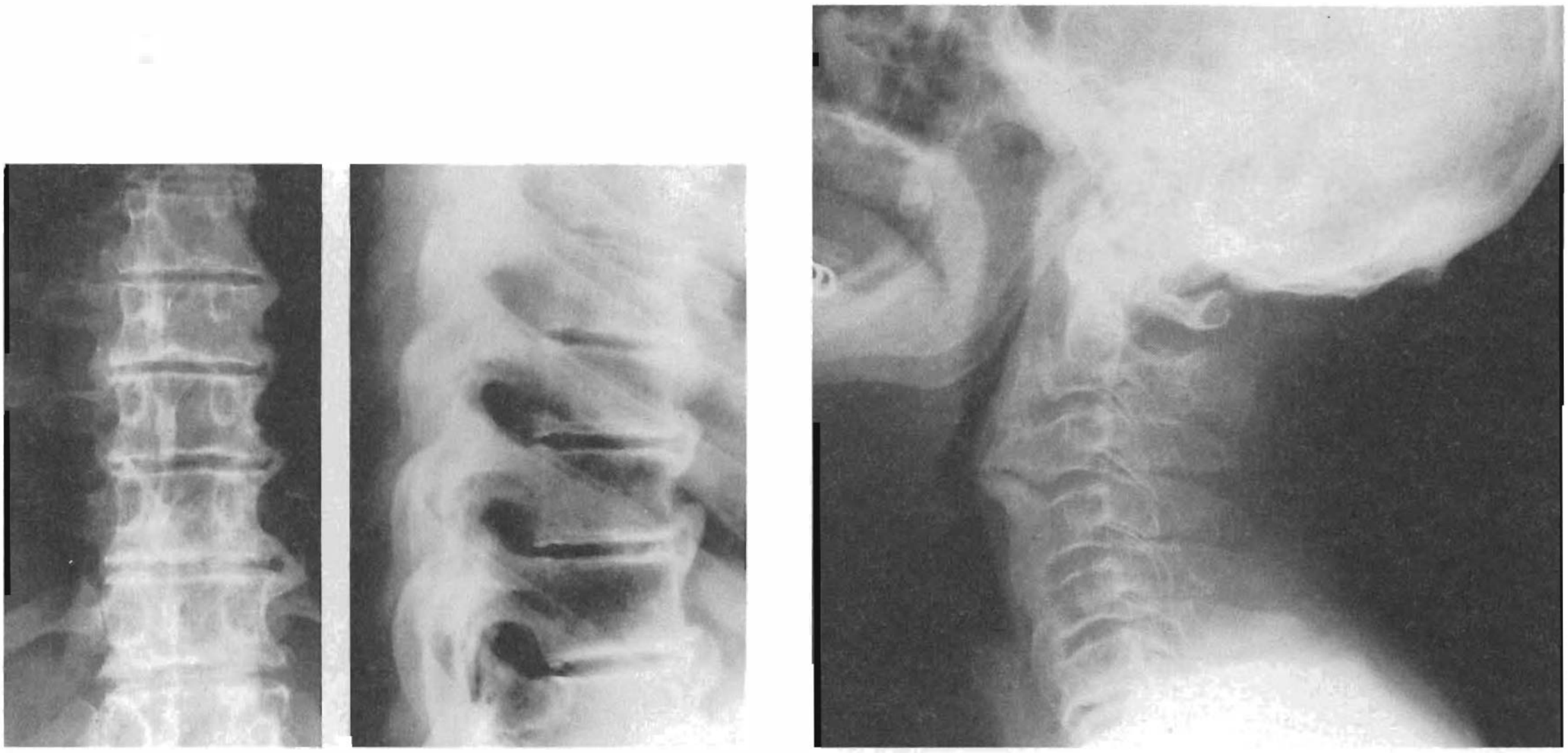

(A) (B)

Fig. 9.2 (A) Thoracic spine with DISH syndrome (AP and lateral views). Note long bony bridging between the vertebrae, sometimes called 'kissing osteophytes'. Right: Lateral view showing the bony bridging and ossification of the anterior longitudinal ligament. (B) DISH syndrome involving the cervical spine. Note the extremely heavy ossification of the anterior longitudinal ligament, nearly 0.8–1.0 mm of bone added onto the vertebrae.

column, largely antero-laterally (Fig. 9.2). Clinically, the disease becomes apparent with pain and stiffness, most particularly in the thoracic spine. Cervical and lumbar spinal symptoms may be associated with similar complaints and similar lesions in other joints peripherally. Physical examination discloses compromised flexion and loss of normal lumbar lordosis. Spinal tenderness is seen in the great majority of patients; such tenderness may be seen at other involved points. Most frequently, the thoracic X-ray shows calcification of antero-lateral aspects of affected vertebral bodies; zygapophysial joints are not commonly involved, and the intervertebral disc heights are peculiarly preserved. Treatment of DISH syndrome is non-operative, although some patients may develop cord compression from fractures similar to those seen in ankylosing spondylitis (Case records of the Massachusetts General Hospital, 1989). A few patients display neurological signs from associated posterior osteophytes or ossification of the posterior longitudinal ligament (PLL). This circumstance is very common among Japanese, but more recently has been recognized in Western populations (Wsuyama, 1984). An association between DISH and ossification of the PLL has been recognized (Jobanputra *et al.*, 1988). Ossification of the PLL is most common in the cervical spine but may also occur in the thoracic spine, most commonly in the T4–T8 segments. Patients with cord compression from ossification of the PLL may require surgery, using either an anterior or a posterior approach.

Scheuermann's disease

Scheuermann's disease (osteochondrosis juvenilis) (Fig. 9.3) is a strange but not uncommon degenerative process, occurring in children or adolescents. It is characterized by wedge-shaped deformities of vertebral bodies that result in a kyphotic spinal deformity. Pathologically, there is disruption of the growth plate and protrusion of intervertebral disc material into the vertebral body, known as Schmorl's node. This event is the most characteristic aspect of the disease (Wilcox and Spencer, 1986). The disease presents in juvenile patients as back pain, either thoracic or lumbar, and frequently seems to follow an injury. The pain generally corresponds to the site of injury, somewhat peculiarly. Physical examination discloses local tenderness at the site of the lesion, loss of lumbar lordosis and general spinal stiffness with decreased spinal mobility. Radiographs demonstrate wedging of adjacent vertebral bodies, Schmorl's nodes, loss of disc height, fragmentation of the epiphyseal rings and sclerosis of adjacent vertebral margins. Most frequently, minimal conservative treatment with rest, moderate exercise and analgesics is successful. A few patients with marked kyphosis require bracing. Operative treatment is indicated only for correction of a severe spinal deformity, or to treat spinal cord compression in patients with severe kyphosis, which is rare. Surgical management is that of anterior disc resection and fusion followed by posterior instrumentation and arthrodesis.

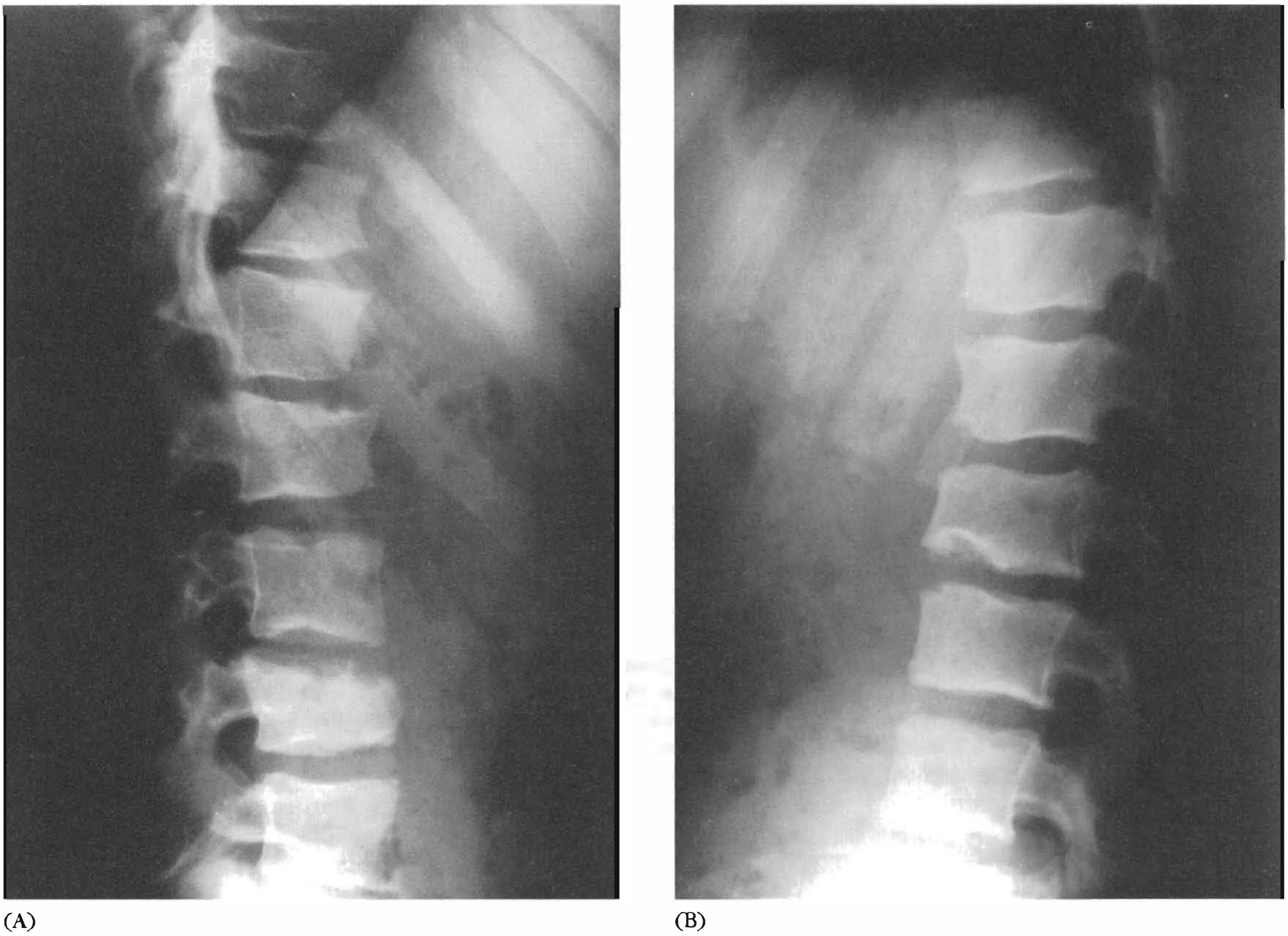

Fig. 9.3 (A) Scheuermann's disease, thoracic with some extension into the lumbar spine. Note that most vertebrae have lost their expected anatomical outline, have radiolucent areas and holes in the bone particularly anteriorly. The second vertebra from the bottom has a mottled density. The spine has lost its normal curvature, being nearly straight. There is some disc involvement, with varying thickness, radiolucency and radiodensity. (B) Scheuermann's disease with more striking involvement in the third vertebra from the bottom (14-year-old male). Clinically, the child had a definite kyphosis in the thoracic spine.

Ankylosing spondylitis

Ankylosing spondylitis is a form of inflammatory arthritis occurring mainly in young people, primarily males, resulting in ankylosis of varying magnitudes - the worst causing a near statue-like condition. Ossification of the intervertebral discs occurs, with bulging of anterior and posterior surfaces by bony osteophyte-like structures called syndesmophytes. The zygapophysial joints also are commonly fused, leading to a rigid immobile spine (Fig. 9.4A). The radiological appearance is the so-called 'bamboo' spine (Fig. 9.4B, C). Usually the disease manifests itself with pain, stiffness and progressive loss of motion. Neurological symptoms may appear in some patients in association with destructive lesions of the spine. It is thought that such destructive lesions are traumatic in origin, perhaps secondary to a fracture or to an injury at a mobile joint in an otherwise rigid spine. These structures should be differentiated from osteomyelitis or metastatic tumours, and this is frequently a difficult task. The disease is strongly genetic, characterized by an HLA B27 antigen, a test for which establishes the diagnosis in 90-95% of cases (Ryall and Helliwell, 1998). Surgical stabilization and decompression are rarely required.

Bony thoracic canal stenosis

Compressive myelopathy in the lumbar and cervical spines, consequent to osteoarthritis, and proliferative degenerative changes in the laminae and zygapophysial joints are well known and have long been recognized. In the past 15 years it has been recognized that dorso-lateral compression also occurs in the thoracic spine (Barnett *et al.*, 1987). Thoracic canal stenosis occurs in the absence of any systemic disease. The syndrome occurs primarily in older patients presenting with general symptoms of gait disturbance, pain and 'pins and needles' sensations in the legs. Sensory symptoms commonly appear when the person stands or starts to walk, and are relieved

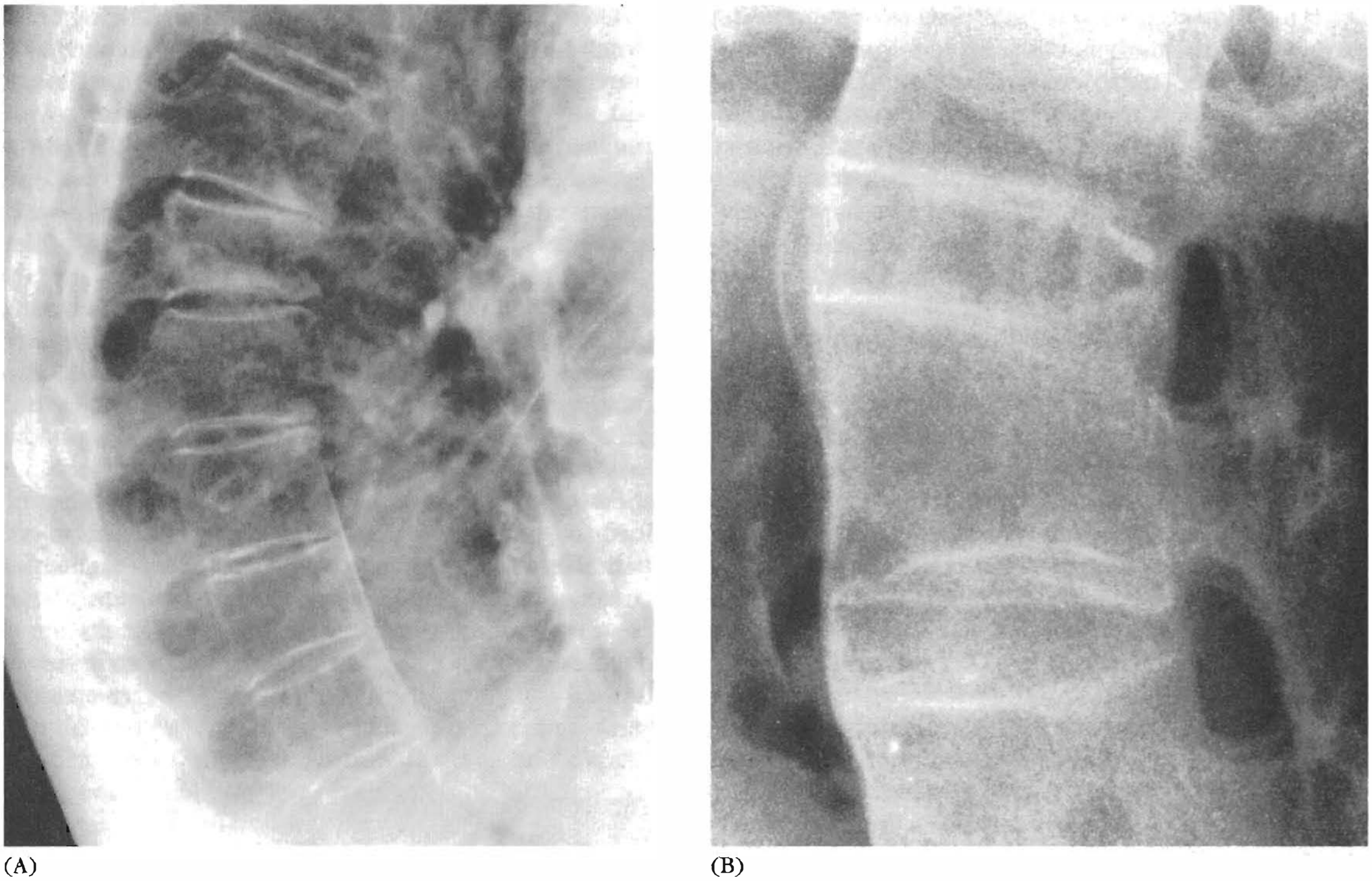

(A)

(B)

(C)

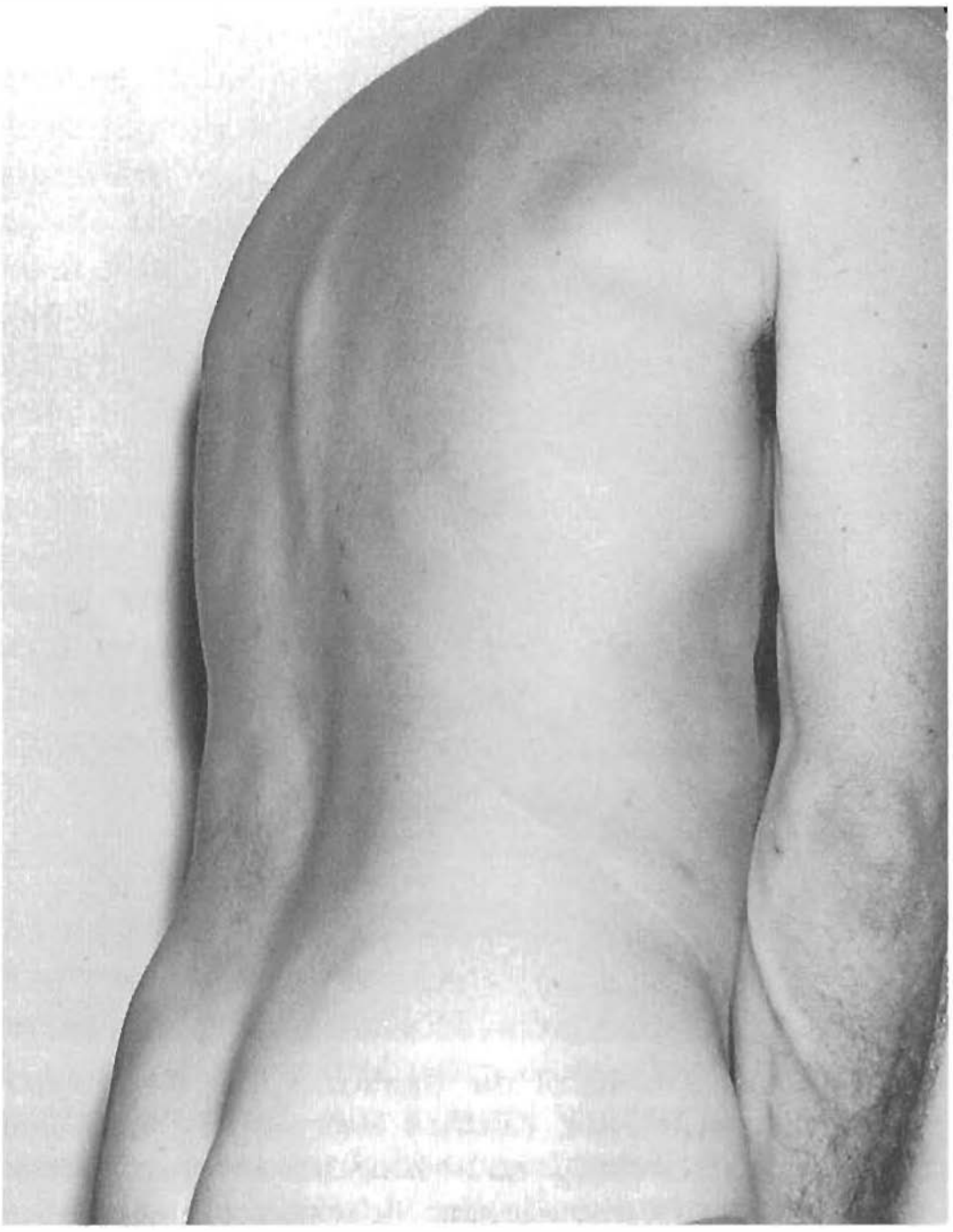

Fig. 9.4 Ankylosing spondylitis. (A) Note calcified anterior longitudinal ligament in the lower half of the photograph, 'squaring' of the vertebrae and compression fracture in upper portion of the illustration.
severe, near total ankylosis of the lower thoracic spine. Note, to the right, severe ankylosis including the zygapophysial joints and complete calcification of the anterior longitudinal ligament. (C) Clinical appearance of the nearly completely ankylosed spine in the above patient, with mid-dorsal kyphosis and rigid thoracolumbar lordosis.

by lying down. Thoracic stenosis may mimic the symptoms of lumbar canal stenosis, since both lesions involve narrowing of the bony canal. On neurological examination, spastic paraparesis is commonly found accompanied by lower thoracic sensory level changes, which are readily demonstrable clinically. Reflexes are virtually uniformly hyperactive, and the Babinski response is characteristically extensor. The compressive lesion is noted in the lower thoracic spine, and consists of zygapophysial joint hypertrophy, short pedicles and striking thickening of the laminae. The ligamentum flavum is usually thickened, hypertrophied and sometimes calcified, resulting in constriction of the spinal canal and cord compression. In most patients, anterior disc herniation is not observed. This is an important point, as thoracic stenosis is best treated with decompressive laminectomy, the approach for which is inadequate for removal of herniated thoracic discs. The lesion itself is difficult to identify on plain X-ray or myelogram films, which is perhaps why the condition has often gone undiagnosed. Thoracic stenosis is readily and thoroughly visualized on CT scan with or without accompanying contrast media. Magnetic resonance scans with high quality axial and parasagittal images are likewise wonderfully diagnostic. It is important that the parasagittal MR scans be carefully examined, for the lesion could be missed if only midline images are considered. Thoracic spinal canal stenosis can usually be successfully treated with decompressive laminectomy, including resection of the medial zygapophysial joints and the ligamentum flavum. Commonly the disc need not be removed, and removal should not be attempted. Occasionally there is the issue of whether a modest disc protrusion is contributing to neural compression, and decision-making at the operating table is crucial. Such has occurred in younger patients with congenitally (rather than acquired) narrow canals when symptoms followed known trauma. In these unusual cases, laminectomy can be combined with transpedicular disc removal to achieve effective decompression.

Osteoarthritis of the thoracic spine

Osteoarthritis affects three sites in the thoracic spine: the intervertebral disc; the zygapophysial joints; and the articulations of the rib with the vertebral body and the transverse process. The osteoarthritic changes in discs and zygapophysial joints sometimes result in neural compression, either of nerve roots or the spinal cord (Fig. 9.5). Osteoarthritis of the costovertebral and costotransverse joints is frequently a source of chronic pain, but is not associated with neurological changes. In most cases, the intervertebral disc begins to lose water content in the third to fourth decade of life and microscopic alterations appear. Grossly, the nucleus pulposus is shrunken and fragmented, and the anulus fibrosus also thickens and deteriorates with significant changes being tears in concentric fibrous bands. As in osteoarthritis generally, the tissue changes strongly indicate biological attempts to repair. This results in anular tears with nuclear displacement and osteophytosis. The term 'spondylosis deformans' is used to describe the process anteriorly, and osteochondrosis when it involves the vertebral body and the end-plates of the discs. Abrupt disc herniation into the vertebral body results in a Schmorl's node. Most medical clinicians believe that the pain and loss of spinal mobility are mainly due to lack of use, failure of stretching, relative immobilization, weight bearing stresses and making demands upon the tissues involved. Spondylosis deformans and osteochondrosis do not, in themselves, cause pain or loss of spinal mobility or lead to neurological symptoms. Compression of neural structures may occur if there is acute or chronic nucleus pulposus protrusion, posteriorly or postero-laterally. When a larger disc fragment is displaced into the spinal canal or the lateral recesses (neural foramina), symptoms and signs can occur

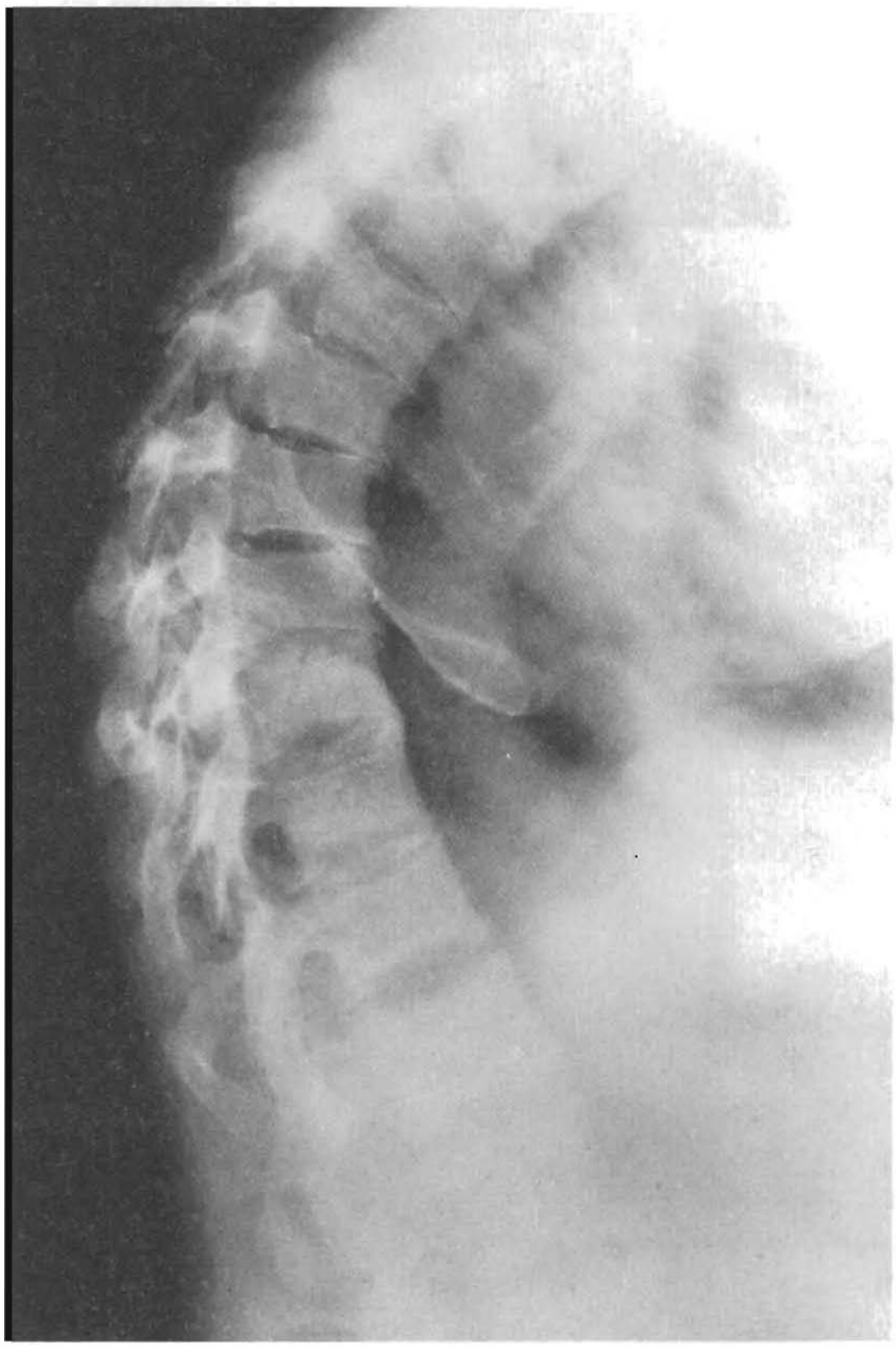

Fig. 9.5 Osteoarthritis of the thoracic spine. Note osteophytes, mainly anterior, calcified intervertebral discs and that T12 (fifth vertebra from bottom) has collapsed following herniation of a thoracic disc.

either acutely or gradually. A series of small protrusions may lead to osteophyte formation, and cord signs develop when the disc fragment or osteophyte encroaches upon the canal. Nerve root signs develop as neural compression occurs in the lateral aspect of the canal or in the foramen. In the thoracic spine, clinically important disc protrusion results in spinal cord compression, but lateral compression leads almost entirely to radicular symptoms; however, combinations of the two can occur. Patients use the following words to describe radicular pain: electric, shock-like, pins and needles, radiating from proximal to distal, a narrow band, bright, sharp, stabbing and intermittent. Myelopathy is generally more common in clinical practice than radiculopathy. Osteoarthritic changes in the zygapophysial joints, quite common in the cervical or lumbar spine, are less so in the thoracic spine. Such changes may lead to spinal canal narrowing and consequent neurological symptoms. Symptoms may follow osteoarthritic changes superimposed on a congenital stenosis. Changes include thickening and hypertrophy of zygapophysial joints, their capsules and the laminae, thickening and calcification of the ligamentum flavum, and short, thick pedicles. Minor disc protrusions, insufficient to be symptomatic in normal patients, may contribute to the clinical picture in those with stenosis (Yamamoto *et al.*, 1988). Osteoarthritis of the costovertebral and costotransverse joints also may lead to local thoracic spine pain as well as pain in the paraspinal region. These osteoarthritic changes may perhaps lead to symptoms and intercostal nerve compression, but this is difficult to verify and to separate as an individual syndrome from root entrapment at the foramen. In the absence of definitive spinal cord and nerve root signs, management consists of as little as education of the patient and rest. Analgesics, or muscle relaxants such as methocarbamol (1 g four times daily) or diazepam (5 mg three times a day), plus local cold applications - ethyl chloride spray has been used - may be useful. Basic exercises are designed to improve posture and to increase abdominal and spinal muscle control. Stretching exercises are very important. Local application of heat, massage and electrical stimulation has been employed. Myofascial syndromes resulting in thoracic pain have been treated with trigger-point injections of local anaesthetic or a combination of local anaesthetic and corticosteroids.

Herniations of thoracic discs

Herniated thoracic intervertebral discs are clearly quite uncommon compared to the frequency of herniation of the lumbar or cervical discs. When they do occur, thoracic disc protrusions may threaten the spinal cord and can require emergency surgery. Herniated thoracic discs occur mainly in the lower thoracic spine, probably related to increased mobility in that portion of the thoracic spine (Fig. 9.5; see also Fig. 12.5). Trauma can be a factor, for instance a history of a hard fall on the buttocks. Protrusions can be lateral or central, with central being the more common. Lateral protrusions usually produce radicular symptoms accompanied by spinal cord signs. Central herniation results in symptoms and signs of cord compression, which may be chronic or acute, rapid progression constituting a surgical emergency. Radicular symptoms are usually in the distribution of the lower thoracic roots. Evaluating such patients presents a diagnostic problem, as root pain in the abdomen may mimic visceral disease. A detailed neurological examination will disclose dermatomal sensory loss, lower motor weakness of abdominal muscles or asymmetrical abdominal reflexes. With central disc protrusions, radicular pain may or may not be present. Back pain is a common but variable symptom. Symptoms of cord compression include gait disturbance, paraesthesias of the legs, and bladder or bowel disturbance. Neurological signs may include a sensory level; spastic or in very acute cases flaccid paraparesis; hyperactive deep reflexes, clonus, positive long tract signs and Beevor's sign. With a spinal cord lesion causing paralysis of the lower but not the upper abdominal muscles, the umbilicus rises; this is Beevor's sign. Breathing patterns should be observed to ascertain whether the intercostal muscles are functioning. If the C3-C5 nerve roots to the diaphragm are intact and a spinal cord lesion is present (caused by trauma or tumour) resulting in paralysis of the intercostal muscles, respiratory movements will be entirely abdominal. If abdominal musculature is paralysed on one side only, the umbilicus tends to be pulled toward the normal side on inspiration. During coughing, the paralysed side bulges more than the unaffected side. When the patient flexes the head and neck toward the trunk, the equal tension of the entire abdominal musculature keeps the umbilicus in the central position.

Radiating pain and paraesthesias are commonly produced in gross herniation of thoracic intervertebral discs or in intraspinal obstruction secondary to tumours. These conditions raise intracranial and intraspinal fluid pressure. Coughing, sneezing, straining to move the bowels, twisting the back while stooping, heavy lifting or even standing for a long period of time may cause such pain and paraesthesia. The pain reflects an increase in intraspinal fluid pressure, and can also be produced by compressing the jugular veins in the neck, thereby increasing the intracranial and intraspinal pressure by distending intraspinal veins. This is call Naffziger's test. With a history and neurological examination findings pointing to a compressive lesion in the lower thoracic spinal cord, a plain X-ray should be obtained to exclude a gross lesion (metastatic lesion to the spine). Such films may disclose discal calcification or other osteoarthritic changes, but these do not, in themselves, establish a diagnosis. Formerly, the next step in evaluation of suspected herniated thoracic discs was a water-soluble myelogram and CT scan; however, alternative imaging strategies are now possible. Magnetic resonance imaging has advanced to the point where many spine surgeons obtain an MR scan and, if the diagnosis is clear-cut, omit any further studies. If doubt remains after the MR scan, a water-soluble myelogram and CT scan should be performed as the next step. Surgical decompression is the only treatment option for a patient with progressive myelopathy from a herniated thoracic disc. Historically these lesions were treated by laminectomy and an attempt at posterior removal, with disastrous results. Since these lesions compress the cord anteriorly and are frequently calcified, posterior decompression of itself cannot relieve the compression, and surgical attempts at disc removal from a posterior approach usually result in cord trauma secondary to manipulation and retraction. For that reason, antero- and posterolateral operations have been developed to reach the lesions directly. A combined laminectomy/transpedicular operation seems now to be the operation of choice, resulting in far more satisfactory postoperative consequences.

Referral to a medical or surgical physician

If the complete interview, history taking and physical examination indicate some clear involvement of nerve roots, peripheral nerves or the spinal cord, referral to a specialist physician or surgeon is mandatory. Often time is of the essence, and neurological damage can be arrested or even reversed, especially in circumstances in which the neurological symptoms and signs are of short duration.

References

Barnett, G.H., Hardy, R.W., Little, J.R. *et al.* (1987) Thoracic spinal stenosis. *J. Neurosurg.* **66:** 338-344.

Bullough, P.G., Shenoba, B.A. (1988) *Atlas of Spinal Diseases*. New York: Gomer Medical Publishing.

Case records of the Massachusetts General Hospital Weekly Clinicopathological Exercise (1989) Case No. 43-189. A 79-year-old woman with an osteolytic lesion of the spine and increasing paraparesis after a fall. *N. Eng. J. Med.* **321:** 1178-1179.

Gloobe H., Nathan, H. (1971) The costovertebral joint; anatomical observations in various mammals. *Anat. Ann.* **127:** 22-31.

Heywood, A.W.B., Meyers, O.L. (1986) Rheumatoid arthritis of the thoracic and lumbar spine. *J. Bone Joint Surg.* **68B:** 362-368.

Jobanputra, P., Kirkam, B., Duke, O. *et al.* (1988) Discovertebral destruction in ankylosing spondylitis complicated by spinal cord compression. *Ann. Rheum. Dis.* **47:** 344-347.

Lee, K.S., McWhorter, J.M., Angelo, J.H. (1988) Spinal epidural hematoma associated with Paget's disease. *Surg. Neurol.* **30:** 131-134.

Ryall, N.H., Helliwell, P.S. (1998) A critical review of ankylosing spondylitis. *Crit. Rev. Phys. Rehab. Med.* **10:** 265-301.

Wilcox, P.G., Spencer, D.W. (1986) Dorsolumbar kyphosis or Scheuermann's disease (osteochondrosis). *Clin. Sports Med.* **5:** 343-351.

Wsuyama, N. (1984) Ossification of the posterior longitudinal ligament of the spine. *Clin. Orthop.* **184:** 71-83.

Yamamoto, I., Matsumae, M., Ikeda, A. *et al.* (1988) Thoracic spinal canal stenosis; experience with seven cases. *J. Neurosurg.* **68:** 37-40.

10

Cervicothoracic and thoracolumbar spinal pain syndromes

J.-Y. Maigne

Cervicothoracic spinal pain syndromes

The anatomical cervicothoracic junction (CTJ) is comprised of two vertebrae; C7 and T1. However, from a functional point of view the neighbouring vertebrae and their degree of mobility must also be considered. The seventh cervical vertebra is a transitional vertebra with an upper half that is cervical, and a lower half that is thoracic. Despite the favourable orientation of the zygapophysial joints, the mobility of C7–T1 and T1–T2 is restricted by the adjoining ribs. Thus, pathology involving these two latter segments is very uncommon. Conversely, C5–C6 and C6–C7 should be considered as part of the CTJ because they are much more mobile (especially C5–C6) and prone to painful minor intervertebral dysfunction. Thus it is considered that the CTJ is comprised of C5–C6 in addition to C7–T1.

The CTJ may be the source of many pain syndromes, including neck pain, cervical radiculopathies, shoulder pain, elbow pain, and even upper thoracic or periscapular pain. This unexpected referral pattern is due to the distribution of the nerves and the presence of some muscles, which transmit or perpetuate the pain. This chapter deals with upper thoracic/periscapular pain syndromes of cervical origin, referred to as cervicothoracic pain syndromes.

The course of the lower dorsal rami

C5–T2

Just after their exit from the intervertebral foramen, each of the four lower cervical roots (C5–C8) subdivides into ventral and dorsal rami. The dorsal ramus, after a short course, passes through a vertical opening limited cranially and caudally by the transverse processes of two contiguous vertebrae, medially by the zygapophysial process and laterally by the intertransverse ligament. This opening allows easy passage of the nerve. It separates the ventral and the dorsal compartments (regarding the nerve and vascular supply) of the spine. Upon emerging from this passageway, the dorsal ramus subdivides into lateral and medial branches. The lateral branch runs caudally and laterally and supplies the lateral cervical muscles. The medial branch runs dorsally in the angle between the transverse and the zygapophysial processes of the corresponding vertebra and supplies two joint capsules. Each joint is therefore innervated by two different nerves. The medial branch continues its course, following the lamina and the spinous process, and supplies the corresponding periosteum and the inner compartment of the neck muscles before it reaches the apex of the spinous process of the corresponding vertebra. Up to C5, the medial branch becomes superficial at this level by passing through the tendons of the neck muscles and spreading out laterally, innervating the skin of the neck. The dorsal cutaneous rami of C5 and T1 are only present in 30% of cases. The cutaneous branches of C6, C7 and C8 tend to be very short and thin. In most cases, the medial branch terminates at the apex of the spinous process.

The second thoracic vertebral level has a dorsal cutaneous branch (medial branch) supplying a large strip of skin extending up to the acromion. Consequently, on the trunk, the dermatomes C4 and T2 are neighbours. It could be hypothesized that during embryological development the dermatomes C5 to T1 are drawn out into the upper limbs, whose sensitivity is highly developed; thus there is no dorsal dermatome for these roots. The same phenomenon is observed in the lower limb (the L1 and S1 dorsal dermatomes are contiguous as there is no dermatome supplied by L2–L5), and in the face there is no dorsal dermatome between C2 and the trigeminal nerve.

T2–T6

From a personal previous study of 16 dissections of the thoracic spine, Maigne *et al.* (1991) observed that the pattern of innervation was basically the same at this level. The major difference is that the medial branches of the dorsal rami of T2–T6 continue their course superficially after reaching the tip of the spinous process. Lateral to this process they pass through rigid orifices constituted by paravertebral tendons, which can occasionally compress them. In four of the 16 cases, one of the cutaneous dorsal branches appeared to be compressed in this fashion. This upper thoracic or periscapular pain, although such entrapments may be symptom-free in the majority of cases. The dorsal cutaneous branches of the second, third and fourth thoracic nerves then lie under the tendon of the splenius cervicis muscle, easily found by its triangular-shaped tendon that inserts mainly on the spinous processes of T4. The nerves pass through the tendinous fibres of the rhomboideus muscle and then move laterally. In this last portion of their course, the nerves are directed obliquely and laterally, increasing this angle caudally. They do not become superficial until they have passed through the muscle portion of the trapezius at 1–3 cm from the midline. The dorsal cutaneous branch of the second thoracic nerve continues laterally to the acromion, whereas the adjacent cutaneous branches are shorter. Distal to T6, the pattern is reversed; the medial branches terminate at the tip of the corresponding spinous processes and the lateral branches, which have both motor and sensory fibres, continue their course distally, perforating the thoracolumbar fascia and becoming superficial to innervate the subcutaneous tissues and the skin.

Pain patterns from the cervicothoracic junction: experimental data

The following is a summary of the data pertaining to pain referral from the neck to the upper thoracic and periscapular regions.

Clinical observations

The connection between the upper thoracic/interscapular region and the lower cervical spine is acknowledged in cases of cervical radiculopathy, as the acute or chronic phase of this condition is often accompanied by upper thoracic pain. The same pain referral is observed in the rare cases of tumours of the cervical medulla.

Cloward (1960), while performing cervical discographies in patients with radicular pain, noted several cases where pain referred to the upper thoracic/interscapular region, either medially or laterally, during injection of contrast into the affected disc. More precisely, the needling and stimulation of the postero-lateral part of the anulus of the lower cervical discs referred pain to the shoulder with radiation into the upper arm, while stimulation of the anterior part of the anulus selectively referred pain to muscles along the vertebral border of the scapula or into the middle of the back. According to Cloward (1960), the involved muscles could be the levator scapulae in the first case and the rhomboideus major and minor in the second. This author gave two possible explanations: the sclerotomal correspondence between the stimulated disc and the muscles (C3–C5); or the fact that, embryologically, the ventrolateral sheath of musculature of the lower cervical region undergoes subsequent migration to obtain a secondary skeletal attachment to the vertebral column at a considerable distance from its origin. Periscapular pain is also a frequent adverse reaction to incorrect cervical manipulation.

Experimental studies

Dwyer *et al.* (1990) presented the patterns of pain referral from the cervical zygapophysial joints in normal volunteers. Injection of the lower zygapophysial joints (C5–C6 and C6–C7) led to pain radiating to the posterior shoulder, the scapula or the upper thoracic spine, varying according to the injected level.

Thoracic pain syndromes from the cervicothoracic junction

Two thoracic pain syndromes from the CTJ are described; interscapular pain and lateral upper thoracic spine pain.

Interscapular pain

Thoracic interscapular pain is a very common complaint, especially in women, where it is very often considered to be psychogenic. However, although women may perhaps have this type of involvement more often than men, it is seen in both genders and at all ages. The ensuing disability varies according to the profession (e.g. typists can suffer badly). An essential point is the usual cervical origin of the pain, which has a clinical stereotyped picture of interscapular vertebral pain. This cervical origin of interscapular thoracic pain was acknowledged by Robert Maigne more than 30 years ago (Maigne, 1964).

Fig. 10.1 The interscapular point (*). The pain is experienced at this level and elicited by pressure on it. Technique of palpation requires an oblique pressure directed toward the lateral aspect of the spinous process of T4.

Symptoms

Usually the pain is experienced as a very painful point between the scapulae, at T4 or T5. This point is felt either medially or slightly laterally, with both sides being equally involved. It can be accompanied by cervical pain, or may present in isolation. The pain is sometimes increased by prolonged neck flexion; for example, working at a desk. Ipsilateral rotation or lateral bending of the cervical spine may be painful.

Clinical signs

The physical examination reveals the same signs in all cases. These include both thoracic and cervical signs.

1. Thoracic signs:
   a. Palpation of the interscapular point reveals a specific tender point or zone (described by Maigne, 1964), always close to the apex of the spinous process of T4 (i.e. seen on fluoroscopy to overlie the body of T5), localized to either the right or left side (Fig. 10.1). The pressure of the palpating finger must be directed obliquely toward the lateral aspect of the spinous processes, and not sagittally toward the zygapophysial joints. This point is very tender in a localized area, and pressure on it reproduces the familiar periscapular pain. This periscapular point has been called the 'cervical point of the back' (Maigne, 1964).
   b. The other clinical sign is the presence of an area of skin that may appear slightly thickened and is always extremely sensitive to the pinch-roll manoeuvre (cellulalgia). This area includes all or part of the cutaneous territory of the dorsal branch of the first and second thoracic nerves, which extends to the acromion. This cellulalgia is located ipsilateral to the periscapular point.
2. Cervical signs:
   a. With the patient lying supine and relaxed with the head gently supported by the physician's hands, palpation of the cervical spine (segment by segment, one side after the other) reveals tenderness of one or occasionally two segments, often C5-C6 or C6-C7, ipsilateral to the periscapular point, and cellulalgia. In the absence of other diagnoses such as disc herniation or synovitis, this tenderness corresponds to a painful minor intervertebral dysfunction (PMID), or a minor mechanical dysfunction of the motion segment caused by either a disc or a zygapophysial disorder.

In addition to these findings, assessment of the response to treatment is important. Thus in many cases cervical manipulation leads to resolution of the cervical PMID and the accompanying painful periscapular point. The sensitivity of the overlying skin to the pinch-roll test clearly decreases. This relief may occur instantly, or in some cases three to five sessions may be required.

Connection between the interscapular point and the lower cervical spine

There is no obvious anatomical link between the interscapular point and the lower cervical spine. It can only be hypothesized that the interscapular point might correspond to the distal attachment of the splenius cervicis (the splenius of the neck, to be distinguished from the splenius capitis, the splenius of the head). This muscle shares its proximal attachment to the upper two or three cervical transverse processes with the levator scapula. Its major distal attachment is to the lateral aspect of the spinous process of T4, corresponding closely to the clinically painful spot (Fig. 10.2). The distal attachment extends to the interspinous ligaments above and below (T3-T4 and T4-T5), with some tendinous fibres also inserting on the spinous processes of T3 and T5. It would seem that this insertion is the only one that could correspond to the precise location of the interscapular point; the insertions of other muscles are spread out over several vertebral levels or over too large an area. The splenius cervicis is supplied by

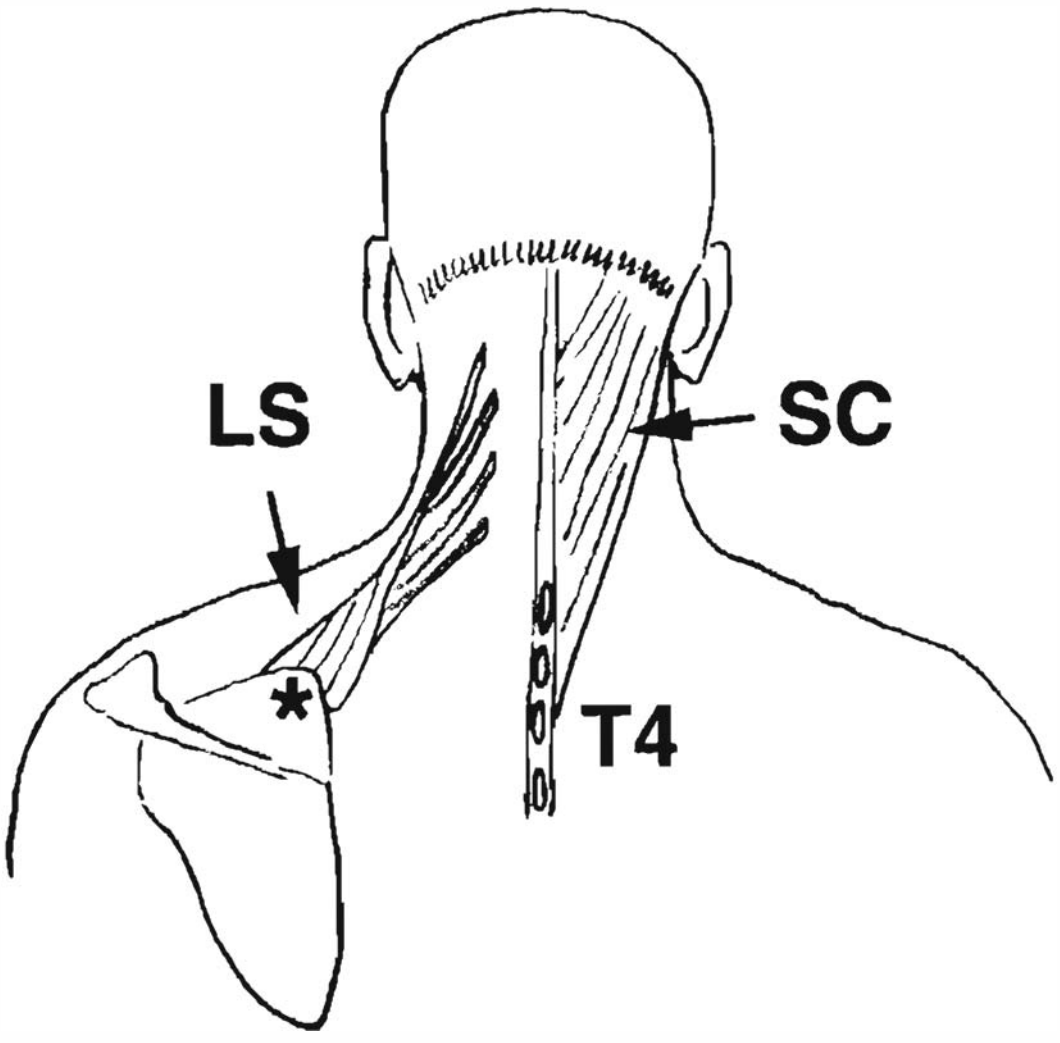

Fig. 10.2 Caudal attachment of the splenius cervicis (SC) to the spinous process of T4 and to the adjacent interspinous ligaments. Caudal attachment of the levator scapulae (LS) to the inner angle of the scapulae. This point (*) corresponds to the 'levator point'.

the dorsal rami of C5, C6 and C7 (Gray, 1973), and these levels correspond to the level involved by the PMID. Thus, it appears that the interscapular point could correspond to an insertional pain of a spasming or painful muscle. The mechanism for the presence of cellulalgia in the dermatomes of T1 and T2 is more difficult to understand, and Maigne (1964) suggested the following explanation. In the trunk, the dermatomes C4 and T2 are neighbours, as the dermatomes C5-T1 are drawn out into the upper limbs during embryological development. The cutaneous branches of the lowest cervical spinal nerves are described as being vestigial or non-existent. It is possible that, at the thoracic level, the cutaneous dorsal branch of T2 represents the sensory supply for the lower cervical levels (C5, C6, C7, C8, T1).

Treatment

The treatment for this type of back pain is applied at the cervical level, no matter what the pathogenic mechanism might be. Treatment options include manipulation, injection of the involved cervical zygapophysial joint, or the use of physical modalities (collar, short-wave diathermy, etc.).

1. *Manipulation*. Spinal manipulation is a very effective therapeutic tool for the treatment of upper thoracic/periscapular pain of cervical origin. It should be applied only by trained practitioners because of the potential risk of injury of the vertebral arteries, although in fact these accidents appear to be very rare taking into consideration the high number of manipulations performed every day throughout the world. Their definition and their possible mechanisms of action are described in the next section (see below). Three basic manoeuvres acting on the CTJ are advocated: rotation, lateral flexion and the 'chin-pivot', a manoeuvre combining rotation, extension and lateral flexion. Because the hypothesized mechanism of the pain is a 'spasm' of the muscle splenius cervicis, manipulations of the upper thoracic spine in flexion are also used, which stretches this muscle. Usually, one to three sessions are sufficient. If there is no result after the second session, treatment by manipulation should be abandoned and referral for conservative management considered.
2. *Zygapophysial joint injections*. If manipulation is not applicable (e.g. lack of improvement, a technical contraindication such as stiff neck or pain with mobilization), zygapophysial joint injections present a suitable alternative. The zygapophysial joint that was tender on palpation has to be infiltrated, and the injection is normally performed under fluoroscopic guidance. The patient sits facing the examining table desk with the head resting forward on crossed hands, thus flexing the neck in a relaxed position. The tender spot is carefully marked. The needle is inserted about 10 mm from the midline, in the centre of the spot, and penetrates until periosteum is contacted. After aspirating to ensure that the needle is not intervascular, the injection itself should be easy and without resistance or pain. The author uses 1-2 ml of corticosteroid (Hydrocortancyl™). Anaesthetic block of the joint without fluoroscopy guidance is considered risky, and is strongly contraindicated. This technique is suitable for every cervical zygapophysial joint from C2-C3 to C7-T1. The patient must be informed of a possible adverse reaction (increased pain) a few hours later, which may, on occasion, last for up to 24 hours.
3. *Pharmacotherapy*. Analgesics are often useful in the acute phase, as are non-steroidal anti-inflammatory drugs if osteoarthritis is likely.

Lateral upper thoracic pain (the levator scapulae syndrome)

When a patient is suffering from neck pain, the pain often radiates to the superior angle of the vertebral border of the scapula. In other cases, only the radiated pain is present, without any neck complaint. In these cases, the levator scapula plays a role in the pain referral. In neck pathology, this syndrome (the levator scapulae syndrome) involves pain referral to the shoulder and the periscapular point. The examination reveals the same thoracic and cervical signs in all cases.

Clinical signs

1. Thoracic signs:
   Pressure over the scapular insertion of the levator scapula is tender and reproduces the patient's pain. This point is called the 'levator point' (Fig. 10.2). The pinch-roll test is positive in the contiguous dermatome of either C4 or T1-T2. The cellulalgia is located ipsilateral to the levator point.
2. Cervical signs:
   The position and the palpation technique have been described above. Palpation reveals a very tender vertebral level, which may be at C4-C5 or C5-C6, ipsilateral to the painful insertion and the cellulalgia. Provided that a disc herniation or synovitis has been ruled out, this tenderness should correspond to a PMID caused by either a disc or a zygapophysial joint disorder.

Connection between the levator point and the lower cervical spine

There is no doubt about the nature of this point, which corresponds exactly to the distal attachment of the fibres of the levator scapulae to the superior angle of the scapula's vertebral border. Interestingly, this muscle shares its upper insertion on the superior cervical transverse processes with the splenius cervicis, both being derived embryologically from the same muscle. Both are superficial, and are innervated by the dorsal rami of the lower cervical roots (C4-C6 for the levator scapula, C5-C7 for the splenius cervicis). Thus, it appears that the levator point could correspond to an insertional pain of a spasming or painful muscle due to a cervical painful dysfunction.

Treatment

The treatment of the levator scapula syndrome is the same as that for periscapular pain of cervical origin.

Notalgia paraesthetica

Notalgia paraesthetica was first described by Astwazaturow in 1933 (cited in Bernard-Pleet and Wayne-Massey, 1978). Notalgia comes from a Greek root meaning 'pain in the back'. Six cases have been described by Wayne-Massey (1981). Clinically, notalgia paraesthetica consists of pruritus and localized dysaesthesia and hyperaesthesia in the distribution of one of the cutaneous dorsal rami of the upper thoracic area. The aetiology proposed was that of a neuropathy of the dorsal ramus of the second to sixth thoracic nerves. The study by Maigne *et al.* (1991) lends anatomical support for this hypothesis, because compression of a nerve trunk was observed in four out of 16 cases. These compressions could be the cause of the pain and other related symptoms, although their anatomical incidence may be greater than the clinical presentation of this pathology. The author has encountered only a few clinical cases meeting these diagnostic criteria. In these cases, there was a trigger point at the lateral aspect of the spinous process, where the nerve is likely to be compressed by the tendons. Injection of local anaesthetic at this point abolished the signs and symptoms. The presence of an anaesthetic strip of skin in a dermatomal pattern confirms the neural blockade. The author's group recommends treatment by injection with a corticosteroid. They have insufficient experience with this condition to determine whether surgery is an efficacious therapeutic option.

Thoracolumbar junction and thoracolumbar spinal pain syndromes

The thoracolumbar junction (TLJ) is comprised of the T10-T11, T11-T12 and T12-L1 motion segments. This transitional area, interposed between the thoracic and lumbar spines, is often the source of a characteristic pain syndrome characterized by a referral of the pain in the related dermatomes (T10-L1).

Although Judovich and Bates (1950) were the first to report low back and groin pain referred from the TLJ, this syndrome was subsequently fully described by Maigne (1974, 1980). He coined the term 'thoracolumbar junction syndrome', described the terminology and stressed the implication of the thoracolumbar zygapophysial joints in this syndrome. He emphasized its frequency among low back pain sufferers, and advocated treatment by spinal manipulation. He has authored 15 papers on this topic, with the majority of these published in the French medical journals.

Course of the thoracolumbar nerves

Standard pattern

The thoracolumbar nerve roots divide into two rami, ventral and dorsal, after exiting the intervertebral foramen. The findings of two previous studies dealing with the course of these nerves are reported here (Maigne *et al.*, 1986, 1989).

The thoracolumbar ventral rami

The T10 and T11 ventral rami are intercostal nerves. They run under the ribs and end in the abdominal wall. They supply the intercostal and abdominal

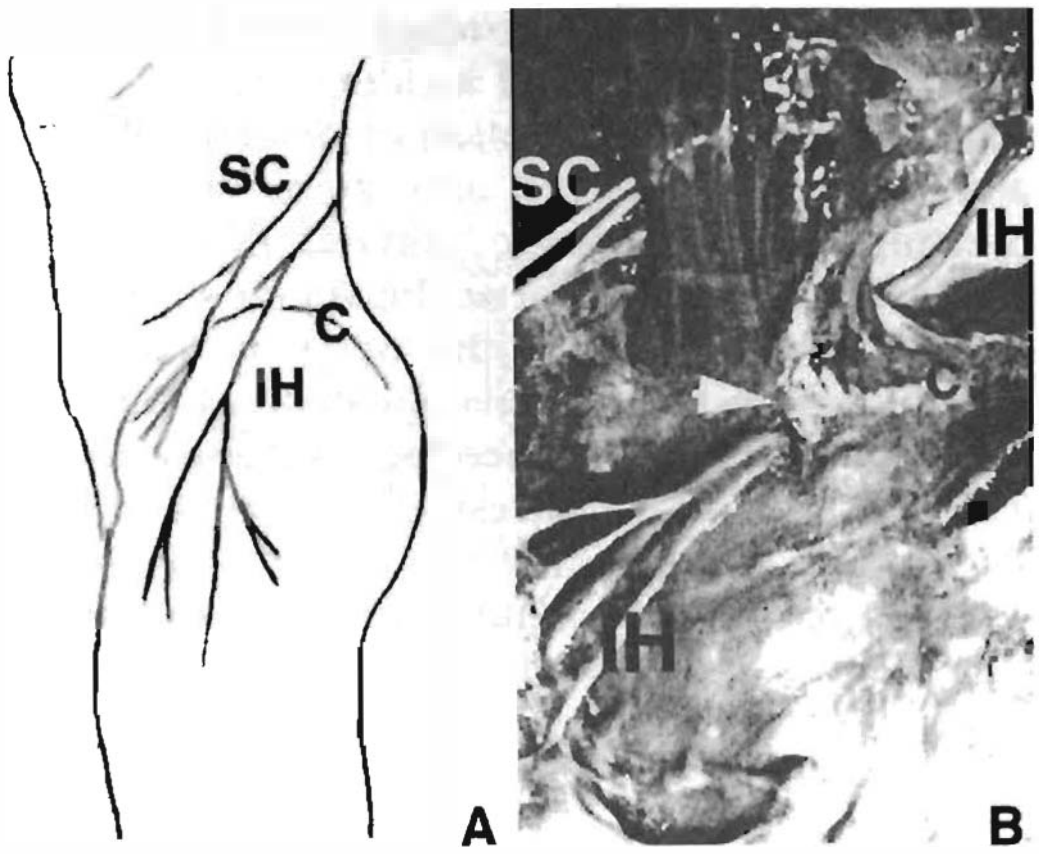

Fig. 10.3 (A) The lateral cutaneous branches of the subcostal and iliohypogastric nerves sweep anteriorly. Both nerves become superficial as they cross the iliac crest (C). (B) The branch of the subcostal nerve (SC) passes through a muscular orifice (oblique muscles), the branch of the iliohypogastric nerve (IH) through a rigid fibro-osseous tunnel (white arrow head).

muscles as well as a strip of skin parallel to each vertebral level, representing the dermatome. The T12 and L1 ventral rami are the subcostal and iliohypogastric nerves respectively. They run parallel to the iliac crest and supply the lower muscles of the abdominal wall and the skin of the groin area. When they pass over the lateral aspect of the iliac crest, they give rise to a lateral cutaneous branch descending along the lateral surface of the hip. In most cases, this branch terminates at the level of the greater trochanter (Fig. 10.3A); however, at times it courses 5-10 cm distally. Interestingly, the branch of the iliohypogastric nerve becomes superficial by passing through a rigid fibro-osseous tunnel formed by the fibres of the muscle obliquus externus and the superior rim of the iliac crest. As seen in the author's own dissections, this orifice may occasionally entrap the nerve. The branch of the subcostal nerve passes through a weaker, purely muscular orifice (Fig. 10.3B).

The thoracolumbar dorsal primary rami

The thoracolumbar dorsal primary rami are of smaller diameter than the ventral rami. They are very short, dividing after a few millimetres into medial and lateral branches. The medial branch runs dorsally along the angle between the transverse and zygapophysial processes of the corresponding vertebra and gives off branches supplying the zygapophysial joint capsule at that level. These nerves are very thin and are difficult to study macroscopically. A second inconsistent branch runs caudally to supply the zygapophysial joint capsule at the level below. The medial branch then passes along the spinous process, supplying the periosteum of both the lamina and the spinous process prior to terminating at the tip of the latter. It also innervates the multifidus muscle, one or two levels caudal to the vertebral exit (Hayashi *et al.*, 1992).

The lateral branch is directed caudally, laterally and dorsally, supplying the erector spinae muscles and passing through the thoracolumbar fascia two to four levels caudal to their exit (Maigne *et al.*, 1989), where it becomes superficial. This branch gives cutaneous innervation to the subcutaneous tissues of the lumbar and buttock areas as distal as the greater trochanter in some cases (Fig. 10.4). The skin covering the sacral area is innervated by the S1-S4 or S5 dorsal rami.

The most common pattern presents with the T12 branch lying laterally and the L1 branch medially as they traverse the iliac crest. At this level, the distance between the two branches varies from 1-5 cm. The L1 branch crosses the crest at a very consistent distance of 7 cm from the midline. Of particular interest is the fact that the L1 dorsal ramus becomes superficial by passing over the crest through a fibro-osseous tunnel and the superior rim of the iliac crest. This fibro-osseous tunnel is a rigid structure, which makes the nerve prone to compression. An entrapment neuropathy is thus possible at this level.

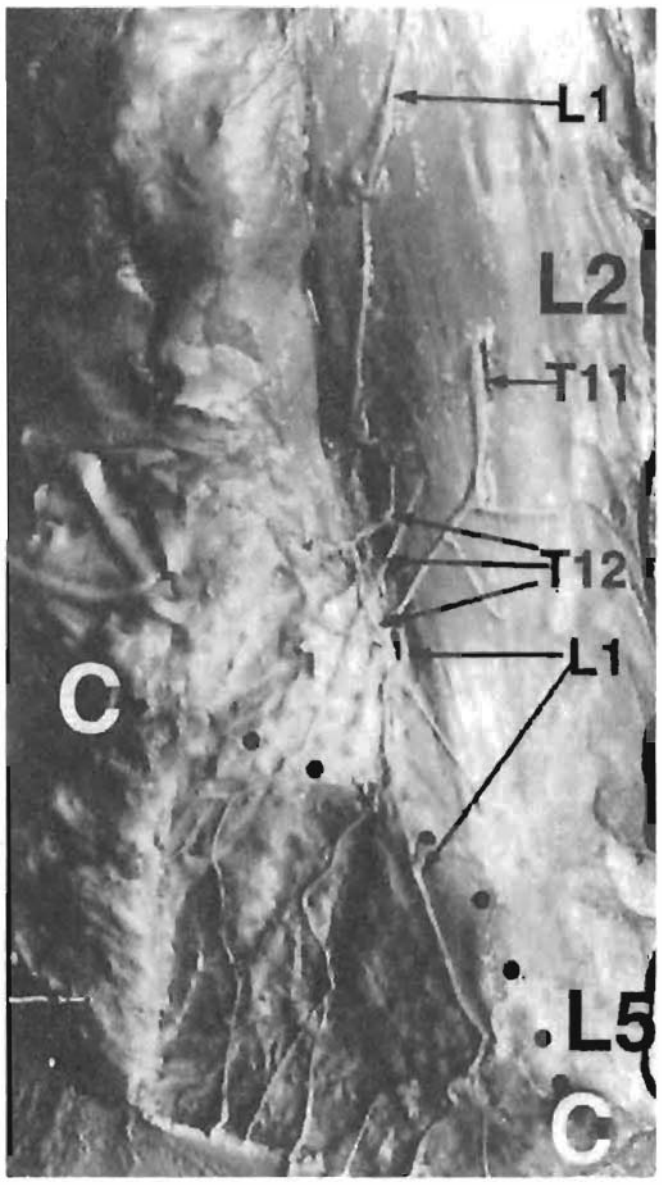

Fig. 10.4 Dorsal cutaneous rami of T12 and L1 supplying the lower lumbar area and crossing the iliac crest (C) (dotted line). The spinous processes of L2 and L5 are noted to the right of the image.

Variations

The iliac crest is usually traversed by two or three branches of the dorsal rami, which supply the cutaneous region of the buttock. Data from the dissections carried out by the author and his colleagues indicate some anatomical variations in that the L1 dorsal ramus supplies a significant area of skin in 65% of the cases. In the remaining 35%, the L2 ramus (receiving a contribution from L3 in up to 10% of cases) is the major cutaneous branch for the buttock, although this relationship was variable. The fourth and fifth lumbar levels have no significant dorsal cutaneous territory.

Pain patterns

The different pain patterns have been studied in healthy volunteers and in patients. The TLJ appears as a pain generator with a special feature; the radiation of pain downward in the corresponding dermatomes. This was first illustrated by Kellgren (1939), who injected the thoracolumbar interspinous ligaments in normal volunteers and noticed a referral of the pain to the iliac crests. McCall and co-workers (1979) noticed the same type of referral when injecting the upper lumbar zygapophysial joints. In patients, it is common to reproduce the radiation of the pain by needling or injecting around the zygapophysials of the TLJ.

Pain syndromes of the thoracolumbar junction syndrome

The thoracolumbar junction syndrome is defined by a dysfunction of the TLJ referring pain in the whole or part of the territory of the corresponding dermatomes (e.g. T11-L1 or L2). Depending on the branch involved, the pain could refer to the low back (cutaneous dorsal rami) (Fig. 10.5A), to the groin (subcostal or iliohypogastric nerve) or to the lateral aspect of the hip (lateral cutaneous rami of the subcostal or iliohypogastric nerve) (Fig. 10.5B). All combinations of these clinical presentations are possible with one, two or three involved territories. Furthermore, even if the patient is unaware of symptoms in the above regions, the clinical examination may reveal tenderness of the cutaneous and subcutaneous tissues in the involved dermatome.

Low back pain

Symptoms

Low back pain is certainly the most frequently encountered pain complaint in the TLJ syndrome. The pain is distributed in the dermatomes of T11, T12, L1 or L2; however, because the limits of these dermatomes are ill defined, due to overlapping and anastomosis, the pain is usually spread in the lateral part of the low back without corresponding exactly to a specific dermatome. Rarely, the pain is bilateral (the sacral area being pain-free); more often, it is unilateral. Oddly, the right side is more commonly involved than the left. In a personal series of 100 cases, the pain was on the right in 62%, but the author has no explanation for this fact. Vernon-Roberts *et al.* (1997), studying the course of the degenerative process at the disc T12-L1, pointed out that the anular radial tears were twice as frequent on the right than on the left part of the anulus. They related this to the fact that most people are right-handed.

The pain is usually acute, of less than 2-3 months' duration, often appearing after a false rotatory movement of the trunk, prolonged strenuous posture, lifting or, occasionally, without any obvious precipitating factors. Repeated attacks are, of course, possible. Less commonly the pain may have a more chronic course, but the disability is always less than that seen with lumbar pain syndromes. The pain is

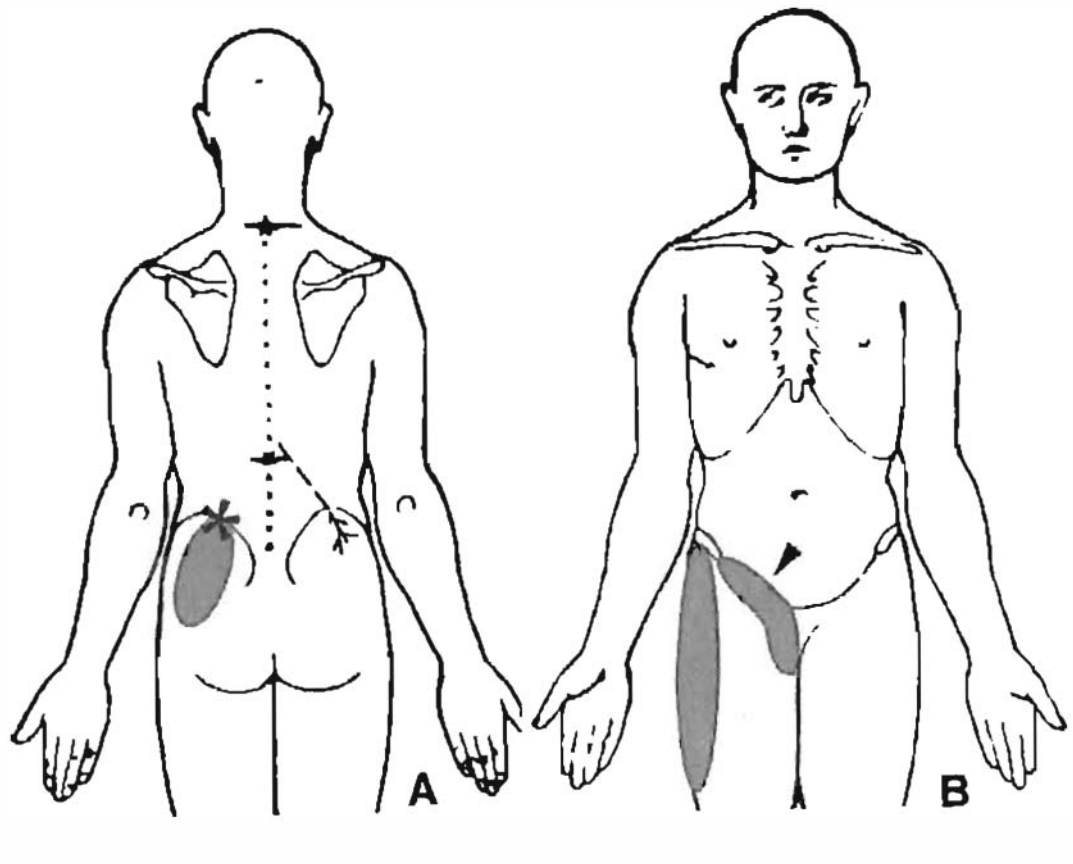

Fig. 10.5 Areas of pain and tenderness in the thoracolumbar junction syndrome. (A) Unilateral low back pain (cutaneous dorsal rami of T10-L1 or L2 roots). The 'iliac crestal point' (*) is characteristically located 7 cm from the midline. (B) Pain on the lateral aspect of the hip area (lateral cutaneous branch of the subcostal and iliohypogastric nerves). Pain on the groin area (arrow head) (subcostal and iliohypogastric nerves).

frequently increased by contralateral side bending, whereas ipsilateral side bending is pain free. This is likely to be due to the stretching of the cutaneous nerves between the TLJ and the iliac crest, where they are more or less fixed, and appears to be fairly characteristic of the TLJ syndrome. This is in contrast to the lumbosacral junction pain syndromes, where ipsilateral side bending increases the pain. This mechanism could be compared to a Lasegue sign of the trunk. Extension is often painful, as is ipsilateral rotation. Flexion is normal or painful, but without stiffness. This could be due to a mild protective guarding of the lumbar paraspinal muscles. Interestingly, this syndrome occurs more frequently after the sixth decade, as low back pain in younger patients usually has a lumbar discogenic origin.

Clinical signs in the low back

When examining the lumbar spine, care must always be taken to look carefully for two clinical signs. The first is the presence of a 'posterior iliac crestal point'; the second a positive 'pinch-roll' test.

The posterior iliac crestal point is present when pain and deep tenderness are located at the level of the iliac crest at a point which is consistently located 7 cm from the midline. Pressure at this point causes a sharp pain similar to the patient's complaint. The pain is usually excruciating, whereas the crest is much less painful even 1 cm to the left or right of this point. A small bony groove can be palpated at this level, corresponding to the passage of the cutaneous branch of L1. This sign requires careful and precise localization, which is facilitated by placing the patient in a forward flexed position across the examining table, in order to open up the spine into flexion and gap the posterior elements. This is a very convenient and comfortable position to examine the spine from the TLJ to the sacrum, because the lordosis is reversed. The examiner places a finger along the iliac crest with moderate pressure every 0.5 cm, in an attempt to isolate the tender point. The finger is moved slightly laterally, medially and vertically in a probing manner. Once the irritated nerve is located, deep pressure and gentle movement produce marked tenderness, which is clearly demonstrated by the patient's reaction. The opposite iliac crest is examined in a similar manner and is commonly unaffected.

A positive pinch-roll test is achieved because referred pain is accompanied by hyperalgesia of the skin and subcutaneous tissues in the involved dermatomes. This hyperalgesia or hypersensitivity can be revealed by gently grasping a fold of skin between the thumbs and forefingers, lifting it away from the trunk and rolling the subcutaneous surfaces against one another in a pinch and roll fashion. On the involved side the skin overlying the buttock and iliac crest is found to be tender when compared to the opposite side. This sign is difficult to elicit if the patient is obese or if the examination is hurried.

Examination of the thoracolumbar junction

Examination of the TLJ should be systematic in patients presenting with low back pain, especially when the pain is unilateral, located in the area of the iliac crest and buttock, and when an iliac crestal point is found.

Clinical examination of the thoracolumbar junction should be carried out with the patient in the position described above (lying across the examining table). Two manoeuvres are used: the first is longitudinal friction pressure over the zygapophysial joints; the second is lateral pressure against the spinous process.

To apply friction pressure over the zygapophysial joints, pressure is applied deeply and longitudinally approximately 1 cm lateral to the spinous process and is followed by a slow, gentle friction movement by the palpating finger. Tenderness is elicited over one or two joints ipsilateral to the lower back pain. Interestingly, clinical examination under fluoroscopic control has shown that the tender spot always corresponds to a zygapophysial joint, provided the palpation is slow and careful. T11-T12 is the most frequently involved joint, followed by T10-T11 and T12-L1. This is likely to be due to the orientation of the articular processes. T11-T12 has a thoracic orientation in almost 59% of cases (Maigne *et al.*, 1992), and the widest range of rotation - 5.2 ± 2 degrees on each side, as demonstrated in a previous study using normal volunteers who were positioned in rotation at the TLJ and then underwent computerized tomography (Maigne *et al.*, 1988). This could lead to unusual stress and overuse of the joints at this level. In 40% of the cases, T11-T12 has a lumbar, sagittal orientation, thus restricting the range of rotation at this level to 0.5°. T10-T11 then undergoes the greatest amount of rotation instead of T11-T12. When T10-T11 is tender, it is often due to this transitional abnormality.

Pressure against the lateral aspect of the spinous process is applied with the thumb slowly and tangentially at each level. This manoeuvre imparts rotation to the vertebra. Ipsilateral rotation is frequently tender at the involved level.

Routine X-rays, CT or magnetic resonance imaging (MRI) scans of the TLJ are unremarkable in the majority of cases. They are often considered normal although, in anatomical studies, degenerative discs are frequent at this level. These imaging studies have no predictive value regarding the diagnosis or the response to treatment. In a previous study, Maigne *et al.* (1992) demonstrated an increased frequency of ossification at the attachments of the ligamentum flavum at this level as compared to other levels of the thoracic spine, by using CT scan cuts. They hypothesized that this frequency was due to the high level of rotational strain involving this zone (Maigne *et al.*, 1992).

Confirmation that the pain is referred from the TLJ to the iliac crest and the buttock can be demonstrated by an anaesthetic block of the dorsal ramus and the painful zygapophysial joint. The needle is inserted in the centre of the tender spot overlying the zygapophysial joint, 1-1.5 cm from the midline. The point for injection is generally located on a horizontal line crossing the interspinous ligament. The needle is inserted until periosteum is contacted. After aspiration for blood, 3 ml of anaesthetic (lidocaine 1%) is injected around the zygapophysial joint, and more laterally around the dorsal ramus. The cutaneous branch of the dorsal ramus can also be blocked as it crosses the iliac crest (iliac crestal point). The technique is easy; the needle is inserted at the level of the tender point and directed toward the superior rim of the crest. The anaesthetic is then injected around the nerve. Whatever the technique, the injection should, within minutes, suppress the pain and discomfort previously produced by the patient's rotation, flexion or extension movements, and diminish the tenderness over the iliac crestal point, thus confirming the diagnosis.

Pain in the groin

Symptoms

Because it is acknowledged that the dermatomes covering the groin are T12 and L1, groin pain is easily related to a TLJ origin, provided that hip pathology has been ruled out. Groin pain may accompany low back pain or be an isolated complaint. The pain may sometimes be located above the groin, in the T10 or T11 dermatomes, depending on the involved level of the TLJ.

Clinical signs in the groin

Two clinical features are characteristic of the involvement of the ventral rami (subcostal and iliohypogastric nerves); a positive pinch-roll test and tenderness over the superior aspect of the pubis.

The pinch-roll test is performed with the patient lying supine. The test has to be performed on both sides.

Tenderness over the superior aspect of the pubis is found with friction over the periosteum of this area. This hypersensitivity is probably due to a lowering in the pain threshold.

Examination of the thoracolumbar junction

The examination of the TLJ is conducted as described above, and the findings are basically the same. A diagnostic block may be useful for establishing the diagnosis. However, blocking the zygapophysial joint and the dorsal ramus is insufficient, and it is mandatory to infiltrate around the ventral ramus as well. It can be easily done without fluoroscopic control, by inserting the needle as described above for the block of the dorsal ramus and by conducting it in a forward direction toward the intervertebral foramen and the ventral ramus. The injection of 3 ml of lidocaine blocks the nerve and relieves the pain.

Pain over the lateral aspect of the hip

The third feature of the TLJ syndrome is pain over the lateral aspect of the hip. It is a referred pain in the territory of the lateral cutaneous branch of either the iliohypogastric or the subcostal nerve.

Clinical signs in the lateral aspect of the hip

Referred pain in this territory is characterized by its distribution, a positive pinch-roll test and a lateral iliac crestal point. The lateral cutaneous branch usually reaches the trochanteric area, but can sometimes descend 5-10 cm distally. A shorter variety may be found, ending a few centimetres below the iliac crest (Maigne *et al.*, 1986). When the pain is referred to this area, the pinch-roll test is positive, as compared to the other side.

The lateral iliac crestal point has the same characteristics as the posterior iliac crestal point (see: Low back pain of thoracolumbar origin, above). The crest has to be carefully palpated by the index or middle finger with the patient in the lateral decubitus position, painful side up, to reveal the tender point. It is located on the lateral part of the iliac crest, 10-13 cm from the antero-superior iliac spine, at the intersection of the crest by a vertical line drawn from the greater trochanter. This location corresponds to the crossing of the iliac crest by the nerve, where a bony groove is often palpable.

Clinical pictures of the thoracolumbar junction syndrome

Each of the different pain syndromes characterizing the TLJ syndrome can appear in isolation or in combination in a given patient. Furthermore, when the pain complaint is isolated to only one of the regions (often in only one precise area), the clinical examination may reveal a positive pinch-roll test in the other territories, an iliac crestal point, or tenderness over the superior aspect of the pubis, independent of the patient's primary complaint. Another very common pattern is low back pain originating from the TLJ associated with pain emanating from the lower lumbar discs or zygapophysial joints.

Causes of the thoracolumbar junction syndrome

At the TLJ

The most common cause of the TLJ syndrome is a minor intervertebral dysfunction at the TLJ (T10-T11, T11-T12 or T12-L1). One, two or three levels can be involved. Patients are often unaware of symptoms at the level of the TLJ, and pain is usually felt distally in the corresponding dermatomes. The nature of this dysfunction remains unknown, although the involvement of either the zygapophysial joints or the disc is very likely. More than any other part of the spine, the TLJ is involved in rotatory movements. At the lumbar levels, the total amount of rotation is limited because of the orientation of the zygapophysial joints in the sagittal plane. Above T10, despite a more favourable orientation, the rotation is restricted by the ribcage, which is fixed to the thoracic spine. The major part of the rotation is thus concentrated between T10 and T12. This may lead to an overuse of the motion segment, which could initiate disc or zygapophysial degeneration. On the other hand, the frequent zygapophysial asymmetry at T11-T12 could disrupt the smooth rotation (see also Chapter 7) and initiate painful blockages or hypomobility in case of false motions, particularly if rotation is combined with forward flexion. Some other causes are possible, although very rare, such as a disc herniation or a collapse of the vertebral body of T11, T12 or L1 referring pain only to the low back.

Other causes

There are other possible causes for referred pain in the cutaneous nerves of T11, T12 or L1. Although the primary cause for pain may not be located at the TLJ, the symptomatology and the clinical signs are similar to the TLJ syndrome. Moreover, both TLJ and non-TLJ causes can be associated in a given patient, and thus have to be diagnosed and treated simultaneously.

Nerve entrapment

Entrapment of the cutaneous dorsal ramus of L1 (Maigne *et al.*, 1989) may occur. When the cutaneous dorsal rami cross the iliac crest, the most medial among them (L1 in the majority of cases, sometimes L2) become superficial by perforating a rigid fibro-osseous tunnel formed by the thoracolumbar fascia above and the rim of the crest below. This orifice, located approximately 7 cm from the midline, may entrap the nerve, leading to pain in its cutaneous territory (Fig. 10.6). The clinical signs are very similar to those observed in the TLJ syndrome, except for the fact that the TLJ is normal to palpation. The major feature is the iliac crestal point, where pressure reproduces the patient's pain (Fig. 10.5A). The anaesthetic block of this point must abolish all signs and symptoms to establish the diagnosis. The author's group has, at the present time, a series of 21 patients with this syndrome. All were older patients (mean age, 67 years) and all were operated on (neurolysis), allowing a confirmation of the diagnosis and immediate relief in the majority of cases. None of them had hyperaesthesia in the territory of distribution of the nerve, possibly due to overlapping of dermatomes. It seems likely that this entrapment might be associated in many cases with a TLJ syndrome, thus reinforcing the symptoms in the low back.

Entrapment of the lateral cutaneous branch of the iliohypogastric nerve (Maigne *et al.*, 1986) may also

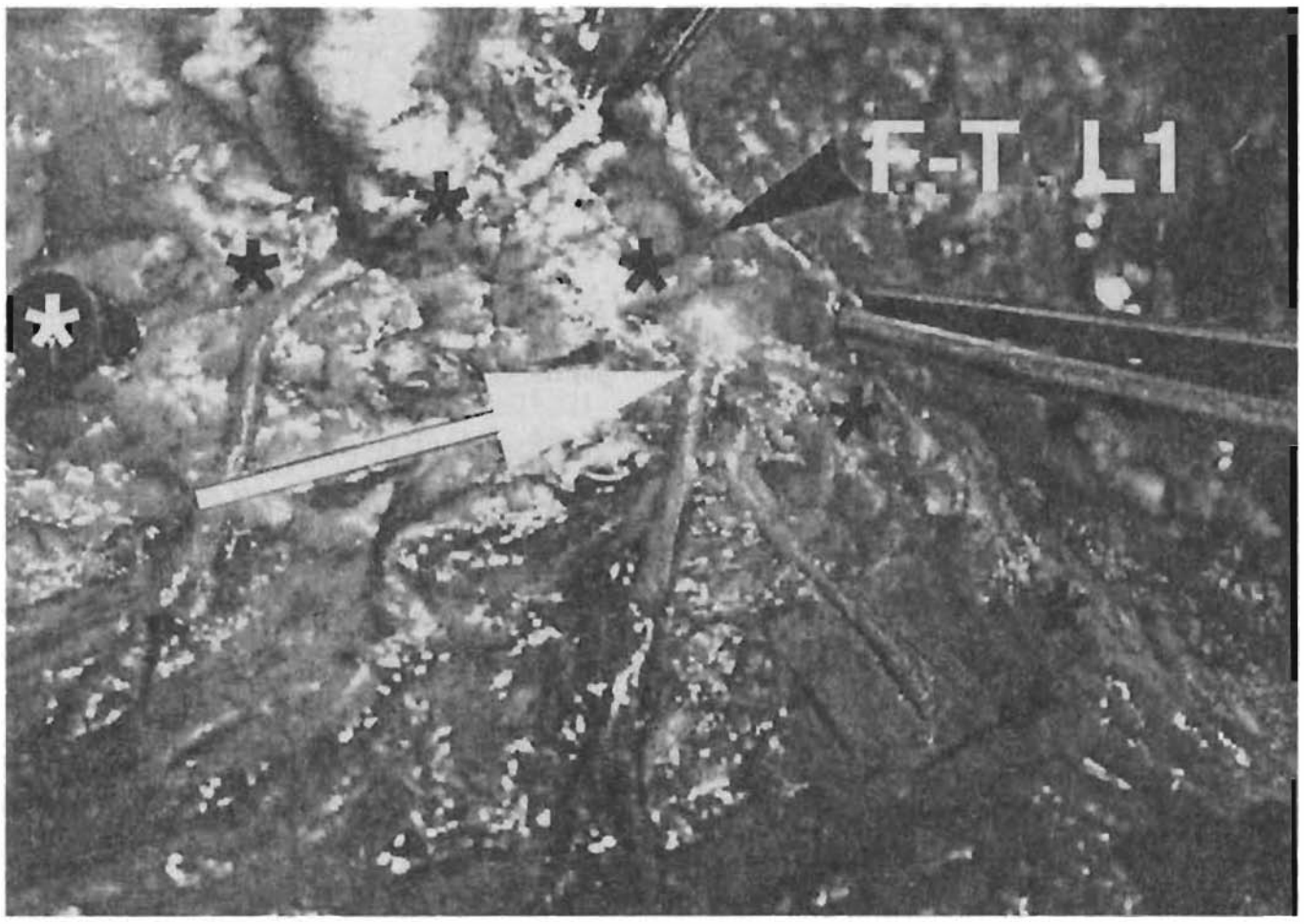

Fig. 10.6 Left side. Superficial emergence of the dorsal cutaneous nerve of L1 though a fibro-osseous tunnel (arrow, F-T). Dotted line (*) is the iliac crest.

occur. A similar arrangement to that described above may be observed for the lateral cutaneous branch of the iliohypogastric nerve (L1), which becomes superficial by passing through the same sort of fibro-osseous tunnel located at the intersection of the lateral part of the iliac crest and a vertical line passing over the greater trochanter (10–13 cm from the antero-superior iliac spine) (Fig. 10.3B). This orifice is demarcated by the rim of the crest below and the aponeurosis of the obliquus externus muscle above, and may sometimes entrap the nerve. The pain is located on the crest and radiates downward, to the trochanter or even lower. The pinch-roll test is positive in the affected dermatome, and pressure over the lateral iliac crestal point reproduces the patient's pain. Here, too, the TLJ is normal to palpation.

This entrapment neuropathy is much less frequent than entrapment of the cutaneous dorsal ramus of L1, with very few patients requiring surgical decompression.

New advances: pain from the lumbosacral junction projecting in the TLJ dermatomes

Japanese authors have recently addressed the question of why sciatic pain is often accompanied by radiation to the groin area. They demonstrated (in the rat) a possible link between the L5–L6 disc and the L2 root. This disc could be partially innervated by dichotomizing sensory C fibres present in the L2 spinal nerve or higher levels which also innervate the groin skin (Takahashi *et al.*, 1993). Furthermore, by blocking the L2 spinal nerve in low back pain patients with degenerated lumbar discs, they were able to relieve the pain temporarily, supporting the premise that discogenic pain from the lower lumbar spine could project to the L2 dermatome (Nakamura *et al.*, 1995).

Clinical treatment options for the thoracolumbar junction

The treatment of the TLJ syndrome is at first the treatment of the TLJ itself. Complementary treatment of the nerves may also be required.

Spinal manipulation

Definition and mechanism of action

The TLJ syndrome is particularly responsive to spinal manipulative therapy. Manipulation is a forced movement applied to a joint within the anatomical limits. This movement is characterized by a 'cracking' sound due to a vacuum phenomenon as the zygapophysial joints separate. This vacuum phenomenon, or cavitation, results from the sudden separation of the articular surfaces. Thus, the cavitation appears as a motion accelerator, which could play a role by stretching hypertonic muscles. This is true not only for the TLJ but also for any part of the spine. The separation of the zygapophysial joints may also unblock the motion segment. Manipulation may act on the disc as well. In an unpublished study using intradiscal pressure transducers into the lumbar discs, the author and colleagues demonstrated that the manipulative thrust initiated a sudden and temporary negative intradiscal pressure. This could alter the load transmission through the disc, thought to be one of the factors transforming a pain-free degenerated disc into a painful one.

Technique

The first session is very important, because a good result is often obtained after one or two manoeuvres, thereby confirming the diagnosis. The most frequently used manipulative techniques are described in detail elsewhere (Maigne, 1996). One to five sessions are necessary to treat the patient, with one to four manoeuvres in each session. If there is no improvement after the second one, the treatment and the diagnosis should be re-evaluated.

Therapeutic injection

Technique

Zygapophysial injections are best performed with fluoroscopic control, according to the technique described above for the anaesthetic block above. A steroid such as Hydrocortancyl™ (3 ml) is used. Injections are also the treatment of choice in cases of nerve entrapment at the iliac crest (posterior or lateral part). The needle is inserted in the centre of the iliac crestal point, until contact is made with periosteum. The needle is then directed upwards to the rim of the crest and around the nerve.

Indications

The zygapophysial injections can be performed as a first attempt, especially in elderly patients where osteoarthritis is likely, or after the failure of a first manipulative treatment. One or two injections are usually sufficient. A negative result should lead to reconsideration of the diagnosis. The same applies for injection of the cutaneous branch, which may be performed as a primary treatment when the TLJ appears normal or the iliac crestal point is very sensitive.

References

Bernard-Pleet, A. Wayne-Massey, E. (1978) Notalgia paresthetica. *Neurology* **28:** 1310-1312.

Cloward, R. (1960) The clinical significance of the sinuvertebral nerve of the cervical spine in relation to the cervical disk syndrome. *J. Neurol. Neurosurg. Psychiatr.* **23:** 321-326.

Dwyer, A., Aprill, C., Bogduk, N. (1990) Cervical zygapophysial joint pain. A study in normal volunteers. *Spine* **15:** 453-457.

Gray, H. (1973) *Gray's Anatomy*, 35th edn. Edinburgh: Longman, p. 510.

Hayashi, N., Tamaki, T., Yamada, H. (1992) Experimental study of denervated muscle atrophy following severance of posterior rami of the lumbar spinal nerves. *Spine* **17:** 1361-1367.

Judovich, B., Bates, W. (1950) *Pain Syndromes. Treatment by Paravertebral Nerve Block*, 3rd edn. Philadelphia: F.A. Davis Co. Publishers, pp. 177-217.

Kellgren, J.H. (1939) On the distribution of pain arising from deep somatic structures with charts of segmental pain areas. *Clin. Sci.* **4:** 35-46.

Maigne, J.-Y., Maigne, R., Guérin-Surville, H. (1986). Anatomical study of the lateral cutaneous rami of the subcostal and iliohypogastric nerves. *Surg. Radiol. Anat.* **8:** 251-256.

Maigne, J.-Y., Buy, J.N., Thomas, M. *et al.* (1988). Rotation de la charnière thoraco-lombaire. Étude tomodensitométrique chez vingt sujets normaux. *Ann. Readapt. Med. Phys.* **31:** 239-243.

Maigne, J.-Y., Lazareth, J.P., Guérin-Surville, H. *et al.* (1989). The lateral cutaneous branches of the dorsal rami of the thoracolumbar junction. A study on 37 dissections. *Surg. Radiol. Anat.* **11:** 289-293.

Maigne, J.-Y., Maigne, R., Guérin-Surville, H. (1991). Upper thoracic dorsal rami: anatomic study of their medial cutaneous branches. *Surg. Radiol. Anat.* **13:** 109-112.

Maigne, J.-Y., Ayral, X., Guérin-Surville, H. (1992). Frequency and size of ossifications in the caudal attachments of the ligamentum flavum of the thoracic spine. Role of rotatory strains in their development. *Surg. Radiol. Anat.* **14:** 119-124.

Maigne, R. (1964). Sur l'origine cervicale de certaines dorsalgies benignes et rebelles de l'adulte. *Rev. Rhum.* **9:** 497-503.

Maigne, R. (1974). Origine dorso-lombaire de certaines lombalgies basses. Rôle des articulations zygapophysaires et des rameaux dorsaux des nerfs rachidiens. *Rev. Rhum.* **41:** 781-789.

Maigne, R. (1980). Low back pain of thoracolumbar origin. *Arch. Phys. Med. Rehabil.* **61:** 389-395.

Maigne, R. (1996) *Diagnosis and Treatment of Pain of Vertebral Origin.* Baltimore: Williams & Wilkins.

McCall, I.W., Park, W.M., O'Brien, J.P. (1979). Induced pain referral from posterior lumbar elements in normal subjects. *Spine* **4:** 441-446.

Nakamura, S., Takahashi, Y., Yamagata, M. *et al.* (1995). Afferent pathway of low back pain: Evaluation with L2-soinal-nerve infiltration. *Annual Meeting of the International Society for the Study of the Lumbar Spine*, Helsinki, Finland, Abstract 39.

Takahashi, Y., Nakajima, Y., Sakamoto, T., *et al.* (1993). Capsaicin applied to rat lumbar intervertebral disc causes extravasation in the groin skin: a possible mechanism of referred pain of the intervertebral disc. *Neurosc. Lett.* **161:** 1-3.

Vernon-Roberts, B., Fazzalari, N.L., Manthey, B.A. (1997) Pathogenesis of tears of the anulus investigated by multiple-level transaxial analysis of the T12-L1 disc. *Spine* **22:** 2641-2646.

Wayne-Massey, E. (1981). Electromyographic evaluation of notalgia paresthetica. *Neurology* **31:** 642.

Henry F. Farfan, MSc, MD CM, FRCS (C)

Harry Farfan (1924-1994) is acknowledged as a pioneer spinal surgeon and researcher. In 1975 he co-ordinated the establishment of the International Society for the Study of the Lumbar Spine, and subsequently helped form the North American Spine Society in 1984. He contributed extensively to the literature on mechanical disorders of the spine, and challenged many with his theories on spine pathology, particularly concerning the disc. Through debate, he sought to encourage all who were interested in these issues. His textbook, *Mechanical Disorders of the Low Back,* is considered a classic in clinical biomechanics of the lumbar spine. In this text and his many other publications he disclosed his interest in spinal evolution, mathematical analysis of spinal mechanics, posture, manual therapy, biomechanics, pathoanatomy and spinal surgery. His final paper, published in *Spine* (Farfan, 1995), provided insight into his lasting interest in mathematical analysis of the relationships between structure and function. Dr Farfan was a mentor to many around the world. He was very supportive of the multidisciplinary approach to spine research and stimulated the development of theories of clinical practice. However, his interest in spine research was based, first and foremost, on his concern for achieving the best outcome for his patients.

I record my indebtedness to Mrs Aurelie Farfan for kindly granting permission to incorporate into this text previously unpublished work by Dr Farfan on the association between thoracic spine pain and upper limb and neck disorders. I am grateful to Dr Charles Aprill, radiologist, a long-time friend and colleague of Dr Farfan, for making me aware of this manuscript. I also express my appreciation to Drs Simmons and Hadjipavlou for permission to cite their obituary tributes.

Kevin P. Singer

References

Farfan, H.F. (1973) *Mechanical Disorders of the Low Back.* Philadelphia: Lea and Febiger.

Farfan, H.F. (1995) Form and function of the musculoskeletal system as revealed by mathematical analysis of the lumbar spine. *Spine* **20:** 1462-1474.

Simmons, J.W. (1995) A tribute to Harry Farfan. *Spine* **20:** 1533-1534

Simmons, J. W. and Hadjipavlou, A. (1996) Harry Farfan. *NASS News* **10:** 6-7.

11

The thoracic spine and the 'tired neck syndrome'

H. F. Farfan

The primary source of cervical-dorso-brachialgia is often thought to be the cervical intervertebral joints, and little thought has been given to the thoracic spine as the source of this complaint. The emphasis in this chapter is given to a primary source at T5-T6, causing widespread pain in the thoracic spine, pseudo-angina, pain and stiffness in the neck, pain in the upper extremities, temporomandibular joint (TMJ) problems, and other complaints on the face. The pathomechanics are discussed, and symptoms and treatment are outlined.

The tired neck syndrome

In the literature, there are many conditions involving pain in the neck, in the upper back and in the upper extremities. These have been given names describing the geographical distribution of the pain, such as cervicalgia, brachialgia, cervico-brachialgia, cervico-dorsalgia and cervico-dorso-brachialgia. These conditions are often associated with fibromyalgia, or the more fashionable myofascial syndrome. These were originally classed as 'muscular rheumatism' (Hult, 1954).

Cervicalgia and brachialgia have long been associated with the cervical joints, and are well understood. In these, there is a definite and direct relationship between the injured joints and the distribution of symptoms in the upper extremities. However, locating the specific joint affected may remain a problem, especially when the neurological signs and symptoms do not conform to the normal pattern. When there is no correlation between a specific neck problem and the upper extremity symptoms, the cause of the brachialgia is in doubt.

Some of the brachialgias are also clearly due to problems arising somewhere other than the cervical joints, such as when the thoracic outlet is compromised. Several variations of the thoracic outlet syndrome have been described, but the presence of a cervical rib is almost mandatory in order to make this diagnosis. Signs to confirm vascular compression, accompanied by signs of neurologic involvement, are generally surgical prerequisites. Even then the results of surgical intervention may leave something to be desired, as much of the symptomatology can remain even after extensive surgery.

In patients with chronic neck pain, recent emphasis has been placed on the zygapophysial joints of the cervical spine as the source of pain because these joints can refer pain to the upper back. While it is true that the cervical joints may refer pain to the face and upper back (Bogduk and Marsland, 1988) (Fig. 11.1), treatments based on the theory that a cervical joint is the source of pathology have not been overly successful in resolving the back or upper extremity symptoms. The extent of referred pain from cervical joints has sometimes obscured the possibility that pain in the upper back may arise from intervertebral joints in the upper thoracic region; hence the reason for dropping the 'dorsalgia' in cervical-dorso-brachialgia.

Discounting the groups of cervical brachialgia that can be explained either by cervical discs, arthritis or cervical zygapophysial joint syndromes, and the brachialgias that are due to thoracic outlet syndrome, a large group of syndromes that are essentially unexplained still remain. These have been classed under different names.

In 1958, there was an epidemic of what the Japanese called 'occupational cervical-brachial disorder' (Ohara *et al.*, 1982). In Australia, certain

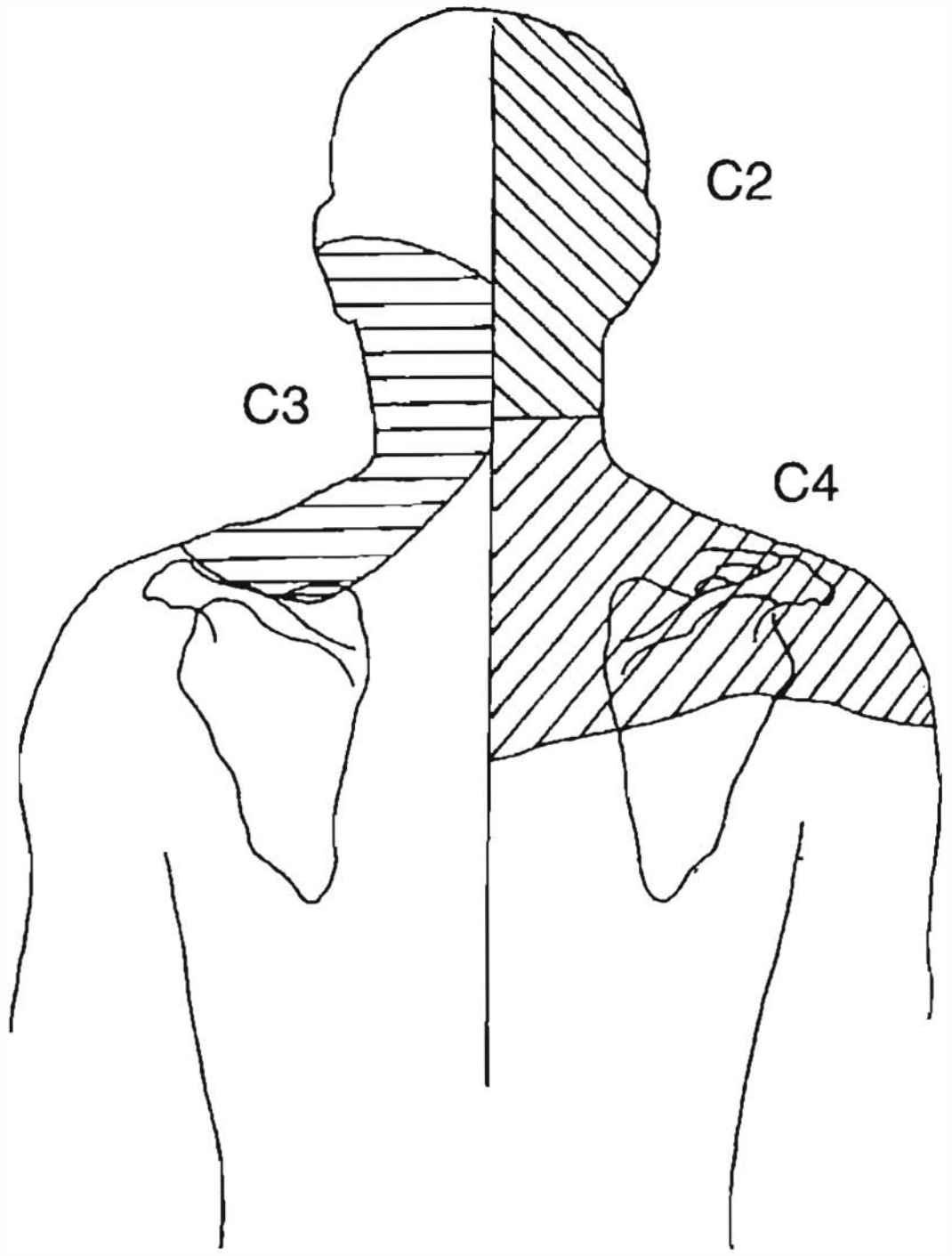

Fig. 11.1 Referral patterns originating from cervical zygapophysial joints.

disabilities such as epicondylitis, cramp of forearm muscles, tenosynovitis at the wrist and hand, and carpal tunnel syndrome were originally grouped together under the term 'repetitive strain injuries' (Ferguson, 1971). Later, this group came to include the cervico-brachialgias of unknown origin. In Scandinavia, the cervico-brachialgias of unknown origin were called 'tension neck syndrome' (Waris, 1980).

In this chapter, it is proposed to draw attention to the role played by certain muscles of the neck and thoracic spine, and their effect on the joints of the upper thoracic spine.

At the present time, there is no known neurological connection between an upper thoracic intervertebral joint and either the neck or the upper extremity. However, biomechanical considerations led the author to conclude that a relationship does, in fact, exist (Farfan and Baldwin, 1986).

Biomechanical factors

The head balances at the tip of the cervical column and, in normal relaxed posture, this balance is maintained without continuous muscular activity (Basmajian, 1974). The centre of gravity of the head falls in front of the cervical spine, so it is evident that, to avoid excess muscle activity, it is necessary to have a 'counterweight' behind the centre of motion in the spine to counteract the tendency of the head to nod forward. This counterweight is supplied by the weight of the shoulders, each with its muscles, suspended by the levator scapulae and rhomboid muscles from the neck. The system balances within a narrow range of head flexion and extension. Thus, when the head is extended slightly, the shoulders are naturally brought forwards. When the head is flexed, the shoulders tend to move backwards.

However, it is fairly easy to unbalance the system by interfering with the position of the head or that of the shoulders. When this occurs, there is an immediate response in the longus colli, longissimus, levator scapulae and rhomboid muscles, which contract. Both scapulae are then spontaneously stabilized by the action of the lower fibres of the trapezius muscle. This response is easily verifiable. When advancing the head or extending the arms, active contraction of the levator scapulae becomes palpable. Electromyographic (EMG) studies confirm this action (Basmajian, 1974).

Because contraction of the levator scapulae and rhomboid muscles produces a turning movement on the levator scapulae, this tendency must be counteracted by contraction of the lowest portion of the trapezius. The action of the middle and upper portions of the trapezius is minimal during this response. These only come into action when an extra burden is placed on the shoulders or extended arms.

Therefore, with imbalance of the system there is activity from the levator scapulae (rhomboids) and from the lower trapezius. When these muscles contract, a compressive force is created between C1 and T12. This force tends to increase the lordosis of the neck and the kyphosis of the thoracic spine. The intervertebral joint most likely to suffer is the one with the smallest cross-sectional area of its disc and that which lies close to the apex of the thoracic curve. In most individuals, this vertebra is the fifth thoracic vertebra, with variation from T3 to T7 (Kazarian, personal communication).

There are other reasons why this vertebral level is the most frequently affected. Among them is the fact that at this level, there is often a slight scoliotic curve. It is also a common site of a vertebral malformation.

Relation of the head in balance to symptomatology

Muscular effects (fibromyalgia)

Striated muscle cannot maintain a sustained effort for long periods of time. Any such activity will cause a painful fatigue in the levator scapulae, rhomboids and lower portion of trapezius. These muscles become tender to the touch, principally at their points of origin and insertion (Fig. 11.2A). Occasionally the tenderness may be felt in the trapezius, which may be recruited when the levator scapulae is fatigued. The affected muscles are contracted to the touch. Sometimes the induration may be patchy, giving the muscle a fibrous, ropy feel, often with tender nodules.

The cause of pain is thought to be due to waste products produced by muscle; however, no abnormal build-up of expected chemicals has been detected (Mooney, 1991), despite increased EMG activity (Fowler and Kraft, 1974). Abnormal muscle enzyme blood levels may be elevated (Bjelle *et al.*, 1979). Muscle biopsies have shown degeneration and inflammatory exudates (Bengtsson *et al.*, 1986), but this is inconclusive because the same changes have been reported from so-called normal muscles.

Contraction of the levator scapulae and rhomboid muscles causes the neck to be stiff. This stiff neck is not accompanied by a loss of cervical lordosis and, characteristically, the loss of motion is symmetrical. These two findings may allow a distinction between this and a stiff neck arising from a cervical disc or zygapophysial joint problem.

Effects on the T5–T6 joint

The unaccustomed increased compression force has a deleterious effect on the T5–T6 joint and, to a lesser extent, on the adjacent joints (Fig. 11.2B). They undergo early degeneration, with typical changes appearing in the discs as well as in the zygapophysial joints. In a series of four chronic cases treated by the author with spinal fusion, there was severe degeneration of the zygapophysial joints in all cases. The degenerative T5–T6 joint may cause paraspinal muscle spasm, and it may refer pain around the chest wall (usually unilaterally) to the epigastrium at the appropriate level. This pain may be of sufficient intensity to cause the mistaken diagnosis of an upper gastrointestinal problem or a cardiac crisis (pseudo-angina).

Tenderness is often palpated in the midline, at the T5–T6 interspinous ligament and, to a lesser extent, at adjacent levels.

It may be mentioned that ganglia of the autonomic nervous system lie in close relation to the intervertebral discs at this level. It should also be noted that the ganglia in this region (T3, T4) are concerned with the blood supply of the upper extremities (Dohn and Sara, 1978).

The fifth intercostal space is not the only tender location in the thoracic wall. Tenderness is also found in the pectoralis muscles and the anterior chest wall. The reason for this is not clear, and it may be due to referred pain from the brachial plexus; this will be discussed later.

Effects on the face

When the cervical lordosis is increased it is accompanied by extension of the head, which is necessary to minimize shear stress at the atlanto-occipital joint (Helleur, 1983). The extension of the head is resisted

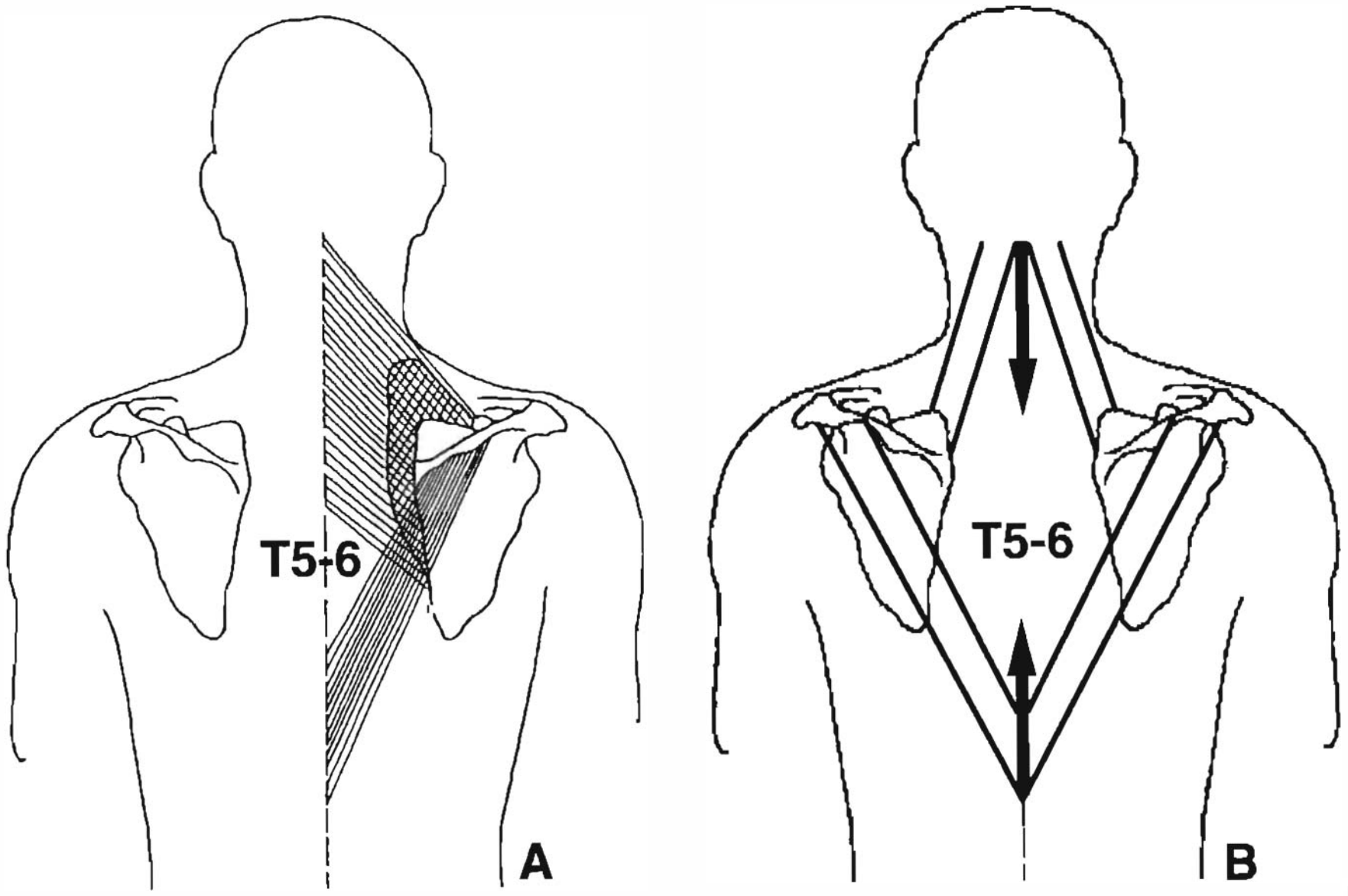

Fig. 11.2 (A) Origin and insertion of levator scapulae and lower fibres of trapezius. (B) The collective force moments result in compressive forces commonly crossing the T5–T6 segment.

by the 'strap' muscles and the muscles of the floor of the mouth, and also by the elastic resistance of the trachea and bronchi - especially during inspiration. These forces act together to move the lower jaw backwards and downwards. This makes it difficult to close the mouth normally when the head is extended, and individuals with this problem become 'mouth breathers'. This improper breathing pattern causes a dry mouth and often a non-allergic rhinitis and a postnasal drip.

The effect on the TMJ of the habitual 'mouth open' position of the mandible may lead to displacement, perforation or trauma to the TMJ cartilaginous disc. Temporomandibular joint problems are well-recognized sources of facial pain and, because of the close relationship of the joint to the C2 and C3 nerves, advancing TMJ dysfunction may also be the source of headache and pain in the side of the neck.

The importance of the relationship between head and neck posture and the TMJ problem must be appreciated for successful treatment to be implemented. While it is certain that a problem of posture may result in a TMJ problem, it is not known if there is reciprocity such that a primary TMJ problem could cause a postural imbalance of the head.

Effects on the upper extremities

Increased lordosis of the cervical spine with the forward-downward displacement of the shoulders has an effect on the structures exiting through the thoracic outlet. The cords of the brachial plexus are brought closer to the first rib, and the situation is aggravated by the presence of a cervical rib. In those individuals with high supraclavicular ribs (15% males, 85% females), the incidence of upper extremity symptoms is greater and they are more severe. This factor accounts for the gender difference in reported cases, with problems occurring six times more commonly in females than in males (Maeda *et al.*, 1982). In individuals with asymmetrical first ribs, the symptoms occur earlier and more severely on the side with the high rib.

The brachial plexus cords are tender to palpation and in some cases appear swollen. In connection with this, it should be noted that pressure on the shoulders exacerbates the symptoms in the upper extremities and causes increased upper back pain. This is in contrast with a brachial plexus problem stemming from a cervical joint, where pressure on the head causes an aggravation of symptoms but not those affecting the upper extremities.

There is often a complaint of numbness in the ulnar or median nerve distribution. However, sensation to pin prick may be normal, although a light touch with cotton wool may be poorly perceived. Wasting of the thenar eminence may be present.

The tendon reflexes are all normal. The EMG may show the presence of carpal tunnel syndrome or ulnar neuritis, but it seldom shows changes about the elbow. There is frequently a complaint of swelling in the hands, as evidenced by the patient noting that rings become more difficult to put on or remove from fingers. Complaints of colour change in the hand and of increased sweating do occur, but they are infrequent.

These vascular, thermal changes and the headache are thought to be due to irritation of the sympathetic nervous system in the neck, or possibly of the upper thoracic chain. Headache has been thought to relate to involvement of the autonomic system, which runs along the innominate artery.

Lateral epicondylitis of the elbow (2%) and bursitis/tendonitis (30%) occur frequently in association with this condition (Hult, 1954), and these may be due to irritation of the branches of the plexus. The tenderness at the lateral epicondyle can usually be palpated along the radial nerve above the epicondyle. Periarthritis of the scapulo-humeral joint may be due to a similar irritation of the musculocutaneous nerve.

Other important considerations

A large proportion (27%) of these patients suffer from sleep disorders or insomnia (McDermott, 1986), and there is often a psychological overlay caused by (or causing) job dissatisfaction (Kiesler and Finholt, 1988).

Aetiology

Any condition that leads to a change in posture sufficient to unbalance the head on the neck will lead to the development of the tired neck syndrome. Thus, in theory, a number of traumatically induced pathologies could lead to upper back and neck pain - for instance, compression fractures of the cervical, thoracic or even lumbar spine, trauma to the soft tissues of the neck (such as whiplash), or trauma to the shoulder where the shoulder is forced downward and forward by a fall or a falling object. In addition, postural changes following cervical joint surgery could lead to the development of chronic pain.

However, habitual bad posture in the workplace is by far the commonest cause leading to this chronic condition, and the numerous occupational situations have been summarized by Andersson (1991). The three commonest forms of poor posture are:

1. Head forward. This is commonly due to the need to see a computer screen clearly. Classically, the person's head is extended forward to view the screen. The situation is somewhat ameliorated by tilting and lowering the screen. However, there is the problem of focal length of the eyes; lenses that

are suitable for comfortable reading of a book may not be suitable for the reading distance between the eyes and the computer screen. In this respect, it is worth noting that reading with bifocal lenses may actually aggravate the posture problem.

2. Arms extended. As the arms are extended, the shoulders drop down. Stability of the shoulder blades during this activity is supplied by the cervical and thoracic musculature. Demand on the muscle is increased when the elbows are straightened, and is further increased when the arms are at shoulder height or above. Thus, it helps if individuals sit as close to their work as possible, with a keyboard at a comfortable height - normally at the level of the waist or slightly lower. Workers on an assembly line need similar protection. In addition, workers should not be required to reach upward for tools or parts, especially if they are heavy. Arm rests or supports for the arms, which prevent the depression of the shoulders, are important aids in prevention of these stresses. The rests should be at the correct height to cause only slight shoulder elevation.
3. Shoulders down. Anything that forces the shoulders downward, such as bags with heavy straps, heavy coats, or tight brassieres, should be avoided. Carrying heavy parcels such as briefcases or groceries at arm's length is also to be avoided; the packages should be clutched close to the body and, if possible, carried under the arm.

Treatment

It is essential that patients understand clearly what the problem is and the necessity for taking responsibility for their own rehabilitation. If the condition has lasted longer than 6 months it has reached a stage of chronicity, and complete recovery cannot be guaranteed although amelioriation is possible. Standard therapy modalities for stiff neck are seldom of value in these cases.

The methods of unbalancing the head and neck are demonstrated to the patient, as well as the countermeasures. The necessity of resting the joints of the upper back is stressed, which involves relieving the compression on the spine by the weight of shoulders (approximately 9 kg) and, less importantly, the head (about 2 kg).

Patients are taught the following simple technique of relaxing the muscle cramps in the neck. The patient lies supine, with the head supported in the flexed position by a firm support (book or pillow). The head is turned to one side and one hand is placed on the side of the patient's face. A forceful contraction of the neck muscles to bring the head back to the centre is made against the resistance of the hand. This is repeated facing to the other side. The duration of the contraction is 3-5 s. This isometric-type contraction is repeated as necessary until relaxation of the cramped muscle is obtained. Many patients achieve sufficient relief from this technique, and do not require further treatment.

If more active treatment is required, the first objective is to localize the offending joint. Radiographs are of little help. A few days of non-steroidal anti-inflammatory medication, if tolerated, will usually serve to allow identification, via palpation, of the point of maximum tenderness in the midline.

A local injection of 1.0 ml 2% xylocaine at the identified level will reach the zygapophysial joints if the injection is carried out deep to the fascia overlying the paraspinal musculature and close to the spinal process. This infiltration serves the purpose of proving to the patient and surgeon alike that the main problem has been localized because, following the injection, most of the pain in the neck, upper back and upper extremities disappears. The trigger points are not injected.

Exactly what is the connection between T5 and the widespread pain in the cervical and thoracic spines and upper extremities? Does degeneration of the joint come first, causing the muscular contracture of the levator scapulae and lower trapezius muscles, or is it the reverse? In any case, the effect of the injection may be prolonged by the inclusion of a soluble steroid. Occasionally a second joint may be involved, and this may also require similar treatment.

Maintenance

The best maintenance is produced by a change in work habits; however, this may fall into the category of 'easy to say but hard to do'.

Theoretically the muscles could be retrained and strengthened, but this is very difficult to achieve when the faulty muscles are totally fatigued. The least bit of exercise may bring on a return of pain. Exercises of the shoulders, which require the shoulders to remain behind the plane of the cervical spine, are helpful. An aerobic routine may help (Mooney, 1991).

Upper extremity problems

Fluid retention in the female seems to cause aggravation of upper extremity symptoms. Anti-inflammatory medication in these patients seems to exacerbate the symptoms further.

Local nerve entrapment syndromes are best not treated until the upper back problem has been controlled for fear of recurrence of the problem. Ulnar nerve neuritis or medial epicondylitis should be treated by transposition of the nerve. If care is utilized to remove a section of the medial intermuscular septum, transposition of this nerve may release the cords of the brachial plexus. This minor surgical procedure is best tried before removal of the first rib, as it has a reasonable chance of success in relieving the brachial plexus symptoms. Lateral epicondylitis and bursitis of the shoulder are treated in the usual manner.

Bursitis of the shoulder and lateral epicondylitis

Epicondylitis

As stated above, bursitis and epicondylitis have a clear relationship to cervical-(dorso)-brachialgia, but this relationship has not previously been explored.

In an anatomic study by the author of 101 cadaveric shoulders, every one demonstrated that the coracobrachialis muscle did not only insert into the tip of the coracoid process. Invariably, a portion of this muscle missed the coracoid attachment and proceeded to insert at the tendinous intermuscular septae of the middle deltoid. This prolongation of coracobrachialis was continuous with the coraco-acromial ligament, forming a wide band which covered the area of attachment of supra- and infraspinatus and was under muscular control. This ligament is not identified in standard anatomy texts. The significance of this ligament is that it is under neural control, and irritation of the musculocutaneous nerve may give rise to bursitis/tendonitis, by clamping down on the rotator cuff.

Lateral epicondylitis can be explained similarly as being due to irritation of the radial nerve. The epicondylitis often manifests itself as tenderness of the radial nerve as it exits from the musculospinal groove onto the dorso-lateral aspect of the arm.

The connection between medial epicondylitis and the ulna nerve is even more direct. The ulna nerve at the elbow is invariably tender to touch, and the small vegetative branch entering the area just above the epicondyle is often swollen and tender.

Summary

Tired neck syndrome characterizes the commonest group of cervico-dorso-brachialgias, the common element being the thoracic spine. Patients are often in chronic pain by the time they are diagnosed, and are best treated by a multidisciplinary approach from specialized health professionals including physicians, dentists, manual therapists and ergonomists. Treatment must include education and a change of occupation or work pattern.

References

Andersson, G.B. (1992) Epidemiology of spinal disorders. In: *The Adult Spine* (Frymoyer, J., ed.). New York: Raven Press, pp. 138-140.

Basmajian, J. (1974) *Muscles Alive*. Baltimore: Williams & Wilkins, pp. 192, 403.

Bengtsson, A., Kenriksson, K.G., Larsson, J. (1986) Muscle biopsy in primary fibromyalgia: Light microscopical and histochemical findings. *Scand. J. Rheum.* **15:** 1-6.

Bjelle, A., Hagberg, M., Michaelson, G. (1979) Occupational and individual factors in acute shoulder/neck disorders among industrial workers. *Br. J. Industrial Med.* **38:** 356-363

Bogduk, N., Marsland, A. (1988) The cervical zygapophysial joints as source of neck pain. *Spine* **13:** 610-617.

Dohn, D.F., Sara, G.M. (1978) Sympathectomy for vascular syndromes: hyperhidrosis of the upper extremities. In: *Clinical Neurosurgery. Congress Neurological Surgeons*, Vol. 25. Baltimore: Williams & Wilkins, pp. 637-647.

Farfan, H.F., Baldwin, J. (1986) Tired neck syndrome: chronic postural strain. In: *Trends in Ergonomics/Human Factors III* (Karwowski, W., ed.). North-Holland: Elsevier Science Publishers, pp. 651-658.

Ferguson, D. (1971) An Australian study of telegraphist's cramps. *Br. J. Med.* **28:** 280-285.

Fowler, R.S. Jr, Kraft, G.H. (1974) Tension perception in patients having pain associated with chronic muscle tension. *Arch. Phys. Med. Rehabil.* **55:** 28-30.

Helleur, C. (1983) *Cervical Spine Model*. Doctoral Thesis. Concordia University, Montreal.

Hult, L. (1954) Cervical, dorsal and lumbar spine syndromes. *Acta Orthop. Scand.* **17(Suppl.):** 10-34.

Kiesler, S., Finholt, K.T. (1988) The mystery of RSI. *Am. Psychol.* **43:** 1009-1015.

Maeda, K., Horiguchi, S., Hosokawa, M. (1982) History on the studies on occupational cervicobrachial disorder in Japan and remaining problems. *J. Human Ergo.* **11:** 17-29

McDermott, F.T. (1986) Repetition strain injury: A review of current understanding. *Med. J. Aust.* **144:** 196-200.

Mooney, V. (1991) Differential diagnosis of back disorders: Principles of classification. In: *The Adult Spine* (Frymoyer, J., ed.). New York: Raven Press, pp. 1550-1555.

Ohara, H., Itani T., Aoyama, H. (1982) Prevalence of occupational cervicobrachial disorder among different occupational groups in Japan. *J. Human Ergo.* **11:** 53-63

Waris, P. (1980) Occupational cervicobrachial syndrome - a review. *Scand. J. Work Environ. Health* **3(Suppl.):** 3-14.

12

Radiology of the thoracic spine

I. W. McCall

Radiological anatomy

The thoracic vertebral bodies increase progressively in size from cranial to caudad (see Fig. 2.5). The pedicles arise from the upper half of each vertebral body, pass postero-laterally and are angled slightly inferiorly to the neural arch. The laminae are continuous with the lateral mass and are relatively flat and overlap with the adjacent laminae. The articular processes arise from the pedicle in a superior and inferior direction, and the zygapophysial joints are aligned primarily in the coronal plane. The spinous process is long and passes downwards and posteriorly, with close apposition at each level. The transverse processes extend outward, upward and posteriorly from the lateral articular mass. The intervertebral foramen is directed laterally at the level of the inferior half of the vertebral body and the superior and inferior margins are formed by the pedicles, with the neck of the rib antero-laterally. The ribs articulate with the transverse process posteriorly. The head of the rib articulates with the vertebral body of the same level as the rib, but there is also a smaller demi-facet articulating with the vertebral body above. The crest of the head of the rib is joined at the intervertebral disc by an intra-articular ligament, which lies parallel to the plane of the intervertebral disc.

The thoracic spinal canal has abundant epidural fat posteriorly between the neural arch and the dura and laterally in the intervertebral foramen. There is little epidural fat anteriorly. The vertebrae are linked anteriorly by the anterior longitudinal ligament, which is thicker in the thoracic spine than the cervical or lumbar regions and is more prominent opposite the vertebral bodies. The anterior longitudinal ligament is contiguous with the anterior fibres of the anulus. The posterior longitudinal ligament extends along the posterior aspect of the vertebral bodies and is not attached to the central part of the vertebral body but is attached to the posterior vertebral rim and is continuous with the anular fibres. The thoracic posterior longitudinal ligament is also thicker than in the cervical or lumbar spines. The ligamentum flavum is less prominent, and links the lamina at each level

The dural sac is significantly larger than that of the spinal cord, and the dural sheath extends along the thoracic nerve roots for a shorter distance than in the lumbar region. The thoracic cord is circular compared to the cervical cord, and the median fissure indents the ventral surface of it. In the upper thoracic spine the neurological level of the cord is two levels lower in number than the corresponding vertebra, whilst in the lower thoracic spine the difference is three levels between cord and vertebra. The nerve roots are seen within the subarachnoid space at the side of the cord until they exit at the appropriate intervertebral foramen. The termination of the cord normally occurs in the region of T12, with a widening of the cord at the conus medularis. The thoracic discs have a nucleus pulposus, which is more centrally located than in the lumbar spine region. The disc is thinner vertically than in the lumbar spine, with a uniform thickness from anterior to posterior.

The thoracic spine has a kyphosis, which has a normal range of 20-40° although an upper limit of 45° has been suggested (Fon *et al.*, 1980). The normal kyphosis results from a disparity between the anterior and posterior heights of the vertebral bodies. The vertebral bodies are supplied by a central artery and drain via the basi-vertebral vein. The central vessels arborize to the upper and lower vertebral end-plates, where there is a prominent end vessel plexus (Crock and Yoshizawa, 1977). The interspinous ligament is between each spinous process, with the superficial interspinous ligament along the tip of the spinous process.

The standard radiographic investigation consists of lateral and antero-posterior (AP) plain films. The lateral view will demonstrate the vertebral body and discs satisfactorily, but the zygapophysial joints and pedicles may be difficult to visualize due to the overlying ribs and superimposition of the joints (Fig. 12.1). The joints themselves will not be seen on an AP view due to their alignment in the coronal plane. The paravertebral shadow is seen on the AP view of the chest as a well-defined soft tissue line parallel to the spine, and is slightly wider on the left compared to the right (Fig. 12.1).

The transaxial images, which are created either by computerized tomography (CT) or magnetic resonance (MR), demonstrate the relationship of the vertebra, pedicles, lamina and dural sac, and will also identify the nerve roots and relationship to the foramen (Fig. 12.2) Magnetic resonance is required to differentiate the cord from the remainder of the cerebrospinal fluid (CSF) in the dural sac while also providing detailed anatomical differentiation of the anulus and nucleus. Individual nerve roots can be visualized in the foramen on the transaxial scans of CT, but are better seen on the transaxial or sagittal MR scans (Fig. 12.3). The muscles of the thoracic spine include multifidus, erector spinae and trapezius (Moore, 1997).

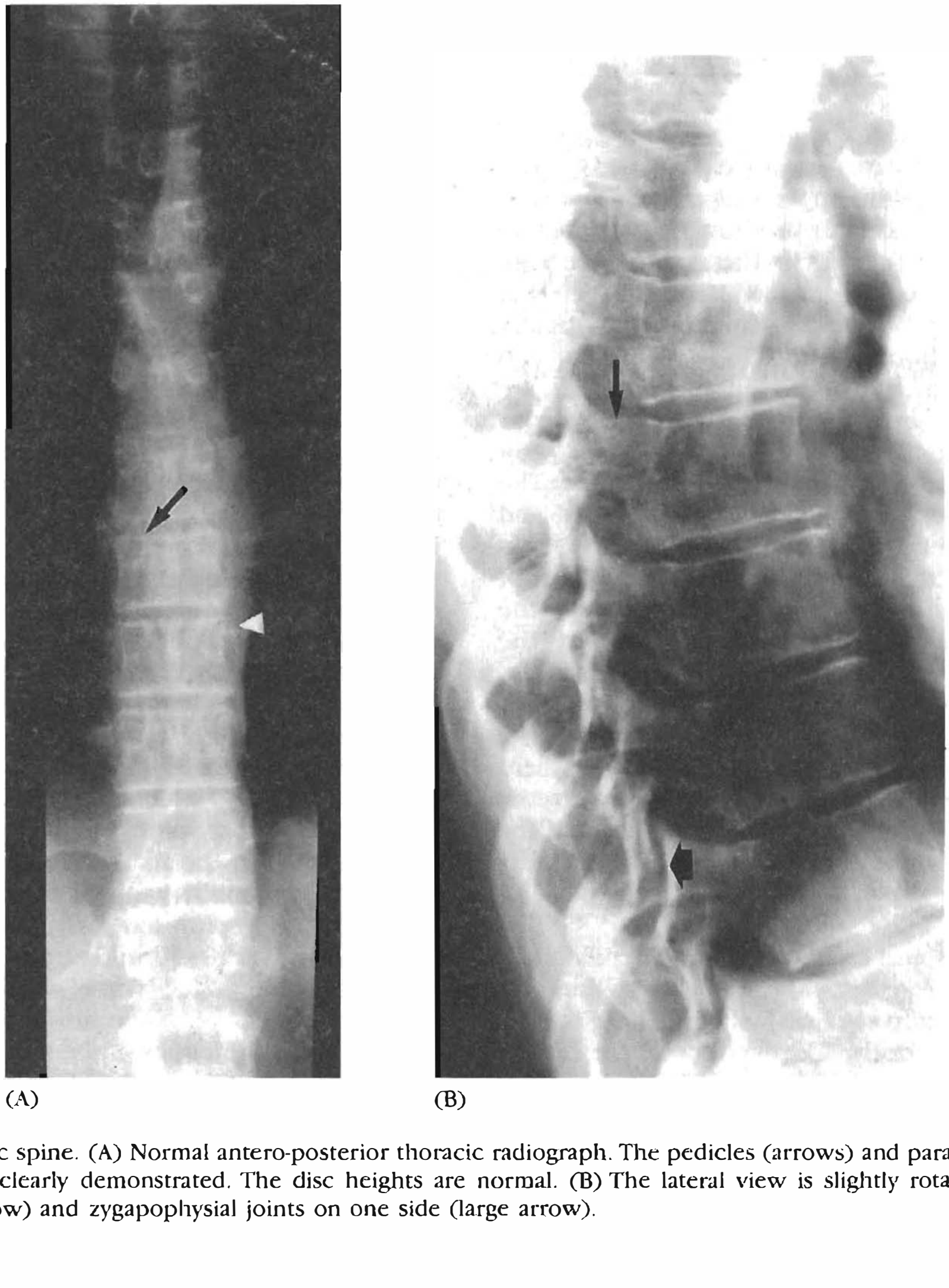
(A) (B)

Fig. 12.1 Thoracic spine. (A) Normal antero-posterior thoracic radiograph. The pedicles (arrows) and paravertebral shadow (arrow head) are clearly demonstrated. The disc heights are normal. (B) The lateral view is slightly rotated, showing the pedicles (thin arrow) and zygapophysial joints on one side (large arrow).

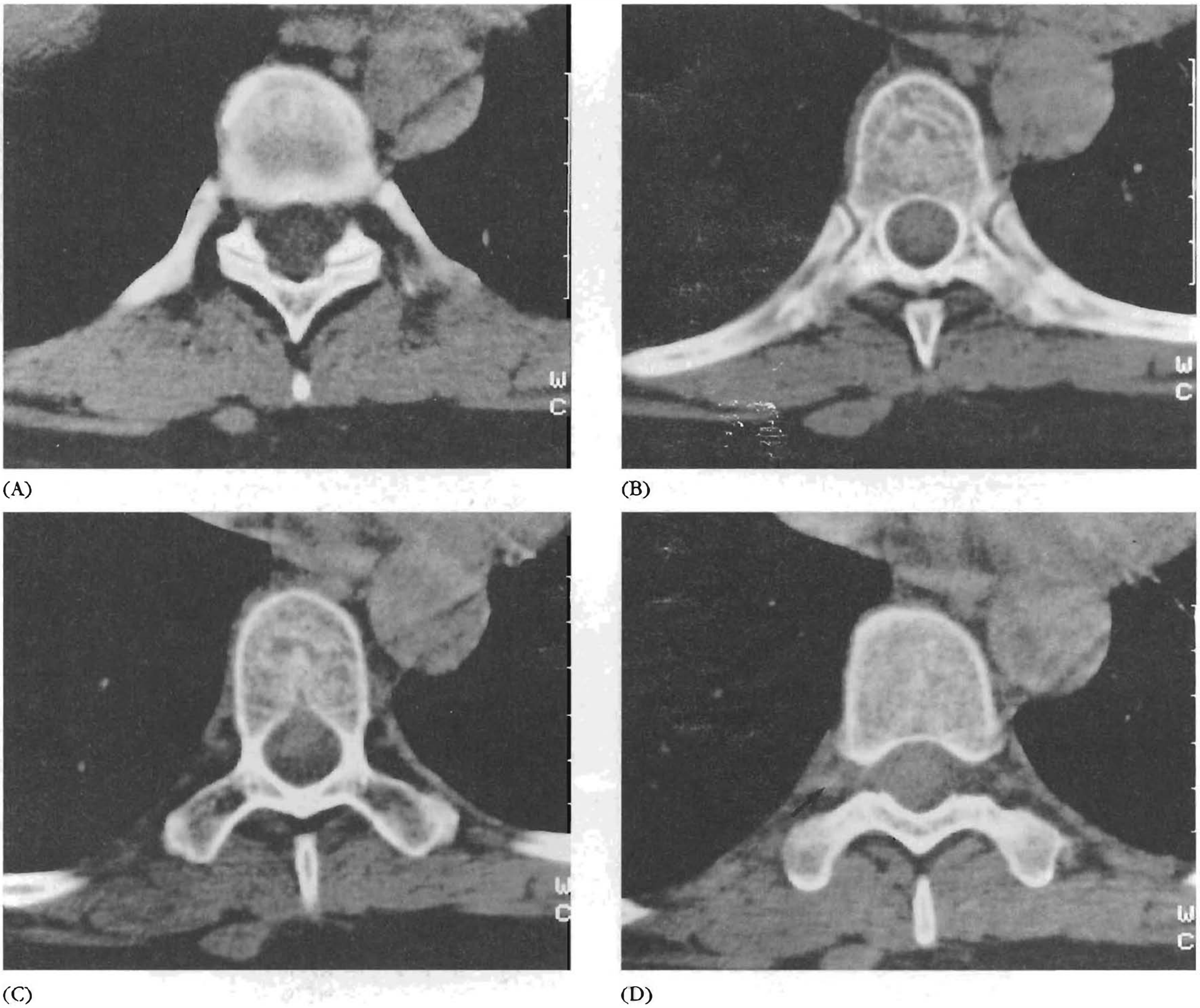

(A)

(B)

(C)

(D)

Fig. 12.2 CT thoracic spine. (A) Transaxial anatomy at the level of intervertebral disc, with coronally aligned zygapophysial joints. The upper parts of the ribs are seen articulating across the disc space. (B) Lamina, with costovertebral and costotransverse joints. (C) Lower part of pedicle. (D) Foramen with dorsal ganglia (arrow).

Disorders of the thoracic spine

Disc degeneration

Changes of ageing that occur in the disc are initially reflected in a gradual decrease in water content in both nucleus and anulus, associated with a loss of chondral cells and a change in the protein polysaccharides. The nucleus becomes dry, resulting in granular changes and clefts occurring in the centre of the disc parallel to the end-plates. These clefts may extend into the anulus, both anteriorly and posteriorly in the thoracic spine, with some extending to the full width of the anulus. Concentric cracks may also occur, due to degeneration of the collagen fibres within the anulus. Degenerative changes in the discs may also extend to the cartilage end-plate, with fissure formation, horizontal clefts and increased vascular penetration from the vertebral bodies. In the later stages, calcification and ossification of the end-plate cartilage occurs. The degenerative process of the disc may result in a gradual disruption of the posterior anular fibres, potentially leading to a portion of the nucleus protruding through the defect. Tears may be acute following a traumatic episode, but more commonly occur without any recognized predisposing factor. Herniation of the nucleus pulposus tends to occur in the third or fourth decade, where there is some degeneration of the disc but a reasonable degree of hydration in the nucleus persists. However, disc herniations in younger subjects can occur, usually related to underlying disc disorders such as Scheuermann's disease. A substantial proportion of thoracic disc prolapses may be present without causing symptoms. Prospective studies using

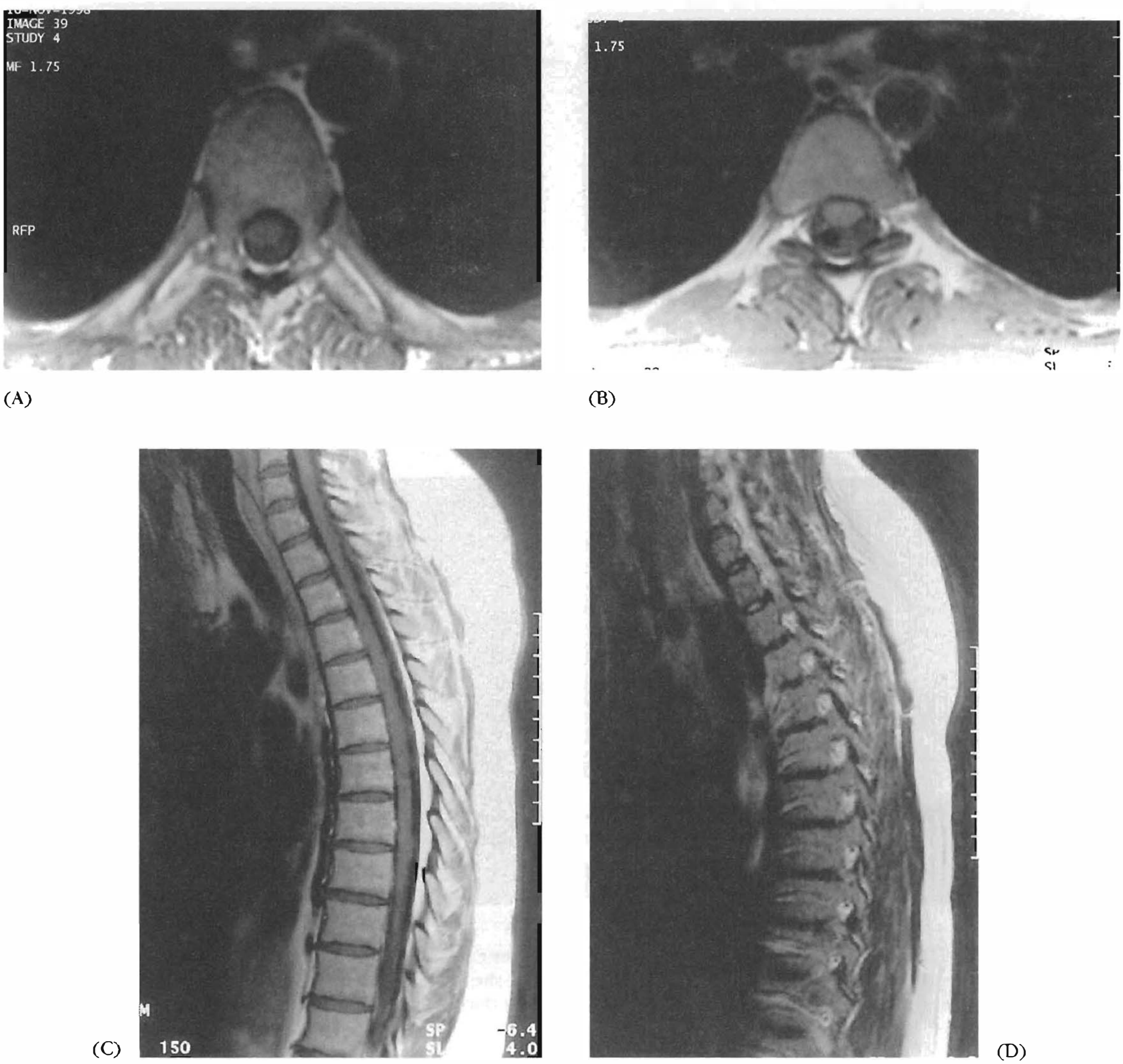

Fig. 12.3 Magnetic resonance image of normal thoracic spine showing the cord within the canal at the level of the pedicles and the nerve roots in the foramen on T1 weighted images in the axial plane (A, B). The thoracic cord is depicted in the mid-sagittal plane (C) and the exiting nerve roots at the level of the intervertebral foramen (D).

MR on asymptomatic volunteers have demonstrated thoracic disc herniation in 37% of subjects. The distribution of their location was wide, but the majority were located between T5-T6 and T10-T11 (Wood *et al.*, 1995). Disc bulging due to degenerative changes without true herniation was present in 48 of the 90 asymptomatic subjects (53%) in this study (Wood *et al.*, 1995). Other studies have shown an incidence of about 15% of incidental disc herniations (Williams *et al.*, 1989). In the thoracic spine, symptomatic disc herniations most commonly present with back pain or myelopathy, which includes progressive paraparesis, hyper-reflexia, altered sensation to pin prick and occasionally urinary problems. The presenting back pain is non-specific, occurring locally or in a radicular fashion, and can be mistaken for cardiac, thoracic or abdominal pathology.

The most appropriate imaging technique for demonstrating disc lesions in the thoracic spine is MR. Disc herniations are not identified with plain radiographs unless they contain significant calcification (Fig. 12.4). Computerized tomography will demon-

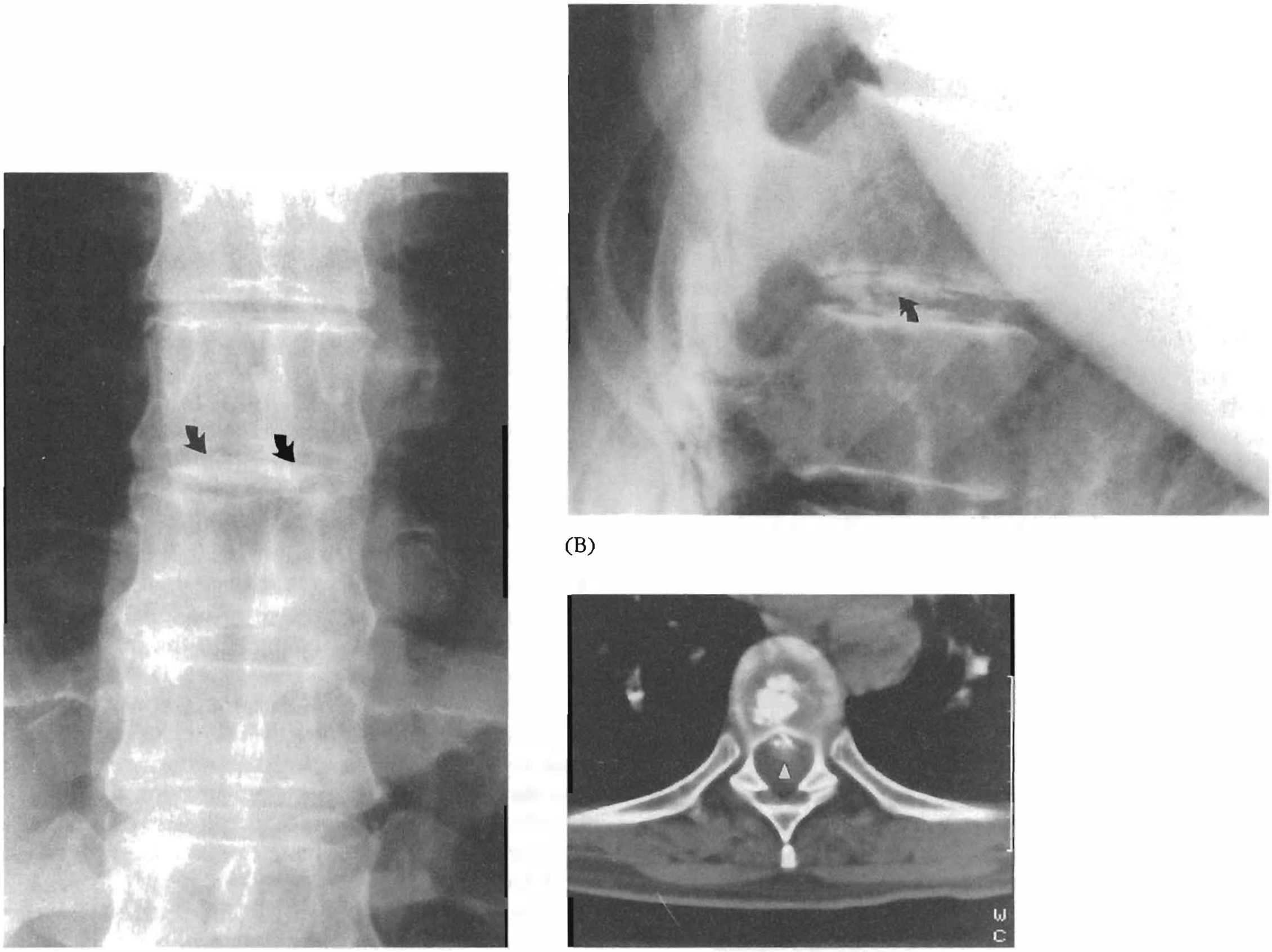

(B)

(A)

(C)

Fig. 12.4 Radiographs show extensive calcification within the intervertebral disc on the AP (A) and lateral (B) views (curved arrows), while CT (C) shows the extension of the calcification into the spinal canal (arrow head).

strate a disc herniation, but the differential attenuation between disc and cord is not great and the absence of fat in the anterior epidural space removes the marked contrast differential that is so useful in diagnosing a disc herniation on CT in the lumbar spine. Computerized tomography associated with contrast medium in the dural sac provides a good evaluation of a disc herniation but this requires a lumbar puncture, which may result in post-procedural headache and vomiting. On MR, the features of herniated nucleus pulposus can be clearly seen on the sagittal and axial planes in both T1 and T2 weighted images. The T1 weighted image demonstrates a normal intermediate signal intensity of the nucleus, extending posteriorly beyond the line of the posterior rim of the vertebral body in one or two images, with the low signal intensity dural sac being indented by the disc prolapse (Fig. 12.5). On T2 weighted spin echo or gradient echo sequences, the nuclear material may show increased signal within the disc herniation unless longstanding, in which case the signal may be reduced (Fig. 12.5). The outer fibres of the anular/posterior ligament complex are intact in a disc protrusion, and will be seen as a low signal rim around the protrusion. If the disc material has penetrated this barrier and is extruded, the low signal outline will be lost against the line of the higher signal CSF. The axial scan will identify the precise location of the disc herniation and its relationship with the nerve roots and cord. The cord may be significantly indented by the protrusion in the thoracic spine. The nerve roots within the canal are more difficult to identify. If extrusion has occurred, careful analysis of the sagittal and axial scans is required to assess whether a free fragment has migrated from the disc, particularly if it is in the nerve root canal. Calcification may also be present within the disc

Fig. 12.5 A sagittal T2 weighted MR image demonstrates a large disc herniation, which is causing severe compression of the cord. The signal intensity within the herniated material is reduced, indicating a significant loss of water content. Irregular end-plates and multiple Schmorl's nodes are evident at adjoining levels.

prolapse and this is best seen on CT, which demonstrates the high attenuation of the calcium (Fig. 12.4). This is more discriminatory than MR, where low signal may represent chronic discs either with or without calcification. Computerized tomography should therefore be undertaken in the evaluation of thoracic disc herniation if surgery is being considered. On CT, a herniation will be demonstrated as a focal soft tissue mass, contiguous with the disc encroaching on the spinal canal either centrally or postero-laterally, having an attenuation value of between 50 and 100 Hounsfield units. Low attenuation of the dural fat, if present, will be obliterated and the dural sac deformed but, in the absence of fat, CT myelography may be required to assess the degree of cord compression and obstruction. This may also be achieved by using CT units to highlight the dural sac, which falls between minus 20 and plus 20 Hounsfield units, but differentiation from the epidural venous plexus may still cause confusion.

The natural history of disc herniation is for gradual resorption, the majority showing a reduction in size of 30 to perhaps 100% on conservative treatment. There is a poor correlation between symptom resolution and the rate of reduction in the size of the herniated disc, the latter often being slower than the former. A follow-up study of asymptomatic thoracic disc herniations showed that all subjects remained asymptomatic. There was some fluctuation in size of the disc herniations, but only 27% changed in size by more than 8% (Wood *et al.*, 1997). Large disc herniations tended to decrease in size and small herniations tended to increase a little, but overall, significant change did not occur in the majority of herniations (Wood *et al.*, 1997).

Disc degeneration may proceed without causing disc herniation and, although some mild disc bulging may occur posteriorly, the predominant anular bulging occurs anteriorly. This is often associated with osteophyte formation on the anterior rim of the vertebral body, primarily to the right of the midline of the vertebral body. The presence of the descending aorta, closely applied to the thoracic vertebra to the left of the midline, appears to reduce osteophyte formation at this site. Anterior disc degeneration is well demonstrated on plain radiographs, which show a loss of disc height and often adjacent sclerotic changes in the anterior part of the vertebral end-plate (Fig. 12.6). The osteophyte formation appears as an anterior extension of the end-plate and may show diffuse calcification, but marrow extension into the osteophyte rim may be demonstrated. The decrease in anterior disc height may accentuate the thoracic kyphosis, producing a degenerative kyphosis of the dorsal spine (Manns *et al.*, 1996).

The degree of kyphosis is less severe than that resulting from osteoporotic collapse, but is probably more common (Manns *et al.*, 1996). The relationship between disc degeneration, kyphosis and thoracic back pain is unclear. Irregularity of sclerosis of the vertebral end-plates also occurs in conjunction with Schmorl's nodes, and vacuum phenomena are occasionally demonstrated within the disc; this is accentuated by flexion and extension views. Disc degeneration is well demonstrated on MR, with the height loss seen on the T1 weighted images (Fig. 12.6). On T2 weighted spin echo sequences, there is a reduction in the normal high signal intensity of the nucleus and, in severe degeneration, the extensive loss of signal results in a uniform low signal throughout the disc. Disc degeneration is commonly demonstrated on MR in asymptomatic subjects, being present in 56%, with a very similar incidence in those under 39 years of age as compared to those of 40 years or more. Degenerative changes were more common in men than women at both ages (Williams *et al.*, 1989). Occasionally, increased signal within the disc on T1 has been reported in the thoracic spine. This has been shown on CT to be due to the presence of calcification within the degenerate disc (Tyrell *et al.*, 1995). This hyperintensity is thought to be due to a shortened T1 related to the surface relaxation phenomenon caused by the binding of a layer of water on the surface of the calcium crystal (Bangert *et al.*, 1995). In the later stages of calcification, the high concentration produces decreased signal on T1. As there is no clear relationship between radiographic evidence of disc degeneration and pain, in the presence of pain with multiple levels of disc degeneration, further investigation to define the site of pain will be required. Discography, which is an invasive investigation, is required to stimulate the disc by direct injection into it. Discography is not performed regularly in the thoracic region, but is an entirely feasible examination. The needle placement requires precision to avoid penetrating the pleura but, with careful guidance, the injection of contrast into the nucleus is undertaken and the pain response, due to the injection, is assessed (Fig. 12.7). Local anaesthetic may then be injected into the disc to assess whether this relieves the induced symptoms. Evaluation of the disc by discography may be further enhanced by undertaking CT, which will demonstrate the exact distribution of the contrast medium.

In a series of 100 patients, discography was reported by Schellhas *et al.* (1994) to have determined whether the observed disc pathology related to the clinical pain complaints in all patients. Clinically concordant extra-spinal pain, such as chest wall, intrathoracic and upper abdominal pain, was frequently provoked by thoracic disc injection (Schellhas *et al.*, 1994).

Thoracic zygapophysial joint degeneration

Pain can be induced by the injection of a noxious stimulus into the zygapophysial joints of the thoracic spine. The distribution of pain is dependent on the level of stimulation but considerable overlap occurs, involving three to five different joint referral zones (Dreyfuss *et al.*, 1994), partially due to the fact that the zygapophysial joints are innervated by the medial branches of the dorsal rami in each joint, supplied by at least two levels (see Chapter 8 for a detailed presentation on this subject). The area of pain referral is around and below the joint level. The exact margin of the induced pain may be difficult to define. Plain radiological assessment of the thoracic zygapophysial joints for degeneration is difficult, due to the overlap of the ribs and the coronal alignment of the zygapophysial joints. Increased sclerosis around the joint and narrowing of the joint space are the main features of degeneration. Computerized tomographic scans, however, are the most effective method of evaluating

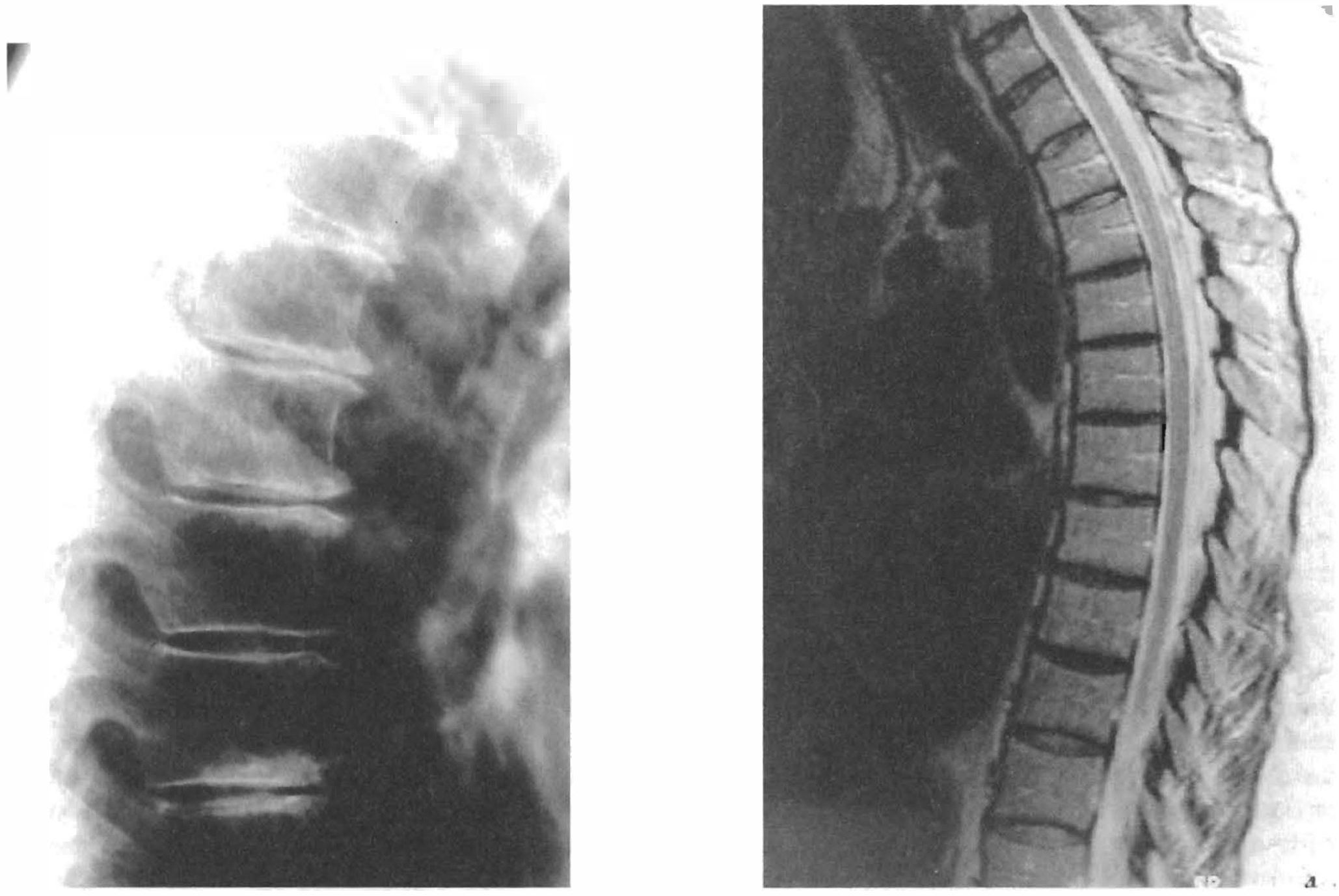

(A) (B)

Fig. 12.6 Disc degeneration. (A) Radiographs demonstrate anterior reduction in disc height, with sclerosis of the end-plate and anterior osteophyte formation. (B) MR image of disc degeneration shows loss of disc signal intensity on T2 weighted images, as well as height loss.

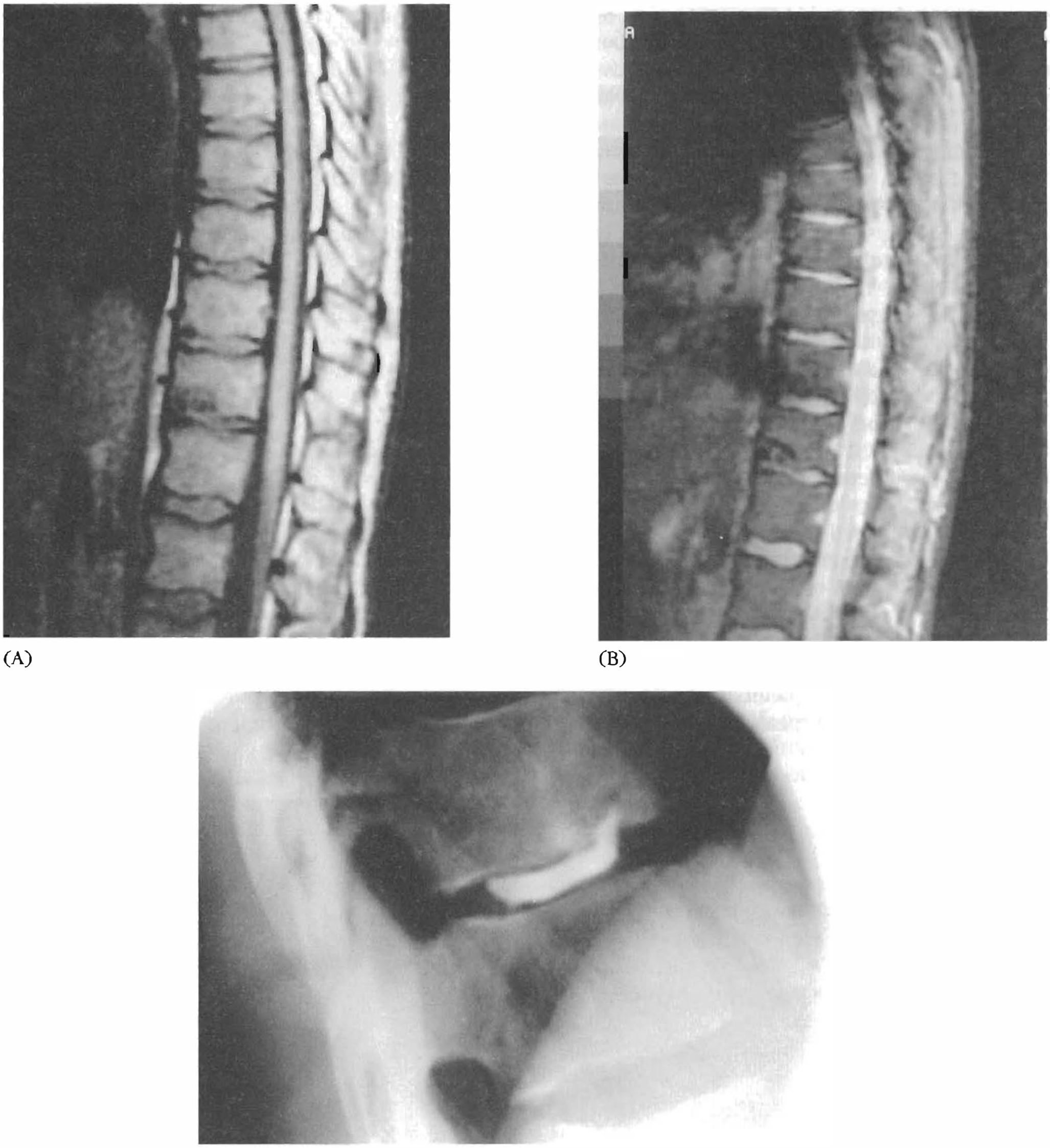

(A)

(B)

(C)

Fig. 12.7 Thoracic discography. (A) T1 weighted sagittal MR image shows loss of disc height at T11-T12, with end-plate disruption of T11 anteriorly. (B) T2 weighted images show slightly increased signal within the disrupted end-plate. (C) The discogram shows the contrast outlining the interosseous disc herniation and injection reproduced the symptomatic low thoracic back pain.

degeneration of the zygapophysial joints, and will demonstrate osteophytic bone formation around the joint margins. Irregularity and sclerosis of the joint surface is also clearly demonstrated by CT (Fig. 12.8). The joint may be visualized on MR, but the osteophyte formation is less easily seen. Zygapophysial joint cartilage is best demonstrated on the axial T1 weighted MR images, but if the thoracic cartilage is thinned it is not easily evaluated. Correlation between radiographic zygapophysial joint osteoarthritis, as demonstrated on CT, and the presence of thoracic or lumbar pain, has not been evaluated. However, since no relationship is present in the lumbar spine (Schwarzer *et al.*, 1995), it is unlikely to be any more specific in the thoracic spine. Severe osteoarthritis of the thoracic zygapophysial joints may also demonstrate increased isotope activity with technetium MDP scanning. This is more sensitive if single photon emission CT is used, and is best seen on axial views. Increased isotope uptake suggests

Fig. 12.8 Thoracic zygapophysial joint osteoarthritis: there is marked joint space narrowing and sclerosis of the zygapophysial joints, demonstrated well by CT.

very active bone production and sclerosis around the joint, but in the lumbar spine the correlation between symptoms and zygapophysial joint activity is not substantiated. No studies of the thoracic spine have, to date, been undertaken. The most effective method of relating symptoms of thoracic pain to the zygapophysial joints is by local anaesthetic injection into the joint or by block of the medial branch of the posterior primary ramus. This is appropriate for patients who have persistent thoracic pain for 3 months or more and who have no root or neurological deficit. A long-acting local anaesthetic (0.5 ml) is injected, with or without steroid, to increase the therapeutic element, although studies have shown no benefit from the intra-articular steroids (Caretta *et al.*, 1991). The total quantity of the injection should be less than 1 ml, as the capacity of the zygapophysial joint capsule in the thoracic spine is small. Avoiding rupturing the capsule, which would lead to epidural or pericapsular spread of the local anaesthetic, is necessary to maximize the specificity of the examination.

Chronic neurological compression

The spinal canal may become narrowed over a period of time due to degenerative changes, which consist of a combination of anular bulging and degenerative hypertrophy of the zygapophysial joints along with thickening or buckling of the ligamentum flavum. The degree of narrowing may be increased by the presence of an old disc herniation that has become calcified, and calcification of the ligamentum flavum may also increase the severity of the stenotic effect. However, canal stenosis due to disease of the vertebral bodies, such as Paget's disease or ossification of the posterior longitudinal ligament, is rare. Stenosis may be developmental in conditions such as achondroplasia or Morquio's disease. In the thoracic spine, stenosis may result in dural sac or cord compression. If the spinal cord is compressed myelopathy may ensue, which presents clinically as a degree of spasticity and weakness below the level of the compression through the involvement of the corticospinal or spinothalamic tracts. Associated with compression of the cord or nerve roots, the stenosis may result in epidural venous congestion, which further reduces the available space in the spinal canal and may cause oedema of the nerve roots. Moreover, the arterial supply to the cord and nerve roots may also be compromised by direct compression or by generalized increased intraspinal pressure. The lateral plain film is of limited value for measuring the dimensions of the thoracic spinal canal due to overlapping ribs, but a calcified disc with extension into the canal may be demonstrated. The AP view will enable the interpedicular distance to be measured. This varies depending on age and level, being most narrow at T6 and T7 and measuring between 15 and 20 mm in the adult at this level. Computerized tomography enables the cross-sectional area and shape of the canal to be assessed, and also evaluates the effect of the disc and ligamentum flavum on its functional capacity. Measurement of the cross-sectional size of the dural sac and cord may be difficult on un-enhanced CT in the thoracic spine as the amount of low attenuation epidural fat is variable, but a small amount of contrast injected in the spinal canal will be sufficient to provide a CT myelogram that will allow accurate assessment, providing the contrast is not obstructed. Computerized tomography is also the most effective way of demonstrating calcification or ossification of the posterior longitudinal ligament or the ligamentum flavum, which has been shown to be a significant cause of thoracic spinal stenosis (Fig. 12.9). Magnetic resonance imaging, however, is the investigation of choice for the assessment of the spinal canal and cord. The T2 weighted fast spin echo (FSE), or gradient echo sequences, will demonstrate the dural sac and cord and identify the degree of compression. Midline sagittal scans will depict the effect of bulging discs, and off-centre scans will show the postero-lateral indentation due to the combined effect of zygapophysial hypertrophy or ligamentum flavum and a bulging disc (Fig. 12.9). Axial scans should demonstrate the nerve roots surrounded by the high signal CSF. The loss of CSF around the nerve roots, which may be combined with deformity, indicates stenotic compression. In the thoracic spine, interpretation of the T1 weighted images may be difficult as the low signal of CSF will be similar to that of the cortical bone of the vertebra, the posterior longitudinal ligament and, if present, a calcified ligamentum flavum. On the T2 weighted image, however, the degree of compression of the cord will be clear, with an absence of high signal CSF anteriorly and posteriorly. In severe cases of cord compression, increased signal within the cord on the T2 weighted

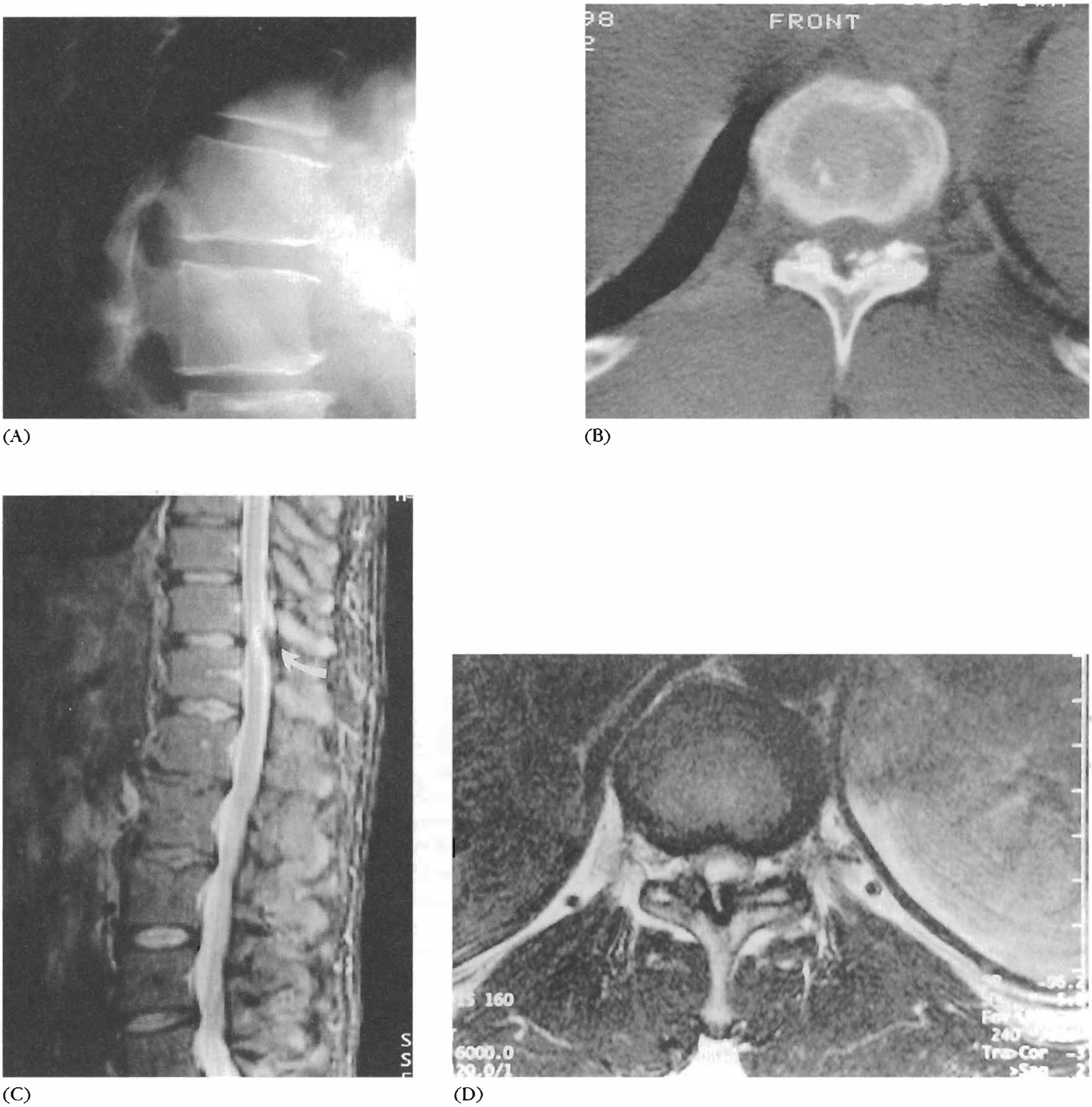

(A) (B) (C) (D)

Fig. 12.9 Some examples of spinal stenosis. (A) The lateral radiographs shows only minor evidence of canal narrowing. (B) Computerized tomography shows that the spinal canal is narrowed by ligamentum flavum calcification and osteoarthritis of the zygapophysial joints. Sagittal (C) and axial (D) MR T2 weighted sagittal views show compression of the cord, causing a high signal within it due to myelomalacia. The disc is well preserved, with high signal in the nucleus, in (D).

sequences may be seen. A relationship between the presence of myelopathy and a high signal in the cord on T2 weighted images has been demonstrated in the cervical spine (Takahashi *et al.*, 1989). This may well also be the case in the thoracic spine, although it is yet to be confirmed. Foraminal stenosis is best demonstrated on MR, particularly in the T1 weighted images. These clearly identify loss of the high signal of fat within the foramen and loss of differentiation of the intermediate signal nerve root and low signal vessels by the fat, compared to other non-stenotic levels. The front/back stenosis of the foramen can be demonstrated on axial scans by showing the narrowing of the space between the posterior vertebral margin and the articular process, but the absence of fat makes this less easy to evaluate on T1 as compared to T2 weighted sequences. Computerized tomography will also demonstrate front/back stenosis satis-

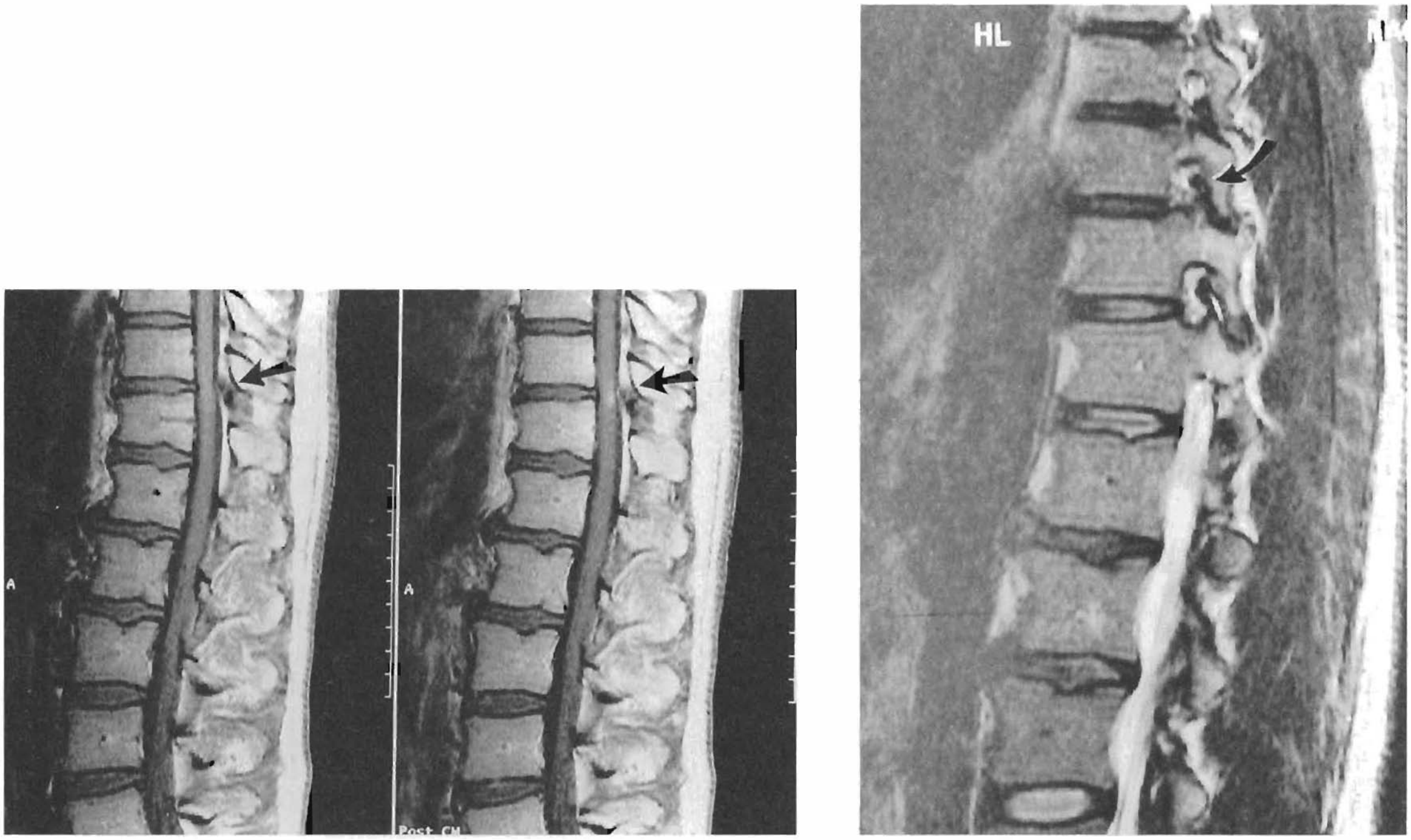

(E) (F)

Fig. 12.9 (E) T1 weighted sequence before and after gadolinium. DTPA contrast injection shows enhancement of the cord at the site of compression (arrows). (F) Parasagittal study shows narrowing of the foramen by the osteoarthritic zygapophysial joint (arrow).

factorily, but up/down stenosis will require reformatting of the images. This can easily be achieved with a block of images on a conventional system, or through the use of spiral CT.

Scheuermann's disease

This usually presents around puberty with thoracolumbar pain or, occasionally, as a kyphosis of the thoracic spine. The kyphosis may initially be attributed to poor posture but pain, if present, is often exacerbated by standing, sitting and heavy physical activity. The pain typically subsides with the cessation of growth, although adults who have untreated disease may have back pain, especially if there is a moderate kyphosis (Lowe, 1990). Pain is located in the area of the deformity but may also occur in the lower lumbar spine, especially if there is a hyperlordosis.

The kyphosis is accentuated by forward bending, and does not disappear on hyperextension. There is also a group of patients, usually young males with an athletic or heavy working background, who have lower lumbar pain without kyphosis and also have radiographic features of Scheuermann's disease. The aetiology of Scheuermann's disease is unclear although there is a familial relationship, and microscopic studies suggest that the matrix of the cartilage end-plate is abnormal, with a decrease in the collagen to proteoglycan ratio resulting in an alteration of the endochondral ossification (Ascani *et al.*, 1982). Scheuermann's disease has also been found to be associated with endocrine diseases, hypervitaminosis, inflammatory diseases, neuromuscular disorders and spondylolysis. The radiographic appearances are best assessed on the lateral erect study. To fulfil Scheuermann's criteria, there should be wedging of 5° or greater at three or more adjacent vertebrae. The end-plates are irregular, often with anterior Schmorl's nodes, and may be mildly sclerotic (Fig. 12.10). The intervertebral discs are commonly narrowed, although it is not clear whether this is resultant from, or causative of, the end-plate abnormalities. Detachment of the anterior vertebral rim apophysis has also been described, especially in the lumbar spine. The end-plate changes may be present without significant vertebral wedging and prominent interosseous disc herniations may be seen, particularly in the lumbar spine, where sclerotic endosteal rims within the vertebral body are associated with some remodelling and an increased AP diameter of the vertebra (Heitoff *et al.*, 1994). The AP radiograph will sometimes show an associated mild scoliosis. A severe kyphosis may occasionally develop, and there is a risk of thoracic disc herniation in these cases. If clinical symptoms of increasing pain or weakness and alteration of sensation in the lower limbs develop, the patient should be evaluated with MR imaging. The vertebral wedging will be well demonstrated, usually with a normal yellow marrow high signal on T1 weighted sequences, indicating the chronic and benign nature of the vertebral changes. The end-plate irregularity is reasonably well defined, and the high signal in the nucleus on the T2 weighted spin echo sequences will be diminished or absent (Fig. 12.10).

A disc herniation may be present, indenting the dural sac; this results in a high signal on T2, and cord compression, if present, can be assessed for severity. The cord may be closely applied to the anterior wall of the vertebral canal if the kyphosis is severe, and this will be clearly demonstrated on the sagittal and axial projections.

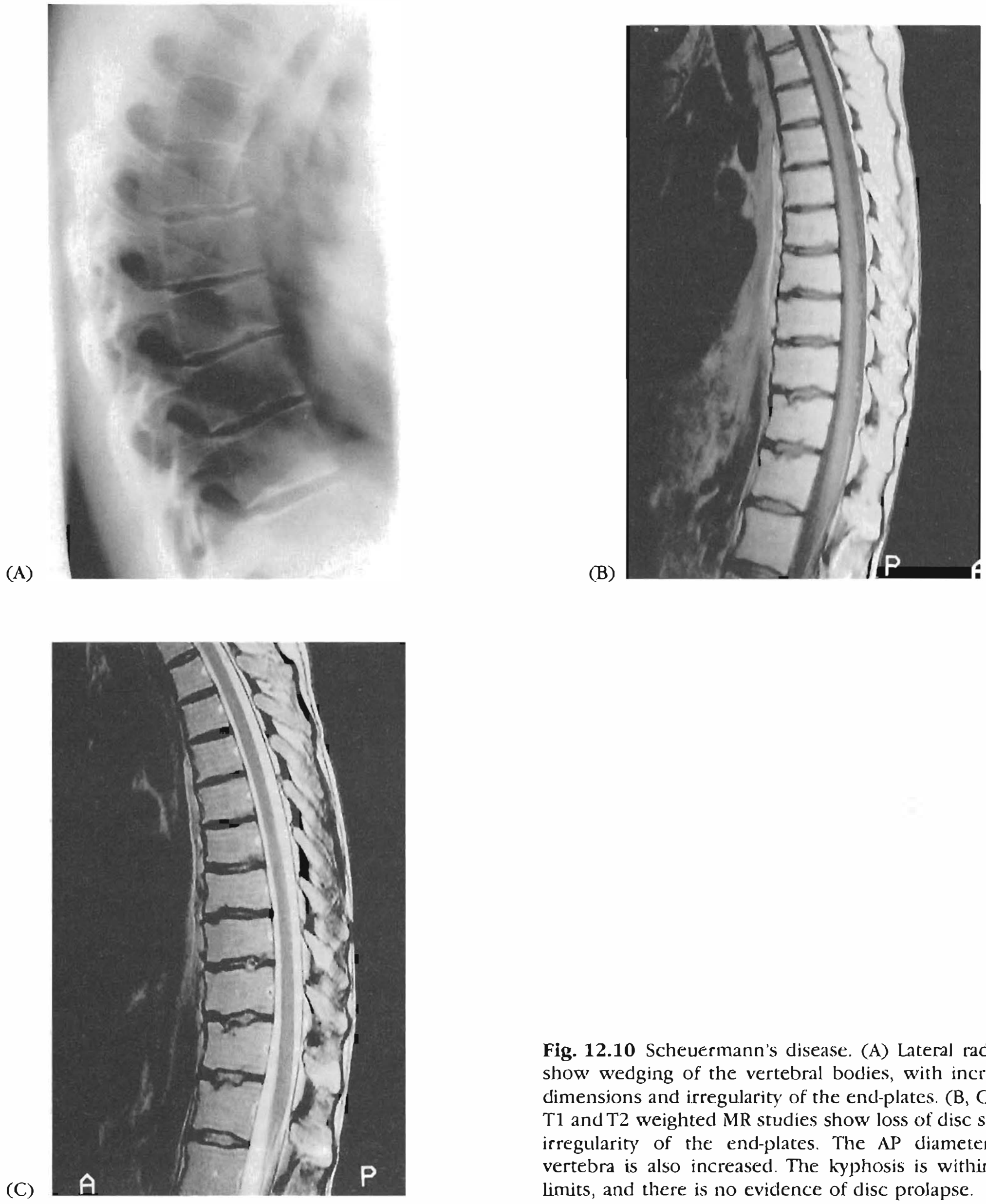

Fig. 12.10 Scheuermann's disease. (A) Lateral radiographs show wedging of the vertebral bodies, with increased AP dimensions and irregularity of the end-plates. (B, C) Sagittal T1 and T2 weighted MR studies show loss of disc signal and irregularity of the end-plates. The AP diameter of the vertebra is also increased. The kyphosis is within normal limits, and there is no evidence of disc prolapse.

Trauma

The thoracic spine is a common site of vertebral injury due to compression forces. It is also affected by burst or flexion rotation forces in severe injury, which are particularly serious because of the potential for spinal cord damage. In the acute stage careful evaluation is particularly important, as neurological injury may not be fully appreciated initially and there may be inherent instability of the spine which is not recognized. Radiographs are the initial imaging technique, and it is crucial in the investigation of all patients who have had significant injury of the thoracic spine that the entire spine is demonstrated, particularly the transitional junctions. Both AP and lateral views should be performed to include all vertebrae relating to the injured area, and the lateral view should be undertaken on a 'shoot through' basis, without moving the patient where possible. If the upper thoracic spine is not seen then a 'swimmer's view' should be attempted, but CT imaging, particularly using the latest spiral CT process with multiplanar reconstruction, may be more effective in imaging this part of the spine. Although it may be helpful in the interpretation to consider the mechanism of injury, the process of injury may be complex, particularly in severe motor vehicle accidents. Evaluating the extent and pattern of the injury may be assisted by using the 'three column concept' (Denis,

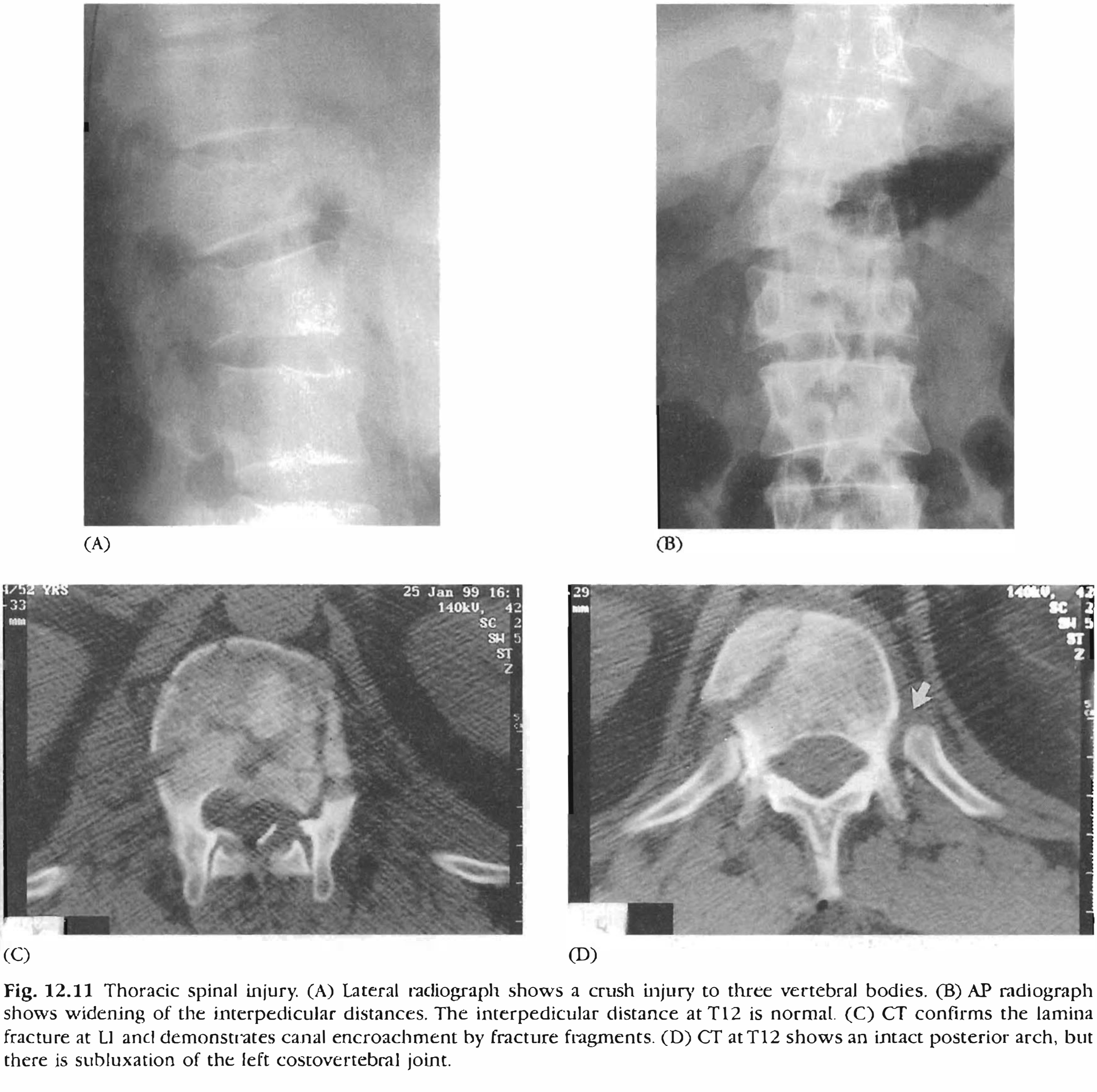

Fig. 12.11 Thoracic spinal injury. (A) Lateral radiograph shows a crush injury to three vertebral bodies. (B) AP radiograph shows widening of the interpedicular distances. The interpedicular distance at T12 is normal. (C) CT confirms the lamina fracture at L1 and demonstrates canal encroachment by fracture fragments. (D) CT at T12 shows an intact posterior arch, but there is subluxation of the left costovertebral joint.

1989). The anterior column is formed by the anterior half of the vertebral body, while the posterior half of the vertebra forms the middle column. The pedicles, lamina, zygapophysial joints and spinous process make up the posterior column. Injury involving only the anterior column, with the middle column and the posterior elements remaining intact, usually results from a hyperflexion injury and is stable. Injuries with disruption of the middle column invariably involve either anterior or posterior columns as well, and are often unstable. Three column fractures, which usually result from flexion-rotation or lateral forces, are always unstable. Evaluation of the plain films is important, and the appearances may range from a minor compression fracture of the anterior half of the vertebral body with no loss of height of the posterior vertebral wall to more extensive disruption of the vertebral body with loss of height of both anterior and posterior vertebral walls (Fig. 12.11). Compression of the vertebral body may result in a burst fracture, with fragmentation of the body posteriorly into the spinal canal. Compression injuries of the thoracic spine that involve the posterior half of the vertebral body are likely to result in

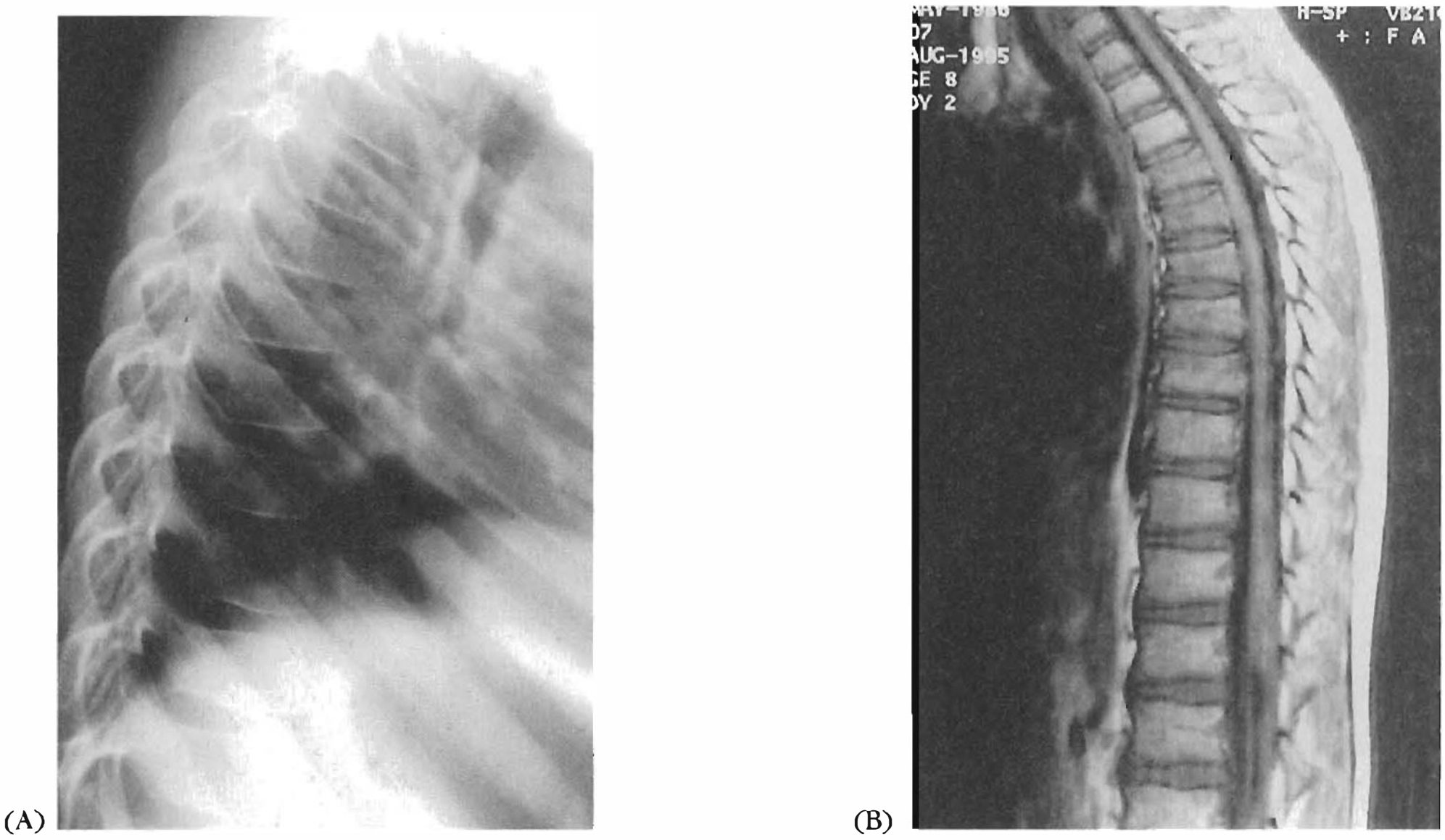

Fig. 12.12 Thoracic spinal injury. (A) Lateral radiograph shows wedging of the mid-thoracic vertebral bodies in a child's spine. (B) T1 weighted sagittal image shows decreased signal in most of the mid-thoracic vertebrae. (C) The T2 weighted sequence shows high signal in the upper vertebrae at five levels, confirming the multiple level compression injuries.

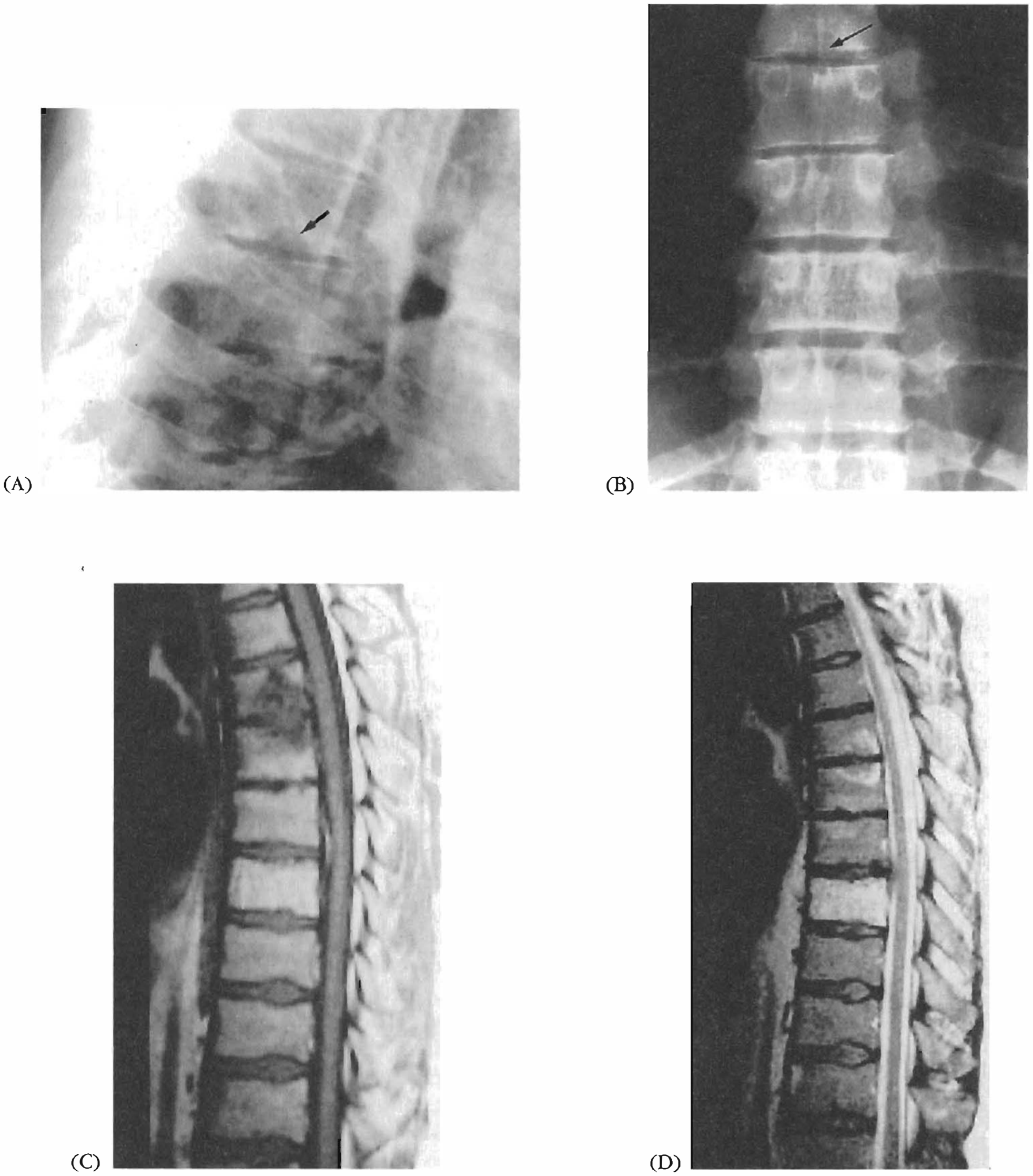

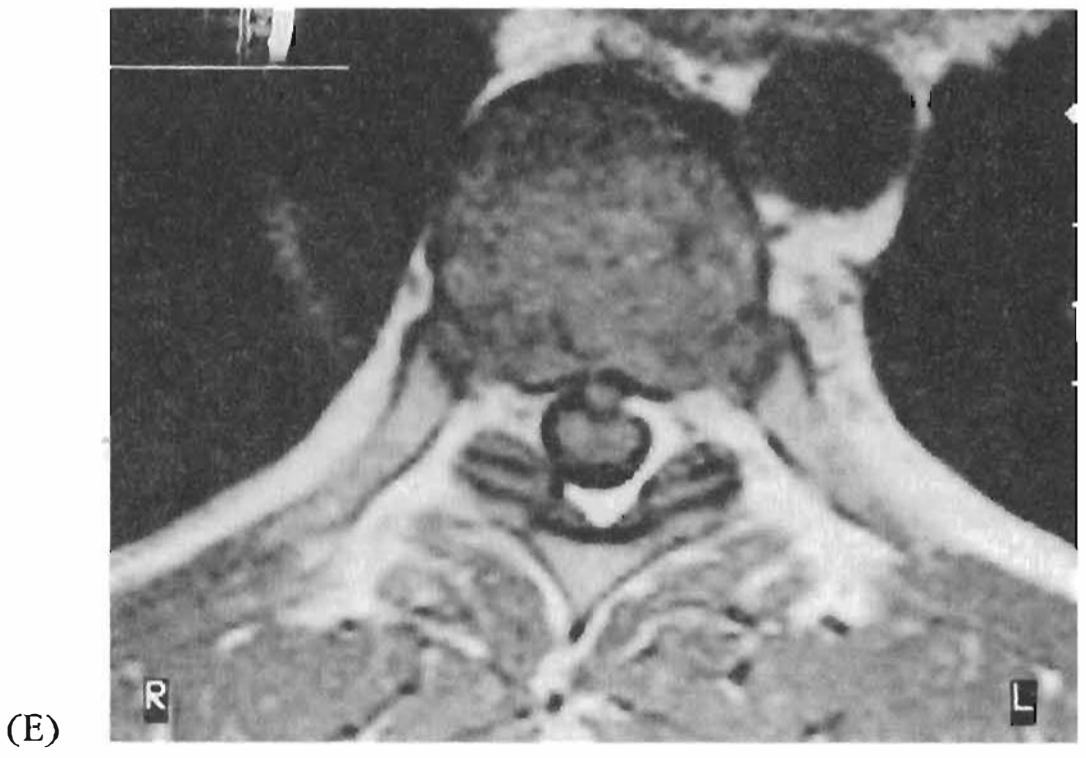

Fig. 12.13 Spondyloathropathy. (A) Lateral and (B) antero-posterior radiographs show focal irregularity of the end-plate and lucency in the adjacent vertebral body (arrow). There is a suggestion of coarsening of the vertebral trabeculae in the third vertebra below. (C) The T1 weighted MR shows irregularity of the end-plate and low signal in the vertebra, with high signal on the T2 image. (D) Sacroiliitis was present in this patient. High signal in the vertebrae on both T1 and T2 indicates a haemangioma, and a small prolapse is present at the disc above, which is best seen on the axial T1 weighted image (E), which also shows the haemangioma with no evidence of a paravertebral soft tissue mass.

fractures of the lamina or pedicles. This may be recognized on the AP view by increased separation of the pedicles, and a lucent line may be seen vertically through the lamina or across the pars interarticularis. The AP view will also demonstrate widening of the paravertebral shadow due to local haemorrhage and oedema; this may extend well above and below the actual fracture site (Fig. 12.11). Hyperflexion injuries may result in fractures of the spinous process, and these should also be evaluated. Severe injuries that result in displacement of one vertebra on another inevitably result in fractures or dislocation of the zygapophysial joints or both. Hyperextension injuries are uncommon in the thoracic spine due to the restraining influence of the ribcage. The main feature of these injuries is disruption of the anterior longitudinal ligament, which may be associated with an avulsion fracture of the anterior vertebral body and compression injury of the lateral masses of the spine. Computerized tomography is an essential investigation if there is doubt about the extent of the injury and the integrity of the posterior elements. The axial images will show fractures in the lamina and pedicles, and also define the retropulsed fragments and residual canal dimensions (Fig. 12.12). Magnetic resonance imaging is of value for the demonstration of spinal cord injury and is able to differentiate between cord haemorrhage and oedema, which may have a bearing on the longer term prognosis (Flanders *et al.*, 1990). Magnetic resonance imaging will also demonstrate vertebral body oedema as low signal on T1 weighted sequences and increased signal intensity on T2 weighted studies due to trauma in vertebrae that appear normal on plain radiographs. The number of vertebrae involved may be greater than is apparent from the plain radiographs.

Conditions where medical referral and management is recommended

Inflammatory arthropathy

The thoracic spine is commonly affected by seronegative spondyloarthopathies. These present with characteristic low backache and stiffness over the region of the sacroiliac joints. The symptoms are most pronounced on waking in the morning, and gradually improve with movement and exercise. Thoracic pain, however, may also be an early feature, and careful assessment of the thoracic spine is indicated. The initial examination comprises AP and lateral plain films of the thoracic and lumbar spines, and a prone AP view of the sacroiliac joints. The early features of sacroiliitis are subtle, with the normal sharp articular margin of the synovial part of the joint becoming slightly irregular. The joint space may become widened and, at a later stage, subchondral sclerosis develops in association with the irregular surface (Fig. 12.13). Care must be exercised to prevent overdiagnosing sacroiliitis. If there is any doubt about the normality of the sacroiliac joints, either a Tc^{99} MDP bone scan with single photon emission CT (SPECT) or a dynamic contrast-enhanced fat-suppressed MR study of the sacroiliac joints should be performed. The isotope bone scan should be assessed quantitatively by comparing the activity in the sacroiliac joints with that of the sacrum. There is a wide normal range, but clinically significant increases usually result in ratios above 1:5. Magnetic resonance in the coronal or axial plane will show the cartilage on the T1 and T2 weighted images. Initial erosions of the cartilage may be difficult to visualize and the earliest features are increased subchondral oedema, seen as high signal in the bone on either the short tau inversion recovery (STIR) sequence or the fat-suppressed T2 weighted FSE sequence. If gadolinium DTPA is injected rapidly, with dynamic imaging, a rapid rise of signal on T1 in the sacroiliac joints will indicate an inflammatory process (Bollow *et al.*, 1995).

In the thoracic spine, the lateral radiograph may demonstrate early changes in the enthesis at the site of insertion of the anterior longitudinal ligament and anular complex anteriorly. The earliest stage is that of focal erosions at the anterior rim of the end-plates, sometimes associated with some localized sclerosis in the adjacent vertebral body (Fig. 12.14). The normal concavity of the anterior surface of the thoracic vertebrae is lost, producing the appearance of squaring.

On the AP film, the lateral edge of the vertebral end-plates may also show irregularities due to focal erosions, and there may also be some localized widening of the paravertebral shadow. Assessment of the heads of the ribs should also be undertaken, as erosive changes at the costovertebral joints may be seen. Imaging of the thoracic spine with Tc^{99} IMP isotope scanning in the initial stages of the disease may also be of value. The planar views show increased uptake, particularly in the region of the costovertebral joints, and the use of SPECT increases the sensitivity of the examination and enables identification of the precise site of activity in the axial plane (Fig. 12.14).

As the disease progresses to a more advanced stage, ossification of the paravertebral ligaments occurs, particularly involving the anterior and lateral ligaments, producing syndesmophytes (Fig. 12.15). Ossification of the syndesmophytes is closely applied to the disc and vertebral body, as it involves the anulus and longitudinal ligaments. It differs from the osteophyte that projects outwards from the end-plate rim due to bulging of the anulus, causing traction on the ligament bone interface. Posterior ossification of the long interspinous ligaments and erosive changes in the zygapophysial joints may be difficult to see on the

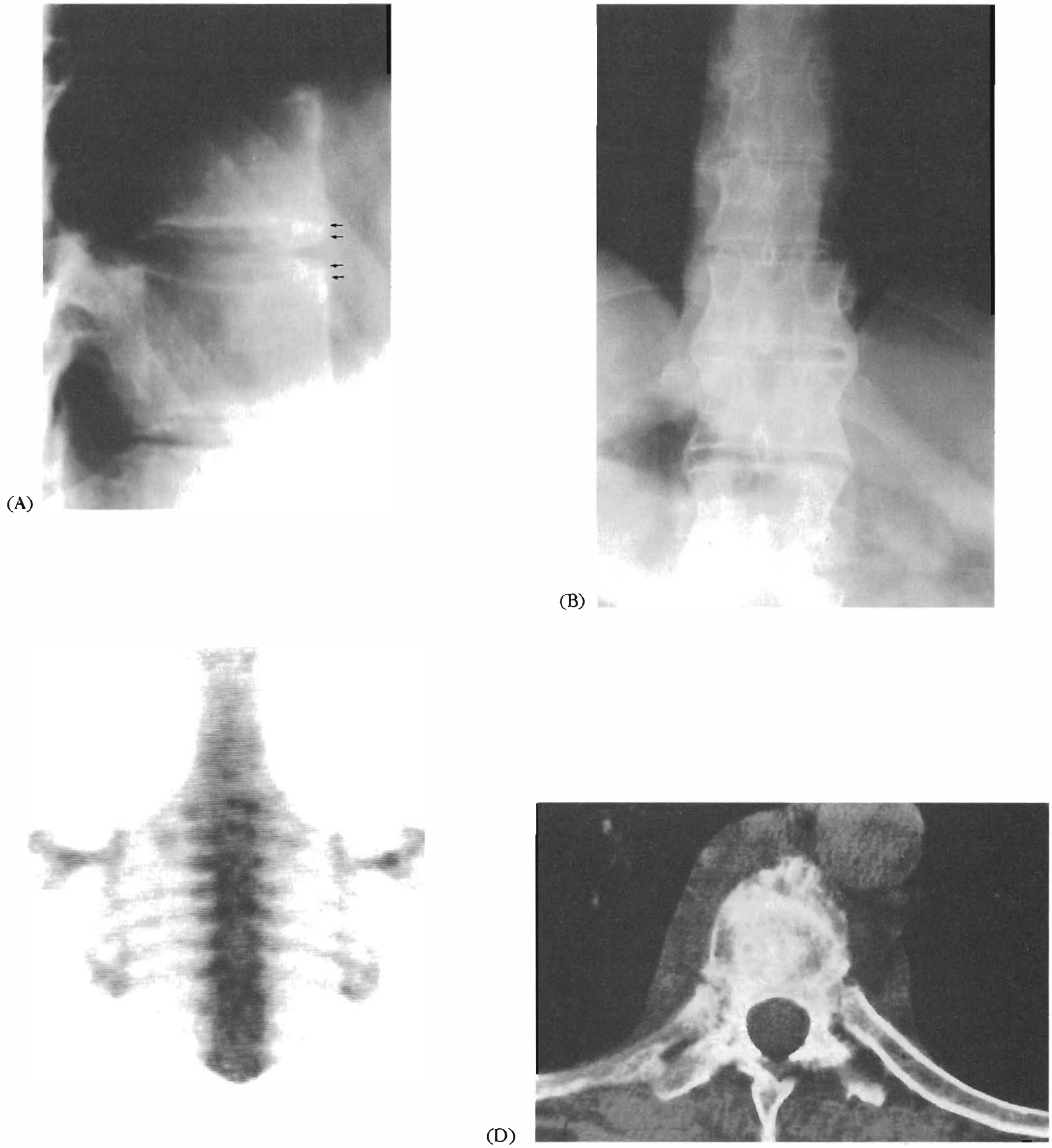

Fig. 12.14 Spondyloathropathy. (A) Lateral radiograph shows anterior squaring of the thoracic vertebral bodies, due to focal erosions of the anterior rim of the end-plate, with localized sclerosis (the 'shiny corner' sign). (B) Ossification between adjacent vertebrae. (C)ATc^{99} MDP bone scan shows increased activity in the costovertebral joints. (D) CT shows irregularity and sclerosis of the articular surface of the ribs and zygapophysial joints.

plain film. The ossification seen on the AP view of the thoracic spine in cases of psoriatic arthropathy or Reiter's disease may differ, as the paravertebral ossification bridging the disc originates from the vertebral wall away from the end-plate as opposed to the syndesmophyte formation (Fig. 12.15).

Computerized tomography examination of the thoracic spine will prove useful for demonstrating erosive changes in the zygapophysial joints and in the costovertebral and costotransverse articulations (Fig. 12.14). The role of MR imaging in the earlier stages of spondyloarthropathy has not been established, although squaring of the vertebral body and erosive changes can be demonstrated on the vertebral rim. More commonly, however, the T2 weighted fat-suppressed FSE sequence or STIR sequence, which suppresses the fat and enhances the high signal of water, may show increased signal along the anterior

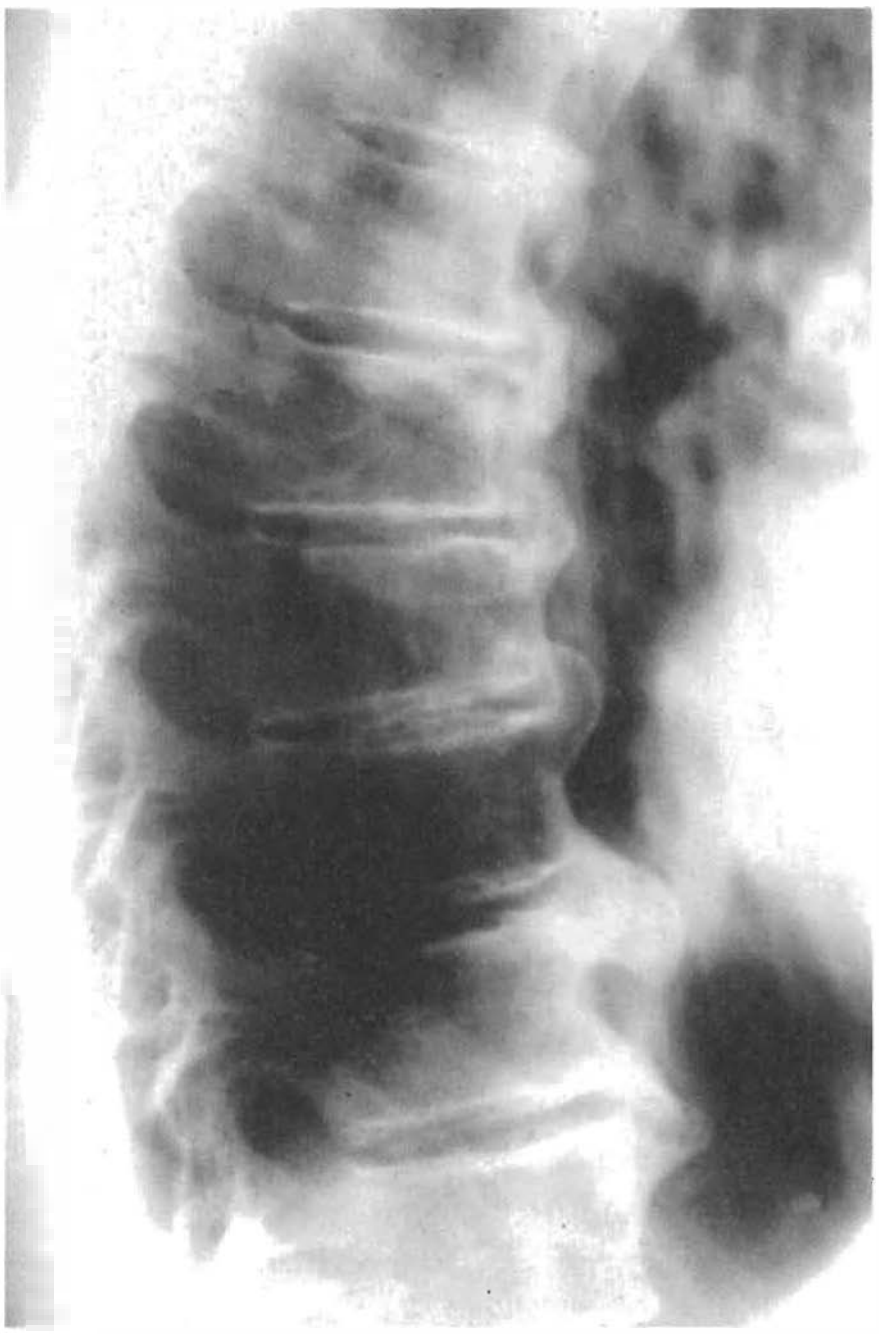

Fig. 12.15 Diffuse idiopathic skeletal hyperostosis (DISH). The flowing ossification along the anterior surface of the vertebrae bridging the disc space is clearly seen.

vertebral body and at the enthesis. In more advanced cases of inflammatory spondyloarthropathy the end-plates of the vertebral bodies may be extensively eroded, with the inflammatory process extending along to the disc. Radiographs demonstrate the end-plate irregularity, which may also be sclerotic, while some disc narrowing and the irregularity of the end-plate and inflammatory changes in the adjacent vertebral body are clearly seen on MR. Occasionally in these circumstances there is increased signal on the T1 weighted image due to calcification within the disc, associated with the disease, commonly in more solidly fused levels. If the calcification is heavy, however, it will appear as a low signal and be obvious on the plain films. The presence of extensive destruction of the vertebral body, extending fully along the vertebral end-plate, is usually associated with either a pseudarthrosis of the posterior elements or incomplete fusion above and below other fused segments. Radiographs show extensive destruction, and Tc^{99} MDP isotope studies show increased activity in the vertebrae and particularly in the posterior elements. Both MR and CT imaging will demonstrate defects in the posterior elements, and MR in particular will demonstrate increased signal in the discs and end-plate and identify any element of cord compromise (Kenny *et al.*, 1990).

Ossification of the anterior longitudinal ligament may occur in conditions that have to be differentiated as they have less clinical significance. In particular, the ossification of diffuse idiopathic skeletal hyperostosis (DISH) is a common finding in older subjects and produces flowing ossification of the anterior longitudinal ligament (see Chapter 5). It projects well beyond the vertebral body and is usually seen on the right of the midline in the thoracic spine, as the abdominal aorta is closely applied to the left anterior vertebral surface and has the effect of arresting any significant ossified projections (Fig. 12.15). The extensive ossification may be present in conjunction with normal disc spaces, and is well demonstrated on CT. Although DISH will restrict thoracic movement, it does not appear to have any other symptomatic relationship. Degenerative osteophyte formation due to anular bulging also produces a classical picture, with a narrowed anterior disc space, sclerosis of the end-plate and, occasionally, well defined thickening and buttressing associated with ossified projections from the rim of the vertebral body (Fig. 12.5). On MR, the osteophytes are shown to have a marrow content.

Infection

Mechanical thoracic pain must be differentiated from an infective focus in the thoracic spine. Adult disc infection may be blood-borne, or result from surgery or direct puncture of the disc. In the case of blood-borne infection, this develops in the adjacent vertebral body and only secondarily involves the discs. In young and middle-aged patients there is often a history of previous illness, which may be associated with septicaemia and which is followed by the onset of persistent or increasingly severe thoracic pain. Occasionally tuberculous infection may present with a partial or complete long tract neurological deficit, but there is usually a history of persistent pain. The pain of infection tends to be constant and not relieved by rest. Unless there has been a very short history, the initial diagnosis can usually be made from changes evident on plain films. These include a loss of sharpness of the vertebral end-plates and discontinuity of the line of subchondral bone, with a mixture of adjacent bone lucency, or, in more developed infection, a degree of sclerosis. Initially the disc space may be of normal height but it becomes narrow as the infection progresses, and this is associated with widening of the paravertebral shadow on the AP view. Pus may track anteriorly to the vertebral body under the longitudinal ligament, resulting in scalloping of the anterior vertebral body surface (Fig. 12.16). This feature is more commonly seen in tuberculosis but is also a feature of pyogenic infection, and has not proved to be a good discriminant between the two types of infection. In severe cases of infection extensive vertebral body destruction may be

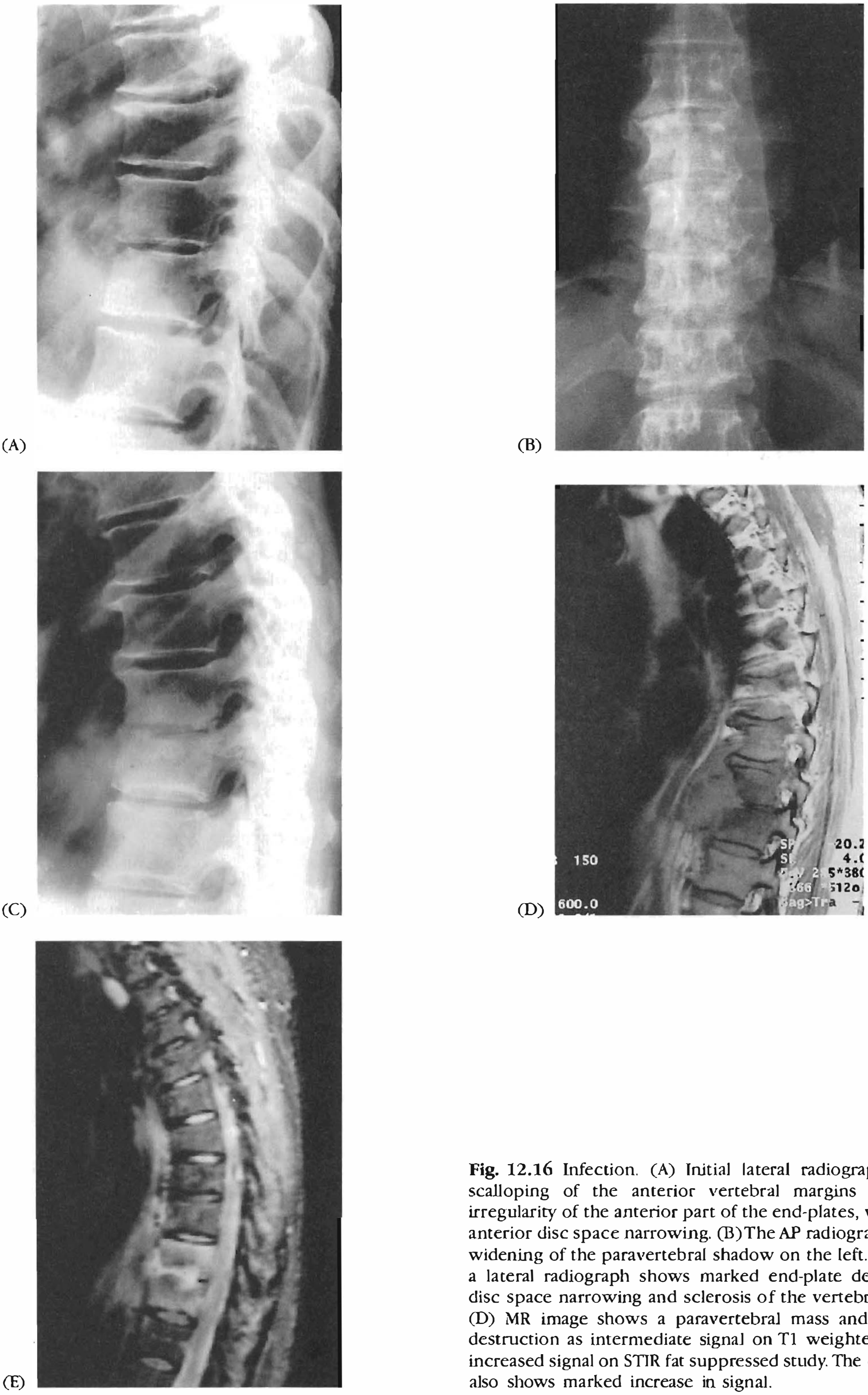

Fig. 12.16 Infection. (A) Initial lateral radiograph shows scalloping of the anterior vertebral margins and mild irregularity of the anterior part of the end-plates, with some anterior disc space narrowing. (B) The AP radiograph shows widening of the paravertebral shadow on the left. (C) Later, a lateral radiograph shows marked end-plate destruction, disc space narrowing and sclerosis of the vertebral bodies. (D) MR image shows a paravertebral mass and vertebral destruction as intermediate signal on T1 weighted and (E) increased signal on STIR fat suppressed study. The disc space also shows marked increase in signal.

demonstrated, with complete loss of the intervening disc space and collapse of the vertebral bodies into each other. This may result in a local kyphosis in the early stages of the infection. These plain film changes may not be obvious, and in patients with constant pain an isotope scan may be helpful by providing a rapid evaluation of the whole spine, which may demonstrate other occult infective foci. The use of SPECT will increase the sensitivity of the study and define the anatomical site of increased activity more precisely. Indium^{111}- or technetium^{99m}-labelled white cells provide a more specific demonstration of sites of infection, with the labelled white cells accumulating in the infective site. However, results have been disappointing in the spine, with significant accumulation only occurring in an acute abscess (Whalen *et al*., 1991). Chronic infections, with low white cell accumulation, are difficult to see and may produce false negative examinations, and spinal lesions may also be obscured by white cell accumulation in the liver and spleen. Computerized tomography will evaluate the extent of bone destruction and may demonstrate extensive bone fragmentation, which has been suggested to be indicative of tuberculosis rather than septic spondylitis (Jain *et al*., 1993). Magnetic resonance imaging has established itself as a valuable method of demonstrating infection in the early stages of the disease, and will also demonstrate the presence of epidural abscess and cord compression. On the T1 weighted images there are areas of decreased signal intensity within the disc, vertebral end-plates and vertebral bodies, associated with irregularity of the vertebral end-plate. On the T2 weighted images, high signal is present in the disc and vertebral body due to inflammatory exudate and oedema and this is particularly enhanced on the STIR sequences (Fig. 12.16). The use of gadolinium DTPA on the T1 weighted fat-suppressed sequences is also valuable in areas of infection (Post *et al*., 1990). This technique is particularly useful in the case of an epidural abscess, which appears as a well-defined soft tissue mass with tapered edges, and is typically isointense within the spinal cord on T1 and hyperintense on T2. Following gadolinium injection the abscess may enhance with a diffuse homogeneous or heterogeneous mass, or have a thin peripheral line of enhancement around the main abscess mass. In the early stages of disc infection after invasive radiological and therapeutic procedures, the plain film will be normal until the infection of the disc invades the end-plate. Early changes on MR may show increased signal within the disc prior to the radiograph becoming positive in these circumstances. Occasionally tuberculous spondylitis may demonstrate atypical findings, including vertebral involvement without disc disruption and/or involvement of the posterior elements, without destruction of the body or disc. These features would be well demonstrated with either MR or CT. Where doubt exists, a needle biopsy should be performed to identify the organism and to initiate appropriate treatment following culture and histology.

Osteoporosis

The onset of thoracic pain in the elderly may occur as an acute episode, but thoracic pain is more commonly associated with a gradual kyphosis of the thoracic spine. Lateral radiographs of the spine demonstrate loss of bone density with increased radiolucency of the vertebral bodies, which exhibit a sharp white outline described as being like a pencil line. In the more advanced stages, vertebral collapse may occur. This may only involve the upper end-plate of the vertebral body, and is often more pronounced in the central part of the vertebra (Fig. 12.17). It produces a degree of wedging anteriorly, but with a curved upper vertebral surface. Both end-plates may collapse, producing a biconcave pattern, but usually this degree of severity results in a markedly flattened vertebra which can appear sclerotic due to the condensation of residual osteoporotic trabeculae. Some slight disc widening may occur in the central part of the disc due to the vertebral collapse. Occasionally, in severe cases, a black line of very low attenuation may be seen in the vertebra, a vacuum phenomenon due to nitrogen being drawn in from the blood around the collapsed trabeculae. This may be outlined by increased density due to condensation of the collapsed trabeculae. Multiple levels may be involved, with an increased kyphosis. The appearances are usually diagnostic on the radiographs, but differentiation from myeloma or occasionally metastatic disease may be difficult. Destruction of the pedicles on the AP view will help differentiate forms of metastatic disease from osteoporosis, where the pedicles are usually clearly seen even if there is extensive osteoporotic vertebral collapse. If differentiation is not clear, whole body isotope scans may be of value, as metastatic disease can affect other areas and these will show increased uptake. Increased isotope uptake may well occur in osteoporotic collapse, and can be identified as a line of uptake along the upper part of the vertebral body and not extending beyond the line of the vertebra on the AP view (Fig. 12.17). Metastatic tumour expands beyond the vertebral outline and often involves the whole vertebra so that the increased isotope activity is much more extensive and beyond the vertebral line. Myeloma may not be demonstrable as increased uptake on an isotope scan, although reduced vertebral activity has been shown to occur in some cases. The differentiation and diagnosis of osteoporosis and metastatic disease is best achieved with MR. Recent studies have identified features that enable differentiation of the collapsed vertebra. The malignant

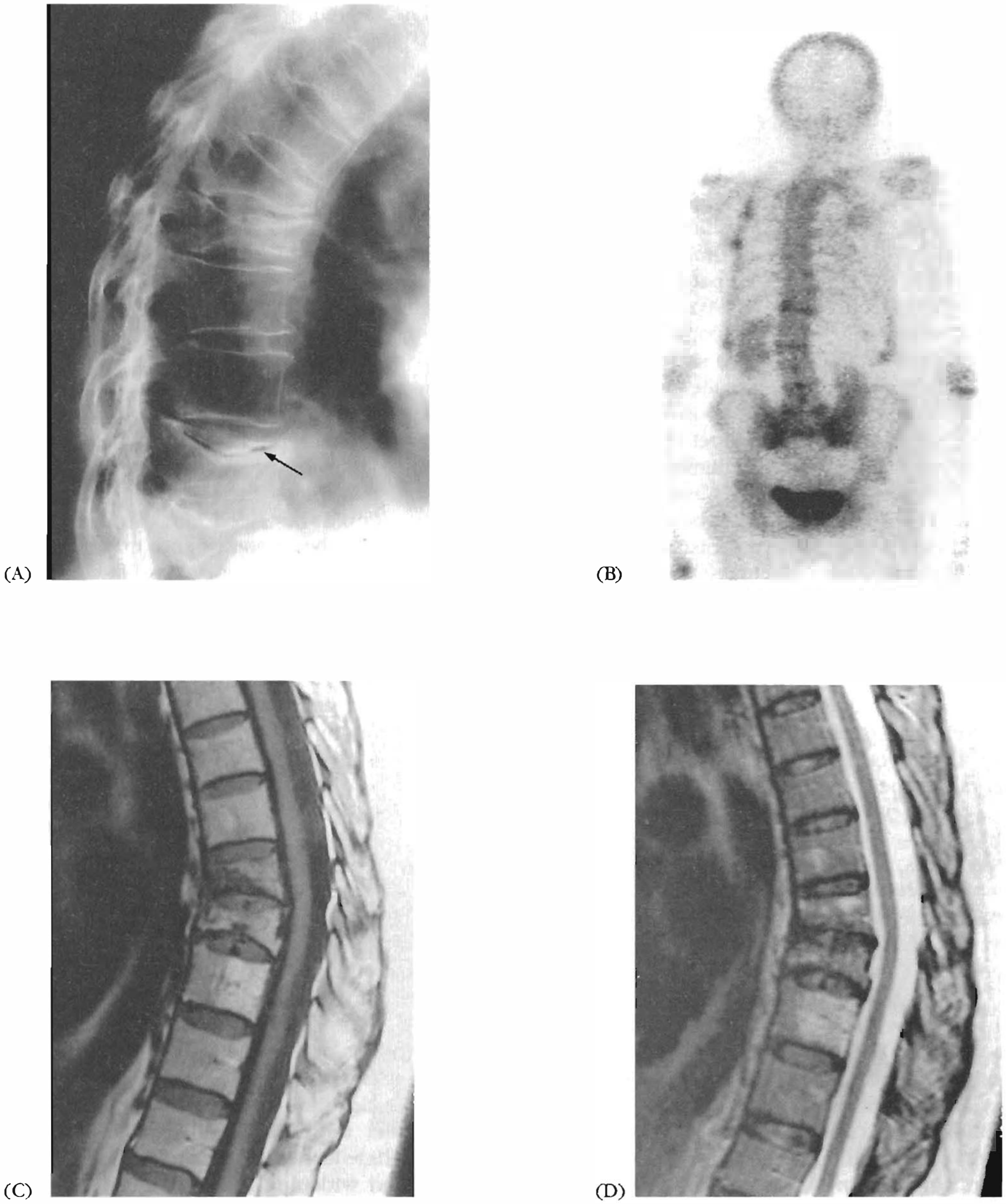

Fig. 12.17 Osteoporosis. (A) Severe osteoporosis is demonstrated on the lateral radiograph, with increased lucency in the vertebral bodies, wedge compression of the mid-thoracic vertebrae and upper and central end-plate collapse in the lower thoracic vertebrae. A vacuum sign (arrow) is seen in the fragmented upper vertebral body of T11. (B) The Tc^{99} MDP study depicted is of a patient with osteoporosis and a mild scoliosis, showing linear increased activity on the upper aspect of the vertebra, which does not extend beyond the vertebral margin. Activity is also seen in fractured ribs. (C) The MR T1 weighted image shows two collapsed vertebral bodies, the lower with normal marrow signal. Some sign reduction is seen in the vertebra above. The vertebra below shows high signal with coarse striations, consistent with a haemangioma. (D) T2 weighted sagittal study shows normal or only slightly increased signal in the collapsed vertebral bodies.

vertebral body shows a convex posterior cortex, and the presence of an epidural mass is a highly discriminating feature. The signal on the T1 weighted sequence is low diffusely throughout the vertebral body, while there is an inhomogeneous increase in signal on T1 after IV gadolinium DTPA and on T2 weighting. Low signal on T1 in the pedicles may also be present (Chenod *et al.*, 1996). On the other hand, in osteoporotic collapse there may be a retropulsion of bone. The T1 weighted signal is normally high in the majority of the vertebra and, following gadolinium, the signal rapidly returns to normal (Fig. 12.17). There is a horizontal band-like pattern and isointensity on T2 (Chenod *et al.*, 1996). The pedicles have normal signal on T1 in osteoporosis. Using similar criteria, Moulopoulos (1996) showed a statistically significant ($p < 0.01$) difference between the two features. The diagnosis of osteoporosis is usually made by means of bone densitometry using dual X-ray absorptiometry (DXA) of the lumbar spine and femoral neck, although whole body assessment can also be made. The dual energy X-ray beam scans the lumbar vertebrae and produces a measure of mineral content, which has a high accuracy and precision, but errors may occur in the elderly in the presence of extensive aortic calcification, diffuse idiopathic hyperostosis or severe osteoarthritis of the zygapophysial joints. If these features are present, quantitative CT bone densitometry may be undertaken; this can assess vertebral trabecular bone density without measuring the overlying aortic calcification and paravertebral ligament ossification.

Scoliosis

The thoracic spine is the most common site for spinal deformity, and the most common cause is an idiopathic scoliosis. This primarily involves adolescents between the age of 10 and 15 years, and is progressive in a percentage of subjects, most commonly in females. The condition is often identified due to clothes not fitting or by the recognition of a rib deformity. The diagnosis is made clinically by the demonstration of a rib hump on forward bending and by palpation of the spinous processes. The diagnosis will be confirmed on an AP radiograph, which will show the curvature of the spine; this is usually right sided associated with rotation of the vertebrae producing asymmetry of the pedicles, which is maximal at the apex of the curve (Fig. 12.18). The curve may be a single thoracic curve, but double curves of the thoracic and lumbar spine occur, and also single thoraco-lumbar curves. Occasionally the curve will be 20° or more, and may require a full scoliosis series. In these circumstances, the AP projection may be supplemented with an AP view with the spine under traction or with lateral bending films. These will show the degree of flexibility of the curves and help to differentiate structural from compensatory curves. Finally, a lateral view will define the degree of lordosis or kyphosis. Rotating the patient under screening control so that the apical vertebra is in a true AP position will enable a reliable evaluation of the degree of lateral curvature, allowing for the vertebral rotation. Wedging of the vertebral bodies may be present in a more established scoliosis, with the disc displaced to the convex aspect of the end-plate. Assessment of the ring apophysis of the vertebral bodies and the position of the iliac crest apophysis in relation to the main iliac bone will assist in establishing the degree of skeletal maturity and thus the potential for further deformity of the curve during the growth that remains. Fusion of the iliac apophysis medially usually indicates the end of the growth spurt, but spinal growth may continue slowly until the early twenties. Idiopathic scoliosis is usually painless, so if pain is present, or if the curve is rapidly progressive, then other causal factors such as intraspinal and paraspinal tumour or herniated nucleus pulposus should be ruled out. In these circumstances, a whole body isotope scan may be of value to exclude tumours such as an osteoid osteoma or osteoblastoma; if positive, a CT scan in the locality is indicated. Magnetic resonance imaging of the spine is recommended in patients who have pain or evidence of neurological abnormality or where there is an unusual aspect such as a left sided curve, rigidity, or rapid deterioration (Fig. 12.18).

Tumours

The most common tumour in the spine is metastatic disease, which may present with pain, often of an unremitting nature. Metastatic spinal tumour may be associated with neurological symptoms and signs, sometimes without evidence of a primary cause. More often, however, the patient is known to have a primary tumour, and imaging is required to evaluate new symptoms or as a routine to exclude metastatic spread. Radiographs of the thoracic spine remain the initial investigation of symptomatic patients, and features that are strongly indicative of metastatic disease include loss of the pedicular outline, vertebral collapse and widening of the paravertebral shadow (Fig. 12.19), although tuberculosis may produce similar features. Plain radiographs are not sensitive for the diagnosis of early lesions, as the vertebral bodies may appear normal with as much as 50% bone loss. Isotope bone scanning with Tc^{99m} MDP, using the whole body facility, is therefore indicated if the radiographs are normal or if assessment of the extent of spread of a known primary tumour is required. Magnetic resonance imaging is also a very accurate method of demonstrating metastatic involvement of the thoracic vertebrae, which appears as focal areas of low signal in the high signal fat on T1 weighted

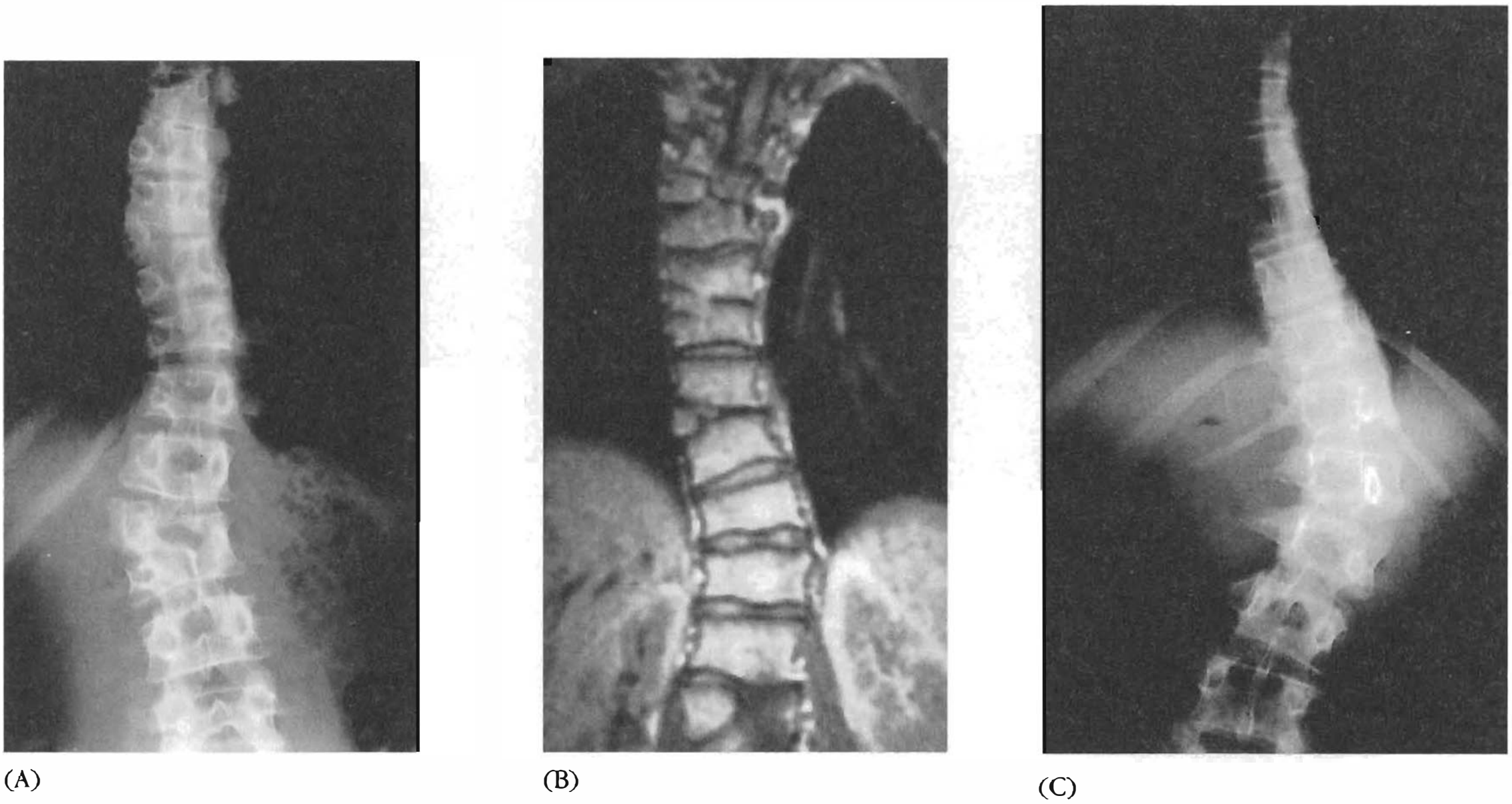

(A) (B) (C)

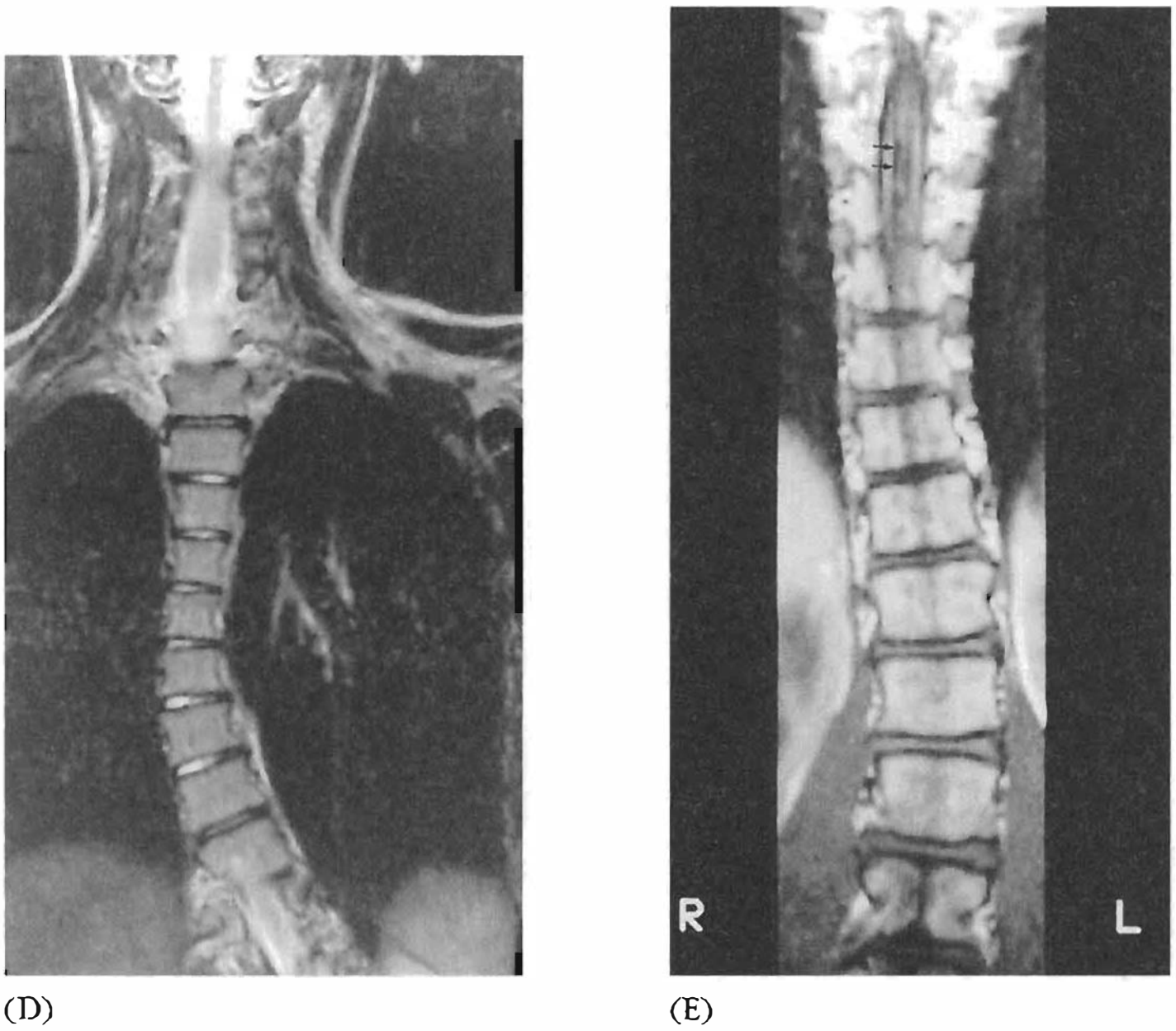

(D) (E)

Fig. 12.18 Scoliosis. (A) An anteroposterior radiograph demonstrates lateral curve of the thoracic spine, due to congenital scoliosis, with multiple vertebral anomalies including hemi-vertebrae and block vertebrae. (B) The coronal plane MR scan clearly demonstrates the vertebral anomalies. (C) Idiopathic thoracolumbar scoliosis is demonstrated, with some vertebral rotation. (D) MR demonstrates the displacement of the nucleus pulposus to the convexity in the thoracic spine. (E) A coronal MR scan demonstrates the curve with a low signal line in the cord on T1 in the upper thoracic and cervical region, due to a syrinx (arrow).

sequences, often with relatively ill defined outlines. These lesions may show increased signal on T2 weighted sequences, but usually have a high signal on fat-suppressed STIR sequences (Meirowitz *et al.*, 1994) (Fig. 12.19). Magnetic resonance imaging is more accurate for diagnosing metastatic lesions in the thoracic vertebra, but isotope studies are more appropriate for whole body assessment.

Primary bone tumours are rare in the spine. However, the most common lesion is a haemangioma, which may involve both the vertebral body and posterior elements. This is visualized on the plain radiographs as vertical striations of increased and decreased density and widened spaces between the trabeculae (Fig. 12.20). Expansion of the vertebral body may occur and, if present, can be difficult to differentiate from Paget's disease (Fig. 12.20). These areas are well demonstrated on MR where the striations are high, and low signal on T1 due to the thickened trabeculae, vascular sinusoids and fat, with similar linear high signal on T2. Haemangiomatous foci are often small, round areas of slightly increased

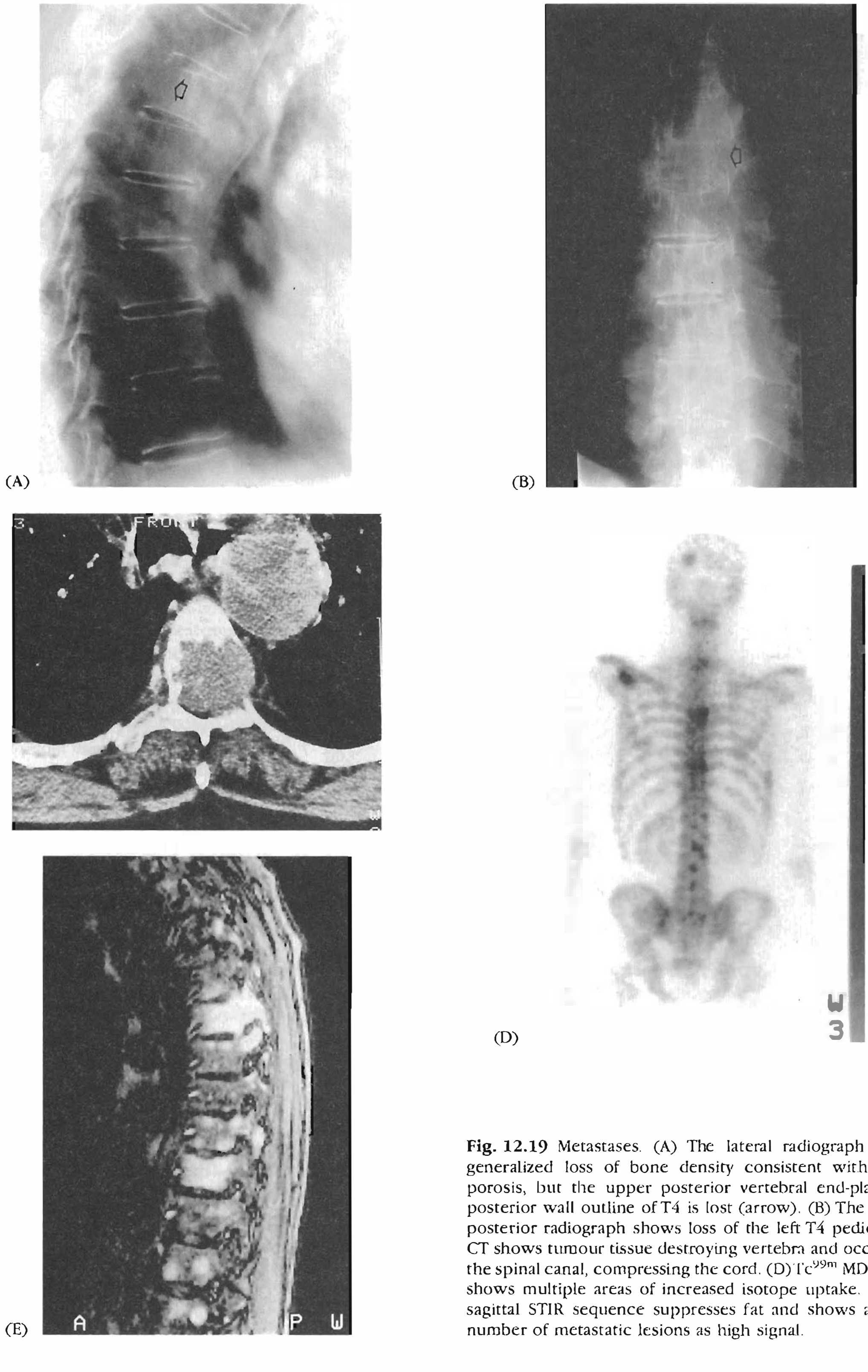

Fig. 12.19 Metastases. (A) The lateral radiograph shows generalized loss of bone density consistent with osteoporosis, but the upper posterior vertebral end-plate and posterior wall outline of T4 is lost (arrow). (B) The antero-posterior radiograph shows loss of the left T4 pedicle. (C) CT shows tumour tissue destroying vertebra and occupying the spinal canal, compressing the cord. (D) Tc^{99m} MDP study shows multiple areas of increased isotope uptake. (E) MR sagittal STIR sequence suppresses fat and shows a larger number of metastatic lesions as high signal.

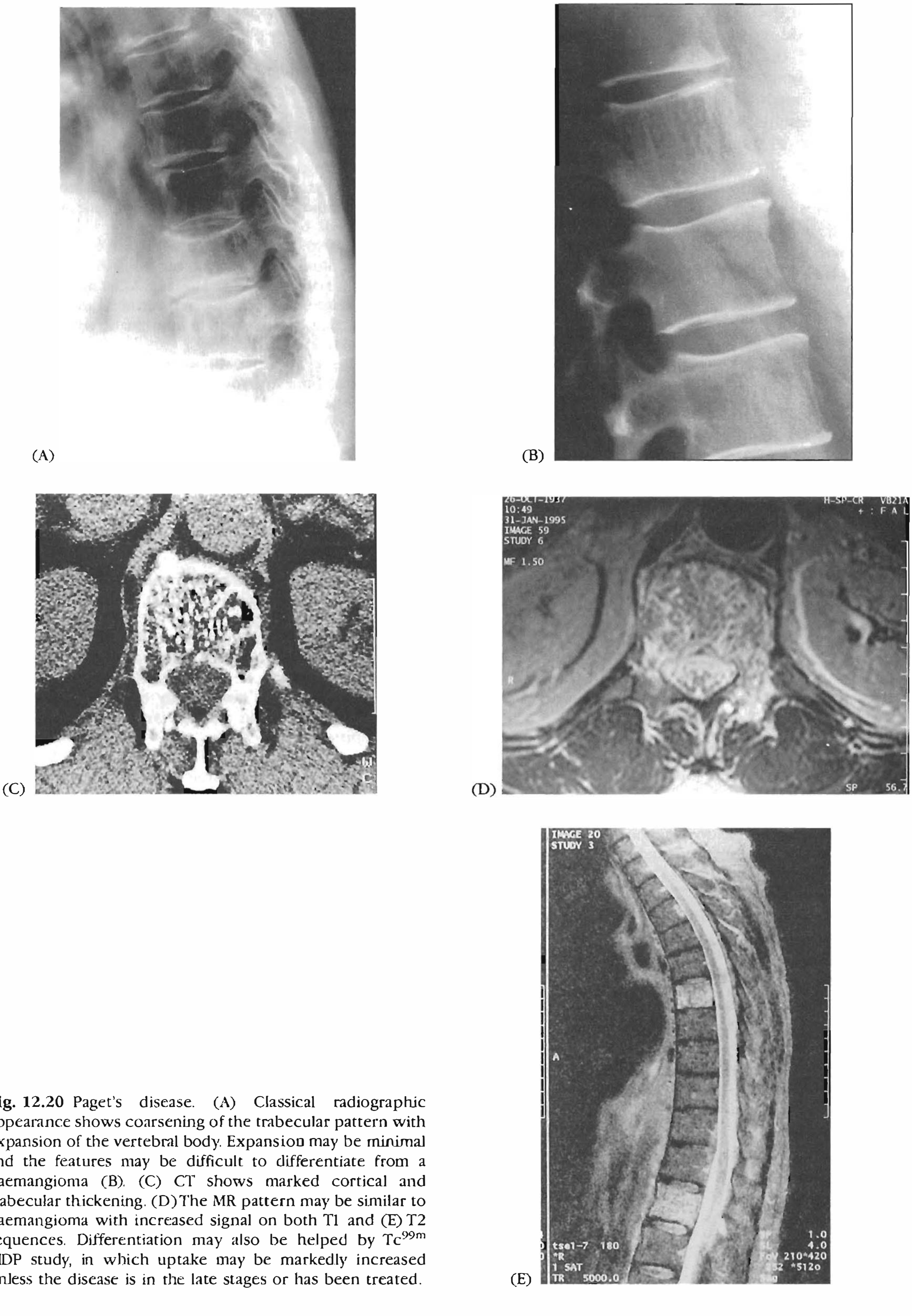

Fig. 12.20 Paget's disease. (A) Classical radiographic appearance shows coarsening of the trabecular pattern with expansion of the vertebral body. Expansion may be minimal and the features may be difficult to differentiate from a haemangioma (B). (C) CT shows marked cortical and trabecular thickening. (D) The MR pattern may be similar to haemangioma with increased signal on both T1 and (E) T2 sequences. Differentiation may also be helped by Tc^{99m} MDP study, in which uptake may be markedly increased unless the disease is in the late stages or has been treated.

signal on both the T1 and T2 weighted images. Rare lesions include eosinophilic granuloma, which is demonstrated on plain films as a vertebra plana; aneurysmal bone cysts, which may cause quite extensive resorption of the vertebral body and posterior elements; and malignant tumours, such as Ewing's tumour which also causes extensive permeative bone destruction and vertebral collapse. Bone-producing tumours occasionally occur, and the sclerosis is seen on the plain radiographs, more commonly in the posterior elements. Such lesions may be osteoid osteomas or osteoblastomas, the latter showing a mass effect. These are well demonstrated on Tc^{99} MDP isotope scans by the localized high uptake of isotope, and CT will confirm the presence of the tumour and evaluate its size and compressive effect on the neighbouring tissues, particularly the cord.

References

Ascani, E., Borelli, P., Larosa, G. *et al.* (1982) Malattia di Scheuermann. I: Studio ormonale. *Progressi in Patologia Vertebrale*. Le cifosa Bologna: A. Gaggi, 5A: 97.

Bangert, B.A., Modic, M.T., Ross, J.S. *et al.* (1995) Hyperintense discs on T1 weighted MR images: correlation with calcification. *Radiology* **195:** 437-443.

Bollow, M., Braun, J., Hamm, B. *et al.* (1995) Early sacroiliitis in patients with spondyloarthropathy evaluation with dynamic gadolinium enhanced MR imaging. *Radiology* **194:** 529-536.

Caretta, S., Marcoux, S., Truchon, T. *et al.* (1991) A controlled trial of corticosteroid injections into zygapophysial joints for chronic low back pain. *N. Engl. J. Med.* **325:** 1002-1007.

Chenod, C.A., Laredo, J.-D., Chevrer, S. *et al.* (1996) Acute vertebral collapse due to osteoporosis or malignancy: appearance on unenhanced and gadolinium-enhanced MR images. *Radiology* **199:** 541-549.

Crock, H., Yoshizawa, H. (1977) *The Blood Supply of the Vertebral Column and Spinal Cord in Man.* New York: Springer-Verlag.

Denis, F. (1989) Spinal instability as defined by the three column spine concept in acute spinal trauma. *Clin. Orthop. Rel. Res.* **189:** 65-76.

Dreyfuss, P., Tibiletti, C., Dreyer, S.J. (1994) Thoracic zygapophyseal joint pain patterns. A study in normal volunteers. *Spine* **19:** 807-811.

Flanders, A.E., Schaefer, D.M., Doan, H.T. (1990) Acute cervical spine trauma: correlation of MR imaging findings with degree of neurological deficit. *Radiology* **177:** 25-33.

Fon, G.T., Pitt, M.J., Thies, A.C. (1980) Thoracic kyphosis: range in normal subjects. *Am. J. Roentgenol.* **134:** 979-983.

Heitoff, K.B., Gundry, C.R., Burton, C.V. (1994) Juvenile discogenic disease. *Spine* **14:** 335-340.

Jain, R., Saawhney, S., Berry, M. (1993) Computed tomography of vertebral tuberculosis: patterns of bone destruction. *Clin. Radiol.* **47:** 196-199.

Kenny, J.B., Hughes, P.L., Whitehouse, G.H. (1990) Discovertebral destruction in ankylosing spondylitis and the role of computed tomography and magnetic resonance. *Br. J. Radiol.* **63:** 448-455.

Lowe, T.G. (1990) Current concepts review: Scheuermann's disease. *J. Bone Joint Surg.* **72A:** 940-945.

Manns, R.A., Haddaway, M.J., McCall, I.W. *et al.* (1996) The relative contribution of disc and vertebral morphometry to the angle of kyphosis in asymptomatic subjects. *Clin. Radiol.* **51:** 258-262.

Meirowitz, S.A., Apicella, P., Reinus, W.R. *et al.* (1994) Imaging of bone marrow lesions: relative conspicuousness on T1 weighted fat suppressed T2 weighted and STIR images. *Am. J. Roentgenol.* **162:** 215-221.

Moore, K.L. (1997) Muscles and ligaments of the back. In: *Clinical Anatomy and Management of Low Back Pain*, Vol. 1 (Giles, L.G.F., Singer, K.P., eds). Oxford: Butterworth-Heinemann, pp. 156-165.

Moulopoulos, L.A. (1996) MR prediction of benign and malignant vertebral compression fractures. *J. Mag. Res. Imag.* **6:** 667-674.

Post, M.J.D., Sze, G., Quencer, R.M. *et al.* (1990) Gadolinium enhanced MR in spinal infection. *J. Comput. Assist. Tomogr.* **14:** 721-729.

Schellhas, K.P., Rollei, S.R., Dorwart, R.H. (1994) Thoracic discography. *Spine* **19:** 2103-2109.

Schwarzer, A.C., Wang, S., O'Driscoll, D. *et al.* (1995) The ability of computed tomography to identify a painful zygapophyseal joint in patients with chronic low back pain. *Spine* **20:** 907-912.

Takahashi, M., Yamashita, Y., Sakamoto, Y. *et al.* (1989) Chronic cervical cord compression: clinical significance of increased signal intensity on MR images. *Radiology* **173:** 219-224.

Tyrrell, P.N.M., Davies, A.M., Evans, N. (1995) Signal changes in the intervertebral disc on MRI of the thoracolumbar spine in ankylosing spondylitis. *Clin. Radiol.* **50:** 377-383.

Whalen, J.L., Brown, M.C., McLeod, R. (1991) Limitations of indium leucocyte imaging for the diagnosis of spine infections. *Spine* **16:** 193-197.

Williams, M.P., Cherryman, G.R., Husband, J.E. (1989) Significance of thoracic disc herniation demonstrated by MR imaging. *J. Comput. Assist. Tomogr.* **13:** 211-214.

Wood, K.B., Garvey, T.A., Gundry, C., Heithoff, K.B. (1995) Magnetic resonance imaging of the thoracic spine. *J. Bone Joint Surg.* **77A:** 1631-1638.

Wood, K.B., Blair, J.M., Aepple, D.M. *et al.* (1997) The natural history of asymptomatic thoracic disc herniations. *Spine* **22:** 525-530.

Section

IV

Management of Thoracic Spine Pain

13

Medical and invasive management of thoracic spinal pain

R. J. Stolker and G. J. Groen

Introduction

Acute spinal pain is a common problem for many patients (Andersson, 1991). However, these complaints tend to heal spontaneously. Independent of the treatment given, only 1% of patients with acute spinal pain are still suffering after 90 days (Nachemson, 1985). In the acute phase, patients are treated with drugs, physical therapy and injections of local anaesthetics. These measures may make the patient feel more comfortable, but they will not affect the prognosis (Nachemson, 1985).

According to the definition of the International Association for the Study of Pain (IASP), pain lasting for more than 3 months is classified as chronic (Merskey, 1986). In these chronic pain patients, it is not easy to make a precise diagnosis after specific back pain caused by tumour, infection or inflammation have been ruled out. Signs and symptoms are often non-specific and fail to correlate with findings at radiological imaging (Wood and Badley, 1987; Mayer, 1991; Jensen *et al.*, 1994). Furthermore, the pain pattern may not be specifically related to the origin of pain. As a result, a definite diagnosis can seldom be made initially. The patient will undergo a variety of diagnostic and unsuccessful therapeutic procedures, or will be referred on. It is important to emphasize that, if possible, the treatment of patients should be cause-related. Only if the cause cannot be found, despite extensive attempts, or in cases where a cause-related treatment is not available, it is justified to treat patients symptomatically. Such treatment may comprise drug therapy, various forms of manual therapy including physical therapy, transcutaneous electric nerve stimulation (TENS), or a combination of these and other modalities. In some countries a series of injections of local anaesthetics, with or without steroids, is not unusual. Despite all attempts, a group often classified as 'therapy-resistant' will remain. This group of patients comprises about 40-50% of the population visiting a pain clinic (Vervest *et al.*, 1993a). The localization of complaints, cervical:thoracic:lumbar, has been determined as 5:2:20 (Stolker *et al.*, 1993a). Consequently, it would seem that thoracic pain is the major problem in only 3-4% of the patients presenting to a pain clinic. This percentage is in accordance with the findings of others (Brose *et al.*, 1991).

Classification

Several classification systems of chronic spinal pain have been developed. Some systems concern the whole field of pain, while others are restricted to spinal pain only. The most well known is based on the organ system from which the pain originates (Bonica and Sola, 1990). In this system, musculoskeletal, neurogenic, referred and psychogenic pain can be distinguished. Another system, which applies to the spine only, is based on the localization of the nociceptive source and the irradiation pattern (Wyke, 1987). This classification system distinguishes between primary, secondary, referred and psychogenic pain. Pain is classified as primary pain if it originates from structures of the spine itself, i.e. joints, bone, ligaments, vessels, muscles or meninges. Secondary pain is pain projected to the skin, supplied by a nerve which is affected by a degenerative or compressive process. The majority of spinal pain is considered to be primary pain (Brose *et al.*, 1991; Vervest *et al.*, 1993a).

An anatomical classification system for spinal pain has been proposed, first by Steindler and Luck (1938), and later by Bogduk (1983). It divides the spine into ventral and dorsal compartments, which are separated by a virtual frontal plane through the posterior wall of the intervertebral foramen. The clue to this division is the innervation of the compartments. The ventral compartment consists of the vertebral body, the intervertebral disc, the anterior and posterior longitudinal ligaments, the ventral part of the dura, and the prevertebral muscles (Groen, 1991). The zygapophysial joints, the intrinsic back muscles, the dorsal part of the dura, and the dorsal ligaments are situated in the dorsal compartment (Bogduk *et al.*, 1981; Bogduk, 1982).

A five-axis system for all pain syndromes has been proposed by the Sub Committee on Taxonomy of the IASP (Merskey, 1986) and recently updated (Merskey and Bogduk, 1994). In this system, several subgroups are dedicated to spinal pain.

As none of these systems are completely suitable in clinical practice, more recently a modification has been designed by combining the four systems above (Stolker *et al.*, 1994a). This system is based on signs, pain pattern, symptoms, data from radiological imaging and electrophysiological examination and results of test blocks. The following clinical syndromes can be distinguished: dorsal compartment syndrome, instability, anular tear, myogenic pain, herniated disc, segmental pain, epidural adhesions and spinal stenosis. However, most patients with spinal pain will not suffer from a single 'clean' syndrome, but from a mix of syndromes (Schwarzer *et al.*, 1994a). In general, a differential diagnosis or working hypothesis can be made with this classification, which is important to answer the question: where is the pain coming from? It should be emphasized that for patients with central pain syndromes and other deafferentation syndromes this model may only be suitable for diagnostic purposes, as blocks of affected nerves are not of therapeutic or prognostic value despite a positive response to a local anaesthetic in the test procedure. Deafferentation syndromes, characterized by low sensory input, will not respond to definitive blocks (Loeser, 1972; Ovelmen-Levitt *et al.*, 1984). In patients with spinal pain from malignant disease, local blocks are often contraindicated because of local tumour growth. Furthermore, tumour pain is usually not restricted to certain nerves or other structures of the spine if invasive growth is present. Moreover, denervation following function loss may be present (Stolker *et al.*, 1993b).

In clinical practice, the following syndromes occur most frequently in the thoracic area: post-thoracotomy syndrome, intercostal neuralgia, dorsal compartment syndrome, segmentally irradiating spinal pain (in the lower thoracic area), myogenic pain and pain referred from the internal organs.

General and regional characteristics

In order to search for a substrate for the pain, knowledge of the innervation pattern of the spine is mandatory. As almost all spinal structures are known to be innervated (with the exception perhaps of the flaval ligaments, the internal venous plexus and the inner part of the nucleus pulposus), they can all act as a source of pain. Detailed information about the innervation is given in Chapter 8. It is important to mention that the general innervation pattern of the spine shows a multisegmental overlapping (up to eight segments for the ventral dura), and sometimes a bilateral, design (Stilwell, 1956; Groen, 1986; Groen *et al.*, 1987, 1988, 1990). In the dorsal compartment, only a bisegmental pattern has been reported (Bogduk, 1982; Bogduk *et al.*, 1982; Auteroche, 1983; Stolker *et al.*, 1994b; Chua and Bogduk, 1995). The zygapophysial joints are innervated by the medial branches, while the costovertebral joints by the lateral branches of the dorsal rami (Vrettos and Wyke, 1974). The costovertebral joint (articulatio capitis costae) is situated in the ventral compartment, and is innervated by the plexus of the anterior longitudinal ligament (Groen *et al.*, 1987).

The design of the innervation of the spine is the reason why spinal pain is often felt in segment, pain may overlap, pain patterns are non-specific, and it may be referred to a dermatomal distribution that is different from that which might be expected. For example, pain originating from the L3-L4 disc may be felt in the groin (L1). This stresses the need for a cautious use of the term 'non-organic signs' for unexpected findings which suggest the presence of major psychological involvement (Waddell *et al.*, 1980). This anatomical convergence in humans has been found to correlate with the neurophysiological convergence on the level of the wide dynamic range neurons in the cat (Groen *et al.*, 1990; Gillette *et al.*, 1993). Thus, blockades in the peripheral nervous system may be helpful in determining the origin of pain (Stolker *et al.*, 1994a).

As pain in the lumbar and cervical area is more common, less attention has been paid to the thoracic region. Although the innervation pattern is comparable to that of other spinal regions, special conditions are present in the thoracic spine. The vicinity of the pleura and the different orientation of the zygapophysial joints have consequences for percutaneous procedures. The presence of ribs, rib cartilage, the sternum and costovertebral joints may lead to additional pain syndromes (Pascual *et al.*, 1992).

The mobility of the thoracic spine is less than in other regions. Lateral flexion is almost impossible because of the costovertebral joints. Flexion and extension are said to be restricted to a few degrees (Grieve, 1981). It seems reasonable to assume that this may explain the lower incidence of pain arising from the thoracic zygapophysial joints in comparison to the incidence in the lumbar and cervical regions. In clinical practice, in the thoracic region, the dorsal compartment syndrome, myogenic pain and segmental pain occur most frequently. The ventral compartment syndrome, herniated disc, spinal stenosis, epidural adhesions or autonomic related pain syndromes are, compared to the lumbar region, seldom encountered (Schirmer, 1985; Dietze and Fessler, 1993), which emphasizes again the relationship between spinal mobility and strain.

Treatment

Non-invasive treatment

Medical pharmacology

The medical treatment of thoracic spinal pain is the same as for other areas of the spine. Drug therapy starts with prescribing paracetamol, which has an analgesic and antipyretic effect. It has a peripheral and a central site of action. In recommended doses the side effects are minor; only an acute overdose may lead to a lethal hepatic failure.

As secondary muscle spasms can occur, it may be helpful to prescribe additional benzodiazepines such as diazepam (2 mg three times a day).

The second step in medication is the prescription of non-steroidal anti-inflammatory drugs (NSAIDs), which are used worldwide (Koch-Weser, 1980). The mode of operation is by peripheral inhibition of the biosynthesis of the prostaglandins. Long-term administration may affect the kidneys and lead to haematopoietic reactions such as neutropenia, thrombopenia, and, rarely, aplastic anaemia (Flower *et al.*, 1985). Another major side effect is the damage to the gastrointestinal system, especially to the stomach wall. All side effects are a result of the mechanism of action, the binding at the cyclo-oxygenase receptor. In general, the severity of side effects correlates with the potency of the drug. As the structure of NSAIDs differ, it is possible to switch to another NSAID from a different group in case of an allergic reaction (Flower *et al.*, 1985). It has been claimed that some NSAIDs, especially sulindac, should affect the kidneys less than others (Erikson *et al.*, 1990; Whelton *et al.*, 1990). More recently, nabumeton, which selectively binds the cyclo-oxygenase 2 receptor, has become available for clinical use. It is expected that, with the use of this drug, the incidence of all inherent side effects due to binding the cyclo-oxygenase 1 receptor will be diminished (Hyneck, 1992; Roth *et al.*, 1994).

It has been questioned whether chronic spinal pain is an indication for the use of opioids (Houde, 1974; Newman, 1983; Portenoy and Foley, 1986; McQuay, 1989; Brena and Sanders, 1991). However, the use of weak opioid-agonists, such as codeine and tramadol, has gained more widespread use. Usual doses are six times 5-20 mg and three times 50-100 mg daily, respectively. The major side effects are constipation and nausea. The frequency of constipation after use of tramadol is substantially lower than following use of the other opioid-agonists. Of the partial opioid-antagonists and agonist-antagonists, such as buprenorphine, pentazocine, nalbuphine and butorphanol, the first agent is used most frequently. Sublingual administration of buprenorphine may sometimes be advantageous, its usual dose being 0.2-0.4 mg three to four times daily, with a ceiling effect at a dose of 2.4 mg daily. The disadvantage of pentazocine and butorphanol is the possibility of developing a dysphoric state of the patient. The major disadvantage of nalbuphine, and to a lesser extent all other drugs of this group, is nausea (Jaffe and Martin, 1985).

The prescription of strong opioids is even more controversial (Portenoy, 1994; Schug and Large, 1995). As psychological involvement and financial compensation problems may play an important role in a small category of patients with chronic spinal pain, meticulous restriction of the prescription of strong opioids is mandatory in order to avoid addiction. In many countries legal restrictions prohibit widespread use for pain of a benign origin. It is recommended that strong opioids only be prescribed under the following conditions:

- A clear diagnosis of the origin of the pain has been made
- There is an absence of major psychologic and/or psychiatric pathology
- Tablet administration is controlled, in order to avoid the use of the prescribed drugs by others
- There is no long-term parenteral use
- All other treatments have failed
- Initial control of effects and side effects has been achieved
- Provision is made for re-evaluation after a test period of 4 weeks
- There is restriction of prescription to one physician only (Porter and Jick, 1980; Maruta and Swanson, 1981; Gourlay and Cherry, 1991; Liebeskind, 1991; Portenoy, 1994; Schug and Large, 1995).

The drug which has been most commonly used is sustained-release morphine sulphate. The dose has to be titrated, and its major side effect is constipation, which can be reduced by the administration of transdermal fentanyl (Ahmedzai *et al.*, 1994). This has been introduced more recently, with major experience limited to cancer patients. However, the problem of drug tolerance in chronic opioid administration remains unsolved.

If deafferentation is present, tricyclic antidepressants may be considered as monotherapy or as co-medication. As the greatest experience is in the use of amitriptyline, this is usually considered as the drug of first choice. The analgesic effect is achieved with low doses (10-100 mg), which are insufficient to cause an antidepressive effect (Sullivan *et al.*, 1992). The analgesic effect is often partial. The side effects are many, but a dry mouth from the anticholinergic effect and drowsiness are the most clinically relevant. This drowsiness can be an advantage in patients with a disturbed sleep pattern. Long-term administration is reported as not-problematic (Baldessarini, 1985; Max, 1994).

Other conservative measures

Several methods of physical therapy, either in isolation or as part of a rehabilitation programme, belong to the modalities mostly used in conservative management. Passive movement manoeuvres and exercise programmes also have their place, and are described elsewhere in the book (see Chapters 15-17).

Transcutaneous electric nerve stimulation has gained widespread use in the symptomatic treatment of acute and chronic spinal pain in general. The efficacy of TENS could not be demonstrated in a prospective, double-blind, placebo-controlled trial (Deyo *et al.*, 1990); however, other authors claim that patients may benefit from the application of TENS (Meyler *et al.*, 1994; Woolf and Thompson, 1994; Verdouw *et al.*, 1996). Although their success rate barely exceeds the placebo effect (assumed to be about 30%), these authors claim a place for this treatment because the alternative to TENS is often no treatment at all, and it has no serious side effects.

Several other modalities for treating pain by short sensory hyperstimulation have been described (Melzack, 1994); examples are intense TENS, injection with irritating fluids (such as hypertonic saline), needling, ice massage, scarring, cauterization and acupuncture. These therapies, which have their origins in folk medicine, are based on the principle of administration of 'pain to abolish pain' or 'hyperstimulation analgesia' (Melzack, 1994). Substantial investigation at the basic science level has provided compelling evidence for the (possibly different) mechanisms responsible for these phenomena (Kunesh *et al.*, 1987; Le Bars and Villaneuva, 1988; Wahren *et al.*, 1989; Le Bars *et al.*, 1992); however, some authors still consider that their clinical efficacy requires further investigation (see Willer *et al.*, 1984).

Invasive treatment

Invasive therapy includes both surgical and percutaneous procedures. In general, invasive treatment is only to be considered after failure of proper, conservative treatment, or in the case of imminent damage to the spinal cord in severe spinal stenosis. However, the estimated risk of chronic drug intake should always be compared to the risk of an invasive procedure, because the side effects of conservative treatment are not always milder than the side effects of invasive therapy.

Neurosurgical/orthopaedic treatment

Previously, neurectomy of an intercostal nerve and surgical rhizotomies were performed in order to treat intercostal pain referred from the spine. However, this therapy has to be considered obsolete, as it may lead to loss of sensation and, occasionally, denervation (Loeser, 1972; Ovelmen-Levitt *et al.*, 1984; Pagni *et al.*, 1993). For this reason, percutaneous partial rhizotomy has been advocated in the treatment of this pain syndrome (Stolker *et al.*, 1994c).

The main purpose of surgery of the thoracic spine is to correct severe scoliosis or to protect the spinal cord in the presence of a fracture or severe spinal stenosis with imminent neurological deficit (Skubic and Kostuik, 1991). As the incidence of a thoracic herniated disc is 500-1000 times lower than in the lumbar region, disc surgery will seldom be performed (Dandy, 1942; Schirmer, 1985; Skubic and Kostuik, 1991). In general, pain syndromes not associated with severe scoliosis or neurological sequelae are rarely an indication for surgery in the thoracic spine, in contrast to the situation in the lumbar spine.

Dorsal column stimulation has been applied in many patients with chronic spinal pain (North *et al.*, 1993; Krainick and Thoden, 1994). However, the experience in the thoracic spine is very small. Furthermore, the 'failed back syndrome', which is infrequent in the thoracic spine, is considered to be one of the principal indications for dorsal column stimulation; consequently its place in the treatment of chronic thoracic spinal pain remains unclear.

Percutaneous procedures

These include test blocks and therapeutic blocks, which may be by injection of trigger points, epidural injection of steroids or neurolytic blocks.

Injection of trigger points

Injection of trigger points, with local anaesthetic or saline, is the simplest means of invasive treatment. These injections gained popularity in the 1980s, and a complete map of these trigger points has been achieved (Travell and Simons, 1983). Nowadays, their effectiveness in managing chronic spinal pain is questioned. In the authors' experience, these injections seem to be more appropriate in acute pain problems than in chronic pain.

Epidural steroids

Injections of corticosteroids have gained widespread clinical use. However, the exact indications for this therapy and its effectiveness remain unclear (Kepes and Duncalf, 1985; Benzon, 1986; Nelson, 1993). Reported indications include acute herniated disc, acute back pain, chronic back pain with or without radiation, and the post-laminectomy syndrome. Almost all studies concern injections in the lumbar area, and no data for the thoracic region are available. In this region, possible indications may be acute back pain and chronic pain with or without radiation. A recent systematic review of all controlled studies concerning lumbar epidural injections concludes that there is no evidence for the effectiveness of this therapy in chronic back pain without radiation (Koes *et al.*, 1995). Furthermore, none of these studies has involved follow-up of more than 6 months. White *et al.* (1980) concluded that no patient was cured definitively. Incorrect needle placement may play a role in negative findings, as fluoroscopic control was not routinely used in guiding the needle insertion. Incorrect needle position has been reported in 25% of cases (White *et al.*, 1980). In other studies, this percentage was even higher (El-Khoury *et al.*, 1988; Renfrew *et al.*, 1991); therefore, fluoroscopic guidance for needle insertion is strongly advocated.

Adverse reactions of epidural injection seem to be rare (Delaney *et al.*, 1980). However, serious side effects have been described in several case reports, for instance: transient hypercorticism (Knight and Burnell, 1980; Stambough *et al.*, 1984; Tuel *et al.*, 1990); intraocular haemorrhage (Clark and Whitwell, 1961); epidural haematoma (Williams *et al.*, 1990); dural tap (Barry *et al.*, 1982); and meningitis, described by Dougherty and Fraser (1978) after accidental intrathecal injection and, as a rare complication of regular epidural administration, by Gutknecht (1987).

In conclusion, there seems to be little place for epidural administration of steroids in chronic thoracic spinal pain, only in cases of acute spinal pain and radiating chronic pain.

Test blocks

Traditionally, test blocks are thought to serve diagnostic and/or prognostic purposes. However, the prognostic advantage lies in the possibility of estimating the result of a neurolytic blockade (White and Kjellberg, 1973). Others doubt or reject the prognostic value of a block (Loeser, 1972; Onofrio and Campa, 1973; Jackson *et al.*, 1988; Lilius *et al.*, 1989, 1990; Jackson, 1992), having used blocks with local anaesthetic to predict the outcome of surgical rhizotomies and spinal fusions, respectively. Moreover, inadequate technical procedures and incomplete clinical evaluation of the patient before starting blockades may lead to a negative result of a definite procedure after a positive block. Furthermore, even after 'correct' procedures, false-negative and false-positive results are possible. The reasons for these results are listed in Tables 13.1 and 13.2.

Diagnostic block may be helpful, or even essential, in establishing a clinical diagnosis (Stolker *et al.*, 1993a, 1994a, 1994d; Schwarzer *et al.*, 1994a, 1994b); moreover, it achieves a possible target of therapy (Sluijter and Mehta, 1981; Nash, 1986; Vervest and Stolker, 1991).

In order to enhance the reliability of test blocks, it is absolutely necessary to perform these blocks under radiologic control with the use of contrast medium if necessary. Furthermore, it is mandatory to use only small amounts of contrast dye (i.e. maximum of 1 ml for a spinal nerve and 0.5 ml for a zygapophysial joint) in order to avoid overflow of dye to neighbouring structures. In many cases additional blocking of these structures and adjacent levels may be required in order to obtain a negative response. This confirms the location of the target structure. It is recommended that blockades be repeated with different local anaesthetics and patients be examined during the action of the local anaesthetic agent, preferably by an independent, blinded investigator (Bonica, 1974; Schwarzer *et al.*, 1994b; Stolker *et al.*, 1994a; North *et al.*, 1996). However, a cascade of blockades will confuse the patient, decreasing the reliability of the

Table 13.1 *Causes of false-positive test blocks*

- Overflow of local anaesthetics to the epidural space (Goldstone and Pennant, 1987; El Khoury *et al.*, 1988; Purcell-Jones *et al.*, 1989)
- Overflow of local anaesthetics to sympathetic fibres (Purcell-Jones *et al.*, 1987)
- Systemic uptake of local anaesthetics and spread into the central nervous system (Woolf and Wiesenfeld-Hallin, 1985)
- Denervation
- Placebo response (Lilius *et al.*, 1989; Silvers, 1990; Schwarzer *et al.*, 1994a)

Table 13.2 *Causes of false-negative test blocks*

- Too small an amount of local anaesthetic
- (Partial) intramuscular/intravenous injection (Vervest and Stolker, 1991)
- Multicausal pain syndrome (Stolker *et al.*, 1994a)
- Multilevel pain syndrome (Tajima *et al.*, 1980; Kikuchi *et al.*, 1981, 1984; White, 1983; Kirkaldy-Willis, 1984; Tile, 1984; Dooley *et al.*, 1988; Purcell-Jones *et al.*, 1989; Stanley *et al.*, 1990)
- Failing communication between patient and doctor

response to the test procedure. Therefore, planning in advance, based on clinical findings, is advocated (see below).

It is possible to achieve an effect of a local anaesthetic which is longer or shorter than the duration of pharmacological action. This may be the result of a placebo effect (Lilius *et al.*, 1989; Silvers, 1990; Schwarzer *et al.*, 1994b), an incomplete block, an additional sympathetic block (Purcell Jones *et al.*, 1987), or the interrruption of the 'vicious pain circle' (O'Brien, 1984). This is a mechanism that occurs more frequently in acute pain syndromes. However, the treatment of chronic pain by a series of blockades with local anaesthetics is based on the same working mechanism.

Formerly, electrostimulation, direct stimulation of the structure via a needle or by pressure (as in provocative discography) and injections of hypertonic solutions were used more commonly in clinical practice (Steindler and Luck, 1938; Inman and Saunders, 1944; Mooney and Robertson, 1976; Kellgren, 1977). As patients tend to 'recognize' their pain, a negative response after stimulation is more reliable than a positive response. Therefore, the use of stimulation as a diagnostic tool is limited nowadays, perhaps with the exception of provocative discography (Walsh *et al.*, 1990). However, it remains a useful tool in mapping pain patterns in volunteers (Mooney and Robertson, 1976; Dwyer *et al.*, 1990; Dreyfuss *et al.*, 1994).

Neurolysis

Neurolytic blocks should be considered only after a positive test procedure, i.e. for temporary pain relief (Saris, 1986; Dubuisson, 1989). Techniques of neurolysis include surgical, chemical and physical modalities. Surgical treatment has a poor long-term outcome (Onofrio and Campa, 1972; Loeser, 1972). In many patients sensory loss may develop which can be followed by a constant burning pain, even worse than the original complaint and sometimes over a larger area, the so-called 'expanded fields' (Ovelmen-Levitt *et al.*, 1984). This may be attributed to plasticity of the spinal cord following denervation. The same problems have been described after chemical neurolysis with alcohol, phenol or glycerin. The advantages of chemical techniques are the cost and the simplicity of the technique. Disadvantages are the short time of pain relief; this can last, in many cases, for several months only despite potentially permanent loss of sensation. In case of return of normal sensation, the block could be repeated. Another disadvantage is the unpredictability of the site of action of the fluids. Control of their spread is lost once they have left the syringe, even where fluoroscopic control and radiocontrast dye has been used (Dubuisson, 1989; Swerdlow, 1988; Wood, 1989).

Surgical and chemical techniques may have many disadvantages, which can be avoided by using physical techniques. Electrocoagulation has been abandoned as a result of the unpredictability of the size of the lesion; instead, cryocoagulation has been advocated as a method of neurolysis (Katz, 1989). However, its effect only lasts a few months. Moreover, the probes used are thick (14G), and there is a potential risk of damaging the nerve. This technique may only be used on exclusively sensory nerves. The sensory loss seems to be reversible. Presently, indications for cryocoagulation are restricted to the treatment of neuromas.

Another physical method of neurolysis is radiofrequency (R-F) lesioning. Lesions induced in this manner are reported to be reproducible, controllable in size, and of longer lasting duration (Cosman *et al.*, 1984; Cosman and Cosman, 1985; Vervest and Stolker, 1995). Small 22G needles can be used for temperature-controlled lesioning (Sluijter and Mehta, 1981). If properly performed, R-F lesions are partial lesions, not leading to permanent sensory loss nor, in the longer term, to deafferentation (Sweet and Wepsic, 1974; Stolker *et al.*, 1994d, 1994e; Van Kleef *et al.*, 1999). However, no difference could be demonstrated in a study comparing 67°C with 40°C lesions in cervical PPR (percutaneous partial rhizotomy) (Slappendel *et al.*, 1997).

It has been claimed that thin unmyelinated fibres are less susceptible to heat by R-F current than thick fibres (Letcher and Goldring, 1968; Sweet and Wepsic, 1974; Sluijter and Mehta, 1981). However, other authors found that it is more probable that R-F lesions are non-specific, and that all fibres within reach of the current will be lesioned equally (Klumpp and Zimmerman, 1980; Smith *et al.*, 1981; Bogduk *et al.*, 1987; Arendzen, 1989; Hamann and Hall, 1992; Stolker *et al.*, 1996). The partial character of an R-F lesion depends on the position of the electrode and the size of the lesion.

As the size of a R-F lesion is always smaller than the size of the blocked area with local anaesthetics, a positive test block may be followed by a negative result of the definitive procedure (Cosman *et al.*, 1984; Bogduk *et al.*, 1987; Moringlane *et al.*, 1987; Vinas *et al.*, 1992). Technical failure and alternative anatomical pathways may be other sources of negative results (Pallie, 1959; Coggeshall *et al.*, 1975; Bogduk and Long, 1980; Cosman and Cosman, 1985; Lang, 1985; Umeda *et al.*, 1987; Groen *et al.*, 1988; Haynsworth and Noe, 1991; Vervest *et al.*, 1993b; Stolker *et al.*, 1994c, 1994e). Since the innervation shows a multisegmental pattern, multilevel treatment will often be required.

Radiofrequency lesions seem to have a half-life of about 3 (Vervest *et al.*, 1994). Caution is recommended if sensory loss is already present and in the case of central pain syndromes (Stolker *et al.*, 1993b).

Percutaneous zygapophysial denervation

A percutaneous zygapophysial (facet) denervation (PFD) is indicated if the following signs and symptoms are present: (almost) continuous paravertebral pain in a region of the spine without neurological deficit; paravertebral tenderness; and temporary pain relief after a block of the medial branch of the dorsal ramus or an intra-articular zygapophysial joint block with local anaesthetics (Stolker *et al.*, 1993a). Concomitant, but not always present, are pain provocation on extension or rotation of the spine, diminished movement in the affected part of the spine, non-segmental radiation pattern, and pain after sitting or standing for a prolonged time (Lippit, 1984; Lynch and Taylor, 1986; Eisenstein and Parry, 1987; Helbig and Lee, 1988). Moreover, radiological signs like spondylosis, zygapophysial joint arthritis in the lower thoracic area, osteoporosis and vertebral collapse have been described in relation to this syndrome.

In 1976, a lumbar 'facet syndrome' was described by Mooney and Robertson. Remarkably, the syndrome in the thoracic spine had already been treated in the 1970s (Lora and Long, 1976; Shealy, 1976), but was described much later (Stolker *et al.*, 1993a). All the signs and symptoms are rather non-specific (Revel *et al.*, 1992; Schwarzer *et al.*, 1994c) so, in the current authors' opinion, the combination of the four obligatory signs is mandatory to the diagnosis. Therefore, it has been suggested that only the test block should be relied upon as a diagnostic tool (Schwarzer *et al.*, 1994c). Furthermore, as a consequence, these authors advocate the use of the term 'facet pain' instead of syndrome; the current authors believe that this is not justifiable.

In the thoracic area, the form of the articular processes of the vertebra makes a nerve block more suitable than an intra-articular block. The dorsal approach is impossible, and a lateral approach is dangerous because of the vicinity of the pleura. In the lumbar area, nerve blocks and articular blocks are considered to be of equal value (Carrera, 1980; Dory, 1981; Destouet *et al.*, 1982; Marks, 1989; Nash, 1990; Marks *et al.*, 1992; Schwarzer *et al.*, 1994b, 1994c). This opinion makes the existence of a really selective intra-articular block unlikely, because the dorsal compartment contains more innervated structures than the joints alone (Raymond and Dumas, 1984; Carette *et al.*, 1991; Stolker *et al.*, 1994b; Chua and Bogduk, 1995). Furthermore, these investigators used more than 0.5 ml of local anaesthetic, making a selective block unlikely (Jackson *et al.*, 1988; Carette *et al.*, 1991; Jackson, 1992). In conclusion, the term 'dorsal compartment pain' is more suitable, as the exact structure in the dorsal compartment acting as the origin of pain remains uncertain (Stolker *et al.*, 1994a).

Concerning the term PFD, it suggests a denervation but is in fact nothing more than a lesion of the medial branch. As the medial branch has already divided into several branches, some of which branch very proximal to the ventral side of the joint, it is obvious that a denervation is impossible (Stolker *et al.*, 1994b). Thus the term 'percutaneous medial branch neurotomy' is more suitable for the procedure, which interrupts nerves supplying the dorsal compartment, and not the zygapophysial joints exclusively (Stolker *et al.*, 1994b).

As the innervation pattern is bisegmental, a PFD for one level should be performed at the same level and one level more cranially. The patient is placed in the prone position and, under fluoroscopic guidance, 22G electrodes (10 cm long, with a 5-mm bare tip) are placed lateral to the point where the lateral process meets the superior articular process. The needle is advanced until there is bony contact (Fig. 13.1). After checking the position on antero-posterior and lateral views, a physiological control is performed with stimulation current. If these parameters are satisfactory an R-F lesion is made under

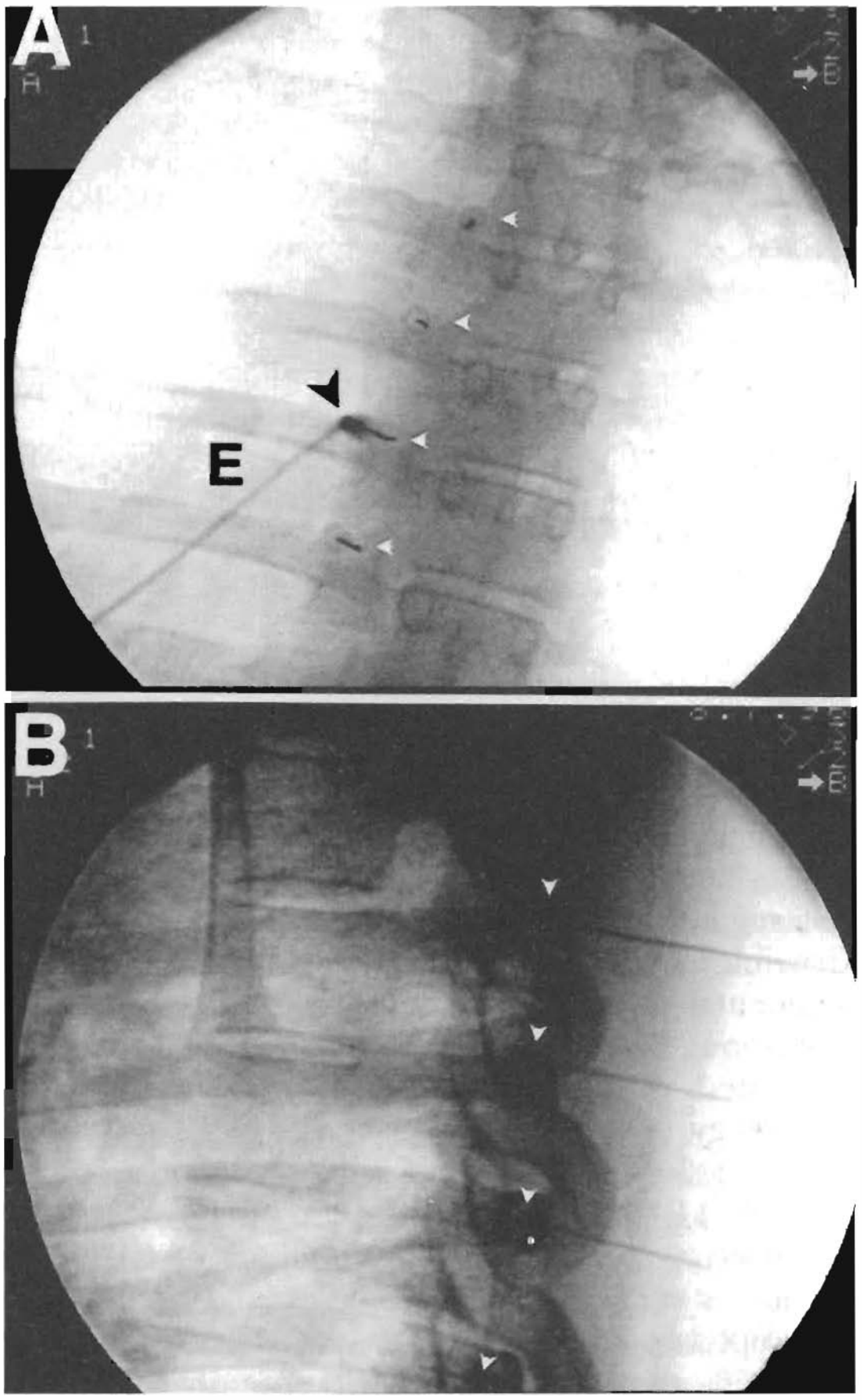

Fig. 13.1 Fluoroscopic view of percutaneous facet denervation at T4–T7. The white arrows indicate the tip of the needles. (A) Antero-posterior view. (B) Lateral view.

local anaesthesia, administered through the needle. A more extensive description of the technique is given elsewhere (Stolker *et al.*, 1993a). After anatomical control investigations, a more lateral position than that mentioned in this description has proved useful (Stolker *et al.*, 1994b, 1994c). This is due to the observation that, following the original technique, repositioning of the electrode was necessary because of unsatisfactory electrophysiological stimulation criteria.

Only three papers deal with thoracic PFD. In two of these studies, nine and ten patients were described respectively. They were treated with the 14G Shealy electrode according to the original technique (Lora and Long, 1976; Shealy, 1976). Fifty per cent or greater reduction of pain was achieved in 33% and 60%, respectively, of the patients in these two studies. The follow-up was for 3 years. In a more recent study by Stolker *et al.* (1993a), greater than 50% pain relief was achieved in 83% of the patients, with a follow-up of 4 years. An explanation for the difference in results may be the differences in technique and a more strict indication for the procedure, i.e. presence of all four of the above-mentioned signs and symptoms and a positive (greater than 50% relief) response to a test block. The only side effect reported is transient postoperative pain in 12% of the patients. Currently, results of a prospective, randomized, placebo-controlled trial are only available for the lumbar spine (Gallagher and Petriccione di Vadi, 1994). These authors reported a significant result compared to placebo after 6 months. Other open studies in the lumbar and cervical spines show good results in 21–89% of patients (Stolker *et al.*, 1994a). The success rate in all studies decreases with time. This may be due to nerve regeneration, as observed in animals after a few weeks (Hamann and Hall, 1992).

Percutaneous partial rhizotomy

The indications for a percutaneous partial rhizotomy (PPR) are segmentally radiating pain (segmental pain) lasting more than 3–6 months, without a treatable cause, failure of conservative therapy, and response to a segmental blockade for the time of the pharmacodynamic action of a local anaesthetic. The classic segmental pain pattern occurs in the herniated disc syndrome. Segmental pain is distinguished from the herniated disc related pain in that compression pathology is absent on MRI and there is no neurological deficit. The causes of segmental pain are listed in Table 13.3. In the thoracic area, intercostal blocks are used as segmental blocks (Tajima *et al.*, 1980; Dooley *et al.*, 1988; Purcell-Jones *et al.*, 1989). It must be emphasized that sensory loss is a contraindication for a PPR, as nerve lesioning will not only fail to help but may actually worsen a (partial) denervation pain. As a consequence, post-herpetic neuralgia is not a suitable indication for PPR (Stolker *et al.*, 1993b).

Table 13.3 *Causes of thoracic segmental pain syndrome*

- Intercostal neuralgia
- Post-thoracotomy syndrome
- Pathology of the ribs (tumour, pseudarthrosis, 12th rib syndrome)
- Osteoporosis
- Vertebral metastasis
- Traumatic collapse of a vertebra
- Herniated disc
- Segmental pain
- Ossification of spinal ligaments

The mechanism of segmental pain remains controversial (Epstein *et al.*, 1973; Murphy, 1977; Hasue *et al.*, 1983; Rydevik *et al.*, 1984, 1989; Parke and Watanabe, 1985; Weinstein, 1986, 1991; Weinstein *et al.*, 1988; Xiuqing *et al.*, 1988; Abram, 1988). Sometimes the pain pattern in segmental pain syndrome is completely segmental. This may be explained by the nerves in the dural sleeves and in the posterior longitudinal ligament, variations in segmental innervation, and intersegmental connections (Pallie, 1959; Hasue *et al.*, 1983; Kikuchi *et al.*, 1984; Groen *et al.*, 1990).

The technique of PPR was first described by Uematsu *et al.* (1974), and was later modified by Sluijter and Mehta (1981). In the upper thoracic spine the classical approach is not possible because of the shape of the vertebrae and the proximity of the pleura (Uematsu, 1982; Pagura, 1983; Arbit, 1989); therefore a dorsal approach is applied, using a hole in the lamina made with a Kirschner wire (Stolker *et al.*, 1994d). The target point is the same as in the classic dorso-lateral approach (Fig. 13.2). It must be emphasized that, in the literature, the position of the dorsal root ganglion has been described as inside the intervertebral foramen (Rickenbacher, 1982). However, more recently the position has been found to be variable, rather more lateral, and sometimes even partially outside the foramen (Hasue *et al.*, 1989; Stolker *et al.*, 1994e).

The target structure in PPR is the dorsal root ganglion and not the dorsal root, as suggested by the name of the procedure (Sluijter and Mehta, 1981; Nash, 1986; Stolker *et al.*, 1994d, 1994e). Under fluoroscopy, in 15° oblique and lateral views, the 22G cannula (with a length of 10 cm and a bare 5-mm tip) is placed cranio-dorsally into the intervertebral foramen. In the antero-posterior view, the target point is caudal from the lateral border of the pedicle (Stolker *et al.*, 1994e). Once the anatomical positioning has been completed, a stimulation current of 50 Hz is applied, which produces a tingling feeling in the corresponding dermatome within a range of 0.4–0.8 V. A stimulation current of 2 Hz should not elicit contractions of the intercostal muscles within a voltage twice as high as the threshold for sensation.

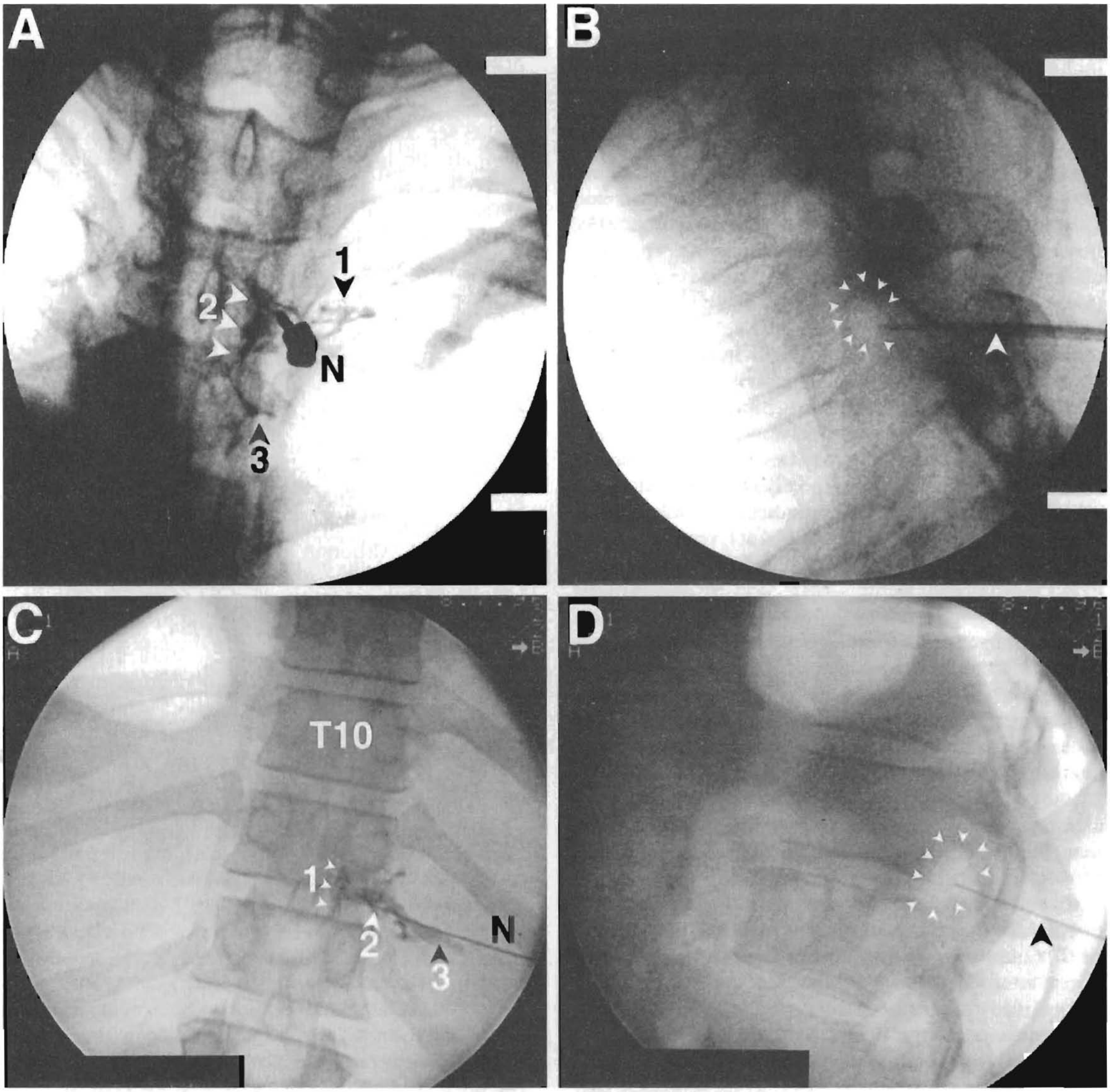

Fig. 13.2 Fluoroscopic view of percutaneous partial rhizotomy. (A) Dorsal approach at T4 after contrast injection, antero-posterior view. Note the contrast to the intercostal nerve (1), the epidural space (2), and to the intercostal nerve one level below (3). (B) Same patient as in (A), dorsal approach, lateral view. Note the tip of the needle in the intervertebral foramen. (C) Lateral approach at T11 after contrast injection, antero-posterior view. (D) Same patient as in (C), lateral view.

If the electrophysiological parameters are insufficient, the cannula has to be replaced. After injection of a radiocontrast dye to visualize the nerve and/or the epidural space and to exclude an intravasal position, local anaesthetic is administered and a R-F lesion of 67°C of 90 s duration is applied. Further details are given elsewhere (Sluijter and Mehta, 1981; Stolker *et al.*, 1994d).

Although the PPR has been performed for many years, only a few reports are available concerning the results, especially for the thoracic area. All studies have an open retrospective design (Uematsu *et al.*, 1974; Verdie and Lazorthes, 1982; Pagura, 1983; Nash, 1986; Niv and Chayen, 1992; Stolker *et al.*, 1994d). Success rates vary from 39–85% with a follow-up time of up to 6 years. Some studies describe the results in cancer patients only (Pagura, 1983; Nash, 1986; Niv and Chayen, 1992); others concern patients suffering from pain distal to the spine (Niv and Chayen, 1992; Stolker *et al.*, 1994d). However, thoracic segmental pain from spinal origin seems to be a good indication for a PPR. The side effects include a transient hypoaesthesia and transient postoperative pain in 15-20% (Nash, 1986; Dubuisson, 1989; Niv and Chayen, 1992; Stolker *et al.*, 1994d). It is important to emphasize that sensory loss is a side effect and not a goal. After a surgical rhizotomy, sensory loss is the rule (Loeser, 1972; Onofrio and Campa, 1973; Kocks *et al.*, 1988; Pagni *et al.*, 1993); however, it may be difficult to detect this loss clinically due to the extensive overlap of dermatomes (Sherrington, 1898; Foerster, 1933; Dykes and Terzis, 1981). The technique with PPR of achieving lesions under general anaesthesia until hypoalgesia and hypoaesthesia develop, as described by Pagura (1983), has the same disadvantage and must therefore be abandoned. Permanent loss of sensation may lead to deafferentation, which may be followed by expansion of the painful area to adjacent dermatomes, which may subsequently require treatment. This phenomenon of 'expanding fields' (Ovelman-Levitt *et al.*, 1984; Sweet, 1984) has never been observed in PPR (Sluijter and Mehta, 1981; Vervest and Stolker, 1991; Van Kleef *et al.*, 1993; Stolker *et al.*, 1994d). However, in PPR a hyperaesthesia may occur, but it is transient in nature (Van Kleef *et al.*, 1993; Stolker *et al.*, 1994d). The partial nature of a PPR has been confirmed in an electrophysiological study of cervical PPR (Van Kleef *et al.*, 1993), as well as in an anatomical study in thoracic PPR (Stolker *et al.*, 1994e). However, it may be possible that somewhere a 'point of no return', with irreversible nerve damage, may be passed, as described by Gybels and Sweet (1989) in the R-F lesion of the Gasserian ganglion with thick needles. The use of thin 20G and 22G needles, in combination with an applied temperature of 67°C, assures a lesion smaller than the size of most dorsal root ganglia.

As already mentioned, the tip of the cannula has to be positioned in the dorsal part of the foramen, not only to avoid lesioning motor fibres but also because the radicular arteries are located in the anterior part of the foramen. Damage to these arteries may lead to serious neurological sequelae, in particular in the lower thoracic and upper lumbar area, where, theoretically, the anterior spinal artery of Adamkiewicz may be lesioned. Because of the limited reliability of the antero-posterior position of the cannula in the lateral view due to overprojection of the foramina, electrophysiological thresholds are not only of value in avoiding motor loss (which probably would be undetected, especially in the thoracic region), but also and more importantly to verify a dorsal position in the intervertebral foramen.

Spinal cord lesions have been described as complications after thoracic PPR (Verdie and Lazorthes, 1982; Koning *et al.*, 1991). They are without doubt the result of technical failure, as discussed elsewhere (Stolker *et al.*, 1994d, 1994e; see also Chapter 8).

Percutaneous sympathectomy

The sympathetic chain contributes to the nerve plexus of the anterior longitudinal ligament, which innervates the anterior part of the spine (Groen *et al.*, 1990; see also Chapter 8). This is the rationale for sympathetic blocks in the treatment of spinal pain derived from the ventral compartment (Sluijter, 1988). However, until now ventral compartment pain has only been described extensively in the lumbar spine, and, to a lesser extent, in the cervical area, whereas the thoracic region is seldom affected. Most thoracic ventral compartment pain originates from the intervertebral disc (Skubic and Kostuik, 1991). As noted above, the incidence of a disc herniation is 500-1000 times less frequent in the thoracic spine than in the lumbar area (Schirmer, 1985; Dietze and Fessler, 1993); accordingly, the incidence of thoracic ventral compartment syndrome is probably also very low. However, the clinical importance and the incidence of this syndrome have to be definitively determined. Although the technique of a percutaneous thoracic sympathectomy has been known for a longer time, and a technique using R-F lesioning has been described (Wilkinson, 1984, 1985), to the current authors' knowledge no studies have been performed on this technique in relation to thoracic spinal pain. Percutaneous thoracic sympathectomy has only been used in the treatment of causalgia, reflex sympathetic dystrophy and arterial insufficiency of the upper limb. Because of the risk of pneumothorax, sympathetic blockade in this region is often restricted to the stellate ganglion.

Discussion

Controlled studies

At present it is only acceptable adequately to evaluate the effectiveness of pain therapy using a randomized, double-blind, placebo-controlled design. In order to carry out such a study, several conditions have to be met. Firstly, there must be a standardized indication for the therapy, the terminology used must be generally accepted, and there must be agreement on inclusion and exclusion criteria. Secondly, a proper pilot study has to be performed in order to assess the potential benefits. Thirdly, the technique has to be verified and standardized. Finally, a long-term follow-up is necessary, measuring the result by comparable pain scales.

In the case of thoracic PPR and PFD, these criteria have only recently been fulfilled. Moreover, the problem of individual skill has not been solved. This is an important issue in percutaneous techniques, in which objective criteria for measuring technical performance are so far completely lacking.

On the other hand, it may be questioned whether, in the case of PPR, such a double-blind, placebo-controlled design is even possible. Sometimes, a rash in the corresponding dermatome may occur during and after R-F lesioning, and a transient sensory loss (longer than the duration of action of the local anaesthetic) may be detectable. Nevertheless, the first placebo-controlled studies have been instigated in several centres. The first report concerning lumbar PFD demonstrated its effectiveness (Gallagher and Petriccione di Vadi, 1994). Initial short-term results in Dutch studies on cervical PPR and lumbar PFD show a significant difference between R-F and sham lesions (Van Kleef *et al.*, 1996). Longer follow-up is now being undertaken. PFD has proven to be more effective in a prospective, double-blind controlled study than sham-lesioning on the medial branch (Lord *et al.*, 1996).

It must be emphasized that good results in the pilot studies are not only due to skilled technical performance and the use of imaging techniques, but also to the correct patient selection procedure. These elements are crucial for a successful outcome.

In the authors' clinical studies (Stolker *et al.*, 1993a, 1994d), power calculations were used (in the absence of a control group) in order to exclude the possibility that results were due to a placebo effect. Calculations in all studies revealed a power of > 0.99, showing that a placebo effect alone was unlikely to be responsible for these results. The placebo effect is speculative. It has been reported to be related to the therapy assumed to have been given (Evans, 1974); thus, if patients are expecting opioids, the placebo effect is stronger than if they are expecting to be treated by paracetamol. In invasive pain treatment, the incidence of a placebo effect has been reported to be fairly high - up to 36% (Jackson *et al.*, 1988; Lilius *et al.*, 1989, 1990; Carette *et al*, 1991). For this reason, a 50% placebo effect was used in the calculations instead of the usual 25-30%.

However, in some studies a success rate even lower than the placebo effect has been reported (Loeser, 1972; Onofrio and Campa, 1974; Andersen *et al.*, 1987; Kocks *et al.*, 1988; North *et al.*, 1991; Van Kleef *et al.*, 1993). This may be due to a longer follow-up time, incorrect patient selection, or inadequate technical performance. It has been reported that a placebo effect should decrease, or even disappear, in time (King and Lagger, 1976).

Strategy

If a mix of pain syndromes is detected, the working hypothesis may be tested by test blocks. In the case of a multisegmental radiating pain, testing and, in the case of a positive response, treating the dorsal compartment syndrome first is recommended. Segmental pain is never to be tested or treated first except in cases where a monosegmental syndrome is present as single syndrome. The reason for this advice is that the dorsal compartment syndrome may present as multilevel segmental pain.

Following treatment, the first review should be done after at least 2 months in order to avoid recording a false-positive result lasting only some days or weeks, or a false-negative result due to the presence of postoperative pain which usually only lasts for several weeks.

Role of the sympathetic nervous system

In patients suffering from spine-related pain syndromes, autonomic symptoms are observed quite frequently. It is not easy to assess whether this is a primary mechanism of pain or a phenomenon secondary to chronic pain. However, in general the sympathetic nervous system is thought to play a role in maintaining pain (Livingston, 1943; Roberts, 1986; Bonica, 1990; Jänig, 1990; Weinstein, 1991). This may be explained by the sprouting of sympathetic fibres in the dorsal root ganglion, which has been reported to occur after peripheral nerve lesions in the rat (McLachlan *et al.*, 1993). Features of autonomic dysfunction may be very impressive; for example, in reflex sympathetic dystrophy, diffuse pain, cold, blue/pale or red/warm limb, sudomotor abnormalities, sensory and/or motoric loss, trophic changes and an increase of pain on exercise may occur (Bonica, 1990).

In patients with cervical and lumbar spinal pain these features are not as prominent and not always simultaneously present as they are in sympathetically maintained pain (Lücking and Blumberg, 1988). Signs such as diffuse pain with a colder, blue or pale limb are encountered most frequently, but these may also be due to disuse of the limb. Sometimes the patient states that the complaint worsens with changes in the weather. It may be questioned whether something such as sympathetically maintained spinal pain exists (Livingston, 1943), and the signs of this syndrome in the thoracic spine are largely unknown.

In general, the diagnosis 'sympathetically maintained pain' is assumed if blockade of the sympathetic trunk is followed by sympathicolysis and abolishment of pain (Boas, 1990; Stanton Hicks, 1990; Wilson, 1990). More recently, the phentolamine test has been advocated as a diagnostic manoeuvre in the limb (Arnér, 1991; Raja *et al.*, 1991). Perhaps this test could also be used to determine thoracic sympathetic spinal pain.

As the common pathways with sensory fibres come from the ventral compartment of the spine, pain originating in the anterior longitudinal ligament, the anterior part of the disc and the vertebral body is blocked as well following sympathetic blockade

(Bogduk *et al.*, 1981, 1988; Groen *et al.*, 1988, 1990, 1992); this refutes any possibility of these blocks being specific enough to prove the sympathetic origin of spinal pain.

Thus, the observation that a sympathetic block achieves pain relief, even without signs of sympathicolysis (Sluijter, 1988), may not only be explained by a placebo effect but also by a blockade of common fibres coming from the anterior part of the ventral compartment (Groen *et al.*, 1992). On anatomical grounds it is possible for such a phenomenon to occur in the dorsal compartment as well, because of common pathways of sympathetic and somatosensory fibres in the dorsal ramus (Dass, 1952; Groen *et al.*, 1990). This is confirmed by the authors' observation in a number of patients that sympathetic symptoms subside after a percutaneous zygapophysial denervation. More central convergence of afferent fibres at the level of wide dynamic range neurons in the dorsal horn of the spinal cord provides another explanation for this phenomenon (Roberts, 1986; Gillette *et al.*, 1993).

The current authors believe that thoracic sympathetic spinal pain is always a secondary phenomenon.

Long-term results and recurrence rate

There are only a few reports available with a follow-up of longer than 4 years (Verdie and Lazorthes, 1982; Nash, 1986; North *et al.*, 1994; Vervest *et al.*, 1994); in all studies the success rate diminishes with time, and a recurrence rate is reported in all cases. It must be emphasized that, in the authors' clinical studies, repeat interventions had to be performed in a substantial number of patients, mostly with a result comparable to that of the primary intervention. As with surgical neuroablative procedures, R-F lesioning cannot be considered a permanent treatment (Loeser, 1972; White and Kjellberg, 1973).

In the authors' studies of the thoracic spine, additional treatment was rarely mandatory (after PPR, $n = 5$: 11%; after PFD, $n = 3$: 7.5%); whereas in their cervical long-term study not only were more repeat interventions necessary ($n = 23$: 43%), but additional treatment was also frequently required (Stolker *et al.*, 1993a, 1994d; Vervest *et al.*, 1994). This may not be due solely to features particular to the cervical spine, but may also be a result of the longer follow-up (4 years compared with 5.5 years). A repeat intervention may be considered as a 'booster'. The restricted duration of effect is not a major problem, since the procedure only causes minor side effects and is repeatable. A half-life of 34 months of pain relief could be calculated from this test for a complete course of treatment with cervical PFD and PPR. Observing the long-term results, a comparable half-life could be expected for thoracic PPR and PFD. The finding of a half-life of 34 months conflicts with the opinion that R-F lesioning will not cause any long-term effects, this being one of the major criticisms of R-F lesioning.

In the group with poor results, this may have been due to incorrect indications for treatment or to other factors as yet unknown. Psychological factors may play a role in some patients (Hildebrandt and Argyrakis, 1983), but the authors failed to identify such cases prior to treatment.

R-F lesioning in pain therapy: its position today

It may be questioned whether it is justifiable to perform therapeutic procedures which are as yet not completely established, even in patients often considered to be 'therapeutic outcasts'. In the authors' clinical experience, after careful diagnosis in order to exclude causal treatment or the presence of a major psychiatric disorder, promising long-term follow-up results with only minor side effects were observed. These results perhaps serve as a justification for this approach.

The next question is whether a wider and earlier application of these techniques is to be recommended. It must be emphasized that caution is required in applying the results of uncontrolled studies in small selected patient groups more extensively. It may even be possible that this 'negative' patient selection is the key to success.

Therefore, at present the authors would not advise the application of these procedures to the considerably larger group of patients suffering (sub) acute spinal pain. The decreasing probability of return to work does not justify the use of incompletely established treatment in a period in which the chance of spontaneous recovery still exists. Moreover, no reports are available on R-F procedures in the acute phase of spinal pain.

The IASP classify sub-acute pain as lasting less than 3 months; consequently an interval of at least 3 months between the onset of pain and commencement of invasive R-F treatment is obligatory before the chance of spontaneous recovery (Nachemson, 1985) can be finally abandoned.

Fulfilment of the following conditions is essential for the performance of R-F lesions:

- The exclusion of cause-related therapy
- Duration of the complaint of at least 3 months
- A proper indication
- An adequate technique in skilled hands
- The use of an imaging technique to control needle positioning and allow verification and acquisition of hard copies.

Conclusions

Thoracic spinal pain occurs relatively seldom, when compared to cervical and lumbar pain syndromes. In accordance with Rosomoff *et al.* (1989), the authors believe that chronic spinal pain can be classified into several 'syndromes' (Stolker *et al.*, 1994a). This classification may be helpful in selecting patients for medical, physical and invasive treatment. Invasive therapy, both surgical and percutaneous techniques, is only indicated after failure of conservative treatment. R-F lesioning may be helpful in the treatment of pain originating from the dorsal compartment and in thoracic segmental pain, and will not lead, if properly performed, to deafferentation. The indications for PPR and PFD have been discussed; however, their exact place has to be elucidated further in controlled studies with long-term follow-up. The sympathetic nervous system may play a role as a secondary pain mechanism, but the clinical consequences of this remain unclear.

References

Abram, S.E. (1988) Pain mechanisms in lumbar radiculopathy. *Anesth. Analg.* **67:** 1135-1137.

Ahmedzai, S., Allan, E., Fallon, M. *et al.* (1994) Transdermal fentanyl in cancer pain. *J. Drug Dev.* **6:** 93-97.

Andersen, K.H., Mosdal, C., Vårnet, K. (1987) Percutaneous facet denervation in low-back and extremity pain. *Acta Neurochir. (Wien)* **87:** 48-51.

Andersson, G.B.J. (1991) The epidemiology of spinal disorders. In: *The Adult Spine* (Frymoyer, J.W., ed.). New York: Raven Press, pp. 107-146.

Arbit, E., Galicich, J.H., Burt, M. *et al.* (1989) Modified open thoracic rhizotomy for treatment of intractable chest wall pain of malignant etiology. *Ann. Thorac. Surg.* **48:** 820-823.

Arendzen, J.H. (1989) *Percutane Thermocoagulatie van Perifere Zenuwen.* Thesis, Amsterdam.

Arnér, S. (1991) Intravenous phentolamine test: diagnostic and prognostic use in reflex sympathetic dystrophy. *Pain* **46:** 17-22.

Auteroche, P. (1983) Innervation of the zygapophyseal joints of the lumbar spine. *Anat. Clin.* **5:** 17-28.

Baldessarini, R.J. (1985) Drugs and the treatment of psychiatric disorders. In: *Goodman and Gilman's The Pharmacological Basis of Therapeutics*, 7th edn (Goodman-Gilman, A., Goodman, R.S., Rall, T.W., Murad, F., eds). New York: Macmillan, pp. 387-445.

Barry, P.J.C., Hume-Kendall, P. (1982) Cortico-steroid infiltration of the epidural space. *Ann. Phys. Med.* **6:** 267-273.

Benzon, H. (1986) Epidural steroid injections for low back pain and lumbo-sacral radiculopathy. *Pain* **24:** 277-295.

Boas, R.A. (1990) Sympathetic nerve blocks: their role in sympathetic pain. In: *Reflex Sympathetic Dystrophy* (Stanton-Hicks, M., Jänig, W., Boas, R.A., eds). Boston: Kluwer Academic Publishers, pp. 101-112.

Bogduk, N. (1982) The clinical anatomy of the cervical dorsal rami. *Spine* **7:** 319-330.

Bogduk, N. (1983) The innervation of the lumbar spine. *Spine* **8:** 286-293.

Bogduk, N., Long, D.M. (1980) Percutaneous lumbar medial branch neurotomy, a modification of facet denervation. *Spine* **5:** 193-200.

Bogduk, N., MacIntosh, J., Marsland, A. (1987) Technical limitations to the efficacy of radiofrequency neurotomy for spinal pain. *Neurosurgery* **20:** 529-535.

Bogduk, N., Tynan, W., Wilson, A.S. (1981) The nerve supply to the human intervertebral discs. *J. Anat* **132:** 39-56.

Bogduk, N., Wilson, A.S., Tynan, W. (1982) The human dorsal rami. *J. Anat.* **134:** 383-397.

Bogduk, N., Windsor, M., Inglis, A. (1988) The innervation of the cervical intervertebral discs. *Spine* **13:** 2-8.

Bonica, J.J. (1974) Floor discussion: dorsal rhizotomy. In: *Pain. Advances in Neurology*, Vol. 4 (Bonica J.J., ed.). New York: Raven Press, p. 626.

Bonica, J.J. (1990) Causalgia and other reflex sympathetic dystrophies. In: *The Management of Pain*, 2nd edn (Bonica, J.J., Loeser, J.D., Chapman, C.R. *et al.*, eds). Philadelphia: Lea and Febiger, pp. 220-243.

Bonica, J.J., Sola, A.E. (1990) Chest pain caused by other disorders. In: *The Management of Pain*, 2nd edn (Bonica, J.J., Loeser, J.D., Chapman, C.R. *et al.*, eds). Philadelphia: Lea and Febiger, pp. 1114-1145.

Brena, S.F., Sanders, S.H. (1991) Opioids in non-malignant pain: questions in search of answers. *Clin. J. Pain* **7:** 324-325.

Brose, W.G., Cherry, D.A., Plummer, J. *et al.* (1991) IASP taxonomy: questions and controversies. In: *Proceedings of the VIth World Congress on Pain* (Bond, M., Charlton, J.E., Woolf, C.J., eds). Amsterdam: Elsevier, pp. 503-507.

Carette, S., Marcoux, S., Truchon, R. *et al.* (1991) A controlled trial of corticosteroid injections into facet joints for chronic low back pain. *N. Engl. J. Med.* **325:** 1002-1007.

Carrera, G.F. (1980) Lumbar facet joint injection in low back pain and sciatica. Description of technique. *Radiology* **137:** 661-664.

Chua, W.H., Bogduk, N. (1995) The surgical anatomy of thoracic facet denervation. *Acta Neurochir. (Wien)* **136:** 140-144.

Clark, C.J., Whitwell, J. (1961) Intraocular haemorrhage after epidural injection. *Br. Med. J.* **ii:** 1612-1613.

Coggeshall, R.E., Applebaum, M.L., Fazen, M. (1975) Unmyelinated axons in human ventral roots, a possible explanation for the failure of dorsal rhizotomy to relieve pain. *Brain* **98:** 157-166.

Cosman, E.R., Cosman, B.J. (1985) Methods of making nervous system lesions. In: *Neurosurgery* (Wilkins, R.H., Renchary, S.S., eds). New York: McGraw-Hill, pp. 2490-2499.

Cosman, E.R., Nashold, B.S., Ovelman-Levitt, J. (1984) Theoretical aspects of radiofrequent lesions in the dorsal root entry zone. *Neurosurgery* **15:** 945-950.

Dandy, W.E. (1942) Serious complications of ruptured intervertebral disks. *JAMA* **119:** 474-477.

Dass, R. (1952) Sympathetic components of the dorsal primary divisions of human spinal nerves. *Anat. Rec.* **113:** 493-501.

Delaney, T.J., Rowlingson, J.C., Carron, H. *et al.* (1980) Epidural steroid effects on nerves and meninges. *Anesth. Analg.* **59:** 610-614.

Destouet, J.M., Gilula, L.A., Murphy, W.A. (1982) Lumbar facet joint injection: indication, technique, clinical correlation, and preliminary results. *Radiology* **145:** 321-325.

Deyo, R.A., Walsh, N.E., Martin, D.C. (1990) A controlled clinical trial of transcutaneous nerve stimulation (TENS) and exercise for chronic low back pain. *N. Engl. J. Med.* **322:** 1627-1634.

Dietze, D.D., Fessler, R.G. (1993) Thoracic disc herniations. *Neurosurg. Clin. North Am.* **4:** 75-90.

Dooley, J.F., McBroom, R.J., Taguchi, T. (1988) Nerve root infiltration in the diagnosis of radicular pain. *Spine* **13:** 79-83.

Dory, M.A. (1981) Arthrography of the lumbar facet joints. *Radiology* **140:** 23-27.

Dougherty, J.H., Fraser, R.A.R. (1978) Complications following intraspinal injections of steroids. *J. Neurosurg.* **48:** 1023-1025.

Dreyfuss, P., Tibilette, C., Dreyer, S.J. (1994) Thoracic zygapophyseal joint pain patterns. A study in normal volunteers. *Spine* **19:** 807-811.

Dubuisson, D. (1989) Root surgery. In: *Textbook of Pain*, 2nd edn (Wall, P.D., Melzack, R., eds). Edinburgh: Churchill Livingstone, pp. 784-794.

Dwyer, A., Aprill, C., Bogduk, N. (1990) Cervical zygapophyseal joint pain patterns I: a study in normal volunteers. *Spine* **15:** 453-457.

Dykes, R.W., Terzis, J.K. (1981) Spinal nerve distributions in the upper limb: the organization of the dermatome and afferent myotome. *Philos. Trans. R. Soc. Lond. B* **293:** 509-554.

Eisenstein, S.M., Parry, C.R. (1987) The lumbar facet arthrosis syndrome. Clinical presentation and articular surface changes. *J. Bone Joint Surg.* **69B:** 3-7.

El-Khoury, G.Y., Ehara, S., Weinstein, J.N. (1988) Epidural steroid injection: a procedure ideally performed with fluoroscopic control. *Radiology* **168:** 554-557.

Epstein, J.A., Epstein, B.S., Lavine, L.S. (1973) Lumbar nerve root compression at the intervertebral foramina caused by arthritis of the posterior facets. *J. Neurosurg.* **39:** 362-369.

Erikson, L.O., Stufelt, G., Thysell, H. (1990) Effects of sulindac and naproxen on prostaglandin excretion and function in patients with impaired renal function and rheumatoid arthritis. *Am. J. Med.* **89:** 313-321.

Evans, F.J. (1974) The placebo response in pain reduction. In: *Advances in Neurology*, Vol. 4 (Bonica, J.J., ed.). New York: Raven Press, pp. 289-296.

Flower, R.J., Moncada, S., Vane, J.R. (1985) Analgesics-antipyretics and anti-inflammatory agents; drugs employed in the treatment of gout. In: *Goodman and Gilman's The Pharmacological Basis of Therapeutics*, 7th edn (Goodman-Gilman, A., Goodman, L.S., Rall, T.W., *et al.*, eds). New York: Macmillan Publishing Co., pp. 674-716.

Foerster, O. (1933) The dermatomes in man. *Brain* **56:** 1-39.

Gallagher, J., Petriccione di Vadi, P.L. (1994) Radiofrequency facet joint denervation in the treatment of low back pain: a prospective controlled double-blind study to assess its efficacy. *Pain Clin.* **7:** 193-198.

Gillette, R.G., Kramis, R.C., Roberts, W.J. (1993) Characterization of spinal somatosensory neurons having receptive fields in lumbar tissues of cats. *Pain* **54:** 85-98.

Goldstone, J.C., Pennant, J.H. (1987) Spinal anaesthesia following facet joint injection. *Anaesthesia* **42:** 754-756.

Gourlay, G.K., Cherry, D.A. (1991) Response to controversy corner: can opioids be successfully used to treat severe pain on nonmalignant conditions? *Clin. J. Pain.* **7:** 347-349.

Grieve, G.P. (1981) *Common Vertebral Joint Problems.* Edinburgh: Churchill Livingstone, pp. 36-53, 129-138.

Groen, G.J. (1986) *Contributions to the Anatomy of the Peripheral Nervous System.* Thesis. Amsterdam.

Groen, G.J. (1991) De innervatie van de wervelkolom bij de mens. *Ned. Tijdschr. Man. Ther.* **10:** 48-60.

Groen, G.J., Baljet, B., Boekelaar, A.B. *et al.* (1987) Branches of the thoracic sympathetic trunk in the human fetus. *Anat. Embryol.* **176:** 401-411.

Groen, G.J., Baljet, B., Drukker, J. (1988) The innervation of the spinal dura mater: anatomy and clinical implications. *Acta Neurochir. (Wien)* **92:** 39-46.

Groen, G.J., Baljet, B., Drukker, J. (1990) Nerves and nerve plexuses of the human vertebral column. *Am. J. Anat.* **188:** 282-296.

Groen, G.J., Stolker, R.J., Vervest, A.C.M. (1992) Anatomische Grundlagen destruktiver Eingriffe. *Der Schmerz* **6:** S5.

Gutknecht, D.R. (1987) Chemical meningitis following epidural injections of corticosteroids. *Am. J. Med.* **82:** 570.

Gybels, J.M., Sweet, W.H. (1989) *Neurosurgical Treatment of Persistent Pain.* Basel: Karger, pp. 10-69.

Hamann, W., Hall, S. (1992) Acute effect and recovery of primary afferent nerve fibres after graded radiofrequency lesions. *Br. J. Anaesth.* **68:** 443.

Hasue, M., Kikuchi, S., Sakuyama, Y. (1983) Anatomic study of the interrelation between lumbosacral nerve roots and their surrounding tissues. *Spine* **8:** 50-58.

Hasue, M., Kunogi, J., Konno, S. (1989) Classification by position of dorsal root ganglia in the lumbosacral region. *Spine* **14:** 1261-1264.

Haynsworth, R.F., Noe, C.E. (1991) Percutaneous lumbar sympathectomy: a comparison of radiofrequency denervation versus phenol neurolysis. *Anesthesiology* **74:** 459-463.

Helbig, T., Lee, C.K. (1988) The lumbar facet syndrome. *Spine* **13:** 61-64.

Hildebrandt, J., Argyrakis, A. (1983) Die perkutane zervikale Facettdenervation - ein neues Verfahren zur Behandlung chronischer Nacken-Kopfschmerzen. *Manuelle Medizin* **21:** 45-49.

Houde, R.W. (1974) The use and misuse of narcotics in the treatment of chronic pain. In: *Advances in Neurology*, Vol. 4 (Bonica, J.J., ed.). New York: Raven Press, pp. 527-536.

Hyneck, M.L. (1992) An overview of the clinical pharmacokinetics of nabumetone. *J. Rheumatol.* **19(Suppl. 36):** 20-24.

Inman, V.T., Saunders, J.B.C.M. (1944) Referred pain from skeletal structures. *J. Nervous Mental Dis.* **99:** 660-667.

Jackson, R.P. (1992) The facet syndrome. myth or reality? *Clin. Orthop.* **279:** 110-121.

Jackson, R.P., Jacobs, R.R., Montesano, P.X. (1988) Facet joint injection in low-back pain. *Spine* **13:** 966-971.

Jaffe, J.H., Martin, W.R. (1985) Opioid analgesics and antagonists. In: *Goodman and Gilman's The Pharmacological Basis of Therapeutics*, 7th edn (Goodman-Gilman, A., Goodman, L.S., Rall, T.W., Murad, F., eds). New York: Macmillan Publishing Co., pp. 491-531.

Jänig, W. (1990) The sympathetic nervous system in pain: physiology and pathophysiology. In: *Pain and the Sympathetic Nervous System* (Stanton-Hicks, M., ed.). Boston: Kluwer Academic Publishers, pp. 17-89.

Jensen, M.C., Brant-Zawadski, M.N., Obuchowski, N. (1994) Magnetic resonance imaging of the lumbar spine in people without back pain. *N. Engl. J. Med.* **331:** 69-73.

Katz, J. (1989) Cryoanalgesia for post-thoracotomy pain. *Ann. Thorac. Surg.* **48:** 5.

Kellgren, J.H. (1977) The anatomical source of back pain. *Rheumatol. Rehabil.* **16:** 3-12.

Kepes, E.R., Duncalf, D. (1985) Treatment of backache with spinal injections of local anesthetics, spinal and systemic steroids. *Pain* **22:** 33-47.

Kikuchi, S., MacNab, I., Moreau, P. (1981) Localisation of the level of symptomatic cervical disc degeneration. *J. Bone Joint Surg.* **63B:** 272-277.

Kikuchi, S., Hasue, M., Nishiyama, K. (1984) Anatomic and clinical studies of radicular symptoms. *Spine* **9:** 23-30.

King, J.S., Lagger, R. (1976) Sciatica viewed as a referred pain syndrome. *Surg. Neurol.* **5:** 46-50.

Kirkaldy-Willis, W.H. (1984) The relationship of structural pathology to the nerve root. *Spine* **9:** 49-52.

Klumpp, D., Zimmermann, M. (1980) Irreversible differential block of A- and C-fibres following local nerve heating in the cat. *J. Physiol.(Lond.)* **298:** 471-482.

Knight, C.L., Burnell, J.C. (1980) Systemic side-effects of extradural steroids. *Anaesthesia* **35:** 593-594.

Koch-Weser, J. (1980) Nonsteroidal anti-inflammatory drugs. *N. Engl. J. Med.* **302:** 1179-1185.

Kocks, W., Roosen, K., Demmer, G. *et al.* (1988) Indikationen und Ergebnisse der sensiblen. Rhizotomie bei narbenbedingten lumbalen Wurzelreizsyndromen. *Zent. Bl. Neurochir.* **49:** 336-339.

Koes, B.W., Scholtenm, R.J.P.M., Mens, J.M.A. *et al.* (1995) Efficacy of epidural steroid injections for low-back pain and sciatica: a systematic review of randomized clinical trials. *Pain* **63:** 279-288.

Koning, H.M., Koster, H.G., Niemeijer, R.P.E. (1991) Ischaemic cord lesion following percutaneous radiofrequency spinal rhizotomy. *Pain* **45:** 161-166.

Krainick, J.U., Thoden, U. (1994) Spinal cord stimulation. In: *Textbook of Pain* (Wall, P.D., Melzack, R., eds). Edinburgh: Churchill Livingstone, pp. 1219-1224.

Kunesch, E., Schmidt, R., Nordin, M., *et al.* (1987) Peripheral neural correlates of cutaneous anaesthesia induced by skin cooling in man. *Acta Physiol. Scand.* **129:** 247-257.

Lang, J. (1985) Anatomie der BWS und des benachbarten Nervensystems. In: *Neuroorthopädie 3* (Hohmann, D., Kügelgen, B., Liebig, K., eds). Berlin: Springer, pp. 14-73.

Le Bars, D., Villanueva, L. (1988) Electrophysiological evidence for the activation of descending inhibitory controls by nociceptive afferent pathways. *Prog. Brain Res.* **77:** 275-299.

Le Bars, D., Villanueva, L., Bouhassira, D., Willer, J-C. (1992) Diffuse noxious inhibitory control [DNIC] in animals and man. *Path. Physiol. Exp. Ther.* **4:** 55-65.

Letcher, F.S., Goldring, S. (1968) The effect of radiofrequency current and heat on peripheral nerve action potential in the cat. *J. Neurosurg.* **29:** 42-47.

Liebeskind, J.C. (1991) Pain can kill. *Pain* **44:** 3-4.

Lilius, G., Laasonen, E.M., Myllynen, P. *et al.* (1989) Lumbar facet joint syndrome. *J. Bone Joint Surg.* **71B:** 681-684.

Lilius, G., Harilalinen, A., Laasonen, E.M. *et al* (1990) Chronic unilateral low-back pain. Predictors of outcome of facet joint injections. *Spine* **15:** 780-782.

Lippit, A.B. (1984) The facet joint and its role in spine pain. Management with facet joint injections. *Spine* **7:** 746-750.

Livingston, W.K. (1943) Pain mechanisms. A physiologic interpretation of causalgia and its related states. New York: Plenum Press, pp. 128-139.

Loeser, J.D. (1972) Dorsal rhizotomy for the relief of chronic pain. *J. Neurosurg.* **29:** 745-750.

Lora, J., Long, D.M. (1976) So-called facet denervation in the management of intractable back pain. *Spine* **1:** 121-126.

Lord, S.M., Barnsley, L., Wallis, B.J. *et al.* (1996) Percutaneous radio-frequency neurotomy for chronic cervical zygapophysial-joint pain. *N. Engl. J. Med.* **335:** 1721-1726.

Lücking, C.H., Blumberg, H. (1988) Kausalgie und sympathische reflexdystrophe. In: *Nerven Schmerz* (Lücking, C.H., Thoden, U., Zimmerman, M., eds). Stuttgart: Fischer, 170-178.

Lynch, M.C., Taylor, J.F. (1986) Facet joint injection for low back pain. *J. Bone Joint Surg.* **68B:** 138-141.

Marks, R.C. (1989) Distribution of pain provoked from lumbar facet joints and related structures during diagnostic spinal infiltration. *Pain* **39:** 37-40.

Marks, R.C., Houston, T., Thulbourne, T. (1992) Facet joint injection and facet nerve block: a randomised comparison in 86 patients with chronic low back pain. *Pain* **49:** 325-328.

Maruta, T., Swanson, D.W. (1981) Problems with the use of oxycodone compound in patients with chronic pain. *Pain* **11:** 389-396.

Max, M.B. (1994) Antidepressants as analgesics. In: *Pharmacological Approaches to the Treatment of Chronic Pain: New Concepts and Critical Issues* (Fields, H.L., Liebeskind, J.C., eds). Seattle: IASP Press, pp. 229-246.

Mayer, T.G. (1991) Rationale for modern spine care. In: *Contemporary Conservative Care for Painful Spinal Disorders*. Philadelphia: Lea and Febiger, pp. 3-9.

McLachlan, E.M., Jänig, W., Devor, M. *et al.* (1993) Peripheral nerve injury triggers noradrenergic sprouting within dorsal root ganglia. *Nature* **363:** 543-546.

McQuay, H.J. (1989) Opioids in chronic pain. *Br. J. Anaesth.* **63:** 213-226.

Melzack, R. (1994) Folk medicine and the sensory modulation of pain. In: *Textbook of Pain* (Wall, P.D., Melzack, R., eds). Edinburgh: Churchill Livingstone, pp. 1209-1218.

Merskey, H. (1986) Classification of chronic pain. *Pain* **695(Suppl. 3):** 1-225.

Merskey, H., Bogduk, N. (1994) *Classification of Chronic Pain*, 2nd edn. Seattle: IASP Press.

Meyler, W.J., De Jongste, M.J., Rolf, C.A. (1994) Clinical evaluation of pain treatment with electrostimulation. A study on TENS in patients with different pain syndromes. *Clin. J. Pain* **10:** 22-27.

Mooney, V., Robertson, J. (1976) The facet syndrome. *Clin. Orthop.* **115:** 149-156.

Moringlane, J.R., Koch, R., Schäfer, H. *et al.* (1987) Experimental radiofrequency (RF) coagulation with computer-based on line monitoring of temperature and power. *Acta Neurochir. (Wien)* **96:** 126-131.

Murphy, R.W. (1977) Nerve roots and spinal nerves in degenerative disk disease. *Clin. Orthop.* **129:** 46-60.

Nachemson, A.L. (1985) Advances in low back pain. *Clin. Orthop.* **200:** 266-278.

Nash, T.P. (1986) Percutaneous radiofrequency lesioning of dorsal root ganglia for intractable pain. *Pain* **24:** 67-73.

Nash, T.P. (1990) Facet joints. Intra-articular steroids or nerve block? *Pain Clin.* **3:** 77-82.

Nelson, D.A. (1993) Intraspinal therapy using methylprednisolone acetate: twenty-three years of clinical controversy. *Spine* **18:** 178-186.

Newman, R.G. (1983) The need to redefine 'addiction'. *N. Engl. J. Med.* **308:** 1096-1098.

Niv, D., Chayen, M.S. (1992) Reduction of localised cancer pain by percutaneous dorsal root ganglia lesions. *Pain Clin.* **5:** 229-234.

North, R.B., Kidd, D.H., Campbell, J.N. *et al.* (1991) Dorsal gangliectomy for failed back surgery syndrome: a 5-year follow-up study. *J. Neurosurg.* **74:** 236-242.

North, R.B., Kidd, D.H., Zahurak, M. *et al.* (1993) Spinal cord stimulation for chronic intractable pain: experience over two decades. *Neurosurgery* **32:** 384-395.

North, R.B., Han, M., Zahurak, M. *et al.* (1994) Radiofrequency lumbar facet denervation: analysis of prognostic factors. *Pain* **57:** 77-83.

North, R.B., Kidd, D.H., Zahurak, M., Piantadosi, S. (1996) Specificity of diagnostic nerve blocks: a prospective, randomized study of sciatica due to lumbosacral spine disease. *Pain* **65:** 77-85.

O'Brien, J. P. (1984) Mechanisms of spinal pain. In: *Textbook of Pain* (Wall, P.D., Melzack, R., eds). Edinburgh: Churchill Livingstone, pp. 240-251.

Onofrio, B.M., Campa, H.K. (1972) Evaluation of rhizotomy. Review of 12 years' experience. *J. Neurosurg.* **36:** 751-755.

Ovelmen-Levitt, J., Johnson, B., Bedenbaugh, P. *et al.* (1984) Dorsal root rhizotomy and avulsion in the cat: a comparison of long-term effects on dorsal horn neuronal activity. *Neurosurgery* **15:** 921-927.

Pagni, C.A., Lanotte, M., Canavero, S. (1993) How frequent is anesthesia dolorosa following spinal rhizotomy? A retrospective analysis of fifteen patients. *Pain* **54:** 323-327.

Pagura, J.R. (1983) Percutaneous radiofrequency spinal rhizotomy. *Appl. Neurophysiol.* **46:** 138-146.

Pallie, W. (1959) The intersegmental anastomoses of posterior spinal rootlets and their significance. *J. Neurosurg.* **16:** 188-196

Parke, W.W., Watanabe, R. (1985) The intrinsic vasculature of the lumbosacral spinal nerve roots. *Spine* **10:** 508-515.

Pascual, E., Castellano, J.A., Lopez, E. (1992) Costovertebral joint changes in ankylosing spondylitis with thoracic pain. *Br. J. Rheumatol.* **31:** 413-415.

Portenoy, R.K. (1994) Opioid therapy for chronic nonmalignant pain. In: *Pharmacological Approaches to the Treatment of Chronic Pain: New Concepts and Critical Issues* (Fields, H.L., Liebeskind, J.C., eds). Seattle: IASP Press, pp. 247-288.

Portenoy, R.K., Foley, K.M. (1986) Chronic use of opioid analgesics in non-malignant pain: report of 38 cases. *Pain* **25:** 171-186.

Porter, J., Jick, H. (1980) Addiction rare in patients treated with narcotics. *N. Engl. J. Med.* **302:** 123.

Purcell-Jones, G., Speed, H.M, Justins, D.M. (1987) Upper limb sympathetic blockade following intercostal nerve blocks. *Anaesthesia* **42:** 984-986.

Purcell-Jones, G., Pither, C.E., Justins, D.M. (1989) Paravertebral somatic nerve block: a clinical, radiographic, computed tomographic study in chronic pain patients. *Anesth. Analg.* **68:** 32-39

Raja, S.N., Treede, R.D., Davis, K.D. *et al.* (1991) Systemic alpha-adrenergic blockade with phentolamine: a diagnostic test for sympathetically maintained pain. *Anesthesiology* **74:** 691-698.

Raymond, J., Dumas, J.M. (1984) Intra-articular facet block: diagnostic test or therapeutic procedure? *Radiology* **151:** 333-336

Renfrew, D.L., Moore, T.E., Kathol, M.H. *et al.* (1991) Correct placement of epidural steroid injections: fluoroscopic guidance and contrast administration. *Am. J. Neuroradiol.* **12:** 1003-1007

Revel, M.E., Listrat, V.M., Chevalier, X.J. (1992) Facet joint block for low back pain: Identifying predictors of a good response. *Arch. Phys. Med. Rehabil.* **73:** 824-828.

Rickenbacher, J., Landolt, A.M., Theiler, K. *et al.* (1982) *Rücken. Praktische Anatomie* (von Lanz, T., Wachsmut, W., Lang, J., eds). Berlin: Springer, p. 254.

Roberts, W.J. (1986) A hypothesis on the physiological basis for causalgia and related pains. *Pain* **24:** 297-311.

Rosomoff, H.L, Fishbain, D.A., Goldberg, M. *et al.* (1989) Physical findings in patients with chronic intractable benign pain of the neck and/or back. *Pain* **37:** 279-287.

Roth, S.H., Benett, R., Caldron, P. *et al.* (1994) A long-term endoscopy evaluation of patients with arthritis treated with nabumetone versus naproxen. *J. Rheumatol.* **21:** 1118-1123

Rydevik, B., Brown, M.D., Lundborg, G. (1984) Pathoanatomy and pathophysiology of nerve root compression. *Spine* **9:** 7-15.

Rydevik, B.L., Myers, R.R., Powell, H.C. (1989) Pressure increase in the dorsal root ganglion following mechanical compression. Closed compartment syndrome in nerve roots. *Spine* **14:** 574-576.

Saris, S.C., Silver, J.M., Vieira, J.F.S. *et al.* (1986) Sacrococcygeal rhizotomy for perineal pain. *Neurosurgery* **19:** 789-793.

Schirmer, M. (1985) Thorakale Bandscheibenvorfalle. In: *Neuroorthopädie 3* (Hohmann, D., Kügelgen, B., Liebig, K., eds). Berlin: Springer-Verlag, pp. 169-176.

Schug, S.A., Large, R.G. (1995) Opioids for chronic noncancer pain. *Pain Clinical Updates*; **3(3):** 1-4.

Schwarzer, A.C., Aprill, C.N., Derby, R. *et al.* (1994a) The relative contribution of the disc and zygapophyseal joint in chronic low back pain. *Spine* **19:** 801-806.

Schwarzer, A.C., Aprill, C.N., Derby, R. *et al.* (1994b) The false positive rate of uncontrolled diagnostic blocks of the lumbar zygapophysial joints. *Pain* **58:** 195-200.

Schwarzer, A.C., Aprill, C.N., Derby, R. *et al.* (1994c) Clinical features of patients with pain stemming from the lumbar zygapophyseal joints. Is the lumbar facet syndrome a clinical entity? *Spine* **19:** 1132-1137.

Shealy, C.N. (1976) Facet denervation in the management of back and sciatic pain. *Clin. Orthop.* **115:** 157-164.

Sherrington, C.S. (1896) Experiments in examination of the peripheral distribution of the fibres of the posterior roots of some spinal nerves. *Proc. R. Soc.* **60:** 403-411.

Silvers, H.R. (1990) Lumbar percutaneous facet rhizotomy. *Spine* **15:** 36-40.

Skubic, J.W., Kostuik, J.P. (1991) Thoracic pain syndromes and thoracic disc herniation. In: *The Adult Spine. Principles and Practice* (Frymoyer, J.W., ed.). New York: Raven Press, pp. 1443-1464.

Slappendel, R., Crul, B.J.P., Braak, G.J.J. *et al.* (1997). The efficacy of radiofrequency lesioning of the cervical spinal dorsal root ganglion in a double-blind randomized study: no difference between 40°C and 67°C treatments. *Pain* **73:** 159-163.

Sluijter, M.E. (1988) The use of radiofrequency lesions for pain relief in failed back patients. *Int. Disabil. Studies* **10:** 37-43.

Sluijter, M.E., Mehta, M. (1981) Treatment of chronic back and neck pain by percutaneous thermal lesions. In: *Persistent Pain, Modern Methods of Treatment*, Vol. 3 (Lipton, S., ed.). London: Academic Press, pp. 141-179.

Smith, H.P., McWhorter, J.M., Challam V.R. (1981) Radiofrequency neurolysis in a clinical model. *J. Neurosurg.* **55:** 246-253.

Stambough, J.L., Booth, R.E., Rothman, R.H. (1984) Transient hypercorticism after epidural steroid injection. *J. Joint Bone Surg.* **66A:** 1115-1116.

Stanley, D., McLaren, M.I., Euinton, H.A. *et al.* (1990) A prospective study of nerve root infiltration in the diagnosis of sciatica. A comparison with radiculography, computed tomography, and operative findings. *Spine* **15:** 540-543.

Stanton-Hicks, M.A. (1990) Blocks of the sympathetic nervous system. In: *Pain and the Sympathetic System* (Stanton-Hicks, M.A., ed.). Boston: Kluwer Academic Publishers, pp. 125-164.

Steindler, A., Luck, J.V. (1938) Differential diagnosis of pain low in the back. Allocation of the source of pain by the procaine hydrochloride method. *JAMA* **110:** 106-113.

Stilwell, D.L. (1956) The nerve supply of the vertebral column and its associated structures in the monkey. *Anat. Rec.* **125:** 139-169.

Stolker, R.J., Vervest, A.C.M., Groen, G.J. (1993a) Percutaneous facet denervation in chronic thoracic spinal pain. *Acta Neurochir. (Wien)* **122:** 82-90.

Stolker, R.J., Sluijter, M.E., Rohof, O.J.J.M. (1993b) Toename van pijn door pijnbehandeling. *Ned. Tijdschr Geneeskd.* **137:** 2108.

Stolker, R.J., Vervest, A.C.M., Groen, G.J. (1994a) The management of chronic spinal pain by blockades: a review. *Pain* **58:** 1-20.

Stolker, R.J., Vervest, A.C.M., Groen, G.J. *et al.* (1994b) On the innervation of the dorsal compartment of the thoracic spine. In: *Pain Management by Radiofrequency Procedures in the Cervical and Thoracic Spine: A Clinical and Anatomical Study* (Stolker, R.J., Vervest, A.C.M., eds). Unpublished thesis, Department of Functional Anatomy, Utrecht University, Utrecht, pp. 133-144.

Stolker, R.J., Vervest, A.C.M., Groen, G.J. (1994c) Parameters in electrode positioning in thoracic percutaneous facet denervation: an anatomical study. *Acta Neurochir. (Wien)* **128:** 32-39.

Stolker, R.J., Vervest, A.C.M., Groen, G.J. (1994d) The treatment of chronic thoracic segmental pain by radiofrequency percutaneous partial rhizotomy. *J. Neurosurg.* **80:** 986-992.

Stolker, R.J., Vervest, A.C.M., Ramos, L.M.P. *et al.* (1994e) Electrode positioning in thoracic percutaneous partial rhizotomy: an anatomical study. *Pain* **57:** 241-251.

Stolker, R.J., Groen, G.J., Matthijssen, M.A.H. *et al.* (1996) Histopathological analysis of percutaneous partial radiofrequency rhizotomy, a first report in humans. *Abstracts 8th World Congress on Pain.* Seattle: IASP Publications.

Sullivan, M.J.L., Reesor, K., Mikail, S. *et al.* (1992) The treatment of depression in low back pain: review and recommendations. *Pain* **50:** 5-13.

Sweet, W.H. (1984) Deafferentation pain after posterior rhizotomy, trauma to a limb, and herpes zoster. *Neurosurgery* **15:** 928-932.

Sweet, W.H., Wepsic, J.G. (1974) Controlled thermocoagulation of trigeminal ganglion and rootlets for differential destruction of pain fibers. *J. Neurosurg.* **39:** 143-156.

Swerdlow, M. (1988) Complications of neurolytic blockade. In: *Neural Blockade in Clinical Anesthesia and Management of Pain* (Cousins, M.J., Bridenbaugh, P.O., eds). Philadelphia: Lippincott, pp. 719-735.

Tajima, T., Furukawa, K., Kuramochi, E. (1980) Selective lumbosacral radiculography and block. *Spine* **5:** 68-77.

Tile, M. (1984) The role of surgery in nerve root compression. *Spine* **9:** 57-64.

Travell, J.G., Simons, D.G. (1983) *Myofascial Pain and Dysfunction. The Trigger Point Manual.* Baltimore: Williams & Wilkins.

Tuel, S.M., Meythaler, J.M., Cross, L.L. (1990) Cushing's syndrome from epidural methylprednisolone. *Pain* **40:** 81-84.

Uematsu, S. (1982) Percutaneous electrocoagulation of spinal nerve trunk, ganglion, and rootlets. In: *Operative Neurosurgical Techniques: Indications, Methods, and Results* (Schmidek, H., Sweet, W.H., eds). New York: Grune and Stratton, pp. 1177-1198.

Uematsu, S., Udvarhelyi, G.B., Benson, D.W. *et al.* (1974) Percutaneous radiofrequency rhizotomy. *Surg. Neurol.* **2:** 319-325.

Umeda, S., Arai, T., Hatano, Y. *et al.* (1987) Cadaver anatomic analysis of the best site for chemical lumbar sympathectomy. *Anesth. Analg.* **66:** 643-646.

Van Kleef, M., Spaans, F., Dingemans, W. *et al.* (1993) Effects and side effects of a percutaneous thermal lesion of the dorsal root ganglion in patients with cervical pain syndrome. *Pain* **52:** 49-53.

Van Kleef, M., Liem, L., Lousberg, R. *et al.* (1996) Radiofrequency lesion adjacent to the dorsal root ganglion (RF-DRG) for cervicobrachial pain: a prospective double-blind randomized study. *Neurosurgery* **38:** 1127-1132.

Van Kleef, M., Barendse, G.A.M., Voets, H., Van Kessel, F., Weber, W.E.J. (1999) Randomised trial of radio frequency lumbar facet denervation for chronic low back pain. *Spine* **24:** 1937-1942.

Verdie, J.C., Lazorthes, Y. (1982) Thermocoagulation percutanée analgésique des racines rachidiennes. *Nouv. Presse Méd.* **11:** 2131-2134.

Verdouw, B.C., Zuurmond, W.W.A., De Lange, J.J. *et al.* (1996) Long term use and effectiveness of transcutaneous electrical nerve stimulation in treatment of chronic pain patients. *Pain Clin.* **8:** 341-346.

Vervest, A.C.M., Stolker, R.J. (1991)The treatment of cervical pain syndromes with radiofrequency procedures. *Pain Clin.* **4:** 103-112.

Vervest, A.C.M., Stolker, R.J. (1995) Radiofrequency lesioning for pain treatment: a review. *Pain Clin.* **8:** 175-189.

Vervest, A.C.M., Stolker, R.J., Schimmel, G.H. (1993a) Computerized data-acquisition and reports in the pain clinic. *Pain Clin.* **6:** 83-95.

Vervest, A.C.M., Stolker, R.J., Ramos, L.M. *et al.* (1993b) Anatomical electrode positioning in cervical radiofrequency posterior partial rhizotomy. In: *Abstracts 7th World Congress on Pain.* Seattle: IASP Publications, p. 568.

Vervest, A.C.M., Stolker, R.J., Groen, G.J. *et al.* (1994) Radiofrequency procedures in chronic cervical pain syndromes: a long-term follow-up study. In: *Pain Management by Radiofrequency Procedures in the Cervical and Thoracic Spine: A Clinical and Anatomical Study*

(Stolker, R.J., Vervest, A.C.M., eds). Unpublished thesis, Department of Functional Anatomy, Utrecht University, Utrecht, pp. 51-62.

Vinas, F.C., Zamorano, L., Dujovny, M. *et al.* (1992) In vivo and in vitro study of the lesions produced with a computerized radiofrequency system. *Stereotact. Funct. Neurosurg.* **58:** 121-133.

Vrettos, X.C., Wyke, B.D. (1974) Articular reflexogenic systems in the costovertebral joints. *J. Bone Joint Surg.* **56B:** 382.

Waddell, G., McCulloch, J.A., Kummel, E. *et al.* (1980) Non-organic physical signs in low-back pain. *Spine* **5:** 117-125.

Wahren, L.L., Torebjörk, E., Jörum, E. (1989) Central suppression of cold-induced C-fibre pain by myelinated fibre input. *Pain* **38:** 313-319.

Walsh, T.R, Weinstein, J.N., Spratt, K.F. *et al.* (1990) Lumbar discography in normal subjects. *J. Bone Joint Surg.* **72A:** 1081-1088.

Weinstein, J.N. (1986) Mechanisms of spinal pain. The dorsal root ganglion and its role as a mediator of low-back pain. *Spine* **11:** 999-1001.

Weinstein, J.N. (1991) Anatomy and neurophysiologic mechanisms of spinal pain. In: *The Adult Spine. Principles and Practice.* New York: Raven Press, pp. 593-610.

Weinstein, J., Pope, M., Schmidt, R. *et al.* (1988) Neuropharmacologic effects of vibration on the dorsal root ganglion. An animal model. *Spine* **13:** 521-525.

Whelton, A., Stout, R.L., Spilman, P.S. *et al.* (1990) Renal effects of ibuprofen, piroxicam, and sulindac in patients with asymptomatic renal failure. *Ann. Int. Med.* **112:** 568-576.

White, A.H. (1983) Injection techniques for the diagnosis and treatment of low back pain. *Orthop. Clin. North Am.* **14:** 553-567.

White, A.H., Derby, R., Wynne, G. (1980) Epidural injections for the diagnosis and treatment of low-back pain. *Spine* **5:** 78-86.

White, J.C., Kjellberg, R.N. (1973) Posterior spinal rhizotomy: a substitute for cordotomy in the relief of localized pain in patients with normal life-expectancy. *Neurochirurgia* **16:** 141-170.

Wilkinson, H.A. (1984) Percutaneous radiofrequency upper thoracic sympathectomy: a new technique. *Neurosurgery* **15:** 811-814.

Wilkinson, H.A. (1985) Radiofrequency percutaneous upper-thoracic sympathectomy. *N. Engl. J. Med.* **311:** 34-37.

Willer, J-C., Roby, A., le Bars, D. (1984) Psychological and electrophysiological approaches to the pain-relieving effects of heterotropic nociceptive stimuli. *Brain* **107:** 1095-1112.

Williams, K.N., Jackowski, A., Evans, P.J.D. (1990) Epidural haematoma requiring surgical decompression following repeated cervical steroid injections for chronic pain. *Pain* **42:** 197-199.

Wilson, P.R. (1990) Sympathetically maintained pain: diagnosis, measurement, and efficacy of treatment. In: *Pain and the Sympathetic Nervous System* (Stanton-Hicks, M., ed.). Boston: Kluwer Academic Publishers, pp. 91-124.

Wood, K.M. (1989) Peripheral nerve and root chemical lesions. In: *Textbook of Pain,* 2nd edn (Wall, P.D., Melzack, R., eds). Edinburgh: Churchill Livingstone, pp. 768-772.

Wood, P.H.N., Badley, E.M. (1987) Epidemiology of back pain. In: *The Lumbar Spine and Back Pain* (Jayson, M.I.V., ed.). Edinburgh: Churchill Livingstone, pp. 1-15.

Woolf, C.J., Thompson, J.W. (1994) Stimulation fibre-induced analgesia: trancutaneous electrical nerve stimulation (TENS) and fibration. In: *Textbook of Pain* (Wall, P.D., Melzack, R., eds). Edinburgh: Churchill Livingstone, pp. 1191-1208.

Woolf, C.J., Wiesenfeld-Hallin, Z. (1985) The systemic administration of local anaesthetics produces a selective depression of C-afferent fibre evoked activity in the spinal cord. *Pain* **23:** 361-374.

Wyke, B.D. (1987) The neurology of back pain. In: *The Lumbar Spine and Back Pain* (Jayson, M.I.V., ed.). Edinburgh: Churchill Livingstone, pp. 56-99.

Xiuqing, C., Bo, S., Shizhen, Z. (1988) Nerves accompanying the vertebral artery and their clinical relevance. *Spine* **13:** 1360-1364.

14

Surgical treatment of diseases and trauma of the thoracic spine

G. F. Findlay and S. Eisenstein

The nature of the disease processes of the thoracic spine that demand surgical therapy differs significantly from that of the cervical and lumbar spines. In those regions, the commonest reason for surgical intervention is degenerative disease. In the thoracic spine, whilst degenerative processes are common, they only infrequently necessitate surgical treatment. The clinical challenge presented by the thoracic spine is not only to identify those diseases of a sinister pathology, but also to diagnose accurately those patients for whom there might be a surgical solution to their problem.

The range of diseases that may affect the thoracic region is huge. Degenerative disease is common and may manifest its presence in many ways, ranging from mild discomfort to severe myelopathy with a calcified thoracic disc protrusion. Neoplastic disease may present with alacrity in metastatic disease, or with a very long evolution in some primary bony neoplasia. Tumours arising in the axial skeleton will present in a totally different manner to those arising from the intradural structures. Trauma usually presents as an acute situation, but late complications related to post-traumatic deformity may present many years after the initial event. Deformity may cause problems from the paediatric age group right through to the elderly. Many other processes such as infection, metabolic or vascular disease can affect this area of the spine.

As in other areas, the key to successful management lies in early and accurate diagnosis. The diagnosis of many soft tissue and degenerative pathologies in the thoracic spine can be extremely difficult, as can be seen from the preceding chapters. Whilst severe instability or neurological deficit is fortunately rarely the result of conditions of the thoracic spine, the diagnosis is often delayed. However, certain features available in the history and examination of patients should alert the clinician to the presence of significant disease. In the lumbar spine, such features have been designated as 'red flags' (Clinical Standards Advisory Group, 1994). These 'red flags' may be adapted for the thoracic spine, and are shown in Table 14.1.

Table 14.1 *Red flags for possible serious thoracic spinal pathology*

- Age less than 10 or greater than 60 years
- Previous history of malignancy
- Weight loss
- Pyrexia
- Systemic
- HIV/drug abuse
- Violent trauma
- Instability-type pain
- Progressive axial pain
- Intercostal root pain
- Sphincteric disturbance
- Kyphos deformity
- Symptoms/signs of myelopathy

Adapted from: Clinical Standards Advisory Group (1994).

Pathology

Clinical presentation

Disease of the thoracic spine may present essentially in one of three manners. There may be an incidental occurrence, or the patient may present with a pain syndrome or with neurological symptoms or signs. As elsewhere, asymptomatic degenerative changes are common in the thoracic spine and will be discussed later. However, certain lesions may remain asymptomatic for a long period and occasionally will be diagnosed by chance during an unrelated investigation such as a chest X-ray (Fig. 14.1).

Pain is a particularly prevalent symptom in many different pathologies. It is basically due to one of the following mechanisms: degenerative, destructive, structural, visceral or neurological. Degenerative mechanisms may affect several structures, thereby producing pain. Most such episodes of pain will be transient and, as in the lumbar spine, resolve spontaneously. Potential sites for painful degenerative disease are the disc itself (even in the absence of actual herniation), the thoracic zygapophysial joints and the costovertebral joints. Due to the multiplicity of these joints within the thoracic spine and their relative difficulty to image accurately, diagnosis is often difficult. The pain shares many of the features seen in the lumbar spine with axial pain, which may or may not be exacerbated by movement. Pain may be referred to adjacent myotomal areas, and radicular pain may also be present if the process impinges on the segmental nerve. Pain in the interscapular area may actually be referred from degenerate cervical segments, and is a common finding in the form of local painful trigger points.

Destructive lesions such as tumours or infection are potent causes of pain. The expansion of a tumour causes periosteal stretching and hence pain. The inflammatory reaction to acute infection produces intense pain, especially if the abscess extends into the extradural space. Either process as it advances may cause sufficient destruction to permit collapse, angulation and instability of the spinal column, resulting in severe pain which is exacerbated by any movement (Jenkins and Findlay, 1995). If the process compresses or infiltrates the intercostal nerve root, then radicular pain may be present. Such pain may be most severe in the distal radiation of the affected nerve root, falsely giving the impression of intra-abdominal pathology (Findlay, 1997).

Structural disease resulting in scoliosis or kyphotic deformity may produce sufficient abnormal stresses on the thoracic spine that pain results. In long-standing cases, this may also be associated with degenerative change at the apex or at either end of the curve producing pain. However, an important warning sign is that of an adolescent with scoliosis who complains of persistent severe pain in the spine. An intraspinal tumour must be excluded by appropriate imaging.

Visceral disease may affect the spine directly, causing spinal pain. Examples include direct spinal infiltration by either a bronchogenic or a pancreatic tumour, although other lesions such as an aortic aneurysm may also cause spinal pain. In contrast, many patients may present with apparent visceral disease when in fact the cause of the pain is of spinal origin (Whitcomb *et al.*, 1995). As long ago as 1937, Oille reported that, of 600 patients presenting with chest pain, the pain was due to degenerative spinal disease in one-third.

Pain of neurological origin usually originates from the radicular nerve root. However, intramedullary lesions may cause pain due to damage to central cord structures. Such pain is characteristically described as a diffuse, dysaesthetic, burning sensation affecting segments distal to the lesion.

All lesions affecting the thoracic spine may be associated with the onset of neurological deficit. The basic presentation is similar in all disease processes, although clearly the rate of onset and severity will differ. Neurological deficit due to nerve root involvement is rare. This is due to the considerable overlap in

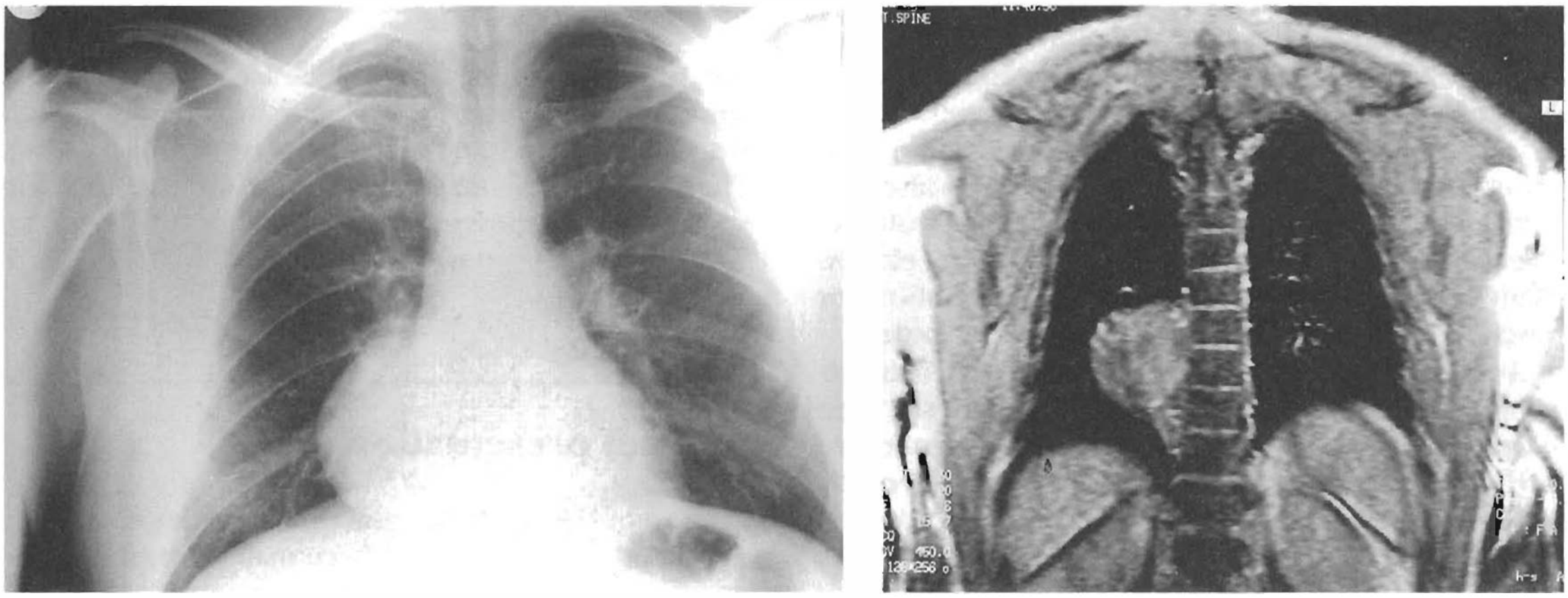

(A)

(B)

Fig. 14.1 A) Chest X-ray showing asymptomatic paraspinal mass on right side due to a large Schwannoma. (B) Coronal MR scan of the same case.

both motor and sensory innervation of the intercostal nerves, and the fact that paresis of individual sections of intercostal or abdominal musculature cannot be identified. However, careful sensory examination may identify an area of dermatomal hypoalgesia.

Impairment of spinal cord function produces sensory, motor and sphincteric dysfunction. Sensory involvement produces loss of feeling in the feet and legs. There is a sensation of numbness and heaviness in the legs. Occasionally, loss of temperature sensation may manifest itself on entering a hot bath. Loss of proprioceptive awareness leads to ataxia of the gait that is noticeably worse in the dark.

Weakness also produces an initial heavy feeling in the legs. As this progresses, the inability to walk becomes gradually more evident; the patient has difficulty rising from the seated position, frequently stumbles and eventually has to hold on to furniture or use walking aids. Sphincteric loss is usually a late feature, with loss of awareness of bowel and bladder fullness and ultimately painless urinary retention or overflow. Patients with disease processes which affect the conus of the cord are more likely to have early sphincteric disturbance, and will often show a mixed picture of upper and lower motor neurone signs.

Examination of the patient with thoracic spine disease may show signs referable to axial column disease and also neurological deficit. Pathology of the axial thoracic spine should be carefully sought; it may show evidence of local disease such as deformity, local tenderness or a soft tissue mass. Neurological signs may help to identify the spinal level involved. Thus, a sensory level to pinprick examination may be evident. Spastic weakness of the limbs is often asymmetrical, and in mild cases is usually most evident by examination of the patient's gait. Reflexes will be increased and there may be clonus and extensor plantar responses. An asymmetric lesion may produce evidence of a Brown-Séquard lesion, with ipsilateral weakness and contralateral sensory loss in the limbs.

It is very difficult to produce a precise diagnosis of the exact pathology simply by clinical examination, but the syndrome of spinal cord compression should be readily identified. Regrettably the diagnosis is often grossly delayed as shown by the study of Peña *et al.* (1992), who found a median delay in diagnosis of 2.5 years.

Assessment

If a clinical diagnosis of a soft tissue lesion has been made, further investigation may be indicated only if the pain syndrome fails to resolve spontaneously or with appropriate therapy. However, if sinister structural disease or neurological signs are present, then appropriate investigations to clarify the exact pathological process are necessary. The speed at which these investigations are performed will depend on the clinical situation. Patients presenting with rapidly evolving myelopathy demand urgent investigation. A prompt diagnosis not only increases the chance of neurological recovery, but may also allow less aggressive treatment. For example, a patient presenting with metastatic disease which has not caused vertebral body destruction or marked neurological deficit can, in some situations, be adequately treated by radiotherapy, whereas the patient with kyphotic deformity and marked cord compression will always require surgical intervention.

Plain radiography is frequently unhelpful in the thoracic spine. It is clearly of importance in trauma, and may reveal the presence of neoplasia if there is marked bony destruction. It can be of considerable help in the diagnosis of osteomyelitis, where the involvement of the end-plates and intervertebral disc is typical. Deformities are clearly seen, as are extraspinal lesions such as aortic aneurysms.

The standard investigation for a patient with suspected disease of the thoracic spine is magnetic resonance imaging (MRI). Although imaging with a whole spine coil has the advantage of showing the

Fig. 14.2 Small intramedullary cavernoma.

Fig. 14.3 Multiple metastatic deposits from primary breast cancer.

Fig. 14.4 Staphylococcal osteomyelitis with kyphotic deformity and extradural abscess.

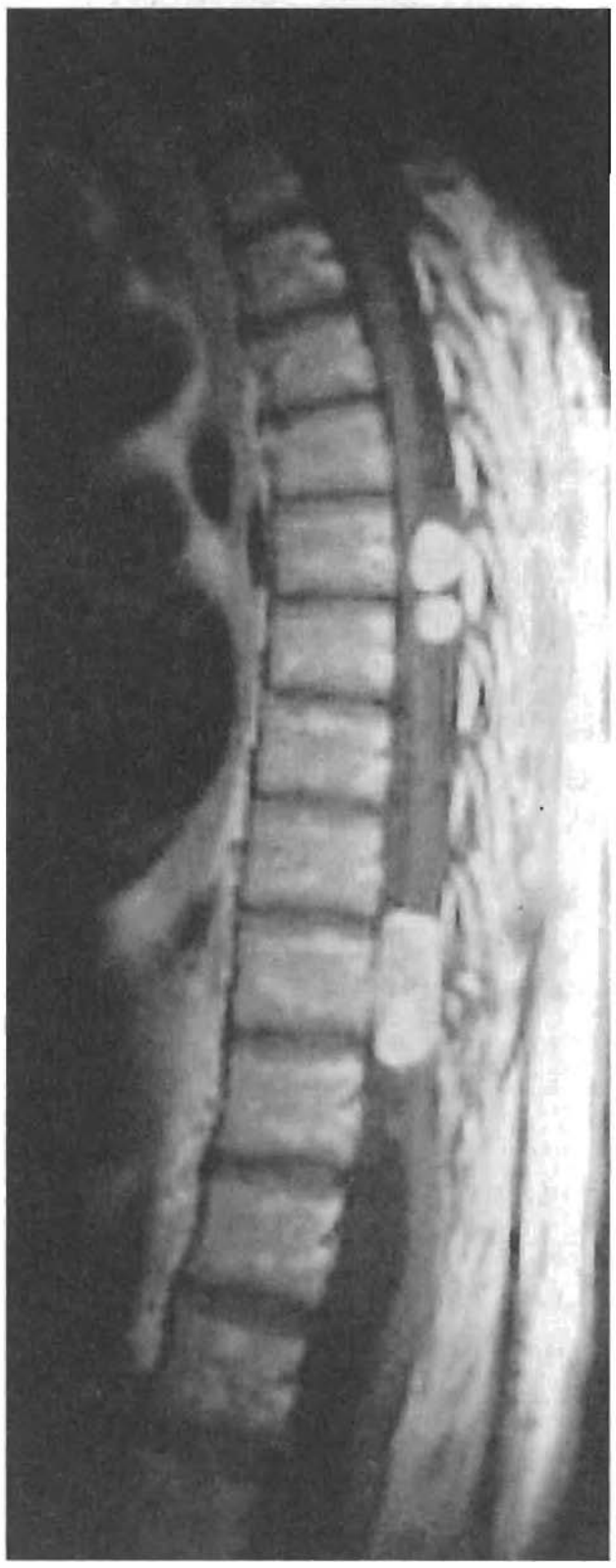

Fig. 14.5 Multiple neurofibromata, after gadolinium enhancement, in a patient with neurofibromatosis.

entire spine, it must be realized that the sensitivity of such an examination is decreased. If such a study reveals no pathology, it is often wise to repeat the examination on a regional coil as small intramedullary lesions in particular may be revealed (Fig. 14.2). Metastatic disease (Fig. 14.3) and infection (Fig. 14.4) are particularly well displayed. Degenerative disc disease is less clearly shown than in the lumbar spine, and it should be realized that it is often asymptomatic.

Details of bony architecture are poorly seen on MRI, but computerized tomography (CT) scanning complements the MRI pictures. There is no place for CT as a screening tool, but it is the best method for displaying foraminal lesions or lesions of the zygapophysial or costovertebral joints. Calcified lesions such as thoracic disc protrusions are more exactly imaged with CT than with MRI, which can give a false impression of their true architecture and size. Intradural lesions are normally well displayed by MRI (Fig. 14.5), but lesions such as arachnoid cysts or arachnoiditis are best imaged by CT myelography.

Discography is infrequently used in the thoracic spine, but is feasible via a CT-guided postero-lateral approach. As in the lumbar spine, its place in the assessment of patients with possible painful disc degeneration is unclear. Schellhas *et al.* (1994) undertook discography examination of 100 patients with abnormal thoracic discs as diagnosed by MRI. They found that the examination elicited pain in only 75% of cases, and the pain was concordant in only 50%.

Other diagnostic tests may be indicated, depending on the clinical picture. Patients with suspected visceral causes of thoracic pain should be appropriately investigated. If a demyelinating disease is possible, then cerebral MRI may support the diagnosis if multiple plaques are seen. Patients with malignant disease but no structural lesion should have their CSF examined for the presence of neoplastic cells on cytology.

Surgical approaches

Prior to considering individual disease processes that may require surgical treatment, it is appropriate to consider the varying surgical approaches that may be necessary to treat thoracic spinal disease. As any disease process may affect different sectors of the axial thoracic skeleton, it is essential that the surgical approach is not only appropriate to the situation of the lesion but is also performed in a manner that will ensure a stable spine following the intervention.

The traditional laminectomy approach is entirely appropriate for the management of diseases affecting the posterior elements of the spine. It is also the preferred approach for the management of the great majority of intradural lesions, whether they lie within or without the cord itself. A laminectomy in the thoracic spine of an adult, which does not compromise the zygapophysial joints and is performed in a patient with an intact spinal column, will not cause iatrogenic instability. However, such a procedure in the presence of a destructive lesion of the anterior column may well produce instability.
child, even a simple laminectomy that spares the zygapophysial joints may produce progressive kyphotic deformity (Yasuoka *et al.*, 1982).

Because of the potential for laminectomy to produce iatrogenic instability, and owing to the relative inaccessibility of many lesions via this approach, surgical procedures designed to give direct access to lesions without compromising spinal stability have evolved. Access to the postero-lateral and lateral aspects of the thoracic spine can be gained with both the transpedicular and costotransversectomy approach, and each may be combined with posterior instrumentation and fusion if necessary. Access to the anterior thoracic column requires a transthoracic approach, which may be either extrapleural or transpleural. The correct exposure demands that the thoracotomy be performed at the correct level – usually two ribs higher than the spinal level – to gain optimum access to the spinal lesion. The thoracotomy should extend posteriorly to the angle of the rib to permit adequate access within the thoracic cavity. The excised rib itself is normally insufficiently substantial to provide a weight-bearing bone graft, but is useful in supplementing it.

Anterior access to the upper three thoracic vertebrae is difficult due to the presence of the great vessels. Additionally, the major biomechanical forces that occur at the cervicothoracic junction, coupled with any destructive lesion in the vertebral body, readily combine to produce kyphosis, further limiting surgical access. Standard anterior cervical approaches will give adequate access down to T1 and occasionally to T2, and have been combined with a separate transthoracic incision to give more caudal access (Micheli and Hood, 1983). Sundaresan *et al.* (1984) described an anterior sternoclavicular approach with the removal of part of the manubrium and the medial third of one clavicle, allowing access from C3 to T4. This approach was further modified by Charles and Govender in 1989, and by Kurz and colleagues in 1991.

More recently, the place of endoscopic surgical techniques has been explored. Initially the techniques were limited to simple biopsy or drainage procedures (Mack *et al.*, 1993), but they have been extended to include the performance of anterior release procedures in scoliosis, the removal of thoracic discs and the management of neoplastic, infective and traumatic lesions of the thoracic spine, including the application of instrumentation. Potential drawbacks of such surgery include: the need for great endoscopic experience by the surgeon; multiple access portals; specially designed and expensive equipment; and the potential for uncontrollable vascular injury. Advantages claimed for the techniques include: less postoperative pain; a reduction in respiratory complications; and fewer postoperative shoulder problems. Reduced hospital stay and costs are also claimed. The status of such procedures has been well reviewed by Regan and McAfee (1997).

In addition to the careful selection of the appropriate surgical approach, attention must be paid to the stability of the spine. Feiertag *et al.* (1995) showed that isolated simple discectomy, a rib-head excision or unilateral total removal of the zygapophysial joint did not affect spinal stability in the thoracic spine. However, the combination of rib-head excision and discectomy extending right back to the neural foramen did result in significantly increased spinal motion. The presence of the ribcage does give excellent support to most areas of the thoracic spine. However, the effects of destructive lesions, both anteriorly and posteriorly, may, in combination with a decompressive surgical procedure, render the thoracic spine unstable.

To counter the problem of potential or actual instability, several methods of instrumentation have been developed. It is of course necessary to supplement such fixation techniques with adequate bone grafting, as instrumentation alone will always fail eventually. In anterior surgery, several designs of plating systems are available using screw fixation into the vertebral bodies. These must be low profile to avoid impingement and erosion of the great vessels, and all must be incorporated with a weight-bearing graft in the anterior spinal column. This may be tricortical iliac crest or morselized bone graft contained within some type of metallic cage. Alternative fixation using a parallelogram construction with appropriately angulated screws connected to parallel and cross-linked rods offers greater stability, but still requires a weight-bearing graft.

Posterior fixation devices are more varied. The use of distraction rods with hook fixation has become less common. Fixation may be achieved by the application of contoured rectangular loops fixed with sublaminar cables. Due to the need to control long bending moments with simple sublaminar fixation, such instrumentation needs to be performed over several segments. However, this is not a problem clinically due to the inherent relative inflexibility of the thoracic spine. Alternatively, contoured rods held by transpedicular screws provide excellent fixation. The thoracic pedicles are significantly shorter and narrower than in the lumbar spine, and the insertion of pedicle screws in this region is much more demanding and potentially dangerous. To counter this, Dvorak *et al.* (1993) described an anatomical study of extrapedicular screw insertion showing that, *in vitro*, such a screw showed greater pull-out strength - especially in the upper thoracic spine - than conventional transpedicular screws. The use of such instrumentation techniques ensures that the spine is inherently stable at the completion of the surgical procedure, and permits the rapid mobilization of the patient without external orthoses.

Management of specific disease entities

Non-specific pain that potentially arises from the structures of the thoracic spine is a not infrequent clinical complaint that normally defies an exact pathoanatomical diagnosis. Non-specific pain is common in athletes, especially those involved in throwing actions such as javelin, or quarterbacks in American Football. It is also a common complaint in adults in the 30-50 years age range, and seems more common in females. Fortunately, the condition is often self-limiting and responds to rest and gradual physical reactivation.

More persistent cases are, however, seen in all spinal clinics. Often simple reassurance that there is no significant underlying disease, explanation of the benign nature of the condition and encouragement to gradually resume normal activity is sufficient. Only in rare cases will the severity and longevity of the problem be sufficient to warrant consideration of surgical therapy in the absence of any neurological symptoms or signs. Investigation of such patients is problematic. There are so many joints and possible sources of pain within the thoracic spine that exact localization of the pain source seems often impossible. Plain radiographs and MRI may show - as in the lumbar spine - evidence of degenerative change. This is most frequent at the rostral and caudal ends of the thoracic spine, but is normal evidence of ageing in the majority. By the age of 40 years, 50-60% of people will show asymptomatic degenerative change (Nathan *et al.*, 1964). Schellhas *et al.* (1994) showed that thoracic discography was safe, and strongly advocated the procedure in the search for a discogenic cause of thoracic pain. They suggested that anterior anular tears caused pain referred to anterior sites such as the ribs and sternum, while lateral tears could produce radicular type pain. However, the place of discography in this area is even more open to debate than it is in the lumbar spine. Skubic and Kostuik (1991) presented a classification of the causes of thoracic pain. over an 18-year period they were able to identify only 13 cases in whom they were prepared to consider an anterior thoracic fusion. Two of these had only fair or poor outcomes, but the remainder experienced improvement or complete pain relief.

Other structures may be the source of thoracic pain, such as the zygapophysial or the costovertebral articulations, but are even more difficult to prove as the pain source. Finally, it should be recalled that many visceral diseases may present with pain referral to the thoracic area (see Chapters 5 and 9).

Love and Schorn (1965) reported that the first description of surgical treatment of a thoracic disc herniation was by Adson in 1922. As in all areas of the spine, asymptomatic degenerative change and protrusion of thoracic discs is common. Wood *et al.* (1997) estimated the incidence of asymptomatic thoracic disc herniation to be 37%. They followed up 20 asymptomatic patients with MRI scans, and revealed 48 separate thoracic disc herniations over a mean period of 2 years. None of the patients developed symptoms referable to the disc lesions. Only 8% of the lesions increased in size over that period, but 15% actually reduced in size. Brown *et al.* (1992) retrospectively reviewed 55 cases of thoracic disc herniation, and found that only 27% had eventually required surgical treatment.

The morphology of thoracic disc herniations may be similar to that of the lumbar spine, with soft, contained or extruded protrusions. Sequestration is very uncommon. However, many thoracic herniations differ significantly from those of the cervical or lumbar spine. They have a peculiar tendency to calcify or even to ossify (Fig. 14.6). The striking factor of calcified discs in this region is that, rather than seeming to arise from the disc itself, the calcification seems to arise from the posterior longitudinal ligament. It assumes a pyramidal shape and can grow to a large size, resulting in severe cord compression. The origin of the process from the posterior longitudinal ligament permits the base of the herniation to extend well beyond the disc margins, a point of considerable importance in the planning of surgical approach (Fig. 14.7). The cause of the calcifying or ossifying nature of such protrusions remains obscure, but they can be sufficiently impressive that the apex of the pyramidal herniation can erode through the dura and become embedded in the cord itself (Findlay, 1991; Stone *et al.*, 1994).

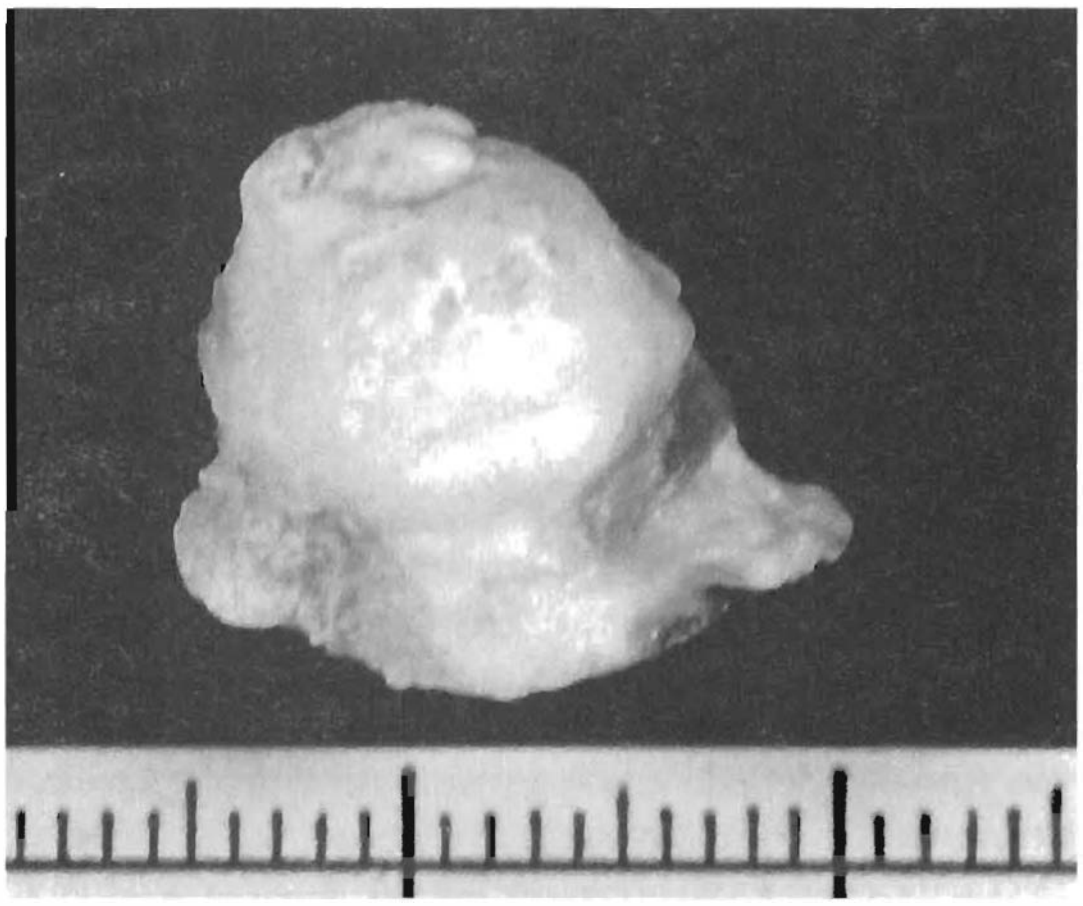

Fig. 14.6 Ossified thoracic disc protrusion removed by transthoracic approach

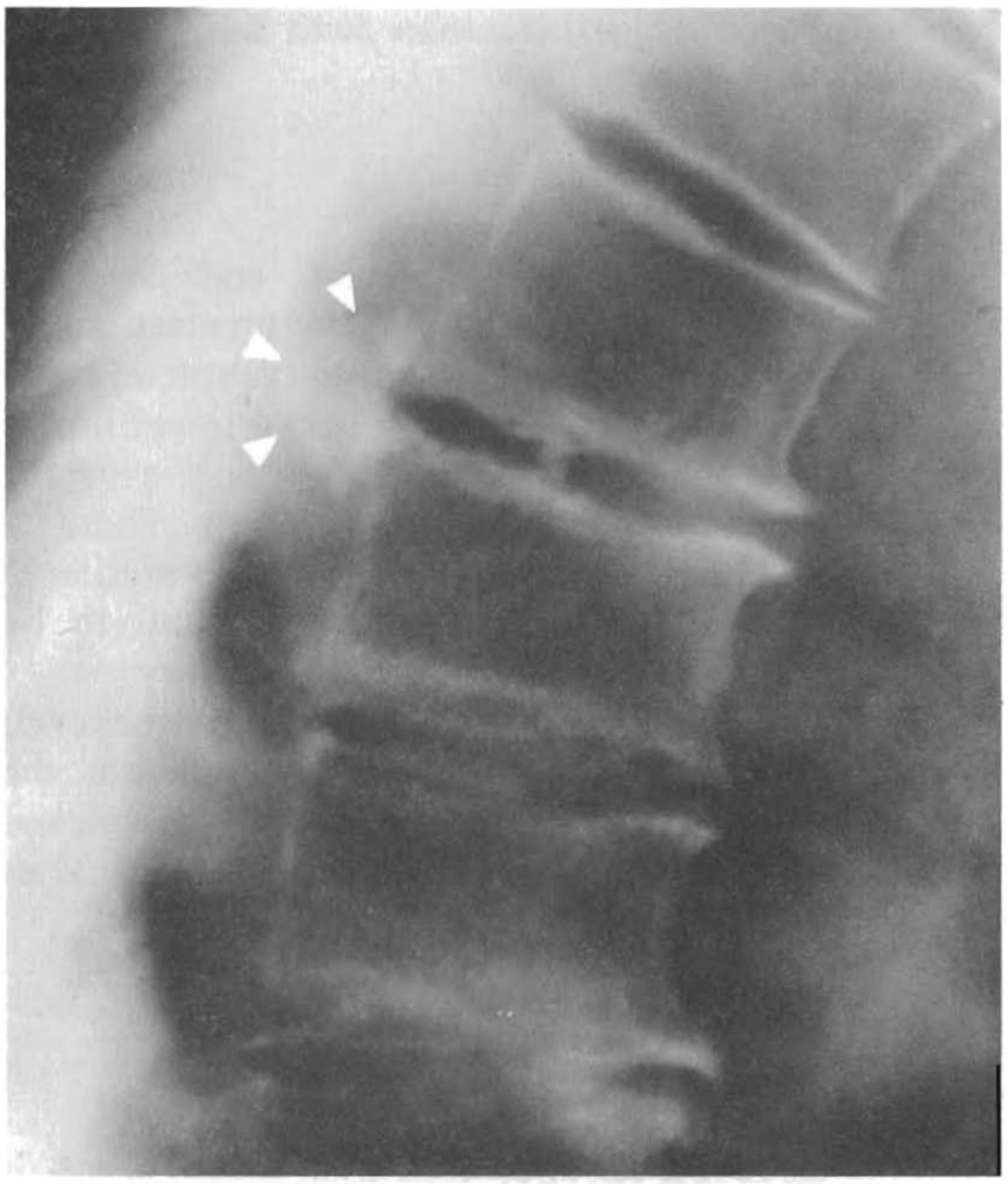

Fig. 14.7 Pyramidal shaped ossified thoracic disc protrusion arising from the posterior longitudinal ligament.

Thoracic disc herniations may become symptomatic by causing either radicular pain or, more commonly, myelopathy. There is little debate that the presence of significant or progressive neurological deficit due to a large thoracic disc demands surgical removal. However, intercostal pain on its own may often be managed by pain-relieving techniques such as intercostal or nerve root blocks. Patients with myelopathy will often experience no, or only mild, axial pain, but those with significant cord damage may describe central cord type pain with its characteristic burning dysaesthetic discomfort felt in the lower limbs. It has long been recognized that laminectomy is exceptionally dangerous in the surgical treatment of such lesions. Hulme (1960) developed the costotransversectomy approach for such lesions, and this immediately improved outcome and decreased the morbidity associated with laminectomy. Patterson and Arbit (1978) described a transpedicular approach that affords excellent access to postero-lateral herniations. However, for large calcified midline lesions the current trend is towards an anterior approach. This was first described by Craaford and colleagues in 1958; since then, several other authors have advocated a transthoracic approach. Drawing on experience of radical transthoracic excision of tumours, Findlay (1991) described a radical approach involving the partial osteotomy of the adjacent vertebral bodies to allow even greater access to the intraspinal lesion. This approach has been used in more than 30 cases, with excellent clinical results and very low morbidity. On the other hand, a more minimally invasive approach, again with excellent results, using an endoscopic technique, has been described by Rosenthal *et al.* (1994).

Trauma

The thoracic spine has a daunting task. It must be sufficiently rigid to carry the ribcage and its contents, as well as the head, neck and shoulder girdles. It must be sufficiently flexible to allow some movement in all planes. While combining these conflicting requirements, it must protect its own contents, the spinal cord. The thoracic spine can perform its tasks remarkably well for decades without maintenance of any kind, but it was never designed to withstand the stresses it has had to suffer since the industrial revolution. Modern machines, modern transport and modern leisure pursuits all provide trauma hazards beyond the capability of the spine to protect the cord.

The thoracic spine is normally curved slightly and gradually forwards (kyphosis). Most injuries of a serious nature produce varying degrees of crush of the vertebral bodies, with downward wedging in front (compression), backward shunting of bone and disc fragments (burst), or sharp kinking (kyphos). These injuries can be combined with forward shift of the top part of the spine (dislocation) (Figs 14.8, 14.9). The result can be pain, deformity and paralysis. Paralysis of varying degrees (paraparesis to paraplegia) represents the most serious consequence of thoracic spine trauma. The least kind of injury is also the most common, and is nothing more than a ligament or muscle strain; however, even this little injury can produce chronic debility and a diminished lifestyle.

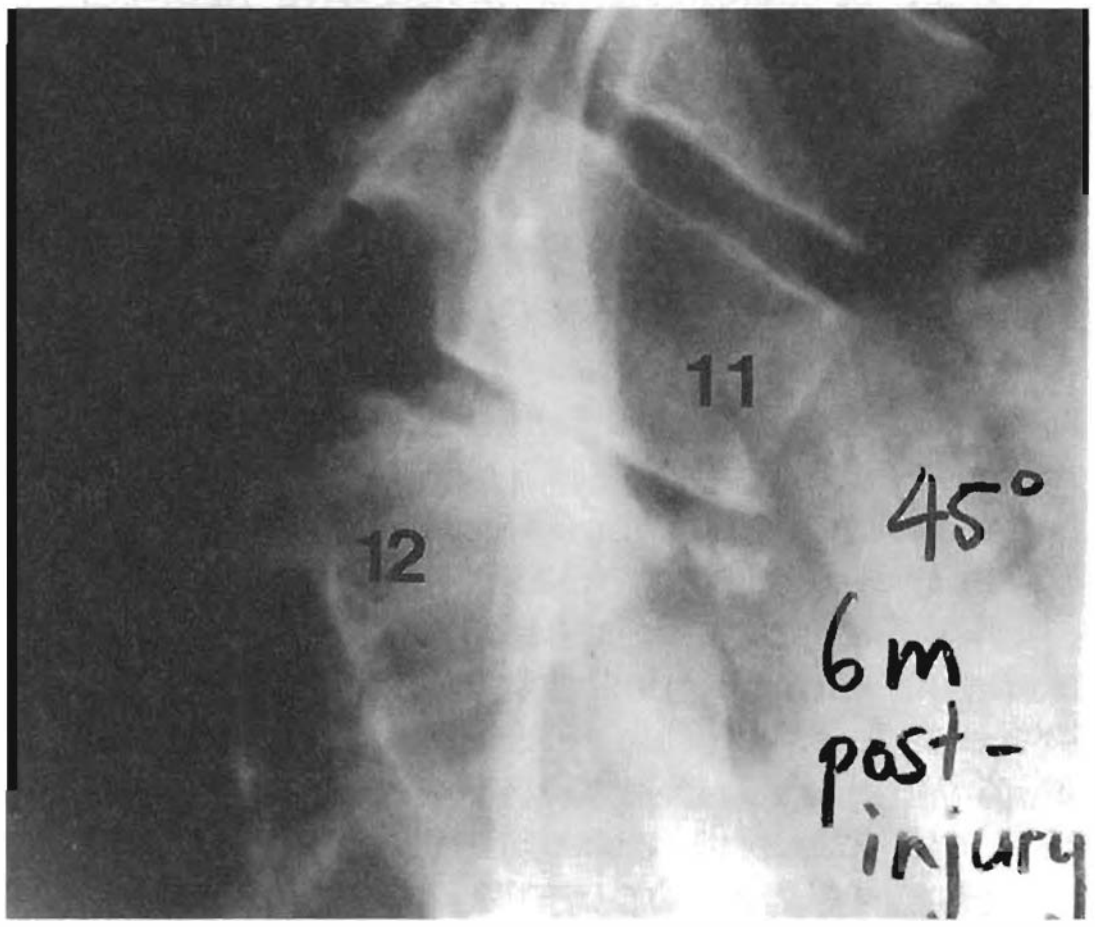

Fig. 14.8 Fracture-dislocation T11-T12 caused in a road traffic accident. T12 demonstrates an anterior wedge compression of vertebral body; T11-T12 demonstrates kyphosis of 45° and dislocation of T11 forwards on T12.

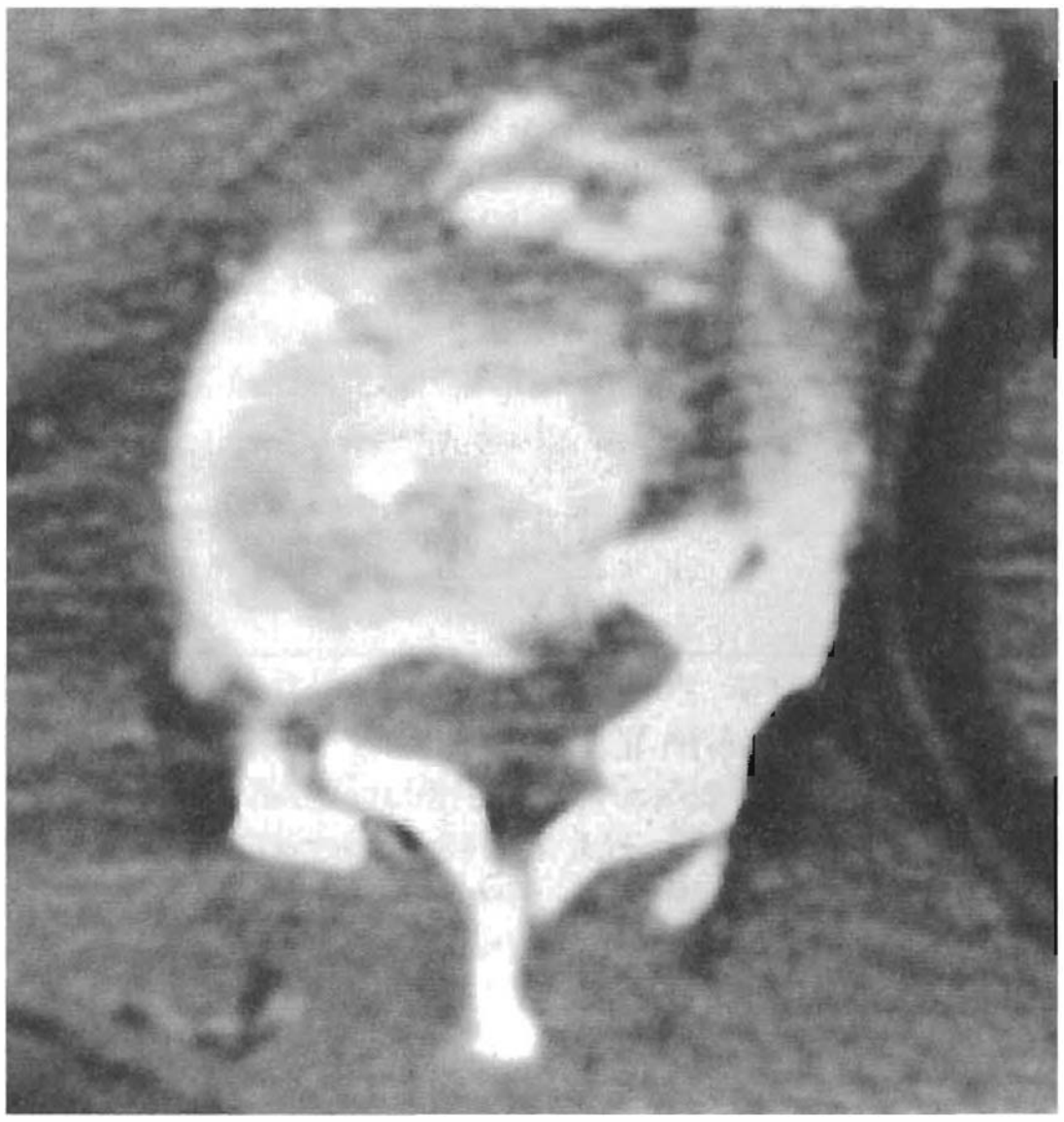

Fig. 14.9 CT image of T12 showing 'burst' element of vertebral body injury (same patient as Fig. 14.8).

Classification

The purpose of any classification is to help define the extent of injury, to reveal a possible threat of further injury, and to be able to make some prediction as to the final result. As soon as possible after injury, it is important to assess instability and neurological deficit.

Instability

Instability is one word summarizing the risk of injury to the spinal cord (or of further injury to a cord already damaged) in the ensuing few weeks after trauma, leading to a decision as to how the patient and the spine should be protected. Obvious burst fractures and dislocations mean that the spine can continue to shift about; this is obvious 'instability'. Severe wedge compression (down to less than half the normal height of the vertebral body) is often regarded as an unstable situation, by definition. Instability implies a need for protection. Protection may require nothing more than rest in bed, or it may require a major operation with internal metal fixation.

Neurological deficit

This is either present or absent, and must be documented, either way, in detail. Of greatest importance is to note whether a deficit is 'complete' (total loss of all movement and feeling in the lower limbs) or 'incomplete' (some 'escape' of function, even the smallest patch of sensation remaining). There is always some hope of a useful recovery of function in a paralysed patient if the deficit is found to be incomplete in the first few hours after injury.

The level of loss of sensation (the dermatome level) is also of importance in the documentation; the discovery of a rising level must cause some alarm, and may be the result of bleeding in the spinal canal or inadequate immobilization of the patient.

Mechanisms of injury

Many texts reveal an obsession with mechanisms or manner of injury, but in most cases of severe trauma the mechanism can only be guessed at, and this information does not contribute to the management of the patient or the pathology. Mechanisms of injury can be categorized as follows:

1. Flexion/compression: this is the most frequent mechanism, and is seen in road traffic accidents and heavy falls. It is traditionally the injury suffered by miners in a rock fall. An important part of the examination of any injured patient, and especially an unconscious patient, is the examination of the front of the chest; a sterno-manubrial dislocation is a clue to the great likelihood of a compression fracture.
2. Flexion/distraction: for example, seat belt injuries.
3. Extension: caused, for example, by a road traffic accident or a heavy fall backwards onto a hard object.
4. Rotation: caused by any high velocity force with a twisting component.

Consequences of injury

1. Pain, from any bone and soft tissue injury. Even if cord damage results in loss of sensation below the level of injury, there can be chronic pain arising from the actual site of injury, 'neuritic' pain from the cord itself, or intercostal neuralgia from nerve root injury.
2. Posture (deformity), usually in the form of a kyphos (forward kink) and/or scoliosis (sideward kink). A kyphos may produce severe discomfort against the back of a chair or even when lying supine.
3. Paralysis, involving not only loss of muscle power and sensation in lower limbs, but also loss of control of bladder and bowels.

Management of injury

Management of spinal injury has both general and special aspects:

1. General. A spinal injury is frequently only one of a number of serious injuries suffered by an individual patient, and a careful examination of the whole patient is required. A thoracic spine injury may be associated with trauma to the chest wall and any of its contents (Fig. 14.10). Basic plain radiography should include chest films to rule out haemo/pneumothorax and enlargement of the cardiac shadow.
2. Special. A paralysed patient will need a urinary catheter and an urgent MRI scan to determine the extent of cord damage. Good-quality plain spine films are necessary to exclude the possibility of injury at two or more different levels. An intravenous line may be needed for feeding.

Spinal injuries are managed differently in different centres, depending very much on the culture pervading a particular centre. That may even depend on a national culture, rather than on some internationally agreed ideal. It is sufficient to state that, even in the presence of cord injury and paralysis, no study has shown that aggressive surgical decompression and internal fixation has ever, of itself, achieved spinal

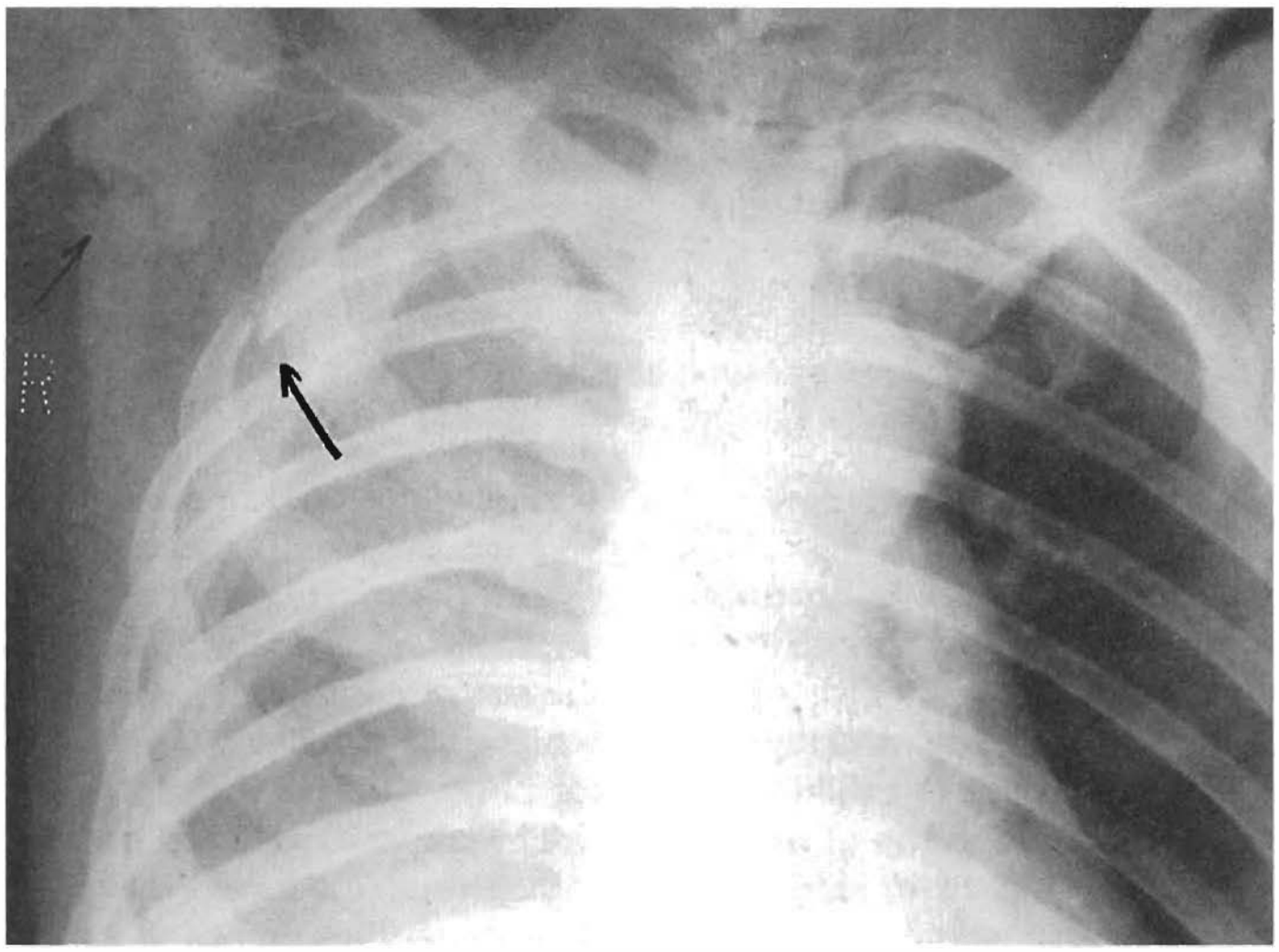

Fig. 14.10 Chest radiograph of case illustrated in Figs 14.1 and 14.2: arrows indicate fracture neck of scapula and rib. There is a haemothorax on the same (right) side.

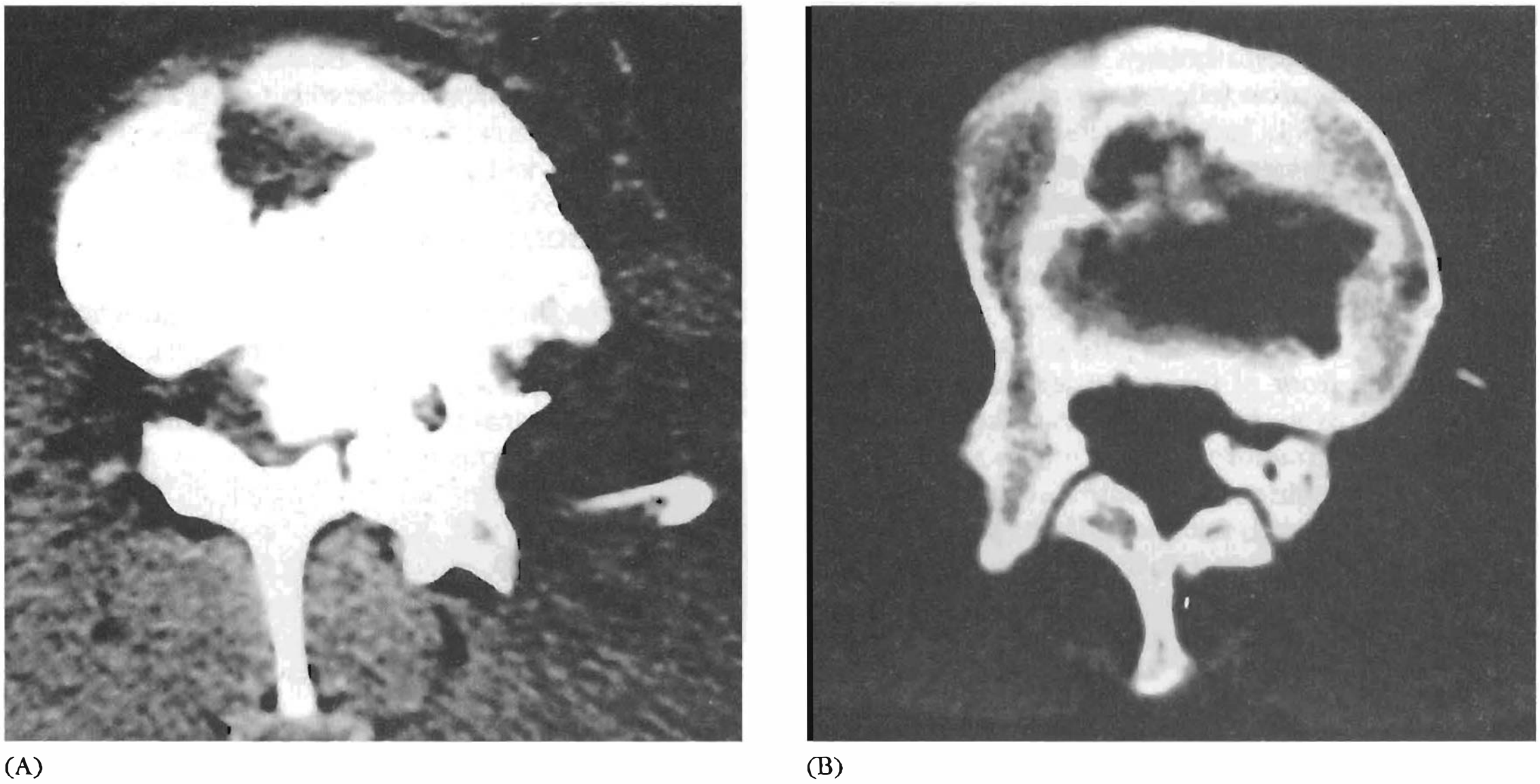

Fig. 14.11 (A) CT scan (transverse section) of burst fracture with large vertebral body fragment pushed posteriorly into spinal canal. (B) The same case, some months later, showing spontaneous remodelling with restoration of patency of spinal canal without surgical intervention. (Illustration courtesy of Mr W. El Masry, FRCS.)

cord recovery over and above that which could be achieved by intensive non-surgical management. Indeed, there is an inevitable, if small, incidence of complication of surgery that will leave the patient in a worse condition than if surgery had not been performed at all. There is (surprisingly) general agreement that cord injury occurs mainly at the moment of impact. Part of the justification for surgery is the opportunity to remove bone and other tissue that is compressing the cord, but there is no evidence that a decompression will produce an earlier or better return of cord function than the passage of time alone. On the other hand, there is ample evidence that time alone will produce a remodelling of the spinal canal and a dramatic resorption of the bone seen to intrude into the canal shortly after injury (Fig. 14.11).

Intensive non-surgical management

Some would have called this 'conservative' management, suggesting an element of benign neglect. This is far from the truth in a modern spinal cord injury centre, where great attention is paid to posturing the spine in order to achieve a degree of correction in bed, to constant monitoring and recording of neurological status, urinary function and care, skin care and control of pain and muscle spasm. Counselling, mobilization, preparation for independent living and modification of home facilities are all part of this intensive management, which continues after discharge from hospital and for life.

Surgical management

Spinal fusion, with or without internal fixation, is appropriate soon after injury where a spine is so unstable that there is a distinct danger of cord damage or of aggravation of cord damage even from the limited but necessary movements required by nursing in bed.

Early surgery is not appropriate simply to achieve early mobilization. There is a daunting list of complications of surgery. With the most careful technique there may yet be some loss of segmental level of neurological function, infection, pseudarthrosis and implant failure. There are other aspects of spinal cord injury that make early mobilization problematic; dysautonomia can cause severe hypotension, which will be aggravated by sitting too early, and time alone will see this complication settle.

Late surgical stabilization (months rather than weeks after injury) is appropriate for chronic pain at the site of injury, and for a deformity such as kyphosis which is increasing in spite of adequate time allowed for bone and soft tissue healing.

The most useful technique is that of anterior (transthoracic) bone strut grafting and metal fixation of robust design. This can be supplemented by posterior grafting and rod/hook fixation if considered necessary (Fig. 14.12).

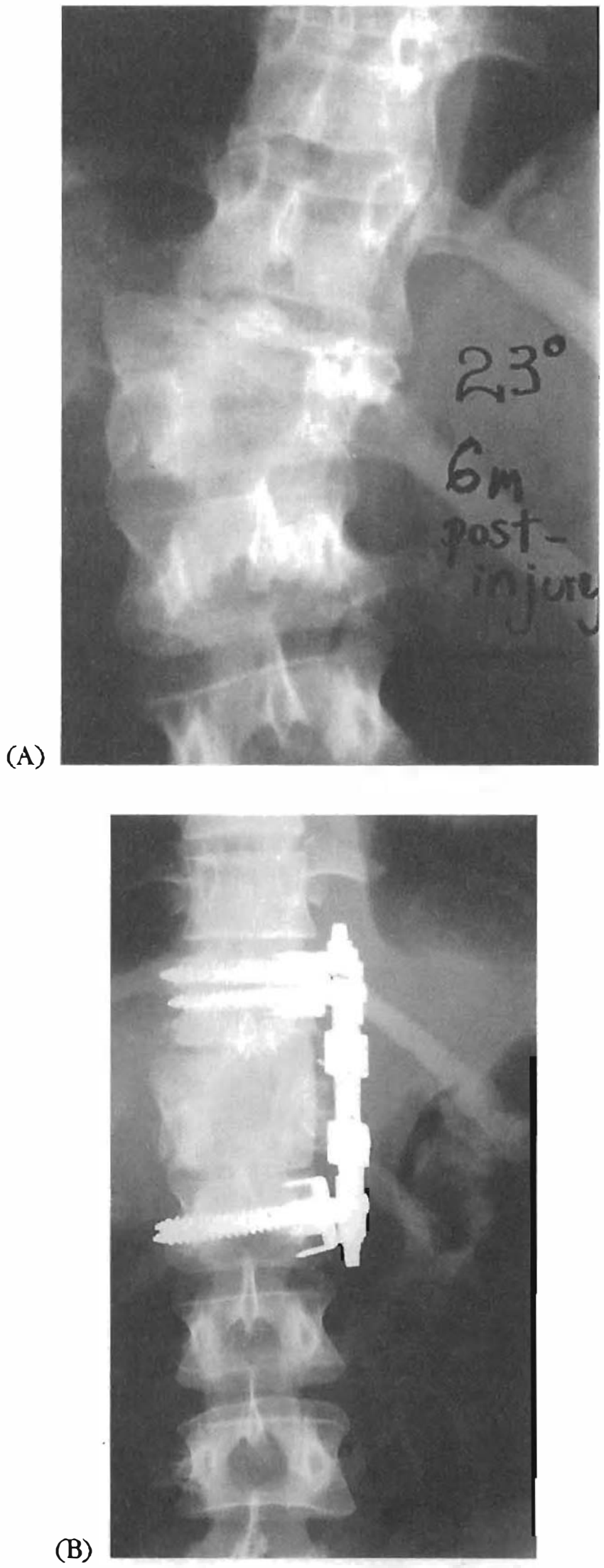

Fig. 14.12 Traumatic scoliosis of 23° with chronic pain at site of fracture-dislocation of T11–T12 (same case as shown in Figs 14.8–14.10). (A) Preoperative deformity. (B) Correction with fusion of T11 to L1 using iliac tricortical bone block and KANEDA fixation



Fig. 14.13 (A) Andry's crooked sapling, from *Orthopaedia*, 1743. (B) Representation in the crest of the British Orthopaedic Association. (Photograph reproduced by permission of *The Journal of Bone and Joint Surgery*, British volume.)

Deformity

Introduction

The management of spinal deformity represents a return to the origin of orthopaedic philosophy and the earliest traditions of orthopaedic practice; the achievement of 'straight children'. In those early days almost all of orthopaedics was conducted by external splintage rather than by surgery, as exemplified by the many representations of Andry's crooked sapling lashed to a stake (Fig. 14.13) (Andry, 1743, reproduced 1961). Modern surgical treatment for spinal deformity often requires the insertion of a 'stake' alongside the crooked spine, in a remarkable recreation of Andry's illustration. The badges of orthopaedic professional associations around the world proudly display this emblem.

For the newcomer to spinal deformity practice, there is a new language to learn. This should not be regarded by novices as a deterrent, but more as a challenge when joining a fascinating and rewarding clinical endeavour.

The deformities

The great majority of spinal deformity, whether idiopathic, congenital or neuromuscular, is to be found in the thoracic spine. This is not to say that deformities are not found frequently in the cervical and lumbar spine, but that the deformity is clinically most obvious in the thoracic spine.

Scoliosis

Scoliosis is a side-to-side 'S' bend in the spine, or part of an 'S' bend, produced by something more than just temporary asymmetric posture (Fig. 14.14A). The term implies an element of permanence because of some structural abnormality inherent in the spine of a particular individual. In addition, there is almost always some degree of twist in the spine (rotation), where several vertebrae are permanently turned about their vertical axis so that the spinous processes point into the concavity of the bend. This rotation can be the most important feature in a scoliotic spine, because it is the rotation of thoracic vertebrae which causes the unattractive rib hump. It is the rib hump (Fig. 14.14B) that is usually seen as the obvious deformity in the patient, and not the curved spine. The ribs are attached to the sides of the vertebrae; as the vertebrae rotate with the development of scoliosis, the ribs rise up on one side to form the hump.

Kyphosis

Kyphosis is a smooth forward bend of the spine. The thoracic spine has a normal forward bend of up to 40°, so that in this instance the kyphosis is normal or physiological. In clinical practice, the term implies an excessive forward bend (Fig. 14.15), and may be found together with scoliosis - i.e. kyphoscoliosis.

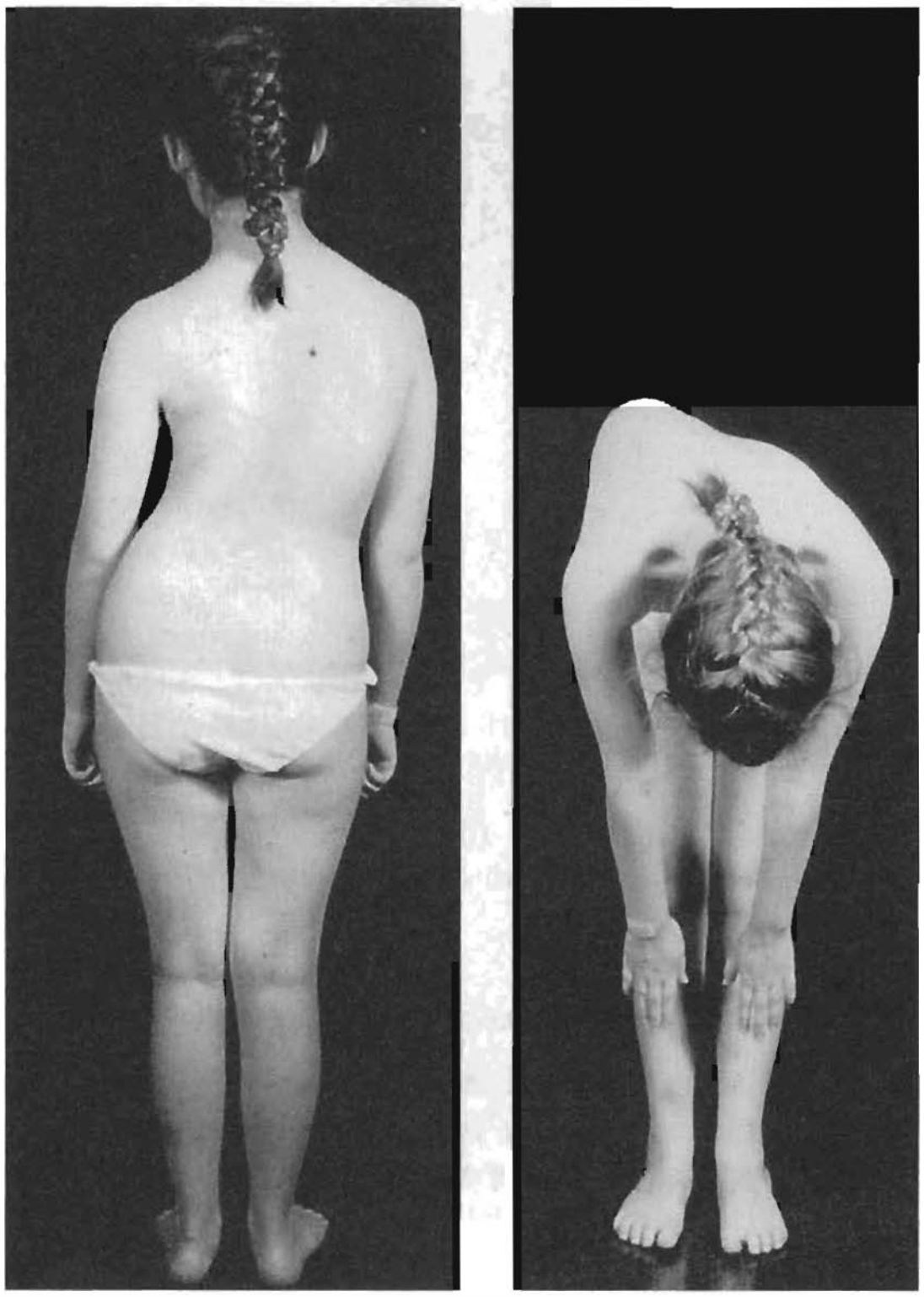
(A) (B)

Fig. 14.14 Adolescent idiopathic scoliosis typically involving the thoracic spine in females. (A) Scoliosis with a spinal curve convex to the right. (B) The rib hump is more obvious on forward bending.


Fig. 14.15 Kyphosis in Scheuermann's disease.

Kyphos or gibbus

Kyphos (or gibbus) is a sharp forward bend, but more like a kink or a knuckle in the spine. This is traditionally the term applied to the deformity resulting from the destruction caused by tuberculosis (Fig. 14.16), but it can be found wherever vertebrae have collapsed into wedges - such as in osteoporosis, cancer, injury or infection of any kind - and in any disease that weakens bone. It is also rarely found at birth or soon after, in children born with imperfectly formed vertebrae (congenital kyphos).

Lordosis

Lordosis is the opposite of kyphosis (see above). It is a smooth backward bend of the spine, found as normal posture in the cervical and lumbar spines to balance the thoracic kyphosis, but the term may also indicate an excessive or pathological condition. It may be found in the lumbar spine as compensation for a pathological kyphosis in the thoracic spine. A relative lordosis of the thoracic spine (loss of normal kyphosis) is frequently associated with idiopathic scoliosis.

Spondylolisthesis

Spondylolisthesis is a horizontal shift of one vertebra in relation to another, as if the vertebra slides along the one below it, in any direction, to take up a new but abnormal position. As it happens, the direction of shift is usually forward. (Spondylolisthesis must not be confused with similar sounding words such as spondylosis, meaning degenerative changes in the spine, and spondylolysis, meaning an un-united fracture of the lamina of a vertebra.) Spondylolisthesis is rare in the thoracic spine other than as a result of major injury (Fig. 14.17).

Nature of the deformity

It is sometimes held that spinal deformities are 'only cosmetic', as if they did not matter much because they are usually painless and no longer associated with a diminished life expectancy. The fact is that there is a degree of deformity that is so pervasive as to go well beyond a question of vanity. Severe scoliosis and kyphosis are just such deformities. The whole body shape may be altered to a degree that is simply

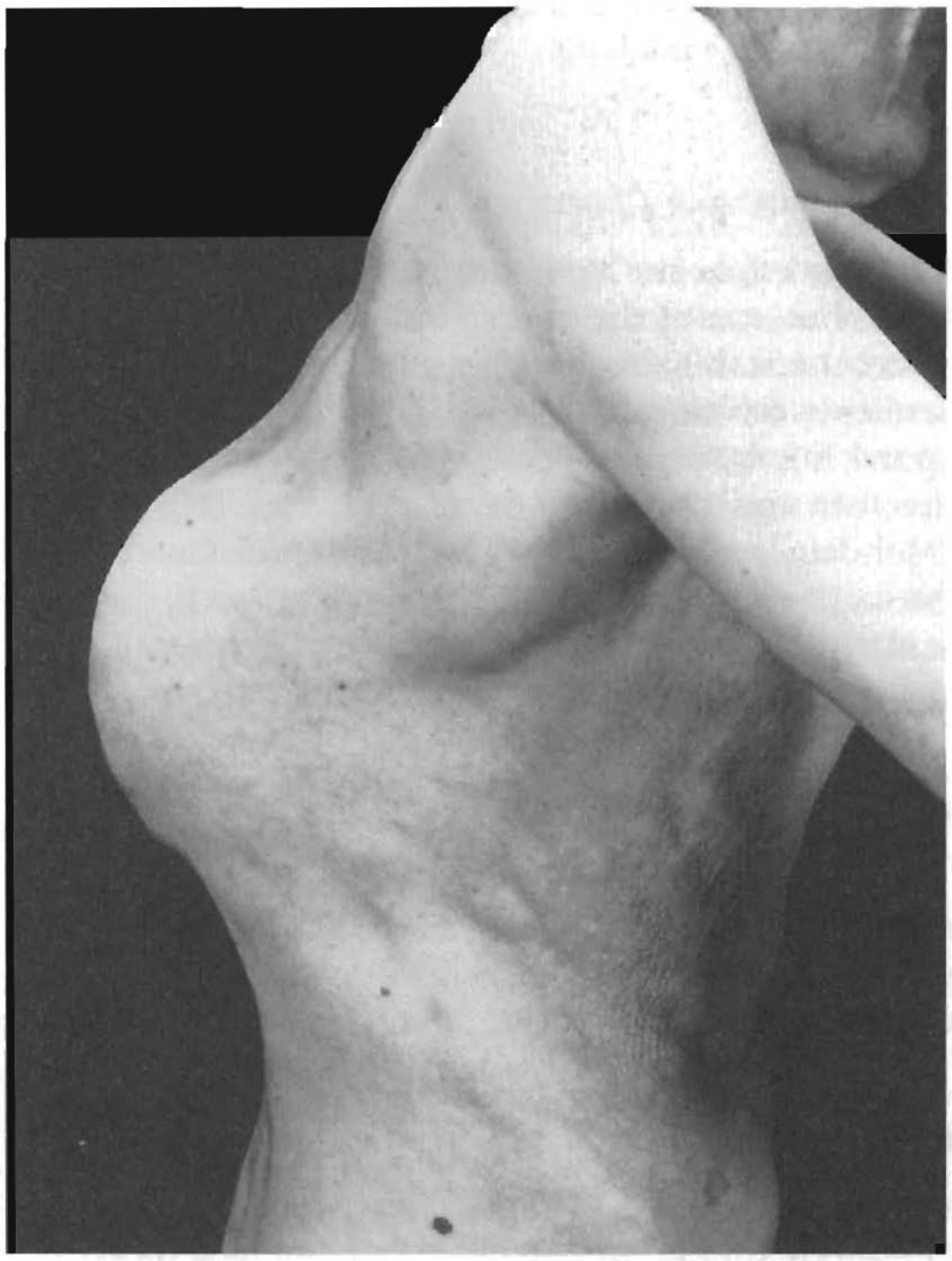

Fig. 14.16 Kyphos or gibbus in healed tuberculosis of the spine.

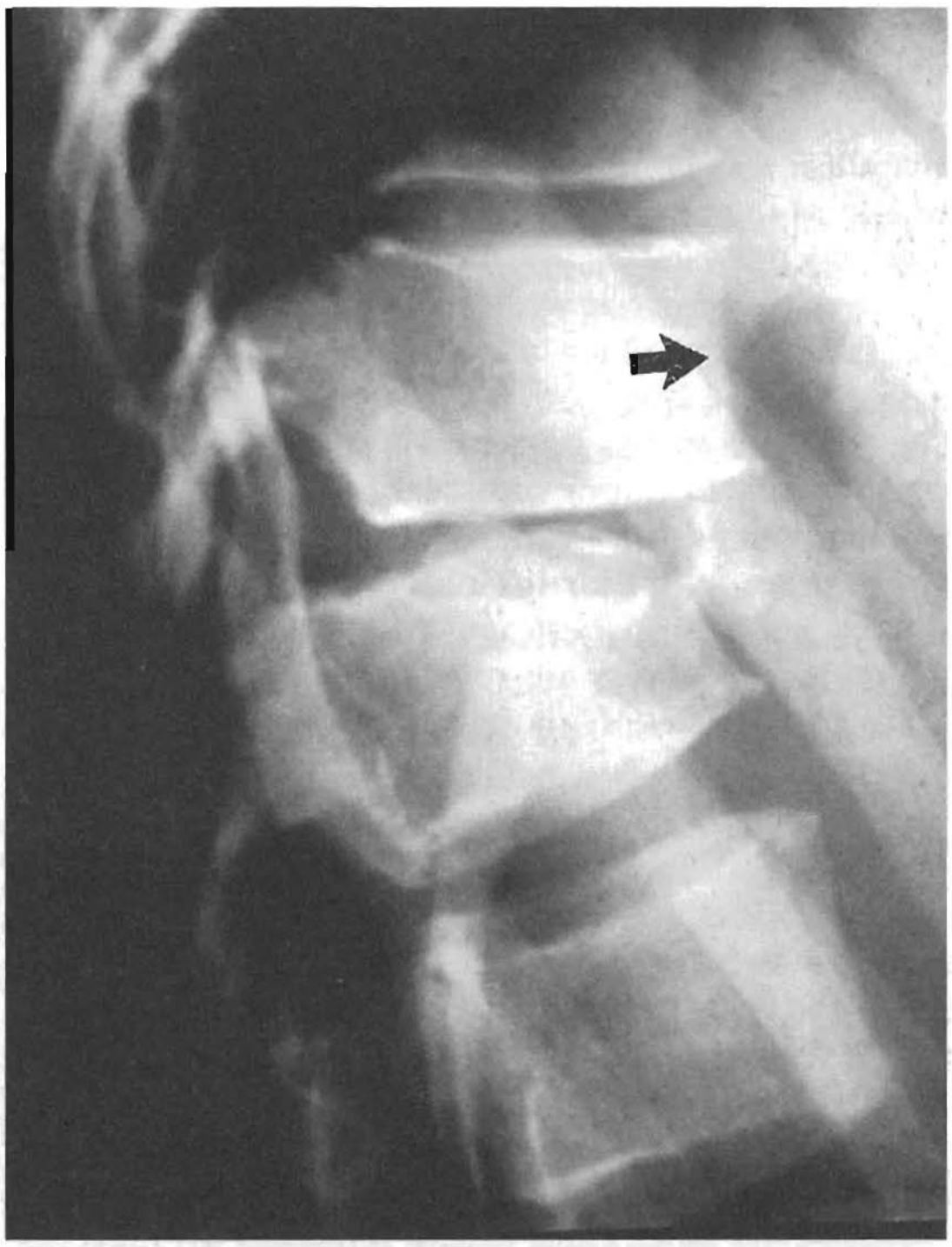

Fig. 14.17 Post-traumatic spondylolisthesis: translation of one vertebra, and the rest of the spine above it, anteriorly on the rest of the spine beneath it.

unacceptable to the patient and materially affects patients' perceptions of their place in society. Moreover, the deformity is very likely to be progressive and may indeed cause disabling pain later in adult life.

The causes

Scoliosis

By far the most common spinal deformity to require treatment is scoliosis. There are several types of scoliosis, classified according to cause, and each type needs a different treatment programme.

Idiopathic ('cause not known')

This is the most common diagnosis (ironically, in a condition classified by 'cause'), affecting mostly adolescent girls and generally producing a thoracic curve to the right, with a right-sided rib hump. The spine appears perfectly normal at birth but deforms in the adolescent years of rapid growth, for reasons not yet understood. Because the curve is associated with a loss of the normal thoracic kyphosis, the deformity is more correctly termed 'lordoscoliosis' (Professor Robert Dickson, Leeds). Despite the term 'idiopathic', it is known that this type of scoliosis runs in families; consequently there must be a genetic influence of varying importance.

Idiopathic scoliosis can also appear in infants and juveniles, less commonly, but then it presents major problems in management because of the early start in the deformity.

Extensive research worldwide and over many years has failed to produce a convincing and conclusive answer to the question of the cause of the disease. Theories are many, based on suspicions of genetic tendencies, hormone imbalances, neuromuscular imbalance and the various stresses of childhood, physical and emotional (Goldberg *et al.*, 1997). The answer is likely to be found in a gradual realization that all these factors are relevant, in varying proportions, in all cases of 'idiopathic' scoliosis.

Congenital

The spine is deformed from the start of its development in the foetus, either through failure of the vertebrae to form symmetrically, or through failure of the vertebrae to separate completely from each other (Fig. 14.18). The worst of these deformities are found when the two types of failure occur together. This type of scoliosis presents the greatest treatment challenge of all because of its tendency to increase from birth despite major and repeated attempts to achieve correction.

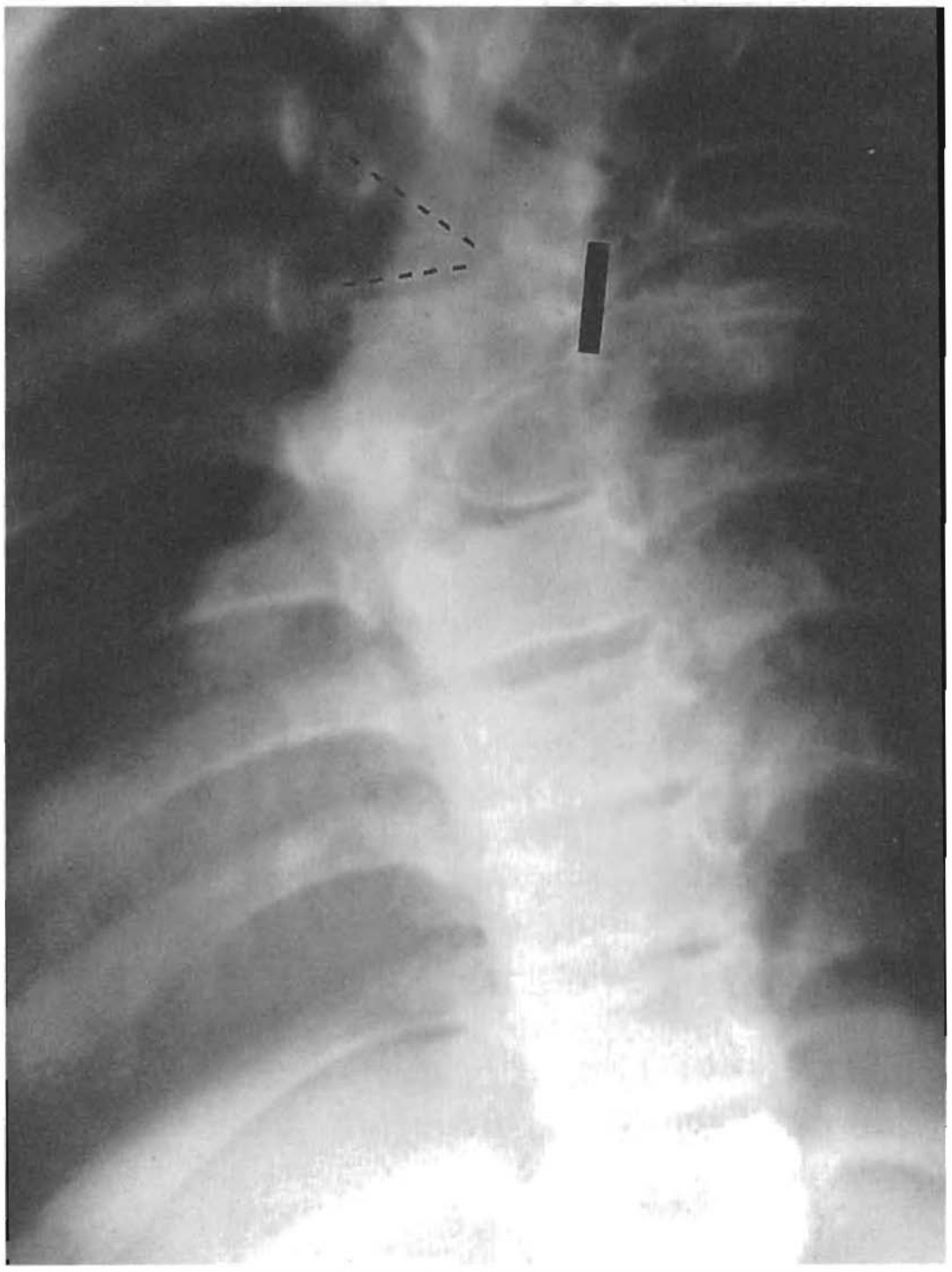

Fig. 14.18 Congenital scoliosis upper thoracic spine: combination of hemivertebra (dotted lines) and unsegmented bar (alongside solid line).

Neuromuscular ('paralytic')

In these cases the spinal column may be normal at birth, but one of the many paralysing conditions that affect the stabilizing muscles of the spine occurs, and scoliosis develops. These paralysing conditions are spinal injury, cerebral palsy, poliomyelitis, transverse myelitis and the muscular dystrophies (Fig. 14.19) (Mehdian *et al.*, 1989). The paralysis of myelodysplasia (spina bifida) will be present at birth, and any scoliosis may be compounded by the presence of congenital abnormalities, as described above.

Other causes

This is a disparate group of rarer causes, such as the scoliosis secondary to spinal tumours, acute back strains, disc prolapse, advanced lumbar spondylosis and (very rarely) hysteria.

Kyphosis

Kyphosis is far less common than scoliosis, but successful treatment may be more difficult to achieve.

Juvenile osteochondrosis (Scheuermann's disease) is a mysterious condition, and is probably the most common cause of mild-to-moderate kyphosis in

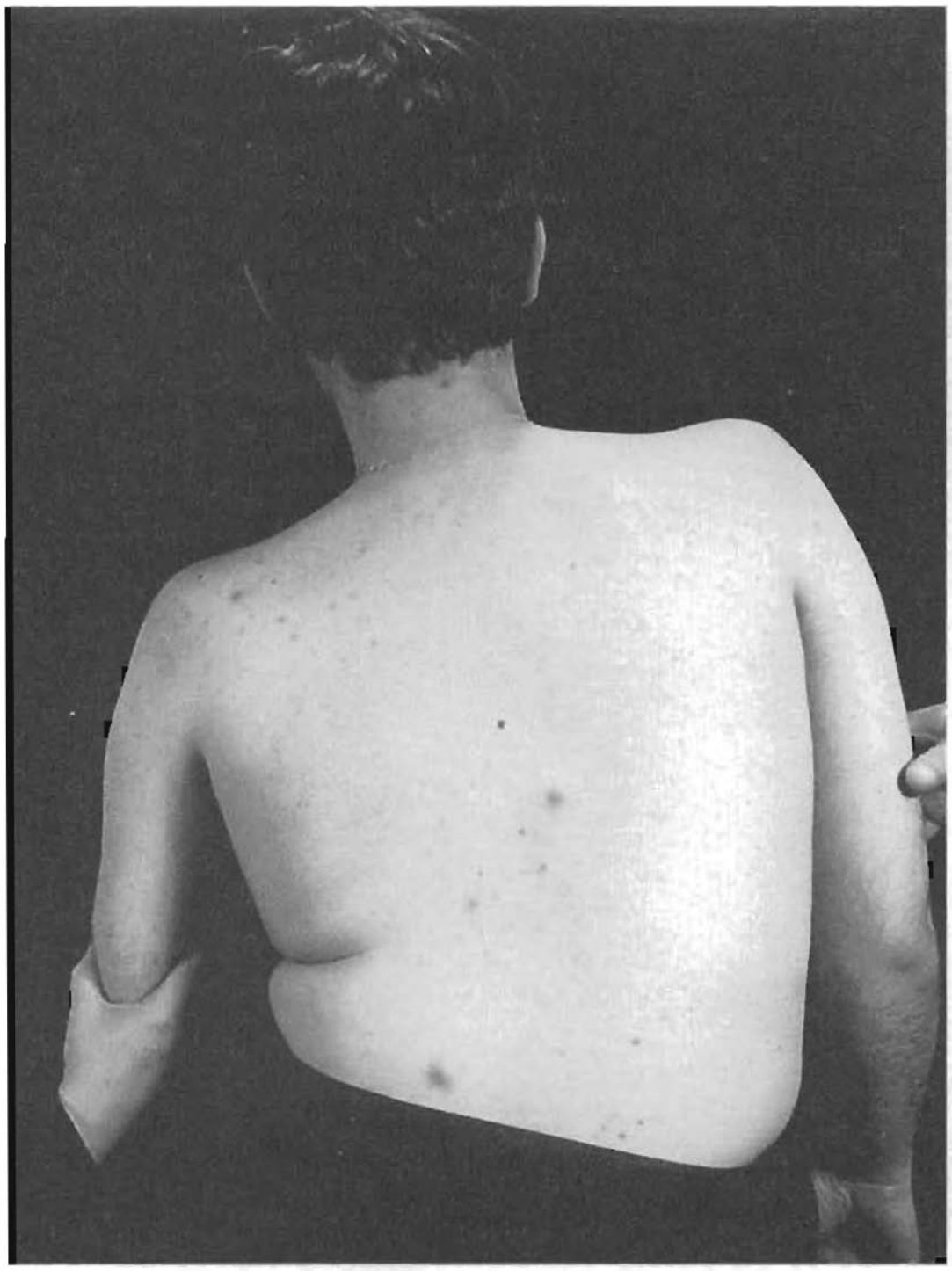

Fig. 14.19 Neuromuscular or paralytic scoliosis (Duchenne's muscular dystrophy) with loss of independent sitting stability.

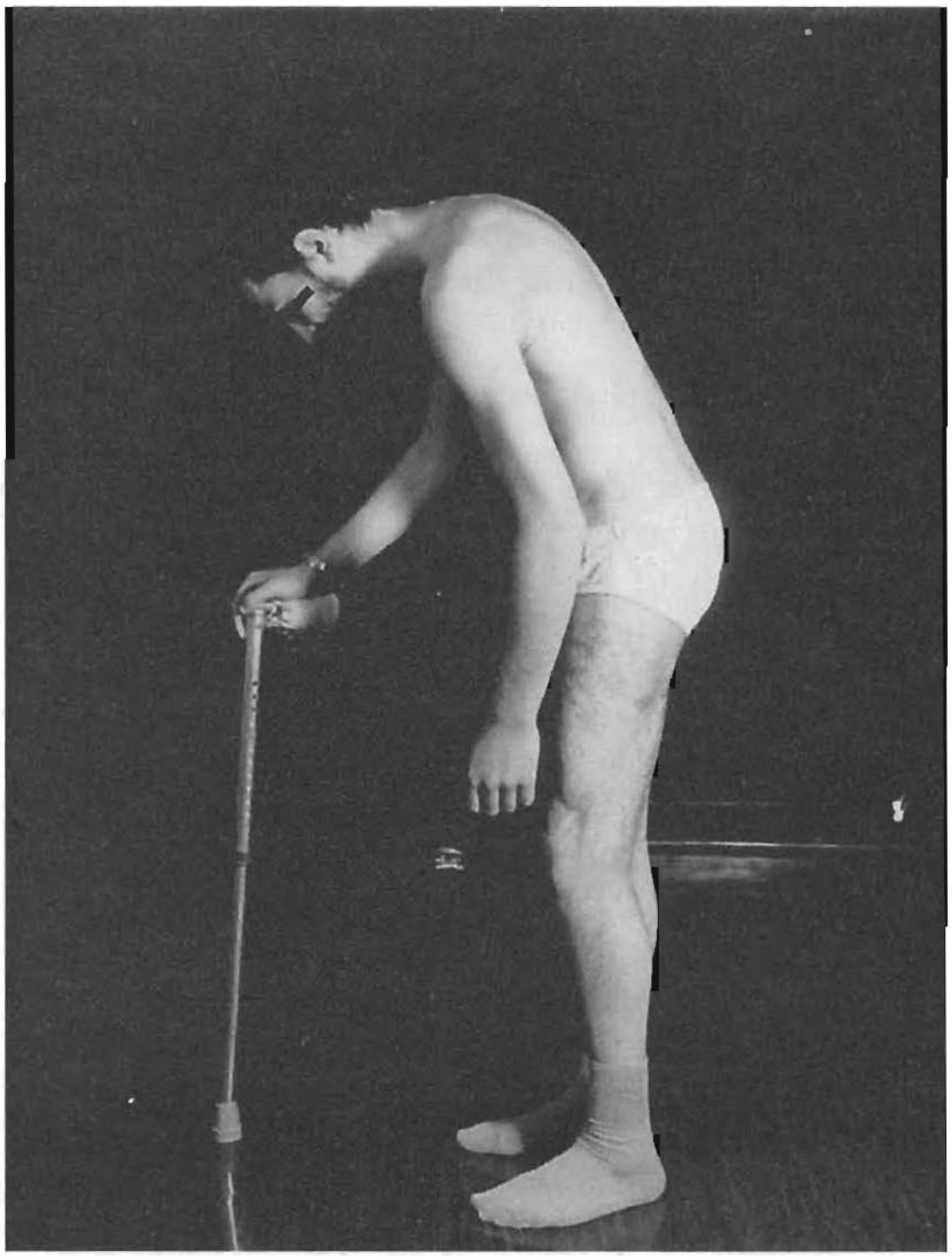

Fig. 14.20 Fixed high thoracic kyphosis in ankylosing spondylitis.

developed nations (Scheuermann, 1920). The endplates of the thoracic vertebrae of teenage boys are damaged in some way that produces anterior wedging of the vertebral bodies and results in the 'round shoulders' (Fig. 14.15) which parents sometimes blame on bad posture in a lazy child. Patients often complain of low back pain from a compensatory lumbar lordosis.

Infection in the form of tubercular destruction of one or more adjacent thoracic vertebrae is probably the most common cause of a pathological kyphosis in under-developed countries. The deformity is likely to be sharply angled (a gibbus) and cause spinal cord compression with paralysis (Fig. 14.16).

Spinal injury (see above) is a frequent cause of kyphosis because the injury is so often a crush of one or more vertebral bodies, and associated with paralysis through direct damage to the spinal cord at the level of the crush (Fig. 14.8).

Osteoporosis associated with the menopause, alcoholism and dietary inadequacy is the most important cause of kyphosis in adults. The loss of mineral content of the bone so weakens the vertebral bodies that they collapse into wedges under the normal loads of daily living. The pain produced in this condition is severe and almost incurable.

Congenital abnormalities occur less frequently in the sagittal plane, but they can cause a severe and progressive kyphosis with a likelihood of producing paralysis if untreated.

Rheumatoid disease of the spine, as exemplified in ankylosing spondylitis, can produce a kyphosis and loss of forward gaze in young adults (Fig. 14.20).

Idiopathic kyphosis is rare, and is probably the forward-deforming counterpart of idiopathic lordoscoliosis. The thoracic vertebrae are all very slightly wedged, as are the disc spaces between them.

Degenerative changes of ageing in the discs of the cervical and lumbar spine are frequently associated with a relative kyphosis (loss of lordosis) in these areas, producing the typical stoop of the elderly.

Lordosis

Excessive lordosis is almost always a deformity to compensate for a primary kyphosis deformity elsewhere in the spine. It is also the logical response to fixed flexion deformities at the hip. In the thoracic spine it is seen as a relative loss of the normal kyphosis in idiopathic scoliosis.

Spondylolisthesis

Spondylolisthesis may result from disc degeneration (spondylosis) which allows one vertebra to slide forwards on the one below, but this is an uncommon feature in the thoracic spine. It is more likely to be the result of a traumatic dislocation.

Diagnosis and assessment

On the basis that scoliosis is by far the most common deformity dealt with, the remainder of this chapter is devoted largely to it.

Scoliosis is a problem not only because of the abnormal body shape, but also because it tends to be progressive. The greater problem is that advanced scoliosis is very much more difficult to treat well than mild or moderate scoliosis, but there is no certain way of knowing which curve will progress, nor how far it will progress. The partial solution to this problem is a combination of early diagnosis and continued vigilance; in other words, a long-term programme of regular visits to the clinic for examination and repeat imaging, at least until bone maturity is achieved sometime between the ages of 16 and 19 years. Once progression is confirmed, a scheme of treatment, possibly including surgery, can be planned for the individual patient.

Early detection was only partially successful when left to parents and teachers, because it is difficult to notice subtle changes in posture in someone who is seen casually on a daily basis. A formal programme of clinical examination at school (school screening) was expected to solve this problem, but proved to be too expensive for the small number of cases discovered. Most school nurses and doctors are now quite capable of detecting early scoliosis during routine health checks in schools.

The clinical examination is extremely simple and merely requires the inspection of the back of a child bending forward, looking for a tell-tale rib hump (Fig. 14.14B). Other asymmetries of the trunk, which can be seen quite easily in the erect posture, are waist creases, shoulder heights, and a prominence of one shoulder blade. General awareness of scoliosis has increased in recent years, but the ideal of consistent early detection has not yet been achieved, and is probably an unrealistic goal.

Imaging of the spinal curvature is the next step, once the consultant staff are satisfied that the deformity warrants an accurate baseline measurement against which to judge future developments. For the majority of scoliosis clinics this imaging will be in the form of X-rays, at least for the first examination. Thereafter many clinics will repeat the imaging in the form of one of the new computerized trunk-shape measurements, which can quantify the asymmetry of the deformity without the risk of exposure to X-rays (Fig. 14.21) (Singer *et al.*, 1999).

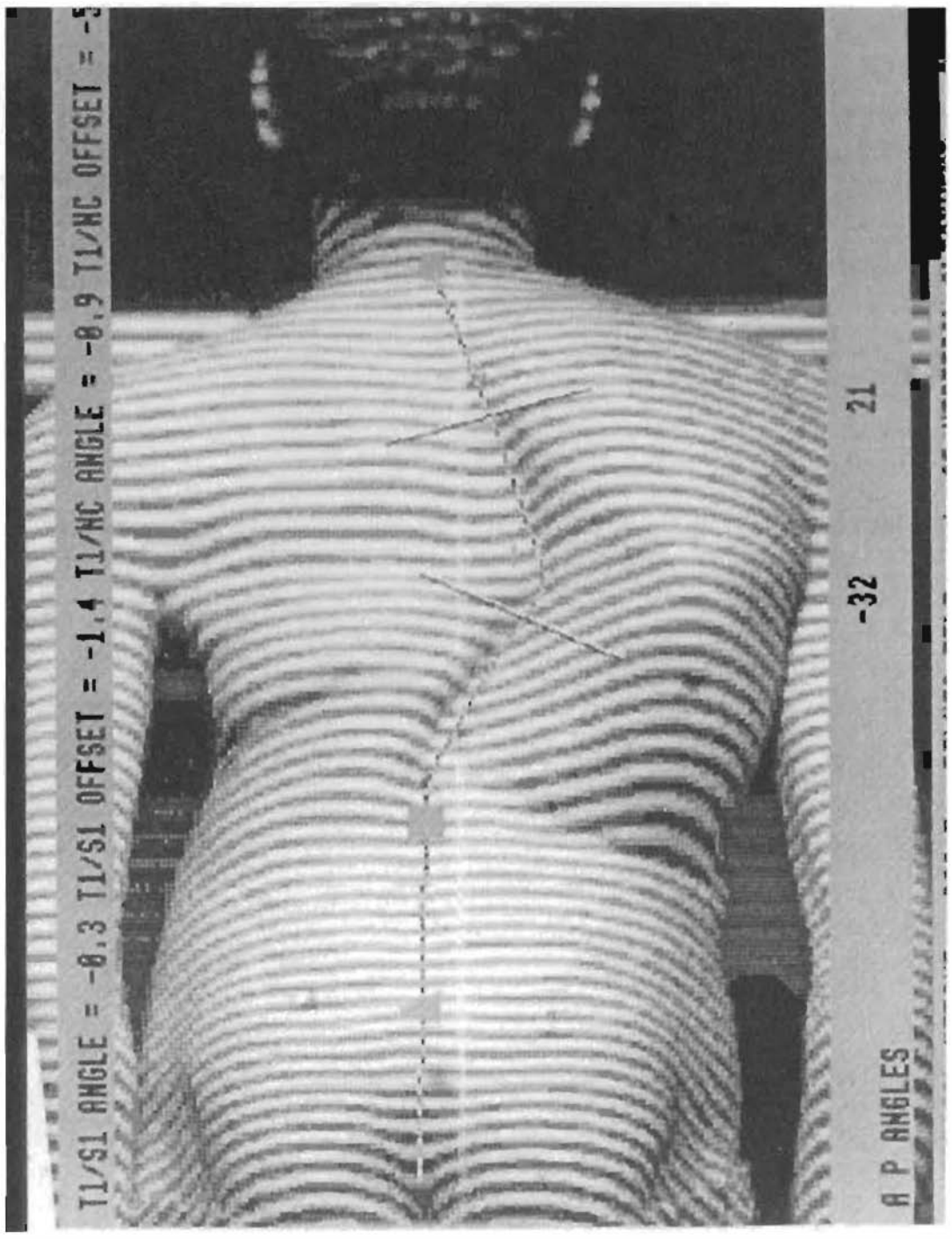

Fig. 14.21 QUANTEC Imaging (Liverpool, UK) of chest wall asymmetry in scoliosis, capable of estimating spinal curvature as well as volumetric difference between rib hump and opposite side.

On the erect standing antero-posterior X-ray view, a standard measurement of the side-to-side bend (Cobb, 1948) and the rotation (Perdriolle and Vidal, 1985) allows comparison with similar measurements made at intervals of months or years. The Cobb method uses an ordinary protractor to measure the curve(s) in degrees, and the Perdriolle method uses a specially designed protractor to measure the rotation. On this view, the extent to which the spine is out of balance – that is, by how many centimetres the cervicothoracic junction is shifted off to one side of the lumbosacral junction – can also be measured (Fig. 14.22). This information is of particular importance when considering the possible need for surgery.

These X-rays should also show the iliac crests so that a rough assessment can be made of the patient's skeletal maturity (Risser, 1958); in general, idiopathic spinal curvatures will cease or slow in their progression as skeletal maturity is reached (Fig. 14.23). The lateral view (standing) is used to assess the extent of lordosis or kyphosis.

The rib hump

The rib hump is measured by one of a number of devices available for this purpose, either directly on the patient's back or by one of the photographic

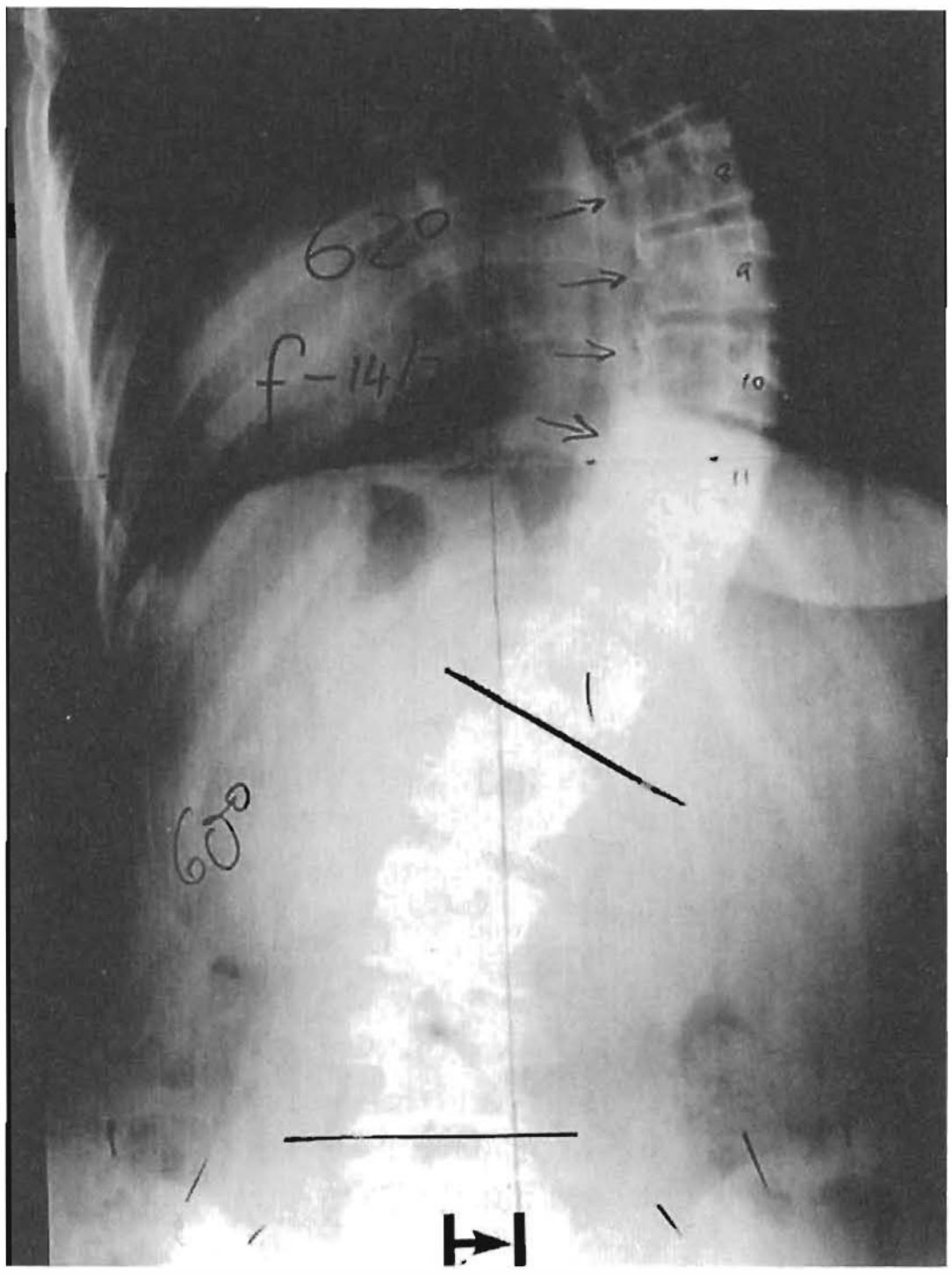

Fig. 14.22 Antero-posterior view of spine from behind, taken with patient standing erect. Both curves measured by the Cobb method and showing spine approximately 2 cm out of balance to the right.

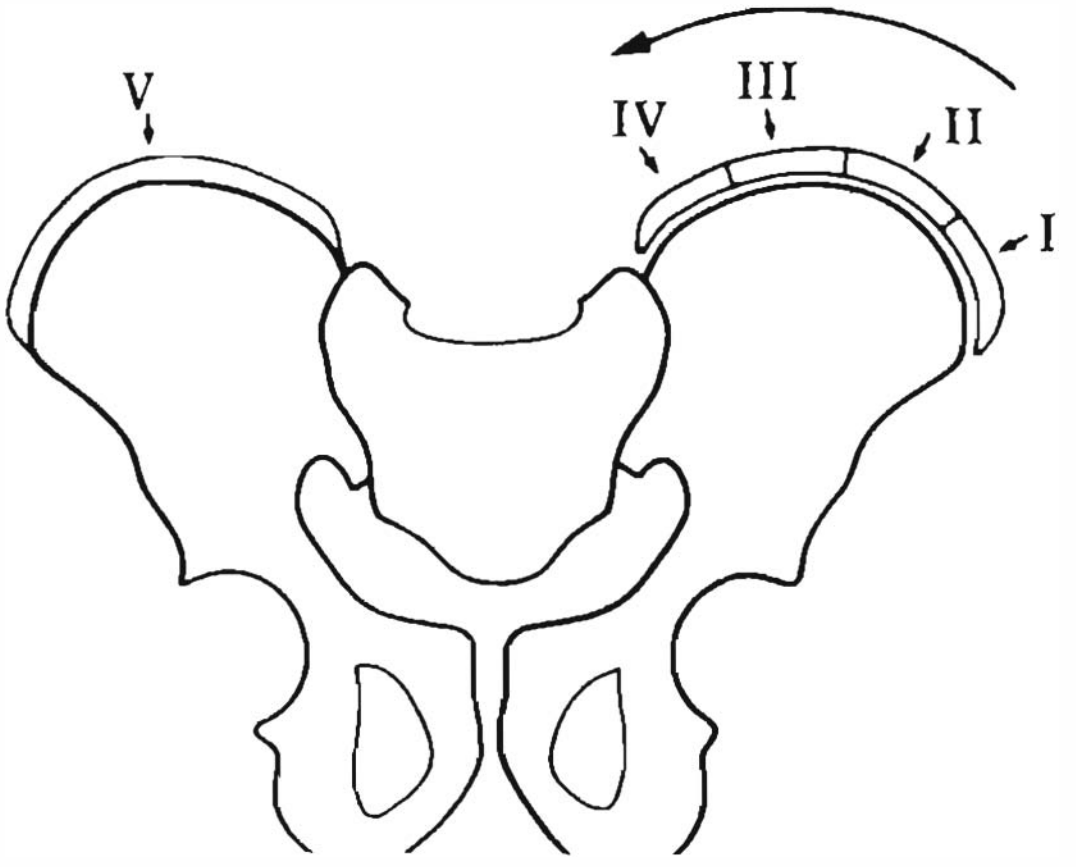

Fig. 14.23 Iliac apophysis appears progressively from lateral to medial as child reaches bone growth maturity. Risser IV indicates maturity, often coinciding with a halt in the progression of mild to moderate curvatures.

imaging techniques (FORMETRIC; ISIS; QUANTEC). A very simple but useful measure is that produced by a spirit level (inclinometer) placed transversely across the rib hump in the forward-bending position. However, the QUANTEC technology can provide a volumetric measure of the rib hump, reflecting more accurately the part of the deformity that most distresses the patient.

Further examinations

Further examinations depend on circumstances; if the patient with idiopathic scoliosis is being considered for surgical treatment, AP X-rays will be needed with the patient bending to each side as far as possible in order to assess curve stiffness. In congenital scoliosis, there is always the suspicion that there may be other abnormalities in the spinal canal (split cord or diastematomyelia), kidneys and heart. Consequently, CT, MRI, myelography, intravenous pyelography and cardiac and lung function tests are necessary (in varying combinations) in preparation for surgery.

Treatment

Conservative

For many years there was a widely accepted rule of thumb whereby idiopathic scoliosis was left untreated if the Cobb angle was less than 20°; treated conservatively in a brace ('Milwaukee' or 'Boston') if it was between 20° and 40°; and treated by a spinal fusion operation if it was beyond 40°.

This rule remains current in many centres, but variations are appearing in others; bracing has been abandoned, not only because it is unacceptable to self-conscious teenagers but also because recent studies have raised serious doubts as to its efficacy (Dickson *et al.*, 1980). There is a trend to recommending surgery for curves reaching 35°. The controversy over bracing is far from settled. The non-bracing philosophy relies on the progression of the scoliosis halting spontaneously, or on the scoliosis progressing to 35° and beyond to prove the need for surgical treatment. However, a recent report by Lupparelli *et al.* (1999) indicates that considerable benefit may be gained through the use of braces that permit motion away from the deformity. This results in forces being generated which act to correct the deformity. There was a time when it was thought that certain exercises had some influence on the deformity, but this has been disproved; the only exercises now prescribed are as part of a bracing regimen.

Electrical stimulation of the muscles on the convexity of the curved spine (at night-time) has been used as a substitute for bracing mild curves because it is more acceptable to patients, and because it was seen to counteract some muscular imbalance thought to have produced the scoliosis in the first place. This treatment again remains controversial, but is certainly less popular than previously.

Surgical

The decision to opt for surgery is based on three factors:

1. Curve severity - the degrees of bend (Cobb angle) and rotation with rib hump
2. Curve dynamics - the rate of curve progression, the curve stiffness, and spinal balance
3. The skeletal maturity of the patient - the level of development of the whole patient as well as the bone of the spine, irrespective of the patient's chronological age.

A decision in favour of surgical treatment is likely to be made for patients:

- with a progressive curve which barely corrects on side-bending and shows a definite list to one side
- where the curve is greater than 35°
- with an unsightly rib hump
- with a Risser sign of III or less and who have not yet reached the menarche (Fig. 14.23).

The purpose of surgery is not only to halt progression of the curve, but also to achieve some correction of the curve and its rib hump. All the operations involve a spinal fusion (bone graft) of some sort, in order to slow the growth of the spine and to stabilize it in the grafted position. All modern operations involve the insertion of some system of metal fixation to stabilize the spine until fusion is complete; all these systems provide some correction as well.

In congenital scoliosis, the purpose of surgery is to set the stage for future growth to halt the progression of the deformity and possibly reverse it, but striving too much to achieve correction during the operation can be dangerous for the spinal cord.

The operations most commonly performed (together with bone grafting) are:

1. Harrington posterior instrumentation (Harrington, 1960). A rod supports hooks at either end so as to spread open the concavity of the curve (distraction); this is sometimes combined with a compression system on the convex side.
2. The Harrington-Luque technique. This is as above, but sublaminar wire loops along the concavity are used to help pull the curved spine towards the straight rod (thus most closely resembling the old orthopaedic symbol of Andry's deformed tree, see Fig. 14.24).

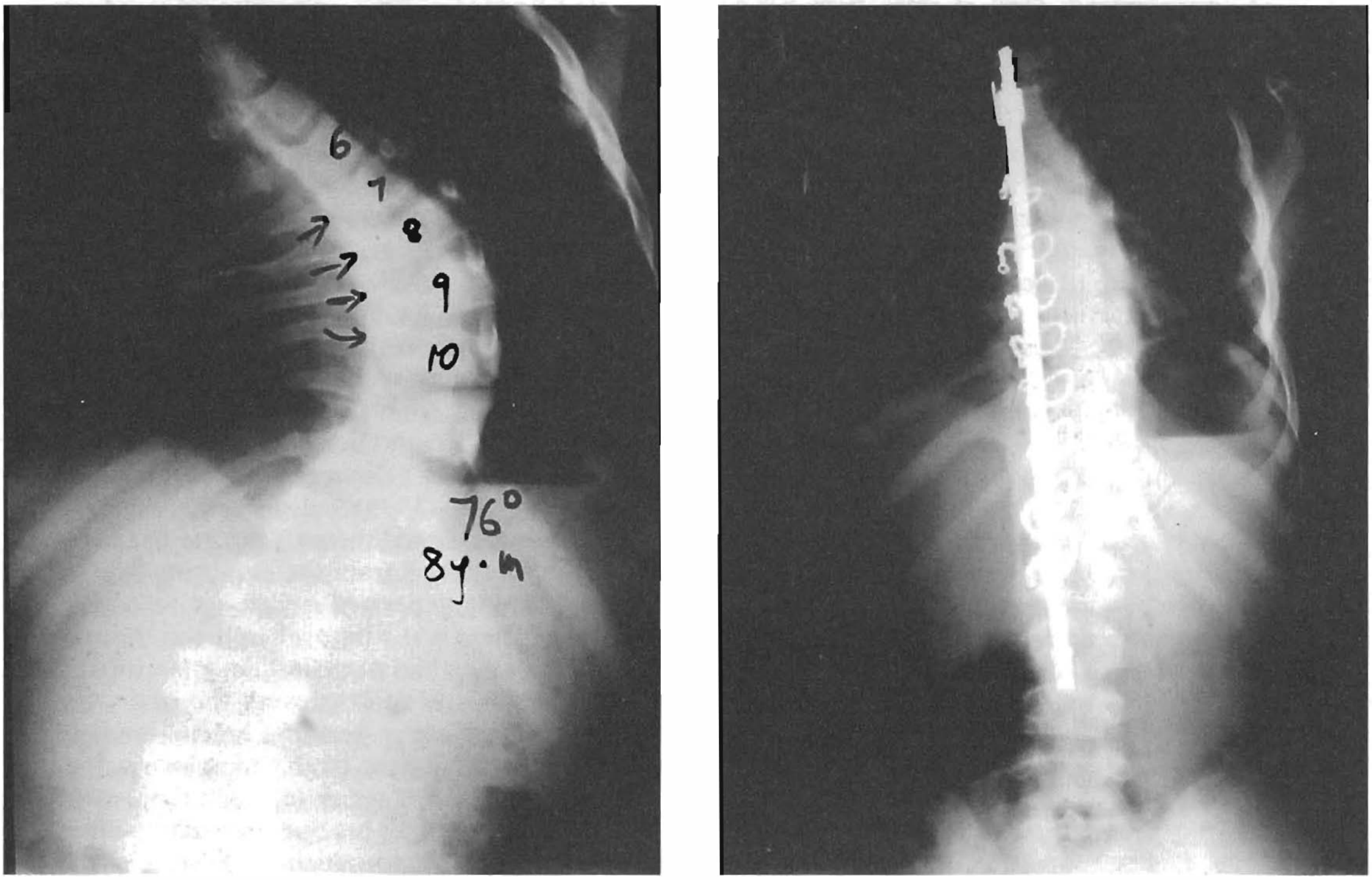

(A) (B)

Fig. 14.24 (A) Severe (76°) progressive curve of early onset scoliosis in an 8-year-old boy. (B) The effective use of Harrington distraction rod and sublaminar wire loops in achieving impressive correction of curve and restoration of balance is demonstrated in the same patient.

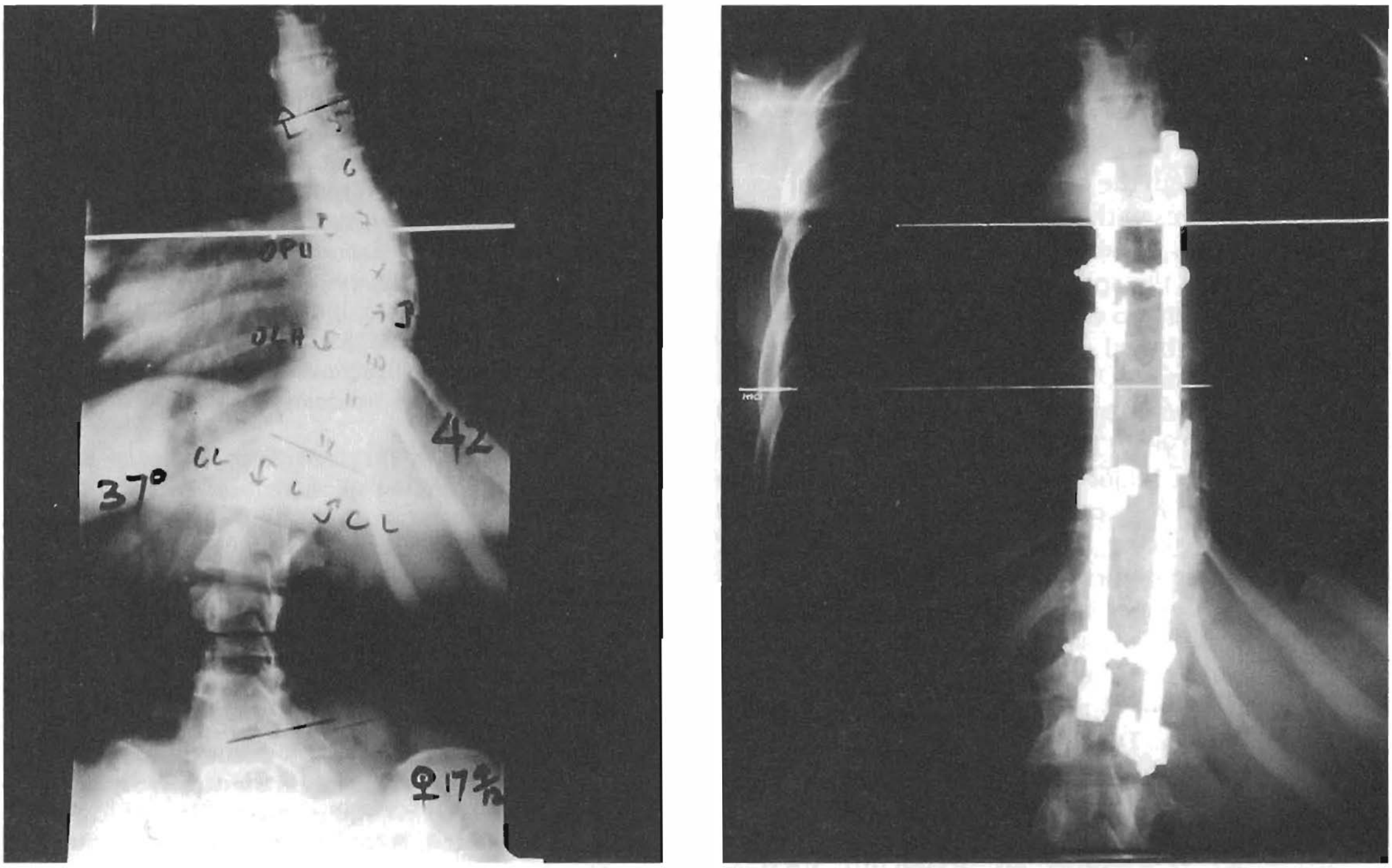

(A) (B)

Fig. 14.25 Adolescent idiopathic scoliosis 42°. (A) Out of balance. (B) Corrected to 15° with restoration of balance by the more recent Cotrel-Dubousset technique.

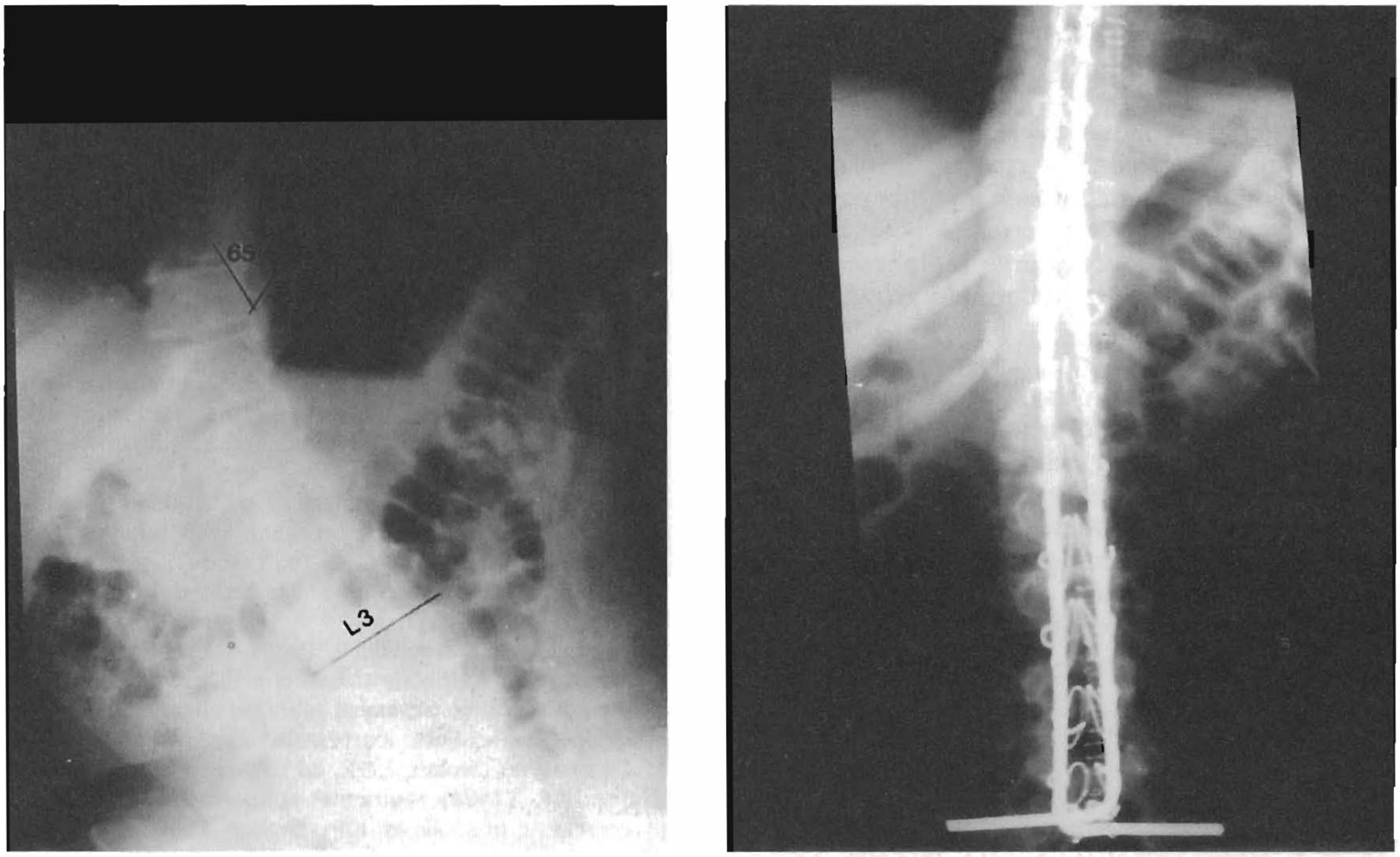

(A) (B)

Fig. 14.26 Long C-shaped curve of neuromuscular (Duchenne's) scoliosis. (A) Markedly out of balance. (B) Reduced and balanced by Luque segmental sublaminar wiring to rods.

3. The Zielke method (Zielke, 1982). This is an anterior instrumentation through the chest (and through the diaphragm into the abdomen, if necessary) which places screws transversely through the vertebral bodies, supporting a rod passing through the screw heads. This technique is ideal for curves with an apex at the thoracolumbar junction. It is capable of an impressive degree of derotation of the spine. The Webb-Morley system is a British version of this German method, which in turn was based on the pioneering design of Dwyer in Australia.
4. The Cotrel-Dubousset (CD) method (Cotrel and Dubousset, 1985). This system is applied posteriorly and is a major advance on the Harrington system, using rods on both sides of the spine, and multiple hooks or screws. It is also capable of impressive derotation (Fig. 14.25).
5. The Luque segmental sublaminar system (Luque, 1982). This is a posterior procedure, ideal for neuromuscular (paralytic) scoliosis, where most of the thoracic and lumbar spine has to be fused in one operation. Double rods are secured to the spine by wires looped around the laminae (Fig. 14.26).

Two other procedures are frequently used in conjunction with the above operations, usually under the same anaesthetic: anterior discectomy at several levels, most often through a thoracotomy, to loosen a particularly stiff curve; and excision of part of several ribs in the rib hump (costoplasty) to improve the appearance of the distorted chest wall (Barrett *et al.*, 1993).

In congenital scoliosis it is sometimes necessary to remove all of a 'wedge' vertebrae by a combined anterior and posterior approach. In other patients it is necessary to destroy the vertebral body end-plates along the convexity of a curve (epiphyseodesis) in order to slow down the deforming growth on that side.

In the presence of a stiff, severe kyphosis, such as in juvenile osteochondrosis (Scheuermann's disease), it is necessary to perform an anterior release and posterior compression with fusion. In ankylosing spondylitis, it is too dangerous to operate on the thoracic spine directly for fear of producing paralysis. A combination of osteotomies (cutting across vertebrae) in the lumbar spine and at the cervicothoracic junction, will produce gratifying improvements in posture and forward gaze.

References

Andry, N. (1961) *Orthopaedia*. 1743. Facsimile reproduction of the First English Edition. Philadelphia: J.B. Lippincott Co.

Barrett, D.S., MacLean, J.G., Bettany, J. *et al.* (1993) Costoplasty in adolescent idiopathic scoliosis. Objective results in 55 patients. *J. Bone Joint Surg.* **75B:** 881-885.

Brown, C.W., Duffer, P.A. Jr, Akmakjian, J. *et al.* (1992) The natural history of thoracic disc herniation. *Spine* **17(6):** S97-S102.

Charles, R., Govender, S. (1989) Anterior approach to the upper thoracic vertebrae. *J. Bone Joint Surg.* **71B:** 81-84.

Clinical Standards Advisory Group (1994) *Back Pain*. London: HMSO.

Cobb, J. (1948) Outline for the study of scoliosis. In: *Instructional Course Lectures*, Vol. V (Edwards, J.W., ed.). New York: American Academy of Orthopaedic Surgery, pp. 261-275.

Cotrel, Y., Dubousset, J. (1985) New segmental posterior instrumentation of the spine. *Orthop. Trans.* **9:** 118.

Craaford, C., Hiertonn, J., Lindblom, K. *et al.* (1958) Spinal cord compression caused by a protruded thoracic disc. Report of case treated with anterolateral fenestration of the disc. *Orthop. Scand.* **28:** 103-107.

Dickson, R.A., Stamper, P., Sharp, A.M. *et al.* (1980) School screening for scoliosis: cohort study of clinical course. *Br. Med. J.* **281:** 265-267.

Dvorak, M., Macdonald, S., Gurr, K.R. *et al.* (1993) An anatomic, radiographic, and biomechanical assessment of extrapedicular screw fixation in the thoracic spine. *Spine* **18:** 1689-1694.

Feiertag, M., Horton, W.C., Norman, J.T. *et al.* (1995) The effect of different surgical releases on thoracic spinal motion. *Spine* **20:** 1604-1611.

Findlay, G.F. (1991) Transthoracic approach for thoracic disc and kyphectomy. In: *Operative Spinal Surgery* (Torrens, M.J., Dickson, R.A., eds). Edinburgh: Churchill Livingstone, pp. 81-104.

Findlay, G.F. (1997) Intrinsic spinal cord tumours. In: *Handbook of Clinical Neurology* (Vinken, P.J., Bruyn, G.W., eds). Amsterdam: Elsevier NV, pp. 497-510.

Goldberg, C.J., Fogarty, E.E., Moore, D.P. *et al.* (1997) Scoliosis and developmental theory. Adolescent idiopathic scoliosis. *Spine* **22:** 2228-2238.

Harrington, P.R. (1960) Surgical instrumentation for management of scoliosis. *J. Bone Joint Surg.* **42A:** 1448.

Hulme, A. (1960) The surgical approach to thoracic intervertebral disc protrusion. *J. Neurol. Neurosurg. Psych.* **21:** 133-137.

Jenkins, N., Findlay, G.F. (1995) Spinal metastatic disease. In: *Oxford Textbook of Oncology* (Pockham, M., Pinedo, H.M., Veronesi, C., eds). Oxford: Oxford University Press, pp. 2276-2285

Kurz, L.T., Pursel, S.E., Herkowitz, H.N. (1991) Modified anterior approach to the cervicothoracic junction. *Spine* **16:** S542-547.

Love J.G., Schorn, V.G. (1965) Thoracic disk protrusions. *JAMA* **191:** 627-631.

Lupparelli, S., Tamburrelli, F., Padua, R. *et al.* (1999) The progression action short brace: a different approach to the conservative treatment of thoracolumbar and lumbar ideopathic scoliotic curves. In: *Research into Spinal Deformities* (Stokes, I.A.F., ed.). Amsterdam: IOS Press.

Luque, E.R. (1982) Segmental spinal instrumentation for correction of scoliosis. *Clin. Orthop.* **163:** 192-198.

Mack, M.J., Regan, J.J , Bobechko, W.P. (1993) Application of thoracoscopy for diseases of the spine. *Ann. Thoracic Surg.* **56:** 736-738

Mehdian, H., Shimizu, N., Draycott, V. *et al.* (1989) Spinal stabilization for scoliosis in Duchenne muscular dystrophy. Experience with various sublaminar instrumentation systems. *Neuro. Orthop.* **7:** 74-82.

Micheli, L.J., Hood, R.W. (1983) Anterior exposure of the cervicothoracic spine using a combined cervical and thoracic approach. *J. Bone Joint Surg.* **65A:** 992-997.

Nathan, H., Weinberg, H., Robin, G.C. *et al.* (1964) The costovertebral joints. Anatomical-clinical observations in arthritis. *Arth. Rheum.* **7:** 228-240.

Oille, J.A. (1937) Differential diagnosis of pain in the chest. *Can. Med. Assoc. J.* **37:** 209-216.

Patterson, R.H. Jr, Arbit, E. (1978) A surgical approach through the pedicle to protruded thoracic discs. *J. Neurosurg.* **48:** 768-772.

Peña, M., Galasko, C.S., Barrie, J.L. (1992) Delay in diagnosis of intradural spinal tumors. *Spine* **17:** 1110-1116.

Perdriolle, P., Vidal, J. (1985) Thoracic idiopathic scoliosis curve evaluation and prognosis. *Spine* **10:** 785-791.

Regan, J.J., McAfee, P.C. (1997) Thoracoscopy and laparascopy of the spine. In: *The Textbook of Spinal Surgery*, 2nd edn (Bridwell, K.W., DeWald, R.L., eds). Philadelphia: Lippincott-Raven, pp. 2313-2331.

Risser, J.C. (1958) The iliac apophysis: an invaluable sign in the management of scoliosis. *Clin. Orthop.* **11:** 111.

Rosenthal, D., Rosenthal, R., De Simone, A. (1994) Removal of a protruded thoracic disc using microsurgical endoscopy. A new technique. *Spine* **39:** 1087-1091.

Schellhas, K.W., Pollei, S.R., Dorwart, R.H. (1994) Thoracic discography. A safe and reliable technique. *Spine* **19:** 2103-2109.

Scheuermann, H.W. (1920) Kyphosis dorsalis juvenilis. *Ugeskr. Laeger.* **82:** 385.

Singer, K.P., Goh, S., Leedman, P. *et al.* (1999) Reliability of rasterstereography of thoracic kyphosis. In: *Research into Spinal Deformities* (Stokes, I.A.F., ed.). Amsterdam: IOS Press, pp. 29-32.

Skubic, J.W., Kostuik, J.P. (1991) Thoracic pain syndromes and thoracic disc herniation. In: *The Adult Spine: Principles and Practice* (Frymoyer, J.W., ed.). New York: Raven Press, pp. 1443-1461.

Stone, J.L., Lichtor, T., Banerjee, S. (1994) Intradural thoracic disc herniation. *Spine* **19:** 1281-1284.

Sundaresan, N., Shah, J., Feghall, J. (1984) The trans-sternal approach to the upper thoracic vertebra. *Am. J. Surg.* **198:** 473-477.

Whitcomb, D.C., Martin, S.P., Schoen, R.E. *et al.* (1995) Chronic abdominal pain caused by thoracic disc herniation. *Am. J. Gastroenterol.* **90:** 835-837.

Wood, K.B., Blair, J.M., Aepple, D.M. *et al.* (1997) The natural history of asymptomatic thoracic disc herniations. *Spine* **22:** 525-530.

Yasuoka, S., Peterson, H.A., MacCarty, C.S. (1982) Incidence of spinal column deformity after multilevel laminectomy in children and adults. *J. Neurosurg.* **57:** 441-445.

Zielke, K. (1982) Ventral derotation spondylodesis: results of treatment of idiopathic lumbar scoliosis. *Z. Orthop.* **120:** 320-329.

15

Chiropractic management of thoracic spine pain of mechanical origin

D. J. Lawrence and B. Bakkum

Examination

Conservative management of a patient begins with a thorough medical history and physical examination. This is especially true for patients with thoracic spine pain. Several pathologies that are potentially life-threatening have thoracic pain as part of their clinical picture. It is imperative that the health care practitioner understands the nature of a given patient's problem(s) so that an informed decision can be made as to whether or not a patient is a candidate for conservative management.

Taking a history is the first step in evaluating a patient's condition. It is essential to take a complete history because, in the vast majority of cases, the information gathered will lead the physician to the correct diagnosis. It is in the history that the patient's subjective complaints or symptoms are discussed. A patient's history usually consists of a chief complaint, present illness and a past medical history (Prior and Silberstein, 1977).

The complement to the history is the physical examination. This is the process by which the objective findings or signs of a patient's condition are noted by the physician. It entails not only the actual physical examination of the patient (DeGowin and DeGowin, 1976) but includes orthopaedic and neurological testing (Hoppenfeld, 1976). Diagnostic imaging and laboratory procedures may also be performed.

Subjective findings associated with thoracic spine problems

The most common presenting symptom that patients have is pain. Thoracic spine pain can have many causes, and a careful history is very important in beginning to discern the source of the pain (Sportelli and Tarola, 1992). It is necessary to ascertain the location of the pain by having the patient point to where it hurts. Even though it is sometimes difficult for the patient to reach the location of thoracic spine pain, this procedure usually keeps misunderstandings between the doctor and patient to a minimum. It can also help the physician determine whether the pain is localized or diffuse in nature. The patient is usually able to locate the pain of most injuries accurately. Referred pain from viscera usually results in pain that is difficult for the patient to localize. It is important to find out not only where the pain is presently, but also if it has changed location since onset. Similarly, ask the patient whether the pain radiates. For example, a peculiar set of symptoms has been identified as the T4 syndrome (McGukkin, 1986; DeFranca and Levine, 1995). A mid- to upper thoracic joint dysfunction can cause radiating pain into the head and into both upper extremities. Glove-like paraesthesia in both extremities is also recognized with this syndrome. If the pain radiates to the low back, head/neck or extremities, these areas must be examined as well. Neural irritation usually causes pain that radiates along the course of the peripheral nerve; for example, the pain of intercostal neuralgia is usually severe and runs between the ribs.

The patient should describe the quality of the pain. Different types of tissues have characteristic pain qualities. Ligament pain is usually sharp and well localized, while muscle or tendon pain is dull and aching.

history of trauma. Bone pain, e.g. from a tumour or osteoporosis, usually feels very deep and boring. Fractures, which involve irritation to the periosteum, result in sudden, sharp pain. Vascular pain is poorly localized and usually achy; it often gets worse with exertion and is relieved by rest. Nerve pain is sharp and stabbing, but may also have a burning quality.

Find out when the problem began, and whether there was a sudden onset or if it was gradual or insidious. Usually with a sudden onset there is some associated trauma. Slow onset problems are often visceral, metabolic or degenerative in nature.

Ask the patient about the progress of the problem: is it getting worse, staying about the same or getting better? This information, along with the timing of the onset, can help determine whether the problem is acute or chronic and whether it is of a progressive nature.

It is important to ascertain the setting of the pain. Acute injuries usually cause constant pain in the short term, while chronic disorders may be more episodic. Metabolic or visceral problems, especially tumours, tend to cause constant pain. The time of day that the pain is better or worse should be determined. Tumours tend to hurt more at night.

Determine the provocative and palliative factors associated with the condition. Specific movements or positions that improve or worsen the pain are usually associated with musculoskeletal injuries. Respiratory movements are commonly seen to exacerbate thoracic spine and rib problems. Other types of pain, such as viscerogenic or neurogenic, are not usually affected by changes in position or other movements. Pain from ligament injuries tends to improve with rest and worsen with use. Muscle strains may be worse in the morning and feel somewhat better after the muscle is used. Pain from degenerative arthritis is usually worse first thing in the morning and gets better with mild movement; however, as the day progresses, the pain usually gets worse again.

In order to determine the severity of the pain, have the patient fill out a visual analogue scale. This entails having the person put a mark on a 10 cm line to indicate the perceived severity of the pain. Indicate that the left side of the line represents no pain and the right side of the line is the worst imaginable pain. The location of the mark can then be measured for a quantitative estimation. Visual analogue scales are also useful during the course of treatment in order to ascertain the patient's perception of improvement in pain severity.

Objective findings associated with thoracic spine problems

General

Examination of the patient usually begins as soon as the doctor and patient meet. Gait can begin to be analysed as the patient walks down a hall or enters the examination room. Gross postural changes and abnormalities can be noted. Persistent pain may cause patients to move or shift around to try to find a comfortable position during the history-taking procedure. The patient's discomfort can be generally assessed during the history.

It must be remembered that examination of the thoracic spine may be quite extensive. A chest examination must be performed whenever a thoracic spine problem is suspected. If the history or examination indicate that the head, neck, low back, abdomen or extremities are involved, these areas must be examined in addition to the thoracic spine and chest.

Vital signs

The vital signs should be recorded at the beginning of the physical examination. Establish the patient's height and weight by questioning and then measurement. An unexpected decrease in height could be the result of compression fracture. An increased temperature usually indicates an infection. Pulse, respiratory rates and blood pressure (Reeves, 1995) give information about the cardiovascular and respiratory systems, which form part of a differential diagnosis.

Observation

The patient must be appropriately undressed for the actual inspection. The skin of the back and chest should be inspected, and any lesions or swelling noted. Herpes zoster (shingles) is commonly associated with intercostal nerves and has a characteristic lesion pattern following the course of the affected nerve.

Posture is usually examined with the patient standing and looking forward. Frequently, the use of a plumb line makes visualization of alterations in posture easier. When seen from the side, the patient should normally exhibit a balanced amount of lordosis (anterior curve) in the cervical and lumbar regions and kyphosis (posterior curve) in the thoracic region. There should be gentle transitions between these curves, with no sudden angulations. Excessive kyphosis is most commonly seen in the thoracic spine, and usually indicates that imaging of the spine is necessary (Keim and Hensiger, 1989). Scheuermann's disease (epiphysitis of the spine) is a cause of kyphosis in adolescents. A sharp posterior angulation (gibbus) may indicate a compression fracture. Dowager's hump is a severely kyphotic upper dorsal region from multiple compression fractures usually due to postmenopausal osteoporosis. Round back (i.e. thoracolumbar hyperkyphosis with decreased pelvic inclination) may be indicative of ankylosing spondylitis.

From behind, the patient's spine should be orientated vertically with symmetrical musculature. Any alterations of the ribs, sternum or costal cartilages should be noted. Scoliosis (lateral curvature) is never normal. Most scoliosis is idiopathic, and begins to manifest itself in the pre-adolescent years (Baron, 1991), although degenerative (*de novo*) scoliosis is also commonly encountered (Ogilvie, 1992). Radiographic examination is appropriate to characterize the scoliosis, and the Cobb method of mensuration is commonly used to quantify the condition.

The posture can also be assessed with the patient sitting and bending forward at the hips. Changes in the spinal curves, body symmetry and muscle tone should be noted. Unilateral rib hump or persistent scoliosis during forward bending (Adam's sign) is indicative of a structural scoliosis. A scoliometer may be used to quantify the amount of deformity (Murrell *et al.*, 1993). A myriad of problems outside of the thoracic spine can cause postural changes, and these should be addressed as necessary by the physician.

Musculoskeletal evaluation of the thoracic spine

Active ranges of motion

The active ranges of motion of the torso in the cardinal planes should be evaluated (Magee, 1992). Most of the motion of the thoracic spine is limited by the ribs, except for rotation. The majority of trunk rotation below the level of C2 occurs in the thoracic spine. Since motion of the thoracic spine is linked with lumbar spine and hip motion, the physician must note where the motion is occurring during this portion of the examination. Usually these motions are performed standing, but sometimes they may be done seated, which reduces the effects of hip motion. This examination should be always performed only to the point of pain. Quantification of the motion of the thoracic spine is difficult, but there are a variety of goniometers and inclinometers that are available (Triano *et al.*, 1992).

The patient should be able to flex the trunk to about 90°, with approximately 20-45° of this coming from the thoracic spine. While fully flexed, the patient's spine should be observed for a smooth, even forward curve. With a non-structural scoliosis, the curve will disappear upon forward flexion of the spine. Vertebral rotation due to structural scoliosis will cause a unilateral hump (convex side of curve) and a concomitant hollow (concave side of the curve) on the other side of the spine in full flexion.

Trunk extension (backward bending) in the thoracic spine is typically 25-45°. The thoracic spine should straighten during this movement, or even curve slightly backward. If the patient has an excessive kyphosis, it will remain during this motion.

Lateral (side) flexion should be about 20-40°, and equal to both right and left. Normal trunk rotation is approximately 35-50° to both right and left.

Chest (costovertebral) expansion should be measured with a tape measure at the level of the fourth intercostal space. The difference between full expiration and inspiration is from 4-7.5 cm. Any pain caused by this motion should be noted.

Passive ranges of motion

The passive ranges of motion of the thoracic spine should be determined only after the active ranges of motion have been performed. This will minimize the likelihood of the doctor exacerbating any problems by trying to move the trunk too far. These motions are in the same directions as those for active ranges of motion, and the ranges should be similar or slightly increased. Motions that are painful during the active but not the passive portion of the examination are usually musculotendinous in origin. Pain that is provoked by both active and passive motions may be ligamentous.

Resisted isometric contraction

These are performed in the same directions as the active and passive ranges of motion. Since the thoracic spine is influenced by many muscles that are innervated by multiple spinal cord levels and motor nerves, it is usually difficult to isolate specific muscle weaknesses in this region. Pain of musculotendinous origin is usually made worse during this portion of the examination. Pain that is exacerbated by motion but not by resisted isometric contraction is probably ligamentous.

A recent development is the computerized muscle-dynamometer system (Triano *et al.*, 1992). Various systems can measure not only isometric strength, but also isokinetic, isoinertial and dynamic variable resistance. Many of these systems are designed to test the lumbar spine, but application to the thoracic spine is beginning.

Static palpation

The spinous and transverse processes and paraspinal musculature must be palpated. The entire extent of the ribs and costal cartilages, along with the anterior abdomen, should be examined. The scapulae and surrounding musculature should be palpated. Tenderness, temperature alterations, muscle spasm and areas of diffuse or focal swelling should be noted. Special attention should be paid to areas of pain. Painful areas that are not tender to the touch may be sites of referred pain. With a major deviation of a spinous process associated with trauma, imaging may be necessary to rule out fracture or dislocation (locked zygapophysial joints) (Sharafuddin *et al.*, 1990).

The muscles in the region of the thoracic spine should be palpated for muscle spasm and for trigger points (Travell and Simons, 1983; Vecchiet *et al.*, 1991). Differential diagnosis between myofascial pain syndromes and fibromyalgia is problematic, mostly because of definition misunderstandings (Goldman and Rosenberg, 1991; Goldenberg, 1992). Whenever trigger points are located, the precipitating factors associated with those points should be identified.

Orthopaedic examination

The spinous processes and other bony prominences may be percussed with a reflex hammer. If tenderness is encountered, especially with a history of trauma or neurological deficit, fracture must be ruled out by imaging procedures (Denis, 1983; Meyer, 1992; Wood and Hanley, 1992; El-Khoury and Whitten, 1993).

The Soto-Hall test can help localize the site of injury, especially in the upper thoracic spine. If during this manoeuvre the legs involuntarily bend to relieve pressure in the back/neck (Brudzinski's sign), meningeal irritation is suspected. Naffziger's test may be performed to test for space-occupying lesions in regions of the spinal canal. Kemp's test may help indicate a sprain of the zygapophysial (facet) joints in the lower thoracic spine.

Neurological examination

In the thoracic region, the distribution of cutaneous nerves is such that there is considerable overlapping of the areas of skin they supply. Therefore, if just one spinal cord level or spinal nerve root is compromised, there may be no detectable sensory loss. Several landmarks for locating thoracic dermatomes include the nipple line (T4), xyphoid process (T7), umbilicus (T10), and groin above the inguinal ligament (T12).

The patellar and Achilles' reflexes should be tested, since compromise of the spinal cord in the thoracic region will affect the deep tendon reflexes below that level. Also, with thoracic spinal cord compromise, a Babinski reflex will be present. Alterations of the superficial abdominal reflex and Beevor's sign may be present with lower thoracic spinal cord compromise. Patients with hard central nervous system signs and symptoms are not usually candidates for conservative therapy.

Chiropractic mechanical examination

Static palpation

Static palpation for paravertebral muscle spasm is still considered an important component of the manual examination of the spine.

Joint play assessment

Assessment of joint play or end-feel was developed by Maitland (1986). With the patient in a prone position, the examiner's thumbs are used to press the spinous process of each vertebra in a posterior-to-anterior direction. This pressure is applied in a slow, controlled manner. A slight amount of motion can be detected as the vertebra is moved between the ones above and below. The end of this motion should feel slightly springy. If the normal amount of this 'springing' movement is not detected, or the end-feel stops suddenly (feels 'hard'), hypomobility is suspected. Often this type of joint dysfunction is associated with sharp localized pain that does not linger after the pressure is released. With inflamed joints, the pain is not immediately relieved by pressure release.

Posterior-to-anterior pressure may be applied unilaterally to the transverse processes in a similar manner. Likewise, pressure can be applied to the side of each spinous process in a lateral direction. These procedures test each zygapophysial joint separately. The tests should be performed on both sides of each vertebra. If increased radiation of radicular pain is associated with the pressure, foraminal encroachment is suspected.

End-feel of rib motion can also be assessed. With the patient prone, the examiner's hands are placed over the angles of the ribs with the fingers pointing out at approximately 45°. Posterior-to-anterior pressure is exerted on the ribcage. If one rib appears hypomobile or hypermobile with respect to its neighbours, it may be tested individually by pressing with the thumb on the tubercle of the rib in an anterior-to-posterior direction.

Motion palpation

During the 1930s, Gillet was frustrated with the static misalignment theory of the chiropractic subluxation (Palmer, 1910). He developed the theory that these problems were more accurately described as a lack of the proper subjective degree of motion in the motor unit, and coined the term 'fixation' (Faye and Wiles, 1992). He began to use motion palpation, in which the practitioner induces motion in the joints, to detect these fixations. Today, motion palpation is one of the mainstays of the chiropractic examination of the spine and other joints.

Motion palpation methods are used to determine not only which joints are dysfunctioning, but also the specific direction of motion loss. This information is used to decide the vertebral level(s) that are to be manipulated (some chiropractors prefer the term 'adjusted'), and the line of drive or vector of the force used. It is imperative that other causes of pain, besides joint dysfunction, are ruled out before manipulative therapy is performed so as not to exacerbate a pathological problem.

Motion palpation of the spine is usually performed with the patient sitting. There are also special mobile adjusting tables that allow motion assessment to be performed with the patient prone. A quick evaluation of the entire spine is usually performed before examining the specific problem site(s). Since the whole spine is a single kinetic chain, it is important to assess all of the portions of the spine and not only the areas of pain. Joint dysfunction(s) in one area of the spine may influence and lead to symptoms in another area.

The thoracic spine is very complex to motion palpate because of the extra joints associated with the ribs. For normal motion of the thoracic motor units to occur, the costotransverse joints must also be fully mobile. The influence of the costovertebral joints is not known, as there is currently no protocol to assess the motion of those joints. It is of paramount importance for the physician to recognize the feel of the stabilizing factor the ribs have on the thoracic motor units, even when those joints are normal. The ribs limit lateral flexion in this region to such an extent that motion palpation of lateral flexion in the thoracic spine is usually not performed. Motion of the thoracic spine is assessed in the other cardinal planes of motion: flexion, extension and rotation.

Flexion palpation of the thoracic spine is performed by having the patient seated on a stool or examining table with the practitioner seated behind the patient with one arm placed over the patient's shoulder in order to control the movement of the patient. The thumb of the other (palpating) hand is placed between the patient's spinous processes. The patient's trunk is moved forward in a series of short flexion motions, and the examiner feels for the normal separation of the spinous processes. By changing the level at which the trunk flexion occurs, and the position of the palpating thumb, all of the motor units of the thoracic spine can be examined. Most examiners begin at the bottom of the thoracic spine and move upwards during the examination. Areas of hypomobility (or hypermobility) and areas where pain is elicited are noted.

Extension of the thoracic spine is similarly tested, but the patient's trunk is extended instead of flexed. The spinous processes should normally approximate with this movement. Usually this motion is assessed by placing the examiner's thumb first to one side of the spinous process and then the other. The patient may need to be hyperextended, especially in the upper thoracic region, in order to examine fully the extension of the zygapophysial joints.

Rotation of the thoracic spine is examined in a similar manner. The palpator's thumb is placed first on one side of the spinous process and then the other while the patient's trunk is rotated to one side. Rotation should be assessed in both directions. In assessing rotation of the thoracic spine, it is very important to prevent simultaneous lateral flexion of the trunk occurring.

Costotransverse joint motion of the second to the ninth ribs is assessed by contacting the tubercle of the rib with the palpating thumb. The examiner's other arm reaches in front of the patient to grasp the contralateral shoulder, and the patient's trunk is rotated away from the side of the rib that is being palpated. If the rib is hypomobile, it will feel more prominent than a rib with normal motion at the costotransverse joint. Usually this motion will also induce pain in the hypomobile joint. The pain should diminish once the rotational motion is relaxed. End-feel can also be assessed with this procedure.

To motion palpate the costotransverse joint of the first rib, the practitioner contacts the first rib by palpating in the posterior triangle of the neck. The head and neck are then extended and rotated away from the side of palpation by using the non-palpating hand. At the end of this motion, the first rib should be difficult to palpate. A hypomobile rib will remain palpable. If so, testing the end-feel of the rib in this position will elicit a hard, non-springy end-feel and, usually, pain.

The actual procedures of motion palpation vary from individual to individual such that this can be considered a diagnostic art. Reliability studies involving motion palpation have produced conflicting outcomes (Faye and Wiles, 1992). As future research is conducted, these examination techniques should be refined to as close to a gold standard as science applied to art can produce.

Thermographic recording

Local variations in skin temperature are largely accepted as resulting from changes in the underlying blood vascularity (Plaugher, 1992). Several thermocouple devices, such as the Nervoscope, have been developed for the manual determination of these variations. Reliability studies have not shown consistently good results (Lopes, 1993), and these devices are not widely used at the present time. Infrared thermography appears promising as a clinical procedure, although presently what its appropriate uses should be and its degree of reliability are still questions to be answered (Triano *et al.*, 1992).

Leg-length inequality

There is much interest and controversy regarding leg-length inequality (Manello, 1992). Radiographic procedures appear to be the most reliable techniques for measuring leg-length inequality, especially anatomical short legs. The reliability of measurement methods for determining leg-length inequality is much more controversial, although these methods are commonly used in chiropractic practices. Much more research is necessary into the methods for determining leg-length inequality and the clinical significance of this phenomenon.

Radiographic examination

Some chiropractors use plain film radiography for more than examining for bone pathology. Certain chiropractic techniques use information from X-ray films, along with other procedures, for determining dysfunctional motion segments (Rowe, 1993). In fact, for Medicare reimbursement in the USA, chiropractors are required by the US federal government to show the subluxation(s) they are treating on an X-ray. With research pointing more to the chiropractic subluxation being a dynamic, functional problem, static measurement of bony misalignments on X-rays, while still quite common, is probably declining.

Presenting patterns of signs and symptoms of common thoracic problems (Wyatt, 1992)

Musculoskeletal

The chiropractic subluxation/motor unit dysfunction, which includes segmental hypomobility and, in some cases hypermobility, is usually characterized by localized tenderness and pain. The pain may radiate in some cases, e.g. T4 syndrome. Hypomobile segments are associated with a hard end-feel and decreased motion upon motion palpation.

Myofasciitis, including trigger points, usually has focal muscle tenderness with characteristic referred pain patterns. Attempts to stretch the affected muscle usually exacerbate the pain, as does palpation of the trigger point.

Chronic, dull pain is the hallmark of degenerative disc disease. The pain is usually worse in the morning and becomes somewhat better as the person moves around. By late in the day, the pain begins to worsen again. Radiating pain is possible if spinal canal stenosis, or lateral stenosis, has developed. This radiating pain may be relieved by spine flexion.

Degenerative joint disease of the zygapophysial joints or joints associated with the ribs is characterized by local pain and tenderness at the site of degeneration. In the case of the zygapophysial joints, radiation of the pain is possible if foraminal encroachment has occurred. Rib joint pain is usually exacerbated by exaggerated respiratory movements. Again, the typical daily pattern of pain with degenerative joint diseases is common.

There are various rheumatoid arthridities that can affect the thoracic spine, but most of them usually begin in other regions of the body and affect the thoracic spine only late in the course of the disease. They may all have chronic pain with acute exacerbations. Locally inflamed joints are warm and tender.

Aseptic discitis is most commonly found in the thoracic spine of young people. It produces moderate to severe local pain in the affected disc. Radiographically, a calcified disc may be located.

Infections of the spine, e.g., tuberculosis, are accompanied by fever and poorly localized pain in the early stages. These problems can be devastating, with severe destruction of the disc and vertebrae resulting in gibbus and severe pain.

Osteoporosis is most commonly seen in postmenopausal women, and may present as chronic dull pain from microfractures of the vertebral body. Acute localized pain can result from a frank compression fracture.

Trauma is the cause of many thoracic spine conditions. Vertebral fractures are usually associated with a history of significant trauma, although pathological fractures may have no precipitating incident. Pain and possible neurological deficit are characteristic of these injuries.

Disc herniation is relatively rare in the thoracic spine (Vernon and Cala, 1992; Davies and Kaar, 1993). Localized pain, with radiation if spinal nerve roots are compromised, is a hallmark of this condition.

'Facet syndrome' or sprain of the zygapophysial joint capsule has localized pain and tenderness, especially with movement. Kemp's test may indicate this problem in the lower thoracic spine.

Sprain of any of the joints associated with the ribs is usually characterized by localized tenderness. The pain associated with these problems will often radiate through the chest, and is exacerbated by respiratory movements. Patients may think that they are having a heart attack.

Muscle strains are common in the thoracic region. They characteristically have localized pain and tenderness that is exacerbated by contraction of the injured muscle. Also, if the injured muscle is stretched, the pain will increase.

Whenever a bone tumour is suspected, imaging and diagnostic tests, including blood chemistry, are always warranted. Benign bone tumours are usually associated with a localized and chronic deep, boring pain. If the tumour is expansile it can cause spinal canal stenosis or foraminal encroachment, with the associated symptoms.

Malignant bone tumours, whether primary or metastatic, cause pain that may be focal or diffuse, depending on location. These conditions are always progressive.

Referred pain

Referred pain is usually poorly localized, non-tender to palpation, and does not change with movements or alterations of posture. The following structures and diseases can refer pain to the region of the thoracic spine.

Problems with the inferior surface of the diaphragm can refer pain to the top of the shoulder region.

Conditions that can refer pain to the mid-thoracic or interscapular region include hiatus hernia, coronary artery disease and aortic aneurysm. In the case of a dissecting aortic aneurysm, the pain can be severe.

Problems with the gallbladder, such as stones or inflammation, can refer pain to the right scapula. The spleen, e.g. with rupture, will often refer pain to the left scapula.

The lower thoracic region can be the site of referred pain from peptic ulcers and from an inflamed pancreas. Pancreatic cancer also refers pain to this area.

Renal problems, which can include infections, inflammation and calculi (among others), commonly refer pain to the ipsilateral lower costovertebral angles.

Management considerations for the thoracic spine

Manipulative and adjustive procedures

Introduction

Manipulation has been a well-studied therapy, gaining increasing scientific acceptance. It is of great benefit when joint hypomobility exists and for the treatment of a variety of musculoskeletal conditions.

A host of clinical conditions have been thought to benefit from manipulation. These include uncomplicated and complicated acute or chronic low back pain, disc degeneration and herniation, zygapophysial joint syndromes, sacroiliac joint syndromes and spinal stenosis. Studies such as those by RAND (Shekelle, 1991) and Manga *et al.* (1993) provide extensive literature overviews concerning the effectiveness of chiropractic care and other forms of manipulation in managing back conditions.

Positioning

The thoracic spine may be manipulated in a variety of positions, including prone, supine, side-lying, standing, and using the knee-chest table. Each position has its advantages and may work best for particular motions or a combination of motions.

The prone patient position allows for the use of short-lever, high-velocity thrusts, where easy and effective contacts on the patient's body may be made, and where the weight of the practitioner can be brought to bear on the patient if needed. In addition, the prone position is easily modifiable, so that either flexion or extension of the thoracic spine can be easily achieved. Prone thoracic procedures are in common usage, and may be performed for a variety of restrictions both in the lower and upper thoracic spine. Most often the thrust is delivered through the extended arms of the practitioner, although at times a body drop procedure can be used.

Sitting procedures are best used to create either rotation or lateral bending in thoracic spine joints. The patient's arms are usually crossed in front of the body; the practitioner then uses an indifferent hand contact that reaches around the front of the patient and uses the crossed arms as a lever for the creation of the needed motion. After a contact is made by the contact hand, usually on the transverse process of the vertebra, the thrust can be delivered predominantly by that hand, though the indifferent hand may help in its delivery. Such procedures are used most often for rotational restrictions in the lower thoracic spine; the upper thoracic spine would better be served in such cases by a prone procedure.

The knee-chest position, while less frequently used than the prone position, does confer some benefits similar to that of the prone position, with the addition that it allows for greater induction of extension. This can have benefit for the obese or pregnant patient. It is best used for the lower thoracic spine, again especially for extension restrictions.

Standing techniques allow for the creation of significant amounts of long-axis traction, which the practitioner can induce by taking upward traction on the patient's body prior to adjusting. In general, the patient is asked to relax and 'slump' forward, while at the same time the practitioner induces the upward long-axis traction. Adjustive forces are initiated through the angle of zygapophysial orientation.

Bergmann *et al.* (1994) noted that many within the chiropractic profession feel that supine thoracic procedures are not especially specific and are thus suspect. However, they also noted that there is no evidence to support such a contention and that the procedures do merit serious investigation. The difference between prone and supine procedures is mainly with regard to the specificity of contact by the contact hand. Here, the contact hand necessarily remains passive in the adjustment, acting as a fulcrum point around which the force of the adjustment acts. Adjustive forces are generated by the practitioner's body on the patient, while long-axis traction is created at the same time to help open the joint space and thus allow for optimal movement. Specific contact hand position and placement is important in creating the necessary and desired motion. Care must also be given to specific patient arm positions, which might be crossed or not, depending upon parameters such as patient size, comfort, breast size, etc.

Brief outline of basic types of adjustments

Flexion and extension procedures

Restrictions may be adjusted/manipulated using any of the common patient positions. With a patient placed in the knee-chest or prone position (Fig. 15.1), flexion can be created by contacting the spinous or transverse process of the involved vertebra and thrusting antero-superiorly, thus separating the joint below the level of contact.

Similar motion can also be created by contacting the lower vertebra of a motion unit and thrusting antero-inferiorly; in such cases the practitioner would stand at the head of the table facing caudal, rather than at the side of the table facing cephalad. Such a procedure is best used for upper thoracic flexion restrictions.

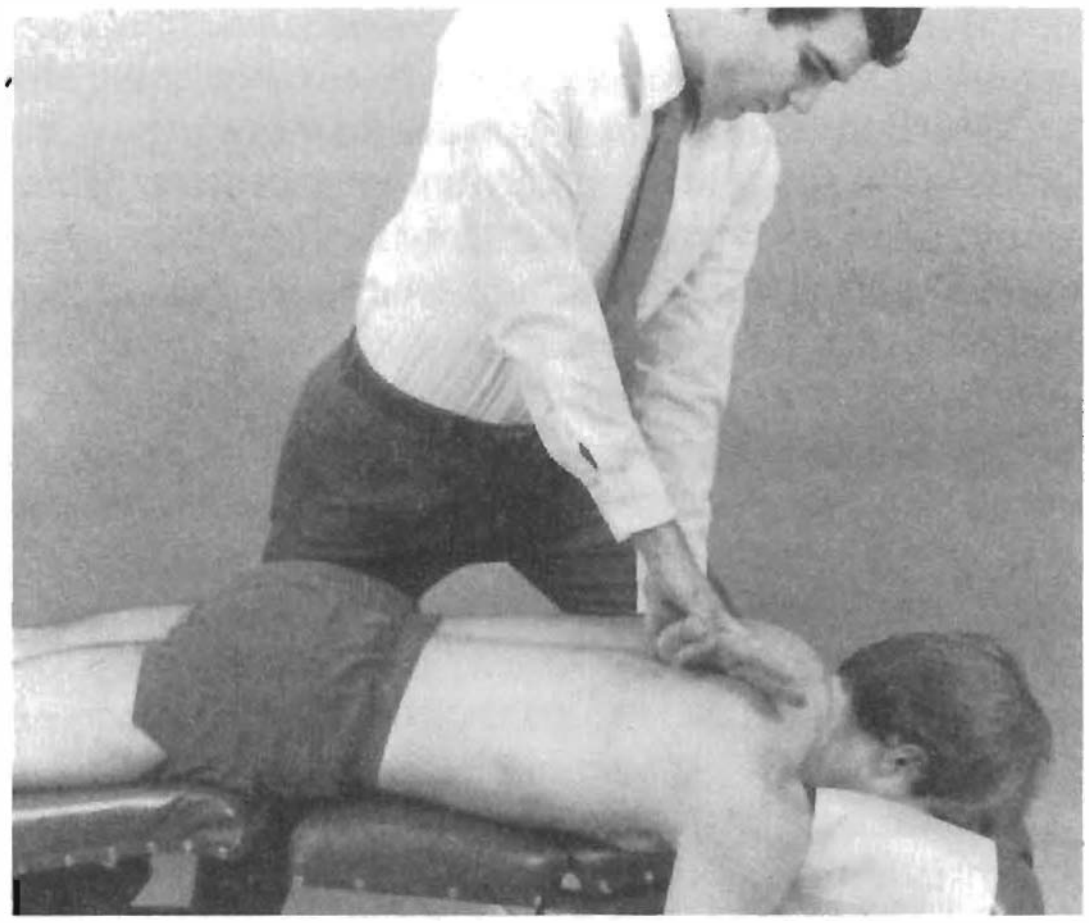

Fig. 15.1 Adjustment for flexion of any thoracic vertebra.

Supine procedures are quite effective for adjusting flexion restrictions; standing procedures are somewhat less so. Both help to create long-axis traction. In the standard supine procedure, the practitioner flexes the patient forward while reaching around the body to make an indifferent hand contact (Fig. 15.2). A contact is made by the contact hand on either the superior or inferior vertebra of the motion unit; placement will determine how the hand acts as a fulcrum. For example, if the contact hand is placed on the superior vertebra, then distraction of the motion segment below the contact will occur; if on the lower vertebra, then distraction of the superior motion segment will occur. Traction and tissue pull aids the practitioner in creating such movement, as does the practitioner's body as it makes its contact through hands on the patient, i.e., the body helps in delivering the thrust.

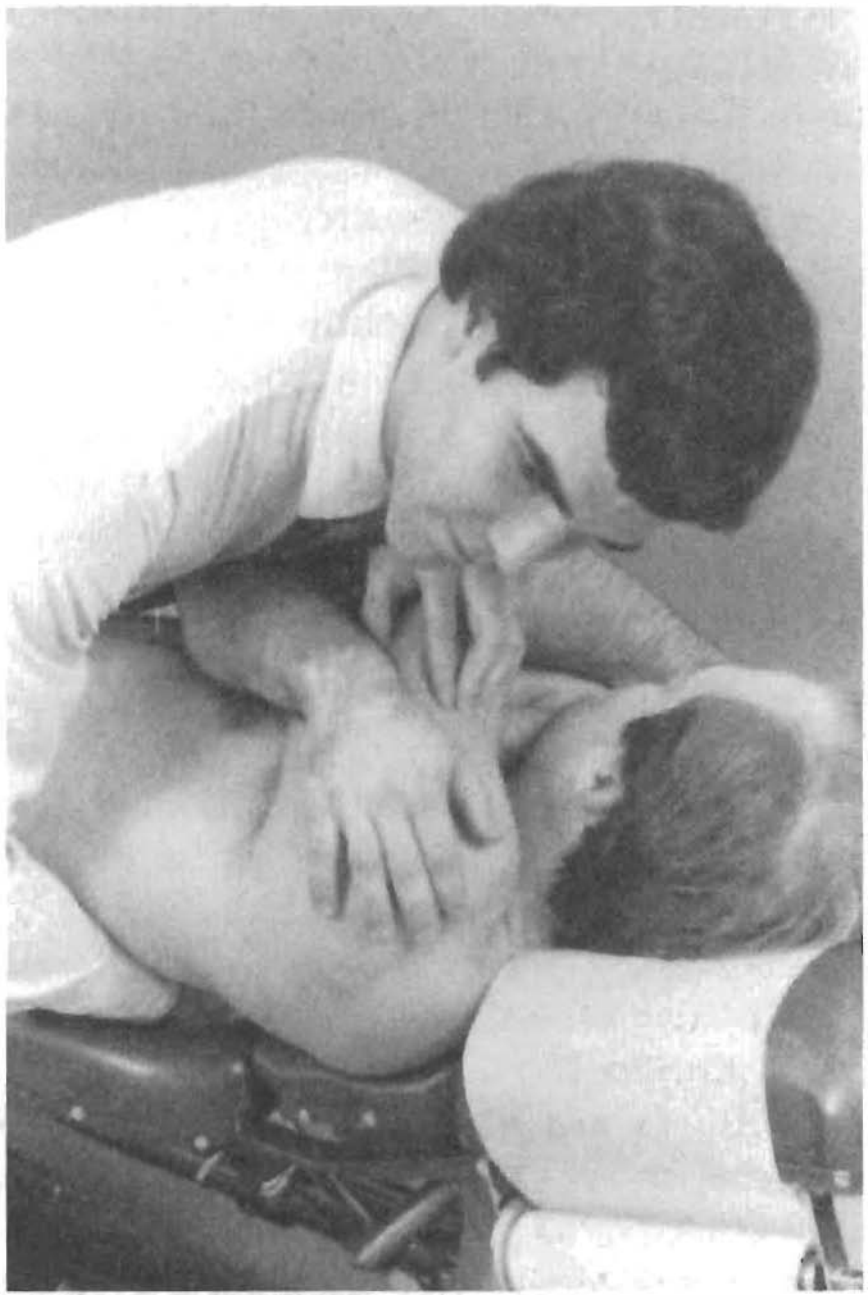

Fig. 15.2 Adjustment for flexion restrictions of any thoracic vertebra.

Lateral flexion

Bergmann *et al.* (1994) noted that 'lateral flexion dysfunction in the thoracic spine may result from a loss of inferior glide of the zygapophysial joint on the side of lateral flexion dysfunction (open wedge side) and/or contralateral superior glide on the side opposite the lateral flexion restriction (closed wedge side)'. While such dysfunction can be adjusted in any of the standard patient positions, the optimal procedures involve the prone or side-lying positions. The prone position requires contact to be made upon the transverse process of the involved vertebra, while the side-lying position uses a contact upon the spinous process. If the lateral flexion restriction has caused a loss of superior glide, contact is made on the transverse process of the superior vertebra on the side that is opposite to the lateral flexion; thrust is made supero-anteriorly. This is the side of closed wedge.

In the prone position, the bilateral transverse process contact is common (Fig. 15.3).

The hand that contacts the side of lateral flexion restriction – that is, the side of open wedge – thrusts antero-inferiorly, inducing inferior glide motion; the opposite hand thrusts in the opposite direction (antero-superiorly), creating superior glide. Breathing instructions are given to the patient so that the thoracic cage is emptied of air and is at rest.

Rotation

Decreased motion of the zygapophysial joints can occur uni- or bilaterally. Fixation may occur on either the side of rotational restriction or the side opposite to it. If on the homolateral side of restriction, there will be a loss of medial and inferior glide with gapping of the zygapophysial joint relative to the one above it. On the contralateral side of restriction, there will be loss of lateral and superior glide relative to the superior facet. Rotational dysfunctions can be adjusted with the patient sitting, prone or supine, although the prone procedure is most commonly used. Contacts are typically made on the transverse process opposite the side of anterior vertebral rotation or opposite the rotation restriction. The thrust is given in an antero-superior direction (Fig. 15.3).

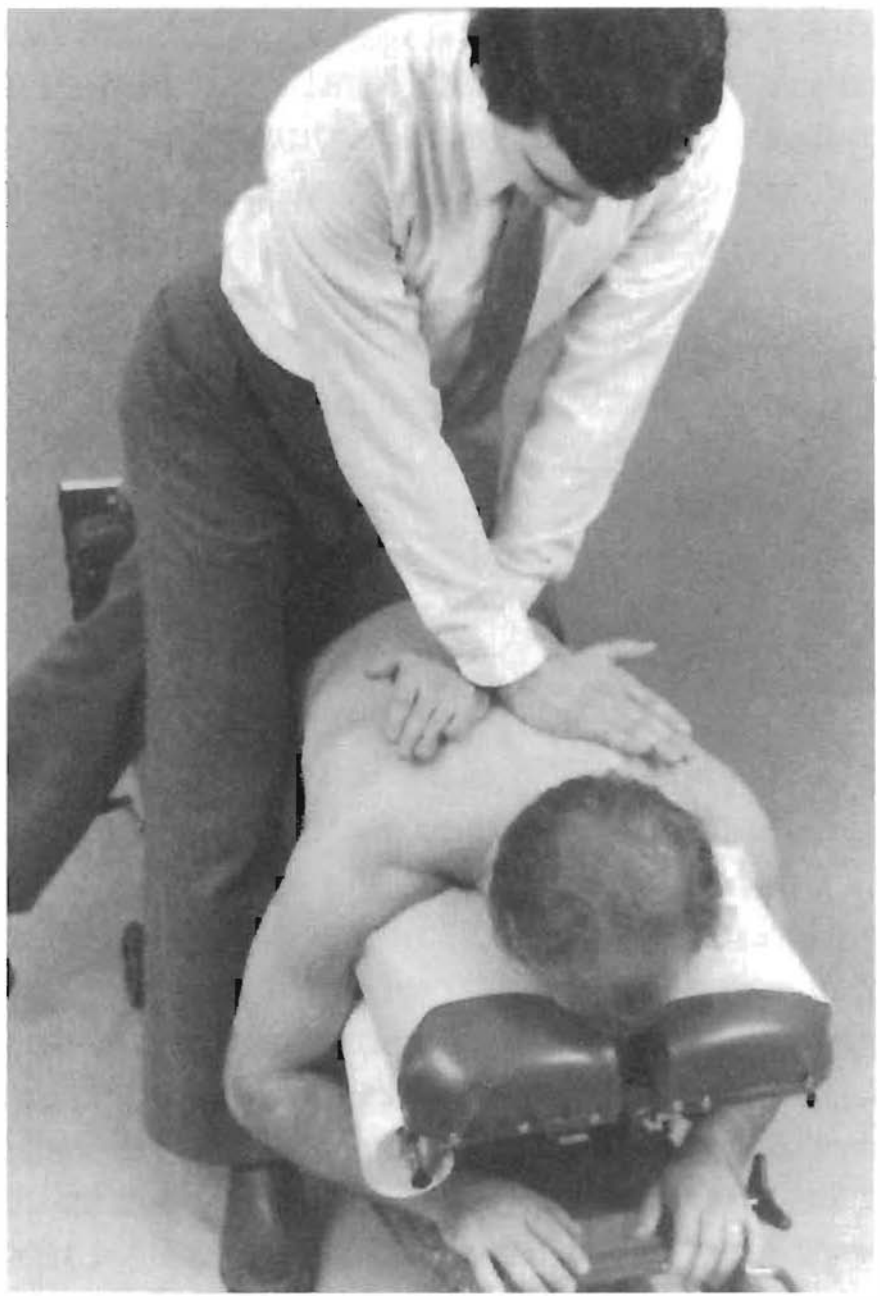

Fig. 15.3 Bilateral transverse process contact.

For the sitting procedure, the contact will again be made on the transverse process, on the side of posterior vertebral body rotation. The patient may be supported by a contact made by the practitioner reaching around to support the patient's crossed arms; also, the contact might be made by grasping the arm of the patient and using it to help create further rotation. It may be necessary to use a second person to hold the patient's legs against the table and keep them steadier during the manipulative procedure.

Classification of spinal manipulation

Grice and Vernon (1992) classify spinal manipulation into three classes: adjustive and manipulation techniques, physiological therapeutics, and non-manual techniques. Of particular interest here are the adjustive and manipulation techniques, which can be further sub-classified as short-lever, long-lever and non-thrust procedures.

One of the more common short-lever procedures is the toggle recoil, wherein a rapid contraction of the triceps muscle allows contacts made by the hands to provide the needed leverage. Thrusts in such cases are high-velocity and short-amplitude. The toggle recoil technique is often used in the thoracic spine with the patient in the prone position. However, the prestressed directional thrust, where a body drop is used while the contact arms are kept extended, is even more common in the thoracic spine.

Long-lever contacts use a contact on the body coupled with a second contact located at some distance from the first. This is best used for a more general contact or for widespread effect upon musculature rather than for specific joint restrictions. Long-lever procedures are less common in the thoracic spine unless a sitting technique is used; they are more common in side-lying procedures for the lumbar spine.

Thrust procedures are generally used for treatment of specific joint restrictions. Mobilizing procedures are used more for joint rehabilitation.

Specific adjustive procedures

A substantial number of chiropractic texts provide information on adjustment for the thoracic spine, and the following procedures are by no means a complete list.

Indication – rotational restrictions of the thoracic vertebrae

In this procedure the patient is placed prone in an antigravity position, in which the thoracic and pelvic sections of the table are slightly elevated with the table headpiece lowered (Fig. 15.1). The practitioner stands on the contralateral side of the table at the level of the patient's thoracic spine, facing the patient at a right angle.

The caudal hand is the contact hand; it makes a calcaneal (heel pad of the hand) contact on the transverse processes with the hand flexed at the metacarpo-phalangeal joints and the fingers pointed obliquely lateral. The indifferent hand makes its contact on the homolateral side of the patient's spine. The contact is palmar in nature.

After instructing the patient to exhale fully and after the joint has been gently moved to articular lock, the thrust is then given in a posterior-to-anterior direction through the caudal hand contact. The indifferent hand remains inactive during the thrust, thus avoiding any excess torque or rotation to the spine.

Indication – flexion of any thoracic vertebra

The patient lies supine for this procedure, with the arms crossed on the chest and the arm contralateral to the practitioner placed on top (Fig. 15.2).

The head of the table should be raised. The practitioner stands at the side of the table in a fencer's stance, positioned at the waist level of the patient. The practitioner will reach across the anterior of the patient with the caudal arm to help in lifting the patient's torso from the table when the thrust is delivered. The contact hand is placed by lifting the patient, then making one of three possible contacts on the involved vertebra: a flat hand contact, where the spinous processes are placed in the palm of the flat hand (best used for thinner patients); a contact where the interphalangeal joints are flexed, so that the spinous process is placed between the calcaneal region and the flexed finger (best used for moderate body builds); and a fist contact, where the spinous process is placed between the calcaneal region and the row of flexed fingers.

The practitioner's sternum is then placed on the patient's crossed arms. As the patient exhales a breath the practitioner tractions the arms both caudally and posteriorly, thus flexing the thoracic spine. Once the exhalation ends, the practitioner uses a deft body drop on the patient, with a line of drive that is posterior and obliquely caudal.

Indication – extension restrictions in the entire thoracic spine

There are a number of variants to the standard standing thoracic technique. These variations centre on the position of the patient's arms, with a consequent modification of the practitioner's body position and contacts made to take the arm position into account. The patient's arm positions can include that shown in Fig. 15.4. The patient crosses the arms in front of the body, and the practitioner then reaches around the front of the patient to hold each arm proximal to the elbow; the patient is flexed forward and the thrust is delivered anteriorly and obliquely cephalad. The thrust is delivered after patient exhalation.



Fig. 15.4 Crossed arm standing thoracic extension technique.

Specific clinical management

It is important that a complete assessment and diagnosis be made; for example, many non-musculoskeletal conditions present with findings quite similar to musculoskeletal ones. Grieve has noted that lesions in the thoracic spine often simulate visceral disease, and at rates higher than might be expected (Grieve, 1986). He also stated that it is possible for the thoracic spine to cause such symptoms as changes in pulse rate, pallor, nausea and dyspnoea. Assessment must therefore combine elements of standard medical diagnosis coupled with accurate palpatory motion and static analysis.

Intervertebral joint lesions

A good number of professionals from a variety of disciplines such as physical therapy, chiropractic, physiatry and osteopathy have discussed pain that arises from zygapophysial joint involvement. Bourdillon (1982) gave this condition the appellation of the 'intervertebral joint lesion'. The concomitants of this lesion include joint hypomobility, tenderness and muscle spasm. Such lesions may also involve elements of the intervertebral disc and/or costovertebral joint (Howley, 1995). It is important to attempt to discern exactly which tissues are implicated in the lesion.

Manipulation has great use in the treatment of intervertebral joint lesions. The procedure is dependent upon which particular restrictions of motion exist. The osteopath Stoddard (1972) advocates the use of the 'fist' technique; Bergmann *et al.* (1994) offer the supine thoracic 'pump handle' procedure.

Mobilization rather than manipulation can be considered when the exact pathology is not well delineated, and where specific vertebral thrusts are not desired. Flexion distraction therapy, as advocated by Cox (1990), is a very useful treatment modality. Cox (1990) noted that the following benefits may accrue: the improvement of metabolite transfer into the disc, reduction of stress on the zygapophysial joints and posterior anulus fibrosus, and the addition of high compressive strength to the spine. Flexion distraction should be instituted when pain can be shown to decrease under distraction, after first perhaps altering its character (such as sharp, localized pain turning into a duller, more generalized pain).

Table 15.1 lists contraindications to flexion distraction therapy.

Cox (1990) places a roll under the patient's abdomen as the patient lies on the specialized distraction table. This has the effect of flattening the spine and bringing the superior facet of one vertebra into a caudal direction to increase the vertical

Table 15.1 *Contraindications to the use of flexion distraction for management of intervertebral joint lesions (Adapted from Cox, 1990)*

- When adhesions have developed in the spinal canal post-surgery
- When adhesions exist around the nerve root
- When a prolapse remains in the boundaries of the vertebral margins but relocates into the spinal canal during traction
- When a shear force influences a displaced disc fragment
- If a patient has hypomobile segments coupled with muscular insufficiency or weakness

diameter of the intervertebral foramen. Goading pressure is then applied to the paravertebral muscles. Careful flexion distraction is applied, with contact being made on the spinous process of the vertebra above the level of zygapophysial joint involvement. Only 5 cm of downward movement is allowed. A pumping type of motion is used while the contact hand maintains a thenar contact on the spinous process. According to Cox (1990), this allows the zygapophysial joint facets to be brought into an open non-hyperextended position. Once the flexion procedure is complete, the motion unit can be moved through its various motions: lateral flexion, rotation and circumduction.

In contrast to Cox (1990), McKenzie (1981) has long advocated extension procedures and, in cases such as this, would use repeated extension.

The T4 syndrome

The T4 syndrome has, as its symptomatology, the following clinical findings: upper extremity paraesthesia and numbness, and generalized headache. DeFranca and Levine (1995) present a thorough treatment protocol for the T4 syndrome, the title of which is somewhat of a misnomer since it can certainly involve other upper thoracic vertebrae. Treatment includes both mobilization and manipulation of the involved vertebra(e). Manipulation can be applied using central posterior-to-anterior pressure on the spinous processes of the involved level using a hypothenar contact. Furthermore, restricted segments may be manipulated using a bilateral pisiform contact procedure (see above), with the impulse thrust affecting existing extension restrictions. Mobilizations consist of 'oscillations were performed slowly at about one to two cycles per second for thirty seconds near the end range of motion (grade IV mobilization)' (DeFranca and Levine, 1995).

Exercises may be provided to increase upper thoracic flexibility and muscle strength. McGuckin (1986) has noted that postural strain is involved in producing the T4 syndrome; thus, postural improvement by exercise may be of benefit. Emphasis should be placed upon correcting slumped posture of the forward carry of the head and shoulders. In particular, the pectoral muscles seem implicated quite frequently, and measures to relieve tightness, such as stretching procedures, are helpful in this regard.

Scoliosis

To date, there is no known way to predict which child will ultimately develop idiopathic adolescent scoliosis. Thus, early identification is of paramount importance, and the goals of therapy are to prevent and if possible correct any deformity, and decrease the rate of progression to ensure that skeletal maturity is reached with as straight and stable a spine as possible.

While older forms of therapy included the use of static devices such as braces or corsets, perhaps coupled with the use of exercise, these were at best only modestly effective. Exercise alone has not been found to be effective in arresting or affecting the scoliotic curvature. Its use with bracing has shown greater promise; for that reason, the Milwaukee brace has been termed 'kinetic' in that exercises performed while wearing the brace can synergistically act to increase the effects of the brace alone.

Today, the use of a kinetic device such as the Milwaukee brace is common. The brace is typically applied when a progressive scoliosis approaches 20°, and it is removed when the curvature has ceased progression over a period of several months and other indicators suggest that skeletal maturity has been reached. For curvatures of less than 20°, watchful waiting is best. The Milwaukee brace was originally designed in 1945, and has since undergone several refinements. It is a cervical-thoracic-lumbar-sacral orthosis (CTLSO); other braces also exist, including a TLSO and an LSO. The brace accomplishes several things: by applying lateral forces against the curvature, it can help to prevent or decrease the existing curvature; it can help to derotate the rib deformity that frequently accompanies the lateral curvature; and it can also help to reduce the existing lordosis while causing distraction forces on the spine.

Curvatures that are above 50° require surgical intervention. At that point, the patient runs the risk of cardiorespiratory impairment due to decreased vital capacity and expiratory peak flow rate.

Fig. 15.5 presents a simplified flow chart for therapeutic decisions in scoliosis.

A Milwaukee brace is typically worn for 23 out of every 24 hours, coming off only to allow for stretching, exercise or bathing.

The lateral electrical stimulator, developed by Axelgard and Brown (1983), is also in use. The stimulator acts to create microcurrents that help to

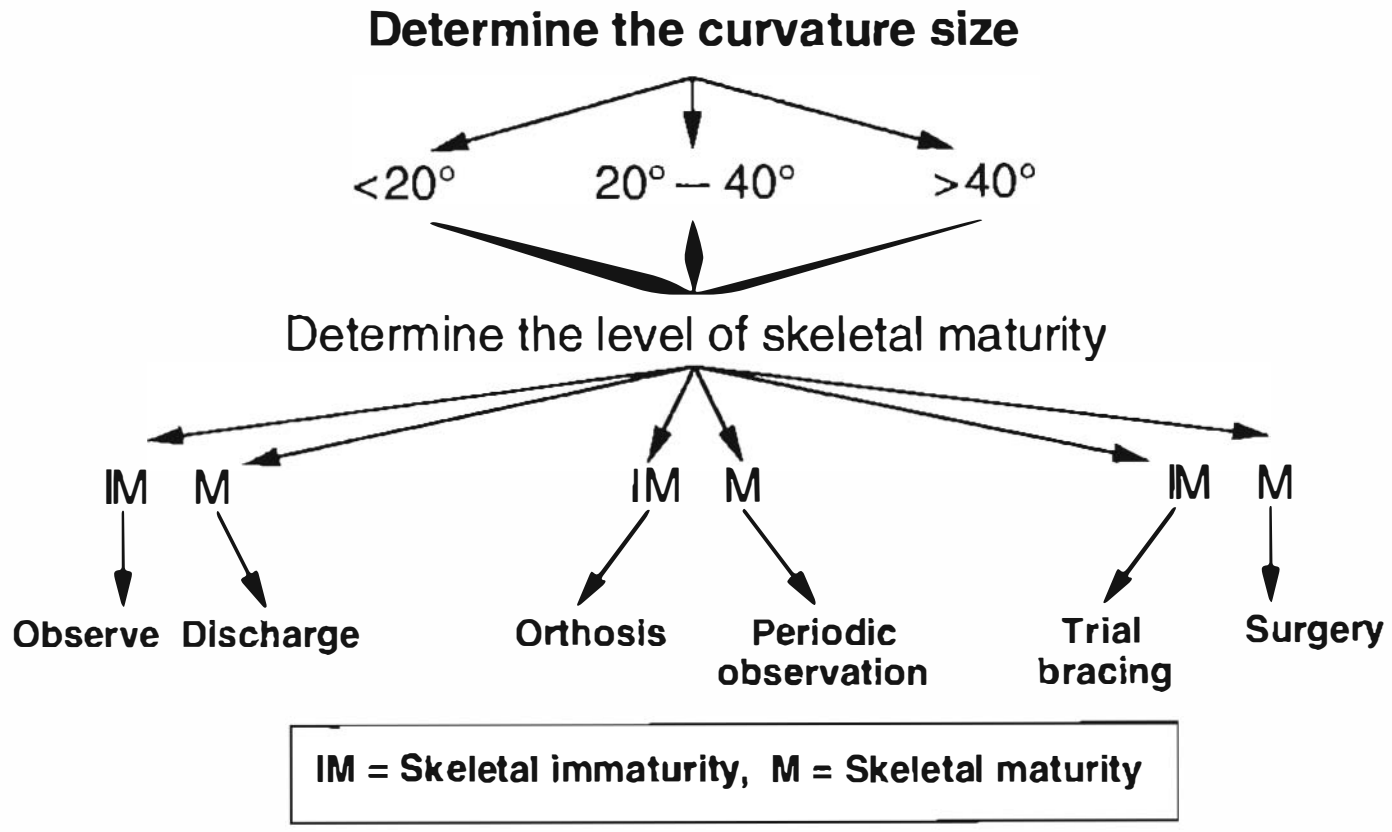

Fig. 15.5 Simplified decision analysis for therapy in scoliosis. (Modified from Bunch and Patwardhan, 1989.)

arrest or decrease curvature status. While initial results held out substantial hope for true correction, later results seem to indicate that effectiveness of the device is similar to that of the Milwaukee brace; that is, it helps to decrease progression and maintain current curvature status. Pads are generally placed at locations in proximity to the apex of the curvature, next to the spine, along the midscapular line and along the posterior axillary line. One advantage of this device is that it is cosmetically more desirable than the brace. These units are typically applied in scolioses between 20° and 30° with curvature apex at or below the fifth thoracic vertebra, and which are at risk for progression.

According to Aspegren (1990), the use of manipulation in the management of scoliosis may help to enhance spinal flexibility. This is thought to be associated with a better prognosis, as flexible curvatures may be less likely to progress and more susceptible to the forces generated by a Milwaukee brace.

However, it is important to note that there are no controlled clinical trials that demonstrate the effectiveness of chiropractic manipulation in the reduction of curvature in scoliosis. Thus, Gatterman (1990) lists a number of roles for the chiropractic physician to play in managing scoliosis. These are listed in Table 15.2 and may vary from one jurisdiction to another, depending upon legislation.

Table 15.2 *The role of the chiropractor in conservatively managing scoliosis (Adapted from Gatterman, 1990)*

- Establish an accurate diagnosis, making use of radiographic confirmation of curvature status
- Provide advice about proper good health habits - diet, exercise, manipulation
- Institute the use of a brace or a lateral electrical stimulator as required
- Monitor treatment through skeletal maturity
- Ensure appropriate non-radiographic clinical follow-up as indicated
- Refer to a specialist if curvature progression warrants - orthotic consultation, surgical consultation

References

Aspegren, D. (1990) Scoliosis. In: *Low Back Pain*, 5th edn (Cox, J.M., ed.). Baltimore: Williams & Wilkins, pp. 309–338

Axelgard, B., Brown, J.C. (1983) Lateral electrical surface stimulation for the treatment of structural adolescent scoliosis. *Spine* **8:** 242–260.

Baron, F.S. (1991) Musculoskeletal system: spine. In: *Fundamentals of Chiropractic Diagnosis and Management* (Lawrence, D.J., ed.). Baltimore: Williams & Wilkins, pp. 331–346.

Bergmann, T., Peterson, D., Lawrence, D. (1994) *Chiropractic Technique*. New York: Churchill Livingstone.

Bourdillon, J. (1982) *Spinal Manipulation*. London: Heinemann.

Bunch, W.H., Patwardhan, A.G. (1989) *Scoliosis: Making Clinical Decisions*. St Louis: Mosby.

Cox, J.M. (1990) *Low Back Pain*, 5th edn. Baltimore: Williams & Wilkins.

Davies, P.R., Kaar, G. (1993) High thoracic disc prolapse in a rugby player: the first reported case. *Br. J. Sports Med.* **27:** 177–178.

DeFranca, G.G., Levine, L.J. (1995) The T4 syndrome. *J. Manip. Physiol. Ther.* **18:** 34–37.

DeGowin, E.L., DeGowin, R.L. (1976) *Bedside Diagnostic Examination*. New York: Macmillan.

Denis, F. (1983) The three column spine and its significance in the classification of acute thoracolumbar spinal injuries. *Spine* **8:** 817–831.

El-Khoury, G.Y., Whitten, C.G. (1993) Trauma to the upper thoracic spine: anatomy, biomechanics and unique imaging features. *Am. J. Radiol.* **160:** 95–102.

Faye, L.J., Wiles, M.R. (1992) Manual examination of the spine. In: *Principles and Practice of Chiropractic* (Haldeman, S., ed.). Norwalk: Appleton & Lange, pp. 301–318.

Gatterman, M. (1990) *Chiropractic Management of Spine Related Disorders*. Baltimore: Williams & Wilkins.

Goldenberg, D.L. (1992) Fibromyalgia, chronic fatigue, and myofascial pain syndromes. *Curr. Opin. Rheum.* **4:** 247-257.

Goldman, L.B., Rosenberg, N.L. (1991) Myofascial pain syndrome and fibromyalgia. *Sem. Neurol.* **11:** 274-280.

Grice, A., Vernon, H. (1992) Basic principles in the performance of chiropractic adjusting: historical review, classification and objective. In: *Principles and Practice of Chiropractic*, 2nd edn (Haldeman, S., ed.). Norwalk: Appleton & Lange, 443-458.

Grieve, G. (1986) *Manual Therapy of the Vertebral Column*. Edinburgh: Churchill Livingstone.

Hoppenfeld, S. (1976) *Physical Examination of the Spine and Extremities*. Norwalk: Appleton-Century-Crofts.

Howley, P. (1995) The thoracic and abdominal region. In: *Sports Physiotherapy* (Zuluaga, M., Briggs, C., Carlisle, J. *et al.*, eds). Edinburgh: Churchill Livingstone, pp. 343-356.

Keim, H.A., Hensiger, R.N (1989) Spinal deformities: kyphosis and scoliosis. *Clin. Symposia* **41:** 3-32.

Lopes, M.A. (1993) Spinal examination. In: *Textbook of Clinical Chiropractic: A Specific Biomechanical Approach* (Plaugher, G., ed.). Baltimore: Williams & Wilkins, pp. 73-111.

Magee, D.J. (1992) *Orthopedic Physical Assessment*. Philadelphia: W.B. Saunders, pp. 304-334.

Maitland, G.D. (1986) *Vertebral Manipulation*. London: Butterworths.

Manello, D.M. (1992) Leg length inequality. *J. Manip. Physiol. Ther.* **15:** 576-590.

Manga, P., Angus, D., Papodopoulos, C. *et al.* (1993) *The Effectiveness and Cost-effectiveness of Chiropractic Management of Low Back Pain*. Ottawa: Manga and Associates.

McGuckin, N. (1986) The T4 syndrome. In: *Modern Manual Therapy of the Vertebral Column* (Grieve, G.P., ed.). New York: Churchill Livingstone, pp. 370-376.

McKenzie, R. (1981) *The Lumbar Spine. Mechanical Diagnosis and Therapy.* Lower Hutt: Spinal Publications.

Meyer, S. (1992) Thoracic spine trauma. *Sem. Roentgen.* **27:** 254-261.

Murrell, G.A.C., Coonrad, R.W., Moorman, C.T. *et al.* (1993) An assessment of the reliability of the scoliometer. *Spine* **18:** 709-712.

Ogilvie, J.W. (1992) Adult scoliosis: evaluation and nonsurgical treatment. *Instruct. Course Lect.* **41:** 251-255.

Palmer, D.D. (1910) *The Chiropractor's Adjuster: The Science, Art and Philosophy of Chiropractic.* Oregon: Portland Printing House.

Plaugher, G. (1992) Skin temperature assessment for neuromusculoskeletal abnormalities of the spinal column: a review of the literature. *J. Manip. Physiol. Ther.* **15:** 365-381.

Prior, J.A., Silberstein, J.S. (1977) *Physical Diagnosis.* St Louis: Mosby.

Reeves, R.A. (1995) Does this patient have hypertension? *JAMA* **273:** 1211-1218.

Rowe, S.H. (1993) Plain film radiography in chiropractic. In: *Textbook of Clinical Chiropractic: A Specific Biomechanical Approach* (Plaugher, G., ed.). Baltimore: Williams & Wilkins, pp. 112-149.

Sharafuddin, M.J.A., Hitchon, P.W., El-Khoury, G.Y. *et al.* (1990) Locked facets in the thoracic spine: report of three cases and a review. *J. Spinal Disorders* **3:** 255-258.

Shekelle, P.G., Adams, A.H., Chassin, M.R. *et al.* (1991) *The Appropriateness of Spinal Manipulation for Low Back Pain.* Santa Monica: RAND/R-4025/1-CCR/FCER.

Sportelli, L., Tarola, G.A. (1992) The history and physical examination. In: *Principles and Practice of Chiropractic* (Haldeman, S., ed.). Norwalk: Appleton & Lange, pp. 261-300.

Stoddard, A. (1972) *Manual of Osteopathic Technique.* London: Hutchinson.

Travell, J.G., Simons, D.G. (1983) *Myofascial Pain and Dysfunction.* Baltimore: Williams & Wilkins.

Triano, J.J., Skogsbergh, D.R., Kowalski, M.H. (1992) The use of instrumentation and laboratory examination procedures by the chiropractor. In: *Principles and Practice of Chiropractic*, 2nd edn (Haldeman, S., ed.). Norwalk: Appleton & Lange, pp. 319-360.

Vecchiet, L., Giamberardino, M.A., Saggini, R. (1991) Myofascial pain syndromes: clinical and pathophysiological aspects. *Clin. J. Pain* **7(Suppl. 1):** 16-22.

Vernon, L.F., Cala, B.M. (1992) High-level disc herniations - are they more prevalent than originally thought? *J. Man. Med.* **6:** 205-207.

Wood, E.G., Hanley, E.N. (1992) Thoracolumbar fractures: an overview with emphasis on the burst injury. *Orthopedics* **15:** 319-323.

Wyatt, L.H. (1992) *Handbook of Clinical Chiropractic.* Gaithersburg: Aspen.

16

Osteopathic management of thoracic spine pain

T. McClune, C. Walker and K. Burton

Introduction

Thoracic spine pain of somatic origin is seemingly less prevalent than lumbar or cervical spine pain, and the literature has less to offer in terms of investigation or reporting of clinical presentations. Nevertheless, patients complaining of pain in the thoracic region are not uncommon in manipulative practice. Estimates vary for the proportion of patients presenting to osteopaths with pain of thoracic origin. In one audit of a UK osteopathic practice, a figure of 13% is given (Burton, 1981); in another, approximately 14% (Hinkley and Drysdale, 1995). A figure as low as 3% has been reported (Welch *et al.*, 1995); however, the difference may be due more to classification of patients than any real difference in presentation. In chiropractic practice in Europe, some 7% of patients present with thoracic dysfunction (Pedersen, 1994). The frequency of conditions specifically related to the ribs was found to be 1.6% in a single osteopathic practice (Pringle and Tyreman, 1993). Obviously, in some patients thoracic symptoms are not of somatic origin and are part of a more serious pathological process within the viscera of the thoracic or abdominal cavity; this must be a dominant thought when presented with a patient complaining of thoracic pain. A part of traditional osteopathic philosophy is that there are viscerosomatic and somaticovisceral reflexes giving rise to a high frequency of somatic manifestations in visceral diseases, particularly notable in the thoracic or cervical spinal segments (Kelso *et al.*, 1980; Beal and Dvorak, 1984). Palpatory findings of muscle tension over the tips of the transverse processes and reduction in costovertebral motion in the left upper thoracic spinal region have been claimed to predict the presence of cardiac or gastrointestinal disease (Beal, 1983). However, this chapter concerns itself largely with what might be termed mechanical or non-specific pain (or related symptoms) occurring in the thoracic region of the back, i.e. the region between T1 and T12, including symptoms radiating laterally and anteriorly around the ribs, together with symptoms affecting the periscapular areas. It is recognized that the source of symptoms may be any part of the thoracic musculature, ligaments and zygapophysial joints, as well as costovertebral structures and periscapular musculature; some symptoms may be referred to other areas such as the upper limbs.

In a general medical practice setting, it is probable that thoracic pain will have a higher presentation rate than that quoted above for manipulative practice. A proportion of these presentations result from disease processes of non-somatic origin, which can be expected to be diagnosed by the doctor and never present to a manipulative practitioner. Fewer than two-thirds of patients presenting to osteopaths in the UK will have had prior medical contact (Burton, 1978), so the osteopath cannot assume that the presenting patient has been fully screened and must initially be concerned with excluding conditions for which manipulation is not appropriate or is frankly dangerous. Once contraindications have been eliminated, then the musculoskeletal assessment and management can begin. However, throughout the management of the case, the signs or symptoms that are considered 'red flags' for serious pathology must always be respected.

The Clinical Standards Advisory Group (1994) quotes thoracic pain as a red flag when relating to spinal symptoms. Whilst thoracic pain may be a red flag if the primary complaint is low back pain, if the presenting symptoms are limited to the thoracic area this recommendation may not be valid. Other factors would perhaps direct decision making; for instance, disease processes within the viscera of the thorax or abdomen may give rise to thoracic pain; this would therefore be an important factor if accompanied by other indications of a serious, possibly life-threatening, condition. However, local spinal tissues may be responsible for symptoms. Thus the clinician must eliminate the possible non-somatic causes of such pain. The reverse of this is that thoracic pain of somatic origin may be confused with visceral disease, with the possibility of unnecessary expensive investigations and much distress to the patient. Financial considerations, particularly within a state-funded national health system, are important, and carry moral and ethical implications. Unnecessarily exposing the patient to fear of a serious disease is also unacceptable.

This chapter will endeavour to outline the approach taken by a 'typical' osteopath, within the clinical setting, towards a patient presenting with thoracic symptoms. It will attempt to illustrate the thought processes that operate when assessing patients and the treatment or management of the presenting condition.

Assessment

The processes detailed below assume prior checking for the red flags detailed in Fig. 16.1 during the course of the assessment. Whilst not necessarily of red flag status, the possibility disease should be borne in mind and specialist opinion sought as appropriate.

Interview

A clinician faced with a patient and a presenting problem needs to progress through a system of fact-finding leading towards a conclusion; this will establish causation and a relevant management strategy for the patient. The first step in this process is the interview. This is probably the first contact between patient and practitioner, and is the start of the relationship. The osteopath needs to build trust and confidence with patients, allowing them to relax and divulge all relevant information. The following areas are of concern:

1. The nature and site of the presenting symptoms
2. The apparent cause of the symptoms
3. The reported history since onset
4. Any relevant previous medical history
5. Symptom modifying factors (aggravating and relieving factors) and diurnal patterns
6. The patient's working environment and psychosocial status
7. Treatment already prescribed, and response to that treatment
8. Signs or symptoms of general ill-health.

There should, in theory, be little difference between the osteopath's interview and that of other clinicians. It is suggested that osteopaths working in an office setting have the time and relationship with the patient to assess the effects of daily activity and the implications they have on the cause and development of the presenting condition.

As stated earlier, something of the order of 11% of patients presenting in a manual therapy practice have pain of thoracic spine origin. The nature and site of this pain can help identify a cause and the likely tissues involved. Local pain signifies joint involvement, particularly if mobility is affected. Diffuse pain indicates muscular involvement, particularly if accompanied by a fatigue pattern in the daily activities. Mild discomfort of a chronic nature may indicate degenerative joint disease. Persistent mid- and upper thoracic pain may indicate a fibromyalgic state.

The reported onset of the problem should indicate both a mechanism of causation and the expected severity of symptoms. The onset may be sudden, involving an identifiable incident (e.g. lifting a heavy object, sneezing), or it may be gradual, following prolonged postural stress (e.g. sedentary work, a prolonged period of stooping). A long, gradual onset may involve degenerative changes within the spinal joints and fibrotic changes within the soft tissues. An acute injury may involve damage to soft tissue or bone. In a case with no identifiable cause, further investigation will be warranted.

The pattern of events since onset can indicate the severity of the condition and hint at the likely response to treatment. A progressively deteriorating situation may be a red flag warning, whilst a gradual improvement in the symptom picture is a positive sign. These considerations may shed light on which point in the natural history of the presenting condition the patient has reached, but, in common with most musculoskeletal problems, a fluctuating course may be expected.

Symptom modifying factors (aggravating and relieving factors) can guide us to tissues responsible for symptoms; they may also have some predictive value here, as in the lumbar spine (Burton and Tillotson, 1991). Early morning stiffness and discomfort suggest inflammatory joint involvement, possibly involving a degenerative process in the affected joints, particularly in a chronic condition. A gradual increase of symptoms and progressive disability throughout the day may indicate a fatigue effect, which indicates the musculature as the primary site of concern.

The patient's working environment may play an important role in the genesis of mechanical thoracic dysfunction. A large proportion of upper thoracic muscular conditions is associated with sedentary work

from medical history	*from clinical examination*
significant trauma mild trauma in the elderly, or osteoporotic **FRACTURE**	visual haematoma acute tenderness to palpation muscle guarding on percussion of vertebrae or rib swelling or palpable heat **FRACTURE**
tobacco abuse age <20ys or >60ys previous history of cancer severe night time pain patient generally unwell ± weight loss patient immunosuppressed (HIV, drug abuse, steroids) neurological symptoms below level of thoracic pain unexplained cough **TUMOUR or INFECTION**	pyrexia palpable swelling acute tenderness to palpation unexplained skin lesions signs of Horner's syndrome finger clubbing enlarged lymph nodes **TUMOUR or INFECTION**
symptoms of cardiac disease symptoms of respiratory disease symptoms of gastrointestinal disease **VISCERAL DISEASE**	positive signs from a cardiovascular examination positive signs from a respiratory examination positive signs from an abdominal examination **VISCERAL DISEASE**

Fig. 16.1 Red flags for potentially serious conditions when presented with thoracic spine pain.

(Kahn and Monod, 1989), particularly such tasks as sitting at a computer or driving a motor vehicle. The amount of time sitting at the work station or in the motor vehicle, combined with ergonomic considerations, are examples of occupational factors which are important in the assessment of the condition.

A growing acceptance that psychosocial issues are relevant in low back pain should lead to exploration of this area with regard to chronic or recurring thoracic pain, though this component has been little investigated. Response to any previous treatment will help to direct treatment, and avoid wasting time on ineffective therapy.

Once a thorough case history has been taken, the clinical examination can commence. It is essential to carry out a comprehensive and thorough examination prior to formulation of an appropriate treatment plan.

Clinical examination

Observation

The patient is observed standing from all sides. General posture is noted, as well as overall morphology, skin appearance, spinal contours and the presence of any deformities. More specifically, the symmetry of the shoulders, scapulae and waist creases are checked from behind. Muscle bulk, especially the trapezei, latissimus dorsi, rhomboid, levator scapulae and the erector spinae muscles, can be compared on either side and related to the right- or left-handedness of the patient. Any readily apparent alteration in muscle tone is noted. The spine is observed for any lateral curvature (scoliosis). In the presence of a scoliosis, the pelvis is also examined for symmetry by placing the thumbs on the three prominent landmarks - the posterior superior iliac spine, the iliac crest and anterior superior iliac spine - to see if they are level.

From the side, the curvature of the spine is examined to see whether the thoracic kyphosis is exaggerated or reduced, either locally or regionally, and the shoulder position is observed for protraction or retraction. The efficiency of posture can be calculated by the centre of line of gravity. This should run from the mastoid process, through the bodies of C1, C6 and T9, anterior to the sacral promontory and acetabulum, through the patella and finally through the talo-navicular joint. Any deviation will place increased stress on the supporting soft tissues.

The patient is then asked to sit down. Ease of movement and adaptation of posture is observed. Normal changes that occur on sitting are an increase in kyphosis and protraction of the shoulders. Sitting should be maintained with minimal effort; the onset of any pain should be noted. Pelvic levels are re-examined to see if they are now equal. The lateral curvature is also re-examined. A temporary lateral curve (i.e. functional scoliosis), which may be due to a leg-length discrepancy, will reduce or disappear on sitting, whereas a permanent lateral curve (i.e. organic scoliosis) will remain. A local protective posture (functional scoliosis) may alter depending on patient posture, and can help indicate the tissue causing pain.

Musculoskeletal assessment

Neurological tests of lower (and possibly upper) extremities, including reflexes, muscle power, sensation and plantar responses, should be carried out if indicated by the symptoms to preclude any spinal cord involvement.

With the patient sitting, a vertebral percussion test can be carried out. The patient slumps forward and the examiner gently taps each spinous process, noting any discomfort. The production of an acute protective spasm may indicate an underlying fracture or pathological condition.

Whilst standing, the patient is asked to carry out active (gross) spinal movements. The overall ease of these movements can indicate pain intensity and give some insight as to the area of dysfunction. All movements should be examined (i.e. flexion, extension, side-bending and rotation). The examiner observes the willingness to move and the overall quality of movement. If there is any limitation in the range of movement through, for example, muscle spasm or a reluctance or fear of moving, then the extent and nature of the limitation is noted. The severity, location, speed of development of any pain associated with limitation, and when it occurs, is also noted. Breathing mechanics can be assessed by placing a thumb horizontally on the rib angle at either side and noting symmetry of movement during inhalation and exhalation. The examiner will now have an idea of which spinal movements reproduce or increase the symptoms, thus giving an indication of the tissues involved.

Passive movement can be assessed with the patient either seated or lying prone. It allows the examiner to assess the state of the skin, muscles and periarticular tissues and the segmental vertebral movement.

Palpation commences with the skin. This is tested for temperature, texture, moistness, colour change and any evidence of dysaesthesia, hyperaesthesia or anaesthesia, which all suggest altered vasomotor activity. Elasticity can be assessed by pinching the skin between thumb and forefinger and observing how quickly it resumes its former tautness. Reduced elasticity occurs in dehydration, ageing and some metabolic diseases.

The subcutaneous tissues are felt for the presence of oedema, which gives a 'doughy' feel. Any areas of (fibrotic) thickening or tenderness, which are often associated with chronic spinal dysfunction, are noted. The paraspinal and periscapular muscles are palpated to assess their physical state. Muscle tone is assessed; normal tone gives a soft feel with a small degree of resistance. A protective muscle state may involve only a few segments or a large area of the thoracic spine; however, it must be noted that the distribution of the protective tone cannot always be used to identify the lesion causing it. The muscle is checked for contracture, which gives a 'ropy' or 'stringy' feel indicative of chronic hypertonicity.

The periarticular tissues are palpated, where possible, for thickening or tenderness, and pressure is applied to the interspinous spaces to check for ligamentous tenderness.

Passive joint mobility can be assessed with the patient lying prone. Downward (postero-anterior) pressure is applied to a spinous process of one vertebra, whilst the interspinous space above is palpated. The spinous process is moved into flexion or extension and actual movement at the interspinous space, as well as an impression of joint 'give', can be assessed. Similarly, side-bending and rotation can be tested using a cross-handed technique on the transverse processes on either side (one hand above, one below the intersegmental joints) using a downward and caudad-cephalad movement. This may be carried out on all segments of the thoracic spine. One hand can then be moved on to the angle of the rib on one side, and movement at the costovertebral joints may be tested - again in any desired plane of movement. If the springing produces a reflex muscular guarding this may indicate an unstable spinal segment (possibly of pathological origin), so care must be taken.

Joint mobility can also be assessed with the patient sitting. The examiner stands behind and side on to the patient, reaching round with the nearest arm clasping the patient's folded arms and palpating either the spinous processes or transverse processes with the other hand. The patient's trunk is moved into flexion, extension, side-bending or rotation using the arms as a lever. The degree of movement and end-point resistance are assessed at each segment on both sides. Soft tissue restriction will give an elastic end-feel with further movement painful but possible, whereas a blocking due to ankylosis has a solid end-feel and may be painless.

Mechanical dysfunction

The assessment of thoracic function aims to compare accepted criteria of normal movement and tissue states to those of the patient being examined. The assessment includes observation and analysis of active and passive movement. The approximate physiological norms need to be known to compare any alterations meaningfully. If it is accepted that alteration of function can be a cause of pain or, less commonly, other symptoms (numbness, pins and needles), the next step is to decide where the dysfunction is occurring. The alterations from normal may reflect structural changes in, for example, the intervertebral discs, or zygapophysial joint arthrosis. The term 'dysfunction' may therefore be misleading, as irreversible pathological change may have taken place in the tissues. The earlier part of the chapter described how the assessment is achieved; this section will attempt to classify dysfunction.

Intervertebral disc

Symptomatic intervertebral disc disease is less common in the thoracic than in the cervical or lumbar spine, though it is a not infrequent incidental finding on spinal imaging (Videman *et al.*, 1994). The anatomy of the vertebral bodies in the thoracic spine tends to protect the intervertebral disc, but if nuclear material does prolapse posteriorly there is potential for nerve root and cord compression. Referred pain in a dermatome may arise not from discal compromise of the root but from other spinal structures or from the adjacent costovertebral joint; in the case of the latter, the pain will tend to follow the line of the rib or intercostal space.

Zygapophysial and costovertebral joints

When the thoracic spine is assessed, there are two groups of synovial joints to be aware of; the zygapophysial joints and the costovertebral joints. Problems can occur within either of these articulations or in both simultaneously; there can be a dysfunction of the zygapophysial joint and/or the costovertebral joint. The cause of the dysfunction will create different clinical presentations (the site of local tenderness and referral pattern will help with discrimination). A muscular component is often present; this can affect the intercostal muscles causing radiating costal pain (the possibility of herpes zoster should, of course, be borne in mind).

Acute joint strain will normally recover within the expected 4-6 weeks. The chronic joint conditions that occur in the lumbar spine are not as evident in the thoracic spine. Degenerative joint changes are also less evident, though diffuse idiopathic spinal hyperostosis (DISH) can extend into the thoracic region.

Muscle

If intervertebral disc disease is frequently asymptomatic, thoracic joint degeneration may cause only a mild degree of discomfort and ligamentous damage is uncommon (due to the relatively limited mobility in the thoracic region), it follows that the tissues most likely to be implicated in chronic or recurrent symptoms are the spinal and periscapular musculature. Adaptive tissue changes occur as fibrosis of the muscle, fascia and connective tissue. This appears to cause reduced aerobic cellular respiration and ischaemic changes in the muscle, with a decrease in elimination of metabolites (notably potassium); fatigue of the muscles occurs with symptoms of muscular aching. There will follow further adaptive fibrotic changes in the muscle tissue. The chronic and recurrent thoracic conditions that often have a large muscular involvement appear to be more prevalent in sedentary workers (Kahn and Monod, 1989).

Viscerosomatic confusion

The clinical picture associated with thoracic pain can be confusing; symptoms may have a visceral or a somatic cause, and the differential diagnosis of thoracic pain includes visceral disease as a cause of the presenting symptoms. Differentiation is not always simple. Even in the absence of any evidence of visceral disease, there still need to be specific signs and clinical findings of mechanical dysfunction to conclude a mechanical origin for the symptoms. There is some reference to this viscerosomatic confusion in the research literature, e.g. pseudovisceral pain referred from costovertebral arthropathies (Benhamou *et al.*, 1993) and diabetic thoracoabdominal neuropathy as a cause of chest and abdominal pain (Harati and Niakan, 1986), but it remains an enigma (Dyck and Embree, 1981). Appropriate investigations obviously depend on the target organ and are outside the scope of this chapter; the issue is mentioned here as a simple warning.

Specific conditions

Other conditions of the thoracic spine, with a specific disease process and pathology, may have a secondary mechanical effect on the spinal structures. The mechanical element may be amenable to assessment and treatment by osteopaths, but details of aetiology, pathology and diagnosis need not be considered here.

Asthma

The thorax is usually held in inspiration with horizontal ribs, giving an impression of a 'barrel chest'. There is either a long kyphosis or an extension group from T2-T4 with a flexed T1-T2. There is hypertonia of the intercostal, respiratory and thoracic paraspinal musculature with possible hypertrophy. The lower ribs become flared, and the upper ones hypermobile. There is a shortening of the antero-posterior diameter of the thoracic inlet, resulting in possible involvement of the brachial plexus. The acromioclavicular and sternoclavicular joints also may show restricted mobility, along with an internal rotation of the glenohumeral joint.

Ankylosing spondylitis

Clinical features include intermittent backache and progressive stiffness, especially of the lower thoracic and thoracolumbar region. The pain and stiffness are worse in the morning, easing after about 1 hour. On examination, there is a reduced lumbar lordosis with an increased thoracic kyphosis and protraction of the shoulders. Spinal movements are severely limited, especially in side-bending, and chest expansion is often reported to be reduced. The sacroiliac joints can be tender with pain reproduced on sacral springing. Neurological signs may be present in the lower extremities due to cauda equina compression, which necessitates immediate surgical referral.

Osteochondrosis

This condition leads to an anterior narrowing of the intervertebral disc with anterior wedging of the vertebral bodies. There is initial pain and tenderness over the affected segments, which subsides after a few months, leaving a kyphosis of varying severity and marked protraction of the shoulders. These changes are, of course, irreversible, and may cause problems later in life due to their effects on posture and a subsequent breakdown of compensatory mechanisms, with a predisposition to spondylarthrosis.

Scoliosis

Adolescent idiopathic scoliosis is known to be associated with back pain and consequent disability and handicap later in life (Mayo *et al.*, 1994). Limited mobility and reduction of antero-posterior curves, notably a tendency to thoracic lordosis (Deacon *et al.*, 1984), have been demonstrated (Ohlen *et al.*, 1988; Poussa and Mellin, 1992), so it is tempting to think that early intervention using physical modalities could be helpful for symptom reduction and improvement of respiratory difficulties, if not necessarily for limiting curve progression.

Management

Aims

Once the osteopath is confident that the patient is presenting with a musculoskeletal problem without serious underlying pathology, an appropriate treatment plan can be formulated. This will be based on information collected during the interview and the findings from the clinical examination.

The underlying principle of treatment is to affect the various component parts to allow them to regain their appropriate function within the general movement of the thoracic spine. This, theoretically, should lead to an improvement in flexibility and normalization of neural input, with subsequent reduction of pain, disability and dysfunction. Treatment consists of a variety of manual techniques
and soft tissues.

Treatment of mechanical dysfunction

Soft tissue techniques

These are slow, rhythmical techniques applied to areas of hypertonic or fibrotic muscles. They aim to induce relaxation, thus increasing circulation to promote oxygen supply and clear metabolites; arguably this should also allow increased range of movement of related joints. Soft tissue techniques can be applied to the majority of the muscle groups of the thorax (the periscapular, erector spinae, trapezei, pectoral muscles, etc.).

Kneading

This is a slow, rhythmical
degree of pressure applied across the muscle fibres. A rate of 10-15 cycles per minute produces a relaxing response; progressive increases in frequency can produce a stimulatory effect to a normal maximum of 36 cycles per minute (Hartman, 1985). The amount of force applied will depend on the build of the patient and depth of the target tissues. The operator places a thenar or hypothenar eminence on the muscle belly, and uses body weight to slowly apply pressure deep enough to affect the tissues without causing undue pain. The response of the tissue is constantly monitored, and once a degree of relaxation is sensed the pressure is eased off. The procedure is repeated until the operator feels that the desired change has occurred.

Stretching

This can be applied across the direction of the muscle fibres or in a longitudinal direction.

In the cross-fibre technique, the operator places a thumb at the medial side of the muscle parallel to the fibres. This is reinforced with the thenar eminence of the other hand; gentle anterior and lateral pressure is applied and held for 3-4 s, and then slowly released. A small extra stretch can be applied at the end of each movement to produce rapid tension release.

Longitudinal stretching is most easily carried out with the patient lying prone. The operator's forearms are crossed with the heel of each hand placed on the muscle belly and the fingers of the hands parallel to each other and to the muscle fibres. The hands are brought slightly together to create slackening of the skin, preventing excessive drag, and then a steady downward pressure is applied as the hands are slowly separated, held for a few seconds and released gently.

Inhibition is a slow, deep, sustained pressure applied to a small localized area. The applicator is usually the thumb, perhaps reinforced by the thenar eminence of the other hand. Pressure is gradually applied and then held for 15–20 s, or until tissue relaxation is sensed, and then slowly released.

Effleurage is a gentle technique working on the more superficial tissues to promote lymphatic drainage or ease acute muscle spasm. A light pressure is applied with a stroking movement in a longitudinal direction. Massage oil or powder can be used to prevent tissue drag.

Articulatory techniques

These techniques employ repetitive passive movements of a joint using a lever and fulcrum; the aim is to improve joint mobility. The joint can be taken to its 'easy' end of range and gently stretched further, or small amplitude movements may be applied. Articulation can also be applied in mid-range, combining different planes of movement. The intensity of pressure and degree of stretch is altered depending on feedback obtained by the operator from the periarticular tissues. The techniques are used in various patient positions, and numerous positions are likely to be used during any treatment session.

Seated

Operator and patient positioning is similar to that previously described for passive movement examination. The operator uses a thumb as a fulcrum on the spinous or transverse processes, and leverage is applied using the patient's arms and upper body to produce movement into flexion, extension, side-bending and rotation. A combination of these movements can also be produced.

Prone

A similar cross-handed springing technique to that used for prone musculoskeletal assessment is employed. Slow, rhythmical pressure is applied over the transverse processes, either in a postero-anterior direction to encourage rotation or a caudad–cephalad direction to induce side-bending. This approach can be modified to articulate the costochondral joints by moving one hand onto the angle of the rib. Gentle pressure on the spinous process with the thenar eminence of one hand will move the joint into flexion or extension. Similar movements can be induced by using the patient's arms or shoulder as a lever, with the practitioner's thumb holding down on the spinous or transverse process.

Side-lying

The patient lies on one side with the hips and knees bent for stability. The practitioner places one hand on the patient's shoulder and, with the other arm, reaches under the patient's upper arm to fix the fingers on the lower transverse process. The shoulder is gently moved backwards to produce rotation of the thorax, and this can be reinforced by varying degrees of pressure on the transverse process. Side-bending can be introduced by reaching under the patient's arm and grasping below two adjacent spinous processes. The practitioner leans backwards whilst pulling upwards on the spinous processes. The ribs can be articulated in this position by fixing on the rib angle and using the patient's abducted arm as a lever to produce side-bending of the thorax.

High-velocity thrust techniques

These involve the rapid application of a force perpendicular to the plane of a joint, producing a joint-gapping effect. Varying degrees of leverage are applied to place the joint in an optimal position so as to target a specific joint, and a high-velocity, low-amplitude force is applied. The speed ensures that gapping can be achieved with the joint in mid-range rather than at end-range, thus minimizing tissue trauma. The sudden force usually (but not necessarily) produces a popping sound, which is probably a result of cavitation in the synovial fluid (Unsworth *et al.*, 1971); the force at which cavitation occurs in a postero-anterior thrust has been found to be on average some 360 N (Conway *et al.*, 1993). The mechanism by which cavitation may change the function of the affected synovial joint is not fully understood, although there is evidence that changes produced within the type II articular mechanoreceptors in the synovial joint capsule induce a response in the spinal muscle tone (Suter *et al.*, 1994). The result is a relaxed muscle and the ability of the adjacent zygapophysial joint to move through a greater range.

Seated

The patient interlinks the fingers behind the neck if the upper thorax is to be thrusted, or crosses the arms so that the right hand is on the left shoulder and the left hand is on the right shoulder if the mid- to lower thorax requires thrusting. The operator stands behind the patient and places a pad (cushion) over his or her own lower chest to act as a fulcrum localizing the force to a specific area in the thoracic spine. The operator reaches round and clasps the patient's elbows, which are used as a lever. Compression then traction and flexion are applied, combined with small amounts of side-bending and rotation. These forces are then rapidly exaggerated in a posterior direction along the patient's humerus. This technique is called a 'lift off'.

Supine

The patient lies with arms crossed as for seated mid- or lower thoracic thrusts, grasping the shoulders tightly. The operator faces towards the patient, reaches across and then places a hand with curled fingers under the patient's thoracic spine so that the thenar eminence and bent fingers are on either side of the spinous processes. This acts as a fulcrum and localizes the thrust to a specific segment. Gentle compression is applied centrally through the patient's arms in an antero-posterior direction. The thrust is applied with the operator's chest along the axis of the humerus.

Prone

This procedure is an extension of the cross-handed prone articulation technique previously described. Using combinations of side-bending and rotation, the thrust is directed in a postero-anterior direction.

Table 16.1 gives a summary of the common therapeutic options that may be considered.

Treatment of specific conditions

Scoliosis

The prevalence of back pain in subjects with adolescent idiopathic scoliosis is high (Mayo *et al.*, 1994), thus many osteopaths are likely to be consulted by patients with scoliosis. However, care must be taken when presented with an idiopathic scoliosis in a growing child; the determinants of curve progression are ill-understood, and there is now good evidence that bracing can be successful. The authors suggest that these patients only be treated under the guidance of a hospital consultant. Later, after curve progression has stabilized, it may be possible to offer symptomatic relief. A range of techniques may be useful, including gentle soft tissue stretching and articulatory approaches to thoracic musculature, intervertebral and costovertebral joints, perhaps combined with a variety of exercises. Although there is no scientific evidence that manipulative treatment can alter structural scoliosis (Nykoliation *et al.*, 1986; Danbert, 1989), it has been claimed that manipulation, especially that aimed at the apex of the curve, may increase flexibility, improve function and possibly give a better prognosis (Danbert, 1989). Thoracic flexion exercises in Milwaukee brace wearers have been shown to have a short-term effect on curvature (Miyasaki, 1980). Whilst there is some doubt that flexion exercises alone can influence thoracic mobility in healthy individuals (Spinal Research Unit, University of Huddersfield, UK – unpublished data), it has been shown that exercises in a small sample of scoliotics did render the spine less rigid (Dickson and Leatherman, 1978). It remains possible that a combination of manual therapy and exercises may improve spinal function and reduce symptoms; any effect on the extent of curvature or rate of progress remains a matter of speculation.

Asthma

Osteopathic treatments can be used to promote the overall wellbeing of the patient rather than having

Table 16.1 *Guidelines to osteopathic treatment of mechanical dysfunction*

Dysfunction	*Soft tissue*	*Articulation*	*High velocity thrust*	*Pain relief*	*Activity/ exercise*	*Advice*
Joint dysfunction (zygapophysial or costovertebral)	paraspinal cross-fibre, stretching	chronic: large amplitude; acute: small amplitude	chronic: springing, AP thrust; acute: AP thrust lift-off	acute: ice packs, NSAIDs	shoulder exercises and thoracic exercises	postural, ergonomic and psychosocial advice
Muscular						
Acute (tissue tear)	gentle cross-fibre, stretch, relaxation	small amplitude	AP springing, lift-off thrust	ice packs, NSAIDs	gentle stretching exercises	gentle activity with gradual increase
Chronic (fibrosis, fatigue)	gentle cross-fibre, stretch, deep friction	large amplitude	AP springing, lift-off thrust	heat	daily shoulder and thoracic stretching exercises	postural and ergonomic advice, daily periods of relaxation

any influence on the disease *per se*. Breathing mechanics can be improved by increasing costovertebral mobility and reducing hypertonia in intercostal muscles, accessory muscles and, in particular, the scaleneii. The thoracic spine is treated to improve mobility and function, although thrust techniques are not recommended, especially if the patient has been taking corticosteroids.

Osteochondrosis

It would be unrealistic to expect to restore full mobility of the thoracic spine, due to the nature of the disease. Therefore treatment aims to improve and maintain mobility of the kyphosis as much as possible, thus reducing the strain on neighbouring structures and aiding their ability to compensate. This can be achieved through a combination of soft tissue, articulatory and, possibly, gentle thrust techniques. Treatment is also directed at improving posture and attempting to limit the subsequent increase in cervical and lumbar lordosis. The young patient is advised to avoid heavy lifting and excessive activity, especially that causing jarring to the spine, to minimize any further deformity.

Ankylosing spondylitis

Arguably, the main aim of treatment in this case is to delay complete ankylosis, thus limiting the deformity and consequent restriction of respiration. How successful this may be is a matter for speculation, but it seems at least reasonable to use physical methods to reduce stiffness. Indeed, it has been shown that exercises reduce longstanding stiffness to the same extent as in recent cases (Hidding and van der Linden, 1995). Osteopathic manual treatment may be expected to have a similar effect. Firm articulation can be used to maintain as much flexibility of the thoracic spine and costovertebral joints as possible (with some care being taken in the early stages), and can be used alongside an appropriate exercise regimen.

Table 16.2 gives a summary of the various therapeutic and management options that an osteopath may choose for the above conditions.

Exercises

Osteopaths regularly prescribe exercises for patients with spinal disorders (Burton, 1981), but do so less frequently than, say, physiotherapists. As well as promoting mobility and increasing muscle strength, daily exercises will also give patients some responsibility for helping their problem. The following exercise regimens may variously be considered appropriate for patients with thoracic spine disorders.

Extension exercises

These are beneficial for patients with a kyphosis, as in osteochondrosis or ankylosing spondylitis. The patient lies supine on the floor over a rolled up towel placed across the thoracic spine to act as a fulcrum. The patient inhales and raises the arms over the head to rest on the floor. This position is held for a few seconds, and the arms are returned on exhalation. This also promotes mobility of the costovertebral

Table 16.2 *Guidelines to osteopathic treatment of specific conditions*

Type	*Soft tissue*	*Articulation*	*High velocity thrust*	*Pain relief*	*Activity/ exercises*	*Advice*
Asthma	stretching of paraspinal and rib muscles	AP springing	small amplitude		shoulder and thoracic exercises to encourage chest expansion	encourage regular exercises and periods of relaxation
Ankylosing spondylitis	stretching of paraspinal muscles	thoracic and lumbar large amplitude movement	small amplitude	NSAIDs and local ice packs during an acute phase	extension exercises	sleeping prone
Osteochondrosis	stretching of paraspinal muscles	large amplitude	small amplitude	NSAIDs during acute phase	extension exercises	postural advice, particularly in adolescents
Idiopathic scoliosis	stretching of paraspinal muscles	small amplitude	small amplitude		flexion exercises	general exercise

joints. To strengthen the thoracic muscles as well as promoting extensibility, the patient sits back onto the heels on the floor and bends forward to rest the forehead on the floor. The arms rest by the sides of the legs, with palms facing outwards. The thoracic spine is then extended, arms externally rotated and head and shoulders raised to flatten the kyphosis whilst ensuring the lumbar region remains flexed. This position is held for an increasing number of seconds. The effect can then be reinforced by abducting the arms to 90°.

Flexion exercises

These can be suggested to patients with adolescent idiopathic scoliosis, in an attempt to increase the length of the posterior spinal structures (Roaf, 1966) and hence reduce the lordotic element of the curve. The patient is seated and reaches back with both hands over the shoulders as far as possible to grasp either side of the upper thoracic spine. The elbows are brought down and together and the patient bends forward, reinforcing the flexion by pulling down with the hands. This position is held for 10-15 s and is then repeated.

Rotational exercises

A combined rotation of the spine and stretch of the erector spinae muscles is achieved by the patient sitting on a stool with folded arms and slowly turning the head and upper body to one side as far as possible without pain and holding this position for 5 s. This is repeated for the other side. The thoracic spine may be stretched by the 'figure-of-eight' exercise. For this, the patient sits in a chair supporting the lumbar spine, interlinks the fingers behind the neck and brings the elbows together, a figure-of-eight is 'drawn' in the air by the elbows, but it is the thoracic spine that makes the movement and not the shoulders. This is carried out for a few minutes, three or four times a day.

General exercise

Swimming is a good form of exercise for the thoracic spine, as well as improving cardiovascular performance. Breaststroke with the head held out of the water is not recommended because patients with thoracic (or cervical problems) often find it uncomfortable. Front crawl and any backstroke are effective styles of swimming. Swimming will stretch shoulder and spinal muscles, stretch thoracic and costovertebral joints, and improve spinal muscle tone.

Advice

The sort of advice offered by osteopaths will have much in common with that offered by other clinicians, and can conveniently be presented in list form:

- Use of ice packs or non-steroidal anti-inflammatory preparations (oral or topical)
- Rehabilitation exercises
- Ergonomic advice
- Training advice for sport
- Relaxation techniques.

The advice appropriate for different conditions is given in Tables 16.1 and 16.2. The concept of a biopsychosocial approach, such as advocated for low back problems (Waddell, 1987), may well be appropriate in cases of thoracic pathology, but has not been investigated in great detail for this group of patients. However, clinicians would be well advised to consider a possible psychological component, particularly for instances of chronic pain with no objective findings.

Summary

Thoracic pain is a not uncommon presentation in osteopathic practice, and many cases will be of mechanical origin with involvement of the soft tissues around the scapulae and ribs, as well as the thoracic spine. In addition, some specific, essentially non-mechanical conditions will have musculoskeletal components that are amenable to osteopathic intervention. Once any red flags for serious pathology or disease have been eliminated, a detailed history and physical examination should be able to give some clue as to the tissues involved and the possible causes. Management will involve a variety of manual treatment methods directed, in the main, to improving functional mobility by attempts to reverse adaptive soft tissue changes or induce muscular relaxation. Many of the soft tissue techniques (as well as exercises) used by osteopaths probably have a biomechanical effect via the viscoelastic nature of the muscle-tendon units. Stretching will elongate these structures and facilitate improved joint movement, but further research is required to optimize such parameters as stretch frequency and velocity (Taylor *et al.*, 1990). The traditional use of high-velocity thrust techniques by osteopaths has applications in the thoracic spine as well as other spinal regions; the effects may well be mediated through reflex responses (Suter *et al.*, 1994). In contrast to the lumbar spine, where there is accumulating evidence for the efficacy of manipulative methods (Shekelle, 1994), clinical trials are lacking for thoracic pain; however, it seems reasonable to assume that a similar level of efficacy will apply, at least for thoracic pain of mechanical origin.

References

Beal, M.C. (1983) Palpatory testing for somatic dysfunction in patients with cardiovascular disease. *JAOA* **82:** 73-82.

Beal, M.C., Dvorak, J. (1984) Palpatory examination of the spine: a comparison of the results of two methods and their relationship to visceral disease. *Man. Med.* **1:** 25-32.

Benhamou, C.L., Roux, C., Tourliere, D. *et al.* (1993) Pseudovisceral pain referred from costovertebral arthropathies: Twenty eight cases. *Spine* **18:** 790-795.

Burton, A.K. (1978) The prior medical contact of osteopaths' patients. *Br. Osteopath. J.* **11:** 19-23.

Burton, A.K. (1981) Back pain in osteopathic practice. *Rheumatol. Rehabil.* **20:** 239-246.

Burton, A.K., Tillotson, K.M. (1991) Prediction of the clinical course of low-back trouble using multivariable models. *Spine* **16:** 7-14.

Clinical Standards Advisory Group (1994) *Back Pain.* London: HMSO.

Conway, P.J.W., Herzog, W., Zhang, Y. *et al.* (1993) Forces required to cause cavitation during spinal manipulation of the thoracic spine. *Clin. Biomech.* **8:** 210-214.

Danbert, R.J. (1989) Scoliosis: biomechanics and rationale for manipulative treatment. *J. Manip. Physiol. Ther.* **12:** 38.

Deacon, P., Flood, B.M., Dickson, R.A. (1984) Idiopathic scoliosis in three dimensions. A radiographic and morphometric analysis. *J. Bone Joint Surg.* **66B:** 509-512.

Dickson, R.A., Leatherman, D. (1978) Cotrel traction, exercises, casting in the treatment of idiopathic scoliosis. *Acta Orthop. Scand.* **49:** 46-48.

Dyck, V.G., Embree, B.E. (1981) The enigma of referred abdominal pain in chiropractic practice: a literature review and case report. *J. Manip. Physiol. Ther.* **4:** 11-14.

Harati, Y., Niakan, E. (1986) Diabetic thoraco-abdominal neuropathy: a cause for chest and abdominal pain. *Arch. Intern. Med.* **146:** 1493-1496.

Hartman, L.S. (1985) *Handbook of Osteopathic Technique*, 2nd edn. London: Chapman & Hall.

Hidding, A., van der Linden, S. (1995) Factors related to change in global health after group physical therapy in ankylosing spondylitis. *Clin. Rheumatol.* **14:** 347-351.

Hinkley, H.J., Drysdale, I.P. (1995) Audit of 1000 patients attending the clinic of the British College of Naturopathy and Osteopathy. *Br. Osteopath. J.* **16:** 17-22.

Kahn, J.F., Monod, H. (1989) Fatigue induced by static work. *Ergonomics* **32:** 839-846.

Kelso, A.F., Larson, N.J., Kappler, R.E. (1980) A clinical investigation of the osteopathic examination. *JAOA* **79:** 460-467.

Mayo, N.E., Goldberg, S., Poitras, B. *et al.* (1994) The Ste-Justine adolescent idiopatic scoliosis cohort study: Part III: Back pain. *Spine* **19:** 1573-1581.

Miyasaki, R.A. (1980) Immediate influence of the thoracic flexion exercise on vertebral position in Milwaukee brace wearers. *Phys. Ther.* **60:** 1005-1009.

Nykoliation, D.C., Cassidy, J.D., Arthur, B.E. *et al.* (1986) An algorithm for the management of scoliosis. *J. Manip. Physiol. Ther.* **9:** 1-14.

Ohlen, G., Aaro, S. and Bylund, P. (1988) The sagittal configuration and mobility of the spine in idiopathic scoliosis. *Spine* **13:** 413-416.

Pedersen, P. (1994) A survey of chiropractic practice in Europe. *Eur. J. Chiropr.* **42:** 3-28.

Poussa, M., Mellin, G. (1992) Spinal mobility and posture in adolescent idiopathic scoliosis at three stages of curve magnitude. *Spine* **17:** 757-760.

Pringle, M., Tyreman, S. (1993) Study of 500 patients attending an osteopathic practice. *Br. J. Gen. Pract.* **43:** 15-18.

Roaf, R. (1966) The basic anatomy of scoliosis. *J. Bone Joint Surg.* **48B:** 786-792.

Shekelle, P.G. (1994) Spinal manipulation. *Spine* **19:** 858-861.

Suter, E., Herzog, W., Conway, P.J. *et al.* (1994) Reflex response associated with manipulative treatment of the thoracic spine. *J. Neuromusculoskel. Syst.* **2:** 124-130.

Taylor, D.C., Dalton, J.D., Seaber, A.V. *et al.* (1990) Viscoelastic properties of muscle-tendon units. The biomechanical effects of stretching. *Am. J. Sports Med.* **18:** 300-309.

Unsworth, A., Dowson, D., Wright, V. (1971) Cracking joints: a bioengineering study of cavitation in the metacarpophalangeal joint. *Ann. Rheum. Dis.* **30:** 348-358.

Videman, T., Gill, K., Battie, M.C. *et al.* (1994) The occurrence rates and intercorrelations of MRI findings of the thoracic and lumbar spine from a male population sample, Seattle, June 21-25: International Society for the Study of the Lumbar Spine.

Waddell, G. (1987) A new clinical model for the treatment of low back pain. *Spine* **12:** 632-644.

Welch, M., Fletcher, P., Piper, C. (1995) A statistical package for clinic audit analysis: a pilot study at the European School of Osteopathy. *Br. Osteopath. J.* **15:** 21-27.

17

Physiotherapy management of thoracic spine pain

D. G. Lee

Introduction

The thorax has received little attention in the literature pertaining to back pain, yet clinicians are presented daily with the challenge of treating both acute and chronic thoracic pain. It was this challenge which initiated the clinical work presented in the text *Manual Therapy for the Thorax – A Biomechanical Approach* (Lee, 1994a). This chapter contains some of the material from this work, and is reproduced with permission.

The thorax can be divided into four regions according to anatomical and biomechanical differences:

1. The vertebromanubrial region (upper thorax) includes the first two thoracic vertebrae, ribs one and two and the manubrium
2. The vertebrosternal region (middle thorax) includes T3–T7, the third to seventh ribs and the sternum
3. The vertebrochondral (middle/lower thorax) region includes T8, T9 and T10 together with the eighth, ninth and tenth ribs
4. The thoracolumbar junction is the lowest region, and includes the T11 and T12 vertebrae and the eleventh and twelfth ribs.

The intent of this chapter is to present the examination and treatment of the thorax following a biomechanical model which has been used clinically (Lee, 1993, 1994a, 1994b) for mechanical dysfunctions of both the spinal and costal joints. Some parts of this model have been substantiated through experimental study (Panjabi *et al.*, 1976), while others remain empirical. For a complete review of this biomechanical model, the reader is referred to Lee (1993, 1994a, 1994b). Examination and treatment techniques for the vertebromanubrial and thoracolumbar regions differ from those for the rest of the thorax, and will not be covered in this chapter.

Conditions of the thorax

According to the medical model, conditions of the thorax may be classified as visceral, metabolic, infective, neoplastic and spondylogenic in origin. It is important for all primary contact clinicians to recognize that visceral disorders can refer pain to the thorax. The pain tends to be dull and deep and not influenced by changes of posture. Rest may not afford relief from the pain.

In addition, some metabolic conditions can affect the thorax. These include ankylosing spondylitis, diffuse idiopathic skeletal hyperostosis (DISH), rheumatoid arthritis, osteoporosis, fibromyalgia, ochronosis, gout, tuberculosis and Paget's disease (see also Chapter 5). Although manual therapy is not necessarily contraindicated when these conditions are present, the clinician may need to modify the intensity of treatment and possibly expect a reduced outcome.

Bacterial and viral infections can occur within the skeletal components of the thorax. The patient usually feels systemically unwell, and the characteristics of the pain behaviour should alert the clinician to suspect a non-mechanical source of pain. Systemic inflammatory and/or infective disorders can be differentiated from traumatic inflammation by the lack of trauma in the history and the inconsistent response of the joint to mechanical stress and rest, as well as the lack of resolution with appropriate therapy over a short period of time. Patterns of response to therapy that deviate from the norm should be quickly recognized and subsequent medical investigation pursued.

Both benign and malignant tumours can occur in the skeletal components of the thorax. Secondary metastases are common from the lung and breast, and a past history of carcinoma should alert the clinician to this possibility.

Spondylosis can arise from dysfunction of the musculoskeletal system secondary to major or minor trauma. Scoliosis is a complex, multifactorial problem of both known and unknown causes. It may be congenital or acquired, either from disease or injury. It has long been recognized (Kendall *et al.*, 1993) that idiopathic scoliosis involves muscle imbalance. In 1930, Kendall noted that the muscle weakness was almost always found in the lateral abdominal, anterior abdominal, pelvic, hip and leg muscles. This weakness caused the body to deviate from either the lateral median plane or the anterior-posterior median plane, causing the patient to compensate for the deviation by substituting other muscles in order to maintain equilibrium. As a consequence of this substitution, the patient invariably tended to develop muscles which cause lateral rotatory movements and thus lateral curvature with rotation resulted (Kendall *et al.*, 1993).

However, even the most compliant patient and diligent therapist cannot prevent the progression of some scoliotic curves with exercise. Current research on the aetiology of idiopathic scoliosis has revealed a possible central processing or neural component (Machida *et al.*, 1993; Maguire *et al.*, 1993). The reader is referred to Kendall *et al.* (1993) for information regarding the evaluation and treatment of muscle imbalances of the trunk and lower extremities and to the referenced material for further information on the neural basis of idiopathic scoliosis.

Although the medical model of classification is useful for understanding the aetiology of pain, classifications that follow a biomechanical model based on mobility and stability are more useful for the manual therapist. In keeping with this latter model, disorders within the thorax can be classified into three groups, each of which describes the objective findings noted on mobility testing and suggests the appropriate treatment. They include:

1. Hypomobility
2. Hypermobility with or without pain
3. Normal mobility with pain.

This classification does not provide a specific anatomical or physiological cause for the aberrant mobility noted; however, since manual therapy techniques are specific to restoring movement patterns, the cause is not required for formulating a treatment plan. The aim of all evaluation procedures is to identify the system (i.e. articular, myofascial, neural) that is affecting function. Treatment can then be modified to either mobilize or stabilize the appropriate system. If the biomechanics are restored, and if the underlying aetiology is biomechanical in nature, symptomatic and objective improvement usually follows.

Clinical examination

Subjective examination

When a consistent approach to examination is followed, the patterns of mechanical dysfunction emerge. An outline of the subjective examination follows:

1. Patient's name, age and doctor
2. Current history and past history, along with details of past treatment
3. Details of pain/dysaesthesia:
    location
    relieving/aggravating activities
    distal paraesthesia
    bowel/bladder function
    effect of sustained slump and/or neck flexion
4. Questions concerning sleep:
    surface/position
    night wakening
    status in morning
5. General information:
    occupation/sport/hobbies
    general health
    medication
6. Adjunctive tests and their results.

Current medical history

The mode of onset of symptoms should be established – was the onset sudden or insidious? Was there an element of trauma? If so, was there a major traumatic event over a short period of time, such as a motor vehicle accident, or was there a series of minor traumatic events over a long period of time? Is the patient presenting during the substrate, fibroblastic or maturation phase of healing (Peacock, 1984; Lee, 1994a)? Is this the first episode requiring treatment, or is this a recurring problem?

Pain/dysaesthesia

Where is the pain and/or dysaesthesia? Is it localized or diffuse? Where does it radiate to, and can the quality be described? If there is symptom referral, does it tend to refer around the chest or through the chest? What activities, if any, aggravate the symptoms? How long does it take for this activity to produce symptoms? Which activities (including how much) provide relief?

Sleep

Are the symptoms interfering with sleep? What kind of bed is being slept in, and what position is most frequently adopted? Does rest provide relief?

Occupation/leisure activities/sports

What level of physical activity does the patient consider his or her normal and essential level, with respect to a return to full function? What are the patient's goals from therapy?

General information

How is the patient's general health? Is any medication being taken for this or any other condition? What are the results of any adjunctive diagnostic tests (i.e. X-rays, computed tomography or magnetic resonance scans, laboratory tests)?

The answers to the subjective examination indicate the nature, irritability and severity of the presenting problem.

Objective examination

The objective examination is outlined in Table 17.1.

Postural analysis

Deviation of the thorax from the three cardinal body planes is common, and is not necessarily associated with symptoms. However, mechanical dysfunction often presents with postural deviation, and therefore postural analysis in relation to the sagittal, coronal and transverse body planes is essential.

In the sagittal plane, a vertical line should pass through the external auditory meatus, the cervicothoracic junction and the glenohumeral joint, transect the vertebrae at the thoracolumbar junction and pass through the sacral promontory slightly posterior to the hip joint and slightly anterior to the talocrural joint and naviculo-calcaneo-cuboid joint (see Chapter 2, Fig. 2. 2).

In the coronal plane, the clavicles should be horizontal, the manubrium and sternum vertical, and the scapulae should rest such that the medial border is parallel to the thoracic spine with the inferior angle approximated to the chest wall. Deviations of the spinous processes are common and often insignificant. The resting tone of the muscles of the back should be noted.

Habitual movement tests

These tests examine the habitual movement patterns of the trunk. The quantity and quality of available motion as well as the presence/location of evoked symptoms are noted. The results of these tests alone are not sufficient to diagnose a local dysfunction. They are used as screening tests to direct further mobility testing.

Table 17.1 *Objective examination*

Postural analysis
Habitual movement tests
Forward and backward bending
Lateral bending
Axial rotation
Respiration
Combined movement testing

Articular function
  Forward bending
  Backward bending
  Lateral bending
  Rotation
  Respiration

Passive mobility tests of arthrokinematic function
  Zygapophysial joints
  Costotransverse joints
  Medio-lateral translation

Passive stability tests of arthrokinetic function
  Vertical (traction/compression)
  Anterior translation - spinal
  Posterior translation - spinal
  Transverse rotation - spinal
  Anterior translation - posterior costal
  Inferior translation - posterior costal
  Anterior/posterior translation - anterior costal
  Superior/inferior translation - anterior costal
  Medio-lateral translation

Muscle function
Nerve function
Adjunctive tests

Forward and backward bending

The patient is standing or sitting and is instructed to bend the trunk forward. The quantity and symmetry of motion is observed. Neither rotation nor sideflexion should occur during forward bending, and if present this requires further specific mobility testing. When examining backward bending of the vertebrosternal and vertebrochondral regions of the thorax, it is critical to note that the region being examined is actually backward bending. Some movement modification may be required to ensure that the motion is being performed correctly.

Lateral bending

The patient is standing or sitting and is instructed to laterally bend the trunk to either side. The ability of the thorax to produce a smooth regional curve is noted. A flat region or a kink in the curve requires further specific mobility testing to determine the cause.

Axial rotation

The patient is standing or sitting and is instructed to rotate the trunk to either side. The ability of the thorax to produce a smooth regional 'S' curve is noted. Lack of movement or a kink in the curve requires further specific mobility testing to determine the cause.

Respiration

The patient is standing or sitting and is instructed to take a deep breath in and a long breath out. Any asymmetry of chest expansion and release is noted, and when present requires further specific mobility testing to determine the cause.

Combined movement testing

Hypomobile joints present a consistent clinical picture when combined movements are tested. The patient is standing or sitting and is instructed to:

- forward bend and then right lateral bend the trunk
- forward bend and then left lateral bend the trunk
- backward bend and then right lateral bend the trunk
- backward bend and then left lateral bend the trunk.

Any restriction in movement or kinks in the curve are noted. The response to these combined movements can be charted on the letter I (Fig. 17.1A). The forward/backward bending component of the motion is denoted by the vertical band of the I, and the lateral bending component by the horizontal band. When an abnormal movement pattern is detected, an X is placed on the 'arm' of the I that manifested the abnormal pattern. For example, when a zygapophysial joint is restricted in superior gliding on the left, an abnormal movement pattern will be detected on forward bending combined with right lateral bending. This is charted by placing an X over the right top horizontal band of the letter I (Fig. 17.1B).

The patient is then instructed to:

- right lateral bend and then forward bend the trunk
- left lateral bend and then forward bend the trunk
- right lateral bend and then backward bend the trunk
- left lateral bend and then backward bend the trunk.

Any restriction in movement or kinks in the curve are noted. The response to these combined movements can be charted on the letter H (Fig. 17.1C). The forward/backward bending component of the motion is denoted by the vertical band of the H and the lateral bending component by the horizontal band. When an abnormal movement pattern is detected, an X is placed on the 'arm' of the H that manifested the abnormal pattern. For example, when a zygapophysial joint is restricted in superior gliding on the left, an abnormal movement pattern will be detected on right lateral bending combined with forward bending. This is charted by placing an X over the right top vertical band of the letter H (Fig 17.1D).

A hypomobile joint is consistent in that an abnormal movement pattern is detected in the same 'arm' of the H and I tests. It does not matter which movement is induced first – lateral bending or forward bending – the abnormal motion shows up in both. Hypermobile joints are inconsistent in the pattern they present. An abnormal movement pattern may occur when forward bending occurs first, but not when lateral bending is the initial motion.

Articular function tests

When a mobility abnormality is detected during habitual movement tests, further examination is

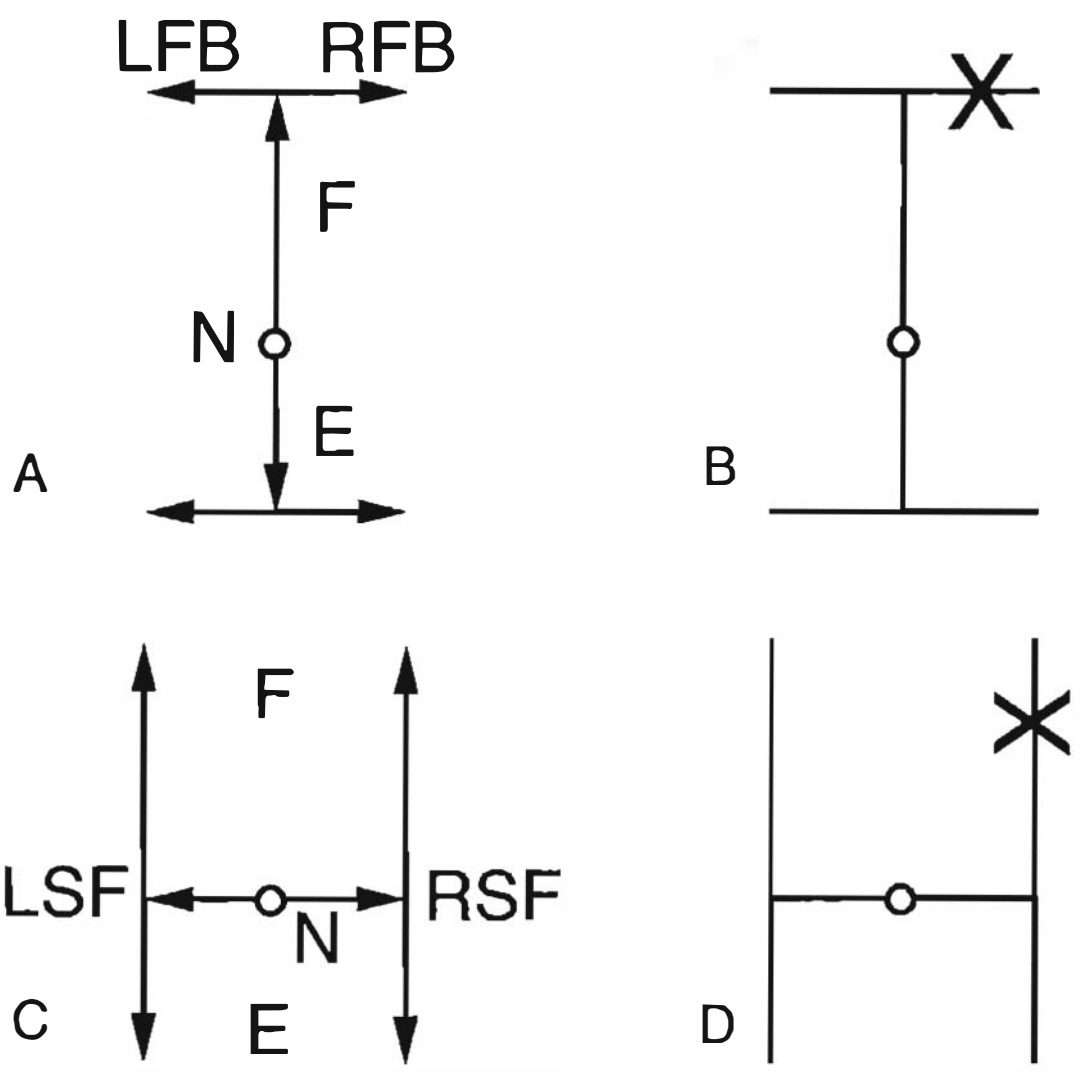

Fig. 17.1 Movement diagrams may be used to define motion testing of the trunk and to designate points of restrictions in different planes away from the neutral (N) starting position. (A) In sagittal plane assessment, lateral movements are superimposed. (B) An example of right forward bend (RFB) restriction. (C) Side-flexion may be used to commence the test followed by flexion (F) or extension (E). (D) An example of side-flexion coupled with forward flexion restriction.

required to determine the aetiology. The specific segmental tests of osteokinematic and arthrokinematic function are used to differentiate an intra-articular from a myofascial cause for the abnormal motion noted. They include active physiological mobility tests (habitual movement tests - active mobility tests of osteokinematic function), passive physiological mobility tests (passive mobility tests of osteokinematic function), and passive accessory mobility tests (passive mobility tests of arthrokinematic function). The active physiological mobility tests examine the osteokinematics of a functional spinal and costal unit, which includes two adjacent thoracic vertebrae, the two ribs which attach to these vertebrae and the manubrium/sternum. The passive physiological mobility tests provide further information on the end-feel of motion. The passive accessory mobility tests examine the arthrokinematic function of the zygapophysial joints and the costotransverse and costovertebral joints, and help to differentiate the cause of the abnormal motion noted on the habitual movement tests. By correlating the findings from these tests, the therapist can determine if the abnormal movement pattern is due to a hypomobile joint or an outside influence (myofascial, neural). Further tests are required to detect a hypermobile or unstable joint.

Active mobility tests of osteokinematic function

The following test is used to determine the osteokinematic function of two adjacent thoracic vertebrae during forward bending of the trunk. The transverse processes of two adjacent vertebrae are palpated with the index finger and thumb of both hands. The patient is instructed to forward bend the trunk, and the quantity and symmetry of motion is noted during flexion of the thoracic segment. Both index fingers should travel superiorly an equal distance. When interpreting the mobility findings the position of the joint at the beginning of the test should be correlated with the subsequent mobility noted, since alterations in joint mobility may merely be a reflection of an altered starting position. To determine the position of the superior vertebra, the dorsoventral relationship of the transverse processes to the coronal body plane is noted and compared with the level above and below. If the left transverse process of the superior vertebra is more dorsal than the left transverse process of the inferior vertebra, the segment is left rotated. If the left transverse process of the superior vertebra is less dorsal than the left transverse process of the inferior vertebra, but more dorsal than the right transverse process of the superior vertebra, then the superior vertebra is relatively right rotated

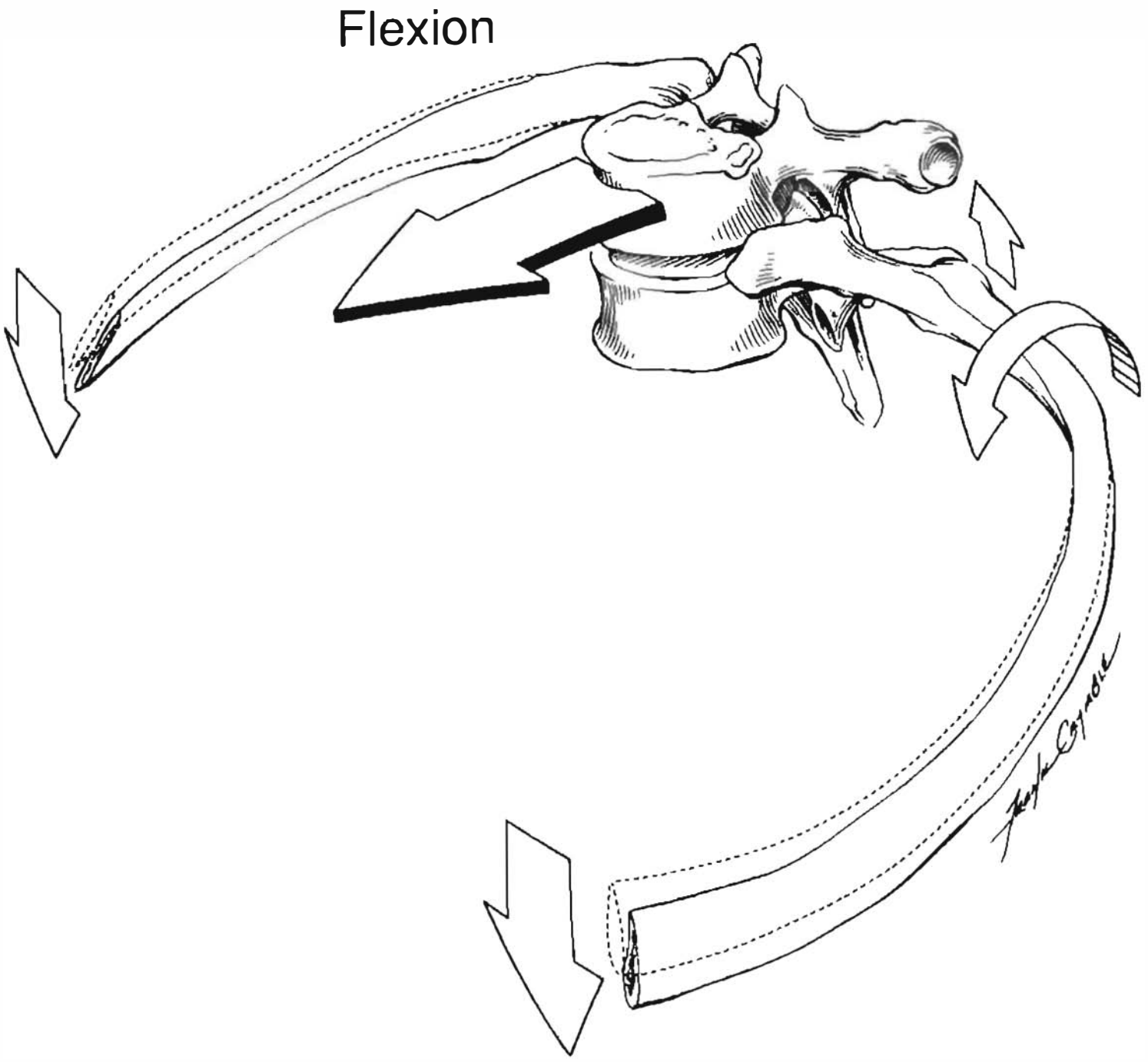

Fig. 17.2 The osteokinematic and arthrokinematic motion proposed to occur in the mobile thorax during forward bending of the trunk - vertebrosternal region. (Reproduced with permission from Lee, 1994a.)

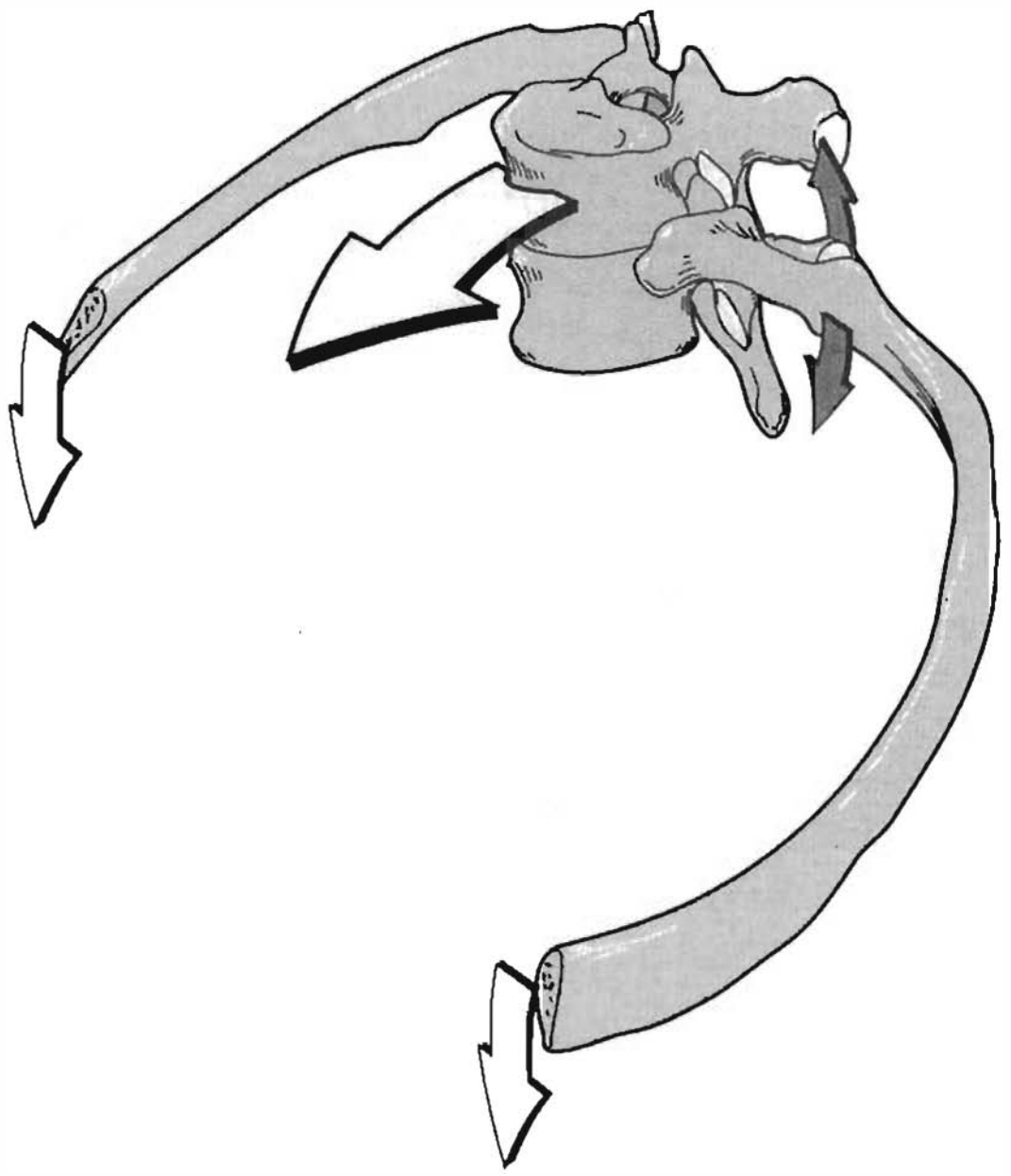

Fig. 17.3 The osteokinematic and arthrokinematic motion proposed to occur in the stiffer thorax during forward bending of the trunk - vertebrosternal region. (Reproduced with permission from Lee, 1994a.)

compared to the level below but left rotated when compared to the coronal body plane. This may represent a compensatory pattern seen when a superior segment is derotating or unwinding a primary rotation at a lower level.

The following test is used to determine the osteokinematic function of a rib relative to the vertebra of the same number during forward bending of the trunk. The transverse process is palpated with the thumb of one hand. The rib is palpated just lateral to the tubercle and medial to the angle with the thumb of the other hand, and the index finger of this hand rests along the shaft of the rib. The patient is instructed to forward bend the trunk, and the relative motion between the transverse process and the rib is noted.

In the mobile thorax, the rib should rotate anteriorly and the tubercle of the rib travel further superiorly than the transverse process. In the stiffer thorax, the rib should rotate anteriorly and the tubercle of the rib stop before full thoracic flexion is achieved, such that the transverse process travels further superiorly than the rib. When the relative mobility between the thoracic vertebra and the rib is the same, no motion is palpated between the vertebra and the rib during forward bending. Figs 17.2 (mobile thorax) and 17.3 (stiffer thorax) illustrate the biomechanics of the thoracic segment during forward bending of the trunk (Lee, 1994a). To determine the patient's normal movement pattern, it is critical to evaluate levels above, below and contralateral to the tested segment.

The osteokinematic function of the thoracic segment during backward bending, lateral bending, rotation and respiration is examined in the same manner. Below T3, the superior thoracic vertebra should lateral bend in the coronal plane until the last few degrees of movement. At this point, the superior vertebra should rotate contralateral to the direction of the lateral bend. The superior transverse process on the side of the concavity should move inferiorly and ventrally. Below T7, the direction of motion coupling depends on the apex of the curve. The direction of rotation should be congruent with the levels above and below.

During rotation, the superior thoracic vertebra should laterally bend and rotate to the same side such that the superior transverse process on the side of the concavity moves dorsally and inferiorly. Below T7, the direction of the conjunct lateral bend is variable; it may be to the same side as the rotation or to the opposite side (Lee, 1994a).

Passive mobility tests of osteokinematic function

Passive physiological mobility tests are used to confirm the level of the abnormal movement pattern noted on active mobility testing. In addition, the quality of the end-feel of motion is determined during these tests. With the patient sitting with the arms crossed to the opposite shoulders, the transverse processes of the superior vertebra are palpated. The trunk is passively flexed, extended, laterally bent and rotated. The quantity of motion and the quality of the end-feel is noted and compared to the levels above and below.

Passive mobility tests of arthrokinematic function

These tests are used to differentiate an intra-articular from an extra-articular cause of an abnormal

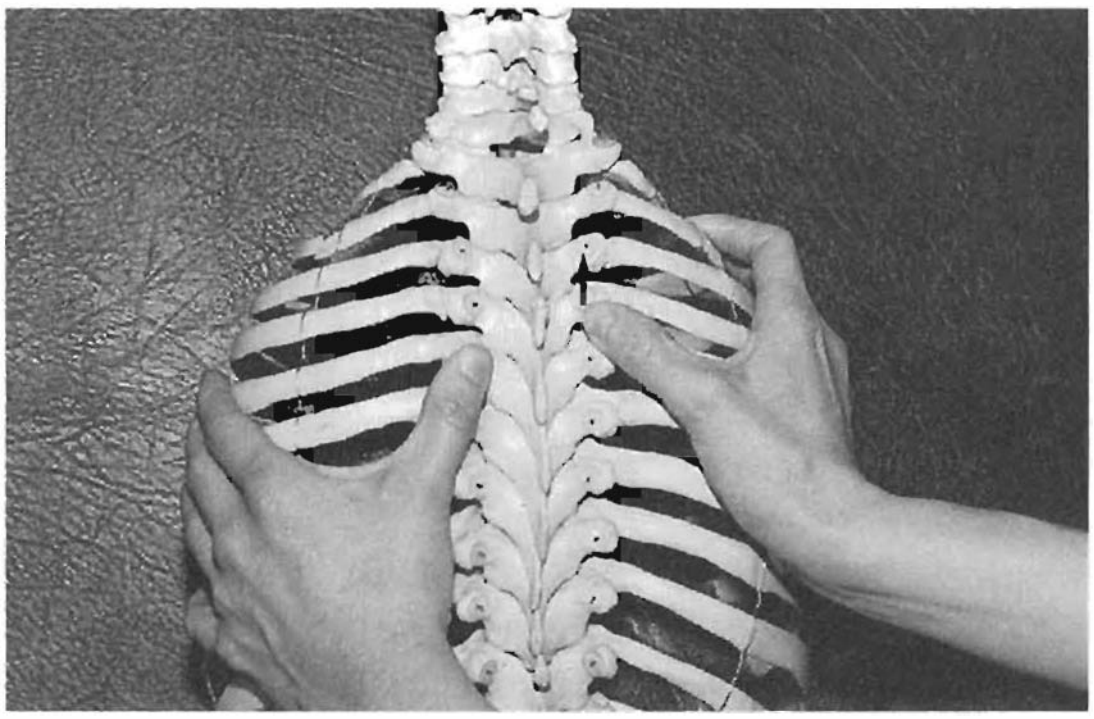

Fig. 17.4 Passive mobility tests of arthrokinematic function - points of palpation for superior glide of the right T4-T5 zygapophysial joint. (Reproduced with permission from Lee, 1994a.)

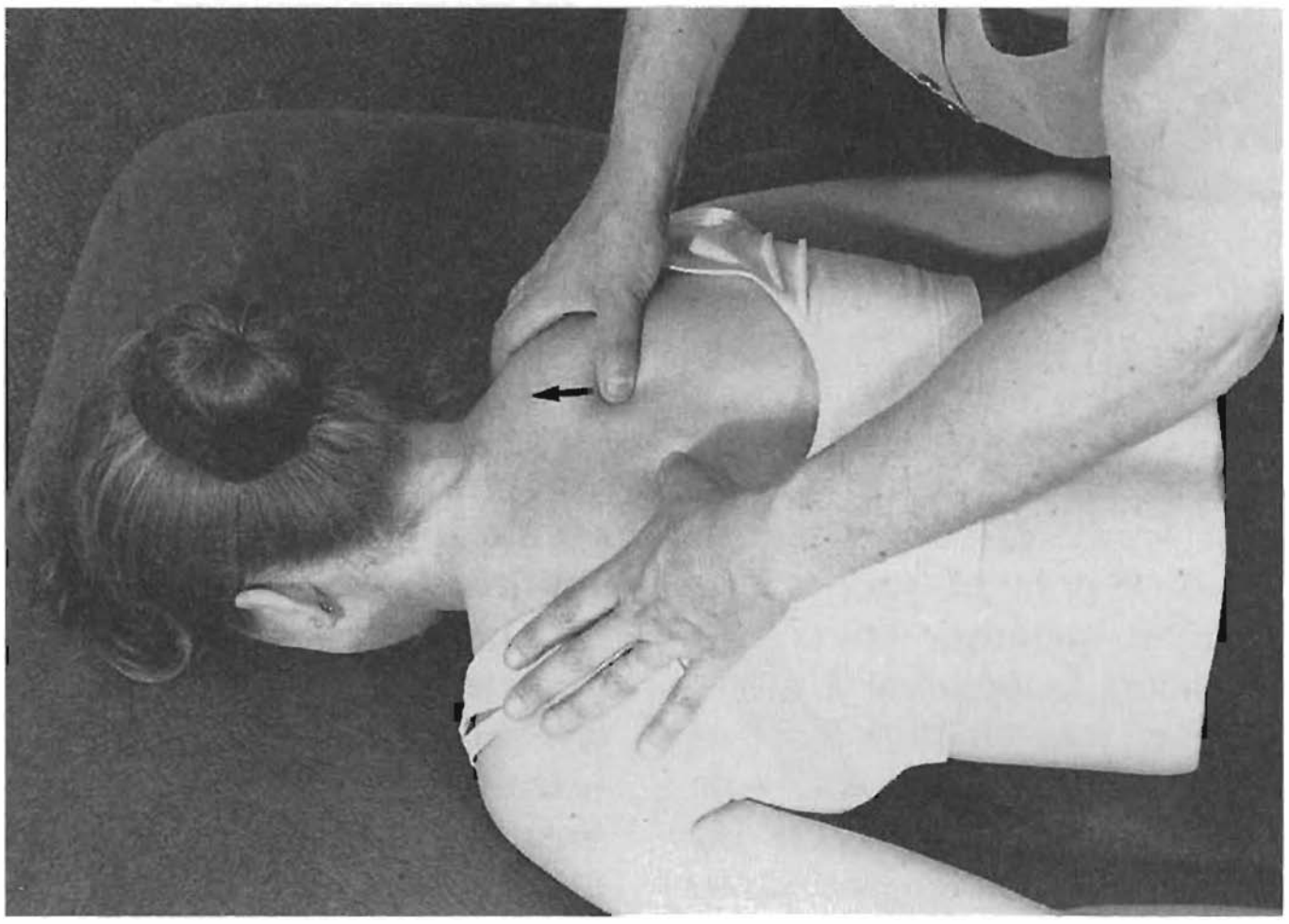

Fig. 17.5 Passive mobility tests of arthrokinematic function – superior glide of the right T4–T5 zygapophysial joint. (Reproduced with permission from Lee, 1994a.)

movement pattern. If the movement abnormality is due to intra-articular factors, the arthrokinematic glide will be restricted. The following test is used to determine the ability of, for example, the right inferior articular process of T4 to glide *superiorly* relative to the superior articular process of T5. With the patient prone and the thoracic spine in neutral, the inferior aspect of the left transverse process of T5 is palpated with the left thumb. The right thumb palpates the inferior aspect of the right transverse process of T4. The left thumb fixes T5, and a supero-anterior glide is applied to T4 with the right thumb (Figs 17.4 and 17.5). The quantity and end-feel of motion is noted and compared to the levels above and below. This technique can be used for all thoracic segments.

The following test is used to determine the ability of, for example, the right inferior articular process of T4 to glide *inferiorly* relative to the superior articular process of T5. With the patient prone and the thoracic spine in neutral, the inferior aspect of the transverse process of T5 is palpated with the left thumb. The right thumb palpates the superior aspect of the right transverse process of T4. The left thumb fixes T5, and an inferior glide is applied to T4 with the right thumb. The quantity and end-feel of motion is noted and compared to the levels above and below. This technique can be used for all thoracic segments.

The ability of the rib to glide superiorly and inferiorly relative to the transverse process at the costotransverse joint in the vertebrosternal region is examined in a similar manner (Lee, 1994a). Between T7 and T10 the orientation of the costotransverse joint changes (Figs 17.6 and 17.7) such that the direction of the glide is antero-latero-inferior/postero-medio-superior. The position of the right hand is modified to facilitate this change in joint direction such that the index finger of the right hand lies along the shaft of the rib and assists in gliding the rib.

Medio-lateral translation of the thoracic segment is necessary for full rotation/side-flexion to occur. At the sixth segment, right rotation requires the right sixth rib to glide antero-medially relative to the left transverse process of T6 and the left sixth rib to glide postero-laterally relative to the right transverse process of T6 (Fig. 17.8). This motion is tested in the following manner. The patient is seated with the arms crossed to opposite shoulders. With the right hand/

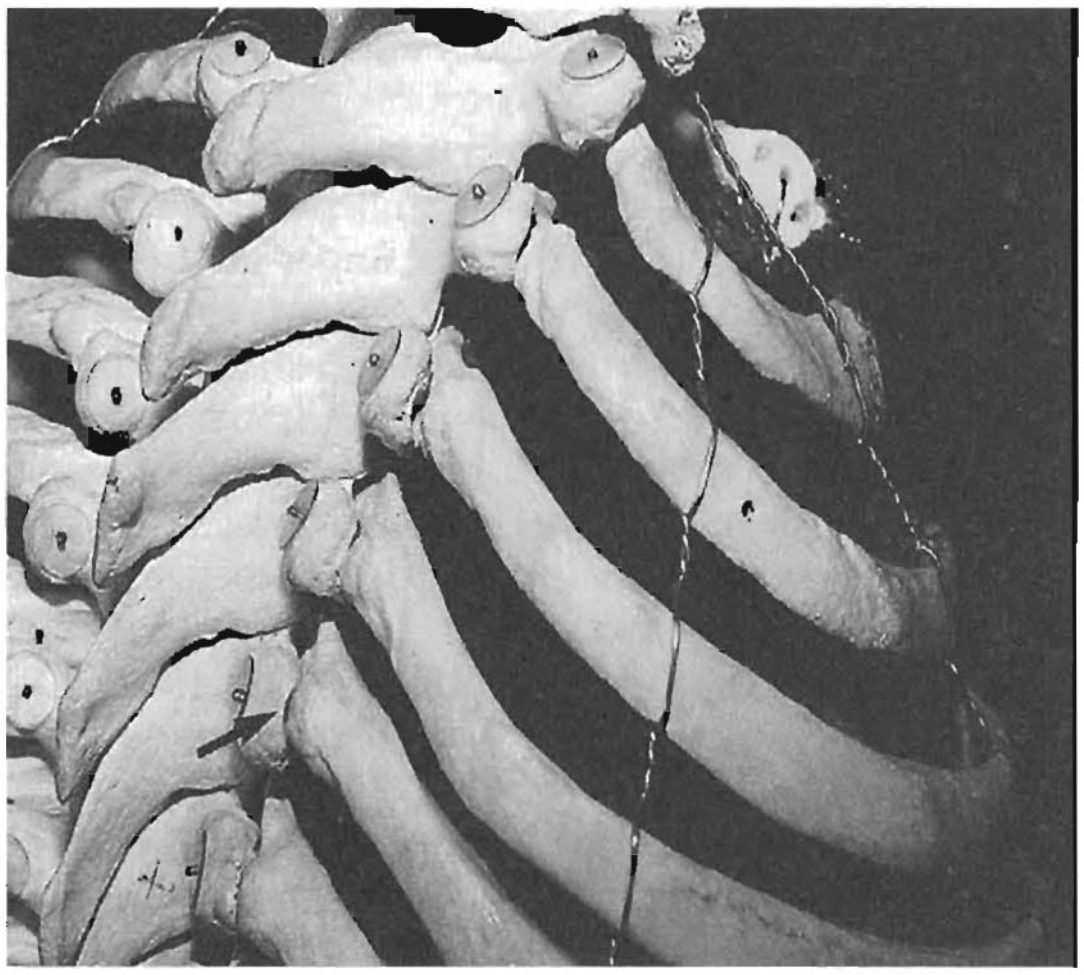

Fig. 17.6 Postero-lateral view of the articulated thorax, vertebrosternal region. Note the curvature of the fifth costotransverse joint (arrow). (Reproduced with permission from Lee, 1994a.)

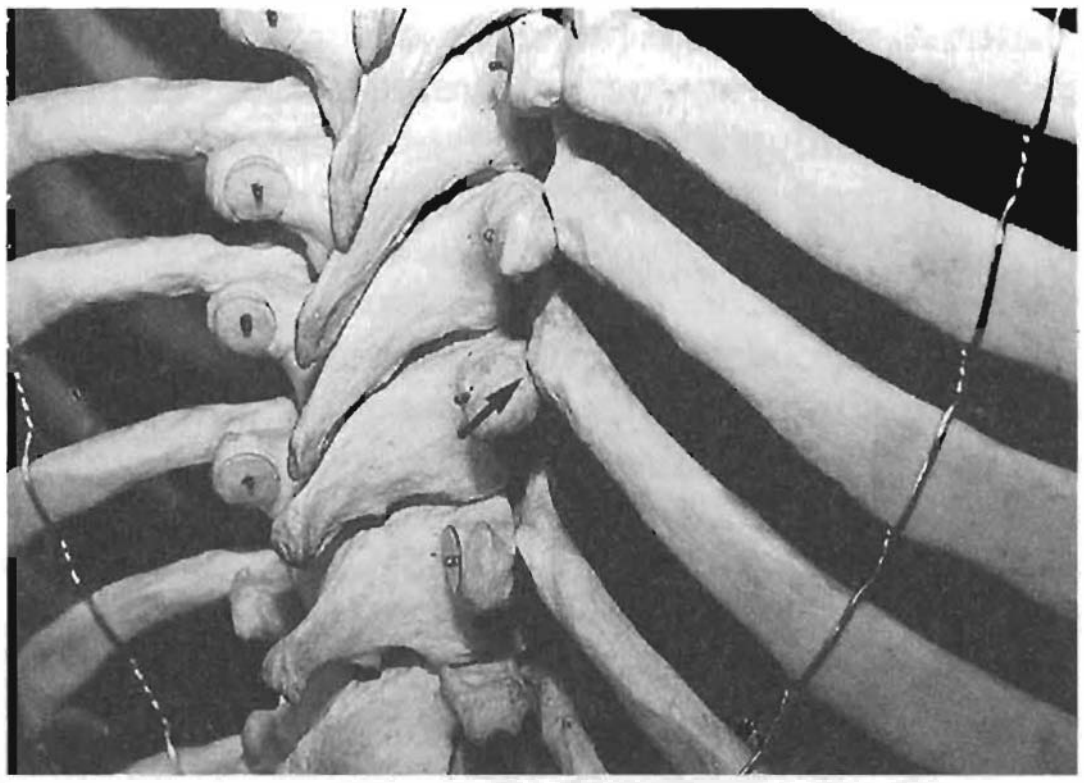

Fig. 17.7 Postero-lateral view of the articulated thorax, vertebrochondral region. Note the planar nature of the ninth costotransverse joint (arrow). (Reproduced with permission from Lee, 1994a.)

arm, palpate the thorax such that the fifth finger of the right hand lies along the right sixth rib. With the left hand, fix the transverse processes of T6. With the right hand/arm, translate the T5 vertebra and the ribs purely to the left in the transverse plane. The quantity and, in particular, the end-feel of motion is noted and compared to the levels above and below.

Passive stability tests of arthrokinetic function (Lowcock, 1990)

Traction and compression stress the anatomical structures that resist vertical forces. Traction is applied to the middle and lower thorax by applying a vertical force through the patient's crossed arms. Compression is applied to the middle and lower thorax by applying a vertical force through the top of the patient's shoulders. A positive response is the reproduction of the patient's pain, as opposed to a sense of increased motion.

Anterior spinal translation stresses the anatomical structures that resist anterior translation of the spinal unit. With the patient lying prone, the transverse processes of the superior vertebra are palpated. With the other hand, the transverse processes of the inferior vertebra are fixed. A postero-anterior force is applied through the superior vertebra while fixing the inferior vertebra. A positive response is the reproduction of the patient's symptoms together with an increase in the quantity of motion and a decrease in the resistance felt at the end of the range.

Posterior spinal translation stresses the anatomical structures that resist posterior translation of the spinal unit. The patient is seated with the arms crossed to opposite shoulders. The thorax is stabilized with the therapist's hand/arm under/over (depending on the level) the patient's crossed arms, and the contralateral scapula is grasped. The transverse processes of the inferior vertebra are fixed with the dorsal hand. Static stability is tested by applying an antero-posterior force to the superior vertebra through the thorax while fixing the inferior vertebra. A positive response is the reproduction of the patient's symptoms, together with an increase in the quantity of motion and a decrease in the resistance felt at the end of the range. Dynamic stability can be

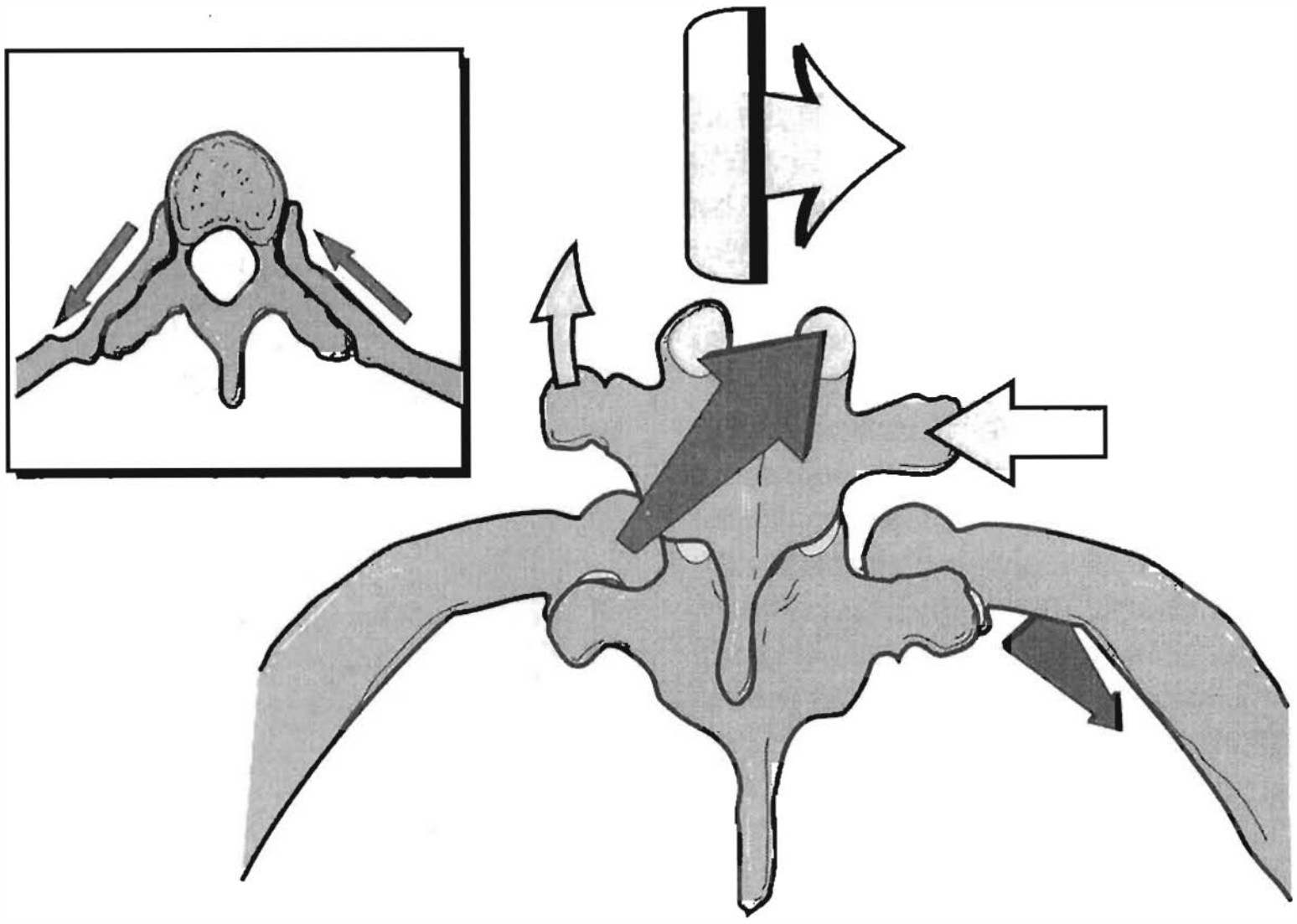

Fig. 17.8 The osteokinematic and arthrokinematic motion proposed to occur in the vertebrochondral region during right rotation of the trunk. (Reproduced with permission from Lee, 1994a.)

tested by resisting elevation of the crossed arms. If the segmental musculature is able to control the excessive posterior translation, no posterior translation will be felt and there is no instability.

Transverse spinal rotation stresses the anatomical structures that resist rotation of the spinal unit. A unilateral postero-anterior force is applied to the superior vertebra with the inferior vertebra stabilized.

Anterior costal translation stresses the anatomical structures that resist anterior translation of the posterior aspect of the rib relative to the thoracic vertebrae. With the patient lying prone, the contralateral transverse processes of the thoracic vertebrae to which the rib is attached are palpated. For example, when testing the right seventh rib, the left transverse processes of T6 and T7 are palpated. With the other hand, the rib is palpated just lateral to the tubercle. A postero-anterior force is applied to the rib while fixing the thoracic vertebrae. A positive response is the reproduction of the patient's symptoms, together with an increase in the quantity of motion and a decrease in the resistance felt at the end of the range. The inferior stability of the rib, at its posterior aspect, is tested by applying an inferior force to the rib while stabilizing the two thoracic vertebrae.

The joints of the rib anteriorly are also tested for stability. When the sternocostal and/or costochondral joints have been separated, a gap and a step can be palpated at the joint line. The positional findings are noted prior to stressing the joint. With one thumb, the anterior aspect of the sternum/costocartilage is palpated. With the other thumb, the anterior aspect of the costocartilage/rib is palpated. An antero-posterior/postero-anterior force is applied to the costocartilage/rib. A positive response is the reproduction of the patient's symptoms, together with an increase in the quantity of motion and a decrease in the resistance felt at the end of the range. Supero-inferior stability is tested in a similar manner by applying an inferior or superior force through the joint.

Medio-lateral translation stresses the anatomical structures that resist horizontal translation between two adjacent vertebrae when the ribs between them are fixed. This test is used between the segments T3-T4 and T10-T11. The primary structure being tested is the intervertebral disc. When the ribs are fixed bilaterally there should be very little, if any, medio-lateral translation between two thoracic vertebrae. To test the T5-T6 segment, the patient is seated with the arms crossed to opposite shoulders. With the right hand/arm, the thorax is palpated such that the fifth finger of the right hand lies along the fifth rib. With the left hand, T6 and the sixth ribs are fixed bilaterally by compressing the ribs centrally towards their costovertebral joints. The T5 vertebra is translated through the thorax purely in the transverse plane. A positive response is an increase in the quantity of motion and a decrease in the resistance felt at the end of the range.

Muscle function tests

If the specific tests of articular function are normal, then the muscles that influence the thorax are assessed. Hypertonicity secondary to altered segmental facilitation manifests as a multisegmental dysfunction (rotoscoliosis) during the habitual movements that require lengthening of the muscle. Muscle imbalances due to faulty recruitment patterns also produce a multisegmental dysfunction. In both instances, the passive mobility tests of arthrokinematic function are normal. The muscles that stabilize and move the scapula are often found to be imbalanced in patients with chronic thoracic pain. Muscles that are habitually in a shortened position will eventually become structurally shorter. When the muscle is inappropriately facilitated, a neurophysiological technique aimed at restoring the resting tone of the muscle will yield an immediate change in mobility. When the muscle is structurally shortened, stronger stretching techniques and more time is required to achieve normal mobility. The reader is referred to Kendall and colleagues' work (1993) for further discussion of this topic.

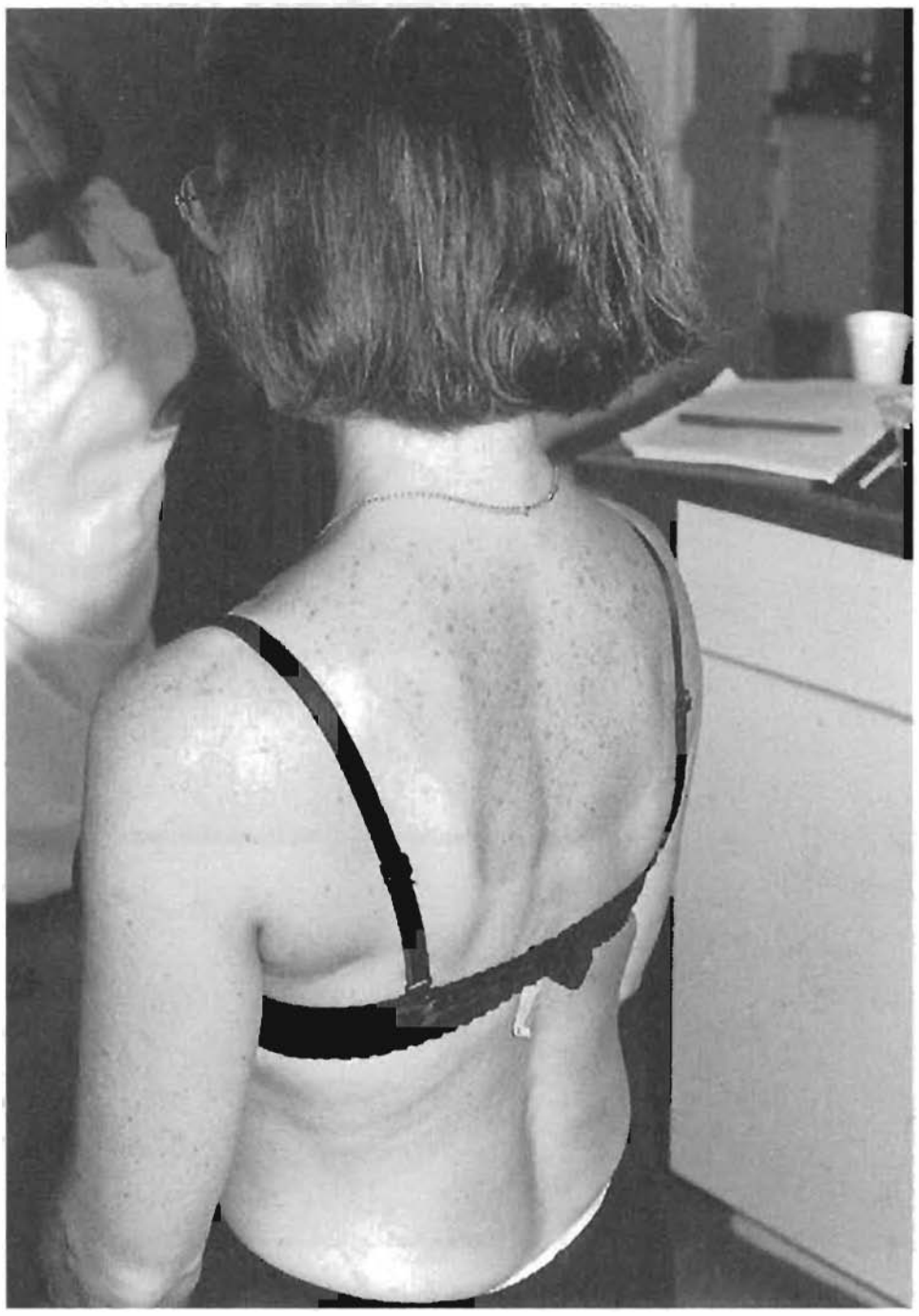

Fig. 17.9 When the diaphragm is hypertonic, over-activity of the mid-thoracic spinal extensors can produce a localized lordosis.

The diaphragm is often involved in postural dysfunction, and tends to be a flexor of the thorax when it is hypertonic. In clinical practice it has been observed to produce a lordosis at the thoracolumbar junction. In addition, insufficient relaxation of the diaphragm can lead to overuse of the mid-thoracic spinal extensors, causing a mid-thoracic lordosis (Fig. 17.9). These curve reversals do not respond to segmental mobilization techniques. Correction requires relaxation of the diaphragm and treatment of the breathing disorder.

Nerve function tests

These tests examine the conductivity of the motor and sensory nerves, as well as the mobility of the dura and the intercostal nerves in the spinal canal and intervertebral foramen. The sensory function of the intercostal nerves is examined by testing skin sensation in the intercostal spaces. Altered sensation is not uncommon, although it is rarely reported as a primary complaint. Hyperaesthesia can be one of the first signs of neurological interference, and tends to occur long before sensation becomes reduced (hypoaesthesia).

The motor function of the intercostal nerves is examined by observing and palpating the intercostal muscles. Altered segmental facilitation leads to hypertonicity of the intercostal muscle, and the increased tone can be palpated along the intercostal space. The tonal change is often associated with tender points within the muscle. Reduced motor function of the intercostal nerves causes atrophy of the intercostal muscles.

Reflex tests are used to detect spinal cord or upper motor neuron lesions. The plantar response test and the test for clonus should be done on every patient presenting with pain in the thorax.

The mobility tests for the neural and dural tissue include the 'slump test' and variations thereof. The mobility of the intraspinal tissues can be tested by fully lengthening the dural/neural system. This is achieved by having the seated patient fully flex the head and neck, slump the thoracolumbar spine and extend the knee with the ankle dorsiflexed. The dura is released by then having the patient extend the head and neck. The change in symptom response is noted. If the thoracic pain is brought on by full slump and relieved with extension of the head and neck, involvement of the dura is suggested (Butler, 1991).

The intercostal nerves can be further tensed by having the 'slumped' patient twist the thorax to the left and right. Often, the patient will present with a normal movement pattern when rotation occurs in a position of relative neural relaxation and an abnormal movement pattern (segmental kink in the thoracic curve) when the rotation occurs in a position of relative neural tension. It is interesting to postulate on the aetiology of the 'apparent segmental dysfunction' in this situation. Unless the nervous system is addressed, the symptoms persist regardless of the articular and myofascial treatments employed. The emphasis of this chapter is on the assessment and treatment of articular dysfunction, and the reader is referred to Butler (1991) for further review.

Adjunctive tests

While X-rays exclude serious bone disease and significant mechanical defects, they rarely provide guidance for manual therapy. Asymmetry is the rule in the thorax, and deviations of the spinous processes are to be expected. For the manual therapist, the primary reason for obtaining the results of any adjunctive imaging tests is to rule out serious pathology and to identify anatomical anomalies that may influence the interpretation of mobility testing. The findings noted on adjunctive testing of the thorax must be correlated with the findings observed on clinical examination if the significance is to be understood.

Management of thoracic back pain

This section will focus on the mechanical syndromes of the thorax, recognizing that referral of pain to the thorax from the viscera, respiratory syndromes and metabolic, infective and neurological conditions may co-exist. The model for classification will follow the manual therapy model based on the objective findings noted on mobility testing.

Treatment principles

The principles upon which treatment is based follow those of the body's natural healing process and its three phases – the substrate, fibroblastic and maturation (Peacock, 1984; Lee, 1994a). Left alone, wounded tissue will repair; the end result of the healing process is the production of fibrous (or scar) tissue. Scar tissue can create pain and disability within the musculoskeletal system, depending on how the repaired tissue differs from that which it replaces. Essentially, the repair process restores the structure with little regard to function. For example collagen is non-contractile, and when it repairs a torn muscle both the contractility and extensibility of the muscle will be affected.

The role of therapy is to guide the deposition and remodelling of the scar at each stage of repair such that *optimal* structure and function are restored. To achieve this goal successfully it is paramount that the patient becomes involved in his or her own rehabilitation through a home exercise programme that follows the principles of tissue healing.

In the substrate and the early fibroblastic stage (acute), vigorous exercise programmes or aggressive passive mobilizations are contraindicated because the wound is very weak. Gentle passive mobilizations (Grades 2, 3-) and exercises within the pain-free range of motion will facilitate the proper orientation of collagen deposition at the wound site. The patient will find that the best resting position for acute thoracic pain is semi-sitting. Supine lying on a hard surface forces the thorax into an extended posture, while side lying often induces side-flexion and rotation.

As cross-linking of collagen fibres occurs, organized, restrictive adhesions can develop during the maturation phase, especially if the range of motion is not restored within the fibroblastic phase. While the structure may be restored, function may be adversely affected by the adhesion. More vigorous mobilization techniques (Grades 3+, 4, 5) and frequent exercises at home will be required to facilitate a return of the range of motion.

If the sympathetic chain is affected by the pathology, symptoms can be referred into the upper or lower extremity, or even into the cranium, and the patient may report temperature changes, heavy sensations associated with fatigue, and non-specific numbness of the involved segment.

Hypomobility with or without pain

The essential objective finding for classification here is *decreased* osteokinematic motion of either the thoracic vertebrae or the ribs. The aetiology may be articular, myofascial or both, and is often the result of excessive bending or rotational force. The arthrokinematic tests differentiate the underlying cause of the osteokinematic restriction.

The mode of onset may be either insidious or sudden, depending upon the degree of trauma. The irritability of the wounded tissue dictates the intensity of the pain, the amount of radiation, the degree of physical activity that tends to aggravate it and the amount of rest required to relieve it. The aim of the subjective examination is to determine the stage and nature of the pathology so that treatment may be modified accordingly.

The location of the pain may be on the ipsilateral or contralateral side of the hypomobility, and may radiate around or through to the anterior aspect of the chest. An acute zygapophysial joint sprain tends to produce very localized pain over the involved joint. A chronic restriction of either the vertebra or rib tends to produce symptoms removed from the source, and some of these may be secondary to compensation of the adjacent levels. Referral of pain from the articulations of the thorax tends to be around the chest rather than through it. Referral of pain from the intervertebral disc tends to be through the chest.

Magnetic resonance imaging techniques have increased the frequency of diagnosis of thoracic disc herniation (Brown *et al.*, 1992; Wood *et al.*, 1995, 1997). Thoracic discs are no longer thought to be an uncommon cause of thoracic pain. In the study by Brown and colleagues (1992), the most common symptom in patients with confirmed thoracic disc herniation was anterior chest pain (67%). Other symptoms included lower extremity dysaesthesia and weakness (20%), interscapular pain (8%) and epigastric pain (4%). The highest incidence according to level was T7-T8; the second highest were T6-T7 and T9-T10.

Hypomobile joints are very consistent in the pattern they present on habitual movement testing. The findings for each joint restriction will be described below. If the joint is truly hypomobile, the arthrokinematic glide will also be restricted. If the myofascia is the source of the restriction, the joint glide will be normal. Disorders in this classification do not exhibit a loss of arthrokinetic function.

The neural/dural mobility tests may be positive if the mobility of the sympathetic chain is affected by a change in position of the head of the rib. Restrictions of the zygapophysial joint rarely involve the neural/dural tissue.

Bilateral restriction of flexion

A lordotic mid-thoracic region is often indicative of an underlying breathing dysfunction. Over-activity of the spinal extensors compensates for a hypertonic diaphragm, which tends to flex the thorax (Fig. 17.9). In addition to specifically mobilizing the mid-thorax, it is crucial that the breathing pattern be addressed if a more neutral position of the spine is to be achieved. When the mid-thoracic segments become fixed in extension, active mobility tests of forward bending of the trunk will reveal a limitation of the superior excursion of the transverse processes bilaterally. Passive mobility testing of the superior arthrokinematic glide at the zygapophysial joint will be restricted bilaterally if the dysfunction is intra-articular.

The presence or absence of pain depends upon the stage of the pathology (substrate, fibroblastic, maturation) and the irritability of the surrounding tissue. The grade of the mobilization technique is directed by these factors.

Longitudinal traction will produce a superior glide of the zygapophysial joint bilaterally. This technique may be done with the patient either lying supine or sitting. With the patient positioned supine, grade 1 and 2 techniques are better controlled and can be applied for pain relief. The stronger mobilizations can be done with the patient positioned either lying or sitting.

The supine technique is performed as follows. Initially, the patient is side-lying with the head supported on a pillow and the arms crossed to the opposite shoulders. With the tubercle of the scaphoid bone and the flexed proximal interphalangeal (PIP) joint of the middle finger, the transverse processes of the inferior vertebra are palpated. The other hand/arm lies across the patient's crossed arms to control the thorax. Segmental localization is achieved by flexing the joint to the motion barrier with the hand/arm controlling the thorax. This localization is maintained as the patient is rolled supine, but only until contact is made between the table and the dorsal hand. From this position, longitudinal traction is applied through the thorax to produce a superior glide of the zygapophysial joint bilaterally. This is an arthrokinematic mobilization. By restoring the accessory glide, the osteokinematic motion will be restored. The technique can be graded from 1 to 5.

An active mobilization assist (muscle energy technique) can effect a change in the muscle tone segmentally. When the motion barrier has been localized, the patient is instructed to elevate the crossed arms gently. The motion is resisted by the therapist and the isometric contraction is held for up to 5 s, followed by a period of complete relaxation. The joint is then passively taken to the new motion barrier, the technique is repeated three times and is then followed by re-evaluation of osteokinematic function.

To maintain the mobility gained, the patient is instructed to perform specific mid-thoracic flexion frequently (up to 10 repetitions, 10 times per day). The amplitude of the exercise should be in the pain-free range, and should not aggravate any symptoms.

Unilateral restriction of flexion

Unilateral restriction of flexion will produce a segmental rotoscoliosis as well as a compensatory multisegmental curve above and below the restricted level. Active forward bending of the trunk will reveal this asymmetry. For example, a unilateral restriction of flexion on the left at T5-T6 will produce a left rotation/left side-flexion position of T5 at the limit of forward bending. The right transverse process of T5 will travel further superiorly than the left. The left transverse process of T5 will be more dorsal than the right. Right rotation and right lateral bending of the trunk will be restricted and produce a kink in the mid-thoracic curve in a consistent pattern in both the H and I combined movement tests. The superior arthrokinematic glide of the left zygapophysial joint at T5-T6 will be restricted if the dysfunction is intra-articular.

As outlined above, the grade of the mobilization technique is directed by tests to determine the stage of the pathology.

The mobilization used to restore unilateral flexion on the left at T5-T6 is an arthrokinematic technique. The patient is positioned right side-lying with the head supported on a pillow and the arms crossed to the opposite shoulders. With the tubercle of the right scaphoid bone and the flexed PIP joint of the right middle finger, the left transverse process of T6 and the right transverse process of T5 are palpated. The therapist's other hand/arm lies across the patient's crossed arms to control the thorax. Segmental localization is achieved by flexing the joint to the motion barrier with the hand/arm controlling the thorax. This localization is maintained as the patient is rolled supine, but only until contact is made between the table and the dorsal hand. From this position, a right side-flexion force is applied through the thorax to produce a superior glide of the left zygapophysial joint. By restoring the accessory glide, the osteokinematic motion will be restored. This technique can be graded from 1 to 5.

An active mobilization assist (muscle energy technique) can effect a change in the muscle tone segmentally. When the motion barrier has been localized, the patient is instructed to gently elevate the crossed arms. The motion is resisted by the therapist, and the isometric contraction is held for up to 5 s, followed by a period of complete relaxation. The joint is then passively taken to the new motion barrier, the technique is repeated three times and is then followed by re-evaluation of osteokinematic function.

When the myofascia is thought to be the main cause of the osteokinematic restriction, the following technique can be useful. The patient is seated with the arms crossed to the opposite shoulders. With the dorsal hand, the therapist palpates the intertransverse space. The ventral hand is placed on the contralateral shoulder. The motion barrier is localized by flexing and right side-flexing the thorax. From this position, the patient is instructed to hold still while the therapist applies resistance to the trunk. The direction of the applied resistance is determined by the neurophysiological effect desired from the technique. A hold-relax technique applies the principles of autogenic inhibition, and is used primarily for a shortened muscle. The involved muscle is recruited strongly and then maximally stretched in the immediate post-contraction relaxation phase. A contract-relax technique applies the principles of reciprocal inhibition, and is used primarily for a hypertonic muscle. The antagonist muscle is recruited gently. The contraction results in reciprocal inhibition of the antagonistic hypertonic muscle.

The isometric contraction is held for up to 5 s, following which the patient is instructed to completely relax. The new flexion/side-flexion barrier is localized, and the mobilization repeated three times.

To maintain the mobility gained, the patient is instructed to perform specific mid-thoracic right side-flexion in slight flexion frequently (up to 10 repetitions, 10 times per day). The amplitude of the exercise should be in the pain-free range, and should not aggravate any symptoms.

Unilateral restriction of extension

A unilateral restriction of extension will produce a segmental rotoscoliosis as well as a compensatory multisegmental curve above and below the restricted level. Active backward bending of the trunk will reveal this asymmetry. For example, a unilateral restriction of extension on the left at T5-T6 will produce a right rotation/right side-flexion position of T5 at the limit of backward bending. The right transverse process of T5 will travel further inferiorly than the left. The right transverse process of T5 will be more dorsal than the left. Left rotation and left lateral bending of the trunk will be restricted and produce a kink in the mid-thoracic curve in a consistent pattern in both the H and I combined movement tests. The inferior arthrokinematic glide of the left zygapophysial joint at T5-T6 will be restricted if the dysfunction is intra-articular.

The grade of the mobilization technique is directed by pathological stage (see above); the specific technique is described elsewhere (Lee, 1994a).

Unilateral restriction of rotation (posterior or anterior) – ribs 3 to 10

This dysfunction is seen when the muscles are imbalanced, or when the arthrokinematic glide of the rib is restricted at the costotransverse joint. The clinician must be aware of relative flexibility between the thoracic vertebrae and the ribs when interpreting the findings of the habitual movement tests and passive tests of arthrokinematic function. The direction of the costotransverse joint glide can be either superior or inferior during forward and backward bending (Figs 17.2 and 17.3). The patient's normal pattern must be ascertained before the findings can be interpreted. Respiration produces the most consistent movement pattern, and is the most reliable habitual movement to test when evaluating the osteokinematic function of the ribs. If the dysfunction is intra-articular, the arthrokinematic glide of the costotransverse joint will be reduced.

Active mobilization techniques are useful when the myofascia is imbalanced. Respiration may produce asymmetry in the thorax, but the arthrokinematic glide of the costotransverse joint is normal.

When the myofascia is thought to be the main cause of an osteokinematic restriction of posterior rotation of the right fifth rib, the following technique can be useful. The patient sits with the arms crossed to opposite shoulders. With the dorsal hand, the therapist palpates the fifth rib. The ventral hand is placed on the patient's contralateral shoulder. The motion barrier is localized by left side-flexing and right rotating the thorax. From this position, the patient is instructed to hold still while the therapist applies resistance to the trunk. The direction of the applied resistance is determined by the neurophysiological effect desired from the technique, as outlined in the section above.

The isometric contraction is held for up to 5 s, following which the patient is instructed to completely relax. The new motion barrier is localized, and the mobilization repeated three times.

To maintain the mobility gained, the patient is instructed to perform specific mid-thoracic left side-flexion and right rotation frequently (up to 10 repetitions, 10 times per day). The amplitude of the exercise should be in the pain-free range, and should not aggravate any symptoms.

To restore anterior rotation of the rib, the motion barrier is localized by right side-flexing and left rotating the thorax. Otherwise, the technique is similar to the one described for restoring posterior rotation.

Hypermobility with or without pain

Hypermobility can be the result of major trauma over a short period of time, or minor repetitive trauma over a long period of time. The essential objective finding for classification here is the presence of *increased* osteokinematic motion of either the thoracic vertebrae or ribs.

The mode of onset may be either insidious or sudden, depending upon the degree of trauma. As outlined previously, the aim of the subjective examination is to determine the irritability of the wounded tissue - that is, the stage of the pathology and its nature - so that treatment may be adjusted accordingly.

An acute subluxation of either a rib or a 'ring' (see below) tends to produce very localized pain over the involved joint. In longstanding conditions, the location of the pain is poorly localized to a specific segment and tends to radiate over a region of the thorax. Referral of pain is variable, and can be either around the chest or through it.

Hypermobile joints are very inconsistent in the pattern they present on habitual movement testing. The active mobility tests reveal an abnormal movement pattern that is variable depending upon the order in which the combined movements are performed. Specific mobility and stability testing reveals the hypermobility/instability, since disorders in this classification exhibit a loss of arthrokinetic function. The neural/dural mobility tests may be positive if the mobility of the sympathetic chain is affected by a change in position of the head of the rib.

Subluxation of the costotransverse and costovertebral joints

Subluxations of the costotransverse joints are not uncommon and occur secondary to rotational trauma or a direct blow to the chest. The rib will be either superior or inferior on positional testing, and all movements, including the arthrokinematic glides, will be blocked. The joint is hypomobile until the subluxation is reduced. Following reduction of the subluxation, the stability tests for arthrokinetic function reveal the underlying hypermobility of the rib. Stabilization is then required. The treatment technique to reduce a subluxed costotransverse joint is a grade 5 distraction technique (Lee, 1994a).

If the reduction is successful, the arthrokinematic glide at the costotransverse joint will be restored. An active mobilization technique (see hypomobile classification) may be required to attain myofascial balance and optimal osteokinematic function.

Anteriorly, the costochondral and sternochondral joints can also become hypermobile/unstable and a source of localized anterior chest pain. Causes include excessive rotational trauma and/or a direct blow to the anterior chest. There is a palpable step or gap between the rib/cartilage or the cartilage/sternum; the arthrokinetic test reveals a greater amplitude of movement and is associated with local tenderness. When the two joint surfaces are displaced or subluxed, reduction is not possible. The acute joint is treated with rest and the patient educated regarding limiting the use of the shoulder (to avoid further separation of the joint with contraction of the serratus anterior and/or pectoralis major/minor muscles). Local electrotherapeutic modalities for pain relief and control of inflammation, and taping to limit the motion of the thorax, may also be required.

Subluxation of the 'ring'

This subluxation involves the entire 'ring', which includes two adjacent thoracic vertebrae, the intervertebral disc, the two ribs and their associated anterior and posterior joints and the sternum. It occurs primarily in the vertebrosternal region and occasionally in the vertebrochondral region. It can occur when excessive rotation is applied to the unrestrained thorax, or when rotation of the thorax is forced against a fixed ribcage (e.g. seat belt injury). At the limit of right rotation in the mid-thorax, the superior vertebra has translated to the left, the left rib has translated postero-laterally and the right rib has translated antero-medially such that a functional U joint is produced. Further right rotation results in a right lateral tilt of the superior vertebra (Fig. 17.10). Subluxation of the superior vertebra occurs when the left lateral translation exceeds the physiological motion barrier and the vertebra is unable to return to its neutral position. For subluxation to occur, it is proposed that a horizontal cleft through the posterior one-third of the intervertebral disc must exist.

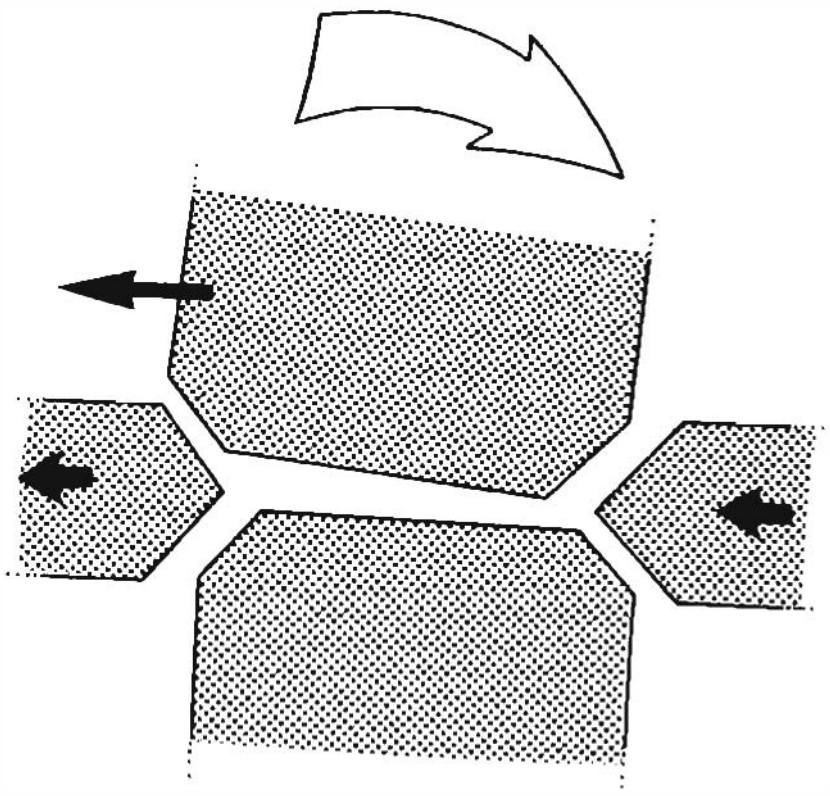

Fig. 17.10 At the limit of left lateral translation, the superior vertebra side-flexes to the right along the plane of the pseudo U joint (analogous to the uncovertebral joint of the mid-cervical spine) formed by the intervertebral disc and the superior costovertebral joints. (Reproduced with permission from Lee, 1994a.)

Positionally, the following findings are noted with a left lateral shift subluxation of the sixth ring (T5-T6 and the sixth ribs). The T5-T6 segment is right rotated in hyperflexion, neutral and extension, the right sixth rib is antero-medial and the left sixth rib is postero-lateral at their posterior aspects. All active movements produce a 'kink' at the level of the subluxation; the worst movement is often rotation (Fig. 17.11). The passive mobility tests of arthrokinematic function of the zygapophysial and costotransverse joints are reduced but present. The right medio-lateral translation mobility test is completely blocked. Following reduction of the subluxation (Lee, 1994a), the arthrokinetic tests for medio-lateral translation and rotation will reveal the underlying instability of the ring. Stabilization is then required.

Stabilization therapy

In addition to major trauma to the thorax, cumulative microtrauma can lead to postural changes, altered movement patterns and associated functional instability. Stabilization therapy considers the integrated relationship between the legs, pelvic girdle, trunk and upper extremity. The central feature of this concept is that the trunk muscles must hold the vertebral column stable in order that independent upper and lower extremity movement may occur, and also so that load may be transferred from the upper extremity to the ground (Snijders *et al.*, 1993).

Briefly, the patient is taught specifically to recruit the trunk muscles isometrically and then to maintain this brace as the upper and lower extremities are

Fig. 17.11 This patient sustained a left lateral shift lesion of T5 and the left and right sixth ribs in a motor vehicle accident. Note the complete block of right rotation at the subluxed segment.

moved independently. Initially, the base of support must be very stable. The programme is progressed by increasing the degree of difficulty by reducing the base of support, by making the base more unstable and/or by increasing the load, which must be controlled (Jull and Richardson, 1994). The programme is directed by the patient's needs, and is limited only by the therapist's imagination. The use of gymnastic balls, rolls, balance boards and pulleys (Farrell *et al.*, 1994) can make stabilization therapy cost-effective, fun and still very challenging.

Normal mobility with pain

Patients presenting with pain in the thorax without objective mechanical findings can be a challenge to treat. Given the nature of visceral referral of pain to the thorax, a team approach to the problem is best. If all medical conditions are ruled out and no specific articular, muscular, neural or dural mobility dysfunction is identified, then a postural approach following the principles of stabilization therapy can be tried. Repetitive overuse of the articular and myofascial tissue will respond to the appropriate correction of resting and working postures together with an exercise programme aimed at balancing the trunk musculature and restoring optimal movement patterns. Diligence and commitment on the part of the patient and therapist is required to achieve successful rehabilitation.

References

Brown, C.W., Deffer, P.A., Akmakjian, J. *et al.* (1992) The natural history of thoracic disc herniation. *Spine* **17:** S97-S102.

Butler, D.S. (1991) *Mobilization of the Nervous System*. Edinburgh: Churchill Livingstone.

Farrell, J., Drye, C., Koury, M. (1994) Therapeutic exercises for back pain. In: *Physical Therapy of the Low Back*, 2nd edn (Twomey, L.T., Taylor, J.R., eds). Edinburgh: Churchill Livingstone, pp. 379-410.

Jull, G.A., Richardson, C.A. (1994) Rehabilitation of active stabilization of the lumbar spine. In: *Physical Therapy of the Low Back*, 2nd edn (Twomey, L.T., Taylor, J.R., eds). Edinburgh: Churchill Livingstone, pp. 251-274.

Kendall, F.P., Kendall McCreary, E., Provance, P.G. (1993) *Muscles Testing and Function*, 4th edn. Baltimore: Williams & Wilkins.

Lee, D.G. (1993) Biomechanics of the thorax: a clinical model of in vivo function. *J. Man. Manip. Ther.*, **1:** 13-21.

Lee, D.G. (1994a) *Manual Therapy for the Thorax - A Biomechanical Approach*. Published by DOPC 302 11946 80th Ave. Delta, B.C. Canada V4C 1Y2.

Lee, D.G. (1994b) Biomechanics of the thorax. In: *Physical Therapy of the Cervical and Thoracic Spine* (Grant, R., ed.). Edinburgh: Churchill Livingstone, pp. 47-64.

Lowcock, J. (1990) Thoracic joint stability and clinical stress tests. In: *Proc. Canad. Orthop. Manip. Physiother.*, pp. 15-19, Society Newsletter.

Machida, M., Dubousset, J., Imamura, Y. *et al.* (1993) An experimental study in chickens for the pathogenesis of idiopathic scoliosis. *Spine* **18:** 1609-1615.

Maguire, J., Madigan, R., Wallace, S. *et al.* (1993) Intraoperative long-latency reflex activity in idiopathic scoliosis demonstrates abnormal central processing: a possible cause of idiopathic scoliosis. *Spine* **18:** 1621-1626.

Panjabi, M.M., Brand, R.A., White, A.A. (1976) Mechanical properties of the human thoracic spine. *J. Bone Joint Surgery* **58A:** 642-652.

Peacock, E.E. (1984) *Wound Repair*, 3rd edn. London: W.B. Saunders.

Snijders, C.J., Vleeming, A., Stoeckart, R. (1993) Transfer of lumbosacral load to iliac bones and legs. Part 1: Biomechanics of self-bracing of the sacroiliac joints and its significance for treatment and exercise. Part 2: Loading of the sacroiliac joints when lifting in a stooped posture. *Clin. Biomech.* **8:** 285-301.

Wood, K.B., Garvey, T.A., Gundry, C. *et al.* (1995) Magnetic resonance imaging of the thoracic spine. Evaluation of asymptomatic individuals. *J. Bone Joint Surg.* **77A:** 1631-1638.

Wood, K.B., Blair, J.M., Aepple, D.M. *et al.* (1997) The natural history of asymptomatic thoracic disc herniations. *Spine* **22:** 525-530.

18

Diagnosis of thoracic spine pain and contraindications to spinal mobilization and manipulation

L. G. F. Giles

Introduction

In the preceding chapters a general outline of diagnosis for the management of thoracic spine pain of mechanical origin, with or without intercostal pain, by specific disciplines (i.e. medicine and surgery, chiropractic, osteopathy and physiotherapy) has been considered. The purpose of this chapter is to provide a synopsis of diagnosis for thoracic spine pain syndromes in the overall topic of spinal pain, and to outline contraindications to thoracic spine mobilization and manipulation.

Although only 7-14% of the population experience thoracic spine pain (Pedersen, 1994; Hinkley and Drysdale, 1995), compared to 34-40% who experience neck and arm pain (Hardin and Halla, 1995) and 80-90% who experience low back pain (Deen, 1996), musculoskeletal thoracic spine pain can be a significant health problem.

Thoracic spine pain syndromes must be viewed in the context of (i) clearly defined pathological conditions, and (ii) the less well defined, but much more prevalent, condition of spinal pain of mechanical origin (Stoddard, 1969; Kenna and Murtagh, 1989). It is imperative to distinguish mechanical causes of spinal pain from other causes, as only those patients with mechanical disorders of the thoracic spine are likely to respond dramatically to manual treatment (Kenna and Murtagh, 1989).

One of the major difficulties involved in evaluating a patient with thoracic spine pain of mechanical origin, with or without root symptoms, is that there are many potential causes. A tentative diagnosis is usually arrived at, for an individual case, by taking a careful case history and employing a thorough physical examination, with the additional use of imaging and laboratory procedures as indicated.

There are four main areas of patient evaluation:

1. Clinical history
2. Assessment of pain (incorporating subjective self-report measures estimating pain severity, quality and location)
3. Investigation of personality structure, including the use of appropriate subjective questionnaires
4. Clinical identification of signs and symptoms, including those deemed excessively, or inappropriately, abnormal (Main and Waddell, 1982).

However, caution has to be exercised when making judgements on an individual's behavioural responses to examination, as serious misuse and misinterpretation of behavioural signs has occurred in medicolegal contexts using such signs (Main and Waddell, 1998).

There is still little consensus, either within or among specialties, on the use of diagnostic tests for patients with thoracic spine pain syndromes, and the underlying pathology responsible for various spinal pain problems often remains elusive (Videman *et al.*, 1998). Furthermore, in spite of following a thorough examination procedure, overt pathologies may be merely eliminated rather than identifying conclusively the precise cause of thoracic spine pain of mechanical origin which often remains obscure (Turner *et al.*, 1998), especially when multi-joint dysfunction and degenerative pathology is present.

Specifically, diagnostic problems relate to the following:

1. The limitations of many diagnostic procedures, including plain film radiography, computed tomography (CT), magnetic resonance imaging (MRI), myelography, discography and bone scans

2. The potential for some diagnostic and therapeutic chemical agents to be harmful, for example when such chemicals injected into intervertebral discs extravasate into the epidural space (Weitz, 1984; Adams *et al.*, 1986; MacMillan *et al.*, 1991), causing complications due to contact with neural structures (Dyck, 1985; Merz, 1986; Watts and Dickhaus, 1986)
3. Inadequacies in the precise anatomical knowledge of the spine, including its nociceptive tissues
4. Roentgenographic diagnosis often proving difficult because of the anatomical complexity of the spine (Le-Breton *et al.*, 1993)
5. There sometimes being multifactorial causes of pain at a given spinal level.

There is a lack of consensus on which imaging procedures have diagnostic validity for mechanical back pain, although it is generally agreed that, for plain film X-ray examinations, two views of the same anatomical region taken at right angles to each other is the minimum requirement (Henderson *et al.*, 1994). Furthermore, Buirski and Silberstein (1993) note that MRI can only be used as an assessment of nuclear anatomy and not for symptomatology.

Thoracic intervertebral disc herniations have traditionally been considered to be very uncommon (Arce and Dohrman, 1983; Boriani *et al.*, 1994), representing only 0.6-4% of all disc herniations (El-Kalliny *et al.*, 1991; Giunti and Laus, 1992). However, current thinking is that such herniations may be more prevalent (Vernon *et al.*, 1993) and, when they do occur, they are most frequently located at the T11-T12 level followed by the T8-T9 level (Brugger, 1977). In some cases, intradural herniation of a thoracic disc can occur (Stone *et al.*, 1994).

The reported incidence of symptomatic thoracic disc herniations is relatively low - estimated at 1 per million population - whilst the incidence of asymptomatic thoracic disc protrusions may be as high as 37% (Wood *et al.*, 1997). Spontaneous recovery from disc herniation is well known, and is an important consideration in developing a treatment strategy (Fager, 1994). Furthermore, a retrospective review by Brown *et al.* (1992) of 40 patients with symptomatic thoracic disc herniations managed conservatively suggested a relatively good prognosis, with 77% returning to their previous level of activity. Lumbar intervertebral disc herniations have been shown to morphologically change in a manner consistent with resorption when managed without surgical intervention (Saal *et al.*, 1990), so it is reasonable to consider that this may also occur with thoracic disc protrusions. In fact, although Wood *et al.* (1997) found a trend for small disc herniations either to remain unchanged or to increase in size, large disc herniations often tended to decrease. Caution is necessary in making such statements, however, as it is extremely difficult to duplicate thin MRI sections *in vivo*, as Kaiser (1997) correctly points out. Nonetheless, surgical intervention may be necessary, and the indications for surgery are discussed in Chapter 14.

Although the most common cause of thoracic spine pain syndromes is dysfunction and degeneration of spinal intervertebral joints and their associated rib articulations (Kenna and Murtagh, 1989), root compression due to mechanical dysfunction, with resulting signs and symptoms of intercostal radiculopathy, such as pain, paraesthesiae and sensory disturbances, has to be differentiated from overt pathological conditions or disc protrusions causing radiculopathy. Thoracic disc protrusion has long been a difficult clinical entity to diagnose (Brown *et al.*, 1992), as symptoms can vary dramatically from none at all to motor and sensory deficits resulting from spinal cord compression (myelopathy) - pain, muscle weakness, and neural dysfunction are the most common clinical symptoms (Cramer, 1995). Rarely, thoracic disc protrusion with cord compression can produce incontinence in association with generalized upper motor neuron signs (Kenna and Murtagh, 1989) and, occasionally, paraplegia. As the thoracic cord is immobilized by the dentate ligaments, the anterior spinal artery may be significantly compressed by a relatively small central disc protrusion (Pate and Jaeger, 1996). Similarly, because of the limited extradural space in the thoracic spinal canal, even a small disc protrusion may have pronounced neurological effects (Hoppenfeld, 1977).

It is still only rarely possible to validate a diagnosis for spinal pain (White and Gordon, 1982) and, because the pathological basis of spinal pain can only be established in 10-20% of cases (Chila *et al.*, 1990; Spratt *et al.*, 1990; Pope and Novotny, 1993), this leads to diagnostic uncertainty and suspicion that some patients have a 'compensation neurosis' or other psychological problem. Although the complex interaction of psyche and soma in the aetiology of spinal pain is not well understood, a psychogenic component may be primary (conversion disorder), secondary (depression caused by chronic pain), contributory (myofascial dysfunction) or absent (Keim and Kirkaldy-Willis, 1987). It is appropriate for the clinician to recognize the role of psychosocial factors in back pain. These are discussed in detail by James and McDonald (1997) in a previous volume in this series (Volume 1, Chapter 19).

An important issue to be considered is whether acute mechanical pain can be prevented from becoming chronic and subsequently generating large health care costs. Definitions vary for the time factor associated with acute and chronic spinal pain depending on the viewpoint of various authors (Nachemson and Andersson, 1982; Deyo *et al.*, 1988; Bigos *et al.*, 1994; Henderson *et al.*, 1994). However, it is reasonable to broadly classify acute spinal pain as being of 7 days or less duration, which may be followed by a sub-acute stage of up to 12 weeks; after this the pain can be considered chronic (Deyo *et al.*, 1988).

The anatomy of the thoracic spine has been described in detail earlier. Therefore it is not necessary to reiterate it here, other than to highlight clinically important aspects under the following subheadings and to emphasize that it is mandatory for patients presenting with thoracic spine pain to undergo a comprehensive case history interview, followed by a thorough and careful physical examination and, when necessary, further diagnostic procedures, in order to make a differential diagnosis.

Nerve roots

The relationship of the thoracic roots of the spinal nerves to the vertebrae and intervertebral discs is of major clinical significance (Fig. 18.1), and is discussed in detail in Chapter 8.

The contents of the intervertebral canal are the spinal nerve root, spinal ganglion, recurrent meningeal branch of the spinal nerve, spinal branch of the segmental artery or its branches, epidural fat, and numerous veins (Rickenbacher *et al.*, 1982) and lymph nodes (Swanberg, 1915).

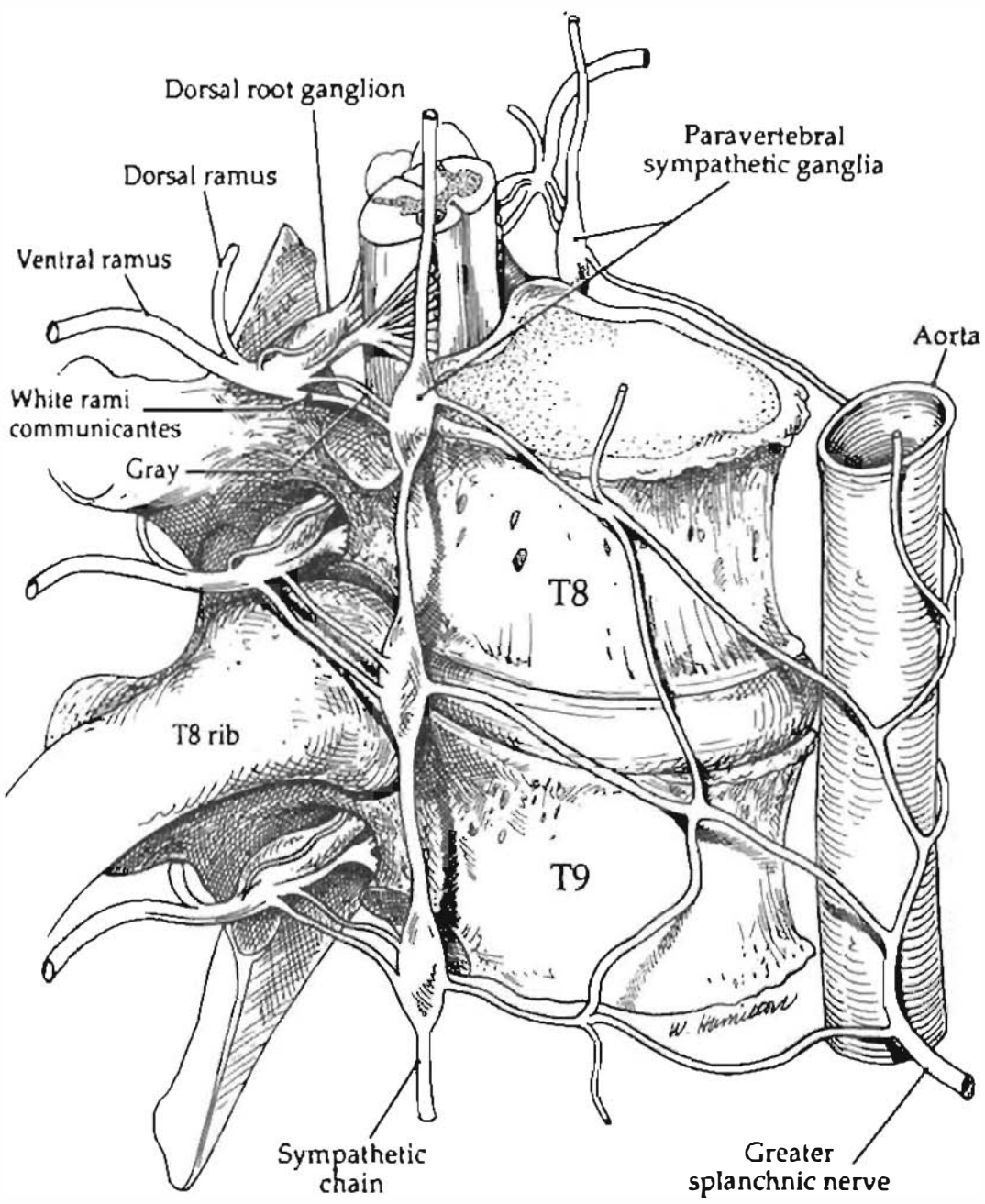

Fig. 18.1 Thoracic spinal cord, nerve roots, spinal ganglia, spinal nerves and the paravertebral sympathetic chain ganglia showing their relationship to adjacent structures. (Reproduced with permission from Harati, 1993).

It is more difficult to make a clinical diagnosis of a herniated thoracic disc than a herniated cervical or lumbar disc (Hoppenfeld, 1977). The position of an intervertebral disc herniation is important when correlating symptoms with signs; for example, depending on its size, a postero-lateral herniation will primarily affect the nerve root, while a midline posterior herniation may affect the dural tube, which has a rich ventral spinal dural nerve plexus (Chapter 8). Although Wood and colleagues (1997) concluded that asymptomatic thoracic disc herniations may well remain asymptomatic, Klein and Garfin (1995) considered that a thoracic disc herniation will usually cause cord as well as root symptoms. In addition, it should be remembered that a midline disc herniation presents primarily with a *symmetrical* myelopathy and mild or no radiculopathy, that thoracic spinal stenosis is extremely rare, and that intradural medullary tumours are usually postero-lateral (Weinstein *et al.*, 1995).

Diagnosis

History of spinal pain

The importance of an exhaustive case history cannot be overemphasized. This should take into account factors such as the patient's age and occupation, the onset of pain, previous injuries, medication, recreational activities, pain aggravation and characteristics, location, distribution and any related neurological symptoms (numbness, paraesthesia, weakness). Some conditions provide reasonably characteristic patterns, while others do not. For example, pain that occurs at night and is relieved by aspirin may be associated with an osteoid osteoma, which is a benign tumour of bone (Keim and Kirkaldy-Willis, 1987).

Pain diagrams, which have been designed to give a patient's subjective interpretation of pain, its location, characteristics, frequency and intensity, should be used to complete the history (Huskisson, 1974; Mooney and Robertson, 1976; Chan *et al.*, 1993) (Fig. 18.2).

An important neurological concept that has been recognized for anatomically normal spines, and which must be considered during the examination, is that the dermatomal distributions (i.e. the cutaneous areas supplied with afferent nerve fibres by single posterior spinal nerve roots) (Dorland, 1974; Barr and Kiernan, 1983) have been fairly well established (Fig. 18.3).

According to Keim and Kirkaldy-Willis (1987), this enables deficits of a specific nerve root to be accurately localized during sensory examination, although Jinkins (1993) and Slipman *et al.* (1998) question this concept and suggest that there is, in fact, some overlap of sensation.

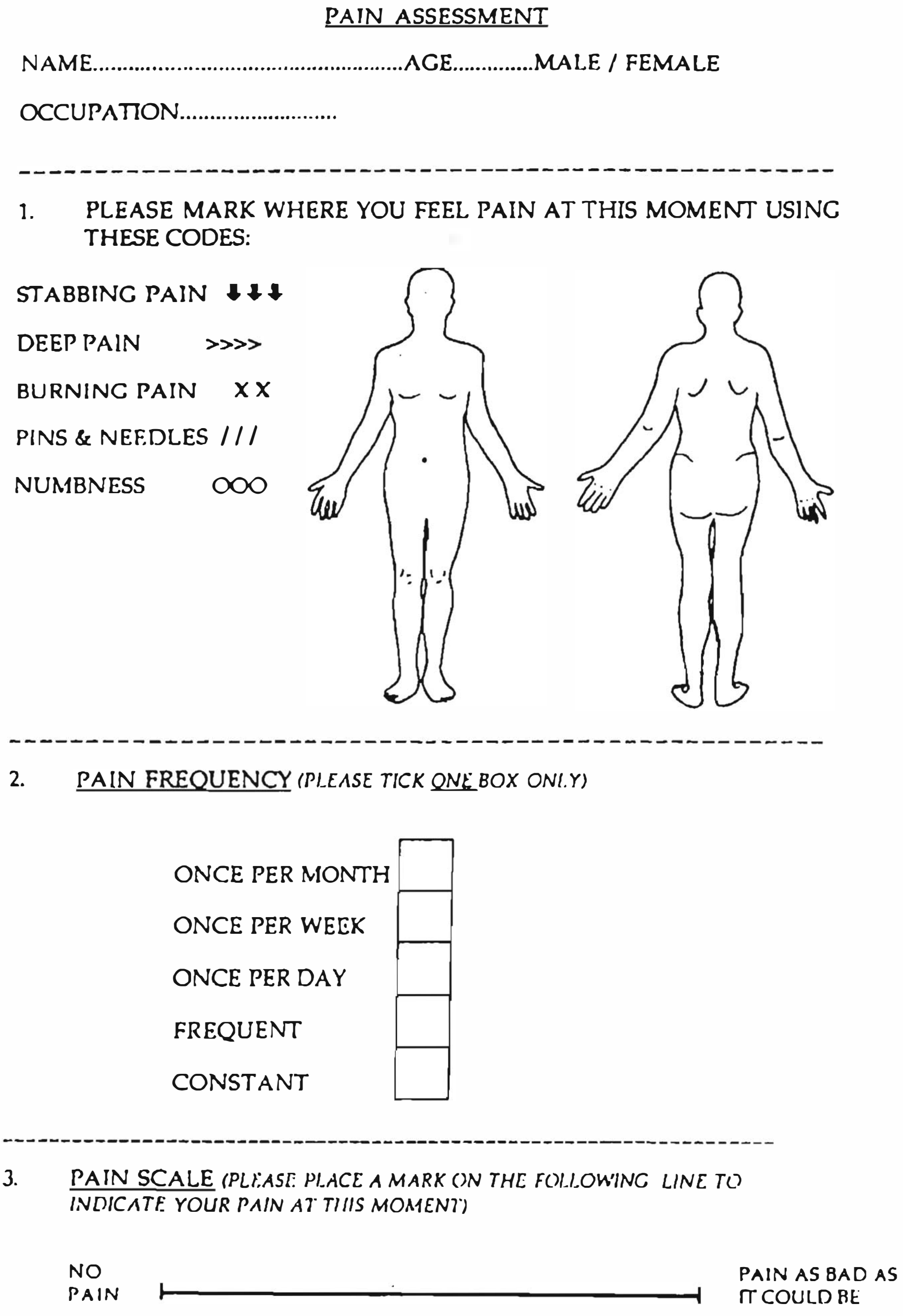

PAIN ASSESSMENT

NAME..AGE...............MALE / FEMALE

OCCUPATION............................

1. PLEASE MARK WHERE YOU FEEL PAIN AT THIS MOMENT USING THESE CODES:

STABBING PAIN ⬇⬇⬇
DEEP PAIN >>>>
BURNING PAIN XX
PINS & NEEDLES ///
NUMBNESS OOO

2. PAIN FREQUENCY *(PLEASE TICK ONE BOX ONLY)*

- ONCE PER MONTH ☐
- ONCE PER WEEK ☐
- ONCE PER DAY ☐
- FREQUENT ☐
- CONSTANT ☐

3. PAIN SCALE *(PLEASE PLACE A MARK ON THE FOLLOWING LINE TO INDICATE YOUR PAIN AT THIS MOMENT)*

NO PAIN |————————————————| PAIN AS BAD AS IT COULD BE

Fig. 18.2 Subjective pain assessment: pain diagram, pain frequency, and visual analogue pain scale.

If only one thoracic nerve root is affected, no anaesthesia may be found, although hypoaesthesia will probably be present (Hoppenfeld, 1977) and, when spinal and/or neural anomalies are present, Wigh (1980) warns of the difficulty of correctly localizing the level of involvement. In addition, careful examination of motor innervation of trunk musculature allows the nerve roots causing a specific motor deficit to be identified. For example, weakness of the lower abdominal muscles may be apparent using Beevor's sign to test the integrity of the segmental innervation of the rectus abdominus muscles (ask the patient to do a quarter sit-up with arms crossed and observe the umbilicus, which normally should not move at all)

weakness may vary from mild paresis to complete

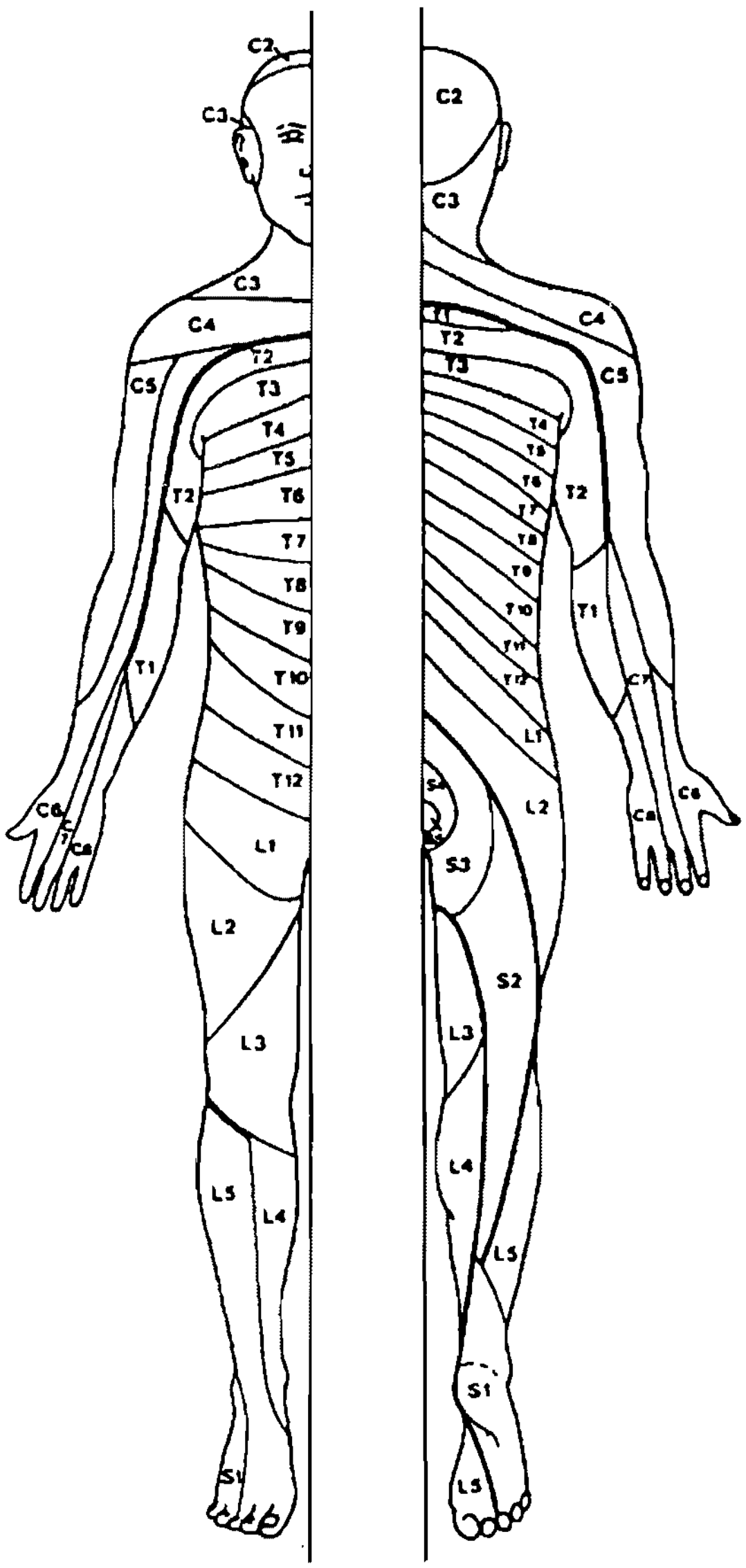

Fig. 18.3 Sensory (dermatomes) on the anterior and posterior surfaces of the body. Axial lines, where there is numerical discontinuity, are drawn thickly. (Modified from Wilkinson, 1986.)

paraplegia, and leg weakness may be unilateral or bilateral; patellar and achilles deep tendon reflexes are brisk or exaggerated while abdominal and cremasteric reflexes are absent, with Babinski's and Oppenheim's signs usually present. Sensory involvement is usually one or two levels lower than the bony level depicted on a myelogram (Hoppenfeld, 1977). Muscle tone is increased in most patients, as expected with an upper motor neuron lesion (Hoppenfeld, 1977) (see Chapter 9).

Thus, until a thorough history has been taken and a complete physical examination and any imaging or laboratory tests have been performed, it is not wise to label a patient as being neurotic or a malingerer, particularly as it is thought that such patients form only a small minority of cases (Teasell, 1997).

Physical examination

The physical examination should be systematic and is summarized in Table 18.1.

Some possible causes of thoracic spine pain

Possible causes of thoracic spine pain that should be considered in the differential diagnosis are summarized in Table 18.2.

If a lesion is suspected within the spinal canal, motor and sensory examination of the thoracic spine, according to neurological levels, should be performed; motor function is assessed as mentioned above (Hoppenfield, 1977). If myelopathy is suspected, upper motor neuron reflexes should be tested including the superficial abdominal reflex (if absent suggests upper motor neurone lesion) (Klein and Garfin, 1995).

Deep tenderness of the spine, with or without cutaneous hyperalgesia, is usually due to local disease of, or injury to, the tissues at the site of tenderness. Almost entirely cutaneous tenderness is a referred phenomenon found in visceral disease (Mackenzie, 1985). It is necessary to differentiate between cutaneous and deep tenderness and, in the case of the latter, between tenderness elicited by pressing upon the spinous processes and tenderness in the adjacent muscles (Mackenzie, 1985). Spinal disease is usually accompanied by local muscular spasm and the muscles thus affected become tender, although they are not themselves the site of the disease. This is important in the differential diagnosis, as local spasm can be a response to disease of the vertebrae, intervertebral discs, or the spinal cord and its membranes (Mackenzie, 1985). The chief morbid conditions causing spinal tenderness are summarized in Table 18.3.

Mechanical thoracic spine pain

Thoracic spine pain syndromes of mechanical origin are the most commonly encountered; consequently these deserve special mention. Poor muscle tone and posture are important factors in the aetiology of mechanical spinal pain and can lead to hyperkyphosis. In particular, the intervertebral and zygapophysial joints can be affected by postural deficiencies

Table 18.1 *Elements of the physical examination*

ERECT POSTURE EXAMINATION	
Observe for: fluidity of movement body build skin markings - e.g. café-au-lait spots, lipomata, melanoma postural deformities scoliosis (idiopathic, postural with pelvic obliquity) spine alignment	*Intercostal expansion at nipple line*: 5-7.5 cm (normal) < 2.6 cm (ankylosing spondylitis)
Test spinal column motion for: flexion extension side bending rotation	*Palpate for*: muscle spasm trigger zones myofascial nodes supraspinous and interspinous ligament tenderness adjacent muscle tenderness relative motion between adjacent vertebrae (by motion palpation)
Compression of rib cage	*Observe gait* heel walking (tests foot and great toe dorsiflexion) toe walking (tests calf muscles)
SEATED	
Knee jerk, ankle jerk	Straight leg raising
Sensation on torso and lower limbs	Calf circumference measurement
SUPINE	
Kernig test (spinal cord stretch)*	Palpation of abdomen Auscultation - listen for bruit (abdominal and inguinal) Palpate for peripheral pulses and skin temperature
Tests to increase intrathecal pressure: Milgram test* Naffziger test* Valsalva manoeuvre*	*Measure* thigh circumference bilaterally
Test sensation and motor power	
PRONE	
Palpate thoracic spine, over related joints, and trigger points	

*See Giles (1997b).
(Adapted from Hoppenfeld, 1976; Hart, 1985; Mackenzie, 1985; Keim and Kirkaldy-Willis, 1987.)

and injury. Subsequent mechanical degenerative changes can lead to zygapophysial joint and nerve root syndromes, the pathogenesis of which has been described by Keim and Kirkaldy-Willis (1987). Although the zygapophysial joint is now universally accepted as an important source of spinal pain (Mooney and Robertson, 1976; Schwarzer *et al.*, 1994a, 1994b; Stolker *et al.*, 1994), and its neurology is more accurately understood (Chapter 8), the existence of the 'facet syndrome' (Ghormley, 1958) as a clinical entity is still questioned by some (Kuslich *et al.*, 1991; Jackson, 1992; Schwarzer *et al.*, 1994a, 1994b). However, its existence in the lumbar spine is supported by others (Kirkaldy-Willis and Tchang, 1988; Weinstein, 1988; Yong-Hing, 1988; Empting-Koschorke *et al.*, 1990; El-Khoury and Renfrew, 1991; Goupille *et al.*, 1993). Dreyfuss *et al.* (1994) have discussed pain referral patterns from thoracic zygapophysial joints.

The role of osteophytes affecting the autonomic chain (Nathan, 1968, 1987; Giles, 1992) should be considered, as well as the effect of intervertebral disc protrusion on the recurrent meningeal nerve, the epidural blood vessels between the protrusion and the dural tube, and the the rich ventral spinal dura nerve plexus (see also Chapter 8).

Table 18.2 *Possible causes of thoracic spine pain*

1. *Traumatic, mechanical or degenerative*:
    (a) Thoracic spine strain; fatigue; obesity; pregnancy
    (b) Degenerative disease of the spine (osteoarthrosis)
    (c) Intervertebral disc lesions
    (d) Scoliosis: primary and secondary
    (e) Spinal stenosis
    (f) Injuries of bone, joint or ligaments causing musculoskeletal thoracic spine pain:
        - Spinal origin - cervical spine (especially C4–C7), cervicothoracic junction, thoracic spine including joints (e.g. costovertebral, zygapophysial, intervertebral with disc), thoracolumbar junction
        - Other thoracic joints - sternoclavicular, manubriosternal, costochondral, sternocostal, scapulothoracic
        - Disorders of ribs (including 12th rib syndrome, rib tip syndrome, slipping rib syndrome), muscles, ligaments
        - Other - costochondritis, Tietze's syndrome, xiphoidalgia, myofascial syndrome, thoracic outlet syndrome
2. *Metabolic*:
    Osteoporosis, osteomalacia, hyper- and hypo-parathyroidism, ochronosis, fluorosis, hypophosphataemic rickets
3. *Unknown causes*:
    Inflammatory arthropathies of the spine, such as ankylosing spondylitis and the spondylitis of Reiter's (Brodie's) disease, psoriasis. Rarely, polymyositis and polymyalgia rheumatica. Paget's disease of bone, osteochondritis (Scheuermann's disease in which vertebral body Schmorl's nodes are located anteriorly)
4. *Infective conditions of bone, joint and theca of spine*:
    Osteomyelitis, herpes zoster, tuberculosis, undulant fever (abortus and melitensis), typhoid and paratyphoid fever and other *Salmonella* infections, syphilis, yaws. Very rarely, Weil's disease (leptospirosis icterohaemorrhagica). Spinal pachymeningitis, chronic meningitis, subarachnoid or spinal abscess
5. *Psychogenic*:
    Anxiety, depression, hysteria (compensation neurosis) malingering
6. *Neoplastic - benign or malignant, primary or secondary*:
    Osteoid osteoma, eosinophilic granuloma, metastatic carcinomatosis, bronchial carcinoma, oesophageal carcinoma, sarcoma, myeloma, primary and secondary tumours of spinal canal and nerve roots (ependymoma, neurofibroma, glioma, angioma, meningioma, lipoma, rarely cordoma). Reticuloses, e.g. Hodgkin's disease
7. *Cardiac and vascular*:
    Myocardial infarction, coronary insufficiency, pericarditis, pulmonary embolism, sub-acute bacterial endocarditis, grossly enlarged left atrium in mitral valve disease, luetic or dissecting aneurysm, subarachnoid or spinal haemorrhage
8. *Pulmonary*:
    Embolus, pneumothorax, pneumonia, pleurisy, pleurodynia (Bornholm's disease)
9. *Oesophageal*:
    Spasm, rupture, oesophagitis, aerophagy
10. *Acute sub-diaphragmatic disorders*:
    Stomach, gallbladder, duodenum, pancreas, sub-phrenic collections
11. *Blood disorders*:
    Sickle-cell crises, acute haemolytic states
12. *Drugs*:
    Corticosteroids, methysergide, compound analgesic tablets

Modified from Hart (1985) and Kenna and Murtagh (1989).

Imaging

Routine radiographs of the spine and chest should be taken, to establish a baseline and to rule out metabolic, inflammatory, and malignant conditions (Keim and Kirkaldy-Willis, 1987). As long as proper coning of the X-ray beam is used, in conjunction with high-speed screens and films and appropriate filtration of the X-ray beam, there is minimal radiation exposure to the patient while obtaining maximum quality X-ray films. These radiographs should be taken in the erect posture, using carefully standardized procedures; for example, to accurately determine whether possibly significant leg-length inequality is present with corresponding pelvic obliquity (Giles and Taylor, 1981; Giles, 1984, 1989) causing postural (compensatory) scoliosis in the thoracic spine. Further imaging procedures may be necessary, such as: MRI, which can provide very good detail of soft tissue structures in and about the spinal column without the need of contrast; CT scans, which are particularly good at showing bony structures and are useful for some neural problems; myelography, for demonstrating lesions of the spinal cord and canal such as neoplasm and disc herniation; and bone scans, when tumour, infection or small fracture(s) are suspected (see Chapters 6 and 12).

Unfortunately, all the preceding procedures have some limitations; for example, plain film radiographs will not show an osseous erosion until an approximately 40% decrease in bone density has occurred (Michel *et al.*, 1990; Perry, 1995). MRI may not show

Table 18.3 *Summary of chief conditions causing spinal tenderness*

1. *Diseases of the overlying skin and subcutaneous tissue*

   These are usually clinically obvious and include potentially serious conditions such as melanoma

2. *Diseases of the vertebral column*:

   (a) Inflammatory
      Pott's disease
      Staphylococcal spondylitis
      Typhoid spine
      Spondylitis ankylopoietica
      Actinomycosis
      Hydatid cyst
      Paget's disease
   (b) Degenerative
      Spondylosis
      Osteochondritis (rare)
      Nucleus pulposus herniation
   (c) Neoplastic
      Primary tumour
      Secondary deposit
      Myelomatosis
      Leukaemic deposits
   (d) Traumatic
      Fracture
      Dislocation
      Nucleus pulposus herniation
   (e) Erosion by aortic aneurysm

3. *Diseases of the spinal cord and meninges*:

   Metastatic epidural abscess or tumour
   Meningioma
   Neurofibroma
   Syringomyelia
   Herpes zoster
   Meningitis serosa circumscripta
   Tumour of the spinal cord

4. *Hysteria and malingering: (compensation neurosis)*

5. *Metabolic disorders*: osteoporosis, osteomalacia, hyperparathyroidism

Reproduced with permission from Mackenzie (1985).

signs of traumatic thoracic disc herniation until some months later, and there is the potential for false-positive findings as a result of asymptomatic degenerative changes. Therefore, imaging procedures may only give a 'shadow of the truth'; this is particularly true when a patient's physical examination and imaging studies are unremarkable (Giles and Crawford, 1997). The limitation of present diagnostic imaging procedures in not being able to show all soft tissues, such as some of those shown histologically in Figs 18.4 and 18.5, is a serious shortcoming.

When a thoracic nerve root dysfunction is suspected, electromyography (EMG) and nerve root conduction studies can be helpful (Hoppenfeld, 1977).

Laboratory tests

When bony pathology is suspected, serum calcium, phosphorus, alkaline phosphatase (particularly alkaline phosphatase isoenzyme determination by electrophoresis, which differentiates alkaline phosphatase of osteoblastic origin from alkaline phosphatase from other sources – Brown, 1975) and acid phosphatase or prostatic specific antigen (for males over 40 years of age) may be helpful in detecting bone disease. Early inflammatory changes may be detected by an increase in C-reactive protein and in the erythrocyte sedimentation rate (ESR). An abnormal full blood count can be helpful; for example, in cases where there is suspicion of primary haematological disorders and for some infections (Henderson *et al.*, 1994).

Immunoelectrophoresis of serum and urinary proteins may also be useful diagnostic procedures in the identification of multiple myeloma (Brown, 1975). Other tests that should be considered, when indicated, are latex flocculation for rheumatoid spondylitis, and serum and urine amylase and lipase for chronic pancreatitis (Collins, 1968; Schroeder *et al.*, 1992). In addition, it may be necessary to assess bone density using dual energy X-ray absorption (DEXA) bone densitometry.

In this chapter it is not necessary to list every spine-related condition with its possible abnormalities in serology, haematology, urinalysis and other laboratory tests, as these have been well documented in numerous clinical diagnosis texts, including illustrated versions (Collins, 1968). In addition, particular reference to painful syndromes associated with the spine in some cases has already been made

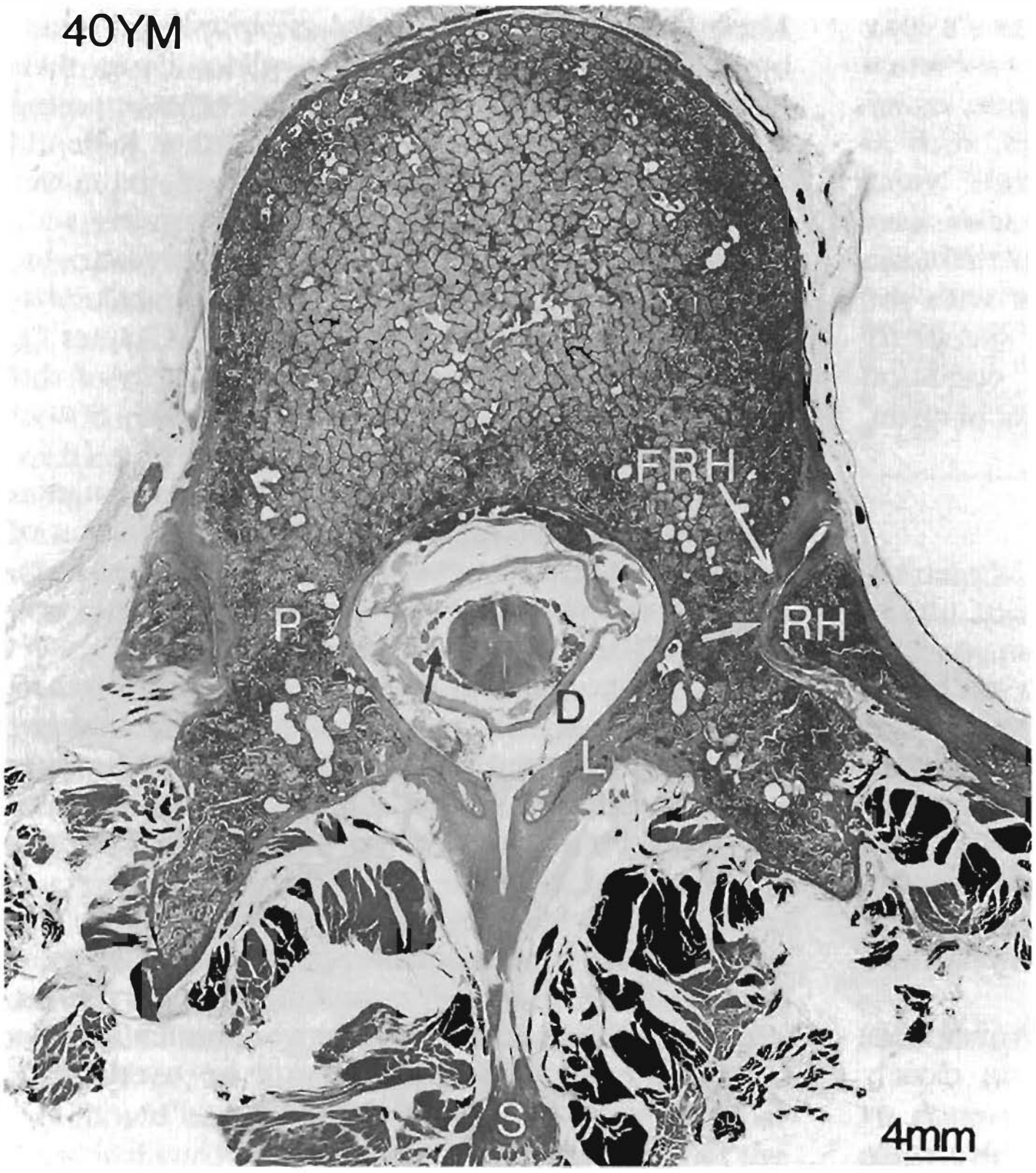

Fig. 18.4 Superior to inferior view of a 200-μm thick histological section cut through the rib head level of a T11 vertebra from a 40-year-old male. Note the contents of the spinal canal where the spinal cord is protected within the dural tube (D) with an adequate amount of epidural fat. The black arrow shows a denticulate ligament, between the anterior and posterior nerve roots, which helps to protect the cord against and sudden displacement as it floats within the cerebrospinal fluid. FRH, facet (with hyaline articular cartilage) for rib head; L, lamina; P, pedicle; RH, rib head with hyaline articular cartilage; S, spinous process with muscles on its left and right sides. Note the synovial fold (short white arrow) projecting into the right costovertebral joint 'cavity' from its posterior margin. These synovial folds are innervated by axons expressing immunoreactivity to substance P and are a likely source of pain, (Erlich's haematoxylin and light green counterstain). (Reproduced with permission from Giles and Singer, 1997a.)

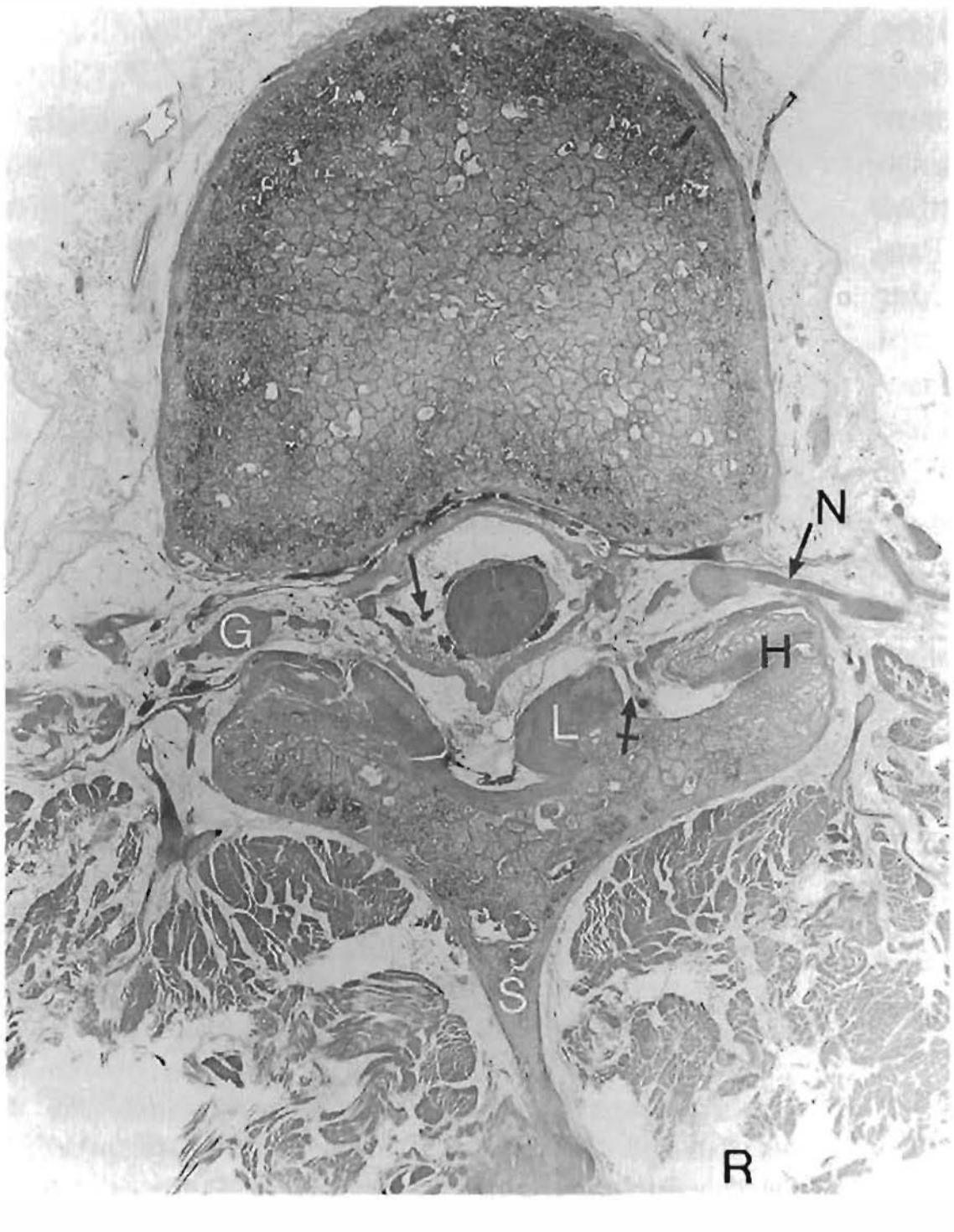

Fig. 18.5 Superior to inferior view of a 200-μm thick histological section cut through the T10–T11 intervertebral foramen of a 40-year-old male. Note the anatomical deviation of the spinous process (S) to the right side. The spinal ganglia (G) are seen in the outer half of each intervertebral canal (foramen). Arrow, nerve roots; N, spinal nerve. The section has been cut in a slightly oblique plane, so the right zygapophysial joint's hyaline articular cartilages (H) are seen more clearly than on the left. Note the epidural fat communicating with fat inside the joint capsule (through the disrupted ligamentum flavum (L)) in this individual (tailed arrow). R, right side.

(Haldeman *et al.*, 1993; Henderson *et al.*, 1994). However, laboratory evaluations are important when the clinician suspects metabolic disturbance, malignancy, infection or one of the arthritides, such as ankylosing spondylitis or rheumatoid arthritis. Nonetheless, it should be noted that various tests have different levels of *accuracy*, which is calculated from the *sensitivity* (proportion of individuals with the condition whose tests are positive) and *specificity* (proportion of individuals without the condition whose tests are negative) (Bloch, 1987; Nachemson, 1992; Henderson *et al.*, 1994).

Treatment

Effective treatment must be based on an exclusion diagnosis of the aetiology of thoracic spine pain syndromes, bearing in mind that, in the majority of cases of pain of mechanical origin, a precise diagnosis cannot be made (Margo, 1994). However, it is essential to exclude disease processes and psychological conditions which should be treated by another specialist rather than by spinal mechanical therapy.

As described in a number of previous chapters, pain referred from the thoracic spine can closely mimic the symptoms of visceral disease such as angina pectoris and biliary colic (Kenna and Murtagh, 1989). Consequently it is essential for a careful diagnosis to be made in order not to manipulate the spine for inappropriate conditions, which will be listed later in this chapter. For example, a patient presenting with cervicothoracic and shoulder pain, who does not have reproducible shoulder pain on movement, requires cervical and thoracic spine radiographs as well as chest films to exclude Pancoast's tumour, which can refer pain to the shoulder (Hart, 1985). In addition, such tumours can interrupt the cervical sympathetic pathways, leading to vasomotor paralysis with sudomotor abnormalities and Horner's syndrome (Khurana, 1993).

Contraindications

Against the preceding diagnostic approach to thoracic spine pain syndromes, contraindications must be considered.

When a diagnosis of mechanical pain of the thoracic spine has been made, a manipulative thrust can be made to any part of the thoracic spine. A detailed knowledge of the anatomical peculiarities of the thoracic region, for example the planes of the zygapophysial joints, will allow such manoeuvres to be applied safely and with maximum benefit to the patient. Furthermore, manipulation of the thoracic spine should be performed carefully at all times. Manipulation should allow the zygapophysial joint's opposing cartilage surfaces to glide along their normal plane and not in such a manner that opposing surfaces are compressed against each other. It should be noted particularly that treatment of the lower thoracic spine (T11-T12 and T12-L1) requires additional precautions due to the extremely variable morphological configuration of the thoracolumbar zygapophysial joints (Singer *et al.*, 1988, Chapter 7). In fact, 'mortice' type joints are a peculiarity of this part of the spine, and occur in approximately 80% of the population (Davis, 1955; Singer, 1989) (Fig. 18.6).

In such joints there is marked restriction to rotation and extension, so clinicians these anatomical features when examining and managing thoracolumbar junction disorders (Singer and Giles, 1990).

In order to prevent injury to the costovertebral joints during a manipulative thrust their anatomy must be understood, as these joints have soft tissue structures such as synovial folds and joint capsules that could be injured if due caution and skill are not applied (See Fig. 18.4).

When a clinician is completely familiar with the bony anatomy of the thoracic spine, interpretation of imaging films will be routine and diagnostic errors are less likely to occur. Therefore, bony contraindications to spinal manipulation should not be overlooked;

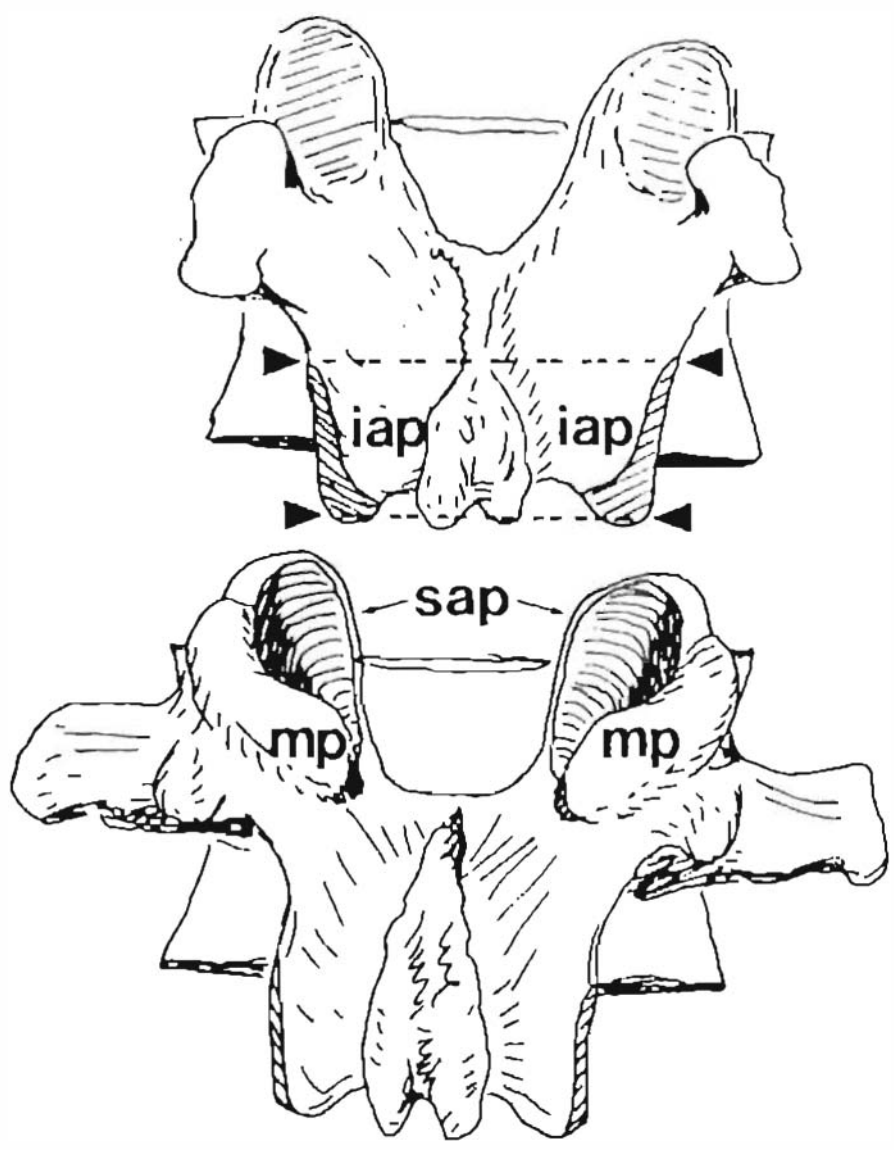

Fig. 18.6 An illustration of one type of mortice joint showing the superior and inferior joint levels, which shows the tapered effect of this articulation (sap, superior articular process; iap, inferior articular process; mp, mammillary process). Note how the inferior articular processes of the superior vertebra would be 'locked' into the superior articular processes of the lower vertebra. (Reproduced with permission from Singer and Giles, 1990.)

however, possible existing osseous and soft tissue disease or injury, not evident on some radiographic images, should always be borne in mind (Giles and Crawford, 1997).

Manipulation of the spine is performed on millions of patients each day and, although most attention has been paid to injuries of the cervical spine (Terrett, 1995; Klougart *et al.*, 1996), followed by lumbar spine injuries (Haldeman and Rubinstein, 1992), very little has been reported regarding thoracic spine injuries secondary to manipulation. However, it is possible to fracture or dislocate ribs and injure costal cartilage using direct thrusting techniques with the patient lying prone (Kenna and Murtagh, 1989). It has been suggested by Powell *et al.* (1993) that the main factors which result in lumbar or cervical complications following spinal manipulation are misdiagnosis, failure to identify the onset or progression of neurological signs and symptoms, inappropriate technique, and manipulation when a blood coagulation disorder exists. The same principles apply to the thoracic spine.

Manual therapy practitioners should remember that spinous processes are notoriously anomalous and, therefore, that it is unwise to rely on static palpation of spinous processes as a guide to the delivery of spinal manipulative thrusts. An example of a deviated spinous process to illustrate this principle is shown in Fig. 18.5.

It should be remembered that the largest artery of the spinal cord (diameter up to 1.2 mm) is one of the anterior radicular arteries, 'Adamkiewicz's artery' (1882), which is in the vicinity of the thoracolumbar junction (Williams and Warwick, 1980; Rickenbacher *et al.*, 1982). This is the chief vessel supplying the lumbar enlargement of the cord and usually stems from one of the lowermost intercostal arteries of the descending aorta, being on the left side in 73% of cases (Williams and Warwick, 1980; Rickenbacher *et al.*, 1982). This artery, also known as the arteria radicularis magna (of Adamkiewicz), most frequently lies at the T9 or T10 levels (Rickenbacher *et al.*, 1982) and can be principally responsible for the blood supply of up to two-thirds of the lower part of the spinal cord (Williams and Warwick, 1980). If injury to this artery were to occur, the results would be disastrous in view of the blood supply to the lower part of the spinal cord.

The indications and contraindications for thoracic spine manipulation

The *indication* for manipulation is a diagnosis of uncomplicated mechanical pain of the thoracic spine, and may include conditions listed in Table 18.4.

Table 18.4 *Indications for spinal manipulation: these are dependent upon at least the patient's history, presenting signs and symptoms, and reportedly normal plain film radiographs*

- Idiopathic zygapophysial joint dysfunction (Cavanaugh and Weinstein, 1994)
- Costovertebral or costotransverse joint dysfunction
- Costovertebral joint synovial fold 'nipping'
- Minor to moderate osteoarthrosis
- Paraspinal muscle syndromes
- The T4 syndrome (Maitland, 1986)

With experience, the clinician is able to differentiate between those signs and symptoms that contraindicate manipulation and those that permit careful application of manipulative techniques.

Contraindications, which are essentially the same as for the lumbar and cervical spines, apart from anatomical regional variations, can be divided into two categories; relative and absolute (Table 18.5). Relative contraindications should be considered on a case-by-case basis. In cases of absolute contraindications, however, manipulation should not be performed.

Misdiagnosis of thoracic spine pain

Misdiagnosis refers to the unidentified presence of disease processes that may mimic thoracic spine pain symptoms. As a result of misdiagnosis, complications arise through delays in initiating referral for appropriate treatment and injuries due to existing overt but unrecognized pathology. Manipulation of diseased vertebrae may induce spinal fractures or dislocations, resulting in acute compression syndromes of the thoracic spinal cord or nerve roots. In the extreme case, paraplegia may be induced by inappropriate manipulation of the thoracic spine.

Vascular accidents

Practitioners must establish what medications are being taken by their patients and recognize the potential risk to those on anticoagulant therapy such as warfarin, heparin or aspirin. Vascular pathology of significance includes advanced arteriosclerosis and dissecting aneurysm.

Trauma of the thoracic spine

Direct and indirect trauma of the thoracic spine, leading to functional disorders, is relatively infrequent. However, traumatically induced burst fractures, disc herniations, vertebral instability, and bony lesions with neurogenic signs should be considered as contraindications for spinal manipulation. Minor costovertebral joint osteoarthrosis (Nathan *et al.*, 1964) is not a contraindication for spinal manipulation.

Table 18.5 *Contraindications for spinal manipulation: these are dependent upon the patient's history, presenting signs and symptoms, imaging results and, when indicated, laboratory findings*

Relative:
- Degree of osteopenia
- Advanced arthropathies
- Insignificant bony spinal anomalies
- Patients on anticoagulant medication
- Vascular disorders
- Psychological overlay and undiagnosed pain
- Herpes zoster
- Spinal manipulation should not be used if there is a possibility of miscarriage. Techniques involving compression and rotation of the thoracolumbar spine are probably best avoided in the latter stages of pregnancy

Absolute (often due to co-existing disease):
- Primary and secondary neoplastic lesions of the spine and/or ribs
- Primary and secondary neoplastic lesions of the soft tissue structures of the chest, including tumours of neural structures
- Non-neoplastic bone disease (e.g. advanced osteoporosis)
- Infection (e.g. osteomyelitis, tuberculosis)
- Inflammation (e.g. acute rheumatoid arthritis or ankylosing spondylitis)
- Synovial cyst (Hodges *et al.*, 1994)
- Healing fracture or dislocation
- Intervertebral disc herniation (Boriani *et al.*, 1994)
- Gross segmental instability and significant spinal anomalies (e.g. advanced idiopathic scoliosis)
- Spinal cord compression
- Thoracic aneurysm
- Visceral referred pain
- Obvious advanced spinal deformity
- Congenital generalized hypermobility

Modified from Grieve (1981), Dvorak (1991), Terrett and Kleynhans (1992) and Singer (1997).

Unnecessary force application during spinal manipulation

Fortunately, few cases have been reported where excessive force has resulted in long-term complications. However, the production of rib and vertebral fractures has been documented (Patijn, 1991; Terrett and Kleynhans, 1992).

Osteoporosis

Assessment of fracture risk using bone density measurements is the preferred management strategy when osteoporosis is present. There may be a role for very gentle mobilization, but this must be considered on a case-by-case basis and should not be performed if there is any risk of injury to the patient.

Inflammatory disease of the spine and degenerative spondylosis

Rheumatoid arthritis may present with signs of spinal instability, and must be assessed cautiously by the practitioner. In the acute inflammatory stage of ankylosing spondylitis, spinal manipulation is contraindicated. Chronic degenerative osteoarthritis, spondylosis osteochondrosis and diffuse idiopathic skeletal hyperostosis (DISH) are relative contraindications for spinal manipulation. Mobilization may, however, be recommended in place of high-velocity low-amplitude thrust techniques. Cases with advanced osteoarthritis of the intervertebral joints may not benefit from manipulation. Spinal degenerative disorders with resultant soft-tissue hypertrophy of the ligamentum flavum can induce spinal stenosis, and patients with spinal stenosis usually do not benefit from spinal manipulation (Grieve, 1981).

Spinal manipulative therapy in patients with psychogenic disorders

Patients who present with psychogenic disorders must be evaluated carefully, preferably by a psychologist and/or a psychiatrist, before spinal manipulation is recommended. In patients in whom a functional joint disorder of the spine cannot be determined there is no point in using spinal manipulation, as patients with psychogenic disorders can develop an 'addiction' to manipulation. Such patients may even attempt to coerce the unsuspecting practitioner into administering such therapy.

Clinical reasoning for continuing or abandoning mechanical therapy of the thoracic spine

Spinal manipulation may be continued or discontinued according to the presenting signs and symptoms compared with a follow-up examination. As previously mentioned, an exacting history is mandatory in determining the appropriateness of mechanical therapy. A clinical guide that provides a logical sequence for considering or re-evaluating the role of spinal manipulation is outlined in Table 18.6.

Despite the lack of any systematic study into thoracic spine complications following spinal manipulation, the incidence is considered to be low, although Terrett and Kleynhans (1992) suggest that rib fractures are possibly an under-reported complication of spinal manipulation. The true rate of complications can only be assessed using prospective surveys.

Table 18.6 *Clinical reasoning for continuing or abandoning spinal manipulation of the thoracic spine*

1. *The patient reports improvement following treatment*:
   - Treatment is repeated within reason until the patient is symptom free, or until the treatment goal has been attained
2. *The patient's symptoms are exacerbated within hours following treatment but improve the day after treatment*:
   - Re-evaluate the patient and continue treatment on a short trial basis if indicated before re-evaluating
3. *The patient's symptoms are exacerbated immediately after treatment*:
   - The patient should be reassured
   - Re-evaluate in the light of previous findings
   - Consider substituting a different form of treatment
   - Consider massage of the paravertebral muscles
   - Carefully detail and document the physical findings, including neurological assessment
4. *Progressively worsening symptoms over days or a week*:
   - Reassess previous diagnostic findings
   - Discontinue manipulative treatment
   - Consider substituting a different treatment modality
   - Consider medical referral for local infiltration with anaesthetic ± steroid suspension
   - Neurological, rheumatological or orthopaedic consultations may become necessary and should not be postponed
5. *In case of neurological complications e.g. anaesthesia, sensory changes and weakness*:
   - Reassess urgently; complete documentation of the incident and all findings
   - Consider immediate hospitalization via emergency
6. *The patient's status remains unchanged (i.e. neither improvement nor worsening of the initial symptoms) after several (6) treatments*:
   - Reassess diagnostic findings
   - Change mechanical therapy approach
   - Consider the patient's psychosocial situation
   - Consider appropriate referral
7. *In every situation the following guide applies*:
   - Economy of vigour in technique
   - Treatment must be guided by assessment and reassessment

Modified from Dvorak (1991), Terrett and Kleynhans (1992) and Singer (1997).

In summary, major complications arising from spinal manipulation reflect misdiagnosis, the inability of imaging procedures to define some pathological conditions clearly, failure to identify correctly the onset or progression of neurological signs or symptoms, the choice of inappropriate management techniques, spinal manipulation performed in the presence of a significant herniated disc or a blood coagulation disorder, and the use of inappropriate mechanical therapy techniques.

References

Adamkiewicz, A. (1882) Die Blutgefasse des menschlichen Ruckenmarkes, 2 Theil. Die Gefabe der Ruckenmarksoberflache S-B Akad Wiss. *Wien Math-nat. Kl.* **3(85):** 101.

Adams, M.A., Dolan, P., Hutton, W.C. (1986) The stages of disc degeneration as revealed by discogram. *J. Bone Joint Surg.* **68B:** 36.

Arce, C.A., Dohrman, G.J. (1983) Herniated thoracic discs. *Neurol. Clin.* **3:** 383-392.

Barr, M.L., Kiernan, J.A. (1983) *The Human Nervous System. An Anatomical Viewpoint*, 4th edn. Philadelphia: Harper and Row.

Bigos, S., Bowyer, O., Braen, G. *et al.* (1994) *Acute Low Back Problems in Adults: Assessment and Treatment.* Rockville: Quick Reference Guide for Clinicians Number 14, US Department of Health and Human Services, Public Health Service, Agency for Health Care Policy and Research. AHCPR Pub. No. 95-0643

Bloch, R. (1987) Methodology in clinical back pain trials. *Spine* **12:** 430.

Boriani, S., Biagini, F., De Lure, F. *et al.* (1994) Two-level thoracic disc herniation. *Spine* **19:** 2461-2466.

Brown, C.W., Deffer, P.A., Akmakjian, J. *et al.* (1992) The natural history of thoracic disc herniation. *Spine* **17:** S97-S102

Brown, M.D. (1975) Diagnosis of pain syndromes of the spine. *Orthop. Clin. North Am.* **6:** 233-248.

Brugger, A. (1977) *Die Erkrankungen des Bewegungsapparates und seines Nervensystems.*, Stuttgart: Fischer.

Buirski, G., Silberstein, M. (1993) The symptomatic lumbar disc in patients with low back pain: Magnetic resonance imaging appearances in both a symptomatic and control population. *Spine* **18:** 1808-1811.

Cavanaugh, J.M., Weinstein, J.N. (1994) Low back pain: epidemiology, anatomy and neurophysiology. In: *Textbook of Pain* (Wall, P.D., Melzack, R., eds). Edinburgh: Churchill Livingstone, pp. 441-455.

Chan, C.W., Goldman, S., Ilstrup, D.M. (1993) The pain drawing and Waddell's non-organic physical signs in chronic low-back pain. *Spine* **18:** 1717-1722.

Chila, A.G., Jeffries, R.R., Levin, S.M. (1990) Is spinal manipulation for your practice? *Patient Care* **24:** 77-92.

Collins, R.D. (1968) *Illustrated Manual of Laboratory Diagnosis.* Philadelphia: J.B. Lippincott Co.

Cramer, G.D. (1995) The thoracic region. In: *Basic and Clinical Anatomy of the Spine, Spinal Cord, and ANS* (Cramer, G.D., Darby, S.A., eds). Baltimore: Mosby, p. 166.

Davis, P.R. (1955) The thoracolumbar mortice joint. *J. Anat.* **89:** 370-377.

Deen, H.G. (1996) Concise review for primary-care physicians. Diagnosis and management of lumbar disc disease. *Mayo Clin. Proc.* **71:** 283-287.

Deyo, R.A., Bass, J.E., Walsh, N.E. *et al.* (1988) Prognostic variability among chronic pain patients: Implications for study design, interpretation, and reporting. *Arch. Phys. Med. Rehabil.* **69:** 174-178.

Dorland's Illustrated Medical Dictionary (1974) 25th edn. Philadelphia: W.B. Saunders.

Dreyfuss, P., Tibiletti, C., Dreyer, S. *et al.* (1994) Thoracic zygapophysial joint pain: a review and description of an intra-articular block technique. *Pain Digest* **4:** 46-54.

Dvorak, J. (1991) Inappropriate indications and contraindications for manual therapy. *Man. Med.* **6:** 85-88.

Dyck, P. (1985) Paraplegia following chemonucleolysis. *Spine* **10:** 359.

El-Kalliny, M., Tew, J.M. Jr, van Loveren, H. *et al.* (1991) Surgical approaches to thoracic disc herniations. *Acta Neurochir. (Wien)* **111:** 22-32.

El-Khoury, G.Y., Renfrew, D.L. (1991) Percutaneous procedures for the diagnosis and treatment of lower back pain: Discography, facet-joint injection and epidural injection. *AJR* **157:** 685-691.

Empting-Koschorke, L.D., Hendler, N., Kolodny, A.L. *et al.* (1990) Tips on hard-to-manage pain syndromes. *Patient Care* April 30, 26-46.

Erwin, W.M., Jackson, P.C., Homanko, D. (1999) *Innervation of the Human Costovertebral Joint: Implications for Clinical Back Pain Syndrome.* World Federation of Chiropractic Symposium Proceedings.

Fager, C.A. (1994) Observations on spontaneous recovery from intervertebral disc herniation. *Surg. Neurol.* **42:** 282-286.

Ghormley, R.K. (1958) An etiologic study of back pain. *Radiology* **70:** 649-652.

Giles, L.G.F. (1984) Letter to the Editor. *Spine* **8:** 842.

Giles, L.G.F. (1989) *Anatomical Basis of Low Back Pain.* Baltimore: Williams & Wilkins.

Giles, L.G.F. (1992) Paraspinal autonomic ganglion distortion due to vertebral body osteophytosis: A case of vertebrogenic autonomic syndromes? *JMPT* **15:** 551-555.

Giles, L.G.F., Crawford C.M. (1997) Shadows of the truth in patients with spinal pain: A review. *Can. J. Psychiatry* **44:** 44-48.

Giles, L.G.F. (1997a) Introductory graphic anatomy of the lumbosacral spine. In: *Clinical Anatomy and Management of Low Back Pain* (Giles, L.G.F., Singer K.P., eds). Oxford: Butterworth-Heinemann, p. 40.

Giles, L.G.F. (1997b) Abbreviations and Definitions. In: *Clinical Anatomy and Management of Low Back Pain* (Giles, L.G.F., Singer K.P., eds). Oxford: Butterworth-Heinemann, pp. 395-399.

Giles, L.G.F., Taylor, J.R. (1981) Low back pain associated with leg length inequality. *Spine* **6:** 510-521.

Giunti, A., Laus, M. (1992) *Le radicolopatie spinali.* Bologna: Aulo Gaggi Editore.

Goupille, P., Fitoussi, V., Cotty, P. *et al.* (1993) Arthro-infiltrations des articulaires posterieures lombaires dans les lombalgies chroniques. Resultats chez 206 patients. *Rev. Rheum. Ed. Fr.* **60:** 797-801.

Grieve, G. (1981) *Common Vertebral Joint Problems.* Edinburgh: Churchill Livingstone, pp. 465-466.

Haldeman, S., Rubinstein, S.M. (1992) Cauda equina syndrome in patients undergoing manipulation of the lumbar spine. *Spine* **17:** 1469-1473.

Haldeman, S., Chapman-Smith, D., Paterson, D.M. (1993) *Guidelines for Chiropractic Quality Assurance and Practice Parameters.* Gaithersburg: Aspen, pp. 55-80.

Harati, Y. (1993) Anatomy of the spinal and peripheral autonomic nervous system. In: *Clinical Autonomic Disorders* (Low, P.A., ed.). Boston: Little, Brown and Company, p. 21.

Hardin, J.G., Halla, J.T. (1995) Cervical spine and radicular pain syndromes. *Curr. Opin. Rheum.* **7:** 136-140.

Hart, F.D. (1985) Back pain. In: *French's Index of Differential Diagnosis,* 12th edn (Hart, F.D., ed.). London: Butterworth and Co. Ltd, pp. 72-73, 76, 764-767.

Henderson, D., Chapman-Smith, D., Mior, S. *et al.* (1994) Clinical guidelines for chiropractic practice in Canada. *J. Can. Chiro. Assoc.* **38(Suppl.):** 25.

Hinkley, H.J., Drysdale, I.P. (1995) Audit of 1000 patients attending the clinic of the British College of Naturopathy and Osteopathy. *Br. Osteopath. J.* **16:** 17-22.

Hodges, S.D., Fronczak, S., Zindrick, M.R. *et al.* (1994) Extradural synovial thoracic cyst. *Spine* **19:** 2471-2473.

Hoppenfeld, S. (1976) *Physical Examination of the Spine and Extremities.* New York: Appleton-Century-Crofts.

Hoppenfeld, S. (1977) *Orthopaedic Neurology: A Diagnostic Guide to Neurologic Levels.* Philadelphia: J.B. Lippincott Co., pp. 45, 100, 101.

Huskisson, E.C. (1974) Measurement of pain. *Lancet* **2:** 1127-1131.

Jackson, R.P. (1992) The facet syndrome. Myth or reality? *Clin. Orthop. Rel. Res.* **279:** 110-121.

James, B., McDonald, F. (1997) Psychosocial aspects of back pain. In: *Clinical Anatomy and Management of Low Back Pain.* Oxford: Butterworth-Heinemann, pp. 322-333.

Jinkins, J.R. (1993) The pathoanatomic basis of somatic and autonomic syndromes originating in the lumbosacral spine. *Neuroimaging Clin. North Am.* **3:** 443-463.

Kaiser, J.A. (1997) Point of view. *Spine* **22:** 529-530.

Keim, H.A., Kirkaldy-Willis, W.H. (1987) *Clinical Symposia. Low Back Pain,* 39. Jersey: Ciba-Geigy.

Kenna, C., Murtagh, J. (1989) *Back Pain and Spinal Manipulation.* Sydney: Butterworths, pp. 165, 166, 171, 173.

Khurana, R.K. (1993) Acral sympathetic dysfunctions and hyperhidrosis. In: *Clinical Autonomic Disorders* (Low, P.A., ed.). Boston: Little, Bown and Company, pp. 767-775.

Kirkaldy-Willis, W.H., Tchang, S. (1988) Diagnostic techniques. In: *Managing Low Back Pain* (Kirkaldy-Willis, W.H., ed.). New York: Churchill Livingstone, pp. 155-181.

Klein, J.D., Garfin, S.R. (1995) History and physical examination. In: *Essentials of the Spine* (Weinstein, J.N., Rydevik, B.L., Sonntag, V.K.H., eds). New York: Raven Press, pp. 71-96.

Klougart, N., Leboeuf-Yde, C., Rasmussen, L.R. (1996) Safety in chiropractic practice. Part II: Treatment to the upper neck and the rate of cerebrovascular incidents. *JMPT* **19:** 563-569.

Kuslich, S.D., Ulstrom, C.L., Michael, E.J. (1991) The tissue origin of low back pain and sciatica: a report of pain response to tissue stimulation during operations on the lumbar spine using local anesthesia. *Orthop. Clin. North Am.* **22:** 181-187.

Le-Breton, C., Meziou, M., Laredo, J.D. (1993) Sarcomes pagetiques rechidiens. A propos de huit observations. *Rev. Rheum. Ed. Fr.* **60:** 16-22.

Mackenzie, I. (1985) Spine, tenderness of. In: *French's Index of Differential Diagnosis* (Hart, F.D., ed.). London: Butterworth and Co. Ltd, p. 788.

MacMillan, J., Schaffer, J.L., Kambin, P. (1991) Routes and incidence of communication of lumbar discs with surrounding neural structures. *Spine* **16:** 167-171.

Main, C.J., Waddell, G. (1982) Chronic pain, distress and illness behaviour. In: *Clinical Psychology and Medicine: A Behavioural Perspective* (Main, C.J., ed.). New York: Plenum Publishing Corp., pp. 1-62.

Main, C.J., Waddell, G. (1998) Spine update. Behavior responses to examination. A reappraisal of the interpretation of 'non-organic signs'. *Spine* **23:** 2367-2371.

Maitland, G.D. (1986) *Vertebral Manipulation*, 5th edn. Boston: Butterworths, p. 344.

Margo, K. (1994) Diagnosis, treatment and prognosis in patients with low back pain. *Am. Fam. Physician* **49:** 171-179.

Merz, B. (1986) The honeymoon is over: Spinal surgeons begin to divorce themselves from chemonucleolysis. *JAMA* **256:** 317.

Michel, B.A., Lane, N.E., Jones, H.H. *et al.* (1990) Plain radiographs can be used in estimating lumbar bone density. *J. Rheumatol.* **17:** 528-531.

Mooney, V., Robertson, J. (1976) The facet syndrome. *Clin. Orthop. Rel. Res.* **115:** 149-156.

Nachemson, A.L. (1992) Newest knowledge of low back pain. A critical look. *Clin. Orthop. Rel. Res.* **279:** 8-20.

Nachemson, A.L., Andersson, G.B.J. (1982) Classification of low-back pain. *Scand. J. Work Environ. Health* **8:** 134-136.

Nathan, H. (1968) Compression of the sympathetic trunk by osteophytes of the vertebral column in the abdomen: An anatomical study with pathological and clinical considerations. *Surgery* **63:** 609-625.

Nathan, H. (1987) Osteophytes of the spine compressing the sympathetic trunk and splanchnic nerves in the thorax. *Spine* **12:** 527-533.

Nathan, H., Weinberg, H., Robin, G.C., Aviad, I. (1964) The costovertebral joints. Anatomical-clinical observations in arthritis. *Arthr. Rheum.* **7:** 228-240.

Pate, D.M., Jaeger, S.A. (1996) Thoracic spine. In: *Advances in Chiropractic*, Vol. 3 (Lawrence, D.J., ed.), St Louis: Mosby, pp. 111-145.

Patijn, J. (1991) Complications in manual medicine; a review of the literature. *Man. Med.* **6:** 89-92.

Pedersen, P. (1994) A survey of chiropractic practice in Europe. *Eur. J. Chiropract.* **42:** 3-28.

Perry, W. (1995) Measurement of bone density in osteoporosis (letter). *Br. Med. J.* **311:** 952.

Pope, M.H., Novotny, J.E. (1993) Spinal biomechanics. *J. Biomech. Eng.* **115:** 569-574.

Powell, F.C, Hanigan, W.C., Olivero, W.C. (1993) A risk/benefit analysis of spinal manipulation therapy for relief of lumbar or cervical pain. *Neurosurg.* **33:** 73-78.

Rickenbacher, J., Landolt, A.M., Theiler, K. (1982) *Applied Anatomy of the Back*. Berlin: Springer-Verlag, pp. 93, 184-186, 251.

Saal, J.A., Saal, J.S., Herzog, R.J. (1990) The natural history of lumbar intervertebral disc extrusions treated non-operatively. *Spine* **15:** 683-686.

Schroeder, S.A., Tierney, L.M., McPhee, S.J. *et al.* (1992) *Current Medical Diagnosis and Treatment*. Connecticut: Appleton & Lange.

Schwarzer, A.C., Aprill, C.N., Derby, R. *et al.* (1994a) Zygapophyseal joint in chronic low back pain. *Spine* **19:** 801-806.

Schwarzer, A.C., Aprill, C.N., Derby, R. *et al.* (1994b) Clinical features of patients with pain stemming from the lumbar zygapophysial joints. Is the lumbar facet syndrome a clinical entity? *Spine* **19:** 1132-1137.

Singer, K.P. (1989) The thoracolumbar mortice joint. Radiological and histological observations. *Clin. Biomech.* **4:** 137-143.

Singer, K.P. (1997) Contraindications to spinal manipulation. In: *Clinical Anatomy and Management of Low Back Pain* (Giles, L.G.F., Singer, K.P., eds). Oxford: Butterworth-Heinemann, p. 387.

Singer, K.P., Giles, L.G.F. (1990) Manual therapy considerations at the thoracolumbar junction: An anatomical and functional perspective. *JMPT* **13:** 83-88.

Singer, K.P., Breidahl, P.D., Day, R.E. (1988) Variations in zygapophyseal joint orientation and level of transition at the thoracolumbar junction. Preliminary survey using computed tomography. *Surg. Rad. Anat.*, **10:** 291-295.

Slipman, C.W., Plastaras, C.T., Palmitier, R.A. *et al.* (1998) Symptom provocation of fluoroscopically guided cervical nerve root stimulation. Are dynatomal maps identical to dermatomal maps? *Spine* **23:** 2235-2242.

Spratt, K.F., Lehmann, T.R., Weinstein, J.N. *et al.* (1990) A new approach to the low-back physical examination. Behavioural assessment of mechanical signs. *Spine* **15:** 96-102.

Stoddard, A. (1969) *Manual of Osteopathic Practice*. London: Hutchinson.

Stolker, R.J., Vervest, A.C.M., Goren, G.J. (1994) The management of chronic spinal pain by blockades; a review. *Pain* **58:** 1-20.

Stone, J.L., Lichtor, T., Banerjee, S. (1994) Intradural thoracic disc herniation. *Spine* **19:** 1281-1284.

Swanberg, H. (1915) The intervertebral foramina in man. *Medical Records* **87:** 176-180.

Teasell, R.W. (1997) The denial of chronic pain. *Pain Res. Man.* **2:** 89-91.

Terrett, A.G.J. (1995) Misuse of the literature by medical authors in discussing spinal manipulative therapy injury. *JMPT* **18:** 203-210.

Terrett, A.G.J., Kleynhans, A.M. (1992) Complications from manipulation of the low back. *Chiropr. J. Aust.* **22:** 129-140.

Turner, J.A., LeResche, L., Von Korff, M. *et al.* (1998) Back pain in primary care. Patient characteristics, content of initial visit, and short-term outcomes. *Spine* **23:** 463-469.

Vernon, L., Dooley, J., Acusta, A. (1993) Upper lumbar and thoracic disc pathology: a magnetic resonance imaging analysis. *J. Neuromusculoskel. Syst.* **1:** 59-63.

Videman, T., Leppavuori, J., Kaprio, J. *et al.* (1998) Intragenic polymorphisms of the vitamin D receptor gene associated with intervertebral disc degeneration. *Spine* **23:** 2477-2485.

Watts, C., Dickhaus, E. (1986) Chemonucleolysis: a note of caution. *Surg. Neurol.* **26:** 236.

Weinstein, J.N. (1988) The perception of pain. In: *Managing Low Back Pain*, 2nd edn (Kirkaldy-Willis, W.H., ed.). New York: Churchill Livingstone, pp. 83-90.

Weinstein, J.N., Rydevik, G.L., Sonntag, V.K.H. (1995) Case histories: questions and answers. *Essentials of the Spine*. New York: Raven Press, p. 243.

Weitz, E.M. (1984). Paraplegia following chymopapain injection. *J. Bone Joint Surg.* **66A:** 1131.

White, A.A., Gordon, S.L. (1982) Synopsis: workshop on idiopathic low back pain. *Spine* **7:** 141-149.

Wigh, R. (1980) The thoracolumbar and lumbosacral transitional junctions. *Spine* **5:** 215-222.

Wilkinson, J.L. (1986) *Neuroanatomy for Medical Students*. Bristol: John Wright & Sons, p. 29.

Williams, P.L., Warwick, T. (1980) *Grays Anatomy*, 36th edn. London: Churchill Livingstone, p. 896.

Wood, K.B., Blair, J.M., Aepple, D.M. *et al.* (1997) The natural history of asymptomatic thoracic disc herniations. *Spine* **22:** 525-530.

Yong-Hing, K. (1988) Surgical techniques. In: *Managing Low Back Pain* (Kirkaldy-Willis, W.H., ed.). New York: Churchill Livingstone, pp. 315-343.

Index

Absorptiometry, dual X ray, 198
Acetylcholinesterase staining of nerves, 119
Achondroplasia, 93
Adamkiewicz artery, 117, 293
Adams sign, 246
Adjustive procedures, chiropractic, 252
Agenesis of vertebra, 86
Albers-Schonberg's disease, 96
Alkaptonuria, 97, 98
Allodynia, 117
Amitryptiline for pain, 208
Ankylosing spondylitis, 63, 245, 289, 292, 294
Anulus fibrosus, 37
  innervation, 126
Aorta, 285
  cross clamping, causing spinal ischaemia, 117
Arteries of cord, 116, 117
Articular cartilage, 291
Arthrokinematic motion, tests, 273, 275
Articulatory techniques, osteopathic, 263
Asymmetry of spine normal, 46
Autonomic chain, 285, 288
Axial rotation and stiffness at thoracolumbar junctional zone, 106, 107
Axis of rotation, helical, 49

Babinski, 287
Beevor's sign, 155
Biomechanics, 45
Block vertebra, 86
Blount's disease, 57
Bone grafts for spinal surgery, 228
Bone mineral density, 289
  in osteoporosis, 51
Boston brace, 58
Braces for scoliosis, 58, 239
Burst fractures, 293
  at thoracolumbar junctional zone, 107

Calcitonin gene-related peptide immunoreactive nerve fibres, 199
Canal encroachment by fractures, 55, 230
Canal stenosis, 152, 185, 285, 289, 294
Capsaicin, 136
Cellulalgia, 159
Cervical joints, referred pain from, 172, 289
Cervical rib, 171
Cervicothoracic spinal pain syndromes, 157, 292
Chiropractic:
  flexion-distraction therapy, 253
  management, 244
  flexion distraction therapy, 253
  management, 244
Clinical examination of spine, 145
Cobb angle measurements of scoliosis, 57, 92, 238
Compartment, ventral and dorsal, 206
  dorsal, innervation, 134
  ventral, innervation, 120
Compression of cord, 116
Computed tomography, *see* CT
Contraindications to manipulation, 283, 292, 293, 294
Cord compression, 116
Costotransversectomy approach to spine, 229
Costovertebral:
  attachments, 41
  joint, 291
    degeneration, 67
    innervation, 120, 291
Cotrel-Dubousset instruments, 59, 241, 242
Coupling, 56
Crankshaft phenomenon, 59
Cryocoagulation, 210
CT, 283
  myelogram, 185
  zygapophysial joint degeneration, 183

Deformity, hemimetameric segmental, 86
Densitometry, 198
Dermatomes, 287
Development of thoracic spine, 83
Diagnosis, thoracic spine pain, 288, 289, 290, 292
Diastematomyelia. 89
Diffuse idiopathic skeletal hyperostosis, *see* DISH
Disc, *see* Intervertebral

Discography, 183
  provocative, 210
DISH syndrome, 65, 66, 294
  diagnosis, 150
Dorsal:
  column medial lemniscus, 115
  compartment pain, 211
Dual photon absorptiometry, 51
Dura mater:
  innervation, 128
  usual origin of pain, 145
  multisegmental referred, 132
Dural tube, 291
Dysaesthetic pain, 116
Dysostosis multiplex, 94

Ehlers-Danlos syndrome, 96
Elastic range of deformation, 48
Electrical stimulation of trunk muscles for scoliosis, 58
Electromyography to measure muscle forces in trunk, 53
Endoscopic techniques in spinal surgery, 227
End-plate lesions, 70
Enigma of thoracic spine, 3
Enthesophytes, 65
Epicondylitis, 176
Epidural steroids for pain, 209
Examination of thoracic spine, 145, 287
  by chiropracters, 244
  by osteopaths, 254
  by physiotherapists, 269
  importance of history, 285
  mechanical, chiropractic, 247
  physical, 288
Exercises, osteopathic, 265

Fentanyl patches, 207
Fibromyalgia, 172
Flexibility matrix, 50
Football collision, case report, 3
Fractures, *see* Injuries
Funiculus dorsalis, 115

GABA-ergic neurons, 117
Gadolinium DTPA MRI, 196
Gibbus, 146, 235

Haemangioma, imaging, 199
Harrington rod, 240
Harrington-Luque technique, 240
Hemivertebra, 86, 87
History, *see* Examination
HLA-B27 antigen in ankylosing spondylitis, 63
  sensitivity, specific, 292
Homocystinuria, 97, 98
Hueter-Volkmann law, 57
Hunter's syndrome, 95
Hurler's syndrome, 94
Hypermobility, physiotherapy for, 280
Hypomobility disorders, 9
  physiotherapy for, 278
Hysteresis, 48

Imaging:
  limitation, 289
  magnetic resonance, *see* MRI
  myelogram, 289
Indications that origin of pain is serious disease, 259
Injuries:
  causing instability and neurological deficit, 230
  classification, 54, 230
  imaging for, 189
  impact and blast, 55
  pathology, 75
  spinal fusion for unstable fracture, 232
  three column concept, 189
  to cord, pain following, 116
  treatment, 55
    decompression seldom indicated 231, 232
Instability, spinal, 54
Intercostal nerves, 114
Intercostal radiculopathy, 284
Interscapular pain, cervical origin of, 158
Intervertebral canal, contents, 285, 291
Intervertebral disc:
  anatomy, 23
  contributed to flexibility and strength, 51
  degeneration, 67
    imaging of, 179, 181
  herniation, 8, 77, 284, 285, 290
    diagnosis, 155, 286
    operation rarely indicated, 228
    spontaneous recovery, 284
Intra-articular synovial folds, 23, 25 , 205, 291
  in zygaphophysial joints of thoracolumbar junctional zone, 105
Intramedullary lesions, 116

Javelin thrower, 17
Joint:
  costovertebral and costotransverse, 28, 291
  locking, acute, 9
  play assessment, 247
  zygapophysial, *see* Zygapophysial

KANEDA fixation, 233
Kneading, osteopathic, 262
Kyphosis, 236

Laboratory tests, 290
  sensitivity, specific, 292
Laminectomy may cause instability, 227
Lateral corticospinal tract, 115
Lateral upper thoracic pain, 160
Lemniscus medialis, 115
Levator point, 161
Levator scapulae syndrome, 160
Lifting, mechanics of, 53
Ligaments, 34
  anterior longitudinal, 35
    innervation, 121
  are tensile members, 50
  denticulate, 291
  encapsulated nerve endings in, 136

Ligaments - *continued*
  iliolumbar, 40
  interspinous, 40
  ossification in, 69
  posterior longitudinal, 35
    calcification causing cord compression, 229
    innervation, 125
  sacrospinous and sacrotuberous, 41
  supraspinous, 40
  transverse, 40
Ligamentum flavum, 38, 291
  ossification in, 68
Low back pain in thoracolumbar junction pain syndrome, 163
Luque segmental sublaminar system, 242
Lymph node, 285

Mamillary process, 20, 23
Manipulation for cervicothoracic spinal pain, 160
Manipulation:
  chiropractic, 250, 252, 253
  contraindications, 283, 292, 293, 294
  for spinal pain, 56, 292
  for thoracolumbar junction pain syndrome, 167
  indications, 293
  reasons for abandoning, 295
  safety of, 293
  vascular accidents, 293
Marfan's syndrome, 96
Matrix, flexibility and stiffness, 50
Mechanics:
  of lifting, 53
  of thoracic spine, 287
  of thoracolumbar junctional zone, 106
Meningoceles, neurofibromatosis with, 95
Metastases, 73
  imaging, 198, 200
Mobilization and manipulation, contraindications, 283
Morquio's disease, 88, 95
Mortice joint, 292
  at T11-T12, 104
Motion of thoracic spine, 47
MRI:
  in diagnosis of thoracic spine disease, 225
  is investigation of choice for spine, 185
  of large disc herniation, 182
  of normal thoracic spine, 181
Mucopolysaccharidoses, 94
Myelopathy, 285, 287

Naffziger's test, 155
Nerves:
  anatomy, 114, 285
  entrapment causing thoracolumbar junction pain syndrome, 166
  paravertebral, 285
  recurrent meningeal, 285
  supply to spine, 158
Neurofibromatosis, 95, 226
Neurological deficit, 224, 230, 285
Neurolysis, 210
Non-steroidal anti-inflammatory drugs, 207

Notalgia paraesthetica, 161
Notochord, 83

Opioid drugs, 207
Ossification centres in spine, 83
Osteoarthritis of spine, diagnosis, 154
Osteogenesis imperfecta, 96, 97
Osteoid osteoma, 285
Osteokinematic function, tests of, 272, 273
Osteomyelitis, 73, 194, 289
Osteopathic management, 257
Osteopetrosis, 96, 97
Osteophytes, 68, 288
Osteoporosis, imaging, 196, 197
Osteoporosis:
  imaging, 196, 197
  pathology, 72

Pacinian corpuscles, 136
Paget's disease:
  diagnosis, 150
  imaging, 201
Pain:
  chronic:
    defined as more than 3 months, 205
    spinal, classification, 205
    thoracic, causes of, 206, 289
      drug treatment, 207
  diagram, 286
  from serious diseases, 223
  from thoracic spine, diagnosis, 145
  referred, visceral, 133, 288
Painful minor intervertebral dysfunction, 159
  as cause of thoracolumbar junction pain, 166
Palpation, 246, 247, 288, 293
Pancreatitis mimicked by thoracic spine pain, 4
Paraesthesia, 285
Pathology of thoracic spine, 63
Pedicle screws, 55
Percutaneous:
  facet denervation, 211
  partial rhizotomy, 212
Perdriolle measurement of scoliosis, 238
Physiotherapy management, 268
Pinch-roll test in diagnosis of spinal pain, 164
Placebo effect, 215
Plastic deformation, 48
Plates for spinal surgery, 228
Posterior iliac crestal point, 164, 166
Posture in workplace, cause of tired neck syndrome, 174
Psychogenic back pain, 284, 294

QUANTEC imaging for scoliosis, 238, 239

Radicular arteries, 117
Radiculopathy, 285
Radiofrequency neurolysis, 210, 216
Radiology of thoracic spine, 177

Rami communicantes, 119, 122, 285
Randomized controlled trials, difficulty of, 214
Recurrence of pain after treatment, 216
Red flags for potentially serious conditions, 223, 259
Referred pain from visceral sources, 78, 79, 249, 287, 289
Repetitive strain injury, 172
Rheumatoid arthritis, diagnosis, 150, 290
Rhizotomy:
  percutaneous partial, 208, 212
  posterior, causing ischaemia, 118
Rib hump in scoliosis, 238, 246
Ribs 1 and 2, movement dysfunction, 9
Risser sign, 240
Rods for spinal surgery, 228
Root pain, 146
Rotations in three axes, 47
Ruffini corpuscles, 136

Scheuermann's disease, 70, 91, 245, 289
  diagnosis, 151, 152
  radiology, 187, 188
Schmorl's nodes, 67, 70, 289
  anterior in Scheuermann's disease, 91, 289
  at thoracolumbar junctional zone, 109
Schwannoma, 224
Sclerotome, 83
Scoliosis:
  aetiology and progression, 56
  classification, 90, 236, 245, 288, 289
  Cobb technique to measure, 57, 92, 238
  development of, 86
  imaging, 198, 199
  measurement of, 57, 92, 238
  neurofibromatosis with, 95
  pathology, 74
  treatment:
    brace if less than 35°, 239, 255
    non-operative, 58, 255
    operative, 59, 255
Segmental pain syndrome, 212
Sinuvertebral/recurrent meningeal nerves, 124, 285
Somites, 83
Spinal:
  arteries, 116, 117
  cord, 285, 291, 293
  dysraphism, 89
  ganglion, 285, 291
  nerves, 114
Spinothalamic tract, 115
Splanchnic nerves, 118
Spondylitis, ankylosing, diagnosis, 152, 153
Spondyloarthropathy, imaging, 191, 192, 193
Spondyloepiphyseal dysplasia, 93
Spondylolisthesis, 235
Spondylosis deformans, 69
Stabilization therapy, physiotherapy, 281
Stenosis of thoracic canal, 285
  diagnosis, 152, 185
Sternum, 31
Stiffness matrix, 50
Stress-strain graph, 47
Stretching, osteopathic, 262
Subluxation:
  of costotransverse and costovertebral joints, 281
  of the ring, 281
Substance P-immunoreactive nerve fibres, 119, 291
Sympathectomy, percutaneous, 214
Sympathetic:
  dystrophy, 215
  trunk, 118, 120, 285
Syndesmophytes, 192
Syringomyelia, 116

T4 syndrome, 254
Technetium MDP scan, 184, 194, 198
TENS, 208
Test blocks, false positive and false negative, 209
Tethering, 57
Thoracic outlet syndrome, 171, 174
Thoracic spine:
  anatomy, 17, 285, 291
  development, 17
  kyphosis, 17, 18, 31
  muscles and ligaments, 20
  ossification centres, 19
  pain:
    bus drivers, 5
    epidemiology, 5
    intervertebral disc prolapse, 8, 284
    kyphosis, 6
    management, 10, 244
    nerve compression, 7, 284, 285
    non-mechanical causes, 8, 287, 289
    prevalence, 5, 283
    referred, somatic and visceral, 7, 287, 289
Thoracolumbar:
  fascia, 40
  junction
    anatomy, 100, 109
    inflexion point, 102
    pain syndromes, 161, 163
    imaging unhelpful, 164
  spine innervation, 162
Thoracotomy:
  for spinal surgery, 227, 229
  pain after, 114
Thrust techniques:
  chiropractic, 250
  osteopathic, 263
Tired neck syndrome, 171
Tracts in cord, 115
Transcutaneous electric nerve stimulation, 208
Translations in three axes, 47
Trauma, *see* Injuries
Trigger points, injection of, 208
Tuberculosis, 194
Tyrosine hydroxylase immunoreactive nerve fibres, 119

Upper motor neuron lesion, 287

Vasoactive intestinal polypeptide immunoreactive nerve fibres, 119
VATER association, 86
Ventral compartment syndrome, rare, 214

Vertebra:
  agenesis, 86
  block, 86
  butterfly, 88
  hemi, 86, 87
  limbus, 93
Vertebral:
  bars, 89
  bodies contribute to flexibility and strength, 51
Viscoelasticity, 48

Workplace, bad posture in, 174

X ray, *see* Radiology, Imaging

Zielke method, 242
Zygaphophysial joints, 10, 23, 291
  contribute to flexibility and strength, 52
  degeneration, 66
    CT for diagnosis, 183
  innervation, 134, 157
  injection of for pain, 160, 165, 167
  lumbar, contribute to load bearing, 103
  morphology, 45
  of thoracolumbar junctional zone, 100
    arthritis common, 108
    intra-articular synovial folds, 105
  source of thoracic pain, 135, 288
  tropism, 103