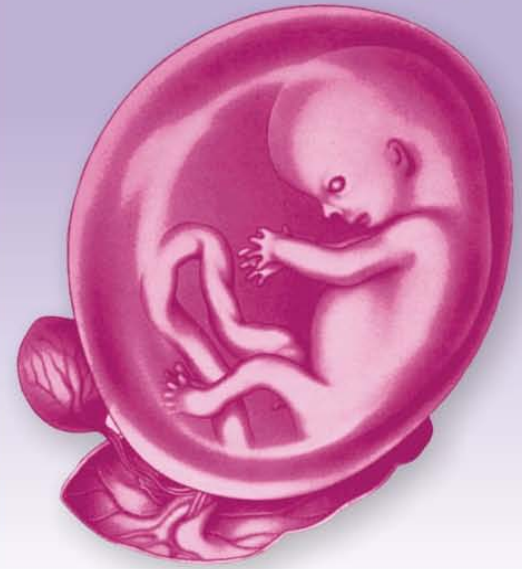

Textbook of

**CLINICAL
EMBRYOLOGY**

Vishram Singh

Textbook of Clinical Embryology

"This page intentionally left blank"


Textbook of Clinical Embryology

Vishram Singh, MS

Professor & Head, Department of Anatomy, Professor-in-Charge, Medical Education Unit,
Additional Senior Superintendent of Examination, Santosh Medical College,
Santosh University, Ghaziabad, NCR, Delhi.

Examiner in National and International Universities; Member, Academic Council, Santosh University;
Member, Editorial Board, Indian Journal of Otolaryngology; Vice President, Anatomical Society of India;
Medicolegal Advisor, ICPS, India; Consulting Editor, ABI,
North Carolina, USA.

Formerly at: GSVM Medical College, Kanpur; King George Medical College, Lucknow;
Al-Arab Medical University, Benghazi (Libya);
All India Institute of Medical Sciences, New Delhi.



ELSEVIER

A division of

Reed Elsevier India Private Limited

Textbook of Clinical Embryology, 1e
Vishram Singh

ELSEVIER

A division of

Reed Elsevier India Private Limited

*Mosby, Saunders, Churchill Livingstone, Butterworth-Heinemann and
Hanley & Belfus are the Health Science imprints of Elsevier.*

© 2012 Elsevier

All rights are reserved.

No part of this publication may be reproduced, stored in a retrieval system,
or transmitted in any form or by any means, electronic, mechanical, photocopying,
recording or otherwise, without the prior written permission of the publisher.

ISBN: 978-81-312-3048-0

Medical knowledge is constantly changing. As new information becomes available,
changes in treatment, procedures, equipment and the use of drugs become necessary.
The authors, editors, contributors and the publisher have, as far as it is possible,
taken care to ensure that the information given in this text is accurate and up-to-date.
However, readers are strongly advised to confirm that the information, especially with
regard to drug dose/usage, complies with current legislation and standards of practice.

Published by Elsevier, a division of Reed Elsevier India Private Limited.

Registered Office: 305, Rohit House, 3, Tolstoy Marg, New Delhi 110 001.

Corporate Office: 14th Floor, Building No. 10B, DLF Cyber City, Phase-II, Gurgaon 122002, Haryana, India.

Senior Commissioning Editor: Shukti Mukherjee

Managing Editor: Shabina Nasim

Development Editor: Goldy Bhatnagar

Copy Editors: Richa Srivastava and Shrayosee Dutta

Manager – Publishing Operations: Sunil Kumar

Manager – Production: NC Pant

Cover Designer: Raman Kumar

Typeset by Olympus Premedia Pvt. Ltd. (*formerly* Olympus Infotech Pvt. Ltd.), Chennai, India.

www.olympus.co.in

Printed and bound at Ajanta Offset, New Delhi.

Dedicated to the Sacred Memory of
My Parents

"This page intentionally left blank"

Preface

Textbook of Clinical Embryology has been carefully planned for the first year medical and dental students. It follows the revised anatomy curriculum of the Medical Council of India. Following the current trends of clinically oriented study of Anatomy, I have adopted a parallel approach of imparting basic embryological knowledge to students and simultaneously providing them its applied aspects.

To help students score high in examinations the text is written in simple language. It is arranged in easily understandable small sections. While embryological details of little clinical relevance, phylogenetic discussions, and comparative analogies have been either omitted or described in brief, all clinically important topics are described in detail. Because of increasingly significant role of molecular biology and genetics in embryology and study of birth defects, the basic molecular and genetic principles are discussed throughout the text. In addition, a separate chapter on medical genetics has been added. The tables and flowcharts given in the book summarize important and complex information into digestible knowledge capsules. Multiple choice questions have been given chapter-by-chapter at the end of the book to test the level of understanding and memory recall of the students. The numerous simple four-color illustrations and clinical photographs further assist in fast comprehension and retention of complicated information. *All the illustrations are drawn by the author himself to ensure accuracy.*

Throughout the preparation of this book one thing I have kept in mind is that thorough knowledge of embryology is required by Clinicians, especially Gynecologists, Pediatricians, and Pediatric Surgeons for physical examination, prenatal diagnostic tests, and surgical procedures. Therefore, embryological events relevant to prenatal diagnostic and surgical procedures are clinically correlated throughout the text. Further, patient-oriented problems and their embryological and genetic basis are presented at the end of each chapter for problem-based learning so that the students could use their embryological knowledge in clinical situations. Moreover, keeping in mind the relevance of embryological knowledge in day-to-day clinical practice, a separate chapter on developmental events during the entire period of gestation and their application in clinical practice is given at the end of the book.

I pay my heartfelt tribute to all the authors of various embryology books, especially *Developing Human: Clinically Oriented Embryology*, 8th edition by Keith L Moore and TVN Persaud, which I have consulted during the preparation of this book. From *Developing Human* and few other books, some photographs have been used in this book after obtaining due permission from concerned authorities (please refer to page 331 for Figure Credits).

As a teacher, I have tried my best to make the book easy to understand and interesting to read. For further improvement of this book, I would greatly welcome comments and suggestions from the readers. All these comments and suggestions can be e-mailed at indiacontact@elsevier.com and drvishramsingh@gmail.com.

'Mind perceives new ideas best only when put to test.'

Vishram Singh

"This page intentionally left blank"

Acknowledgments

At the outset, I express my gratitude to Dr P Mahalingam, CMD; Dr Sharmila Anand, DMD; and Dr Ashwyn Anand, CEO at Santosh University, Ghaziabad, NCR, Delhi for providing me an appropriate academic atmosphere and encouragement which helped me a lot in preparing this book.

I am highly grateful to Dr Devkinandan Sharma, Chancellor and Dr VK Arora, Vice Chancellor, Santosh University for appreciating my work.

I sincerely thank my colleagues in the Anatomy Department, Professor Nisha Kaul, Dr Latika Arora, Dr Ruchira Sethi, and Dr LK Pandey for their cooperation, especially to Dr Ruchira Sethi for seeing the proofs sincerely.

I highly appreciate the help rendered by my students Miss Radhika Batra and Mr Divyansh Bhatt and their parents Dr Shailly Batra, Senior Gynecologist, Batra Hospital, New Delhi and Dr Arun Bhatt, Chief Medical Superintendent, SGPGIMS Lucknow, respectively, who also happen to be my students and helped in procuring some of the clinical photographs used in this book.

I gratefully acknowledge the feedback and support of fellow colleagues in anatomy, particularly,

- Professors AK Srivastava (HOD), Ashok Sahai, PK Sharma, Mahdi Hasan, MS Siddiqui, and Punita Manik, King George Medical College, Lucknow.
- Professor NC Goel (HOD), Hind Institute of Medical Sciences, Barabanki.
- Professors Shashi Wadhwa (HOD), Raj Mehra, and Ritu Sehgal, AIIMS, New Delhi; Gayatri Rath (HOD), RK Suri, and Dr Hitendra Loh, Vardhman Mahavir Medical College and Safdarjung Hospital, New Delhi; Shipra Paul and Shashi Raheja, Lady Harding Medical College, New Delhi; JM Kaul (HOD) and Smita Kakkar, Maulana Azad Medical College, New Delhi; and Veena Bharihoke (HOD), UCMS, Shahadra, Delhi.
- Professor GS Longia (HOD), People's Dental Academy, Bhopal.
- Professors AK Asthana (Dean) and Satyam Khare (HOD), Subharti Medical College, Meerut and Namita Mehrotra (HOD), Rama Medical College, Hapur, Meerut.
- Professor Vinod Kumar (HOD), UP RIMS & R Safai, Etawah, UP.
- Professors Gajendra Singh (Director) and SK Pandey, Institute of Medical Sciences, BHU, Varanasi.
- Professors RK Srivastava (HOD and Vice Principal), Rama Medical College, Kanpur.
- Professors SL Jethani (HOD), RK Rohtagi, and Dr Deepa Singh, Himalayan Institute of Medical Sciences, Jolly Grant, Dehradun.
- Professor SD Joshi (HOD and Dean), Sri Aurobindo Institute of Medical Sciences; Dr VK Pandit, Associate Professor, MGM Medical College; Professor GP Paul (HOD), Modern Dental College and Research Center, Indore (MP).
- Professor Sudha Chhabra (HOD) and SK Srivastava, Medical College, Rohtak, Haryana.
- Professor S Ghatak (HOD), Adesh Medical College, Bhatinda and Dr Anjali Jain (HOD), CMC, Ludhiana, Punjab.
- Professors TC Singel (HOD), MP Shah Medical College, Jamnagar and R Rathod (HOD), PDUMC, Rajkot, Gujarat.
- Professors P Parchand (HOD and Dean), GMC, Miraj; Ksheersagar Dilip Dattatraya, NKP Salve IMC & RC; Meena Malikchand Meshram, GMC, Nagpur; Vasanti Arole and P Vatsalaswamy, DY Patil Medical College, Pune, Maharashtra.

- Professors Damayanti N (HOD), Regional Institute of Medical Sciences, Imphal; Manjari Chatterji, Medical College, Calcutta and Kalyan Bhattacharya (HOD), Kalyani, West Bengal.
- Professors PS Jevoor (HOD) and Daksha Dixit, JNMC, Belgaum, Karnataka.
- Professor Kuldeep Singh Sood (HOD), Medical College, Budhera, Haryana.
- Professor JK Das (HOD), Darbhanga Medical College, Bihar.
- Dr Pradeep Bokatiya, Mahatma Gandhi Institute of Medical Sciences, Sevagram, Wardha.
- Professors Dr Sundara Pandian (HOD) and SN Kazi, SRM Medical College, Potheri, Chennai.

Lastly I eulogize the patience of my wife Mrs Manorama Rani Singh and my children Dr Rashi Singh and Dr Gaurav Singh for not only happily tolerating my preoccupation but also helping me in preparation of the manuscript.

I gratefully acknowledge the help and cooperation received from the staff of Elsevier, a division of Reed Elsevier India Pvt. Ltd., especially Mr Vidhu Goel (Director, Clinical Education and Reference Division), Mrs Shabina Nasim (Managing Editor), Mrs Shukti Mukherjee (Senior Commissioning Editor), Mrs Goldy Bhatnagar (Development Editor), and Mrs Richa Srivastava and Mrs Shrayosee Dutta (Copy Editors). I highly appreciate the sincerity and dedication of Mrs Shabina Nasim and Mrs Goldy Bhatnagar. Lastly I would like to acknowledge the support of the typesetter in bringing out the diagrams and text much to my satisfaction in a short time.

Vishram Singh

Contents

<i>Preface</i>	<i>vii</i>
<i>Acknowledgments</i>	<i>ix</i>
1 Introduction to Human Embryology	1
2 Reproductive System	9
3 Cell Division and Gametogenesis	20
4 Fertilization and Formation of Germ Layers	34
5 Formation of Primitive Streak, Notochord, Neural Tube, Subdivisions of Intraembryonic Mesoderm, and Folding of Embryo	46
6 Extraembryonic Membranes and Twinning	57
7 Integumentary System	76
8 Skeletal System	84
9 Muscular System	103
10 Pharyngeal Apparatus	110
11 Development of Tongue and Thyroid	122
12 Development of Face, Nose, and Palate	130
13 Digestive Tract	140
14 Major Digestive Glands and Spleen	158
15 Development of Oral Cavity (Mouth)	168
16 Respiratory System	176
17 Body Cavities and Diaphragm	186
18 Development of Heart	196
19 Development of Blood Vessels	212
20 Development of Urinary System	233
21 Genital System	246
22 Development of Nervous System	265
23 Pituitary, Pineal, and Adrenal Glands	275
24 Eye and Ear	279
25 Medical Genetics	292
26 Application of Embryology in Clinical Practice	307
<i>Multiple Choice Questions</i>	<i>317</i>
<i>Figure Credits</i>	<i>331</i>
<i>Index</i>	<i>333</i>

"This page intentionally left blank"

1

Introduction to Human Embryology

Overview

Embryology is the science that deals with development and growth of an individual within the uterus (female genital tract). It begins with fertilization of an ovum and culminates with the birth of the baby. The whole period of development from fertilization to birth is termed **prenatal development**. The development of an individual continues even after birth up to age of 25 years. This period of development is termed **postnatal development**.

Prenatal Development

The prenatal development is a fascinating and awesome event. It begins with a single cell—the zygote (fertilized ovum) and culminates after 9 months (38 weeks or 266 days) with a complex organism—the **newborn**—made of billion of cells. This involves a process called **morphogenesis**, which includes cell division, transformation or specialization, migration, and even programmed cell death (apoptosis).

During morphogenesis, genetic or environmental factors may affect the normal development of baby and cause congenital anomalies.

Thus embryology helps us not only in understanding the rationale of structure and functions of each body system but also in understanding the factors responsible for causing congenital anomalies. The appreciation of these factors may assist the clinicians in preventing and treating such anomalies.

Divisions of Prenatal Period

Clinically the **prenatal period** is divided into two parts: (a) embryonic period and (b) fetal period.

1. The **embryonic period** extends from fertilization to the end of eight week and the developing organism is called an **embryo**. The embryonic period is further divided into two parts: (a) pre-embryonic period and (b) embryonic period proper.
2. The **fetal period** extends from beginning of the ninth week (third month) until the birth.

Embryologically the prenatal period is divided into three parts: (a) pre-embryonic period, (b) embryonic period, and (c) fetal period.

1. **Pre-embryonic period:** It extends from conception (fertilization) to the end of second week of intrauterine life (IUL). The morphogenic events during this period include fertilization, transportation of zygote through the uterine tube, mitotic divisions/cleavage, implantation, and formation of primordial embryonic tissues.
2. **Embryonic period:** It extends from beginning of the third week to the end of eighth week of IUL. The morphogenic events during this period include differentiation of the germ layers into specific body organs and the formation of placenta, umbilical cord, and extraembryonic membranes.
3. **Fetal period:** It extends from beginning of the ninth week to birth. During this period, there is tremendous growth and specialization of the body structures.

The subdivisions of prenatal period and events occurring in these periods are shown in Flowchart 1.1.

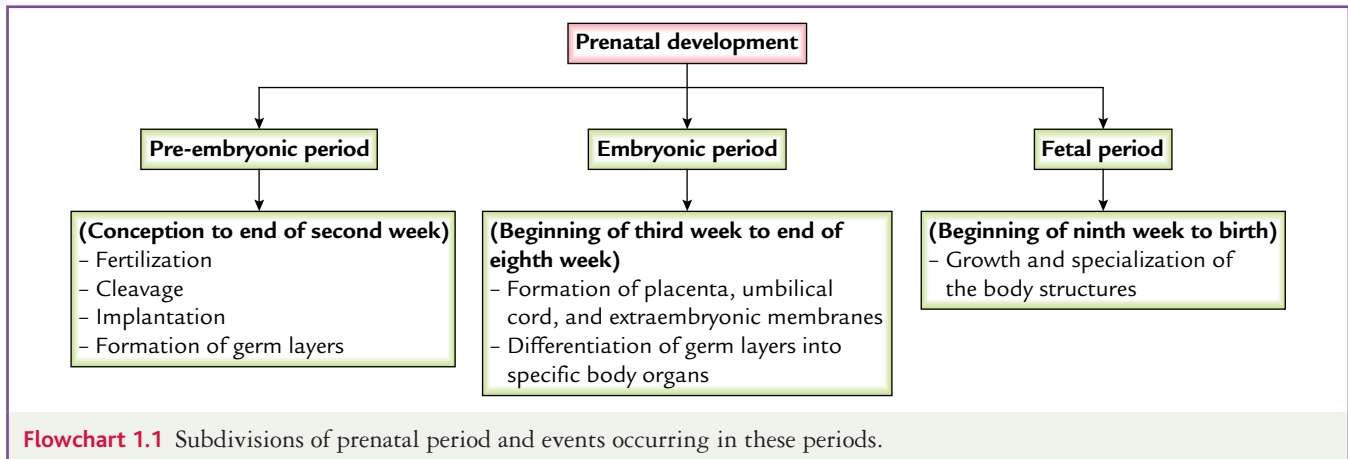
Postnatal Development

The postnatal development extends from birth to about 25 years. The postnatal development is divided into following five parts/periods.

1. Infancy (from birth to first year)
2. Childhood (from 2nd to 12th year)
3. Puberty (from 13th to 16th year)
4. Adolescence (from 17th to 18th year)
5. Adulthood (from 19th to 25th year).

Infancy

The infancy period extends from birth to 1 year and newborn during this period is termed **infant**. The first four weeks of this period are very critical for the survival of the **newborn** because the transition from intrauterine to the extrauterine existence requires many



changes especially in the cardiovascular and respiratory systems. During this there is a rapid growth of the body. This period is called **neonatal period** and the newborn during this period is termed **neonate**. If newborn survives first few hours after birth, his/her chances of survival are usually good. The care of baby during the neonatal period is termed **neonatology**.

N.B. The term '**perinatal period**' used by clinicians extends from 28th week of pregnancy to the end of 6th day after birth.

Childhood

The period of childhood extends from beginning of the second year to 12 years. The care of children during this period is exciting because of the constancy of change in their growth and development. The children do not stay the same. As the child grows the rate of growth slows down; however, just before puberty the growth accelerates. It is called **prepubertal growth spurt**. The medical subject dealing with care of children in health and disease is termed **pediatrics**.

Puberty (*Latin: Pubertas, which means development of sex characteristics*)

The puberty period extends from 12 to 15 years in females and 13 to 16 years in males. During this period there is a very rapid physical growth and development of secondary sexual characters. During this period the capability of sexual reproduction is attained. The growth at puberty is dependent upon the interaction of growth hormone [insulin-like growth factor 1 (IGF-1)] and sex steroids.

Adolescence

The adolescence period extends from 17 to 18 years. This period is characterized by rapid physical growth and sexual maturation. The gonads begin to secrete

testosterone and estrogen. During this period the ability to reproduce is achieved.

Adulthood (*Latin: Adultus, which means grown up*)

The adulthood period extends from 19 to 25 years. During this period full growth and development of body organs including ossification of bones is virtually completed.

Subdivisions of Embryology

General Embryology

It deals with the development of an individual during first eight weeks after fertilization (i.e., with pre-embryonic and embryonic periods). During this period a single cell called zygote (fertilized ovum) is converted into a form that externally resembles with the features of an adult individual and all organs and systems are formed.

Systemic Embryology

It deals with the functional maturation of various organs and systems that are formed during the embryonic period.

Descriptive Embryology

It deals with the structure of different organs at various stages of development.

Comparative Embryology

It deals with the study of embryos in various species of animals.

Experimental Embryology

It deals with the results obtained from experiments of living embryos/fetuses of the lower animals.

Chemical Embryology

It deals with the biochemical aspect of the prenatal development.

Teratology

It deals with abnormal embryonic and fetal development. It is a branch of embryology that is concerned with the congenital anomalies or birth defects.

Recent Advances in Embryology

1. **Prenatal diagnosis:** It is detection of congenital abnormalities in an unborn child. The various techniques used for this purpose are:
 - (a) Amniocentesis
 - (b) Chorionic villous sampling
 - (c) Ultrasonography
 - (d) Fetoscopy
 - (e) Fetal blood sampling
 - (f) Maternal serum screening
 - (g) MRI, etc.
2. **In vitro fertilization:** In vitro fertilization (IVF) of human ova and embryo transfer in the uterus has now become a standard procedure throughout the world to solve the problems of infertility. On 25th July 1978, Louis Joy Brown, the first test tube baby was born to Leslie Brown.
3. **Gene therapy:** It deals with the replacement of a deficient gene product or correction of an abnormal gene. It can be done in vitro or in vivo.
4. **Cloning:** The advancement in molecular biology has led to many sophisticated techniques that are now widely used in research laboratories for genetic regulation of morphogenesis. Now the researchers have started understanding how, when, and where selected genes are activated and expressed in the embryo during development. For examples:
 - (a) Now cloning is possible. The first mammal clone, **Dolly** the sheep, was cloned in 1997 (Fig. 1.1) by using the technique of somatic cell nuclear transfer.
 - (b) The interest in *human cloning* has generated a considerable debate because of social, moral, ethical, and legal implications.
 - (c) More recently the cloning of a human embryo was reported.
5. **Stem cell therapy:** The *stem cells* are cells found in multicellular organisms. These cells have the ability to renew themselves and differentiate into a diverse range of specialized cell types. There are two broad types of mammalian stem cells: (a) *Embryonic stem cells* that are isolated from the inner

cell mass of the blastocysts (Fig. 1.2). They are pluripotent, i.e., they have ability to form different cell types. (b) *Adult stem cells* that are found in adult tissues, e.g., bone marrow. These cells are restricted in their ability to form different cell types and therefore are *multipotent*, not pluripotent.

N.B. The isolation and programmed culture of human embryonic stem cells hold a great potential for the treatment of degenerative, malignant, and genetic diseases. (The embryonic stem cells are pluripotent. They are capable of self-renewal and are able to differentiate into specialized cell types.) Ruth R Faden of Johns Hopkins University once said that we believe the obligation to relieve human suffering, which binds us all and justifies the instrumental use in early embryonic life.

Utility and Scope of Embryology in Medicine

A thorough knowledge of embryology is important for following reasons.

1. It explains the positions and relations of various organs and neurovascular structures in adult gross anatomy.



Fig. 1.1 Dolly, the sheep, the first cloned sheep.

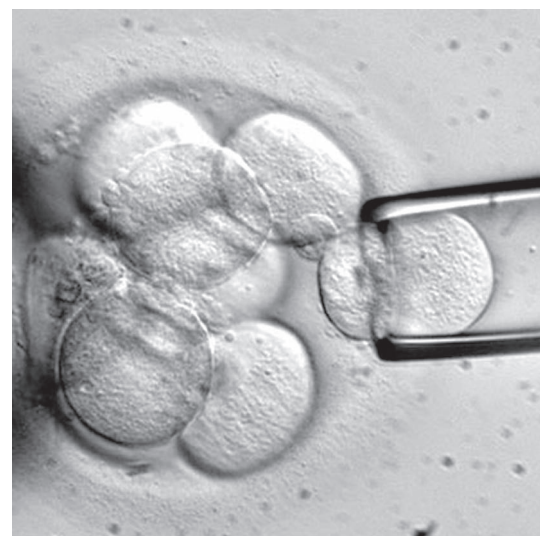


Fig. 1.2 Embryonic stem cells.

2. It helps to understand the cause of development of various congenital anomalies such as tracheoesophageal fistula, polycystic kidney, subhepatic cecum, etc.
The knowledge of various factors causing congenital anomalies (such as use of alcohol, smoking, drugs, viral infections, teratogens, etc.) can be useful in preventing their occurrence by rendering advice and adopting preventive measures.
3. Some aspects of general embryology such as gametogenesis, fertilization, and implantation are of great importance to understand the cause of infertility and its management. It also helps in family planning.
4. It forms the basis of concept of growth, repair, and regeneration of tissues, and understanding of the development of various embryonic tumors.
5. Ex-utero surgery is now-a-days possible to treat certain congenital anomalies, viz., congenital diaphragmatic hernias, repair of spina bifida, etc., only due to in-depth study of embryology.
6. It provides the basis for medical termination of pregnancy in various congenital diseases, which are incompatible with life.
7. It provides insight for use of molecular biology for genetic regulation of human development.

History of Embryology

The following text provides only a brief account of history of embryology as a mark of respect to some legends who have a significant contribution in the field of embryology.

'If I have seen further, it is by standing on the shoulders of the earlier giants.'

– Sir Issac Newton

1. **Ancient Egyptians** (3000 BC) knew about the methods of incubation of eggs of the birds. They also believed that the Sun god Aten is the creator of germ in woman and seed in man, and gives life to the baby in the body of mother.
2. The *Garbha Upanishad*, an ancient scripture of Hindus (written in around 1416 BC), describes following ideas about embryo:
 - (a) Embryo comes into existence from conjugation of blood and semen during the period favorable for conception after sexual intercourse.
 - (b) Developmental stages of an embryo are as under:

• 1-day-old embryo	Formation of Kalada
• After 7 nights	Formation of vesicle
• After a month	Formation of spherical mass
• After 2 months	Formation of head
• After 3 months	Formation of limbs

3. **Hippocrates** (460–377 BC) (Fig. 1.3) gave the following advice to understand the development of the embryo.

Take 20 or more eggs and let them be incubated by two or more hens. Then from the second day to the day of hatching remove one egg every day, break it, and examine it. You exactly see how embryo develops. This development of chick embryo can be similar to that of man.

4. **Aristotle** (384–322 BC) (Fig. 1.4) wrote a treatise on embryology in which he described the development of the chick and other embryos. Aristotle is regarded as the *Founder of Embryology*. According to him embryo develops from a formless mass, which he described as a fully concocted seed with a nutritive soul and all body parts. The mass arose from menstrual blood after activation by semen.
5. **Claudeus Galen** (130–201 AD) (Fig. 1.5) wrote a book on the *formation of the fetus* in which he described the development and nutrition of fetuses. He also described structures that are now called **allantois**, **amnion**, and **placenta**.
6. **Samuel-el-Yehudi** (second century AD) described six stages in the formation of embryo from a 'formless, rolled-up thing' to a 'child whose months have been completed.'
7. The *Quran* (seventh century AD), the holy book of the Muslims, describes that the human beings are produced from a mixture of secretions from the male and female. It also mentions that the human being is created from *nufila* (small drop). It also states that the resulting organism settles in the womb like a seed 6 days after its beginning. The early embryo resembles a leech and later it resembles a 'chewed substance.'
8. **Leonardo da Vinci** (1452–1519) (Fig. 1.6) made accurate drawings of dissections of uterus of pregnant women containing fetuses (Fig. 1.7).




Fig. 1.3 Hippocrates.



Fig. 1.4 Aristotle.




Fig. 1.6 Leonardo da Vinci.



Fig. 1.5 Claudius Galenus.

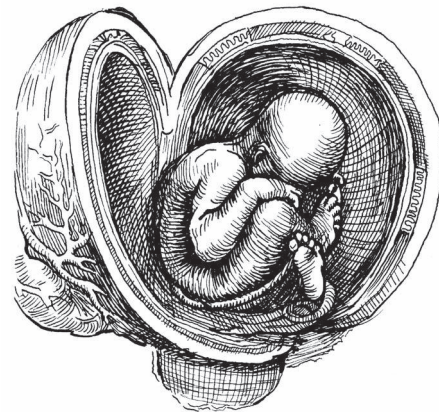


Fig. 1.7 Reproduction of Leonardo da Vinci's drawing made in the 15th century AD to show a fetus in the uterus.

9. **William Harvey** (1578–1657) believed that male seeds or sperms after entering the womb or uterus get metamorphosed into an egg-like substance that gives rise to an embryo.
10. **Regnier de Graaf** was first to observe vesicular ovarian follicles in 1672 with the help of simple microscopes, which are still called *Graafian follicles*.
11. **Johan Ham van Arnheim** and **Anton van Leeuwenhoek** were first to observe a human sperm. They thought that sperms contain a miniature preformed human being that gets enlarged when sperm is deposited in the female genital tract.

Other embryologists at this time thought that the oocyte contained a miniature human being that enlarged when it was stimulated by a sperm (Fig. 1.8).

12. **Caspar Friedrich Wolff** (1759) proposed the *layer concept*, i.e., zygote produces layers from which the embryo develops. His ideas formed the basis of the *theory of epigenesis*, which states that the development results from growth and differentiation of specialized cells. The mesonephros and mesonephric duct are called *Wolffian body* and *Wolffian duct*, respectively, after his name.
13. **Lazaro Spallanzani** said (1775) that both oocyte and sperm are necessary for initiating the development of an individual.
14. **Heinrich Christian Pander** discovered the *three germ layers* in 1817.

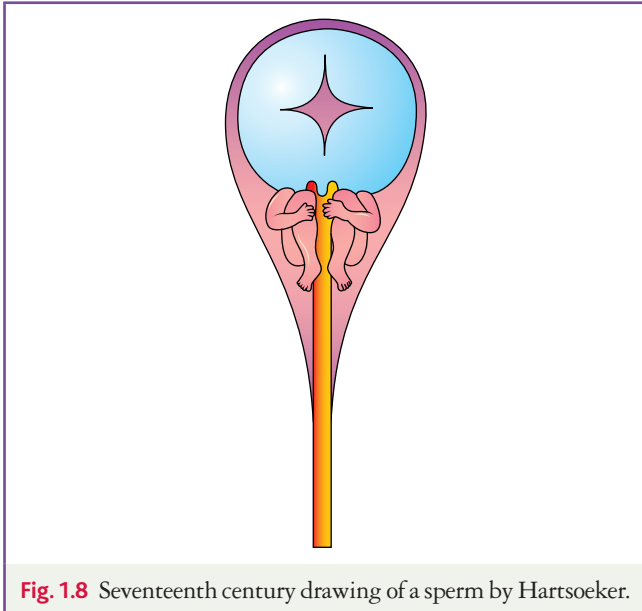


Fig. 1.8 Seventeenth century drawing of a sperm by Hartsoecker.

15. Etienne Saint Hilaire and Isidore Saint Hilaire made the significant studies of abnormal development in 1818, initiating what we now know as the *science of teratology*.
16. **Karl Ernst von Baer** (Fig. 1.9) described the *oocyte* in the ovarian follicle of the dog in 1827. He also noted cleaving zygote in uterine tube and blastocysts in the uterus. They provided new knowledge about the origin of tissues and organs from three germ layers of the embryo that formulated two embryological concepts: (a) *corresponding stages of embryonic development* and (b) *that general characteristics precede specific ones*. For his significant and far-reaching contributions he is regarded as the *Father of Modern Embryology*.
17. **Hans Spemann** (1869–1941) discovered the phenomenon of *primary induction*, i.e., how one tissue determines the fate of another. He was awarded Nobel Prize in 1935.
18. **Patrick Steptoe** and **Robert G Edwards** (Fig. 1.10) pioneered the development of the technique of *in vitro fertilization*. The Louise Brown is the first ‘*test tube baby*’ born in 1978.
19. **James Till** (1931–) (Fig. 1.11) along with **Ernest McCulloch** discovered stem cells in 1960. Since the discovery of stem cells by James Till, the hope for treatment of terminal diseases has become enormous.
20. **Ian Wilmut** (1944), an English embryologist (Fig. 1.12), is best known for leading a team that cloned a mammal from an adult somatic cell in 1996—a Finnish Dorset lamb named Dolly (Fig. 1.1). The cloning is a cell, cell product, or organism that is genetically identical to the unit or individual from which it was derived. Clones are duplicates of each other resembling in anatomy and physiology.



Fig. 1.9 Karl Ernst von Baer.



Fig. 1.10 Patrick Steptoe.

Embryological Terms

Most of the terms used in embryology are of *Latin* (L.) or *Greek* (Gr.) origin. Following text deals only with those terms that are commonly used.

1. **Oocyte** (L. *Ovum* = egg): Female germ or sex cells produced by ovaries.
2. **Sperm** (Gr. *Sperma* = seed): Male germ cells produced by testes.
3. **Zygote**: Cell formed by union of a sperm and secondary oocyte (ovum). The zygote is the earliest stage of embryo (i.e., the beginning of the new human being).
4. **Conceptus**: Product of conception, i.e., embryo along with its extraembryonic membranes.
5. **Cleavage**: Series of mitotic divisions of the zygote to form early embryonic cells—the *blastomeres*.
6. **Morula** (L. *Morus* = mulberry): Solid ball of 12–32 cells (blastomeres) formed 3–4 days after fertilization, just at the time when embryo enters the uterus.

➤ First mammal cloned	Dolly, the female domestic sheep (5th July 1996–14th February 2003)
➤ Inventor of first mammal cloning	Ian Wilmut (1944)
➤ Most famous siamese twins	Chang and Eng Bunker (born in 1811 in Siam Thailand)
➤ Discoverer of stem cells	James Till (1931–)
➤ Stem cells were discovered in	1960 by James Till
➤ Longest period of prenatal development	Fetal period
➤ Earliest period of extrauterine life	Infancy (first year after birth)

CLINICAL PROBLEMS

1. How do the terms zygote and conceptus differ?
2. What do you understand by the term teratology?
3. What are stem cells? Which are the diseases that are likely to be benefited by the stem cells?

CLINICAL PROBLEM SOLUTIONS

1. The zygote is a diploid single cell formed after fertilization by the union of haploid male and female gametes. The term *conceptus* refers to the product of conception, i.e., embryo and its extraembryonic membranes.
2. This is the branch of embryology that deals with the congenital anomalies and defects.
3. The cells of embryoblast are capable of generating all the three germ layers, viz., ectoderm, mesoderm, and endoderm. Hence cells of embryoblast (inner cell mass) are termed embryonic stem cells. They can be kept in an undifferentiated state in culture medium. By using growth factors they can be made to form different tissue cells, e.g., muscle cells, neurons, blood cells, etc. The diseases that are likely to be benefited by stem cells are Parkinson's disease, Alzheimer disease, spinal cord injury, etc.

2

Reproductive System

Male Reproductive System

Overview

The primary reproductive organ in male is testis. The secondary reproductive organs in male are scrotum, epididymis, ductus deferens, seminal vesicles, urethra, prostate gland, bulbourethral glands, and penis (Fig. 2.1). The **male genital tract** consists of vasa efferentia (efferent ductules), epididymis, vas deferens, ejaculatory duct, and urethra. The male genital tract carries the sperms produced in the testis to the urethra, from where they are deposited in the vagina during copulation (intercourse).

Testes

These are a pair of ovoid organs within the scrotum that produce sperms and testosterone. Each one is 4–5 cm long lying within the scrotum. Each testis is suspended in the scrotum by the spermatic cord. Spermatic cord provides vascular, lymphatic, and nerve supply to the testes, and provides passage to the vas deferens. The outer part of each testis is made of thick, white capsule—the

tunica albuginea (Fig. 2.2). The fibrous septum from the capsule extends inside and divides each testis into 200–300 cone-shaped lobules. Each lobule contains one to three convoluted **seminiferous tubules**. The epithelial lining of their walls contains cells that develop into *spermatozoa* by a process of cell division. Surrounding the tubules are **interstitial cells of Leydig**, which secrete male hormone—the **testosterone**.

The seminiferous tubules empty their secretion (e.g., spermatozoa) into tubular network—the **rete testis** that in turn empty into 15–20 **efferent ductules**. The efferent ductules enter into the epididymis to form the **duct of epididymis**.

Epididymis

It is a comma-shaped structure lying posteriorly and slightly lateral to each testis with vas deferens along its medial side. The epididymis consists of a single convoluted duct (**duct of epididymis**) formed by the union of the efferent ductules of the testis. Within the duct of epididymis the spermatozoa mature, develop some motility, and learn a little bit of swimming. They show circular or even forward directional movements.

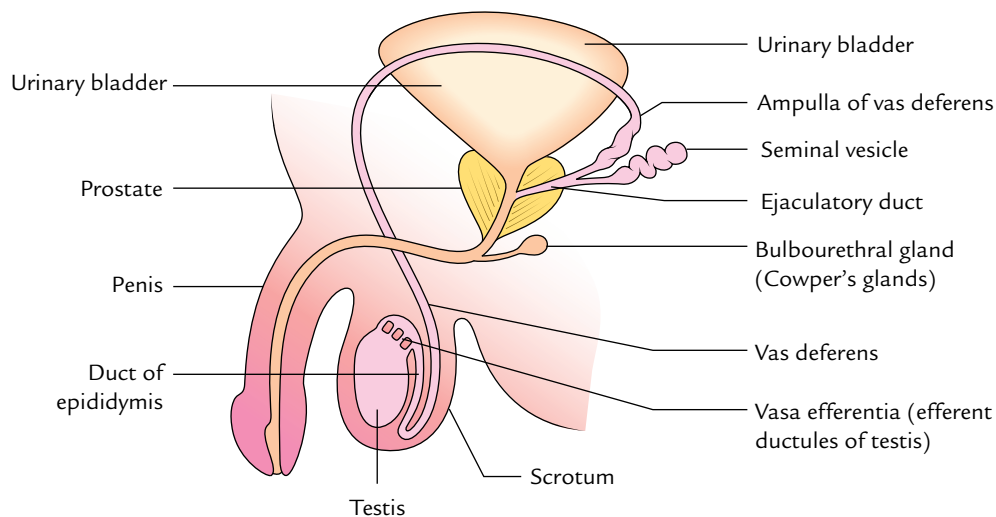


Fig. 2.1 Male reproductive system.

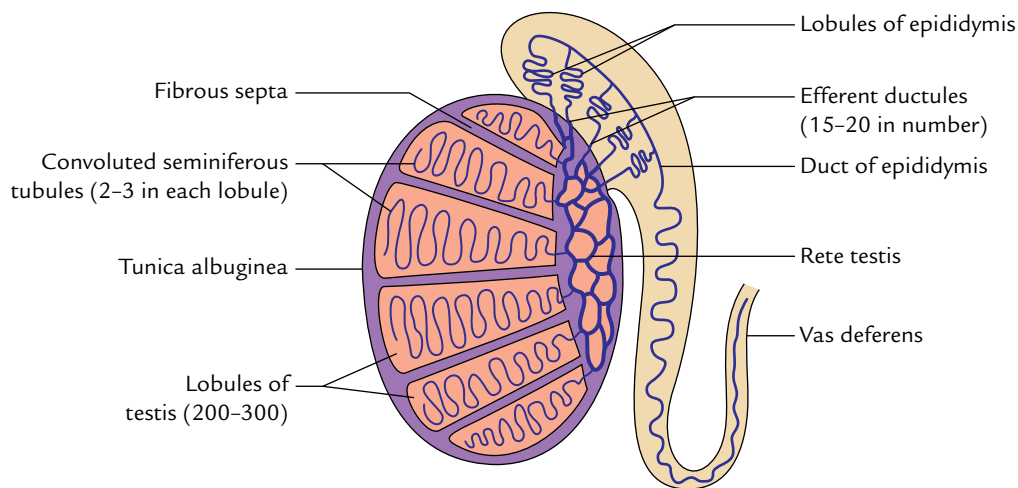


Fig. 2.2 Schematic vertical section of the testis to show the basic structure of testis, epididymis, and vas deferens.

Vas Deferens

It is a thick-walled muscular tube, about 45 cm (18 inches) long, which begins at the tail of the epididymis as the direct continuation of the duct of the epididymis. It runs upward along with vessels within the spermatic cord. The terminal part of each vas deferens is sacculated and called **ampulla of vas deferens**. It serves as a reservoir of sperm and tubular fluid. The terminal narrow part of vas deferens joins the duct of seminal vesicle to form the **ejaculatory duct** at the base of the prostate gland. *Main function of vas deferens is to transport spermatozoa from the epididymis to ejaculatory duct.* Peristaltic contractions of smooth muscle help in propelling the semen. The vas deferens is cord like when grasped between thumb and index finger because of its thick wall and small lumen.

Seminal Vesicles and Ejaculatory Ducts

The seminal vesicle (5 cm long) is a sacculated coiled tube adjacent to ampulla of each vas deferens. The paired seminal vesicles secrete a major portion of volume of ejaculate. These are located behind the bladder near the prostate gland. Each vesicle ends in a small duct that joins ampulla of vas deferens to form an **ejaculatory duct**. Two ejaculatory ducts are slender tubes that open into the prostatic part of the urethra. The secretion of seminal vesicles is thick and mucous like. It contains fructose that provides nutrition to sperms.

Prostate Gland

It is a pyramidal fibromuscular gland of about the size of a chestnut. It is gray to reddish in color. It consists mainly of glandular and muscular tissue.

The prostate gland surrounds the proximal part of the urethra and two ejaculatory ducts. Gland is enclosed by a thin but strong fibrous capsule. The capsule is continuous with several fibromuscular partitions. The prostatic glands secrete the **prostatic fluid**, which is poured into the prostatic urethra through 10–20 ducts. The prostatic fluid contains acid phosphatase, fibrinolytin, citric acid, amylase, prostate specific antigen, and prostaglandins. The prostatic fluid forms the bulk of the semen (i.e., ejaculate).

Bulbourethral Glands (Cowper's Glands)

These are two yellow, pea-sized glands located one on each side of membranous urethra. These glands secrete alkaline mucus that is poured into the penile urethra just before ejaculation of the semen. The secretion of these glands mixes with sperms and other glandular secretions to form semen. They contribute 5–6% of total ejaculate. Alkalinity of their secretion protects sperms against the acidity of the urethra and vagina. The secretions of bulbourethral glands also provide lubrication during coitus.

Penis

It is the male organ of copulation. It is pendulous and visibly consists of glans penis and shaft of penis. Two of erectile columns forming the dorsal portion and the sides of penis are called corpora cavernosa. The third erectile column forming the ventral portion of penis is termed corpus spongiosum. The distal end of corpus spongiosum expands to form a triangular enlargement called **glans penis**. Urethra travels through the corpus

spongiosum and opens as **external urethral orifice** on the tip of glans penis.

N.B. Semen: It is the fluid ejaculated into the vagina at the time of orgasm. It consists of sperms produced by seminiferous tubules of testes and secretion of seminal vesicles, prostate, and bulbourethral glands. The average volume of ejaculate is 2.5–3.5 ml. Semen has a pH of 7.35–7.5 with average sperm count of 100 million per ml. It is white and opalescent. The approximate contribution by various reproductive glands is as under:

- Seminal vesicles: 60%
- Prostate: 30%
- Testes: 5%
- Bulbourethral glands: 5%

Thin milky secretion of the prostate gland is alkaline in nature and neutralizes the acidic pH of the vagina. The movement of sperms is best at pH of 6–6.5 while vaginal pH is about 3.5–4.

The enzymes of prostatic secretion break down the coagulated proteins secreted by seminal vesicles and make the semen more liquid.

Female Reproductive Organs

Overview

The primary reproductive organ in the female is ovary. The secondary reproductive organs in the female are uterine tubes, uterus, vagina, vulva, and vestibular glands. The female genital tract consists of fallopian tube, uterus, and vagina (Fig. 2.3). The female genital tract provides the site of fertilization and site for the development of the embryo.

Ovaries

These are a pair of small ovoid organs (3 cm long \times 2 cm wide \times 1 cm thick) of about the size and shape of an almond. They are situated in the lateral wall of the lesser pelvis on either side of the uterus below and behind the uterine tubes. Each ovary is attached to the upper part of the uterus by the round ligament of the ovary. One end of the ovary is in contact with the fimbria of the uterine tube.

The ovary consists of a thick cortex surrounding a very vascular medulla. The cortex surrounding the medulla consists of a framework of connective tissue covered by the **germinal epithelium**. Before puberty, it contains numerous **primordial follicles**. After puberty, it contains ovarian follicles in various stages of maturity. Each one of them contains an ovum. Till puberty the ovaries remain inactive but stroma still contains immature follicles.

During childbearing age, one ovarian follicle matures and ruptures to release its ovum into the peritoneal cavity. This process is called **ovulation** and recurs (**ovarian cycle**) throughout the reproductive life of the female. If the woman becomes pregnant, the ovarian cycle stops temporarily.

Ovarian Cycle (Figs 2.4 and 2.5)

The **ovarian cycle** is the cyclic release of ovum from the ovary. This cycle is controlled by hormones secreted by the pituitary gland. At the onset of puberty, the pituitary

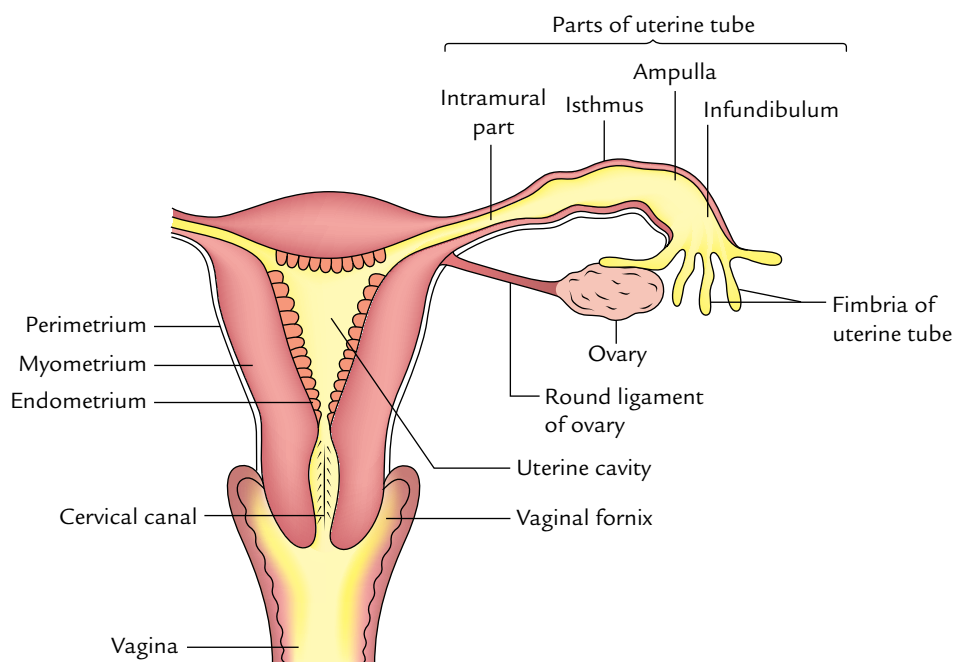


Fig. 2.3 Female reproductive system.

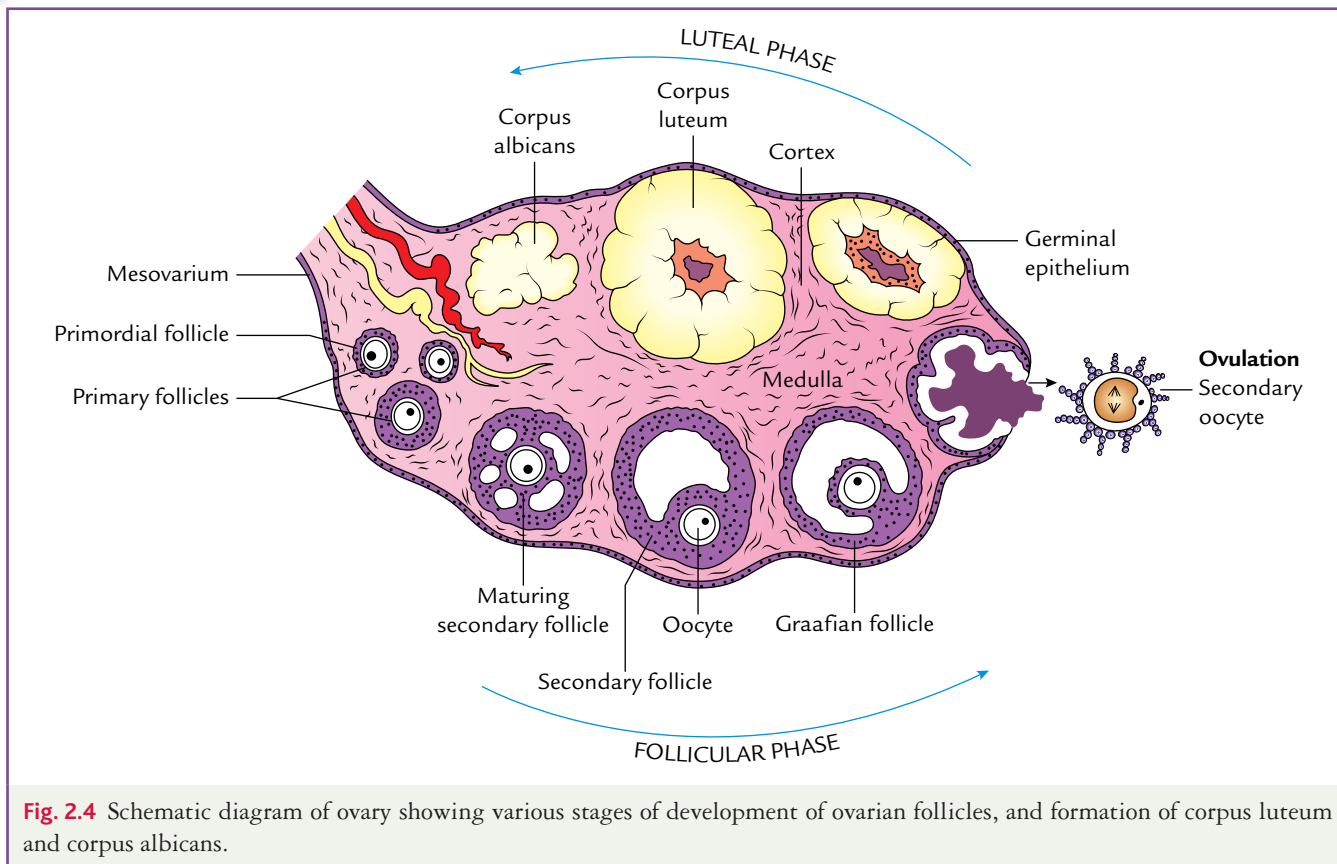


Fig. 2.4 Schematic diagram of ovary showing various stages of development of ovarian follicles, and formation of corpus luteum and corpus albicans.

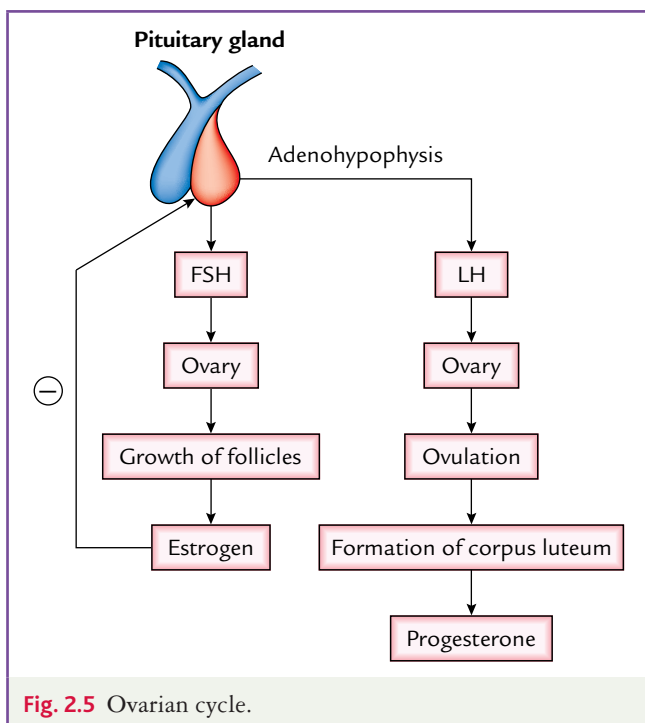


Fig. 2.5 Ovarian cycle.

gland secretes **follicle stimulating hormone (FSH)**. Under the influence of this hormone, the primordial follicles in the ovary start growing. The growing/maturing follicles produce the hormone **estrogen**. Only one follicle reaches the full development and forms Graafian follicle. By the feedback mechanism, the increased level of estrogen hormone inhibits the

secretion of FSH from the anterior pituitary. The pituitary gland also secretes **luteinizing hormone (LH)**. Under the influence of a large amount of LH, the Graafian follicle bursts and ovulation takes place. The ovum is released due to action of proteolytic enzymes formed by the theca externa cells that cause dissolution of capsular wall. There is plasma transudation within the follicles. As a result, they swell and pressure within them increases. Due to increased intrafollicular pressure and simultaneous dissolution of follicular capsular wall, the follicle ruptures and ovum is released (ovulation). After ovulation, the empty follicle develops into **corpus luteum** that secretes hormone **progesterone**. The corpus luteum degenerates after 10 days if the ovum is not fertilized. The level of progesterone decreases, and again the pituitary secretes FSH and a new cycle starts. Thus, the cyclic changes in the ovary comprising of development of ovarian follicles, ovulation, and formation of corpus luteum constitute the ovarian cycle.

The corpus luteum persists for 2–3 months if the ovum is fertilized. By that time placenta develops and starts secreting progesterone and estrogen. The high levels of these hormones in blood further suspends the ovarian cycle during pregnancy.

N.B. The ovarian cycles normally persist throughout the reproductive life of women except during pregnancy. The ovarian cycle terminates at menopause.

Two phases of the ovarian cycle: The ovarian cycle is divided into two phases: (a) follicular phase and (b) luteal phase.

1. The **follicular phase** corresponds to the *first half of the menstrual cycle*. During this phase follicles develop and discharge only one mature oocyte.

Changes in the endometrium of uterus take place due to secretion of the hormone *estrogen* produced by the developing follicles.

2. The **luteal phase** corresponds to the *second half of the menstrual cycle*. During this phase, there is formation of the corpus luteum following ovulation. Changes in uterine endometrium take place due to secretion of the hormone *progesterone*.

Uterus (Fig. 2.6)

It is a hollow, thick-walled muscular organ where fetus develops. It is a pear-shaped organ, which is flattened anteroposteriorly. It lies in anteverted and anteflexed position in the lesser pelvis.

It is about 7.5 cm long, 5 cm wide, and its walls are about 2.5 cm thick. It weighs about 30–40 g.

It has three parts: fundus, body, and cervix.

- **Fundus** is the upper dome-shaped part of the uterus above the openings of uterine tubes. It is devoid of cavity.
- **Body** is the main part of the uterus where fetus develops.
- **Cervix** is the lower cylindrical part of the uterus that protrudes into the vagina.

Structure

The uterus consists of three layers. From superficial to deep these are perimetrium, myometrium, and endometrium.

1. **Perimetrium:** It consists of peritoneum covering the uterus.
2. **Myometrium:** It is the thickest layer and consists of smooth muscle. The smooth muscle fibers are arranged in longitudinal, oblique, transverse, and circular layers. Hence the wall of the uterus is very strong. During pregnancy, the muscle fibers undergo **hyperplasia** and **hypertrophy**. This layer contains blood vessels and nerves; hence it is also called **stratum vasculare**.
3. **Endometrium:** It is the mucous lining of the body of the uterus containing a large number of mucus-secreting glands.

The endometrium consists of following three layers (Fig. 2.7). From outside to inside these are:

- (a) **Stratum basale/basal layer:** It is thin and has a separate blood supply.
- (b) **Stratum spongiosum/spongy layer:** It is thick and edematous.
- (c) **Stratum compactum/compact layer:** It is thin and superficial towards the uterine lumen. It consists of compactly arranged stromal cells.

Mnemonic: BSC = Basal layer; Spongy layer; Compact layer.

N.B. The compact and spongy layers together form **stratum functionalis** (functional layer), which is sloughed off during menstruation. The basal layer is never sloughed off.

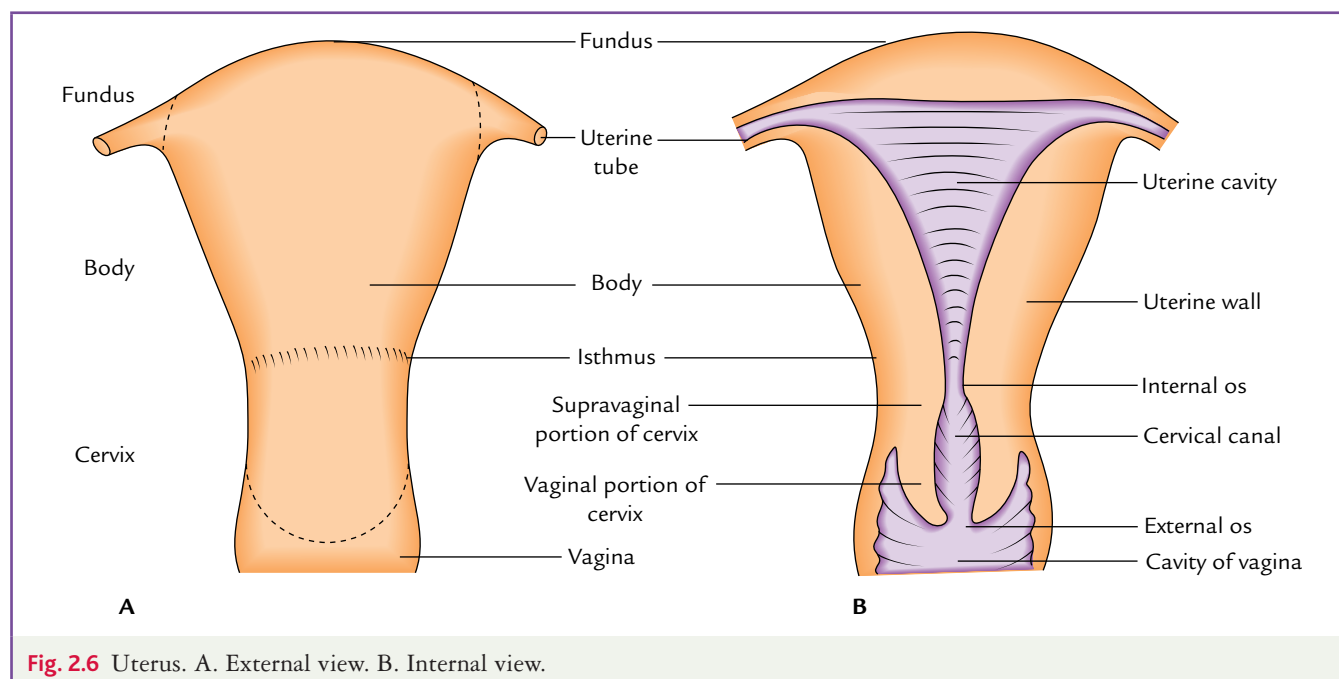


Fig. 2.6 Uterus. A. External view. B. Internal view.

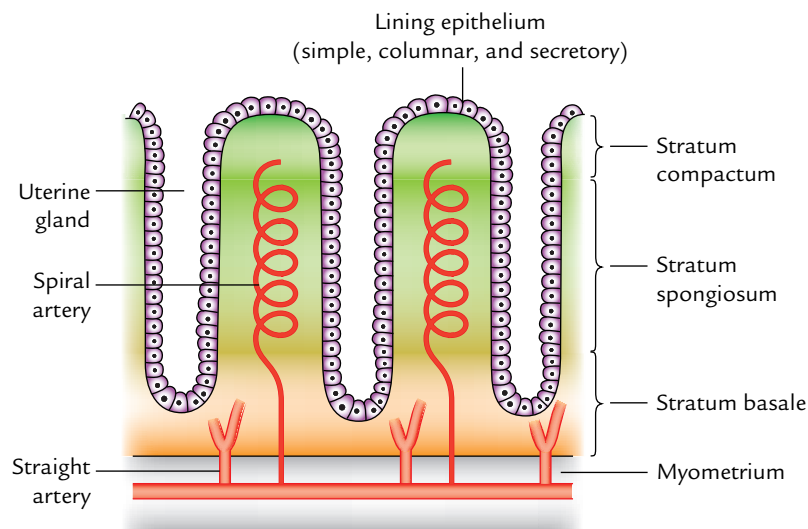


Fig. 2.7 Layers of endometrium.

Menstrual Cycle (Fig. 2.8)

The uterine endometrium undergoes monthly cyclic changes during reproductive life of a woman called **endometrial cycle**, which is commonly referred to as the **menstrual cycle** because of menstruation (flow of blood from the uterus) as a notable feature. At the age of 45 years, the menstruation ceases and this stage is termed **menopause**. (cf. Similar cyclic changes occur in ovaries, which constitute the ovarian cycle, see page 11.)

Each menstrual cycle in most of the women consists of roughly 28 days. **Day 1** is the day when the menstrual flow starts. The ovulation occurs in the middle of the cycle (i.e., 14th day).

Each menstrual cycle is divided into four phases on the basis of changes that occur in the endometrium.

The phases are:

1. Menstrual phase
2. Proliferative phase
3. Secretory phase
4. Premenstrual phase.

N.B. Changes in the endometrium occur as a result of hormones (estrogen and progesterone) secreted by the ovaries (ovarian cycle), which in turn is controlled by the hormones secreted by the hypothalamus and pituitary gland.

1. **Menstrual phase (menses)** (1–4 days): If the ovum is not fertilized, the corpus luteum degenerates; and level of progesterone drops down. The coiled endometrial arteries undergo spasm. The blood supply to the spongy and compact layers of the endometrium is reduced. The functional layer undergoes necrosis and sloughed off, and there is hemorrhage from the stumps of the endometrial

arteries. The sloughing continues until only raw surface of the stratum basale is left.

N.B. It takes about 14 days after ovulation in breaking down the spongy and compact layers of endometrium. Note the basal layer of endometrium remains intact.

If the ovum is fertilized, first the **corpus luteum** and then the **placenta** continue to secrete progesterone, and the menstrual cycle remains suspended during pregnancy.

2. **Proliferative phase/follicular phase** (5–14 days): The proliferative phase coincides with the secretion of the estrogen by the maturing follicles of the ovary.
3. **Secretory phase/luteal phase** (15–25 days): The secretory phase coincides with the secretion of progesterone by the corpus luteum.
4. **Premenstrual phase** (26–28 days): The females, usually the younger ones, often complain of severe spasmodic pain and external spotting of blood during this phase due to ischemia of the uterine wall following drop in the level of progesterone hormone.

Clinical Correlation

1. Abnormal menstrual cycles

- (a) **Hypomenorrhea**: It is scanty blood flow during the menstrual cycle.
- (b) **Menorrhagia**: It is profuse blood flow during the menstrual cycle.
- (c) **Metrorrhagia**: It is the occurrence of bleeding between the menstrual cycles.
- (d) **Oligomenorrhea**: It is reduced frequency of menstrual cycles.

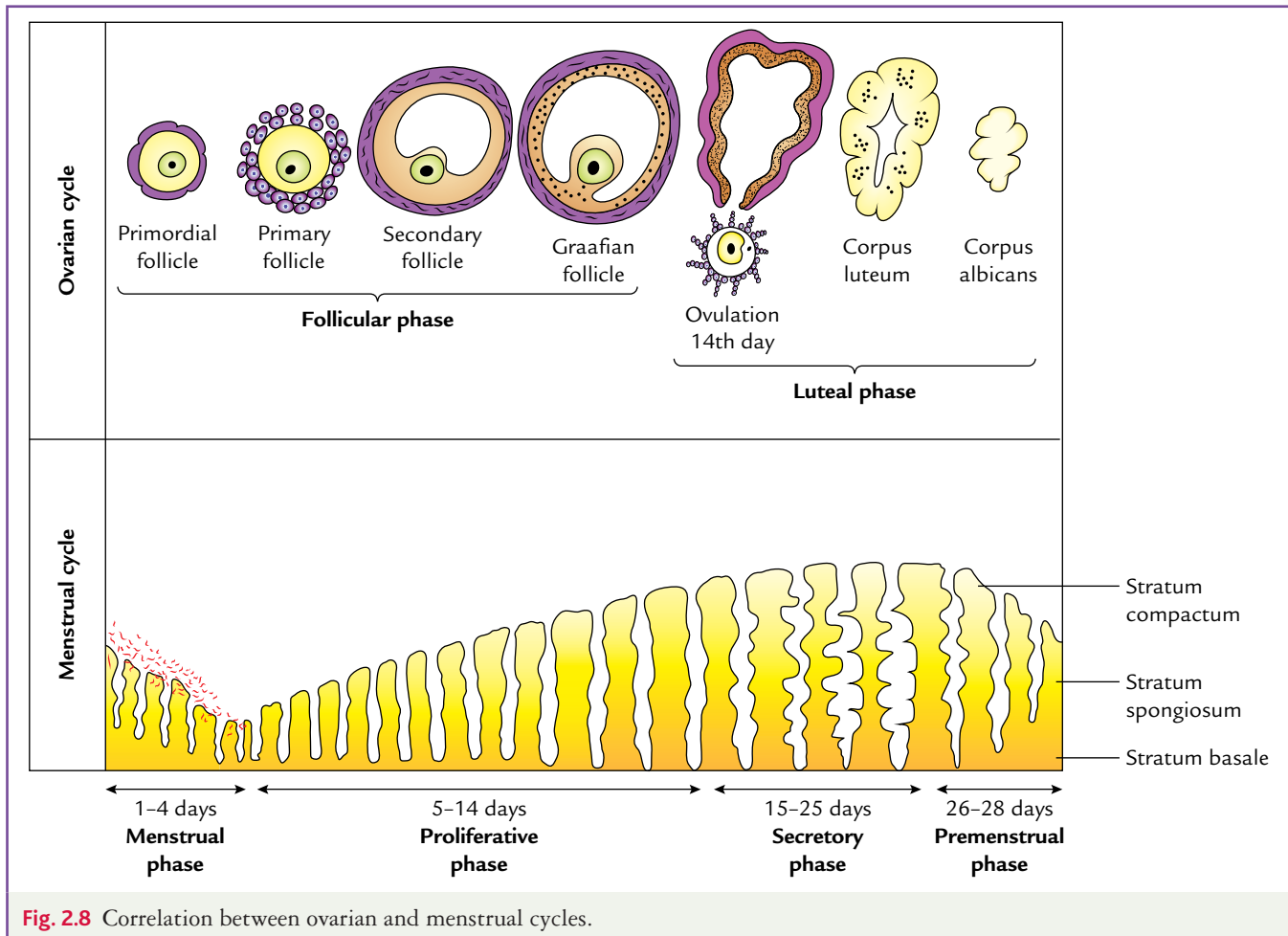


Fig. 2.8 Correlation between ovarian and menstrual cycles.

2. **Amenorrhea:** It is the absence of menstruation. Amenorrhea may be of two types: primary and secondary.
- Primary amenorrhea:** It is the condition when menstrual bleeding does not occur after 16 years of age.
 - Secondary amenorrhea:** It is stoppage of menstrual cycles with normally occurring menstrual cycles before. Most common cause of amenorrhea is pregnancy.

The features of different phases of menstrual cycle are summarized in Table 2.1.

N.B. The menstrual cycle is a continuous process, and each phase gradually passes into the next one.

Hormonal Control of Menstrual Cycle (Fig. 2.9)

The menstrual cycle is controlled by the hormonal secretions of hypothalamus, adenohypophysis, and ovary as follows (Fig. 2.9):

1. The hypothalamus secretes gonadotrophin–releasing hormone (GnRH).

Table 2.1 Features of different phases of the menstrual cycle

Phase	Features
Menstrual phase (1–4 days)	Necrosis and shedding of the functional layer of the endometrium associated with bleeding
Proliferative phase (5–14 days)	Regeneration of the functional layer of the endometrium
Secretory phase (15–25 days)	Endometrium becomes thick and soft due to increased secretory activity of endometrial glands
Premenstrual phase (26–28 days)	Ischemia of endometrium due to reduced blood supply. Cramping or pain and external spotting of blood

2. The GnRH acts on the adenohypophysis that in turn secretes FSH and LH.
3. The FSH causes maturation of one or more ovarian follicles. The secondary follicle is converted into the Graafian follicle.
4. The granulosa cells of the secondary and Graafian follicles secrete estrogen.

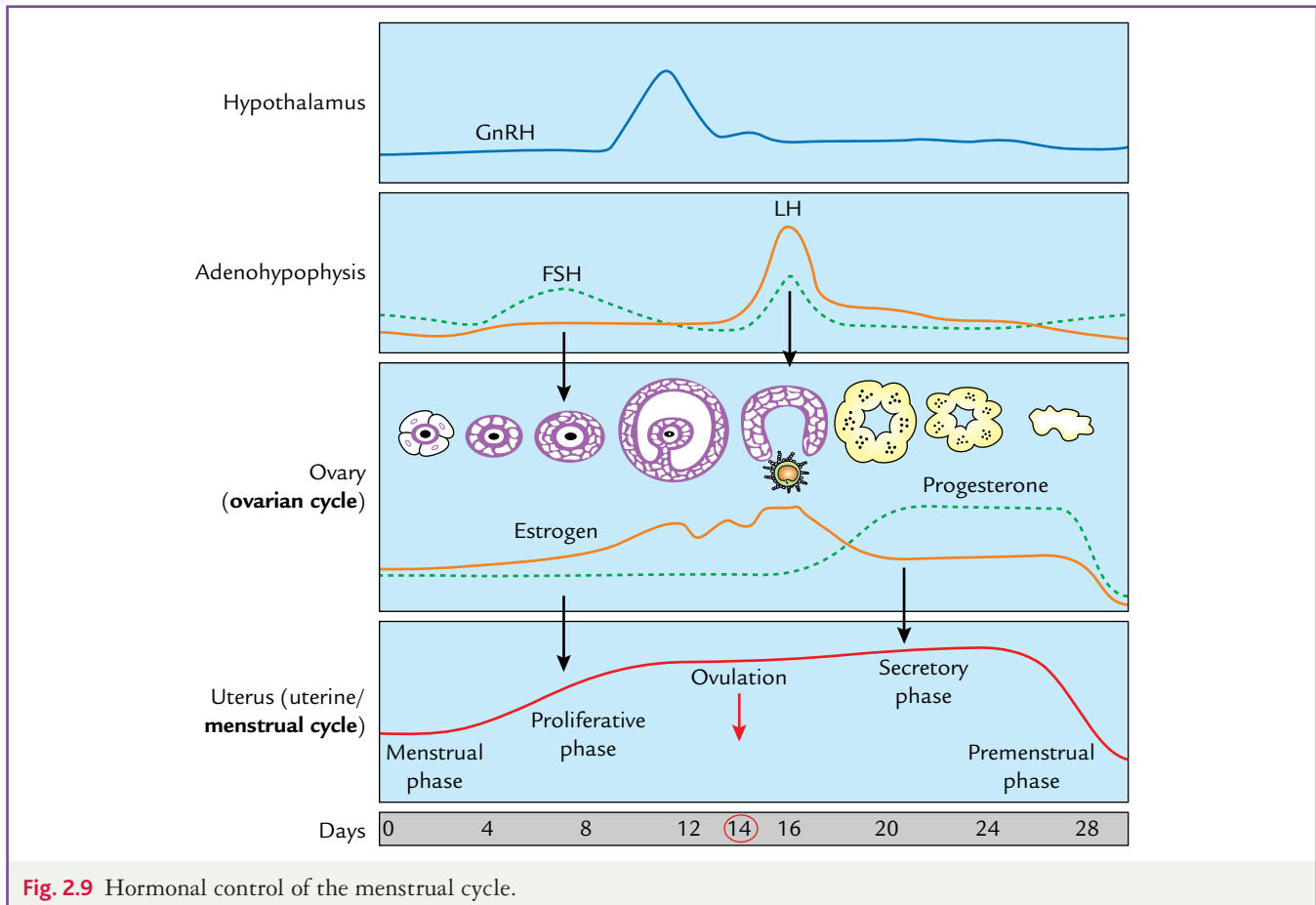


Fig. 2.9 Hormonal control of the menstrual cycle.

5. The estrogen stimulates the uterine endometrium to enter the proliferative phase (the level of estrogen rises to a peak just before the LH surge).
6. The LH surge stimulates ovulation.
7. Following ovulation, the lutein cells of the corpus luteum secretes **progesterone**.
8. The progesterone stimulates the uterine endometrium to enter the secretory phase.

N.B. The hormones secreted by hypothalamus, adenohypophysis, and ovary prepare the endometrium of the uterus for implantation of the conceptus (blastocyst). If fertilization does not occur, the granulosa cells produce **inhibin**, a protein that acts on adenohypophysis and inhibits the secretion of gonadotrophins, which leads to the regression of corpus luteum. The endometrium undergoes **ischemic necrosis** due to decrease in the level of progesterone and estrogen, especially progesterone secretion by the degenerating corpus luteum.

For details see Chapter 3.

The ovarian and menstrual cycles go on hand-in-hand throughout the reproductive life of women except during pregnancy. These cycles terminate at **menopause** usually between the ages of 45 and 55 years.

N.B. Correlation between ovarian and menstrual cycles: The ovarian and menstrual cycles run parallel to each other. Both of these cycles are of 28 days duration.

In fact, the menstrual cycle is dependent on the ovarian cycle because the uterine endometrium undergoes cyclic changes under the influence of hormones secreted by the developing ovarian follicles and corpus luteum of the ovary.

Clinical Correlation

Use of hormones in birth control (contraceptive) pills: The sex hormone estrogen with or without progesterone is used in the preparation of contraceptive pills. These hormones in contraceptive pills act on the hypothalamus and pituitary gland resulting in inhibition of secretion of GnRH, and FSH and LH, the secretion of which is essential for ovulation to occur. **The suppression of ovulation is the basis for the contraceptive pills.**

The most common variety of the contraceptive pill distributed by the government of India contains **progestin (norethisterone acetate)** 1 mg and estrogen (estradiol) 50 µg. These pills are distributed in packets with each packet containing 28 pills. Out of which 21 pills contain these hormones and 7 pills do not contain hormones. The woman is asked to start taking these pills 5 days after the onset of menstruation and continue without any break as long as pregnancy is not desired. Normal menstruation occurs during 7 days in which she takes pills without hormone. If the contraceptive pills are taken on a regular basis, the menstrual cycles occur regularly, each with 28 days. As she

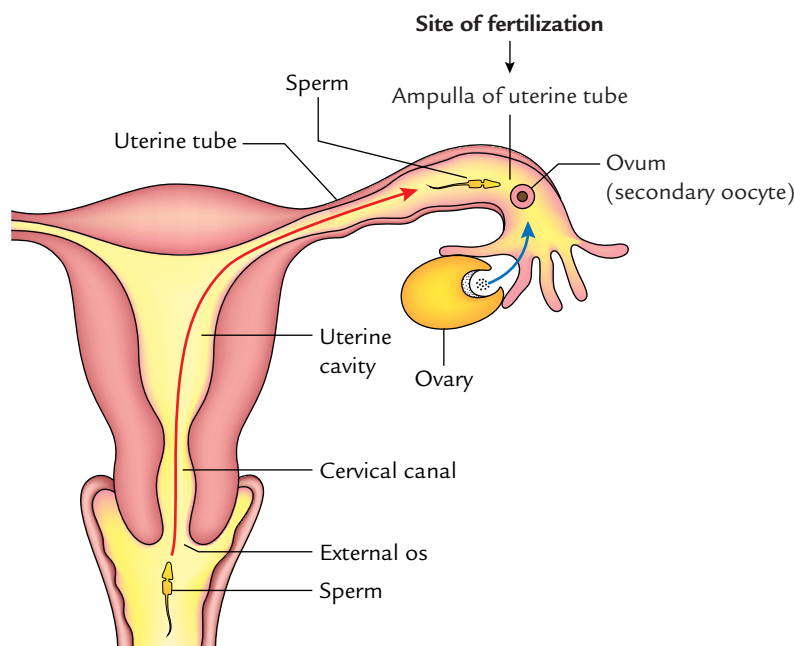


Fig. 2.10 Transport of sperms and ovum to the site of fertilization.

starts taking pills without hormones after 21 days, the withdrawal of hormone induces menstruation after 2 days.

N.B. Only about 200 sperms reach the fertilization site. Most of them degenerate and are absorbed by the female genital tract.

Sperm Transport (Fig. 2.10)

During coitus (sexual intercourse) about 200–600 million sperms are deposited around the external os of the cervix and in the fornices of the vagina. The following factors are responsible for passage of sperms from the uterus to uterine tubes:

1. Muscular contractions of the walls of the uterus and fallopian tube (main factor). The **prostaglandins** of semen are thought to stimulate uterine contractions at the sexual intercourse.
2. Movements of the sperms: The fructose secreted by the seminal glands provides energy to sperms.

Oocyte Transport (Fig. 2.10)

During ovulation, the fimbriated end of the fallopian tube becomes closely applied to the surface of the ovary and the finger-like fimbriae start moving back and forth (**sweeping action**) over the ovarian surface. The sweeping action of fimbriae and fluid currents produced by cilia of the mucous lining of fimbria sweeps the ovum (secondary oocyte) into the infundibulum of the uterine tube as soon as it is discharged from the ovarian follicle.

From infundibulum, the oocyte passes to the ampulla of the tube mainly by the peristaltic movements of the tubal wall.

GOLDEN FACTS TO REMEMBER

- Total number of seminiferous tubules in each testis 400–600
- Most important function of testis (a) Formation of sperms
(b) Production of testosterone hormone
- Reproductive period of woman's life Period in which she can bear children
- Most important event of the ovarian cycle Ovulation

➤ Menarche	Onset of first menstruation (takes place at about 12 years of age)
➤ Menopause	Age at which menstruation ceases to occur
➤ Most important feature of menstrual cycle	Monthly flow of blood per vaginum
➤ Most important factor to initiate menstruation	Withdrawal of estrogen and progesterone hormones
➤ Most common cause of amenorrhea (i.e., absence of menstruation)	Pregnancy

CLINICAL PROBLEMS

1. Why male fertility is evaluated first when an infertile (childless) couple visits a doctor, by advising **semen analysis**?
2. What are the causes of male infertility?
3. What is the most effective permanent method of contraception in males?
4. In some women cause of infertility is anovulation (i.e., cessation of ovulation). Is it possible to induce ovulation in these women?
5. How ovulation is assessed clinically?
6. What is the importance of determining the time of ovulation?
7. Which is most precarious time of prenatal development? Give the embryological basis.

CLINICAL PROBLEM SOLUTIONS

1. This is because the semen analysis is easier to perform. The average volume of semen ejaculated in the vagina during sexual intercourse is 2–6 ml (average 3.5 ml). There are usually more than 100 million sperms per ml of semen of normal males. A man with less than 10 million sperms per ml of semen is likely to be sterile, especially when the specimen contains immotile and abnormal sperms.
2. The common causes of male infertility are low sperm count (oligospermia), poor sperm motility, abnormal sperms, and obstruction of the genital tract (e.g., vas deferens), etc.
3. The most effective permanent method of contraception in males is '**vasectomy**.' This procedure involves the excision of a segment of each ductus (vas) deferens. Following vasectomy there are no sperms in the semen or ejaculate, but the volume remains the same.
4. Some women do not ovulate due to inadequate secretion of FSH and LH. The ovulation can be induced in these women by the administration of gonadotrophins or an ovulatory agent such as **clomiphene citrate**. By competing with estrogen for binding sites in the adenohypophysis, the clomiphene citrate suppresses the normal negative feedback loop of estrogen on the adenohypophysis. This in turn stimulates the release of pituitary gonadotrophins (FSH and LH) secretion, which causes maturation of several ovarian follicles and thus induces ovulation.
5. The ovulation is accompanied by:
 - (a) A variable amount of abdominal pain in some women because ovulation results in slight bleeding in the peritoneal cavity.
 - (b) A slight drop in the basal body temperature.

In a 28-day menstrual cycle, the ovulation takes place at about the middle of the cycle, to be exact on day 14 before the start of next menstrual bleeding.

There are many methods to find out the exact time of ovulation, but the one that is easy and commonly used is a **temperature method**. In this method, woman's body temperature is recorded every morning before getting up and plotted on a graph. The temperature is low during menstruation, subsequently it rises, and at about the middle of the cycle it suddenly falls to rise again. The rise in temperature after sudden fall indicates that ovulation has occurred.

Following ovulation basal body temperature increases by 0.3–0.5°C.

6. The importance of determining the time of ovulation is twofold:
 - (a) *Rhythm method of family planning* (i.e., pregnancy is not desired): After ovulation, the ovum remains viable only for 2 days and sperms deposited in vagina remain viable only for 4 days. Therefore, fertilization can occur only if intercourse is done 4 days before ovulation to 2 days after the ovulation. Barring these 6 days, the remaining days of the menstrual cycle are regarded as **safe period**. Thus pregnancy can be avoided if intercourse is done during safe period.
 - (b) *Achievement of pregnancy* (i.e., pregnancy is desired): In case of infertility (failure to conceive), the couples are advised to have sexual intercourse during the unsafe period (i.e., 4 days before ovulation to 2 days after the ovulation) because this period is most favorable for conception.
7. The most precarious time of prenatal development is during the embryonic period (i.e., from the beginning of the third week to the end of the eighth week). This is because there is much tissue differentiation and organ formation during this period. Mostly, however, a woman does not realize that she is pregnant until it is very late. Therefore, a woman should consistently take care of herself and abstain from taking certain drugs including antibiotics (especially during 14 days before next menstruation) even if there is a remote chance that she is pregnant or might become pregnant in the near future.

3

Cell Division and Gametogenesis

Overview

The body is essentially a cellular structure and begins its existence as a single cell—the zygote. It develops by multiplication and differentiation of cells. It matures as the cells and substance secreted by them achieve the mature state. The senescence (i.e., beginning of old age) and death pursues as a result of decay and cessation of the cellular activities. The human body is made up of 60–100 trillion of cells. The body cells are broadly divided into two types: **somatic cells** and **germ cells**. The **somatic cells** are essential for growth, development, regeneration, and maintenance of various tissues of the body, whereas **germ cells** are essential for the production of gametes.

The life begins as a single cell—the zygote (vide supra)—formed by union of male and female gametes or germ cells. In humans, the male gametes are spermatozoa or **sperms**, which are produced by testis from puberty onward. The female gametes are **secondary oocytes**, which are released from ovary in a cyclic fashion throughout the reproductive life of a female.

The gametes are specialized cells for reproduction. Each gamete cell has a haploid (half) number of chromosomes (i.e., 23 chromosomes). Each body cell (somatic cell) has diploid (double) number of chromosomes (i.e., 46 chromosomes). The 46 chromosomes are arranged in 23 pairs. The 22 pairs of these chromosomes are called **autosomes** whereas the 23rd pair is called **sex chromosomes**. The sex chromosomes are of two types: X and Y. Females have two X chromosomes while males have one X and one Y chromosome. Conventionally this is expressed as a formula 44XX in females and 44XY in males.

Each gamete has only 23 chromosomes. In females, secondary oocytes are of only one type, i.e., each secondary oocyte has 22 autosomes and one X chromosome (22X). In males, there are two types of sperms—one containing X (22X) and the other containing Y (22Y). The sperm containing X chromosomes is called X-bearing sperm or **gynospERM** and sperm containing Y chromosomes is called Y-bearing sperm or **androsperm**.

Cell Division

There are two types of cell divisions: mitosis and meiosis.

Mitosis

This type of cell division occurs in somatic cells. The mitotic cell division is a process whereby one cell divides into two daughter cells that are genetically identical to the parent cell. Each daughter cell receives the complete complement of 46 chromosomes. The period between the two mitotic divisions is called **interphase**. During interphase, i.e., before mitosis begins, each chromosome replicates its deoxyribonucleic acid (DNA). During this period, the chromosomes are in the form of long and thin threads (chromatin threads), which spread diffusely within the nucleus. They cannot be recognized with a light microscope (Fig. 3.1).

The various stages of mitosis are as follows (Fig. 3.2):

1. **Prophase:** In this stage, nucleolus disappears. The chromosomes become coiled.* They condense, shorten, and thicken. Each chromosome now consists of two parallel subunits called *chromatids*, which remain joined to each other at a narrow common region called *centromere*. But the chromatids cannot be recognized.
2. **Prometaphase:** In this stage, the chromatids become distinguishable.
3. **Metaphase:** In this stage, the nuclear membrane breaks. The double structured chromosomes (vide supra) line up in the equatorial plane of the spindle and get attached to the microtubules of the spindle extending between two centrioles, one at each pole.
4. **Anaphase:** In this stage, the centromere of each chromosome splits and the two chromatids are separated from each other. They are now called *daughter chromosomes*. The spindle fibers attached to the centromere, of the chromosomes contract and pull the daughter chromosomes towards poles. Due to pull on centromere, the daughter chromosomes become V-shaped with their arms trailing as they move towards the poles.

*Shortening of chromosomes by coiling reduces the chances of pinching off of the fragments of chromosomes.

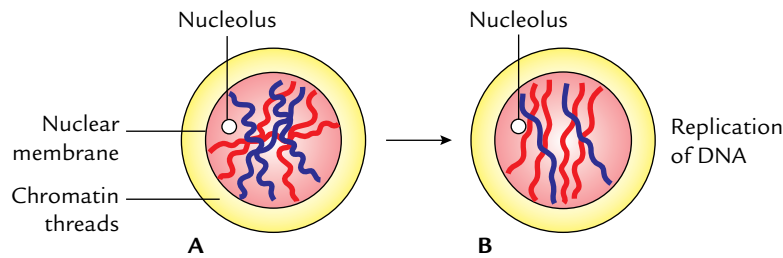


Fig. 3.1 Cell in interphase: A. Early interphase. B. Late interphase.

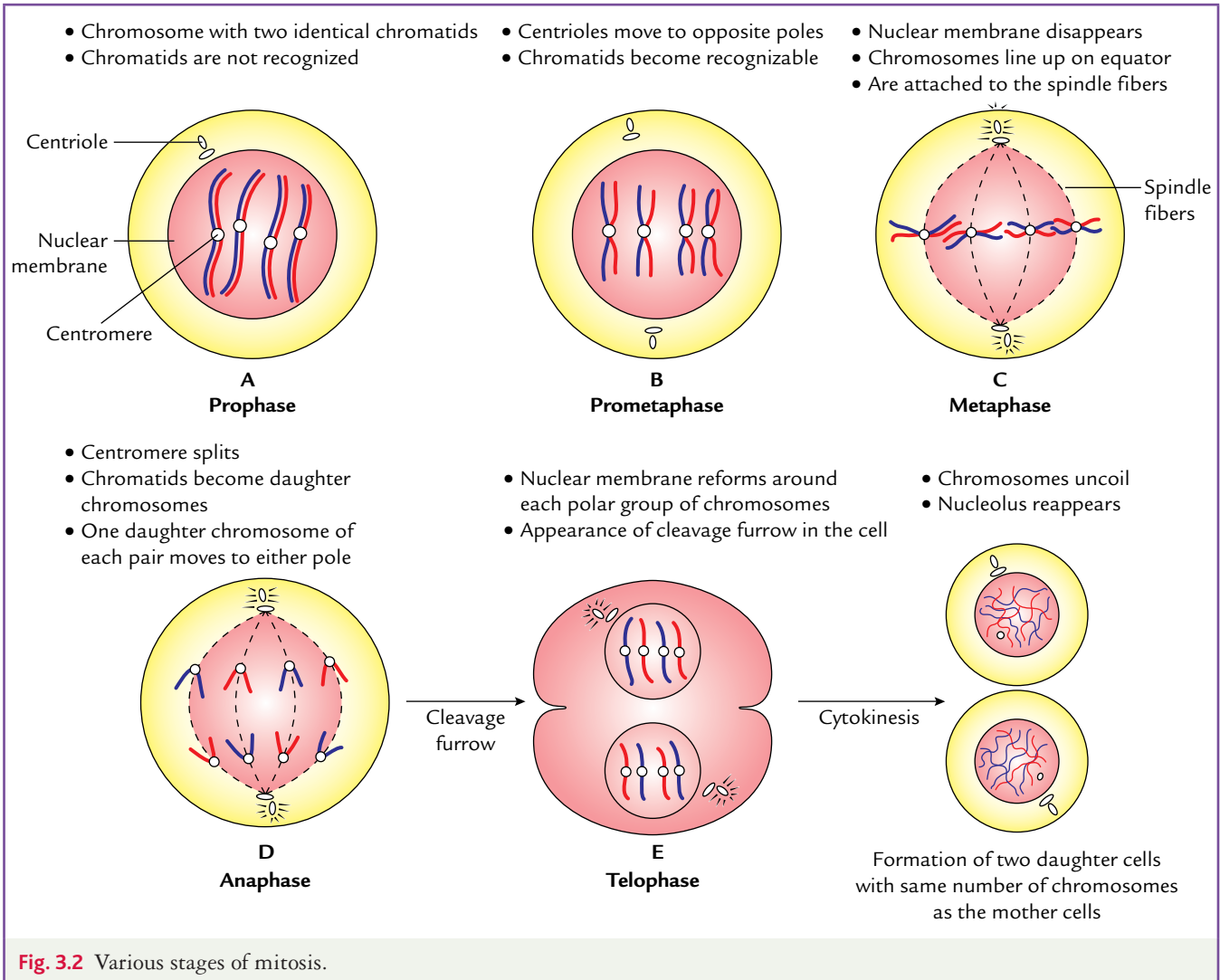


Fig. 3.2 Various stages of mitosis.

5. **Telophase:** In this stage, the separated chromatids are migrated to the opposite poles of the spindle. The spindle fibers disappear and nuclear membrane appears around each polar group of daughter chromosomes. The chromosomes uncoil and become less compact. The nucleolus reappears. There appears a cleavage furrow beneath the equator that deepens and separates the two daughter cells (*cytokinesis*).

Clinical Correlation

Significance of mitosis

- Genetic stability:** It ensures continuous succession of identical cells through generations.
- Growth and development:** It helps in growth and development of the body.
- Regeneration, replacement, and repair:** It helps in regeneration of new cells to replace the dead or damaged cells.

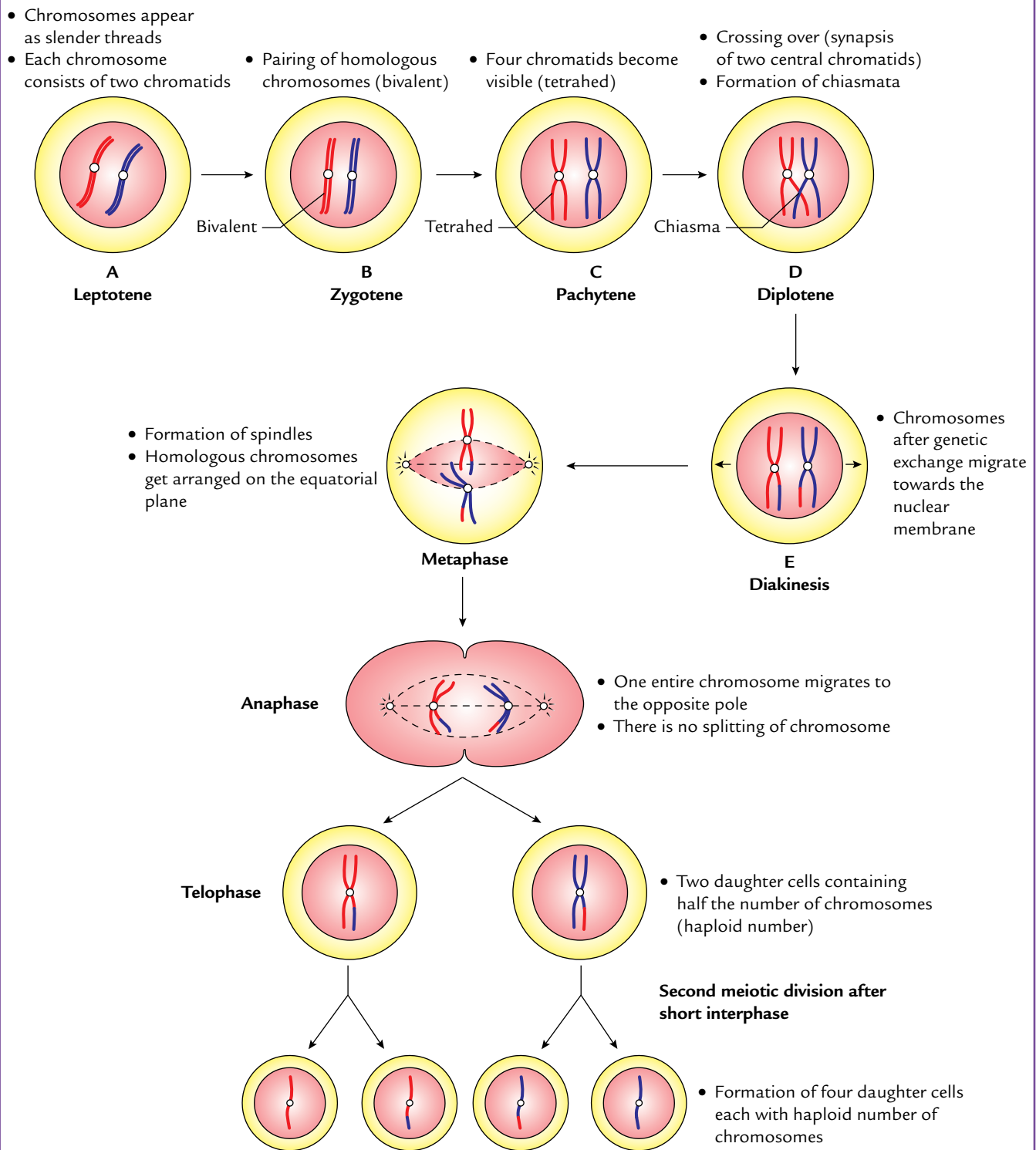


Fig. 3.3 Meiotic division I and II: A, B, C, D, and E showing five stages of prophase of first meiotic division.

Meiosis (Fig. 3.3)

The meiosis is a special type of cell division that takes place only in the reproductive organs to produce gametes. The meiosis consists of two phases of cell divisions that take place one after the other. (a) **First meiotic**

division (also known as **reductional division**): In this the number of chromosomes of the daughter cells is reduced to half of the mother cell. (b) The **second meiotic division**: It is the mitotic division similar to one described above except that there is no duplication of DNA during short interphase.

I. First Meiotic Division

1. **Prophase:** Prophase of the first meiotic division is very long and complicated. It is therefore divided into following five stages.
 - (a) *Leptotene:* In this stage, the chromosomes, as in mitosis, appear as slender threads. Note: Although each chromosome consists of two chromatids that are joined at centromere, the chromatids are not visible at this stage.
 - (b) *Zygotene:* In this stage, the lengthwise pairing of homologous chromosomes begins. One of the two homologous chromosomes is from the father (**paternal chromosome**) and the other is from the mother (**maternal chromosome**). This event is called **synapsis** and each synapsing pair is called **bivalent**.
 - (c) *Pachytene:* This stage is very long and may extend even for years. It is characterized by following changes.
 - The chromatids of each chromosome become visible separately. Each bivalent chromosome thus appears to have four chromatids and is called **tetrahed**. Each chromatid pair is united by a **kinetochore**. There are two central chromatids and two peripheral chromatids (one from each chromosome).
 - The two central chromatids (one belonging to each chromosome) of tetrahed, coil over each other so that they cross at a number of points. This is called **crossing over**. Due to crossing over the central chromatids present a cross-like configuration called **chiasmata**.
 - (d) *Diplotene:* It is characterized by following changes.
 - The paired homologue of tetrahed starts separating.
 - During this process, the central chromatids break at the point of crossing over and unite to the opposite chromatid. This results in exchange of genetic material between these chromatids.
 - (e) *Diakinesis:* The chromosomes become more contracted and migrate towards the nuclear membrane. At the end of prophase, the nuclear membrane disappears.
2. **Metaphase:** The homologous pairs of chromosomes become arranged on the equatorial plane of the spindle.
3. **Anaphase:** In this stage, the homologous chromosomes migrate to the opposite poles of the spindle. Unlike mitosis the chromosomes move randomly. The shorter chromosomes move earlier than the longer chromosomes.

4. **Telophase:** This stage presents following features.
 - The nuclear membrane is formed around the polarized group of chromosomes.
 - The cell membrane constricts and two daughter cells are formed (**cytokinesis**). Each daughter cell thus formed contains only half the number of chromosomes (**haploid number**) with exchanged genetic material.

II. Second Meiotic Division

The **second meiotic division** is essentially similar to mitosis. It, however, differs from mitosis in that the DNA does not duplicate. By second meiotic division, the two daughter cells of first meiotic division form four daughter cells, each with haploid number of chromosomes.

Clinical Correlation

Significance of meiosis

1. **Sexual reproduction:** As the chromosome number is reduced to half during meiosis, each germ cell has *haploid number* of chromosomes. When two germ cells unite to form a *zygote* the chromosome number is restored to normal (*diploid number of chromosomes*). Thus, because of meiosis the chromosome number is maintained for the species.
2. **Genetic variation:** Because of random assortment of paternal and maternal chromosomes, and exchange of genetic material during crossing over in the meiosis, the daughter cells (i.e., gametes) have a new genetic configuration. This causes individual variations within the species, which is essential for evolution.
3. **Hybrid vigor:** Helps to maintain vigor in progeny through sexual reproduction.

The distinguishing features between the mitosis and meiosis are given in Table 3.1.

Table 3.1 Distinguishing features between mitosis and meiosis	
Mitosis	Meiosis
• Takes place in somatic cells	• Takes place in germ cells
• Completes in one sequence	• Completes in two sequences, i.e., there are two successive divisions, viz., meiosis I and meiosis II
• Crossing over of chromatids does not take place	• Crossing over of chromatids takes place
• Daughter cells have the same number of chromosomes as parent cells	• Daughter cells have half the number of chromosomes as parent cells
• Daughter cells are identical to each other and to the parent cell	• Daughter cells are not identical to each other and to the parent cell
• Equational division	• Reductional division

Spermatogenesis

The **spermatogenesis** is the process of formation of spermatozoa from primordial germ cells (PGCs)/spermatogonia present in the walls of the seminiferous tubules of the testis.

The PGCs remain dormant in the seminiferous tubules of testes till puberty. At puberty, they undergo a series of divisions to form spermatogonia. The various stages of spermatogenesis are (Fig. 3.4) as under:

1. The PGCs divide by mitosis to form dark type A spermatogonia, which act as stem cells. Each dark type A spermatogonium undergoes mitosis to form one dark A spermatogonium and other light type A spermatogonium. The dark type A spermatogonia are kept in reserve for repetition of the next cycle. The light type A undergoes mitotic division to form two dark type B spermatogonia.
 2. The type B spermatogonium undergoes mitotic division to form two **primary spermatocytes** (largest germ cells).
- N.B. Spermatocytogenesis:** In this process, PGCs undergo a series of mitotic divisions to form a large number of spermatogonia. Depending upon their appearance, three types of spermatogonia are distinguished, viz., (a) dark type A spermatogonia, (b) light type A spermatogonia, and (c) type B spermatogonia.
3. The **primary spermatocytes** undergo first meiotic division (reductional division) to form two **secondary spermatocytes**. The secondary spermatocytes thus have haploid number of chromosomes.
 4. Each secondary spermatocyte immediately undergoes second meiotic division (i.e., mitotic division) to form **two spermatids**, each with haploid number of chromosomes.
- Thus, four haploid spermatids are produced from the meiotic division of one primary spermatocyte. The spermatids are small cells of about half the size

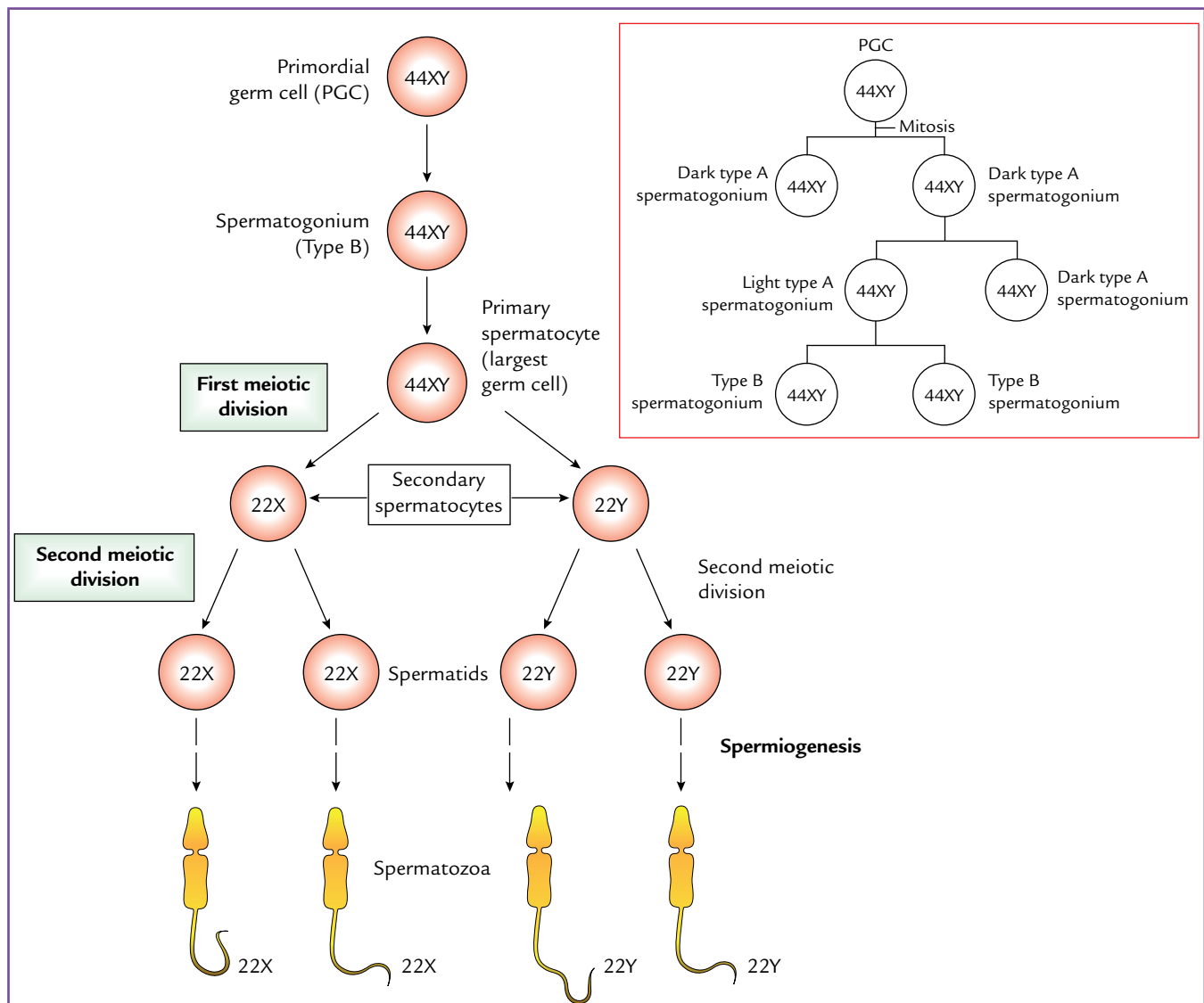
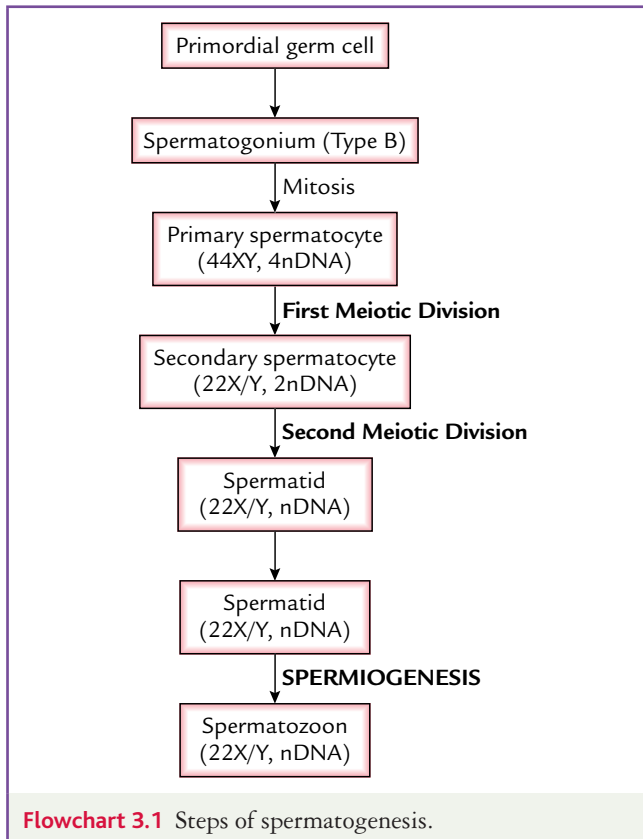


Fig. 3.4 Spermatogenesis (simplified form). Figure in the inset shows spermatocytogenesis.



of the secondary spermatocyte, and have round and darkly stained nuclei.

The spermatids lie close to the lumen of seminiferous tubule.

- Each spermatid gradually changes its stage to become spermatozoon or sperm. This transformation of circular spermatid into an elongated spermatozoon is called **spermiogenesis**.

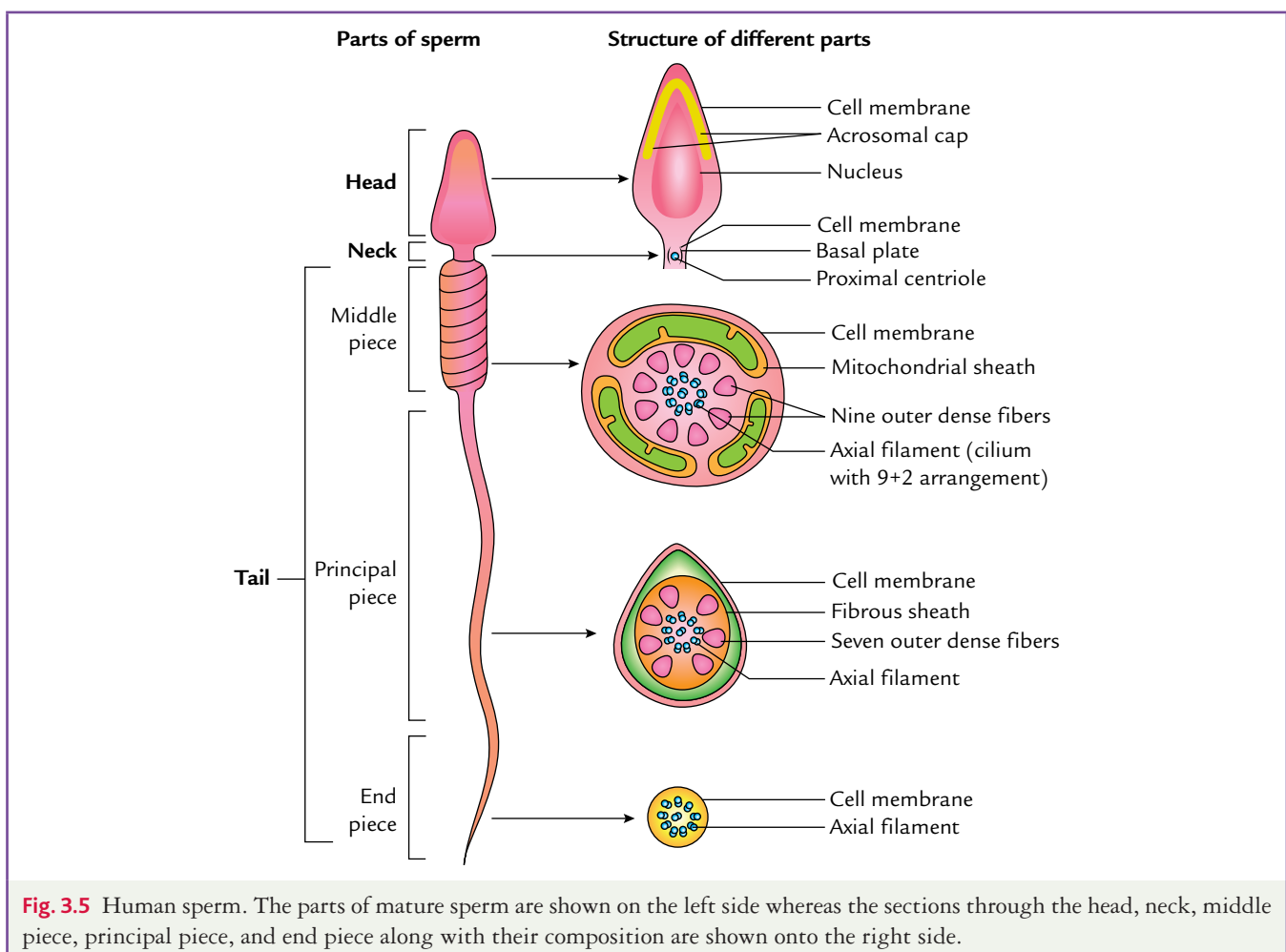
Thus from one primary spermatocyte four spermatozoa are formed; two with 22 autosomes and one X chromosome (22+X, 22+X) and two with 22 autosomes and one Y chromosome (22+Y, 22+Y) (Fig. 3.4).

The steps of spermatogenesis are summarized in Flowchart 3.1.

To understand the process of spermiogenesis, the student must first understand the structure of spermatozoon (Fig. 3.5).

Structure of Spermatozoon (Fig. 3.5)

The spermatozoon (50 μ in length) consists of head, neck, and tail. The tail is further divided into three parts: middle piece, principle piece, and end piece. Tail forms four-fifth of the length.



Head The head of sperm appears somewhat like a spearhead in section. It mainly consists of a **nucleus** that contains the condensed chromatin material (mostly DNA). Anterior two-third of the nucleus is covered by an **acrosomal cap** that contains various enzymes including **hyaluronidase** and **acrosin**.

Neck The neck is narrow. It contains a funnel-shaped **basal plate** and a **centriole**. The centriole gives rise to axial filament that extends throughout the tail.

Tail The tail consists of three parts: middle piece, principal piece, and end piece.

1. **Middle piece:** It contains the axial filament in the center that is surrounded by spirally arranged mitochondrial sheath. At the distal end of the middle piece there is a ring-like structure through which axial filament passes. It is called *annulus* and is derived from the other centriole.
2. **Principle piece:** It is made of axial filament covered by seven outer dense fibers.
3. **End piece:** It is made up of only the axial filament.

N.B.

- Structure of the axial filament is very similar to that of the cilium.
- The whole spermatozoon is covered by plasma membrane.

Figure 3.5 shows parts of the mature sperm (on the left) and sections through head, neck, middle piece, principal piece, and end piece along with their composition (on the right).

N.B. The axial filament is responsible for the movements of the spermatozoon, while mitochondria supply energy for these movements.

Spermiogenesis

The process by which the spermatids are transformed into mature spermatozoa is known as spermiogenesis.

Process of Spermiogenesis (Fig. 3.6)

The spermatid is more or less a circular cell containing a nucleus, golgi apparatus, centrosome, and mitochondria. The spermatid is transformed into the spermatozoon as follows:

1. Nuclear material (chromatin) gets condensed and the nucleus moves towards one pole of the cell to form the **head of the spermatozoon**.
2. Golgi apparatus forms the **acrosomal cap** that covers anterior two-third of the nucleus.

3. Centrosome divides into two centrioles. One centriole becomes spherical and moves towards the posterior end of nucleus to occupy the neck region. It gives rise to the **axial filament**. The other centriole moves away from the first centriole and becomes ring shaped. It forms an **annulus/ring around the distal end of the middle piece** through which axial filament passes.
4. The part of the axial filament between the neck and annulus becomes surrounded by the mitochondria, and together with them forms the middle piece.
5. The remaining part of the axial filament elongates to form the principle and end pieces or tail. Most of the cytoplasm of spermatid is shed off but the cell membrane remains, which covers the entire spermatozoon.

The structural components of the spermatid and the spermatozoon are compared in Table 3.2.

Clinical Correlation

Abnormal sperms: The abnormality of sperms is common as compared to the oocytes. Morphologically for clinicians the sperm consists of two parts of head and tail.

Types of abnormalities are as under.

1. **Morphological abnormalities**

- (a) Head and tail of sperms may be abnormal (viz., two heads, two tails)
- (b) Sperms may be giant or dwarf
- (c) Sperms may be joined

2. **Immotility:** For potential fertility, 50% sperms should be motile after 2 hours of ejaculation and some should be motile after 24 hours.

3. **Genetic abnormalities:** Sperm having abnormal chromosomal content (rare as compared to the oocytes).

Oogenesis (Fig. 3.7)

The **oogenesis** is the process of formation of female gametes—the oocytes from PGCs. The process of oogenesis begins long before birth in the cortex of the ovary.

The PGCs divide by mitosis to form a large number of oogonia. Each oogonium then enlarges to form a **primary oocyte**. The primary oocyte enters the prophase of **first meiotic division** before birth. But this division is arrested till puberty due to the presence of an oocyte maturation inhibitor (**OMI**) factor secreted by the follicular cells surrounding the oocyte. The first meiotic division gets completed only when primary oocytes start maturing and are getting prepared for ovulation.

At puberty in each ovarian cycle, 5–50 primary oocytes re-assume their first meiotic division, which is

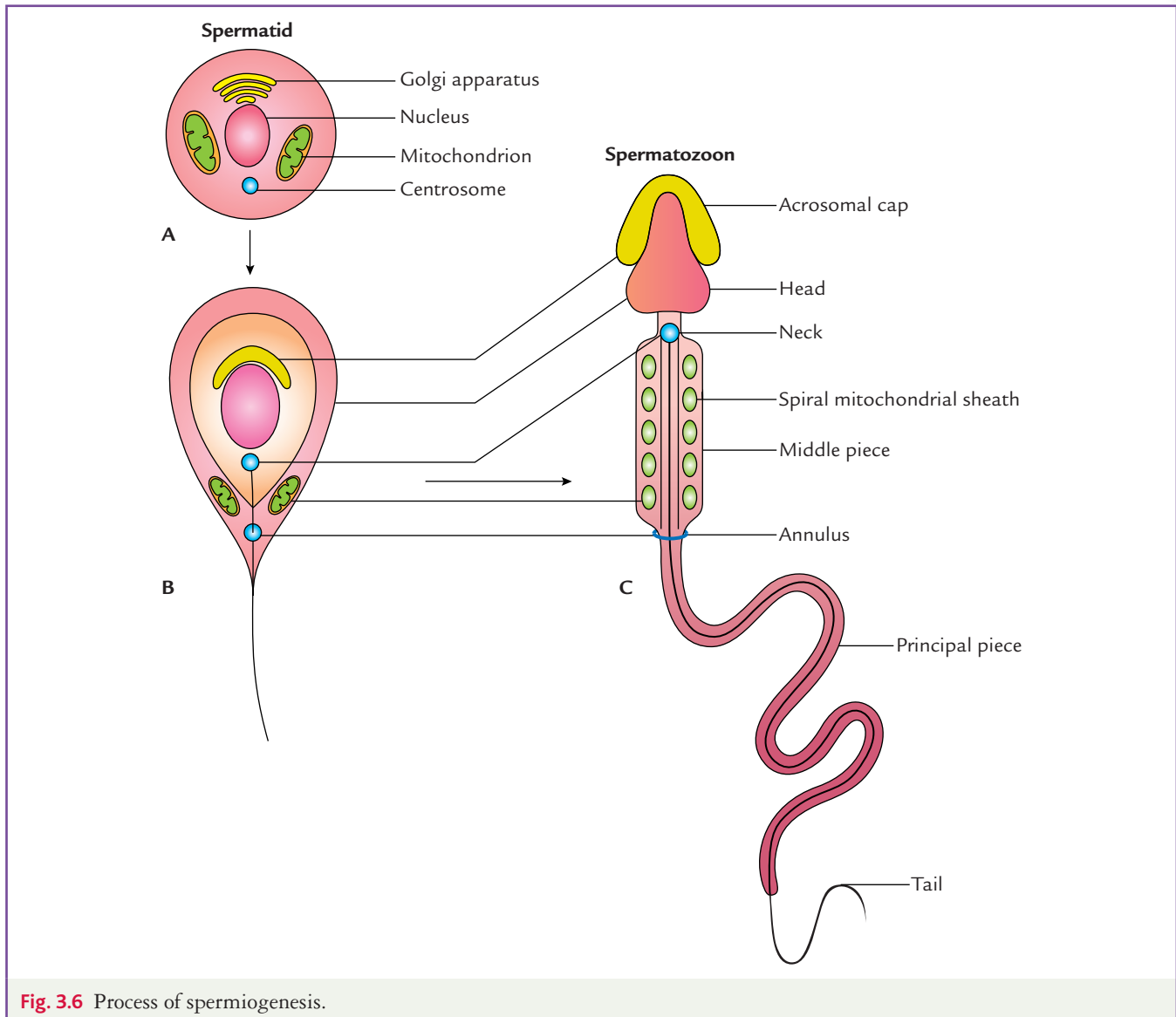


Fig. 3.6 Process of spermiogenesis.

Table 3.2 Comparison of structural components of the spermatid and the spermatozoon	
Spermatid (round cell)	Spermatozoon (elongated cell)
• Nucleus	• Head
• Golgi apparatus	• Acrosomal cap
• One centrosome	• Two centrioles (a) One lies in the neck and forms axial filament (b) Other forms annulus at the distal end of middle piece
• Mitochondria	• Spirally surround the axial filament between the neck and annulus to form the middle piece; the remaining axial filament forms the tail
• Cell membrane	• Cell membrane

completed just before the ovulation, forming two daughter cells each with haploid number of chromosomes. The first meiotic division is unequal; most of the cytoplasm goes to one daughter cell forming **secondary oocyte**, while the other daughter cell receives minimal cytoplasm and forms the **first polar body**.

The **secondary oocyte** enters the **second meiotic division** at the time of ovulation, but this division is completed only after the sperm has penetrated the secondary oocyte. The second meiotic division is also unequal so that one daughter cell receives most of the cytoplasm and forms the ovum, while the other daughter cell receives a very small amount of cytoplasm and forms the **second polar body**.

Thus, one primary oocyte forms only one ovum with 22 autosomes and one X chromosome; and three polar

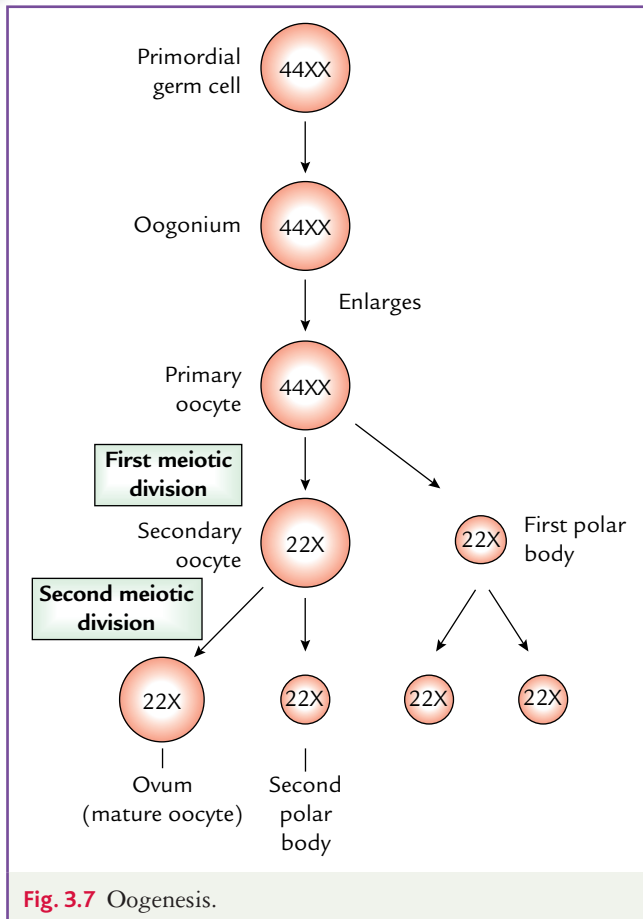


Fig. 3.7 Oogenesis.

bodies each with 22 autosomes and one X chromosome are formed.

N.B.

- The primary oocyte enters into first meiotic division before birth and completes it at puberty just before ovulation.
- Primary oocytes are not formed after birth.
- The secondary oocyte, at the time of ovulation is in metaphase stage of second meiotic division, which continues till fertilization. The secondary oocyte completes its meiotic division only when it is fertilized.
- At birth, the ovary contains about two million germ cells. Thereafter most of them degenerate and, by puberty, when ovulation begins only about 40,000 oocytes are left in the ovary.

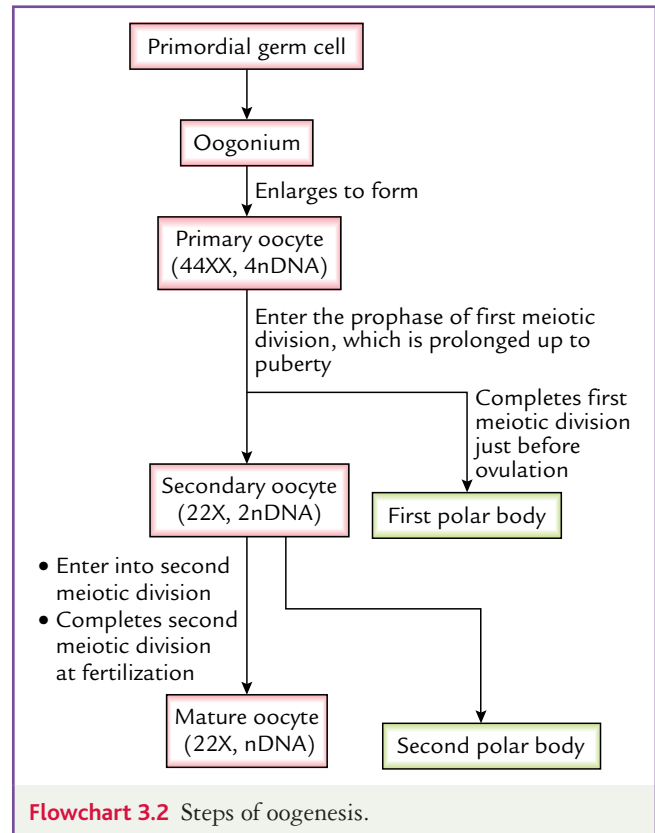
The steps of oogenesis are summarized in Flowchart 3.2. The differences between the male and female gametes are given in Table 3.3.

Oogenesis is accompanied by development and growth of the follicles.

Development of Ovarian Follicles and Ovulation

A. Development of follicles. The various stages of development of ovarian follicles are as follows (Fig. 3.8).

1. The oogonium gets covered by a single layer of flat epithelial cells—the **follicular cells** (which



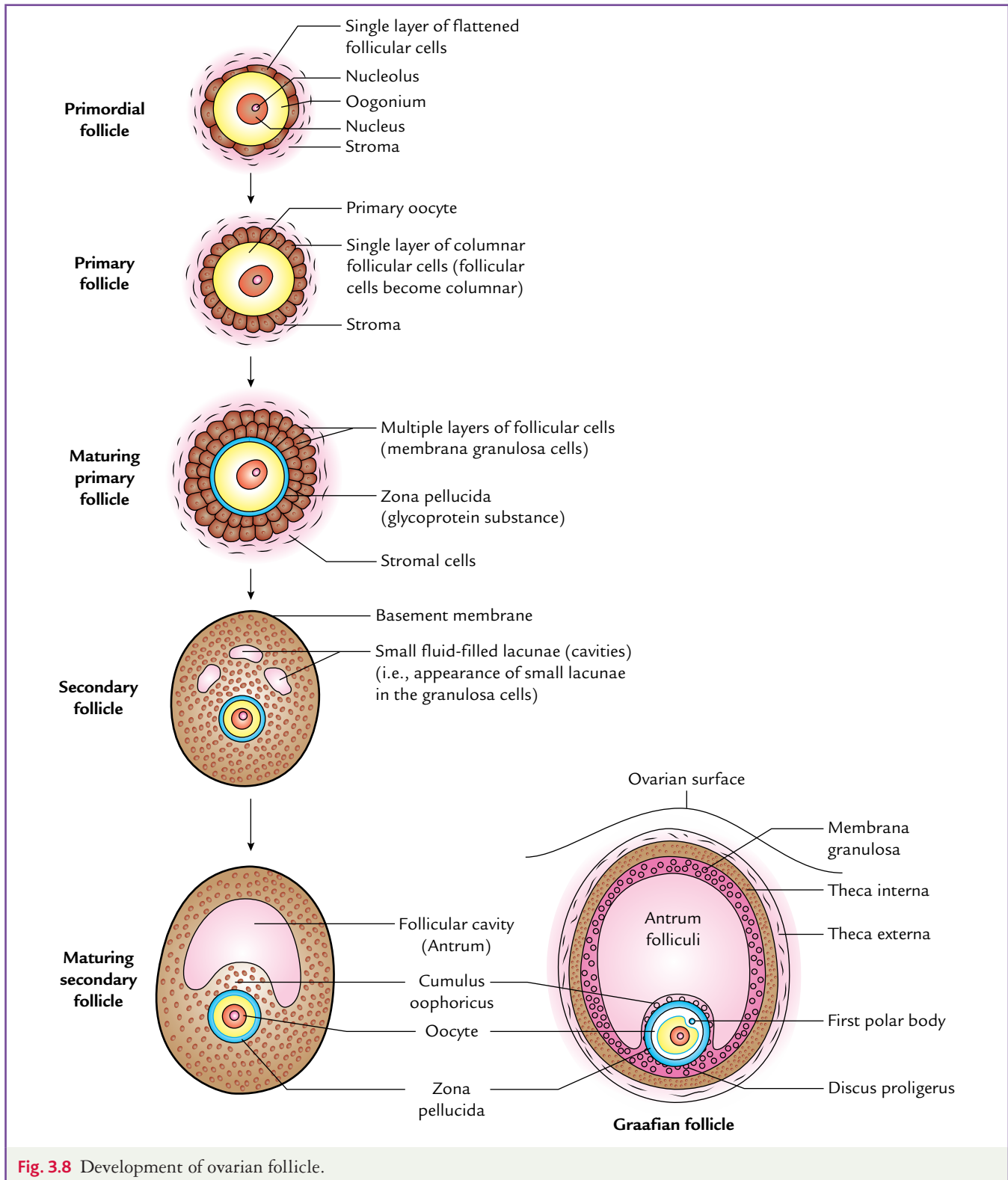
Flowchart 3.2 Steps of oogenesis.

Table 3.3 Differences between male and female gametes

Features	Sperm (male gamete)	Secondary oocyte (female gamete)
Size	Very small, about 2 μm	Very large, about 120 μm
Length	More	Less
Motility	Highly motile	Immotile
Amount of cytoplasm	Absent/very little cytoplasm	Large amount of cytoplasm
Types	Two types: (a) X-bearing sperms (22+X) and (b) Y-bearing sperms (22+Y)	Only one type (22+X)

are derived from stromal cells of ovary or from the surface epithelium of the ovary) to form the **primordial follicle**. The oogonium within the follicle contains single large nucleus with prominent eccentric nucleolus.

2. The flattened follicular cells become columnar and form the unilaminar **primary follicle**. The follicular cells proliferate to form several layers for the formation of **membrana granulosa**. The follicular cells are now called **granulosa cells**. The primary oocyte and its granulosa cells secrete a glycoprotein



substance that forms a thick homogeneous membrane between the granulosa cells and the primary oocyte. This membrane is termed **zona pellucida**. The granulosa cells rest on the basement membrane that separates these cells from the surrounding stromal cells. This is called **multilaminar (maturing) primary follicle**.

3. The small fluid-filled cavities appear between the follicular cells. These cavities fuse together to form a large cavity—the antral cavity/antrum and the follicle is termed **secondary (vesicular) follicle**.
4. The antrum gradually increases in size and pushes the oocyte towards one side of the follicle. The granulosa cells that surround the oocyte are called

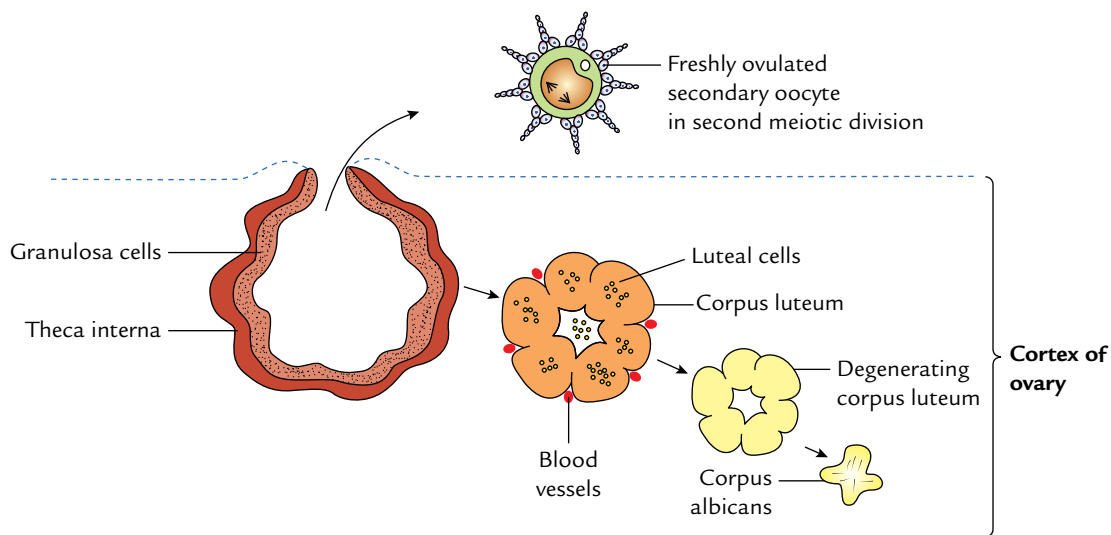


Fig. 3.9 Ovulation and formation of corpus luteum.

cumulus oophoricus (or cumulus ovaricus) and those that attach the oocyte to the wall of the follicle are called **discus proligerus**.

As the follicle expands the stromal cells surrounding the granulosal cells become condensed to form a covering called theca interna (theca = covering). Outside the theca interna some fibrous tissues get condensed to form another covering of the follicle and is called theca externa. The ovarian follicle is now fully matured and is termed Graafian follicle.

N.B. Thecal gland: The cells of theca interna later secrete estrogen hormone and together they form the *thecal gland*.

B. Ovulation (Fig. 3.9): It is a process of shedding off an ovum from the ovary.

The Graafian follicle enlarges and becomes so big that it not only reaches the surface of the ovary but also forms a bulge on the surface of ovary. The theca and stroma on this side of follicle become very thin. An avascular area (**stigma**) appears in the most convex superficial position of the follicle and, at the same time, the cells of cumulus oophoricus become loosened by the accumulation of intercellular fluid. Ultimately the follicle ruptures and the ovum is released from the cortex of the ovary (**ovulation**). The expelled secondary oocyte is surrounded by zona pellucida and one or more layers of follicular cells, which are radially arranged as **corona radiata**. It is picked up by fimbriated end of uterine tube and put into the lumen of the uterine tube. The empty Graafian follicle is converted into the corpus luteum. If the ovum is not fertilized the corpus luteum lasts for 10–12 days, and for 2–3 months if the ovum is fertilized and pregnancy continues. The cells of Graafian follicle secrete the estrogen while the cells of corpus luteum secrete the progesterone.

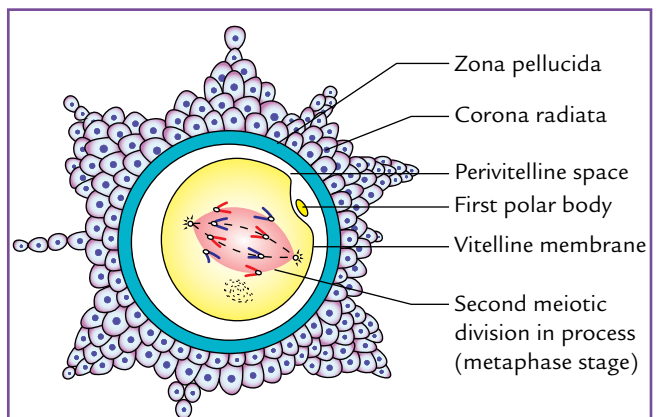


Fig. 3.10 Structure of an ovum (female gamete).

Structure of the Female Gamete (Secondary Oocyte) (Fig. 3.10)

The secondary oocyte is a very large cell and measures more than 100 μm in diameter. The structure of secondary oocyte shed from the ovary is as follows:

1. It undergoes a second meiotic division to shed off the second polar body.
2. No nucleus is seen as nuclear membrane dissolves for second meiotic division. Spindle and chromosomes attached on it in the equatorial plane (metaphase stage) are seen.
3. It is surrounded by the zona pellucida, which in turn is surrounded by the cells of corona radiata.
4. A distinct space is present between the cell membrane called **vitelline membrane** and zona pellucida. It is termed **perivitelline space**. It contains first polar body when it was derived from the ovum during the first meiotic division.

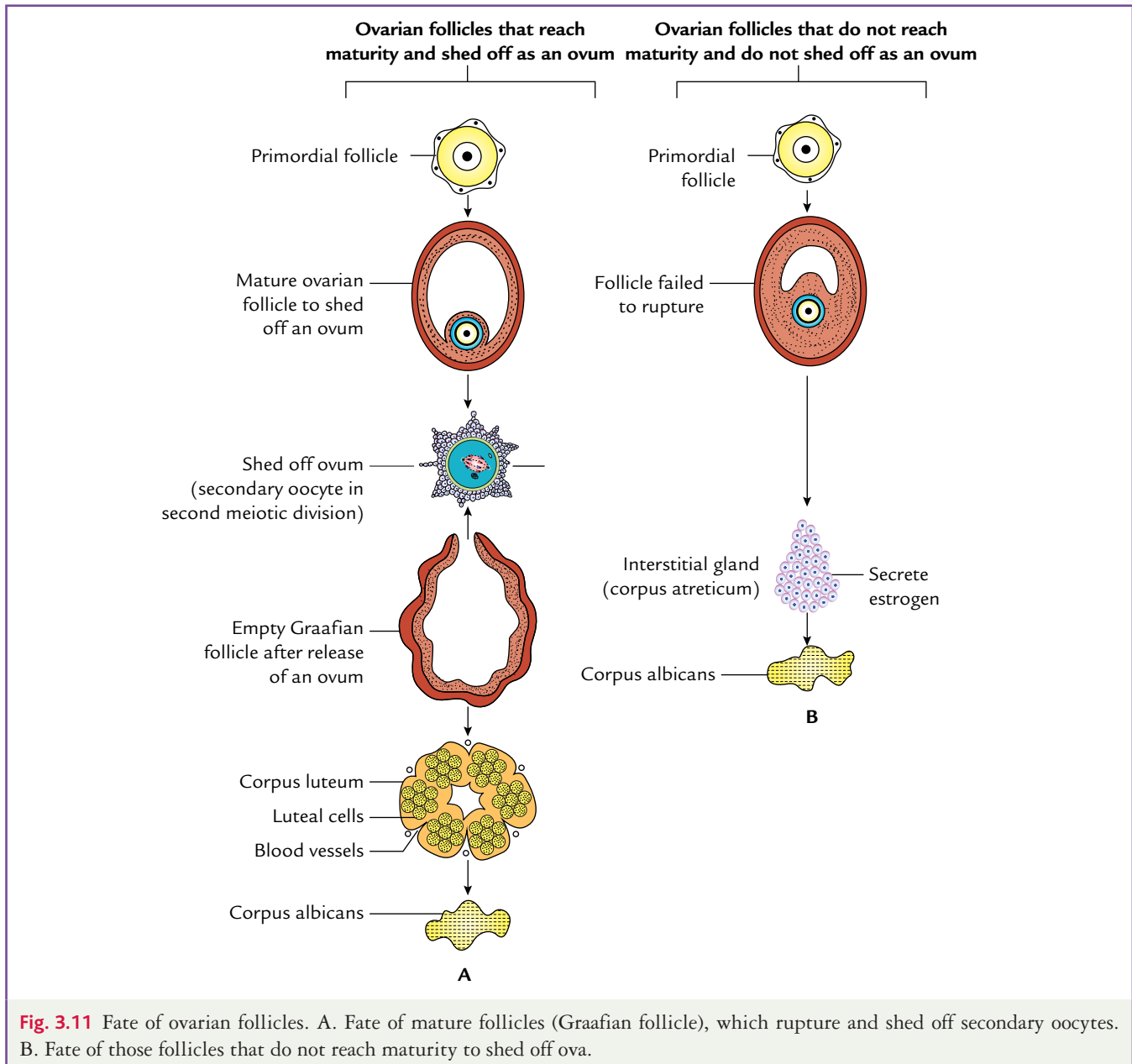


Fig. 3.11 Fate of ovarian follicles. A. Fate of mature follicles (Graafian follicle), which rupture and shed off secondary oocytes. B. Fate of those follicles that do not reach maturity to shed off ova.

Corpus Luteum

After ovulation the wall of the ruptured follicle (consisting of granulosa cells and cells of theca interna) collapses and gets transformed into a glandular structure known as **corpus luteum**. Under the influence of LH (secreted by the pituitary gland), the yellowish pigment develops in the cells of corpus luteum, which are now called **lutein/luteal cells**. These cells secrete **progesterone** and some estrogen. Under the influence of progesterone together with some estrogen, the uterine endometrium enters into secretory phase in preparation for the implantation of embryo.

The corpus luteum lasts only for 10–14 days if pregnancy does not occur. Thereafter it degenerates and is gradually transformed into a mass of fibrous tissue called **corpus albicans** (white body). This corpus luteum is called the **corpus luteum of menstruation**.

The corpus luteum persists for 3–4 months if the ovum is fertilized (i.e., pregnancy occurs) under the influence of HCG secreted by the trophoblast of embedded blastocyst in the endometrium. It is called the **corpus luteum of pregnancy**. Progesterone secreted by the corpus luteum maintains the pregnancy for initial 3–4 months and thereafter the pregnancy is maintained by progesterone secreted by the **placenta**.

Fate of Ovarian Follicles (Fig. 3.11)

In each ovarian cycle, a number of ovarian follicles begin to develop but only one reaches maturity. The fate of ovarian follicles is as under:

1. One that reaches maturity, ruptures and sheds off a secondary oocyte. The wall of empty follicle collapses to form corpus luteum (vide supra).

2. The follicles that fail to reach maturity, contrary to what one might expect, do not persist in the next ovarian cycle. They undergo degeneration. The oocyte and granulosa cells of each follicle disappear. However, the cells of theca interna proliferate to form **interstitial gland (corpora atretica)**. These glands secrete estrogen for some period of time and then degenerate to form a mass of fibrous tissue similar to the corpus albicans.

Clinical Correlation

The occurrence of abnormal oocyte is rare as compared to sperms. The various types of abnormalities of oocyte are:

1. Oocytes may be binucleated or trinucleated. Although such oocytes may give rise to twins or triplets, but they usually degenerate before reaching the maturity.
2. Oocytes with abnormal chromosomal contents. It may occur due to nondisjunction of chromosomes in meiosis I or meiosis II. The abnormal oocyte instead of having 23 chromosomes may contain 24 chromosomes or 22 chromosomes.

If oocyte with 24 chromosomes is fertilized by a normal sperm (23 chromosomes), a zygote with 47 chromosomes is produced (i.e., trisomy). The **trisomy 21** or **Down's syndrome** is most common type of trisomy. Similarly, if an ovum with 22 chromosomes is fertilized by a normal sperm (23 chromosomes), a zygote with 45 chromosomes will be produced, i.e., **monosomy**, e.g., **Turner's syndrome** (45, X0). For details see Chapter 25.

GOLDEN FACTS TO REMEMBER

- | | |
|---|--|
| ➤ Largest germ cells in the seminiferous tubules | Primary spermatocytes |
| ➤ Secondary oocyte completes its second meiotic division | Soon after fertilization |
| ➤ Usual period of viability of sperm after ejaculation | 48 hours (but may service up to 4 days in female genital tract) |
| ➤ Usual period of viability of an unfertilized secondary oocyte is | 24 hours (but may service up to 2 days) |
| ➤ Three oocyte barriers are | (a) Corona radiata
(b) Zona pellucida
(c) Vitelline membrane |
| ➤ Number of spermatozoa formed from one primary spermatocyte | 4 |
| ➤ Number of secondary oocyte formed from one primary oocyte | 1 |
| ➤ A person is likely to be sterile if number of healthy sperms per ml is less than | 10 million |
| ➤ Number of ovarian follicles that undergo ovulation during entire reproductive life of a woman (i.e., 12–50 years) | 400–500 |
| ➤ Number of ovarian follicles present at puberty | 40,000 |
| ➤ Number of primary oocytes that get matured and complete their first meiotic division before ovulation | 5–30 |
| ➤ Total period required for the process of spermatogenesis | 60 days |
| ➤ State of secondary oocyte at the time of ovulation | In the state of metaphase of second meiotic division |

CLINICAL PROBLEMS

1. During evaluation of male fertility an analysis of semen is made. Why?
2. Is it possible to have a baby of desired sex?
3. What is the **safe period** of the menstrual cycle? Give the embryological/anatomical basis.
4. Give the embryological basis of high incidence of chromosomal abnormalities in the offsprings of women who marry late?
5. Can the offsprings of men who marry late be affected?

CLINICAL PROBLEM SOLUTIONS

1. The analysis of semen is done: (a) to count the number of sperm per ml of semen, (b) to see morphological abnormality, and (c) to see motility of sperm. The knowledge of the above facts is essential to clinicians because a man with less than 10 million sperm per ml of semen is likely to be sterile, especially when specimen contains immotile and abnormal sperms.
2. Yes, it is possible now-a-days.
The sperms are of two types: **X-bearing sperms (gynosperms)** and **Y-bearing sperms (androsperms)**. When an ovum (X) is fertilized by a Y-bearing sperm the offspring will be a **baby boy** and if an ovum (X) is fertilized by an X-bearing sperm the offspring will be a **baby girl**.
Various **in vitro techniques** are now used to separate X and Y sperms using:
 - (a) Difference in swimming abilities of X- and Y-bearing sperms.
 - (b) Different speeds of migration of sperms. The Y-bearing sperms move faster than X-bearing sperms.
 - (c) Difference in the appearance of X- and Y-bearing sperms. The Y-bearing sperms are long and thin while X-bearing sperms are short and thick.
 - (d) Difference in DNA content of X- and Y-bearing sperms. The DNA content is 2.8% more in X-bearing sperm than that in Y-bearing sperm.

N.B. Thus, the use of a selected sperm sample in artificial insemination may produce a baby of desired sex.

There is also a claim that the couple can choose the sex of their child, if they can manage the following things:

 - (a) If the sexual intercourse is done on day of ovulation, i.e., 14th day (counted backwardly from the first day of the next menstrual cycle) ± 1 day.
 - (b) If the sexual intercourse is done after female takes an alkaline douche.
 - (c) If the frequency of sexual intercourse is reduced as much as possible.
3. The ovulation occurs on the 14th day of the menstrual cycle before the start of the next menstruation with variation of ± 1 day. The 14th day is counted backwardly from the last day of the menstrual cycle. The viability of sperm is not more than 2–3 days and viability of ovum is only 24 hours. Keeping all these factors in mind if coitus (intercourse) is avoided for 1 week between 11th and 17th day the pregnancy can be avoided. Barring this week the rest of the period of the menstrual cycle is termed **safe period**.
4. The commonest cause of abnormal chromosome number in a gamete is the nondisjunction during meiosis I or II.
Prolonged dormancy of primary oocytes may be the reason for the high incidence of chromosomal abnormalities in offsprings of older women. Remember primary oocytes are formed by the fifth month of intrauterine life. The primary oocyte enters the prophase of first meiotic division before birth, but this division is arrested till puberty. At puberty, the primary oocyte reassumes first meiotic division, which is completed just before ovulation.
The secondary oocyte enters the first meiotic division at the time of ovulation, but gets completed only if it is fertilized. The **Trisomy 21 (Down's syndrome)** is the most common chromosomal abnormality in offsprings born to women older than 35 years.
5. Yes. An increased incidence of achondroplasia (a congenital skeletal anomaly due to disturbance of endochondral ossification at the epiphyseal plate, particularly of long bones during fetal life) is associated with paternal age. The achondroplasia is the common cause of **dwarfism** (shortness of stature).

4

Fertilization and Formation of Germ Layers

Fertilization

Overview

The **fertilization** is the process of fusion of male and female gametes (pronuclei) to form a zygote. It takes place within 24 hours of ovulation, in the most dilated part of the uterine tube—the **ampulla**. The results of fertilization are: (a) determination of genetic sex of embryo, (b) restoration of diploid number of chromosomes, and (c) initiation of cleavage. The fertilization is essential for propagation of species and their evolution.

For a proper understanding, fertilization is described under the following headings: approximation of gametes, fusion of gametes, and results of fertilization.

Approximation of Gametes (Fig. 4.1)

During coitus (sexual intercourse), a male ejaculates about 200–300 million sperm into the female's vagina. This high number is needed because of the high rate

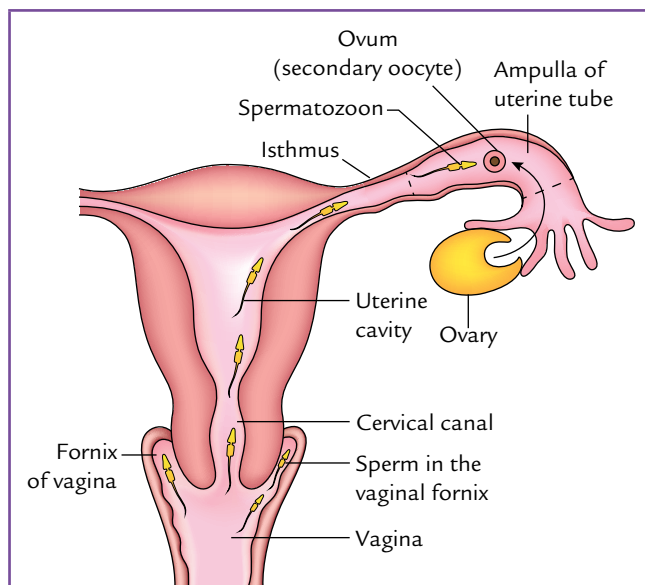


Fig. 4.1 Paths taken by male and female gametes (i.e., spermatozoon and ovum) to approximate each other in the ampulla of the uterine tube.

of sperm mortality in the female genital tract. Only 200–300 sperm survive (i.e., only hundreds out of millions) to contact the female gamete—the secondary oocyte in the uterine tube.

The journey of sperm from the vagina to the ampulla of uterine tube is promoted by prostaglandins present in the semen. The prostaglandins cause powerful contraction of uterine muscle, which is substantiated by oxytocin released by neurohypophysis. Uterine contractions create a negative pressure in the uterine cavity. Consequently the sperm are sucked in from the vagina into the uterine cavity. The movement of sperm from the cervix to the isthmus of the uterine tube occurs primarily by their own propulsive action, and to some extent it is also assisted by fluid currents created by uterine cilia. It takes about 2–7 hours for the sperm to reach from the cervix to the isthmus of the tube; there they become less motile and stop migrating.

After **ovulation**, the oocyte reaches the ampullary region of the tube due to movements of cilia and contraction of the smooth muscle of the uterine tube.

The sperm again become motile due to **chemoattractants** produced by cumulus cells surrounding the oocyte and swim to the ampulla for fertilization. Majority of sperm dies within 24 hours.

Before fertilization, the sperm must gain the ability to disintegrate the various oocyte barriers. These barriers of an oocyte are:

1. **First barrier** is formed by cells of *corona radiata*.
2. **Second barrier** is formed by *zona pellucida* made of glycoproteins, ZP1, ZP2, and ZP3.
3. **Third barrier** is formed by *vitelline membrane* of oocyte itself.

This ability is achieved by two processes: (a) **capacitation** and (b) **acrosome reaction**.

Capacitation

It is a process of conditioning of sperm in the female genital tract; it lasts about 7 hours. During capacitation, the glycoprotein coat and seminal plasma proteins covering the plasma membrane of sperm in the acrosomal

region are removed. Only capacitated sperm undergoes acrosome reaction and fertilizes the ovum.

Acrosome Reaction

It occurs when capacitated sperm comes in contact with the zona pellucida (i.e., acrosome reaction is induced by zona proteins). The acrosomal reaction leads to release of enzymes from acrosomal cap such as **hyaluronidase** and **acrosin**. The antigenic coating of the sperm initiates an immunological reaction between the **oocyte's fertilizin** and the **sperm's antifertilizin**.

Clinical Correlation

It is now confirmed by experiments that the freshly ejaculated sperms are infertile and must be in the female genital tract for at least 7 hours before they can fertilize a secondary oocyte. During in vitro fertilization, the capacitation of sperms is induced artificially by treating the ejaculate with a solution consisting of γ -globulin, free serum, follicular fluid, dextran, serum dialysate, and adrenal gland extract.

Steps/Phases of Fertilization (Fig. 4.2)

The fusion of pronuclei of male and female gametes involves a sequence of coordinated events. These events are as follows.

1. **Penetration of corona radiata:** The capacitated sperm can freely penetrate through the corona radiata to reach the zone pellucida by the movements of its tail.
2. **Penetration of zona pellucida:** The head of the sperm is capped by an organelle called **acrosome**. The acrosome contains a trypsin-like protein digesting enzyme and hyaluronidase, which digests the hyaluronic acid—an important constituent of the connective tissue. When the head of sperm comes in contact with zona pellucida, an **acrosome reaction** is induced by the zona proteins. The acrosome releases digestive enzymes (acrosin and pepsin-like substances), which cause lysis of the zona pellucida and plasma membrane around the head of the sperm. This allows sperm to penetrate through the zona pellucida and reach into the perivitelline space. Once the sperm penetrates the zona pellucida a change in the properties of zona pellucida (**zona reaction**) occurs that makes it impermeable to other sperms.
3. **Fusion of sperm and oocyte cell membranes:** The plasma membranes of sperm and oocyte come in contact and breakdown at the site of fusion. The head and tail of sperm enter the cytoplasm of the oocyte but its plasma membrane and mitochondrial sheath are left behind on the oocyte surface.

As soon as the sperm enters the oocyte a **calcium wave** appears in the cytoplasm of oocyte that makes oocyte membrane impermeable to other sperms.

N.B. The **polyspermy** is prevented by vitelline membrane and zona pellucida by not allowing the entry to more than one sperms (vide supra).

4. **Completion of second meiotic division of oocyte and formation of female pronucleus:** The penetration of oocyte by the sperm activates the oocyte to complete its **second meiotic division**. The two cells are produced—one cell containing all the cytoplasm called **mature oocyte** and second cell containing hardly any cytoplasm called **second polar body**.

The maternal chromosomes (22+X) of mature oocyte condense and arrange themselves in a vesicular pattern to form the **female pronucleus**.

5. **Formation of male pronucleus:** The sperms move forward to come in close contact with the **female pronucleus**. Its nucleus becomes swollen and forms the **male pronucleus**. The tail detaches and degenerates. Morphologically, the male and female pronuclei are indistinguishable. Each chromosome in male and female pronuclei is made up of only one chromatid. The pronuclei (both haploid) grow and replicate their DNA, i.e., change from haploid (n) to diploid ($2n$). Now each chromosome in male and female pronuclei consists of two chromatids. The oocyte containing two haploid nuclei is called **ootid**.
6. **Formation of zygote:** The male and female pronuclei lose their cell membrane and chromosomes of two nuclei (23 in each) mix together to form diploid (i.e., 46 chromosomes). The ootid becomes a zygote. The chromosomes in zygote become arranged on a cleavage spindle in preparation for cleavage of zygote. The chromosomes split longitudinally at the centriole and sister chromatids move to the opposite poles providing each cell of the zygote with a normal diploid number of chromosomes and DNA. As the sister chromatids move to the opposite poles, a furrow appears on the surface of the cell and two cells are formed.

Results of Fertilization

When the oocyte is fertilized by the sperm a life of new individual begins. The main results of fertilization are as follows.

1. **Completion of second meiotic division of the female gamete (i.e., secondary oocyte):** As soon

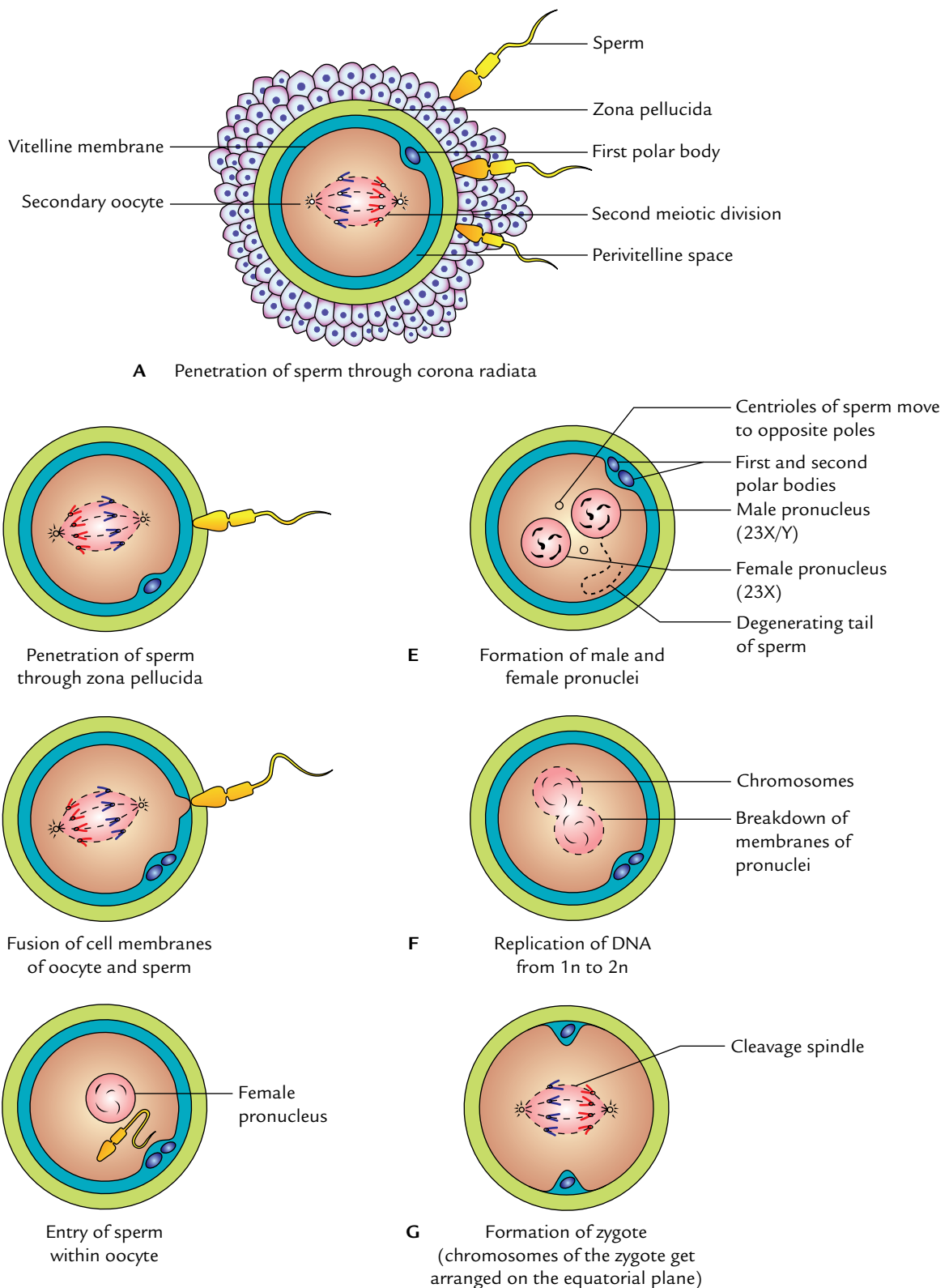


Fig. 4.2 Steps/phases of fertilization and formation of the zygote.

as the sperm enters into the secondary oocyte the latter completes its second meiotic division and extrudes the second polar body into the perivitelline space.

- 2. Restoration of diploid number of chromosomes:** The male and female pronuclei (both haploid) fuse

with each other to restore normal diploid number of chromosomes.

- 3. Determination of chromosomal sex of the new individual:** The oocytes are only of one type, i.e., they contain only 'X' chromosomes whereas the

sperms are of two types: (a) 'Y'-bearing sperms (androsperms) and (b) 'X'-bearing sperms (gynosperms). If an oocyte (X) is fertilized by 'Y'-bearing sperm the result will be a **male baby** and if an oocyte is fertilized by an 'X'-bearing sperm the result will be a **female baby**. *Therefore, it is the father who is responsible for determination of the sex of the baby and not the mother.*

- Initiation of cleavage:** After fertilization, the zygote undergoes a series of rapid mitotic divisions. This is called **cleavage**.
- Variation of human species:** It occurs due to mingling of maternal and paternal chromosomal complements of two new species. If the ovum of one species, viz., Tiger is fertilized by the sperm of other species, viz., Lion, the baby born will be called **Liger**. Similarly, if the ovum of female donkey is fertilized by the sperm of horse the baby born will be called **mule**.

Clinical Correlation

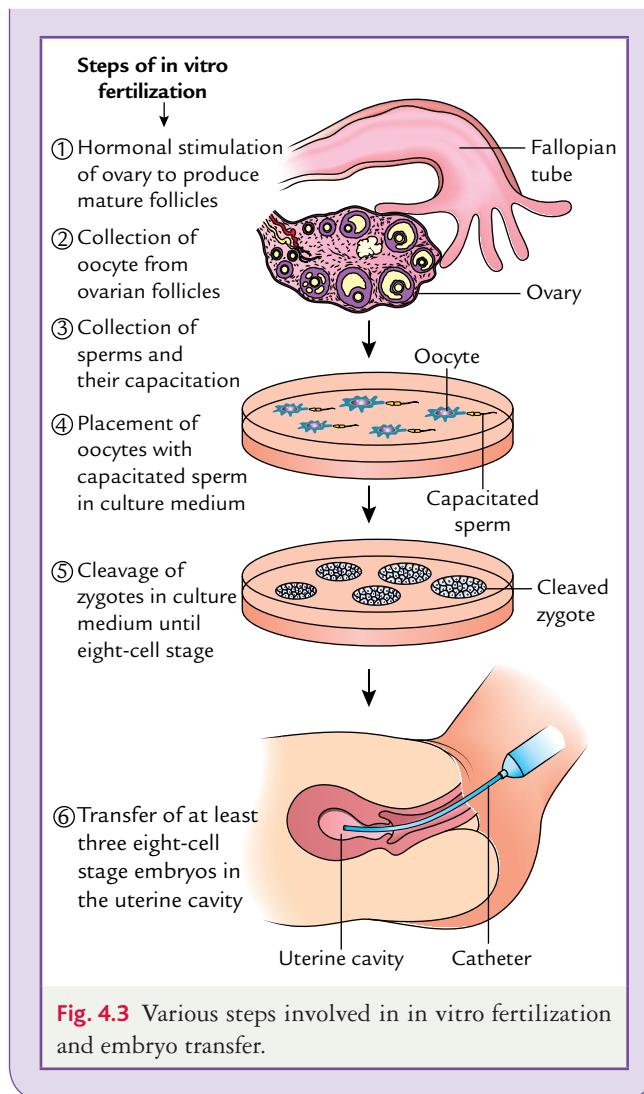
In vitro fertilization (IVF): The IVF is now a common procedure used in various laboratories to help the parent where normal pregnancy is not possible due to tubal occlusion.

The following techniques are used in a sequential manner for IVF and embryo transfer (Fig. 4.3).

- The follicular growth in the ovary is stimulated by administration of gonadotrophins/clomiphene citrate.
- Several mature oocytes are collected by needle aspiration from ovarian follicles by laparoscopy or with the assistance of ultrasound visualization.
- The ejaculate is collected by masturbation, and the sperms are separated from the seminal fluid and capacitated artificially by exposure to ionic solution (see Clinical Correlation on page 35).
- The oocytes are placed in the culture medium and capacitated sperms are added immediately (i.e., oocytes and sperms are cultured together).
- The cleavage is allowed to proceed in vitro till the eight-cell stage of the embryo.
- At least three eight-cell stage embryos are transferred into the uterus to develop to full-term fetus. At least three embryos are placed in the uterus because of the low success rate of implantation. The remaining embryos are frozen for further use in case the first attempt of IVF fails to cause pregnancy.

N.B. IVF of oocytes and transfer of cleaving zygotes into the uterus have provided an opportunity for many women who are sterile due to tubal occlusion.

Surrogate mothers: Some women have normal ovaries and produce mature oocytes but are unable to become pregnant due to agenesis of the uterus or hysterectomy. In such cases, IVF may be performed and the embryos are transferred to another woman's uterus (after pretreatment with progesterone) for development and delivery.



Cleavage and Blastocyst Formation

Cleavage (Fig. 4.4)

The cleavage consists of repeated mitotic divisions of the zygote into smaller units. This results in a rapid increase in the number of cells. These cells are called **blastomeres**. They become smaller with each successive cleavage division. The division of zygote starts just after fertilization and continues as the zygote passes along the uterine tube. During cleavage the zygote is surrounded by a rather thick zona pellucida.

The zygote divides to form two cells of which one is smaller than the other (**two-cell stage of embryo**). The larger cell divides first giving rise to **three-cell stage**. The smaller cell divides next and embryo consists of four cells that divide to form eight cells. The 8 cells further divide to form 16 cells.

A **16-cell stage embryo** resembles a mulberry fruit and is termed **morula**. In **morula**, the **blastomeres** are very small and contain very little cytoplasm to survive.

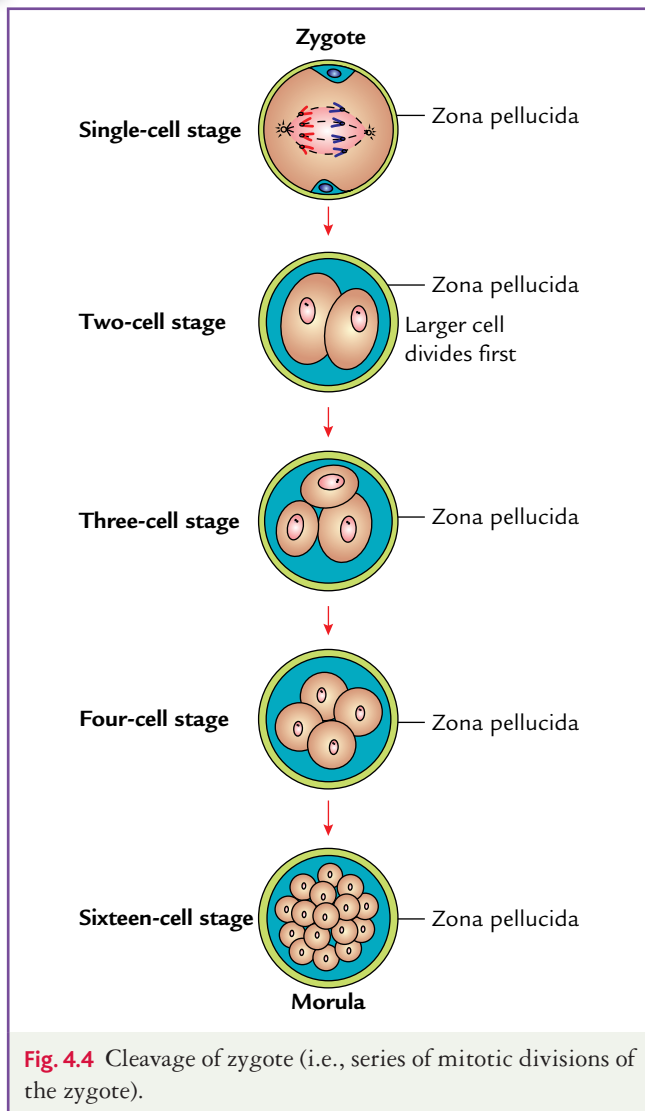


Fig. 4.4 Cleavage of zygote (i.e., series of mitotic divisions of the zygote).

The blastomeres are enclosed by the zona pellucida. The cells now get arranged into two groups: (a) a group of cells in the center of morula is called **inner cell mass (embryoblast)** and those that are present at the periphery of morula are called outer cell mass (**trophoblast**).

Blastocyst Formation (Fig. 4.5)

The morula enters into the uterine cavity. The endometrial fluid penetrates the zona pellucida and enters into the intercellular spaces of the morula. Gradually the intercellular spaces become confluent and finally a single large cavity is formed. This cavity is called **blastocoel** and at this stage the embryo is called **blastocyst**. The **blastocoel** is filled with fluid rich in nutrients, which is secreted by the endometrium of the uterus. This fluid is also termed **uterine milk**.

As the cavity enlarges the outer cells forming trophoblast become flattened. The inner cell mass called **embryoblast** becomes compact and is attached to the trophoblast at one pole—the **embryonic pole**.

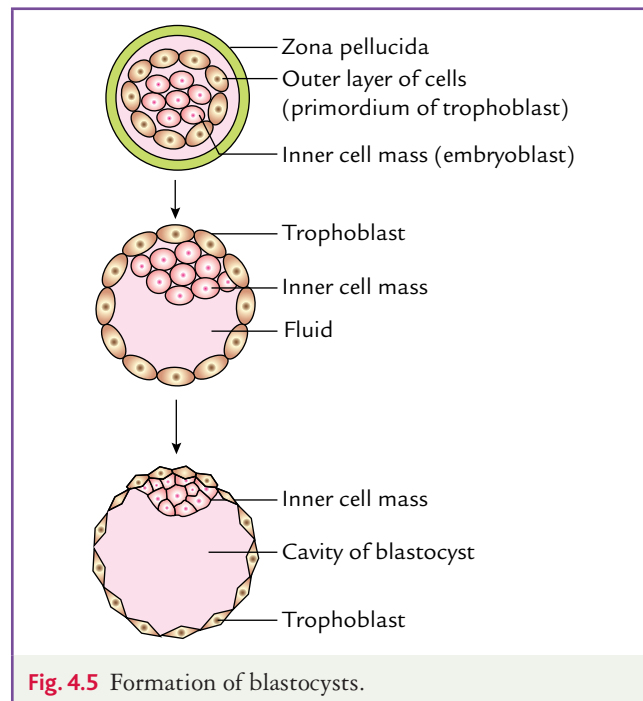


Fig. 4.5 Formation of blastocysts.

The resultant whole structure is now called **blastocyst**. The **embryoblast** gives rise to the **embryo** and the **trophoblast** provides **nutrition** to the **embryo**.

The blastocyst enlarges in size and the zona pellucida disappears. Now the blastocyst becomes ready for implantation.

N.B. Role of zona pellucida: The trophoblast has a strong tendency to stick with the endothelium to which it comes in contact with. The zona pellucida prevents the sticking of the trophoblast with the endothelium during the journey of fertilized oocyte from ampullary region of the uterine tube to the uterine cavity. The most important function of zona pellucida is to prevent implantation of the blastocyst at sites other than the normal, thus preventing **ectopic pregnancy**.

Clinical Correlation

Hydatidiform mole: The abnormalities of blastocyst are common. A blighted blastocyst leads to death of the embryo. This is followed by an excessive (hyperplasia) proliferation of trophoblast to form a vesicular or polycystic mass called **hydatidiform mole**. Actually when the embryo dies, the developing villi could not develop further (e.g., tertiary villi) due to lack of blood supply. They start degenerating and cystic swellings develop in degenerating villi. Moles secrete higher level of human chorionic gonadotrophins (HCG). The clinical features of hydatidiform mole are:

- ◆ Preeclampsia during the first trimester
- ◆ Elevated levels of HCG (> 100,000 mIU/ml)
- ◆ Enlarged uterus and bleeding
- ◆ Hydatidiform mole resembles a **bunch of grapes**
- ◆ Presence of vesicles in urine
- ◆ No fetal movements
- ◆ No fetal heart sounds
- ◆ Ultrasound reveals **snowstorm appearance** of the uterine cavity

N.B.

- Around 3–5% of hydatidiform moles undergo malignant change forming **choriocarcinoma**.
- There are two types of hydatidiform mole: (a) complete type in which there is no existence of embryo at all and (b) partial type in which part of the embryo is seen.
- Majority of hydatidiform moles are monospermic, i.e., an empty oocyte having no female pronucleus is fertilized by a single sperm.

Formation of Germ Layers

Overview

During the third week, the embryoblast acquires the form of a disc and becomes trilaminar (i.e., consists of three layers). From superficial to deep these layers are: ectoderm, mesoderm, and endoderm.

It is utmost important for the student to understand the formation of three germ layers from embryoblast because all the tissues and organs of the body are derived from one or more of these layers.

Gastrulation

The gastrulation is the most characteristic event occurring during the third week of gestation because it forms the three germ layers that form all the tissues and organs of the body. The process of formation of three germ layers is called **gastrulation**.

The three germ layers are formed as follows.

1. First, the embryoblast differentiates into two layers: (a) a superficial layer consisting of flat cells called **endoderm** and (b) deep layer consisting of columnar cells called **ectoderm**. The embryo at this stage is termed **bilaminar embryonic disc**.
 2. Now the ectoderm forms a linear thickening in the midline of embryonic disc called **primitive streak**. The primitive streak gives rise to third layer—the **mesoderm**—that lies between ectoderm and endoderm. The embryo at this stage is called **trilaminar embryonic disc**. During the formation of the three germ layers other embryonic structures also develop. The details of formation of three germ layers along with other embryonic structures are described in the following text.
- (a) **Formation of bilaminar embryonic disc (Fig. 4.6)**
- First, the cells of the inner cell mass towards the cavity of blastocyst become flattened and get arranged in a single layer. This layer is called the **endoderm**. The remaining cells of inner cell mass then become columnar to form another layer called the **ectoderm**. The embryo at this

stage is in the form of a disc having two layers and is termed **bilaminar embryonic disc**.

(b) **Formation of amniotic cavity and primary yolk sac (Fig. 4.6)**

- A small cavity appears between the ectoderm and trophoblast forming the **amniotic cavity**. Few cells of trophoblast delaminate and form the roof of the amniotic cavity. The cells derived from trophoblast are called **angiogenic cells** and secrete amniotic fluid within the amniotic cavity.
- The cells of the endoderm proliferate and line the cavity of blastocyst. The cavity of blastocyst/blastocoele is now called **primary yolk sac**. The flattened cells lining the primary yolk sac form the **Heuser's membrane**.

Note: Now the bilaminar embryonic disc lies between the amniotic cavity above it and primary yolk sac below it.

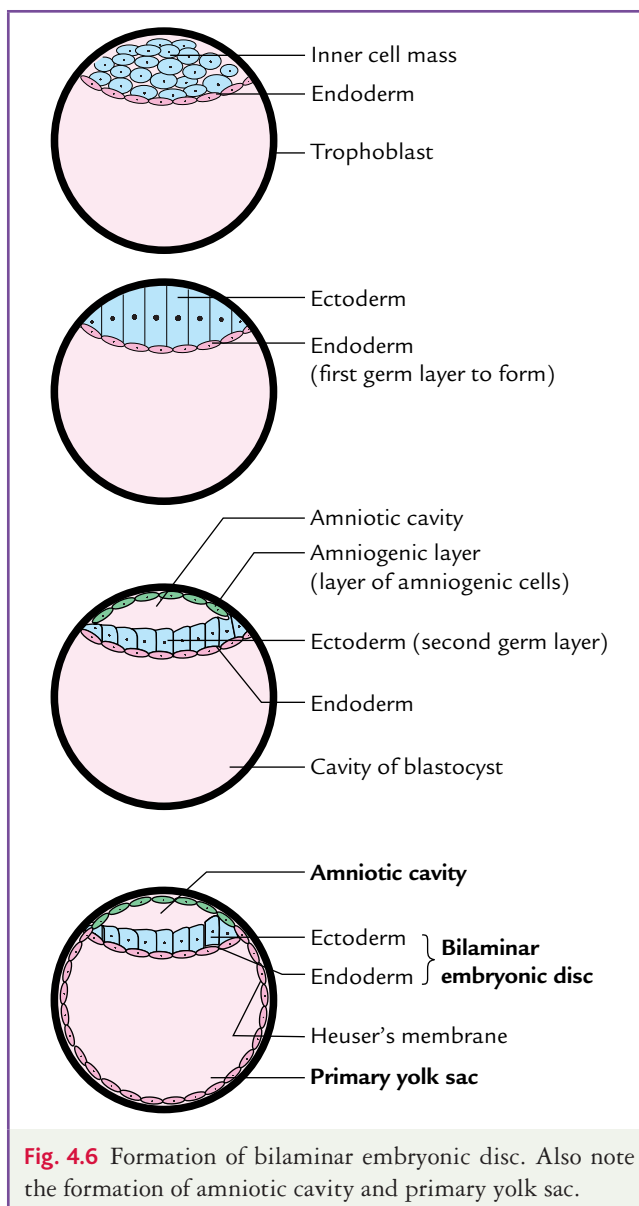


Fig. 4.6 Formation of bilaminar embryonic disc. Also note the formation of amniotic cavity and primary yolk sac.

(c) **Formation of extraembryonic mesoderm, extraembryonic celom, and connecting stalk (Fig. 4.7)**

- The cells of trophoblast give rise to a mass of cells that separate the amniotic cavity and primary yolk sac from the trophoblast. This cell mass is termed **extraembryonic mesoderm**. (According to some authorities **extraembryonic mesoderm** is derived from the cells lining the primary yolk sac.) The extraembryonic mesoderm is also termed **primary mesoderm**.
- The term extraembryonic mesoderm is so coined because this mesoderm lies outside the embryonic disc and does form tissues of the embryo itself.
- A number of small cavities appear in the extraembryonic mesoderm that later coalesce together to form **extraembryonic celom**. Due to development of **extraembryonic celom**, the primary yolk sac becomes smaller and is now termed **secondary yolk sac**.
- The extraembryonic celom does not extend into the cranial part of extraembryonic mesoderm that lies between amniotic cavity and trophoblast. This part of extraembryonic mesoderm forms the **connecting stalk**.
- Due to the formation of extraembryonic celom the extraembryonic mesoderm splits into two layers:
 - The part lining the trophoblast is called **somatopleuric layer of extraembryonic**

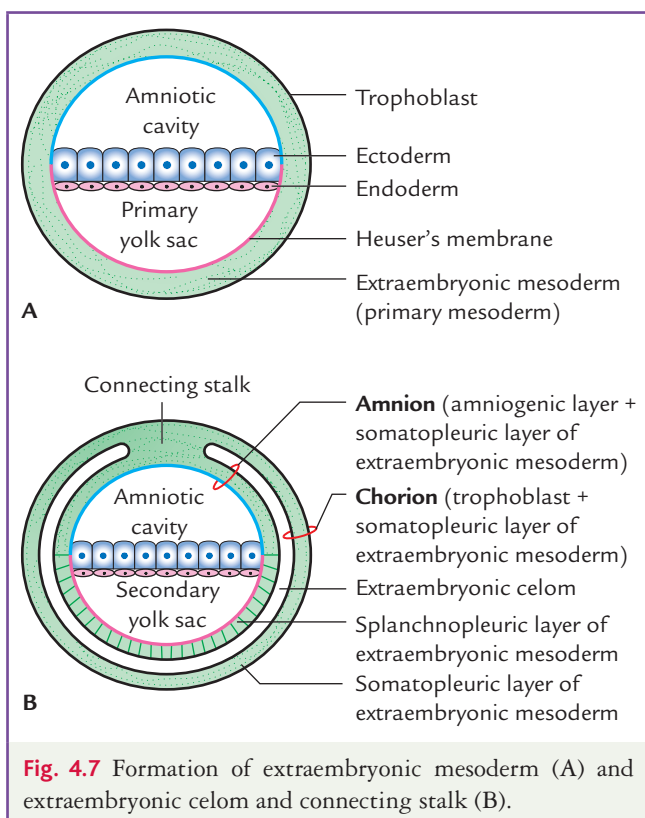


Fig. 4.7 Formation of extraembryonic mesoderm (A) and extraembryonic celom and connecting stalk (B).

mesoderm or parietal layer of the extraembryonic mesoderm.

- The part lining the yolk sac is called **splanchnopleuric layer of extraembryonic mesoderm** or **visceral layer of extraembryonic mesoderm**.

(d) **Formation of chorion and amnion:** The development of extraembryonic celom leads to the formation of two membranes: (i) chorion and (ii) amnion.

- **Chorion:** It consists of somatopleuric layer of extraembryonic mesoderm and trophoblast covering it.
- **Amnion:** It consists of roof of amniogenic layer consisting of amniogenic cells and somatopleuric layer of extraembryonic mesoderm covering it.

(e) **Formation of prochordal plate (Fig. 4.8):** At one end of the embryonic disc, a rounded area becomes thicker than the rest of the disc. This rounded area is termed **prochordal plate**.

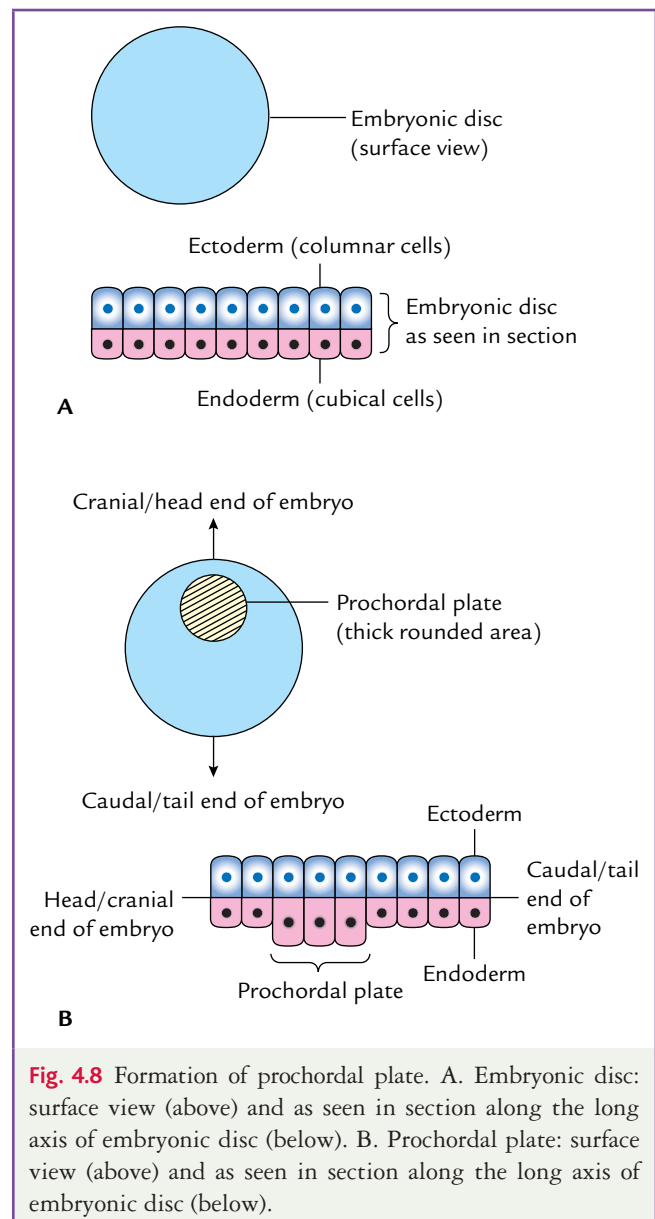


Fig. 4.8 Formation of prochordal plate. A. Embryonic disc: surface view (above) and as seen in section along the long axis of embryonic disc (below). B. Prochordal plate: surface view (above) and as seen in section along the long axis of embryonic disc (below).

- In the region of prochordal plate, the cuboidal endodermal cells become columnar.
 - With the development of prochordal plate, the cranial and caudal ends of the embryo are determined. The end at which the prochordal plate appears is called **cranial (head) end** and the other end is termed **caudal (tail) end**. The prochordal plate also determines the central axis of the embryo.
- (f) **Formation of primitive streak (Fig. 4.9):** At the beginning of the third week, a longitudinal ridge appears in the midline at the caudal end of the dorsal aspect of the bilaminar embryonic disc. This longitudinal ridge is called primitive streak. The **primitive streak** is visible on the dorsal aspect of the embryonic disc, i.e., towards the amniotic cavity as an opaque streak, hence the name primitive streak.
- It is formed due to proliferation of the ectodermal cells. The ectodermal cells proliferate and move towards the midline. In the midline, cells from both sides heap up to form an elevation called **primitive streak**.
- At the cranial end of the primitive streak, the cells proliferate and form a **rounded elevation** called **primitive node/primitive knot/Hensen's node**.
 - The embryonic disc elongates and becomes **pear shaped**. As a result of elongation of embryonic disc, the primitive streak also elongates along the central axis of the embryonic disc.
- (g) **Formation of notochord:** A depression appears in the center of Hensen's node called **blastopore**. A solid cord of cells grow cranially from the bottom of blastopore between the ectoderm and mesoderm up to the prochordal plate and form the **notochord** (for details see page 46).
- (h) **Formation of intraembryonic mesoderm (Fig. 4.9):** The cells of the primitive streak invaginate towards the endoderm forming a groove on its surface called **primitive groove**.
- From the bottom of this groove, the cells of the primitive streak spread in between the endoderm and ectoderm to form the **intraembryonic mesoderm—the third germ layer**.

Mode of spread of intraembryonic mesoderm: The *intraembryonic mesoderm* spreads in cranial, caudal, and

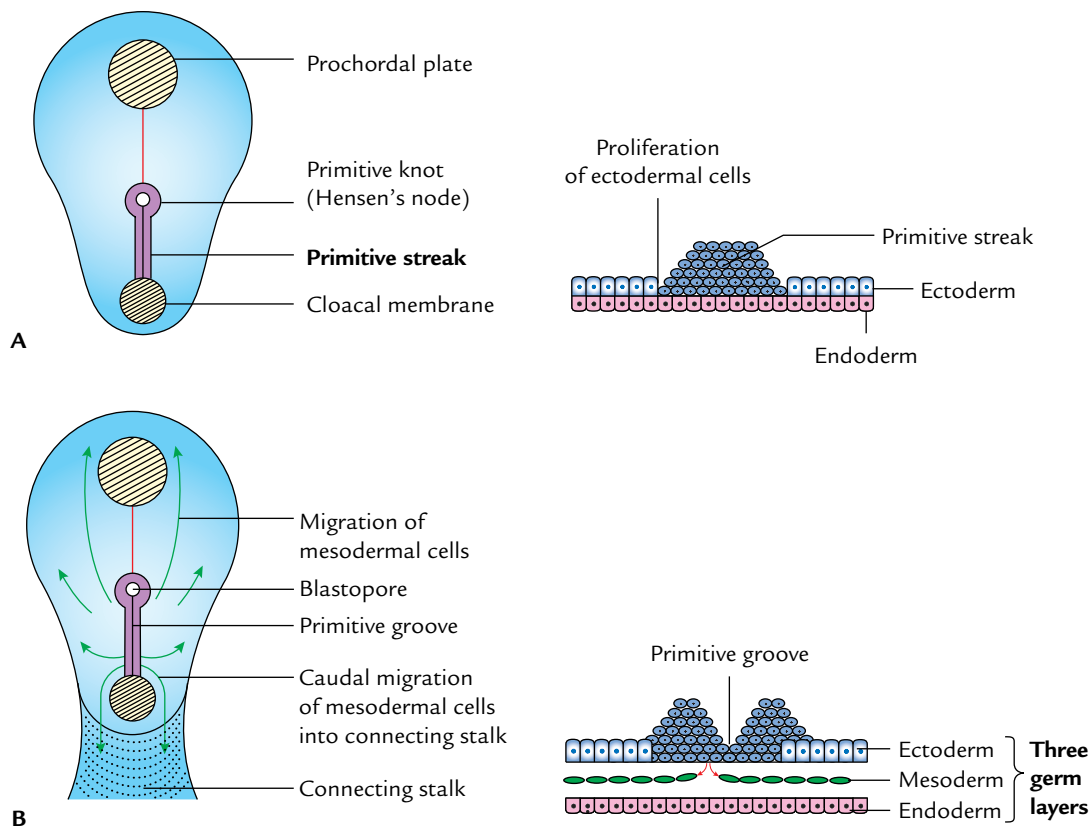
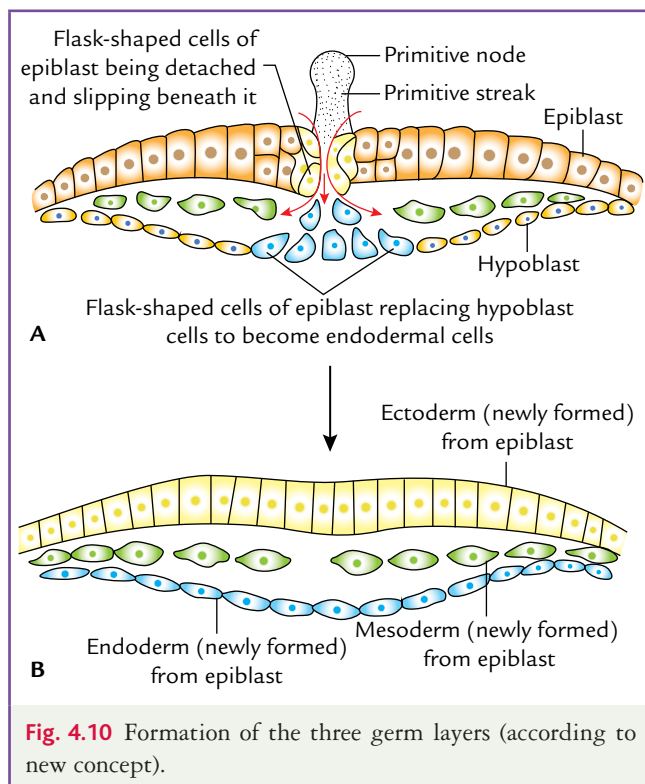


Fig. 4.9 Formation of intraembryonic mesoderm. A. Formation of primitive streak (surface view on the left) and as seen in transverse section of embryo on the right. B. Formation of primitive groove and migration of the cells of the primitive streak between the ectodermal and endodermal layers to form intraembryonic mesoderm (surface view) on the left and as seen in transverse section of embryo on the right.

lateral directions into all parts of the embryonic disc except in the following three regions.

- *Region of prochordal plate* where the ectoderm and endoderm are in firm contact with each other and form the **buccopharyngeal membrane**.
- *Region of cloacal membrane (circular area at the caudal end of the disc)*: Here also the ectoderm and endoderm are in an intimate contact with each other.
- *Region of notochord*: Midline between the prochordal plate and primitive knot; this area is occupied by the notochord.



N.B.

- Anterior to the prochordal plate the intraembryonic mesoderm of two sides is continuous with each other. The mesoderm in this area forms the **septum transversum**.
- As the embryonic disc enlarges and elongates, the connected stalk becomes smaller and comes to lie at the caudal end of the embryo.
- At the caudal end of the embryo, the intraembryonic mesoderm passes beyond the embryonic disc and becomes continuous with the mesoderm of the connecting stalk made up of extraembryonic mesoderm.

Current Concept of Formation of Three Germ Layers

According to the current concept, *all the three primary germ layers are derived from epiblast*. The details are as follows (Fig. 4.10):

1. The cells of embryoblast differentiate and arrange themselves into two layers: (a) a superficial layer of columnar cells called the **epiblast** and (b) a deep layer of flattened cells called the **hypoblast**. (Thus, embryoblast becomes a **bilaminar germ disc**.)
2. Cells of epiblast migrate towards the primitive streak. As they reach in the region of the primitive streak, they become flask shaped, detach themselves from the epiblast, and slip beneath it.

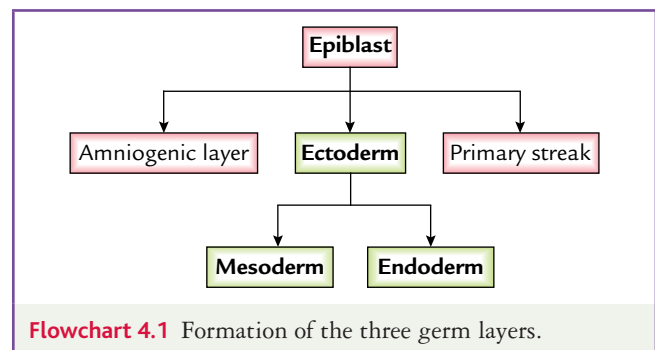


Table 4.1 Derivatives of the germ layers

Ectoderm	Mesoderm	Endoderm
<ul style="list-style-type: none"> • Epidermis of skin and its derivatives such as hair, nails, sweat, and sebaceous glands • Epithelial lining of: <ul style="list-style-type: none"> – Lower part of the anal canal – Distal part of the male urethra – Lower part of the vagina – External auditory meatus – Oral cavity – Nasal cavity • Lens of eye • Enamel of teeth • Adenohypophysis of the pituitary gland • Adrenal medulla • Nervous tissue and sense organs 	<ul style="list-style-type: none"> • Muscles: smooth, cardiac, and skeletal • Bones and cartilages • Connective tissue • Heart, blood vessels, and lymph vessels • Epithelial lining of blood vessels, lymph vessels, body cavities, and joint cavities • Spleen • Kidney and ureters • Adrenal cortex • Testes and ovaries 	<ul style="list-style-type: none"> • Epithelial lining of the gastrointestinal tract (GIT) <ul style="list-style-type: none"> – Respiratory tract – Urinary tract – Biliary tract – Auditory tube and middle ear cavity – Uterus and upper part of vagina • Liver (hepatocytes) • Pancreas (acinar and islet cells) • Thyroid (follicular cells) • Parathyroid (principle and oxyphil cells)

- The flask-shaped cells of epiblast move inward (invaginate) towards the hypoblast. Some of these cells replace the hypoblast cells to form the **endoderm** and others come to lie between the epiblast and the newly formed endoderm to form the **mesoderm**. The remaining cells of the epiblast now form the **ectoderm**. It is shown in Flowchart 4.1.

Derivatives of Three Germ Layers

The three germ layers are ectoderm, mesoderm, and endoderm. The structures derived from these layers are given in Table 4.1.

From Table 4.1 it is clear that the nervous system and sense organs are formed by the ectoderm; musculoskeletal

system, cardiovascular system, and most of the urogenital system are formed by the mesoderm; and lining of the gastrointestinal tract (GIT), respiratory tract, and urogenital tract is formed by the endoderm.

N.B. Morphological types of body constitution: It is believed by some authorities that dominance of one of the three primary germ layers in the embryonic life manifests in following three types of morphological constitutions of body in postnatal life.

- Ectomorphic:* If there is ectodermal dominance. These individuals are long and thin.
- Endomorphic:* If there is endodermal dominance. These individuals are short and thick/stout.
- Mesomorphic:* If there is mesodermal dominance. These individuals are well built, i.e., intermediate between the upper two types.

GOLDEN FACTS TO REMEMBER

- | | |
|--|---|
| ➤ Commonest site of fertilization | Ampulla of uterine tube |
| ➤ Most important function of zona pellucida | Prevention of implantation of blastocyst at unwanted/abnormal sites |
| ➤ Three barriers of oocytes | (a) Corona radiata
(b) Zona pellucida
(c) Vitelline membrane |
| ➤ Three glycoproteins forming zona pellucida | ZP1, ZP2, and ZP3 |
| ➤ Most of the hydatidiform moles are | Monospermic |
| ➤ Most characteristic event occurring during the third week of gestation | Gastrulation (process of formation of three germ layers, i.e., beginning of morphogenesis) |
| ➤ Three two of second week of embryonic development | (a) Trophoblast differentiates into two layers: cytotrophoblast and syncytiotrophoblast
(b) Embryoblast differentiates into two layers: ectoderm (epiblast) and endoderm (hypoblast)
(c) Extraembryonic mesoderm splits into two layers: somatopleure and splanchnopleure |
| ➤ First sign of gastrulation | Appearance of the primitive streak |

CLINICAL PROBLEMS

1. What are the primary causes of infertility in men and women?
2. The incidence of infertility has increased in the past few decades. What are the possible reasons?
3. A woman with bilateral tubal block but proper oogenesis is not able to conceive (i.e., become pregnant). She is prepared to go to any extent to have a child. What clinician will like to suggest to her?
4. Give the embryological basis of **pregnancy testing**.
5. What is **human chorionic gonadotrophin**? What is its clinical significance?
6. Why during growth of male and female pronuclei each pronucleus replicates its DNA?
7. What factors prevent polyspermy?
8. What is the embryological/anatomical basis of fertility control in males and females (i.e., family planning)?

CLINICAL PROBLEM SOLUTIONS

1. The term infertility means inability to conceive (i.e., become pregnant). The infertility occurs in about 20% of married couples. The major cause of infertility in women is the **blockage of uterine tubes** whereas the major cause of infertility in men is low sperm count (**oligospermia**).
2. This is probably because of the high incidence of pelvic inflammatory diseases (PID) in women due to poor hygiene. A good number of young working women miss their morning bath due to high demanding job duties. The PID may lead to blockage of uterine tubes. The possible cause of **oligospermia** in men in recent times is due to bearing of tight inner garments and jean pants, and keeping mobile phones in the pockets of their pants.
3. The clinician will suggest her to go for IVF (for details see page 37), although the success rate is low (about 20%).
4. The pregnancy test is done by assaying HCG in maternal blood at day 8 and in maternal urine at day 10.
5. The human chorionic gonadotrophin (HCG) is a glycoprotein produced by syncytiotrophoblast, which stimulates the production of progesterone by corpus luteum. This is clinically significant because the progesterone produced by the corpus luteum is essential for maintenance of pregnancy until the eighth week. Thereafter, placenta takes over the production of the progesterone.
6. Both male and female pronuclei (both haploid) replicate their DNA, so that each cell of the two-cell stage zygote has a normal amount of DNA (i.e., $2n$).
7. The polyspermy is prevented due to following two events during fertilization.
 - (a) **Zona reaction:** As the sperm penetrates, a change in the properties of zona pellucida occurs that makes it impermeable to other sperms.
 - (b) **Vitelline block:** As the sperm enters into the oocyte, the **calcium waves** appear in its cytoplasm. The calcium wave initiates the release of enzymes from the cortical granules lining the plasma membrane of the oocyte. Due to release of cortical granules the vitelline membrane undergoes a change. The changed vitelline membrane becomes impermeable to other sperms (i.e., works as a vitelline block).

8. In males and females, the methods of fertility control are given in the tabular form below.

In females	In males
<ul style="list-style-type: none"> • Temporary methods 1. <i>Prevention of union of sperm and oocyte:</i> <ul style="list-style-type: none"> (a) By avoiding coitus during the fertile period of the menstrual cycle (10–17 days). The remaining days of the menstrual cycle are safe. (b) By using mechanical barrier such as diaphragm/ cervical cap. (c) By using spermicidal jellies/cream (not really useful). 2. <i>Prevention of implantation:</i> By using intrauterine contraception devices (IUCD) such as a copper-T. 3. <i>Prevention of ovulation by using contraceptive pills with or without suppressing normal menstrual cycle.</i> A contraceptive pill is a combination of progesterone analogue—progestin and estrogen. 4. <i>Medical termination of pregnancy (MTP):</i> This is done till 12 weeks of pregnancy only. 	<ul style="list-style-type: none"> • Temporary methods 1. <i>Prevention of union of sperm and oocyte:</i> By mechanical barrier, viz., use of condom during coitus. The discharged seminal fluid then collects in the condom and not in the vagina. 2. <i>Prevention of production of sperms by using the contraceptive pill:</i> A male 'pill' has been developed and tested in clinical trials. It contains synthetic androgen that prevents both LH and FSH secretion that either stop the production of sperms (70–90% of men) or reduce it to the level of infertility.
<ul style="list-style-type: none"> • Permanent methods <i>Tubectomy:</i> The fallopian tube on each side is ligated at two places and intermediate part is removed. 	<ul style="list-style-type: none"> • Permanent methods <i>Vasectomy:</i> The vas deferens on each side is ligated at two pieces and the intermediate part is removed.

5

Formation of Primitive Streak, Notochord, Neural Tube, Subdivisions of Intraembryonic Mesoderm, and Folding of Embryo

Overview

The knowledge of primitive streak, notochord, and neural tube is of utmost importance for students to understand various congenital anomalies such as teratomas, neural tube defects, and gastroschisis. The proper understanding of intraembryonic mesoderm helps the students to understand development of somites, urogenital and cardiovascular systems, and body cavities (pericardial, pleural, and peritoneal cavities). Knowledge of folding of embryo helps to understand the acquisition of miniature human form by flat embryonic disc.

Primitive Streak

It is a linear thickened band of ectodermal cells at the caudal end of embryo in the midline. It is formed due to proliferation and migration of cells of ectoderm on the superior surface of embryonic disc in the midline. The cells forming primitive streak are **pluripotent**, i.e., they have the ability to transform into any type of cells.

- It becomes visible on the dorsal surface of embryonic disc on day 15 of embryonic development as a narrow groove flanked by a slight bulge on either side.
- The cranial end of the primitive streak presents a rounded and elevated area (**primitive node**) surrounding a small **primitive pit**. The development of the primitive streak is discussed in Chapter 4 on page 41.

Functions of Primitive Streak

The primitive streak gives rise to following structures:

1. Intraembryonic mesoderm
2. Septum transversum
3. Notochord

4. Determines the future craniocaudal axis of the embryo
5. Demarcates the embryo into left and right halves.

Fate of Primitive Streak

The primitive streak actively forms intraembryonic mesoderm by ingression of its cells up to the end of the third week of intrauterine life (IUL). Thereafter it regresses craniocaudally and completely disappears by the end of the fourth week or becomes an insignificant structure in the sacrococcygeal region of the embryo.

Clinical Correlation

Sacrococcygeal teratoma: Normally the primitive streak undergoes degenerative changes and disappears by the end of the fourth week of IUL (vide supra). If the cells of the primitive streak remain after the fourth week, the totipotent (pluripotent) cells of the primitive streak give rise to a large **precoccygeal tumor** called **sacrococcygeal teratoma**. Its large size may cause an obstructed labor or even death of the baby.

The sacrococcygeal teratoma is the most common tumor in newborns, occurring in 1:37,000 pregnancies. It occurs more commonly in female babies. The tumor usually becomes malignant during infancy and therefore must be removed before 6 months of age.

Formation of Notochord

The **notochord** is a midline structure that develops in the region between the *primitive streak* and the *prochordal plate*. It develops from the primitive knot (Hensen's node) of the primitive streak (Fig. 5.1).

Understanding of development of notochord is essential because it forms the central axis of the embryonic disc and induces the formation of neural tube.

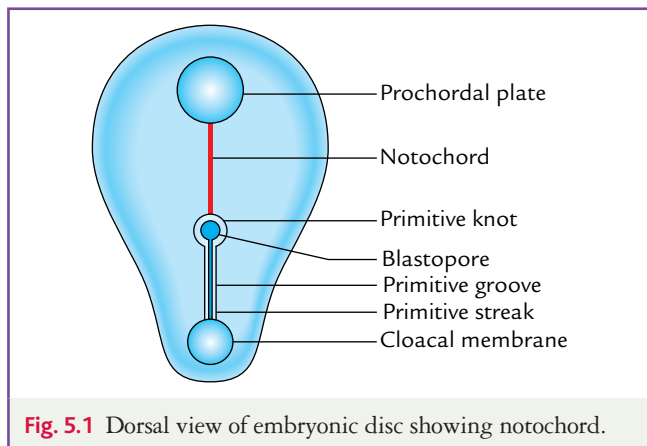


Fig. 5.1 Dorsal view of embryonic disc showing notochord.

The notochord develops from the primitive knot. The various stages of development of notochord are as follows (Fig. 5.2):

1. The cells of **primitive knot** of the primitive streak proliferate to form *prenotochordal cells* that move inward (i.e., invaginate) to produce a central depression called **blastopore**.

From the bottom of the blastopore, the *prenotochordal cells* of the primitive knot migrate forward in the midline between the ectoderm and the endoderm of the bilaminar germ disc to form a solid cord of cells called **notochordal process** or **head process**.

2. The notochord increases in length by extending caudally as the primitive streak recedes caudally and regresses.

The notochordal process gets canalized to form **notochordal canal**. The notochordal canal is continuous with the blastopore.

3. The floor of notochordal canal fuses with the endoderm.
4. Later both the fused parts (wall of notochordal canal and part of endoderm) breakdown. The notochordal canal now communicates with the yolk sac at one end and with the amniotic cavity at the other end. At this stage, the amniotic cavity and the yolk sac are in communication with each other.
5. Gradually the walls of the canal become flattened to form a flattened plate called **notochordal plate**.
6. The notochordal plate becomes curved to form a tube.
7. The proliferation of cells of the tube converts it into a solid cord of cells to form **definitive notochord**. The endoderm is restored, and now the notochord is completely separated from the endoderm.

N.B. The proximal part of *notochordal canal* persists temporarily as **neurenteric canal** and forms a transitory communication between the amniotic cavity and yolk sac (umbilical vesicle).

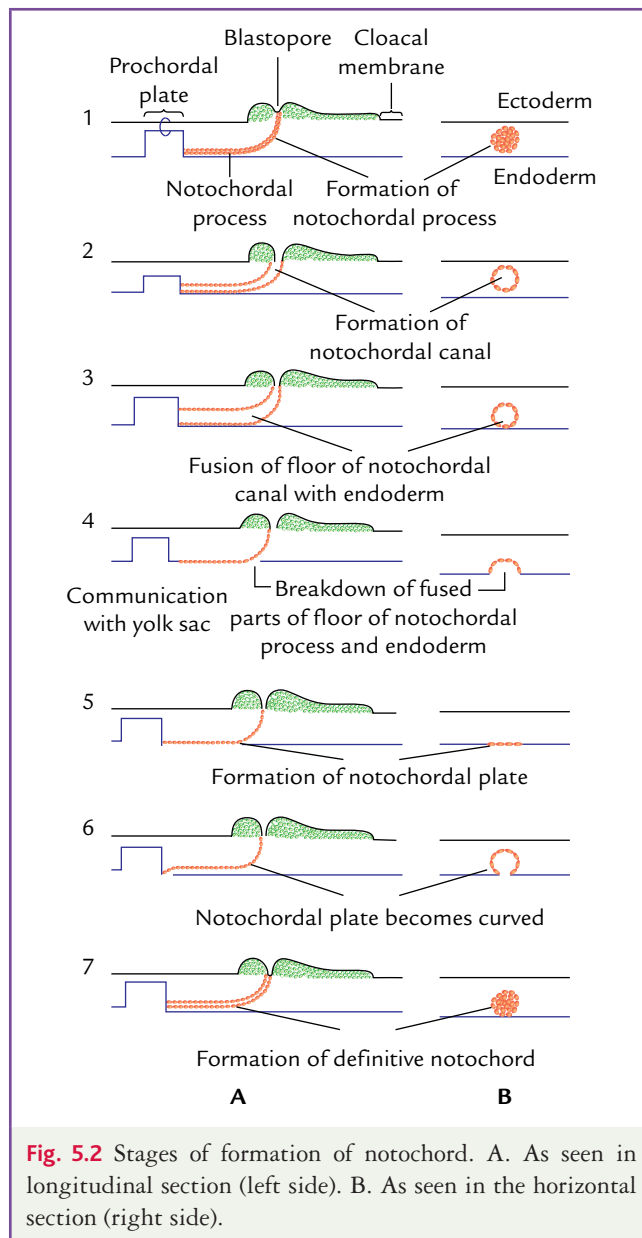


Fig. 5.2 Stages of formation of notochord. A. As seen in longitudinal section (left side). B. As seen in the horizontal section (right side).

Functions of Notochord

1. It forms the central axis of the developing embryo (embryonic disc).
2. It induces the formation of neural tube from the overlying ectoderm.
3. It provides central column around which vertebral bodies and intervertebral discs develop.

Fate of Notochord

1. The notochord is present in all the animals belonging to phylum Chordata.
2. In human beings, it appears only in embryo. In later life, it disappears but its remnants are seen in the form of **nucleus pulposus** of the intervertebral discs and **apical ligament of dens** of second cervical vertebra.

Clinical Correlation

Chordoma: This tumor arises from the remnants of notochord. It is formed either in the cranial region or in the sacral region. In the cranial region, it is seen at the base of the cranium and has a tendency to spread into the nasopharynx. It commonly occurs in men late in life, viz., over 50 years of age. About 30% of these tumors are malignant.

Formation of the Neural Tube (Fig. 5.3)

The process of formation of neural tube is called **neurulation**. The neural tube is formed from the ectoderm overlying the notochord as follows:

1. The cells of ectoderm overlying the notochord get differentiated into specialized cells called **neuroectodermal cells**.
2. The neuroectodermal cells proliferate to form a thick plate called **neural plate**. The neural plate extends in midline from prochordal plate to the primitive knot.
3. The margins of the neural plate get elevated (**neural folds**) as paraxial mesoderm proliferates on either side of the notochord. This leads to the formation of

neural groove flanked by **neural folds**. The neural groove becomes deeper and neural folds move towards midline to fuse with each other to form a cylindrical **neural tube**. The fusion of neural folds (i.e., closure of neural tube) begins in the middle and gradually extends in cephalic and caudal directions. During the closure of the neural groove, the cells at the tips of neural folds (**neural crests**) do not take part in the formation of neural tube. When the surface ectoderm is restored they form bilateral masses dorsolateral to the neural tube, deep to surface ectoderm. The cranial part of neural tube enlarges and forms the brain while the caudal part of neural tube remains tubular and forms the spinal cord. Further development of the brain and spinal cord and derivatives of neural crests is described in detail in Chapter 22.

Subdivisions of Intraembryonic Mesoderm

The **intraembryonic mesoderm** on either side of neural tube divides into three parts. From the medial to lateral side, these are **paraxial mesoderm**, **intermediate mesoderm**, and **lateral plate mesoderm** (Fig. 5.4).

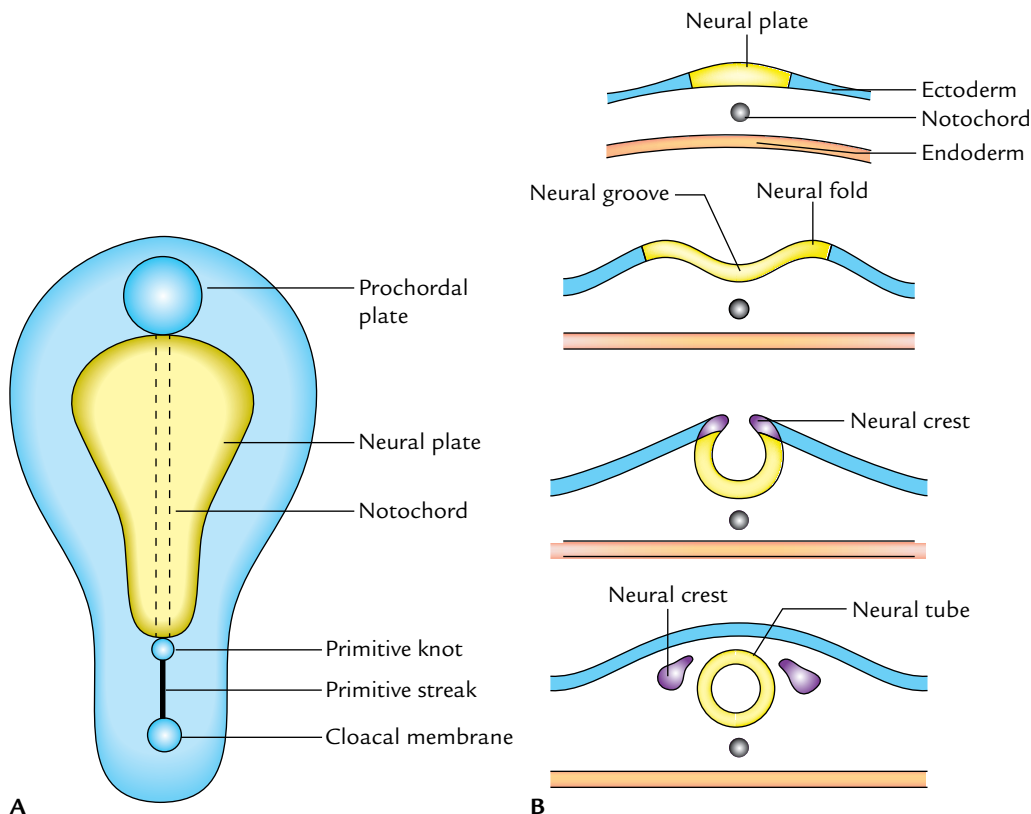


Fig. 5.3 Formation of neural tube. A. Neural plate as seen on the dorsal surface of the pear-shaped embryonic disc. B. Horizontal sections of embryo showing various stages of development of neural tube.

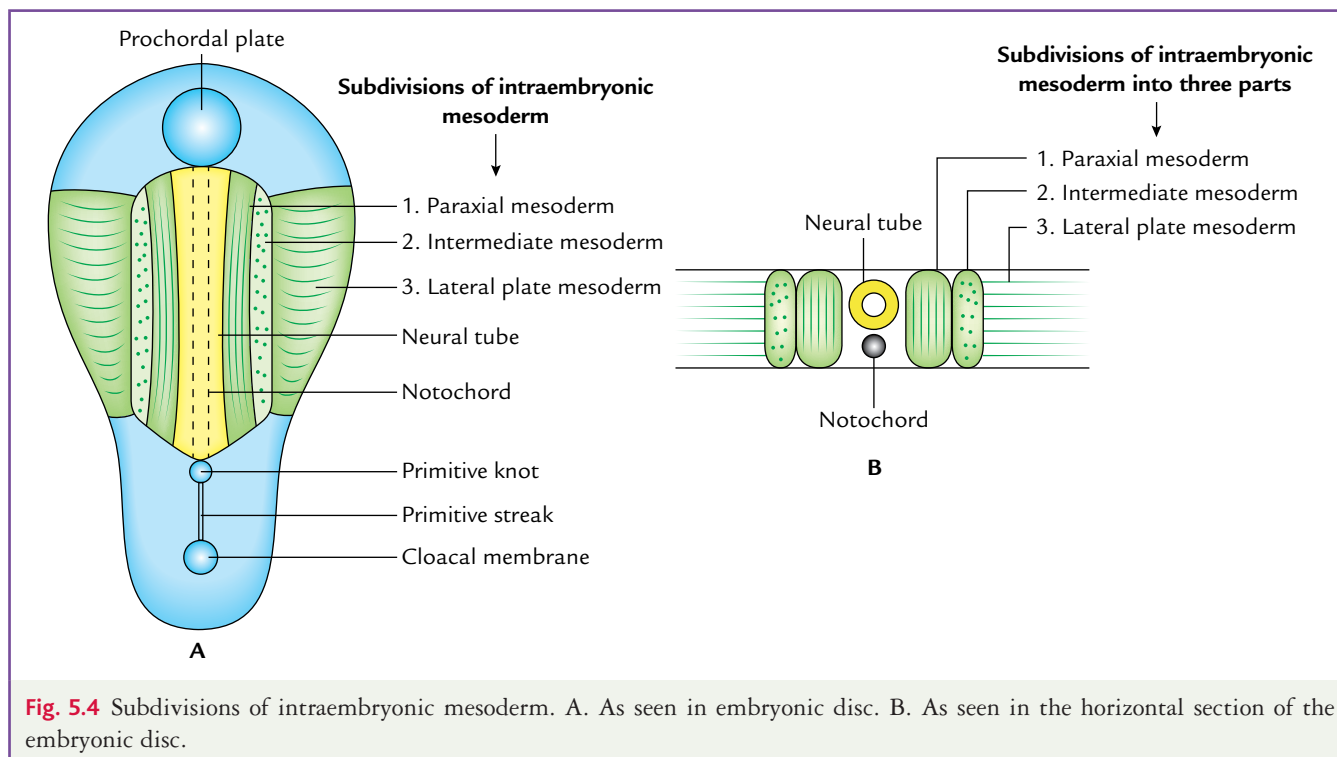


Fig. 5.4 Subdivisions of intraembryonic mesoderm. A. As seen in embryonic disc. B. As seen in the horizontal section of the embryonic disc.

- 1. Paraxial mesoderm:** The mesoderm lateral to neural tube condenses to form the paraxial mesoderm.
- 2. Intermediate mesoderm:** The mesoderm in between the paraxial mesoderm and lateral plate mesoderm is termed intermediate mesoderm. It is not only intermediate in position but also intermediate in thickness as compared to paraxial and lateral plate mesoderms.
- 3. Lateral plate mesoderm:** The mesoderm in the lateral part of embryonic disc remains thin and forms lateral plate mesoderm.

Fate of Paraxial, Intermediate, and Lateral Plate Mesoderms

Paraxial Mesoderm

The paraxial mesoderm undergoes segmentation to form somatomes and somites.

Development of somatomes The paraxial mesoderm is a thick longitudinal column of mesodermal cells that lies on each side of the notochord and the developing neural tube.

The paraxial mesoderm (longitudinal column of mesoderm) undergoes segmentation and gets organized into segments known as **somatomes**. The somatomes are formed in the craniocaudal sequence.

The **first pair of somatomes** appears in cephalic region of the embryo and their formation proceeds craniocaudally. Each somatome consists of mesodermal

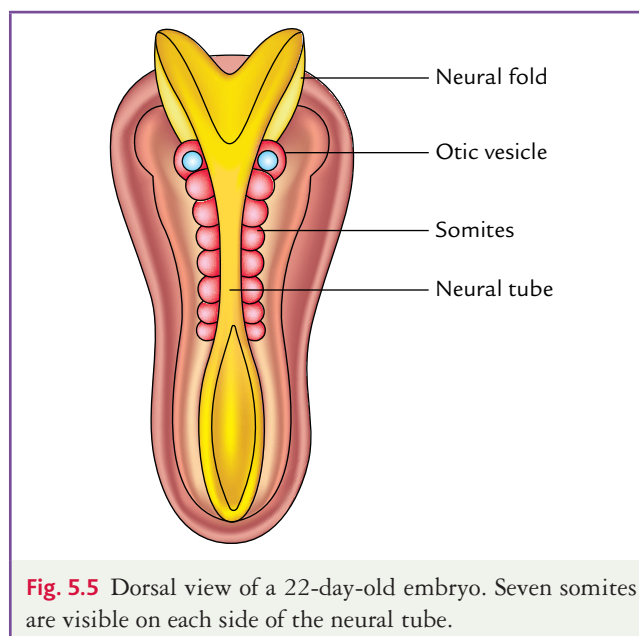


Fig. 5.5 Dorsal view of a 22-day-old embryo. Seven somites are visible on each side of the neural tube.

cells arranged in concentric whorls around the center of the unit.

Somatomes 1–7, which are located from cephalic to otic vesicle, do not condense to form somites but contribute to mesoderm of the head and neck region, which forms all the striated muscles in this region.

The remaining somatomes located caudal to otic vesicle condense to form well-defined cubical blocks called **somites**.

Development of somites (*Gr. Soma = body*) (Figs 5.5 and 5.6) These are cubical blocks of mesoderm located

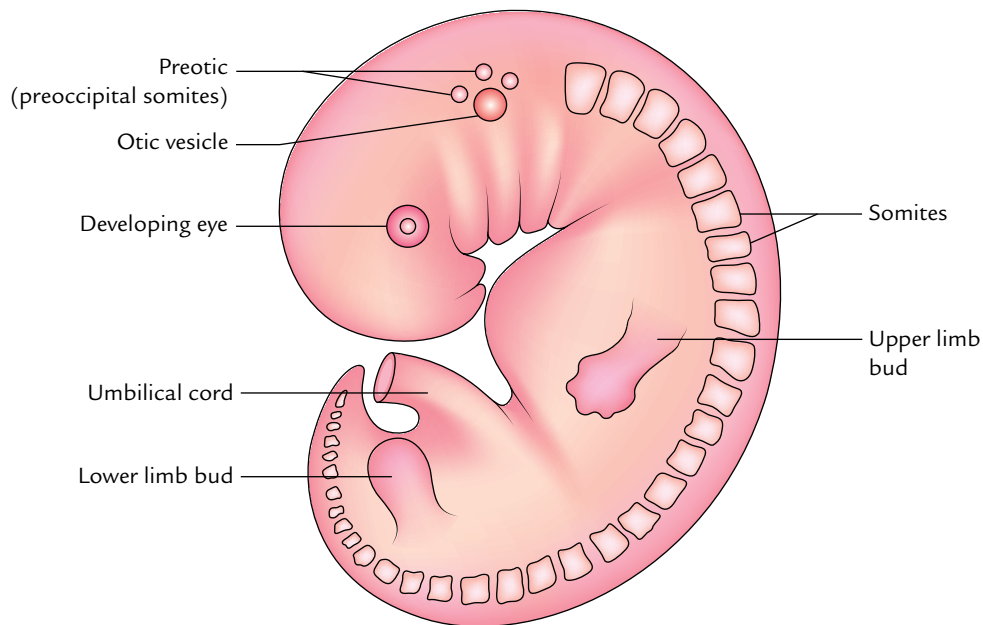


Fig. 5.6 Lateral view of a 30-day-old embryo. Thirty four somites are visible.

Table 5.1 Estimation of the approximate age of embryo according to number of somites

Approximate age of embryo (days)	Number of somites (pairs)
20	1–4
21	4–7
22	7–10
23	10–13
24	13–16
25	16–19
26	19–21
27	21–24
28	24–27
29	27–30
30	30–33

caudal to otic vesicle on each side of developing neural tube. The somites first appear in the future occipital region of the embryo. The first pair forms on day 20—a short distance caudal to the otic vesicle/placode. Subsequent pairs form in craniocaudal sequence. Thus, cranial somites are oldest and caudal somites are youngest.

About 38 pairs of somites appear between days 20 and 30 of development (**somite period of human development**). By the end of the fifth week, about 42 days, 44 pairs of somites are formed in the human embryo. Out of these 4 are occipital, 8 are cervical, 12 are thoracic, 5 are lumbar, 5 are sacral, and from 8 to 10 are coccygeal. The somites form visible surface elevations on either side of the midline.

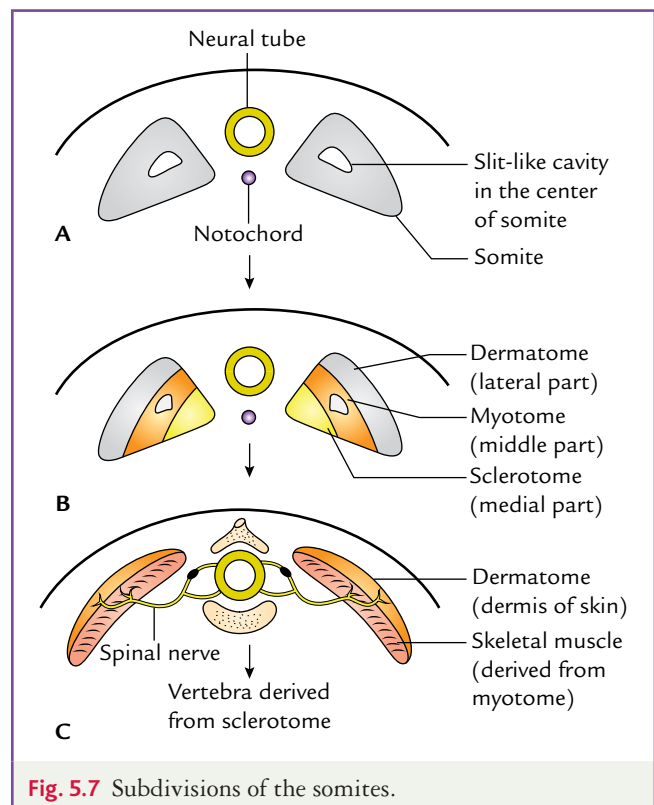


Fig. 5.7 Subdivisions of the somites.

The first pair of somites appears in the occipital region on day 20 (vide supra) and subsequently approximately three pairs of somites are added each day until the end of the fifth week. Thus, while the somites are forming, the number of somites provides a good index of the age of the embryo (Table 5.1).

Correlation between somites and spinal nerves As discussed earlier, somites begin to form at the cranial

end of the paraxial mesoderm and continue to do so caudally. In craniocaudal direction, they are termed occipital, thoracic, lumbar, and coccygeal somites. Caudal to the occipital region, the number of somites corresponds to the number of spinal nerves in the region. Thus, there are 8 cervical, 12 thoracic, 5 lumbar, and 5 sacral somites corresponding to same number of spinal nerves in these regions. The number of coccygeal somites however exceeds the number of coccygeal nerve, but the extra coccygeal somites degenerate.

Structure and fate of somites (Fig. 5.7)

- Each somite is triangular in shape with a small slit-like cavity in its center.
- Each somite is divided into three parts: medial, middle, and lateral.
 - The **medial part** is called **sclerotome**, which forms vertebrae and ribs.
 - The **middle part** is called **myotome**, which forms skeletal muscles.
 - The **lateral part** is called **dermatome**, which forms the dermis of the skin.

Intermediate Mesoderm

The intermediate mesoderm forms most of the genitourinary system, e.g., kidneys, testes, ovaries, etc.

Lateral Plate Mesoderm

The lateral plate mesoderm forms body wall and body cavities. Initially it is involved in the formation of intraembryonic celom.

Formation of intraembryonic celom (Fig. 5.8) The lateral plate of mesoderm of two sides is continuous with each other anterior to the prochordal plate (primitive buccopharyngeal membrane).

A large number of small cavities appear on each side in the lateral plate mesoderm and mesoderm anterior to the prochordal plate. All these cavities coalesce (fuse) together to form a single large horseshoe-shaped cavity called **intraembryonic celom**.

Subdivisions of intraembryonic celom During the second month, the intraembryonic celom is divided into three parts:

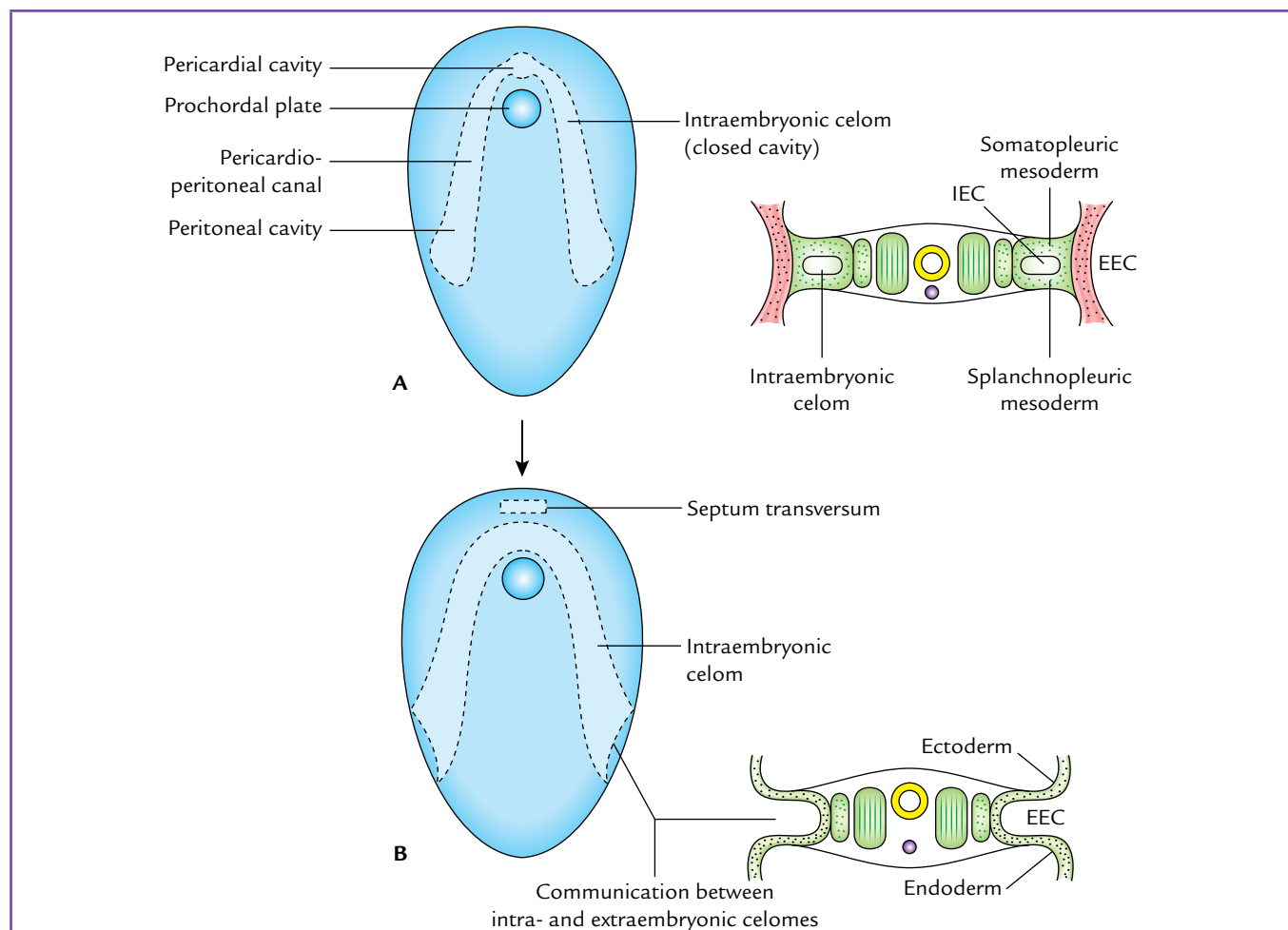


Fig. 5.8 Intraembryonic celom (surface view on the left and transverse view on the right). A. Early stage. Note it is a closed cavity. B. Late stage. Note it is communicated with extraembryonic celom. IEC=intraembryonic celom; EEC=extraembryonic celom.

- Part anterior to the prochordal plate called **pericardial cavity**.
- Right and left limbs of the intraembryonic celom called **peritoneal cavities**.
- Canals through which pericardial cavity communicates with the peritoneal cavities are termed **pericardioperitoneal canals**.

N.B. Initially the horseshoe-shaped intraembryonic celom is a closed cavity, but soon it establishes communication with the extraembryonic celom (Fig. 5.8).

Formation of somatopleuric and splanchnopleuric layers of mesoderm As a result of formation of intraembryonic celom the lateral plate mesoderm is divided into two layers: somatopleuric mesoderm and splanchnopleuric mesoderm.

1. **Somatopleuric (parietal) layer:** It lies in contact with the ectoderm.
2. **Splanchnopleuric (visceral) layer:** It lies in contact with the endoderm.

The **somatopleuric mesoderm** contributes to the development of the body wall while **splanchnopleuric mesoderm** contributes to the development of walls of the viscera (e.g., viscera of GIT and respiratory tracts).

- The intraembryonic mesoderm lying anterior to the pericardial cavity is called **septum transversum**, which contributes to the development of **liver** and **diaphragm**.
- The epicardium of heart develops from **splanchnopleuric mesoderm** lying in front of the prochordal plate.

Folding of Embryo

The folding of an embryo is a significant event in establishment of the primitive form of the human body. As a result of folding, the flat embryonic disc becomes somewhat cylindrical embryo.

The folding occurs in both median and horizontal planes due to rapid growth of the embryo.

Folding of Embryo in the Median Plane

The folding of embryo in the median plane occurs as follows (Fig. 5.9):

- There is a progressive increase in the length of embryo (embryonic disc), but its head and tail ends remain relatively close together. Consequently, the embryonic disc bends producing a convexity dorsally and bulges upward into the amniotic cavity.
- With further increase in the length of embryonic disc, the head and tail ends also get folded on itself to

form **head fold** and **tail fold**, respectively. As a result of formation of head and tail folds, the head and tail ends of embryo move ventrally.

- Due to the formation of head and tail folds, the part of yolk sac becomes enclosed within the embryo to form a

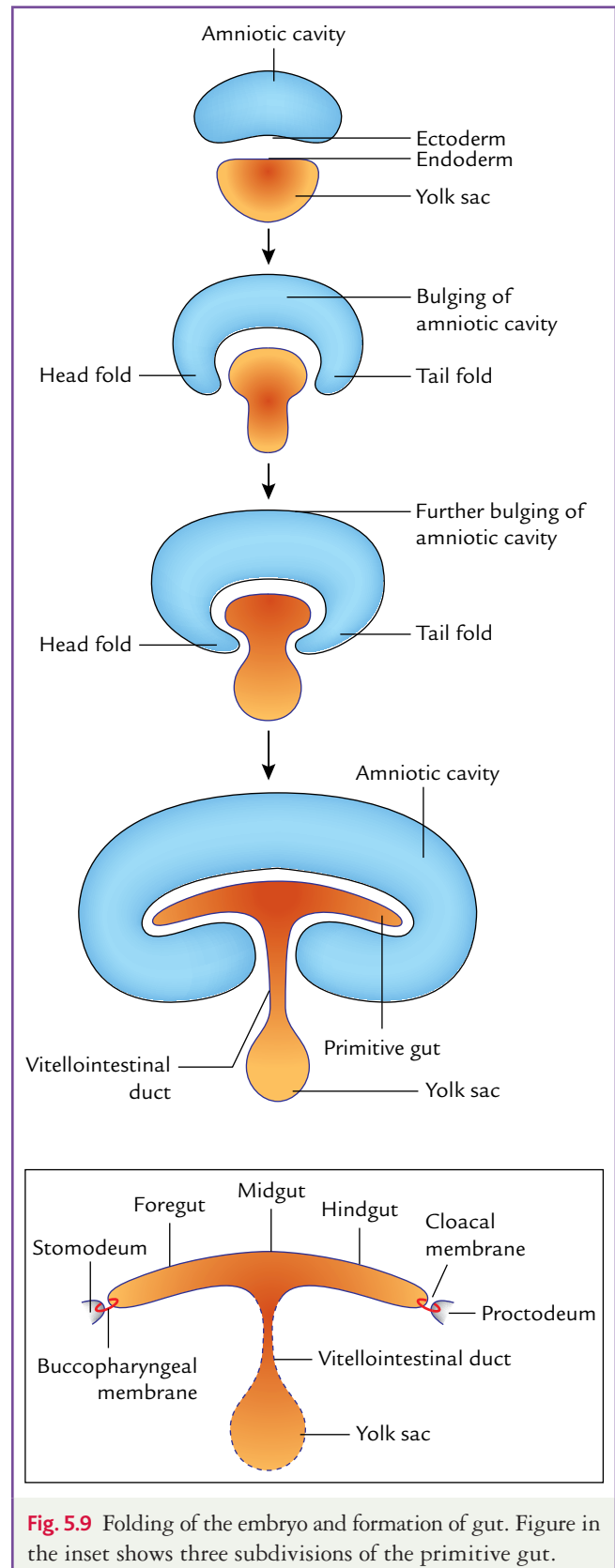


Fig. 5.9 Folding of the embryo and formation of gut. Figure in the inset shows three subdivisions of the primitive gut.

long tubular structure called **primitive gut**. The primitive gut forms most of the gastrointestinal tract (GIT).

- The primitive gut is divisible into three parts: foregut, midgut, and hindgut. The midgut is in wide communication with the yolk sac through a wide channel—the primordium of **vitellointestinal duct (yolk stalk)**.
- A small diverticulum arises from the caudal part of the yolk sac and grows into the connecting stalk attached to the caudal end of the embryo called **allantois (allantoic diverticulum)** (Fig. 5.10).

Folding of Embryo in the Horizontal Plane

- The folding of sides of the embryo forms right and left lateral folds. The lateral folds move medially and fuse to each other to form the anterior abdominal wall. However, in the center of the anterior abdominal wall a somewhat circular aperture remains, which represents the future umbilicus.
- With the formation of lateral folds in embryo, communication between midgut and yolk sac narrows to form the **vitellointestinal duct (omphaloenteric duct)**.

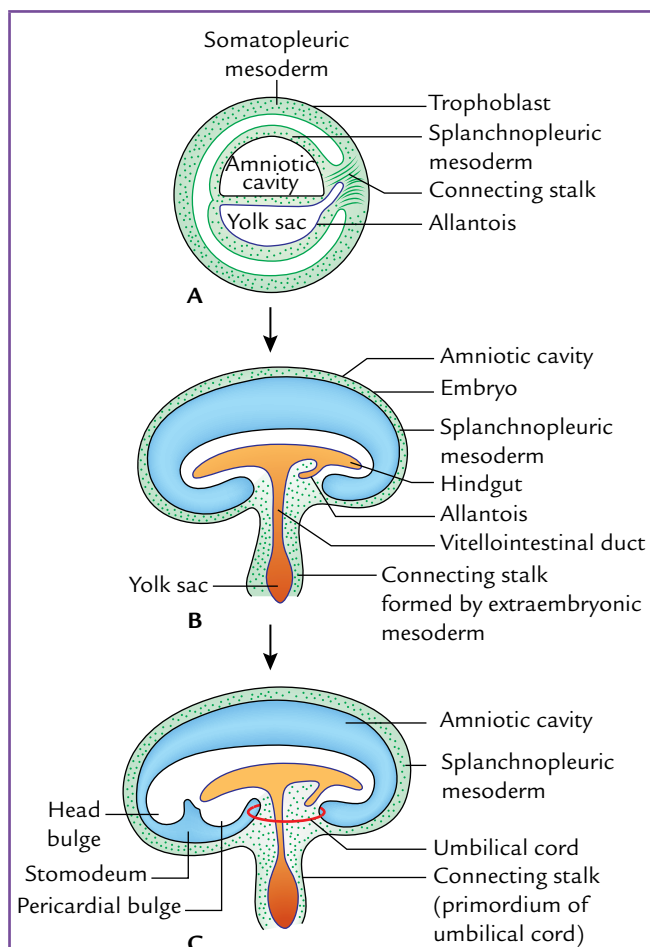


Fig. 5.10 Folding of the embryo and formation of the umbilical cord.

- As the embryo folds on itself, the amniotic cavity expands enormously and completely surrounds the embryo. Now the embryo freely floats in the amniotic fluid within amniotic cavity, which serves as a *swimming pool* for the embryo.
- Due to enormous expansion of amniotic cavity, the extraembryonic celom gets almost completely obliterated and the amnion forms the covering of the umbilical cord.

Effects of Folding of Embryo (Fig. 5.11)

These are as follows:

1. Due to the formation of folds on all sides, the flat embryonic disc becomes cylindrical leaving an

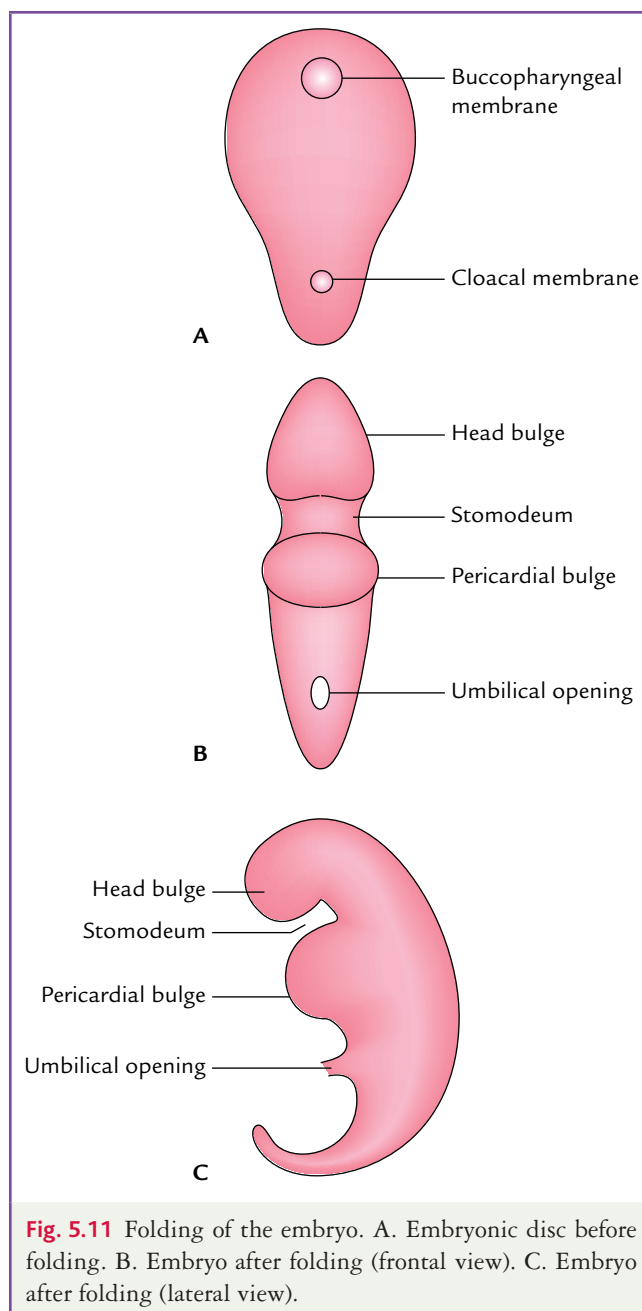


Fig. 5.11 Folding of the embryo. A. Embryonic disc before folding. B. Embryo after folding (frontal view). C. Embryo after folding (lateral view).

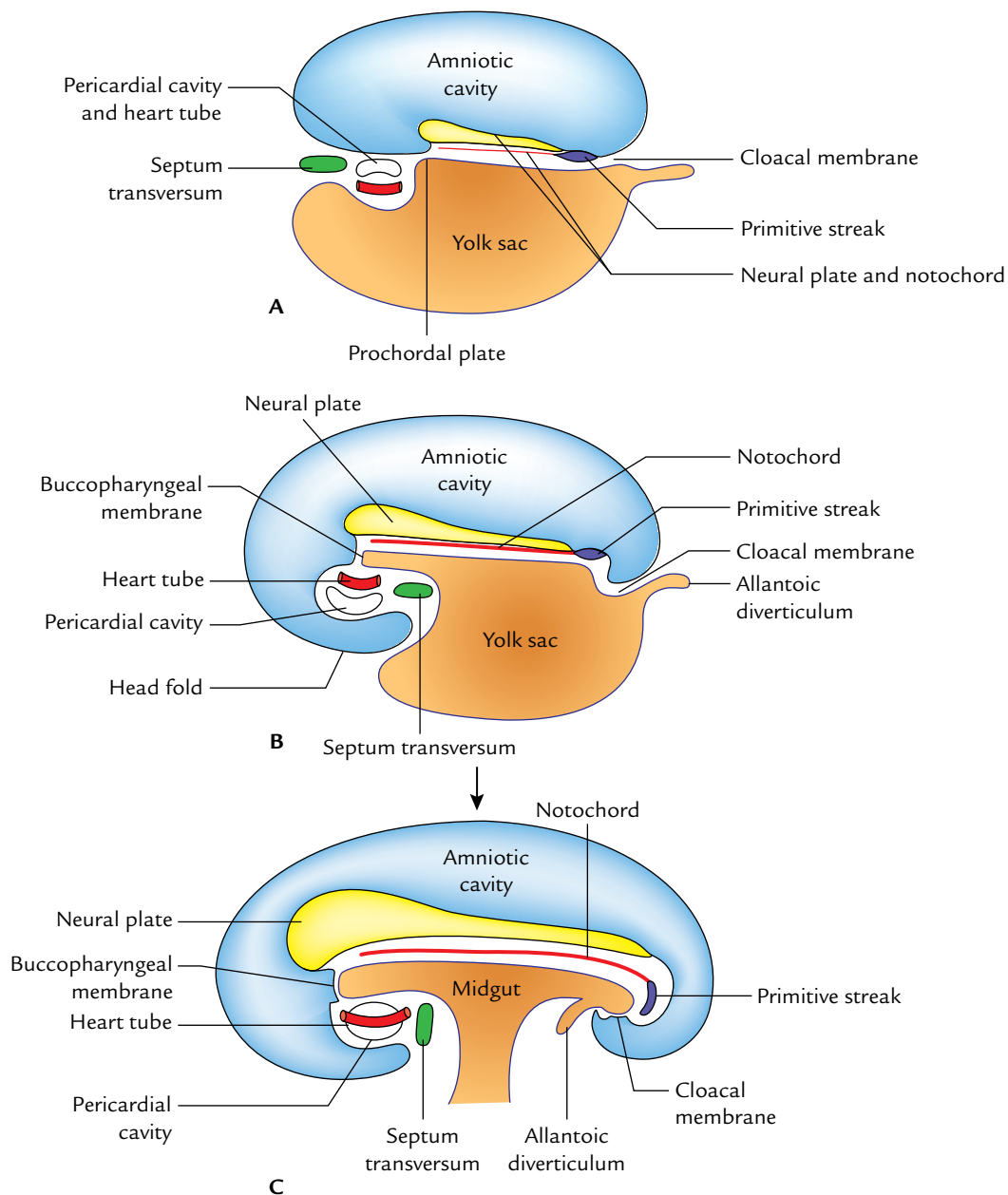


Fig. 5.12 Arrangement of structures of embryo before and after the formation of head and tail folds as seen in longitudinal sections. A. Embryonic disc with its important components. B. Embryonic disc after formation of head fold. Note the heart tube comes to lie on the roof of the pericardial cavity and septum transversum becomes caudal to the pericardial cavity. C. Note the changed relations septum transversum, pericardial cavity, heart tube, and cloacal membrane.

- opening on the ventral aspect called **umbilical ring**.
2. The ectoderm forms the outer covering of the embryo.
3. The embryo becomes completely surrounded by the amniotic cavity.
4. The part of yolk sac gets incorporated in the embryo to form the **primitive gut**.
5. The cranial end of primitive gut is now separated from **stomodeum** by **buccopharyngeal membrane**, and the caudal end of primitive gut is separated from **proctodeum** by the **cloacal membrane**.
6. The connected stalk (future umbilical cord) now becomes attached to the ventral aspect of embryo around the umbilical opening.
7. The allantois now gets connected to the terminal part of the hindgut.
8. The head containing brain now forms the cranial most part of the embryo.
9. The **septum transversum** and **pericardial cavity** now lie on the ventral aspect of the cranial end of the embryo, with heart tube lying dorsal to the pericardial cavity.

Table 5.2 Arrangement of important structures of embryo before and after the folding in craniocaudal direction

Before folding of embryo	After folding of embryo
• Septum transversum lies cranial to the pericardial cavity and heart tube	• Septum transversum lies caudal to the pericardial cavity and heart tube
• Heart tube lies below the pericardial cavity	• Heart tube lies above the pericardial cavity (i.e., heart tube jumps from the floor of the pericardial cavity to its roof)
• Prochordal plate	• Prochordal plate forms buccopharyngeal membrane/oral membrane
• Cranial part of the neural plate lies above and behind the primitive buccopharyngeal membrane	• Cranial part of the neural plate lies above and in front of buccopharyngeal membrane/oral membrane, and forms the most cranial structure of the embryo
• Yolk sac lies below the embryo	• Most of yolk sac is taken up with the embryo to form primitive gut
• Connecting stalk is attached at the caudal aspect of the embryo	• Connecting stalk is attached on the ventral aspect of the embryo
• Allantois is directed caudally	• Allantois is directed ventrally

10. The septum transversum now lies caudal to the primitive heart tube and pericardial cavity.
11. A depression is formed between head bulge and pericardial bulge (Fig. 5.11). It is called **stomodeum** and is separated from the cranial end of foregut by the buccopharyngeal membrane.
12. Two halves of the peritoneal cavity now fuse to form a single peritoneal cavity.

The arrangement of structures of embryo before and after the folding (formation of head and tail folds) are shown in Fig. 5.12 and summarized in Table 5.2.

N.B. All the major organ systems begin to develop during the embryonic period causing craniocaudal and lateral folding of the embryo. **By the end of this period, i.e., during the eighth week, the human embryo has a distinct human appearance but still has no limbs.**

GOLDEN FACTS TO REMEMBER

- Primitive streak appears on 15th day of embryonic development
- First pair of somites appears at the end of Third week
- Most of the axial skeleton is derived from Somites
- Oldest somites Occipital somites
- Youngest somites Coccygeal somites
- Genes responsible for orderly sequencing of somites Notch signaling genes
- Teratoma Tumor arising from the remnant of primitive streak
- Chordoma Tumor arising from the remnant of notochord
- Remnants of notochord in adults (a) Nucleus pulposus
(b) Apical ligament of dens
- Swimming pool of embryo Amniotic cavity
- Gestation period when embryo presents a distinct human appearance Eighth week
- Neurulation Process of transformation of neural plate into neural tube

CLINICAL PROBLEMS

1. Why period of pregnancy from third to eighth week is so important for normal development of the baby and most sensitive for teratogens?
2. What do you understand by the term **teratomas**. Give the embryological basis?
3. The **teratomas** are located either in the midline structures or in the paramedian structures of the body. Why? Give the embryological basis?

CLINICAL PROBLEM SOLUTIONS

1. The period of pregnancy from third to eighth week of gestation is critical because it is this period during which cell populations responsible for organ formation are established and primordia of various organs are being formed.
Early in the third week of gestation, three primary germ layers responsible for organogenesis begin to form. Later in the third week, the differentiation of central nervous system begins and over the next five weeks the primordia for major organ systems are established.
Thus, in third to eighth week of pregnancy the cells are rapidly proliferating and critical cell-cell signals are occurring. These phenomena are extremely sensitive to disruption by teratogens. Therefore, if developing baby during this period is exposed to teratogens it will suffer from various types of birth defects (congenital malformations).
2. The teratomas are congenital tumors that arise from pluripotent embryonic cells of remnants of the primitive streak. These tumors commonly contain tissues derived from all the three germ layers such as hair tissues, neural tissues, etc. (derivatives of ectoderm); intestinal and respiratory epithelium (derivatives of endoderm); and muscle, connective tissue, fat, cartilage, and bone (derivatives of mesoderm). Consequently, the teratoma consists of a heterogeneous mass.
3. The teratoma arises from remnants of pluripotent cells of *primitive streak*—a midline structure in embryo. In the embryonic life, these cells lie in the midline beneath the celomic epithelium in association with the hindgut. Normally they migrate to the gonadal ridges forming ovaries and testis. Therefore, teratomas commonly arise in gonads (i.e., testis and ovaries), which are located in the paramedian regions of the body; but they may also arise in the midline structures of the body, viz., in mediastinum, presacral, and coccygeal regions.

N.B. Most common site of teratoma is ovary.

6

Extraembryonic Membranes and Twinning

Overview

The extraembryonic/fetal membranes are structures that develop from zygote but do not form any part of the embryo proper.

In other words, while the many intraembryonic events are forming organs and tissues of the embryo, a number of extraembryonic structures develop as well. These are called extraembryonic membranes, which are amnion, yolk sac, allantois, chorion, placenta, and umbilical cord (Fig. 6.1).

The extraembryonic membranes are responsible for protection, respiration, excretion, and nutrition of embryo and fetus. At birth, placenta, umbilical cord, and other extraembryonic membranes are separated from the fetus and expelled from uterus as an afterbirth. The knowledge of extraembryonic membranes is essential to perform prenatal diagnostic procedures such as amniocentesis and chronic villous biopsy.

Amnion (Fig. 6.2)

- It is a thin extraembryonic membrane that loosely envelops the embryo forming an amniotic sac that is filled with the amniotic fluid.
- The amniotic sac is lined by ectodermal cells of inner cell mass and amniogenic cells of trophoblast. Note: Amniogenic cells line the roof and lateral walls of the amniotic sac and do not cover its floor.
- As the amniotic sac enlarges during the late embryonic period (at about 8 weeks) due to collection of more amniotic fluid within it, the amnion gradually surrounds the whole embryo and ensheathes the developing umbilical cord.
- The amniotic cavity grows at the expense of extraembryonic celom, which gets obliterated and fusion occurs between amnion and chorion.

N.B. Amnion consists of two layers: an outer layer made up of somatopleuric layer of extraembryonic membrane and an inner layer made up of amniogenic cells.

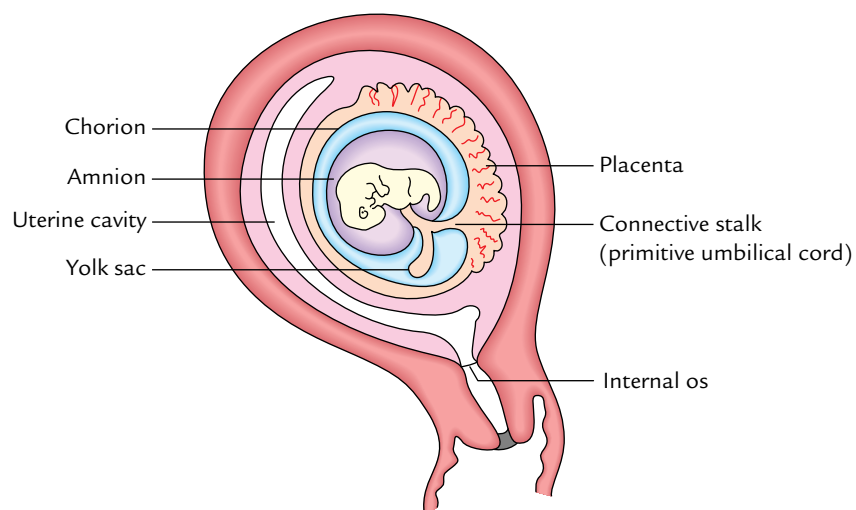


Fig. 6.1 Fetal membranes.

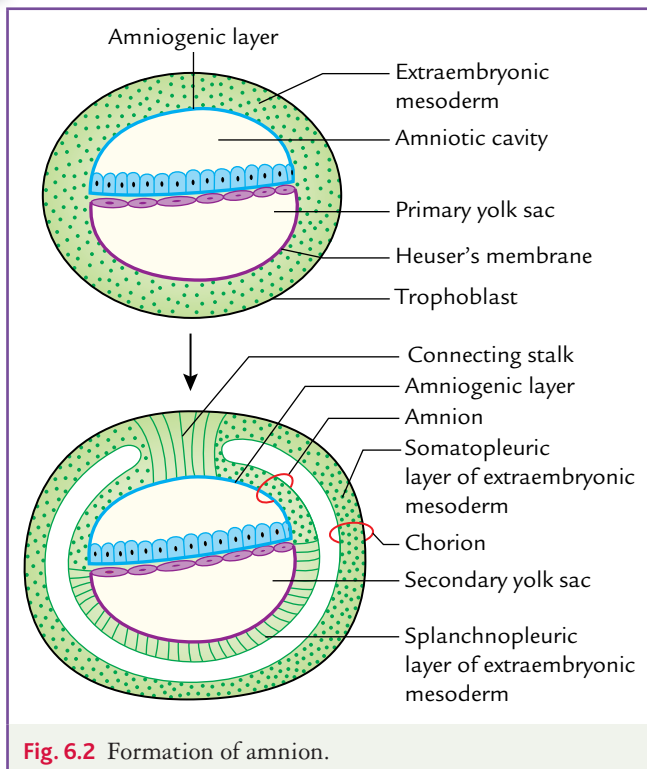


Fig. 6.2 Formation of amnion.

Amniotic Fluid

It is a clear, watery fluid containing salt, sugar, urea, and proteins. It is derived from:

- A. Amniotic cells by filtration or secretion
- B. Fetal urine when kidneys start functioning
- C. Secretion of lung cells
- D. Secretion by placenta.

Constituents of Amniotic Fluid

The amniotic fluid contains:

1. Metabolites and hormones (HCG, HPL).
2. Cells that are sloughed off from fetal lungs, placenta, and amniotic sac (all these cells have same genetic composition).
3. Fetal urine.

Functions of the Amniotic Fluid

As a buoyant medium, it performs following functions for the embryo and the subsequent fetus:

1. It permits symmetrical development and growth.
2. It provides a water-cushion to protect the developing embryo and fetus from jolts that the mother may receive.
3. It helps to maintain a consistent pressure and temperature.
4. It allows free fetal movements—an important prerequisite for musculoskeletal development and blood flow.

5. It forms hydrostatic bag (**bag of waters**) that helps in dilatation of the cervix at the beginning of the labor (child birth).

N.B. The addition of fetal urine and swallowing of amniotic fluid by the fetus maintains the quantity of the amniotic fluid to the optimum.

Clinical Correlation

1. **Amniocentesis (Fig. 6.3):** It is a procedure by which the amniotic fluid is aspirated from the amniotic cavity for diagnostic purposes. It is usually done at 14th or 15th week of pregnancy, when the amniotic sac contains 175–225 ml of amniotic fluid. It is done: (a) to examine the chromosomes in cells of amniotic fluid for detection of genetic diseases such as Down's syndrome; (b) to detect defective enzyme involved in the formation of myelin sheath in *Tay-Sachs* disease by biochemical techniques; and (c) to detect neural tube defects.

The **sex of a fetus** can also be detected by chromosomal studies. Since the fetal urine is added to the amniotic fluid, it can be used to study fetal enzymes and fetal hormones. Presence of **high level of α -fetoprotein in amniotic fluid indicates neural tube defects.**

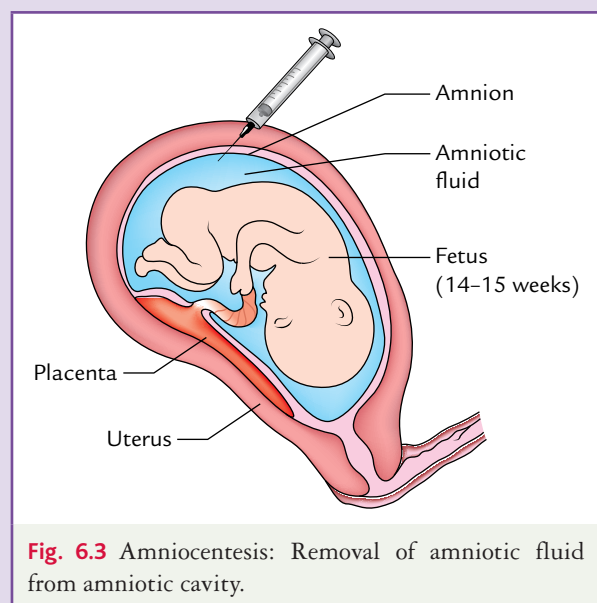


Fig. 6.3 Amniocentesis: Removal of amniotic fluid from amniotic cavity.

2. **Oligohydramnios:** It is a clinical condition in which the volume of amniotic fluid in the amniotic cavity is less than normal. Normal amount of fluid at full-term is 700–1000 ml. If it becomes 400 ml or less, it is termed oligohydramnios. The causes of oligohydramnios are placental insufficiency with reduced placental blood flow, agenesis of kidneys, and loss of amniotic fluid due to preterm rupture of amnion.
3. **Polyhydramnios:** The excessive accumulation of amniotic fluid (e.g., 2000 ml or more) in the amniotic cavity leads to a clinical condition called *polyhydramnios*. It occurs due to esophageal atresia or defects of central nervous system (CNS) because of which the fetus is unable to swallow the amniotic fluid and consequently it is not absorbed in the gastrointestinal tract (GIT) of fetus.

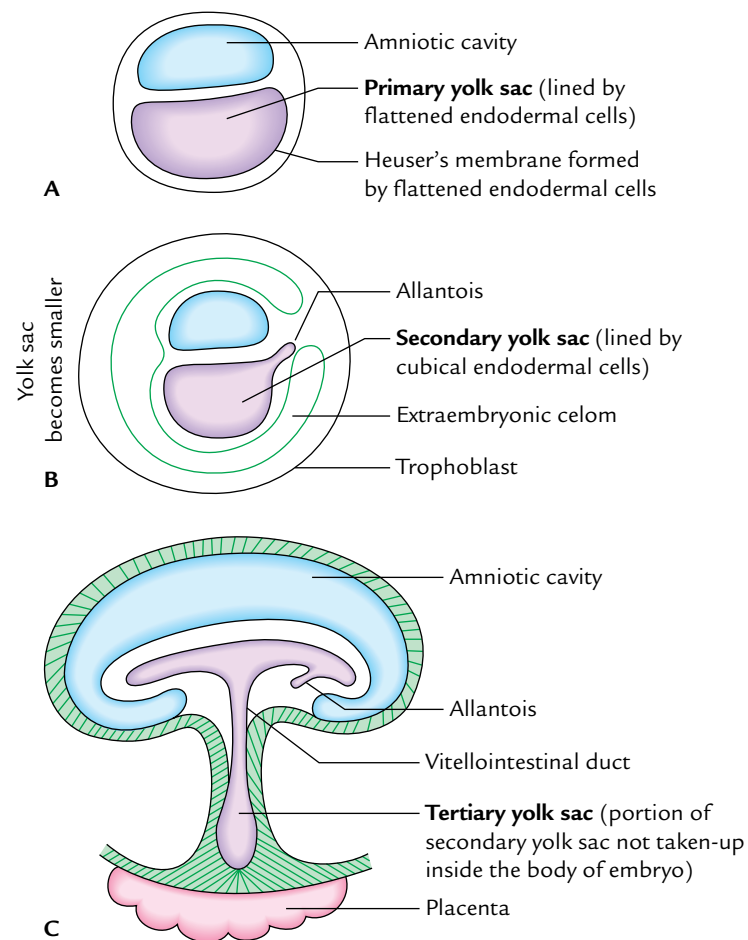


Fig. 6.4 Yolk sac. A. Primary yolk sac (lined by Heuser's membrane made of flattened cells derived from endoderm). B. Secondary yolk sac (becomes smaller due to the formation of extraembryonic celom and cells lining it becomes cuboidal). C. Tertiary yolk sac (part of secondary yolk sac which is not taken up inside the embryonic disc).

Yolk Sac

The yolk sac is an endodermal sac lying ventral to the embryonic disc (Fig. 6.4). It is a vestigial structure in humans with hardly any nutritive yolk inside it.

Development of Yolk Sac

The yolk sac develops from the cavity of blastocyst (blastocoele) and passes through following three stages of development.

- 1. Primary yolk sac:** The cavity of blastocyst is converted into primary yolk sac when it is lined by flattened cells derived from endoderm of embryoblast (or according to some from trophoblast). This lining formed of flattened cells is called Heuser's membrane. It is attached to the undersurface of the embryonic disc. The primary yolk sac is formed at the end of the second week.
- 2. Secondary yolk sac:** With the appearance of extraembryonic celom, the primary yolk sac becomes

smaller and is termed secondary yolk sac. The cells lining the yolk sac becomes cuboidal.

- 3. Tertiary yolk sac or definitive yolk sac:** It is a remnant of the secondary yolk sac. As embryo folds, it takes up most of the yolk sac inside the body of the embryo to form primitive gut. The portion of yolk sac not taken up inside the body of the embryo is termed tertiary/definitive yolk sac. It communicates with the midgut via *vitellointestinal duct*.

Functions of Yolk Sac

- 1. Hemopoiesis:** It produces blood for the embryo until the liver is formed during the sixth week.
- 2. Formation of primitive gut:** Its dorsal portion forms the *primitive gut*.
- 3. Formation of primordial germ cells:** The primordial germ cells form from the wall of the yolk sac and migrate to the developing gonads during the fourth week, where they form primitive germ cells (spermatogonia or oogonia).

4. **Formation of allantois:** A small diverticulum that arises from the caudal part of the yolk sac.

Clinical Correlation

Meckel's diverticulum: The stalk of the yolk sac (vitellointestinal duct) usually detaches itself from the midgut by the sixth week and the yolk sac gradually sinks as the pregnancy advances. But sometimes it persists as Meckel's diverticulum (for details see page 151).

Allantois (Allantoenteric Diverticulum)

It is a small diverticulum that arises from the caudal part of the yolk sac during the third week. It develops and grows into the connecting stalk (also see page 54).

After the folding of embryo, the allantois is connected with the dilated terminal part of the hindgut called cloaca.

Functions of Allantois

1. It is vascularized by allantoic vessels that later become fetal umbilical arteries and vein.
2. In adults, it is represented by **median umbilical ligament**.
3. It also contributes a bit to the formation of urinary bladder.

N.B. In lower animals, the allantois acts as a reservoir of urine. In humans, it is a vestigial structure.

Clinical Correlation

Urachal cyst, sinus, or fistula: The extraembryonic portion of allantois degenerates during the second month of intrauterine life.

The part of intraembryonic portion gets incorporated into apex of urinary bladder and the remaining part involutes to form a thick urinary tube called **urachus**. After birth, the urachus becomes a fibrous cord called **median umbilical ligament**, which extends from apex of urinary bladder to the umbilicus. The failure of urachus to obliterate/fibrose leads to the formation of **urachal cyst, sinus, or fistula** (for details see page 242).

Chorion (Fig. 6.2)

- It is a highly specialized extraembryonic membrane that participates in the formation of the placenta.
- It is formed by the somatopleuric layer of extraembryonic mesoderm and trophoblast. Numerous small finger-like projections arise from its surface called **villi**.
 - On the side of decidua capsularis, the chorion villi regress/disappear, leaving a smooth surface called **chorion laeve (smooth chorion)**.
 - On the side of decidua basalis, the chorion villi further develop and grow in the decidua basalis to

contribute the fetal portion of the placenta. It is called **chorion frondosum (leafy chorion)**. For details see page 63.

Placenta

For proper understanding of the placenta, students should first understand implantation and decidua.

Implantation (Fig. 6.5)

- It is a process by which the embryo is embedded and fixed with the endometrium of the uterus. **At the**

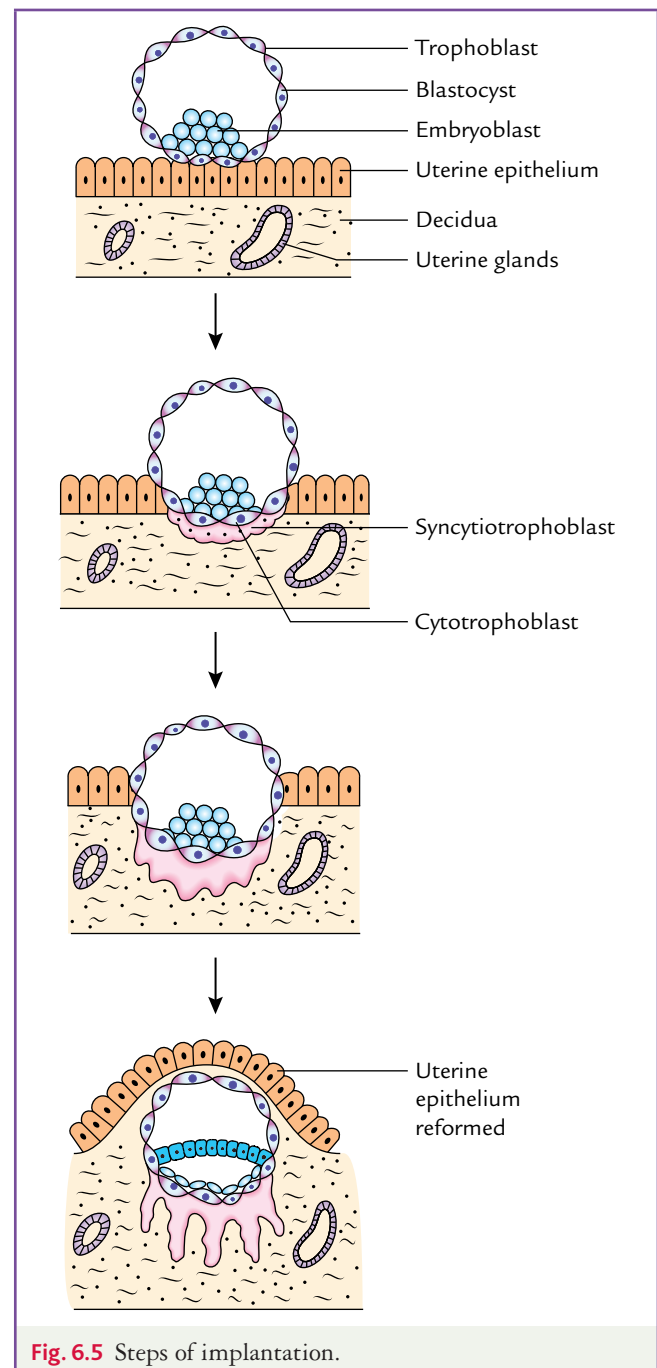


Fig. 6.5 Steps of implantation.

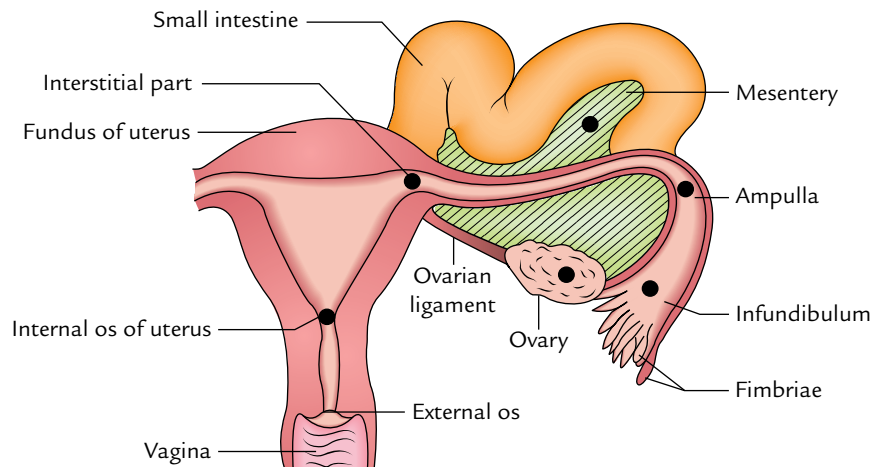


Fig. 6.6 Abnormal sites of implantation (ectopic pregnancy).

time of implantation, the embryo is in the form of blastocyst. It usually occurs during 6–10 days after ovulation.

The intimate contact of fetal and maternal tissues occurs by implantation of the embryo.

- The blastocyst surrounded by zona pellucida enters the uterus on the sixth day. The zona pellucida prevents it from sticking to the wall of the uterus.
- As the blastocyst enlarges, the zona pellucida covering it becomes stretched and ultimately disappears. Consequently the trophoblast is exposed.
- The trophoblast has the property of attaching itself to any tissue with which it comes in contact with.
- The trophoblast sticks to the uterine endometrium. The cells of trophoblast divide mitotically and form new cells that lose their cell membranes and form a mass of cells called **syncytiotrophoblast**. The syncytiotrophoblast invades the endometrium with the help of proteolytic enzymes secreted by its cells. The blastocyst goes deeper and deeper until it completely lies within the endometrium (**interstitial implantation**).

N.B.

- **Timing of implantation:** The implantation occurs during a restricted time period of 6–10 days after ovulation in humans.
- **Types of implantation**
 - *Interstitial implantation:* In this type, the blastocyst is embedded in the endometrium of the uterine wall (e.g., human).
 - *Eccentric implantation:* In this type, the blastocyst is embedded in the uterine crypts, e.g., rat.
 - *Central implantation:* In this type, the blastocyst is implanted in the uterine cavity, e.g., cow.

Normal Site of Implantation

Normally the blastocyst is implanted in the upper part of the posterior wall of the uterine cavity (strictly speaking, cavity of the body of uterus).

Abnormal Sites of Implantation

These may be within the uterus or outside the uterus (Fig. 6.6).

1. **Abnormal sites of implantation within the uterus:** In the lower uterine segment near the *internal os*.
2. **Abnormal sites of implantation outside the uterus.**
 - (a) *In the uterine tube (tubal implantation):* Here it may take place (a) in the ampulla, (b) in the infundibulum, or (c) in the interstitial part in order of frequency of occurrence.
 - (b) *In the abdominal cavity (abdominal implantation):* Here it implants (a) most frequently in the peritoneal lining of the rectouterine pouch (pouch of Douglas); (b) but may implant at any place covered by peritoneum, e.g., mesentery.
 - (c) *In the ovary (ovarian implantation):* Fertilization and implantation may occur while ovum is still within the ovary.

Clinical Correlation

1. **Placenta previa (Fig. 6.7):** Normally the blastocyst implants along the posterior wall of the cavity of body of the uterus and the developed placenta is attached to the *upper uterine segment* (upper two-third of the body). Occasionally, the blastocyst implants near the internal os and then the developed placenta is attached to the *lower uterine segment* (lower one-third of the body of uterus). It is termed **placenta previa**.

The various degrees of placenta previa are as follows (Fig. 6.7).

- (a) *First degree:* The attachment of the placenta does not extend up to the internal os.
- (b) *Second degree:* The attachment of the placenta extends up to the internal os but does not cover it.

- (c) *Third degree*: The edge of the placenta covers the internal os but when the os dilates during child birth the placenta no longer occludes it.
- (d) *Fourth degree*: The placenta completely covers/bridges the internal os even when the os is fully dilated during childbirth. The placenta previa of the fourth degree is also sometimes termed '*central placenta previa*.'

The placenta previa, especially the fourth degree, can cause severe bleeding after the first trimester of pregnancy or during parturition (i.e., birth of the baby).

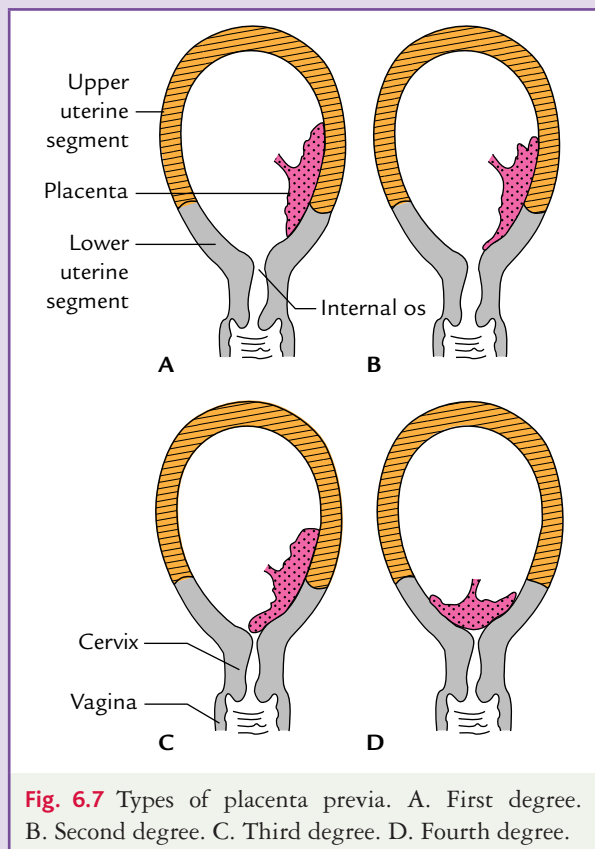


Fig. 6.7 Types of placenta previa. A. First degree. B. Second degree. C. Third degree. D. Fourth degree.

2. **Ectopic pregnancy**: Occasionally, the blastocyst implants outside the uterus, it is called '**ectopic pregnancy**' (Fig. 6.6).

In about 95% of the cases, the ectopic pregnancies occur within the uterine tube mostly in the ampullary region and are referred to as '**tubal pregnancies**.' Tubal pregnancies are terminated through medical intervention. If a tubal pregnancy is permitted to progress the uterine tube may generally rupture at about the second month of pregnancy resulting in severe internal hemorrhage.

The other sites of an ectopic pregnancy are:

- Peritoneal lining of the rectouterine pouch (*pouch of Douglas*)
- Mesentery of the intestinal loop or the omentum
- Ovary (primary ovarian pregnancy)

Ectopic pregnancies usually do not develop normally in unfavorable locations and lead to death of the embryo and severe hemorrhage of the mother during the second month of pregnancy. Rarely does an extrauterine embryo develops to full-term.

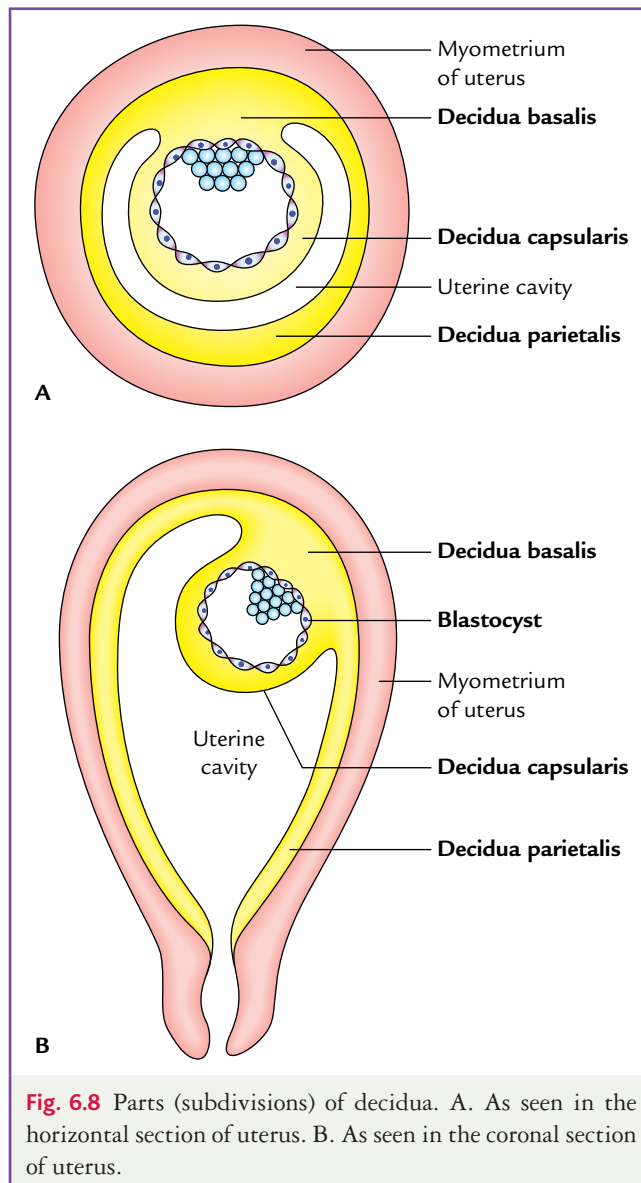


Fig. 6.8 Parts (subdivisions) of decidua. A. As seen in the horizontal section of uterus. B. As seen in the coronal section of uterus.

Decidua (Gravid Endometrium)

After implantation of the blastocyst, the functional layer of the endometrium of the uterus is termed **decidua**.

The endometrium of the uterus is in the secretory phase of menstruation at the time of implantation.

As the embryo is implanted the syncytiotrophoblast starts secreting human chorionic gonadotrophin (HCG) hormone, which intensifies the changes that occur in the secretory phase, viz., stromal cells enlarge, vacuolate, and get filled to the brim with glycogen and lipids; this change in the stromal cells is called **decidual reaction** and changed character of the endometrium after implantation of the ovum is now called **decidua**.

N.B. The molecular mechanism of implantation involves synchronization between the invading blastocyst and receptive endometrium (i.e., implantation occurs due to mutual interaction between the cells of trophoblast and endometrium). The functional layer of endometrium (decidua) is shed off after the childbirth: (L. *Deciduus* = tending to be shed).

Parts of Decidua

The decidua is divided into following three parts (Fig. 6.8).

1. **Decidua basalis:** It is that part of decidua which lies deep to the embryo (developing blastocyst). It is *decidua basalis*, which contributes to the development of the placenta.
2. **Decidua capsularis:** It is that part of decidua which forms a capsule around the embryo and separates it from the uterine cavity.
3. **Decidua parietalis:** Rest of the decidua (excluding decidua basalis and decidua capsularis) is termed *decidua parietalis*.

Development of Placenta

Overview

- The placenta is a highly vascular disc-like structure by which the unborn child (fetus) is attached to its mother's uterine wall.
- The placenta consists of two components: maternal and fetal. The **fetal component** develops from *chorion* and the **maternal component** develops from the *endometrium* of the uterus.
- The placenta provides exchange of gases, nutrients, and metabolic waste products between mother and embryo.

N.B. The placenta is the only organ in the body that develops from two different individuals, i.e., fetus (chorion) and mother (endometrium).

The placenta develops from two entirely different sources.

The **fetal portion** develops from **chorion frondosum** and the **maternal portion** from the **decidua**

basalis. By the end of third week, the anatomical arrangements necessary for physiological exchange between the mother and embryo are established. By the end of fourth week, a complex vascular network is formed within the placenta, which facilitates the exchange of gases, nutrients, and metabolic waste products between the mother and embryo.

Various events involved in the development of placenta are described in the following text.

1. Formation of chorion frondosum and chorion laeve (Fig. 6.9)

- (a) During the development of placenta small finger-like projections arise from chorion (trophoblast and underlying mesoderm) into the decidua.
- (b) Initially chorionic villi are formed all around the chorionic sac.
- (c) As the chorionic sac enlarges the chorionic villi in relation to decidua capsularis get compressed and degenerate. As a result, this part of chorion becomes smooth and is now called **chorion laeve**.
- (d) The chorionic villi in relation to decidua basalis grow extensively into the decidua basalis. This part of the chorion is called **chorion frondosum**.

N.B. The well-developed chorionic villi from chorion frondosum along with tissues of decidua basalis form a disc-shaped mass called **placenta**.

2. Formation of trabeculae and intervillous spaces (Fig. 6.10)

- (a) The cells of trophoblast (made up of single layer of cells) proliferate, move on the surface, and lose their cell membranes to form a continuous sheet of cytoplasm containing many nuclei. This

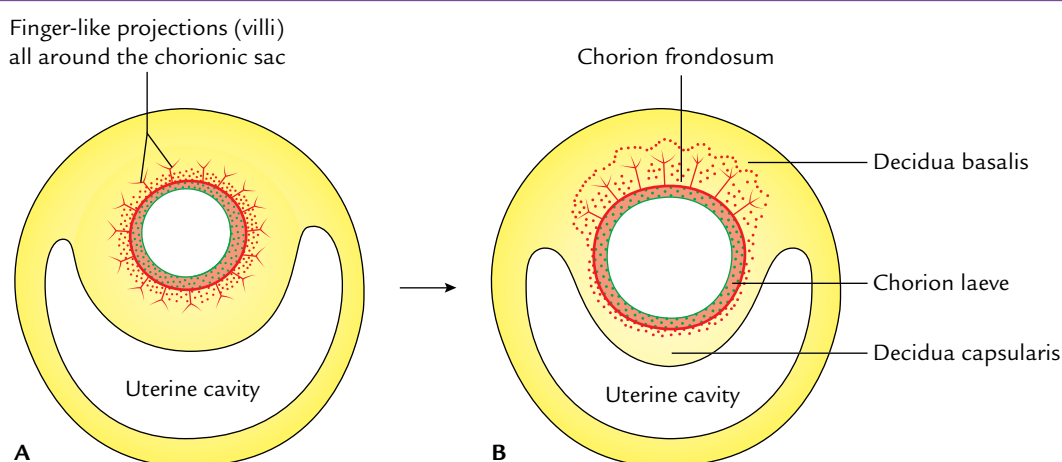


Fig. 6.9 Formation of chorion frondosum and chorion laeve. A. Formation of villi all around the chorionic sac. B. Regression of chorionic villi in relation to decidua capsularis.

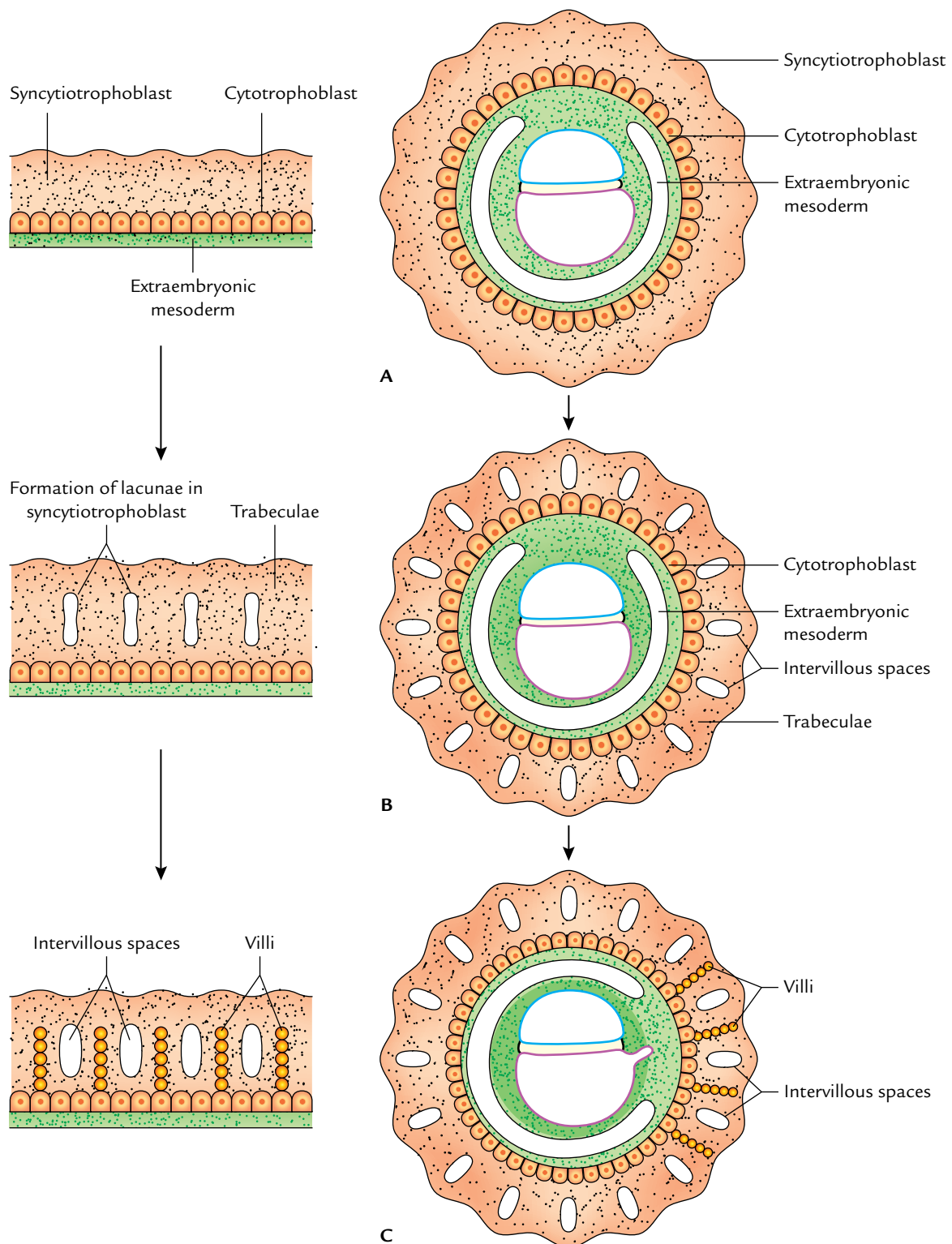


Fig. 6.10 Formation of trabeculae and intervillous spaces.

sheet/layer is called **syncytiotrophoblast**. Thus, trophoblast is differentiated into two layers: (a) a deep layer called **cytotrophoblast** and (b) a superficial layer called **syncytiotrophoblast**.

- (b) The syncytiotrophoblast grows rapidly and erodes the decidua basalis, and becomes thick. The small cavities (**lacunae**) appear in

thickened syncytiotrophoblast. The syncytiotrophoblast continues to erode the decidua basalis. The lacunae increase in size. They lie radially around the developing embryo (blastocyst). They are separated from each other by portions of syncytiotrophoblast termed **trabeculae (villous primordia)**.

- (c) As the syncytiotrophoblast further grows it erodes the blood vessels of the endometrium and the blood enters into the lacunae along with the secretions of the endometrial glands. Later the lacunae communicate with each other around the trabeculae and form the **intervillous spaces**. Thus, each trabeculus gets surrounded all around by the blood-filled space in the endometrium.

Development of Villi (Fig. 6.11)

The following three types of villi develop in succession:

1. **Primary villi:** The cytotrophoblast forms finger-like projections that invade the trabeculae in its center. This finger-like projection of cytotrophoblast surrounded by a layer of syncytiotrophoblast is called the *primary villus*.
2. **Secondary villi:** The extraembryonic somatopleuric mesoderm lying deep to the cytotrophoblast now invades the center of each villus.

As a result, now each villus consists of three layers. From inside to outside these are mesoderm,

cytotrophoblast, and syncytiotrophoblast. This villus is now termed *secondary villus*.

3. **Tertiary villi:** The blood vessels develop in the mesoderm of the secondary villi. The secondary villus with blood vessels in its mesoderm is called *tertiary villus*.

Anchoring villi (Fig. 6.12) The cells of cytotrophoblast in the apical region of each villus proliferate and pass across the syncytiotrophoblast to form a continuous layer of cytotrophoblast on the surface of decidua. This layer is called **cytotrophoblastic shell**. Now the syncytiotrophoblast is completely cut off from the decidua basalis. The cytotrophoblastic shell (Fig. 6.13) fixes (anchors) all villi to the decidua. These villi are now called *anchoring villi* that are attached at one end with chorion (fetal side) and with the decidua at the other end (maternal side). The branching pattern of anchoring villus is as under:

- Truncus chorii
- Ramus chorii
- Ramuli chorii

The ramuli chorii are attached to the cytotrophoblastic shell.

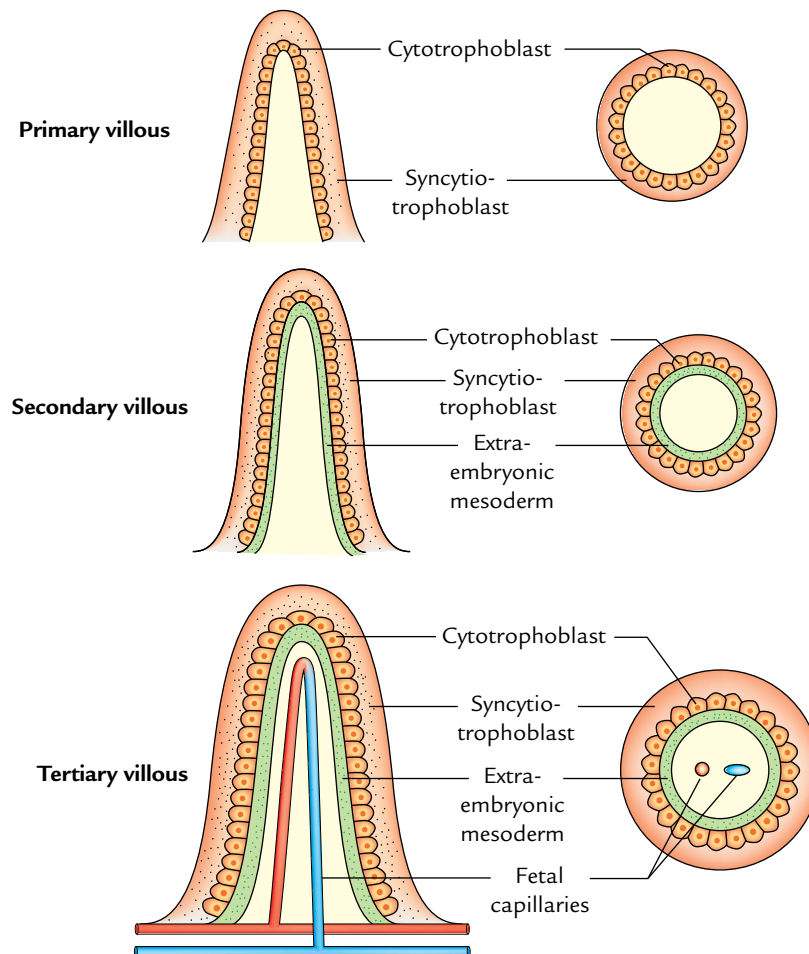


Fig. 6.11 Three stages of development of villi. Figures on the right side are the sectional views of three types of villi.

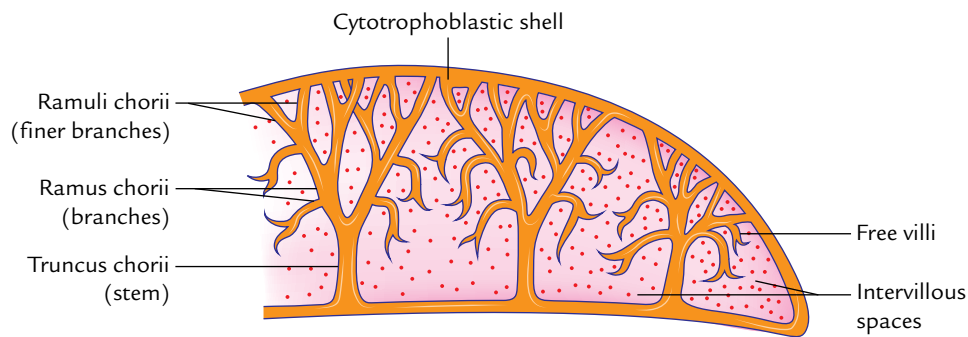


Fig. 6.12 Anchoring villi. Note each anchoring villi consists of a stem called *truncus chorii*, which divides into a number of branches called *ramus chorii*, which in turn divides into a number of finer branches called *ramuli chorii*.

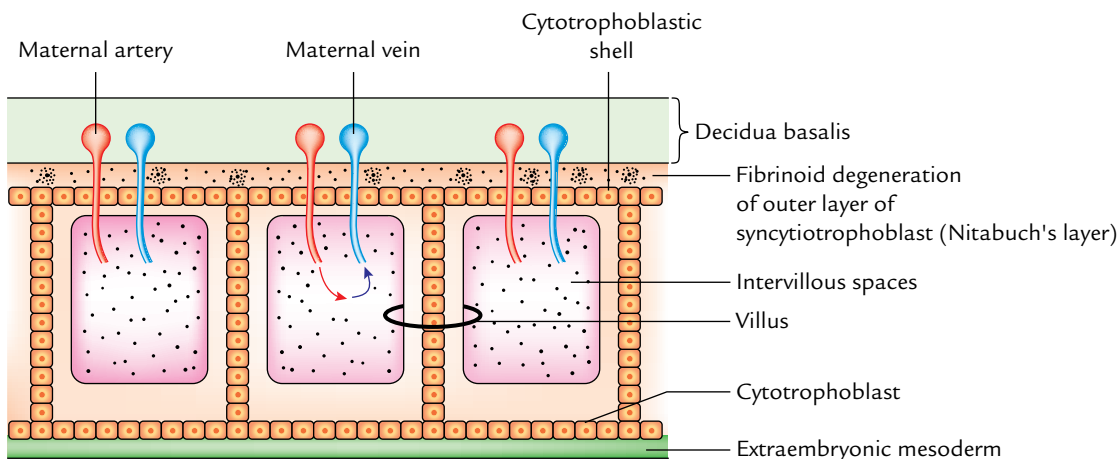


Fig. 6.13 Formation of cytotrophoblastic shell.

The anchoring villi give off numerous offshoots that grow and move freely into intervillous spaces as free villi.

In addition to this, the new villi are further added from chorionic side; thus converting the intervillous spaces into a 'bag of vascular sponges.'

The formation of cytotrophoblastic shell divides the syncytiotrophoblast into outer and inner layers. The outer layer undergoes fibrinoid degeneration to form Nitabuch's layer.

Clinical Correlation

Chorionic villus biopsy: The chorionic villus biopsy is done to detect the genetic disorders much earlier than the amniocentesis permits (for details see page 315).

Lobulation of Placenta (Fig. 6.14)

After the formation of anchoring villi, a number of septae grow inward from the uterine endometrium into the intervillous spaces and divide the placenta into (15–20) lobes called **cotyledons**. Each cotyledon contains 2–3 anchoring villi. As the pregnancy proceeds the placenta also enlarges

to meet the need of the fetus. At term the placenta covers nearly 30% of the internal surface of the uterus.

Full-term Placenta

The fully formed placenta is a disc-shaped compact mass of vascular tissue.

Features of a full-term placenta (Fig. 6.15)

1. It is like a flat circular disc (i.e., discoid).
2. It has a diameter of 15–20 cm.
3. It weighs about 500 g.
4. It presents two surfaces: maternal and fetal.
 - (a) Its maternal surface presents 15–20 lobes/cotyledons.
 - (b) Its fetal surface presents a smooth shining surface, at the approximate center of which the umbilical cord is attached.

N.B. The maternal surface of placenta has grooves and rounded elevations (cotyledons) and presents a *cobblestone appearance* (cobble=rounded stone). The cobblestones are generally used by engineers for paving the roads, particularly in public gardens. The fetal surface of the placenta is smooth and shiny. It is covered with amnion. It presents chorionic vessels running in the chorionic plate deep to the amnion.

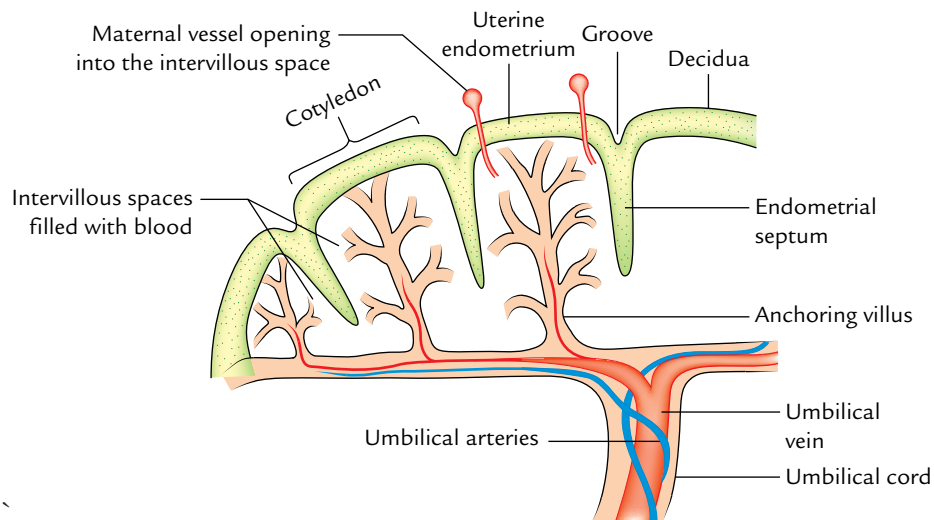


Fig. 6.14 Formation of cotyledons (lobes) of placenta. Placenta consists of 15–20 cotyledons, and each cotyledon contains 2–3 anchoring villi.

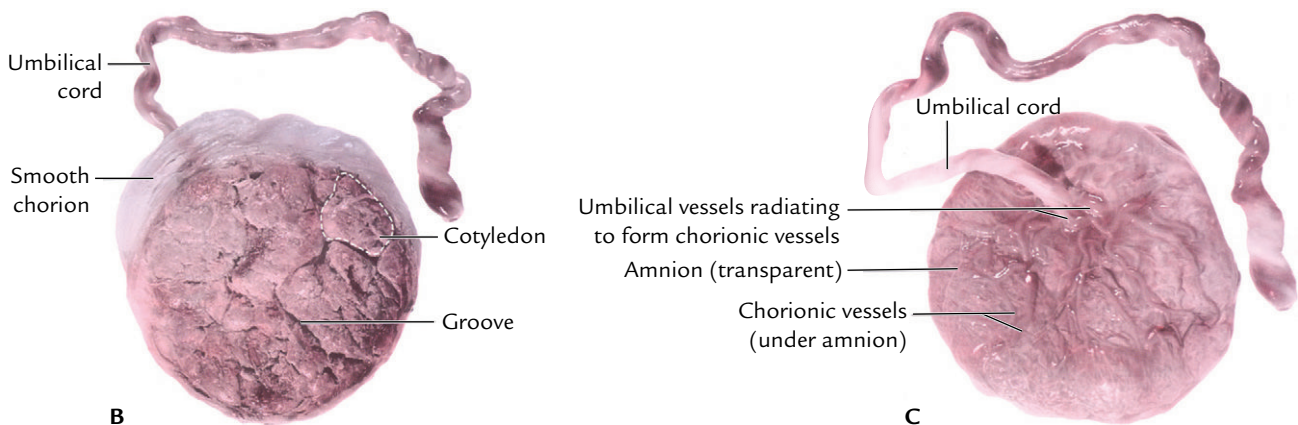
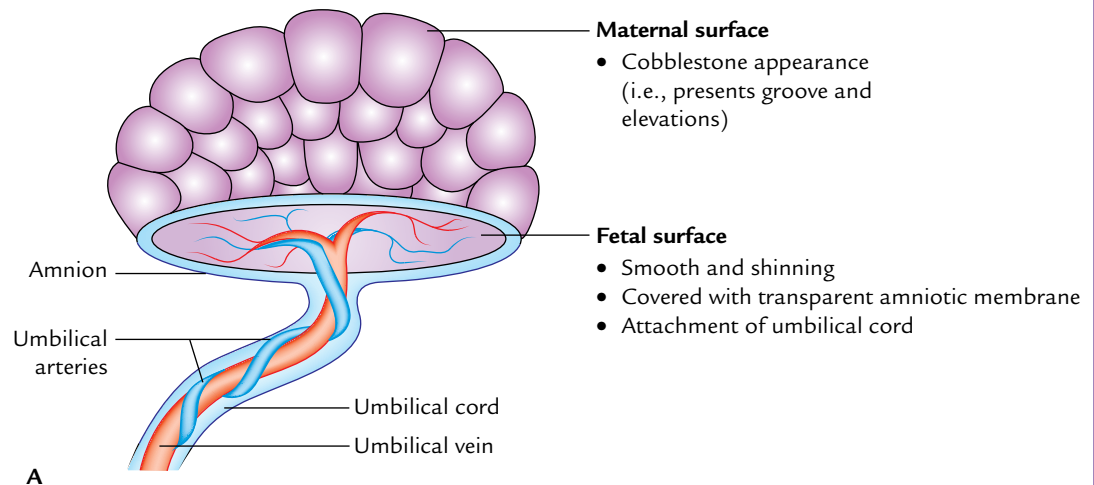


Fig. 6.15 Full-term placenta. A. Schematic diagram showing features on the maternal and fetal surfaces of placenta. B. Real specimen of placenta showing features on its maternal surface. C. Real specimen of placenta showing features on its fetal surface.

Placental Barrier or Placental Membrane

The **placental membrane** separates maternal and fetal blood within placenta. Thus, there is no mixing of maternal and fetal blood in the placenta.

The intervillous spaces are filled with maternal blood derived from endometrial arteries and drained by endometrial veins. The chorionic villi contain fetal blood vessels.

The **maternal blood** in the intervillous space is separated from the **fetal blood** within the fetal blood

vessels present in the villi by placental membrane (also called placental barrier).

It is across this membrane that the exchange of gases, nutrients, and waste products take place between maternal and fetal blood.

Constituents of Placental Membrane (Fig. 6.16)

The placental membrane is made up of five layers. From the maternal side to fetal side these are:

1. Syncytiotrophoblast
2. Cytotrophoblast (up to 20 weeks)
3. Basement membrane of cytotrophoblast
4. Mesoderm in the core of villus
5. Endothelium and basement membrane of fetal capillaries.

In later part of pregnancy, as the fetus and its nutritional demands increase the placental membrane becomes thin to increase the efficiency of transport of nutrients across it. Thus in the early part of pregnancy the placental membrane is about 0.025 mm thick, but in the later parts of pregnancy it remains only 0.002 mm thick.

However, at the end of pregnancy the efficiency of placental membrane reduces due to deposition of fibrinoid material on the surface of the membrane.

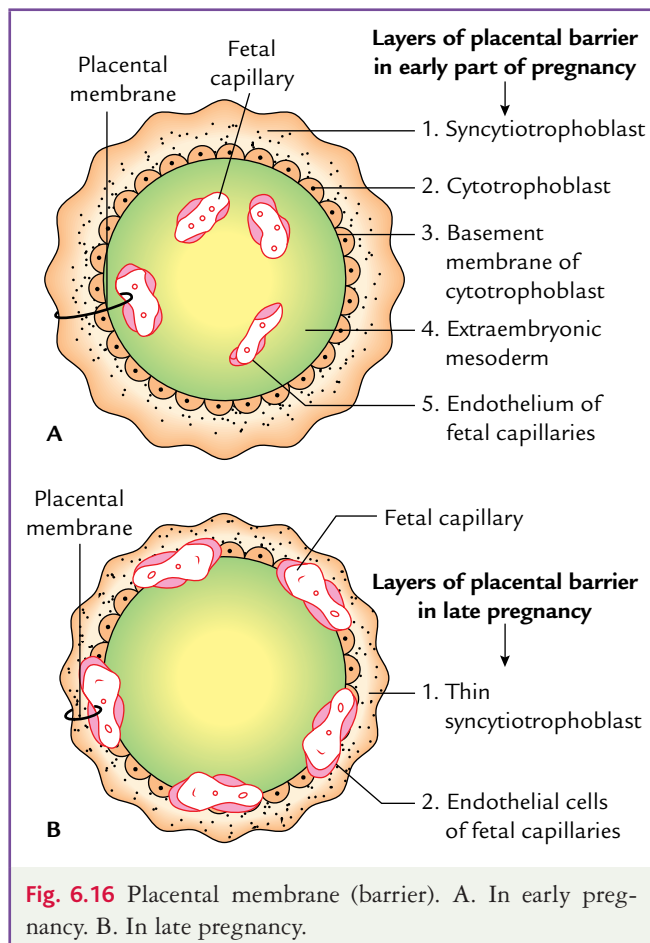


Fig. 6.16 Placental membrane (barrier). A. In early pregnancy. B. In late pregnancy.

Factors responsible for thinning of placental membrane

1. Syncytiotrophoblast becomes thin.
2. Cytotrophoblast disappears from the villi.
3. Two basement membranes disappear.
4. Endothelial cells of fetal capillaries become thin.

N.B. The placental membrane/barrier measures about 14m², i.e., roughly equal to the absorptive area of the GIT.

In humans maternal blood is separated from fetal blood by chorionic tissue; hence human placenta is termed **hemochorial**.

N.B. Phylogenetic classification of placenta: It is based on maternal and fetal tissues that come in contact. Phylogenetically the placenta is classified into following five types.

	Type	Maternal tissue	Fetal tissue
1	Epitheliochorial	Uterine epithelium	Chorion
2	Endotheliochorial	Endothelium of blood vessel	Chorion
3	Hemochorial	Blood	Chorion
4	Hemoendothelial	Blood	Endothelium of blood vessel
5	Endothelioendothelial	Endothelium of maternal blood vessel	Endothelium of fetal blood vessel

Placental Circulation (Fig. 6.17)

The circulation of blood in the placenta is of two types: maternal and fetal.

Maternal Placental Circulation

About 80–100 spiral arteries and number of veins of uterine endometrium (decidua basalis) open into the intervillous spaces. The blood enters the intervillous space through spiral arteries, and under the pressure of blood in arteries, the blood reaches right up to the **chorionic plate**. It then slowly passes around the branches of villi for exchange across the very thin placental membrane. Then the blood from intervillous space is drained by the veins of decidua basalis.

N.B.

- Blood circulation in the intervillous spaces begins as early as on ninth day of pregnancy.
- In fully formed placenta, the intervillous space contains 150 ml of blood, which is replaced every 15–20 seconds (i.e., 3–4 times per minute).

Fetal Placental Circulation

The fetal blood comes to placenta through the umbilical arteries. These arteries after entering the placenta ramify freely in the chorion and their branches enter the chorionic villi.

Congenital Anomalies of the Placenta

The congenital anomalies of the placenta are grouped into two types: (a) anomalies due to abnormal shape and (b) anomalies due to abnormal site of attachment of umbilical cord.

A. Anomalies Due to Abnormal Shape (Fig. 6.18)

Normally the placenta is circular and discoid/discoidal (circular disc shaped). The various anomalies of the shape of placenta are discussed below.

1. **Bilobed (bidiscoidal) placenta:** The placenta consists of two lobes (Fig. 6.18A).

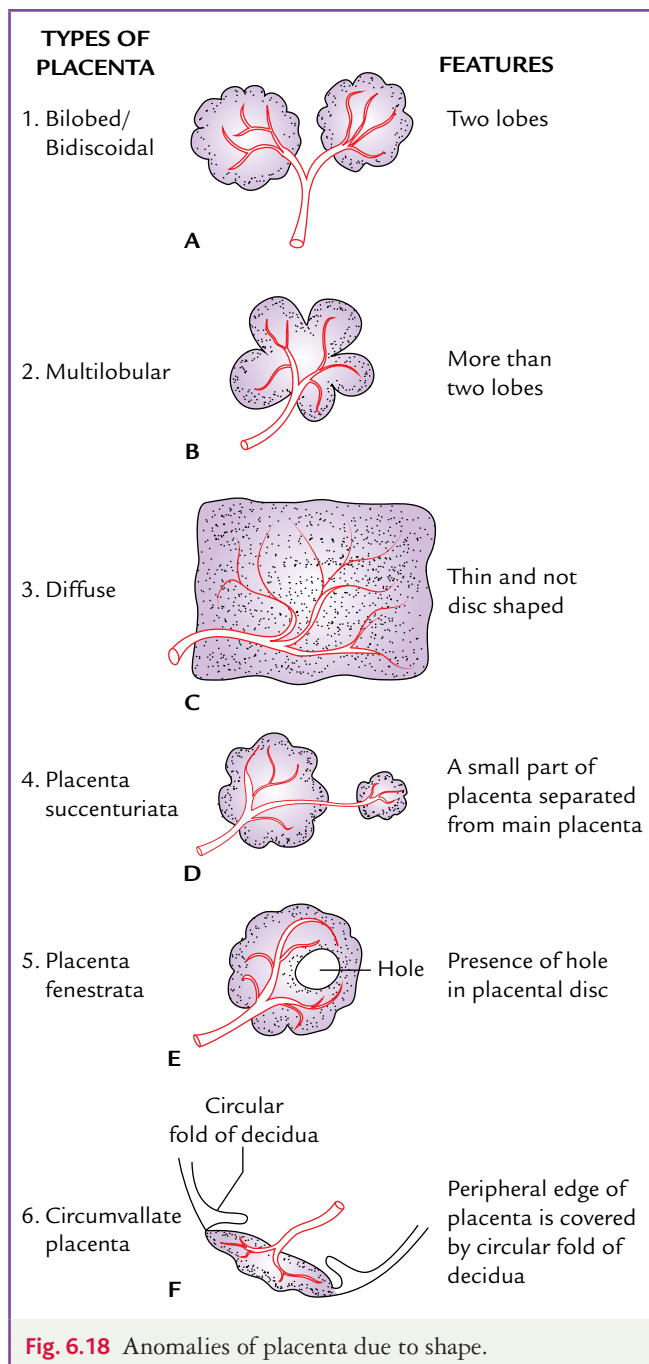


Fig. 6.18 Anomalies of placenta due to shape.

2. **Multilobular placenta:** The placenta consists of more than two lobes (Fig. 6.18B).
3. **Diffuse placenta (Fig. 6.18C):** The placenta is thin and not disc shaped. It occurs when chorionic villi persist all around the blastocyst.
4. **Placenta succenturiata (Fig. 6.18D):** In this type, a small part of the placenta is separated from the main (rest) part of the placenta, but remains connected through blood vessels and placental membranes.
5. **Placenta fenestrata (Fig. 6.18E):** In this type, a hole is present in the placental disc.
6. **Circumvallate placenta (Fig. 6.18F):** In this type, the peripheral edge of the placenta is covered by a circular fold of the decidua.

B. Anomalies Due to Abnormal Site of Attachment of Umbilical Cord (Fig. 6.19)

Normally the umbilical cord is attached to the center of placenta on its fetal side. The various anomalies of placenta due to abnormal attachment of umbilical cord are mentioned below.

1. **Marginal (Battledore) placenta (Fig. 6.19A):** When the cord is attached to the margin of the placenta.
2. **Furcate placenta (Fig. 6.19B):** When blood vessels of umbilical cord divide before reaching the placenta.
3. **Velamentous placenta (Fig. 6.19C):** When the umbilical blood vessels are attached to amnion and ramify there before reaching the placenta.

N.B. Anomalies due to abnormal site of attachment of placenta to the uterine wall, e.g., placenta previa (see page 61).

Umbilical Cord

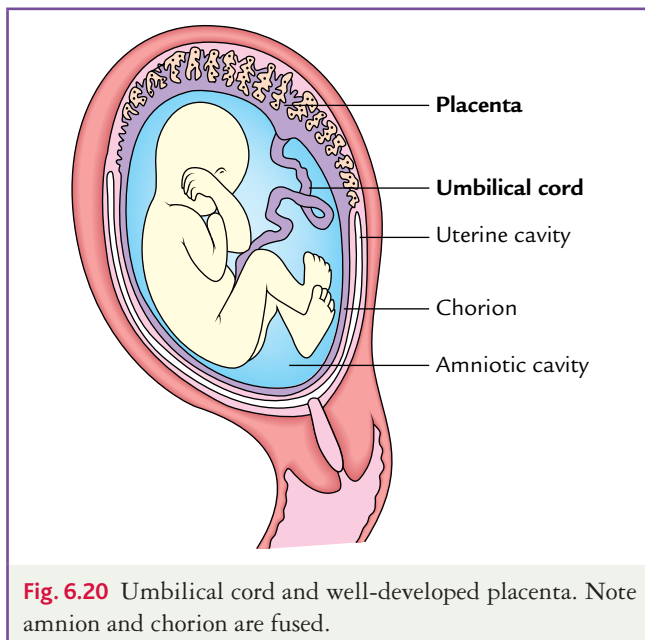
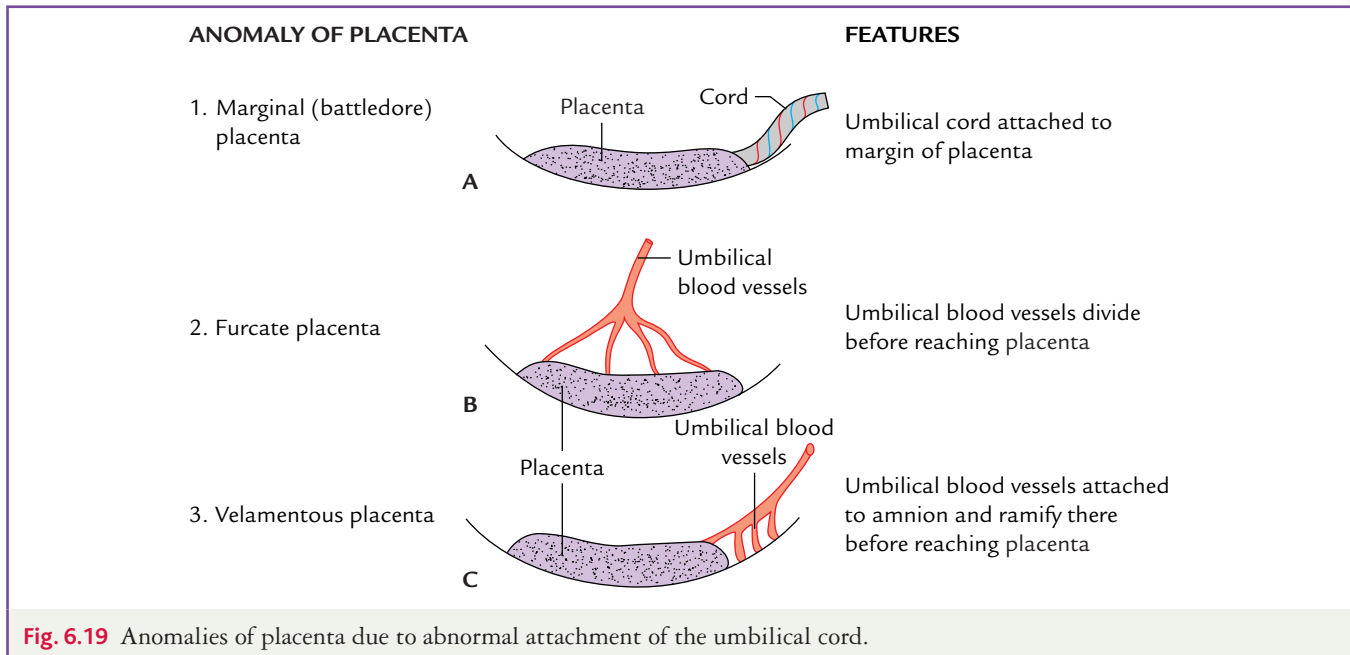
The umbilical cord is a long cord-like structure by which fetus is attached to the uterine wall via placenta. It connects umbilicus of a fetus to the center of fetal surface of the placenta (Fig. 6.20). It is covered by glistening amniotic membrane. At full-term, one end of this cord is attached to the center of anterior abdominal wall of fetus (umbilical region) and the other end is attached to the center of fetal surface of the placenta. The cord is twisted and presents false knots.

N.B. The umbilical cord has natural twists because the umbilical vein is longer than the umbilical arteries.

Measurements (At Full-term)

Length: 50–55 cm (about 2 ft)

Breadth: 1–2 cm

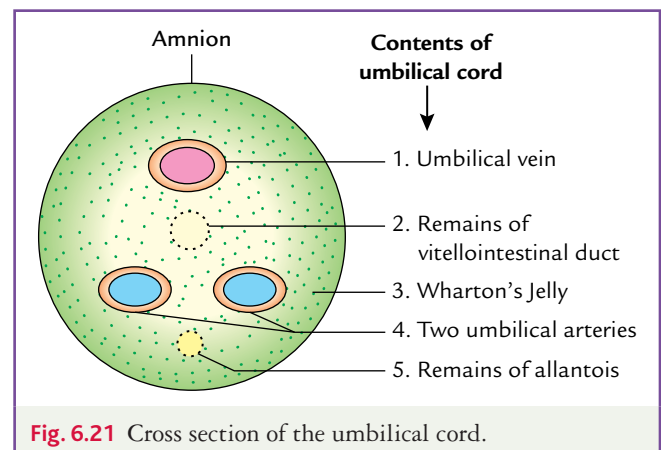


The umbilical cord develops from connecting stalk (the part of extraembryonic mesoderm in which the extraembryonic celom does not develop).

Initially, the connecting stalk is attached to the roof of amniotic cavity at one end and trophoblast at the other end.

Gradually, with the further development of embryo, it becomes narrower and moves to the caudal end of the embryo. Later with the formation of tail fold, it moves ventrally in the region of umbilicus (for details see Fig. 5.10, page 53). Now it connects the embryo with chorion. As the placenta develops the connecting stalk connects the fetus with the placenta.

The umbilical vessels develop in the connecting stalk and the primary mesoderm of connecting stalk



undergoes mucoid generation to form a gelatinous substance called **Wharton's jelly**. The Wharton's jelly protects the umbilical vessels.

As the amniotic cavity enlarges it obliterates the extraembryonic celom and forms a tubular sleeve around the umbilical cord.

Contents of Umbilical Cord (Fig. 6.21)

1. Two umbilical arteries
2. One umbilical vein (left umbilical vein)
3. Wharton's jelly
4. Remains of allantoic diverticulum
5. Remains of vitellointestinal duct (remnant of yolk sac).

Functions of Umbilical Cord

The umbilical arteries arising from ventral divisions of internal iliac arteries carry deoxygenated blood from

fetus to the placenta. After oxygenation in the placenta, the umbilical vein carries oxygenated blood from the placenta to the fetus. Note **placenta is an organ of respiration in fetus**.

Clinical Correlation

Cord prolapse: The umbilical cord due its long length is likely to prolapse through the uterus during parturition (child birth) leading to a clinical condition called *cord prolapse*. In this condition, the cord is likely to be compressed between fetal head and pelvic wall of mother. This may lead to hypoxia to the fetus.

- In about one-fifth of all deliveries, the cord may encircle the neck of the fetus and may cause strangulation.
- Too short cord may create difficulty in parturition by pulling the placenta.

Twinning and Fetal Membranes

The nurturing of two conceptuses at the same time is termed twinning.

Two infants born at the same time are called **twins**. Similarly, there can be birth of three (**triplets**), four (**quadruplets**), or more at the same time. There are two types of twins: (a) monozygotic and (b) dizygotic.

The arrangement of fetal membranes in twins varies considerably, depending upon the type of twins.

Dizygotic (Fraternal) Twins (Fig. 6.22)

About two-third of twins are dizygotic (fraternal) twins. Their incidence increases with maternal age (7–10 per 1000 births).

They result from the fertilization of two different secondary oocytes by two different sperms. The resultant two zygotes form two blastocysts—each of which implants separately into the uterine endometrium. These twins are not genetically alike. They do not look alike and can be of different sex. In such twins, the placenta, chorionic, and amniotic sacs are separate and independent. Since these twins have totally different genetic constitutions, they have no more resemblances than any other two brothers and sisters (siblings).

N.B. Sometimes two placentas are so close together that they fuse. In this condition, sometimes each dizygotic twin possesses two different types of red blood cells (**erythrocyte mosaicism**) because of exchange of red blood cells between two placentas.

- In humans, the **dizygotic twins** are more frequent than the **monozygotic twins** (3:1 ratio).
- In twin births, **twin boys are the most common**, next common are a boy and a girl, and least common are twin girls.

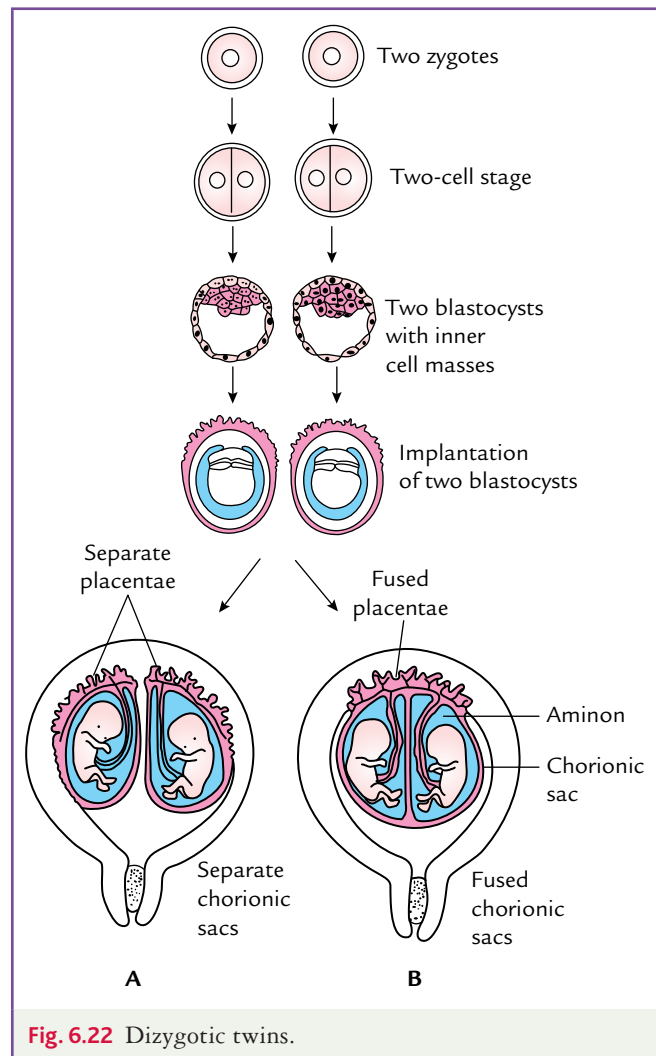


Fig. 6.22 Dizygotic twins.

Monozygotic (Identical) Twins (Fig. 6.23)

The monozygotic twins result from fertilization of one secondary oocyte by one sperm. The resultant zygote forms a blastocyst in which inner cell mass (**embryoblast**) splits into two. Therefore, the monozygotic twins are genetically identical. These twins are of the same sex and look alike. They have common chorionic and amniotic sacs. The placenta is, however, one but with two umbilical cords.

Sometimes two independent placentas are formed, which may fuse with each other but do not have anastomosis of blood vessels.

N.B. The cells formed by first few mitotic divisions (cleavage) are totipotent, i.e., each cell is capable to form one embryo. If two cells of two-cell stage of cleavage separate they develop independently. In this condition, the twins have separate amniotic and chorionic sacs as in dizygotic twins.

The zygote normally develops till morula stage. But when it is converted into blastocyst two inner cell masses (two embryoblasts) form within it. Each of

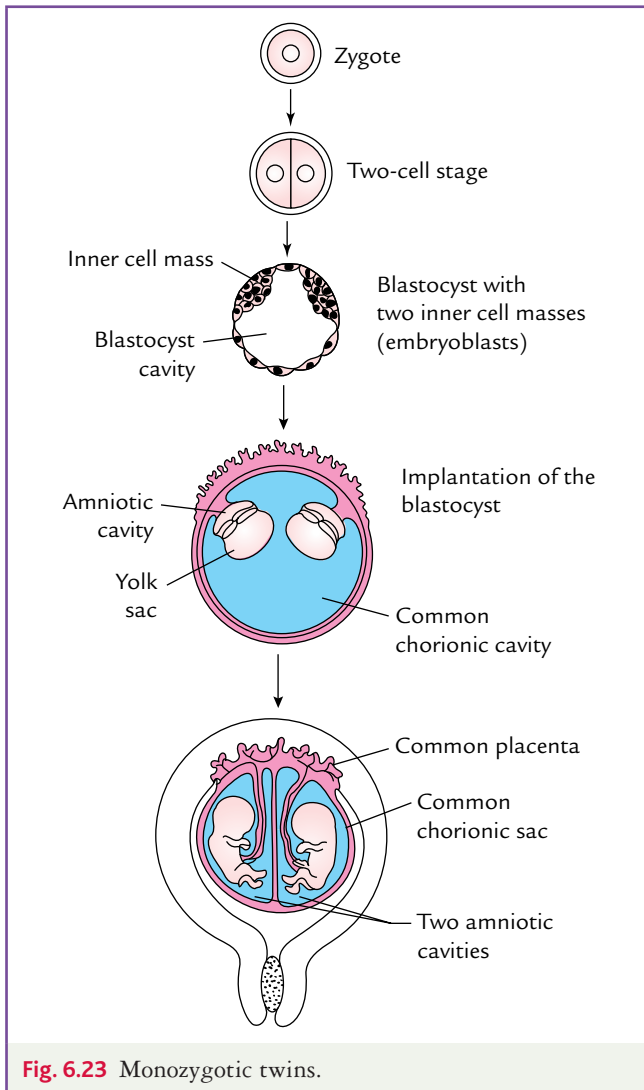


Fig. 6.23 Monozygotic twins.

Table 6.1 Differences between monozygotic and dizygotic twins	
Monozygotic twins	Dizygotic twins
• Form from single zygote	Form from two zygotes
• Incidence is more common	Incidence is less common
• Genetically identical	Genetically not identical
• Twins are of the same sex	Twins are of the same sex or of different sex
• Resemblance is similar	Resemblance is just like any other two siblings
• Mostly diamniotic, mono-chorionic, with single placenta	Mostly have two amnions, two chorions, and two placentas
• Are often called conjoined twins	Not seen as conjoined twins

which develops into the fetus. In this condition, the two fetuses have a common placenta, but each lies in an independent amniotic sac.

The differences between the monozygotic and dizygotic twins are given in Table 6.1.

Clinical Correlation

Twins have a high incidence of morbidity and mortality due to preeclampsia, congenital anomalies, premature delivery, etc.

1. **Conjoint (Siamese) twins:** This condition is seen in monozygotic twins. Monozygotic twins in which the inner cell mass (embryoblast) does not completely split. In this condition, two fetuses are joined to each other by a tissue bridge.

Classification of conjoint twins: The conjoint twins are classified into following four types based on the site and extent of fusion (Fig. 6.24).

- (a) Craniophagus: Fusion of heads
- (b) Thoracophagus: Fusion of thorax
- (c) Cephalothoracophagus: Fusion of head and thorax
- (d) Pygophagus: Fusion of sacral regions

The conjoint twins can be separated only if they have no vital parts in common.

N.B. Phagus = Fastened

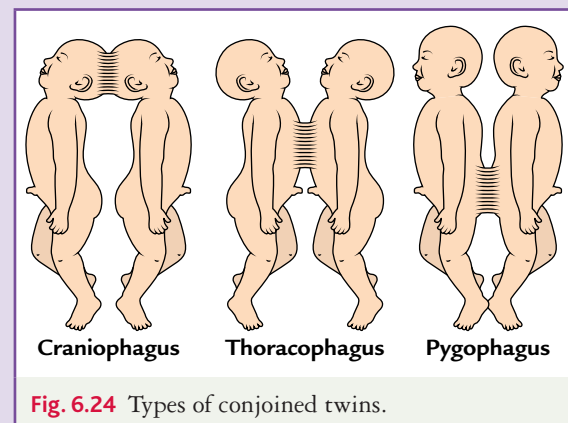


Fig. 6.24 Types of conjoined twins.

2. **Parasitic twins:** When one member of conjoint twins remains rudimentary due to diminished blood supply and grows like a parasite from the body of the well-developed co-twin, it is termed **parasitic twin** (Fig. 6.25).

Occasionally the parasitic twin may be completely enclosed within the body of the co-twin. In this condition, the fetus is termed **fetus in fetu**.

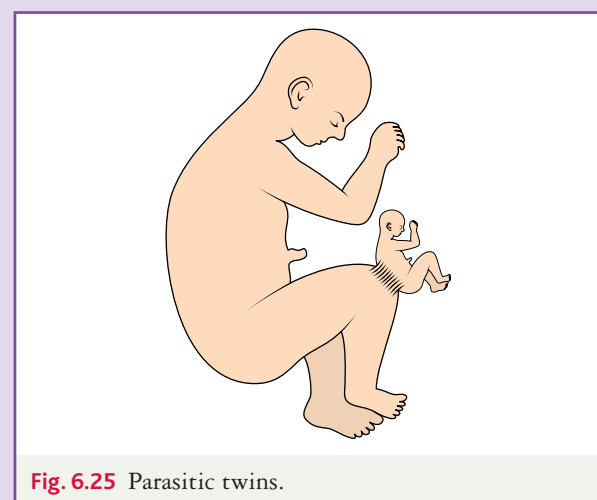


Fig. 6.25 Parasitic twins.

GOLDEN FACTS TO REMEMBER

- | | |
|--|---|
| ➤ Most unique feature of placenta | Only organ that develops from two different individuals (mother and fetus) |
| ➤ Three main functions of placenta | (a) Transport of gases and nutrients
(b) Metabolism (e.g., synthesis of glycogen)
(c) Endocrine secretion (e.g., human chorionic gonadotrophin) |
| ➤ Number of cotyledons in fully developed placenta | 60–100 |
| ➤ Weight of placenta at full-term | 500 g |
| ➤ Total surface area of placental membrane | 14 m ² (i.e., equal to absorptive area of the gastrointestinal tract) |
| ➤ Langer's layer | Cytotrophoblast |
| ➤ Syncytiotrophoblast | Multinucleated mass of cells (derived from trophoblast) in which cell boundaries are not discernible |
| ➤ Following the birth of a baby the placenta is shed off | After about half an hour |
| ➤ Definitive placenta is formed at the end of | Second month of IUL |

CLINICAL PROBLEMS

1. An ultrasound of a pregnant mother with 7 months of gestation revealed excessive accumulation of fluid in the amniotic cavity. Name the clinical condition and give its embryological basis.
2. The thyrotoxic mothers give birth to babies with normal thyroid function. Give the embryological basis?
3. The pregnant ladies are advised not to take drugs during pregnancy without prescription by a specialist. They are also advised to avoid cigarette, smoking, and ingestion of alcohol during pregnancy. Why?
4. The leakage of fetal blood or syncytial tissue in the mother may lead to immune responses such as **erythroblastosis fetalis**. Explain in detail.
5. Out of following two techniques: **amniocentesis** and **chorionic villus biopsy**, which technique can detect genetic disorder in fetus earlier?
6. The fetus possesses paternal antigens, which should act as foreign antigens to the tissue of the uterine wall of the mother. But mother tolerates these antigens of fetus until pregnancy reaches the full-term. Explain.
7. What is **superfetation**? Give its embryological basis.

CLINICAL PROBLEM SOLUTIONS

1. The excessive accumulation of amniotic fluid in the amniotic sac is called **polyhydramnios** (or hydramnios). This clinical condition occurs due to esophageal atresia and CNS defects (anencephaly) because of which fetus is unable to swallow the amniotic fluid. The high incidence of polyhydramnios (25%) is noted in diabetic mothers. In 35% cases, the cause is not known.
2. This is because the **placental membrane** acts as a **barrier** for the passage of maternal hormones such as ACTH and TSH into the fetal blood.

3. This is because alcohol and certain drugs such as thalidomide, phenytoin, diazepam, etc., can cross the placental barrier and cause congenital anomalies in the fetus.
The alcohol and cigarette smoking may be hazardous for embryo. The cigarette smoking may be responsible for the low birth weight. The alcohol may be responsible for certain congenital anomalies such as mental retardation, microcephaly, etc.
4. If the fetus is Rh +ve and mother is Rh -ve, in such a case if the fetal blood cells enter into maternal blood during parturition at the time of birth, they act as antigen. They enter the maternal blood and act as antigen. As a result, there occurs an **antigen-antibody response**, and antibodies are formed in the maternal blood. This baby will not be affected by these antibodies in the present case, but in subsequent pregnancies the maternal antibodies (against the fetal antigens) pass across the placenta into the fetus and cause breakdown of fetal red blood cells producing a clinical condition called **erythroblastosis fetalis** (or **hemolytic disease of the fetus**).
5. Both these techniques are used to detect the genetic disorders such as Down's syndrome by examining the chromosomes in the fetal cells. The **amniocentesis** is usually performed at the 14th or 15th week of pregnancy to obtain the amniotic fluid. The **chorionic villus biopsy** is a technique used to detect the genetic disorder much earlier than amniocentesis permits. The chorionic villus biopsy can provide genetic information at 10 to 12 weeks of gestation.
6. The mother does not reject the fetus because maternal tissue fails to recognize HLA antigens of trophoblastic cells as the entire trophoblastic shell is covered or coated by the layer of **fibrinoid material (Nitabuch's layer)**. The fibrinoid material is negatively charged and hence repels the negatively charged material lymphocytes.
7. The **superfetation** is an embryological event in which fetuses are of different ages in a single pregnancy.
Under normal conditions, the ovulation ceases during pregnancy, but sometimes an aberrant ovulation may take place during pregnancy, and if an ovum is fertilized at a subsequent period then it leads to multiple births with newborns of different ages.

7

Integumentary System

Overview

The skin and its appendages (sebaceous glands, sweat glands, hair, and nails) constitute the **integumentary system**.

The skin is the largest organ of the body and covers over 76,000 cm² (300 inches²) of the body surface of an average adult.

The skin consists of two layers: a superficial layer, the **epidermis** and a deep layer, the **dermis** or **corium**.

The skin develops from two sources: (a) the **epidermis** develops from surface ectoderm and (b) the **dermis** develops from the underlying mesoderm. In addition to the above two sources, the melanoblasts (dendritic cells) of epidermis develop from the **neural crest cells**. The **appendages of skin** (e.g., sebaceous and sweat glands, hair, and nails) are derived from the epidermis.

Development of Skin

Epidermis (Fig. 7.1)

The epidermis develops from surface ectoderm. Initially the surface ectoderm consists of a single layer of cells. In the second month, these cells proliferate and form a second layer of flattened cells called **periderm/epitrichium**.

The epidermis now consists of two layers: superficial layer of flattened cells (**periderm**) and deep layer of cuboidal cells (**basal layer**).

With further proliferation of cells in the basal layer, a third **intermediate layer** is formed.

The **basal layer** functions as a germinative layer and is called **stratum germinativum**. The cells of the basal layer proliferate and differentiate to form the various layers (strata) of the epidermis.

At the end of the third month, the epidermis consists of four layers. From deep to superficial these are:

1. Basal layer (stratum germinativum)
2. Spinous layer (stratum spinosum)
3. Granular layer (stratum granulosum)
4. Horny layer (stratum corneum).

1. The **basal layer** consists of columnar cells. They constantly divide mitotically and move superficially to renew the epidermis. It usually takes 6–8 weeks for the cells to move from the basal layer to surface of the skin.

2. The **spinous layer** consists of numerous irregular prickle cells (cells with spine-like processes).

The spiny appearance of this layer is due to the shape of the prickle cells (keratinocytes).

3. The **granular layer** consists of three or four flattened rows of cells. The cytoplasm of the cells of the granular layer contains *keratohyalin granules* due to the process of *keratinization*.

The cells superficial to granular layer are cells with scanty nuclei, and form a homogeneous layer called **stratum lucidum**. Histologically, this layer appears clear. It exists only in lips and thick skin of the soles and palms.

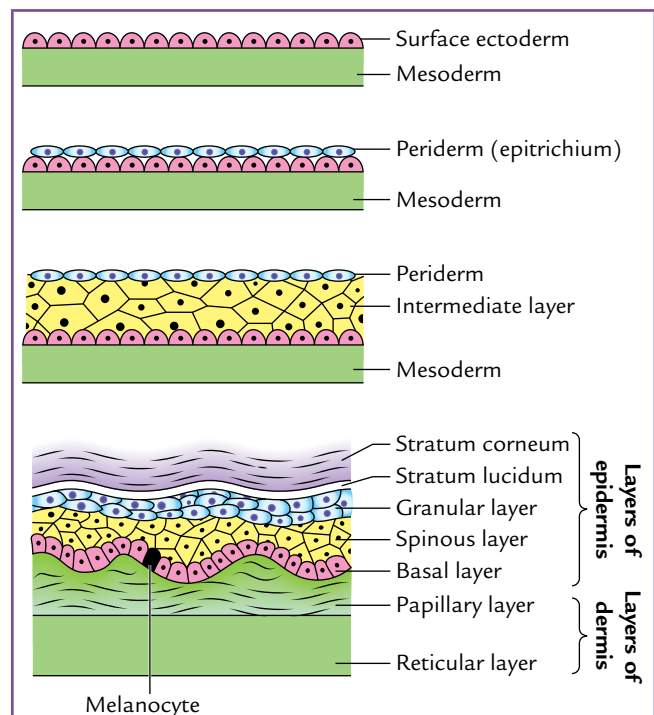
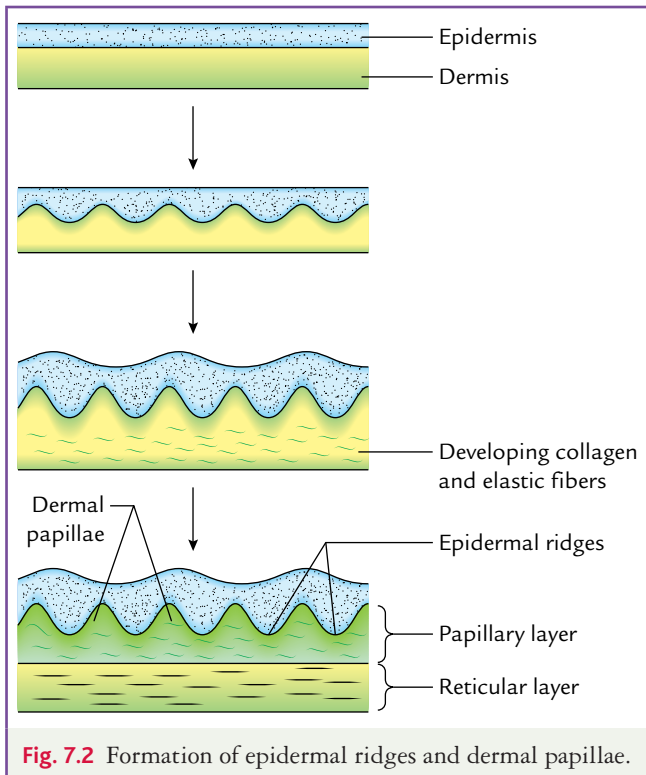


Fig. 7.1 Stages of development of skin.



4. The **horny layer** consists of several layers of flattened scale-like cells that are continuously shed off as flake-like residues of cells deprived of their nuclei and eventually die. The cytoplasm of these cells is filled with *keratin granules*.

The **melanoblasts (dendritic cells)** appear in the basal layer during the third month. They are derived from **neural crest cells**.

N.B. The periderm disappears when the stratum corneum is formed.

Formation of Epidermal Ridges and Dermal Papillae

The epidermis shows thickenings that project in the dermis to form **epidermal ridges**. The parts of dermis projecting between the epidermal ridges are called **dermal papillae** (Fig. 7.2).

Clinical Correlation

Fingerprints: On the palm, sole, and ventral surface of fingers and toes the epidermal thickenings produce surface ectodermal ridges. These ridges form the typical patterns, the development of which is genetically controlled and these patterns are unique for each individual including identical twins. This forms the basis of personal identification from the fingerprints for the medico-legal purpose. In children with chromosomal abnormalities, the ectodermal patterns on the hands and fingers are used as a

diagnostic tool. For example, these patterns are abnormal in mongolism or trisomy 21.




Fig. 7.3 Four basic types of dermatoglyphic patterns in the digits.

The study of **epidermal ridge pattern** is called '**dermatoglyphics**' and it can be used as one of the diagnostic tools in various genetic disorders.

The four basic types of dermatoglyphic patterns in the digits are (Fig. 7.3): (a) arch, (b) whorl, (c) loop, and (d) composite (i.e., combination of earlier three patterns).

Dermis

The **dermis** develops from mesenchyme lying underneath the surface ectoderm. This mesenchyme is derived from three sources: (a) paraxial mesoderm, (b) somatopleuric layer of lateral plate mesoderm, and (c) neural crest cells.

The mesenchymal cells differentiate into connective tissue cells that form **connective tissue fibers** (collagen and elastic fibers) and amorphous **ground substance** of the connective tissue.

During third and fourth months dermis forms many irregular ridges called **dermal papillae**, which project into the epidermis and interdigitate with the **epidermal ridges**. The dermis differentiates into two layers:

1. Superficial papillary layer
2. Deeper reticular layer.

Most of the dermal papillae of **papillary layer** of dermis contain a small loop of capillary plexus and a sensory receptor (sensory nerve end organ). The loops of capillary plexus provide nourishment to the epidermis and to the sensory nerve end organ.

The deeper reticular layer of dermis contains large amount of fatty tissue.

The blood vessels in the dermis develop initially as endothelium-lined structures that differentiate from the mesenchyme. These primordial vessels give rise to the capillaries (**angiogenesis**). The angiogenesis of the dermis is completed by the end of first trimester of pregnancy.

Clinical Correlation

1. **Ichthyosis** (Gr. *Ichthys* = fish): It is a clinical condition characterized by dryness of skin with fish-like scaling in part or entire body. It occurs due to excessive keratinization of the skin.

In severe cases ichthyosis may result in a **grotesque appearance**, e.g., **harlequin fetus**.

2. **Albinism**: It is a clinical condition characterized by reduced or absence of pigmentation in the skin, hair, and eyes (retina lacks pigment; however iris usually shows some pigmentation). In most cases, it occurs due to abnormal synthesis of melanin by the melanocytes.

N.B. The generalized albinism is an autosomal recessive disorder whereas localized albinism is autosomal dominant disorder.

3. **Vitiligo**: It is a clinical condition characterized by patchy loss of pigmentation in the skin and overlying hair. It results from loss of melanocytes due to an autoimmune disorder.

Development of Hair (Fig. 7.4)

The hairs or pili (L. *Pilus* = hair) begin to develop early in the fetal life (7–12 weeks).

Each hair develops from downgrowth of the epidermis into underlying dermis. The cells of the stratum germinativum proliferate to form a solid epithelial cord that extends obliquely downward in the dermis to form **hair bud**. The terminal part of the hair bud becomes club shaped and forms the **hair bulb**. It is invaginated by the mesenchymal condensation of the dermis and the hair bulb now becomes **inverted cup-shaped structure**. The dermis within the cup-shaped hair bulb is called **dermal papilla**. The cells of the hair bulb at the summit of dermal papilla form the '**germinal matrix**' that later produces the hair.

The peripheral cells of developing hair follicle form **epithelial root sheath**. The dermis condenses around this sheath to form **dermal root sheath**.

The cells of the germinal matrix proliferate to form **root of the hair**. As it grows, it is pushed outside the hair follicle on the surface of skin as a **shaft of the hair**. The root and shaft of hair become keratinized.

The melanoblasts migrate into the hair bulbs and differentiate into the **melanocytes**. Melanin formed by these melanocytes is transferred to proliferating cells of the germinal matrix. This melanin is responsible for color of hair.

First hairs that appear are fine, soft, lightly pigmented, and silky. They help to hold the vernix caseosa on the skin surface. These hairs are called **lanugo**.

The lanugos (downy hairs) are replaced by **coarser hairs** during the perinatal period, which persists over most of the body except in axillary and pubic regions where they are replaced at puberty by even coarser **terminal hair**. In men similar coarse hairs appear on the face (e.g., moustaches and beard) and often on the chest.

The **definitive hair** grows to a certain length and then cease to grow, e.g., hairs of eyelashes, eyebrows, pubic, and axillary regions.

At certain sites, e.g., scalp of males and females and the face of males, the hair grows continuously throughout life. They are called **angora**.

Arrector Muscle of Hair (Arrector Pili Muscle)

The small bundle of smooth muscle fibers differentiate from the mesenchyme surrounding the hair follicle usually on one side and attach the dermal root sheath of hair follicle and papillary layer of the dermis to form **arrector pili muscle**. The contraction of arrector pili muscles causes 'goose bumps.'

Clinical Correlation

1. **Hypertrichosis** (excessive hairiness): It results due to development of unusual abundance of hair follicles or due to persistence of **lanugo hairs** that normally disappear during the perinatal period.
2. **Congenital alopecia** (absence or loss of hair): It may occur alone or with other skin abnormalities of the skin and its derivatives. It occurs either due to failure of hair follicles to develop or due to production of poor quality hairs.

Glands of the Skin

There are two types of glands in the skin: sebaceous and sweat. Both these types of glands are derived from the epidermis and grow into the dermis.

Sebaceous Glands (Fig. 7.4)

The sebaceous gland develops as a bud from the epithelial root sheath of hair follicle. The bud grows into the surrounding dermis and divides into a number of

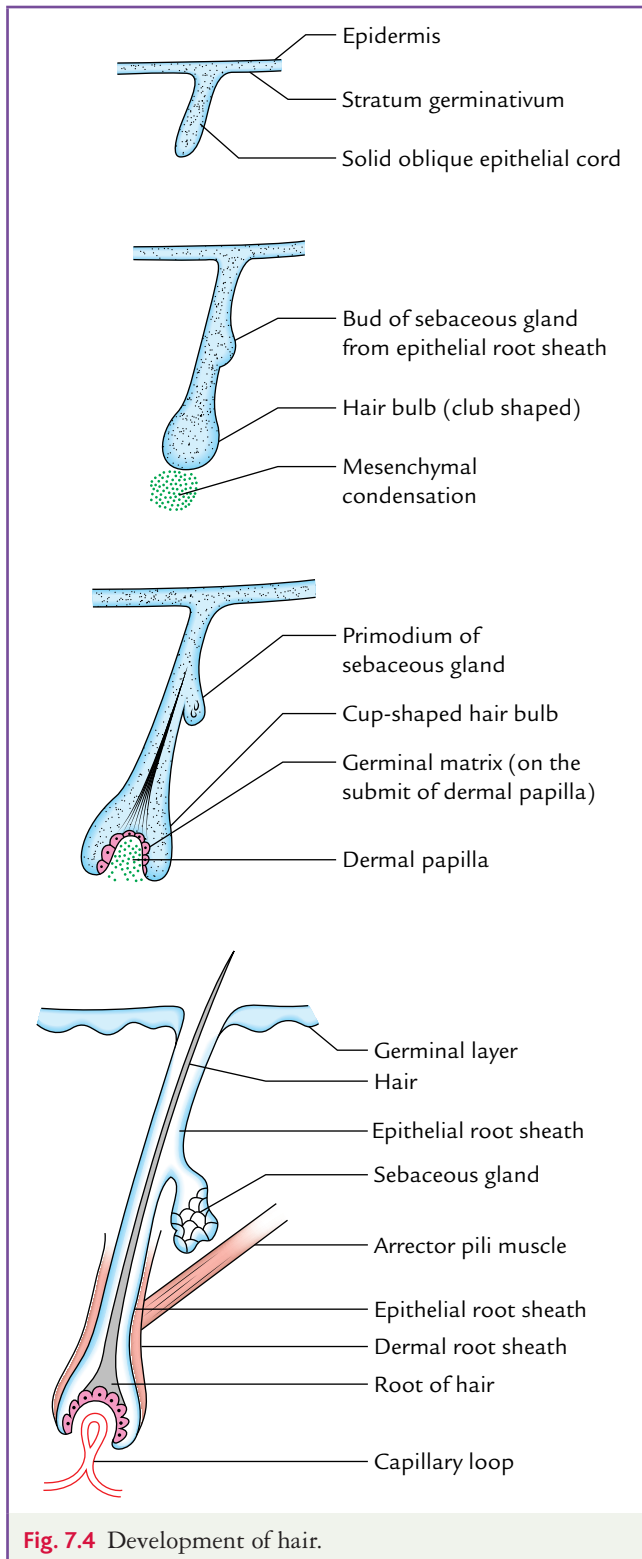


Fig. 7.4 Development of hair.

branches to form primordia of several alveoli and their associated ducts. The cells in the center of alveoli (acini) degenerate to produce an oily secretion called **sebum**. It is released into the hair follicle and from here it passes to the surface of the skin.

N.B. At few places (e.g., glans penis, labia minora), the sebaceous glands develop independent of the hair follicles as buds from the epidermis.

Sweat Glands (Fig. 7.5)

The sweat glands are of two types: **eccrine** and **apocrine**.

Eccrine sweat glands are found in the skin of most parts of the body.

The *eccrine sweat gland* develops from downgrowth of the epidermis into the underlying dermis. The cells of stratum germinativum proliferate to form a solid mass of epithelial cells that extend downward in the underlying dermis to form the bud of sweat gland. This downgrowth elongates and its terminal part becomes coiled. Later on this solid downgrowth is canalized to form lumen. The terminal coiled part of downgrowth forms *secretory part of the sweat gland*, while the proximal straight part forms *duct of the sweat gland*. The site of beginning of downgrowth from the surface epithelium forms *pore of the duct of the sweat gland*. The eccrine sweat glands start functioning shortly after birth.

Apocrine sweat glands are found in the axilla, pubic and perineal regions, and areolae of nipples. They begin to develop during puberty. They develop from same epidermal buds that form the hair follicles. Consequently these glands open into the hair follicles instead of opening on the skin surface.

N.B. The sweat produced by apocrine sweat glands contains **lipids, proteins, and pheromones**. The odor produced from these sweat glands is due to breakdown of these products. It is thought to act as a **sexual attractant**.

The difference between eccrine and apocrine sweat glands is given in Table 7.1.

Development of Nails (Fig. 7.6)

The nail develops at tips of digits of toes and fingers approximately at 10 weeks. The ectoderm at the tip of each digit thickens to form **primordium of nail**—the **primary nail field**. The first indication of development of the nail is the formation of fold of thickened epidermis. This fold is ‘U’ shaped and is called **nail fold**. The formation of nail fold defines certain structures in the terminal part of the digit—like **nail groove** and **nail bed**. The cells of germinal layer at the base of nail groove proliferate to form a thick layer of cells called **germinal matrix**.

The cells of germinal matrix proliferate, get keratinized, and form **nail plate**, which corresponds to the stratum lucidum of the epidermis. With continued proliferation of germinal matrix, the nail plate grows and slides over the nail bed. With the formation of the nail plate, the part of epidermis overlapping proximal part of the developing nail is called **eponychium**. This eponychium degenerates and exposes the nail, except at its base where it persists as cuticle. The epidermis below

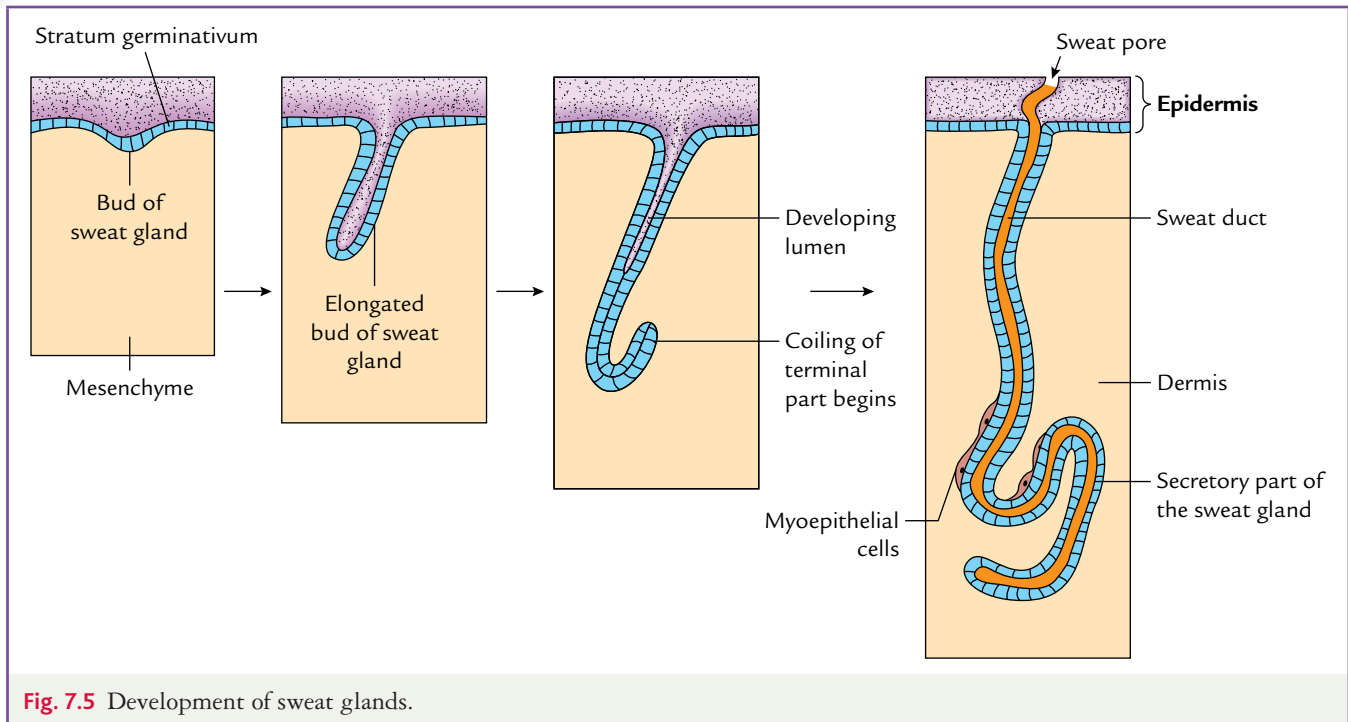


Fig. 7.5 Development of sweat glands.

Table 7.1 Difference between eccrine and apocrine sweat glands

Eccrine sweat gland	Apocrine sweat gland
<ul style="list-style-type: none"> • Found over most parts of the body 	<ul style="list-style-type: none"> • Confined to axilla, pubic and perineal regions, and areolae of the nipples
<ul style="list-style-type: none"> • Develop before birth 	<ul style="list-style-type: none"> • Develop after birth at puberty
<ul style="list-style-type: none"> • Develop directly from surface epithelium 	<ul style="list-style-type: none"> • Develop from epidermal bud that produces hair follicle
<ul style="list-style-type: none"> • Pours its secretion directly on the skin surface 	<ul style="list-style-type: none"> • Pours its secretion in the hair follicles just above the opening of sebaceous gland
<ul style="list-style-type: none"> • Secrete by merocrine mechanism (exocytosis) 	<ul style="list-style-type: none"> • Secrete by apocrine mechanism (a portion of secretory cells is shed/ pinched off and incorporated into the secretion)
<ul style="list-style-type: none"> • Secretion is watery and involved in temperature control 	<ul style="list-style-type: none"> • Secretion is thick and produces an odor that acts as a sexual attractant

free margin of the nail is called **hyponychium**. The part of the nail in the groove is called **root of the nail**.

Points to Note

- The development of finger nails precedes that of toe nails by approximately 4 weeks.
- The finger nails grow at the rate of about 1 mm per week; the growth rate of toe nails is somewhat slower.

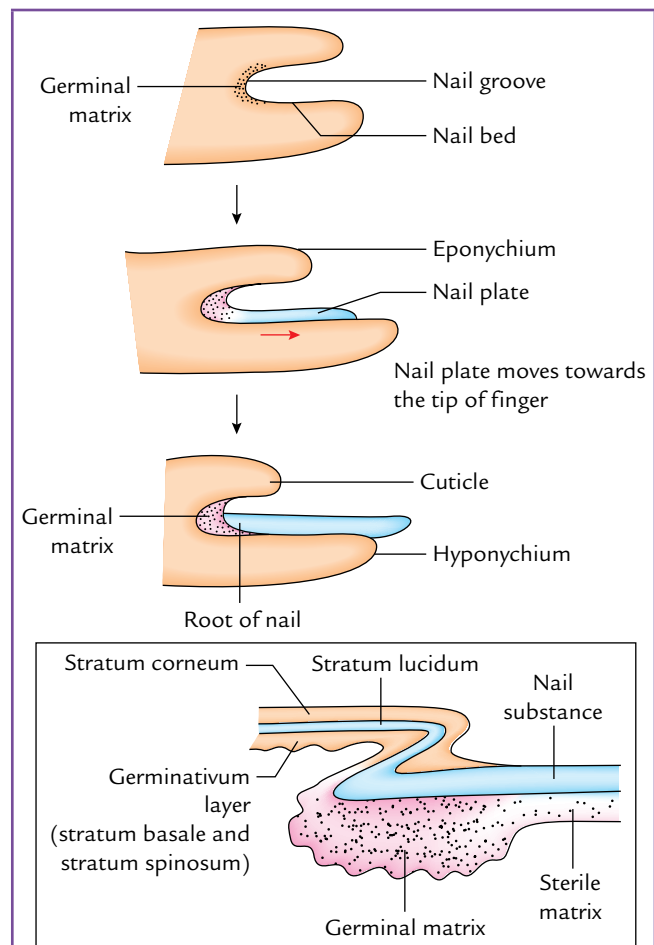


Fig. 7.6 Stages of development of a finger nail. Figure in the inset shows the detailed structure. Note finger nail reaches the end of the finger by 32 weeks (8 months).

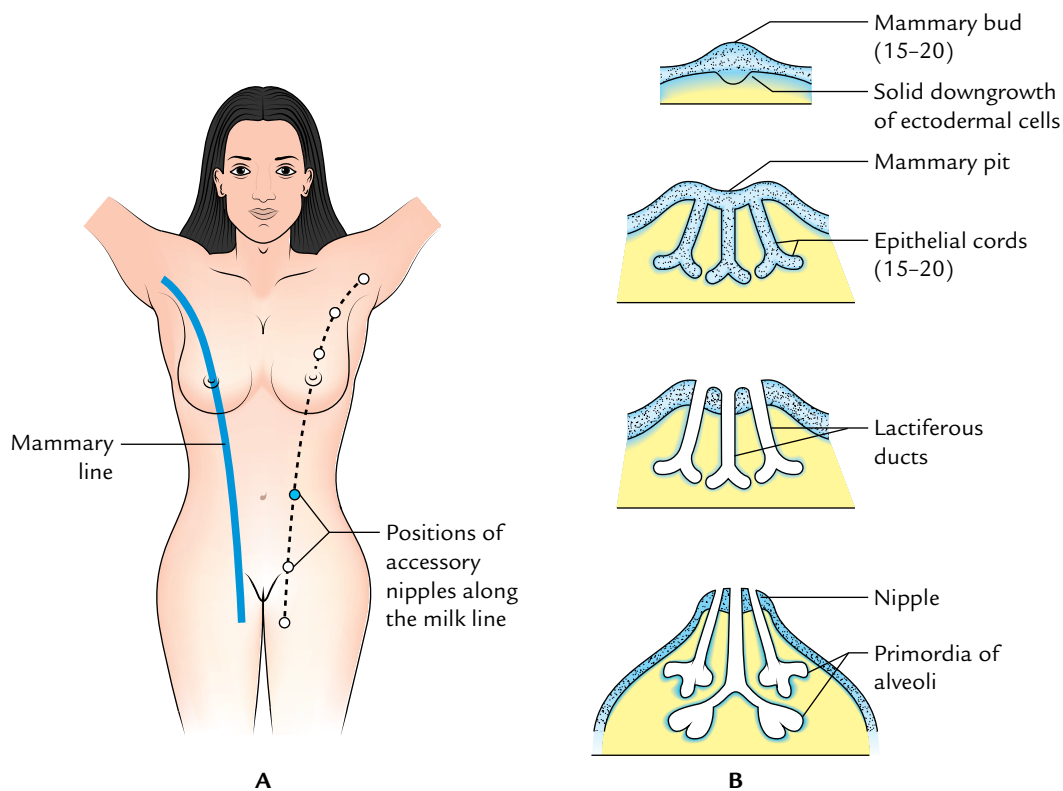


Fig. 7.7 Development of mammary gland. A. Mammary ridge (left side) and positions of accessory nipples (right side). B. Stages of development of mammary glands.

- The finger nails reach the finger tips at about 32 weeks. The toe nails reach the toe tips at about 36 weeks.
 - The growth area of the nail is **nail matrix**, which is exhibited on the surface as **lunula** (half moon shaped area) at the base of the nail.
 - Morphologically the nail substance corresponds to the stratum lucidum.
- Clinical Correlation**

Anonychia (absence of nails at birth): It is extremely rare and occurs due to failure of **nail fields** to form or failure of the proximal nail fold to form **nail plates**. The anonychia may be restricted to one or more nails.
- ### Development of Mammary Glands (Fig. 7.7)
- The mammary glands are modified and highly specialized sweat glands and therefore develop from the surface ectoderm. The development occurs as follows:
- In the fourth week, the surface ectoderm thickens on either side of the ventral aspect of trunk of embryo along the line extending from the axilla to the inguinal region to form **mammary ridge or line**.
 - About 15–20 **mammary buds** develop as solid downgrowths of the epidermis into the underlying mesenchyme along the mammary ridge on each side.
 - Normally mammary ridge and associated mammary buds disappear, except in the pectoral region.
 - In the pectoral region, the mammary bud presents a surface depression called **mammary pit**.
 - About 15–20 epithelial cords grow inwards from the bottom of the pit into the underlying dermis. The epithelial cords are **primordia of lactiferous ducts**.
 - The deeper ends of the epithelial cords subdivide further and terminate as ampullated ends—the **primordia of ductules and alveoli**.
 - At the end of fetal life, the epithelial cords and their branches are canalized and form lactiferous ducts.
 - Initially the lactiferous ducts open into the bottom of the mammary pit.
 - Shortly before birth the pit is evaginated by the growth of underlying mesoderm and form the nipple.
 - The rudimentary mammary glands of newborn males and females are similar. This condition persists throughout life in males. In females, however, infantile form of mammary gland grows in size at puberty under the influence of sex hormones and assumes a hemispherical outline. The full development of breast occurs at about 19 years of age.

N.B. In some animals, viz., **bitches**, a series of mammary glands develop on either side of midline on the ventral aspect of the trunk (**polymastia**).

The polymastia is common in lower mammals. Its persistence in human is an example of **atavism**.

Clinical Correlation

Developmental (congenital) anomalies of the mammary glands

1. **Amastia** (absence of breast) and **athelia** (absence of nipple): This condition occurs due to failure of formation of mammary ridge or failure of formation of mammary bud. Clinically it presents as the absence of breast on one or both

sides. Bilateral complete absence of mammary glands is a rare anomaly.

2. **Polythelia** (presence of supernumerary nipples): They may be found along the milk line/ridge, but are most commonly seen in the region of axilla.
3. **Polymastia** (accessory breasts): Accessory breast develops due to the formation of extramammary buds along the milk line/ridge. The occurrence of accessory breasts is less common than polythelia.
4. **Inverted (or crater) nipple**: It occurs due to failure of evagination of the mammary pit. In such a case, lactiferous ducts open into a pit causing **difficulty in suckling**.

GOLDEN FACTS TO REMEMBER

- | | |
|---|---|
| ➤ Dermatoglyphics | Study of the patterns of the epidermal ridges |
| ➤ Most important factor responsible for different skin color in different individuals | Amount of melanin in skin |
| ➤ Most common site of accessory/supernumerary nipples | Region of axilla |
| ➤ Witch milk | Milk expressed from mammary gland of newborn (both sexes) |
| ➤ Full development of breast in female occurs at the age of | 19 years |

CLINICAL PROBLEMS

1. The developing fetal skin is constantly exposed to the amniotic fluid that has high urine content, but still it is not affected by it. Why?
2. What is the embryological basis of **fingerprints** and how they form the basis for many studies in medical genetics and criminal investigation?
3. What is **nevus**? Give its embryological basis.
4. The dorsal aspect of digits near their tips are innervated by the nerves of the ventral aspect of the digits.
5. What is '**witch milk**'? Give its embryological basis.
6. What is **gynecomastia**? Give its embryological/anatomical basis.
7. An adult female has an accessory breast in her axilla. Give its embryological basis.
8. A young, adult, newly married female complained that there is a marked difference in size of her breasts. Explain.

CLINICAL PROBLEM SOLUTIONS

1. The cells of periderm (a layer of cells derived from surface ectoderm) undergo keratinization and desquamation. They are more or less completely cast off (desquamated) during the second part of the intrauterine life and along with oily secretion of sebaceous glands (**sebum**) form white greasy substance called **vernix caseosa** that covers the fetal skin (L. *Vernix* = varnish). The vernix caseosa protects the developing fetal skin from constant exposure to amniotic fluid with its high urine content.
2. The epidermal ridges are formed by the proliferation of cells in the basal layer of the epidermis and extend into the developing dermis. These ridges produce typical pattern of grooves on the surface of the finger tips, palms of the hands, toe tips, and soles of feet. These patterns are genetically determined. No two individuals, including monozygotic twins, have the same pattern. Therefore, it forms the basis of criminal investigation. Abnormal chromosome complements affect the development of ridge patterns, e.g., infants with Down's syndrome have distinctive patterns on their hands (e.g., **Simian's crease**) and feet. This forms the basis of genetic study as a diagnostic tool.
3. The nevus is a birthmark that appears at birth or shortly thereafter. The nevus occurs due to persistence of some primitive blood capillaries. There are three main types of nevus: (a) capillary nevus, (b) strawberry nevus, and (c) port-wine nevus.
 - A **capillary nevus** is a flat pink or pinkish-brown area.
 - A **strawberry nevus** is a bright red raised area up to 10 cm (4 in) across.
 - A **port-wine nevus** is a purplish-red, often extensive, which occurs singly on the face or neck (Fig. 7.8).
4. The nails develop at the tips of digits by thickening of the surface ectoderm called **primary nail fields**. Later the primary nail fields migrate from the tips of digits to their dorsal aspects. This explains innervation of the dorsal aspect of digits near their tips by nerves of ventral aspect of the digits.
5. The rudimentary mammary glands of newborns are often enlarged and secrete some milk called '**witch milk**.' This occurs due to action of maternal hormones that cross the placental barrier and affect the developing fetal breasts.
6. The **gynecomastia** is a clinical condition where rudimentary mammary glands in males may increase in size as in females and may even secrete milk (Gr. *Gyne* = woman + *Mastos* = breast) (Fig. 7.9). It occurs due to development of rudimentary lactiferous ducts into male mammary tissue. During mid-puberty about two-third of boys present varying degrees of gynecomastia. It is caused by decreased ratio of testosterone to estradiol. About 80% males with **Klinefelter's syndrome** (47, XXY) have gynecomastia.
7. The mammary gland (breast) develops from a bud arising from (**mammary ridge**) in the pectoral region. Occasionally, a mammary bud might develop at an accessory site along the mammary ridge usually in the axillary region. It is called **accessory breast**.
8. The marked difference in the size of two breasts is regarded as an anomaly because both the mammary glands are exposed to same hormones at puberty. In most of such cases, one of the breasts appears small because there is often an associated rudimentary development of muscles underneath the breast, usually pectoralis major.

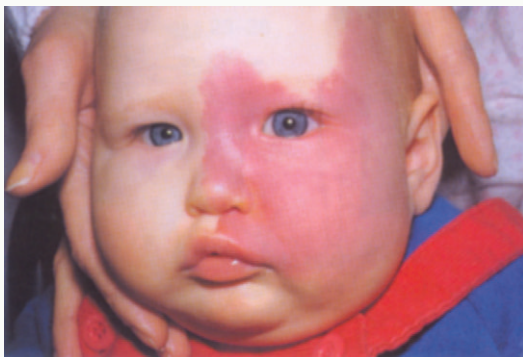

Fig. 7.8 Port-wine nevus in an infant.

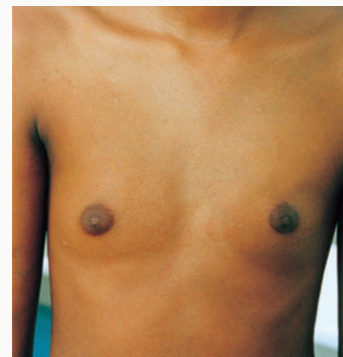

Fig. 7.9 Bilateral gynecomastia.

8

Skeletal System

Overview

The skeletal system consists of bones and cartilages. Both bones and cartilages develop from mesenchyme (loose tissue of mesoderm). The mesenchyme forming bones and cartilages is derived from following three sources:

1. Paraxial mesoderm (main source)
2. Parietal layer of lateral plate mesoderm
3. Neural crest cells

Whatever may be the source of origin of mesenchyme, the general process of formation of cartilages and bones is same.

Formation of Cartilage

The mesenchymal cells become closely packed (**mesenchymal condensation**) in an area where the cartilage is to be formed. The mesenchymal cells then proliferate and differentiate into cartilage forming cells called **chondroblasts**. The chondroblasts form the collagen fibers and ground substance of the matrix (intercellular substance). Some chondroblasts get imprisoned within the intercellular substance of developing cartilage and are called **chondrocytes**. Depending upon the presence and predominance of collagen or elastic fibers the cartilages are classified into three types: *fibrocartilage, hyaline cartilage, and elastic cartilage*.

The **hyaline cartilage** has a homogeneous, glassy, bluish, and opalescent appearance. The collagen fibers present in the matrix are fine and not seen easily.

The **fibrocartilage** is a dense, fasciculated, opaque white tissue. The collagen fibers present in fibrocartilage are numerous and very obvious.

The **elastic cartilage** is pliable and imparts yellowish tinge. The intercellular substance of elastic cartilage, as the name indicates, is permeated by elastic fibers.

The mesenchymal cells surrounding the surface of developing cartilage form the **perichondrium**.

Formation of Bones

All the bones are mesodermal in origin. They are formed either from preformed cartilaginous model or directly from the mesenchyme. **The process of bone formation is called ossification**. The processes of bone formation from cartilage and mesenchyme are termed **cartilaginous and membranous ossifications**, respectively.

Membranous Ossification (Fig. 8.1)

At the site where the **membrane bone** is to be formed, the mesenchyme condenses and becomes highly vascular (**mesenchymal model**). Some cells of mesenchymal model differentiate into **osteoblasts**. The osteoblasts lay down the matrix of bone called **osteoid**. The osteoid tissue consists of collagen fibers and ground substance. The osteoid tissue under the influence of osteoblasts becomes mineralized with calcium salts and becomes the bone (Flowchart 8.1). The osteoblasts are trapped in the bone that is formed around it and are converted into **osteocytes**. The bone formed by membranous ossification is in the form of spicules or trabeculi that are arranged irregularly with spaces between them. This type of bone is called **spongy bone**. In the spaces of spongy bone, the mesenchyme differentiates into **hemopoietic tissue**. On the surface of the spongy bone osteocytes lay down the compact bone.

The bones of the cranial vault and face are formed by membranous ossification.

Cartilagenous (Endochondral) Ossification (Fig. 8.2)

In this type of bone formation, the *preformed cartilaginous models of bones are converted into bones*. The process starts in the diaphysis of shaft of long bones or at one point in case of other bones; this is called **primary center of ossification**. The cartilage cells enlarge and matrix surrounding them gets calcified under the influence of an enzyme (**alkaline phosphatase**) secreted by cartilage cells.

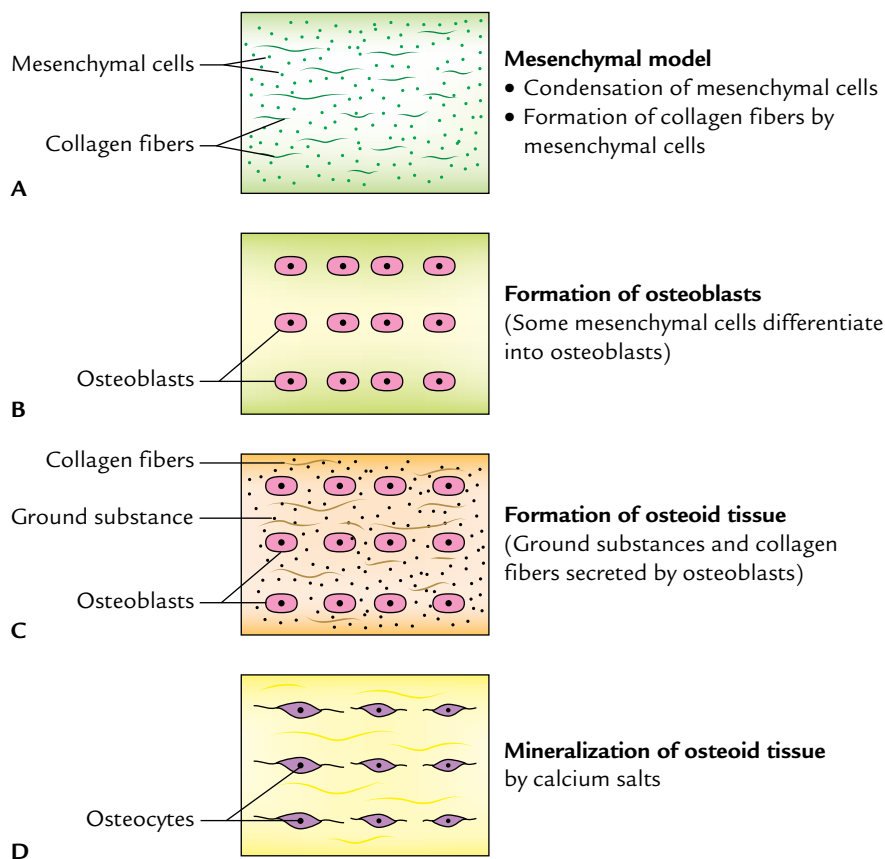
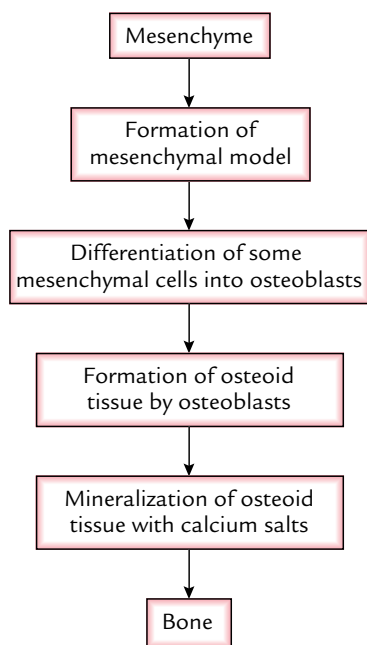


Fig. 8.1 Membranous ossification.



Flowchart 8.1 Membranous ossification.

The cartilage cells die and disappear, leaving behind the empty spaces (**primary areolae**). The cells on the surface of cartilage, i.e., cells of perichondrium (primodium of periosteum) differentiate into **osteoblasts**.

These osteoblasts along with blood vessels (**periosteal bud**) migrate inward. Most of the calcified cartilage is absorbed leaving behind only thin layers of calcified matrix (thin bars of calcified matrix) around the enlarged spaces (**secondary areolae**). The new bone (osteoid) is laid down on the surface of these bars by the osteoblasts. The mineralization of osteoid tissue leads to bone formation. The process of ossification spreads to other parts of cartilage and is replaced by bone. Note when the cartilage cells die the calcified matrix of cartilage acts only as a support for the developing trabeculae of bone (Flowchart 8.2). With bone formation the perichondrium is called periosteum.

N.B. The process of bone formation by osteoid tissue in case of cartilaginous ossification is same as that in the membranous ossification.

For details of ossification refer to *General Anatomy* by Dr Vishram Singh.

The bones of base of skull and long bones of limbs are formed by cartilaginous (enchondral) ossification.

N.B. Some bones of the body are formed by both membranous and cartilaginous ossification (i.e., membranocartilaginous ossification).

The bones formed by membranous, cartilaginous, and membranocartilaginous ossifications are given in Table 8.1.

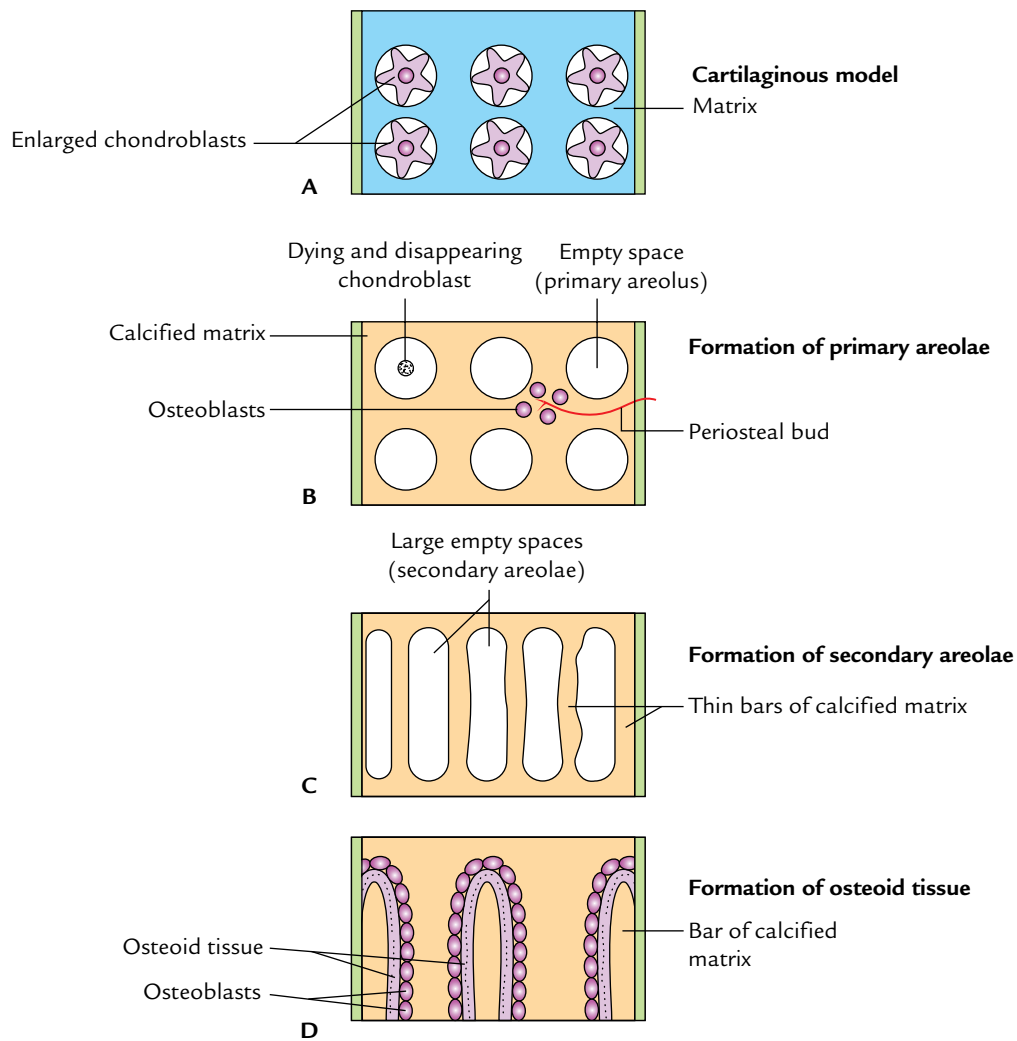
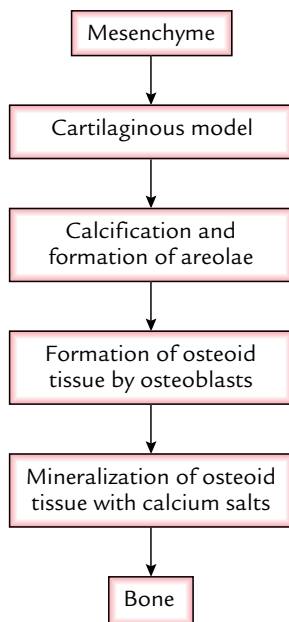


Fig. 8.2 Important stages of cartilaginous ossification.



Flowchart 8.2 Cartilaginous (endochondral) ossification.

Table 8.1 Classification of bones according to their ossification

Membranous bones	Cartilaginous bones	Membranocartilaginous bones
<ul style="list-style-type: none"> Bones of cranial vault Facial bones 	<ul style="list-style-type: none"> Bones of limbs Bones of the base of skull Bones of the vertebral column (vertebrae) Bones of the thoracic cage (ribs, and sternum) 	<ul style="list-style-type: none"> Mandible Clavicle Occipital bone Temporal bone Sphenoid bone

Clinical Correlation

1. **Cleidocranial dysostosis** (Fig. 8.3): The cleidocranial dysostosis is the congenital abnormality in which there is complete or partial absence of the clavicles. In the event of bilateral

absence of clavicles both shoulders of the subject nearly touch each other. It is accompanied by defective ossification of cranium with large fontanelles and delayed closing of sutures. This condition occurs due to defective intramembranous ossification.

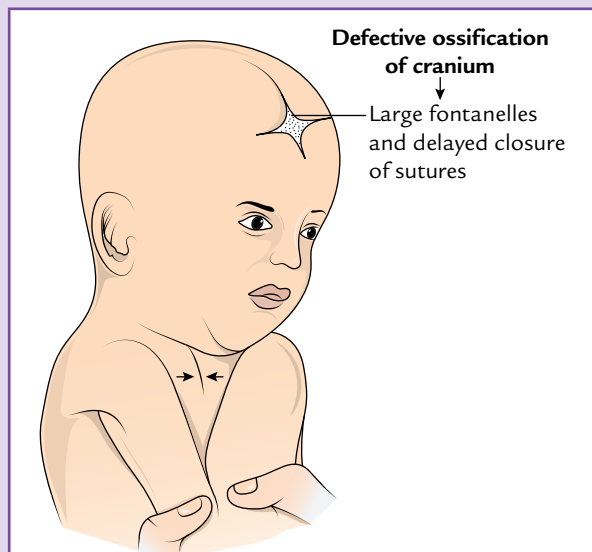


Fig. 8.3 Cleidocranial dysostosis (congenital absence of the clavicles). Note approximation of the shoulders.

2. **Achondroplasia/dwarf** (Fig. 8.4): It is an inherited autosomal dominant trait. The mutation in *FGFR 3* gene leads to abnormal endochondral ossification. As a result, the individual is abnormally short (dwarf) with short curved arms and legs, dorsal kyphosis, and lumbar lordosis; however the head and trunk remain normal (also see page 100).



Fig. 8.4 Achondroplasia.

Development of Axial Skeleton

The axial skeleton consists of skull (cranium), vertebral column, sternum, and ribs. Development of skull for being little difficult to students is discussed at the end of this section.

Development of Vertebral Column

The vertebral column develops from somites derived from paraxial mesoderm. Each somite differentiates into the ventromedial part called **sclerotome** and a dorsolateral part called **dermomyotome** (for details see page 103). The sclerotomes take part in the development of the vertebral column.

Development of Vertebrae

The cells of sclerotome become large, polymorphic, and get loosely arranged to form embryonic tissue called **mesenchyme**. The mesenchymal cells have potential to differentiate into fibroblasts, chondroblasts, and osteoblasts (bone forming cells).

The mesenchymal cells from the sclerotomes migrate medially towards notochord to form the vertebral column as follows (Fig. 8.5).

The mesenchymal cells condense (a) around the notochord to form the **centrum**, (b) around the neural tube to form right and left **neural (vertebral) arches**, and (c) in the body wall adjacent to the proximal part of neural arches to form **costal processes**.

The adult derivatives of these structures are as follows:

- The **centrum** forms the **vertebral body**.
- The **vertebral arches** form the **pedicles, laminae, spine, articular processes, and transverse processes**.
- The **costal processes** form the **costal elements of the transverse processes**.

The costal elements of transverse processes in the thoracic region form ribs (Fig. 8.6).

The relative contribution of centrum, neural arch, and costal element (process) to the vertebrae in different regions is shown in Fig. 8.7.

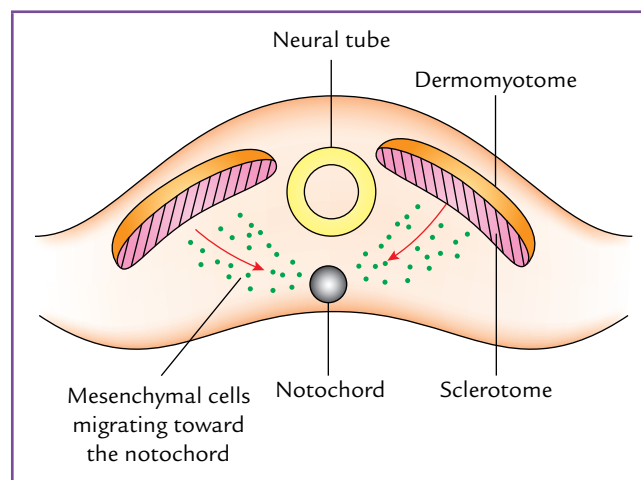


Fig. 8.5 Differentiation of somites into sclerotome (ventromedial part) and dermomyotome (dorsolateral part). Note the migration of mesenchymal cells towards the notochord (red arrows).

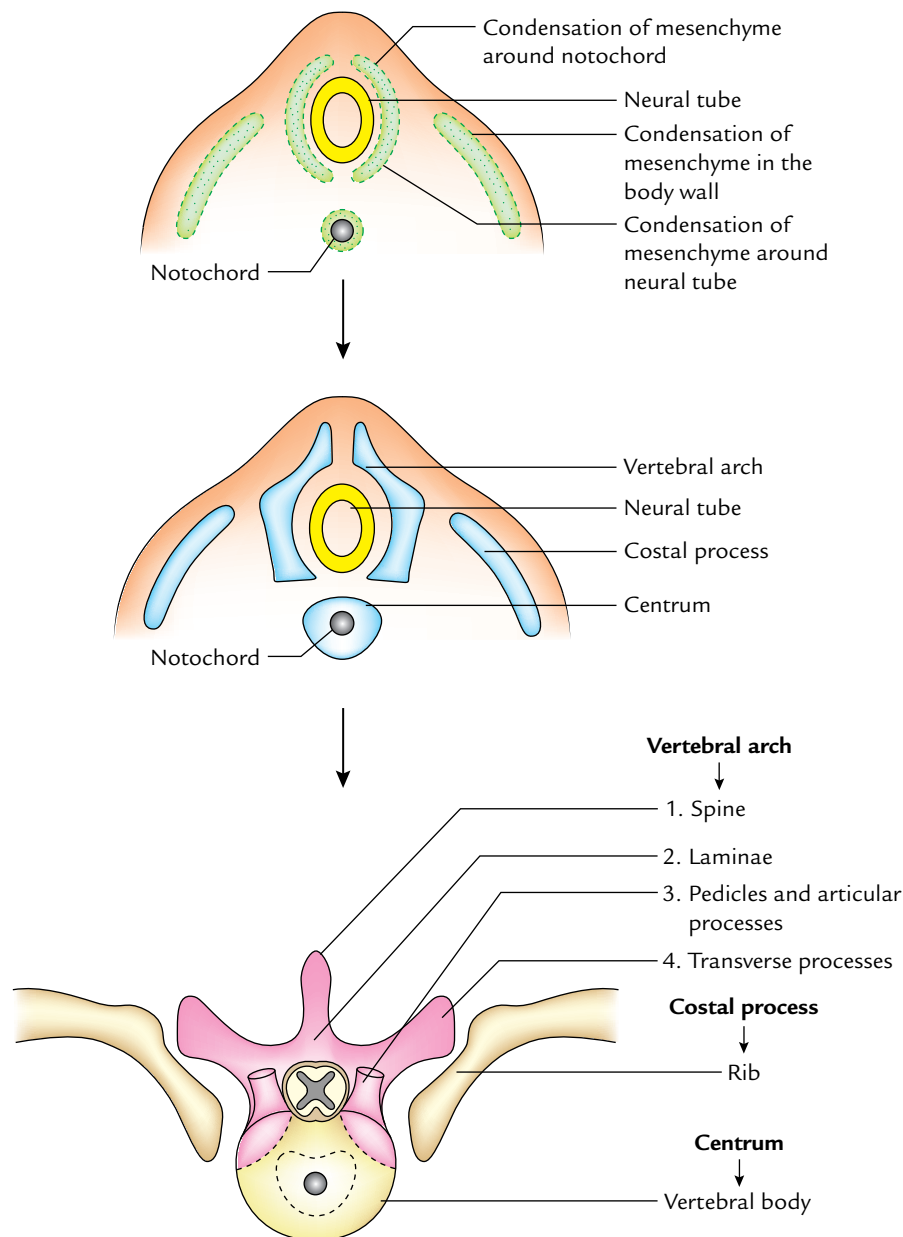


Fig. 8.6 Development of typical thoracic vertebra.

Intersegmental Position of Vertebrae and Segmental Position of Intervertebral Discs (Figs 8.8 and 8.9)

The mesenchymal cells derived from sclerotomes migrate medially and surround the notochord and neural tube, but the mesenchyme derived from each somite maintains its segmental character [i.e., *it can be seen as a distinct mesenchymal segment in developing vertebral column (Fig. 8.8A)*] even after migration.

Initially the mesenchymal cells in each segment are uniformly distributed.

Later mesenchymal cells in the central part of each segment become condensed to form **perichordal disc**. The parts above and below the perichordal disc remain less dense. The body of each vertebra is formed by fusion of adjoining less condensed parts of the two

sclerotomes (somites). The vertebra is thus an intersegmental structure being derived from two mesenchymal segments representing sclerotomes (somites). The part of notochord trapped in the body of the vertebra degenerates and disappears.

The *perichordal disc* forms the peripheral part of the intervertebral disc (**annulus fibrosus**). The notochord trapped within the perichordal disc persists and forms the central part of the intervertebral disc—the **nucleus pulposus**. The intervertebral disc is therefore a segmental structure.

The resegmentation of mesenchymal segments (sclerotomes) into definitive vertebrae causes myotomes to bridge the intervertebral disc, and this provides them the capacity to move the spine.

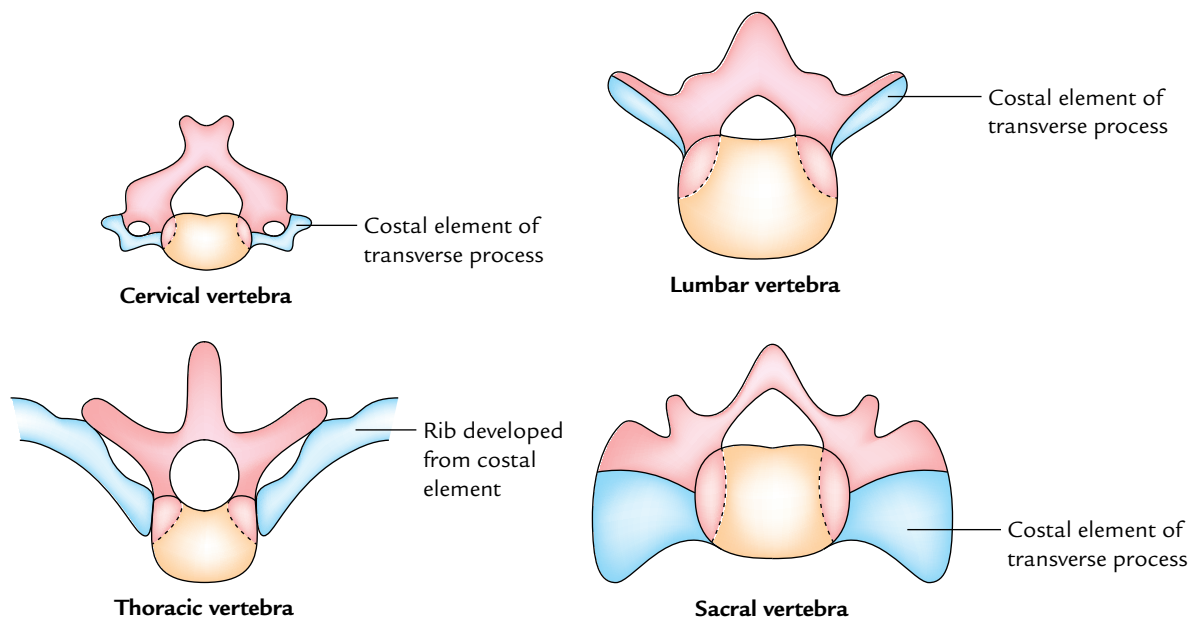


Fig. 8.7 Position of costal elements (rudimentary costal processes) in the transverse processes of cervical, lumbar, and sacral vertebrae. Note the development of rib from the costal process in the thoracic region.

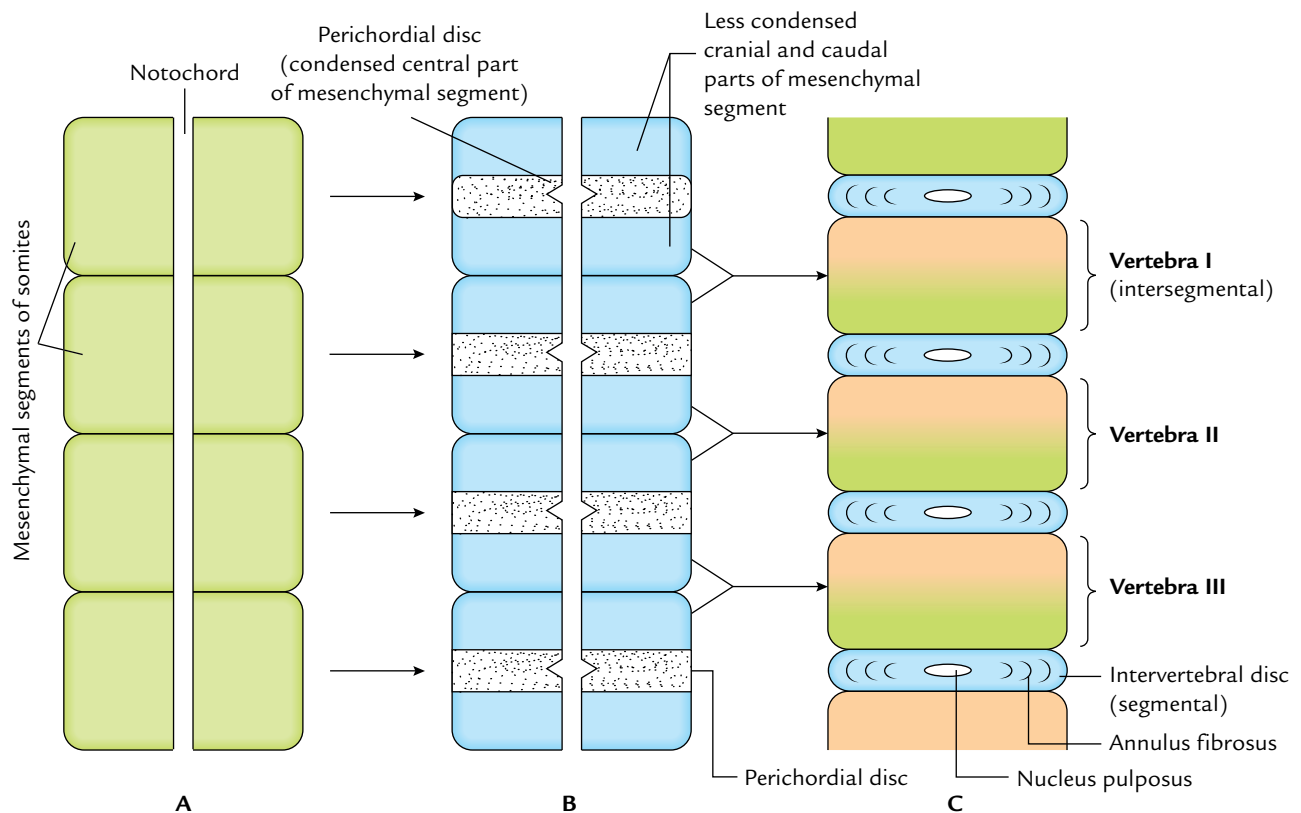


Fig. 8.8 Development of vertebral bodies and intervertebral discs. A. Mesenchymal segments around the notochord. B. Differentiation of mesenchymal segment into three parts: condensed central part and less dense cranial and caudal parts. C. Resegmentation due to the formation of vertebrae from adjoining two less condensed parts of two adjacent mesenchymal segments (somites).

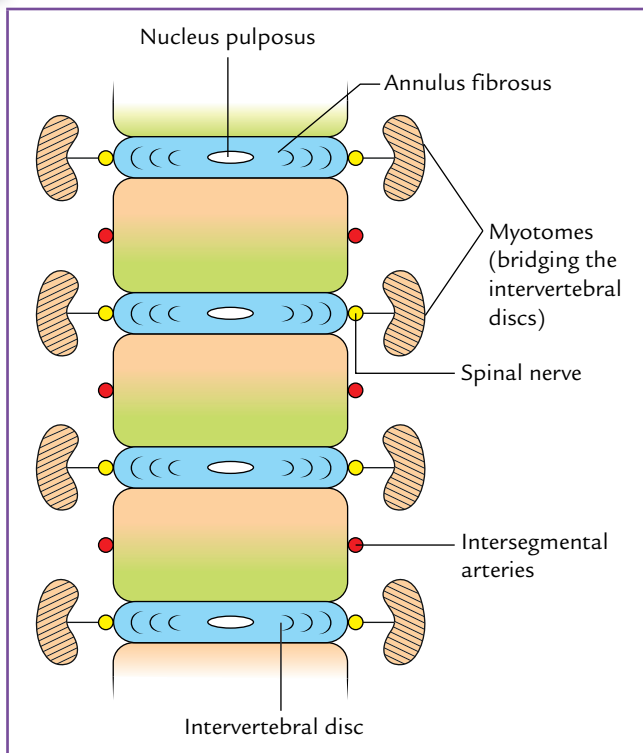


Fig. 8.9 Vertebrae are formed by the upper and lower halves of two successive sclerotomes. The myotomes bridge the intervertebral discs so that they can move in the vertebral column.

Salient Features of Development of Vertebral Column

These are as follows:

1. Vertebrae are intersegmental structures because each vertebra is derived from portions of two adjacent somites (e.g., caudal half of one somite and cranial half of the other somite below it).
2. The transverse processes and ribs are intersegmental, and hence separate the muscles derived from two adjoining myotomes.
3. The spinal nerves are segmental and hence emerge between the two adjacent vertebrae.

N.B. Each vertebra is formed by caudal half of one somite and cranial half of other somite below it. The **patterning of shapes of different vertebrae** is regulated by *Hox* genes.

Ossification of a Typical Vertebra (Fig. 8.10)

The newly formed vertebra is cartilaginous. This cartilaginous model of vertebra is soon converted into bone by ossification. The vertebrae ossify by the three primary centers of **ossification**: one for each vertebral (neural) arch and one for the centrum. At birth, each vertebra consists of three bony parts: two vertebral arches and a centrum connected by a cartilage. The vertebral arches fuse posteriorly by 3–5 years of age to form **spinous process**. The vertebral arches articulate with the centrum at cartilaginous **neurocentral joints**,

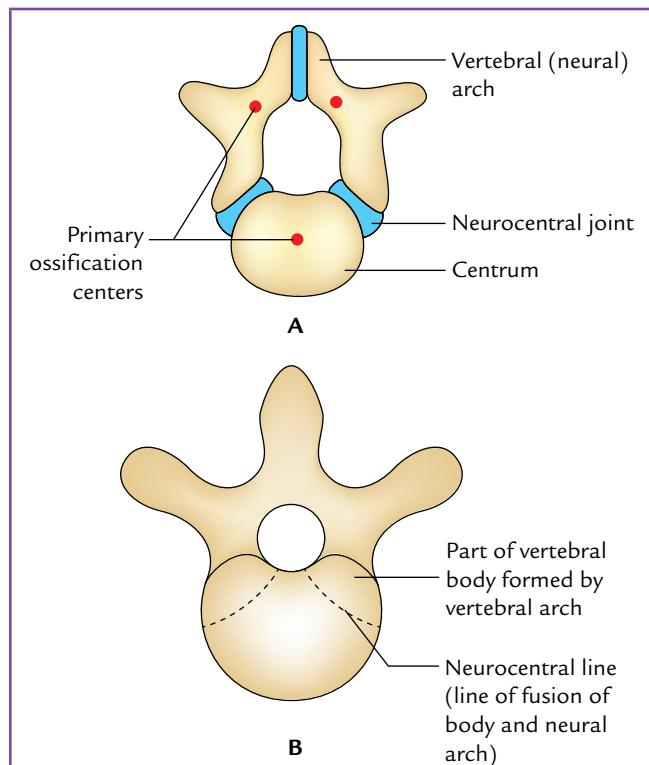


Fig. 8.10 Ossification of typical vertebra. A. Three parts of vertebra joined by cartilage at birth. B. Fusion of three parts.

which disappear by 3–6 years of age. Posterolateral part of body on each side receives a contribution from neural arch. Line of junction between part derived from the centrum and part derived from the neural arch represents the site of **neurocentral joint**.

Clinical Correlation

Spina bifida: It is a large gap in vertebra dorsally that occurs when two embryonic neural arches fail to fuse with each other. It is one of the most serious vertebral defects. This defect occurs in 1 per 1000 births and may be prevented in many cases by giving folic acid to mothers prior to conception. It occurs more frequently in girls than boys. Depending upon the severity of lesion the spina bifida is divided into following types (Fig. 8.11).

1. *Spina bifida occulta* (closed spina bifida): The bone defect is covered by skin and no neurological deficit occurs. The skin at the site is pigmented, with hairy patches, fatty lump, or a dermal sinus.
2. *Spina bifida with meningocele*: The bone defect is covered by skin but the meninges herniate through the gap to form meningeal sac filled with cerebrospinal fluid (CSF).
3. *Spina bifida with meningomyelocele*: The bone defect is covered by skin but the meninges and spinal cord herniate through the gap.
4. *Spina bifida aperta* (spina bifida with rachischisis): This is the most severe form of spina bifida. There is no skin covering. The neural tube is open and lies on the surface of the back of the body.

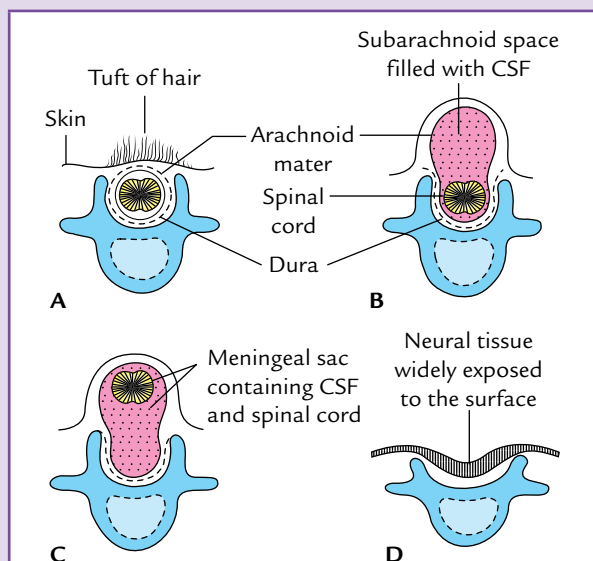


Fig. 8.11 Types of spina bifida.

N.B. The prenatal diagnosis of spina bifida can be made by ultrasound and by detecting elevated levels of α -fetoprotein in the amniotic fluid.

Some other congenital anomalies of the vertebrae (Fig. 8.12)

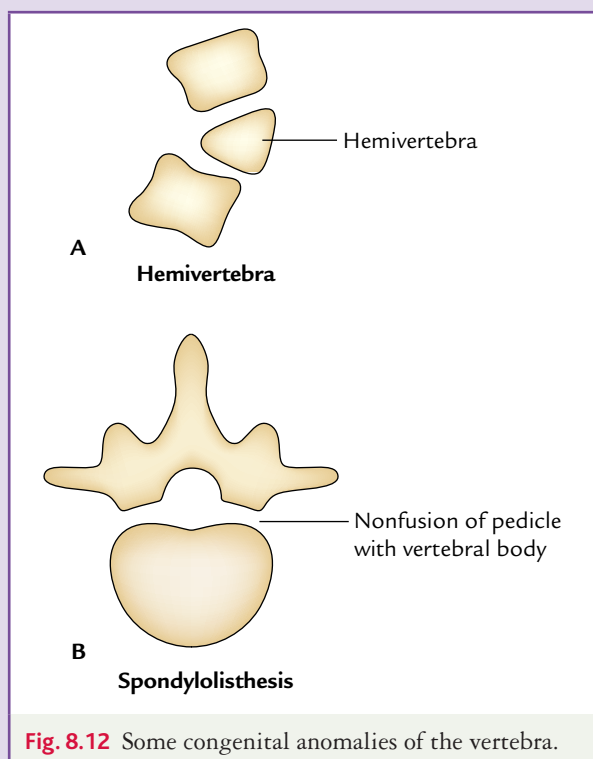


Fig. 8.12 Some congenital anomalies of the vertebra.

1. **Hemivertebra** (Fig. 8.12A): At times the vertebral body ossifies from two separate primary centers. In such an event if one center fails to appear only half of the vertebra will form. This may lead to a clinical condition called **congenital scoliosis** (i.e., lateral bending of the spine).

2. Congenital fusion of vertebral bodies

- Occipitalization of atlas vertebra:** It occurs due to fusion of atlas vertebra with occipital bone.
- Sacralization of the fifth lumbar vertebra:** It occurs due to partial or complete fusion of the fifth lumbar vertebra with the sacrum.
- Lumbarization of the first sacral vertebra:** It occurs due to partial or complete fusion of first sacral vertebra with the fifth lumbar vertebra.

3. **Spondylolisthesis** (Fig. 8.12B): It occurs when the pedicles of vertebral arch fail to fuse with the vertebral body. This allows the vertebral body to slip anteriorly over the body of the vertebra below. This condition commonly affects the L5 vertebra. As a result, the body of the fifth lumbar vertebra slips forward over the sacrum.

Development of Ribs

The ribs develop from **costal processes in the thoracic region**. The costal processes at first elongate to form cartilaginous costal arches, which are then ossified to form the ribs.

In cervical, lumbar, and sacral regions, the costal processes remain rudimentary and are represented by a small part of the transverse process of each vertebra called **costal element**.

Clinical Correlation

Accessory ribs

- Accessory lumbar rib:** It is the commonest rib anomaly. However, it does not attract much attention of clinicians as it is symptomless.
- Accessory cervical rib:** It occurs only in 0.5–1% of the cases. It can be unilateral or bilateral. It develops from the costal element of seventh cervical vertebra. The accessory cervical ribs may exert pressure on lower trunk of brachial plexus and subclavian artery leading to a clinical condition called **superior thoracic outlet syndrome**. For details see *Clinical and Surgical Anatomy* by Dr Vishram Singh.

Development of Sternum (Fig. 8.13)

The sternum develops as follows:

At first, two mesenchymal vertical plates, one on either side of midline, develop in anterior body wall due to condensation of somatic mesoderm. These plates are called **mesenchymal sternal bars**. Later two sternal bars are converted into cartilage to form **cartilaginous sternal bars**. The two cartilaginous sternal bars start fusing with each other in a craniocaudal sequence. After their fusion, the **cartilaginous model of the sternum** is formed. It consists of **manubrium, body**

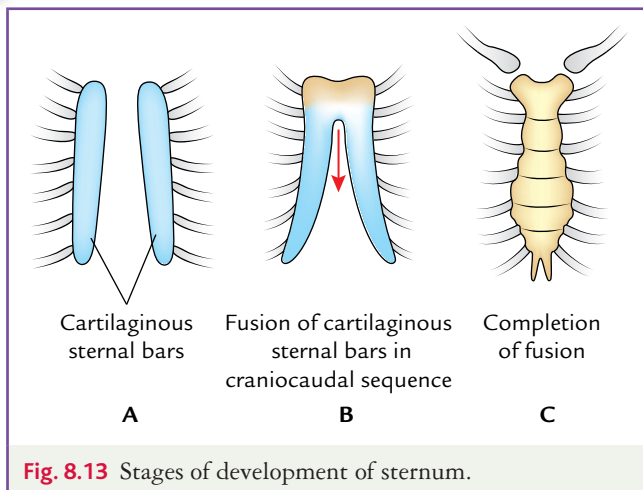


Fig. 8.13 Stages of development of sternum.

(made up of four segments called **sternebrae**), and **xiphoid process**. The cartilaginous model of sternum gets ossified to form the sternum.

Manubrium and body ossify by five double centers from above downward during fifth, sixth, seventh, eighth, and ninth months. The upper pair of centers form manubrium and the lower four pairs of centers form four sternebrae that fuse with each other from below upward. The fusion is complete by 25 years of age. The xiphoid process ossifies late in life. The center for xiphoid process appears during the third year or later and fuses with the body of sternum at about 40 years.

Clinical Correlation

1. **Sternal foramen and sternal cleft** (Fig. 8.14): It occurs when the two sternal bars fail to fuse completely. The defect ranges from *sternal foramen* to *sternal cleft*. The latter may be associated with *ectopia cordis*. It is fairly common but of no clinical significance, if small. Fusion of the two sternal bars is often incomplete in the caudal part producing the *bifid xiphoid process* or a *hole in xiphoid process*.

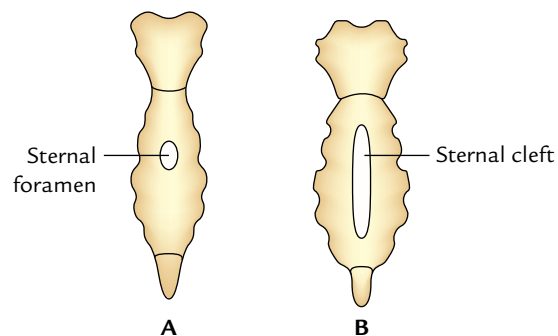


Fig. 8.14 A. Sternal foramen. B. Sternal cleft.

2. **Funnel chest (*pectus excavatum*)** (Fig. 8.15): It is the most common congenital anomaly of the chest. In this condition, the chest is compressed anteroposteriorly and sternum is pushed backwards compressing the heart. Clinically it presents

as a depression in the anterior median region of the chest wall that may extend from manubrium to the xiphoid process. An early surgical intervention is recommended not only to improve cosmetic appearance but also to alleviate cardio-pulmonary restriction.

The funnel chest occurs because lower half of the sternum and attached costal cartilages are pulled inward due to abnormally short tendon of diaphragm.

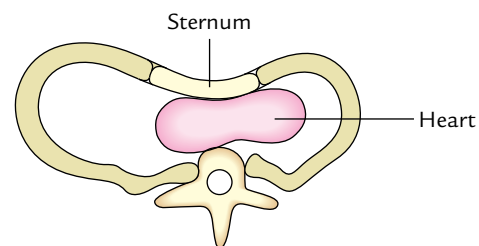


Fig. 8.15 Funnel chest.

3. **Pigeon chest (*pectus carinatum*)** (Fig. 8.16): In this condition upper part of the sternum and related costal cartilages project forward in the midline as in birds (e.g., pigeon), hence the name pigeon chest.

In this case, the chest is compressed from side-to-side causing forward projection of the sternum and related cartilages.

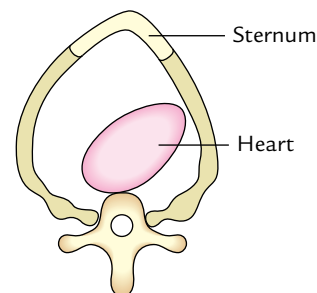


Fig. 8.16 Pigeon chest.

Development of Skull

The skull (cranium) develops from mesenchyme around the developing brain. The skull (cranium) is divided in two parts: (a) **neurocranium** that encloses cranial cavity and protects the brain, and (b) **viscerocranium** that forms the skeleton of the face.

Neurocranium

The neurocranium consists of a cartilaginous portion that forms the **base of the skull** and a membranous portion that forms **cranial vault**.

Base of skull (Fig. 8.17) The base of skull, at first, is cartilaginous (cartilaginous neurocranium). It is formed by the fusion of several cartilages. These cartilages are

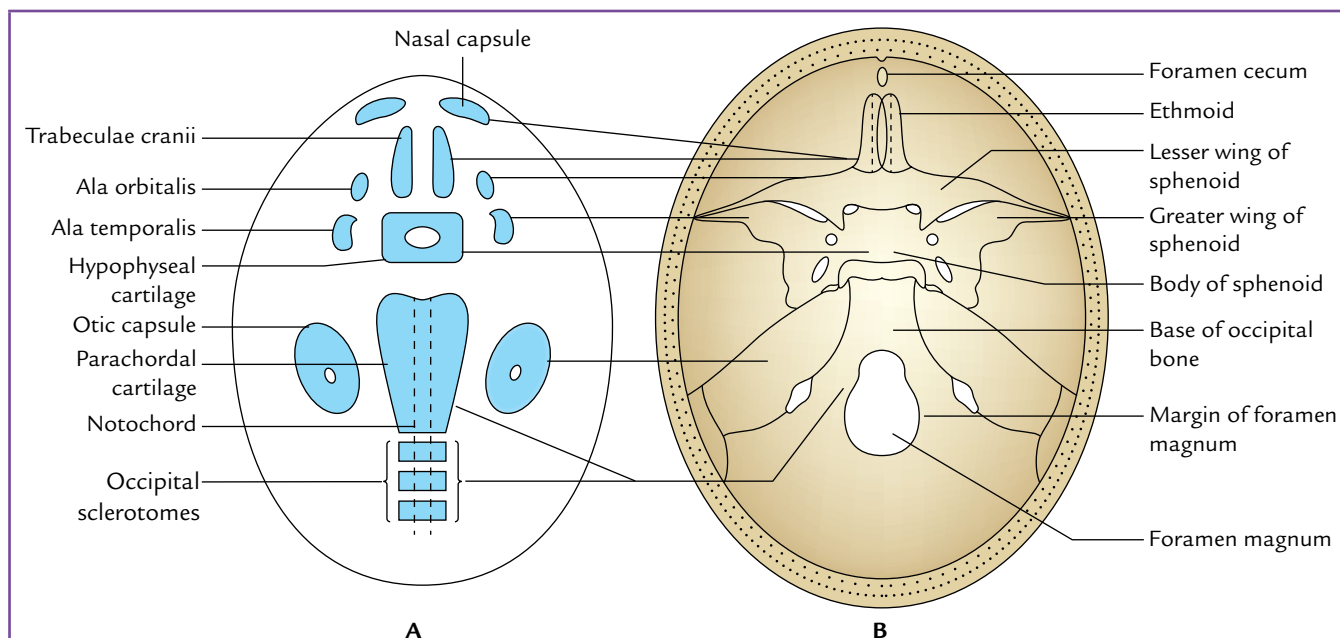


Fig. 8.17 Development of the base of the skull (dorsal view). A. Cartilages that form cartilaginous neurocranium. B. Bones of the base of the skull formed by various cartilages of neurocranium by endochondral ossification.

Table 8.2 Adult derivatives of various cartilages forming the cartilaginous base of developing skull

Embryonic structure	Adult derivatives
Trabeculae cranii and nasal capsules	Ethmoid bone
Hypophyseal cartilage	Body of sphenoid
Ala orbitalis	Lesser wing of sphenoid
Ala temporalis	Greater wing of sphenoid
Parachordal plate and cartilages derived from four occipital somites (sclerotomes)	Base of the occipital bone including boundaries of foramen magnum
Otic capsule	Petrous and mastoid parts of the temporal bone

formed by chondrification of mesenchyme below the brain.

The various cartilages that form the cartilaginous neurocranium are as follows:

1. *Parachordal cartilage (basal plate)*: It forms around cranial end of notochord.
2. *Hypophysial cartilage*: It forms around developing pituitary gland.
3. *Trabeculae cranii (two in number)*: They form in front of hypophysial cartilages.
4. *Ala orbitalis*: It develops on either side lateral to the trabeculae cornii.
5. *Ala temporalis*: It develops on either side lateral to the hypophyseal cartilage.

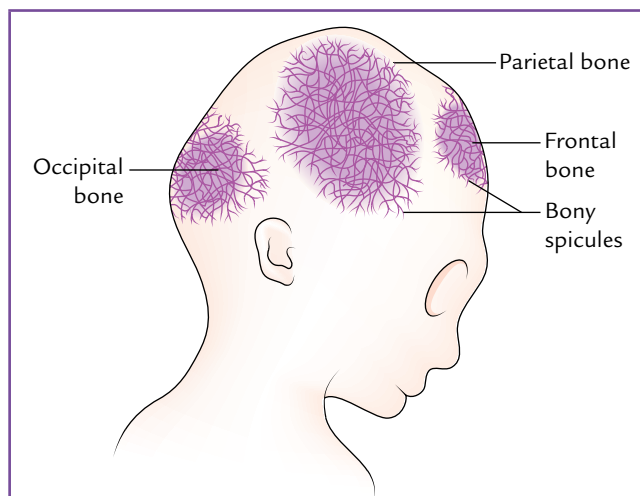


Fig. 8.18 Spread of bony spicules from primary ossification centers in the flat bones of skull in 3-month-old fetus.

6. *Otic capsules*: They develop around otic vesicles—the primordia of internal ears.

7. *Nasal capsules*: They develop around nasal sacs.

The bones of the base of skull derived from these cartilages are given in Table 8.2.

The cartilaginous base is subsequently ossified to form the base of the skull.

Cranial vault (vault of skull) (Fig. 8.18) The vault of skull develops from mesenchyme on superior and lateral aspects of developing brain (**membranous neurocranium**). This mesenchyme is derived from the neural crest cells and paraxial mesoderm.

The vault of the skull is first membranous in nature that later undergoes membranous ossification to form a number of flat membranous bones, which together form the vault (top) of the skull.

The primary centers appear where the bones start ossifying and grow towards the periphery by forming needle-like bony spicules.

Viscerocranium (Fig. 8.19)

The major part of viscerocranium develops from the mesenchyme derived from first (having maxillary and mandibular processes) and second pharyngeal arches. This mesenchyme undergoes membranous ossification to form the bones of the facial skeleton.

The mandibular process of the first pharyngeal arch contains Meckel's cartilage. The mesenchyme around the Meckel's cartilage condenses and ossifies by membranous ossification to form the mandible.

The Meckel's cartilage disappears; however its perichondrial sheath remains in the form of sphenomandibular ligament. The maxillary process of first pharyngeal arch gives rise to maxilla, zygomatic bone, and part of the temporal bone.

The dorsal tip of the mandibular process along with the second pharyngeal arch gives rise to three ear ossicles, viz., malleus, incus, and stapes (see Fig. 10.8, page 116). The lacrimal and nasal bones are derived from neural crest cells.

N.B. Initially, the neurocranium is larger than viscerocranium (face) due to the absence of paranasal air sinuses and smaller size of the bones of the face, especially jawbones.

The bones of the skull are formed by membranous ossification, or cartilaginous ossification, or both (vide supra). Accordingly the bones of the skull are of three types: membranous bones, cartilaginous bones, and membranocartilaginous bones (Table 8.3).

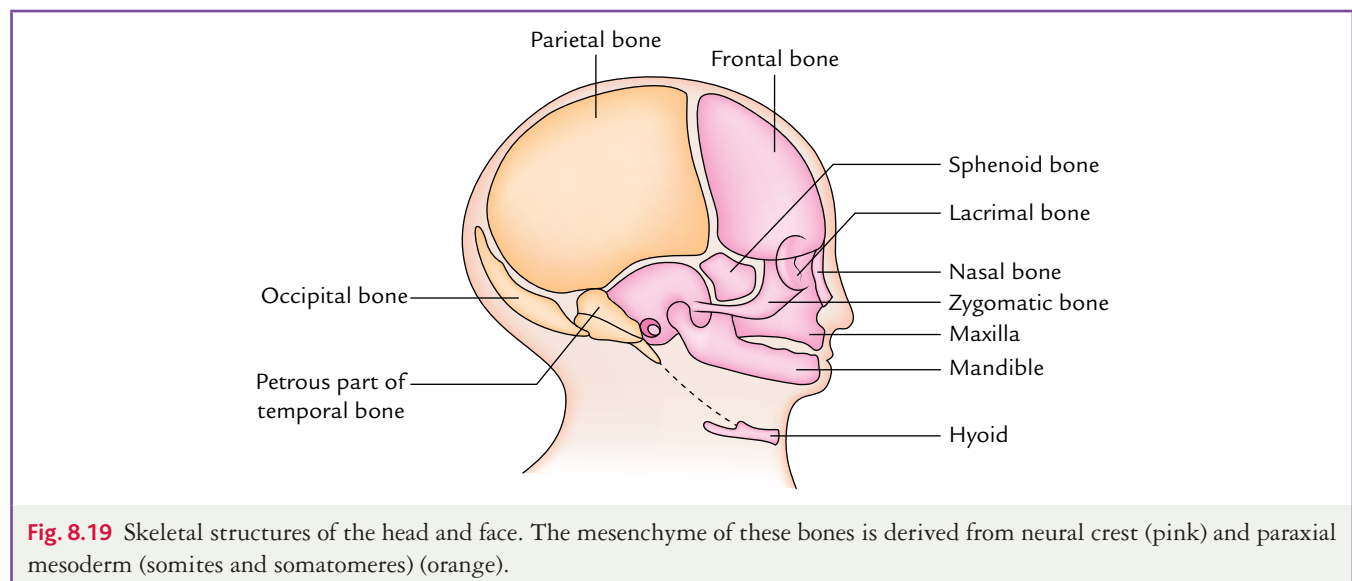


Fig. 8.19 Skeletal structures of the head and face. The mesenchyme of these bones is derived from neural crest (pink) and paraxial mesoderm (somites and somatomes) (orange).

Table 8.3 Types of bones of skull according to their development (ossification)

Membranous bones (ossify in membrane)	Cartilaginous bones (ossify in cartilage)	Membranocartilaginous bones (ossify both in membrane and cartilage)
<ul style="list-style-type: none"> • Frontal • Parietal • Maxilla (excluding premaxilla) • Zygomatic • Nasal • Lacrimal • Vomer 	<ul style="list-style-type: none"> • Ethmoid • Inferior nasal concha 	<ul style="list-style-type: none"> • Occipital (part above the superior nuchal line is membranous and the remaining part is cartilaginous) • Sphenoid (lateral parts of greater wings and pterygoid processes are membranous and rest is cartilaginous) • Temporal (squamous) and tympanic parts are membranous while petromastoid part and styloid process are cartilaginous • Mandible (condylar and coronoid processes are cartilaginous and the rest of the mandible is membranous)

Newborn Skull

The newborn skull presents two striking features:

1. Small viscerocranium (facial skeleton) as compared to neurocranium
2. Presence of fontanelles.

Factors Responsible for Disproportion Between Viscerocranium and Neurocranium

Relatively huge size of **neurocranium** is due to fast and enormous development of brain. The brain reaches 25% of its adult size at birth and 75% by the age of 4 years.

The face (**viscerocranium**) is small because of small size of facial bones, particularly the jaws (maxillae and mandibles) and virtual absence of paranasal air sinuses.

N.B. With the eruption of teeth and development of paranasal air sinuses, the face loses its babyish look.

Fontanelles (Fig. 8. 20)

The fontanelles are soft membranous areas in the vault of newborn skull. They are also sometimes termed **soft spots**. At birth, the flat bones of the skull are separated from each other by narrow seams of fibrous tissue called **sutures**. At sites where more than two bones meet the sutures are wide and are called **fontanelles**. There are **six fontanelles at birth**—one at each angle of the parietal bone. Thus, two are located in the median plane on top of the skull and two on either side of the skull.

The two median fontanelles are **anterior** and **posterior**, and two paired lateral fontanelles are **anterolateral (or sphenoid)** and **posterolateral (or mastoid)**. The most prominent of these is **anterior fontanelle**. It is diamond shaped and located where two halves of the frontal bone and two parietal bones meet. All the fontanelles

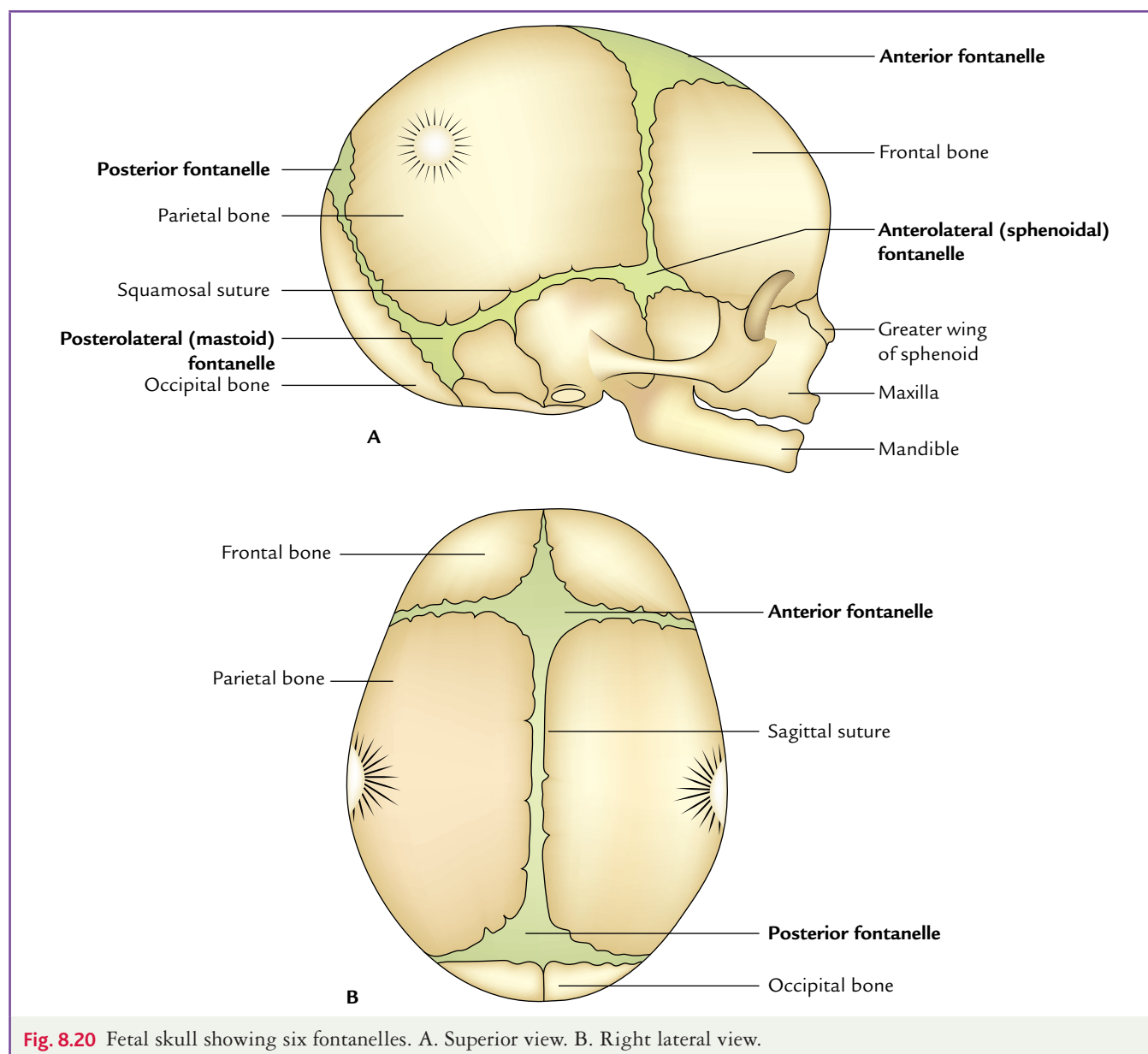


Fig. 8.20 Fetal skull showing six fontanelles. A. Superior view. B. Right lateral view.

except anterior fontanelle are closed within three or four months after birth. The anterior fontanelle is usually closed between second and third year of age.

Functions of fontanelles

1. Allow bones of the skull to overlap (**moulding**) during parturition to facilitate the baby birth.
2. Permit postnatal growth of skull bones, especially bones of the vault to increase the cranial capacity.
3. Allows postnatal development of the brain.

Clinical significance of fontanelles In first few years after birth, palpation of anterior fontanelle provides following valuable information to the clinician:

1. As to whether ossification of the skull is proceeding normally or not.
2. As to whether intracranial pressure is normal or not, viz., the depressed (sunken) fontanelle indicates **dehydration** and bulging fontanelle indicates **increased intracranial pressure**.

Clinical Correlation

1. **Anencephaly (Fig. 8.21):** In this condition, major portion of the cranial vault fails to form (**cranioschisis**). It occurs if anterior neuropore of neural tube fails to close. The brain tissue is exposed to amniotic fluid and gradually degenerates. Children with such severe skull and brain defects cannot survive (i.e., *anencephaly is incompatible with extrauterine life*). If not, stillborn infants with anencephaly survive only few hours or weeks.

The anencephaly is the most serious birth defect seen in stillborn infants. The anencephaly is easily diagnosed by ultrasonography and raised serum α -fetoprotein level. The therapeutic abortion should be performed with mother's consent.

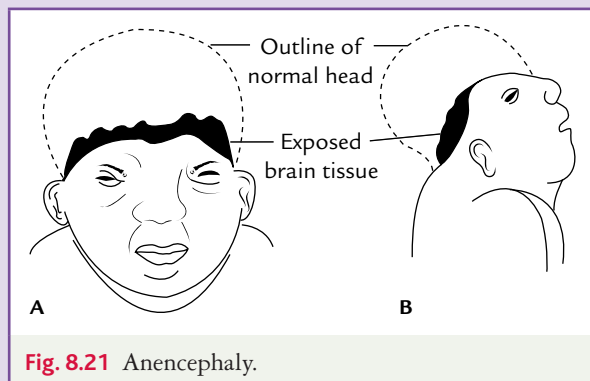


Fig. 8.21 Anencephaly.

2. **Encephalocele:** It occurs due to small defects in the skull through which meninges and/or brain tissue herniate. Depending upon severity, the encephalocele is divided into three types: *meningocele*, *meningoencephalocele*, and *meningohydroencephalocele* (Fig. 8.22).

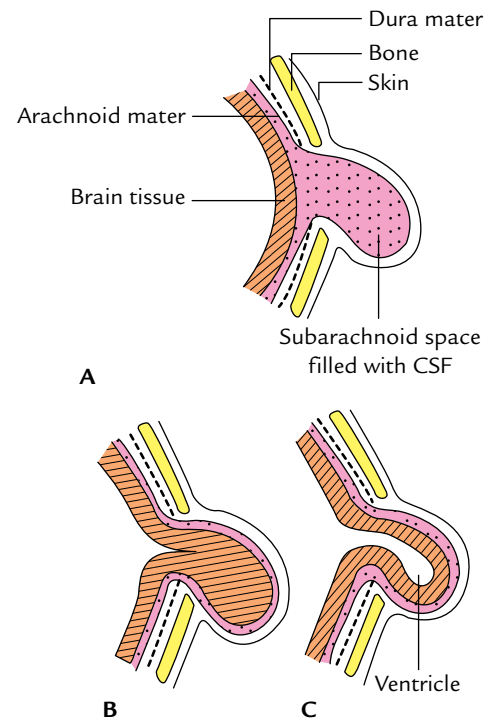


Fig. 8.22 Schematic diagrams showing A. meningocele, B. meningoencephalocele, and C. meningohydroencephalocele.

3. Abnormalities of the shape of the skull

- (a) **Scaphocephaly:** Boat-shaped skull due to frontal and occipital expansions. It occurs due to early closure of the sagittal suture (57% of cases).
- (b) **Brachiocephaly:** Short skull due to premature bilateral synostosis (closure) of the coronal suture.
- (c) **Plagiocephaly:** It occurs due to premature closure of coronal and lambdoid sutures on one side only. It results in grossly unequal curvatures of skull on two sides.
- (d) **Acrocephaly:** Pointed skull due to premature closure of the coronal suture.
- (e) **Microcephaly:** Small skull due to failure of proper development of the brain.

Development of Appendicular Skeleton

The appendicular skeleton consists of pectoral and pelvic girdles and limb bones.

The lateral plate mesoderm migrates into limb buds and condenses along the central axis to form skeletal components of the limbs.

The bones in the limbs develop in a proximodistal sequence and are regulated by **Hox genes**.

It is necessary for students to first understand the development of limbs before they go to understand the development of the appendicular skeleton.

Development of Limbs

The limb buds appear as outpouchings from the ventrolateral aspects of the body wall at the end of the fourth week of embryonic development (Fig. 8.23). The **forelimbs** appear first followed by **hind limbs** 1 or 2 days later.

The various stages in the development of upper limb are as follows (Fig. 8.24):

The ectoderm at the tip of the limb bud thickens to form **apical ectodermal ridge (AER)**.

In the sixth week of embryonic development, terminal part of the limb bud becomes flattened to form **hand and foot plates**, and are separated from the rest of the limb bud by a circular constriction. The expanded plate exhibits five longitudinal mesodermal condensations or **digital rays**. Later second constriction divides the rest of the limb bud into two segments. Now main parts of the limb become recognizable (e.g., **arm, forearm, and hand** in upper limb; and **thigh, leg, and foot** in lower limb). Now the digits are formed in the hand and foot plates following cell death in the ectodermal ridges.

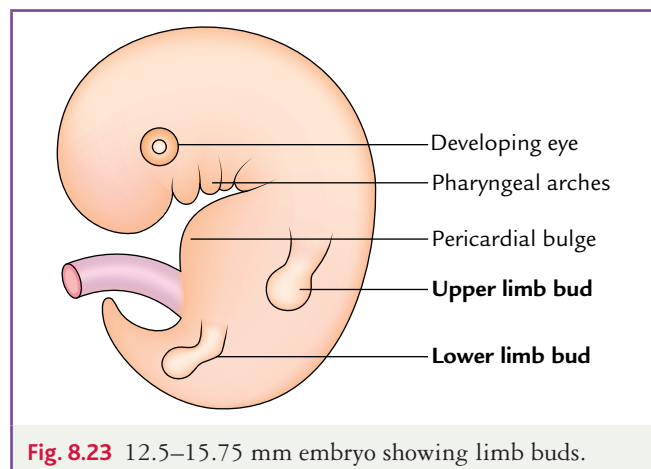


Fig. 8.23 12.5–15.75 mm embryo showing limb buds.

Rotation of Limb Buds

Initially the limb buds are paddle shaped and each bud has **preaxial** and **postaxial border**, with former being directed towards the cranium (head).

The digit formed along the preaxial border is **thumb** in the upper limb and **great toe** in the lower limb.

The limbs now rotate. The **upper limb rotates 90° laterally** and as a result, its preaxial border and thumb come to lie on the lateral side. On the other hand, the **lower limb rotates 90° medially** and as a result, its preaxial border and great toe come to lie on the medial side.

N.B. The development of upper and lower limbs is similar except following facts:

1. The development of lower limb starts 1 or 2 days later to that of the upper limb.
2. During the seventh week of gestation, upper limb rotates 90° laterally whereas the lower limb rotates 90° medially (Fig. 8.25).

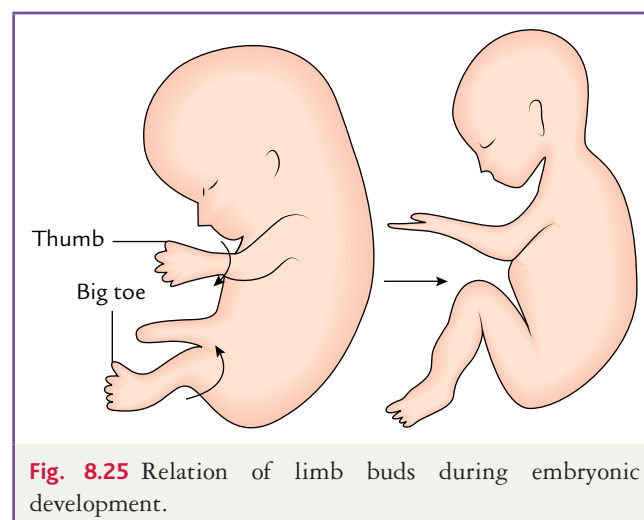


Fig. 8.25 Relation of limb buds during embryonic development.

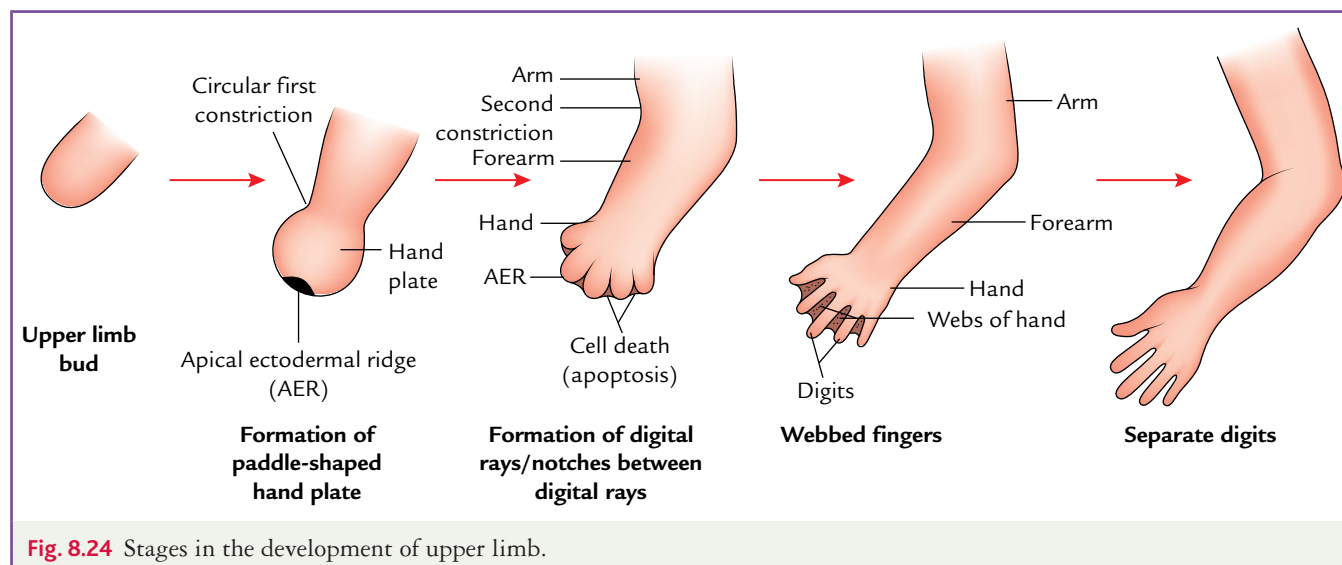
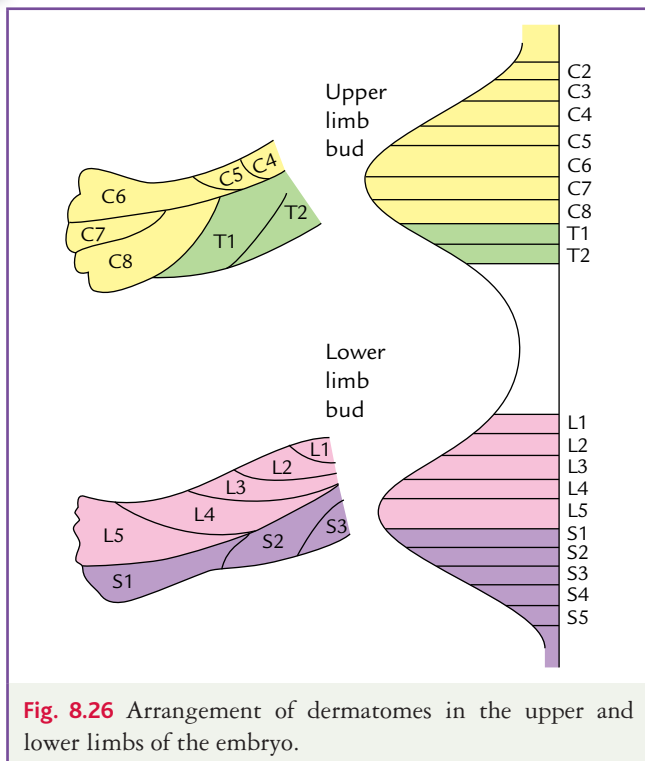


Fig. 8.24 Stages in the development of upper limb.



Arrangement of Dermatomes in the Upper and Lower Limbs

Area of skin supplied by a single spinal nerve and therefore by a single spinal segment is termed **dermatome**.

1. The upper limb develops from the body wall opposite C4, C5, C6, C7, C8, T1, and T2 spinal segments, hence innervated by corresponding spinal nerves.
2. The lower limb develops from the body wall opposite L2, L3, L4, L5, S1, and S2 spinal segments, hence innervated by the corresponding spinal nerves.

The arrangement of dermatome in the upper and lower limbs of the embryo is shown in Fig. 8.26.

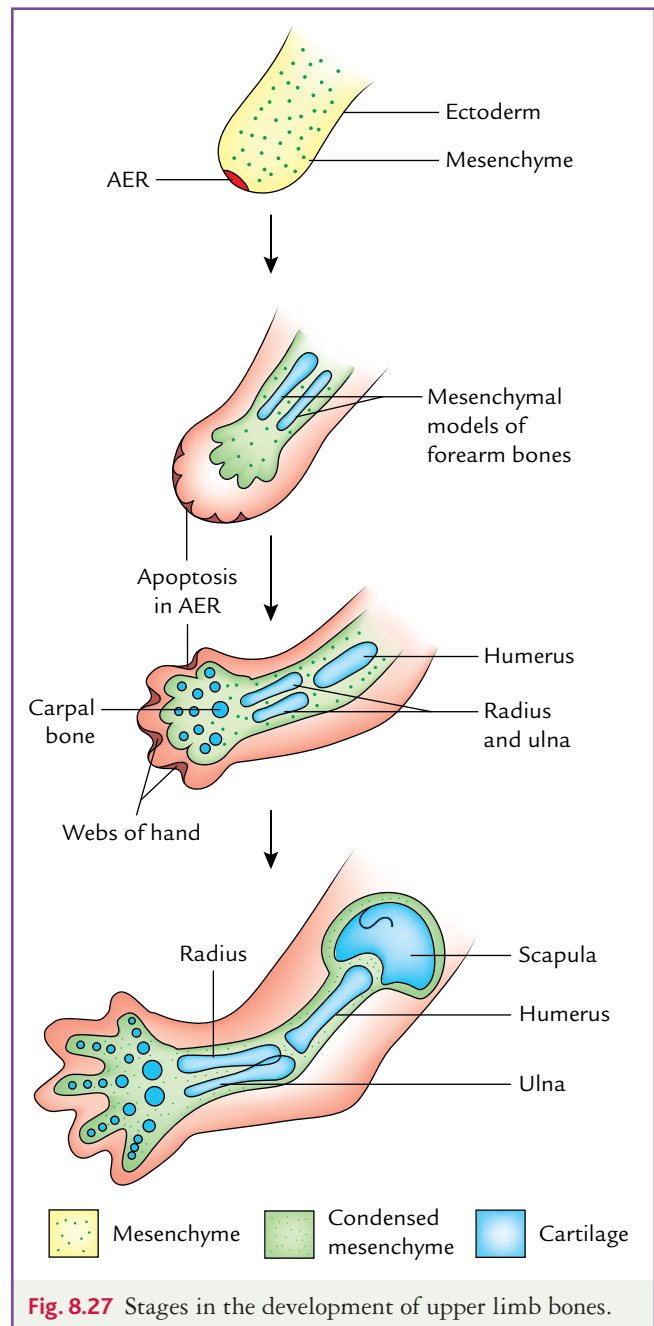
N.B. The positioning of limbs along the craniocaudal axis in the body wall is regulated by **Hox genes**.

Development of Upper Limb Bones

All the bones of upper limb, viz., scapula, clavicle, humerus, radius, ulna, carpals, metacarpals, and phalanges develop from somatic layer of lateral plate mesoderm.

The sequence of events of formation of upper limb bones is as follows (Fig. 8.27)

1. During the fifth week, the mesenchyme derived from lateral plate mesoderm migrates along the central axis of limb bud and condenses to form **mesenchymal models of bones**.



2. During the sixth week, the **mesenchymal models of bones** undergo chondrification to form **hyaline cartilage models of bones**.
3. The hyaline cartilage models undergo **ossification** to form bones.

Ossification

All the bones of the upper limb are formed by **endochondral ossification**; however clavicle is formed by both **membranous (mainly) and endochondral ossification**. The clavicle is the first bone to ossify in the entire body. For ossification of individual bones refer *Textbooks of Osteology*. However, as a classical example of ossification, only ossification of long bone is given

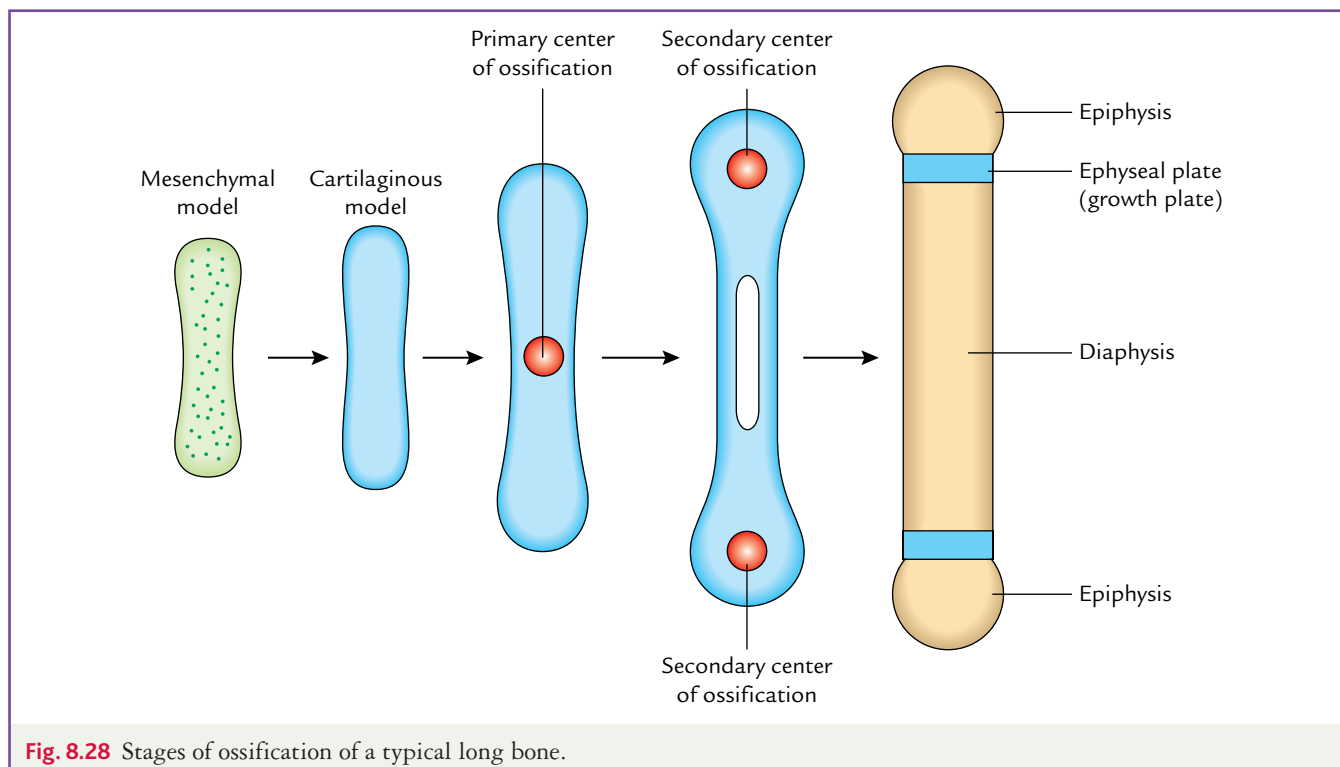


Fig. 8.28 Stages of ossification of a typical long bone.

here. The ossification of a typical long bone occurs as under (Fig. 8.28):

1. During the eighth week, primary center of ossification appear in the middle of the long bone.
2. During childhood, secondary centers appear at the ends of long bone.
3. The primary center forms the diaphysis of long bone whereas the secondary centers form the epiphyses of long bone.
4. The bone formed by the primary center in the diaphysis does not fuse with bone formed by the secondary center in the epiphysis. They remain separated from each other by a plate of cartilage called **epiphyseal cartilage**. The growth of bone in length occurs at the epiphyseal cartilage. Hence, it is also called **growth plate**. When the epiphyseal cartilage ossifies the growth of bone ceases.

Development of Lower Limb Bones

Like upper limb all the bones of lower limb, viz., hip bone, femur, tibia, fibula, tarsals, metatarsals, and phalanges develop from somatopleuric layer of lateral plate mesoderm.

The sequence of events involved in development of bones of lower limb is same as in upper limb.

Ossification

The bones of the lower limb ossify in the same fashion as those of the upper limb.

N.B. The primary centers of ossification of limb bones appear at different times in different bones, but most of them appear between 7th and 12th week, i.e., virtually all primary centers of ossification are present at birth and most of the secondary centers appear after birth.

Clinical Correlation

1. **Medicolegal importance of ossification center at the lower end of femur:** The secondary center of ossification at the lower end of femur usually appears during the last month of intrauterine life. Therefore, visibility of this center in radiograph (Fig. 8.29) is used as a medicolegal evidence to confirm the fact that newborn infant found dead was near full-term and viable.

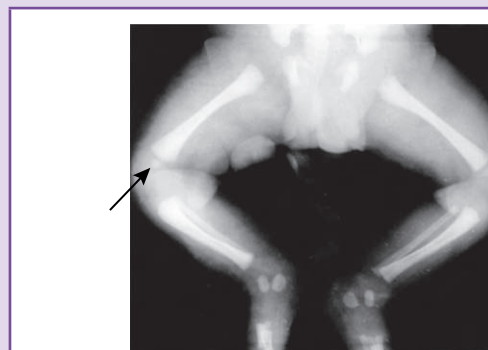


Fig. 8.29 Radiograph of full-term child showing the presence of secondary center of ossification at the lower end of the femur (arrow).

2. **Achondroplasia (ACH):** It is the most common type of dwarfism (shortness of stature). It occurs due to defective **endochondral ossification** at the epiphyseal plates of cartilage, particularly of long bones. It occurs in about 1 in 26,000 live births. The limbs become bowed and short; trunk remains normal and head is enlarged with bulging forehead.
3. **Amelia:** In this condition, there is a complete absence of all four limbs.
4. **Phocomelia:** In this condition, rudimentary hands and feet are directly attached to the trunk.
5. **Meromelia:** In this condition, all three segments of limbs are short.

N.B. **Amelia, phocomelia, and meromelia** are characteristically seen in children whose mothers have used an antiemetic drug—the **thalidomide**—between the sixth and eighth week of gestation. Hence children with these abnormalities are called 'thalidomide babies.'

6. **Syndactyly (webbed fingers or toes):** It is the common limb anomaly and results from failure of hand and foot webs to degenerate between the digits.
7. **Polydactyly:** In this condition, there is a **supernumerary digit** in hand or foot, most commonly the thumb that may have an extra phalanx. It is the most common congenital anomaly of the hand and may occur due to mutation of autosomal dominant genes (Fig. 8.30).

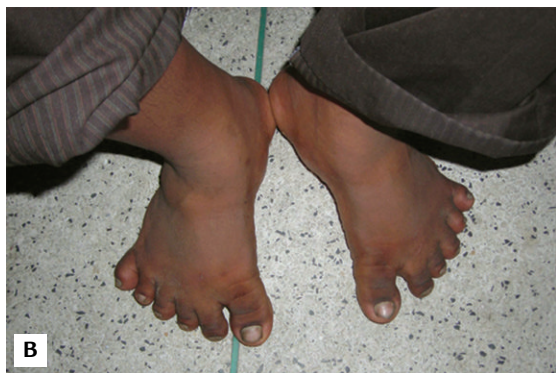
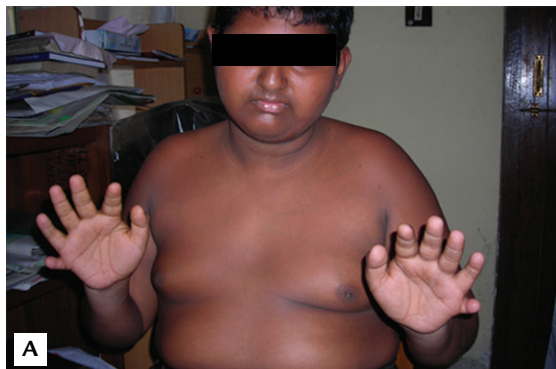
Fig. 8.30 Polydactyly. A. Supernumerary digit in hand (six fingers). B. Supernumerary digit in foot (six toes).

8. **Lobster claw hand or foot:** In this condition, third digit is missing and the second and fourth digits are separated by a wide cleft. Medial two digits are fused; lateral two digits may also be fused.
9. **Talipes or clubfoot:** Any deformity of foot involving talus is called **talipes** or **clubfoot**. There are various types but **talipes equinovarus** is the most common type occurring about 1 in 1000 births. In this condition, the foot is turned medially and is inverted. This prevents normal weight bearing. It results from abnormal positioning or restricted movements of fetus's lower limbs in utero.
10. **Congenital dislocation of hip:** In this condition, joint capsule is lax at birth and there is underdevelopment of acetabulum. The dislocation almost always occurs after birth. It occurs about 1 in 1500 newborn infants and is more common in female babies.

Development of Joints (Fig. 8.31)

The joints are classified into three types: (a) fibrous joints, (b) cartilaginous joints, and (c) synovial joints.

The joints develop from interzonal mesenchyme between primordia of developing bones during sixth and seventh weeks of IUL.

1. In a **fibrous joint (syndesmosis)** intervening mesenchyme between the developing bones differentiates into fibrous tissue.

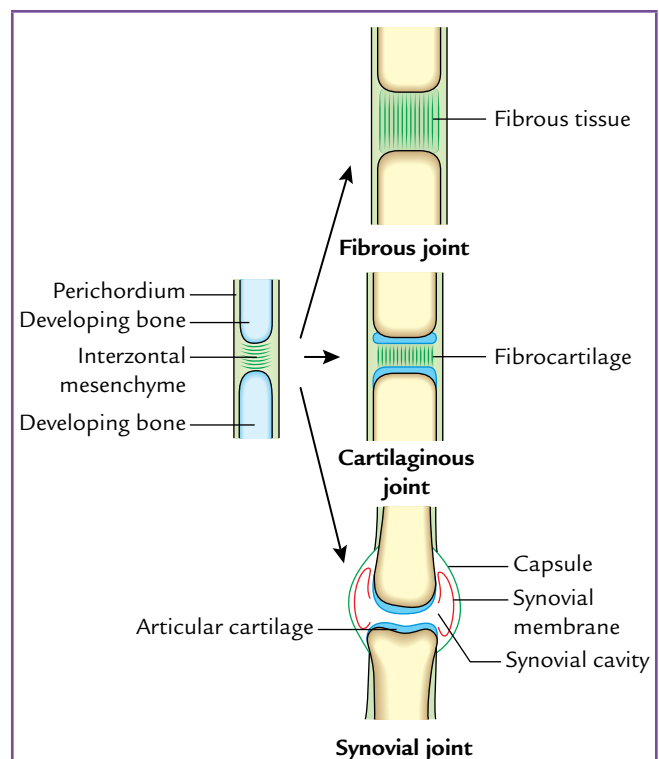


Fig. 8.31 Development of joints.

2. In a **cartilaginous joint** mesenchyme between the developing bones differentiates into a cartilage.

N.B. In some cartilaginous joints, viz., primary cartilaginous joints (synchondrosis), cartilage connecting the bones (epiphysis and diaphysis) is later ossified with the result that the two bones become continuous with each other.

3. In a **synovial joint**, a cavity is formed in mesenchyme between the developing bones. This mesenchyme also gives rise to synovial membrane, joint capsule, and other ligaments of the joint.

GOLDEN FACTS TO REMEMBER

- | | |
|--|--|
| ➤ Most serious vertebral defect | Spina bifida |
| ➤ Most severe form of spina bifida | Spina bifida aperta (spina bifida with rachischisis) |
| ➤ Commonest accessory rib | Accessory lumbar rib |
| ➤ Most common congenital anomaly of the chest | Funnel chest |
| ➤ Most serious birth defect seen in stillborn infants | Anencephaly |
| ➤ Most (largest) prominent fontanelle | Anterior fontanelle |
| ➤ First bone to ossify in the body | Clavicle |
| ➤ Most common congenital defect due to defective endochondral ossification | Achondroplasia (dwarfism) |
| ➤ Most common limb anomaly of fingers and toes | Polydactyly (supernumerary finger or toe) |

CLINICAL PROBLEMS

- All cervical spinal nerves emerge out of the vertebral canal through intervertebral foramina except C1, which emerges out between the base of skull and first cervical vertebra. Give the embryological basis.
- Give the embryological basis of various deformities of shape of heads in newborns.
- A mother noticed a difference in lengths of the legs of her 12-months-old daughter while she was standing up. Give the embryological basis.
- A newborn baby has clubfoot. What is clubfoot and what is its most common variety? Give its embryological basis.
- A pregnant mother took thalidomide—an antiemetic drug—during her pregnancy. What congenital anomalies are likely to occur in the newborn baby?
- What are the factors that cause congenital limbs defects? Give an example of defect associated with each factor.
- In a breech (buttock first) presentation, delivery is more difficult than in vertex (head first) presentation. Give the embryological basis.

CLINICAL PROBLEM SOLUTIONS

- This is because in the cervical region fourth occipital sclerotome fuses with cranial portion of first cervical sclerotome to form base of the occipital bone. As a result, the C1 spinal nerve emerges out of the vertebral canal through a gap between occipital bone and atlas (C1) vertebra.

2. The developing bones of the skull are separated by narrow seams of fibrous tissue called **sutures**.
Premature closure of one or more sutures (**craniosynostosis**) causes deformities in shape of head of the newborn (for details see page 96).
3. The difference in the lengths of legs of her daughter is due to **congenital dislocation of the hip joint**, which is about eight times more common in female infants than male. It occurs due to congenital laxity of capsule of the hip joint and underdevelopment of acetabulum. The congenital dislocation of hip always occurs after birth and becomes obvious only when baby attempts to stand at about 12 months after birth.
4. The **clubfoot** is a congenital anomaly of the foot in which the foot is turned inward, adducted, and plantarflexed. The foot is fixed in the tiptoe position, resembling the foot of a horse (L. *Equinus* = horse). The most common type of clubfoot is **talipes equinovarus**. It is thought to occur due to abnormal positioning of fetus's lower limb in utero and follows a multifactorial pattern of inheritance.
5. The newborn baby of the mother who took thalidomide during her pregnancy is likely to suffer from following congenital anomalies of their limbs: (a) Amelia, (b) phocomelia, and (c) meromelia (also see page 100).
6. The congenital anomalies of limbs are caused by following factors.
 - (a) *Genetic factors* (such as chromosomal abnormalities due to mutant genes, e.g., brachydactyly (short digits).
 - (b) *Environmental factors* such as thalidomide, e.g., amelia, meromelia, and phocomelia (for details see page 100).
 - (c) *Combination of genetic and environmental factors* (multifactorial inheritance), e.g., congenital dislocation of the hip.
 - (d) *Ischemia*, e.g., reduction in size of limbs.
7. During normal parturition, moulding of the fetal skull is such that occipital bone is usually pressed under two parietal bones. In addition, one parietal bone overlaps the other. The depressed parietal bone comes to lie against the sacral promontory of the mother.
In case of breech delivery, the molding does not occur as a result, the delivery is more difficult.

9

Muscular System

Overview

All muscles of the body develop from mesoderm except the muscles of iris, arrector pili of skin, and myoepithelial cells of glands, which develop from ectoderm.

Muscles are classified into three types: skeletal (striated or **voluntary**), smooth (unstriated or **involuntary**), and **cardiac** (structurally striated but functionally smooth muscle).

1. The **skeletal muscles** mostly develop from somites (paraxial mesoderm).
2. The **smooth muscles** mostly develop from splanchnic mesoderm.
3. The **cardiac muscle** develops from splanchnic mesoderm surrounding developing heart tube.

Development of Skeletal Muscles

The skeletal muscles of axial skeleton, body wall, limbs, and head develop from somites and somatomes that extend from occipital to sacral region (Fig. 9.1). Each somite differentiates into two distinct zones: **sclerotome** and **dermomyotome**. The sclerotome forms bones of axial skeleton. The dermomyotome consists of two components: a deeper part called **myotome** and a superficial part called **dermatome**. The myotome forms muscular tissue whereas the dermatome forms dermis of skin (Fig. 9.2).

Muscles of eyeball (extraocular muscles) develop from **preotic myotomes**, muscles of tongue from **occipital myotomes**, muscles of limbs from myotomes present in upper and lower limb bud regions, and muscles of the body wall from myotomes in the trunk region (Fig. 9.2).

Myogenesis (muscle formation) of skeletal muscle (Fig. 9.3): The skeletal muscles develop from mesenchyme derived from myotomal mesoderm. The mesenchymal cells differentiate into primordial muscle cells called **myoblasts**. This differentiation includes elongation of cell and its nucleus. The myoblasts fuse with each other end-to-end to

form an elongated multinucleated cylindrical syncytial cell called **myotube**. The myotubes synthesize **actin**, **myosin**, and **other muscle proteins**. These proteins aggregate to form **myofilaments** and **myofibrils**. Now, the myotubes are called **muscle fibers**. A number of these muscle fibers are bound together by connective tissue to form **individual muscles**, which secondarily get attached to skeletal elements.

N.B.

- During myogenesis myofilaments and myofibrils develop in the cytoplasm of muscle fibers.
- All the skeletal muscles develop by birth.
- Mitotic activity of myoblasts ceases after birth. Therefore, all the muscle fibers that an individual is destined to have are formed by birth.

Development of Skeletal Muscles in Different Regions of the Body

In the human body, the skeletal muscles are divided into following groups:

- Muscles of the body wall (trunk)
- Muscles of head and neck
- Extraocular muscles
- Muscles of tongue
- Muscles of limbs.

Muscles of the Body Wall (Figs 9.4 and 9.5)

These are derived from **myotomes** (somites) of the trunk region. Each myotome is supplied by a single spinal nerve. Each myotome divides into two parts: a smaller dorsal part called **epaxial part (epimere)** and a larger ventral part called **hypaxial part (hypomere)**. The muscles derived from **epimere** are supplied by dorsal ramus of spinal nerve and muscles derived from **hypomere** are supplied by ventral ramus of spinal nerve.

The **epimeres of myotomes** form extensor muscles of the vertebral column (e.g., erector spinae).

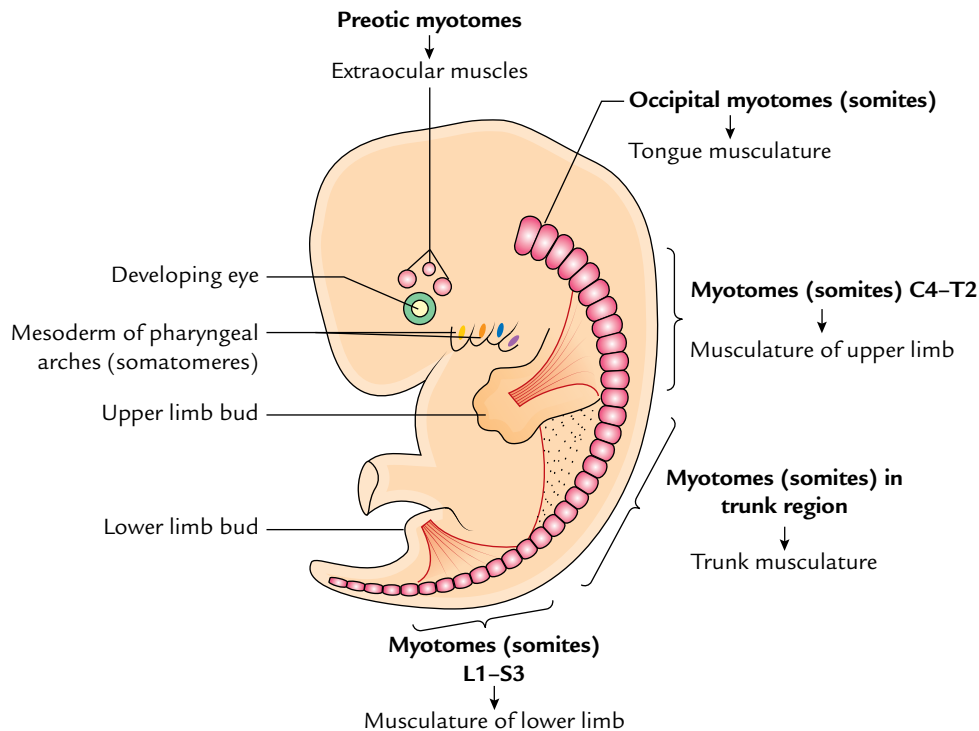


Fig. 9.1 Myotomes derived from somites and somatomes in different regions of the body which form skeletal muscles.

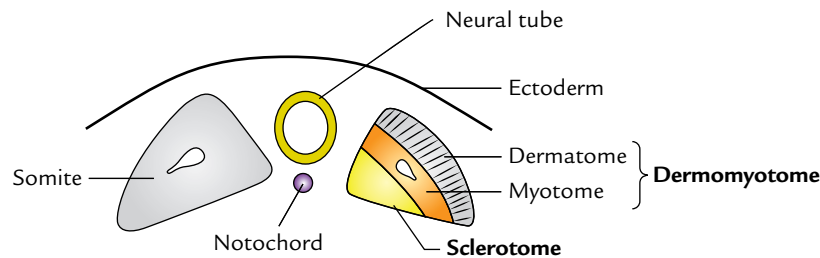


Fig. 9.2 Somite (on the left side) and its subdivisions (on the right side).

The hypomeres of myotomes extend ventrolaterally along the somatopleuric layer of celomic cavity and form following muscles of the body wall.

1. They form three layers of muscles in the thorax, viz., external intercostal, internal intercostal, and intercostal intimus (transversus thoracis).
2. In the abdomen also they form three layers of muscles, viz., external oblique, internal oblique, and transversus abdominis.
3. In the neck, they form longus colli, longus capitis, and scalene muscles. *The scalene muscles in the neck represent intercostal muscles.* On each side of midline on the ventral aspect of body, three primitive muscles of the body wall fuse to form the

longitudinal column of muscle. This longitudinal column of muscle in humans is represented by:

- (a) Rectus abdominis in abdomen
- (b) Rectus sternalis in thorax (present sometimes only)
- (c) Infrahyoid muscles in the neck.

N.B. Innermost muscle of primitive body wall in the thoracic region (e.g., transversus thoracis) is gradually peeled off by developing lung buds and subsequently blends with septum transversum to form **diaphragm**.

Muscles of Head and Neck

1. **Extraocular muscles (extrinsic muscles) of eyeball (Fig. 9.6):** They develop from three **preotic myotomes** that are arranged around developing eye.

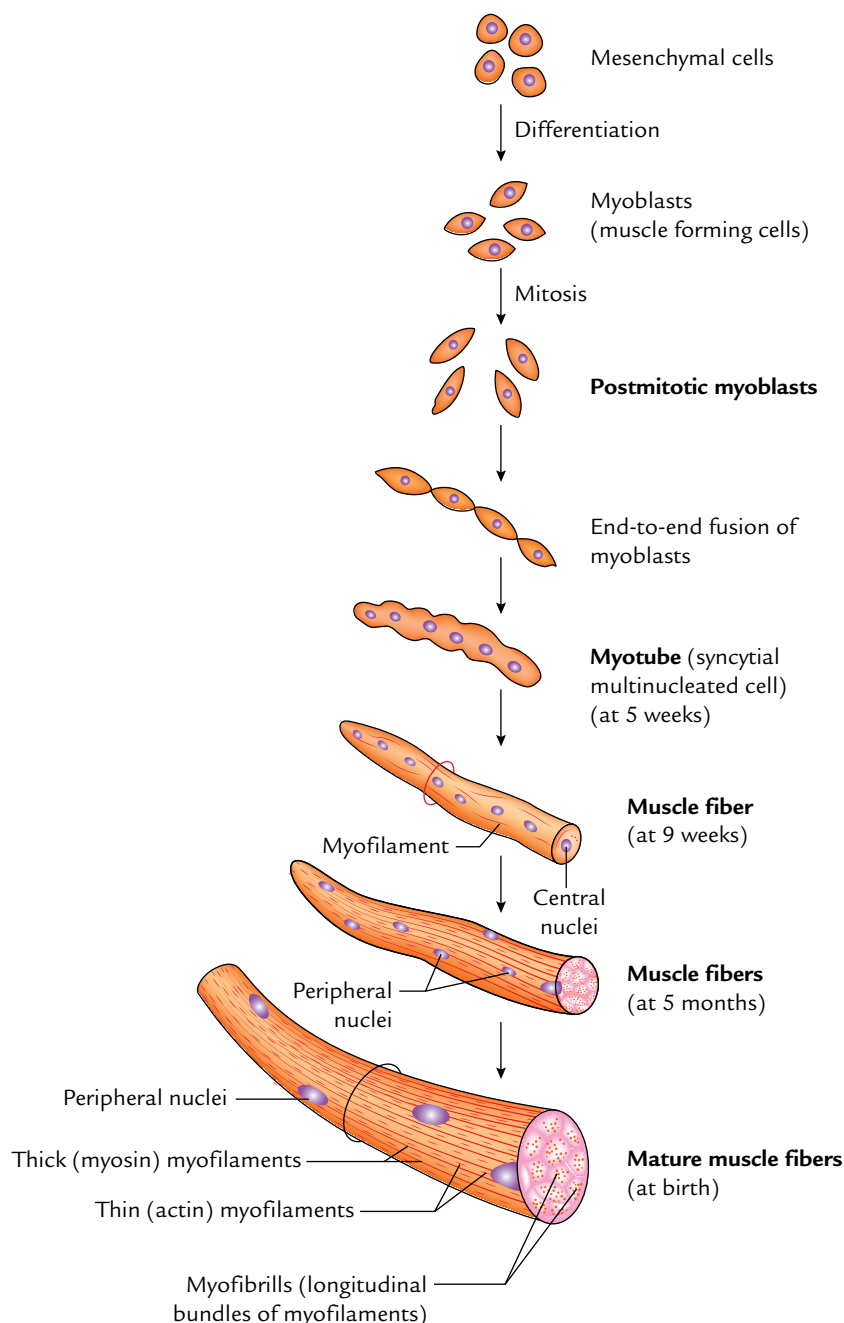


Fig. 9.3 Myogenesis of a skeletal muscle.

These myotomes are innervated by IIIrd, IVth, and Vth cranial nerves; hence the extraocular muscles are supplied by IIIrd, IVth, and Vth cranial nerves.

2. **Muscles of tongue (Fig. 9.6):** They develop from precervical somites called **occipital somites**. The occipital myotomes are innervated by **precervical nerves** that subsequently fuse to form composite **hypoglossal nerve**. When the tongue develops in floor of pharynx, the occipital myotomes migrate forward along **epipericardial ridge**, invade substance of the developing tongue, and form all intrinsic and extrinsic muscles of the tongue except

palatoglossus. Therefore, the hypoglossal nerves supply all the intrinsic and extrinsic muscles of the tongue except palatoglossus, which truly speaking is not a muscle of the tongue but that of a palate.

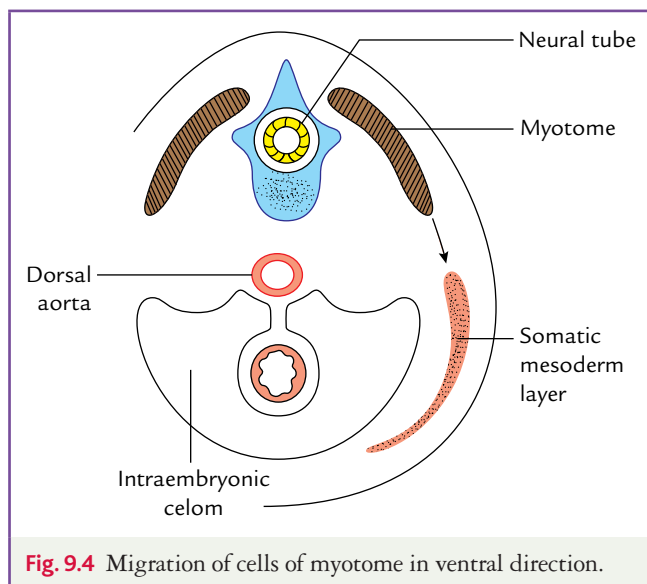
3. **Muscles of pharyngeal arches:** They develop from mesoderm of pharyngeal arches derived from somatomeres. The muscles derived from mesoderm of pharyngeal arches are muscles of mastication, facial expression, pharynx, and larynx. These muscles are innervated by nerves of the respective pharyngeal arches. The muscles of pharyngeal arches are described in detail in Chapter 10.

Muscles of Limbs (Fig. 9.7)

They develop from myotomes present in the upper and lower limb bud regions. The mesoderm derived from these myotomes migrates into the limb bud during the fifth week and forms **anterior and posterior condensations**.

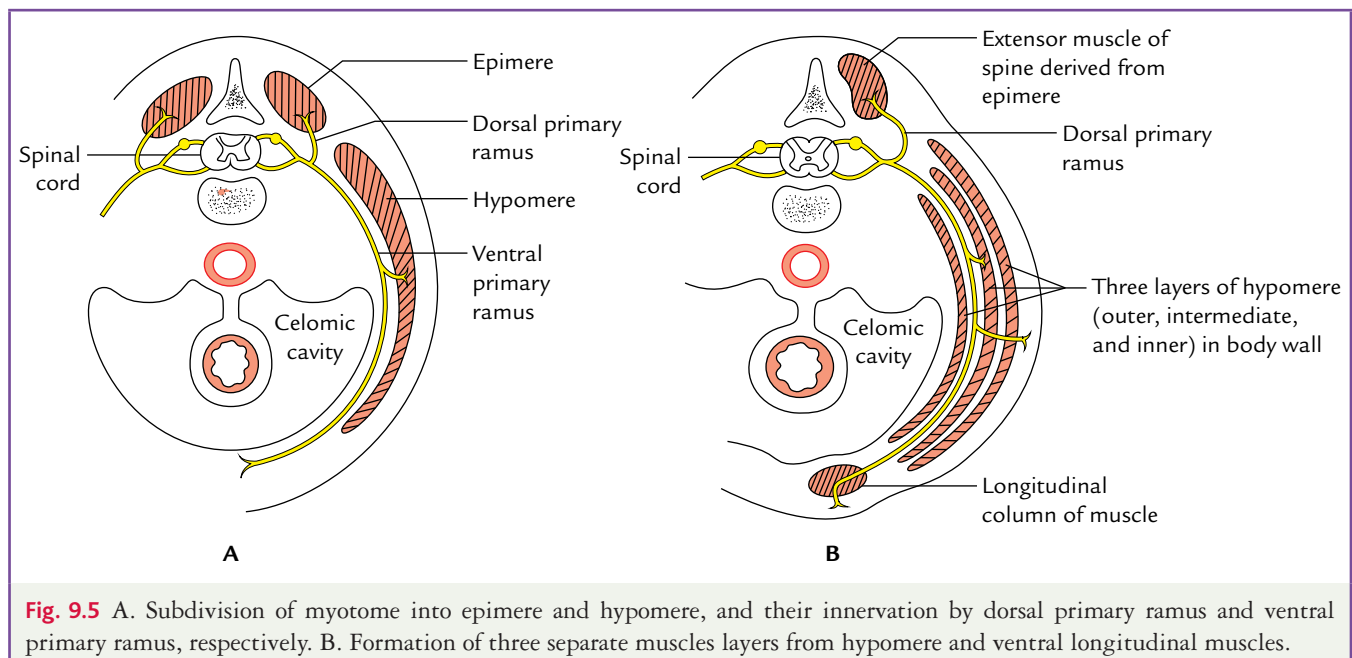
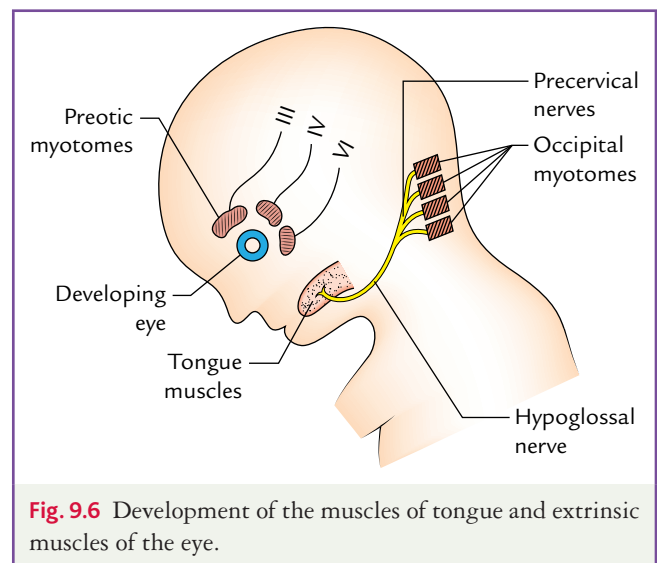
The **anterior condensation** of mesoderm gives rise to flexor and pronator muscles of the upper limb and extensor and adductor muscles of the lower limb.

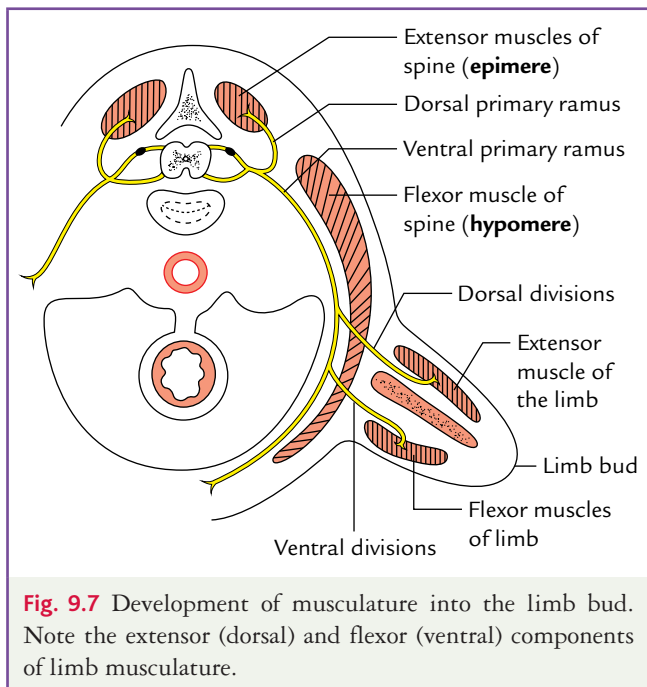
The **posterior condensation** of mesoderm gives rise to **extensor and supinator muscles of the upper limb** and flexor and adductor muscles of the lower limb.



N.B. The upper limb bud lies opposite the lower five cervical and upper two thoracic (C4,5,6,7,8, and T1,2) segments while the lower limb lies opposite the lower four lumbar and upper two sacral (L1,2,3,4,5, and S1,2) segments. Hence, the muscles of upper limb are innervated by lower five cervical and upper two thoracic segments, while the muscles of lower limb are supplied by lower four lumbar and upper two sacral spinal segments.

As the limb buds are formed various spinal nerves enter into the mesenchyme. At first they enter as isolated dorsal and ventral divisions of ventral primary rami (Fig. 9.7); but soon these divisions unite to form large dorsal and ventral nerves. Thus, radial nerve, which supplies to the extensor muscle, is formed by the union of dorsal divisions whereas the ulnar and median





nerves, which supply the flexor muscles, are formed by the union of ventral divisions.

Clinical Correlation

- Duchenne muscular dystrophy (DMD):** It is a hereditary disease of skeletal muscles that usually affects males. The DMD occurs due to mutation of a gene responsible for the formation of protein (**dystrophin**) on the inner surface of sarcolemma of muscle fibers. In this condition, the skeletal muscle becomes progressively weak from early childhood and by adulthood the person becomes practically immobile.
- Congenital anomalies of the skeletal muscles**
 - Partial or complete absence of one or more muscles:** It is a rather common phenomenon. One of the best examples is partial or complete absence of pectoralis major muscle. The other examples are palmaris longus, serratus anterior, and quadratus femoris.
 - Congenital torticollis:** It is congenital shortening of the sternocleidomastoid muscle, which occurs due to excessive stretching of this muscle during delivery. The excessive stretching causes hemorrhage in the muscle and subsequent shortening due to fibrosis.

Development of Smooth (Involuntary) Muscles

- The smooth muscle in the wall of digestive and respiratory tracts develops mainly from **splanchnic mesoderm** surrounding primordia of digestive and respiratory tracts.
- The smooth muscle in the wall of most of the blood and lymph vessels develops in situ from surrounding

splanchnic mesoderm. The somatic mesoderm may also form smooth muscle in the wall of many blood and lymph vessels.

- Muscles of iris (**spincter** and **dilator pupillae**), arrector pili muscles of skin, and myoepithelial cells of sweat and mammary glands develop from mesenchymal cells derived from ectoderm. The muscles of iris develop from ectoderm of the optic cup.

N.B. Axiom: Mesenchyme present anywhere in the body is a potential source of smooth muscle tissue.

Myogenesis of the Smooth Muscle

The mesenchymal cells differentiate into the myoblasts. The myoblasts become spindle shaped and their nuclei become oval. The myoblasts do not fuse with each other as in skeletal muscle; consequently muscle fibers of smooth muscle remain mononucleated.

The contractile elements develop in the cytoplasm of the muscle fiber but are nonsarcomeric.

Development of Cardiac Muscle

The cardiac muscle develops from myoepicardial mantle, which is formed by thickening of **splanchnic mesoderm** surrounding the developing heart tube.

Myogenesis of the Cardiac Muscle

The cardiac muscle fibers develop from differentiation and growth of single myoblasts, unlike skeletal muscle fibers that develop from fusion of a number of myoblasts. The growth of cardiac muscle fibers occurs due to formation of new myofilaments and myofibrils. The cardiac muscle fibers elongate and give rise to numerous side branches. The side branches as well as ends of one cardiac muscle fiber adhere to side branches and ends of other cardiac muscle fibers, but the intervening cell membranes persists (i.e., they do not disintegrate). These sites of adhesion of the cell membranes between cardiac muscle fibers persist as **intercalated discs**.

Therefore, the cardiac muscle does not form true syncytium.

The myofibrils around the central nucleus of the cardiac muscle fibers present cross striated appearance.

N.B. Late in the embryonic period some myoblasts develop cardiac muscle fibers that have relatively few myofibrils and relatively larger diameters than the typical cardiac muscles fibers. These **atypical cardiac muscle fibers** form bundles called **Purkinje fibers**, which form conducting system of the heart.

GOLDEN FACTS TO REMEMBER

- | | |
|---|--|
| ➤ Purkinje fibers | Bundles of atypical cardiac muscle fibers (having few myofibrils and large diameters) |
| ➤ Contractile cells in the body other than those in skeletal, cardiac, and smooth muscles | (a) Myoepithelial cells (associated with secretory acini)
(b) Myofibroblasts (involved in wound healing)
(c) Myoid cells (found around seminiferous tubules) |
| ➤ All the skeletal muscle fibers a man is destined to have are formed | By birth (mitotic activity of myoblasts ceases after birth) |
| ➤ Rectus abdominis muscle of abdomen in the thorax is represented by | Rectus sternalis |
| ➤ Occipital group of segmental nerves are represented by | Hypoglossal nerve |
| ➤ Occipital myotome which disappears soon after its formation | First occipital myotome |
| ➤ Best example of partial or complete absence of skeletal muscle | Pectoralis major |
| ➤ Most skeletal muscles develop from | Myotomes |
| ➤ Most smooth muscles and cardiac muscles develop from | Splanchnic mesoderm |

CLINICAL PROBLEMS

1. What is **Duchenne muscular dystrophy**? Give its embryological basis and discuss its clinical presentation.
2. A newborn female infant presented with an absence of right anterior axillary fold and displacement of her right nipple below and towards the axilla. What is the most probable clinical diagnosis? Discuss its functional and cosmetic implications.
3. Discuss the molecular regulation of development of muscle.
4. The human baby takes several months after birth to crawl, while babies of most mammals can walk or even run within few hours after they are born. Why?

CLINICAL PROBLEM SOLUTIONS

1. The **Duchenne muscular dystrophy (DMD)** is a clinical condition characterized by **progressive muscle weakness and wasting**. It generally leads to death of an individual in his teens or 20s due to cardiac or respiratory failure.

The Duchenne muscular dystrophy is caused by genetic mutation of DMD gene. The **DMD gene** is located in the short arm (p) of chromosome X in band 21 (Xp 21) and encodes for protein termed **dystrophin** on the inner surface of sarcolemma. This protein anchors cytoskeleton (e.g., actin) of muscle fibers to extracellular matrix through a transmembrane protein and stabilizes the cell membrane.

A **mutation of DMD gene** destroys the ability of **dystrophin** to anchor the cytoskeleton (actin) of muscle fibers to the extracellular matrix.

The DMD is an X-linked condition caused by a **recessive allele**. The males who have only defective allele of the DMD gene from the mother suffer from this disease.

2. The most likely clinical diagnosis is **Poland syndrome**. This syndrome is characterized by partial (often sternal part) or complete absence of pectoralis major muscle. The absence of pectoralis major is occasionally associated with the absence of mammary gland and/or hypoplasia of the nipple. In this case, the cause of abnormal surface feature is the absence of pectoralis major. The affected individuals may present shortness of middle digits (**brachydactyly**) and fusion of digits (**syndactyly**).

Loss of the pectoralis major muscles produces little or no functional loss as other muscles associated with shoulder joint compensate for the loss of the pectoralis major; but disfigurement of the chest is a cause of concern, particularly, in females.

3. The molecular signals for muscle cell induction arise from tissues adjacent to prospective muscle cells. The myogenic cells express two types of genes: **MyoD** (a helix–loop–helix transcription factor) and **MYFs** (myogenic regulator factors).

Following induction myogenic cells enter the cell cycle (i.e., undergo mitosis). The **MyoD** genes remove myogenic cells from the cell cycle (i.e., mitosis stops) and switches on muscle-specific genes (**MYF**) to form **postmitotic myoblasts**.

N.B. The damaged muscles fail to regenerate because they develop from postmitotic myoblasts.

4. The development of skeletal muscle tissue begins to develop from specialized mesodermal cells (myoblasts) during the fourth week of intrauterine life. At ninth week, primitive myofilaments develop in the cytoplasm of developed muscle fibers. The muscles of entire muscular system get differentiated and correctly positioned by the eighth week. The orientation of developing muscle is preceded and influenced by cartilaginous models of bones. The muscles of the trunk and limbs are supplied by spinal nerves.

It is not certain when skeletal muscles are sufficiently developed to sustain contractions but by week 17, the fetal movements (known as **quickening**) are strong enough to be recognized by mother.

Muscle coordination is an ongoing process of achieving a fine neural control of muscle fibers, viz., 1 year after birth in humans whereas in lower mammals such as quadrupeds it is achieved before birth. This is the reason why human baby takes several months to crawl while babies of lower animals can walk or even run immediately after birth.

Overview

The **pharyngeal apparatus** consists of pharyngeal arches, pharyngeal pouches, pharyngeal clefts (grooves), and pharyngeal membranes. All these structures largely contribute to the formation of head and neck region (e.g., face, neck, definitive mouth, pharynx, and larynx).

Early in the fourth week of intrauterine development, a series of surface elevations appear in the lateral wall of primitive pharynx caudal to stomodeum. These elevations are termed **pharyngeal arches** (Figs 10.1 and 10.2). The pouches between them on the inner aspect of the pharyngeal wall are termed pharyngeal pouches and grooves between them on the outer aspect of the pharyngeal wall are called **pharyngeal clefts**.

Initially the pharyngeal arches are confined in the lateral wall of the primitive pharynx. But gradually they extend ventrally and fuse with their counterparts of the opposite side in floor of the primitive pharynx to form horseshoe-shaped cylindrical bars. Initially there are six arches. The **fifth arch** is small and rudimentary, and soon disappears. Thus, only five pharyngeal arches remain. The pharyngeal arches are numbered craniocaudally as 1, 2, 3, 4, and 6.

Salient Features of Various Components of Pharyngeal Apparatus

- Pharyngeal arches:** Five in number and present in the lateral wall and floor of the primitive pharynx.
- Pharyngeal clefts (grooves):** Four in number and present externally between the arches. They are lined by **ectoderm**.
- Pharyngeal pouches:** Four in number and located internally between the two pharyngeal arches. They are lined by **endoderm**.
- Pharyngeal membranes:** Four in number and located between the two adjacent arches where pharyngeal cleft and pouches are opposed to each other.

Pharyngeal Arches

These are horseshoe-shaped cylindrical bars in the lateral and ventral walls of the primitive pharynx.

The pharyngeal arches provide support to the wall of primitive pharynx laterally as well as ventrally.

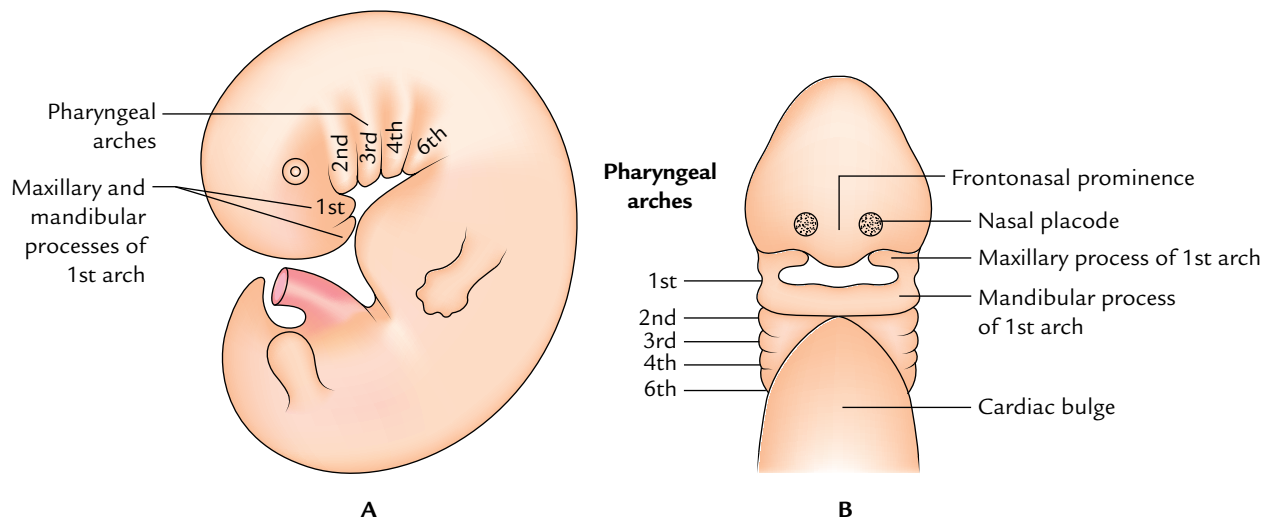


Fig. 10.1 Formation of pharyngeal arches. A. Lateral view. B. Frontal view. Note that first pharyngeal arch consists of maxillary and mandibular processes.

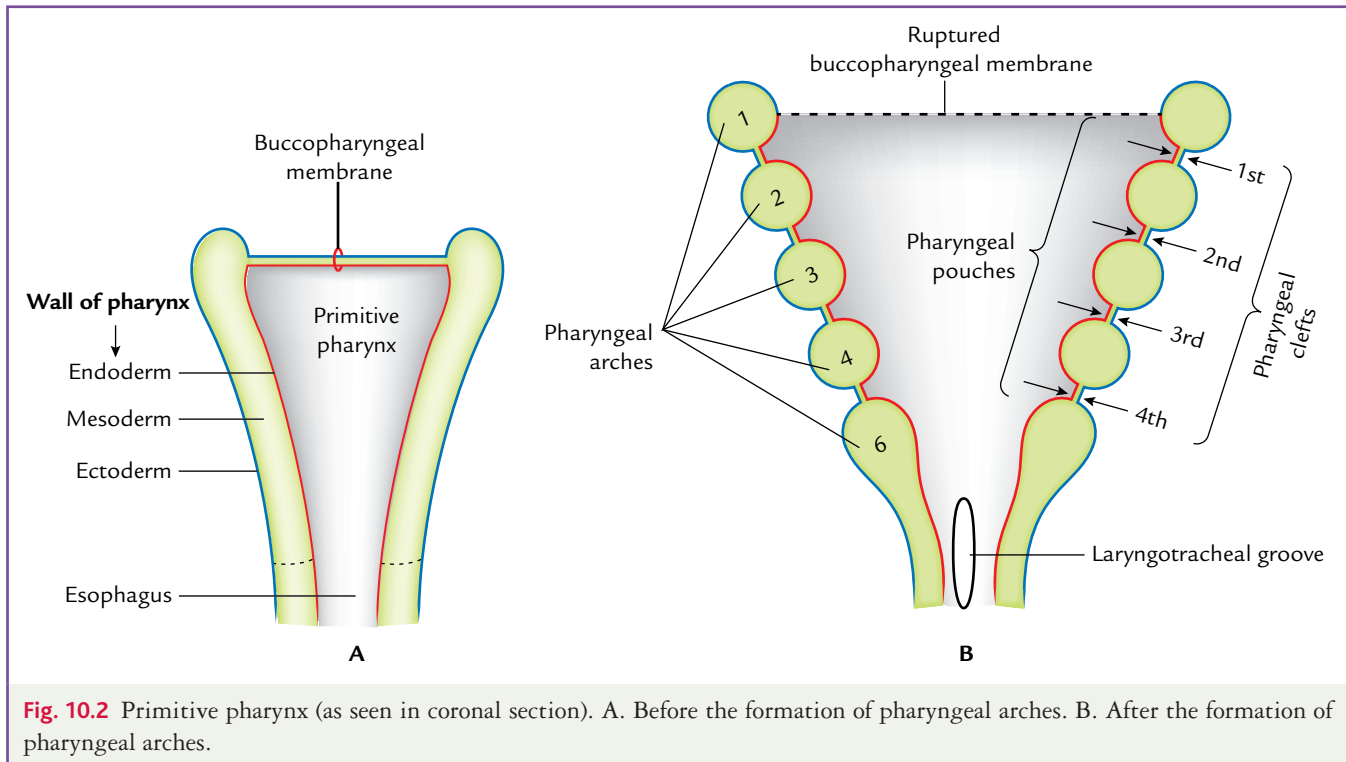


Fig. 10.2 Primitive pharynx (as seen in coronal section). A. Before the formation of pharyngeal arches. B. After the formation of pharyngeal arches.

Components of a Pharyngeal Arch

A typical pharyngeal arch consists of following components (Fig. 10.3):

- A **core of mesoderm** derived from paraxial mesoderm and neural crest cells. It is covered externally by ectoderm and internally by endoderm.
- A **cartilaginous bar/rod** derived from neural crest mesenchyme.
- A **pharyngeal arch artery** that arises from corresponding horn of aortic sac (truncus arteriosus) of primitive heart.
- A **nerve** derived from hind brain vesicle.

Fate of Pharyngeal Arch Components

The **arch mesoderm** derived from paraxial mesoderm gives rise to most of the muscles of head and neck region. Whereas the arch mesoderm derived from neural crest cells gives rise to skeletal elements and connective tissue of the head and neck region.

A **cartilaginous rod of arch** forms the skeletal derivatives of the arch. Part of cartilage forms permanent skeletal elements (e.g., bone and cartilage) and part of it disappears. Sometimes the cartilage disappears but its perichondrium persists to form ligament/raphe.

The **arch arteries** are connected ventrally to ventral aorta. They pass around the primitive pharynx to open in the dorsal aorta.

The **nerve of arch** provides motor innervation to muscles derived from arch and sensory innervation to skin and mucosa derived from the arch, respectively.

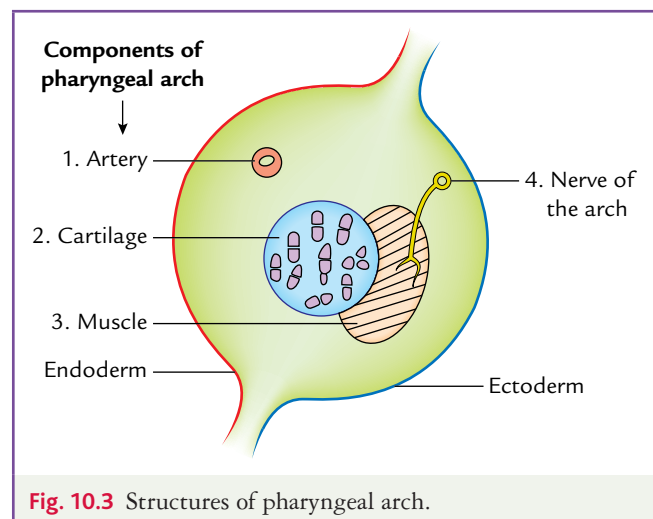


Fig. 10.3 Structures of pharyngeal arch.

The arch arteries develop into major arteries close to the heart. They are described in detail in Chapter 19 on Development of Blood Vessels.

N.B. Morphologically each pharyngeal arch is supplied by two nerves. The nerve that runs along cranial border of the arch is known as **post-trematic nerve** and nerve that runs along its caudal border is called **pretrematic nerve**. In human beings, the pretrematic nerves disappear from all arches except first arch where it persists as **chorda tympani nerve**. Some authorities consider that the **tympanic branch of glossopharyngeal nerve** and **auricular branch of vagus nerve** represent the pretrematic branches of these nerves (Fig. 10.4).

Muscles of the Pharyngeal Arches

The mesoderm of each arch (derived from paraxial mesoderm and lateral plate mesoderm) gives rise to

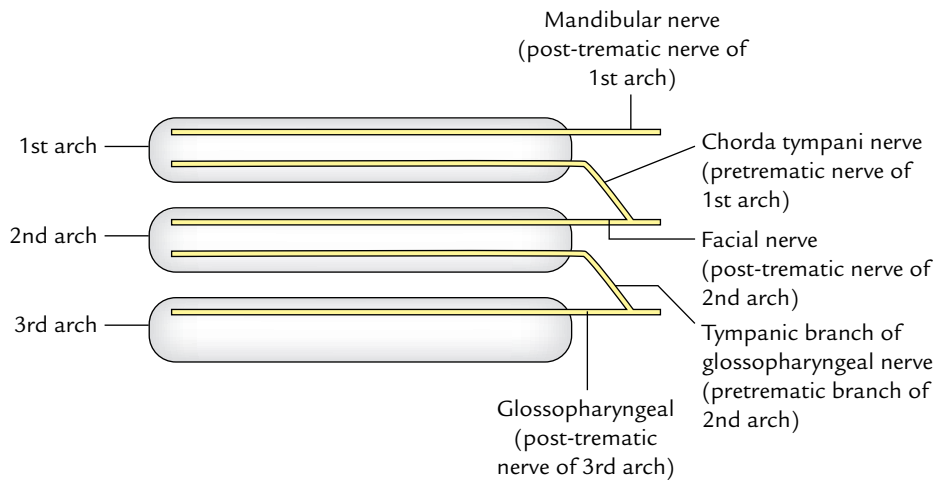


Fig. 10.4 Arrangement of post-trematic and pretrematic nerves.

muscles. These muscles are either attached to skeletal elements developed from the same arch or migrate elsewhere. However, all of them are supplied by nerve of the arch from which they develop. Hence, nerve supply of the muscle indicates its origin from the particular arch.

Muscles of First Arch

The muscles derived from first arch are muscles of mastication (viz., temporalis, masseter, lateral pterygoid, and medial pterygoid), anterior belly of digastric, mylohyoid, tensor tympani, and tensor palati.

All these muscles are supplied by **mandibular nerve**.

Muscles of Second Arch

The muscles derived from second arch are muscles of the facial expression, posterior belly of digastric, stylohyoid, and stapedius.

All these muscles are supplied by **facial nerve**.

Muscles of Third Arch

The only muscle derived from the third arch is stylopharyngeus. It is supplied by **glossopharyngeal nerve**.

Muscles of Fourth and Sixth Arches

The muscles derived from fourth arch are cricothyroid, levator veli palati, and constrictors of the pharynx. They are supplied by **superior laryngeal nerve**.

The muscles derived from sixth arch are intrinsic muscles of the larynx. They are supplied by **recurrent laryngeal nerve**.

Nerves of the Pharyngeal Arches (Fig. 10.5)

Nerve of the First Arch

Trigeminal nerve (CN V) (maxillary and mandibular divisions) is the nerve of the first arch. The first arch is also supplied by the **chorda tympani nerve**, a pretrematic branch of the facial nerve—the nerve of second arch.

Motor branches from mandibular nerve supply muscles derived from the first arch (see page 114).

Sensory branches from maxillary and mandibular nerves supply the skin of face, mucous membrane of the nasal cavity, oral cavity, soft palate and tongue, and teeth of upper and lower jaw.

The chorda tympani nerve supplies taste fibers to the anterior two-third of tongue.

Nerve of the Second Arch

Facial nerve is the nerve (CN VII) of the second arch and supplies the motor branches to all the muscles derived from second arch (see page 114).

Nerve of the Third Arch

Glossopharyngeal nerve (CN IX) is the nerve of the third arch. Its motor component supplies stylopharyngeus muscle while its sensory component supplies mucous membrane of the pharynx.

Nerves of the Fourth and Sixth Arches

Superior laryngeal nerve, a branch of vagus nerve, is the nerve of the fourth arch, and **recurrent laryngeal nerve**, also a branch of the vagus, is the nerve of the sixth arch.

Superior laryngeal nerve supplies cricothyroid muscle of the larynx while the recurrent laryngeal nerve supplies rest of the intrinsic muscles of the larynx.

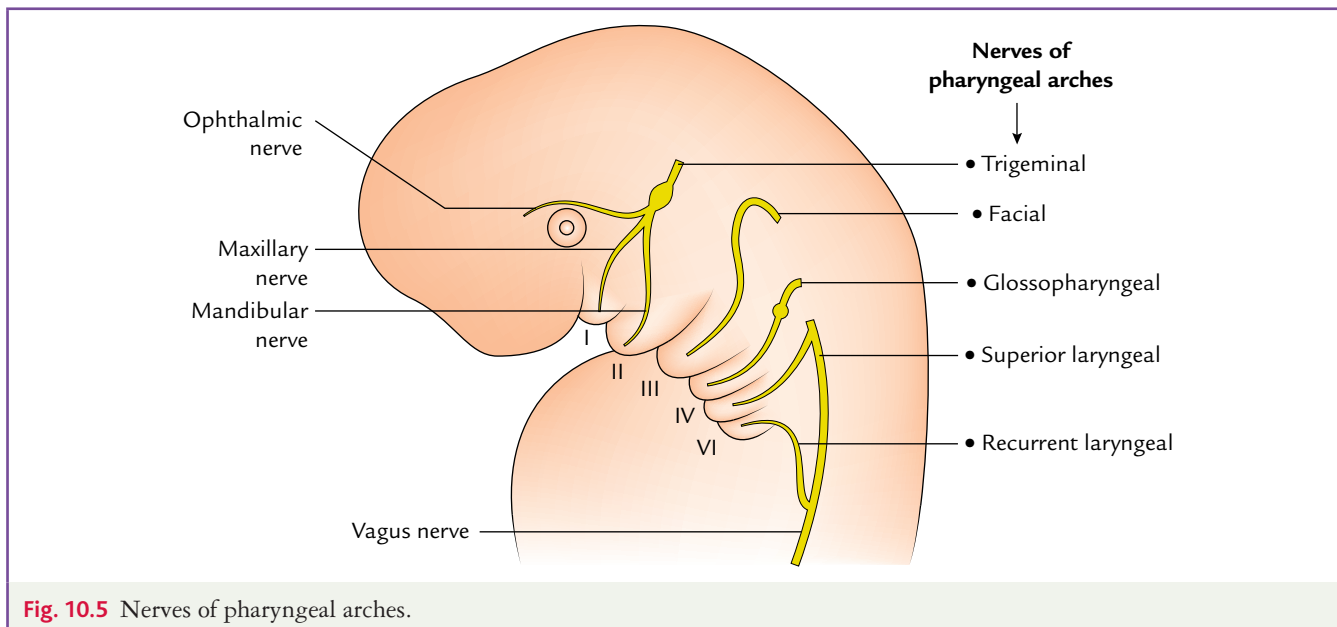


Fig. 10.5 Nerves of pharyngeal arches.

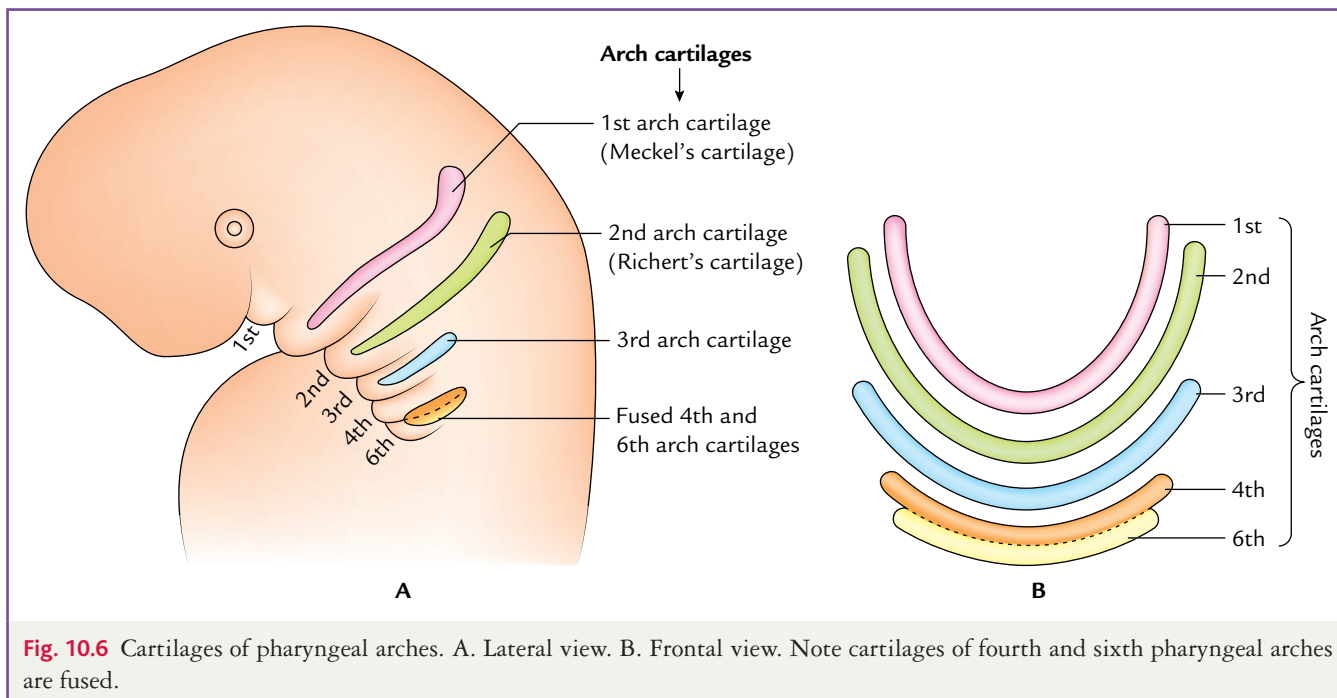


Fig. 10.6 Cartilages of pharyngeal arches. A. Lateral view. B. Frontal view. Note cartilages of fourth and sixth pharyngeal arches are fused.

Sensory branches from both these nerves supply mucus membrane of the larynx. Superior laryngeal nerve supplies the mucus membrane above vocal cords, while recurrent laryngeal nerve supplies the mucous membrane below vocal cords.

Cartilages of the Pharyngeal Arches (Fig. 10.6)

Each cartilage is horseshoe shaped with its ends directed dorsally. The dorsal ends lie at a higher level than the ventral part of the arch.

First Arch Cartilage

First arch cartilage is called **Meckel's cartilage**. (It forms in the ventral portion of the first arch called **mandibular process**.) The dorsal end of this cartilage lies close to developing middle ear cavity.

Dorsal end of Meckel's cartilage persists and forms two small bones—**malleus** and **incus**—the ear ossicles that are then incorporated in the middle ear cavity.

Ventral part of Meckel's cartilage is surrounded by mesenchyme that forms mandible by membranous ossification. The Meckel's cartilage trapped within bone

Table 10.1 Nerves and derivatives of the pharyngeal arches

Pharyngeal arch	Nerve/nerves	Muscles	Skeleton	Ligaments
First arch (mandibular and maxillary processes)	(a) Maxillary and mandibular nerves (b) Chorda tympani nerve	Muscles of mastication (temporalis, masseter, medial and lateral pterygoids), mylohyoid, anterior belly of digastric, tensor veli palatini, and tensor tympani	Premaxilla, maxilla, zygomatic bone, part of temporal bone, Meckel's cartilage, mandible, malleus, and incus	Anterior ligament of malleus, and sphenomandibular ligament
Second arch	Facial nerve	Muscles of facial expression (buccinator, auricularis, occipitofrontalis, platysma, orbicularis oris, orbicularis oculi), posterior belly of digastric stylohyoid, and stapedius	Stapes, styloid process, lesser cornu of the hyoid bone, and upper part of body of the hyoid bone	Stylohyoid ligament
Third arch	Glossopharyngeal nerve	Stylopharyngeus	Greater cornu and lower part of body of the hyoid bone	
Fourth and sixth arches	Superior laryngeal branch of vagus nerve (nerve of fourth arch) Recurrent laryngeal branch of vagus nerve (nerve of sixth arch)	Cricothyroid, levator palati, constrictors of pharynx, and intrinsic muscles of the larynx	Laryngeal cartilages (thyroid, cricoid, arytenoids, corniculate, cuneiform)	

degenerates and disappears. Thus, the mandible is formed around ventral part of the Meckel's cartilage.

Remaining part of the Meckel's cartilage between mandible and ear ossicles disappears but its perichondrium persists to form two ligaments: (a) **anterior ligament of malleus** and (b) **sphenomandibular ligament**.

N.B. Mandible is not formed from Meckel's cartilage but is moulded around it by membranous ossification of surrounding mesoderm.

The mesenchyme of dorsal portion—the maxillary process of the first pharyngeal arch—gives rise to premaxilla, maxilla, zygomatic bone, and part of the temporal bone by membranous ossification.

Second Arch Cartilage

Second arch cartilage is called **Reichert's cartilage**. Dorsal end of second arch cartilage ossifies to form the third ear ossicle—the 'stapes.' It is later incorporated into the middle ear cavity. Caudal to stapes the second arch cartilage forms **styloid process of the temporal bone**. Ventral part of the Reichert's cartilage ossifies to form **lesser cornu** and **upper part of body of the hyoid bone**. The part of cartilage between hyoid bone and styloid process disappears but its perichondrium persists to form **stylohyoid ligament**.

Third Arch Cartilage

The third arch cartilage is located in the ventral part of the arch.

The ventral part of the third arch cartilage ossifies to form the lower part of the body and **greater cornu** and lower part of the body of hyoid bone. The rest of the cartilage disappears.

Fourth and Sixth Arch Cartilages

Fourth and sixth arch cartilages fuse to each other. They together form all the cartilages of the larynx, viz., thyroid, cricoid, arytenoid, corniculate, and cuneiform cartilages except epiglottis, which develops from caudal part of hypobranchial eminence (for details see page 123).

The nerves and structures derived from pharyngeal arches are given in Table 10.1. The skeletal derivatives of pharyngeal arches are shown in Figs 10.7 and 10.8.

Arteries of Pharyngeal Arches

Each pharyngeal arch has its own artery that connects aortic sac with the dorsal aorta. They are described in detail in Chapter 19. The fate of pharyngeal arch arteries is given in Table 10.2.

Pharyngeal Pouches (Fig. 10.9)

There are four pairs of pharyngeal pouches. These are evaginations of endoderm, lining the interior to primitive pharynx between the two *arches*. The pharyngeal pouches are numbered in craniocaudal direction. Thus, the first pouch is between the first and second arch, the

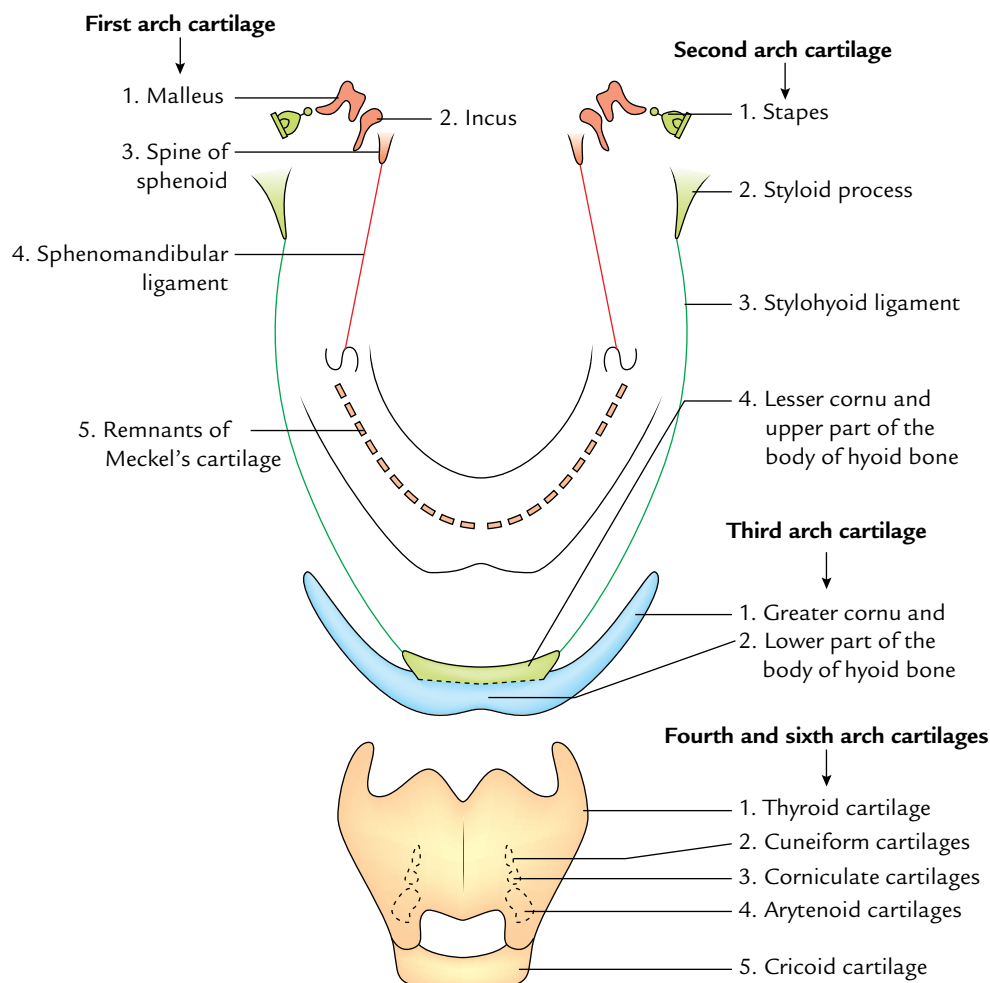


Fig. 10.7 Structures derived from various arch cartilages (frontal view). Structures derived from first arch cartilage (red color), structures derived from second arch cartilage (green color), structures derived from third arch cartilage (blue color), and structures derived from fourth and sixth arch cartilages (yellow color).

Table 10.2 The fate of pharyngeal arch arteries

Arch artery	Derivatives
First arch artery	Maxillary artery
Second arch artery	Hyoid and stapedia arteries
Third arch artery	(a) Common carotid artery (b) Internal carotid artery
Fourth arch artery	(a) Aortic arch (on the left side) (b) Subclavian artery (on the right side)
Sixth arch artery	(a) Ductus arteriosus (on the left side) (b) Pulmonary artery (on the right side)

second pouch is between the second and third arch, and so on.

First Pharyngeal Pouch

The first pharyngeal pouch elongates to form a diverticulum called **tubotympanic recess**. Distal part of

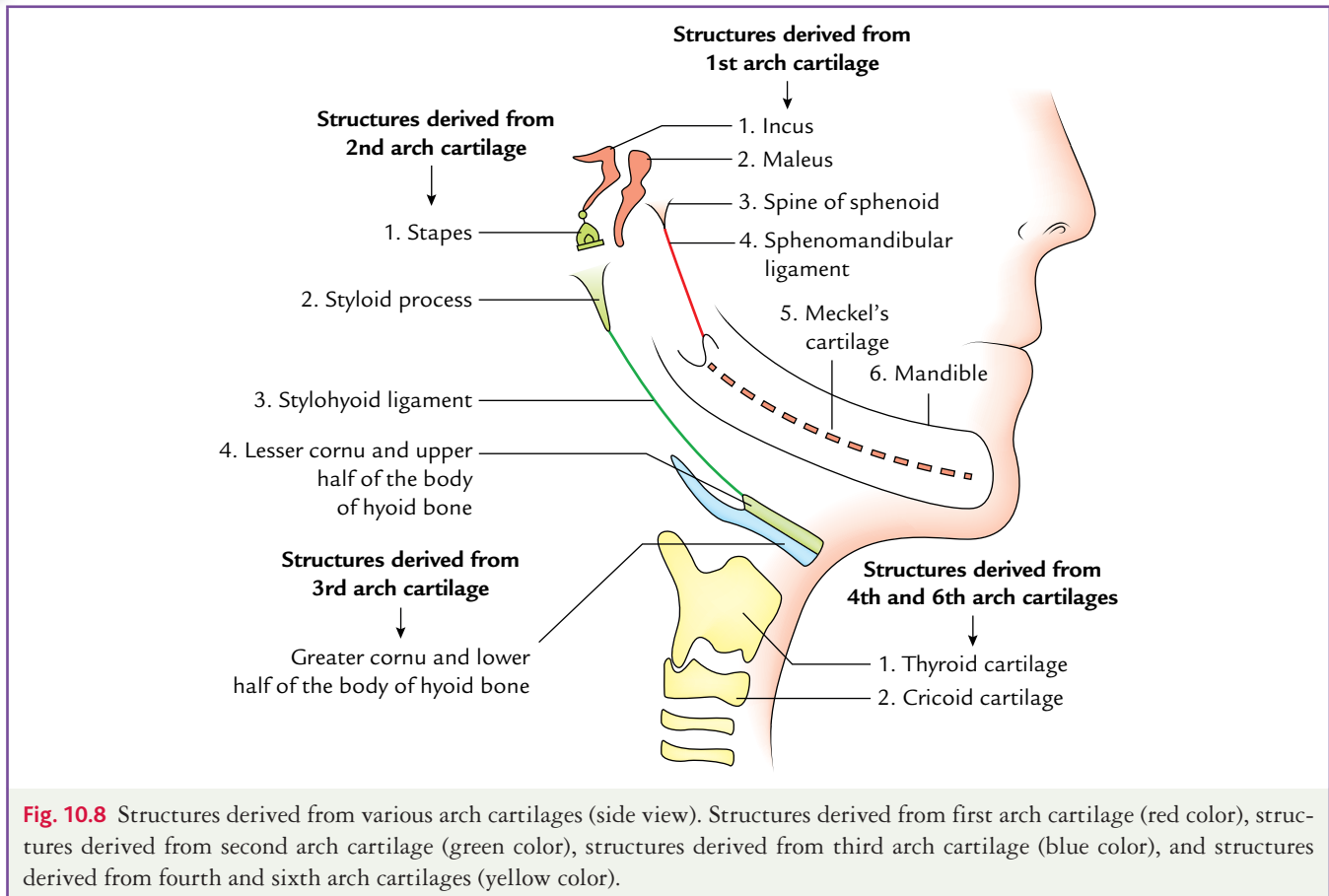
this recess expands while proximal part remains tubular. The distal expanded part of tubotympanic recess comes in contact with the first pharyngeal groove. The distal expanded part of tubotympanic recess forms the **middle ear cavity** (tympanum) and **mastoid antrum**.

The proximal tubular part of tubotympanic recess forms the **pharyngotympanic**/(eustachian/auditory) **tube**, which forms a communication between nasopharynx and tympanic cavity (middle ear).

Second Pharyngeal Pouch

The endoderm of the second pouch proliferates to form number of tiny solid buds that extend into the underlying mesoderm. The mesoderm condenses around these buds. The central core of these buds breaks down to form **tonsillar crypts**.

The endoderm of second pharyngeal pouch forms the stratified squamous, nonkeratinized epithelium lining



tonsillar crypts on pharyngeal (medial) surface of tonsil. The mesoderm forms lymphoid tissue, fibrous capsule, and connective tissue elements of the tonsil.

The second pouch is mostly obliterated by developing palatine tonsil. In adults, part of this pouch remains as **intratonsillar cleft** (crypta magna).

N.B. According to some authorities the dorsal part of second pharyngeal pouch along with dorsal part of first pharyngeal pouch forms the tubotympanic recess and ventral part of second pharyngeal pouch forms the tonsil.

Third Pharyngeal Pouch

The third pharyngeal pouch expands and differentiates into **dorsal bulbar part** and **ventral tubular part**. The communication of the third pouch with the pharynx narrows down and ultimately the pouch is cut off from the pharynx. The pouch is now lying in the mesoderm outside the pharynx.

The endoderm of **dorsal bulbar part** of the third pouch proliferates to form **parathyroid III** or **inferior parathyroid gland**. The endoderm of ventral tubular part of the third pouch proliferates and gives rise to

thymus. The developing thymus and parathyroid glands later on lose their connection with pharynx.

Fourth Pharyngeal Pouch

Fourth pouch expands and differentiates into **dorsal bulbar part** and **ventral tubular part**. The communication of the fourth pouch with the pharynx becomes narrow and soon disappears.

The endoderm of dorsal bulbar part of the fourth pouch proliferates to form **superior parathyroid gland (parathyroid IV)**.

Parathyroid III, developing from third pouch, migrates caudally along with thymus. Hence, its position is lower than the parathyroid IV developing from fourth pouch (Fig. 10.10).

N.B. The fifth (ultimobranchial) pouch appears for a very brief period, gets incorporated with the fourth pouch, and together forms the **caudal pharyngeal complex**.

The neural crest cells that migrate into this complex form **parafollicular or 'C' cells of the thyroid gland**.

The derivatives of pharyngeal pouches are given in Table 10.3 and shown in Figs 10.9 and 10.10.

Pharyngeal Clefts (Grooves)

There are four pharyngeal clefts (grooves) (1, 2, 3, and 4). These are invaginations of surface ectoderm between the pharyngeal arches.

In the region of pharyngeal membrane, the pharyngeal wall is very thin but consists of three layers. From inside out these are endoderm, mesoderm, and ectoderm (cf., three-layered embryonic disc).

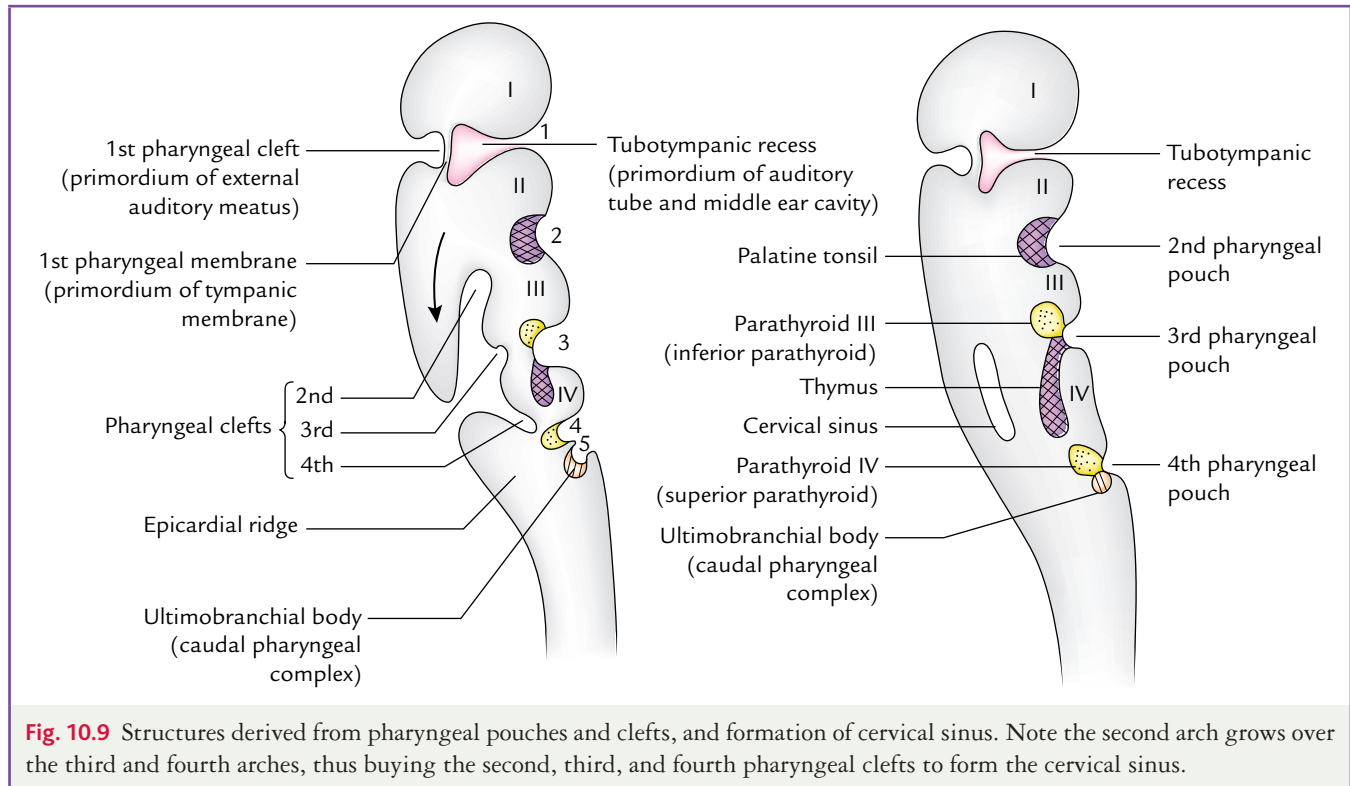


Fig. 10.9 Structures derived from pharyngeal pouches and clefts, and formation of cervical sinus. Note the second arch grows over the third and fourth arches, thus buying the second, third, and fourth pharyngeal clefts to form the cervical sinus.

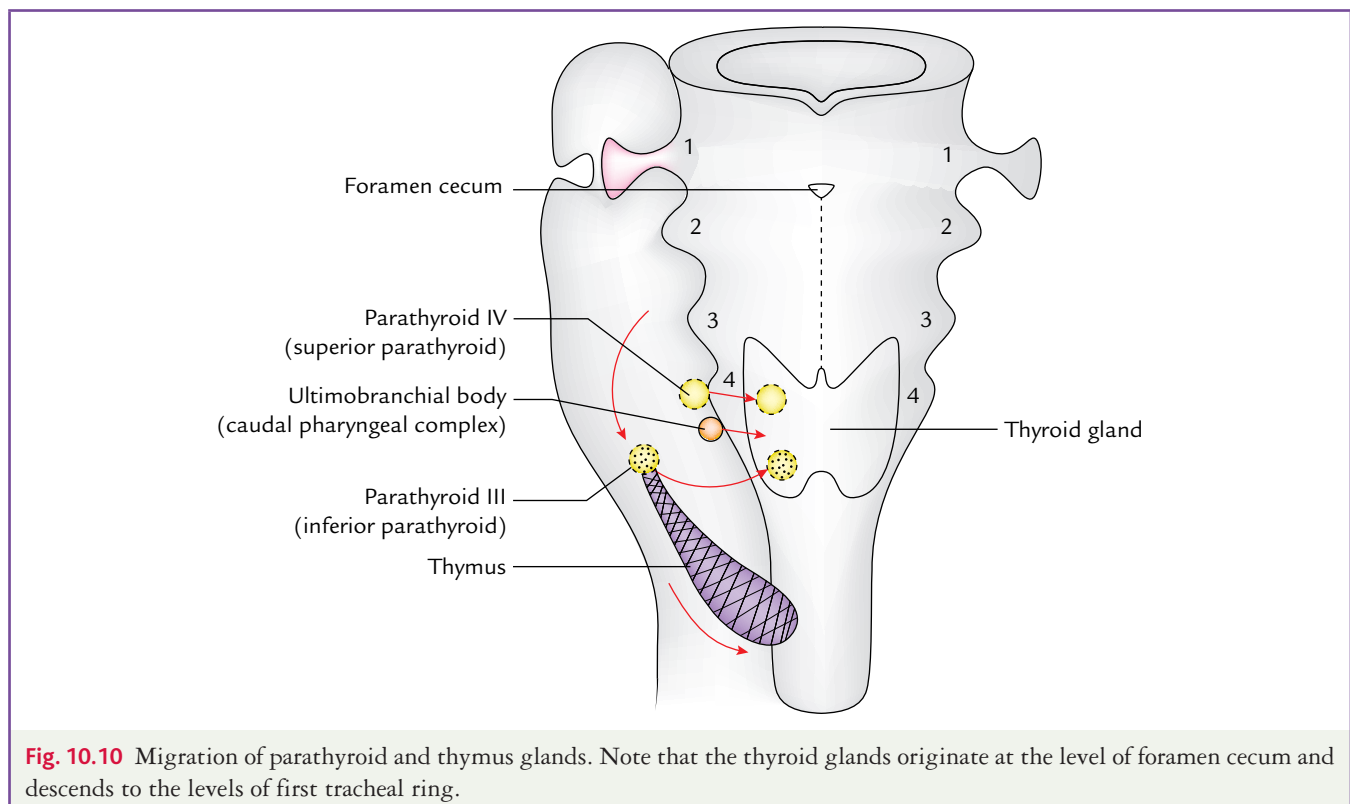


Fig. 10.10 Migration of parathyroid and thymus glands. Note that the thyroid glands originate at the level of foramen cecum and descends to the levels of first tracheal ring.

Only first pharyngeal cleft gives rise to a definitive structure—the **external auditory meatus**—whereas all other clefts (2, 3, and 4) are obliterated.

Cervical Sinus

The mesenchyme of second pharyngeal arch rapidly grows downward, overlaps the second, third, and fourth pharyngeal clefts (grooves), and fuses with the epicardial ridge. Thus, second, third, and fourth pharyngeal clefts get buried under the surface and form a slit-like cavity—the **cervical sinus** that is lined by ectoderm. The cervical sinus soon disappears as the neck develops. Consequently the side of the neck that was so far marked by the pharyngeal grooves now becomes smooth (Fig. 10.9).

Table 10.3 Derivatives of pharyngeal pouches	
Pouch	Derivatives
First pouch	Pharyngotympanic tube Tympanic (middle ear) cavity
Second pouch	Palatine tonsil Intratonsillar cleft
Third pouch	Inferior parathyroid gland Thymus
Fourth pouch	Superior parathyroid gland Caudal pharyngeal complex* (ultimopharyngeal body)

*The neural crest cells that migrate into caudal pharyngeal complex (ultimobranchial body) form parafollicular/C cells of the thyroid gland.

Clinical Correlation

Branchial cyst and branchial fistula: The mesenchyme of second pharyngeal arch rapidly grows caudally (as an operculum of second arch) over third and fourth arches burying second, third, and fourth pharyngeal clefts to fuse with the epicardial ridge. The remnants of second, third, and fourth pharyngeal clefts form **cervical sinus**. (A cavity is enclosed between the operculum of second arch superficially and third, fourth, and sixth arches deeply.) The cervical sinus is lined by ectoderm (Fig. 10.9). Normally the cavity of cervical sinus disappears as the neck develops but if it fails to obliterate, it leads to the formation of **branchial cyst**.

The branchial cyst appears along the anterior border of the sternocleidomastoid at the junction of its upper one-third and lower two-third, below and behind the angle of mandible.

When branchial cyst ruptures a **branchial fistula** is formed. Such a fistula usually opens on the surface of the neck and is found on the lateral aspect of the neck along the anterior border of sternocleidomastoid (Fig. 10.11).

Rarely the branchial fistula passes deep between the external and internal carotid arteries (carotid fork) and opens into the **tonsillar sinus**. It is called **internal branchial fistula**. Such a branchial fistula occurs due to rupture of membrane between the second pharyngeal cleft and second pharyngeal pouch (Fig. 10.12).

First arch syndromes: These syndromes occur due to lack of migration of neural crest cells into the first pharyngeal arch. Clinically, they present with various facial anomalies called first arch syndromes. The important first arch syndromes are (a) **Treacher Collins syndrome**, (b) **Pierre Robin syndrome**, and (c) **DiGeorge syndrome**.

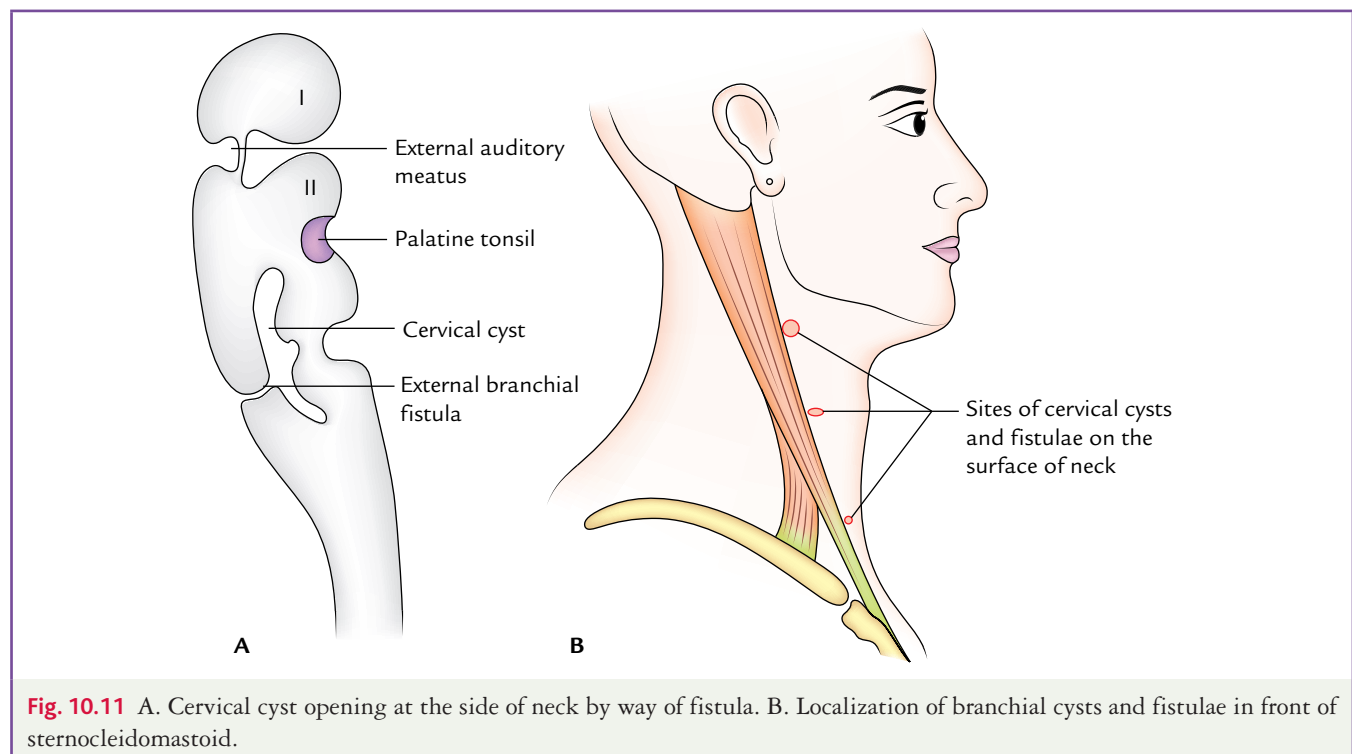


Fig. 10.11 A. Cervical cyst opening at the side of neck by way of fistula. B. Localization of branchial cysts and fistulae in front of sternocleidomastoid.

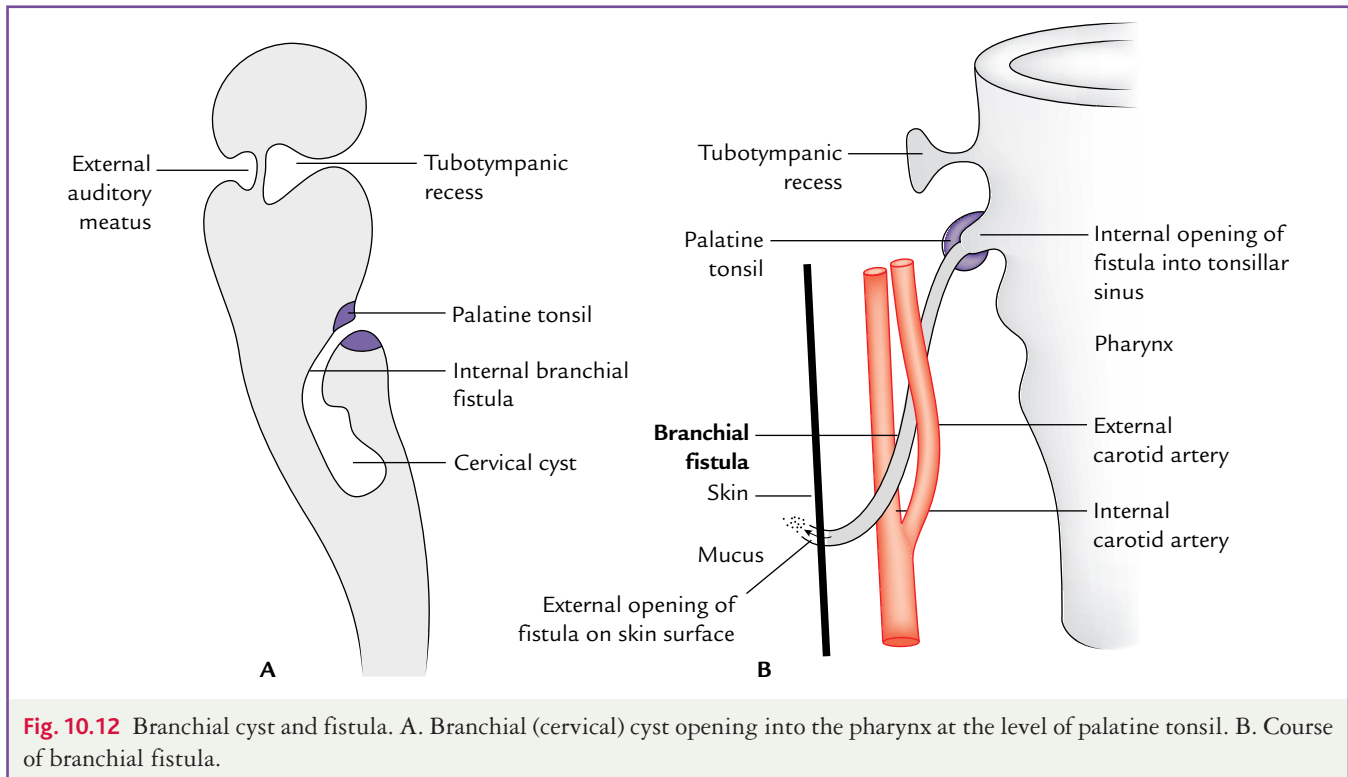


Fig. 10.12 Branchial cyst and fistula. A. Branchial (cervical) cyst opening into the pharynx at the level of palatine tonsil. B. Course of branchial fistula.

The first two are most important first arch syndromes.

- 1. Treacher Collins syndrome (mandibulofacial dysostosis):** It is inherited as an *autosomal dominant trait*, i.e., caused by an autosomal dominant gene. It occurs in about 1/85,000 births. Clinically it presents as (Fig. 10.13):
 - ♦ Malar hypoplasia (due to underdevelopment of zygomatic bones)
 - ♦ Mandibular hypoplasia
 - ♦ Down slanting palpebral fissures
 - ♦ Deformed external ears.
- 2. Pierre Robin syndrome:** It is an autosomal recessive disorder and occurs in approximately 1/85,000 births. The affected infant usually presents triad of anomalies: (a) micrognathia (small mandible), (b) cleft palate, and (c) glossoptosis (posteriorly placed tongue). The primary defect is small mandible.
- 3. DiGeorge syndrome:** It is caused due to microdeletion on the long arm of chromosome 22. This leads to abnormal development of neural crest cells. It occurs in 1/25,000 births and represents the most severe example of disorders related to pharyngeal arches. The infants with *DiGeorge syndrome* are without thymus and parathyroid glands, and have defects in their cardiac outflow tracts. Clinically it presents as:
 - ♦ Fish mouth deformity (shortened philtrum)
 - ♦ Low set notched ears
 - ♦ Increased susceptibility to infection.

Pharyngeal Membranes

There are four pharyngeal membranes (1, 2, 3, and 4). They are located between the pharyngeal arches and are initially formed of two layers: (a) an inner layer formed

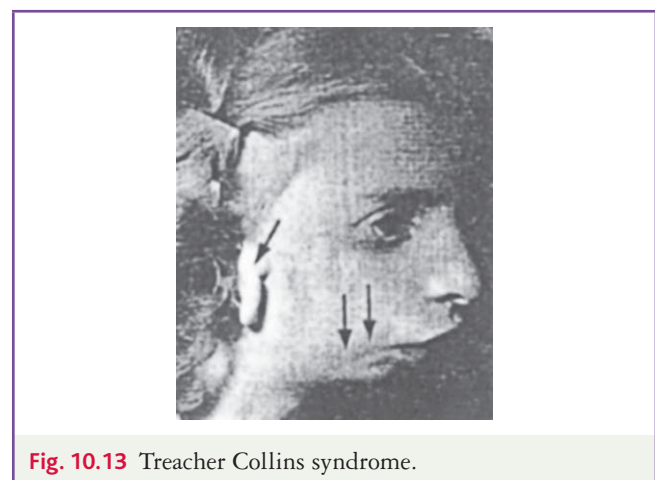


Fig. 10.13 Treacher Collins syndrome.

Table 10.4 Derivatives of pharyngeal clefts and pharyngeal membranes

Cleft	Adult derivatives
First	External auditory meatus Outer ectodermal layer of tympanic membrane
Second	Obliterate/disappear
Third	
Fourth	
Membrane	Adult derivatives
First	Tympanic membrane
Second	Obliterate/disappear
Third	
Fourth	

by the *endodermal lining of the pouch* and (b) an outer layer formed by the *ectodermal lining of the pharyngeal cleft*. Later these two layers become separated by thin layer of mesoderm. Now it consists of three layers: outer layer of ectoderm, middle layer of mesoderm, and inner layer of endoderm (cf., arrangement of layers in the trilaminar embryonic disc).

Only first pair of pharyngeal membrane forms the **definitive structure**—the tympanic membrane; the remaining pharyngeal membranes disappear.

The derivatives of pharyngeal clefts and membranes are given in Table 10.4.

GOLDEN FACTS TO REMEMBER

- | | |
|--|---|
| ➤ All the pharyngeal arches are supplied by one nerve <i>except</i> | First arch, which is supplied by two nerves
(a) Trigeminal nerve (CN V) (maxillary and mandibular divisions)
(b) Chorda tympani nerve—a branch of facial nerve (CN VII) |
| ➤ Only pharyngeal arch that has two processes | First arch (it presents maxillary and mandibular processes) |
| ➤ All the cartilages of larynx develop from fourth and sixth arch cartilages <i>except</i> | Epiglottis, which develops from caudal part of hypobranchial eminence |
| ➤ Meckel's cartilage | First pharyngeal arch cartilage |
| ➤ Reichert's cartilage | Second pharyngeal arch cartilage |
| ➤ Two most important first arch syndromes | Treacher Collins syndrome
Pierre Robin syndrome |
| ➤ All the pharyngeal membranes disappear <i>except</i> | First (which gives rise to the tympanic membrane) |
| ➤ All the pharyngeal clefts disappear <i>except</i> | First (which gives rise to external auditory meatus) |
| ➤ Most common location of branchial cyst/fistula | Just below the angle of jaw anterior to sternocleidomastoid muscle |

CLINICAL PROBLEMS

1. A mother took her 1½-year-old son to a pediatrician and complained of an intermittent discharge of pus from a small opening on the side of her son's neck. On physical examination, the pediatrician found a small dimple in the neck at the junction of middle one-third and lower one-third of the anterior edge of the sternocleidomastoid muscle. The area **around** it was swollen and red. What is the most likely diagnosis? Give its embryological basis.
2. A male infant was born with a very small mandible, reduced malar prominences, down-slanting palpebral fissures, and malformed external ears. What is the most likely diagnosis? Give its embryological basis.
3. A male infant was born with very small mandible (micrognathia), cleft palate, and posteriorly placed tongue (glossoptosis). What is the most likely diagnosis? Give its embryological basis.
4. A pediatrician was called to examine a child with a very small philtrum of the upper lip (**fish mouth deformity**) and low-set notched ears. The child had numerous episodes of pneumonia. He made diagnosis of **DiGeorge syndrome**. Give its embryological basis.

CLINICAL PROBLEM SOLUTIONS

1. The most likely diagnosis is **branchial sinus or fistula**. It is a rare congenital anomaly and occurs when the **cervical sinus** fails to disappear and ruptures on the surface of the neck. The branchial fistula may also occur if second pharyngeal arch fails to grow caudally over the third and fourth arches, and thus leaving second, third, and fourth pharyngeal clefts open on the surface of the neck by a narrow canal. When branchial sinus is infected it becomes swollen, painful, and starts discharging mucoid material (for details see page 118).
2. The most likely diagnosis is Treacher Collins syndrome. It occurs due to an inherited autosomal dominant trait/gene (for details see page 119).
3. Most likely diagnosis is **Pierre Robin syndrome**. It occurs in 1/85,000 births (for details see page 119).
4. The **DiGeorge syndrome** occurs when the third and fourth pharyngeal pouches fail to differentiate into thymus and parathyroid glands. The loss of thymic tissue compromises the immune system, especially defective T-cell function, which leads to numerous infections, viz., **pneumonia**. It occurs in 1/2000–3000 births and is caused by the **deletion of long arm of chromosome 22**. Hence it is also called **22q deletion syndrome**.

11

Development of Tongue and Thyroid

Development of Tongue

Overview

The tongue is divided into two parts: **oral part** (anterior two-third) and **pharyngeal part** (posterior one-third).

- The **oral part** of tongue develops from three swellings associated with first pharyngeal arch. These swellings are two lateral **lingual swellings** and one **median swelling**—the **tuberculum impar** (Fig. 11.1).
- The **pharyngeal part** of tongue develops from a median swelling called **hypobranchial eminence** or **copula of His** associated with second, third, and fourth pharyngeal arches (Fig. 11.1A).
- Muscles of tongue develop from **occipital myotomes**.

The tongue develops in the floor of developing mouth from first, second, third, and fourth pharyngeal arches. At the end of the fourth week of intrauterine life (IUL), a small median triangular swelling called **tuberculum impar** develops in the floor of primitive pharynx, just cranial to foramen cecum.*

Soon after the appearance of tuberculum impar the two lateral oval swellings called lingual swellings develop one on each side of tuberculum impar. The two lateral lingual swellings are placed slightly distal to the tuberculum impar, hence they are also called **distal tongue buds**.

Caudal to tuberculum impar a second large median swelling called **hypobranchial eminence (copula of His)** develops in the floor of primitive pharynx in relation to second, third, and fourth pharyngeal arches. The hypobranchial eminence soon subdivides into large cranial part and small caudal part (Fig. 11.1B).

Development of Various Parts of Tongue (Fig. 11.2)

The two lateral **lingual swellings** overgrow the tuberculum impar and merge with each other to form

***Foramen cecum**: A blind depression in the floor of primitive pharynx, which marks the site of development of thyroid gland.

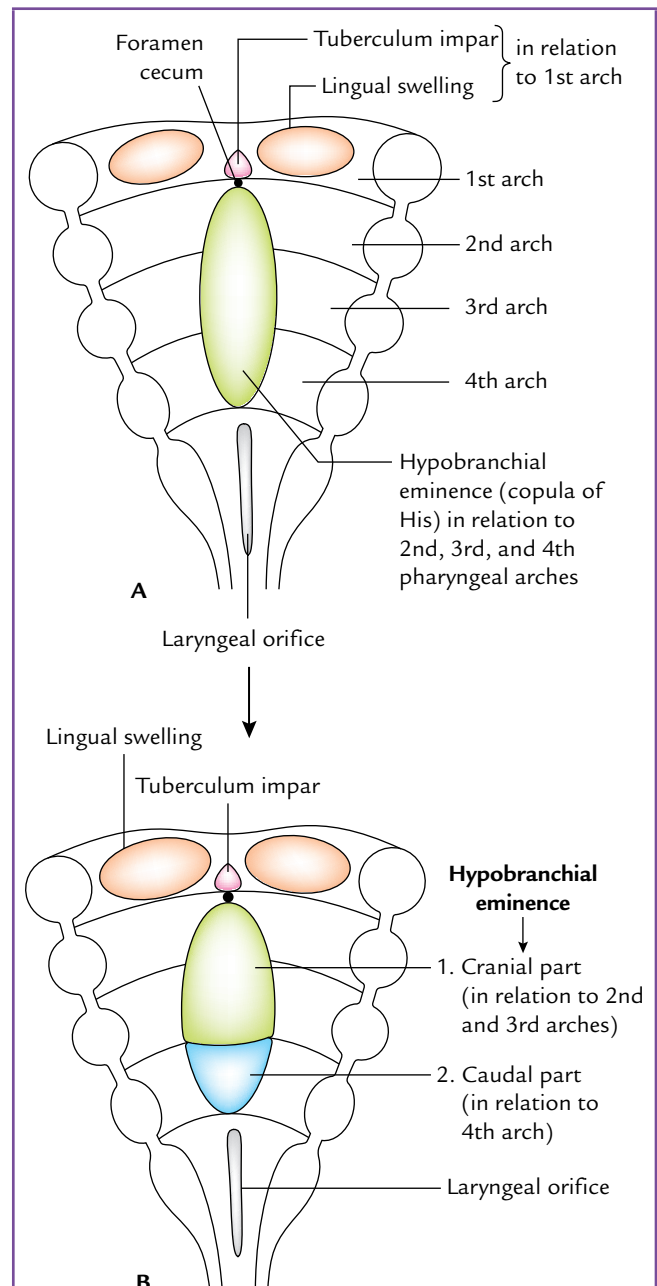
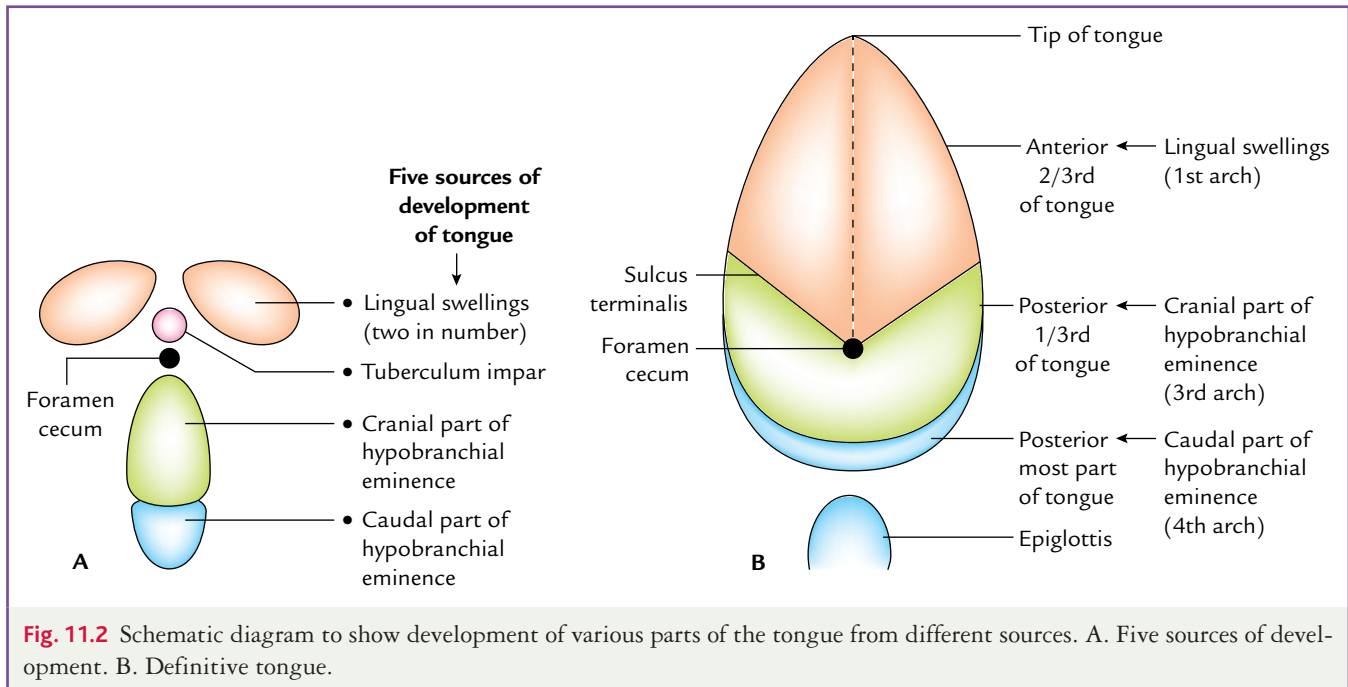


Fig. 11.1 Development of tongue. A. Appearance of four swellings (tuberculum impar, two lingual swellings, and hypobranchial eminence), which give rise to the various parts of the tongue. B. Subdivision of hypobranchial eminence into cranial and caudal parts.



anterior two-third of the tongue. The line of fusion of two lingual swellings in the median plane forms **median sulcus** on the dorsal surface of the tongue.

The tuberculum impar does not form any recognizable part of the adult tongue.

Since mucous membrane covering the anterior two-third of the tongue develops from the first pharyngeal arch, it is innervated by **mandibular branch** of trigeminal nerve—the nerve of first arch.

The **posterior one-third of the tongue including circumvallate papillae** develops from cranial part of hypobranchial eminence.

The line of fusion of the anterior two-third and posterior one-third of the tongue is indicated by a V-shaped groove—the **sulcus terminalis**. Since the mucous membrane of the posterior one-third of tongue (including vallate papillae) develops from the third pharyngeal arch, it is supplied by **glossopharyngeal nerve**—the nerve of third arch.

The **posterior most part of the tongue and epiglottis** develop from the caudal part of the hypobranchial eminence. Since the mucous membrane of the posterior most part of tongue and epiglottis develop from fourth pharyngeal arch, it is supplied by the **superior laryngeal nerve**—the nerve of the fourth arch.

During these sequence of events, the third arch mesoderm grows over the mesoderm of the second arch and fuses with the mesoderm of the first arch. Thus, second arch gets buried underneath the third arch and thereby gets excluded from the tongue development (Fig. 11.3).

The **muscles of tongue** develop from myoblasts that migrate into developing tongue from the **occipital myotomes**. The hypoglossal nerve—the nerve of occipital myotomes—accompanies the myoblasts during their migration to the pharyngeal arches and innervates the muscles of tongue as they develop (Fig. 11.4). The migration of the occipital myotomes to the developing tongue explains the course of the hypoglossal nerve. Some muscles of tongue probably develop **in situ**.

N.B. At birth both the anterior and posterior parts of the tongue are located within the oral cavity; later the posterior third of tongue descends into the oropharynx by 4 years of age and forms its anterior wall (pharyngeal part of the tongue). Consequently, in adults, the anterior part of tongue is located in the oral cavity and posterior part of tongue is located in the oropharynx.

Correlation of Nerve Supply of Tongue with its Development

The correlation of nerve supply of the tongue with its development is given in Table 11.1.

N.B. Taste sensations from anterior two-third of the tongue are carried by lingual nerve, from posterior one-third by glossopharyngeal nerve and from posterior most part by the internal laryngeal nerve.

The beer is tasted at the posterior most part of the tongue which is supplied by the internal laryngeal nerve. For this reason, the internal laryngeal nerve is also called '**beer drinker's nerve**.'

Points to Remember

1. Mucous membrane of the tongue is derived from the endoderm of the primitive foregut.

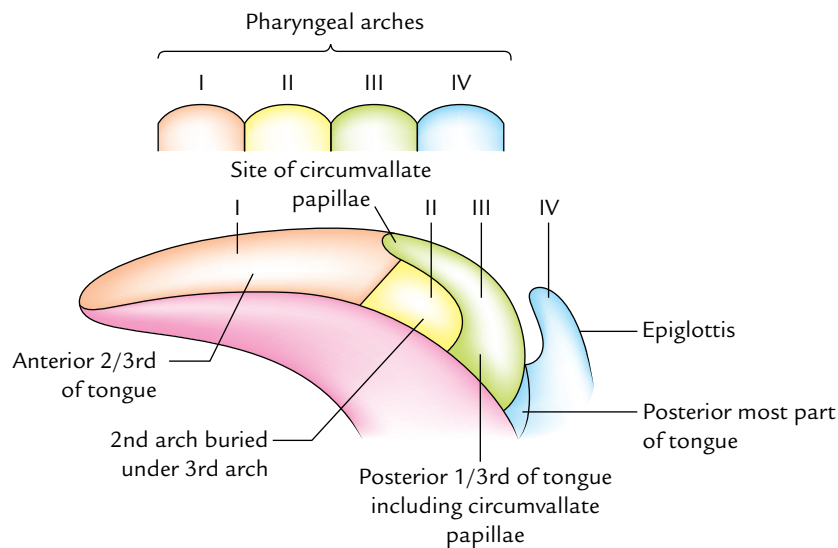


Fig. 11.3 Overgrowth of third arch over the second arch. Note second arch is buried under third arch.

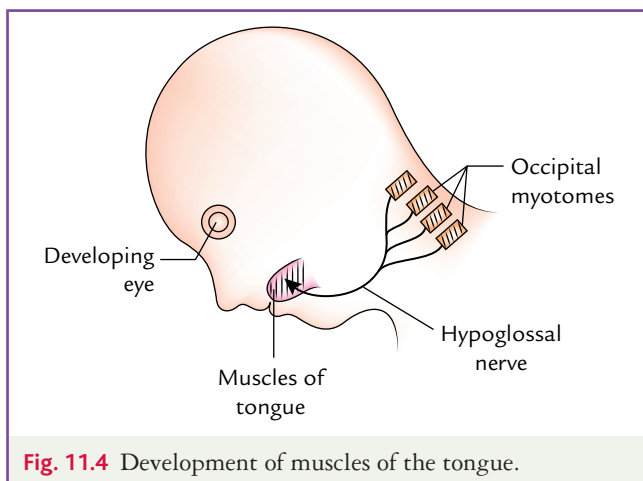


Fig. 11.4 Development of muscles of the tongue.

2. Taste buds are formed in relation to the terminal branches of nerves carrying taste sensations.
3. Muscles of the tongue develop from occipital myotomes.
4. Fibroareolar tissue that binds the tongue muscles develops from mesenchyme of the pharyngeal arches.

Relation of Anterior Part of Tongue with the Floor of the Mouth (Fig. 11.5)

In the region of floor of the mouth, mandibular process forms three structures: (a) lower lip and lower parts of cheeks, (b) lower jaw, and (c) tongue.

At first these structures are not discernible from each other. Soon the tongue forms a recognizable

Table 11.1 Correlation of nerve supply of the tongue with its development

Structure	Source of development	Nerve supply
• Mucous membrane and taste buds of anterior two-third of the tongue	• Endodermal lining of first and second arches	• Lingual nerve (a branch of mandibular nerve—a nerve of first arch) • Chorda tympani nerve (a branch of facial nerve—the nerve of second arch)
• Mucous membrane and taste buds of posterior one-third of the tongue	• Endodermal lining of the third arch	• Glossopharyngeal nerve—the nerve of third arch
• Mucous membrane and taste buds of the posterior most part of the tongue	• Endodermal lining of the fourth arch	• Superior laryngeal nerve—the nerve of fourth arch
• Muscles of tongue	• Occipital myotomes	• Hypoglossal nerve—the nerve of occipital myotomes

swelling in the middle. A sulcus called **linguogingival sulcus** develops on either side of this swelling and separates the developing tongue from the floor of the mouth.

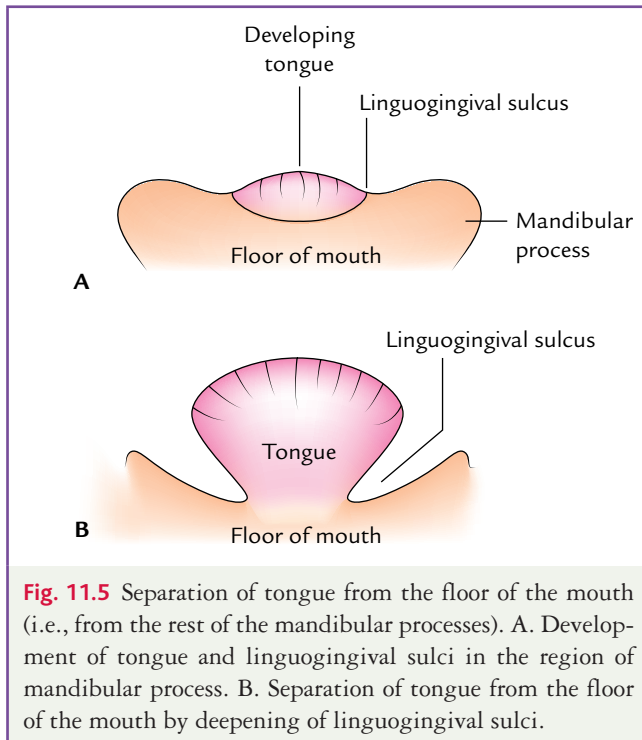


Fig. 11.5 Separation of tongue from the floor of the mouth (i.e., from the rest of the mandibular processes). A. Development of tongue and linguoingival sulci in the region of mandibular process. B. Separation of tongue from the floor of the mouth by deepening of linguoingival sulci.

Clinical Correlation

1. **Aglossia** (absence of tongue): It is very rare and occurs due to complete agenesis of tongue primordia.
2. **Hemiglossia** (half tongue): It occurs if one of the lingual swelling fails to develop.
3. **Microglossia**: Tongue is too small.
4. **Macroglossia**: Tongue is too large.
5. **Tongue tie (ankyloglossia)** (Fig. 11.6): It occurs when frenulum of tongue extends to the tip of the tongue, thus preventing its protrusion and causing difficulty in speech (also see Clinical Problem No. 2).

N.B. Occasionally the tongue may be adherent to the palate (ankyloglossia superior).
6. **Bifid tongue**: In this condition, the anterior portion of the tongue splits into two parts. It is caused by failure of fusion of two lingual swellings (cf. The tongue of snakes is always bifid.).

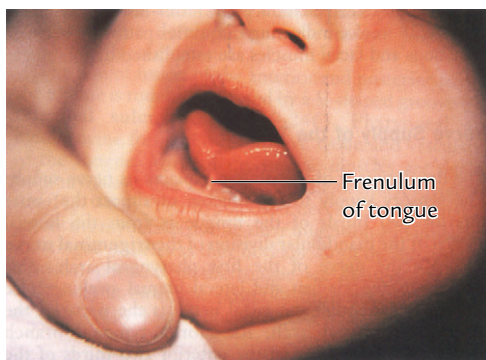


Fig. 11.6 Tongue tie (ankyloglossia).

7. **Lingual thyroid**: It is a clinical condition in which thyroid tissue is present in the tongue, either under the mucosa or within the muscles.
8. **Fissuring of tongue and hypertrophy of the lingual papillae**: It is a characteristic of infants with Down's syndrome.

Development of Thyroid Gland (Fig. 11.7)

Overview

The thyroid gland develops from endodermal diverticulum—the **thyroglossal duct** that forms in the floor of primitive pharynx. Site of formation of this diverticulum is indicated in adults by the **foramen cecum**.

The **parafollicular cells** or **C cells** of thyroid gland develop from **neural crest cells** that migrate into **ultimobranchial body (caudal pharyngeal complex)** formed by fusion of fourth and fifth pharyngeal pouches.

N.B. The term ultimobranchial body is not correctly used in reference to humans. In some species the fifth pharyngeal pouch gives rise to the ultimobranchial body. In humans, it is believed that the fifth pharyngeal pouch gets incorporated into the fourth pharyngeal pouch and forms a **caudal pharyngeal complex**.

The thyroid gland begins to develop during the third week of IUL as an endodermal thickening in the mid-line of the floor of primitive pharynx between the **tuberculum impar** and **copula**.

This thickening forms a small outpouching (i.e., becomes depressed) below the surface to form a diverticulum called **thyroglossal duct**. This duct first grows downward and slightly forward across the tongue and then descends on the front of the neck. In the neck first it passes in front of the hyoid bone, then winds around its lower border to become **retrohyoid**, and finally descends below the hyoid bone with a slight inclination to one side, usually to the left. By the end of the seventh week of IUL, it reaches to its definitive position where its tip becomes a solid mass of cells and soon bifurcates. The proliferation of cells of this bifid tip of thyroglossal duct gives rise to **two lobes of the thyroid gland** that are connected to each other by an **isthmus**. The isthmus of the thyroid gland lies anterior to developing second and third tracheal rings. The **parafollicular** or **C cells** to the lateral lobes of the thyroid gland are contributed by neural crest cells of caudal pharyngeal complex.

The connecting link between the thyroid gland and the floor of primitive pharynx—the **thyroglossal duct**—gets obliterated and disappears. The proximal opening of the thyroglossal duct persists as a small pit on the dorsum of tongue as **foramen cecum**.

In 50% people, a **pyramidal lobe** differentiates from the distal end of the thyroglossal duct, which is often

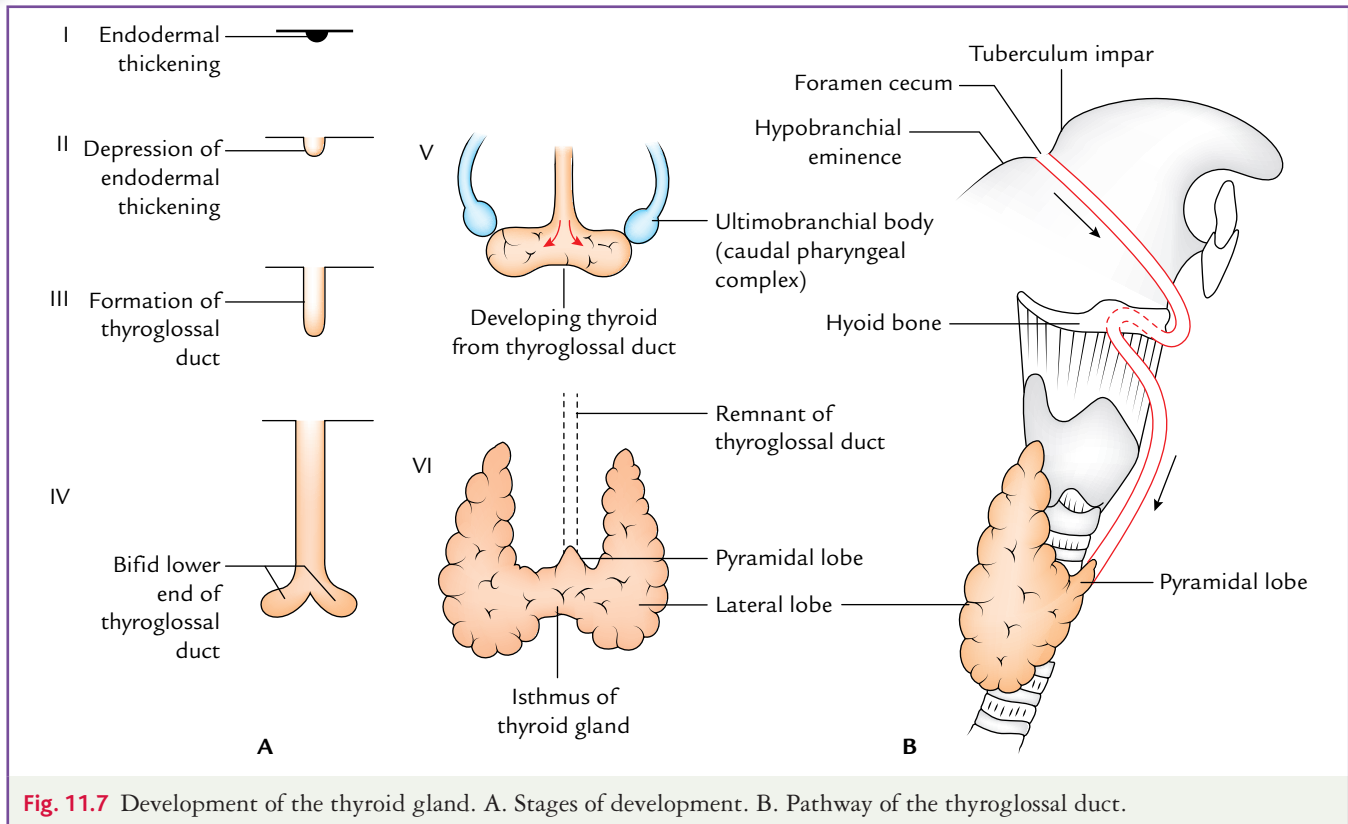


Fig. 11.7 Development of the thyroid gland. A. Stages of development. B. Pathway of the thyroglossal duct.

attached to the hyoid bone by a band of fibrous tissue and/or smooth muscle—the **levator glandulae thyroideae**.

N.B. The thyroid gland is the first endocrine gland to develop. It starts functioning by the end of third month.

Histogenesis of Thyroid Gland

The thyroid primordium consists of solid mass of endoderm cells. It breaks up into a network of epithelial cords as it is

invaded by the surrounding mesenchyme. Later, these cords divide in smaller cell groups/clusters. A lumen soon forms in each of these cell clusters and cells get arranged around a lumen, thus forming **thyroid follicles**. By the end of the third month (12th week), follicular cells start producing colloid, a source of thyroxine and triiodothyronine in the lumen. At the same time, **parafollicular cells (C cells)** derived from neural crest cells in the caudal pharyngeal complex start producing **calcitonin**. The C cells of thyroid gland are so named because they produce **calcitonin hormones**.

Clinical Correlation

1. **Anomalies of position of thyroid:** The important anomalous positions of the thyroid are as follows.

- Lingual thyroid:** The thyroid tissue infrequently forms anywhere along the course of the thyroglossal duct (Fig. 11.8). But the commonest abnormal site of thyroid tissue formation is the tongue, where it is termed *lingual thyroid*. It may be just below the mucosa of tongue at the foramen cecum or within the muscles of the tongue. The lingual thyroid is seen in as many as 10% of the autopsies. The lingual swelling due to lingual thyroid may cause difficulty in swallowing (Fig. 11.8).
- Sublingual thyroid** (Fig. 11.9): It is a thyroid tissue present high in the neck above, at, or just below the hyoid bone.

N.B. The sublingual thyroid always and invariably forms the only functioning thyroid tissue. If it is removed by mistake, then after its removal the patient is left at the mercy of thyroid drug regime for the rest of his/her life.

- Intrathoracic thyroid:** Sometimes the whole gland or part of it may lie in the thorax (intrathoracic thyroid).
2. **Ectopic thyroid tissue:** The small masses of thyroid tissue may be present at the abnormal sites, for example, in:
- ◆ Larynx
 - ◆ Trachea
 - ◆ Esophagus
 - ◆ Pericardium

- Pleura
- Ovaries

N.B. Lateral aberrant thyroids: Truly speaking, the lateral aberrant thyroid does not exist. Earlier the ectopic thyroid tissue in relation to cervical lymph node was described an aberrant thyroid. Now it has been established that this thyroid tissue

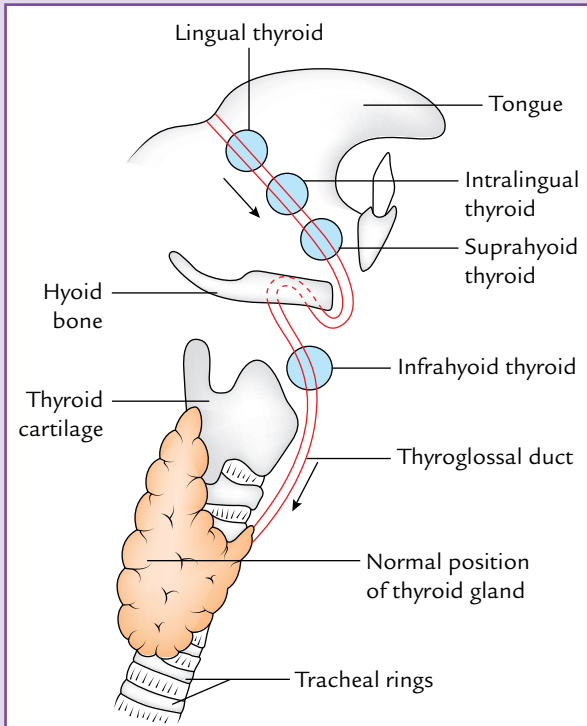


Fig. 11.8 Path of thyroglossal duct. Note the possible locations of thyroid tissue and thyroglossal cysts in this path.

formed in relation to the cervical lymph node is actually metastasis in these nodes from *occult carcinoma of the thyroid*. When the carcinoma of the thyroid is less than 1.5 cm in diameter, then it is termed *occult carcinoma of thyroid*.

3. Anomalous lobes and shapes

- One of the lateral lobes of thyroid gland may be missing. Thyroid hemiagenesis is commonly seen on the left side.
- Pyramidal lobe:** It often arises from upper aspect of the isthmus, usually on the left side. It may arise from one of the lobes or may be detached from thyroid. It may be too small or too large to reach the hyoid bone.
- Isthmus may be absent.

4. **Thyroglossal cyst or fistula (Fig. 11.8):** The thyroglossal cyst may form anywhere along the course of the thyroglossal duct. Normally the thyroglossal duct atrophies and disappears but a part of it may persist and form a cyst called **thyroglossal cyst**. The thyroglossal cysts are always formed in the midline of the front of the neck and observed by the age of 5 years. If thyroglossal cyst ruptures, it communicates to the exterior by a secondary opening on the surface of the neck and it is called **thyroglossal fistula**.

5. **Accessory thyroid:** Sometimes small nodules of thyroid tissue are found in close proximity to the thyroid gland. They are often of insufficient size to maintain the normal function if the thyroid gland is removed.

N.B.

- When the thyroid tissue is present in an anomalous position the thyroid gland may or may not be present at its normal site.
- In surgical removal of thyroglossal cyst or fistulae, it is essential to remove all remnants of the thyroglossal duct. Also, remember that the thyroglossal duct is intimately related to the hyoid bone.

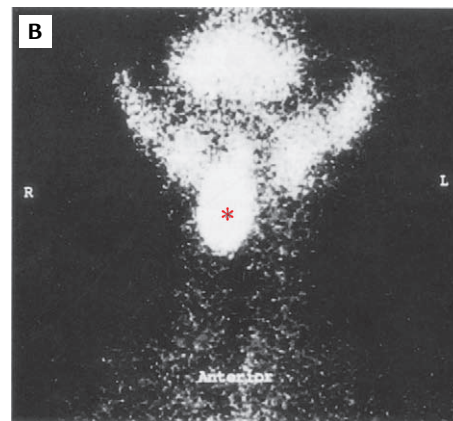
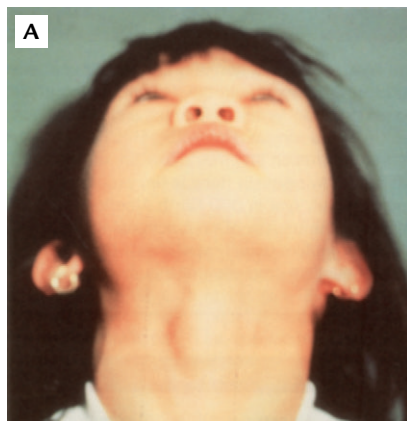

Fig. 11.9 Sublingual thyroid. A. Surface view. B. Technetium-99m scan showing sublingual thyroid gland (*).

GOLDEN FACTS TO REMEMBER

- | | |
|---|--|
| ➤ First indication of development of tongue | Appearance of tuberculum impar |
| ➤ First lingual papillae to develop | Vallate and foliate papillae |
| ➤ Beer drinker's nerve | Internal laryngeal nerve |
| ➤ First endocrine gland to develop | Thyroid gland (It develops approximately 24 days after fertilization.) |
| ➤ First endocrine gland to start functioning | Thyroid gland starts functioning at the end of third month of IUL |
| ➤ At birth whole of tongue is located | In the oral cavity |
| ➤ Commonest site of abnormal position of thyroid tissue | Tongue (e.g., lingual thyroid) |
| ➤ Reflex pathways between taste buds and muscles of facial expressions are established by | Seventh month of IUL |

CLINICAL PROBLEMS

1. Although the tongue develops from first, second, third, and fourth pharyngeal arches, the facial nerve (nerve of second arch) does not provide the general sensory innervation to the tongue. Why?
2. What is tongue tie? Give its embryological basis.
3. Fetal facial responses can be induced by bitter tasting substances at 26–28 weeks of IUL. Embryologically what does it indicate?
4. A 17-year-old girl consulted her physician about a small swelling in the anterior part of her neck just inferior to the hyoid bone. A probable diagnosis of thyroglossal cyst was made by the physician. What is the embryological basis of thyroglossal cyst and also tell with what other entity/condition such a swelling may be confused with? What precautions should be taken by a surgeon before removing the **thyroglossal cyst**?

CLINICAL PROBLEM SOLUTIONS

1. It is because the third arch mesoderm (**copula**) grows over the mesoderm of the second arch to fuse with the mesoderm of the first arch and thus burying the second arch mesoderm. Therefore, facial nerve, the nerve of second arch, does not provide the general sensory innervation to the tongue. However, its **chorda tympani nerve**, a branch of facial nerve, does provides the special sensory innervation (taste sensation) to anterior two-third of the tongue. This is because the taste buds develop in relation to terminal branches of the nerves carrying taste sensations.
2. **Tongue tie:** It is a clinical condition that occurs due to overdevelopment of frenulum linguae. As a result, apical part of the tongue is anchored to the floor of the mouth by **frenulum linguae**. Clinically it presents as disturbed speech due to restriction of movements of the tongue.

N.B. Along the front and sides of primitive tongue, an endodermal **alveolingual sulcus** develops, which gradually separates the tongue from the floor of the primitive mouth. If this separation is incomplete the apical part of the tongue remains attached to the floor of the mouth by the frenulum linguae (**tongue tie**).

3. The taste buds of tongue develop during 11–12 weeks of IUL by inductive interaction between the epithelial cells of the tongue and invading gustatory nerves cells from nerves of taste, viz., chorda tympani, glossopharyngeal, and superior laryngeal. The fetal facial responses induced by bitter tasting substances at 26–28 weeks of IUL indicates that reflex pathways between the taste buds and muscles of facial expression are established by this age.
4. The **thyroglossal duct** extends from foreman cecum to jugular notch in the median plane of front of the neck. Normally it atrophies and disappears. A remnant of duct may form a cyst anywhere along the course of the thyroglossal duct called **thyroglossal cyst**.

A **thyroglossal cyst** may be confused with abnormal position of thyroid tissue.

It is important for a surgeon to differentiate a thyroglossal cyst from an abnormal thyroid tissue, which may also be present anywhere along the course of thyroglossal duct to prevent inadvertent removal of the thyroid tissue. Because this may be the only thyroid tissue present. Failure to do so may leave the person to suffer permanently from **hypothyroidism**.

12

Development of Face, Nose, and Palate

Development of Face

Overview

The face develops from five swellings/processes that form around primitive mouth (stomodeum). These processes are (Fig. 12.1A):

- Single frontonasal process
- Paired maxillary processes
- Paired mandibular processes
- **Frontonasal process** forms forehead, external nose, nasal cavity, nasal septum, and philtrum of the upper lip
- **Maxillary processes** form lateral parts of the upper lip and upper parts of the cheek
- **Mandibular processes** form chin, lower lip, and lower parts of the cheek.

At the end of the fourth week, five swellings (**facial primordia**) appear around the primitive mouth (stomodeum).

The **five facial primordia** consist mainly of mesenchyme (derived from neural crest cells) covered by an ectoderm.

1. The **frontonasal process** is formed by the proliferation of mesenchyme lying ventral to forebrain vesicle and forms middle part of the upper border of the stomodeum.
2. The paired **maxillary processes** of first arch form the lateral parts of the upper border of the stomodeum.
3. The paired **mandibular processes** of the first arch form the whole lower border of the stomodeum.
4. On each side of the median plane in the ventrolateral part of frontonasal process, the surface ectoderm thickens to form an ectodermal elevation—the **olfactory placode**. The olfactory placodes invaginate into the underlying mesoderm to form **olfactory pits** or **nasal pits**. The pits are continuous with the stomodeum below. The mesenchyme around margins of nasal pits proliferates to form horseshoe-shaped elevations. Medial half of horseshoe-shaped elevation is called **medial nasal process** and lateral half is called **lateral nasal process**.

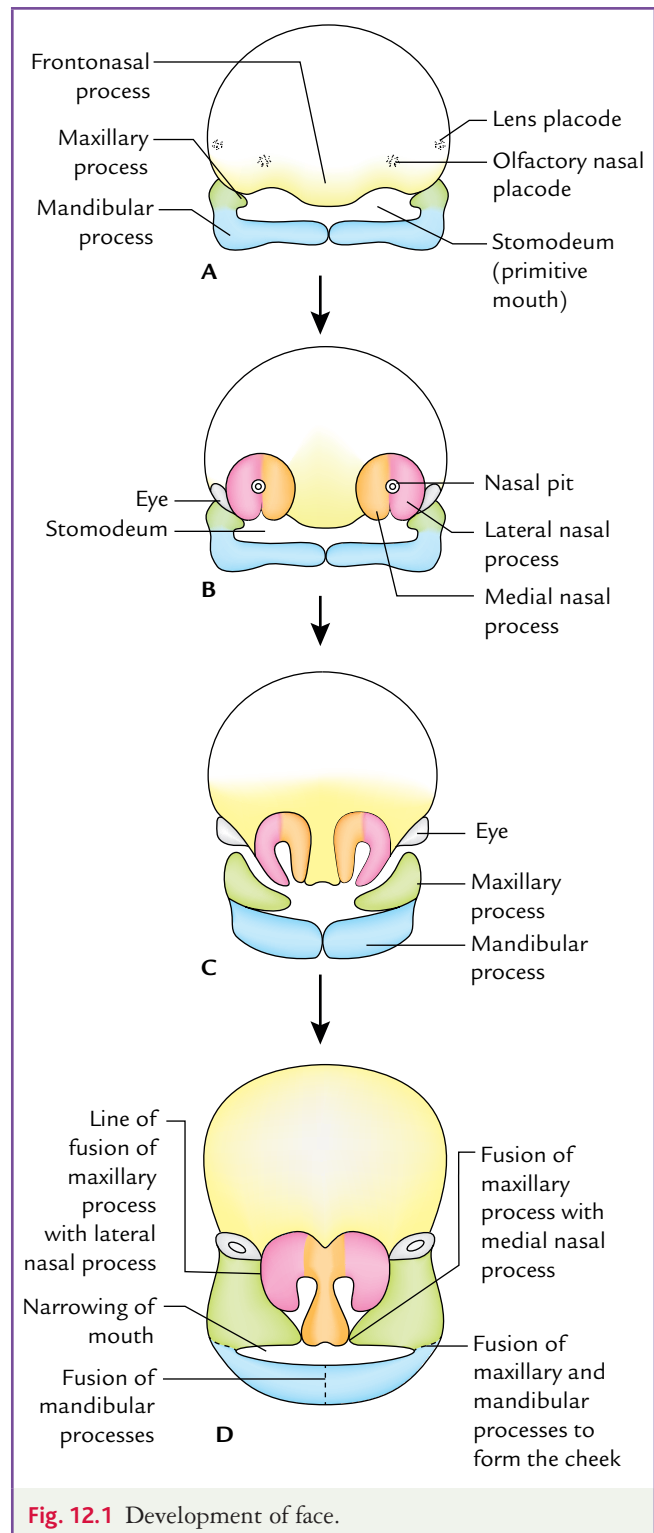


Fig. 12.1 Development of face.

The medial nasal processes extend more towards the stomodeum and form two globular processes that are separated by a small triangular notch.

Development of Various Parts of the Face

The various parts of the face develop as follows (Fig. 12.2):

1. The olfactory pits grow deeper to form nasal cavities.
2. The median nasal process thins out gradually to form primitive nasal septum.
3. The globular processes of medial nasal processes fuse to form philtrum of the upper lip.
4. The two maxillary processes grow medially below developing eyes and fuse with the lateral nasal process to form the lateral part of the upper lip and upper part of the cheek.
5. The two mandibular processes form the lower lip and lower part of the cheek.
6. The surface opening of stomodeum forms the oral fissure. Lateral angles of the oral fissure are formed by fusion of maxillary and mandibular processes.

N.B. Developmental enigma of upper lip: The upper lip develops from three sources: the median part, the **philtrum** from globular process derived from frontonasal processes and lateral parts from two maxillary processes.

- The mesodermal basis of **lateral parts of the upper lip** is derived from the mesenchyme of the maxillary processes, and skin over these parts is derived from ectoderm covering these processes.
- The mesodermal basis of the median part of the upper lip (**philtrum**) is derived from the mesenchyme of the

frontonasal process. The ectoderm overlying the maxillary processes overgrows the mesoderm of the philtrum to form skin over it (Fig. 12.3).

- According to the recent clinical and embryological evidences, the upper lip is entirely formed from the maxillary processes. The lower parts of medial nasal processes become deeply positioned and get covered by medial extensions of maxillary processes to form the philtrum. Hence sensory innervation of upper lip is derived from maxillary nerves.

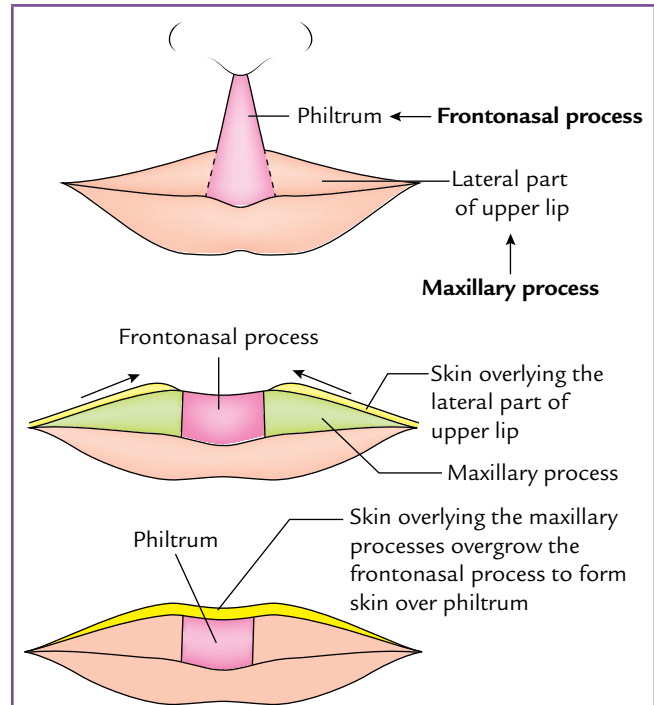


Fig. 12.3 Diagram showing how skin covering maxillary processes (forming lateral parts of lips) overgrows over the frontonasal process to form the skin covering the philtrum.

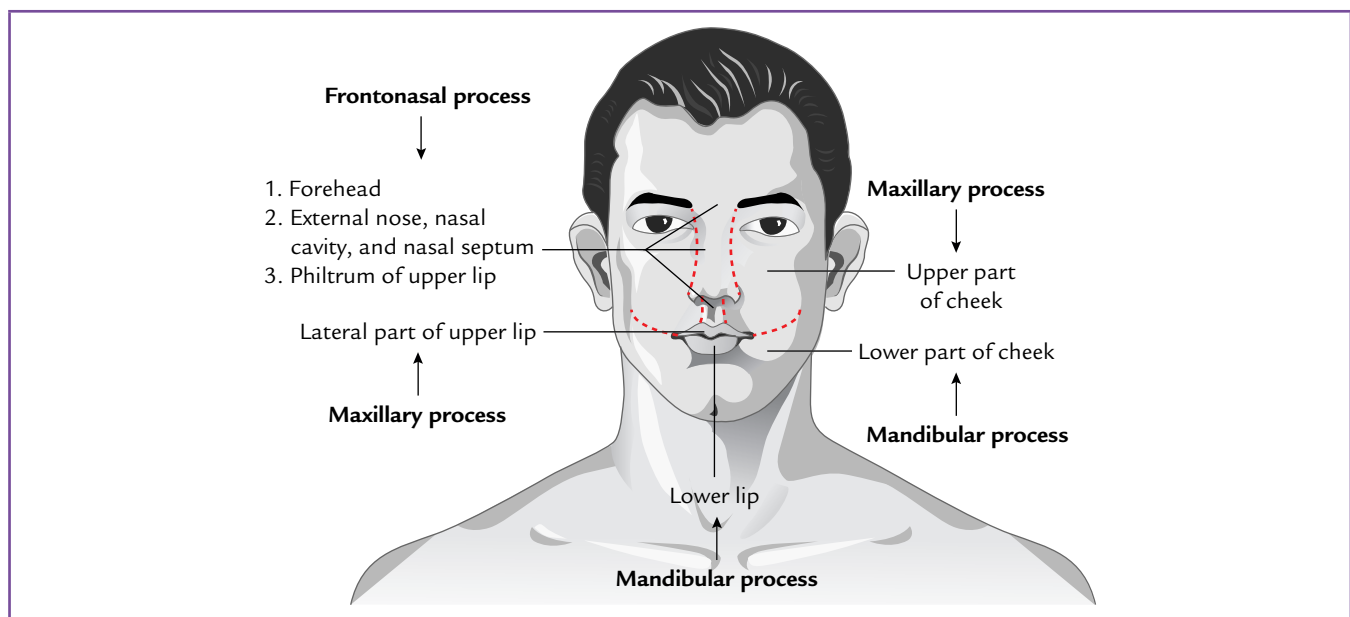


Fig. 12.2 Derivation of the various parts of face.

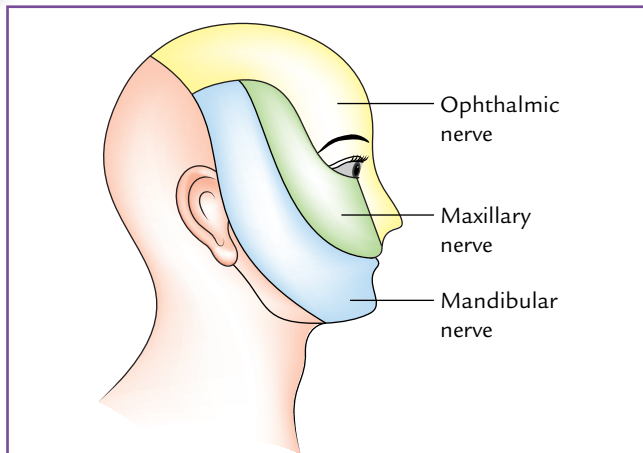


Fig. 12.4 Embryological basis of the sensory innervations of the face. Note area derived from the frontonasal process is supplied by ophthalmic nerve (yellow color), area derived from maxillary processes by maxillary nerve (green color), and area derived from mandibular processes by mandibular nerve (blue color).

Table 12.1 Correlation of nerve supply of various components of face and their source of development

Component of face	Develops from	Nerves
Forehead	Frontonasal process	Ophthalmic division of Vth nerve (V_1)
Nose	Frontonasal process	Ophthalmic division of Vth nerve (V_1)
Cheek		
(a) Upper part	Maxillary process	Maxillary division of Vth nerve (V_2)
(b) Lower part	Mandibular process	Mandibular division of Vth nerve (V_3)
Upper lip	Fusion of maxillary processes of two sides with the frontonasal process*	Maxillary division of Vth nerve (V_2)
Lower lip	Fusion of mandibular processes of two sides	Mandibular division of Vth nerve (V_3)

*The skin of the philtrum of the upper lip is derived from skin overlying the maxillary processes; hence it is supplied by the maxillary nerve.

Embryological basis of innervation of structures in the region of head and face (Fig. 12.4)

- The structures derived from frontonasal process are supplied by *ophthalmic nerve* (V_1).
- The structures derived from maxillary processes are supplied by *maxillary nerve* (V_2).
- The structures derived from mandibular processes are supplied by the *mandibular nerve*.

The details are given in Table 12.1.

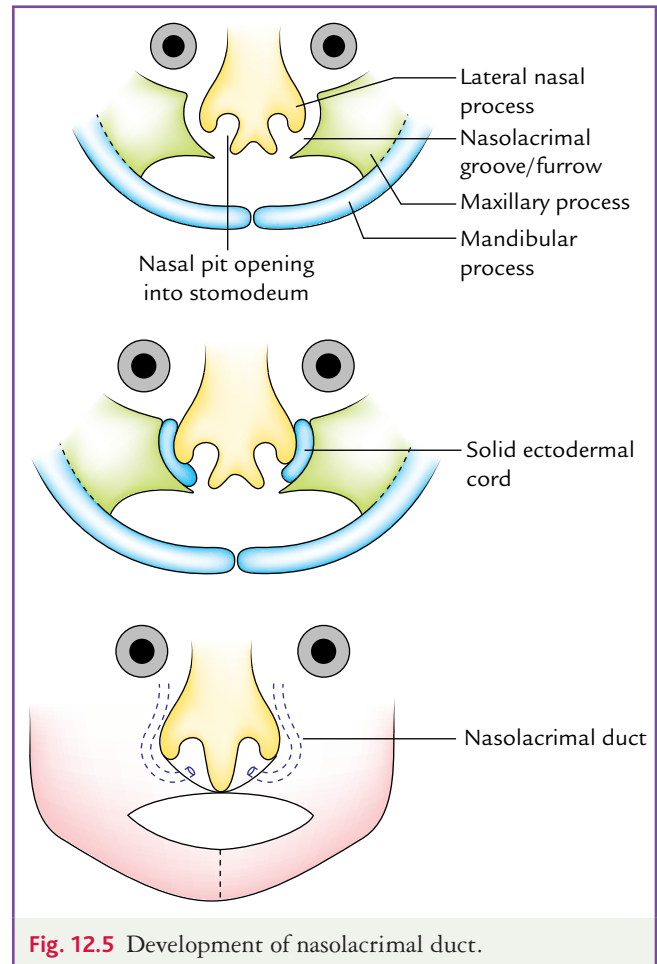


Fig. 12.5 Development of nasolacrimal duct.

Development of Nasolacrimal Duct and Sac (Fig. 12.5)

The line of fusion of maxillary and lateral nasal processes presents a groove called **nasolacrimal groove**. This groove is lined by surface ectoderm.

The ectoderm in floor of this groove proliferates to form a solid epithelial cord (**ectodermal cord**). Later on this epithelial cord is detached from the surface ectoderm and gets canalized to form **nasolacrimal duct**.

Upper end of nasolacrimal duct widens to form the **lacrimal sac**. The nasolacrimal duct becomes completely patent only after birth. The nasolacrimal duct communicates secondarily with the nasal cavity at its caudal end and with the conjunctival sac at its cephalic end. In adults the nasolacrimal duct runs from medial angle of the eye to inferior meatus of the nasal cavity.

Development of Nose

The nose consists of **external nose** and **nasal cavities**.

Development of External Nose (Fig. 12.6)

The external nose develops from five facial processes, viz., frontonasal process, two medial nasal processes, and two lateral nasal processes as follows:

- The frontonasal process forms the **bridge of the nose**.
- Two fused medial nasal processes form **dorsum and tip of the nose**.
- Two lateral nasal processes form **sides and alae of the nose**.

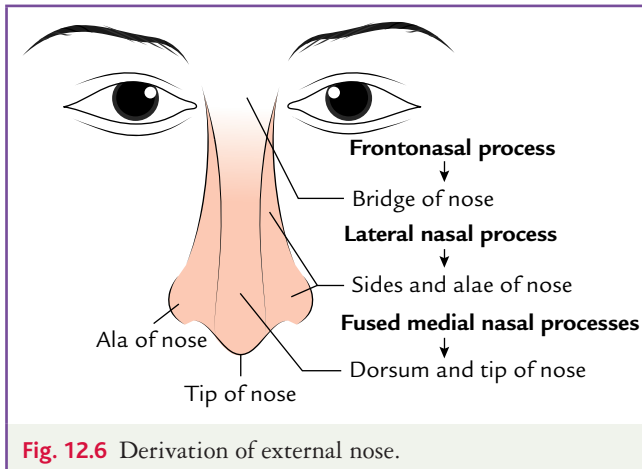


Fig. 12.6 Derivation of external nose.

Development of Nasal Cavities (Figs 12.7 and 12.8)

The nasal cavities develop from ectodermal **nasal pits**.

The *nasal pits* deepen dorsally during the sixth week of intrauterine life to form **nasal sacs**. Each nasal sac grows dorsoventrally to developing forebrain to form **primitive nasal cavity**. Dorsal end of primitive nasal cavity is separated from oral cavity by **oronasal membrane**. At the end of sixth week this membrane ruptures to form **primitive choanae** and as a result the nasal cavity communicates with the primitive oral cavity. The primitive choanae lie at the junction of primitive nasal and oral cavities, immediately behind **primary palate**. Later with further growth of primitive nasal cavity (**definitive nasal cavity**) and formation of secondary palate the **definitive choanae** lie at junction of the nasal cavity and the nasopharynx.

External openings of the nasal pits persist as **external nares**. While these changes are occurring the following events take place:

1. **Superior, middle, and inferior nasal conchae** develop as curved elevations from the lateral wall of the nasal cavity.

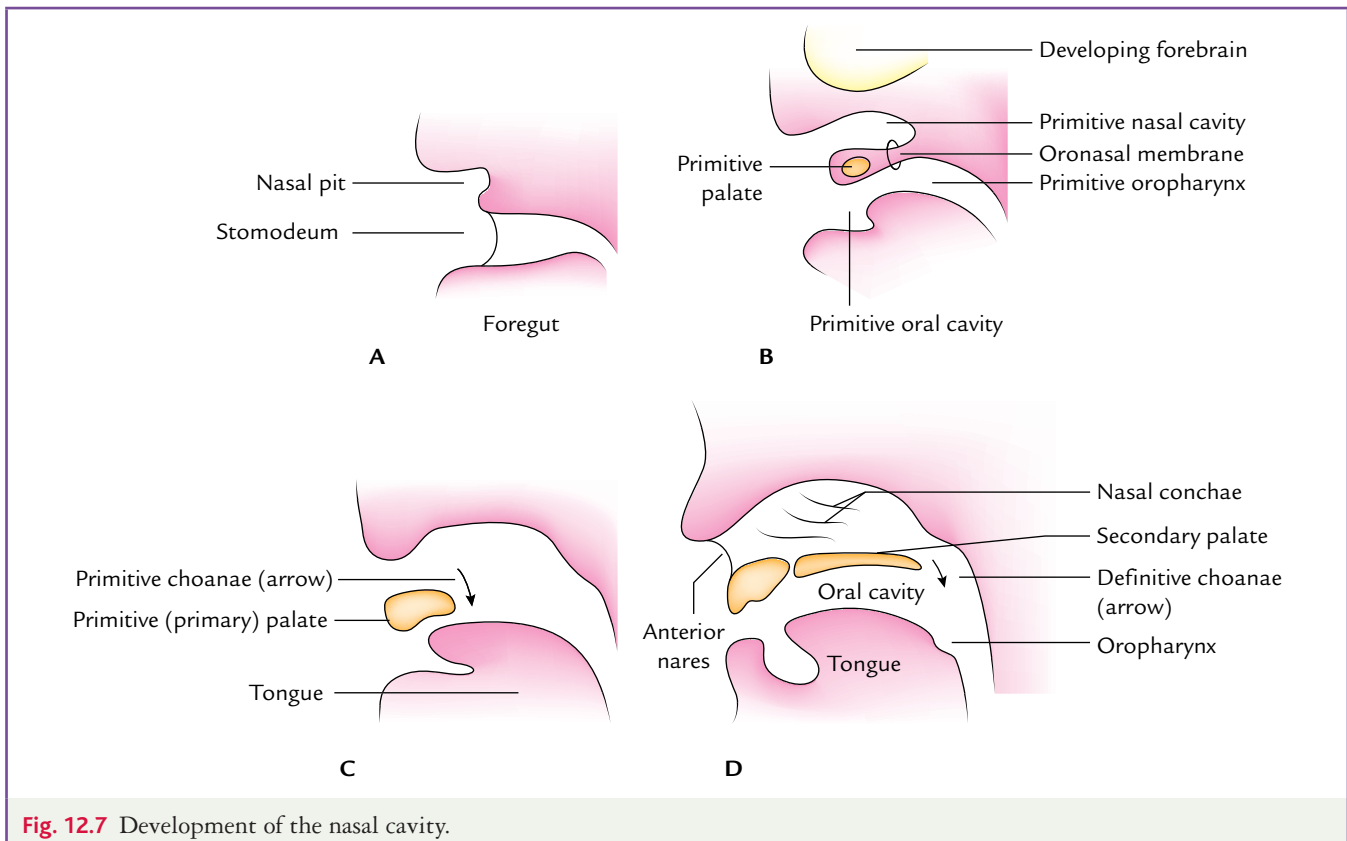


Fig. 12.7 Development of the nasal cavity.

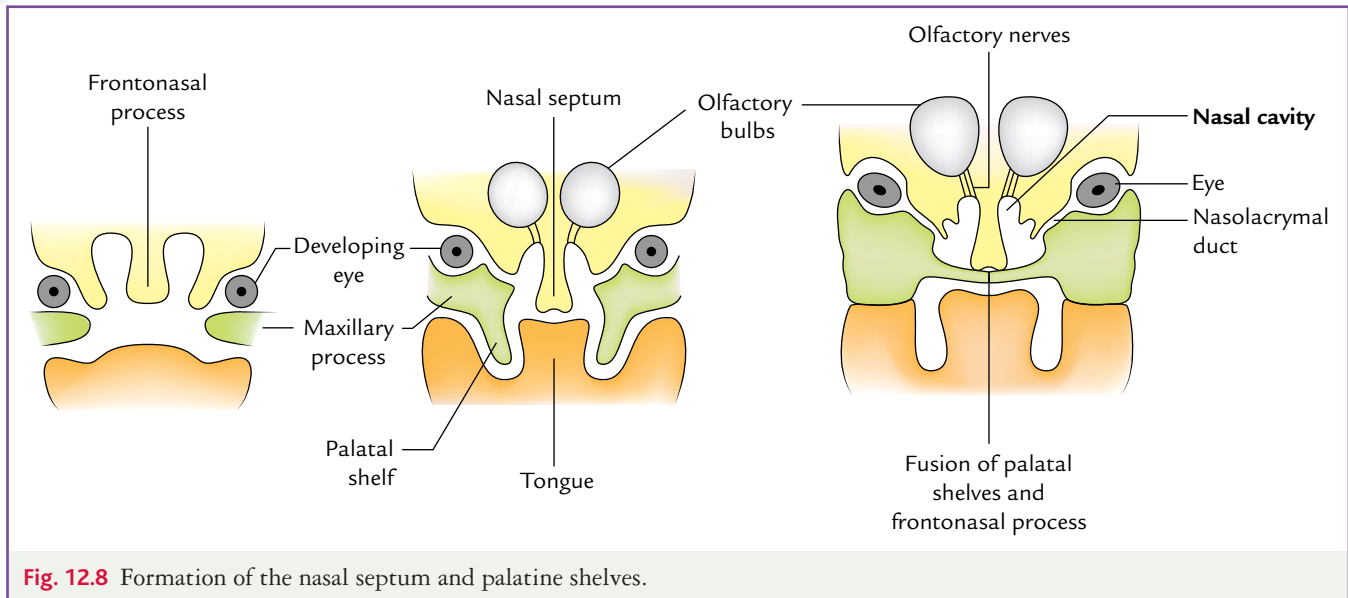


Fig. 12.8 Formation of the nasal septum and palatine shelves.

Table 12.2 Development of the various components of the nose and their source of development

Components	Develop from
• Dorsum and tip of nose	Frontonasal process
• Nasal cavities	Nasal sacs formed by elongation of nasal pits
• Nasal septum	Frontonasal process
• Nostrils (anterior nares)	Nasal pits
• Choanae (posterior nares)	Rupture of oronasal membrane (in the second month)

2. Ectoderm lining the roof of the nasal cavity becomes specialized to form **olfactory epithelium**, which provides origin of olfactory nerves (Fig. 12.8).

The development of various components of the nose is summarized in Table 12.2.

Development of Paranasal Air Sinuses

The paranasal air sinuses develop as **diverticulæ from the walls of the nasal cavities**. They grow into surrounding bones, viz., maxilla, ethmoid, frontal, and sphenoid, and become air filled. They are named after the name of the bone that they invade, viz., maxillary air sinus in maxillary bone, frontal air sinus in frontal bone, ethmoid air sinus in ethmoid bone, and sphenoid air sinuses in sphenoid bone. The primitive openings of diverticulæ persist as orifices of the adult sinuses. The lining of paranasal air sinuses is ectodermal as that of the nasal cavity.

All the sinuses begin to develop before birth except frontal air sinuses, which begin to develop after birth.

Maxillary air sinuses are first to develop, and they appear as shallow groove on the medial surface of each maxilla during the third month of intrauterine life.

The frontal air sinuses develop by fifth or sixth post-natal year.

The paranasal air sinuses reach their maximum size at puberty and subserve following functions:

1. Contribute to definitive shape of face
2. Reduce weight of skull
3. Add resonance to the voice.

Other Developmental Events

Lens placode: The sites of development of lens placodes indicate the sites of development of the eyes in the region of the face. Here, only a brief account of their development is given. The development of the eye is described in detail in Chapter 24.

The surface ectoderm at the sites of development of eyes thickens to form *lens placodes—primordia of eye lenses*. The formation of lens placode is induced by underlying developing optic vesicle from the forebrain. The developing eyeballs produce bulges at these sites. These bulges at first lie in angles between the maxillary and lateral nasal processes, but later due to narrowing of maxillary processes they come forwards.

Intermaxillary Segment of Face

Due to medial growth of the maxillary processes the two medial nasal processes fuse to form **intermaxillary segment of face**.

The intermaxillary segment of face consists of three components:

1. *Labial component* that forms the philtrum of the upper lip.
2. *Upper jaw component* (alveolar process) that carries four incisor teeth.
3. *Palatal component* that forms triangular primary palate (also called premaxilla).

Development of Palate

Embryologically the palate consists of two parts: **primary palate** and **secondary palate**. The primary palate develops from the frontonasal process and secondary palate develops from the maxillary processes.

Development of palate begins in the sixth week and completes by the end of the twelfth week. The palate develops in two stages:

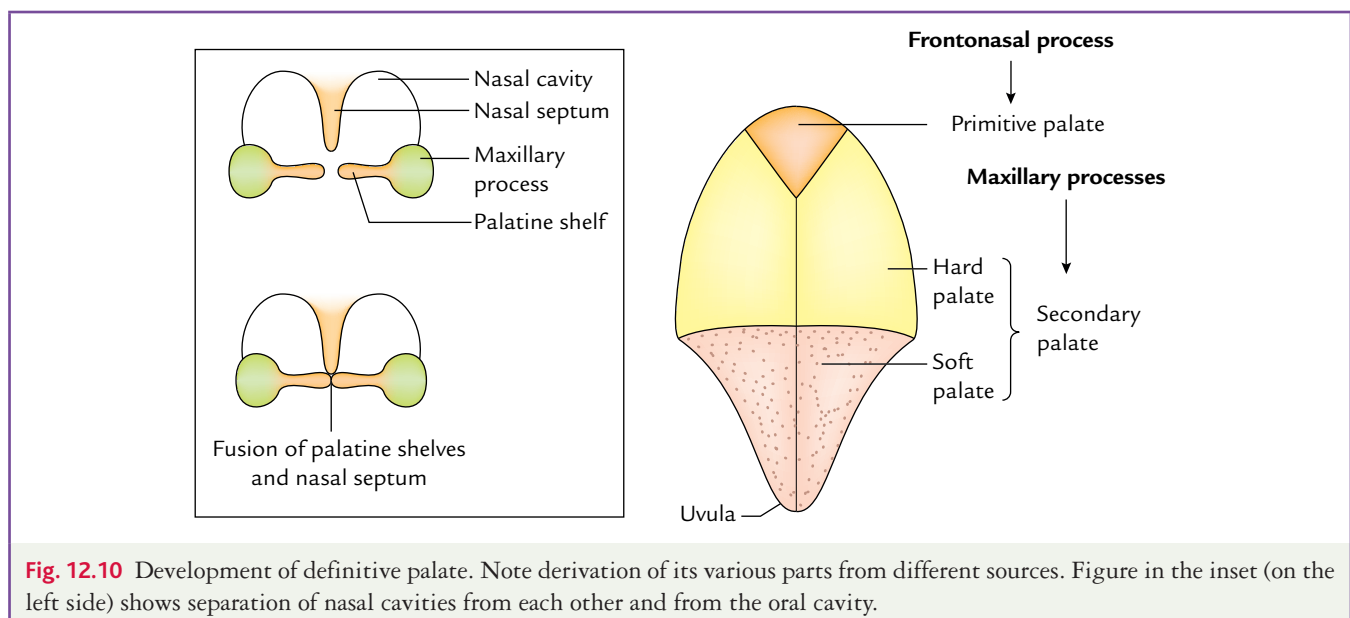
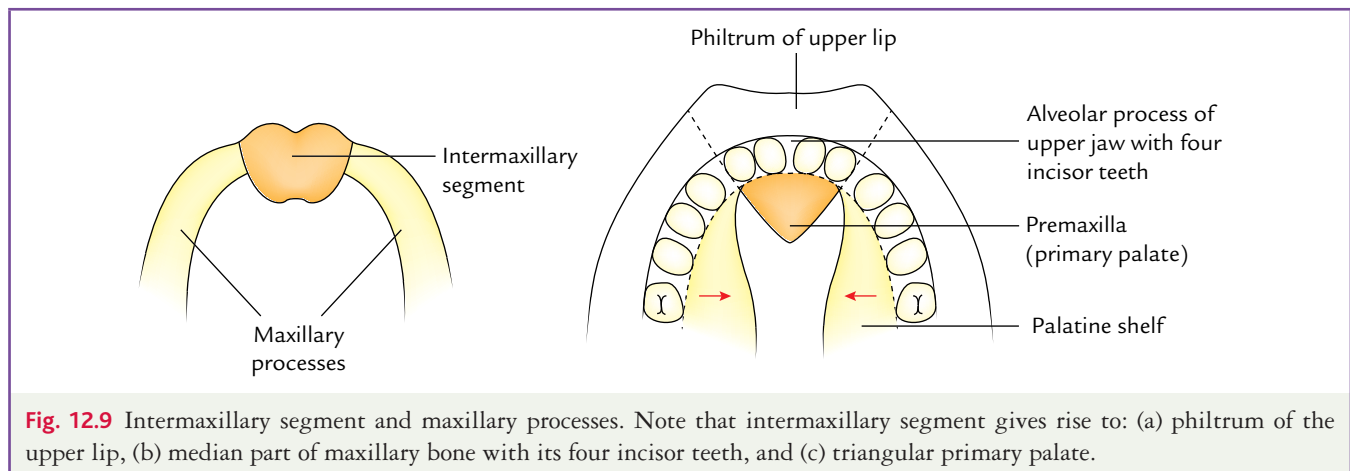
1. Development of primary palate
2. Development of secondary palate.

Development of Primary Palate (Fig. 12.9)

The primary palate is formed by fusion of two medial nasal processes of the frontonasal process. The fusion of these processes (at a deeper level) forms a wedge-shaped mass of mesenchyme opposite upper jaw carrying four incisor teeth called **primary palate**. It ossifies to form premaxilla.

Development of Secondary Palate (Fig. 12.10)

It is the main part of definitive palate. It is formed by fusion of two shelf-like outgrowths called **palatine shelves** from inner aspects of the maxillary processes. The palatine shelves appear in the sixth week of development. Initially they grow downward and medially on each side of and below the tongue. Later, during the seventh and eighth week they assume horizontal position above the tongue and fuse with each other to form the **secondary palate**.



The secondary palate is the primordium of most of hard part and whole of soft part of the adult palate.

Once the palatine shelves are fused the ossification extends from the maxillae and palatine bones into these shelves to form the hard palate. The posterior parts of these processes that extend posteriorly beyond the nasal septum fail to ossify and form the **soft palate**, including its soft conical projection—**uvula**.

Development of Permanent Palate

Anteriorly the secondary palate fuses with the primary palate by a Y-shaped suture and each limb of Y passes between the lateral incisor and canine teeth. Junction between the primitive and secondary palates is represented in adults by **incisive fossa** into which opens two incisive foramina.

The nasal septum grows down and joins superior aspect of anterior three-fourth of the hard palate in the midline. The nasal septum develops as a downgrowth from the frontonasal process. The fusion between nasal septum and secondary palate begins anteriorly during the ninth week and is completed posteriorly by the twelfth week.

The *anterior three-fourth of permanent palate* ossifies in membrane and forms the *hard palate*.

The *posterior one-fourth of the permanent palate* that fails to join with the nasal septum and fails to ossify as well forms the **soft palate**. The soft palate hangs as a curtain to form the posterior margin of the hard palate.

The components of adult palate and their sources of development are summarized in Table 12.3.

Table 12.3 Development of various components of the adult palate

Component	Source of development (i.e., develops from)
1. Hard palate	
(a) In front of incisive fossa (premaxilla) carrying four incisor teeth	Fused medial nasal processes of frontonasal process
(b) Behind the incisive fossa	Fusion of palatine shelves (palatal processes) of maxillary processes of two sides
2. Soft palate	Unossified part of fused palatine shelves (palatal processes) of two maxillary processes, which extend posteriorly beyond the nasal septum

Clinical Correlation

- Cleft lip:** It commonly occurs in the upper lip. The incidence of cleft lip is 1 in 1000 births and 60–80% of children involved are males. The *cleft upper lip* presents three varieties (Fig. 12.11).
 - Unilateral cleft lip:** It occurs due to failure of fusion of maxillary process with the medial nasal process of the same side.
 - Bilateral cleft lip:** It occurs due to failure of fusion of maxillary processes with the frontonasal process.
 - Central cleft lip/hair lip:** It occurs due to failure of development of philtrum of the upper lip from the frontonasal process.

Very rarely the two mandibular processes may fail to fuse in the midline to cause *cleft lower lip*.
- Oblique facial cleft** (also called **orbitofacial fissure** Fig. 12.12): It is a rare congenital anomaly of the face, which occurs when maxillary process fails to fuse with the lateral nasal process. The fissure extends from medial angle of the eye to the upper lip. Consequently, the nasolacrimal duct is exposed to the exterior. This anomaly is usually bilateral.
- Microstomia** (small mouth) and **macrostomia** (large mouth): Lateral angles of oral fissure are formed at the junction of the maxillary and mandibular processes. Initially the lateral angle of mouth extends much laterally close to auricle. Subsequently in normal conditions the angles of mouth gradually shift medially by fusion between the maxillary and mandibular processes till normal adult position is reached. The excessive fusion of these processes lead to *microstomia* and arrest of this fusion leads to *macrostomia*.

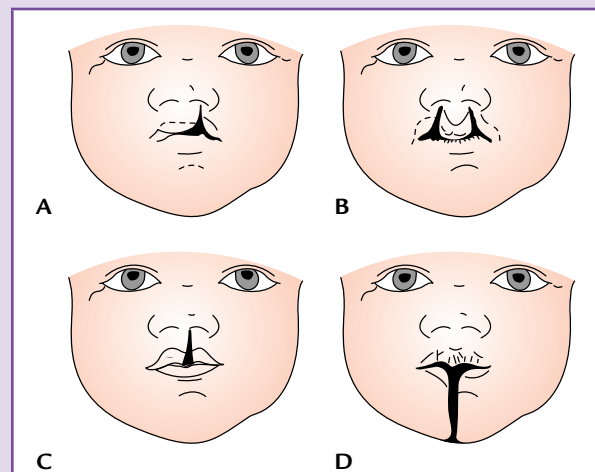


Fig. 12.11 Types of cleft lip. A. Unilateral cleft upper lip. B. Bilateral cleft of the upper lip. C. Median cleft of the upper lip (hair lip). D. Cleft lower lip.

- Cleft palate:** The defective fusion of various segments of palate gives rise to clefts in the palate. These vary considerably in degree, leading to varieties of cleft palate as follows:
 - Complete cleft palate** (Fig. 12.13)
 - Unilateral complete cleft palate** occurs if maxillary process on one side does not fuse with the premaxilla. It is always associated with the cleft lip on the same side.

- *Bilateral complete cleft palate* occurs if both the maxillary processes fail to fuse with the premaxilla. In this type, secondary palate is divided into two equal halves by a median cleft with an anterior V-shaped cleft separating the premaxilla completely.

(b) **Incomplete or partial cleft palate (Fig. 12.14):** The following types may occur.

- *Bifid uvula*: Cleft involving only uvula. It is of no clinical importance.

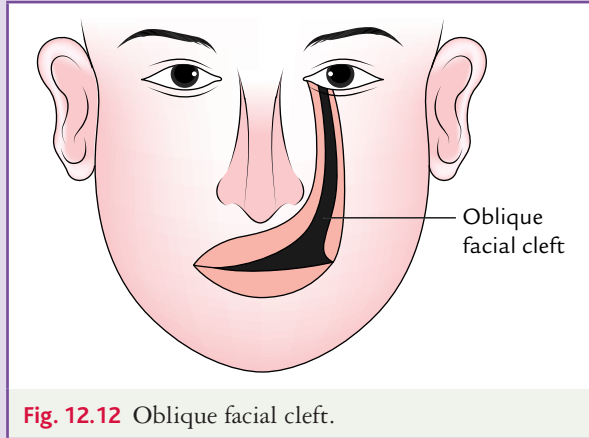


Fig. 12.12 Oblique facial cleft.

- *Cleft of the soft palate*: Involving uvula and adjoining part of the soft palate.
- *Cleft of the soft palate*: Involving uvula, whole of the soft palate, and extends into the hard palate.

Clinical photographs of cleft lip and cleft palate are shown in Fig. 12.15.

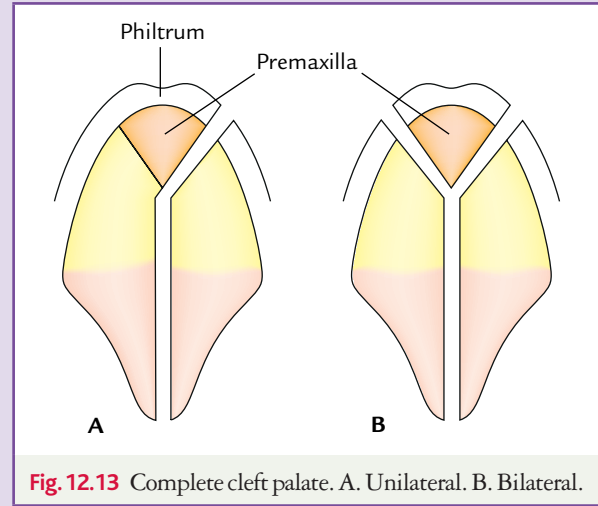


Fig. 12.13 Complete cleft palate. A. Unilateral. B. Bilateral.

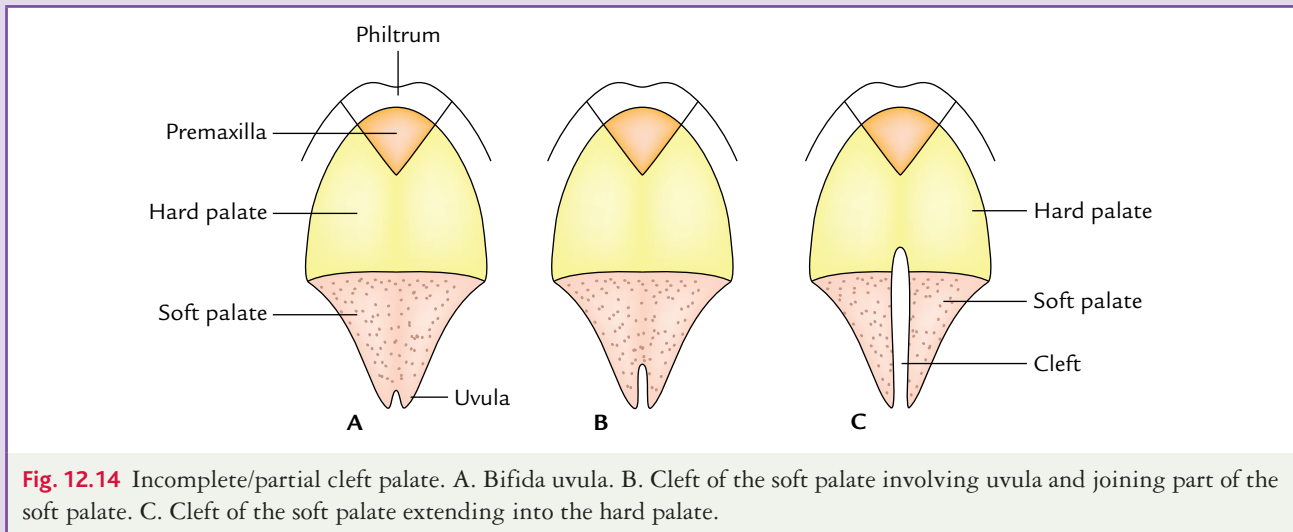


Fig. 12.14 Incomplete/partial cleft palate. A. Bifida uvula. B. Cleft of the soft palate involving uvula and joining part of the soft palate. C. Cleft of the soft palate extending into the hard palate.

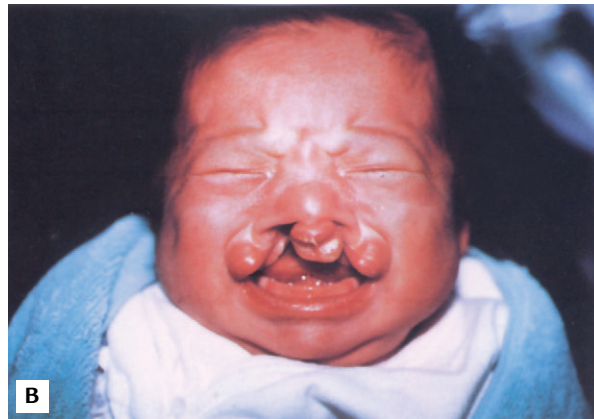
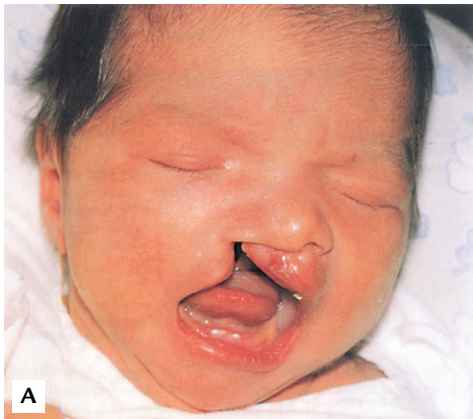
Fig. 12.15 Congenital anomalies of cleft lip and cleft palate. A. Infant with unilateral cleft lip and cleft palate. B. Infant with bilateral cleft lip and cleft palate.

GOLDEN FACTS TO REMEMBER

- | | |
|---|---|
| ➤ Nasolacrimal duct and sac develops from | Epithelial cord derived from ectodermal lining of the floor of nasolacrimal groove |
| ➤ Most common craniofacial congenital anomalies | Clefts of lip and palate |
| ➤ Critical period of palate development | End of sixth week to beginning of ninth week |
| ➤ Most common cleft lip | Unilateral cleft of upper lip |
| ➤ Most rare cleft lip | Median cleft of lower lip |
| ➤ Commonest cause of cleft lip with or without cleft palate | Multifactorial inheritance (i.e., combination of genetic and environmental factors) |
| ➤ Commonest congenital anomaly of face | Unilateral cleft of upper lip |

CLINICAL PROBLEMS

1. A baby was born with unilateral cleft lip extending through alveolar process of the maxilla into the palate. What is the embryological basis of this anomaly and discuss symptoms from which the child suffers?
2. The cleft lip is often associated with the cleft palate. Give the embryological basis.
3. Although the upper lip develops from two different sources: frontonasal process and maxillary processes, but general sensory innervation is provided only by nerves of maxillary processes (i.e., maxillary nerves). Why? Give the embryological basis.
4. The clefts of the lip and palate are the most common congenital anomalies. Can they be recognized/identified before birth by ultrasonography?
5. An epileptic mother who was treated with an anticonvulsant drug **phenytoin** during her pregnancy gave birth to a male child with cleft lip associated with cleft palate. Tell if there is any evidence to suggest that this drug increases the incidence of these anomalies.

CLINICAL PROBLEM SOLUTIONS

1. The unilateral cleft lip is a gap between the philtrum and lateral part of the upper lip. It occurs when the maxillary process of first pharyngeal arch fails to fuse with the medial nasal process of the same side. It is often associated with cleft palate because the palate develops from same sources as that of the upper lip. The symptoms of the cleft lip and cleft palate are:
 - (a) Disfigurement
 - (b) Inability to suckle
 - (c) Interference with the speech, particularly with the formation of consonants, viz., D, T, and G
 - (d) Distortion of teeth
2. The philtrum, alveolar arch bearing incisor teeth, and primary palate develop from frontonasal process (intermaxillary segments) whereas the lateral part of the upper lip, associated alveolar arch, and secondary palate develop from the maxillary processes (palatine shelves) of the first pharyngeal arches.

The cleft lip occurs due to nonfusion of frontonasal and maxillary processes; therefore it often involves alveolar arch and palate due to a common source of development.

3. The skin overlying the mesenchymal masses of maxillary processes overgrows the mesenchymal mass of frontonasal process. Thus the skin of whole upper lip is derived from the skin overlying the two maxillary processes, hence it is supplied by two maxillary nerves. Also see page 131.
N.B. According to Frazer the human upper lip develops only from maxillary processes whereas the frontonasal process (globular processes) grows deeply to form premaxilla/primary palate. This is substantiated by the fact that sensory innervation of the upper lip is provided by the maxillary nerves (vide supra).
4. The facial features of fetus become visible by beginning of the second trimester of pregnancy. Therefore they can be recognized before birth by ultrasonography.
5. There is substantial clinical and experimental evidence that anticonvulsant drugs such as **phenytoin** if given during pregnancy increase the incidence of cleft lip and cleft palate, two- to threefold more as compared to the normal population.

13

Digestive Tract

Overview

The digestive tract (gastrointestinal tract) develops from primitive gut that is derived from the dorsal part of *endodermal yolk sac*.

The primitive gut forms during the fourth week of intrauterine life by the incorporation of a larger portion of the yolk sac (umbilical vesicle) into the embryonic disc during craniocaudal and lateral folding of embryo (Fig. 13.1). The tubular primitive gut extends in the median plane from buccopharyngeal membrane at its cranial end to cloacal membrane at its caudal end. It freely communicates with the remaining yolk sac by the **vitellointestinal duct**. The part of gut cranial to this communication is called **foregut**, part caudal to this communication is called **hindgut**, and part intervening between foregut and hindgut is called **midgut** (Fig. 13.1).

The cranial end of foregut is separated from the **stomodeum** by **buccopharyngeal membrane** while caudal end of hindgut is separated from the **proctodeum** by **cloacal membrane**.

At later stage of development buccopharyngeal and cloacal membranes rupture, and gut communicates to exterior at its both ends.

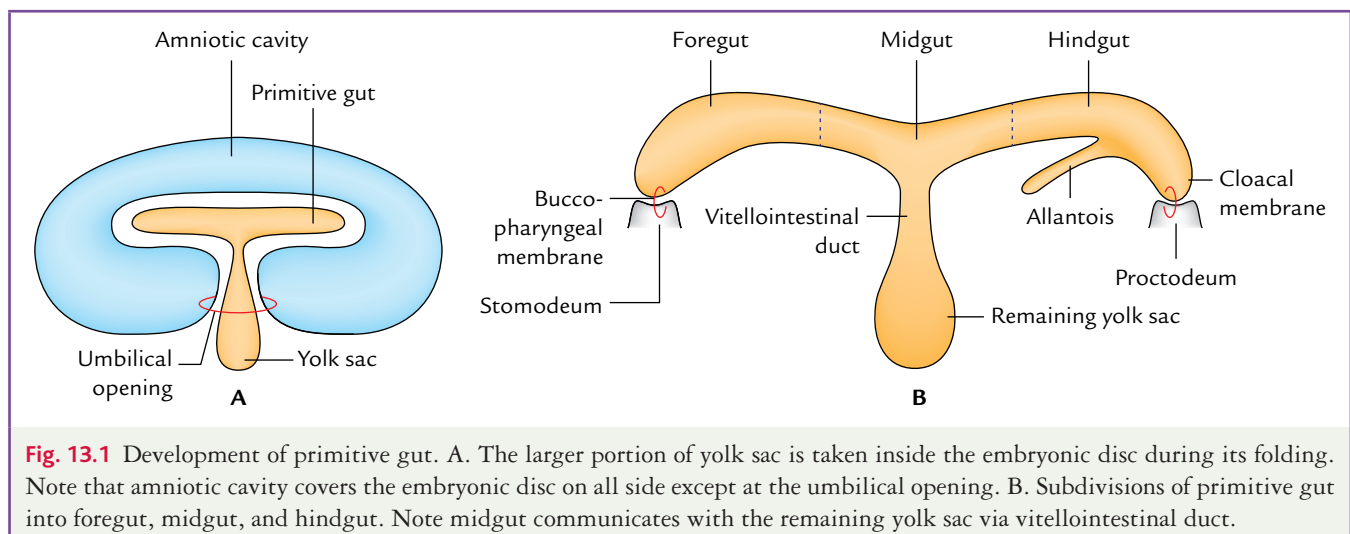
The endoderm of primitive gut forms the endothelial lining of all parts of the gastrointestinal tract except part of mouth and distal part of anal canal that are derived from ectoderm of *stomodeum* and *proctodeum*, respectively.

The muscular, connective tissues, and other layers of wall of the digestive tract are derived from splanchnopleuric mesoderm surrounding the primitive gut (Fig. 13.2).

While the primitive gut is being formed the midline artery, **dorsal aorta**, gives off a series of ventral branches to the gut. Those in the region of midgut run right up to the yolk sac and are, therefore, termed **vitelline arteries**. Later most of these ventral branches of dorsal aorta disappear and only three of them remain: one of foregut (the **celiac artery**), one of midgut (the **superior mesenteric artery**), and one of hindgut (the **inferior mesenteric artery**) (Fig. 13.3).

The development of digestive (gastrointestinal) tract showing foregut, midgut, and hindgut along with primordia of structures derived from them is shown in Fig. 13.4.

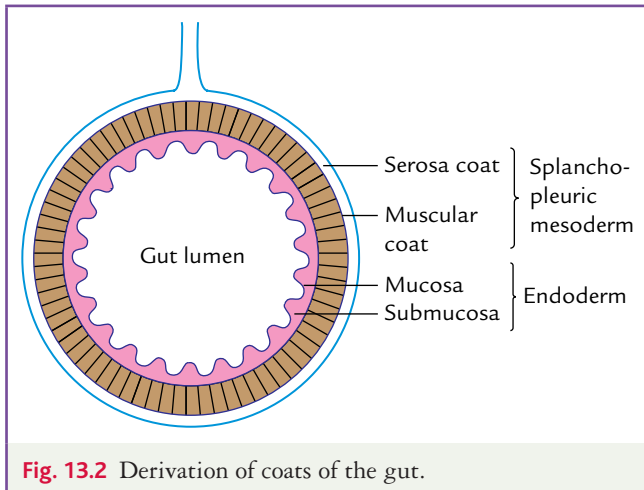
N.B. Molecular regulation of regional differentiation of primitive gut to form its different parts is done by *Hox* and *ParaHox* genes, and sonic hedgehog (SHH) signals.



The derivatives of the foregut, midgut, and hindgut are given in Table 13.1 and shown in Figs 13.4 and 13.5.

N.B. The junction between the foregut and midgut is known as **anterior intestinal portal**, whose position in adult gut corresponds with the termination of the bile duct in second part of the duodenum.

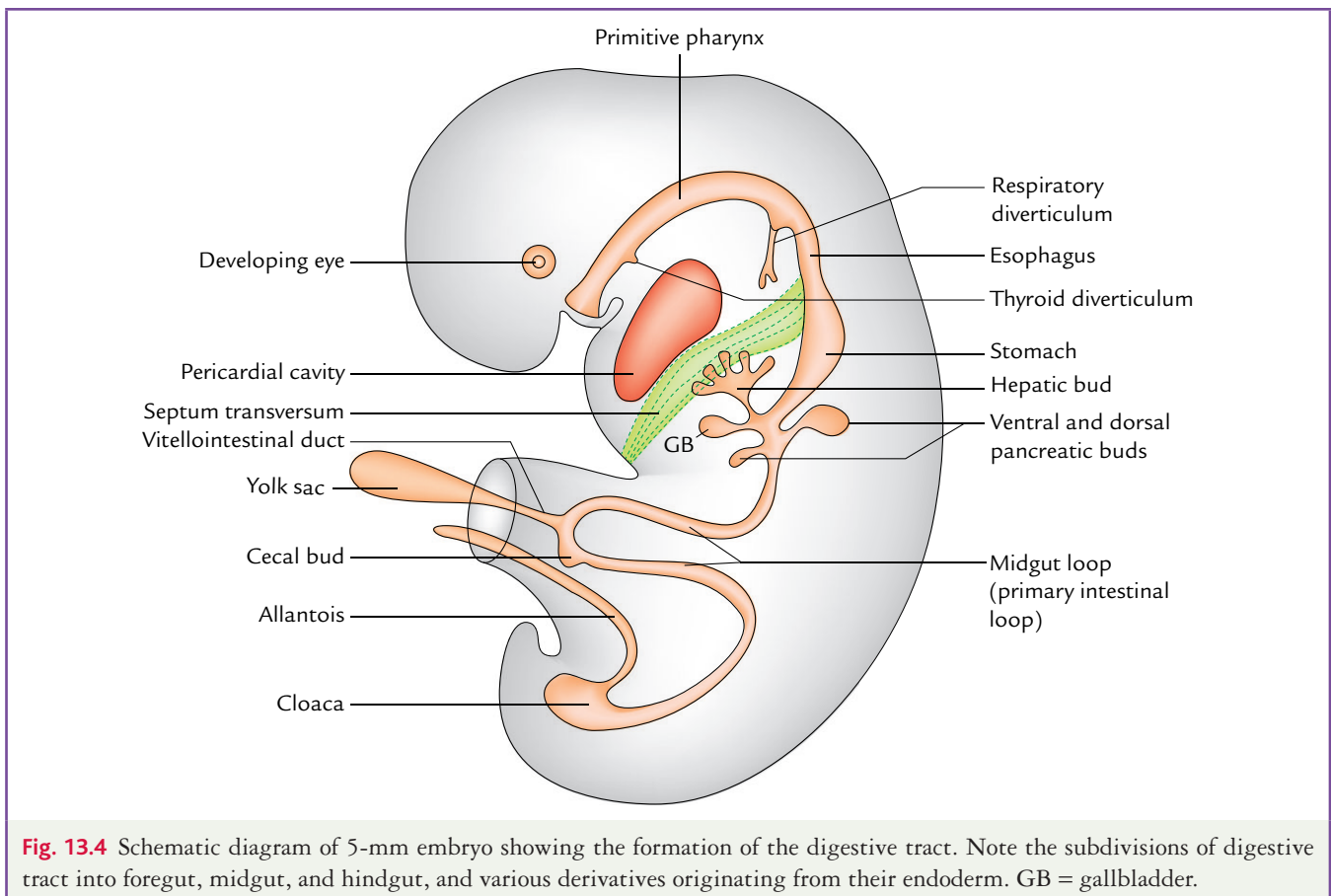
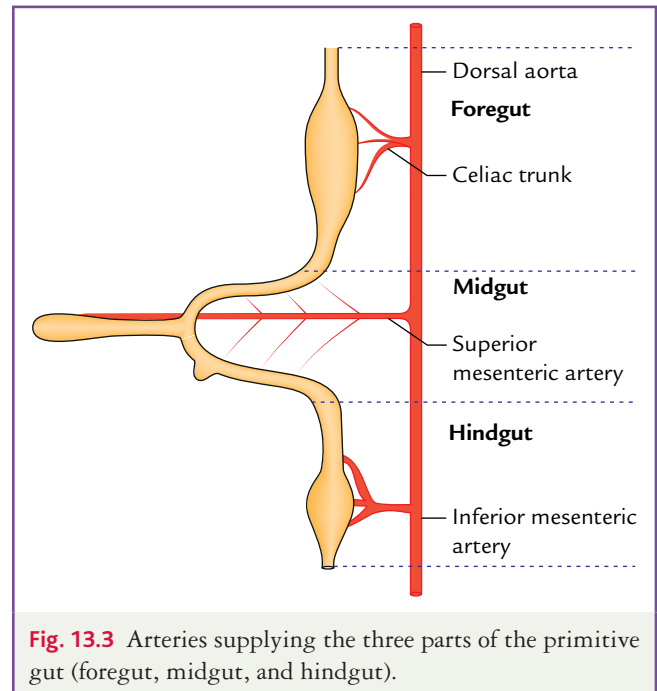
The junction between the midgut and hindgut is known as **posterior intestinal portal**, whose position in adult gut corresponds with the junction of proximal two-third and distal one-third of transverse colon. Figure 13.5 shows various derivatives of abdominal part of the gut with location of anterior and posterior intestinal portals.



Development of Foregut Derivatives

Esophagus

The esophagus develops from the part of foregut between the pharynx and the stomach. Ventrally at the



pharyngoesophageal junction, the foregut presents a median **laryngotracheal groove**. The groove bulges forward and caudally to form tracheobronchial (respiratory) diverticulum. The **tracheoesophageal septum** divides the foregut caudal to the pharynx into the

esophagus and trachea (Fig. 13.6) (for details see page 177). Initially the esophagus is short but later it elongates due to:

1. Formation of neck,
2. Descent of diaphragm, and
3. Descent of heart and lungs

Initially the lumen of the esophagus is almost obliterated by the proliferation of endodermal cells. Later on these cells breakdown and esophagus is recanalized.

The lining epithelium of the esophagus is derived from the endoderm of the foregut while musculature as well as connective tissue of the esophagus is derived from splanchnic mesenchyme surrounding the foregut. *The upper one-third part of the esophagus has striated musculature, middle one-third has mixed (striated and smooth) musculature, and lower one-third has smooth musculature as in the rest of the gut.*

Table 13.1 Derivatives of the three parts of the primitive gut	
Part of gut	Derivatives
Foregut	<ul style="list-style-type: none"> • Floor of mouth • Tongue • Pharynx • Derivatives of pharyngeal pouches • Thyroid • Esophagus • Respiratory system • Stomach • Proximal (upper) half of the duodenum
Midgut	<ul style="list-style-type: none"> • Liver • Pancreas • Extrahepatic biliary system • Distal (lower) half of the duodenum • Jejunum • Ileum • Cecum and appendix • Ascending colon • Right two-third of transverse colon
Hindgut	<ul style="list-style-type: none"> • Left one-third of transverse colon • Descending colon • Sigmoid (pelvic) colon • Rectum • Upper part of the anal canal

Clinical Correlation

1. **Esophageal atresia:** It occurs due to failure of recanalization of the developing esophagus.
 - The esophageal atresia is often associated with **tracheoesophageal fistula**. It is produced by extreme posterior deviation of **tracheoesophageal septum**.
 - In esophageal atresia, the fetus is unable to swallow amniotic fluid; hence there is an abnormal increase in the amount of amniotic fluid producing a clinical condition called **polyhydramnios**.
 - The newborn with esophageal atresia accepts the first feed (viz., milk or fluid diet) normally, but when given

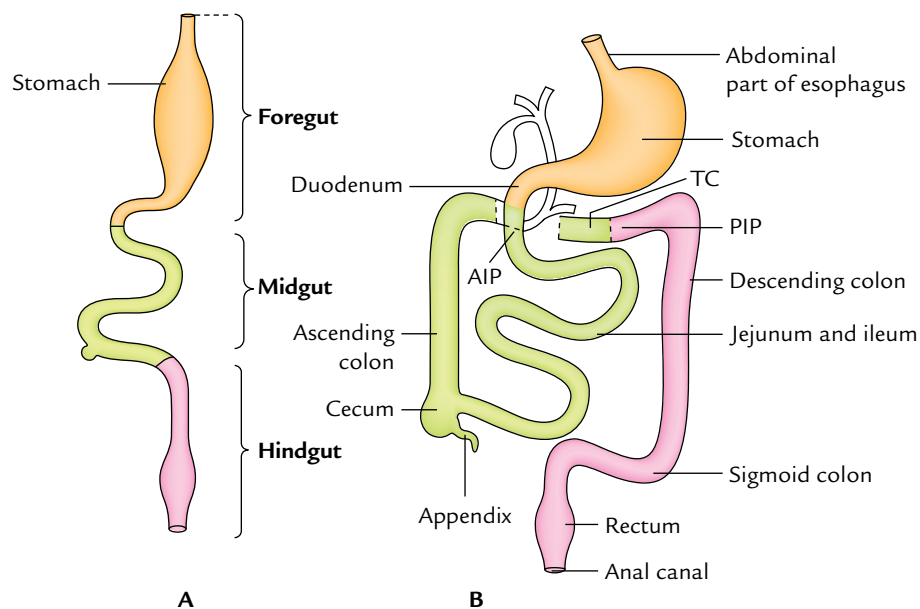


Fig. 13.5 Derivatives of various abdominal parts of the gut. A. Primitive gut. B. Adult gut. TC = transverse colon; AIP = anterior intestinal portal; PIP = posterior intestinal portal.

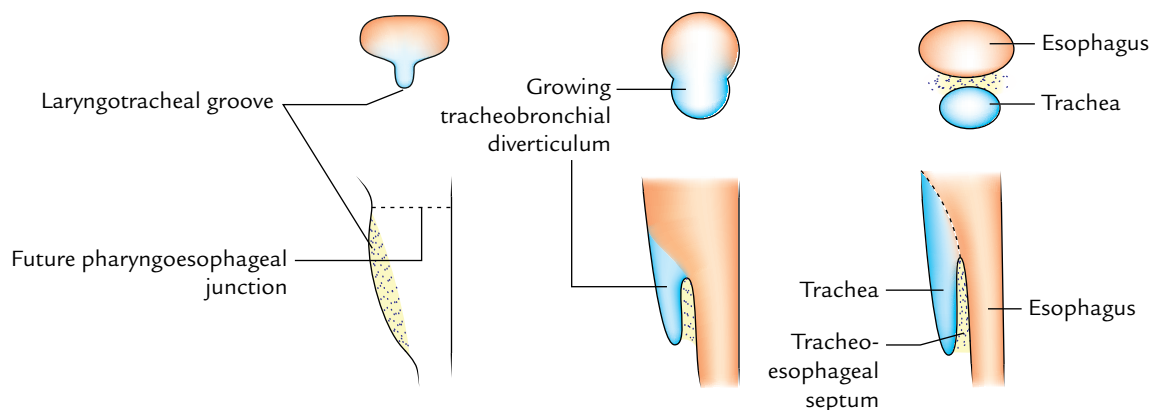


Fig. 13.6 Development of esophagus.

subsequent feed, it regurgitates through the mouth and nose; and may cause respiratory distress and cyanosis.

- The surgical correction (treatment) gives 85% survival rate.
2. **Esophageal stenosis:** In this anomaly, the lumen of the esophagus is narrow usually in *lower third part*. It is caused by incomplete esophageal recanalization and vascular abnormalities. Depending upon grade and extent of stenosis, symptoms may be mild or severe. In severe cases, the symptoms are similar to that of esophageal atresia.
 3. **Tracheoesophageal fistula:** It occurs due to failure of separation of *tracheobronchial diverticulum* from esophagus due to nonformation of tracheoesophageal septum (for details see page 178). In most of the cases (85%) the lower segment of esophagus communicates with the trachea. Clinically it presents as follows:

An infant vomits every feed that he/she is given. The presence of air in the stomach is the diagnostic sign of tracheoesophageal fistula (Fig. 13.7).

4. **Achalasia cardia:** It occurs due to failure of relaxation of the musculature in the lower part of the esophagus following loss of ganglionic cells in Aurbach's plexus. Clinically patient complains of difficulty in swallowing. On barium swallow, the lower part of esophagus presents pencil-shaped narrowing (**bird beak deformity**).
5. **Dysphagia lusoria:** See page 218.

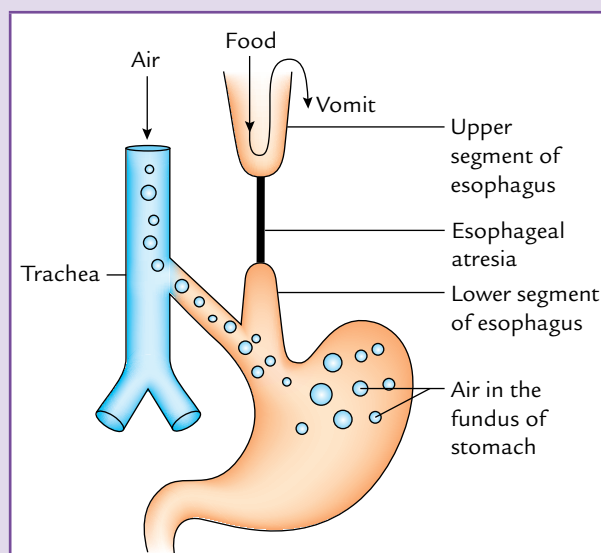


Fig. 13.7 Tracheoesophageal fistula.

6. **Short esophagus:** It occurs when esophagus fails to elongate during development. When the esophagus fails to elongate, the stomach is pulled up into the esophageal hiatus of diaphragm causing congenital hiatal hernia.

Stomach

The stomach appears as a fusiform dilatation of foregut distal to the esophagus in the fourth week of intrauterine life (IUL).

This dilatation presents a **ventral border** and **dorsal border**, a **left surface** and **right surface**, and an **upper end** and a **lower end**. The dorsal border provides attachment to dorsal mesentery (**dorsal mesogastrium**) that extends from the stomach to posterior abdominal wall. The ventral border provides attachment to ventral mesentery (**ventral mesogastrium**) that extends from the stomach to septum transversum and anterior abdominal wall.

Change in Shape and Position of Stomach (Fig. 13.8)

The **change in shape** of stomach occurs due to differential growth in its different regions.

Dorsal border grows much more than ventral border and forms **greater curvature** of the stomach, while the ventral border forms **lesser curvature** of the stomach.

The **changes in position** of the stomach can be easily explained by assuming that it rotates twice: (a) around a longitudinal axis and (b) around an anteroposterior axis.

Rotation of stomach The stomach rotates twice: first around its **longitudinal axis** and then around its

anteroposterior axis (vide supra). Line connecting cardiac and pyloric ends of stomach marks its **longitudinal axis**.

- First the stomach rotates 90° clockwise around its longitudinal axis. As a result, its left surface now faces anteriorly and forms anterior surface. Similarly, its right surface faces posteriorly to form posterior surface. For this reason left vagus nerve initially supplying the left surface of stomach now supplies its anterior surface and right vagus nerve initially supplying the right surface now supplies its posterior surface.
- The cephalic and caudal ends of stomach originally lie in the midline.

Now the stomach rotates around its **anteroposterior axis**. As a result, the cardiac end of stomach

originally lying in the midline moves to the left and slightly downward, and pyloric end originally lying in the midline moves to the right and slightly upward.

Change in the Mesenteries of the Stomach Due to its Rotation (Figs 13.9 and 13.10)

Initially the **ventral mesogastrium** of stomach extends from its lesser curvature to septum transversum and anterior abdominal wall. When liver develops in the septum transversum, the ventral mesogastrium is divided in two parts. The part extending from the stomach to the liver is called **lesser omentum**, and the part extending between the liver and anterior abdominal wall is called **falciform ligament** of the liver.

Initially the dorsal mesogastrium of stomach extends from its greater curvature to the posterior abdominal

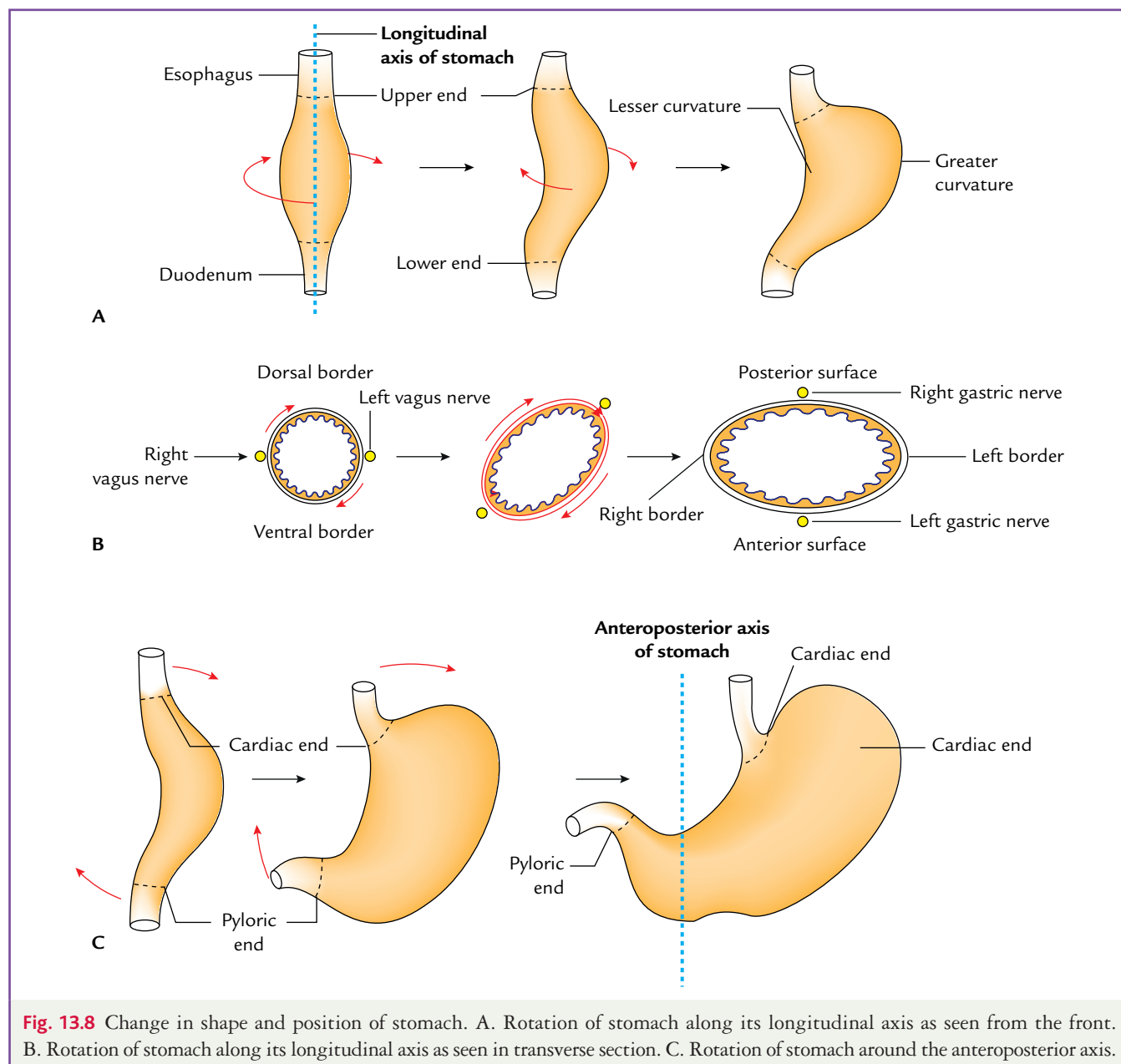


Fig. 13.8 Change in shape and position of stomach. A. Rotation of stomach along its longitudinal axis as seen from the front. B. Rotation of stomach along its longitudinal axis as seen in transverse section. C. Rotation of stomach around the anteroposterior axis.

wall. When the spleen develops from mesoderm lying between the two layers of dorsal mesogastrium, the dorsal mesogastrium is divided in two parts. The part extending from greater curvature (fundus) of the stomach to spleen forms the **gastrosplenic ligament**, while the part extending from spleen to posterior abdominal wall forms the **lienorenal ligament**. The dorsal mesogastrium attached to rest of greater curvature elongates and forms a large apron-like fold of peritoneum called **greater omentum**.

The rotation of stomach along its longitudinal axis pulls the dorsal mesogastrium to the left, creating a space behind the stomach called **lesser sac of peritoneum (omental bursa)** (Fig. 13.11). The development of lesser sac is described in detail in Chapter 17.

Histogenesis of the Stomach

The **epithelial lining and gastric glands** of the stomach are derived from the endoderm of the primitive foregut, while

the rest of the layers of the stomach (viz., muscular and serous coats) are derived from surrounding splanchnic intra-embryonic mesoderm.

- **Gastric glands** appear in the **third** month of the IUL.
- **Oxyntic and zymogenic cells** appear in the **fourth** month of IUL.

Clinical Correlation

Congenital hypertrophic pyloric stenosis: It occurs due to hypertrophy of circular muscle layer at pylorus. It causes narrowing of pylorus, converting it into probe admitting channel (**probe patency**). This causes consequent obstruction to passage of food through pylorus.

The newborn appears normal at birth, but 2–3 hours after feeding there is **forceful progressive projectile vomiting** and epigastrium shows distension of the stomach. The vomit does not contain bile. Clinically it presents as an enlargement of the abdomen with a palpable mass in right hypochondriac region with visible peristalsis. The condition can be surgically corrected. For details see *Anatomy of Abdomen and Lower Limb* by Vishram Singh.

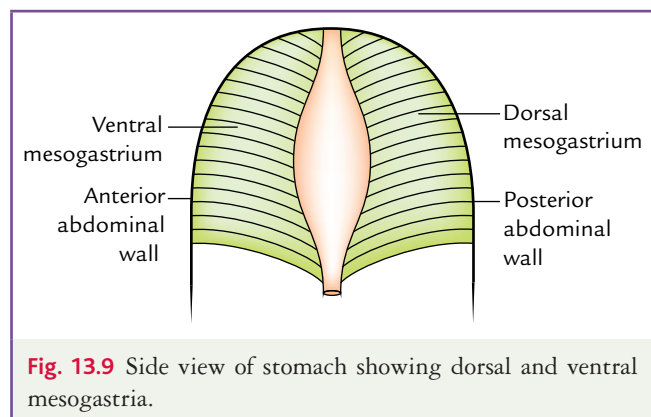


Fig. 13.9 Side view of stomach showing dorsal and ventral mesogastric folds.

Duodenum

The duodenum develops from two sources (dual origin): (a) proximal half is derived from foregut and (b) distal half is derived from midgut.

The details are as follows:

(a) The first and second part of duodenum up to the opening of common bile duct develop from foregut, and (b) the second part of the duodenum below the opening of common bile duct along with third and fourth part develop from midgut (Fig. 13.12).

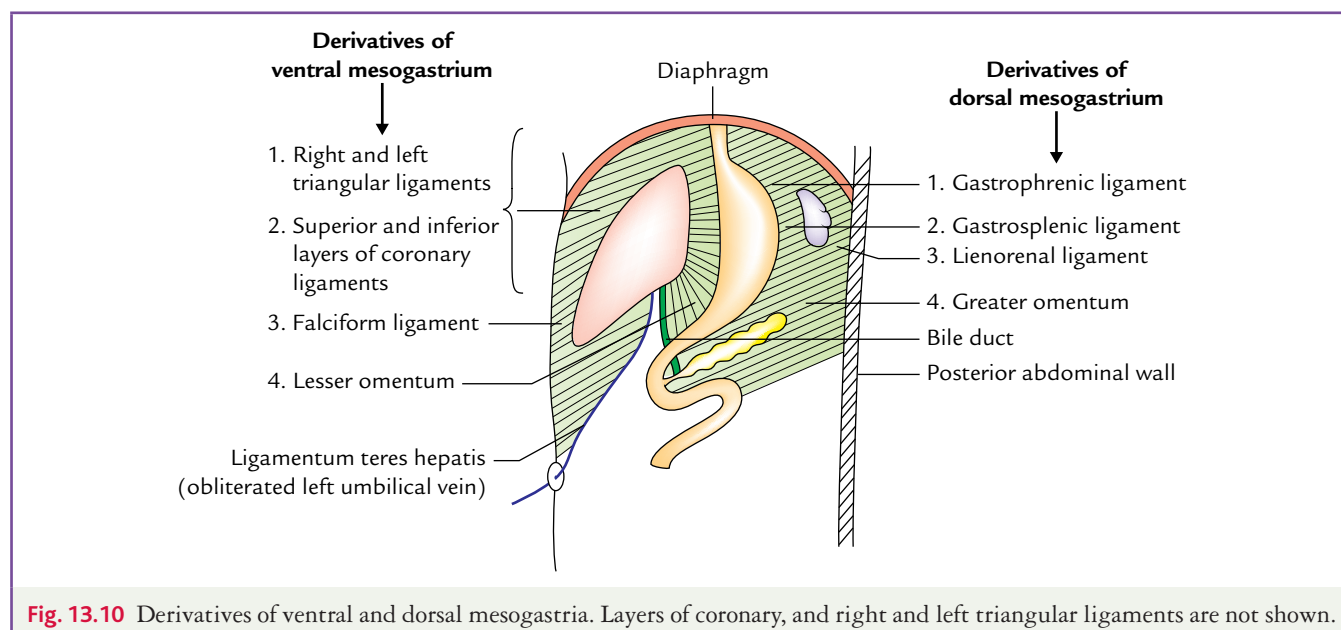


Fig. 13.10 Derivatives of ventral and dorsal mesogastric folds. Layers of coronary, and right and left triangular ligaments are not shown.

The developing duodenum forms a loop that is attached to posterior abdominal wall by a mesentery called **mesoduodenum** (Fig. 13.13). The loop is present in the sagittal plane; its apex is at the junction of

foregut and midgut. The clockwise rotation of the stomach to the left makes the duodenal loop to fall on the right side. Its mesentery (mesoduodenum) is absorbed by zygosis and becomes retroperitoneal (Fig. 13.14).

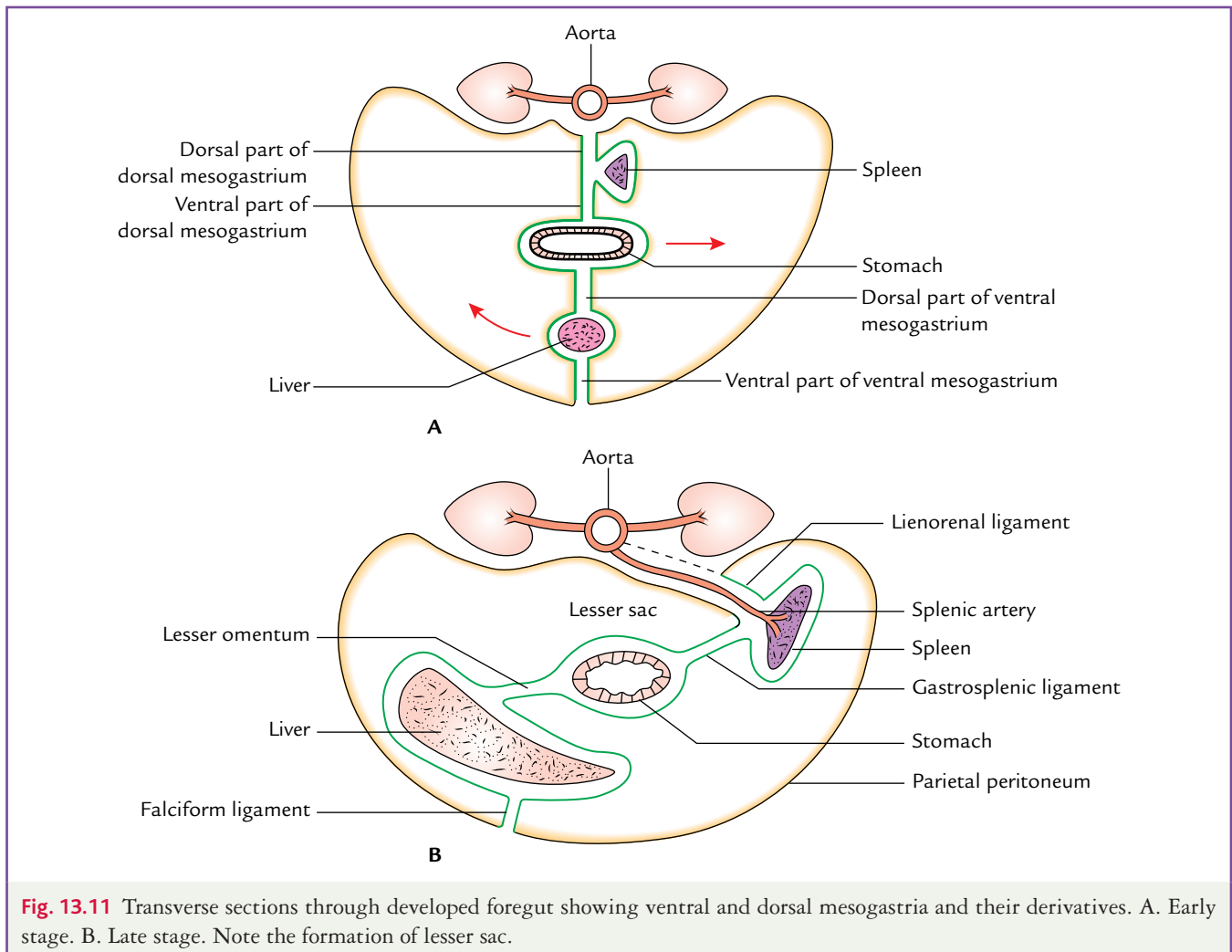


Fig. 13.11 Transverse sections through developed foregut showing ventral and dorsal mesogastria and their derivatives. A. Early stage. B. Late stage. Note the formation of lesser sac.

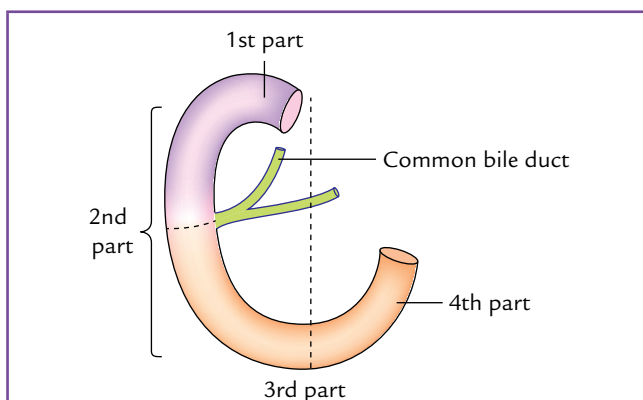


Fig. 13.12 Development of duodenum. Note, first part and second part up to the opening of common bile duct is derived from foregut (violet color). The second part of the duodenum (distal to opening of common bile duct) along with third and fourth parts is derived from midgut.

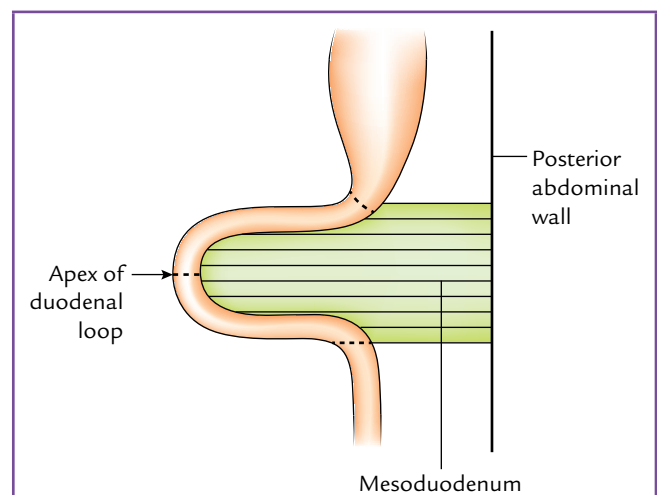
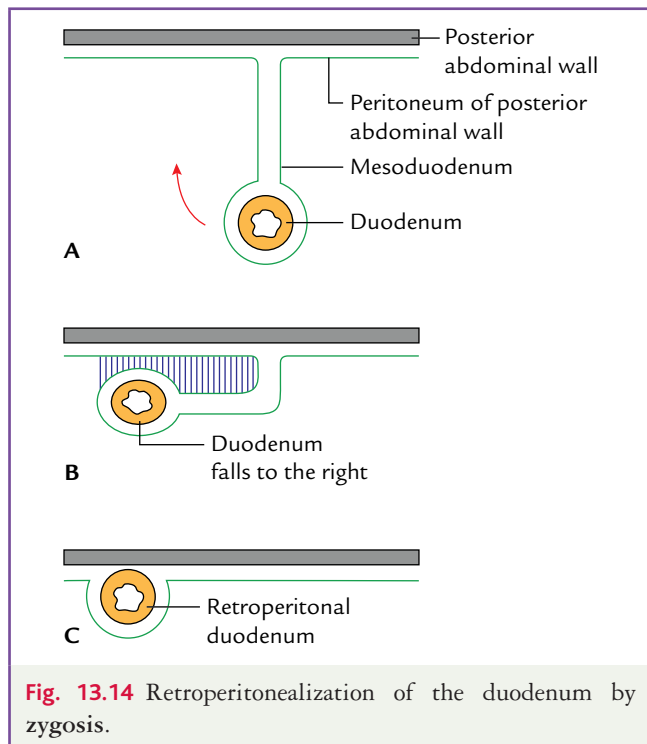


Fig. 13.13 Duodenal loop formed from parts of foregut and midgut. Note the mesoduodenum extending between duodenal loop and posterior abdominal wall.



However, the mesoduodenum persists in relation to a small portion of duodenum adjoining pylorus. This part is seen as a triangular shadow—the **duodenal cap** in barium meal X-ray abdomen.

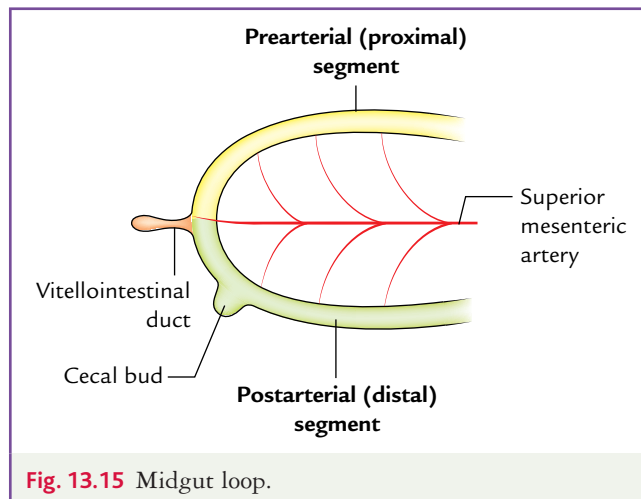
Initially development of the lumen of the duodenum is obliterated by the proliferation of endodermal cells. Later on cells in the lumen disintegrate and the duodenum gets recanalized.

N.B. The proximal half of duodenum, i.e., up to the opening of common bile duct, develops from foregut, hence it is supplied by artery of the foregut—the **celiac trunk**.

The distal half of duodenum develops from the midgut, hence it is supplied by artery of the midgut—the superior mesenteric artery.

Clinical Correlation

- Duodenal stenosis:** It occurs because of incomplete recanalization of the duodenum. The cells in lumen disintegrate only in small central part producing a narrow lumen. Duodenal stenosis commonly affects third and fourth parts of the duodenum. Duodenal stenosis produces partial obstruction.
- Duodenal atresia:** It occurs due to failure of recanalization of the duodenum. The duodenal atresia nearly always occurs just distal to opening of hepatopancreatic ampulla, but occasionally involves third part of the duodenum. Clinically, in infants with duodenal atresia vomiting begins a few hours after birth. The vomit almost always contains bile (*bilious emesis*). The 'double bubble sign' seen in X-ray abdomen or ultrasound indicates duodenal atresia.
- Duodenal diverticuli:** They are seen along the inner border of the second and third part of the duodenum.



Development of Midgut Derivatives

The midgut elongates to form a **U-shaped primary intestinal loop**. This U-shaped loop is suspended from posterior abdominal wall by a short mesentery and at its apex, it communicates with the **yolk sac** through narrow **vitelline duct/vitellointestinal duct/yolk stalk**. (In adults, the midgut extends from just distal to opening of common bile duct in the duodenum to junction between the proximal two-third and distal one-third of the transverse colon.)

The *superior mesenteric artery*, the artery of midgut, runs posteroanteriorly through the middle of the mesentery of the midgut loop. The superior mesenteric artery divides the midgut loop into two segments:

1. Prearterial (proximal) segment
2. Postarterial (distal) segment

The **prearterial segment** is cranial and the **postarterial segment** is caudal. The postarterial segment near the apex of midgut loop develops a small conical diverticulum—the **cecal bud** at its antimesenteric border (Fig. 13.15).

The **prearterial segment** of midgut loop gives rise to:

1. Distal half of duodenum
2. Jejunum
3. Ileum, except its terminal part.

The **postarterial segment** of midgut loop gives rise to:

1. Terminal part of ileum
2. Cecum
3. Appendix
4. Ascending colon
5. Proximal (right) two-third of the transverse colon.

Table 13.2 Source of development of adult derivatives of midgut

Adult structure	Source of development
Jejunum	Prearterial segment of midgut loop
Ileum	<ul style="list-style-type: none"> • Prearterial segment of midgut loop • Small postarterial segment of midgut loop proximal to the cecal bud
Cecum and appendix	Cecal bud of postarterial segment of midgut loop
Ascending colon and proximal two-third of transverse colon	Postarterial segment of midgut loop beyond the cecal bud

N.B. All parts derived from **midgut** are supplied by superior mesenteric artery.

The exact sources of development of different adult derivatives of the midgut are given in Table 13.2.

Physiological Umbilical Hernia

During the third week of IUL, the midgut loop elongates rapidly particularly its prearterial segment. As a result of rapid growth of midgut loop and enlargement of liver at the same time, the abdominal cavity temporarily becomes too small to accommodate all the loops of midgut (i.e., intestine). Consequently, during the sixth week of IUL the loops of midgut (intestine) herniate through umbilical opening (i.e., go outside the abdominal cavity) to enter into remains of extraembryonic celom (in the proximal part of umbilical cord). This herniation of intestinal loops through umbilical opening is called **physiological umbilical hernia**.

Rotation of Midgut Loop (Syn. Rotation of Gut) (Figs 13.16 and 13.17)

The rotation of gut occurs when herniated intestinal loops return back to the abdominal cavity.

The rotation of gut not only helps in return of herniated loops back into the abdominal cavity but also helps in establishing definitive relationships of various parts of the intestine.

Therefore, students must clearly understand the steps of rotation.

The herniated loops of intestine begin to return into the abdominal cavity at the end of the third month of IUL.

- Before rotation, the prearterial segment of midgut loop, superior mesenteric artery, and postarterial segment of midgut loop, from above to downward, lie in the vertical (sagittal) plane.

- In order to return in the abdominal cavity, the midgut loop undergoes rotation of 90° in anticlockwise direction thrice. Thus, there is a total rotation of 270° out of which first 90° rotation occurs within umbilicus (i.e., outside the abdominal cavity) and remaining 180° rotation occurs within the abdominal cavity.

The detailed steps of rotation of the gut are as follows:

1. Before return into the abdominal cavity, the prearterial segment of midgut loop undergoes 90° anticlockwise rotation. As a result (as seen from the front), the **prearterial segment** comes to the right and the **postarterial segment** goes to the left. The prearterial segment of midgut loop elongates extensively and forms coils of jejunum and ileum, which lie on the right side of superior mesenteric artery, outside the abdominal cavity.
2. As these coils of jejunum and ileum return to the abdominal cavity, the midgut loop undergoes second 90° anticlockwise rotation so that coils of jejunum and ileum (derived from prearterial segment) pass behind the superior mesenteric artery. As a result, the duodenum goes behind the superior mesenteric artery.
3. Lastly when the postarterial segment returns to the abdominal cavity it undergoes **third 90° anticlockwise rotation**. As a result, **cecum and an appendix that develop from cecal bud now come to lie on the right side just below the liver**. *The orientation of pre- and postarterial segments of midgut loop at different phases of rotation (three 90° anticlockwise rotations) are shown in Fig. 13.17.*

The ascending colon is not visible at this stage. Ascending colon is formed when cecum descends to right iliac fossa. The transverse and descending colon also gets defined. The transverse colon lies anterior to superior mesenteric artery.

The development of the cecum and appendix is described in detail in the following text.

Development of Cecum and Appendix (Fig. 13.18)

The cecum and appendix develop from cecal bud—a conical dilatation that appears in the postarterial segment of the midgut loop near its apex (i.e., site of attachment of vitelline duct).

The proximal part of the bud grows rapidly and forms cecum, while its distal part remains narrow to form the appendix.

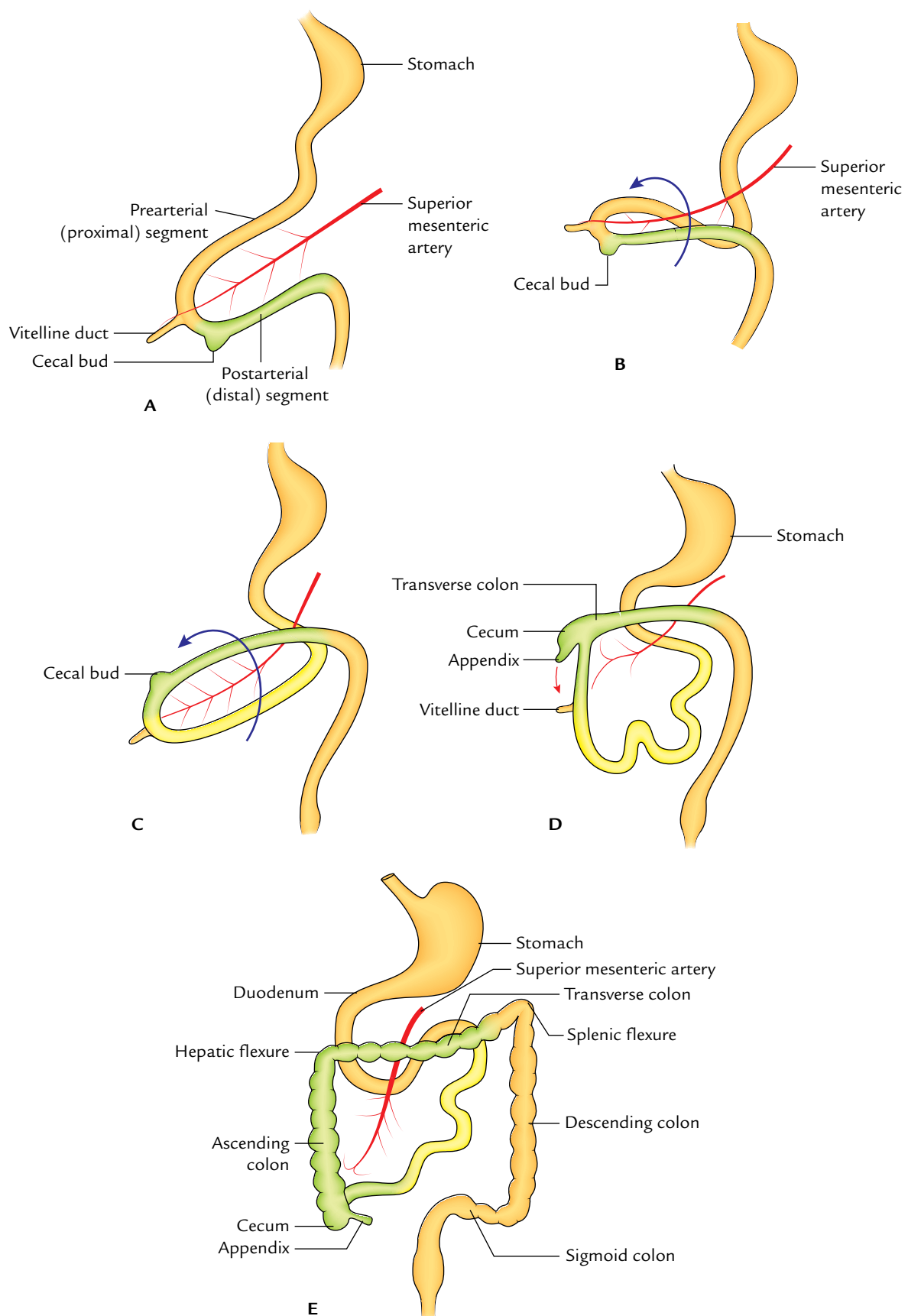


Fig. 13.16 Rotation of midgut loop as seen in left side view. A. Primitive loop before rotation. B. Anticlockwise 90° rotation of midgut loop while it is in the extraembryonic celom in the umbilical cord. C. Anticlockwise 180° rotation of midgut loop as it is withdrawn into the abdominal cavity. D. Descent of cecum takes place later. E. Intestinal loops in final position.

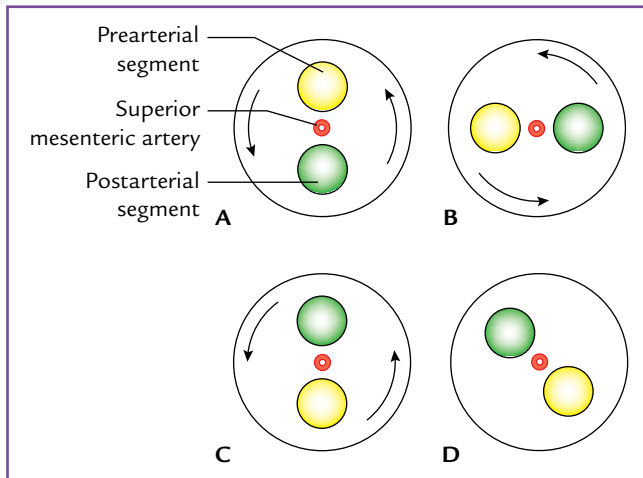


Fig. 13.17 Schematic diagrams to show the orientation of prearterial and postarterial segments of midgut loop during different phases of its rotation.

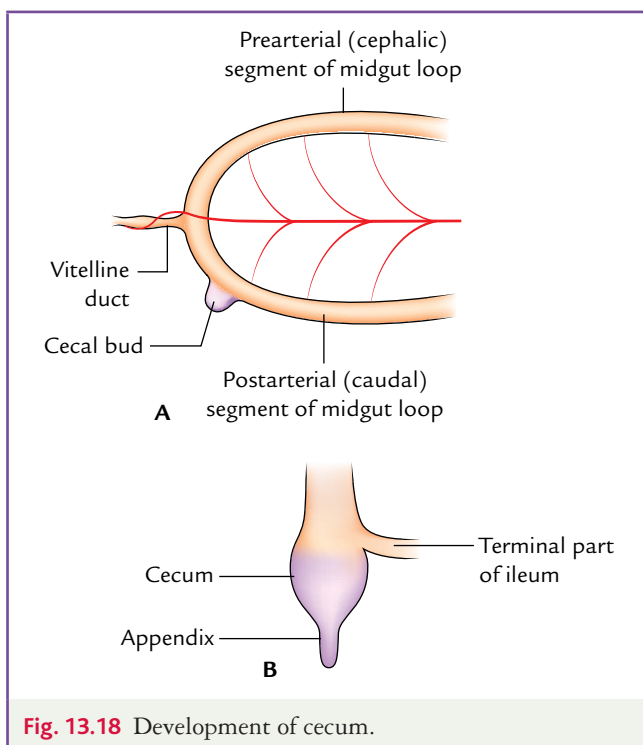


Fig. 13.18 Development of cecum.

Change in Shape of Cecum and Appendix

The growth of the cecum after birth leads to a change in its shape and change in position of attachment of the appendix.

At birth, the cecum is conical in shape and vermiform appendix is attached at its apex. Later cecal growth results in formation of two **saccules**—one on either side.

The **right saccule** grows faster than the left. As a result, the apex of the cecum and the base of the appendix is pushed towards left, nearer to ileocecal junction. For this reason in adults, the base of the appendix is attached to posteromedial wall of the cecum, near the ileocecal junction.

On the basis of shape of the cecum and site of attachment of appendix, the cecum is classified into following four types (Fig. 13.19):

1. Conical (fetal) type (2%)
2. Infantile (quadrate) type (3%)
3. Normal type (80–90%)
4. Exaggerated type (4–5%).

For details refer book on *Anatomy of Abdomen and Lower Limb* by Vishram Singh, pages 156–157.

Clinical Correlation

1. **Exomphalos or omphalocele** (Fig. 13.20): This anomaly results from failure of coils of the small intestine to return into abdominal cavity from their physiological herniation into extraembryonic celom during sixth to tenth week of IUL. It occurs in 2.5/10,000 births and could be associated with cardiac and neural tube defects.

Clinically, it presents as a rounded mass protruding from the umbilicus. This mass contains coils of the small intestine and is covered by a transparent amniotic membrane.

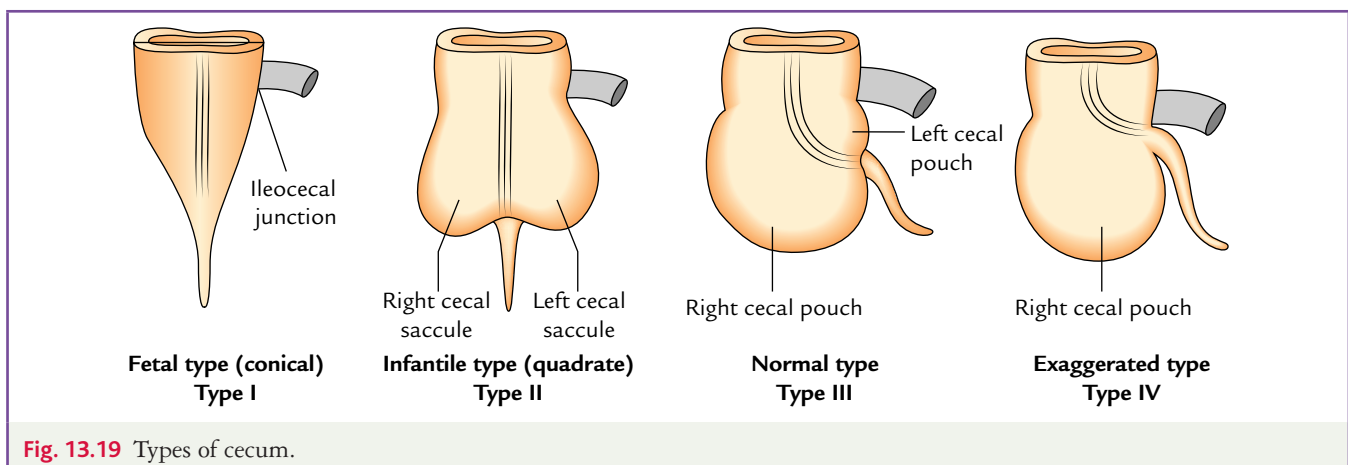


Fig. 13.19 Types of cecum.

2. **Congenital umbilical hernia:** In this anomaly, there is herniation of abdominal viscera through the weak umbilical opening (poorly closed umbilicus). Clinically, it presents as a protrusion in the linea alba. The contents are covered with peritoneum, subcutaneous tissue, and skin. This hernia can be reduced by pushing the intestines back into the abdominal cavity through the umbilical opening. The size of hernia increases during crying, coughing, and straining because of increased abdominal pressure.

N.B. The congenital umbilical hernia gets reduced on its own within 2–3 years of life. Therefore, child is subject to surgery only when the hernia stays up to age 2–3 years.

The box below shows the differences between the omphalocele and congenital umbilical hernia.

Omphalocele	Congenital umbilical hernia
Herniation of bowel loops occurs through umbilical opening as a normal event of development (physiological herniation) but fail to return in abdominal cavity later	Herniation of bowel loops occurs through weak umbilical opening (i.e., occurs when umbilicus fails to close properly)
Covered by peritoneum, Wharton's jelly, and amnion	Covered by peritoneum, subcutaneous tissue, and skin
Has genetic basis	Has no genetic basis
Has bad prognosis (mortality rate 25%)	Has a good prognosis

3. **Gastroschisis:** In this anomaly, there is a linear defect in anterior abdominal wall through which abdominal contents herniate out. It occurs lateral to the umbilicus, usually on to the right.

This defect is produced when lateral folds of embryo fail to fuse with each other around connecting stalk.

4. **Anomalies of vitellointestinal duct:** Vitellointestinal duct connects the apex of midgut loop to yolk sac. Normally it disappears

completely. The failure to disappear completely or in part will produce following anomalies of vitellointestinal duct.

(a) **Meckel's diverticulum (Fig. 13.21):** A small part of vitellointestinal duct close to midgut (ileum) persists and forms the Meckel's diverticulum. It may be connected to the umbilicus by a fibrous cord (the obliterated remaining part of vitellointestinal duct).

Meckel's diverticulum is a small diverticulum arising from antimesenteric border of ileum; it is about 2 inches (5 cm) in length, is present about 2 feet (60 cm) proximal to ileocecal junction, and occurs in about 2% of people. It may contain gastric mucosa or pancreatic tissue. There might be ulceration, bleeding, or even perforation of Meckel's diverticulum. It may undergo inflammation, symptoms of which may mimic to that of appendicitis.

(b) **Umbilical sinus (Fig. 13.22A):** It occurs when part of vitellointestinal duct close to umbilicus persists, i.e., fails to close. The sinus communicates with the umbilicus.

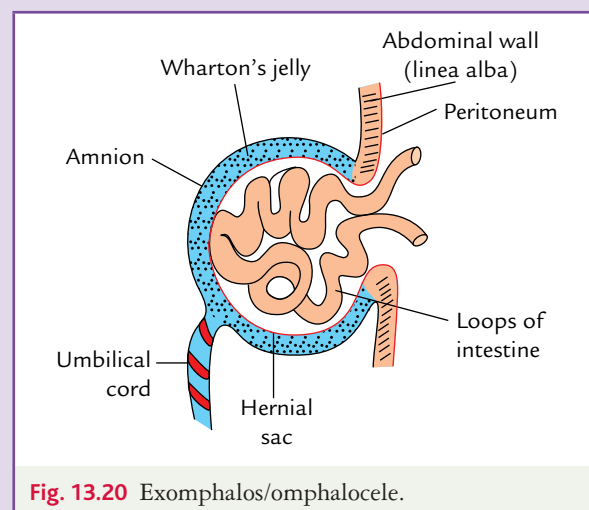


Fig. 13.20 Exomphalos/omphalocele.

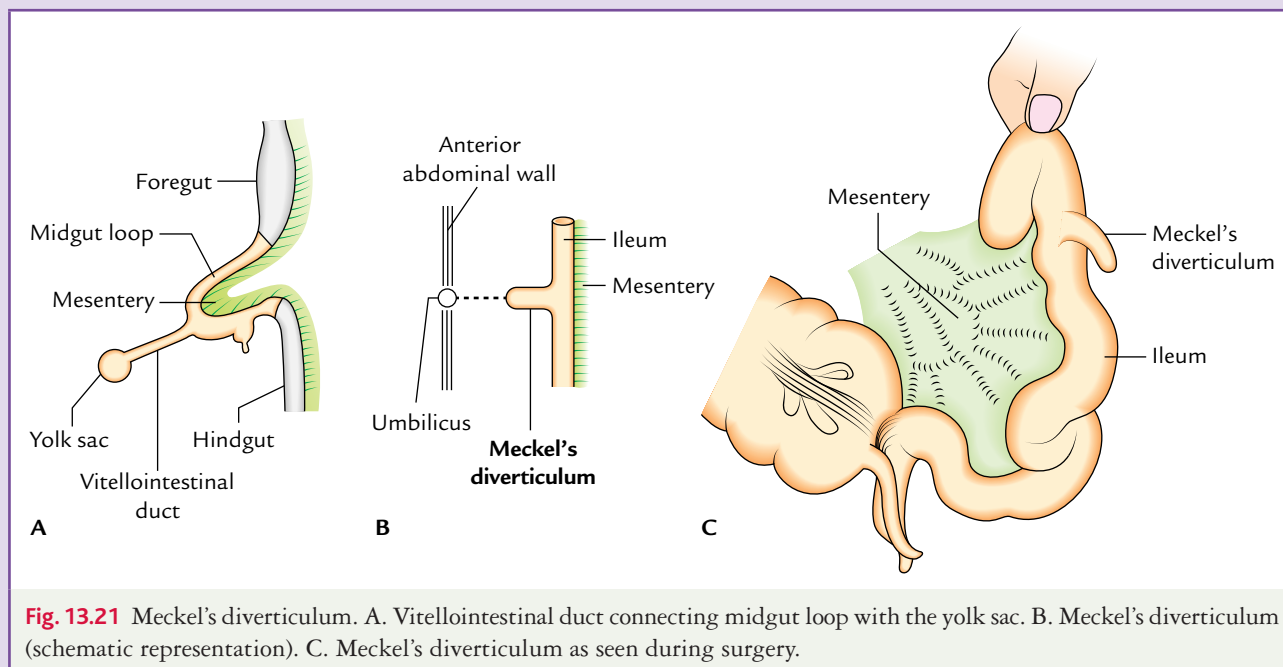


Fig. 13.21 Meckel's diverticulum. A. Vitellointestinal duct connecting midgut loop with the yolk sac. B. Meckel's diverticulum (schematic representation). C. Meckel's diverticulum as seen during surgery.

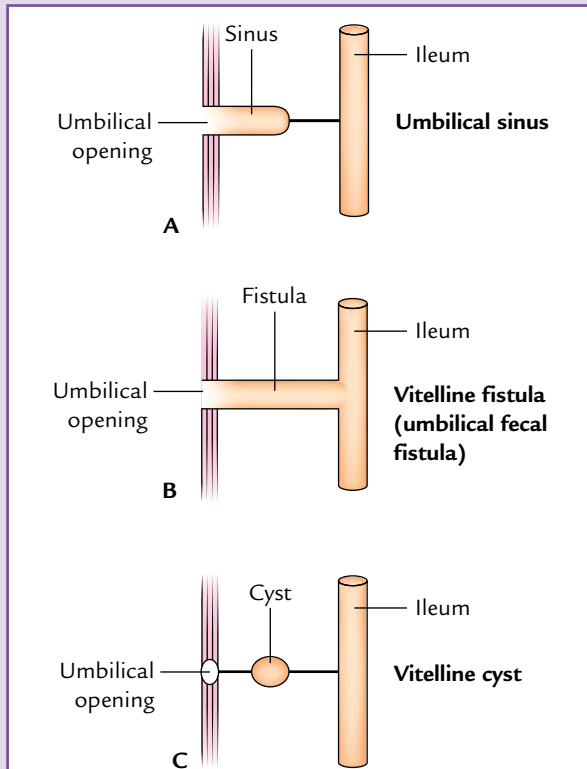


Fig. 13.22 A. Umbilical sinus. B. Umbilical fistula. C. Vitelline cyst.

(c) *Vitelline (umbilical) fistula* (Fig. 13.22B): It occurs when vitellointestinal duct fails to obliterate along its entire extent. This fistula communicates with ileum at one end and opens to exterior at the umbilicus at the other end.

Clinically, the ileal contents may be discharged through the umbilicus.

(d) *Vitelline cyst* (Fig. 13.22C): When small middle part of vitellointestinal duct persists (i.e., fails to obliterate), it forms cyst.

5. Anomalies due to errors of rotation of midgut loop

(a) *Nonrotation*: In this anomaly, the midgut loop fails to rotate. The caudal or postarterial segment returns first in the abdominal cavity.

Hence, large intestine occupies the left side of the abdominal cavity while the small intestine derived from pre-arterial segment returns later and occupies the right side of the abdominal cavity (Fig. 13.23A).

(b) *Partial rotation*: In this anomaly, first 180° of rotation takes place normally but last 90° of rotation does not take place. As a result, cecum and appendix, instead of being on the right side of the abdominal cavity, are located just below pylorus of stomach.

(c) *Reversed rotation*: In this anomaly, the midgut loop rotates clockwise instead of anticlockwise. In this condition, transverse colon passes behind duodenum and lies behind the superior mesenteric artery (Fig. 13.23B).

6. *Subhepatic cecum and appendix (undescended cecum and appendix)*: The cecum develops from a cecum bud—a small conical dilatation that appears in the caudal segment of midgut loop near its apex at about the sixth week of IUL.

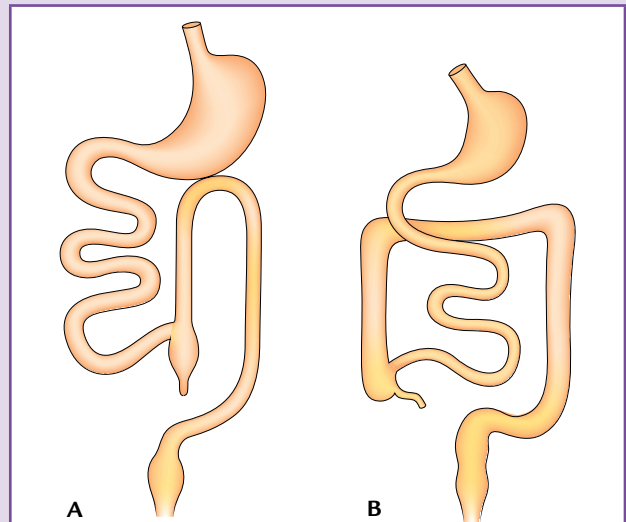


Fig. 13.23 Anomalies due to errors of rotation of gut. A. Location of colon on the left half of the abdomen and small coils of the small intestine on the right side of abdomen due to nonrotation. B. Location of transverse colon behind the duodenum due to reversed rotation.

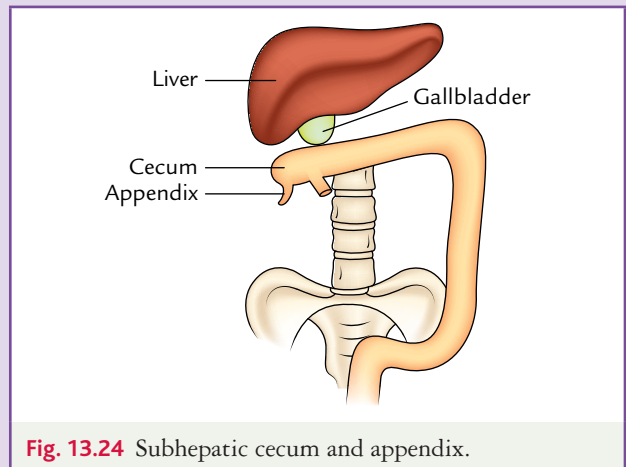


Fig. 13.24 Subhepatic cecum and appendix.

When the caudal segment of midgut loop returns to the abdominal cavity cecum comes to lie below liver (**subhepatic position**).

As the postarterial segment of midgut loop elongates to form ascending colon, the cecum and appendix acquire a definitive position in the right iliac fossa.

But if ascending colon does not form or remains too short, the cecum does not descend and remains permanently below the liver leading to congenital anomaly called **subhepatic cecum and appendix** (Fig. 13.24).

In cases of subhepatic cecum and appendix, the inflammation of appendix (**appendicitis**) would cause tenderness in right hypochondrium that may lead to mistaken diagnosis of **cholecystitis** (inflammation of gall bladder).

N.B. Sometimes the cecum may descend only partially in the lumbar region or may descend too much to reach in the pelvic region.

Fixation of Midgut Derivatives

The midgut loop has a dorsal mesentery (**mesentery proper**) that is attached to posterior abdominal wall in midline. As coils of small intestine return to the abdominal cavity, the line of attachment of its mesentery shifts and lies obliquely from *duodenojejunal flexure* to *ileocecal junction*. It undergoes profound changes with rotation. When the caudal (postarterial) limb of the loop moves to the right side of the abdominal cavity, the dorsal mesentery twists around **superior mesenteric artery**.

The **ascending colon** has a short mesentery at first, but as the ascending colon elongates its mesentery fuses with parietal peritoneum and the ascending colon becomes retroperitoneal by **zygosis**.

The transverse colon retains its mesentery, the attachment of which runs transversely from right to left on the posterior abdominal wall. This orientation of the **transverse mesocolon** can be explained by the last 90° rotation of midgut loop when postarterial segment returns to the abdominal cavity.

Development of Hindgut Derivatives

The hindgut gives rise to following parts of the gastrointestinal tract.

1. Left one-third of transverse colon
2. Descending colon
3. Sigmoid colon
4. Rectum
5. Upper part of the anal canal.

Development of Transverse Colon

The right two-third of transverse colon develops from the postarterial segment of the midgut loop while the left one-third of transverse colon develops from the hindgut. For this reason, the right two-third of transverse colon is supplied by superior mesenteric artery (the artery of midgut) and left one-third of transverse colon is supplied by the inferior mesenteric artery (the artery of hindgut).

Development of Descending Colon

It develops from hindgut.

Development of Sigmoid Colon

It also develops from hindgut.

Development of Rectum (Fig. 13.25)

The terminal dilated part of the hindgut distal to allantois is called **cloaca**. It is divided into two parts by urorectal septum: (a) a broad ventral part called **primitive urogenital sinus** and a narrow dorsal part is called **primitive rectum**.

The **urogenital sinus** gives rise to the urinary bladder and urethra, while the primitive rectum gives rise to the rectum and upper part of the anal canal.

Development of Anal Canal (Fig. 13.26)

The anal canal develops from two sources: (a) hindgut and (b) proctodeum. The details are as follows.

The upper half of the anal canal is endodermal in origin and develops from primitive rectum.

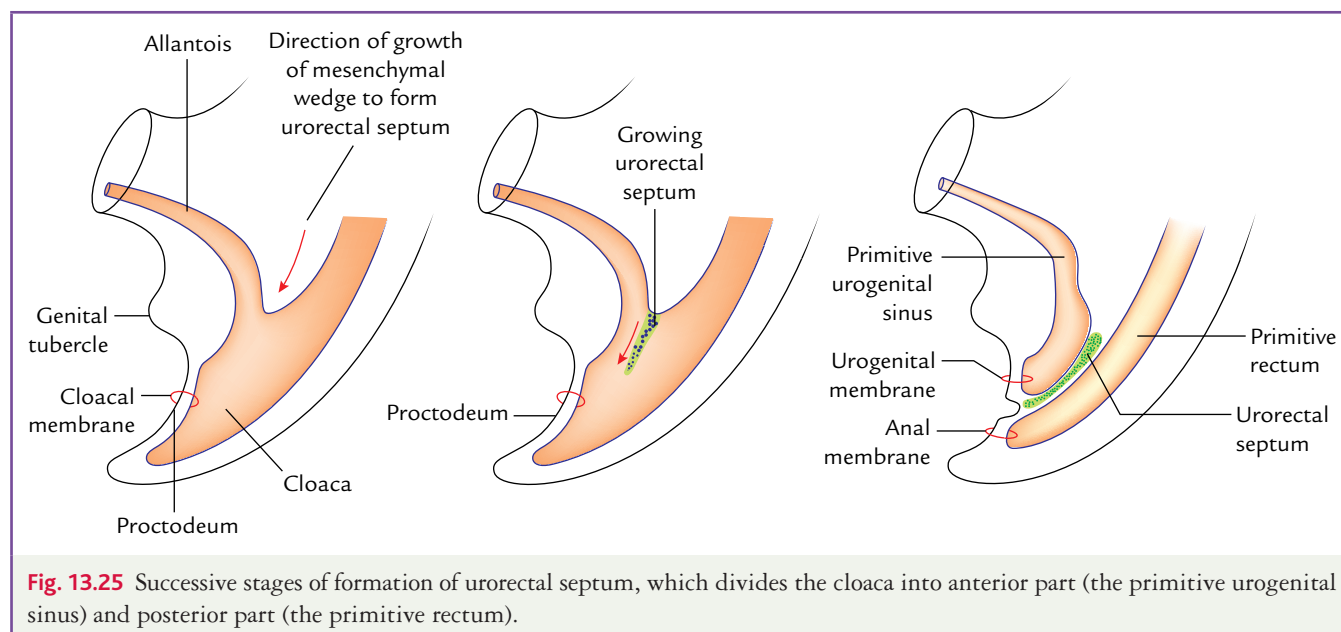


Fig. 13.25 Successive stages of formation of urorectal septum, which divides the cloaca into anterior part (the primitive urogenital sinus) and posterior part (the primitive rectum).

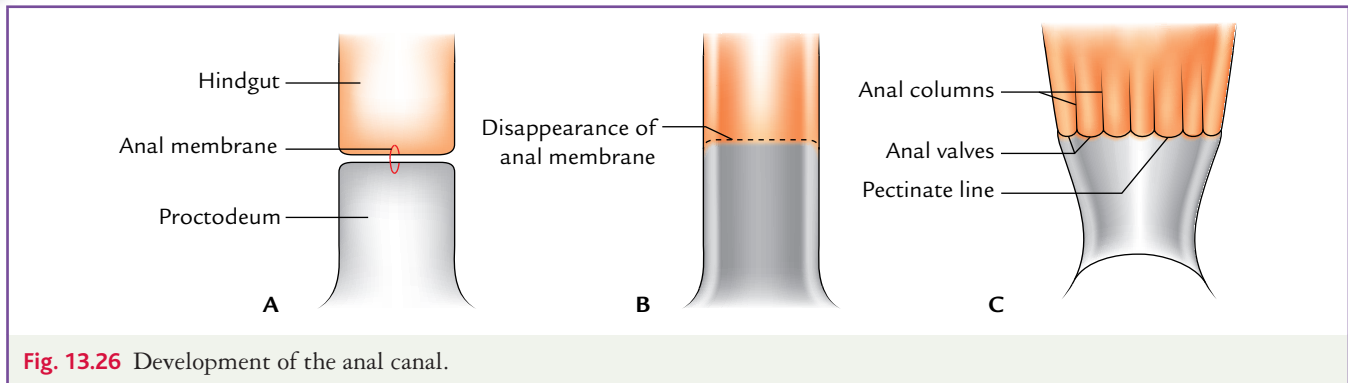


Fig. 13.26 Development of the anal canal.

Table 13.3 Differences between the upper and lower halves of the anal canal

	Upper half of anal canal	Lower half of anal canal
Development	Primitive rectum (endodermal in origin)	Proctodeum/anal pit (ectodermal in origin)
Arterial supply	Superior rectal artery	Inferior rectal artery
Venous drainage	Superior rectal vein (portal vein)	Inferior rectal vein (systemic veins)
Nerve supply	Autonomic	Somatic

The lower half of the anal canal is endodermal in origin and develops from **anal pit** called **proctodeum**.

Initially, the two parts are separated from each other by **anal membrane**. Later when this membrane ruptures the two parts communicate with each other. The site of anal membrane is represented by **pectinate line** in adults.

The main differences between upper and lower halves of the anal canal regarding their development, arterial supply, venous drainage, and nerve supply are given in Table 13.3.

Clinical Correlation

1. Congenital megacolon (Hirschsprung's disease, Fig. 13.27):

In this anomaly, a segment of the colon is dilated. However, it is the segment distal to dilatation that is abnormal. In this abnormal segment, autonomic parasympathetic ganglia are absent in the myenteric plexus. As a result there is no peristalsis in this segment. Since contents of colon cannot pass through this segment, the segment proximal to it grossly dilates.

It occurs 1 in 5000 newborns.

This anomaly is produced due to failure of migration of **neural crest cells** in the wall of the affected segment of the colon. This anomaly is commonly seen in the sigmoid colon or rectum. Clinically it presents as: (a) loss of peristalsis, (b) fecal retention, and (c) abdominal distension.

N.B. The newborns with aganglionic congenital megacolon may fail to pass **meconium** in first 24–48 hours after birth.

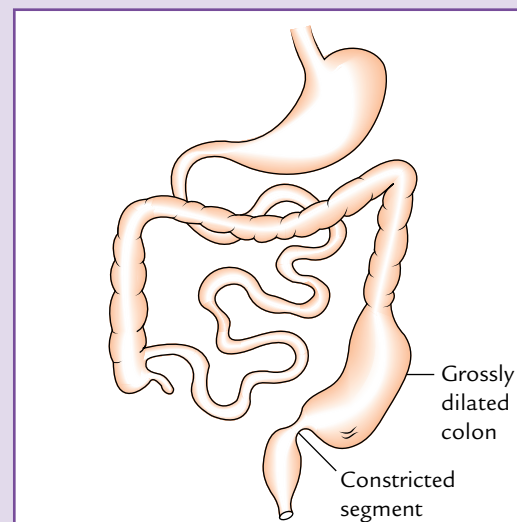


Fig. 13.27 Congenital megacolon (Hirschsprung's disease).

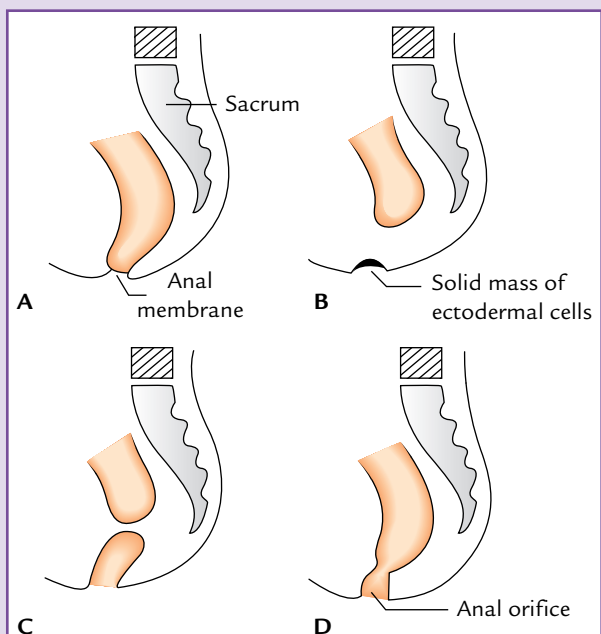


Fig. 13.28 Various types of imperforated anus. A. Persistence of anal membrane. B. Failure of anal pit to develop. C. Upper and lower parts of rectum separated by a gap. D. Stenosis of the anal canal.

2. **Imperforate anus:** It is a clinical condition in which the lower part of gut (GIT) fails to communicate with exterior.

The various types of imperforated ani are (Fig. 13.28):

- The rectum and anal canal develop normally but anal membrane fails to breakdown. The anal membrane bulges out with accumulated contents proximal to it. This is a minor form of imperforated anus and can be corrected by excision of the anal membrane.
- The proctodeum remains a solid mass of ectodermal cells, and there is a big gap between it and upper part of the anal canal.

(c) The upper and lower parts of the anal canal remain separated by a gap.

(d) The anal canal is stenosed. In this condition, anal canal and anal orifice are extremely narrow. It occurs when urorectal septum deviates dorsally as it reaches cloacal membrane.

3. **Rectal fistulae (Fig. 13.29):** The rectal fistulae are frequently seen in association with the imperforated anus. The common types of rectal fistulae are (a) rectovaginal fistula, (b) rectovesical fistula, and (c) rectourethral fistula. The rectal fistulae are usually associated with rectal atresia.

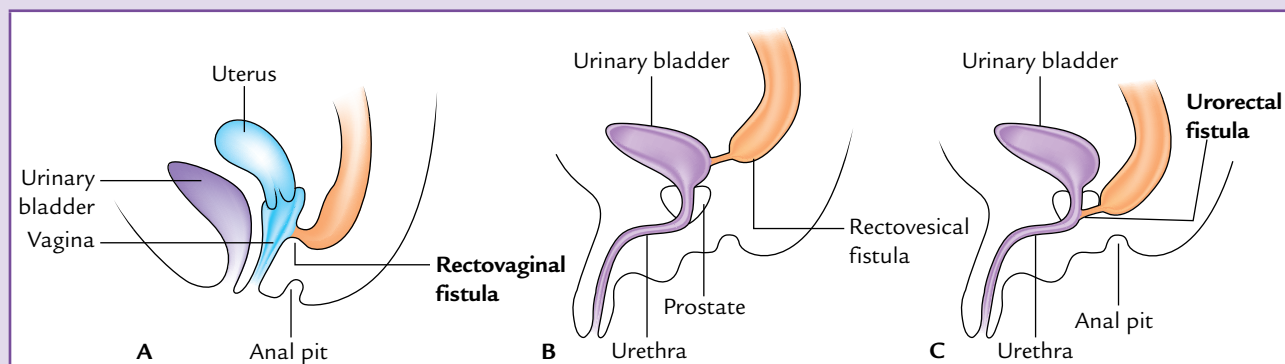


Fig. 13.29 Rectal fistulae. A. Rectovaginal fistula. B. Rectovesical fistula. C. Rectourethral fistula. Note, rectal fistulae are associated with rectal atresia.

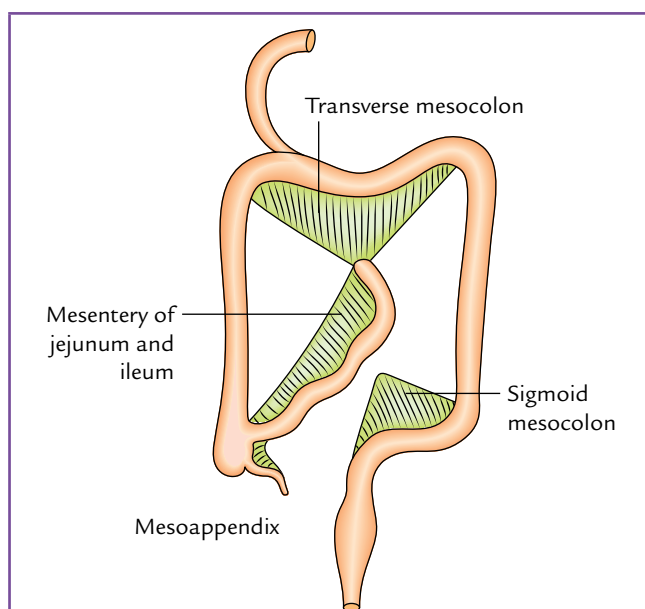


Fig. 13.30 Fate of dorsal mesentery of midgut and hindgut.

Fixation of Mesentery of the Gut as a Whole

Initially all parts of small and large intestine have mesentery through which they are suspended from the posterior abdominal wall. But once the rotation of the gut is complete the mesentery of (a) duodenum (except first inch of its first part), (b) ascending colon, (c) descending

colon, and (d) rectum fuse with parietal peritoneum lining the posterior abdominal wall and undergo zygosis. As a result, these structures become **retroperitoneal**. The original mesentery of intestine now persists as: (a) mesentery of the small intestine (**mesentery proper**), mesentery of transverse colon (**transverse mesocolon**), mesentery of the sigmoid colon (**sigmoid mesocolon**), and mesentery of the appendix (**mesoappendix**) (Fig. 13.30).

Clinical Correlation

1. Congenital anomalies due to errors of fixation of the gut

- The parts of intestine that normally become retroperitoneal may retain mesentery. As a result, they become highly mobile due to hypermotility—a portion of intestine twist along with its blood vessels on the axis of mesentery. Consequently the blood supply is compromised. This condition is called **volvulus**. If volvulus is not corrected timely, it may cause an ischemic necrosis of part of the intestine involved.
- The parts of intestine that normally retain their mesentery may be fixed particularly with any other organ by abnormal adhesions of peritoneum.

2. **Situs inversus:** In this condition, all the abdominal and thoracic viscera present on one side goes to the opposite side, i.e., they are laterally transposed. The good examples are:

- Appendix and duodenum lie on the left side
- Stomach lies on the left side
- Right atrium lies on the left side
- Superior and inferior vena cavae lie on the left side.

GOLDEN FACTS TO REMEMBER

- | | |
|--|---|
| ➤ Most important confirmatory signs of esophageal atresia | Continous pouring of saliva from mouth |
| ➤ Most important role of rotation of gut | (a) Helps in the retraction of herniated loops of intestine into the abdominal cavity
(b) Helps in establishing definitive relationships of various parts of the intestine |
| ➤ Total anticlockwise rotation of midgut loops during its return to abdominal cavity | 270° |
| ➤ Most anorectal anomalies result from | Abnormal partitioning of the cloaca by urorectal septum |
| ➤ Commonest congenital anomaly of intestine | Meckel's diverticulum |

CLINICAL PROBLEMS

1. The left vagus nerve innervates the anterior surface of the stomach and right vagus nerve innervates the posterior surface of the stomach. Give the embryological basis.
2. A female baby started vomiting few hours after her birth. On physical examination a marked distention in epigastric region was noted. The vomitus contained bile; the radiograph of the abdomen revealed gas in the stomach and proximal half of duodenum. What is the most probable diagnosis? Give its embryological basis.
3. Umbilicus of a newborn infant was swollen, and there was a persistent discharge (mucus and feces) from the umbilicus. The fluoroscopy using radiopaque oil revealed a fistulous tract that was communicating with distal part of the ileum. What is this sinus tract called? Give its embryological basis.
4. A newborn was born with a shiny mass of about the size of an orange that was protruding from the umbilicus. The mass was covered by a thin, transparent membrane. After exposure to air the transparent membrane lost its shiny appearance. What is the most probable diagnosis? Give its embryological basis.

CLINICAL PROBLEM SOLUTIONS

1. Initially left and right vagus nerves innervate the left and right sides of the stomach, respectively. Following 90° clockwise rotation of stomach along its longitudinal axis, the left and right sides of stomach become the anterior and posterior surfaces of the stomach, respectively. As a result, left and right vagus nerves supply the anterior and posterior surfaces of the stomach, respectively.
 2. The most probable diagnosis is **duodenal atresia**. It usually affects second part of duodenum distal to the opening of bile duct. The duodenal atresia (obstruction) results from incomplete recanalization of lumen of the duodenum during the eighth week of intrauterine life (IUL).
The obstruction causes bilious vomiting as the obstruction is distal to the opening of bite duct. The obstruction also causes distension of the stomach and proximal duodenum because fetus swallows amniotic fluid and subsequently newborn baby swallows air. This leads to distension in epigastric region.
- N.B.** Duodenal atresia is common in infants with Down's syndrome (trisomy 21).

3. The vitellointestinal duct (omphaloenteric tract) normally completely obliterates by the tenth week of IUL. In about 2% of cases, a remnant of vitellointestinal duct persists as a small diverticulum called **Meckel's diverticulum**. In the present case, the entire vitellointestinal duct persisted and formed vitellointestinal fistula.
4. This is a congenital anomaly called exomphalos (omphalocele). It occurs when intestine fails to return to the abdominal cavity during the tenth week of IUL. Their transparent membrane covering is derived from amnion. Once this membrane is exposed to air it rapidly loses its shiny appearance. It becomes thicker and gets covered with an opaque fibrinous exudate. The students often confuse exomphalos with congenital umbilical hernia (for details see page 151).

14

Major Digestive Glands and Spleen

Overview

The major glands associated with digestive (alimentary) tract are salivary glands, liver, and pancreas. All these glands develop from endodermal lining of gut except parotid gland, which develops from ectodermal lining of the oral cavity. Ducts of these glands open into different parts of the digestive tract. Although the spleen is not a gland of the digestive tract but is described here because of its close association with the digestive tract. Note that the spleen develops between two layers of dorsal mesogastrium.

Salivary Glands

There are three pairs of major salivary glands: (a) parotid, (b) submandibular, and (c) sublingual. They are so named because of their location. Secretion of these glands called *saliva* poured in the oral cavity through the ducts of these glands. The salivary glands are described in detail in Chapter 15.

Liver

Overview

The liver, the largest gland in the body, develops from following three sources:

1. **Parenchyma of the liver** is derived from **endodermal hepatic bud of foregut**.
2. **Fibrous stroma of the liver** is derived from **mesenchyme of septum transversum**, a plate of intraembryonic mesoderm at the cranial edge of embryonic disc.
3. **Sinusoids of liver** develop from absorbed and broken vitelline and umbilical veins within the septum transversum.

The liver develops from an **endodermal hepatic bud** that arises from ventral aspect of the distal part of foregut, just at its junction with the midgut (Fig. 14.1).

The hepatic bud grows into the ventral mesogastrium and through it into the **septum transversum**. The bud soon divides into two parts: a large cranial part called **pars**

hepatica and a small caudal part called **pars cystica**. The pars hepatica forms the **liver**, while pars cystica forms the **gallbladder** and **cystic duct**. The part of bud proximal to pars cystica forms **common bile duct (CBD)**.

The pars hepatica further divides into right and left portions that form right and left lobes of the liver respectively. Initially both lobes of the liver are of equal size.

As the right and left portions of the pars hepatica enlarge, they extend into the septum transversum. The cells arising from *them form interlacing hepatic cords or cords of hepatocytes*. In this process, **vitelline and umbilical veins** present within the septum transversum get absorbed and broken to form the **liver sinusoids** (Fig. 14.2). The cells of hepatic cords later become radially arranged in hepatic lobules. The **bile canaliculi and ductules** are formed in liver parenchyma and establish connections with extrahepatic bile ducts secondarily at a later stage (Fig. 14.3). Due to rapid enlargement, liver occupies major portion of the abdominal cavity forcing the coils of the gut to herniate through umbilicus (physiological hernia). The oxygen-rich blood supply and proliferation of hemopoietic tissue are responsible for the massive enlargement of the liver.

Adult derivatives of various components of liver from embryonic structures are given in Table 14.1.

N.B.

- The liver is an important centre of **hemopoiesis** (i.e., blood formation). The hemopoiesis begins in the liver at about the sixth week of intrauterine life (IUL) and continue till birth. Later, the hemopoietic function of the liver is taken over by the spleen and bone marrow.
- The hepatocytes start secreting bile at about twelfth week (3 months) of IUL. The bile enters intestine and imparts a dark green color to first stools (**meconium**) passed by newborn.

Clinical Correlation

Congenital anomalies of the liver

1. **Riedel's lobe**: It is a tongue-like extension from the right lobe of the liver (Fig. 14.4). It develops as an extension of normal hepatic tissue from the inferior margin of the right lobe of the liver.
2. **Polycystic disease of the liver**: The biliary tree within the liver (i.e., bile canaliculi and bile ductules) normally connects

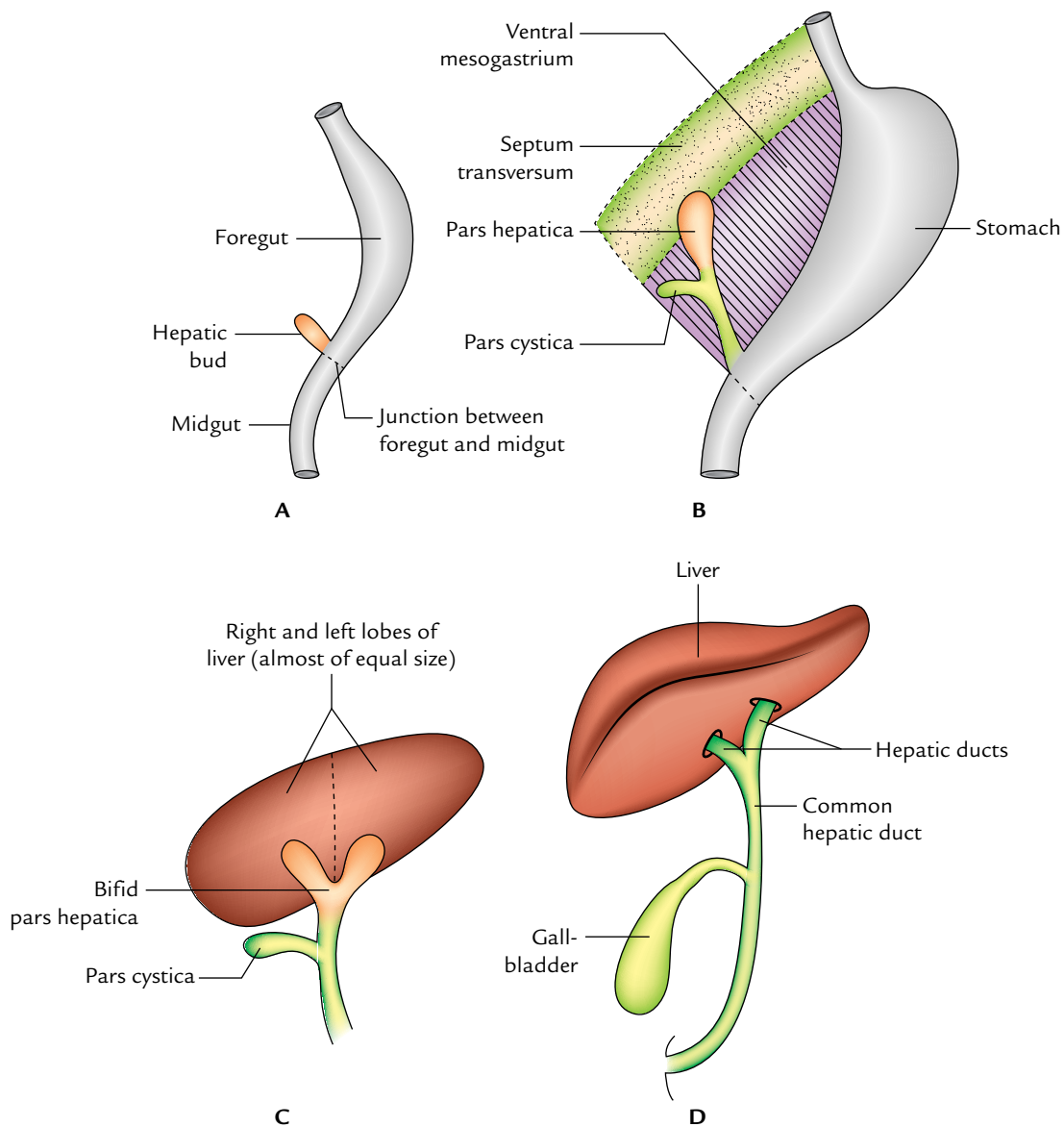


Fig. 14.1 Successive stages of the development of the liver. A. Hepatic bud arising from foregut at its junction with the midgut. B. Growth of hepatic bud towards septum transversum through ventral mesogastrium. Note the subdivision of hepatic bud into pars hepatica and pars cystica. C. Division of pars hepatica into right and left portions. D. Fully formed liver and gallbladder along with their ducts.

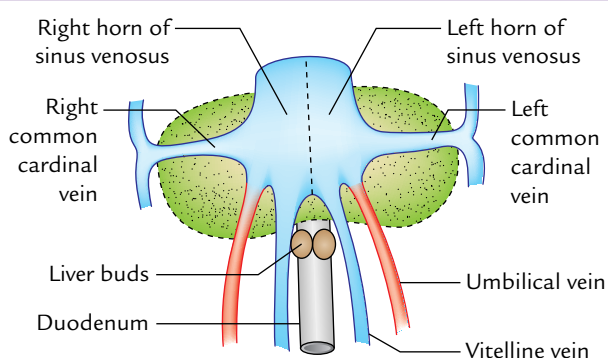


Fig. 14.2 Umbilical and vitelline veins passing through the septum transversum to enter the sinus venosus.

them with the extrahepatic bile ducts. Failure of union of some of these ducts may cause the formation of cysts within the liver. The polycystic disease of liver is usually associated with cystic disease of kidney and pancreas.

- 3. Intrahepatic biliary atresia:** It is a *very serious anomaly*. The intrahepatic biliary atresia cannot be subjected to surgical correction. As a result, there are only two options for parents: (a) to go for liver transplant of the child or (b) to let the child die.
- 4. Caroli's disease:** It is characterized by *congenital dilatation of intrahepatic biliary tree*, which may lead to the formation of *sepsis, stone, and even carcinoma*.
- 5. Others:** They include rudimentary liver, absence of quadrate lobe and presence of accessory liver tissue in the falciform ligament.

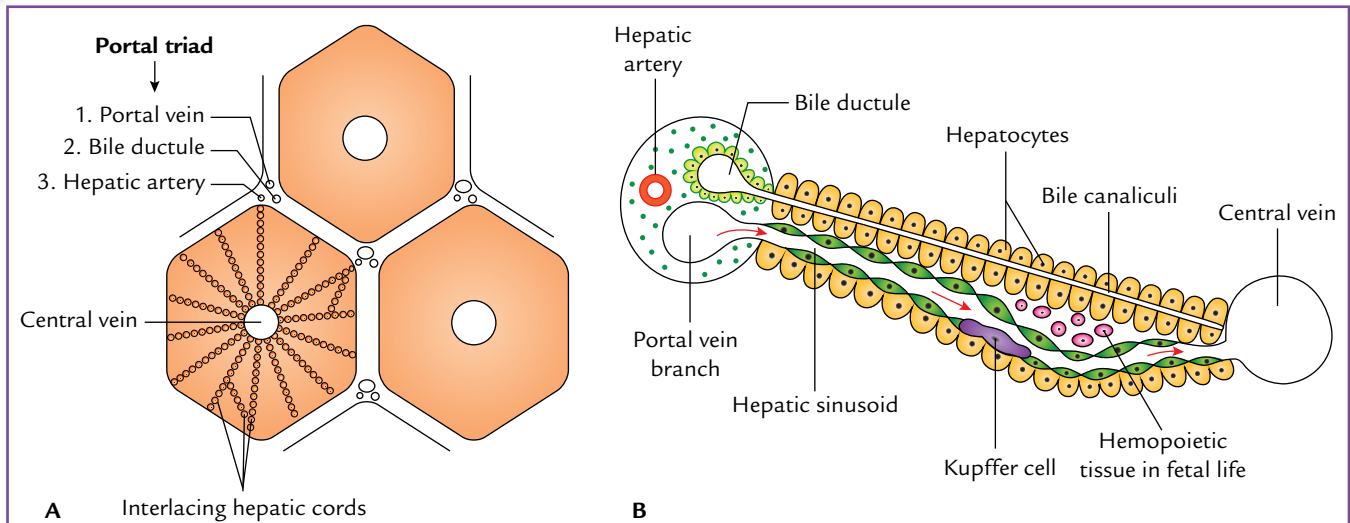
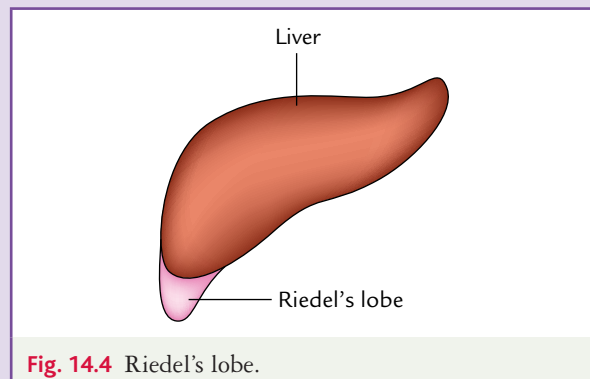


Fig. 14.3 Histological components of developing liver. A. Arrangement of hepatic cords. Note, they radiate from central vein towards periphery. B. Location of bile canaliculi and bile ductule (derivatives of hepatic bud), liver sinusoids (derivatives of vitelline and umbilical veins), and hemopoietic tissue (derivative of septum transversum).

N.B. The congenital anomalies of the liver are rarest.



Development of Gallbladder and Extrahepatic Biliary Ducts (Extrahepatic Biliary Apparatus)

The **gallbladder** and **cystic duct** develop from **pars cystica**. The part of hepatic bud proximal to the pars cystica forms **CBD**. Initially the CBD/bile duct opens on the ventral aspect of developing duodenum. However as the duodenum grows and rotates the opening of CBD is carried to dorsomedial aspect of the duodenum along with ventral pancreatic bud.

N.B. Initially the extrahepatic biliary apparatus is occluded with epithelial cells, but later it is recanalized by way of vacuolation resulting from degeneration of the cells.

Table 14.1 Source of development of various components of the liver

Embryonic structure	Adult derivatives
• Hepatic bud	Liver parenchyma Bile canaliculi and bile ductules
• Vitelline and umbilical veins within septum transversum	Liver sinusoids
• Septum transversum (mesodermal in origin)	• Connective tissue stroma of the liver including Glisson's capsule (fibrous capsule of the liver) • Peritoneal coverings of liver • Kupffer cells • Hemopoietic cells • Blood vessels of liver

Clinical Correlation

Anomalies of the extrahepatic biliary apparatus: The anomalies of the extrahepatic biliary apparatus are very common.

1. Anomalies of gallbladder (Fig. 14.5)

- Agenesis of gallbladder (absence of gallbladder):** If the pars cystica from the hepatic bud fails to develop, the gallbladder and cystic duct will not develop.
- Absence of the cystic duct:** It occurs when entire growth of cells of the hepatic bud form gallbladder. In such a case, the gallbladder drains directly into the CBD. It is called **sessile gallbladder**. The surgeon may fail to recognize this condition while performing *cholecystectomy* and consequently may cause serious damage to the CBD.
- Anomalies of shape**
 - **Phrygian cap:** It occurs when fundus of the gallbladder folds on itself to form a cap-like structure—the **Phrygian cap**.

- **Hartmann's pouch:** It is a pouch formed when the posterior medial wall of the neck (infundibulum) of gallbladder projects downward. This pouch may be adherent to the cystic duct or even to the CBD. The gallstone is usually seen lodged in this pouch.
- **Septate gallbladder and double gallbladder:** In humans, the gallbladder may be partially or completely subdivided by a septum. On the other hand, in some cases gallbladder may be partially or completely duplicated.

(d) **Anomalies of the positions**

- **Gallbladder may lie transversally** on the inferior surface of the right or left lobe of the liver.
- **Intrahepatic gallbladder:** In this condition gallbladder is embedded within the substance of the liver.
- **Floating gallbladder:** In this condition gallbladder is completely surrounded by peritoneum and attached to the liver by a fold of peritoneum (mesentery).

2. **Anomalies of extrahepatic biliary ducts (Fig. 14.6):** These anomalies occur due to failure of recanalization of these ducts. Some common anomalies of extrahepatic biliary ducts are:

(a) **Atresia of ducts**

- Atresia of bile duct
- Atresia of entire extrahepatic biliary duct system
- Atresia of common hepatic duct
- Atresia of hepatic ducts

N.B. The atresia of the bile duct manifests as persistent progressive jaundice of newborn and may be associated with the absence of the *ampulla of Vater*.

(b) **Accessory ducts**

- **Small accessory bile ducts** may open directly from the liver into the gallbladder. In this case, there may be leakage of bile into the peritoneal cavity after cholecystectomy if they are not recognized at the time of surgery.
- **Choledochal cyst** rarely develops due to an area of weakness in the wall of bile duct. It may contain—2 L of bile and thus may compress the bile duct to produce an obstructive jaundice.
- **Moynihan's hump:** In this condition, the hepatic artery lies in front of the common bile duct forming a caterpillar-like loop.

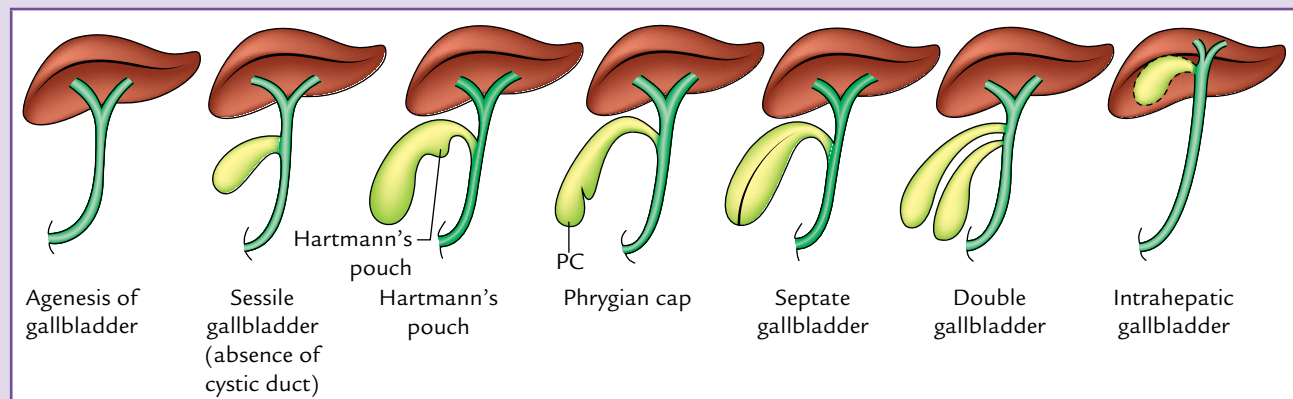


Fig. 14.5 Some common congenital anomalies of the gallbladder. PC = Phrygian cap.

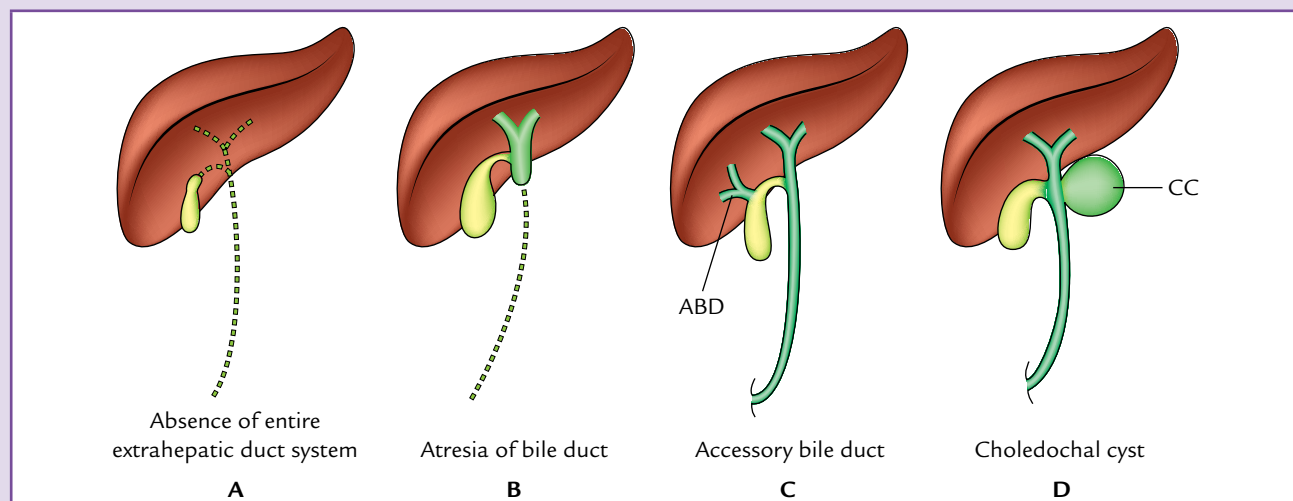


Fig. 14.6 Some congenital anomalies of the extrahepatic biliary ducts. ABD = accessory bile duct; CC = choledochal cyst.

Development of Pancreas (Fig. 14.7)

Overview

The pancreas develop from two endodermal pancreatic buds that arise from junction of foregut and midgut. The **dorsal bud** forms the upper part of the head, neck, body, and tail of the pancreas while **ventral bud** forms the lower part of the head and uncinete process. The main pancreatic duct is formed by the distal three-fourth of the duct of dorsal bud and proximal one-fourth of the duct of the ventral bud. The accessory pancreatic duct is formed by proximal one-fourth of the duct of dorsal bud.

The **dorsal pancreatic bud** arises from dorsal wall, foregut, a short distance above the **ventral bud**, and grows between two layers of the dorsal mesentery of duodenum (also called mesoduodenum). A little later the **ventral pancreatic bud** arises from ventral wall of foregut in common with/or close to the hepatic bud and

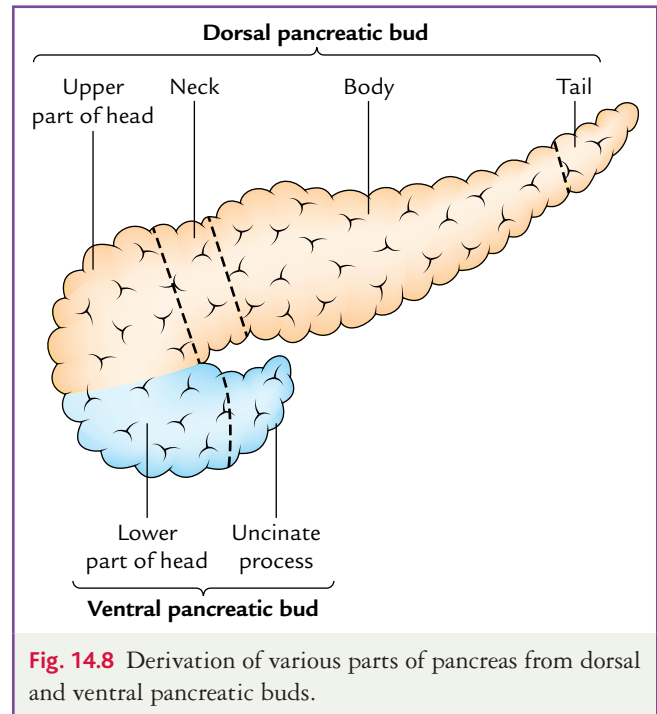


Fig. 14.8 Derivation of various parts of pancreas from dorsal and ventral pancreatic buds.

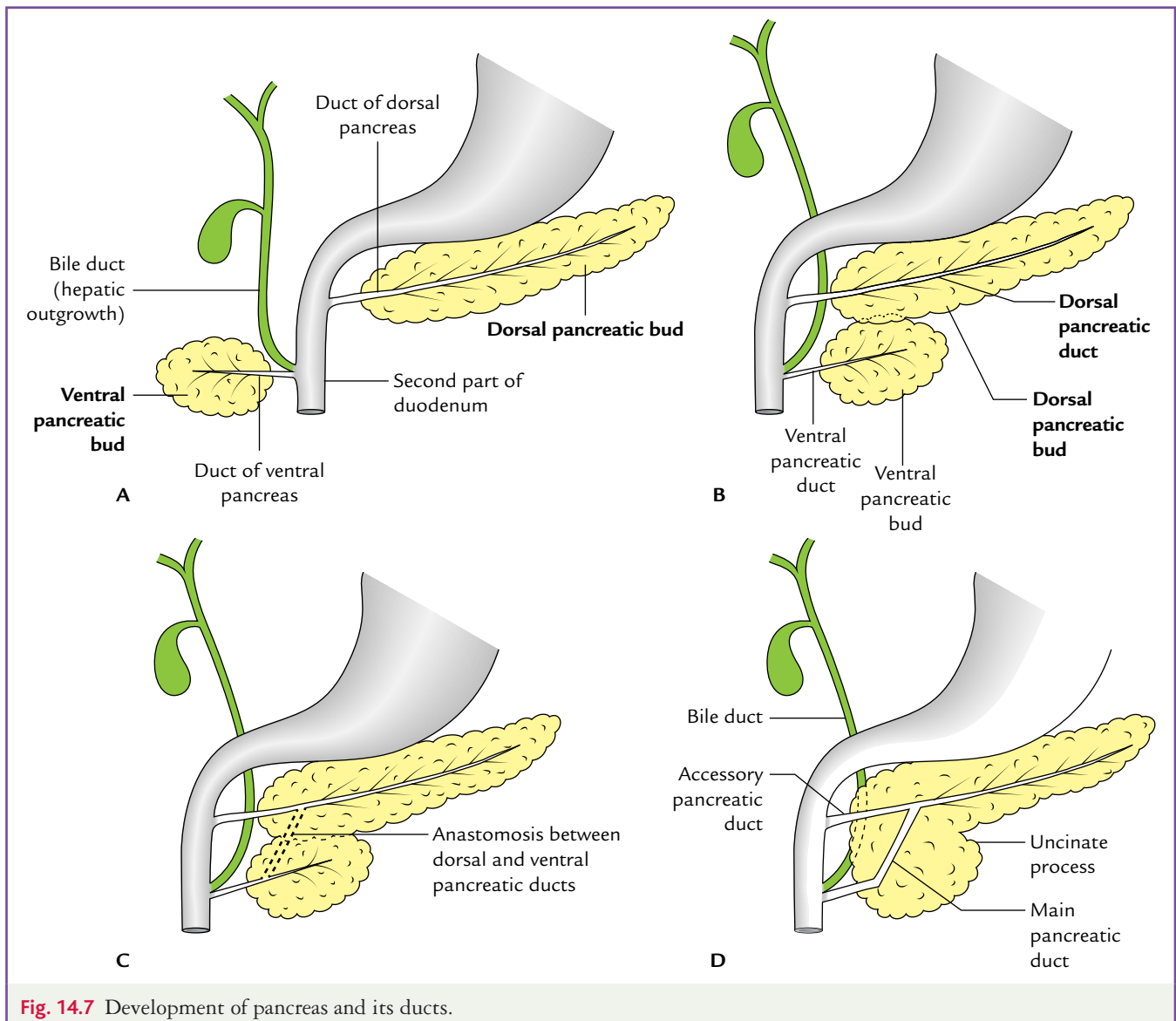


Fig. 14.7 Development of pancreas and its ducts.

grows between the two layers of ventral mesentery (Fig. 14.8).

When the duodenum rotates to right and becomes C shaped, the ventral pancreatic bud is on the right and the dorsal pancreatic bud is on the left of the duodenum. With rapid growth of right duodenal wall, the ventral pancreatic bud shifts from right to left and lies just below the dorsal pancreatic bud.

The dorsal and ventral pancreatic buds grow in size and fuse with each other to form the pancreas. The *dorsal pancreatic bud* forms the upper part of head, neck, body, and tail of the pancreas while *ventral pancreatic bud* forms the lower part of the head and uncinete process of pancreas.

N.B. At first the ventral pancreatic bud forms a bilobed structure that subsequently fuses to form a single mass.

Development of Ducts of the Pancreas (Fig. 14.9)

Initially two parts of the pancreas derived from two pancreatic buds have separate ducts called **dorsal and ventral pancreatic ducts** that open separately into the duodenum. Opening of dorsal pancreatic duct is about 2 cm proximal to opening of the ventral pancreatic duct. The ventral pancreatic duct opens in common with the bile duct derived from the hepatic bud.

Now communication (anastomosis) develops between the dorsal and ventral pancreatic ducts.

The **main pancreatic duct (duct of Wirsung)** develops from: (a) dorsal pancreatic duct distal to anastomosis between the two ducts, (b) anastomosis (communication) between the two ducts, and (c) ventral pancreatic duct proximal to the anastomosis. From its development, it is clear that the main pancreatic duct that opens in the duodenum is common with the bile duct at the major duodenal papilla. The proximal part of the dorsal pancreatic duct may persist as **accessory pancreatic duct (duct of Santorini)** that opens in the duodenum at **minor duodenal papilla** located about 2 cm proximal to major duodenal papilla.

N.B. In about 9% of people, the dorsal and ventral pancreatic ducts fail to fuse resulting into two ducts.

Histogenesis of Pancreas

Parenchyma of the pancreas is derived from endoderm of the pancreatic buds.

The pancreatic buds branch out in surrounding mesoderm and form various ducts [such as intralobular (intercalated), interlobular, and main duct]. The pancreatic acini begin to develop from cell clusters around the terminal parts of the

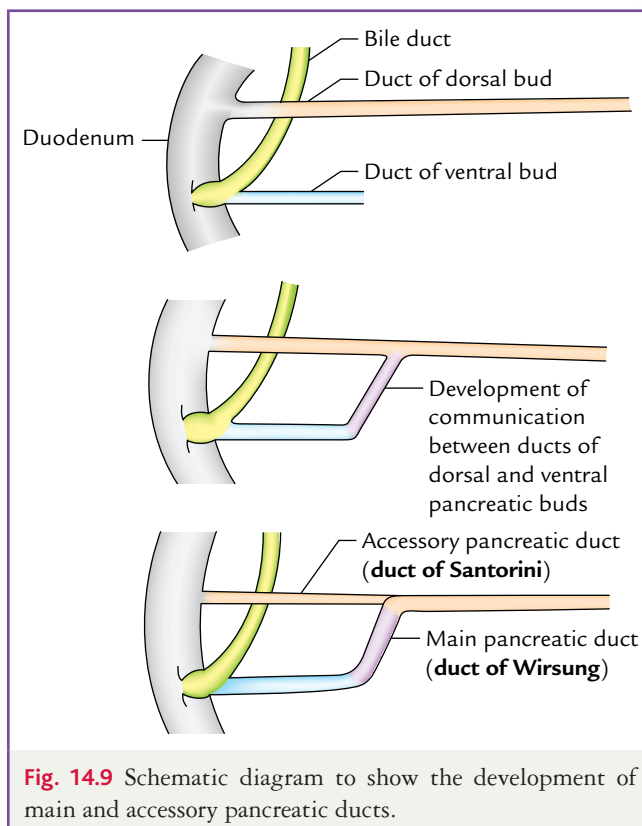


Fig. 14.9 Schematic diagram to show the development of main and accessory pancreatic ducts.

ducts. **Islets of Langerhans** develop from groups of cells that separate from the duct system. The capsule covering the gland, septa, and other connective tissue elements of the pancreas with blood vessels develop from surrounding mesoderm.

N.B. The β cells of islets of Langerhans start secreting insulin by tenth week of IUL. The α cells, which secrete somatostatin, develop prior to the insulin-secreting β cells.

Clinical Correlation

Anomalies of pancreas

- Annular pancreas (Fig. 14.10):** In this condition, the pancreatic tissue completely surrounds second part of the duodenum causing its obstruction. This anomaly is produced as follows: The bifid ventral pancreatic bud fails to fuse to form a single mass. The two lobes (right and left) of the ventral pancreatic bud grow and migrate in opposite directions around the second part of the duodenum and form a **collar of pancreatic tissue** before it fuses with dorsal pancreatic bud. Thus, duodenum gets completely surrounded by the pancreatic tissue that may cause *duodenal obstruction*.

Clinical features

- Vomiting may start a few hours after birth.
- Radiograph of abdomen reveals *double-bubble appearance*. It is associated with duodenal stenosis. It is due to gas in the stomach and dilated part of the duodenum proximal to the site of obstruction.

Early surgical intervention to relieve the obstruction is necessary. The surgical procedure consists of duodenum-jejunostomy and not cutting of the pancreatic collar.

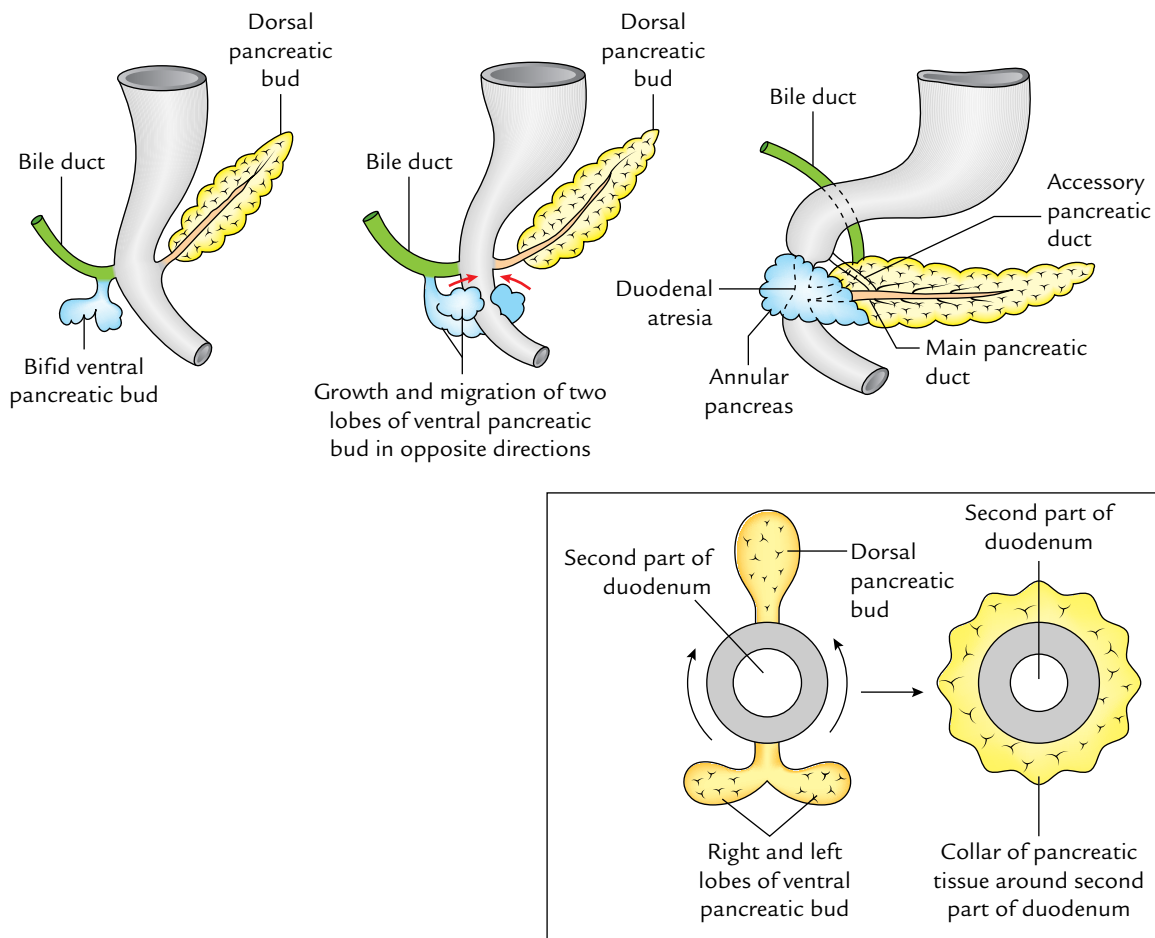


Fig. 14.10 Formation of annular pancreas. Figure in the inset is a highly schematic diagram to show the formation of collar of pancreatic tissue around second part of the duodenum.

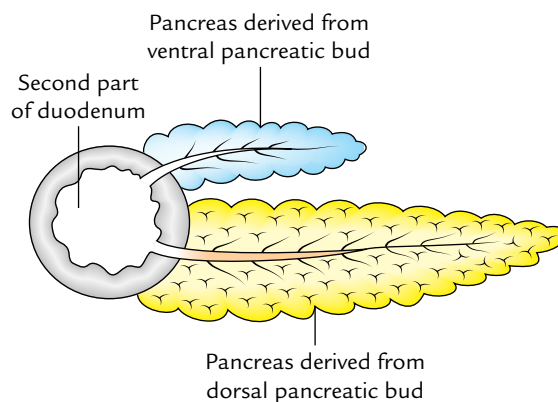


Fig. 14.11 Divided pancreas.

2. **Divided pancreas** (Fig. 14.11): It occurs when the dorsal and ventral pancreatic buds fail to fuse with each other. As a result, the two parts of pancreas derived from two buds remain separate from each other.
3. **Accessory (ectopic) pancreatic tissue:** The heterotropic small masses/nodules of pancreatic tissue may be formed at the following sites:
 - (a) Wall of duodenum
 - (b) Meckel's diverticulum

- (c) Gallbladder
- (d) Lower end of esophagus
- (e) Wall of stomach

4. **Inversion of pancreatic ducts** (Fig. 14.12): In this condition, the main pancreatic duct is formed by duct of the dorsal pancreatic bud and opens on the *minor duodenal papilla*. It drains most of the pancreatic tissue. The duct of ventral pancreatic bud poorly develops and opens on *major duodenal papilla*.

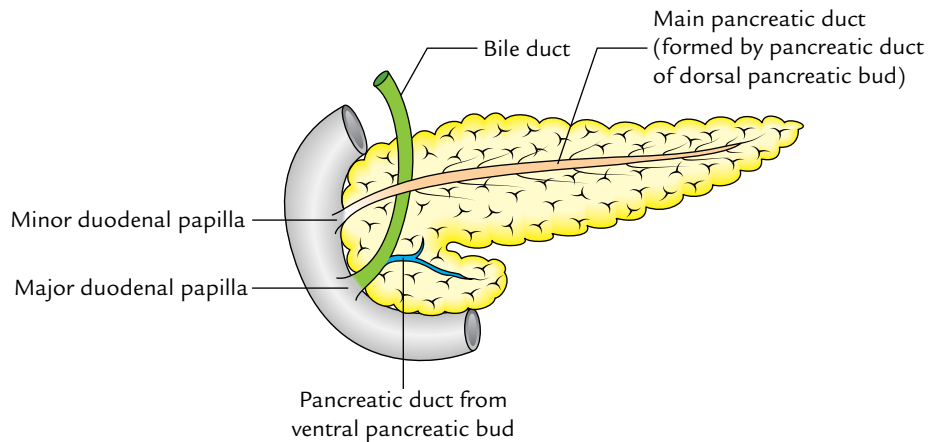


Fig. 14.12 Inversion of pancreatic duct.

Development of Spleen

The spleen is mesodermal in origin. It is a lymphoid organ and develops in the dorsal mesogastrium in close relation to stomach.

The mesenchymal cells lying between the two layers of dorsal mesogastrium condense to form a number of small mesenchymal masses (called lobules of splenic tissue/**spleniculi**) that later fuse to form a single mesenchymal mass (**splenic mass**), which projects from under cover of left layer of the mesogastrium.

The development of the spleen in the dorsal mesogastrium divides the later into two parts: (a) part that extends between hilum of the spleen and greater curvature of the stomach is called **gastrosplenic ligament**, while (b) the part of dorsal mesogastrium that extends between the spleen and left kidney on the posterior abdominal wall is called **splenorenal ligament/lienorenal ligament**.

N.B. The presence of splenic notches on the anterior (superior) border of adult spleen indicates lobulated origin of the spleen.

Histogenesis of Spleen

All elements of the spleen are derived from mesoderm. The mesodermal cells form capsule, septa, and connective tissue network including reticular fibers. The primordium of splenic tissue forms branching cords and isolated free cells. Some of the free cells form lymphoblasts while the others differentiate into hemopoietic cells.

The process of blood formation in spleen begins in early embryonic life and continues during fetal life but stops after

birth. The production of lymphocytes, however, continues in the postnatal period.

Clinical Correlation

Anomalies of spleen

1. **Accessory spleen (spleniculi):** Accessory nodules of splenic tissue (supernumerary spleens) may be found at many sites such as hilum of spleen, gastrosplenic ligament, lienorenal ligament, in the tail of the pancreas, along the splenic artery, greater omentum (rarely), and left spermatic cord (very rarely).

The clinical importance of accessory spleens is that they may undergo hypertrophy after splenectomy and may be responsible for symptoms of disease for which the splenectomy was done.

2. **Lobulated spleen** (Fig. 14.13): It is persistence of fetal spleen, which is formed due to fusion of a number of small lobules of splenic tissue (spleniculi).

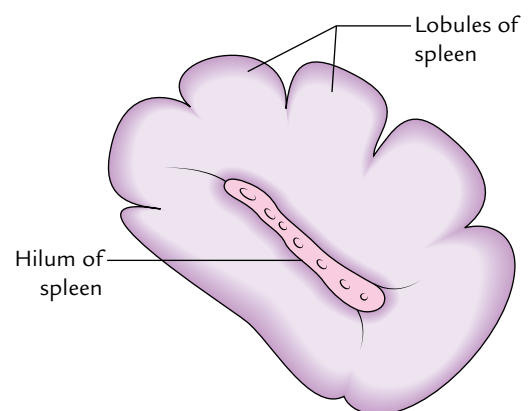


Fig. 14.13 Lobulated spleen.

GOLDEN FACTS TO REMEMBER

- | | |
|---|---|
| ➤ Most common site of the accessory pancreatic tissue | Mucosa of the stomach and Meckel's diverticulum |
| ➤ Annular pancreas | Pancreatic tissue forming a collar around the second part of the duodenum |
| ➤ Most fatal congenital anomaly of the liver | Intrahepatic biliary atresia |
| ➤ Spleniculi | Accessory spleens |
| ➤ Most common source of aberrant right hepatic artery | Superior mesenteric artery |
| ➤ Most common source of aberrant left hepatic artery | Left gastric artery |

CLINICAL PROBLEMS

1. In adults the left lobe of the liver is smaller than the right lobe. Give its embryological basis.
2. Give the embryological basis of presence of notches on the superior/anterior border of the spleen.
3. Give the embryological basis of Riedel's lobe and discuss its clinical significance.
4. What is Phrygian cap? Give the embryological basis of Phrygian cap.
5. What is the embryological basis of extensive enlargement of liver in the intrauterine life. Give reasons for the proportionately large size of the liver in early postnatal life?
6. Intrahepatic biliary atresia has a very poor prognosis as compared to extrahepatic biliary atresia. Why?

CLINICAL PROBLEM SOLUTIONS

1. In early development both the lobes of liver (right and left) are of equal size. After the ninth week of intrauterine life (IUL), the growth rate of left lobe of the liver regresses and some of its hepatocytes degenerate due to reduced nutritional and oxygen supply to this part of the liver. Such degeneration may be complete at the left end of the left lobe so as to leave only a fibrous appendage at the left extremity of the liver called **appendix of liver**. (Also see answer to Clinical Problem No. 5.)
2. The spleen develops by condensation of mesenchymal cells between two layers of dorsal mesogastrium. At first small lobules of splenic tissue are formed by condensation of mesenchymal cells lying between the two layers of the dorsal mesogastrium. Later the lobules of splenic tissue fuse together to form the spleen.
The notches on superior (anterior) border of adult spleen are a reflection of lobular origin of the spleen.
3. The Riedel's lobe is a tongue-like downward extension of right lobe of the liver. It develops as an extension of normal hepatic tissue from inferior margin of the liver, usually from the right lobe.
Its clinical significance is that it may be mistaken for an abnormal abdominal mass.
N.B. Rarely there may be an anomalous extension of the hepatic tissue through the diaphragm into chest.

4. It is a folded fundus of gallbladder. It may occur due to failure of canalization of the fundus of the gallbladder. This anomaly is so named because the folded fundus of gallbladder looks like a cap worn by people of **Phrygia**—an ancient country of Asia Minor.
5. During the early phase of development, liver is far more highly vascularized than rest of the gut. As a result, liver parenchyma gets abundant oxygenated blood, which stimulates its extensive growth. Moreover, fetal liver is hemopoietic in function. At three months of gestation, the liver almost fills abdominal cavity and its left lobe is nearly as large as right. When the hemopoietic function of the liver is taken over by the spleen and bone marrow, the left lobe undergoes some regression and becomes smaller than the right.
 - In the early part of development, the liver forms about 10% of body weight and in the later part, it comes down to about 5% of body weight.
 - The hemopoietic function of the liver is sufficiently diminished during last two months of pregnancy.
6. The extrahepatic biliary atresia is surgically correctible, whereas the intrahepatic biliary atresia is surgically untreatable. Therefore, the intrahepatic biliary atresia has a very poor prognosis.

15

Development of Oral Cavity (Mouth)

Overview

The oral cavity develops from two sources: (a) **stomodeum**—a surface depression lined by ectoderm and (b) a cephalic part of **foregut** lined by endoderm.

The oral cavity consists of two parts: (or) primitive oral cavity and (b) definitive oral cavity.

The **primitive oral cavity** develops from **ectodermal stomodeum** whereas the **definitive oral cavity** develops from **cephalic part of endodermal foregut**. At first the two parts are separated from each other by **buccopharyngeal membrane**.

The two parts communicate with each other when **buccopharyngeal membrane** ruptures during the third week of intrauterine life (IUL) (Fig. 15.1).

After rupture of **buccopharyngeal membrane** the line of junction of ectodermal and endodermal parts cannot be defined.

N.B. Imaginary location of buccopharyngeal membrane in adult: If the buccopharyngeal membrane were to persist into the adults, it would occupy an imaginary plane extending downward obliquely from the body of sphenoid, through the soft palate to the inner surface of the body of mandible inferior to the incisor teeth.

Whole of **adult oral cavity** is derived from **ectodermal stomodeum** except floor of the mouth, which is derived from cephalic part of endodermal foregut.

Thus, epithelial lining of the cheeks, lips, gums, and hard palate are ectodermal in origin, whereas epithelial lining of tongue (developing in floor of the oral cavity), floor of mouth, most of the soft palate, and palatoglossal palatopharyngeal folds are endodermal in origin.

In the region of floor of mouth, mandibular processes form following three structures (Fig. 15.2):

1. Lower lip and adjoining parts of cheeks
2. Alveolar process of the lower jaw
3. Tongue.

At first these structures are not demarcated from each other and from rest of the oral cavity. As the tongue begins to develop and forms a recognizable swelling, its anterior and lateral margins become separated from the floor of definitive mouth by development of an endodermal **linguogingival sulcus**.

Soon thereafter **ectodermal labiogingival sulcus** appears far lateral to the *linguogingival sulcus*, which separates lips and cheeks from the gum and teeth of the lower jaw. As the linguogingival and labiogingival

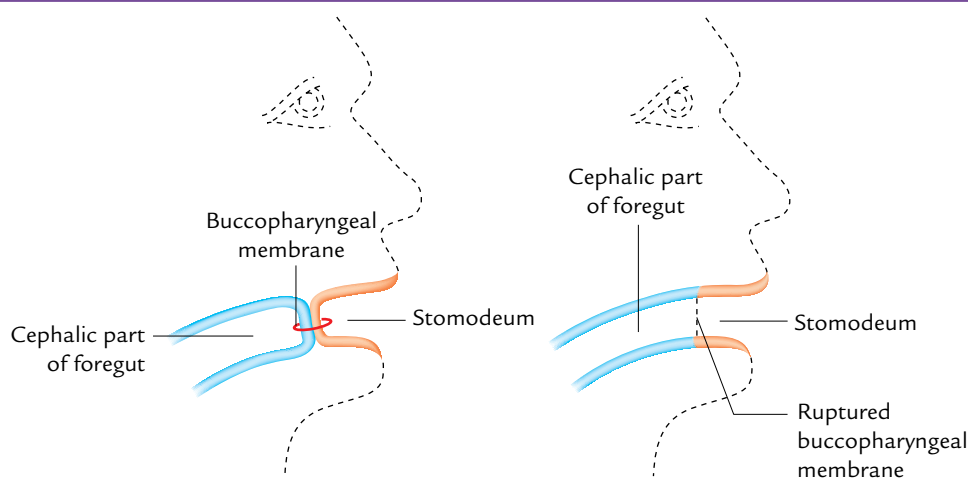
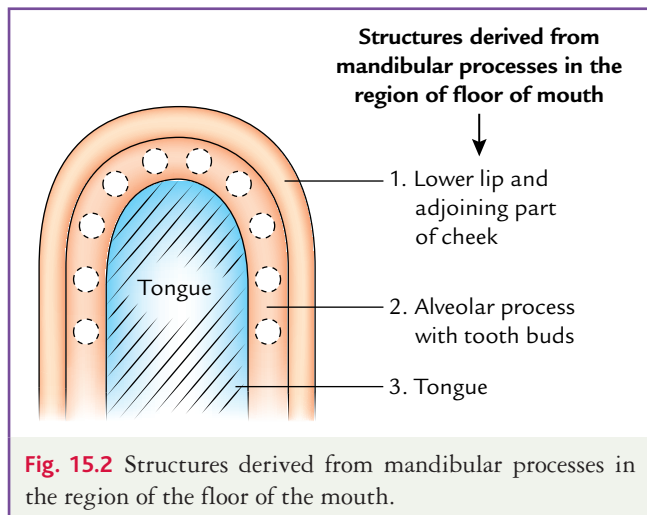


Fig. 15.1 Development of the oral cavity from stomodeum and cephalic part of the foregut.



sulci deepen, area between the sulci is raised to form **alveolar process** (Fig. 15.3).

The roof of the oral cavity is formed by palate (Fig. 15.4; see development of the palate on page 135). The alveolar process of the upper jaw is separated from the upper lip and the cheek by the *labiokingival sulcus* similar to that of the lower jaw. Medial margin of the alveolar process of the upper jaw becomes defined only when the palate becomes well arched.

Development of Salivary Glands

The salivary glands develop as **solid outgrowths of epithelial lining of the oral cavity**. These outgrowths branch repeatedly and invade surrounding mesenchyme. At first, the outgrowths and their branches are solid cords of epithelial cells. Later they become canalized to form **duct system of gland**. The **secretory acini** of gland develop from rounded terminal ends of epithelial cords.

The capsules septae and connective tissues of the glands are formed from the mesoderm.

Major Salivary Glands

There are three pairs of major salivary glands, viz., parotid, submandibular, and sublingual.

The parotid gland develops as an ectodermal outgrowth from the cheek at the angle of the stomodeum. The submandibular gland develops as an endodermal outgrowth from the floor of the mouth. The sublingual gland develops as multiple endodermal outgrowth from the floor of the mouth (Fig. 15.5).

The development of individual salivary glands is described in detail in the following text.

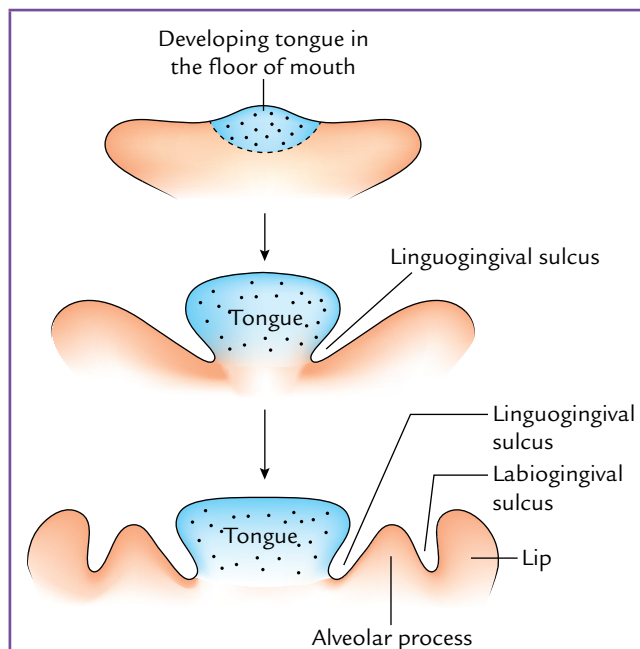


Fig. 15.3 Differentiation of the floor of the mouth into tongue, alveolar processes, and lips.

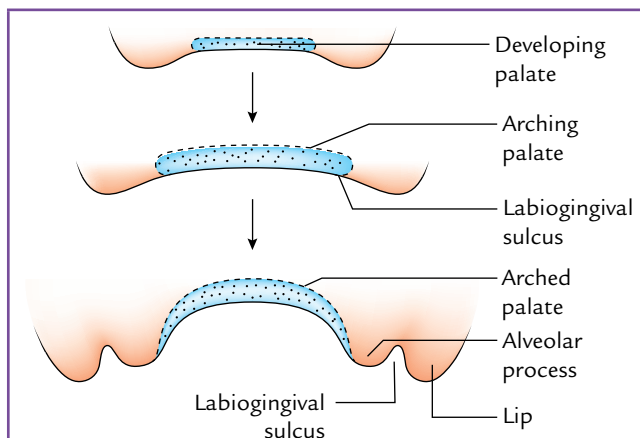


Fig. 15.4 Development of the roof of the oral cavity.

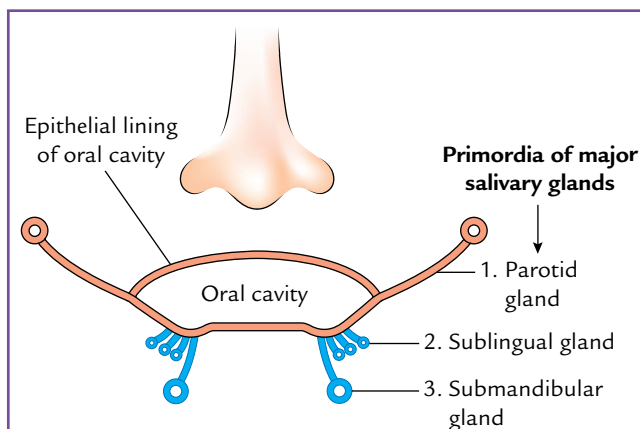
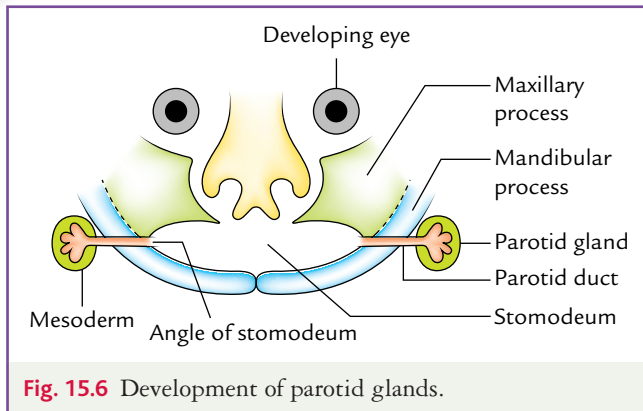


Fig. 15.5 Schematic diagram to show the sites of origin of parotid, submandibular, and sublingual glands.



Parotid Glands

The parotid gland, one on each side, develops during the fifth week as an ectodermal furrow (an outgrowth) from the cheek at the angle of the stomodeum. The ectodermal furrow grows outwards between mandibular and maxillary processes. Later the furrow is converted into a tube, which forms the **parotid duct**. The medial end of the duct opens into the angle of primitive mouth while from its lateral end, the cords of ectodermal cells project into the surrounding mesoderm.

Subsequently, these cords are canalized to form **acini and ductules** of the parotid gland. Elongation of jaws causes elongation of the parotid duct; however, the gland remains at its site of origin. Later, the angle of mouth is shifted more medially due to fusion of mandibular and maxillary processes (Fig. 15.6).

In adults, the parotid gland opens into the vestibule of mouth opposite upper second molar tooth, which indicates position of angle of the primitive oral orifice.

Submandibular Glands

The submandibular glands, one on each side, develop during the sixth week as a solid endodermal outgrowth from the floor of stomodeum, actually floor of alveololingual groove. The endodermal outgrowths grow posteriorly lateral to developing tongue. A linear groove forms lateral to the tongue that soon closes from behind to forward to form the **submandibular duct** that opens on a **sublingual papilla** on each side of the frenulum linguae.

Sublingual Glands

The sublingual glands develop in the eighth week, about two weeks later than the other salivary glands; they develop as multiple endodermal outgrowths from the linguogingival sulcus and submandibular duct. Each outgrowth canalizes separately and opens independently on the summit of sublingual fold. Some of these ducts may join to form a sublingual duct.

Table 15.1 Development of major salivary glands

Gland	Source of development	Time of development
Parotid	Ectodermal outgrowth from cheek at an angle of stomodeum	Fifth week
Submandibular	Endodermal outgrowth from the floor of stomodeum	Sixth week
Sublingual	Multiple endodermal outgrowths from the floor of linguogingival sulcus	Eighth week

Minor Salivary Glands

They are small submucosal glands that are distributed throughout the wall of the oral cavity except gingivae. They develop in a similar fashion as the major salivary glands, except that they do not undergo branching at all or undergo very little branching. They open independently on the surface of oral mucosa.

The development of major salivary glands is summarized in Table 15.1.

Development of Teeth

Overview

In humans two sets of teeth develop at different times of life (i.e., humans are diphyodont animals).

First set called **deciduous teeth (primary dentition)** is temporary. Second set called **permanent teeth (secondary dentition)** is permanent.

The teeth develop from **ectodermal oral epithelium** and underlying **neural crest mesenchyme**.

Enamel of the tooth is derived from ectoderm whereas all other tissues of tooth (viz., dentine, pulp, cementum, and periodontal ligaments) are derived from neural crest mesenchyme.

The teeth develop in relation to alveolar process involving reciprocal induction between neural crest mesenchyme and overlying ectodermal oral epithelium.

Stages of Development of Tooth (Figs 15.7 and 15.8)

For descriptive purposes, the development of tooth is divided into five stages: (a) dental lamina stage, (b) bud stage, (c) cap stage, (d) bell stage, and (e) apposition stage. The following text deals with the development of the lower incisor teeth.

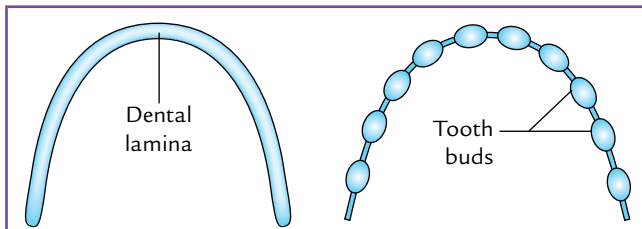


Fig. 15.7 Formation of dental lamina and tooth buds (enamel organs). Note the dental lamina acquires the shape of the alveolar arch.

Dental Lamina Stage

The ectodermal epithelium overlying the upper convex border of the alveolar process becomes thickened and projects into underlying mesoderm to form the **dental lamina**. Since the alveolar process is U shaped, the dental lamina is also U shaped.

Bud Stage

The dental lamina now proliferates at ten sites to produce local swellings called **tooth buds (enamel organs)** that grow into the underlying mesenchyme. Thus, there are ten such enamel organs (five on each side) in each alveolar process. **These ten enamel organs first form 20 deciduous teeth and later form permanent teeth when the deciduous teeth are shed off.**

Cap Stage

The mass of underlying neural crest mesenchyme invaginates the tooth bud/enamel organ. As a result, the enamel organ becomes cap shaped. This mass of mesenchyme that invaginates the tooth bud is called **dental papilla**.

Bell Stage

The enamel organs differentiate into three layers:

1. Outer cell layer called **outer enamel epithelium**
2. Inner cell layer called **inner enamel epithelium**
3. Central core of loosely arranged cells called **enamel reticulum**.

As the enamel organ differentiates, the developing tooth assumes the shape of a bell, hence it is called bell stage.

The cells of the enamel organ that line the dental papilla (cells of the inner layer enamel epithelium) become columnar and are now called **ameloblasts**.

The mesodermal cells of dental papilla adjacent to ameloblasts arrange themselves as a continuous epithelial layer. The cells of this layer are called **odontoblasts**.

The ameloblasts derived from inner enamel epithelium of the **enamel organ** form the **enamel** and the odontoblasts derived from **dental papilla** form the **dentine** and **dental pulp**.

As the enamel organ and dental papilla develop, the mesenchyme surrounding the tooth condenses to form **dental sac**. The **dental sac** is primordium of **cementum** and **periodontal ligament**. Figure 15.9 shows the photomicrographs of bell stage of developing lower incisor teeth.

Apposition Stage

Formation of the enamel and dentin occurs in this stage.

The ameloblasts (enamel frame) form enamel in the form of long prisms over the dentin. As the amount of enamel increases, the ameloblasts move towards the outer enamel epithelium. As a result, enamel reticulum and outer enamel epithelium disappear.

After the enamel is fully formed ameloblasts also regress, leaving only a thin membrane—the **dental cuticle**. After the eruption of tooth, this membrane is gradually sloughed off.

Odontoblasts produce **predentine** deep to the enamel. Later predentine calcifies and forms second hardest tissue of body—the **dentine**. As the dentine thickens cell bodies of odontoblasts regress, but their cytoplasmic processes called **odontoblastic processes (Tomes processes)** remain embedded in the dentine.

The **root of the tooth** begins to develop after the formation of enamel and dentine is well advanced.

The outer and inner enamel epithelia come together at the neck of the tooth where they form a fold—the **Hertwig's epithelial root sheath**. This sheath grows in the mesenchyme and initiates the formation of the root.

The odontoblasts adjacent to root sheath produce dentine, which is continuous with that of the crown.

As more and more dentine is produced, the **pulp cavity** narrows and forms the **pulp canal** through which nerve and vessels pass.

The inner cells of dental sac differentiate into **cementoblasts** that produce the cementum (a specialized bone).

The mesenchyme cells of the outside cement layer give rise to the **periodontal ligament** that holds the root of the tooth firmly with the bony alveolar socket and also functions as a shock absorber. With further elongation of the root, the crown of the tooth is pushed through the overlying tissue of alveolus into the oral cavity, i.e., **eruption occurs**.

The characteristic features of the various stages of development of the teeth are given in Table 15.2.

Development of Permanent Teeth (Fig. 15.10)

The permanent teeth are 32 in number, 16 in each jaw. They develop in a manner similar to that of deciduous teeth.

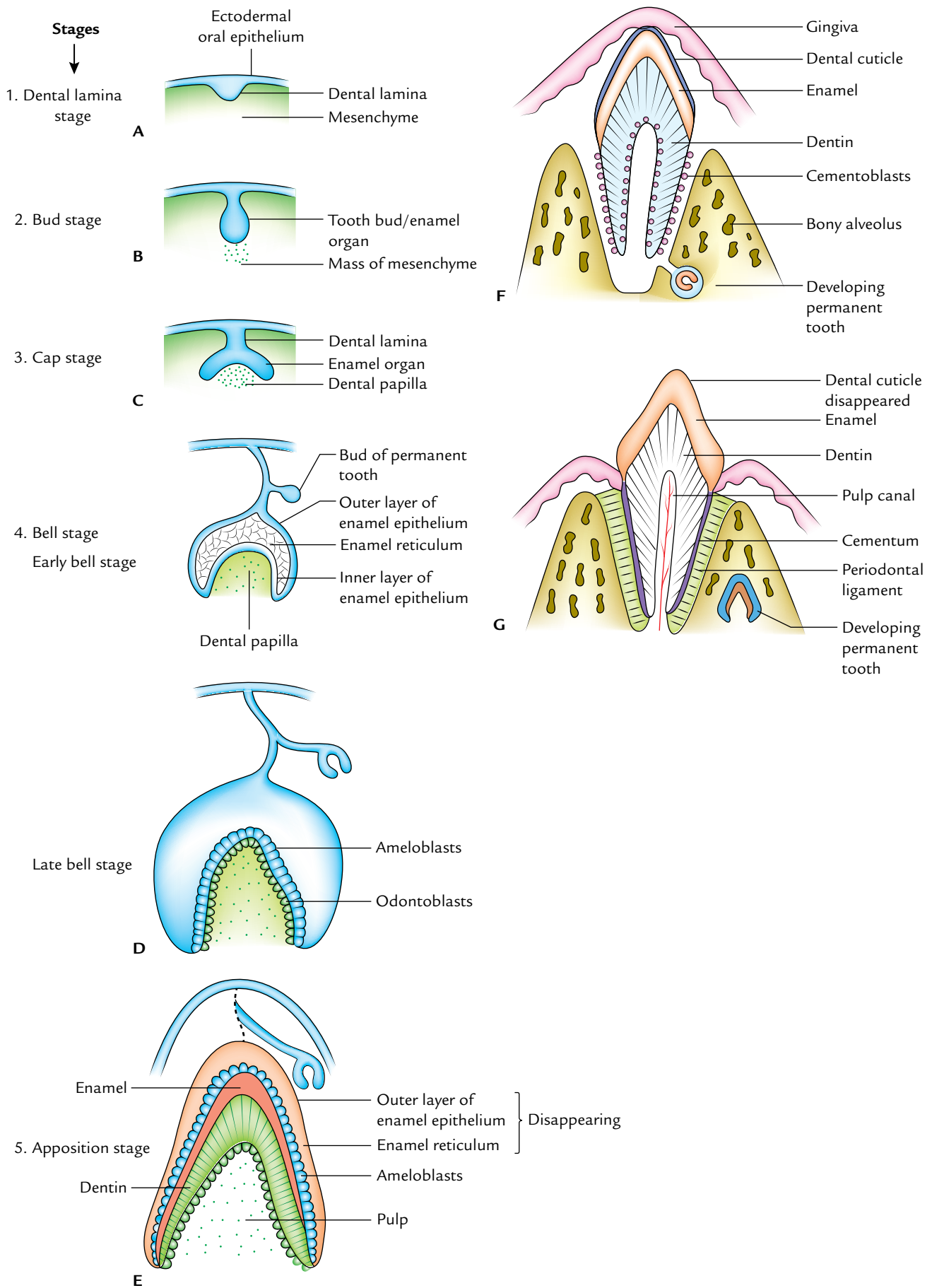


Fig. 15.8 Successive stages in the development of tooth (A, B, C, D, and E) and eruption of tooth (F and G).

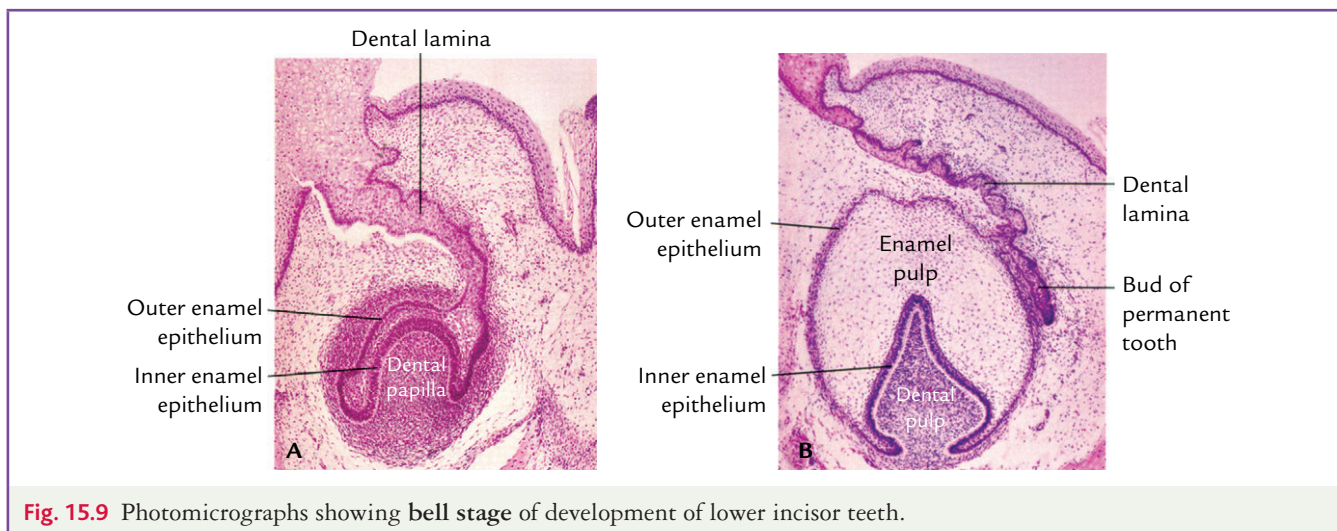


Fig. 15.9 Photomicrographs showing bell stage of development of lower incisor teeth.

Table 15.2 Stages of development of the tooth and their characteristic features	
Stage	Characteristic features
1. Dental lamina stage	Thickening of ectoderm overlying the alveolar process and its invagination into the underlying mesenchyme to form dental lamina
2. Bud stage	Proliferation of dental lamina at ten centers/spots to form tooth buds (enamel organs)
3. Cap stage	<ul style="list-style-type: none"> • Tooth bud (enamel organ) is invaginated by the mesenchyme • Invaginated mesenchyme forms dental papilla • Tooth bud becomes cap shaped
4. Bell stage	<ul style="list-style-type: none"> • Histodifferentiation of ameloblasts from enamel organ and odontoblasts from the pulp • Developing tooth assumes the shape of a bell
5. Apposition stage	<ul style="list-style-type: none"> • Formation of enamel and dentin matrix

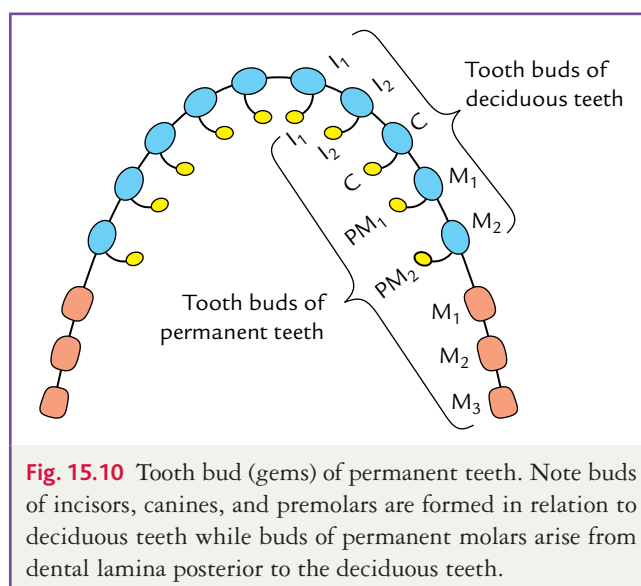


Fig. 15.10 Tooth bud (gems) of permanent teeth. Note buds of incisors, canines, and premolars are formed in relation to deciduous teeth while buds of permanent molars arise from dental lamina posterior to the deciduous teeth.

During the third month of IUL, the dental lamina gives off a series of tooth buds on the lingual (medial) side of developing deciduous teeth. They give rise to permanent incisors, canines, and premolars.

These buds remain dormant until about sixth year of postnatal life. As the tooth buds of permanent teeth grow, they push the deciduous teeth up from below. As a result the deciduous teeth are shed off. As the permanent teeth grow, the roots of overlying deciduous teeth are reabsorbed by osteoclasts.

The permanent molars do not develop from tooth buds arising from dental lamina forming deciduous teeth; rather they are formed from tooth buds that arise

directly from the dental lamina posterior to the region of lost milk teeth.

N.B. The tooth bud arising from dental lamina of first deciduous molar gives rise to first premolar and tooth bud arising from second molar gives rise to second premolar (Fig. 15.10).

Thus, 20 deciduous or milk teeth are replaced by 32 permanent teeth.

- Deciduous teeth are two incisors, one canine, and two molars.

The deciduous teeth begin to erupt at about 6 month of postnatal life, and all get erupted by the end of second year or soon after. The teeth of the lower jaw erupt somewhat earlier than the corresponding teeth of the upper jaw.

- Permanent teeth are two incisors, one canine, two premolars, and three molars.

The permanent teeth begin to erupt at about 6 years and all get erupted by 18–25 years.

Table 15.3 Time of eruption and shedding of the teeth

Tooth	Eruption time	Shedding time
Deciduous		
Central incisors	6–7 months	6–7 year
Lateral incisors	8–9 months	7–8 year
Canine	16–19 months	10–12 year
First molar	12–16 months	9–11 year
Second molar	20–24 months	10–12 year
Permanent		
Central incisor	7–8 year	Permanent
Lateral incisor	8–9 year	Teeth
Canine	10–12 year	Not shed off
First premolar	10–11 year	
Second premolar	11–12 year	
First molar	6–7 year	
Second molar	12 year	
Third molar	18–25 year	

The approximate time of eruption of teeth (deciduous as well as permanent) and time of shedding of deciduous teeth is given in Table 15.3.

Clinical Correlation

Congenital anomalies of the teeth

- Anodontia:** The complete absence of tooth or teeth is called *anodontia*. In this condition one or two teeth may be absent.
- Supernumerary teeth (extra teeth):** The extra tooth may be located posterior to normal teeth or wedged between the normal teeth disrupting positions of the teeth. The alignment of upper and lower teeth may be improper (*malocclusion*).
Sometimes the total number of teeth may be even less.
- Natal teeth** (eruption of teeth before birth): Sometimes teeth are already erupted at the time of birth. These are called *natal teeth*. Such teeth may cause injuries to nipple during breast feeding.

- Fused teeth:** This condition occurs when a tooth bud divides or two tooth buds partially fuse with each other.
- Impaction of tooth:** In this condition there is a delay in the eruption of tooth. It commonly involves last (third) molar tooth.
- Anomalies of enamel formation**
 - The defective enamel formation may cause pits or fissures on the surface of the enamel of the tooth.
 - The enamel may be soft and friable, if there is hypocalcification. The enamel appears yellow or brown in color (**amelogenesis imperfecta**). This condition is often caused by vitamin D deficiency (**rickets**).
- Dentinogenesis imperfecta (Fig. 15.11):** It is an autosomal dominant genetic anomaly with a genetic defect located in most cases on chromosome 4q. In this, the teeth are brown or gray in color. Enamel wears down easily; as a result the dentin is exposed on the surface.

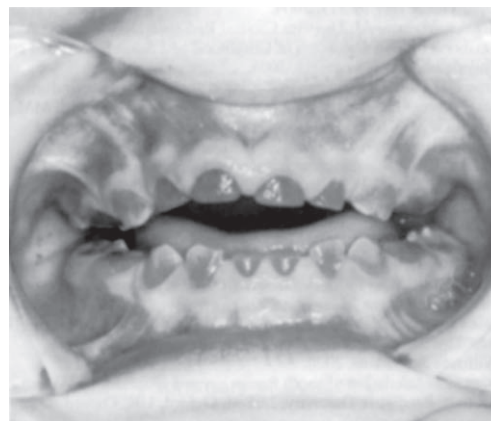


Fig. 15.11 Dentinogenesis imperfecta.

- Discoloration of teeth:** If infants and children are given tetracyclines, it is incorporated into the developing enamel causing yellow discoloration of teeth (both deciduous and permanent).
- Dentigerous cyst:** It is a cyst within mandible or maxilla and contains unerupted permanent tooth.

GOLDEN FACTS TO REMEMBER

- Two sources from which oral cavity forms
 - Stomodeum
 - Cephalic part of foregut
- Natal teeth
Teeth present at birth
- Amelogenesis imperfecta
Defective formation of enamel (an autosomal dominant disorder)
- Whole oral cavity is derived from stomodeum except
Floor that is derived from foregut

- | | |
|--|---|
| ➤ Critical period of tooth development | 6–12 weeks |
| ➤ Dentigerous imperfecta | Defective formation of dentin (an autosomal dominant trait) |
| ➤ All the dental tissues (tissues of tooth) are derived from neural crest mesenchyme <i>except</i> | Enamel that is produced by ameloblasts derived from oral ectoderm |
| ➤ Hardest tissue in the body | Enamel |
| ➤ Second hardest tissue in the body | Dentin |

CLINICAL PROBLEMS

1. A male baby was born with two mandibular incisor teeth. What are these teeth called and what problem they may cause?
2. Tetracyclines (a group of antibiotics) are not prescribed to the pregnant women and children below 8 years of age. Why?
3. Although all the salivary glands begin to develop near the primitive oral fissure; but in adults the parotid glands are located far away from the oral fissure near the auricle. Give its embryological basis.

CLINICAL PROBLEM SOLUTIONS

1. These teeth are called **natal teeth** (L. *Natus* = to be born). They are prematurely erupted primary (milk) teeth. The natal teeth may cause maternal discomfort during breast feeding. They may also injure the baby's tongue.
2. This is because tetracycline are extensively incorporated into the enamel and dentine of developing teeth causing yellow discoloration and hypoplasia of the enamel.
3. This is because the parotid glands develop as an outgrowth of epithelium from the angle of oral fissure. Initially the angles of mouth extend much laterally, nearly up to the ear. Subsequent fusion between maxillary and mandibular processes shifts the angles of the mouth more medially until they reach the adult position, but the parotid gland remains/located near auricle.

16

Respiratory System

Overview

The respiratory tract is divided into two parts: **upper respiratory tract (URT)** and **lower respiratory tract (LRT)**.

- The URT consists of nose, nasopharynx, and oropharynx.
- The LRT consists of larynx, trachea, principal bronchi, intrapulmonary bronchi, and lungs.

The development of various components of URT is described separately in other chapters. The present chapter deals with development of the LRT, which is conventionally termed **development of the respiratory system** by embryologists.

Development of Respiratory System

The respiratory system is endodermal in origin. *It develops from a median diverticulum of foregut called respiratory diverticulum (Fig. 16.1).* Therefore, lining epithelium of larynx, trachea, bronchi, and lungs is derived from endoderm. The cartilages, muscles, and connective

tissue components of the respiratory system develop from **splanchnic mesoderm** surrounding the foregut.

Development of Respiratory (Laryngotracheal) Diverticulum

The respiratory diverticulum develops as an outgrowth from ventral part of the cranial part of foregut.

This diverticulum is first seen as a midline groove (**laryngotracheal groove**) in the endodermal lining of floor of primitive pharynx just caudal to hypobranchial eminence (to be very precise *epiglottal swelling*) during the fourth week of the intrauterine life (IUL) (Fig. 16.2). The groove is flanked by sixth pharyngeal arches. The groove deepens to form a longitudinal diverticulum called **laryngotracheal diverticulum** (Fig. 16.3).

The distal part of this diverticulum is separated from the esophagus by development of **tracheoesophageal septum**, whereas its cranial part continues to communicate with the pharynx. This communication with pharynx forms **laryngeal inlet**.

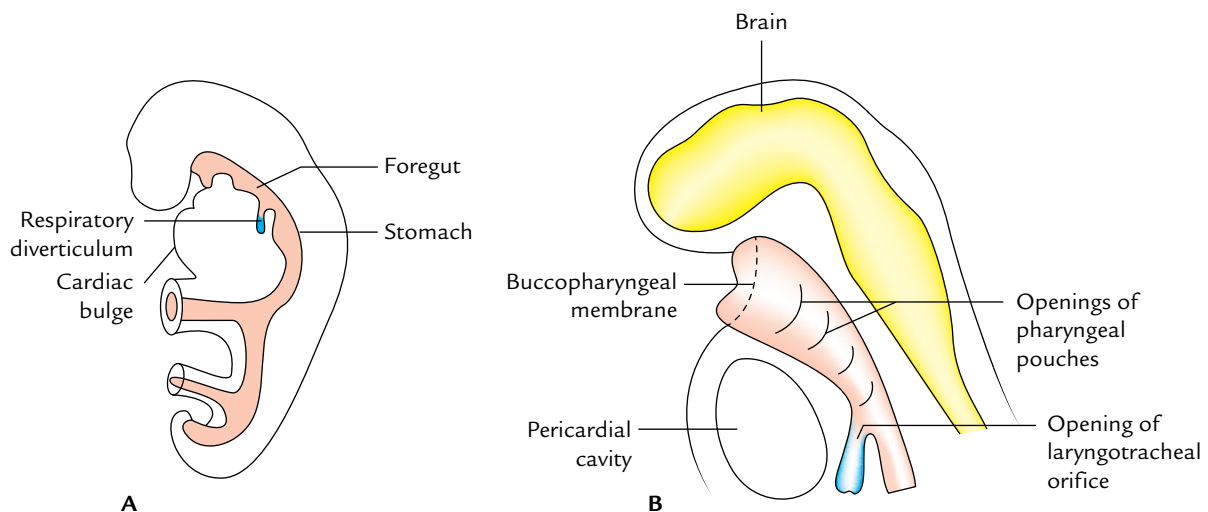


Fig. 16.1 Site of respiratory diverticulum as seen in embryo. A. A 25-day-old embryo. Note the relationship of diverticulum to stomach. B. Sagittal section of 5-week-old embryo showing openings of pharyngeal pouches and laryngotracheal orifice.

The **tracheoesophageal septum** develops from two lateral folds—the **tracheoesophageal folds** that grow medially and fuse with each other in the midline to form this septum.

The laryngotracheal diverticulum grows downward to enter thorax, where it becomes bifid to form **two** (right and left) **bronchial/lung buds**.

The part of diverticulum proximal to bifurcation forms the larynx and trachea, whereas the bronchial buds form the bronchi and lung parenchyma.

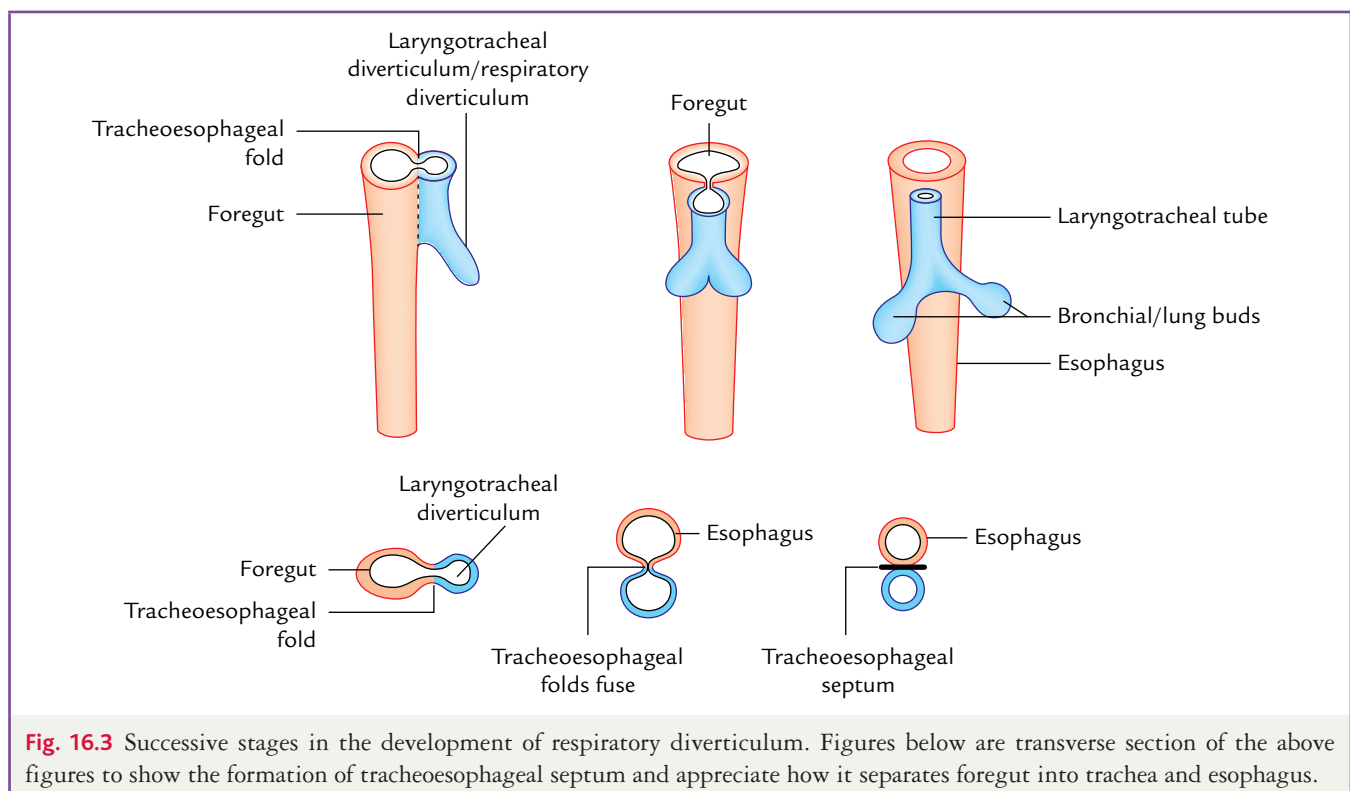
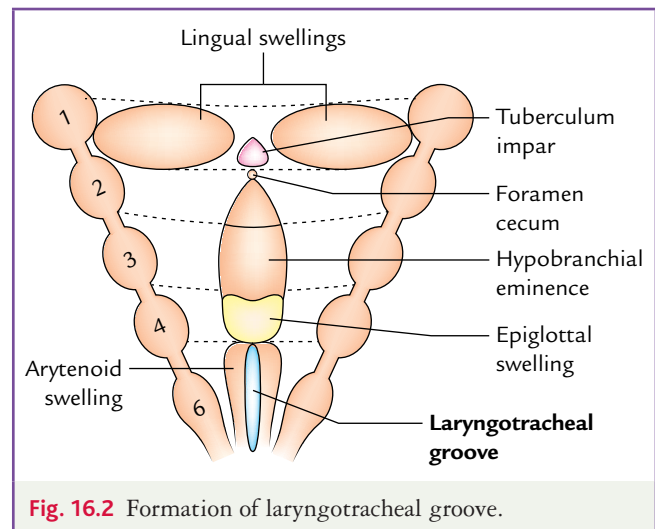
Each lung bud invaginates into **pericardioperitoneal canal**. The right and left pericardioperitoneal canals form the right and left pleural cavities, respectively.

adult shape (Fig. 16.4). The lining epithelium of larynx develops from endoderm of this diverticulum. At first the endodermal cells proliferate and completely obliterate lumen of larynx. Later on the cells obliterating the lumen breakdown and recanalization of larynx takes place. During recanalization, the endodermal cells form two pairs of folds: an upper pair of **vestibular folds** and a lower pair of **vocal folds**, which extend antero-posteriorly in the lumen of the larynx and give rise to **false and true vocal cords**, respectively. A pair of lateral recesses bound by these folds is called **laryngeal ventricles**.

Development of Individual Parts of the Respiratory System

Larynx

The larynx develops from the cranial most part of **laryngotracheal diverticulum**. The communication between the laryngotracheal diverticulum and primitive pharynx persists as a **laryngeal inlet**. The mesenchyme (of fourth and sixth pharyngeal arches) surrounding the laryngeal orifice proliferates. As a result, the slit-like laryngeal orifice becomes T shaped. Subsequently, mesenchyme of fourth and sixth pharyngeal arches forms thyroid, cricoid, and arytenoids cartilages, and laryngeal orifice acquires a characteristic



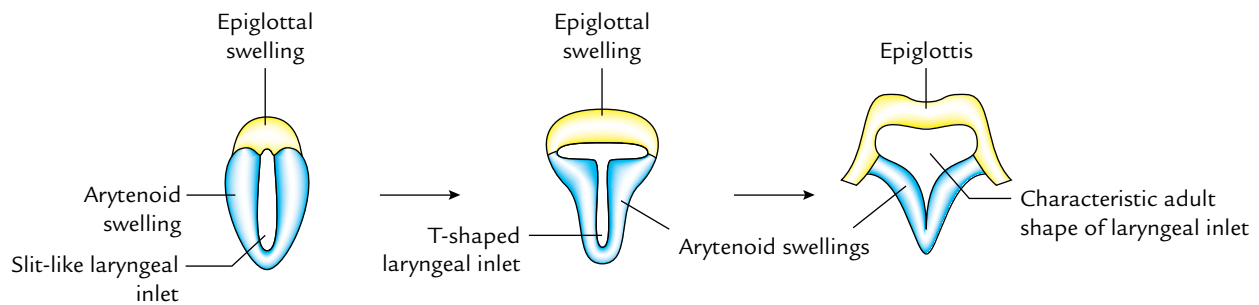


Fig. 16.4 Change in shape of laryngeal inlet during development of larynx.

All the cartilages of the larynx (e.g., thyroid, cricoid, arytenoids, and cuneiform) except epiglottis develop from mesenchyme of fourth and sixth pharyngeal arch, which is derived from neural crest cells. The epiglottis develops from the caudal part of **hypobranchial eminence**.

The muscles of the larynx develop from the mesoderm of fourth and sixth pharyngeal arches. Therefore, these muscles are supplied by nerve of the fourth arch (**superior laryngeal nerve**) and nerve of the sixth arch (**recurrent laryngeal nerve**).

Clinical Correlation

Anomalies of larynx

- Laryngeal atresia and stenosis:** This rare anomaly of larynx results from failure of recanalization of the larynx that leads to obstruction of the upper respiratory tract (also called *congenital high airway obstruction syndrome*) due to narrowing of some sites. Most commonly the atresia (blockage) and stenosis (narrowing) is seen at the level of vocal folds.
- Laryngeal web:** In this anomaly membranous, web-like tissue is present in the laryngeal lumen, usually at the level of vocal folds, which may partially obstruct the airway. This web-like tissue is derived from endodermal cells that fail to break out during recanalization of larynx.

Trachea

The trachea develops from part of the laryngotracheal diverticulum (respiratory diverticulum), which lies between the larynx and point of division of the diverticulum into **bronchial buds**. The endoderm of laryngotracheal diverticulum forms the lining epithelium and glands of the trachea. The cartilage, muscle, and connective tissue of trachea develop from surrounding splanchnopleuric intraembryonic mesoderm surrounding laryngotracheal groove.

N.B. Trachea is separated from the esophagus by a tracheoesophageal septum (see page 177).

Clinical Correlation

Anomalies of trachea

- Tracheoesophageal fistula (TEF):** It is an abnormal communication between the trachea and esophagus. This anomaly is often associated with *esophageal atresia*. It occurs in 1/3000–4500 births.

The TEF occurs due to defective development of *tracheoesophageal septum*. The tracheoesophageal folds fail to fuse with each other in a small segment, producing an abnormal communication between the trachea and esophagus—the TEF.

The various types of TEF are (Fig. 16.5):

- Upper part of the esophagus ends in a blind pouch and lower part communicates with the trachea (85–90%) (Fig. 16.5A).
- As type (a) but the tracheoesophageal communication/canal is replaced by a fibrous cord (Fig. 16.5B).
- Both upper and lower parts of the esophagus communicate with the trachea by a common narrow canal. It is called H-shaped TEF (4%) (Fig. 16.5C).
- Upper part of the esophagus communicates with the trachea and lower end forms a blind pouch (Fig. 16.5D).
- Both upper and lower parts of the esophagus communicate with the trachea separately (Fig. 16.5E).

When milk or fluid is given to newborn infants with TEF, there occurs coughing and choking because milk or fluid enters into the respiratory tract. It may also lead to lung infection (pneumonia).

- Tracheal stenosis (narrowing of trachea):** It is rare and occurs due to anterior deviation of the tracheoesophageal septum.
- Tracheal atresia (tracheal obstruction):** It occurs due to the presence of a web of tissue within tracheal lumen. This tissue is derived from proliferation of endodermal cells.
- Tracheal bronchus and tracheal lobe:** Sometimes the trachea presents a diverticulum that may either end blindly (blind bronchus) or supply a lobe of lung called *tracheal lobe*, which is not a normal part of the lung. Sometimes it may replace a normal bronchus, viz., apical bronchus of upper lobe of lung (Fig. 16.6).

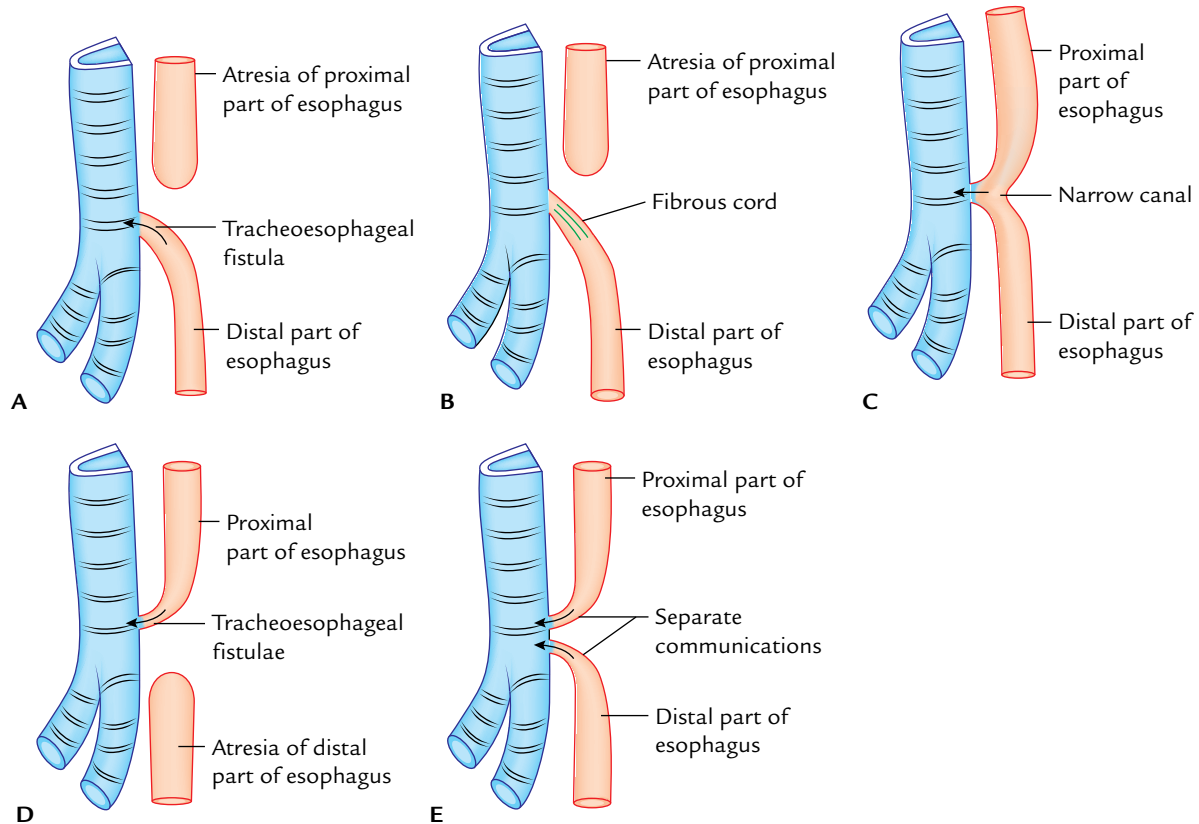


Fig. 16.5 Types of tracheoesophageal fistulae. A. Atresia of the esophagus and tracheoesophageal fistula. B. Atresia of the esophagus and connection between the distal part of esophagus and trachea by a fibrous cord. C. Both proximal and distal parts of esophagus connected to the trachea by a narrow canal. D. Atresia of distal part of esophagus and connection between the proximal part of esophagus and trachea. E. Separate communications of proximal and distal parts of esophagus to the trachea.

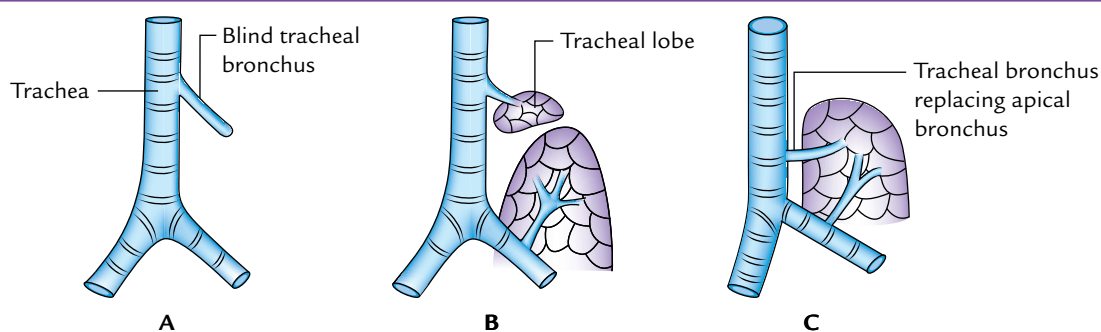


Fig. 16.6 Accessory bronchi arising from trachea. A. Blind tracheal bronchus. B. Tracheal bronchus supplying an accessory mass of lung tissue. C. Tracheal bronchus replacing apical bronchus.

Bronchi and Lungs (Fig. 16.7)

The laryngotracheal (respiratory) diverticulum divides into two **bronchial buds**. Each bronchial bud develops into a **principal bronchus**. The two primary divisions of the caudal part of respiratory diverticulum form **right and left principal bronchi**. The right principal bronchus is slightly larger than the left and oriented more in line with the trachea. The left principal bronchus comes to lie more transversely than the right.

This embryonic relationship persists in the adult, therefore foreign body is more likely to enter into the right principal bronchus.

The principal bronchi subdivide into **secondary bronchi**, which further divide and subdivide to form **lobar, segmental, and intersegmental bronchi**, respectively.

On the right side, the **superior lobar bronchus** supplies superior lobe of the lung whereas the **inferior lobar bronchus** subdivides into two bronchi—one to

the middle lobe and other to the inferior lobe. Thus, **right principal bronchus gives rise to three lobar bronchi—upper, middle, and lower**, which supply the upper, middle and lower lobes of the right lung.

On the left side, the left **principal bronchus** gives rise to two lobar bronchi (upper and lower) that supply the superior and inferior lobes of the left lung, respectively.

The lobar bronchus undergoes progressive branches. Each lobar bronchus divides into ten segmental bronchi for each lung.

The **segmental bronchi** are formed by the seventh week of IUL. Each segmental bronchus with its surrounding mass of mesenchyme forms the **bronchopulmonary segment**. Therefore, each lung consists of ten bronchopulmonary segments.

By the end of sixth month, about 17 generations of bronchial subdivisions are formed. Before the bronchial tree reaches the final stage about six to seven divisions form after birth.

Thus, divisions and subdivisions of each segmental bronchus form the distal part of the bronchial tree consisting of **bronchioles, respiratory bronchioles, alveolar ducts, and alveoli**.

The **endoderm** of respiratory diverticulum and its various subdivisions give rise to **lining epithelium of the bronchial tree**. All other elements in the wall of the bronchial tree such as cartilages, smooth muscles, and connective tissue are derived from surrounding splanchnic mesoderm. The splanchnic mesoderm also forms the connective tissue and capillaries of the lung.

Thus, the parenchyma of lungs develops from bronchial tree derived from further subdivisions of the lobar bronchi. The lung parenchyma developing from bronchi is separated from each other by mesoderm. The mesoderm also forms the connective tissue basis of the lung and pleura lining its surface. Because pleura lines the surface of each lobe separately, the lobes become separated by the **fissures**.

N.B. The bifurcation of the trachea at the time of birth lies opposite to T4 vertebra.

Maturation of the Lungs

Maturation of the lungs is divided into four stages/periods (Fig. 16.8): pseudoglandular stage, canalicular stage, terminal sac stage, and alveolar stage (Table 16.1).

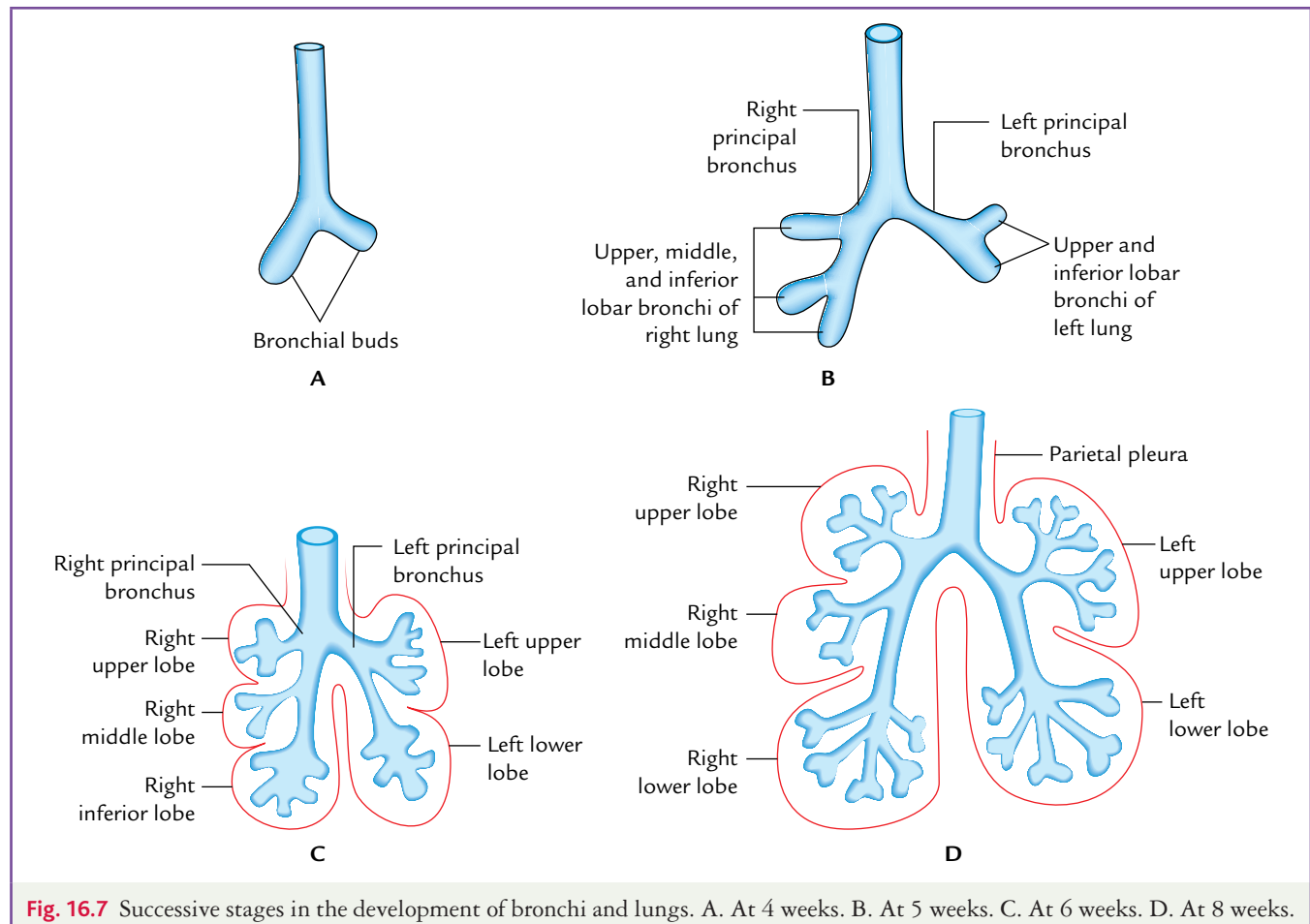
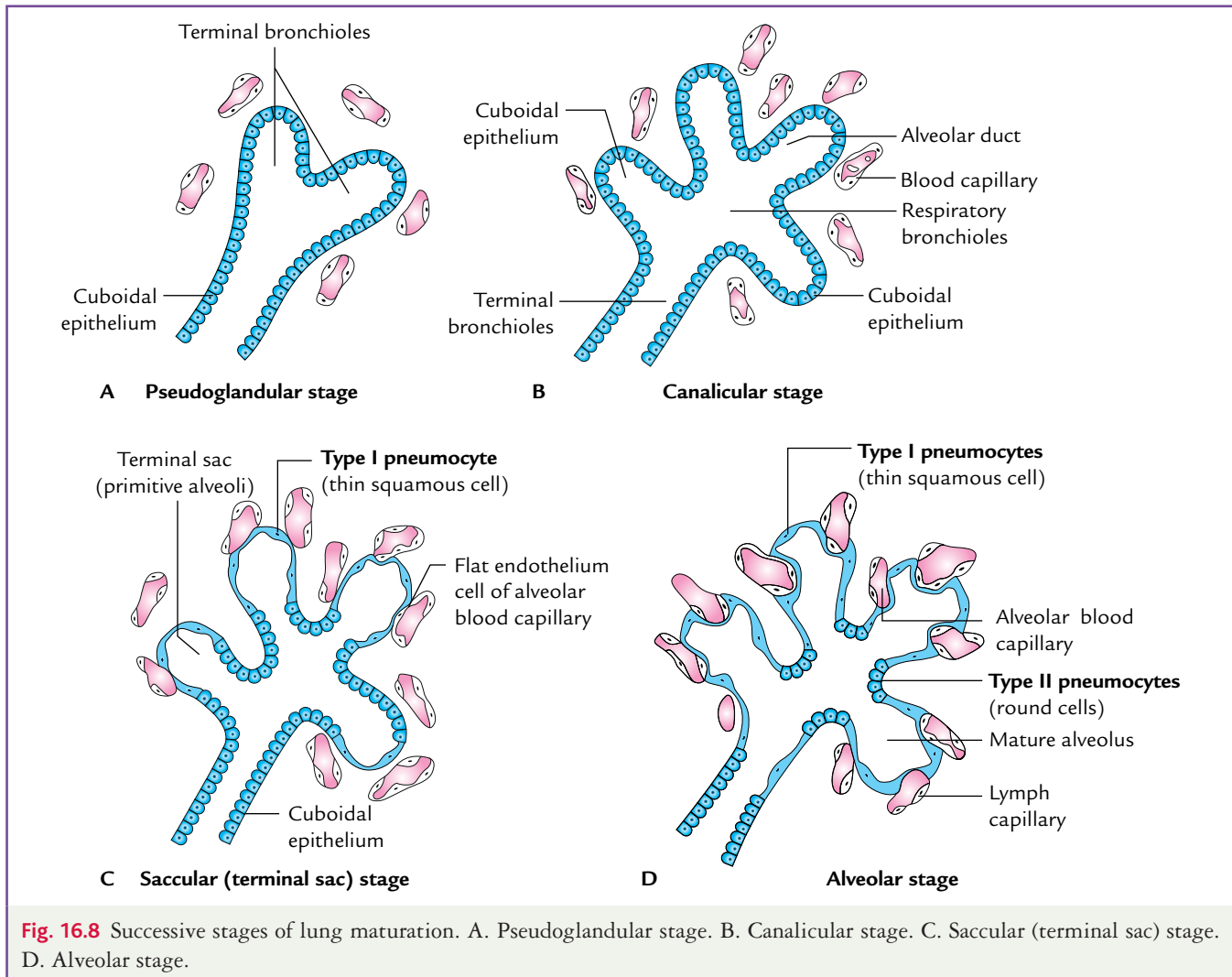


Fig. 16.7 Successive stages in the development of bronchi and lungs. A. At 4 weeks. B. At 5 weeks. C. At 6 weeks. D. At 8 weeks.



Stage	Period	Development changes
Pseudoglandular stage	5–16 weeks	<ul style="list-style-type: none"> Bronchial tree is formed up to terminal bronchioles Elements of the bronchial tree involved in respiration (e.g., respiratory bronchioles, alveolar ducts, and alveoli) are not formed Respiration is not possible at this stage; hence premature fetuses cannot survive if born at this stage
Canalicular stage	16–26 weeks	<ul style="list-style-type: none"> Respiratory bronchioles and alveolar ducts are formed Few alveolar sacs are also formed Lung tissue is well vascularized Fetus born at the end of the stage can survive if given intensive care
Terminal sac (saccular) stage	26 weeks to birth	<ul style="list-style-type: none"> Large number of terminal sacs (primitive alveoli) develop Capillaries bulge into developing sacs Intimate contact develops between epithelium of sac and endothelium of capillary to permit adequate exchange of gases for survival of fetus, if born prematurely. Fetuses born at this stage survive
Alveolar stage	8 months to 8 years	<ul style="list-style-type: none"> Formation of definitive (true) alveoli with an increase in their number Type II pneumocytes produce a sufficient amount of surfactant Free exchange of gases across the blood–air barriers formed by epithelium of alveoli and endothelium of capillaries

1. Pseudoglandular stage/period (5–16 weeks):

During this period, histologically the appearance of the lung resembles a developing exocrine gland. The divisions of bronchi are reached up to terminal bronchioles (i.e., all major elements of the lung are formed), but respiratory elements (e.g., respiratory bronchioles and alveoli) that are involved in respiration are not formed. Hence **fetus born during this period cannot survive.**

2. Canalicular stage (16–26 weeks): During this stage, lumens of terminal bronchioles dilate and there is a further subdivision of terminal bronchioles into respiratory bronchioles. The respiratory bronchioles divide into alveolar ducts. Few terminal sacs (primitive alveoli) may also be formed at the ends of respiratory bronchioles. The **fetus born towards the end of this period may survive if given intensive care.**

The main thing that happens in this stage is that the lung tissue is well vascularized.

3. Terminal sac stage (26 weeks to birth): During this period, a large number of terminal sacs (primitive alveoli) develop. The capillaries also proliferate and form a plexus around the terminal sacs. The wall (epithelium) of terminal sacs becomes very thin and capillaries bulge into these sacs. The intimate contact between epithelial and endothelial cells establishes the **blood–air barrier**, which permits adequate exchange of gases for survival of the fetus if born prematurely. Terminal sacs are mainly lined by endodermal squamous cells called **type I alveolar epithelial cells (type I pneumocytes)** across which gaseous exchange takes place. Scattered among the squamous epithelial cells (type I pneumocytes), a few rounded **type II alveolar epithelial cells (type II pneumocytes)** are also present. The type II pneumocytes secrete **surfactant** and their number gradually increases towards the full-term. There is also an increase in number of lymphatic capillaries.

4. Alveolar stage (8 months to 8 years): In this stage, the terminal sacs and respiratory bronchioles divide and form the alveolar ducts; at the end of alveolar ducts, the **definitive (true) alveoli are formed.** The formation of mature (true) alveoli continues even after birth till age of about 8 years.

The true alveoli that are formed have extremely thin wall and are lined by type I and type II pneumocytes. The **type II pneumocytes produce a sufficient amount of surfactant** for survival. The capillaries also proliferate and vascularize the newly formed alveoli. A number of alveoli reach the adult level by the eighth year.

N.B.

- The characteristic mature alveoli do not form until after birth.
- About 95% of mature alveoli develop after birth.

Fetal Breathing Movements

The real time ultrasonography has revealed that fetal breathing movements (FBMs) start before birth. They occur intermittently and exert sufficient force to cause aspiration of amniotic fluid in the lungs. The FBMs are essential for the normal lung development and increase as the time of delivery approaches.

N.B. Before birth, the fetus undergoes breathing exercises for several months.

At birth, the lungs are approximately half filled with the fluid, which is derived from amniotic fluid and tracheal glands.

Aeration of lung at birth rapidly replaces the intra-alveolar fluid by the air.

This fluid from the lungs is cleared by following three routes:

1. Through the mouth and nose by pressure on the fetus's thoracic wall during vaginal delivery
2. Through pulmonary arteries, veins, and capillaries
3. Through lymphatics.

N.B. Three important factors essential for normal lung development are: (a) adequate thoracic space to allow lung growth, (b) fetal breathing movements, and (c) an adequate volume of amniotic fluid.

Clinical Correlation

1. Medicolegal importance of the newborn lung: The lungs of a newborn infant *born alive* always contain some air within it; hence they float in water and crepitate on pressure. The lungs of a newborn infant *born dead (stillborn)* are firm and sink when placed in water because they contain fluid, not air. For this reason, it is firm and does not crepitate on pressure.

This fact is of medicolegal importance because it tells whether the newborn infant was born alive or born dead (stillborn).

2. Respiratory distress syndrome (RDS): This clinical condition affects about 2% of live newborn infants. As the name suggests infants born with this condition develop rapid, labored breathing shortly after birth. This condition is common in premature infants. The most common cause of RDS is deficiency of surfactant.

In this disease, alveoli of lungs are often filled with fluid having high protein content, which resembles glassy hyaline membrane. Hence RDS is also known as **hyaline membrane disease**.

The hyaline membrane disease accounts for about 20% of deaths among newborn infants.

The corticosteroids (glucocorticoids) and thyroxine, which are involved in lung maturation and production of surfactant, may be used therapeutically.

3. Congenital anomalies of the lung

- (a) **Agensis (nondevelopment) of the lung:** It is a rare condition and occurs if one of the bronchial buds fails to develop. Agensis of both the lungs is still rare. The unilateral agensis of the lung is compatible with life.
- (b) **Hypoplasia of lungs:** In this condition, the lungs are small and underdeveloped. It usually occurs due to *congenital diaphragmatic hernia (CDH)* in which abdominal contents herniate into thorax and the lung is unable to develop normally because it gets compressed by abdominal viscera. The lung hypoplasia is characterized by a markedly reduced lung volume and hypertrophy of smooth muscle of pulmonary arteries.
- (c) **Abnormal lobes of lungs (Fig. 16.9):** In this condition, sometimes the right lung may consist of two lobes instead of three or left lung may consist of three lobes instead of two. These anomalies occur due to abnormal division of principal bronchi into lobar bronchi, and are associated with anomalies of lung fissures. These anomalies are not clinically significant.
- (d) **Azygos lobe of the lung (Lobe of Wisberg) (Fig. 16.10):** It is a portion of upper lobe of the right lung that lies medial to *arch of the azygos vein*. The azygos vein lies in floor of vertical fissure lined by pulmonary pleura. The azygos lobe is found in the right lung because azygos vein itself is on the right side. **Azygos lobe is commonest accessory lobe of the lung.** For details see *Clinical and Surgical Anatomy* by Vishram Singh.
- (e) **Ectopic lung lobes (Fig. 16.11):** They arise from trachea or esophagus. These lobes probably form additional respiratory

buds of the trachea and foregut that develop independently of main respiratory system.

- (f) **Congenital polycystic lung:** Multiple cysts are formed in the lung due to abnormal dilatation of terminal bronchioles. These cysts are small and multiple, giving the lung a **honey-comb appearance**, which can be seen in the radiograph. Because these cysts usually drain poorly, therefore they frequently cause chronic infections. For this reason, congenital polycystic lung is clinically most important.

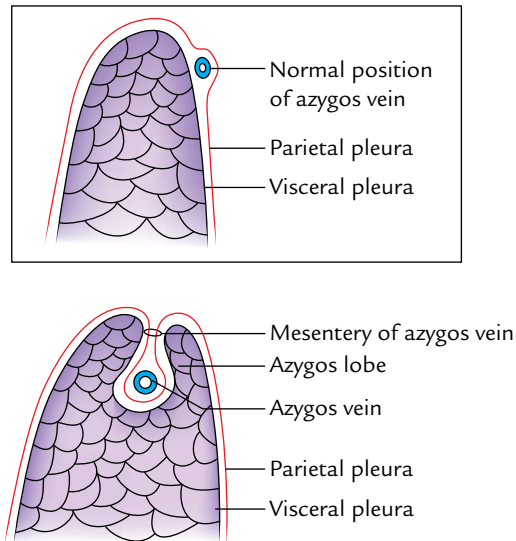


Fig. 16.10 Azygos lobe of the lung. Figure in the inset shows normal relationship of azygos vein with the lung.

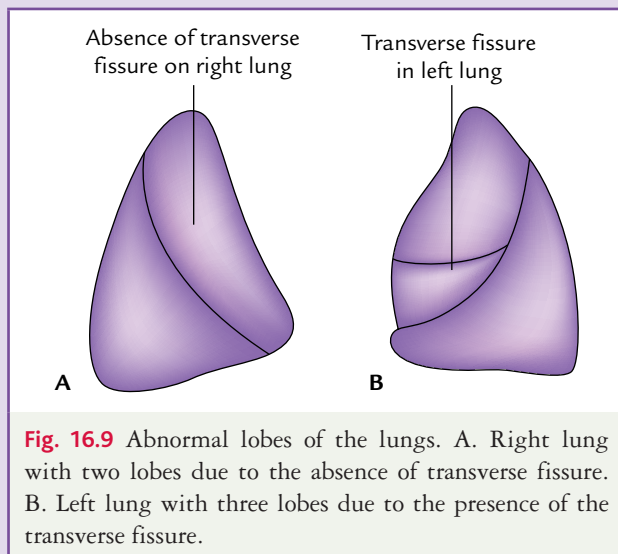


Fig. 16.9 Abnormal lobes of the lungs. A. Right lung with two lobes due to the absence of transverse fissure. B. Left lung with three lobes due to the presence of the transverse fissure.

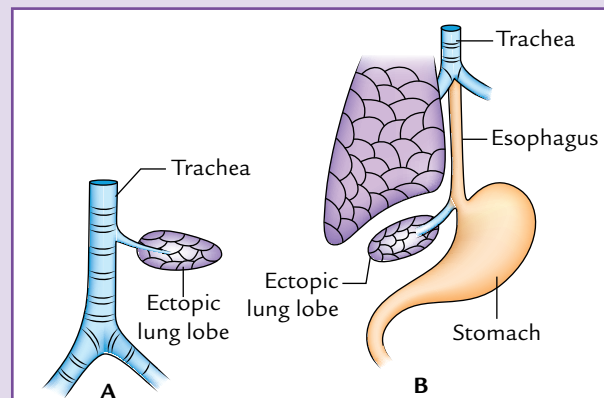


Fig. 16.11 Ectopic lung lobes. A. Arising from trachea. B. Arising from esophagus.

GOLDEN FACTS TO REMEMBER

- All the cartilages of larynx develop from neural crest cell mesenchyme of fourth and sixth pharyngeal arches *except* Epiglottis, which develops from caudal part of the hypopharyngeal/hypobranchial eminence
- Commonest type of tracheoesophageal fistula One in which the upper part of esophagus ends in a blind pouch and lower end of esophagus communicates with the trachea
- Commonest accessory lobe of the lung Azygos lobe
- Production of surfactant begins by 20th week of IUL
- Most of mature (true) alveoli are formed After birth
- Most common cause of respiratory distress syndrome Deficiency of surfactant
- Most important congenital anomaly of the lung (clinically) Congenital polycystic lung

CLINICAL PROBLEMS

1. An obstetrician observed continuous choking and coughing in a newborn baby boy. A pediatrician was called for expert opinion and management of the case. He noted that the infant's mouth was full of saliva, and he had difficulty in breathing. The pediatrician tried to pass a catheter through the esophagus into the stomach, but he failed to do so. A radiograph revealed the presence of air in the stomach. What is the most likely diagnosis? Give its embryological basis.
2. A premature infant has labored breathing immediately after birth. The baby soon became cyanotic and died. What is the most likely diagnosis? Give its embryological basis.
3. A newborn baby was born with **tracheoesophageal fistula (TEF)**. What is the most common type of TEF? Give the embryological basis of TEF.
4. Babies born after 7 months of gestation usually survive. Why?
5. Babies born at 6 months of gestation develop respiratory distress syndrome and die. Give its embryological basis.
6. What is surfactant? How does it reduce the surface tension of the alveoli to prevent their collapse?
7. Which therapy is used during pregnancy for prevention of respiratory distress syndrome (RDS) in preterm labor?
8. On chest radiograph shadows of lungs of a newborn infant are denser than those of adults. Why?

CLINICAL PROBLEM SOLUTIONS

1. The most likely diagnosis is **tracheoesophageal fistula** associated with atresia of the upper part of the esophagus. The catheter could not be passed due to atresia of the esophagus. The air could enter the stomach through communication between the esophagus and lower part of the esophagus (also see page 143).
2. The most likely diagnosis is **respiratory distress syndrome**. In this disease, the lungs are underinflated and alveoli are filled with fluid. It occurs due to deficiency of surfactant produced by type-II pneumocytes. By labored breathing (characterized by increased rate and depth of respiration, flaring of nostrils, and retraction of the sternum and intercostal spaces) the baby was trying to overcome respiratory problems, in which he failed, became cyanotic, and finally died.
3. The tracheoesophageal fistula (TEF) occurs due to incomplete separation of the esophagus from trachea due to incomplete development of tracheoesophageal septum. The most common type of TEF is one in which trachea communicates with the lower part of the esophagus, and upper part of esophagus ends as a blind pouch.
4. A premature baby born after 7 months of gestation can survive due to following two reasons:
 - (a) By the seventh month of gestation sufficient number of blood capillaries make close contact with the wall of alveolar sac to allow exchange of gases.
 - (b) After 7 months of gestation lung alveoli (type II pneumocytes) produce a sufficient amount of surfactant to reduce the surface tension of alveoli to prevent their collapse during expiration. This leads to normal lung function.
5. A baby born before or at 6 months of gestation does not produce a sufficient amount of surfactant to reduce surface tension in the alveoli to permit normal lung function. Consequently, alveoli collapse, baby develops respiratory distress syndrome, and usually dies.
6. The surfactant is a complex mixture of phospholipids and proteins. It is produced by type-II pneumocytes and its production begins by 20th week of gestation.

Before actual breathing takes place the alveoli of the lung are filled with fluid, containing surfactant and mucus from bronchial glands. When respiration begins after birth the fluid is cleared from the lung alveoli (see page 182), but surfactant remains as a thin layer lining the alveoli. The surfactant prevents collapse of lung alveoli during expiration of newborn babies.
7. The **maternal glucocorticoid during pregnancy** accelerates fetal lung development and surfactant production. Based on this finding corticosteroid (betamethasone) are now routinely used to prevent the RDS in preterm labor.
8. On chest radiograph the lungs of a newborn infant appear denser than those of adults because they have fewer alveoli.

17

Body Cavities and Diaphragm

Overview

There are three body cavities: **pericardial**, **pleural**, and **peritoneal**. The **pericardial cavity** is related to heart, the **pleural cavity** to lungs, and the **peritoneal cavity** to abdominal viscera. All these cavities develop from intraembryonic celom.

Initially, the intraembryonic celom is one continuous space. Later it is divided into three parts: pericardial, pleural, and peritoneal cavities by the development of two partitions: *paired pleuropericardial membranes* and *diaphragm*.

The two important events involved in the development of body cavities are: (a) formation of intraembryonic celom and (b) partitioning of intraembryonic celom.

Formation of Intraembryonic Celom

Intraembryonic celom develops in lateral plate mesoderm. Due to development of the intraembryonic celom, the lateral plate mesoderm is split in two layers: **splanchnopleuric layer** related to endoderm and **somatopleuric layer** related to ectoderm (Fig. 17.1).

The intraembryonic celom appears as a *horseshoe-shaped cavity* during the fourth week of intrauterine life (IUL). Its narrow central part lies cranially in the midline behind the septum transversum and in front of prochordal

plate. It represents the future **pericardial cavity**. Its right and left lateral parts represent the future **peritoneal cavities**. The canals that connect the pericardial and peritoneal cavities are called **pericardioperitoneal canals**. They represent the future **pleural cavities** (Fig. 17.2A). Later the two primitive peritoneal cavities fuse to form a single **peritoneal cavity** (Fig. 17.2B).

After folding of embryo pericardial cavity lies ventrally and the two **pericardioperitoneal canals** pass on either side of the foregut (Fig. 17.3). The two lung buds arising from foregut invaginate the pericardioperitoneal canals. With the growth and enlargement of lung buds, these canals also expand and form the **pleural cavities**.

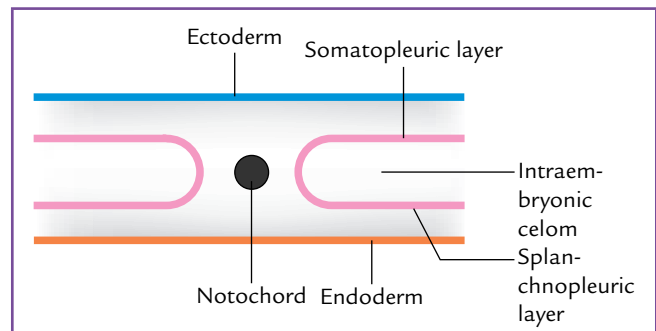


Fig. 17.1 Splitting of lateral plate mesoderm by intraembryonic mesoderm.

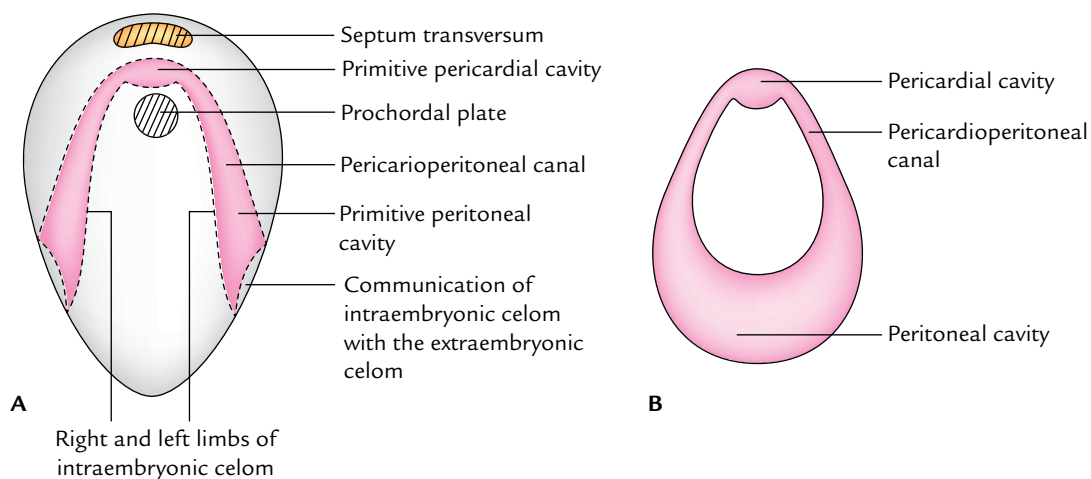
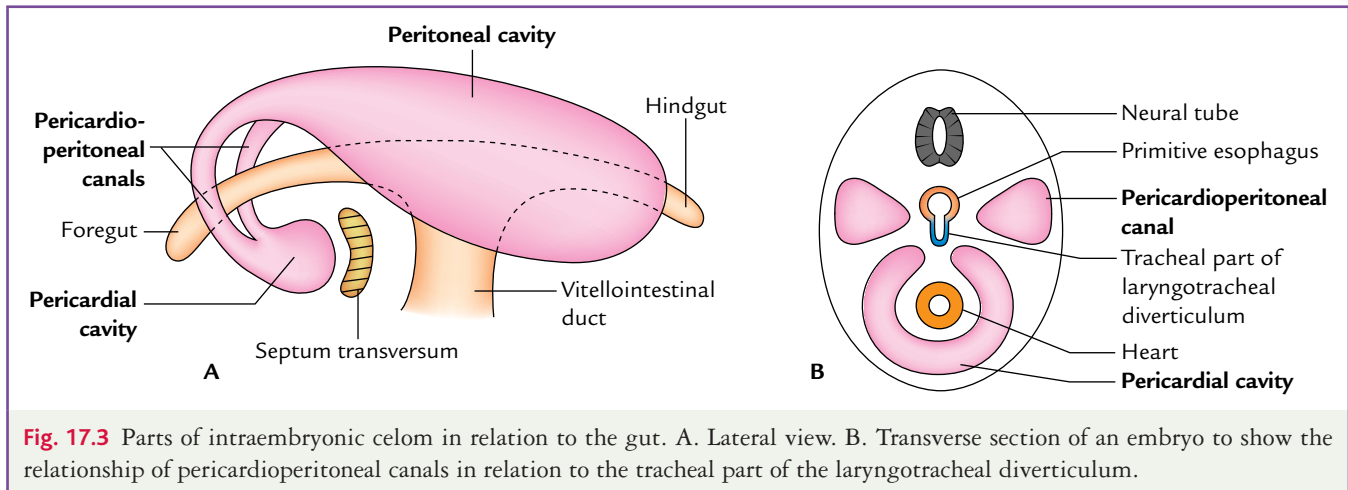


Fig. 17.2 Primitive intraembryonic celom. A. Subdivisions of intraembryonic celom. B. Fusion of two primitive cavities to form single peritoneal cavity.



N.B. The intraembryonic celom provides room for organs to develop and move.

Partitioning of the Intraembryonic Celom

To form the definitive pericardial, pleural, and peritoneal cavities from a single intraembryonic celom, three partitions develop. These are:

- Paired pleuropericardial membranes
- Diaphragm.

Development of Pleuropericardial Membranes (Fig. 17.4)

Each pleuroperitoneal canal lies lateral to the **primitive esophagus** and dorsal to the **septum transversum**. The septum transversum is a thick plate of mesodermal tissue that occupies space between the thoracic and abdominal cavities.

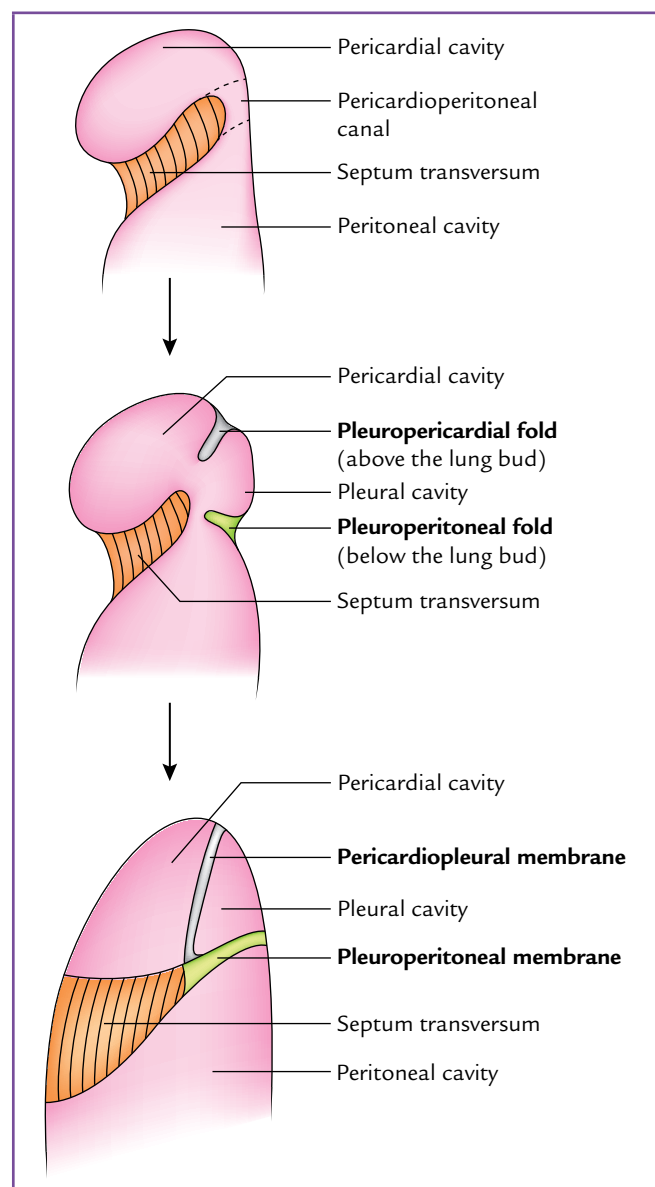
A partition forms in each pericardioperitoneal canal that separates the pericardial cavity from the peritoneal cavity.

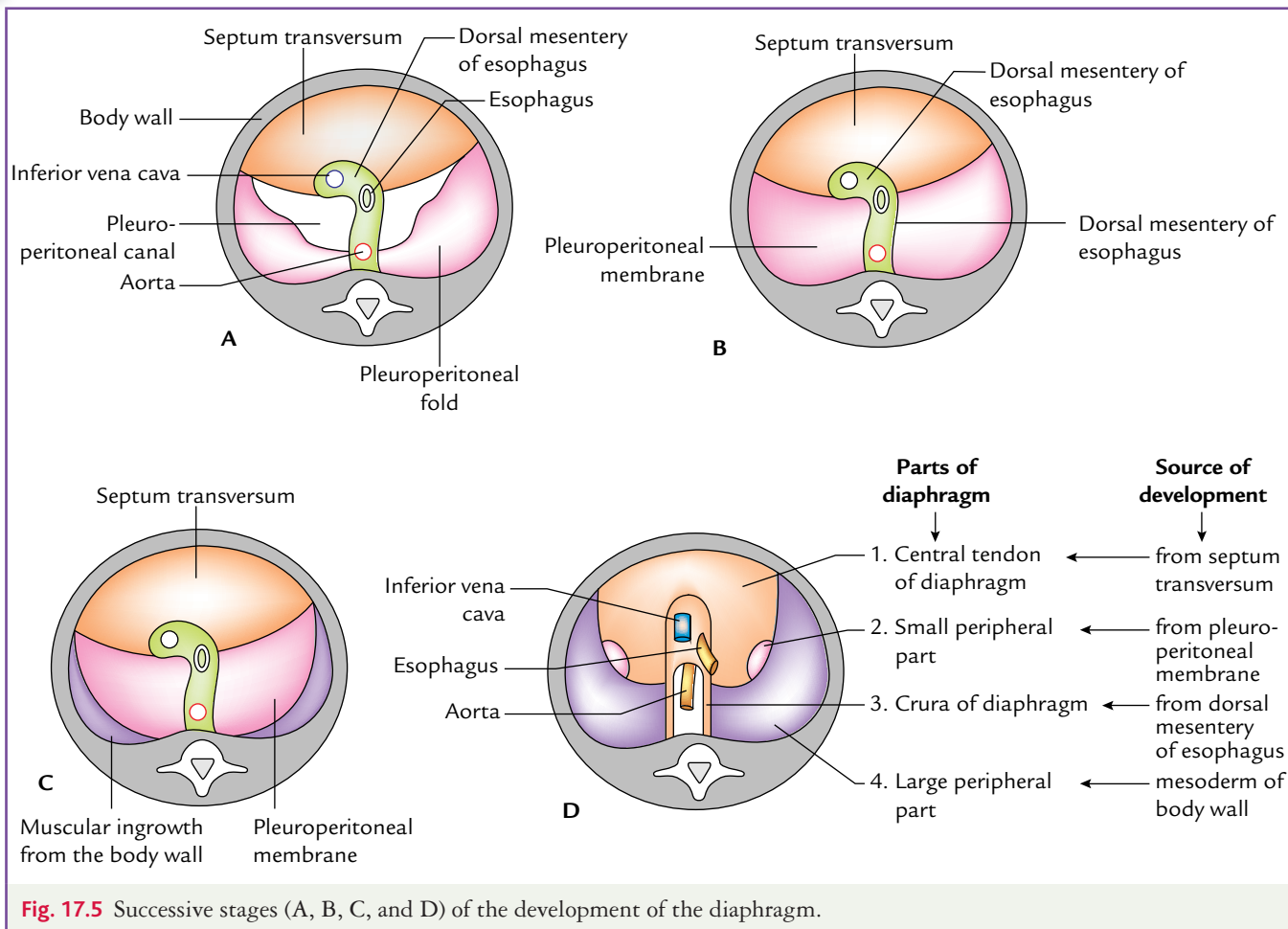
With the growth of lung bud into the pericardioperitoneal canal, a pair of membranous ridges is produced in the lateral wall of this canal. These are:

1. A cranial ridge called **pleuropericardial fold** above the developing lung.
2. Caudal ridge called **pleuroperitoneal fold** below the lung bud.

The pleuropericardial folds separate the pericardial cavity from the pleural cavities as they enlarge. Gradually the folds become membranous and form the **pleuropericardial membranes**.

As the pleuroperitoneal fold enlarges, it projects into the pericardioperitoneal canal. Gradually the fold becomes membranous and forms the **pleuroperitoneal membrane**.





Development of the Diaphragm (Figs 17.5 and 17.6)

The diaphragm is a dome-shaped musculotendinous partition that separates thoracic cavity from the abdominal cavity. The pericardial and pleural cavities lie above the diaphragm while the peritoneal cavity lies below the diaphragm.

The diaphragm is a composite structure that develops from four embryonic components. These are:

1. Septum transversum
2. Paired pleuroperitoneal membranes
3. Dorsal mesentery of esophagus
4. Mesoderm of body wall

N.B. Several genes on the long arm of chromosome 15 (15q) play a critical role in the development of the diaphragm.

1. The **septum transversum** lies between pericardial and peritoneal cavities. Dorsal to it lies esophagus with its surrounding mesoderm and mesentery (**dorsal mesentery of esophagus**). On each side, dorsolateral to septum transversum, pleural and peritoneal cavities communicate with each other through **pleuroperitoneal canals**.

The liver develops in the caudal part of septum transversum. The cranial part of septum transversum forms the central tendon of diaphragm.

2. The **pleuroperitoneal membranes** develop and close the pleuroperitoneal canals. They fuse with the dorsal mesentery of the esophagus and the septum transversum. The pleuroperitoneal membranes not only form a large portion of early fetal diaphragm but also represent only small portion of the diaphragm in the newborn.
3. The **dorsal mesentery of the diaphragm** is invaded by myoblasts and forms **crura of the diaphragm**.
4. On each side, the developing pleural cavity (pleuroperitoneal canal) burrows into the lateral body wall and splits it into two layers: external and internal (Fig. 17.6).
 - (a) The external layer forms the definitive body wall.
 - (b) The internal layer forms the peripheral parts of the diaphragm external to the parts derived from the pleuroperitoneal membranes.

The development of the diaphragm is summarized in Table 17.1.

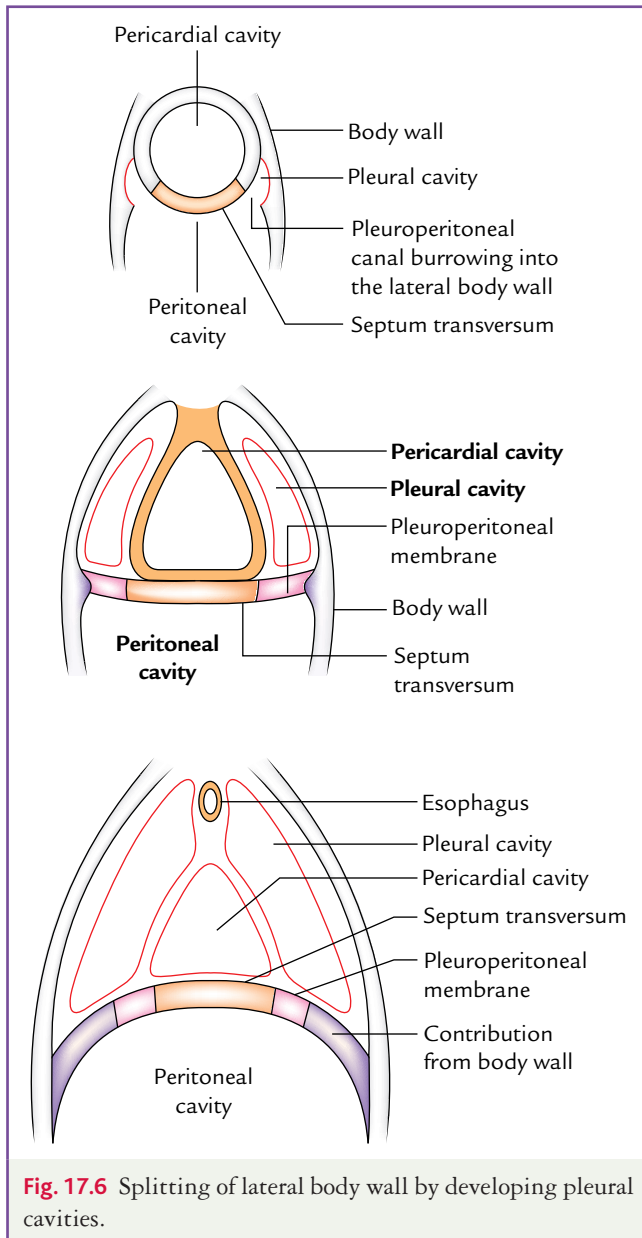


Fig. 17.6 Splitting of lateral body wall by developing pleural cavities.

Table 17.1 Development of diaphragm

Embryonic structures	Adult derivatives
1. Septum transversum	Central tendon of diaphragm
2. Pleuroperitoneal membranes	Small peripheral part of diaphragm
3. Dorsal mesentery of esophagus	Crura of diaphragm
4. Mesoderm of the body wall	Large peripheral parts of diaphragm external to parts derived from pleuroperitoneal membranes

Nerve Supply of Diaphragm

At first (viz., during the fourth week of IUL), the septum transversum lies in the cervical region opposite third, fourth, and fifth cervical somites and is supplied by corresponding cervical spinal segments (i.e., C3, C4, and C5).

The **phrenic nerve** (root value C3, C4, and C5) reaches the diaphragm through pleuropericardial folds. Later (viz., by the sixth week of IUL) the diaphragm descends caudally to its definitive position—the thoracoabdominal junction opposite T7–T12 spinal segments. The descent of diaphragm occurs due to elongation of neck, descent of heart, and expansion of pleural cavities. When the diaphragm descends, it carries its nerve supply with it; hence the diaphragm is supplied by the phrenic nerve.

Since the peripheral parts of the diaphragm develop from the lateral body wall, it receives its sensory innervation from lower intercostal nerves.

N.B. Position of septum transversum: During the fourth week, the septum transversum lies opposite to cervical somites (C3, C4, and C5) and by the sixth week, it lies at the level of thoracic somites (T7–T12).

Clinical Correlation

1. **Congenital diaphragmatic hernia (CDH):** It is a herniation of abdominal contents into the pleural cavity through a large gap/defect present in posterolateral part of diaphragm most commonly on the left side (Fig. 17.7).

This defect (also called **foramen of Bochdalek**) occurs due to defective development of **pleuroperitoneal membrane** or failure of fusion of pleuroperitoneal membrane with other elements of the diaphragm.

When the abdominal contents like intestines, stomach, and/or spleen herniate in the thorax, they compress the developing lungs and cause their hypoplasia (Fig. 17.8).

The diaphragmatic hernia is more common on the left side probably because right pleuroperitoneal canal closes earlier than the left one.

2. **Congenital hiatus hernia (CHH):** It is a herniation of part of fetal stomach through an excessively large esophageal hiatus

in the diaphragm, through which esophagus and vagus nerves pass.

The congenital hiatal hernia is uncommon. But the congenitally enlarged esophageal hiatus may be a predisposing factor for **acquired hiatal hernia**.

3. **Retrosternal hernia (parasternal hernia):** Here there is a large gap in sternocostal part of the diaphragm between the sternal and costal slips of diaphragm (**foramen of Morgagni**) through which the intestines may herniate into the pericardial cavity or conversely a part of heart may herniate into the epigastric region.
4. **Eventration of diaphragm:** In this condition, musculature in one-half of the diaphragm remains thin and membranous, and hence balloons out in the thorax forming a diaphragmatic pouch because of upward displacement of abdominal viscera. This anomaly occurs when muscular tissue does not develop in pleuroperitoneal membrane. It is more common on the left side.

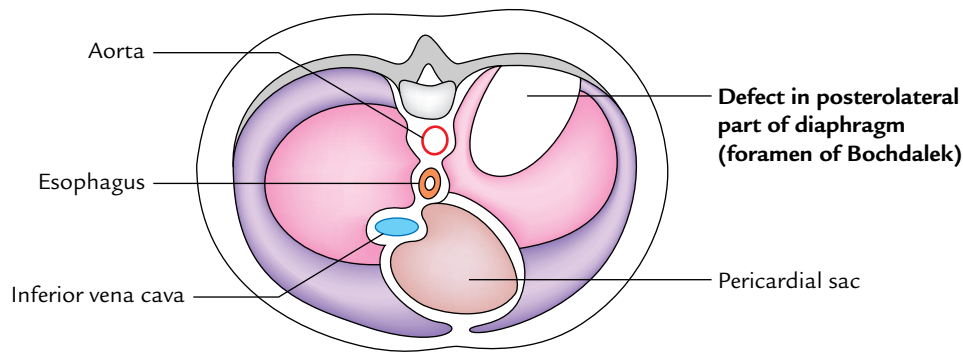


Fig. 17.7 Defect in the posterolateral part of the diaphragm.

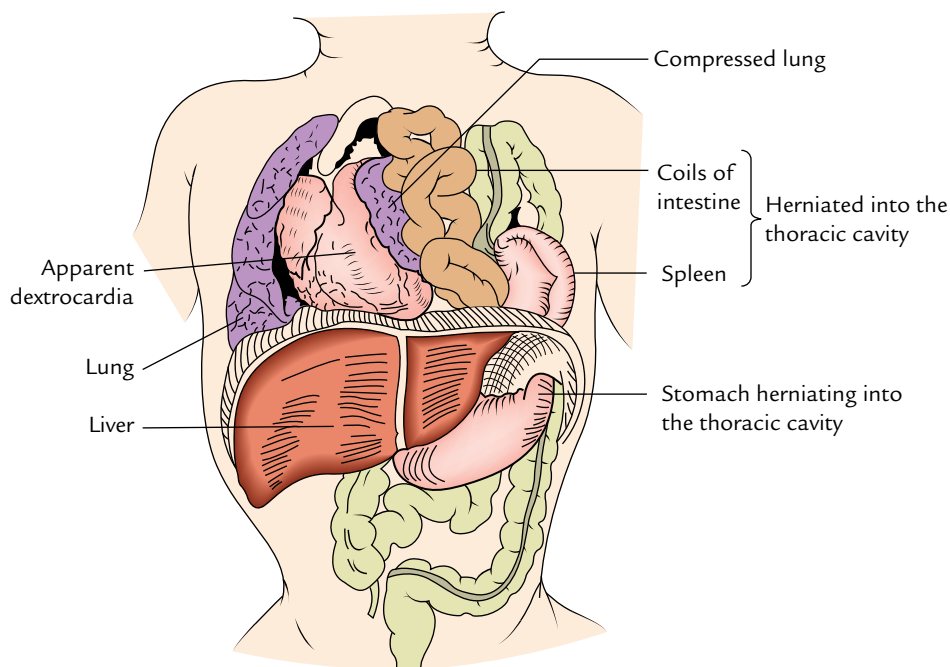


Fig. 17.8 Congenital diaphragmatic hernia.

This anomaly is similar to congenital diaphragmatic hernia because there is superior displacement of abdominal viscera into the pocket-like outpouching of the diaphragm. But note, it is not a true diaphragmatic hernia.

N.B. The clinical manifestations of eventration of the diaphragm may simulate CDH. The defect can be corrected surgically by mobilizing a muscular flap from a muscle of the back, e.g., latissimus dorsi or prosthetic patch to strengthen the diaphragm.

Further Details of Body Cavities

Further details of the three body cavities and associated structures are discussed in the following text.

Pericardial Cavity

The primitive pericardial cavity bulges ventrally between the stomodeum (cranially) and the septum transversum (caudally). The primitive heart tube lies dorsal to the pericardial cavity. The development of the

pericardial cavity is closely related to development of the heart; hence it is described in detail in Chapter 18.

Pleural Cavity

Right and left pleural cavities develop from right and left pericardioperitoneal canals.

The pleural cavities at first lie dorsolateral to the pericardial cavity and communicate with it by pericardiopleural canals. As the pleural cavities enlarge and heart descends, the *pleuropericardial membranes* derived

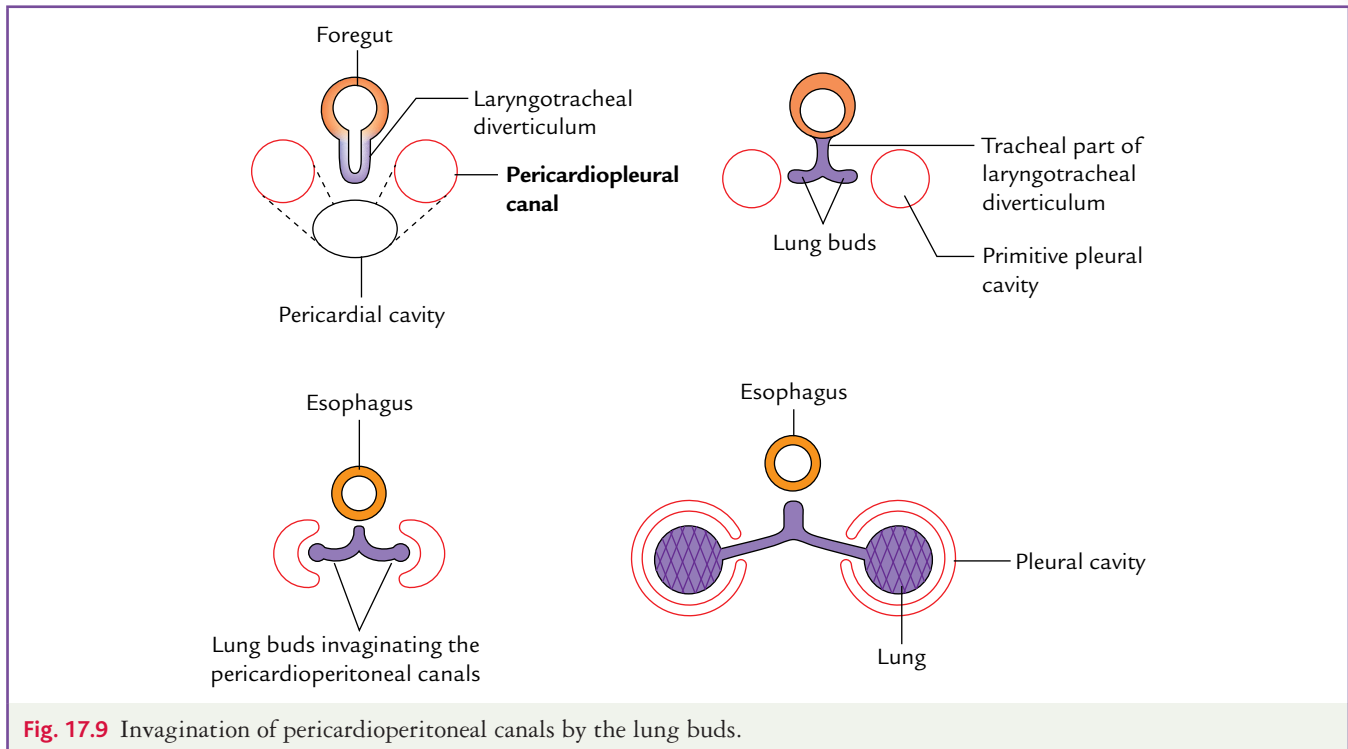


Fig. 17.9 Invagination of pericardioperitoneal canals by the lung buds.

from *pleuropericardial folds* project into the pleuropericardial canals and ultimately separate the pleural cavities from pericardial cavity. The lung buds arise from tracheal part of the laryngotracheal diverticulum and invaginate the primitive pleural cavities to form the definitive pleural cavities (Fig. 17.9).

Each pleural cavity communicates caudally with peritoneal cavity by a wide **pleuroperitoneal canal**. Later on this communication is closed by pleuroperitoneal membrane.

N.B. It is important to note that with the expansion of the pleural cavity the mesoderm of the body wall splits into two parts: (a) an outer part that forms the thoracic wall, and (b) an inner part that lies over the pericardial cavity and is called **pleuropericardial membrane**. The phrenic nerve runs through this membrane (Fig. 17.10). Later the pleuropericardial membrane forms the fibrous pericardium. This provides the embryological basis of **course of the phrenic nerve** over fibrous pericardium.

Peritoneal Cavity

It is the largest of the three body cavities. During lateral folding of embryo, the distal parts of the lateral limbs of the horseshoe-shaped intraembryonic celom come closer to each other and fuse to form a single large peritoneal cavity. The peritoneal cavity is connected with the extraembryonic celom at the umbilicus. The peritoneal cavity loses its connection with the extraembryonic celom during the tenth week of IUL following return of midgut loop into the abdomen from the umbilicus. The **splanchnopleuric intraembryonic**

mesoderm in addition to forming the wall of the gut also differentiates into a layer of mesothelial cells—the **mesothelium**—which lines the peritoneal cavity. It is called the **visceral layer of peritoneum**; the **parietal layer of peritoneum** lines the body wall. The line of reflection of parietal peritoneum to visceral peritoneum forms the **mesentery of various organs**.

Mesentery

The mesentery is a double-layered fold of visceral peritoneum that connects the primitive gut with the body wall and conveys nerves and vessels to it.

Transiently the dorsal and ventral mesenteries divide the peritoneal cavity into right and left halves (Fig. 17.11A).

The ventral mesentery soon disappears, except where it is attached to the distal part of the foregut (which forms stomach and proximal part of the duodenum). As a result, the peritoneal cavity now becomes a continuous space (Fig. 17.11B).

Development of Lesser Sac

The lesser sac is a part of the peritoneal cavity that lies behind the stomach and lesser omentum. It communicates with the peritoneal cavity through a small opening called **foramen epiploicum** (*foramen of Winslow*).

Development of lesser sac is closely related to the development of the stomach and involves following three distinct processes of peritoneum to occur (Figs 17.12 and 17.13).

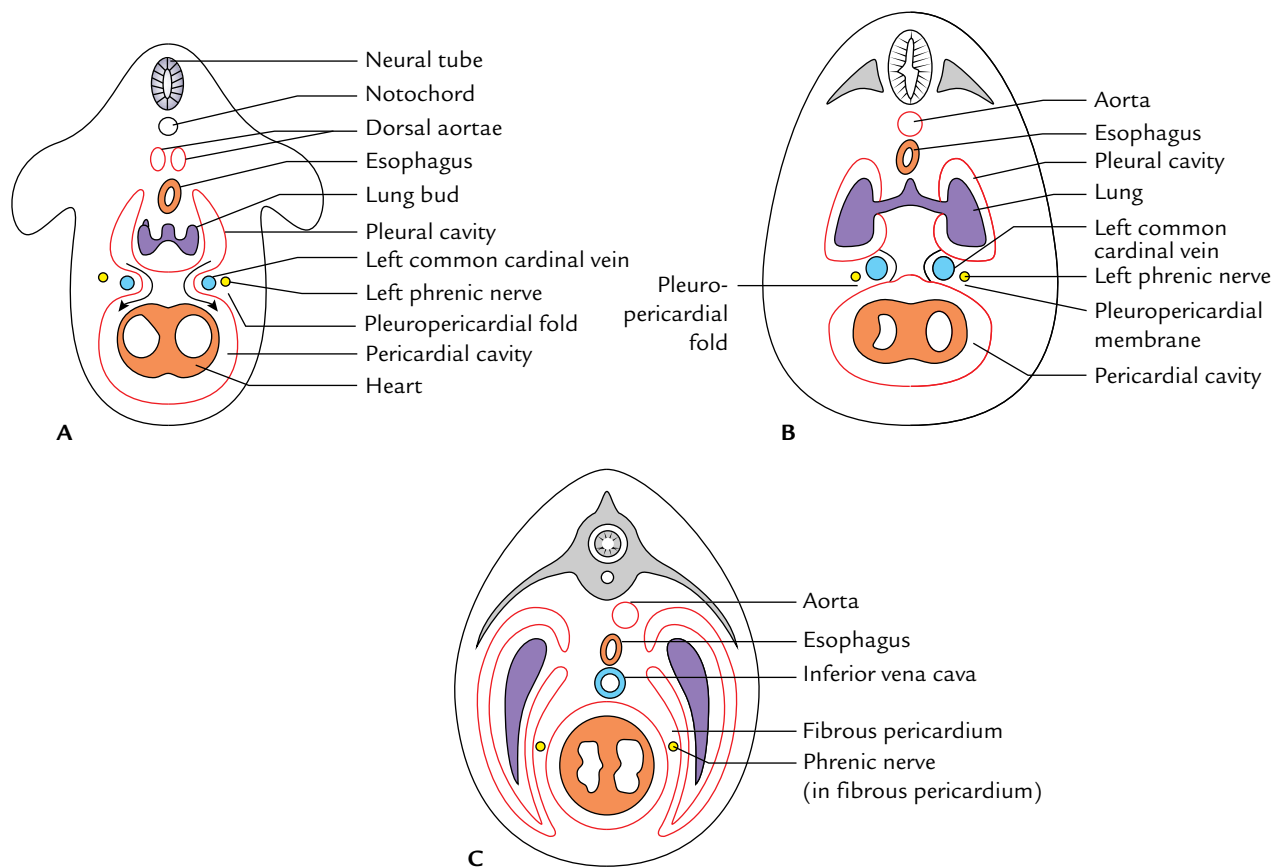


Fig. 17.10 Transverse section through embryos cranial to septum transversum. A. Position of pleuropericardial canals and pleuropericardial folds. B. Development of pleural cavities due to growth of lungs and formation of pleuropericardial membrane. Fusion of pleuropericardial membranes. Note the position of phrenic nerve in the fibrous pericardium.

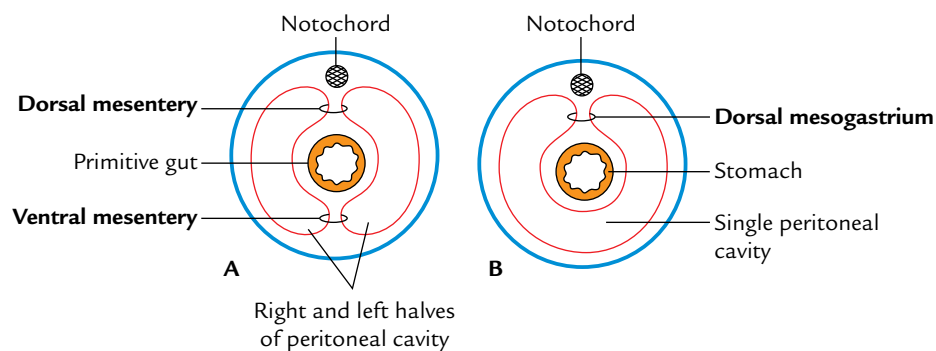


Fig. 17.11 Mesentery of the primitive gut.

First process Two small cavities appear in thick dorsal mesogastrum—the **right and left pneumoenteric recesses** (Fig. 17.12B). The **left pneumoenteric recess** disappears. The **right pneumoenteric recess** enlarges and extends to the left to open into the peritoneal cavity.

The right pneumoenteric recess also extends cranially behind the liver and by the side of esophagus to form the **superior recess of lesser sac**. With the

development of diaphragm, the part of superior recess above the diaphragm becomes detached and forms the **infracardiac bursa**.

N.B. Part of cranial extension of right pneumoenteric recess below the diaphragm forms **infracardiac recess**.

Second process When the right pneumoenteric recess extends to the left, there occurs a counterclockwise rotation of the stomach around the longitudinal axis. As a

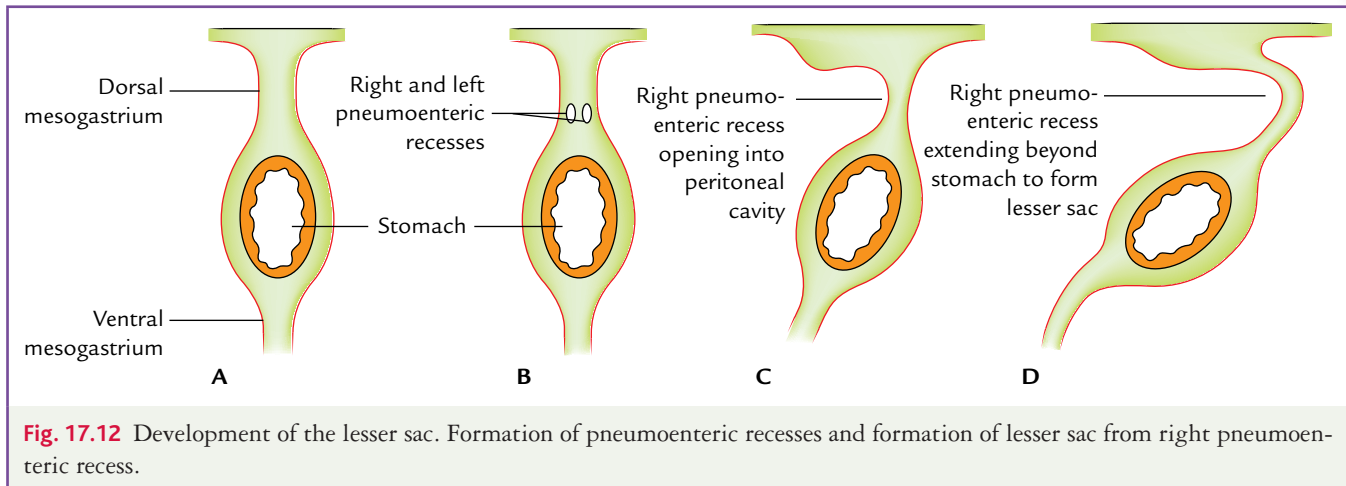


Fig. 17.12 Development of the lesser sac. Formation of pneumoenteric recesses and formation of lesser sac from right pneumoenteric recess.

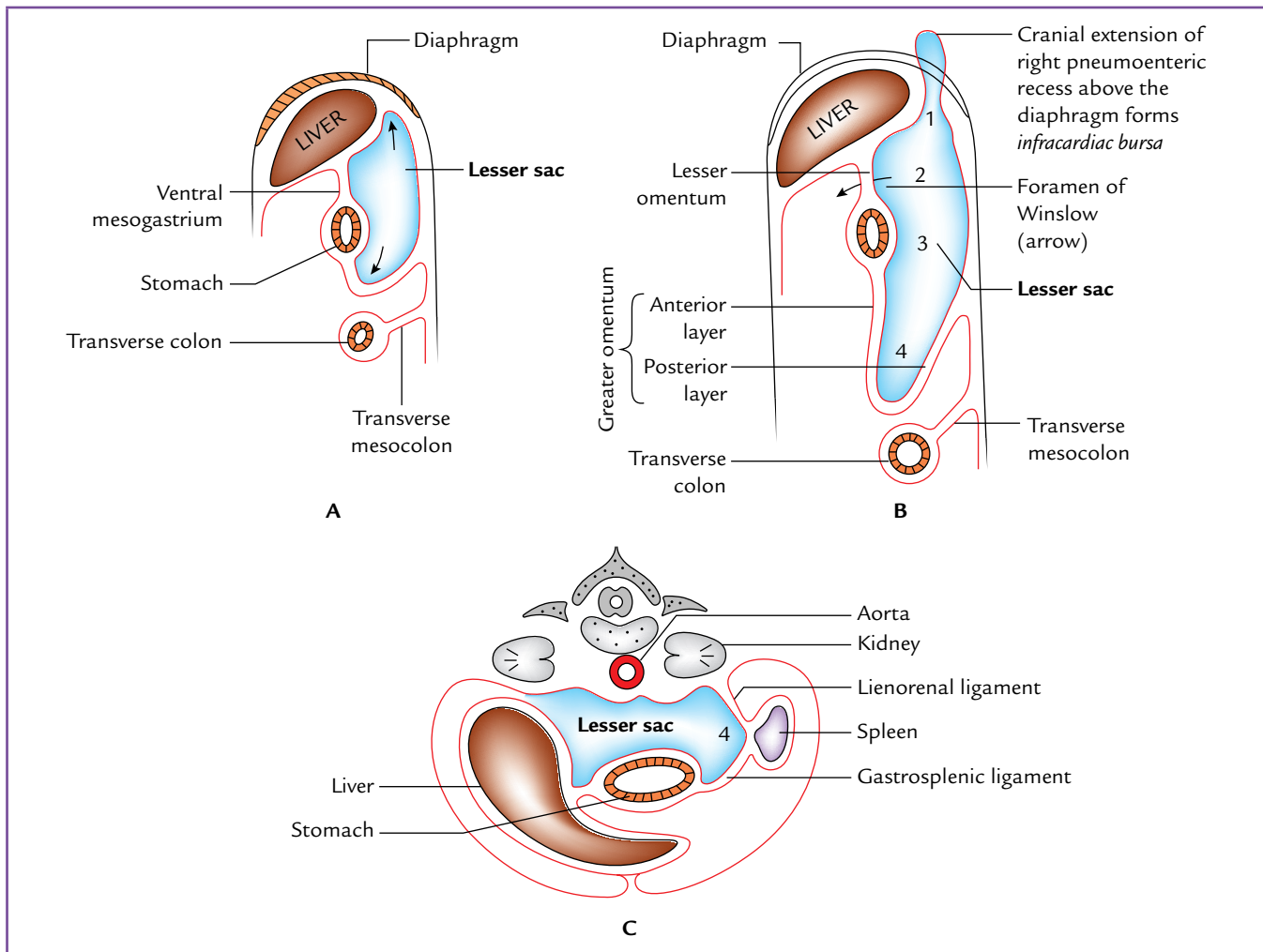


Fig. 17.13 Sagittal section of developing peritoneal cavity showing the development of lesser sac. A. and B. Downward and cranial extensions of lesser sac. C. Formation of splenic recess. Note, derivations of parts of sac are numbered by Arabic numerals: 1. from cranial extension of pneumoenteric recess, 2. from parts of the peritoneal cavity that come to lie behind ventral mesogastrium, 3. from right pneumoenteric recess, and 4. from cavity provided by elongation and folding of the greater omentum on itself and from cavity between gastrosplenic and lienorenal ligaments.

result, the ventral mesogastrium shifts to the right (**lesser omentum**), dorsal mesogastrium shifts to the left, left surface becomes anterior, and right surface becomes posterior. As a result of this rotation, the part of the

peritoneal cavity now lies behind the stomach and lesser omentum; it forms the **vestibule of lesser sac**, which is continuous on the left side with the small part of lesser sac developed from **right pneumoenteric recess**.

CLINICAL PROBLEM SOLUTIONS

1. The diaphragm is innervated by phrenic nerves (C3, C4, and C5) because diaphragm develops in the cervical region opposite C3, C4, and C5 spinal segments. When the diaphragm descends in the thoracic region it carries its nerve supply (phrenic nerves) with it.
The lateral parts of diaphragm develop from lateral thoracic wall opposite T7–T12 spinal segments, hence it receives its sensory innervation from the lower thoracic spinal (intercostal) nerves.
2. Due to expansion (burrowing) of primitive pleural cavity (pleuroperitoneal canal) into the lateral body wall → the mesoderm of lateral thoracic wall splits into two parts: lateral and medial. The lateral part forms the thoracic wall, while medial part forms the pleuropericardial membrane. The **phrenic nerve** runs through this membrane, which later forms the fibrous pericardium. This provides the embryological basis of intimate relationship of phrenic nerve with the fibrous pericardium.
3. The most likely diagnosis is **congenital diaphragmatic hernia (CDH)**. In this condition the abdominal viscera, viz., loops of small intestine herniate through a defect in the posterolateral part of the diaphragm (usually on the left side) into the thoracic cavity. This causes compression and hypoplasia of lungs, especially the left one and consequent severe respiratory distress and cyanosis.
The defect in the diaphragm causing CDH can be detected prenatally by ultrasonography. The ultrasonography reveals characteristic air- and/or fluid-filled spaces indicating loops of the small intestine in the left hemithorax.
4. The congenital defect in this condition is enlarged **sternocostal hiatus (foramen of Morgagni)** between the sternal and adjoining costal slips of origin of diaphragm. This defect either leads to herniation of intestine into the pericardial sac or displacement of heart into the superior part of the peritoneal cavity. The defect occurs if the sternal and costal slips of the diaphragm are poorly developed or fail to develop.

N.B. The radiologists often note the fatty herniation through the sternocostal hiatus, but it is of no clinical relevance.

18

Development of Heart

Overview

The heart is mesodermal in origin. It develops from **primitive heart tube**, which forms from mesenchyme in the **cardiogenic area of the embryo**. This tube forms the **endocardium** of the heart. The splanchnic mesoderm surrounding the primitive heart tube forms **myocardium** and **epicardium**. The heart starts functioning at the end of the third week of intrauterine life (IUL), i.e., on day 22. The blood flow begins during the fourth week of IUL and can be visualized by Doppler ultrasonography.

N.B. Cardiogenic area (Fig. 18.1): It is an area at the cranial end of trilaminar embryonic disc between the septum transversum and prochordal plate. The part of intraembryonic celom lying in this area forms pericardial cavity and the splanchnopleuric mesoderm underneath the pericardial cavity forms the heart tube.

Formation of Heart Tube and its Subdivisions

The mesenchymal cells in the cardiogenic area located ventral to the developing pericardial cavity condense to form two angioblastic cords called **cardiogenic cords**. These cords get canalized to form two **endothelial heart tubes** (Fig. 18.2).

These tubes fuse with each other in a craniocaudal direction to form a **single primitive heart tube**.

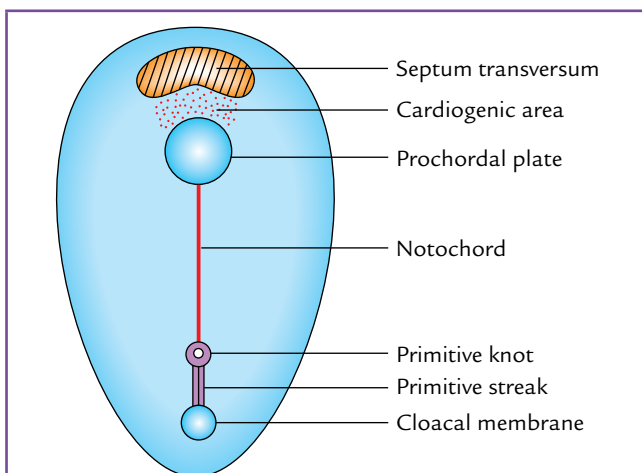


Fig. 18.1 Location of cardiogenic area.

However, the caudal ends of two heart tubes fail to fuse with each other. As a result, the caudal end of the heart tube remains bifurcated.

The heart tube forms five dilatations. From cranial-to-caudal end, these are (Fig. 18.3) as follows:

1. Truncus arteriosus
2. Bulbus cordis
3. Primitive ventricle
4. Primitive atrium
5. Sinus venosus.

The truncus arteriosus is the arterial end of the primitive heart tube, while sinus venosus is the venous end of this tube.

Since the fusion of the heart tube is partial in the region of sinus venosus, it consists of a central part that communicates with the primitive atrium and right and left horns of sinus venosus that represent unfused caudal parts of the two heart tubes.

Arterial and Venous Ends of the Heart Tube

Arterial End

The truncus arteriosus represents the arterial end of the heart (vide supra). Cranially it is continuous with aortic

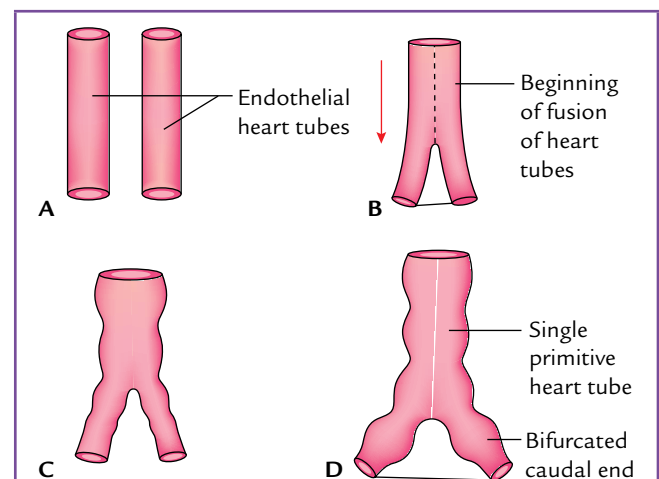
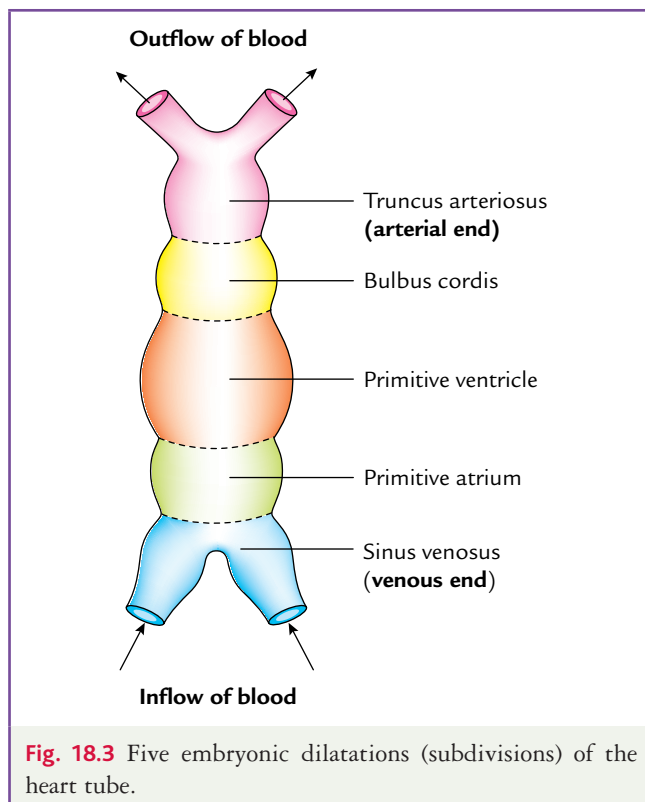


Fig. 18.2 Fusion of the endothelial heart tubes.

sac having right and left horns. From each horn of aortic sac, the **first pharyngeal arch artery** arises and passes backwards on the lateral side of the foregut to become continuous with the **respective dorsal aorta** (Fig. 18.4A).

Venous End

The sinus venosus represents the venous end of the heart (vide supra). Each horn of sinus venosus receives three primitive veins: (a) *vitelline vein* from the yolk sac, (b) *umbilical vein* from the placenta, and (c) *common cardinal vein* from the body wall (Fig. 18.4B).



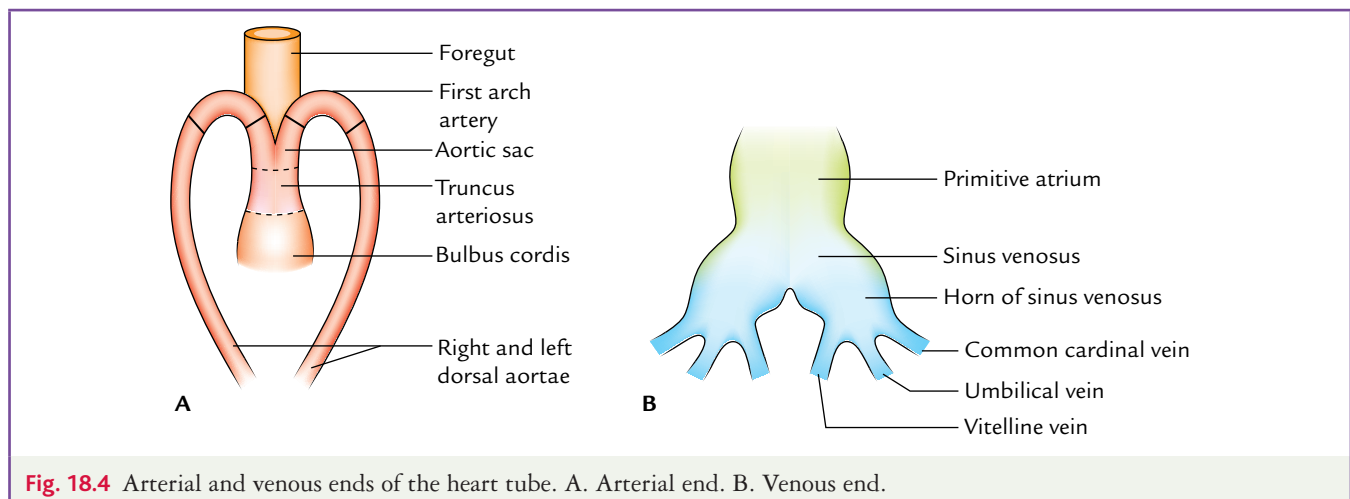
Fate of Various Dilatations of the Heart Tube

1. The **central part and right horn of sinus venosus** are absorbed into the primitive atrium to form the smooth part of the right atrium. The **left horn of sinus venosus** forms part of coronary sinus that opens into the smooth part of the right atrium.
2. **Primitive atrium** is partitioned to form rough part of right and left atria.
3. **Primitive ventricle and bulbus cordis** are partitioned to form the right and left ventricles.
 - (a) The *primitive ventricle* forms the rough inflowing part of the right and left ventricles.
 - (b) The *bulbus cordis* forms the smooth outflowing part of the right and left ventricles.
4. **Truncus arteriosus** is partitioned to form the ascending aorta and pulmonary trunk.

The fate of embryonic dilatations of the primitive heart tube is summarized in Table 18.1.

Table 18.1 Fate of the embryonic dilatations of the primitive heart tube

Embryonic dilatation	Adult derivatives
1. Truncus arteriosus	Ascending aorta Pulmonary trunk
2. Bulbus cordis	Smooth upper part of the right ventricle (conus arteriosus) Smooth upper part of the left ventricle (aortic vestibule)
3. Primitive ventricle	Trabeculated part of the right ventricle Trabeculated part of the left ventricle
4. Primitive atrium	Trabeculated part of the right atrium Trabeculated part of the left atrium
5. Sinus venosus	Smooth part of the right atrium (sinus venarum) Coronary sinus Oblique vein of the left atrium



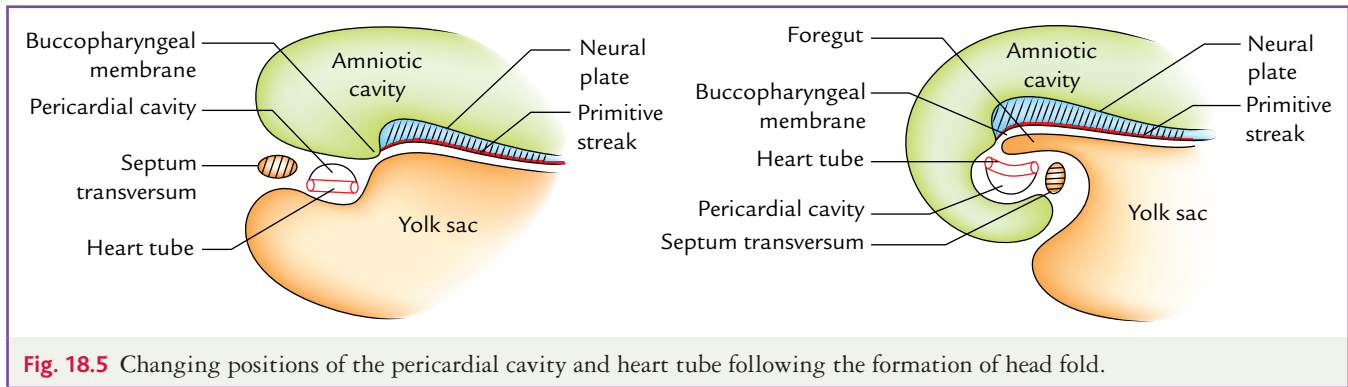


Fig. 18.5 Changing positions of the pericardial cavity and heart tube following the formation of head fold.

N.B. The smooth part of the left atrium is formed by the incorporation of pulmonary veins into the left atrium.

Position of Heart Tube in Relation to Pericardial Cavity

Before the formation of the head fold, the endothelial heart tube lies in the floor of the pericardial cavity caudal to septum transversum. After the formation of the head fold, the pericardial cavity and heart tube comes to lie ventral to the foregut and cranial to the septum transversum, with heart tube lying on the roof of the pericardial cavity.

N.B. During formation of head fold, the pericardial cavity and heart tube undergoes 180° rotation; as a result, the heart tube comes to lie on the roof of the pericardial cavity (Fig. 18.5).

Formation of Cardiac Wall

The cardiac wall is made up of three layers. From inside to outside, these are:

1. Endocardium
2. Myocardium
3. Epicardium

These layers develop as follows (Fig. 18.6):

The splanchnopleuric mesoderm on dorsal aspect of the pericardial cavity proliferates and becomes thick to form **myoepicardial mantle**, which invests the front and sides of endothelial heart tube. At this stage, the heart tube is separated from myoepicardial mantle (primordial myocardium) by a cellular gelatinous connective tissue called **cardiac jelly**, which is an acellular matrix secreted by developing myocardium. Subsequently it is replaced by the myocardium.

- The **endothelial heart tube** forms the **endocardium** of the heart.
- The **myoepicardial mantle** forms the **myocardium** and the **epicardium**.

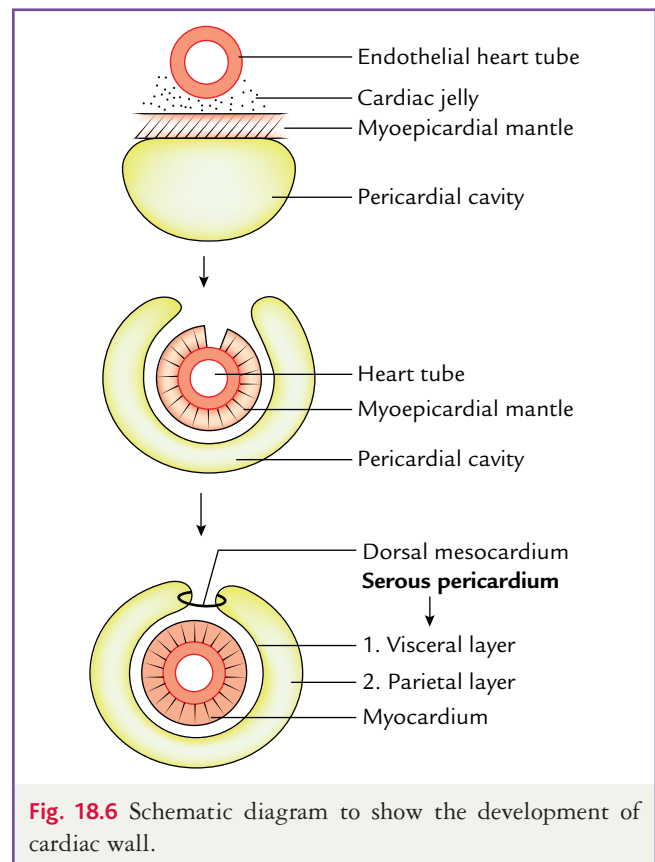


Fig. 18.6 Schematic diagram to show the development of cardiac wall.

Acquisition of External Adult Form of the Heart (Figs 18.7 and 18.8)

The sacculated primitive heart tube acquires adult form of the heart as follows:

1. As the development progresses, the sacculated heart tube particularly bulbus cordis and primitive ventricle grows rapidly in a limited space dorsal to the pericardial cavity. Since the arterial and venous ends of the heart tube are fixed, it gradually invaginates into the pericardial cavity in a 'U' shaped manner; thus forming a **cardiac loop**. This cardiac loop mainly involves **bulbus cordis** forming **cephalic limb of the loop** and primitive ventricle forming

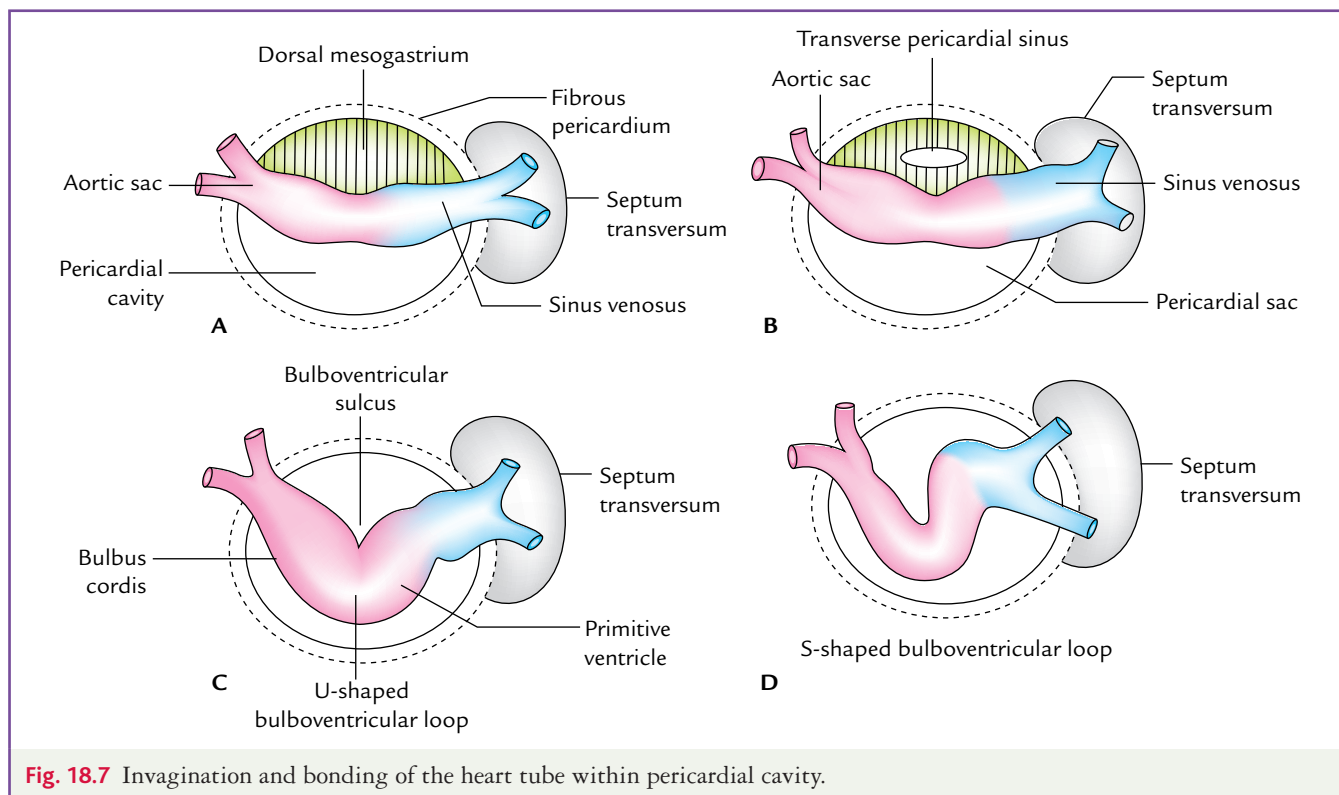


Fig. 18.7 Invagination and bonding of the heart tube within pericardial cavity.

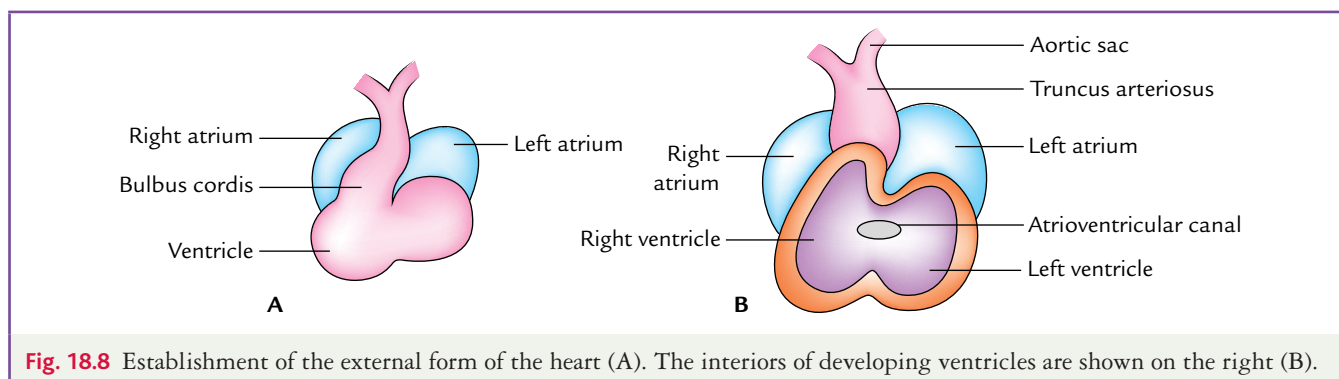


Fig. 18.8 Establishment of the external form of the heart (A). The interiors of developing ventricles are shown on the right (B).

the **caudal limb of the loop**. Hence this loop is also called **bulboventricular loop**.

- Initially the bulboventricular loop is suspended from the dorsal wall of the pericardial sac by a mesentery called **dorsal mesocardium**, but the central part of this mesentery soon degenerates forming a communication between the right and left sides of the pericardial cavity—the **transverse pericardial sinus**.
- As the transverse pericardial sinus forms, the bulboventricular loop lies free in the pericardial cavity, but the primitive atrium and sinus venosus lies outside the pericardial cavity embedded in the septum transversum.
- As the primitive atrium and sinus venosus get freed from the septum transversum, they enter in

the pericardial cavity and occupy position postero-superior to the ventricle. The heart tube now becomes S shaped.

- The bulboventricular sulcus disappears, and bulbus cordis and primitive ventricle together form a common chamber.
- The atrial chamber that lies behind the above truncus arteriosus expands. As it does so parts of it come to project forwards on either side of truncus arteriosus as auricles.

Clinical Correlation

- Dextrocardia (Fig. 18.9):** In this condition, all the chambers of the heart and associated blood vessels are reversed as a mirror image, i.e., all the structures that normally lie on to the

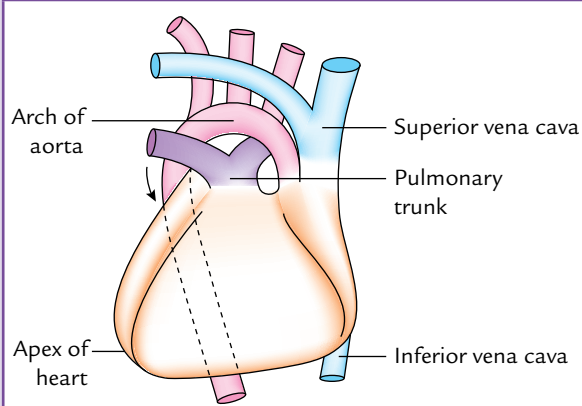


Fig. 18.9 Dextrocardia.

right side are on to the left. It occurs if heart tube bends to the left instead of the right, the heart is displaced to the right, and there is transposition. The dextrocardia may be associated with **situs inversus** (transposition of abdominal viscera). The **dextrocardia is the most common positional anomaly of the heart.**

2. **Ectopia cordis (Fig. 18.10):** It is a rare condition in which the heart lies exposed on the surface of the thorax. It occurs due to nonunion of two sternal plates of developing sternum. Death occurs in most of the cases during first few days of the birth.

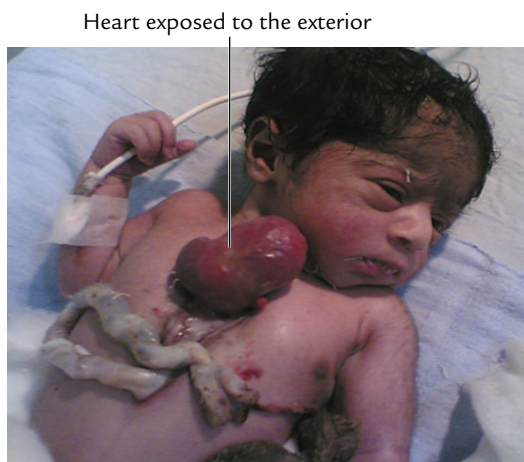

Fig. 18.10 A newborn baby with ectopia cordis.

Development of Various Chambers of the Heart

The primitive heart tube has a single lumen. This lumen is partitioned into four definitive chambers by the formation of four septa. These septa are:

1. Atrioventricular septum
2. Interatrial septum
3. Interventricular septum
4. Aorticopulmonary septum.

In addition to the formation of septae, other embryological events such as regression and absorption of sinus venosus into the right atrium and absorption of pulmonary veins into the left atrium also help in the formation of definitive chambers of the heart.

Formation of Atrioventricular Septum (Fig. 18.11)

The atrioventricular (AV) septum divides the AV canal into right and left AV canals (partitioning of AV canal). The AV septum is formed by the fusion of AV cushions as under:

Two thickenings appear—one on dorsal wall and one on ventral wall of AV canal. These are called **atrioventricular cushions** or **endocardial cushions** or **AV cushions**. They grow towards each other and fuse together to form **AV septum** (also called **septum intermedium**) that divides the AV canal into right and left AV canals (vide supra).

Formation of Interatrial Septum (Fig. 18.12)

The interatrial septum divides the primitive atrium into the right and left atria.

It is formed as under:

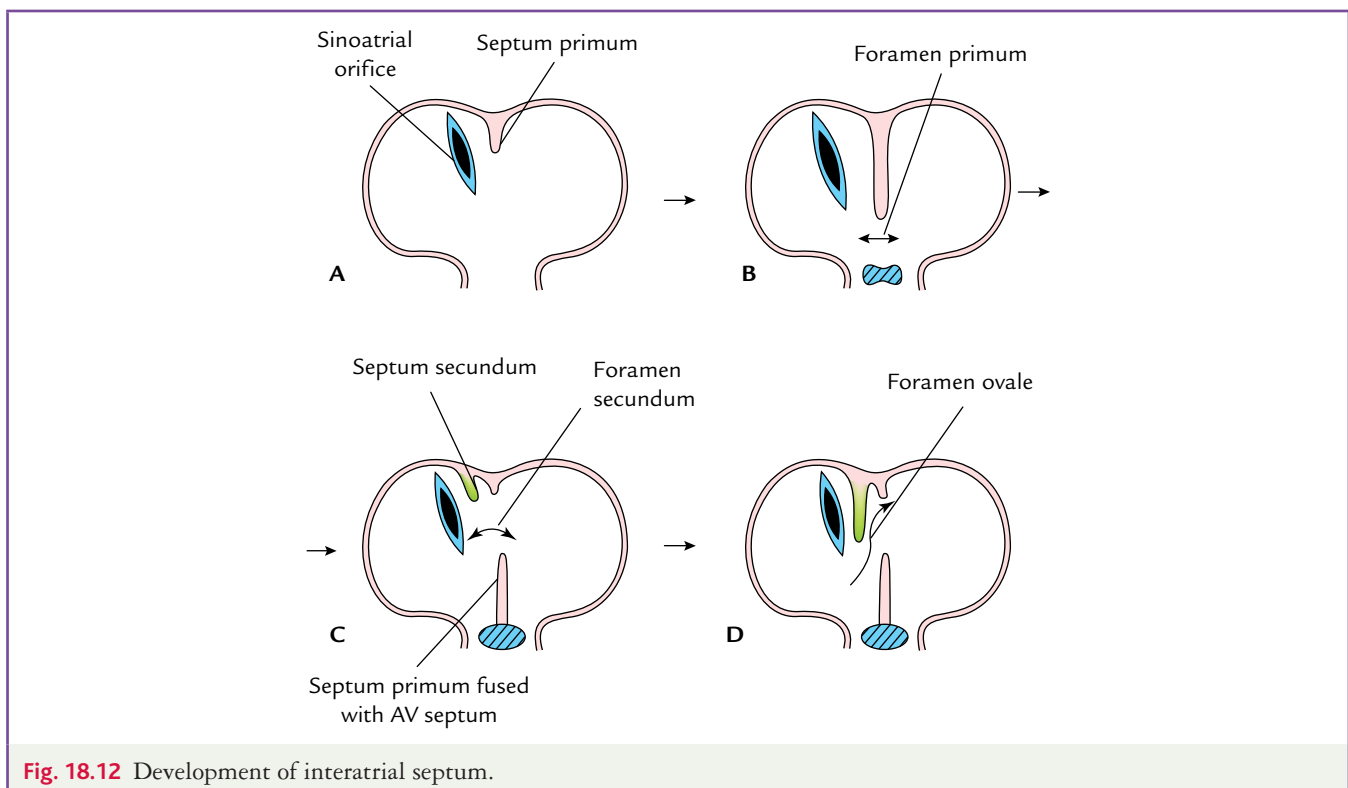
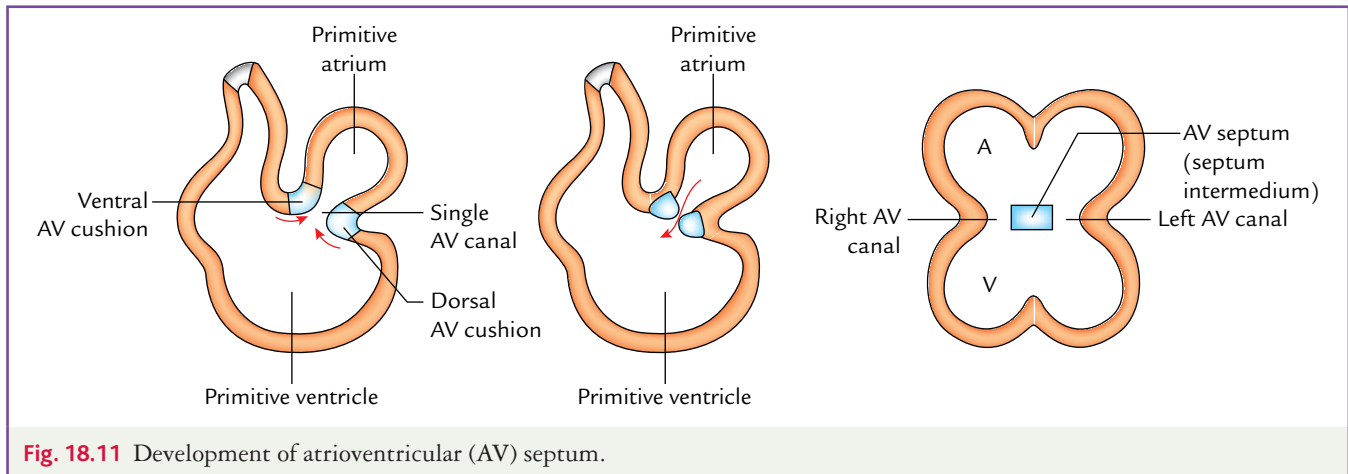
The interatrial septum is formed by two septa—*septum primum* and *septum secundum*. *Septum primum* starts developing from the roof of the primitive atrial chamber a little to the left of the opening of sinus venosus. It is crescent shaped and is present in an oblique plane. It grows downward towards **septum intermedium** (AV septum). The gap between the lower edge of *septum primum* and *septum intermedium* is called **foramen primum**.

As **septum primum** fuses with AV septum (*septum intermedium*), the upper part of *septum primum* breaks down. The foramen thus formed is called **foramen secundum** (**ostium secundum**).

A second crescent-shaped septum now arises from the roof of primitive atrial chamber immediately to the right of *septum primum*. It is called **septum secundum**.

The *septum secundum* grows downward towards *septum intermedium*. It overlaps the **foramen secundum**. The right and left atria now communicate with each other through an oblique valvular passage between the upper margin of *septum primum* and lower margin of *septum secundum*. This passage is called **foramen ovale**.

The interatrial septum is thus formed by two septa: (a) *septum primum* that forms the lower part of



interatrial septum; and (b) septum secundum that forms the upper part of interatrial septum.

Functional Mechanism of Foramen Ovale

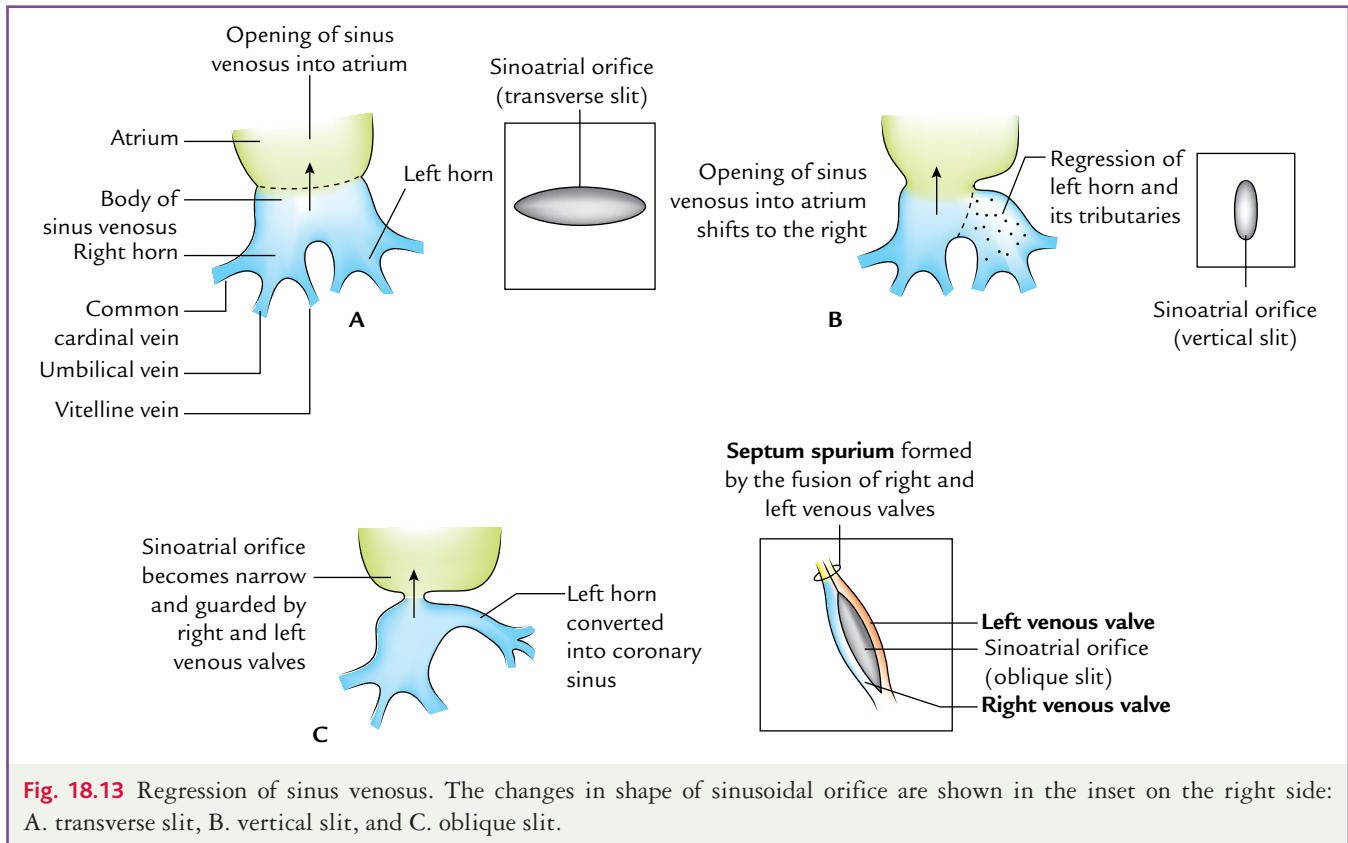
The foramen ovale acts like one-way valve from right to left. Septum primum is thin and mobile-like flap while septum secundum (crista dividens) is thick, firm, and immobile. When blood accumulates in the right atrium, it pushes the septum primum towards left and foramen ovale opens and blood flows from the right atrium to the left atrium. When the blood flows from the right to the left atrium, the thin flap of septum primum moves away and there is no obstruction to the blood flow. But after birth the left atrium

receives blood from lungs and pressure within it becomes greater than that in the right atrium. As the pressure of blood in the left atrium increases, it pushes the septum primum to the right. It comes in opposition with septum secundum and foramen ovale is closed (physiological closure); thus the blood is prevented from flowing from the left atrium to the right atrium.

N.B. In adults, the **fossa ovalis** represents the **septum primum**, and **annulus fossa ovalis** represents the lower free edge of the septum secundum.

Fate of Sinus Venosus

Regression of sinus venosus (Fig. 18.13) The sinus venosus consists of a small transverse part called body

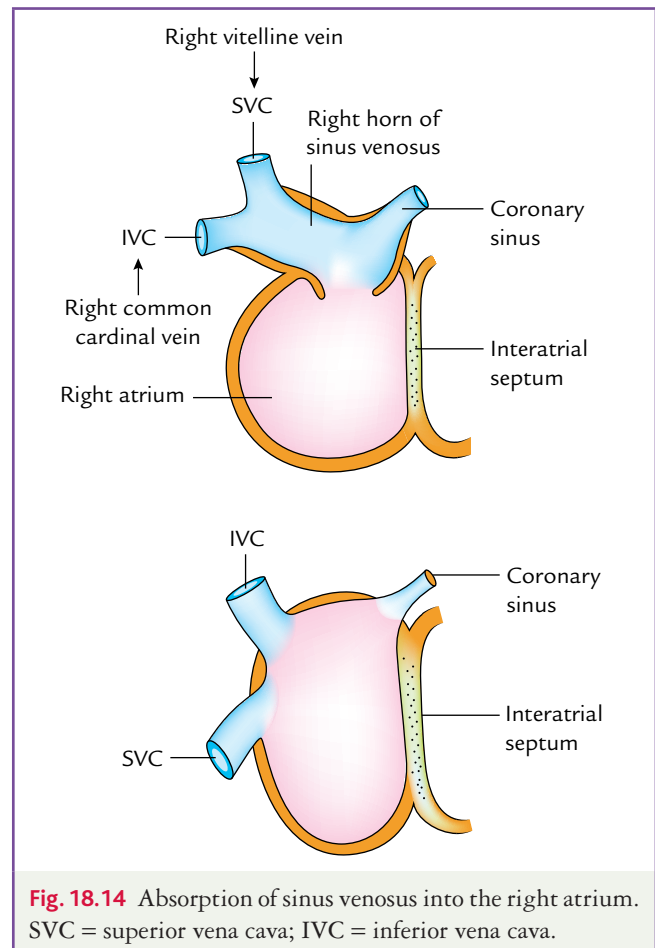


and two horns—right and left. At first sinus venosus and primitive atrium are in open communication with each other. This communication (sinoatrial orifice) is transverse and located in the middle of posterior aspect of the atrial chamber and its two horns are of equal size. Because of left to right shunts developing between the primitive veins, most of blood is drained into the right horn of sinus venosus, which therefore increases in size whereas the left horn becomes smaller. Because of these changes opening of sinus venosus in atrium shifts to right and becomes vertical. It is guarded by two distinct lips—the **right and left venous valves**. The upper ends of two valves fuse to form **septum spurium**.

Right horn of sinus venosus receives all the venous blood through superior and inferior vena cava and left horn becomes **coronary sinus**.

Absorption of sinus venosus into the right atrium (Fig. 18.14) After formation of interatrial septum the right horn and body of sinus venosus are absorbed into the right atrium so that superior vena cava (SVC), inferior vena cava (IVC), and coronary sinus (regressed left horn) now open in the right atrium.

With the absorption of sinus venosus in the right atrium, right and left venous valves separate from each other.



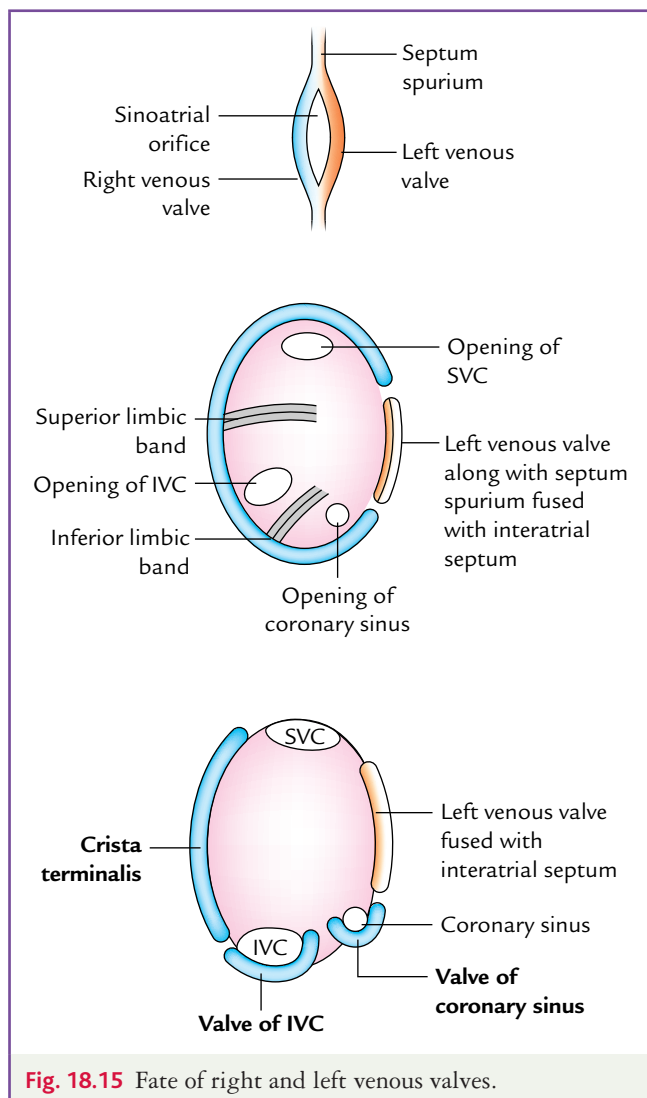


Fig. 18.15 Fate of right and left venous valves.

Fate of Left and Right Venous Valves (Fig. 18.15)

The left venous valve along with septum spurium fuses with the interatrial septum.

The right venous valve is greatly stretched out and becomes subdivided into three parts by formation of two muscular bands—the **superior and inferior limbic bands**. Three parts of right venous valves from above to downward form: (a) **crista terminalis**, (b) **valve of IVC**, and (c) **valve of coronary sinus**.

Absorption of Pulmonary Veins into the Left Atrium

Initially a single large pulmonary vein opens into the left atrium. It then divides into right and left pulmonary vein. Each of the right and left pulmonary vein further divides in two branches before entering the corresponding lung. In this way, four pulmonary veins (two on each side) are formed (Fig. 18.16). Gradually parts of pulmonary veins nearest to the atrium are absorbed into the atrium. As a result, four separate

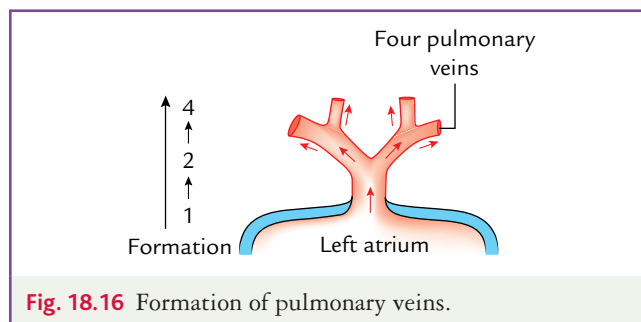


Fig. 18.16 Formation of pulmonary veins.

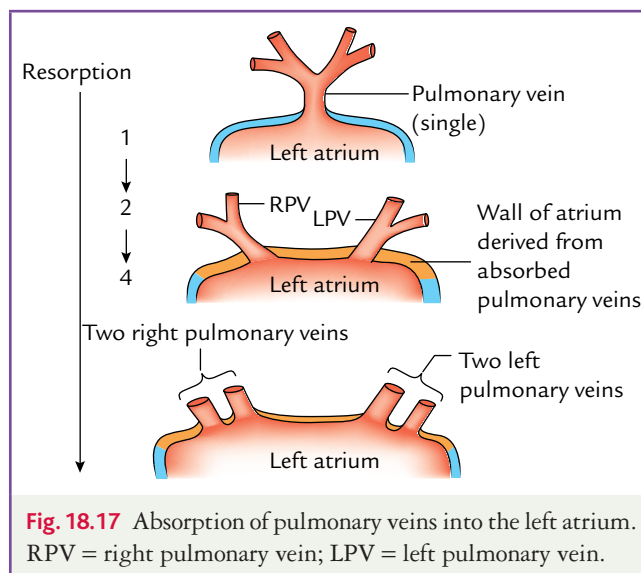


Fig. 18.17 Absorption of pulmonary veins into the left atrium. RPV = right pulmonary vein; LPV = left pulmonary vein.

veins, two from each side, come to open into the left atrium (Fig. 18.17).

N.B.

- The **pulmonary vein** develops as an outgrowth of the dorsal atrial wall, just to the left of the **septum primum**.
- Left auricle is derived from primitive atrium; hence its internal surface is rough and trabeculated.

The large-smooth and posterior-smooth part of the left atrium is derived from absorbed pulmonary veins, while the small, rough, anterior part is derived from primitive atrium (atrium proper).

The embryonic structures forming different components of right and left atria of adult heart are given in Table 18.2.

Clinical Correlation

Atrial septal defects (ASD) (Fig. 18.18): In this condition, there is a defect in interatrial septum, which results in the communication between right and left atrium. It occurs in 6.4/10,000 births with a 2:1 prevalence in the female-to-male ratio. There is a mixing of oxygenated and deoxygenated blood thereby giving rise to symptoms like cyanosis, breathlessness, etc.

The different types of atrial septal defects (ASDs) are as follows (Fig. 18.18).

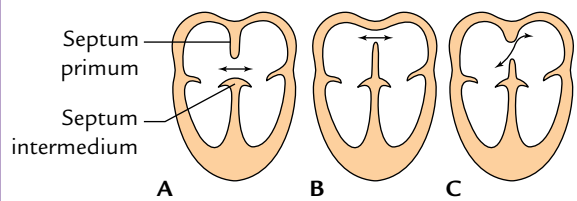


Fig. 18.18 Atrial septal defects.

- Septum primum defect:** The septum primum fails to reach the septum intermedium. As a result, *persistent foramen primum* persists.
- Septum secundum defect:** It occurs if the septum secundum does not grow downward adequately to overlap the septum primum or the septum primum may undergo *excessive resorption*, because of which septum secundum fails to overlap the septum primum. As a result, foramen secundum remains large and unclosed—*ostium secundum defect*. This results in patent foramen ovale. It is the most significant atrial septal defect (Fig. 18.8B).
- Persistent foramen ovale [probe patency of foramen ovale (Fig. 18.18C)]:** The oblique passage between septum primum and septum secundum is closed functionally but remains patent anatomically so that a probe can be passed through it.

N.B. The ASD is most common congenital anomaly of the atria. If the ASD is small, the clinical symptoms may be delayed up to the 30 years of age.

- Premature (prenatal) closure of foramen ovale:** In this condition, the closure of foramen ovale occurs during prenatal life. This results in the massive hypertrophy of the right side of the heart and underdevelopment of the left side of the heart.
- Cor triloculare-biventricular/common atrium:** In this condition there is a complete absence of the interatrial septum. It results in three-chambered heart. It is the most serious congenital anomaly of the atria and is always associated with other defects of the heart.

Table 18.2 Adult components of right and left atria and their embryonic source of development

Adult component	Embryonic sources of development
Right atrium	
• Rough trabeculated part (atrium proper) in front of crista terminalis	Primitive atrium (right half)
• Right auricle	
• Smooth part behind crista terminalis (sinus venarum)	Sinus venosus
• Crista terminalis valve of IVC and valve of coronary sinus	From right venous valve
• Most ventral smooth part	Right half of AV canal
Left atrium	
• Posterior smooth part between the openings of pulmonary veins	Absorption of pulmonary veins near the atria
• Anterior rough part and left auricle	Left half of primitive atrium
• Most ventral smooth part	Left half of the AV canal

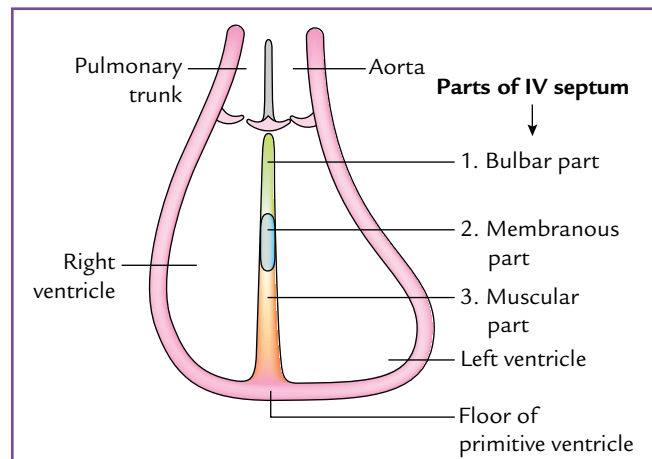


Fig. 18.19 Components of the interventricular (IV) septum.

Formation of Interventricular Septum

The interventricular (IV) septum consists of three parts. From below upward these are: (a) **muscular part**, (b) **bulbar part**, and (c) **membranous part** (Fig. 18.19). These three parts develop from three different sources (Fig. 18.20).

- Muscular part develops from the floor of the ventricle:** A median muscular ridge grows upward from the floor of primitive ventricle (near its apex) and reaches almost up to the AV cushions. It forms the muscular part of the IV septum. It is

present in the oblique plane and its upper margin is concave.

- Bulbar part develops from right and left bulbar ridges:** From the conical part of common ventricular chamber the two ridges (i.e., *right and left bulbar ridges*) develop in the distal part of bulbus cordis. They grow and approach each other to fuse together to form the *bulbar part of the IV septum*. The gap between the upper margin of muscular septum and lower margin of bulbar septum is called *IV foramen*.

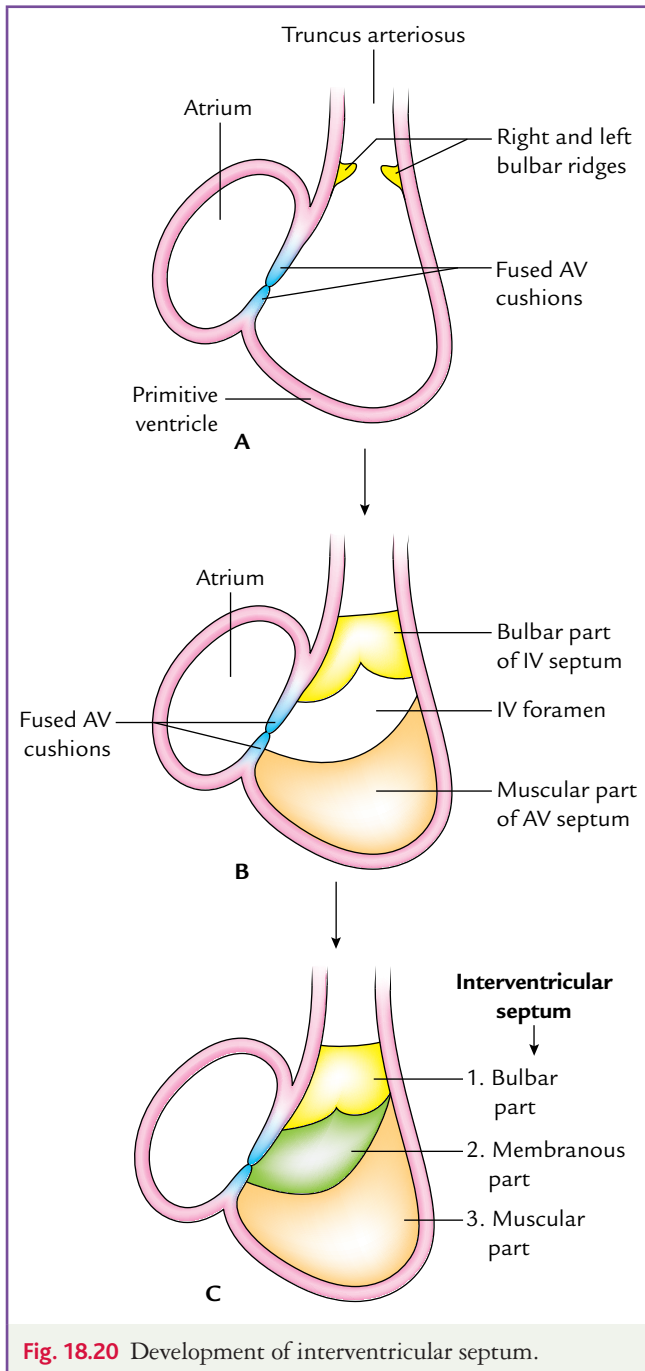


Fig. 18.20 Development of interventricular septum.

Table 18.3 Adult components of right and left ventricles and their embryonic source of development

Adult component	Embryonic source of development
Right ventricle	
• Inflowing rough part	• Primitive ventricle
• Outflowing smooth part (infundibulum)	• Bulbus cordis
Left ventricle	
• Inflowing rough part	• Primitive ventricle
• Outflowing smooth part (aortic vestibule)	• Bulbus cordis

3. **Membranous part develops as under:** The gap between the upper edge of the muscular part of the IV septum and lower end of the bulbar part of IV septum is filled by proliferation of tissue from the right side of the AV cushions and from the right and left bulbar ridges. Thus, the membranous part of IV septum is derived from three sources: right bulbar ridge, left bulbar ridge, and AV cushions. Formation of membranous part closes the IV foramen.

N.B. Once the right and left ventricles are formed, the proximal part of the bulbus cordis becomes incorporated into the right ventricles as the **conus arteriosus** or **infundibulum** and into the left ventricle as the **aortic vestibule**. The embryonic source of development of different components of adult right and left ventricles are summarized in Table 18.3.

Clinical Correlation

1. **Ventricular septal defect (VSD)**, Fig. 18.21: It is most common congenital anomaly of the heart. This defect is most common in the membranous part of the IV septum. It is caused by failure of fusion of right and left bulbar ridges with the AV cushions, which form the membranous part of the IV septum. Thus, there occurs a defect in the IV septum that results in communication between right and left ventricles. Blood flows from the left to the right ventricle. As a result of left-to-right shunting of blood, the output from the left ventricle is reduced. Consequently, the patient complains of excessive fatigue on exertion. Rarely, the defect may be present in muscular part of the IV septum.
2. **Fallot's tetralogy [tetralogy of Fallot (Fig. 18.22)]**: This condition occurs due to combinations of four cardiac anomalies, viz., (a) pulmonary stenosis, (b) overriding aorta (i.e., displacement of aortic orifice to the right to override the IV septum), (c) IV septal defect, and (d) hypertrophy of the right ventricle. The resultant right-to-left shunting of blood leads to cyanosis. *The Fallot's tetralogy is the commonest congenital cyanotic heart disease.*

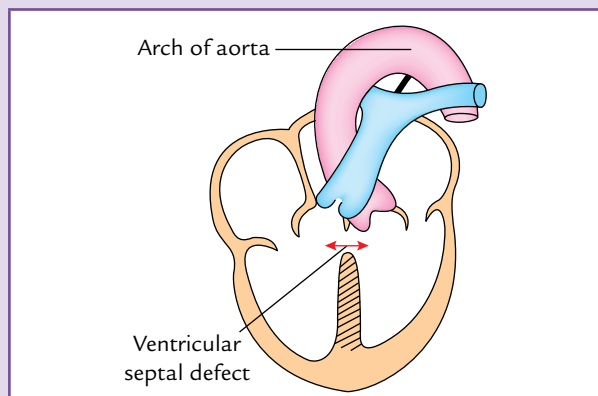
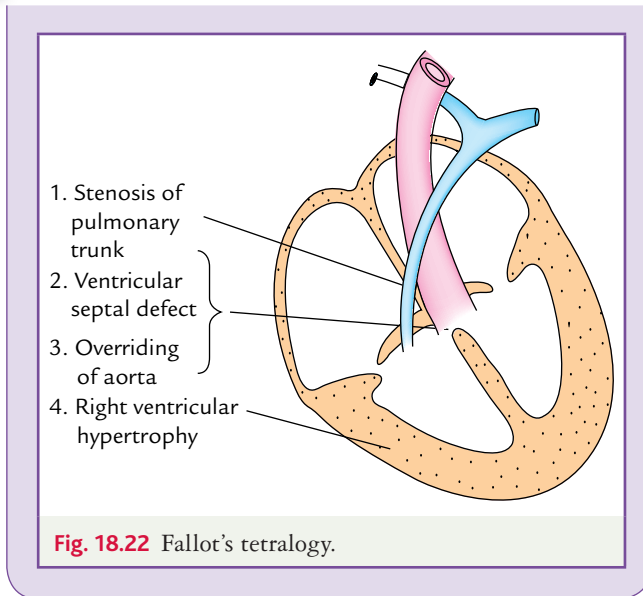


Fig. 18.21 Ventricular septal defect.



Formation of Aorticopulmonary Septum (Fig. 18.23)

The aorticopulmonary septum is a **spiral septum** that divides the truncus arteriosus into the aorta and

pulmonary trunk. It develops from two truncal ridges. The truncal ridges develop due to proliferation of mesenchymal cells derived from neural crest cells that migrate in the walls of truncus arteriosus near the conus. The truncal ridges grow and fuse with each other to form the **spiral septum** close to the conical part of the ventricle; because the pulmonary trunk and aorta are separated from each other by a septum that is spiral, the relationship of the pulmonary trunk and aorta with each other differs in the lower, middle, and upper parts. The details are as under.

- 1. In the lower part:** The *spiral septum* and *bulbar septum* are in the same plane and continuous with each other close to the ventricle. The spiral septum here is in the coronal plane. As a result, the pulmonary trunk is in front and ascending aorta is posterior.
- 2. In the middle part:** The spiral septum is in the sagittal plane so that pulmonary trunk and ascending aorta are situated side-by-side, with aorta being on right side and pulmonary trunk on left side.
- 3. In the upper part:** The spiral septum is again in the coronal plane but the aorta lies anteriorly and pulmonary trunk lies posteriorly.

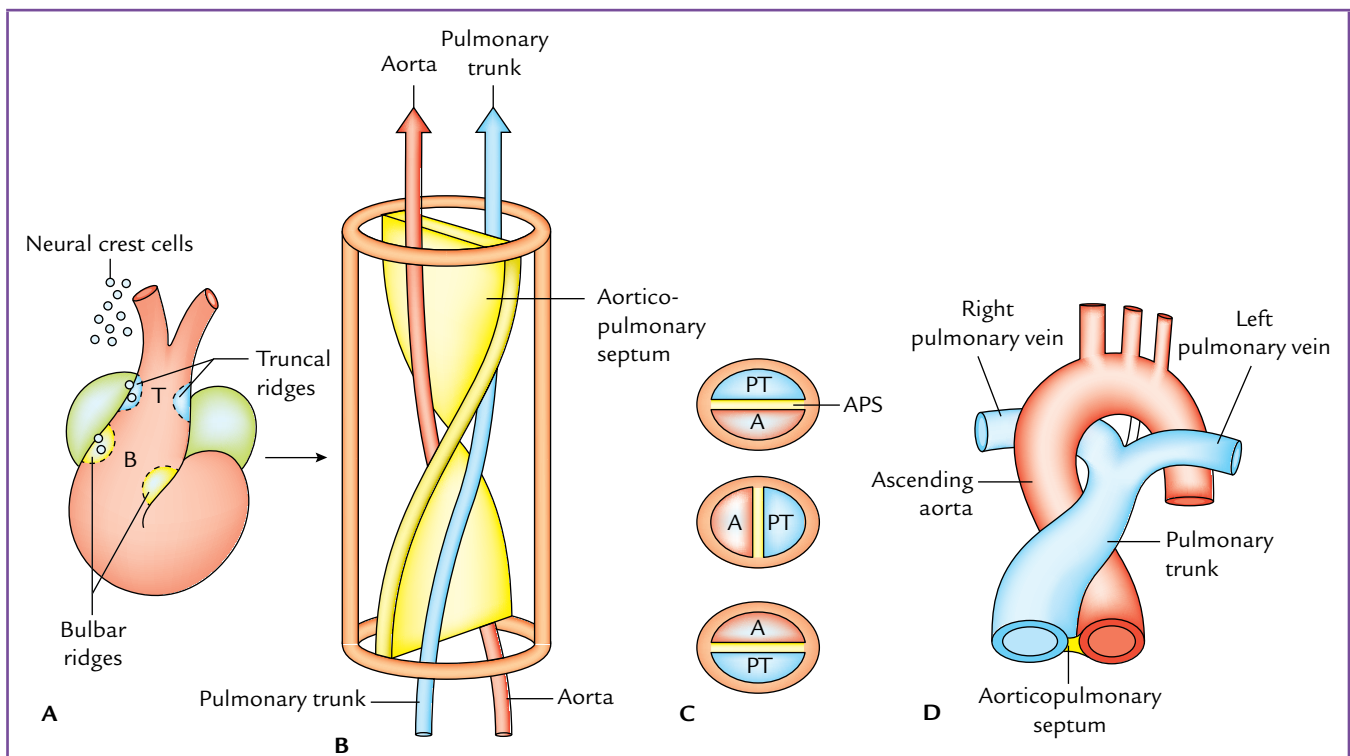


Fig. 18.23 Formation of aorticopulmonary septum. A. Partitioning of truncus arteriosus and bulbus cordis involves migration of neural crest cells from truncal and bulbar ridges. B. Aorticopulmonary septum develops in a spiral fashion. C. Sections through the newly formed aorta (A) and pulmonary trunk (PT) showing the position of aorticopulmonary septum in upper, middle, and lower parts. D. Adult gross anatomical relationship between ascending aorta and pulmonary trunk. T = truncus arteriosus. B = bulbus cordis; PT = pulmonary trunk; APS = aorticopulmonary septum.

Clinical Correlation

Anomalies of truncus arteriosus

1. **Persistent truncus arteriosus:** In this anomaly spiral septum (aorticopulmonary septum) fails to develop. Pulmonary arteries and aorta arise from a common vessel.
2. **Defect in development of spiral septum** results in communication between ascending aorta and pulmonary trunk.
3. **Transposition of great vessels** (Fig. 18.24): In this anomaly ascending aorta arises from the right ventricle and pulmonary trunk arises from the left ventricle. It occurs due to non-spiral development of aorticopulmonary septum.

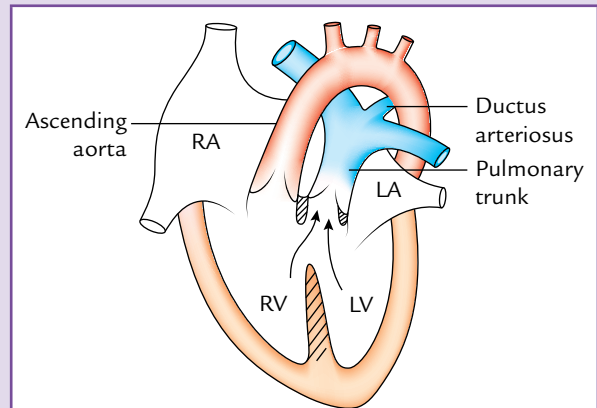


Fig. 18.24 Transposition of great vessels. RA = right atrium; LA = left atrium; RV = right ventricle; LV = left ventricle.

N.B. The errors in formation of spiral septum are caused by abnormal migration of neural crest cells in truncal ridges of truncus arteriosus.

Development of Valves of the Heart

Atrioventricular Valves

Tricuspid Valve (Fig. 18.25)

It is present between the right atrium and right ventricle, and guards the right AV canal. In the AV canal, subendocardial mesenchyme proliferates and forms three swellings (anterior, posterior, and septal) that project in the AV canal. The swellings enlarge and meet each other in the lumen. But the free margins of these swellings do not fuse with each other. When the blood stream starts flowing, the mesenchymal tissue degenerates and is replaced by connective tissue. The ventricular surface of these swellings is hollowed and cusps are formed. There are three cusps: the anterior, posterior, and septal, and consists of connective tissue covered by endocardium. The free margin ventricular surfaces of these valves are connected to thick trabeculae in the wall of the ventricle (the **papillary muscles**) by thin tendinous cords (the **chordae tendinae**) much like the cords attaching to a parachute.

Mitral Valve

It is present between the left atrium and left ventricle, and guards the left AV canal. It develops by the proliferation of subendocardial mesenchyme forming two swellings: anterior and posterior in the same way as the tricuspid valve. There are only two cusps in left AV valve (anterior and posterior) that are obliquely placed. It is also called **bicuspid valve**.

N.B. The left AV valve is called **mitral valve** due to valve's resemblance to a bishop's miter (headdress).

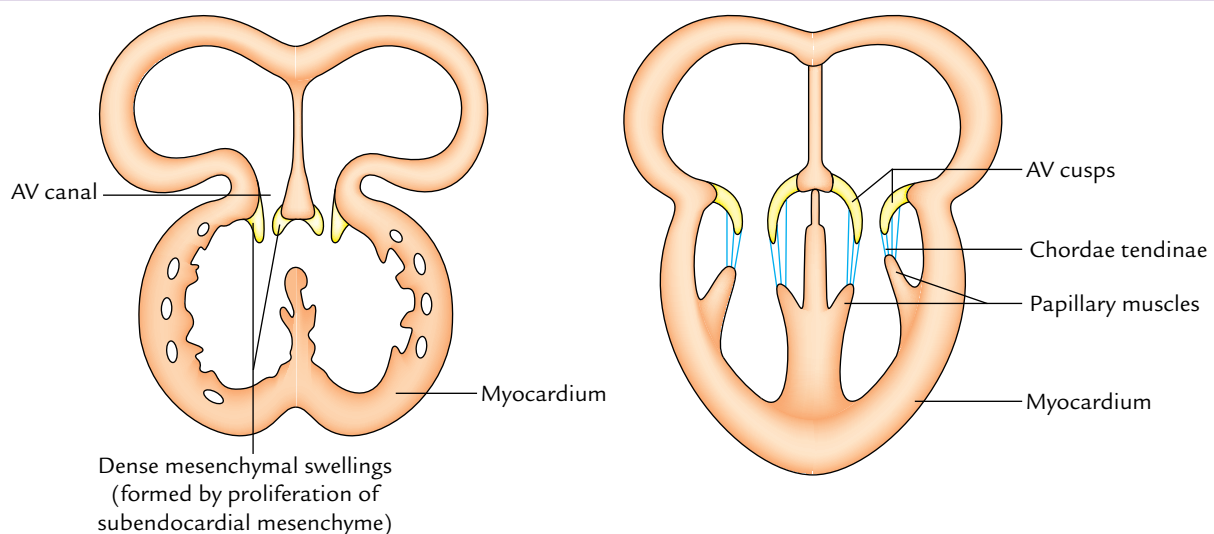


Fig. 18.25 Formation of atrioventricular valves.

Clinical Correlation

Tricuspid atresia: In this condition, there is complete agenesis of tricuspid valves. It is caused by an insufficient amount of tissue in AV cushion for the formation of tricuspid valve.

The tricuspid atresias are always associated with (a) patent foramen ovale, (b) VSD, (c) underdeveloped right ventricle, and (d) hypertrophy of the right ventricle.

N.B. The blood reaches the right ventricle through patent foramen ovale and IV foramen.

Pulmonary and Aortic Valves (Fig. 18.26)

They develop from endocardial cushions that are formed at the junction of truncus arteriosus and conus. The two endocardial cushions develop in the right and left wall. Simultaneously two more cushions, anterior and posterior, appear. The truncus arteriosus now has four cushions: anterior (A), posterior (P), right (R), and left (L). With the separation of aortic and pulmonary openings by aorticopulmonary septum, the right and left cushions divide into two parts. The one part goes to aortic opening and other part goes to pulmonary opening. Now each opening has three cushions from which three cusps of the corresponding opening develop. The pulmonary opening is first ventral to the aortic opening.

Now the heart undergoes partial rotation to the left. As a result, the pulmonary opening comes to lie anterior and to the left of the aortic opening; and cusps acquire their definitive relationship, i.e., pulmonary trunk has one posterior and two anterior (right and left) cusps; and aorta has one anterior (right and left) and two posterior cusps.

N.B. Embryologically, the pulmonary valve has right, left, and anterior cusps, whereas the aortic valve has right, left, and posterior cusps. This terminology is in accordance with the origin of coronary arteries as the right coronary artery arises from the right aortic sinus, superior to the right cusp of the aortic valve, and the left coronary artery arises from the left aortic sinus superior to the left cusp of the aortic valve. The posterior cusp and sinus do not give rise to the coronary artery, hence it referred as noncoronary cusp.

Development of the Conducting System of the Heart

The conducting system of the heart consists of four components:

1. SA node (pacemaker of the heart)
2. AV node
3. Bundle of His
4. Purkinje fibers.

1. **SA node:** Sinoatrial node develops during the fifth week of IUL. Initially, it is located in the right wall of the sinus venosus, but when the sinus venosus is incorporated (absorbed) into the right atrium then it comes to lie in the wall of the right atrium near the opening of the superior vena cava.

2. and 3. **AV node and AV bundle of His:** They are derived from cells in the left wall of the sinus venosus and AV canal. After incorporation of sinus venosus into the right atrium (vide supra), these cells come to lie on the base of interatrial septum just anterior to the opening of coronary sinus. Here these cells form **AV node and AV bundle of His**.

4. **Purkinje fibers:** The fibers arising from AV bundle pass from atrium into the ventricle and split into **right and left bundle branches**. The branches from

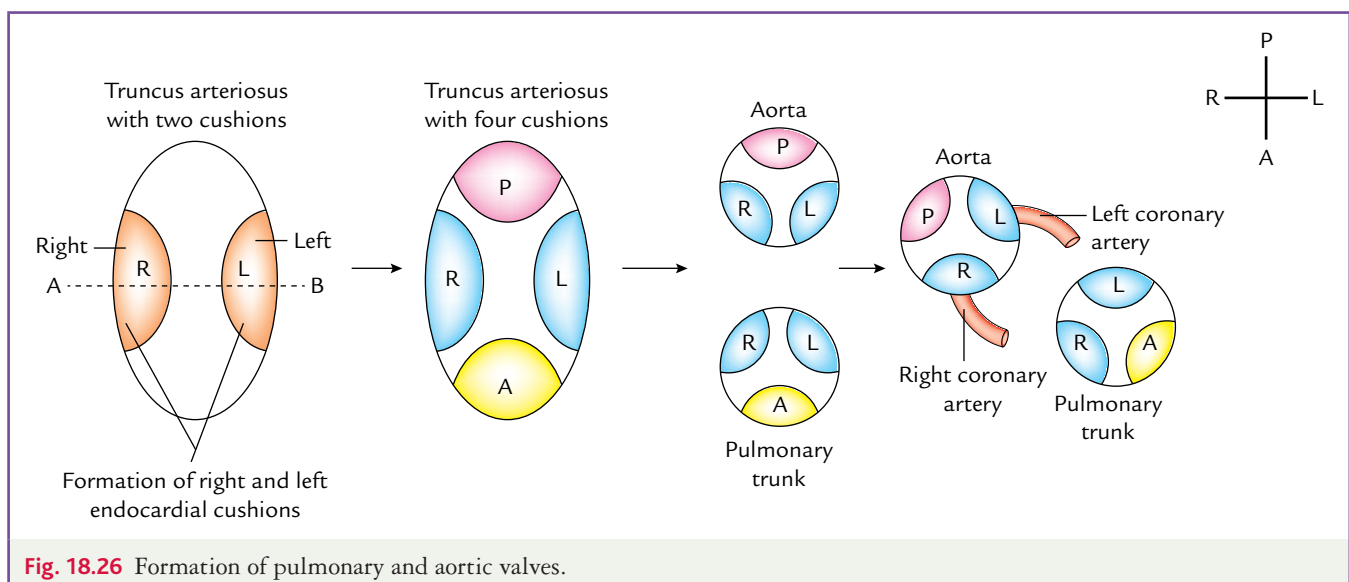


Fig. 18.26 Formation of pulmonary and aortic valves.

these bundles are distributed throughout the ventricular myocardium and are termed *Purkinje fibers*.

N.B. The SA node, AV node, and AV bundle are richly innervated by autonomic nerve fibers; however, conducting system is well developed before these nerve fibers enter the heart. The conducting system is made up of specialized cardiomyocytes and normally it is the only pathway that initiates impulses and conducts them rapidly throughout the heart. Thus, contraction of cardiac muscle is **myogenic** and not **neurogenic**.

Formation of Pericardium

The pericardium consists of two components: (a) serous pericardium and (b) fibrous pericardium. The serous pericardium consists of two layers: (a) visceral layer and (b) parietal layer.

Embryological Source of Development

- Visceral layer of serous pericardium is derived from splanchnopleuric mesoderm lining the dorsal side of the pericardial cavity.
- Parietal layer of serous pericardium and fibrous pericardium is derived from somatopleuric mesoderm lining the ventral side of the pericardial cavity.

Mode of Formation of Two Layers of Serous Pericardium and Fibrous Pericardium (Figs 18.27 and 18.28)

1. The pericardial cavity is derived from the part of intraembryonic celom that lies in the midline cranial to prochordal plate.
2. Following the formation of head fold, the pericardial cavity comes to lie on the ventral aspect of the foregut.
3. The splanchnopleuric mesoderm on the dorsal aspect of the pericardial cavity forms myoepicardial mantle.
4. The heart tube invaginates the pericardial cavity from the dorsal aspect; hence it gets completely covered by myoepicardial mantle and a layer of the pericardial cavity. The myoepicardial mantle forms the myocardium and layer of the pericardial cavity applied to it forms the visceral layer of the pericardium (also called epicardium).
5. Initially, the heart tube becomes suspended within the pericardial cavity by a double-layered fold of the layer of the pericardial cavity called **dorsal mesocardium**.
6. With the folding of the heart tube, the arterial and venous ends come close. The dorsal mesogastrium disappears to form **transverse sinus** of

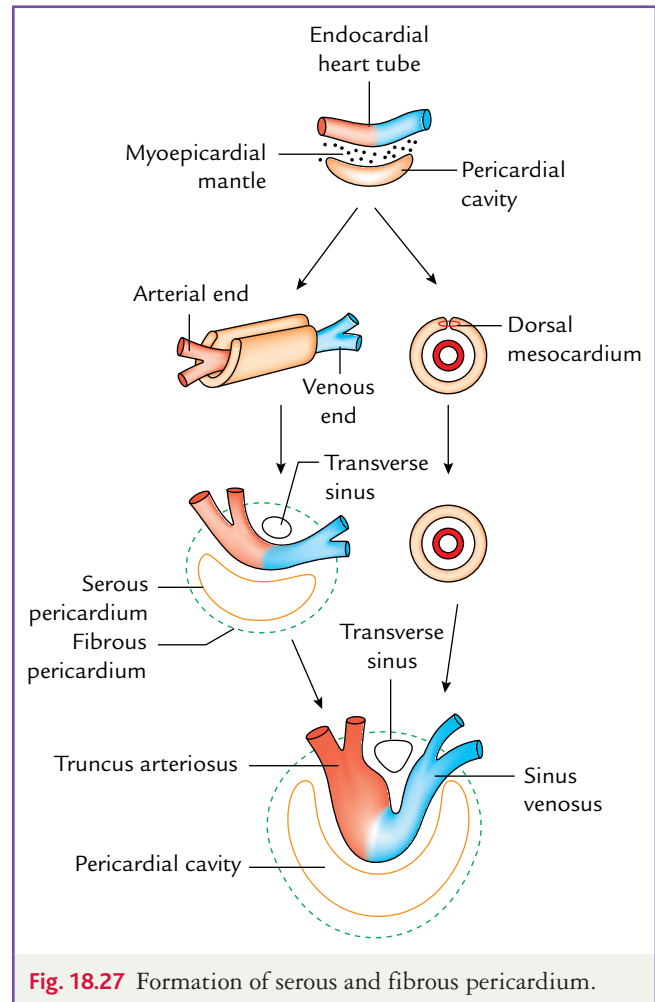


Fig. 18.27 Formation of serous and fibrous pericardium.

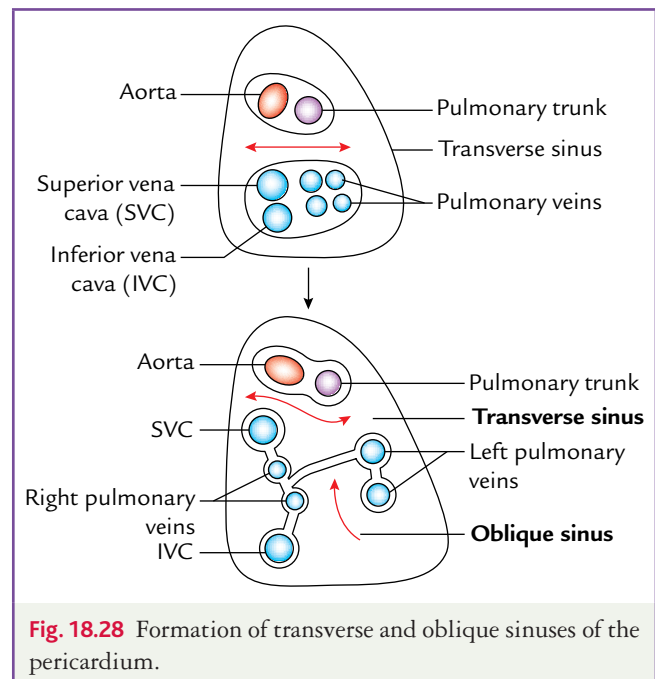


Fig. 18.28 Formation of transverse and oblique sinuses of the pericardium.

pericardium. Now the parietal and visceral layers of serous pericardium become continuous with each other at the arterial and venous ends of the heart tube, i.e., serous pericardium gets arranged

into two tubes: one enclosing the aorta and pulmonary trunk, and the other enclosing the superior vena cava, inferior vena cava, and four pulmonary veins. The two tubes are separated by the transverse sinus of pericardium.

The definitive reflections of the pericardium in accordance with the rearrangement of SVC, IVC, and pulmonary veins at the venous end lead to the formation of an isolated pouch of pericardium called **oblique sinus of the pericardium**.

GOLDEN FACTS TO REMEMBER

- | | |
|---|---------------------------|
| ➤ First system to start functioning in embryo | Cardiovascular system |
| ➤ First organ of the body to start functioning | Heart |
| ➤ Most common positional anomaly of the heart | Dextrocardia |
| ➤ Most common congenital anomaly of the heart | Ventricular septal defect |
| ➤ Most common congenital cyanotic heart disease | Fallot's tetralogy |

CLINICAL PROBLEMS

1. A mother took her 7-year-old son to a pediatrician and complained that her child complains of excessive fatigue upon exertion. After thorough investigations the pediatrician detected a cardiac defect in the child and told his mother that your son is suffering from a defect in the heart that is a common birth defect of heart in children. Answer the following questions:
 - What is the most common congenital defect of the heart?
 - What is its incidence?
 - Discuss the blood flow in this defect and explain the cause of excessive fatigue on exertion.
2. A full-term male child, on the first day itself, presented generalized cyanosis. A chest radiograph (PA view) revealed slightly enlarged heart with a narrow base and increased pulmonary vascular markings. A probable diagnosis of '**complete transposition of the great blood vessels**' was made. Give the embryological basis of this anomaly and tell how the infant was able to survive after birth with such a severe anomaly?
3. The retinoic acid (vitamin A), which is very effective in treating **acne** (a common ailment in young women), should not be given/prescribed to the pregnant ladies. Why?

CLINICAL PROBLEM SOLUTIONS

1. The ventricular septal defect (VSD) is the most common congenital cardiac defect. It occurs in about 25% of the children. In this condition, there exists an opening between the right and left ventricles. Initially, this defect allows **left-to-right shunting** of blood through the IV foramen due to increased left ventricular pressure. The child complains of excessive fatigue on exertion due to shunting of blood from left to right. Later pulmonary hypertension causes marked proliferation of tunica intima and tunica media of pulmonary arteries and arterioles, thus narrowing their lumen.

Consequently, the pulmonary resistance becomes higher than the systemic resistance and leads to right-to-left shunting of blood causing **cyanosis**. At this stage, the condition is called **Eisenmenger complex**.

2. The transposition of the great blood vessels is caused by abnormal migration of neural crest cells in the wall of truncus arteriosus. The migration of these cells is such that there is nonspiral development of AV septum (also see Clinical Correlation on page 207). The infant was able to survive after birth because this anomaly is often associated with patent ductus arteriosus, ASD, and/or VSD that allows mixing of blood between two circulations.

N.B. The complete transposition of the great blood vessels is incompatible with life; if there is no PDA or atrial and ventricular septal defects.

3. This is because retinoic acid (vitamin A) is a potent teratogen that targets the neural crest cells, which contributes towards much of the development of face and spiral aortopulmonary septum. Therefore, if retinoid acid is given to young pregnant ladies, it can cause craniofacial defects and transposition of the great blood vessels in the newborns.

19

Development of Blood Vessels

Overview

The blood vessels develop from mesenchymal cells derived from mesoderm. They are formed by two processes: *vasculogenesis* and *angiogenesis*.

1. **Vasculogenesis:** It is the process of formation of new vessels by coalescence (assembly) of angioblasts (specialized mesenchymal cells).
2. **Angiogenesis:** It is the process of formation of new vessels by budding and branching from preexisting vessels.

N.B.

- Major blood vessels of the vascular system of the body, viz., dorsal aortae and cardinal vessels are formed by vasculogenesis, and remaining vessels are formed by angiogenesis.
- Both the processes of vasculogenesis and angiogenesis are patterned, and guided by vascular endothelial growth factor and other growth factors.

The details of vasculogenesis and angiogenesis are given below (Fig. 19.1).

Vasculogenesis (Fig. 19.1A)

- The mesenchymal cells differentiate into angioblasts (vessel-forming cells) that aggregate to form isolated angiogenic cell clusters or cords.
- Lumen appears in these clusters and cords, and primitive blood vessels are formed.
- The angioblasts flatten to form endothelial cells that arrange themselves around cavities in clusters and cords to form the endothelial lining of the blood vessels.
- The primitive blood vessels get interconnected with each other to form a network of endothelial vascular channels—the blood vessels.
- Because of hemodynamic and genetic factors certain channels enlarge to form blood vessels and channels connected to them form branches or tributaries, while other channels disappear.

Angiogenesis (Fig. 19.1B)

- Vessels sprout into the adjacent areas by endothelial budding and fuse with other vessels.
- Finally, in this way, permanent vascular system is formed.

N.B. The primitive blood vessels cannot be distinguished structurally as arteries or veins. However, they are named according to their future fate and relationship to the heart.

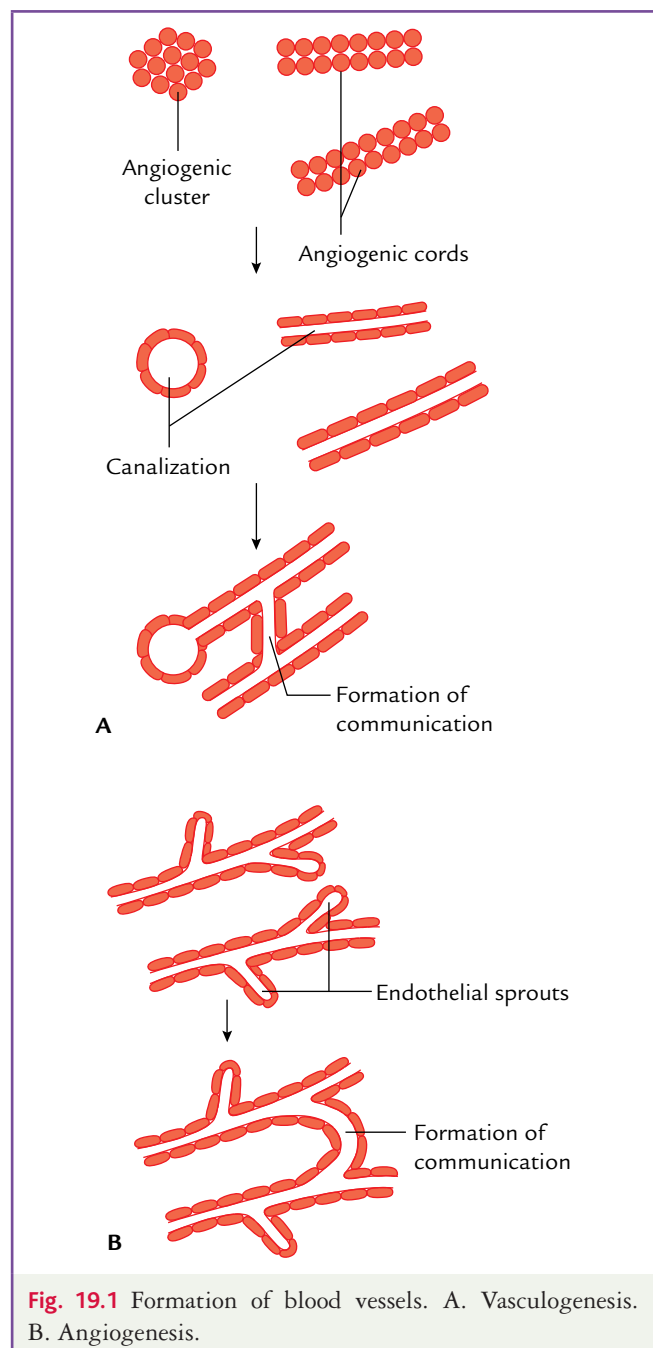


Fig. 19.1 Formation of blood vessels. A. Vasculogenesis. B. Angiogenesis.

Development of Arterial System

The arteries of body develop from two main sources: **pharyngeal (aortic) arch arteries** and **dorsal aorta**.

The *aortic arches* give rise to the arteries of head and neck region.

The *dorsal aorta* gives rise to the arteries of rest of the body.

The blood vessels as seen in a 26-day-old embryo are shown in Fig. 19.2.

Pharyngeal Arch Arteries and Their Derivatives

1. First arteries to appear in a developing embryo are **right and primitive aortae**. They become continuous with two primitive heart tubes (Fig. 19.3).
2. Each primitive aorta is divided into three parts: ventral aorta, first aortic arch artery, and dorsal aorta as follows (Fig. 19.3 inset):
 - (a) The part lying ventral to foregut is called *ventral aorta*.
 - (b) The part lying dorsal to gut is called *dorsal aorta*.

- (c) The arched portion connecting the ventral and dorsal aortae lies in the first pharyngeal arch. It forms *first aortic arch artery*.

After fusion of two primitive heart tubes the two ventral aortae partially fuse to form *aortic sac* (Fig. 19.4).

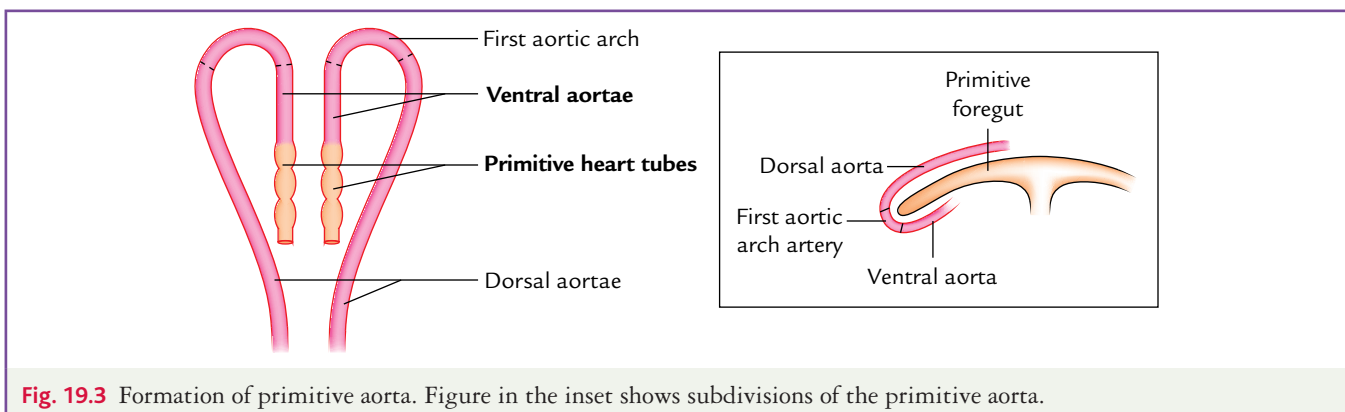
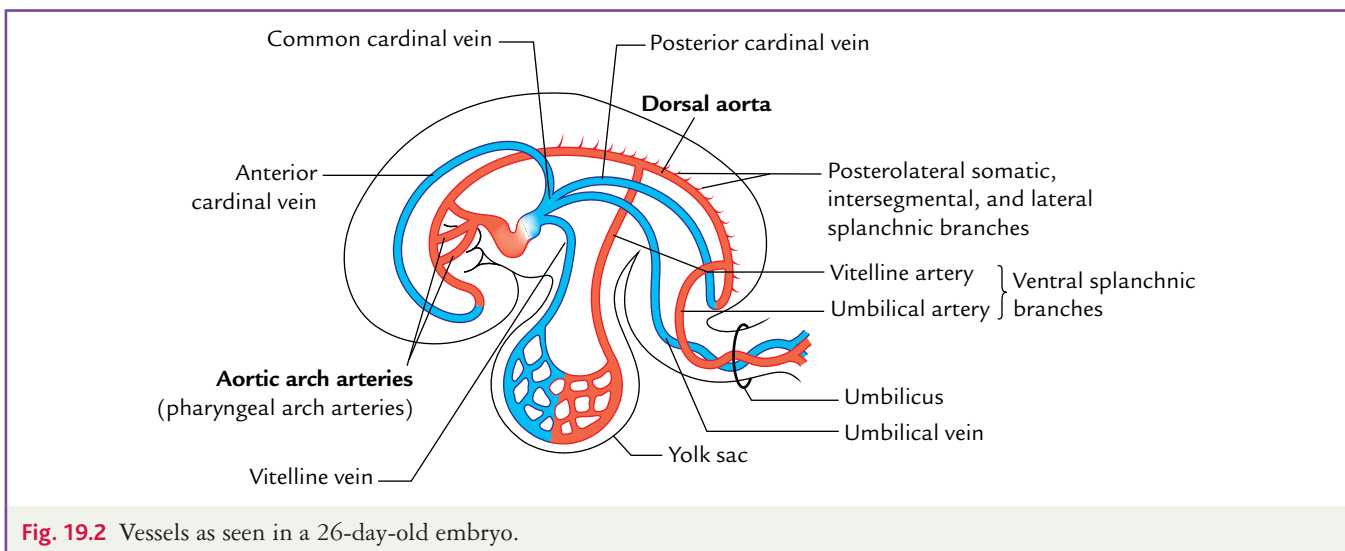
The unfused parts of ventral aortae form *right and left horns of the aortic sac*.

Pharyngeal (Aortic) Arch Arteries

As the pharyngeal arches develop during fourth and fifth weeks, each arch is supplied by an artery—the **pharyngeal arch artery** derived from the aortic sac (i.e., aortic sac contributes a branch to each new arch as it forms). Thus, aortic sac gives rise to six pairs of aortic arch arteries. The fifth pair appears to disappear.

Hence, the five aortic arch arteries are numbered as I, II, III, IV, and VI (Fig. 19.5).

The aortic arch arteries are embedded in the mesenchyme of the pharyngeal arches and on each side connect the aortic horn with dorsal aorta of the corresponding side.



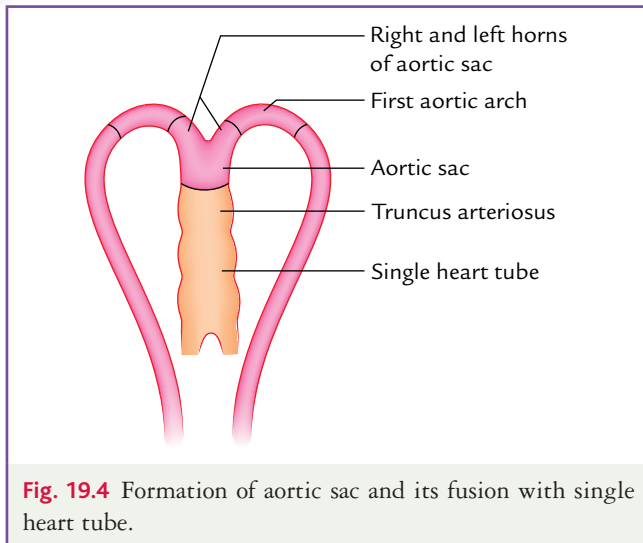


Fig. 19.4 Formation of aortic sac and its fusion with single heart tube.

In the region of pharyngeal arches, the dorsal aortae remain paired, but caudal to this region they fuse to form a single vessel.

Development of Main Arteries of Head, Neck, and Thorax

The major arteries of the head, neck, and thorax are derived from: (a) aortic arch arteries and (b) aortic sac and its right and left horns. The details are as follows (Fig. 19.6):

- Greater part of the first arch artery disappears but its remaining part forms *maxillary artery*.
- The greater part of second arch artery disappears but its remaining part forms the *hyoid* and *stapedial arteries* in the fetal life.
- The third and fourth arch arteries open into the ventral part of aortic sac while the sixth arch artery into the dorsal part of the aortic sac (Fig. 19.6A).

Spiral septum of truncus arteriosus extends into the aortic sac in such a way that blood from ascending aorta passes into the third and fourth arch arteries, while blood from the pulmonary trunk passes into the sixth arch arteries.

Now further changes occur in the arterial arches to produce final fetal arterial pattern/arrangement as follows:

1. Two dorsal aortae grow cranially beyond the point of attachment of first arch arteries (Fig. 19.6B).
2. Portion of the dorsal aorta, between the entrance of third and fourth arch arteries, called **carotid duct (ductus caroticus)** disappears on both sides (Fig. 19.6B).

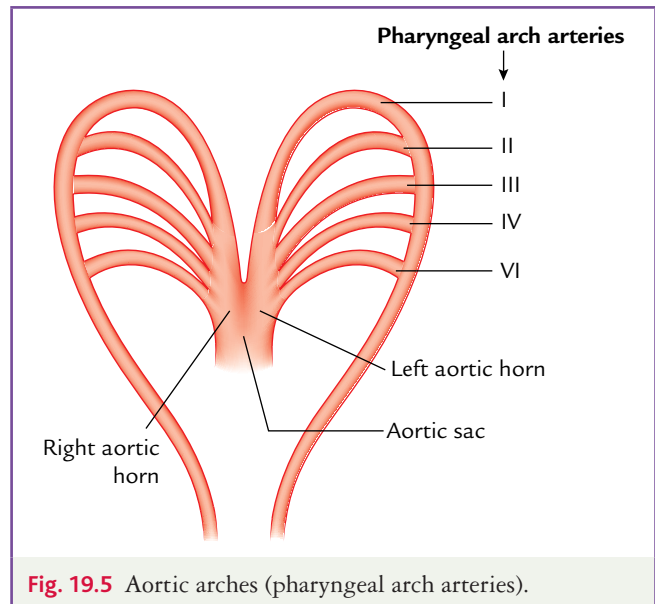


Fig. 19.5 Aortic arches (pharyngeal arch arteries).

3. Right dorsal aorta below the fourth arch artery disappears.
4. Sixth arch artery on each side gives off an artery to the developing lung bud.
 - (a) On the right side, 'portion of the sixth arch artery beyond the artery to lung bud disappears (Fig. 19.6C).'
 - (b) On the left side, portion of the sixth arch artery beyond the artery to lung bud remains patent and forms the **ductus arteriosus**.
5. Each third arch artery gives off a bud that grows cranially to form the **external carotid artery**.
6. Seventh cervical intersegmental artery supplying upper limb bud on each side comes to be attached to the dorsal aorta at the site of attachment of the fourth arch artery.

The development of main arteries of head, neck, thorax, and upper limb is given in Table 19.1 and shown in Fig. 19.7.

N.B. On the right side, the third and fourth arch arteries arise from right horn of aortic sac that forms brachiocephalic artery.

As a result, right common carotid artery and right subclavian artery appear as branches of the brachiocephalic artery.

The derivatives of aortic arch arteries are given in Table 19.2.

Clinical Correlation

1. **Patent ductus arteriosus (PDA)** (Fig. 19.8): It occurs when ductus arteriosus, a connecting channel between left pulmonary artery and the arch of aorta, fails to close. The PDA causes shunting of blood from aorta back into the pulmonary

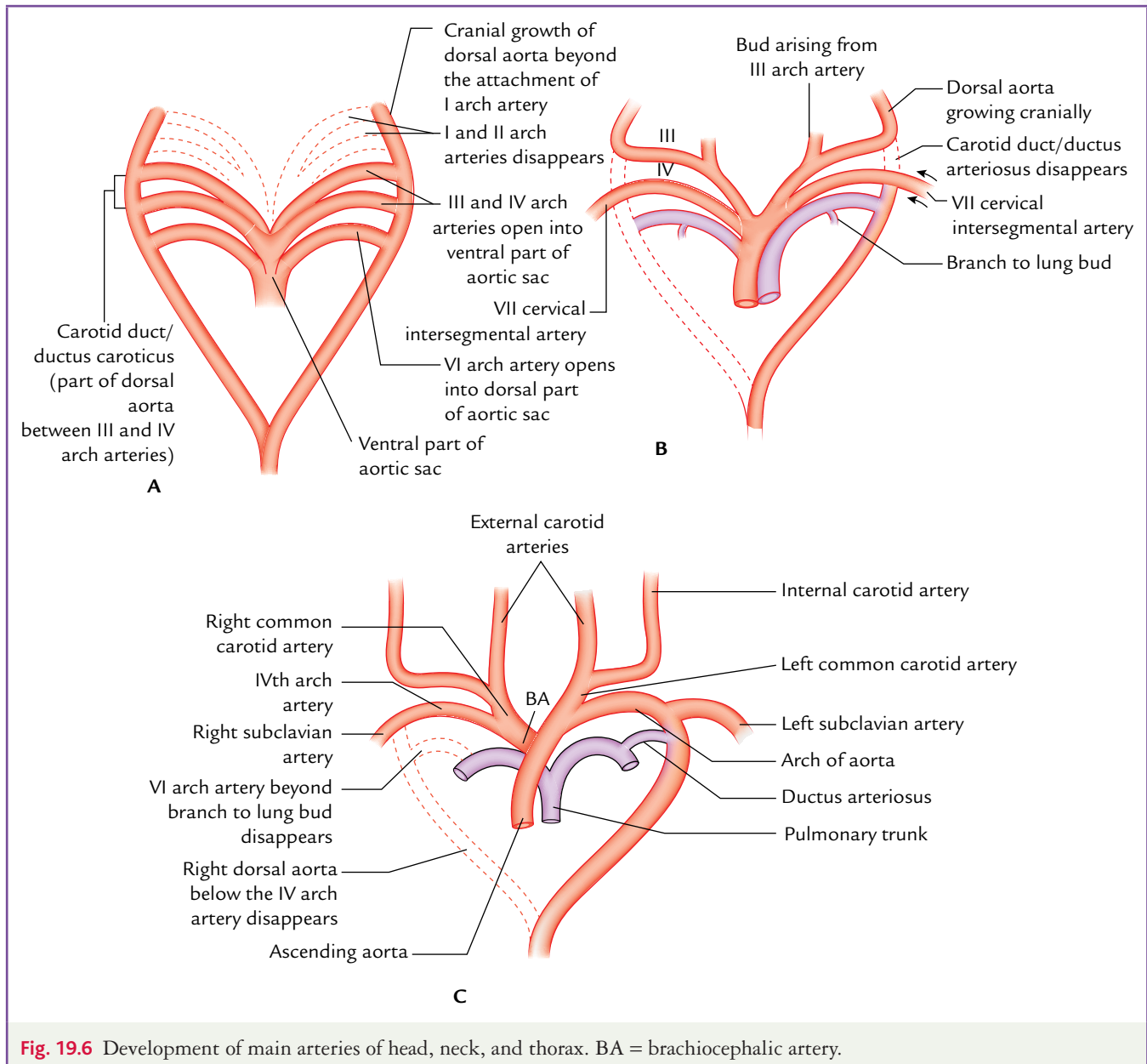


Fig. 19.6 Development of main arteries of head, neck, and thorax. BA = brachiocephalic artery.

Table 19.1 Source of development of main arteries

Arteries	Source of development
Arch of aorta	(a) Aortic sac (ventral part), (b) left horn of aortic sac, and (c) left fourth arch artery
Brachiocephalic artery	Right horn of aortic sac
Right subclavian artery	Proximal part from right fourth arch artery and (b) distal part from right seventh cervical intersegmental artery
Left subclavian artery	Left seventh cervical intersegmental artery
Common carotid artery	Third arch artery proximal to the external carotid artery bud
Internal carotid artery	Third arch artery distal to the external carotid bud and cranial part of dorsal aorta distal to the attachment of third arch artery
External carotid artery	Bud from third arch artery
Pulmonary arteries	Part of the sixth arch artery between pulmonary trunk and branch to lung bud on each side
Descending aorta	(a) Proximal part from left dorsal aorta distal to attachment of fourth arch artery and (b) distal part from fused dorsal aortae forming single median artery

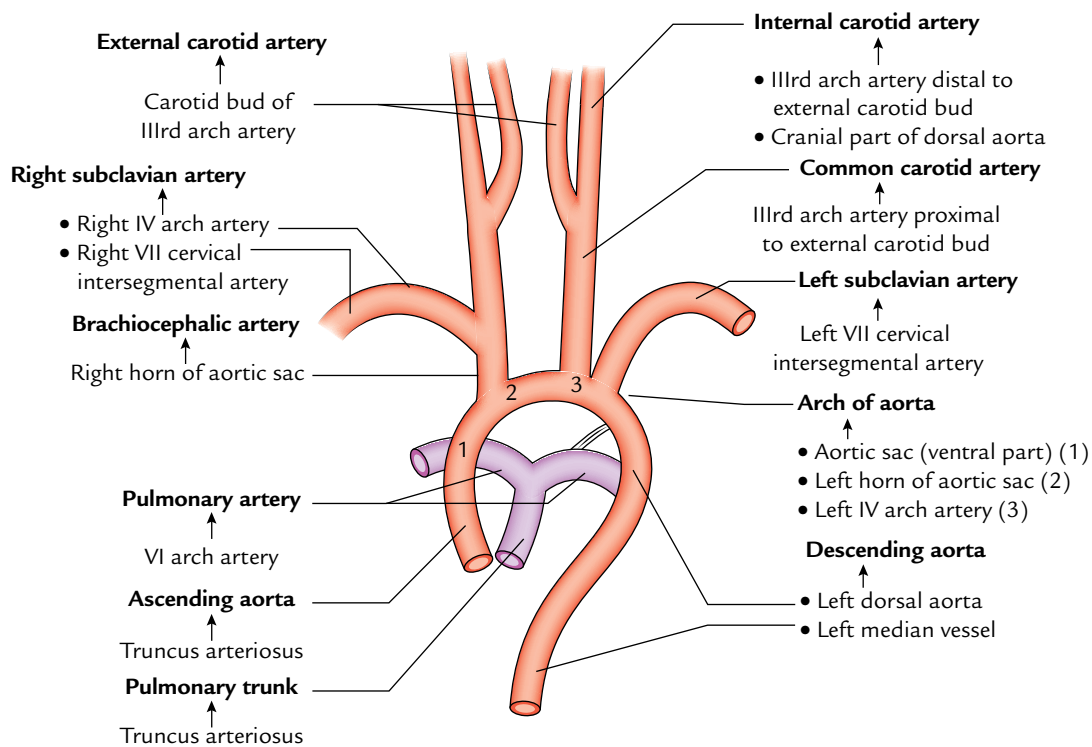


Fig. 19.7 Source of development of major arteries of head and neck, upper limb, and thorax.

Table 19.2 Derivatives of aortic arch arteries

Arch artery	Derivatives
First arch artery	Maxillary artery
Second arch artery	Hyoid and stapedial arteries
Third arch artery	Common carotid artery, proximal part of the internal carotid artery, and external carotid artery
Fourth arch artery	<i>On the left side:</i> Part of the arch of aorta <i>On the right side:</i> Proximal part of the right subclavian artery
Sixth arch artery	<i>On the left side:</i> Left pulmonary artery and ductus arteriosus <i>On the right side:</i> Right pulmonary artery

circulation. The PDA is one of the most common congenital anomalies of the great vessels occurring in 8/10,000 births, especially in premature female babies born to mothers who had suffered from *rubella infection* in the early part of pregnancy.

Functional closure of the ductus arteriosus (DA) occurs at birth by contraction of smooth muscles of the DA. **Anatomical closure** occurs by proliferation of tunica intima of DA 1–3 months after birth. It is mediated by **bradykinin**—a substance released from lungs, during their initial inflation.

N.B. The **prostaglandin E** and **intrauterine asphyxia** sustain the patency of DA. Therefore prostaglandin inhibitors (e.g., indomethacin) promote closure of the DA. The surgical treatment of PDA is limited to its ligation and resection.

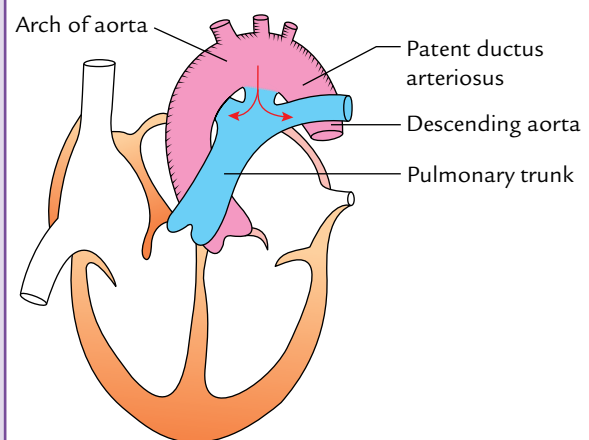


Fig. 19.8 Patent ductus arteriosus.

2. **Coarctation of aorta (Fig. 19.9):** The coarctation means narrowing of the aorta. It occurs due to extension of the process of obliteration of DA into the aorta. The coarctation of aorta is of two types: *preductal* and *postductal*.

(a) **Preductal type of coarctation of aorta:** In this type, a narrow segment of arch of aorta is proximal to entrance of the DA. The DA persists (Fig. 19.9A) in this type.

(b) **Postductal type of coarctation of aorta:** In this type, a narrow segment of arch of aorta is distal to the entrance of the DA. The DA usually obliterates in this type.

N.B. The narrowing in the arch of aorta in both types is distal to the left subclavian artery. The **postductal coarctation** of aorta is more common.

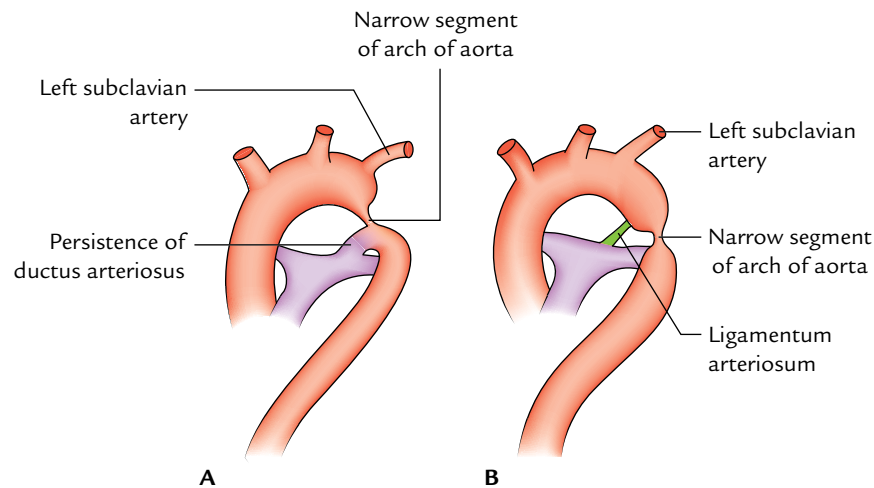


Fig. 19.9 Coarctation of aorta.

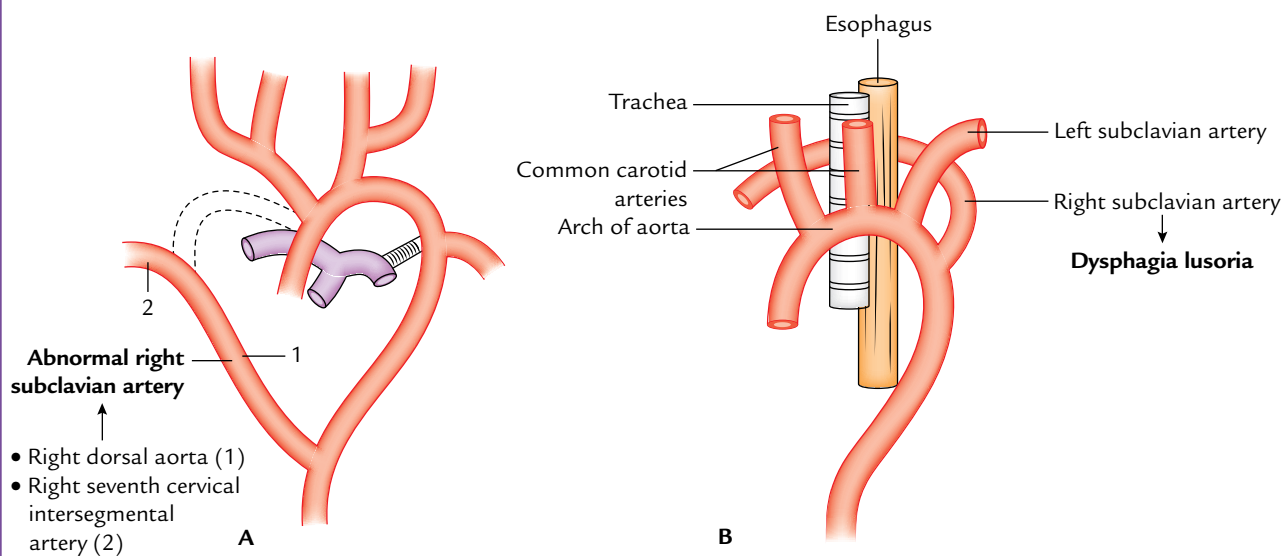


Fig. 19.10 Abnormal origin of the right subclavian artery. A. Right fourth aortic arch and proximal portion of right dorsal aorta disappears. The right subclavian artery is formed by distal portion of right dorsal aorta and right intersegmental subclavian artery, and then crossing the midline behind esophagus and trachea. B. Vascular ring around trachea and esophagus formed by right subclavian artery and aortic arch.

Clinically coarctation of aorta presents as:

- Increased blood pressure in the upper limbs, lack of femoral pulse, and a high risk of cerebral hemorrhage.
- Collateral circulation between part of aorta proximal to and part of aorta distal to narrowing involves internal thoracic, intercostal, superior epigastric, inferior epigastric, and external iliac arteries.

Dilatation of intercostal arteries causes erosion of the lower border of ribs called **notching of ribs**, which can be visualized in chest radiographs.

3. **Abnormal origin of the right subclavian artery (Fig. 19.10):** In this anomaly, the right subclavian artery arises from the descending aorta, and passes behind trachea and esophagus. The brachiocephalic artery is absent, and right common carotid artery arises directly from the arch of aorta.

This anomaly occurs when right fourth arch artery along with part of right dorsal aorta cranial to seventh cervical intersegmental artery disappears. The part of right dorsal aorta, caudal to seventh intersegmental artery, persists and forms proximal part of the right subclavian artery; distal part being formed by seventh intersegmental artery (Fig. 19.10A). Sometimes the right subclavian artery may arise as a last branch of the arch of aorta and runs to the right behind the esophagus and trachea.

In this condition a vascular ring is formed around the trachea and esophagus (right subclavian being posterior to the trachea and esophagus, and arch of aorta being anterior to them) (Fig. 19.10B). Compression of the trachea and esophagus usually does not occur as the ring is too wide. Sometimes such an abnormal right subclavian artery may compress esophagus causing difficulty in swallowing. Clinically this condition is termed '**dysphagia lusoria**.'

4. **Double aortic arch (Fig. 19.11):** In this anomaly, the right dorsal aorta between the origin of seventh cervical intersegmental artery and its junction with the left dorsal aorta does not disappear. As a result, there is formation of arch of the aorta on both sides. In this anomaly, the right arch of aorta passes behind the trachea and esophagus, while the left arch passes in front of them.

The vascular ring thus formed between right and left aortic arches commonly causes compression of trachea and esophagus, leading to difficulty in breathing and swallowing.

5. **Right arch of aorta:** This anomaly is a mirror image of the normal pattern. In this anomaly, the left dorsal aorta distal to the origin of seventh intersegmental artery disappears while the right dorsal aorta persists giving rise to right aortic arch. The right pulmonary artery is connected with right arch of the aorta by the DA that subsequently forms ligamentum arteriosum. Sometimes when the ligamentum arteriosum lies on the left side and passes below the esophagus, it may cause difficulty in swallowing.

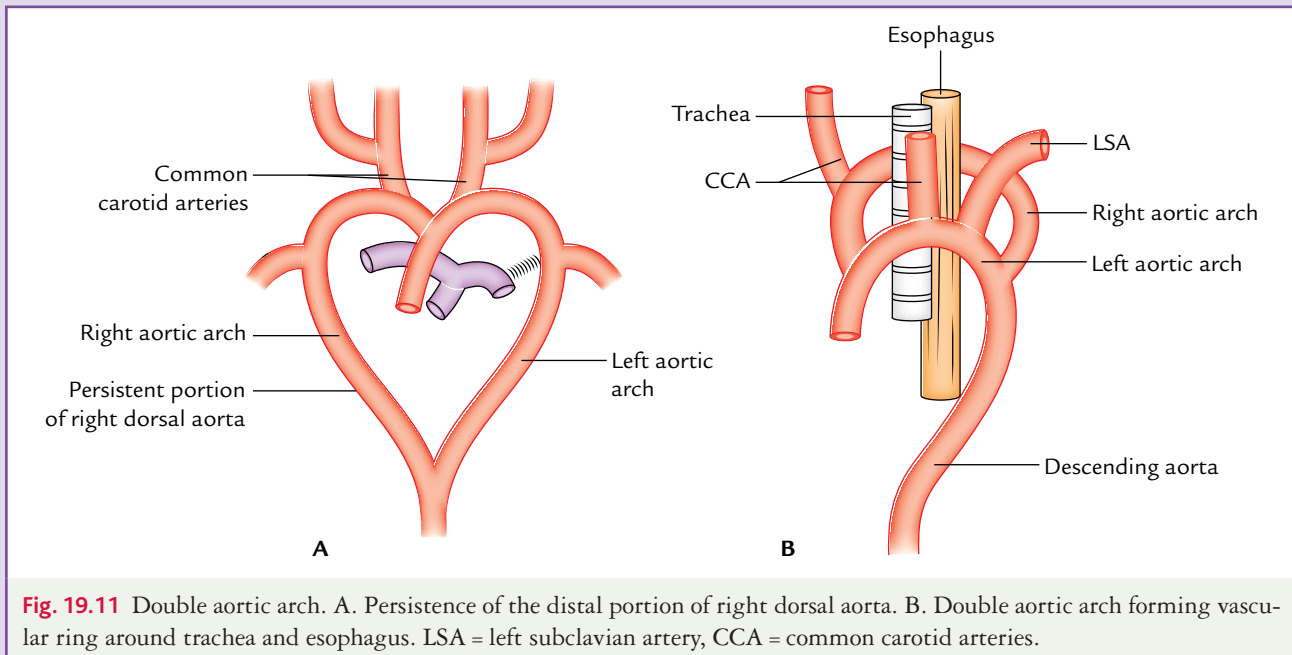


Fig. 19.11 Double aortic arch. A. Persistence of the distal portion of right dorsal aorta. B. Double aortic arch forming vascular ring around trachea and esophagus. LSA = left subclavian artery, CCA = common carotid arteries.

Development of Other Arteries of the Body

They develop from primitive dorsal aortae. The primitive dorsal aorta gives off three sets of branches: dorso-lateral (somatic intersegmental), lateral splanchnic, and ventral splanchnic (Fig. 19.12, also see Fig. 19.2).

1. The **dorsolateral (somatic intersegmental) branches** form arteries of upper and lower limbs, intercostal lumbar, and lateral sacral arteries.
2. The **lateral splanchnic branches** form phrenic, suprarenal, renal, and gonadal vessels.
3. The **ventral splanchnic branches** form *vitelline* (*celiac*, *superior*, and *inferior mesenteric*) and *umbilical arteries*. The arteries for bronchi and esophagus also arise from ventral splanchnic branches.

The arteries derived from the branches of the dorsal aorta are given in Table 19.3.

Development of Umbilical Arteries (Fig. 19.13)

The two umbilical arteries (right and left) arise as *ventral splanchnic branches* of the dorsal aorta in the sacral

Table 19.3 Arteries derived from the dorsal aorta

Embryonic structure	Adult derivatives
• Posterolateral (somatic intersegmental) branches	• Arteries of upper and lower limbs • Intercostal, lumbar, and lateral sacral arteries
• Lateral splanchnic branches	• Phrenic arteries • Suprarenal arteries • Renal arteries • Gonadal (testicular and ovarian) arteries
• Ventral splanchnic branches (a) Vitelline arteries	• Celiac artery • Superior mesenteric artery • Inferior mesenteric artery
(b) Umbilical arteries	• Superior vesical arteries

region: Each umbilical artery develops a communication with fifth lumbar intersegmental artery. The fifth intersegmental artery becomes internal iliac artery. The part of umbilical artery between the dorsal aorta and its site of anastomosis with the fifth intersegmental artery

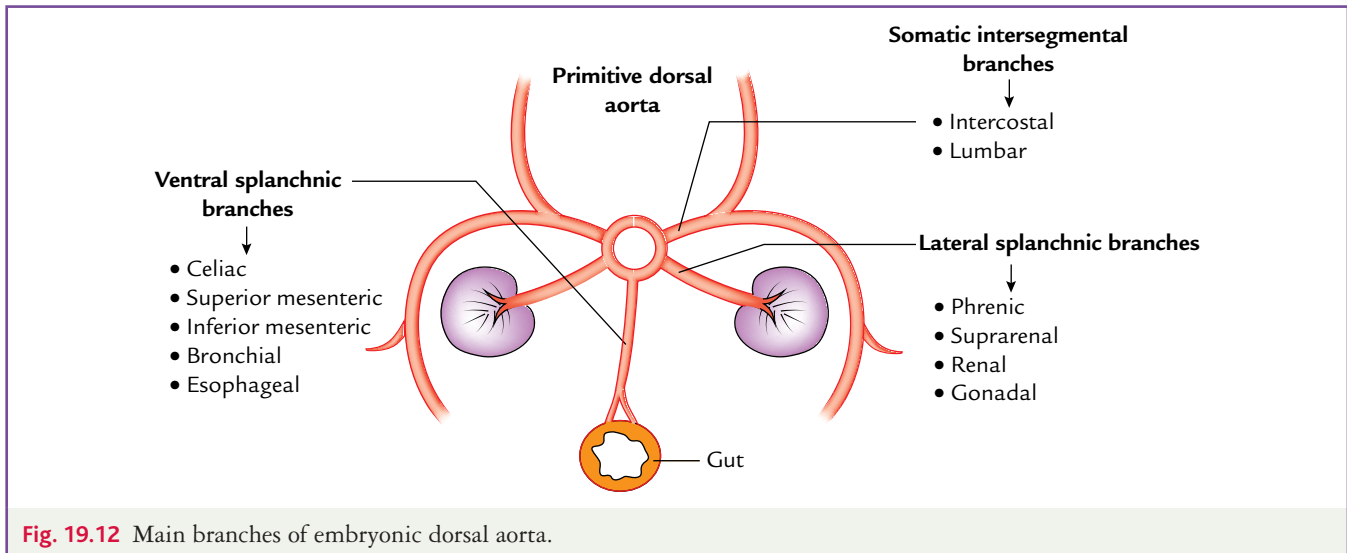


Fig. 19.12 Main branches of embryonic dorsal aorta.

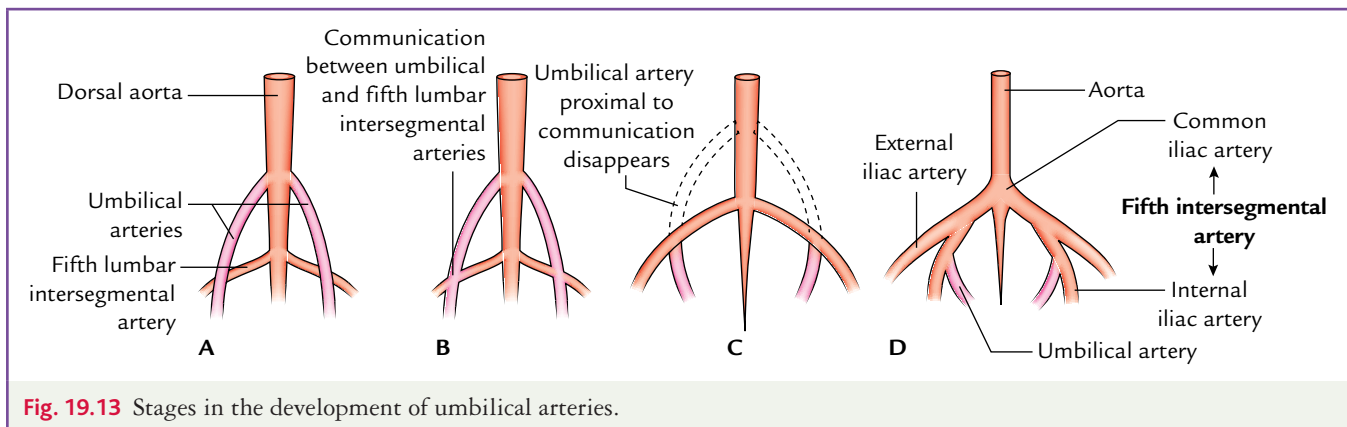


Fig. 19.13 Stages in the development of umbilical arteries.

disappears. As a result, the definitive umbilical artery arises from the internal iliac artery. The common iliac artery continues as internal iliac artery whereas external iliac artery sprouts from common iliac artery secondarily. In postnatal life, the proximal part of umbilical artery becomes **superior vesicle artery** whereas its distal part becomes obliterated to form **medial umbilical ligament**.

N.B. The right and left umbilical arteries develop in the connecting stalk and then develop a connection with dorsal aorta secondarily in the sacral region.

Development of the Arteries of the Limbs

Each limb is supplied by an **axis artery** that is derived from intersegmental arteries. The axis artery runs along the central axis of the limb.

Axis Artery of the Upper Limb (Fig. 19.14)

The axis artery of the upper limb is derived from **seventh cervical intersegmental (subclavian) artery**. This artery grows distally along the ventral axial line and terminates in a palmar capillary plexus in hand.

Main trunk of axis artery forms *axillary artery*, *brachial artery*, *anterior interosseous artery*, and *deep palmar arch*. The digital arteries of the hand arise from the palmar capillary plexus.

The median artery develops later from the anterior interosseous artery and grows distally to communicate with the palmar capillary plexus.

Radial and ulnar arteries develop later as sprouts of the axis artery close to bend of the elbow.

N.B. The radial artery arises somewhat proximal to the ulnar artery from the axis artery.

Clinical Correlation

The knowledge of congenital anomalies of radial artery is important because nowadays it is used for introduction of cardiac catheter (earlier femoral artery was used for this purpose). The three common anomalies of radial artery related to its origin are:

1. It may arise from the axillary artery.
2. It may arise from both axillary and brachial arteries.
3. It may arise mostly from the brachial artery and partly from the axillary artery.

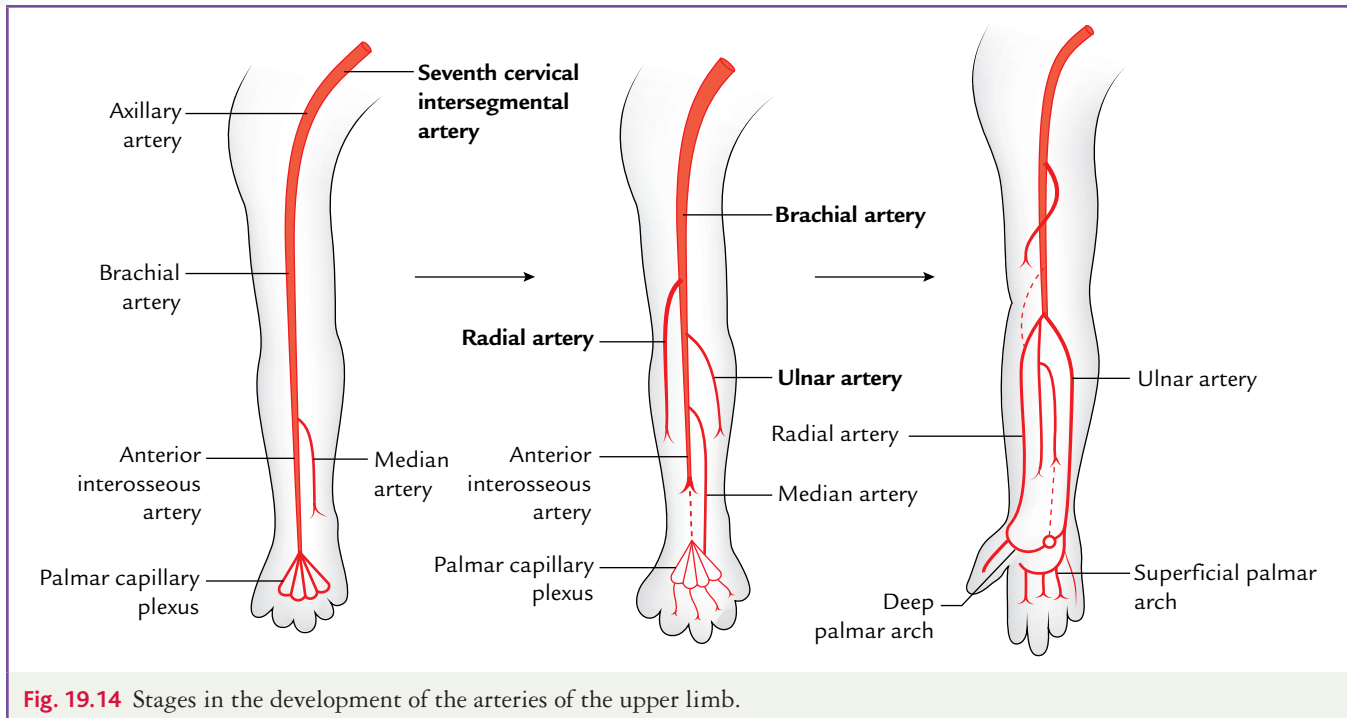


Fig. 19.14 Stages in the development of the arteries of the upper limb.

Axis Artery of the Lower Limb (Fig. 19.15)

The axis artery of the lower limb is derived from **fifth lumbar intersegmental artery**.

The axis artery runs on the posterior aspect of the lower limb. It forms **inferior gluteal artery**—a small artery accompanying the sciatic nerve (called *ischadic artery/arteria comitans nervi ischiadici*)—part of **popliteal artery** above the popliteus muscle, **distal part of peroneal artery**, and part of **plantar arch**.

The **femoral artery** appears as an entirely new vessel formed on the ventral aspect of thigh. It develops a connection with the external iliac artery above and popliteal artery below.

N.B. The external iliac artery is an offshoot of the axial artery.

The adult derivatives of axis arteries of the upper and lower limbs are given in Table 19.4.

Development of Venous System

Overview

The veins of the body develop from three sets of primitive veins: vitelline, umbilical, and cardinal, which drain into sinus venosus (Fig. 19.16). These veins undergo remodeling (due to left-to-right shunting of blood to drain into the right atrium) and form adult veins.

In the fifth week of intrauterine life (IUL), three pairs of major primitive veins are seen in the developing embryo (Fig. 19.16). These are:

- **Vitelline veins**, which return poorly oxygenated blood from yolk sac.

- **Umbilical veins**, which carry well oxygenated blood from placenta
- **Common cardinal veins**, which return poorly oxygenated blood from the body of the embryo.

N.B. Common cardinal vein on each side is formed by union of anterior and posterior cardinal veins.

The primitive veins of embryo are classified into two groups: visceral and somatic.

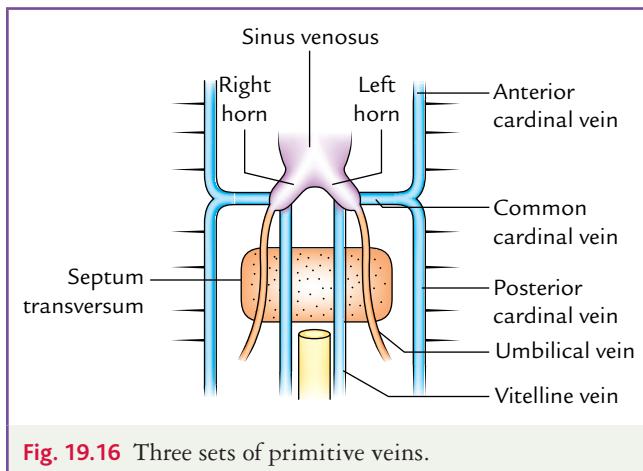
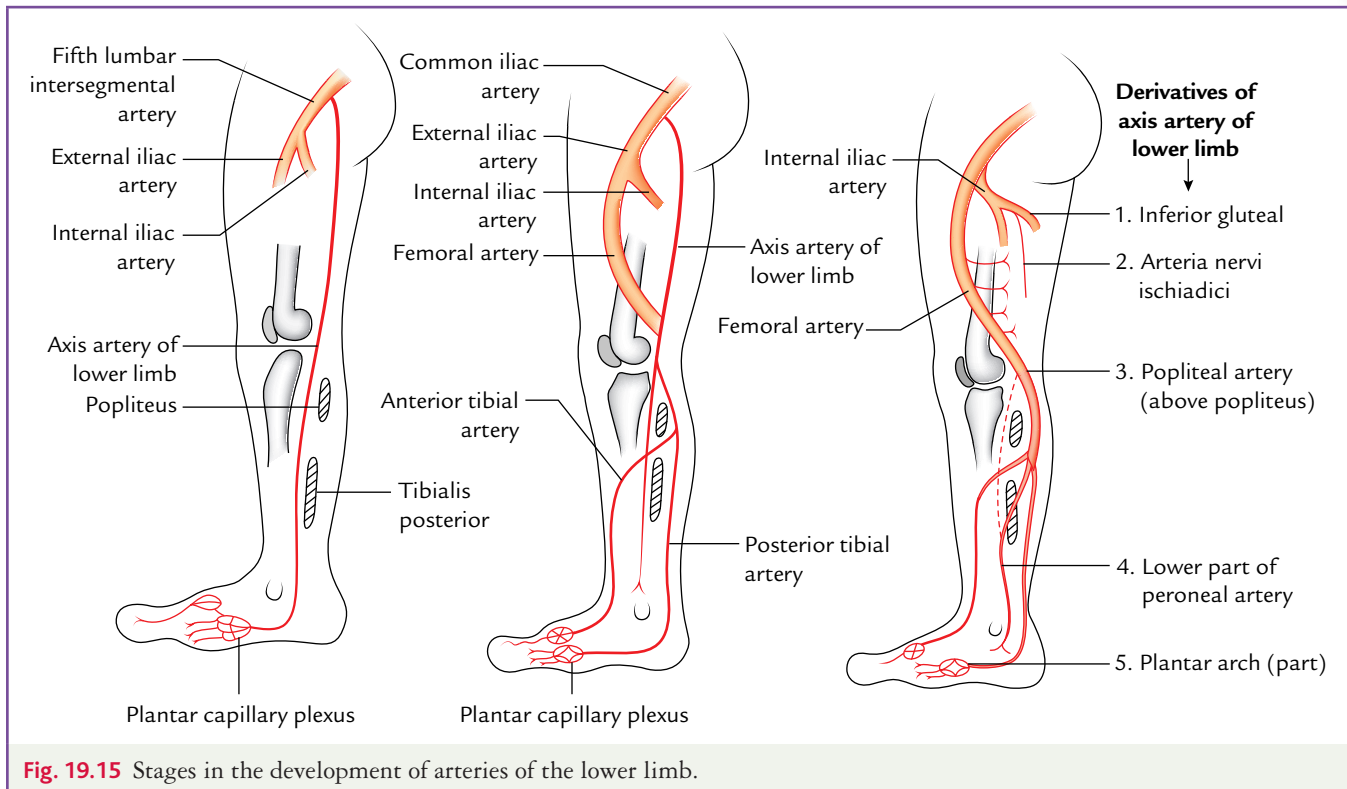
Visceral Veins

There are two pairs of visceral veins in the embryo: (a) a pair of vitelline veins and (b) a pair of umbilical veins.

Vitelline Veins

The vitelline veins arise from the yolk sac. Initially they pass from the yolk sac to the sinus venosus. When the yolk sac disappears these veins pass on either side of duodenum to form plexus around it and open in corresponding horn of the sinus venosus. Before opening in the sinus venosus, they pass through septum transversum. These veins drain derivatives of the gut.

As liver develops in the septum transversum, portions of vitelline veins passing through the septum transversum break up and form extensive vascular anastomosis—*liver sinusoids*. Parts of vitelline veins distal to liver sinusoids form *right and left hepatocardiac channels* (Fig. 19.17A).



Umbilical Veins

Initially there are two umbilical veins—right and left. They arise in the placenta and course through the umbilical cord to enter the fetal body through umbilicus. They carry oxygenated blood from the placenta to the fetus and open into right and left horns of the sinus venosus, respectively (Fig. 19.17).

With the development of liver in the septum transversum, the umbilical veins are absorbed and broken up within the septum transversum.

The parts of umbilical veins distal to septum transversum and the remainder of right umbilical vein disappear so that only left carries blood from the placenta to the liver. When there is an increase in placental circulation, to facilitate the rapid transport of blood

Table 19.4 Adult derivatives of axial arteries of the upper and lower limbs

Axis artery	Adult derivatives
Axial artery of upper limb	<ul style="list-style-type: none"> • Axillary artery • Branchial artery • Anterior interosseous artery • Deep palmar arch
Axial artery of lower limb	<ul style="list-style-type: none"> • Inferior gluteal artery • Arteria nervi ischiadici • Popliteal artery above popliteus • Lower part of peroneal artery • Some parts of plantar arch

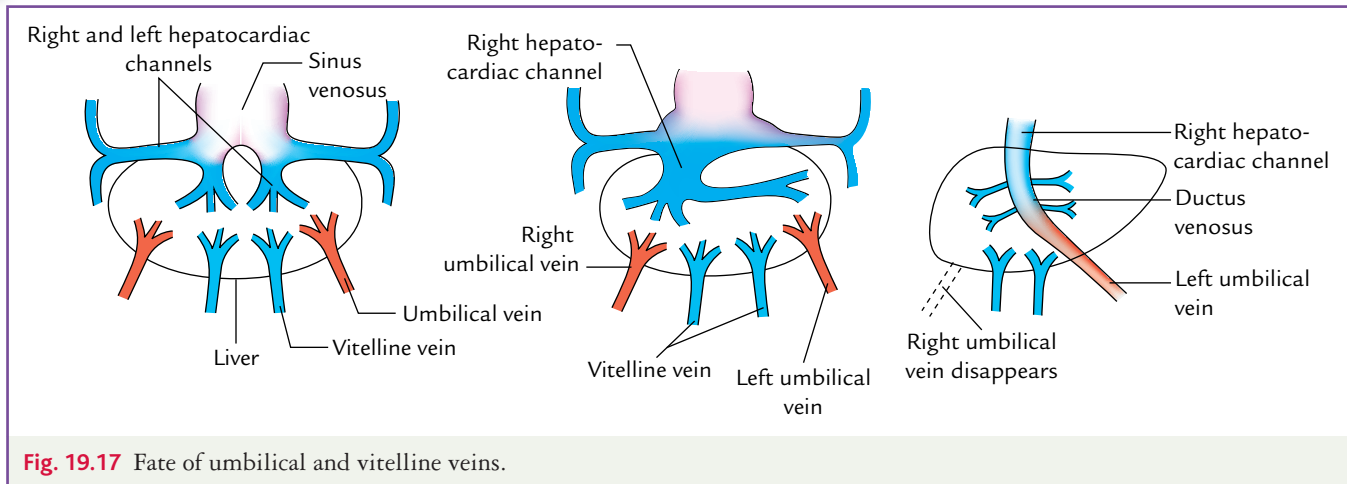
through the liver, a large passage is formed between left umbilical vein and right hepatocardiac channel. This passage is called **ductus venosus**.

When the portal vein develops the ductus venosus connects the left branch of portal vein to the primitive inferior vena cava (IVC) (the *right hepatocardiac channel*) and *left umbilical vein* connects with the left branch of the portal vein inside the liver.

N.B. After birth, the left umbilical vein obliterates to form *ligamentum teres hepatis* and ductus venosus obliterates to form *ligamentum venosum*.

Development of Portal Vein (Fig. 19.18)

The two vitelline veins lie one on either side of developing duodenum. They soon get interconnected by three anastomotic channels: two ventral and one dorsal.



These anastomotic channels are (Fig. 19.18B):

- Proximal ventral anastomosis
- Middle dorsal anastomosis
- Distal ventral anastomosis

The superior mesenteric and splenic veins that develop independently unite with the left vitelline vein just below dorsal anastomosis.

The portal vein develops from three components:

1. Caudal part of left vitelline vein between point at which superior mesenteric and splenic vein open, and the point where dorsal anastomosis joins the left vitelline vein.
2. Middle dorsal anastomosis.
3. Part of right vitelline vein between the dorsal and proximal ventral anastomosis.

The *right branch of portal vein* develops from the part of right vitelline vein distal to proximal ventral anastomosis.

The *left branch of portal vein* develops from proximal ventral anastomosis and left vitelline vein distal to proximal ventral anastomosis.

Remaining parts of vitelline veins and distal ventral anastomosis disappear along with left hepatocardiac channel.

N.B. The development of portal vein explains that it is formed by union of superior mesenteric and splenic veins; it passes dorsally to the duodenum and divides into right and left branches that enter the liver.

Somatic Veins

There are two pairs of somatic veins in the embryo.

1. A pair of right and left **anterior cardinal veins** that drain venous blood from cranial part of the embryo.

2. A pair of right and left **posterior cardinal veins** that drain the venous blood from caudal part of the embryo.

The anterior and posterior cardinal veins on each side join to form common cardinal vein (or **duct of Cuvier**). The right and left common cardinal veins thus formed open into the right and left horns of the sinus venosus, respectively.

N.B.

- The anterior and posterior cardinal veins receive a series of intersegmental veins that drain various segments of the body.
- The intersegmental veins in the region of upper limb bud enlarge to form the *subclavian veins*.

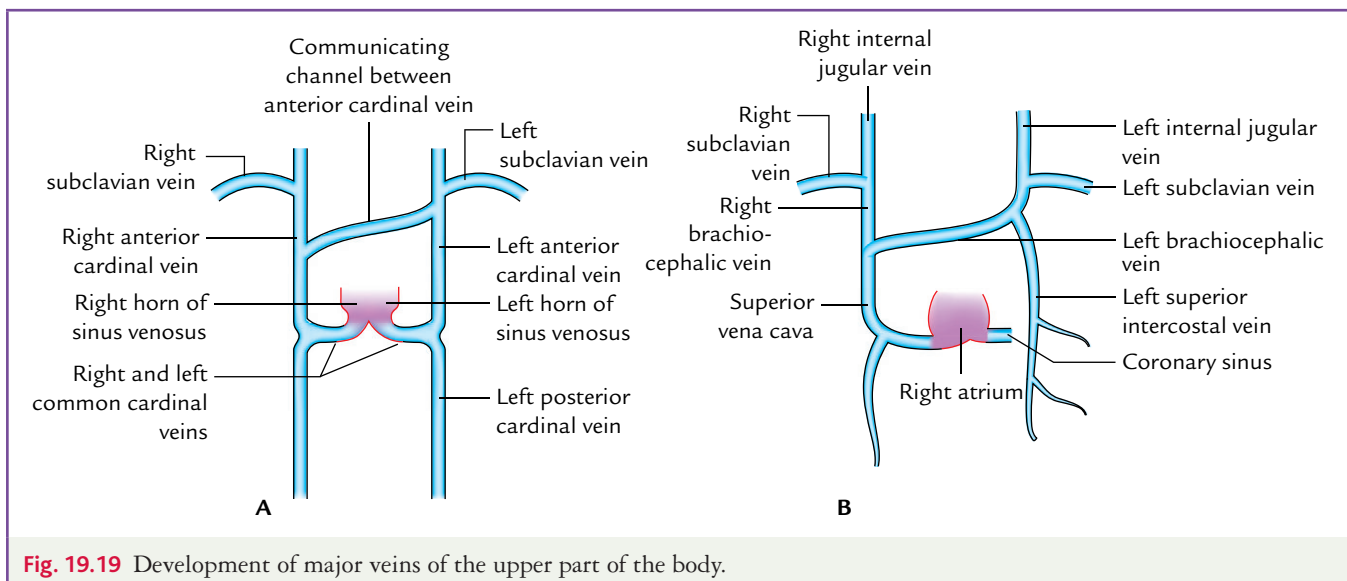
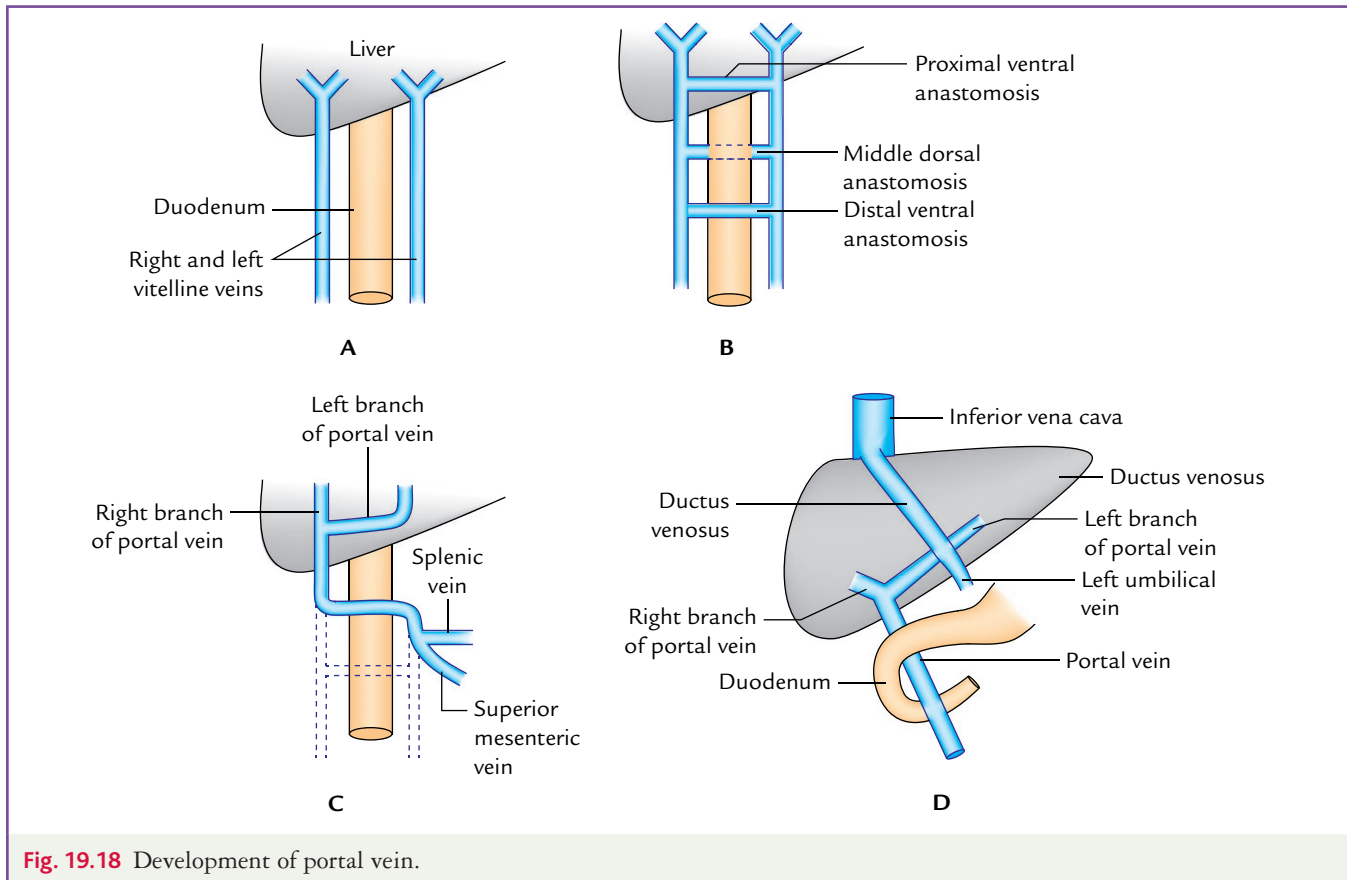
Development of Major Veins in the Upper Part of the Body (Fig. 19.19)

Overview

- The anterior cardinal vein receives the subclavian vein that develops by enlargement of intersegmental vein in the region of upper limb bud.
- An oblique communicating channel develops and connects the two anterior cardinal veins distal to opening of the subclavian veins.

The major veins of the upper part of the body, viz., internal jugular veins, subclavian veins, right and left brachiocephalic vein, and superior vena cava are derived as follows:

1. **Internal jugular vein:** It develops from anterior cardinal vein cephalic to the opening of the subclavian vein.
2. **Subclavian vein:** It develops in the region of the upper limb bud by enlargement of the intersegmental veins in this region.



3. **Right brachiocephalic vein:** It develops from right anterior cardinal vein above the opening of oblique communicating channel and below the opening of the right subclavian vein.
4. **Left brachiocephalic vein:** It develops from oblique channel connecting left and right anterior cardinal veins, and left anterior cardinal vein

between the opening of communicating channel (vide supra) and left subclavian vein.

5. **Superior vena cava:** Developmentally it consists of two parts: first and second.

The *first part* develops from the right anterior cardinal vein caudal to the oblique transverse anastomosis.

The *second part* develops from the right common cardinal vein.

As the right common cardinal vein opens into the right horn of sinus venosus, the superior vena cava at first opens into the right horn of sinus venosus. As and when the right horn of sinus venosus is absorbed into the right atrium, the superior vena cava finally opens into the right atrium.

6. **Other veins:** As most of the blood is shunted from left to right the following changes occur:
- Part of the left anterior cardinal vein below the transverse anastomosis obliterates.

- The most of left posterior cardinal vein also regresses. The small cranial part of left posterior cardinal vein along with regressed part of the left anterior cardinal vein caudal to transverse anastomosis forms **left superior intercostal vein**.
- The left horn of sinus venosus regresses and forms **coronary sinus**. The left common cardinal vein obliterates in its lateral part and forms oblique vein of the left atrium (**oblique vein of Marshall**) while its medial part contributes to the formation of coronary sinus.

External jugular veins develop as separate channels.

Clinical Correlation

Anomalies of superior vena cava (Fig. 19.20)

- Double superior vena cava (Fig. 19.20A):** It occurs when the anastomosis between the two anterior cardinal veins fails to form and left anterior cardinal vein persists. Thus, anterior cardinal vein on both sides develops into the superior vena cava. The *left superior vena cava* opens into the coronary sinus, which in turn opens into the right atrium.

- Left superior vena cava (Fig. 19.20B):** It occurs when the anastomosis does not develop between the two anterior cardinal veins, but the blood is shunted from right to left through brachiocephalic vein. As a result, the right anterior cardinal vein below the oblique transverse anastomosis regresses and the left anterior cardinal vein develops into the superior vena cava. The left superior vena cava opens into the coronary sinus.

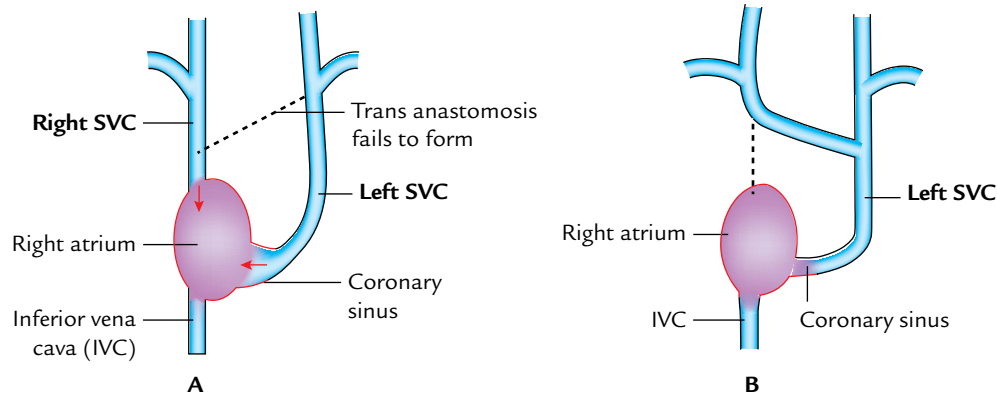


Fig. 19.20 Anomalies of the superior vena cava (SVC).

Development of the Veins of Abdomen

Overview

- The **posterior cardinal veins** are paired longitudinal channels that lie on the dorsolateral aspect of the mesonephros and drain the caudal part of the embryo.
- At the cranial end, it joins the anterior cardinal vein to form the common cardinal vein of the respective side.
- At the caudal ends, they receive the external iliac and internal iliac veins from the lower limb bud and the pelvis.
- There develops an anastomosis between the two posterior cardinal veins above opening of iliac veins.

- The **subcardinal veins** develop on ventromedial aspect of the mesonephros. Cranially and caudally they communicate with the posterior cardinal veins. They receive the veins from the developing kidneys.
- At the level of renal veins, the two subcardinal veins get connected in front of the aorta by a transverse channel. The cranial part of the right subcardinal vein develops a communication with the **right hepatocardiac channel**.
- The two new longitudinal channels called **supracardinal veins** develop lateral to subcardinal veins. They communicate cranially and caudally with the posterior cardinal veins. The supracardinal veins drain the body wall by way of intercostal veins and take over functions of posterior cardinal veins.

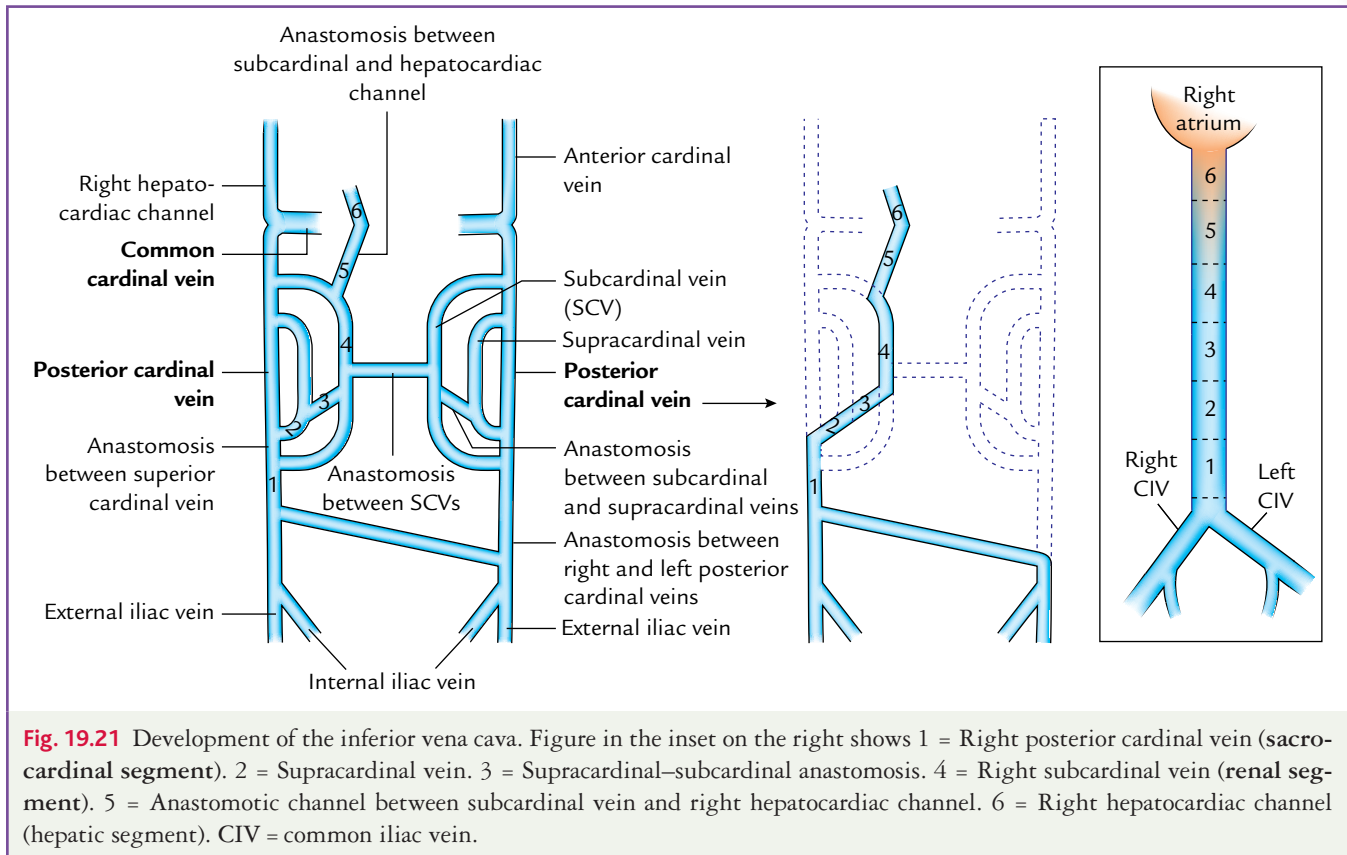


Fig. 19.21 Development of the inferior vena cava. Figure in the inset on the right shows 1 = Right posterior cardinal vein (sacrocardinal segment). 2 = Supracardinal vein. 3 = Supracardinal–subcardinal anastomosis. 4 = Right subcardinal vein (renal segment). 5 = Anastomotic channel between subcardinal vein and right hepatocardiac channel. 6 = Right hepatocardiac channel (hepatic segment). CIV = common iliac vein.

On each side, the supracardinal vein gets connected with subcardinal vein below the transverse anastomosis between two subcardinal channels.

The veins of the abdomen, viz., inferior vena cava, renal veins, gonadal veins, and suprarenal veins develop from posterior cardinal veins and related venous channels. Following shunting of blood from the left to the right, many parts of longitudinal venous channels (vide supra) disappear.

1. Inferior vena cava (IVC): It is the largest vein of the body and develops from six components. From caudal to cranial these components are (Fig. 19.21) as follows:

- Right posterior cardinal vein (between the transverse anastomosing channel and caudal opening of the right suprascardinal vein). It is termed **sacrocardinal segment of IVC** (1).
- Caudal part of right suprascardinal vein (2).
- Right suprascardinal–subcardinal anastomosis (3).
- Right subcardinal vein between (i) the suprascardinal–subcardinal anastomosis and (ii) anastomotic channel connecting the right subcardinal vein with right hepatocardiac channel. It is called **renal segment of the IVC** (4).

- Anastomosing channel that connects the right subcardinal vein to the right hepatocardiac channel (5).
- Right hepatocardiac channel forms terminal segment (**hepatic segment**) of the inferior vena cava that first opens into right horn of sinus venosus, and, after the right horn is absorbed in the right atrium, in the right atrium itself (6).

N.B. At birth, the three segments of the IVC are:

- Sacrocardinal segment
- Renal segment
- Hepatic segment

- Right common iliac vein (Fig. 19.23):** It develops from the caudal part of right posterior cardinal vein below the transverse anastomosis between the two posterior cardinal veins.
- Left common iliac vein (Fig. 19.23):** It develops from the transverse anastomosis between the two posterior cardinal veins and part of left posterior cardinal vein below the anastomosis.
- External iliac veins (Fig. 19.23):** On each side, the external iliac vein develops from one of the intersegmental veins in the region of lower limb bud. It drains the lower limb and joins the caudal end of posterior cardinal vein of the respective side.

Clinical Correlation

Anomalies of inferior vena cava (Fig. 19.22)

- 1. Double inferior vena cava (Fig. 19.22A):** It occurs because the anastomosis between two posterior cardinal veins does not develop. Hence the left posterior cardinal vein below the level of the renal vein develops into the inferior vena cava while normal inferior vena cava develops on the right side. As a result, inferior vena cava is duplicated only below the renal veins. The left inferior vena cava opens into left renal vein.
- 2. Absence of inferior vena cava (Fig. 19.22B):** In this condition, the anastomosing channel between right subcardinal vein and right hepato-cardiac channel fails to develop. The cranial part of right subcardinal vein, which normally disappears, persists and carries the blood from the inferior vena cava to the superior vena cava. The hepatic veins directly open into the right atrium at the site of the inferior vena cava.
- 3. Preureteric vena cava:** In this condition, right ureter passes behind the inferior vena cava (*retrocaval ureter*). It occurs when infrarenal part of IVC develops from subcardinal vein that lies anterior to the ureter instead of supracardinal vein that lies posterior to the ureter.

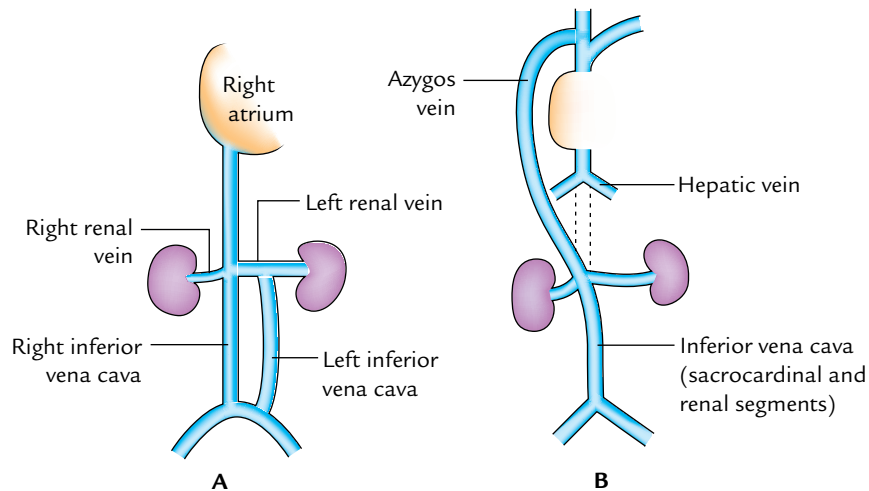


Fig. 19.22 Anomalies of the inferior vena cava. A. Double inferior vena cava. B. Absence of the inferior vena cava.

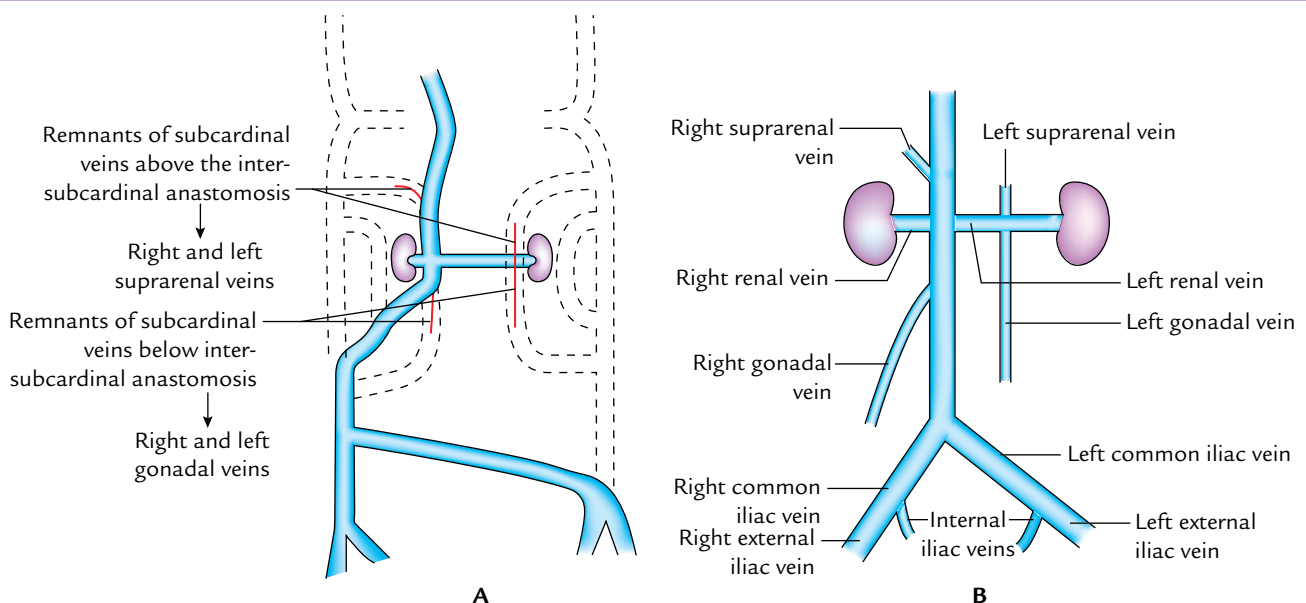


Fig. 19.23 Development of renal, suprarenal, and gonadal veins. A. Suprarenal and gonadal veins are indicated by red lines. B. Definitive suprarenal and gonadal veins are shown.

5. **Internal iliac veins (Fig. 19.23):** The internal iliac veins drain the pelvis and join the caudal end of the posterior cardinal veins.
6. **Right renal vein (Fig. 19.23):** It develops from the vein that drains the right mesonephros. At first it drains into the right subcardinal vein; then as this part of right subcardinal vein forms part of the inferior vena cava, it drains into the inferior vena cava.
7. **Left renal vein (Fig. 19.23):** It is longer than the right renal vein and develops from following three sources:
 - (a) Mesonephric vein that drains the left mesonephros.
 - (b) Part of left subcardinal vein that receives the left mesonephric vein.
 - (c) Anastomotic channel between the two subcardinal veins.
8. **Suprarenal veins (Fig. 19.23):** The suprarenal veins are the remnants of parts of subcardinal veins above the anastomotic channel (intersubcardinal anastomosis).
9. **Gonadal (testicular and ovarian) veins (Fig. 19.23):** The testicular and ovarian veins are the remnants of parts of subcardinal veins below the intersubcardinal anastomosis.

This explains why right suprarenal and right gonadal veins open into the vena cava while left suprarenal and left gonadal veins open into the left renal vein.

N.B. Major part of the right subcardinal vein forms the renal segment of the inferior vena cava (on the right side) while left subcardinal vein forms part of left renal vein (on the left side).

Azygos System of Veins (Fig. 19.24)

The azygos system of veins consists of following veins:

1. Azygos vein
2. Hemiazygos vein
3. Accessory hemiazygos vein.

These veins develop as follows:

A pair of longitudinal venous channels develops one on either side—medial to sympathetic chain. These are called **veins of azygos line**. At the cranial end they open into the **posterior cardinal veins**.

In the thoracic region, the azygos line of veins receives the intersegmental veins that later on form the intercostal veins.

The two anastomotic channels develop between the veins of right and left veins of azygos line that pass dorsal to the aorta. When most of the blood is shunted from the left to the right side, the left posterior cardinal

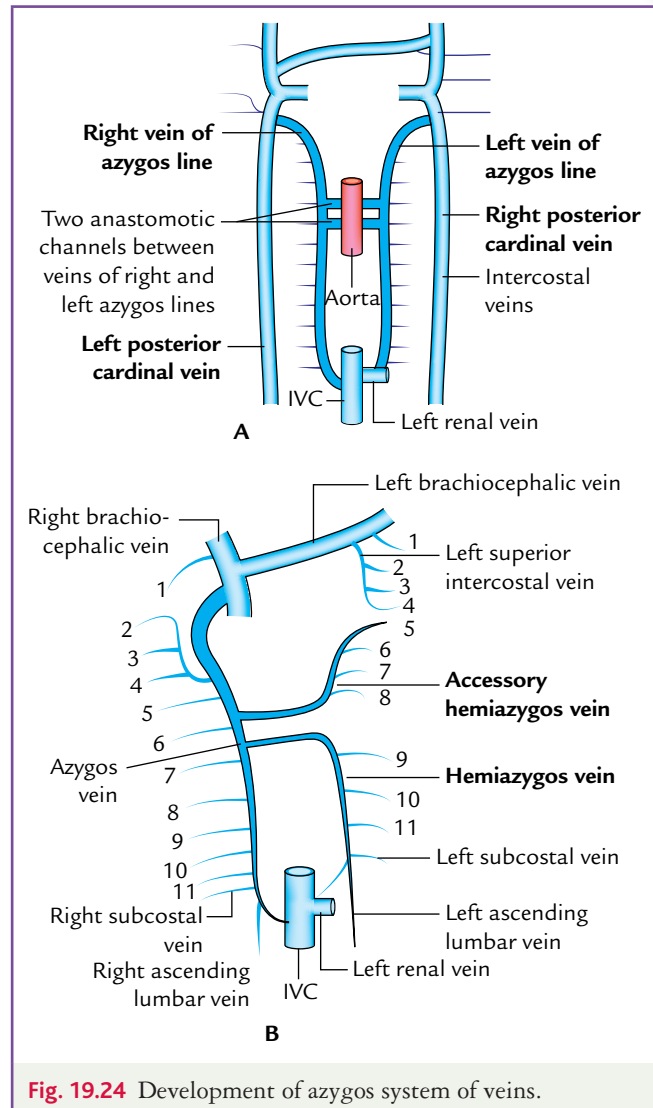


Fig. 19.24 Development of azygos system of veins.

vein regresses. The blood from the vein of left azygos line passes to the vein of right azygos line through these two anastomotic channels.

The various azygos veins are formed as follows.

Azygos Vein

It is formed caudocranially from (a) the vein of right azygos line and (b) the cranial part of posterior cardinal vein. It opens into the superior vena cava and receives the hemiazygos and accessory hemiazygos veins as its tributaries.

The vein of right azygos line communicates with right subcardinal vein, which forms part of the inferior vena cava; hence the azygos vein communicates with inferior vena cava.

Hemiazygos Vein

It is formed from the lower part of vein of the left azygos line and the caudal postaortic anastomosis between the veins of right and left azygos lines.

N.B. The vein of left azygos line communicates below with the left subcardinal vein that forms part of left renal vein; hence, the hemiazygos vein communicates with left renal vein.

Accessory Hemiazygos Vein

It is formed by the upper part of vein of the left azygos line and cranial postaoortic anastomosis between the veins of right and left azygos lines.

N.B. The cranial part of posterior cardinal vein regresses and forms the **left superior intercostals vein**. The cranial part of vein of left azygos line loses its communication with the posterior cardinal vein.

- The part of vein of left azygos line between the two anastomosing channels disappears.
- Thus, both hemiazygos and accessory hemiazygos veins drain into the azygos vein.

Fetal Circulation (Fig. 19.25)

Overview

The fetal circulation is different from that of adult circulation.

There are three basic reasons for this difference:

1. Blood in the fetus is oxygenated by placenta and not by lungs.
2. During fetal life, the lungs are collapsed, hence the resistance to blood flow through the lung is much higher. As a result, only minimal amount of blood passes through the lungs to supply oxygen and nutrients to the lungs.
3. Portal circulation is of little significance.

Before birth, the oxygenated blood (80% saturated with O₂) from the placenta returns to the fetus by way of the **left umbilical vein**. The umbilical vein traverses through the umbilical cord, enters the abdomen through umbilicus, and passes to the liver through falciform ligament. In the liver, the left umbilical vein joins the left branch of portal vein. Here, most of blood from left umbilical vein bypasses the sinusoids of the liver by passing through *ductus venosus*—a channel that connects left branch of portal vein to the inferior vena cava. Only small amount of blood of left umbilical vein enters the liver sinusoids and mixes with the blood from the portal circulation.

After a short course, the inferior vena cava opens into the right atrium. In the inferior vena cava, richly oxygenated blood mixes with the deoxygenated blood returning from the lower limbs. As this blood enters in the right atrium, it is guided by the valve of inferior vena cava towards foramen ovale. Thus, most of blood from the inferior vena cava passes through foramen ovale into the left atrium. Only small amount of blood from the inferior vena

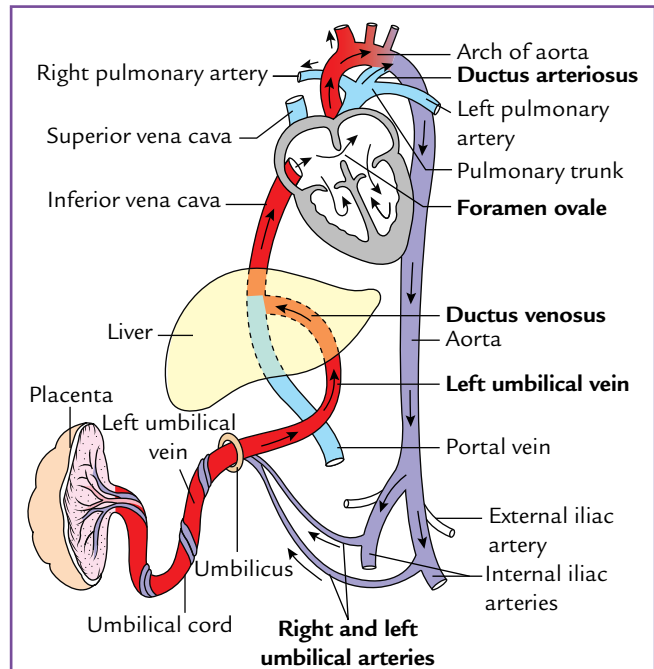


Fig. 19.25 Fetal circulation.

cava is prevented from doing so by the lower edge of septum secundum—the *crista dividens*. It remains in the right atrium. Here, it mixes with the deoxygenated blood from the superior vena cava and passes to the right ventricle.

Blood from the right ventricle passes through pulmonary trunk, and right and left pulmonary arteries. But due to high resistance in pulmonary tissue during fetal life only a small amount of blood enters the **pulmonary circulation**, and most of it passes into the aorta through the **ductus arteriosus (DA)**—a channel that connects the left pulmonary artery to arch of aorta.

The left atrium receives mainly rich oxygenated blood from the right atrium through the **foramen ovale**. Only a small amount of deoxygenated blood enters the left atrium from the lungs through the pulmonary veins. Blood from the left atrium passes to the left ventricle.

Blood from the left ventricle enters into the ascending aorta, which through its three large branches (brachiocephalic artery, left common carotid artery, and left subclavian artery) supply oxygenated blood to head, neck, brain, and superior extremity. Since the coronary and carotid arteries are the first branches of the aorta, the heart musculature and brain are supplied by well-oxygenated blood. Thereafter the arch of aorta receives poorly oxygenated blood from the pulmonary trunk through the ductus arteriosus. Then the blood is distributed by the aorta and common iliac arteries to the lower part of the body. The lower part of the body is thus supplied with relatively less oxygenated blood as compared with the upper part of the body.

The two umbilical arteries arising from internal iliac branches of common iliac arteries pass through umbilicus and enter the placenta through the umbilical cord, where it is oxygenated. The oxygen saturation in umbilical arteries is about 58%.

Changes in Fetal Circulation Just after Birth

After birth, the placenta—**fetal organ of respiration**—is separated from newborn and lung starts oxygenating the blood, i.e., respiration is established. Now the oxygenated blood comes to heart from the lungs. As a result, the following changes take place in fetal circulation:

1. **Umbilical vein**, as it no longer carries any blood from the placenta, obliterates and forms a fibrous ligament called *ligamentum teres hepatis*.
2. **Ductus venosus** obliterates to form a fibrous ligament called *ligamentum venosum*.
3. As the lungs are inflated and the pulmonary circulation is established, pulmonary veins bring more blood to the left atrium. Now, as the pressure of blood in the left atrium is more than that in the right atrium the septum primum is pushed to the right and the foramen ovale is closed. At first the closure of foramen ovale is physiological, but later on septum primum fuses with the septum secundum and there is an anatomical closure of foramen ovale. The closed **foramen ovale** forms *fossa ovalis*.
4. DA obliterates to form a fibrous ligament called the *ligamentum arteriosum*.
5. **Umbilical arteries** (right and left) obliterate. However, their proximal parts remain open. The proximal parts of umbilical arteries form *superior vesicle arteries* whereas their distal parts form fibrous ligaments called *medial umbilical ligaments*.

The remnants of fetal circulatory structures that occur after birth due to start of neonatal circulation are summarized in Table 19.5.

Development of Lymphatic System

The lymphatic system is essentially a drainage system that is accessory to the venous system. Hence it is described here.

The lymphatic system develops at the end of the fifth week, about one week later to that of the cardiovascular system. The exact development of lymph vessels is not clear but they may develop in the following two ways: (a) They may form from mesenchyme in situ or (b) they may arise as **sac-like outgrowths** from the

Table 19.5 Remnants of fetal circulatory structures after birth

Fetal structure	Remnants after birth
1. Umbilical vein	Ligamentum teres hepatis
2. Ductus venosus	Ligamentum venosum
3. Foramen ovale	Fossa ovalis
4. Ductus arteriosus	Ligamentum arteriosum
5. Right and left umbilical arteries	<ul style="list-style-type: none"> • Superior vesicle arteries • Medial umbilical ligaments

endothelium of veins. In whatever way they develop they connect themselves with the venous system.

Development of Lymph Sacs and Lymph Vessels

The following six **primary lymph sacs** are formed during the embryonic period (Fig. 19.26):

1. **Two jugular lymph sacs** at the junction between the subclavian veins and anterior cardinal veins (future internal jugular veins).
2. **Two iliac lymph sacs** at the junction of iliac and the posterior cardinal veins.
3. **One retroperitoneal lymph sac** in the root of the mesentery on the posterior abdominal wall.
4. **One cisterna chyli** lying posterior to the retroperitoneal lymph sac.
5. Numerous small lymph channels/vessels connect the lymph sacs with each other and pass along the main veins to drain lymph from limbs, body wall, head, and neck.
6. Two large lymph channels (right and left lymph channels) connect the jugular lymph sacs with the cisterna chyli. Soon large anastomosis forms between these ducts.

Development of Thoracic Duct (Fig. 19.27)

There are three steps in the development of the **thoracic duct**:

1. **Stage I:** A network of lymph channels is formed in front of the thoracic part of the vertebral column.
2. **Stage II:** In this network of lymph channels, two large longitudinal channels appear—one left and another right with a number of cross communications.
3. **Stage III:** Formation of cross communication between two longitudinal channels opposite to the body of fifth thoracic vertebra. Now the right longitudinal channel below cross communication and the left longitudinal channel above communication

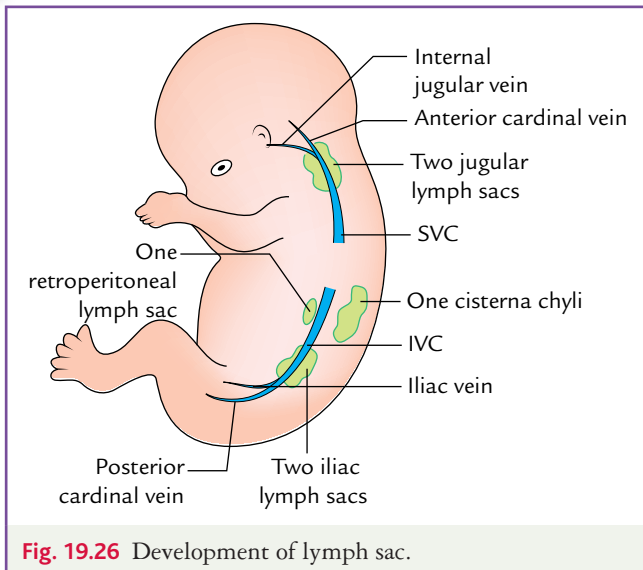


Fig. 19.26 Development of lymph sac.

persists and gives rise to the thoracic duct. All other channels disappear.

Thus thoracic duct is derived from the following three sources:

- (a) Caudal part of the right longitudinal lymph channel.
- (b) Anastomosis between the right and left longitudinal lymph channel.
- (c) Cranial portion of the left longitudinal lymph channel.

Development of Right Lymphatic Duct

It develops from the cranial portion of the right longitudinal lymph channel. Both thoracic and right lymphatic ducts open into the junction of the internal jugular and subclavian vein of the left and right side, respectively.

Development of Lymph Nodes

The lymph nodes develop from the mesenchymal cells in relation to the primary lymph sacs.

Except for the upper part of cisterna chyli all the lymph sacs are transformed into groups of lymph nodes during early fetal life as follows:

1. Mesenchymal cells invade each lymph sac and break up its cavity into a network of lymph channels to form *lymph sinuses*.
2. Other mesenchymal cells give rise to the capsule and connective tissue network of the lymph nodes.

Development of Lymphocytes

Early on the lymphocytes first develop from stem cells in the mesenchyme of the yolk sac and later on from the liver and spleen.

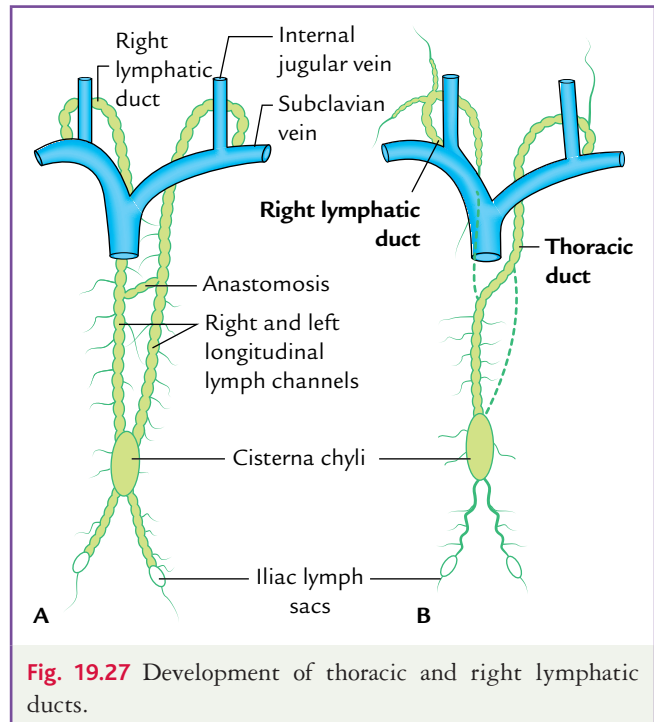


Fig. 19.27 Development of thoracic and right lymphatic ducts.

The early lymphocytes enter into bone marrow, from where they divide to form the **lymphoblasts**.

The lymphocytes that appear in the lymph nodes before birth are derived from thymus. The small lymphocytes leave the thymus to reach other lymphoid organs through circulation. Later some mesenchymal cells of lymph nodes also differentiate into the lymphocytes.

N.B. The lymph nodules do not appear in the lymph nodes until just before and/or just after birth, as there is no exposure to foreign antigens.

Development of Spleen and Tonsils

1. **Spleen** develops from an aggregation of mesenchymal cells between the two layers of dorsal mesogastrium (for details see page 165).
2. **Palatine tonsil** develops from the endodermal lining of second pharyngeal pouch and underlying mesenchyme.
3. **Tubal tonsil** develops from an aggregation of the lymph nodules around the opening of pharyngotympanic tube in the nasopharynx.
4. **Pharyngeal tonsil** develops from an aggregation of the lymph nodules in the posterosuperior wall of the nasopharynx.
5. **Lingual tonsil** develops from an aggregation of the lymph nodules on dorsum of the posterior one-third of the tongue.

N.B. The lymph nodules also develop into the mucosa of gastrointestinal and respiratory tracts.

GOLDEN FACTS TO REMEMBER

- | | |
|--|---|
| ➤ First arteries to appear in the embryo | Right and left primitive aortae |
| ➤ Most common congenital anomaly of great vessels | Patent ductus arteriosus |
| ➤ Two embryonic sources that form all the arteries of the body | (a) Pharyngeal arch arteries
(b) Dorsal aorta |
| ➤ Fate of seventh cervical intersegmental artery | (a) Its stem forms subclavian artery
(b) Its dorsal division forms stem of vertebral artery
(c) Its superolateral division forms artery of upper limb bud
(d) Its ventral division forms stem of internal mammary artery |
| ➤ Two important radiological features seen in coarctation of aorta | (a) Notching of the lower border of ribs
(b) Double aortic knuckle |
| ➤ Vein of Marshall | Oblique vein of left atrium |
| ➤ Coronary sinus develops from | Left horn of sinus venosus and proximal part of left common cardinal vein |
| ➤ Three sources from which left renal vein forms | (a) Mesonephric vein
(b) Left subcardinal vein
(c) Intersubcardinal anastomosis |

CLINICAL PROBLEMS

1. Explain why course of recurrent *laryngeal nerves* differs on two sides?
2. Why newborn baby develops cyanosis (i.e., face becomes blue) when he/she cries?
3. The blood in the umbilical vein gradually loses its high oxygen content during its course from the placenta to the fetus. Why?

CLINICAL PROBLEM SOLUTIONS

1. The recurrent laryngeal nerves (the nerves of the sixth pharyngeal arches) initially hook around the sixth arch artery on the respective side on their way to the developing larynx (Fig. 19.28).
 - (a) **On the right side** because the distal part of the sixth arch artery disappears, the *right recurrent laryngeal* nerve moves superiorly and hooks around the proximal part of the right subclavian artery (the derivative of fourth pharyngeal artery).
 - (b) **On the left side**, the left recurrent nerve hooks around the distal part of sixth arch artery, which persists as ductus arteriosus (DA), so it hooks around it. When DA obliterates after birth to form *ligamentum arteriosum* the recurrent laryngeal nerve hooks around the ligamentum arteriosum and the arch of aorta (left fourth arch artery).

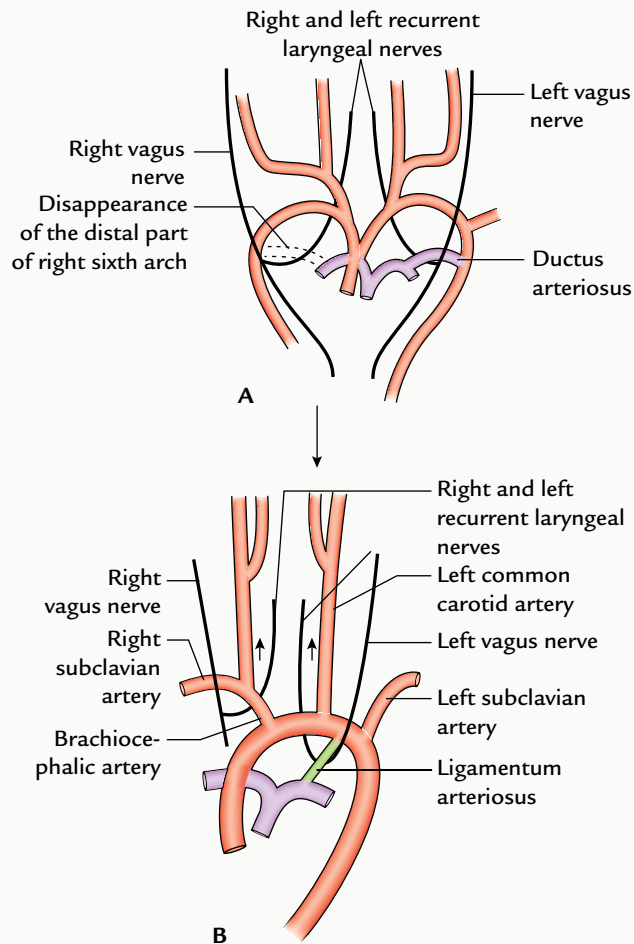


Fig. 19.28 Changing relationship of recurrent laryngeal nerves with aortic arch system. After the disappearance of the distal part of the sixth arch artery on the right side, the right recurrent laryngeal nerve hooks around the right subclavian artery. On the left side, the left recurrent laryngeal nerve remains in place and hooks around the ductus arteriosus (A) and subsequently ligamentum arteriosum (B).

2. In the first few days after birth, there is only a physiological closure of the foramen ovale; hence this closure is reversible. The crying of the baby creates a shunt from right to left, which accounts for cyanotic periods during crying in the newborn.
3. The placenta is an **organ of respiration in fetus**. The fetal blood is oxygenated in placenta. The blood leaving the placenta is about 80% saturated with oxygen. It loses its high oxygen content as it enters into the fetal circulation because it mixes with desaturated blood from the body of the fetus. The oxygenated blood from placenta gets mixed up with the deoxygenated blood from fetal body at following sites:
 - (a) Where *ductus venosus* opens into the *inferior vena cava (IVC)*, the oxygenated blood from the umbilical vein is mixed with deoxygenated blood of IVC, which it drains from lower extremities, pelvis, and kidneys.
 - (b) In the *right atrium*, the blood from IVC is mixed with the blood from superior vena cava, draining venous blood from head and upper extremities.
 - (c) In the *left atrium*, the blood from IVC, which is comparatively rich in oxygen content, is mixed with the blood from the pulmonary veins, which is poor in oxygen content.
 - (d) Where *DA* opens in the *aorta*, the blood in aorta that is comparatively rich in oxygen is mixed with the blood from the right ventricle that is poor in oxygen content.

Overview

The urinary system consists of kidneys, ureters, urinary bladder, and urethra. The urinary system develops from **intermediate mesoderm** and **primitive cloaca**. The urinary system begins to develop before the genital system.

Intermediate mesoderm The intermediate mesoderm is a longitudinal strip of intraembryonic mesoderm lying on either side of notochord between paraxial mesoderm and lateral plate mesoderm (Fig. 20.1A).

After folding of embryo the intermediate mesoderm forms a longitudinal elevation of mesoderm along the dorsal body wall on each side of dorsal aorta/dorsal mesentery of gut. This longitudinal elevation is called **urogenital ridge** (Fig. 20.1B).

The *medial part of urogenital ridge* that gives rise to the genital system is called **genital ridge** and *lateral part of urogenital ridge* that gives rise to the urinary system is called **nephrogenic cord**.

Cloaca The part of hindgut caudal to attachment of allantois is called **cloaca**. It is divided into two parts: ventral and dorsal by a **urorectal septum** (which develops from an angle between the allantois and cloaca).

Ventral part of cloaca is called **primitive urogenital sinus** and dorsal part is called **primitive rectum** (Fig. 20.2).

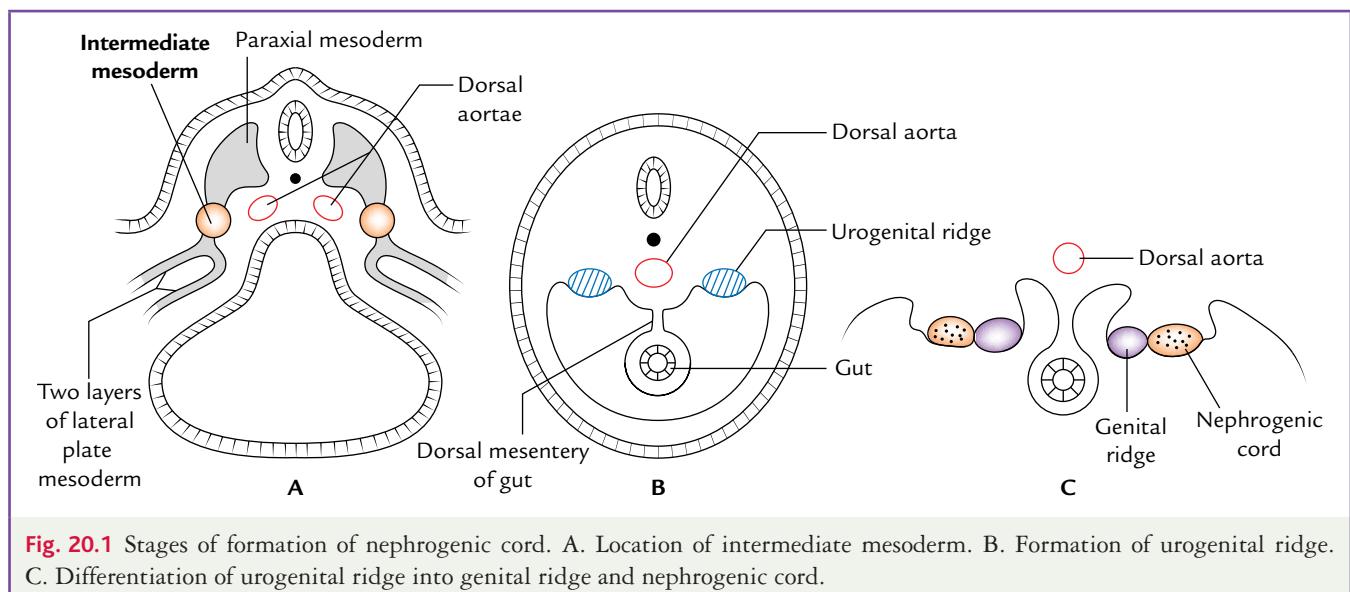
Evolutionary History of Kidney

The development of kidney begins in the fourth week of intrauterine life (IUL) from intraembryonic mesoderm. **Nephrogenic cord** derived from intermediate mesoderm forms a longitudinal ridge on posterior abdominal wall on each side of the dorsal aorta. It extends from cervical to sacral region of the embryo. The surface of the nephrogenic cord is covered by the epithelial lining of the peritoneal cavity (celomic cavity).

During the development of human kidney, the evolutionary history of the kidney is repeated and displays a classical example of what is called **ontogeny repeats phylogeny**.

N.B. The **evolutionary stages of the kidney** are: (a) pronephros in fishes, (b) mesonephros in fishes and amphibians, and (c) metanephros in humans.

The nephrogenic cord forms three successive kidneys: pronephros, mesonephros, and metanephros—succeeding



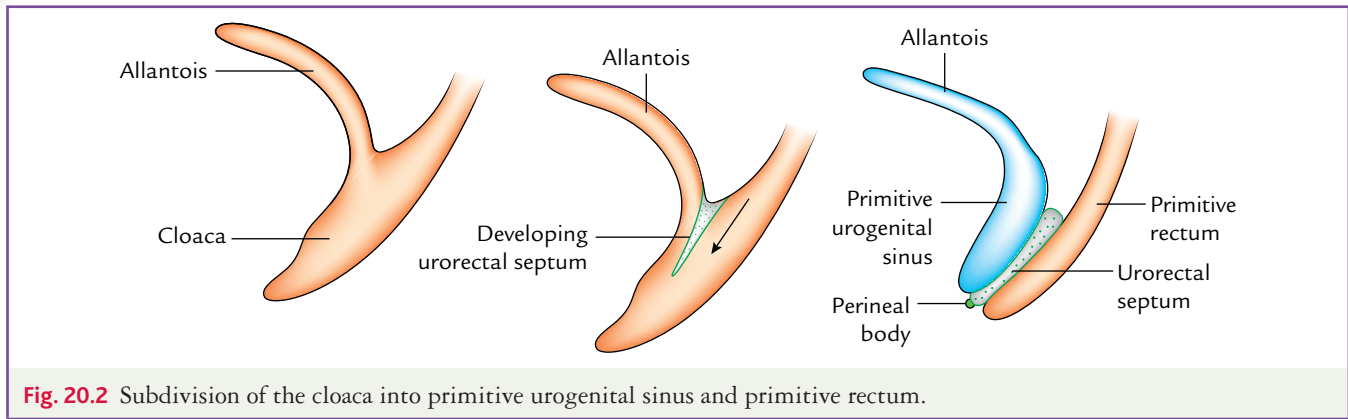


Fig. 20.2 Subdivision of the cloaca into primitive urogenital sinus and primitive rectum.

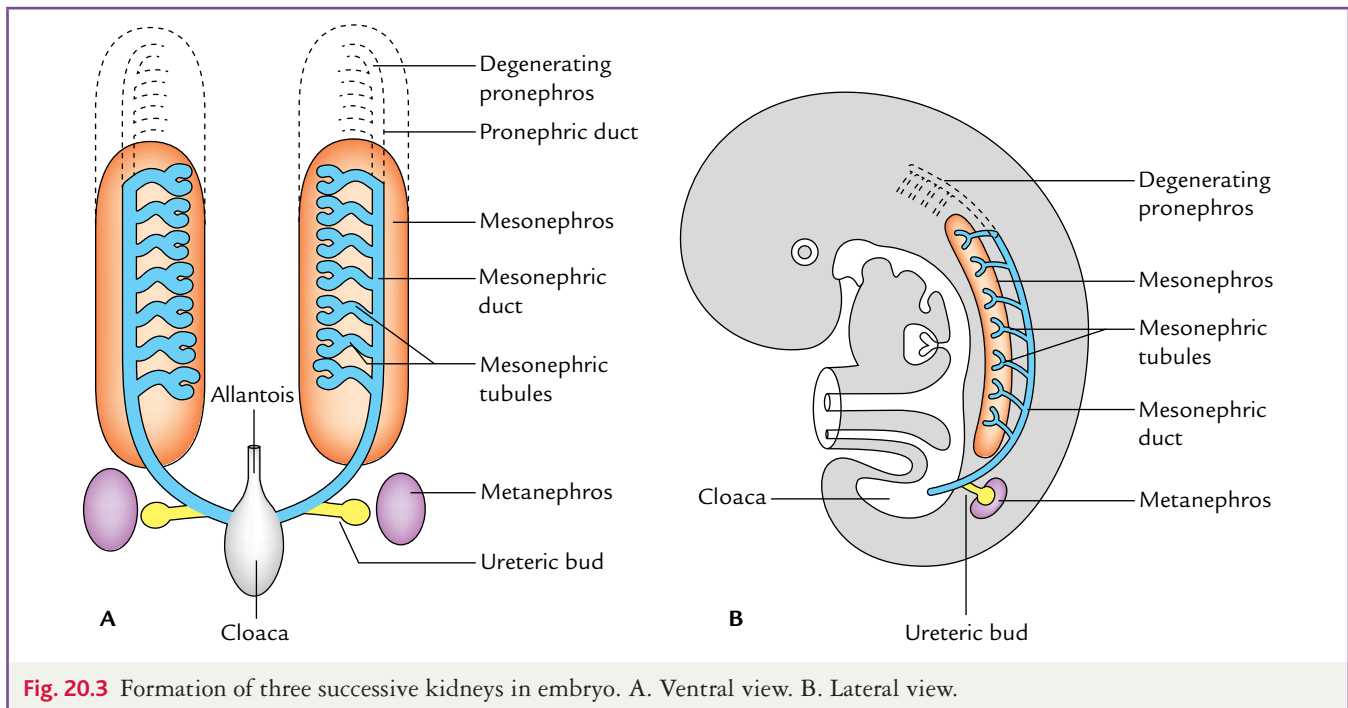


Fig. 20.3 Formation of three successive kidneys in embryo. A. Ventral view. B. Lateral view.

each other in time and space such that last to develop is retained as **permanent kidney**. The details are as follows (Fig. 20.3):

1. The **pronephros** forms at the beginning of the fourth week in the *cervical region*. It is nonfunctional and completely regresses. However, its duct—the **pronephric duct**—which opens in cloaca persists, which is subsequently annexed by mesonephros and forms the mesonephric duct. The pronephros persists as permanent kidney in some cyclostomes and some teleost fishes.
2. The **mesonephros** forms at the end of the fourth week in *thoracolumbar region*. It is functional for a short period and completely regresses. A series of excretory tubules develop in mesonephros, which drain into the **mesonephric duct**.

Most of mesonephric tubules disappear, but some of them are modified and take part in formation of

vasa efferentia of testis. The mesonephros persists as permanent kidney in amphibians and most of the fishes.

3. The **metanephros** forms at the beginning of the third month in the sacral region. It persists permanently in humans. It drains into ureter.

The sequence of events of pronephros, mesonephros, and metanephros are given in Table 20.1.

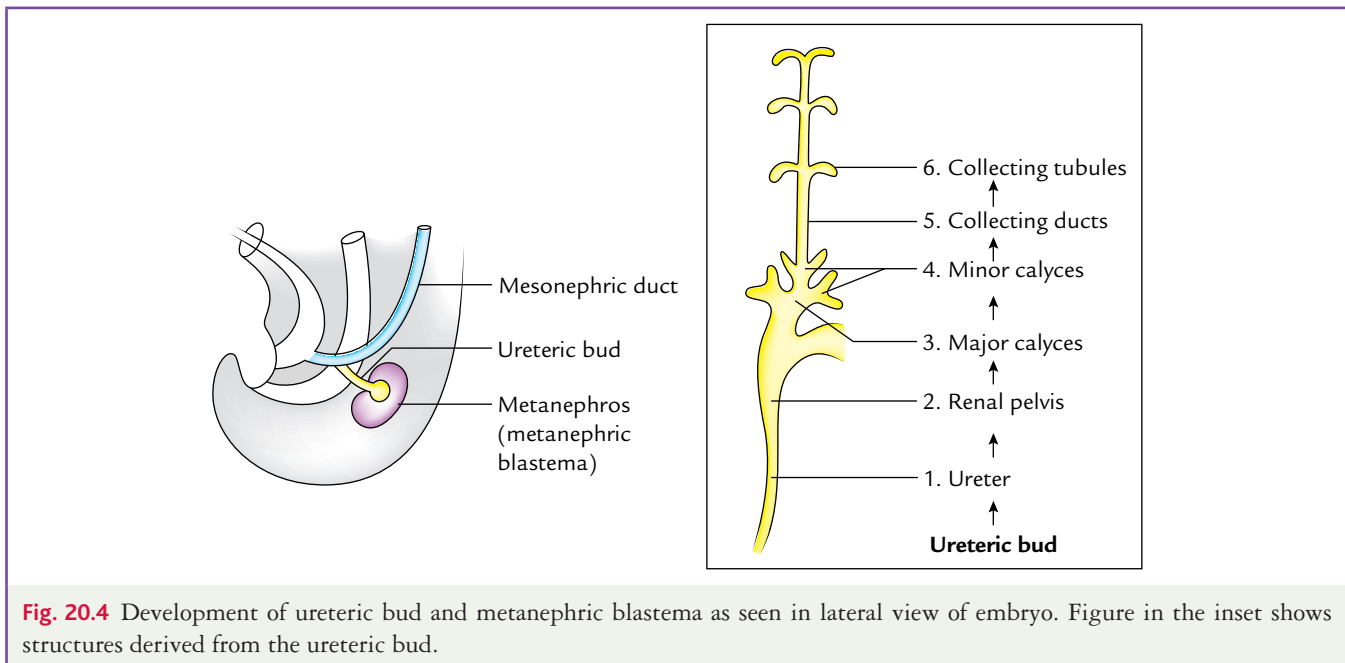
Development of Permanent Kidneys and Ureter

The permanent kidneys develop in the sacral region. Each kidney develops from two distinct sources: (a) **metanephros** and (b) **ureteric bud**.

The metanephros forms **secretory system** and the ureteric bud forms **collecting system** of the kidney.

Table 20.1 The sequence of events of pronephros, mesonephros, and metanephros

Nephrogenic cord/tissue	Location	Segmentation	Time of appearance	Functional status	Duct
Pronephros	Cervical region	Segmented	Beginning of the fourth week	Nonfunctional/disappears	Pronephric duct persists
Mesonephros	Thoracolumbar region	Segmented	End of the fourth week	Functional for a short period then disappears, except for its caudal excretory tubules	Mesonephric duct persists
Metanephros	Sacral region	Nonsegmented	Beginning of the third month	Functional	Ureter

**Fig. 20.4** Development of ureteric bud and metanephric blastema as seen in lateral view of embryo. Figure in the inset shows structures derived from the ureteric bud.

Development of Collecting System

The ureteric bud arises from mesonephric duct and grows cranially behind the peritoneal cavity towards the metanephros. The distal end of ureteric bud becomes capped by metanephric blastema (Fig. 20.4). The growing end of ureteric bud becomes dilated like a funnel to form the **pelvis of ureter/renal pelvis**. The ureteric bud divides dichotomously and its 13 generations form the collecting system of the kidney. The renal pelvis undergoes repeated divisions to form **major calyces**, **minor calyces**, **collecting ducts**, and **collecting tubules** (Fig. 20.4 inset).

The collecting tubules thus formed vary in number from 1 to 3 million.

The development of **pelvicalyceal system** of kidney consisting of renal pelvis, major calyces, and minor calyces is shown in Fig. 20.5.

Development of Excretory System (Fig. 20.6)

The cells of metanephros form **metanephric blastema**. The cells of metanephric blastema when come in contact

with each collecting tubule condense around it to form solid clump of cells called **metanephric cap**. Each metanephric cap is soon converted into a vesicle called **metanephric vesicle**. The metanephric vesicle first becomes a *pear-shaped vesicle*, which soon forms *S shaped tubule* (called **primitive renal tubule**). The proximal end of this S-shaped tubule is narrow and abuts on the collecting tubule. The distal dilated end of this tubule forms Bowman's capsule. It becomes invaginated by a tuft of capillaries to form renal glomerulus. (The renal glomerulus develops from angioblastic tissue of the nephrogenic cord.) The primitive renal tubule eventually forms nephron (excretory unit) consisting of **glomerular (Bowman's) capsule**, **proximal convoluted tubule**, **loop of Henle**, and **distal convoluted tubule**.

Each distal convoluted tubule joins with the collecting tubule derived from the ureteric bud to form **uriniferous tubule** (Fig. 20.6).

The development of the kidney is summarized in Flowchart 20.1. The adult derivatives of embryonic structures forming collecting and secretory systems of the kidney are summarized in Table 20.2.

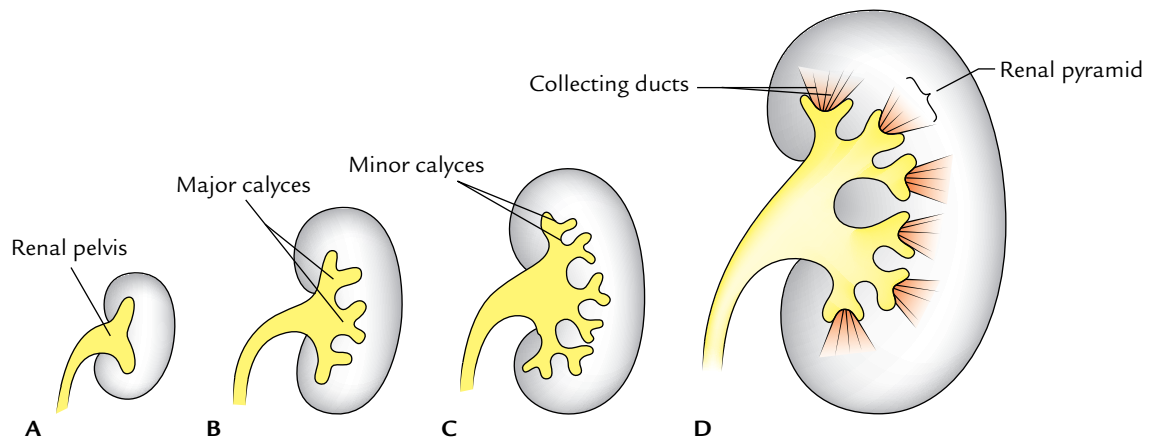


Fig. 20.5 Development of pelvicalyceal system of kidney (renal pelvis, major calyces, and minor calyces). Note pyramid contains collecting ducts that enter into the minor calyces.

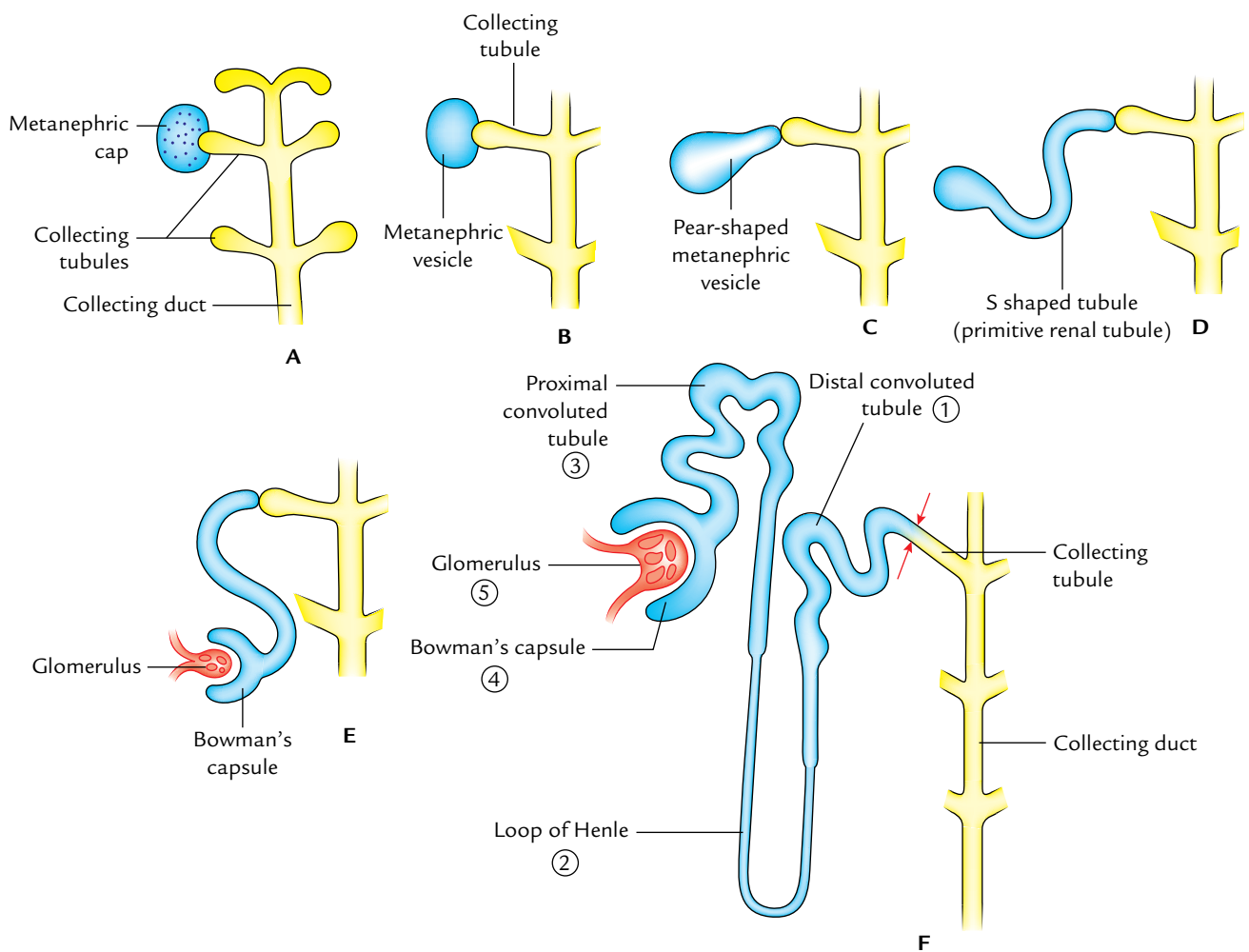
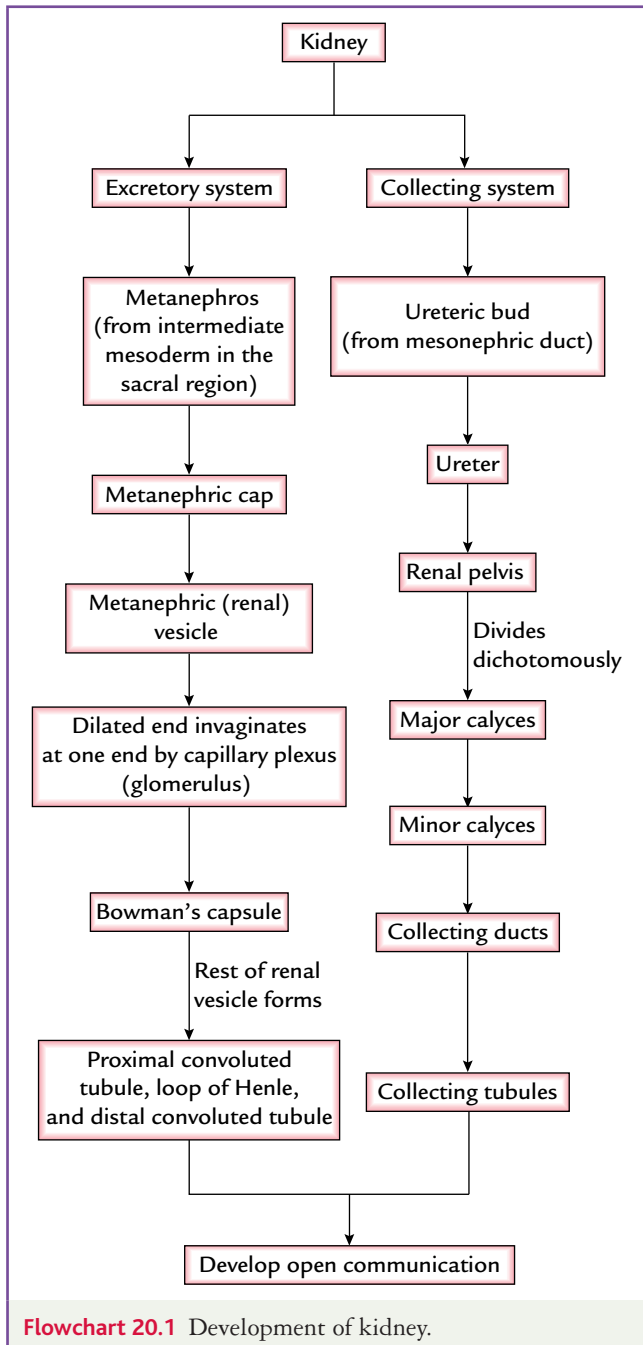


Fig. 20.6 Stages of development of nephron (excretory system of the kidney consisting of 3 million nephrons). Note each nephron consists of distal convoluted tubule (1), loop of Henle (2), proximal convoluted tubule (3), Bowman's capsule (4), and glomerulus (5). Arrows (red) indicate the place where excretory unit (blue) establishes a communication with the collecting system (yellow).



N.B. The fetal kidneys are lobulated and remain in the lobulated form up to first year of life.

Other Developmental Events

Ascent of Kidney (Fig. 20.7)

At first the permanent kidney (derived from metanephros) lies in the **sacral region**. Later due to differential growth of posterior abdominal wall and reduction of fetal curvature the kidney ascends to reach the thoracolumbar region (T12–L3 vertebral levels). The ureter elongates accordingly as the kidney ascends.

Table 20.2 Development of the kidney and ureter

Embryonic structures	Adult derivatives
Ureteric bud	Ureter Renal pelvis Major calyces Minor calyces Collecting ducts Collecting tubules
Metanephric blastema	Renal glomerulus Renal (Bowman's) capsule Proximal convoluted tubule Loop of Henle Distal convoluted tubule

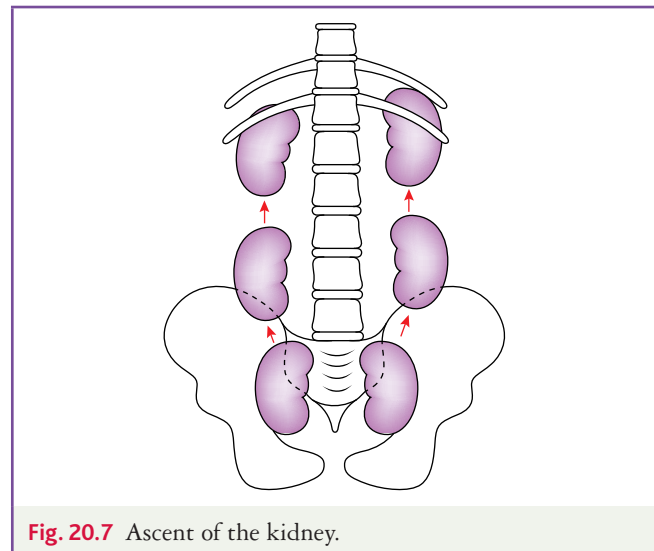


Fig. 20.7 Ascent of the kidney.

N.B. Physiologically the kidney ascends for two reasons: (a) It faces space crunch in smaller pelvic cavity and (b) it ascends in search for better blood supply.

Arterial Supply of the Kidney (Fig. 20.8)

The blood supply of kidney changes as it undergoes ascent. Initially the kidney lies in the pelvis and is supplied by **median sacral artery**—a *pelvic continuation of the aorta*. As the kidney ascends, it is supplied successively by higher lateral splanchnic branches of the aorta at successively higher levels. The kidney reaches its final position opposite the second lumbar vertebra. The **definitive renal artery** supplying the kidney arises at L2 vertebral level and represents lateral splanchnic branch of the aorta.

Rotation of the Kidneys

At first hilum of each kidney lies/faces anteriorly. But during the ascent of the kidney it rotates 90° medially so that hilum of each kidney now faces medially.

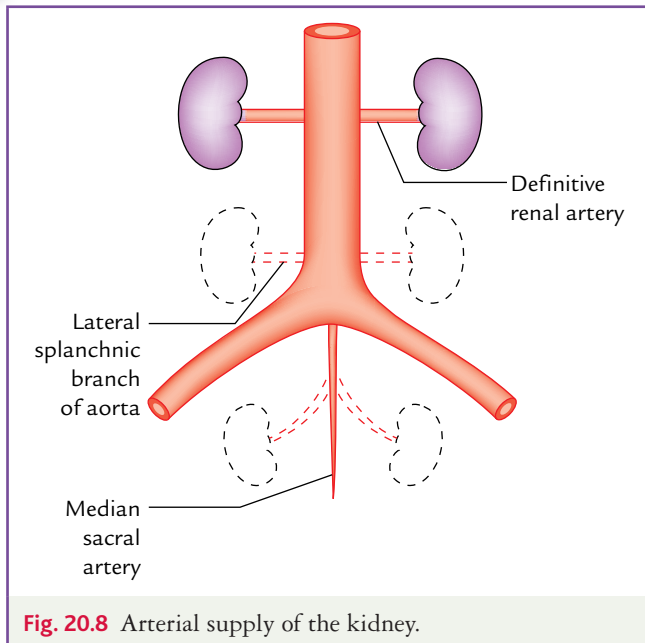


Fig. 20.8 Arterial supply of the kidney.

Clinical Correlation

Congenital anomalies of kidney

1. **Renal agenesis (absence of kidney):** The renal agenesis occurs when ureteric bud fails to develop. It can be unilateral or bilateral. Note **ureteric bud induces the metanephric tissue to form metanephric blastema.**

(a) *Unilateral renal agenesis*

- It is relatively common (therefore, a clinician should never presume that a patient always has two kidneys).
- It is more common in males.
- It is asymptomatic and compatible with life because the other kidney hypertrophies to meet requirements of the body.
- It is usually detected while carrying out investigation for some other diseases.

(b) *Bilateral renal agenesis*

- It is relatively uncommon.
- It is incompatible with life and newborn infant usually dies shortly after birth, unless a suitable donor is available for a kidney transplant.
- It causes oligohydramnios that allows the uterine wall to compress the fetus. As a result, there occurs **Potter's syndrome**. The clinical features of Potter's syndrome are deformed limbs, wrinkling of skin, and abnormal facial appearance.

2. **Duplication or multiplication of the kidneys:** More than one kidney may be present either on one or both sides. This occurs due to early division of the ureteric bud.

3. **Congenital polycystic kidney (Fig. 20.9):** In this condition, numerous cysts filled with urine are present in substance of the kidney. This condition is usually bilateral. The embryological basis of congenital polycystic kidney is as under:

- (a) Earlier it was thought that it occurs when excretory/secretory and collecting tubules fail to connect with each other.

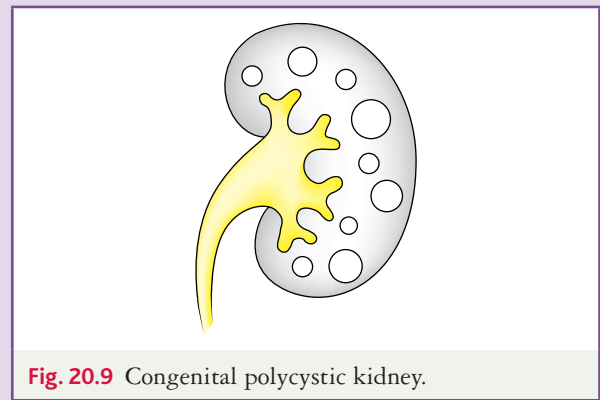


Fig. 20.9 Congenital polycystic kidney.

(b) But now it is thought that it occurs due to abnormal dilatation of different parts of the uriniferous tubules, especially the loops of Henle.

- It is a relatively common hereditary disease and is clinically associated with cysts of the liver, pancreas, and lungs.
- It is of two types: childhood type and adult type. The prevalence of childhood type is 1:5000 births and prevalence of adult type is 1:600 births (also see page 245).
- The treatment regime includes dialysis and kidney transplantation.

4. **Horseshoe-shaped kidney (also called horseshoe kidney) (Fig. 20.10).**

- In this condition, inferior poles of both the kidneys are fused.
- During the ascent, the horseshoe kidney gets trapped underneath the **inferior mesenteric artery**. Hence horseshoe kidney usually lies at the level of the lower lumbar vertebrae.
- The ureters arise from the anterior surface of the kidney and pass in front of isthmus in a caudal direction.
- It occurs because sometimes the kidneys are pushed so close together during their passage through the arterial fork (formed by the umbilical arteries) that their lower ends get fused.

5. **Lobulated kidney (Fig. 20.11):** It is persistence of normal lobulated fetal kidney. The metanephric kidney is lobulated throughout the fetal life, but this condition usually disappears during the first year after birth. But if it fails to do so then it leads to lobulated kidney.

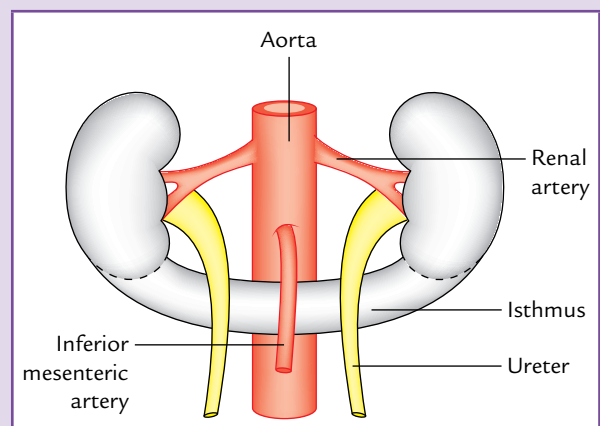


Fig. 20.10 Horseshoe kidney.

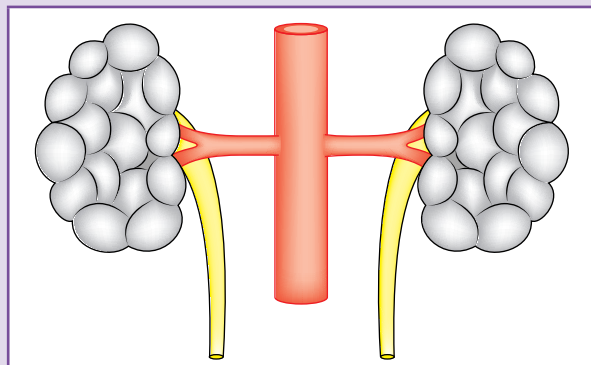


Fig. 20.11 Lobulated kidneys.

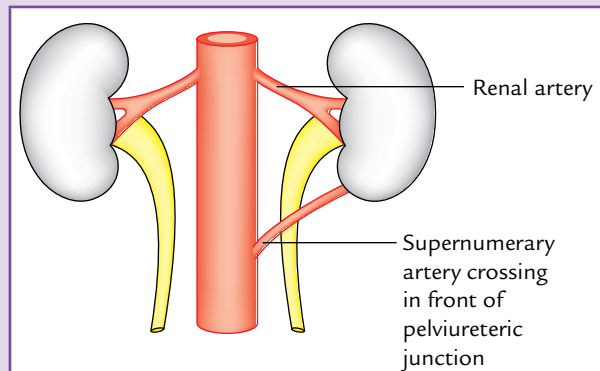


Fig. 20.12 Supernumerary/accessory renal arteries.

- 6. Pelvic kidney:** In this condition, the kidney is located in the pelvis. It occurs when kidney fails to ascend. The commonest cause of failure of ascent of the kidney is the presence of sickle-shaped fold of peritoneum (containing umbilical artery) that projects from lateral pelvic wall.
- 7. Pancake kidney:** In this condition, two kidneys fuse to form a single mass that lies in midline or on one side.

- 8. Supernumerary/aberrant renal arteries (Fig. 20.12):** They are relatively common. They represent **persistent fetal renal arteries**. The fetal renal arteries arise successively in sequence from the aorta as the kidney ascends from the pelvic to the lumbar region. Occurrence of aberrant arteries is clinically important because they may cross the pelviureteric junction and obstruct the out-flow of urine leading to **hydronephrosis**.

Development of Ureter (Refer Fig. 20.3)

The ureter develops from ureteric bud, which arises as a diverticulum from the mesonephric (Wolffian duct)

duct just before it opens onto the cloaca (vesicourethral canal).

Clinical Correlation

Congenital anomalies of ureter (Fig. 20.13)

- 1. Double renal pelvis:** In this condition, upper end of ureter presents two renal pelvises: upper and lower. The *upper renal pelvis* drains the upper group of calyces whereas the *lower renal pelvis* drains the middle and lower groups of calyces. This condition

occurs due to premature division of the ureteric bud near its termination.

- 2. Bifid ureter:** In this condition, the upper end of the ureter is bifid. In lower third of course two ureters join and open by a common orifice into the urinary bladder. Like double pelvis, this

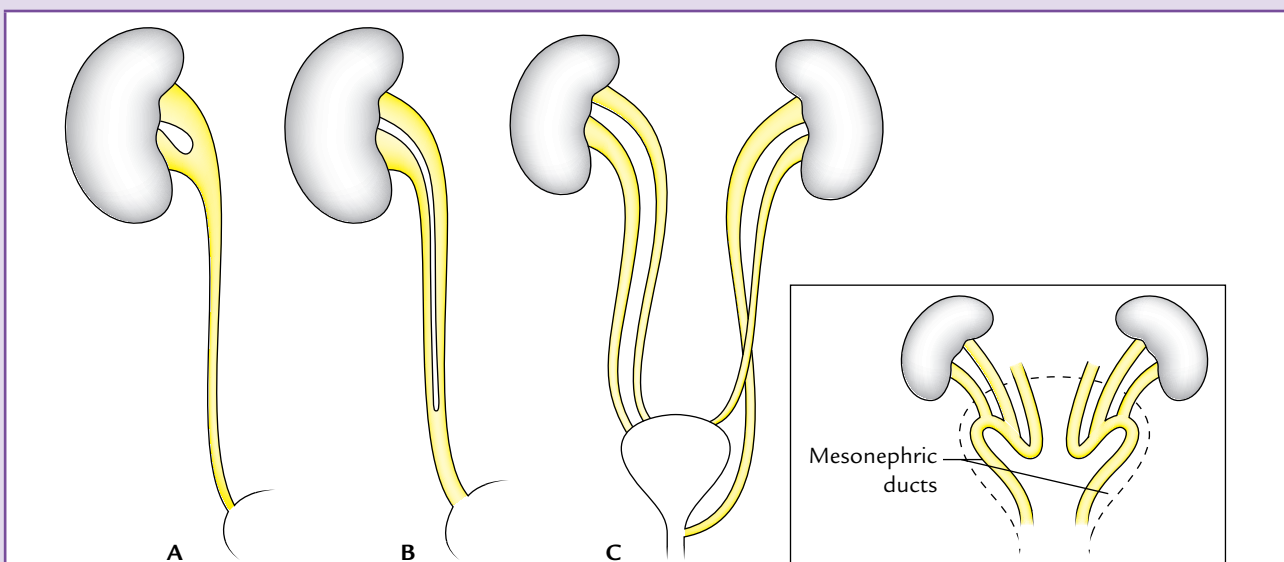


Fig. 20.13 Congenital anomalies of the ureter. A. Double renal pelvis. B. Bifid ureter. C. Double ureter. Figure in the inset shows loop of formation of part of mesonephric duct.

condition occurs due to premature division of the ureteric bud.

3. **Double ureters:** Duplication of the abdominal part of the ureter and renal pelvis is common. It occurs due to division of the ureteric bud as it arises from the mesonephric duct. In such a case, one ureter crosses across its fellow and may produce a urinary obstruction.

N.B. The double pelvis and double ureters are more liable to get infected and to be the seat of calculus formation than the normal ureter.

In case of double ureters, the *lower ureter* opens in the bladder at normal site, whereas *upper ureter* migrates more caudally due to caudal shift of the terminal part of the mesonephric duct and opens in the ectopic position. This is due to the fact that the terminal part of mesonephric duct undergoes loop formation in the posterior wall of the urinary bladder (Fig. 20.13 inset).

4. **Ectopic ureter:** In this condition, the ureter does not open into the urinary bladder.
 - (a) In males, the ectopic ureter usually opens into the neck of urinary bladder or into prostatic part of the urethra.
 - (b) In females, the ectopic ureter usually opens into bladder neck, urethra, or vagina.
 - (c) The *incontinence of urine* is a common complain by patients with ectopic ureters. It occurs because urine flowing from the orifice of ureter does not enter into the urinary bladder.
 - (d) An ectopic ureter occurs when the ureter is not incorporated into the trigone of the urinary bladder.

N.B. Ureters usually open into the urinary bladder when both the ureters form on one side.

5. **Postcaval ureter:** It occurs if right ureter ascends posterior to the inferior vena cava.

Development of Urinary Bladder (Fig. 20.14)

The urinary bladder develops from endodermal cloaca as follows:

1. The cloaca is divided into two parts by a mesodermal **urorectal septum** during fourth to seventh week of development (see page 153). The anterior part is called **urogenital sinus** and the posterior part is called **primitive rectum**. The tip of the urorectal septum forms **perineal body**. The cloacal membrane also divides into *anal membrane* posteriorly and *urogenital membrane* anteriorly (Fig. 13.25).
2. The **mesonephric ducts** now open into the primitive urogenital sinus. The urogenital sinus now becomes divisible into two parts by the openings of the mesonephric ducts.

Part above the openings of mesonephric ducts is called **vesicourethral canal** and part below the openings of mesonephric ducts is called **definitive urogenital sinus**. The definitive urogenital sinus is further divided into two parts: (a) cranial **pelvic part** and (b) caudal **phallic part** (Fig. 20.14). The subdivisions of cloaca are shown in Flowchart 20.2.

The allantois opens at the cranial end of the vesicourethral canal.

3. The upper large part of the vesicourethral canal expands while its lower part remains narrow.
4. The upper large dilated part of the vesicourethral canal forms the **urinary bladder**. It is continuous with the allantois at the apex. The allantois obliterates and forms a fibrous band called **urachus**, which extends from apex of the urinary bladder to the umbilicus. The urachus is called **median umbilical ligament** in adult.

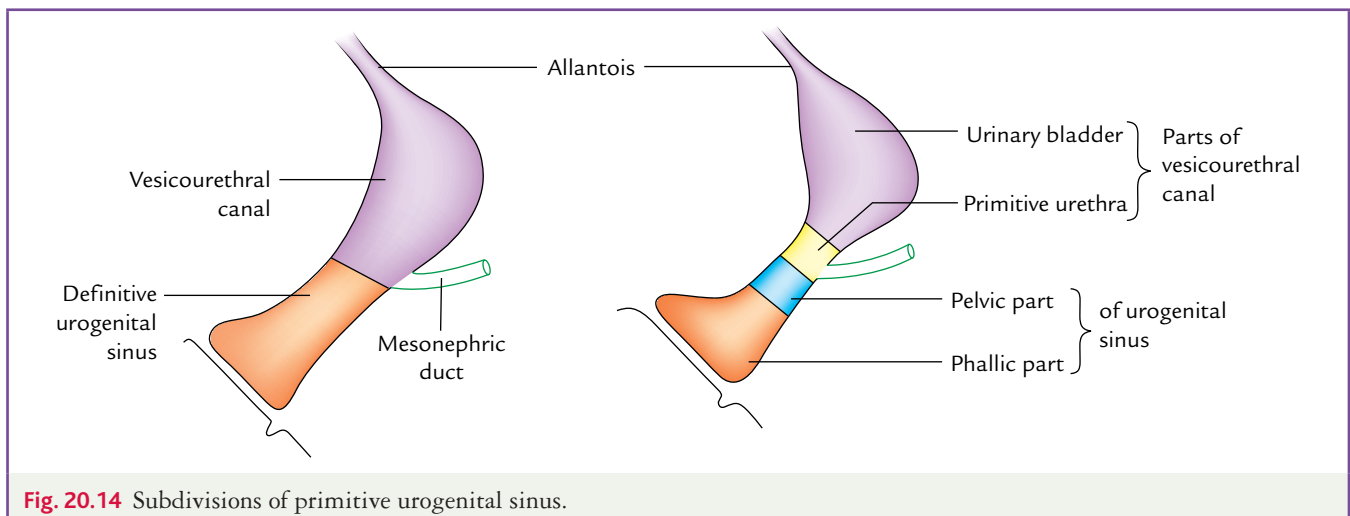
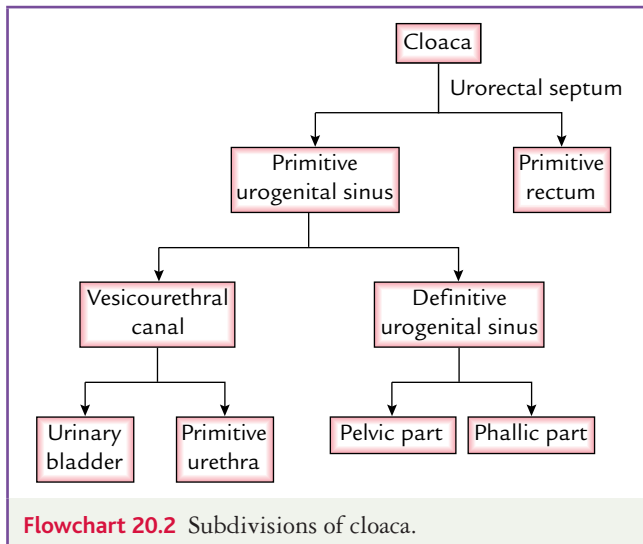


Fig. 20.14 Subdivisions of primitive urogenital sinus.

- The lower narrow part of vesicourethral canal forms **primitive urethra**.
- The parts of the mesonephric ducts distal to ureteric buds are now absorbed into the wall of vesicourethral canal (Figs 20.15 and 20.16). As a result, the mesonephric ducts and ureters now open separately in the vesicourethral canal. As the kidneys ascend, the openings of ureters move upward and laterally.

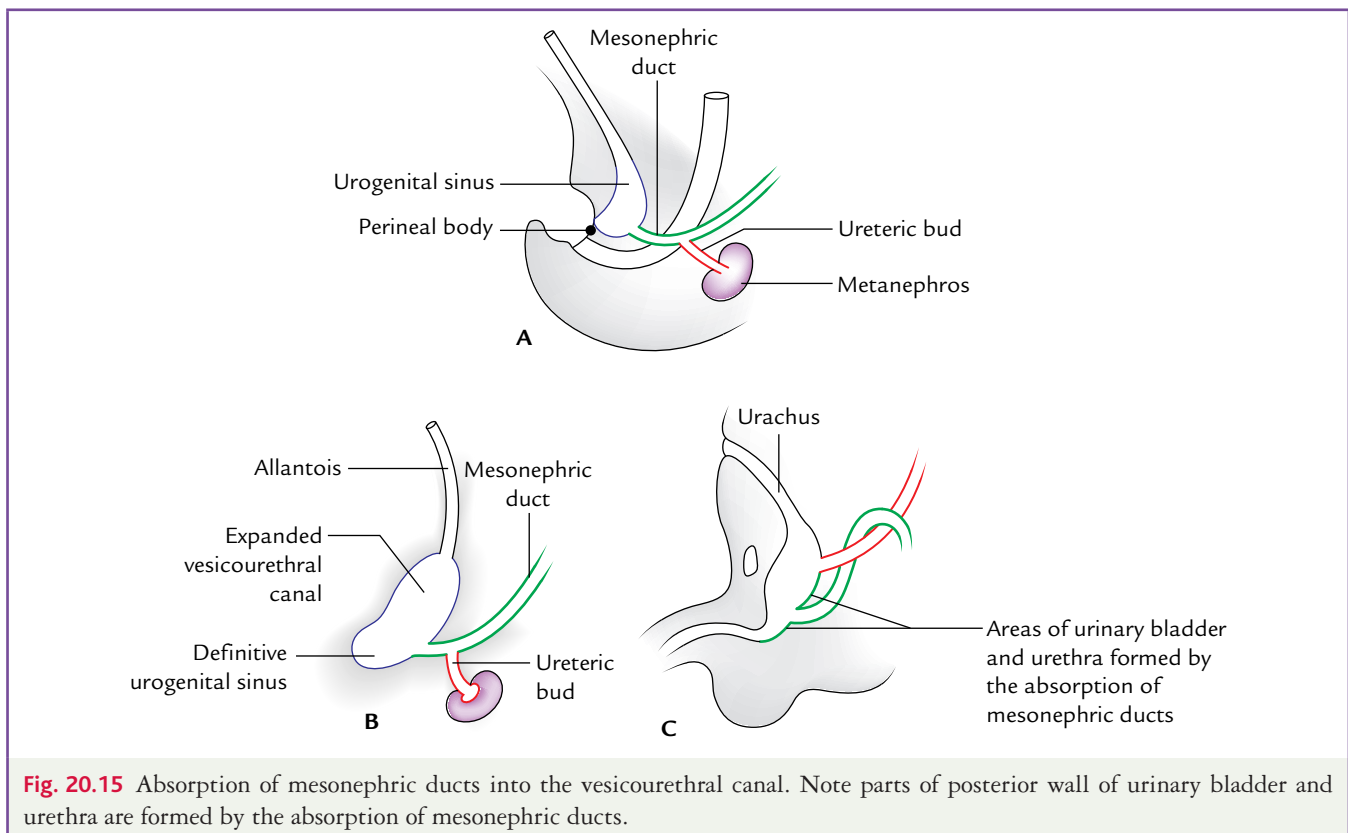


Development of Trigone of Urinary Bladder (Fig. 20.16)

- Due to absorption of mesonephric ducts into the vesicourethral canal, the mesonephric ducts and ureteric buds now have separate openings in the vesicourethral canal (primitive urinary bladder) (Fig. 20.16B).
- At first the openings of mesonephric ducts and ureteric buds are close together, but later the openings of ureteric buds move cranially and laterally.
- The triangular area on the dorsal wall of vesicourethral canal between the openings of ureteric buds and mesonephric ducts is called **trigone of urinary bladder**. It is derived from absorption of the mesonephric ducts.

Development of Coats of Bladder Wall

- The epithelial lining of whole of urinary bladder is derived from endodermal vesicourethral canal, except in the triangular area on its dorsal wall (**trigone of urinary bladder**) that is derived from mesoderm derived from the absorbed parts of the mesonephric ducts.
- The muscular and serous coats of the urinary bladder are derived from splanchnopleuric intraembryonic mesoderm.



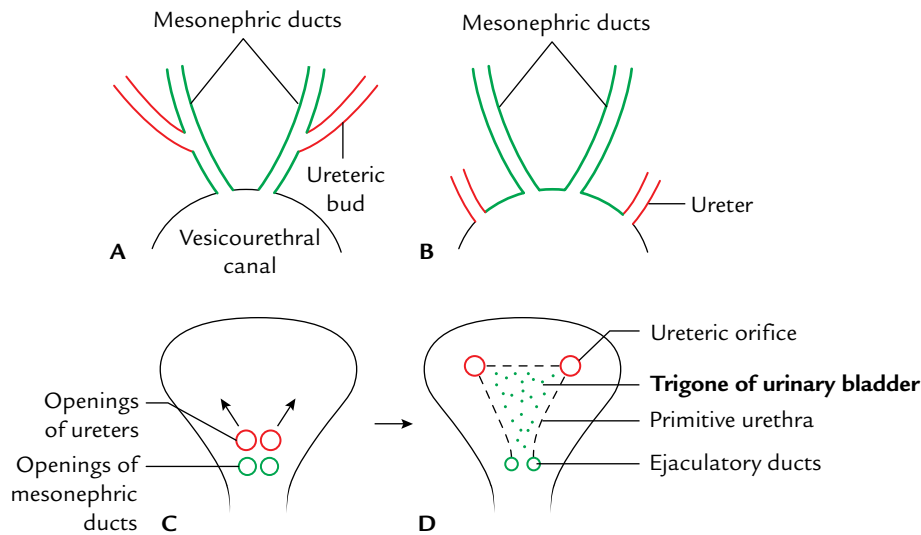


Fig. 20.16 Formation of trigone of the urinary bladder. A. Opening of mesonephric ducts into the vesicourethral canal. B. Absorption of mesonephric ducts into the vesicourethral canal. C. At first, openings of ureters and mesonephric ducts are close together. D. Further absorption of ureters causes ureteric openings to shift laterally and upward.

Table 20.3 Development of the urinary bladder

Embryonic structure	Adult derivatives
Cranial dilated part of vesicourethral canal	Endodermal epithelial lining of the whole urinary bladder except in the region of trigone
Absorption of mesonephric ducts in the dorsal wall of the vesicourethral canal	Mesodermal epithelial lining in the region of trigone of urinary bladder
Splanchnopleuric intra-embryonic mesoderm surrounding vesicourethral canal	Muscular and serous coats of the urinary bladder
Allantois	Urachus (median umbilical ligament) and apex of urinary bladder

The adult derivatives of various embryonic structures forming urinary bladder are summarized in Table 20.3.

Clinical Correlation

1. **Congenital anomalies of urachus:** The urachus is adult derivative of the allantois. Normally it obliterates to form a fibrous cord in adult called *median umbilical ligament*. Following congenital anomalies may occur in urachus (Fig. 20.17).
 - (a) **Urachal sinus:** If the lumen persists in the upper part of urachus (i.e., close to the umbilicus) it is called *urachal sinus*. The urachal sinus opens at the umbilicus.
 - (b) **Urachal fistula:** If the lumen persists along the entire extent of urachus the *urachal fistula* is formed. The urachal fistula opens in the urinary bladder at one end and at the umbilicus at the other end. As a result, the urine is discharged through umbilicus.

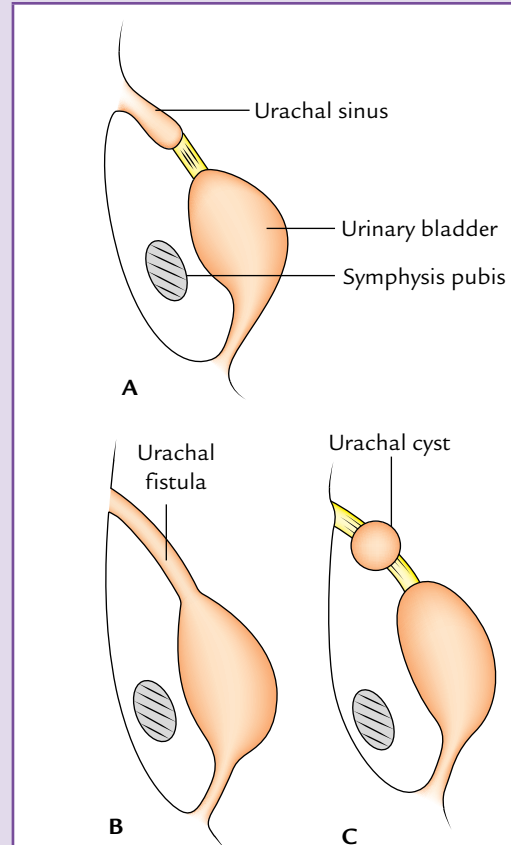


Fig. 20.17 Congenital anomalies of urachus. A. Urachal sinus. B. Urachus fistula. C. Urachal cyst.

- (c) **Urachal cyst:** If only a small part of the urachus remains patent the secretory activity of its lining epithelium leads to the formation of a cystic dilatation called *urachal cyst*.

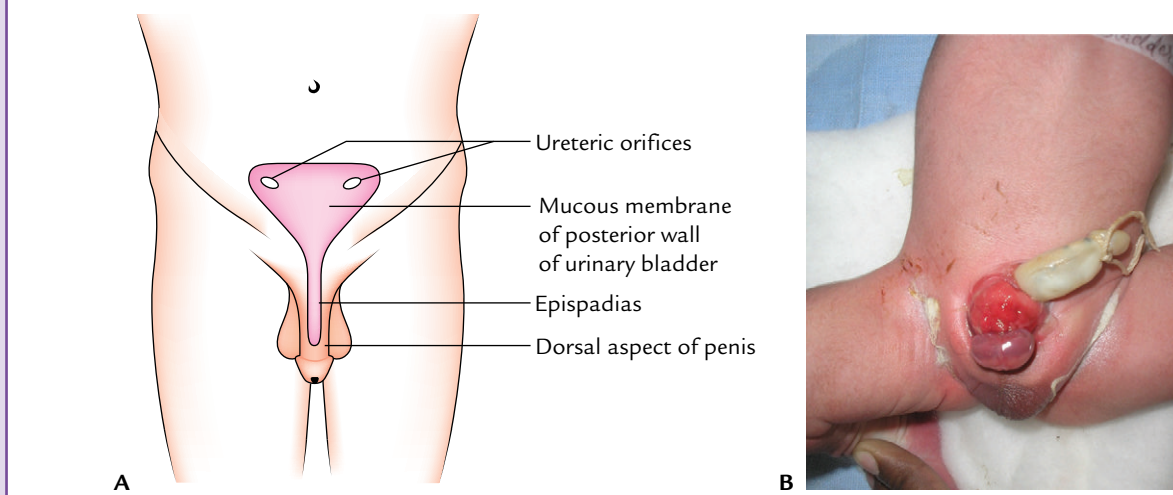


Fig. 20.18 Ectopia vesicae (exstrophy of urinary bladder). A. Line diagram. B. Actual clinical photograph.

2. **Exstrophy of the bladder (ectopia vesicae) (Fig. 20.18):** In this condition, the lower median part of anterior abdominal wall and anterior wall of the urinary bladder is absent. The mucosal surface of posterior wall of the urinary bladder showing ureteric orifices is exposed to the surface. The urine can be seen dribbling intermittently from the ureteric orifices. The epispadias is a constant feature in this condition.

This anomaly occurs due to lack of migration of mesoderm in lateral folds of the embryo in the hypogastric region. Normally, during lateral folding of embryo the lateral folds are formed;

they grow medially and fuse with each other. The mesoderm migrates in these lateral folds and forms the muscles of anterior abdominal wall.

In exstrophy of the bladder, the anterior abdominal wall muscles are not formed in the hypogastric region (between the umbilicus and genital tubercle). As a result, the surface ectoderm comes in contact with endoderm of vesicourethral canal (future urinary bladder). The ectoderm and endoderm breakdown and posterior wall of the urinary bladder is exposed onto the surface. The exstrophy of the bladder is rare and occurs in 1:10,000 births.

Development of Urethra (Fig. 20.19)

The female urethra is short and its development is very simple, whereas the male urethra is long and its development is little complicated. The development of male urethra is intimately related to the development of external genital organs.

The epithelium of entire female urethra and most of the male urethra is derived from urogenital sinus.

Female Urethra

Whole of the female urethra develops from narrow caudal part of the **vesicourethral canal** except a small terminal part, which develops from the **pelvic part** of the **definitive urogenital sinus**. The **phallic part** of the **definitive urogenital sinus** forms vestibule of vagina into which the urethra opens.

N.B.

- The female urethra corresponds to the prostatic part of the male urethra above the colliculus seminalis.
- The whole of the female urethra is endodermal in origin (derived from urogenital sinus) except its dorsal wall that is mesodermal in origin, derived from absorption of mesonephric ducts.

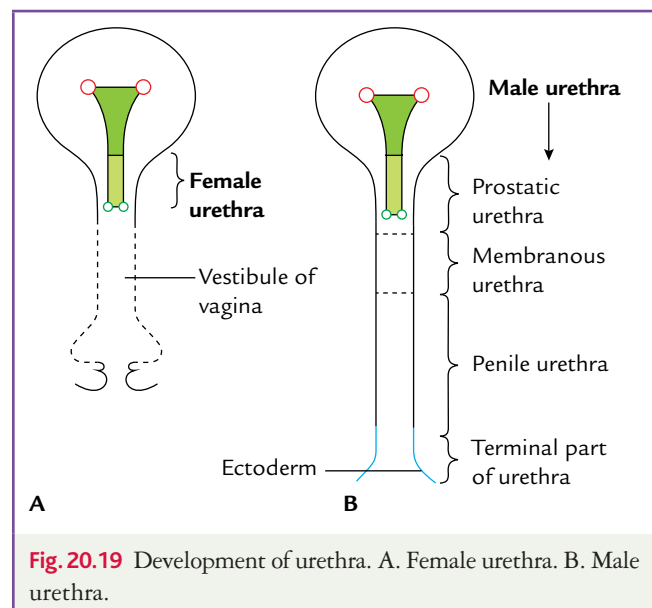


Fig. 20.19 Development of urethra. A. Female urethra. B. Male urethra.

Male Urethra

The male urethra is divided in three parts: (a) prostatic part, (b) membranous part, and (c) spongy part.

1. **Prostatic part:** It is part of the urethra above the openings of ejaculatory ducts. It develops from the

caudal part of vesicourethral canal. The posterior wall of this part is derived from **absorbed mesonephric ducts** (mesoderm). The part of the prostatic urethra below the openings of ejaculatory ducts develops from *upper pelvic part of definitive urogenital sinus*.

2. **Membranous urethra:** This small part of the urethra lies in deep perineal pouch. It develops from *lower pelvic part of definitive urogenital sinus*.
3. **Spongy part:** It is a part of the urethra that lies in the bulb (*bulbar part*) and shaft of the penis (*penile part*). Both these parts are derived from the *phallic part of definitive urogenital sinus*, except the terminal part of the urethra, which lies in glans penis (*glandular part*) that is derived from the *surface ectoderm*. Development of spongy part of the urethra is intimately related to development of male external genitalia; hence it is described in detail in Chapter 21.

N.B. Only the lining epithelium of the urethra is derived from endoderm of urogenital sinus. Connective tissues and smooth muscles of urethra are derived from surrounding splanchnopleuric layer of intraembryonic mesoderm.

The development of male and female urethra is summarized in Table 20.4.

Table 20.4 Development of male and female urethra	
Urethra	Embryonic source of development
Female urethra	<ul style="list-style-type: none"> • Caudal part of vesicourethral canal • Pelvic part of definitive urogenital sinus
Male urethra	
1. Prostatic part	
(a) Above the level of opening of ejaculatory ducts (colliculus seminalis)	• Caudal part of vesicourethral canal
(b) Below the level of openings of ejaculatory ducts	• Pelvic part of definitive urogenital sinus
2. Membranous part	• Pelvic part of definitive urogenital sinus
3. Penile part	• Phallic part of definitive urogenital sinus
4. Terminal part (which occupies the glans penis)	• Surface ectoderm

GOLDEN FACTS TO REMEMBER

- Precursor of nephron
- Commonest congenital anomaly of kidney
- Commonest cause of failure of ascent of kidney
- Accessory/supernumerary renal arteries
- Epithelial lining of entire urinary bladder is derived from endodermal urogenital sinus *except*
- Commonest urethral anomaly associated with exstrophy of urinary bladder
- Most common primary renal tumor of childhood
- Renal vesicle
- Polycystic kidney
- Presence of sickle-shaped fold of peritoneum containing umbilical arteries
- Persisting fetal renal arteries
- In the region of trigone of urinary bladder, which is derived from absorbed mesodermal mesonephric ducts
- Epispadias
- Wilm's tumor

CLINICAL PROBLEMS

1. Give the embryological basis of accessory or supernumerary renal arteries and discuss their clinical significance.
2. If the ectopic ureteric orifice opens inferior to the urinary bladder it results in urinary incontinence. Give the anatomical basis.
3. What is Wilm's tumor? Give its embryological/genetic basis.
4. Give the embryological basis of congenital polycystic kidney (CPK). Give its types and discuss the prognosis of each type.
5. Agenesis of the kidney is not fatal for fetus but is fatal for newborn baby (i.e., after the birth). Why?

CLINICAL PROBLEM SOLUTIONS

1. Persistence of these fetal arteries form accessory renal arteries. For details see Clinical Correlation on page 239.
 - They are more common on the left side.
 - They are twice as common as supernumerary renal veins.
 - They usually arise at the level of the kidney and enter the lower pole of the kidney.

Clinical significance: The supernumerary renal arteries may cross the pelviureteric junction and hinder the urine outflow. This causes dilatation of renal pelvis and calyces (*hydronephroses*). The hydronephrotic kidney frequently becomes infected (*pyelonephritis*), which may lead to the destruction of the kidney.

2. Normally the ureter takes a sinuous course through the bladder wall musculature (**detrusor muscle**) before it opens into its cavity. The oblique passage of the ureter through the bladder wall allows the contraction of detrusor muscle to act as a sphincter for the ureter and controls the flow of urine from it. If ectopic ureteric orifice opens below the urinary bladder, there is no such control; hence the urinary incontinence results.
3. The **Wilm's tumor** is a malignant tumor of the kidney that usually affects children up to 5 years of age. It occurs due to mutation in *WT1* gene on 11p13 chromosome.

Clinically the Wilm's tumor presents as large, soft, solitary, and well-circumscribed mass, which on section appears homogenous and grayish in color.
4. In congenital polycystic kidney, numerous cysts filled with urine appear in the substance of the kidney. They are formed due to dilatation of parts of the nephrons, particularly the loops of Henle. Also see Clinical Correlation on page 238.

The polycystic kidney disease is of two types: (a) childhood type of polycystic kidney disease (CPKD) and (b) adult type of polycystic kidney disease (APKD). The differences between the two types are given in box below.

Childhood type of polycystic kidney disease (CPKD)	Adult type of polycystic kidney disease (APKD)
Autosomal recessive	Autosomal dominant
Less common (occurs in 1:5000 births)	More common (occurs in 1:500 to 1:1000 births)
Disease manifests in childhood	Disease manifests above the age of 20 years
More progressive	Less progressive
Renal failure occurs in infancy or childhood	Renal failure usually does not occur until adulthood
Death occurs at an early age	Death occurs at a late age (longevity of life may extend up to 60 years of age)

5. The kidney becomes functional at the end of the first trimester of pregnancy. Urine is excreted into the amniotic cavity. It is swallowed by the fetus, absorbed into the blood from the gut, and circulated into the placenta. From placenta, it is excreted into the maternal blood. Thus, **placenta functions as true kidney in fetal life**; hence agenesis of the kidney is not fatal for the fetus but is fatal after *birth*.

21

Genital System

Overview

The **genital system** consists of: (a) a pair of gonads (testes or ovaries), (b) duct system of gonads that carries the germ cells, and (c) external genital organs. The genital system develops from the following three sources:

- Intermediate mesoderm
- Part of cloaca
- Celomic epithelium covering the intermediate mesoderm.

The development of genital system begins during the fourth week of intrauterine life (IUL). The genetic sex (genotype XY or XX) of embryo is established at time of fertilization, but gonads do not acquire male or female morphological characteristics till seventh week of the development. Initially (week 1–6 of development) the gonads are structurally similar and hence this is called **indifferent stage of gonad**. From seventh week onward, the development proceeds in different directions in males and females, and gonadal sex can then be determined morphologically. By 12th week some male and female characteristics of the external genitalia can also be recognized. By the end of 20th week phenotypical differentiation is complete. This difference of development between male and female is because of chromosomal and hormonal factors.

The phenotypical differentiation is determined by **SRY gene** located on the short arm of Y chromosome (Yp11).

The **SRY gene** encodes for a protein called **testis determining factor (TDF)**. The presence of TDF leads to development of male genital organs. As the indifferent gonad develops into the testis, the Leydig and Sertoli cells differentiate to produce **testosterone** and **Mullerian inhibiting factor (MIF)**. This results in phenotypically male embryo.

In the absence of the **TDF, testosterone, and MIF**, the indifferent gonad will develop into ovary and embryo will be phenotypically female. The genetic basis of phenotypical differentiation of sex is summarized in Flowchart 21.1.

Development of Gonads

The gonads develop from following three sources:

1. Intermediate mesoderm

2. Celomic epithelium covering the intermediate mesoderm
3. Primordial germ cells.

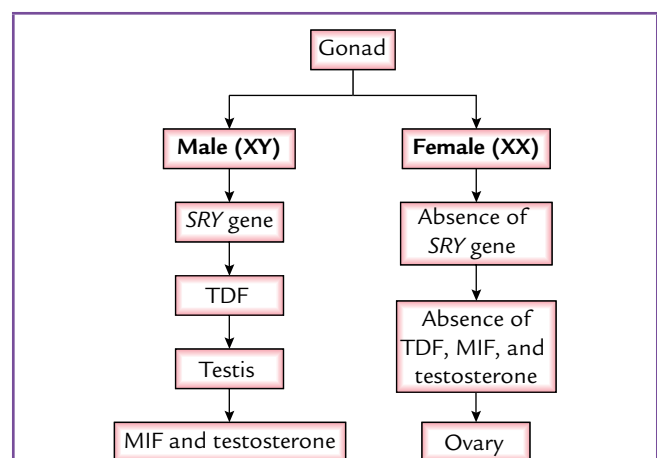
Initially the development of testis or ovary is similar (**indifferent stage**) and only after this stage the development proceeds either in male or female direction (**definitive stage**).

Indifferent Stage

The gonads develop in the intermediate mesoderm—medial to middle part of mesonephros.

The first indication of development of **primitive gonad** is seen at about fourth week. An elongated elevation called **genital ridge** appears on medial side of **mesonephric ridge**. The genital ridge is formed by condensation of intermediate mesoderm and proliferation of overlying celomic epithelium (Fig. 21.1).

The **primordial germ cells** differentiate in the wall of yolk sac close to allantois during second week. During the fourth week, the primordial germ cells migrate along dorsal mesentery of hindgut by active amoeboid movement and reach the genital ridges at beginning of fifth week and invade the genital ridges in the sixth week (Fig. 21.2).



Flowchart 21.1 Genetic basis of phenotypical differentiation of testis and ovary.

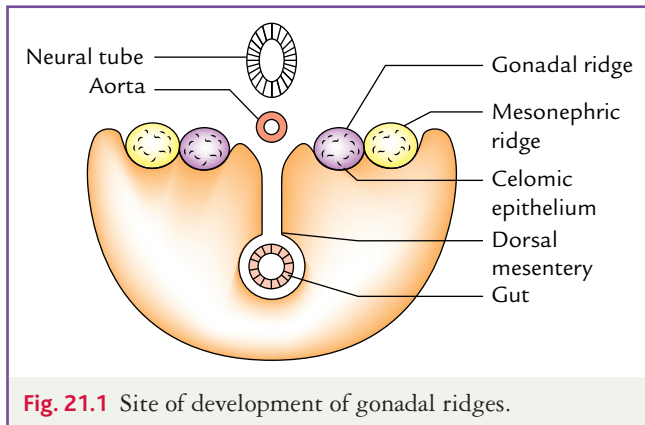


Fig. 21.1 Site of development of gonadal ridges.

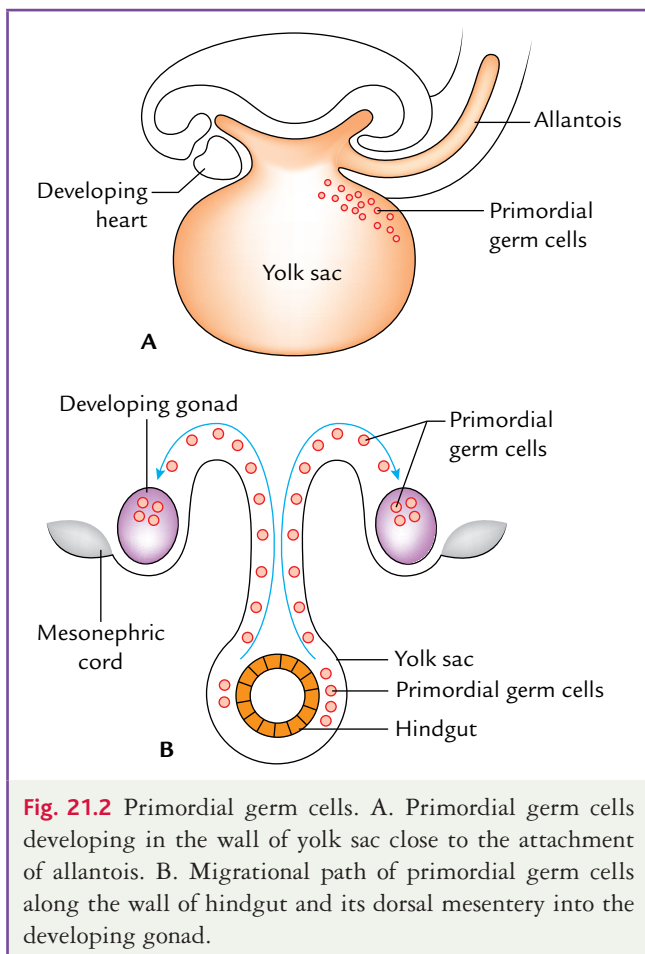


Fig. 21.2 Primordial germ cells. A. Primordial germ cells developing in the wall of yolk sac close to the attachment of allantois. B. Migrational path of primordial germ cells along the wall of hindgut and its dorsal mesentery into the developing gonad.

N.B. If the primordial germ cells fail to reach the genital ridges, gonads do not develop. Thus, primordial germ cells have an inductive influence on the development of gonads into testis or ovary.

On arrival of germ cells into the genital ridge, the cells of surface epithelium of the genital ridge (celomic epithelium) proliferate and penetrate underlying mesenchyme to form finger-like cords called **primitive sex cords**.

In both male and female embryos, the primitive sex cords are connected to the surface epithelium; hence it is impossible to differentiate between male and female gonads. Hence, the gonad at this stage is termed

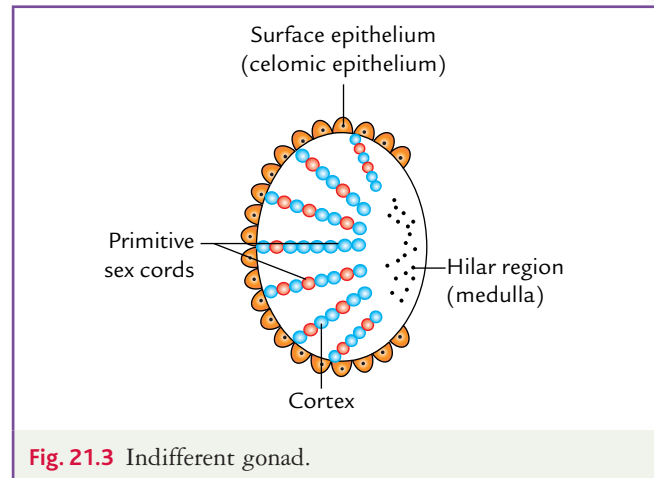


Fig. 21.3 Indifferent gonad.

indifferent gonad (Fig. 21.3). The outer part of the indifferent gonad is called **cortex** and its central part is called **medulla**.

Till this stage the development of testis and ovary is similar. Here onward the development of testis and ovary follows a different path, i.e., the development of testis and ovary proceeds into a **definitive stage**.

Definitive Stage

The indifferent gonad enters into the *definitive stage*, i.e., it develops into testis or ovary depending upon the chromosome complement of the primordial germ cells. If the primordial germ cells carry XY sex chromosome complement the indifferent gonad will develop into testis and if the primordial germ cells carry XX chromosome complement the indifferent gonad will develop into an ovary. The development of testis and ovary is described in following text.

Development of Testis (Fig. 21.4)

If the embryo is genetically male (i.e., the primordial germ cells carry XY chromosome complement) under the influence of *SRY* gene on the short arm of Y chromosome (Yp11), which encodes for the TDF, the primitive sex cords increase in length and extend deep into central part—*medulla* of the indifferent gonad. These are called **testis or medullary cords**. Toward hilum of gonad the medullary cords regress and break up into tiny cell strands that anastomose with each other. The sex cords then become horseshoe shaped and subsequently get canalized to form **seminiferous tubules**. The anastomosing tiny cell strands in medulla also get canalized to form 'rete testis.' In the fourth month, communication is established between the seminiferous tubules and rete testis.

The **seminiferous tubules** are lined by two types of cells: (a) sex cord cells (cells derived from surface celomic

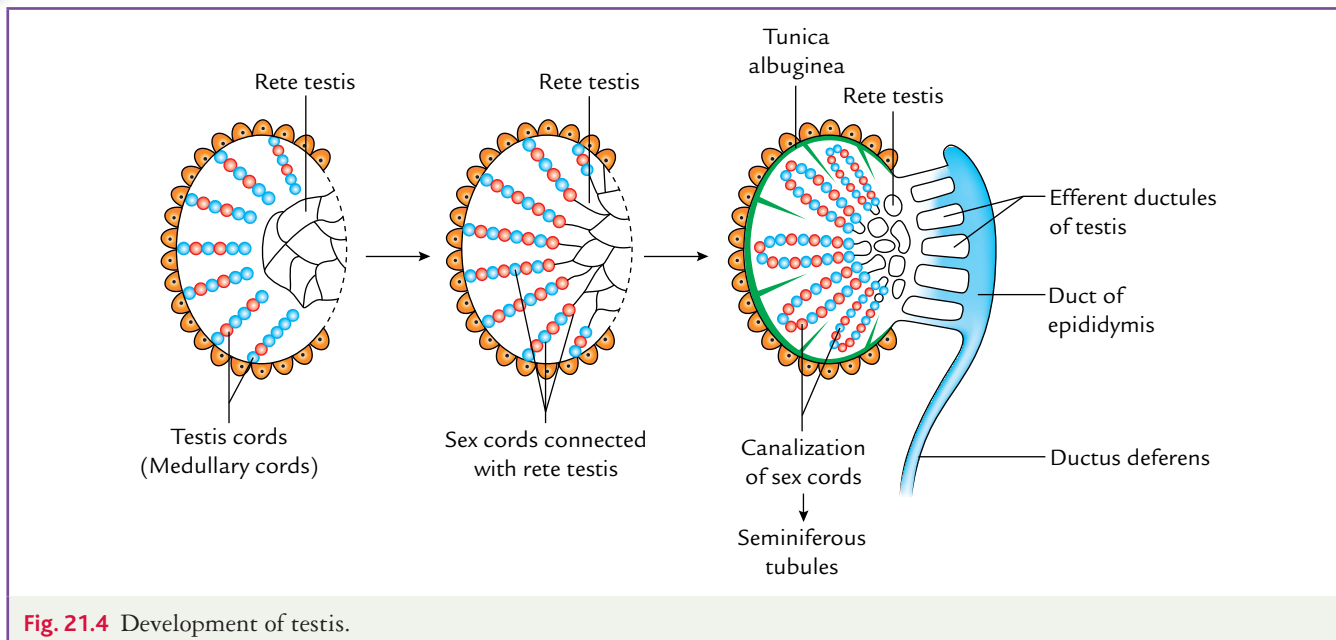


Fig. 21.4 Development of testis.

epithelium) and (b) primordial germ cells (derived from wall of the yolk sac). The primordial germ cells form spermatogonia and the sex cord cells form **sustentacular cells of Sertoli**.

Now the mesenchyme migrates beneath the celomic epithelium, forms a tough fibrous layer around the developing testis, and separates (cuts off) the sex cords from the celomic epithelium (germinal epithelium), thus blocking its contribution to the formation of sex cords permanently. This tough fibrous layer covering the testis is called **tunica albuginea**. Mesoderm also forms mediastinum testis. The fibrous septa arise from mediastinum, extend toward periphery, and divide the testis into various lobules. Mesoderm around the seminiferous tubules forms **interstitial cells of Leydig**. By eighth week, the Leydig cells start secreting testosterone—the male hormone that influences sexual differentiation of genital ducts (from mesonephric duct) and external genitalia.

The tubules of rete testis extend into the mesonephric tissue, where they join the mesonephric tubules. The mesonephric tubules become **efferent ductules of the testis**. **Duct of epididymis, vas deferens, seminal vesicle, and ejaculatory duct** are formed from the mesonephric duct.

As the testes develop they project in the celomic cavity and are suspended from posterior abdominal wall by a mesentery called ‘**mesorchium**.’

Clinical Correlation

The medullary cords/sex cords of testes (primordia of seminiferous tubules) remain solid until puberty. Therefore spermatogonia develop and form sperms only after puberty when the

seminiferous tubules are formed by canalization of the sex cords. For this reason testicular tumor called **seminoma** is unknown before puberty as the seminoma arises from the seminiferous tubules, which do not develop before puberty.

Development of Ovary (Fig. 21.5)

If the embryo is genetically female (i.e., primordial germ cells carry XX chromosome complement and no Y chromosome), the indifferent gonad develops into an ovary. The **primitive sex cords** containing the primordial germ cells do not become prominent but extend into the medulla. These cords dissociate into irregular cell clusters called **rete ovarii**, which occupy the medullary part of the ovary close to the mesonephric tubules. Later they disappear and are replaced by vascular stroma, which forms **ovarian medulla**.

N.B. The X chromosomes bear genes for ovarian development.

The surface epithelium (germinal epithelium) of female gonad, unlike that of male gonad, continues to proliferate and in the seventh week forms **second generation of sex cords**. The second generation of sex cords containing the primordial germ cells do not extend into medulla. Hence, they are also called **cortical cords**. In the third month, the cortical cords get fragmented and form isolated cell clusters. Each cell cluster consists of a primordial germ cell in the center surrounded by a layer of celomic epithelial cells. The primordial germ cells form **oogonia** and celomic epithelial cells form **follicular cells**. The resulting structure is

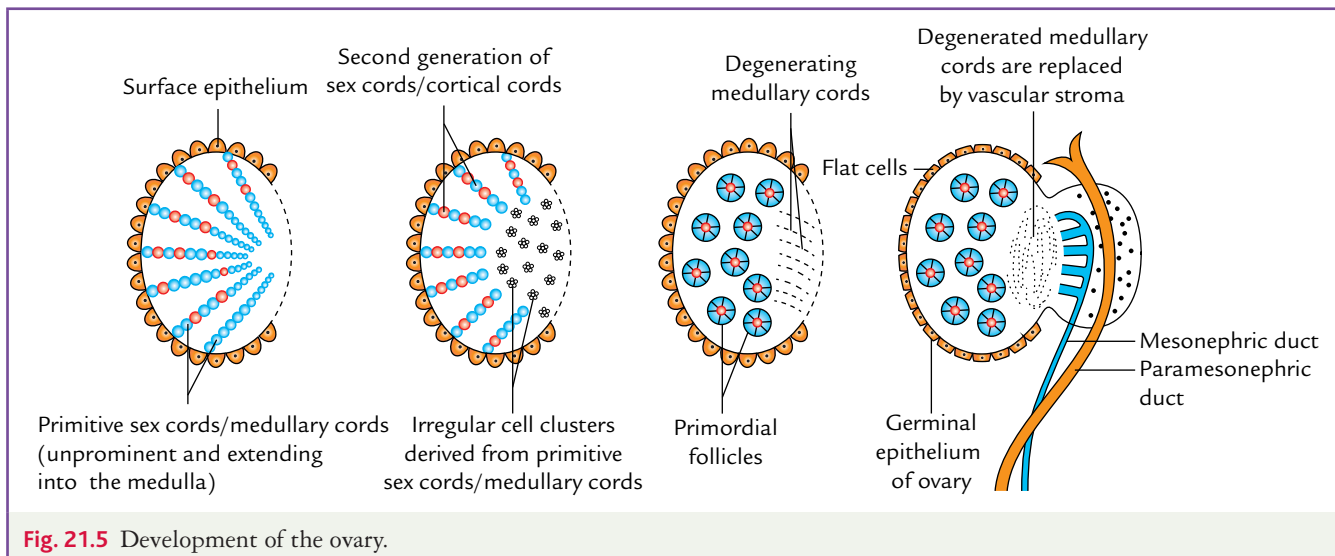
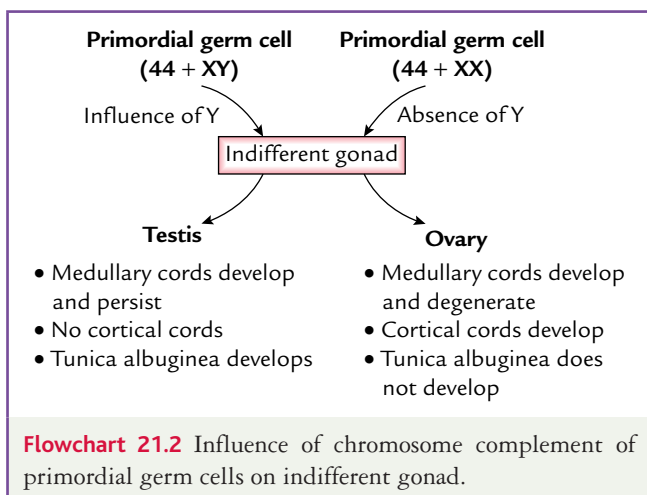


Fig. 21.5 Development of the ovary.



Flowchart 21.2 Influence of chromosome complement of primordial germ cells on indifferent gonad.

called 'primordial follicle.' All the primordial follicles remain confined in cortex of the ovary.

N.B. A large number of primordial follicles are formed during fetal life. No new primordial follicles are formed after birth. Further development of the primordial follicles takes place after puberty.

The mesoderm does not form thick fibrous layer (tunica albuginea) around ovary as in case of testis. Therefore the ovarian follicles are not separated from surface epithelium of the ovary. The surface epithelium of ovary flattens to form a single layer of cells that is continuous with the peritoneum at hilum of the ovary. The layer of these cells is called **germinal epithelium**, though it does not form germ cells anymore. The mesoderm forms a thin connective tissue covering for the ovary and connective tissue stroma of the ovary.

The ovary is suspended from posterior abdominal wall by a mesentery called 'mesovarium.'

The influence of genetic constitution of primordial germ cells on the indifferent gonad is shown in Flowchart 21.2.

Table 21.1 Differences in development of testis and ovary

Testis	Ovary
<ul style="list-style-type: none"> • Formation of only one generation of sex cords (medullary cords) that produce seminiferous tubules and rete testis 	Formation of two generations of sex cords: <ol style="list-style-type: none"> (a) First generation of sex cords (medullary cords) form stroma of ovarian medulla (b) Second generation of sex cords (cortical cords) form primordial follicles (ovarian follicles)
<ul style="list-style-type: none"> • Formation of tunica albuginea separating seminiferous tubules from surface epithelium 	<ul style="list-style-type: none"> • No formation of tunica albuginea. Hence ovarian follicles are not separated from surface epithelium

The differences in the development of testis and ovary are summarized in Table 21.1.

N.B. The testis and ovary are not identifiable histologically until tenth week.

Genital Ducts

Development of Genital Ducts

The genital ducts of male include vasa efferentia, duct of epididymis, vas deferens, and ejaculatory duct, the genital ducts of female include fallopian tube, uterus, and vagina.

Initially two pairs of genital ducts develop in both the sexes (Fig. 21.6): (a) **mesonephric ducts (Wolffian ducts)** and (b) **paramesonephric ducts (Mullerian ducts)**. In male the mesonephric ducts form the definitive

genital ducts and paramesonephric ducts mostly disappear, while in female paramesonephric ducts form the female genital ducts and the mesonephric ducts mostly disappear.

The differentiation of genital ducts and external genitalia into male and female direction is influenced by the gonads.

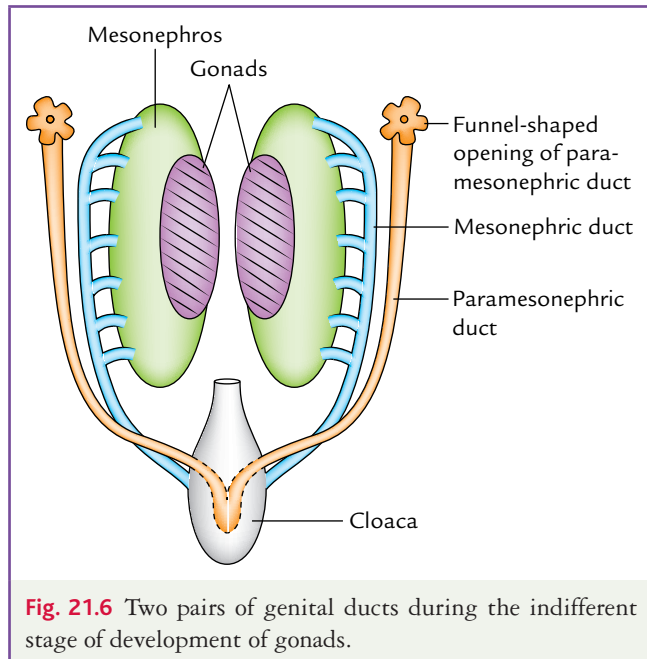


Fig. 21.6 Two pairs of genital ducts during the indifferent stage of development of gonads.

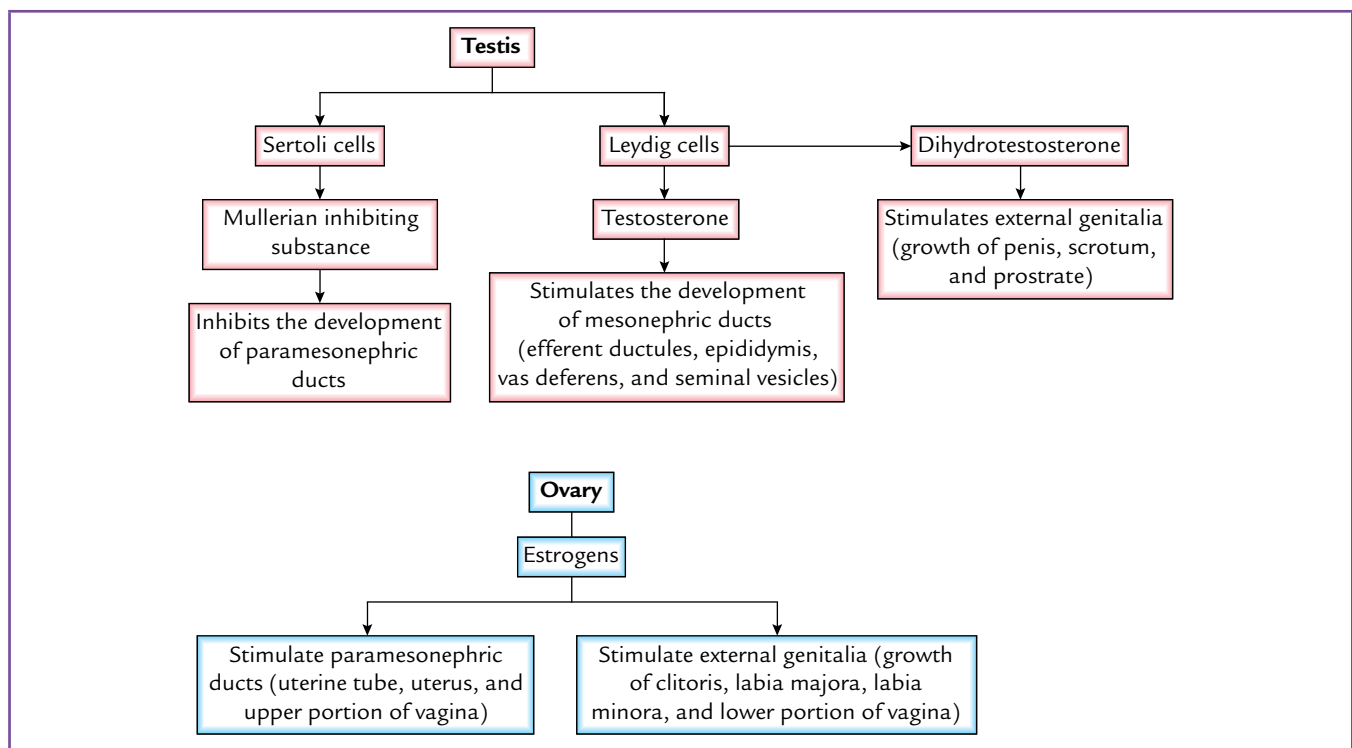
The influence of gonads on further sex differentiation (i.e., development of genital ducts and external genitalia) is as follows:

- The secretion of **Mullerian inhibiting substance** by **Sertoli cells** of testis inhibits the development of paramesonephric ducts—the primordia of female genital ducts.
- The production of **testosterone** by interstitial cells (**Leydig cells**) stimulates the mesonephric ducts to form genital ducts, viz., **efferent ductules, epididymis, vas deferens, seminal vesicles, and ejaculatory ducts**. The secretion of **dihydrotestosterone** by Leydig cells stimulates the development of male external genitalia, viz., **penis, scrotum, and prostate**.
- The secretion of **estrogens** by the ovaries stimulates the paramesonephric ducts to form **uterine tube, uterus, and upper part of the vagina**. It also stimulates the development of female external genitalia, viz., **labia majora, labia minora, clitoris, and lower portion of vagina**.

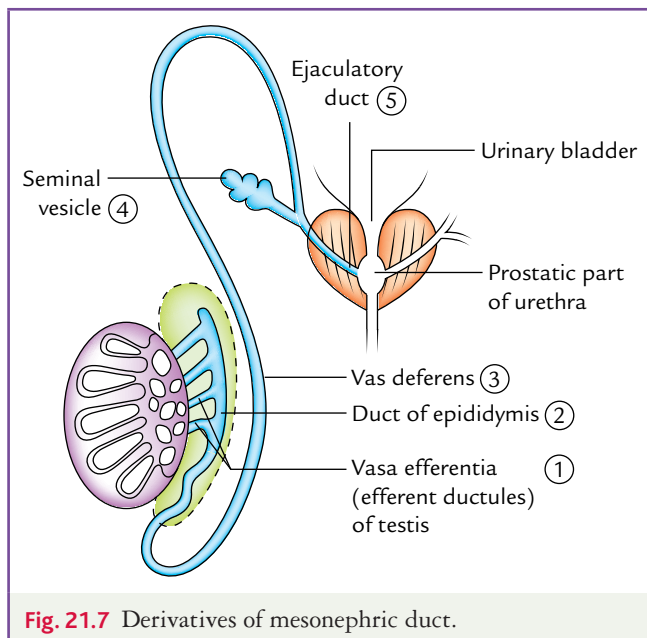
The influence of gonads on further differentiation of gonads is shown in Flowchart 21.3.

Development of Genital Ducts in Male (Fig. 21.7)

The **genital ducts in male** develop from mesonephric duct. Mesonephric duct develops in relation to mesonephros and opens into the cloaca (urogenital sinus).



Flowchart 21.3 Influence of gonads on further sex differentiation.



When the mesonephros is functional the **mesonephric tubules** open into the mesonephric duct.

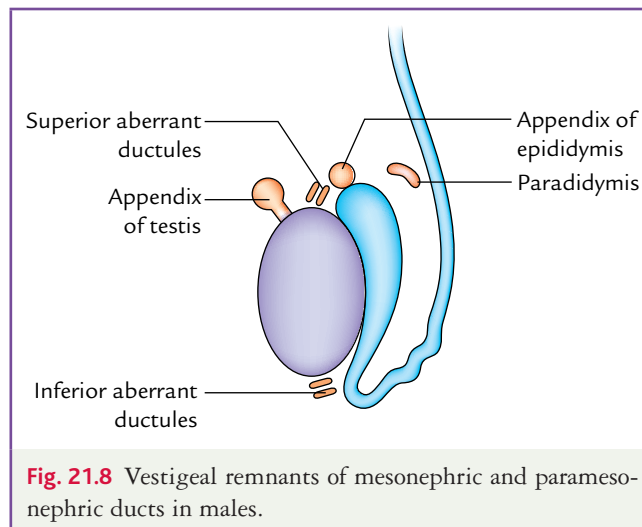
When mesonephros degenerates, most of the **mesonephric tubules** disappear. Only few mesonephric tubules in the vicinity of testis persist and establish connection with rete testis to form the **vasa efferentia** or **efferent ductules of testis**.

The upper part of mesonephric duct, which receives the efferent ductules, becomes elongated and highly coiled to form **duct of epididymis**. This highly coiled duct of epididymis becomes wrapped in connective tissue to form a comma-shaped structure called **epididymis**. The epididymis is attached to the posterior border of testis. Next part of the mesonephric duct develops a thick muscular coat and forms the **vas deferens**. Just before the mesonephric duct opens into the definitive urogenital sinus (future prostatic urethra), it gives a diverticulum that develops into **seminal vesicle**. The part of mesonephric duct distal to seminal vesicle forms the **ejaculatory duct** that opens into prostatic urethra.

N.B.

1. Vestigial remnants of mesonephric duct and mesonephric tubules in male (Fig. 21.8)

- Appendix of epididymis:** The cranial end of the mesonephric duct may persist as a small body called *appendix of the epididymis*, which is usually attached to head of the epididymis.
- Paradidymis:** The mesonephric tubules that fail to connect with the rete testis may persist and form a small body called *paradidymis*, which lies close to the upper part of the epididymis.
- Superior aberrant ductules:** These are remnants of mesonephric tubules cranial to efferent ductules (vasa efferentia) of the testis.
- Inferior aberrant ductules:** These are remnants of mesonephric tubules caudal to efferent ductules (vasa efferentia) of testis.



2. Vestigial remnants of paramesonephric duct in male

- Appendix of testis:** The cranial end of paramesonephric duct may persist as a small vesicular body called *appendix of the testis*. It is found attached to the upper pole of the testis.
- Prostatic utricle:** It is a small blind sac that opens into the posterior wall of the prostatic urethra. The prostatic utricle is homologous to *uterus and vagina in females*.

N.B. Appendix of epididymis is a remnant of mesonephric duct whereas appendix of testis is a remnant of paramesonephric duct.

Development of prostate and bulbourethral glands

Although these two structures do not form part of the male genital duct. But due to their close anatomical and functional relationship with the male genital duct they are described here.

Development of prostate (Fig. 21.9) The prostatic gland develops from five epithelial buds that arise from the epithelial lining of the prostatic urethra and grow in the surrounding mesoderm. These are one anterior, two posterior, and two lateral. The buds arising from mesodermal posterior wall of the urethra above the openings of ejaculatory ducts form **inner glandular zone of the gland** while the buds arising from rest of the prostatic urethra (endodermal in origin) form **outer glandular zone of the prostate**. The surrounding mesoderm forms dense fibrous stroma and smooth muscle of the prostate gland. It also forms **prostatic capsule**.

Clinical Correlation

The outer glandular zone of the prostate gland differentiates earlier than the inner glandular zone. In later life (above 50 years of age) the outer (endodermal) zone is prone to develop **prostate cancer**, whereas the inner (mesodermal) zone is prone to undergo **benign hypertrophy of prostate**.

Development of bulbourethral glands These are small pea-sized paired glands that develop from paired outgrowths from the spongy part of urethra. The glandular part of the gland develops from the endoderm of urethra while the

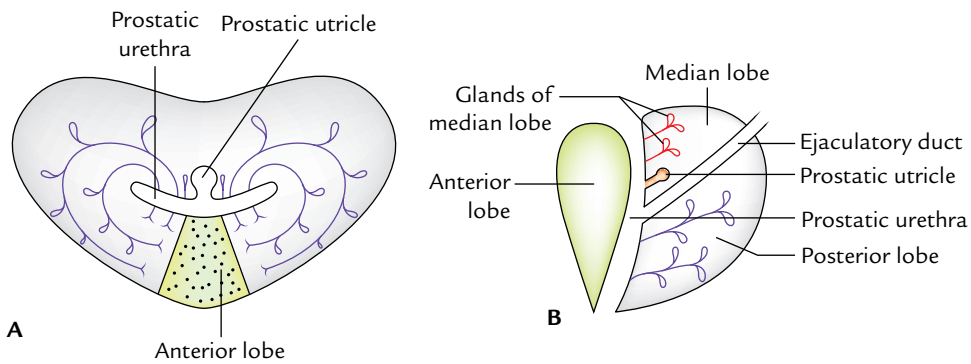


Fig. 21.9 Development of the prostate gland. A. Transverse section of the prostate gland above the level of openings of ejaculatory ducts. B. A sagittal section of the prostate gland. Note the glands of median lobe which open into the posterior wall of the prostatic urethra above the openings of ejaculatory ducts are mesodermal in origin.

smooth muscle and fibrous stroma develop from the surrounding mesoderm. The secretion of bulbourethral glands lubricates the urethral lumen and is often seen to come out of external urethral orifice at the tip of glans penis as a sticky material before ejaculation.

Development of Genital Ducts in Female

The genital ducts in female consist of fallopian tubes, uterus, and vagina. The genital ducts in female develop from **paramesonephric ducts**. The paramesonephric duct develops lateral to mesonephric ducts by a vertical invagination of celomic epithelium (Fig. 21.10) (mesothelium); when traced caudally they cross in front of the mesonephric ducts from lateral to medial side and come close to each other in the midline. Here two paramesonephric ducts fuse together in midline to form a vertical duct called **uterovaginal canal**. Upper ends of the paramesonephric ducts remain open into the celomic cavity (future peritoneal cavity). The caudal end of uterovaginal canal grows down and comes in contact with the dorsal wall of the phallic part of the definitive urogenital sinus (Fig. 20.11). At first fusion between the two paramesonephric ducts is incomplete, being separated by a fenestrated septum.

The paramesonephric duct is divided into three parts: (a) cranial vertical part, (b) middle horizontal part, and (c) caudal vertical part.

The various components of female genital duct develop as follows:

Fate of paramesonephric ducts in female (Fig. 21.12).

In females, the paramesonephric ducts form:

1. Uterine tubes
2. Uterus
3. Upper part of vagina.

1. **Development of uterine tubes:** The uterine tube, on each side, is formed by unfused part (the

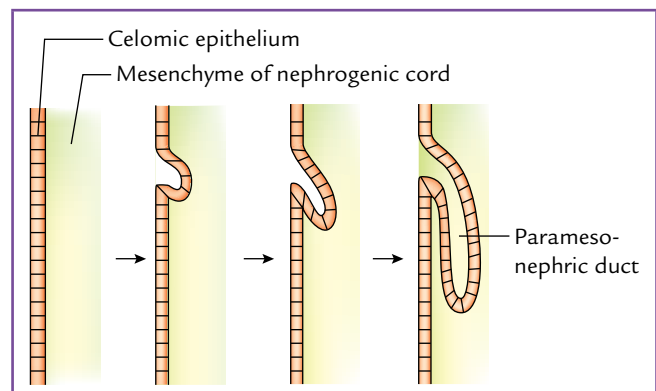


Fig. 21.10 Stages of development of paramesonephric ducts.

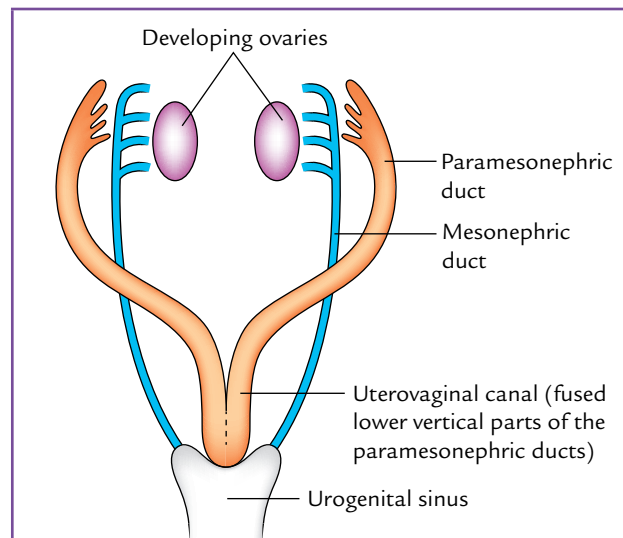


Fig. 21.11 Formation of uterovaginal canal.

cranial, vertical, and middle horizontal part) of the paramesonephric duct. The fallopian tube elongates and becomes tortuous.

The original site of evagination of the paramesonephric duct from celomic cavity forms **abdominal**

ostium of uterine tube. The fimbria develops later around the margin of the ostium.

2. **Development of the uterus (Fig. 21.13):** The uterus is formed from the uterovaginal canal (fused, caudal vertical parts of the paramesonephric ducts). The primitive uterus soon differentiates into two parts: (a) body and (b) cervix. In fetus, cervix is larger than the body of uterus. The initial angular junction between the two paramesonephric ducts becomes a convex dome and forms fundus of uterus.

Myometrium of the uterus is derived from surrounding mesoderm.

3. **Development of the vagina (Fig. 21.13):** A little recapitulation of various parts of primitive urogenital sinus (see page 240, Fig. 20.14) helps student to understand the development of vagina.

The vagina develops as follows:

As solid caudal tip of the **uterovaginal canal** comes in contact with dorsal wall of pelvic part of the definitive urogenital sinus, it induces formation of two outgrowths (evaginations) from the dorsal wall of the pelvic part of the definitive urogenital sinus called **sinovaginal bulbs**. The endodermal cells of the sinovaginal bulbs proliferate rapidly and form solid plate of cells called **vaginal plate**. The cells from tip of the uterovaginal canal (mesodermal) also proliferate and add to the *vaginal plate*. Now the vaginal plate is interposed between the uterovaginal canal and the urogenital sinus. The vaginal plate is therefore of composite origin—the upper part of vaginal plate is derived from the mesodermal cells of uterovaginal canal while the lower part of vaginal plate is derived from the endodermal cells of sinovaginal bulbs.

The upper end of vaginal plate expands and surrounds the caudal end of uterovaginal canal.

N.B. There is a controversy regarding the formation of *vaginal plate*. Some authorities consider that whole vaginal plate is derived from endodermal sinovaginal bulbs while the other believe that upper part of vaginal plate is derived from mesodermal uterovaginal canal and lower part is derived from endodermal sinovaginal bulbs.

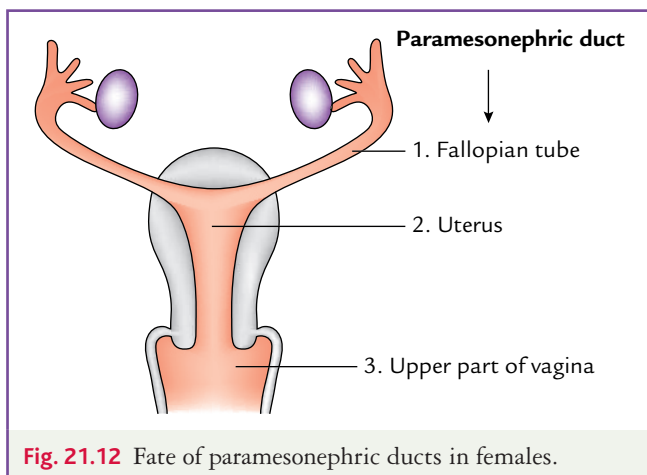


Fig. 21.12 Fate of paramesonephric ducts in females.

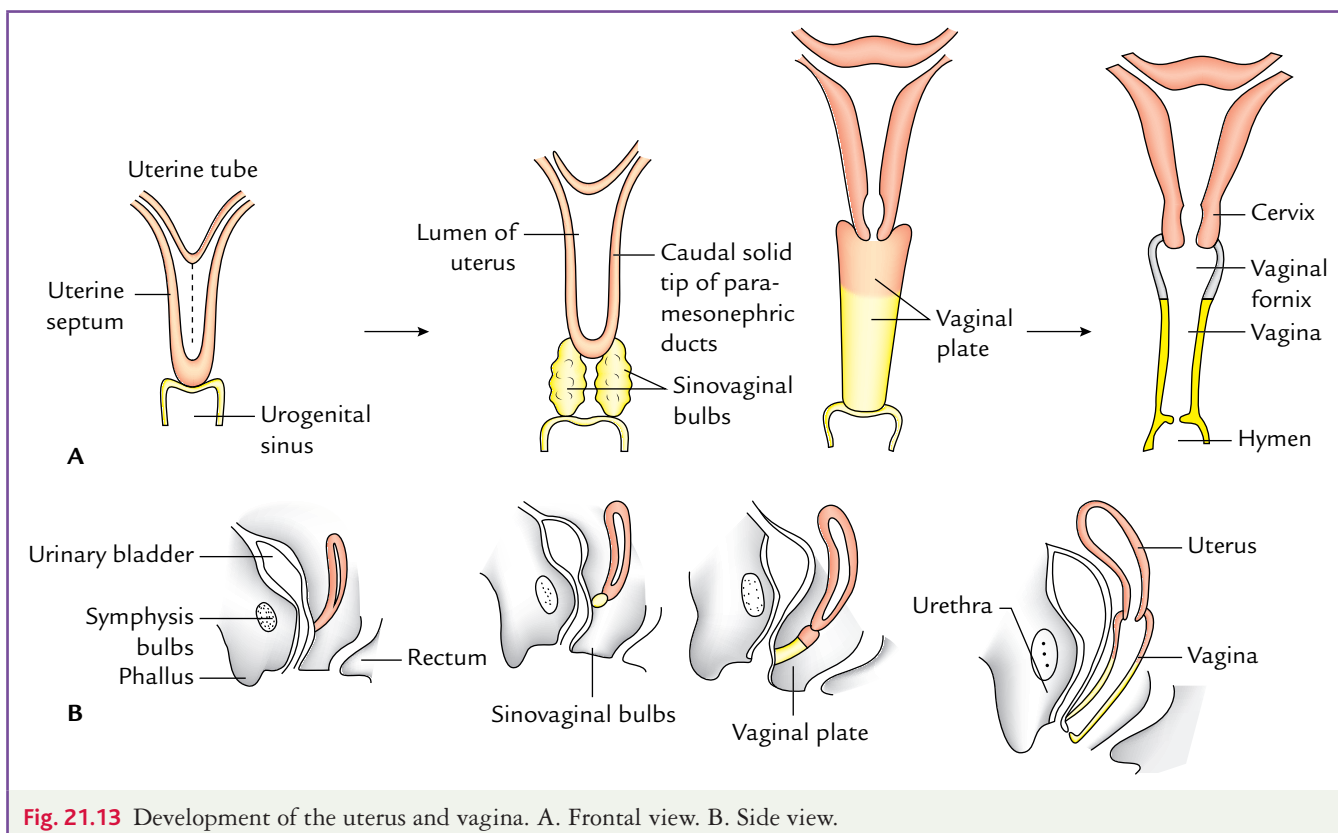


Fig. 21.13 Development of the uterus and vagina. A. Frontal view. B. Side view.

Table 21.2 Development of vagina and its associated structures

Embryonic structures	Adult derivatives
<ul style="list-style-type: none"> Mesodermal upper part of vaginal plate (derived from uterovaginal canal) 	<ul style="list-style-type: none"> Upper part of vagina including fornices of vagina
<ul style="list-style-type: none"> Endodermal lower part of vaginal plate (derived from sinovaginal bulbs) 	<ul style="list-style-type: none"> Lower part of vagina
<ul style="list-style-type: none"> Thin plate of tissue separating vagina and phallic part of urogenital sinus 	<ul style="list-style-type: none"> Hymen
<ul style="list-style-type: none"> Phallic part of definitive urogenital sinus 	<ul style="list-style-type: none"> Vestibule of vagina

The central cells of vaginal plate breakdown and by the fifth month the plate is completely canalized to form lumen of the vagina. The wing-like expansion of vagina around the cervix forms **fornices of vagina**. The vagina remains separated from the phallic part of definitive urogenital sinus by a thin plate of tissue called **hymen**, which consists of a thin layer of vaginal cells superiorly and epithelial lining of sinus inferiorly. Thus, both the surfaces of the hymen are lined by endoderm. The hymen usually develops a small opening in its center during perinatal life.

N.B. At first, the phallic part of the definitive urogenital sinus is closed/separated from the surface by the **urogenital membrane**. But this membrane breaks and the phallic part opens to the exterior. The phallic part of definitive urogenital sinus forms the vestibule of vagina, into which vagina and urethra open (derived from pelvic part of definitive urogenital sinus).

The development of vagina and associated structures, viz., hymen and vestibule of vagina, is summarized in Table 21.2.

Clinical Correlation

Congenital anomalies of the uterus (Fig. 21.14)

- Double uterus with double vagina:** In this condition, there are two uteruses and two vaginas. It occurs due to *complete lack of fusion of the paramesonephric ducts and the sinovaginal bulbs*.
- Double uterus with single vagina:** It occurs when paramesonephric ducts fail to fuse but lie close to each other. As a result, the uterus is entirely double (**uterus didelphys**). The *vaginal plate* formed in relation to each duct fuses with each other to form a single vagina.
- Bicornuate uterus:** In this condition, there is one vagina and one cervix but the body of uterus is duplicated. Each half of the body is called horn or cornu of the uterus. One fallopian tube opens in each horn of the uterus.

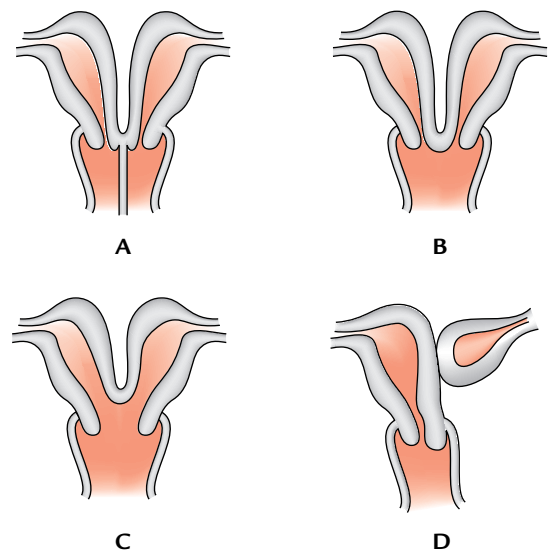


Fig. 21.14 Main congenital anomalies of the uterus. A. Double uterus (uterus didelphys) with double vagina. B. Double uterus with single vagina. C. Bicornuate uterus. D. Unicornuate uterus.

It occurs when the paramesonephric ducts fuse with each other only in their lower parts while they remain separate in upper part, thus giving rise to two horns of the uterus.

- Unicornuate uterus:** In this condition, half of the uterus is missing. It occurs when one paramesonephric duct degenerates so that only one horn of the uterus with one fallopian tube persists.
- Septate uterus:** In this condition, the two paramesonephric ducts fuse with each other but the septum separating them does not disintegrate. As a result, a vertical septum separates cavity of the uterus into two halves.
- Agenesis of uterus:** A rare condition in which uterus is completely absent. It occurs due to failure of the paramesonephric ducts to develop.
- Infantile uterus:** It is a clinical condition in which an adult female possesses a much smaller uterus than normal. The infantile uterus resembles to that present before puberty. The vagina and ovaries are normal. Clinically it presents as *amenorrhea*.

Congenital anomalies of vagina

- Agenesis of vagina:** In this condition the vagina is absent. It occurs when the urogenital sinus fails to form the sinovaginal bulbs and hence the vaginal plate. Absence of the vagina is usually associated with absence of the uterus and uterine tubes.
- Atresia of vagina (imperforate vagina):** This occurs when the vaginal plate fails to get canalized. Sometimes only middle part of the vaginal plate fails to disintegrate giving rise to horizontal septum in the lumen of vagina.
- Imperforate hymen:** It occurs when the endodermal cells of the vaginal plate adjacent to the urogenital sinus fail to

disintegrate. This condition causes retention of menstrual flow—a clinical condition called **hematocolpos**.

4. **Duplication of vagina:** This condition is generally associated with double uterus.
5. **Rectovaginal and vesicovaginal fistulae:** In these conditions the vagina communicates with rectum and urinary bladder, respectively (Fig. 21.15).

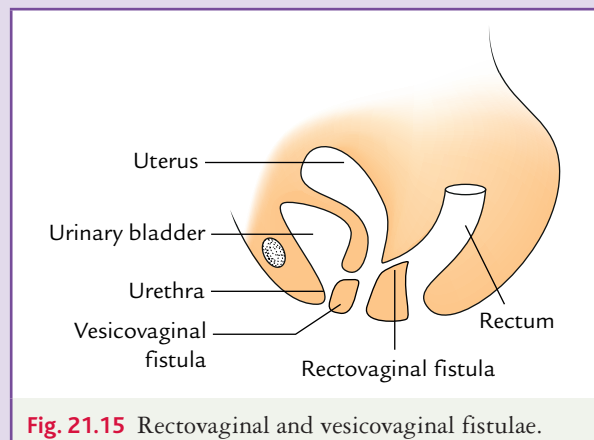


Fig. 21.15 Rectovaginal and vesicovaginal fistulae.

- (a) **Epoophoron:** It consists of a longitudinal duct running parallel to the uterine tube (persistent cranial part of the mesonephric duct) and number of transverse ductules that open into this duct (persistent mesonephric tubules) are present vertically above the ovary in the mesovarium. The *epoophoron* corresponds to efferent ductules of testes and epididymis of males (epi = above, oo = egg, and phoron = basket).
- (b) **Paroophoron:** A few mesonephric tubules are detached from the mesonephric duct and persist as small blind tubules between the ovary and uterus. These are called *paroophoron* (para = near, oo = egg, and phoron = basket).
- (c) **Gartner's duct:** A part of the mesonephric duct persists and lies between the two layers of broad ligament by the side of the body of uterus. It may open into the cervix or vagina. This corresponds to the vas deferens in males. This duct may undergo abnormal cystic dilatations to form *Gartner's cysts*.

N.B. Vestigial remnants of mesonephric duct and mesonephric tubules in female (Fig. 21.16).

Development of External Genitalia

Overview

The development of external genitalia is similar in both males and females till the sixth week of IUL (**indifferent stage**). After this stage the development proceeds to either in male or female direction under the influence of hormones.

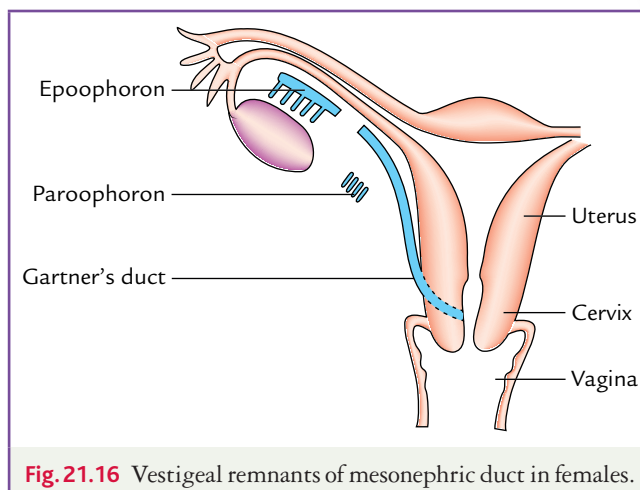


Fig. 21.16 Vestigial remnants of mesonephric duct in females.

Indifferent Stage (Fig. 21.17)

The **external genitalia** develop in the region of **cloacal membrane**.

Early in the fourth week, the embryonic mesoderm grows around the cloacal membrane to form a pair of swellings called **cloacal folds**. Cranial to the cloacal membrane these folds unite to form **genital tubercle**. Caudally each fold is subdivided into two parts: (a) a large anterior part called **urethral fold** and (b) a small posterior part called **anal fold**.

Simultaneously the cloacal membrane is divided in two parts by **urorectal septum**: (a) the anterior part called **urogenital membrane** and (b) the posterior part called **anal membrane**. The genital tubercle and urethral folds are now related to the urogenital membrane. In the meantime another pair of elevations called **genital swellings** appears—one on each side of the urethral folds. At this stage the urogenital membrane in each sex is related on each side to the **urethral fold** medially, **genital swelling** laterally, and **genital tubercle** anteriorly. The morphological sex cannot be differentiated at this stage. Hence, the name **indifferent stage**. From this stage onward development proceeds in different directions in male and female.

Definitive Stage

Development of Male External Genitalia (Figs 21.18 and 21.19)

Under the influence of androgens (testosterone and dihydrotestosterone) secreted by Leydig cells of fetal testes, the development of external genitalia proceeds in the male direction.

Genital tubercle enlarges rapidly and becomes cylindrical to form **phallus (primitive penis)**. The enlargement of phallus forms the penis.

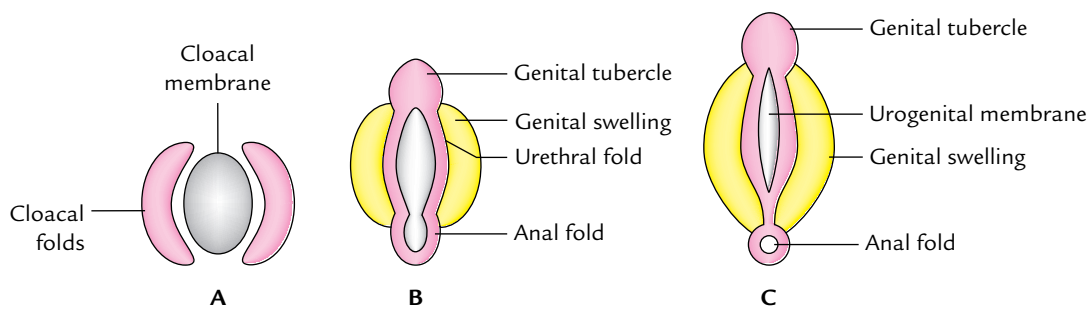


Fig. 21.17 Indifferent stages of external genitalia.

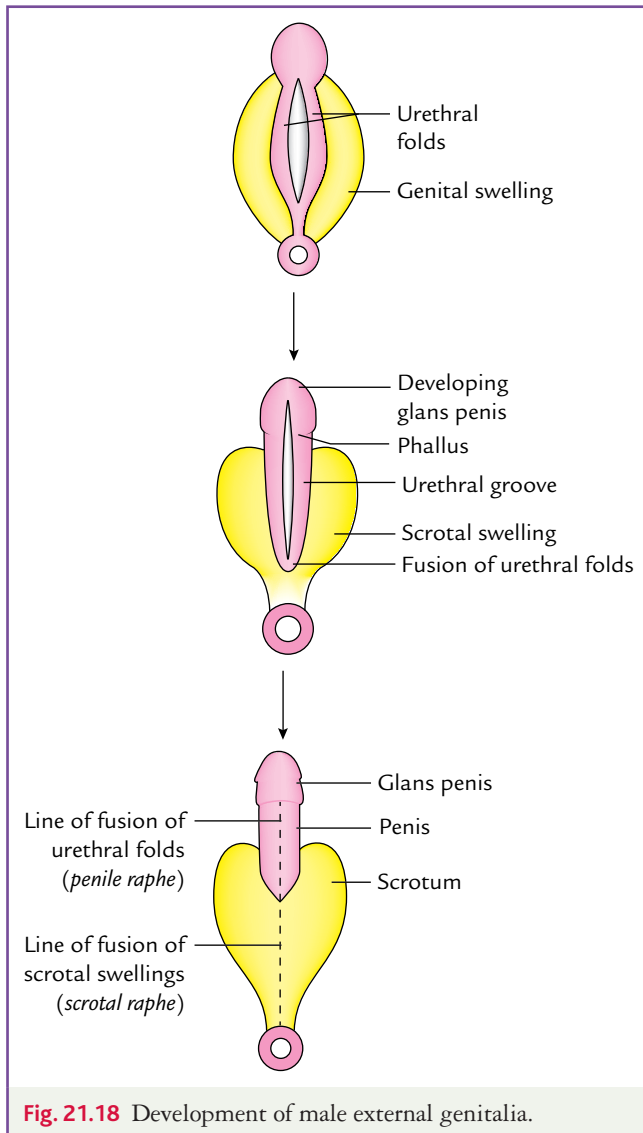


Fig. 21.18 Development of male external genitalia.

- 1. Development of penile urethra:** As the phallus elongates, it pulls the primitive urethral folds forward under it. With extension of primitive urethral folds on the undersurface of phallus, the **primitive urethral groove** also extends on the undersurface of phallus, up to the tip of phallus (primordia of the glans penis). Concurrently the phallic part of

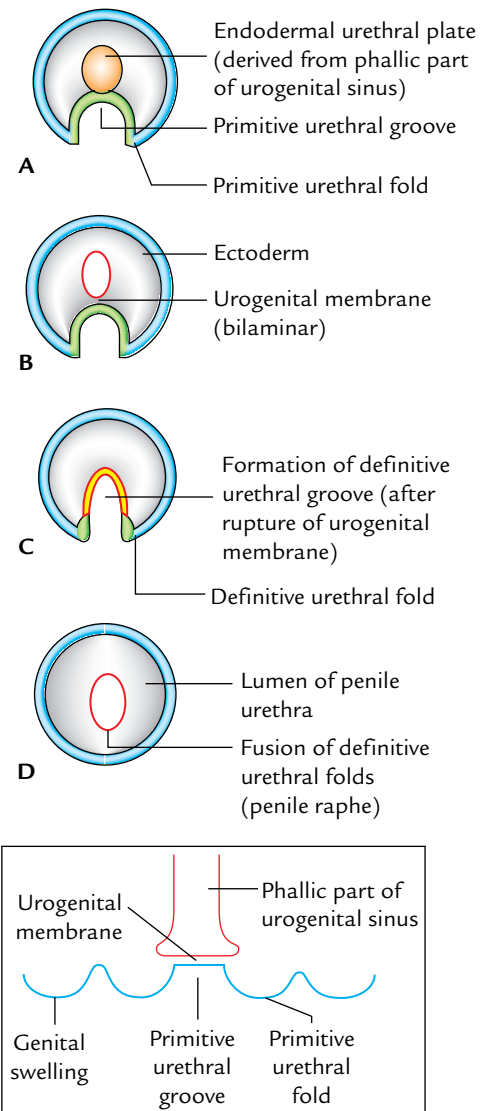


Fig. 21.19 Stages in the development of penile urethra in the body of penis (as seen in cross sections of the body of phallus). Figure in the inset shows relationship of phallic part of urogenital sinus and primitive urethral groove.

the urogenital sinus also extends up to base of the developing glans penis.

The endodermal epithelial lining of the phallic part of the urogenital sinus proliferates to form

urethral plate. The urethral plate also extends forward within the phallus along the floor the primitive urethral groove up to the base of developing glans penis. The solid urethral plate gets canalized to form hollow tube. The bilaminar urogenital membrane separates the newly formed endodermal tube from the primitive urethral groove. Now the urogenital membrane breaks to form the **definitive urethral groove** flanked by the **definitive urethral folds**. At the end of third month, the two definitive urethral folds fuse in craniocaudal direction to form **penile urethra** up to the base of the glans. The surface ectoderm fuses in the median plane of penis to form the **penile raphe**.

The **spongy part of penile urethra** thus formed extends only up to the base of the glans. During the fourth month, the ectodermal cells from the tip of glans penis **penetrate inward** and form a short solid ectodermal epithelial cord. The cord canalizes and forms **terminal part of the urethra** and **external urethral meatus** (Fig. 21.20).

- Development of prepuce of the penis** (Fig. 21.21): Close to the tip of the phallus a circular sulcus (**coronary sulcus**) appears, which separates the glans penis from rest of the penis. The surface ectoderm covering the glans proliferates and grows inward forming double-layered fold of ectoderm. Later, these two layers of ectoderm separate from each other to form the *prepuce*. The prepuce is retractable fold of skin that can slide over the surface of the glans penis.
- Development of scrotum:** After fusion of the definitive urethral folds, the two genital swellings are now called **scrotal swellings**. They move medially and fuse with each other to form the scrotum. The scrotum thus lies below root of the penis. Each

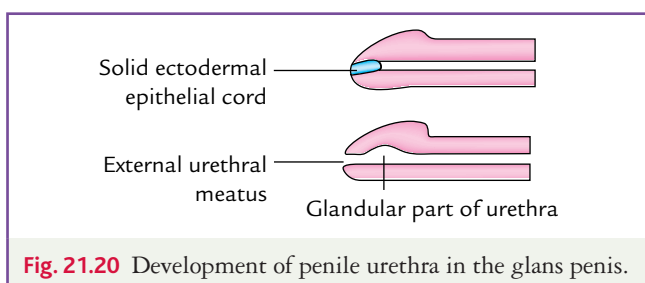


Fig. 21.20 Development of penile urethra in the glans penis.

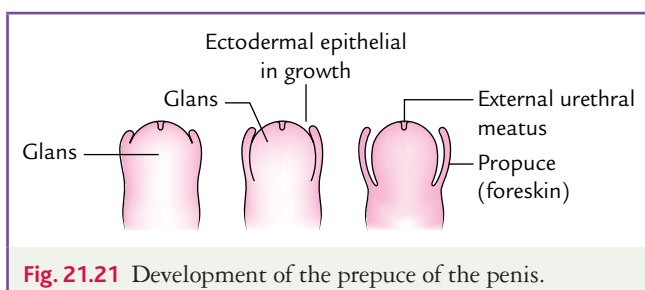


Fig. 21.21 Development of the prepuce of the penis.

scrotal swelling forms half of the scrotum. The two halves of scrotum are separated from each other by **scrotal septum**. The line of fusion of these folds in the midline forms **scrotal raphe**.

Clinical Correlation

1. Congenital anomalies of urethra

- Hypospadias:** It is the commonest congenital anomaly of the urethra (occurring in 3–5/100 births). In this condition the external urethral orifice (EUO) is located on ventral aspect of penis, instead of at the tip of the penis. It occurs due to failure of canalization of the ectodermal cord in the glans and/or failure of fusion of the urethral folds. Usually the penis is underdeveloped and curved ventrally, producing a clinical condition called **chordae**.

Types of hypospadias (Fig. 21.22): Depending upon the location of EUO, the hypospadias is classified into following five types.

- Glandular:** When the EUO is located on the ventral aspect of the glans.
- Coronal/balanic:** When urethra opens at the base of glans penis. In this case the glans is often grooved on its ventral aspect.
- Penile:** When urethra opens anywhere between the base of the glans and in front of the scrotum.
- Penoscrotal:** When urethra opens at junction of the penis and scrotum.
- Perineal:** When a wide sagittal slit is found along entire length of the penis and scrotum. The two scrotal swellings closely resemble labia majora.

N.B.

The hypospadias occur due to inadequate production of androgens by fetal testes.

The incidence of hypospadias has doubled in the last 15–20 years probably due to rise in environmental estrogens.

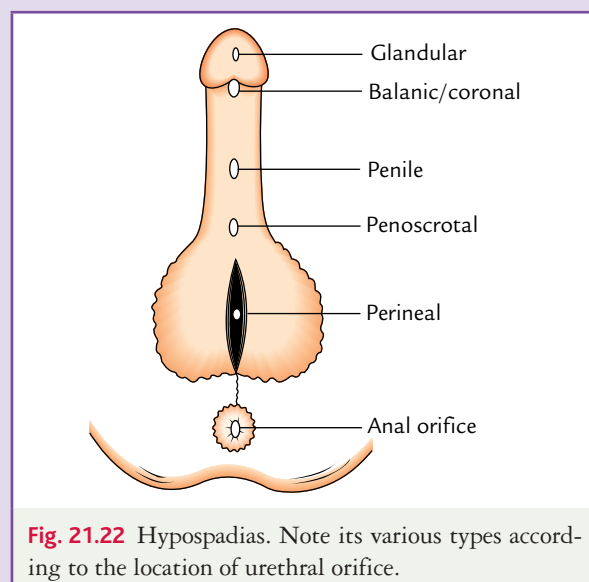


Fig. 21.22 Hypospadias. Note its various types according to the location of urethral orifice.

- Epispadias:** In this condition, the urethral orifice is located on the dorsal aspect of the penis. It is a rare anomaly and

occurs in 1/30,000 births. Although epispadias may occur as an isolated defect, it is mostly associated with exstrophy of the urinary bladder (ectopia vesicae). The exact embryological basis for this condition is not clear. Probably it occurs when genital tubercle instead of being formed cranial to the cloacal membrane is formed more dorsally in the region of urorectal septum, and thus part of the urogenital membrane is seen cranial to the genital tubercle. When this membrane ruptures then the urogenital sinus opens on the dorsal aspect of the penis and then the urethral groove extends on the dorsal aspect of the penis.

2. Congenital anomalies of penis

- Agenesis of penis (absence of penis):** It occurs when the genital tubercle fails to develop.
- Micropenis (very small penis):** It occurs due to underdevelopment of the genital tubercle.
- Bifid penis and double penis:** The bifid penis occurs when the genital tubercle splits. The double penis is formed when the two genital tubercles develop.

3. Congenital anomalies of prepuce (foreskin)

Phimosis: The prepuce is a fold of skin covering the glans of penis. It develops during 12th week of IUL. It remains adherent to the glans up to 3 years of age and is not easy to retract. Thereafter it separates progressively from glans and is non-adherent by 6 years of age. The phimosis is a condition in which prepuce is so tight that it cannot be retracted fully from glans. It is usually congenital and is often associated with *pinhole meatus*.

Development of Female External Genitalia (Fig. 21.23)

The female external genital organs develop from the indifferent stage of external genitalia due to influence of estrogens (derived from maternal and paternal sources). The estrogen stimulates the development of external genitalia of female. The changes are less extensive in the indifferent external genitalia than those in the males. The female external genital organs develop as follows:

- The genital tubercle elongates only slightly to form small phallus, which bends to form **clitoris**. **The clitoris does not contain urethra.**
- The **primitive urethral folds** do not fuse and form the **labia minora**.
- The **genital swellings** now enlarge to form the **labia majora**. The labia majora fuses with each other posterior to the urogenital membrane but anterior to the anal membrane to form **posterior labial commissure**. The labia majora also fuses anteriorly to form **mons pubis** and **anterior labial commissure**. The labia majora overlaps the labia minora.
- The urogenital membrane ruptures so that the phallic part of urogenital sinus forms the **vestibule of vagina**, which has openings of the urethra and vagina and communicates to the exterior (Fig. 21.24).

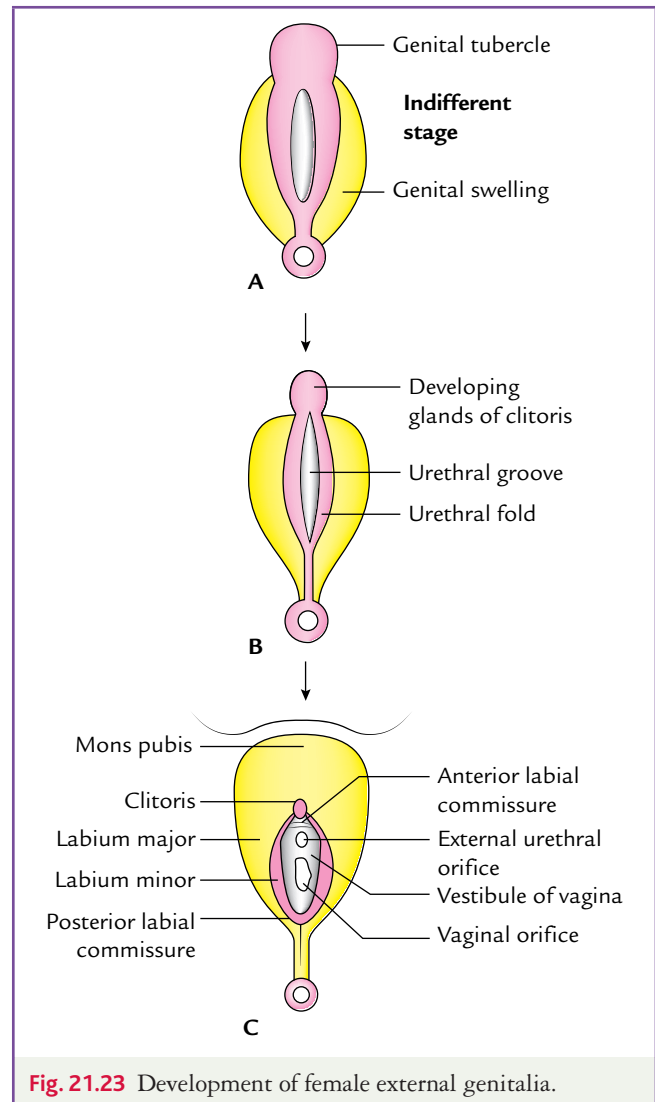


Fig. 21.23 Development of female external genitalia.

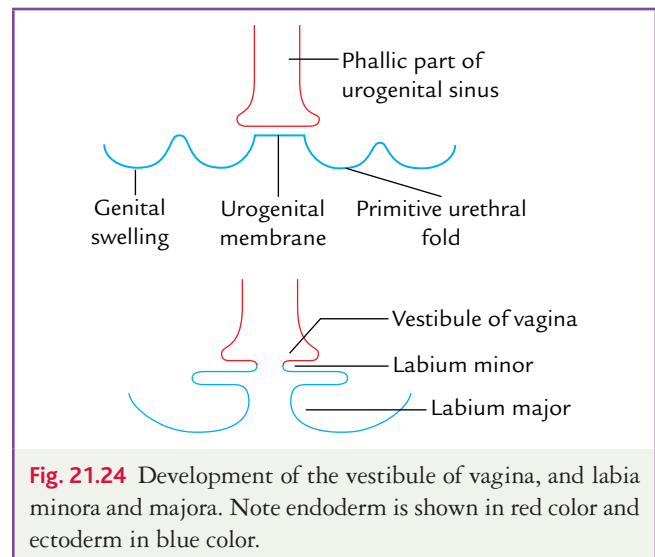


Fig. 21.24 Development of the vestibule of vagina, and labia minora and majora. Note endoderm is shown in red color and ectoderm in blue color.

N.B. Although genital tubercle does not elongate extensively in female, it is larger than male during early stages of the development.

The labia minora has outer ectodermal and inner endodermal lining.

Clinical Correlation

1. **Klinefelter's syndrome** (Fig. 21.25): It is the most common major abnormality of sexual differentiation occurring in 1/500 births. It is a trisomic condition found only in males with a karyotype of 47XXY. The most common cause is nondisjunction of XX homologues. The characteristic clinical features are:

- ◆ Hypogonadism associated with testicular atrophy
- ◆ Infertility
- ◆ Gynecomastia
- ◆ Eunuchoid habitus
- ◆ Elevated gonadotrophin levels
- ◆ Poorly developed secondary sexual characters

For details see Chapter 25.

2. **Hermaphrodites:** The sexual development of males and females begins in an identical fashion. Hence it is not surprising that abnormalities in sex differentiation and sex determination may occur.

(a) **True hermaphrodites:** The *true hermaphroditism* is an extremely rare condition in which both testes and ovaries

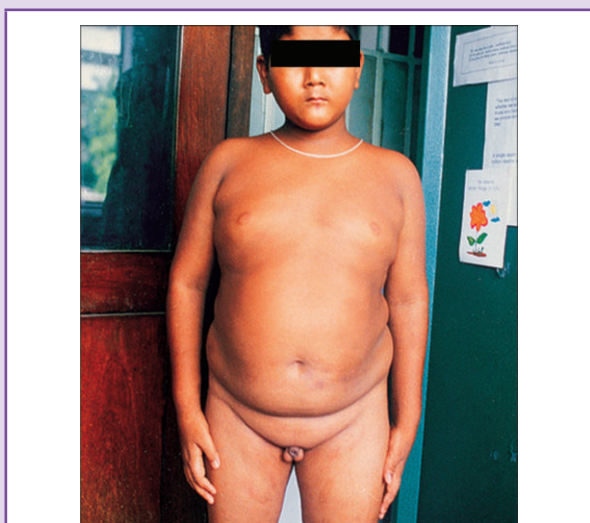

Fig. 21.25 Klinefelter's syndrome.

are present (usually combined as ovotestes) and the external genitalia are ambiguous (neither completely male nor completely female).

The testes and ovaries are usually nonfunctional. The chromosomal sex is usually female (80%) with 46XX karyotype.

The uterus is present but the external genitalia are ambiguous or predominantly female. Most of these individuals are brought up as females.

(b) **Pseudohermaphrodites:** These are individuals in whom *genotypic sex* is masked by *phenotypic appearance*, which closely resembles the other sex.

If a pseudohermaphrodite has a testis, the individual is called *male pseudohermaphrodite* and if a pseudohermaphrodite has an ovary, the individual is called *female pseudohermaphrodite*. The differences between male and female pseudohermaphrodites are given in Table 21.3.

3. **Androgen insensitivity syndrome (AIS):** It is a clinical condition in which affected individual is phenotypically female (i.e., normal appearing female) despite the presence of testes and 46XY chromosome complement. It is also called **testicular feminization syndrome**. It occurs in 1/20,000 births due to a defect in androgen receptor mechanism.

Characteristic clinical features:

- ◆ Normal appearing female
- ◆ Normal female external genitalia
- ◆ Normal development of breasts at puberty
- ◆ Vagina is short and usually ends in a blind pouch
- ◆ Uterus and uterine tubes are absent or rudimentary
- ◆ Absence of menstruation
- ◆ Psychosexual orientation of women
- ◆ Testes are in inguinal canal

N.B.

- Socially, mentally, and psychologically the women with AIS are entirely female.
- Embryologically these females represent an extreme form of male pseudohermaphroditism.

Table 21.3 Difference between male and female pseudohermaphrodites

	Male pseudohermaphrodite	Female pseudohermaphrodite
Gonads	Testes	Ovaries
Chromosome complement	46XY	46XX
External genitalia	Resemble to that of female <ul style="list-style-type: none"> • Phallus remains rudimentary and looks like clitoris • Scrotal swellings fail to fuse, giving an appearance of labia majora 	Resemble to that of male <ul style="list-style-type: none"> • Excessive enlargement of clitoris resembling penis • Partial fusion of labia majora, giving an appearance of a scrotum
Most common cause	Lack of androgen receptors (hence androgens produced by fetal testes are ineffective in inducing differentiation of male genitalia)	Congenital adrenal hyperplasia with excessive production of androgens. Excessive production of androgens masculinizes external genitals

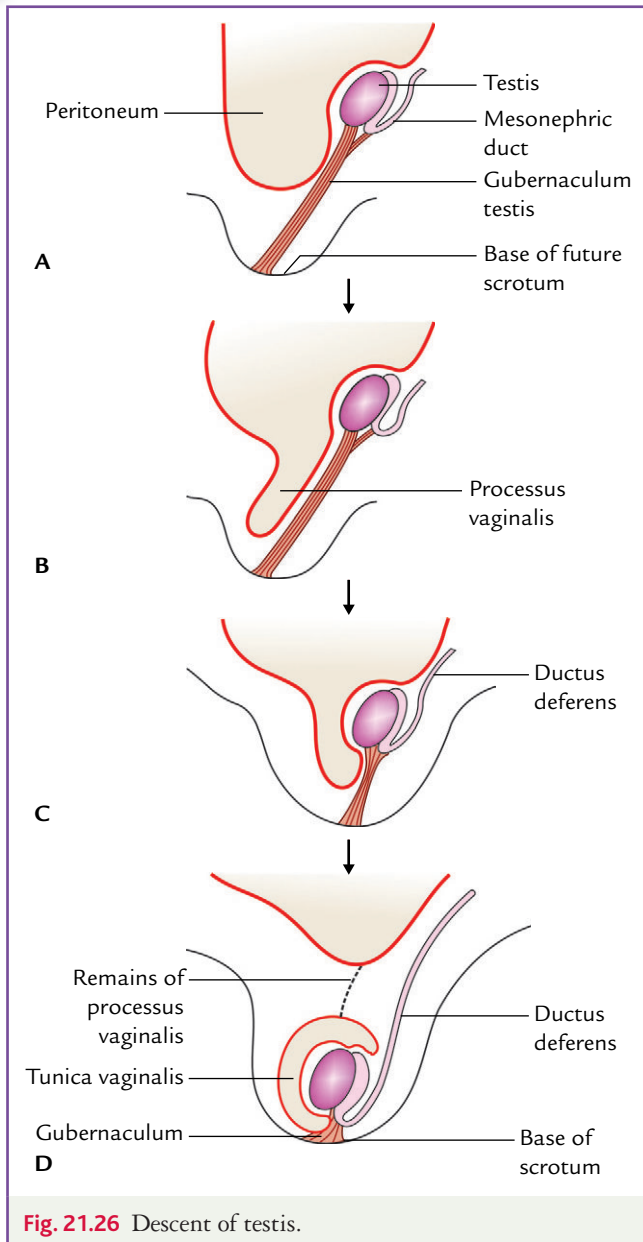


Fig. 21.26 Descent of testis.

Relocation of Testes and Ovaries

Descent of Testis (Fig. 21.26)

The testis develops on posterior abdominal wall in upper lumbar region. From here it descends into the scrotum at or just after birth. The various stages of the descent of testis are given in Table 21.4.

Factors Responsible for Descent of Testis

The descent of testis is assisted by a number of factors, which are discussed below.

1. Differential growth of the posterior abdominal wall.
2. **Formation of inguinal bursa:** An outpouching of various layers of abdominal wall toward the

Table 21.4 Stages of descent of testis (Fig. 21.26)

Extent of descent	Time
• Testis reaches iliac fossa	During third month
• Reaches deep	At the end of sixth month
• Inguinal ring	
– Travels through inguinal canal	During seventh month
– Reaches at superficial inguinal ring	At eighth month
– Reaches scrotum	By end of ninth month

scrotum. The cavity of inguinal bursa forms the *inguinal canal*. Note inguinal bursa is formed before the testis enters into it.

3. **Gubernaculum testis:** A mesenchymal band extending from lower pole of the testis to bottom of the scrotum. It helps to dilate inguinal bursa and lays down the path for the descent of testis.

During growth of the posterior abdominal wall, there is no corresponding increase in length of gubernaculum. Due to relative shortening of gubernaculum, the testis progressively assumes a lower position.

4. **Processus vaginalis:** A diverticulum of peritoneal cavity that grows into the inguinal canal and scrotum. As the testis descends into the scrotum, it invaginates processus vaginalis from behind. Once the descent of testis is completed, the part of processus vaginalis between the testis and the deep inguinal ring is obliterated. The part of processus vaginalis that covers the testis is now known as **tunica vaginalis of testis**.

5. **Increased intra-abdominal pressure** helps to push the testis out of abdomen.
6. **Male sex hormones** greatly influence descent of testis.
7. A specific neurotransmitter called calcitonin gene related peptide is secreted by genitofemoral nerve supplying muscle fiber of the gubernaculum testis.

N.B. When testis descends into scrotum from the posterior abdominal wall it carries vas deferens and blood vessels along with it. This provides an embryological basis of '*crossing of vas deferens anterior to ureter near the urinary bladder.*'

Clinical Correlation

1. **Cryptorchidism (undescended testis)** (Fig. 21.27): It is a clinical condition in which one or both the testes may fail to descend into the scrotum.
 - (a) In about 97% of newborns, the testes are present in the scrotum before birth; in remaining cases the descent occurs postnatally during first 3 months.
 - (b) In less than 1% of infants one or both testes fail to descend.

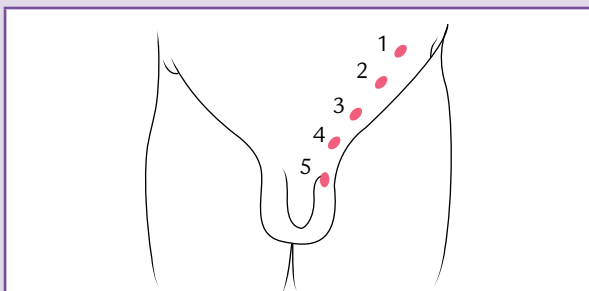


Fig. 21.27 Cryptorchidism.

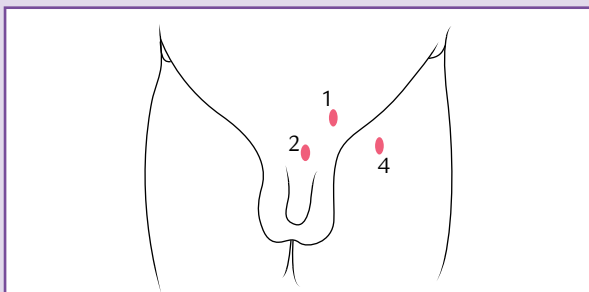


Fig. 21.28 Ectopic testis.

Table 21.5 Types of cryptorchidism according to location

Type	Location
• Lumbar	• Lumbar region of abdomen
• Iliac	• At deep inguinal ring
• Inguinal	• Within inguinal canal
• Pubic	• At superficial inguinal ring
• Scrotal	• High up in the scrotum

- (c) The cryptorchidism may occur due to decreased androgen (testosterone) production.
- (d) The testes may become arrested at any point during their journey from upper lumbar region of abdominal cavity to the scrotum. Depending upon their location, the cryptorchidism is classified into four types (Table 21.5).

N.B. The term cryptorchidism means hidden testis.

Clinical significance of cryptorchidism

- The undescended testes fail to produce mature spermatozoa due to higher abdominal temperature. In bilateral cryptorchidism the individual is sterile.
- The undescended testes are susceptible to injury.
- The undescended testes are likely to develop malignancy.
- The undescended testes are likely to atrophy.

N.B. In case of cryptorchidism testicular hormones are used to promote the descent. If it fails, the testes are surgically mobilized and fixed to the scrotal floor (**orchidopexy**).

2. **Ectopic testis (Fig. 21.28)**: It is a clinical condition in which the testis is present elsewhere away from expected path of descent. The sites of ectopic testis are:

- (a) In superficial fascia of the anterior abdominal wall (**interstitial type**). It is the commonest site of ectopic testis.
- (b) Anteromedial aspect of thigh (in the region of femoral triangle).
- (c) At the root of penis.
- (d) In the perineum behind scrotum.

N.B. The ectopic testis occurs due to **hypothetic bands of Lockwood** (fibrous bands extending from lower pole of testis to the ectopic sites).

3. **Congenital indirect inguinal hernia**: The processus vaginalis (diverticulum of peritoneal cavity) forms a communicating channel between the peritoneal cavity within the abdomen and the tunica vaginalis within the scrotum. Normally it obliterates by first year of life.

If the processus vaginalis fails to obliterate and remains open, the loops of intestine may descend through it into the scrotum causing congenital indirect inguinal hernia.

4. **Congenital hydrocele (intermittent hydrocele)**: Hydrocele is accumulation of fluid in the peritoneal sac within the scrotum and/or inguinal canal. It occurs due to incomplete obliteration of the processus vaginalis providing a tiny communication between the peritoneal cavity and tunica vaginalis, which permits the escape of fluid but not entry of intestine into the sac.

The various types of hydroceles (Fig. 21.29) are given in Table 21.6.

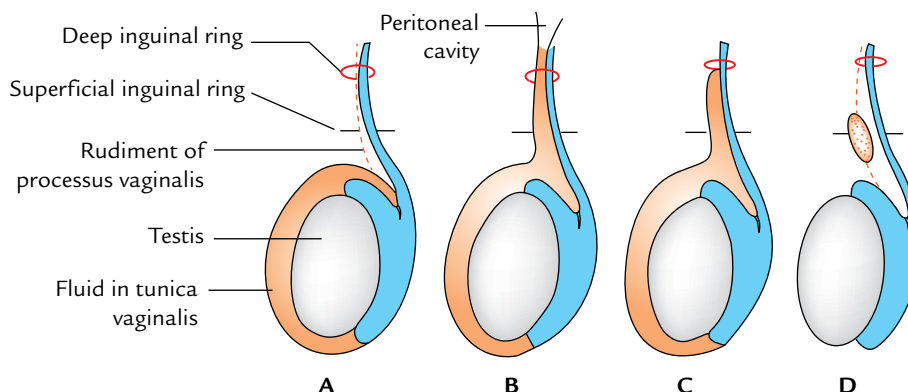


Fig. 21.29 Types of hydroceles. A. Vaginal. B. Congenital. C. Infundibular. D. Hydrocele of cord.

Table 21.6 Type of congenital hydroceles

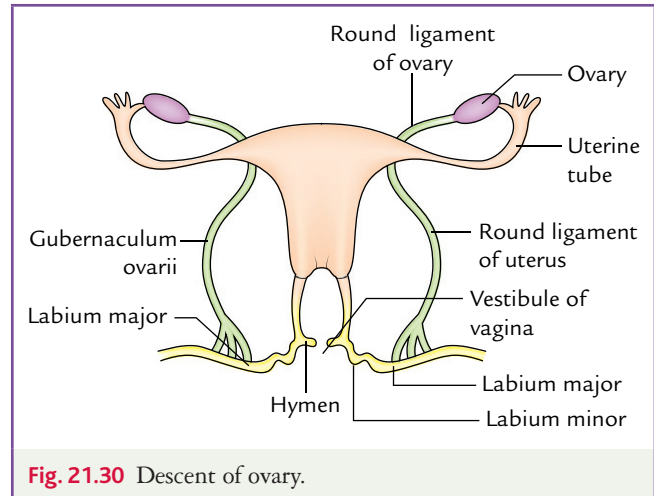
Types of hydrocele	Feature
Vaginal	Confined to scrotum
Congenital	Extends upward into the peritoneal cavity
Infantile/infundibular	Extends upward up to the deep inguinal ring
Hydrocele of cord	Confined only in the spermatic cord

Descent of Ovary (Fig. 21.30)

The ovary develops on the posterior abdominal wall in the upper lumbar region. From here it descends into the true pelvis, where it lies on its lateral wall in a fossa called **ovarian fossa**.

The caudal end of ovary is attached to the genital swelling (primordium of labium majus) by a fibromuscular band called **gubernaculum ovarii**. It is believed

that the descent of ovary occurs due to pull of the gubernaculum. Its descent is arrested at the pelvis due to development of the uterus and broad ligament. This is because the gubernaculum gets attached to angle of the developing uterus. As a result, it gets divided into two parts: proximal and distal. The proximal part of

**Fig. 21.30** Descent of ovary.**Table 21.7** Embryonic structures and their homologous adult derivatives in male and female

Embryonic structure	Adult derivatives	
	In male	In female
1. Indifferent gonad	Testis	Ovary
(a) Primordial germ cells	Spermatogonia	Oogonia
(b) Surface epithelium of gonad	Sertoli cells/supporting cells	Follicular cells
(c) Mesenchyme	Leydig cells (interstitial cells)	Theca cells (forming theca interna and externa)
2. Gubernaculum	Gubernaculum testis	(a) Round ligament of ovary (b) Round ligament of uterus
3. Mesonephric tubules		
(a) Cranial tubules	Efferent ductules	Epoophoron
(b) Caudal tubules	Paradidymis	Paroophoron
4. Mesonephric duct	Duct of epididymis Vas deferens Seminal vesicle Ejaculatory duct	Gartner's duct
5. Paramesonephric duct	Appendix of testis Prostatic utricle	Uterine tubes Uterus Cervix Upper part of vagina
6. Urogenital sinus	Urinary bladder Urethra (prostatic membranous and penile) Prostate gland Bulbourethral glands	Urinary bladder Urethra (membranous) and vestibule of vagina Paraurethral glands (of Skene) Greater vestibular glands
7. Mullerian tubercle	Seminal colliculus (verumontanum)	Hymen
8. Genital tubercle	Penis	Clitoris
9. Urethral folds	Penile urethra	Labia minora
10. Genital swellings	Scrotum	Labia majora

gubernaculum drags the ovary into the pelvic cavity and becomes the **ligament of ovary**. The distal part of the gubernaculum becomes **round ligament of the uterus**. The round ligaments of uterus pass through the inguinal canal and terminate in the labium majus.

During the descent of the ovary a tubular prolongation of peritoneum, the **processus vaginalis** (also called **canal of Nuck**) extends into the inguinal canal along the gubernaculum. The processus vaginalis (canal of Nuck) usually obliterates and disappears much before birth.

Clinical Correlation

- ♦ If the processus vaginalis (**canal of Nuck**) persists after birth, it may **cause congenital inguinal hernia in female**.
- ♦ If the gubernaculum of ovary fails to attach to angle of the uterus, the ovary may be present in the inguinal canal or in the labium; although it is very rare.

The embryonic structures, their adult derivatives, and homologies in male and female are given in Table 21.7.

GOLDEN FACTS TO REMEMBER

- | | |
|---|---|
| ➤ Master gene for development of testes | SRY gene |
| ➤ Commonest congenital anomaly of the urethra | Hypospadias |
| ➤ Most common type of hypospadias | Glandular type (urethra opens on the undersurface of the glans) |
| ➤ Hermaphrodite | Person who is both a male and a female at the same time |
| ➤ True hermaphrodite | Individual with both testes and ovaries or ovotestes |
| ➤ Extreme form of male pseudohermaphroditism | Complete androgen insensitivity syndrome |
| ➤ Pseudohermaphrodite | Individual with gonads of one sex and external genitalia of other sex |
| ➤ Commonest site of ectopic testis | Superficial fascia of anterior abdominal wall (interstitial type) |
| ➤ Canal of Nuck | Persistence of processus vaginalis in female |

CLINICAL PROBLEMS

1. There is enormous variation in sperm counts between individual men, whether fertile or infertile. Give the embryological basis.
2. The **antenatal sex determination** during third and fourth months of gestation by ultrasonography is often misleading (i.e., gives false results). Give the embryological basis.
3. During physical examination of a male infant the pediatrician noted presence of urethral orifice on the ventral aspect of shaft of the penis. He also noted that the glans was curved ventrally. What is the most likely diagnosis? Give its embryological basis.
4. A mother brought her one-and-a-half-year-old boy to OPD and complained to the doctor on duty that few days back she noticed a lump in groin of her child. After a thorough physical examination the boy was diagnosed as a case of **congenital indirect inguinal hernia**.
Give the embryological basis of congenital indirect inguinal hernia and mention whether or not congenital indirect inguinal hernia can occur in females.
5. A 19-year-old girl was disqualified to take part in the Olympic games because her buccal smear test was sex chromatin negative. On the basis of your embryological knowledge tell whether she is male or female and provide the genetic basis for her failing to pass the sex chromatin test.

CLINICAL PROBLEM SOLUTIONS

1. The supporting **Sertoli cells** of testis develop from the surface epithelium of early gonad. They proliferate throughout antenatal development and may do so up to childhood. Then they stop proliferating. Once they stop proliferating they cannot be activated. Each Sertoli cell can only support a fixed number of germ cells during their development into spermatozoa, i.e., number of Sertoli cells determines the maximum limit of sperm output.

Therefore, the variation in the Sertoli cell number is probably the most important factor in accounting for the enormous variation in sperm counts between individual men.
2. The genital tubercle elongates extensively in males to form penis, whereas it does not elongate much in females and forms clitoris.

During early stages of development (3–4 months of gestation), the rate of growth of genital tubercle is same in both males and females, and often larger in females than that in males. Therefore, using length of the genital tubercle as a criterion (as monitored by an ultrasound) for sex determination is often misleading.
3. The most likely diagnosis is **hypospadias**. The hypospadias is a clinical condition in which the urethral orifice is located on the ventral aspect of the penis instead of the tip of the glans penis. For details see Clinical Correlation on page 257.
4. The **indirect inguinal hernia** is herniation of a loop of intestine into the inguinal canal through deep inguinal ring. The embryological basis of indirect inguinal hernia is persistence of the processus vaginalis (for details see page 261).

Since the **processus vaginalis** also forms in females, the persistent processus vaginalis in female is called the **canal of Nuck**, into which abdominal contents may herniate. Hence congenital inguinal hernia can also occur in females; although it is rare as compared with males.
5. Phenotypically this girl is entirely female but genetically she is male. Such an individual is an example of extreme form of **male pseudohermaphroditism**. This girl had 46XY chromosome complement; hence cells of her buccal smear are sex chromatin negative. For this reason she could not pass her **sex chromatin** test.

Overview

Study of development of the nervous system helps to understand its complex organization and occurrence of various congenital anomalies.

Whole of the nervous system is derived from ectoderm except its blood vessels and some neuroglial elements.

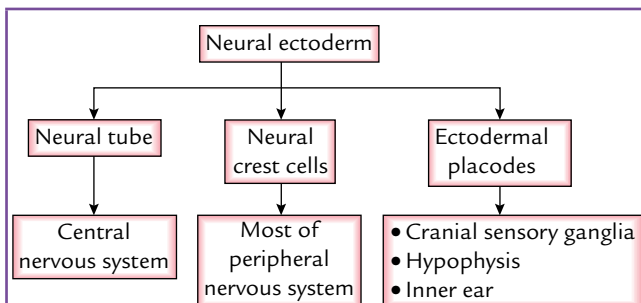
The specific cell population of early ectoderm, which gives rise to entire nervous system and special sense organs, is termed **neural ectoderm**. The neural ectoderm later differentiates into three structures: neural tube, neural crest cells, and ectodermal placodes. **The neural tube gives rise to the central nervous system (CNS)**, the neural crest cells form nearly entire peripheral nervous system, and ectodermal placodes contribute to cranial sensory ganglia, hypophysis, and inner ear (Flowchart 22.1).

Formation of Neural Tube (Fig. 22.1)

In early embryonic disc, at about 16th day of embryonic life, the ectoderm overlying the newly formed notochord thickens in midline forming **neural plate**. Initially the neural plate is flat and slipper shaped with narrow end toward the primitive node. The somatic mesoderm develops on either side of the notochord. The margins of neural plate are elevated as **neural folds**. As a result center of the plate sinks, creating **neural groove**. The neural folds gradually move together toward the midline and finally fuse to form a cylindrical **neural tube** that loses its connection with

the surface ectoderm. The process of neural tube formation is termed **neurulation**.

The fusion of neural folds begins in the middle (region of fourth somite on 20th day of embryonic development) and it simultaneously proceeds in the cephalic and caudal directions. The fusion at the cranial and caudal ends of neural tube is somewhat delayed, forming small openings called **anterior** and **posterior neuropores**. The neural tube and overlying amniotic cavity, therefore, remain temporarily in open communication with each other through these pores. The anterior neuropore closes earlier, in the middle of the fourth week at 18–20 somite stage (i.e., on 25th day), and the posterior



Flowchart. 22.1 Genesis of nervous system and special sense organs.

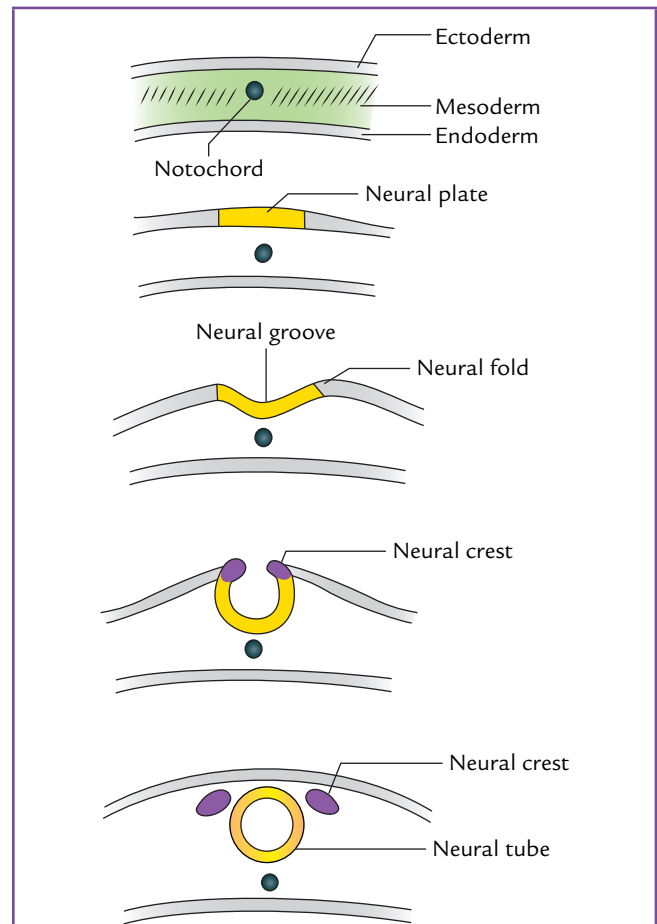


Fig. 22.1 Formation of neural tube and neural crest.

neuropore closes later at the end of fourth week at about 25 somite stage. By the time the neural tube is completely closed, it is divided into an enlarged cranial part and an elongated caudal part, which later on gives rise to **brain** and **spinal cord**, respectively.

Formation of Neural Crest Cells

As the neural folds come together and fuse, cells at the tips of neural folds break away from the neuroectoderm to form the neural crest cells. The surface ectoderm of one side becomes continuous with the surface ectoderm of opposite side over the neural tube.

Thus cells at the tips of neural folds (**neural crest cells**) do not participate in the neural tube formation. The neural crest cells at first remain in the midline between the dorsal surface of the neural tube and the surface ectoderm, and then forms two-cell clusters dorso-laterally, one on either side of the neural tube.

The neural crest cells differentiate to form cells of dorsal root ganglia, sensory ganglia of cranial nerves, autonomic ganglia, adrenal medulla, chromaffin tissue, melanocytes, and Schwann cells (Fig. 22.2).

Formation of Ectodermal Placodes

Prior to the neural tube closure, the neural fold contains two types of cell populations: neural crest cells and neuroepithelial cells. During *neurulation*, the neural crest cells are detached and neuroepithelial cells get incorporated into the surface ectoderm. These areas of neuroepithelium within the surface ectoderm are termed **ectodermal placodes**.

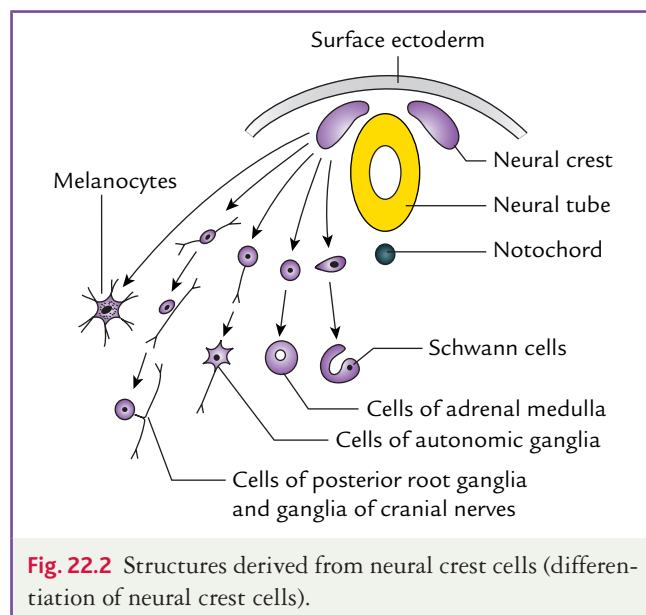


Fig. 22.2 Structures derived from neural crest cells (differentiation of neural crest cells).

Clinical Correlation

1. **Anencephaly (craniorachischisis):** Failure of the cephalic part of the neural tube to close and associated defective development of the vault of the skull produces a congenital anomaly called **anencephaly**.

Characteristic features

- Vault of skull is absent.
- Brain is represented by a mass of degenerated tissue exposed to the surface.
- Cord is open in the cervical region.
- Appearance of child is characteristic with prominent eyes bulging forward, and chin continuous with chest due to absence of neck.

2. **Rachischisis (a severe form of spina bifida):** An incomplete closure of caudal neuropore and defective development of associated vertebral arches cause a congenital anomaly called **rachischisis**.

Characteristic features

- Failure of dorsal portions of the vertebral arches to fuse with each other.
- Usually localized in the lumbosacral region.
- Neural tissue is widely exposed to the surface.
- Occasionally the neural tissue shows considerable overgrowth, usually, however, the excess tissue becomes necrotic shortly before or after the birth.

N.B. Anencephaly and rachischisis are common and severe forms of congenital anomalies of CNS due to defective development of the neural tube.

Development of Spinal Cord

The spinal cord develops from caudal elongated part of the neural tube.

Histogenesis of Neural Tube

The neural tube increases in thickness due to repeated mitosis of its epithelial lining. By the middle of fifth week of embryonic development, the transverse section of recently closed neural tube (**according to classical theory**) reveals three distinct layers or zones. From within outward these are (a) matrix (ependymal) zone, (b) mantle zone, and (c) marginal zone (Fig. 22.3).

Matrix (ependymal) zone is thick and lines the enclosed cavity (neurocele). Its numerous cells undergoing mitosis produce neuroblasts and spongioblasts; the former develop into neurons and latter into neuroglial cells.

The neuroblasts migrate to the adjacent **mantle zone**, the future spinal gray matter and their axons enter the external **marginal zone**, the future white matter.

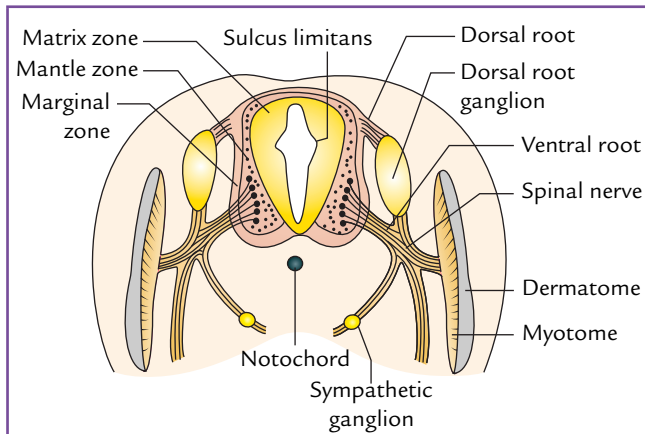


Fig. 22.3 Differentiation of the neural tube into three distinct layers, zones, and associated structures.

Some central processes of dorsal root ganglia ascend in the marginal zone while others synapse with neurons in the mantle zone.

Once histogenesis is complete, the remaining matrix cells differentiate into ependymal cells lining the central canal.

Recently, on the basis of microspectrophotometric, radioautographic, and electron microscopic observation the concept of classical theory is changed.

Now according to current theory wall of recently closed neural tube consists of only one cell type—the *pluripotent neuroepithelial cells*. These cells extend over the entire thickness of the wall and form a thick pseudostratified neuroepithelium. This zonal appearance merely reflects different phases of their proliferative cycle—the sequence being termed *interkinetic migration*.

As development proceeds, these neuroepithelial cells give rise to another cell type having round nuclei with dark staining nucleoli called nerve cells or *neuroblasts*. The neuroblasts form a zone that surrounds the neuroepithelial layer. It is known as mantle zone. Mantle zone later forms the gray matter of the spinal cord. The outermost layer of the spinal cord contains fibers emerging from neuroblasts in the mantle layer and is known as the marginal layer. Myelination of nerve fiber gives this layer a white appearance and is referred as the white matter of the spinal cord.

Development of Functional Columns

On cross section, the cavity of neural tube appears like a vertical slit. Due to formation of vertical slit, the dorsal and ventral walls of neural tube remain thin and are called roof and floor plates, respectively. The lateral walls of neural tube get thickened. On each side, the lateral wall of neural tube is demarcated into dorsal and

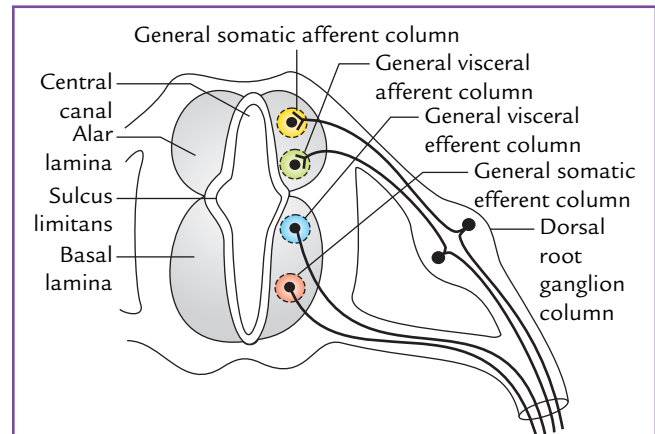


Fig. 22.4 Transverse section of the developing spinal cord showing four longitudinal cell columns.

ventral regions by an inner longitudinal sulcus called **sulcus limitans**.

The cells of dorsal region or **alar lamina** are functionally afferent/sensory while those of **basal lamina** are efferent/motor. The axons of cells of basal lamina leave the cord as ventral roots and join with peripheral processes of dorsal root ganglia to form **spinal nerves** (Fig. 22.4).

The cells of alar and basal laminae are arranged into longitudinal columns. Each lamina reveals two columns.

The **two afferent columns of alar lamina** receive axons from dorsal root ganglia.

1. **General somatic afferent column:** It extends throughout the spinal cord and receives impulses from superficial (cutaneous) and deep (proprioceptive) receptors.
2. **General visceral afferent column:** It is confined to thoracolumbar and sacral regions only and receives impulses from viscera and blood vessels

The **two efferent columns of basal lamina** give rise to motor fibers.

1. **General visceral efferent column:** It is confined to thoracolumbar and sacral regions only and provides preganglionic fibers (synapsing in ganglia) to viscera, glands, and blood vessels.
2. **General somatic efferent column:** It extends throughout the spinal cord and provides fibers that innervate skeletal muscles.

N.B. The four cell columns in the spinal cord are termed 'general' because three additional 'special' columns exist in brainstem.

Positional Changes of the Spinal Cord (Fig. 22.5)

At week 8 lengths of spinal cord and vertebral column are equal. The spinal cord extends along entire length

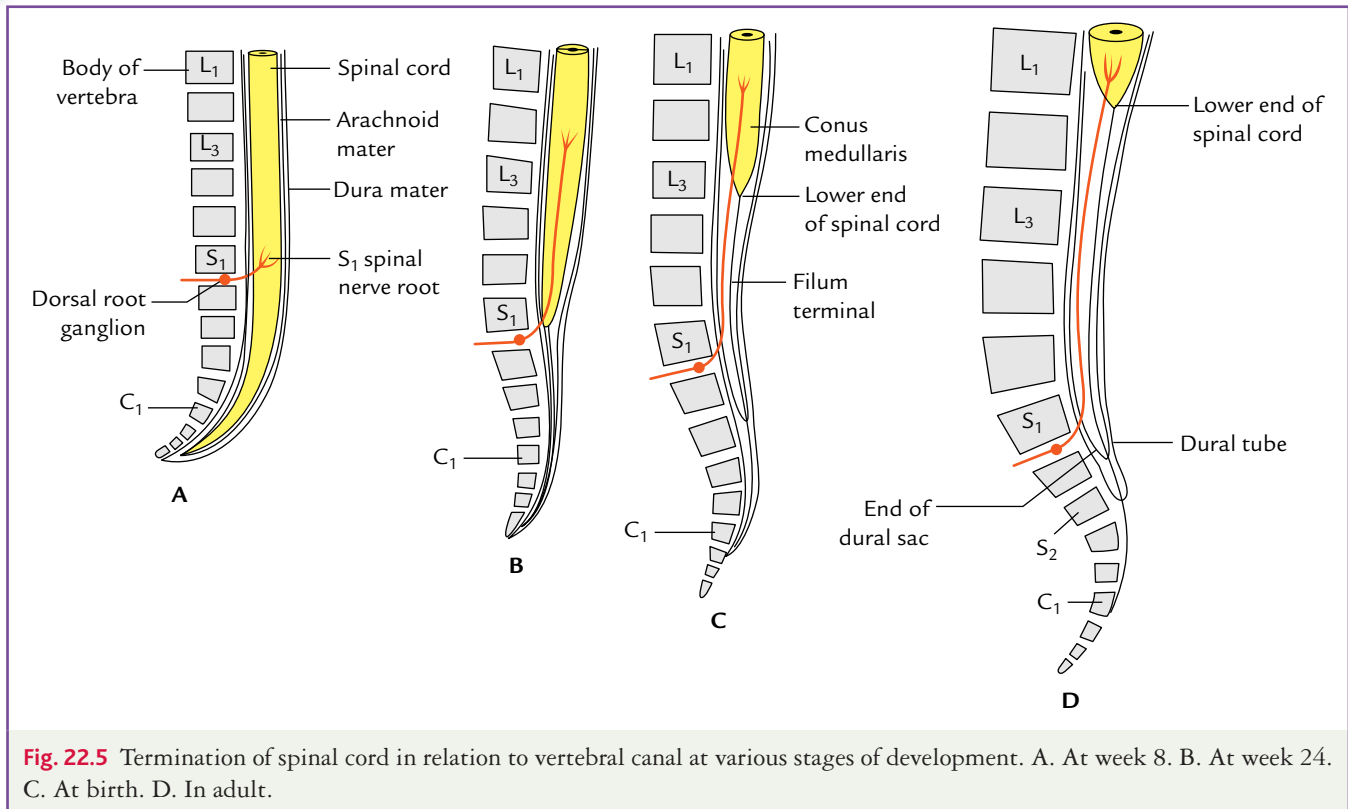


Fig. 22.5 Termination of spinal cord in relation to vertebral canal at various stages of development. A. At week 8. B. At week 24. C. At birth. D. In adult.

of vertebral canal and the spinal nerves exit intervertebral foramina at the level of their origin.

Due to differential growth of the cord and vertebral column, the intervertebral foramina do not remain at the level of the spinal nerves. In order to exit from corresponding intervertebral foramina due to recession of the spinal cord, the spinal nerves are forced to go down in oblique direction.

At week 24, the lower end of spinal cord ends at S1 vertebrae.

- **At birth**, the lower end of spinal cord ends at the level of L3 vertebra.
- **In adults**, due to further recession of the cord, the lower end of spinal cord ends at the lower border of L1 vertebra.

N.B. The obliquity of spinal nerves is minimum in cervical region and maximum in sacral and coccygeal region.

- The nerve roots (viz., lumbar, sacral, and coccygeal) that descend below the lower end of spinal cord (the **conus medullaris**) surround thin thread-like prolongation of pia mater from tip of conus medullaris (the **filum terminalis**) and form **cauda equina**.

Development of Brain

The brain develops from enlarged cranial part of the neural tube. At about end of fourth week, enlarged cephalic part shows three distinct dilatations called **primary brain vesicles** (Fig. 22.6). Craniocaudally,

these are (a) prosencephalon (forebrain), (b) mesencephalon (midbrain), and (c) rhombencephalon (hindbrain). Their cavities form ventricular system of adult brain. During fifth week both prosencephalon and rhombencephalon subdivide into two vesicles, thus producing five **secondary brain vesicles**.

The **prosencephalon** gives a rostral telencephalon and caudal diencephalon (interbrain). The **telencephalon** develops lateral diverticula by evagination, which enlarge, overgrow and cover the caudal diencephalon to form cerebral hemispheres. The **diencephalon** thus becomes hidden in the lower parts of the cerebral hemispheres and forms thalamus, hypothalamus, epithalamus, etc.

The **mesencephalon** gives rise to midbrain. It does not show much changes in early part of development except that its cavity gets progressively narrowed to form **cerebral aqueduct**.

The **rhombencephalon** divides into rostral **metencephalon**, which eventually develops into pons and cerebellum, and caudal **myelencephalon**, which gives rise to medulla oblongata.

The adult derivatives of brain vesicles are summarized in Table 22.1.

Flexures of the Brain

Primitive brain presents three flexures:

1. **Pontine flexure** at the middle of rhombencephalon.
2. **Cervical flexure** at the junction of rhombencephalon and spinal cord.

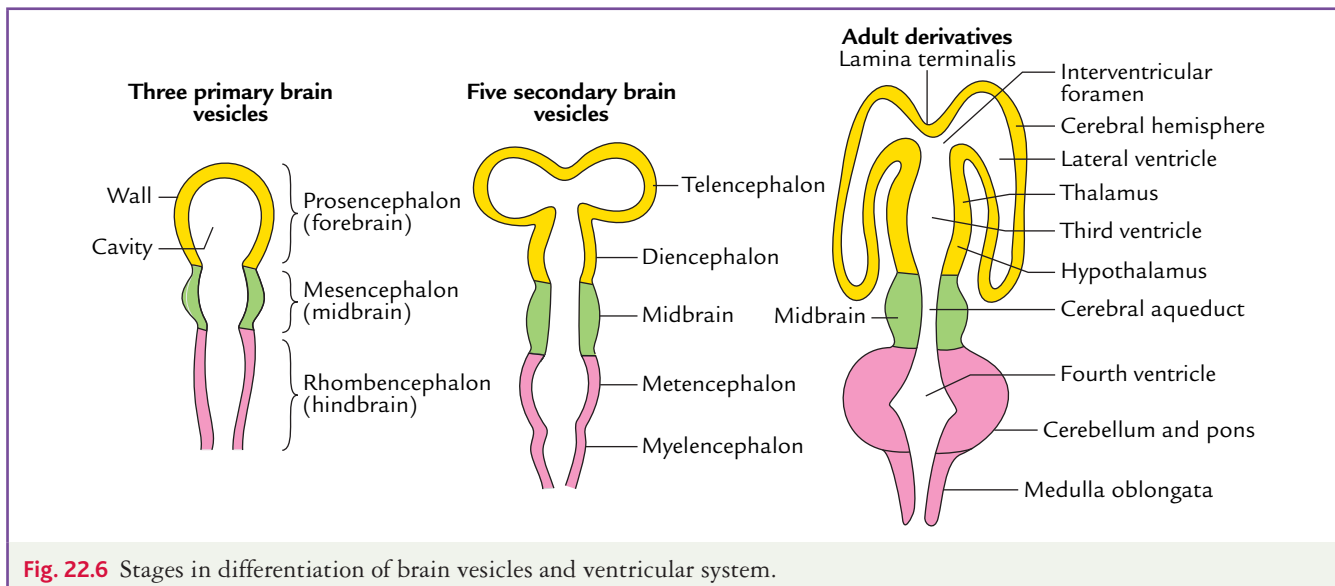


Fig. 22.6 Stages in differentiation of brain vesicles and ventricular system.

Table 22.1 Adult derivatives of brain vesicles

Primary brain vesicles (3 in number)	Secondary brain vesicles (5 in number)	Parts of adult brain	Parts of ventricular system
Prosencephalon (forebrain)	<ul style="list-style-type: none"> • Telencephalon • Diencephalon 	Cerebral hemispheres – Thalamus – Metathalamus – Hypothalamus – Subthalamus – Epithalamus	Lateral ventricles Third ventricle
Mesencephalon (midbrain)	Mesencephalon	Midbrain	Cerebral aqueduct
Rhombencephalon (hindbrain)	<ul style="list-style-type: none"> • Metencephalon • Myelencephalon 	– Pons – Cerebellum – Medulla oblongata	Fourth ventricle

3. Cephalic (*mesencephalic*) flexure in the region of midbrain.

The cephalic and cervical flexures are concave ventrally, whereas the pontine flexure exhibits a ventral convexity (Fig. 22.7).

The cervical flexure makes a 90° bend between hind-brain and spinal cord, causing the brain to be oriented almost at 90° to the spinal cord.

The brain assumes its configuration as a result of differential growth of its vesicles and flexures.

Pontine Flexure

Hindbrain is folded at its middle so that it forms an acute angle ventrally. This changes shape of the tube dramatically. The cavity becomes a diamond-shaped space called **fourth ventricle**, which is widest at line of folding (junction of two parts of the hindbrain—pons and medulla oblongata) and tapers superiorly to narrow canal of the midbrain, the aqueduct of Sylvius and inferiorly to the central canal in the lower part of medulla

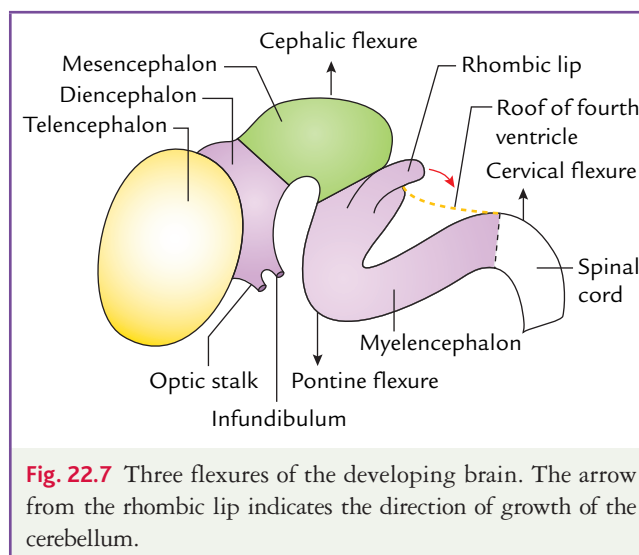


Fig. 22.7 Three flexures of the developing brain. The arrow from the rhombic lip indicates the direction of growth of the cerebellum.

oblongata (Fig. 22.8). The thin roof is pulled out to cover the space posteriorly, and the line of folding extends far laterally as roof of the lateral recesses of the fourth ventricle. At tips of these recesses and inferior

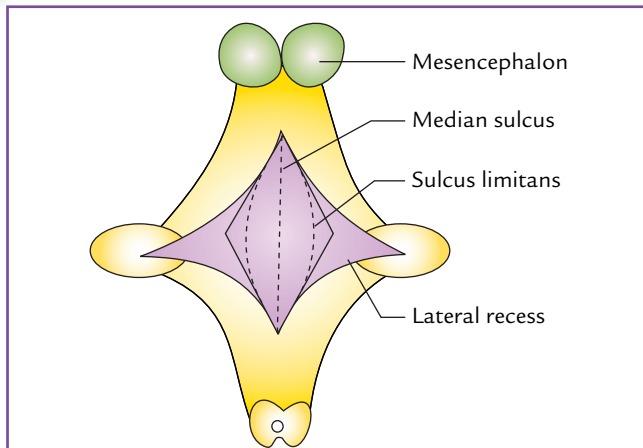


Fig. 22.8 Posterior view of developing rhombencephalon showing role of pontine flexure in the formation of fourth ventricle. Note, opposite to line of pontine flexure, the neural tube is flattened out. As a result slit-like cavity of rhombencephalon becomes diamond shaped.

angle of the ventricle, the thin roof breaks down forming apertures (lateral foramina of Luschka and median foramen of Magendie) through which the cavity of neural tube communicates with the surrounding subarachnoid space.

N.B. To understand the formation of rhomboid-shaped cavity of fourth ventricle due to pontine flexure, take a 4-inch-long piece of a rubber tube, make a vertical slit, and then bend it. This converts linear slit into a rhomboid-shaped aperture.

I have a pleasant memory of my teacher Prof. A. Halim, the most popular teacher of anatomy of his time, of bringing a rubber tube in the pocket of his white apron to demonstrate it to students.

The flattening of the hindbrain, which results from folding, displaces alar laminae so that they lie lateral to basal laminae (buckling effect). Thus sensory nuclei, which arise from the alar laminae, are lateral to motor nuclei, which arise from the basal laminae. *For this reason sensory cranial nerves are attached laterally and motor cranial nerves medially to brainstem.*

The part of hindbrain caudal to the pontine flexure is called *myelencephalon* (the future medulla oblongata) and rostral part from which pons and cerebellum develop is called *metencephalon*.

Cervical Flexure

Cervical flexure is convex dorsally and appears at the junction of hindbrain and spinal cord, making a right angled bend between them.

Cephalic Flexure

Cephalic flexure is convex dorsally and appears at the midbrain level.

N.B. The closed rostral end of the neural tube persists as a thin *lamina terminalis*.

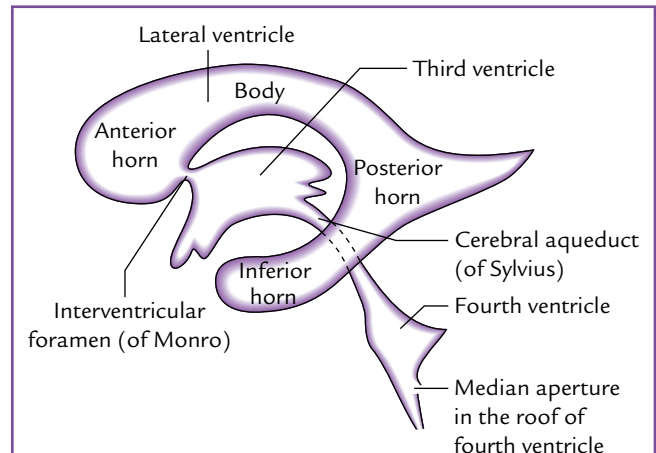


Fig. 22.9 Ventricular system of brain.

Development of Ventricular System (Fig. 22.9)

The cavities of brain vesicles form the ventricular system of adult brain.

- The hindbrain cavity becomes the *fourth ventricle*.
- The narrowed mesencephalic cavity becomes the *cerebral aqueduct (aqueduct of Sylvius)*.
- The diencephalic cavity becomes the *third ventricle*.
- The twin telencephalic cavities become *lateral ventricles*.

Thus, the brain contains four ventricles: **two lateral ventricles**, a **third ventricle**, and a **fourth ventricle**. The **two lateral ventricles** communicate with the third ventricle via **interventricular foramina (of Monro)**. The third ventricle communicates with the fourth ventricle through the **cerebral aqueduct**. The fourth ventricle is continuous below with central canal of the spinal cord, which presents a small dilatation at inferior end called **terminal ventricle**.

Cerebrospinal fluid (CSF) is formed in the ventricles, mainly in lateral ventricles by choroid plexuses. The CSF leaves the ventricular system through apertures in the roof of ventricle (viz., foramen of Magendie and foramina of Luschka) into subarachnoid spaces around the brain and spinal cord.

Clinical Correlation

1. **Hydrocephalus (Fig. 22.10):** It is a clinical condition characterized by dilatation of ventricles due to excess accumulation of CSF within them. It occurs either due to overproduction of CSF or obstruction to its circulation. (For details see *Textbook of Clinical Neuroanatomy* by Dr Vishram Singh.)
2. **Dandy-Walker syndrome:** It occurs due to atresia and blockage of apertures in the roof of fourth ventricle (e.g., foramen of Magendie and foramina of Luschka). This syndrome consists of dilatation of fourth ventricle, agenesis of cerebellar vermis, occipital meningocele, and often agenesis of splenium of corpus callosum.

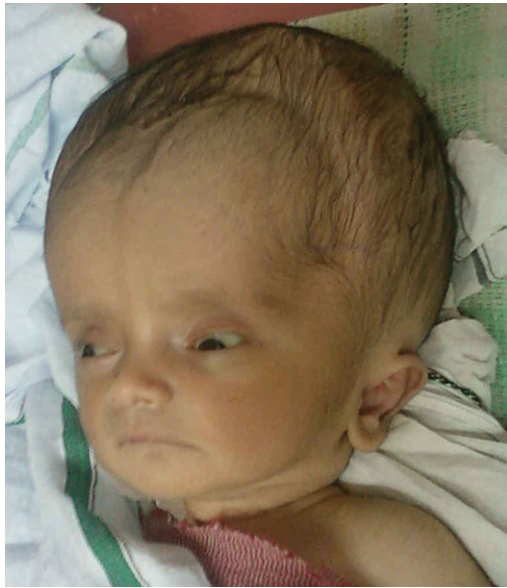

Fig. 22.10 Hydrocephalus. Note the disproportionately large size of head and typical setting-sun appearance of the eyes.

N.B. The enlargement of brain in Dandy–Walker syndrome is limited to the posterior cranial fossa.

Further development of hindbrain, midbrain, and fore-brain is discussed below in brief.

Hindbrain (Rhombencephalon)

The caudal part of myelencephalon has a central canal and forms the closed part of **medulla oblongata**. Rostrally the central canal expands as the cavity of the fourth ventricle, and thus the rostral part of myelencephalon forms the open part of the medulla oblongata.

The floor of fourth ventricle is derived from myelencephalon (medulla) and metencephalon (pons). On either side of midline, the floor consists of the basal and alar laminae, which are separated from each other by a longitudinal sulcus called **sulcus limitans**. The basal and alar laminae, similar to that of spinal cord, contain motor and sensory nuclei, respectively. These nuclei are arranged into longitudinal columns. In spinal cord as discussed earlier, each lamina contains two columns, somatic and visceral, but **in the brainstem to supply the derivatives of the branchial arches that develop around this region, a special branchial column appears between somatic and visceral columns of each lamina**. In addition, a special somatic column appears in the most lateral part of the alar lamina to receive impulses of special sensations of hearing and balance. Thus in brainstem, the basal lamina contains three columns and alar lamina contains four columns as under:

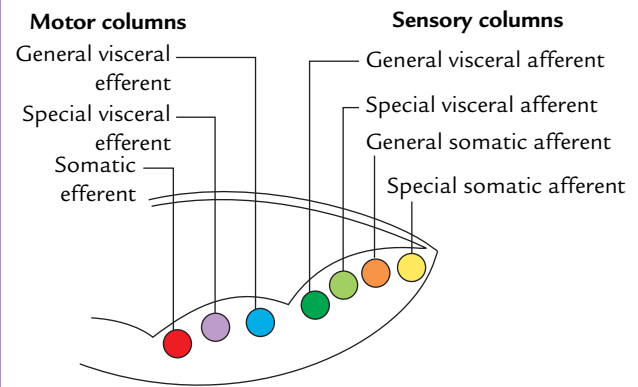


Fig. 22.11 Functional columns of gray matter in brainstem.

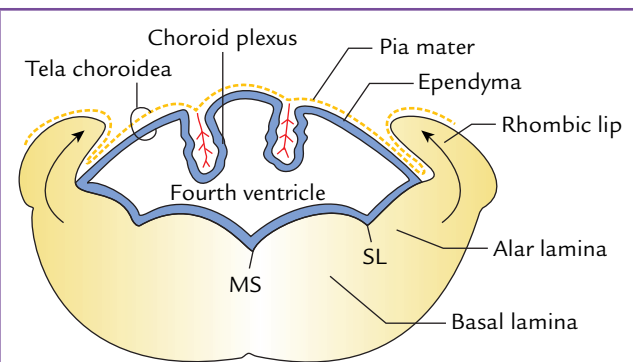


Fig. 22.12 Developing fourth ventricle and cerebellum. Note: (a) Vascular pia mater invaginates ependyma to form choroid plexus, (b) alar lamina lies lateral to basal lamina, and (c) rhombic lips derived from alar laminae grow together to form cerebellum dorsal to the roof of fourth ventricle. MS = median sulcus, SL = sulcus limitans.

1. Functional column with basal lamina of brainstem
 - (a) Somatic efferent
 - (b) Special visceral efferent
 - (c) General visceral efferent.
2. Functional columns in the alar lamina of brainstem
 - (a) General visceral afferent
 - (b) Special visceral afferent
 - (c) General somatic afferent
 - (d) Special somatic afferent.

Note: All motor nuclei of the brainstem are derived from functional columns of its basal plate, and all the sensory nuclei from the functional columns of the alar plate (Fig. 22.11).

The stretched roof plate of rhombencephalic vesicle forms the roof of fourth ventricle. The roof consists of a single layer of ependymal cells covered by a vascular mesenchyme—the pia mater. Pia mater along with covering layer of ependymal cells forms **tela choroidea**. Owing to active proliferation of vascular mesenchyme, the tuft of capillaries of blood vessels invaginates into the ventricular cavity. These sac-like invaginations consisting of tela choroidea and tuft of capillaries form **choroid plexus** (Fig. 22.12).

Dorsolateral parts of the alar laminae of metencephalon extend medially and dorsally to form **rhombic lips**. These meet and fuse in the midline over the roof of the fourth ventricle and then grow dorsally to form **cerebellum**.

The marginal layer of basal plates of metencephalon expands considerably to serve as a bridge for nerve fibers connecting cerebral cortex and cerebellar cortex (cortico-ponto-cerebellar pathways). Since this portion of metencephalon serves as a bridge, it is known as **pons** (pons=bridge).

Midbrain (Mesencephalon)

Morphologically the midbrain is the most primitive of the brain vesicles. It generally retains a cylindrical form and its narrowed cavity forms the cerebral aqueduct, which is continuous below with the fourth ventricle and above with the third ventricle.

- Anterior to the cerebral aqueduct, the basal laminae give rise to **tegmentum** and **substantia nigra**. The marginal layer of each basal lamina enlarges and forms **crus cerebri**. These crura serve as pathways for nerve fibers descending from the cerebral cortex to the lower centers in pons, medulla, and spinal cord.
- The cells of alar laminae invade the roof plate to form bilateral longitudinal elevations separated by a shallow midline groove. With further development, each elevation is subdivided by a transverse groove into upper and lower parts called **superior and inferior colliculi**, respectively. Thus, four colliculi (also called corpora quadrigemina) develop into the roof plate dorsal to the aqueduct of Sylvius and form **tectum**.

Forebrain (Prosencephalon)

1. The diencephalon develops from the median portion of the prosencephalon. Its cavity is called the **third ventricle**. The primitive diencephalon consists of two thick lateral walls, a thin roof, and floor plates.

Each lateral wall presents a sulcus, the **hypothalamic sulcus**, which appears to be rostral continuation of **sulcus limitans**. The hypothalamic sulcus divides lateral wall into dorsal and ventral regions. The dorsal region develops into **thalamus**. The ventral region encroaches on the floor plate and forms **hypothalamus**.

A downgrowth from the floor of anterior hypothalamus, the *neurohypophysis*, joins an upgrowth from the stomodeum, the *adenohypophysis*, to form **hypophysis cerebri** (pituitary gland).

The **epithalamus** comprising *pineal gland* and *habenular nuclei* develops posteriorly in the roof plate. The **pineal gland** grows posteriorly from the roof plate at its junction with the midbrain, and lies on the dorsal surface of midbrain between the two superior colliculi.

2. The telencephalon consists of a median part and two lateral diverticula or cerebral vesicles. The median part forms a small anterior part of the third ventricle, and the lamina terminalis, which limits the ventricle rostrally.

The lamina terminalis represents the cephalic end of the primitive neural tube and corresponds with the site of closure of anterior neuropore.

The lateral diverticula or cerebral vesicles represent rudiments of cerebral hemispheres. The cavities of hemispheres, the **lateral ventricles**, communicate with the cavity of diencephalon, the third ventricle, through the interventricular foramina.

The developing cerebral hemisphere enlarges forward, upward, and backward in that order. As the vesicle grows backward it overlaps successively diencephalon, mesencephalon, and cerebellar rudiments. The lowest parts of medial walls of hemispheres in the region where they are attached to the roof of diencephalon remain very thin due to disproportionate growth of various parts of the hemispheres.

Through this thin wall, the choroid plexus of third ventricle protrudes laterally into lateral ventricle along a line known as **choroid fissure**.

Immediately above the choroid fissure, the medial wall of the hemisphere thickens to form **hippocampus**. With subsequent massive expansion of the cerebral

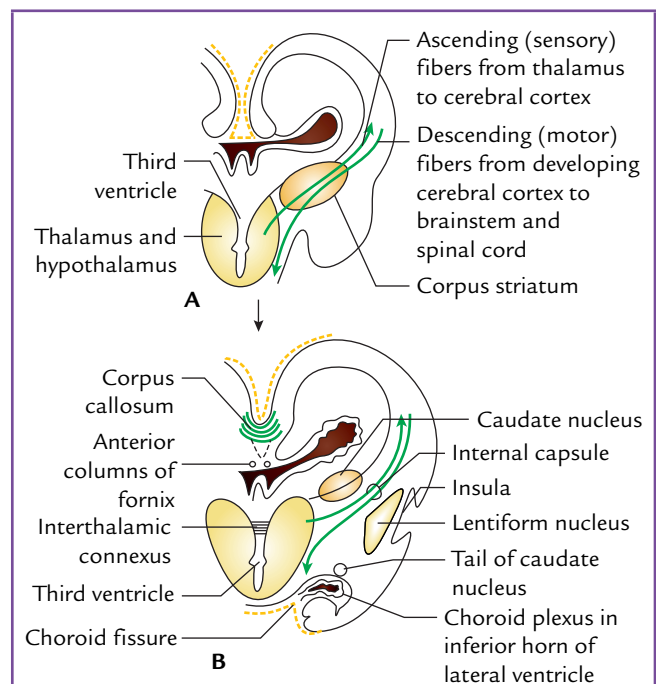


Fig. 22.13 Coronal sections through the developing forebrain showing development of internal capsule and establishment of corpus striatum. Note the ascending and descending fibers traversing through corpus striatum (A), and the division of corpus striatum into caudate and lentiform nuclei, and formation of internal capsule (B).

hemispheres (neocortex), the hippocampus is displaced posteroinferiorly into the lateral ventricle; the **fornix** is drawn out as an efferent tract on its medial aspect. The choroid fissure also becomes curved, interposed between the fornix and diencephalon.

Corpus striatum develops bilaterally in the floor of telencephalon adjacent to thalami. Primitively these areas of gray matter (corpus striatum) are **sensory–motor control centers**. Subsequent to massive development of neocortex, a major pathway must develop for descending fibers from the cerebral cortex and ascending fibers from the thalamus to the cerebral cortex; the only possible route is through this region. Hence, these fibers that form **internal capsule** on each side divide the corpus striatum into two parts: (a) a dorsomedial portion, the **caudate nucleus**, and (b) a ventrolateral portion, the **lentiform nucleus** (Fig. 22.13A, B).

N.B. The *cerebral hemisphere* starts growing/expanding in the region of interventricular foramen. It grows rapidly forward (forming

frontal lobe), dorsally (forming parietal lobe), posteriorly (forming occipital lobe), and then anteroinferiorly (forming temporal lobe). This curved pattern of expansion of cerebral hemisphere from interventricular foramen around the diencephalon causes structures related to it (*viz.*, lateral ventricle, corpus callosum, fornix, choroid fissure, and caudate nucleus) to acquire C-shaped forms.

The **three meninges/membranes** (i.e., *pia mater*, *arachnoid mater*, and *dura mater*) surrounding the brain and spinal cord are derived from mesenchyme surrounding the neural tube. However, according to some workers, the *pia mater* and the *arachnoid mater* (*leptomeninges*) are derived from neural crest and do not from mesenchyme.

Clinical Correlation

The mitotic activity within the neural tissue is completed during prenatal development. Thus, a person is born with all neurons he was destined to have. However the nervous tissue continues to grow and specializes even after birth, particularly in initial several years of postnatal life.

GOLDEN FACTS TO REMEMBER

- Most common serious birth defect seen in stillborn infants Anencephaly
- Most fatal brain tumor Glioblastoma multiforme
- Commonest tumor of spinal cord Schwannoma
- Most common site of intracranial tumors Posterior cranial fossa
- Most common congenital anomaly of brain involving cerebellum Arnold–Chiari malformation
- Most common tumor of posterior cranial fossa Medulloblastoma
- Most common brain tumor Glioma
- Most severe congenital anomaly of brain in fetal alcohol syndrome Holoprosencephaly/arhinencephaly (telencephalon with single ventricular cavity)
- Most common cause of congenital hydrocephalus Congenital stenosis of aqueduct of Sylvius (cerebral aqueduct)
- Hortegea cells Microglia

CLINICAL PROBLEMS

1. A newborn baby has no cranial vault, and its brain substance is exposed to the surface as an irregular, degenerated mass. Name the congenital anomaly and mention whether a physician can detect it prenatally (i.e., before birth).
2. Why is anencephalic fetus associated with **hydramnios**?
3. What do you understand by **meningocele**, **meningoencephalocele**, and **meningohydroencephalocele**? Give their embryological basis.
4. What do you understand by a clinical condition called **spina bifida** and its several forms? Give their embryological basis.
5. What is **Arnold–Chiari malformation**. Discuss its clinical features.

CLINICAL PROBLEM SOLUTIONS

1. This is a typical case of **anencephaly** where brain tissue and associated vault of skull fail to develop due to failure of closure of anterior neuropore. A physician can detect this anomaly: (a) by ultrasonography in later part of pregnancy or (b) by detecting the α -fetoprotein level of amniotic fluid after transabdominal amniocentesis.
N.B. The level of α -fetoprotein is raised in anencephaly.
2. The amniotic cavity is normally filled with clear, watery fluid derived mainly from maternal blood and partly from amniotic cells, and amounts to about 300–1000 ml at 37th week of gestation.
 From beginning of the fifth month fetus swallows about 400 ml of fluid every day. The swallowed fluid is absorbed through gut and passes into maternal blood. In anencephalic baby the swallowing reflex does not develop due to defective development of brain, leading to excessive accumulation of amniotic fluid (1500–2000 ml). It is termed **hydramnios**.
3. These are congenital malformations of the nervous system which occur due to defective ossification of skull bones, particularly squamous part of the occipital bone.
 A gap in the skull caused by defective ossification makes meninges surrounding the brain to bulge out of the cranial cavity producing **meningocele**. If defect is large, a part of brain tissue may also herniate producing **meningoencephalocele**. If herniated part of the brain contains a part of ventricular cavity, it is termed **meningohydroencephalocele**.
4. The **spina bifida** is a congenital malformation produced due to failure of fusion of vertebral arches. Consequently vertebral canal (also called spinal canal) remains defective posteriorly. Depending upon herniation of structures present within the spinal canal through the defect, it is classified into following forms.
 - (a) **Spina bifida occulta**: No herniation of structures of spinal canal through the gap. A tuft of hair is often present over the skin at the site of defect.
 - (b) **Meningocele**: Meninges surrounding the spinal cord bulge out through the defect in the vertebral arches, forming a cystic swelling beneath the skin containing cerebrospinal fluid (CSF).
 - (c) **Meningomyelocele**: Spinal cord and spinal nerve roots also herniate along with the meninges if the defect is large.
 - (d) **Rachischisis**: The neural tissue is exposed to surface. It is, in fact, due to failure of fusion of caudal neuropore (see page 266).
5. The **Arnold–Chiari malformation** occurs when **medulla oblongata**, and inferior vermis and tonsils of cerebellum herniate through foramen magnum. Clinically it presents (a) hydrocephalus due to obstruction of CSF circulation, (b) spastic dyspnoea, (c) difficulty in swallowing, (d) laryngeal stridor, (e) diminished gag reflex, etc., due to compression of medulla oblongata and stretching of Xth, XIth, and XIIth cranial nerves.

Overview

1. The **pituitary gland/hypophysis cerebri** develops from two entirely different sources: (a) ectoderm, lining the roof of stomodeum and (b) neuroectoderm of hypothalamus.
2. The **pineal gland** develops as a diverticulum from the roof of the third ventricle.
3. The **adrenal gland** develops from two entirely different sources: (a) celomic epithelium and (b) neural crest.

Pituitary Gland (Hypophysis Cerebri)

The pituitary gland consists of two distinct parts: (a) **adenohypophysis (anterior pituitary)** and (b) **neurohypophysis (posterior pituitary)**. These two parts develop from two different sources as follows:

1. **Adenohypophysis** develops from an evagination of ectoderm lining the roof of primitive oral cavity

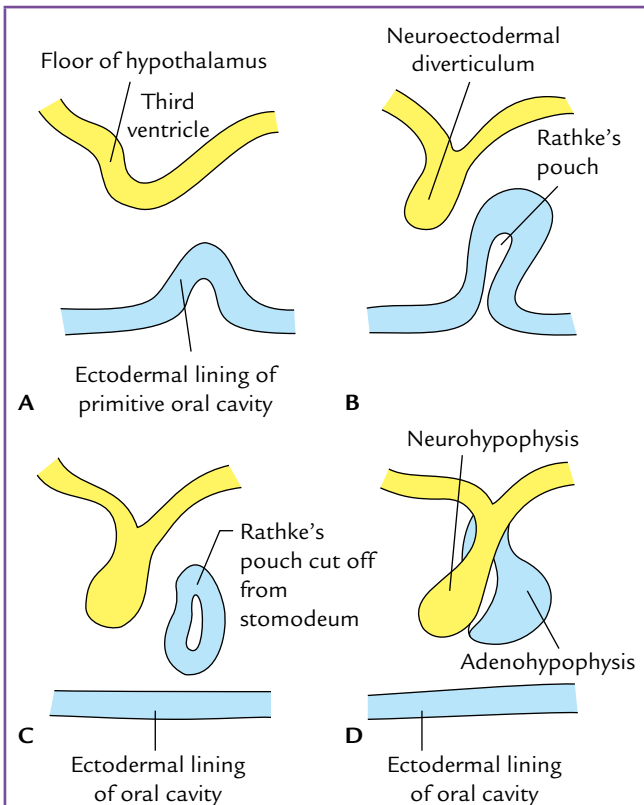


Fig. 23.1 Stages of development of the pituitary gland.

called **Rathke's pouch** (Fig. 23.1). The Rathke's pouch develops in the third week of intrauterine life (IUL). Later the Rathke's pouch is cut off from the primitive mouth or stomodeum.

- (a) Anterior wall of **Rathke's pouch** proliferates extensively to form **pars anterior (anterior lobe)** of the hypophysis cerebri.
 - (b) Posterior wall of **Rathke's pouch** remains thin and forms **pars intermedia**.
 - (c) Cleft of **Rathke's pouch** persists as hypophyseal cleft, which separates the two parts.
 - (d) A small extension of pars anterior grows upward along the infundibular stalk and eventually surrounds it to form **pars tuberalis**.
2. **Neurohypophysis** develops from an evagination of neuroectoderm of hypothalamus/floor of the third ventricle. The neurohypophysis differentiates into two parts: pars posterior (**posterior lobe/pars nervosa**) and **stalk of the hypophysis (infundibulum)**.

The neuroectodermal diverticulum from the floor of the third ventricle and the ectodermal pouch from the roof of stomodeum (two primordia of hypophysis cerebri) fuse with each other to form hypophysis cerebri.

The various components of definitive pituitary gland are shown in Fig. 23.2 and Flowchart 23.1.

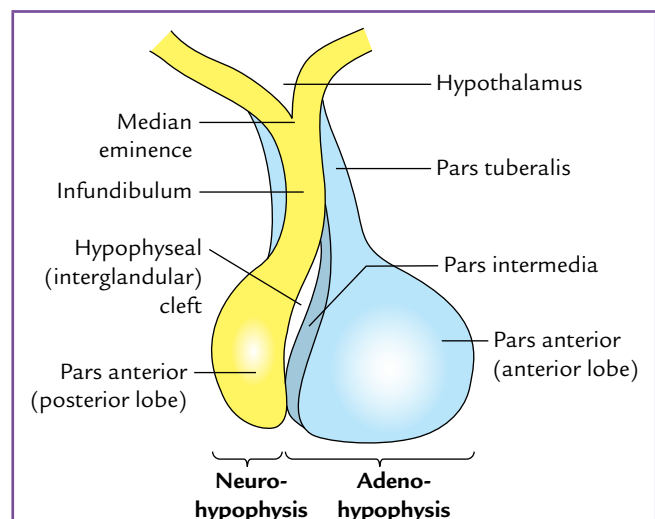
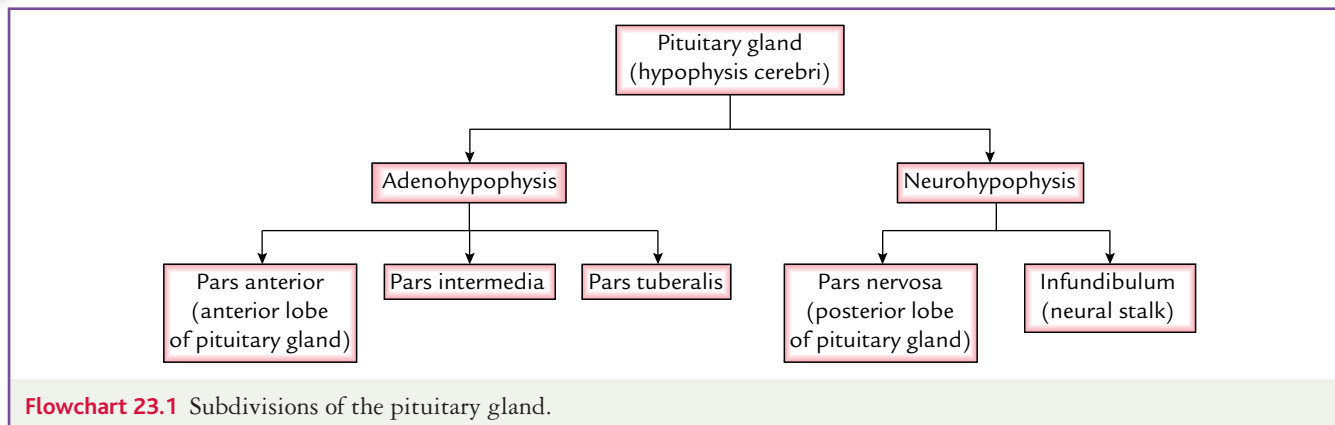


Fig. 23.2 Subdivisions of hypophysis cerebri.



Clinical Correlation

1. **Craniopharyngiomas:** The Rathke's pouch is detached from the primitive oral cavity to form adenohypophysis. With the formation of definitive oral cavity and pharynx, the original site of attachment of this pouch to the roof of primitive oral cavity (stomodeum) comes to lie in roof of nasopharynx. The tract of Rathke's pouch forms craniopharyngeal canal. Remnant of the craniopharyngeal canal sometimes gives rise to peculiar tumors called **craniopharyngiomas** that are seen in relation to sphenoid bone forming the roof of nasopharynx.

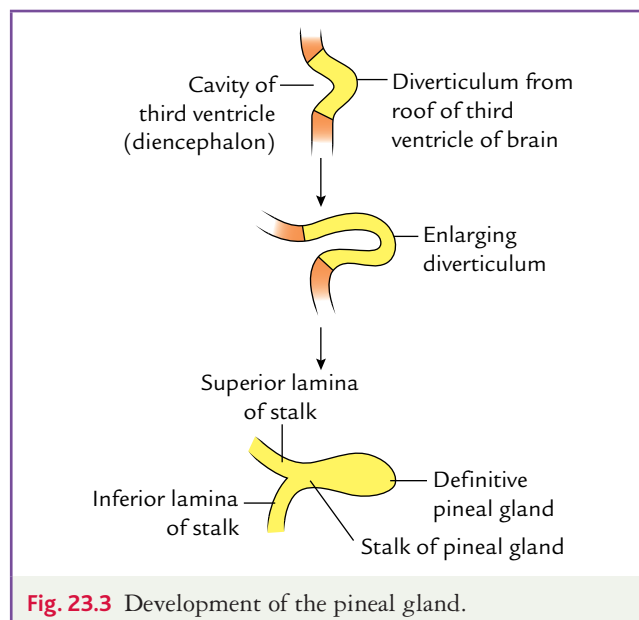
N.B. The craniopharyngeal canal runs between the roof of nasopharynx and floor of hypophyseal fossa. In the event of agenesis (nondevelopment) of the hypophysis, the **accessory hypophyseal tissue** may develop in the posterior wall of the pharynx.

2. **Pituitary adenomas:** They are of three types according to cells of their origin. (Note adenohypophysis mainly consists of three types of cells: chromophobes, acidophils, and basophils.)

- Chromophobe adenoma** usually affects women between 20 and 50 years of age; clinically it presents as headache and bitemporal hemianopia.
- Acidophil adenoma** gives rise to **gigantism** in children and **acromegaly** in adults.
- Basophil adenoma** gives rise to **Cushing's syndrome**. Females are most affected. There is accumulation of fat on the face, neck, and trunk.

Pineal Gland (Epiphysis Cerebri) (Fig. 23.3)

The **pineal gland** develops as a small diverticulum from the roof of the third ventricle. The cells of diverticulum proliferate to fill its lumen. As a result, the diverticulum becomes a solid structure—the **pineal gland**. The pineal gland is made up of modified neuroglial cells called **pinealocytes**. The pinealocytes secrete a hormone called **melatonin**.



The melatonin inhibits the secretion of gonadotrophin (GnRH) from the hypothalamus and thus has an inhibitory effect on the reproductive system. The pineal gland probably holds back the development of reproductive system until a suitable age. For details see *Textbook of Clinical Neuroanatomy, 2e* by Dr Vishram Singh.

Adrenal Gland

The adrenal gland consists of two parts: (a) a large outer part called **cortex** and (b) a small inner part called **medulla**.

The adrenal gland develops from two entirely different sources:

1. The **adrenal cortex** is mesodermal in origin and develops from *celomic epithelium*.

- The **adrenal medulla** is neuroectodermal in origin and develops from *neural crest*.

The adrenal gland begins to develop in the fifth week of IUL.

The details of development are shown in Fig. 23.4.

Development of Adrenal Cortex

The cells of dorsal wall of celomic epithelium (in the region of angle between developing gonad and root of dorsal mesentery) proliferate to form a ridge called **suprarenal ridge**.

The adrenal cortex develops from two episodes of mesodermal proliferation of suprarenal ridge. **First batch** of cells of suprarenal ridge consists of large acidophilic cells; they reach the site of development and surround the cells of the adrenal medulla to form **fetal cortex** of the adrenal gland.

Subsequently **second batch** of cells of suprarenal ridge consists of small cells that reach the site of development and surround the fetal cortex from outside to form **definitive cortex** of the adrenal gland.

At birth the fetal cortex retrogresses and its involution is mostly completed in first few weeks of life.

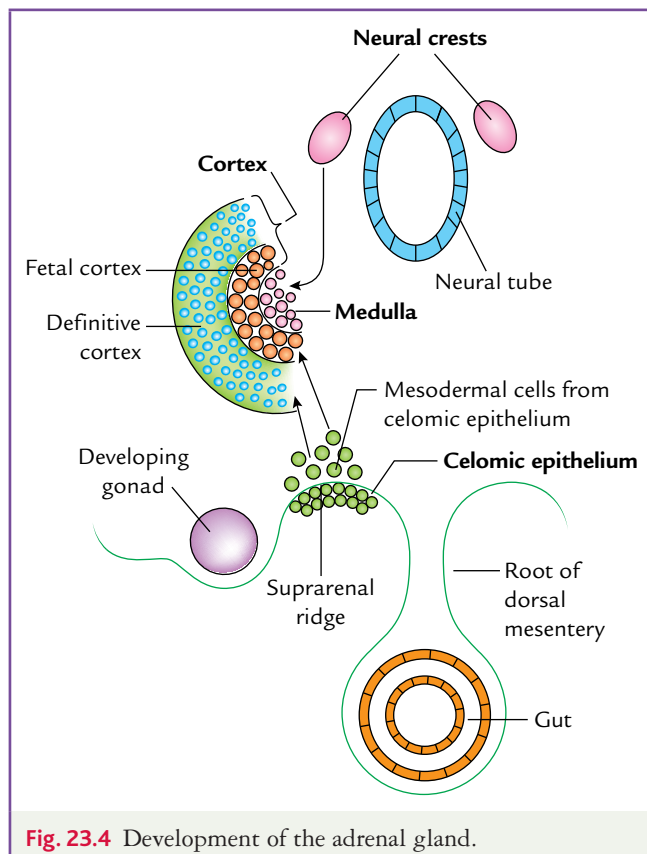


Fig. 23.4 Development of the adrenal gland.

Formation of Layers in Adrenal Cortex

The adrenal cortex consists of three layers. From superficial to deep these are:

- Zona glomerulosa
 - Zona fasciculata
 - Zona reticulata.
- The zona glomerulosa and zona fasciculata are formed at birth due to differentiation of the cells of the definitive cortex.
 - The zona reticularis, however, is identifiable only during the third year of life.

Development of Adrenal Medulla

The adrenal medulla is formed by **sympathochromaffin cells** derived from neural crest. The cells of the adrenal medulla are similar to postganglionic neurons of sympathetic ganglia. Preganglionic sympathetic neurons terminate by synapsing with these cells.

The cells forming the medulla of the adrenal gland migrate from neural crest and enter the fetal cortex from the medial side.

N.B. The fetal adrenal gland is 10–20 times larger than adult adrenal gland.

Clinical Correlation

- Ectopic adrenal tissue/adrenal gland:** The adrenal tissue or complete adrenal gland may be found fused to kidney deep in its capsule or in the right lobe of the liver.
- Congenital adrenal hyperplasia:** It is most commonly caused by mutation of genes for enzymes involved in adrenocortical steroid biosynthesis (e.g., 21-hydroxylase deficiency), which may cause elevation of androgen levels that may culminate in pseudointersexuality.
- Adrenogenital syndrome:** It occurs due to congenital hyperplasia of the cells of the adrenal cortex, which secrete androgen. The clinical manifestations differ in male and female as under:
 - In male:** It leads to a very early development of secondary sexual characters. This condition is termed **adrenogenital syndrome**.
 - In female:** It leads to an enormous enlargement of the clitoris, and the child may be mistaken as a male. This condition is termed **pseudohermaphroditism**.

Chromaffin Tissue

The chromaffin tissue is made up of cells similar to those of the adrenal medulla. Like the cells of the adrenal medulla, the cells of chromaffin tissue are derived from neural crests.

Sites of chromaffin tissue The chromaffin tissue is found at the following sites:

1. In relation to the abdominal aorta, where it forms **para-aortic bodies (organ of Zuckerkandl)**
2. Along sympathetic chain near sympathetic ganglia
3. Along sympathetic plexuses
4. Near splanchnic nerves.

Clinical Correlation

Pheochromocytoma: It is a tumor arising from chromaffin cells. It usually arises from extra-adrenal chromaffin tissue. There is an excessive secretion of both adrenaline and noradrenaline. Clinically pheochromocytoma presents as hypertension and features of sympathetic overdrive such as palpitation, sweating, apprehension, fear of death, etc.

GOLDEN FACTS TO REMEMBER

- | | |
|--|---|
| ➤ Most complex endocrine gland in the body | Pituitary gland |
| ➤ Master endocrine gland | Pituitary gland |
| ➤ Third eye | Pineal gland |
| ➤ Fetal adrenal gland is | 10–20 times larger than adult adrenal gland |
| ➤ Organs of Zuckerkandl | Para-aortic bodies made up of chromaffin tissue |

CLINICAL PROBLEMS

1. Fetal adrenal gland is 10–20 times larger than the adult adrenal gland. Give its embryological basis.
2. A mother told her family physician that her son of about 10-year age is getting tall very fast. The physician after thorough physical examination and investigation made the diagnosis of gigantism. Based on your knowledge of embryology, answer the following questions.
 - (a) What is gigantism?
 - (b) In what way gigantism differs from acromegaly?

CLINICAL PROBLEM SOLUTIONS

1. The large size of fetal adrenal gland is attributed to large size of fetal cortex.
The regression of fetal cortex begins at birth and completes by the end of first year of life.
N.B. One-third weight of the adrenal gland is lost during first 3 months after birth.
2. **Gigantism** is a clinical condition characterized by excessive growth of body. It occurs due to excessive production of growth hormone by the pituitary gland when it is affected by pituitary adenoma.
The main difference between gigantism and acromegaly is that acromegaly occurs when the limb bones have stopped growing, and gigantism occurs when they are still growing.

Development of Eye

Overview

The eye develops from four sources:

1. Neuroectoderm of forebrain
2. Surface ectoderm of head
3. Mesoderm between neuroectoderm of forebrain and surface ectoderm of head
4. Neural crest cells

The **neuroectoderm** of forebrain forms retina, posterior layers of iris, and optic nerve.

The **surface ectoderm** of the head forms lens of the eye and corneal epithelium (epithelium covering the superficial surface of the cornea).

The **mesoderm** between the neuroectoderm of forebrain and surface ectoderm of the head forms fibrous and vascular coats of the eye.

The **neural crest cells** migrate into mesenchyme from the neural crests and form choroid, sclera, and corneal epithelium.

Optic Cup and Lens Vesicle (Figs 24.1 to 24.3)

The development of eye begins on day 22. At first, a pair of shallow groove or sulcus appears on either side in the forebrain. It is called **optic groove/sulcus**. The optic sulcus invaginates the surrounding mesenchyme to form **optic vesicle**.

Each optic vesicle grows laterally. Its distal part expands to form **optic vesicle**; its proximal part connected to the forebrain constricts to form **optic stalk**. As the optic vesicle comes in contact with the surface ectoderm, it induces it to thicken and forms **lens placode**—the **primordium of lens**.

The lens placode gets depressed below the surface to form **lens pit**. As the lens pit deepens its edges approach each other and fuse to form spherical **lens vesicle**, which is soon cut off from the surface ectoderm.

As the lens vesicle is being formed, optic vesicle begins to invaginate to form double-layered **optic cup**. The margins of the optic cup grow and enclose the lens vesicle, i.e., lens vesicle enters into the optic cup.

Subsequently, a fissure called **choroidal fissure** develops on the inferior aspect of the optic cup and the optic stalk. The vascular mesoderm enters into the choroidal fissure and gets trapped in the optic vesicle and optic stalk. The choroidal fissure is closed. This vascular mesoderm within it forms hyaloid vessels (**hyaloid artery and hyaloid vein**), which supply to the layers of the optic cup, mesoderm in the optic cup, and lens vesicle (Fig. 24.4).

The distal parts of hyaloid vessels eventually degenerate whereas their proximal parts persist as **central artery and vein of retina**.

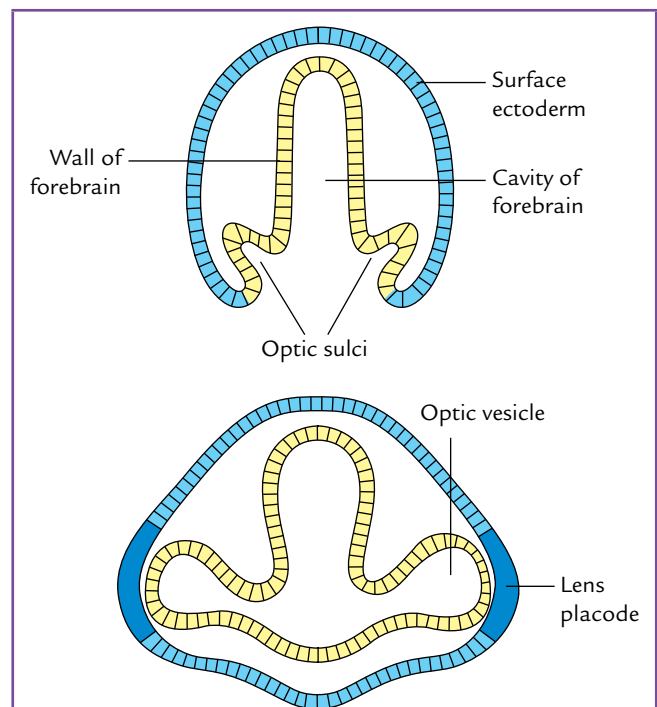
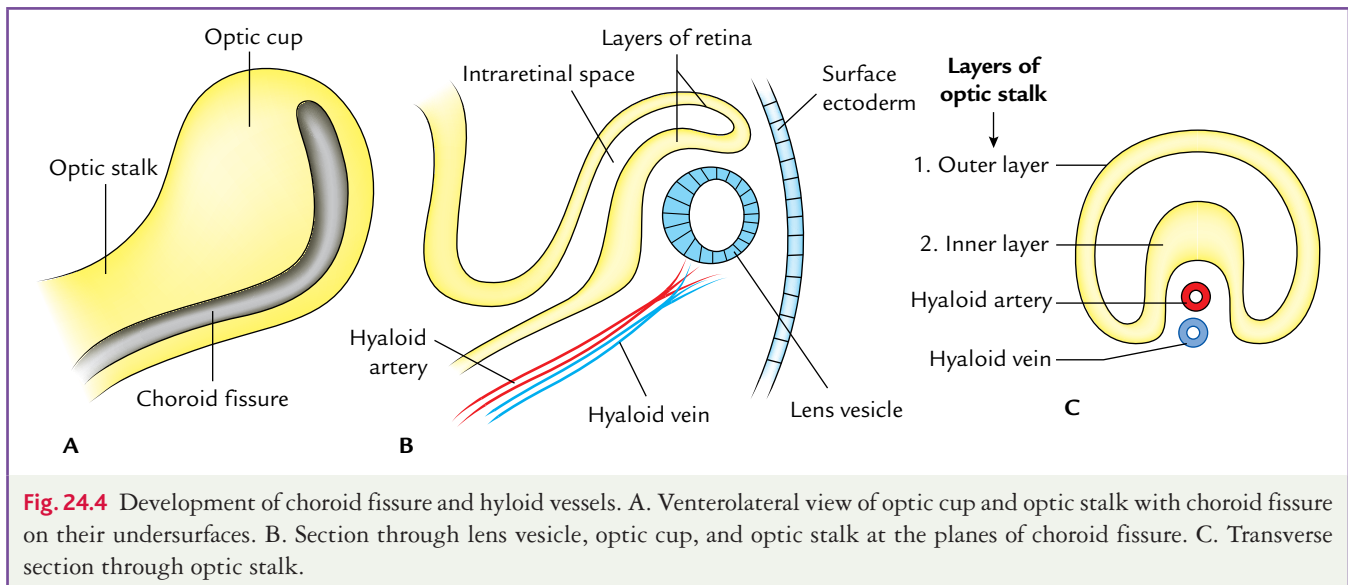
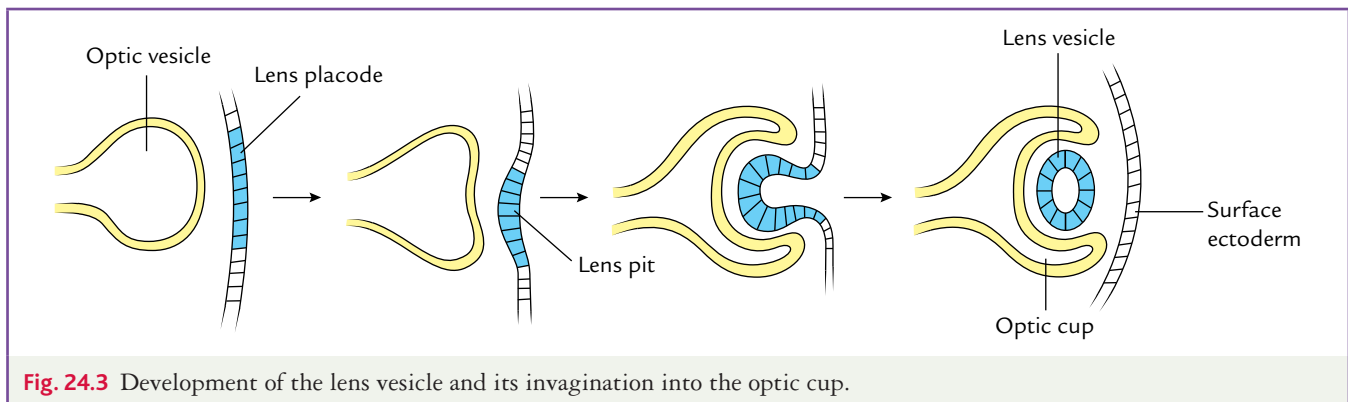
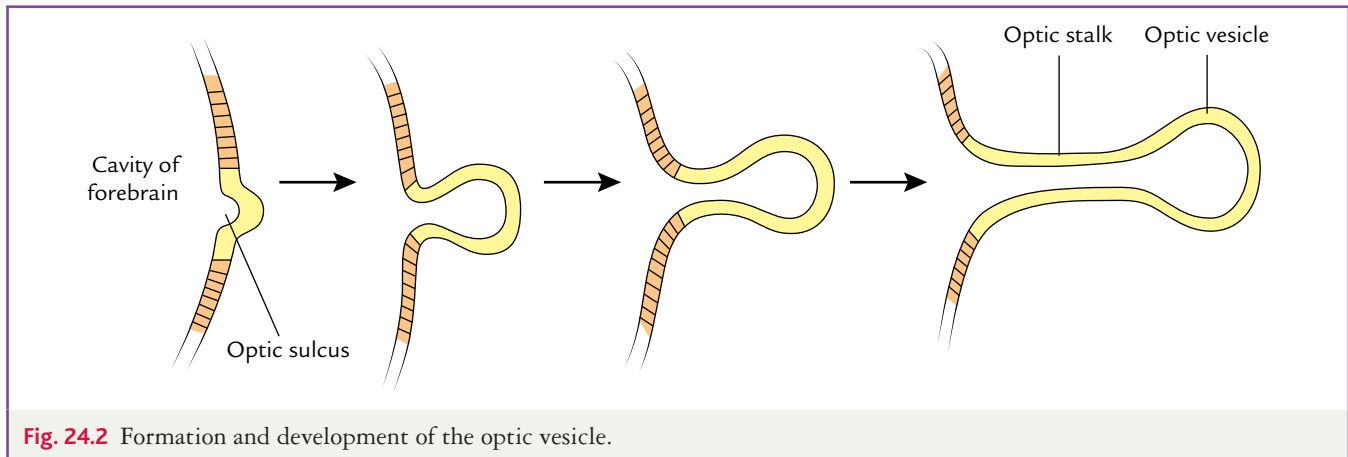


Fig. 24.1 Development of the optic vesicle and lens placode.



Development of Various Parts of Eyeball

Retina (Fig. 24.5)

The retina develops from walls of the optic cup. Outer thin layer of the optic cup forms **pigment layer of the retina**. Inner thick layer of the optic cup forms **neural layer of the retina**. The cells of the neural layer proliferate to form various cells of retina, i.e., **photoreceptor cells (rods and cones)**, **bipolar cells**, and

ganglionic cells. The rods and cones are modified neurons. The axons of ganglionic cells form nerve fiber layer, which passes through the optic stalk and forms **optic nerve**. During embryonic and early fetal periods, the pigment and neural layers of the retina are separated from each other by an **intraretinal space** representing the original cavity of the optic cup. Before birth the space between the inner and outer layers of the optic cup is obliterated with the proliferation of cells of the

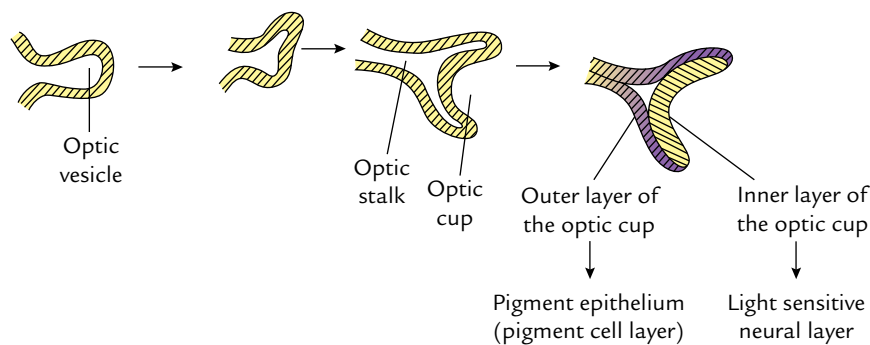


Fig. 24.5 Stages in the development of retina.

inner layer. As a result, the rod and cone cells come in contact with pigment layer of the retina.

Optic Nerve

As discussed earlier, the optic stalk contains choroid fissure, which contains hyaloid vessels. The hyaloid vessels later become **central artery and vein of retina**. The optic stalk contains nerve fibers derived from ganglionic cells of the retina. The choroid fissure closes in week 7. As a result, the optic stalk along with axons of ganglionic cells forms the optic nerve.

N.B. The **optic nerve is a tract of diencephalon** and not a peripheral nerve because:

1. It is myelinated by oligodendrocytes in the third month.
2. It is not capable of regeneration after transaction.
3. It is surrounded by meninges and subarachnoid space filled with cerebrospinal fluid (CSF).

Clinical Correlation

1. **Retinal detachment:** There is a separation of pigment epithelium from the neural layer of the retina in retinal detachment. The retinal detachment may be congenital or can occur because of a blow to the eye.

This can be easily explained embryologically because during development the two layers of the retina are separated by a space called the **intraretinal space**, which later on gets obliterated.

The integrity of the retina depends upon the pressure of the vitreous humor in adults, which keeps the two layers of the retina adhered to each other. When a hole or tear occurs in retina, then the fluid may accumulate between the pigment and neural layers of the retina and may separate these layers.

2. **Papilledema:** The optic nerve is surrounded by three meninges that were invaginated by developing optic vesicle and stalk. Consequently, it is surrounded by subarachnoid space (filled with CSF), which is continuous with the subarachnoid space around the brain.

Therefore, an increase in CSF pressure due to increased intracranial pressure hampers the venous return from retina. As a result, fluid accumulates in optic disc leading to its swelling (**papilledema**).

This occurs because the retinal vessels are covered by pia mater and lie in the subarachnoid space that surrounds the optic nerve.

Lens (Fig. 24.6)

The lens develops from the **lens vesicle**—a derivative of surface ectoderm (see page 279). Initially the lens vesicle is lined by a single layer of cuboidal cells. The cells of anterior wall of the vesicle remain cuboidal whereas the cells of posterior wall of the lens vesicle elongate, become columnar, and extend into the cavity of lens vesicle. As a result, the cavity of lens vesicle is obliterated. The elongated cells of posterior wall of the lens vesicle further elongate considerably and lose their nuclei to form highly transparent **primary lens fibers**. The lens grows because new lens fibers (**secondary lens fibers**) are added to it by cells in the **equatorial zone of lens**. The cells of anterior layer persist as **epithelium**.

Although the secondary lens fibers continue to form during childhood and lens increases in its diameter, the primary lens fibers become old and harder.

N.B. At first the lens is supplied by hyaloid artery—a branch of the ophthalmic artery. Later on distal part of hyaloid artery disappears, and blood supply to the lens is stopped. Consequently, the lens becomes an avascular structure.

Clinical Correlation

Cataracts

The **cataract** is opacity of the lens. It may be congenital or acquired.

1. **Congenital cataracts:** The congenital cataracts are opacities of the lens since birth. They are usually bilateral. They are caused by rubella virus, toxoplasmosis, Down's syndrome (trisomy 21), or galactosemia (an inborn error of metabolism due to enzymatic deficiency).

Note: The lenses are vulnerable to rubella virus between fourth and seventh week, when the primary lens fibers are formed.

2. **Acquired cataract:** They occur due to ageing. In old age central part of the lens becomes harder than peripheral part. Old primary lens fibers complete their lifetime and degenerate. As a result, there is accumulation of a special set of proteins called *crystalline* within the lens, which causes opacity of the lens.

Sclera and Choroid (Fig. 24.7)

The mesoderm around the optic cup differentiates into two layers: (a) an inner vascular layer that forms choroid and (b) an outer fibrous layer that forms sclera. Anteriorly the sclera is continuous with substantia propria of the cornea whereas posteriorly it is continuous

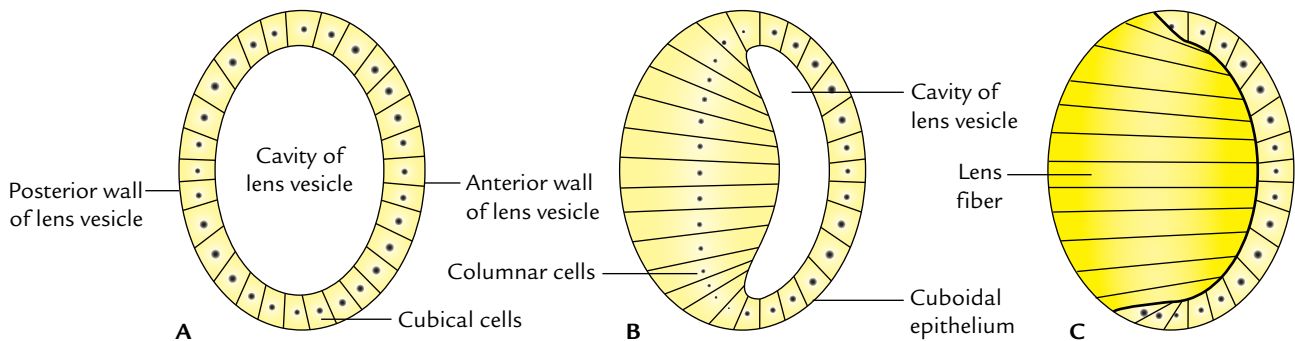


Fig. 24.6 Developmental stages in the formation of the lens. A. Lens vesicle lined by cubical cells. B. Cells of anterior wall remain cuboidal, the cells of posterior wall elongate and become columnar. C. Columnar cells of posterior wall elongate to form lens fibers.

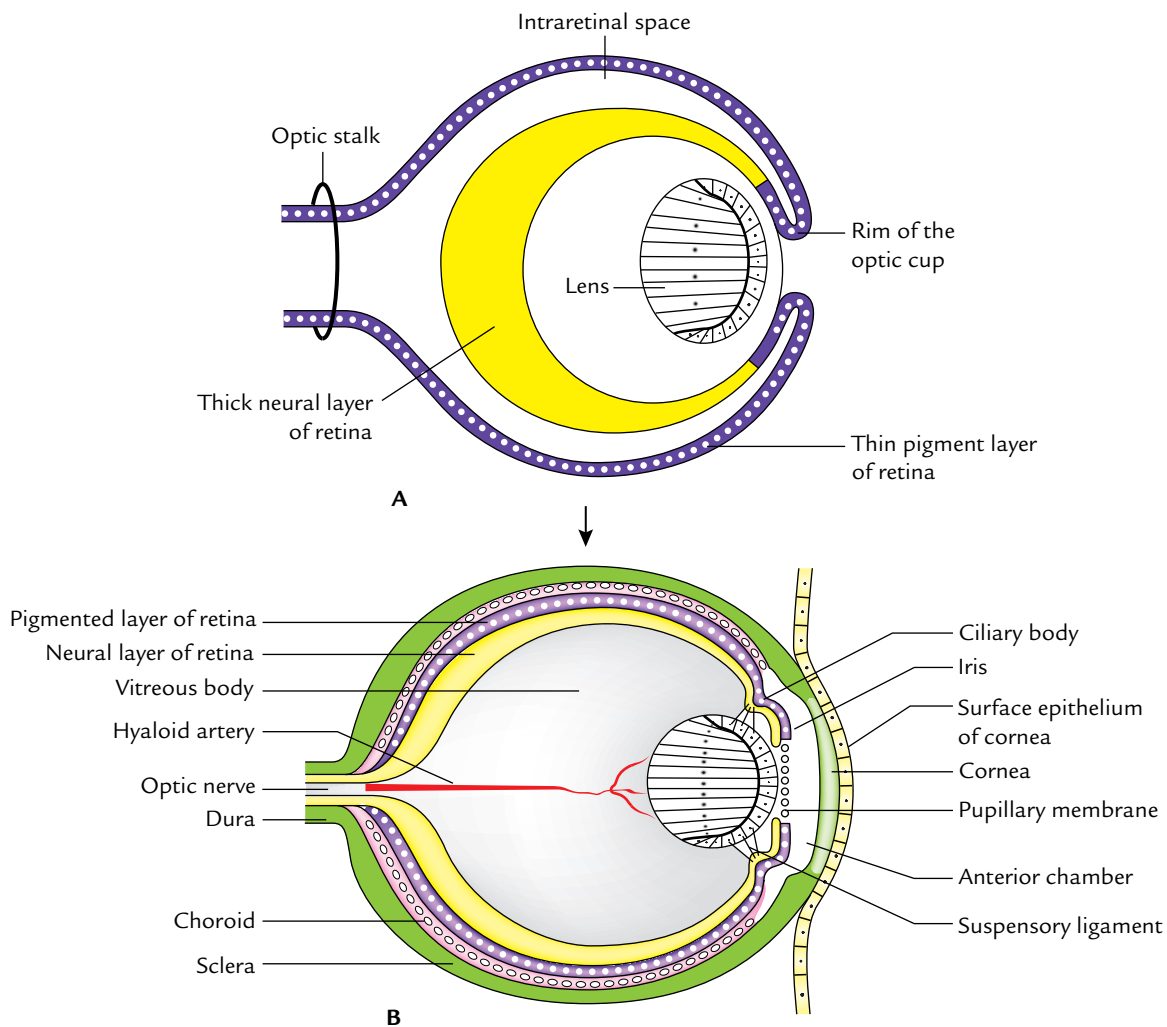


Fig. 24.7 Development of the coats of the eye. A. Development of retinal layers. B. Development of sclera, choroid, ciliary body, and iris.

with the dura mater surrounding the optic nerve. The choroid is continuous anteriorly on each side with ciliary body whereas posteriorly it is continuous with pia-arachnoid around the optic nerve.

Ciliary Body (Fig. 24.7)

The ciliary body is a wedge-shaped extension of the choroid anteriorly. It is formed by the mesoderm around the anterior part of the optic cup. The ciliary muscle and connective tissue of the ciliary body are derived from mesoderm. The pigment epithelium lining inner aspect of the ciliary body, including the ciliary processes, is derived from the outer layer of the optic cup. It is continuous with the retinal pigment epithelium.

The nonpigmented epithelial layer of the ciliary body is derived from the inner layer of the optic cup. Thus, there are two layers of the ciliary epithelium. The ciliary epithelium over the ciliary processes becomes secretory and secretes the **aqueous humor**.

The nonpigmented ciliary epithelium represents anterior prolongation of the neural layer of the retina.

Iris

The iris develops from the rim of optic cup (i.e., anterior extension of two layers of the optic cup), which grows inward and partially covers the lens. Thus, the epithelium of iris is derived from both layers of the optic cup. It is continuous posteriorly with the double-layered epithelium of the ciliary body. The neuroectodermal cells of the optic cup give rise to muscles of the iris (**sphincter and dilator pupillae**). The two layers of epithelium of the iris constitute iridial part of the retina. The vascular connective tissue of the iris is derived from mesoderm located anterior to the optic cup.

The anterior extension from the rim of the optic cup, which forms iris, does not extend up to the center. As a result, almost circular gap remains in the center of the iris—the **pupil**.

N.B. The smooth muscle of the sphincter and dilator pupillae results from the transformation of epithelial cells into smooth muscle fibers.

Clinical Correlation

Color of the iris: The color of the iris depends upon concentration and distribution of pigment-containing cells (**chromatophores**) in the iris. When melanin pigment is confined to the pigment epithelium on the posterior surface of the iris, then the iris appears blue and when the melanin is also distributed in the stroma of the iris then the eye appears brown.

Cornea

The development of cornea is induced by the lens vesicle.

The cornea is derived from following sources:

1. *Outer stratified squamous epithelium* is derived from the **surface ectoderm**.
2. *Lamina propria of the cornea* is derived from the **mesoderm**. It is continuous with sclera.
3. *Inner corneal epithelium* is derived from the **neural crest cells**.

Anterior and Posterior Chambers of the Eye (Fig. 24.8)

The mesoderm located between developing iris and cornea splits to form a space called the **anterior chamber**. The mesoderm anterior to this space forms substantia propria of the cornea and mesothelium of the anterior chamber.

The mesoderm located between the developing iris and lens splits to form a space called the **posterior chamber**.

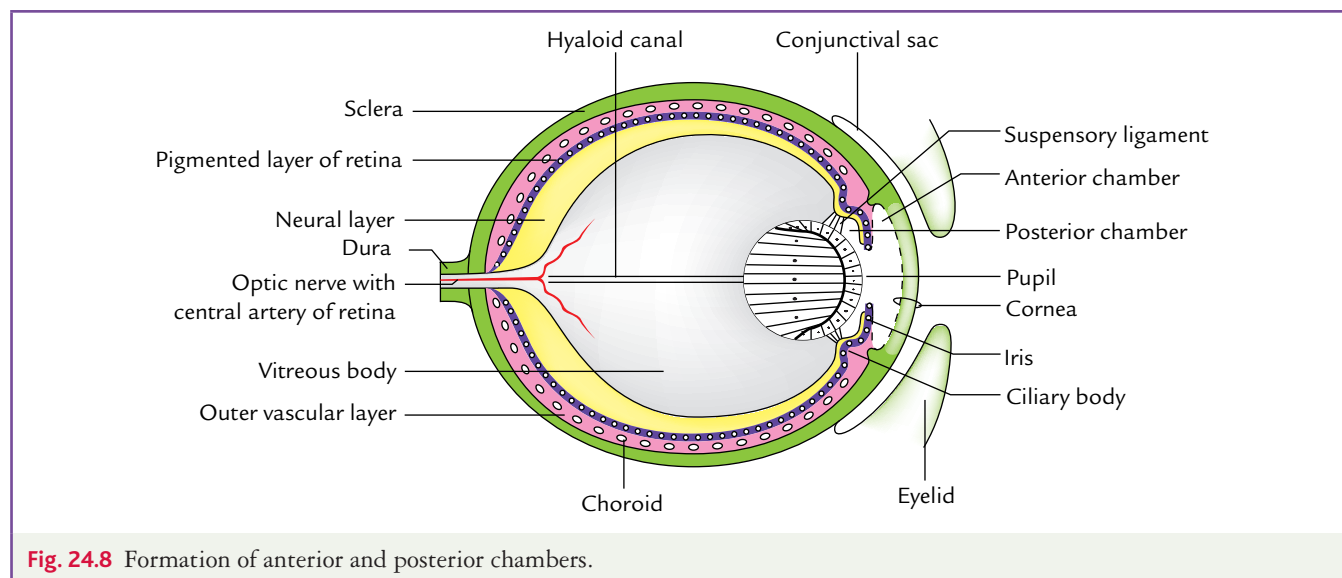


Fig. 24.8 Formation of anterior and posterior chambers.

When the pupillary membrane disappears then the pupil forms a communication between the anterior and posterior chambers of the eye.

The anterior and posterior chambers are filled by aqueous humor secreted by ciliary processes of the ciliary body.

The aqueous humor is drained by **sinus venosus sclerae** (a circumferential scleral venous sinus encircling the anterior chamber).

Vitreous Body (Vitreous Humor)

At first the vitreous humor is formed by neural crest mesoderm present in the optic cup. It is called **primary vitreous humor**. Later on it is replaced by gelatinous **secondary vitreous humor** derived mainly from the inner layer of the optic cup and a little bit from the lens vesicle. Vitreous body is made up of a vascular mass of transparent gel-like intracellular substance. It contains hyaloid artery that later obliterates to form a **hyaloid canal** of adult eye.

The adult components of eyeball derived from various embryonic structures are given in Table 24.1.

Table 24.1 Adult components of eye derived from various embryonic structures	
Embryonic structure	Adult derivatives
Neuroectoderm (of forebrain)	
(a) Optic cup	Retina Dilator pupillae Sphincter pupillae Epithelium of iris and ciliary body
(b) Optic stalk	Optic nerve
Surface ectoderm	
	Lens Anterior epithelium of cornea
Mesoderm	
	Sclera Substantia propria and posterior epithelium of cornea Choroid, ciliary body, and stroma of iris Vitreous body Central artery and vein of retina Extraocular muscles

Clinical Correlation

Congenital anomalies of the eye (Fig. 24.9)

- Anophthalmia** (absence of an eye): It occurs when the optic vesicle fails to form.
- Microphthalmia** (a small eye): It occurs when the optic vesicle is small or there is underdevelopment of eye. The lens is usually not formed. The microphthalmia is usually associated with intrauterine infections from toxoplasma, rubella virus, cytomegalovirus, and herpes simplex virus group of organisms.

- Cyclopia** (single eye) (Fig. 24.9A): The cyclopia is severely uncommon anomaly of the face. There develops a **single median eye**. The nose is usually absent at the normal site but may be represented by a tubular appendage called **proboscis** above the median eye. The cyclopia is transmitted by recessive inheritance. The two eyes may fuse (**synophthalmia**) to form a single eye.
- Persistent pupillary membrane** (Fig. 24.9B): The pupillary membrane may persist as a whole or it may persist in the form of few strands of connective tissue. It may obstruct the vision completely or partially.
- Coloboma of the iris** (Fig. 24.9C) (Gr. *Coloboma* = a part that is cut off or missing): It is a congenital notch or cleft on the inferior aspect of the iris. It occurs due to failure of choiroid fissure to close.
- Congenital aniridia** (complete absence of the iris): It occurs from an arrest of development at the rim of the optic cup.
- Congenital glaucoma (buphthalmos)**: It is an increased intraocular pressure that results due to impaired drainage of the aqueous humor, following abnormal development of *canal of the Schlemm* or *iridocorneal filtration angle*.
- Congenital aphakia** (aphakia: absence of the lens of the eye): It occurs if lens placode fails to develop following failure of lens induction by the optic vesicle.

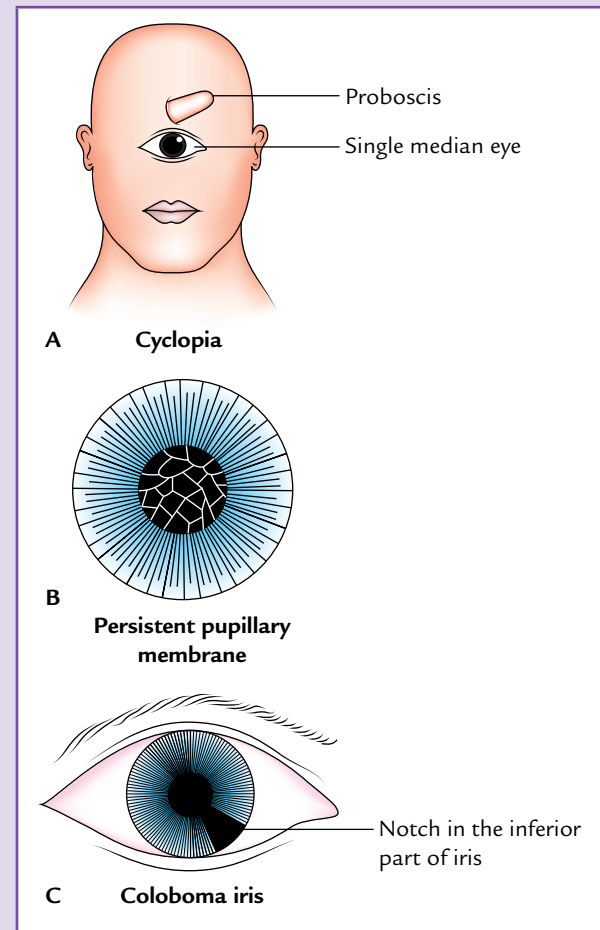


Fig. 24.9 Some congenital anomalies of the eye.

Accessory Structures of the Eyeball

Overview

The accessory structures of the eyeball include: eyelids, conjunctival sac, lacrimal gland, lacrimal sac, and nasolacrimal duct.

Eyelids (Fig. 24.10)

The upper and lower eyelids develop from reduplication of surface ectoderm above and below the cornea, respectively. These ectodermal folds contain a core of mesoderm. As the upper and lower folds grow, they approach and fuse with each other. Thus, enclosing a space between them and cornea called **conjunctival sac**. Therefore, the conjunctival sac is of ectodermal origin and lined by ectoderm.

The eyelids remain fused with each other till the beginning of 10th week and remain adhered to each

other until 28th week (seventh month) of IUL. Thereafter the eyelids get separated from each other to form the upper and lower eyelids, respectively.

(cf. *In many lower mammals, viz., cats, the offsprings are born with closed eyelids*).

The central core of the mesoderm in the ectodermal folds (developing eyelids) forms **tarsal plate** and connective tissue of the eyelids.

The **eyelashes** and **glands in the eyelids** develop from surface ectoderm covering the eyelids in a similar manner as in the skin (see Chapter 7).

Lacrimal Glands (Fig. 24.10)

Each lacrimal gland develops from 15 to 20 buds that grow from the superolateral angle of the conjunctival sac. These buds elongate and get canalized to form the ducts. The secretory acini develop at the ends of these ducts. The ducts of lacrimal gland therefore open in the conjunctival sac.

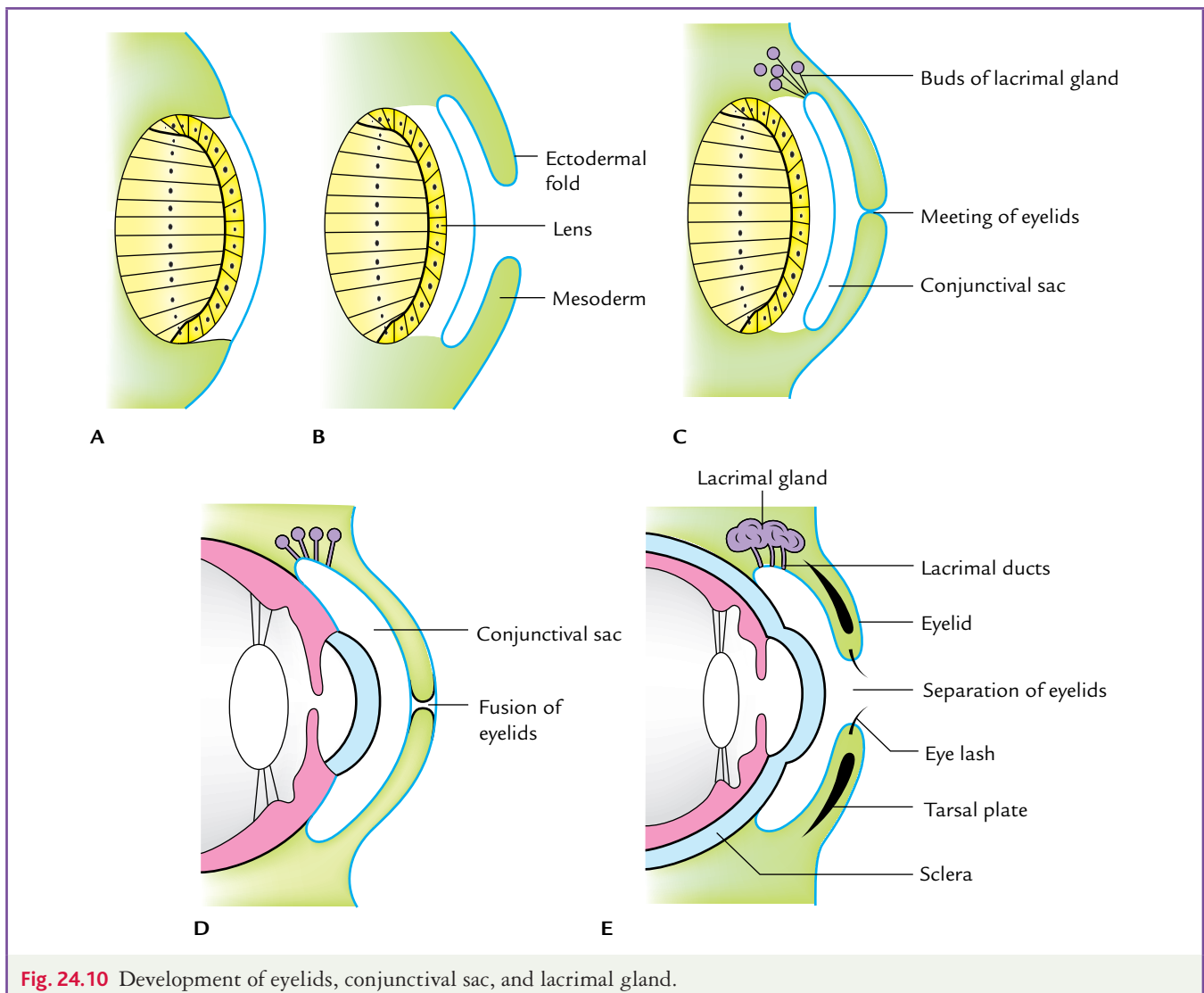


Fig. 24.10 Development of eyelids, conjunctival sac, and lacrimal gland.

Lacrimal Sac and Nasolacrimal Duct

They develop from the ectoderm of **nasolacrimal/naso-optic groove** present along the line of fusion of maxillary and lateral nasal processes. It is described in detail on page 132.

The **lacrimal canaliculi** develop from canalization of the ectodermal buds that grow from the margin of each eyelid near their medial ends to the lacrimal sacs.

Clinical Correlation

1. Anomalies of the eyelids

- Coloboma of eyelid:** A congenital condition in which part of the eyelid is missing. Coloboma of eyelid usually occurs as a small notch in the upper eyelid. The coloboma of inferior eyelid is rare.
- Entropion and ectropion:** When the lid margins are turned inward then the condition is called *entropion*, and when the lid margins are turned outwards then the condition is called *ectropion*.
- Congenital ptosis** (drooping of the upper eyelid): It occurs if the levator palpebrae superioris muscle fails to develop; it may be transmitted as an autosomal dominant trait.
- Epicanthus:** It is the development of crescentic fold of skin that extends from upper eyelid to canthus. It is a normal feature in Mongolian races.
- Cryptophthalmos** (L. *Kryptos* = hidden): It occurs due to congenital absence of the eyelids. The eyeball is small and defective. It is covered by the skin (i.e., absence of palpebral fissure between the eyelids).

2. Anomalies of the lacrimal apparatus

- Lacrimal gland may be absent or nonfunctional.
- Complete absence of lacrimal passages** in whole, in part, or atresia of some part.
- Supernumerary puncta or canaliculi.
- Presence of cysts in any part of the lacrimal apparatus, mostly close to the lacrimal puncta.

- The **external ear** collects the sound waves.
- The **middle ear** transfers the sound waves from the external to internal ear.
- The **internal ear** performs dual functions.
 - It converts sound waves into nerve impulses that lead to hearing.
 - It registers changes in equilibrium and balance, and subsequently maintains them.

N.B.

- Developmentally internal ear appears first.
- Internal ear, tympanic cavity (middle ear), mastoid antrum, and ear ossicles assume adult size at the time of birth.

External Ear

- External auditory meatus** (Fig. 24.11): It develops from **ectodermal first pharyngeal cleft**.

At first it gets filled with the ectodermal cells forming a temporary solid **meatal plug**. These ectodermal cells are derived from lining ectodermal epithelium of the first pharyngeal cleft. The meatal plug gets canalized at birth to form external auditory meatus.

- Auricle or pinna** (Fig. 24.12): It develops from six mesodermal thickenings (called **auricular hillocks/tubercles**) around the first pharyngeal cleft, three along caudal border of the mandibular arch, and three along cephalic border of the hyoid arch.

These hillocks fuse with one another to contribute in the formation of auricle of the ear. It is believed that the tragus, crus of helix, and helix are derived from auricular hillocks of the mandibular arch while antihelix, antitragus, and ear lobule are derived from auricular hillocks of the hyoid arch.

Development of Ear

Overview

The ear is an **organ of hearing and balance**. It consists of three anatomical parts. From the lateral to medial side, they are arranged as follows:

- External ear** consisting of the pinna and external auditory meatus.
- Middle ear** consisting of a slit-like cavity containing three small ear ossicles.
- Internal ear** consisting of bony and membranous labyrinths.

The external, middle, and internal ears develop from three distinctly different sources. However in adults they form a single anatomical unit to serve the function of hearing as well as balance.

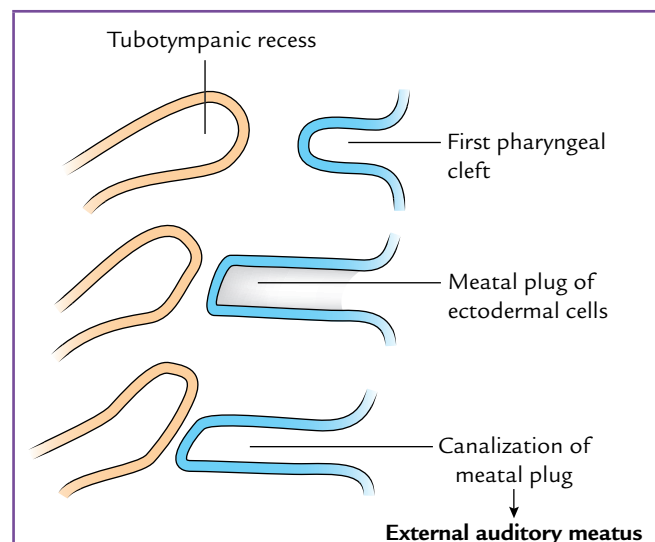


Fig. 24.11 Development of the external auditory meatus.

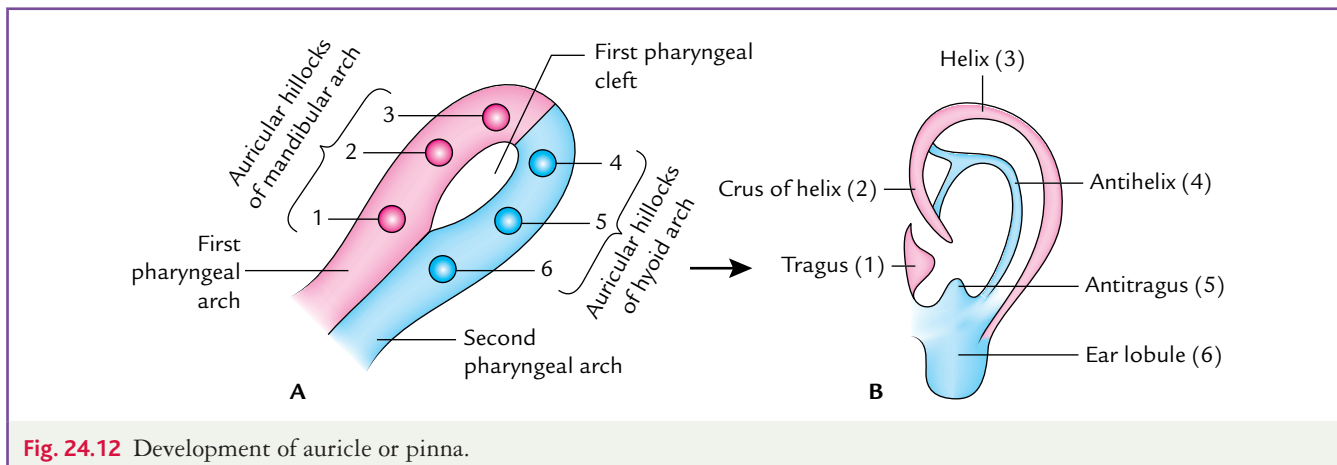


Fig. 24.12 Development of auricle or pinna.

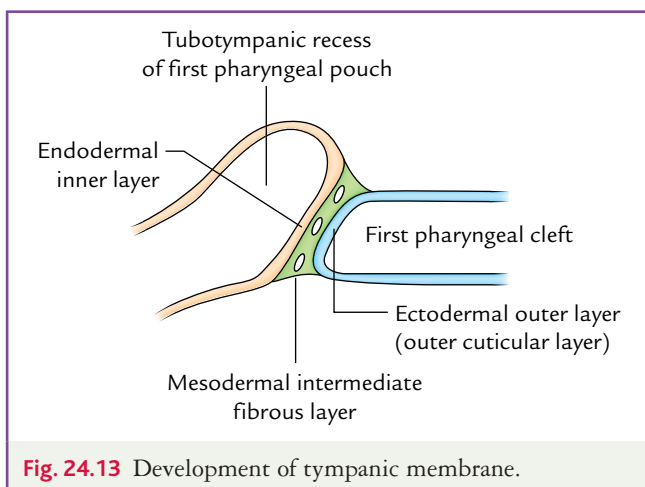


Fig. 24.13 Development of tympanic membrane.

Tympanic Membrane (Fig. 24.13)

It develops by the apposition of the tubotympanic recess and first pharyngeal cleft, i.e., from the first pharyngeal membrane.

1. The *outer cuticular layer* of the tympanic membrane is derived from the ectodermal lining of the first pharyngeal cleft.
2. The *inner endodermal layer* of the tympanic membrane is derived from the endodermal lining of the first pharyngeal pouch.
3. The *intermediate fibrous layer* of the tympanic membrane is derived from the mesoderm intervening between the first pharyngeal cleft and the first pharyngeal pouch.

N.B. The handle of malleus and chorda tympani nerve extends into the tympanic membrane between its intermediate fibrous layer and inner endodermal (mucous) layer.

Clinical Correlation

Congenital anomalies of external ear

1. **Anotia (absence of the auricle):** It occurs due to failure of mesenchymal proliferation to form auricular hillocks. It is rare but commonly associated with *first arch syndrome*.

2. **Preauricular appendages and pits:** These are skin tags and shallow depressions that are usually seen anterior to the ear. The *preauricular appendages* occur due to development of accessory hillocks, whereas the *preauricular pits* occur due to abnormal development of auricular hillocks. Most of the anomalies of the external ear are associated with various chromosomal syndromes such as Down's syndrome (trisomy 21), Patau's syndrome (trisomy 13), and Edward's syndrome (trisomy 18).
3. **Atresia of the external auditory meatus:** It occurs due to failure of the meatal plug to canalize. Clinically it presents as *conduction deafness* and is often associated with first arch syndrome.

N.B. The ear is most sensitive to teratogens during fourth to ninth weeks of gestation.

Middle Ear (Fig. 24.14)

1. The **middle ear (tympanic cavity)** develops from the distal part of tubotympanic recess, which develops mainly from the dorsal part of the first pharyngeal pouch with a little contribution from the second pharyngeal pouch. The mastoid antrum and mastoid air cells are formed by extensions of the tympanic cavity.
2. The **ear ossicles (malleus, incus, and stapes)** develop as follows:
 - (a) The **malleus** and **incus** develop from the cartilage of the first pharyngeal arch—the *Meckel's cartilage*.
 - (b) The **stapes** develops from the cartilage of the second pharyngeal arch—the *Reichert's cartilage*.

The ear ossicles are initially embedded in mesenchyme. When the mesenchyme surrounding the ossicles dissolves then the endodermal epithelial lining of primitive tympanic cavity extends along the newly developing space and connects the ossicles with the wall of tympanic

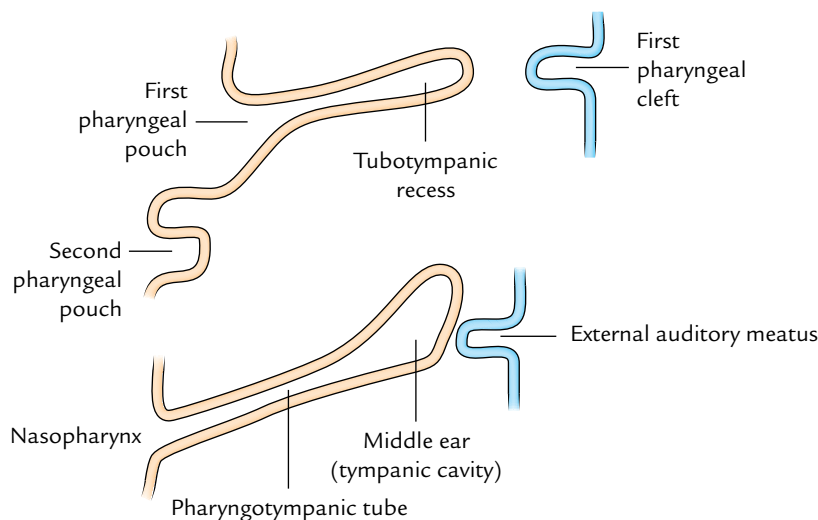


Fig. 24.14 Development of middle ear (tympanum) and pharyngotympanic tube.

cavity in a mesentery-like fashion. The supporting ligaments of the ossicles develop later within the mesenteries.

Mastoid Antrum

The dorsal expansion of tympanic cavity gives rise to the **mastoid antrum**. The mastoid antrum is almost of adult size at birth; however mastoid air cells are not present in the newborn infants. The mastoid air cells develop at the age of 2 years.

Muscles of Middle Ear

1. **Tensor tympanic muscle:** It is attached to the upper part of handle of malleus and also develops from the first pharyngeal arch like malleus. It is supplied by **mandibular branch of trigeminal nerve**—the nerve of the first arch.
2. **Stapedius muscle:** It is attached to the stapes and also develops from the second pharyngeal arch like stapes. It is supplied by **facial nerve**—the nerve of the second pharyngeal arch.

Pharyngotympanic Tube

(Auditory tube/Eustachian tube) (Fig. 24.14)

It is derived from narrow proximal part of the tubotympanic recess. It connects the tympanic cavity with nasopharynx.

Internal Ear

The internal ear is first of the three parts of the ear to develop. Early in the fourth week, the surface ectoderm on either side of myelencephalon shows a localized

thickening called **otic placode**. The otic placode soon invaginates the underlying mesoderm to form **otic pit**. Margins of the otic pit approach each other and fuse together to form **otic vesicle** (Fig. 24.15). The otic vesicle gets separated from the surface. The **otic vesicle is primordium of the membranous labyrinth**.

Otic vesicle then grows and forms various parts of the membranous labyrinth of the internal ear as follows:

The otic vesicle divides into two components: **ventral saccular portion** and **dorsal utricular portion**.

1. The **saccular portion of otic vesicle** gives rise to **sacculle, cochlear duct (organ of Corti), and spiral ganglion of vestibulocochlear nerve**.
2. The **utricular portion of otic vesicle** gives rise to **utricle, semicircular ducts, endolymphatic duct and sac, and vestibular ganglion of vestibulocochlear nerve**.

All these components, viz., cochlear duct, sacculle, utricle, and endolymphatic duct and sac together constitute the membranous labyrinth.

Sacculle, Cochlear Duct, and Organ of Corti (Fig. 24.16)

During the sixth week, the sacculle forms a tubular diverticulum—the **cochlear duct** that grows in a spiral fashion till it completes two and half turns. Later its connection with the sacculle becomes narrow forming **ductus reuniens**.

The mesenchyme condenses around the membranous labyrinth. This condensation is converted into cartilage to form **otic capsule**. The space between the otic capsule and membranous labyrinth is called **perilymphatic space**. Cartilage of the otic capsule is converted

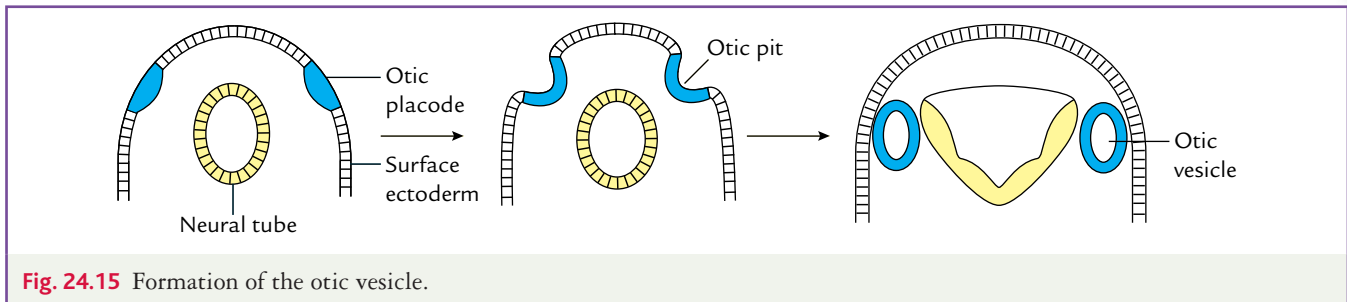


Fig. 24.15 Formation of the otic vesicle.

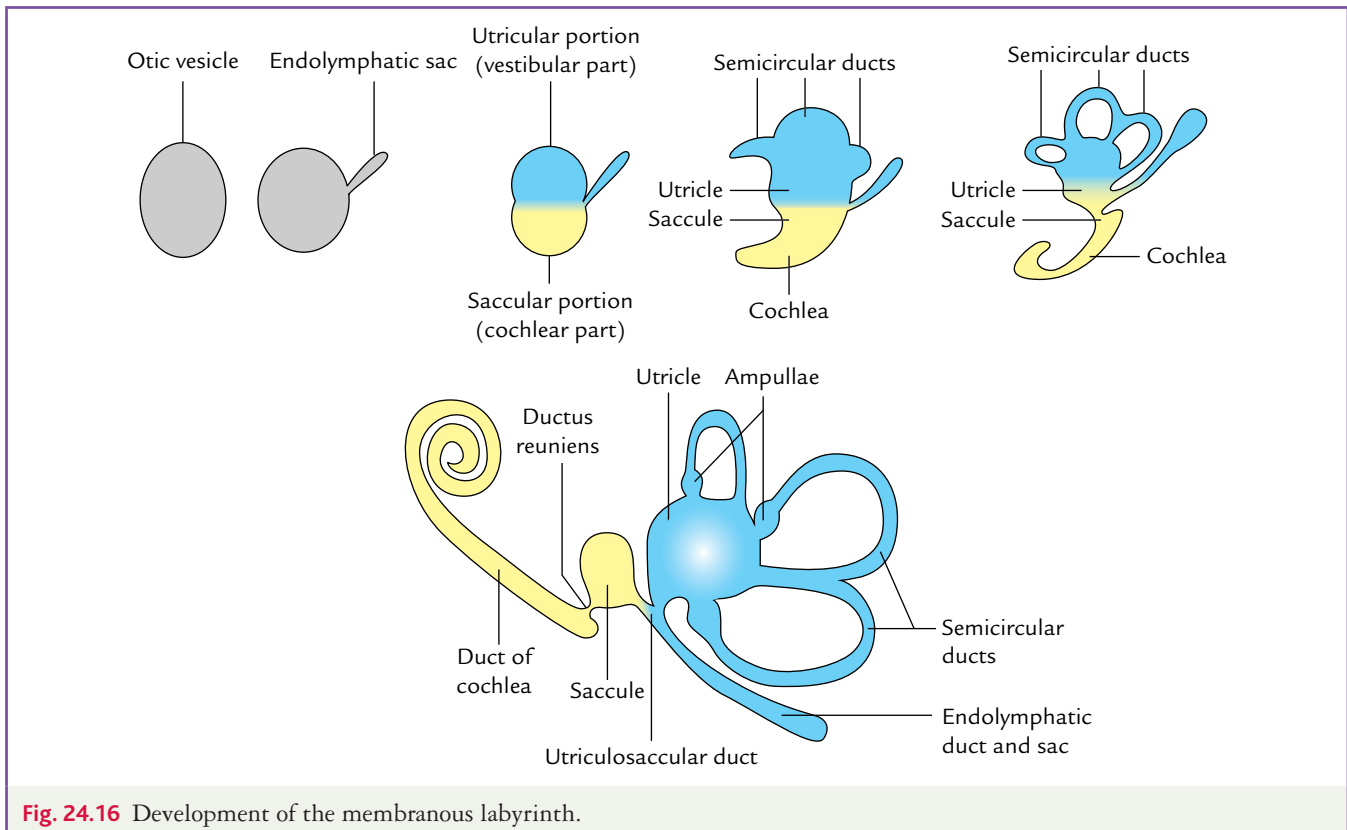


Fig. 24.16 Development of the membranous labyrinth.

into bone to form bony labyrinth. The perilymphatic space between the bony labyrinth and membranous labyrinth is filled with a fluid called **perilymph**. The membranous labyrinth is filled with a fluid called **endolymph**. Special sense organs for hearing and equilibrium develop in the wall of membranous labyrinth. They are innervated by vestibulocochlear nerve that is attached to the brain stem at junction of pons and medulla.

The mesenchyme of the bony labyrinth forms two perilymphatic spaces around the cochlear duct (Fig. 24.17):

- *Scala vestibuli* above the duct and
- *Scala tympani* below the cochlear duct.

The scala vestibuli is separated from the duct by **vestibular membrane (Reissner's membrane)** and scala tympani is separated from the duct by **basilar membrane**.

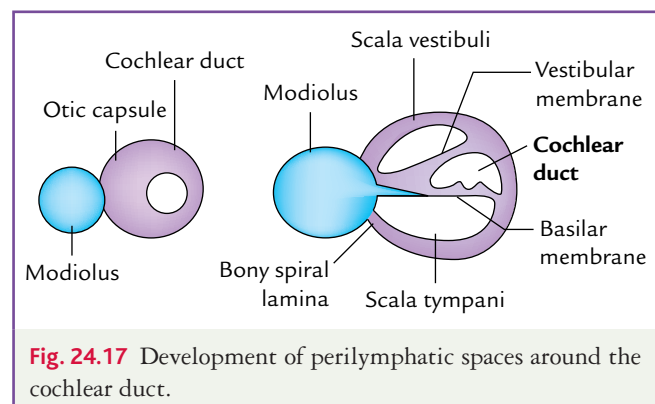


Fig. 24.17 Development of perilymphatic spaces around the cochlear duct.

The lateral end of the cochlear duct is attached to the surrounding cartilage by **spiral ligament**, whereas its medial end is connected to a long cartilaginous process the **modiolus**—the future axis of bony cochlea.

Two ridges develop on the basilar membrane. These are called **inner and outer ridges**.

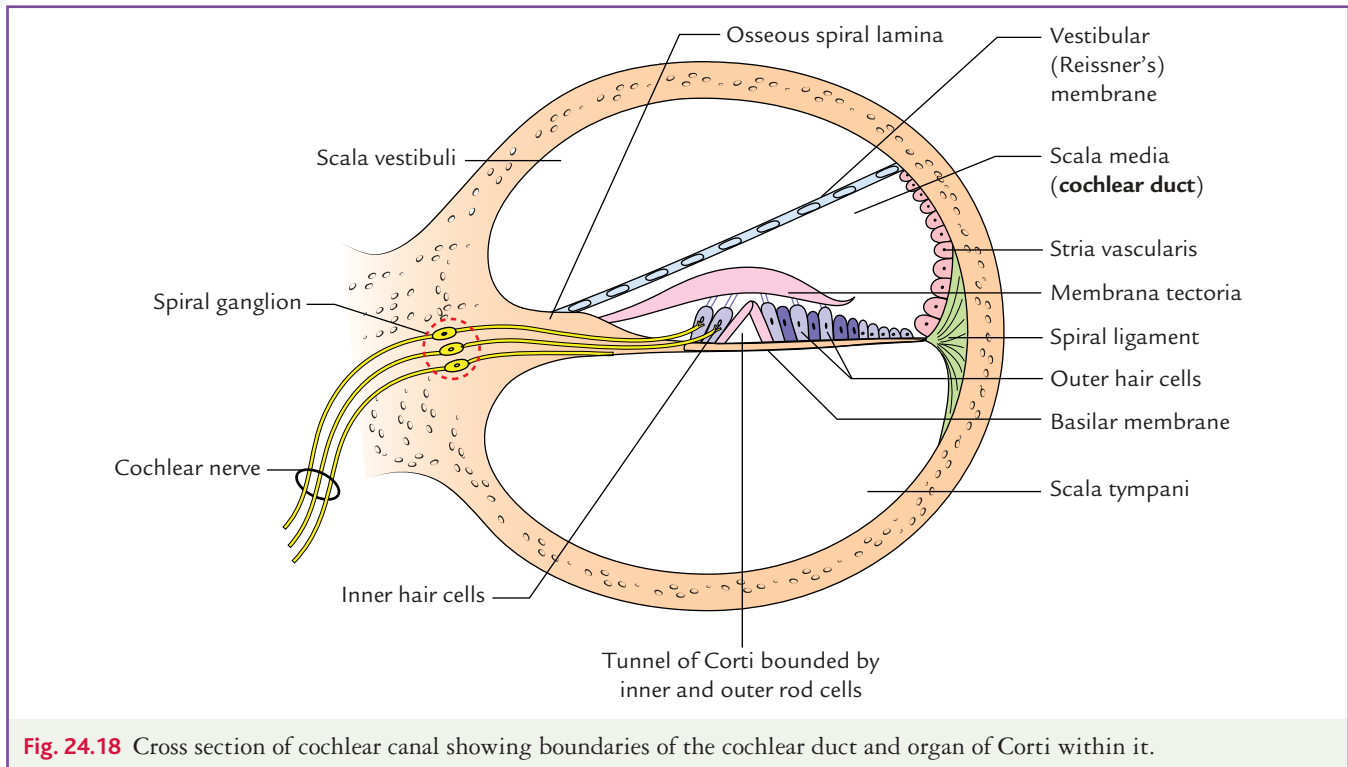


Fig. 24.18 Cross section of cochlear canal showing boundaries of the cochlear duct and organ of Corti within it.

- Cells of the inner ridge form **spiral limbus**, which gives attachment to *membrana tectoria*.
- The cells of outer ridge form two rows of **inner hair cells** and three or four rows of **outer hair cells**. The hair cells are sensory cells of the auditory system.
 - These sensory cells and tectorial membrane together form **organ of Corti**.
 - When the membrana tectoria touches the hair cells then it produces sound waves in the form of vibrations that are carried to brain through **auditory nerve** (Fig. 24.18).

Utricle and Semicircular Canals

During the sixth week of IUL, three **semicircular canals** develop as outpouchings of the utricle. One end of each duct dilates to form the **ampulla**, whereas its other end remains narrow to form **crus nonampullare**. The crus ampullare of anterior and posterior semicircular canals fuse. As a result, the **three semicircular canals communicate with utricle by five openings**.

The cells in the crus ampullare form a crest called *crista ampullaris*—the sensory receptors of equilibrium. The cristae ampullare are sensory receptors for kinetic balance.

In the same manner, **maculae** (the **sensory receptors for static balance/gravity**) develop in the medial walls of utricle and saccule.

Table 24.2 Derivatives of various components of the ear

Embryonic structure	Adult derivatives
Internal ear	
• Saccular portion	Saccule and cochlear duct
• Utricular portion	Utricle, semicircular ducts, endolymphatic duct, and sac
Middle ear	
• First pharyngeal arch	Malleus, incus, and tensor tympani muscle
• Second pharyngeal arch	Stapes and stapedius muscle
• First pharyngeal pouch	Pharyngotympanic tube and middle ear (tympanum)
• First pharyngeal membrane	Tympanic membrane
External ear	
• First pharyngeal cleft	External auditory meatus
• Auricular hillocks in mandibular and hyoid arches	Pinna/auricle

The impulses generated in sensory cells of **maculae** and **cristae ampullaris** due to change in position of the body are carried to the brain by **vestibular nerve**.

For details see *Anatomy of Head, Neck, and Brain* by Dr Vishram Singh.

The adult components of ear derived from various embryonic structures are given in Table 24.2.

GOLDEN FACTS TO REMEMBER

- | | |
|---|--|
| ➤ First indication of the development of eye | Formation of optic sulcus (optic groove) |
| ➤ Most important refractive medium of the eye | Cornea |
| ➤ First of the three parts of the ear (external, middle, and internal) to develop | Internal ear |
| ➤ Most common cause of congenital deafness | Failure of canalization of the meatal plate |
| ➤ Ear is most sensitive to teratogens during | Weeks 4–9 |
| ➤ Parts of ear which assume adult size at birth | Middle ear, ear ossicles, mastoid antrum, and internal ear |

CLINICAL PROBLEMS

1. A male baby was born with partial detachment of retina in both eyes. Give the embryological basis.
2. An infant was born with the absence of lens (**aphakia**) in both the eyes (**bilateral aphakia**). Give the embryological basis of bilateral aphakia.
3. A pregnant woman during the sixth week of gestation contracted rubella virus. On the basis of your knowledge of embryology, what types of congenital defects might occur in her offsprings.
4. While taking the round of ward Professor and HOD of ENT asked the final year MBBS student to tell the role played by the otic placode in the development of internal ear. Discuss the differentiation of otic vesicle into different components of internal ear.
5. An infant was born with bilateral microtia. Give its embryological basis and tell whether the presence of microtia makes the ENT surgeon to think of other associated anomalies.

CLINICAL PROBLEM SOLUTIONS

1. The retinal detachment occurs due to separation of two layers of the retina. For details see page 281.
2. The lens develops from thickening of surface ectoderm (**lens placode**) adjacent to the optic cup of forebrain. In addition to molecular and cellular signals essential for lens development, the contact of optic cup with lens placode is utmost essential for its differentiation into the lens.
Therefore, when molecular and cellular signals essential for lens development are disrupted or when the optic cup fails to contact the lens placode then the lens fails to develop causing aphakia.
3. The rubella virus is a well-known teratogenic agent to cause congenital cataracts, deafness, and other congenital malformations, especially if the mother contracts this virus during fourth to eighth week of gestation (pregnancy).
4. The **otic placode** forms as a result of thickening of surface ectoderm and appears on each side of rhombencephalon, as they can be seen in approximately 22-day-old embryo. They rapidly invaginate to form otic vesicles (otocysts). The tubular outpouchings from otocyst differentiate into various components of the internal ear, viz., sacculle, utricle, semicircular canals, and endolymphatic and cochlear ducts.
5. The term microtia stands for small or rudimentary auricle. The auricle develops from six mesenchymal proliferations at the dorsal ends of first and second pharyngeal arches. The microtia results from suppressed mesenchymal proliferation. The presence of microtia serves as an indicator of associated congenital anomalies such as an atresia of external auditory meatus, hemifacial microsomia, etc.

N.B. The neural crest cell population plays a key role in most of ear malformations.

Overview

Genetics is the study of heredity—a process by which children inherit certain characteristics (traits) from their parents.

These are called **inherited traits** that include physical, mental, normal, as well as abnormal characteristics in an individual.

The characteristics (traits) pass from parents to children through the inheritable material (**genetic code**) present in the nucleus of the cell. The genetic code is carried by the deoxyribonucleic acid (DNA) molecules. The functional unit of DNA is called **gene**.

The DNA molecules are arranged in linear sequences in chromosomes inside the nucleus of the cell. The total genetic information present in a cell is called **genome**. The human genome comprises about 50,000–100,000 genes.

The gene expression occurs by formation of different types of proteins. The protein is synthesized by transcription of genetic code into the ribonucleic acid (RNA), perpetuated by DNA replication. The RNA forms protein by translation using genetic code. Thus RNA is an intermediary molecule to execute gene expression.

Deoxyribonucleic Acid

The deoxyribonucleic acid (DNA) is a double-stranded molecule, made up of two chains of nucleotides, coiled around each other, forming what is commonly described as a **double helix**. The double helix model of DNA was first introduced by James Watson and Francis Crick in 1953 (Fig. 25.1).

The nucleotides are the basic structural units of the DNA.

Each nucleotide consists of three subunits:

1. A sugar
2. A phosphate group
3. A nitrogenous base.

Each strand of the double helix consists of alternate units of sugar and phosphate. The sugar is **deoxyribose**. The two strands are held together by **hydrogen bonds**

between the nitrogenous bases, which are attached to the sugars as side groups and point toward center of the helix. Thus, structure of a DNA molecule is like a twisted ladder. The nitrogenous bases are adenine (A), guanine (G), thymine (T), and cytosine (C). The nitrogenous base of two strands in normal conditions pair by hydrogen bonds in a specific manner. For example:

- Adenine binds with thymine by two hydrogen bonds (A = T).
- Guanine binds with cytosine by three hydrogen bonds (G ≡ C).

However, under abnormal conditions, when the bases are in **enol form**, adenine may pair with cytosine and guanine with thymine. This is the basis of **mutation of genes**.

The two strands of a DNA molecule are complementary to each other, i.e., if the base sequence of one strand is known the base sequence of other strand can be formulated.

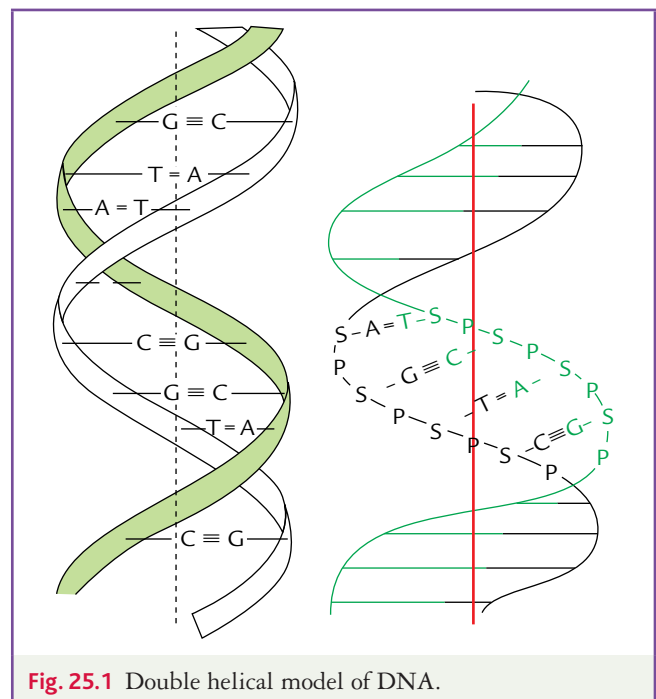


Fig. 25.1 Double helical model of DNA.

The functions of DNA molecule are as follows:

1. **Self-replication:** During nuclear division the two strands of DNA separate and each strand acts as a template to form a new complementary strand.
2. **Synthesis of RNA and proteins:** Certain regions of DNA serve as a template for the synthesis of RNA, which in turn synthesizes proteins.
3. **Recombination:** During crossing over in meiosis, there is an exchange of genetic material between homologous chromosomes, which leads to shuffling of genes, and the process is called **recombination**.
4. **Mutation:** It is the major source of genetic variation. Change of base sequence in a gene or gene sequence in the DNA molecule is called **gene mutation**. The mutation may be spontaneous or induced. The inducing agents include chemicals, radiation, etc.

Branches of Genetics

1. **Cytogenetics:** It deals with the study of chromosomes and genes.
2. **Molecular genetics:** It deals with the study of chemical structure of genes at molecular level.
3. **Developmental genetics:** It is the study of genetic control of embryonic development.
4. **Immunogenetics:** It deals with the genetics of production of various types of antibodies.
5. **Behavioral genetics:** It deals with influence of genes on the behavior of individual.
6. **Population genetics:** It deals with the laws of genetics applicable on human population.
7. **Biochemical genetics:** It deals with the inborn errors of metabolism.

Applications of Genetics in Medicine

- To study various diseases that have a genetic background.
- To study factors that control embryonic development.
- To study immunological status of an individual.
- To study the inborn errors of metabolism.
- To make prenatal diagnosis and treatment.
- To do genetic counseling for helping in planning pregnancies.
- To do gene therapy in patients who have a genomic defect.

Chromosomes

The chromosomes (Gr. *Chromosoma* = a readily staining body) are deeply stained minute rod-like structures in the nucleus of the cell formed by condensation of

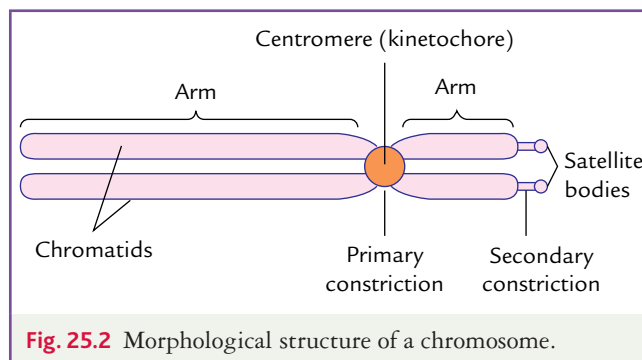


Fig. 25.2 Morphological structure of a chromosome.

chromatin during cell division. They contain DNA encoding genetic information inherited from parents. The individual chromosomes are best defined (visible) under microscope only during metaphase stage of cell division.

Morphological Structure of Chromosomes

Each chromosome presents a primary constriction called **centromere** or **kinetochore**. During cell division (prophase) each chromosome splits longitudinally into two **chromatids** except at centromere. The centromere divides each chromatid into two arms and is associated with movement of chromosomes during cell division. The free ends of chromatids are known as **telomeres**. The chromatids of some chromosomes present a secondary constriction near one end. The segment of chromatid distal to secondary constriction is called a **satellite body** (Fig. 25.2). Such chromosomes are sometimes called **SAT chromosomes**.

Morphological Types

Depending upon the location of centromere, the chromosomes are classified into four types (Fig. 25.3).

1. **Metacentric:** Centromere is located in the middle.
2. **Submetacentric:** Centromere is located close to the middle.
3. **Acrocentric:** Centromere is located close to the end of chromosome.
4. **Telocentric:** Centromere is located at the end of the chromosome.

Number of Chromosomes

The number of chromosomes is constant in a species. In humans, this number is 46 in somatic cells* and 23 in

*All the cells of body are somatic cells *except* the germ cells.

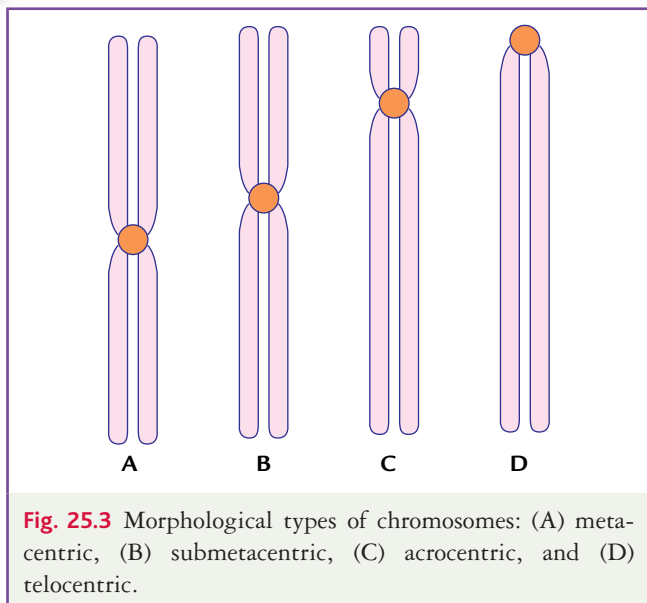


Fig. 25.3 Morphological types of chromosomes: (A) metacentric, (B) submetacentric, (C) acrocentric, and (D) telocentric.

germ cells. In somatic cells they are arranged into 23 pairs, whereas in germ cells they are not arranged in pairs. A cell with 23 pairs of chromosomes is called **diploid cell** and a cell with 23 chromosomes is called **haploid cell**.

In each pair of chromosomes, one is inherited from mother and one from father. The chromosomes belonging to the same pair are called **homologous chromosomes**. The complete set of chromosomes from a cell is called its **karyotype**.

Two of the 46 chromosomes are called **sex chromosomes** and remaining 44 chromosomes are called **autosomes**.

A normal female has two **X** chromosomes (XX) in each somatic cell, whereas a normal male has one **X** and one **Y** chromosome (XY) in each somatic cell. For convenience, the autosomes are numbered in pairs from 1 to 22. Some genetic disorders occur due to abnormal chromosomal number, e.g., Down's syndrome occurs due to absence of one X chromosome (XO).

Karyotyping

It is a process of arranging the chromosomes of a cell to study the complete chromosomal complement of an individual. According to Denver System of Classification (1960), the chromosomes, including sex chromosomes, are arranged into seven groups depending upon their (a) size, (b) position of centromere, (c) length-ratio between their arms, and (d) presence of satellite bodies on their arms. These groups are referred to by capital letters A to G. This arrangement of chromosomes is called a **karyotype** (Fig. 25.4). The karyotype provides the chromosomal constitution of a cell of an individual.

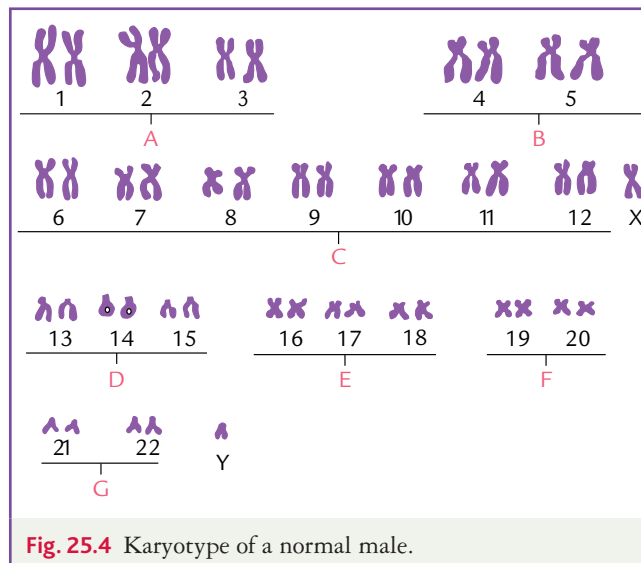


Fig. 25.4 Karyotype of a normal male.

Table 25.1 The characteristic features of pairs of chromosomes in karyotype

Group	Pairs of chromosomes	Features
A	1, 2, and 3	Long and metacentric
B	4 and 5	Fairly long and submetacentric
C	6 to 12+ X chromosome	Medium sized and submetacentric
D	13 to 15	Medium sized and acrocentric A <i>satellite body</i> is attached to the free end of short arm of each chromosome
E	16 to 18	Fairly short and submetacentric
F	19 and 20	Short and metacentric
G	21 and 22+ Y chromosome	Very short and acrocentric with <i>satellite bodies</i> on their short arms

The features of chromosomes in different groups are presented in Table 25.1.

N.B.

- Group A consists of longest metacentric chromosomes.
- Group G consists of shortest acrocentric chromosomes.

The precise identification of individual chromosome is now made possible by noting the patterns of bands on chromosomes by special staining techniques such as G-banding (Fig. 25.5).

Clinical Correlation

The karyotyping is of clinical significance as one can identify the structural and numerical variations in chromosomes, and with chromosomal banding pattern one can note certain abnormalities of chromosome structure such as *deletion* and *translocation* of specific regions of chromosomes.

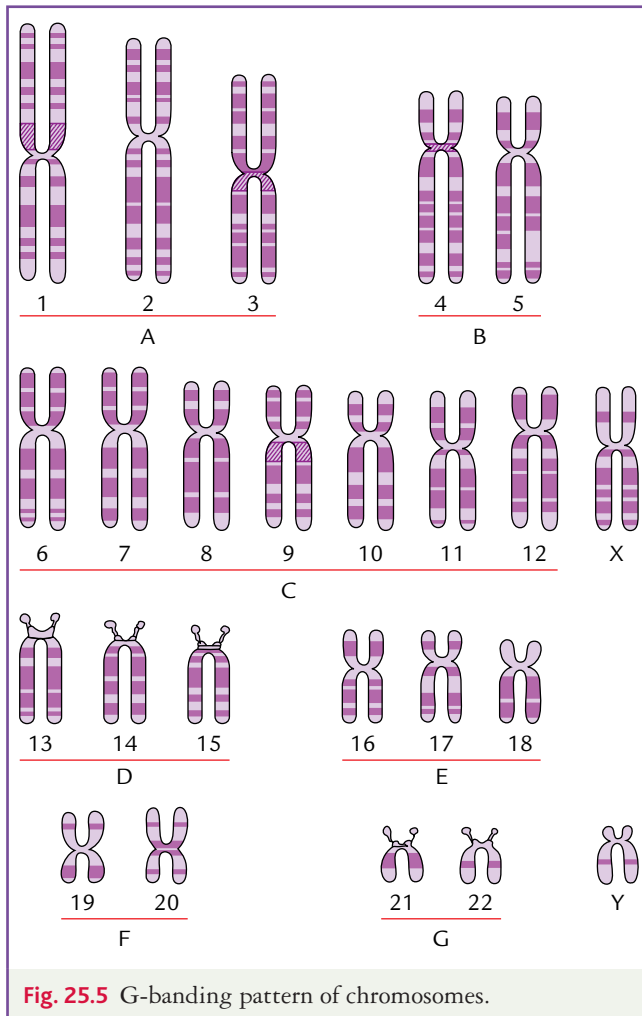


Fig. 25.5 G-banding pattern of chromosomes.

Sex Chromatin (Barr Body)

It is a darkly stained condensed clump of chromatin located subjacent to the nuclear membrane of somatic cells of normal (XX) females. It represents inactivated X chromosome.** During interphase (resting phase) of cell cycle, the chromosomes become uncoiled and thinned out; consequently they cannot be identified. The nucleus thus contains a network of **chromatin threads**. However, at some places the chromosome still remains coiled and these are visualized as **chromatin granules**. The uncoiled segments of chromosomes, the **euchromatin**, are genetically active. The coiled segments of chromosomes, the **heterochromatin**, are genetically inactive, i.e., inert. During cell division, each chromosome becomes thicker, shorter, and tightly coiled along its entire length. As a result, the individual chromosomes are visualized and identified.

During interphase in females, out of two X chromosomes one becomes highly coiled (genetically inactive)

**In female embryo at a particular stage of embryogenesis (usually at the blastocyst stage) one of the two X chromosome is inactivated on a random basis.

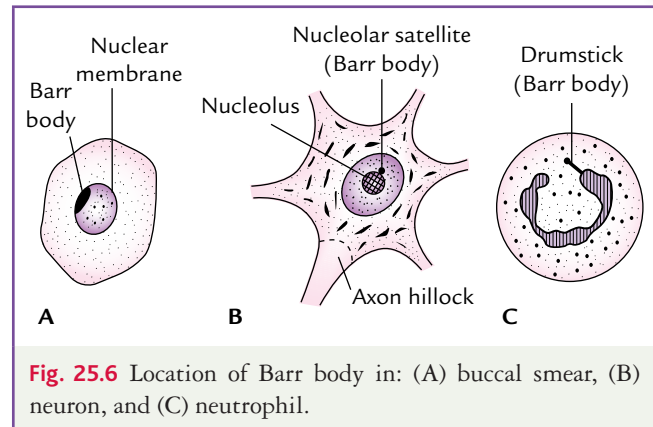


Fig. 25.6 Location of Barr body in: (A) buccal smear, (B) neuron, and (C) neutrophil.

and other remains uncoiled (genetically active). The coiled (genetically inactive) X chromosome is seen as heterochromatic body called **sex chromatin**. It is also called **Barr body** after the name of a Canadian geneticist Murray Barr. It was first noticed by Barr and Bertram (in 1949) in the nucleus of nerve cell of a female cat.

The Barr body is generally located on the inner surface of nuclear membrane as a dark basophilic body of chromatin in most of the cells of the body. It is generally ovoid or planoconvex. However, in neurons it appears as a small, dark body opposite to the nucleolus and in neutrophils it appears as a knob of 1.5 μm in diameter known as drumstick (Fig. 25.6).

N.B. Structurally, the sex chromatin is an extra X chromosome which is heterochromatic and genetically inactive.

N.B. Y chromosome: During interphase, the Y chromosome in male exhibits within the nucleus of a cell an intensely fluorescent mass called '**F body**' when stained with fluorochrome dye and examined under fluorescent microscope.

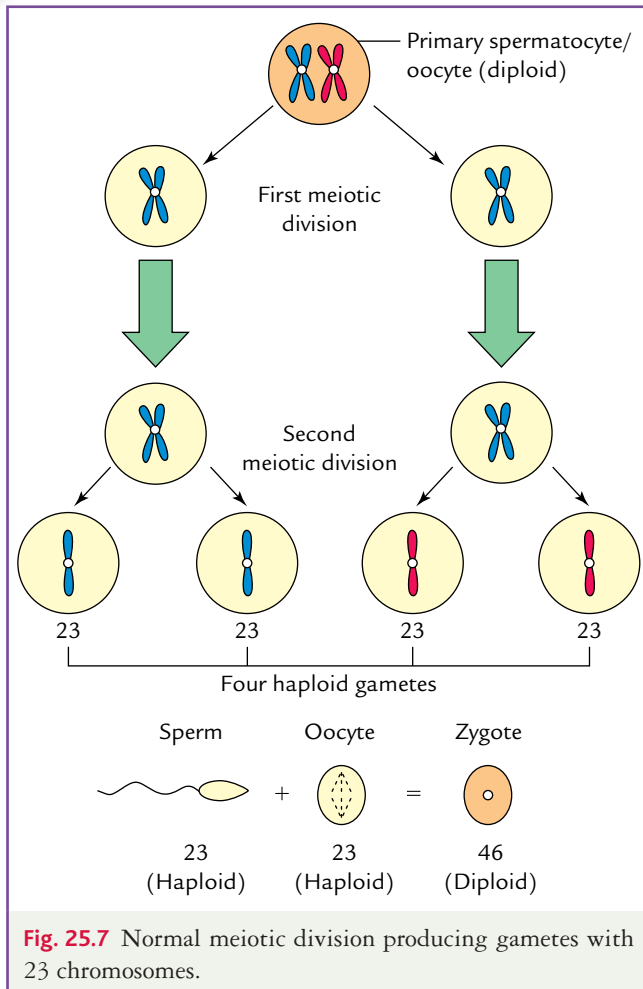
Chromosomal Abnormalities

The study of chromosomal abnormalities is of great clinical importance because they produce number of genetic disorders causing various clinical conditions.

Classification

The chromosomal abnormalities may be classified in a number of ways.

1. **On the basis of type of abnormality:**
 - (a) Numerical: Involving changes in the number of chromosomes, e.g., polyploidy and aneuploidy.
 - (b) Structural: Involving changes in the structure of chromosomes, e.g., deletion and translocation.
2. **On the basis of types of chromosomes involved:**
 - (a) Involving autosomes, e.g., Down's syndrome.
 - (b) Involving sex chromosomes, e.g., Turner's syndrome and Klinefelter's syndrome.



Numerical Abnormalities

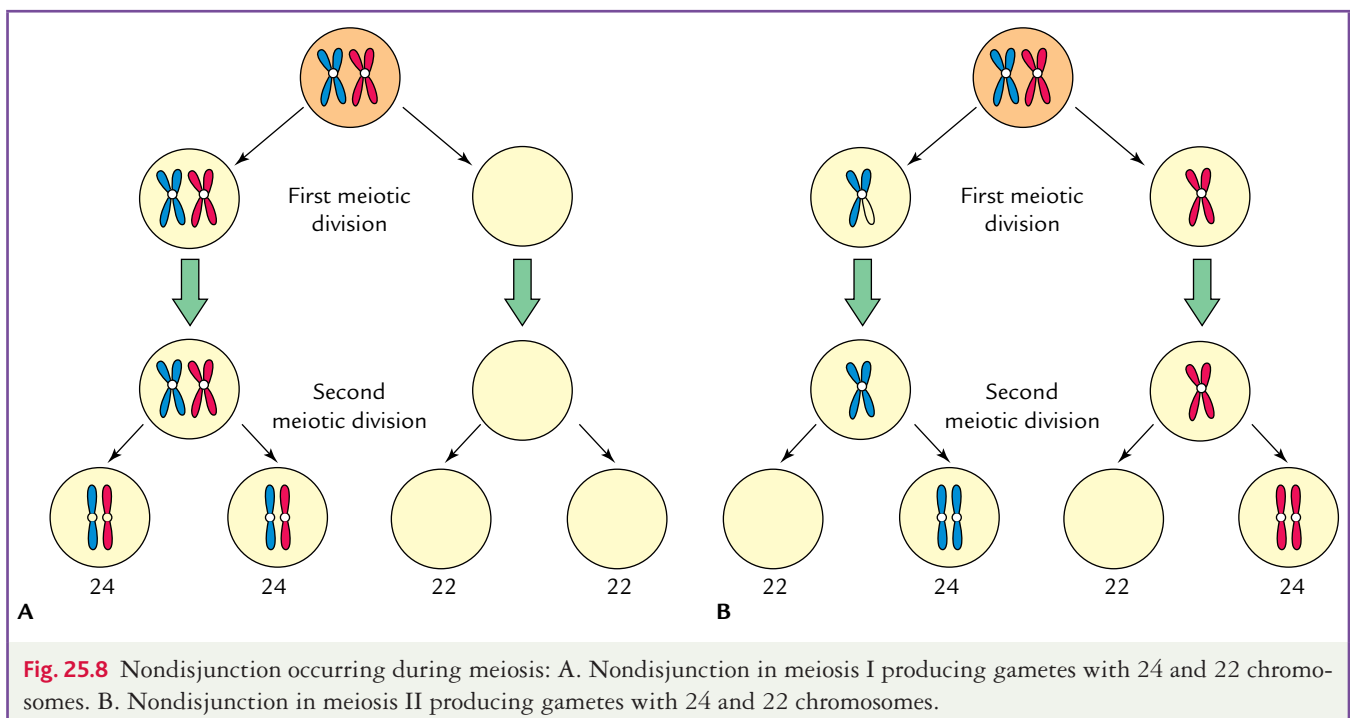
The numerical abnormalities of chromosomes occur due to failure of meiotic division to occur or due to abnormal meiotic division during the formation of gametes. In normal meiotic division during gametogenesis, both primary spermatocytes and primary oocytes produce four daughter cells, each with 23 chromosomes; and when haploid sperm fertilizes haploid ovum, the diploid zygote (46 chromosomes) is produced (Fig. 25.7).

Sometimes separation of two chromosomes does not occur (**nondisjunction**) either during first meiotic division (Fig. 25.8A) or during second meiotic division (Fig. 25.8B), and then both the members of a pair move into one cell.

As a result of the nondisjunction of the chromosome (Fig. 25.9), one gamete receives 24 chromosomes and the other 22. Consequently, at fertilization, when a gamete (e.g., sperm) having 23 chromosomes fuses with a gamete (e.g., ovum) having 24 or 22 chromosomes, the result will be an individual with either 47 chromosomes (**trisomy**) or 45 chromosomes (**monosomy**).

The numerical abnormalities include following conditions.

1. **Polyploidy:** It is a condition in which chromosome number is increased in a multiple of haploid (23) set of chromosomes, of course, in addition to



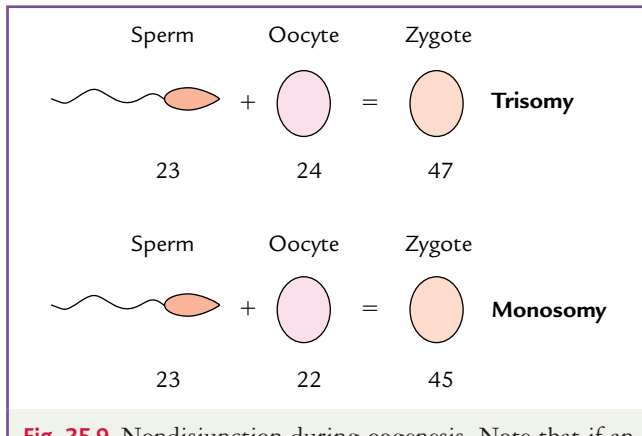


Fig. 25.9 Nondisjunction during oogenesis. Note that if an abnormal oocyte with 24 chromosomes is fertilized by a normal sperm with 23 chromosomes then a zygote with 47 chromosomes is produced (i.e., trisomy). If an abnormal oocyte with 22 chromosomes is fertilized by a normal sperm with 23 chromosomes then a zygote with 45 chromosomes is produced (i.e., monosomy).

the diploid number. In other words, polyploidy is the condition of extra haploid set/sets of chromosomes (i.e., 23) to normal diploid set of chromosomes (i.e., 46). The examples are given below.

(a) **Triploidy:** In this condition the cells contain 69 chromosomes (23×3). It occurs either due to failure of meiosis in germ cell, e.g., fertilization of diploid ovum by a haploid sperm or fertilization of haploid ovum by two haploid sperms (dispermy).

N.B. Triploidy results in spontaneous abortion of the conceptus or brief survival of live-born infant after birth.

(b) **Tetraploidy:** In this condition the cells contain 92 chromosomes (23×4). It occurs due to failure of first cleavage division.

N.B. Tetraploidy results in spontaneous abortion of the conceptus.

2. **Aneuploidy:** It is a condition in which chromosome number is altered by one, i.e., there is an addition of one chromosome (**trisomy**) or loss of one chromosome (**monosomy**). It occurs due to nondisjunction during meiosis (Figs 25.8 and 25.9).

N.B. *Trisomy* usually results in spontaneous abortion of the conceptus; however, *trisomy 13* (Patau's syndrome), *trisomy 18* (Edward's syndrome), *trisomy 21* (Down's syndrome), and Klinefelter's syndrome are found in live-born population.

Monosomy also usually results in spontaneous abortion of the conceptus; however, monosomy of X chromosome ($45 : XO$), i.e., Turner's syndrome is found in live-born population.

Structural Abnormalities

These abnormalities involve change in the structure of chromosome. The types of structural abnormalities

include deletions, microdeletions, translocation, fragile sites, isochromosomes, inversions, and breakage.

The abnormalities in structure cause following conditions.

1. **Deletions:** It is a condition in which there is a loss of segment of a chromosome.

The clinical conditions caused due to deletions include Wolf–Hirschhorn syndrome (due to deletion in the short arm of chromosome 4) and cri-du-chat or cat's cry syndrome (due to deletion in the short arm of chromosome 5).

N.B. Sometimes chromosome is deleted at both the ends, and then the two broken ends adhere/unite in the form of ring called *ring chromosome*, commonly seen due to break points of chromosome 14.

2. **Microdeletions:** In this condition there is a loss of a segment of chromosome, which can be detected only by a high-resolution banding. The clinical conditions caused by microdeletions include the following.

(a) *Prader–Willi syndrome:* Caused due to microdeletion in the long arm of chromosome 15 derived from father.

(b) *Angelman's syndrome or happy puppet syndrome:* Caused due to microdeletion in the long arm of chromosome 15 derived from mother.

(c) *DiGeorge syndrome:* Caused due to microdeletion in the long arm of chromosome 2.

(d) *Miller–Dieker syndrome:* Caused due to microdeletion in the short arm of chromosome 17.

3. **Translocation:** In this condition, there is breakage and exchange of segments between chromosomes. The examples include the following.

(a) *Robertsonian translocation:* It is a special type of translocation in which breaks occur at the centromeres, e.g., translocation between long arms of chromosomes 13 and 14 (**most common translocation found in humans**), and chromosomes 21 and 22. The short arms of these chromosomes involved in Robertsonian translocations are generally lost.

(b) *Reciprocal translocation between chromosome 15 and chromosome 17:* It leads to *acute promyelocytic leukemia*.

(c) *Reciprocal translocation between chromosome 9 and chromosome 22 (Philadelphia chromosome):* It leads to *chronic myeloid leukemia*.

4. **Fragile sites:** In this condition there are gaps or breaks in chromosomes. The clinical examples caused due to this condition include **Fragile X syndrome** (*Martin–Bell syndrome*).

5. **Isochromosomes:** In this condition the centromere divides transversely instead of longitudinally.

As a result, two arms of a chromosome are separated forming two isochromosomes.

6. **Inversions:** In this condition a part of chromosome is detached and later unites with the same chromosome in inverted position. As a result, there is a reversal of order of DNA between two breaks in the chromosome. It can be **pericentric** if inversions occur on sides of the centromere or **paracentric**, if inversions occur on the same side of the centromere.
7. **Breakage:** In this condition there occurs a break in chromosome due to ultraviolet radiation and ionizing radiation.

Genes

Gene, the functional unit of DNA, is the unit of inheritance. The term 'gene' was coined by Johanssen (1909). The properties of gene include:

1. To determine traits, e.g., color of skin, intelligence, height, etc.
2. To undergo replication
3. To undergo mutation.

About 50,000–100,000 genes are present in the human genome; out of these, about 450 genes are linked to human diseases.

Functions of Genes

1. Maintain the genetic specificity of an individual.
2. Play key role in transmission of traits from parents to offspring.
3. Synthesize various proteins and enzymes of cell.

Types of Genes

The genes are classified into various types. It is beyond the scope of this book to describe all the types. The present account is of two major types of genes. These are as follows.

1. **Structural genes:** These are those DNA segments that code for specific amino acid sequences in a protein.
2. **Regulatory genes:** These are those DNA segments that control structural genes being transcribed for synthesis of a protein.

Location of Genes

Each gene occupies a specific **locus** on a chromosome. Both chromosomes of a given pair contain similar genes. The two chromosomes of a pair are homologous

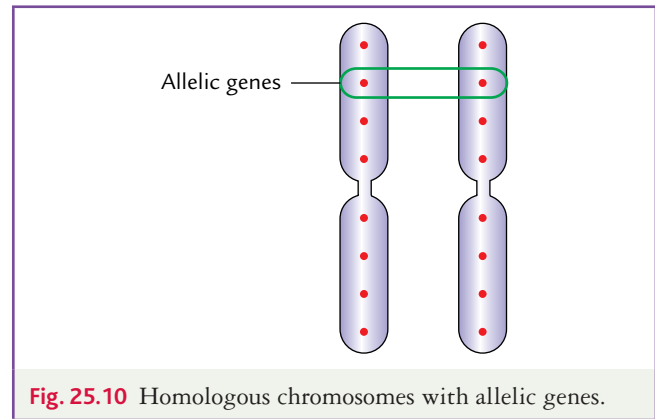


Fig. 25.10 Homologous chromosomes with allelic genes.

and genes occupying the same locus on homologous chromosomes are called **alleles**. If two allelic genes are identical, the person is **homozygous** for the trait specified by that gene locus. For example, ability to roll one's tongue is coded on a single gene. Since one chromosome of each pair is inherited from father and one from mother, an individual has two genes controlling the ability to roll the tongue. Such paired genes are **alleles**. If the two alleles are different, the person is **heterozygous** for that trait. For example, one copy of tongue rolling gene may code for the ability to roll the tongue, whereas the corresponding gene on the other chromosome may code for inability to roll the tongue. Note that this example involves only two forms of the same gene. Some traits like eye color is controlled by more than one genes.

During reproduction each male and female contributes 23 chromosomes to the zygote. Therefore, for any given pair of alleles controlling a given trait, the female contributes one allele and male contributes one allele.

An exception occurs with X and Y chromosomes as there are no alleles on the Y chromosome for most of the loci on the X chromosome.

The paired chromosomes are called homologous chromosomes (Fig. 25.10). In females, the two sex chromosomes (XX) are identical in length, hence they are homologous. In males, the two sex chromosomes (XY) are unequal in length—X chromosome is longer than short chromosome, hence they have homologous and nonhomologous parts (Fig. 25.11).

Dominant and Recessive Genes

If gene produces its effect, whether it is present either upon one or upon both chromosomes of a pair of chromosome, it is called **dominant gene**. If it produces its effect only when it is present on both chromosomes, it is called **recessive gene**. Thus diseases are inherited through both dominant and recessive genes called dominant inheritance and recessive inheritance, respectively.

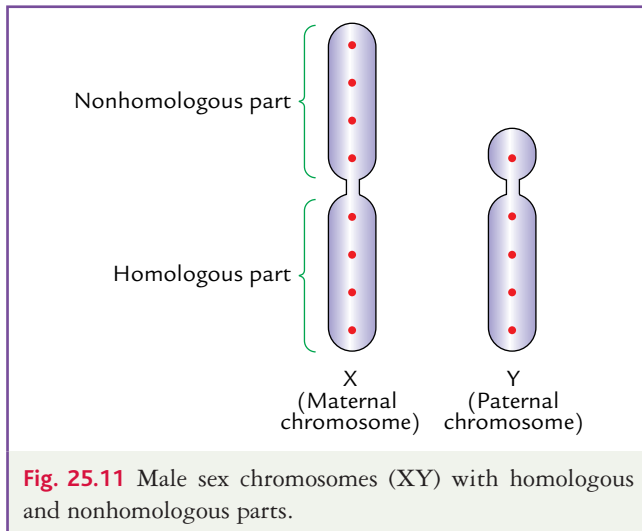


Fig. 25.11 Male sex chromosomes (XY) with homologous and nonhomologous parts.

Inheritance

Overview

When genetic disorders are studied, it is important to know the patterns of inheritance for the following reasons:

- To make accurate diagnosis of a genetic disorder.
- To calculate the risk of genetic disorder occurring in offsprings.
- To counsel for prevention of occurrence of genetic disorder.

Inheritance is the process of transmission of characters/traits from generation to generation. The reproduction is an essential requisite for the inheritance to take place. The inheritance of traits from parents to offspring takes place through genes which carry all information about all types of traits. The genes are located in both autosomes and sex chromosomes. The inheritance occurring through genes of autosomes is called **autosomal inheritance**, whereas inheritance occurring through genes of sex chromosomes is called **sex-linked inheritance**.

The inheritance which occurs due to interaction of gene and environmental factors, viz., infectious agents, drugs, or ionizing radiation is called **multifactorial inheritance**.

Types of inheritance: There are three types of inheritance (vide supra) as follows:

1. Autosomal inheritance
2. Sex-linked inheritance
3. Multifactorial inheritance.

Principles of Inheritance

- A disease exhibits **autosomal dominant inheritance** when an abnormal allele in an autosomal locus is sufficient to cause disease in both homozygous as

well as heterozygous states (e.g., TT or Tt; T = tall and t = short).

- A disease exhibit autosomal recessive inheritance when one abnormal allele in an autosomal locus is able to express only in a homozygous state (e.g., tt; t = short).
Sex-linked genes are abnormal genes located on X or Y chromosome.

Each chromosome of a homologous pair contains genes for the same traits.

Autosomal Inheritance

Autosomal Dominant Inheritance

When one parent is affected (i.e., have an abnormal dominant allele) then 50% children are affected. The pedigrees involving autosomal dominant disease exhibit vertical pattern of inheritance from one generation to the other. The examples of disorders caused by autosomal inheritance are:

- Marfan's syndrome
- Achondroplasia
- Brachydactyly
- Neurofibromatosis

N.B. The unaffected members of family do not transmit the trait further.

Autosomal Recessive Inheritance

In this, the disease is transmitted by a couple, both of whom are carriers of an abnormal gene, but they themselves are not affected, i.e., only siblings are affected but parents are normal. This inheritance shows horizontal pattern where many individuals in a single generation are affected. The risk of children affected is 25% in carrier couple. The parents are usually close relatives (cousins). The examples of autosomal recessive disorders are:

- Inborn errors of metabolism
- Hemoglobinopathies, e.g., sickle cell anemia and thalassemia.

N.B. The presence consanguinity alerts parents to the possibility of an autosomal recessive disorder in children.

Sex-linked Inheritance

The Y chromosome is shorter than X chromosome. Therefore, traits coded on the nonhomologous part of X chromosome have no corresponding traits on the Y chromosome. These genes on sex chromosomes are called **sex linked**, those on X chromosome are X linked, and those on Y chromosome are Y linked.

X-linked Inheritance

X-linked genes are exclusive to X chromosome. For example, the gene that codes for normal **color vision** is carried on X chromosome only. It is the dominant form of gene. There is a rare, faulty, recessive form of this gene that codes for **red–green blindness**. If female inherits a faulty gene, she is likely to have a normal gene on her other chromosome that provides normal color vision. A female carrying the faulty gene (color blindness gene), even though she is not a color blind may pass the faulty gene onto her children and thus she is called a **carrier**. If the gene is faulty in male, he will be color blind because he has only one X chromosome and so will have only one copy of the gene.

N.B. The ability to discern red–green color depends entirely on X chromosome.

If normal gene is represented by capital 'C' and faulty gene is represented by small 'c' then the genotype possibilities in this condition are shown in Fig. 25.17.

Clinical Correlation

For a female to be color blind for red and green color, she has to have a recessive allele (color blind gene) on both of her X chromosomes (XcXc). This is possible only if her mother is a carrier (XCXc) and her father is a color blind (XcY).

Clinical Correlation

Hemophilia is a clinical condition associated with repeated episodes of severe and prolonged bleeding at any site with little trauma. It is a sex-linked condition caused by a recessive allele responsible for faulty clotting. If 'H', represents normal clotting and 'h' represents abnormal clotting, then males with XHY will be normal and males with XhY will be hemophilic. The females with XhXh will also be hemophilic.

N.B. In hemophilia clotting factor VIII is abnormal.

Y-linked Inheritance

Since males have only one Y chromosome, the gene is necessarily unpaired. Therefore, if present it will be expressed and the question of dominance and recessiveness does not arise. Further the gene will be passed on from affected male to all his sons, e.g., characteristic growth of hair on the pinna of ear. This is the only Y linked gene inheritance and hence for all practical purposes, sex linked means X linked.

Multifactorial Inheritance

The multifactorial inheritance occurs as a result of interaction of genes and environmental factors. Some

		FATHER (Normal)	
		XC (Normal gene)	Y (Gene absent)
MOTHER (Carrier)	XC (Normal gene)	XCXC Normal girl	XCY Normal boy
	Xc (Color-blindness gene)	XCXc Carrier girl without color blindness	XcY Color blind boy

Fig. 25.12 Punnett square showing sex-linked inheritance.

		PATERNAL GENES	
		T	t
MATERNAL GENES	T	TT	Tt
	t	Tt	tt

Fig. 25.13 Punnett square showing probabilities of genetic combination of tongue rolling gene.

examples of congenital disorders caused by multifactorial inheritance are:

- Cleft lip
- Cleft palate
- Club foot
- Congenital dislocation of hip
- Congenital heart disease.

N.B. Nongenetic factors that contribute to multifactorial inheritance include:

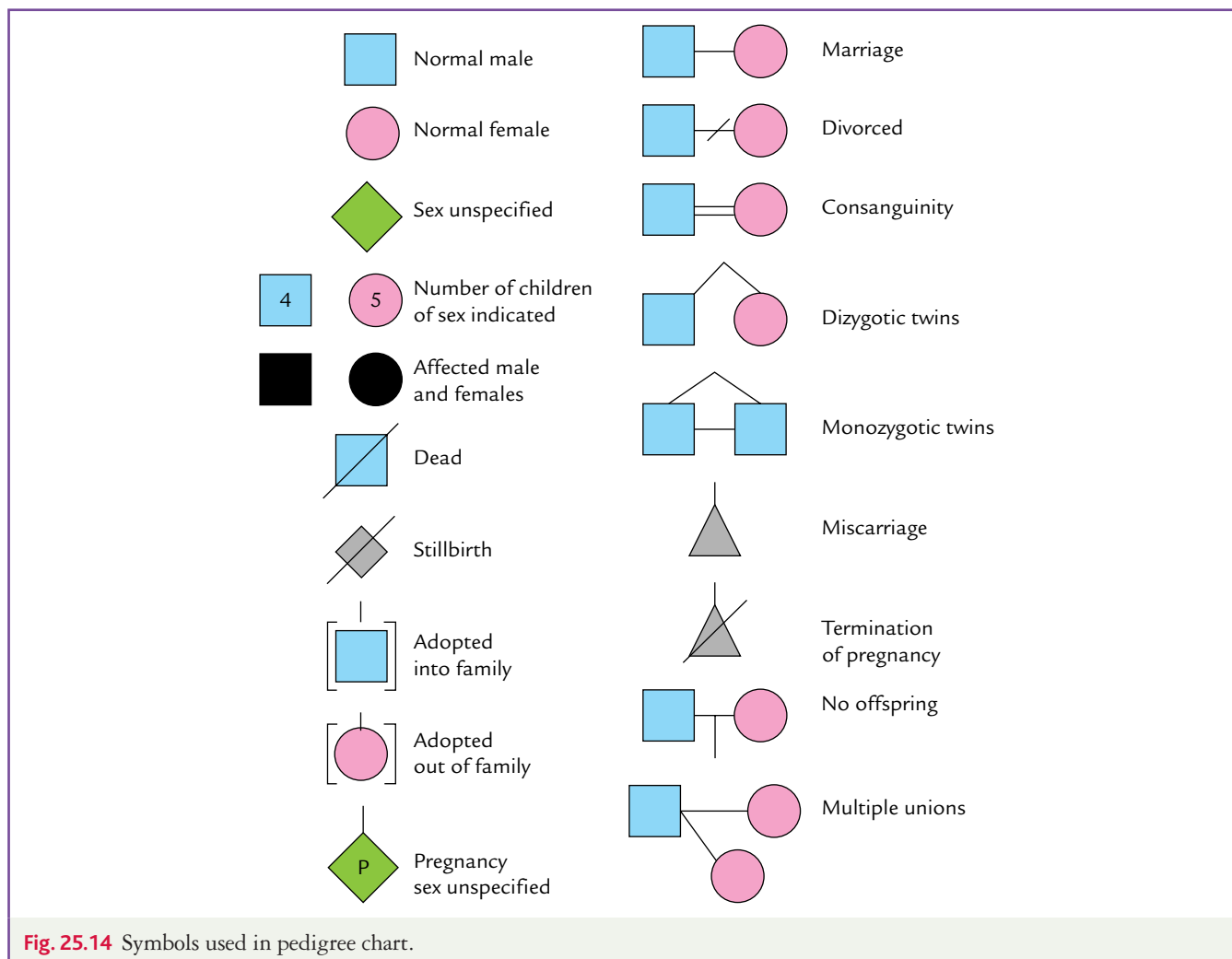
- *Drugs*, e.g., thalidomide and anticonvulsants
- *Infections*, e.g., Rubella virus
- *Ionizing radiations*, e.g., X-rays and radioactive substances

Punnett Squares

The probability of occurrence of a given genetic combination for certain trait can be predicted by Punnett squares (Fig. 25.13).

TT = Tongue-roller homozygous

Tt = Tongue-roller heterozygous



Tt = Tongue-roller heterozygous

tt = Nonroller homozygous.

Pedigree Chart (Figs 25.14 and 25.15)

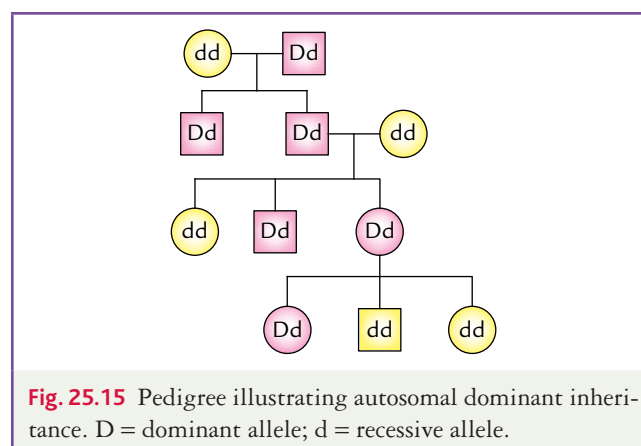
The preparation of a pedigree chart is a procedure through which gene mapping is done.

- It is dependent on the study of segregation of *marker genes* in families with genetic disorders.
- The pedigree chart is a useful document that helps in determining mode of inheritance of a particular genetic disorder, which is an essential requisite in *genetic counseling*. By preparing pedigree chart one can explain the inheritance patterns and predict risks for various family members to have offsprings with genetic diseases (recurrence risks).

Methodology of preparing a pedigree chart A graphic representation of a generation of a family is made by using various symbols. The symbols represent relationships, clinical findings, etc.

The steps of making pedigree chart are:

- Extract information



- Use standard symbols with key for interpretation
- Identify information and use other family members for documentation of information
- Ask details about adoption, abortion, stillbirth, etc.
- Ask about history of consanguinity.

The standard symbols used for making pedigree chart are given in Fig. 25.14.

The pedigree chart showing autosomal dominant inheritance is shown in Fig. 25.15.

Clinical Correlation

Disorders due to chromosomal abnormalities

Disorders due to chromosomal abnormalities can be due to numerical or structural abnormalities of chromosomes.

I. Numerical chromosomal abnormalities affecting autosomes

A. Down's syndrome (mongolism) or trisomy 21: In this disorder there are three copies of chromosome 21 (trisomy 21), i.e., there is an extra chromosome 21. The karyotype of patient is 47XY +21.

The trisomy 21 is of two types.

- 1. Triplo-21 (nonfamilial mongolism):** It is common and the affected babies possess 47 chromosomes, including two X chromosomes. It occurs during meiosis due to nondisjunction of 21st pair of chromosomes.
- 2. Translocation mongolism (familial mongolism):** In this an individual possesses 46 chromosomes. In this condition the extra chromosome becomes attached to one of the other autosomes.

The Down's syndrome occurs one in every 700 births (1/700).

Majority of the mongoloid babies have 47 chromosomes with trisomy 21, but about 3% have normal 46 chromosomes with translocation of two 21 chromosomes.

Characteristic clinical features (Fig. 25.16):

The affected individual presents the following features:

- Round face with oblique palpebral fissures and inner epicanthic folds, i.e., mongoloid facies, hence the name mongolism.
- Small nose with shallow bridge and low-set square ears.
- Short and broad hands with single transverse crease in the palm (*Simian crease*) across the bases of four fingers.
- Open mouth with long protruding tongue.
- Mental retardation (IQ 25–50).
- Short stature with hyperflexibility of joints (hypotonia).

N.B.

- Down's syndrome is the best known and one of the most common chromosomal abnormality in humans. It was first described in 1886 by L. Down.
- Down's syndrome is the most common numerical chromosomal abnormality.

B. Patau's syndrome: In this disorder there are three copies of chromosome 13 (*trisomy 13*).

C. Edward's syndrome: In this disorder there are three copies of chromosome 18 (*trisomy 18*).

N.B. The Patau's and Edward's syndromes are very rare conditions and infants with these syndromes usually die within few weeks after birth.

II. Structural chromosomal abnormalities affecting autosomes

1. Cri-du-Chat syndrome (cat's cry syndrome): This condition is caused by a deletion in the short arm of chromosome 5 so that part of chromosome 5 is missing.

Characteristic clinical features:

- Round face
- Characteristic cat-like cry (i.e., meowing cry) of a child
- Hypertelorism
- Congenital heart defects
- Microcephaly
- Mental retardation

2. Prader-Willi syndrome: This condition occurs due to microdeletion in the long arm of chromosome 15 derived from father (i.e., *paternal imprinting*).

Characteristic clinical features

The affected children presents the following features:

- Hyperphagia (insatiable appetite) and obesity
- Short stature with small hands and feet
- Hypotonia
- Hypogonadism
- Mild to moderate mental retardation
- Behavioral problems such as rage and violence

3. Angelman's syndrome (happy puppet syndrome): It occurs due to microdeletion in the long arm of chromosome 15 derived from mother (i.e., *maternal imprinting*). Angelman's syndrome is the counterpart of Prader-Willi syndrome.

Characteristic clinical features

- Happy disposition with inappropriate laughter.

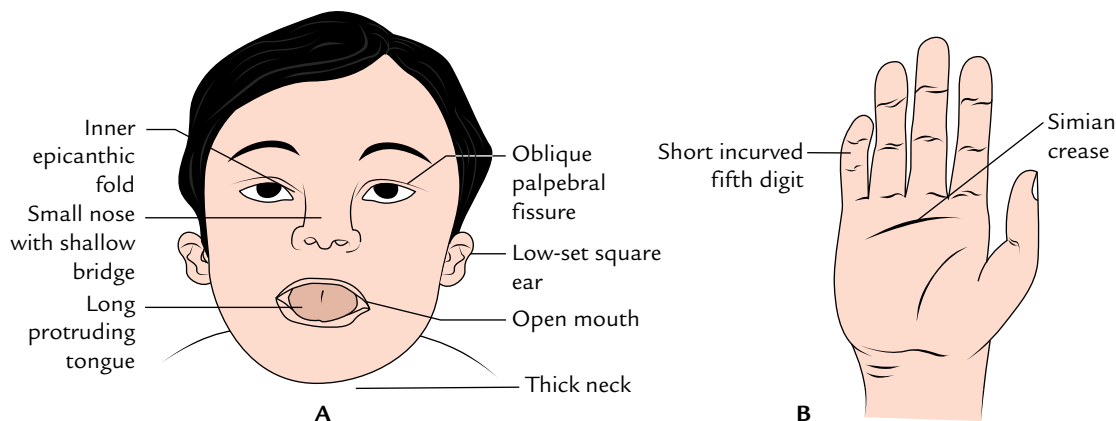


Fig. 25.16 Down's syndrome (47XY +21): A. Facial features of an infant with Down's syndrome. B. Simian crease.

- Severe mental retardation (IQ: 5–10)
- Ataxic gait (stiff, jerky, unsteady)
- Seizures

Chromosomal abnormalities affecting sex chromosomes

1. Klinefelter's syndrome: It is a trisomic condition found only in males. It is caused by nondisjunction of XX chromosome during gametogenesis. As a result the chromosomal complement in somatic cells is XXY. The individual is phenotypically a male but is sex chromatin (Barr body) positive due to presence of an extra X chromosome. The karyotype of the individual is 47XXY.

Characteristic clinical features (Fig. 25.17)

- Affected individual is phenotypically a male with eunuchoid habitus.
- Hypogonadism and associated azoospermia and sterility.
- Gynecomastia.
- Axillary and pubic hair absent, chest hair reduced.
- Mental retardation.
- Length of legs and arms are usually longer than normal.
- Increased gonadotropin levels.

N.B. The incidence of Klinefelter's syndrome is about 1:500 male births and it increases with advancing maternal age.

2. Turner's syndrome: It is a monosomic condition found only in females. It occurs due to loss of one X chromosome following non-disjunction of X chromosome during meiosis. As a result the chromosomal complement in somatic cells is 45XO. The karyotype of an individual is 45X.

Characteristic clinical features (Fig. 25.18)

- Affected individual is phenotypically a female

- Short stature and webbing of neck (due to delayed maturation of lymphatics)
- Shield chest with pin-point nipples
- Bilateral cubital valgus
- Low-set ears.
- Infantile external genitalia.
- Gonadal dysgenesis associated with amenorrhea.
- Coarctation of aorta.

N.B. The incidence of Turner's syndrome is 2 : 3000 female births. This syndrome is the common cause of *primary amenorrhea*. In 75% of Turner's patients, the X chromosome is maternal in origin. Turner's syndrome is the only viable monosomy in human beings.

The key differences between Klinefelter's and Turner's syndromes are presented in Table 25.2.

3. Super female or triple X syndrome: It occurs due to fertilization of XX-containing oocyte by an X-containing sperm (gynosperm).

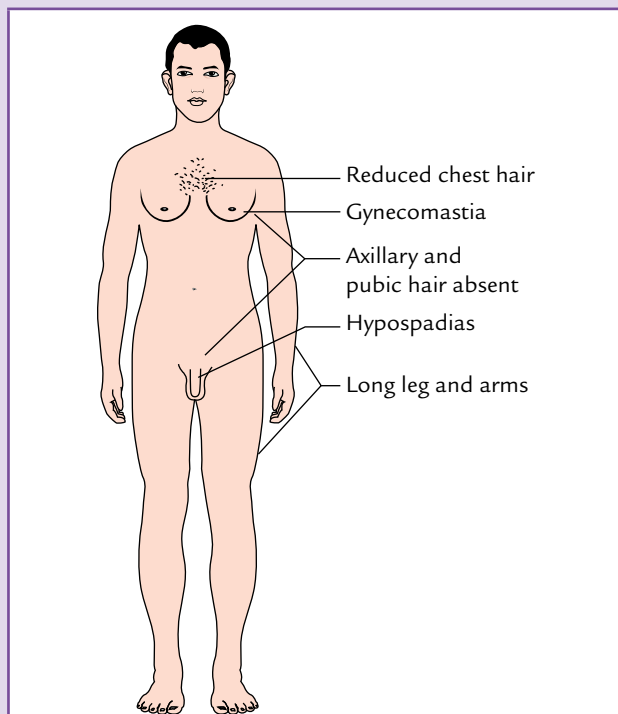


Fig. 25.17 An individual with Klinefelter's syndrome (47XXY karyotype; individual is tall, thin, shy, and nervous).

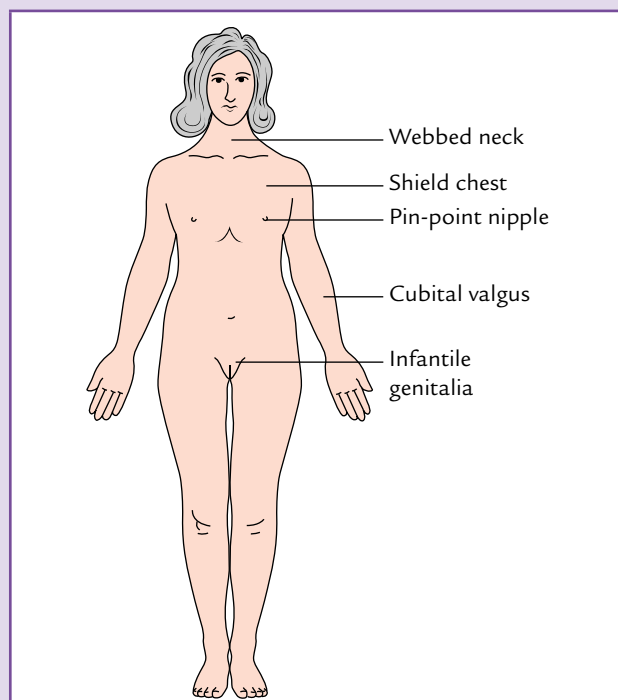


Fig. 25.18 An individual with Turner's syndrome (45XO karyotype).

Table 25.2 Differences between Klinefelter's and Turner's syndromes

Klinefelter's syndrome	Turner's syndrome
Trisomic condition found only in males	Monosomic condition found only in females
Chromosomal complement in somatic cells is 47XXY	Chromosomal complement in somatic cells is 45XO
Affected individuals are phenotypically males	Affected individuals are phenotypically females
Long stature	Short stature

The karyotype shows 47 chromosomes. The individual is phenotypically a female with two Barr bodies, hence referred to as '**super female**'. The chromosome complement in somatic cell is 47XXX.

Characteristics clinical features

- ◆ Female phenotype
- ◆ Some degree of mental retardation
- ◆ Scanty menses
- ◆ Infantile personality.

Single gene inherited diseases

1. Autosomal dominant inheritance: The disease caused by autosomal dominant inheritance need only one defective copy of the gene from either of parent, e.g., Marfan's syndrome.

Marfan's syndrome (Fig. 25.19): It is an inherited autosomal dominant connective tissue disorder.

Characteristic clinical features

- ◆ Long spidery fingers (arachnodactyly)
- ◆ Arm span greater than height
- ◆ Saucer or funnel-shaped chest (pectus excavatum)
- ◆ Scoliosis
- ◆ A high arched palate
- ◆ Ectopic lens
- ◆ Aortic dilatation or dissection.

2. Autosomal recessive inheritance: A disease that occurs due to autosomal recessive inheritance affects only those individuals who receive two copies of the defective gene one from each parent, e.g., cystic fibrosis.



Fig. 25.19 Marfan's syndrome.

Cystic fibrosis (CF): It is caused by autosomal recessive mutation. The CF gene is located on the long arm of chromosome 7.

It causes production of abnormally thick secretion of mucus by epithelial cells lining the respiratory and gastrointestinal tracts, particularly in the first one.

Characteristic clinical features

The affected individual presents the following features:

- ◆ Obstruction of respiratory airways
- ◆ Recurrent respiratory infections

3. X-linked recessive inheritance: In X-linked recessive inheritance the disease is usually observed only in the males because males have only one X chromosome.

The female may also be affected, but rarely. In females, one X chromosome is inactivated to form a Barr body. The choice whether the maternally derived or paternally derived X chromosome is deactivated is a random and permanent event. If X chromosome with normal gene is deactivated then the female has one X chromosome with the abnormal gene and will, therefore, be affected by the disease.

The examples of X-linked recessive inheritance diseases are: Duchenne muscular dystrophy (DMD), hemophilia, red and green color blindness.

(a) *Duchenne muscular dystrophy:* It is a hereditary disease of skeletal muscle which usually affects males. The DMD is caused by X-linked recessive mutation. The DMD gene is located on the short arm of chromosome X. The DMD gene encodes for a protein called **dystrophin**, which anchors the actin (cytoskeleton) of skeletal muscle cells to extracellular matrix. Thus, mutation of DMD gene destroys the ability of dystrophin to anchor actin to the extracellular matrix. Consequently the skeletal muscles become progressively weak from early childhood, and by the time he reaches adolescence, he becomes completely immobile.

Characteristic clinical features

The affected individual presents the following features:

- ◆ Progressive muscle weakness and wasting.
- ◆ Premature death due to cardiac and respiratory failure.

(b) *Hemophilia:* The hemophilia results due to deficiency or dysfunction of clotting factor VIII. It occurs due to mutation of X-linked recessive gene located on one X chromosome, which is responsible for clotting factor VIII.

Characteristic clinical features

- ◆ Excessive bleeding, particularly from gums, but virtually no tissue is exempted
- ◆ When bleeding follows trauma, it is characteristically prolonged.
- ◆ Bleeding tendency may range from mild to severe.
- ◆ Excessive bleeding is unusual until the baby is about 6 months old.

The red and green color blindness is described on page 300.

GOLDEN FACTS TO REMEMBER

- | | |
|--|---|
| ➤ Father of Genetics | Gregor Johann Mendel (discovered fundamental laws of inheritance in 1865) |
| ➤ Correct structure of DNA was first deduced by | James Watson and Francis Crick (1953) |
| ➤ Structural unit of DNA | Gene |
| ➤ The term 'gene' was first coined by | Johannsen (1909) |
| ➤ Unit of inheritance | Gene |
| ➤ Number of genes in human genome | 50,000–100,000 |
| ➤ Most important intermediary molecule for gene expression | RNA |
| ➤ Best known and most common chromosomal abnormality | Down's syndrome (trisomy 21) |
| ➤ Only viable monosomy in human beings | Turner's syndrome (45XO) |
| ➤ Most common translocation in chromosomes of human beings | Robertsonian translocation |
| ➤ Commonest hereditary bleeding disorder | Hemophilia |
| ➤ Commonest X-linked gene disorder | Red and green color blindness |
| ➤ Most important process required for inheritance | Reproduction |
| ➤ Most X-linked disorders are recessive conditions <i>except</i> | Vitamin D resistant rickets that is X-linked dominant condition |
| ➤ Only known condition that is Y linked | Hairy pinna in male |
| ➤ In all living organisms the genetic information is stored in DNA <i>except</i> | In some viruses (RNA viruses) in which the genetic information is stored in RNA |
| ➤ All cells in the body contain 46 chromosomes <i>except</i> | Gametes (sex cells) that contain 23 chromosomes |

CLINICAL PROBLEMS

- A mother took her 5-year-old son to the pediatrician and complained that her child always keeps his tongue protruded and appears dull as compared to other children of his age. His eyes also appear abnormal. On examination, the pediatrician made following observations: (a) round face with epicanthic folds, (b) mental retardation, (c) hypotonia, and (d) single line in the palm. On the basis of these observations the child was diagnosed as a case of Down's syndrome. Give the embryological and genetic basis of this syndrome.
- A 40-year-old woman went to a gynecologist for a check up when she missed her period. On pelvic examination the doctor told her that she is pregnant. The gynecologist was very much concerned as it was her first pregnancy. Answer the following questions on the basis of your knowledge of embryology and developmental genetics.
 - Do women above 35 years of age are of at risk of giving birth to abnormal children?
 - If a 40-year-old woman becomes pregnant what tests you would like to advise.
 - What genetic abnormality is likely to occur?
- What is mosaicism. Give its genetic basis?
- In consanguinity (marriage among cousins) which genetic disorders are likely to occur.

CLINICAL PROBLEM SOLUTIONS

1. The Down's syndrome (trisomy 21) is the most common numerical abnormality that leads to various defects which are seen in this case.

The most common cause of abnormal chromosome number is nondisjunction during meiosis. Nondisjunction during meiosis I or II results in half of the gametes having no copy and half having two copies of chromosomes.

In this case, the fertilization had occurred between gamete with two copies and a normal one. As a result, the zygote has 47 chromosomes (**trisomy**). The trisomy 21 occurs during meiosis due to nondisjunction of 21st pair of chromosomes.

2.
 - (a) Yes, because women above 35 years of age are likely to have child with Down's syndrome and other malformations.
 - (b) She will be advised following tests: chronic villi biopsy and/or amniocentesis to determine chromosomal disorders such as trisomy 21, trisomy 13, etc.
 - (c) Down's syndrome.
3. The mosaicism is a state of being mosaic. A person who has at least two cell lines with two or more different constitution. In this condition either the autosomes or sex chromosomes are involved. The mosaicism usually occurs from nondisjunction during early cleavage of zygote.
4. Autosomal recessive disorders.

26

Application of Embryology in Clinical Practice

Overview

Gone are the days when embryology was learnt from models, charts, and museum specimens of aborted fetuses. Now-a-days, with the advent of new imaging techniques, particularly ultrasonography, one can learn about developing embryo and fetus within the uterus along entire period of pregnancy in a woman (living embryology), and apply this knowledge in one's clinical practice.

To learn living embryology, one should precisely know various developmental events that take place continuously from the date of fertilization to birth of baby.

Pregnancy (Gestation Period)

Pregnancy is a state of a female starting from time of conception until delivery of products of conception (L. *Pregnancy* = carrying products of conception).

Length of pregnancy (gestation period) is considered to be of **280 days** or **40 weeks** after the onset of last normal menstrual period.

Or

More accurately, the length of pregnancy (gestation period) is considered to be of **266 days** or **38 weeks** after fertilization.

Clinically, the pregnancy/gestation period responsible for prenatal development of an individual is divided into following two parts:

1. Embryonic period
2. Fetal period.

Embryonic Development in Days

Gestation period from fertilization to end of the eighth week is termed **embryonic period**. Development of embryo during this period in days is given in Table 26.1.

Some key developmental events that occur during the embryonic period are given in Table 26.2.

Table 26.1 Embryonic development in days

Weeks	Days						
Week 1	Day 1 Fertilization	Day 2 Embryo with two-cell stage	Day 3 Formation of morula	Day 4 Early stage of blastocyst	Day 5 Late stage of blastocyst	Day 6 Implantation	Day 7
Week 2	Day 8 • Formation of bilaminar embryonic disc • Trophoblast differentiates into cytotrophoblast and syncytiotrophoblast	Day 9 Formation of lacunae in syncytiotrophoblast	Day 10 Embryo gets completely implanted in endometrium	Day 11	Day 12 Formation of extraembryonic mesoderm	Day 13 Formation of primary villi	Day 14 Formation of prochordal plate and connecting stalk
Week 3	Day 15 Formation of primitive streak	Day 16 • Migration of mesenchymal cells from epiblast • Formation of secondary and tertiary villi	Day 17 Migration of cells from primitive streak	Day 18 Formation of trilaminar embryonic disc	Day 19 • Neurulation begins • Formation of neural plate	Day 20 Formation of neural folds and neural groove	Day 21 Formation of first pair of somites

Table 26.1 Embryonic development in days (*Continued*)

Weeks	Days						
Week 4	Day 22 Closure of neural tube begins	Day 23 • Closure of neural tube with cranial and caudal neuropore • Formation of lens and otic placodes	Day 24 • Appearance of pericardial heart bulge • Rostral neuropore closes • Two pairs of pharyngeal arches appear	Day 25 • Formation of optic pit • Three pairs of pharyngeal arches appear	Day 26 Upper limb bud appears	Day 27 Formation of otic pit	Day 28 Neurulation completes
Week 5	Day 29 Upper and lower limb buds become paddle shaped	Day 30 Development of face begins	Day 31 Formation of primitive gut tube	Day 32 Embryo completely surrounded by amnion lies in chorionic cavity	Day 33 Formation of: • Umbilical ring • Tertiary yolk sac • Umbilical cord	Day 34 Formation of optic cup and lens placode	Day 35 Formation of pharyngeal arches and cartilages
Week 6	Day 36 Physiological umbilical hernia occurs	Day 37 Developing face	Day 38 Development of muscles	Day 39 Endodermal derivatives of primitive gut	Day 40 Formation of auricular hillocks	Day 41 Atrial septum is formed	Day 42 Formation of digital rays
Week 7	Day 43 Formation of cartilages in developing limb	Day 44 Developing face (an advanced stage)	Day 45 Conotruncal and ventricular septa form	Day 46 • Subdivision of decidua • Well-formed amniotic cavity and chorion	Day 47 Indifferent stage of development of external genitalia	Day 48 Fusion of facial prominences	Day 49 • Formation of eyelid • Formation of external ear • Presence of digits
Week 8	Day 50 • Upper limbs are longer and appear bent at elbow • Finger distinct but webbed	Day 51 Eye, external ear, nose, finger, and toes are clearly visible	Day 52 Large forehead	Day 53 External genitalia begin to differentiate	Day 54 Genital tubercle, urethral groove, and anus are clearly visible	Day 55 Eye, ear, elbow, wrist, knee, and toes are clearly visible	Day 56 Embryo acquires a miniature human form

Table 26.2 Key developmental events during the embryonic period

Developmental events	Day/days of gestation
Fertilization	Day 1
Blastocyst	Day 4
Bilaminar embryonic disc	Day 8
Implantation	Day 10
Primary streak appears	Day 15
Primitive heart tube	Day 17
Neurulation, first pair of somite	Day 21
Limb buds	Days 26–28
Primitive gut	Day 31
Physiological herniation	Day 36
Face appears	Day 37
External genitalia	Day 53
Miniature human form	Day 56

Criteria for Estimation of Age of Embryo in Days

The age of embryo in days can be accurately determined during early time period by counting somites because they appear with a specified periodicity (for details see page 50). Later it can be determined by measuring the length of the embryo (Table 26.3).

Fetal Development in Weeks

Gestation period from beginning of ninth week to birth is termed **fetal period**. The development of fetus during this period in weeks is given in Table 26.4.

Changes in external appearance of the fetus during the fetal period (from weeks 9 to 38) are shown in Fig. 26.1. Size of head in relation to rest of the body at different periods of fetal development is shown in Fig. 26.2.

Criteria for Determination of Fertilization Age During Fetal Period

The criteria taken for the determination of age of the fetus are:

1. Length of the fetus
2. Weight of the fetus.

The length of a fetus is usually measured from top (vertex) of the skull to bottom of buttock. It is termed

Age (days)	Number of somites	Length (mm)
20–21	1–3	1.5–3
22–23	4–12	2–3.5
24–25	13–20	2.5–4.5
26–27	21–29	3–5
28–30	30–35	4–6
31–32	–	5–7
33–36	–	7–9
37–40	–	8–11
41–43	–	11–14
44–46	–	13–17
47–48	–	16–18
49–51	–	18–22
52–53	–	22–24
54–55	–	23–28
56	–	27–31

crow–rump length (CRL)/sitting height. Or It is measured from top (vertex) of the skull to heel. It is termed crown–heel length (CHL) (Fig. 26.3).

Age (weeks)	Developmental events
9	Closed or closing eyes, more rounded head, and herniation of intestines in umbilical cord
10	Intestines in abdomen and early development of fingernails
12	Differentiated external genitalia and well-defined neck
14	Erect head, well-developed lower limb, and early finger nail development
16	External ears standing out from the head
18	Vernix caseosa and early toe nail development
20	Lanugo hair
22	Wrinkled and red skin
24	Fingernails and lean body
26	Partially open eyes and eyelashes
28	Open eyes, hair, and slightly wrinkled skin
30	Toe nails and descending testes
32	Fingernails up to finger tips, and pink and smooth skin
36	Plumb body, absence of lanugo hair, toe nails up to toe tips, flexed limbs, and a firm grasp
38	Prominent chest, protruding breasts, testes in the scrotum or inguinal canals, and fingernails beyond finger tips

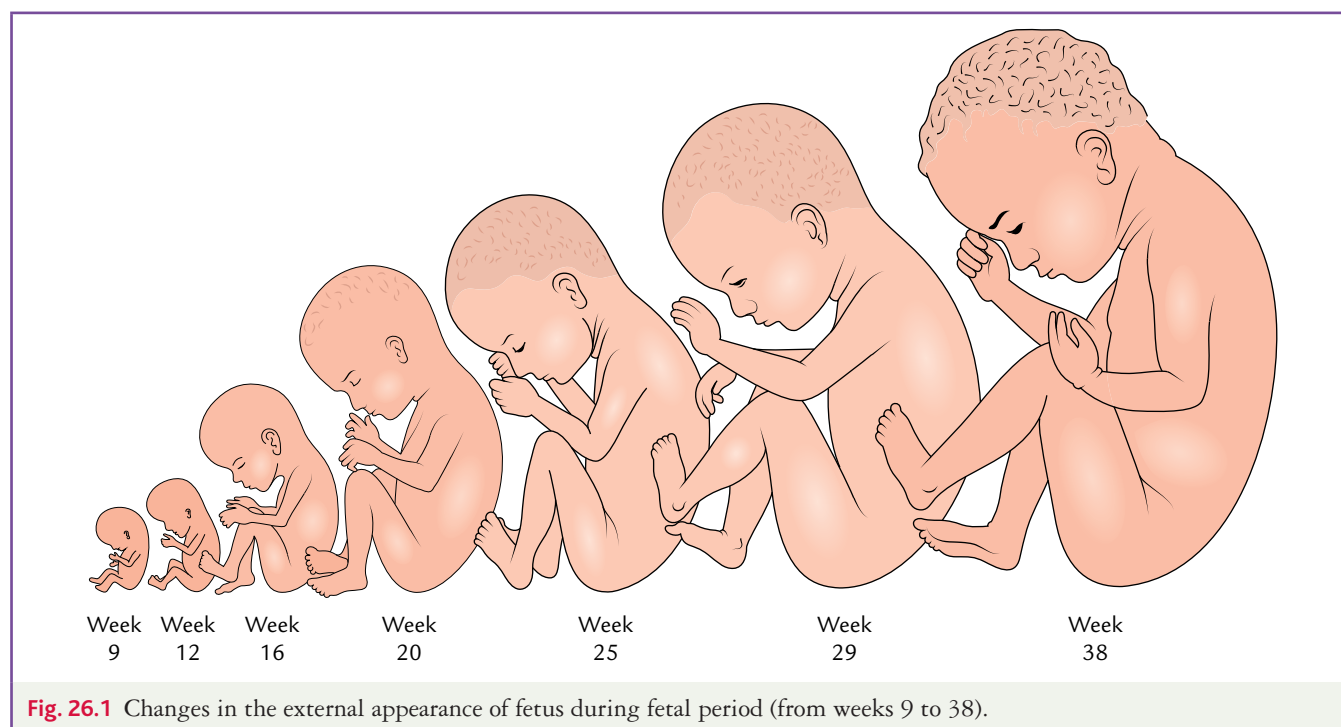


Fig. 26.1 Changes in the external appearance of fetus during fetal period (from weeks 9 to 38).

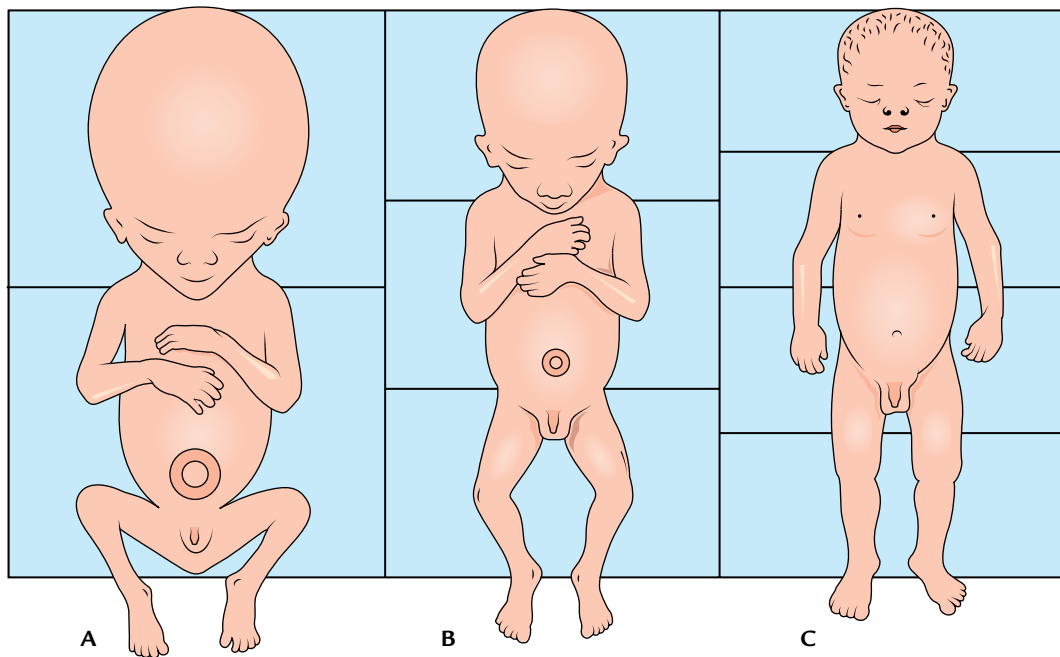


Fig. 26.2 Changing proportions of body during the fetal period. Note size of the head in relation to rest of the body at various gestation ages: A. Third month. B. Fifth month. C. At birth.

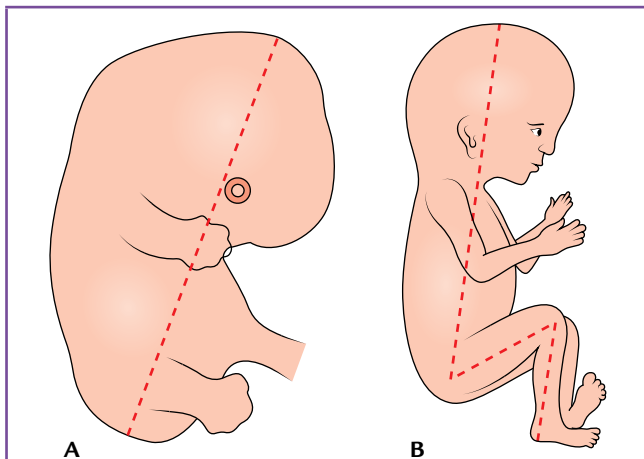


Fig. 26.3 Measurement of the length of the embryo. A. Crown-rump length. B. Crown-heel length.

During the fetal period, there is a rapid increase in weight due to maturation of tissues and organs. The weight is seen as 8 g at ninth week (beginning of fetal period) to 3400–3500 g at birth.

N.B. Most of the weight is gained during last 8 weeks (2 months) of pregnancy.

Criteria for estimation (determination) of age of the fetus are given in Table 26.5.

Pregnancy Dating

Estimated date of confinement is calculated on the basis of assumption that a woman has 28-days menstrual

Table 26.5 Criteria for estimation of age of the fetus

Age (weeks)	Crown-rump length (mm)	Foot length (mm)	Weight (g)
9	50	7	8
10	61	9	14
12	87	14	45
14	120	20	110
16	140	27	200
18	160	33	320
20	190	39	460
22	210	45	630
24	230	50	820
26	250	55	1000
28	270	59	1300
30	280	63	1700
32	300	68	2100
36	340	79	2900
38	360	83	3400

cycle, with ovulation on day 14. In general, duration of pregnancy is 280 days (40 weeks) from the first day of last menstrual period (LMP).

N.B. Nagele's rule for estimation of duration of pregnancy: It is commonly used by gynecologists. According to this rule, first count back 3 months from the first day of LMP and then add 1 year 7 days. This method is reasonably accurate in women with regular menstrual cycles.

Trimesters of Pregnancy/Milestones of Pregnancy

Clinically gestation period is divided into three trimesters, each lasting for about 3 months.

The important events of each trimester are given below.

First Trimester (From First Day of LMP to End of Week 12)

1. From days 8–10, pregnancy test by human chorionic gonadotrophin (HCG) essay comes positive.
2. At week 4.5–5, gestational sac is seen in posterior wall of the uterus.
3. At weeks 5–6, embryonic heart rate is about 100 beats per minute; by weeks 8–9 it enhances to about 140 beats per minute.
4. At week 10, fetus starts swallowing amniotic fluid.
5. At week 12, fundus of the uterus is palpable above pubic symphysis.
6. Face becomes more human looking.
7. By week 12, **primary ossification centers** are present in long bones and skull.
8. By week 12, external genitalia develop to such an extent that sex of the fetus can be determined by ultrasound.

Second Trimester (From End of First Trimester to Week 27)

1. At weeks 14–18, amniocentesis is performed to detect fetal chromosomal abnormalities.
2. At week 16, fundus of the uterus is palpable midway between pubic symphysis and umbilicus.
3. At weeks 14–16, respiratory movements begin.
4. At weeks 16–18, movements of the fetus (**quicken- ing**) can be felt by women who have had one or more previous pregnancies.
5. At weeks 17–20, the fetal heart sounds are audible with fetoscope.
6. At week 18, female and male external genitalia can be distinguished by ultrasound (**antenatal sex determination**).
7. At weeks 18–20, movements of the fetus (**quicken- ing**) can be felt by a woman in her first pregnancy.
8. At week 20, fundus of the uterus is palpable at the umbilicus.
9. At week 24, sucking movements begin.
10. At weeks 24–26, some sound can be heard.
11. At weeks 25–27, the fetal lungs become capable of respiration.
12. At week 28, eyes become sensitive to light.

N.B. There are 70–80% chances of survival of an infant born at the end of second trimester.

Third Trimester (Gestation Period From End of Second Trimester to Week 40/Until Term)

1. Papillary light reflex is present.
2. Descent of the fetal head to pelvic inlet occurs.
3. Rupture of fetal membranes (amniochorionic membranes) occurs with labor pains, which usually begins 24 hour later.

Teratology

The **teratology** is the study of causes, mechanisms, and patterns of birth defects/congenital defects. The presence of small anomalies such as small ear may be an indication of major underlying defects.

An agent or factor that may cause congenital abnormality is called **teratogen**. The mechanism of production of congenital abnormality is termed teratogenesis.

Teratogens

They are classified into following groups:

1. *Infectious agents* such as virus (e.g., rubella virus, cytomegalovirus, etc.)
2. *Ionizing radiation*
3. *Chemical agents* such as organic mercury, lead, potassium iodide, etc.
4. *Drugs* such as thalidomide, phenytoin, etc.

N.B. Table 26.6 provides a small list of some of the drugs that are absolutely contraindicated in pregnancy and some drugs that have a definitive evidence of risk to the fetus, as examples.

Table 26.6 List of drugs that should not be given to a pregnant woman at all or to be avoided at best

Drugs absolutely contraindicated in pregnancy	Drugs with definitive evidence of risk to fetus	
1. Thalidomide (an antinausea drug)	1. Tetracycline 2. Doxycycline 3. Streptomycin 4. Amikacin 5. Tobramycin } Antibiotics	
2. Methotrexate, busulfan chlorambucil (anticancerous drugs)		
3. Phenytoin (Dilantin)—an antiepileptic drug		6. Phenobarbital (a barbiturate)—a sedative
4. Triazolam—a hypnotic drug		7. Valproic acid—an antiepileptic drug
5. Warfarin—an anticoagulant drug		8. Diazepam—an antianxiety drug
6. Clomiphene—an ovulatory stimulant	9. Alprazolam—an antianxiety drug	

Periods of Susceptibility to Teratogenesis

Fundamental concept of teratology is that clinician must know that certain periods of gestation (pregnancy) are more susceptible to teratogenesis than others. In general, the periods of susceptibility to teratogens are divided into three groups (Table 26.7).

Prenatal Diagnosis

Now-a-days various techniques are available to assess growth and development of the fetus in utero and to detect congenital malformations of an unborn child. One can also detect abnormalities of the placenta and uterus.

Techniques

The various techniques used for prenatal diagnosis are:

1. Ultrasonography
2. Fetoscopy
3. Amniocentesis
4. Chorionic villus sampling
5. Fetal blood sampling
6. Maternal serum screening
7. New implantation genetic diagnosis, etc.

N.B. All of the above-mentioned prenatal diagnostic tests are not done routinely except ultrasonography. But in cases of high-risk pregnancy, advanced maternal age (more than 35 years), family history of neural tube defects, and history of genetic disorders may require all above-mentioned prenatal diagnostic tests.

In the following text, therefore, only ultrasonography will be discussed in great detail and only brief account will be given about other tests.

Ultrasonography

The ultrasonography is an extremely useful, safe, and noninvasive technique in hands of radiologists to confirm pregnancy and differentiate between normal and abnormal gestations. Common ultrasonographic

techniques used are (a) transabdominal sonography (TAS), (b) transvesical sonography (TVS), and (c) endovaginal sonography (EVS).

Aims of ultrasonography The ultrasonography during pregnancy is done for following purposes:

1. Localization of gestational sac (if present)
2. Estimation of menstrual age of embryo or fetus
3. Early identification of embryonic death
4. Determination of the number of embryos
5. Determination of fetal abnormalities
6. Determination of growth, progress, or retardation of growth of embryo/fetus
7. Determination of ectopic pregnancy
8. Guidance to perform chorionic villus biopsy and/or amniocentesis

N.B. Now-a-days the ultrasonography has become an inseparable and integral part of diagnostic care and management of pregnancies.

The ultrasonographic scanning is done routinely for all pregnant women (Fig. 26.4).

Ultrasonography during the first trimester

1. Gestational sac is seen at week 5–5.5 of gestation.
2. Yolk sac within the gestational sac is visualized by week 5.5–6.
3. Embryonic heart beat is identifiable by week 6–6.5.
4. Crown–rump length can be measured week 6 onwards.

Ultrasonography during the second and third trimesters

1. Fetal heart
 - (a) Shows four chambers
 - (b) Echogenic flap of foramen ovale moves into left atrium

Table 26.7 Periods of susceptibility to teratogens	
Period	Susceptibility to teratogen
0–2 weeks (period of morphogenesis)	<ul style="list-style-type: none"> • Embryo is not sensitive to teratogens • High rate of lethality (prenatal death and/or spontaneous abortion may occur)
3–8 weeks (period of organogenesis)	<ul style="list-style-type: none"> • Most sensitive period • Each organ system will also have a period of high sensitivity
9–38 weeks (period of maturation)	<ul style="list-style-type: none"> • Less sensitive period

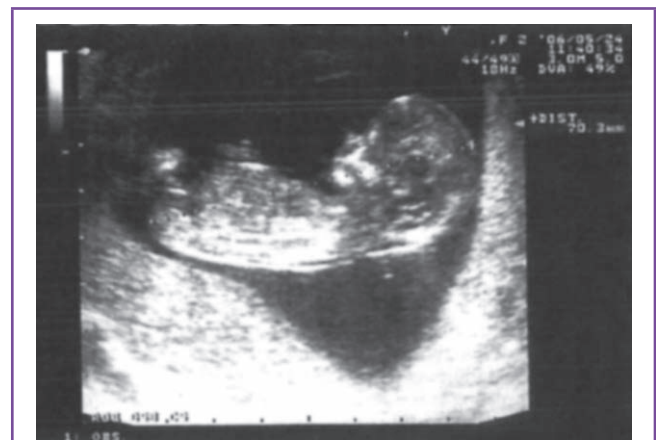

Fig. 26.4 Transabdominal ultrasound at week 12 showing measurement of the crown–rump length to calculate the gestational age.

- (c) Pulmonary veins are seen entering into left atrium
- (d) Superior vena cava (SVC) and inferior vena cava (IVC) are seen entering into the right atrium
- (e) Papillary muscles may be seen as echogenic foci within ventricles
- (f) Left ventricle shows smooth inner wall
- (g) Right ventricle reveals a coarse surface with bright echoes.

2. Fetal chest

- (a) Only heart and lungs are seen
- (b) Thymus is seen between heart and sternum as hyperechoic shadow before week 27 and hypoechoic shadow after week 27.

3. Fetal abdomen: Stomach is seen between weeks 9 and 13 of gestational age as a fluid-filled structure in upper abdomen on the left side. **Echogenic linear rugae** distinguish it from other structures.

N.B. If the stomach is not visualized during the second/third trimester, it indicates abnormal fetal outcome. Nonvisualization is usually accompanied by esophageal atresia.

(a) *Pancreas*

- It is usually visible between weeks 14 and 20 of gestational age.
- Tail of fetal pancreas is visualized between left kidney and stomach. It is more echogenic than liver.

(b) *Liver*: Left lobe of liver (Note: It is larger than right lobe in fetus.) can be measured after week 20 of gestational age.

(c) *Spleen*

- It is visualized as an echogenic organ situated in left upper abdomen inferior or posterior to the stomach and lateral to spine.
- Its position varies according to fetal position.
- Its size is measured from week 18 onward.

(d) *Suprarenal glands*

- They can be seen after weeks 20–30 of gestational age.
- They are seen superior and medial to corresponding kidney.
- They reveal hypoechoic periphery and central echogenic areas.
- Their size increases with age.

(e) *Intestine*

- Physiological herniation of midgut is seen between weeks 8 and 11 of gestational age.
- Small intestine appears as a central, amorphous, and echogenic area in the abdomen.
- Large intestine is visible at periphery of the abdomen at weeks 22–28 of gestational age.
- Haustra are identifiable by week 30.

N.B. Abdominal wall defect in fetus: As two lateral folds of the embryo move medially and fuse to each other, the anterior abdominal wall is closed. This process occurs by week 8 of menstrual age. At the same time, midgut loop elongates and herniates into the umbilical cord. Midgut loop rotates 90° anticlockwise around the axis of superior mesenteric artery. By the end of 12th menstrual week, the midgut rotates by another 180° anticlockwise and returns to the abdominal cavity. So *diagnosis of abdominal wall defect cannot be made before 12th menstrual week.*

- (f) *Kidney and ureter*: Permanent kidney forms within the pelvis during seventh week of gestational age and ascends to adult position by week 11. Nephrons start getting formed by week 10 and urine is formed at week 15 of gestational age. Urine production during second half of pregnancy accounts for most of amniotic fluid volume.

Kidney is identifiable by ultrasound during early second trimester. These are seen as paired hypoechoic structures adjacent to fetal spine in transverse scans. Renal sinus may be seen as a central echogenic area. Kidneys are better visualized later due to perinephric fat, which provides better contrast. During middle of the second trimester anatomic detail improves, and cortex and pyramids are distinguishable by weeks 23–26.

N.B.

- Renal length in millimeters is almost same as fetal menstrual age in weeks.
- Renal to abdominal circumference ratio is 0.27–0.30.

- (g) *Urinary bladder*: Presence of urine in the urinary bladder shows renal function by week 13 of gestational age. The urinary bladder is seen at week 16. Normal bladder fills and empties every 30–45 minutes.

Amniotic fluid volume estimation gives further information about proper renal function.

4. External genitalia: The gender of fetus is identifiable in late first or early second trimester.

5. Fetal brain: The central nervous system starts developing at fifth menstrual week, i.e., third week after conception. The process of formation of the neural tube begins on the day 20.

Anterior (cranial) neuropore closes by middle of week 4 and posterior (caudal) neuropore closes by week 6. Lumen of the neural tube becomes central by end of week 4.

By week 6, the cephalic end enlarges to become brain vesicle, which forms the brain. Most of the brain structures are developed in 12–15 menstrual weeks. Only corpus callosum and septum pellucidum develop later by weeks 18–20.

At 18–20 menstrual weeks, neuroblasts and neurons migrate from germinal layer of ventricles to surface of the cortex. These cells proliferate to form gray matter. After migration of neuroblasts and neurons, sulci and gyri are formed to accommodate more neurons in limited space.

During the first trimester, embryo is examined transvaginally. At 8 weeks, the cephalic end is seen. The bones of vault show mineralization by weeks 10–11. Brain mantle is thin to begin with, whereas ventricles are large and full of choroid.

A large space behind hindbrain represents cavity of rhombencephalon, which forms fourth ventricle.

6. **Fetal face:** The development of face starts by 5th menstrual week and gets completed by 10th menstrual week.

7. **Fetal spine:** Formation of the neural tube takes place within 12 days, i.e., 16–28 days of conception/30–42 days of menstrual age/1.2 mm–5 mm CRL.

The mesoderm around developing caudal part of the neural tube forms vertebrae.

Ossification begins in the fetal spine at about 10th week of gestation. By 13th gestational week, ossification appears in neural processes, and gradually extends into laminae and pedicles. By weeks 18–20, spina bifida can be diagnosed by ultrasound.

8. **Fetal skeleton:** The skeletal system is formed due to proliferation of mesenchyme. Few bones like clavicle, mandible, and parts of calvaria are formed by intramembranous ossification, i.e., ossification process begins in the mesenchyme directly.

Most of other bones ossify from intracartilaginous models. The mesenchyme is changed to cartilage models. A primary center of ossification appears in the center of cartilaginous model and proceeds toward both its ends. Increase in length of the bones occurs due to proliferation of epiphyseal cartilage (growth plate) at diaphyseal–epiphyseal junction. The secondary centers of ossification at ends of the bones occur after birth, except in the lower end of femur and the upper end of tibia.

The limb buds appear at weeks 4–6 of menstrual age. The bud is a mass of mesenchyme covered by a layer of ectoderm. As the limb elongates, its distal end forms hand/foot plate with digital rays.

The order in which ossification centers appear are given in Table 26.8.

N.B.

- Abnormalities of digits are identifiable during early/middle second trimester.
- The fetal age and growth can be assessed by measuring the CRL during weeks 5–10 of gestation, and after that by measuring

Table 26.8 Time of appearance of ossification centers

Bone	Time of appearance of ossification centers
• Clavicle	• 8 week of menstrual age
• Mandible and palate	• 9 week
• Vertebral body and neural arch	• 9 week
• Frontal bone	• 10–11 weeks
• Femur, humerus, scapula, ileum, and phalanges	• 11 week
• Skull base	• 12–14 weeks
• Skull calvaria	• 16 week
• Metatarsals and metacarpals	• Early second trimester
• Calcaneum	• 24–26 weeks

length of femur and biparietal diameter (BPD) and abdominal circumferences.

- The ultrasound measurements are taken to determine the size and probable age of the fetus to provide a prediction of the expected date of delivery (EDD).

Fetoscopy

It involves visualization of fetus by an endoscope. It is usually done in the second trimester to detect any subtle structural abnormalities that may point to serious underlying defects/diseases.

Amniocentesis

It involves aspiration of 20–30 ml of amniotic fluid. It is usually performed at week 16 of gestation (for details see page 58).

Chorionic Villus Sampling (CVS)

In this procedure, a small sample of chorionic tissue (10–30 mg) is removed under guidance of ultrasound. It is usually carried out at weeks 10–11 of gestation.

N.B. CVS allows first trimester diagnosis. The chorionic tissue will provides a rich source of DNA.

Fetal Blood Sampling

It is routinely used in the management of rhesus isoimmunization. It can also be used to obtain fetal blood samples for chromosomal analysis.

Maternal Serum Screening

In this, blood sample is taken from mother at week 16 of gestation to measure α -fetoprotein (AFP), HCG, estriol, and inhibin A. It is usually done to screen neural tube defects, Down's syndrome, etc.

For example, level of AFP increases in maternal serum in cases of neural tube defects, and concentrations of

HCG and inhibin A are raised with low estriol levels in Down's syndrome.

New Implantation Genetic Diagnosis

It is also called preimplantation genetic technique. By this technique, an ovum (secondary oocyte) is removed

from wife and is fertilized *in vitro*. The fertilized oocyte is cultured up to eight-cell stage. A single cell called *blastomere* is removed and analyzed by polymerase chain reaction to see whether *zygote* is affected/not affected by the disorder for which it is at risk. If normal (i.e., not affected), it is implanted into mother's uterus.

GOLDEN FACTS TO REMEMBER

- | | |
|---|--|
| ➤ Most susceptible period of pregnancy for teratogenesis | 3–8 weeks |
| ➤ Most common test for prenatal diagnosis | Ultrasonography |
| ➤ Movements of fetus can be felt by mother during | Fifth month of pregnancy |
| ➤ Body part with largest circumference at end of ninth month of pregnancy | Skull |
| ➤ Menstrual length of pregnancy | 280 days or 40 weeks |
| ➤ Fertilization length of pregnancy | 266 days or 38 weeks |
| ➤ Respiratory movements in fetus begin | During weeks 14–16 |
| ➤ Sucking movements in fetus begin | At week 24 |
| ➤ Fetus starts swallowing amniotic fluid | At week 10 |
| ➤ Three cardinal signs of preeclampsia | Hypertension, proteinuria, and edema |
| ➤ Most of congenital defects occur | Between weeks 3 and 8 of gestation (period of organogenesis) |

"This page intentionally left blank"

Multiple Choice Questions

Chapter 1

- Pre-embryonic period completes when
 - Blastocyst reaches the uterus
 - Blastocyst implants in the uterus
 - Placenta forms
 - Primary germ layers form
- All are features of pre-embryonic period *except*
 - Cleaving of zygote
 - Formation of blastocyst
 - Implantation of blastocyst
 - Formation of extraembryonic membranes
- All are features of the embryonic period *except*
 - Differentiation of germ layers into specific body organs
 - Formation of extraembryonic membranes
 - Formation of umbilical end
 - Body growth
- Who is called the father of modern embryology?
 - Aristotle
 - Galen
 - Karl Ernst von Baer
 - Joham Ham van Arnheim
- First mammal was cloned in year
 - 1875
 - 1960
 - 1978
 - 2002
- Regarding stem cells all are correct *except*
 - They were first discovered by James Till
 - They were discovered in 1960
 - They can divide and develop into specialized cells
 - They are found only in embryonic tissue
- Period of growth from birth to the end of fourth week is called
 - Neonatal
 - Infancy
 - Fetal
 - Childhood
- Select the *incorrect statement*
 - Neonatal period* extends from birth to the end of fourth week

- Infancy* extends from the end of fourth week until the end of the first year
- Childhood* extends from beginning of the second year to the end of 12 years
- Adolescence extends from 19 to 40 years

Answers

1. *d*, 2. *d*, 3. *d*, 4. *c*, 5. *c*, 6. *d*, 7. *a*, 8. *d*.

Chapter 2

- Regarding testis all are correct *except*
 - It is primary reproductive organ in male
 - It contains 100–200 seminiferous tubules
 - It forms sperms
 - It produces testosterone hormone
- Select the *incorrect statement* about the epididymis
 - It lies posteriorly and slightly lateral to the testis
 - It plays an important role in the maturation of sperms
 - Its duct is continuous with the vas deferens
 - Its duct begins in rete testis
- Prostate gland
 - Is a pyramidal fibromuscular gland
 - Surrounds into ejaculatory ducts
 - Pours its secretion into the membranous urethra by 10–20 ducts
 - Secretes prostatic fluid, which forms the bulk of the semen
- Approximate contribution to semen by reproductive glands is
 - Seminal vesicles: 30%
 - Prostate: 30%
 - Testis: 5%
 - Bulbourethral gland: 5%
- Regarding ovary all are correct *except*
 - It is primary reproductive organ of female
 - It contains about 2 million ovarian follicles at birth
 - It contains about 40,000 ovarian follicles at puberty
 - It is involved in the ovulation of only 40–50 ova during entire reproductive period of a woman

6. Select the *incorrect statement* about the ovarian cycle
 - (a) It usually consists of 28 days
 - (b) It is regulated by estrogen and progesterone hormones
 - (c) Unlike menstrual cycle, it is continuous during pregnancy
 - (d) It is divided into follicular and luteal phases
 7. Regarding menstrual cycle all are correct *except*
 - (a) It is characterized by monthly cyclic changes in the uterine endometrium
 - (b) The changes in the endometrium occur due to hormones secreted by the ovaries
 - (c) It is most obvious as monthly bleeding (menstruation) in females
 - (d) It occurs throughout the life of a female
 8. Ovulation usually occurs at
 - (a) 7 days after menstruation
 - (b) 14 days after menstruation
 - (c) 7 days before menstruation
 - (d) 14 days before the next menstruation
 9. Regarding corpus luteum all are correct *except*
 - (a) It prepares the uterus for implantation of fertilized ovum
 - (b) It lasts for 14 days if fertilization does not take place
 - (c) It lasts for 3 months if the ovum is fertilized
 - (d) It is formed whether ovulation takes place or not
 10. Select the *incorrect statement*
 - (a) Proliferation of endometrium occurs due to estrogen secreted by the ovary
 - (b) Ovulation occurs 14th day before the start of next menstruation
 - (c) Fertilization leads to persistent corpus luteum
 - (d) LH hormone corresponds to the estrogenic phase of the ovary
- (a) 80 million
 - (b) 60 million
 - (c) 40 million
 - (d) 10 million
4. The usual period of viability of an ovum in female genital tract is
 - (a) 12 hours
 - (b) 24 hours
 - (c) 48 hours
 - (d) 72 hours
 5. At puberty, the number of ovarian follicles present in each ovary is about
 - (a) 400,000
 - (b) 40,000
 - (c) 4000
 - (d) 400
 6. The number of ovarian follicles that undergo ovulation during the entire reproductive period of women is about
 - (a) 40,000
 - (b) 4000
 - (c) 400
 - (d) 100
 7. Ovum completes its second meiotic division
 - (a) Just before ovulation
 - (b) Soon after ovulation
 - (c) Just before fertilization
 - (d) Soon after fertilization
 8. Second meiotic division gives rise to
 - (a) Primary spermatocytes
 - (b) Secondary spermatocytes
 - (c) Spermatids
 - (d) Spermatozoa
 9. Number of female gametes (ova) formed from single oogonium is
 - (a) 1
 - (b) 2
 - (c) 3
 - (d) 4
 10. Spermiogenesis is transformation of
 - (a) Spermatogonium into primary oocyte
 - (b) Primary spermatocyte into secondary spermatocyte
 - (c) Secondary spermatocyte into spermatid
 - (d) Spermatid into sperm
 11. Number of chromosomes in primary spermatocyte is
 - (a) 22 + Y
 - (b) 22 + XY
 - (c) 44 + XY
 - (d) 44 + X
 12. Primary oocyte completes its first meiotic division at the time of
 - (a) Ovulation
 - (b) Fertilization

Answers

1. b, 2. d, 3. c, 4. a, 5. d, 6. c, 7. d, 8. d, 9. d, 10. d.

Chapter 3

1. Number of sperms formed from single spermatogonium is
 - (a) 2
 - (b) 4
 - (c) 6
 - (d) 8
2. In which stage of spermatogenesis, the chromosome number is halved
 - (a) Spermatogonium to primary spermatocyte
 - (b) Primary spermatocyte to secondary spermatocyte
 - (c) Secondary spermatocyte to spermatid
 - (d) Spermatid to sperm
3. An individual is likely to be sterile if the number of healthy sperms per ml of semen is below
 - (a) 80 million
 - (b) 60 million
 - (c) 40 million
 - (d) 10 million
4. The usual period of viability of an ovum in female genital tract is
 - (a) 12 hours
 - (b) 24 hours
 - (c) 48 hours
 - (d) 72 hours
5. At puberty, the number of ovarian follicles present in each ovary is about
 - (a) 400,000
 - (b) 40,000
 - (c) 4000
 - (d) 400
6. The number of ovarian follicles that undergo ovulation during the entire reproductive period of women is about
 - (a) 40,000
 - (b) 4000
 - (c) 400
 - (d) 100
7. Ovum completes its second meiotic division
 - (a) Just before ovulation
 - (b) Soon after ovulation
 - (c) Just before fertilization
 - (d) Soon after fertilization
8. Second meiotic division gives rise to
 - (a) Primary spermatocytes
 - (b) Secondary spermatocytes
 - (c) Spermatids
 - (d) Spermatozoa
9. Number of female gametes (ova) formed from single oogonium is
 - (a) 1
 - (b) 2
 - (c) 3
 - (d) 4
10. Spermiogenesis is transformation of
 - (a) Spermatogonium into primary oocyte
 - (b) Primary spermatocyte into secondary spermatocyte
 - (c) Secondary spermatocyte into spermatid
 - (d) Spermatid into sperm
11. Number of chromosomes in primary spermatocyte is
 - (a) 22 + Y
 - (b) 22 + XY
 - (c) 44 + XY
 - (d) 44 + X
12. Primary oocyte completes its first meiotic division at the time of
 - (a) Ovulation
 - (b) Fertilization

- (c) Puberty
- (d) None of the above

Answers

1. *b*, 2. *b*, 3. *d*, 4. *b*, 5. *b*, 6. *c*, 7. *d*, 8. *c*, 9. *a*, 10. *d*, 11. *c*, 12. *a*.

Chapter 4

1. Fertilization occurs
 - (a) In the upper part of uterine cavity
 - (b) In the lower part of uterine cavity
 - (c) Inside uterine tube
 - (d) Inside cervix
2. Oocyte remains viable after ovulation without fertilization up to
 - (a) 8 hours
 - (b) 12 hours
 - (c) 24 hours
 - (d) 36 hours
3. All act as a barrier of oocyte *except*
 - (a) corona radiata
 - (b) Zona pellucida
 - (c) Vitelline membrane
 - (d) Perivitelline space
4. Process/processes which sperms must undergo to be able to fertilize an oocyte are
 - (a) Capacitation
 - (b) Acrosome reaction
 - (c) Both capacitation and acrosome reaction
 - (d) Zonal reaction
5. Conventional phases of fertilization include all *except*
 - (a) Penetration of corona radiata
 - (b) Penetration of zona pellucida
 - (c) Fusion of oocyte and sperm cell membranes
 - (d) Disintegration of sperm head
6. All are primitive germ layers *except*
 - (a) Ectoderm
 - (b) Neuroectoderm
 - (c) Mesoderm
 - (d) Endoderm
7. Process of gastrulation includes all *except*
 - (a) Formation of primitive streak
 - (b) Form of intraembryonic mesoderm
 - (c) Formation of primitive gut
 - (d) Formation of three germ layers
8. All are results of fertilization *except*
 - (a) Restoration of diploid number of chromosomes
 - (b) Determination of genetic sex of the embryo
 - (c) Initiation of cleavage
 - (d) Implantation of zygote

Answers

1. *c*, 2. *c*, 3. *d*, 4. *c*, 5. *d*, 6. *b*, 7. *c*, 8. *d*.

Chapter 5

1. Which structure represents remnant of notochord?
 - (a) Centrum of body of vertebra
 - (b) Nucleus pulposus
 - (c) Membrane tectoria
 - (d) Odontoid process of second cervical vertebra
2. All are true statements about notochord *except*
 - (a) It develops from Hensen's node
 - (b) It induces formation of neural tube
 - (c) It forms part of intervertebral disc
 - (d) It extends headwards beyond prochordal plate
3. Somites differentiate to form all *except*
 - (a) Notochord
 - (b) Sclerotome
 - (c) Myotome
 - (d) Dermatome
4. Developing embryo has a distinct human appearance by the end of
 - (a) Fourth week
 - (b) Fifth week
 - (c) Seventh week
 - (d) Eighth week
5. Lateral plate mesoderm is divided into two distinct layers due to the formation of
 - (a) Extraembryonic celom
 - (b) Amniotic cavity
 - (c) Intraembryonic celom
 - (d) Yolk sac
6. Regarding somites, which of the following statement is *incorrect*
 - (a) They are formed by the segmentation of paraxial mesoderm
 - (b) Somite period extends from 20 to 30 days
 - (c) First pair of somites appears in the occipital region
 - (d) They form most of the appendicular skeleton
7. Chordoma arises from remnants of
 - (a) Spinal cord
 - (b) Nephrogenic cord
 - (c) Notochord
 - (d) Umbilical cord
8. All are derivatives of intraembryonic mesoderm *except*
 - (a) Septum transversum
 - (b) Somatopleuric mesoderm
 - (c) Splanchnopleuric mesoderm
 - (d) Connecting stalk
9. Notochord
 - (a) Lies between mesoderm and endoderm
 - (b) Is connected to yolk sac via neurenteric canal
 - (c) Extends from buccopharyngeal membrane to the cloacal membrane
 - (d) Provides axis for the development of axial skeleton

Answers

1. *b*, 2. *d*, 3. *a*, 4. *d*, 5. *c*, 6. *d*, 7. *c*, 8. *d*, 9. *d*.

Chapter 6

- Placenta develops from
 - Decidua capsularis and chorion
 - Decidua capsularis and amnion
 - Decidua basalis and chorion
 - Decidua parietalis and trophoblast
- Placental membrane in later stages of pregnancy mainly consists of
 - Cytotrophoblast and syncytiotrophoblast
 - Syncytiotrophoblast and fetal endothelium
 - Mesoderm and fetal endothelium
 - Syncytiotrophoblast only
- All are main functions of placenta *except*
 - Transport of nutrients
 - Excretion of waste products
 - Growth of embryo and fetus
 - Exchange of gases O₂ and CO₂
- Normal amount of amniotic fluid at full term is
 - 250 ml
 - 500 ml
 - 1000 ml
 - 200 ml
- Intervillous spaces of placenta contains
 - Fetal blood
 - Amniotic fluid
 - Maternal blood
 - Both fetal and maternal blood
- Type of human placenta is
 - Epitheliochorial
 - Hemochorial
 - Endotheliochorial
 - Endothelioendothelial
- In early stages of pregnancy, the placental barrier consists of all the structures *except*
 - Cytotrophoblast
 - Syncytiotrophoblast
 - Intraembryonic mesoderm
 - Endothelium of fetal blood vessels
- Pregnancy is maintained till term by
 - Follicle stimulating hormone
 - Luteinizing hormone
 - Progesterone
 - Prostaglandins

Answers

1. *c*, 2. *b*, 3. *c*, 4. *c*, 5. *c*, 6. *b*, 7. *c*, 8. *c*.

Chapter 7

- Skin develops from
 - Mesoderm and endoderm
 - Ectoderm and mesoderm
 - Ectoderm and endoderm
 - Surface ectoderm and neuroectoderm
- Dendritic cells (melanoblasts) of skin are derived from
 - Ectoderm
 - Bone marrow
 - Endoderm
 - Neural crest
- All develops from ectoderm *except*
 - Sweat glands
 - Dermis
 - Nail
 - Hair
- Select *incorrect statement* about development of skin
 - Epidermis is derived from ectoderm
 - Melanocytes are derived from neural crest cells
 - Langerhans cells are derived from endoderm
 - Dermis is derived from mesoderm
- Three-layered epidermis in early development of skin does not consist of
 - Stratum basale
 - Intermediate layer
 - Periderm
 - Horny layer
- Incorrect statement* about vernix caseosa
 - It forms from exfoliated peridermal cells
 - It contains sebum
 - It protects fetal skin from toxic effects of amniotic fluid
 - It hinders the birth of fetus
- All are absent in the thick skin *except*
 - Hair follicles
 - Arrector pili muscles
 - Sweat glands
 - Sebaceous glands
- Incorrect statement* about melanocytes of the skin
 - They develop from neural crest cells
 - They produce increased amount of melanin in response to ultraviolet light
 - In white races their cell bodies are usually confined to basal layers
 - They begin producing melanin after birth

Answers

1. *b*, 2. *d*, 3. *b*, 4. *c*, 5. *d*, 6. *d*, 7. *c*, 8. *d*.

Chapter 8

- All develop by intramembranous ossification *except*
 - Frontal bone
 - Parietal bone
 - Body of sphenoid bone
 - Tympanic part of temporal bone
- All bones develop by endochondral ossification *except*
 - Ethmoid bone
 - Pterygoid processes of sphenoid
 - Petromastoid part of temporal bone
 - Occipital bone below superior nuchal line
- All are intersegmental in origin *except*
 - Bodies of vertebrae
 - Intervertebral discs
 - Muscles of vertebral column
 - Spinal nerves supplying muscles of vertebral column
- The mesodermal cells of sclerotomes
 - Around notochord forms centrum of bodies of vertebrae
 - Around neural tube form vertebral arches
 - In body wall form trunk muscles
 - In between centrams of adjacent vertebrae form intervertebral disc
- The costal element in the typical vertebra is a part of
 - Superior articular process
 - Inferior articular process
 - Transverse process
 - Spinous process
- Structure responsible for growth in length of bone is
 - Epiphysis
 - Diaphysis
 - Metaphysis
 - Epiphyseal cartilage
- Fusion of two or more fingers or toes is called
 - Brachydactyly
 - Syndactyly
 - Polydactyly
 - Ectrodactyly
- Secondary ossification center present at or just before birth (ninth month of IUL) is present
 - At the distal end of femur
 - At the lower end of tibia
 - At the medial end of clavicle
 - At the lower end of radius

Answers

1. c, 2. b, 3. b, 4. c, 5. c, 6. d, 7. b, 8. a.

Chapter 9

- Limb muscles develop from
 - Paraxial mesoderm
 - Lateral plate mesoderm
 - Splanchnic mesoderm
 - Neural crest cells
- Muscles of tongue develop from
 - Preotic myotomes
 - Preoccipital myotomes
 - Occipital myotomes
 - Cervical myotomes
- All are preaxial muscles *except*
 - Scalenes
 - Geniohyoid
 - Infrahyoid
 - Prevertebral
- The hypomeric musculature of the body does not include
 - Extensor muscles of the vertebral column
 - Scalene muscles
 - Quadratus lumborum
 - Pelvic diaphragm
- Select the *incorrect statement* about the development of muscles
 - Epimeres form extensor muscle of spine
 - Hypomeres form prevertebral, intercostals, and abdominal muscles
 - Muscles derived from epimeres are supplied by ventral rami of spinal nerves
 - Cardiac muscle develops from splanchnic mesoderm
- Muscle not derived from hypomeres in the cervical region are
 - Prevertebral
 - Infrahyoid
 - Laryngeal
 - Pharyngeal
- All are responsible for molecular regulation of muscle development *except*
 - BMP4*
 - MyoD* genes
 - MRFs*
 - Homeobox genes
- Select the *incorrect statement*
 - Most of the muscles of head and neck region are derived from somatomes
 - Cardiac muscle and most of the smooth muscles are derived from splanchnic mesoderm
 - Extraocular muscles develop from preotic myotome
 - Muscles of iris develop from surface ectoderm

9. Preotic myotomes are arranged around
- Otic capsule
 - Optic vesicle
 - Nasal capsule
 - None of the above

Answers

1. *a*, 2. *c*, 3. *c*, 4. *a*, 5. *c*, 6. *d*, 7. *d*, 8. *d*, 9. *b*.

Chapter 10

- Pharyngeal arch supplied by two cranial nerves is
 - First pharyngeal arch
 - Second pharyngeal arch
 - Fourth pharyngeal arch
 - Sixth pharyngeal arch
- Nerve supplying the muscles of sixth arch is
 - External laryngeal
 - Internal laryngeal
 - Recurrent laryngeal
 - None of the above
- Derivatives of first pharyngeal arch does not include
 - Maxilla
 - Mandible
 - Masseter muscle
 - Orbicularis oculi muscle
- Endodermal lining of tonsil is derived from
 - First pharyngeal pouch
 - Second pharyngeal pouch
 - Third pharyngeal pouch
 - Fourth pharyngeal pouch
- First pharyngeal pouch forms
 - External auditory meatus
 - Middle ear and pharyngotympanic tube
 - Internal ear
 - Both middle and internal ears
- First pharyngeal cleft forms
 - Internal auditory meatus
 - External auditory meatus
 - Tympanic cavity
 - Epitympanic recess
- Parafollicular cells or C cells of thyroid gland develop from
 - First pharyngeal pouch
 - Second pharyngeal pouch
 - Third pharyngeal pouch
 - Caudal pharyngeal complex
- Cartilage of the larynx that does not develop from fourth and sixth arch cartilages is
 - Epiglottis
 - Thyroid
 - Cricoid
 - Arytenoid

Answers

1. *a*, 2. *c*, 3. *d*, 4. *b*, 5. *b*, 6. *b*, 7. *d*, 8. *a*.

Chapter 11

- The tongue develops from all the pharyngeal arches *except*
 - First
 - Third
 - Fourth
 - Sixth
- The parafollicular cells or C cells of thyroid gland develop from
 - First pharyngeal pouch
 - Second pharyngeal pouch
 - Third pharyngeal pouch
 - Fourth pharyngeal pouch
- Select the *incorrect statement* about the development of the tongue
 - Development of tongue begins in the fourth week of IUL
 - Anterior two-third of tongue develops from two lingual swellings
 - Muscles of the tongue develop from occipital myotomes
 - Posterior most part of tongue develops from third pharyngeal arch
- Select the *incorrect statement* about development of tongue
 - Mucous membrane of the tongue is derived from the endoderm of the primitive foregut
 - Muscles of tongue develop from the mesoderm of the pharyngeal arches
 - Fibroareolar septa binding the muscles of tongue develop from mesenchyme of the pharyngeal arches
 - Muscles of tongue develop from occipital myotomes
- All provide general sensory innervation to the tongue *except*
 - Lingual nerve
 - Chorda tympani nerve
 - Glossopharyngeal nerve
 - Superior laryngeal nerve
- All are true about development of lingual papillae and taste buds *except*
 - Lingual papillae appear towards the end of the eighth week of IUL
 - Fungiform and filiform papillae appear first
 - Vallate and foliate papillae appear first
 - Taste buds develop by the inductive interaction between the epithelial cells of tongue and terminal branches of gustatory nerves innervating them

7. Select the *incorrect statement* about the development of thyroid
- (a) First endocrine gland to develop
 - (b) Begins to develop about 24 days after fertilization
 - (c) Pyramidal lobe develops from the distal end of the thyroglossal duct
 - (d) Starts functioning by the end of the sixth month
8. Thyroid gland starts functioning by the end of
- (a) Third month
 - (b) Fourth month
 - (c) Fifth month
 - (d) Sixth month

Answers

1. *d*, 2. *d*, 3. *d*, 4. *b*, 5. *b*, 6. *b*, 7. *d*, 8. *a*.

Chapter 12

1. Upper lip develops from all processes *except*
- (a) Frontonasal process
 - (b) Medial nasal processes
 - (c) Lateral nasal processes
 - (d) Maxillary processes
2. Nasolacrimal groove lies in the line of fusion of maxillary process and
- (a) Lateral nasal process
 - (b) Medial nasal process
 - (c) Mandibular process
 - (d) Frontonasal process
3. Commonest congenital anomaly of face
- (a) Median cleft of upper lip
 - (b) Unilateral cleft of upper lip
 - (c) Unilateral cleft of upper lip with cleft palate
 - (d) Unilateral cleft palate
4. *Incorrect statement* about development of nose
- (a) Dorsum is formed by frontonasal process
 - (b) Nasal cavities are formed by nasal pits
 - (c) Choanae are formed by rupture of oronasal membranes
 - (d) Apex is formed by lateral nasal process
5. All the paranasal air sinuses develop before birth *except*
- (a) Maxillary
 - (b) Ethmoidal
 - (c) Frontal
 - (d) Sphenoidal
6. Primary palate develops from
- (a) Frontonasal process
 - (b) Maxillary processes
 - (c) Mandibular processes
 - (d) Lateral nasal processes
7. Secondary palate develops from
- (a) Frontonasal process
 - (b) Median nasal process
 - (c) Maxillary processes
 - (d) Lateral nasal processes
8. Nasal septum develops from
- (a) Lateral nasal process
 - (b) Frontonasal process
 - (c) Nasobuccal membrane
 - (d) Maxillary processes

Answers

1. *c*, 2. *a*, 3. *b*, 4. *d*, 5. *c*, 6. *a*, 7. *c*, 8. *b*.

Chapter 13

1. All arteries supply primitive gut *except*
- (a) Celiac artery
 - (b) Superior mesenteric artery
 - (c) Inferior mesenteric artery
 - (d) Median sacral artery
2. Buccopharyngeal membrane ruptures during which week of IUL
- (a) Fourth
 - (b) Sixth
 - (c) Eighth
 - (d) Tenth
3. Cloacal membrane ruptures during which week of intra-uterine life (IUL)
- (a) Fifth
 - (b) Seventh
 - (c) Ninth
 - (d) Eleventh
4. All part of the gastrointestinal tract (GIT) are solely derived from foregut *except*
- (a) Pharynx
 - (b) Esophagus
 - (c) Stomach
 - (d) Duodenum
5. All are derivatives of the midgut *except*
- (a) Duodenum distal to the entrance of common bile duct
 - (b) Cecum
 - (c) Left one-third of transverse colon
 - (d) Appendix
6. All are true for physiological hernia of midgut loop *except*
- (a) It occurs because abdominal cavity fails to accommodate enlarging midgut loop
 - (b) It occurs at the sixth week of IUL
 - (c) It is reduced at the tenth week of IUL
 - (d) It occurs only in female fetus
7. About Meckel's diverticulum all are correct *except*
- (a) Arises from antimesenteric border of ileum
 - (b) Is persistence of vitellointestinal duct
 - (c) Is about 2 cm in length
 - (d) Is present about 2 feet proximal to ileocecal junction

8. All are true about midgut rotation *except*
 - (a) Total anticlockwise rotation is 270°
 - (b) First 90° anticlockwise rotation occurs within the umbilicus
 - (c) Remaining 180° anticlockwise rotation occurs within the abdominal cavity
 - (d) Nonrotation may cause gastroschisis
9. Select the *incorrect statement* about congenital megacolon
 - (a) Occurs due to the absence of parasympathetic ganglion in the colonic wall
 - (b) Is produced due to failure of migration of neural crest cells in the wall of colon
 - (c) Commonly affect sigmoid colon and rectum
 - (d) Occurs due to the absence of sympathetic ganglia in the wall of colon

Answers

1. *d*, 2. *a*, 3. *b*, 4. *d*, 5. *c*, 6. *d*, 7. *c*, 8. *d*, 9. *d*.

Chapter 14

1. Liver develops from all *except*
 - (a) Endoderm
 - (b) Ectoderm
 - (c) Septum transversum
 - (d) Breaking of vitelline and umbilical veins
2. All are derivatives of foregut *except*
 - (a) Stomach
 - (b) Liver
 - (c) Spleen
 - (d) Pancreas
3. Dorsal pancreatic bud forms all parts of pancreas *except*
 - (a) Upper part of head
 - (b) Body
 - (c) Tail
 - (d) Uncinate process
4. Proximal part of main pancreatic duct (duct of Wirsung) develops from
 - (a) Hepatic duct
 - (b) Cystic duct
 - (c) Ventral pancreatic duct
 - (d) Dorsal pancreatic duct
5. Mesoderm of septum transversum forms all elements of liver *except*
 - (a) Glisson's capsule
 - (b) Peritoneal coverings
 - (c) Blood vessels
 - (d) Epithelial lining of bile ductules
6. Ectopic splenic tissue may be found at all sites *except*
 - (a) Gastrosplenic ligament
 - (b) Hepatogastric ligament
 - (c) Greater omentum
 - (d) Left spermatic cord
7. Most fatal congenital anomaly of the liver is
 - (a) Riedel's lobe
 - (b) Appendix of liver
 - (c) Intrahepatic biliary atresia
 - (d) Polycystic liver
8. Commonest variation of pancreatic duct system
 - (a) Occlusion of accessory pancreatic duct
 - (b) Discontinuation between dorsal and ventral pancreatic ducts
 - (c) Inversion of pancreatic ducts
 - (d) Absence of duodenal end of accessory pancreatic duct

Answers

1. *b*, 2. *c*, 3. *d*, 4. *c*, 5. *d*, 6. *b*, 7. *c*, 8. *a*.

Chapter 15

1. All are involved in the development of mouth *except*
 - (a) Stomodeum
 - (b) Oronasal membrane
 - (c) Foregut
 - (d) Buccopharyngeal membrane
2. Epithelium of all is ectodermal in origin *except*
 - (a) Hard palate
 - (b) Sides of mouth
 - (c) Lips
 - (d) Tongue
3. Epithelial lining of all is endodermal in origin *except*
 - (a) Tongue
 - (b) Floor of mouth
 - (c) Soft palate
 - (d) Hard palate
4. Select the *incorrect statement* about development of major salivary glands
 - (a) All develop from epithelial lining of primitive oral cavity
 - (b) Epithelial buds of parotid glands arise from the angles of stomodeum
 - (c) Epithelial buds of submandibular glands arise from the floor of linguogingival sulcus
 - (d) Epithelial buds of sublingual gland arise from the floor of labiogingival sulcus
5. All are the stages of development of tooth *except*
 - (a) Bud stage
 - (b) Cap stage
 - (c) Balloon stage
 - (d) Bell stage
6. Which of the following provides the bulk and general form of the tooth?
 - (a) Enamel
 - (b) Dentin
 - (c) Pulp
 - (d) Cementum

7. All are involved in the development of teeth (dentition) *except*
- (a) Ameloblasts
 - (b) Odontoblasts
 - (c) Osteoclasts
 - (d) Osteocytes
8. Second hardest tissue in the body
- (a) Enamel
 - (b) Dentin
 - (c) Bone
 - (d) Hyaline cartilage

Answers

1. *b*, 2. *d*, 3. *d*, 4. *d*, 5. *c*, 6. *b*, 7. *d*, 8. *b*.

Chapter 16

1. First sign of development of the respiratory system is development of
- (a) Laryngotracheal groove
 - (b) Primitive foregut
 - (c) Respiratory diverticulum
 - (d) Hypobranchial eminence
2. All are true about surfactant *except*
- (a) It is produced at the end of the sixth month of IUL
 - (b) It forms a thin lining of alveoli
 - (c) It reduces surface tension at the air–alveolar surface
 - (d) It is produced by type-I alveolar epithelial cells (type-I pneumocytes)
3. *Blood–air barrier* in the lung consists of
- (a) Endoderm only
 - (b) Mesoderm only
 - (c) Mesoderm and endoderm
 - (d) Mesoderm and ectoderm
4. Regarding respiratory diverticulum all are correct *except*
- (a) Is an outgrowth of the ventral wall of foregut
 - (b) Appears when embryo is about 4 weeks old
 - (c) Is mesodermal in origin
 - (d) First appears as a midline laryngotracheal groove
5. Select the *incorrect statement* about the development of lung
- (a) Right principal bronchus divides into three lobar bronchi
 - (b) Left principal bronchus divides into two lobar bronchi
 - (c) By the end of sixth month seven generations of subdivision of bronchi are formed
 - (d) Respiratory bronchioles are formed during canalicular stage of lung maturation
6. The stage of maturation of the lung that extends from 16–26 weeks is called

- (a) Pseudoglandular stage
- (b) Canalicular stage
- (c) Terminal sac stage
- (d) Alveolar stage

7. All laryngeal cartilages develop from neural crest mesenchyme of fourth and sixth pharyngeal arches *except*
- (a) Epiglottis
 - (b) Thyroid cartilage
 - (c) Cricoid cartilage
 - (d) Arytenoid cartilages
8. All are features of alveolar stage of lung maturation *except*
- (a) Number of alveolar sac increases
 - (b) Blood capillaries come in intimate contact with the alveolar sacs
 - (c) Alveolar sac is lined by *type-I* and *type-II* pneumocytes
 - (d) *Type-I pneumocytes* secrete surfactant

Answers

1. *a*, 2. *d*, 3. *c*, 4. *c*, 5. *c*, 6. *b*, 7. *a*, 8. *d*.

Chapter 17

1. The embryonic structure that does not contribute to the formation of the diaphragm is
- (a) Septum transversum
 - (b) Pleuroperitoneal membranes
 - (c) Dorsal mesogastrium
 - (d) Mesoderm of the body wall
2. Pericardial cavity is separated from the pleural cavity by
- (a) Pleuroperitoneal membrane
 - (b) Pleuropericardial fold
 - (c) Pleuropericardial membrane
 - (d) Septum transversum
3. All of the following embryological events are involved in the development of the lesser sac *except*
- (a) Development of pneumoenteric recesses in the dorsal mesogastrium
 - (b) Regression of right pneumoenteric recess
 - (c) Rotation of stomach
 - (d) Formation of the greater omentum
4. Select the *incorrect statement* about intraembryonic celom
- (a) It begins to develop near the end of the third week
 - (b) It becomes horseshoe shaped by the fourth week
 - (c) Cranially it communicates with extraembryonic celom
 - (d) It divides lateral plate mesoderm into two layers
5. Select *incorrect statement* about pericardial cavity
- (a) It develops from part of intraembryonic celom that develops first
 - (b) It develops in the region of pericardial bar

- (c) It communicates with the peritoneal cavity until the third week
 - (d) It is separated from the pleural cavity by the pleuropericardial membrane.
6. All are correct about esophageal *hiatal hernia* except
 - (a) Herniation of stomach through esophageal opening into the diaphragm
 - (b) It makes esophageal hiatus incompetent
 - (c) It causes projectile vomiting when infant is laid on it back after feeding
 - (d) It causes respiratory distress when infant is laid on the either side after feeding
 7. All are correct statements about CDH except
 - (a) It occurs in about once in 2200 births
 - (b) It occurs through foramen of Bochdalek
 - (c) About 99% newborns die
 - (d) Cause of death is respiratory distress
 8. *Incorrect statement* about congenital diaphragmatic hernia is
 - (a) Occurs through a defect in the posterolateral aspect of the diaphragm
 - (b) Causes hypoplasia of the lungs
 - (c) Can be detected prenatally in about 50% cases
 - (d) Occurs mostly on the right side

Answers

1. c, 2. c, 3. b, 4. c, 5. c, 6. d, 7. c, 8. d.

Chapter 18

1. Heart starts beating on day
 - (a) 16
 - (b) 22
 - (c) 28
 - (d) 34
2. U-shaped loop of the heart tube
 - (a) Has cranial arterial end
 - (b) Has caudal venous end
 - (c) Invaginates pericardial cavity from the dorsal side
 - (d) Is initially suspended from ventral wall of the pericardial cavity by ventral mesogastrium
3. All are dilatations of primary heart tube except
 - (a) Bulbus cordis
 - (b) Primitive ventricle
 - (c) Right atrium
 - (d) Sinus venosus
4. All contribute to the formation of interatrial septum except
 - (a) Septum primum
 - (b) Septum secundum
 - (c) Spiral septum
 - (d) Septum spurium
5. Right valve of sinoatrial orifice forms all except
 - (a) Crista terminalis

- (b) Valve of inferior vena cava
 - (c) Valve of coronary sinus
 - (d) Septum spurium
6. All are features of Fallot's tetralogy except
 - (a) Interventricular septal defect
 - (b) Overriding of aorta
 - (c) Aortic stenosis
 - (d) Hypertrophy of the right ventricle
 7. All form interventricular septum except
 - (a) Right bulbar ridge
 - (b) Left bulbar ridge
 - (c) Atrioventricular cushions
 - (d) Spiral septum
 8. Ventricles develop from
 - (a) Distal part of bulbus cordis
 - (b) Proximal part of bulbus cordis
 - (c) Atrioventricular canals
 - (d) Primitive ventricular chamber

Answers

1. b, 2. d, 3. c, 4. c, 5. d, 6. c, 7. d, 8. d.

Chapter 19

1. All are true about aortic arch arteries except
 - (a) They are five in number
 - (b) They are numbered I, II, III, IV, and V
 - (c) They are numbered I, II, III, IV, and VI
 - (d) They connect aortic sac horns with the dorsal aortae
2. Arch aorta does not develop from
 - (a) Ventral part of aortic sac
 - (b) Left horn of aortic sac
 - (c) Left fourth aortic arch artery
 - (d) Left seventh intersegmental artery
3. First aortic arch artery gives rise to
 - (a) Maxillary artery
 - (b) Hyoid artery
 - (c) Stapedial artery
 - (d) Facial artery
4. Select *incorrect statement* about ductus arteriosus
 - (a) It is derived from the distal part of the left sixth arch artery
 - (b) It carries blood from the right ventricle to the dorsal aorta
 - (c) The bradykinin secreted by lungs helps in its closure
 - (d) It forms ligamentum venosum after birth
5. All arteries represent axis artery of upper limb except
 - (a) Axillary
 - (b) Brachial
 - (c) Posterior interosseous
 - (d) Anterior interosseous

6. Axis artery of lower limb is represented by all *except*
 - (a) Inferior gluteal
 - (b) Popliteal artery
 - (c) Femoral artery
 - (d) Plantar arch
7. All contribute to the formation of the inferior vena cava *except*
 - (a) Posterior cardinal vein
 - (b) Supracardinal vein
 - (c) Intersubcardinal veins
 - (d) Supracardinal–subcardinal anastomosis
8. Left renal vein is derived from all *except*
 - (a) Mesonephric vein
 - (b) Subcardinal vein
 - (c) Anastomosis between subcardinal veins
 - (d) Supracardinal vein
9. Superior mesenteric vein is formed by
 - (a) Vitelline vein
 - (b) Umbilical vein
 - (c) Anterior cardinal vein
 - (d) Posterior cardinal vein
10. Left gonadal vein is formed by
 - (a) Left supracardinal vein
 - (b) Left sacrocardinal vein
 - (c) Left posterior cardinal vein
 - (d) Anastomosis between subcardinal veins
4. Ureteric bud arises from
 - (a) Mesonephric duct
 - (b) Paramesonephric duct
 - (c) Vesicourethral canal
 - (d) Urogenital sinus
5. Metanephric blastema gives rise to all *except*
 - (a) Bowman's capsule
 - (b) Loop of Henle
 - (c) Distal convoluted tubule
 - (d) Collecting tubules
6. Definitive kidney develops from
 - (a) Metanephros
 - (b) Pronephros
 - (c) Mesonephros
 - (d) Wolffian duct
7. Regarding horseshoe kidney all are true *except*
 - (a) Occurs due to fusion of lower poles of two kidney
 - (b) Inferior mesenteric artery lies ventral to isthmus
 - (c) Lies at L1 vertebra level
 - (d) Ureters pass anterior to the isthmus
8. Polycystic kidney
 - (a) May be inherited as an autosomal recessive disorder
 - (b) May be inherited as an autosomal dominant disorder
 - (c) May occur due to splitting of ureteric bud
 - (d) May occur due to dilatations in loops of Henle

Answers

1. *b*, 2. *d*, 3. *a*, 4. *d*, 5. *c*, 6. *c*, 7. *c*, 8. *d*, 9. *b*, 10. *b*.

Chapter 20

1. Select the *incorrect statement* about the development of kidney
 - (a) Three successive kidneys develop in craniocaudal direction
 - (b) The one which persists in the lumbar region to form a permanent kidney
 - (c) The collecting system of kidney develops from ureteric bud
 - (d) The development of the excretory system is induced by ureteric bud
2. Mesonephros
 - (a) It forms in thoracolumbar region
 - (b) It gives rise to excretory tubules
 - (c) It appears at the beginning of the third month
 - (d) It functions till the tenth week of IUL only
3. All are adult derivatives of ureteric bud *except*
 - (a) Renal pelvis
 - (b) Minor calyces
 - (c) Collecting tubules
 - (d) Distal convoluted tubule
10. Absorption of mesonephric ducts in the urogenital sinus
 - (a) Forms epithelial lining of trigone of urinary bladder
 - (b) Makes mesonephric ducts and ureters to open separately in the urogenital sinus
 - (c) Forms ejaculatory ducts in males
 - (d) Forms ducts of Bartholin glands in females

Answers

1. *b*, 2. *c*, 3. *d*, 4. *a*, 5. *d*, 6. *a*, 7. *c*, 8. *c*, 9. *c*, 10. *a*.

Chapter 21

1. Regarding development of testis all are correct *except*
 - (a) Primordial germ cells migrate from wall of yolk sac to the developing testis
 - (b) Seminiferous tubules develop from second generation of sex cords
 - (c) Rete testis is formed by first generation of sex cords
 - (d) Leydig cells develop from mesoderm

2. Regarding development of ovary all are correct *except*
 - (a) It develops from genital ridge in the upper lumbar region of posterior abdominal wall
 - (b) Its primordial follicles are formed from primordial germ cells and celomic epithelial cells
 - (c) Two generation of sex cords form during its development
 - (d) Its first generation of sex cords form primordial follicles
3. In females, the paramesonephric duct (Mullerian duct) gives rise to all *except*
 - (a) Fallopian tubes
 - (b) Cervix
 - (c) Upper part of vagina
 - (d) Vestibule of vagina
4. Genital swellings in the females give rise to
 - (a) Clitoris
 - (b) Labia majora
 - (c) Labia minora
 - (d) Vagina
5. In males, mesonephric (Wolffian) duct gives rise to all *except*
 - (a) Rete testis
 - (b) Efferent ductules
 - (c) Duct of epididymis
 - (d) Seminal vesicle
6. Genital swellings in the male gives rise to
 - (a) Penis
 - (b) Scrotal sac
 - (c) Penile urethra
 - (d) Prostate
7. Seminal vesicle develops from
 - (a) Mullerian duct
 - (b) Wolffian duct
 - (c) Prostatic urethra
 - (d) Membranous urethra
8. Congenital inguinal hernia in females may occur due to
 - (a) Indecent of ovary
 - (b) Presence of canal of Nuck
 - (c) Shortening of gubernaculum of ovary
 - (d) Absence of urogenital mesentery
9. Sinovaginal bulbs fuse to form
 - (a) Clitoris
 - (b) Vestibule of vagina
 - (c) Vaginal plate
 - (d) Uterovaginal canal
10. The phenotypic sexual differentiation of external genitalia begins at
 - (a) Fifth week of IUL
 - (b) Seventh week of IUL
 - (c) Ninth week of IUL
 - (d) Eleventh week of IUL

11. Embryologically the labia minora arises from
 - (a) Paramesonephric ducts
 - (b) Urethral folds
 - (c) Sinovaginal bulbs
 - (d) Genital swellings

Answers

1. *b*, 2. *d*, 3. *d*, 4. *b*, 5. *a*, 6. *b*, 7. *b*, 8. *b*, 9. *c*, 10. *b*, 11. *b*.

Chapter 22

1. All are derivatives of neural crest *except*
 - (a) Neurons of dorsal root ganglia
 - (b) Schwann cells
 - (c) Melanoblast of skin
 - (d) Microglia
2. Lower end of spinal cord of 24-week-old embryo ends at the level of lower border of
 - (a) First coccygeal vertebra
 - (b) First sacral vertebra
 - (c) Third lumbar vertebra
 - (d) First lumbar vertebra
3. In adults the lower end of spinal cord ends at following lumbar vertebral level
 - (a) Lower border of L3
 - (b) Lower border of L2
 - (c) Upper border of L1
 - (d) Lower border of L1
4. All are primary brain vesicles *except*
 - (a) Prosencephalon
 - (b) Diencephalon
 - (c) Mesencephalon
 - (d) Rhombencephalon
5. Cerebellum develops from
 - (a) Basal plate of metencephalon
 - (b) Alar plate of metencephalon
 - (c) Basal plate of myelencephalon
 - (d) Alar plate of myelencephalon
6. During histogenesis of neural tube, the neuroepithelial cells lining neural canal forms all *except*
 - (a) Ependymal cells
 - (b) Neurons of ventral horns
 - (c) Neurons of dorsal horns
 - (d) Neurons of dorsal root ganglia
7. Fourth ventricle represents cavity of
 - (a) Prosencephalon
 - (b) Diencephalon
 - (c) Mesencephalon
 - (d) Rhombencephalon
8. Regarding Arnold–Chiari malformation all are true *except*
 - (a) It is not a congenital anomaly
 - (b) Tonsils of cerebellum herniate through foramen magnum

- (c) Increase in CSF pressure
(d) Stretching of IX, X, XI, and XII cranial nerves
9. All functional columns are present in the basal plate of hindbrain *except*
(a) General somatic efferent
(b) General visceral efferent
(c) Special somatic afferent
(d) Special visceral afferent
10. Regarding hydrocephalus all are true *except*
(a) Occurs due to excessive production of CSF
(b) Occurs due to blockage of passage of CSF circulation
(c) Causes decreased intracranial pressure
(d) Occurs due to microcephaly

Answers

1. *d*, 2. *b*, 3. *d*, 4. *b*, 5. *b*, 6. *d*, 7. *d*, 8. *a*, 9. *d*, 10. *c*.

Chapter 23

1. Neural crest cells form which of the following component in the adrenal gland
(a) Zona glomerulosa
(b) Zona fasciculata
(c) Zona reticulata
(d) Medulla
2. Rathke's pouch forms all *except*
(a) Pars anterior
(b) Pars nervosa
(c) Pars intermedia
(d) Pars tuberalis
3. Infundibulum that grows from the floor of the third ventricle forms part of
(a) Adenohypophysis
(b) Neurohypophysis
(c) Pars intermedia
(d) Pars tuberalis
4. Regarding the development of adrenal gland all are correct *except*
(a) Its cortex forms from two episodes of proliferation of mesodermal cells of celomic epithelium
(b) Its medulla forms from neural crest
(c) Its fetal cortex is absent at birth
(d) The zona reticularis in its cortex is not formed until 3 years of age
5. Vitreous body develops from endoderm
(d) Sclera develops from mesoderm
2. Dilator and sphincter pupillae muscles of the iris develop from
(a) Surface ectoderm
(b) Neuroectoderm
(c) Mesoderm
(d) Neural crest cells
3. All are derivatives of the dorsal part of otic vesicle *except*
(a) Sacculus
(b) Utricle
(c) Semicircular canals
(d) Endolymphatic duct
4. Auricular hillocks develop around the dorsal end/ends of
(a) First pharyngeal arch
(b) First and second pharyngeal arches
(c) Second pharyngeal arch
(d) Second and third pharyngeal arches
5. All develop from hyoid arch *except*
(a) Helix
(b) Antihelix
(c) Tragus
(d) Antitragus
6. All develop from mesoderm *except*
(a) Substantia propria of the cornea
(b) Ciliary muscle
(c) Sphincter pupillae
(d) Vitreous body
7. All develop from first pharyngeal arch *except*
(a) Tensor tympani muscle
(b) Stapedius muscle
(c) Malleus
(d) Incus
8. Select the *incorrect statement* regarding development of ear
(a) External auditory meatus develops from first pharyngeal cleft
(b) Tubotympanic cavity develops from first pharyngeal pouch
(c) Outer layer of tympanic membrane is ectoderm in origin
(d) Antitragus develops from mandibular arch

Answers

1. *c*, 2. *b*, 3. *a*, 4. *b*, 5. *c*, 6. *c*, 7. *b*, 8. *d*.

Chapter 24

1. Select *incorrect statement* regarding the development of various components of the eye
(a) Retina develops from neuroectoderm
(b) Lens develops from surface ectoderm
1. Each nucleotide consists of all of the following subunits *except*
(a) A molecule of deoxyribose sugar
(b) A molecule of ribose sugar
(c) A molecule of nitrogenous base
(d) A molecule of phosphate

2. All of the following nitrogenous bases are present in a DNA molecule *except*
 - (a) Adenine
 - (b) Thymine
 - (c) Uracil
 - (d) Guanine
3. Select the *incorrect statement* about the chromosomes
 - (a) Each chromosome presents a primary constriction called centromere
 - (b) Number of chromosomes is not constant in a species
 - (c) Each somatic cell contains 23 pairs of chromosomes
 - (d) Females have two X chromosomes (XX) in each somatic cell
4. Select the *incorrect statement* about the Barr body
 - (a) Structurally it represents an X chromosome that is genetically inactive
 - (b) Generally it is located on the outer surface of nuclear membrane
 - (c) The number of Barr bodies in a cell is equal to the total number of X chromosomes minus one
 - (d) In neurons it appears as a small dark body opposite the nucleolus
5. Select the *correct statement* about karyotyping
 - (a) Chromosomes are arranged in seven groups, referred to by letters A to G
 - (b) Chromosomes of group A and F are submetacentric
 - (c) Chromosomes of group D and group G are metacentric
 - (d) X chromosome belongs to group G and Y chromosome belongs to group C
6. Clinical conditions caused by trisomy include all of the following *except*
 - (a) Patau's syndrome
 - (b) Down's syndrome
 - (c) Klinefelter's syndrome
 - (d) Cri-du-chat syndrome
7. Clinical features of Down's syndrome include all *except*
 - (a) Oblique palpebral fissures with epicanthic folds
 - (b) Presence of simian crease
 - (c) Long protruding tongue
 - (d) Long legs and arms
8. Select the *incorrect statement* about Klinefelter's syndrome
 - (a) It is a trisomic condition found only in females
 - (b) The affected individual is sex-chromatin positive
 - (c) The affected individual has increased level of gonadotrophin
 - (d) Lengths of legs and arms are usually longer than normal
9. Which of the following clinical condition is caused by monosomy?
 - (a) Klinefelter's syndrome
 - (b) Turner's syndrome
 - (c) Down's syndrome
 - (d) Cri-du-chat syndrome
10. Select the *incorrect statement* about X-linked recessive inheritance
 - (a) It usually affects males
 - (b) It usually affects females
 - (c) It may affect females rarely
 - (d) Females act as a carrier

Answers

1. *b*, 2. *c*, 3. *b*, 4. *b*, 5. *a*, 6. *d*, 7. *d*, 8. *a*, 9. *b*, 10. *b*.

Chapter 26

1. Most susceptible period of pregnancy to teratogenesis is
 - (a) 0–2 weeks
 - (b) 3–8 weeks
 - (c) 9–14 weeks
 - (d) 15–38 weeks
2. Common cause of congenital birth defects is
 - (a) Infection
 - (b) Radiation
 - (c) Genetic
 - (d) Trauma
3. Amniocentesis is usually done between weeks
 - (a) 8 and 10
 - (b) 10 and 12
 - (c) 12 and 14
 - (d) 14 and 16
4. Which prenatal diagnostic test is done routinely?
 - (a) Amniocentesis
 - (b) Chorionic villus biopsy
 - (c) Maternal serum screening
 - (d) Ultrasonography

Answers

1. *b*, 2. *c*, 3. *d*, 4. *d*.

Figure Credits

Chapter 1

Fig. 1.7 Modified from figure published in Publication *The Developing Human: Clinically Oriented Embryology*, 8th edition by Keith L Moore and TVN Persaud, ISBN: 9781416037064, page 9, Fig. 1.4, Copyright Elsevier, 2008.

Fig. 1.8 Modified from figure published in Publication *The Developing Human: Clinically Oriented Embryology*, 8th edition by Keith L Moore and TVN Persaud, ISBN: 9781416037064, page 10, Fig. 1.6, Copyright Elsevier, 2008.

Chapter 6

Fig. 6.15B&C This figure was published in Publication *The Developing Human: Clinically Oriented Embryology*, 8th edition by Keith L Moore and TVN Persaud, ISBN: 9781416037064, page 126, Fig. 7.13 A&B, Copyright Elsevier, 2008.

Chapter 7

Fig. 7.8 This figure was published in Publication *The Developing Human: Clinically Oriented Embryology*, 8th edition by Keith L Moore and TVN Persaud, ISBN: 9781416037064, page 444, Fig. 19.6, Copyright Elsevier, 2008.

Fig. 7.9 This figure was published in Publication *Short Cases in Clinical Medicine*, 4th edition by ABM Abdullah, ISBN: 9788131226698, page 24, Chapter 1, Copyright Elsevier, 2009.

Chapter 8

Fig. 8.4 This figure was published in Publication *Short Cases in Clinical Medicine*, 4th edition by ABM Abdullah, ISBN: 9788131226698, page 209, Chapter 5, Copyright Elsevier, 2009.

Fig. 8.29 This figure was published in Publication *Textbook of Forensic Medicine and Toxicology*, 5th edition by Krishan Vij, ISBN: 9788131226841, page 147, Fig. 7.1, Copyright Elsevier, 2011.

Fig. 8.30 This figure was published in Publication *Short Cases in Clinical Medicine*, 4th edition by ABM Abdullah, ISBN: 9788131226698, page 52, Chapter 1, Copyright Elsevier, 2009.

Chapter 10

Fig. 10.13 This figure was published in Publication *Recognizable Patterns of Human Malformation: Genetic, Embryologic and Clinical Aspects*, 3rd edition by David W Smith, ISBN: 9780721683812, page 185, Copyright Elsevier, 1982.

Chapter 11

Fig. 11.6 This figure was published in Publication *The Developing Human: Clinically Oriented Embryology*, 8th edition by Keith L Moore and TVN Persaud, ISBN: 9781416037064, page 178, Fig. 9.25, Copyright Elsevier, 2008.

Fig. 11.9 This figure was published in Publication *The Developing Human: Clinically Oriented Embryology*, 8th edition by Keith L Moore and TVN Persaud, ISBN: 9781416037064, page 177, Fig. 9.23, Copyright Elsevier, 2008.

Chapter 12

Fig. 12.15A This figure was published in Publication *The Developing Human: Clinically Oriented Embryology*, 8th edition by Keith L Moore and TVN Persaud, ISBN: 9781416037064, page 190, Fig. 9.39, Copyright Elsevier, 2008.

Fig. 12.15B This figure was published in Publication *The Developing Human: Clinically Oriented Embryology*, 8th edition by Keith L Moore and TVN Persaud, ISBN: 9781416037064, page 192, Fig. 9.41, Copyright Elsevier, 2008.

Chapter 15

Fig. 15.9 This figure was published in Publication *The Developing Human: Clinically Oriented Embryology*, 8th edition by Keith L Moore and TVN Persaud, ISBN: 9781416037064, page 451, Fig. 19.15, Copyright Elsevier, 2008.

Fig. 15.11 This figure was published in Publication *The Developing Human: Clinically Oriented Embryology*, 8th edition by Keith L Moore and TVN Persaud, ISBN: 9781416037064, page 455, Fig. 19.21, Copyright Elsevier, 2008.

Chapter 18

Fig. 18.10 Courtesy of Dr Basant Kumar, Assistant Professor, Department of Pediatric Surgery, SGPGIMS, Lucknow.

Chapter 20

Fig. 20.18B Courtesy of Dr Basant Kumar, Assistant Professor, Department of Pediatric Surgery, SGPGIMS, Lucknow.

Chapter 22

Fig. 22.10 Courtesy of Dr Basant Kumar, Assistant Professor, Department of Pediatric Surgery, SGPGIMS, Lucknow.

Index

A

Abdominal implantation, 61
Achondroplasia, 87, 100
Acrocephaly, 96
Acrosomal cap, 26
Acrosome reaction, 35
Adrenal gland, 276–277
Aglossia, 125
Albinism, 78
Allantoenteric diverticulum, 60
Allantois, 60
Alopecia, 78
Amastia, 82
Amelia, 100
Ameloblast, 170
Amelogenesis imperfecta, 174
Amenorrhea, 15
Amniocentesis, 75, 315
Amnion, 40, 58–59
Amniotic fluid, 58
Anal canal, 153–155
Anencephaly, 96
Angiogenesis, 213
Ankyloglossia, 125
Anodontia, 174
Anonychia, 81
Anophthalmia, 284
Anus, imperforate, 155
Aorta
 arch of, 216
 double, 218
 right, 215
 ascending, 216
 coarctation of, 216
 descending, 216
 dorsal, 216
 pharyngeal arch, 214
 primitive, 213
 ventral, 213
Aortic sac, 214
Aphakia, 284
Apparatus
 extrahepatic, 160–161
 pharyngeal, 110–121
Appendix, 148
 of epididymis, 251
 of liver, 166
 of testis, 251
 subhepatic, 152

Arch/arches

 aortic, 214
 branchial, 110–116
 pharyngeal, 110–116
Area, cardiogenic, 196
Arnold–Chiari malformation, 274
Arrector pili muscle, 78
Artery/arteries
 arch, 213
 of body, 218
 of head and neck, 214
 of limbs, 219, 220
 pharyngeal arch, 213
 umbilical, 218

B

Barriers, oocyte, 34
Bladder
 gall, 160
 urinary, 240
Blastocyst, 38
Bochdalek, foramen of, 189
Body
 Barr, 295
 pineal, 276
 ultimobranchial, 125
Bone, 84
 areolae
 primary, 85
 secondary, 85
 cartilage, 84
 formation of, 84
 ossification of, 84
Brachiocephaly, 96
Brachydactyly, 96
Brain, 268–273
 flexors, 268–270
 hind, 271
 mid, 272
Bronchi, 179
Bud/buds
 bronchial, 179
 hepatic, 158
 lungs, 177
 pancreatic
 dorsal, 163
 ventral, 163
 periosteal, 85
 taste, 124, 129

Bud/buds (*Contd.*)

tongue, 122

ureteric, 234

Bulb, sinovaginal, 253

Bulbus cordis, 197, 198

Bursa

infracardiac, 192

inguinal, 260

C

Canal

anal, 153

uterovaginal, 252

vesicourethral, 240

Cap, acrosomal, 26

Caroli's disease, 159

Cartilage, 82

epiphyseal, 99

Meckel's, 113

Richert's, 144

Cataract, 281–282

Caudal pharyngeal complex, 116

Cavity/cavities

body, 186–195

nasal, 134

pericardial, 190

peritoneal, 191

pleural, 190

Cecum, 148–150

foramen, 125

Cell

of Leydig, 248

Sertoli, 248, 264

Celom

extraembryonic, 40

intraembryonic, 186

Chondroblast, 78

Chordoma, 48

Chorion, 40, 60

Chorion frondosum, 63

Chorion laeve, 63

Chorionic villi, 65

Choroid, 282

Choroidal fissure, 279

Chromaffin tissue, 277, 278

Chromatid, 2

Chromosome, 293–295

abnormalities, 295–298

sex, 294

Circulation

fetal, 228–229

placental, 68

Cleavage, 37

Cleft/clefts

facial

oblique, 136

intratonsillar, 147

lip, 136

palate, 136

pharyngeal, 117

Cleidocranial dysostosis, 86–87

Clitoris, 258

Cloaca, 153

Coarctation of aorta, 216

Coloboma, 284

Conjunctival sac, 285

Connecting stalk, 40

Connective tissue, 80

Contraception, 18–19

Copula, 122

Cor trilobulare biventriculare, 204

Cord

medullary, 247

nephrogenic, 233

sex, 247

spinal, 274

umbilical, 70–72

Cornea, 283

Corpora atretica, 32

Corpus callosum, 293

Corpus luteum, 30–31

of menstruation, 31

of pregnancy, 31

Corpus striatum, 272

Corti, organ of, 290

Cotyledons

of placenta, 66

Cowper's gland, 10

Cryptorchidism, 260

Cumulus oophoricus, 16

Cup, optic, 279

Cycle

menstrual, 14–16

ovarian, 11

Cyclopia, 284

Cyclops, 132

Cyst/cysts

branchial, 118

dentigerous, 174

thyroglossal, 127

vitelline, 152

Cytotrophoblast, 63

Cytotrophoblastic shell, 65

D

Dandy–Walker syndrome, 270

Decidua, 62

basalis, 63

capsularis, 63

parietalis, 63

Decidual reaction, 62

Dental cuticle, 171

Dental lamina, 171

Dental papilla, 171

Dentigerous imperfecta, 174

Dentine, 171

Deoxyribonucleic acid, 292

Dermatoglyphics, 77

Dermatome, 51

Dermis, 77

Desired sex of baby, 33

Development of

axial skeleton, 87

face, 130

- genital system, 246–264
 - joints, 100
 - lymphatic system, 229–230
 - ribs, 91
 - skull, 92
 - cardiac muscle, 107
 - skeletal muscle, 103
 - smooth muscle, 107
 - sternum, 91
 - thyroid, 125–127
 - tongue, 122–125
 - urinary system, 233–245
 - Dextrocardia, 199
 - Diagnosis, prenatal, 312
 - Diaphragm, 188, 189
 - clinical correlation, 189
 - Diaphysis, 99
 - DiGeorge syndrome, 118
 - Diverticulum
 - laryngotracheal, 176
 - Meckel's, 151
 - respiratory, 176
 - DNA, 292
 - Duchenne muscular dystrophy, 107
 - Duct/ducts
 - biliary, extrahepatic, 160
 - genital, 249
 - lymphatic, right, 229
 - mesonephric, 250–251
 - nasolacrimal, 132
 - of Santorini, 162
 - of Wirsung, 163
 - pancreatic, 163
 - inversion of, 164
 - paramesonephric, 252
 - thoracic, 229
 - thyroglossal, 125
 - vitelline, 52
 - vitellointestinal, 141
 - Ductus
 - arteriosus, 214
 - patent, 214
 - caroticus, 214
 - deferens, 10
 - venosus, 221, 228
 - Duodenum, 145–147
 - Dwarfism, 87
 - Dysostosis
 - cleidocranial, 86
- E**
- Ear, 286–290
 - anomalies of, 287
 - external, 286
 - internal, 288
 - middle, 287
 - Ectopia cordis, 200
 - Ectopia vesicae, 243
 - Embryoblast, 38
 - Encephalocele, 96
 - Endolymph, 289
 - Epiblast, 42
 - Epidermis, 76
 - Epididymis, 9
 - appendix of, 251
 - Epispadias, 257
 - Esophagus, 141–142
 - Erythroblastosis fetalis, 75
 - Exomphalos, 150
 - Exstrophy of
 - urinary bladder, 243
 - External genitalia
 - female, 258
 - male, 255–258
 - Eye, 279–286
- F**
- Face, 131–132
 - intermaxillary segment, 134
 - Fallopian's tetralogy, 205
 - Fertilization, 34–37
 - in vitro, 37
 - site, 34
 - steps, 35
 - Fingerprints, 77
 - Fistula
 - branchial, 118
 - thyroglossal, 127
 - tracheoesophageal, 143, 178
 - vitelline, 152
 - Flexure
 - cervical, 268
 - mesencephalic, 269
 - pontine, 269
 - Fluid, amniotic, 58
 - Fold, urethral, 253
 - Folding of embryo, 52–55
 - Follicle
 - Graafian, 30
 - ovarian, 28
 - Foramen
 - of Bochdalek, 189
 - of Morgagni, 189
 - ovale, 204
 - patent, 204
 - primum, 200
 - secundum, 200
 - sternum, 92
 - Fossa
 - ovalis, 196
 - ovarian, 262
 - Funnel chest, 92
- G**
- Gallbladder, 160
 - anomalies of, 160–161
 - floating, 161
 - sessile, 160
 - Gastroschisis, 151
 - Gastrulation, 39
 - Genes, 298
 - dominant, 298
 - location, 298
 - recessive, 298

- Genes (*Contd.*)
 types, 298
- Genetics, 292–306
 behavioral, 293
 biochemical, 293
 cytogenetics, 293
 developmental, 293
 immunogenetics, 293
 molecular, 293
 population, 293
- Germ layer, 39–43
- Germ layers, 42–43
- Gigantism, 278
- Gland
 adrenal, 276–277
 bulbourethral, 10, 251
 Cowper's, 10
 digestive, 158–165
 mammary, 81–82
 parathyroid, 116
 parotid, 170
 pineal, 276
 salivary, 158, 169–170
 sebaceous, 78
 sublingual, 170
 submandibular, 170
 sweat, 79
 thyroid, 125–126
- Gonads, 247–249
 definitive, 247
 indifferent, 246
- Groove
 laryngotracheal, 176
 nasolacrimal, 132
 urethral, 256
- Gubernaculum
 ovarii, 262
 testis, 260
- Gut
 fore, 141
 hind, 153
 mid, 147
 primitive, 140
 rotation of, 148–150
- Gynecomastia, 82
- H**
- Hair, 78
- Hartmann's pouch, 161
- Heart, 196–211
 anomalies of, 199, 203–205
 conducting system of, 208
 valve of, 207
- Heart tube, 196
- Hemolytic disease of fetus, 75
- Hemophilia, 300, 304
- Henson's node, 46
- Hepatic bud, 159
 pars cystica, 159
 pars hepatica, 159
- Hermaphrodites, 259
- Hermaphroditism, 259
- Hertwig's
 epithelial root sheath, 171
- Hernia
 diaphragmatic, 189
 inguinal, 261
 umbilical, 151
- Hindgut, derivatives of, 153
- Hirsprung's disease, 154
- His, cupola of, 122
- History of embryology, 4
- Hormone
 estrogen, 12
 follicle stimulating, 12
 for contraception, 16
 FSH, 12
 GnRH, 15
 gonadotrophin-releasing, 15
 HCG, 44
 LH, 12
 luteinizing, 12
- Human chorionic gonadotrophin, 44
- Hydatiform mole, 38
- Hydrocele
 congenital, 261
- Hydrocephalus, 270–271
- Hypobranchial eminence, 122–123
- Hypophysis cerebri, 275
- Hypospadias, 257
- I**
- Ichthyosis, 78
- Implantation, 60
 abnormal, 61
 types of, 61
- Infertility, 18–19, 40
- Inheritance, 299
 autosomal, 299
 multifactorial, 300
 sex-linked, 299
- K**
- Karyotyping, 294–295
- Kidney, 233
 anomalies of, 238
 ascent of, 237
 horseshoe, 238
 lobulated, 238
 pancake, 239
 polycystic, 238, 245
- Klinefelter's syndrome, 83
- L**
- Labyrinth, 177–178
 bony, 289
 membranous, 288–289
- Larynx, 177–178
- Lens, 281
- Lens placode, 279
- Levator glandulae
 thyroidea, 126
- Ligament
 falciform, 144

- gastrosplenic, 145, 194
 - lienorenal, 145, 194
 - of ovary, 263
 - round, of uterus, 263
 - umbilical, medial, 229
 - Ligamentum
 - arteriosum, 229
 - teres, of liver, 229
 - venosum, 229
 - Lingual swelling, 122–123
 - Lip, 131
 - Liver, 158–160
 - anomalies of, 158–160
 - Lobster claw
 - hand, 100
 - foot, 100
 - Lumbarization, of S1 vertebra, 91
 - Lungs, 179–183
 - anomalies of, 182
 - maturation, 180–182
 - Lusoria, dysphagia, 217–218
 - Lutein
 - Lymph sacs, 229
 - Lymphocytes, 230
 - Lymph nodes, 230
- M**
- Macroglossia, 125
 - Macromastia, 136
 - Macrostomia, 136
 - Malleus, 287
 - Mantle
 - myoepicardial, 198
 - Meckel's diverticulum, 151
 - Megacolon, congenital, 154
 - Meiosis, 22–23
 - Membrane/membranes
 - amniochorionic,
 - anal, 54
 - buccopharyngeal, 54, 168
 - extraembryonic, 58–72
 - Heuser's, 40
 - pharyngeal, 119–120
 - pericardiopleural, 187
 - placental, 67–68
 - pleuroperitoneal, 187
 - Menarche, 18
 - Menopause, 14
 - Menstruation, 14
 - Meromelia, 100
 - Mesoderm
 - derivatives of
 - intermediate, 44
 - intraembryonic, 42, 48
 - lateral plate, 51
 - paraxial, 49
 - parietal, 40
 - somatopleuric, 40
 - splanchnopleuric, 40
 - Mesonephros, 234–235
 - Metanephros, 234–235
 - Microcephaly, 96
 - Microglossia, 125
 - Microphthalmia, 284
 - Microstomia, 136
 - Midbrain, 272
 - Midgut
 - derivatives of, 147
 - postarterial segment, 147
 - prearterial segment, 147
 - Mitosis, 120–121
 - Morgagni, foramen of, 189
 - Morula, 37
 - Muscle, 103–109
 - cardiac, 107
 - of body wall, 103
 - of head and neck, 104
 - of limbs, 106
 - of tongue, 105
 - skeletal, 103
 - smooth, 107
 - striated, 103
 - Myoblast, 103–105
 - Myogenesis of,
 - cardiac muscle, 107
 - skeletal muscle, 103
 - smooth muscle, 107
- N**
- Nail, 79–81
 - Nasolacrimal duct, 132
 - Neural crest, 48
 - Neural tube, 48
 - Neuroblast, 267
 - Nevus, 83
 - Nitabuch's layer, 66, 75
 - Node
 - AV node, 208
 - Henson's, 47
 - primitive, 47
 - sinuatrial, 208
 - Nose, 132
 - Notochord, 46–47
- O**
- Occipitalization, of C1 vertebra, 91
 - Odontoblast, 171
 - Omphalocele, 150–151
 - Optic
 - cup, 279
 - nerve, 281
 - sulcus, 279
 - vesicle, 279
 - Organ
 - of Corti, 290
 - of Zuckerkandl, 278
 - Ossification
 - endochondral, 84
 - membranous, 84
 - Ovary, 11
 - descent, 262
 - determining factor, 249
 - development of, 248
 - ligament of, 262

Ovulation, 28, 30
time of, 33

P

Palate, 135–137
hard, 136
permanent, 136
primary, 135
secondary, 135

Pancreas, 162–165
annular, 163
anomalies, 163–165
histogenesis, 163

Papilla, dental, 171

Papilledema, 281

Paradidymis, 251

Patent ductus arteriosus, 214

Pedigree chart, 301

Pericardium, 198, 209

Perilymph, 289

Phimosis, 258

Phocomelia, 100

Phrygian cap, 160

Pierre Robin syndrome, 119

Pigeon breast, 92

Pineal body, 276

Pineal gland, 276

Pituitary gland, 275, 276

Pit
nasal, 130, 133
otic, 288

Placenta, 63–70
anomalies of, 70
attachment of cord, 71
Battledore, 70
bidiscoidal, 70
circumvallate, 70
diffuse, 70
full-term, 66
functions of, 69
lobulation, 66
previa, 61
succenturiata, 70

Placental barrier, 67

Placental membrane, 67–68

Placode
lens, 279
olfactory, 130
otic, 288

Plagiocephaly, 96

Plate
epiphyseal, 99
neural, 48
prochordal, 47
urethral, 257
vaginal, 253

Poland syndrome, 109

Polycystic disease of,
liver, 158–159

Polydactyly, 100

Polymastia, 82

Polythelia, 82

Pouch

Hartmann's, 161
pharyngeal, 115–118
Rathke's, 275

Pregnancy

abdominal, 62
dating, 310
ectopic, 62
milestones, 311
trimesters, 311
tubal, 62

Primitive knot, 47

Primitive node, 47

Primitive streak, 41, 46

Proboscis, 284

Process

notochordal, 47

Processus vaginalis, 260

Prochordal plate, 40

Pronephros, 234–235

Prostate, 10

development, 251

utricle prostate, 251

Pseudohermaphrodites, 259

Punnett squares, 300

Q

Quickening, 109

R

Rachischisis, 266

Rami chorii, 65

Ramuli chorii, 65

RDS, 182, 185

Reaction

acrosomal, 35

decidual, 62

Recess

infracardiac, 192

pneumoenteric, 192

tubotympanic, 287

Rectum, 153

primitive, 153

Respiratory system, 177–185

Retina, 280

Rib, 87

cervical, 91

lumbar, 91

Ridge

bulbar, 206

genital, 246

mammary, 81

Riedel's lobe, 158

S

Sac

aortic, 197, 213

conjunctival, 285

iliac, 229

jugular, 229

lacrimal, 132

lesser of peritoneum, 191

- lymph, 229
 - nasal, 133
 - retroperitoneal, 229
 - Sacralization, of 5th lumbar vertebra, 91
 - Scala tympani, 289
 - Scala vestibule, 289
 - Scaphocephaly, 96
 - Semen, 11
 - Septum
 - aorticopulmonary, 206
 - atrioventricular, 200
 - interatrial, 200
 - intermedium, 200
 - interventricular, 204
 - primum, 200
 - secundum, 200
 - spiral, 206
 - tracheoesophageal, 177
 - transversum, 42
 - Sertoli cells, 248
 - Sex chromatin, 295
 - Sex determination, 36
 - Sinus/sinuses
 - cervical, 118
 - paranasal, 134
 - umbilical, 151
 - Situs inversus, 155
 - Skull
 - abnormalities, 96
 - bones, 94
 - fontanelles, 95–96
 - neurocranium, 92
 - newborn, 95
 - viscerocranium, 94
 - Somatomeres, 49
 - Somites, 49–51
 - Spermatogenesis, 24–25
 - Sperms
 - abnormal, 26
 - capacitation of, 35
 - Spermatozoon, 25–26
 - Spermiogenesis, 26
 - Spinal cord, 266–268
 - functional columns, 267
 - positional changes, 267
 - Spleen, 165
 - Spondylolisthesis, 91
 - SRY* gene, 246
 - Stalk
 - connecting, 40
 - of hypophysis, 276
 - optic, 280
 - Stapes, 287
 - Stomach, 143–145
 - Stomodeum, 168
 - Stratum basale, 14
 - Stratum compactum, 13
 - Stratum spongiosum, 13
 - Streak, primitive, 39, 46, 47
 - Sulcus
 - labiokingival, 169
 - limitans, 267
 - linguogingival, 169
 - optic, 280
 - Superfetation, 74
 - Syndactyly, 100
 - Syndrome/syndromes,
 - adrenogenital, 277
 - Angelman, 302
 - cri-du-chat, 302
 - Dandy Walker, 270
 - DiGeorge, 118
 - Down's, 302
 - Edward, 302
 - first arch, 118
 - Klinefelter's, 259, 303
 - Marfan's, 304
 - Pierre Robin, 119
 - respiratory distress, 182
 - Treacher Collins, 119
 - Turner's, 303
 - Synophthalmia, 284
- T**
- Teeth, 170–174
 - congenital anomalies, 174
 - eruption, 174
 - development, 170
 - permanent, 171
 - primary, 170
 - natal, 174
 - Teratogen, 311
 - Teratogenesis, 312
 - Teratology, 311
 - Teratomas, 56
 - sacrococcygeal, 46
 - Testis, 9
 - anomalies of, 260, 261
 - appendix of, 251
 - descent of, 260
 - determining factor, 249
 - development, 247
 - ectopic, 261
 - Tetrology, Fallot's, 205
 - Thoracic duct, 229, 230
 - Thymus, 116
 - Thyroid, 125–126
 - ectopic, 126
 - lingual, 126
 - sublingual, 126
 - Tongue, 122–125
 - Tongue tie, 125
 - Tonsil
 - lingual, 230
 - palatine, 116, 117, 230
 - pharyngeal, 230
 - tubal, 230
 - Tooth, 170
 - bell stage, 171
 - buds, 171
 - cap stage, 171
 - dental lamina stage, 171
 - dentine of, 171

- Tooth (*Contd.*)
 enamel of, 171
 pulp of, 171
- Trachea, 178
 anomalies, 178, 179
- Tube
 neural, 265
- Tuberculum impar, 123
- Twinning, 72–73
- Twins
 conjoint, 73
 dizygotic, 72
 fraternal, 72
 monozygotic, 72
 parasitic, 73
- U**
- Ultimobranchial body, 125
- Ultrasonography, 312–315
- Umbilical cord, 70–72
 formation, 53
- Umbilical opening, 53
- Urachus, 240
 anomalies of, 242
- Ureter, 239
 anomalies of, 239
- Urethra, 243
 development of, 243–244
 female, 243
 male, 243
- Urinary bladder, 240
 coats, 241
 trigone, 241
- Uterine tube, 252
- Uterus, 12
 anomalies of, 254
 development of, 253
- V**
- Vagina
 anomalies of, 254
 development of, 253
- Valve/valves
 aortic, 208
 mitral, 207
 of coronary sinus, 203
 of inferior vena cava, 203
 pulmonary, 208
 tricuspid, 207
- Vas deferens, 10
- Vasculogenesis, 212
- Vein
 azygos, 227
 cardinal
 anterior, 220
 common, 220
 gonadal, 226
 posterior, 220
 hemiazygos, 227
 hepatocardiac channel, 221
 iliac, common, 225
 intercostal, left superior, 228
 jugular
 external, 224
 internal, 222
 Marshall, 224
 oblique, of the left atrium, 224
 of abdomen, 224
 portal, 221
 renal, 227
 somatic, 222
 subcardinal, 224
 supracardinal, 224
 suprarenal, 227
 testicular, 227
 umbilical, 221
 vitelline, 220
- Vena cava
 inferior, 225
 double, 226
 left, 226
 superior, 223
 double, 224
 left, 224
- Ventricle
 of brain
 fourth, 269
 lateral, 270
 third, 270
- Vernix caseosa, 83
- Vertebra
 development of, 87
- Vertebral column
 development of, 87–91
- Vesicle
 lens, 280
 optic, 279
 otic, 288
 seminal, 10
- Villi
 anchoring, 65
 chorionic, 65
- Vitelline block, 44
- Vitiligo, 78
- Vitreous
 body, 284
 humor, 284
- W**
- Wharton's jelly, 71
- Wilm's tumor, 245
- Winslow
 foramen of, 194
- Witch milk, 82
- Y**
- Yolk sac, 59–60
- Z**
- Zona pellucida, 29, 38
- Zona reaction, 35
- Zygote, 35