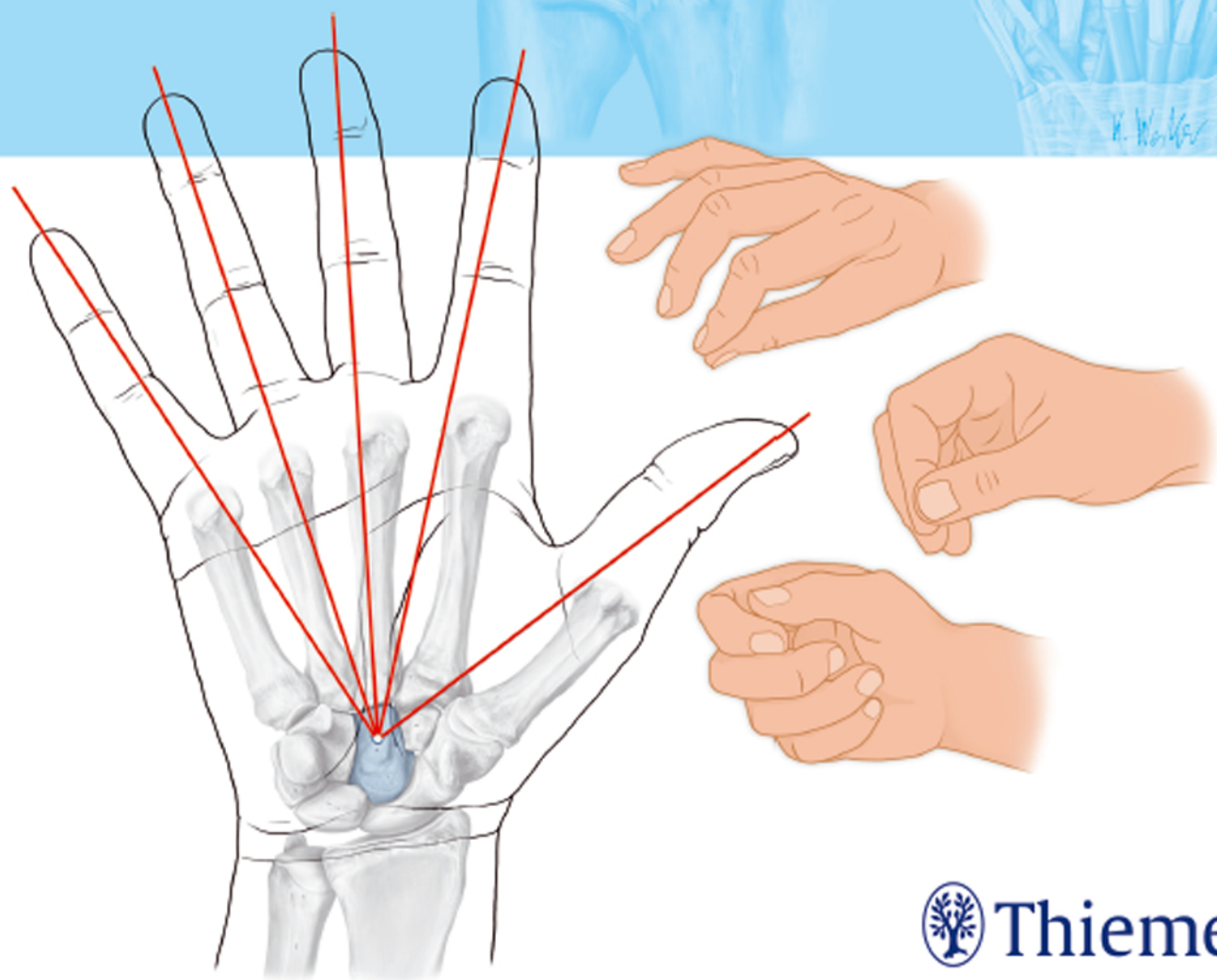


Hand and Wrist Anatomy and Biomechanics

A Comprehensive Guide

Bernhard Hirt
Harun Seyhan
Michael Wagner
Rainer Zumhasch



Thieme

Hand and Wrist Anatomy and Biomechanics

A Comprehensive Guide

Bernhard Hirt, MD

Professor
Institute for Clinical Anatomy
University of Tübingen
Tübingen, Germany

Harun Seyhan, MD

Assistant Medical Director
Department of Plastic Surgery
Hand Surgery – Burn Center
University of Witten/Herdecke
Cologne-Merheim Medical Center (CMMC)
Cologne, Germany

Michael Wagner, PT

Private Practice
Hannover, Germany

Rainer Zumhasch, OT

Director
Academy for Hand Rehabilitation
Bad Pyrmont, Germany

130 illustrations

Thieme
Stuttgart • New York • Delhi • Rio de Janeiro

Library of Congress Cataloging-in-Publication Data
is available from the publisher.

This book is an authorized translation of the 3rd German edition published and copyrighted 2015 by Georg Thieme Verlag, Stuttgart. Title of the German edition: Anatomie und Biomechanik der Hand

Translator: Karen Leube, PhD, Aachen, Germany

Illustrator: Markus Voll, Munich, Germany; anatomical water colors: from THIEME Atlas of Anatomy, General Anatomy and Musculoskeletal System. 2nd ed, © Thieme 2014, illustrations by M. Voll and K. Wesker; adaptations by WEYOU, Leonberg, Germany

© 2017 by Georg Thieme Verlag KG

Thieme Publishers Stuttgart
Rüdigerstrasse 14, 70469 Stuttgart, Germany
+49 [0]711 8931 421, customerservice@thieme.de

Thieme Publishers New York
333 Seventh Avenue, New York, NY 10001 USA
+1 800 782 3488, customerservice@thieme.com

Thieme Publishers Delhi
A-12, Second Floor, Sector-2, Noida-201301
Uttar Pradesh, India
+91 120 45 566 00, customerservice@thieme.in

Thieme Publishers Rio de Janeiro,
Thieme Publicações Ltda.
Edifício Rodolpho de Paoli, 25º andar
Av. Nilo Peçanha, 50 – Sala 2508
Rio de Janeiro 20020-906 Brasil
+55 21 3172 2297 / +55 21 3172 1896

Cover design: Thieme Publishing Group
Typesetting by DiTech Process Solutions Pvt. Ltd., India

Printed in Germany by CPI Books

5 4 3 2 1

ISBN 978-3-13-205341-0

Also available as an e-book:
eISBN 978-3-13-205351-9

Important note: Medicine is an ever-changing science undergoing continual development. Research and clinical experience are continually expanding our knowledge, in particular our knowledge of proper treatment and drug therapy. Insofar as this book mentions any dosage or application, readers may rest assured that the authors, editors, and publishers have made every effort to ensure that such references are in accordance with **the state of knowledge at the time of production of the book.**

Nevertheless, this does not involve, imply, or express any guarantee or responsibility on the part of the publishers in respect to any dosage instructions and forms of applications stated in the book. **Every user is requested to examine carefully** the manufacturers' leaflets accompanying each drug and to check, if necessary in consultation with a physician or specialist, whether the dosage schedules mentioned therein or the contraindications stated by the manufacturers differ from the statements made in the present book. Such examination is particularly important with drugs that are either rarely used or have been newly released on the market. Every dosage schedule or every form of application used is entirely at the user's own risk and responsibility. The authors and publishers request every user to report to the publishers any discrepancies or inaccuracies noticed. If errors in this work are found after publication, errata will be posted at www.thieme.com on the product description page.

Some of the product names, patents, and registered designs referred to in this book are in fact registered trademarks or proprietary names even though specific reference to this fact is not always made in the text. Therefore, the appearance of a name without designation as proprietary is not to be construed as a representation by the publisher that it is in the public domain.

This book, including all parts thereof, is legally protected by copyright. Any use, exploitation, or commercialization outside the narrow limits set by copyright legislation without the publisher's consent is illegal and liable to prosecution. This applies in particular to photostat reproduction, copying, mimeographing or duplication of any kind, translating, preparation of microfilms, and electronic data processing and storage.

Contents

1	Anatomy and Functional Anatomy of the Hand	2		
1.1	Introduction	2	Blood Supply to the Wrist Joint and Hand	46
			Lymphatics of the Hand	47
1.2	Structure and Function of the Proximal and Distal Radioulnar Joints	2	1.4	Thumb
1.2.1	Anular Ligament of the Radius	3	1.4.1	Movements and Range of Motion
1.2.2	Oblique Cord	4		Movements of the Thumb CMC Joint
1.2.3	Interosseous Membrane of the Forearm	4		Range of Motion of the Thumb MCP and IP Joints
1.2.4	Structure and Function of the Triangular Fibrocartilage Complex	6	1.4.2	Structure and Function of the Thumb CMC Joint
	Ulnocarpal Disc and Meniscal Homologue	8		Ligaments of the Thumb CMC Joint
	Palmar and Dorsal Radioulnar Ligaments	8		Muscles of the Thumb CMC Joint
	Ulnolunate and Ulnotriquetral Ligaments	8	1.4.3	Structure and Function of the Thumb MCP and IP Joints
	Ulnar Collateral Ligament of Wrist Joint	8		MCP Joint of the Thumb
	Tendon Sheath of the Extensor Carpi Ulnaris Muscle	9		IP Joint of the Thumb
1.2.5	Muscles of the Radioulnar Joint—Pronation and Supination	9	1.5	Structure and Function of the Palm
	Pronator Muscles	9	1.5.1	Structure and Function of the Second to Fifth Metacarpals
	Supinator Muscles	10	1.5.2	Muscles of the Metacarpals
1.3	Wrist and Movement Axes	10		Dorsal and Palmar Interossei
1.3.1	Movement Axes	10		Lumbricals
1.3.2	Structure and Function of the Wrist Joint	12		Abductor Digiti Minimi Muscle
	Carpal Bones	12		Flexor Digiti Minimi Brevis Muscle
	Joints	14	1.5.3	Opponens Digiti Minimi Muscle
1.3.3	Ligament System and Wrist Stability	16		Palmar Aponeurosis (Metacarpal Area)
	Superficial Layer of the Ligaments of the Wrist	17		Longitudinal Fibers
	Middle Layer of Ligaments of the Hand	19		Transverse Fibers
	Deep Layer of the Ligaments of the Hand	23	1.6	Structure and Function of the Finger Joints
	Conclusions	25	1.6.1	Structure and Function of the MCP Joints
1.3.4	Muscles of the Wrist: Extension–Flexion, Radial Deviation–Ulnar Deviation, and Circumduction	25		Collateral Ligaments
	Muscles Involved in Flexion and Ulnar Deviation of the Wrist	26		Palmar and Dorsal Connective Tissue Plate
	Muscles Involved in Extension and Radial Deviation of the Wrist	28		Deep and Superficial Transverse Metacarpal Ligaments
1.3.5	Arthrokinematics of the Wrist Joint	28	1.6.2	Structure and Function of the PIP Joints
	Kinematics of the Wrist: General Aspects	30		Collateral Ligaments of the PIP Joint
	Arthrokinematics of the Wrist Joint: Specific Aspects	30		Palmar and Dorsal Fibrocartilage Plate
1.3.6	Other Important Anatomical Structures of the Wrist	33		Anular and Cruciate Ligaments
	Dorsal and Palmar Tendon Compartments	33	1.6.3	Dorsal Digital Expansion
	Carpal Tunnel, Ulnar Tunnel, and Innervation of the Hand	38	1.6.4	Structure and Function of the DIP Joints
				Range of Motion of the MCP, PIP, and DIP Joints

1.6.5	Extrinsic Muscles of the Finger: Flexors and Extensors	75	Extrinsic Flexors of the Finger	76
	Extensor Apparatus of the Finger	75		
2	Surface Anatomy of the Forearm, Wrist, and Hand Structures	82		
2.1	Introduction	82	Second Dorsal Tendon Compartment	88
2.2	Practical Foundations of Surface Anatomy	82	Third Dorsal Tendon Compartment	89
2.3	Practical Procedure for Surface Anatomy of the Forearm, Wrist, and Hand	83	Fourth Dorsal Tendon Compartment	89
			Fifth Dorsal Tendon Compartment	90
			Sixth Dorsal Tendon Compartment	90
2.3.1	Surface Anatomy of the Distal Radioulnar Joint and Wrist	83	2.3.3 Surface Anatomy of the Extrinsic Dorsal Forearm Muscles	91
	Radiocarpal Joint Line and Its Structures	83	2.3.4 Surface Anatomy of the Palmar Wrist, Three Palmar Tendon Compartments, and Palmar Nerves and Vessels	92
	Metacarpophalangeal Joint Line and Its Structures	84	2.3.5 Surface Anatomy of the Extrinsic Palmar Forearm Muscles	96
	Dorsal Carpal Bones	84	2.3.6 Surface Anatomy of the Palm, Thumb, and Fingers	96
2.3.2	Surface Anatomy of the Six Dorsal Tendon Compartments	86	2.3.7 Surface Anatomy of the Intrinsic Muscles of Thenar, Palm, and Hypothenar Areas	98
	First Dorsal Tendon Compartment	87		
	References			100
	Index			106

Preface

In order to diagnose and treat hand disorders, medical professionals must be intimately familiar with the anatomical structures in question. They must also understand their specific functions in terms of biomechanics and have the practical skills needed to determine and palpate them. These skills are indispensable for physicians, occupational therapists, and physical therapists when choosing the best treatment for the patient.

While there are many books available on the anatomy, surface anatomy, and kinematics of the hand, no book to date has gathered all of these disciplines in a single volume. When practitioners work with patients, they need to address these aspects simultaneously. They are forced to consult a number of different books when treating a single patient. In many cases the particular reference needed is not in the practitioner's library—or the information in the book to hand is too detailed for a salient answer to be found

in the time available. As we planned this book, we felt that several features were essential: it needed to have a convenient format; it should cover all important aspects of this broad spectrum; and can be referred to quickly and easily wherever hand injuries and conditions are diagnosed and treated.

We hope that we have met our goal in *Anatomy and Biomechanics of the Hand* with regard to both subject matter and ease of use. This book is intended to help health care professionals diagnose and treat patients more efficiently and to provide a solid foundation for interdisciplinary communication among all of the professionals involved. "If we expect to understand each other, we all need to speak the same language."

*Prof. Bernhard Hirt, MD
Harun Seyhan, MD
Michael Wagner, PT
Rainer Zumhasch, OT*

Acknowledgments

We would like to thank Mr. Klausch for editing the images for this book, as well as Ms. Cornelia Paries for the wealth of tips and suggestions for improving the text. We are also grateful to our family members, to whom we dedicate this book, *Anatomy and Biomechanics of the Hand*. They picked up the slack for us, allowing us to complete this book in a timely manner despite all of our other professional commitments. Special thanks go to the wife of Rainer Zumhasch, who exhibited a great deal of patience and understanding as she allowed us to draw the anatomical structures on her arms and hands. In so doing, she made a valuable contribution to conveying the knowledge in a way that is easy to see and understand.

Furthermore, we would like to thank all of the participants in our seminars at the Academy of Hand Rehabilitation, Bad Münders, Germany. It was their

requests for information on various topics that inspired us to write this book.

We also gratefully acknowledge the entire staff of Thieme Publishers. Our cooperation was always pleasant and quickly grew into a collaboration characterized by friendship. When selecting the numerous anatomical illustrations, they respected our wishes, worked meticulously and ensured that the images underpinned the individual text passages.


Particular thanks go to the Department of Anatomy at the University of Tübingen, Germany, which assisted us in both word and deed at all times.

Finally, we would also like to thank all of the readers of this book. We thank you for choosing this publication and hope that we have been able to address your needs.

Chapter 1

Anatomy and Functional Anatomy of the Hand

1.1	Introduction	2
1.2	Structure and Function of the Proximal and Distal Radioulnar Joints	2
1.3	Wrist and Movement Axes	10
1.4	Thumb	48
1.5	Structure and Function of the Palm	60
1.6	Structure and Function of the Finger Joints	66



1 Anatomy and Functional Anatomy of the Hand

1.1 Introduction

In their biological taxonomy and status as “higher-level mammal—homo sapiens,” humans owe their distinction from primates to the miraculous structure of the hand. With its 19 degrees of freedom and its opposing thumb, the hand is a highly developed and complex grasping organ. This enables a wide range of movement combinations while simultaneously allowing adaptation of force, speed, and facileness. Moreover, the hand also features a highly specific sensory and tactile organ that human beings use to perceive and assess themselves and their surroundings. Owing to its capacity for making gestures, the hand plays an important role in interpersonal communication. In writing, music, and the visual arts, the hand acts as a means of expression for the human mind.²²⁹ These gross and fine motor skills, along with sensory capacities, enable humans to take care of and nourish their bodies, as well as communicate and shape their environment. With all these possibilities, the hand also plays a major role in self-expression and in developing the human mind, and significantly contributes to modifying human motor capacities.²⁰² The mobilizing of this functionality requires exceptional interaction between the central control system and anatomical structures such as bones and joints, muscles and tendons, nerves and blood vessels, making the hand an extremely complex organ.

The distal area of the lower arm consists of the distal radioulnar joint, the thumb and finger carpometacarpal (CMC) joints, the palm, and the fingers. In total, there are 27 bones with 36 articulations and 39 active muscles. In order for the hand to translate its wide range of fine and gross motor capabilities into its complex range of motion, these structures must all be coordinated.

1.2 Structure and Function of the Proximal and Distal Radioulnar Joints

The forearm skeleton consists of two bones: the **ulna** (elbow bone) and the **radius**. These two bones form two radioulnar joints, one near the elbow (**proximal radioulnar joint**) and one near the wrist (**distal radioulnar joint**) (► Fig. 1.1). Pronation and supination movements are performed by these two joints with a contribution from the **shoulder joint** (► Fig. 1.2).²³³ During this movement, the radius takes a conical path, in which the rotation axis courses from the radial head through to the distal end of the ulna.³ In so doing, the radial head rotates around itself within the annular ligament (wide ringlike band) in the proximal radioulnar joint, while the radius

simultaneously moves around the ulna (ulnar head) in the distal radioulnar joint. During **supination**, the radius and ulna are parallel, whereas these two cross during pronation, with the radius overlying the ulna. The range of the forearm’s rotational motion is between 140° and 150°.¹⁹⁰ During **pronation**, the ulna glides more toward the dorsal aspect, and during supination it glides more toward the palmar aspect,²⁶² which extends the movement to 180°.²²⁹ The range of motion from the neutral zero position for pure pronation and supination is therefore approximately 80° to 90°–0–80° to 90°, or an average of 85° supination and 90° pronation.²³³ With the contribution of the shoulder joint (continued movement), this range can increase to up to 230°.²⁵⁶ These possibilities of additional and substitute movements can simulate movements in the radioulnar joint by means of “pseudo-movements.”¹⁴⁹ The hand must follow these movements, since the proximal condyloid wrist joint does not allow any compensatory movements.¹⁴⁹

In functional terms, the **proximal radioulnar joint** is a **pivot joint**. It consists of the convex surface of the articular circumference of the radius and the concave surface of the radial notch of the ulna.

The **distal radioulnar joint**, also functionally a **pivot joint** (► Fig. 1.3), consists of the convex semicylindrical surface of the articular circumference of the ulna, which is completely covered with cartilage, and the associated concave joint surface of the ulnar notch on the distal radius. The joint is enclosed by a thin connective-tissue capsule that has no stabilizing properties.⁴⁹ Its loose

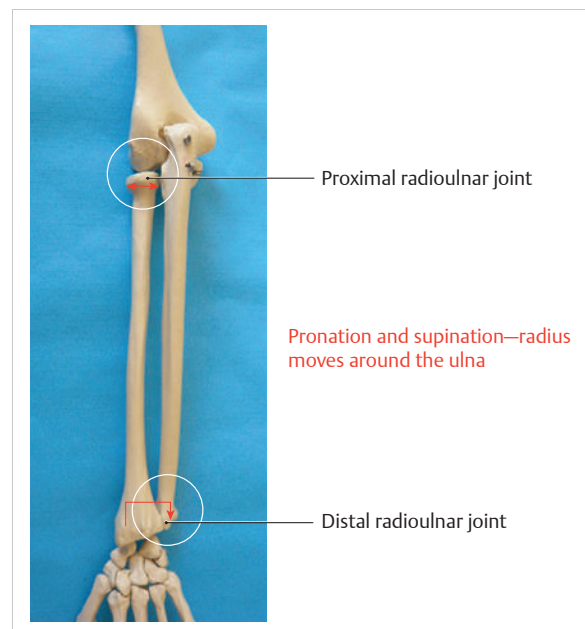


Fig. 1.1 Distal and proximal radioulnar joints.

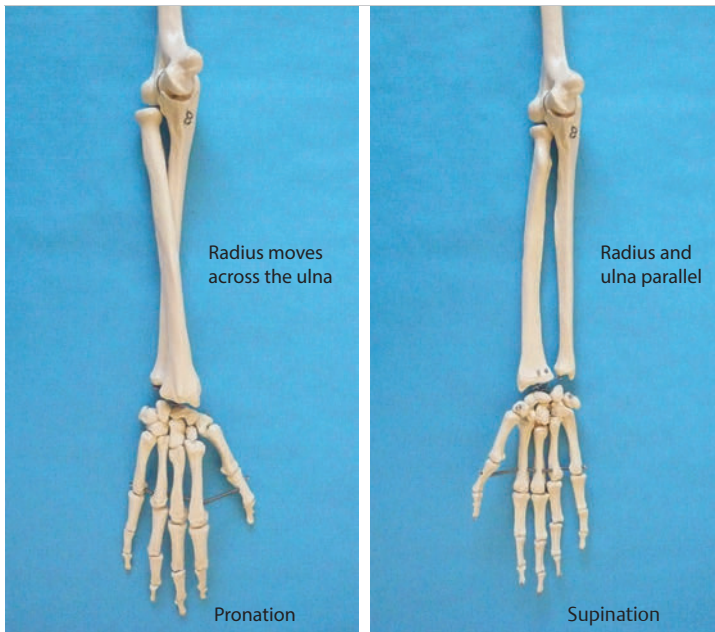


Fig. 1.2 Pronation and supination of the hand.

structure, with deep recesses (e.g., the sacciform recess), lines the joint cavity with a synovial membrane and provides the joint with enough leeway for a total of 180° pronation and supination.¹⁶⁰

Rotation in the distal radioulnar joint takes place around the ulna, which acts as a static reference point about which the radius rotates with the hand.²³³ Functionally, the radius sweeps across the surface of a conical segment.²³³ The greatest possible congruence of the joint surfaces occurs in the neutral zero position. In pronation and supination, the joint surfaces of the ulnar head and the ulnar notch of the radius have less contact.²³³

Practical Tip

In the case of immobilization, the joint capsule of the distal radioulnar joint is unlikely to degenerate to the point where it will cause a restriction in movement. Even if the capsule shrinks, the only symptom will be a slightly limited range of motion. For this reason, it is usually not necessary to mobilize the joint.¹⁶⁰

The proximal radioulnar joint is stabilized in the area of the radial head by the anular ligament of the radius and the oblique cord. In the area of the shaft, it is stabilized by the interosseous membrane of the forearm. Moreover, the radius and ulna are firmly attached to the interosseous membrane, which regulates the ulna's relative lengthening during pronation and its relative shortening in supination.⁵³ This means that during supination, the radius deviates distally and during pronation it deviates proximally.¹⁶⁰ The distal radioulnar joint is stabilized on the palmar side by the pronator quadratus muscle,⁹⁹ the

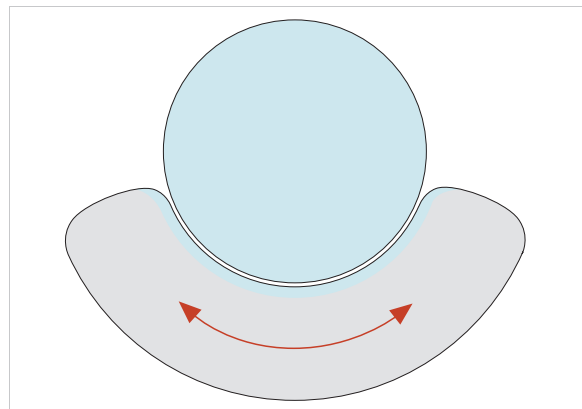


Fig. 1.3 Functionally, the distal radioulnar joint is a pivot joint.

tendon and tendon sheath of the extensor carpi ulnaris muscle¹⁴⁵ and for the most part, by the triangular fibrocartilage complex (TFCC).^{112,145}

1.2.1 Anular Ligament of the Radius

The anular ligament of the radius **encircles the proximal radioulnar joint** (ligamentous “bracketing” between the radial head and the ulna²²⁹), **guides the radial head, and absorbs pressure** (► Fig. 1.4). This ring-shaped band, approximately 1 cm wide, inserts in front of and behind the radial notch at the ulna. It is funnel-shaped distally and surrounds the neck of the radius.¹⁵⁷ Proximally, the anular ligament of the radius is fused to the collateral radial ligament²⁰⁰ and the collateral ulnar ligament; deeper below, it is fused with the elbow joint capsule.¹⁶⁰ Together, they operate as a functional unit. The anular

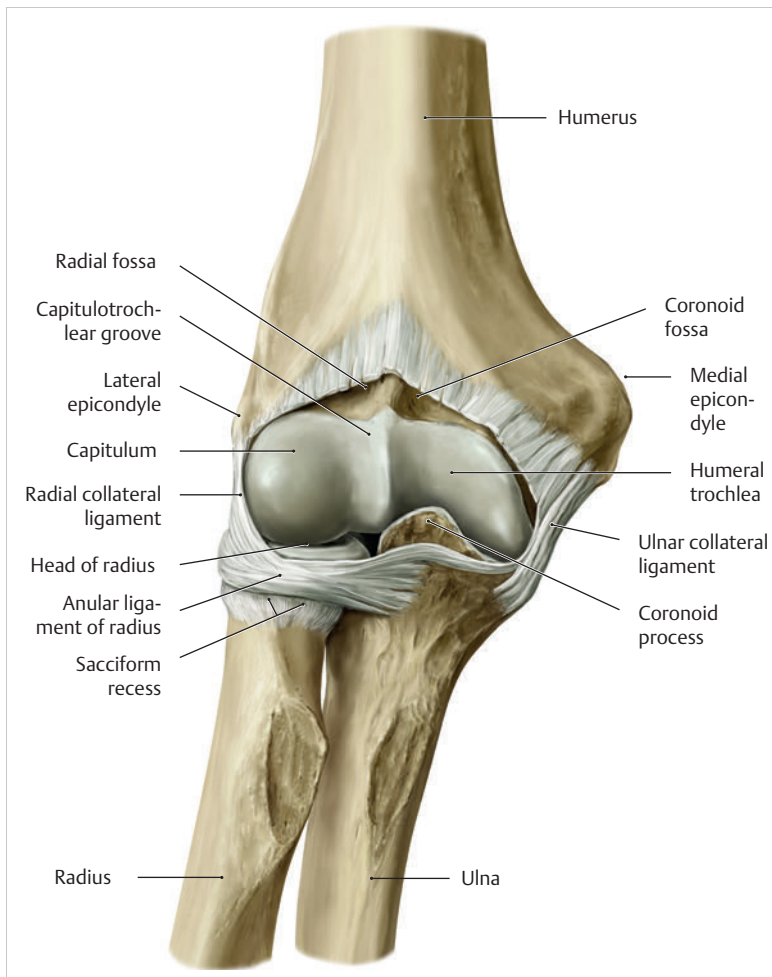


Fig. 1.4 Anular ligament of the radius, front view. (From THIEME Atlas of Anatomy, General Anatomy and Musculoskeletal System. 2nd ed. © Thieme 2014, illustration by Karl Wesker.)

ligament consists of strong connective tissue; additional cartilage cells are present in the radial notch area⁷⁸ for absorbing pressure.²⁰⁰ The anterior part of the ligament is under tension during supination; during pronation, the posterior part of the ligament is under tension.¹⁵⁷ However, this tension is unlikely to restrict range of motion.¹⁶⁰ According to Morris (1879),¹⁷³ the interosseous membrane, oblique cord, ligaments of the basal joint and distal radioulnar joint, and various antebrachial muscles are more likely to serve as control structures between pronation and supination.

Practical Tip

If axial deviation persists, for example after a radial head fracture, the anular ligament of the radius may become prematurely malformed during pronation and supination. According to Matthijs et al (2003),¹⁶⁰ however, this is not enough to restrict motion. Slipping of the radial head during rotation may explain why functionality remains intact.

1.2.2 Oblique Cord

This **small, bandlike structure** arises below the radial notch of the ulna and attaches directly below the radial tuberosity.⁷⁸ It is a flat, fibrous band at the proximal end of the interosseous membrane, which acts as a stabilizing ligament²²⁹ and runs in the opposite direction (► Fig. 1.5). In combination with the extensor carpi ulnaris muscle and the palmar radioulnar ligament²²⁹ it is another key contributor to decelerating supination,^{19,200} and **with the interosseous membrane, it prevents the radius from deviating distally relative to the ulna.**²⁷⁸ In contrast, the tendon of the biceps brachii muscle, which wraps around the radius during pronation, contributes to deceleration of pronation.²⁰⁰

1.2.3 Interosseous Membrane of the Forearm

This **interosseous membrane** originates approximately 1 cm below the radial tuberosity and inserts shortly before the distal radioulnar joint (► Fig. 1.6), with several

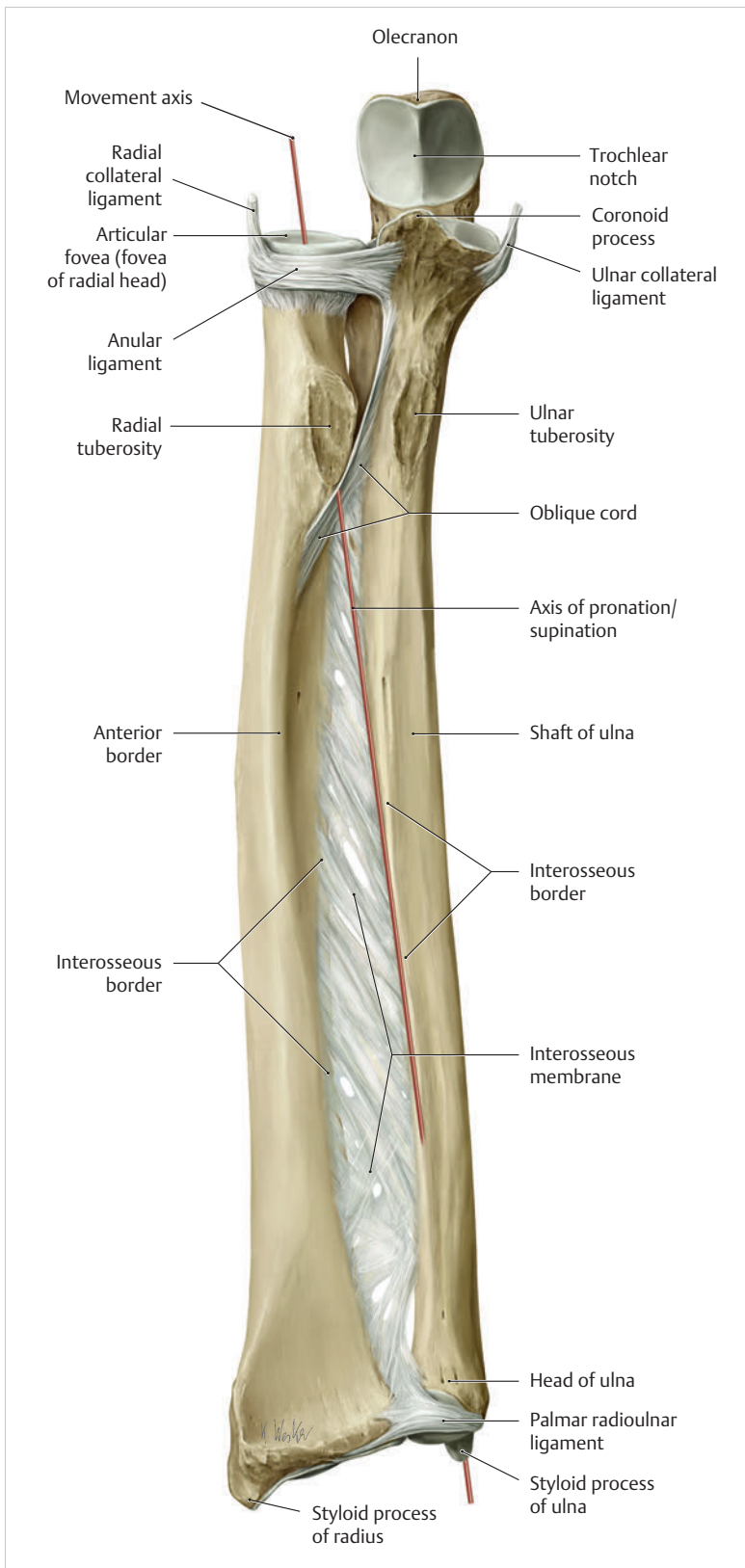


Fig. 1.5 Oblique cord und interosseous membrane of forearm. (From THIEME Atlas of Anatomy, General Anatomy and Musculoskeletal System. 2nd ed. © Thieme 2014, illustration by Karl Wesker.)

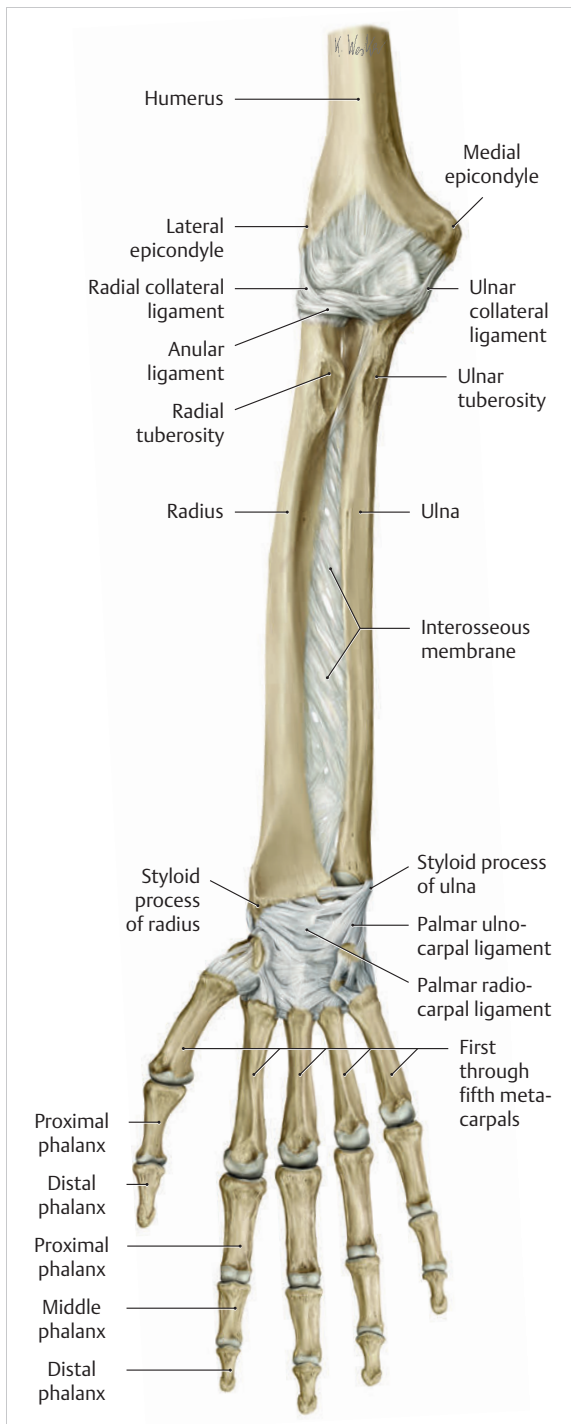


Fig. 1.6 Interosseous membrane of forearm. (From THIEME Atlas of Anatomy, General Anatomy and Musculoskeletal System. 2nd ed. © Thieme 2014, illustration by Karl Wesker.)

fibers extending into the joint capsule.⁹¹ Near the center of the radius, it reaches its maximum thickness of approximately 1 mm. It **consists of strong connective tissue** whose tensile strength reaches 84% that of the

patellar ligament.¹⁶⁰ This sheet of connective tissue holds together the radius and ulna.²⁰⁰ Functionally, it serves to protect the two bones from longitudinal shifts and acts as a surface from which various muscles originate.²⁰⁰

Moreover, the interosseous membrane of the forearm contains **two types of oblique collagen fibers**, which Zancolli (1992)²⁸² referred to as oblique A (OA) fibers and oblique B (OB) fibers. The OA fibers occupy the entire interosseous space and in general run from the proximal radius to the distal ulna. The OB fibers form two separate palmar bundles (one proximal and one distal) and run in the exact opposite direction.¹⁶⁰ The OA fibers become taut in neutral position and in supination, while the OB fibers become taut in pronation. In each case, the opposing fiber is relaxed. Furthermore, Gabl et al (1998)⁷⁰ described a **dorsal stabilizing ligament** of approximately 8 mm width, 30 mm length, and 1 mm thickness. It **stabilizes the capsule** of the distal radioulnar joint, and during pronation holds the ulnar head like a sling. Its opposing fiber is a falciform septum approximately 2 mm in thickness on the palmar aspect of the membrane. Measuring about 3 mm wide, this structure arises from the far distal portion of the membrane beneath the deep muscular portion of the pronator quadratus muscle.²²⁹

The interosseous membrane therefore **delimits or decelerates pronation and supination**. Its tissue also contains gaps through which vessels can traverse⁹¹ and it has a large share of mechanoreceptors.²⁰⁵

Practical Tip

Since most of the interosseous membrane is relaxed during maximum pronation and supination, it is usually not considered to be a possible source of pronation and supination disturbances.¹⁶⁰ However, with respect to oblique A and oblique B fibers, it may be deduced that the interosseous membrane may be involved in this type of restriction in the case of fracture-related instability, for example.¹¹⁹ This is particularly the case for instability of the triangular fibrocartilage complex (TFCC). This means that only angular techniques (rotation) may be used for traction. Translatory movements could intensify the pathological process of the TFCC, since this structure is largely responsible for stabilizing pronation and supination.¹⁶⁰ Thus, prior to any kind of treatment, the exact cause needs to be established.

1.2.4 Structure and Function of the Triangular Fibrocartilage Complex

The triangular fibrocartilage complex (TFCC) (► Fig. 1.7) is formed from the following structures:

- The ulnocarpal disc
- The ulnocarpal meniscus homologue¹⁸⁷
- The ulnar collateral ligament of the wrist joint

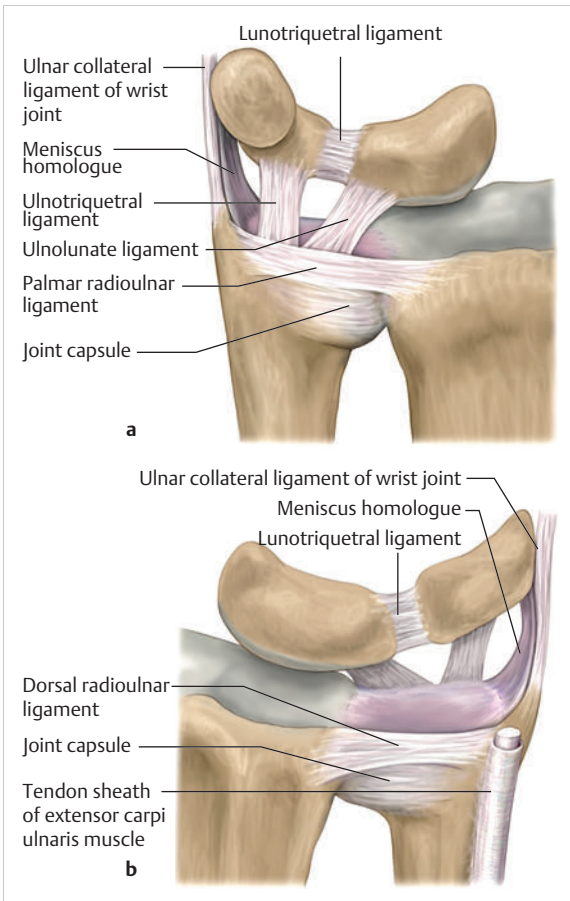


Fig. 1.7 Triangular fibrocartilagenous complex. (a) Palmar view. (b) Dorsal view.

- The sixth tendon compartment
- The ulnocarpal ligaments (dorsal and palmar radioulnar ligaments as well as the ulnolunate and ulnotriquetral ligaments)

The TFCC therefore extends from the distal ulnar end of the radius to the base of the fifth metacarpal.⁹² During surgical dissection, it is very difficult to separate these elements, since they merge continuously.²²⁹

The **functions of the TFCC** include stabilization of the distal radioulnar joint (i.e., during pronation and supination) and the carpal side of the ulna (with its supporting ligaments) for movements in the proximal and distal wrist, as well as regulation of pressure in the wrist.²³¹ The tendon sheath of the extensor carpi ulnaris muscle and the muscle itself decelerate supination, while the dorsal and plantar radioulnar ligaments of the TFCC decelerate pronation. The arrangement of the joint capsule is relatively flaccid.²²⁹ The task of distributing impacts

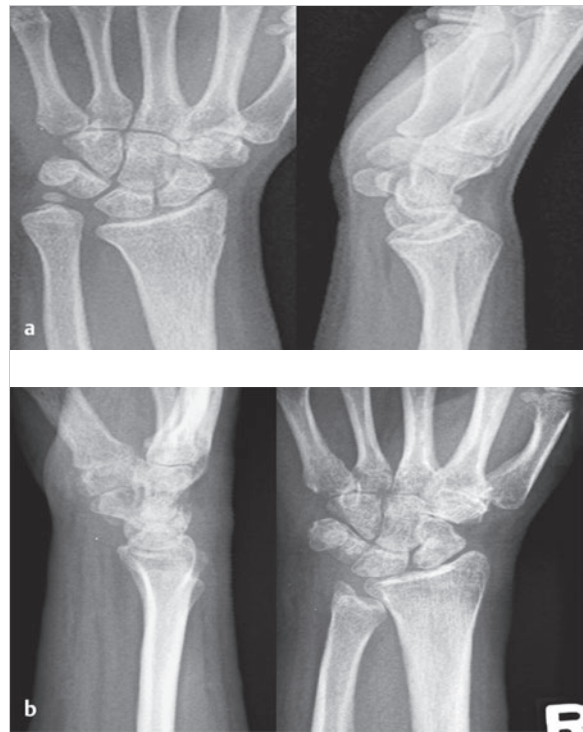

Fig. 1.8 Positive and negative ulnar variances. (a) Post-traumatic positive ulnar variance. (b) Post-traumatic negative ulnar variance.

and pressure is assumed by the ulnocarpal disc²²—that is, with approximately 84% assumed by the radius and approximately 19% by the ulna.⁸⁶

Occasionally, the ulna is shortened (“**negative ulnar variance**”) or lengthened (“**positive ulnar variance**”) in relation to the radius due to trauma or genetic predisposition (► Fig. 1.8).

Practical Tip

Unphysiological differences in the length of the radius and the ulna cause disturbed pressure relationships in the proximal radiocarpal joint and can therefore lead to severe pathologies. For example, negative ulnar variance causes pressure to increase near the articulation of the distal radius, which can contribute to necrosis of the lunate (Kienbock’s disease) (► Fig. 1.8a).^{113,120} Positive ulnar variance leads to an ulnar impingement syndrome, that is, degenerative tears in the TFCC combined with chondral lesions of the lunate and triquetrum (► Fig. 1.8b).^{36,94,160} Furthermore, variations in the length of the ulna and in relation to the radius influence the form and orientation of the joint surfaces in the distal radioulnar joint,⁶⁶ whose incongruities (e.g., due to trauma) lead to degenerative changes of the joint.²¹³

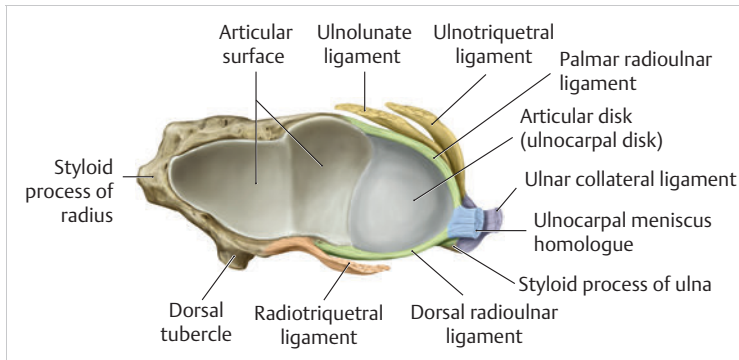


Fig. 1.9 Ulnocarpal disc in the distal view. (From THIEME Atlas of Anatomy, General Anatomy and Musculoskeletal System. 2nd ed. © Thieme 2014, illustration by Karl Wesker.)

The supporting ligaments of the TFCC stabilize the proximal and distal radiocarpal joint. The following outline and description based on Schmitt (2007)²³¹ describes the structure and function of the individual structures of the TFCC.

Ulnocarpal Disc and Meniscal Homologue

The **ulnocarpal disc** (► Fig. 1.9) arises from the hyaline joint cartilage of the radius at the level of the ulnar notch and in most cases inserts broadly at the tip of the ulnar styloid process with one fascicle and at the base with another fascicle. The base of the ulnocarpal disc is located in the plane of the distal ulna. At its radial insertion, it is approximately 2 mm thick, and at the ulnar insertion, it is around 5 mm thick,¹⁶⁰ in contrast to its thinner center, which is responsible for its biconcave form. In patients with negative ulnar variance, the ulnocarpal disc is thicker and in those with positive ulnar variance, it is thinner. The insertion segments are highly vascularized, while the much larger central and radial parts are avascular. The ulnocarpal disc is the **most important part of the TFCC**, with the involvement of the palmar and dorsal radioulnar ligaments.¹⁶⁰ It primarily contributes to transferring axial compression from the hand to the ulna (“shock absorber”), extends the joint surface between the radius and the ulna, and stabilizes the ulnar side of the wrist.²³⁵

The **ulnocarpal meniscus homologue** consists of a synovial mucosal fold and loose connective tissue. It arises at the margin from the ulnocarpal disc or the ulnar notch and inserts obliquely at the ulnar styloid process palmarward, as well as at the palmar side of the triquetrum and hamate and the bases of the fourth and fifth metacarpals. The ulnocarpal meniscus homologue helps **stabilize the ulnar wrist and the distal pisotriquetral joint**. The palmar and dorsal radioulnar ligaments, the ulnolunate ligament, and the ulnotriquetral ligament are fused with the lateral side of the ulnocarpal disc.

Note

Since the ulnocarpal meniscus homologue also contains synovial tissue, it is vulnerable to inflammatory processes, especially in patients with rheumatoid arthritis,¹⁶⁰

which can result in continued damage of the TFCC tissue. An inflamed dorsal synovial fold is enough to cause load-dependent pain symptoms similar to that of a disc lesion. Here, synovial villi form on the dorsal aspect of the ulnocarpal wrist joint, which causes painful impingement.

Palmar and Dorsal Radioulnar Ligaments

The palmar radioulnar ligament arises from the palmar aspect and the dorsal radioulnar ligament originates from the dorsal aspect of the distal, ulnar and very compact portion of the radius within the joint capsule of the distal radioulnar joint. Their fibers blend together and form a type of ring that is firmly attached to the ulnar head and the ulnocarpal disc. These two ligaments are considered to be **guiding ligaments and stabilizers for pronation and supination**. During supination, the extensor carpi ulnaris muscle and the palmar radioulnar ligament tighten, and during pronation the dorsal radioulnar ligament tightens.²²⁹ These two ligaments are therefore important parts of the TFCC and **secure all pronation and supination movements of the distal radioulnar joint** (► Fig. 1.10).

Ulnolunate and Ulnotriquetral Ligaments

These two ligaments are considered to be **stabilizing ligaments of the TFCC** for the proximal radiocarpal joint. They both originate from the palmar radioulnar ligament either in isolation or together. The first stabilizing ligament (ulnolunate ligament) inserts onto the palmar horn of the lunate (there is frequently also a connection to the lunotriquetral ligament) and the second stabilizing ligament (ulnotriquetral ligament) inserts onto the palmar aspect of the triquetrum. Both ligaments **contribute to stabilizing the radioulnar and radiocarpal joints**.

Ulnar Collateral Ligament of Wrist Joint

According to Taleisnik (1985)²⁵¹ and De Leeuw (1962),¹⁴² this ligament is a component of the extensor retinaculum,

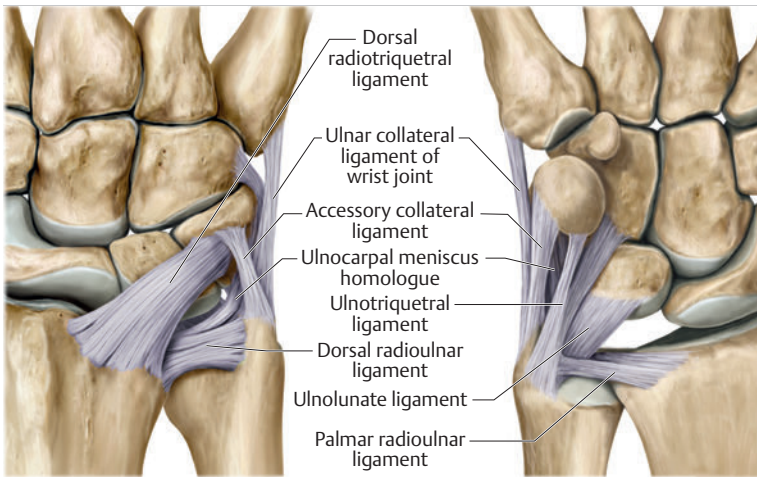


Fig. 1.10 Ligaments of the TFCC. Left: dorsal view; Right: palmar view.

the tendon sheath of the extensor carpi ulnaris muscle, and of the joint capsule. It contributes to stabilizing radius deviation in the proximal radiocarpal joint. During this movement, the carpal bones are displaced toward the ulnar side, and this displacement is decelerated by this ligament.¹⁰⁹

Tendon Sheath of the Extensor Carpi Ulnaris Muscle

The tendon sheath of the extensor carpi ulnaris muscle with its retinaculum of the extensor muscles is an integral component of the dorsal portion of the TFCC. It runs in a troughlike groove on the dorsal aspect of the ulnar head and, with several tendon fibers, inserts onto the triquetrum,²⁵¹ pisiform, pisometacarpal ligament, and the base of the fifth metacarpal.²²⁹ Functionally, it **decelerates supination in the radioulnar joint** (► Fig. 1.11) and acts to **stabilize radial deviation** with the ulnar collateral ligament synergistically.²²⁹

Practical Tip

The TFCC is frequently the site of traumatic and degenerative processes. Most cases of traumatic disc lesions involve a tear in the disc at the ulnar insertion, in some cases combined with avulsion of the ulnar styloid process. If the distal radioulnar joint becomes unstable, arthroscopically assisted refixation is recommended. Furthermore, there will be disc perforations in the avascular zone, that is, at the radial insertion or in the center of the disc. Moreover, the ulnocarpal ligaments can tear off. Impaction syndromes often cause chronic disc lesions. In some cases, a major central lesion can be visualized arthroscopically (► Fig. 1.12). Injuries of the radioulnar ligaments always result in instability of the distal radioulnar joint. If the palmar radioulnar ligament is affected,

the radius will become dislocated toward the palmar aspect, and if the dorsal radioulnar ligament is affected the radius will become dislocated toward the dorsal aspect. Ruptures of the ulnolunate and radiocarpal ulnotriquetral ligaments can promote structural disturbances of the arrangement of the carpal bones with associated degeneration.²³¹

1.2.5 Muscles of the Radioulnar Joint—Pronation and Supination

The most important muscles for pronation and supination are located in the upper arm and forearm.

Pronator Muscles

Pronation is carried out by the pronator teres and pronator quadratus muscles:

- The powerful two-headed **pronator teres muscle** belongs to the superficial layer of the flexors (► Fig. 1.13). With its larger head (humeral head), it originates from the medial epicondyle and from the medial intermuscular septum. With its smaller, deep-seated head (ulnar head), it originates from the coronoid process. The common insertion is located laterally in the center of the pronator tuberosity (shaft of the radius). It is covered by the brachioradialis muscle at the insertion site.⁶⁰
- The pronator quadratus muscle, which is square and very flat and is also located in the deep layer of the palmar flexors, courses in the area of the distal forearm bones. It originates from the margin of the ulna and inserts onto the volar surface of the radius. Functionally, it pulls the radius toward the ulna and contributes to stabilizing pronation.

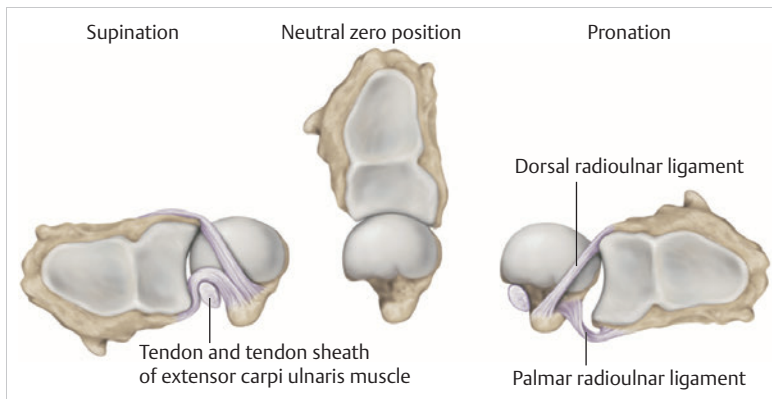


Fig. 1.11 Pronation and supination decelerator. Distal view. The ulnocarpal disc is not depicted.

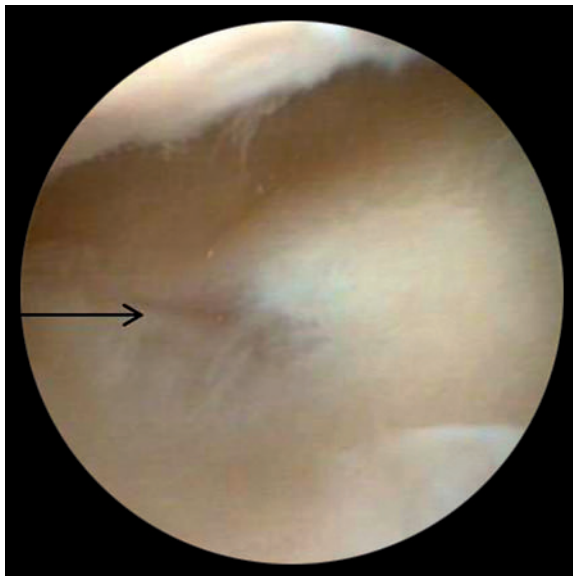


Fig. 1.12 Arthroscopic image of a tear of the ulnocarpal disc on the radial side.

Note

The pronator quadratus muscle is the more important pronator, since it is involved in all inward rotations, while the pronator teres muscle becomes active only during rapid movements and against resistance.^{256,259} To a limited extent, the flexor carpi radialis muscle, for example, is involved in pronation.

Supinator Muscles

Supination is carried out by the biceps brachii and supinator muscles:

- The two-headed **biceps brachii muscle** originates from the supraglenoid tubercle with its long head and from the coracoid process with its short head. The two heads generally unite at the level of the deltoid tuberosity.

The biceps brachii muscle inserts onto the radial tuberosity with a thick tendon (in association with the bicipitoradial bursa). A second flat tendon develops into the bicipital aponeurosis (lacertus fibrosus) and radiates into the antebrachial fascia. Its supination effect increases with increasing flexion in the elbow.

- The **supinator muscle** belongs to the deep layer of extensors (► Fig. 1.13). Its shape is that of a trapezoid-like, 1-cm thick muscle plate. It originates from the olecranon of the ulna, the lateral medial epicondyle of the humerus, the radial collateral ligament and the annular ligament of the radius. The supinator muscle inserts at the radius between the radial tuberosity and the insertion of the pronator teres muscle. As an outward rotating muscle, the supinator muscle is much stronger and more important than the biceps brachii muscle, since the supinator is able to work in all positions of the arm at the same strength.²⁵⁶ This means that even if the biceps brachii muscle is paralyzed due to trauma, a supination movement is still possible. In the reverse scenario, however, the biceps brachii muscle is not able to take over.

When the elbow is flexed at a 90° angle, the supinators are much stronger than the pronators. For this reason, it is much easier to perform actions such as turning a screwdriver if the elbow is flexed. The **brachioradialis muscle** is not involved in pronation or supination. It only returns the forearm to mid-position. In this position, it also serves as a flexor. As a one-headed muscle located on the surface, it originates from the lateral supra-epicondylar ridge and the lateral intermuscular septum. It inserts onto the radial surface of the radial styloid process.

1.3 Wrist and Movement Axes

1.3.1 Movement Axes

With the involvement of the ulnocarpal meniscus homologue, the collateral ulnar carpal ligament is considered to be one of the decelerators of radial deviation of the wrist.¹⁰⁶ The TFCC is therefore a key factor for the

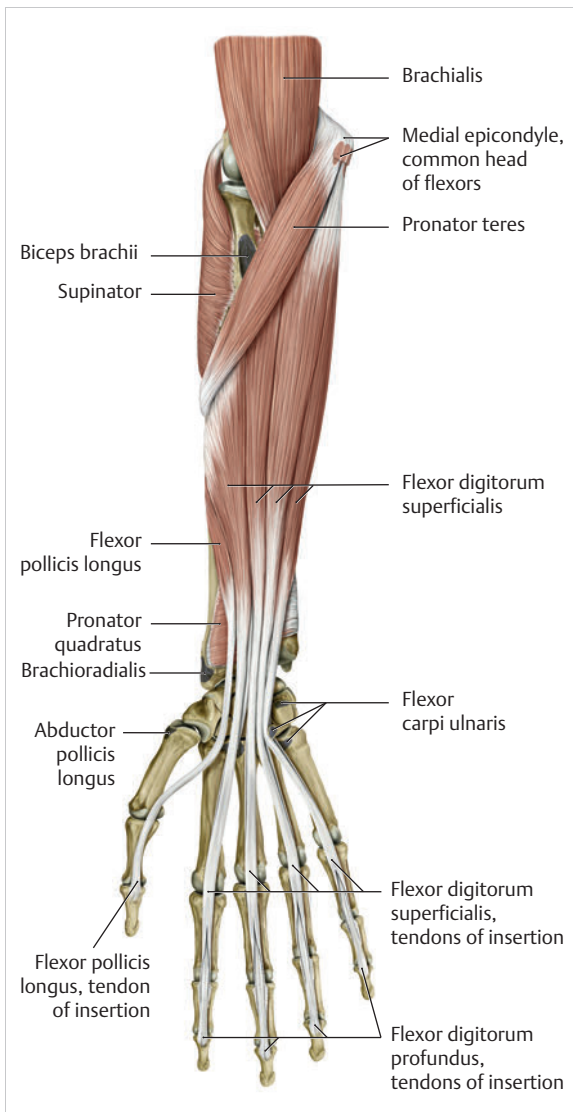


Fig. 1.13 Pronator teres and supinator muscles. (From THIEME Atlas of Anatomy, General Anatomy and Musculoskeletal System. 2nd ed. © Thieme 2014, illustration by Karl Wesker.)

inclusion of the distal radioulnar joint in the function of the wrist joint. The wrist joint is thus composed of the radiocarpal joint, the midcarpal joint and the carpometacarpal joint (as a bridge to the carpal bones²²), in cooperation with the distal radioulnar joint. **Hand movements** take place as follows²⁵⁶:

- The **rotation movements** pronation and supination are carried out in the proximal and distal radioulnar joint in cooperation with the shoulder joint (► Fig. 1.14). The wrist joint is not involved in these movements and is more or less carried along. However, the selective movements in the plane of the hand and the marginal movements are controlled by the wrist joint alone.
- **Movements in the plane of the hand** include extension (bending the back of the hand toward the forearm) and flexion (bending the palm toward the forearm).
- **Marginal movements** include radial deviation (moving the hand toward the thumb) and ulnar deviation (moving the hand toward the little finger).
- **Circumduction** (► Fig. 1.15) is a combination of the two degrees of freedom: 1) extension and flexion; and 2) radial and ulnar deviation. This circling movement of the wrist can be supported by pronation and supination to some extent. Pure rotation movements are only passively possible.¹⁴⁹

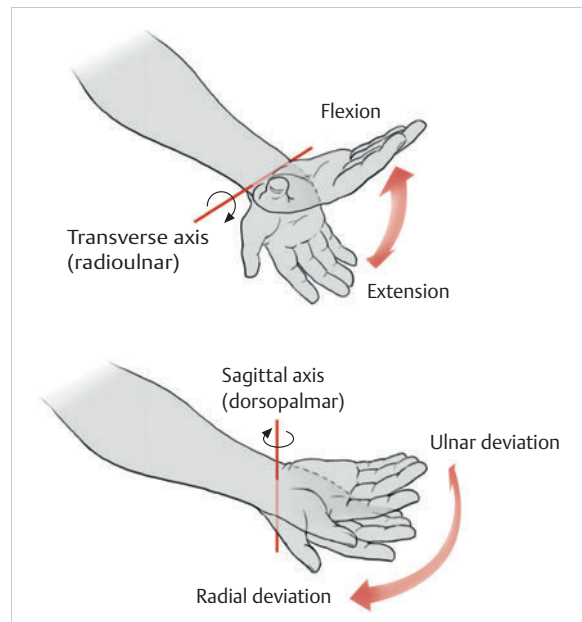


Fig. 1.14 Movement axes of the wrist joint.

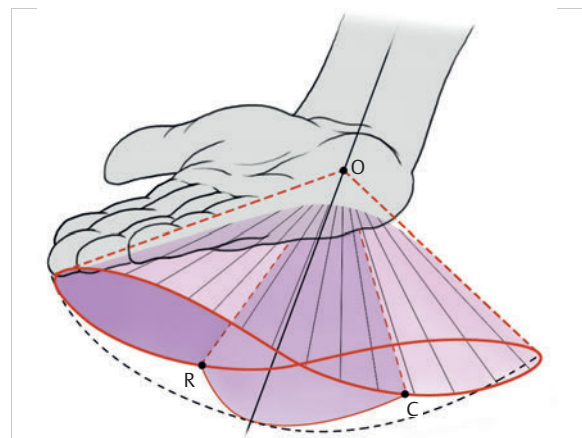


Fig. 1.15 Circumduction of the hand (circling the wrist).

1.3.2 Structure and Function of the Wrist Joint

In functional terms, the wrist is considered to be a single joint. Morphologically, however, it consists of two separate joints: the **proximal** and the **distal wrist joints**. These two joints have **two degrees of freedom** and are composed of **eight carpal bones** (seven “regular” bones and one sesamoid bone; ▶ Fig. 1.16). The proximal row contains the scaphoid, lunate, triquetrum, and pisiform, while the distal row contains the trapezium, trapezoid, capitate, and hamate. In the section below, the characteristics of the individual carpal bones are discussed.

Carpal Bones

Scaphoid

The scaphoid is around 16 mm long and around 28 mm wide,²¹⁵ making it the largest of the four proximal carpal bones. It is somewhat curved toward the distal and ulnar aspect. One-quarter of the total area has no cartilage and serves as the entry portal for various vessels²²⁹—that is, the area of insertion of the radial collateral ligament and the tubercle of the scaphoid.¹⁶⁰ The flexor retinaculum, palmar radioulnar ligaments, and abductor pollicis brevis muscle insert onto this tubercle, whose palmar distal aspect is somewhat radially oriented. It is located below the tendon of the flexor carpi radialis muscle and serves it as a hypomochlion.²²⁹ With its convex joint surfaces, the scaphoid has contact to the radius, the trapezium, and the trapezoid. It has contact to the capitate with its concave surface and to the lunate with its flat surface. According to Linscheid (1986),¹⁴⁸ this bone located on the radial side is not actually part of the proximal carpal row but rather serves to **connect the proximal and distal carpal rows**.

Practical Tip

Pseudarthrosis is a post-traumatic pathological condition involving an unstable scaphoid fracture. The instability can result from a proximal fracture or a humpback deformity or it can occur if the fracture gap is more than 1 mm wide. It is the result of inadequate fracture healing with the formation of connective tissue in the fracture gap.¹⁵ This leads to a false joint, which allows movement between the bone fragments and in turn leads to tilting. This malalignment leads to progressive arthrosis, which successively affects various joint segments, culminating in scaphoid nonunion advanced collapse (SNAC). The condition is classified by stage:

- Stage 1: Arthrosis of the styloid process due to palmar malalignment of the distal scaphoid fragment

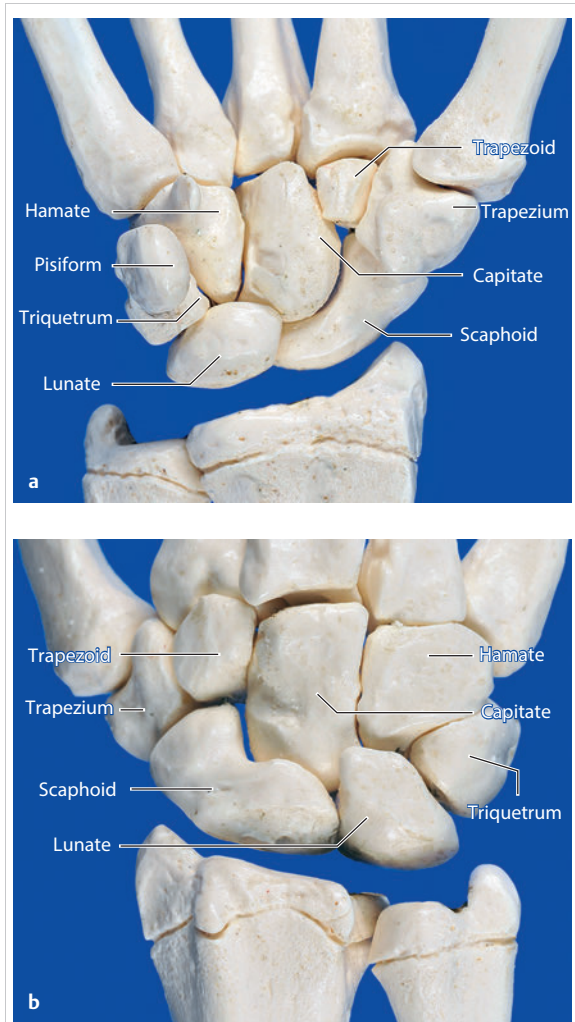


Fig. 1.16 Carpal bones. (a) Right hand and palm in the palmar view. (b) Right hand and palm in the dorsal view.

- Stage 2: Extension to the joint surface between the distal fragment and the radius
- Stage 3: Additional midcarpal arthrosis (between the lunate and capitate) due to dorsal positioning of the lunate and proximal positioning of the capitate.

If the retrograde blood flow to the scaphoid is disrupted in a proximal fracture, this frequently results in osteonecrosis of the proximal pole.

Lunate

This carpal bone is wedge-shaped, with the dorsal surface smaller than the palmar surface. The lunate is around

19 mm long, around 18 mm wide, and around 13 mm thick.²¹⁵ It is located in the center of the proximal wrist joint and articulates equally in the wrist joint abutting the radius with a convex joint surface and in the midcarpal joint abutting the capitate with a concave surface. Two flat articular facets of the bone also articulate with the triquetrum and scaphoid. Sixty-five percent of individuals have an additional fifth medial facet that articulates with the hamate.¹⁵⁵ Among the few vessels supplying the lunate, the proximal portion of the joint surface is the most poorly vascularized. This plays a particularly important role for the wrist, since it is involved in all movements, **both longitudinally and transversally**.²²⁹ In these movements, it controls flexion with the radius and, in conjunction with the radius and the scaphoid, all other functions.²⁴²

Additional Information

In 44% of the individuals studied with a joint between the lunate and hamate, chondromalacia was found in this fifth medial facet.¹⁵⁵ In addition to a negative ulnar variance involving an articular connection between the lunate and hamate,^{110,117} venous congestion in the lunate may cause lunate necrosis. The circulatory disorder may be triggered by overextension of the wrist and simultaneous increased pressure by the flexor tendons, increased capsule tension, and compression of the lunate by the radial margin and of the hamate. One of the suspected causes continues to be microtrauma of the hand.

Triquetrum

The triquetrum is the **ulnar part of the radiocarpal bones**. It is around 14 mm long and around 19 mm wide.²¹⁵ It articulates with the ulnocarpal complex with a proximal convex joint surface and articulates with the lunate with a facet that is smooth on the proximal and radial aspect, with a noncartilaginous ulnar dorsal facet for insertion of the ulnar collateral ligament of the wrist joint, and it articulates the hamate with a spiral-shaped ulnar distal facet. Although it is not actually a sellar joint, the ulnar distal facet has a convex and a concave segment, which enables spiral movement during ulnar deviation.¹⁶⁰ Moreover, on the palmar aspect there is a slightly concave-shaped joint surface on which the pisiform lies.²²⁹ The radial surface of this bone forms the ulnar part of the ulnar canal, which allows passage of the ulnar nerve through the wrist joint.

Pisiform

The pisiform as a **sesamoid bone** inserts into the **triquetrum** with a flat facet. A sesamoid bone is a circumscribed ossification of a tendon caused by pressure or friction.¹⁶⁰ The pisiform is firmly integrated into the

tendon of the flexor carpi ulnaris muscle and its carpal continuations of the pisohamate and pisometacarpal ligaments.²²⁹ The extensor and flexor retinaculum, the tendon from which the abductor digiti minimi muscle originates, and distal continuations of the meniscal homologue also insert at the pisiform. Together these structures exert a stabilizing influence toward the distal aspect of the wrist. The pisiform therefore resembles the hub of a wheel from which the fibrous attachments extend in all directions like spokes holding the bone in place on the triquetrum yet allowing it to move.¹⁸⁶ Navarro (1935)¹⁷⁷ described these two carpal bones as functionally counteracting the scaphoid.

Trapezium

The trapezium is around 17 mm long and around 24 mm wide.²¹⁵ As the first carpal bone of the distal wrist, it is located behind the scaphoid. The palmar, radial, and dorsal aspects of the bone are rough and free of cartilage.²²⁹ At the level of the scaphoid tubercle, this bone has on its palmar aspect a tubercle and a groove containing the flexor carpi radialis muscle. The radial collateral carpal ligament of the wrist inserts onto the radial aspect. The trapezium can be clearly recognized owing to the concave and convex saddle-like joint surface on the radiodistal aspect. It articulates with an oppositely rotating curved surface of the first metacarpal. The **carpometacarpal joint of the thumb** is firmly integrated in the wrist and is one of the most important joints, since it is the opposition of the thumb that enables the wide range of hand movements possible in the first place. The adjacent ulno-distal aspect of the trapezium is firmly attached to the second metacarpal with a flat square facet. Proximally, the concave surface articulates with the scaphoid. Medially, this carpal bone faces the trapezoid with its second-largest, slightly concave¹⁶⁰ and spiral surface.²²⁹

Trapezoid

After the pisiform as a sesamoid bone, the trapezoid is the **smallest carpal bone**. It is around 12 mm long and around 17 mm wide. This bone articulates a convex and concave facet distally with the second metacarpal. In 34% of cases, it also articulates with the third metacarpal.⁵⁰ The ulnar facet articulating with the capitate is slightly concave to irregularly shaped, while the radial aspect articulating with the trapezium is flat to slightly convex; the proximal aspect articulating with the scaphoid has a slightly concave shape. Owing to its wedgelike shape, it is the **least mobile carpal bone**.

Capitate

The capitate is the **largest carpal bone**. It is around 24 mm long and around 16 mm wide.²¹⁵ Proximally, its convex head fits into the concave surface of the scaphoid

and lunate. Distally, it articulates with the third metacarpal with a nearly flat surface. The distal radial aspect has a slightly concave facet to the second metacarpal and a convex surface to the trapezoid. On the distal ulnar aspect there are two flat facets to the fourth metacarpal and on its side to the hamate. All of the joint surfaces are fully covered with cartilage.

Hamate

This carpal has the **shape of a pyramid**. It is around 21 mm long and around 16 mm wide.²¹⁵ Its base is directed toward the metacarpals and its apex is directed toward the lunate. On the palmar aspect in the distal area, the hook of hamate is located, with its concave curve toward the radial aspect. Proximally, there may be a convex facet to the lunate on the radial aspect (in 65% of cases¹⁵⁵), and on the ulnar aspect there is a screw-shaped articular surface that articulates with the triquetrum. Distally, there are two more joint surfaces toward the fourth and fifth metacarpals, respectively.

Joints

In the proximal radiocarpal joint, these carpal bones form an **ovoid or ellipsoid joint** (► Fig. 1.17) and in the distal radiocarpal joint a more or less functional **ball-and-socket joint**.^{136,137} Furthermore, all of the carpal bones form flexible, amphiarthrotic connections to each other, namely the carpal joints.²²⁹

Wrist Joint

The **proximal wrist joint** connects the hand to the two bones of the forearm, the radius and the ulna, with involvement of the ulnocarpal disc (► Fig. 1.18). The two bones together form the proximal biconcave socket, in the first place, from the bifaceted radial surface (scaphoid and lunate facets) and, in the second place, from the concave surface of the ulnocarpal disc (ulnar notch²³³). Three-quarters of this surface corresponds to the radius and one-quarter to the ulna.²³³ The angle of deviation of the radius in the sagittal plane can amount to as much as 20°,⁵⁸ and the dorsopalmar angle of deviation can amount to as much as 15° (► Fig. 1.19).²²⁹ While deviations contribute to **deceleration of flexion and ulnar deviation by the bones**, they can also **promote dislocation in both directions**.

The **distal ovoid convex joint head** is formed by the scaphoid, lunate, and triquetrum and is covered with hyaline cartilage. These bones are held together by short ligaments (scapholunate and lunotriquetral ligaments), which are fully enclosed by these carpal bones and therefore give the false impression that the cartilage covering is uniform.²⁷² The pisiform is not involved in the actual arthrokinematics but rather serves as a sort of sesamoid bone that stabilizes the joint by means of ligaments and

muscles. Between the two articulating joint surfaces, there is thus an incongruity because the convex joint head (in the shape of a curved arch) is much larger than the socket (approx. 1:1.5 in the radioulnar direction²²² and approx. 1:2 in the dorsopalmar direction⁹¹). The scaphoid abuts the lower end of the radius while the lunate partially abuts both the radius and the ulnocarpal disc. The triquetrum is in contact with the ulnar collateral ligament of the wrist joint on the ulnar side beyond the ulnocarpal disc.²⁵⁶

About 48 to 50% of compressive stresses transferred when **the wrist joint is in neutral zero position** occur by means of the scaphoid fossa, 35 to 40% through the lunate fossa, and 12 to 15% through the ulnocarpal disc.^{72,82,229} It is therefore understandable that during trauma with the arm extended, the delicate ulna is less often damaged than the much more robust radius.²⁵⁶ The end of the proximal radiocarpal joint is formed by a relatively wide, thin capsule secured by a strong ligament system. The

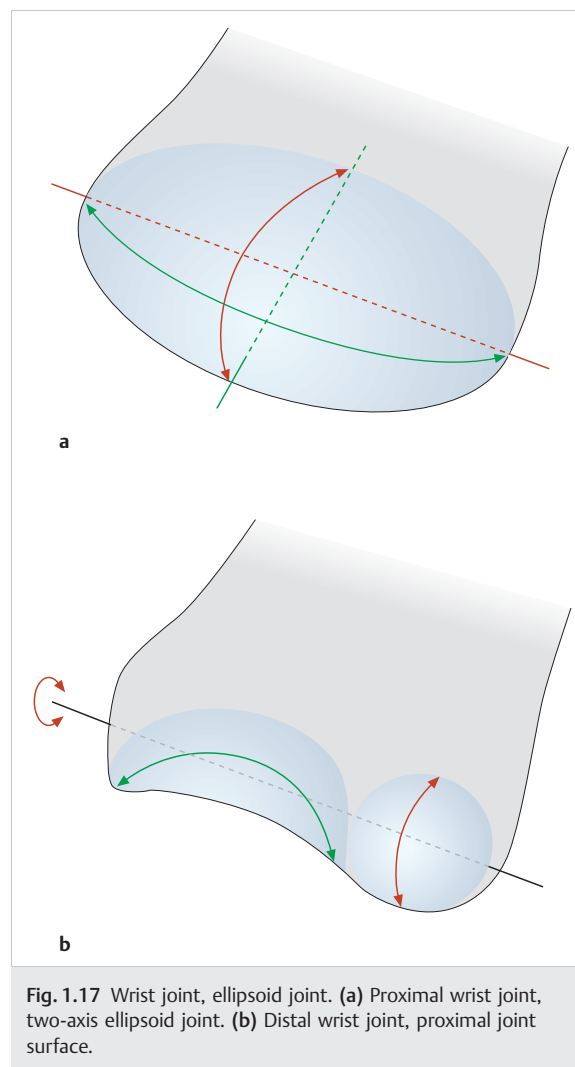


Fig. 1.17 Wrist joint, ellipsoid joint. (a) Proximal wrist joint, two-axis ellipsoid joint. (b) Distal wrist joint, proximal joint surface.

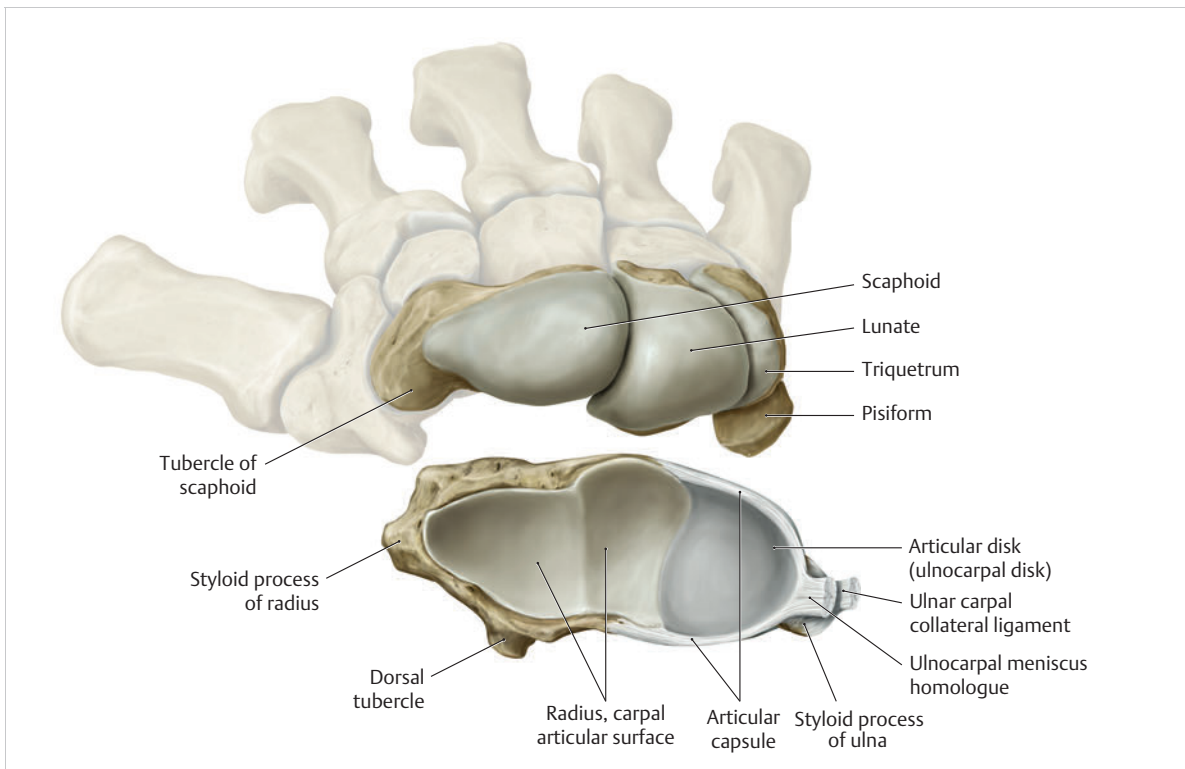


Fig. 1.18 Proximal wrist joint. (From THIEME Atlas of Anatomy, General Anatomy and Musculoskeletal System. 2nd ed. © Thieme 2014, illustration by Karl Wesker.)

range of motion of this joint is always measured taking the midcarpal joint into account, since the two joints are in a direct reciprocal relationship.²²⁹ This results in extension of around 80°, flexion of around 80°, radial deviation of around 15 to 25°, and ulnar deviation of around 40 to 50°.²²⁹

Midcarpal Joint

Over the course of evolution, the carpus lost contact to the ulnar styloid process, which enabled the hand to have a stable torsional movement.¹⁶⁹ The **distal wrist** is formed from the proximal and distal row of the carpal bones (► Fig. 1.20). In contrast to the arc-shaped proximal wrist, the distal carpal row (i.e., compared to the proximal row) runs in a straighter, undular direction (S-shaped). The scaphoid begins radially with a convex curvature, across from which a socket formed by the trapezium and trapezoid is located. Toward the ulnar aspect, the capitate and hamate protrude against it, similar to a joint head. Both bones are embedded in the socket formed by the scaphoid, lunate, and triquetrum.²²⁹ Forty-six percent of all individuals have additional joint surfaces in the proximal hamate and in the distal lunate. These additional joint surfaces can trigger degenerative processes.²⁶⁶ This arch leads to a certain interlocking of the two carpal rows²⁵⁶ with a narrow intra-articular space.²² With the

involvement of stable ligament connections, this creates **more limited mobility compared with the proximal radiocarpal joint** (with the exception of dorsal extension of 50% due to the very mobile lunate¹⁰⁶). This stability of the distal carpal row also impacts the palm (which is a functionally rigid unit) and helps **stabilize the palmar arch**.

Carpal Joints

The individual carpal bones are flexibly interconnected (amphiarthroses). Owing to the different bony formations and the rigid interosseous ligament connections, functional range of motion is limited. The respective joint capsules are stabilized by the small interosseous ligaments. The greatest mobility occurs in the proximal row between the lunate and scaphoid in the form of rotation movements. Between the triquetrum and pisiform, there is also an **independent intercarpal joint** with a thin rigid capsule. In terms of function, the triquetrum is centered, stabilized and also guided by the pisiform²²⁹ and counteracts the pulling action of the flexor carpi ulnaris muscle.⁶⁰ With the involvement of fibers of the extensor carpi ulnaris muscle and the extensor retinaculum running palmarward,²²⁹ this results in a nearly extra-articular spin¹³² that contributes to the rotational stability of the wrist.²²⁹ It also counteracts palmar dislocation of the wrist and is

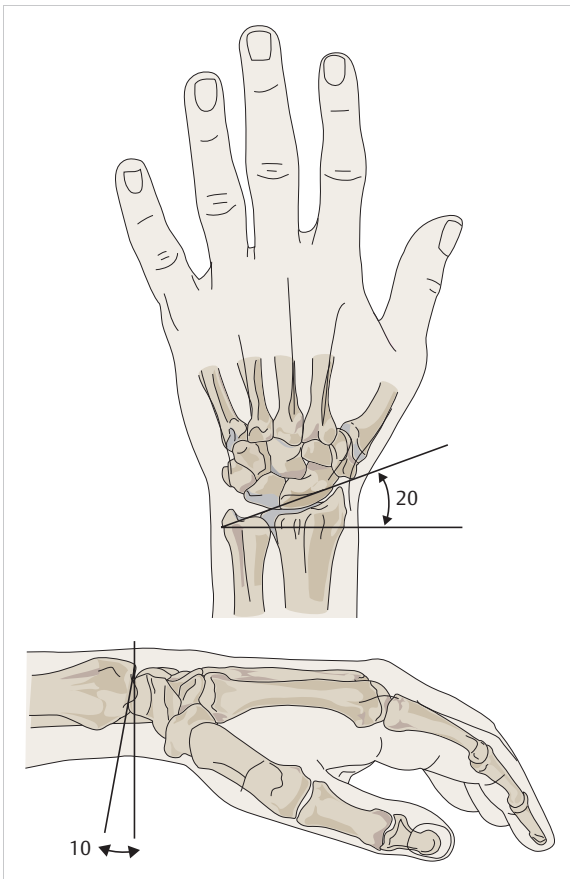


Fig. 1.19 Radial deviation (From Hochschild J. *Functional Anatomy for Physical Therapists*. Stuttgart: Thieme; 2016.)

involved in the formation of the ulnar canal (allows passage of the ulnar nerve).³⁸

Second to Fifth Carpometacarpal Joints and Intermetacarpal Joints

The second to fifth carpometacarpal (CMC) joints connect the distal carpus and the bases of the metacarpals, thus **connecting the carpus with the metacarpus** (► Fig. 1.21). The carpal articular surfaces are slightly convex and the bases of the metacarpals are concave.¹³⁵ Parts of the bases of the second to fifth metacarpals are positioned on the carpal bones in a conical fashion.²²⁹ The second metacarpal interlocks with the trapezoid bone with the involvement of the trapezium and capitate. In a similar fashion, the third metacarpal juts into the space between the trapezoid and capitate with its styloid process in a conical manner. The second and third metacarpals therefore form a firm bony connection with the opposing carpal bones. The fourth and fifth metacarpals abut the hamate together. A Y-shaped ligament of the third metacarpal (attached to the capitate and hamate), as well as

the palmar and dorsal carpometacarpal ligaments, demonstrate the close connection between the carpus and the metacarpals, the so-called amphiarthroses with only limited mobility.²²⁹ The greatest range of motion occurs in the fourth and fifth CMC joints, in particular in the fifth CMC joint, whose joint surface has a sellar shape in 60% of people.²²⁹ Functionally, however, the only possible movement is flexion, which supports the opposition of the little finger toward the thumb.

The entire carpus is a concave structure and forms the shape of a palmar arch, namely the **carpal tunnel** (space for the tendons of the hand and the median nerve). The carpus is stabilized by several muscles and, in particular, by its complex ligament system.

1.3.3 Ligament System and Wrist Stability

There are **33 different ligament structures** in the carpal area,²⁴ most of which are firmly attached to the joint capsule (capsular stabilizers). The aspects facing the joints are covered by a synovial membrane, while the lateral aspects have a fibrous layer.¹⁶⁰ During dissection, it is nearly impossible to expose all the ligaments separately.²²⁹ The distal part of the ligament structure is much stronger than the ulnar part, which is evident reciprocally in terms of mobility. This is also true for the stronger palmar ligaments compared to the weaker dorsal ligaments, which have more densely packed collagen fibers.¹⁶⁰ The axial compression on the carpus and the oblique joint surface between the radius and the proximal carpal row (i.e., dorsal and distal to palmar and proximal) tend to translate the carpus in a palmar direction. The palmar ligaments are therefore subjected to higher load and must therefore be more stable.¹⁶⁰ The oblique course of the joint surface (i.e., from radial and distal to ulnar and proximal) and the axial compression cause the carpal bones to deviate ulnarward. For this reason, an additional ligament system extends from radial and proximal to ulnar and distal, and therefore compensates for this translatory process.¹⁶⁰ Each carpal bone is in contact with another carpal bone, more or less directly or indirectly.¹⁶⁰ The carpal ligament system is assigned the tasks of stabilizing the wrist as well as inhibiting and limiting extreme movements.²⁵⁶ Lichtman et al (1981)¹⁴⁶ and Fisk (1984)⁶³ described this complex carpal region as a dynamic ring system of carpal bones that is under constant tension. These bones must be held together tightly by ligaments,²²⁹ which are also important components of proprioception of the wrist.¹⁶⁰

The ligaments of the hand are arranged in **three dorsal and three palmar layers**.¹⁰⁹ Schmidt and Lanz (2003)²²⁹ classified this ligament system into superficial, middle, and deep layers (three-layer structure²⁰⁰).

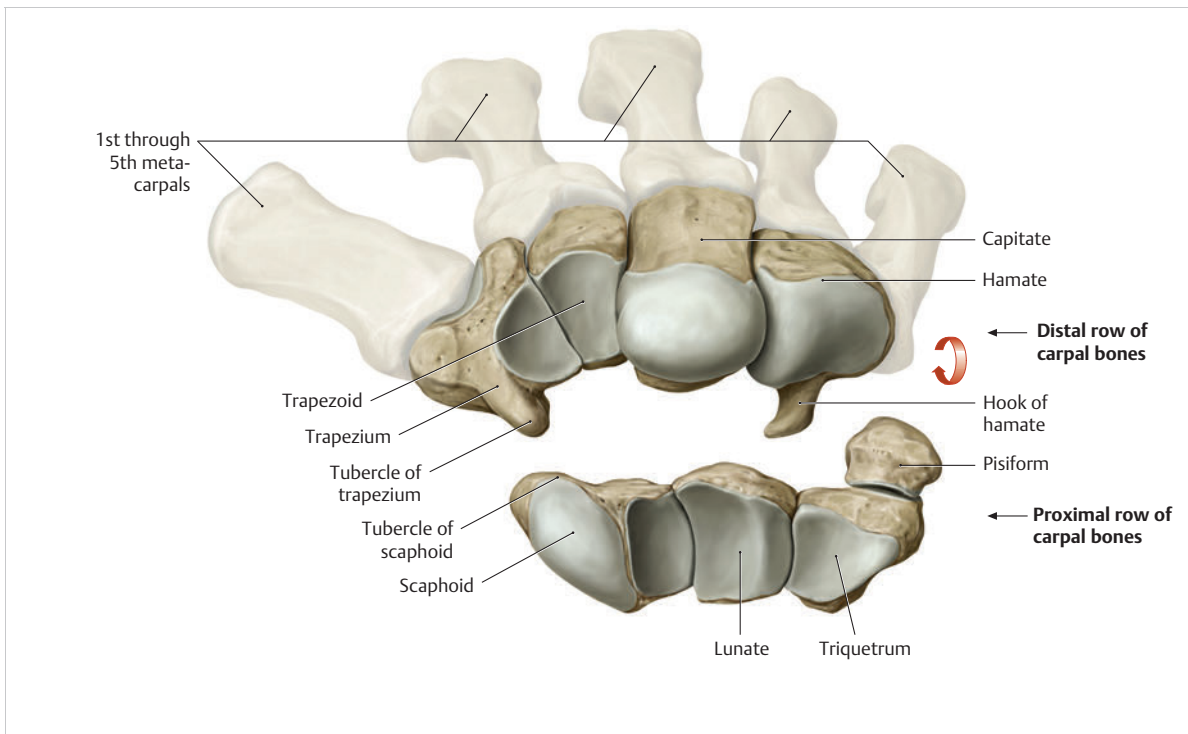


Fig. 1.20 Distal wrist joint. (From THIEME Atlas of Anatomy, General Anatomy and Musculoskeletal System. 2nd ed. © Thieme 2014, illustration by Karl Wesker.)

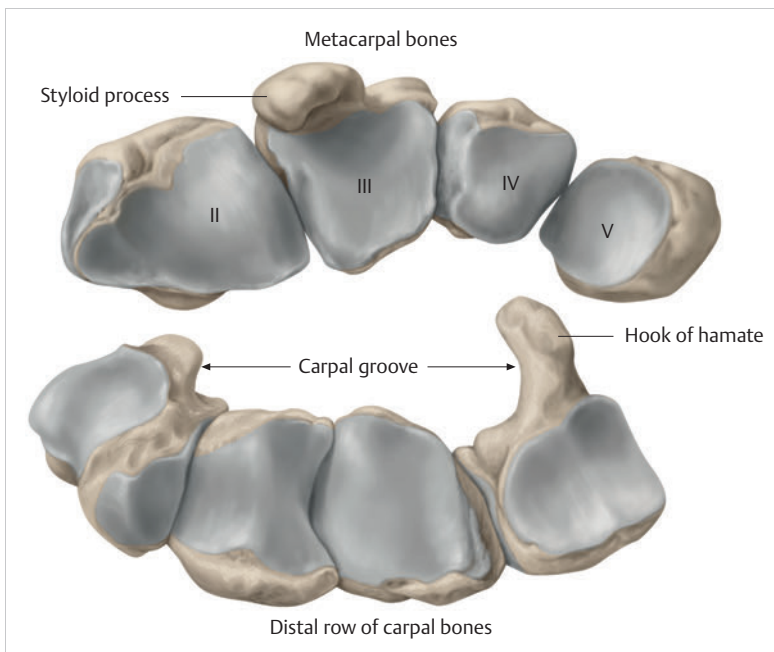


Fig. 1.21 Second to fifth CMC joints and intermetacarpal joints.

Superficial Layer of the Ligaments of the Wrist

The superficial layer consists of the flexor retinaculum and the extensor retinaculum. The **retinacula** are

responsible for positioning and guiding the tendons.²²⁹ In addition, the flexor retinaculum centers the pisiform on the triquetrum and in so doing prevents it from slipping ulnarward.²²⁹ The extensor retinaculum contributes to the carpal stability.

Flexor Retinaculum

Proximal to the palmar carpal region, the antebrachial fascia is continuous with the superficial (palmar carpal ligament) and deep stabilizing ligaments of the flexor retinaculum.²²⁹ The palmar carpal ligament spans between the tendon of the flexor carpi ulnaris muscle and the tendon of the palmaris longus muscle. The radial aspect of the latter muscle is attached to the flexor retinaculum (► Fig. 1.22).

The flexor retinaculum spans between the ulnar (pisiform and hook of hamate) and the radial eminences of the wrist (tubercle of trapezium and tubercle of scaphoid) and forms the roof of the carpal tunnel.²⁰⁰ The fibers of the retinaculum resemble a woven structure and are firmly fused.⁸⁷ Schmidt and Lanz (2003)²²⁹ described this rigid ligament system as an **important component of the finger flexor pulley system**. The ligament also **prevents bowstringing during wrist flexion**.^{179,180} However, it does not appear to have a great influence on the stability of the wrist joint, since dissecting the flexor retinaculum has little impact on carpal stability.²²⁹

Additional Information

Several segments of the distal portion of the retinaculum form an aponeurosis that is positioned between the thenar and hypothenar muscles.¹⁶⁰ Changes in the tension of the flexor retinaculum and its attachment to the thenar muscles may be responsible for reducing the range of motion of the thumb during wrist extension.

However, an important task of these fibers involves transmitting proprioceptive information of the wrist.¹⁵⁸

Extensor Retinaculum

The extensor retinaculum arises together with the palmar carpal ligament from the deep fibrous layers of the antebrachial fascia and radiates into the dorsal fascia of the hand without any sharp delineation (► Fig. 1.23). Proximally, it is around 51 mm long on average and distally around 54 mm. On the radial side, it is around 15 mm wide, in the center around 26 mm, and on the ulnar side around 20 mm.²²⁷ It is divided into superficial supratendinous and deep infratendinous layers²⁵⁰:

- The **supratendinous layer** arises from the palmar antebrachial fascia with the inclusion of the palmar carpal ligament, the tendon of the flexor carpi radialis muscle, the radial styloid process, and the thenar fascia. The fibers on the ulnar side extend across the tendon of the extensor carpi ulnaris muscle and ultimately radiate into the antebrachial fascia. There are additional insertions at the triquetrum and pisiform, and distally into the fascia of the hypothenar muscles.²²⁹
- The **infratendinous layer** is thin and short and occurs only in the area of the fourth and fifth extensor tendon compartments. This layer is fused to the joint capsule of the distal radioulnar joint, extends below the sixth extensor tendon compartment, and inserts together with the joint capsule of the wrist and the superficial layer onto the palmar surface of the triquetrum.²²⁹

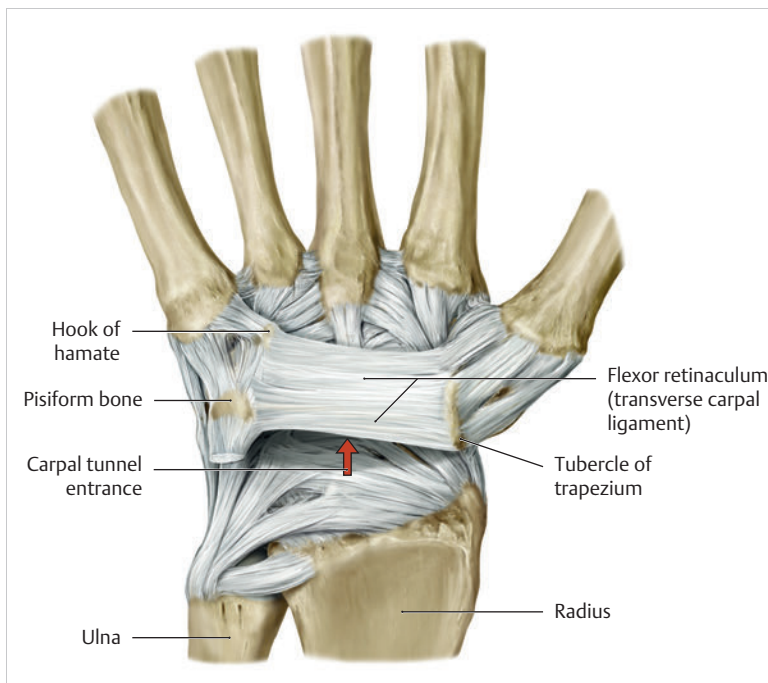


Fig. 1.22 Flexor retinaculum. (From THIEME Atlas of Anatomy, General Anatomy and Musculoskeletal System. 2nd ed. © Thieme 2014, illustration by Karl Wesker.)

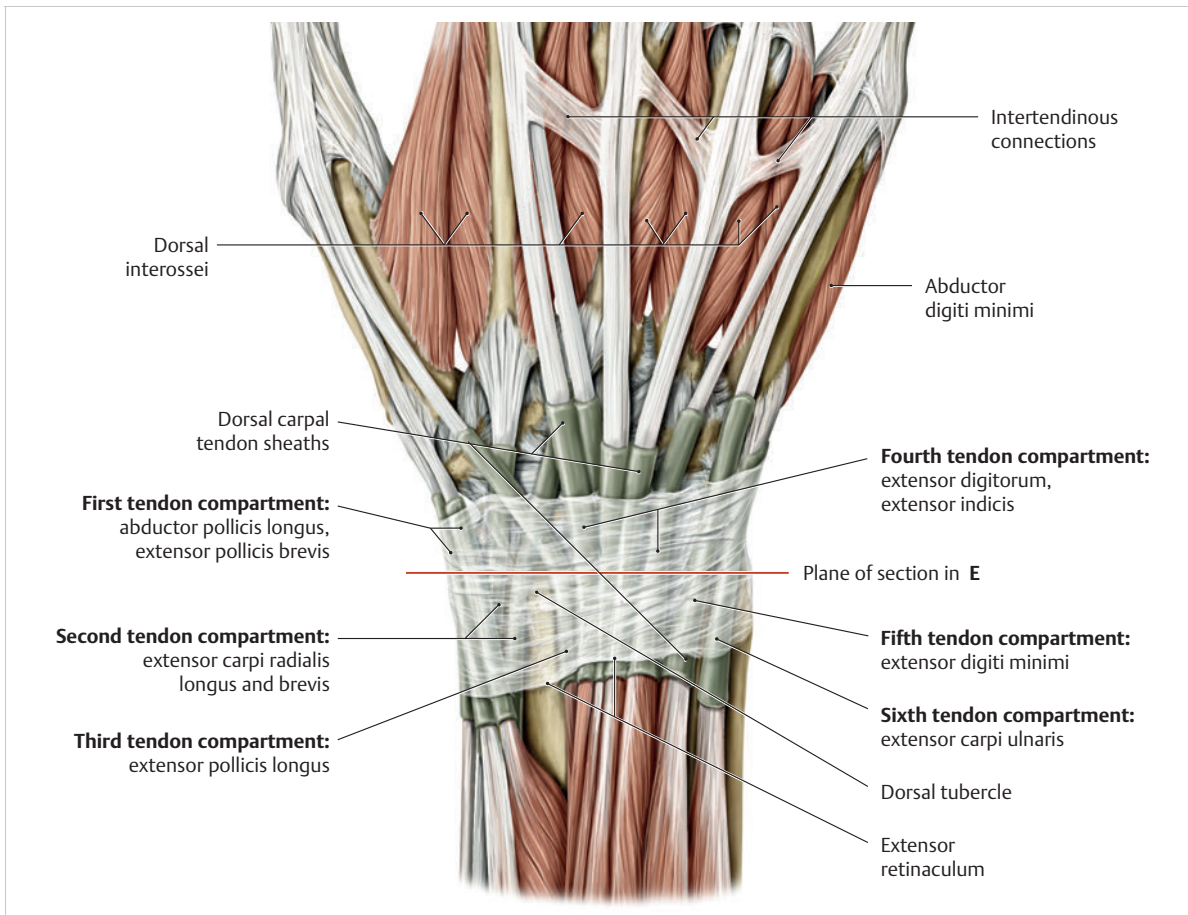


Fig. 1.23 Extensor retinaculum. (From THIEME Atlas of Anatomy, General Anatomy and Musculoskeletal System. 2nd ed. © Thieme 2014, illustration by Karl Wesker.)

As a result, the extensor retinaculum stabilizes the extensor carpi ulnaris muscle without direct contact with the ulna. The mobility of the bone during pronation and supination is therefore not affected.¹⁶⁰

The extensor retinaculum is responsible for forming six vertically positioned connective tissue septa that are fused to the periosteum at the radius, the capsule of the carpal and radioulnar joints, and the TFCC.²²⁹ The ensuing six osteofibrous tendon compartments serve to provide passage for the extensor tendons of the thumb, wrist, and fingers. The extensor retinaculum prevents bowstringing and extensive radial and ulnar lateral slipping of the extensor tendons,¹⁸⁸ and supports the TFCC.²²⁹

Middle Layer of Ligaments of the Hand

This layer comprises the radial collateral carpal ligament of the wrist, various palmar and dorsal radiocarpal ligaments, the TFCC, and the dorsal intercarpal ligament. The palmar ligaments are thicker than the dorsal ligaments.²³¹ These ligaments limit and stabilize radial and ulnar deviation, as well as extension and, in particular,

flexion. They also play a key role in physiological pressure distribution in the carpus. The middle layer is composed of three groups of ligaments.

Radial Collateral Carpal Ligament

This ligament is actually more part of the palmar ligament apparatus than the radial ligament system.²⁵¹ It arises from the palmar border of the radial styloid process and extends in an oblique direction across the carpal articular space toward the scaphoid tubercle and toward the sheath wall of the tendon of the flexor carpi radialis muscle²²⁹ up to the trapezium.⁷⁸ One of the ligament's important functions involves the transmission of proprioceptive stimuli from the ligament's area of origin and insertion.¹⁹³

Dorsal and Palmar Radiocarpal Ligaments

These ligaments run in a thin, superficial layer above a strong, thick, deep intracapsular fibrous layer.²²⁹ The superficial parts of the ligaments arise from the palmar surface of the radial styloid process and insert at the

capitate and lunate. The deep parts arise together from the radial styloid process, or broad-based from the volar lip of the radius, and are divided into three fibrous tracts: the radioscapohcapitate ligament, and the long and short radiolunate ligaments. The radioscapohcapitate ligament runs across the waist of the scaphoid and spans the distal wrist¹⁶⁰ with an insertion at the capitate, while at the ulnar side of this ligament, the long and short radiolunate ligaments run in a flat and somewhat oblique direction toward the lunate.²²⁹

Ligaments of the “Distal V”

Together with the scaphotrapezoid ligament and the arcuate ligament (triquetrocapitoscapoid ligament), the radioscapohcapitate ligament forms the **distal palmar V-shaped ligament (V ligament)**. The long and short radiolunate ligaments, together with the ulnolunate ligament and the ulnotriquetral ligaments, form the **proximal palmar V-shaped ligament**.²³¹

► **Radioscapohcapitate ligament.** This ligament primarily serves to **stabilize the joint between the lunate and capitate**.¹⁴⁷ It can be stretched by around 30%.¹⁵⁰ The ligament becomes stretched during ulnar deviation and during extension with radial deviation of the distal carpal row—which is what enables extension across two joints in the first place.¹⁶² Furthermore, during radial deviation, the ligament controls palmar flexion of the scaphoid, which is associated with extension of the capitate.¹⁶⁰ It also works together with the long radiolunate ligament to stabilize the proximal pole of the scaphoid.¹⁷

Note

If the proximal half of the scaphoid is fractured, the radioscapohcapitate ligament can fold into the fracture gap and lead to scaphoid pseudarthrosis.²³¹

► **Arcuate ligament.** The ulnar side of the distal group of V-shaped ligaments is formed by a ligament with an arching course (“deltoid ligament”²³¹). The arcuate ligament (TCSL: triquetrocapitoscapoid or radiate ligament, deltoid ligament¹⁵⁴) arises on the palmar aspect of the triquetrum, extends in a bow shape over the tip of the hamate, and terminates on the palmar side of the distal third of the scaphoid.²³¹ As a fairly loose ligamentary connection, the arcuate ligament permits the triquetrum to slide over the spiral-shaped joint surface of the hamate, which is responsible for the high and low triquetral positions during radial and ulnar deviation.²³¹ Tighter sections of the ligament prevent flexion of the proximal carpal row. In many cases, the central fibers to the lunate are absent, which creates a weak point in the wrist (the space of Poirier^{161,229}).

► **Scaphotrapeziotrapezoid ligament.** In a wider sense of the term, the scaphotrapeziotrapezoid ligament also belongs to the ligaments of the “distal V”²³¹ and the deep layer of the ligament system.¹⁶⁰ This V-shaped ligament connects the scaphoid with the trapezium and the trapezoid.¹⁶⁰

► **Function of the palmar “distal V”.** The main function of this palmar ligament complex is to hold the scaphoid in place like a hypomochlion, and to fixate and stabilize the capitate.²³¹

Ligaments of the Palmar “Proximal V”

The radiocarpal ligaments also include the long and short radiolunate ligaments. Together with the ulnolunate and ulnotriquetral ligaments, they form the palmar “proximal V” (► Fig. 1.24).

► **Radiolunotriquetral ligament (long and short radiolunate ligaments).** The long part of the radiolunate ligaments tightens during radial and ulnar deviation¹⁶⁰ and is able to be stretched by approximately 30%.¹⁵⁰ Since it courses across the distal pole of the scaphoid, it may control palmar flexion of the scaphoid during radial deviation.¹⁶⁰ In contrast, the short radiolunate ligament can stretch by around 47% and during flexion, by around 55%.²¹⁶ The long radiolunate ligament courses first to the lunate and continues to the triquetrum, therefore corresponding to the radiolunotriquetral ligament.²³¹ Together, they form the radiopalmar leg of the proximal V and are considered to be the wrist’s strongest radiocarpal ligaments.¹⁶⁰ These ligaments perform the important function of preventing the carpus from slipping along the joint surface of the radius, which has a 25° angle of inclination to the ulnar aspect.²³¹ Because of their alignment with the ulnar inclination of the radial joint surface and their function of keeping the carpus in a stable position, the radiolunotriquetral and dorsal radiotriquetral ligaments are also known as the “**extra-articular slingshot**.”²³¹

► **Ulnolunate ligament and ulnotriquetral ligament.** The ulnar leg of the proximal V consists of the palmar ligamentary structures of the triangular fibrocartilage complex (TFCC), that is, the ulnolunate and the ulnotriquetral ligaments. They originate on the palmar radioulnar ligament and proceed to the anterior horn of the lunate and/or to a depression on the palmar side of the triquetrum.²³¹ The two ligaments are key components of the TFCC and are important stabilizers of the distal part of the carpus and prevent nondissociative forms of instability.

► **Function of the palmar “proximal V” ligament.** The function of the proximal V-shaped ligament (► Fig. 1.24) involves the longitudinal transference of force between

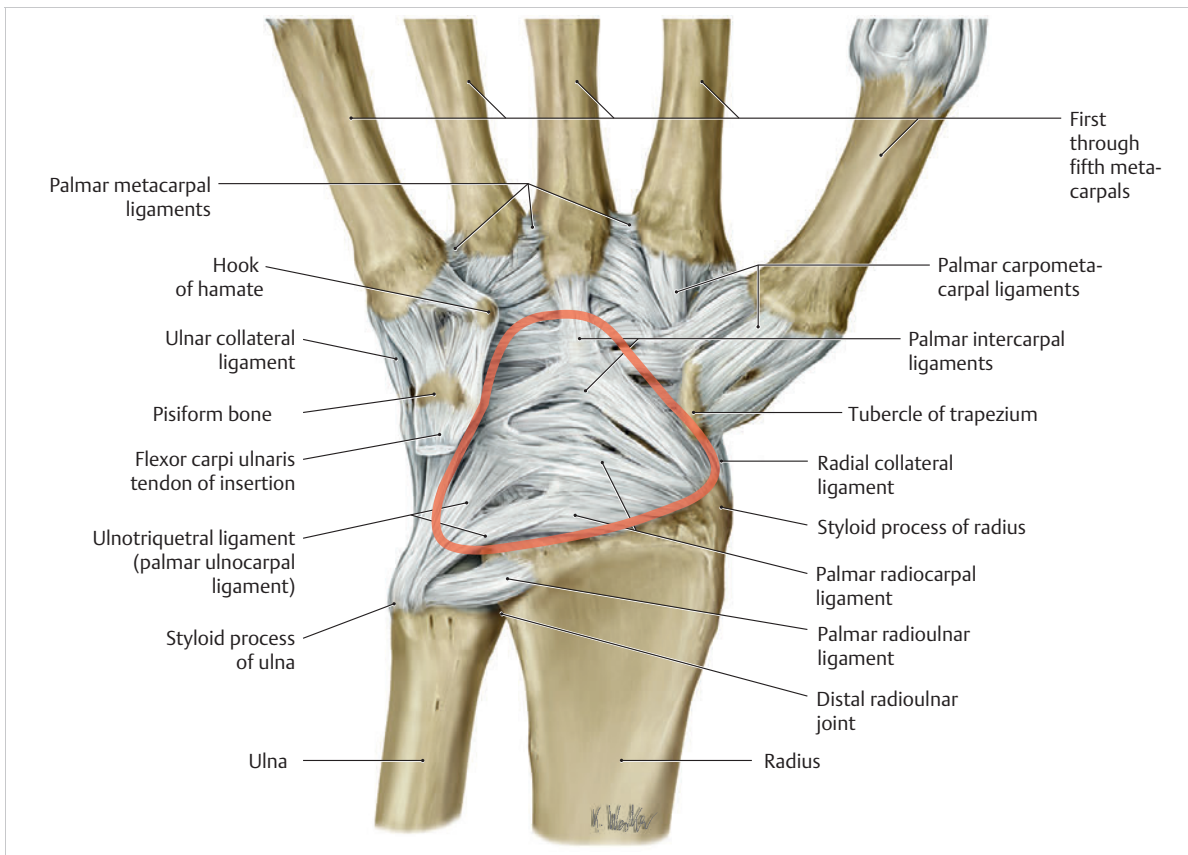


Fig. 1.24 Carpal ligament structures in the palmar view. Red = palmar V-shaped ligaments. (From THIEME Atlas of Anatomy, General Anatomy and Musculoskeletal System. 2nd ed. © Thieme 2014, illustration by Karl Wesker.)

the ulna and the carpus and fixation of the proximal carpal row, especially the lunate as the most important intermediate element of movement (“intercalated segment”).²³¹

“Dorsal V” Ligament

One of the dorsal radiocarpal ligaments is the radiotriquetral ligament located on the dorsal aspect. Together with the dorsal intercarpal ligament, it forms the dorsal V-shaped ligaments (► Fig. 1.25). While the two ligaments are stabilized by the joint capsule, they are weaker than the palmar ligaments.²³¹

► **Dorsal radiotriquetral ligament.** The dorsal radiotriquetral ligament arises from the dorsal border of the radius, immediately distal to Lister’s tubercle (dorsal tubercle¹⁶⁰). Its course crosses the proximal scaphoid pole and the posterior horn of the lunate and ultimately inserts onto the dorsal aspect of the triquetrum.²³¹ The ligament is about 20 mm long; proximally it is 5 mm wide and distally around 5 mm wide.²⁶⁵

► **Dorsal intercarpal ligament.** This ligament originates at the dorsal side of the triquetrum and after taking a

horizontal course, inserts with one fascicle on the back of the scaphoid and with another fascicle on the back of the trapezium and at the radial collateral carpal ligament.²³¹ It is approximately 36 mm long and 6 mm wide.²⁶⁵

► **Function of the “dorsal V” ligament.** Since both dorsal ligaments cover the middle carpal column, the lunate is stabilized by the dorsal radiotriquetral ligament and the capitate is stabilized by the dorsal intercarpal ligaments, which hold the two bones in colinear alignment.²³¹ Neither flexion nor extension is compromised.¹⁶⁰ In synergy with the radiolunotriquetral ligament on the palmar side, the dorsal V-shaped ligament prevent the carpus from sliding along the radial joint surface, which slopes to the ulnar side.²³¹ In terms of function, it resembles an accordion, viz. during extension, the dorsal V becomes narrower, and during flexion it becomes wider.¹⁶⁰ This configuration permits extensive movement while ensuring stability at the same time, since the ligaments hardly need to become longer.¹⁶⁰ As one of the “slingshot” ligaments it is therefore among the most important carpal structures providing stability.²³¹

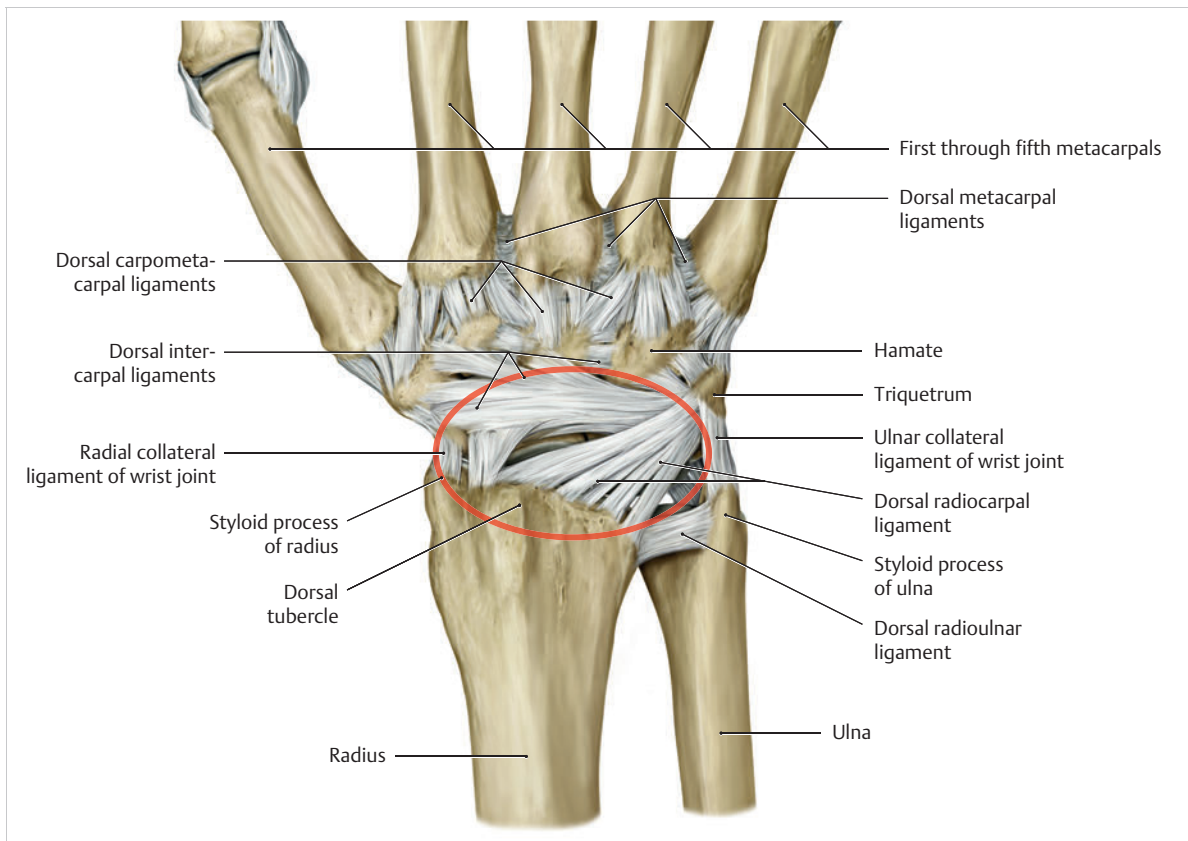


Fig. 1.25 Carpal ligament structures in the dorsal view. Red = dorsal V-shaped ligaments. (From THIEME Atlas of Anatomy, General Anatomy and Musculoskeletal System. 2nd ed. © Thieme 2014, illustration by Karl Wesker.)

Interaction of the V-shaped Ligaments

Summary

All in all, the V-shaped ligaments provide the functional connection between all pillars of carpal kinematic function. The distal V-shaped ligament stabilizes the capitate and decelerates the scaphoid, while the proximal V-shaped ligament helps to regulate the proximal transfer of force between the ulna and the carpus and stabilizes the proximal carpal row, with the lunate as the intermediate element of movement.²³¹ The dorsal V-shaped ligament and the ulnotriquetral ligament on the palmar side (part of the TFCC) prevent the carpus from sliding along the radial joint surface, which slopes to the ulnar side (“slingshot ligaments”).²³¹ The dorsal V ligament also stabilizes the lunate and the capitate and holds them in colinear alignment, since their fascicles span the middle carpal column.²³¹ These V-shaped ligaments function as key decelerators of wrist movement, especially for

radial and ulnar deviation and, with the involvement of intermediate ligaments, for extension and flexion. Moreover, they coordinate and center individual carpal bones and thus contribute to physiological transfer of force.

The palmar V- and the dorsal V-shaped ligaments work in synergy to stabilize radial and ulnar deviation, with individual ligaments alternating as agonists and antagonists.²³³ During **ulnar deviation**, the radioscaphocapitate, radiolunotriquetral, and dorsal radiotriquetral ligaments tighten and the ulnolunate, ulnotriquetral, arcuate, and dorsal intercarpal ligaments relax. The opposite is true for **radial deviation**.²³³ During **extension**, the palmar ligaments between the radius and the triquetrum, pisiform as well as hamate and the dorsal ligaments between the hamate and the triquetrum are subjected to tension, while the dorsal ligaments relax the dorsal connections of the radius and ulna with the triquetrum. The opposite is true for **flexion**.⁹¹

Note

Ruptures of the proximal palmar V-shaped ligament can therefore promote dorsiflexed intercalated segment instability (DISI) and ruptures of the distal V-shaped ligament can promote rotational malalignment of the scaphoid. A tear in the dorsal V predisposes to ulnar translocation.²³¹

Triangular Fibrocartilage Complex (TFCC)

The TFCC is separated into the following components: the ulnocarpal disc, the palmar and dorsal radioulnar ligaments, the ulnolunate ligament, the ulnotriquetral ligament, the palmar and dorsal ulnocarpal ligaments, the ulnar collateral ligament of the wrist joint, and the tendon sheath of the extensor carpi ulnaris muscle. As described above, as the **key element of stabilization for the distal radioulnar joint** and the wrist, the TFCC serves to regulate pressure in the carpus and operates as an important decelerator of radial deviation.

Dorsal Intercarpal Ligaments

The course of these ligaments is from the triquetrum to the scaphoid. They are involved in the formation of the

dorsal V-shaped ligament (see section on “Dorsal V Ligament”).

Radiate Carpal Ligament

The structure of the radiate carpal ligament varies among individuals.²²⁹ It usually has fibers that fan out from the capitate to the triquetrum, lunate, and scaphoid. However, frequently the central fibers to the lunate are absent, which creates a weak point for this carpal bone (the space of Poirier¹⁶¹; ► Fig. 1.26).

Deep Layer of the Ligaments of the Hand

The palmar, dorsal, and interosseous intercarpal ligaments efficiently connect the carpal bones into a functional unit (► Fig. 1.27). Some of these ligaments are aligned toward each other on both sides and between the skeletal elements (e.g., palmar, dorsal, and interosseous trapeziotrapezoid ligaments). These small ligaments have a membranous attachment to the articular cartilage and some cross the cartilage and insert directly onto the bone as Sharpey’s fibers.²³¹ The fibers take a longitudinal course between the radius and the scaphoid and lunate or run transversely between the two carpal rows.²³¹ The ligaments described below are particularly important.

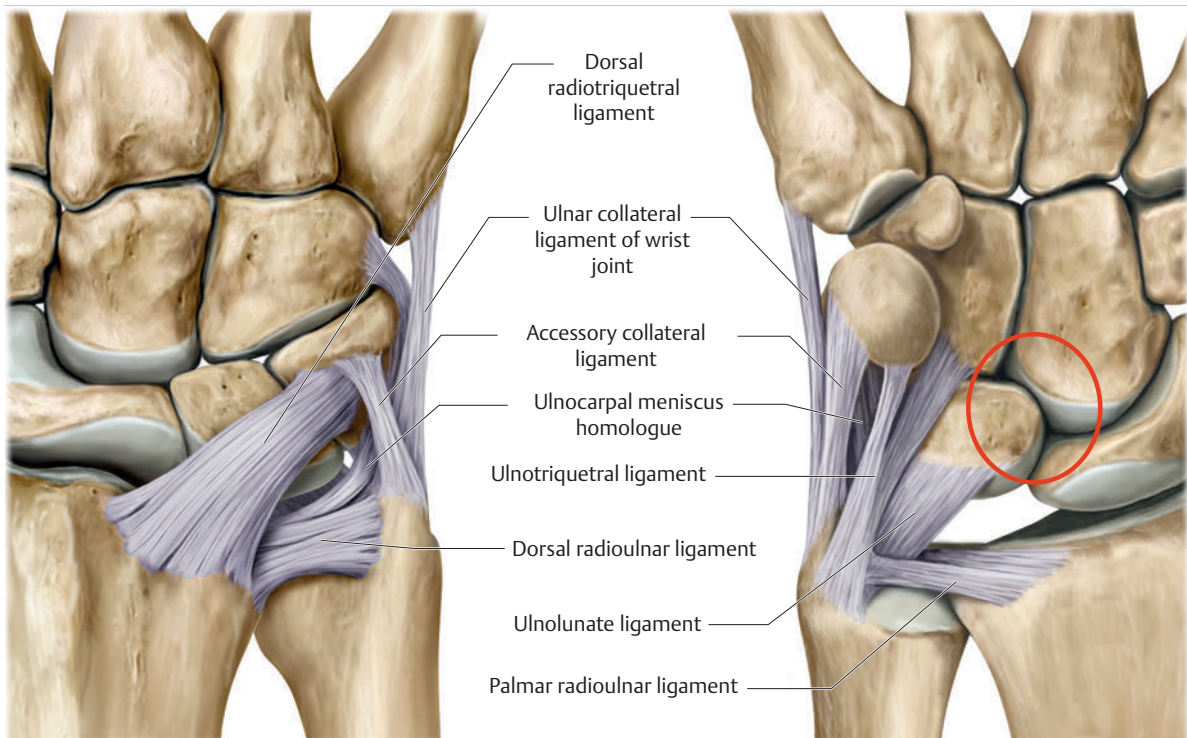


Fig. 1.26 TFCC from the dorsal view (left) and the palmar view (right). Red = space of Poirier.

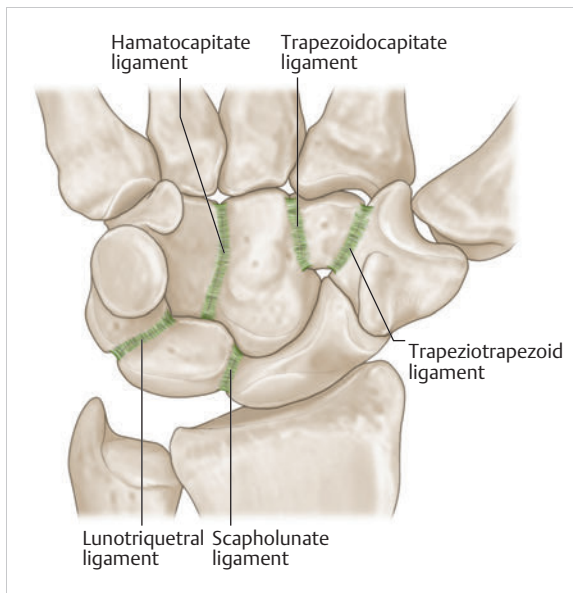


Fig. 1.27 Deep ligaments of the wrist joint.

Trapeziotrapezoid Ligament and Palmar, Dorsal, and Interosseous Trapezoidocapitate Ligaments

These ligaments connect the trapezium with the trapezoid and the trapezoid with the capitate. The superficial and middle parts of the ligament are connected and provide only a minimum of freedom of movement between these carpal bones.¹⁶⁰

Palmar, Dorsal, and Interosseous Hamatocapitate Ligaments

The greatest range of motion of the distal carpal bones occurs between the hamate and the capitate. There is a maximum displacement of 9°. ²¹⁰ The ligament decelerates the slight co-movement between the capitate and the hamate during the movements of the wrist, thus permitting homogeneous interaction of the proximal and distal wrist.²¹⁰

Note

The strong, short trapeziotrapezoid, trapezoidocapitate, and hamatocapitate ligaments consolidate the distal carpal row into a more or less uniform structure¹⁶⁰ and contribute to mobility of the proximal carpal bones.

Lunotriquetral Ligament

The lunotriquetral ligament connects the lunate and triquetrum, allowing the triquetrum to be displaced from

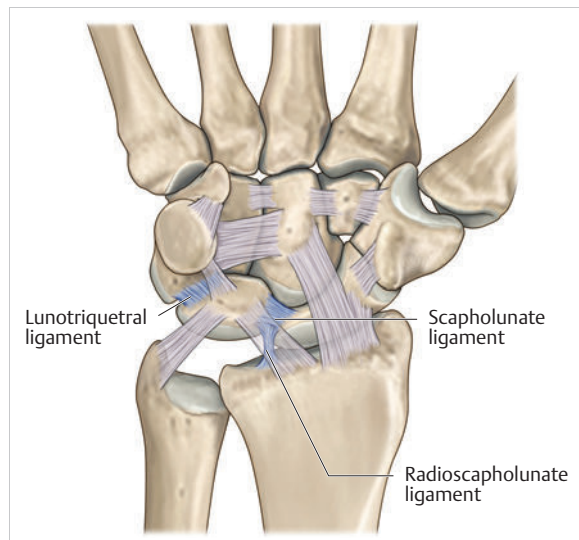


Fig. 1.28 Scapholunate and lunotriquetral ligaments.

proximal to distal during ulnar deviation.²⁶⁷ Its stability is reinforced by interosseous fibrocartilage.²²⁹

Scapholunate Ligament

The scapholunate ligament establishes the functional unit between the scaphoid and the lunate. It is **one of the most important mechanical components in the carpus**. It permits gliding and torsional movements of the two bones against each other. At the same time, the joint surfaces allow functional interaction between the proximal and distal wrist (► Fig. 1.28). This enables the important homogeneous movements between extension and flexion and, in particular, radial and ulnar deviation. This very strong ligament consists of short dorsal fiber bundles, medium-to-long obliquely oriented bundles, and long palmar bundles. The dorsal bundles are stronger and thicker than the palmar bundles (ratio of 3:1 mm).¹⁶

Practical Tip

Their lesser thickness may be why injury to the palmar ligaments is more common than to the dorsal ligaments (scaphoid dislocation) or complete ligamentous injuries (dorsiflexed intercalated segment instability (DISI) position⁴⁰).²⁵⁸ In addition to trauma, carpal ganglia may also trigger this type of injury.²⁵⁸ This pathology always leads to degenerative arthrosis of the wrist, and can even result in carpal collapse, or scapholunate advanced collapse of the wrist (SLAC wrist).²⁶⁹ The condition is classified by stage:

- Stage 1: Flexion position of the scaphoid with arthritis between the proximal pole and the scaphoid fossa
- Stage 2: Extension to the entire scaphoid facet of the radius

- Stage 3: Additional mediocarpal arthrosis (between the lunate and capitate) due to dorsal position of the lunate and proximal position of the capitate

This type of injury occurs more often than is commonly assumed.²² Wrist arthroscopy of 183 radius fractures confirmed scapholunate dissociation in 10.4% of cases (► Fig. 1.29).²⁴¹

Scaphotrapezial Ligament

The strong scaphotrapezial ligament allows the trapezium (and, to some extent, also the trapezoid) to glide on the distal surface of the scaphoid and permits the scaphoid to take a position flexed palmarward during radial deviation.⁴¹

Radioscapholunate Ligament (Testut's Ligament)

This ligament runs from the radius and inserts at the scaphoid and lunate and the interosseous scapholunate ligament, stabilizing the two bones during extension and

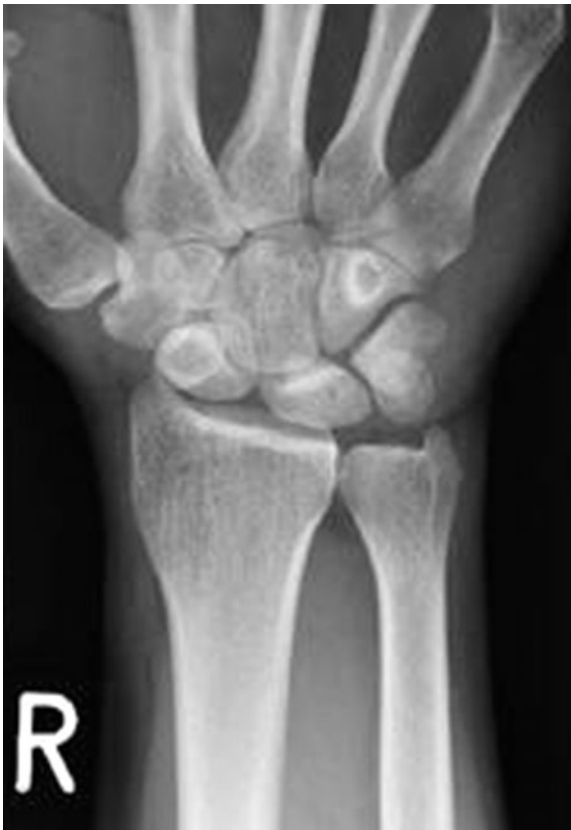

Fig. 1.29 Typical scapholunate dissociation with signet ring sign of the scaphoid.

radial deviation. The ligament is highly vascularized and contains terminal branches of the anterior antebrachial interosseous nerve¹⁸ and may be involved in proprioception of the hand.²²⁹

Conclusions

In summary, the 33 ligaments of the hand coordinate all complex displacements of the individual carpal bones and provide the stability needed for the wide range of possible movements (► Fig. 1.30). Stability and complex movement patterns at the carpus are possible only if the carpal ligaments are intact.²³¹

Practical Tip

A genetically predisposed loose ligament system or trauma-induced ligament injury can cause structural damage between the carpal bones ("snap phenomenon" as described in Ref. 229). This results in the lack of congruency and premature degenerative processes in the carpus.¹⁴³ Many post-traumatic pathological ligament-related conditions are overlooked during clinical examination and conventional radiographic diagnostics. Lack of treatment usually leads to static instability of the carpus, culminating in arthrosis.²³¹ For this reason, injuries to the scapholunate, lunotriquetral, and radioscaphocapitate ligaments, as well as to the TFCC, play an important role in diagnostics. They require the examiner to be well-versed in anatomical circumstances, to understand biomechanical processes, to have a great deal of sensitivity for conservative tests with respect to specific symptoms, and to be able to handle the wide range of options for diagnostic imaging.

In contrast to radial and ulnar deviation of the hand, extension and flexion are largely stabilized by the ligamentary structures. The proximal and distal wrist is always involved in extension and flexion to various degrees. This is because, in the normal position of the hand, the cartilage of the joint head in the radiocarpal joint extends beyond the socket, especially palmarward, and in the midcarpal joint extends more dorsalward. For this reason, **flexion occurs for the most part in the radiocarpal joint, while extension occurs for the most part in the midcarpal joint.**¹³⁵

1.3.4 Muscles of the Wrist: Extension–Flexion, Radial Deviation–Ulnar Deviation, and Circumduction

According to Kummer (2005)¹³⁵ during **radial and ulnar deviation** of the hand, the **muscles also play a key role** with respect to stability, pressure regulation, and kinematics of the wrist.

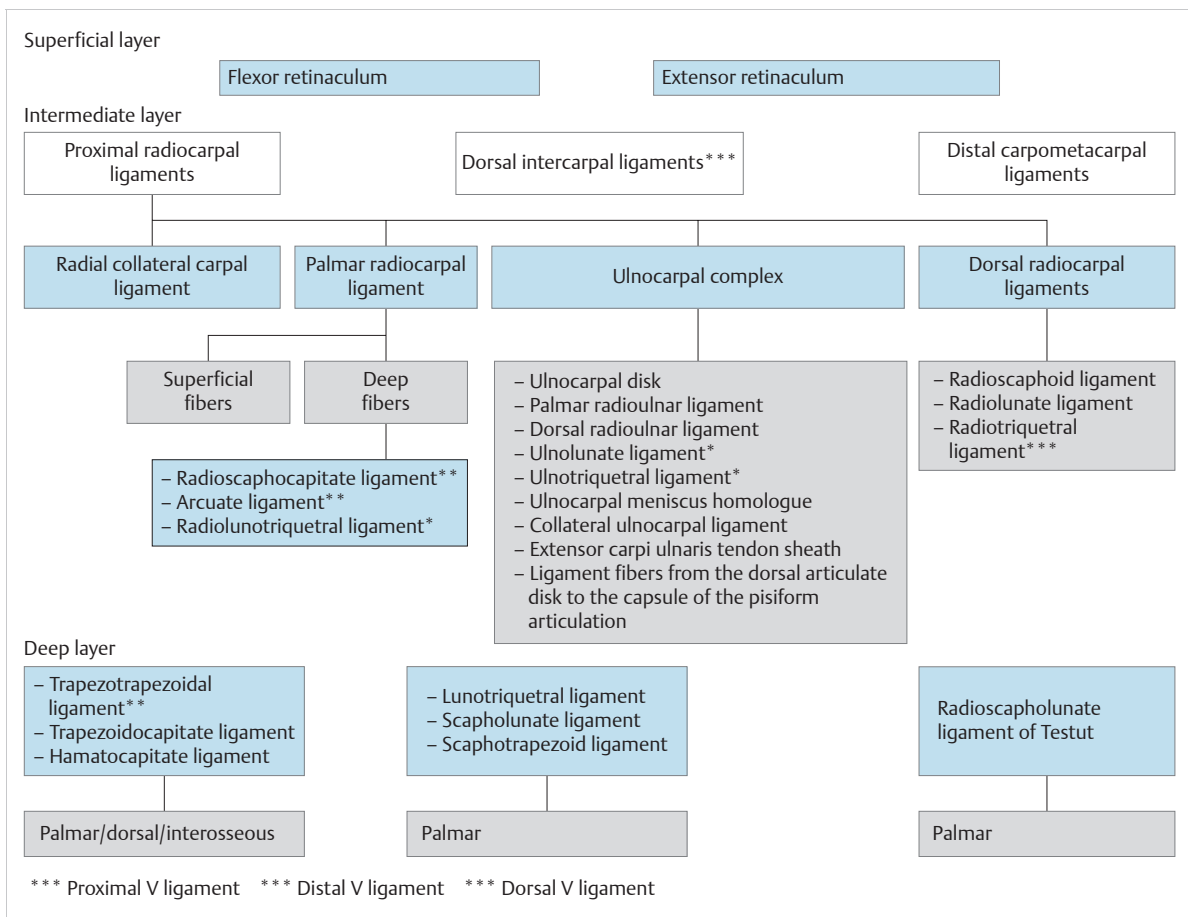


Fig. 1.30 Structure of the carpal ligament systems. (Based on Schmidt HM, Lanz U. Surgical Anatomy of the Hand. Stuttgart: Thieme; 2003 and Schmitt R, Lanz U, eds. Bildgebende Diagnostik der Hand. 2nd ed. Stuttgart: Thieme; 2004.)

- During **radial deviation**, all of the radial muscles have extension or flexion components. Therefore, during pure radial deviation, the flexion components must neutralize each other. Thus the typical combination would involve the interaction of the flexor carpi radialis muscle with the long and short extensor carpi radialis muscles. Furthermore, all muscles whose long tendons are located radial to the radial–ulnar deviation axis (e. g., the long thumb muscles) can participate in radial deviation.
- During **ulnar deviation** too, only muscle combinations in which the flexion components neutralize each other are possible. This condition is primarily met when the extensor and flexor carpi ulnaris muscles contract simultaneously. In addition, the long flexors and extensors of the fingers are involved in a limited ulnar deviation component.

In supination, the **antebrachial muscles** take a proximal to distal course in a nearly conical form, while in pronation, the course is circular, owing to the fact that the radius crosses over the ulna. The muscle bellies of the flexors,

which are thicker and stronger than the extensors, are located more in the proximal area of the forearm. As a result of this position, **long tendons are formed up to the carpus** or up to the distal interphalangeal (DIP) joints, which has the effect of a drive belt. Owing to the tight space of the forearm, the muscles arise from bony parts, from the antebrachial interosseous membrane or from a part of the antebrachial fascia. It is this arrangement that permits the delicate design with all of the possibilities for fine motor movement of the wrist and the finger joints.²⁵⁶

The **carpal muscles are divided into two groups**: those involved in flexion and ulnar deviation, and those involved in extension and radial deviation as well as joint rotation.

Muscles Involved in Flexion and Ulnar Deviation of the Wrist

The most **important muscles involved in flexing the wrist** are the flexor carpi ulnaris and flexor carpi radialis, along with the palmaris longus muscle. The muscle

primarily responsible for **ulnar deviation** is the extensor carpi ulnaris, with the involvement of the flexor carpi ulnaris and the extensor digitorum communis muscles. Some of the finger flexor muscles are also involved in these movements to some extent (► Fig. 1.31).

Flexor Carpi Ulnaris Muscle

The flexor carpi ulnaris muscle arises with two heads. The humeral head originates from the medial epicondyle of the humerus and the antebrachial fascia, and the ulnar head originates from the dorsal aspect of the olecranon and the proximal two-thirds of the posterior border of the ulna. Its muscle belly is around 25 cm long, 4 cm wide, and 1 cm thick.²⁵⁶ Of all the antebrachial muscles, the flexor carpi ulnaris is located the most ulnarward in the superficial area of the muscle layers. The muscle inserts at the pisiform (easily palpable and visible) and in the further course, inserts with one part (with the involvement of the pisohamate ligament) at the hook of hamate and with the other part (with the involvement of the pisometacarpal ligament) at the palmar base of the fifth metacarpal. It is the **strongest wrist flexor** and is **involved in ulnar deviation** (with the involvement of the extensor carpi ulnaris and extensor digitorum muscles).

The insertion fibers of the flexor carpi ulnaris muscle also contribute to forming the ulnar canal (“Guyon’s canal”), which allows passage of the ulnar nerve and ulnar artery.²²⁹ This area is frequently the site of compression of the ulnar nerve (“**ulnar tunnel syndrome**” or “**Guyon’s canal syndrome**”).²⁰⁰ In terms of function, during ulnar deviation, the pisohamate ligament supports the hamate with moving toward the ulnar styloid process, which holds the triquetrum and lunate in a position that is stable for this movement. This allows the flexor carpi ulnaris muscle via the pisohamate ligament to set these carpal bones into motion either directly or indirectly. As a result, ulnar deviation is involved in flexion and flexion is involved during ulnar deviation.¹⁶⁰ Moreover, during ulnar deviation, the distal carpal row rotates ulnarward and the proximal carpal row rotates toward the radius with a slight rotation into extension.²³¹

Flexor Carpi Radialis Muscle

The flexor carpi radialis muscle also originates from the medial epicondyle of the humerus, the lateral and medial intermuscular septa of the upper arm, and the superficial antebrachial fascia. Its muscle belly, a semipennate muscle structure that is about 15 cm long and 1 to 2 cm thick, blends into its tendon (approx. 14 cm long) at about the mid-forearm (becomes visible during flexion.²⁵⁶) The radial artery runs lateral to the tendon. In this area, the artery is very easy to palpate. It is also part of the superficial muscle layer and is located radial to the palmaris longus muscle. In the area of the wrist joint, the flexor carpi radialis muscle moves into a tendon sheath up to

the scaphoid tubercle and exits below the tubercle of trapezium into a narrow bony groove in the form of an osteofibrous canal.²²⁹ This canal is firmly attached to the capsuloligamentous structures²²⁵ and in this area becomes a gliding tunnel owing to the flexor retinaculum.²²⁹ The flexor pollicis longus muscle crosses over this tendon between the scaphoid and the trapezium. The muscle inserts palmar to the base of the second metacarpal. In rare cases, it also inserts at the third metacarpal

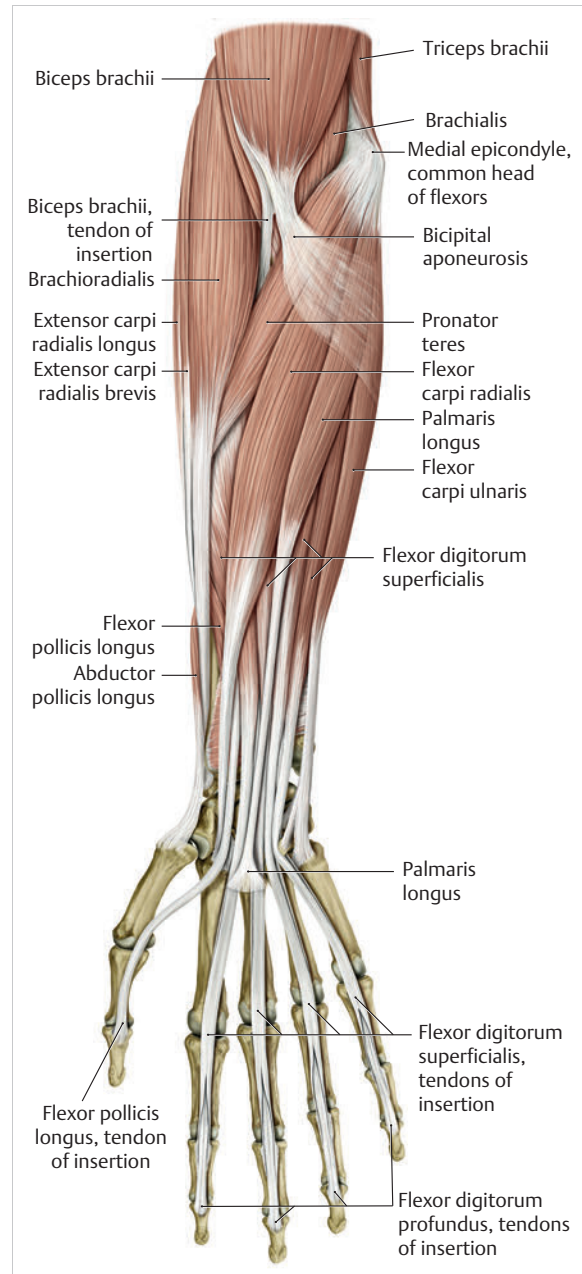


Fig. 1.31 Palmar antebrachial muscles. (From THIEME Atlas of Anatomy, General Anatomy and Musculoskeletal System. 2nd ed. © Thieme 2014, illustration by Karl Wesker.)

with several fibers.⁶⁰ In synergy with the flexor carpi ulnaris and palmaris longus muscles, it performs flexion in the wrist and at the same time, **stabilizes the carpus**. During radial deviation by the extensor carpi radialis longus muscle, the flexor carpi radialis muscle counteracts together with the second metacarpal and in so doing **centers the carpal bones in the joint**.⁴³ During radial deviation, the distal carpal row rotates toward the radius, and the proximal carpal row rotates ulnarward, with a palmarward rotation.²³¹

Palmaris Longus Muscle

The palmaris longus muscle is no longer present in around 12.8% of the population,²⁰⁸ with women making up the majority of the cases.⁷⁴ It also arises from the medial epicondyle and courses between the flexor carpi ulnaris and flexor carpi radialis muscles in the superficial muscle layer. It is one of the structures with the greatest variation in terms of shape, attachment, and bilateral occurrence.²²⁹ Its tendon, which is wide and flat, and on average 11.7 cm long and 0.4 cm wide, radiates into the flexor retinaculum and with some fibers into the palmar aponeurosis.²²⁹ In addition to producing weak flexion, it **helps to stabilize the carpus and can increase the tension in the palmar fascia**.²⁵⁶

Extensor Carpi Ulnaris Muscle

This muscle arises with two heads, with the humeral head from the lateral epicondyle, the radial collateral ligament and the anular ligament of radius, as well as with the ulnar head, from the olecranon, the posterior surface of the ulna, the posterior border of the ulna, and the antebrachial fascia. It takes a superficial ulnarward course from the extensor digitorum muscle, continues lateral to the ulnar head (i.e., in the passage between the ulnar head and the styloid process), then extends into its tendon sheath (approx. 5 cm long) via the sixth tendon compartment.¹²¹ Some tendon fibers run palmarward and insert at the pisiform bone, the pisometacarpal ligament, and at the base of the fifth metacarpal. The tendon compartment, tendon sheath, and the tendon itself are firmly attached to the TFCC and are thus part of the whole structure. In functional terms (apart from enabling weak wrist extension²⁰⁰), it is the **strongest marginal mover for ulnar deviation**. In addition to its dynamic properties, it has an **important influence on the ulnar head**.²²⁹ During rotation of the hand, the muscle participates in guiding the joint bodies in the distal radioulnar joint²⁵⁰ and decelerates supination via the palmar radioulnar ligament.²²⁹ It also **limits and stabilizes the movement of radial deviation** and is involved in **regulating pressure** in the carpus via the TFCC.

The **flexor digitorum superficialis and profundus muscles** are also involved in flexion of the wrist (see chapter on “Extrinsic Flexors of the Finger”).

Muscles Involved in Extension and Radial Deviation of the Wrist

The extensor carpi radialis brevis and extensor carpi radialis longus muscles are the most important **wrist extensors**. In contrast, **radial deviation** is performed only by the extensor carpi radialis longus muscle.²⁵⁶ These two muscles are supported to some extent by the extensor digitorum muscle (see chapter on “Extensor Apparatus of the Finger”) and the extensor carpi ulnaris muscle (► Fig. 1.32).

Extensor Carpi Radialis Longus Muscle

The extensor carpi radialis longus muscle arises distal to the brachioradialis muscle from the lateral supraepicondylar ridge of the humerus, the lateral intermuscular septum of the upper arm, and the lateral epicondyle of the humerus. It courses in the superficial muscle layer and is easily visible and palpable during contraction. The muscle belly already ends in its tendon in the upper part of the forearm. In the area of the distal radial epiphysis (on the dorsal aspect), together with the extensor carpi radialis brevis muscle, it then glides through the approximately 2.3-cm long second tendon compartment with the associated tendon sheath.²²⁹ The two structures are attached at the lateral aspect of the dorsal tubercle of the radius (Lister’s tubercle)²²⁹ which **ensures the passage of the tendons**. In addition, the tendon forms the floor and the deep-lying **ulnar boundary of the anatomic snuffbox (tabatière anatomique)**. In its further course, the extensor carpi radialis muscle finally inserts at the base of the second metacarpal.

Extensor Carpi Radialis Brevis Muscle

This muscle originates from the lateral epicondyle (covered by the fibers of the extensor carpi radialis longus muscle⁶⁰), the radial collateral ligament, and the anular ligament of the radius. In the area in which it originates, the muscle belly of the long wrist extensor covers the muscle belly of the short wrist extensor.²⁵⁶ It also courses in the superficial muscle layer (with a somewhat more lateral course than the extensor carpi radialis longus muscle) and also ends in its tendon in the upper part of the forearm. Via the second tendon compartment, it then inserts at the third metacarpal and the process of the third metacarpal. All of the structures of the extensor carpi radialis brevis and longus muscles are **easy to palpate and visualize**.

1.3.5 Arthrokinematics of the Wrist Joint

Arthrokinematics is understood to mean the **implementation of spatial osteokinematic movements in a joint**, meaning between two articulating joint partners with

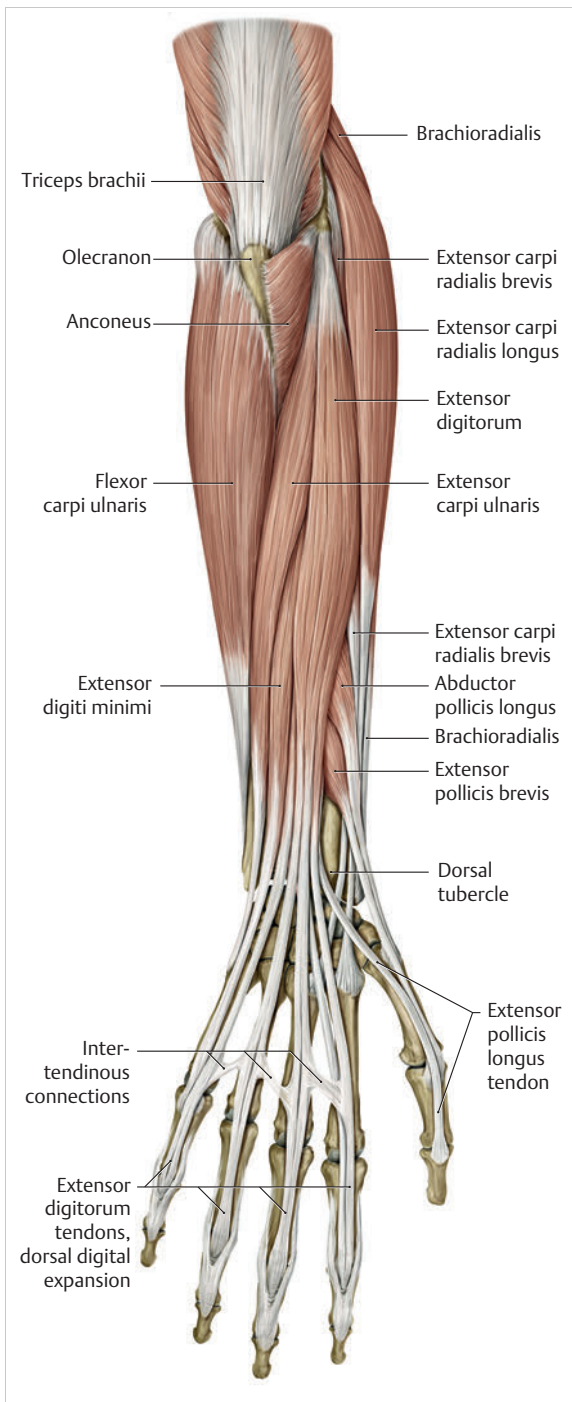


Fig. 1.32 Dorsal antebrachial muscles. (From THIEME Atlas of Anatomy, General Anatomy and Musculoskeletal System. 2nd ed. © Thieme 2014, illustration by Karl Wesker.)

more or less similarly curved joint surfaces. Typical arthrokinematic movements include rolling, gliding, traction, and compression.²³⁴ In contrast, osteokinematics describes the active and passive movements of the associated extremity in space as an angular movement

(rotation) or a movement of the bone in space without rotation (translation).²³⁴ According to Kaltenborn's convex-concave rule, during arthrokinematics, when moving the concave joint partner, there is gliding of the joint surface in the same direction in relation to the movement of the bone in space. When moving the convex joint partner, the joint surface glides in the opposite direction in relation to the movement of the bone in space.²³⁴

The **kinematics of the wrist joint** is a true masterpiece of Nature, whose biomechanical functions are still not fully understood today. The basis of the wide range of movement functions is the form of the individual carpal bones, the radioulnar joint, and the proximal and distal wrist joint, along with the many different ligaments. These structures together are responsible for counteracting the shifts in the positions of the carpal bones occurring as a result of muscle contraction, and therefore play a key role in stabilizing the wrist. According to Schmidt and Lanz (2003),²²⁹ in terms of joint mechanics, the **carpal ligament systems can be divided into three ligament chains:**

1. The **carpal retinacula**, which may be regarded as "extra-articular slingshots." Their oblique fiber structure not only stabilizes the distal radioulnar joint, but also counteracts ulnar displacement of the wrist.²²⁹
2. The **"articular slingshot"** is formed by ligaments with high tensile strength that arise from the radius and extend in palmar and dorsal directions, inserting at the triquetrum. The palmar slips are formed by the more transverse radiolunate and lunotriquetral ligaments. On the dorsal aspect, the dorsal radiotriquetral ligament passes around the ulnar margin of the radius and inserts obliquely into the triquetrum. With the triquetrum as the stone in the slingshot, the ulnar forces caused by the inclination of the radius are brought under control.¹³³ The slingshot controls the range of motion in the proximal and distal wrist joints during both radial and ulnar deviation.²²⁹ It also acts as an ulnar support in flexion and extension of the hand.¹⁹¹ In a wider sense, the radio-scaphocapitate ligament also belongs to the articular slingshot.²³³ It arises from the palmar lip of the radius, extends across the scaphoid, and inserts at the capitate. This ligament primarily serves to couple the movements of the lunate and capitate²²⁹ and to stabilize the joint between the lunate and capitate.¹⁴⁷ The articular slingshot is therefore primarily formed via the triquetrum of the ulnar column and in synergism, via the scaphoid of the radial column, in order to provide the central T-shaped column, described by Taleisnik (1985),²⁵¹ with the stability it requires for movements between the lunate and the capitate.
3. The **palmar support band (V-shaped ligaments)** encompasses the middle and deep palmar fibrous structures. It serves to stabilize the capitate and prevents palmar displacement of the carpal bones in extension.²²⁹

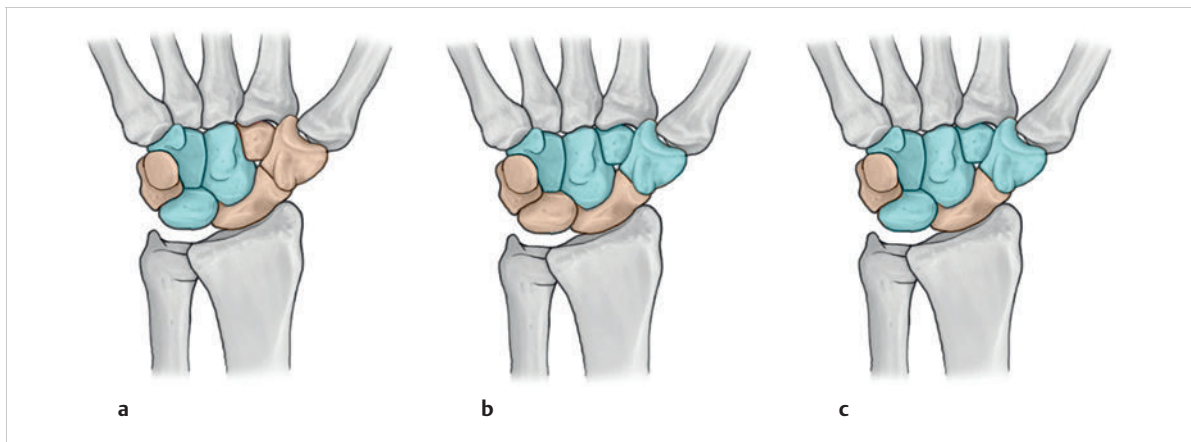


Fig. 1.33 Column models of the hand. (a) Navarro (1937). (b) Lichtman (1981). (c) Taleisnik (1985).

Kinematics of the Wrist: General Aspects

The wrist joint can be regarded as a **modified condyloid joint** whose “condyle” is composed of eight carpal bones.²³³ However, the defined coordinated movements of the carpal bones are not based on a static condyle, but on a **mobile system of joints** that can adapt its form to correspond to the prevailing spatial and force requirements according to the principle of “variable geometry.”²³³ The spatial arrangement in the moving carpus is coordinated by the alignment of the joint surfaces and also by the control of the carpal ligaments. The eight carpal bones may be divided into two horizontal rows and three vertical columns according to their spatial configuration (► Fig. 1.33). The horizontal rows are formed by the proximal carpal bones (from radial to ulnar = scaphoid, lunate, triquetrum, and pisiform) and the distal carpal bones (from ulnar to radial = hamate, capitate, trapezoid, and trapezium). The range of motion between the proximal elements is relatively large. The range of motion is small between the elements of the distal row, which are strongly attached by ligaments²³³ to the second to fifth metacarpals (as a solid block of bone).²²⁹ According to Taleisnik (1985),²⁵¹ the three vertical columns are divided into a radial column, which is formed by the scaphoid, an ulnar column formed by the triquetrum and pisiform²²⁹ (► Fig. 1.33c). The third, central column is T-shaped, whereby the distal carpal row with the trapezium, trapezoid, capitate, and hamate is connected to the radius via the lunate. This gives rise to two degrees of freedom with extension–flexion and radial and ulnar deviation. If the proximal and distal radioulnar joints are also taken into account, pronation and supination are also possible as a third degree of freedom.

Additional Information

There are various theories that describe the arthrokinematics of the wrist and the interaction between the individual carpal bones and columns. The first of these

column theories was proposed by Navarro (1937)¹⁷⁸ (► Fig. 1.33a). Other column theories were advanced by Kuhlmann et al 1978¹³¹ and Lichtman et al 1981,¹⁴⁶ (► Fig. 1.33b) who compared the carpal bones to a ring of proximal and distal bones under tension (► Fig. 1.34), and Taleisnik (1985)²⁵¹, who modified Navarro’s column theory. Taleisnik suggested a central T-shaped column with the scaphoid and triquetrum as rotational axes (► Fig. 1.33c).

Currently, arthokinematic explanations about the function and malfunction, that is, about structural damage of the wrist joint, are based on Lichtman’s 1981 concept of the oval ring of the carpus and Taleisnik’s theory (1985) of a T-shaped column and rotational axes.²⁵¹

Note

The stability of two joint partners is defined as the ability to maintain a physiological position to one another under normal loads.²³³ Static instability is present when the anatomical arrangement of two joint partners is out of alignment at rest. Dynamic instability is present when the regular coordination of the joint partners during movement is functionally disturbed.²³³

Arthrokinematics of the Wrist Joint: Specific Aspects

Lichtman’s concept¹⁴⁶ of the oval ring of the carpus presented in 1981 and Taleisnik’s theory²⁵¹ of a T-shaped column and rotational axes postulated in 1985 (► Fig. 1.33c) complement each other as explanations of the arthrokinematics of the wrist joint. These mechanical models are described below using the functional and vivid descriptions of Schmidt and Lanz (2003).²²⁹

The **distal carpal row** (trapezium, trapezoid, capitate, and hamate) is connected to the radius via the capitate and lunate in a T-shaped fashion.²²⁹ Since the palmar aspect of the lunate is wider than its dorsal aspect, its wedge shape gives the bone a natural tendency to slip out of the wrist palmarward and tilt dorsally over the palmar portion of the capitate (► Fig. 1.35). This is made possible by the concave joint surface of the lunate opposing the convex surface of the capitate. This movement tendency is supported by the convex joint surface of the radius, which takes a course from dorsal and distal to palmar and proximal, with a complementary convex joint surface of the lunate. As a result, the lunate moves in the same direction in the distal wrist joint and moves in the opposite direction in the proximal wrist joint. This mechanism is supported by the tendency of the distal carpal row to move in the opposite direction (proximal and dorsal) for extension and in a palmar and proximal direction for flexion.²²⁹ At the same time, during extension, the lunate glides palmarward around the dorsal aspect of the capitate, and for flexion, glides dorsalward around the palmar aspect.

In the **radial column**, the scaphoid manifests itself as an independent element connecting the proximal and distal carpal rows.¹⁴⁸ According to Fisk,⁶³ the scaphoid bridges both rows and stabilizes the midcarpal joint, which synchronizes the movements.²³³ The scaphoid lends mobility to the radial column. The trapezium and trapezoid both press against its distal pole and the capitate presses against its proximal pole with the hand's proximally directed axial load¹⁶⁰ in an attempt to push the distal part of the scaphoid palmarward and move the proximal part dorsalward.¹⁶⁰ In the transverse plane this carpal bone therefore inclines toward the lunate (supination of the scaphoid and pronation of the lunate²⁷⁹). The opposite movement is canceled out at the level of the capitate by the common coupling of the scapholunate ligament. In extension and flexion, the ligament locks the scaphoid between the trapezium and the trapezoid with simultaneous movement between the scaphoid and the lunate in the plane of the capitate.²⁷⁹ The relative motion between the scaphoid and the lunate is limited to between 15° and 20° by the scapholunate ligament, which passes between the two bones.²³³

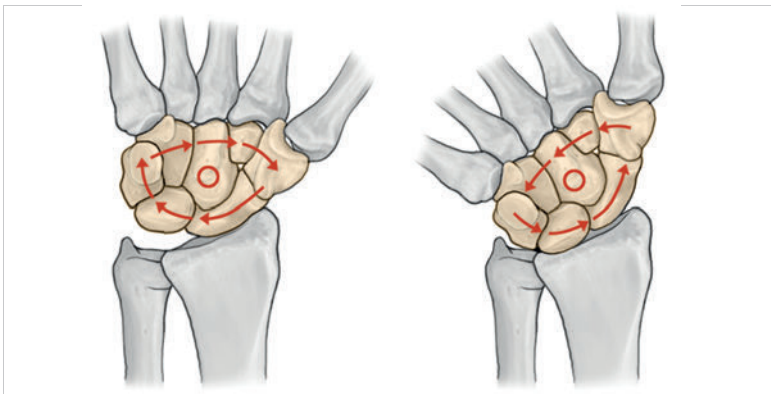


Fig. 1.34 Rotation model as proposed by Lichtman. (From Platzer W. Atlas der Anatomie. Part I: Bewegungsapparat. 6th ed. Stuttgart: Thieme; 1991.)

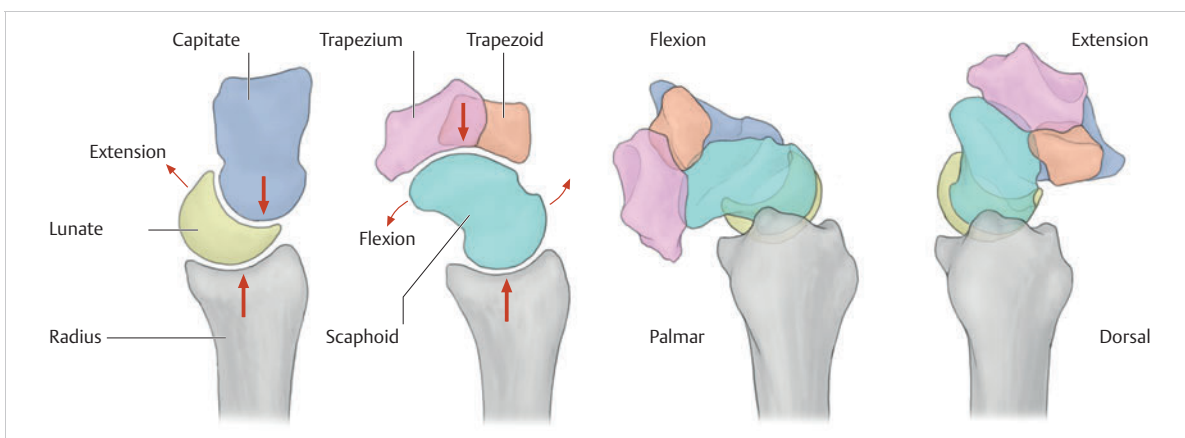


Fig. 1.35 Changes in the position of the lunate and scaphoid.

In the sagittal plane, the scaphoid moves in the opposite direction, with its convex joint surface facing both the concave radius and also the concave surfaces of the trapezium and trapezoid, and moves in the same direction with its concave joint surface to the capitate. This mechanism, which is the opposite of the lunate, is supported by the tendency of the distal carpal row to move in the opposite direction (proximal and dorsal) for extension and in a palmar and proximal direction for flexion.²²⁹

The **ulnar column** is formed by the triquetrum and the pisiform. Lichtman et al (1981)¹⁴⁶ described the carpus as a ring of bones (“oval ring concept”) in which the carpal rows move in opposite directions via the mobile scaphotrapeziotrapezoid and hamatotriquetral joints (radial and ulnar links) and stabilize each other.²³³ Especially during radial and ulnar deviation of the wrist, the triquetrum glides along the corkscrew-shaped articular surface of the hamate.²²⁹

The motion may be compared to that of a piston and cylinder. In radial deviation, the triquetrum slips into a proximal (“high”) position (► Fig. 1.36a), simultaneously moves dorsally, and rotates toward the palm.²³³ During this movement, the hamate moves away from the ulnar styloid process. In ulnar deviation, the triquetrum glides into a distal (“low”) position (► Fig. 1.36b), simultaneously moves toward the palm in relation to the hamate, and also rotates dorsally.²³³ During this lateral movement, the hamate moves closer to the ulnar styloid process. In parallel, the scaphoid moves toward the palmar aspect with a slight dorsal rotation of its proximal pole. The lunate follows the scaphoid in flexion in its natural movement tendencies.²³³ During radial deviation, the movements of the scaphoid and lunate take place in the reverse order. Overall, during radial deviation, the distal carpal row moves to the radial side and the proximal row to the ulnar side. In

ulnar deviation, the distal carpal row moves to the ulnar side and the proximal row glides toward the radial side.²³³ The center of rotation is always the center of the head of the capitate. An average radial deviation of 24° and an average ulnar deviation of 40° are normally possible.²³³ At the end of the range of motion of deviation, the increased tension in the ligaments effectively locks the carpal bones into a “close-packed” position.¹⁵³ The control and stabilization provided by the V-shaped ligaments permits a connection between the radial and ulnar columns via the direct ligamentary interosseous connection of the lunotriquetral ligament between the lunate and the triquetrum and of the scapholunate ligament between the scaphoid and the lunate.²²⁹ This mechanism is supported by the radioscaphocapitate ligament, since it decelerates the palmar inclination of the scaphoid.

The scaphotrapeziotrapezoid joint also plays a major role in the arthrokinematics of the wrist, especially in the midcarpal joint. An oblique movement axis running through the scaphotrapeziotrapezoid joint permits movements of the wrist joint, from extension (40°) in radial deviation (20°) to flexion (0°) in ulnar deviation (20°). This movement occurs during many everyday movements, as well as in the dart-throwing movement, and is therefore referred to as the “dart-throwing motion” (DTM). It courses along a plane oriented toward the flexion-extension plane in approximately 45° supination and is guided through a ridge on the scaphoid¹⁷¹ that divides the distal surface of the scaphoid into two facets. The radiodorsal facet articulates with the trapezium and the ulnopalmar facet articulates with the trapezoid. Since the scaphoid ridge is located at the same level as the carpometacarpal joint, it permits uniform flexion and extension of the trapezium and the trapezoid at the scaphoid. Furthermore, the movement of the capitate and lunate at

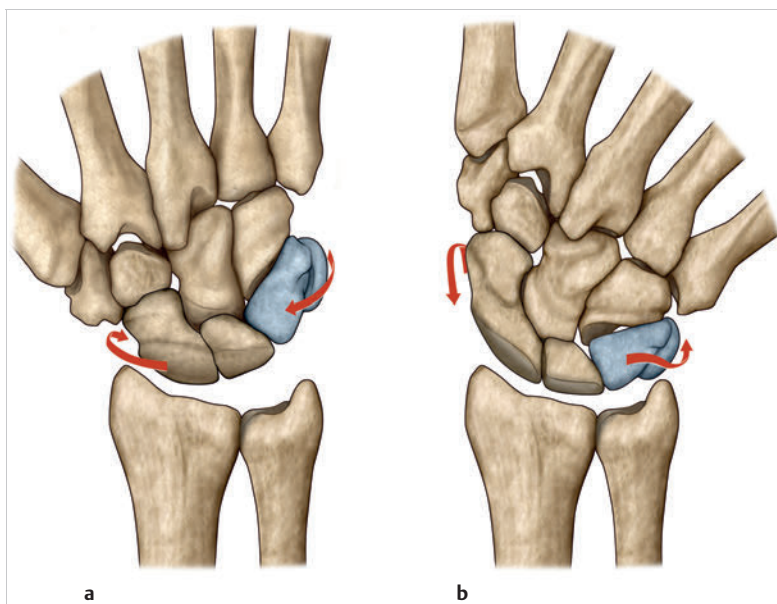


Fig. 1.36 High position and low position.
(a) Radial deviation (high position).
(b) Ulnar deviation (low position).

the scaphoid takes an oblique course along the path of the DTM.¹⁷² Consequently, the naturally occurring movement of the wrist and the scaphotrapeziotrapezoid joint is not sagittal, but mainly follows the oblique DTM path. The axis of this rotation runs through the scaphocapitate ligament and the scaphotrapeziotrapezoidal (STT) ligaments (= ligament complex between the scaphoid, trapezium, and trapezoid); thus they are the two guiding ligaments of the DTM.

Various studies have confirmed that movement in the proximal carpal row is minimized during the DTM. As a result, the transition between the flexion and extension rotation of the scaphoid and lunate is defined as around zero. This motion pattern demonstrates a highly unique degree of stability. Therapeutic records show that this movement is limited during the DTM (scapholunate rotation movement, therefore also limiting tension on the scapholunate ligament), which can support the healing process.³⁵

► Table 1.1 presents an overview of carpal motion patterns during ulnar deviation and radial deviation.

The hamatotriquetral joint also has a stabilizing effect **during pure flexion**. During extension, the palmar slips of the triquetral slingshot tighten, while the dorsal slips relax. During flexion, this mechanism is exactly the opposite.²²⁹

Note

The lunate plays a pivotal role, as it is an interposed link in both longitudinal and transverse motion axes and thus in any motion of the hand relative to the forearm.²²⁹

Together with the radius and the capitate, it controls the motions of the entire wrist complex. Flexion is performed only between the radius and lunate.²⁴²

1.3.6 Other Important Anatomical Structures of the Wrist

Other important carpal structures are the six dorsal tendon compartments, the carpal tunnel, the ulnar tunnel (“Guyon’s canal”), the blood vessels, and the lymphatics. Apart from mechanical and ligamentary pathologies of the hand, inflammatory processes of the tendon sheaths, neuralgia, compression syndromes of the median and ulnar nerves, and disturbed blood flow are common occurrences.

Dorsal and Palmar Tendon Compartments

Tendon sheaths are **guiding canals** for tendons that hold the tendons in the required direction during movement or guide them around bones.⁵⁹ The sheaths **enhance the tendons’ ability to glide**²⁸⁰ and **protect the surrounding tissue from injuries** caused by alternating flexion–extension movements.¹⁰¹ In addition to the stabilizing properties of the retinacula of the forearm for the wrist,¹³² the extensor retinaculum, along with the vertically placed connective tissue septa and the dorsal synovial sheaths, forms six osteofibrous canals for guiding the extensor

Table 1.1 Carpal motion patterns during ulnar deviation and radial inclination²³³

Plane	Anatomical structure	Ulnar deviation	Radial deviation
Coronal	Proximal carpal row	Slides to radial side	Slides to ulnar side
	Distal carpal row	Slides to ulnar side	Slides to radial side
	Radial height	Increased	Decreased
	Ulnar height	Decreased	Increased
	Tensed ligaments	RSCL, RLTL, DRTL	ULL, UTL, TCSL, DICL
	Relaxed ligaments	ULL, UTL, TCSL, DICL	RSCL, RLTL, DRTL
Sagittal	Proximal carpal row:	Global extension	Global flexion
	• Scaphoid	Extension, palmar translation	Flexion, dorsal translation
	• Lunate	Extension, palmar translation	Flexion, dorsal translation
	• Triquetrum	Distal (high) position, palmar translation	Proximal (low) position, dorsal translation
	Distal carpal rotation	Relative flexion	Relative extension

Ligaments: RSCL = radioscaphocapitate, RLTL = radiolunotriquetral, DRTL = dorsal radiotriquetral, ULL = ulnolunate, UTL = ulnotriquetral, TCSL = triquetrocapsoscapoid, DICL = dorsal intercarpal.

tendons.²²⁹ The flexor retinaculum and portions of the palmar joint capsule form a reinforcing tissue only with the tendon sheath of the flexor carpi radialis muscle.²²⁹ The two other osteofibrous compartments traverse the carpal tunnel directly.²⁷ Furthermore, all compartments and tendon sheaths prevent “bowstringing”²⁴⁴ and prevent skeletal muscle insufficiency by increasing their relative length during flexion.¹⁰⁶

Functional Structure of Tendon Sheaths

The tendon sheaths have a similar structure to that of joint capsules and bursae.²⁵⁵ They are **composed of two layers**, namely an external fibrous sheath and an internal synovial sheath that closes off the synovia-filled space²⁵⁵ (► Fig. 1.37).

Fibrous Sheath

According to Schmidt and Lanz (2003),²²⁹ the fibrous sheath is **subdivided into three parts**, namely the outer layer, the middle layer, and the inner layer, in line with their respective reinforcement ligaments (► Fig. 1.37). The **outer layer** consists of loose connective tissue that is rich in blood vessels and can be shifted, similar to adventitia.^{61,111} It anchors the sheath to the surrounding tissue and contains the supplying nerves and blood vessels. The **middle layer** comprises around three-fourths to four-fifths of the total thickness of the sheath wall. It contains a taut collagenous connective-tissue scaffold. These fibers are arranged perpendicular to the course of the tendons. The tissue also contains sparsely distributed fibroblasts and cartilage cells.²²⁹ The **inner layer** consists of a thin, latticelike and basket-weave-like network of collagen fiber bundles with enclosed fibroblasts and cartilage-like cells.²²⁹ This construction allows the fibrous sheath with its reinforcement bands to best absorb the pressure transferred from the tendons.⁷⁹ The inner layer is delineated by the surface epithelium covering the synovial villi.²³⁹

Synovial Sheath

The internal synovial sheath layer **enables the tendon to glide unimpeded** within the fibrous sheath.¹⁰⁶ The synovial sheath forms a self-contained double-walled tube with an inner and outer layer. The inner layer encases the tendon,¹⁰⁶ while the outer layer delineates itself from the fibrous sheath with synovial villi.⁷⁹ The two layers, which merge and are self-contained, delimit an interstitial space.¹⁰⁶ This tightly sealed space is filled with synovial fluid produced by the surface epithelium.²²⁹ When the tendon moves in its sheath, the inner layer glides over the outer layer of the synovial sheath, which is coated with synovial fluid.¹⁰⁶ The synovial sheath is crossed at irregular intervals by channels (mesotendons and vincula tendinum) that are rich in blood vessels; these supply the tendons and stabilize the tendons lengthwise.¹⁰⁶

The Dorsal Tendon Compartments

The deep fibers of the extensor retinaculum arise from the radial styloid process and from the triquetrum and the pisiform toward the proximal forearm.²²⁹ The superficial fibers originate from the antebrachial fascia and radiate into the dorsum of the hand. The supratendinous part is approximately 51 mm wide proximally and about 54 mm wide distally. It is around 15 mm deep on the radial side, 26 mm deep in the middle, and 20 mm deep on the ulnar side.²²⁷ **Six vertically positioned connective-tissue septa** pass through from the underside of the **extensor retinaculum**. They are attached to the periosteum of the radius, wrist capsule, capsule of the distal radioulnar joint, and TFCC (► Fig. 1.38).

First Dorsal Tendon Compartment

This osteofibrous compartment, which is approximately 16 mm long and 8 mm wide, is attached to the distal lateral outer edge of the radius.²²⁹ It contains the tendons of the extensor pollicis brevis muscle and the abductor

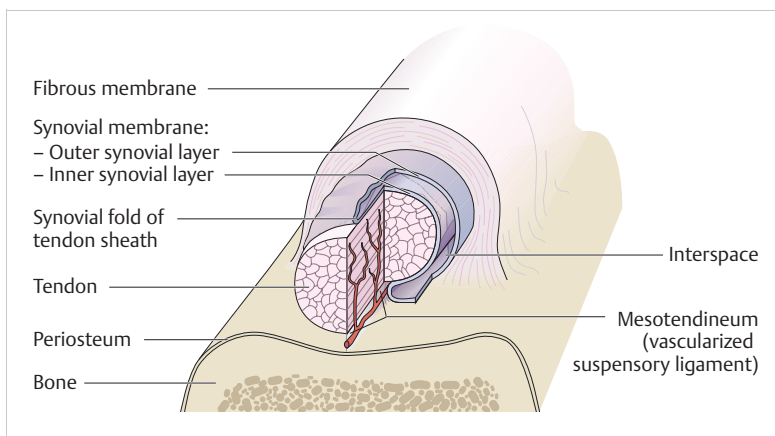


Fig. 1.37 Structure of the tendon sheath.

pollicis longus muscle. The tendon sheath of the extensor pollicis brevis muscle, which is 51 mm long, is noticeably longer than that of the abductor pollicis longus muscle, which is 35 mm long. The ends of the tendon sheath are located about 25 mm from the proximal wrist joint line. The tendon sheath of the extensor pollicis brevis muscle has a 25 mm long distal recess, which allows it to terminate behind the thumb metacarpophalangeal (MCP) joint.²²⁹

Practical Tip

The course of the tendons shows great anatomical variation. The tendon of the abductor pollicis longus muscle can be divided, (up to five times), according to its length and the tendon of the extensor pollicis brevis muscle can proceed in a separate tendon compartment, either completely or in part.^{97,218,272}

De Quervain's stenosing tenosynovitis, also referred to as washerwoman's sprain, is a stenosing inflammation of the first extensor tendon compartment and was first described by Fritz de Quervain in 1895. It is one of the most common types of tenosynovitis. The symptoms of de Quervain's tenosynovitis are painful inflammation of the tendons and their tenosynovium in the first extensor

tendon compartment. The thickened tenosynovium and possibly also the thickened tendon tissue cause narrowing of the tendon compartment. Gliding may become painful and even culminate in crepitus that can be clearly felt and heard. The inflammation can also give rise to adhesions between the tendons and the tendon sheaths. The classic, pathognomic phenomenon is a positive Finkelstein test. With the patient's thumb pulled across the palm of his or her hand and the fingers wrapped around the thumb, making a fist, the examiner suddenly, quickly and forcefully pulls the patient's wrist joint into ulnar deviation. If the patient complains of very sharp pain, in some cases also an electrifying pain, in the first tendon compartment radiating in a distal direction, the test is positive. After all conservative treatment methods have been exhausted, the treatment of choice usually involves splitting the first tendon compartment and removing the inflamed parts of the tenosynovium.

Second Dorsal Tendon Compartment

The second dorsal tendon compartment is approximately 23 mm long, 10 mm wide proximally, and 13 mm distally. As it widens, it prevents the tendons from contacting

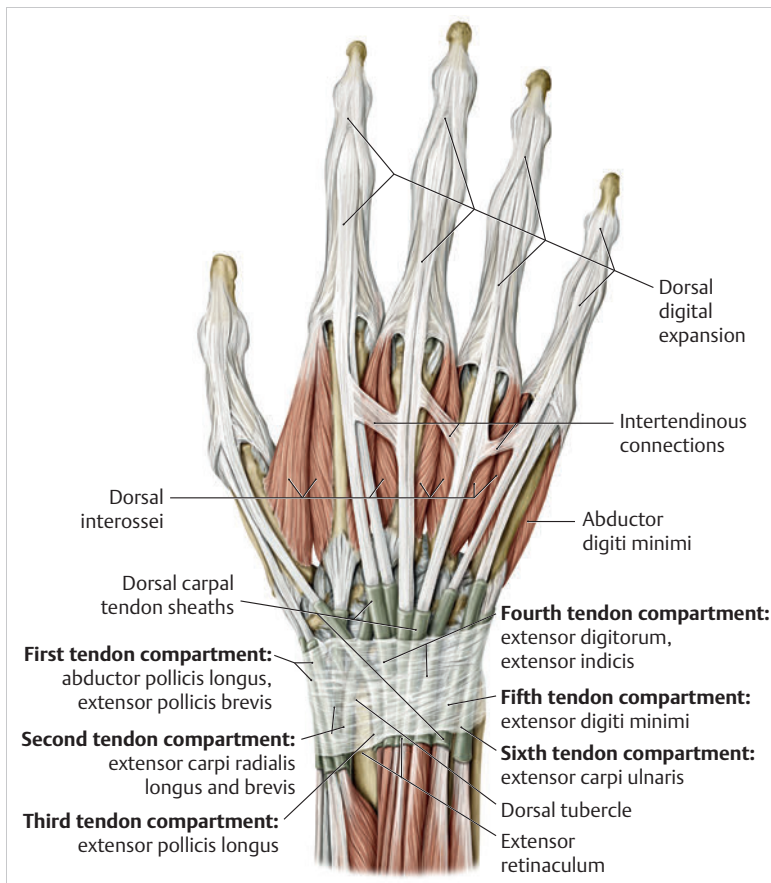


Fig. 1.38 The six dorsal tendon compartments. (From THIEME Atlas of Anatomy, General Anatomy and Musculoskeletal System. 2nd ed. © Thieme 2014, illustration by Karl Wesker.)

each other near their insertions.²²⁹ The compartment is located on the distal radial epiphysis and is firmly attached to Lister's tubercle on the ulnar side. It contains the common tendon sheath of the extensor carpi radialis longus and extensor carpi radialis brevis muscles on the ulnar side.

Practical Tip

In rare cases, intersection syndrome can occur in the second dorsal tendon compartment. Its symptoms include painful swelling indicative of an inflammatory reaction at the level where the tendons from the second dorsal tendon compartment cross those from the first dorsal tendon compartment, approximately 2 cm proximal to the snuffbox. The site exhibits tenderness, and extending the wrist joint against resistance is painful. The Finkelstein test may be false-positive. If conservative treatment involving immobilization and anti-inflammatories does not provide relief, the second tendon compartment can be surgically split and the inflamed parts of the tenosynovium removed.

Third Dorsal Tendon Compartment

This osteofibrous compartment is approximately 25 mm long and its tendon sheath is around 56 mm long. On the ulnar side, it curves around Lister's tubercle up to the distal edge of the radius. The tendon sheath with the extensor pollicis longus muscle extends to the CMC joint of the thumb.²²⁹

Practical Tip

Ruptures of the extensor pollicis longus tendon are observed in patients with fractures of the distal radius due to direct trauma or, more frequently, due to screws that have been incorrectly placed during surgical treatment of the radius fracture with plate osteosynthesis. Spontaneous ruptures are sometimes observed in patients with rheumatoid arthritis.²²⁹ If it is not possible to perform a direct, primary suture of the extensor tendon, reconstruction surgery must be performed to regain extension of the thumb in the distal joint. To this end, the tendon of the extensor indicis muscle is transposed onto the distal stump of the tendon of the extensor pollicis longus muscle and is placed in correct tension with subsequent suture repair.

Fourth Dorsal Tendon Compartment

The fourth dorsal tendon compartment is around 25 mm long. Proximally it measures about 9 mm across, and widens to about 13 mm distally.²²⁹ The tendon sheath originates 5 mm before the extensor retinaculum, where it is approximately 14 mm wide. It is about 13 mm wide in the middle, and at its proximal end near the radius, it narrows to approximately 9 mm. In the distal part, the tendon sheath takes a fan-shaped course over the dorsum of the hand. On the radial side, it is approximately 46 mm wide, medially about 49 mm wide, and on the ulnar side it is about 57 mm wide.²²⁹ As a common sheath, it guides the three extensor digitorum tendons and underneath it is the extensor indicis tendon, which takes an oblique course toward distal and radial. In 70% of all cases, muscular components of approximately 13 mm of the extensor indicis muscle are found in the tendon sheath.²²⁹

Practical Tip

Tenosynovitis does not usually occur in the fourth dorsal tendon compartment. Pathological conditions in this compartment are caused by the muscle belly of the extensor indicis muscle and are referred to as the extensor-indicis syndrome.⁸⁸

Fifth Dorsal Tendon Compartment

The tendon sheath of the fifth dorsal tendon compartment arises approximately 17 mm proximal to the wrist's joint line and is about 29 mm in length.²²⁹ This compartment is therefore the longest dorsal tendon compartment. In 72% of the population, it contains two extensor digiti minimi tendons, and in 9% of the population, three terminal tendons.²²⁹ In 1% of all cases, the tendon is completely absent.²⁷⁷

Sixth Dorsal Tendon Compartment

This osteofibrous compartment is delimited from the fifth tendon compartment by a wide septum.²²⁹ This septum is intertwined with the fascia from supratendinous and infratendinous layers of the extensor retinaculum, the dorsal radioulnar ligament portion of the TFCC, and loose connective tissue.²²⁹ It extends across the dorsal edge of the ulna over the distal row of carpal bones.²⁵⁰ Further along, supratendinous fibers pass over the sixth tendon compartment and radiate into the flexor carpi ulnaris tendon at the pisiform into the pisometacarpal ligament and into the base of the fifth metacarpal without

attaching to the ulna.¹⁸⁸ It is approximately 21 mm long and 6 mm wide. The tendon sheath, which is around 49 mm long, guides the extensor carpi ulnaris muscle.¹²¹ Fifty-one percent of cases have a thin auxiliary tendon that branches off in a radial direction that inserts on the head of the fifth metacarpal or on the dorsal digital expansion of the little finger.²²⁹ The extensor carpi ulnaris muscle with its sixth tendon compartment and its tendon sheath are part of the TFCC, therefore playing a key role in stabilizing the distal radioulnar joint and wrist.

Palmar Tendon Compartments

The **palmar flexor retinaculum** arises proximal to the carpal region with the palmar carpal ligament located on the surface from the antebrachial fascia,²²⁹ coinciding with the carpal tunnel in its extension. It is approximately 26 mm wide, around 22 mm long, and is 1.6 mm thick in the center and about 0.6 mm thick at the edges.³³ This retinaculum consists of firm fibers that cross over each other and are intertwined.⁸⁷ It is made up of four layers and is divided into superficial fibers extending obliquely and fibers extending horizontally underneath them. They

are joined by distally located fibers with an oblique course and deep-lying fibers with a horizontal course, which together form a smooth roof.³⁹ Its firm fibrous structure prevents “bowstringing” during wrist flexion.¹²² It is an **important component of proprioception** of the wrist joint.¹⁵⁸ The three palmar tendon compartments are located below the flexor retinaculum and with the second and third tendon compartment directly traverse the carpal tunnel (► Fig. 1.39). The first palmar tendon compartment is fused in part with the flexor retinaculum.

First Palmar Tendon Compartment

This tendon compartment serves to guide the tendon sheath and the round tendon of the flexor carpi radialis muscle, which is approximately 12 to 14 cm long, in the area of the forearm.²²⁹ It is **easily palpable below the skin** between the palmaris longus and brachioradialis muscles.²²⁹ At the level of the wrist joint, it develops its tendon sheath, which is around 5 mm wide and 2.5 mm thick, within an osteofibrous tunnel that is lined with a cushion of fibrofatty tissue.²²⁹ At the level of the scaphoid

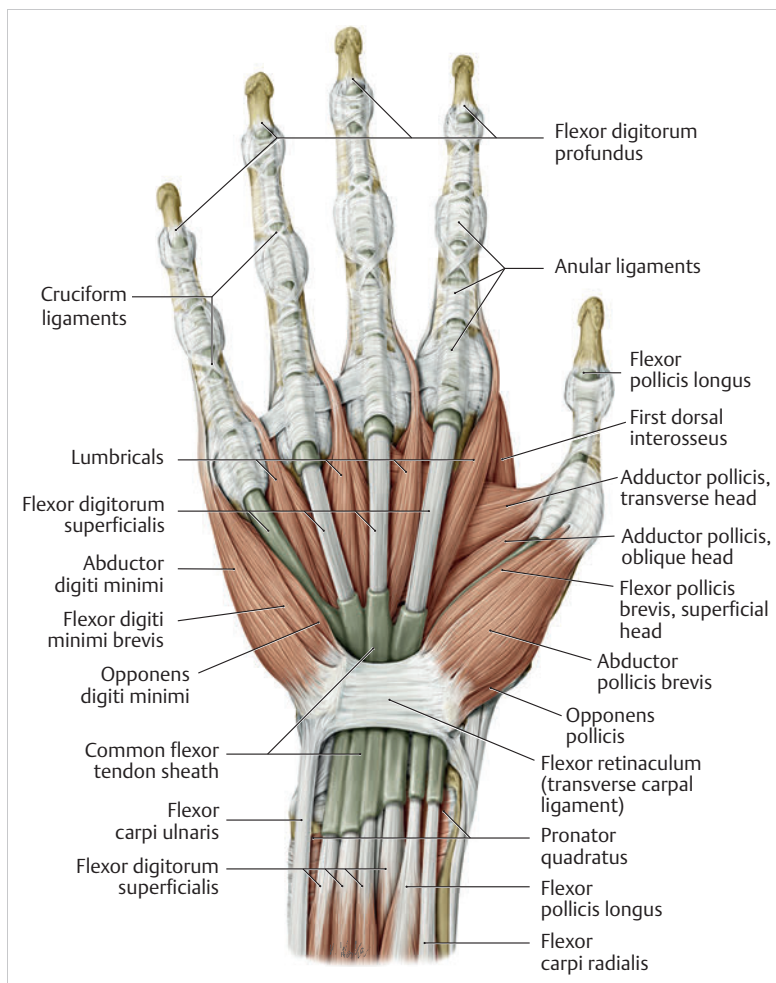


Fig. 1.39 The six palmar tendon compartments. (From THIEME Atlas of Anatomy, General Anatomy and Musculoskeletal System. 2nd ed. © Thieme 2014, illustration by Karl Wesker.)

tubercle below the ledge of the tubercle of the trapezoid, it extends into a bony groove angled dorsalward, and with the flexor retinaculum becomes a gliding tunnel there.²²⁹ The first palmar tendon compartment does not extend directly into the carpal tunnel. This means that only two tendon compartments traverse the carpal tunnel.

Practical Tip

As a result of trauma or osteoarthritis of the wrist, the tendon compartment can lose its capacity to guide the tendon, which can lead to irritation and even rupture of the tendon.²⁵ In particular, pain occurs during loading with the hand flexed. Local tenderness is generally present next to the scaphoid tubercle.¹¹⁶

Second Palmar Tendon Compartment

The tendon sheath of the flexor pollicis longus muscle, which is around 12 to 14 cm long, originates at the level of the radial styloid process.²²⁹ It extends through the radial cavity of the carpal tunnel and inserts at the distal thumb phalanx. The median nerve is fused with this tendon sheath by means of a mesotendon.

Third Palmar Tendon Compartment

The third palmar tendon compartment originates around 5 to 7 cm from the proximal palmar wrist joint line and traverses the carpal tunnel on the ulnar side in the form of a tendon sac.¹³⁴ Distally, this broad tendon sheath extends into the palm to various degrees.²²⁹ The third palmar tendon compartment serves to guide eight tendons, namely four tendons each of the flexor digitorum profundus and flexor digitorum superficialis muscles. The tendons of the flexor digitorum profundus muscle are connected to each other in the carpal tunnel by several intertendinous fibers. If a finger is immobilized in extension, the other fingers can no longer be actively flexed completely in the distal joint.²²⁹ Due to its strong muscle belly and its short fiber length of 8 cm, it is not possible to close the fingers into a fist when the wrist is flexed.⁸⁴ The tendons of the flexor digitorum profundus muscle are located at the level of the carpal bones and from a radial direction proceed ulnarward.²²⁹ The tendons of the flexor digitorum superficialis muscle are located on top in a somewhat less orderly arrangement.²²⁹ The median nerve then lies on top of this tendon compartment. In 50% of the population, this tendon sheath communicates with the tendon sheath of the flexor pollicis longus muscle.¹⁰³

Note

In 85% of all cases, entrapment of the median nerve (carpal tunnel syndrome) is caused by tenosynovitis or chronic fibrosis of the third palmar tendon compartment due to repetitive strain.²⁷

Carpal Tunnel, Ulnar Tunnel, and Innervation of the Hand

The **median nerve** is most frequently exposed to compression-related damage in the area of the carpal tunnel.²⁷ This also applies to the **ulnar nerve**, which is most commonly affected by sulcus-ulnaris syndrome; the second most frequent pathology involves trauma in the ulnar tunnel.²³² Thus, pathological narrowing in the hand is a frequent occurrence and is part of a hand surgeon's daily routine and follow-up treatment of patients.

Carpal Tunnel

The carpal tunnel is the **fibro-osseous passageway that connects the forearm flexors and the hand**. It comprises a dynamic arrangement of carpal bones and ligaments that narrows during flexion and extension of the wrist. The entrance opening narrows during flexion as a result of the flexor retinaculum moving closer to the radius and the capitate shifting toward distal and palmar. During extension, the carpal tunnel is constricted due to the lunate, which is pressed toward the interior of the tunnel.²²⁹ Both motions significantly increase compression inside the tunnel. While the pressure in the neutral position is approximately 2 mm Hg, the pressure in extension increases to around 33 mm Hg and during flexion to approximately 42 mm Hg.¹³ Despite differing measurement values obtained in the two examinations, there is a significant difference in the pressure at rest and the increase in pressure during motion. Any constrictions in the carpal tunnel essentially compromise the conductivity of the median nerve. This is due not only to mechanical pressure but also to the interruption of the blood supply within the nerve sheath.²²⁹ **Carpal tunnel syndrome** is therefore the **most frequent type of peripheral compression neuropathy** (► Fig. 1.40).

Practical Tip

A lesion of the ulnar nerve causes an "ulnar claw" or "claw hand" to develop.^{101,102} The thumb is abducted and the fingers are extended in the proximal joints and flexed in the proximal and distal interphalangeal joints.^{101,102} This characteristic posture is caused by the

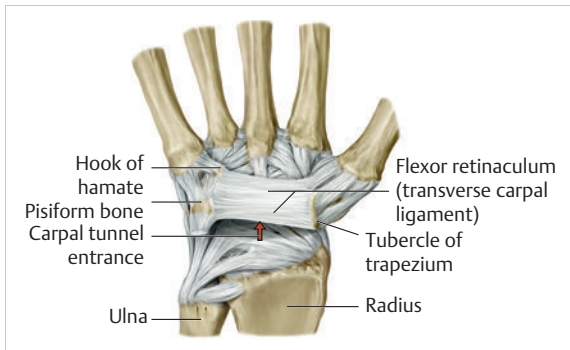


Fig. 1.40 Carpal tunnel. (From THIEME Atlas of Anatomy, General Anatomy and Musculoskeletal System. 2nd ed. © Thieme 2014, illustration by Karl Wesker.)

paralysis of the adductor pollicis and interossei and the fourth and fifth lumbricals. The thumb can no longer be adducted and the fingers can no longer be flexed in the proximal joints or extended in the proximal interphalangeal (PIP) and distal interphalangeal (DIP) joints. As a result, the abductor pollicis brevis muscle supplied by the median nerve immobilizes the thumb, and the extensors supplied by the radial nerve immobilize the fingers in this position. Since the hypothenar muscles are also no longer innervated, opposition of the thumb and little finger is also no longer possible.

► **Anatomical structure of the carpal tunnel.** The carpal tunnel is an osteofibrous canal, approximately 2.5 cm long, on the palmar side of the hand (► Fig. 1.40). In the proximal section, the floor is formed by the capitate, hamate, and triquetrum and in the distal section by the capitate and trapezoid. The radial wall is formed by the proximal scaphoid and the distal trapezium, and the ulnar wall by the proximal triquetrum and distal hamate. The roof of the carpal tunnel is formed by the flexor retinaculum, which inserts onto the radial aspect at the scaphoid tubercle and the tubercle of the trapezium and on the ulnar aspect, at the pisiform and hamate tubercle. The flexor retinaculum is thicker in the distal portion and the carpal space narrows in this less superficial location.²⁷ Two palmar tendon sheaths traverse the carpal tunnel, in the second palmar tendon compartment the flexor pollicis longus muscle, and in the third palmar tendon compartment the eight tendons of the flexor digitorum profundus and superficialis muscles. The median nerve runs between the third tendon compartment and the flexor retinaculum; its course is very variable, but usually radial of the middle line.²⁷

Note

Carpal tunnel syndrome is most frequently caused by inflammatory thickening of the tendon sheaths. Other causes include tumors (e.g., ganglia), crystal deposition arthropathies (e.g., gout), congenital abnormalities (e.g., accessory muscles), osseous carpal stenosis (e.g., dorsiflexed intercalated segment instability [DISI], carpal osteoarthritis), as well as venostasis and edema (e.g., pregnancy, menopause, right ventricular heart failure).²⁷

Ulnar Tunnel

After the sulcus of the ulnar nerve in the elbow, the ulnar tunnel (Guyon's canal, ► Fig. 1.41) is the **second most likely location for entrapment** of the ulnar nerve.²³² The approximately 15-mm long osteofibrous canal guides the ulnar nerve and the ulnar artery into the hand.²³²

► **Anatomical structure of the ulnar tunnel.** The ulnar tunnel is located in a mediopalmar position relative to the carpal tunnel and begins at the level of the pisiform and ends at the hook of the hamate. The floor of the ulnar tunnel is formed by the flexor retinaculum and the pisohamate ligament, while the roof is formed by the palmar carpal ligament and, in some cases, by fibers of the palmaris longus muscle.²³² On the ulnar aspect, the pisiform and the flexor digiti minimi brevis muscle form the boundary of the ulnar tunnel and, on the radial aspect the palmar aponeurosis and the hook of the hamate provide the boundary. Immediately in front of or in the proximal section of the canal, the palmar branch of the ulnar nerve divides into its superficial and deep branches.²³² At the level of the canal exit, the deep nerve branch passes through a narrow area between the hook of the hamate and a fibrous tendinous arch, which serves as the origin of the flexor digiti minimi brevis muscle.²³² Somewhat palmarward and radial to this section, the superficial nerve branch also exits the canal and performs its purely sensory tasks within the hypothenar. The ulnar nerve and its further branches run ulnarward to the ulnar artery.

Note

The most common causes of ulnar tunnel syndrome are acute neural trauma (e.g., cuts, carpal fractures), chronic neural trauma (e.g., long-term use of walking aids, non-union of the hook of hamate), inflammations (e.g., gout), intra-/perineural scars (e.g., after surgery), anatomic variants (e.g., atypical course of the abductor digiti minimi muscle) and various tumors (ganglia, aneurysms, lipoma, etc.).²³²

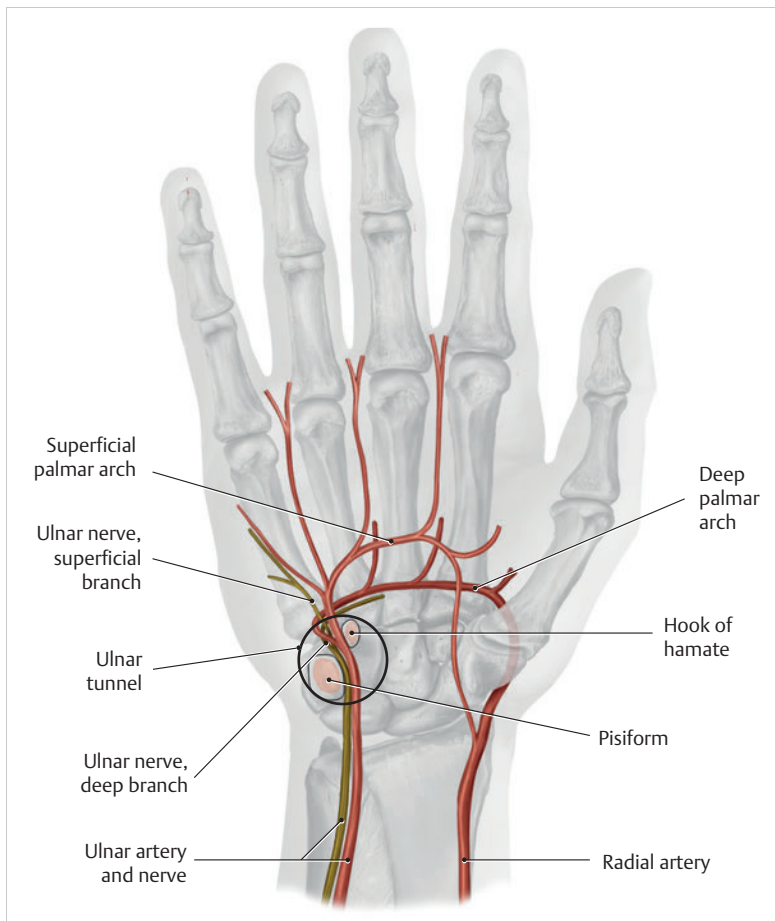


Fig. 1.41 Ulnar tunnel (“Guyon’s canal”). (From THIEME Atlas of Anatomy, General Anatomy and Musculoskeletal System. 2nd ed. © Thieme 2014, illustration by Karl Wesker.)

Innervation of the Hand

The brachial plexus is part of the peripheral nervous system and is formed by the C5 to T1 spinal nerves. A peripheral nerve is also referred to as a mixed nerve, since it contains both afferent and efferent somatic and autonomic nerve fibers.⁵⁶ Somatic fibers run from a receptor (e.g., a cutaneous or pain receptor) to the spinal cord (somatic afferent) or from motor anterior horn cells of the spinal cord to the skeletal muscles (somatic efferent).⁵⁶ Autonomic fibers have both afferent and efferent contact to viscera, vessels, and glands.⁵⁶ From this brachial plexus of peripheral nerves, motor neurons arise for the shoulder girdle muscles and for the upper extremity, as well as sensory branches for the skin of the shoulder and the upper extremity.⁵⁶ For the forearm and hand, the median, ulnar, and radial nerves originate from this plexus.

Median Nerve

The median nerve (C6–T1) arises from the brachial plexus in the area of the axillary artery by union of the median and lateral fascicles (“median sling”). The nerve runs in the bicipital medial sulcus superficial to the brachial

artery downward into the cubital fossa (► Fig. 1.42). There, it is located behind the biceps aponeurosis and the median cubital vein and in front of the insertion of the brachialis muscle and the elbow joint. In this area, the muscular rami branch off and innervate the pronator teres, flexor carpi radialis, palmaris longus, and flexor digitorum superficialis muscles with its radial head and the humeroulnar head, sending several branches to the elbow joint and to the proximal radioulnar joint. The median nerve enters the forearm by traversing the humeral and ulnar heads of the pronator teres muscle. At the level of the cubital fossa, the branch of the anterior antebrachial interosseous nerve arises. It proceeds further on the interosseous membrane of the forearm to the pronator quadratus muscle and gives off further branches to the flexor pollicis longus muscle, the radial part (digitus II and III) of the flexor digitorum profundus muscle, as well as to the distal radioulnar and wrist joints. Between the flexor digitorum superficialis and flexor digitorum profundus muscles, its further course culminates in the wrist joint. Before it enters the carpal tunnel, it lies superficially between the tendons of the flexor carpi radialis and palmaris longus muscles and gives off the sensory palmar branch of the thenar.²⁷ Furthermore, there is regularly an

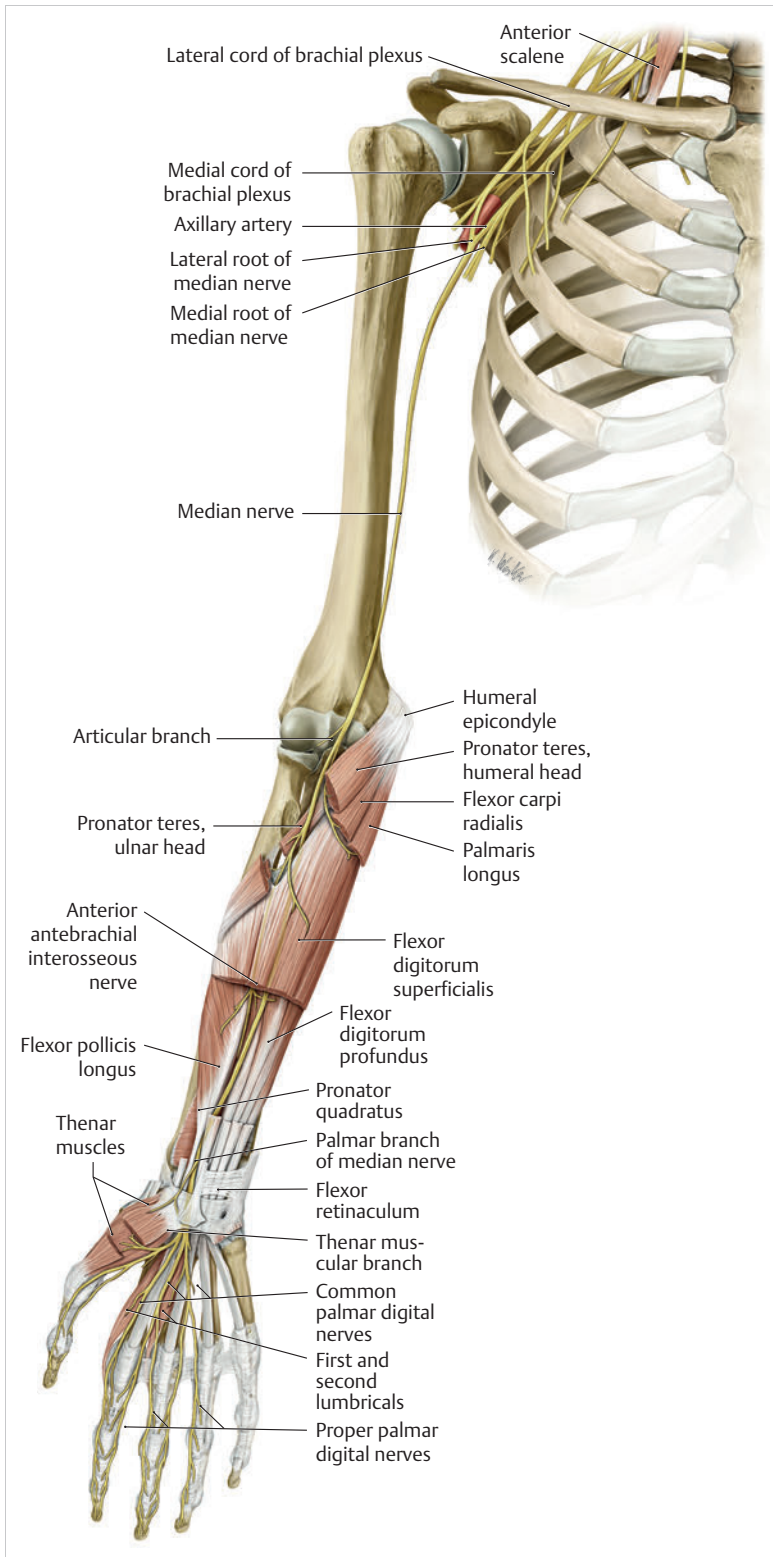


Fig. 1.42 Median nerve. (From THIEME Atlas of Anatomy, General Anatomy and Musculoskeletal System. 2nd ed. © Thieme 2014, illustration by Karl Wesker.)

anastomosis with the ulnar nerve at the level of the carpus.

With a width of around 6 mm and at a thickness of about 2.1 mm, the median nerve enters the carpal tunnel beneath the flexor retinaculum.²²⁹ From proximal to distal, the width of the median nerve increases gradually up to 7.7 mm,²²⁶ while the thickness decreases to 1.9 mm.³⁷ The number of fascicles **increases, and up to 40 may be present.**²³ Direct contact of the flexor tendons causes groove-like recesses to form.²²⁹ In over 60% of cases the nerve courses in a straight line to the palm of the hand; in most cases radial of the middle line.²⁷ Since the median nerve is attached to the surrounding tissues by loose connective tissue, passive longitudinal displacement of the median nerve in the carpal tunnel is possible. Between 60° extension and 65° flexion in the wrist, the nerve glides longitudinally by approximately 20 mm.²⁷⁴ In most cases, at the end of the carpal tunnel, the median nerve gives off its motor branches to the following muscles: the abductor pollicis brevis, the opponens pollicis, the superficial head of the flexor pollicis brevis, and the two radial lumbricals.²⁷ The motor branches of the lumbricals (common palmar digital nerves) course to the interdigital spaces and divide into the proper palmar digital nerves with two pairs of nerves each for the thumb, index and middle fingers, and the radial half of the ring finger.¹⁰² They thus innervate the palmar surface of the thumb, index and middle fingers, as well as the radial half of the ring finger, including the dorsal distal and middle phalanges.¹⁰²

Note

Damage to the median nerve at the level of the forearm results in the clinical picture of ape-hand deformity, which is due to damage of the motor branches to the forearm flexors. A lesion in the area of the carpal tunnel results in anesthesia of the fingers innervated by the median nerve, with atrophy of the thenar muscles. If the anterior interosseous nerve is constricted or damaged, flexion in the interphalangeal (IP) joint of the thumb, as well as in the DIP joints of the index and middle fingers is more difficult or impossible. A typical sign is the inability to form a circle with the thumb and index finger.

Ulnar Nerve

The ulnar nerve (C8–T1) is a major nerve originating from the medial fascicle of the brachial plexus. It courses across the axillary artery and vein to the medial side of the brachial artery in the upper arm and continues its course there at the ulnar side in a distal direction (► Fig. 1.43). At approximately the middle of the upper

arm, it pierces the medial intermuscular septum of the arm and proceeds further downward in front of the medial head of the triceps brachii muscle. In the distal third of the upper arm, it turns into the gap between the medial epicondyle and the olecranon and moves into the forearm via the sulcus nervi ulnaris. In this area, it can be easily palpated and, upon pressure, causes an electric-shock-like feeling (“funny bone”) that radiates downward into the ulnar side of the hand. Proximal to the elbow joint, the ulnar nerve does not give off any constant branches apart from several small branches for the elbow joint.

Between the humeral and ulnar heads of the flexor carpi ulnaris muscle and lying on the flexor digitorum profundus muscle, the ulnar nerve proceeds in a distal direction on the flexor side of the forearm below the muscle belly of the flexor carpi ulnaris muscle. At the site where the muscle blends into the tendon, the nerve and the ulnar artery which accompanies it protrude beneath the lateral border of the muscle and proceed superficially, that is, directly below the antebrachial fascia and guiding its medial tendon surface up to the flexor retinaculum. In the forearm, it gives off branches to the flexor carpi ulnaris muscle and to the medial half of the flexor digitorum profundus muscle.

Via the retinaculum, the **palmar branch** of the ulnar nerve extends into the wrist joint, where it divides into its superficial sensory and deep motor branches immediately in front of or in the proximal section of the ulnar tunnel.²³² The **deep palmar branch** is embedded in the deep part of the palm and curves toward the thenar eminence. It gives off branches for all muscles of the hypothenar, namely the abductor digiti minimi, flexor digiti minimi, and opponens digiti minimi. It also innervates all dorsal and palmar interossei, the fourth and fifth lumbricals, as well as individual muscles of the thenar, that is, the adductor pollicis and the deep head of the flexor pollicis brevis.

At approximately the middle of the forearm, the **sensory dorsal branch of the ulnar nerve** branches off and proceeds until the dorsal ulnar aspect of the dorsal hand to innervate the skin there—that is, the surface of the wrist joint and, with its terminal branches, the proper digital dorsal nerves, up to the PIP joints of the little finger and the ulnar half of the ring finger. The sensory palmar branch, given off somewhat lower, innervates the ulnar section of the wrist flexor side and the proximal hypothenar. The superficial branch arising in the ulnar tunnel²³² innervates the palmaris brevis muscle and provides sensory innervation for the skin of the ulnar palm, with its two digital palmar nerves giving rise to the proper palmar digital nerves, which innervate the lateral and palmar surface of the small and ring fingers and the dorsal surface of their distal phalanges.

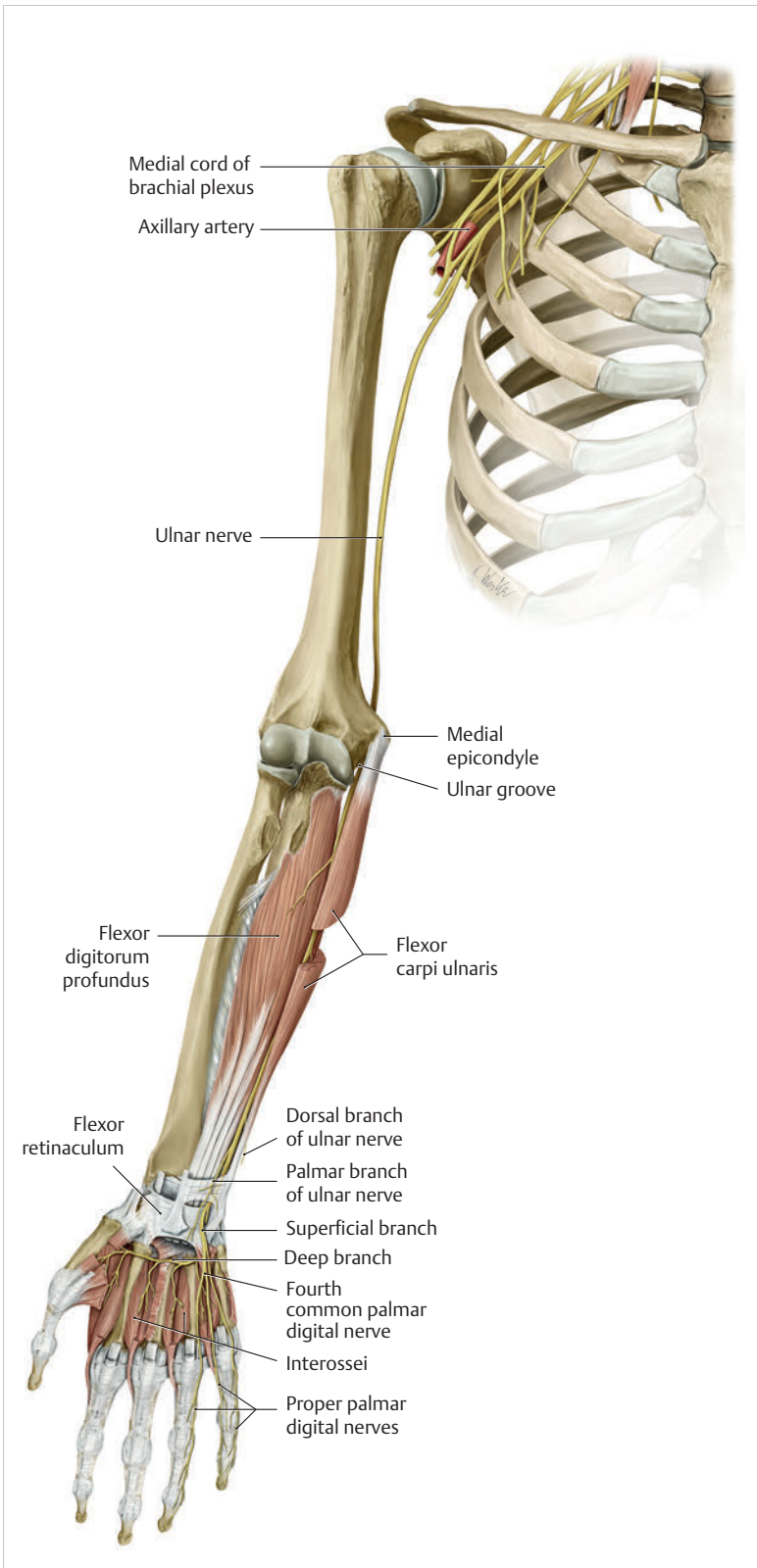


Fig. 1.43 Ulnar nerve. (From THIEME Atlas of Anatomy, General Anatomy and Musculoskeletal System. 2nd ed. © Thieme 2014, illustration by Karl Wesker.)

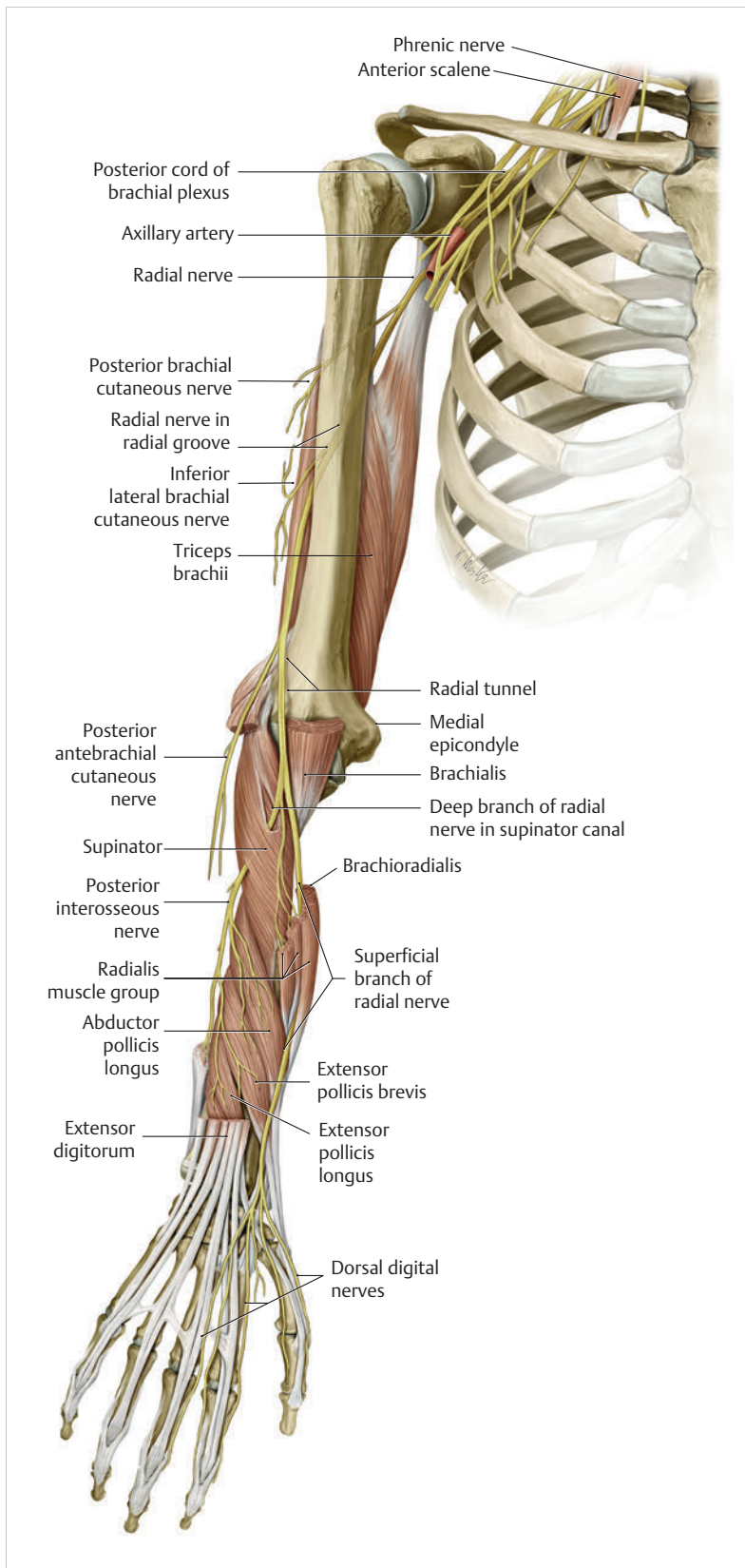


Fig. 1.44 Radial nerve. (From THIEME Atlas of Anatomy, General Anatomy and Musculoskeletal System. 2nd ed. © Thieme 2014, illustration by Karl Wesker.)

Radial Nerve

The radial nerve (C5–C8) **arises from the posterior fascicle** and innervates the upper arm and forearm extensors (► Fig. 1.44).

The **nerve trunk** extends from the axilla into the proximal third of the medial bicipital sulcus and takes a spiral course around the dorsal surface of the humerus through the sulcus nervi radialis. In the distal third of the upper arm, it reaches the brachial and brachioradialis muscles on the flexor side. At this level, it crosses the elbow joint and at the head of the radius divides into its two terminal branches, the superficial and deep branches.

In the axilla the inferior lateral cutaneous nerve of the arm branches off and innervates the skin of the lateral side of the upper arm.²⁰⁰ Somewhat further distally, the posterior cutaneous nerve of the arm follows, providing sensory innervation of the dorsal side. Before the nerve enters the sulcus nervi radialis, the motor muscular branch for the triceps brachii²⁰⁰ and anconeus muscles becomes detached. In the sulcus nervi radialis, the posterior cutaneous nerve of the forearm follows, innervating the skin of the forearm extensor side up to the carpus.

The **superficial branch** continues at the forearm to the medial surface of the brachioradialis muscle, and then extends in the lower third between this muscle and the radius on the dorsal side up to the dorsum of the hand. There, it divides into five dorsal digital nerves for the extensor side of the thumb, index finger, and the radial side of the middle finger.²⁰⁰ There is no autonomic region for sensory innervation of the radial nerve; all innervated cutaneous areas can also be innervated by other nerves.²⁰⁰ Furthermore, at the level of the lateral epicondyle, motor branches extend to the brachioradialis and extensor carpi radialis longus muscles.

The **deep branch** enters the supinator muscle (arcade of Frohse¹⁷⁵) and in this muscle winds around the radius to the extensor side, where it innervates the **entire dorsal muscle group of the forearm**.²⁰⁰ This includes the following muscles:

- Supinator
- Extensor carpi radialis brevis
- Extensor digitorum communis
- Extensor carpi ulnaris
- Proper extensor digiti minimi
- Abductor pollicis longus
- Extensor pollicis brevis
- With the branch of the posterior interosseous nerve:
 - Extensor pollicis longus muscle
 - Proper extensor indicis muscle

► Table 1.2 presents an overview of muscle innervation.

Note

Damage to the main trunk in the upper arm area leads to “wrist drop” due to the paralysis of the hand extensors.¹⁰² Extension is not possible in either the wrist or finger joints and the hand therefore hangs down limply.¹⁰²

Exteroceptive Sensation and Proprioception

Sensation comprises the capacity to perceive various stimuli by means of sensors, via afferent, peripheral, and central nervous pathways to the central nervous system.²⁰¹ A distinction is made between the qualities of epicritic, protopathic, and proprioceptive sensations.¹⁴

- **Epicritic sensation:** Epicritic sensation refers to the tactile sensitivity of the skin.⁶⁹ Mechanical stimuli such as touch, vibration, pressure, and tension can trigger such tactile stimuli.⁶⁹ The quality of the sensitivity triggered on the skin depends largely on the intensity, the temporal order, and the area stimulated.⁶⁹ These manifold receptors represent the mechanoreceptors of the skin, which have a highly dense arrangement. They are divided into intensity, velocity, and acceleration detectors.⁶⁹ These sensors are able to discern two nearby stimuli as distinct sensations (referred to as two-point discrimination¹⁴).

Table 1.2 Overview of muscle innervation²⁷⁵

Median nerve	Ulnar nerve	Radial nerve	Musculocutaneous nerve
<ul style="list-style-type: none"> • Pronator teres • Palmaris longus • Flexor carpi radialis • Flexor digitorum profundus (2nd and third) • Flexor digitorum superficialis • Flexor pollicis longus • Pronator quadratus • Abductor pollicis brevis • Opponens pollicis • Superficial head of flexor pollicis brevis • Lumbricals (first and 2nd) 	<ul style="list-style-type: none"> • Flexor carpi ulnaris • Flexor digitorum profundus muscle (fourth and fifth) • Palmaris brevis • Abductor digiti minimi • Flexor digiti minimi • Opponens digiti minimi • Lumbricals (third and fourth) • Dorsal and palmar interossei • Adductor pollicis • Deep head of flexor pollicis brevis 	<ul style="list-style-type: none"> • Medial, lateral and long head of triceps brachii • Extensor carpi radialis longus and brevis • Brachioradialis • Anconeus • Supinator • Extensor digitorum communis • Extensor carpi ulnaris • Proper extensor digiti minimi • Extensor carpi radialis longus and brevis • Abductor pollicis longus • Proper extensor indicis 	<ul style="list-style-type: none"> • Corobrachialis

- **Intensity detectors:** These mechanoreceptors transmit information about the strength of persistent pressure or stretching of the skin. They comprise the Merkel cells located in the epidermis and the Ruffini corpuscles located somewhat deeper in the dermis.⁶⁹
- **Velocity detectors:** They generate action potentials only while a cutaneous stimulus changes its intensity.⁶⁹ Their stimuli include stroking and vibrations on the skin. Depending on location, Meißner's corpuscles located in the dermis assume this responsibility in hairless regions and in hairy regions, presumably by the hair follicle receptors located in dermis.⁶⁹
- **Acceleration detectors:** The detection of the acceleration of stimuli on the skin is assumed by the Pacini corpuscles located in the hypodermis. They become active only if there are stronger stimuli, such as tactile and vibration sensations.⁶⁹
- **Protopathic sensation:** Protopathic sensation is understood to be the emotionally colored sensation of pain, temperature, and overall perception of pressure that can be less precisely located.¹⁴ In this respect, specific cold and heat receptors, as well as different myelinated and unmyelinated nociceptors are activated and frequently respond in a coupled fashion.⁶⁹ The myelinated A-fiber mechanonociceptors react to pricking stimuli and in addition the A-polymodal nociceptors react to heat and chemical stimuli.⁶⁹ The unmyelinated C-polymodal nociceptors ("C-fibers") respond equally to mechanical, pricking stimuli, as well as stimuli for intense heat. Depending on the intensity of the stimulus, this coupling can allow heat to be perceived as "pain," for example, as a protective response. The myelinated nociceptors make up over 10% of all human cutaneous nerves and the unmyelinated nociceptors make up more than 50% of these nerves.⁶⁹ If they are stimulated after repeated tissue damage and/or in the case of already present inflammation, their sensitivity increases and they then also respond to normal stimuli and become active spontaneously ("sensitization").⁶⁹
- **Proprioceptive sensation:** Proprioceptive sensation provides information about the movement and location of the organism in space.¹⁴ Information from these systems is the result of both arbitrary and reflexlike movements.²¹⁷ Four main types of peripheral mechanoreceptors are responsible for information about the static position and the speed and direction of this movement.²¹⁷ They also determine the intensity of the force required to grasp an object, for example.²¹⁷ These four types of sensors are divided into mechanoreceptors in the muscle-tendon transition zones in the form of Golgi tendon organs and within the tendon by Ruffini corpuscles. In the muscle itself, they are represented by the muscle spindle receptors, and in the joint capsule they may be represented by the Pacini corpuscles. It may be assumed that the Ruffini corpuscles

assume this function in the skin.²¹⁷ As long as the joint angles are in a central position, the information from these spatial receptors is very precise, with differences of 0.2° being recognizable.²¹⁷

Blood Supply to the Wrist Joint and Hand

In the area of the elbow joint, the brachial artery divides into the radial and ulnar arteries, which extend from there toward the wrist joint in a distal direction (► Fig. 1.45). In the lower third of the forearm, only unnamed vessel branches divide up for their supply.⁶⁰

Radial Artery

In 80 to 85% of all cases, the radial artery originates from the brachial artery in the elbow, and in the remaining 15 to 20% of the cases it branches off from the brachial artery higher up or from the axillary artery.⁸⁵ In the periphery, the radial artery extends in a directly lateral direction next to the tendon of the flexor carpi radialis muscle and ends at the level of the wrist, where the pulse can be easily palpated.⁶⁰ Behind the trapezium and the base of the first metacarpal, it merges into the superficial and deep palmar arches, through which it unites with the ulnar artery.⁸⁵ However, before reaching the deep palmar arch, the radial artery takes a dorsal course by leaving the flexor side of the forearm at the level of the anatomic snuffbox and after passing a short distance through the space between the first and second metacarpals, it returns to the palmar side and ultimately ends in the deep palmar arch.⁸⁵

Ulnar Artery

The ulnar artery also originates from the brachial artery at the level of the elbow.⁶⁰ It runs in a distal direction below the superficial forearm flexors and crosses the median nerve in the area of the pronator teres muscle.⁶⁰ Covered by the flexor carpi ulnaris muscle, it continues toward the wrist. Next to the tendinous part of this muscle, it runs directly medial to the ulnar nerve. In the area of the wrist joint, it can be easily palpated in front of the pisiform. In the forearm, the arteria interossea communis, whose dorsal branch provides part of the arterial supply to the back of the hand, branches off from it.⁸⁵ The ulnar artery divides into superficial and a deep palmar arches in the ulnar tunnel. These two arches join with the superficial and deep palmar arches of the radial artery in the palm.⁶⁰

Superficial and Deep Palmar Arches

The superficial palmar arch is mainly fed by the ulnar artery. After passing through the ulnar tunnel, the ulnar artery joins the superficial palmar arch, which ends superficially in relation to the flexor tendons of the fingers and the branches of the median nerve in the middle

of the palm.⁸⁵ In only 42% of cases, the superficial palmar arch is closed and in the remaining 58%, the arch is open with the common digital arteries radiating outward.⁸⁵ The deep palmar arch is fed primarily by the radial artery in 97% of all cases. In 95% of cases, it is closed by an anastomosis with the ulnar artery.⁸⁵ The princeps pollicis and radial indicis arteries and the palmar metacarpal arteries originate from the deep palmar arch.⁸⁵ The deep palmar arch lies on top of the palmar interossei and is located between the two heads of the adductor pollicis muscle deep in the middle of the palmar compartment.⁸⁵

Note

Indications for imaging of arteries in the forearm and the hand are circulatory disturbances, inflammatory vascular diseases, traumatic vascular lesions, and vascularized soft-tissue tumors of the hand.⁸⁵

Lymphatics of the Hand

The lymphatics of the hand are divided into a superficial and a deep layer (► Fig. 1.46). The **superficial lymphatics** are located in the subcutaneous tissue of the palm and

receive the lymph from the fingers, the palm, and to some extent from the finger and wrist joints. The **radial, ulnar, and descending lymph vessels** drain into collecting channels in the dorsum of the hand. Ascending vessels from the central region of the hand remain on the palmar aspect. They join the medial vascular bundle in the forearm.²²⁹ Deep central collecting channels beneath the palmar aponeurosis conduct the lymph into a dorsal collecting channel via a common trunk.²²⁹

Note

An infection of palmar portions of the hand will produce erythema and swelling of the dorsum of the hand (collateral edema of the dorsal hand).

The **collecting channels of the deep lymph system** collect the lymph from the region of the proximal phalanges and follow the common palmar digital arteries and dorsal and palmar metacarpal arteries.²²⁹ At the level of the two arterial palmar arches, they form the deep and superficial palmar lymphatic arches and then are connected through anastomoses.²⁴³ Lymph drains from the superficial arch along the ulnar artery and from the deep

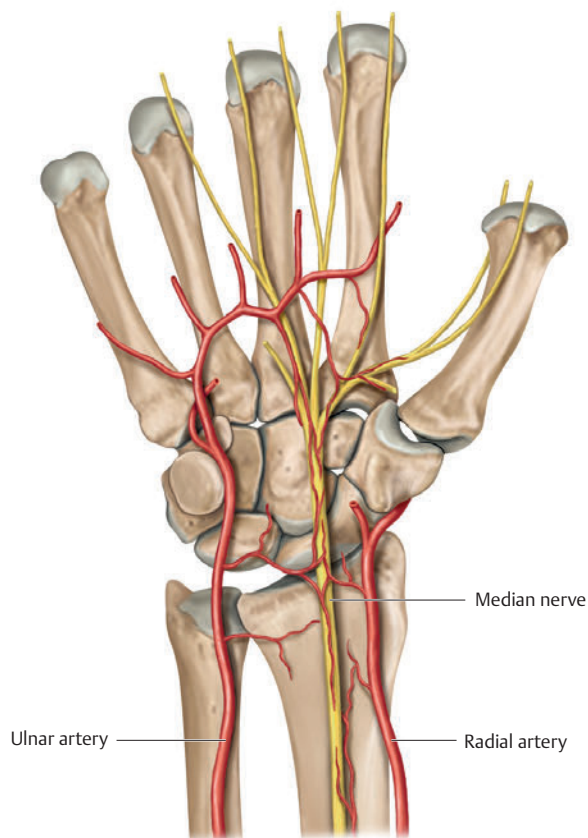


Fig. 1.45 Radial and ulnar arteries.

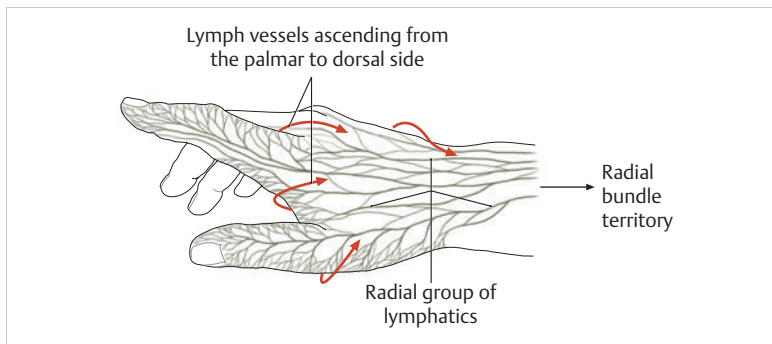


Fig. 1.46 The lymphatics of the hand. (From THIEME Atlas of Anatomy, General Anatomy and Musculoskeletal System. 2nd ed. © Thieme 2014, illustration by Karl Wesker.)

arch parallel to the radial artery.²²⁹ For lymph drainage, the axillary lymph nodes correspond to the superficial vessels and the cubital lymph nodes correspond to the deep vessels.²²⁹

1.4 Thumb

1.4.1 Movements and Range of Motion

Compared to nonhuman primates, which can only adduct the thumb and not oppose it, the thumb represents an evolutionary quantum leap. It is the first and strongest digit of the hand and, owing to its array of possible movements, has special status. The thumb's **opposition position** enables the powerful **closing of the fist** and thus acts as a grasping tool.²⁵⁶ The force occurring during the **pinch grip** amounts to around one-fourth that of the force generated during maximum fist-closing.⁶⁷ All in all, the thumb contributes significantly to **optimizing gross motor and fine motor grasping functions of the hand**.

This complexity is provided by the thumb carpometacarpal (CMC) joint and nine of its own individual muscles having an array of functions. These functions distinctly set apart the thumb from the other fingers. The areas of the brain responsible for the thumb's movement and sensitivity are also considerably more pronounced than for that of the wrist and the other fingers.¹⁹² The functional joints of the thumb are divided into the **CMC joint of the thumb**, which belongs to the wrist joint, and the **thumb metacarpophalangeal (MCP) and interphalangeal (IP) joints**, which belong to the digit itself.

Kapandji (1982)¹⁰⁷ distinguished three functional units between the thumb and the other fingers of the hand:

1. Opposition of the thumb as the most important functional unit.
2. The coordinated movement between the thumb and index and middle fingers.
3. The ring and little fingers as the strengthening unit of the fist and as closed reciprocal opposition to the thumb.

Movements of the Thumb CMC Joint

This gives rise to two degrees of freedom in the thumb CMC joint, which Kaufmann (2005)¹¹⁵ described as follows:

- The **first degree of freedom** comprises abduction and adduction around an axis through the base of the first metacarpal that takes a radiodorsal to ulno-palmar course and forms a 45° angle to the plane of the extended hand. Since 2001, the International Federation of Societies for Surgery of the Hand (IFSSH) has broken down the notion of thumb abduction into palmar abduction and radial abduction.²²⁹
- The **second degree of freedom** comprises flexion and extension. The axis for this movement takes a radiopalmar to ulnodorsal course through the trapezium. If this axis is projected onto the abduction and adduction axis, the two form a 90° angle to each other.
- When the articular surfaces do not touch, **rotation** is possible to a very limited extent (in the sense of pronation and supination)²²⁹ and is automatically coupled to all other motions.¹¹⁵
- The most typical movements of the thumb involve **opposition** and **reposition**. In the opposition movement, the thumb, together with the first metacarpal, is opposed to the other fingers. The inverse motion is reposition. For these movement sequences, the two degrees of freedom, abduction and adduction as well as flexion and extension (in association with rotation), are coordinated.
- **Circumduction** involves the combination of adduction and opposition, as well as abduction and reposition. For circumduction, the first metacarpal and the thumb take a conical path for their entire range of motion, with the tip of the cone located in the thumb CMC joint. The entire thumb ray with its three joints is involved in circumduction.²²⁹ The endpoints of circumduction are reposition and flexion–adduction. The thumb first performs radial abduction, which passes through palmar abduction and ends in opposition.

Cooney and Lucca (1981)³⁴ described the following **range of motion** resulting from these individual movements:

1. 42° of abduction and adduction (approx. 35° abduction and approx. 25° adduction)
2. 53° of flexion–extension (approx. 25° flexion and approx. 45° extension)
3. 10° of rotation in the CMC joint⁹³

Additional Information

The CMC joint, being a saddle joint, assumes the function of a ball-and-socket joint, which results in stresses that promote arthritis.^{124,126} Circumduction of the first metacarpal produces these particular stresses.²²⁹ The rotational components of the motions involved in bringing the thumb into opposition result in lack of congruency between the articular surfaces. This greatly reduces the contact surfaces available for stress transfer and produces peak stresses in the rising slopes of the saddle.²²⁹

Range of Motion of the Thumb MCP and IP Joints

As an **ovoid joint**,²⁰⁹ the MCP joint of the thumb describes two degrees of freedom with the movements flexion–extension and abduction–adduction (► Fig. 1.47a). In contrast, the IP joint of the thumb is a pure **hinge joint**, which allows for extension, flexion, and opposition (► Fig. 1.47b, c).

1.4.2 Structure and Function of the Thumb CMC Joint

Numerous studies have addressed the structure and function of the thumb CMC joint.¹¹⁴ For example, in the past,

it has been described as a double hinge joint as well as a ball-and-socket joint.⁴⁸ It is most frequently described as a **saddle joint** (► Fig. 1.48).

The **trapezial articular surface** is convex from dorsal to palmar and concave from radial to ulnar²²⁹ and is saddle shaped.⁵⁷ It also has a spherical facet directed palmarward,²⁸¹ and in many aspects functions as a pivot joint.^{183,257} In terms of the anatomical planes of the hand, the articulating joint facet of the trapezium toward the first metacarpal has a palmar inclination of 35°, a radial inclination of 15°, and also 15° in supination.²⁸¹ When the first CMC joint is in a neutral position, the **first metacarpal** is aligned with the axis of the trapezium. It forms an angle of 30° with the **second metacarpal**. It articulates with the oppositely curved base of the first metacarpal.²²⁹ The two articular surfaces are congruent in only half of the population.²²³ In the other half, a narrow, slightly curved articular surface on the trapezium articulates with a broader, more sharply curved surface on the first metacarpal (► Fig. 1.49).^{176,223,281} These surfaces are flatter in women and on the whole less congruent than in men,⁵ which may explain the higher probability of arthritis development at this site in women.

During opposition, the contact surface between the two articular surfaces of the **CMC joint** is greatest, at 53%, while during adduction and radial deviation, it is lowest, at 28% and 25%, respectively.¹⁷⁰ This confirms the assumption of Kauer (1987)¹¹⁴ that no position of the joint exists in which maximal congruency occurs. The **capsule of the CMC joint of the thumb** is broad and flaccid to accommodate its wide range of motion. Several **stabilizing ligaments** are necessary to guide the joint securely through its range of motion.²²⁹ This explains the high degree of mobility of the joint, despite its low stability.¹⁶⁰

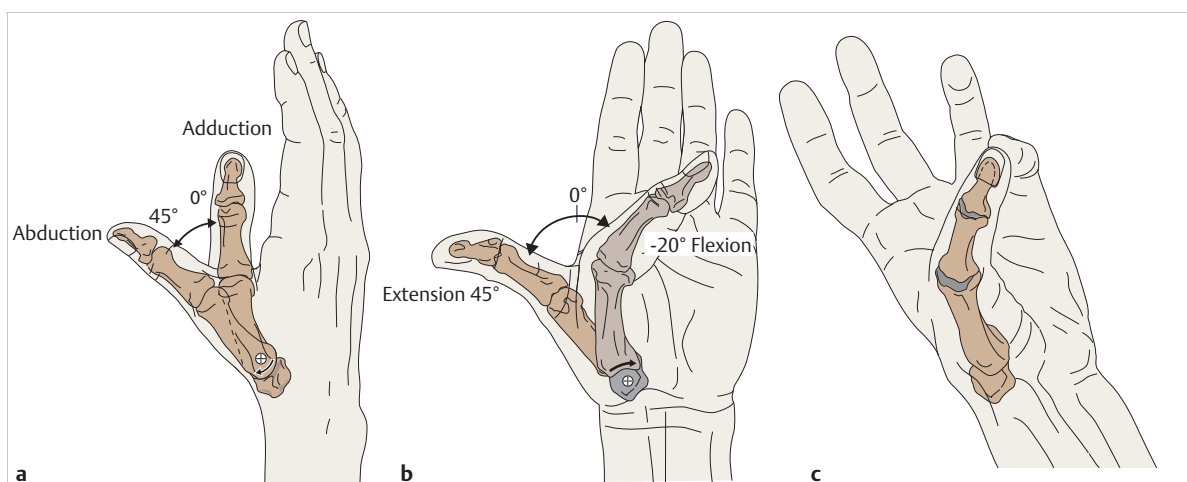


Fig. 1.47 Movements of the thumb MCP and IP joints. (From Hochschild J. *Functional Anatomy for Physical Therapists*. Stuttgart: Thieme; 2016.) (a) Abduction and adduction of the thumb. (b) Extension and flexion of the thumb. (c) Opposition of the thumb.

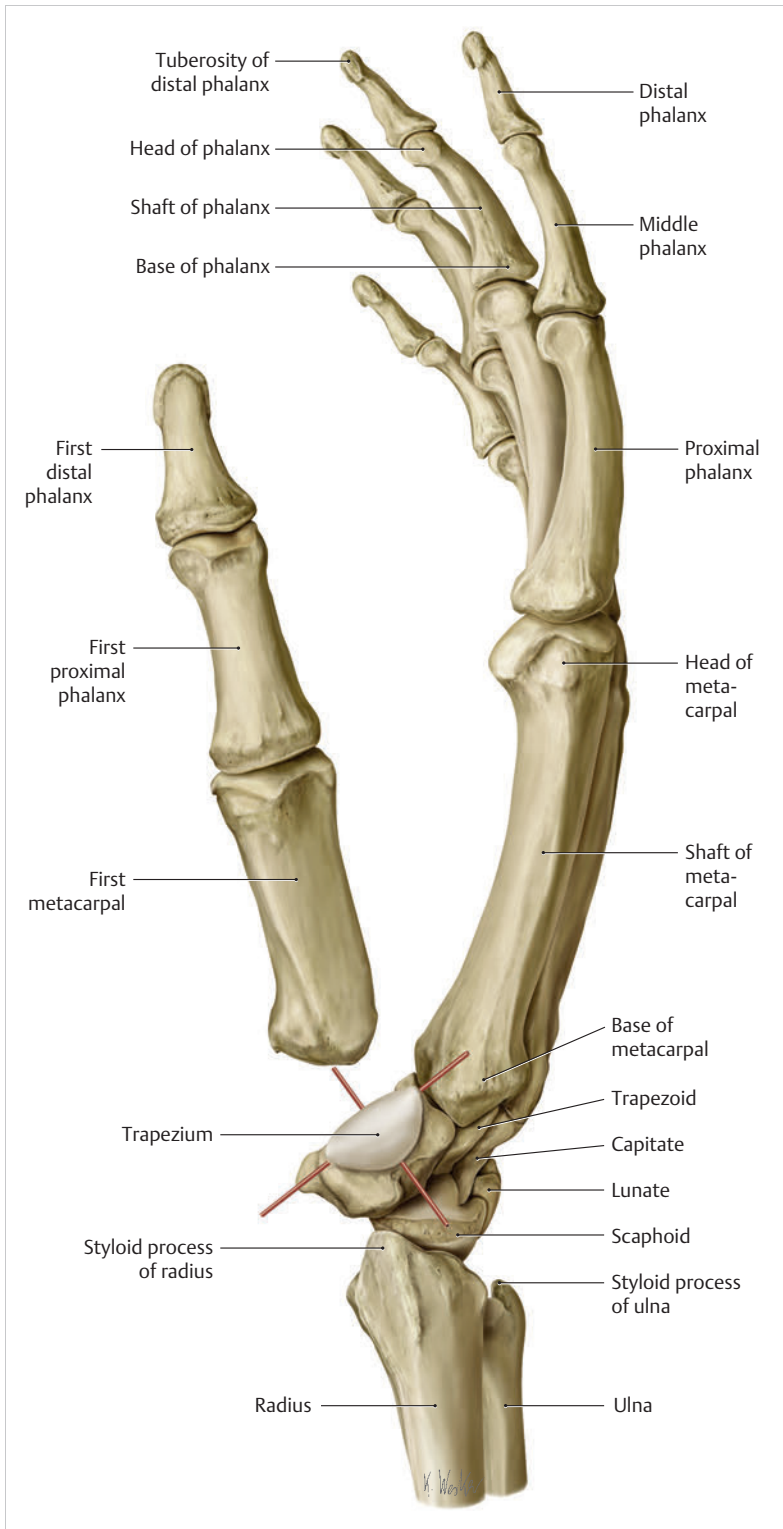


Fig. 1.48 Overview of the CMC joint of the thumb. (From THIEME Atlas of Anatomy, General Anatomy and Musculoskeletal System. 2nd ed. © Thieme 2014, illustration by Karl Wesker.)

Ligaments of the Thumb CMC Joint

A total of 16 ligaments are involved in stabilizing the thumb CMC joint (► Fig. 1.50).¹⁶⁰ One or more of them will be under tension in any given position.⁹⁶ Apart from the direct ligamentary connections between the trapezium and the first metacarpal, all ligaments that insert

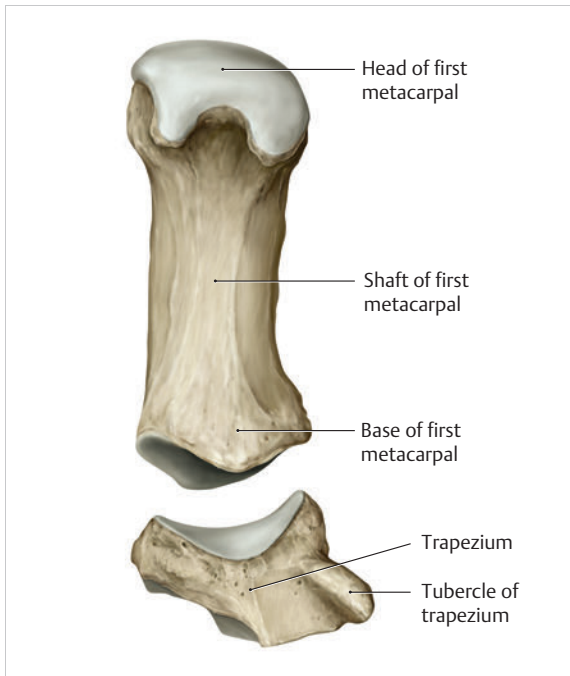


Fig. 1.49 Articular surfaces of the CMC joint of the thumb. (From THIEME Atlas of Anatomy, General Anatomy and Musculoskeletal System. 2nd ed. © Thieme 2014, illustration by Karl Wesker.)

at the trapezium and do not have contact to the first metacarpal must be involved in stabilizing the thumb MCP joint, since they are always involved in the movements of the thumb CMC joint.¹⁶⁰ For this reason, a distinction must be made between direct and indirect ligament stabilization.

Indirect Ligament Stabilization

Indirect stabilization is carried out by 11 ligaments located in the area of the wrist joint and which exert a stabilizing effect only on the trapezium. Wrist instability can therefore alter the arthrokinematics of the thumb CMC joint. Moreover, rotation movements in the thumb CMC joint may also occur as the result of a surface-adapted circumduction movement of the trapezium.¹⁹⁴ Owing to the taut ligament structures, this movement occurs to only a very few degrees between the contact surfaces of the trapezium to the scaphoid as well as to the trapezium.¹⁶⁰ The scaphotrapezium joint permits the trapezium a slight gliding movement palmarward toward the scaphoid tubercle and adds a small flexion movement.¹⁸³ According to Matthijs et al (2003),¹⁶⁰ the following ligaments are significant in this respect:

1. Six ligaments, consisting of the two dorsal and palmar trapeziotrapezoid ligaments, the second dorsal and palmar trapeziometacarpal ligaments, as well as the intermetacarpal and dorsal intermetacarpal ligaments oriented toward the radial column of the wrist and the column of the thumb.
2. Trapeziocapitate and third trapeziometacarpal ligaments oriented toward the central column of the wrist and column of the thumb.
3. Transverse carpal ligament oriented toward the ulnar column of the wrist and column of the thumb.

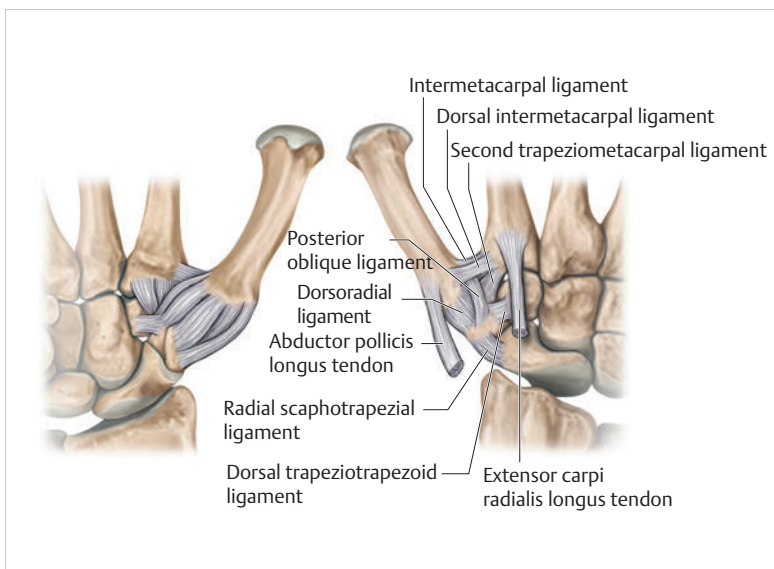


Fig. 1.50 Ligaments of the CMC joint of the thumb. Left: dorsal view; Right: palmar view.

Note

In 55% of cases of existing osteoarthritis of the thumb CMC joint, the scaphotrapezotrapezium joint is involved in the arthritic changes of the adjacent thumb CMC joint.¹⁸¹

Direct Ligament Stabilization

This is the direct ligament connection between the trapezium and the first metacarpal. These **five ligaments are primarily responsible for stabilizing the CMC joint of the thumb.**

Anterior Oblique Carpometacarpal Ligament

Measuring 11 mm long and 7 mm wide, the anterior oblique carpometacarpal ligament arises from the radial margin of the tubercle of the trapezium and extends to a small palmar eminence on the radial surface of the first metacarpal base.²²⁹ This intra-articular ligament takes an oblique course from proximal and radial to distal and ulnar and tightens during radial inclination, opposition, and supination.¹⁶⁰ **Its stabilizing influence on the CMC joint of the thumb** may be compared to that of the palmar plate with respect to the finger joints.⁴⁵ It **prevents hyperextension of the thumb** and dislocation of the base of the first metacarpal in a palmarward direction.¹⁶⁰

Posterior Oblique Carpometacarpal Ligament

The posterior oblique carpometacarpal ligament arises from a dorsoulnar eminence on the trapezium.²²⁹ The ligament is about 15 mm long and 6 mm wide²⁴⁸ and takes a spirallike course from proximal and radial to distal and ulnar to its insertion at the palmar styloid process of the first metacarpal.¹⁶⁰ Functionally, it **prevents extreme abduction**²²⁹ and in turn prevents palmarward dislocation of the base of the first metacarpal (synergistically with the anterior oblique carpometacarpal ligament) and ulnar dislocation of the first metacarpal toward the base of the second metacarpal.¹⁶⁰

Dorsoradial Carpometacarpal Ligament

The dorsoradial carpometacarpal ligament is 12 mm long and 7 mm wide.²²⁹ It is **the thickest and widest ligament among the ligaments arising at the trapezium.**¹⁶⁰ It originates from the dorsoradial eminence of the trapezium, inserts into the opposite margin of the first metacarpal base,¹⁶⁰ and is under tension in every extreme position of the thumb.²²⁹ Since the ligament fibers in the middle third consist of longitudinal fibers and the radial part courses to distal and radial and the ulnar part to distal and ulnar, it prevents dorsal dislocation in all positions of the joint, especially

during ulnar deviation, since it is placed under tension in supination and pronation.¹⁶⁰

Trapeziometacarpal Ligament

This ligament arises immediately from the peripheral radial fibers of the flexor retinaculum on the trapezium tuberosity,^{136,137} and is also referred to as the “volar ligament”¹⁴⁶ or “beak ligament.”^{20,110} Measuring about 11 mm long and 6 to 7 mm wide, this structure extends to the palmar aspect of the first metacarpal base.²²⁹ It also reinforces the flexor carpi radialis tendon sheath immediately adjacent to its insertion.²²⁹ It is under tension in extreme radial deviation or opposition and is a **key structure for ensuring the stability of the CMC joint of the thumb.**²²⁹

Note

Avulsion of the volar ligament from its insertion on the first metacarpal base results in the clinical picture of Bennett's fracture dislocation (► Fig. 1.51b).

A T-shaped or Y-shaped fracture of the base of the first metacarpal is referred to as Rolando's fracture (Fig. 1.51c). Both of these types of fracture are intra-articular fractures. Winterstein's fracture (► Fig. 1.51a) is an extra-articular proximal oblique or horizontal fracture of the shaft without involvement of the joint surface.

These fractures lead to dislocation and instability of the thumb.

The pull of the abductor pollicis longus muscle displaces the first metacarpal proximally,²²⁹ while the short muscles of the thumb lead to an adduction position distally.

In this case, surgery is always indicated.

Dorsal Metacarpal Ligament of the Thumb

This ligament is split into two strands and is approximately 9 mm long. It originates from the radial aspect of the second metacarpal base (adjacent to the insertion of the extensor carpi radialis longus tendon) and inserts into the palmar wall of the capsule of the CMC joint.²²⁹ It is under tension during radial abduction, adduction, and opposition.¹⁸⁴

The involvement of the fascicles in the thenar muscles can cause the **flexor retinaculum** to be responsible for reducing the range of motion of the thumb during wrist extension²²⁹ and therefore exert a stabilizing influence.

Fibers of the abductor pollicis longus tendon close to their insertions also contribute to the **stability of the CMC joint.**²²⁹ At least five tendon slips that are interlaced with the joint capsule and the anterior oblique carpometacarpal ligament arise from the insertion.^{194,263} The musculature presses the articular surfaces together and in so doing represents an important stabilizing factor.²²⁹

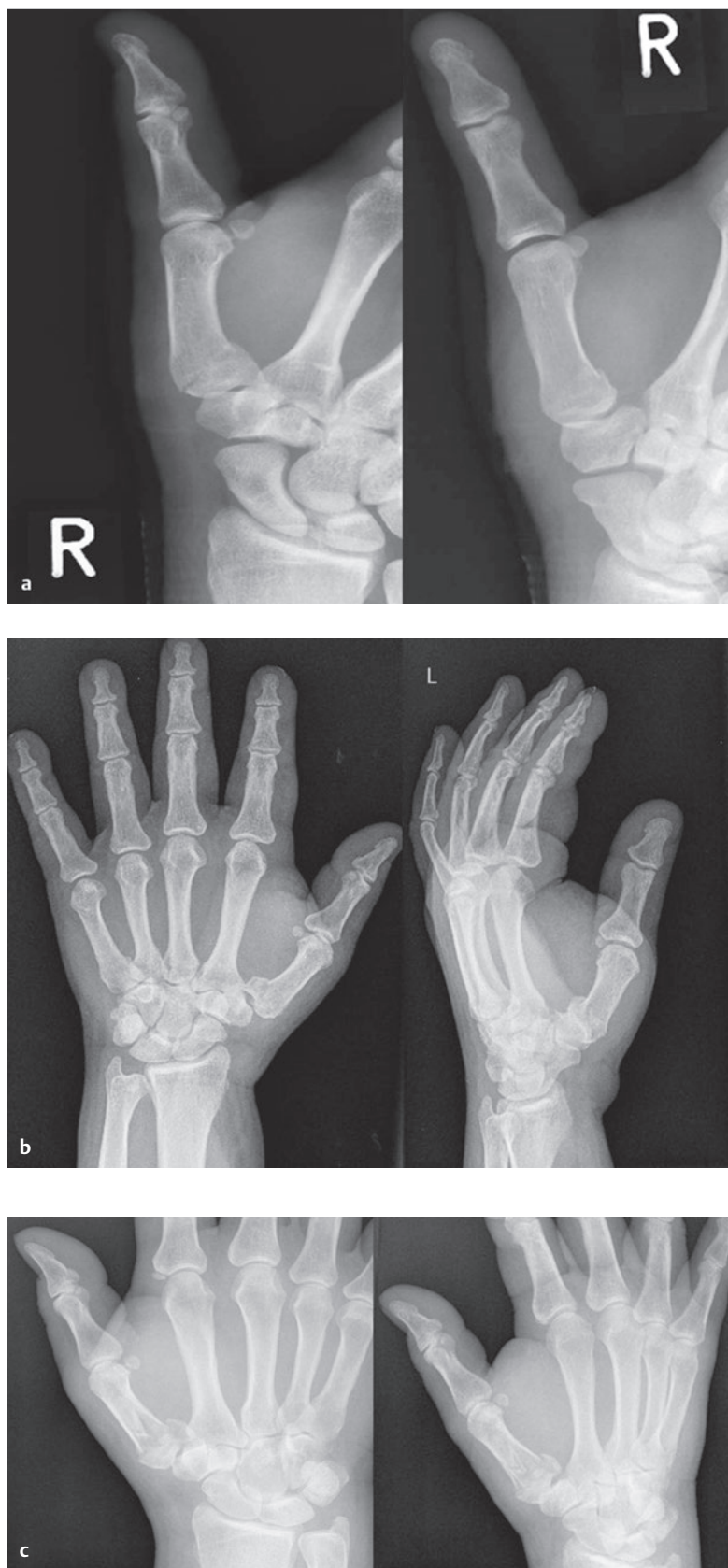


Fig. 1.51 Radiographs of different types of fracture to the base of the thumb. (a) Winterstein's fracture. (b) Bennett's fracture. (c) Rolando's fracture.

Summary

Ligaments that Tighten during Movement

Abduction:

- Dorsal metacarpal ligament of the thumb
- Trapeziometacarpal ligament

Adduction:

- Dorsoradial carpometacarpal ligament
- Anterior oblique carpometacarpal ligament
- Trapeziometacarpal ligament

Opposition:

- Dorsal intermetacarpal ligament of the thumb
- Posterior oblique carpometacarpal ligament
- Dorsoradial carpometacarpal ligament

Muscles of the Thumb CMC Joint

Nine muscles act on the thumb CMC joint. The names of the individual muscles do not provide exact information about their specific movement behavior, however.¹⁶⁰ Each **movement sequence is performed by at least two muscle groups.**¹⁶⁰ The muscles are divided into an extrinsic group and an intrinsic group (► Table 1.3).

Extrinsic Muscles of the Thumb CMC Joint

The extrinsic muscles are **located outside the hand in the area of the forearm.** The individual muscles all course through tendon sheaths in the wrist joint before they insert at the thumb (► Fig. 1.52; ► Fig. 1.53).

Abductor Pollicis Longus Muscle

This muscle arises from the posterior surface of the ulna distal to the ridge of the supinator muscle from the interosseous membrane of the forearm and from the posterior surface of the radius. It passes through the first tendon compartment and inserts at the first metacarpal base at

the joint capsule of the thumb CMC joint with at least five tendon slips. In terms of function, it **stabilizes the thumb CMC joint and abducts the thumb.** It is also involved in flexion and radial deviation of the wrist.

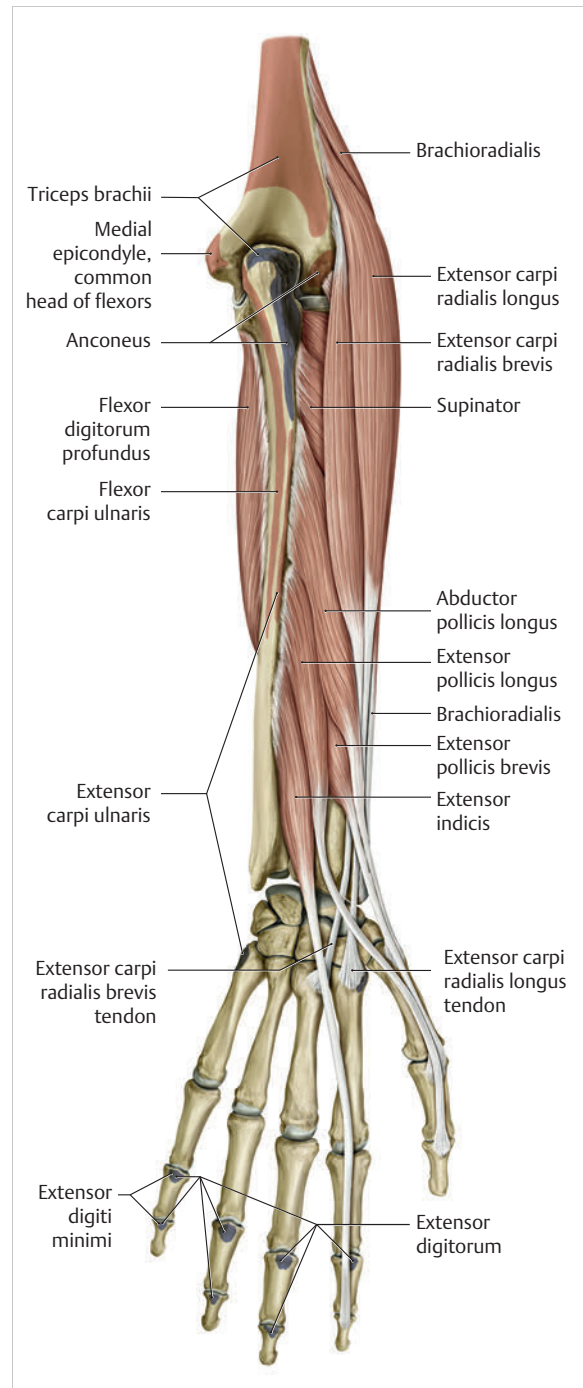


Fig. 1.52 Extrinsic dorsal muscles of the thumb. (From THIEME Atlas of Anatomy, General Anatomy and Musculoskeletal System. 2nd ed. © Thieme 2014, illustration by Karl Wesker.)

Extrinsic muscles	Intrinsic muscles	
	Thenar (lateral)	Thenar (medial)
<ul style="list-style-type: none"> • Abductor pollicis longus • Extensor pollicis brevis • Extensor pollicis longus • Flexor pollicis longus 	<ul style="list-style-type: none"> • Flexor pollicis brevis • Opponens pollicis • Abductor pollicis brevis 	<ul style="list-style-type: none"> • Adductor pollicis • First dorsal interosseous muscle

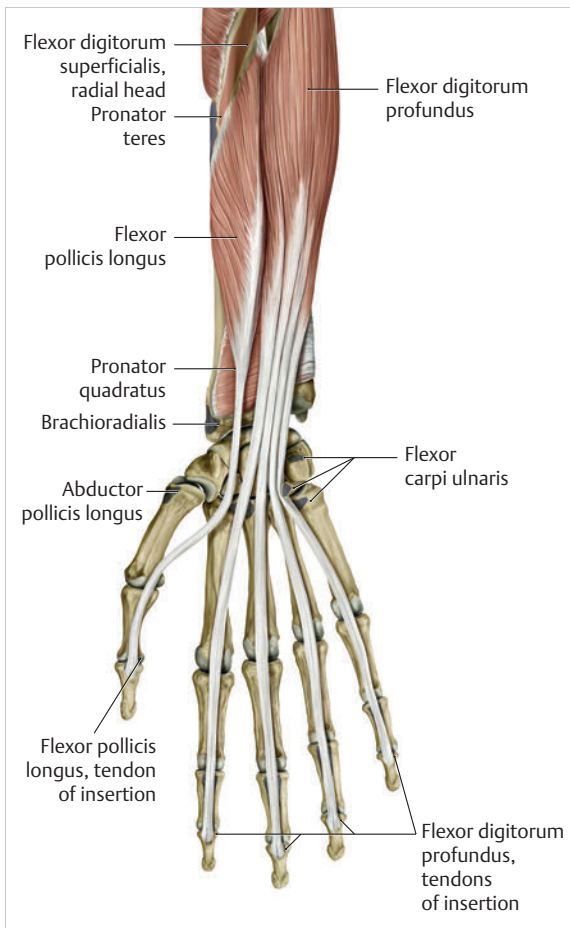


Fig. 1.53 Extrinsic palmar muscles of the thumb. (From THIEME Atlas of Anatomy, General Anatomy and Musculoskeletal System. 2nd ed. © Thieme 2014, illustration by Karl Wesker.)

Extensor Pollicis Brevis Muscle

The extensor pollicis brevis muscle originates distal to the abductor pollicis longus muscle from the interosseous membrane of the forearm and from the posterior surface of the radius. It also passes through the first tendon compartment and inserts at the dorsal base of the proximal phalanx of the thumb. **Together with the abductor pollicis longus muscle, it extends and abducts the thumb.**

Extensor Pollicis Longus Muscle

This muscle arises distal to the posterior surface of the ulna below the extensor pollicis brevis muscle and the interosseous membrane of the forearm. It reaches the dorsum of the hand via the third tendon compartment and inserts at the dorsal base of the distal phalanx of the thumb. Functionally, it serves as a **primary extensor** and provides some support for adduction of the thumb. It is also involved in **radial deviation and extension of the wrist.**

Flexor Pollicis Longus Muscle

The flexor pollicis longus muscle arises from the anterior surface of the radius (distal to the radial tuberosity) and the interosseous membrane of the forearm. In some cases, it also arises from the medial epicondyle. It extends through the carpal tunnel in its own tendon sheath, continues between the two heads of the flexor pollicis brevis muscle, and then inserts at the palmar base of the distal phalanx of the thumb. In terms of function, it is a **flexor of all thumb joints** and is involved in adduction to some extent. In the wrist, it supports radial deviation to a limited extent.

Intrinsic Muscles of the Thumb CMC Joint

The intrinsic muscles are all located within the hand and originate in the wrist or carpus (► Fig. 1.54).

Flexor Pollicis Brevis Muscle

This muscle has two heads. With the superficial head, it arises from the flexor retinaculum and with the deep head it arises from the trapezium, trapezoid, and capitate. It inserts at the radial sesamoid bone at the palmar base of the MCP joint of the thumb. Functionally, it acts as a **flexor, adductor** (deep head) and **abductor** (superficial head) and may also be involved in opposition.

Abductor Pollicis Brevis Muscle

The abductor pollicis brevis muscle originates at the scaphoid tubercle and the flexor retinaculum and inserts at the radial sesamoid bone palmar to the proximal phalanx of the thumb. It is primarily responsible for **abduction of the thumb.**

Opponens Pollicis Muscle

This muscle arises from the tubercle of trapezium and from the flexor retinaculum. It inserts at the radial margin of the first metacarpal. It is involved in **opposition** as well as **adduction and abduction** of the thumb.

Adductor Pollicis Muscle

The adductor pollicis muscle has two heads. The transverse head originates from the entire length of the third metacarpal and the oblique head courses from the palmar surface of the capitate. They insert at the ulnar sesamoid bone below the base of the proximal phalanx of the thumb. The abductor pollicis muscle is responsible for **adduction and opposition of the thumb.**

First Dorsal Interosseous Muscle

This muscle arises with two heads from the medial surface of the first metacarpal and from the radial surface of the second metacarpal. It inserts onto the proximal phalanx at the radial side of the index finger. Apart from its

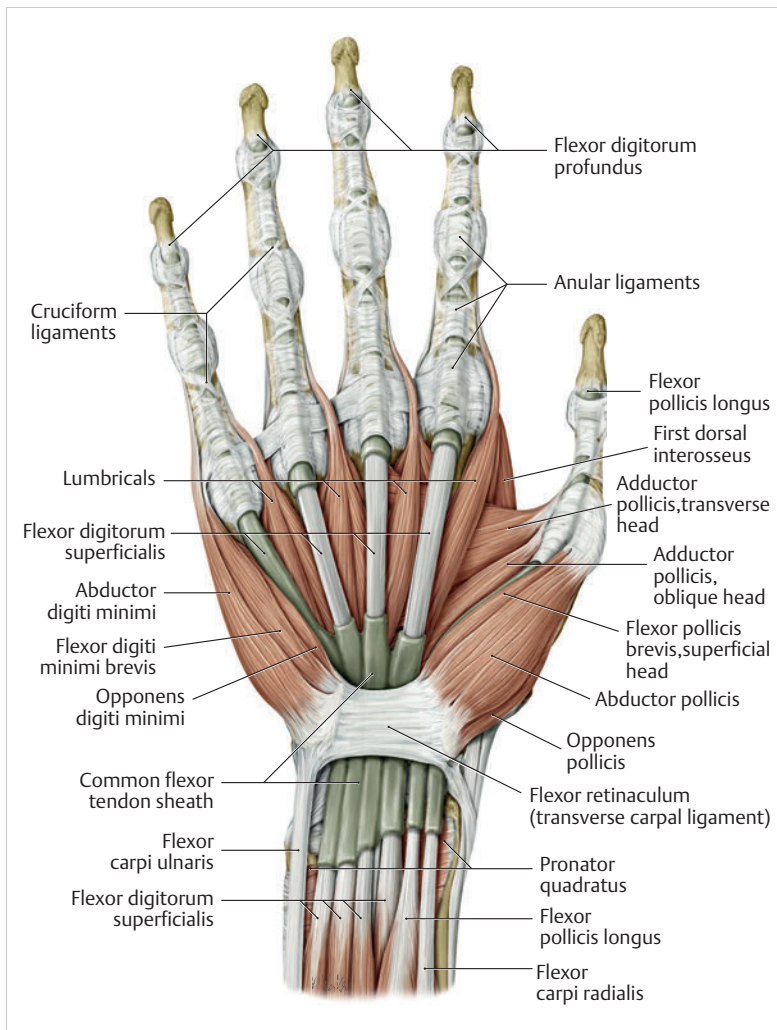


Fig. 1.54 Intrinsic thumb muscles. (From THIEME Atlas of Anatomy, General Anatomy and Musculoskeletal System. 2nd ed. © Thieme 2014, illustration by Karl Wesker.)

primary function, which involves abduction of the second finger ray, it is responsible for **flexion of the index finger MCP joint** and for **extension of the index finger PIP joint**, as well as for **abduction of the thumb**.

Conclusions

The CMC joint of the thumb is primarily influenced by the abductor pollicis longus muscle. Since the extensor pollicis brevis inserts at the base of the proximal phalanx and the extensor pollicis longus inserts at the base of the distal phalanx, joint movements are performed by these two muscles on the CMC, MCP, and IP joints. The extensor pollicis brevis also prevents flexion in the thumb MCP joint, which allows the flexor pollicis longus to perform flexion in the IP joint.¹⁸³ Moreover, one of the five tendon insertion slips of the abductor pollicis longus muscle inserts

directly into the abductor pollicis brevis muscle and can therefore influence the movement of this muscle for synergistic abduction.⁹⁶ Owing to the adhesion of the tendon with the joint capsule, it stabilizes the CMC joint of the thumb and simultaneously coordinates the movements with the abductor pollicis brevis muscle. In contrast, the palmar muscles behave like “dynamic ligaments” by allowing their own possibilities for stabilization and movement to contribute to the thumb movements.

► Table 1.4 provides a summary of the thumb muscles and their respective functions.

There is also synergy between various wrist and thumb muscles. During abduction of the thumb, the hand is stabilized by the extensor carpi radialis and flexor carpi ulnaris muscles with radial deviation in the wrist suppressed at the same time.⁶⁷

Table 1.4 Overview of functions of the thumb muscles

Function	Thumb muscle
Thumb abduction	Extensor pollicis brevis in cooperation with the abductor pollicis longus and opponens pollicis muscles
Thumb adduction	Adductor pollicis, flexor pollicis brevis and longus, opponens pollicis, abductor pollicis longus muscle, and to a limited extent, the first dorsal interosseous muscle
Thumb extension	Extensor pollicis brevis and longus and abductor pollicis longus muscles
Thumb flexion	Adductor pollicis, flexor pollicis brevis and longus, opponens pollicis, abductor pollicis longus, and the first dorsal interosseous muscle
Thumb opposition	Abductor pollicis longus, extensor pollicis longus, adductor pollicis, flexor pollicis brevis and longus, opponens pollicis, and abductor pollicis longus muscles
Thumb reposition	Extensor pollicis brevis and longus, abductor pollicis longus, first dorsal interosseous, and adductor pollicis muscles
Thumb circumduction	All muscles involved in thumb function

Practical Tip

The capsuloligamentous structures of the CMC joint of the thumb play an important role in the pathogenesis of carpometacarpal osteoarthritis. The joint architecture of two opposing saddle-shaped surfaces basically allows movements in the flexion–extension plane and the abduction–adduction plane. With the rotation component arising during opposition, a third movement plane is added. This position of relative surface incongruence causes the capsuloligamentous structures to tighten, which significantly destabilizes the CMC joint of the thumb. It is therefore not surprising that habitual instability contributes to the pathogenesis of degenerative joint diseases.⁴⁶ While carpometacarpal osteoarthritis occurs in around 10% of the population, it affects women 10 times more frequently than men, with over 30% of all women over 50 years old affected by it.²⁸

The most frequent form is idiopathic arthritis of the CMC joint of the thumb, which is caused by laxity of the ligaments surrounding the joint or by reduced curvature of the radial saddle. As a result, the base of the first metacarpal repeatedly assumes a dorsoradial dislocation

position even under physiological load, which gives rise to pressure that overtaxes the joint cartilage over time.^{80,253} Furthermore, the increased laxity of the ligaments causes increased muscle activity to compensate (flexor pollicis longus and abductor pollicis longus muscles) in order to stabilize the joint that is only weakly supported by the ligaments. Alternating precision grasping particularly increases the pressure on the joint surfaces.⁴⁴ As a result, the CMC joint of the thumb embarks on a vicious circle of ligamentary laxity, a tendency toward dislocation, increased muscle guidance, and resulting increased pressure on the joint surfaces that are already overtaxed. This ultimately leads to the degenerative process of osteoarthritis.

Eaton and Littler (1985)⁴⁷ distinguished four stages of osteoarthritis of the CMC joint of the thumb:

- **Stage I:** This stage is characterized by degeneration of the joint cartilage. The joint contours appear to be normal in the radiographic images, with slight joint space widening caused by effusion in conjunction with ligamentous laxity. This stage is considered to be a pre-arthritis stage.
- **Stage II:** There is mild joint space narrowing with no visible destruction of the articulating joint segments. In many cases, osteophytes or joint bodies are detected; these are, however, smaller than 2 mm in size. Ligamentary instability and subluxation increase.
- **Stage III:** Clear destruction of the CMC joint of the thumb is increasingly visible. Pronounced narrowing of the joint space is evident. There is cystic and sclerotic remodeling in the subchondral bone and the osteophytes are larger than 2 mm in size. The CMC joint of the thumb displays various degrees of subluxation. Involvement of the peritrapezoid joints is not yet detectable.
- **Stage IV:** There is widespread destruction of the CMC joint of the thumb and the joint surfaces can barely be distinguished. The subluxation is pronounced. There are now changes to the peritrapezoid joints indicative of pantrapezoid arthritis.

1.4.3 Structure and Function of the Thumb MCP and IP Joints

The thumb MCP and IP joints are involved in all movements of the thumb. The opposition of the thumb is only possible through the combination of extension and flexion with abduction and adduction of the MCP joint in cooperation with the IP joint. Without the thumb MCP and IP joints, opposition of the thumbnail would not be possible.¹⁶⁰ In contrast to the fingers, the thumb has only **two anular ligaments with a Y-shaped ligament in between**. There are no cruciate ligaments.

MCP Joint of the Thumb

The distal part of this ovoid joint is formed by the first metacarpal, which exhibits a significantly more pronounced convex curvature from dorsal to palmar than from radial to ulnar (► Fig. 1.55). Palmarward, the joint has two condyles¹⁰⁸ whose ends are shaped like a spindle truncated at both ends,²²⁹ with the medial part protruding further than the lateral part.¹⁶⁰ This causes the medial facet to move further palmarward during flexion, resulting in abduction with a pronation movement in the further course.¹⁶⁰ On the dorsal side of the distal joint surface of the MCP joint of the thumb there is little cartilage, while the cartilage lining on the volar surface of the first metacarpal extends across the palmar tubercle to the sesamoids.¹²

The two **sesamoids** are consistently observed on the thumb but only sporadically appear in the fingers. They are embedded in the distal portion of the glenoid ligament and, during the flexion–extension movement, move along with the proximal phalanx.¹² In so doing, they articulate with the palmar tubercles of the head of the first metacarpal at all times.¹² As passive stabilizers, they press the collateral ligaments into their gliding channel at the metacarpal head and together with the palmar plate¹⁶⁰ decelerate extension, like brake shoes.²²⁹

The palmar plate is a transverse rectangular structure and is thus significantly shorter than those in the fingers.²²⁹ It is a highly specialized volar thickening of the

joint capsule.¹² The proximal third (membranous part) embeds the two sesamoids¹⁶⁰ and is thinner than the distal two-thirds. This part is attached at the head of the first metacarpal.²²⁹ The distal part (fibrous part), which consists of fibrocartilage and firm connective tissue, is firmly attached to the proximal phalanx.¹²

The two sesamoids are held together by the **phalangoglenoid ligament** and together with the palmar plate and the A1 anular ligament, form a synovial sheath for the tendon of the flexor pollicis longus muscle.²²⁹ It serves to stabilize this tendon when it crosses the MCP joint.¹²

The corresponding **articular surface of the base of the proximal phalanx** of the thumb is less extensive and exhibits a concave curvature in every direction.²²⁹ The difference in the area of contact between the two articular surfaces permits flexion–extension amplitudes between 50° and 70°. Maximum active adduction is between 10° and 20°, and active abduction is also possible to a smaller extent.²²⁹ Rotation is a component motion of circumduction of the thumb.

The **joint capsule, which is rather thin**,¹⁶⁰ is reinforced by the flexor pollicis brevis (insertion and reining of the radial sesamoid) and the adductor pollicis muscles (insertion and reining of the ulnar sesamoid), the palmar plate, and **various collateral ligamentary connections**²²⁹:

1. **Phalangoglenoid ligaments:** The most superficial of these are the radial and ulnar phalangoglenoid ligaments.²²⁹ These ligaments course from the base of the

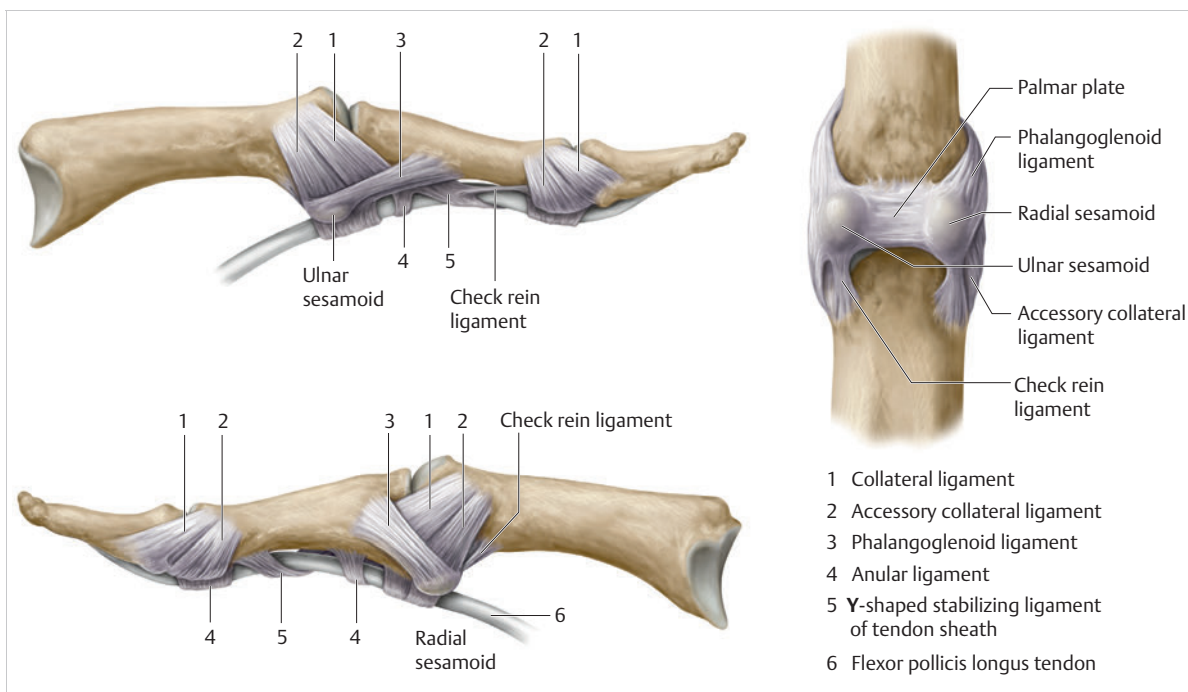


Fig. 1.55 MCP joint of the thumb.

proximal phalanx and the respective sesamoid and are embedded in the joint capsule and the adjacent palmar plate.²²⁹

2. **Proper collateral ligaments:** These collateral ligaments are located relatively close to the surface on the radial and ulnar aspect and are thick structures from 4 to 8 mm wide and around 12 to 14 mm long.⁶⁸ The ulnar part is thicker than the radial part,¹ which enhances the pronation movement in the MCP joint of the thumb.¹⁰⁸ They arise at the radial or ulnar side of the head of the first metacarpal and insert on the medial and lateral surface of the palmar tendon plate and on the proximal and palmar third of the proximal phalanx.¹⁶⁰
3. **Accessory collateral ligaments:** The accessory collateral ligaments, which are located somewhat more superficially, arise at the palmar side of the first metacarpal and are fused with the palmar plate by means of connective tissue.¹⁶⁰ They fan out to insert into the two sesamoids²²⁹ and radiate into the proximal phalanx.¹² They are located below the proper collateral ligaments. The accessory collateral ligament acts reciprocally to the proper collateral ligament and is tightened during extension and relaxed during flexion.

In addition to the active movement of the MCP joint, the muscles influence the stability of the thumb joint. **Three intrinsic and three extrinsic muscles are responsible for guidance.** The most important intrinsic muscle is the adductor pollicis muscle, which supports dynamic resistance during grasping and simultaneously reinforces the ulnar collateral ligament.⁹⁶ The abductor pollicis brevis muscle assumes a similar function on the radial aspect of the thumb, although its effect is weaker due to its more limited muscle strength.⁹⁶ The third intrinsic muscle is the flexor pollicis brevis muscle, which primarily offsets shearing and thus keeps the proximal phalanx from translating dorsalward.⁹⁶ In so doing, it is supported by the flexor pollicis longus muscle.⁹⁶ Although this muscle does not insert at the base of the proximal phalanx, it plays a major role in flexion and stabilization of the joint.⁹⁶ Moreover, the traction forces of the short thumb flexor increase the effectiveness of the flexor pollicis longus muscle by maximizing this lever.⁹⁶ The relatively small extensor pollicis longus and brevis muscles are the other important extrinsic muscles for reinforcing the dorsal joint capsule.¹² With the flexor pollicis brevis muscle, they are able to support the adductor pollicis muscle with compensating for flexion forces during grasping by means of the adduction function.⁹⁶

Practical Tip

Gamekeeper's thumb (also known as skier's thumb) is a common pathology.²³¹ Owing to the course of the ulnar collateral ligament, extreme trauma-related radial deviation (e.g., a fall on the thumb while skiing or misadventure in ball games) causes the ligament to rupture.²³¹ Functionally, the ability to hold an object by opposing the thumb becomes impossible. The clinically unstable MCP joint can be excessively deviated to the radial side by the examiner.²³¹ The dislocated distal fragment can also retract proximally and wrap around the adductor pollicis aponeurosis (Stener's lesion). If the ligament is not reconstructed and the joint remains in a fixed position, the misalignment in the MCP joint of the thumb will cause arthritis.

Note

Range of Motion of the MCP Joint of the Thumb

- Flexion 80° and extension 0°
- Abduction 12° and adduction 7°
- Pronation 20° and supination 6°

IP Joint of the Thumb

The IP joint of the thumb is a **simple hinge joint** whose structure is identical to that of the DIP joints of the fingers. However, the palmar plate is slightly thicker and a sesamoid is often embedded in the palmar wall of the joint capsule (22–73%).¹²⁸ The palmar plate may therefore displace the flexor pollicis longus tendon far palmarward of the joint space, which allows it to be hyperextended to up to 25°.²²⁹ The head of the proximal phalanx has two condyles that articulate with the facets of the distal phalanx. The ulnar condyle is more prominent than the radial condyle, which promotes pronation during flexion.¹⁰⁷ The collateral ligaments fan out from the side of the head of the proximal phalanx to the base of the distal phalanx, while the accessory ligaments extend toward the palmar connective tissue plate.²¹⁴ Cleland's ligaments (continuations of the palmar fascia) reinforce the collateral ligaments on the radial aspect.⁴⁵ The load during flexion is around 30% greater than during extension.² The joint may be flexed to approximately 90° and hyperextended to 25°. Flexion involves a slight rotational component of around 5 to 10° into pronation.²²⁹ The primary muscles responsible are the extensor pollicis longus for extension and the flexor pollicis longus for flexion, with the distal phalanx of the thumb involved in all grasping functions of the thumb.

Conclusions

The construction of the thumb reflects Ockham's Efficiency Theorem, since most of the functions are performed by a minimum of structural elements.⁶⁷ The two most important functions are the power grasp, or fist grasp, and the precision grasp. The fist grasp is described as a spherical, cylindrical and hook grip, and the precision grip is described as a palmar, lateral and tip-to-tip grip.⁶⁷

Note

Range of Motion of the IP Joint of the Thumb

- Flexion 90° and extension 30°
- Pronation 10° and supination 0°

1.5 Structure and Function of the Palm

The **five short tubular bones** of the palm (metacarpal bones) are located next to the many-edged carpal bones (► Fig. 1.56). **The bones can be subdivided into three sections: the base, the body, and the head.** They have articular surfaces, with which they can connect to the carpus and the metacarpals. The thumb metacarpal is connected to the carpus via a saddle joint. The most important task of the metacarpal bones is to **support** the hand's **grasping function**.¹¹ With the palm, they form a firm counter-bearing when grasping or holding onto objects.²⁰⁰ They provide space for the two vascular arches

and serve as a bridge for the sensory nerves and the tendons to the finger joints.²⁰⁰ The metacarpal bones also serve as the area of origin for the various intrinsic muscles of the hand that are indispensable for the functions and for stabilization of the finger joints.²²⁹

1.5.1 Structure and Function of the Second to Fifth Metacarpals

Including the thumb, the five metacarpal bones are short tubular bones of various lengths (► Fig. 1.57). The bases of the third to fifth metacarpals are rectangular and the base of the second metacarpal is triangular. Its dorsal part is wider than the palmar part, which allows it to have a **stable articular connection with the distal carpus** (i.e., wedge-shaped connection).²³⁰ From this rather rigid unit, a convex arch forms on the dorsal side and a concave arch forms on the palmar side, known as the **palmar carpal arch**.⁶⁵ This concavity flattens out to some extent at the level of the metacarpal heads or the metacarpal arch.⁶⁵

The **first to fifth metacarpal bodies** are somewhat convex dorsalward and have a strongly concave shape palmarward, which reinforces the formation of the palm. The thickness of the shaft continuously decreases by up to 20% from dorsal to palmar as well as to proximal and distal.^{196,197} In addition, it has been observed that cortical thickness correlates with strength of grip and in so doing increasingly promotes dexterity.²²⁹ The proximal end of each bone, the **metacarpal base**, is significantly broader than its shaft.²²⁹ At around 67 to 69 mm, the second metacarpal is the longest of the metacarpals, followed by the third metacarpal at 62 to 69 mm, the fourth metacarpal at 55 to 62 mm, and the fifth metacarpal at 52 to

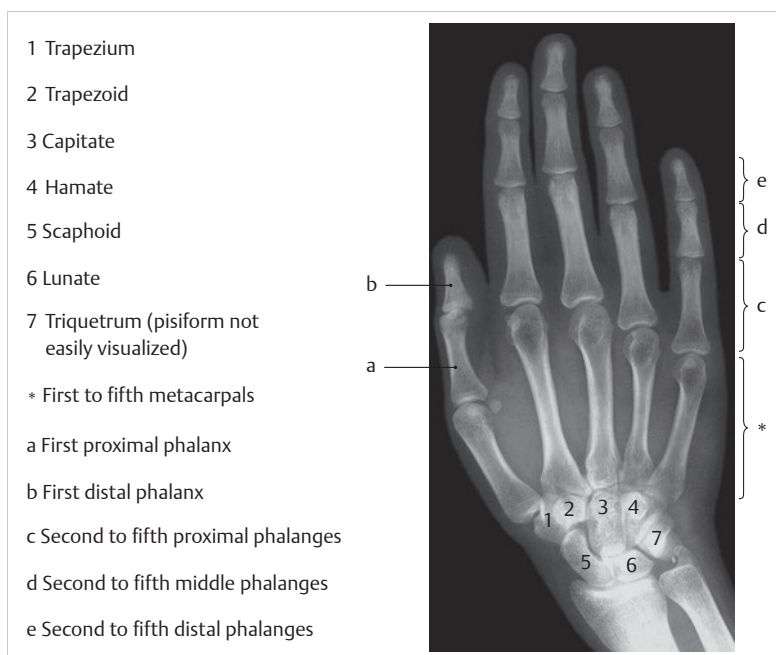


Fig. 1.56 Radiographic visualization of the carpal and metacarpal bones. (From Thiemann HH, Nitz I, Schmeling A. Röntgenatlas der normalen Hand im Kindesalter. 3rd ed. Stuttgart: Thieme; 2006.)

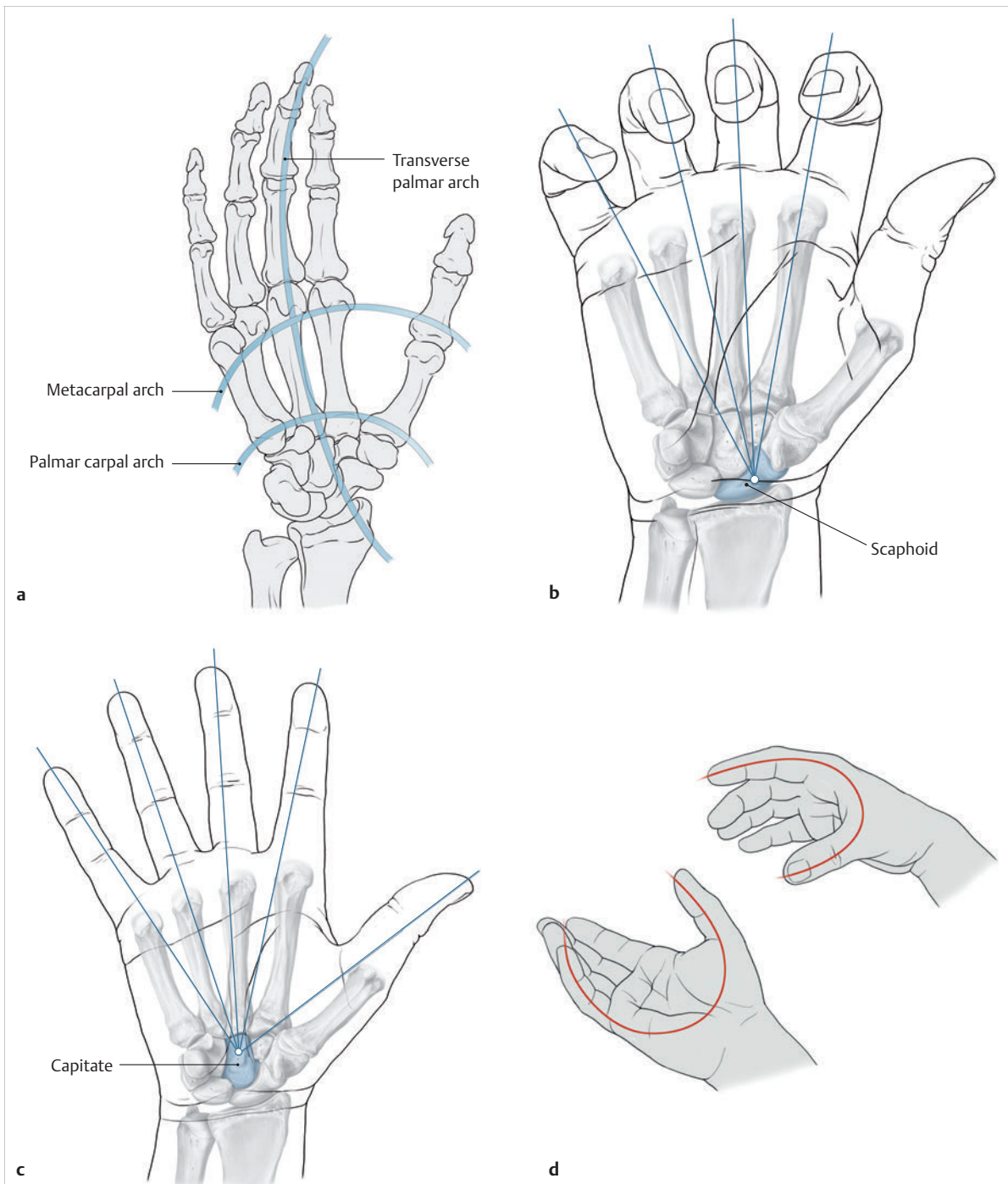


Fig. 1.57 Structure and function of the second to fifth metacarpal bones. **(a)** Longitudinal and transverse arches of the hand. (From THIEME Atlas of Anatomy, General Anatomy and Musculoskeletal System. 2nd ed. © Thieme 2014, illustration by Karl Wesker.) **(b)** The scaphoid axis. (From THIEME Atlas of Anatomy, General Anatomy and Musculoskeletal System. 2nd ed. © Thieme 2014, illustration by Karl Wesker.) **(c)** The capitate axis. (From THIEME Atlas of Anatomy, General Anatomy and Musculoskeletal System. 2nd ed. © Thieme 2014, illustration by Karl Wesker.) **(d)** The palmar arch and opposition.

58 mm.⁸³ The metacarpals fan out from proximal to distal, which additionally increases the breadth of the hand's grip.²²⁹ Like the metacarpal bases, the **metacarpal heads**

are also larger than the shaft. With their convex heads, they form the proximal sections of the second to fifth MCP joints. The heads of the second and third metacarpal

bones are pronated with respect to the base, whereas the heads of the fourth and fifth are supinated with respect to the base.²²⁹ The longitudinal axes of the second and third metacarpals are thus directed toward the scaphoid and those of the fourth and fifth metacarpals are directed toward the lunate.¹²⁷ This torsion enables the index and middle fingers to have a specific precision grip and the ring and little finger to oppose the thumb.

The most limited range of motion is in the second and third MCP joints, which is why these are considered to be the stable columns of the palm followed by the somewhat more mobile fourth and fifth MCP joints.¹⁶⁵ This means that the thumb with its first metacarpal bone is the most mobile metacarpal bone and circles around or toward the other fingers as the pivot of all movements.¹⁶⁵ The **transverse palmar arch** and the **longitudinal arch** are responsible for the coordinated convergent movement of the fingers and the thumb.⁶⁵ While the **proximal palmar arch** retains its shape due to its bony and ligamentary fixation, the **distal palmar arch** adapts to the individual range of motion of the fingers.⁶⁵ The metacarpal arch therefore decreases during flexion, since the fingers must be able to act together to develop strength in the fist grip.²²⁹ The same is true for extension of the fingers in order to enlarge the grasping surface. In so doing, the abducted thumb and outspread fingers converge at a common point of intersection in the center of the capitate.²²⁹ Furthermore, Kapandji (1963)¹⁰⁵ described an **oblique palmar arch** between the highly mobile first metacarpal and the relatively mobile fourth and fifth metacarpals. In cooperation with the torque of the fourth and fifth metacarpal heads, the oblique palmar arch enables opposition between the thumb and the little finger, meaning that the oblique palmar arch increases between the fourth and fifth metacarpals and remains constant for the second and third metacarpals. The mobility of the metacarpal joints is what enables the hand to adapt to the requirements of grasping.

1.5.2 Muscles of the Metacarpals

Various muscles insert onto the bases of the metacarpals (e.g., extensor carpi ulnaris), while other muscles arise from these bones. These include the dorsal and palmar interossei and adductor pollicis with its transverse head, which arise from the shaft. In addition, some intrinsic muscle bellies lie on the metacarpal bones in order to insert into the fingers further on (lumbricals, abductor digiti minimi, flexor digiti minimi brevis and opponens digiti minimi muscles).

Dorsal and Palmar Interossei

The bipennate **palmar interossei** arise with a single head each from the second metacarpal (ulnar side) and the fourth and fifth metacarpals (radial side) and extend with their inserting tendons into the dorsal digital expansion of the index, ring, and little fingers, respectively (► Fig. 1.58). In addition, minor accessory fibers of the tendons of the first and third palmar interossei also insert into the capsule of the radial aspect of the metacarpophalangeal joint or, in 6% of the population, into the radial side of the base of the proximal phalanx.⁵⁴ The second palmar interosseous muscle does not have a bony insertion.⁹⁵ Its tendons extend across the deep transverse metacarpal ligament in palmar direction in the flexion axis of the MCP joints.¹⁹⁸

The two-headed **dorsal interossei** arise from the respective adjacent aspects of the first through fifth metacarpals.¹⁹⁸ The first dorsal interosseous muscle (62 mm in length) lies in the space between the metacarpals of the thumb and the index finger. The other dorsal interossei (measuring between 50 mm and 63 mm in length) fill the metacarpal spaces.²²⁹ The first dorsal interosseous muscle inserts into the base of the proximal phalanx at the radial aspect of the index finger. The first dorsal interosseous muscle is also tightly interlaced with the capsule and the collateral ligament complex of the second MCP joint and passes in a spiral into the radial

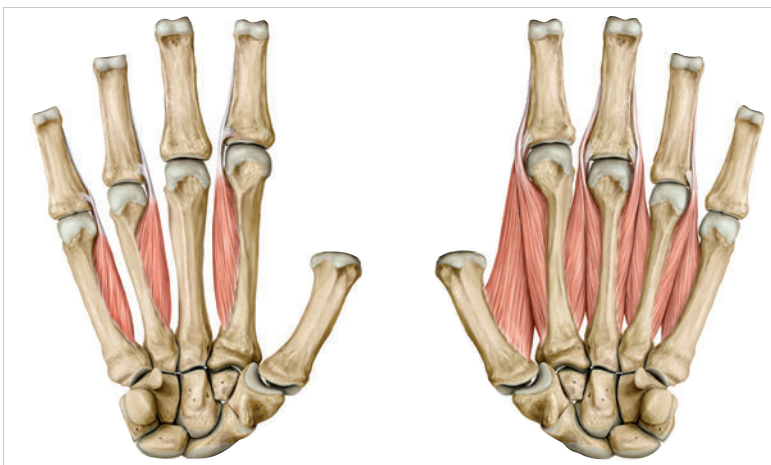


Fig. 1.58 Palmar and dorsal interossei. (From THIEME Atlas of Anatomy, General Anatomy and Musculoskeletal System. 2nd ed. © Thieme 2014, illustration by Karl Wesker.)

interosseous hood of the dorsal digital expansion together with a deep part of the first lumbrical.²²⁹ Its tendon also gives off fibers for the A1 annular ligament and the palmar plate of the index finger.²²⁹ The second dorsal interosseous muscle also inserts into the radial base of the proximal phalanx and the dorsal digital expansion of the middle finger, while the third and fourth interossei insert into the ulnar aspect of the middle and ring fingers at the bases of the proximal phalanges and the dorsal digital expansions.¹⁹⁸

Functionally, the palmar interossei **adduct** the MCP joints and the dorsal interossei **abduct** these joints.¹⁹⁸ They all contribute to **flexion** in the MCP joints and **extension** in the PIP and DIP joints when the MCP joints flex or are held in flexion.¹⁰

Note

Loss of function in all of the short muscles of the hand, as can occur in combined median and ulnar nerve palsy, results in claw hand deformity of the second to fifth metacarpals. Characteristic findings include hyperextension in the second to fifth MCP joints due to the action of the extensor digitorum communis, and flexion in the IP joints due to the flexor digitorum muscles (“intrinsic minus” fingers).²²⁹

Lumbricals

The four lumbricals are embedded in the loose connective tissue between the palmar aponeurosis, flexor tendons, and the palmar interossei (► Fig. 1.59). The unipennate **first and second lumbricals** normally arise from the radial aspect of the flexor digitorum profundus tendons. The first lumbrical is around 65 mm in length⁹⁷ and arises from the flexor digitorum profundus tendon of the index finger. The second lumbrical, which is around 61 mm in length,⁹⁷ arises from the flexor digitorum profundus tendon of the middle finger.²²¹ The two lumbricals extend to the respective dorsal digital expansion.²²⁹

In most cases, the **third and fourth lumbricals** arise with two heads from the respective radial and ulnar parts of the flexor digitorum profundus tendons of the middle, ring, and little fingers.²²¹ In 50% of the population the third lumbrical inserts into the radial aspect of the dorsal digital expansion of the ring finger and in 40% it additionally inserts into the ulnar aspect of the middle finger.²²⁹ The fourth lumbrical normally inserts in the radial aspect of the dorsal digital expansion of the little finger. Furthermore, these two muscles often have additional insertions at the A1 annular ligament of the ring finger and little finger.²²⁹ In addition, insertions of the fourth lumbrical are observed in the capsule of the MCP joint of the little finger and into the flexor tendon sheath.¹⁵⁴

The primary function of the lumbricals is to **regulate tension between the flexor and extensor musculature**,

which is confirmed by the presence of a high number of neuromuscular and tendinous proprioceptors.²⁰³ As a proximal system of oblique muscles, these small muscles actively **reduce the flexing force in the fingers** and are involved in **strengthening extension**.²²⁹ Furthermore, the lumbricals are passively supported by the oblique Landsmeer retinacula for extension of the distal phalanges (distal oblique system). In addition to a slight flexing function in the second to fifth MCP joints,²⁰⁴ they cooperate with the interossei to stabilize these joints and **prevent ulnar deviation of the fingers**.

Abductor Digiti Minimi Muscle

The abductor digiti minimi muscle arises from the pisiform, the pisohamate ligament, and the flexor retinaculum muscle.¹⁹⁸ It inserts at the ulnar margin of the base of the proximal phalanx of the fifth metacarpal, with

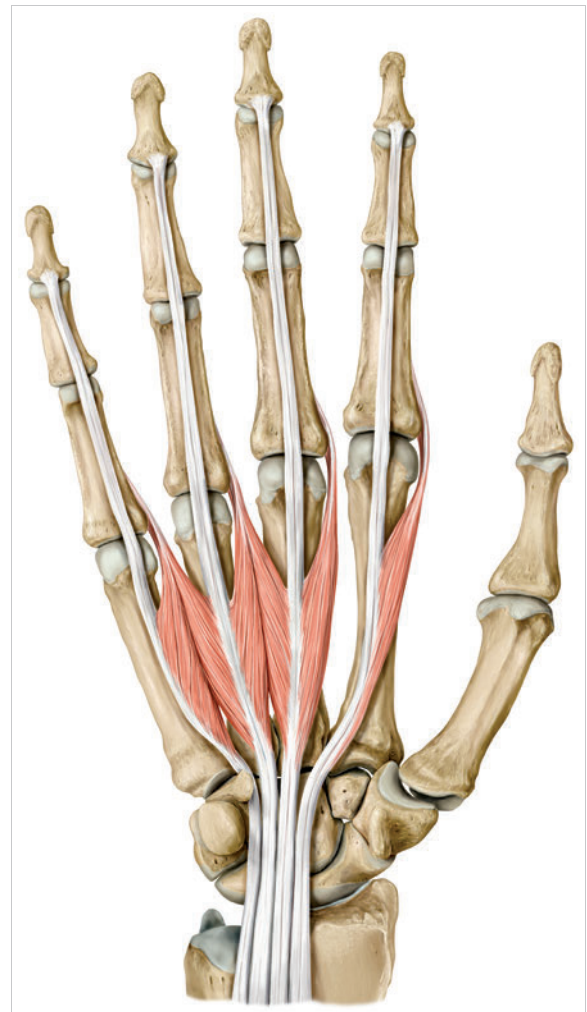


Fig. 1.59 The lumbricals. (From THIEME Atlas of Anatomy, General Anatomy and Musculoskeletal System. 2nd ed. © Thieme 2014, illustration by Karl Wesker.)

several fibers also extending into the dorsal digital expansion.¹⁹⁸ Functionally, it is a **pure abductor for the little finger**.¹⁹⁸

Flexor Digiti Minimi Brevis Muscle

This muscle originates at the flexor retinaculum and hamate.¹⁹⁸ It inserts onto the palmar surface of the base of the proximal phalanx of the fifth finger and supports **flexion of the MCP joint of the little finger**.¹⁹⁸

Opponens Digiti Minimi Muscle

The opponens digiti minimi muscle arises from the hook of hamate and the flexor retinaculum and inserts at the ulnar margin of the fifth metacarpal. It performs **opposition of the little finger in synergy with the opposition of the thumb**.

The abductor digiti minimi, flexor digiti minimi brevis and opponens digiti minimi muscles form the **hypothenar musculature** on the ulnar margin of the hand and support the formation of the palmar arch (► Fig. 1.60).

1.5.3 Palmar Aponeurosis (Metacarpal Area)

The **palmar fascia** forms the continuation of the antebrachial fascia on the flexor side of the forearm and of the palmar carpal ligament.⁶⁰ It extends into the midpalmar space of the palm and from there, broadens into the space up to the first metacarpal for the thenar space and to the fifth metacarpal into the hypothenar space.⁶⁰ The midpalmar space is reinforced by the palmar aponeurosis (► Fig. 1.61).

Note

The anatomical terms “palmar aponeurosis” or “palmar fascia” cannot be compared to the aponeuroses or fascia of other parts of the body, since there are identifiable differences with respect to chemical composition and functional load.¹⁶⁶

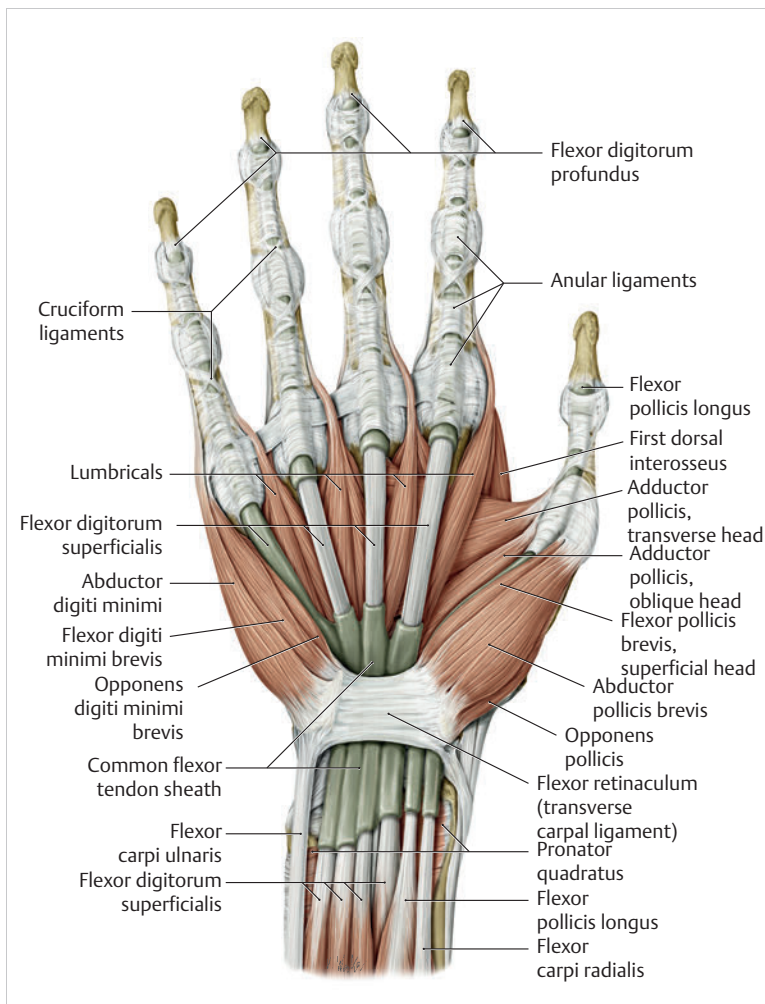


Fig. 1.60 Hypothenar muscles. (From THIEME Atlas of Anatomy, General Anatomy and Musculoskeletal System. 2nd ed. © Thieme 2014, illustration by Karl Wesker.)

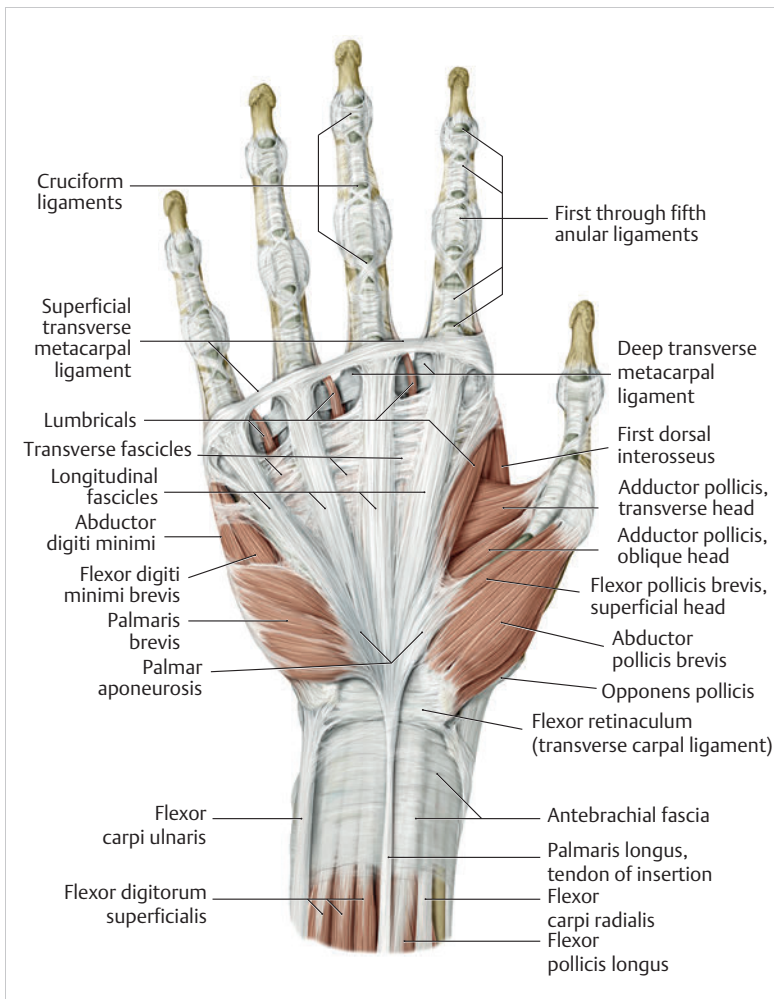


Fig. 1.61 Palmar aponeurosis. (From THIEME Atlas of Anatomy, General Anatomy and Musculoskeletal System. 2nd ed. © Thieme 2014, illustration by Karl Wesker.)

In terms of function, the palmar aponeurosis serves to **protect the underlying flexor tendons, vessels, and sensory nerve fibers of the fingers**. Furthermore, the palmar aponeurosis contributes to **maintaining the arches of the palm** by resisting the forces that would flatten the palm or lift the skin when the hand grasps objects.¹⁹⁹

The **palmar aponeurosis** consists of a superficial layer with longitudinal fibers and a deep layer with fibers taking a transverse course and appears as a nearly triangular limited fibrous plate whose tip is directed toward the wrist.¹⁶³ With its proximal width of around 21 mm,¹⁰⁰ the fibrous plate is firmly fused to the flexor retinaculum and becomes wider as it extends into the palm via the tendon fibers of the palmaris longus muscle as a stabilizing slip.¹²⁹ These tendon fibers are still present in the palmar aponeurosis even if the palmaris longus muscle is absent.⁵⁵ The radial margin toward the thumb is around 50 mm long and the ulnar margin toward the base of the little finger is around 38 mm long. Near the fingers, the palmar aponeurosis expands to around 55 mm¹⁰⁰ and is delineated by loose connective tissue from the groove of the proximal phalanx and the margins of the webs.¹⁶³

The rigid portions of the palmar aponeurosis (floor plate) are located distal to and over the heads of the palmar metacarpal bones.¹⁶³

Longitudinal Fibers

The **longitudinal fibers of the palmar aponeurosis** arise directly from the flexor retinaculum or from the tendinous parts of the palmaris longus muscle. Some of these fibers already exit the aponeurosis below the palmar wrist and take an oblique course to the skin up to the distal groove of the palm.^{229,246} They are supplemented by short connection fibers that attach the skin tautly to the palmar aponeurosis.²⁴⁶ The further portions of the longitudinal fibers join the fiber system on the palmar aspect of the proximal phalanges or become more prominent in the MCP joints in the form of pretendinous ligaments.²⁴⁶ In the distal half of the palm, septalike continuations between the tendon sheaths extend into the deep tissue layers and join the deep palmar fascia.²⁴⁶ These septa form **seven canals** that contain the nerve fiber bundles and flexor tendon sheaths.²⁴⁶

In the distal palm there are gaps between the longitudinal fibers that are filled with loose fatty tissue and exhibit ascending vessels to the skin.¹⁶⁷

On the lateral aspects of the fingers, systems of longitudinal fibers can also be found.²⁴⁶ This fiber system extends from the transverse fibers of the interdigital folds to the joint capsules of the DIP joints,⁷⁵ the **Grayson's ligaments** being a connection to the palmar skin of the fingers,²⁸² and the **Cleland's ligaments** being a connection from the bones and joint capsule to the lateral skin.²⁸²

Transverse Fibers

The **transverse fibers** are located in the superficial distal palmar area and contribute to forming the interdigital ligaments.²⁴⁶ The individual fiber bundles surround the base of a finger or, in some cases, the bases of two fingers,²⁴⁶ and continue in the intertendinous connection.²⁵⁴ In this area, the transverse fibers also merge with longitudinal fibers.⁷⁵ In the center of the palm, a further transverse fiber system is located that connects the fascia of the thenar and the fascia of the hypothenar.³¹

Practical Tip

Dupuytren's contracture is a common pathology of the palm (► Fig. 1.62). It involves a benign nodule and/or fibrosis in the palm and the fingers. An important role is played by fibroblasts, which are induced by the body's own hormones to differentiate into myofibroblasts to generate contractile connective tissue. Ectopic manifestations of Dupuytren's contracture can affect the plantar sole (Ledderhose's disease), the base of the penis, as well as the dorsal PIP joints (knuckle pads). While the exact etiology has not yet been determined, heredity is definitely a factor. If the patient reports impaired range of motion of the hand, surgical correction should be performed. In addition to percutaneous needle fasciotomy, partial or complete aponeurectomy may also be performed depending on the clinical symptoms. There is also a trend to treat Dupuytren's contracture with radiation therapy or collagenase injections.

In addition to the palmaris longus muscle, the palmaris brevis muscle also influences the palmar aponeurosis.²²⁹

The palmaris brevis muscle arises from the ulnar margin of the palmar aponeurosis and extends approximately 40 mm in a distal direction at the level of the pisiform.¹⁰⁰ When the hand grasps an object, the muscle contracts. Together with the fat cushion superficial to the ulnar tunnel ("Guyon's canal"), this helps to protect the nerves on the ulnar aspect of the hand against excessive compression.²²⁹ The palmaris brevis muscle is supported by the inserting tendons of the extensor carpi ulnaris muscle.²²⁹

1.6 Structure and Function of the Finger Joints

With both their fine and gross motor functions, the fingers enable humans to perform basic functions such as feeling, sensing, and grasping objects, as well as communication tasks such as pointing and sign language, as well as writing texts. The function of the finger joints therefore plays a major role in allowing us to cope with everyday tasks that we take for granted.

The fingers refer to the **five terminating members of the human hand**: the thumb, index finger, middle finger, ring finger, and little finger. The **thumb** (section 1.4) has **two phalanges** and the **fingers have three phalanges each**: the proximal, middle, and distal phalanges. The finger can only perform the entire range of the diverse movement requirements in daily life if the actions of these three joints are synergistic and coordinated.

1.6.1 Structure and Function of the MCP Joints

The metacarpal bones, which are in the same plane and run parallel, form the proximal part of the finger joints at the distal end. In the horizontal plane, the metacarpal heads are arranged in a flexible transverse arch.³² In terms of mechanics, they resemble an **ovoid or ellipsoid joint**²⁵² and therefore permit **abduction-adduction movements** along the longitudinal axis, **extension-flexion** along the transverse axis, and **circumduction**, which is a compound movement involving movements along both these axes.²⁵⁶ The round, asymmetrical shape of the metacarpal head is wider on the palmar aspect than on the dorsal aspect.¹⁶⁰ This results in a larger contact

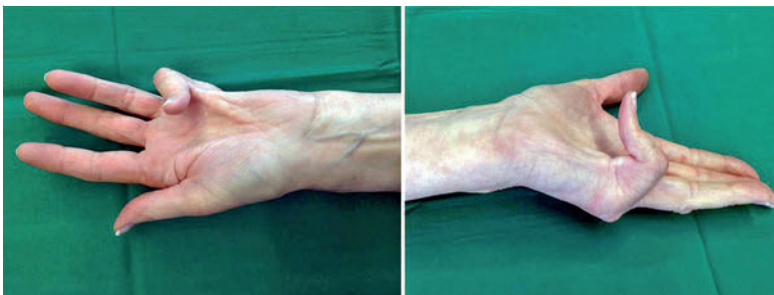


Fig. 1.62 Dupuytren's contracture.

surface of the concave base in flexion than in extension,²⁷⁰ which explains the difference in thickness of the cartilage, viz. from 1.4 mm at the palmar aspect compared to 0.5 mm on the dorsal aspect.²⁵²

The heads of the second and third metacarpal bones are slightly supinated toward the proximal phalanges (for the precision grip) and the metacarpal bones of the ring and little fingers are slightly pronated (for grasping objects).¹⁶⁰ The **strong radial and palmar prominence of the second metacarpal** decreases in an ulnarward direction. It is most prominent at the level of the heads of the fourth and fifth metacarpals, which gives rise to ulnar deviation of the concave base of the proximal phalanx.⁶ With the involvement of the supination of the fourth and fifth metacarpals,¹⁶⁰ the circumduction movement of the fourth and especially of the fifth MCP joint (i.e., the grasping area) is enlarged without radically altering the longitudinal axis of flexion, thus enabling larger objects to be grasped. The converse is true for the precision grip, meaning that the second metacarpal is in a somewhat pronated position and, during flexion the index finger rotates somewhat into supination.¹⁸²

The **distal concave bases** of the proximal phalanges are located across from the joint surfaces of the metacarpal heads. The total area of these **ellipsoidal** sockets is smaller than that of the metacarpal heads. The dorsal-to-palmar distance of the longitudinal axis is significantly shorter than that of the radioulnar transverse axis, which approximately corresponds to the width of the articular surface of the metacarpal head.²²⁹ **Three tubercles** are embedded in the base of the proximal phalanx: A dorsal tubercle allows for the insertion of the medial portion of the extensor tendon and a palmar-to-radial and a palmar-to-ulnar tubercle allows for the insertion of the collateral ligaments.¹³⁹

Owing to a rather **loose joint capsule**, the MCP joints are primarily stabilized by the collateral ligaments with the involvement of a palmar and dorsal connective tissue plate (► Fig. 1.63).¹⁶⁰

Collateral Ligaments

The collateral ligaments are divided into the deep layer, with the collateral ligament, and the superficial layer, with the accessory and phalangoglenoid collateral ligaments (“phalangeal cuff.”²⁴⁹).

The collateral ligaments originate from a tuberosity on the radial and on the ulnar aspect. They are strong, 3-mm thick and 8-mm wide bands that follow an oblique course from dorsal and proximal to distal and palmar. They have two insertions: With a radial and lateral portion, they insert onto the volar base of the phalanx and with a distal and lateral portion, they insert onto the palmar connective tissue plate.¹³⁹ The radial collateral ligament is thicker on the index and middle finger than the ulnar collateral ligament.¹²⁸ During extension, they are more relaxed, and during flexion, they are under tension, with tension shifting from the palmar fibers to the dorsal fibers.²²⁹ In flexion position, the collateral ligaments can stretch approximately 3 to 4 mm (► Fig. 1.64).¹⁶⁸

The thinner accessory collateral ligament arises immediately palmar and proximal to the origin of the collateral ligament and fans out³² distally to insert into the lateral margin of the palmar plate (► Fig. 1.65). These fibers are much less rigid than the collateral ligament and can therefore fan out during flexion.¹⁶⁰ During extension, they are also under tension. However, the steeper course of the taut fibers allows some rotation and shifting of the palmar plate and therefore preserves side-to-side mobility in the extended finger.¹⁴⁰

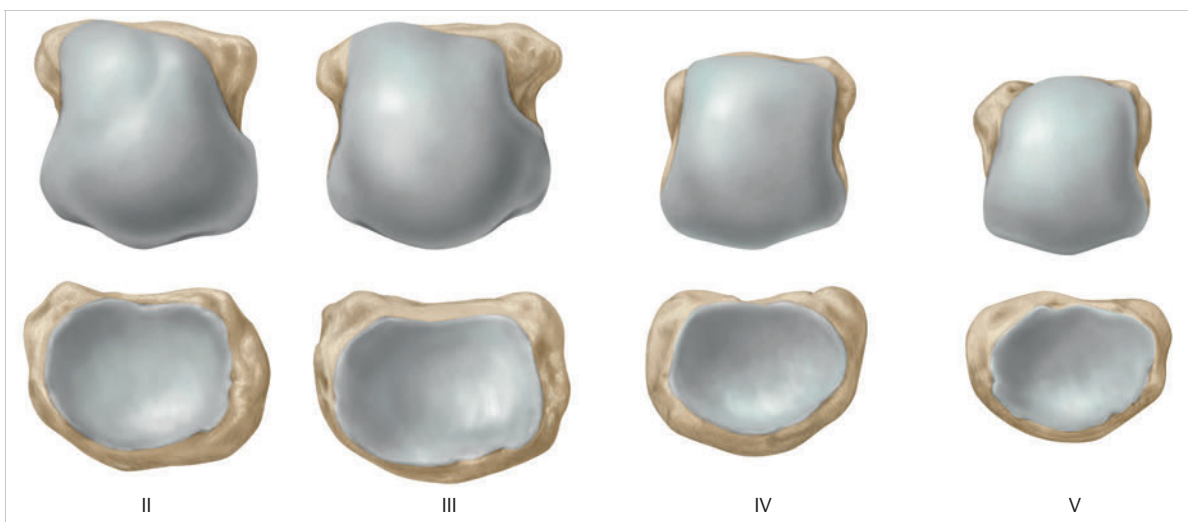


Fig. 1.63 Articulating surfaces of the second to fifth MCP joints.

The most superficial ligament of the collateral capsular ligament structures is the **phalangoglenoid ligament**⁸¹ (► Fig. 1.65). It arises laterally from the base of the proximal phalanx and courses obliquely across the inserting fibers of the collateral ligament to its proximal and palmar insertions. The proximal fibers insert into the palmar plate and the A1 annular ligament.²²⁹ The phalangoglenoid ligament and the accessory collateral ligament act synergistically to counteract tensile forces that in flexion are directed palmarward via the annular ligaments of the flexor tendon sheath.²²⁹ This deflecting pulley (so-called camshaft effect³²) prevents the joint socket from tilting or jamming against the metacarpal head during flexion and in so doing preserves homogeneous gliding of both joint partners.¹⁸⁵

In every joint position of the MCP joints, a certain portion of the collateral ligament complex is under tension.²³⁷ During **maximum flexion** both the deep and the superficial collateral ligaments are under tension, which means that no lateral movements are possible.¹⁰⁸

Note

The snapping sound of the MCP joints when the fingers are pulled can be attributed to the collection of water vapor and blood gases in the partial vacuum of the joint cavity.²¹¹

Palmar and Dorsal Connective Tissue Plate

The **palmar plate** is around 1.5 cm long and 1 cm wide. It consists of a distal fibrous cartilaginous portion around 4 mm thick and a proximal portion of thin, flexible connective tissue.⁴² The proximal portion inserts onto the palmar aspect of the metacarpal neck and the distal portion extends into the palmar margin of the articular cartilage of the base of the phalanx.⁷¹ Dorsalward, the area that has contact with the proximal phalanx increases in size and can be interpreted as the continuation of the joint surface of the metacarpal head.¹⁶⁰ In other words, it acts as a sort of glenoid labrum that enlarges the joint socket and provides an expanded supporting surface for the metacarpal head.²²⁹ The palmar plate also forms part of the fibrous portions of the flexor tendon sheath and acts similarly to a meniscus¹⁶⁰ by **increasing the distance between the tendons of the flexors of the fingers and the axis of flexion**.²²⁹ Together with the accessory collateral ligament, the palmar plate also prevents excessive hyperextension in the MCP joints.²²⁹

The **dorsal connective tissue plate** is a thickening of the dorsal joint capsule of the MCP joints, which serves as a **gliding floor of the extensor tendons** and contributes to **improving joint congruity**.²⁴⁹

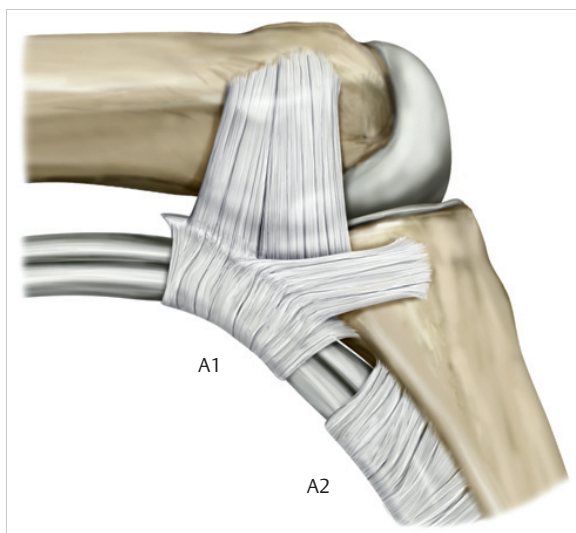


Fig. 1.64 Capsule and ligaments of the second to fifth MCP joints. (From THIEME Atlas of Anatomy, General Anatomy and Musculoskeletal System. 2nd ed. © Thieme 2014, illustration by Karl Wesker.)

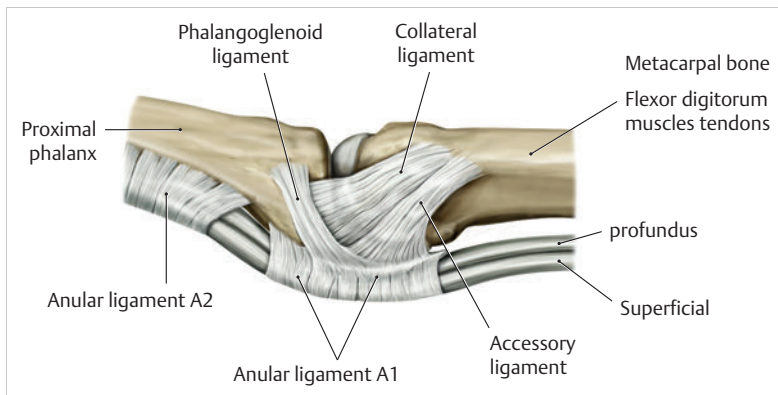


Fig. 1.65 Capsule and ligaments of the second to fifth MCP joints. (From THIEME Atlas of Anatomy, General Anatomy and Musculoskeletal System. 2nd ed. © Thieme 2014, illustration by Karl Wesker.)

Deep and Superficial Transverse Metacarpal Ligaments

The **deep transverse metacarpal ligament** extends in radioulnar direction palmarward to the MCP joints of the fingers.²²⁹ This structure, which is firmly attached to the palmar plate and the A1 anular ligaments, **stabilizes the transverse metacarpal arch and helps to guide the flexor tendons.**²²⁹ The palmar plate with its deep transverse metacarpal ligament is also connected to the palmar capsular ligament system of the wrist via deep metacarpocarpal fascial slips of the interossei.⁷⁷ The deep transverse metacarpal ligament also holds together the metacarpal bones, the palmar aponeurosis, and the skin, especially when the hand is holding objects or is carrying a heavy load.²²⁹ Its distal part is around 62 mm wide, and it is around 0.6 mm thick on the radial aspect and 0.3 mm on the ulnar aspect.⁷

The **superficial transverse metacarpal ligament** is not connected to the carpus and is located directly over the bases of the second to fifth MCP joints immediately below the skin.⁷⁶ It is attached to the flexor tendons and the skin together with the longitudinal fibers of the palmar aponeurosis.²⁷¹ In terms of function, it prevents the fingers from spreading apart excessively⁴² and **limits isolated flexion of the middle and ring fingers when the other fingers are spread.**²²⁹

Note

Damage to one or more structures in the area of the entire stabilizer system of the MCP joints can lead to ulnar deviation, since the forces directed ulnarward would become much stronger and the flexor tendons would no longer be decelerated.⁶⁴

1.6.2 Structure and Function of the PIP Joints

The **proximal interphalangeal joints** (PIP joints), together with the MCP joints, are the most important functional unit for grasping, gripping, and making a fist, and play a significant role in the undisturbed movement of the fingers and the hands.¹⁴⁴ The PIP joint is a hinge joint (ginglymus joint²⁵⁵). For the most part, it allows only flexion and extension,²⁵⁶ although slight side-to-side and rotational motions are also possible.²²⁹ The PIP joints of the index and middle fingers exhibit ulnar deviation in flexion and the PIP joints of the ring and little fingers exhibit radial deviation. The second, third, and fifth PIP joints supinate slightly and the fourth PIP pronates slightly.²²⁹ Therefore, only the PIP joint of the little finger with the fifth metacarpal rotates in the form of supination, which tends to move the little finger palmarward, brings it

closer to the ring finger and can contribute significantly to forcefully making a fist. The opposite is true for extension.

The **forces of the flexor tendons** can be directed via the rotations of the finger joints via the ulnar orientation of the index and middle fingers on the scaphoid or via the more radial orientation of the ring finger, and especially of the little finger on the lunate.¹²⁷ This results in a uniform transfer of forces across the entire surface of the radius. Owing to the more central, slightly radial location of the extensor tendons, when the fingers are extended, the process takes place via the capitate. This system of the transfer of forces requires a stable wrist. Disturbances within this system can promote degenerative pathologies of the finger joints themselves as well as destructive changes in the wrist.

The joint head of the PIP joints has a curved, nearly groove-shaped slit with a roller in which the concave joint socket can move. The joint socket is shaped like a hollow roll with a guide groove.²⁵⁶ These **hinge joints** are characteristic of a strong ligament system that ensures guidance of the joint bodies and stabilizes the joints.²⁵⁶

The **proximal joint head** (head of the proximal phalanx) is shaped like a trapezoidal roller. Asymmetrical radial and ulnar condyles⁴ rise above a shallow central intercondylar depression (► Fig. 1.66). On the index finger, the ulnar condyle is higher than the radial condyle. On the middle, ring, and little fingers, the reverse is true.²⁴⁴ As a result, in flexion there is initial ulnar deviation in the PIP joint of the index finger and initial radial deviation in the PIP joints of the other fingers. In extension, the reverse is true.¹⁶⁰ The intercondylar groove thus extends in the head of the second PIP joint from dorsal and radial to palmar and ulnar, and at the base of the fifth PIP joint it extends from palmar and ulnar to dorsal and radial.¹³⁰ The condyles are wider than they are high, which provides stability when lateral loads are applied.¹⁶⁰

The bases of the second to fifth PIP joints are formed by the medial phalanges, which articulate with the head of the proximal phalanx with two concave facets.¹⁶⁰ Between the two facets, there is a rounded eminence embedded in the groove of the proximal head of the phalanx that serves as a sort of guide groove during flexion and extension.¹⁶⁰ The two articular surfaces are of approximately equal width, with the base of the middle phalanx covering only half the area of the articular surface of the head of the proximal phalanx.²²⁹ Cartilage thickness on the phalangeal heads varies between 0.5 mm to 1 mm and that on the bases between 0.2 mm and 0.5 mm.⁵⁸

Like the head of the proximal phalanx, the **middle phalanx** also exhibits two lateral tubercles for the insertion of the collateral ligaments, and a dorsomedial tubercle for insertion of the dorsal digital expansion.¹³⁹ The more

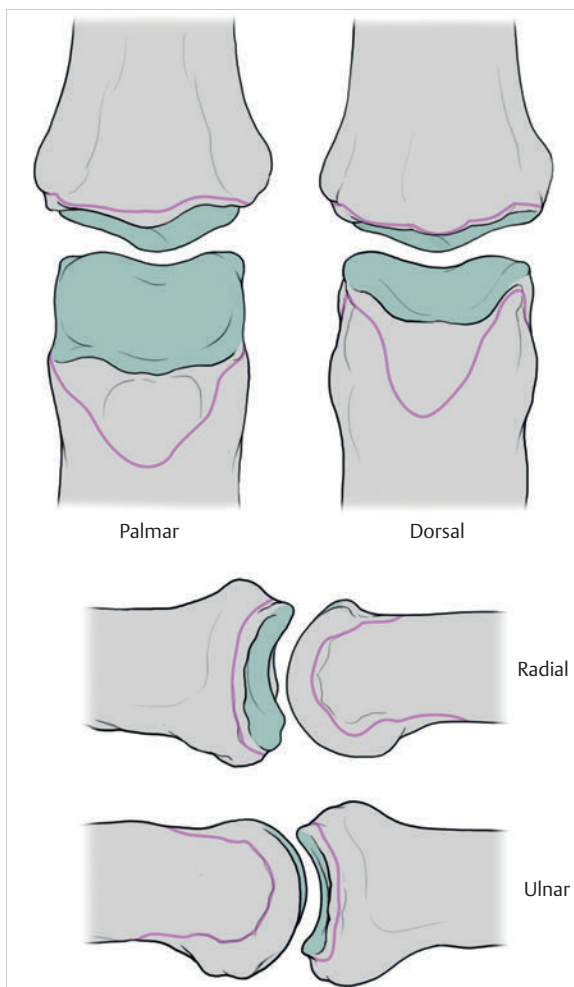


Fig. 1.66 Articulating surfaces of the PIP joints.

flaccid joint capsule is stabilized by a complex ligament system consisting of the collateral ligaments, the palmar and dorsal fibrocartilage plate, the anular and cruciate ligaments, and the dorsal digital expansion in cooperation with the retinacular ligament (ligament of Landsmeer).

Collateral Ligaments of the PIP Joint

The collateral ligaments of the PIP joint comprise the collateral, accessory collateral, and phalangoglenoid ligaments (► Fig. 1.67).

The collateral ligaments arise below and from the lateral tubercles of the head of the proximal phalanx.¹⁶⁰ Some fibers course in a linear fashion to the lateral base of the middle phalanx, while other fibers course obliquely, distally and palmarward, to insert into the small lateral tubercle on the base of the PIP joint. Some fibers also insert into the A4 anular ligament.²²⁹ The collateral

ligament consists of slightly crisscrossed superficial dorsal and deep palmar fibers.⁸⁹ In extension, the superficial fibers are relaxed and the deep fibers are under tension. In flexion, the opposite is the case.⁸⁹

The **accessory collateral ligaments** arise farther proximal and palmar on the head of the proximal phalanx and fan out to their insertion on the palmar plate.²²⁹ The palmar plate contributes to only a small extent to the lateral stability of the PIP joint.²⁰⁶ The accessory ligaments and the palmar plate are under tension in extension and are relaxed in flexion.²⁶¹

In most cases, **phalangoglenoid ligaments** are also present.¹⁸⁵ They extend from lateral eminences on the base of the middle phalanx to the palmar plate of the PIP joint. In doing so, they cross over the fibers of the collateral ligaments.²²⁹ They act synergistically with the accessory ligaments.²⁰⁰ In 15° to 20° flexion all collateral ligaments are under tension.²⁶¹

Palmar and Dorsal Fibrocartilage Plate

The **palmar plate** extends on the palmar aspect between the head and the base of the middle phalanx, taking a proximal course. Its margins are around 10 to 15 mm long and it is around 10 mm wide.¹⁵⁶ Its distal margin is firmly anchored to the palmar surface of the base of the middle phalanx, but only on its lateral aspect.²⁶ The portions lying in between are attached to the middle phalanx by a thin flexion fold.²²⁹ Check rein ligaments arising from the shaft of the proximal part of the proximal phalanx and the A2 anular ligaments insert into the plate of fibrocartilage and extend the dovetail with superficial and deep fibers.¹⁵⁶ Functionally, it expands the available joint surface and inhibits extension of the joint.¹⁶⁰ The central layer forms a lattice from obliquely coursing fibers, which enables it to resist longitudinal and torque stresses.¹⁶⁰ The palmar plate resists tension loads up to 19 kg and is thus significantly stronger than the MCP joints, whose load limit is around 6 kg.²⁷⁰ It also serves as the suspension and gliding floor of the flexor tendons.²⁶⁸ It forms part of the fibrous portions of the flexor tendon sheath, acting similarly to a meniscus.¹⁶⁰

The **dorsal plate** is present at the level of the PIP joint in the area of the extensor digitorum muscle¹⁶⁰ and is connected to the flexor digitorum profundus muscle via a vinculum breve across the palmar plate.¹⁵¹ It contributes to stabilizing the extensor tendon and the PIP joint.²⁴⁵

Anular and Cruciate Ligaments

Each finger has five anular (round) ligaments (A1–A5) and three cruciate ligaments (C1–C3). They are formed by the fibrous layer of the tendon sheaths²²⁹ and are tasked with **guiding the flexor tendons on the skeleton of the**

finger and allowing them to glide.²²⁴ There are empty spaces between the A1 to A5 and C1 to C3 ligaments so that the movement of the fingers is not impeded (► Fig. 1.68). In so doing, these ligaments retain the position of the flexor tendons toward the longitudinal axis of each finger joint and they prevent bowstringing of the flexor tendons during finger flexion.¹⁶⁰ In addition, the tissue of the anular and cruciate ligaments is permeated in part with fibrocartilage²²⁹ and together with the tendon sheaths can optimally absorb the pressure transferred from the tendons⁷⁹ and transfer the muscle forces to the phalanges.²⁴⁷

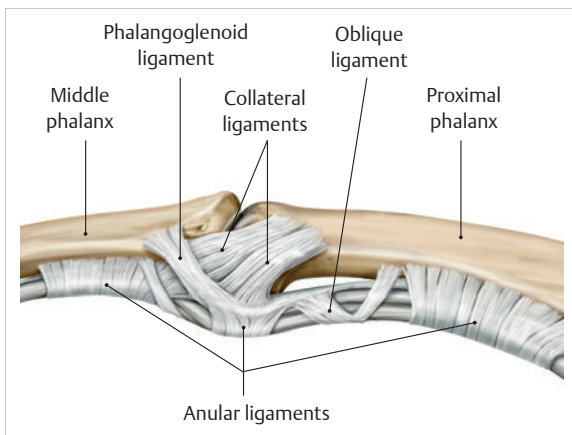


Fig. 1.67 Capsule and ligaments of the PIP joints. (From THIEME Atlas of Anatomy, General Anatomy and Musculoskeletal System. 2nd ed. © Thieme 2014, illustration by Karl Wesker.)

The Five Anular Ligaments and Their Function

The anular ligaments consist of taut fibrous connective tissue and are distributed across the entire finger palmarward.

- **A1 anular ligament.** The A1 anular ligament is located 5 mm proximal to the MCP joint and inserts at both the palmar plate and at the proximal phalanx.¹⁶⁰ This ligament and the flexor tendons are also connected with the deep transverse metacarpal ligament.²²⁹ Owing to this complex involvement of the tendons in the connective tissue structures of the metacarpal palmar arch, a rupture of the A1 anular ligament does not inhibit flexion of the finger.¹⁵² This means that in terms of function, the A1 anular ligament is less significant than the other four anular ligaments.
- **A2 anular ligament.** The A2 guide sheath is the longest and strongest anular ligament of the fingers. It is around 18 mm long and arises on the palmar aspect in the middle of the shaft of the proximal phalanx and extends toward distal.¹⁶⁰ While the distal end of the ligament is thicker, its proximal part is reinforced by fibrocartilage tissue. The A2 and A4 anular ligaments jointly transfer the muscle forces to the finger bones and thus ensure unimpeded finger flexion.²⁴⁷ They also prevent bowstringing in any flexion position and compared to the other three anular ligaments are highly significant.²⁴⁴
- **A3 anular ligament.** The very short A3 anular ligament covers the PIP joint and arises from its palmar plate and the joint capsule.¹⁶⁰ It consists of loose connective

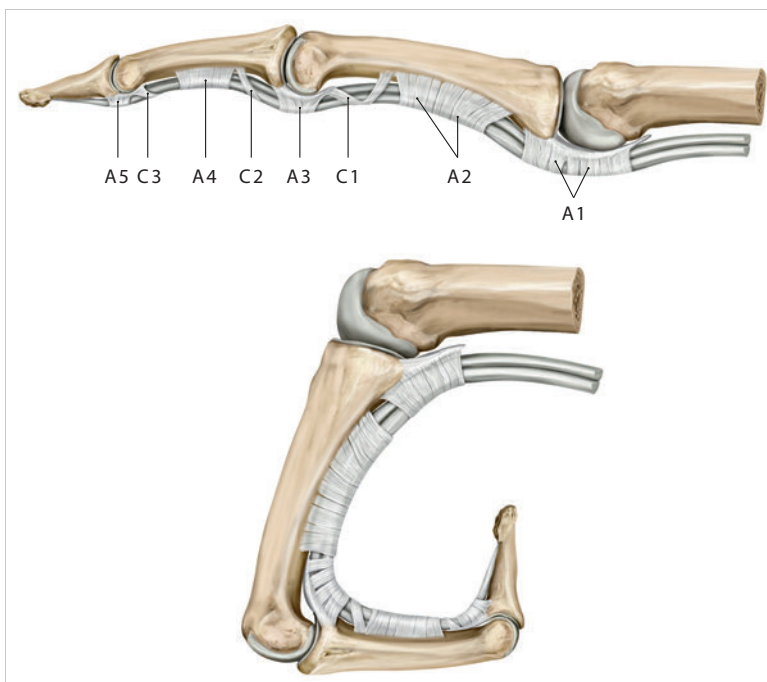


Fig. 1.68 Anular and cruciate ligaments. (From THIEME Atlas of Anatomy, General Anatomy and Musculoskeletal System. 2nd ed. © Thieme 2014, illustration by Karl Wesker.)

A1 to A5 = anular ligaments;
C1 to C3 = cruciate ligaments.

tissue so as not to interfere with the fine motion of the PIP joint.²²⁹

- **A4 anular ligament.** The A4 guiding sheath is around 6 to 7 mm long and is located at the level of the middle third of the palmar middle phalanx and provides the most important functional support for the tendon of the flexor digitorum profundus muscle. It acts synergistically with the A2 anular ligament. Together, they ensure the functional motion sequence of finger flexion.²²⁹
- **A5 anular ligament.** The A5 anular ligament is a thickening of the tendon sheath located at the level of the DIP joint and is fused to the palmar plate and the joint capsule.¹⁶⁰ Its structure corresponds to the same loose connective tissue of the A3 guiding sheath, since it also needs to avoid interfering with the fine motion of the DIP joint.²²⁹

The Three Cruciate Ligaments and Their Function

The three cruciate ligaments are narrower than the anular ligaments and course between the anular ligaments either crossways or obliquely. These ligaments are not always present and in some cases only a few cruciate fibers are present.¹²³ They arise from the periosteum of the finger bones between the A2 and A3, A3 and A4, and A4 and A5 anular ligaments. Coursing distally, they envelop the tendon sheath and insert into the joint capsules of the IP joints.²²⁹

Dorsal Digital Expansion

The dorsal digital expansion is a **complex, triangularly structured connective tissue sheet on the dorsal aspect of the finger** (► Fig. 1.69, ► Fig. 1.70).²⁰⁰ Not attached to the MCP joint, it is wide proximally and narrows distally, and inserts at the bases of the distal joint partners of the PIP and DIP joints, respectively.⁹¹ After crossing the MCP joint cavity, the tendon of the extensor digitorum muscle divides into **three fibrous slips** over the proximal third of the proximal phalanx. These are the unpaired central slip and the paired lateral bands.²²⁹ The extensor digitorum and extensor indicis muscles help to form the dorsal digital expansion on the index finger, and on the little finger the extensor digitorum muscle helps to form the dorsal digital expansion.²⁰⁰

The unpaired medial part of the **central slip** courses distally with its longitudinal fascicles and inserts there at the base of the middle phalanx and the base of the distal phalanx,²⁰⁰ in the nail halter and in the periosteum on the dorsal aspect of the distal phalanx.⁹⁰ The paired lateral parts of the central slip fan out radially and ulnarward²²⁹ and unite with the tendon of the lumbricals and interossei to form the lateral bands, coursing together as the terminal tendon to the base of the DIP joint.

At the level of the distal third of the proximal phalanx, the medial part of the **lateral bands** arises and, immediately distal to the PIP joint, joins the medial part of the central slip.²²⁹ This complex structure enables the finger extensors as well as the interossei and lumbricals to act on all three finger joints. Since the lateral band at the level of the PIP and DIP joints courses dorsal to the movement axis of the two joints, the muscles in these joints

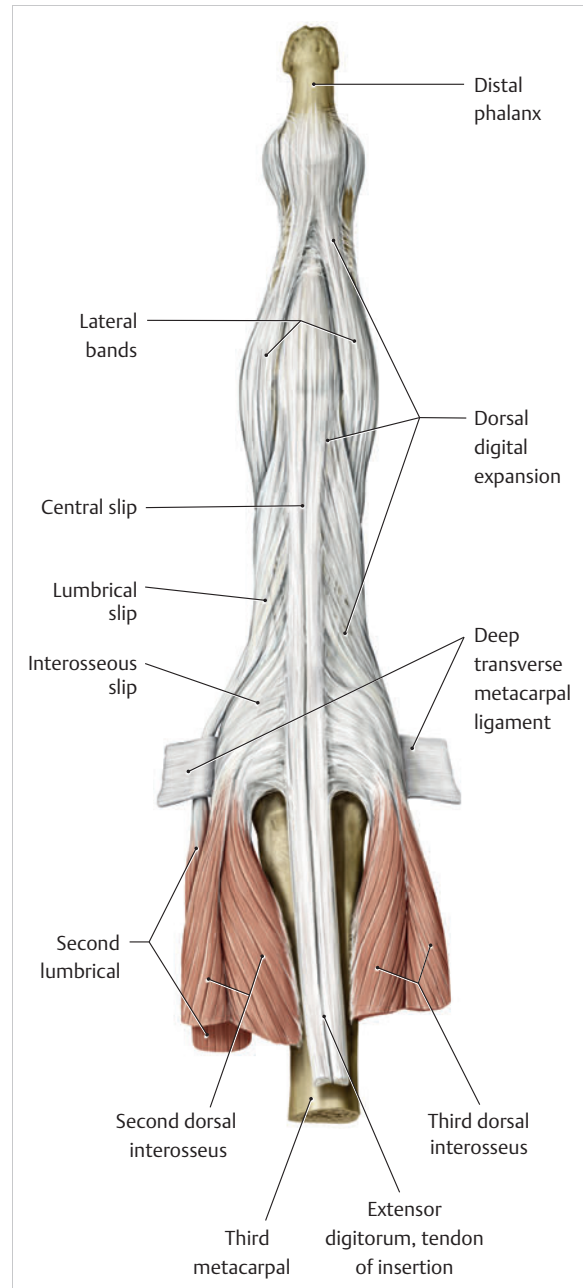


Fig. 1.69 Dorsal digital expansion (dorsal view). (From THIEME Atlas of Anatomy, General Anatomy and Musculoskeletal System. 2nd ed. © Thieme 2014, illustration by Karl Wesker.)

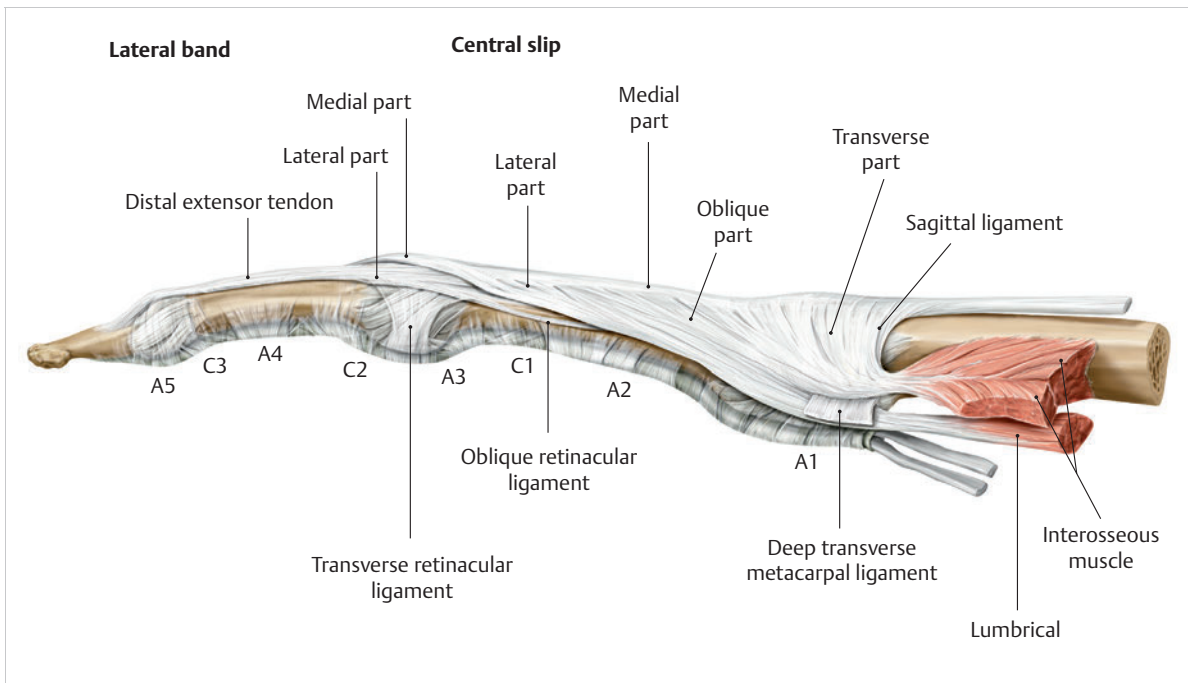


Fig. 1.70 Dorsal digital expansion (lateral view). (From THIEME Atlas of Anatomy, General Anatomy and Musculoskeletal System. 2nd ed. © Thieme 2014, illustration by Karl Wesker.)

bring about extension.²⁰⁰ In the MCP joint, the lateral band runs palmar to the movement axis, which results in flexion of the MCP joints.²⁰⁰

The **superficial intertendinous lamina** helps to center the dorsal digital expansion and provides the extensor digitorum muscle with another important point of insertion.¹³⁸ It arises with fibers coursing transversely toward radial and ulnar that merge toward distal into the oblique part of the superficial intertendinous lamina.²²⁹ It is a triangular fibrous plate that fills the space between the central slip and lateral bands.²⁰⁰ It also connects with the sagittal ligament, the accessory collateral ligament, and the palmar plate of the MCP joints, the deep transverse metacarpal ligament, and the interosseous tendon.²²⁹ This fibrous construct inhibits the extent to which the lateral bands can be displaced during flexion and extension.²³⁶

An additional **triangular ligament** prevents bowstringing when the finger joints are hyperextended.⁵² It is located between the central slip at the base of the PIP joint and the lateral bands that merge at this point.²⁰⁰

In contrast to the capsule of the MCP joint, which can be clearly distinguished from the extensor tendon slips coursing past it, all of the structures of the distal and proximal IP joints are fused with the **extensor apparatus** of the finger.

The **paired oblique retinacular ligament** (ligament of Landsmeer) is an important ancillary structure.²²⁹ The radial part of the ligament is somewhat longer and stronger than the ulnar part.⁵¹ This ligament arises from a

small bony eminence in the distal third of the proximal phalanx and the A2 anular ligament and courses distally and dorsally to join the lateral bands.²⁶⁴ It lies palmar to the axis of motion of the PIP joint and inserts with the extensor apparatus of the finger dorsal to the axis of motion of the DIP joint.²²⁹ This ligament supports the movements in the PIP and DIP joints through passive tension and relaxation. During extension in the PIP joint, it tightens and in so doing supports the extension in the DIP joint. In contrast, full flexion in the DIP joint is only possible with the PIP joint in flexion. It also supports lateral stability of the PIP joint.

The **transverse retinacular ligament** is located very close to the surface of the finger. It arises from the A3 anular ligament and the joint capsule and extends into the lateral bands. During extension of the finger, it inhibits dorsal dislocation of the lateral bands and in so doing centers the dorsal digital expansion of the finger. It also has a stabilizing effect during flexion and extension in the PIP joint.²²⁹

1.6.3 Structure and Function of the DIP Joints

The **DIP joints are similar to the PIP joints**. On the whole, the joint structures are smaller (► Fig. 1.71). As with the PIP joints, the distal bases of the DIP joints have two concave facets, although the eminences are not pronounced and therefore allow for lateral translation.¹⁶⁰ In addition,

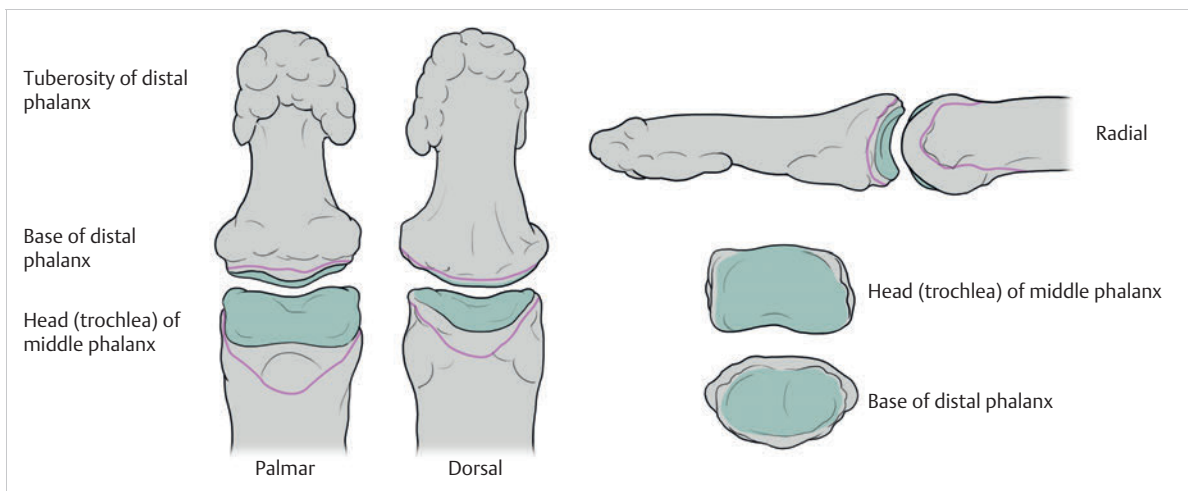


Fig. 1.71 Articulating surfaces of the DIP joints.

the base of the distal phalanx is somewhat wider than the head of the middle phalanx.¹¹⁷ The dorsal portion of the base of the phalanx exhibits a protruding lip that has no significance for joint function.¹⁶⁰ On the radial and ulnar aspects there are two concave facets separated by a crest.¹⁶⁰ A groove between the condyles of the head of the middle phalanx is embedded in this crest. The radial condyle of the index finger is higher than the ulnar condyle and thus forms the exact counterpart to all PIP joints.⁴ As a result, **abduction**, **adduction**, and **rotation** are also possible in the DIP joint, in addition to extension and flexion.⁷³ As with the PIP joints, **supination in the index finger** is possible,¹⁸² which is particularly important for **precision grip** and for **fine motor grasping**.

The **collateral ligament** generally takes a flatter course compared to the PIP joint, while the accessory collateral ligament takes a somewhat steeper course and often covers proximal and palmar parts of the collateral ligament (► Fig. 1.72). In most cases, no **phalangoglenoid ligaments** are present.¹⁸⁵ Near the base of the proximal phalanx, the **palmar plate** arises directly from the A4 annular ligament and parts of the tendon of the flexor digitorum superficialis muscle, and in this region does not have any bony attachments,²⁶ making the DIP joint more susceptible to hyperextension than the PIP joint.¹⁴¹

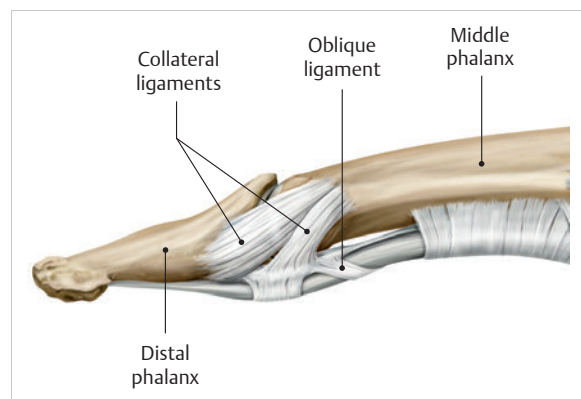


Fig. 1.72 Capsule and ligaments of the DIP joints. (From THIEME Atlas of Anatomy, General Anatomy and Musculoskeletal System. 2nd ed. © Thieme 2014, illustration by Karl Wesker.)

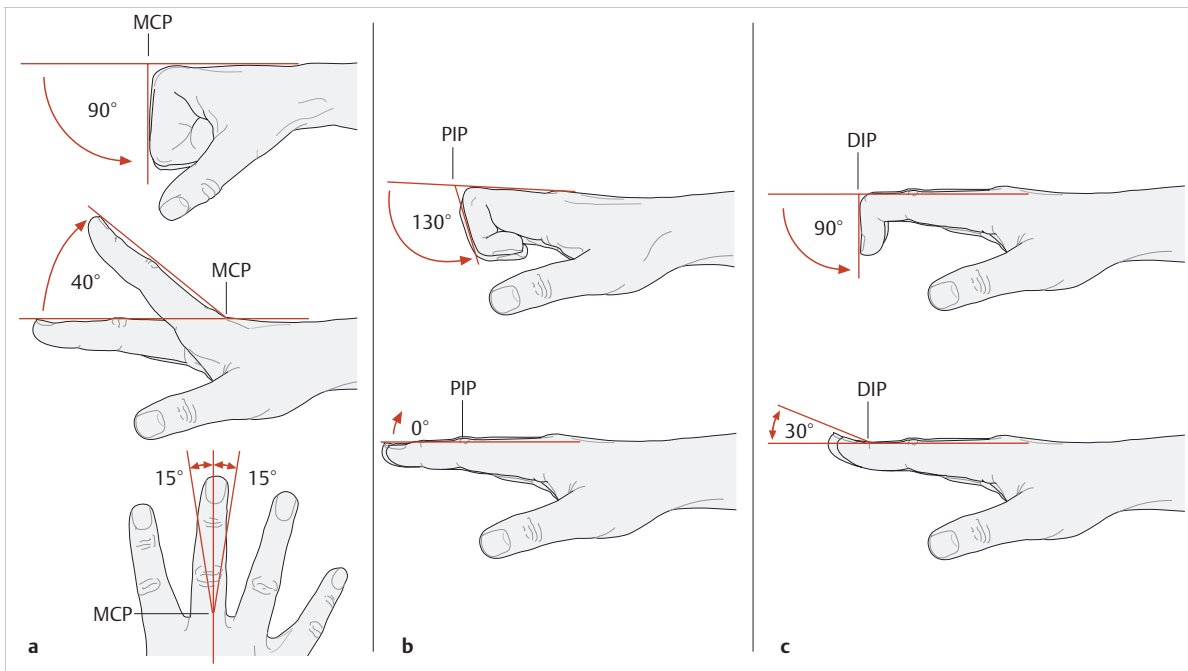


Fig. 1.73 Range of motion of the MCP, PIP, and DIP joints. (From THIEME Atlas of Anatomy, General Anatomy and Musculoskeletal System. 2nd ed. © Thieme 2014, illustrations by Karl Wesker.) (a) Range of motion of the second to fifth MCP joints. (b) Range of motion of the PIP joints. (c) Range of motion of the DIP joints.

1.6.4 Range of Motion of the MCP, PIP, and DIP Joints

(See ► Fig. 1.73.)

- Range of motion of the second to fifth MCP joints: flexion 90° and extension 40°, as well as abduction 15° and adduction 15°
- Range of motion of the second to fifth PIP joints: flexion 130° and extension 0°
- Range of motion of the second to fifth DIP joints: flexion 90° and extension 30°

1.6.5 Extrinsic Muscles of the Finger: Flexors and Extensors

In addition to the interossei, the lumbricals, and the hypothenar muscles, the extrinsic muscles of the finger (flexors and extensors) are particularly important. The extrinsic muscles can only exert their influence on the finger joints in interaction with the intrinsic muscles.

Extensor Apparatus of the Finger

The extensors of the finger comprise the extensor digitorum and proper extensor indicis muscles located in the superficial layer, along with the proper extensor digiti minimi muscle located in the deep layer (► Fig. 1.74).²⁰⁰

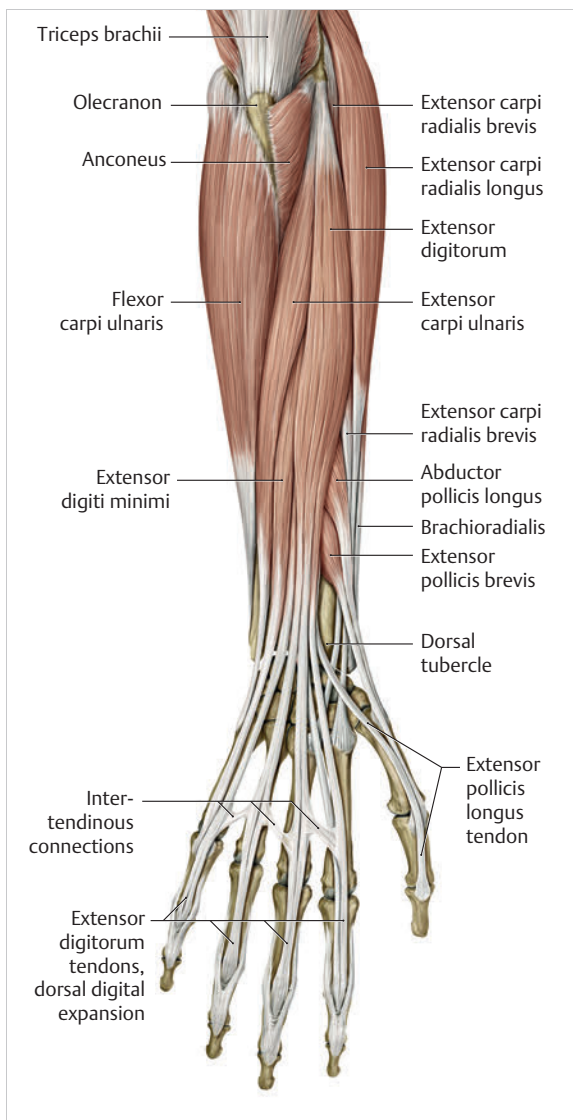


Fig. 1.74 Extrinsic muscles of the fingers. (From THIEME Atlas of Anatomy, General Anatomy and Musculoskeletal System. 2nd ed. © Thieme 2014, illustration by Karl Wesker.)

The **extensor digitorum communis muscle** originates broadly from the lateral epicondyle of the humerus, the radial collateral ligament, the annular ligament of the radius, and the antebrachial fascia.²⁰⁰ Together with its tendons, it forms the dorsal digital expansion of the fingers and is fused to the bases of the MCP joints with fascicles.¹⁹⁸ Proximal to the dorsal digital expansion, the third to fifth extensor tendons are fused to the intertendinous connections.¹⁹⁸ As a result, the extensor digitorum communis muscle inhibits the independent movements of the middle, ring, and little fingers²⁰⁰ and provides support with stabilizing the distal palmar arch.¹⁹⁸ The extensor digitorum muscle extends the fingers from every position of the wrist and is involved in abducting the fingers.¹⁹⁸ Moreover, when the wrist is in flexion, it can extend the fingers in the PIP and DIP joints and is involved in ulnar deviation and extension of the wrist.²⁰⁰

The **proper extensor indicis muscle** originates from the distal third of the dorsal surface of the ulna and the interosseous membrane, and together with the extensor digitorum communis muscle it inserts into the extensor apparatus of the index finger.¹⁹⁸ In 10% of the cases, a proper extensor digiti brevis muscle is also present that merges with the tendon of the extensor indicis muscle.²⁰⁰ Functionally, it brings about isolated extension of the index finger and moves it toward the middle finger.²⁰⁰ To a limited extent, it is also involved in wrist extension.¹⁹⁸

The **proper extensor digiti minimi muscle** arises from the common origins of the extensor digitorum communis muscle and frequently extends into the extensor apparatus with two tendons.¹⁹⁸ It both extends and abducts the little finger and is involved in ulnar deviation and extension of the wrist.

Extrinsic Flexors of the Finger

The extrinsic flexors of the fingers are divided into four layers.²⁰⁰ The flexor digitorum superficialis muscle lies in the second layer and the flexor digitorum profundus muscle lies in the third layer (► Fig. 1.75, ► Fig. 1.76).²⁰⁰

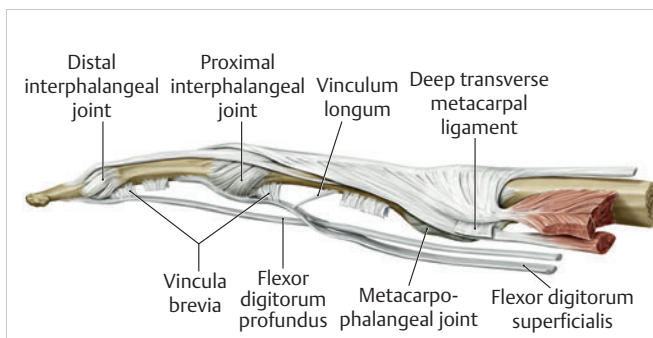


Fig. 1.75 Overview of the structures of the finger. (From THIEME Atlas of Anatomy, General Anatomy and Musculoskeletal System. 2nd ed. © Thieme 2014, illustration by Karl Wesker.)

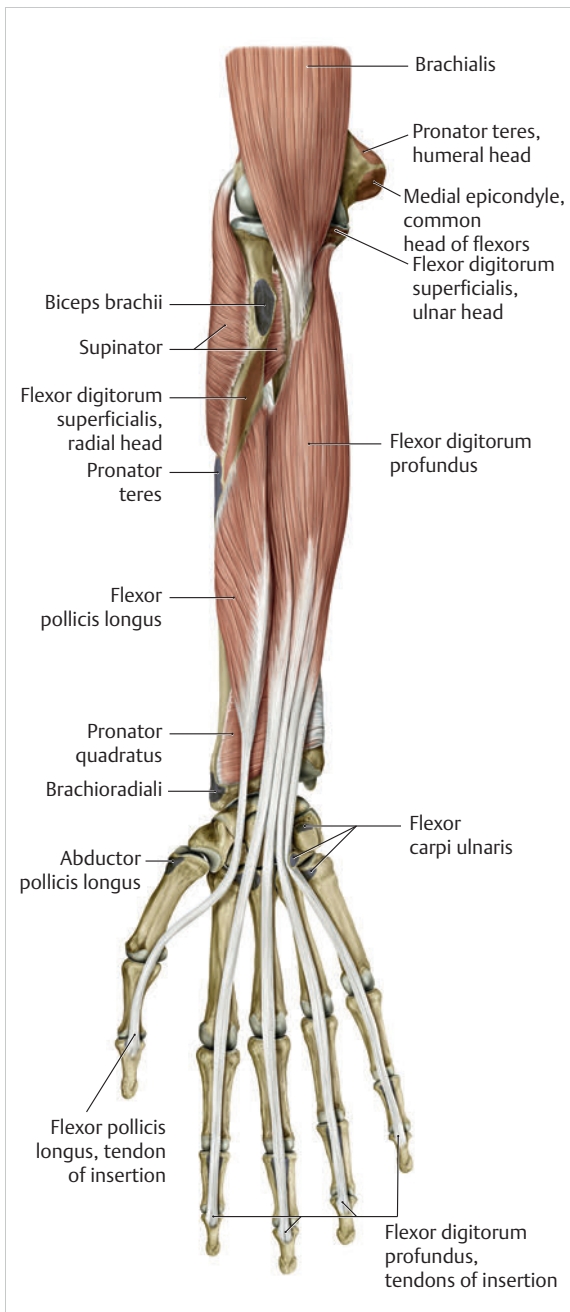


Fig. 1.76 Palmar extrinsic muscles of the finger. (From THIEME Atlas of Anatomy, General Anatomy and Musculoskeletal System. 2nd ed. © Thieme 2014, illustration by Karl Wesker.)

The three-headed **flexor digitorum superficialis muscle** arises with its humeral head from the medial epicondyle of the humerus and with its ulnar head from the coronoid process of the ulna and with the radial head from the anterior surface of the radius below the oblique insertion line of the pronator teres muscle.²⁰⁰ It extends into the palm with four tendons, each of which inserts with two heads onto the bony ridges of the palmar lateral aspect of the respective middle phalanx of the fingers.²⁰⁰ Shortly before they reach the insertion point between the A1 and A2 annular ligaments, each tendon splits into two gently spiraling tendon slips (tendinous hiatus²²⁹), which together form a thin tendinous plate of crisscrossing fibers (tendinous chiasm³⁰) and in the further course insert onto narrow bony ridges and the A4 annular ligament of the middle phalanx.²²⁹ The flexor digitorum profundus tendon glides through this slit in the direction of its insertion. In terms of function, the flexor digitorum superficialis muscle is a strong flexor in the MCP and PIP joints and provides some support for wrist flexion.²⁰⁰

The **flexor digitorum profundus muscle** arises from the proximal two-thirds of the anterior surface of the ulna and the adjacent part of the interosseous membrane and from the ulnar tuberosity with two digitations.²⁰⁰ The four tendons lie next to each other parallel in one plane and penetrate the tendons of the flexor digitorum superficialis. They then insert into the bases of the distal phalanges.²⁰⁰ This muscle flexes all three joints of the fingers, with strength increasing as wrist extension increases.²⁰⁰ It is also involved in flexion and ulnar deviation of the wrist.

► Table 1.5 provides an overview of all extrinsic and intrinsic muscles of the hand.

Table 1.5 Overview of all extrinsic and intrinsic muscles of the hand²³⁸

Muscle	Origin	Insertion	Actions	Innervation
Pronator teres	Humeral head: medial epicondyle of the humerus Ulnar head: coronoid process of the ulna	Lateral surface of the radius (distal to the supinator insertion)	Elbow joint: weak flexion Forearm joints: pronation	Median nerve (C6)
Flexor digitorum superficialis	Humeral head: medial epicondyle of the humerus Ulnar head: Coronoid process of the ulna Radial head: distal to the radial tuberosity	The sides of the middle phalanges of the second through fifth digits	Elbow joint: weak flexion Wrist joints and the MCP and PIP joints of the second through fifth digits: flexion	Median nerve (C7–T1)
Flexor carpi radialis	Medial epicondyle of the humerus	Base of the second metacarpal (and sometimes of the third metacarpal)	Wrist joints: flexion, radial deviation Elbow joint: weak pronation	Median nerve (C6–C8)
Flexor carpi ulnaris	Humeral head: medial epicondyle Ulnar head: olecranon	Hook of the hamate, base of the fifth metacarpal	Wrist joints: flexion, ulnar deviation	Ulnar nerve (C7–T1)
Palmaris longus	Medial epicondyle of the humerus	Palmar aponeurosis	Elbow joint: weak flexion Wrist joints: flexion, tightens the palmar aponeurosis	Median nerve (C8–T1)
Flexor digitorum profundus	Proximal two-thirds of the flexor surface of the ulna and the adjacent interosseous membrane	Palmar surface of the distal phalanges of the second through fifth digits	Wrist joints and the MCP, PIP, and DIP joints of the second through fifth digits: flexion	Median nerve (radial part, second and third digits), C7–T1 Ulnar nerve (ulnar part, fourth and fifth digits), C7–T1
Flexor pollicis longus	Mid-anterior surface of the radius and the adjacent interosseous membrane	Palmar surface of the distal phalanx of the thumb	Wrist joints: flexion and radial deviation CMC joint of the thumb: opposition MCP and IP joints of the thumb: flexion	Median nerve (C6 to C8)
Pronator quadratus	Distal one-fourth of the anterior surface of the ulna	Distal one-fourth of the anterior surface of the radius	Pronates the hand, stabilizes the distal radioulnar joint	Median nerve (C8–T1)
Brachioradialis	Lateral surface of the distal humerus, lateral intermuscular septum	Styloid process of the radius	Elbow joint: flexion Forearm joints: semi-pronation	Radial nerve (C5–C7)
Extensor carpi radialis longus	Lateral surface of the distal humerus, lateral intermuscular septum	Dorsal base of the second metacarpal	Elbow joint: weak flexion Wrist joints: extension (assists in fist closure), radial deviation	Radial nerve (C5–C7)
Extensor carpi radialis brevis	Lateral epicondyle of the humerus	Dorsal base of the third metacarpal	Elbow joint: weak flexion Wrist joints: extension (assists in fist closure), radial deviation	Radial nerve (C5–C7)
Extensor digitorum	Common head (lateral epicondyle of the humerus)	Dorsal digital expansion of the second through fifth digits	Wrist joints: extension MCP, PIP and DIP joints of the second through fifth digits: extension and abduction of the fingers	Radial nerve (C6–C8)

Table 1.5 (continued) Overview of all extrinsic and intrinsic muscles of the hand²³⁸

Muscle	Origin	Insertion	Actions	Innervation
Extensor digiti minimi	Common head (lateral epicondyle of the humerus)	Dorsal digital expansion of the fifth digit	Wrist joints: extension, ulnar deviation MCP, PIP and DIP joints of the fifth digit: extension and abduction of the fifth digit	Radial nerve (C6–C8)
Extensor carpi ulnaris	Common head (lateral epicondyle of the humerus), ulnar head (dorsal surface of the ulna)	Base of the fifth metacarpal	Wrist joints: extension, ulnar deviation	Radial nerve (C6–C8)
Supinator	Olecranon of the ulna, lateral epicondyle of the humerus, radial collateral ligament, anular ligament of the radius	Radius (between the radial tuberosity and the insertion of pronator teres)	Forearm joints: supination	Radial nerve (C5, C6)
Abductor pollicis longus	Dorsal surfaces of the radius and ulna, also the interosseous membrane	Base of the first metacarpal	Proximal wrist joint: radial deviation CMC joint of the thumb: abduction	Radial nerve (C6–C8)
Extensor pollicis brevis	Dorsal surface of the radius and the interosseous membrane (distal to abductor pollicis longus)	Base of the proximal phalanx of the thumb	Proximal wrist joint: radial deviation CMC and MCP joints of the thumb: extension	Radial nerve (C6–C8)
Extensor pollicis longus	Posterior surface of the ulna and the interosseous membrane	Base of the distal phalanx of the thumb	Wrist joints: extension and radial deviation CMC joint of the thumb: adduction MCP and IP joints of the thumb: extension	Radial nerve (C6–C8)
Extensor indicis	Posterior surface of the ulna, also the interosseous membrane	Dorsal digital expansion of the second digit	Wrist joints: extension MCP, PIP, and DIP joints of the second digit: extension	Radial nerve (C6–C8)
Abductor pollicis brevis	Scaphoid, flexor retinaculum	Base of the proximal phalanx of the thumb (via the radial sesamoid)	CMC joint of the thumb: abduction MCP joint of the thumb: flexion	Median nerve (C6, C7)
Adductor pollicis	Transverse head: palmar surface of the third metacarpal Oblique head: capitate, base of second and third metacarpals	Base of the proximal phalanx of the thumb (via the ulnar sesamoid)	CMC joint of the thumb: opposition MCP joint of the thumb: flexion	Ulnar nerve (C8–T1)
Flexor pollicis brevis	Superficial head: flexor retinaculum Deep head: trapezium, trapezoid, capitate	Base of the proximal phalanx of the thumb (via the radial sesamoid)	CMC joint of the thumb: flexion, opposition MCP joint of the thumb: flexion	Median nerve, C6–T1 (superficial head) Ulnar nerve, C8 to T1 (deep head)
Opponens pollicis	Trapezium	Radial border of the first metacarpal	CMC joint of the thumb: opposition	Median nerve (C6, C7)
Abductor digiti minimi	Pisiform	Ulnar base of the proximal phalanx and the dorsal digital expansion of the fifth digit	MCP joint of the fifth digit: flexion and abduction of the fifth digit PIP and DIP joints of the fifth digit: extension	Ulnar nerve (C8–T1)



Table 1.5 (continued) Overview of all extrinsic and intrinsic muscles of the hand²³⁸

Muscle	Origin	Insertion	Actions	Innervation
Flexor digiti minimi brevis muscle	Hook of the hamate, flexor retinaculum	Base of the proximal phalanx of the fifth digit	MCP joint of the fifth digit: flexion	Ulnar nerve (C8–T1)
Opponens digiti minimi	Hook of the hamate	Ulnar border of the fifth metacarpal	Draws the metacarpal in the palmar direction (opposition)	Ulnar nerve (C8–T1)
Palmaris brevis	Ulnar border of the palmar aponeurosis	Skin of the hypothenar eminence	Tightens the palmar aponeurosis (protective function)	Ulnar nerve (C8–T1)
First through fourth lumbrical muscles	Radial sides of the tendons of the first flexor digitorum profundus muscle	First lumbrical: dorsal digital expansion of the second digit Second lumbrical: dorsal digital expansion of the third digit Third lumbrical: dorsal digital expansion of the fourth digit Fourth lumbrical: dorsal digital expansion of the fifth digit	MCP joints of the second through fifth digits: flexion PIP and DIP joints of the second through fifth digits: extension	Median nerve, C8–T1 (first and second lumbricals) Ulnar nerve, C8–T1 (third and fourth lumbricals)
First through fourth dorsal interossei	By two heads from adjacent sides of the first through fifth metacarpals	Dorsal digital expansion of the second through fourth digits, base of the proximal phalanx First interosseous: radial side of the second proximal phalanx (index finger) Second interosseous: radial side of the third proximal phalanx (middle finger) Third interosseous: ulnar side of the proximal phalanx (middle finger) Fourth interosseous: ulnar side of the proximal phalanx (ring finger)	MCP joints of the second to fourth digits: flexion PIP and DIP joints of the second through fourth digits: extension and abduction of the fingers (abduction of the second and fourth digits from the third digit)	Ulnar nerve (C8–T1)
First through third palmar interossei	First interosseous: ulnar side of the second metacarpal (index finger) Second interosseous: radial side of the fourth metacarpal (ring finger) Third interosseous: radial side of the fifth metacarpal (little finger)	Dorsal digital expansion and base of the proximal phalanx of the associated finger	MCP joint of the second, fourth and fifth digits: flexion PIP and DIP joints of the second, fourth, and fifth digits: extension and adduction of the fingers (adduction of the second, fourth, and fifth digits toward the middle finger)	Ulnar nerve (C8–T1)

Chapter 2

Surface Anatomy of the Forearm, Wrist, and Hand Structures

2.1	Introduction	82
2.2	Practical Foundations of Surface Anatomy	82
2.3	Practical Procedure for Surface Anatomy of the Forearm, Wrist, and Hand	83



2 Surface Anatomy of the Forearm, Wrist, and Hand Structures

2.1 Introduction

Surface anatomy provides an opportunity to transfer theoretical knowledge of anatomy to treatment procedures. It enables practitioners to palpate, locate, and define structures of the human body. It also gives therapists an impression of how a specific tissue feels and enables them to assess its structure to distinguish physiological from pathological tissue changes. Surface anatomy therefore provides the basis for making an accurate diagnosis and prescribing an appropriate treatment. Without the ability to implement theoretical and anatomical knowledge in the living patient, appropriate tissue-specific treatment cannot be applied. Lack of familiarity with location and the uneasy feeling that one's knowledge of muscles is inadequate (i.e., origins and attachments, as well as of tendons and tendon sheaths, joint structures, fascia, etc.), often results in an uncontrolled, nonspecific, erratic, and inappropriate choice of treatment techniques. This signifies an unqualified approach to treatment. This in turn results in disproportionately long treatment times and possible progression of the disease process, which is not in the patient's best interest.

Surface anatomy involves the specific systematic implementation of topographic and anatomical knowledge through targeted palpation of the living human body.²⁰⁷ This chapter on surface anatomy intends to provide practitioners with a systematic method for quickly and reliably finding all of the structures that are important for treating the hand. **Targeted palpation of hand structures** is featured in five major areas related to hand treatment:

1. Palpation serves to identify, differentiate, and determine the location of tissues of the forearm, wrist, and hand, and directly compare the types of tissues based on inspection and palpation.
2. Surface anatomy plays an important role in the examination and treatment of skin, muscles, tendons, tendon sheaths and joints, etc.
3. For diagnosis and treatment, surface anatomy specifically helps to identify pathological structures that can then be treated through specific, coordinated movements (e.g., testing of the play in the wrist joint).
4. Surface anatomy is an integral component of a professional therapeutic procedure that is specifically related to the damaged tissue.
5. Practicing surface anatomy on patients on a daily basis is a prerequisite for locating and differentiating tissue (e.g., muscle tone). It is based on experience and requires constant refinement and training, even among therapists who have been practicing for years.

Note

Surface anatomy can be defined as follows:
Surface anatomy =
anatomical topography × technique × experience

Conclusions

Surface anatomy involves the palpation and visualization of visible and nonvisible but inferable structures of the living human body. It helps in applying theoretical anatomical principles to the living human and provides the foundation for functional and kinetic mode of thought in the sense of homeokinesis. Since not all of the structures of the human body can be palpated, in-depth knowledge of the anatomical setting is an absolute prerequisite, since this is the only way to discern the location and trajectory of nonvisible structures. "Surface anatomy" is therefore a prerequisite for proper diagnosis and treatment.

2.2 Practical Foundations of Surface Anatomy

The **fingertips** are the **tools of surface anatomy**. In addition to the face and the tongue with the mouth,⁸ the fingertips, with approximately 300 receptors per square centimeter of skin, are the structures of the body with the largest number of proprioceptors.¹⁰⁴ Owing to its great mobility, the index finger is the most important finger for identifying surface anatomy. By applying pressure from the fingertips, the examiner attempts to feel and analyze the underlying tissue and assign it a specific tissue structure. The amount of pressure used and the structure's resistance to the pressure provide direct feedback about the type of tissue. Dos Winkel et al's classification (1985)²⁷⁵ is helpful for **defining the palpated structures**:

1. **Hard**: Structures that cannot be deformed by the pressure of the examiner's hand (bone or horn).
2. **Firm and elastic**: Structures that yield to pressure and spring back lightly without being able to be deformed (e.g., tendons, ligaments).
3. **Firm**: Structures that yield to pressure easily but are not elastic (e.g., hypertonic muscles, tumors).
4. **Soft**: Easily deformed tissue (e.g., muscles, fatty tissue).

For this classification, it is very important for the examiner to **apply the right amount of pressure**.²⁰⁷ Minimal pressure should be used for surface palpation or

palpation of muscle tone. Strong pressure should be used for deep palpation or for palpating bones. As a guide, you should observe your own fingernails, which will be white when the pressure is strong and will remain red when the pressure is light.

Not all of the tissue structures can be palpated in a certain area. Hence, it is important to be familiar with the topographic anatomy. With this knowledge, the easily palpable structures can be used to locate the nonpalpable structures.

2.3 Practical Procedure for Surface Anatomy of the Forearm, Wrist, and Hand

When examining the muscles of the lower arm and hand, the following landmarks should be identified to help with orientation: **carpal bones**, and the **six dorsal and three palmar tendon compartments** in the wrist area. Once these structures have been located, the superficial and deep extrinsic extensor and flexor muscles of the hand can be identified.

The hand should be in a relaxed position during **palpation**. It is imperative that the patient avoid any muscle activity; otherwise the overlying tendons and muscles will tense up and prevent the examiner from identifying the deeper-lying structures. To indicate **position and direction**, the following terms are used: radial (toward the thumb), ulnar (toward the little finger), distal (away from the body), proximal (toward the body), dorsal (toward the back of the hand), and palmar (toward the palm).²⁰⁷ To **visualize** the palpable tissue, the structures are marked or outlined with a skin marker.

2.3.1 Surface Anatomy of the Distal Radioulnar Joint and Wrist

Radiocarpal Joint Line and Its Structures

To locate the radioulnar joint and the individual carpal bones dorsally, the first step is to mark the delimiting surfaces of the wrist. To do this, the lower arm of the person being palpated is placed in a relaxed, pronated position. To identify the proximal border of the carpus, the radial styloid process, dorsal tubercle of the radius (Lister's tubercle), and styloid process of the ulna with the ulnar head must be palpated. With these three landmarks, the radiocarpal joint line can be identified and the location of the distal radioulnar joint and the proximal wrist joint can be discerned.

- The **index finger** is moved laterally over the anatomic snuffbox proximally, toward the radius. The radial side of the anatomic snuffbox is formed by the tendons of the abductor pollicis longus and extensor pollicis brevis muscles (= first dorsal tendon compartment)

(► Fig. 2.1). On the ulnar side, it is delimited by the tendon of the extensor pollicis longus muscle. When the thumb is extended, the anatomic snuffbox is easy to see, as it forms a hollow space. The large, blunt radial process can be felt as a clear bony edge and is marked with a skin marker.

- **Lister's tubercle** is located in the middle of the distal radius, slightly proximal/ulnar to the radial styloid process. The index finger used for palpation follows between the second and third metacarpals to the distal radius. Lister's tubercle can be felt directly as a prominent bony tuberosity at the dorsal radial surface. If the finger moves slightly distally from this point, it will directly meet the proximal edge of the wrist joint. A skin marker can be used to mark two landmarks at the same time, namely Lister's tubercle and the proximal wrist joint line.
- The **ulnar head** can be easily seen and palpated at the distal end of the ulna and should be circled with the marker. Then, the index finger used for palpation is moved proximally and laterally to the hypothenar, toward the ulnar head. At the ulnar head, the **ulnar styloid process** can be easily palpated as a rod-shaped process and it is marked to serve as an additional reference point.

If all the marked points are connected, the radioulnar joint line will become visible (► Fig. 2.2). In so doing, it will become clear that the **orientation of the joint line** is not exactly at a right angle to the forearm, but instead follows a proximal trajectory from the radial aspect toward the ulna at an angle of approximately 15°.

If the palpating index finger is moved from the ulnar head toward the radius, the fingernail will end up directly between the ulna and the radius, that is, across the **joint line of the distal radioulnar joint** (► Fig. 2.3).

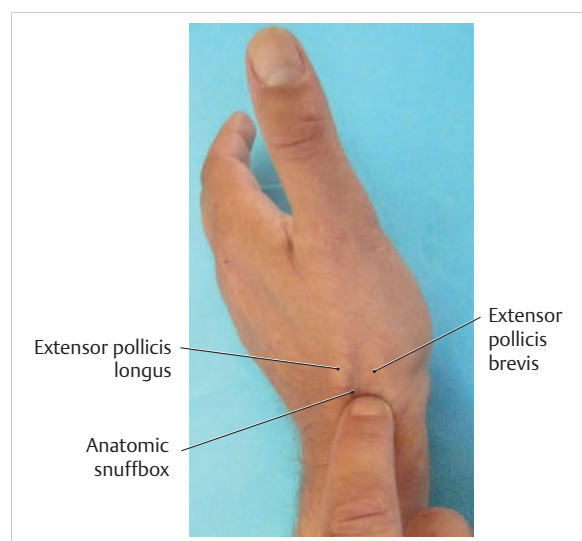


Fig. 2.1 Anatomical snuffbox.

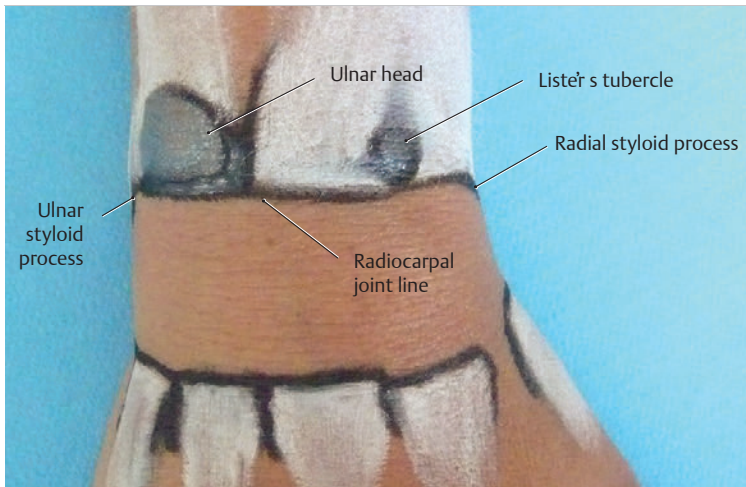


Fig. 2.2 Radiocarpal joint line and its structures.

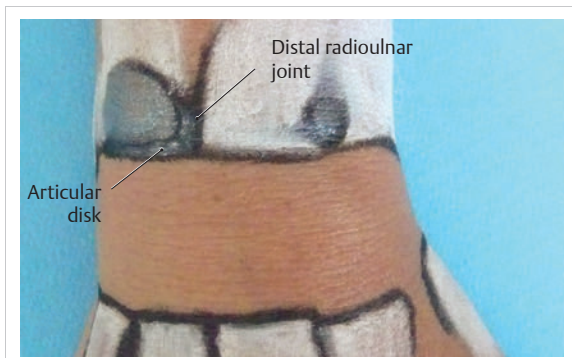


Fig. 2.3 Distal radioulnar joint.

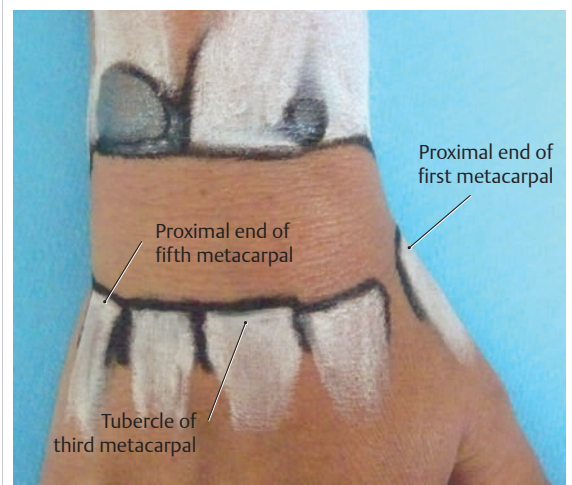


Fig. 2.4 Proximal part of the metacarpals.

Metacarpophalangeal Joint Line and Its Structures

The metacarpophalangeal joint line is described based on the following three reference points:

- **Proximal end of the first metacarpal:** The palpating finger is placed in the snuffbox. During the alternating reposition and opposition of the thumb, the prominent part of the proximal end of the first metacarpal can be palpated and then is marked with the marker as the first reference point.
- **Tubercle of third metacarpal:** The palpating index finger is moved in proximal direction toward the wrist across the middle finger and the third metacarpal. Directly after the base of the metacarpal bone, a definite hollow can be felt in which the capitate is located. The second reference point is located directly in front of the hollow of the capitate and marked.
- **Proximal end of the fifth metacarpal:** Palpation continues in a proximal direction across the lateral part of the little finger and across the hypothenar. Shortly behind the fifth metacarpal, a small hollow can be

palpated in which the lateral surface of the hamate is located. The area in front of the hamate hollow is marked as the third reference point (► Fig. 2.4).

The three bone points are then connected with the marker and the metacarpal joint line becomes visible. Between this and the proximal radiocarpal joint line, the location of the seven carpal bones can be nearly exactly defined and palpated (► Fig. 2.5). The eighth carpal bone, the pisiform, can only be palpated from the palmar side. However, it is also possible to locate it indirectly from the dorsal aspect via the triquetrum.

Dorsal Carpal Bones

The starting point for palpating the seven dorsal carpal bones is the **capitate** (► Fig. 2.6a). Its hollow distinguishes it from the other carpal bones, making it easy to palpate.

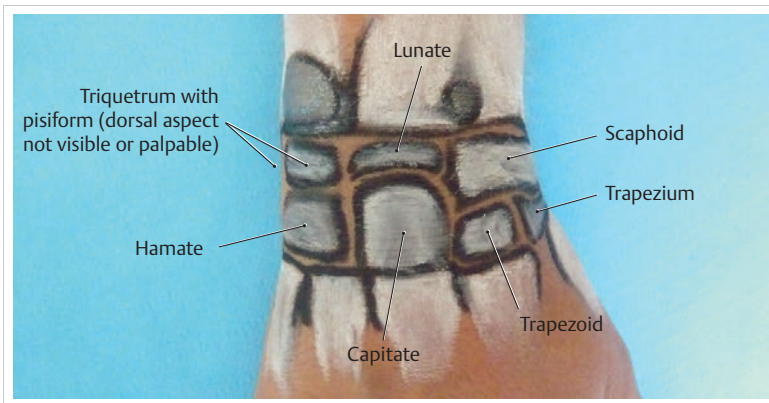


Fig. 2.5 Carpal bones.

The **lunate** is located proximal to the capitate (► Fig. 2.6b), while the **trapezoid** is located on the radial side of the capitate (► Fig. 2.6c) and the **hamate** is located on the ulnar side of the capitate (► Fig. 2.6d).

After these carpal bones have been palpated, the **trapezium** is palpated radially via the trapezoid (► Fig. 2.7a). The **scaphoid** is located between the trapezium and the radius (► Fig. 2.7b). On the radial side, these two bones can also be palpated easily via the snuffbox. To do this, both of the palpator's index fingers are placed in this hollow with the proximal index finger making contact with the scaphoid and the distal index finger making contact with the trapezium. While alternating between ulnar and radial deviation of the wrist, the finger gliding down the radial styloid process and, palpating deeply, feels the joint line between the scaphoid and the radius. The **radial collateral carpal ligament** is located here, but cannot be palpated.

With the wrist in ulnar deviation, the **joint line** can be felt one fingerbreadth further distal between the scaphoid and trapezium (► Fig. 2.8).²⁷⁵ The **radial artery** and its pulse can also be palpated at the radial styloid process below the tendon of the abductor pollicis longus muscle, lateral of the snuffbox.

The palpation then continues across the capitate to the hamate. The **triquetrum** is in front of or proximal to this bone with the **pisiform** located on the palmar aspect (► Fig. 2.7d, ► Fig. 2.9). The articular disk is located proximal to the triquetrum, with the ulna next to this carpal bone.

The proximal joint line of the wrist is located between the proximal carpal bones (triquetrum, lunate, and scaphoid) and the ulna and radius. Between the proximal carpal bones on one side and the hamate, capitate, trapezoid, and trapezium on the other side, the **S-shaped joint line of the distal wrist can be palpated**. All of the carpal bones and the two joint lines are outlined with the skin marker.

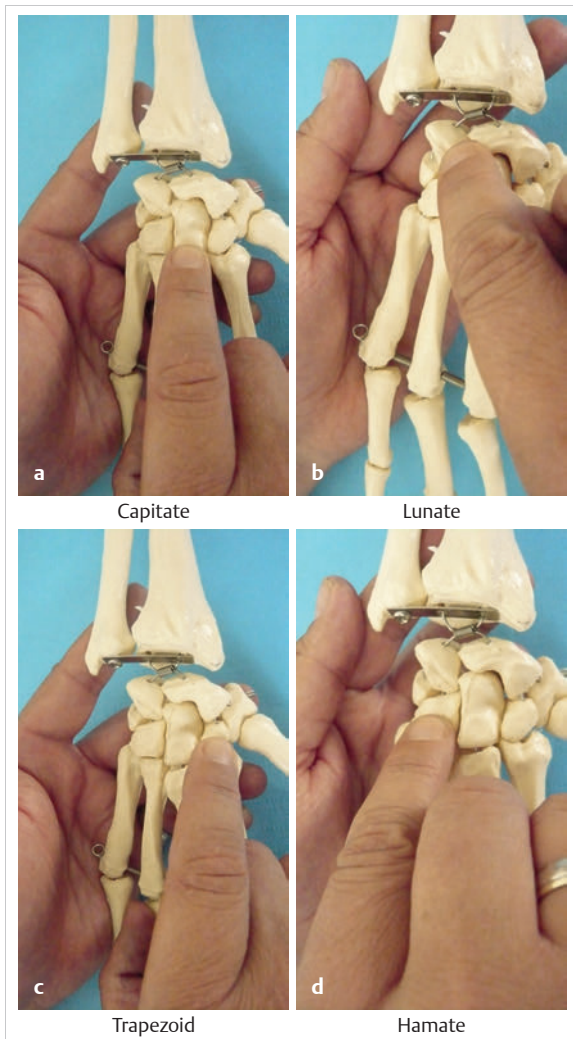


Fig. 2.6 Palpation of carpal bones I. (a) Capitate. (b) Lunate. (c) Trapezoid. (d) Hamate.

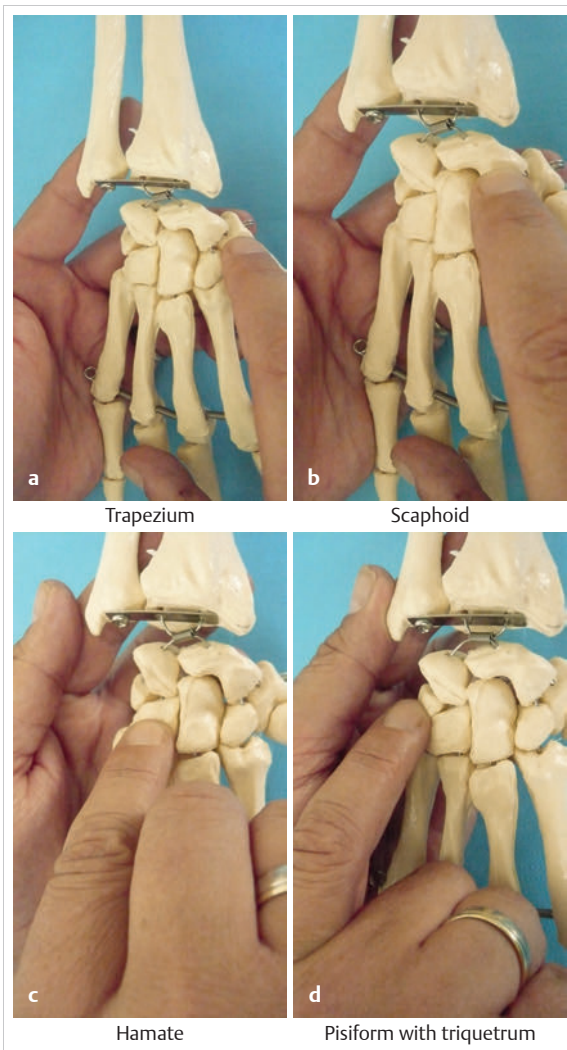


Fig. 2.7 Palpation of carpal bones II. (a) Trapezium. (b) Scaphoid. (c) Hamate. (d) Pisiform with triquetrum.

Note

The ability to palpate the carpal bones competently is a basic prerequisite for diagnosing and treating wrist problems. Improper palpation or failure to maintain mobilization between the individual carpal bones (“joint play mobilization”) leads to inadequate results that can actually worsen the existing pathology.

2.3.2 Surface Anatomy of the Six Dorsal Tendon Compartments

The central part of the extensor retinaculum arises from the radial styloid process (► Fig. 2.10). It is approximately 1.5 cm wide, courses proximally and is attached to the

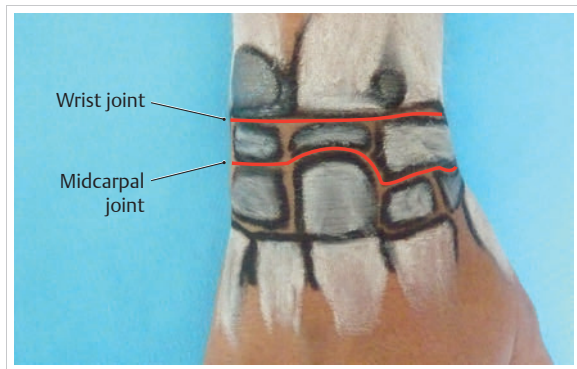


Fig. 2.8 Proximal and distal wrist.

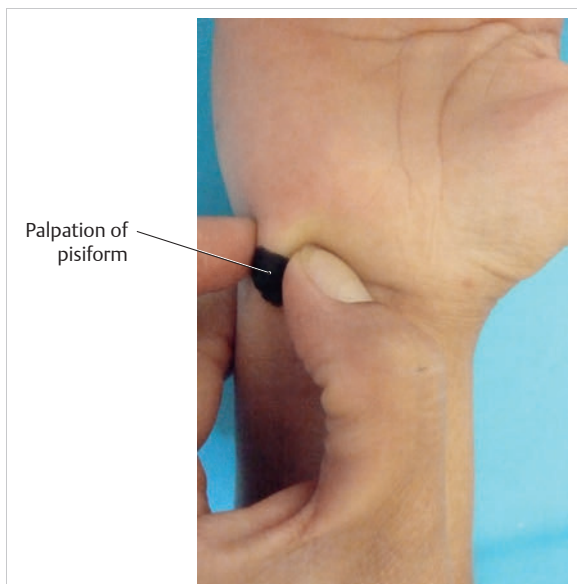


Fig. 2.9 Palpation of the pisiform.

ulnar styloid process up to the palmar surface of the triquetrum. Its fibers fan out proximally and distally up to around 5 cm. It forms six osteofibrous canals and is fused with the tendons and tendon sheaths running within it, as well as with the underlying bones and the distal radioulnar joint.²²⁹ Via the **extensor retinaculum**, all extrinsic extensor tendons of the hand retain their relationship to the forearm, even during extensive movements of the hand and during pronation and supination (► Fig. 2.11).²⁰⁷

The radial border of the central fibers of the retinaculum extending from the styloid process is marked 1.5 cm proximally with the skin marker. An additional mark is placed 2 cm proximal to the ulnar aspect of the triquetrum and the ulnar styloid process. The marks on both sides are connected and filled in. Then all six tendon compartments are located from radial to ulnar and are

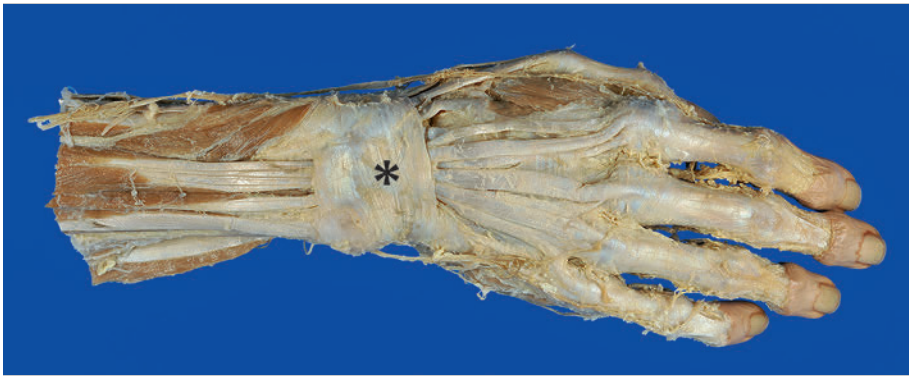

Fig. 2.10 Extensor retinaculum (*) in a specimen.

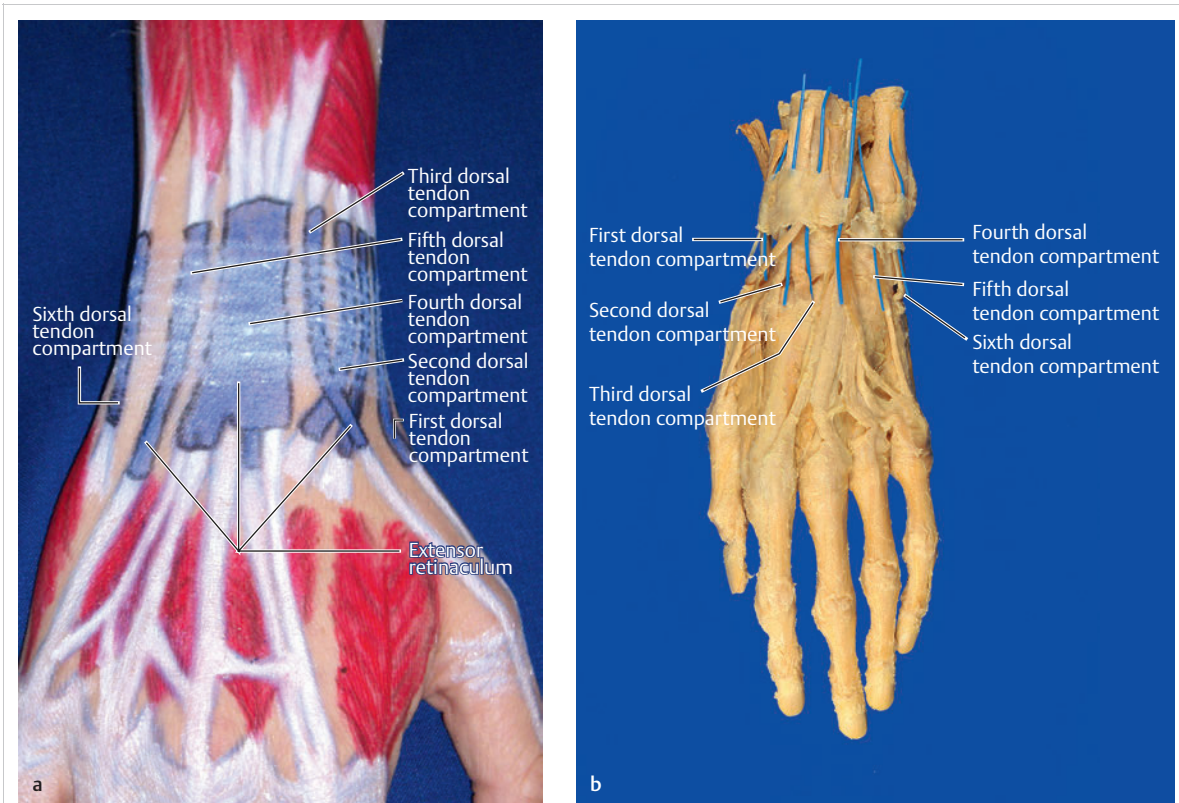


Fig. 2.11 The six dorsal tendon compartments. (a) Overview of the six dorsal tendon compartments. (b) The six dorsal tendon compartments in a specimen.

marked in accordance with their approximate length and their path into the extensor retinaculum (► Fig. 2.12).

First Dorsal Tendon Compartment

The index finger palpates along the radial aspect of the wrist to the radial styloid process on the flattened margin of the radius. The first dorsal tendon compartment is approximately 15 mm long and 8 mm wide. With the tendons of the abductor pollicis longus and extensor pollicis brevis muscles, it courses in a proximal direction

from this side of the radius (► Fig. 2.13). This tendon compartment is located more laterally (toward the radius) than the other dorsal tendon compartments. In the area of the **first metacarpal**, both tendons, along with the tendon of the extensor pollicis longus muscle, form the **anatomic snuffbox**. Only part of the abductor pollicis brevis muscle is visible because the tendon of the abductor pollicis longus lies below it. The two tendons can only be seen during active thumb reposition. They form a smaller hollow, the **small snuffbox**. The abductor pollicis longus muscle inserts at the base of the first metacarpal and the

extensor pollicis brevis muscle inserts at the dorsal base of the first proximal phalanx (► Fig. 2.13).

Practical Tip

Entrapment of the superficial branch of the radial nerve (Wartenberg's syndrome, ► Fig. 2.14) in the distal forearm is often mistaken for tenosynovitis of the first dorsal tendon compartment (de Quervain's stenosing tenosynovitis).¹⁶⁴ In many cases, this nerve branch runs in the area of the radial styloid process; firmer palpation can irritate the nerve and cause paresthesia and trigger pain (► Fig. 2.14). Wartenberg's syndrome may be caused by a tight watch strap or by handcuffs ("handcuff neuropathy"¹⁵⁹). Similar to tenosynovitis of the first dorsal extensor tendon compartment, the symptoms are triggered by the Finkelstein test. For this reason, the test for Tinel's sign (tapping of the nerve) and pure ulnar deviation of

the wrist must be performed for differential diagnosis. If there is entrapment of the superficial branch of the radial nerve (Wartenberg's syndrome), the test for Tinel's sign will clearly produce the distinguishing symptoms (pain in the dorsal hand and paresthesia of the thumb)¹⁶⁴ in contrast to de Quervain's syndrome.

Second Dorsal Tendon Compartment

Lister's tubercle (dorsal tubercle of the radius) delineates the ulnar aspect of the second dorsal extensor tendon compartment (► Fig. 2.15). It is about 10 mm wide and extends proximally about 25 mm from the distal radial epiphysis. In younger people, the V-shaped attachment of the extensor carpi radialis longus and brevis muscles at the second and third metacarpals is visible during small extension movements.

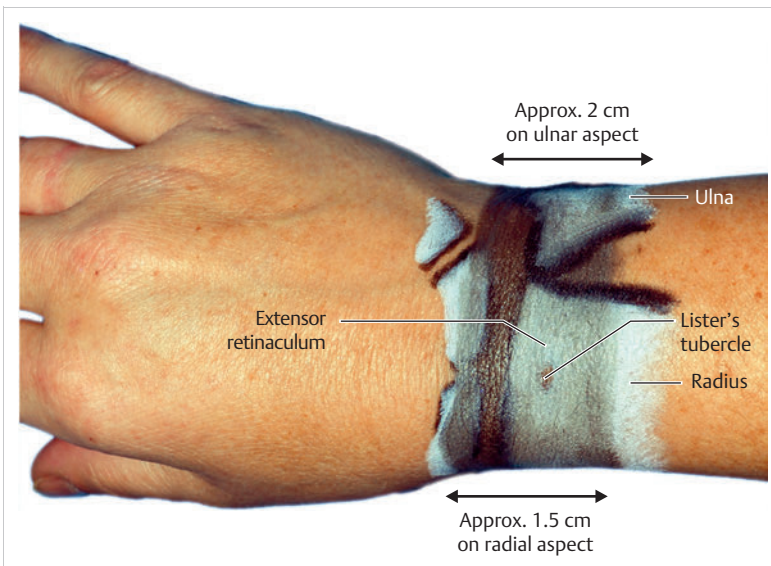


Fig. 2.12 Extensor retinaculum.

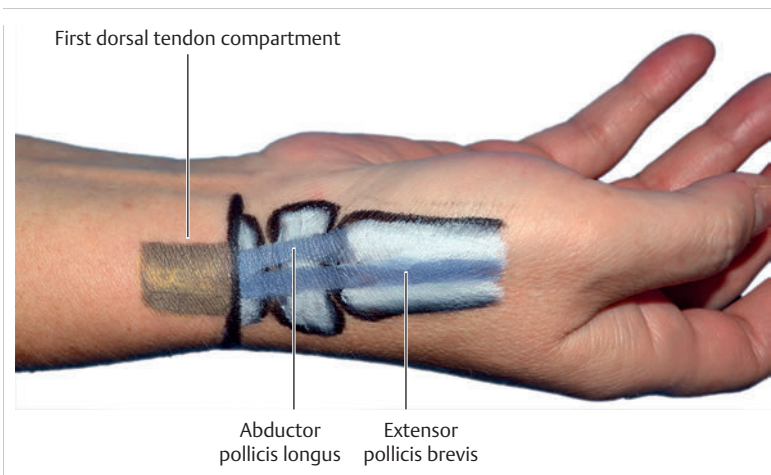


Fig. 2.13 First dorsal tendon compartment.

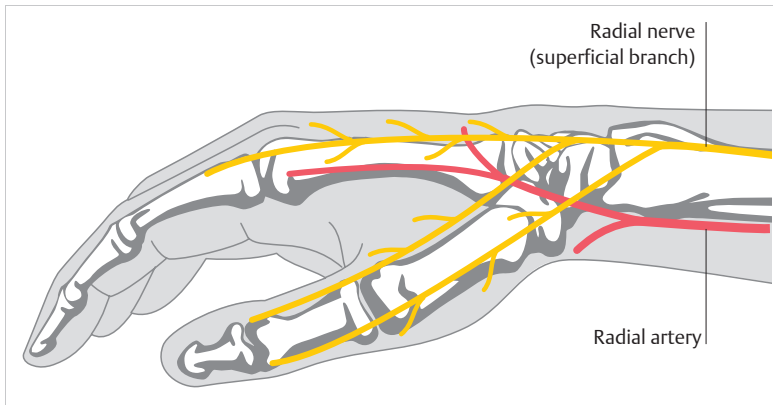


Fig. 2.14 Superficial branch of the radial nerve. (From Reichert B. *Palpation Techniques. Surface Anatomy for Physical Therapists*. 2nd ed. Stuttgart: Thieme; 2015)

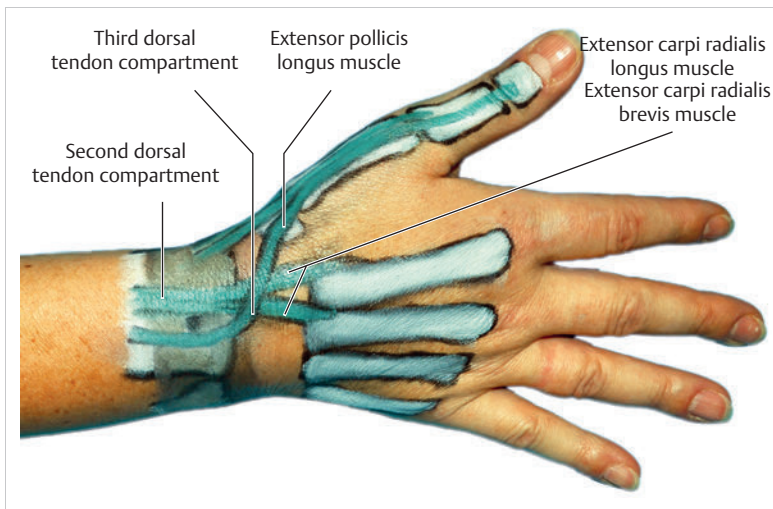


Fig. 2.15 Second and third dorsal tendon compartments.

Third Dorsal Tendon Compartment

The third dorsal tendon compartment is located on the ulnar aspect of Lister's tubercle (► Fig. 2.15). It is about 25 mm long, **takes an arc-shaped trajectory** around Lister's tubercle, and lies over the second tendon compartment. Lister's tubercle acts as a deflection pulley for the extensor pollicis longus muscle and enables reposition. The tendon is easy to palpate at Lister's tubercle during small extension movements.

Fourth Dorsal Tendon Compartment

The fourth dorsal tendon compartment is located directly next to the ulnar aspect of the third dorsal tendon compartment (► Fig. 2.16). It is about 25 mm long and 10 mm wide, and begins its course 5 mm proximal to the extensor retinaculum. In the distal part, the tendon sheath adopts a fan-shaped path over the dorsum, ending in a recess. On the radial side, it is about 46 mm wide. Medially it is about 49 mm wide and on the ulnar side about 57 mm wide.²²⁹ In a common sheath, it guides the three extensor digitorum communis tendons and underneath, on the floor of the tendon compartment, the proper

extensor indicis tendon, which takes an oblique trajectory distally and radially.

The **path of the finger extensor tendons** through the fourth tendon compartment is easy to see during small alternating finger extension movements (e.g., playing the piano, ► Fig. 2.17). The proper extensor indicis tendon is located on the dorsum of the hand, ulnar to the tendon of the extensor digitorum communis muscle of the index finger. It can be palpated when the affected index finger is extended, with accompanying sideways movements of the palpating finger. In some cases, it is also visible.²⁰⁷ All three extensor tendons are connected to the **intertendinous connection** in the distal part of the metacarpals, which together with this ligament form a functional unit. For this reason, it is not possible to move any of the four fingers in isolation. However, independent movement of the index and little fingers is possible as the extensor indicis muscle allows the index finger to move and the extensor digiti minimi muscle also allows the little finger to move. The first tendon of the common finger extensor muscle extends to the index finger, the second tendon extends to the middle finger, and the third tendon divides into two branches in the intertendinous connection

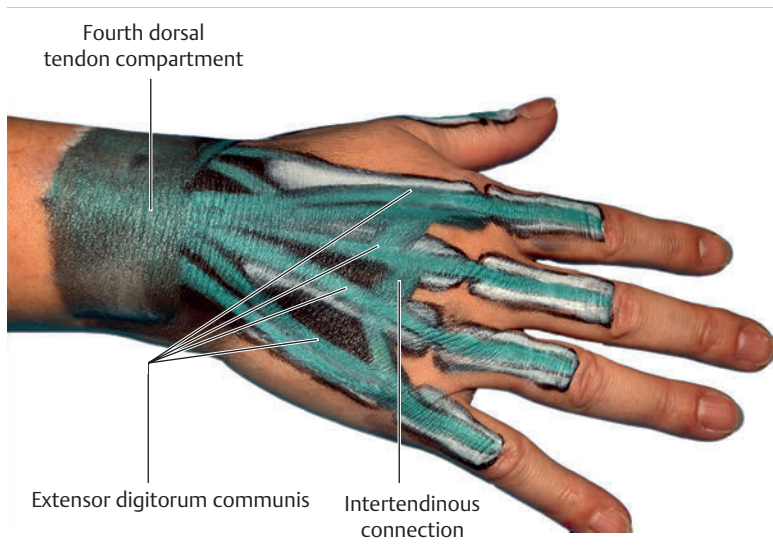


Fig. 2.16 Fourth dorsal tendon compartment.

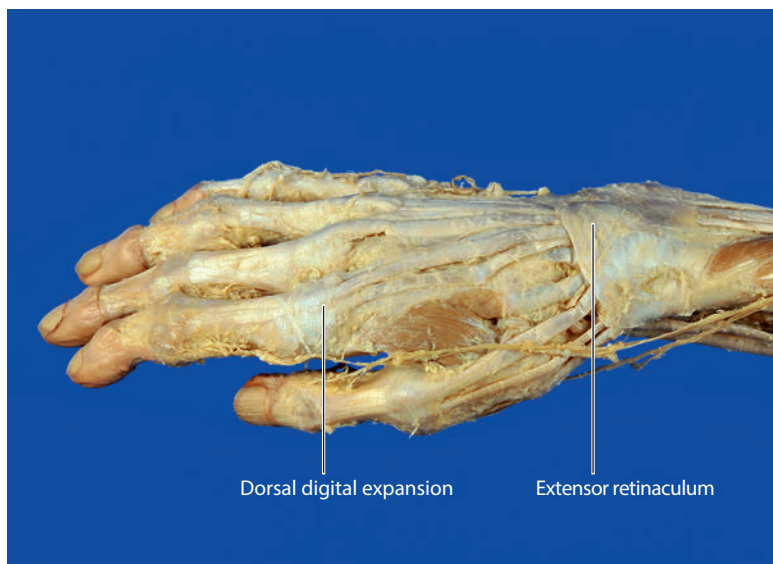


Fig. 2.17 Dorsal digital expansion in a specimen.

before each branch establishes contact with the ring and little fingers, respectively.

Fifth Dorsal Tendon Compartment

The fifth dorsal tendon compartment is located directly radial to the ulnar head above the joint line of the distal radioulnar joint (► Fig. 2.18). It arises about 17 mm from the joint line of the proximal wrist and extends distally about 29 mm. It is the longest dorsal tendon compartment and guides the tendon of the extensor digiti minimi muscle in the direction of its **insertion onto the dorsal digital expansion of the little finger**. The tendon can easily be palpated across its entire course if the patient slightly activates this muscle. To make sure the fifth dorsal tendon compartment is not mistaken for the extensor digitorum communis muscle, the extensor digitorum

communis muscle should be inhibited by means of reciprocal inhibition. This is accomplished by asking the patient to press the fingertips of all the fingers except the thumb on a surface, and then extend only the little finger. This will make it easier to palpate the tendon of the extensor digiti minimi.²⁰⁷ The tendon of the fifth dorsal tendon compartment is considered a **landmark for identifying the joint line of the distal radioulnar joint**.

Sixth Dorsal Tendon Compartment

The sixth dorsal tendon compartment contains the extensor carpi ulnaris tendon and is located **directly ulnar to the ulnar head** (► Fig. 2.19). It is approximately 21 mm long and 6 mm wide, and extends through a bony groove between the ulnar head and the ulnar styloid process. It extends up to the base of the fifth metacarpal and has

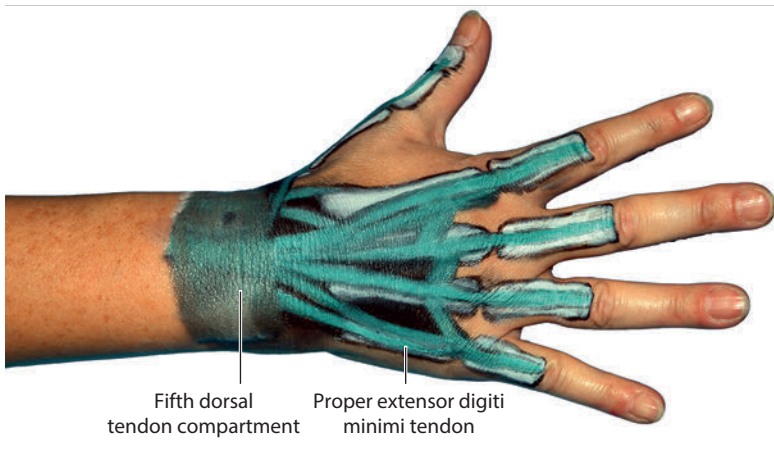


Fig. 2.18 Fifth dorsal tendon compartment.

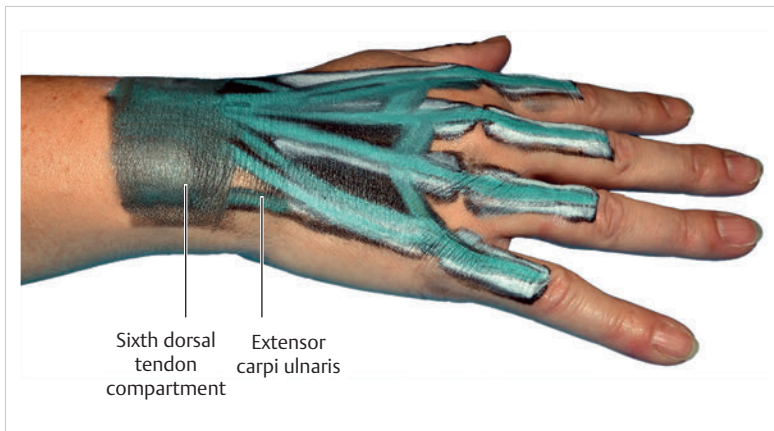


Fig. 2.19 Sixth dorsal tendon compartment.

additional insertions at the pisiform, hook of hamate, and pisometacarpal ligament. Owing to the large range of motion of this tendon compartment, it rotates in a somewhat radial direction toward the ulnar head during supination. It is easiest to palpate the sixth dorsal tendon compartment directly next to, and distal to, the ulnar head.

Practical Tip

Various types of tendinitis can be diagnosed by specifically stretching the compartment in question. In the case of de Quervain's tenosynovitis, the examiner places the thumb in maximum adduction and sharply deviates the wrist ulnarward (Finkelstein's sign²²⁰).

2.3.3 Surface Anatomy of the Extrinsic Dorsal Forearm Muscles

The **superficial dorsal muscles** of the forearm, which include the brachioradialis, extensor carpi ulnaris longus and brevis, extensor digitorum, extensor digiti minimi, and extensor carpi ulnaris muscles, **arise entirely in the**

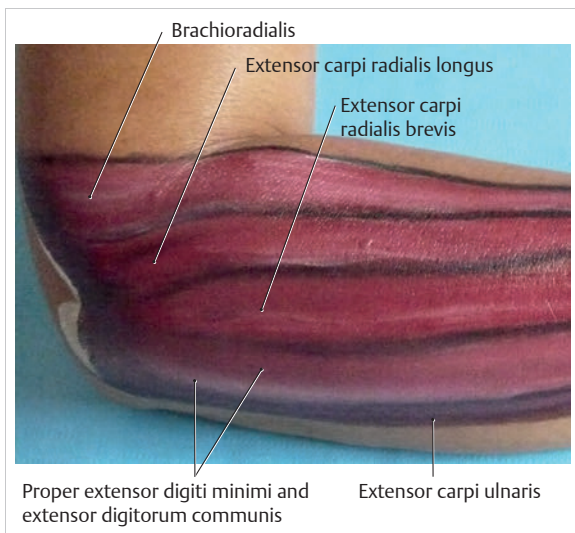


Fig. 2.20 Overview of the extrinsic muscles of the dorsal upper forearm.

area of the lateral epicondyle (► Fig. 2.20). Their muscle bellies are visible up to the lower part of the forearm, and become flatter from proximal to distal. The supinator

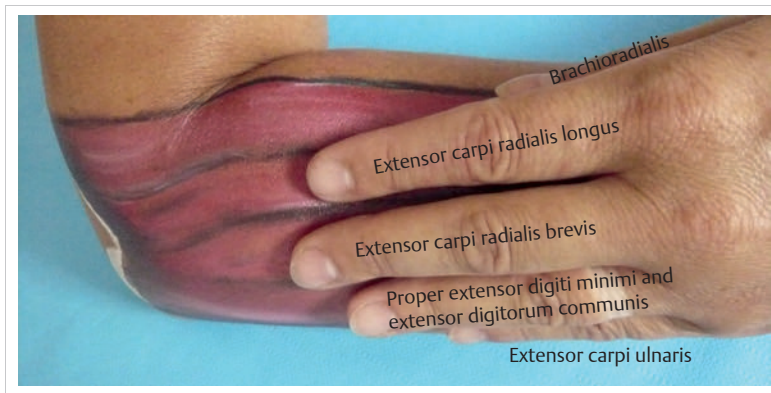


Fig. 2.21 Ring finger palpation technique for palpating the extrinsic muscles of the dorsal upper forearm.

muscle cannot be palpated at its origin because it is too deep; this makes it difficult to assess hypertonicity of this muscle. The dorsal muscles, which are located deep and distal, include the abductor pollicis longus, extensor pollicis brevis and longus, and extensor indicis. The thin, flat overlying muscle layer makes it difficult to locate and palpate these deep muscles.

The **extensor digitorum communis** muscle can be used as a landmark for palpating all of the superficial muscles of the forearm. If the patient makes small finger extension movements, slight contractions in the area of the lateral epicondyle make this muscle easy to see. Once the muscle has been located, the examiner's ring finger is placed on the muscle with the ring finger pointed proximally (► Fig. 2.21). The examiner then places the other fingers of the hand on the forearm so that they are located above the structures as described in the following. Below the ring finger, the extensor digiti minimi muscle is located next to the **extensor digitorum communis** muscle. Since both muscles have a common tendon origin and are more or less fused together, they cannot be palpated separately. The **extensor carpi ulnaris** muscle can be palpated below the little finger, the **extensor carpi radialis brevis** muscle can be palpated below the middle finger, the **extensor carpi radialis longus** muscle below the index finger, and the **brachioradialis** muscle below the thumb.

The **ring finger palpation technique**, in which palpation is performed by the ring finger, can also be used to **palpate the deep dorsal muscles** (► Fig. 2.22). To do this, the thumb is brought into reposition, which makes the **extensor pollicis longus tendon** easy to see. The palpating ring finger follows this tendon toward the ulna with the little finger resting on the ulnar head. The **extensor pollicis longus** muscle is located below the ring finger, the **proper extensor indicis** muscle is located below the little finger, the **extensor pollicis brevis** muscle is located below the middle finger, and the **abductor pollicis longus** muscle is located below the index finger.

Note

Using the ring finger palpation technique is a good way to locate and assess the muscle tone of the superficial and deep dorsal forearm muscles.

2.3.4 Surface Anatomy of the Palmar Wrist, Three Palmar Tendon Compartments, and Palmar Nerves and Vessels

On the palmar aspect and ulnar side, the pisiform, the flexor carpi ulnaris muscle and ulnar artery, and the hook of hamate can be palpated (► Fig. 2.23). The palmaris longus muscle can be palpated on the medial aspect and the flexor carpi radialis muscle, the **first palmar tendon compartment** and the flexor carpi radialis tendon can be palpated on the radial aspect. The tendon of the flexor carpi radialis lies laterally to the radial artery and rests on top of it (► Fig. 2.25).

From these structures, the triquetrum and hamate with the ulnar nerve (ulnar tunnel) can be located on the ulnar aspect. The trapezium, trapezoid, scaphoid, and medially the capitate and lunate, can then be located on the radial aspect. With these structures as landmarks, the flexor retinaculum with the carpal tunnel can be located. The **third palmar tendon compartment** with the superficial and deep flexor digitorum muscles can be located on the ulnar aspect. The **second palmar tendon compartment** of the flexor pollicis longus muscle can be located on the radial aspect.

Note

Fewer structures can be palpated directly on the palmar surface of the hand than on the dorsal surface. However, it is still very important to be familiar with the approximate location of the nonpalpable structures. For

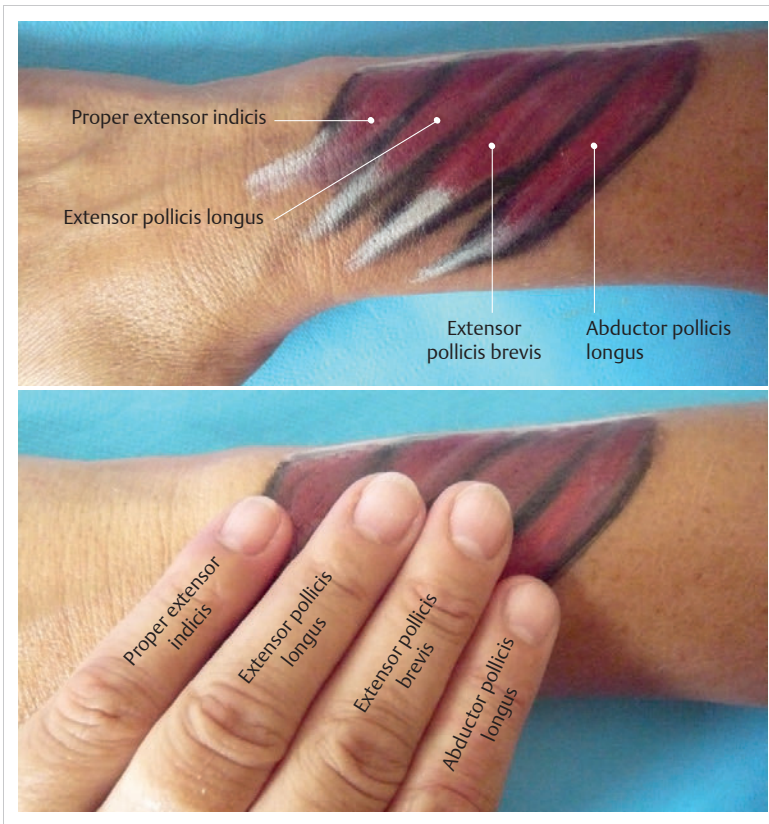


Fig. 2.22 Ring finger palpation technique for palpating the extrinsic muscles of the dorsal lower forearm.

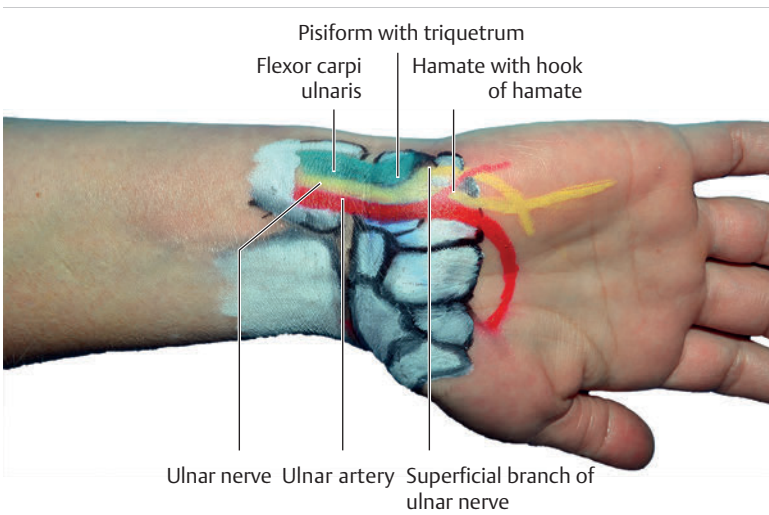


Fig. 2.23 Palmar ulnar palpation surface.

example, in cases of median nerve entrapment, the only way to identify this pathology is to use a specific provocation test with manual pressure (Tinel's sign).

The first step is to look for the **pisiform**, which is easy to palpate. This bone is located at the level of the distal wrist crease on the lateral side of the proximal end of the

margin of the hand.²⁷⁵ It is embedded in the flexor carpi ulnaris tendon as a spherical sesamoid bone over the triquetrum bone that can be shifted in all directions if the muscle is relaxed. The hand is placed in pronation position with the wrist slightly flexed and the pinch grip is used to immobilize the pisiform. From this position, the mobility of the pisiform can be tested easily. The **flexor carpi ulnaris tendon** is located directly proximal to the pisiform. It extends across the pisiform and the hook of

hamate to its insertion at the palmar base of the fifth metacarpal. The flexor carpi ulnaris tendon is easy to palpate if the wrist is placed in isometric ulnar deviation. The ulnar nerve—which cannot be palpated—lies on the radial aspect of the flexor carpi ulnaris muscle, with the ulnar artery at the end (the pulse, which is rather weak, is easy to palpate here).

The **ulnar tunnel** is located near the pisiform and the hook of hamate (► Fig. 2.24). Within this tunnel, the ulnar nerve divides into a superficial sensory branch and a deep motor branch. On the ulnar aspect, the superficial branch gives off a branch for sensory innervation of the hypothenar eminence between the pisiform and the hook of hamate. The main branch runs past the hook of hamate on the radial aspect and then divides into smaller branches for tactile innervation of the little finger and ulnar half of the ring finger (► Fig. 2.23). Nerve entrapment between the pisiform and the hook of hamate causes paresthesia in the area of the hypothenar eminence, directly radial to the hook of hamate in the little finger and half of the ring finger.

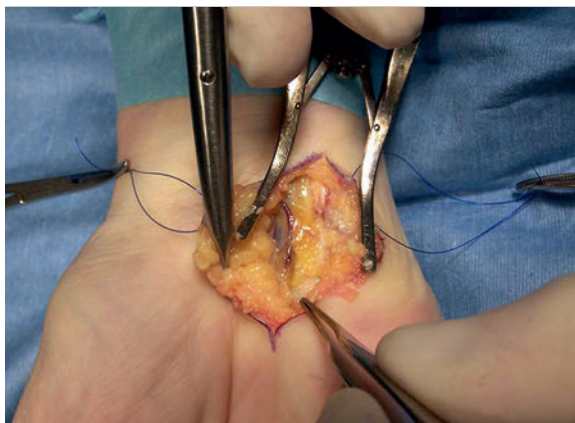


Fig. 2.24 Ulnar nerve decompression in the ulnar tunnel with the palmar carpal ligament exposed.

Note

Ongoing pressure (such as during cycling) in the area of the ulnar tunnel can lead to paresthesia in the region of the hypothenar, the little finger, and half of the ring finger, and the entire area innervated by the ulnar nerve (in some cases with the involvement of the intrinsic hand muscles innervated by the ulnar nerve) (► Fig. 2.24).

On the radial aspect, the flexor carpi radialis tendon is easy to see and extends into the **first palmar tendon compartment of the wrist**. The radial artery passes directly lateral to this tendon and can be clearly felt as a strong pulse on the flat palmar plateau of the radius. In the area of the wrist, it is diverted dorsally shortly before the scaphoid tubercle. If one follows the flexor carpi radialis tendon from proximal to distal, the **scaphoid tubercle** is easy to palpate at the level of the pisiform. During radial deviation, the hand tilts the scaphoid palmarly and during ulnar deviation, it tilts the scaphoid dorsally. These tilting movements can be clearly detected.

The radial artery extends across the scaphoid into the snuffbox. In so doing, it crosses under the extensor pollicis longus tendon, extends across the first and second intermetacarpal space back toward the palmar aspect, and finally merges with the deep palmar arch.⁸⁵ When the muscles are relaxed, the **pulse in the area of the snuffbox** can be perceived faintly.

The **palmaris longus tendon** is located in the medial palmar wrist and is easily visible; however, it is not present in about 15% of the population.²⁰⁸ It can be easily palpated if the wrist is flexed slightly with the thumb and little finger in opposition. The palmaris longus muscle plays only a minor role in the hand's function. The flexor carpi radialis muscle, radial artery, and palmaris longus muscle are also referred to as the **"radial trio"** (► Fig. 2.25).⁶⁰

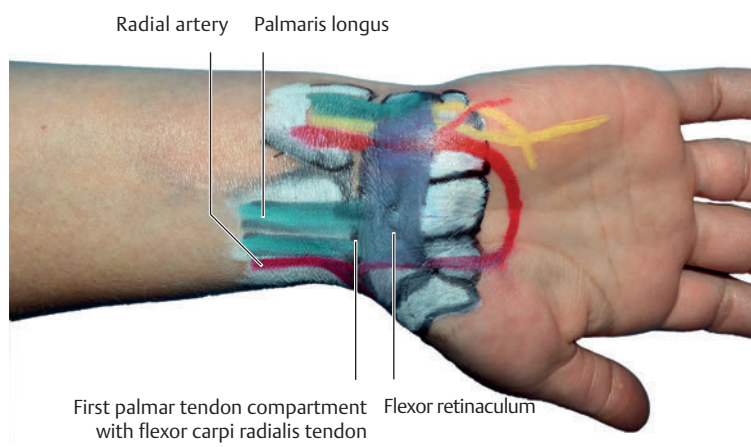


Fig. 2.25 The radial trio.

The trapezium is located lateral and distal to the scaphoid. The trapezium cannot be palpated from the palmar side. The trapezoid is located distally in front of the scaphoid (► Fig. 2.26). The lunate is located medial to the scaphoid and the capitate is located next to the trapezoid. These two carpal bones (capitate and lunate) cannot be palpated from the palmar side because of the soft tissue within the carpal tunnel that covers them.

The very significant **carpal tunnel** is formed from eight carpal bones. The radial border of the carpal tunnel is formed by the scaphoid and trapezoid tubercles and the ulnar border is formed by the pisiform and the hook of hamate (► Fig. 2.27). The roof of the carpal tunnel is formed by the lunate and the capitate. The flexor retinaculum spans across the floor of the tunnel (► Fig. 2.26). It arises from the aforementioned radial and ulnar borders. The **third palmar tendon compartment**, with its four tendons of the superficial and deep flexor digitorum muscles, is located between the flexor carpi ulnaris and palmaris longus tendon in the deep carpal tunnel. This tendon compartment cannot be palpated. The median nerve runs on the medial ulnar side of the palmaris

longus muscle. Resting on top of the third palmar tendon compartment, it extends directly into the carpal tunnel, where it divides into its motor and sensory branches (► Fig. 2.28). The palmaris longus muscle and the median nerve are also referred to as the “**median duo**.”⁶⁰ The flexor pollicis longus muscle, which cannot be seen or palpated, is also located in the **second palmar tendon compartment** of the carpal tunnel between the flexor carpi radialis and palmaris longus muscles.

Practical Tip

The most common pathological condition affecting the carpal tunnel is carpal tunnel syndrome. This entrapment neuropathy of the median nerve can be caused either by stenosis of the tunnel or by an increase in the volume of its contents.²⁷ In up to 85% of cases, tenosynovitis or chronic fibrosis of the third palmar tendon compartment is found in patients with carpal tunnel syndrome. This is usually the result of repetitive stress.²⁷

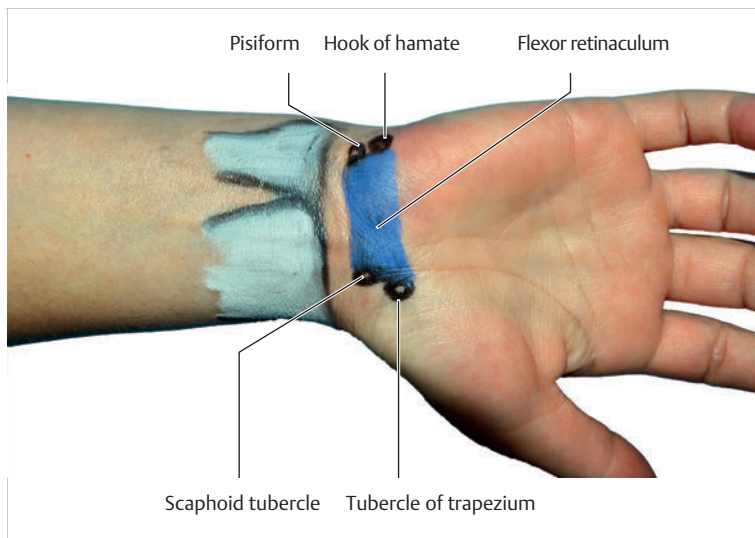


Fig. 2.26 Flexor retinaculum.

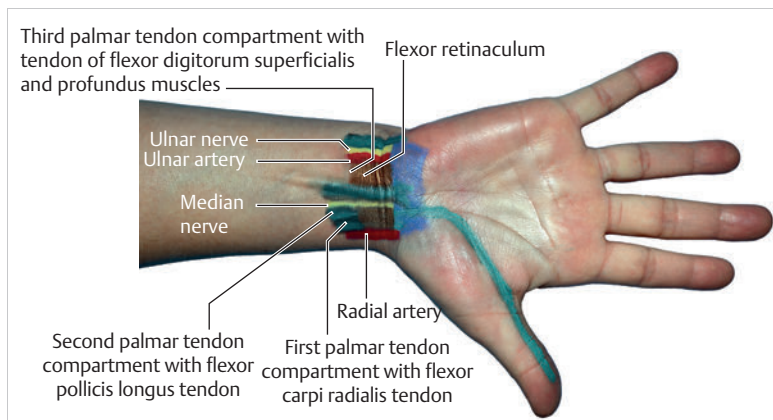


Fig. 2.27 The three palmar tendon compartments.

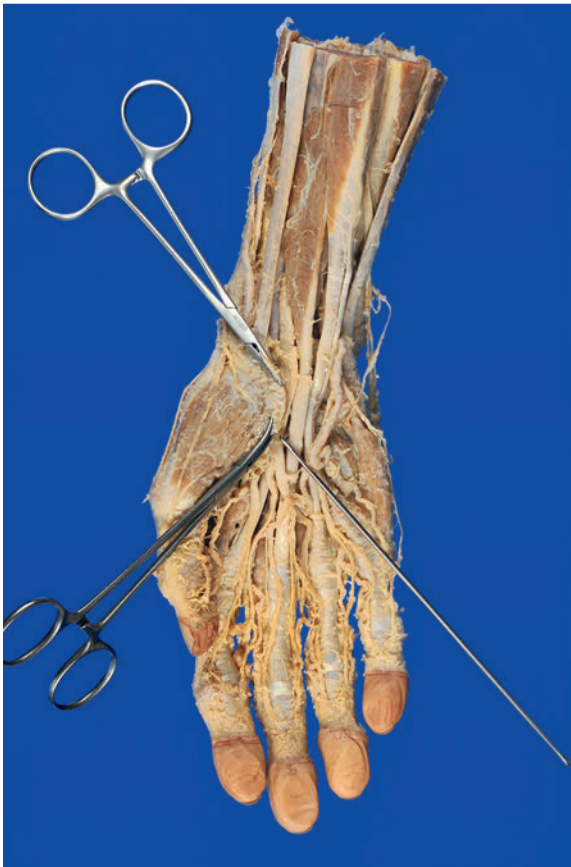

Fig. 2.28 Median nerve in a specimen. The tip of the probe is pointing to the median nerve. The clamps are holding the flexor retinaculum.

2.3.5 Surface Anatomy of the Extrinsic Palmar Forearm Muscles

The **deep layer of the palmar forearm muscles**, comprising the flexor digitorum profundus, flexor pollicis longus, and pronator quadratus muscles, cannot be palpated. The superficial muscle layer of the forearm, which is made up of the flexor carpi ulnaris, flexor digitorum superficialis, palmaris longus muscle, flexor carpi radialis, and pronator teres muscles, can be located and palpated to a limited extent (► Fig. 2.29).

For palpation, it is helpful to **use the little finger placement technique**, in which the little finger serves as the anchor for the palpating fingers, while asking the examinee to actively activate the muscle in question to some extent. The examiner places the base of his or her fifth metacarpal on the **medial epicondyle**. The **flexor carpi ulnaris muscle** is located beneath the little finger, the **flexor digitorum superficialis muscle** beneath the ring finger, the **palmaris longus muscle** beneath the middle finger, the **flexor carpi radialis muscle** beneath the index finger, and the **pronator teres muscle** beneath the thumb.

2.3.6 Surface Anatomy of the Palm, Thumb, and Fingers

The dorsal aspect of the **metacarpals** is easy to palpate, but from the palmar aspect, they can be palpated only indirectly. The base of the first metacarpal, together with the trapezium, forms the carpometacarpal (CMC) joint of the thumb. The intra-articular space is easy to palpate in the distal part of the snuffbox (► Fig. 2.30). During thumb extension, the base of the **first metacarpal** presses against the examiner's finger. By sliding the finger slightly radially and distally, the convex part of the base of the first metacarpal can be palpated during active reposition. The radial and ulnar sesamoid bone can be palpated beneath the palmar part of the metacarpophalangeal (MCP) joint of the thumb in the distal part of the first metacarpal (► Fig. 2.30). The abductor pollicis brevis muscle inserts on the radial condyle of the first metacarpal and the adductor pollicis muscle inserts on the ulnar condyle.

The base of the **second metacarpal** articulates with the trapezium and trapezoid. The second CMC joint, which is immobile, is easy to palpate on the back of the hand, distal to the trapezoid. The base of the **third metacarpal** stands out due to the styloid process on the radial aspect. It articulates with the capitate as an immobile joint; its distal part is easy to palpate on the back of the hand. The base of the **fourth metacarpal** shares a joint surface with both the capitate and hamate. It is only slightly mobile and it is easy to palpate on the back of the hand. The base of the **fifth metacarpal** has only one contact surface to the hamate. It is the most mobile of all the finger metacarpals, and can be palpated using the same technique as for the other metacarpals. During palpation, the head of the fifth metacarpal glides somewhat palmarly when it is rotated at the same time.²⁷⁵

The metacarpal heads are on the distal ends of the second to fifth metacarpals. If the index finger is placed on the base of the proximal phalanx of interest, the **intra-articular space of the second MCP joint** can be palpated when the finger of interest is extended and flexed slightly (► Fig. 2.31).

The **palmar aponeurosis** is difficult to palpate, since it is firmly attached to the ridged skin of the palm. In the area of the volar plate, the **A1 annular ligaments of the fingers** can be palpated if the muscles are relaxed and the examiner's technique is well-developed (► Fig. 2.32).

Practical Tip

Stenosing tenosynovitis ("trigger finger") commonly occurs in the area of the A1 annular ligament. The greatest prevalence is among patients over 50 years of age.²¹² In adults, the condition tends to present as thickening of the flexor tendon with its subsynovial connective

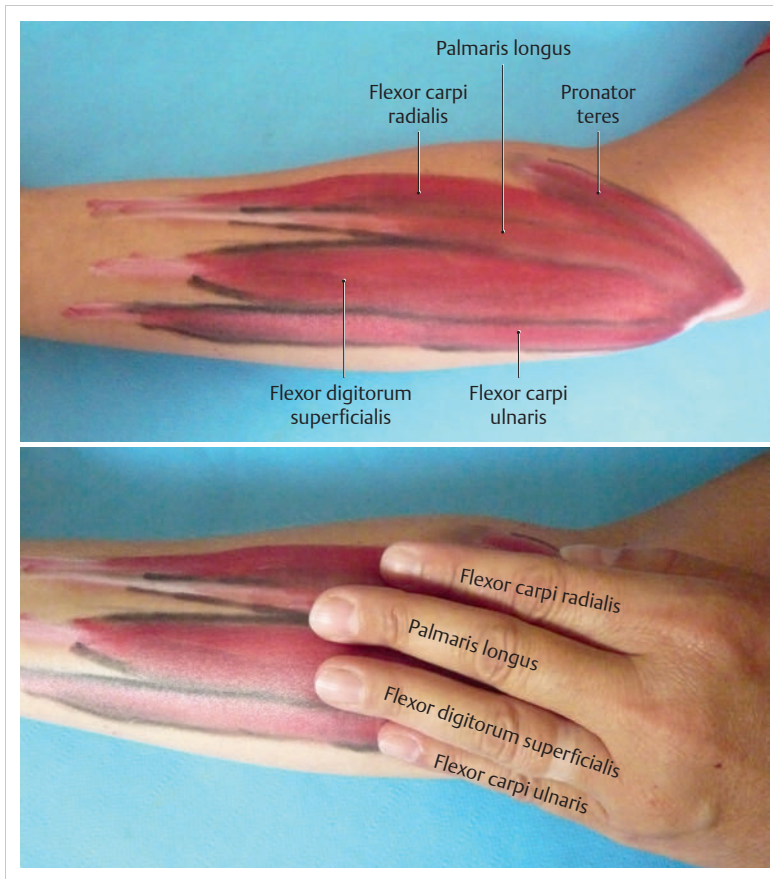


Fig. 2.29 Little finger placement technique for palpating the palmar extrinsic forearm muscles.

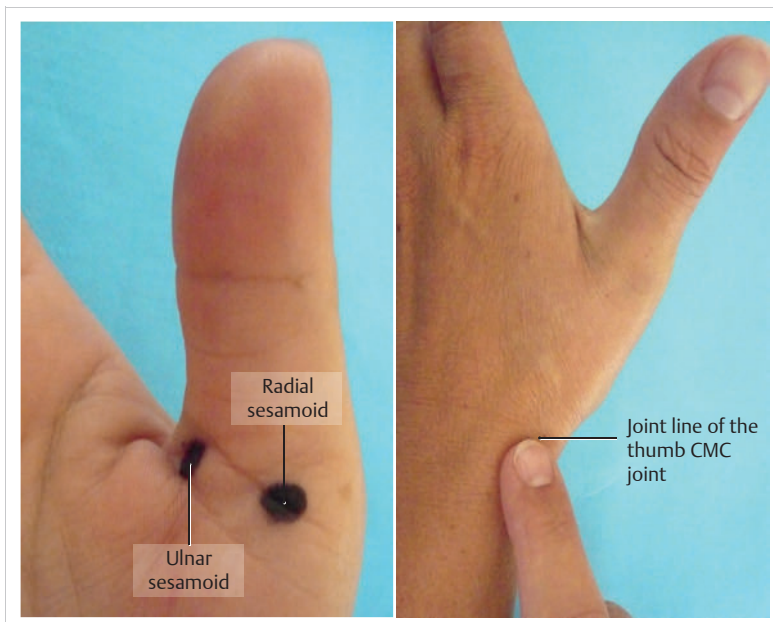


Fig. 2.30 Radial and ulnar sesamoid— intra-articular space of the MCP joint of the thumb.

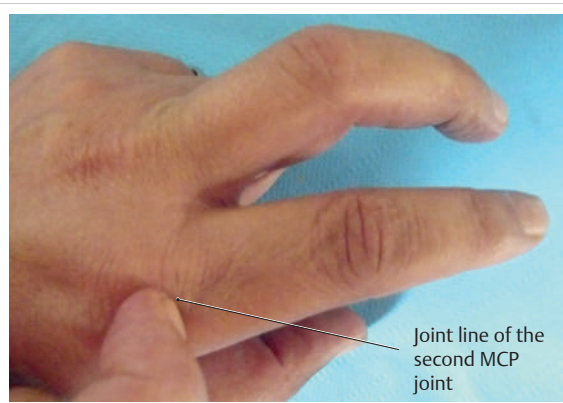


Fig. 2.31 Intra-articular space of the second MCP joint.

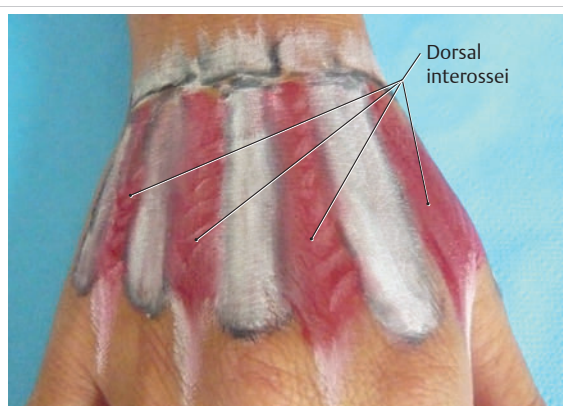


Fig. 2.33 Dorsal interossei muscles.

tissue.²¹² The condition is caused by a degenerative process in conjunction with short-term overuse.²¹² The affected tendon is entrapped proximally and distally to the anular ligament. In the early stages, the patient can overcome this obstruction by increasing muscle force, which causes the characteristic trigger action of the affected finger during flexion and extension.²¹² In later stages, the finger remains in permanent extension or, more frequently, in permanent flexion. If the condition is not treated surgically, it may be exacerbated by contracture of the capsule in the adjacent finger joints.²¹² In some cases, the patient may experience severe pain during the actual trigger action.²¹² Cortisone injections and immobilization only provide temporary relief; surgical release of the anular ligament is the best treatment option for trigger finger. Stenosing tenosynovitis may also present in infants' thumbs ("trigger thumb"). In this case, the symptoms are caused by a thickening of the flexor tendon with nodular formation. Here too, surgical correction is required.

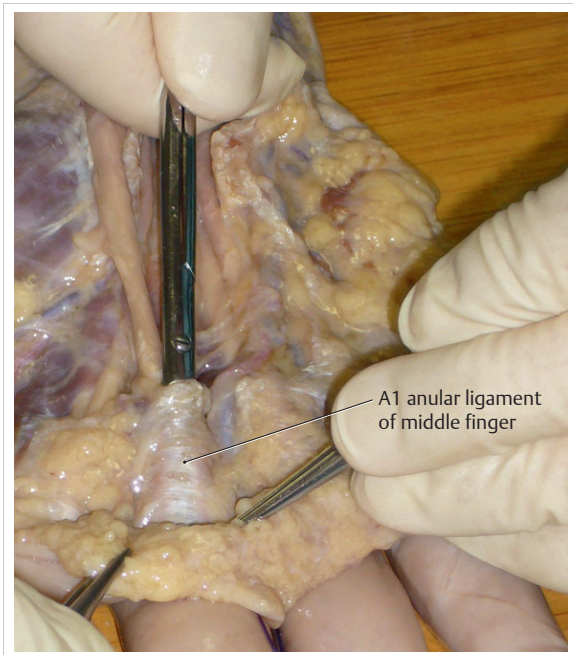


Fig. 2.32 A1 anular ligament of the middle finger.

2.3.7 Surface Anatomy of the Intrinsic Muscles of Thenar, Palm, and Hypothenar Areas

All of the **thenar and hypothenar muscles** are easy to palpate. In the palm, only the dorsal interossei can be palpated (► Fig. 2.33). The palmar interossei are covered by the rigid palmar aponeurosis and the lumbricals lie between the interossei.

The adductor pollicis and first dorsal interosseous muscles are easy to palpate in the web space between the thumb and index finger. The **index finger placement technique, in which the index finger serves as the anchor for the palpating fingers**, can be used to discern all the other intrinsic muscles of the thumb (► Fig. 2.34). The index finger is placed on the lateral radial aspect of the first metacarpal. The opponens pollicis muscle is located beneath the index finger, the abductor pollicis brevis muscle is beneath the middle finger, the flexor pollicis brevis muscle is beneath the ring finger, and the transverse head of the adductor pollicis muscle is located beneath the little finger.

The dorsal interossei can be palpated between the second and fifth metacarpals. The **ring finger placement technique** can be used to distinguish between the individual **hypothenar muscles** (► Fig. 2.35). The ring finger is placed on the lateral aspect of the hypothenar without the little finger touching the surface. The abductor digiti minimi muscle is located beneath the ring finger, the flexor digiti minimi muscle is beneath the middle finger, and the opponens digiti minimi muscle is beneath the index finger. Pathological conditions of the hypothenar muscles are uncommon.

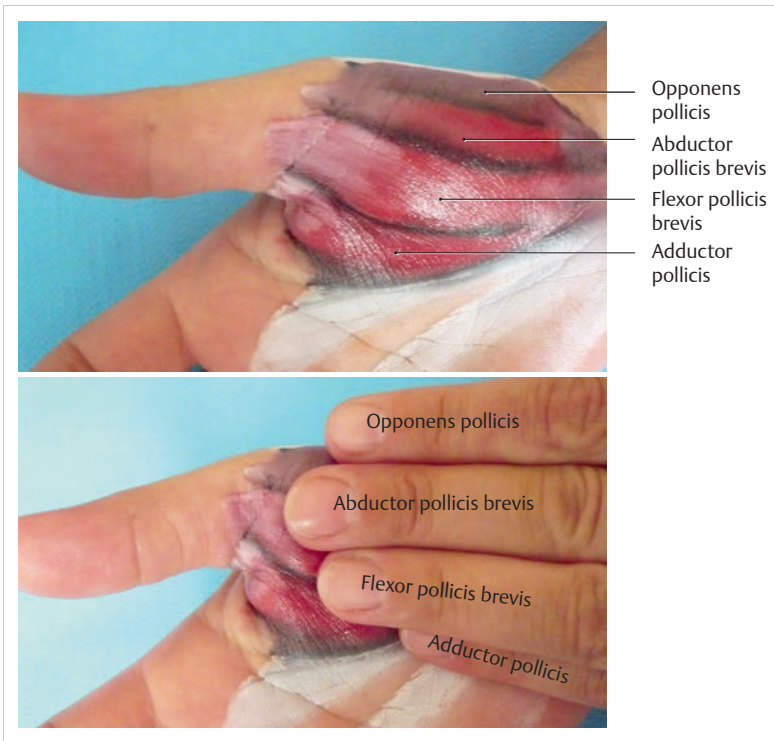

Fig. 2.34 Index finger placement technique for palpating the thenar muscles.

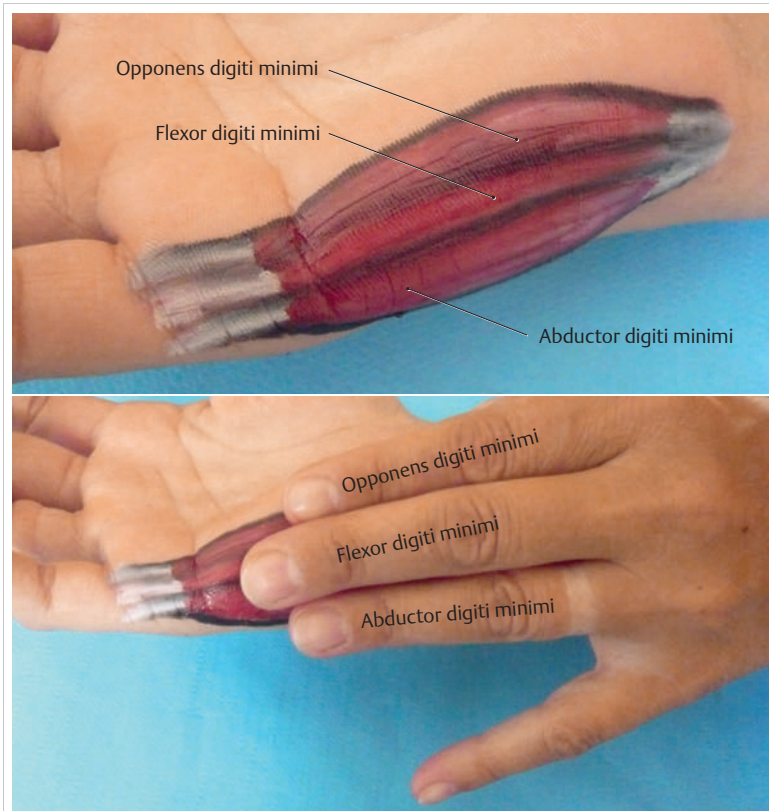


Fig. 2.35 Ring finger placement technique for palpating the hypothenar muscles.

References

- [1] Aebriot JH. The metacarpophalangeal joint of the thumb. In: Tubiana R, ed. *The Hand*. Philadelphia: Saunders; 1981
- [2] Apfel E. The effect of thumb interphalangeal joint position on strength of key pinch. *J Hand Surg Am* 1986; 11(1):47–51
- [3] Appell HJ, Stang-Voss C. *Funktionelle Anatomie*. 4th ed. Heidelberg: Springer; 2008: 60–61
- [4] Ash HE, Unsworth A. Proximal interphalangeal joint dimensions for the design of a surface replacement prosthesis. *Proc Inst Mech Eng H* 1996; 210(2):95–108
- [5] Ateshian GA, Rosenwasser MP, Mow VC. Curvature characteristics and congruence of the thumb carpometacarpal joint: differences between female and male joints. *J Biomech* 1992; 25(6):591–607
- [6] Backhouse KM. Mechanical factors influencing normal and rheumatoid metacarpophalangeal joints. *Ann Rheum Dis* 1969; 28(5) Suppl.:15–19
- [7] Bade H, Schubert M, Koebke J. Functional morphology of the deep transverse metacarpal ligament. *Ann Anat* 1994; 176(5):443–450
- [8] Bartels R, Bartels H. Haut, Schmerz und Lagesinn. In: Jürgens KD, ed. *Physiologie—Lehrbuch der Funktionen des menschlichen Körpers*. 7th ed. Munich: Elsevier; 2004: 272
- [9] Barton NJ. Fractures and joint injuries of the hand. In: Wilson JN, ed. *Fractures and joint injuries*. 6th ed. New York: Churchill Livingstone; 1982
- [10] Basmajian JV. Electromyography—dynamic gross anatomy: a review. *Am J Anat* 1980; 159(3):245–260
- [11] Batmanabane M, Malathi S. Movements at the carpometacarpal and metacarpophalangeal joints of the hand and their effect on the dimensions of the articular ends of the metacarpal bones. *Anat Rec* 1985; 213(1):102–110
- [12] Bausenhardt D. Über das Carpo-Metacarpalgelenk des Daumens. *Z Anat Entwickl Gesch* 1949/1950; 114:250–250
- [13] Bauman TD, Gelberman RH, Mubarak SJ, Garfin SR. The acute carpal tunnel syndrome. *Clin Orthop Relat Res* 1981(156):151–156
- [14] Bechmann I, Nitsch R et al. Zentrales Nervensystem, Systemnervensystem, Gehirn, Encephalon und Rückenmark, Medulla spinalis. In: Fanghänel J, Pera F, Anderhuber F, Nitsch R, eds. *Walddeyer. Anatomie des Menschen*. 17th ed. Berlin: de Gruyter; 2003: 481
- [15] Berger A, Towfigh H, Hierner R. Rekonstruktive Eingriffe an der Hand. In: Schmit-Neuerburg KP, Towfigh H, Letsch R, eds. *Ellenbogen, Unterarm, Hand. Tscherne Unfallchirurgie*. Vol 2. Berlin: Springer; 2001: 519
- [16] Berger RA, Blair WF. The radioscapholunate ligament: a gross and histologic description. *Anat Rec* 1984; 210(2):393–405
- [17] Berger RA, Landsmeer JMF. The palmar radiocarpal ligaments: a study of adult and fetal human wrist joints. *J Hand Surg Am* 1990; 15(6):847–854
- [18] Berger RA. The anatomy of the ligaments of the wrist and distal radioulnar joints. *Clin Orthop Relat Res* 2001(383):32–40
- [19] Bert JM, Linscheid RL, McElfresh EC. Rotatory contracture of the forearm. *J Bone Joint Surg Am* 1980; 62(7):1163–1168
- [20] Bettinger PC, Linscheid RL, Berger RA, Cooney WP III An KN. An anatomic study of the stabilizing ligaments of the trapezium and trapezometacarpal joint. *J Hand Surg Am* 1999; 24(4):786–798
- [21] Böhler J, Ender HG. Pseudarthrosis of the scaphoid. [Article in German.] *Orthopäde* 1986; 15(2):109–120
- [22] Böhlinger G. Arthroskopie des Handgelenks. In: Schmit-Neuerburg KP, Towfigh H, Letsch R, eds. *Ellenbogen, Unterarm, Hand. Tscherne Unfallchirurgie*. Vol 1. Berlin, Heidelberg: Springer; 2001: 267–269
- [23] Bonnel F, Mailhe P, Allieu Y et al. The general anatomy and endoneural fascicular arrangement of the median nerve at the wrist. *Anat Clin* 1981; 2:201–207
- [24] Bonnel F, Allieu Y. Radioulnocarpal and mediocarpal articulations. Anatomic organization and biomechanical bases. [Article in French.] *Ann Chir Main* 1984; 3(4):287–296
- [25] Bowe A, Doyle L, Millender LH. Bilateral partial ruptures of the flexor carpi radialis tendon secondary to trapezoidal arthritis. *J Hand Surg Am* 1984; 9(5):738–739
- [26] Bowers WH. The anatomy of the interphalangeal joint. In: Bowers WH, ed. *The Hand and Upper Limb*. Vol 1: The Interphalangeal Joint. Edinburgh: Churchill Livingstone; 1987
- [27] Buchberger W, Schmitt R. Carpal Tunnel Syndrome. In: Schmitt R, Lanz U, eds. *Diagnostic Imaging of the Hand*. Stuttgart and New York: Thieme Publishers; 2007: 524–531
- [28] Buck-Gramcko D, Helbig B. *Daumensattelgelenksarthrose*. Stuttgart: Hippokrates; 1994
- [29] Bunnell P. *Surgery of the Hand*. 5th ed. Philadelphia: J.B. Lippincott; 1970
- [30] Camper P. *Demonstrationum anatomico-pathologicarum liber primus. Continens brachii humani fabricum et morbos*. Amstelaedami 4, 19 (1760). In: Spinner M. *Kaplan's Functional and Surgical Anatomy of the Hand*. 3rd ed. Philadelphia: J.B. Lippincott; 1984
- [31] Candiolo L. Comparative anatomical studies on the tensor tympani muscle, with reference to proprioceptive innervation. [Article in Italian.] *Z Zellforsch Mikrosk Anat* 1965; 67(1):34–56
- [32] Chase RA. Anatomy and kinesiology of the hand. In: Jupiter JB, ed. *Flynn's Hand Surgery*. 4th ed. Baltimore: Williams and Wilkins; 1990
- [33] Cobb TK, Dalley BK, Posteraro RH, Lewis RC. Anatomy of the flexor retinaculum. *J Hand Surg Am* 1993; 18(1):91–99
- [34] Cooney WP III, Lucca MJ, Chao EY, Linscheid RL. The kinesiology of the thumb trapeziometacarpal joint. *J Bone Joint Surg Am* 1981; 63(9):1371–1381
- [35] Crisco JJ, Coburn JC, Moore DC, Akelman E, Weiss AP, Wolfe SW. In vivo radiocarpal kinematics and the dart thrower's motion. *J Bone Joint Surg Am* 2005; 87(12):2729–2740
- [36] Darrow JJC Jr, Linscheid RL, Dobyms JH, Mann JM III, Wood MB, Beckenbaugh RD. Distal ulnar recession for disorders of the distal radioulnar joint. *J Hand Surg Am* 1985; 10(4):482–491
- [37] De Krom MCTFM, Renssema JW, Lataster LMA et al. The connective tissue apparatus in the region of the carpal tunnel. *Verh Anat Ges* 1987; 81:335–336
- [38] Denman EE. The anatomy of the space of Guyon. *Hand* 1978; 10(1):69–76
- [39] Denman EE. The anatomy of the incision for carpal tunnel decompression. *Hand* 1981; 13(1):17–28
- [40] Dobyms J, Linscheid R. Traumatic instability of the wrist. *Instr Course Lect* 1975; 24:182–199
- [41] Drewniansy JJ, Palmer AK, Flatt AE. The scaphotrapezial ligament complex: an anatomic and biomechanical study. *J Hand Surg Am* 1985; 10(4):492–498
- [42] Dubouset JF. The digital joint. In: Tubiana R, ed. *The Hand*. Vol 1. Philadelphia: Saunders; 1981
- [43] Duchenne GBA. – De Boulogne (1867). *Physiologie des mouvements*. In: Réédition en facsimilé. *Ann Med Physique*, Lille 1959; ed. Translated by E.B. Kaplan (1949). Philadelphia and London: W.B. Saunders
- [44] Eaton RG, Littler JW. A study of the basal joint of the thumb. Treatment of its disabilities by fusion. *J Bone Joint Surg Am* 1969; 51(4):661–668
- [45] Eaton RG. *Joint Injuries of the Hand*. Springfield: C.C. Thomas; 1971
- [46] Eaton RG, Littler JW. Ligament reconstruction for the painful thumb carpometacarpal joint. *J Bone Joint Surg Am* 1973; 55(8):1655–1666
- [47] Eaton RG, Glickel SZ, Littler JW. Tendon interposition arthroplasty for degenerative arthritis of the trapeziometacarpal joint of the thumb. *J Hand Surg Am* 1985; 10(5):645–654
- [48] Ebskov B. *De motibus motoribusque pollicis humani* [Dissertation]. Copenhagen: University of Copenhagen; 1970
- [49] Ekenstam F. Anatomy of the distal radioulnar joint. *Clin Orthop Relat Res* 1992(275):14–18
- [50] El-Bacha A. The carpometacarpal joints (excluding the trapeziometacarpal). In: Tubiana R, ed. *The Hand*. Vol 1. Philadelphia: Saunders; 1981

- [51] el-Gammal TA, Steyers CM, Blair WF, Maynard JA. Anatomy of the oblique retinacular ligament of the index finger. *J Hand Surg Am* 1993; 18(4):717–721
- [52] Engelhardt E, Schmidt HM. Zur klinischen Anatomie der Dorsalaponeurose der Finger beim Menschen. *Verh Anat Ges* 1987; 81:311–313
- [53] Epner RA, Bowers WH, Guilford WB. Ulnar variance—the effect of wrist positioning and roentgen filming technique. *J Hand Surg Am* 1982; 7(3):298–305
- [54] Eyler DL, Markee JE. The anatomy and function of the intrinsic musculature of the fingers. *J Bone Joint Surg Am* 1954; 36-A(1):1–9, passim
- [55] Fahrer M. The proximal end of the palmar aponeurosis. *Hand* 1980; 12(1):33–38
- [56] Faller A, Schünke M. *The Human Body—An Introduction to Structure and Function*. Stuttgart and New York: Thieme Publishers; 2004: 585–589
- [57] Fick A. Die Gelenke mit sattelförmigen Flächen. *Z Med* 1854; 4:314–321
- [58] Fick R. *Handbuch der Anatomie und Mechanik der Gelenke. Part 1: Anatomie der Gelenke*. In: von Bardeleben K. *Handbuch der Anatomie des Menschen*. Jena: Gustav Fischer; 1904
- [59] Filler TJ, Peucker ET, Pera F, et al. Bauplan des menschlichen Körpers. In: Fanghänel J, Pera F, Anderhuber F, Nitsch R, eds. *Waldeyer. Anatomie des Menschen*. 17th ed. Berlin: de Gruyter; 2003: 47
- [60] Firbas W. *Bewegungsapparat I. Anatomie, Embryologie, Physiologie und Stoffwechselerkrankheiten*. In: Netter FH. *Farbatlanten der Medizin*. Vol 7. Stuttgart: Thieme 1992: 46, 51–56, 60, 70
- [61] Fischer A. *Die Ringbänder der digitalen Sehnscheiden der menschlichen Hand [Inaugural-Dissertation]*. Münster: Westfälische Wilhelms-Universität Münster; 1996
- [62] Fisk GR. The influence of the transverse carpal ligament (flexor retinaculum) on carpal stability. *Ann Chir Main* 1984; 3(4):297–299
- [63] Fisk GR. The wrist. *J Bone Joint Surg Br* 1984; 66(3):396–407
- [64] Flatt AE. *The pathomechanics of the ulnar drift. A biomechanical and clinical study [Dissertation]*. Social and Rehabilitation Services. University of Iowa; 1971
- [65] Flatt AE. *The Care of the Rheumatoid Hand*. 3rd ed. St. Louis: C.V. Mosby; 1974
- [66] Förstner H. The distal radio-ulnar joint. Morphologic aspects and surgical orthopedic consequences. [Article in German.] *Unfallchirurg* 1987; 90(11):512–517
- [67] Forwood M, Kippers V. *Biomechanics of the thumb [Dissertation]*. University of Queensland; 2000
- [68] Frank WE, Dobyns J. Surgical pathology of collateral ligamentous injuries of the thumb. *Clin Orthop Relat Res* 1972; 83(83):102–114
- [69] Fruhstorfer H. Somatoviszzerale Sensibilität. In: Klinker R, Silbernagl S, eds. *Lehrbuch der Physiologie*. 4th ed. Stuttgart: Thieme; 2003: 555–562
- [70] Gabl M, Zimmermann R, Angermann P et al. The interosseous membrane and its influence on the distal radioulnar joint. An anatomical investigation of the distal tract. *J Hand Surg [Br]* 1998; 23(2):179–182
- [71] Gad P. The anatomy of the volar part of the capsules of the finger joints. *J Bone Joint Surg Br* 1967; 49(2):362–367
- [72] Genda E, Horii E. Theoretical stress analysis in wrist joint—neutral position and functional position. *J Hand Surg [Br]* 2000; 25(3):292–295
- [73] Gigis PI, Kuczynski K. The distal interphalangeal joints of human fingers. *J Hand Surg Am* 1982; 7(2):176–182
- [74] Gościcka D, Stepień J, Gościcka J. Long palmar muscle (M. palmaris longus) in human fetuses. [Article in German.] *Gegenbaurs Morphol Jahrb* 1981; 127(2):292–299
- [75] Gosset J. Dupuytren's disease and the anatomy of the palmo-digital aponeurosis. [Article in French.] *Ann Chir* 1967; 21(9):554–565
- [76] Grapow M. Die Anatomie und physiologische Anatomie der Palmaraponeurose. *Arch Anat Physiol* 1887: 143–158
- [77] Gratzner J, Vökt CA, Brenner P. Morphological and functional interface between palmar plates of metacarpophalangeal joints and intrinsic muscle of the hand. [Article in German.] *Handchir Mikrochir Plast Chir* 2001; 33(5):299–309
- [78] Gray H, Williams P, Warwick R, Dyson M, Bannister LH. *Gray's Anatomy*. 37th ed. New York: Churchill Livingstone; 1989
- [79] Greulich M. *Experimentelle und klinische Untersuchungen zur Naht von Beugesehnen im Sehnscheidenbereich der Finger [Habilitation]*. Würzburg; 1982
- [80] Gschwend N. *Rhizarthrose Akt Rheumatol* 1986; 11:51–52
- [81] Hakstian RW, Tubiana R. Ulnar deviation of the fingers. The role of joint structure and function. *J Bone Joint Surg Am* 1967; 49(2):299–316
- [82] Hara T, Horii E, An KN, Cooney WP, Linscheid RL, Chao EY. Force distribution across wrist joint: application of pressure-sensitive conductive rubber. *J Hand Surg Am* 1992; 17(2):339–347
- [83] Harris EF, Aksharanugraha K, Behrents RG. Metacarpophalangeal length changes in humans during adulthood: a longitudinal study. *Am J Phys Anthropol* 1992; 87(3):263–275
- [84] Hazelton FT, Smidt GL, Flatt AE, Stephens RI. The influence of wrist position on the force produced by the finger flexors. *J Biomech* 1975; 8(5):301–306
- [85] Helmlinger T, Schmitt R. *Arteriography*. In: Schmitt R, Lanz U, eds. *Diagnostic Imaging of the Hand*. Stuttgart and New York: Thieme Publishers; 2007: 36–44
- [86] Hempfling H. *Farbatlas der Arthroskopie großer Gelenke*. Vol 1. Stuttgart: Fischer; 1995
- [87] Henle J. *Handbuch der Bänderlehre des Menschen*. 2nd ed. Braunschweig: Vieweg; 1872
- [88] Heuck A, Schmitt R, Hahn P. Soft-Tissue Lesions Caused by Overuse and Sports. In: Schmitt R, Lanz U, eds. *Diagnostic Imaging of the Hand*. Stuttgart and New York: Thieme Publishers; 2007: 335–350
- [89] Hintringer W, Leixnering M. Osseous or ligamentous injuries of the phalango-interphalangeal joint and their treatment. [Article in German.] *Handchir Mikrochir Plast Chir* 1991; 23(2):59–66
- [90] Hoch J, Fritsch H, Frenz C. Does osseous extensor tendon avulsion or rupture really exist? Histologic plastination studies of insertion of the extensor aponeurosis and significance for operative therapy. [Article in German.] *Chirurg* 1999; 70(6):705–712
- [91] Hochschild J. *Functional Anatomy for Physical Therapists*. Stuttgart: Thieme; 2016
- [92] Hogikyan JV, Louis DS. Embryologic development and variations in the anatomy of the ulnocarpal ligamentous complex. *J Hand Surg Am* 1992; 17(4):719–723
- [93] Hollister A, Giurintano DJ. Thumb movements, motions, and moments. *J Hand Ther* 1995; 8(2):106–114
- [94] Hulsizer D, Weiss AP, Akelman E. Ulna-shortening osteotomy after failed arthroscopic debridement of the triangular fibrocartilage complex. *J Hand Surg Am* 1997; 22(4):694–698
- [95] Ikebuchi Y, Murakami T, Ohtsuka A. The interosseous and lumbrical muscles in the human hand, with special reference to the insertions of the interosseous muscles. *Acta Med Okayama* 1988; 42(6):327–334
- [96] Imaeda T, An KN, Cooney WP III, Linscheid R. Anatomy of trapezio-metacarpal ligaments. *J Hand Surg Am* 1993; 18(2):226–231
- [97] Jackson WT, Viegas SF, Coon TM, Stimpson KD, Frogameni AD, Simpson JM. Anatomical variations in the first extensor compartment of the wrist. A clinical and anatomical study. *J Bone Joint Surg Am* 1986; 68(6):923–926
- [98] Jacobson MD, Raab R, Fazeli BM, Abrams RA, Botte MJ, Lieber RL. Architectural design of the human intrinsic hand muscles. *J Hand Surg Am* 1992; 17(5):804–809
- [99] Johnson RK, Shrewsbury MM. The pronator quadratus in motions and in stabilization of the radius and ulna at the distal radioulnar joint. *J Hand Surg Am* 1976; 1(3):205–209
- [100] Jovers B. *Zur Anatomie der Mittelhandstrukturen [Inaugural-Dissertation]*. Würzburg; 1991
- [101] Jürgens D. *Der Bewegungsapparat*. In: Huch R, Jürgens D, eds. *Mensch, Körper, Krankheit*. Munich, Jena: Urban & Fischer; 2007: 128

- [102] Kahle W. Color Atlas of Human Anatomy. Vol 3. 7th ed. Stuttgart: Thieme; 2015: 74–83
- [103] Kanaval AB. Infections of the Hand. 7th ed. Philadelphia: Lea & Febiger; 1939
- [104] Kandel ER, Schwartz JH, Jessell T. Principles of Neural Science. 4th ed. New York and London: McGraw-Hill; 2000
- [105] Kapandji IA. Physiologie Articulare, Vol 1. Paris: Maloine; 1963
- [106] Kapandji IA. Funktionelle Anatomie der Gelenke. 3rd ed. Thieme: Stuttgart; 1980; 138, 148, 190
- [107] Kapandji IA. Biomechanics of the interphalangeal joint of the thumb. In: Tibiana R, ed. The Hand. Vol 1. Philadelphia: Saunders; 1981
- [108] Kapandji IA. The Physiology of the Joints. Vol 1. 5th ed. New York: Churchill Livingstone; 1982
- [109] Kapandji A. Biomechanics of the carpus and wrist joint. [Article in German.] Orthopade 1986; 15(2):60–73, 144
- [110] Kaplan EB. Functional and Surgical Anatomy of the Hand. 3rd ed. Philadelphia: J.B. Lippincott; 1984
- [111] Katzman BM, Klein DM, Garven TC, Caligiuri DA, Kung J. Comparative histology of the annular and cruciform pulleys. J Hand Surg [Br] 1999; 24(3):272–274
- [112] Kauer JMG. The collateral ligament function in the wrist joint. Acta Morphol Neerl Scand 1979; 17:252–253
- [113] Kauer JMG. Functional anatomy of the wrist. Clin Orthop Relat Res 1980(149):9–20
- [114] Kauer JMG. Functional anatomy of the carpometacarpal joint of the thumb. Clin Orthop Relat Res 1987(220):7–13
- [115] Kaufmann P. Bewegungsapparat. In: Schiebler HT, ed. Anatomie. 9th ed. Heidelberg: Springer; 2005: 269–272
- [116] Keller HP, Lanz U. Stenosing tendovaginitis of the flexor carpi radialis tendon. [Article in German.] Handchir Mikrochir Plast Chir 1984; 16(4):236–237
- [117] Kenesi C. The interphalangeal joints of the fingers. Anat Clin 1981; 3:41–48
- [118] Keon-Cohen B. De Quervain's disease. J Bone Joint Surg Br 1951; 33-B(1):96–99
- [119] Kihara H, Short WH, Werner FW, Fortino MD, Palmer AK. The stabilizing mechanism of the distal radioulnar joint during pronation and supination. J Hand Surg Am 1995; 20(6):930–936
- [120] Kim PR, Giachino AA, Uthoff HK. Histologic analysis of fetal ulnar variance. J Hand Surg Am 1996; 21(1):114–116
- [121] Klein C. Klinische Anatomie des Muskelsehnenkomplexes des M. extensor carpi ulnaris [Dissertation]. Bonn, 1996
- [122] Kline SC, Moore JR. The transverse carpal ligament. An important component of the digital flexor pulley system. J Bone Joint Surg Am 1992; 74(10):1478–1485
- [123] Knott C, Schmidt HM. Connective tissue reinforcing structures of the digital tendon sheaths of the human hand. [Article in German.] Gegenbaurs Morphol Jahrb 1986; 132(1):1–28
- [124] Koebeke J, Thomas W. Biomechanical investigations on the aetiology of arthrosis of the first carpometacarpal joint (author's transl). [Article in German.] Z Orthop Ihre Grenzgeb 1979; 117(6):988–994
- [125] Koebeke J, Thomas W. Funktionell-morphologische Untersuchungen zur Daumensattelgelenkarthrose. Verh Anat Ges 1979; 73:181–184
- [126] Koebeke J, Thomas W, Winter HJ. The dorsal metacarpal ligament I and arthrosis of the saddle joint of the thumb. [Article in German.] Morphol Med 1982; 2(1):1–8
- [127] Koepeke J, Peters D. Zur Torsion der Ossametacarpalia II–V. Verh Anat Ges 1991; 85 Suppl 170:205–206
- [128] Kraemer BA, Gilula LA. Anatomy affecting the metacarpal and phalangeal bones of the hand. In: Gilula LA, Yin Y, eds. Imaging of the Wrist and Hand. Philadelphia: Saunders; 1996
- [129] Krebs H. Experiences with therapy of 350 cases of Dupuytren's contraction (author's transl). [Article in German.] Langenbecks Arch Chir 1975; 338(1):67–80
- [130] Kuczynski K. Less-known aspects of the proximal interphalangeal joints of the human hand. Hand 1975; 7(1):31–33
- [131] Kuhlmann N, Gallaire M, Pineau H. Displacements of the navicular and lunarium during the wrist movements (author's transl). [Article in French.] Ann Chir 1978; 32(9):543–553
- [132] Kuhlmann JN. Experimentelle Untersuchungen zur Stabilität und Instabilität des Karpus. In: Nigst H. Frakturen, Luxationen und Dissoziationen der Karpalknochen. Stuttgart: Hippokrates; 1982
- [133] Kuhlmann JN, Tubiana R. Mécanisme du poignet normal. In: Razemon JP, Fisk GR, eds. Le Poignet, Paris: Expansion Scientifique Française; 1983
- [134] Kuhlmann JN, Guerin-Surville H, Baux S. The carpal synovial sheaths and their vascularization. [Article in French.] Bull Assoc Anat (Nancy) 1992; 76(233):27–34
- [135] Kummer B. Biomechanik—Form und Funktion des Bewegungsapparates. Cologne Deutscher Ärzteverlag 2005; 461:470–471
- [136] von Lanz T, Wachsmuth W. Praktische Anatomie 1. Vol 3. Chapter – Arm. 2nd ed. Berlin: Springer; 1959
- [137] von Lanz T, Wachsmuth W. Praktische Anatomie 1. Vol 4. Chapter – Arm. 2nd ed. Berlin: Springer; 1959
- [138] Landsmeer JM. The anatomy of the dorsal aponeurosis of the human finger and its functional significance. Anat Rec 1949; 104(1):31–44
- [139] Landsmeer JMF. Anatomical and functional investigations of the human finger and its functional significance. Acta Anat (Basel) 1955; 25 Suppl 24:1–69
- [140] Landsmeer JMF, Ansingh HR. X-ray observations on rotations of the fingers in the metacarpophalangeal joints. Acta Anat (Basel) 1957; 30:404410
- [141] Landsmeer JMF. Atlas of Anatomy of the Hand. Edinburgh: Churchill Livingstone; 1976
- [142] Leeuw B. The stratigraphy for the dorsal wrist region as basis for an investigation of the position of the M. extensor carpi ulnaris in pronation and Supination of the forearm [Dissertation]. University of Leiden; 1962
- [143] Legrand JJ. The lunate bone: a weak link in the articular column of the wrist. Anat Clin 1983; 5:57–64
- [144] Leibovic SJ, Bowers WH. Anatomy of the proximal interphalangeal joint. Hand Clin 1994; 10(2):169–178
- [145] Lengsfeld M, Strauss JM, Koebeke J. Functional importance of the m. extensor carpi ulnaris for distal radioulnar articulation. [Article in German.] Handchir Mikrochir Plast Chir 1988; 20(5):275–278
- [146] Lichtman DM, Schneider JR, Swafford AR, Mack GR. Ulnar midcarpal instability-clinical and laboratory analysis. J Hand Surg Am 1981; 6(5):515–523
- [147] Lichtman DM, Bruckner JD, Culp RW, Alexander CE. Palmar midcarpal instability: results of surgical reconstruction. J Hand Surg Am 1993; 18(2):307–315
- [148] Linscheid RL. Kinematic considerations of the wrist. Clin Orthop Relat Res 1986(202):27–39
- [149] Loeweneck H. Funktionelle Anatomie für Krankengymnasten. 2nd ed. Munich: Pflaum; 1994: 185–186
- [150] Logan SE, Nowak MD, Gould PL, Weeks PM. Biomechanical behavior of the scapholunate ligament. Biomed Sci Instrum 1986; 22:81–85
- [151] Lohmann AHM. Vorm en Beweging. Utrecht: Bohn, Scholtema en Holkema; 1986
- [152] Low CK, Pereira BP, Ng RT, Low YP, Wong HP. The effect of the extent of A1 pulley release on the force required to flex the digits. A cadaver study on the thumb, middle and ring fingers. J Hand Surg [Br] 1998; 23(1):46–49
- [153] Macconnaill MA. The mechanical anatomy of the carpus and its bearings on some surgical problems. J Anat 1941; 75(Pt 2):166–175
- [154] McFarlane RM, Curry GI, Evans HB. Anomalies of the intrinsic muscles in camptodactyly. J Hand Surg Am 1983; 8(5 Pt 1):531–544
- [155] Malik AM, Schweitzer ME, Culp RW, Osterman LA, Manton G. MR imaging of the type II lunate bone: frequency, extent, and associated findings. AJR Am J Roentgenol 1999; 173(2):335–338
- [156] Mall EG. Die Palmarplatte der Fingergelenke. Makroskopische densitometrische und histologische Untersuchungen [Dissertation]. Cologne; 1994
- [157] Martin BF. The annular ligament of the superior radio-ulnar joint. J Anat 1958; 92(3):473–482
- [158] Mashoof AA, Levy HJ, Soifer TB, Miller-Soifer F, Bryk E, Vigorita V. Neural anatomy of the transverse carpal ligament. Clin Orthop Relat Res 2001 386:218–221

- [159] Massey EW, Pleet AB. Handcuffs and cheiralgia paresthetica. *Neurology* 1978; 28(12):1312–1313
- [160] Matthijs O, van Paridon-Edauw D, Winkel D. Manuelle Therapie der peripheren Gelenke. Ellenbogen Hand. Vol 2. Munich: Urban & Fischer; 2003: 3–12, 41–51, 129–171
- [161] Mayfield JK, Johnson RP, Kilcoyne RF. The ligaments of the human wrist and their functional significance. *Anat Rec* 1976; 186(3):417–428
- [162] Mayfield JK. Wrist ligamentous anatomy and pathogenesis of carpal instability. *Orthop Clin North Am* 1984; 15(2):209–216
- [163] Meinel A. Dupuytren contracture: new aspects on form pathogenesis and surgical principle. [Article in German.] *Handchir Mikrochir Plast Chir* 1999; 31(5):339–345
- [164] Merle M, Rehart S. Chirurgie der Hand—Rheuma—Arthrose—Nervengpässe. Stuttgart: Thieme; 2009: 429–430
- [165] Meuli HC, Dbaly J. Zur Phylogenie, Anatomie und Biomechaniker der Mittelhand. In: Segmüller G, Huber H, eds. *Das Mittelhandskelett in der Klinik*. Bern: Huber; 1978
- [166] Millesi H. Zur Pathogenese und Therapie der Dupuytren-Kontraktur. *Ergeb Chir Orthop* 1965; 47:51–101
- [167] Millesi H. Dupuytren-Kontraktur. In: Nigst H, Buck-Gramcko D, Millesi H, ed. *Handchirurgie*. Stuttgart: Thieme; 1981: 15
- [168] Minami A, An KN, Cooney WP III, Linscheid RL, Chao EY. Ligamentous structures of the metacarpophalangeal joint: a quantitative anatomic study. *J Orthop Res* 1984; 1(4):361–368
- [169] Mörücke KD. Zur Herkunft und Funktion des ulnaren Diskus am Handgelenk. *Morphol Jb* 1963; 105:365–374
- [170] Momose T, Nakatsuchi Y, Saitoh S. Contact area of the trapeziometacarpal joint. *J Hand Surg Am* 1999; 24(3):491–495
- [171] Moritomo H, Viegas SF, Nakamura K, Dasilva MF, Patterson RM. The scaphotrapezio-trapezoidal joint. Part 1: An anatomic and radiographic study. *J Hand Surg Am* 2000; 25(5):899–910
- [172] Moritomo H, Apergis EP, Herzberg G, Werner FW, Wolfe SW, Garcia-Elias M. 2007 IFSSH committee report of wrist biomechanics committee: biomechanics of the so-called dart-throwing motion of the wrist. *J Hand Surg Am* 2007; 32(9):1447–1453
- [173] Morris H. *The Anatomy of the Joints of Man*. London; 1879
- [174] Muckart RD. Stenosing tendovaginitis of abductor pollicis longus and extensor pollicis brevis at the radial styloid (de Quervain's disease). *Clin Orthop Relat Res* 1964; 33(33):201–208
- [175] Mumenthaler M, Stöhr M, Müller-Vahl H. *Läsionen peripherer Nerven und radikuläre Syndrome*. 9th ed. Stuttgart: Thieme; 2007: 258–260
- [176] Napier JR. The form and function of the carpo-metacarpal joint of the thumb. *J Anat* 1955; 89(3):362–369
- [177] Navarro A. *Anales del Instituto de Clinica Quirurgica Y Cirurgia Experimental*. Montevideo: Imprenta Artistica de Dornaleche Hnos; 1935
- [178] Navarro A. Anatomía y fisiología del carpo. *Ann Inst Clin Quir Chir Exp* 1937; 1:162–250
- [179] Netscher D, Mosharrafa A, Lee M et al. Transverse carpal ligament: its effect on flexor tendon excursion, morphologic changes of the carpal canal, and on pinch and grip strengths after open carpal tunnel release. *Plast Reconstr Surg* 1997; 100(3):636–642
- [180] Netscher D, Dinh T, Cohen V, Thornby J. Division of the transverse carpal ligament and flexor tendon excursion: open and endoscopic carpal tunnel release. *Plast Reconstr Surg* 1998; 102(3):773–778
- [181] Oberlin C, Daunois O, Oberlin F. Scapho-trapezo-trapezoid arthrosis. Its effects on the carpus. [Article in French.] *Ann Chir Main Memb Super* 1990; 9(3):163–167
- [182] Orset G, Lebreton E, Assouline A, Giordano P, Denis F, Pomel G. The axial orientation of the phalanges following the curling up of the fingers. [Article in French.] *Ann Chir Main Memb Super* 1991; 10(2):101–107
- [183] Örü M. Biomechanische Aspekte und postoperative Ergebnisse nach Resektions-Interpositions-Arthroplastik mit der hälftig gestielten Musculus-flexor-carpi-radialis-Sehne bei Rhizarthrose [Dissertation]. Hannover: Medizinische Hochschule Hannover; 2006
- [184] Pagalidis T, Kuczynski K, Lamb DW. Ligamentous stability of the base of the thumb. *Hand* 1981; 13(1):29–36
- [185] Pahnke JW. Über die Articulationes metaphalangeales und interphalangeales der menschlichen Hand [Dissertation]. Würzburg; 1987
- [186] Paley D, McMurtry RY, Cruickshank B. Pathologic conditions of the pisiform and pisotriquetral joint. *J Hand Surg Am* 1987; 12(1):110–119
- [187] Palmer AK, Werner FW. The triangular fibrocartilage complex of the wrist—anatomy and function. *J Hand Surg Am* 1981; 6(2):153–162, 189
- [188] Palmer AK, Skahan JR, Werner FW, Glisson RR. The extensor retinaculum of the wrist: an anatomical and biomechanical study. *J Hand Surg [Br]* 1985; 10(1):11–16
- [189] Palmer AK, Werner FW, Murphy D, Glisson R. Functional wrist motion: a biomechanical study. *J Hand Surg Am* 1985; 10(1):39–46
- [190] Palmer AK, Werner FW. Biomechanics of the distal radioulnar joint. *Clin Orthop Relat Res* 1984(187):26–35
- [191] Pechlaner S, Putz R. Traumatic scapho-lunate dissociation. Functional analysis, surgical therapy and results. [Article in German.] *Aktuelle Traumatol* 1987; 17:1–8
- [192] Peck VE, Wedel AH. Funktionsfelder des Großhirns. In: Zalpour C, ed. *Anatomie—Physiologie*. Munich: Urban & Fischer; 2010: 173–174
- [193] Petrie S, Collins J, Solomonow M, Wink C, Chuinard R. Mechanoreceptors in the palmar wrist ligaments. *J Bone Joint Surg Br* 1997; 79(3):494–496
- [194] Pieron AP. The mechanism of the first carpometacarpal (CMC) joint. An anatomical and mechanical analysis. *Acta Orthop Scand Suppl* 1973; 148:1–104
- [195] Plato CC, Norris AH. Bone measurements of the second metacarpal and grip strength. *Hum Biol* 1980; 52(1):131–149
- [196] Plato CC, Wood JL, Norris AH. Bilateral asymmetry in bone measurements of the hand and lateral hand dominance. *Am J Phys Anthropol* 1980; 52(1):27–31
- [197] Plato CC, Purifoy FE. Age, sex and bilateral variability in cortical bone loss and measurements of the second metacarpal. *Growth* 1982; 46(2):100–112
- [198] Platzer W. *Color Atlas of Human Anatomy*. 7th ed. Stuttgart and New York: Thieme; 2014: 158–169, 172–179
- [199] Poisel S. Die topographische Anatomie der Gefäße und Nerven der Hohlhand. *Therapiewoche* 1973; 37(3):3339–3344
- [200] Prescher A, Schmidt HM. Arm, obere Gliedmaße, Membrum superius. In: Fanghänel J, Pera F, Anderhuber F, Nitsch R, eds. *Walddeyer. Anatomie des Menschen*. 17th ed. Berlin: de Gruyter; 2003: 679–691, 706–720, 735
- [201] Pschyrembel. *Klinisches Wörterbuch*. 260th ed. Berlin: de Gruyter; 2004: 1669
- [202] Putz RV, Tuppek A. Evolution of the hand. [Article in German.] *Handchir Mikrochir Plast Chir* 1999; 31(6):357–361
- [203] Rabischong P. L'innervation proprioceptive des muscles lombricaux de la main chez l'homme. *Rev Chir Orthop Repar Appar Mot* 1962; 48:234–245
- [204] Ranney D, Wells R. Lumbrical muscle function as revealed by a new and physiological approach. *Anat Rec* 1988; 222(1):110–114
- [205] Rauber A, Kopsch F. *Human Anatomy*. Part I. In: Tillmann B, Töndury G, eds. *Musculoskeletal System*. Stuttgart: Thieme; 1987
- [206] Rhee RY, Reading G, Wray RC. A biomechanical study of the collateral ligaments of the proximal interphalangeal joint. *J Hand Surg Am* 1992; 17(1):157–163
- [207] Reichert B. *Palpation Techniques. Surface Anatomy for Physical Therapists*. 2nd ed. Stuttgart: Thieme; 2015
- [208] Reimann AF, Daseler EH, Anson BJ et al. The palmaris longus muscle and tendon. A study of 1600 extremities. *Anat Rec* 1944; 89:495:505
- [209] Reimann R, Ebner I. The basic human thumb joint—an egg-shaped joint. [Article in German.] *Acta Anat (Basel)* 1980; 108(1):1–9

- [210] Ritt MJ, Berger RA, Bishop AT, An KN. The capitohamate ligaments. A comparison of biomechanical properties. *J Hand Surg [Br]* 1996; 21(4):451–454
- [211] Roston JB, Haines RW. Cracking in the metacarpo-phalangeal joint. *J Anat* 1947; 81(Pt 2):165–173
- [212] Rudigier J. *Kurzgefasste Handchirurgie. Klinik und Praxis*. 5th ed. Stuttgart: Thieme; 2006: 343–345
- [213] Sagerman SD, Zogby RG, Palmer AK, Werner FW, Fortino MD. Relative articular inclination of the distal radioulnar joint: a radiographic study. *J Hand Surg Am* 1995; 20(4):597–601
- [214] Sandzen SC Jr. *Atlas of the Wrist and Hand Fractures*. 2nd ed. Littleton: PGS Publishing; 1986
- [215] Sarasin F. Die Variationen im Bau des Handskeletts verschiedener Menschenformen. *Z Morphol Anthropol* 1932; 30:252–314
- [216] Scaramuzza RFJ. El movimiento derotacionelcarposurelacion con la fisiopatologia de sus lesiones traumaticas. *Bol Trabaja Soc Argentina Orthop Traum* 1969; 34:337
- [217] Schewe H. Sinnesorgane—Gemeinsame Struktur- und Funktionsprinzipien der sensorischen Systeme. In: van den Berg F, ed. *Angewandte Physiologie*. Vol 2. 2nd ed. Stuttgart: Thieme; 2005: 441–445
- [218] Shirashi N, Matsumura G. Anatomical variations of the extensor pollicis brevis tendon and abductor pollicis longus tendon—relation to tenosynovectomy. *Okajimas Folia Anat Jpn* 2005; 82(1):25–29
- [219] Schiebler TH. *Anatomie*. 9th ed. Heidelberg: Springer; 2005: 275–286
- [220] Schiltenswolf M. Erkrankungen der Sehnen und Sehnenscheiden. Insertionstendinosen. In: Wirth CJ, Zichner L, Martini AK, eds. *Orthopädie und Orthopädische Chirurgie. Ellenbogen, Unterarm, Hand*. Stuttgart: Thieme; 2003: 433–435
- [221] Schmidt R, Kienast W, Sommer H et al. Vergleich der Mm. lumbricales und ihre Varietäten an der menschlichen Hand bei verschiedenen Völkern (Amerikanern, Deutschen, Franzosen und Russen). *Gegenbaurs Morphol Jahrb* 1965; 107:491–515
- [222] Schmidt HM, Geissler F. Articular surfaces of the human proximal wrist joint. [Article in German.] *Z Morphol Anthropol* 1983; 74(2):145–172
- [223] Schmidt HM, Geissler B. Joint surfaces of the carpometacarpal articulation of the thumb in man. [Article in German.] *Gegenbaurs Morphol Jahrb* 1983; 129(5):505–531
- [224] Schmidt HM, Knott C, Pahnke JW. Über die Skelettbefestigung der Verstärkungen digitaler Sehnenscheiden beim Menschen. *Verh Anat Ges* 1983; 77:329–331
- [225] Schmidt HM. Clinical anatomy of the m. flexor carpi radialis tendon sheath. *Acta Morphol Neerl Scand* 1987; 25(1):17–28
- [226] Schmidt HM, Moser T, Lucas D. Klinisch-anatomische Untersuchungen des Karpaltunnels der menschlichen Hand. *Handchirurgie* 1987; 19:145–152
- [227] Schmidt HM, Lahl J. Studies on the tendinous compartments of the extensor muscles on the back of the human hand and their tendon sheaths. II. [Article in German.] *Gegenbaurs Morphol Jahrb* 1988; 134(3):309–327
- [228] Schmidt HM, van Schoonhoven J, Lanz U. Cartilage-ligament attachment of the ulnar head. [Article in German.] *Handchir Mikrochir Plast Chir* 1998; 30(6):382–386
- [229] Schmidt HM, Lanz U. *Surgical Anatomy of the Hand*. Stuttgart: Thieme; 2003: 1, 21, 29–30, 35–77, 107–119, 133, 144–160, 186, 201–212, 223–229
- [230] Smith RJ, Peimer CA. Injuries to the metacarpal bones and joints. *Adv Surg* 1977; 11:341–374
- [231] Schmitt R. Triangular Fibrocartilage Complex (TFCC). In: Schmitt R, Lanz U, eds. *Imaging of the Hand*. Stuttgart: Thieme; 2007: 114–121
- [232] Schmitt R, Hahn P. Ulnar Tunnel Syndrome (Guyon's Canal Syndrome). In: Schmitt R, Lanz U, eds. *Diagnostic Imaging of the Hand*. Stuttgart: Thieme; 2007: 532–535
- [233] Schmitt R, Prommersberger KJ. Carpal Morphometry and Function. In: Schmitt R, Lanz U, eds. *Diagnostic Imaging of the Hand*. Stuttgart: Thieme; 2007: 123–132
- [234] Schomacher J. *Orthopedic Manual Therapy. Assessment and Management*. Stuttgart: Thieme; 2014: 11–16
- [235] Schuind F, An KN, Berglund L et al. The distal radioulnar ligaments: a biomechanical study. *J Hand Surg Am* 1991; 16(6):1106–1114
- [236] Schultz RJ, Furlong J II, Storace A. Detailed anatomy of the extensor mechanism at the proximal aspect of the finger. *J Hand Surg Am* 1981; 6(5):493–498
- [237] Schultz RJ, Storace A, Krishnamurthy S. Metacarpophalangeal joint motion and the role of the collateral ligaments. *Int Orthop* 1987; 11(2):149–155
- [238] Schünke M, Schulte E, Schumacher U, et al. *THIEME Atlas of Anatomy. General Anatomy and Musculoskeletal system*. 2nd ed. Stuttgart: Thieme; 2014
- [239] Schumacher HR. Morphology and physiology of normal synovium and the effects of mechanical stimulation. In: Gordon SL, Blair SJ, Fine LJ. *Repetitive Motion Disorders of the Upper Extremity*. Rosemont: J Am Acad Orthop Surg; 1995: 263–276
- [240] Schütz K, Middendorp J, Meyer VE. Ulnodorsal impingement syndrome: meniscus lesions of the wrist. [Article in German.] *Handchir Mikrochir Plast Chir* 1996; 28(5):227–232
- [241] Seibert FJ, Peicha G, Grechenig W et al. Radiusfraktur loco typico - Arthroskopisch assistierte Versorgung. *Arthroskopie* 1998; 11:259–270
- [242] Seradge H, Owens W, Seradge E. The effect of intercarpal joint motion on wrist motion: are there key joints? An in vitro study. *Orthopedics* 1995; 18(8):727–732
- [243] Shdanow DA. Lymphgefäße der Muskeln an der oberen Extremität des Menschen. *Anat Anz* 1931; 72:369–403
- [244] Simmons BP, de la Caffinière YJ. Physiology of flexion of the fingers. In: Tubiana R, ed. *The Hand*. Vol 1. Philadelphia: Saunders; 1981
- [245] Slattery PG. The dorsal plate of the proximal interphalangeal joint. *J Hand Surg [Br]* 1990; 15(1):68–73
- [246] Soheil E. Duputren-Kontraktur [Dissertation]. Münster: Westfälische Wilhelms-Universität Münster; 2005: 14–18
- [247] Spinner M. *Kaplan's Functional and Surgical Anatomy of the Hand*. 3rd ed. Philadelphia: J.B. Lippincott; 1984
- [248] Stolle C. Neuere Untersuchungen zur klinischen Anatomie der dorsalen Bänder der Handgelenke und des Daumensattelgelenks [Dissertation]. Bonn; 2001
- [249] Takagoshi H, Hashizume H, Nishida K, Masaoka S, Asahara H, Inoue H. Fibrous structure and connection surrounding the metacarpophalangeal joint. *Acta Med Okayama* 1998; 52(1):19–26
- [250] Taleisnik J, Gelberman RH, Miller BW, Szabo RM. The extensor retinaculum of the wrist. *J Hand Surg Am* 1984; 9(4):495–501
- [251] Taleisnik J. *The Wrist*. Edinburgh and New York: Churchill Livingstone; 1985
- [252] Tamai K, Ryu J, An KN, Linscheid RL, Cooney WP, Chao EY. Three-dimensional geometric analysis of the metacarpophalangeal joint. *J Hand Surg Am* 1988; 13(4):521–529
- [253] Thomas W. The aetiology of arthrosis of the first metacarpophalangeal joint and its treatment with joint-replacement (author's transl). [Article in German.] *Z Orthop Ihre Grenzgeb* 1977; 115(5):699–707
- [254] Thomine JM. The digital fascia and fibrous elements of the interdigital commissure. [Article in French.] *Ann Chir Plast* 1965; 10(3):194–203
- [255] Timm J, Filler E, Peuker T, et al. Bauplan des menschlichen Körpers. In: Fanghänel J, Pera F, Anderhuber F, Nitsch R, eds. *Waldeyer Anatomie des Menschen*. 17th ed. Berlin: de Gruyter 2003: 35–38
- [256] Tittel K. *Beschreibende und funktionelle Anatomie des Menschen*. 12th ed. Jena and Stuttgart: Gustav Fischer; 1994: 52, 139–149
- [257] Imaeda T, An KN, Cooney WP III. Functional anatomy and biomechanics of the thumb. *Hand Clin* 1992; 8(1):9–15
- [258] Towfigh H. Frakturen und Luxationen. In: Schmit-Neuerburg KP, Towfigh H, Letsch R, eds. *Tscherne Unfallchirurgie*. Vol 2: Ellenbogen, Unterarm, Hand. Berlin: Springer; 2001: 484–486
- [259] Travill A, Basmajian JV. Electromyography of the supinators of the forearm. *Anat Rec* 1961; 139:557–560

- [260] Tubiana R, Fahrer M. The role of the retinaculum extensorum in the stability of the wrist (author's transl). [Article in French.] *Rev Chir Orthop Repar Appar Mot* 1981; 67(3):231–234
- [261] Valentin P. Physiology of extension of the fingers. In: Tubiana R, ed. *The Hand*. Vol 1. Philadelphia: Saunders; 1981: 389
- [262] Van der Heijden EP, Hillen B. A two-dimensional kinematic analysis of the distal radioulnar joint. *J Hand Surg [Br]* 1996; 21(6):824–829
- [263] van Oudenaarde E. The function of the abductor pollicis longus muscle as a joint stabiliser. *J Hand Surg [Br]* 1991; 16(4):420–423
- [264] van Zwieten KJ. The extensor assembly of the fingers in man and non-human primates [Dissertation]. University of Leiden; 1980
- [265] Viegas SF, Yamaguchi S, Boyd NL, Patterson RM. The dorsal ligaments of the wrist: anatomy, mechanical properties, and function. *J Hand Surg Am* 1999; 24(3):456–468
- [266] Viegas SF. The dorsal ligaments of the wrist. *Hand Clin* 2001; 17(1):65–75, vi
- [267] Virchow H. Die Weiterdrehung des Navikulare carpi bei Dorsalflexion und die Bezeichnung der Handbänder. *Anat Anz* 1902; 21:111–126
- [268] Watanabe H, Hashizume H, Inoue H, Ogura T. Collagen framework of the volar plate of human proximal interphalangeal joint. *Acta Med Okayama* 1994; 48(2):101–108
- [269] Watson HK, Ballet FL. The SLAC wrist: scapholunate advanced collapse pattern of degenerative arthritis. *J Hand Surg Am* 1984; 9(3):358–365
- [270] Weeks PM. *Acute Bone and Joint Injuries of the Hand and Wrist: a Clinical Guide to Management*. St. Louis: CV Mosby; 1988
- [271] Weis-Walter U. *Das Schwimmband. Beitrag zum anatomisch-funktionellen Verständnis des Bindegewebsgerüsts der Hand* [Dissertation]. Bonn; 1989
- [272] Wetterkamp D, Rieger H, Brug E. 100 years tendovaginitis stenosans de Quervain—review of the literature and personal results. [Article in German.] *Handchir Mikrochir Plast Chir* 1997; 29(4):214–217
- [273] Wildenauer E. Die Oberfläche der proximalen Gelenkfläche. *Z Anat Entwickl Gesch* 1952; 116:348–350
- [274] Wilgis EFS, Murphy R. The significance of longitudinal excursion in peripheral nerves. *Hand Clin* 1986; 2(4):761–766
- [275] Winkel D, Vleeming A, Meijer OG. *Anatomie in vivo für den Bewegungsapparat* (1985). 3rd ed. Munich: Elsevier; 2004: 13–14, 128, 137–139, 148–154
- [276] Winslow JB. *Exposition Anatomique de la Structure du Corps Humain*. 2nd ed. Amsterdam; 1752
- [277] Yoshida Y. A study on the extensor digiti minimi muscle in man. [Article in Japanese.] *Kaibogaku Zasshi* 1985; 60(3):185–196
- [278] Zalpour C, ed. *Anatomie—Physiologie*. Munich: Urban & Fischer; 2002: 324
- [279] Zalpour C. *Springer Lexikon Physiotherapie*. Berlin: Springer; 2010: 302
- [280] Zalpour C, Engelhardt S, Guzek B, Haamann A, Schäffler A. Binde- und Stützgewebe. In: Zalpour C, ed. *Anatomie—Physiologie*. Munich: Urban & Fischer; 2010: 71
- [281] Zancolli EA, Ziadenberg C, Zancolli E Jr. Biomechanics of the trapeziometacarpal joint. *Clin Orthop Relat Res* 1987(220):14–26
- [282] Zancolli EA, Cozzi EP. *Atlas of Surgical Anatomy of the Hand*. Edinburgh and New York: Churchill Livingstone; 1992
- [283] Zumhasch R. *Die Dupuytren-Kontraktur*, *Ergotherapie*. Zeitschrift für angewandte Wissenschaft 2. Dortmund: Borgmann; 2004

Index

Note: Page numbers set **bold** or *italic* indicate headings for figures, respectively.

A

A1 annular ligament 71, 96, 98
A2 annular ligament 71
A3 annular ligament 71
A4 annular ligament 72
A5 annular ligament 72
abduction 48, 57, 66
abductor digiti minimi 63, 78, 98
abductor pollicis brevis 55, 56, 59, 78, 98
abductor pollicis longus 35, 54, 56, 78, 87, 92
acceleration detectors 46
accessory collateral ligaments
– distal interphalangeal joints 74
– interphalangeal joint, thumb 59
– metacarpophalangeal joints 59, 67, 68
– proximal interphalangeal joints 70
adduction 48, 57, 66
adductor pollicis 55, 59, 78, 98
amphiarthroses 15
anatomic snuffbox 28, 83, 83, 87, 94
anterior antebrachial interosseous nerve 42
anterior oblique carpometacarpal ligament 52
annular ligament of the radius 2–3, 3, 4
annular ligaments, fingers 70, 71
– See *also* individual ligaments (e.g A1 annular ligament)
ape-hand deformity 42
arcuate ligament 20, 23
arteria interossea communis 46
arthritis 49, 52, 57
arthrokinematics, wrist joint 28
articular slingshot 29
axillary lymph node 48

B

beak ligament 52
Bennett's fracture dislocation 52, 53
biceps brachii 10
blood vessels, palmar 92
brachial plexus 40
brachioradialis 10, 78, 92

C

camshaft effect 68
capitate 13, 84, 85, 92, 95
carpal bones 12, 12, 60
– See *also* individual bones
– collapse 24
– distal row stability 15
– ligament system 16
– motion patterns 30, 33

– structural damage 25
– surface anatomy 84, 85, 92, 95, 95
carpal ganglia 24
carpal joints 14, 15
carpal retinacula 29
carpal tunnel 38, 95, 95
– anatomic structure 39, 39
carpal tunnel syndrome 38–39, 95
carpometacarpal (CMC) joint
– of thumb, *see* thumb carpo-metacarpal joint
– second to fifth 16, 17, 96
circumduction
– fingers 67
– hand 11, 11
– thumb 48, 57
– wrist 11, 11
claw hand 38, 63
Cleland's ligament 59, 66
collateral edema of the dorsal hand 47
collateral ligaments
– distal interphalangeal joints 74
– metacarpophalangeal joint, thumb 59
– metacarpophalangeal joints, fingers 67
– proximal interphalangeal joints 70, 71
– thumb interphalangeal joint 59
column models, hand 30
column theories 30, 30
common palmar digital nerves 42
cruciate ligaments 70, 71
cubital lymph node 48

D

dart-throwing movement (DTM) 32
de Quervain's tenosynovitis 35, 88, 91
deep lymph system 47
deep palmar arch 46
deep palmar lymphatic arch 47
deep transverse metacarpal ligament 69
deltoid ligament 20
distal interphalangeal (DIP) joints 73, 74–75
distal palmar arch 62
distal palmar V-shaped ligament (V ligament) 20
distal radioulnar joint 2, 2
– degenerative changes 3, 7
– immobilization 3
– joint line 83, 84, 90
– stabilization 3
– surface anatomy 83, 84
distal radioulnar ligament 9
dorsal digital expansion 72, 72, 73, 89, 90

– central slip 72
– lateral bands 72
dorsal digital nerves 45
dorsal hamatocapitate ligament 24
dorsal intercarpal ligaments 23, 23
dorsal interossei 62, 62
– first 55, 62, 78, 98
– fourth 63, 78
– second 63, 78
– surface anatomy 98, 98
– third 63, 78
dorsal metacarpal ligament of the thumb 52
dorsal plate 68, 70
dorsal radiocarpal ligaments 19
dorsal radiotriquetral ligament 29
dorsal radioulnar ligament 8, 9
dorsal stabilizing ligament 6
dorsal tendon compartments 19, 34, 35, 36
– fifth 36, 90, 91
– first 34, 87, 88
– fourth 36, 89, 90
– second 35, 88, 89
– sixth 90, 91
– surface anatomy 86, 87
– third 36, 89, 89
dorsal trapezoidocapitate ligament 24
dorsal tubercle of the radius 83
dorsal V ligament 21, 22
dorsiflexed intercalated segment instability (DISI) 23–24
dorsoradial carpometacarpal ligament 52
Dupuytren's contracture 66, 66
dynamic instability 30

E

epicritic sensation 45
extension
– carpal tunnel 38
– fingers 62, 67, 69, 73
– hand 11, 25
– thumb 48, 57
– wrist 28, 29
extensor apparatus of the finger 73, 75, 76
extensor carpi radialis brevis 28, 78, 92
extensor carpi radialis longus 28, 78, 92
extensor carpi ulnaris 28, 37, 78, 92
– tendon sheath 9, 10
extensor digiti brevis 76
extensor digiti minimi 76, 78, 90, 92
extensor digitorum 72, 76, 78
extensor digitorum communis 76, 89, 92
extensor indicis 72, 76, 78, 89, 92
extensor pollicis brevis 34, 55, 56, 59, 87, 92
extensor pollicis longus 36, 55, 56, 59, 78, 92
extensor retinaculum 18, 19, 87
– structure 18, 34
– surface anatomy 86, 87–88
extensor-indicis syndrome 36
exteroceptive sensation 45
extra-articular slingshot 20

F

fibrous sheath 34, 34
fingers
– anesthesia 42
– definition 66
– extrinsic muscles 75, 76–77
– joints 66
– surface anatomy 96
fingertips 82
Finkelstein test 35, 88, 91
fist grasp (power grasp) 60
fist, making 69
flexion
– carpal tunnel 38
– fingers 62, 67–68, 73
– hand 11
– thumb 48, 57
– V-shaped ligaments 22
– wrist 25, 26, 27
flexor carpi radialis 27, 78, 92, 94, 94, 96
flexor carpi ulnaris 27, 78, 94, 96
flexor digiti minimi 98
flexor digiti minimi brevis 64, 78
flexor digitorum profundus 38, 77–78
flexor digitorum superficialis 38, 77–78, 96
flexor pollicis brevis 55, 59, 78, 98
flexor pollicis longus 38, 55, 59, 78
flexor retinaculum 18, 18, 37, 37, 52
– surface anatomy 92, 95, 95
forearm
– bones 2
– dorsal muscles 91, 91, 91, 92
– range of motion 2
funny bone 42

G

gamekeeper's thumb (skier's thumb) 59
grasping 67, 74
Grayson's ligament 66
Guyon's canal, *see* ulnar tunnel

H

hamate 14, 15, 85, 85–86, 92, 95

hamatocapitate ligaments 24, 24
 hamotriquetral joint 33
 hand
 – anatomy 2
 – blood supply 46, 47
 – column models 30
 – functional anatomy 2
 – functional units 48
 – importance of 2
 – innervation 40, 45
 – ligaments 26
 – deep layer 23, 24
 – middle layer 19
 – stability 25
 – lymphatics 47, 48
 – movements 11
 – muscles 78
 – surface anatomy 82
 handcuff neuropathy 88
 hook of hamate 14
 hypothenar muscles 64, 64, 98

I

index finger 82, 90
 index finger placement technique 98, 99
 inferior lateral cutaneous nerve of the arm 45
 intensity detectors 46
 intercarpal joint 15
 intercondylar groove 69
 intermetacarpal joints 16, 17
 interosseous hamatocapitate ligament 24
 interosseous intercarpal ligaments 23
 interosseous membrane of the forearm 3, 4, 5–6
 interosseous trapezoidocapitate ligament 24
 interphalangeal (IP) joint
 – distal, *see* distal interphalangeal (DIP) joints
 – proximal, *see* proximal interphalangeal (PIP) joints
 – thumb 48, 49, 57, 60
 intersection syndrome 36
 intertendinous connection 89
 intrinsic minus fingers 63

J

joint bodies (osteophytes) 57
 joint play mobilization 86

K

Kaltenborn's convex-concave rule 29
 Kienbock's disease 7
 knuckle pads 66

L

Ledderhose's disease 66

ligament of Landsmeer (oblique retinacular ligament) 73
 Lister's tubercle 83
 little finger placement technique 96, 97
 little finger, movement 90
 long radiolunate ligament 19–20
 longitudinal arch 62
 lumbricals 63, 63, 78
 lunate 12, 14–15
 – arthrokinematics 30, 31
 – movements 30, 31, 33
 – necrosis 7, 13
 – surface anatomy 84, 85, 92, 95
 lunotriquetral ligament 14, 24, 24, 25, 29, 32
 lymphatics 47, 48

M

mechanoreceptors 45
 median duo 95
 median nerve 40, 41, 45
 – damage 42
 – entrapment 93
 – longitudinal displacement 42
 – muscular rami branch 40
 – surface anatomy 95, 96
 median sling 40
 metacarpal bones 60, 60
 – base 60
 – bodies 60
 – fifth 16, 60, 61, 67, 84, 96
 – first 84, 96
 – fourth 16, 60, 61, 67, 96
 – head 62
 – in grasping 60
 – muscles of 62
 – palmar 96
 – proximal part 84, 84
 – second 16, 60, 61, 67, 96
 – structure/function 60
 – third 16, 60, 61, 84, 96
 metacarpophalangeal (MCP) joints
 – fifth 62
 – fingers
 – articulating surfaces 67, 67
 – capsule 68
 – damage to 69
 – ligaments 67, 68
 – movements 66
 – range of motion 75, 75
 – structure/function 66
 – fourth 62
 – joint line 84
 – second 62, 96, 98
 – third 62
 – thumb 48
 – articulating surfaces 58
 – cartilage 58
 – joint capsule 58
 – ligaments 58
 – range of motion 49, 49, 59
 – structure/function 57, 58
 mixed nerve (peripheral nerve) 40
 muscle spindle receptors 46
 muscles, *see* individual muscles
 musculocutaneous nerve 45

N

negative ulnar variance 7, 7, 13
 nociceptors 46

O

oblique cord 3, 4, 5
 oblique palmar arch 62
 oblique retinacular ligament (ligament of Landsmeer) 73
 opponens digiti minimi 64, 78, 98
 opponens pollicis 55, 78, 98
 opposition 48, 57
 osteoarthritis, thumb 52
 osteokinematics 28
 osteophytes (joint bodies) 57
 oval ring concept 32

P

pain perception 46
 palm 60
 – intrinsic muscles 98
 – surface anatomy 96
 palmar aponeurosis 64, 65
 – function 65
 – longitudinal fibers 65
 – structure 65
 – surface anatomy 96
 – transverse fibers 66
 palmar carpal arch 15, 60
 palmar forearm muscles 96, 97
 palmar hamatocapitate ligament 24
 palmar intercarpal ligaments 23
 palmar interossei 62, 62, 78
 palmar metacarpal arteries 47
 palmar nerves 92
 palmar plate
 – distal interphalangeal joints 74
 – interphalangeal joint, thumb 59
 – metacarpophalangeal joint, thumb 58
 – metacarpophalangeal joints, fingers 68
 – proximal interphalangeal joints 70
 palmar radiocarpal ligaments 19
 palmar radioulnar ligament 8, 9, 9
 palmar tendon compartments 37, 37
 – first 37, 92, 94, 94
 – second 38, 92, 95
 – surface anatomy 92, 95
 – third 38, 92, 95
 palmar trapezoidocapitate ligament 24
 palmaris brevis 66, 78
 palmaris longus 28, 78, 92, 94, 96
 peripheral nerve (mixed nerve) 40
 phalangeal cuff 67
 phalanges 66
 – middle 69
 – proximal 67, 69
 phalangoglenoid ligaments 58, 68, 68, 70
 pinch grip 48

pisiform 13, 84–85, 86, 93, 95
 pisohamate ligament 27
 positive ulnar variance 7, 7
 posterior cutaneous nerve of the arm 45
 posterior cutaneous nerve of the forearm 45
 posterior oblique carpometacarpal ligament 52
 power grasp (fist grasp) 60
 precision grip 60, 67, 74
 princeps pollicis artery 47
 pronation 2, 2, 3, 3, 4
 – control structures 4
 – deceleration 4, 7, 10
 – distal radioulnar joint 3
 – distal radioulnar ligament 8
 – hand 11
 – interosseous membrane 6
 – muscles 9
 pronator quadratus 9, 78
 pronator teres 9, 11, 78, 96
 proper palmar digital nerves 42
 proprioception 45
 proprioceptive sensation 46
 protopathic sensation 46
 proximal interphalangeal (PIP) joints 69
 – articulating surfaces 69, 70
 – capsule 70
 – force transfer 69
 – ligaments 70, 71
 – range of motion 69, 75, 75
 proximal palmar arch 62
 proximal palmar V-shaped ligament (V ligament) 20, 23
 proximal radiocarpal joint 14
 proximal radioulnar joint 2, 2, 7
 – stability 3
 pseudarthrosis 12
 pseudo-movements, forearm 2

R

radial artery 46, 47, 85, 94
 radial collateral carpal ligament 19, 85
 radial collateral ligament 3, 67
 radial condyle 69
 radial deviation 11, 26
 – carpal motion patterns 32–33
 – proximal interphalangeal joints 69
 – V-shaped ligaments 22
 – wrist 28, 29, 32
 radial indicis artery 47
 radial lymph vessels 47
 radial nerve 44, 45, 45, 89
 – entrapment 88
 – in axilla 45
 radial phalangoglenoid ligament 58
 radial trio 94, 94
 radiate ligament (arcuate ligament) 20, 23
 radiocarpal joint line 83, 84
 radiolunate ligaments 29
 radiolunotriquetral ligament 20

- radioscaphocapitate ligament 20, 25, 29, 32
 radioscapholunate ligament (Testut's ligament) 25
 radioulnar joint line 83
 radioulnar joint, muscles 9
 radius 2
 – angle of inclination 14, 16
 – dislocation 9
 – length variations 7
 reposition, thumb 48, 57
 ring finger palpation technique 92, 92–93
 ring finger placement technique 98, 99
 Rolando's fracture 52, 53
 rotation 3, 11, 48
 rotation model, wrist 30, 31
- S**
- scaphoid 12, 14
 – arthrokinematics 31, 31
 – fracture 12, 20
 – osteonecrosis 12
 – rotational malalignment 23
 – sagittal plane movements 32
 – surface anatomy 85, 86, 92, 95, 95
 scaphoid dislocation 24
 scaphoid nonunion advanced collapse (SNAC) 12, 25
 scaphoid pseudarthrosis 20
 scaphoid tubercle 94
 scapholunate advanced collapse of the wrist (SLAC wrist) 24
 scapholunate ligament 14, 24, 24, 31–32
 – injury 25
 scaphotrapezial joint 51
 scaphotrapezial ligament 25
 scaphotrapeziotrapezoid joint 32
 scaphotrapeziotrapezoid ligament 20
 sensation 45
 sensitization 46
 sesamoid bones 13, 58–59, 97
 Sharpey's fibers 23
 short radiolunate ligament 20
 shoulder joint 2
 signet ring sign 25
 skier's thumb (gamekeeper's thumb) 59
 slingshot ligaments 22
 small snuffbox 88
 snap phenomenon 25
 Space of Poirier 20, 23, 23
 static instability 30
- Stener's lesion 59
 stenosing tenosynovitis (trigger finger) 96
 sulcus-ulnaris syndrome 38
 superficial intertendinous lamina 73
 superficial lymphatics 47
 superficial palmar arch 46
 superficial palmar lymphatic arch 47
 superficial transverse metacarpal ligament 69
 supination 2, 2, 3–4
 – antebrachial muscles 26
 – control structures 4
 – deceleration 4, 7, 10
 – distal radioulnar joint 3
 – hand 11
 – index finger 74
 – interosseous membrane 6
 – muscles 10, 11
 – palmar radioulnar ligament 8
 – proximal interphalangeal joints 69
 supinator 10, 11, 78, 91
 surface anatomy 82
 – See also individual structures
 – definition 82
 – hand positioning 83
 – landmarks 83
 – palpated structure types 82
 – practical foundations 82
 – practical procedure 83
 – pressure application 82
 – terminology 83
 synovial sheath 34
- T**
- targeted palpation 82
 tendinitis 91
 tendinous chiasm 77
 tendinous hiatus 77
 tendon sheaths 34, 34
 Testut's ligament (radioscapholunate ligament) 25
 thenar muscles 98
 thenar nerve 42
 thumb 48
 – dislocation 52
 – extrinsic muscles 54, 54, 54, 55, 59
 – intrinsic muscles 54, 55, 56, 59
 – joints 48
 – movements 48
 – range of motion 48
 – surface anatomy 96
 – wrist muscle synergy 56
- thumb carpometacarpal joint 13, 48, 49
 – arthritis 49, 52
 – articulating surfaces 49, 51
 – capsule 49
 – degrees of freedom 48
 – direct ligament stabilization 52
 – function 49
 – indirect ligament stabilization 51
 – intra-articular space 96, 97
 – ligaments 51, 51
 – movements 48
 – muscles 54, 57
 -- extrinsic 54, 54, 54, 55
 -- intrinsic 54, 55, 56
 – stability 52
 – structure 49, 50–51
 – surface anatomy 97
 Tinel's sign 88, 93
 transverse palmar arch 62
 transverse retinacular ligament 73
 trapeziometacarpal ligament 52
 trapeziotrapezoid ligament 24, 24
 trapezium 13, 85, 86, 92, 95, 95
 trapezoid 13, 85, 85, 92, 95
 trapezoidocapitate ligaments 24, 24
 triangular fibrocartilage complex (TFCC) 6, 7, 23, 23
 – degenerative processes 9
 – function 23
 – injury 25
 – instability 6
 – trauma 9
 triangular ligament 73
 trigger finger (stenosing tenosynovitis) 96
 trigger thumb 98
 triquetrocaptitoscaphoid ligament (TCCL) 20, 23
 triquetrum 13, 14, 32, 32
 – surface anatomy 85, 86, 92
 two-point discrimination 45
- U**
- ulna 2, 7, 83
 ulnar artery 46, 47
 ulnar canal 27
 ulnar claw 38
 ulnar collateral ligament 3, 8, 67
 ulnar condyle 69
 ulnar deviation 11
 – carpal motion patterns 32–33
 – metacarpophalangeal joint instability 69
- proximal interphalangeal joints 69
 – V-shaped ligaments 22
 – wrist 26, 26, 27, 32
 ulnar impingement syndrome 7
 ulnar lymph vessels 47
 ulnar nerve 42, 43, 45
 – decompression 94
 – entrapment 94
 – palmar branches 42
 – sensory branches 42
 – surface anatomy 93, 94
 ulnar phalangoglenoid ligament 58
 ulnar styloid process 83
 ulnar tunnel 39, 40
 – anatomic structure 39
 – surface anatomy 94, 94
 ulnar tunnel syndrome 27, 39
 ulnocarpal disc 7, 8, 10
 ulnocarpal meniscal homologue 8
 ulnolunate ligament 8, 9, 20
 ulnotriquetral ligament 8, 9, 20
- V**
- V-shaped ligaments 29, 32
 – See also individual ligaments
 – interactions 22
 velocity detectors 46
 volar ligament 52
- W**
- Wartenberg's syndrome 88
 washerwoman's sprain 88, 91
 Winterstein's fracture 52, 53
 wrist 10
 – arthrokinematics 28
 – blood supply 46
 – bones 12, 12
 – distal 12, 14, 15, 17
 – function 12
 – joints 11, 14, 14
 – ligaments 16, 26
 -- chains 29
 -- deep layer 23, 24
 -- superficial layer 17
 – movement axes 10, 11
 – muscles 25
 – palmar, surface anatomy 92, 93
 – proximal 12, 14, 14, 15
 – stability 16, 16, 29
 – structure 12
 – surface anatomy 83, 86
 – thumb muscles synergy 56
 wrist drop 45