



G. Schlag, H. Redl (Editors)

# Fibrin Sealant in Operative Medicine

Volume 5

*Thoracic Surgery – Cardiovascular Surgery*

Springer-Verlag  
Berlin Heidelberg New York  
London Paris Tokyo

Professor Dr. Günther Schlag  
Doz. Dipl.-Ing. Dr. Heinz Redl  
Ludwig-Boltzmann-Institut für  
experimentelle Traumatologie  
Donaueschingenstraße 13  
A-1200 Vienna

---

Tissucol or Tisseel are registered trademarks of IMMUNO's two-component fibrin sealant in different countries

---

ISBN-13: 978-3-540-17141-6  
DOI: 10.1007/978-3-642-71633-1

e-ISBN-13: 978-3-642-71633-1

This work is subject to copyright. All rights are reserved, whether the whole or part of the material is concerned, specifically those of translation, reprinting, re-use of illustrations, broadcasting, reproduction by photocopying machine or similar means, and storage in data banks. Under § 54 of the German Copyright Law where copies are made for other than private use, a fee is payable to "Verwertungsgesellschaft Wort", Munich.

© by Springer-Verlag Berlin Heidelberg 1986

The use of general descriptive names, trade names, trade marks, etc. in this publication, even if the former are not especially identified, is not to be taken as a sign that such names, as understood by the Trade Marks and Merchandise Marks Act, may accordingly be used freely by anyone. Product Liability: The publisher can give no guarantee for information about drug dosage and application thereof contained in this book. In every individual case the respective user must check its accuracy by consulting other pharmaceutical literature.

2127/3140-543210

# Preface

Fibrin plays a prominent role in wound healing. It has a hemostatic effect, induces cellular response to wound damage, and, by forming strands to build a matrix, assists in neovascularization and fibroblast proliferation.

The concept of using clotting substances from human blood for wound management and to achieve hemostasis in bleeding parenchymatous organs can be traced to 1909, when Bergel [1] reported on the hemostatic effect of fibrin powder. In 1915, Grey [3] employed fibrin to control bleeding in neurosurgical operations of the brain. A year later, Harvey [4] used fibrin patches to stop bleeding from parenchymatous organs in general surgery.

It took more than two decades for this ingenious idea to be rediscovered. In 1940, Young and Medawar [8] reported on experimental nerve anastomosis by sealing. Similarly, Tarlov and Benjamin [7] reunited nerves with plasma clots in 1943. Tarlov improved the results obtained with clot anastomosing of nerves by avoiding tension at the nerve stumps. In 1944, Cronkite et al. [2] reported on an initial series of eight cases in which fibrinogen and thrombin had been used successfully for anchoring skin grafts.

Although these early attempts suggested the basic advantages of using a biomaterial for wound closure – such as complete absorption, improved wound healing, and excellent tissue tolerance – the failure rate was relatively high, mainly because the fibrinogen employed had poor adhesive strength and the sealing did not last. It was because of these unsatisfactory results that the technique was not further pursued in the decades to follow.

In 1972, the use of fibrin as a biologic adhesive was revived by Matras et al. [6], who successfully employed a fibrinogen cryoprecipitate for reuniting peripheral nerves in an animal model. Matras and Kuderna used autologous material in the first successful human application in 1975 [5]. It was not until a special cryoprecipitation process had been developed that it was possible to produce a highly concentrated fibrinogen solution with an enriched factor XIII content, as the basis of two-component fibrin sealant.

In the meantime, the controversial issue of virus transmission, including the transmission of HTLV-III, by the blood product Tisseel (Tissucol) has been resolved. In addition to subjecting Tisseel (Tissucol) to in-process virus inactivation, both the source material and final product are routinely screened for HTLV-III antibody.

Following the first international symposium on fibrin sealant in Vienna in 1985, which dealt with the use of the product in various surgical disciplines, this seven-

volume study attempts to present current knowledge relating to the method of fibrin sealing. The disciplines covered are: general and abdominal surgery; ophthalmology and neurosurgery; otorhinolaryngology; plastic, maxillofacial and dental surgery; thoracic and cardiovascular surgery; traumatology and orthopaedics; urology, gynaecology and obstetrics. Each volume is preceded by a general chapter on the principles of fibrin sealing, methods of application, aspects of quality control, and safety studies.

Today, fibrin sealing has become an accepted tool in many fields of surgery. In many areas, fibrin sealing has superseded conventional surgical techniques, increased postoperative safety, and even made new therapeutic approaches possible.

We would like to thank all authors for their excellent contributions and helpful photographs, which have made these seven volumes on fibrin sealing possible.

Vienna, Juni 1986

G. Schlag  
H. Redl

# Table of Contents

## ***I. Principles of Fibrin Sealing***

The Importance of Fibrin in Wound Repair

G. SCHLAG, H. REDL, M. TURNHER and H. P. DINGES . . . . . 3

Fibrin Sealant and Its Modes of Application

H. REDL and G. SCHLAG . . . . . 13

Properties of Different Tissue Sealants with Special Emphasis  
on Fibrinogen-Based Preparations

H. REDL and G. SCHLAG . . . . . 27

Lysis and Absorption of Fibrin Sealant (Tissucol/Tisseel)  
(In Vitro and In Vivo Experiments)

H. PFLÜGER . . . . . 39

Preliminary Results of a Randomized Controlled Study on the Risk of  
Hepatitis Transmission of a Two-Component Fibrin Sealant  
(Tissucol/Tisseel)

G. EDER, M. NEUMANN, R. CERWENKA, and K. BAUMGARTEN . . . . . 51

## ***II. Thoracic Surgery***

The Use of Fibrin Sealant (Tissucol/Tisseel) in Thoracic Surgery

D. GRUNENWALD, P. R. VOUHE, and J. Y. NEVEUX . . . . . 63

The Value of Fibrin Sealant (Tissucol/Tisseel)  
in Surgery of the Thoracic Canal

D. GRUNENWALD, P. R. VOUHE, and J. Y. NEVEUX . . . . . 66

VIII Table of Contents

The Use of Fibrin Adhesives in Thoracic Surgery T. M. ORLOWSKI, J. KOŁODZIEJ, and J. DOMAGALA . . . . .	68
Treatment of Complicated Cases in Pediatric Cardiovascular and Thoracic Surgery Using Fibrin Sealant (Tissucol/Tisseel) I. SMÓLSKA and M. A. KAROLCZAK . . . . .	76
Application of Fibrin Glue in the Treatment of Lung Cysts K. H. LEITZ . . . . .	78
The Application of Fibrin Sealant in Tracheobronchial Surgery F. ECKERSBERGER, E. MORITZ, and W. WOLNER . . . . .	82
Endoscopic Fibrin Pleurodesis in Complicated Pneumothorax W. HEINDL and N. PRIDUN . . . . .	89
Thoracoscopic Fibrin Pleurodesis in the Treatment of Spontaneous Pneumothorax M. SPIEGEL, J. BENESCH, and R. SIEBENMANN . . . . .	95
Fibrin Sealant as an Adjunct in the Operative Care of Recurrent Pneumothorax O. THETTER . . . . .	102
Treatment of Idiopathic Spontaneous Pneumothorax: Transthoracic Endoscopic Use of Fibrin Glue O. ELERT and P. EIGEL . . . . .	107
Thoracoscopic Treatment with Fibrin Sealant of Ruptured Emphysema and Recurring Spontaneous Pneumothorax D. KAISER and J. SCHILDGE . . . . .	115
Animal Studies as for the Problem of the Bronchial Fistula N. PRIDUN, W. HEINDL, H. REDL, G. SCHLAG, and E. MACHACEK . . . . .	121
Endoscopic Occlusion of Bronchus Stump Fistulae Following Pneumonectomy with Fibrin Sealant in Animal Experiments H. W. WACLAWICZEK and F. CHMELIZEK . . . . .	126

A New Approach in Patients with Malignant Pleural Effusions  
 E. D. KREUSER, E. SEIFRIED, and R. HARTMANN . . . . . 130

The Value of Fibrin Sealant in Esophagus Surgery  
 J. BOESE-LANDGRAF, R. HÄRING, and B. SEMSCH . . . . . 137

***III. Cardiovascular Surgery***

Fibrin Sealant (Tissucol/Tisseel):  
 An Effective Aid in Cardiac Surgery Techniques  
 S. EUFRATE, P. PUGLIESE, R. MOSCHETTI, L. SCEBBA, and F. VESCHI . . . . . 143

Sealant Haemostasis in Cardiac Surgery: A Test Case for Fibrin Sealant  
 (Tissucol/Tisseel)  
 J. G. VINCENT . . . . . 148

Fibrin Gluing: A Valid Aid in Coronary Artery Bypass Graft Surgery  
 P. FUNDARÒ, A. R. VELARDI, and C. SANTOLI . . . . . 152

The Effect of Fibrin Sealant on Postoperative Wound Secretion  
 After Aortofemoral Bypass Surgery  
 M. T. CORFITSEN, B. PAASCHBURG NIELSEN, and S. JUUL JØRGENSEN . . . . . 155

Sealing of PTFE Patches and Conduits by Fibrin Glue in Surgery  
 for Congenital Heart Disease  
 C. SQUITIERI, R. DIDONATO, and C. MARCELLETTI . . . . . 159

Use of Fibrin Glue (Tissucol/Tisseel) to Achieve Hemostasis in Patches and  
 Suture Lines in Surgical Repair of Congenital Heart Defects  
 C. HUTH and H.-E. HOFFMEISTER . . . . . 164

Fibrin Glue in Open Heart Surgery  
 K. H. TSCHELIESSNIGG, W. STENZL, B. RIGLER, and J. KRAFT-KINZ . . . . . 176

The Uses of Fibrin Sealant in Cardiac Surgery  
 W. STENZL, K. H. TSCHELIESSNIGG, D. DACAR, F. IBERER, and B. RIGLER . . . 181



The Use of Fibrin Sealant and Fibrin Sealant Combined with Antibiotics in Cardiovascular Surgery	
A. HAVERICH, T. WAHLERS, G. WALTERBUSCH, and H. G. BORST . . . . .	185
Fibrin Seal (Tisseel/Tissucol) in Paediatric Cardiothoracic Surgery. The Experience of the Hospital for Sick Children, Great Ormond Street, London	
M. J. ELLIOTT, M. R. de LEVAL, and J. STARK . . . . .	191
Experience with Fibrin Glue (Tissucol/Tisseel) in Vascular Surgery	
G. VERCELLIO, M. COLETTI, and G. AGRIFOGLIO . . . . .	196
Application of Fibrin Glue for Prevention of Bleeding After Ascending Aorta Aneurysm Replacement	
J. SADOWSKI, A. DZIATKOWIAK, R. PFITZNER, W. TRACZ, B. KAPELAK, and K. TRACZYŃSKI . . . . .	201
Experience with Fibrin Glue in Vascular Surgery	
W. SIMMA and H. HESSE . . . . .	205
Simulation of Wound Healing in Cell Cultures Given that Fibrin Sealant Is Present	
R. P. FRANKE, U. DAUER, W. MÜLLNERS, R. FUHRMANN, and C. MITTERMAYER . . . . .	209
Subject Index . . . . .	217

# List of Contributors

## *I. Principles of Fibrin Sealing*

BAUMGARTEN, K., Prof. Dr.

Geburtshilflich-gynäkologische Abteilung, Wilhelminen-Spital, Montleartstraße 37,  
1160 Wien, Austria

CERWENKA, R., Dr.

Geburtshilflich-gynäkologische Abteilung, Wilhelminen-Spital, Montleartstraße 37,  
1160 Wien, Austria

DINGES, H.P., Dr.

Institut für pathologische Anatomie, Universität Graz, Auenbruggerplatz 25,  
8036 Graz, Austria

EDER, G., Dr.

Immuno AG, Clinical Research, Gastroenterology, Sandwirtgasse 3,  
1060 Wien, Austria

NEUMANN, M., Dr.

Geburtshilflich-gynäkologische Abteilung, Wilhelminen-Spital, Montleartstraße 37,  
1160 Wien, Austria

PFLÜGER, H., Doz.

Urologische Abteilung, Allgemeines österreichisches Krankenhaus,  
Kremser Landstraße 36, 3100 St. Pölten, Austria

REDL, H., Doz.

Ludwig-Boltzmann-Institut für Experimentelle Traumatologie,  
Donaueschingenstraße 13, 1200 Wien, Austria

SCHLAG, G., Prof. Dr.

Ludwig-Boltzmann-Institut für Experimentelle Traumatologie,  
Donaueschingenstraße 13, 1200 Wien, Austria

TURNHER, M., Dr.

Ludwig-Boltzmann-Institut für Experimentelle Traumatologie,  
Donaueschingenstraße 13, 1200 Wien, Austria

## ***II. Thoracic Surgery***

BENESCH, J., Dr.

Klinik für Nuklearmedizin und Radiotherapie, Stadtspital Triemli,  
8000 Zürich, Switzerland

BOESE-LANDGRAF, J., Dr.

Chirurgische Klinik und Poliklinik, Universitätsklinikum Steglitz,  
Hindenburgdamm 30, 1000 Berlin 45, Federal Republic of Germany

CHMELIZEK, F., Dr.

Ludwig Boltzmann-Institut für Experimentelle und Gastroenterologische Chirurgie,  
Landeskrankenanstalten Salzburg, Müllner Hauptstraße 48, 5020 Salzburg, Austria

DOMAGALA, J., Dr.

Department of Thoracic Surgery, Medical Academy of Wrocław,  
195 Grabiszynska Street, 53 439 Wrocław, Poland

ECKERSBERGER, F., Dr.

II. Chirurgische Universitätsklinik, Spitalgasse 23, 1090 Wien, Austria

EIGEL, P., Dr.

Abteilung für Thorax-, Herz- und Gefäßchirurgie, Chirurgische Universitätsklinik,  
Josef-Schneider-Straße 6, 8700 Würzburg, Federal Republic of Germany

ELERT, O., Prof. Dr.

Abteilung für Thorax-, Herz- und Gefäßchirurgie, Chirurgische Universitätsklinik,  
Josef-Schneider-Straße 6, 8700 Würzburg, Federal Republic of Germany

GRUNENWALD, D., Dr.

Service de Chirurgie Cardiovasculaire et Thoracique, Hôpital Laënnec,  
42, rue de Sèvres, 75340 Paris Cedex 07, France

HÄRING, R., Prof. Dr.

Chirurgische Klinik und Poliklinik, Universitätsklinikum Steglitz,  
Hindenburgdamm 30, 1000 Berlin 45, Federal Republic of Germany

HARTMANN, R., Dr.

Zentrum für Innere Medizin, Hämatologie/Onkologie, Universität Ulm,  
Steinhövelstraße 9, 7900 Ulm, Federal Republic of Germany

HEINDL, W., Dr.

Abteilung für Thoraxchirurgie, Pulmologisches Zentrum Wien –  
Baumgartner Höhe, Sanatoriumsstraße 2, 1145 Wien, Austria

KAISER, D., Prof. Dr.

Chirurgische Abteilung der Lungenklinik Heckeshorn, Krankenhaus Zehlendorf,  
Am Großen Wannsee 80, 1000 Berlin 39, Federal Republic of Germany

KAROLCZAK, M. A., Dr.

II. Clinic of Pediatric Surgery, Academy of Medicine, Ul.  
Dzialdowska 1, 01 184 Warsaw, Poland

KOŁODZIEJ, J., Dr.

Department of Thoracic Surgery, Medical Academy of Wrocław,  
195 Grabiszynska Street, 53 439 Wrocław, Poland

KREUSER, E. D., Dr.

Zentrum für Innere Medizin, Hämatologie/Onkologie, Universität Ulm,  
Steinhövelstraße 9, 7900 Ulm, Federal Republic of Germany

LEITZ, K. H., Prof. Dr.

Abteilung für Thorax-, Herz- und Gefäßchirurgie, Krankenhaus „Links der Weser“,  
Senator-Wessling-Straße 1, 2800 Bremen 61, Federal Republic of Germany

MACHACEK, E., Dr.

Ludwig-Boltzmann-Institut für Experimentelle Traumatologie,  
Donaueschingenstraße 13, 1200 Wien, Austria

MORITZ, A., Prof. Dr.

II. Chirurgische Universitätsklinik, Spitalgasse 23, 1090 Wien, Austria

NEVEUX, J. Y., Dr.

Service de Chirurgie Cardiovasculaire et Thoracique, Hôpital Laënnec,  
42, rue de Sèvres, 75340 Paris Cedex 07, France

ORLOWSKI, T. M., Dr.

Department of Thoracic Surgery, Medical Academy of Wrocław,  
195 Grabiszynska Street, 53 439 Wrocław, Poland

PRIDUN, N., Dr.

Abteilung für Thoraxchirurgie, Pulmologisches Zentrum Wien –  
Baumgartner Höhe, Sanatoriumsstraße 2, 1145 Wien, Austria

REDL, H., Doz. Dr.

Ludwig-Boltzmann-Institut für Experimentelle Traumatologie,  
Donaueschingenstraße 13, 1200 Wien, Austria

SCHILDGE, J., Dr.

Abteilung für Lungenchirurgie, Universität Freiburg,  
Hugstetter Straße 55, 7800 Freiburg, Federal Republic of Germany

SCHLAG, G., Prof. Dr.

Ludwig-Boltzmann-Institut für Experimentelle Traumatologie,  
Donaueschingenstraße 13, 1200 Wien, Austria

SEIFRIED, E., Dr.

Zentrum für Innere Medizin, Hämatologie/Onkologie, Universität Ulm,  
Steinhövelstraße 9, 7900 Ulm, Federal Republic of Germany

SEMSCH, B., Dr.

Chirurgische Klinik und Poliklinik, Universitätsklinikum Steglitz,  
Hindenburgdamm 30, 1000 Berlin 45, Federal Republic of Germany

SIEBENMANN, R., Prof. Dr.

Pathologisches Institut, Stadtspital Triemli, 8000 Zürich, Switzerland

SMOLSKA, I., Doz. Dr.

II. Clinic of Pediatric Surgery, Academy of Medicine,  
Ul. Dzialdowska 1,  
01 184 Warsaw, Poland

SPIEGEL, M., Dr.

Medizinische Abteilung, Schwerpunktspital Uster,  
Brunnenstraße 42, 8610 Uster, Switzerland

THETTER, O., Prof. Dr.

Chirurgische Klinik Innenstadt und Chirurgische Poliklinik, Universität München,  
Nußbaumstraße 20, 8000 München 2, Federal Republic of Germany

VOUHE, P. R., Dr.

Service de Chirurgie Cardiovasculaire et Thoracique, Hôpital Laënnec,  
42, rue de Sèvres, 75340 Paris Cedex 07, France

WACLAWICZEK, H. W., Dr.

1. Chirurgie, Landeskrankenanstalten Salzburg,  
Müllner Hauptstraße 48, 5020 Salzburg, Austria

WOLNER, E., Prof. Dr.

II. Chirurgische Universitätsklinik, Spitalgasse 23, 1090 Wien, Austria

### ***III. Cardiovascular Surgery***

AGRIFOGLIO, G., Prof. Dr.

Institute of Vascular Surgery, University of Milan,  
Via Commenda 12,  
20122 Milano, Italy

BORST, H. G., Prof. Dr.

Abteilung für Thorax-, Herz- und Gefäßchirurgie, Chirurgische Klinik,  
Medizinische Hochschule Hannover, Konstanty-Gutschow-Straße 8,  
3000 Hanover 61, Federal Republic of Germany

COLETTI, M., Dr.  
Institute of Vascular Surgery, University of Milan,  
Via Commenda 12,  
20122 Milano, Italy

CORFITSEN, M. T., Dr.  
Surgical Department, FAS Horsholm, 2970 Horsholm, Denmark

DACAR, D., Dr.  
Universitätsklinik für Chirurgie, Auenbruggerplatz 15, 8036 Graz, Austria

DAUER, U., Dr.  
Pathologische Klinik, RWTH Aachen, Neuklinikum,  
Pauwelsstraße, 5100 Aachen, Federal Republic of Germany

DI DONATO, R., Dr.  
Dipartimento Medico-Chirurgico di Cardiologia Pediatrica, Ospedale Bambino  
Gesù, Piazza S. Onofrio, 4, 00165 Roma, Italy

DZIATKOWIAK, A., Prof. Dr.  
Department of Cardiac and Vascular Surgery, Institute of Cardiology,  
N. Copernikus School of Medicine, Pradnicka 80, 31-202 Krakow, Poland

ELLIOTT, M. J., Dr.  
Thoracic Unit, The Hospital for Sick Children, Great Ormond Street,  
London WC1N 3JH, Great Britain

EUFRATE, S., Dr.  
Cardiac Surgery Department, Ospedale Generale Provinciale, 54100 Massa, Italy

FRANKE, R. P., Dr.  
Abteilung für Pathologie, RWTH Aachen, Neuklinikum  
Pauwelsstraße, 5100 Aachen, Federal Republic of Germany

FUHRMANN, P., Dr.  
Abteilung für Pathologie, RWTH Aachen, Neuklinikum  
Pauwelsstraße, 5100 Aachen, Federal Republic of Germany

FUNDARO, P., Dr.  
Department of Thoracic and Cardiovascular Surgery, "L. Sacco" Hospital  
Via G. B. Grassi, 74, 20157 Milano, Italy

HAVERICH, A., Dr.  
Abteilung für Thorax-, Herz- und Gefäßchirurgie, Chirurgische Klinik,  
Medizinische Hochschule Hannover, Konstanty-Gutschow-Straße 8,  
3000 Hannover 61, Federal Republic of Germany

HESSE, H., Dr.

Chirurgische Abteilung, Landeskrankenhaus Vöcklabruck,  
Hatschekstraße 24, 4840 Vöcklabruck, Austria

HOFFMEISTER, H. E., Prof. Dr.

Abteilung für Thorax-, Herz- und Gefäßchirurgie, Chirurgische Universitätsklinik  
und Poliklinik, Calwer Straße 7, 7400 Tübingen, Federal Republic of Germany

HUTH, C., Priv.-Doz. Dr.

Abteilung für Thorax-, Herz- und Gefäßchirurgie, Chirurgische Universitätsklinik  
und Poliklinik, Calwer Straße 7, 7400 Tübingen, Federal Republic of Germany

IBERER, F., Dr.

Universitätsklinik für Chirurgie, Auenbruggerplatz 15, 8036 Graz, Austria

JUUL JØRGENSEN, S. J., Dr.

Surgical Department, FAS Horsholm, 2970 Horsholm, Denmark

KAPELAK, B., Dr.

Department of Cardiac and Vascular Surgery, Institute of Cardiology,  
N. Copernikus School of Medicine, Pradnicka 80, 31-202 Krakow, Poland

KRAFT-KINZ, J., Prof. Dr.

Universitätsklinik für Chirurgie, Auenbruggerplatz 15, 8036 Graz, Austria

DE LEVAL, M. R., Dr.

Thoracic Unit, The Hospital for Sick Children,  
Great Ormond Street,  
London WC1N 3JH, Great Britain

MARCELLETTI, C., Dr.

Dipartimento Medico-Chirurgico di Cardiologia Pediatrica, Ospedale Bambino  
Gesù, Piazza S. Onofrio, 4, 00165 Roma, Italy

MOSCHETTI, R., Dr.

Anaesthesiology Department, Ospedale Generale Provinciale, 54100 Massa, Italy

MITTERMAYER, C., Prof. Dr.

Abteilung für Pathologie, RWTH Aachen, Neuklinikum,  
Pauwelsstraße, 5100 Aachen, Federal Republic of Germany

MÜLLNERS, W., Dr.

Abteilung für Pathologie, RWTH Aachen, Neuklinikum,  
Pauwelstraße, 5100 Aachen, Federal Republic for Germany

PAASCHBURG, NIELSEN, R., Dr.

Surgical Department, FAS Horsholm, 2970 Horsholm, Denmark

PFITZNER, R., Dr.

Department of Cardiac and Vascular Surgery, Institute of Cardiology,  
N. Copernikus School of Medicine, Pradnicka 80, 31-202 Krakow, Poland

PUGLIESE, P., Dr.

Cardiac Surgery Department, Ospedale Generale Provinciale, 54100 Massa, Italy

RIGLER, B., Prof. Dr.

Universitätsklinik für Chirurgie, Augenbruggerplatz 15, 8036 Graz, Austria

SADOWSKI, J., Dr.

Department of Cardiac and Vascular Surgery, Institute of Cardiology,  
N. Copernikus School of Medicine, Pradnicka 80, 31-202 Krakow, Poland

SANTOLI, C., Prof. Dr.

Department of Thoracic and Cardiovascular Surgery, "L. Sacco" Hospital,  
Via G. B. Grassi, 74, 20157 Milano, Italy

SCEBBA, L., Dr.

Anaesthesiology Department, Ospedale Generale Provinciale, 54100 Massa, Italy

SIMMA, W., Dr.

Chirurgische Abteilung, Landeskrankenhaus Vöcklabruck, Hatschekstraße 24,  
4840 Vöcklabruck, Austria

SQUITIERI, C., Dr.

Dipartimento Medico-Chirurgico di Cardiologia Pediatrica, Ospedale Bambino  
Gesù, Piazza S. Onofrio, 4, 00165 Roma, Italy

STARK, J., Dr.

Thoracic Unit, The Hospital for Sick Children, Great Ormond Street,  
London WC1N 3JH, Great Britain

STENZL, W., Doz. Dr.

Universitätsklinik für Chirurgie, Auenbruggerplatz 15, 8036 Graz, Austria

TSCHELIESSNIGG, K. H., Doz. Dr.

Universitätsklinik für Chirurgie, Auenbruggerplatz 15, 8036 Graz, Austria

TRACZ, W., Doz. Dr.

Department of Cardiac and Vascular Surgery, Institute of Cardiology,  
N. Copernikus School of Medicine, Pradnicka 80, 31-202 Krakow, Poland

TRACZYNSKI, K., Dr.

Department of Cardiac and Vascular Surgery, Institute of Cardiology,  
N. Copernikus School of Medicine, Pradnicka 80, 31-202 Krakow, Poland



XVIII List of Contributors

VELARDI, A., Dr.

Department of Thoracic and Cardiovascular Surgery, "L. Sacco" Hospital,  
Via G. B. Grassi, 74, 20157 Milano, Italy

VERCELLIO, G., Prof. Dr.

Institute of Vascular Surgery, University of Milan,  
Via Commenda 12, 20122 Milano, Italy

VESCHI, F., Dr.

Laboratory Services, Ospedale Generale Provinciale, 54100 Massa, Italy

VINCENT, J., Dr.

Institute for Thoracic and Cardiovascular Surgery, Sint Radboud Hospital, Catholic  
University, Geert Grooteplein zu id 10, 6500 HB Nijmegen, The Netherlands

WAHLERS, T., Dr.

Abteilung für Thorax-, Herz- und Gefäßchirurgie, Chirurgische Klinik,  
Medizinische Hochschule Hannover, Konstanty-Gutschow-Straße 8,  
3000 Hannover 61, Federal Republic of Germany

WALTERBUSCH, G.

Abteilung für Thorax-, Herz- und Gefäßchirurgie, Chirurgische Klinik,  
Medizinische Hochschule Hannover, Konstanty-Gutschow-Straße 8,  
3000 Hannover 61, Federal Republic of Germany

## ***I. Principles of Fibrin Sealing***

# The Importance of Fibrin in Wound Repair

G. SCHLAG, H. REDL, M. TURNHER, and H.P. DINGES

*Key words:* wound healing, fibrin, macrophages, granulocytes

## **Abstract**

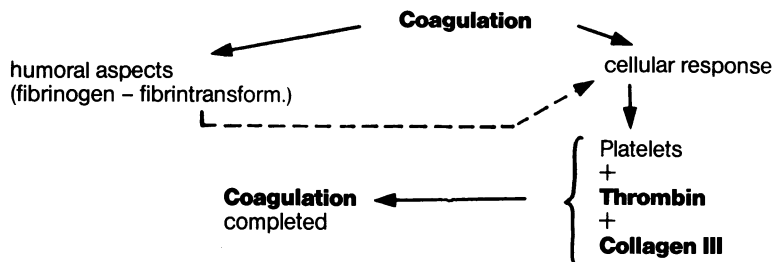
A review is given, beginning with the inflammatory phase of wound healing and explaining the role of macrophages, platelets, and granulocytes. Beside the cellular response the special importance of fibrin and factor XIII is demonstrated, particularly their function for fibroplasia. Special emphasis is put on the effect of highly concentrated fibrin – fibrin sealant. Its beneficial role in promoting the growth of fibroblasts is shown by a study on rats, in which a new model of granulation tissue formation was used. With this model it can be demonstrated that the application of fibrin sealant leads to significantly higher amounts of fibroblasts in newly formed granulation tissue. However, it is also demonstrated that fibrin sealant cannot overcome the inhibition of wound healing caused by, for example, adriamycin, though the beneficial effect of fibrin sealant in other cases of disturbed wound healing, e.g., ulcer cruris, has been demonstrated previously.

## **General Aspects**

Three phases of wound healing are seen following trauma:

- Inflammatory phase
- Fibroplasia
- Protective maturation phase

Tissue trauma is immediately followed by coagulation and hemostasis. Coagulation eventually leads to conversion of fibrinogen into fibrin via the humoral pathway under the influence of thrombin and calcium (Fig. 1).



**Fig. 1.** Primary events following injury

During the coagulation process, a cellular response is seen. Together with thrombin and collagen III, the platelets complete coagulation. Adhesion of the platelets to collagen fibrils of type III [3, 20] leads to platelet aggregation, where the platelets change from a reversible into an irreversible form. 5-Hydroxy-tryptamine and epinephrine are released from the platelets, which undergo further aggregation. Other substances are released from platelets, like platelet factor III, which acts on the formation of thrombin. Platelets are also important for the fibrin network structure, since they make fibrin more resistant to mechanical shear forces and to fibrinolysis [13].

The coagulation activated via humoral as well as cellular pathways leads to the blood clot which acts as a sealant primarily because of its fibrin content. In this way, normal hemostatic mechanisms help to prevent contamination and loss of body fluids as well as providing a substrate material for cell growth [2].

Fibrin is essential since it causes chemotaxis [24] of PMNs (in vitro) in the presence of fibrin degradation products. Fibrin mainly leads to recruitment in the injured tissue and also activates the macrophages.

Immediately after trauma and the ensuing coagulation, the inflammatory phase (lag phase) starts and extends to the 4th or 5th day. This phase is a vital part of the wound repair process. The local neutrophils (PMNs) increase within several hours. The main task of PMNs is to degradate damaged tissue (debriding) and to phagocytose cell debris. The migration of PMNs is presumably caused by chemotactic substances released from aggregated platelets or from plasma components (proteases, fibrinopeptide A). During the first 48 h the PMNs increase markedly and are quickly subject to lysis. Only a few are engaged in phagocytosis [22]. Evidence from studies using antineutrophil serum suggests that the PMNs are not essential in normal wound healing.

After some days, the most important cellular components in the inflammatory phase, i.e., the "monocytes", migrate (Fig. 2), change into macrophages, and reach their maximum number in the wound between the 4th and 5th day. The macrophages serve many different functions. According to Gustafson [15], these include regulation of coagulation (macrophage-induced procoagulant activity, factors V, VII, IX, and X) and fibrinolysis; elimination of cells, tissue debris, and bacteria; and regulation of fibroblast activity (fibroblast growth factor). Their main tasks include

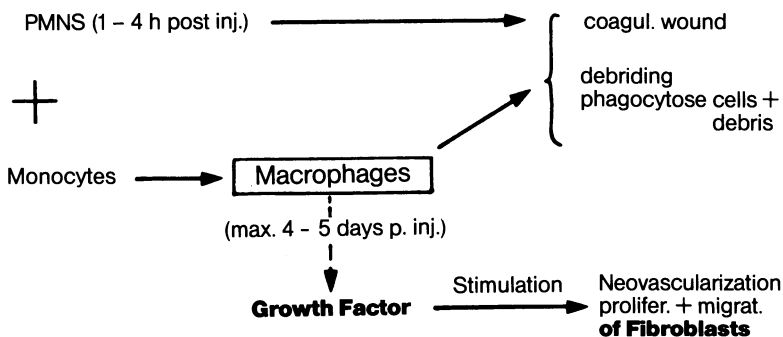


Fig. 2. Inflammatory phase of wound healing

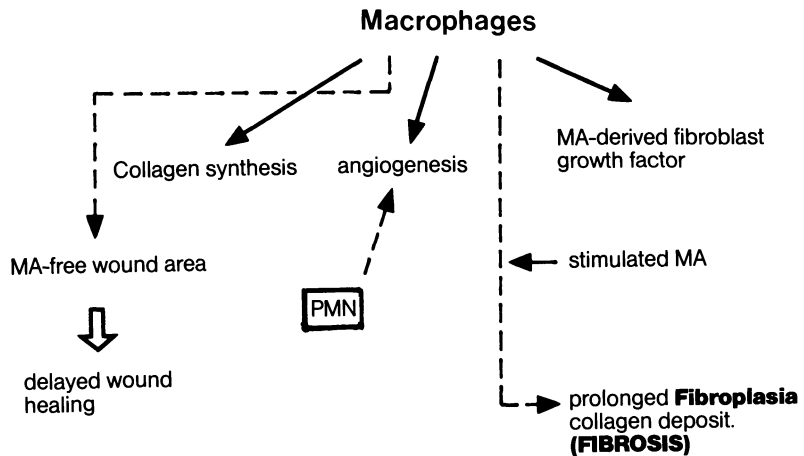


Fig. 3. The role of macrophages during the inflammatory phase of wound healing

phagocytosis of fibrin and the release of growth factors which stimulate fibroblast and endothelial cell proliferation *in vitro* [14, 28]. Induction of angiogenesis by wound macrophages has been confirmed [12, 21] (Fig. 3). Hunt et al [21] reported that this activity involved macrophages more than PMNs; however, a granulocyte component in the production of angiogenesis could not be excluded. Macrophages are responsible not only for neovascularization in the wound but also for stimulation of collagen synthesis. Collagen synthesis requires fibroplasia. Here, the “macrophage-derived fibroblast growth factor” apparently plays a vital part. If antimacrophage serum is administered, wound healing is severely delayed. On the other hand, prolonged activation of macrophages (endotoxin, bacterial products) may result in exaggerated fibroplasia and collagen deposition, which ends in fibrosis [21].

As to the cellular response in wound healing, the platelets in connection with fibrin play an important part [25]. Activated by thrombin, the platelets release a mitogen for fibroblasts and smooth muscle cells and stimulate collagen synthesis. This mitogen was isolated as “platelet-derived growth factor”.

Fibroplasia and collagen synthesis start within 24 h following trauma. The platelets also activate neovascularization. Thus vital factors for wound healing are released by the platelets, which are largely responsible for the healing process (Fig. 4).

Wound healing is influenced by local oxygenation. Banda et al. [4] have shown that anoxia leads to stimulation and activation of the macrophages. This causes production of an angiogenesis factor and a macrophage-derived growth factor which stimulates the fibroblasts.

Knighton et al. [26] have demonstrated hypoxic stimulation of angiogenesis by macrophages in a corneal assay. Hyperoxia appears to suppress angiogenesis as shown in a second experiment with an ear chamber equipped with oxygen-perme-

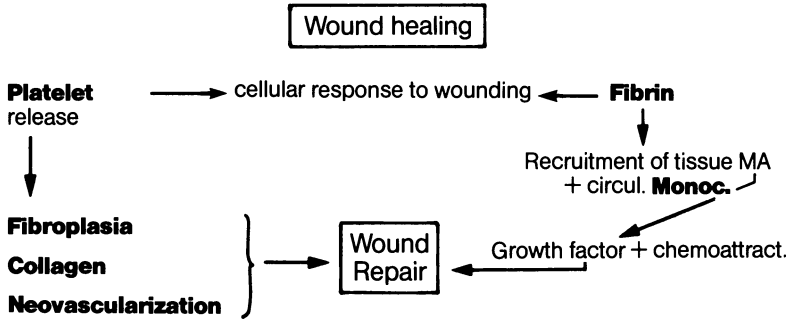


Fig. 4. The concert action of fibrin and platelets

able or -impermeable membranes. The demonstration that respiratory oxygen concentration affects the tensile strength of healing wounds and granulomas may reflect macrophage regulation of angiogenesis or fibroplasia [31, 32].

Granulation tissue plays a key role in the healing of all organs, except for those of epithelial origin. Granulation tissue largely consists of macrophages, endothelial cells, and fibroblasts [36]. The hallmark of granulation tissue is the proliferative response of fibroblasts. Proliferation is stimulated by a substance produced by macrophages (growth factor). It is thus very important that the cellular phase (inflammatory phase) is not influenced as to the quality and quantity of the cells. Macrophages are a crucial component of the initial inflammatory reaction which precedes fibroplasia. The administration of corticosteroids in experimental conditions results in significantly fewer monocytes and macrophages in the cellular infiltrate. The effect of fewer macrophages is that the accumulation of collagen – measured as hydroxyproline content – is decreased and neovascularization is inhibited [38].

Fibroblasts proliferate within the first 3 days after trauma. In connection with neovascularization, fibroblasts become the dominating cells in collagen and proteoglycans synthesis. Collagen is also lysed throughout wound repair, perhaps due to fibroblasts. Fibroblasts are responsible for the synthesis of glycosaminoglycans, which surrounds the collagen network and absorbs the compressive load as a hydrated viscous gel [27, 30].

### *Specific Effects of Fibrin, Thrombin, and Factor XIII*

Fibrin is vital in wound healing since the network formed in the wound acts both as a scaffold for migrating fibroblasts and as a hemostatic barrier [33]. This scaffold is formed by fibrin strands in connection with fibronectin. In large quantities, fibrin has an inhibitory effect on cell migration and may even delay wound healing. Fibroblasts are quickly followed by new capillaries. These are essential for the granulation tissue. The endothelial cells contain plasminogen activator, the subst-

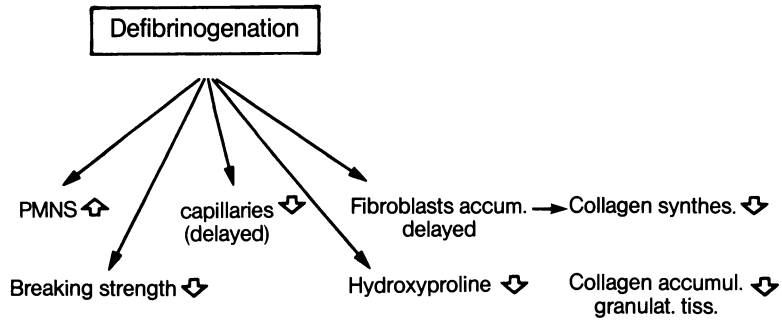


Fig. 5. Effect of defibrinogenation on the different aspects of wound healing

ance that initiates the process of fibrin removal (fibrinolysis). Banerjee and Glynn [5] have demonstrated that implanted fibrin clots are invaded by new capillaries and fibroblasts.

The importance of fibrin in wound repair was confirmed by Brändstedt et al. [7–11]. Defibrinogenation with Arvin has been used in studies on the formation of granulation tissue (Fig. 5). Under these conditions the fibrin strands are irregular and disrupted, and the number of fibroblasts and collagen fibrils is reduced. As a result of this, a reduction of collagen accumulation in the granulation tissue has been observed. Controlled fibrin deposition appears necessary for granulation tissue formation and for normal healing.

Deposited fibrin apparently stimulates the formation of granulation tissue, including increased collagen precipitation [17]. Hydroxyproline directly reflects the collagen concentration and was significantly high in a fibrin-filled Teflon implanted cylinder [16]. Pohl et al. [34] confirmed the influence of fibrin on growing fibroblasts in vitro by showing that fibrin markedly enhances cellular growth as well as mitosis of the fibroblasts. After 10 days, the cell growth stops. The network of fibrin fibers promotes growth and multiplication of the fibroblasts. As long ago as 1960, Banerjee and Glynn [5] demonstrated that implanted fibrin clots are invaded by new capillaries and fibroblasts.

Thrombin has mitogenic characteristics in cell cultures, aside from its effects on platelet activation, such as long-lasting hormone-like influence on fibroblast proliferation [34], on transformation of factor XIII to XIIIa, on conversion of fibrinogen to fibrin, on prostaglandin production, and on activation of protein C [15]. The effect of thrombin in wound healing is manifold and is a vital part of wound repair.

Factor XIII is needed in the cross-linkage of fibrin in order to produce a stable fibrin network which provides the matrix for the ingrowing fibroblasts. The delay in wound healing in factor XIII-deficient patients may be due to lack of stimulation of fibroblast proliferation [23]. The attachment of fibroblasts is not only obtained by the fibrin matrix, but also (indeed, mainly), through the cross-linkage by activated factor XIII. Cross-linkage between fibrin fibers promotes the cellular response and thus subsequent migration and proliferation of fibroblasts. Factor XIII is also cross-linked with collagen, fibronectin, and  $\alpha^2$ -antiplasmin [29].

### ***Fibrin Sealant***

For more than 10 years, fibrin sealant (Tissucol/Tisseel), a two-component sealant, has been widely used in surgical medicine and its disciplines.

Tissucol has a triple effect on wound healing. Due to its hemostatic effect, hematoma formation is avoided; consequently the lengthy process of absorption and possible organization of the hematoma does not take place and the rather negative influence of the hematoma on the quality of the granulation tissue is also avoided.

As far as the adhesive effect of Tissucol is concerned, critics have repeatedly pointed out its limited adhesive strength, which will not tolerate major stress exposure. It should, however, be remembered that the objective of using fibrin sealant is not confined to sealing severed tissue segments. Proper adaptation of dissociated surfaces is just as important because it ensures smooth wound healing unhampered by an artificial barrier such as is introduced with synthetic sealants.

The third effect of a fibrin sealant, at least as far as Tissucol/Tisseel is concerned, is on the physiological network structure [35]. This fibrin network is an excellent substrate for the ingrowth of fibroblasts, which will be demonstrated in the study below.

### ***Materials and Methods***

To determine the effect of Tissucol on the formation of granulation tissue we developed a spongiosa-based granulation tissue model. The model uses blocks of lyophilized Kieler spongiosa. They were decalcified with hydrochlorous acid and fixed with glutaraldehyde to cross-link the collagen structure. The blocks were then subcutaneously implanted into rats. The cavities of the spongiosa were either filled with a substance that influenced local wound healing, e.g., homologous fibrin sealant, or left empty for controls. The spongiosa blocks were removed at certain time intervals. The granulation tissue was biochemically examined after proteolytic removal from the spongiosa, e.g., to determine the DNA and hydroxyproline content. On the other hand, the granulation tissue was morphometrically evaluated following fixation and prepared for electron microscopy using standard techniques. The space filled by granulation tissue within a given time was precisely determined and the composition of the granulation tissue evaluated. With these methods, we determined the quantity of granulation tissue and the cellular (fibroblasts, capillaries) and biochemical (hydroxyproline, DNA) composition. This model seems very useful since no foreign body reaction was seen, in contrast to the reaction frequently observed after cellular sponge implantation according to Hølund [19].

A total of 72 male Wistar rats were distributed into four equally sized groups. The animals were given intramuscular anesthesia with Ketalar-Rompun, and some of them then received adriamycin (6 mg/kg body weight) before implantation of the spongiosa blocks. All animals underwent paravertebral implantation of two sterile spongiosa blocks with or without fibrin sealant under the dorsal skin. The four groups were thus as follows:

Groups O (F + A): Implantation of spongiosa blocks soaked with fibrin sealant with systemic application of adriamycin.



Group 1 (F): Implantation of spongiosa blocks soaked with fibrin sealant without systemic application of adriamycin.

Group 2 (A): Implantation of spongiosa blocks with systemic application of adriamycin, without fibrin sealant.

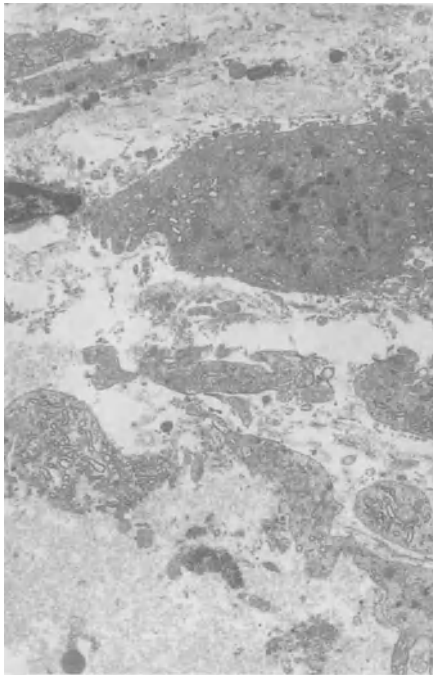
Group 3 (CO): Implantation of spongiosa blocks without further systemic or local treatment (control group).

The animals were killed on the 7th or 14th postoperative day.

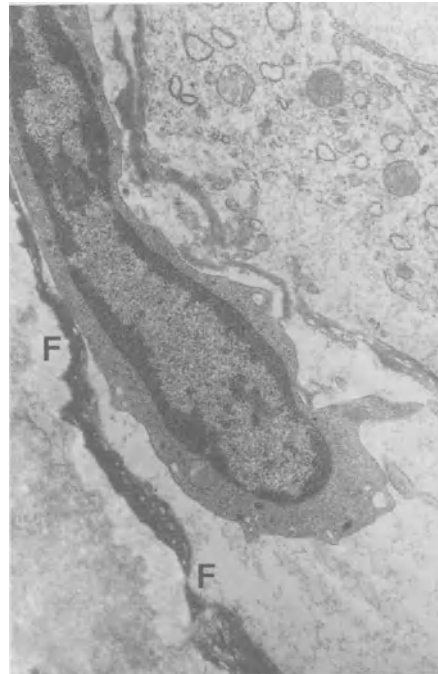
### ***Results and Discussion***

We found a significant fibroblast-stimulating effect of the sealant (16% fibroblasts per volume granulation tissue in controls, 22% in the fibrin sealant group without adriamycin). As opposed to this, the inhibitory effect of the cytostatic agent adriamycin on the formation of granulation tissue was not improved by the sealant (11% without and 10% with sealant). As a cytotoxic chemotherapeutic drug, adriamycin inhibits wound repair. It causes inflammatory arrest, suppresses protein synthesis, and inhibits cell replication [6].

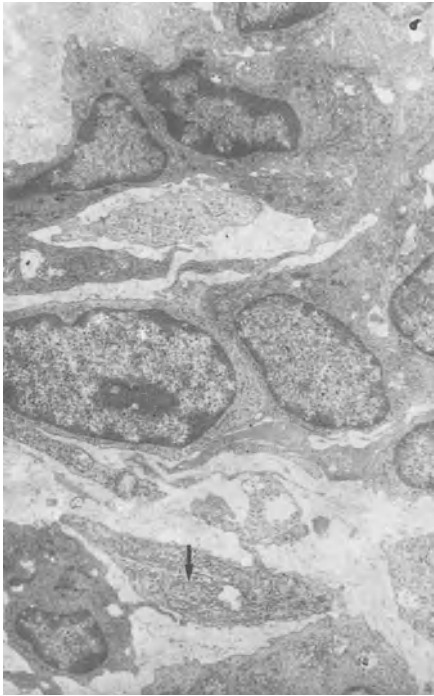
On the electron micrograph, immature (undifferentiated) cells were seen in the adriamycin group (Fig. 6). After 7 days, fibrin strands were markedly visible (Fig. 7), as against the pure fibrin sealant group, in which the fibrin was largely



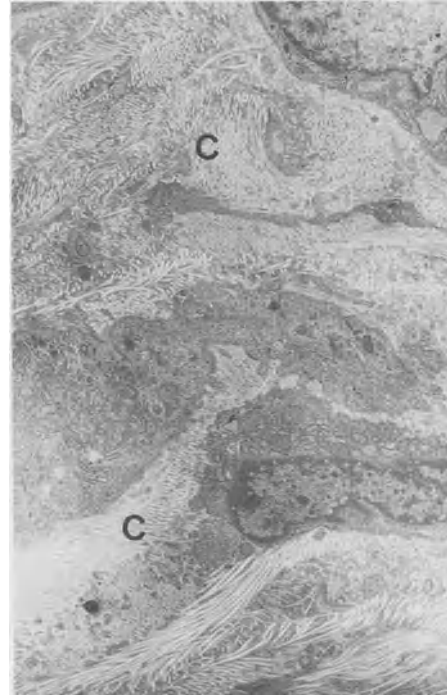
**Fig. 6.** Immature (undifferentiated) cells in granulation tissue of adriamycin-treated rats (7 days after implantation of spongiosa blocks). EM, x5 000



**Fig. 7.** Seven days after implantation – fibrin strands (*F*) of applied sealant are still visible in the adriamycin group



**Fig. 8.** Without adriamycin application fibrin is completely degraded after 7 days; mature cells are seen in which rough endoplasmic reticulum is already visible (*arrow*)



**Fig. 9.** Two weeks after implantation a marked collagen (C) structure is visible in the Tissucol group, which cannot be observed after adriamycin application

degraded (Fig. 8). After 2 weeks, a marked collagen structure was seen in the fibrin sealant group (Fig. 9); such a structure was not observed in the adriamycin-fibrin sealant group. In the latter group, many collagen-free zones were seen around the fibroblasts, as compared with a dense network of collagen fibers along the fibroblasts in the fibrin sealant group, which also showed abundant granular endoplasmic reticulum, corresponding to type B fibroblasts [1], as described in healing rat and human wounds [37].

It stands to reason that fibrin sealant cannot act on wound healing when cytotoxic drugs are applied simultaneously, since the fibroblasts are directly damaged. Nevertheless, in contrast to these findings, it has been shown that other forms of disturbed wound healing, such as *ulcus cruris*, can be cured by fibrin sealant in clinical settings, even when the ulcers have been unresponsive to other kinds of treatment [18].

## References

1. Aho HJ, Viljanto J, Raekallo J, Pelliniemi LJ (1983) Ultra-structural characteristics of cells in human wound collected by cellstic device. *J Surg Res* 35: 498–506
2. Baier RE (1972) Surface chemistry in epidermal repair. In: Maibach HI, Rovee DT (eds) *Epidermal wound healing*. Year Book Medical Publishers, Inc, Chicago, pp. 27–48
3. Balleisen L, Gay S, Marx R, Kühn K (1975) Comparative investigation on the influence of human bovine collagen types I, II and III on the aggregation of human platelets. *Klin Wochenschr* 53: 903–905
4. Banda MJ, Knighton DR, Hunt TK, Werb Z (1982) Isolation of a nonmitogenic angiogenesis factor from wound fluid. *Proc Natl Acad Sci. USA (Cell Biol)* 79: 7773–7777
5. Banerjee SK, Glynn LE (1960) Reactions to homologous and heterologous fibrin implants in experimental animals. *Ann N Y Acad Sci* 86: 1054–1057
6. Bland KI, Palin WE, von Fraunhofer JA, Morris RR, Adcock RA, Tobin GR (1984) Experimental and clinical observations of the effects of cytotoxic chemotherapeutic drugs on wound healing. *Ann Surg* 199: 782–790
7. Brändstedt S, Olson PS (1980) Effect of defibrinogenation on wound strength and collagen formation. A study in the rabbit. *Acta Chir Scand* 146: 483–486
8. Brändstedt S, Olson PS (1981) Lack of influence on collagen accumulation in granulation tissue with delayed defibrinogenation. A study in the rabbit. *Acta Chir Scand* 147: 89–91
9. Brändstedt S, Olson PS, Ahonen J (1980) Effect of defibrinogenation on collagen synthesis in granulation tissue. A study in the rabbit. *Acta Chir Scand* 146: 551–553
10. Brändstedt S, Rank F, Olson PS (1980) Wound healing and formation of granulation tissue in normal and defibrinogenated rabbits. An experimental model and histological study. *Eur surg Res* 12: 12–21
11. Brändstedt S, Rank F, Olson PS, Ahonen J (1980) Cell composition of granulation tissue in defibrinogenated rabbits. *Acta Chir Scand* 146: 545–549
12. Clark RA, Stone RD, Leung DYK, Silver I, Hohn DC, Hunt TK: Role of macrophages in wound healing. *Surg Forum* 27: 16–18
13. Dhall TZ, Shah GA, Ferguson IA, Dhall DP (1983) Fibrin network structure: modification by platelets. *Thromb Haemostas* 49: 42–46
14. Greenberg GB, Hunt TK (1978) The proliferative response in vitro of vascular endothelial and smooth muscle cells exposed to wound fluids and macrophages. *J Cell Physiol* 97: 353–360
15. Gustafson GT (1984) Ecology of wound healing in the oral cavity. *Scand J Haematol* 33, Suppl. 40: 393–409
16. Hedelin H, Johansson S, Peterson HI, Teger-Nilsson AC, Pettersson S (1982) Influence of fibrin clots on development of granulation tissue in preformed cavities. *Surg Gynecol Obstet* 154: 521–525
17. Hedelin H, Lundholm K, Teger-Nilsson AC, Peterson HI, Pettersson S (1983) Influence of local fibrin deposition on granulation tissue formation. A biochemical study in the rat. *Eur surg Res* 15: 312–316 (1983)
18. Holm J (in press) Tissue skin transplants in leg ulcers. In: Schlag G, Redl H (eds) *Fibrin sealant in operative medicine. Plastic, maxillofacial and dental surgery*. Springer Berlin Heidelberg New York
19. Hølund B, Junker P, Garbasch C, Christoffersen P, Lorenzen I (1979) Formation of granulation tissue in subcutaneously implanted sponges in rats. *Acta path microbiol scand Sect A* 87: 367–374
20. Hörmann H, Kühn K (1977) Das Zusammenspiel von humoralen Faktoren, extrazellulärer Matrix und von Zellen bei der Wundheilung. *Fortschr Med* 95: 1299–1304
21. Hunt TK, Knighton DR, Thakral KK, Goodson WH, Andres WS (1984) Studies on inflammation and wound healing: angiogenesis and collagen synthesis stimulated in vivo by resident and activated wound macrophages. *Surgery* 86: 48–54
22. Irvin TT (1981) *Wound healing. Principles and practice*. Chapman and Hall Publ London, New York
23. Kasai S, Kunimoto R, Nitta K (1983) Cross-linking of fibrin by activated factor XIII stimulates attachment, morphological changes and proliferation of fibroblasts. *Biomed Res* 4: 155–160

24. Key AB, Pepper DS, Ewart MR (1973) Generation of chemotactic activity for leukocytes by the action of thrombin on human fibrinogen. *Nature* 243: 56–57
25. Knighton DR, Hunt TK, Thakral KK, Goodson WH (1982) Role of platelets and fibrin in the healing sequence. An in vivo study of angiogenesis and collagen synthesis. *Ann Surg* 196: 379–388
26. Knighton DR, Oredsson S, Banda M, Hunt TK (1984) Regulation of repair: hypoxic control of macrophage mediated angiogenesis. In: Hunt TK, Heppenstall RB, Pines E, Rovee D (eds) *Soft and hard tissue repair. Biological and clinical aspects.* Praeger Scientific, New York, Philadelphia, Eastbourne 1984, pp 41–49
27. Lehto M, Järvinen M (1985) Collagen and glycosaminoglycan synthesis of injured gastrocnemius muscle in rat. *Eur surg Res* 17: 179–185
28. Leibovich SJ, Ross R (1976) A macrophage-dependent factor that stimulates the proliferation of fibroblasts in vitro. *Am J Pathol* 84: 501–513
29. Mishima Y, Nagao F, Ishibiki K, Matsuda M, Nakamura N (1984) Faktor XIII in der Behandlung postoperativer therapie-refraktärer Wundheilungsstörungen. Ergebnisse einer kontrollierten Studie. *Chirurg* 55: 803–808
30. Minns RJ, Soden PD, Jackson DS (1973) The role of the fibrous components and ground substance in the mechanical properties of biological tissues: a preliminary investigation. *J Biochem* 6: 153–165
31. Niinikoski J (1969) Effect of oxygen supply on wound healing and formation of experimental granulation tissue. *Acta Physiol Scand Suppl* 334: 1–72
32. Niinikoski J (1980) Cellular and nutritional interactions in healing wounds. *Med Biol* 58: 303–309
33. Peacock EE (1984) Inflammation and the cellular response to injury. In: *Wound repair*, 3rd edn. W.B. Saunders Company, Philadelphia, London, Toronto, pp 1–14
34. Pohl J, Bruhn HD, Christophers E (1979) Thrombin and fibrin-induced growth of fibroblasts: role in wound repair and thrombus organization. *Klin Wschr* 57: 273–277
35. Redl H, Schlag G, Dinges HP (1985) Vergleich zweier Fibrinkleber. Einfluß ionischer Zusätze auf Fibrinstruktur sowie Morphologie und Wachstum menschlicher Fibroblasten. *Med Welt* 36: 769–776
36. Ross R (1980) Inflammation, cell proliferation, and connective tissue formation in wound repair. In: Hunt TK (ed) *Wound healing and wound infection. Theory and surgical practice.* Appleton Century Crofts, New York, p 1–8
37. Ross R, Odland G (1968) Human wound repair. II. Inflammatory cells, epithelia–mesenchymal interrelations, and fibrogenesis. *J Cell Biol* 39: 152–164
38. Salmela K, Roberts PJ, Lautenschlager I, Ahonen J (1980) The effect of local methylprednisolone on granulation tissue formation. II. Mechanisms of action. *Acta Chir Scand* 146: 541–544

# Fibrin Sealant and Its Modes of Application

H. REDL, and G. SCHLAG

*Key words:* antibiotics, collagen fleece, Duploject system, fibrin glue, hemostasis, spray, tissue adhesive, tissue sealing, wound healing

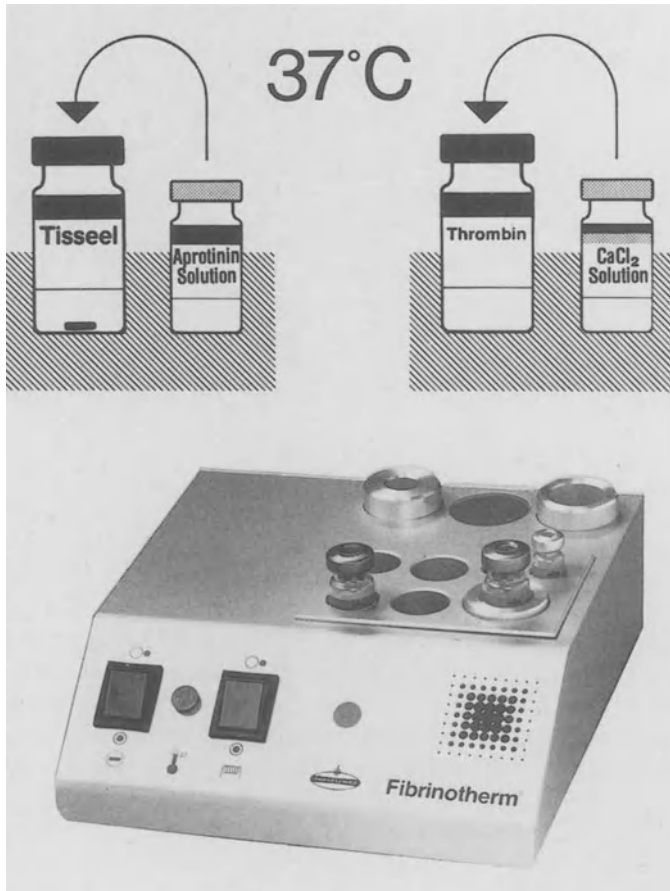
## ***Abstract***

After reconstitution, the two components of fibrin sealant – sealer protein/aprotinin and thrombin/CaCl<sub>2</sub> solution – can be applied in different ways. Besides sequential application or premixing of the reactant, application of the sealant components with the double-syringe applicator (Duploject) is advantageous in a number of ways, e.g., single-handed operation, thorough mixing, thin-layer application. Use of the Duploject is almost universally applicable. Thrombin concentration can be varied depending on the need for rapid or slow clotting of the sealants. The sealant can be delivered using needles, spray heads, or catheters, as indicated by the specific application. The spraying catheter can be easily used through the biopsy channel of an endoscope. Furthermore special micro-application techniques are possible. Fibrin sealant may also be used in connection with other biomaterials such as collagen (fleece), dura, and vascular grafts. Tests are reported on different collagen fleeces as well as on the addition of antibiotics. Finally visibility (including X-ray) and histological techniques are discussed.

## ***The Material***

Fibrin sealant is available under the trade names Tissucol, Tisseel, or Fibrin-kleber Human Immuno as a kit containing freeze-dried powder, freeze-dried thrombin, calcium chloride, and aprotinin solution. The substances mix to form two components: sealer and thrombin solution. To prepare the sealer, protein concentrate is dissolved in the accompanying stock solution of fibrinolysis inhibitor (aprotinin 3000 KIU/ml) or a dilution of it, where applicable. To simplify and speed up reconstitution (5–10) min of the highly concentrated sealer proteins, we developed a combined heating and stirring device – Fibrinotherm (Fig. 1). Thrombin is reconstituted in the accompanying 40 mM of calcium chloride solution, to yield concentrations of either 500 or 4 (NIH) units (NIH-U) of thrombin per milliliter depending on the chosen method of application. As the two components combine during application, fibrin sealant consolidates and adheres to the site of application, i.e., to the tissue.

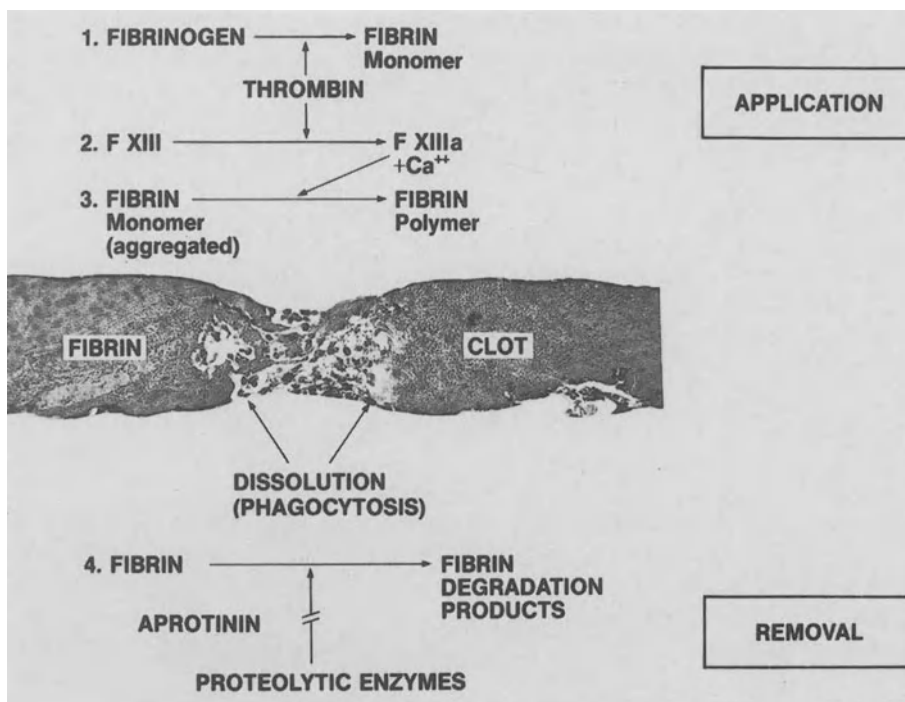
The most important of the sealer proteins is fibrinogen, whose molecular weight is about 340 000 daltons. The molecule consists of six polypeptide chains of three different types –  $\alpha$ ,  $\beta$ , and  $\gamma$ . Through the action of thrombin, the fibrinopeptides A



**Fig. 1.** Component preparation – Fibrinotherm

and B are split off from the resulting fibrin monomer. These fibrin monomers aggregate largely because of hydrogen bonding and thus produce the resulting fibrin clot. These reactions duplicate the last phase of the clotting cascade (Fig. 2). The time required for the onset of coagulation is dependent on the amount of thrombin used.

To achieve maximal tensile strength, cross-linking between fibrin  $\alpha$ -chains is necessary. Fibrin seal itself contains sufficient factor XIII (which is activated by thrombin) to produce a high degree of cross-linking; the latter proceeds slowly, but the initial steepness of the  $\alpha$ -cross-linkage curve results in sufficient tensile strength after about 3–5 min. In previous studies [1, 2], we were able to demonstrate the direct dependency of tensile strength on  $\alpha$ -chain cross-linking. In other experiments [3, 4] we found that the intrinsic tensile strength of a clot formed with fibrin seal was about 1200 g/cm<sup>2</sup> (157 kPa) while that of a sealed rat skin was approximately 200 g/cm<sup>2</sup> (17 kPa) after 10 min cross-linking at 37°C, implying that adhesion of the sealant



**Fig. 2.** Fibrin clot formation and removal

to the tissue is the decisive factor for gluing tissue. The adhesive qualities of consolidated fibrin sealant to the tissue might be explainable in terms of covalent bonding between fibrin and collagen [5] or fibrin, fibronectin, and collagen.

As far as the adhesive effect is concerned, critics have repeatedly pointed out its limited adhesive strength compared with synthetic acrylate adhesives. This is compensated for by the high elasticity of the material [6], which makes the material especially useful for nonstatic tissue, e.g., lung parenchyma. In addition, applications onto wet surfaces are equally possible, as is shown in Table 1. However, the applications of fibrin sealant are not limited to sealing severed tissue segments, as adequate hemostasis is also achieved.

**Table 1.** Tensile strength of sealed rabbit skin in relation to tissue moisture before application of Tisseel (method similar to that described by Redl et al.[26])

Dry (with pads)	Wet (with Ringer's solution)
× 48.2 g STD ± 10.7	53.3 g ± 12.8

To a variable extent, sealant persistence in vivo can be controlled by adding an antifibrinolytic agent [7]. Previous studies have demonstrated that aprotinin, a natural antiprotease, is superior to synthetic antifibrinolytic agents [8]; this has been confirmed by other reports [9]. Sealant degradation rate depends on

- a) the fibrinolytic (or more generally the proteolytic) activity in the area of application,
- b) the thickness of the sealant layer – which should be as thin as possible – and
- c) the amount of aprotinin present.

Thus expected clot persistence can only be dealt with on an individualized basis. However, excessively long survival of the sealant may not be desirable [10].

### ***Application of Fibrin Sealant***

#### *General*

Historically the components were applied sequentially with relatively poor mixing owing to fast buildup of fibrin membranes between them. This prompted us to study mixing ratios, and alternative application techniques and their effects on the seal produced. Ever since the first applications of fibrin sealant the strength obtainable has been known to depend both on the fibrinogen concentration [11] and on the amount of cross-linkage [8]. Using a design for measuring intrinsic clot strength [3], we tried to find the optimum mixing ratio [12]. The mixture of one part sealant and one part thrombin solution gave the best results, although thorough mixing appears to be the decisive factor.

The gross and microscopic data obtained from experiments on rat skin revealed [12] that seals produced with premixed reactants (4 NIH-U thrombin/ml) or with the Duploject applicator (4 or 500 NIH-U/ml) had a superior tensile strength to those obtained with sequential application of reactants. There is no doubt that cavitation, as observed microscopically, is one factor involved. Another factor is insufficient availability of the reactants at the reaction site, since adequate cross-linkage requires a minimum concentration of  $\text{Ca}^{2+}$  [13], which may not be achieved locally if mixing is incomplete.

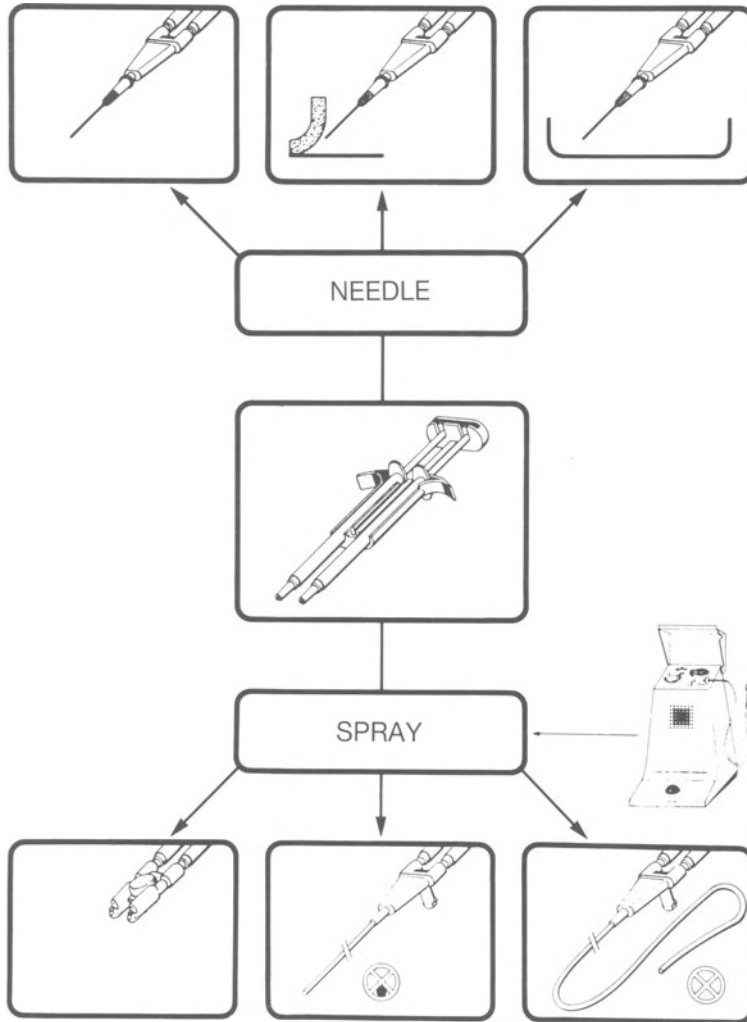
#### *Duploject System with Needle*

While we have repeatedly stressed the disadvantages associated with sequential application (poor mixing and cumbersome handling) [8, 12], the technique has not lost its role in selected cases, e.g., in combination with collagen fleece or vascular graft material so as to facilitate mixing.

In most cases, application of the sealant components with the double-syringe applicator (Duploject) is advantageous, e.g., single-handed operation, thorough mixing, and thin-layer applications. Use of the Duploject is almost universally applicable (Fig. 3).

Low thrombin concentrations (4 NIH-U/ml – slow clotting) are beneficial in all those applications where the parts to be sealed require subsequent adaptation, e.g.,

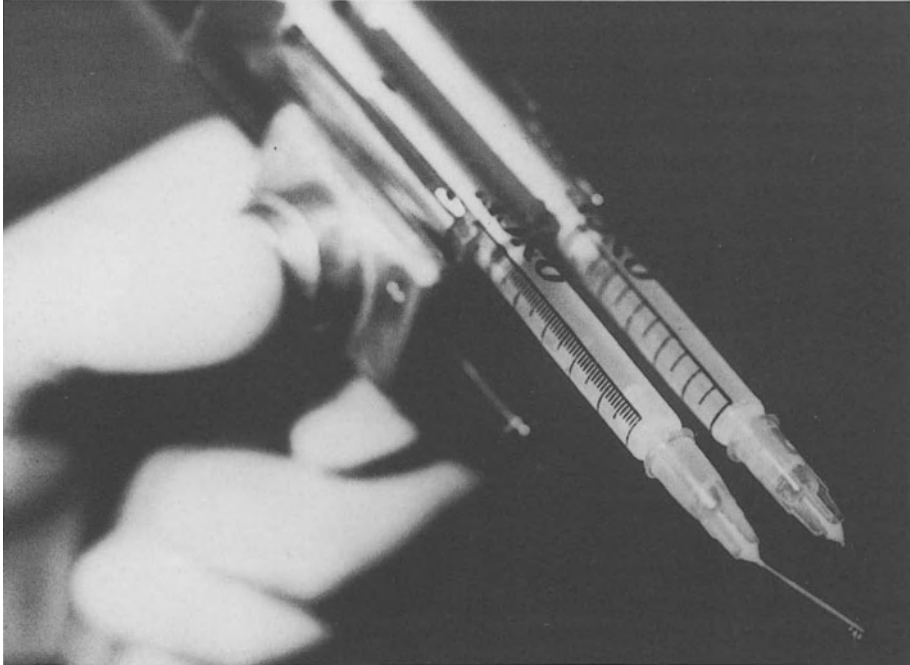




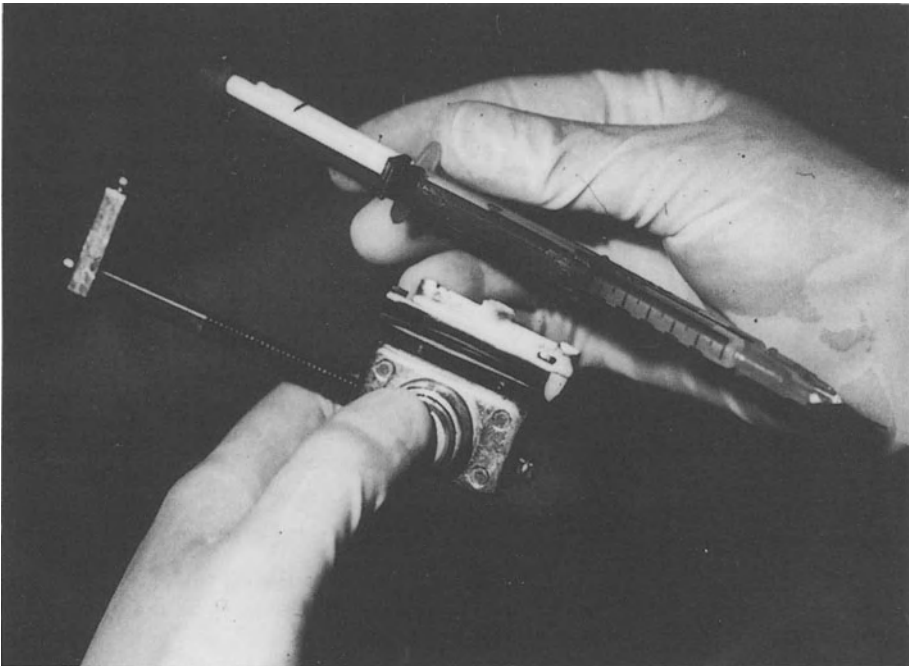
**Fig. 3.** Duploject system

in skin grafting and in some microsurgical operations. If, however, hemostasis is of primary interest, a high thrombin concentration, i.e., 500 NIH-U/ml, should be used as this ensures almost instantaneous clotting.

The double-syringe unit with mixing attachment – needle or catheter – is designed for simultaneous operation of the two barrels so that the two components are ejected at the same time but separately via the exchangeable mixing needle. As long as the sealant is being applied, there will be no clogging of the needle. Once application is interrupted, insertion of a new needle makes the applicator ready for use again.



a



b

**Fig. 4 a, b.** Microapplicator to be used with Duploject system

Certain operations require the use of a microapplicator (Fig. 4) which allows repeated application of the same small volume per ejection; this is especially useful when using 4 NIH-U thrombin per milliliter. A similar system was developed by Tange [14]. An alternative is to mix the two components on a piece of aluminum foil and apply the premixed sealant with a spatula [15]. To get an “ultramicro” dosing (but without mixing) the special device of Chüden [16] may be used.

### *Duploject System – Spray Applications*

The spray head or spray catheter (lower part of Fig. 3) is connected to a conventional pressurized gas source. The gas pressure is reduced to 2 bar (head) or 4 bar (catheter) in order to obtain a gas flow of 5–10 liters/min, which is optimum for use with the Tissomat (Fig. 3). The two components are injected separately into the continuous gas jet. The optimal distance between the spray head and the wound surface is approximately 10 cm for the head and 1 cm for the catheter. As the droplets bombard each other in the air and on the wound surface, they mix, and at a high thrombin concentration instantly form a delicate fibrin film. A thin film so produced is optimum and is required for the sealant to promote wound healing [10]. Spray head application also allows coating of extensive surfaces with a small amount of sealant. Thus an area of about 100 cm<sup>2</sup> can be coated with the 1-ml kit.


The spray head is especially useful for covering large areas, e.g., resected surfaces of parenchymal organs [17], for fixation of skin grafts and coating the donor area [18, 19], and for hemostasis of diffuse epicardial bleeding [20].

In the four-lumen spray catheter (Fig. 5), two lumens are used for the components, the third one for the gas, and in the short version a malleable wire is contained within the fourth lumen. The “spray catheter” can also be used, without spraying gas, to mix the two components in an otherwise inaccessible area, e.g., an esophageal-bronchopleural fistula [21]. In the latter case, the third lumen may be used to apply X-ray contrast dye for catheter localization.

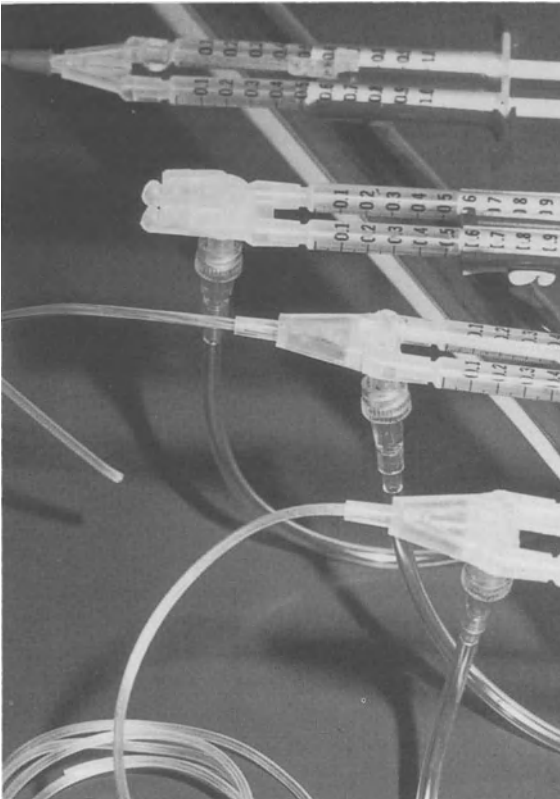
Catheter spray systems can be modified to seal otherwise inaccessible areas by either:

1. The use of endoscopy (with biopsy channels) and a 150-cm-catheter (Figs. 5, 7), or
2. The short catheter with a malleable wire which allows any specific catheter shape (Fig. 6).

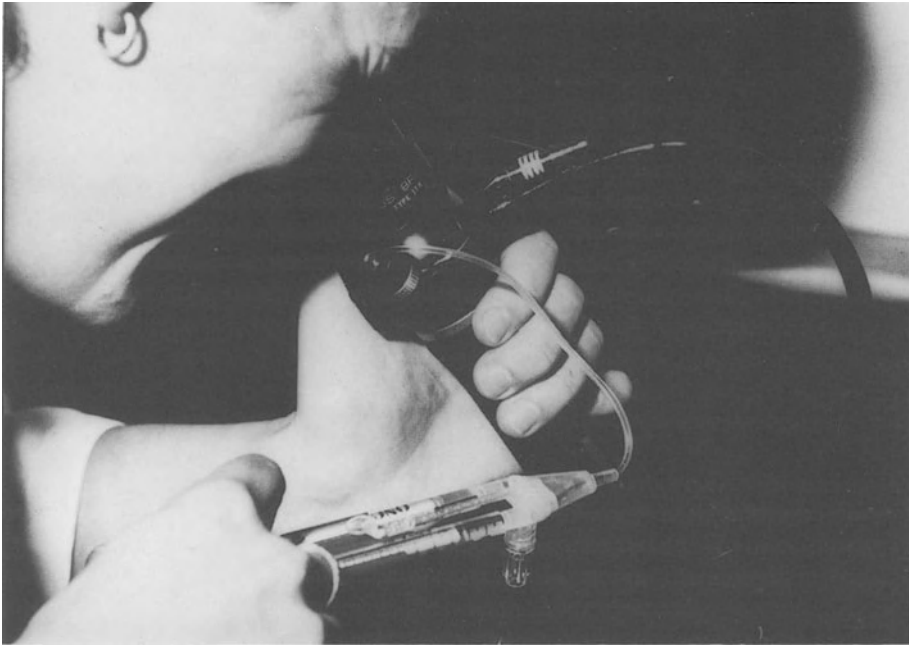
These catheters may be used for pleurodesis in recurrent pneumothorax [22–24], to occlude bronchopleural [25], rectovaginal, and esophageal-bronchopleural fistulas [26], to arrest gastric [27] and esophageal bleeding to ensure tissue sealing of the larynx, to fix flaps in plastic surgery, and to achieve hemostasis in epistaxis and after prostatectomy. An additional advantage offered by spraying with the Duploject spray is that the gas jet can be operated separately and can be used to clean and dry the operating site. The sealant is thus applied to a “dry” surface, which facilitates hemostasis. In addition, no clogging occurs when the sealing procedure is interrupted.



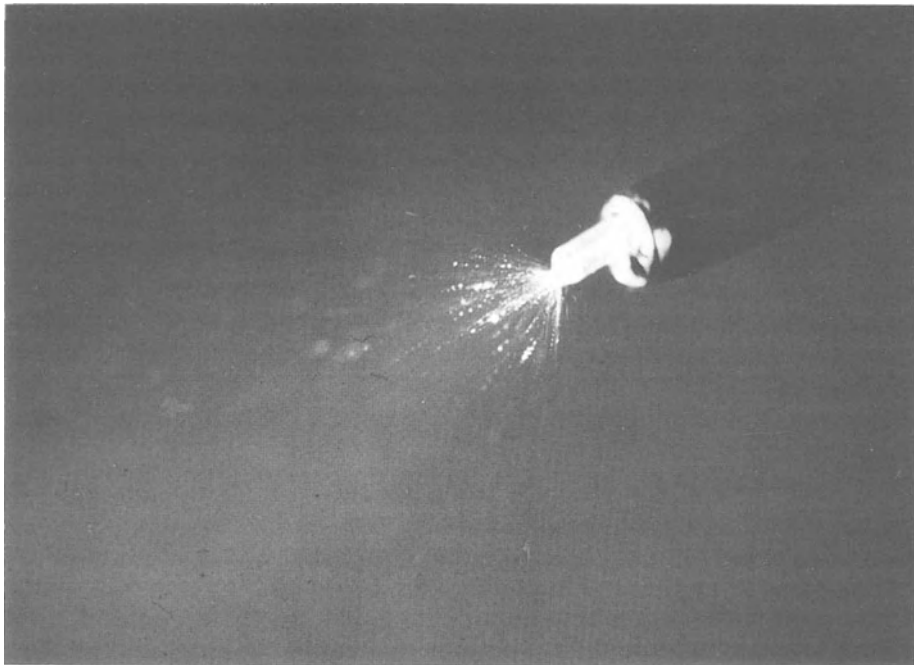
**Fig. 5.** Spray catheter with characteristic four-lumen design



**Fig. 6.** Spray adaptors of the Duploject system



**a**



**b**

**Fig. 7a u. b.** Use of spray catheter through the biopsy channel of the endoscope. **a** Insertion into the channel. **b** Catheter in action, fibrin coming out of the biopsy channel at the tip of the bronchoscope

A cut Swan-Ganz catheter can also be used, as outlined by Linscheer [28]. This technique [15] has been successfully employed to treat patients with pneumothorax [29].

### *Combination of Fibrin Sealant with Matrices*

For some applications the additional use of sealant support, e.g., Dacron patches, lyophilized dura, fascia, or collagen fleece, proved useful. However, not all of the commercially available fleeces are suitable for this purpose, and preliminary tests are therefore mandatory before clinical use. Some fleeces were tested by Stemberger [9] to assess their effects on platelet aggregation. We feel that pliable collagen fleeces are best suited for this purpose. Therefore we performed a preliminary study with some of the available fleeces. Test criteria were:

1. Uptake of liquid
2. Tensile strength in the wet state
3. Ease in handling
4. Tissue reactivity

### Preliminary Results

1. To test the absorption of water, 1×1 cm pieces of collagen fleece of different thickness were used (for results, see Table 2). Absorption of H<sub>2</sub>O was negligible with Collatamp and slow with Gelfix, all other fleeces absorbed H<sub>2</sub>O immediately, which seems to be of essential importance in ensuring adequate soaking with sealant components. Some of the fleeces absorbed H<sub>2</sub>O differently at the upper and the lower surfaces.
2. There were great differences in tensile strength in wet conditions (Table 2). Gelfix showed the highest tensile strength of all the fleeces tested. As expected, the Braun fleece had negligible tensile strength, whereas the Helitrex fleece of only 3 mm showed a remarkable tensile strength of 40–50 g.
3. Most of the collagen fleeces were easy to work with in wet conditions, with the exception of the Braun fleece, which broke into pieces and stuck to the gloves. (However, after our examinations had been completed, an improved fleece was developed.) The application of collagen fleece in dry conditions deserves special

**Table 2.** Test criteria and results of tests on different collagen fleeces in vitro

Company	Hydrophilic surface	Tensile strength	Handling	Tissue reaction
Braun	+	2 g	–	∅
Collatamp	–	10 g	+/-	+
Gelfix	–	150 g	–	+
Pentapharm	+	15 g	+/-	+/-
Helitrex	+	55 g	+	+/-
Savolon	+	50 g	+	∅
(inhomogeneous)				

mention, especially in regard to spray applications. The only fleeces suitable for this mode of application are Helitrex and Savolon 3 mm, whose properties with regard to ease of handling and H<sub>2</sub>O absorption (in particular rapidity and volume of absorption of water) are excellent.

4. For histological examination, moistened pieces of fleece (size: 1×0.5 mm) were applied subcutaneously in rats according to a similar model of wound healing used by Rudas [30]. Blinding evaluation was performed after 14 days. The findings may be summarized as follows: In principle, every fleece tested was still detectable after 14 days; the larger pieces, however, were less disintegrated. The loosely textured Braun fleece and Savolon were absorbed relatively rapidly. The foreign body reaction seemed relatively limited with Braun, Savolon, Pentapharm and Helitrex, while Gelfix and Collatamp cause a more severe reaction. In view of our experience thus far, we recommend the use of Helitrex as a standard fleece for fibrin sealing. In addition to its properties outlined above, it has a further special property: if pressed in a dry condition it may be greatly compressed, yet when absorbing liquid, e.g., fibrin sealant, it expands to its original dimensions. This may result in interesting applications, e.g., endoscopy.

Combination of fibrin sealant with either decalcified bone (ongoing studies in this laboratory) or hydroxyapatite (see orthopedic section) is a further example of heterogenic combination. Fibrin sealant may also be used to fix bioprotheses, such as the middle ear bones [31].

#### *Combination of Fibrin Seal with Antibiotics*

The practice has been to apply fibrin seal only to areas unlikely to become infected. To overcome this limitation, the addition of antibiotics to the fibrin seal seemed desirable. As early as 1950 a patent was described in the USA in which the combined application of fibrin and antibiotics was used [32]. Fibrin seal has also been used in combination with antibiotics both experimentally and clinically [33, 34]. Therefore we studied the *in vitro* properties of mixtures of fibrin seal and antibiotics, particularly their effect on coagulation time, cross-linking, and drug release [3, 4].

For the practical application of fibrin seal, it is important to note that the clotting time can be regulated by the use of higher thrombin concentrations and the rate of fibrin- $\alpha$ -chain cross-linkage with additional factor XIII. Drug release from fibrin seal is probably by simple diffusion, and therefore to a large extent, dependent on the concentration gradient between the clot and its environment. This implies that although antibiotics incorporated into fibrin clots are retained for longer than when they are directly instilled into body cavities, drug retention is much lower than with bone cement-antibiotic mixtures and is insufficient to maintain adequate local drug concentrations for more than 3 days. This observation has also been confirmed in a recent *in vivo* study [35]. The limitations may be overcome by newer, less soluble antibiotics [36]. Nevertheless, infections may be controlled in the early stages after bone surgery using fibrin seal containing relatively high antibiotic concentrations. However, the total dose of drug should be less than the recommended maximal daily systemic dose.

### *Detection of Fibrin Seal in Tissues*

Owing to the opaque white appearance of coagulated fibrin sealant, it is usually easy to detect fibrin in the sealing area. However, for special indications (e.g., in eye surgery) or with sequential application, in which one might wish to observe the delivery of the sealer protein solution, adding disulphine blue dye (ICI) (10  $\mu$ l/ml sealer protein solution) is effective in rendering the fibrin seal visible.

For X-ray detection the addition of different contrast media was tested by Richling [37]. Metrizamide was found to be superior, but its general use cannot be recommended because of slight depression of fibrin- $\alpha$ -chain cross-linking.

Reviews on histological techniques for identifying fibrin sealant have been published by Dinges [30] and Heine [38]. With the phosphotungstic acid method of Mallory and the trichrome technique of Lendrum it is possible to visualize easily the fibrin sealant with light microscopy, but the fibrin sealant does not react as well as endogenous fibrin (perhaps due to the thicker network of fibrin strands). The histological differentiation between exogenous fibrin sealant and endogenous fibrin requires some experience if standard fibrin techniques are employed. If heterologous fibrin glue is used in animal experiments, its demonstration with the immunoperoxidase technique gives optimal results [30]. It is also easily seen with hematoxylin-eosin stain and shows up nicely on trichrome stain.

### *Conclusions*

In summary, for the optimal use of fibrin sealant the application technique should meet the following requirements [12].

1. The sealant components should be fully dissolved and kept at a temperature of 37°C (which is easy with the Fibrino thermssystem — Fig. 7).
2. The wound surfaces should be as dry as possible (though application to wet surfaces is feasible).
3. The components should be thoroughly mixed on application.
4. The thrombin and aprotinin concentrations may be adjusted to the purpose of application.
5. The sealant should be applied as a thin film.
6. After clotting has occurred, further mechanical stresses should be avoided for about 3–5 min because of the time course of  $\alpha$ -chain cross-linking.

Fibrin sealant is useful in controlling microvascular or capillary bleeding from ruptured or surgically dissected tissues. It is particularly beneficial in patients with increased bleeding tendencies undergoing surgery. It might also be used to seal tissue with different kinds of biomaterials. Thus fibrin sealant has a place in all surgical disciplines for the purposes of tissue sealing, hemostasis, and support of wound healing. There seem to be few drawbacks, not even such as the risk of viral transmittance [39, 40]; however, the benefits of combining fibrin sealing with modern-day surgery far outweigh any known risks.



## References

1. Guttman J (1979) Untersuchung eines Fibrinklebers für die Anwendung in der Chirurgie peripherer Nerven. Diplomarbeit, Technische Universität Wien
2. Seelich T, Redl H (1980) Theoretische Grundlagen des Fibrinklebers. In: Schimpf K (ed) Fibrinogen, Fibrin und Fibrinkleber. FK Schattauer-Verlag, Stuttgart, New York (1980) 199–208
3. Redl H, Stanek G, Hirschl A, Schlag G (1982), Fibrinkleber-Antibiotika-Gemische – Festigkeit und Elutionsverhalten. In: Cotta H, Braun A (eds) Fibrinkleber in Orthopädie und Traumatologie. Georg Thieme Verlag, Stuttgart, New York, pp 18–21
4. Redl H, Schlag G, Stanek G, Hirschl A, Seelich T (1983) In vitro properties of mixtures of fibrin seal and antibiotics. *Biomaterials* 4: 29–32
5. Duckert F, Nyman D, Gastpar H (1978) Factor XIII fibrin and collagen. *Coll Platelet Interact.*, FK Schattauer-Verlag, Stuttgart, New York, pp 391–396
6. Redl H, Schlag G (1986) Properties of different tissue sealants with special emphasis on fibrinogen based preparations. In: Schlag G, Redl H (eds) Fibrin sealant in Operative Medicine. Springer-Verlag, Heidelberg, Berlin, this volume
7. Pflüger H, Redl H (1982) Abbau von Fibrinkleber in vivo und in vitro (Versuche an der Ratte mit besonderer Berücksichtigung der klinischen Relevanz). *Z Urol Nephrol* 75: 25–30
8. Redl H, Schlag G, Dinges HP, Kuderna H, Seelich T (1982) Background and methods of fibrin sealing. In: Winter D, Gibbons DF, Plenck H (eds) *Biomaterials*. John Wiley and Sons Ltd (1982) 669–676
9. Stemberger A, Fritsche HM, Haas S, Spilker G, Wriedt-Lübbe I, Blümel G (1982) Biochemische und experimentelle Aspekte der Gewebersiegelung mit Fibrinogen und Kollagen. In: Cotta H, Braun A (eds) Fibrinkleber in Orthopädie und Traumatologie. Georg Thieme Verlag, Stuttgart, New York, pp 290–293
10. Schlag G, Redl H, Thurnher M, Dinges HP (1986) The importance of fibrin in wound repair. In: Schlag G, Redl H (eds) Principles of fibrin sealant. Springer-Verlag, Heidelberg, Berlin, in press
11. Matras H, Dinges HP, Lassmann H, Mamoli B (1972) Zur nahtlosen interfazikulären Nerven- transplantation im Tierexperiment. *Wr Med Wschr* 122: 517
12. Redl H, Schlag G, Dinges HP (1982) Methods of fibrin seal application. *Thorac Cardiovasc Surg* 30: 223–227
13. Seelich T, Redl H (1979) Biochemische Grundlagen zur Klebemethode. *Dtsch Z Mund-Kiefer-Gesichtschir* 3: 22S–26S
14. Tange RA (1986) A new application method for fibrin sealant: glue gun. In: Schlag G, Redl H (eds) Fibrin sealant in Operative Medicine – otorhinolaryngology. Springer-Verlag, Heidelberg, Berlin, this volume
15. Redl H, Schlag G (1984) Background and methods of fibrin sealing. In: Skjoldborg H (ed) Scientific Workshop '82: Tisseel/Tissucol-Symposium – Areas of application, problems and perspectives in current surgery. Immuno Denmark, pp 11–19
16. Chüden HG (1986) Simplified application of fibrinous glue in middle-ear surgery. In: Schlag G, Redl H (eds) Fibrin sealant in Operative Medicine – otorhinolaryngology. Springer-Verlag Heidelberg, Berlin, this volume
17. Servadio L (1983) Tisseel in liver surgery. (Film)
18. Pers M (1984) *Scand. J. Plast. Reconstr. Surg.* 17: 178
19. Riedmiller H, Thüroff JW (1985). In: Melchior H (ed.) Fibrinklebung in der Urologie. Springer-Verlag, Berlin Heidelberg New York, pp 71–76
20. Haverich A, Walterbusch G, Oelert H, Borst HG (1984) In: Scheele J (ed.) Fibrinklebung, Springer-Verlag, Berlin Heidelberg New York, pp 143–149
21. Pridun N, Heindl W, Redl H, Schlag G, Machacek E (1986) In: Schlag G, Redl H (eds) Fibrin sealant in operative medicine, Springer-Verlag, Heidelberg, this volume
22. Jessen C, Sharma P (1985) *Ann. Thorac. Surg.* 39: 521
23. Pridun N, Heindl W (1983) *Wr. Klin. Wochenschr.* 133, Suppl. 75: 40
24. Buchwald J (1984) In: Scheele J (ed.) Fibrinklebung, Springer-Verlag, Heidelberg Berlin, New York, pp 169–172

25. Waclawiczek H, Wayand W, Chmelicek A (1986) In: Schlag G, Redl H (eds.) Fibrin sealant in operative medicine, Springer-Verlag, Heidelberg, this volume
26. Flicker M, Pesendorf FX, Redl H (1985) *Wr. Med. Wochenschrift* 135, Suppl. 90:21
27. Armengol JR (1985) In: Schlag G, Redl H (eds.) Fibrin sealant in operative medicine, Springer-Verlag, Heidelberg, this volume
28. Linscheer WG, Fazio TL (1979) Control of upper gastrointestinal hemorrhage by endoscopic spraying of clotting factor. *Gastroenterology* 77: 642–645
29. Pridun N, Heindl W (1983) Fibrinspraytherapie beim Spontanpneumothorax. *Wr. Klin. Wochenschr* 133, Suppl 75: 40
30. Dinges HP, Redl H, Schlag G (1982) Histologische Techniken und tierexperimentelle Modelle zur Untersuchung der Wechselwirkung zwischen Fibrinkleber und Gewebe. In: Cotta H, Braun A (eds) Fibrinkleber in Orthopädie und Traumatologie. Georg Thieme Verlag, Stuttgart, New York, pp 44–51
31. Siedentop KH, Harris D, Loewy A (1983) Experimental use of fibrin tissue adhesive in middle ear surgery. *Laryngoscope* 93: 1310–1313
32. Ferry JD, Morrison PR (1950) Fibrin clots and methods for preparing the same. United States Patent, Dec 5, 2,533,004
33. Braun A, Schumacher G, Kratzat R, Heine WD, Pasch B (1980) Der Fibrin-Antibiotika-Verband im Tierexperiment zur lokalen Therapie des Staphylokokken infizierten Knochens. *H. Unfallheilkunde* 148: 809
34. Bösch P, Lintner F, Braun F (1979) Die autologe Spongiosatransplantation unter Anwendung des Fibrinklebesystems im Tierexperiment. *Wr. Klin. Wochenschr* 91: 628
35. Stanek G, Bösch P, Weber P, Hirschl A (1980) Experimentelle Untersuchungen für das pharmakokinetische Verhalten lokal applizierter Antibiotika. *Acta Med Austriaca* 4, Suppl 20: 19
36. Wahlig H, Dingeldein E, Braun A, Kratzat R (1982) Fibrinkleber und Antibiotika – Untersuchungen zur Freisetzungskinetik. In: Cotta H, Braun A (eds) Fibrinkleber in Orthopädie und Traumatologie, Georg Thieme Verlag, Stuttgart, New York, pp 182
37. Richling B (1982) Homologous controlled-viscosity fibrin for endovascular embolization. Part. I: Experimental development of the medium. *Acta Neurochir* 62: 159
38. Heine WD, Braun A, Edinger D (1982) Gewebliche Abwehrreaktionen auf das Fibrinklebesystem. In: Cotta H, Braun A (eds) Fibrinkleber in Orthopädie und Traumatologie. Georg Thieme Verlag, Stuttgart, New York, pp 277
39. Barrett PN, Dorner F, Eibl J (1986) In: Schlag G, Redl H (eds) Fibrin sealant in Operative Medicine. Springer-Verlag, Heidelberg, Berlin, this volume
40. Eder G, Neumann M, Cerwenka R, Baumgarten K. In: Schlag G, Redl H (eds) Fibrin sealant in Operative Medicine. Springer-Verlag, Heidelberg, Berlin, this volume

# Properties of Different Tissue Sealants with Special Emphasis on Fibrinogen-Based Preparations

H. REDL, and G. SCHLAG

*Key words:* fine clot, coarse clot, fibrin sealant, fibroblast proliferation, tissue adhesive, fibrinogen, wound healing, hemostasis

## **Abstract**

Different tissue sealants are described with special emphasis on the performance of different fibrinogen-based sealants. Therefore the biochemical properties of four different fibrinogen-based tissue adhesives are compared in detail. The major difference is in clot structure – coarse versus fine. Related to this structural difference are additional dissimilar properties. The coarse type fibrin sealant proved to be superior in tensile strength, cell compatibility and fibroblastic proliferation.

## **Introduction**

The use of tissue adhesives as an alternative method for repairing injured tissues, and more importantly, as a means for improving wound healing, may be based either on natural or synthetic materials. Therefore, it is necessary to compare various natural adhesives (e.g. fibrin sealant) to each other, as well as to synthetic preparations (e.g. cyanoacrylates), in order to assess their relative advantages and disadvantages in regards to clinical applicability (Table 1).

**Table 1.** Tissue Sealants

---

Synthetic	Natural
Acrylates	(Plasma)
Gelatine-Formaldehyde-Resorcin	(Cryoprecipitate)
	Fibrin Sealant

---

One obvious advantage of fibrinogen-based materials is their complete degradation and rapid removal from the body. Thus, local and systemic toxicity are avoided.

In the present study, we compare the biochemical properties of four different fibrinogen-based tissue adhesives; in addition, the similarities and differences of these natural adhesives, as compared to synthetic preparations, are discussed (Tables 2, 3).

**Table 2.** Advantages and Disadvantages of Fibrin Sealant Versus Acrylates

	Fibrin sealant	Acrylates
Application to wet area	Possible	Impossible
Adhesivity	Good	Better
Elasticity	Very good	None
Tissue compatibility	Excellent	Poor
Absorption or degradation	Complete	None
Hemostasis	Excellent	None
Supporting of wound healing	Obtainable	Unobtainable
Application in bone and cartilage	Possible	Impossible
Foreign granulation tissue	None	Invariably present
Risk of virus infection	None*	None

\*according to current knowledge

**Table 3.** Clottable Material [mg/ml]

Cryoprecipitate	AF	Fibrin sealant
29	11	80

Special emphasis is put on two fibrin sealants, which differ mainly in their ionic composition. Ferry and Morrison [1] described the influence of ionic strength on clot structure in 1947. High ionic strength results in “fine” clots and physiological ionic strength in “coarse” clots.

### **Material and Methods**

The four fibrinogen-based, natural adhesives utilized in the study were cryoprecipitate, autologous fibrin (AF)[2] and two fibrin sealants. One fibrin sealant contains a physiological salt concentration (PS) while the second has a high salt concentration (HS) to achieve fast reconstitution.

Protein concentration and composition, kinetics of fibrin alpha-chain crosslinking, factor XIII content, conductivity and osmolarity were measured as described in Redl et al [3]. Intrinsic strength of the formed fibrin clots was tested in an apparatus similar to the one described by Redl et al [4], but using a 0.2 ml butterfly shaped mould for the breaking strength test and a larger one, 0.8 ml with 1.5 cm usable length, for elasticity measurements. The velocity used for stretching the fibrin clots was 1 cm/min.

Human diploid embryonal lung fibroblasts MRC5 were cultivated and their viability tested as described by Redl et al ([3]. Fibroblast proliferation was evaluated according to Mosmann [5] either on cell layers or in cell suspension using the substrate (3-(4,5 Dimethylthiazol-2-yl)-2,5-Diphenyl Tetrazolium Bromide) (Sigma, USA) (= MTT). The effect of the two fibrin sealants on fibroblasts was assessed in either a liquid or solidified state.

In order to assess the influence, if any, of the liquid sealants on the cells, the latter were seeded into the wells of TC Cluster 24 plates (Coster) and incubated at 37°C under 95% air + 5% CO<sub>2</sub> until an almost uniformly dense cell layer had formed. Following dilution of the sealants with equal volumes of isotonic NaCl solution, the cell cultures were covered with 0.5 ml of sealant solution for a maximum of 30 minutes. The effects of dilute sealants on the cells were observed using light microscopy and the supernatants removed at fixed intervals. The cells were then washed with isotonic NaCl solution and stained with Ziel-Neelsen Carbol Fuchsin (diluted 1:10 with water); micrographs were produced using a Polyvar microscope (Reichert).

The proliferation rate was determined according to Mosmann [5] and was used to obtain quantitative data. After incubation with liquid sealant as described above, 50 µl of MTT (5 mg/ml) was added and incubated further for 2<sup>h</sup> at 37°C. Simultaneously 0.1 ml MRC5 cell suspension ( $5 \times 10^5$ /ml) was added to 0.1 ml of each sealant solution, incubated for 30 min. and then incubated further at 37°C after the addition of 20µl MTT solution. The reaction was stopped with 0.4 N HCl in 2-propanol and the accumulated dye extracted. Photometric measurements were done after centrifugation of the supernatant fluid (diluted threefold with 0.4 N HCl/2-propanol) at 570 nm. This test has been shown to correlate well with the <sup>3</sup>H-thymidin uptake test [5].

In order to assess whether the solidified sealants differed in their influence on fibroblasts and to evaluate the fibrin structure, equal volumes of sealant solution were rapidly mixed at 37°C with thrombin-CaCl<sub>2</sub> solution (4 IU of thrombin/ml, 40 mmol of CaCl<sub>2</sub>/l) and 0.5 ml of the mixture was poured into each TC Cluster 24 plate well (Costar) and incubated at 37°C and 100% rel. humidity for 1 hour. Plasma clots were produced similarly by mixing 0.9 ml of citrated human plasma with 0.1 ml of thrombin-CaCl<sub>2</sub> solution (4 IU thrombin/ml, 0.3 mol CaCl<sub>2</sub>/l).

Some of the sealant clots were washed 4 times, each time with 0.2 ml of isotonic NaCl solution for 20 min at 37°C under continuous agitation; the washing efficiency was checked by washing clots of the same type with distilled water and determining the supernatant conductivity after each washing. The nonwashed clots and those washed with isotonic NaCl solution were each cut at a small angle (to obtain a rougher surface), covered with 0.2 ml MRC5 fibroblast suspension ( $5 \times 10^5$  cells/ml medium), and incubated for 24 hours at 37°C under 95% air + 5% CO<sub>2</sub>. Direct examination of cells under the light microscope was possible only with the transparent HS fine clots, not with the milky white PS coarse clots. Therefore, the samples were prepared for histologic examination by fixing them in 3.5% formaldehyde solution followed by standard procedures of dehydration and paraffin embedding. For SEM examination, the samples were fixed with 1% glutaraldehyde (cacodylate buffer), refixed with 1% OsO<sub>4</sub>, alcohol dehydrated, and critical point dried with CO<sub>2</sub>. Dried samples were fractured in order to observe both surface and inner structures and gold sputtered (10 nm, Polaron Sputter) for scanning by a (Jeol-SM 35) SEM at 25 kV accelerating voltage.

## Results

Cryoprecipitate and autologous fibrin (AF) were found to have a low fibrinogen (clottable protein) concentration (Table 3), only moderate  $\alpha$ -chain crosslinking (Table 4) and therefore only limited tensile strength (Table 5).

Both fibrin sealants require approximately the same reconstitution time (5–10 min) when PS dissolved at 37°C by using the combined warming and stirring unit described before [3] and HS at room temperature under manual shaking. Dissolution of HS at 37°C reduces the time required to 3–6 min.

PS and HS were found to be identical in their kinetics of fibrin crosslinking (Table 4) if FXIII is added to the latter.

**Table 4.** Crosslinking of Fibrin  $\alpha$ -Chain (% of  $\alpha$ -Polymer)

Incubation time (min)	Cryoprecipitate	AF	PS (coarse)	HS (fine)
120	35	36	80	80*

\*(with additional factor XIII; see Table 6)

Intrinsic tensile strength was 4 to 5 times higher ( $p < 0.001$ , Student-t-test) in the PS coarse clots (Table 5). Due to the brittle nature of the HS fine clot, more than 50 % of the specimens broke during manipulation and were therefore excluded from the measurements. For the same reason, we were unable to obtain stress-strain results (length-tension relationships) of fine clots (Fig. 1). The decreased elasticity of the fine clots appeared to be unrelated to the fibrin sealant, as standard fibrin fine clots (with minimal lateral aggregation of protofibrils) were also irreversibly deformed, as compared to coarse type clots [6].

As was the case with fibrin structures, the different effects of solidified sealants on fibroblasts were best visualized on the cut surfaces of clots. On smooth PS clot

**Table 5.** Intrinsic Strength [ $\text{g}/\text{cm}^2$ ] (kPa) (incubation temperature = 37°C)

Incubation time (min)	Cryo	AF	PS	HS
10	198.45* (19kPa) n=7	237 (23kPa) n=2	616+101 (60kPa) n=5	
30		not investigated	899+155* (88kPa) n=8	192+41** (19kPa) n=8

\* = signif.  $p < 0.001$  Student t-Test

\*\* = 50% of the fine clot samples had to be eliminated during machine set up

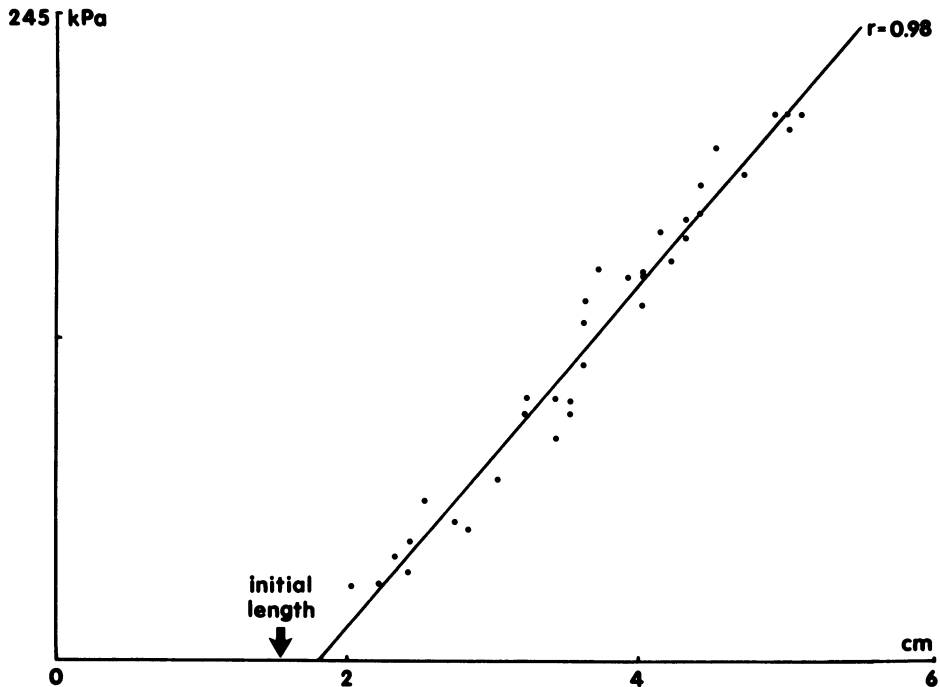


Fig. 1. Stress-strain diagram of PS coarse clot

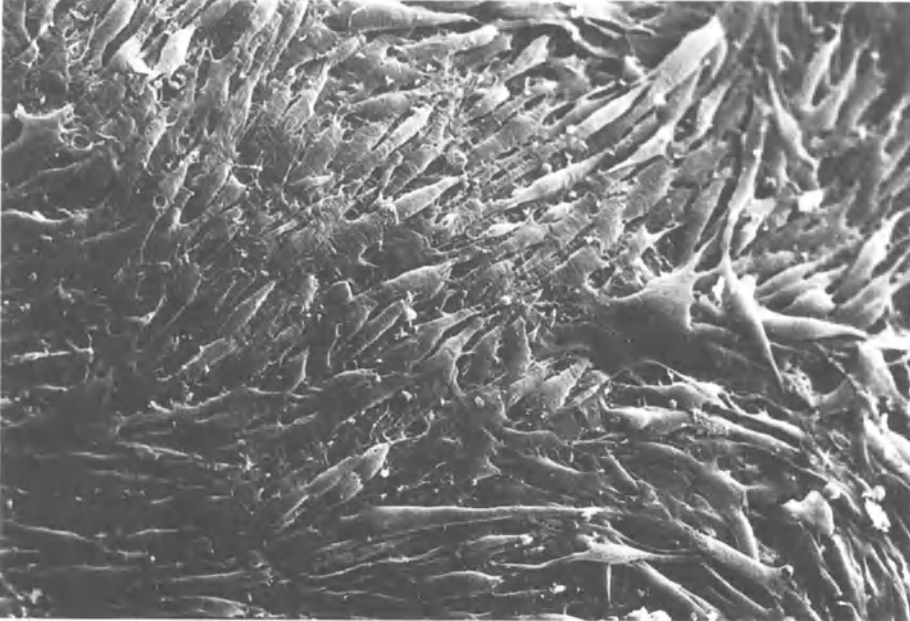
surfaces, we observed a normal proliferation of fibroblasts. Mechanical disturbance of the clot surface greatly accelerated fibroblast proliferation, and the surface became completely covered with fibroblast growth (Fig. 2). HS clots treated in the same manner showed spheroidal deformation of cells, with no detectable proliferation (Fig. 3, Table 7).

The damage of cells on (nonwashed) HS clots was similar to the damage caused by the same sealant in liquid form, but the damaging effect occurred more slowly on the solid sealant.

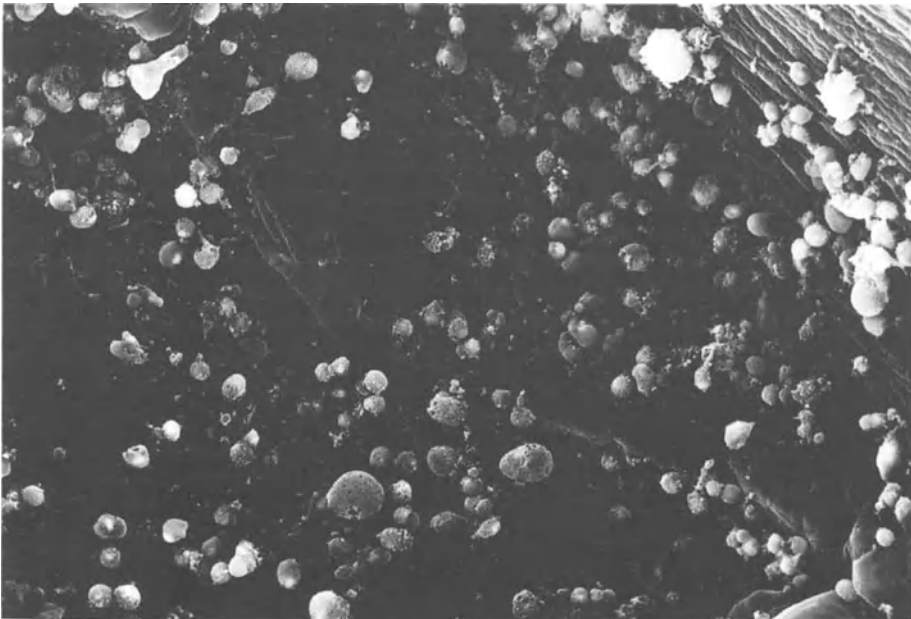
Conductivity measurements on the supernatants of clot washings revealed the removal of more than 95% of salts contained in the clots after 4 washing cycles. Morphology and growth of fibroblasts were identical on washed and nonwashed PS clots, while the cytotoxicity of HS clots was reduced, but not completely eliminated, by extensive washing with isotonic NaCl solution (results not shown).

Table 6. Comparison of Fibrin Sealants

	PS	HS
Factor XIII (U/ml)	12.0	65.0
Conductivity (1:10 dilution with H <sub>2</sub> O) (mS)	1.3	4.0
Osmolarity (mOsmol)	547.0	1 011.0



**Fig. 2.** Rich proliferation of fibroblasts on a cut PS clot. SEM, after critical point drying, x 1000



**Fig. 3.** Spheroidally deformed (damaged) fibroblasts on a HS fine clot after identical treatment as in Fig. 2



**Table 7.** Comparison of the Proliferation Rate of Fibroblasts (Cell Layer and Cell Suspension) when subjected to either PS or HS Sealer Protein Solution

	Photometric extinction at 570 nm		% Inhibition unphysiological - HS
	PS	HS	
Cell layer (mean of 3 diff. experiments $\pm$ SD)	.390 $\pm$ .130	.185 $\pm$ .077	53 $\pm$ 3
cell suspension (mean of 3 diff. experiments $\pm$ SD)	.243 $\pm$ .190	.131 $\pm$ .112	67 $\pm$ 7

### Discussion

Because of the limited strength of Cryo and AF (Table 5), which results from a low clottable protein concentration (Table 3) and only  $\sim 35\%$   $\alpha$ -chain crosslinking even after 2 hours (Table 4) no further experiments concerning histology and cell compatibility were carried out.

Fibrin sealant is a concentrated protein solution. Upon application, fibrinogen is coagulated by mixing with a thrombin-calcium chloride solution, following which the rigidity of the adhesives increases further as a result of fibrin crosslinking. The two preparations studied here produce clots with significantly different characteristics: PS clots are white (non-transparent) and of visco-elastic consistency, whereas HS clots are almost crystalclear and relatively brittle. Ferry and Morrison [1] in 1947 described the formation of two different kinds of fibrin clots: white, non-transparent "coarse clots" formed at an ionic strength and pH value within the physiological range, and transparent "fine clots" produced at a higher ionic strength and/or pH value. Transition from one type to the other is smooth, with fibrinogen concentration, thrombin concentration, and reaction temperature as further influencing factors. In the present study, we determined electrical conductivity, osmolarity, and the kinetics of fibrin crosslinking of both sealants after adjustment of factor XIII content (Tables 4, 6). Micrographs of the fibrin clots produced were obtained under both light and scanning electron (SEM) microscopes and were compared with clots prepared from plasma and thrombin. Because HS differs from PS mainly by its high ionic strength outside the physiological range (causing the formation of almost amorphous clots), we examined the question of how the two sealants would differ in their influence on living cells. Considering the essential role of fibroblast proliferation in wound healing [7], we performed tests with human fibroblasts.

Our investigations were motivated by the striking differences in optical and mechanical properties between the two sealants after setting.

The essential difference between PS and HS is in ion content. PS conductivity is similar to that of isotonic saline solution, whereas HS conductivity is about three times greater.

Our results confirm the basic findings of Ferry and Morrison [1] that visco-elastic, nontransparent fibrin clots are formed at physiological ionic strength ("coarse" clots), whereas transparent, brittle "fine" clots are produced at a higher ionic

strength. Our results indicate that this influence of ionic strength persists over a wide range of fibrinogen concentrations.

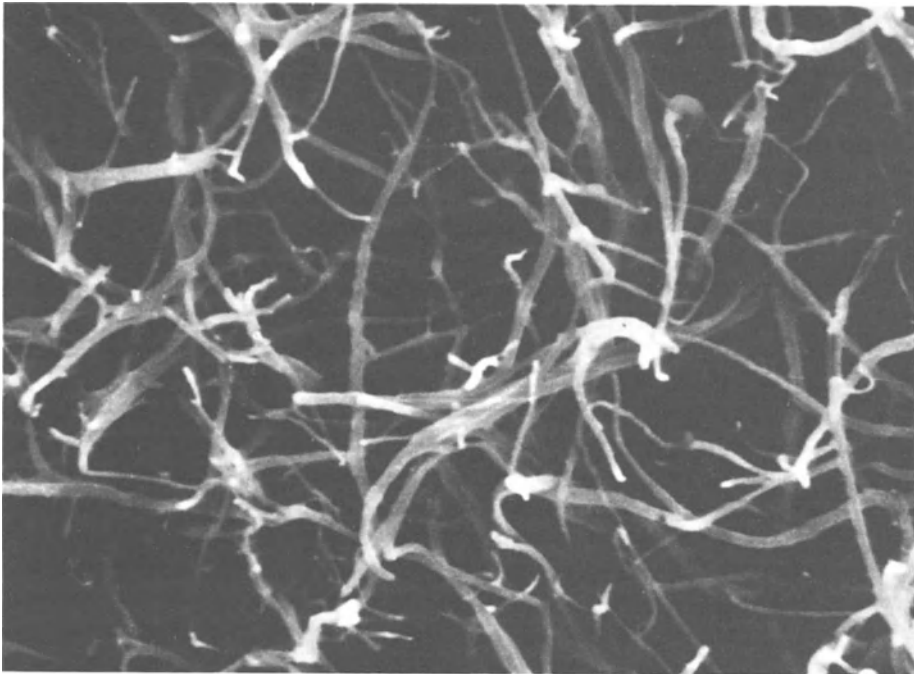
Clots produced from PS or plasma show similar fibrin characteristics, consisting of relatively thick, branching strands (Fig. 4); HS clots appear almost amorphous under identical conditions (Fig. 5). The porosity of HS (with 4 IU/ml thrombin) seen in Fig. 5 might be even less when applied *in vivo* (with 400–500 IU/ml thrombin) as it was found by Blombäck et al. [8] that increasing thrombin concentration results in reduced porosity of fibrin clots.

Both sealants are very similar in terms of fibrin crosslinking kinetics. Ionic strength above the physiological range is known to inhibit fibrin crosslinking [9]; therefore this anticipated effect was compensated for by adding factor XIII.


The significantly higher tensile strength in the coarse clots (PS) is similar to previous shear modulus data from Kanykowski et al. [10]. The elastic rigidity measurements of fine clots (HS) revealed less than one-tenth the shear modulus found for coarse clots. It is possible that the rigidity of the latter clots is primarily due to steric immobilization as has been suggested by Nelb et al. [11].

Because mechanical union is just one aspect of successful surgery, wound healing and hemostatic properties of the sealants must also be simultaneously evaluated.

The formation of fibrin and its crosslinking by factor XIIIa are essential for wound healing. The fibrin network produced under physiological conditions serves as a



**Fig. 4.** Fibrin network in PS coarse clot very similar to plasma clot fibrin network. Scanning electron micrograph (SEM) after critical point drying.

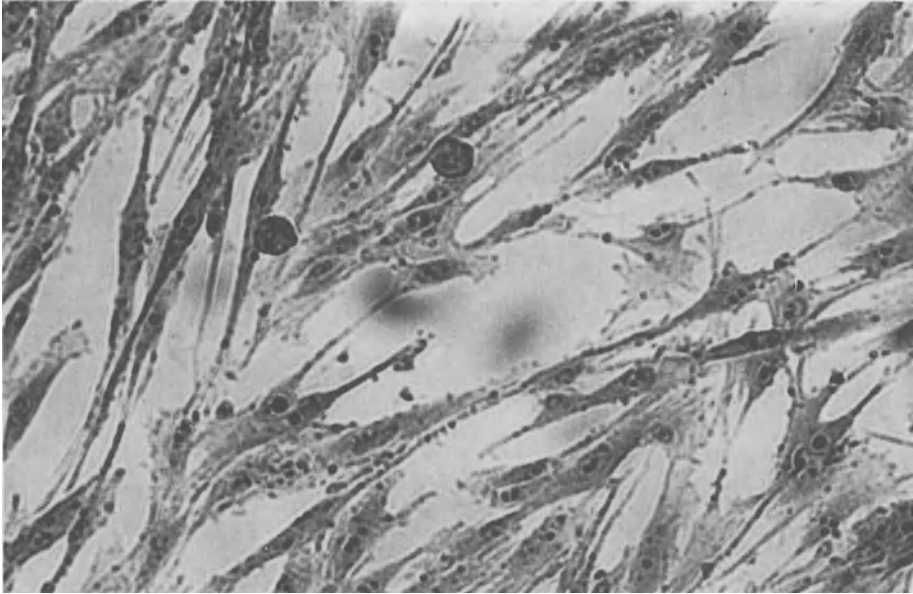


**Fig. 5.** Hardly detectable fibrin strands in a HS fine clot, conditions as in Fig. 4

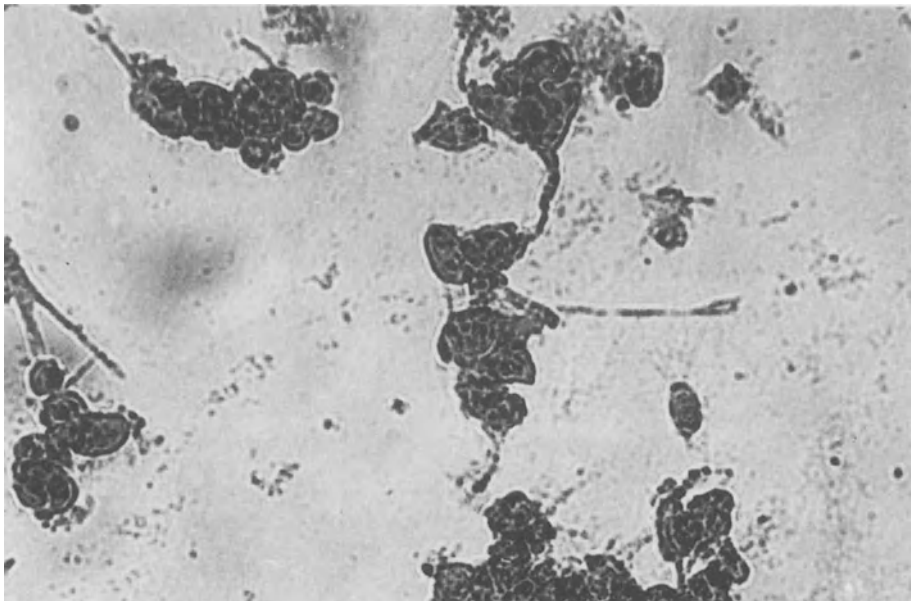
matrix for the ingrowth of fibroblasts and the formation of collagen fibers [7, 12], thereby allowing for optimal wound healing. The formation of crosslinked fibrin is used not only for sealing tissues but for achieving hemostasis as well.

Up to now, many clinical and histologic reports [13, 14, 15, 16] describing satisfactory wound healing after fibrin sealant application have appeared. Thus the question arose whether the higher ion content of HS and the resulting altered fibrin structure of these clots influence fibroblast growth. Given the usual practice of mixing fibrin sealant with an equal volume of thrombin- $\text{CaCl}_2$  solution prior to application, we evaluated the influence of liquid sealants on fibroblasts after 1 + 1 dilution with isotonic NaCl solution. We found that human fibroblasts were severely damaged within minutes by contact with liquid HS, whereas liquid PS does not cause any detectable damage, even after prolonged incubation (Figs. 6, 7). The cytotoxic effect of liquid HS, which is also demonstrated by its 50–60% inhibition of cell proliferation (Table 7), is most easily explained by its high ionic strength and osmolarity. Both HS clots (nonwashed) and liquid HS cause similar damage to cells, but cytotoxicity develops more slowly with the clots. This is understandable if we assume cytotoxicity to arise from soluble additives; the solution trapped in the clot and the cell medium applied take a certain time to equilibrate, by when the damaging additives are further diluted.

In order to distinguish whether the cytotoxicity of HS clots is due to soluble substances trapped in the clot or to the altered fibrin structure, we washed PS and



**Fig. 6.** Layer of fibroblasts 30 minutes after covering with PS, diluted 1 + 1. No detectable differences to controls. LM, carbol fuchsin staining, x 125



**Fig. 7.** Layer of fibroblasts 4 (!) minutes after covering with high salt concentration diluted 1 + 1. Damage to cell structure is clearly visible. Staining and enlargement as in Fig. 6

HS clots with isotonic NaCl solution. Conductivity measurements revealed that this procedure removed more than 95% of the conductive substances originally present in HS clots. Cells proliferated well on washed PS clots; washing reduced but did not eliminate cytotoxicity of HS clots [3].

Thus, the nearly absent structure of transparent fine clots appears to have a certain cytotoxic effect on fibroblasts *in vitro*. We consider this finding to have important implications *in vivo*. Although it may be assumed that the soluble components will diffuse out of a clot slowly, the typical “fine clot” structure will persist.

The importance of a stabilized fibrin network on fibroblast growth deserves special mention. The latter grow faster on cut PS clots than on the very smooth surfaces formed at the liquid-air interface of noncut clots. On the other hand, the same treatment on the cut surface did not improve fibroblast growth of washed HS concentration clots.

Beck et al. [17] in 1962 found that factor XIII is essential for normal fibroblast proliferation, they attributed the wound healing complications associated with factor XIII deficiency to a disturbance of fibroblast growth. These findings were later confirmed and extended by other investigators [18,19, 20]. According to Bruhn et al. [21], fibroblast proliferation is stimulated by the presence of factor XIII, whereas according to Kasai et al. [22], crosslinked fibrin rather than factor XIII is essential for the adherence of fibroblasts to the substrate and for well oriented cell growth. It was shown further that factor XIII itself may have an inhibitory effect on epidermal cell proliferation [23].

Our results indicate that crosslinked fibrin promotes attachment and growth of (human) fibroblasts only if present as PS coarse clots, whereas HS fine clots do not stimulate fibroblast proliferation and actually damage them, even at a comparable degree of crosslinking and after the additives that caused the formation of the fine clot structure have been removed.

Cryoprecipitate and glues from whole blood [2], carry other problems, such as poor standardization, lack of quality control, no virus inactivation, or little strength (e.g. AF, Table 5); the last point was corroborated by Hamm and Beer [24]. Other materials like COHN-fraction [24], though having good tensile strength, have very high viscosity as a major drawback.

It is obvious when comparing their different properties that synthetic sealants like acrylates [25] or gelatine-resorcin-formaldehyde [26, 27] have very limited applications.

## **References**

1. Ferry JD, Morrison PR (1947) Preparation and properties of serum and plasma proteins. VIII. The conversion of human fibrinogen to fibrin under various conditions. *J Amer Chem Soc* 69:388–400.
2. Wolf G, Stammberger H (1984) Erste Berichte über die Anwendung eines autogenen Gewebeklebers in der Hals Nasen Ohrenheilkunde. *HNO* 32:1–4
3. Redl H, Schlag G, Dinges HP (1985) Vergleich zweier Fibrinkleber. Einfluß ionischer Zusätze auf Fibrinstruktur sowie Morphologie und Wachstum menschlicher Fibroblasten. *Med Welt* 36: 769–776

4. Redl H, Stank G, Hirschl A, Schlag G (1982) Fibrinkleber-Antibiotika-Gemische Festigkeit und Elutionsverhalten. In: Cotta H, Braun A (eds) Fibrinkleber in Orthopädie und Traumatologie. Thieme, Stuttgart, pp 178–181
5. Mosmann T (1983) Rapid colorimetric assay for cellular growth and survival: application to proliferation and cytotoxicity assays. *J Immunol Methods* 65:55–63
6. Bale MD, Müller MF, Ferry JD (1985) Rheological studies of creep and creep recovery of unligated fibrin clots: comparison of clots prepared with thrombin and ancord. *Biopolymers* 24: 461–482
7. Ross R (1968) The fibroblast and wound repair. *Biol Rev* 43:51–96
8. Blombäck B, Okada M, Forslind B, Larsson UT (1984) Fibrin gels as biological filters and interfaces. *Biorheology* 21:93–104
9. Seelich T, Redl HT (1980) Theoretische Grundlagen des Fibrinklebers. In: Schimpf K (ed) Fibrinogen, Fibrin und Fibrinkleber. FK Schattauer, Stuttgart, pp 199–208
10. Kamykowski GW, Mosher DF, Lorand L, Ferry JDT (1981) Modification of shear modulus and creep compliance of fibrin by fibronectin. *Biophys Chem* 13:25–28
11. Nelb GW, Gerth C, Ferry JD, Lorand L (1976) *Biophys Chem* 5:377
12. Beck E, Duckert F, Vogel A, Ernst M (1961) The influence of fibrin stabilizing factor on the growth of fibroblasts in vitro and wound healing. *Thromb Diath Haemorrh* 6:485–491
13. Spängler HP, Braun F (1983) Fibrinklebung in der operativen Medizin. Edition Medizin, Verlag Weinheim, Deerfield Beach, Florida, Basel
14. Scheele J (1984) Fibrinklebung. Springer-Verlag, Berlin, Heidelberg, New York
15. Köstering H, Kasten U, Artmann U, Ruskowski H, Beyer JM (1981) Behandlung von Hautnekrosen nach der Extravasation von Zytostatika mit Fibrinkleber. In: Blümel G, Haas S (eds) Mikrozirkulation und Prostaglandinstoffwechsel. Interaktion von Blutgerinnung und Fibrinolyse mit anderen proteolytischen Enzymsystemen. Neues über Fibrinogen, Fibrin und Fibrinkleber. Schattauerverlag, Stuttgart, pp 349–351
16. Rendl KH, Staindl O, Zelger J, Chmelizek-Feurstein CT (1980) Die Hauttransplantation mit Fibrinkleber beim Ulcus cruris. *Akt Dermatol* 6:199–203
17. Beck E, Duckert F, Vogel A, Ernst M (1962) Der Einfluß des fibrinstabilisierenden Faktors (FSF) auf Funktion und Morphologie von Fibroblasten in vitro. *Z Zellforsch* 57:327–346
18. Bruhn HD, Christophers E, Pohl J, Scholl G (1980) Regulation der Fibroblastenproliferierung durch Fibrinogen Fibrin, Fibronectin und Faktor XIII. In: Schimpf K (ed) Fibrinogen, Fibrin und Fibrinkleber. FK Schattauer-Verlag, Stuttgart, pp 217–226
19. Turowski G, Schaadt M, Barthels M, Diehl V, Poliwała H (1980) Unterschiedlicher Einfluß von Fibrinogen und Faktor XIII auf das Wachstum von Primär- und Kulturfibroblasten. In: Schimpf K (ed) Fibrinogen, Fibrin und Fibrinkleber. FK Schattauer-Verlag, Stuttgart, pp 227–237
20. Knoche H, Schmitt G (1976) Autoradiographische Untersuchungen über den Einfluß des Faktors XIII auf die Wundheilung im Tierexperiment. *Arzneimittelforsch – Drug Res* 26:547–551
21. Bruhn HD, Pohl J (1981) Growth regulation of fibroblasts by thrombin, factor XIII and fibronectin. *Klin Wochenschr* 59:145–146
22. Kasai S, Kunimoto T, Nitta J (1983) Cross-linked of fibrin by activated factor XIII stimulated attachment, morphological changes and proliferation of fibroblasts. *Biomed Res* 4:155–160
23. Hashimoto T, Marks R (1984) Factor XIII inhibits epidermal cell migration in vitro. *J Invest Dermatol* 83:441–444
24. Hamm KD, Beer R (1985) Klebefestigkeitsuntersuchungen an biologischen Gewebeklebern. *Z Exp Chir Transplant Künstliche Organe* 18:281–288
25. Stoppa R, Henry X, Odimba E, Verhaeghe P, Largueche S, Myon Y (1980) Dacron tulle prosthesis and biological glue in the surgical treatment of incisional hernias. *Nouv Presse Med* 6:3541–3545
26. Vandor E, Jancsar L, Mozsary P, Reffy A, Demel Z (1980) Experience about the application of gelatin resorcinol formaldehyde tissue adhesive in experimental ruptured liver injury. *Z Exp Chir Transplant Künstliche Organe* 13:52–58
27. Bachet J, Gigou F, Laurian C, Bical O, Goudot B, Guilmet D (1981) 4-year clinical experience with the gelatin-resorcinol-formol biological glue in acute aortic dissection. *J Thorac Cardiovasc Surg* 83:212–217

# Lysis and Absorption of Fibrin Sealant (Tissucol/Tisseel)

(In Vitro and In Vivo Experiments)

H. PFLÜGER

*Key words:* Fibrin, wound repair, fibrinolysis,  $^{125}\text{I}$ -elimination

## **Abstract**

In order to determine the optimal fibrin thrombin adhesive system (FTAS) composition for resistance to fibrinolysis, in vivo lysis was tested by adding increasing amounts of the fibrinolysis inhibitor aprotinin to  $^{125}\text{I}$ -FS; urokinase and plasminogen were administered in vitro while measuring protein and iodine $^{125}$  release. The correlation between protein and iodine $^{125}$  release clearly reflects the interdependence of these parameters; disjunction of radioactivity from the protein molecule was ruled out. In vivo, fibrinolysis is inhibited to a nearly unlimited extent by aprotinin. In vivo, aprotinin improves fibrinolysis inhibition only up to a maximum of 1500 KIU/ml clot, thereby significantly altering the maximum elimination of  $^{125}\text{I}$  iodine and FS half-life as well. Higher doses of aprotinin applied in vivo remain without effect upon FS stability. In human surgery, the addition of aprotinin to FS is recommended for strictly hemostatic application only, not for tissue synthesis such as nerve and microvessel anastomoses in plastic reconstructive surgery.

The aim of the second study was to investigate the degradation of fibrinogen thrombin adhesive system (FTAS) and the process of wound healing after partial kidney resection in rats using FTAS for induction of local hemostasis. In 28 rats partial kidney resection was performed bilaterally. Hemostasis was achieved with FTAS. Four experimental groups were formed. Group F ( $n = 3$ ): hemostasis with unlabeled FTAS, subcutaneous injection of 0.1 ml = 60  $\mu\text{Ci}$  Na  $^{125}\text{I}$ . Group G ( $n = 3$ ): hemostasis with unlabeled FTAS, subcutaneous injection of 0.1 ml = 60  $\mu\text{Ci}$   $^{125}\text{I}$ -labeled FTAS, Group H ( $n = 6$ ): hemostasis with  $^{125}\text{I}$ -labeled FTAS. Group I ( $n = 16$ ): treated like group H. In groups F–H  $^{125}\text{I}$  elimination in 24-h urine samples was determined with a gamma-scintillation counter. Pairs of animals in group I were killed after 2, 6, 12, and 24 h and 3, 7, 14, and 21 days.

Kidneys were examined under the light and electron microscope and by autoradiography. In animals of groups G and H two peaks of  $^{125}\text{I}$  excretion were observed: one peak within the first 48 h postoperatively which corresponded to the amount of free iodine injected with FTAS (FTAS contains 15% free iodine) and a second peak after 120 h which was most probably due to the degradation of FTAS. Fibrinolysis was not observed. FTAS was resorbed mainly by macrophages. The time course of wound healing paralleled that of physiological fibrinogen concentration. Renal parenchymal damage was not observed.

## ***Introduction***

Fibrin plays a central role in the physiological process of wound healing. According to examinations by Key [8] fibrin induces the chemotaxis of polymorphonuclear granulocytes and introduces the initial inflammatory phase of the healing process. There is no doubt that the concentration of fibrin and the platelet content of the thrombus as well as a variety of other factors are in direct interaction and influence the duration of the healing process.

Use of Tissucol, a sealing method that has been employed for years, imitates the physiological process, applying unphysiologically high concentrations of fibrinogen. The influence of the artificial clot on chemotaxis and the resulting induction of macrophages and fibroblasts and of collagen fiber formation is unknown. Other unanswered questions are

- a) the importance of the local potential of the sealed tissue for lysis and degradation of the fibrin clot and
- b) the necessity of adding fibrinolysis inhibitors to the film clots and their appropriate concentrations. It was the objective of the experiments described below to test the fibrinolysis of a Tissucol clot in vitro with and without proteinase inhibitors, and to obtain further results on cellular fibrin degradation in in vivo experiments.

## ***First Study***

### *Materials and Methods*

#### *In Vitro Experiment*

0.1 ml  $^{125}\text{I}$ -FS Human Immuno ( $60\ \mu\text{Ci}/0.1\ \text{ml}$ ) was clotted by adding 0.1 ml thrombin (4 NIH-U/ml) and  $\text{CaCl}_2$  (0.04 M/Liter) and incubated for 30 min at  $37^\circ\text{C}$ . Aprotinin (5000 KIU/ml clot) was added to series A. There was no aprotinin in series B.

In vitro lysis of FTAS was performed by layers of 1 ml urokinase (5.25 Plough-U/ml) and 1 ml plasminogen solution (0.2 CTU/ml) at  $37^\circ\text{C}$  permanent incubation. The supernatant was exchanged every 12 h. Protein content was established photometrically at an extinction of 280 nm, and the content of  $^{125}\text{I}$  was measured by a gamma-scintillation counter.

#### *In Vivo Experiment*

Twenty-one albino rats (Wistar) with an average weight of 320 g were used as test animals. The animals were kept in single metabolite cages and fed with Tagger whole food and water ad libitum. In order to avoid any intermediary retention of  $^{125}\text{I}$  in the thyroid gland, the animals were given 25 drops of Lugol's solution (ÖAB 9, solutio jodi aquosi) in 40 ml drinking water 3 days before the tests were started. In Ketalar (60 mg/kg body weight) and Rompun (8 mg/kg body weight) general anesthesia, two skin pockets of  $1.5 \times 0.5$  were formed on the back of the animals and 0.2 ml FTAS was injected into these pockets.



## Fibrin sealant:

0.1 ml  $^{125}\text{I}$ -FS human Immuno ( $60\ \mu\text{Ci}/0.1\ \text{ml}$ )

0.1 ml thrombin (4 NIH-U/ml)

 $\text{CaCl}_2$  0.04 M/liter

Group C ( $n = 7$ ) was treated without aprotinin, while in group D ( $n = 7$ ) 1500 KIU/ml clot and in group E ( $n = 7$ ) 5000 KIU/ml clot were added to the FTAS. In animals of group C-E  $^{125}\text{I}$  elimination was counted by gamma-scintillation counter in urine collected over 24 h until the 7th day after surgery.

All the results were indicated as mean value with standard deviation.

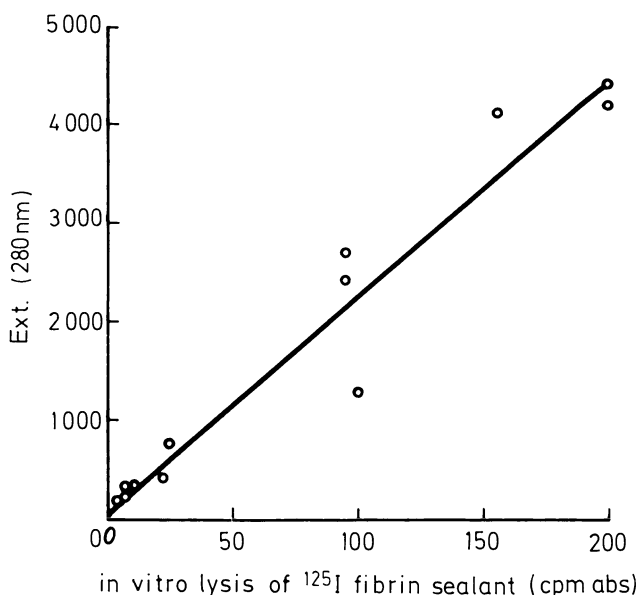
## Results

## In Vitro Experiment

The correlation coefficient of protein concentration (extinction at 280 nm) and radioactivity counted was  $r = 0.97$  for both series A and series B. Regression line  $y = 0.02 \times + 0.04$  (Fig. 1).

The samples with aprotinin (series A) showed slow fibrinolysis. A maximum of 5% of the total activity was absorbed per 12 h and the stability of the clot lasted for more than a week. In the samples without aprotinin (series B) the maximum degradation was found after 36 h, 40% of the total activity being released (Fig. 2). After 60 h the whole FS clot was dissolved. All the animals survived the surgical intervention and the observation period of 7 days.

The maximum  $^{125}\text{I}$  excretion in animals of group C was found after  $1.75 \pm 0.5$  days, in group D (1500 KIU/ml clot) after  $3.2 \pm 0.45$  days, and in group E after  $3.5 \pm 1.29$  days.



**Fig. 1.** Correlation of protein concentration and counted radioactivity. Measurement every 12 hours after lysis of a  $^{125}\text{I}$ . Fibrin sealant clot with urokinase – plasminogen

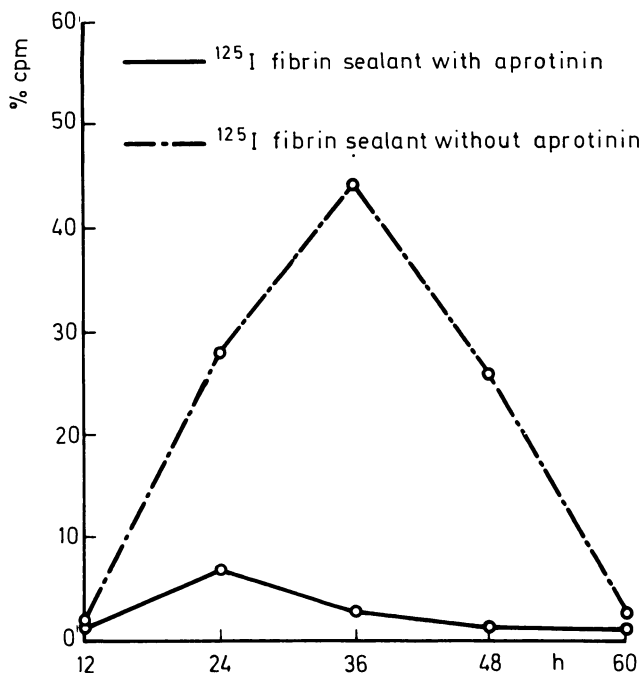


Fig. 2. Fibrinolysis expressed in radioactivity counted in 24<sup>h</sup> urin samples of rats

Statistical evaluation of the results by means of the hour *t*-test showed a significant time difference in the elimination maximum ( $p < 0.01$ ) between animals of groups C and D, and C and E. Comparison of the groups D (1500 KIU/ml) and E (5000 KIU/ml) showed no significant time difference in the <sup>125</sup>I excretion maximum. (Fig. 3) shows mean values of <sup>125</sup>I elimination as a percentage of the total dose applied in animals of groups C and D during an observation period of 7 days. In animals of

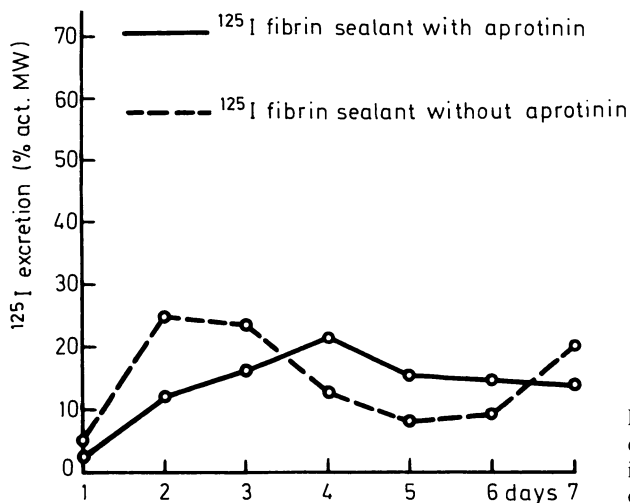


Fig. 3. Mean values and standard deviation of <sup>125</sup>I-excretion in 24<sup>h</sup> total urin, indicated in % of total excretion per 10 days

group C we found a two-stage course of the graph: A first elimination peak occurred after 2 days ( $\bar{x} \sim 24\%$ );  $^{125}\text{I}$  excretion then reached a minimum on the 5th day after surgery ( $\bar{x} \sim 8\%$ ) but a further increase was observed on the 7th day after surgery ( $\bar{x} \sim 20\%$ ). In animals of group D this two-stage course of the graph could not be observed. They showed a slow increase in  $^{125}\text{I}$  excretion, the peak being on the 4th day after surgery ( $\bar{x} \sim 21\%$ ), as well as a slow decrease in  $^{125}\text{I}$  excretion. On the 7th day after surgery 14% of the total dose applied was eliminated.  $^{125}\text{I}$  elimination in animals of group E was almost identical to that in animals of group D.

### FS Half-life

The Half-life (period of time after which half of the iodine dose applied has been eliminated) was  $2.16 \pm 0.13$  days in animals of group C,  $2.82 \pm 0.31$  days in group D, and  $2.92 \pm 0.25$  days in group E. There was a statistically significant difference ( $P < 0.01$ ) between animals of groups C and D, and groups C and E. There was no statistically important difference between groups D and E.

## Second Study

### Materials and Methods

In the second study we examined the degradation of fibrinogen thrombin adhesive system (FTAS) during healing after partial kidney resection in rats, using FTAS for production of local hemostasis. We followed the fate of the autologous fibrin clot histologically and by monitoring the redistribution of  $^{125}\text{I}$  iodinated fibrin fragments.

FTAS was applied on a supporting collagen fleece (Disperger, Vienna), placed on the resection wound [12], and lightly pressed digitally on to the resection area for 60 s. Twenty-eight male albino rats were used (Wistar SPF breed, average weight 350 g). The animals were kept in single cages and fed with Tagger complete food and water ad libitum. In order to achieve complete blockage of iodine absorption into the thyroid gland, all animals were given 25 drops of Lugol's solution (ÖAB 9, solutio jodi aquosi) in 40 ml drinking water 5 days before starting the experiment. Under diethyl ether anesthesia the kidneys were exposed through lumbar incisions, bilateral lower partial kidney resections were performed, and hemostasis of the parenchymatous wound was achieved with FTAS as described above. Twenty percent of the renal parenchyma was removed. The 28 animals were divided into four experimental groups:

*Group F* ( $n = 3$ ): Bilateral partial kidney resection, hemostasis with unlabeled FTAS, subcutaneous injection of 0.1 ml = 60  $\mu\text{Ci}$  Na  $^{125}\text{I}$  (Amersham, IMS, 1 P  $^{125}\text{I}$  sodium thiosulfate).

*Group G* ( $n = 3$ ): Bilateral partial resection, hemostasis with unlabeled FTAS, subcutaneous injection of 0.1 ml = 60  $\mu\text{Ci}$   $^{125}\text{I}$ -FTAS.

*Group H* ( $n = 6$ ): Bilateral partial kidney resection, hemostasis with  $^{125}\text{I}$ -FTAS.

*Group I* ( $n = 16$ ): Bilateral partial kidney resection, hemostasis with  $^{125}\text{I}$ -FTAS.

The  $^{125}\text{I}$ -elimination in a 24-h urine sample from animals in groups F–H was measured by a gamma-scintillation counter daily up to the 10th postoperative day.

For morphological studies pairs of animals of group I underwent laparotomy 2, 6, 12, and 24 h and 3, 7, 14, and 21 days after surgery. The kidneys which had been partially resected were perfused with Hanks' solution to remove all intrarenal blood and then perfused for 10 min with 2.5% glutaraldehyde in 0.1 M cacodylate buffer (pH 7.4) [9]. The tissue samples were embedded in Epon 812 and 1- $\mu$  m sections were stained with 1% toluidine blue. For autoradiography Kodak Nuclear Track-Emulsion was applied to the sections, the exposure time being 28 days at 4°C. Ultrathin sections were examined in an EM9S electron microscope.

Serum creatinine and BUN were determined photometrically on the 3rd and 10th postoperative days.

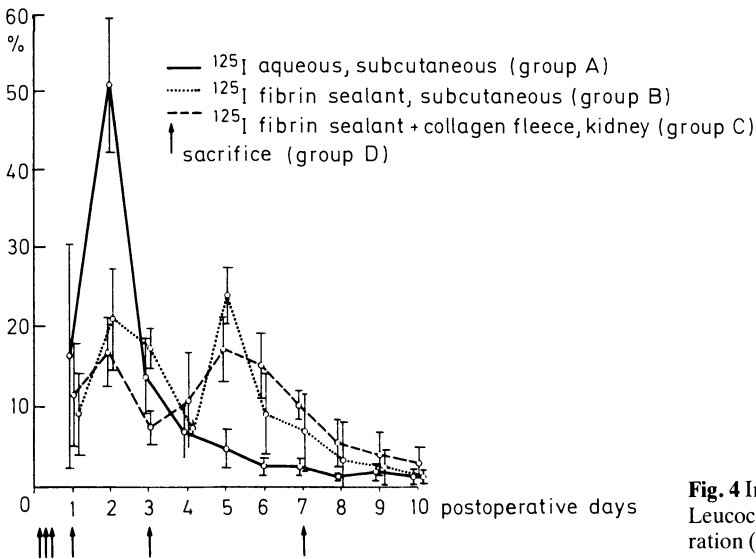
*Results*

General

No animal died immediately after operation or within the period of observation. Three animals developed a unilateral wedge-shaped, ischemic renal infarction. Parenchymatous destruction to a maximum depth of 3–20 tubular lumina could be found in all other kidneys. In two cases a stone was found in the renal pelvis. Diffractometric X-ray analysis showed the stone composition to be calcium oxalate monohydrate. No animal developed uremia.

Dynamics of <sup>125</sup>Iodinated FTAS and <sup>125</sup>I Sodium Thiosulfate

Mean values and standard deviations of the <sup>125</sup>I excretion in 24-h urine samples indicated as a percentage of the <sup>125</sup>I total excretion during the 10-day observation period for animals of groups F–H are shown in Fig. 4.



**Fig. 4** Imigration of Leucocytes 24<sup>h</sup> after operation (× 4.500)

### Group F (Subcutaneous Injection of 60 $\mu\text{Ci Na }^{125}\text{I}$ )

$^{125}\text{I}$  excretion was maximal on the 2nd postoperative day ( $50.5 \pm 8.4\%$ ) and an exponential decrease of  $^{125}\text{I}$  elimination occurred after this time. By the 3rd postoperative day 80% of the measured total dose had been eliminated.  $^{125}\text{I}$  elimination on the 10th postoperative day was  $1.5 \pm 0.75\%$ .

### Group G [Subcutaneous Injection of 0.1 ml (Containing Approximately 75 mg Protein) = 60 $\mu\text{Ci FTAS}$ ]

Maximal  $^{125}\text{I}$  excretion occurred on the 2nd ( $20.6 \pm 6.2\%$ ) and 5th postoperative days ( $23.6\% \pm 3.5\%$ ). The least  $^{125}\text{I}$  elimination occurred during the 4th postoperative day ( $7\% \pm 1.3\%$ ). A slow decrease in  $^{125}\text{I}$  elimination occurred from the 5th postoperative day onwards.  $^{125}\text{I}$  excretion on the 10th postoperative day was  $1.1\% \pm 0.6\%$  of the measured total dose.

### Group H $^{125}\text{I}$ -FTAS for Hemostasis of Kidney Wounds

Maximal  $^{125}\text{I}$  elimination occurred on the 2nd ( $16.5\% \pm 4.2\%$ ) and 5th postoperative days ( $16.5\% \pm 3.8\%$ ). The lowest excretion rate occurred on the 3rd postoperative day ( $7.3\% \pm 2\%$ ). A slow decrease in  $^{125}\text{I}$  elimination occurred after the 5th postoperative day.  $^{125}\text{I}$  elimination on the 10th postoperative day was  $3\% \pm 2\%$  of the measured total dose excreted.

Radioisotope excretion did not depend on the daily volume of urine.

### Histological, Electron Microscopic, and Autoradiographic Findings in Animals of Group I

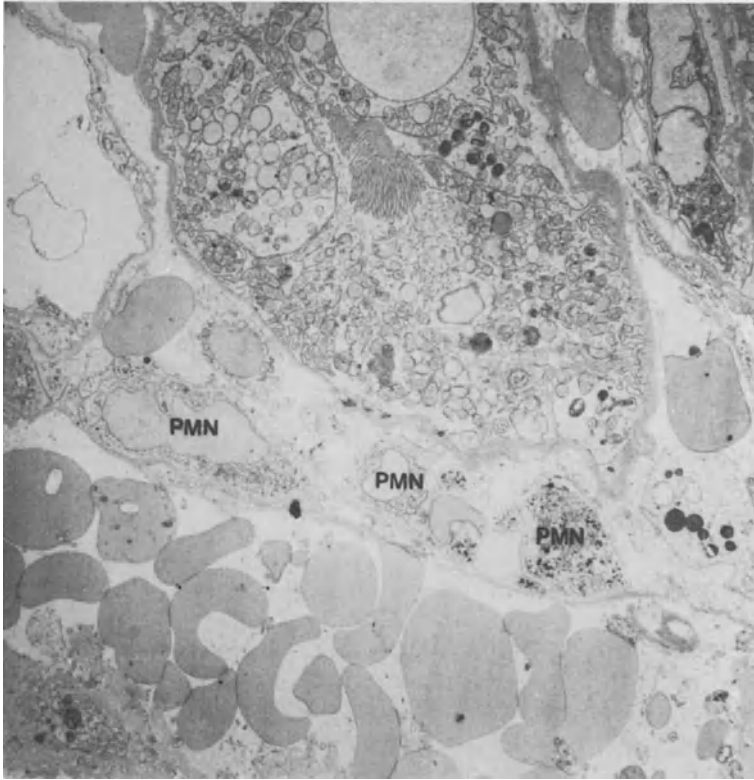
*2, 6, and 12 Hours After Operation.* No reaction of connective tissue was observed under the light or on the electron microscope. Collagen fleece was inhibited with erythrocytes and partly lifted off the parenchymatous area by small hematomas.

*24 Hours After Operation.* Light and electron microscope studies showed emigration of neutrophilic granulocytes and macrophages into the interstitium (Fig. 5). Autoradiography showed larger amounts of labeled fibrin at the area of adhesion.

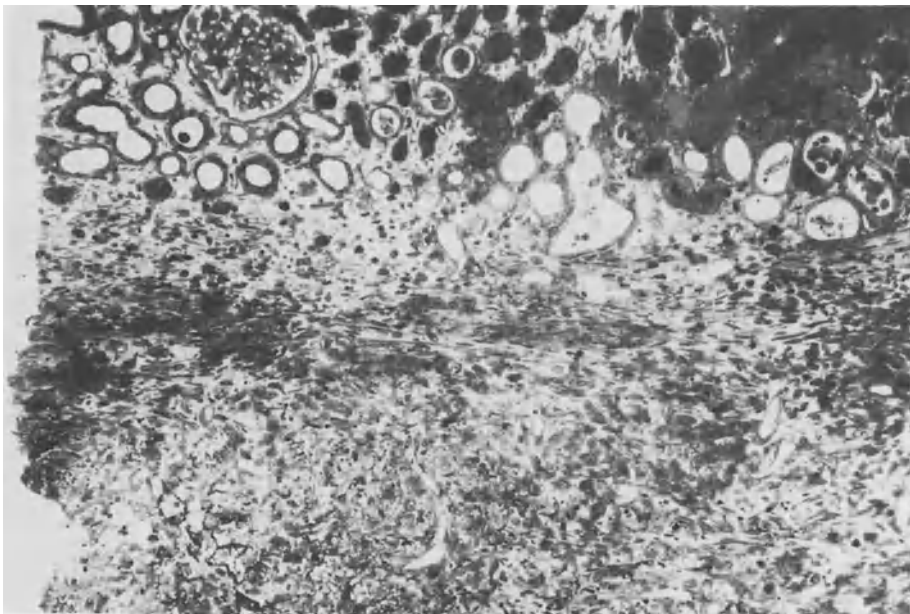
*3 Days After Operation.* Cell-rich granulation tissue and infiltration of granulocytes was seen under the light microscope (Fig. 6). Marked resorption of fibrin clots by phagocytosing macrophages (Figs. 7, 8), as well as capillary outgrowth, was seen under the electron microscope. A high concentration of radioactively labeled FTAS was still present.

*7 Days After Operation.* Collagen fiber appeared and isolated remnants of radioactively labeled fibrin were seen in the granulation tissue with numerous macrophages.

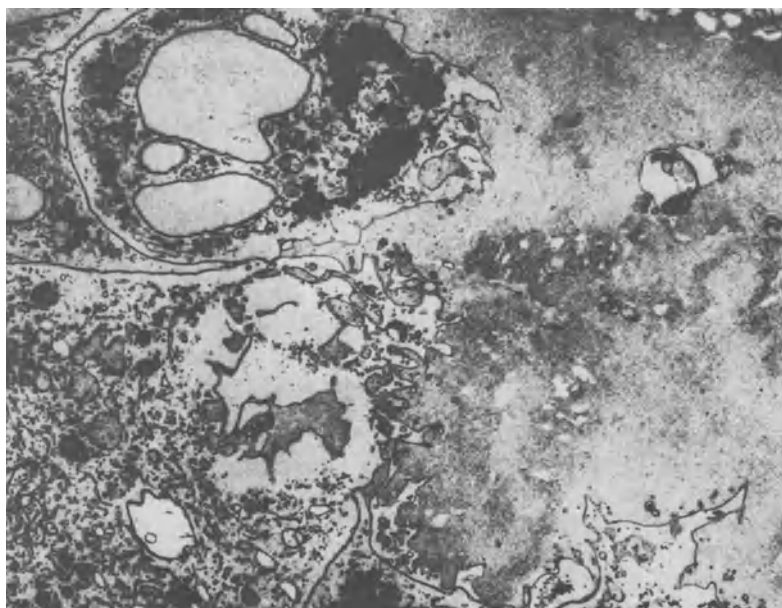
*14 and 21 Days After Operation.* Collagen-rich granulation tissue with a markedly decreased number of infiltrating cells was found. Until the 14th postoperative day,



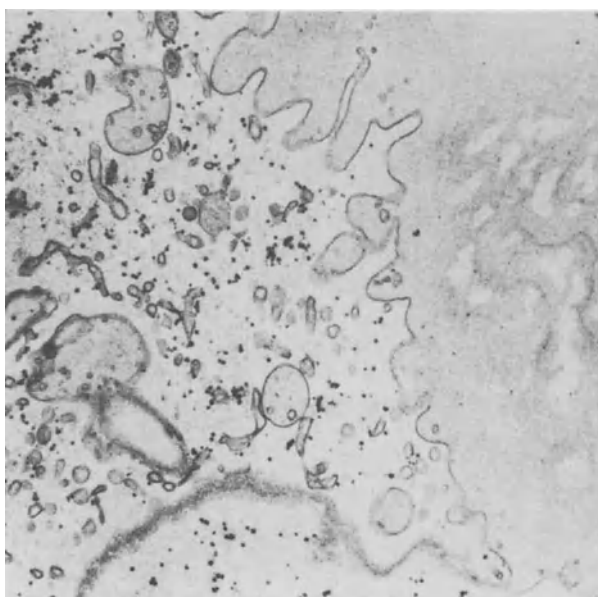
**Fig. 5.** Cell rich granulation tissue and Leucocytes 3 days after Operation ( $\times 32$ )



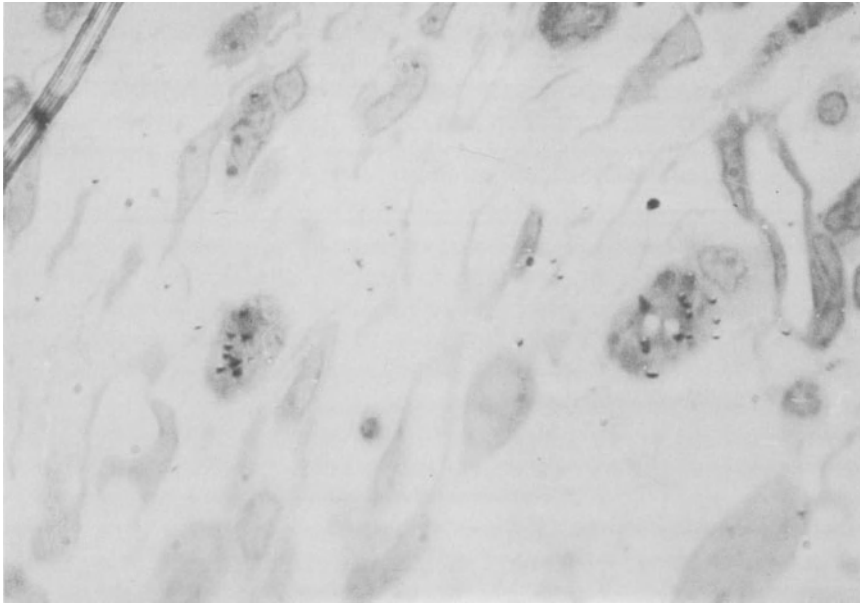
**Fig. 6.** FTAS-resorption by macrophages 3<sup>rd</sup> postoperative days (c 5.700)



**Fig. 7.** Partial enlargement of Fig 6 ( $\times 27,000$ )



**Fig. 8.** Macrophages with stored labeled FTAS-degradation products 14<sup>th</sup> post-operative day ( $\times 320$ )



**Fig. 9.** Macrophages with incorporated degradation products of  $^{125}\text{I}$ -labeled fibrin sealant

radioactively labeled fibrin was found in macrophages (Fig. 9). There was decreasing infiltration of round cells.

### ***Discussion***

Urokinase plasminogen-induced in vitro lysis of  $^{125}\text{I}$ -labeled fibrin sealant shows an excellent correlation of both measuring parameters after measuring protein content and released radioactivity. This seems to prove that in vitro  $^{125}\text{I}$  is not balanced out and washed off by protein molecules. It has to be presumed that measurements of  $^{125}\text{I}$  excretion in 24-h urine in vivo are directly proportional to clot degradation.

In vitro the resistance of FS to urokinase plasminogen-induced lysis may be increased most efficiently and for as long as is wanted by the addition of aprotinin [6,11]. Measurement of  $^{125}\text{I}$  activity released in series A and B supports these findings. As expected, the in vivo experiment showed that FTAS with aprotinin (1500 KIU/ml clot) is more resistant to fibrinolysis than FTAS without aprotinin. Increasing the aprotinin concentration to 5000 KIU/ml clot does not cause a delay in the  $^{125}\text{I}$  elimination maximum nor any prolongation of the biological half-life. This seems to prove that aprotinin (1500 KIU/ml clot) is sufficient for stopping local fibrinolytic activity, and that the physiological degradation of FTAS by phagocytosis cannot be influenced by aprotinin.

$^{125}\text{I}$  is mostly excreted in the urine after absorption of labeled iodine into the thyroid gland has been prevented by prior oral administration of an overdose of stable iodine. Analogous to the in vivo examinations by Alkjaersig [1] and Dudock



[4, 5] the determination of  $^{125}\text{I}$  elimination in urine provides information about the degradation of labeled fibrin clots.

After subcutaneous injection,  $^{125}\text{I}$  sodium thiosulfate was eliminated in the urine maximally on the 2nd postoperative day ( $50.5\% \pm 8.4\%$  of total elimination per 10 days) in a single peak, reflecting the elimination pattern of free  $^{125}\text{I}$  sodium thiosulfate. By contrast, after subcutaneous injection of  $^{125}\text{I}$ -FTAS (Group G) and also after application of  $^{125}\text{I}$ -FTAS in a collagen fleece directly to the renal parenchyma (group H) there were two peaks of  $^{125}\text{I}$  excretion, one on the 2nd and one on the 5th postoperative day. The first peak after 2 days corresponded with the maximal excretion of unbound iodine in FTAS, which consisted of about 15% of the total applied radioactivity. (The TCA precipitable radioactivity of labeled charges of FTAS amounted to an average of 85%.) The operation itself may have delayed the maximum excretion of free, non-protein-bound iodine to the 2nd postoperative day.

The second peak of  $^{125}\text{I}$  excretion between the 3rd and 5th postoperative days in animals of groups G and H coincided with the resorption of the fibrin clot by macrophages (group I) (Fig. 5) and may thus be derived from small iodinated fibrin fragments or from iodine freed in the process of clot organization. These data suggest that the fibrin clot was not dissolved until the 3rd day and could therefore provide hemostasis during this critical time. The protracted secretion of radioactivity after the 5th postoperative day in animals of group H may be caused by slow release of fibrinolytic fragments from macrophages (Fig. 6). We excluded the possibility that the collagen fleece interfered with the resorption of FTAS by finding that urinary iodine excretion was identical in groups G and H.

Wound healing after clot formation is initiated by emigration of granulocytes, macrophages and by capillary sprouting. (The Importance of Fibrin in Wound Repair, see G. Schlag et al.). Bösch [2] claimed that FTAS on a porous carrier accelerated wound healing in bone when compared with controls in which FTAS had not been used. Since proper controls for our kidney resections could not be obtained – because the untreated kidney wound would cause recurrent severe hemorrhage [3] and because mechanical damage of the kidney tissue may also cause conditions different from those caused by surgical treatment – no conclusions concerning the speed of wound healing in our experimental system could be drawn. In addition cyanoacrylate tissue adhesive cannot be used as a control because of its cytotoxic activity. The results of wound healing in rats after partial kidney resection and application of FTAS are similar to studies of wound healing in the rabbit's ear with physiological fibrin concentrations [7]. The use of homologous fibrinogen cryoprecipitate excluded any possible influence of foreign protein on hemostasis. Eosinophilic infiltration as a sign of allergic reaction [10] was not observed.

The wedge-shaped ischemic necroses (3/32) were due to the division at operation of a functional end-artery.

Comparing the results of the in vivo experiments with the data on the physiological wound healing process contained in the chapter "The Importance of Fibrin in Wound Repair" by G. Schlag et al., we find absolute agreement between the physiological process and the application of Tissucol as regards the time of wound healing, the inflammatory phase, and fibroplasia. The highly concentrated fibrin clot with addition of proteinase inhibitors in no way impedes the influx of polymorphonuclear granulocytes and macrophages and thus cellular fibrin degradation. Connec-

tive tissue proliferation and formation of granulation tissue are not influenced either. The excessive increase of proteinase inhibitor concentrations in the clot prevents the urokinase plasminogen-induced lysis of the fibrin clot in the in vitro test, although only a short-term delay in cellular degradation by proteinase inhibitors up to a maximum concentration of 1500 KIU aprotinin is possible. Taking into consideration that even short-term prolongation of fibrin stability induces increased influx of macrophages and thus fibroblasts and collagen fibers, it should be a clinical consequence of this examination to vary the addition of fibrinolysis inhibitors according to the clinical field of application of the fibrin sealant.

If atraumatic tissue synthesis has priority, such as in microvascular anastomoses and nerve anastomoses, no aprotinin should be added, thus avoiding unnecessary connective tissue proliferation, collagen fiber formation, and shrinking cicatrization. Sealing of parenchymatous organs such as the kidney, liver, and spleen certainly requires safe long-term hemostasis, justifying the application of aprotinin (1500 KIU/ml clot) in the fibrin clot.

## References

1. Alkjaersing N, Fletscher AP, Sherry S (1959) The mechanism of clot dissolution by plasmin. *Journal of Clinical Investigation* 38, 1068
2. Bösch P, Braun F, Eschberger J, Kovac W, Spängler HP (1977) The action of high-concentrated fibrin on one healing. *Archiv für Orthopädie und Unfallchirurgie* 89, 259
3. Braun F, Henning K, Holle J, Kovac W, Rauchenwald K, Spängler HP, Urlesberger H (1977) A biological adhesive system (Fibrin) in partial kidney resection. *Zentralblatt für Chirurgie* 102, 1235
4. Dudock de Wit C, Krijnen HW, den Ottolander GJH (1962) The measurement of fibrinolytic activity with I<sup>131</sup>-labeled clots I. The methods. *Thrombosis and Haemostasis (Stuttgart)* 8, 315
5. Dudock de Wit C, Krijnen HW, den Ottolander GJH (1972) The measurement of fibrinolytic activity with <sup>131</sup>I-labeled clots II. Application. *Thrombosis and Haemostasis (Stuttgart)* 8, 322
6. Guttman J (1978) Untersuchungen eines Fibrinklebers für die Anwendung in der Chirurgie peripherer Nerven. Diplomarbeit, Inst f Botanik, Techn Mikroskopie und Organ Rohstofflehre. Techn Univ Wien
7. Jennings MA, Florey HW (1970) Healing. In: *General pathology*. Florey L (ed.), Chapter 17, p. 480. Oxford: Lloyd-Luces
8. Kay AB, Pepper DS, Ewart MR (1973) Generation of chemotactic activity for leukocytes by the action of thrombin on human fibrinogen. *Nature* 243:56–57
9. Maunsbach AB (1966) The influence of different fixatives and fixation methods on the ultrastructure of rat kidney proximal tubule cells. I. Comparison of different perfusion fixation methods and of gluteraldehyde, formaldehyde and osmium tetroxide fixatives. *Journal of Ultrastructure Research* 15, 242
10. Pflüger H, Lunglmayr G, Breitenecker G (1976) Anastomosis of the vas deferense employing concentrated fibrinogen: a experimental study in rabbits. *Wiener klinische Wochenschrift* 88, 24, 800
11. Redl H, Schlag G, Dinges H, Kuderna H, Seelich T (1982) Background and methods of "fibrin sealing". In: *Biomaterials* (Winter D, Gibbons DF, Plenck H – eds.), John Wiley and Sons, Ltd. Chichester, 669–676
12. Spängler HP (1978) Tissue adhesion and local hemostasis using fibrinogen, thrombin and clotting factor XIII. (Experimental investigation – Clinical experience) *Wiener klinische Wochenschrift* 88, Suppl 49

# Preliminary Results of a Randomized Controlled Study on the Risk of Hepatitis Transmission of a Two-Component Fibrin Sealant (Tissucol/Tisseel)

G. EDER, M. NEUMANN, R. CERWENKA, and K. BAUMGARTEN

*Key words:* two-component fibrin sealant, hepatitis, ALT, gamma-GT, cerclage, conization

## **Abstract**

A hundred patients who were to undergo cerclage or conization were entered into the study, being assigned to either group A or B on a random basis, irrespective of the type of surgery planned. Group A received conventional surgery plus two-component fibrin sealant, group B received conventional surgery alone.

The objectives of the study were to demonstrate the efficacy of fibrin sealant as a sealing adjunct in cerclage and as an aid to wound healing in conization. A further objective was to evaluate the risk of hepatitis B and hepatitis non-A/non-B transmission through fibrin sealant. Efficacy results are published elsewhere; here data are presented only on the risk of viral hepatitis transmission.

Of the 100 patients who had entered the study, 69 had a sufficient number of blood samples taken to qualify for evaluation of the hepatitis risk (group A: n = 31; group B: n = 38). None of the patients in either group contracted hepatitis B or non-A/non-B.

## **Introduction**

Tisseel or Tissucol is a biological two-component fibrin sealant which is used to achieve hemostasis, to seal leakages, to glue tissue, or to support sutures. Tisseel has been found also to enhance wound healing [1]. The freeze-dried product is manufactured from pooled plasma of selected donors. Donors of this plasma are tested at every donation for HBs antigenemia using radioimmunoassay. To reduce the risk of nonA/non-B hepatitis transmission [2, 3, 4], only plasma of alanine aminotransferase (ALT) levels below 25 U/liter (reaction temperature 25°C, optimized method; [5] are used for manufacturing fibrin sealant. Thus far, two prospective, nonrandomized studies have been published investigating the risk of hepatitis transmission associated with the use of fibrin sealant. One such study was conducted in general surgery [6], the other in ENT surgery [7]. In neither of the two studies has a case of hepatitis B been seen that might have been attributable to the use of fibrin sealant. In a substudy to the ENT study, two groups of ten patients each were also tested for transaminase at biweekly intervals for a total period of 8 months. In none of these patients could an increase in ALT beyond 50 U/liter be seen.

The study which is described below was a prospective, randomized, controlled study investigating the efficacy of fibrin sealant as an adjunct to conventional surgical techniques employed for cerclage and conization in obstetrics and gynecology, respectively. In its context patients were monitored for potential virus hepatitis associated with its use.

## ***Material and Methods***

### *Patient Group Assignment Procedure*

Patients were assigned to group A or B by computer random numbers, irrespective of whether they were to undergo cerclage or conization. Patients in group A received two-component fibrin sealant in addition to conventional surgical methods; patients in group B served as a control and received conventional surgical treatment only. Cerclage was performed around the 16th week of pregnancy.

When patients were entered, they received envelopes bearing consecutive numbers which assigned them to either group A or B. This made it impossible for the surgeon to give preference to one of the two methods (conventional surgery alone or conventional surgery plus fibrin sealant). Each patient consented to entering the study in writing.

### *Dosage*

All patients in group A were treated with 1 ml of fibrin sealant, which corresponds to approx. 100 mg fibrinogen. One lot of product was used.

### *Laboratory Tests for Viral Hepatitis*

Blood samples were taken immediately before surgery, on the 3rd, 7th, and 14th days postsurgery, and 4, 6, 8, 10, 12 and 24 weeks postsurgery. Shorter intervals, it was felt, would have led to poor patient compliance. From each sample of whole blood, serum was obtained by routine hospital methods. Two milliliters of each serum sample was deep-frozen to provide documentation samples and the rest was tested for ALT,  $\gamma$ -GT, HBsAg, and HBsAb. If a sample proved positive for HBsAg or HBsAb, further tests were done to clarify the patient status, including tests for HBcAb, HBeAg, and HBeAb.

ALT was determined using commercially available reagent kits (Boehringer Mannheim; GPT optimized) at a reaction temperature of 25°C (recommendation of the German Society for Clinical Chemistry) [5]. For internal quality control three commercially available control sera were used (Monitrol I and II, Merz and Dade; and Precinorm U, Boehringer Mannheim) along with an in-house serum. The controls were tested at the beginning and end of each test series. Kinetics were measured using a Beckman spectral photometer (Model 25) and printer. Samples were measured manually and extinctions were printed at 60s. intervals. Extinction

differences per minute ( $\Delta$  U/min) were converted into U/liter using an extinction coefficient of 1756. Measuring time: 3 min; wavelength: Hg 365 nm. The manufacturer defines the normal range for women to be  $\leq 17$  U/liter [8, 9].

$\gamma$ -GT was determined using commercially available kits by Boehringer Mannheim (Monotest Gamma-GT new) [10]. Reaction temperature: 25°C; measuring time: 3 min; print out of extinctions every 60 s.; wavelength: Hg 405 nm. Extinction differences ( $\Delta$  U/min) were converted into U/liter using an extinction coefficient of 1158. The manufacturer defines the normal range for women as between 4 and 18 U/liter [11]. The internal quality control of  $\gamma$ -GT was performed in analogy to ALT determination.

HBsAg and HBsAb were determined using RIA-QUICK (Immuno AG, Vienna), AUSRIA, and AUSAB (Abbott). Determination of HBcAb, HBeAg and HBeAb was performed using CORZYME and HBe-EIA (ELISA Method, Abbott). Four in-house quality control sera which were calibrated against international standards were used to determine HBsAg and HBsAb. For HBsAg determination the internal quality control sera were calibrated against the HBs Reference Antigen (subtypes *ad* and *ay*) of the Paul-Ehrlich-Institute, Frankfurt/Main (concentration 50 000 U/ml), and the British Reference Preparation of Hepatitis B Surface Antigen (1st British Reference Preparation established 1982 – concentration 100 Units by definition) [12]. The limit of detection for HBsAg was also tested using the standard of the Paul-Ehrlich-Institute and was found to be 0.5 ng of HBsAg/ml. For quality control of HBsAb determination the HBV-Referenzserum (IgG) of the Paul-Ehrlich-Institute Frankfurt/Main was used in a concentration of 25 IU/vial and the WHO Anti-Hepatitis B Immunoglobulin Standard, 1st Reference Preparation 1977, lot 26.1.77, in a concentration of 50 IU anti-hepatitis B immune globulin [13, 16]. HBsAg-positive results were confirmed using the inhibition test in the radioimmunoassay. HBsAb-positive findings having a concentration of  $\leq 10$  mU/ml were considered negative.

## Results

Altogether 100 patients (group A,  $n = 50$ ; group B,  $n = 50$ ) were recruited into the study; 72 underwent cerclage, 28 conization (Table 1).

An evaluation of the efficacy of fibrin sealant in the treatment of cerclage and conization has been published elsewhere. In the following only the hepatitis risk associated with fibrin sealant is discussed. To evaluate this risk, only patients were

**Table 1.** Patient sample and group assignment

Group	Treatment	<i>n</i>
A (with Fibrin Sealant)	Cerclage	37
A (with Fibrin Sealant)	Conization	13
B (without Fibrin Sealant)	Cerclage	35
B (without Fibrin Sealant)	Conization	15
	Total	100

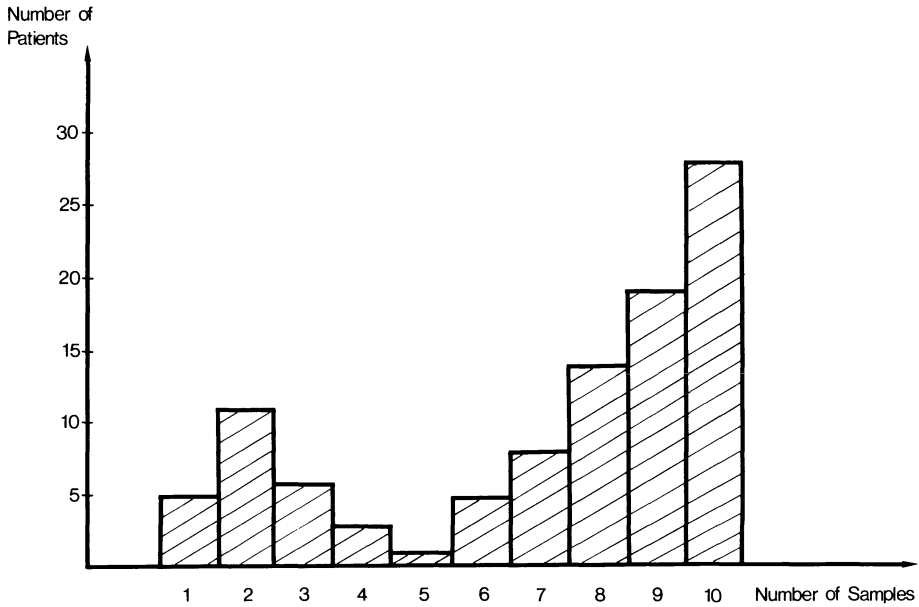


Fig. 1. Frequency distribution of patients and blood samples

used from whom at least seven consecutive blood samples (over a period of at least 10 weeks postsurgery) were available. Of the 100 patients in the study only 69 presented for blood sampling seven times or more (Fig. 1). Table 2 gives the proportion of patients who had at least seven blood samples taken and qualified for evaluation of the hepatitis risk and those who did not. As can be seen, 31 patients (23 cerclage and 8 conization) qualified in group A and 38 patients (29 cerclage and 9 conization) in group B. The percentage of patients undergoing conization in groups A and B was about the same (62% and 60%, resp.). In group B the percentage of patients undergoing cerclage (83%) was higher than in group A (62%).

Table 2. Proportions of patients qualifying and not qualifying for the evaluation of hepatitis transmission

	Nonevaluable patients	Evaluable patients	Sum (100%)
A/cerclage	14 (38%)	23 (62%)	37
A/conization	5 (38%)	8 (62%)	13
B/cerclage	6 (17%)	29 (83%)	35
B/conization	6 (40%)	9 (60%)	15
Total	31	69	100

*Hepatitis B Markers*

From among the 69 patients who had at least seven consecutive blood samples taken, one had to be excluded from evaluation because of receiving hepatitis B vaccination in the 4th, 8th and 12th week post fibrin sealant application.

Of the remaining 68 patients, two tested positive for HBsAb of all blood samples taken, including the preoperative one. These patients must be considered immune to hepatitis B. In three more patients HBsAb was detected on the 2nd and 7th postoperative days in concentrations below 15 mU/ml. Two of these three patients tested negative for HBsAb on all other blood samples. In one patient in group B who underwent cerclage, HBsAb findings were positive, in a concentration of as low as 13 mU/ml 6 months postsurgery. Two of the patients tested positive for HBsAg on all samples, including the preoperative sample.

*Hepatitis Non-A/Non-B Markers*

By definition, non-A/non-B hepatitis can only be suspected if ALT is increased postoperatively to 2.5 times the upper limit of normal. In all, 12 ALT increases (ALT > 20 U/liter) were detected, eight in group A and four in group B. Two patients (both in group B) only had slightly increased values initially (in one case 39 U/liter preoperatively, followed by normal findings on all postoperative samples; in another case a pathological 49 U/liter on the preoperative sample, which normalized in the course of the subsequent 2 weeks). Two more patients in group B had slightly increased ALT values without hepatitis B markers 6 months postoperatively (41 and 46 U/liter). One patient in each group had increased ALT values in postoperative weeks 6 and 8 (46 and 40 U/liter, resp.) without hepatitis B markers. None of the patients had clinical symptoms of non-A/non-B hepatitis.

In addition to ALT,  $\gamma$ -GT was monitored as an indicator of the possible presence of non-A/non-B hepatitis. Nine increased  $\gamma$ -GT values were found in all (six in group A, three in group B). The increased  $\gamma$ -GT results were often borderline. One patient in each group had preoperatively increased  $\gamma$ -GT (114 and 41 U/liter, resp.) which returned to normal in the course of the observation period in one patient and dropped to half the initial value in the other. One more patient in group A had a one-time increase in  $\gamma$ -GT of 46 U/liter 10 weeks postoperatively.

**Discussion**

The main ingredient of two-component fibrin sealant is fibrinogen, which is present in a concentration ranging from 70 to 110 mg/ml. Products made from human plasma are known to have the potential of transmitting viral hepatitis, unless special donor screening methods are used and/or products are subjected to a virus inactivation procedure. To exclude hepatitis B, donations have been tested for HBsAg before such plasma is used for processing into plasma derivatives ever since third generation test methods became available (radioimmunoassay and/or ELISA). This measure dramatically reduced hepatitis B transmission. Nevertheless, a high percen-

tage (up to 98%) of hemophiliacs have been shown to have hepatitis B markers [14]. In addition, chimpanzee trials have shown that infectivity of some plasmas persists despite negative HBsAg findings in the radioimmunoassay, rendering hepatitis B transmission possible [15].

The difference between the infection titer and HBsAg titer in the radioimmunoassay may be as large as two or three orders of magnitude. This means that plasmas testing negative for HBsAg can still transmit hepatitis B.

Probably, there is a relation between dosage and infectivity. As Tabor [16] has demonstrated, hepatitis B virus infectivity which might still be present in such plasmas or plasma derivatives may be neutralized by hepatitis B immunoglobulin. Therefore, addition of anti-HBs either during or after the manufacture of such products is a practical approach to prevent hepatitis B [17]. A similar immunologic neutralization of non-A/non-B hepatitis agent is not possible because neither the agent nor the protective antibody has been identified so far.

To reduce the risk of non-A/non-B hepatitis transmission, the manufacturer of fibrin sealant tests all donations of plasma for ALT levels. As early as 4 years ago serum alanine aminotransferase in donors could be shown to have a correlation with the risk of non-A/non-B hepatitis transmission [2, 3, 4]. However, experience has shown that rigorous quality control criteria – every donation with ALT levels  $\geq 25$  U/liter (25°C reaction temperature) is discarded and excluded from processing – reduce non-A/non-B hepatitis transmission, but do not eliminate it completely. The mechanism involved in the transmission of non-A/non-B hepatitis by fibrinogen or fibrin sealant was investigated in 1980 [18]. At that time, one lot of fibrinogen triggered non-A/non-B hepatitis in two patients and one patient developed chronically persisting hepatitis 2 years after the onset of the acute phase of the disease. The same lot of fibrinogen was injected intravenously into a chimpanzee in a concentration of 200 mg and produced typical non-A/non-B hepatitis with ultrastructural changes of the hepatocytes [19]. The chimpanzee developed an ALT level of 55 Karmen U/ml (five times the baseline 11 weeks after the intravenous administration of that fibrinogen lot). Two milliliters of pooled serum from samples drawn from that chimpanzee in weeks 4–10 postinoculation were given to another chimpanzee by the intravenous route. A typical non-A/non-B hepatitis developed in that chimpanzee 8 weeks postinoculation with that serum pool, manifesting itself in ALT increases of 4–5 times the baseline. In another study [20] a young chimpanzee was inoculated with  $\sim 100$  mg of fibrinogen intravenously. The chimpanzee developed an ALT increase to 227 U/liter after a 16-week incubation period, with light microscopic and ultrastructural changes typical of non-A/non-B hepatitis. The two studies have shown that concentrations ranging from 100 to 200 mg may trigger non-A/non-B hepatitis if given intravenously. It must be borne in mind, however, that fibrinogen is not given intravenously when fibrin sealant is applied, but that clottable protein is transferred into a viscid solution which solidifies rapidly into a rubberlike mass after the addition of aprotinin, thrombin, and calcium chloride. The course of this solidification bears analogy with the physiological process of coagulation. For that reason, it is not likely that fibrinogen enters the circulation. It was the aim of this study to show that fibrinogen given in concentrations which produce non-A/non-B hepatitis if given intravenously, do not transmit non-A/non-B hepatitis if applied in the routine product combination.



### *Evaluation of the Risk of Hepatitis B Transmission*

A prospective study on the viral transmission of hepatitis B carried out from 1979 to 1981 in the same department has shown 23 (or 0.52%) of 4400 pregnant women who were examined consecutively for the presence of hepatitis B markers to be antigen carriers [21]. The prevalence of HBsAg-positive pregnant women is determined by the ethnic composition of a patient population, particularly in countries with a low incidence of HBsAg (22). Sixty-five percent of the antigen carriers identified in the above study came from Southern Europe, Turkey, and the Philippines. The frequency of HBsAg carriers in the 3 year study varied widely. The small patient sample in the fibrin sealant study (68 evaluable patients out of 100) explains the nonrepresentative frequency of HBsAg and HBsAb in this group of women. Since in all samples (including the one taken preoperatively) HBsAb could be identified in only two patients, the percentage of patients considered to be immune to hepatitis B is too low, while the percentage of HBsAg carriers (2 of 68) is too high. One of the HBsAg carriers was a 29-year-old woman with an incompetence of the cervical canal who had a cerclage performed in the 17th week of gestation. HBs antigenemia in patients with normal liver function have been known for well over 4 years. The second case was a 33-year-old woman who had the same problem and the same intervention performed in the 15th week of gestation and gave birth in the 41st week. This patient had no history of HBs antigenemia and none of her relatives had hepatitis B.

The HBsAb which was detected in three patients on the 2nd and 7th postoperative days in concentrations of  $\leq 15$  mU/ml could not be clearly confirmed to have been HBsAb by inhibition. The concentrations were too low. HBcAb could not be detected. This suggests the HBsAb involved to probably have been a nonspecific one [23, 24].

In only one patient (group B) could HBsAb be detected 6 months after cerclage had been performed, in a concentration of 13 mU/ml. Since HBcAb was absent, this could not be considered a seroconversion. The results, therefore, suggest that fibrin sealant does not transmit hepatitis B, since none of the patients underwent hepatitis B infection serologically or clinically within the 6-month observation period.

### *Evaluation of the Risk of Non-A/Non-B Hepatitis Transmission*

Since at the present time no serological test methods are available for the detection of non-A/non-B hepatitis virus(es) [25], the non-A/non-B hepatitis risk can only be assessed based on biochemical tests such as ALT or to a certain extent  $\gamma$ -GT. Some time ago determination of reverse transcriptase was described as an indicator of non-A/non-B hepatitis[26]. The sera available to us cannot be used for this determination, since this requires the plasma or serum samples to be deep-frozen at  $-70^{\circ}\text{C}$  immediately after they are taken, which was not done with the documentation samples collected. If typical clinical and biochemical findings were present, non-A/non-B hepatitis could only be diagnosed by exclusion of other forms of hepatitis, including cytomegaly and Epstein-Barr. Liver biopsies could not be taken for ethical reasons. Therefore, the risk of non-A/non-B hepatitis transmission was assessed

based on elevated ALT and  $\gamma$ -GT levels. Numerous chimpanzee studies have shown that increases in ALT or  $\gamma$ -GT values beyond 2.5 times the baseline or normal upper limit are indicators of non-A/non-B hepatitis.

For well over a decade, statistically significant correlations have been known to exist among age, weight, sex, and enzyme activities. A correlation between weights and ALT levels is more markedly present in men than women. In women, on the other hand, age plays a more important role in younger women (below 30). The normal range of ALT values does not exceed 10 U/liter (0.95 quantile). In women between 30 and 40 years of age, the normal range lies between 5 and 21 U/liter with a median of 9 U/liter [9]. Studies on the normal range of ALT during pregnancy (where higher enzyme activities must in principle be expected) have not been done. The small patient sample did not allow stratification by age, body weight, or weeks of gestation if cerclage was involved. For all of the above reasons, the upper limit of the normal range was defined to be 20 U/liter and the limit beyond which non-A/non-B hepatitis was present was defined to be 50 U/liter (2.5 times the upper limit of normal).  $\gamma$ -GT levels were interpreted analogously. However, little is known about the correlation between  $\gamma$ -GT, age, weight, and sex.

Since  $\gamma$ -GT levels are also expected to be slightly higher during pregnancy, the upper limit of normal was again taken to be 20 U/liter and the limit for non-A/non-B hepatitis 50 U/liter (2.5 times the upper limit of normal). The slightly increased ALT levels of 41 and 46 U/liter 6 months postoperatively in the two patients in group B cannot be correlated with non-A/non-B hepatitis. In one patient ALT levels were increased 5 days before delivery of twins. In the other the increased enzyme activity showed 2.5 months postpartum.

The increased ALT levels of 46 and 40 U/liter in two patients, one in group A, one in group B, are below the defined limit for non-A/non-B hepatitis. The increased  $\gamma$ -GT value of 46 U/liter 10 weeks postoperatively in one patient (group A) cannot be interpreted as indicative of non-A/non-B hepatitis either.

### **Conclusions**

Two-component fibrin sealant does not transmit hepatitis B or non-A/non-B hepatitis. Of 69 patients who qualified for evaluation of viral hepatitis transmission out of 100 entered into a randomized controlled study, none had hepatitis B, seroconversion, or clinically or biochemically manifest non-A/non-B hepatitis.

### **References**

1. Seelich T, Redl H: Theoretische Grundlagen des Fibrinklebers. In: Fibrinogen, Fibrin und Fibrinkleber, ed. Schimpf K FK Schattauer Verlag, Stuttgart – New York, p. 199–208, 1980
2. Alter HJ, Purcell RH, Holland PV, Alling DW, Koziol DE: Donor transaminase and recipient hepatitis. Impact on blood transfusion services. *Jama*, 246:6, p. 630–634, 1981
3. Hornbrook MC, Dodd RY, Jacobs P, Friedman LI, Sherman KE: Reducing the incidence of non-A, non-B post-transfusion hepatitis by testing donor blood for alanine aminotransferase. *N Engl. J Med*, 307:21, 1315–1321, 1982

4. Aach RD, Szmuness W, Mosley JW, Hollinger FB, Kahn RA, Stevens CE, Edwards VM, Werch J: Serum alanine aminotransferase of donors in relation to the risk of non-A, non-B hepatitis in recipients. *N Engl J Med*, 304:17, 989-1035, 1981
5. Empfehlungen der Deutschen Gesellschaft für Klinische Chemie. *Z klin Chem u klin Biochem*, 10, 182-192, 1972
6. Scheele J, Schrickler K TH, Goy D, Lampe I, Panis R: Hepatitisrisiko der Fibrinklebung in der Allgemeinchirurgie. *Med Welt*, 32, 783-788, 1981
7. Panis R, Scheele J: Hepatitisrisiko bei der Fibrinklebung in der HNO-Chirurgie. *Laryng Rhinol Otol*, 60, 367-368, 1981
8. Synopsis der Leberkrankheiten. Editors: H Wallnöfer, E Schmidt und F W Schmidt. G Thieme Verlag, Stuttgart, 1974
9. Thefeld W, Hoffmeister H, Busch EW, Koller PU, Vollmar J: Referenzwerte für die Bestimmungen der Transaminasen GOT und GPT sowie der alkalischen Phosphatase im Serum mit optimierten Standardmethoden. *Dtsch med Wschr*, 99, 343-351, 1974
10. Persijn JP and W van der Slik: A new method for the determination of gamma-glutamyltransferase in serum. *J Clin Chem Clin Biochem*, 14:9, 421-427, 1976
11. Wüst H: Laboruntersuchungen. *Klinische Gastroenterologie in zwei Bänden*. Edited by L. Demling. Volume I: Diagnostische Übersicht, Mundhöhle und Rachen, Speiseröhre, Magen, Darm. 2. Auflage. G Thieme Verlag, Stuttgart - New York, 1984
12. Seagroatt V, Magrath DI, Ferguson M, Anderson SG, Schild GC, and CH Cameron: Preliminary evaluation of a collaborative study of the proposed British standard for hepatitis B surface antigen. *Med Lab Sci*, 38, p. 335-339, 1981
13. Barker LF, Gerety RJ, Lorenz DE, Rastogi SC and EB Seligmann Jr.: Biological standardization in viral hepatitis. In: *Viral hepatitis*. Eds. Vyas GN, Cohe SN, and Schmid R. The Franklin Institute Press, Philadelphia, 1978
14. Seeff LB: Hepatitis in hemophilia: a brief review. In: *Frontiers in liver disease*. Eds. Berk PD, Chalmers TC. Thieme Verlag Stratton Inc., New York, p. 231- 241, 1981
15. Hoofnagle JH: Hepatitis B surface antigen (HBsAg) and antibody (anti-HBs). In: *Virus and the liver. Proceedings of the 28th Falk Symposium on the Occasion of the 5th Int. Congress of Liver Diseases 1979*, p. 27-37. Eds. Bianchi L, Gerok W, Sickinger K, Stalder GA
16. Tabor E, Aronson DL, Gerety RJ: Removal of hepatitis B-virus infectivity from factor IX complex by hepatitis B immunoglobulin. *Lancet II*, p. 68-70, 1980
17. Gerety RJ and Aronson DL: Plasma derivatives and viral hepatitis *Transfusion* 22:5, p. 347-351, 1982
18. Yoshizawa H, Akahane Y, Itoh Y, Iwakiri S, Kitajima K, Morita M, Tanaka A, Nojiri T, Shimizu M, Miyakawa Y, and M Mayumi: Viruslike particles in a plasma fraction (fibrinogen) and in the circulation of apparently healthy blood donors capable of inducing non-A/non-B hepatitis in humans and chimpanzees. *Gastroenterology* 79, 512-520, 1980
19. Jackson D, Tabor E, Gerety RJ: Acute non-A, non-B hepatitis: specific ultrastructural alterations in endoplasmic reticulum of infected hepatocytes. *Lancet I*, p. 1249-1250, 1979
20. Gudat F, Eder G, Eder C, Bianchi L, Stöcklin E, Krey G, Dürmüller U and HP Spichtin: Experimental non-A/non-B hepatitis in chimpanzees: light, electron and immune microscopical observations. *Liver* 3, p. 110-121, 1983
21. Sacher M, Eder G, Baumgarten K and H Thaler: Vertikale Hepatitis B Transmission. Ergebnisse einer prospektiven Studie 1978 bis 1981. *Wr klin Wschr*, 95-13, p. 447-451, 1983
22. Woo D, Cummins M, Davies PA, Harvey DR, Hurley R and AP Waterson: Vertical transmission of hepatitis B surface antigen in carrier mothers in two West London hospitals. *Arch Dis Childhood* 54, p. 670-675, 1979
23. Sherertz RJ, Spindel E and JH Hoofnagle: Antibody to hepatitis B surface antigen may not always indicate immunity to hepatitis B virus infection. *N Engl. J Med*, 309:24, 1983
24. Brotman B and AM Prince: Occurrence of AUSAB test positivity unrelated to prior exposure to hepatitis B virus. *J Inf Dis* 150:5, p. 714-720, 1984
25. Dienstag JL: Non-A, Non-B hepatitis. II. Experimental transmission, putative virus agents and markers, and prevention. *Gastroenterology* 85, p. 743-568, 1983
26. Seto B, Coleman WG jr, Iwarson S and RS Gerety: Detection of reverse transcriptase activity in association with the non-A/non-B hepatitis Agent(s). *Lancet II*, p. 941-943, 1984

## ***II. Thoracic Surgery***

# The Use of Fibrin Sealant (Tissucol/Tisseel) in Thoracic Surgery

D. GRUNENWALD, P.R. VOUHE, and J.Y. NEVEUX

*Key words:* Lung surgery, post-operative course, fibrin sealant

## ***Abstract***

In 60 cases, there was air leakage following lung resection from either the parenchymal sutures or sites stripped of visceral pleura. Application of Tissucol allowed sealing of the leaks and restored acceptable airtightness. Thoracic suction drainage time was thus significantly reduced (mean 48 h). It seems that the intraoperative use of Tissucol decreases the incidence of the usual respiratory complications following partial lung resection and lowers the global hospitalization time in the surgical unit.

## ***Introduction***

Surgery of the lung is frequently complicated by peeling of the lung tissue. Following partial lung resection or decortication, communications between the pulmonary alveolar level and pleural cavity are frequently created. These lesions are responsible for persistent air leakage postoperatively, and prolonged thoracic drainage is often necessary. We would like to show that the use of fibrin sealant improves the postoperative course and reduces the time of thoracic drainage.

## ***Material and Method***

Sixty patients underwent lung surgery complicated by important air leakage. The following operations were performed:

- Seventeen lobectomies
- Nine pulmonary decortications
- Nine surgical treatments of pneumothorax
- Four operations for emphysema
- Fifteen segmentectomies
- Six lung biopsies

The mean age was 40 years with a range from 9 to 82 years (Table 1).

At the end of the procedure all pulmonary areas showing air leakage were coated with Tissucol. Before application of Tissucol, the lung is completely dried and during application the lung is kept quiet and partially inflated. Three minutes later the lung is progressively reventilated using a low inflation pressure.

**Table 1.** Tissucol and lung surgery

	Number	Age
Lobectomy	17	48
Decortication	9	58
Pneumothorax	9	32
Emphysema	4	54
Segmental resection	15	50
Lung biopsy	6	44

Two tubes are left in the thoracic cavity and put on a depression of no more than 25 cm of water. The tubes are removed after complete cessation of leakage of air or liquid.

The time of thoracic drainage and the postoperative hospitalization time observed in this group of patients were compared with those of another similar group in which fibrin sealant was not used.

## Results

Drainage and hospitalization times are given in Table 2.

**Table 2.** Drainage period and postoperative hospitalization time (days)

	Drainage	Hospitalization
Lobectomy	2.5 (1-8)	11.7 (7-25)
Decortication	4.3 (2-7)	14 (8-25)
Pneumothorax	3 (2-8)	11.3 (5-17)
Emphysema	5.3 (1,5)	11.6 (9-18)
Segment resection	2.9 (1-6)	10.1 (7-17)
Lung biopsy	1.2 (1-2)	

Table 3 shows the drainage and postoperative hospitalization times for the group of patients in which fibrin sealant was not used. We did not perform enough other operations in this group to get a valuable comparison.

## Discussion

These results showed a significant difference between the two groups of lobectomies, particularly for the time of thoracic drainage. The effect is less impressive on the time of hospitalization but this time is particularly short in our experience.

As far as decortications are concerned the postoperative course is usually more difficult. The hospitalization time is not reduced by the use of Tissucol, but the time of drainage is markedly reduced.

**Table 3.** Tissucol and lung surgery

	Drainage (days)	Hospitalization (days)
<i>Lobectomy</i>		
With Tissucol	2.5 (1- 8)	11.7 ( 7-25)
Without Tissucol	5.2 (1-15)	13.6 ( 7-24)
<i>Decortication</i>		
With Tissucol	4.3 (2- 7)	14 ( 8-25)
Without Tissucol	9 (6-13)	14.7 (12-17)
<i>Pneumothorax</i>		
With Tissucol	3 (2- 8)	11.3 ( 5-17)
Without Tissucol	11.7 (2-17)	22.7 (11-35)

For the surgical treatment of pneumothorax we always perform concomitant resection of the pulmonary blebs, lung biopsy, and pleurectomy. In the present study, operations in which air leakage was minimal were excluded. But when air leakage was notable there was a clear difference between the two groups with or without Tissucol. It is well known that the postoperative course of such patients is very often long and disappointing.

We have no comparable series for emphysema (Table 4). But it is noteworthy that the time of drainage is short (5.3 days) as is the in-hospital time. The early removal of the tubes reduces the risk of pulmonary complications, which is quite important in these patients with pulmonary insufficiency. Segmentectomies were always complicated by major air leakage and were performed in patients in whom a more extensive resection was not allowed by a reduced pulmonary function. Here again the short time of drainage (2.9 days) may reduce the rate of postoperative complications.

**Table 4.** Tissucol and lung surgery

	Drainage (days)	Hospitalization (days)
Emphysema	5.3 (1-5)	11.6 (9-18)
Segmental resection	2.9 (1-6)	10.1 (7-17)
Lung biopsy	1.2 (1-2)	

Lung biopsies were performed for the diagnosis of severe lung affection. In such cases the suturing of the lung tissue was impossible. The area of biopsy was coated with Tissucol without suture. The drainage time was never greater than 2 days and the surgical biopsy did not worsen the evolution of the pulmonary disease.

The perioperative use of Tissucol following pulmonary operations complicated by air leakage can reduce significantly the time of thoracic drainage. Consequently the complications due to drainage such as pain, retained tracheobronchial secretions and infection are reduced and the total time in hospital can be significantly decreased.

# The Value of Fibrin Sealant (Tissucol/Tisseel) in Surgery of the Thoracic Canal

D.GRUNENWALD, P.R.VOUHE, and J.Y. NEVEUX

*Key words:* Chylothorax, thoracic duct, fibrin sealant

## ***Abstract***

Six patients underwent operations on the thoracic duct. The results of this surgery are usually disappointing, due to the fragility of the wall of the duct. Fragility is even increased by the usual dilatation of the duct seen in cases needing operation. The adjunction of Tissucol led to an immediate and permanent efficacy of the surgical intervention in all cases.

## ***Introduction***

The surgical interruption of the thoracic duct at the diaphragmatic level is indicated in patients with persistent and profuse chylothorax or cervical lymphorrhea. The etiology of the chylothorax may be traumatic (postsurgery or post-traumatic) or secondary to superior and posterior mediastinal compression. The results of direct surgery on the thoracic duct are often disappointing. The wall of the duct is very thin and flimsy. This is particularly true in the presence of dilatation of the duct due to downstream extrinsic compression (tumor, fibrosis) or stenosis. Persistent lymph leakage is often observed following ligation or suture of this thin-walled duct. Usually, this leakage dries up in a few days. But, sometimes, incomplete direct surgery on the duct, for cervical lymphorrhea for example, may change the cervical leakage into chylothorax.

## ***Material and Method, Results***

Fibrin sealant was used in five patients with persistent lymphatic leakage necessitating surgical management. The data are as follows:

1. Age 53 years. Right chylothorax following an aortography (2500 ml/day)
2. Age 22 years. Multiple injuries. Right chylothorax by rupture of the thoracic duct (3000 ml/day)
3. Age 51 years. Cervical profuse lymphatic leak following an operation for cancer of the larynx
4. Age 3 months. Postoperative left chylothorax by surgical injury in the course of a palliative anastomosis for congenital heart disease (100 ml/day)



5. Age 10 years. Bilateral chylothorax by mediastinal fibrosis following complete treatment of a congenital disease

There were three unilateral post-traumatic chylothoraces, one cervical lymphorrhea and one bilateral chylothorax secondary to lymphatic mediastinal compression. All the patients had a poor nutritional status.

At operation, the thoracic duct was ligated or sutured at the level of leakage or at the level of its diaphragmatic hiatus. The operative area was then coated with Tissucol. Surgical methods were:

1. Posterolateral thoracotomy, on the side of the more important effusion
2. Ligature or suture of the thoracic duct
3. Coating with Tissucol of the suture and injecting around the duct in the diaphragmatic orifice

In all cases, immediate and definitive cessation of lymphatic leakage was observed:

1. Removal of the drain before 48 h
2. Volume of postoperative drainage less than 200 ml
3. Permanent drying after removal of the tube

In another case of bilateral chylothorax secondary to mediastinal compression, direct surgery on the duct was performed without fibrin sealant coating. A less profuse, but persistent, lymphatic leakage occurred, which finally resolved spontaneously 10 days later.

### ***Conclusion***

The perioperative use of Tissucol during direct surgery on the thoracic duct leads to immediate cessation of the lymphatic leakage and definitive resolution of the pleural effusion.

# The Use of Fibrin Adhesives in Thoracic Surgery

T.M. ORLOWSKI, J. KOŁODZIEJ, and J. DOMAGALA

*Key words:* fibrin adhesives, thoracic surgery, endoscopy

## ***Abstract***

Tissue adhesives are widely used in thoracic surgery. The most frequent indication for using tissue adhesive is the pulmonary decortication procedure. A very large surface without pleura sometimes causes dangerous postoperative complications. This problem is resolved with fibrin glue application.

We present our own attempts at using tissue adhesive in endoscopy. Small bronchial fistulas were closed endoscopically with a satisfactory result. Fibrin glue has turned out to be very effective in tracheal and bronchial surgery. It was used for wrapping the site of anastomosis with parietal pleura. The application of tissue adhesive is strongly indicated in wound dehiscence during the course of mediastinitis after sternotomy. We have applied it with antibiotics. The application of fibrin adhesives not only supports the precise surgical technique but also offers new possibilities to the surgeon.

## ***Introduction***

Tissue adhesives have been used in surgery for many years. The synthetic substances used originally did not meet all the requirements. Only an introduction of fibrin adhesives has made their application more efficient. Of many surgical branches, adhesives have found the widest, though not always highly valued, application in thoracic surgery.


## ***Materials and Methods***

In the Department of Thoracic Surgery, Medical Academy of Wrocław, fibrin adhesives (Tissucol) have been used for 5 years. They have been applied in the following cases:


– sternal closure	15
– Bronchial stump covering	46
– Tracheal anastomosis covering	28
– Covering of lung surface post-decortication	34
– Covering of suture line on the esophagus	11



**Fig. 1.** Fibrinotherm apparatus



**Fig. 2.** Duploject syringe



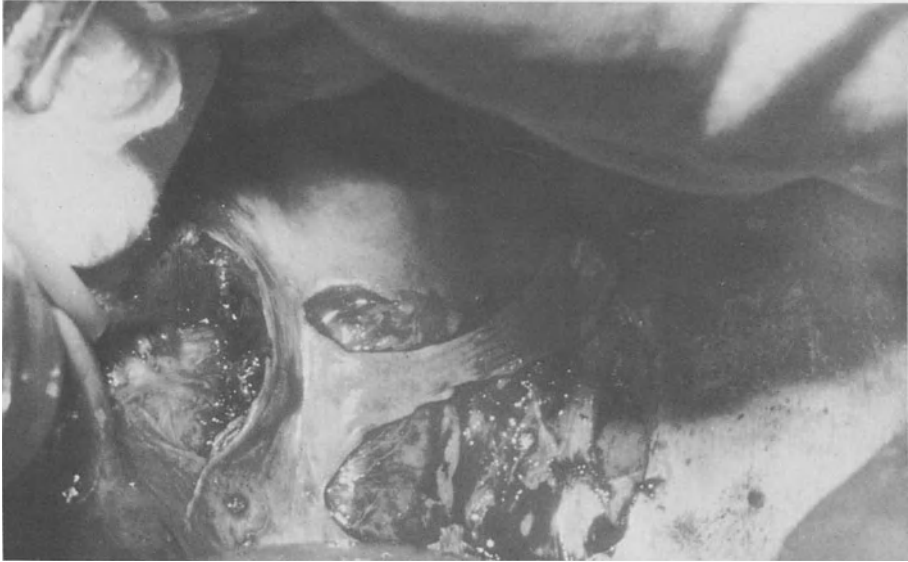**Fig. 3.** Spray apparatus

- Closure of bronchial stump fistula postpneumonectomy 2
- Filling of tuberculous cavity contaminated with aspergilloma 2

It is advisable that in the process of preparation and then application of the adhesives use is made of Immuno equipment. The adhesive consists of human origin fibrinogen which is activated by an optimal mixture of the antifibrinolytic agent aprotinin (3000 kallikrein-inhibitor units/ml), bovine thrombin (500 NIH units/ml) and calcium chloride (40mmol/liter). The components form a firm fibrin clot after contact. The components have to be preheated and mixed together. This can be facilitated by the Fibrinotherm apparatus (Fig. 1). The adhesive in the form of liquid or aerosol is applied to a surface by means of two Duploject syringes (Fig. 2). Dispersion of the adhesive may be accomplished by the Spray apparatus (Fig. 3). The above equipment is easily available and relatively cheap (a Duploject applicator is enclosed with each unit, free of charge).

### *Sternal Closure*

In the first three cases the adhesive mixed with antibiotic was used for a reclosure of the sternum after separation of sutures. In the remaining cases a surface of the sternum was covered with the adhesive without antibiotic. Covering of the sternal surfaces was accomplished after metal stitches had been put and immediately before approximating the wound edges.



**Fig. 4.** Mobilization of the parietal pleura

#### *Bronchial Stump Covering*

After lobectomy and pneumonectomy, in the region of the bronchial stump, the parietal pleura was mobilized (Fig. 4). On the stump with the adhesive applied, the mobilized pleura was placed. The whole was held up with a swab until the adhesive was dry.

#### *Tracheal Anastomosis Covering*

The most serious complication due to resection of the intrathoracic trachea consists in a separation of anastomosis and formation of arteriotracheal fistula. To prevent it the tracheal anastomosis line was covered with the adhesive, and then sternothyroideus muscle or a mobilized pericardium were stuck on its surface. Finally, the elements were placed between the trachea and brachiocephalic trunk.

#### *Covering of the Lung Surface Post Decortication*

In all the post decortication cases the lung surface was covered with the fibrin adhesive in aerosol by means of the Tissomat apparatus. For this purpose the adhesive in combination with antibiotic was used. The covering of the lung surface was performed at the maximal expansion.

### *Covering of the Suture Line on the Esophagus*

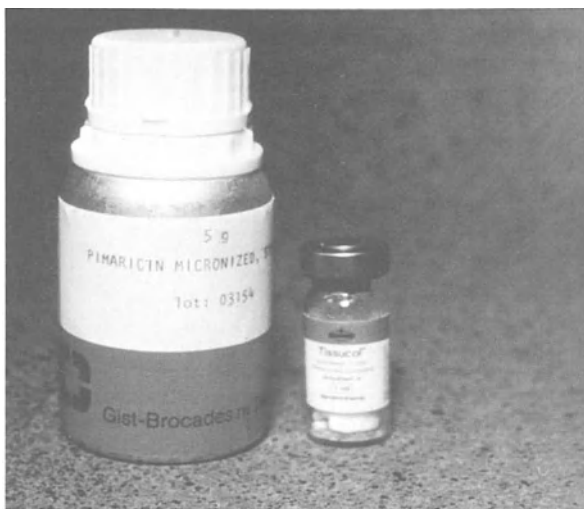
Eleven patients with esophagus perforation were operated on (seven cases of perforation due to swallowing a foreign body, four cases of iatrogenic perforation). In six cases the perforation concerned the medial part of the esophagus and in five its lower part. The time of surgery initiation ranged from 2–72 h. Esophagus lesions were closed with two-layer stitches and then they were treated by the Grillo [3] method using the adhesive instead of sutures.

### *Closure of Bronchial Stump Fistula Postpneumonectomy*

Tissucol was used twice to close the bronchial fistula in postpneumonectomy cases. In the first case the surgery was performed 4 months after pneumonectomy and 1.5 months after a trial of extrapleural closure of fistula by sternotomy. In the second case the fistula was closed 2.5 months after pneumonectomy by means of fibero-scope (Pentax FB 19H). The adhesive was applied using a single-channel polyethylene catheter.

### *Filling of Tuberculous Cavity Contaminated with Aspergilloma*

The adhesive mixed with natamycin (Pimaricin, Gist-Brocades) (Fig. 5) was introduced through a thoracic wall to the tuberculous cavity. Thoracocentesis was done under monitoring.



**Fig. 5.** Pimaricin and Tissucol

### ***Results and Discussion***

This report presents various methods of fibrin adhesive application. Though the group of patients in whom the adhesive has been applied was not large, it gave an idea of many other possibilities of its efficient usage. The adhesives appeared particularly effective in the cases of sternal closure after sternotomy. Their application makes possible substantial reduction of the number of wires inserted into a body structure. In three cases of suture separation application of the adhesives resulted in complete healing. However, the above cases do not provide a basis for general conclusions to be drawn. Obviously, it is not the best and the only method of wound closing in the cases of mediastinitis. On the other hand, when in combination with antibiotic, besides other methods (flow drainage), it increases the possibility of complete recovery.

The percentage of complications due to bronchial fistula after resection of lung tissue is relatively low. However, when such complications occur they are serious in most cases. The question remains of how to prevent bronchial stump insufficiency. Of the few methods known, application of the adhesives evidently lowers the risk of fistula formation. None of 46 cases studied of bronchial stump covering with adhesive, developed a fistula.

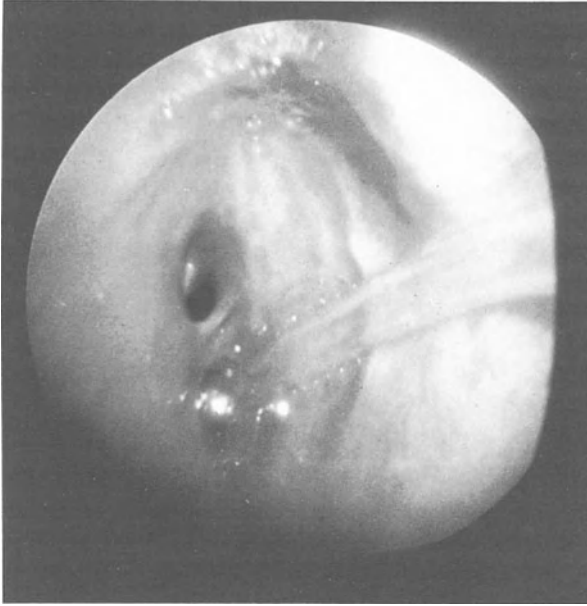It seems that the adhesives are most widely used for covering of the lung surface in an attempt to close the air leak [2, 4]. Of predominant importance are the postdecortication cases. Visceral pleura lesions formed as a result are of considerable size and can be closed only by means of the adhesive. Other merits of the fibrin adhesives are that after drying they form a smooth surface on the lung, imitating the natural pleura. The group of patients in whom the adhesives had been used were retrospectively compared with those who never experienced their application. The results obtained are as follows:

	With adhesive	Without adhesive
No of patients	34	30
Age	42.5	51
Drainage period (days)	4.3±3.0	11.3±5.6

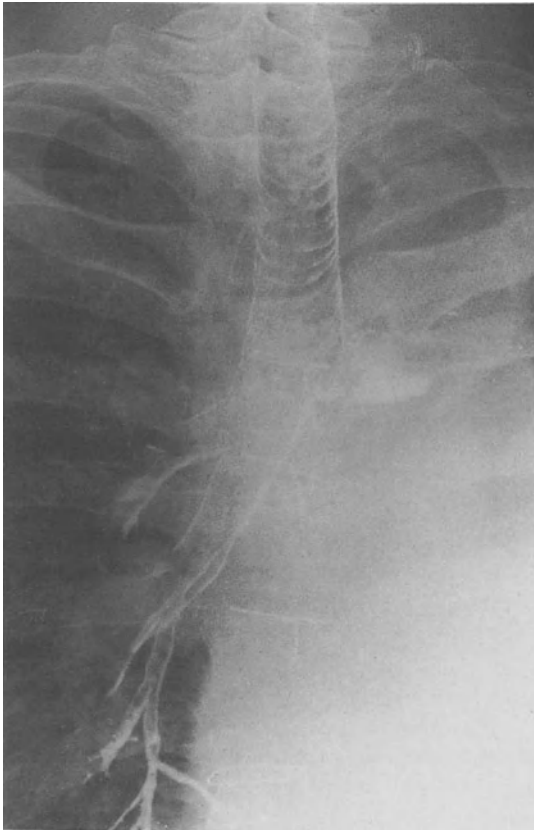The time of air leak in the former group is more than twice as short. This is of considerable significance as far as the time of hospitalization as well as the costs of treatment are concerned.

Still obscure from the therapeutic point of view remain the cases of esophagus perforation [1]. Of the patients treated in our department the postoperative complications were reported in four cases. One patient developed pleural empyema and a small esophagopleural fistula which healed in the course of conservative treatment.

No less problematical is the treatment of long-term bronchial fistulas. Surgical closing is not always possible and safe for a patient. Thus the application of the adhesive seems to be a reasonable alternative. This, however, necessitates using appropriate endoscopic equipment. For this purpose the fiberoscope Pentax FB 19H



**Fig. 6.** Bronchial fistula



**Fig. 7.** Successful closing of a fistula



appeared most effective. Its wide, 2.6 mm canal enables the appropriate applicators to be introduced (Fig. 6). In both of the cases studied the trials to close a fistula ended with success (Fig. 7).

Finally, the adhesive was used as the antimycotic carrier. Operative treatment of patients with a tuberculous cavity contaminated with aspergilloma, with no incidents of hemoptysis, can in some cases be replaced by an intracavitary application of antimycotic with the adhesive as a carrier. In both cases the immediate effect was favourable. The long-term results and evaluation of this method require more time.

In conclusion, the precise surgical technique can hardly be replaced by any other method. It is noteworthy, however, that the application of fibrin adhesives not only supports this technique but offers new possibilities to the surgeon.

### ***References***

1. Finley RJ et al (1980) The management of nonmalignant intrathoracic esophageal perforations. *Ann Thorac Surg* 30:575–583
2. Hartel W (1981) Lungenparenchymabdichtung mit Hilfe von Fibrinkleber nach Lungenresektionen. *Med Welt* 32:67–68
3. Michel L, Grillo HC, Malt R (1981) Esophageal perforation. *Ann Thorac Surg* 33:203–209
4. Türk R et al (1981) Verschluss von Pleura-Lunge-Läsionen mittels Fibrinklebung. *Med Welt* 32:44–46

# Treatment of Complicated Cases in Pediatric Cardiovascular and Thoracic Surgery Using Fibrin Sealant (Tissucol/Tisseel)

I. SMÓLSKA and M.A. KAROLCZAK

*Key words:* Pediatric surgery, fibrin sealant, tracheal fistula, esophageal leak, intraoperative bleeding

## ***Abstract***

Ten patients after cardiovascular and thoracic surgery were treated using two-component fibrin sealant with good effect as the life-saving method. It was possible to reduce the hospitalization period in cases of fistula complications as compared with nonglued defects.

## ***Introduction***

There has always been a great interest in promotion of wound healing and hemostasis especially in surgically complicated cases. The availability of absorbable two-component fibrin sealant has created a new opportunity for many surgeons and their patients. The aim of our report is usefulness of tissue sealing in the field of pediatric surgery. Clinical experience with fibrin glue was gained intraoperatively in four patients in cardiovascular surgery, four patients with complications during esophagus surgery, one patient with tracheal fistula and one with congenital diaphragmatic hernia.

## ***Cardiovascular Surgery***

In the course of total correction of tetralogy of Fallot using extracorporeal circulation we observed increased and prolonged bleeding in a patch implanted into the wall of the right ventricle and rows of sutures. The disturbances of different coagulation factors were noted. The bleeding surfaces were coated with fibrin films (thrombin concentration 500 IU/ml) with a satisfactory result and an uncomplicated postoperative course.

## ***Esophageal Surgery***

In cases of esophageal atresia where the esophageal ends are widely separated, gastric tube interposition was performed after the neonatal period. Even after the most carefully constructed anastomoses, leaks occur leading to various types of

oppressive fistulas. Three patients 8–14 months old with cutaneous esophageal fistulas were treated by administration of Tissucol glue through a small-size catheter (thrombin concentration 100–150 IU/ml). This procedure was sufficient in one patient and the healing period was – compared with others – very short, not requiring further surgery.

After the Heller procedure for achalasia, the hole of the esophagus was resutured and sealed up with a film of Tissucol despite coexisting pyothorax. An uneventful postoperative course with total resolution of all the symptoms was achieved. We have tried to put Tissucol during bronchoscopy into the tracheopleural fistula, which was a complication after surgery or esophageal atresia type III. The treatment was unsuccessful.

### ***Thoracic Surgery***

A 13 1/2 year-old boy was operated on for a diaphragmatic hernia and a large (32×18 cm) intrathoracic spleen. The replacement of the spleen was unworkable due to a small foramen of Bochdalek. The partial splenectomy was performed using Tissucol as a hemostatic agent upon the surface of resection. No bleeding complications were observed.

### ***Conclusion***

According to our 1 year of experience in the use of Tissucol we may say that its introduction into pediatric surgery has brought a solution to previously unsolved problems and has offered us a really safe method in various unsuspected situations. Further improvement of our knowledge about application of various concentrations of sealant is necessary; nevertheless, nowadays we can confirm its usefulness in arresting medium-sized hemorrhages and shortening the time of the operation. It offers greater security to the surgeon and patient during complicated operations even into infected tissues as well.

### ***References***

1. Kalińska D, Kuś H, Zwinogrodzki J (1970) Tworzywa sztuczne w medycynie. Wydawn Nauk Techn. Warszawa
2. Seelich T (1982) Biochemistry and methods of application. *J Head and Neck Pathol* 3:65–69
3. Thetter O (1981) Fibrin adhesive and its application in thoracic surgery. *Thorac Cardiovasc Surgeon* 29:290–292
4. Turk J W, Weidringer R, Hartel W, Blumel G (1983) Closure of lung leaks by fibrin gluing. Experimental investigations and clinical experience *Thorac Cardiovasc Surgeon* 31:185–186

# Application of Fibrin Glue in the Treatment of Lung Cysts

K. H. LEITZ

*Key words:* lung cysts, fibrin glue

## ***Abstract***

A new method of treatment of lung cysts is presented. The cysts are unroofed, covered by fibrin glue, and closed by bovine pericardium, which is sutured patch like to the surrounding lung tissue. No lung resection takes place. To date three patients have been treated successfully by the new method presented.

## ***Introduction***

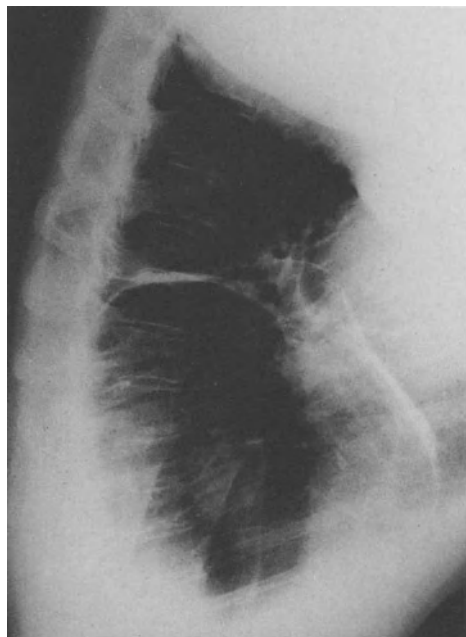
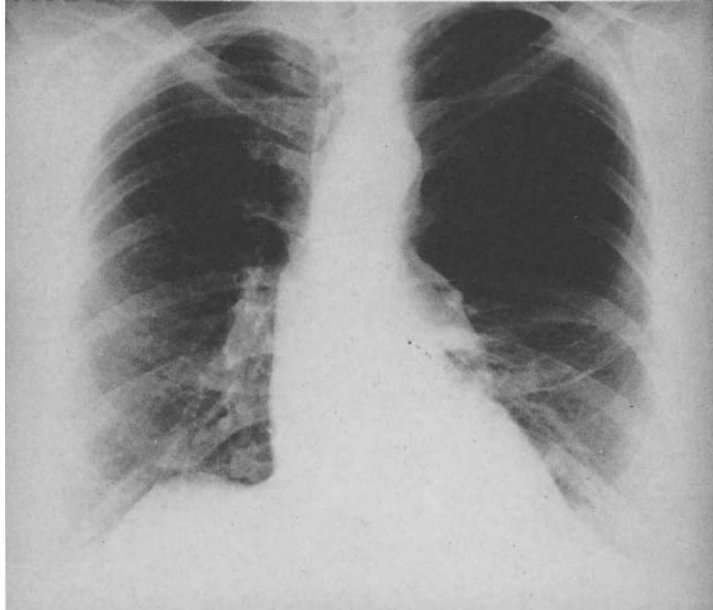
Under the term "lung cyst" there is hidden a variety of clinical and pathologic pictures. The Armed Forces Institute of Pathology has counted 28 synonyms for the term lung cyst; a common nomenclature is expected for the future.

According to Svanberg [1] a cavity surrounded by lung tissue is named a "bullae." The walls of the cavity are built from alveolar tissue, which is covered by visceral pleura. Often such a bulla is drained by a small bronchus. A bleb is filled by air and is always situated in the subpleural space, whereas pulmonary cysts are covered by endothelial cells. Cysts lead to compression of the surrounding lung tissue, sometimes accompanied by a lowering of the diaphragm and by a mediastinal hernia. Cysts are sometimes infected. Some cysts bleed and show the clinical picture of hemoptysis. Finally cysts can burst and are a cause of pneumothoraces. Compression of surrounding lung tissue is a typical characteristic of large cysts called "giant cysts". Patients with such giant cysts can present the clinical picture of pulmonary insufficiency. The indication for surgery exists in patients with giant cysts and severe dyspnea to prevent further pulmonary insufficiency. If the cysts occupy more than one-third of the hemithorax and the residual lung tissue is not changed by chronic infection, the surgical results will be good. Often the disease lasts years. Emergency operation in the final stage of the disease has a high rate of complications. Therefore we recommend surgery in an earlier stage.

The surgical therapy has until now consisted in excision of the cysts or in resection. Especially resection therapy takes out functioning lung tissue; therefore patients are worse from a functional standpoint after surgery.

**Method**

After intubation by a double-channelled tube patients receive thoracotomy in the bed of the 5th rib. After opening the chest the visceral pleura covering the cyst is incised. Air leakages of the bronchial tree are closed by fine suture material.



**Fig. 1.** 64-year-old woman with left-sided large lung cyst, Chest X-ray, anteroposterior and lateral

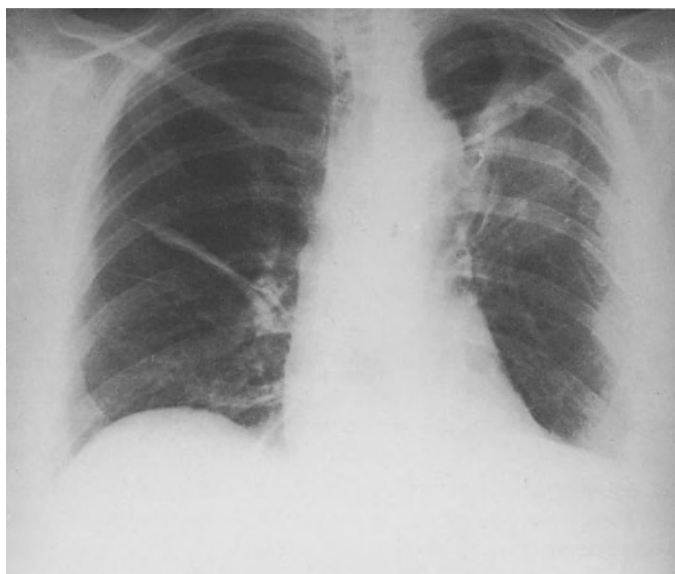Thereafter the anesthesiologist ventilates the non-open chest so that the affected lung collapses. Fibrin glue is spread or sprayed on the open cyst.

Homologous pericardium (supplied by Danimed, Hannover) of corresponding size is put on the cyst like a patch. The rim of the pericardial patch is fixed to the surrounding lung tissue by a running 5/0 Prolene suture. After drying of the fibrin glue the lung is ventilated again. The previously collapsed parts of the lung usually expand nicely. The water test detects any further air leak. A partial pleurectomy for better fixation completes the procedure.

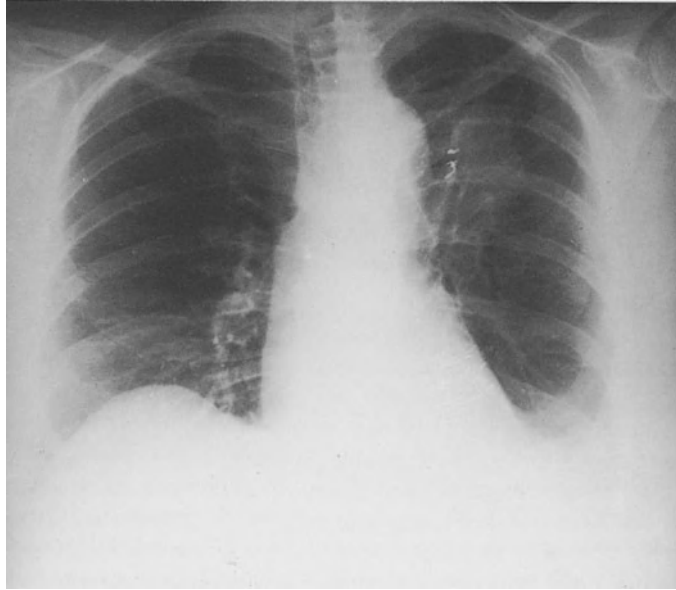
## **Results**

Three patients (52–64 years old) have been operated on by the above-described method, two females and one male. All three survived the operation, and there were no complications. By exclusion of the affected lung from the ventilation, the fibrin glue had enough time for polymerization. The gained strength was strong enough to withstand the expansion of the surrounding lung tissue. Postoperative air leaks did not exist in any patients. The drainage tubes were pulled out on the first postoperative day in all patients. All patients were seen regularly over 2 years, and there were no recurrences.

The course of one patient is presented by way of an example: A 64-year-old woman suffered dyspnea for many years. On chest X-ray a cyst attracted attention which had increased in size during recent months (Fig. 1). The lady was operated on. On postoperative chest X-ray the patch material is observed (Fig. 2). On further control (Fig. 3) it disappeared almost totally. The patient now feels fine and is no longer dyspneic.



**Fig. 2.** Five days after operation, on the left side of the chest the pericardial patch is to be observed. The left lung is fully expanded



**Fig. 3.** Four months after operation the patch is shrunken and the left lung is expanded

*In summary*, the presented method can be recommended, since no resection of lung tissue takes place; consequently the functional state of the lung is preserved. Owing to the fibrin glue, an airtight seal is possible, which facilitates the operation. The operative injury to the patients is minimal.

### ***Reference***

1. Svanberg L (1979) Chirurgische Möglichkeiten bei Emphysem, Lungenfibrose, Embolie und Infarkt. In: Schaudig A, Zenker R (ed) Chirurgie der Gegenwart, Band III, München, Urban und Schwarzberg 1972

# The Application of Fibrin Sealant in Tracheobronchial Surgery

F. ECKERSBERGER, E. MORITZ, and E. WOLNER

*Key words:* Fibrin sealant, tracheobronchial surgery, tracheal resection, sleeve resection, tracheobronchial rupture, sealing of tracheal anastomoses

## ***Abstract***

Since 1976 fibrin sealant has been used in 41 patients for the sealing of sutures in surgery of the tracheobronchial system. Thirty cases were partial resections of the trachea, seven cases were sleeve or wedge resections of the main bronchi, three cases were rows of sutures in traumatic ruptures and one case was a bifurcation resection. By superimposing anastomoses and sutures they were immediately sealed airtight and the puncture channel tightly closed to prevent the penetration of air or mucus. Thus healing of the row of sutures was guaranteed under aseptic conditions. The application of fibrin sealant minimizes the number of stitches in favor of blood circulation; the covering of sutures with pedicle tissue flaps becomes more effective.

## ***Introduction***

The importance of blood supply in surgery of the tracheobronchial system is well known [7]. Arterial blood flow and venous outflow are important factors for the uncomplicated healing of a row of sutures. It is also of utmost importance to avoid infections in the area. It is a prerequisite for the rapid and bland healing of a row of sutures to minimize the number of stitches in favor of stimulated blood circulation and to immediately seal the anastomosis and the puncture channels tight against penetration of air and mucus, to avoid the contact of infectious mucus from the lumen with the anastomosis area.

This may be achieved by using a fibrin sealant. It prevents insufficiency of the anastomosis with its often life-threatening consequences. In 1975 Moritz [3,4] was able to prove in dogs that alloplastic tracheal replacement with fibrin sealant shows better stress resistance compared with anastomoses that have not been sealed. He concludes that sealing sutures in the tracheobronchial system helps decrease or prevent the danger of suture insufficiency. In tracheobronchial surgery one should try to reduce sutures as much as possible and to guarantee an airtight sealing of the anastomosis; of course precise surgical skill and subtle surgical preparation of the structures are a prerequisite. After experimental experience with fibrin sealant in 1975 we started clinical application in 1976. Since then fibrin sealant has been applied as a matter of routine in the sealing and closing of sutures in tracheobronchial surgery.

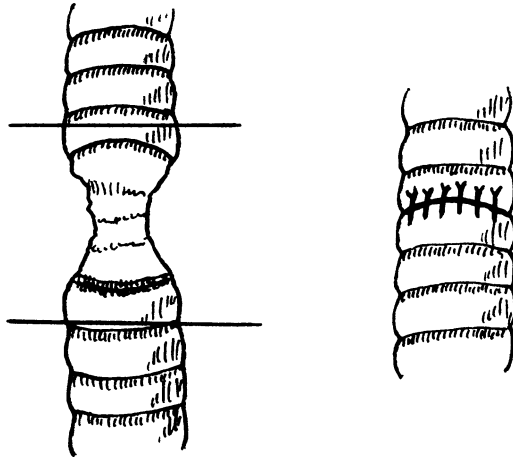


**Material and Method**

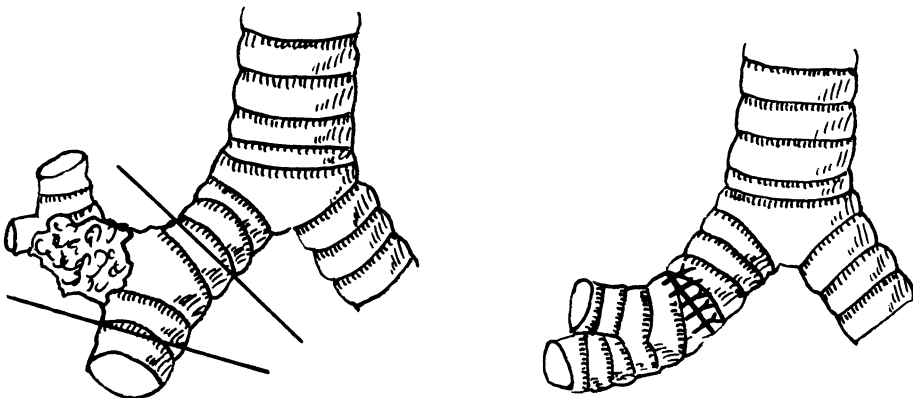
Fibrin sealant was applied in the following operations:

1. Tracheal resections (Fig. 1)
2. Suture in tracheal ruptures (bronchial ruptures)
3. Bronchoplastic operations (Fig. 2)
4. Bifurcation resections

In 30 patients tracheal resection was performed. The primary disease requiring the partial resection of the trachea can be found in Table 1. Because of this primary disease, preceding respiratory treatment of 3 days to 14 weeks had been necessary in 28 patients. The partial resection of the trachea was performed 2 weeks to 16 years after respiratory therapy. In one patient resection was necessary 11 days after tracheal rupture; in the patient with tracheal papilloma the elective operation was performed after routine diagnosis.



**Fig. 1.** Resection of stenosis section of the trachea and end-to-end anastomosis in interrupted suture technique with absorbable suture material. The anastomosis is approximately 1 cm long and covered by a 2- to 3-mm-thick layer of fibrin sealant



**Fig. 2.** Sleeve resection in lobectomy of the right upper lobe with anastomosis of the intermediate bronchus and main bronchus. Sealing technique analogous to that in Fig. 1

**Table 1.** Primary disease of the patients with partial resection of the trachea

Primary disease	Number of patients
Polytrauma	10
Suicide	6
Craniocerebral trauma	3
Tetanus	2
Paraplegia	1
Cerebral hemorrhage	1
Respiratory failure	1
Uremia	1
Laryngeal trauma	1
Tracheal tumor (papilloma)	1
Delirium tremens	1
Serial rib fracture	1
Tracheal rupture	1
Total	30

Fourteen of the patients with tracheal stenosis after respiratory treatment had so-called cuff stenosis, six of them subglottic stenosis; there was one case of stenosis in the area of the top of the tubus and seven cases of extensive stenosis in the area of the tracheostoma. The extension of the lumen stenosis and the length of the resections may be found in Table 2. The trachea had been ruptured in the middle section and the resection had been performed after partial median sternofissure. The tracheal tumor was located in the median thoracal section and required a resection length of 3.5 cm after median sternofissure.

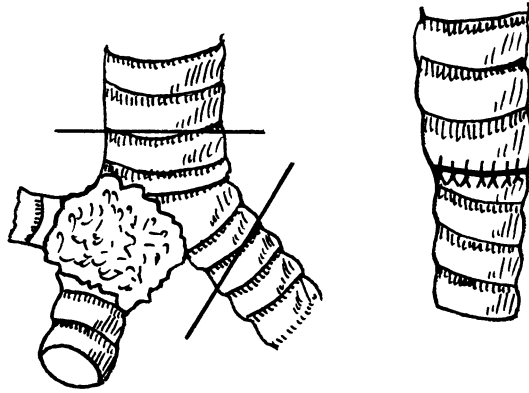
**Table 2.** Diameter of stenosis and length of resection of the trachea ( $n=27$ )

	Range	mean
Diameter of stenosis (mm)	O(Stoma)–7	4.7
Length of resection (mm)	10–55	29

In 20 cases surgical access was made by Kocher's collar incision; in six cases we had to perform median sternofissure, in three cases a collar incision with partial median sternofissure and in one case right thoracotomy. Fibrin sealant was used in all patients to support the sutures.

In three patients fibrin sealant was used to close ruptures of the trachea or the main bronchi. Two cases were ruptures of the cervical trachea; in one case a rupture in the right main bronchus had to be sutured.

In seven patients fibrin sealant was used in bronchoplastic surgery. Lobectomy had to be performed in these five patients because of a malignant growth; in four cases sleeve resection (Fig. 2) was carried out, in two cases wedge resection at the main bronchus. In one patient sleeve resection was necessary because of a carcinoid.



**Fig. 3.** Bifurcation resection in right pneumonectomy. End-to-end anastomosis of the left main bronchus and trachea with absorbable suture material in interrupted suture technique. Sealing technique analogous to that in Fig. 1

Bifurcation resection with pneumonectomy had to be performed in one patient because of a carcinoma on the right side. In this case the left main bronchus was anastomosed directly end to end with the trachea after mobilization and resection of 1.5 cm of the trachea (Fig. 3).

Fibrin sealant was applied according to the technique of Spängler [9] modified for thorax surgery. During the first years we used deepfrozen sealing protein concentrate; for the past several years we have been using Tissucol (Immuno AG, Vienna) lyophilized in combination with Fibrinotherm S, which proved an excellent warming and stirring device for the standardized reconstitution of fibrin sealant. As rapid consolidation of the fibrin sealant is desired in the tracheobronchial area we always used the higher thrombin concentration (thrombin lyophilized, bovine, 500 IU/ml). Application by Duploject (Immuno AG, Vienna) has proved a successful method. After completion of the suture or anastomosis a 2- to 3-mm layer of fibrin sealant was applied on the sutures. It was most important for us that this layer covered the puncture channels of the sutures as well. Within a few minutes a rubber-like mass is formed, covering the sutures as consolidated cover. It always adhered to the adjacent trachea and bronchus edges and completely covered the anastomosis and the sutures. During consolidation of the fibrin sealant the application area should be maintained dry; special attention should be given to the fact that unconsolidated fibrin sealant might be washed away by extravasation of blood from the surrounding tissue. Manipulations and shifting of tissues should be avoided during these few minutes of consolidation of the fibrin sealant, a fact that we always paid special attention to. For the covering and sealing of an end-to-end anastomosis of an adult trachea we needed 4 – 6 ml fibrin sealant; in rows of sutures approximately 1 ml was used per suture length. Even after consolidation of the fibrin sealant, preparations in the anastomosed area should be avoided.

### **Results**

We lost one of the patients with tracheal resection after a 3-cm resection of the stenotic area of the median trachea and subsequent mediastinitis. One patient suffered an arrosion bleeding at the truncus brachiocephalicus, which could be

stopped thanks to immediate surgical intervention [2]. Examinations to analyze the function confirmed and objectified the clinical success of operations in the patients [5]. There was complication-free healing of the tissue union; the radiological and endoscopic control showed a delicate scar completely covered by respiratory epithelium. We lost one patient after dehiscence of the suture. We have to add that this patient had to be treated with oxygen because of the extensive lung contusion. In none of the patients with sleeve resection or wedge resection were complications after surgery. There were no signs of infection or dehiscence. After bifurcation resection with pneumonectomy pneumonic changes took place in the remaining left lung so that the patient died after transient clinical improvement 18 days after surgery because of respiratory failure, the clinical picture being sepsis. There were no signs of infection in the anastomosed area and the cover of fibrin sealant around the tight anastomosis between the trachea and main bronchus had at that point already been replaced by delicate connective tissue.

The pneumonic change in the remaining lung had taken place in spite of repeated daily bronchoscopic suction. During this bronchoscopic suction we could see a well-vascularized, circular anastomosis. There was no spot with signs of air or mucus leak. In no case did we find disadvantages after the application of fibrin sealant. There was no formation of granulation tissue in the anastomosis that might have been caused by the fibrin sealant. Routine diagnosis showed no signs of hepatitis although acute transfusions of whole blood had to be administered especially in patients with polytrauma.

### ***Discussion***

The techniques of tracheobronchial resections and anesthesia in these operations have been described in detail by Grillo et al. [1,6]. In spite of the perfected technique the complication rate in these operations is between 3% and 10%. Dehiscent sutures and arrosion bleedings are the most frequent complications. Dehiscent sutures in the tracheobronchial system are often a life-threatening complication. Their prevention is imperative.

For this reason infections in the sutured area should be prevented and vascularization enhanced. We use fibrin sealant as a matter of routine in sutures of the tracheobronchial system for the following reason: The number of sutures is an essential factor in the complication-free healing of rows of sutures, as every additional suture for the prevention of air or mucus leakage from the lumen decreases vascularization. Sutures should be reduced to a minimum, still assuring safe airtight sealing. Precise surgical technique and subtle preparation of the structures are a prerequisite. Application of fibrin sealant reduces the number of sutures, which has a positive influence on vascularization.

Limited blood flow after the preparation and the mobilization necessary as well as small-sized and short-term contamination with nonsterile bronchial secretion are conducive to infections.

This is an excellent example of unsuitable application of nonabsorbable tissue sealants that moreover have an irritating foreign body effect with granulation tissue formation after incorporation. Airtight sealing of the sutures with fibrin sealant is a

valuable aid in tracheobronchial surgery. Rows of sutures in this area can generally not be regarded as sterile, as the vibrating epithelium is covered by infectious mucus and the puncture channels of the sutures do not show sterile conditions. So intratracheal pressure might increase to up to 150 cm water column, which is conducive to the leakage of infectious mucus into the anastomosis fissure and through the puncture channels along the sutures into the surrounding tissue. This may lead to severe mediastinitis.

The sealing of suture lines with fibrin sealant is thus a barrier to bacteria that cannot be built by any other measure as rapidly, as efficiently and applicable any time without side effects on the healing process. Pedicle, well-vascularized tissue flaps from muscle, pericardium, pleura or fasciae may also be used to seal and cover suture lines in the tracheobronchial system. Healing of these methods depends in the first place on the vitality of the transposed tissue and a necrosis is likely to occur any time which fosters an infection in the sutured area as well. The effect of this closing methods starts simultaneously with wound healing, a point where an infection may already have preceded. It may also happen that the flap shrinks after complication-free healing, inevitably conducting a kinking of the tracheal system with stenosis or stenosis alone. Combined application of fibrin sealant and absorbable mesh work has proved a reliable method to avoid arrosion bleedings. The anastomosis or suture line is first covered conventionally by layers of fibrin sealant, then absorbable mesh is introduced between the sutures and the adjacent, pulsating blood vessel (for example, truncus brachiocephalicus); the mesh is also attached to the blood vessel by means of fibrin sealant. After absorption of the separating wall thus created, the sutures of the trachea have also been absorbed, so that the reasons for an arrosion have already been eliminated at that point. A separating layer of granulation tissue remains. Next to tissue union fibrin sealing is an excellent incentive to vascularization [8] during the first days after operation and enhances rapid wound healing by primary intention.

Thus the application of fibrin sealant must be considered the method of choice to avoid the serious consequences of delayed healing. There is no other method comparable to the excellent results obtained with fibrin sealant. At present there is no alternative method at disposal. We did not use fibrin sealant in typical lobectomies, segment resections or pneumonectomies, as we did not consider sealing necessary in simple terminal sutures. Until now we have not seen any disadvantages in this method. We do not use fibrin sealant for the closure of lobar bronchi or main bronchi with a suturing device.

## **References**

1. Grillo HC (1973) Reconstruction of the trachea. *Thorax* 28:667
2. Moritz E (1978) Erfolgreich behandelte Arrosionsblutung nach Trachealresektion. *Wien klin Wschr* 90:427
3. Moritz E, Braun F (1975) Experimenteller Trachealersatz mit Silastik. *Kong Ber 16 Tag Österr Ges Chir* 248
4. Moritz E, Braun F, Fasol P, Losert U, Spängler HP (1975) Prosthetic tracheal replacement, *ESAO II*:188
5. Moritz E, Schlick W (1979) Spätergebnisse nach Trachealresektion. *Wien klin Wschr.* 91:97-101

6. Naef AP (1972) Tracheobronchialresektion. *Thoraxchir* 20:283
7. Salassa JR, Bruce BS, Pearson W, Spencer W (1977) Gross and microscopical blood supply of the trachea. *Ann Thorac Surg* 24:100
8. Spängler HP (1976) Gewebeklebung und lokale Blutstillung mit Fibrinogen, Thrombin und Blutgerinnungsfaktor. *Wr klin Wschr* 88 (Suppl 49)
9. Spängler HP, Holle J, Braun F (1973) Gewebeklebung mit Fibrin. *Wr klin Wschr* 85:827

# Endoscopic Fibrin Pleurodesis in Complicated Pneumothorax

W. HEINDL and N. PRIDUN

*Key words:* pneumothorax, fibrin, pleurodesis, fibrin sealant, endoscopy

## **Abstract**

Twenty-four patients with complicated pneumothorax were subjected to thoracoscopically directed fibrin pleurodesis treatment. Through a three-lumen catheter, which was inserted via the operating canal of the thoracoscope, the two sealant components (fibrinogen, dissolved in aprotinin, and thrombin in a calcium chloride solution) were instilled. Insufflation of N<sub>2</sub>O (3,5 atm) through the third catheter lumen caused nebulization of the two sealant components at the distal tip of the catheter. As soon as the sealant components mix, a gelatinous fibrin polymer develops on the pleural surface, which leads to formation of a mechanically competent seal. Parenchymatous fistulae of the lung which already exist, or which result from lysis of adhesions or coagulation of blebs, thus could be closed quickly and controlled directly under thoracoscopy.

In all cases, the collapsed lung reexpanded quickly. To the present time, only one recurrence has been observed, and this followed postoperative displacement of the chest tube. This corresponds to a recurrence rate of 4.1%. Pulmonary function tests performed in 11 patients revealed no functional impairment. For the reasons discussed, this method is preferable to the current pleurodesis techniques.

A "complicated" pneumothorax is a recurrent pneumothorax or a pneumothorax persisting for more than 5 days despite drainage. The frequency of recurrence may be related to the nature of the primary treatment. Thus recurrence rates of 25% – 50% are associated with conservative therapy (bedrest), whereas rates of 10%–30% are seen following closed drainage treatment [1–7]. Since the recurrence rate is directly proportional to the number of prior recurrences [5], thoracoscopy is indicated in the management of recurrent pneumothorax. This procedure helps to determine whether pleurodesis treatment or surgical intervention is necessary. In our opinion, surgery is required in the presence of ruptured parenchymal bullae. Therefore we have tried to develop a thoracoscopic technique which:

1. Permits controlled and rapid closure of preexistent bronchopleural fistulae or of fistulae that result from endoscopic coagulation of small blebs or adhesions, thus ensuring rapid reexpansion of the collapsed lung
2. Leads to a sustained pleurodesis with a low rate of pneumothorax recurrence
3. Avoids eventual pleural fibrosis with resultant pulmonary restriction
4. Shortens drainage and thus hospitalization for patients with a complicated pneumothorax.

**Table 1.** Sex, age, and diagnosis of patients who underwent pleurodesis

Nr.	Patient	Sex	Age	Diagnosis	Endoscopic findings	Duration of drainage (days)	Recurrence
1	P.T.	m	17	Pers. traumatic PT l., contusion of the thorax	0	10	0
2	W.I.	f	50	Pers. traumatic PT r., contusion of the thorax	Laceration of the lung	8	0
3	K.A.	m	25	Pers. SPT r.	Parasept. emphysema	6	0
4	I.M.	m	17	Rec. SPT r. (3rd recurrence)	Bullae type I	6	0
5	B.A.	f	59	Rec. SPT l. (1st recurrence)	0	12	3 months
6	T.A.	f	44	Rec. SPT l. (1st recurrence)	Bullae types I + II	6	0
7	S.R.	m	76	Pers. SPT r.	Pneumonia after infarction of the lung; parenchymal fistula	8	0
8	R.E.	m	38	Pers. SPT r. (1st recurrence)	Adhesions of the apex	8	0
9	D.P.	m	21	Rec. SPT r. (1st recurrence)	Adhesions of the apex	8	0
10	O.M.	m	20	Rec. SPT r. (2nd recurrence)	0	8	0
11	M.M.	m	20	Pers. traumatic hemorrhagic PT l.	Bleeding laceration of the lung	10	0
12	O.O.	f	25	Rec. SPT r. (2nd recurrence)	Bullae type I	10	0
13	S.B.	f	73	Pers. SPT r.	Pleuritis carcinomatosa	7	0
14	F.K.	m	59	Pers. SPT l.	Parasept. emphysema	8	0
15	K.J.	m	70	Rec. SPT l. (1st recurrence)	Bullae types I + II	10	0
16	H.M.	f	36	Rec. SPT l. (1st recurrence)	Parasept. emphysema	8	0



**Table 1.** (continued)

Nr.	Patient	Sex	Age	Diagnosis	Endoscopic findings	Duration of drainage (days)	Recurrence
17.	S.I.	f	41	Rec. SPT r. (1st recurrence)	Parasept. emphysema	8	0
18.	B.W.	m	25	Rec. SPT r. (1st recurrence)	Adhesion of the apex	7	0
19.	J.R.	m	19	Rec. SPT l. (2nd recurrence)	Bullae type I	7	0
20.	Z.M.	m	19	Rec. SPT r. (1st recurrence)	Parasept. emphysema	8	0
21.	N.E.	m	32	Rec. SPT r. (1st recurrence)	Bullae type I	8	0
22.	G.E.	m	20	Rec. SPT l. (1st recurrence)	Bullae type I	7	0
23.	M.I.	f	27	Rec. SPT r. (1st recurrence)	Bullae type I	8	0
24.	W.H.	m	37	Rec. SPT l. (1st recurrence)	Parasept. emphysema	7	0

Abbreviation: SPT, spontaneous pneumothorax; PT, pneumothorax; r., right; l., left

### ***Patients and Method***

The fibrin sealant “Tissucol Kit” (Immuno) consists of the sealant component proteins (mainly fibrinogen, factor XIII, and albumin), dissolved in aprotinin solution (3000 KIU/ml) and a thrombin (500 NIH-U/ml) – calcium chloride solution (40 mM). When the two sealant components are mixed, a gelatinous fibrin polymer results.

In 24 patients with complicated pneumothorax, the two sealant components were simultaneously but separately instilled via two lumens of a triple lumen Swan-Ganz catheter. This catheter was passed through the operating canal of the thoracoscope while viewing the visceral pleura. At the tip of the catheter the two sealant components formed a mixture, which was then sprayed by N<sub>2</sub>O insufflated (3.5 atm) through the third lumen. Sealant was applied to the desired portion of the visceral pleural surface in a thin film. About 10 cc of sealant were necessary to spray one upper lobe of a lung.

The thoracoscopic fibrin pleurodesis treatment was performed in 13 patients under full anesthesia and in 11 patients under local anesthesia. At the end of the procedure, a chest tube was placed.

The number of patients and their sex, age distribution, and diagnoses which prompted the pleurodesis treatment are listed in Table 1.

## Results

In Table 1, the endoscopic findings, duration of drainage, and number of recurrences are listed. In three cases (patients 1, 5, and 10) the etiology of the pneumothorax could not be determined endoscopically. In these cases, the upper lobes were assumed to be the source of the pneumothorax and were preventively sprayed with fibrin. In all other cases, the pathogenesis of the pneumothorax was determined endoscopically, allowing directed focal pleurodesis treatment.

In all cases, the lung reexpanded within 24 h of fibrin pleurodesis therapy. To provide further pleural reaction, the drainage tubes were left in place for 6–10 days. Hospitalization averaged 10 days. Of 24 patients, 23 are without recurrence 3–24 months (average 11 months) following treatment. In one female patient (patient 5), the chest tube required repositioning several times after surgery. This patient had a recurrence 3 months after pleurodesis therapy and underwent thoracotomy. Thus, the recurrence rate was 4.1%.

All patients were subjected to a follow-up radiologic examination within 3–24 months after surgery, the average being 11 months. In two patients, thickening of the pleura over the upper lobe was noted. In one patient, a loculated thickening of the pleura near the diaphragmatic sinus was seen. In all other cases the thoracic X-ray was normal. In 11 patients, lung function was analyzed within the same period after fibrin pleurodesis (Table 2). No restrictive ventilatory disturbances were observed.

**Table 2.** Pulmonary function tests after fibrin pleurodesis

Pat. Nr.:	Pat.	VK (l)	VK (%)	FEV <sub>1</sub> (l)	FEV <sub>1</sub> (%VK)	TLC(1)	TLC (%)	RV (l)	RV (% TL-C)	MEF <sub>50</sub> (%)	R <sub>1</sub> (cmH <sub>2</sub> O/l)
1	P.T.	5.0	94	3.85	76	6.80	103	1.75	26	86	1.8
4	I.M.	4.7	100	3.75	79	6.0	103	1.8	30	100	1.6
5	B.A.	3.2	114	2.7	84	6.65	160	3.45	52	97	1.5
6	T.A.	3.2	97	2.2	69	5.95	132	2.75	46	36	3.1
8	R.E.	4.6	110	3.5	76	7.5	134	2.9	39	38	1.5
11	M.M.	5.5	102	4.7	85	7.78	119	2.28	29	76	1.3
12	O.O.	3.3	97	2.95	89	5.80	170	2.5	43	88	2.4
14	F.K.	4.1	101	3.0	73	6.1	105	2.0	33	65	2.2
16	H.M.	2.95	100	2.05	69	4.2	104	1.25	30	45	2.4
21	N.E.	4.25	101	3.0	70	7.6	136	3.35	44	57	1.5
23	M.I.	2.8	100	2.7	71	6.7	113	2.9	43	70	1.6

## ***Discussion***

The aim of pleurodesis treatment is fibrinous inflammation of the pleura with adherence of the two pleural membranes. By limited focal application of fibrin on the pleural surface, this goal can be achieved without problems.

The three-dimensional fibrin network releases chemotactic stimuli to the mesothelium and represents the matrix for the ingrowing fibroblasts. With progressive formation of connective tissue, fibrin is degraded by plasmin and other cell proteases and/or phagocytosed by macrophages [8–11]. The fibrous organization of the sealant site begins around the third postoperative day. Depending on the fibrinolytic activity of the tissue, absorption of the fibrin occurs within 3–18 days.

The biologic degradation of the fibrin seal prevents excessive regeneration of granulation tissue and explains the favorable functional results. These latter are in contrast to results following other pleurodesis techniques. The atomization of the two sealant components permits fibrin polymerization only on the pleural surface itself. Thus, when the two components mix, a gelatinous fibrin polymer develops only at the site monitored by thoracoscopy. Sealant adheres to the tissues due to physical and chemical bonds, and leads to a strong mechanical seal of the fistula. Parenchymatous fistulae of the lung can be closed immediately, allowing the rapid reexpansion of the collapsed lung that we observed. This technique is therefore preferable to the nondirected application of the two sealant components [12].

Other pleurodesis techniques, in particular the use of inorganic powders [13–15] or sclerosing liquids [1, 16], have considerable disadvantages. Fistulae closure and pleurodesis are delayed until the development of a fibrinous inflammation. In addition, the instillation of sclerosing liquids may lead to pleural thickening at the lung base. Finally, the use of inorganic powders may lead to severe foreign body reactions [17, 18].

The complication of subcutaneous emphysema secondary to high-pressure insufflation of N<sub>2</sub>O was seen in one case. The intercostal insertion of a wide-lumen cannula in subsequent cases allowed additional ventilation of the thoracic cavity during spraying, and efficiently prevented this complication. Otherwise, the fibrin method is largely free of complications. To date, we have applied this method in a total of 46 patients. No additional recurrences have been brought to our attention. The entire cohort, however, has not yet been subjected to follow-up examination. Thus, the recurrence rate is assumed to be far below 4%. Also, an even shorter period of chest tube drainage and thus of hospitalization seems possible. The results justify the application of this method in the management of complicated pneumothorax. It may well decrease the need for thoracotomy in patients with recurrent pneumothorax.

## ***References***

1. Andersen I, Nissen H (1968) Results of silver nitrate pleurodesis in spontaneous pneumothorax, *Dis Chest* 54: 230–233
2. Elert O, Eigel P. (1983) Die Behandlung des Spontanpneumothorax unter Berücksichtigung der Rezidivhäufigkeit. *Prax Klin Pneumol* 37: 983–985

3. Greschuchna D (1973) Spontanpneumothorax, Richtlinien der konservativen Behandlung (einschließlich Pleuradrainage). *Thoraxchirurgie* 20: 298–302
4. Kaiser D, Wolfart W (1983) Therapeutische Prinzipien zur Behandlung des Spontanpneumothorax unter besonderer Berücksichtigung der thorakoskopischen Emphysemblasenabtragung und Fibrinverklebung. *Prax Klin Pneumol* 37: 979–982
5. Maaszén W (1974) Spontanpneumothorax – Chirurgische Therapie. *Therapiewoche* 24: 214–218
6. Seremetis M G (1972) The management of spontaneous pneumothorax. *Chest* 57: 65–68
7. Trendelenburg F, Reinert M (1972) Ätiologie und Diagnostik des Spontanpneumothorax. *Thoraxchirurgie* 20: 293–297
8. Dinges H P, Redl H, Kuderna H, Matras H (1979) Histologie nach Fibrinklebung. *Dtsch. Zschr. f. Mund-Kiefer-Gesichts-Chir.* 3: 295
9. Spängler H P, Holle J, Braun F (1974) Prinzip der Fibrinklebung. *Langenbecks Arch Chir Suppl Chir Forum*: 249–250
10. Spängler HP (1976) Gewebeklebung und lokale Blutstillung mit Fibrinogen, Thrombin und Blutgerinnungsfaktor XIII. *Wk Klin Wschr* 88 Suppl. 49
11. Spängler H P, Holle J, Braun F: Gewebeklebung mit Fibrin. *Wk. Klin. Schr.* 85: 827-829, 1973
12. Scheele J, Mühe E, Wopfner F (1983) Fibrinklebung, eine neue Behandlungsmethode beim persistierenden und rezidivierenden Spontanpneumothorax. *Chirurg* 49: 235–243
13. Larriue AJ, Tyers GF, Williams EH, O'Neill MJ, Derrick JR (1979) Intrapleural instillation of quinacrine for treatment of recurrent spontaneous pneumothorax. *Ann Thorac Surg* 28: 146–150
14. Mandi P: Recurrent spontaneous pneumothorax, An effective method of talc poudrage. *Chest* 77: 493-495, 1980
15. Van der Schuren RG (1981) Le talcage pleural dans le pneumothorax spontane. *Poumon-Cœur* 37: 273–276
16. Goldszer RC, Bennet J, Van Dampen J, Rudnitzky J (1979) Intrapleural tetracycline for spontaneous pneumothorax. *Jama* 241: 724–725
17. Jackson J, Benneth M (1973) Chest wall tumor following indized talc pleurodesis. *Thorax* 28: 788–793
18. Weissberg D (1981) Talc pleurodesis: a controversial issue. *Poumon-Cœur* 37: 291–294

# Thoracoscopic Fibrin Pleurodesis in the Treatment of Spontaneous Pneumothorax

M. SPIEGEL, J. BENESCH, and R. SIEBENMANN

*Key words:* Spontaneous pneumothorax, thoracoscopy, fibrin glue, application technique, histology, drainage duration

## **Abstract**

Thoracoscopic pleurodesis using a fibrin glue was performed in 14 patients with recurrent spontaneous pneumothorax. After adhesiolysis and cauterization of blebs the adhesive was sprayed on the pleural apex. Scanning with <sup>99</sup>Tc-labelled fibrinogen showed homogeneous distribution of the sealant film on the pleura. Histological fibroblasts were seen to have invaded the film within 4 days. Four weeks later fibrous obliteration was complete. The procedure was successful in 4 out of 5 patients who had pleural drainage for 2–48 h and 4 out of 5 patients where drainage was continued for 4 days. In 4 further patients the procedure failed because of bronchopleural fistula. The method is simple and well tolerated and seems to be useful even in first pneumothorax. Further studies will show whether the method can increase the success rate and reduce the recurrences of pneumothorax.

The high relapse rate of spontaneous pneumothorax led to the development of numerous methods of pleurodesis [1, 11, 13]. With all methods sclerosing substances are applied into the pleural space without a specific target [4, 7, 10]. Disadvantages of these methods are the impossibility of treating the causes of pneumothorax and the uncontrollable distribution of substances in the pleural space. Serious foreign body reactions and the development of fibrous pleural thickening have frequently occurred after such application [5, 8, 12]. The thoracoscopic instillation of fibrin sealant combines the advantages of thoracoscopy [6, 17] with the selective application of a sclerosing substance on the pleura [14, 18]. In a pilot study the methodology, morphological findings and clinical relevance of this method were evaluated.

## Aims of the pilot study: Methodological

---

### *Methodological*

1. Evaluation of appropriate sealant application
2. Control of sealant distribution in the pleural space
3. Examination of intrapleural fibrin turnover

### *Histological*

1. Examination of the fibrin layer in relapse

### *Clinical*

1. Shortening of drainage duration
  2. Reduction of relapse rate
-

### ***Material and Method***

The study included 14 patients between 18 and 64 years of age and was confined to subjects with at least a second pneumothorax.

Thoracoscopy was performed initially in local anesthesia with adhesiolysis and cauterization of emphysematous bullae. Subsequently in a brief narcosis Tissucol (Immuno) was applied to the pleural apex under thoracoscopic control. Immediately afterwards a large intercostal tube was placed in the pleural space, attached to an underwater seal and the lung expanded with a suction pressure of 30 cm water

#### *Method*

1. Thoracoscopy in local anesthesia
2. Adhesiolysis, cauterization of emphysematous bullae
3. Short general anesthesia
4. Intrapleural instillation
  - a) 10 ml fibrinogen-aprotinin
  - b) 10 ml thrombin-calcium Chloride (Tissucol)
5. Thoracostomy – tube drainage
6. Suction – 30 cm water

In seven patients the components of the fibrin glue were applied separately: 10 ml fibrinogen solution on the visceral pleura and 10 ml thrombin on the parietal pleura. The thrombin concentration was 500 IU/ml; thus fibrin is produced immediately upon contact of the two pleural sheaths.

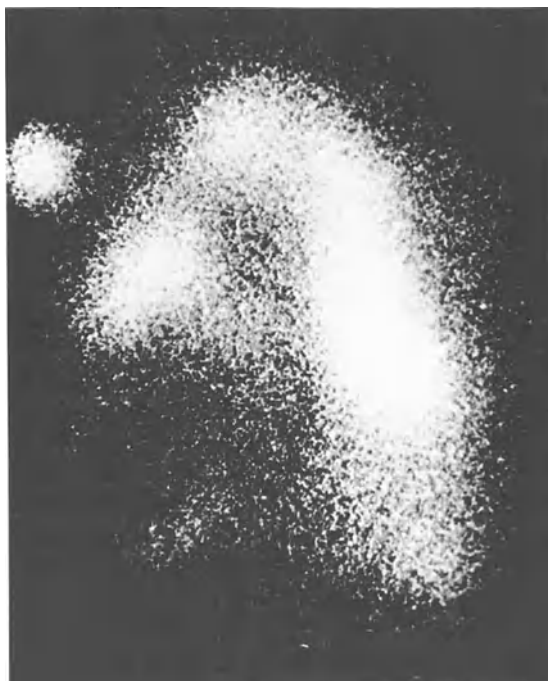
In seven patients the spray method was applied: 10 ml fibrinogen and 10 ml thrombin were separately instilled through a three-luminal catheter. The two solutions form a mixture at the tip of the catheter which is sprayed through the third catheter lumen by means of oxygen insufflation. On the desired pleural surfaces there ensues a thin precipitation of a fibrinogen-thrombin film. The thrombin concentration amounts to 4 U/liter; hence the coagulation into fibrin develops only after 3 min. In this time span, the intercostal tube is introduced and the lung is expanded under suction.

In one patient the fibrinogen was marked with 5 mCi  $^{99}\text{Tc}$  and the distribution of the adhesive was measured scintigraphically. In another patient, the thyroid was blocked with perchlorate and the fibrinogen was marked with 0,1 mCi  $^{131}\text{I}$ . Sequential scintigrams showed the fibrin turnover in the pleural space.

### ***Results***

#### *Method*

Thoracoscopic cauterization of emphysematous bullae and adhesiolysis have been proven as efficient routine methods. The application of adhesive by means of spray is more appropriate than the sequential application of adhesive components. The method is technically simpler and the adhesive more effective. With a separate application of the components more relapses were observed perhaps due to the uneven distribution of fibrinogen and thrombin on the surface of the visceral pleura which enlarges under suction.



**Fig. 1.** Distribution of <sup>99</sup>Tc-labeled fibrin glue in the pleural space

#### *Distribution of Fibrin*

The scintigraphic examinations after <sup>99</sup>Tc-marking of fibrinogen showed a homogeneous distribution of the glue on the coated pleural surface with the spray method (Fig. 1).

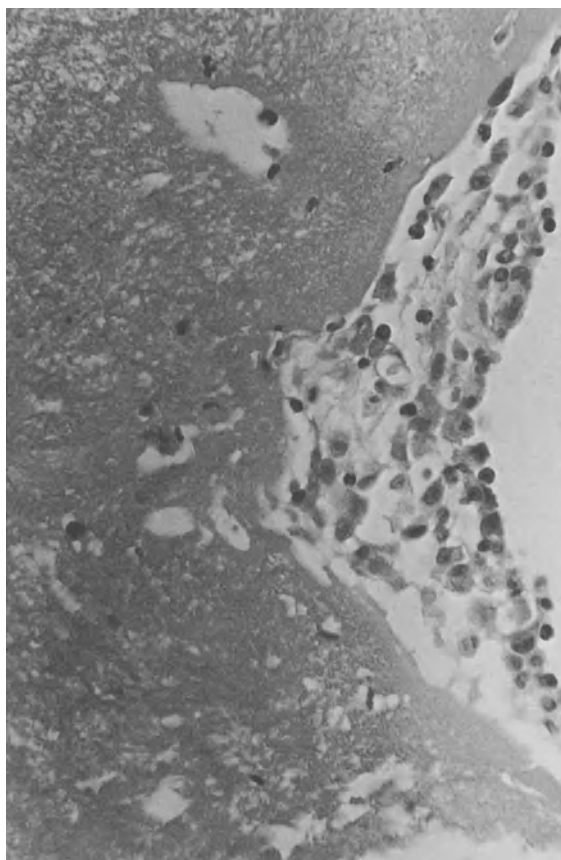
The target application of the glue mixture remains adherent and unchanged in its position.

#### *Fibrin Turnover*

The scintigraphic control of <sup>131</sup>I- marked fibrin glue showed virtually complete disappearance of the tracer from the pleural space within 11 days. As soon as 4 days after instillation a marked decrease in activity was detectable. After 11 days the whole applied iodine was found in the thyroid, which was no longer blocked. Whether the disappearance of the radio nucleoid from the pleural space was caused by fibrinolysis and resorption or by splitting of the iodine due to oxydation processes remains unclear.

#### *Histological Findings*

Histological examinations of the applied fibrin adhesive layer were performed in two cases, where thoracotomy was necessary after 2 and 30 days respectively on account



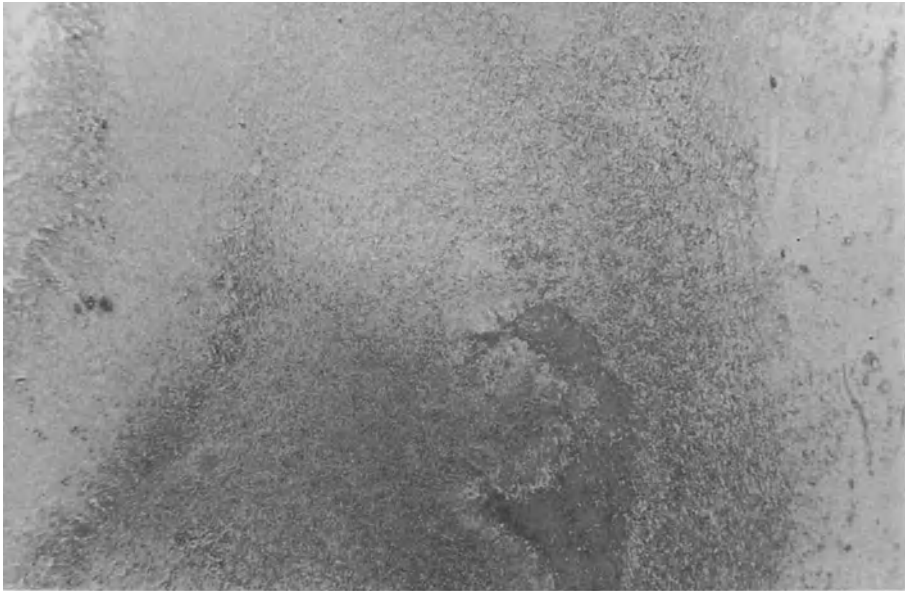**Fig. 2.** Fibrin layer 4 days after instillation with infiltration of fibroblasts

of a pneumothorax relapse: 4 days after fibrin sealant application infiltration of inflammatory and mesothelial cells could be proved on the surface of the fibrin layer. The mesothelial cells partly penetrate the fibrin masses and already transform into fibroblasts (Fig. 2). Thirty days after the instillation of fibrin the pleural space is obliterated by cell-rich granulation tissue, forming collagen fibers close to the pleura (Fig. 3). Remnants of the foreign fibrin are surrounded by foreign-body giant cells and by eosinophils interspersed with newly formed blood vessels (Fig. 4).

#### *Duration of Drainage*

In five patients the drainage lasted for less than 48 h; the shortest drainage was 2 h (Table 1). All patients were released after 2 days of hospitalization. There was one case of pneumothorax relapse in one patient of this group after 2 weeks. The drainage time was subsequently increased to 4 days with the following 5 patients. However, there was a case of relapse in this group as well. A drainage time of 2 days seems to be sufficient; a prolongation is not advisable.





**Fig. 3.** Obliterated pleural space 30 days after instillation of fibrin sealant



**Fig. 4.** Organization of the fibrin layer 30 days after instillation

**Table 1.** Duration of drainage after fibrin pleurodesis in pneumothorax

Drainage	<i>n</i>	Relapse	Fistula	Operation
< 2 days	5	1		
< 4 days	5	1		1
10 days	4		4	2

In four patients bronchopleural fistula was present at the onset of drainage and the pneumothorax persisted. After 10 days of drainage the fistula closed up in one case, in another patient an empyema appeared and in two patients a thoracotomy had to be performed.

#### *Rate of Relapses*

Within an observation time of 2 years there were two patients (20%) with recurrences of pneumothorax. In both cases there had been technical difficulties during the procedure: In one patient the emphysematous bullae could not be reached thoracoscopically on account of their dorsal location. With the other patient the drainage suction was disconnected while fusing the pleural sheets; thus the adhesion became inefficient. Despite the small number of cases the failure rate of 20% seems to be realistic, an improvement being likely with technical experience.

#### *Follow-up*

In five out of eight patients a control was carried out 2 years after successful pleurodesis. In none of the cases could any radiological changes or functional restrictions be discovered.

#### *Discussion*

The combination of thoracoscopic adhesiolysis, cauterization of emphysematous bullae and the target application of fibrin sealant to the pleural apex will probably be an advantageous procedure in the treatment of pneumothorax. The known efficiency of fibrin glueing in pneumothorax [15, 16] has been improved by the spray method, which facilitates the precise dosage and mixing ratio of glue components together with the even and thin-layered distribution of the adhesive substance. The fibrin remains detectable at the region of application for 3–4 weeks, despite the high fibrinolytic activity of the pleura [9]. The organization of the artificial fibrin layer starts as soon as 4 days after its application and is almost completed after 30 days. The fibrin serves as a leading structure for the immigrating fibroblast. The formation of new connective tissue results in an obliteration of the pleural space. Therefore a reduction in the relapse rate of the pneumothorax can be expected.

The experimentally proven rapid increase in stability of the fibrin adhesive strength leads to a decrease in duration of drainage and consequently hospitalization in the case of pneumothorax. Two days of drainage are probably sufficient. Complications have not arisen in the cases of pleurodesis performed so far. The correct carrying out of the method is important, especially the exact timing: with premature suction the adhesive is removed and coagulation occurs in the intercostal tube. With delayed drainage the inflation of the lung can be impeded by fibrin coating of the pleura visceralis. The fibrin glueing fails in the presence of a bronchopleural fistula and is contraindicated if expansibility of the lung is lacking.

In the cost-benefit analysis of pneumothorax treatment the relatively high costs of fibrin sealant are outweighed by the short duration of hospitalization. Further studies will show whether the method can increase the success rate and reduce the incidence of pneumothorax recurrences.

### **References**

1. De Vries W, Wolfe WE (1980) The management of spontaneous pneumothorax and bullous emphysema. *Surgical Clinics of North America* 60: 851–866
2. Dinges HP, Redl H, Kudera H, Matras H (1979) Histologie nach Fibrinklebung. *Dtsch Zschr f Mund-Kiefer-Gesichts-Chir* 3: 295–315
3. Eckert M (1981) Spontanpneumothorax and seine Behandlung. *Fortschr Med.* 99: 528–531
4. Goldszer RC, Bennet J, von Campen J, Rudnitzki J (1979) Intrapleural tetracycline for spontaneous pneumothorax. *Jama* 241: 724–725
5. Jackson J, Bennet M (1973) Chest wall tumor following iodized talc pleurodesis. *Thorax* 28: 788–793
6. Keller R, Guterson J, Herzog H (1974). Die Behandlung des persistierenden Pneumothorax durch thorakoskopische Massnahmen. *Thoraxchirurgie* 22: 457
7. Larrieu AR, Tyers GF, Williams EH, O'Neill MJ, Derrick JR (1979). Intrapleural instillation of quinacrine for treatment of recurrent spontaneous pneumothorax. *Ann Thorac Surg* 28: 146–150
8. Mc Loud Th C, Isler R, Head J (1980) The radiological appearance of chemical pleurodesis. *Diagnostic Radiology* 135: 313–317
9. Merlo G, Fausone G, Barbero C, Castagna B (1980) Fibrinolytic activity of the human peritoneum. *Eur Surg Res* 12: 433–438
10. Nandi P (1980) Recurrent spontaneous pneumothorax. An effective method of the talc poudrage. *Chest* 77: 493–495
11. Nydegger F, Sprenger F (1972) Zur Frage des rezidivierenden Spontanpneumothorax. *Schweiz Med Wschr* 102: 132–134
12. Research committee of the British Thoracic Association and Medical Research Council Pneumoconiosis. A survey of the long-term effects of talc and Koalin pleurodesis (1979) *Brit J Dis Chest* 73: 285–288
13. Shields TW, Oilschlager G Ag (1966) Spontaneous pneumothorax in patients 40 years of age or older. *Ann Thorac Surg* 2: 377–383
14. Spängler HP, Holle J, Braun F (1984) Prinzip der Fibrinklebung. *Langenbecks Arch Chir Suppl Chir Forum* 249–250
15. Scheele J, Mühe E, Wopfner F (1978) Fibrinklebung – Eine neue Behandlungsmethode beim persistierenden und rezidivierenden Spontanpneumothorax. *Chirurg* 49: 235–243
16. Stenzl W, Rigler B, Tschelissnigg KH, Beitzke A, and Metzler H (1983) *Thorac Cardiovasc Surg* 31: 35–36
17. Weissberg D, Kaufmann M (1980) Diagnostic and therapeutic pleuroscopy experience with 127 patients. *Chest* 78: 732–735
18. Workshop on Fibrin seal in cardiovascular surgery, Hannover, Nov. 1981. *Thorac Cardiovasc Surg* 30: 195–242 1982

# Fibrin Sealant as an Adjunct in the Operative Care of Recurrent Pneumothorax

O. THETTER

*Key words:* Recurrent spontaneous pneumothorax, symptomatic pneumothorax, surgical treatment, adjuvant fibrin glueing, artificial pleurodesis

## ***Abstract***

Human fibrinogen cryoprecipitate has found a large field of application as a biological tissue adhesive in thoracic and cardiovascular surgery. Fibrin glue was used routinely to seal porous prostheses in aortic arch replacements and proved successful even in cases of excessive bleeding under extracorporeal circulation.

During 2 years fibrin adhesion was applied in all surgical procedures involving persistent or recurrent pneumothoraces and it was used prophylactically to cover large parenchymal defects following standard lung resections. The benefit of its application on pleura and lung tissue derives from added reinforcement of sutures and sealing of nonsuturable defects.

Twenty-one patients with recurrent spontaneous pneumothoraces revealed a clearly reduced average drainage period as compared with 15 nonglued cases with lesions of comparable size. Similarly, in 20 cases where tissue adhesive was applied to extensive pleural defects following segmental lung resection or lobectomy, suction drainage time was significantly less than in 11 cases of comparable, nonglued defects. Compared with 140 lung resections performed prior to the use of fibrin glue, these 20 cases were found to require the same average drainage time, although the extent of their lesions otherwise would have warranted longer periods of continued suction drainage.

## ***Introduction***

The optimal treatment for recurrent spontaneous and symptomatic pneumothorax is still debated in spite of the voluminous literature on the subject.

In contrast to the purely conservative treatment, consisting of prolonged bed rest and accompanied by a high incidence of recurrence, continuous suction drainage has been shown by Greschuchna [2] to be far superior. Leading in a short time to full pulmonary expansion, the method permits the concomitant evacuation of a pleural effusion or hemothorax if present. At the same time, the chest tube causes considerable irritation of the pleura, resulting in the thickening and partial adhesion of its visceral and parietal layers.

Surgical treatment of the bronchopleural fistula is indicated only in a small percentage of patients with pneumothorax (Maassen [3] : 11%). The indications are the following:

1. Pneumothorax recurring spontaneously after cessation of suction drainage
2. No signs of improvement after 8–10 days of suction drainage, due to:
  - a) Lack of pulmonary expansion under continuous suction
  - b) Further pulmonary collapse under continuous suction
  - c) Immediate recollapse following cessation of suction
3. Evidence of bullous emphysema or cystic lung disease
4. Recurrent hemopneumothorax
5. Unsuccessful thoracoscopic treatment

The type of surgical procedure is determined by the site of the lesion and the extent of the affected pulmonary surface. It should prevent recurrence by eradicating the cause of the pneumothorax, and to reconstitute pulmonary function. The following operative measures have proved beneficial to our patients:

1. Severing of cords or adhesiolysis
2. Resection and suture of one or several large emphysematous bullae
3. Electrocoagulation of small blebs
4. Suture of parenchymal defects
5. Wedge excision and suture of cystically altered lung tissue or of apical scars
6. Plication of emphysematous or microcystic areas with a running suture
7. Segmental resection or lobectomy
8. Abrasion of the parietal pleura with rough gauze, particularly when no lesion is evident or blebs are too numerous to be excised
9. Excision or closure of a bronchopleural fistula
10. Tissue adhesion through the use of a biological adhesive system

Neither partial or total pleurectomy [5], nor additional pleurodesis through the introduction of talcum powder, kaolin, 20% silver nitrate solution, blood, etc. [1, 6, 8] have been applied.

### ***Material and Method***

Following the investigations of fibrin glueing reported by Matras [4] and Spängler [9] tissue adhesion was induced during 2 years through the use of human fibrinogen cryoprecipitate (Tissucol; Immuno, Vienna) in all our surgical procedures involving persistent or recurrent pneumothorax. In addition we applied fibrin adhesive prophylactically whenever large parenchymal defects after standard lung resection needed to be covered. Fibrin glue was applied in 49 cases intraoperatively during thoracic surgery. In 21 cases the fibrin sealant was applied for the treatment of recurrent spontaneous pneumothorax. In seven cases fibrinogen and thrombin solution were used to seal the pleural suture. In another 14 cases, however, pleural abrasion and local pleurodesis using fibrin glue were also performed (Table 1).

In 20 more patients with lobectomy or segmental resections with extensive leaks, the surfaces of resection were coated with a fibrin film and on four occasions covered

**Table 1.** Additive application of the fibrin sealant method on 103 patients

Cardiac surgery		Thoracic surgery	
Aortic valve replacement	10	Recurrent spontaneous pneumothorax	21
Mitral valve replacement	8	Lung resection	20
Double valve replacement	7	Lung tear	3
Ascending aorta replacement	7	Tracheal rupture	2
Aorto-coronary vein bypass	10	Rupture of diaphragm and liver	1
Ventricular aneurysmectomy, ACVB	2	Thoracic duct lesions	2
Repair of tetralogy of Fallot	3		
Ventricular septal defect	4		
Patent ductus arteriosus	3		
	54		49

in addition by collagen fleece (Kollagen-Haemostyptikum Vlies; Braun, Spangenberg) or strips of Tabotamp (Johnson and Johnson, Norderstedt).

After the removal of emphysematous blebs, wedge excision of cystically altered lung tissue, or segmental resections leaving extensive parenchym defects, the surrounding tissue is clamped leaving as wide a margin as possible and plicated with a running mattress suture which is oversewn back to the beginning of the suture, where the two ends are then tied. Since at the sites of needle puncture the pleura often tears under the tension of the reinflated lung, thus giving rise to persisting air leaks, we seal the suture line with fibrin glue. Large nonsuturable defects are coated with a film of fibrin; however, as the escaping air may on occasion impede the process of adhesion, we add adhesive-coated collagen fleece or Tabotamp in such cases and compress lightly for several minutes.

Following local abrasion of the apical parietal pleura with rough gauze and the positioning of a drain, both pleural layers surrounding and overlying the lesion are swabbed with fibrin glue in order to achieve a local pleurodesis. The pulmonary lobe in question is kept inflated until the previously laid thoracic wall sutures are tied.

## Results

In order to compare the therapeutic results of 21 cases of recurrent pneumothorax treated with the fibrin glue method to those of 15 spontaneous pneumothoraces of the previous year treated without fibrin glue, we segregated the pleural lesions into three groups according to size. Both patient groups then are seen to be comparable (Table 2). With fibrin adhesion the mean drainage period is clearly but not significantly shorter. However, the age of patients treated with fibrin glue is markedly higher and considering that in the elderly pleurodesis generally takes longer, our results concerning drainage periods present an additional argument for the fibrin glue method.

Furthermore, the treatment results of 20 cases with extensive pleural lesions following segmental resection or lobectomy indicated a significant decrease in the

**Table 2.** Therapeutic results in the treatment of spontaneous pneumothorax with and without the use of fibrin sealant

	Spontaneous pneumothorax		Level of significance
	With adhesive	Without adhesive	
<i>N</i>	21	15	
Age (years)	46.1 ± 17.9	29.5 ± 14.7	0.01
Lesional size	2.0 ± 0.2	2.0 ± 0.3	NS
Drainage period (days)	3.5 ± 2.5	4.1 ± 3.0	NS
Size of pleural lesion:	1: up to 2 mm Ø		
	2: up to 20 mm Ø		
	3: up to 100 mm Ø		

**Table 3.** Therapeutic results in the treatment of extensive pleural lesions following segmental resection or lobectomy with and without the use of fibrin sealant

	Pulmonary resection		Level of significance
	With adhesive	Without adhesive	
<i>N</i>	20	11	
Age (years)	49.9 ± 6.1	55.2 ± 8.6	0.1
Lesional size	2.4 ± 0.4	2.3 ± 0.3	NS
Drainage period (days)	5.6 ± 3.0	13.3 ± 5.6	0.001
Size of pleural lesion:	1: up to 2 mm Ø		
	2: up to 20 mm Ø		
	3: up to 100 mm Ø		

drainage period when compared with 11 cases of similar defects without the benefit of fibrin adhesion (Table 3).

Finally, when these 20 cases are compared with all 140 partial lung resections performed in the 2 years prior to the advent of the fibrin glue method, it is noted that the cases with adhesive required the same average drainage time, although their extensive pleural defects would have implied far longer periods.

A postoperative or recurrent pneumothorax was not observed in any case. Only one of three cases with a traumatic tear of lung tissue showed an appreciable bronchopleural leak 4 days after the operation with additional use of fibrin sealant. The reoperation revealed a necrosis of the apical segment of the lower lobe.

**Discussion**

Fibrin sealant as a biological tissue adhesive has found wide application in thoracic and cardiovascular surgery. In contrast to the suggestion of Maassen [3] and Zwintz [10], who use a synthetic adhesive (Histacryl Braun Melsungen, Melsungen) with the aid of lyophilized dura or pleural patch, our results recommend the use of fibrin glue in the management of recurrent pneumothorax.

The foremost advantage of a biological adhesive system over acrylic glue is that it involves physiological substances only and repeats normal clotting mechanism. The surfaces in question are sealed with an elastically adherent fibrin layer which then undergoes connective tissue organization while meeting the biomechanical requirements of lung tissue.

Table 1 lists our patients treated over 2 years and gives a survey of the manifold applications that the fibrin glue method offers in thoracic and cardiac surgery.

In cardiovascular surgery under the condition of extracorporeal circulation we find growing indications for the use of the adhesive, particularly in the treatment of bleeding needle puncture wounds and the sealing of Dacron prostheses in aortic arch replacements.

The therapeutic uses of fibrin glue in recurrent spontaneous pneumothorax were pointed out in 1978 by Scheele [7]. Localized apical pleurodesis is achieved with the introduction of both adhesive components through a venous catheter which is placed in the pleural cupola. In one of our patients treated according to this method, persisting pneumothorax necessitated thoracotomy. While an area of adhesion between both pleural linings about 3 cm in diameter was observed at the apex, the bronchopleural fistula at the anterior margin of the lung was still present, unaffected or unreached by the glue. Of particular note were tracks of organized fibrin that extended along the visceral pleura to the base of the lung without having achieved pleural synthesis of visceral and parietal layers.

On the basis of these observations we decided to apply the fibrin glue method in the treatment of pneumothorax only under visual control following thoracotomy. The adhesion serves to secure sutures involving pleura and lung parenchyma as well as to seal parenchymal defects that may at times be covered additionally by collagen fleece or strips of Tabotamp.

We are sure that our results illustrate the advantage of the adjuvant use of fibrin sealant in the operative treatment of the recurrent and spontaneous pneumothorax.

## References

1. Gaensler EA (1956) Parietal pleurectomy for recurrent spontaneous pneumothorax. *Surg Gyn Obstet* 102:293–308
2. Greschuchna D (1972) Spontanpneumothorax – Richtlinien der konservativen Behandlung (einschließlich Pleuradrainage). *Thoraxchirurgie* 20:298–302
3. Maaßen W (1974) Spontanpneumothorax – Chirurgische Therapie. *Therapiewoche* 24:214–218
4. Matras H, Dinges HP, Lassmann H, Mamoli B (1972) Zur nahtlosen interfaszikulären Nerven- transplantation im Tierexperiment. *Wien med Wschr* 37:517–523
5. Salzer GM, Szinicz G (1981) Recurrence of pneumothorax following total parietal pleurectomy for treatment of recurrent spontaneous pneumothorax. *Thorac Cardiovasc Surgeon* 29, Spec Issue 1:23
6. Sattler A, Hatzenberger H (1965) Zur Problematik des sogenannten idiopathischen Spontanpneumothorax *Z Tbk* 123:303–307
7. Scheele J, Mühe E, Wopfner F (1978) Fibrinklebung. Eine neue Behandlungsmethode beim persistierenden und rezidivierenden Spontanpneumothorax. *Chirurg* 49:236–243
8. Schott H, Viereck HJ (1972) Klinik und rationelle Therapie des Spontanpneumothorax. *Dtsch med Wschr* 97:491–496
9. Spängler H P (1976) Gewebeklebung und lokale Blutstillung mit Fibrinogen, Thrombin und Blutgerinnungsfaktor XIII. *Wien klin Wschr* 88, Suppl 49:1–18
10. Zwintz E (1979) Therapievarianten beim Spannungspneumothorax. *Acta chir Austriaca* 11:1–9



# Treatment of Idiopathic Spontaneous Pneumothorax: Transthoracic Endoscopic Use of Fibrin Glue

O. ELERT and P. EIGEL

*Key words:* Idiopathic spontaneous pneumothorax, fibrin glue, transthoracic endoscopy

## **Abstract**

In the period from 1977 to May 1985, 269 patients were treated for idiopathic spontaneous pneumothorax. Methods of treatment were:

1. Air suction by puncture once or several times ( $n = 13$ ; 4.8%)
2. Pleural drainage ( $n = 76$ ; 28.3%)
3. Selective thoracoscopic pleurodesis ( $n = 142$ ; 53.2%)
4. Explorative thoracotomy ( $n = 37$ ; 13.7%)

Transthoracic endoscopic use of fibrin glue enabled the drainage period to be shortened considerably to 2.5 days compared with exclusive treatment with thorax suction drainage (mean duration, 14.3 days) and, thus, hospitalization to be cut down on as well.

Relapse frequency subsequent to primarily successful treatment of spontaneous pneumothorax was 19.7% with the group with drainage treatment alone, 9.0% after endoscopic fibrin pleurodesis and 2.7% after thoracotomy.

No complications were incurred after thoracotomy and selective fibrin pleurodesis.

The advantages of this method of treatment are the precise, endoscopically perceivable representation of pathological findings in the lung and pleura in the assessment of prospects for success subsequent to fibrin pleurodesis, in the short drainage duration and in the low number of relapses.

## **Introduction**

Treatment of idiopathic spontaneous pneumothorax has as its objective to ensure complete expansion of the collapsed lung as quickly as possible and to keep the relapse frequency as low as possible.

Attempts were continually made in the past to seek appropriate methods to prevent symptomatic or idiopathic spontaneous pneumothorax from reoccurring permanently [2, 6, 7, 11, 12, 13, 16, 18, 19, 32, 33].

The results of this therapy – broken down into short-term and long-term success – are reflected in both the duration of treatment with the concomitant complications as well as in the type of treatment employed.

The relapse frequency is specified as 0% – 50%, depending upon the duration of observation and whether a more conservative and reserved or operative and explorative strategy is pursued [17, 23, 25, 30].

Due to the uncertain success and unsatisfactorily high relapse rate with drainage treatment alone, but in selective pleurodesis through liquid or pulverized irritants as well, such as tetracycline, nitrate of silver, glucose, autoblood or talc [7, 19, 26, 33], selective transthoracic endoscopic pleurodesis was introduced in the clinic [19, 24, 32, 33].

### ***Material and Methods***

In the period from 1977 to May 1985, 269 patients were treated for idiopathic or symptomatic spontaneous pneumothorax (including recurrences). Of the persons treated 82% were men and two-thirds were under 35 years of age. In 61% of the cases the right lung side was affected and in two cases two-sided spontaneous pneumothorax was diagnosed and treated.

The types of treatment adopted were air suction once or several times by puncture in 5% of the cases, pleural drainage in 28%, transthoracic endoscopic use of fibrin glue in 53% and explorative thoracotomy in the remaining 14%.

In addition to the duration of treatment (stationary) the relapse frequency as a function of the method of treatment was employed as reference criterion for forthcoming and subsequent success with a postoperative observation period of 6 months up to 7.5 years (mean postoperative observation period, 2.7 patient years).

### ***Therapeutic Procedure for Idiopathic Spontaneous Pneumothorax***

Thoracoscopy with an attempt at pleurodesis is applied as a rule for spontaneous pneumothorax, including recurrent cases (Fig. 1) [10].

Pleural drainage is, as a rule, only applied for relief with patients in a generally poor condition, for whom thoracoscopy entails too high a risk, and with patients refusing thoracoscopy primarily. When the previously collapsed lung is expanded completely, drainage is removed subsequent to being clamped beforehand. Should drainage treatment remain unsuccessful within 48 h or should the lung collapse anew with drainage clamped, thoracoscopy is applied with the endoscopic pleurodesis attempt.

If primarily bullous emphysema is demonstrated by radiography, thoracoscopy is done without, thoracotomy being conducted with operative sublation of the emphysema vesicles. Thoracotomy is carried out when the thoracoscopic insight of the pleura and lung is not possible due to coalescences or extended fibrin deposits; the thoracoscopy shows numerous emphysema vesicles which cannot be sublated endoscopically; or other pathological findings are present, such as cysts, bronchiectases, or metastases, which do not allow pleurodesis to be successful.

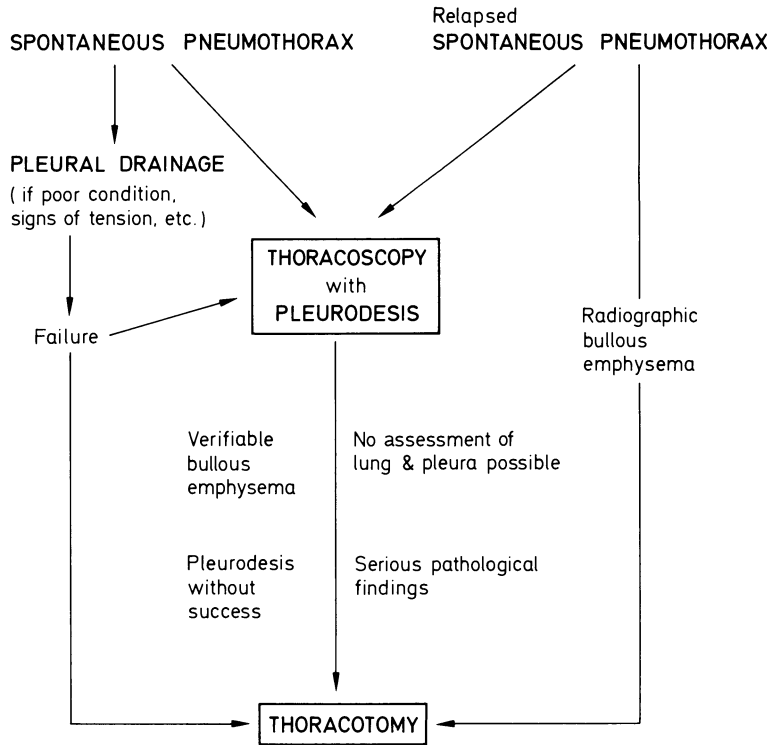
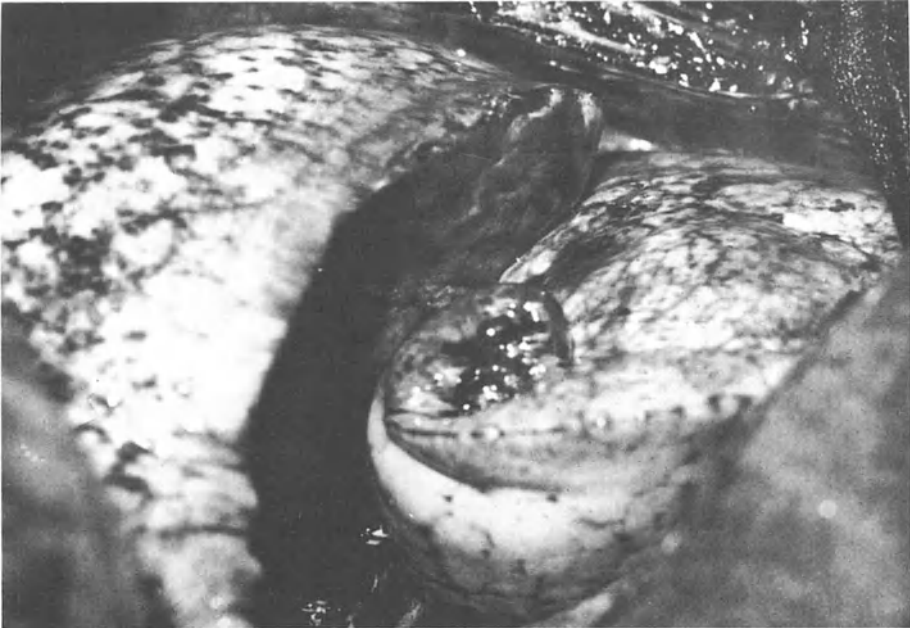

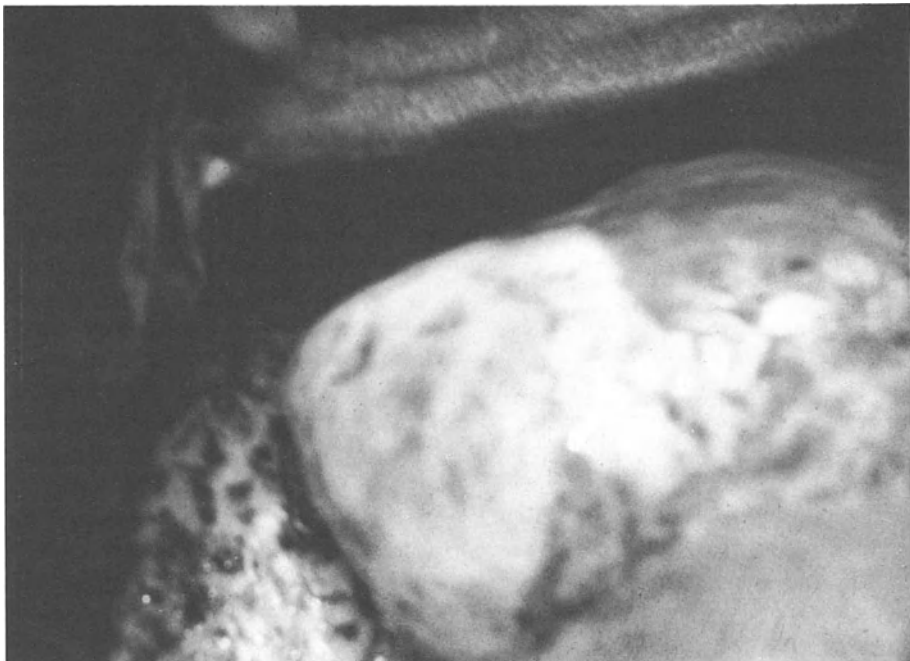
Fig. 1. Therapeutic procedure for idiopathic spontaneous pneumothorax

***Transthoracic Endoscopic Use of Fibrin Glue***

Thoracoscopic pleurodesis has been carried out in cases of idiopathic or symptomatic spontaneous pneumothorax by means of human fibrin glue and only rarely with chemical oblitative substances, such as ethoxylsclerole [10], since 1977. The intervention is carried out with local infiltration anesthetic with the patient in a lateral position or with a laterally raised thorax in the supination position. The thoracoscope is introduced after incision through the third or fourth intercostal space in the forward to central axillary line. The use of optics enables the lung, the visceral and parietal pleura, the sinus and frequently the interlobar fissure to be inspected adequately. Subsequently a polyethylene catheter is introduced via the instrument channel and 1–2 ml highly concentrated human fibrinogen raised to room temperature applied visibly to the leak or in the area of the apex pulmonis. Subsequent to the catheter being rinsed the mixture comprising thrombin, factor XIII and calcium ions is dripped onto the spots in the same manner. After 30–40 s both these components have a jelly-like structure (fibrin polymer), which takes on sufficient elastic consistency after a few minutes and is completely mechanically loadable (Figs. 2, 3). Thorax drainage (as a rule 18 Charr. or greater) is inserted into the pleural cavity and the pneumothorax sucked off straightaway to make immediate contact to the areas to be glued. The reexpansion of the lung should be controlled by



**Fig. 2.** Spontaneous pneumothorax through a burst emphysema vesicle with regard to the lower lobe (operation site thoracoscopy)



**Fig. 3.** Fibrin glue of the burst emphysema vesicle. Whitish deposit is a thin fibrin layer

radiography with permanent suction on the drainage of 6 – 10 cm column of water. Subsequently the patient should be subjected to active physiotherapy with respiratory exercises.

## Results

With an average drainage time after selective thoracoscopic pleurodesis of 2.5 days and an average stationary lying period of 11.7 days (Table 1), this method of treatment shortens hospitalization considerably and cuts down on costs significantly. Compared with drainage treatment alone with an average stationary duration of 17.9 days the result is additional costs amounting to DM 1683 per patient (at a daily rate of DM 271 × 6.2 days) in comparison to pleurodesis treatment. The high costs of fibrin glue frequently quoted [22] as a counterargument to general application of fibrin pleurodesis are to be disregarded in these considerations.

Administration of antibiotics for prophylaxis of infections, as required by many authors [1, 8, 14, 15, 27, 31], is mostly unnecessary even with risky patients, the lying period of the thorax suction drainage being shortened to 2.5 days after endoscopic pleurodesis compared with drainage treatment alone (average drainage time 14.3 days).

Suction of spontaneous pneumothorax by means of puncture once or several times was carried out only with 4.8% of all the patients treated and only with partial pneumothorax of less than a crossed finger on the roentgenogram or with collapse of the lung with less than 5% of patients [28]. This is the reason why this group of patients cannot be compared with the other groups with regard to stationary duration and relapse frequency.

In 12 of 76 patients (15.8%) spontaneous pneumothorax could not be eliminated by pleural drainage being inserted, so that other measures became necessary. Explorative thoracotomy was carried out in 13.7% (37 of 269) of the patients due to bullous emphysema, failure of endoscopic pleurodesis (in 3%), multiple relapsing

**Table 1.** Relapse frequency of idiopathic spontaneous pneumothorax as a function of the type of treatment applied (treatment from 1977 to May 1985)

Type of treatment	Number	Average postoperative observation in patient years	Relapse frequency	
			Number	%
Suction once/several times	13	5.5	2	15.4
Pleural drainage	76	5.9	15	19.7
Selective thoracoscopic pleurodesis	143	3.9	13	9.0
Thoracotomy	37	4.6	1	2.7
Total	269	4.6	31	11.5

pneumothoraces succeeding at short intervals or effusions additionally forming. The surgically operative measures included sublation of emphysema vesicles, partial pneumo or lobe resection, clamp or pneumoedge resection and suturing bronchopulmonary fistulae.

### ***Relapse Frequency and Complications***

Complications with closed drainage treatment are effusion formation, hemothorax, tylosis formation and local inflammations at the drainage outlet point. Thoracic empyema occurred in a patient who had been treated beforehand in an out-of-town hospital with pleura drainage for 46 days. Another patient died as a result of advanced pulmonary cirrhosis with relapsing pneumothoraces.

Complications, which could be put down to thoracoscopy or fibrin pleurodesis, did not occur. In particular pleura tylosis formation could not be verified in any patient. Serological complaints, which could have been associated with fibrin application, were not observed.

One patient with symptomatic spontaneous pneumothorax (marked pneumonecrosis) died of uncontrollable respiratory insufficiency subsequent to thoracotomy.

Despite correctly conducted pleura drainage treatment there was renewed occurrence of pneumothorax in 15 of 76 cases (19.7%) during an average postoperative observation period of 5.9 patient years. Subsequent to selective thorascopic drainage treatment the number of relapses was at 9% considerably below the failures after drainage treatment alone (19.7%), whereby, however, the various long postoperative observation periods should be taken into consideration.

Treatment of idiopathic or symptomatic spontaneous pneumothorax by thoracotomy (in 13.7%) demonstrates the lowest relapse rate of 2.7% despite the fact that the majority of this group of patients comprised primarily unsuccessful or repeatedly pretreated spontaneous pneumothoraces.

### ***Discussion***

Closed intrapleural thorax drainage is still today the most frequent method for treating idiopathic, but also symptomatic spontaneous pneumothorax [2, 8, 11, 16, 18, 26, 28, 31, 33].

In addition to eliminating the air collecting in the pleura cavity this form of therapy also aims at relapse prophylaxis by gluing the membranes as a result of localized pleuritis. In individual cases this form of treatment for eliminating pneumothorax may be adequate; satisfactory long-term success cannot often be obtained [11].

Prior to thorascopic inspection of the lung and pleura being introduced with selective pleurodesis explorative thoracotomy was, in most cases, necessary to eliminate pneumothorax on drainage treatment failing.

By selective endoscopic application of fibrin glue, thoracotomy could be replaced in two of three cases to prevent spontaneous pneumothorax occurring subsequent to frustrane drainage treatment. This means to say that the high rate of thoracotomy of

16% in the first few years could be cut down to 6.6% subsequent to prior drainage treatment in the last 3 years (thoracotomy rate totalling 13.7%), which compared with the available literature data of 10% – 20% can be considered favorable [3, 4, 5, 25, 26, 34, 35].

Protracted waiting for the lung to expand completely and permanently with lying pleural drainage with the well-known complications up to further, mostly operative treatment is on average 8 – 40 days [2, 9, 20, 21, 22, 26].

Selective application of thoracoscopy with pleurodesis has, in most cases, enabled the lying period for pleural drainage to be reduced considerably from 14.3 to 2.5 days, hospitalization accordingly being reduced by an average of 6 days.

The not yet satisfactory relapse frequency of 9% after endoscopic fibrin pleurodesis compared with thoracotomy (2.7%) should not be an argument against this method being widely applied. The general empirical process with regard to indications, the point in time and the technical sophistication of the selected thoracoscopic measure will enable the relapse rates to be lowered, as has been shown by our patients in the past 2 years. A reliable statement about a comparable, long-term prognosis will be able to be made in the near future. Endoscopically controlled fibrin gluing for spontaneous pneumothorax represents a careful method of treatment for us today, which has proven itself well in the majority of our patients. We consider the advantages of our own procedure as being the precise, endoscopically perceivable representation of pathological findings in the lung and pleura, in the assessment of prospects for success, in the short drainage duration, the brief stationary hospitalization and in the low number of relapses.

## References

1. Becker H, Müller HCHR (1970) Fehler bei der Indikationsstellung und Behandlung des Spontanpneumothorax. *Langenbecks Arch klin Chir* 327:567–570
2. Becker H, Ungeheuer E (1971) Zur Behandlung des Spontanpneumothorax. *Fortschr Med* 89:413–415
3. Cadalbert M, Schamann M (1968) Indikation und Technik der Behandlung des Spontanpneumothorax. *Schweiz Med Wschr* 98:1159–1162
4. Clark TA, Hutchison DE, Deaner RM, Fitchett VH (1972) Spontaneous pneumothorax. *Am J Surg* 124:728–731
5. Derra E, Reitter H (1963) Klinik und therapeutische Probleme beim sogenannten Spontanpneumothorax. *Dtsch Med Wschr.* 88:737–742
6. Deucher F (1950) Der idiopathische Spontanpneumothorax. *Langenbecks Arch Klin Chir* 265:181–244
7. Dichtl K (1968) Der Spontanpneumothorax. *Wien Med Wschr* 118:650–654
8. Doerfel G (1968) Die Behandlung des Spontanpneumothorax. *Z Tuberk* 127:263–272
9. Dragojevic D, Borst HG (1974) Idiopathischer Spontanpneumothorax. In: *Indikation zur Operation*. Springer, Berlin Heidelberg New York
10. Elert O, Eigel P (1983) Die Behandlung des Spontanpneumothorax unter Berücksichtigung der Rezidivhäufigkeit. *Praxis und Klinik der Pneumologie* 37:983–985
11. Engel J (1966) Zur Klinik und Behandlung des Spontanpneumothorax. Ein Überblick über 228 Fälle. *Münch Med Wschr* 97:2140–2147
12. Ferlinz R (1972) Therapie des Spontanpneumothorax. *Dtsch Med Wschr.* 97:247–249
13. Friesdorf C (1927) Ein Beitrag zur Aetiologie und Pathogenese des nichttuberkulösen Spontanpneumothorax. *Münch Med Wschr* 74:1672–1674
14. Fuchs HS (1969) Der idiopathische Spontanpneumothorax. *Fortschr Med* 87:248–252

15. Geiger M, Wieser O (1967) Der Spontanpneumothorax in Praxis und Klinik. *Prax Pneumol* 21:81–86
16. Geisler LS (1978) Indikation und Technik der Pneumothoraxbehandlung. *Dtsch Med Wschr* 103:1769–1770
17. Geisler P, Janiak B (1964) Diagnose, Therapie und Prognose des Spontanpneumothorax. *Med Welt* 7:313–319
18. Greschuchna D (1972) Spontanpneumothorax – Richtlinien der konservativen Behandlung. *Thoraxchirurgie* 20:298–302
19. Hessler O (1960) Der idiopathische Spontanpneumothorax und seine Behandlung. *Chirurg* 31:201–206
20. Jones MR, Loyons HA (1954) Spontaneous pneumothorax. *Am J Med Sci* 227:13–20
21. Keller R, Gutersohn J, Herzog H (1974) Die Behandlung des persistierenden Pneumothorax durch thorakoskopische Maßnahmen. *Thoraxchirurgie* 22:457–460
22. Keßler E, Day N (1984) Klinik und Therapie des Spontanpneumothorax. *Prax Klinik Pneumol* 38:523–533
23. Kjaerdaard H (1932) Spontaneous pneumothorax in the apparently healthy. *Acta Med Scand Suppl* 43:1–159
24. Liebeskind R (1961) Die Behandlung des Spontanpneumothorax. *Münch Med Wschr* 103:1774–1777
25. Lindskog GE, Halasz NA (1957) Spontaneous pneumothorax. A consideration of pathogenesis and management with review of 72 hospitalized cases. *Arch Surg* 75:693–698
26. Maassen W (1974) Spontanpneumothorax – Chirurgische Therapie. *Therapiewoche* 24:214–218
27. Matzander U (1963) Zur Problematik in der Beurteilung und Behandlung des sogenannten idiopathischen Spontanpneumothorax. *Med Klin* 58:832–835
28. Mills M, Baisch BF (1965) Spontaneous pneumothorax. A series of 400 cases. *Ann Thoracic Surg* 1:286–297
29. Myers JA (1954) Simple spontaneous pneumothorax. *Dis Chest* 26:420–441
30. Oeser FE (1961) Die Prognose des sogenannten idiopathischen Spontanpneumothorax. *Med Klin* 56:1635–1636
31. Scheel W (1968) Zur Ätiologie und Therapie des Spontanpneumothorax. *Thoraxchirurgie* 16:135–143
32. Scheele J, Mühe E, Wopfner F (1978) Fibrinklebung. Eine neue Behandlungsmethode beim persistierenden und rezidivierenden Spontanpneumothorax *Chirurg* 49:236–243
33. Schott H, Viereck HJ (1972) Klinik und rationelle Therapie des Spontanpneumothorax. *Dtsch Med Wschr* 97:491–496
34. Schwander R, Perruchond A, Kopp C, Herzog H (1979) Therapeutische Empfehlungen beim idiopathischen Spontanpneumothorax. *Schweiz Med Wschr* 109:36–39
35. Unholtz K (1972) Richtlinien der chirurgischen Therapie des Spontanpneumothorax. *Thoraxchirurgie* 20:303–307



# Thoracoscopic Treatment with Fibrin Sealant of Ruptured Emphysema and Recurring Spontaneous Pneumothorax

D. KAISER and J. SCHILDGE

*Key words:* Recurring spontaneous pneumothorax, thoracoscopy, mediastinoscopy, fibrin sealing

## **Abstract**

Thirty-six patients with recurring spontaneous pneumothorax or with pneumothorax resistant to therapy were subjected to thoracoscopy under insufflation anaesthesia. In 89% of the cases changes in the lung surface could be identified as the cause for the recurrence. In 29 patients the changes were removed by thoracoscopy and the airleak sealed with 2 ml fibrin sealant, which was successful in 24 cases (84%). In three cases a parenchymal defect had to be additionally sutured and in four other cases an immediate anterolateral thoracotomy had to be performed subsequently, as the condition did not seem reparable by thoracoscopy. In 75% of all cases thoracotomy with all its disadvantages was avoided by this procedure.

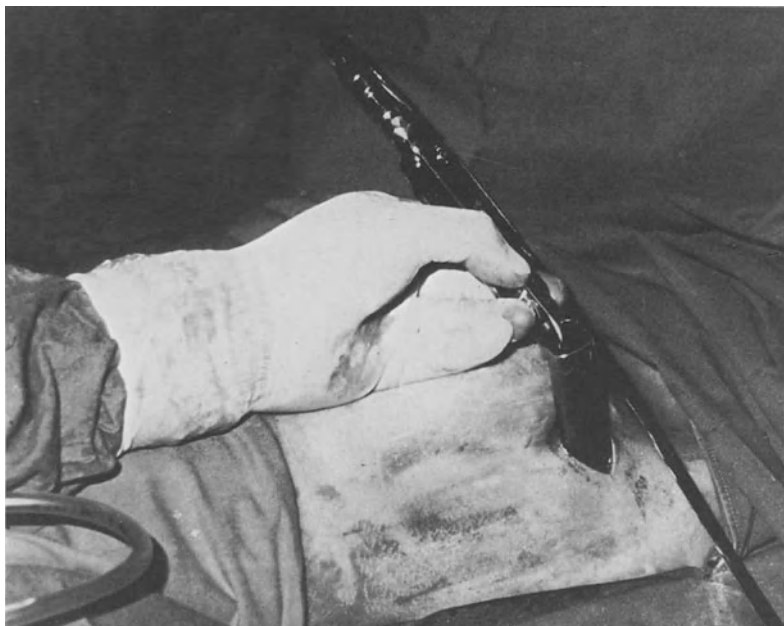## **Introduction**

In 1973 Masshoff and Höfer proved in a series of histological examinations of more than 100 cases that even in so-called idiopathic spontaneous pneumothorax one can always identify pathological morphological changes in the lung and pleura [4].


Thus the leakage of air into the pleural fissure may only be considered the symptom of a change in the area of pleuropulmonary functional interaction in this syndrome. In general, treatment with pleural drainage leads to a reexpansion of the lung; the reasons for the pneumothorax, however, the changes on the lung surface, are not eliminated by this method. This explains the high recurrence rate of 10% – 30% in spontaneous pneumothorax after therapy with only drainage. This recurrence rate even increases to 37% in new recurrences [2].

## **Material and Method**

Since 1980 thoracoscopy with the mediastinoscope as indicated by Maassen (1972) was performed in patients with pneumothorax, where the lung had not dilated in spite of drainage after 5 days, or patients with recurrence after precedent drainage therapy [3]. Patients with radiologically visible large bullae were excepted from this procedure. In these cases mainly thoracotomies were performed.



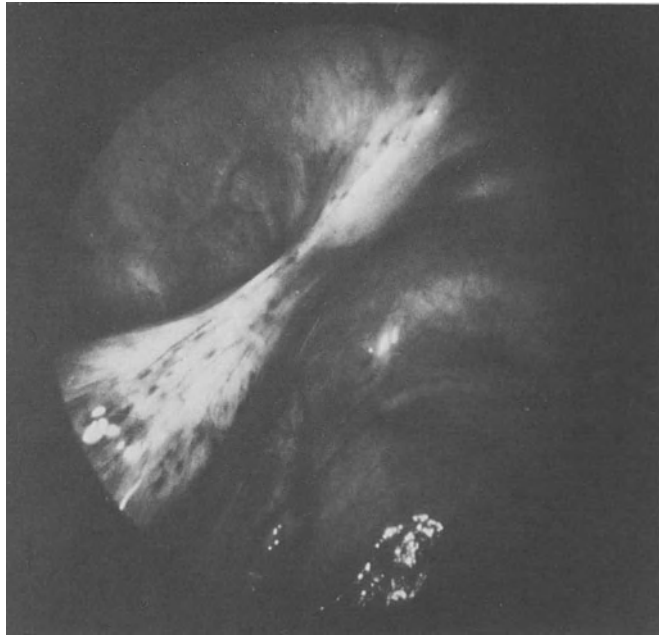
**Fig. 1.** Mediastinoscope in the frontal axillary line of the thorax



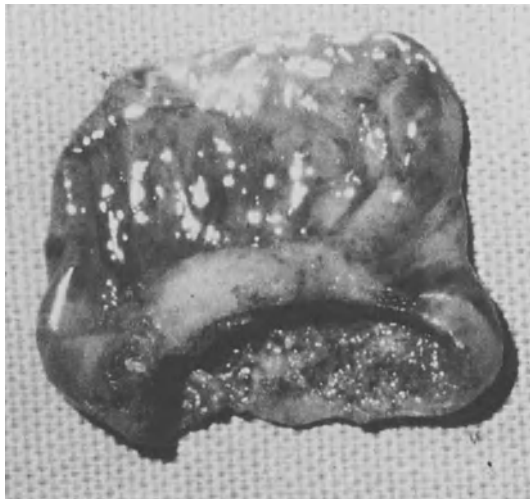**Fig. 2.** Mediastinoscope, special model of Storz Company, 24 cm long

Access was made in the intubated patient in the semilateral position by a skin incision of 3–4 cm relatively high in the frontal midaxillary line. After separating the intercostal muscles and opening the parietal pleura the mediastinoscope was introduced (Fig. 1). For the past 6 months we have been using a mediastinoscope which was made according to our instructions by the Storz company. Its tube length is 24 cm (Fig. 2).

Adhesion thoracocautery is performed by means of a diathermy probe. Emphysematous bullae (Fig. 3) are removed by means of an electric loop (Fig. 4). In the area



**Fig. 3.** Emphysematous bulla and fibrous adhesion in the cupula of the thorax



**Fig. 4.** Emphysematous bulla removed by electric loop, base diameter, 2 cm

of the cervical pleura the parietal pleura is roughened with a dissecting cup to obtain mechanical pleurodesis. The visceral pleural fistula and the resection area of the emphysematous bullae are sealed with 2 ml fibrin sealant under thoracoscopic control.

We then place a pleural drainage Charrière 24 for 48 h next to the thoracoscopic wound. While the anesthetist inflates the lung to close the fistula with the thoracic wall the wound is sealed in layers.

Compared with thoracoscopy with local anesthesia with the “Jacobäus instrumentarium”, our method has the following advantages:

1. Wider instrumentation channel with the open system and thus a better range of action for the surgeon
2. Possible mechanical pleurodesis by roughening of the parietal pleura with a dissecting cup or sponge
3. Inflation of the lung with hyperbaric pressure after sealing, leading to rapid pleurodesis in the sealed area
4. The possibility of closing larger pleural leaks by suturing without extending the incision
5. Possibility of performing anterolateral thoracotomy if the condition cannot be improved thoracoscopically

**Results**

We performed surgical thoracoscopy in a total of 36 patients because of recurring or persisting pneumothorax. In four patients only we found the lung surface macroscopically without pathological findings. In 32 cases, however (89%), there were morphological changes such as thickening of the pleura, adhesions or smaller or larger blisters.

In 29 patients the condition could be improved by thoracoscopic measures and purely endoscopic fibrin sealing; in three other cases the parenchyma leak was secured by an additional suture (Table 1). Surgical thoracoscopy was thus performed as a therapy in 32 cases and was successful in 27 cases (Table 1). The longest observation period was 4 years, the shortest 3 months.

**Table 1.** Thoracoscopy in recurrent spontaneous pneumothorax (n = 36)

Thoracoscopy + sealing	Thoracoscopy + sealing + suture	Thoracoscopy + thoracotomy
29	3	4
success		success
27		4

In five patients (16%) this method was not successful (Table 1).

- 1 × recurrence after 9 days
- 1 × recurrence after 40 days
- 1 × insufficient thoracoscopic control
- 1 × technical mistake
- 1 × unsuitable case

The operation performed afterwards showed only three (9.4%) real failures: In one case thoracotomy on the 9th day showed that the sealed area was not airtight. In another patient with recurrence after 40 days the water test performed during the operation showed no air leak. The third patient had emphysematous bullae at the tip of the lower lobe that we had failed to see during thoracoscopy and that were the reason for the recurrence. The two other failures date from our initial period and cannot be blamed on the method. Once there was a technical mistake, and in the fifth patient we had to find out during subsequent thoracotomy that thoracoscopy was unsuitable for his condition, because of the extensive adhesion of the lower lobe with the cervical pleura as a consequence of cirrhotic tuberculosis of the lung. In four patients we found a condition that could not be improved by thoracoscopy, so we immediately performed anterolateral thoracotomy (Table 1).

### ***Discussion***

Our examinations showed thoracoscopically visible changes of lung and pleura in 89% of patients with spontaneous pneumothorax. It has to be presumed that these changes are responsible for the recurrence of the pneumothorax. The only possible therapy can thus only be the elimination of these changes in order to avoid further recurrences. Extended forced drainage therapy does not seem appropriate in this case. Haphazard measures to accelerate pleurodesis [5,6] only lead to further adhesions without eliminating the morphological changes of the lung surface.

Surgical thoracoscopy constitutes little stress for the patient and is a valuable method for eliminating morphological changes of the lung surface by diathermy and for closing the air leak with 2 ml fibrin sealant under thoracoscopic control. Boutin obtained the same result by means of laser coagulation [1].

A prerequisite for success of the thoracoscopic method is the elasticity of the lung, which means that the lung is not yet covered by a fibrin pannus. In comparison to thoracoscopy according to Jakobäus it is an essential advantage of our method that subsequent thoracotomy may be performed at any time if necessary.

The performance of thoracoscopy in spontaneous pneumothorax helped avoid thoracotomy with all its disadvantages in 75% of the cases.

### ***References***

1. Boutin C, der Nd: YAG Laser in der Thorakoskopie, Laser in der Pneumologie, Internationales Symposium, Essen, 20 – 21 September 1985
2. Kaiser D, Wolfart W (1983) Therapeutische Prinzipien zur Behandlung des Spontanpneumothorax unter besonderer Berücksichtigung der thorakoskopischen Emphysemblasenabtragung und Fibrinklebung. Praxis klinische Pneumologie 37: 979-982

3. Maasen W (1972) Direkte Thorakoskopie ohne vorherige oder mögliche Pneumothoraxanlage  
Endoskopie 4: 95-98
4. Maashoff W, Höfer W (1973) Zur Pathologie des sog. idiopathischen Spontanpneumothorax,  
Deutsche medizinische Wochenschrift 98: 801-805
5. Scheele J, Mühe E, Woptner F (1978) Fibrinklebung, eine neue Behandlungsmethode beim  
persistierenden und rezidivierenden Spontanpneumothorax, Chirurg 49: 236-243
6. Spiegel M, Benesch J, Siebenmann R (1983) Thorakoskopische Pleurodese bei Spontanpneumo-  
thorax, Praxis klinische Pneumologie, 37: 976-978

# Animal Studies as for the Problem of the Bronchial Fistula

N. PRIDUN, W. HEINDL, H. REDL, G. SCHLAG, and E. MACHACEK

*Key words:* Bronchopleural fistula, endoscopic sealing, fibrin sealant, spongiosa – block

## ***Abstract***

An animal study on the closure of bronchopleural fistulas is reported. Fibrin sealant (Tissucol) was combined with decalcified spongiosa. This combination was introduced bronchoscopically into central bronchus fistulas that had been created experimentally in dogs. In 10 mongrels the fistulas were closed immediately, healing was then observed endoscopically and histologically. There was rapid incorporation of the implants. In the long-term experiment fibrin and spongiosa were completely resorbed and the experimental fistula was healed. The experiment allows the conclusion that endoscopic closure of fistulas is possible regardless of the fistula's diameter, and that this method should also be tested in human patients.

## ***Introduction***

Bronchopleural fistulas after lung resection usually occur as postoperative septic lesions and appear on the bronchial stump; the diameter and mechanic strain vary during respiration. This is a dangerous situation for the patient and should be managed as rapidly and carefully as possible. Unfortunately, lethality during corrective operations is high and surgical measures are not always successful.

Endoscopic sealing of these fistulas, however, is a simple method and of little risk to the patient. These sealings are performed with cyanocrylate (Histoacryl) [1, 2, 4] and with fibrin sealant [5]. In both techniques the size of the fistula is the limiting factor. Histoacryl can only be used in very small fistulas at the earliest stage. Sealing with fibrin sealant (Tissucol) has been described in fistulas up to 3 mm in diameter [5]. Central bronchial fistulas after pneumonectomies, the most frequent complication, may be considerably larger.

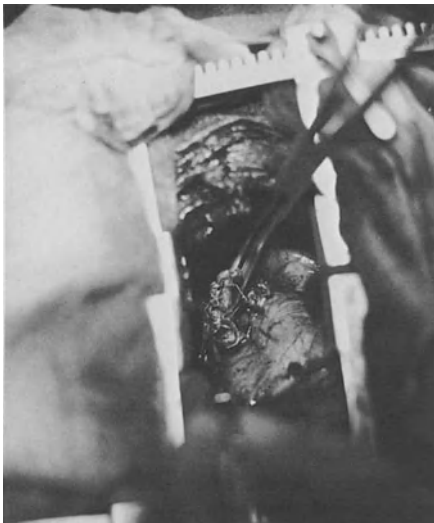In order to close these larger fistulas endoscopically, we have looked for materials that could be used in combination with fibrin sealant. The necessary requirements for such an implant material are that it must be absorbable, deformable, and yet humid. The fistula should be sealed immediately, the implant should be healed or absorbed after some time, allowing natural healing to permanently close the fistula.

It was the solidity requirement that made us think of bone. We decalcified it to make it deformable. If the spongiosa of the bone is used, a spongy, well deformable

and yet very consistent substance is obtained. In combination with fibrin sealant even anatomically complicated fistulas may be sealed; the spongiosa, pressed into the opening, spreads well and resists great mechanic strains. To prove the correctness of these thoughts an animal experiment was performed with a model that attempted to simulate post lung resection bronchopleural fistulas in humans.

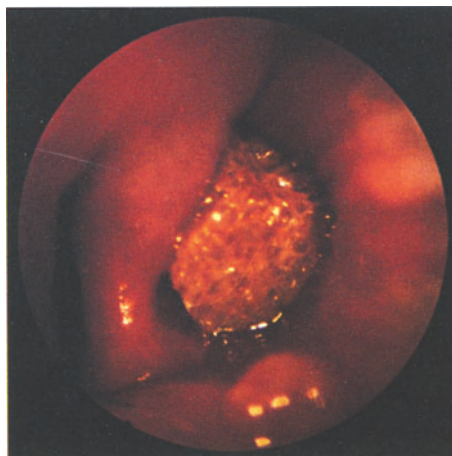
### **Method**

Dogs of up to 10 kg have a bronchial system that is similar in size to the human. Ten mongrels with a mean weight of 9.5 kg were anesthetized with sodium pentobarbital (Nembutal), 2.5% solution, 25 mg/kg intravenously, and intubated with a respiratory bronchoscope. Anesthesia was maintained with a mixture of 60% nitrous oxide, 1%–2% halothane and oxygen. Ventilation was performed by the jet ventilation technique (30 Hz) in the open system, with the dog breathing spontaneously. In right lateral position a left pneumonectomy was performed, a fistula (1.5-cm-diameter) was formed with each the upper lobe bronchus and the lower lobe bronchus (Fig. 1). The epithelium was removed from the “fistula” by means of a brush through the bronchoscope. Decalcified spongiosa, used as implantation material, was obtained from dogs’ femoral heads, shaped to chunks corresponding in size, soaked with the sealing protein, and placed into the fistula with endoscopic forceps (Fig. 2). Thrombin solution was introduced (500 NIH U/ml) and then both components simultaneously into the bronchus by means of a multichannelcatheter (Spray Set Immuno). Only then was the thoracotomy closed without drainage. After the operation the dogs were kept in an ordinary kennel. The animals were controlled by a veterinarian and received antibiotics and analgesics. Healing of the implants was observed endoscopically under general anesthesia with 30 mg/kg i.m. Ketamine hydrochloride (Ketalar), histologically on the 7th and 11th day after surgery and two months after complete incorporation.



**Fig. 1.** Central fistula formed in surgery. Left pneumonectomy



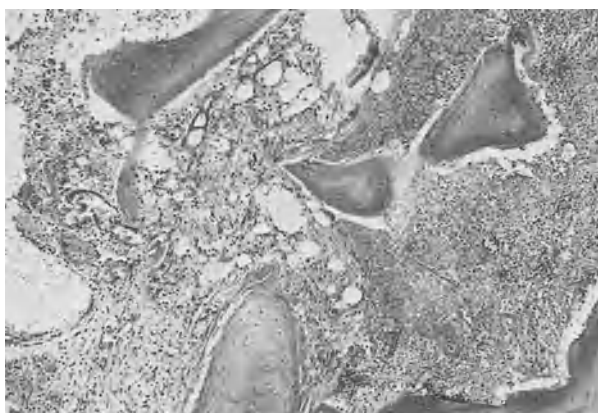


**Fig. 2.** Endoscopically placed spongiosa. The fistula is immediately closed tight

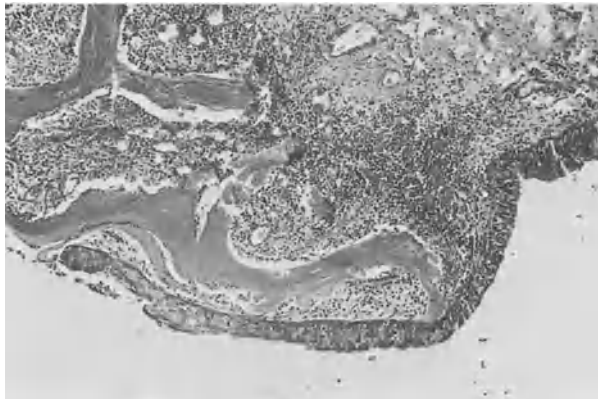### **Results**

In all cases the fistulas were immediately closed tight and resistant to strain after anesthesia. On the 3rd day after surgery granulation tissue was already growing into the implant (Fig. 3). On the 7th day after surgery the fistula began to contract around the spongiosa and the epithelium started to grow from the bronchus to the implant (Fig. 4)

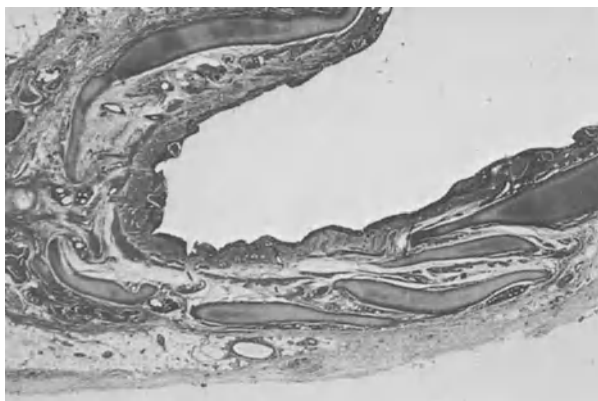
On the 11th day after surgery the spongiosa was completely incorporated (Fig. 5). Two months later, both experimentally formed fistulas are perfectly healed without complications and cannot be differentiated endoscopically (Fig. 6). Histologically we found the plates of hyaline cartilage of the original bronchus and scar tissue. Spongiosa and fibrin were completely absorbed (Fig. 7).



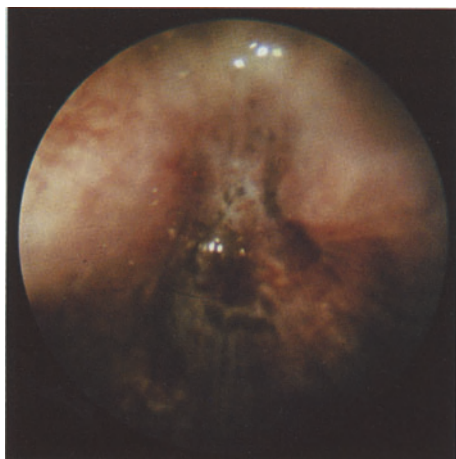
**Fig. 3.** Tissucol and decalcified spongiosa 3 days after surgery. Onset of organization by growing blood vessels and fibroblasts. (H&E,  $\times 100$ )



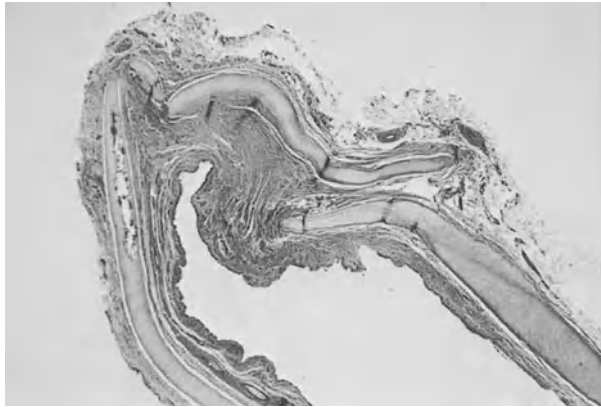
**Fig. 4.** Tissucol and decalcified spongiosa 7 days after surgery. Bronchial epithelium is growing across the decalcified bone. (H&E,  $\times 100$ )



**Fig. 5.** Tissucol and spongiosa 11 days after surgery. Bronchus already healed to a large extent; only remnants of spongiosa trabeculae are seen in the epithelium or the adjacent mucous stroma. (H&E,  $\times 20$ )



**Fig. 6.** Completely healed and endothelialized bronchial stump viewed endoscopically



**Fig. 7.** Two months after surgery: sealed and healed bronchus with small scarred stump. (H&E,  $\times 20$ )

### **Discussion**

In spite of the most modern sealing techniques it is not yet possible to close the bronchus without formation of fistulas [4]. The rate of fistulas in our patients is 2.5% at present with an average of 150 pneumonectomies per year. Fistulas may be very different in size – from the dehiscence between two sutures or clamps, that is a few millimeters, to complete necrosis of the stump, which means a diameter of 2–3 cm.

The most rapid and best tolerated technique to manage the situation is endoscopic sealing. Because of the varying diameter of the fistulas, the septic situation, and the mechanic strain during respiration and coughing, we looked for adequate biological material that could be adjusted to these conditions.

Fibrin sealant (Tissucol) has proved successful in smaller fistulas [5]. For the management of larger fistulas we combined the sealant with decalcified spongiosa. This combination made it possible to close even lobar bronchi endoscopically and to make them heal. The rigid implant triggered a strong foreign body reaction with rapid formation of granulation tissue that proliferated into the spongiosa block. The implant healed very quickly and became epithelialized.

### **References**

1. Arruda RM, Neto FL, Santos P, Starvaggi AG (1979) Fechamento do coto bronquico com adesivo a base de metilcianoacrilat. Estudo experimental. *Rev Assoc Med Brasil* 25:435
2. Barthelemy C, Audigier JC, Fraisse H (1983) A non-tumoral esophago-bronchial fistula managed by isobuty1-2-cyanoacrylate. *Endoscopy* 15:357
3. Maaßen W, Stamatis G, Greschuchna D (1985) Klammernahtgeräte in der Chirurgie der Lunge. *Chirurg* 56:227
4. Moritz E, Eckersberger F (1985) Endoskopische Klebung postoperativer Bronchusfisteln. *Chirurg* 56:127
5. Waclawiczek HW, Wayand W, Chemelizek F (1984) Homologe Fibrinklebung am Bronchusstumpf nach Pneumonektomie im Tierexperiment. 25. Tagg. Österr. Ges. Chir., 21.–23. 6., Graz, 202 (Abstract)

# Endoscopic Occlusion of Bronchus Stump Fistulae Following Pneumonectomy with Fibrin Sealant in Animal Experiments

H. W. WACLAWICZEK and F. CHMELIZEK

*Key words:* Bronchial stump fistula following pneumonectomy, endoscopic occlusion, fibrin sealing

## **Abstract**

An occlusion of the bronchus stump following pneumonectomy was achieved by using only fibrin sealant transthoracically in 14 domestic pigs. Standardized bronchus stump fistulae could also be closed with the fibrin sealant, which was applied through a flexible bronchoscope in ten additional animals. An average quantity of 1 ml fibrin sealant containing 500 units thrombin and 3000 units aprotinin was necessary for the bronchial closure and to prevent early dissolution of the fibrin clot. This endoscopic method was already employed successfully in one clinical case of a bronchus stump fistula.

The bronchus stump fistula is one of the most dreaded complications following pneumonectomy. Since the use of mechanical staplers the rate of this complication has been definitely decreased. But once a fistula occurs its treatment is unsatisfactory. In this experimental study we evaluated the feasibility of an endoscopic occlusion of bronchus stump fistulae by fibrin plugs.

## **Methods**

For pneumonectomy on experimental animals (domestic pigs weighing 20 kg) we developed a modified insufflation anesthesia; this was performed with N<sub>2</sub>O and O<sub>2</sub> (1:1), relaxation and positive pressure ventilation of 20 cm H<sub>2</sub>O. Thoracotomy always took place in the seventh intercostal space; a left-sided pneumonectomy was chosen because the surgical intervention was comparable to that in man. After open dissection of the main bronchus various experiments were carried out:

### 1. Preliminary experiments ( $n = 14$ ):

The bronchial stumps (diameter 12 mm) were closed only with homologous fibrin sealant without using additional sutures (Fig. 1). In half of these cases we used a collagen carrier for the glue. After a clotting time of about 5 min the central clamping of the main bronchus was removed. An average quantity of 1 ml fibrin sealant containing 500 units thrombin was sufficient; 3000 units aprotinin was necessary to avoid early dissolution of this fibrin clot.

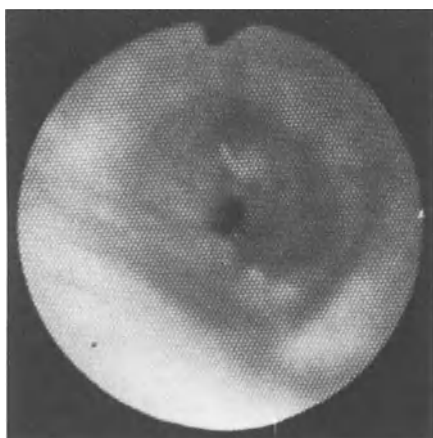
### 2. Endoscopic occlusion of bronchus stump fistulae ( $n = 10$ ):

The bronchus stump was occluded first of all with a stapler TA 30 using a 4.8 loading unit transthoracically. Then the creation of a bronchus stump fistula with

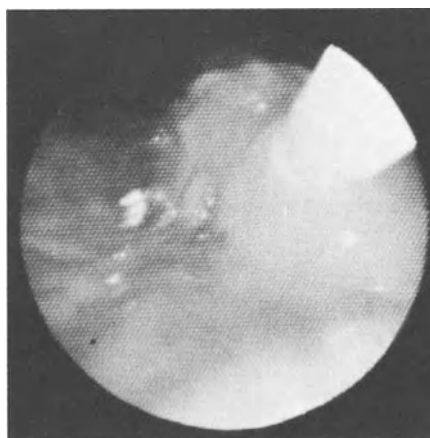


**Fig. 1.** Closure of the bronchus stump by transthoracic application of fibrin sealant alone

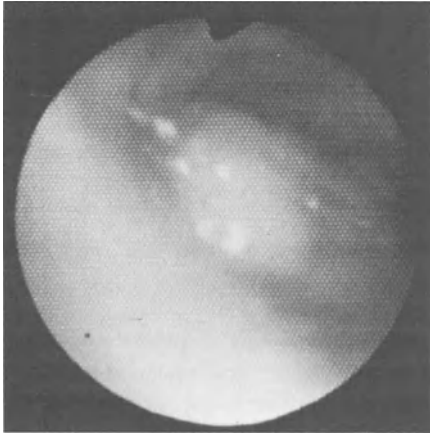
a diameter of 3 mm followed by removing two staples (Fig. 2). Via a flexible bronchoscope a thin plastic catheter was inserted next to the fistula on an endobronchial passage, through which the fibrin sealant was applied (Fig. 3). This fibrin plug (same mixture as described above) occluded the fistula (Fig. 4). The tightness of the closure was always checked transthoracically by filling the chest cavity with water.



**Fig. 2.** Standardized experimentally created bronchus stump fistula (diameter 3 mm) – endoscopic view



**Fig. 3.** Application of the fibrin sealant via a plastic catheter – endoscopic view



**Fig. 4.** Bronchial fibrin plug – endoscopic view

The thorax was closed in standard fashion without inserting a chest tube in all cases. The animals were extubated and fully mobilized within 3 h. Postoperative respiratory function was sufficient. The domestic pigs were killed between the 3rd and the 300th postoperative days.

### **Results**

1. In all 14 pigs an airtight and waterproof occlusion of the bronchus stump was achieved by applying only fibrin sealant transthoracically although positive pressure ventilation was carried out. Furthermore, these experiments showed that the use of a collagen carrier was not required and on the other hand that it was even dangerous because of the risk of aspiration of the fibrin plug into the contralateral bronchus.
  2. It was also possible to achieve a closure of bronchus stump fistulae ( $n = 10$ ) by using fibrin plugs, which were applied endoscopically.
- All animals of both groups survived without complications. On autopsy the fibrin sealant was not found after the 6th day postoperatively and was replaced by growth of fresh connective tissue; chondroneogenesis was noted at the end of the observation period (300 days after surgery).

### **Discussion**

Bronchus stump fistula following lung resections, especially pneumonectomy, occurs in 4% (1%–13%) of all cases and has a mortality of 90% [4]. Its incidence depends on many factors – anemia, malnutrition, local problems including tumor disease, infection and inadequate surgical technique [7, 8] – and has decreased since the introduction of mechanical staplers [9, 11]. Numerous reports of its treatment

have appeared in the medical literature on the transthoracic approach [2, 6, 10], but the results of these attempts have been largely unsatisfactory. The reasons are the rapid deterioration of the patient's general condition caused by frequent pneumonic involvement of the contralateral side and the spreading pleural infection. Therefore transthoracic repair of the bronchus stump fistulae is mostly impossible.

Only a few reports of endoscopic attempts at occlusion of pleurobronchial fistulae have been published [1, 3, 5]. For this reason we undertook this experimental study to develop a new method for the occlusion of bronchus stump fistulae using a fibrin clot endoscopically. This procedure is possible without subjecting the patient to the stress of a formal rethoracotomy and can be repeated on the subsequent days.

The fibrin sealant adheres well to the tissue of the bronchus stump after a clotting time of about 5 min. A high concentration of 500 units/ml thrombin for rapid clotting and of 3000 units/ml aprotinin in order to avoid early dissolution of the clot is necessary. An average quantity of 1 ml is sufficient.

In all our animal experiments we succeeded in the occlusion of bronchus stump fistulae following pneumonectomy by using fibrin plugs, even when positive pressure ventilation was carried out. This endoscopic method was also employed successfully in one patient with a bronchus stump fistula 5 days after left-sided pneumonectomy. To us this procedure seems to have become the method of choice for the closure of bronchus stump fistulae occurring early after lung resections (before the tenth postoperative day) when the extent of infection is still low. This method merits further evaluation; currently we therefore undertake experiments on infected bronchus stump fistulae, in the course of which antibiotics are added to the fibrin sealant.

## References

1. Altaparmakoff A, et al. (1977) Endobronchial treatment of postoperative bronchial fistulae. *Bronchopneumatologie* 27: 75
2. Anderson RP, et al. (1983) Anterior transpericardial closure of a main bronchus fistula after pneumonectomy. *Am J Surg* 145: 630
3. Ellis JH, et al. (1982) Balloon catheter occlusion of bronchopleural fistulae. *AJR* 138: 157
4. Lynn RB, (1958) Survey of the methods of bronchial stump closure. *J Thorac and Cardiovasc Surgery* 36: 70
5. Nakhosteen JA, Massen W (1981) *Bronchology: research, diagnostic and therapeutic aspects*: 111. Martinus Nijhoff Publishers. The Hague-Boston-London
6. Prohazka J (1977) Postoperative Bronchusstumpfinsuffizienz. *Zbl Chirurgie* 102: 657
7. Schoefer G, Demischew M (1977) Bronchusstumpfersorgung konservativ oder maschinell? *Zbl Chirurgie* 102: 661
8. Scott RN, Faraci RP, Hough A, Chretien PB (1976) Bronchial stump closure techniques following pneumonectomy. *Ann Surg* 184: 205
9. Umlauf M, Steiner H, Waclawiczek HW, Wayand W, Zimmermann G (1980) Die Anwendung von Nahtapparaten in der Chirurgie primärer maligner Lungentumoren. *Aktuelle chirurgische Onkologie*, Bd 2: 1098
10. Viglione GC et al. (1982) Resection and suture of left post-pneumonectomy fistulae using the anterior mediastinal and extrapleural approach. *Minerva Chir* 37: 2113
11. Weil PH (1975) Die Anwendung von Nahtapparaten in der Abdominal- und Thoraxchirurgie. *Kongreßbericht der 16. Tagung der Österreichischen Gesellschaft für Chirurgie*, Wien: 320

# A New Approach in Patients with Malignant Pleural Effusions

E.D. KREUSER, E. SEIFRIED, and R. HARTMANN

*Key words:* Malignant pleural effusion, fibrin pleurodesis, fibrin sealing

## **Abstract**

The efficacy of intracavitary fibrin sealant in preventing the recurrence of malignant pleural effusions was assessed in the present study. From 1982 to 1984 30 patients with cytologically and/or histologically proven malignant pleural effusions were treated by fibrin pleurodesis. The median age was 58 years (26–83 years). Chest tube drainage was carried out as completely as possible, confirmed by chest X-ray, and then was followed by administration of 20 000 U aprotinin to decrease fibrinolytic activity. The sealant solution, mainly containing fibrinogen, factor XIII, fibronectin and albumin, was injected into the pleural space through the tube in a dose of 10 ml, promptly followed by the thrombin solution (500 U/ml). The chest tube was removed 24 h after the instillation.

Twenty-seven patients were evaluated. The overall response rate after 30 days was 77 % (21/27) with 70 % complete responders and 7 % partial responders. The toxic side effects were minimal. Fibrin pleurodesis was painless in all patients. In 10 % (3/30) of the patients mild fever was observed 1–3 days after the instillation of fibrin sealant.

We conclude that fibrin pleurodesis, shortening the pathophysiological pathway of pleural symphysis by sclerosing agents, may be an effective approach with minimal toxicity in patients with malignant pleural effusions.

## **Introduction**

Recurrent pleural effusions are prevalent and vexing problems in patients with malignant diseases. Several studies have clearly established malignancies as a major cause of pleural effusion. One-third to one-half of all pleural effusions are secondary to malignancies, most often breast cancer, lung cancer, ovarian cancer and lymphoma (Table 1). Of the patients with malignant effusions (87 %), experience marked respiratory discomfort [2]. At least a dozen different techniques have been used to prevent the recurrence of malignant effusions including thoracentesis, chest tube drainage, external radiotherapy or instillation of one of a variety of agents such as radioactive isotopes, sclerosing agents or cytotoxic drugs (Table 2). Response rates of 4 %–91 % have been obtained using these forms of treatment, but there are problems associated with their use. Radioactive isotopes subject both hospital



**Table 1.** Site of primary tumor most frequently causing malignant pleural effusions. (modified from [5])

Primary tumor	Incidence in series (%)
Breast cancer	26 – 49
Lung cancer	10 – 24
Ovarian cancer	6 – 17
Lymphoma	13 – 24
Non-Hodgkin's lymphoma	13 – 15
Hodkin's disease	7 – 9

**Table 2.** Effectiveness of techniques to control malignant pleural effusions (modified from [1])

Technique	No. of studies	Response rate <sup>a</sup> (%)
Talc	10	91
Quinacrine	9	80
Fibrinogen + thrombin	1	77
Doxorubicin	2	73
Tetracycline	8	72
5 – Fluoruracil	1	66
Bleomycin	2	63
NaOH solution	1	56
Radioisotopes	25	55
Chest tube drainage	4	55
Nitrogen mustard	10	52
Thiotepa	3	46
Thoracentesis	1	4

<sup>a</sup> Complete and partial response

personnel and patients to the risk of radioactive exposure. Cytotoxic drugs may give rise to bone marrow suppression, nausea and vomiting and some sclerosing agents tend to be poorly tolerated because of pleural pain and fever [1]. Repeated thoracentesis is often associated with complications such as pneumothorax, pain, protein depletion, encapsulated effusion and at best provides only temporary symptomatic relief with a response rate of 4% (1: Table 2). Because of these disadvantages there is a need for an agent that is effective, easy to administer and free of side effects. Since the use of fibrinogen and thrombin for tissue adhesion is a well-established method in surgery, we started a prospective study to assess the effectiveness and toxicity of pleural symphysis by intrapleural administration of fibrin sealant through a chest tube in patients with malignant pleural effusions.

## ***Patients and Methods***

### *Patients*

From 1982 to 1984, 30 patients entered this study. We treated 22 females and 8 males with cytologically and/or histologically proven malignant pleural effusion. The median age was 58 years (26 – 83 years). The malignant diseases were breast cancer ( $n = 18$ ), tumor of unknown origin ( $n = 4$ ), lung cancer ( $n = 3$ ), lymphoma ( $n = 3$ ) and germ cell tumor ( $n = 1$ ). Fifty-three percent (13/30) of the patients presented pleural effusion on the left side, 30 % (9/30) on the right side and 17 % (5/30) on both sides.

### *Diagnostic Procedures*

Cytologic examination of the pleural fluid was performed in all patients. If the result was equivocal cytology was repeated to increase sensitivity. A needle biopsy was carried out, if cytologic examination did not reveal a clear diagnosis. In all patients standard PA and lateral chest roentgenograms as well as decubitus films were performed prior to therapy, 1 day after pleurodesis, and again one month afterward.

### *Technique of Fibrin Pleurodesis*

Prior to treatment, informed consent was obtained from each patient. Pleural fluid was removed as completely as possible by chest tube drainage, confirmed by PA and lateral chest roentgenograms and decubitus films; 20000 U aprotinin were then administered into the pleural cavity to decrease fibrinolytic activity. Fibrinogen solution (Tissucol),  $4 \times 2.5$  ml, mainly containing human fibrinogen, factor XIII, fibronectin and albumin, was injected into the pleural space, promptly followed by  $4 \times 2.5$  ml thrombin solution (500 U/ml) with the patient in different positions

**Table 3.** Technique of fibrin pleurodesis

- 
1. Insertion of a polyethylene chest tube  
(length 50 cm, diameter 2.7 mm)
  2. Complete evacuation of pleural space
  3. Intrapleural application of 20000 U aprotinin
  4. Intrapleural instillation of Tissucol
    - $4 \times 2.5$  ml fibrinogen solution
    - $4 \times 2.5$  ml thrombin solution (500 U/ml)
 In four positions of the patient
    - On the left side
    - On the right side
    - Upright
    - On the back
  5. Clamp drain for 2 h
  6. Chest tube drainage for 24 h
  7. Removal of chest tube
-

(Table 3). This procedure was applied to increase the area of adhesion. The drain was clamped for 2 h after instillation. The chest tube was removed 24 h later, if no effusion had reaccumulated.

### *Response to Therapy*

A complete response was defined as no further reaccumulation of fluid within 30 days; a partial response as asymptomatic minimal recurrence not requiring a repeat of chest tube drainage within 30 days. Failure was defined as reaccumulation of the fluid within 30 days requiring further drainage (Table 4). Recurrences of effusion were determined by regular clinical assessment and chest X-ray. Three of 30 patients were not evaluated. They died of progressive disease within 30 days after fibrin pleurodesis. Side effects were documented using WHO criteria grades O-IV [7].

**Table 4.** Criteria of response after pleurodesis in patients with pleural effusions

Complete Response	A complete response is defined as no further reaccumulation of fluid within 30 days
Partial Response	A partial response is defined as an asymptomatic minimal recurrence, not requiring a repeat of chest tube drainage or thoracentesis within 30 days
Failure	Failure is defined as reaccumulation of the fluid requiring further drainage within 30 days

### *Concurrent Systemic Chemotherapy*

Concurrent cytotoxic chemotherapy was administered to 13/30 (43 %) patients, 7/30 (23 %) patients receiving the anti-estrogen tamoxifen and 8/30 (27 %) receiving no systemic therapy during and after fibrin pleurodesis.

## **Results**

### *Clinical Symptoms*

Prior to treatment, 26/30 (87 %) of the patients presented dyspnea and 16/30 (53 %) suffered from coughing. Chest pain was present in 3/10 (10 %) patients prior to the fibrin pleurodesis.

### *Response and Side Effects*

The overall response rate after 30 days was 77 % (21/27) with 70 % (19/27) complete responders and 7 % (2/27) partial responders. Three patients could not be evaluated (Table 5).

**Table 5.** Response rate and side effects in 30 patients with fibrin pleurodesis

Response	Patients	
	(n)	(%)
Complete response	19	70
Partial response	2	7
Failure	6	20
Not evaluated	3	10
Side effects		
Mild fever (less than 38.5°C)	3	10
Pneumothorax	1	3
Pain	0	0
Cough	0	0
Dyspnea	0	0

The instillation of fibrinogen and thrombin into the pleural cavity was painless in all patients. In 10 % (3/30) of the patients mild fever (less than 38.5°C) was observed. Pneumothorax occurred in one patient and another patient developed an empyema. Both patients had been treated with repeated thoracentesis prior to fibrin pleurodesis (Table 5).

### *Lag Time*

The median lag time, the interval between the diagnosis of malignant disease and the development of pleural effusion, was 2 years, with a range from 0 to 11 years.

### *Survival*

The median survival of all patients treated by fibrin pleurodesis was 7 months, the 1-year survival rate 42 %, and the 2-year survival rate 18 %.

### *Discussion*

To develop new treatment strategies for the management of pleural effusions, several requirements have to be considered. First, no treatment regimen should exacerbate the patient's symptoms, since palliation is the main aim. Secondly, seriously ill patients should not be subjected to procedures associated with a high morbidity. Thirdly, since a malignant pleural effusion usually indicates systemic disease, both local and systemic treatment are required.

The primary goal of treatment of malignant pleural effusions is the relief of symptoms. The obliteration of the pleural space prevents reaccumulation of fluid, and thus the effectiveness of an intracavitary agent depends on its ability to produce mesothelial fibrosis and sclerosis rather than its specific antineoplastic activity [1].

Criteria used to determine which patient showed an objective response varied considerably from study to study. To minimize this nonuniformity, we applied well-defined criteria (Table 4).

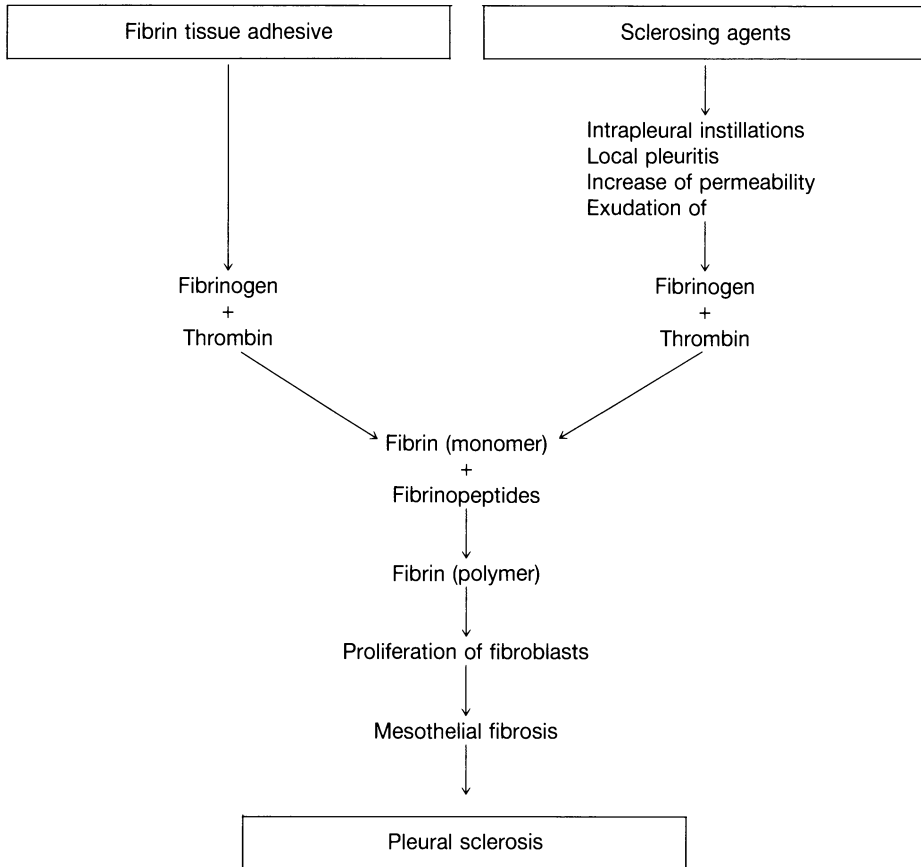
The ideal treatment of malignant pleural effusions should be effective, safe and convenient. On the basis of effectiveness, thoracentesis has a limited role in the treatment of malignant effusions because of the low response rate of only 4 % (Table 2). The greatest drawbacks to the use of radioisotopes are their inconvenience due to the risk of radioactive exposure for both hospital personnel and patients, and the low response rate of 55 % (Table 2). Reports of intrapleurally administered talc have demonstrated good results, achieving a response in 91 % (Table 2). Unfortunately, most authors used general anesthesia, and acute respiratory distress syndrome after the instillation of talc into the pleural cavity has been reported [2]. Although the published experience of tetracycline pleurodesis is small, this approach seems to be the treatment of first choice [1, 3], with a response rate of 72 % (Table 2). However, the intrapleural instillation of tetracycline is accompanied by fever in about 42 % and pleuritic pain in 33 %, mostly requiring narcotic analgesics [1].

We took advantage of the fact that fibrin tissue adhesive imitates the final step of plasmatic coagulation at a highly concentrated level in order to produce pleural symphysis by the intrapleural application of components of the coagulation system, in particular fibrinogen and thrombin. The result of this intrapleural coagulation is a cohesive elastic clot that adheres to adjacent structures by physical force as well as chemical bonds achieving sufficient mechanical strength after 3–5 min [6]. The network of fibrin strands induces proliferation of fibroblasts which causes pleural fibrosis and sclerosis (Fig. 1). Furthermore, the approach of this biologic tissue adhesive was reported to have no side effects.

The results of our study indicate that pleurodesis by intrapleural instillation of components of the coagulation system is effective in controlling malignant effusions with a response of 77 % (Table 5). The response rate is comparable with tetracycline pleurodesis, which achieves a response in 72 % (Table 2) and represents the treatment of choice present [1, 3]. In addition, we are able to demonstrate that the intrapleural application of fibrinogen solution and thrombin, using Tissucol, produced minimal toxic side effects (Table 5). Mild fever in 10 % (3/30) of our patients was the sole side effect we observed. The instillation of Tissucol was painless in all patients. In comparison to tetracycline, fibrin pleurodesis seems to be less toxic.

An effective technique to evacuate the pleural space is recommended. Although thoracentesis is clearly the first approach to establish the diagnosis in patients with pleural effusion, it has only a limited role in the control of recurrent malignant effusion (Table 2). Therefore, we used a chest tube in all patients to evacuate the pleural cavity as completely as possible and to administer fibrinogen solution and thrombin without technical problems.

By shortening the pathophysiologic pathway of pleural symphysis via sclerosing agents, pleurodesis by biologic fibrin adhesive proves to be an effective approach in treating patients with malignant pleural effusions. In addition, fibrin pleurodesis is less toxic than most sclerosing agents. In the future we plan to determine the relative importance of fibrin pleurodesis in the management of malignant pleural effusions in a prospective randomized trial.



**Fig. 1.** Pathophysiology of pleurodesis: comparison of sclerosing agents and fibrin tissue adhesive

**References**

1. Austin EH, Wayne Flye M (1979) The treatment of recurrent pleural effusion. *Ann thorac Surg* 28: 190-203
2. Bouchama AJ, Chastre A, Gaudichet, Soler P, Gibert C (1984) Acute pneumonitis with bilateral pleural effusion after talc pleurodesis. *Chest* 86: 789-795
3. Kreuser ED, Seifried E, Harsch U, Brass B, Schreml W, Heimpel H (1985) Fibrinpleurodesis bei malignen Pleuraergüssen. *Dtsch med Wschr* 110: 1365-1368
4. Kreuser ED (1985) Maligne Pleuraergüsse: Pathophysiologie, Diagnostik und Therapie. *Dtsch med Wschr* 110: 1381-1386
5. Mauch PM (1982) Treatment of malignant pleural effusions. In: DeVita VT, Hellmann S, Rosenberg SA (eds.) *Cancer. Principles and practice of oncology*. Lippincot Company, Philadelphia - Toronto p 1568
6. Scheele J, Gentsch HH, Matteson E (1984) Splenic repair by fibrin tissue adhesive and collagen fleece. *Surgery* 95: 6-13
7. WHO - Handbook for reporting results of cancer treatment. (1979) WHO Offset Publication No. 48, Geneva

# The Value of Fibrin Sealant in Esophagus Surgery

J. BOESE-LANDGRAF, R. HÄRING, and B. SEMSCH

*Key words:* Fibrin sealant, esophagus surgery, insufficiency rate

## **Abstract**

Postoperative suture insufficiency is one of the most serious problems in esophagus surgery. After resections, it has to be expected in 20% of the cases. Special anatomical features of the esophagus are partly responsible for the high insufficiency rate. With the application of fibrin sealant in connection with a change in surgical technique we have been able to reduce the anastomotic insufficiency rate, and we consider the mechanical suture support and the primarily fluid-proof closure to be the major advantages of fibrin sealant.

## **Introduction**

In esophagus surgery, postoperative anastomotic leakage is one of the most serious complications besides cardiorespiratory and renal complications. While smaller insufficiencies, especially when sealed off, have a good chance of healing under conservative therapy, the prognosis for broader insufficiencies is poor due to the occurrence of mediastinitis or peritonitis. With and without reoperation, a lethality of more than 80% has to be expected according to the literature [1].

The following factors are considered responsible for the occurrence of anastomotic leakage in abdominal surgery:

- Insufficient blood circulation in the edges of the esophagus wall to be joined
- Necrobiotic changes in the region of the anastomosis with a reduction in the mechanical wall stability
- An inaccurate suture technique in connection with insufficient hemorrhage control
- Establishment of anastomoses under tension

In esophagus surgery, the insufficiency rate for resections has to be put at between 10% and 20%, according to the literature; it is thus much higher than for other abdominal surgery [2].

Which additional factors are responsible for this? Compared with the other organs of the digestive tract there are special anatomical features of the esophagus which result in suture insufficiency:

The muscular tube of the esophagus is not covered by a serosa. Thus there is no anastomotic sealing that covers the fibrinous infection which otherwise normally runs its course in the serosa. Only the muscularis propria and the collagenous fiber system of the submucosa are suitable for placement of the suture, and, although they are relatively coarse and highly tensile, they do not nearly attain the load capacity of the small intestine.

The musculature of the esophagus consists of a network of apolar screw-like fibers. Due to the myelastical fiber system it tends to retract after severance. If the retractive tendency of the musculature is not taken into consideration, and if there is thus not enough interposition tissue available (i.e., stomach or intestine), the anastomosis necessarily comes under tension.

In the blood supply, too, there are differences as compared with the rest of the intestinal tract. The esophagus is supplied by end arteries, which, as small-caliber branches, originate from arteries that lead primarily to other organs, such as the thyroid, bronchial tree and stomach. The formerly assumed segmental supply of the esophagus by the aorta does not exist. The disadvantage of this end-artery supply of the esophagus by the aorta is that there does not exist a sufficient collateralization via short-circuit connections. There can thus be only limited mobilization in order to keep the degree of devascularization as low as possible.

### ***Materials and Methods***

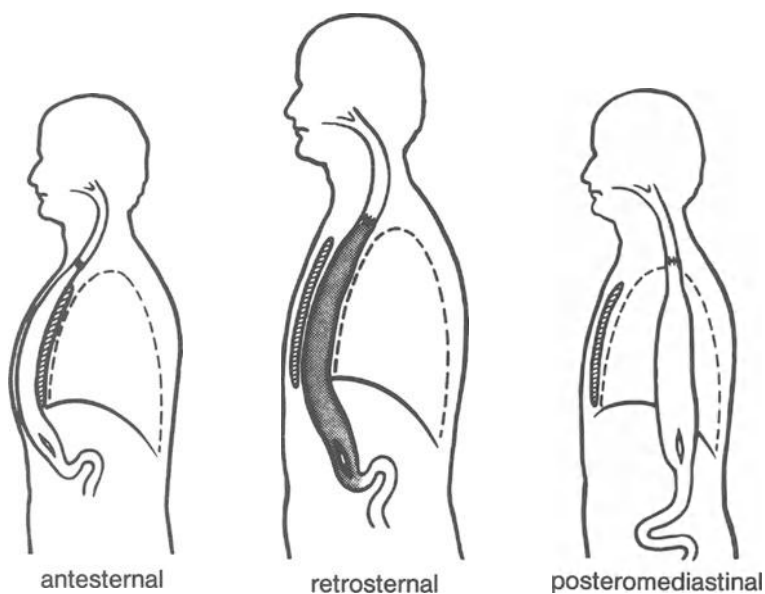
In view of the animal experiments and clinical investigations by the study group of *Scheele*, who were able to prove a positive effect of fibrin sealant on the anastomotic healing on the colon and the stomach, the question arose for us as to whether a similar positive effect on the in itself problematic esophageal anastomosis could be achieved, too, by using fibrin sealant [3].

Apart from individual case observations in pediatric surgery that describe a positive influence of fibrin adhesion on the anastomotic healing in the esophagus, a review of the available literature did not provide an answer to this question, so that I can only report on our own experience [4].

In the period from 1978 to 1984, we performed surgery on 94 patients with disorders of the esophagus. In 84 patients, the reason for the intervention was a histologically confirmed esophageal carcinoma; a curative resection from a macroscopic point of view was only possible in 44 cases.

While in the period 1978–1980, only those anastomoses intraoperatively considered to be problematic were additionally secured with fibrin sealant we began applying fibrin sealant routinely in 1980. In addition, we changed our surgical techniques in such a way (Fig. 1) that, since that time, we prefer performing a subtotal esophagectomy in cases of esophageal carcinomas, and we reconstruct the digestive tract by stomach transposition with a collar anastomosis between the esophagus and stomach. With this method, the esophagus is mobilized by blunt dissection in the mediastinum, after prior abdominal and cervical exposure, and the tumor-carrying section of the esophagus can be removed in an abdominal direction with the help of a vein stripper. The abdomen, which is stretched like a tube, is now displaced in the posterior mediastinum and pulled up to the level of the pleural vault

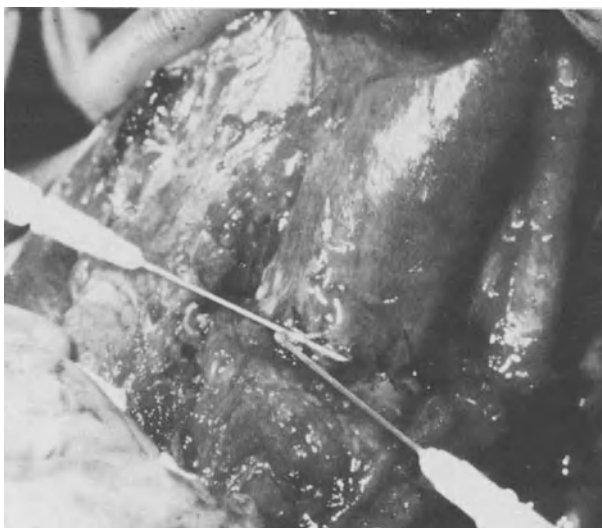



**Fig 1.** Ways of stomach transposition

[5]. We suture the posterior wall of the anastomosis with 4-0 Vicryl interrupted button sutures using the Gambee-Herzog technique, with the knots being in an intraluminal position. For the anterior wall, atraumatic interrupted button sutures of the same strength are performed in a single row on all layers.

The fibrin sealant is then applied as a thin coating on the anterior and posterior wall and we finish the intervention after placement of a lamellar drainage. In individual cases we glue collagenous fleece around the anastomosis (Fig. 2).



**Fig. 2.** Application of fibrin sealant on the anastomotic suture

## **Results**

With this type of surgical technique, in the past 4 years we have been able to lower the anastomotic insufficiency rate to less than 15%. Additionally, we no longer observe an extensive anastomotic insufficiency requiring reintervention.

Although we have only a relatively small patient collective, it is nevertheless our opinion that an additional securing of the esophageal anastomosis with fibrin sealant offers the following advantages:

- Because of the additional glueing, the suture does not have to be applied so closely that there is less danger of an anastomotic stenosis.
- There is a primarily fluid-proof closure,
- The applied glue functions in the sense of a serosa replacement and therefore has the effect of a mechanical suture support.
- An increase in the exterior mechanical stability of the esophagus wall under the influence of the fibrin reduces suture-induced tissue damage, i.e., the danger of severing fibers.
- A reduction of the anastomotic insufficiency rate can be expected as a result.

Despite our positive experience, which can only indicate a trend because of the small number of patients, a definite statement about the value of fibrin sealant in surgery of the esophagus will only be possible after a prospective multicenter study.

## **References**

1. Wittrin G, Langhans P, Kessler B, Jost JO, (1981) Klinik und Therapie der Nahtinsuffizienz an der Ösophagusanastomose. In: Häring R (ed) Chirurgie des Ösophaguskarzinoms, edition medizin, Weinheim Dierfield Beach Florida Basel p 123
2. Inberg M V, Linna M J, Scheinin T M, Vääntinnen E (1971) *Apm J Surg* 122:540–543
3. Scheele J, Herzog J, Mühe E (1978) Anastomosensicherung am Verdauungstrakt mit Fibrinkleber. Nahttechnische Grundlagen, experimentelle Befunde, klinische Erfahrungen. *Zbl Chir* 103:1325–1336
4. Brands W, Joppich J, Lochbühler H (1982) Anwendung von hochkonzentriertem Human-Fibrinogen in der Kinderchirurgie – ein neues Therapieprinzip. *Z Kinderchir* 35:159–162
5. Akiyama H (1980) Surgery of the esophagus. *Curr Probl Surg* 17:72–78

### ***III. Cardiovascular Surgery***

# Fibrin Sealant (Tissucol/Tisseel): An Effective Aid in Cardiac Surgery Techniques

S. EUFRATE, P. PUGLIESE, R. MOSCHETTI, L. SCEBBA, and F. VESCHI

*Key words:* Cardiac surgery, fibrin sealant, bleeding

## **Abstract**

The initial experience using the fibrin sealant "Tissucol" in 68 patients undergoing a variety of cardiac procedures during the period from July 1983 to July 1984 in our Cardiac Surgery Center is reviewed.

The operations comprised open heart procedures – those incorporating cardiopulmonary bypass (CPB) – and closed heart procedures – those without CPB. In the former group, all procedures were carried out using various degrees of hypothermia or deep hypothermia and circulatory arrest. The pathology involved both congenital (CHD) and acquired heart disease (AHD) including valvular, ischemic, and aneurysmal-degenerative disorders. Thus, the patients' ages ranged from 2 days to 70 years.

## **Introduction**

The extreme difficulty inherent in carrying out controlled studies in this field led us to consider application of fibrin glue in either cardiac (group I) or vascular suture lines (group II), although fibrin glue was often applied on both types in the same patient. Sealant was also used in a number of "satellite" situations. No fibrin glue-related complications were observed. Finally, an attempt was made to determine postoperative blood loss in patients in whom Tissucol was used by comparing these cases with a similar group in which fibrin sealant was not used.

We conclude that Tissucol is safe and invaluable for complex procedures (i. e., arterial shunt, aneurysms). Further, it is also very useful in a multitude of different situations where, however, cost may be a deterrent.

Biological glues with characteristics of compatibility with host tissues, ready absorbability and lack of secondary effects have been the subject of research for many years. At first neurosurgeons became interested in nerve-end fixation by means of fibrin [10] in place of sutures and at about the same time plastic surgeons turned their attention to fibrin for the same "fixing" or "stabilizing" purposes [1].

Microsurgery, encompassing several surgical disciplines, has great interest in glues inasmuch as they can reduce considerably the number of sutures required and the probability of bleeding. When microsurgical technique entered the field of clinical cardiovascular surgery it was logical and unavoidable that biological glues would be looked upon with increasing interest [3, 9].

The purpose of this work is to illustrate the use of fibrin glue (Tissucol/Tissel, Immuno) at the Cardiac Surgery Department of Massa Hospital, Massa, Italy, and to outline its advantages and possible fields of future application.

### **Material and Methods**

From July 1983 to July 1984 glue was used in 68 patients operated upon in our Department. Because of the extreme variability of setting and application patients were divided into two groups according to whether glue was applied on "cardiac" suture lines or over "vascular" suture lines. The first group (Table 1), comprised 11 patients (5 males and 6 females) ranging in age from 19 days to 68 years (mean, 29.7 years). In the second group (Table 2) there were 57 patients (31 males and 26 females) ranging in age from 2 days to 70 years (mean, 32.4 years). In group I there

**Table 1.** Group I: Tissucol on "CARDIAC" suture lines (all under CPB)

Congenital		Acquired	
TOF	2	Calcific MVR	3
TGA + VSD <sup>a</sup>	1 (Fontan modified)	LV pseudoaneurysm	1
VSD	1		
CAVC	1		4
TAPVC <sup>b</sup>	1		
PS	1 (Hancock valved conduit)		
	7		

TOF, tetralogy of Fallot; TGA, transposition of the great arteries; VSD, ventricular septal defect; CAVC, complete atrioventricular canal; TAPVC, total anomalous pulmonary venous connection; PS, pulmonary stenosis; MVR, mitral valve replacement; LV, left ventricle

<sup>a</sup> straddling right AV valve + hypoplastic right ventricle

<sup>b</sup> 1 = may be as in straddling (previous line) Infracardiac type

**Table 2.** Group II: Tissucol on "VASCULAR" suture lines

Congenital		Acquired	
TGA	6 (5 switch)	AVR <sup>a</sup>	16
TOF	7	AVR + MVR <sup>a</sup>	7
PS	3	Acute aortic dissection (type I)	4 (3 Bentall)
TA	2	CAD	5
CA	7		
	25 <sup>b</sup>		32 <sup>b</sup>

TGA, transposition of great arteries; TOF, tetralogy of Fallot; PS, pulmonary stenosis or atresia; TA, tricuspid atresia; CA, coarctation of the aorta; AVR, aortic valve replacement; MVR, mitral valve replacement; CAD, coronary artery disease

<sup>a</sup> Includes seven anular aortoplasty posterior patch enlargements (Nicks or Manougiuan II)

<sup>b</sup> 12 CHD and all AHD done in CPB

**Table 3.** "Satellite" use of Tissucol

No. of CASES	Procedure
2	Sealing of pulmonary air leaks
7	Prophylactic coverage of pulmonary electrocautery burn
6	Ventricular fixation temporary pacing wires
3	Atrial
2	Fixation of saphenous aortocoronary bypass graft

**Table 4.** Comparison of 24 h postoperative blood loss

Group I <sub>c</sub>	=	$\overline{82}$ ml/m <sup>2</sup>	<i>P</i> < 0.05
Group II <sub>c</sub>	=	$\overline{110}$ ml/m <sup>2</sup>	
Group I <sub>o</sub>	=	$\overline{238}$ ml/m <sup>2</sup>	<i>P</i> < 0.05
Group II <sub>o</sub>	=	$\overline{328}$ ml/m <sup>2</sup>	
Group I <sub>c</sub>	=	"closed heart" – Tissucol	
Group II <sub>c</sub>	=	"closed heart" – Control	
Group I <sub>o</sub>	=	"open heart" – Tissucol	
Group II <sub>o</sub>	=	"open heart" – Control	

were seven cases of complex congenital heart disease (CHD) and four of acquired heart disease (AHD), all operated upon with cardiopulmonary bypass (CPB).

In group II, 12 of the 25 CHD cases and all 32 AHD cases were operated upon with CPB, and Tissucol by Duploject syringe was often applied prior to removal of the aortic clamp at myocardial temperatures of below 18°C.

In addition there were a number of "satellite" applications of fibrin glue to test its possible use (Table 3).

Six attempts to hold temporary epicardial pacing wires on the ventricular and three attempts on the atrial surface were made. In two cases an attempt was made to glue a saphenous aortocoronary bypass graft to the heart surface to ensure a curvilinear snake-like smooth course. In two cases a pulmonary air-leak was sealed with fibrin glue. In seven patients superficial pulmonary electrocautery burn was prophylactically covered with fibrin glue.

An attempt was made to compare 24 h postoperative blood loss related to body surface area (BSA) in those cases in which Tissucol was used with a comparable group of cases in which it was not. Patients in whom Tissucol was used were divided into "closed heart", group I<sub>c</sub>, and "open hearts" (that is where CPB was used), group I<sub>o</sub>, and compared with similar "control" groups of patients, groups II<sub>c</sub> and II<sub>o</sub>, respectively (Table 4).

## Results

In no patient of either group was reoperation necessary because of bleeding. One patient in group I died on the second postoperative day (9.1%) whereas 3 of 57 patients in group II died (5.3%). No death in either group was due to bleeding.

Comparison of 24 h postoperative blood loss as obtained by drainage tube(s) shows that mean blood loss ( $\text{ml}/\text{m}^2$  BSA) of group I<sub>c</sub> ( $82 \text{ ml}/\text{m}^2$ ) was significantly less ( $P < 0.05$ ) than in group II<sub>c</sub> ( $110 \text{ ml}/\text{m}^2$ ). Similarly mean blood loss of group I<sub>o</sub> ( $238 \text{ mm}^2$ ) was significantly less ( $P < 0.05$ ) than in group II<sub>o</sub> ( $328 \text{ ml}/\text{m}^2$ ) (Table 4). On the "satellite" application of fibrin glue (Table 3):

1. the glue did not hold sufficiently to ensure permanence and function of temporary epicardial pacing wires
2. saphenous aortocoronary grafts were held very nicely in the desired position
3. pulmonary air-leak seal in two cases held nicely when tested before chest closure, and
4. no postoperative air-leaks occurred in the cases of pulmonary electrocautery burn prophylactically covered with Tissucol.

### **Discussion**

A prospective rigidly controlled study on the use of Tissucol is practically impossible for ethical reasons. Similarly a comparative retrospective study is made difficult by:

1. the multiplicity of areas of application,
2. the variability of patient population,
3. the different modes of utilization, and
4. the difficulty in establishing comparison control groups except in some restricted areas.

It is well known for instance that anastomoses with PTFE always bleed at the points of needle passage especially if the patient is anticoagulated. This bleeding, however, may not require the trouble or expense of using sealant fibrin glue. In contrast massive bleeding such as the one that might occur in surgery for aortic aneurysms (including acute dissecting) may be largely avoided by the use of fibrin glue on the open aortic ends between dissected layers, on the suture lines and for preclotting high or low porosity grafts [4, 5, 8].

In distal aortocoronary anastomoses the routine preventive use of fibrin glue is very advantageous in our opinion since additional sutures to stem bleeding are always hazardous and to be avoided if possible. This is even more so in sequential bypass anastomoses and where the internal mammary artery is used in sequential fashion.

The one area in which prevention of bleeding is of utmost importance is in the performance of the "arterial switch" operation for TGA where the use of Tissucol may be thought of as "lifesaving" inasmuch as control of bleeding from the posterior neofomed aorta and transposed coronary arteries by conventional methods may be prevented by the position of the suture lines. This has resulted in time lost in attempts at hemostasis, interference by additional sutures with the coronary artery buttons and in death of the patient from exsanguination. A notable added advantage with the use of fibrin glue in arterial suture lines is increased resistance to bursting pressure [6]. In our series of patients meaningful comparison of postoperative blood loss is tentative but encouraging. In other areas, usefulness of Tissucol is only speculative (i. e., pulmonary surface burn) and in others still totally unproven. Our experience has been negative in the area of fixation of temporary epicardial pacing

wires. Instead the glue has advantageously held saphenous bypasses in the desired smoothly curvilinear position adherent to the epicardium.

We have not found low temperature of tissues to be a negative factor in the formation of fibrin clot. Also, as in the experience of others, the clot forms well even in the presence of bleeding especially when using collagen sponges provided it is not too brisk and arterial.

Areas where studies may turn out to be proficuous are:

1. spraying mediastinal and split sternal surfaces to minimize or avoid bleeding and delayed hemorrhage requiring reoperation,
2. spraying the area of dissection in aortic coarctation to minimize or avoid occurrence of chylothorax,
3. use of antibiotic-fibrin glue mixture in the form of spray especially when using porous grafts.

Cost considerations may not necessarily be determinant [7] especially if saving of operative time and of blood units administered is considered. This will have to be evaluated in each Center in terms of global cost/advantage in large groups of patients. The fear of transmitted hepatitis may be considered overcome. The potential of transmitted AIDS was of concern, the problem has been eliminated by various virus inactivation methods [2, 7]. With advancing experience potential uses of Tissuocol have expanded rapidly and with further time they will become better characterized as well.

In conclusion we believe that the use of fibrin glue is highly valuable in the "arterial switch" operation for TGA and other complex forms of CHD, in surgery for aortic aneurysms (i. e., Bentall operation), and in aortocoronary bypass grafting, especially sequential.

## **References**

1. Cronkite EP, Lozner EL, Deaver JM (1944) Use of thrombin and fibrinogen in skin grafting. *JAMA* 124: 976-978
2. Dresdale A, Rose EA, Jeevanandam V, Reemtsma K, Bowman FO, Malm JR (1985) Preparation of fibrin glue from single-donor fresh frozen plasma. *Surgery* 97: 750-754
3. Eufrate S, Pugliese P, Moschetti R (1983) Aspetti dell'uso del Tissuocol in chirurgia dei grossi vasi e cardiocirurgia. In: *Convegno Multidisciplinare sul Tissuocol*, 3-5 Novembre 1983, Pisa. In Press
4. Guilmet D, Bachet J, Gondot B, Laurian C, Gigon F, Bical O, Barbagelatta M (1979) Use of biological glue in acute aortic dissection: preliminary clinical results with a new surgical technique. *J Thorac Cardiovasc Surg* 77: 516-520
5. Haverich A, Walterbusch G, Borst HG (1981) The use of fibrin glue for sealing vascular prostheses of high porosity. *Thorac Cardiovasc Surgeon* 29: 252-254
6. Jakob H, Campbell CD, Zhao-Kun Q, Pick RL, Replogle RL (1984) The use of fibrin sealant for reinforcing arterial anastomoses. *J Cardiovasc Surg* 25: 262
7. Ronson JA, Engelman RM, Breyer RH (1984) Fibrin glue: an effective hemostatic agent for nonsuturable intraoperative bleeding. *Ann Thorac Surg* 38: 409-410
8. Walterbusch G, Haverich A, Borst HG (1982) Clinical experience with fibrin glue for local bleeding control and sealing of vascular prostheses. *Thorac Cardiovasc Surgeon* 30: 234-237
9. Wolner E (1982) Fibrin gluing in cardiovascular surgery. *Thorac Cardiovasc Surgeon* 30: 236-237
10. Young JZ, Medawar PB (1940) Fibrin suture of peripheral nerves. *Lancet* II: 126-128



# Sealant Haemostasis in Cardiac Surgery: A Test Case for Fibrin Sealant (Tissucol/Tisseel)

J.G. VINCENT

*Key words:* Tissucol collagen felt, oxycellulosis, surgical haemostasis

## ***Abstract***

The clinical application of Tissucol on collagen felt is proven to be efficient for arterial or venous bleeding control. In addition to this experience, a piece of oxycellulosis fabric was used to cover the Tissucol collagen felt on the outside, in order to provide a smooth, non-adhesive external surface and to enhance the sealing effect towards the bleeding site.

## ***Introduction***


One of the achievements of cardiovascular surgery is haemostasis. The suture line of the aneurysmatic aortic or left ventricular wall is supposed to be blood-proof, as well as the suture line of the mammarian artery-anastomosis to the 1-mm large coronary artery branch.

The classical surgical technique of haemostasis can be very difficult, if not impossible, not only because of the friable tissue, but also because of the localization, i.e. the circumflex branch of the left coronary artery on the back of a beating heart or a single supplemental suture point, can seriously compromise a critical anastomosis. The time needed for a secure placement of such a suture point is limited by a few seconds, in which the necessary apex luxation is tolerated without circulatory collapse. The incidental need of a new institution of extracorporeal circulation and new cardiac arrest to correct this kind of bleeding is obvious. Finally superficial oozing from freshly dissected adhesions and friable tissues can cause major bleeding, which is not controllable with additional sutures. These can aggravate the situation, causing new bleedings from the suture point itself. The escape to general coagulation treatment, administration of blood products (fresh frozen plasma) and local application of different haemostatic agents (oxycellulosis fabrics/thrombin powder) hot sponges and local compression remain ineffective in many cases.

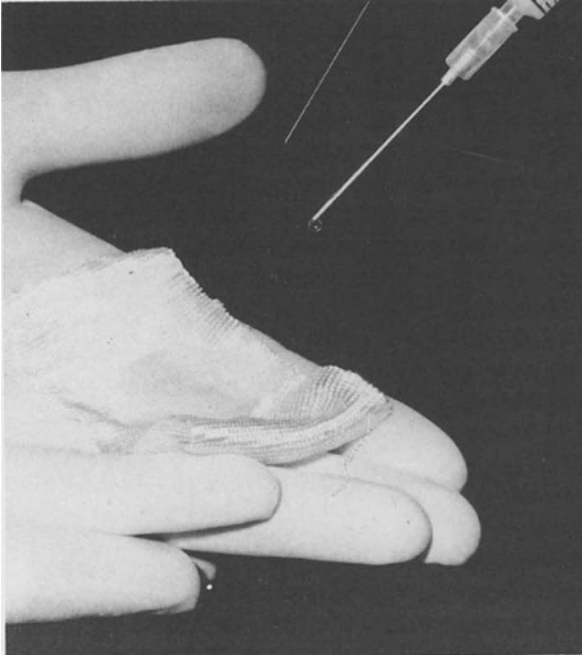
## ***Materials and Methods***

Tissucol fibrinogen, available as a four-compound sealing kit, prepared during the time of surgery and provided with two syringes, can be applied directly to the

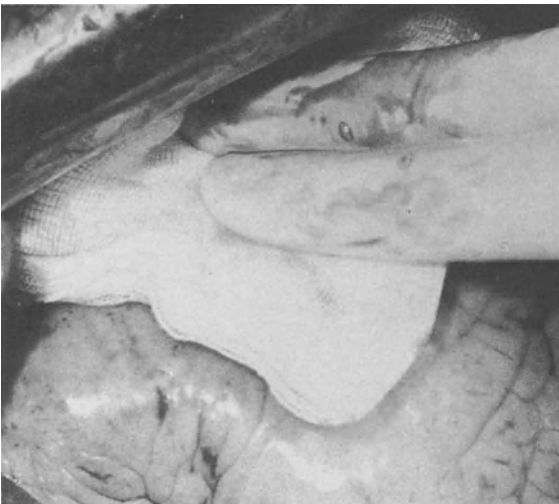bleeding area. One syringe contains fibrinogen with aprotinin and the other thrombin with  $\text{CaCl}_2$ . The excellent properties of this human fibrin sealant were explained and proved to be complication free [1]. Clinical reports on the use of Tissucol in surgery are numerous. Its use in cardiac surgery was proved to be efficient for arterial and venous bleeding control [2,3]. However, the optimal application of Tissucol requires a dry operating field, normothermia and immobilization for at least 5 min [4]. These conditions are difficult to obtain during or directly after cardiac surgery. These conditions can be better fulfilled if Tissucol is used preventively, covering the places or suture at risk during the cardiac arrest on a blood-free heart [5]. Still, most indications for the use of Tissucol appear after the disconnection of the extracorporeal circulation when the heart starts to beat again. In these cases Tissucol, spread or mixed on collagen felt and compressed to the bleeding point, was also effective. In our experience, control of bleeding on the posterior ventricular wall was still difficult, because Tissucol and the collagen felt appeared to adhere immediately to the dry, immobile pericardium or the compressing gauze and not to the place of bleeding on the beating heart, where they were supposed to adhere. A piece of oxycellulosis fabric added as an external cover to the Tissucol collagen patch provided a smooth external layer, non-adhesive to the pericardium, and gave us the possibility of a temporary application to the gauze which compressed the Tissucol collagen patch into the bleeding spot (Figs. 1–3). After a few minutes, the gauze can be carefully removed and the patch remains securely sealed to the bleeding place (Fig. 4). The oxycellulosis collagen Tissucol patch can be prepared by the scrub nurse just before application (Figs. 1, 2) and is passed with an underlying compressing gauze to the surgeon. The application itself is restricted to one single action manoeuvre of the apex luxation so there is no danger of circulatory collapse.



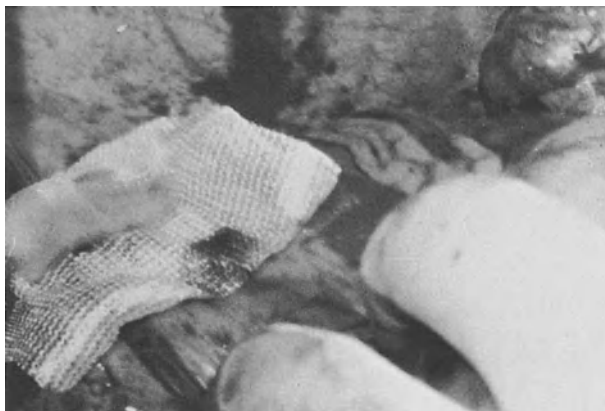**Fig. 1.** Composition of the collagen felt with oxycellulosis fabric cover



**Fig. 2.** Application of Tissucol on the collagen felt



**Fig. 3.** Application of the Tissucol collagen oxycellulosis patch on the bleeding point with a compressing gauze



**Fig. 4.** Tissucol collagen oxycellulosis patch after removal of the compressing gauze adherent to the bleeding site

### **Results**

In our service, the Tissucol collagen oxycellulosis patch was introduced to clinical application in 1981. Up till now, it has been used for postperfusion bleeding control in 114 patients. A single 1-ml kit was efficient in the case of 86 patients. In 20 patients a second 1-ml kit was used for larger bleeding areas and in 8 patients (most during our initial experience period), a second application was needed because of technical application problems. None of these patients figures in our 4% reintervention number after cardiac surgery.

This experience includes only the real haemostatic application of Tissucol. Recently, encouraged by the results of others, we have started to use it to cover the "risky" anastomosis or preparation places preventively on blood-free arrested hearts [5]. In those cases the use of Tissucol alone is successful, without the need for covering layers of collagen felt or oxycellulosis fabric.

### **References**

1. Braun F, Holle J, Knapp W, Kovac W, Passl R, Spängler HP (1975) Immunologische und histologische Untersuchungen bei der Gewebeklebung mit heterologem hochkonzentriertem Fibrinogen. *Wk Klin Wschr* 87, 815–819
2. Redl H, Schlag G (1983) Background and methods of fibrin sealing. *Scient Workshop Aarhus 1982*, H Skoldborg (Hrsg) Immuno Wien, 11-19
3. Haverich A, Oelert H, Maatz W, Borst HG (1984) Histopathological evaluation of woven and knitted Dacron grafts for right ventricular conduits: a comparative experimental study. *Ann Thor Surg* 37, 404–411
4. Borst HG, Haverich A, Walterbusch G, Maatz W (1982) Fibrin adhesive: an important hemostatic adjunct in cardiovascular operations. *J Thorac Cardiovasc Surg* 84, 548–553
5. Haverich A, Borst HG (1981) Fibrin glue for treatment of bleeding in cardiac surgery. In: *Cardiovascular surgery 1980*, W Bircks, J Ostermeyer, HD Schulte (Hrsg), Springer Verlag Berlin Heidelberg New York, 621–624
6. Wolner E (1982) Fibrin gluing in cardiovascular surgery. *Thorac cardiovasc Surg* 30, 236–237

# Fibrin Gluing: A Valid Aid in Coronary Artery Bypass Graft Surgery

P. FUNDARÒ, A.R. VELARDI, and C. SANTOLI

*Key words:* Coronary artery bypass surgery, fibrin adhesive

## **Abstract**

During the past 2½ years, in 96 patients undergoing elective coronary artery bypass graft surgery, fibrin adhesive was used 112 times. The indications were:

1. prophylactic sealing of potential sources of bleeding and
2. topical hemostasis (control of bleeding sites dangerous or difficult to suture).

Moreover, in several cases the glue was employed for the graft's fixation. The methods of glue application under different circumstances are described. The experience suggests that human fibrin glue represents a valid aid in coronary artery bypass graft surgery.

Cardiovascular surgery is often associated with bleeding problems which are hard to control by conventional suturing. In such conditions fibrin gluing seems to represent a valid alternative [1,3]. In coronary artery bypass graft (CABG) surgery, occasionally there are bleeding sites which are very troublesome to control by conventional means of hemostasis. Moreover, not infrequently, some time-wasting conditions may occur in the attempt to position and fix the vein bypass correctly to avoid occlusion. In this report our experience in the management of the above conditions with the human fibrin adhesive is presented.

Our clinical experience with fibrin glue in CABG surgery is of the past 2½ years, during which time we have applied the adhesive in 96 patients. Commercially available lyophilized human fibrin glue (Immuno, Vienna) was used. It was prepared as directed in the instructions and applied with Duploject (Immuno, Vienna), a device which makes possible the simultaneous mixing of the two sealant components at the moment of administration.

The indications were:

1. prophylactic sealing of potential bleeding sources and
2. topical hemostasis (control of sites of bleeding).

All the operations were performed by using standard techniques:

- a) cardiopulmonary bypass with systemic hypothermia (25°–30°C);
- b) multidose crystalloid and topical cooling for myocardial protection; and
- c) first distal anastomoses during anoxic heart arrest, then proximal anastomoses with the beating heart and in the course of rewarming. All the coronary anastomoses were performed with continuous suture by 6–7/0 Prolene, while the 5/0 Prolene was employed for those of the aorta.

The fibrin glue was prophylactically used always in the area of distal anastomoses.

Upon completion of each anastomosis, we checked for leakage by spurting some blood through the graft with a syringe. If any was found in sites such as the proximal or distal end (where stitching may result in inadvertent anastomosis occlusion), or in the presence of fibrocalcific plaques, we sealed the suture using the adhesive. Fibrin glue had good prophylactic indications when extensive dissection of fat and muscle was necessary in the search for a buried coronary artery, when extensive reconstruction of a coronary artery [6] was performed or when the suture lines seemed prone to bleed because of postendarterectomy wall fragility.

In all the above conditions, we applied the glue prior to releasing the aorta cross-clamp, thus having a bloodless field. Keeping the site of the anastomosis as dry as possible and with the heart still hypothermic (15°–20°C), we dripped the adhesive through the Duploject, obtaining a quick and effective sealing of the suture. In many cases, as an auxiliary aid, collagen hemostatic felt (Braun, FRG) was added. After cutting the felt to the desired size and dripping the glue in the site of potential bleeding, the glue-soaked felt was applied by exerting moderate pressure with a dry swab for about 1 min.

Adhesive, alone or with collagen, was effective in every case except a few, in which further administration of glue, with or without collagen, was necessary after the aorta was unclamped.

After resuming the coronary perfusion, fibrin adhesive was employed for topical hemostasis both on the aortic and coronary anastomoses.

We preferred fibrin gluing to conventional suturing in the presence of severe atherosclerotic involvement of the ascending aorta or of bleeding at the proximal end of the coronary suture line. Stitching, in fact, firstly risks tearing the aortic wall and, secondly, may result in anastomosis occlusion.

Under the above circumstances, because of the oozing of blood, one cannot obtain a dry and bloodless field; moreover, the glue-dripping on the bleeding site is useless, since the seepage of blood prevents the formation of the adhesive clot. In these cases, the procedure was a little different. Once the collagen fleece was cut to the desired size, the same, soaked with glue, was pressed on the site of bleeding with a dry swab, thus stopping the hemorrhage. The pressure exerted here had to be more prolonged (2–3 min), taking care to keep the blood collected in the pericardium off the site of application.

This procedure was effective in almost every case, using, when needed, further glue applications.

In one case the aortic anastomosis line was glued. Later on, the patient was reoperated on for abnormal postoperative bleeding, and the source of the hemorrhage was found in the glued aortic site.

In several cases we used the adhesive for the graft fixation, gluing the vein to the cardiac surface along the desired course, dripping the adhesive just before the sternal closure. Usually we prophylactically glued all posterior sequential grafts, while the single or the anterior sequential grafts were glued only if they were prone to kink.

Increasing experience in cardiovascular surgery with fibrin sealing has been reported during recent years [1–4, 8]. In our CABG surgery experience, fibrin glue has proven very helpful in the management of sources of bleeding otherwise

dangerous or difficult to control by conventional means, and in the fixation of the graft. Adhesive seems to expedite and render safer the operation, avoiding the suture of critical sites which may prove troublesome, and continuous hemorrhage, which, depressing the circulation, may jeopardize the patient's life. Simple handling and fast sealing encourage glue application, since neither local nor systemic adverse reactions to it have been reported. (Recent studies [5, 7, 6] failed to support the potential risk of transmitting hepatitis.) We conclude, therefore, that human fibrin adhesive is a valid aid in the CABG surgery.

### **References**

1. Borst HG, Haverich A, Walterbusch G, Maatz W (1982) Fibrin adhesive: an important hemostatic adjunct in cardiovascular operations. *J Thorac Cardiovasc Surg* 84:548-553
2. Huth C, Seybold-Eptin W, Hoffmeister HE (1982) Local hemostasis with fibrin glue (Tissucol) after intracardiac repair of Fallot and transposition of the great arteries (TGA). *J. Thorac Cardiovasc Surg* 30 (Suppl 1): 30-32
3. Koveker G (1982) Clinical application of fibrin glue in cardiovascular surgery. *J Thorac Cardiovasc Surg* 30:228-229
4. Meisner H, Struck E, Schmidt-Habelmann P, Sebening F (1982) Fibrin seal application. Clinical experience. *J Thorac Cardiovasc Surg* 30:232-233
5. Panis R, Scheele J (1981) Hepatitisrisiko bei der Fibrinklebung in der HNO-chirurgie. *Laryng Rhinol tol* 60:367-368
6. Parsonnet V, Gilbert L, Gielchinsky I, Bhaktan EK (1976) Endarterectomy of the left descending and mainstem coronary arteries: a technique for reconstruction of inoperable arteries. *Surg* 80:662-673
7. Scheele J, Schrickler KTh, Goy D, Lampe I, Panis R (1981) Hepatitisrisiko der Fibrinklebung in der Allgemeinchirurgie. *Med Welt* 32:783-788
8. Wolner E (1982) Fibrin gluing in cardiovascular surgery. *Thorac Cardiovasc Surgeon* 30:236-237

# The Effect of Fibrin Sealant on Postoperative Wound Secretion After Aortofemoral Bypass Surgery

M. T. CORFITSEN, B. PAASCHBURG NIELSEN, and S. JUUL JØRGENSEN

*Key words:* Surgical wounds, fibrin sealant, aortofemoral bypass surgery

## ***Abstract***

Eighteen patients who had had an operation with insertion of an aortobifemoral bypass graft joined a prospective, randomised and controlled study in order to investigate the effect of fibrin sealant on postoperative wound secretion. One of the two femoral incisions in each patient was sprayed with 2 ml fibrin sealant (Tisseel) containing 500 IU/ml thrombin and 20000 IU aprotinin. The secretion from the femoral incisions was measured through suction drainage devices and a significant reduction of secretion  $p < 0.05$  was shown within the first 6 hours postoperatively. The total drainage time however could not be reduced. It is concluded that fibrin sealant in the way administered may to some extent reduce the serosanguinolent secretion in major surgical wounds.

## ***Introduction***

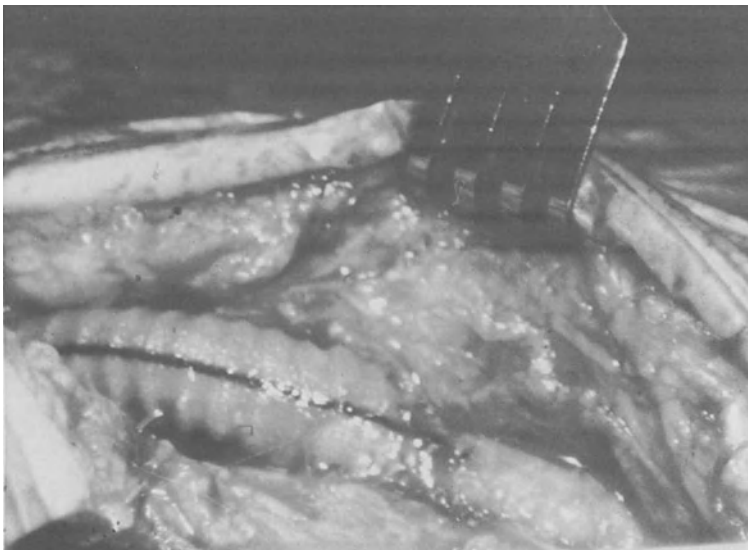
Publications in the past few years have shown fibrin sealant (Tisseel) to be useful in prevention of uncontrolled bleeding [1–4]. With regard to these results and to the known sealing effect of fibrin sealant on the smaller blood and lymphatic vessels we have investigated its effect on postoperative wound secretion after mastectomy. This was done as a prospective, randomized and controlled study. However, spraying of the wound with 2 ml fibrin sealant containing 500 IU/ml thrombin and with 3000 IU aprotinin showed no effect at all [5]. This was explained as a too rapid degradation of the fibrin molecules due to unexpectedly high fibrinolytic activity in the subcutaneous tissue [6].

## ***Material and Method***


Based on these experiences and after consultation with the Immuno Company in Vienna, 2 ml fibrin sealant containing 500 IU/ml thrombin and with 20000 IU aprotinin was used in a prospective, randomized and controlled study of 18 patients, who had had an operation with insertion of an aortobifemoral bypass graft. These patients are normally treated postoperatively with suction drainage devices in the femoral incisions and a decrease in secretion of 30% or more through the drainage devices on the treated side was preset as clinically relevant by reducing the drainage time 1 day. The number of 18 patients was sufficient to give a 5% level of significance.



At the end of the operation and after hemostasis had been obtained, one of the two femoral incisions was treated with fibrin sealant, while the other acted as control. The randomization was unknown to the nurses recording the secretion through the suction drainage devices. The drains were left untouched for 3 days after the operation and then removed when the secretion had decreased to less than 30 ml/day. The lengths of the femoral incisions on the two femora were controlled by a paired *t*-test and *F*-test. Figure 1 shows the femoral incision after insertion of the prosthesis to the femoral artery system before application of the fibrin sealant



**Fig. 1**



**Fig. 2**

**Figs. 1 u. 2.** Femoral incision after insertion of an aortobifemoral bypass graft before (Fig. 1) and after (Fig. 2) spraying of the wound with fibrin sealant. The fibrin is seen in Fig. 2 as a whitish layer covering the prosthesis as well as the artery system and the subcutaneous tissue

**Table 1.** Total secretion (ml) through the femoral incisions on the sprayed and the control sides in all 18 patients

$N = 18$	Total	Mean	Range
Sprayed	1787	99	17–135
Control	2234	124	25–405

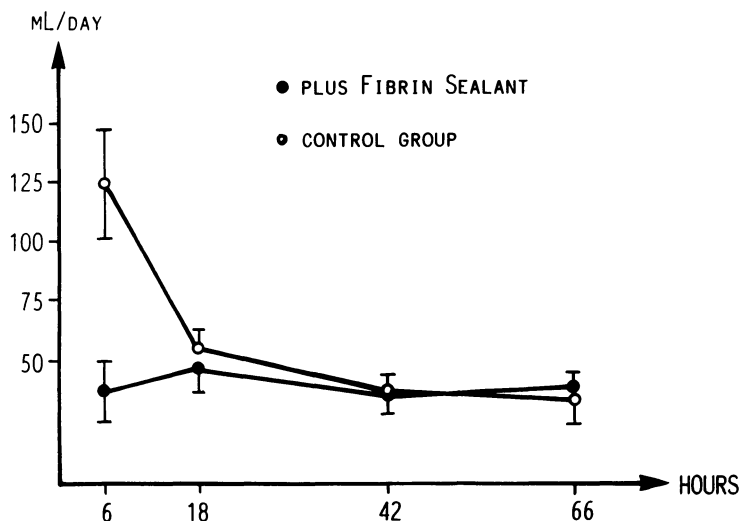
Wilcoxon  $T = 41.5$ ,  $P < 0.1$

(Tisseel). Figure 2 shows the same femoral incision after spraying. The fibrin is seen as a whitish layer covering the prosthesis as well as the arteries and the subcutaneous tissue.

### Results

The femoral incisions in the 18 patients measured a total of 214.5 cm on both sides, with an range of 10–13.5 cm on the sprayed sides and 9–14 cm on the control sides. This difference was shown to be statistically insignificant.

The results showed the least secretion on the side treated with fibrin sealant in 13 patients; one patient showed exactly the same amount of secretion on both sides and four patients showed the most secretion on the treated side. Table 1 shows the total secretion through the drainage systems in the treated and in the untreated groups. The secretion on the control side was 2234 ml and on the sprayed side 1787 ml or a 25% reduction. Table 1 also shows the median secretions and the ranges. A Wilcoxon matched-pair signed-rank test gave  $t = 41.5$  and  $P < 0.1$ . The distribution of secretion throughout the first 66 h postoperatively is shown in Fig. 3 which shows



**Fig. 3.** Mean secretion through the drainage system for the 18 patients during the first 66 h of drainage. The group treated with fibrin sealant is compared with the control group and the vertical bars indicate standard errors of the mean (SEMS). The reduction in secretion concentrated within the first 6 h is shown

a considerable and statistically significant reduction in secretion during the first postoperative day but no difference in secretion on the two sides for the last 60 h of observation. The vertical bars indicate standard errors of the mean.

The selected level for removal of the drainage devices required a total of 47 days of drainage in the sprayed group or a mean of 2.6 days for each patient, compared with a total of 43 days of drainage in the untreated group or a mean of 2.4 days. This difference was statistically insignificant.

There were two cases of lymphocele, one in the treated group and one in the untreated group. One patient died on the 2nd day after the operation due to an acute myocardial infarction.

The results indicate that Tisseel fibrin sealant in the way administered may to some extent reduce serosanguineous secretion in major surgical wounds.

### ***References***

1. Haverich A, Walterbusch G and Borst HG. The use of fibrin glue for sealing vascular protheses of high porosity. *Thorac cardiovasc Surgeon* 1981; 29:252–54
2. Kalmar P, Krebber HJ, Pokar H and Tilsner V (1982) Bioadhesives in cardiac and vascular surgery. *Thorac cardiovasc. Surgeon* 30:230–31
3. Walterbusch G, Haverich A and Borst HG (1982) Clinical experience with fibrin glue for local bleeding control and sealing of vascular protheses. *Thorac cardiovasc Surgeon* 30:234–35
4. Redl H and Schlag G Background and methods of fibrin sealing. *Scientific workshop '82, Immuno*: 11–20
5. Paaschburg Nielsen B, Willumsen H and Rasmussen O. The effect of fibrin sealant on wound secretion after mastectomy. *Acc to Ugeskr læg*
6. Albrechtsen OP. Fibrinolytic activity in the organism. *Doctors paper 1959, Universitetsforlaget Aarhus, DK Denmark.*

# Sealing of PTFE Patches and Conduits by Fibrin Glue in Surgery for Congenital Heart Disease

C. SQUITIERI, R. DiDONATO, and C. MARCELLETTI

*Key words:* Cardiovascular surgery, congenital heart disease, fibrin glue, fibrin seal

## **Abstract**

In 16 out of 114 cardiac operations at the Bambino Gesù Hospital in Rome, fibrin glue was applied on the suture lines of Polytetrafluoroethylene (PTFE) patches and Dacron conduits used in corrective or palliative reconstruction of right ventricular outflow tract or in unconventional repair of congenital heart diseases. In three cases the glue was useless in treating active bleeding. They required successful reoperation. No death was related to hemorrhagic complication. The two unsuccessful outcomes of the patients are explained exclusively by incorrect, or too risky, surgical choices.

## **Introduction**

So far, the successful surgical treatment of congenital heart disease is still mainly dependent on the preoperative conditions of the patient and the type of cardiac malformation [3, 8].

A more timely referral of patients to specialized centers, where, with a lower economic burden, earlier diagnoses favored by more extensive use of echocardiography and better techniques of intensive pre- and postoperative care, based on closer attention to the peculiarities of the cardiovascular system of the neonate and of the child [4], have enabled patients to be operated on in more favorable clinical conditions, with intact functional reserve and increased chances of success.

The progress of cardiopulmonary bypass [1, 10, 13], with the use in humans of the hypothermic strategy of ectothermic animals (the frog), the evolution in myocardial protection and the availability of reliable prosthetic materials (patches and conduits), have made possible palliative or corrective operations, at a progressively earlier age, even for the most complex congenital cardiac malformations [12].

Hemorrhagic complications, for imperfect hemostasis of the suture lines on prosthetic materials, may still, although rarely, be fatal.

Biological glue has been developed to facilitate hemostasis of the suture lines in inaccessible zones and on materials which bleed easily from the needle holes (PTFE and some kinds of Dacron) and to prevent the excessive permeability of Dacron prostheses [5, 6, 7].

### **Material and Method**

At the Bambino Gesù Hospital in Rome, in order to provide our patients with the most advantageous technological resources, aiming at a maximal therapeutic success, since 1 January 1985 we have used biological glue on the suture lines of PTFE patches and Dacron conduits. We have not used the glue for preclotting of Dacron conduits since we are currently employing albumin-coated Tascon conduits.

The glue has been prepared in the rapidly activable form and has been applied by the Duploject device on to a sanguineous field [11].

Between 1 January and 24 March 1985, biological glue has been employed in 16 out of 114 cardiac operations. In seven cases the glue was applied for sealing of the suture lines of PTFE patches used in corrective or palliative reconstruction of the right ventricular outflow tract (Table 1): six patients had tetralogy of Fallot and one had pulmonary atresia and a ventricular septal defect.

In five cases the glue was employed for sealing of the suture lines of Dacron conduits used for the corrective or palliative reconstruction of the right ventricular outflow tract (Table 2): one truncus arteriosus, three transpositions of the great arteries with a ventricular septal defect and one pulmonary atresia with a ventricular septal defect. In four other cases the glue was used on the suture lines of conduits employed for unconventional repairs (Table 3). The patient with univentricular heart and previous pulmonary artery banding, who developed subaortic stenosis for

**Table 1.** Fibrin glue on PTFE patches for RVOTR (1 January – 24 March 1984)

	Patients	Age (mean)	Operation	Reoperation for bleeding	Deaths
Tetralogy of Fallot	6	2 years	Repair	1	–
Pulmonary atresia	1	6 months	RVOTR	–	–
VSD, MAPCAs	—			—	
	7			1	

PTFE, Polytetrafluoroethylene; MAPCAs, Major aortopulmonary collateral arteries; RVOTR, right ventricle outflow tract reconstruction; VSD, ventricular septal defect

**Table 2.** Fibrin glue on conduits for RVOTR (1 January – 24 March 1985)

	Patients	Age (mean)	Operation	Reoperation for bleeding	Deaths
TGA, VSD	3	18 months	Rastelli	2	–
			Palliative	–	
			Rastelli	1	
Truncus	1	6 weeks	Repair	1	–
PA, VSD, MAPCAs	1	2 years	Repair	1	–
	—			—	
	5			3	2

MAPCAs, Major aortopulmonary collateral arteries; TGA, Transposition of great arteries; VSD, Ventricular septal defect

**Table 3.** Fibrin glue on conduits for unconventional repair of congenital heart disease (1 January – 24 March 1985)

	Patients	Age (mean)	Operation	Reoperation for bleeding	Deaths
UVH, previous, Pa bend, subaortal stenosis	1	2 years	Modified Fontan (RA – PA Conduit)	–	1
PA, IVS previous, BT	1	14 months	Modified Damus (PA – AO Conduit)	–	1
Mitral stenosis	1	3 years	Modified Fontan (RA – PA Conduit)	–	–
Hemitruncus	1	7 months	LA – LV Valved Conduit	–	–
	4		Conduit	–	

AO, Aorta; BT, Blalock-Taussig Shunt; IVS, Intact ventricular septum; LA, Left atrium; LPA, Left pulmonary artery; LV, Left ventricle; PA, Pulmonary artery; RA, Right atrium; UVH, Univentricular heart

narrowing of the bulboventricular foramen, underwent orthoterminal repair by application of the Fontan principle and of the Damus Kaye-Stansel operation [2].

The patient with pulmonary atresia with an intact ventricular septum underwent a Fontan procedure associated with a modified Glenn procedure. The patient with mitral stenosis (parachute mitral valve) received an extracardiac bypass of the mitral valve according to Laks [9].

The patient with hemitruncus was treated by ligation of the anomalous origin of the right pulmonary artery from the aorta and its reconnection to the main pulmonary artery with a tubular Dacron prosthesis.

## Results

Among the patients operated on for corrective or palliative reconstruction of the right ventricular outflow tract (Table 1), the glue failed to prevent and treat the bleeding from the suture lines in a case of tetralogy of Fallot, whose surgical steps, as far as the complete removal of the PTFE patch, are shown in Table 4. All the patients survived.

In two cases reoperation for bleeding was necessary among the five patients (Table 2) who underwent corrective or palliative reconstruction of the right ventricular outflow tract using a Dacron conduit. The five patients are alive.

There were no hemorrhagic complications in the last four cases in which the magic glue was used on the suture lines of conduits employed for unconventional repair (Table 3) of congenital heart diseases.

**Table 4.** Surgical steps in a complicated tetralogy of Fallot (1 January – 24 March 1985)

R.E. 21 Months	Tetralogy of Fallot, stenotic PA <sub>s</sub> , previous R. modified Blalock-Taussig shunt
First step	Transannular repair with PTFE patch + <i>Fibrin glue</i> (systemic RV pressure, bleeding)
Second step	Partial replacement of PTFE patch by pericardial Patch (systemic RV pressure)
Third step	Bypass of LPA stenosis with a PTFE conduit between LPA and RVOT patch + <i>fibrin glue</i> (bleeding)
Fourth step	Complete replacement of PTFE patch by pericardial patch

LPA, left pulmonary artery; PA<sub>s</sub>, pulmonary arteries; RV, right ventricle; R, right; RVOT, right ventricle outflow tract

### Discussion

The two patients who received an atriopulmonary anastomosis were the two therapeutic failures in our series. Bleeding was not involved in the failures. Retrospectively the patients died from incorrect application of the Fontan principle for stenotic pulmonary arteries. We feel that, if correctly applied, the glue may be useful in preventing bleeding from the suture lines on the prosthetic materials, but useless in treating active bleeding (Table 4). Anyway, besides the hemorrhagic complications, in our experience the unsuccessful outcomes (of the patients) may be exclusively explained by incorrect, or too risky, surgical choices.

### References

1. Becker H, Vinten-Johansen J, Buckberg GD, Robertson JM, Leaf JD, Lazar HL, Manganaro AJ (1981) Myocardial damage caused by keeping at pH 7.40 during systemic deep hypothermia. *J Thorac Cardiovasc Surg* 82:810–20
2. Corna A, Becker AF, Bulterijs AHK, Lam J, Nijveld A, Schuller JL, Marcelletti C (1982) Univentricular heart: can we alter the natural history? *Ann Thorac Surg* 34:716–26
3. Ebert PA, Turley K (1983) Surgery for cyanotic heart disease in the first year of life. *J Am Coll. Cardiol* 1:274–9
4. Friedman WF, (1972) The intrinsic physiologic properties of the developing heart. *Progr Cardiovasc Dis* 15:87–111
5. Haverich A, Borst HG, (1981) Fibrin glue for treatment of bleeding in cardiac surgery. In: Bircks W, Ostermeyer J, Shulte HD, (ed) *Cardiovascular surgery*. Springer, Berlin Heidelberg New York
6. Haverich A, Walterbusch G, Borst HG (1981) The use of fibrin glue for sealing vascular prostheses of high porosity. *Thorac Cardiovasc Surgeon* 29:252–4
7. Hutch C, Seybold-Epting W, Hoffmeister HE (1982) Local hemostasis with fibrin glue (Tissucol) after intracardiac repair of Tetralogy of Fallot and Transposition of the great arteries (TGA). *Thorac Cardiovasc Surgeon* 30/I:30
8. Kirklin JK, Blackstone EH, Kirklin JW, McKay R, Pacifico AD, Barger LM jr (1981) Intracardiac surgery in infants under age 3 months: incremental risk factors for hospital mortality. *Am J Cardiol* 48:500–6
9. Laks H, Hellenbrand WE, Kleinman C, Talner NS (1980) Left atrial-left ventricular conduit for relief of congenital mitral stenosis in infancy. *J Thorac Cardiovasc Surg* 80:782–7

10. Rahn H, Reeves RB, Howell BJ (1975) Hydrogen ion regulation, temperature and evolution. *Am Rev Resp Dis* 112:165-72
11. Redl H, Schlag G, Dinges HP (1982) Methods of fibrin seal application. *Thorac Cardiovasc Surgeon* 30:223-27
12. Turley K, Tucker WY, Ebert PA (1980) The changing role of palliative procedures in the treatment of infants with congenital heart disease. *J Thorac Cardiovasc Surg* 79:194-201
13. White FN (1981) A comparative physiological approach to hypothermia. *J Thorac Cardiovasc Surg* 82:821-31



# Use of Fibrin Glue (Tissucol/Tisseel) to Achieve Hemostasis in Patches and Suture Lines in Surgical Repair of Congenital Heart Defects

C. HUTH and H.-E. HOFFMEISTER

*Key words:* Local hemostasis, tetralogy of Fallot, transposition of the great arteries, fibrin glue, reduced postoperative blood loss

## **Abstract**

In our first study in 1983 [11], we presented our experience using Tissucol, a fibrin glue, to achieve local hemostasis in 21 patients who underwent surgical repair of tetralogy of Fallot and 10 patients who underwent a Senning operation for transposition of the great arteries (group 1). Postoperative blood loss during the first 24 h in these patients was compared with that of 20 patients with tetralogy of Fallot and 10 with transposition of the great arteries who had undergone the same operation without fibrin glue 1 year earlier (control group). No differences with respect to age, sex, body weight, preoperative coagulation status, and operative management were demonstrable between the two groups. After a marked reduction of postoperative blood loss through the application of fibrin glue was demonstrated in this first study, the results obtained using fibrin glue to achieve local hemostasis during surgery in 52 other patients (36 with tetralogy of Fallot, 16 with transposition of the great arteries; group 2) were added.

Blood loss with fibrin glue 2 h after surgery was 1.4 ml/h/kg BW in the group 2 patients with tetralogy of Fallot or transposition of the great arteries, whereas it was 4.2 ml/h/kg BW in those with tetralogy of Fallot ( $P < 0.01$ ) and 4.5 ml/h/kg BW in those with transposition of the great arteries ( $P < 0.005$ ) in the control group. The difference 6 h after surgery was also significant ( $P < 0.01$ ): 0.9 compared with 2.2 ml/h/kg BW after surgical repair of tetralogy of Fallot and 1.2 compared with 2.5 ml/h/kg BW after the Senning operation for transposition of the great arteries. In the ensuing 18 h, the quantity of blood lost from chest drains was approximately the same in both groups. In contrast to the first study, total blood loss during the first 24 h was also significantly lower in group 2 than in the control group ( $P < 0.01$ ).

In the meantime, the rethoracotomy rate for postoperative bleeding has been reduced.

Fibrin glue reduced postoperative blood loss after intracardiac repair of tetralogy of Fallot and the Senning operation for transposition of the great arteries by securing local hemostasis in patches and suture lines. Moreover, the general reduction of postoperative bleeding leads to better identification of bleeding complications requiring reoperation. The overall rate of these complications, however, was lowered.

## ***Introduction***

After intracardiac repair of the tetralogy of Fallot (ToF) and after the Senning operation for transposition of the great arteries (TGA), persistent and excessive postoperative bleeding may arise from long suture lines at the heart, use of porous patches and grafts, pre-existent clotting disorders, and clotting disorders associated with institution of extracorporeal circulation (heparinization!) or extracorporeal circulation itself. Similar problems were also found in patients who underwent other types of heart surgery (e.g., replacement of aneurysmal segment of aorta with a porous graft). These conditions increase postoperative blood loss from chest drains and the risk of pericardiac tamponade or hematoma in the mediastinum or pleural cavity, for example.

In such cases, differentiation between surgically manageable bleeding and bleeding due to clotting disorders, while extremely difficult, is necessary for establishment of the indication for reoperation in surgically manageable bleeding.

Many methods of preclotting highly porous vascular grafts and patches, gluing anastomoses, and achieving meticulous local hemostasis at various organs have been described [2, 3, 7–10, 13–16, 19, 20, 24]. While good results were reported for each of the described methods, data on the actual quantity of blood lost or the reduction of blood loss with these methods have not been reported. Reduced blood loss, however, is the most reliable and the only index of the efficacy of such methods. The second condition is simplicity of intraoperative application. Other risks associated with these methods should either be excluded or are extremely low.

## ***Material and Methods***

Since May 1980, Tissucol (Immuno, Heidelberg, FRG), a fibrin glue, has been used at the Department of Thoracic, Cardiac, and Vascular Surgery of the University Surgical Hospital in Tübingen to achieve local hemostasis and to preclot highly porous patches and grafts in cardiac and vascular surgery. In a retrospective study, patients who underwent two different surgical interventions with and without fibrin glue were first compared. 20 ToF patients and 10 TGA patients who had undergone intracardiac repair 1 year earlier served as the control group. After closure of the ventricular septal defect of the ToF patients by patching followed by an infundibulectomy, the right ventricular outflow tract was enlarged by patching. In 13 patients, the pulmonary artery was enlarged into the trunk by patching following a commissurotomy of the pulmonary valve; in 7, infra-annular enlargement was adequate. The pulmonary valve ring had to be widened into the pulmonary trunk in 8 of 21 patients in group 1 with fibrin glue; enlargement of the pulmonary valve by commissurotomy, however, was sufficient in the other 13. Only the intra-annular region of the right ventricular outflow tract was enlarged in 20 of the 36 patients in group 2 with fibrin glue; the pulmonary artery was enlarged to the pulmonary trunk following a commissurotomy of the pulmonary valve in the other 16. The proportion of preliminary operations dropped from 35% in the control group to 24% in group 1 and 11% in group 2. Patients with surgical repair of TGA (i.e., bypass of atrium modified according to Senning) were dealt with similarly. Ten patients each are

included in the control group without fibrin glue and group 1 with fibrin glue; 16 patients, in group 2 with fibrin glue. Preliminary operations (usually Blalock-Hanlon) were performed in 20% of the children in the control group and group 1. No preliminary operations were performed in group 2, probably due to the young age of the patients at the time of surgery.

The mean age of the ToF patients was  $86 \pm 86$  months in the control group,  $84 \pm 14$  months in group 1 and  $56 \pm 55$  months in group 2. The mean age of the patients who underwent the Senning operation for TGA was  $15 \pm 6$  months in the control group,  $17 \pm 11$  months in group 1, and  $13 \pm 4$  months in group 2. Additional preoperative data, early mortality, and frequency of rethoracotomies in each group are presented in Tables 1 and 2.

**Table 1.** Preoperative and intraoperative group characteristics in patients with intracardiac repair of tetralogy of Fallot

	Without fibrin glue	With fibrin glue	
		Group 1 21	Group 2 36
	20		
Boys (%)	12 (60)	12 (53)	22 (61)
Age in months: X $\pm$ SD Median (25% - 75%)	86 $\pm$ 86 49 (46-86)	84 $\pm$ 114 46 (27-65)	56 $\pm$ 55 40 (31-53)
Preliminary operations (%)	7 (35.0)	5 (23.8)	4 (11.1)
Rethoracotomies (%)	3 (15.0)	3 (14.3)	1 (2.8)
Early deaths (%)	1 (5.0)	3 (14.3)	2 (5.6)

**Table 2.** Preoperative and intraoperative group characteristics in patients with Senning operation for transposition of great arteries

	Without fibrin glue	With fibrin glue	
		Group 1 10	Group 2 10
	10		
Boys (%)	5 (50)	5 (50)	10 (63)
Age in months X $\pm$ SD Median (25% - 75%)	15 $\pm$ 6 17 (12-18)	17 $\pm$ 11 12 (10-19)	13 $\pm$ 4 12 (11-14)
Preliminary operation (%)	2 (20)	2 (20)	0
Rethoracotomies (%)	0	1 (10)	0
Early deaths (%)	1 (10)	1 (10)	1 (6.3)

No important differences could be established in perfusion time, aortic clamping time, or temperatures at onset of ischemia for the groups with and without fibrin glue (Tables 3, 4). In the course of time, only the method of cardioplegia was changed: prior to 1980, single-dose Kirsch cardioplegic injection (3 ml Cardioplegin/kg BW; Dr. Franz Köhler Chemie KG, Alsbach/Bergstr., FRG) [12]; after 1980 single-dose Bretschneider cardioplegia with HTP, LK 352, or HTK solutions (30 ml/kg BW; Dr. Franz Köhler Chemie KG, Alsbach/Bergstr., FRG) at 4°C [4]. The longer perfusion and ischemic times in group 2 with fibrin glue were due to a change in methods: Application of fibrin glue to suture lines (in group 1, sometimes on beating hearts; in group 2, only on nonbeating hearts) resulted in a prolongation of ischemic and perfusion times.

**Table 3.** Intraoperative changes of hemoglobin and hematocrit as index of blood balance and thrombocytes and intraoperative changes of Quick value and prothrombin time as index of pre-existent or surgically induced clotting disorders in surgical repair of tetralogy of Fallot

	Without fibrin glue		With fibrin glue			
	Preop	Postop	Group 1		Group 2	
			Preop	Postop	Preop	Postop
Hb (g%)	17.3 ± 2.6	17.1 ± 2.7	17.1 ± 2.3	16.8 ± 1.6	16.4 ± 2.4	14.4 ± 1.6
HCT (%)	49 ± 7	49 ± 9	49 ± 7	47 ± 6	48 ± 7	43 ± 5
Thrombocytes (× 1000/mm <sup>3</sup> )	235 ± 95	86 ± 65	226 ± 67	119 ± 67	241 ± 92	121 ± 54
Quick (%)	86 ± 16	65 ± 11	90 ± 16	61 ± 19	92 ± 16	53 ± 13
PTT (s)	47 ± 15	52 ± 11	36 ± 5	55 ± 38	34 ± 8	49 ± 11

**Table 4.** Intraoperative changes of hemoglobin and hematocrit as index of blood balance and thrombocytes and intraoperative changes of Quick value and prothrombin time as index of pre-existent and intraoperative clotting disorders in Senning operation for transposition of great arteries

	Without fibrin glue		With fibrin glue			
	Preop	Postop	Group 1		Group 2	
			Preop	Postop	Preop	Postop
Hb (g%)	18.2 ± 1.7	17.8 ± 1.9	18.6 ± 2.9	17.9 ± 2.3	16.6 ± 4.0	16.3 ± 2.1
HCT (%)	58 ± 8	50 ± 6	51 ± 6	50 ± 6	56 ± 9	52 ± 13
Thrombocytes (× 1000/mm <sup>3</sup> )	143 ± 38	85 ± 41	200 ± 108	97 ± 37	213 ± 96	120 ± 63
Quick (%)	62 ± 38	55 ± 13	86 ± 22	60 ± 11	78 ± 18	56 ± 14
PTT (s)	46 ± 23	61 ± 19	32 ± 3	56 ± 22	38 ± 6	46 ± 7

Perioperative changes of hemoglobin, hematocrit, and thrombocyte count as well as prothrombin time and Quick value, which are important laboratory parameters for plasmic clotting, are presented in Tables 5 and 6.

## Results

Postoperative loss of blood from chest drains, a parameter of hemostatic efficacy, was measured every 2 h in each patient and related to 1-h periods in terms of body weight. After intracardiac repair of ToF and Senning's operation for TGA, significant differences in blood loss were found between the control group without fibrin glue and both groups with fibrin glue 2, 6, and 12 h after surgery. In the ToF patients, blood loss 2 h after surgery was 2.2 ml/h/kg BW in group 1 ( $P < 0.01$ ) and

**Table 5.** Perfusion time, aortic clamping time, temperature at onset of ischemia, and cardioplegic procedure in surgical repair of tetralogy of Fallot

	Without fibrin glue	With fibrin glue	
		Group 1	Group 2
Perfusion time (min)	77 ± 14	77 ± 16	91 ± 21
Ischemic time (min)	41 ± 12	43 ± 14	52 ± 14
Ischemic temperature (°C)			
Blood, venous	21.0 ± 1.8	21.6 ± 2.1	21.8 ± 1.9
Esophagus	21.9 ± 3.3	21.9 ± 2.9	21.6 ± 2.6
Rectal	28.5 ± 2.0	26.0 ± 3.0	26.0 ± 1.6
Cardioplegia (ml/kg BW)	3.3 ± 0.9 Cardioplegin	31.0 ± 7.3 HTP, LK 352	30.3 ± 4.0 LK 352, HTK

**Table 6.** Perfusion time, aortic clamping time, temperature at onset of ischemia, and cardioplegic procedure in Senning operation for transposition of great arteries.

	Without fibrin glue	With fibrin glue	
		Group 1	Group 2
Perfusion time (min)	85 ± 9	86 ± 15	96 ± 16
Ischemic time (min)	44 ± 6	48 ± 12	51 ± 9
Ischemic temperature (°C)			
Blood, venous	19.8 ± 1.7	19.6 ± 2.8	21.2 ± 2.1
Esophagus	19.5 ± 2.8	20.5 ± 3.6	20.2 ± 3.0
Rectal	26.6 ± 2.8	20.5 ± 3.6	24.5 ± 2.0
Cardioplegia (ml/kg BW)	2.8 ± 1.3 Cardioplegin	32.3 ± 6.9 HTP, LK 352	30.9 ± 4.4 LK 352, HTK

1.4 ml/h/kg BW in group 2 with fibrin glue ( $P < 0.005$ ) compared with 4.2 ml/h/kg BW in the control group. In these patients the difference 6 h after surgery remained significant: 1.4 ml/h/kg BW group 1 ( $P < 0.01$ ) and 0.9 ml/h/kg BW in group 2 with fibrin glue ( $P < 0.005$ ) compared with 2.2 ml/h/kg BW in the control group without fibrin glue. The difference was slight 12 h after surgery: 1.1/h/kg BW in group 1 compared with 1.5 ml/h/kg BW in the control group without fibrin glue. In group 2, however, blood loss (mean: 0.7 ml/h/kg BW) was still significantly lower after 12 h ( $P < 0.005$ ). We established similar conditions after the Senning operation for TGA. Blood loss 2 h after surgery was 2.4 ml/h/kg BW in group 1 ( $P < 0.01$ ) and 1.4 ml/h/kg BW in group 2 with fibrin glue ( $P < 0.005$ ) compared with 4.5 ml/h/kg BW in the control group without fibrin glue. The level of significance for blood loss 6 h after surgery dropped slightly ( $P < 0.01$ ): 1.9 ml/h/kg BW in group 1 and 1.2 ml/h/kg BW in group 2 compared with 2.5 ml/h/kg BW in the control group without fibrin glue. The reduction of blood loss by application of fibrin glue was still pronounced 12 h after surgery: 1.5 ml/h/kg BW in group 1 ( $P < 0.05$ ) and 1.0 ml/h/kg BW in group 2 ( $P < 0.01$ ).

Blood loss during the next 12 h did not differ appreciably between patients with fibrin glue and those without. Comparison of the first 24 h after surgery showed that preclotting highly porous patches and sealing suture lines with fibrin glue reduced blood loss significantly after operative repair of ToF (0.5 ml/h/kg BW compared with 1.0 ml/h/kg BW) and after the Senning operation for TGA (0.8 ml/h/kg BW compared with 1.3 ml/h/kg BW) only in group 2 with fibrin glue ( $P < 0.01$ ). Blood loss with or without fibrin glue did not differ in patients requiring reoperation for excessive, but surgically manageable, postoperative bleeding. Use of fibrin glue, therefore, does not obscure the indication for reoperation in surgically manageable, postoperative bleeding. Instead, the marked reduction of mean postoperative blood loss by application of fibrin glue simplifies establishment of the indication, since the difference between patients with reoperation and those without increased. In addition to better identification of surgically manageable postoperative bleeding, the rethoracotomy rate for surgical repair of ToF decreased from 15% to 7%. No statement was possible in one rethoracotomy with Senning operation for TGA.

**Table 7.** Blood loss in postoperative phase (ml/h/kg BW) related to various postoperative intervals after surgical repair of tetralogy of Fallot

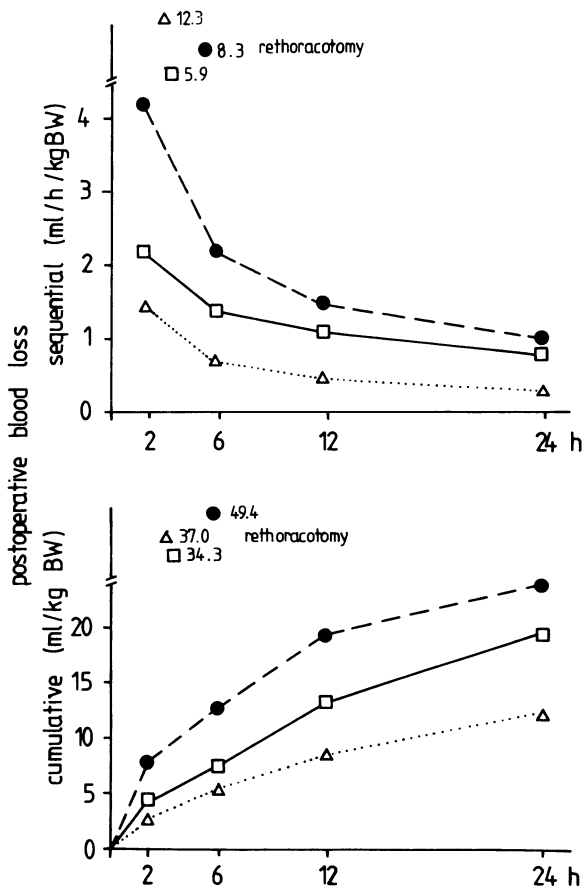
Hours postop	Without fibrin glue	With fibrin glue	
		Group 1	Group 2
0-2	4.2 ± 2.3	2.2 ± 1.4**	1.4 ± 1.0***
3-6	1.2 ± 0.9	1.0 ± 0.8	0.7 ± 0.3**
7-12	0.9 ± 0.7	0.8 ± 0.5	0.5 ± 0.2**
13-24	0.4 ± 0.3	0.5 ± 0.2	0.3 ± 0.2
0-6	2.2 ± 1.4	1.4 ± 1.0**	0.9 ± 0.5**
0-12	1.5 ± 0.8	1.1 ± 0.5*	0.7 ± 0.3**
0-24	1.0 ± 0.5	0.8 ± 0.3	0.5 ± 0.2**

Levels of significance compared with group without fibrin glue:  
 \*  $P < 0.005$ ; \*\*  $P < 0.01$ ; \*\*\*  $P < 0.005$ ;

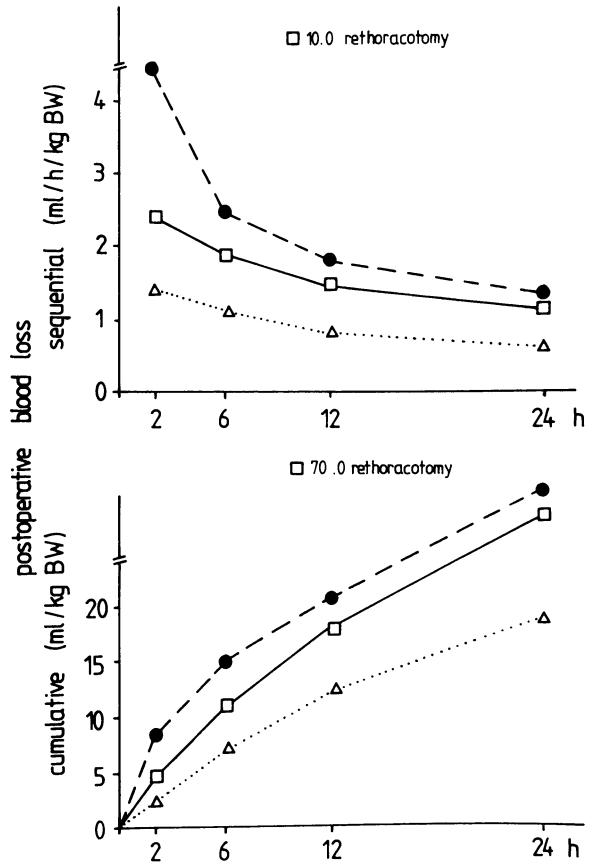
**Table 8.** Blood loss in the postoperative phase (ml/h/kg BW) related to various postoperative phases after Senning operation for transposition of great arteries

Hours postop	Without fibrin glue	With fibrin glue	
		Group 1	Group 2
0-2	4.5 ± 2.2	2.4 ± 1.2**	1.4 ± 0.8***
3-6	1.6 ± 0.7	1.7 ± 0.9	1.1 ± 0.6**
7-12	0.9 ± 0.6	1.1 ± 0.7	0.8 ± 0.5
13-24	0.8 ± 0.5	0.8 ± 0.5	0.6 ± 0.4*
0-6	2.5 ± 1.1	1.9 ± 1.0**	1.2 ± 0.6**
0-12	1.8 ± 0.8	1.5 ± 0.7*	1.0 ± 0.6**
0-24	1.3 ± 0.5	1.2 ± 0.6	0.8 ± 0.4**

Levels of significance compared with group without fibrin glue:  
 \*P < 0.05; \*\*P < 0.01; \*\*\*P < 0.005



**Fig. 1.** Postoperative blood loss after intracardiac repair of tetralogy of Fallot with (group 1, □-; group 2, △) and without fibrin glue (●-). Upper, sequential presentation; lower, cumulative presentation



**Fig. 2.** Postoperative blood loss after Senning operation for transposition of great arteries with (group 1, □-; group 2 △...) and without (●-) fibrin glue. Upper, sequential presentation; lower, cumulative presentation

Complete sequential and cumulative data on blood loss in various postoperative periods are presented in Tables 7 and 8 and Fig. 1 and 2. Comparison of data for group 2 with fibrin glue and for the control group without fibrin glue revealed that, with fibrin glue, blood loss could be reduced by 40% during the first 24 h after surgical repair of ToF and by 50% after TGA ( $P < 0.01$ ).

**Discussion**

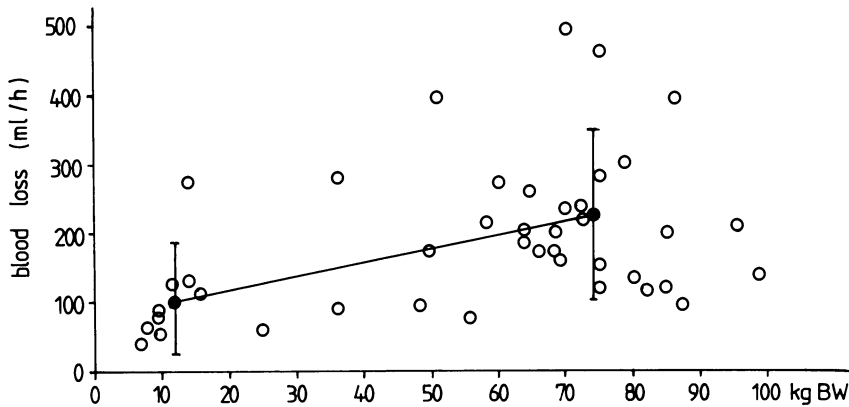
Many methods of sealing patches and grafts as well as gluing and sealing suture lines to achieve local hemostasis have been described in the current literature. While the authors report good results with their methods, clear definitions and estimations of the decrease of postoperative blood loss, however, are absent (2,3,7-10, 13-16,19,20,24). A few studies showed the effect of fibrin glue on reducing the quantity of conserved blood used. The total amount of blood used, however,



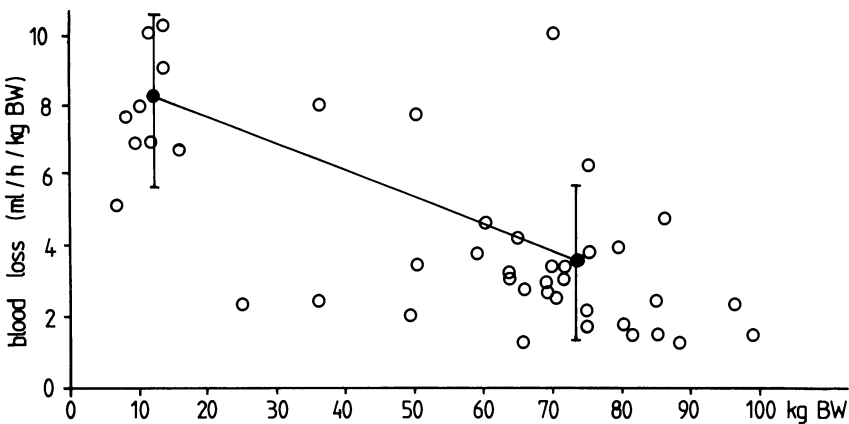
includes transfusion in preoperative blood loss due, for example, to dissection or perforation of an aneurysm of the aorta; intraoperative blood substitution through, for example, the priming volume of the heart-lung machine or intraoperative blood loss; and postoperative blood loss due to poor local hemostasis, clotting disorders, or so-called surgical bleeding. Moreover, a 500-ml transfusion unit of whole blood is too large to be used to compare blood loss in children.

Fibrin glue has an effect only on postoperative blood loss due to poor local hemostasis and not on operative hemorrhages. The total amount of blood used, therefore, cannot serve as an index of the efficacy of fibrin glue.

To obtain a valid index, postoperative blood loss was estimated at reoperation in 50 of our patients who, after open heart surgery, underwent a rethoracotomy in the last few years because of operative hemorrhage. Comparison of blood loss in milliliters per hour, plotted linearly to body weight (Fig. 3), showed that blood loss up until reoperation was significantly lower in patients weighing less than 25 kg (100 ml/h) than in those weighing more than 25 kg (200 ml/h). This index, however, is not



**Fig. 3.** Blood loss at reoperation (ml/h) related to body weight at reoperation in 50 patients who underwent rethoracotomy for bleeding following open heart surgery



**Fig. 4.** Blood loss (ml/h/kg BW) related to body weight at reoperation in 50 patients who underwent rethoracotomy for bleeding following open heart surgery

valid for a comparison of circulating blood volumes. A comparison that includes blood volume and calculates blood loss in ml/h/kg BW, plotted in relation to the body weight of the patient, shows that blood loss at rethoracotomy in our group of patients weighing less than 25 kg (8 ml/h/kg BW) was twice as high as that of patients weighing more than 25 kg (4 ml/h/kg BW) (Fig. 4). Postoperative blood loss, therefore, should always be measured at short intervals and related to the body weight of the individual patient. In thoracic and cardiovascular surgery, short intervals between estimation of postoperative blood loss from chest drains and correlation of drainage fluid with the body weight of the individual patient, on the one hand, ensure accurate estimation of the quantity of lost blood and its hemodynamic relevance and, on the other, when hematocrit is also estimated in the drainage blood, demonstrate a steady decline in hematocrit from hour to hour due to a reduction of hemorrhage and an increase of exudation. For our purposes, blood loss up to 2.5 ml/h/kg BW was considered acceptable, between 2.5 and 5 ml/h/kg BW a relative indication for rethoracotomy, and persistent hemorrhage exceeding 5 ml/h/kg BW an absolute indication for surgery.

A significant decrease of blood loss, a characteristic of improved local hemostasis with use of fibrin glue, occurs only during the first few hours after surgery. By local hemostasis as well as patch, graft, and suture line sealing, fibrin glue reduces hemorrhage. A decrease of exudation, which can always be observed in the operative field, however, cannot be expected.

In the postoperative phase, a general reduction of blood loss in patients not requiring reoperation led to improved identification of hemorrhages that did require surgical management. Fibrin glue, therefore, simplifies establishment of the indication for reoperation in larger hemorrhages.

In all cases in which whole blood, blood products or plasma components were used, the risk of transmitting hepatitis and AIDS should be discussed [6, 21–23]. No cases of hepatitis were observed in our patient group with surgical repair of TGA or ToF after fibrin glue was used to achieve local hemostasis. Our incidence of hepatitis after using fibrin glue to secure local hemostasis and to seal vascular conduits and patches in other patients was no higher than that reported previously without fibrin glue [22]. Due to meticulous screening of blood donors, the rate of so-called post-transfusion hepatitis after open heart surgery was even lowered at our hospital [23]. Whereas a definite association between the use of certain coagulation factors in the postoperative phase and a higher incidence of hepatitis has been demonstrated [22], we have found no evidence of it with respect to our use of fibrin glue. Similar findings have been reported by other investigators. The risk of hepatitis reported by Scheele and coworkers after application of fibrin glue was no higher in two comparable groups of 170 patients who underwent abdominal surgery. The only dependent relationship they established was between the risk of hepatitis and the number of blood transfusions [6, 17, 18, 21]. The risk of postoperative hepatitis, therefore, can be lowered by reducing the quantity of blood used. Our experience indicates that blood loss can be appreciably reduced by using fibrin glue to achieve local hemostasis and to seal patches in the surgical repair of ToF and TGA. Due to the low body weight of the children, this reduction is not always accompanied by a reduction in the quantity of blood used, generally one unit of conserved blood. The volume of one unit (i.e., 500 ml) is too large in comparison to the total blood loss

from chest drains over a 24-h period in a child weighing 10 kg (120–150 ml). When these findings, however, are transferred to adults, a reduction of both the number of postoperative blood transfusions and postoperative blood loss is possible. The first step, however, is reduction of blood loss.

While blood loss can be lowered by using less porous patches and grafts, such material requires longer suture lines, and this could lead to postoperative bleeding if coagulation is impaired. Moreover, an increasing number of restenoses of right ventricular outflow tract reconstructions and conduits have been reported in recent publications. These stenoses were caused by detachment of the neointima from the underlying conduit due to separation by a layer of thrombus with dissection and fenestration [1, 5]. Such complications, which usually require reoperation, can be avoided or at least minimized by improving adherence of the neointima by tissue ingrowth through pores of highly porous conduits. Sealing these highly porous conduits and patches is imperative if extracorporeal circulation is to be instituted (increased clotting time due to heparinization). Compared with other methods [7, 9], fibrin gluing with Tissucol is a simple, reliable, and widely accepted procedure without serious complications.

## References

1. Agarwal KC, Edwards WD, Feldt RH, Danielson GK, Puga FJ, and McGoon DC (1981) Clinicopathological correlates of obstructed right-sided porcine-valved extracardiac conduits. *J Thorac Cardiovasc Surg* 81:591–601
2. Akrami R, Kalmar P, Pokar H, and Tilsner V (1978) Abdichtung von Kunststoffprothesen beim Ersatz der Aorta im thorakalen Bereich. *Thoraxchirurgie* 26:144–147
3. Bachet J, Gigon F, Laurian C, Bical O, Goudot B, and Guilmet D (1982) Four-year clinical experience with the gelatin-resorcin-formol biological glue in acute aortic dissection. *J Thorac Cardiovasc Surg* 83:212–217
4. Bretschneider HJ, Hübner G, Knoll D, Lohr B, Nordbeck H, and Spieckermann PG (1975) Myocardial resistance and tolerance to ischemia. Physiological and biochemical basis. *J Cardiovasc Surg* 16:241–260
5. Ciaravella JM, McGoon DC, Danielson GU, Wallace RB, Mair DD, and Ilstrup DM (1979) Experience with the extracardiac conduit. *J Thorac Cardiovasc Surg* 78:920–930
6. Conrad ME, Knodell RG, Bradley EL, Flannery EP, and Ginsberg AL (1977) Risk factors in transmission of non-A, non-B posttransfusion hepatitis. *Transfusion* 17:579–585
7. Cooley DA, Romagnoli A, Milam JD, and Bossert Ch (1981) A method preparing woven Dacron aortic grafts to prevent interstitial bleeding. *Cardiovasc Dis, Bull Texas Heart Inst* 8:48–52
8. Eckersberger F, Holle J, Spängler HP, and Wollner E (1978) Die Anwendung eines Fibrinklebers in der offenen Herzchirurgie. *Thoraxchirurgie* 26:16
9. Glynn MFX, and Williams WG (1981) A technique for preclotting vascular grafts. *Ann Thorac Surg* 29:182–183
10. Haverich A, Walterbusch G, and Borst HG (1981) The use of fibrin glue for sealing vascular prostheses of high porosity. *Thorac Cardiovasc Surgeon* 29:252–254
11. Huth C, Seybold-Epting W, and Hoffmeister H-E (1983) Local hemostasis with fibrin glue after intracardiac repair of tetralogy of Fallot and transposition of the great arteries. *Thorac Cardiovasc Surgeon* 31:142–146
12. Kirsch U, Rodewald G, and Kalmar P (1972) Induced ischemic arrest: clinical experience with cardioplegia in open-heart surgery. *J Thorac Cardiovasc Surg* 63:121–130
13. Kletter G, Matras H, and Dinges HP (1978) Zur partiellen Klebung von Mikrogefäßanastomosen im intrakraniellen Bereich. *Wien Klin Wschr* 90:415–419

14. Kottmann U-R, and Witzke G (1978) Untersuchungen zur Abdichtung von Gefäßprothesenoberflächen mit und ohne Zusatz von Faktor XIII-Konzentrat. *Thoraxchirurgie* 26:14-19
15. Köveker G, DeVivie ER, and Hellberg KD (1981) Clinical experience with fibrin glue in cardiac surgery. *Thorac Cardiovasc Surgeon* 29:287-289
16. Marczell A, Dufek H, and Hold H (1980) Erfahrungen bei der Blutstillung mittels Fibrinklebung in der Abdominalchirurgie. *Wien Klin Wschr* 92:807-809
17. Panis R, and Scheele J (1981) Hepatitisrisiko bei der Fibrinklebung in der HNO-Chirurgie. *Laryng Rhinol* 60:367-368
18. Scheele J, Schrickler CT, Gay RD, Lampe I, and Panis R (1981) Hepatitisrisiko der Fibrinklebung in der Allgemeinchirurgie. *Med Welt* 32:783-788
19. Scheele J, Mühe E, and Wopfer F (1978) Fibrinklebung – eine neue Behandlungsmethode bei persistierendem und rezidivierendem Spontanpneumothorax. *Chirurg* 49:236-243
20. Spängler HP, Braun F, Holle J, Moritz E, and Wollner E (1976) Die lokale Anwendung von Fibrinogen und Kollagen zur Blutstillung in der Herzchirurgie. *Wien Med Wschr* 126:86-89
21. Stute R, Kriom A, Staudacher B, Schulte HD, and Bürster H (1979) Frequency of hepatitis B after open-heart surgery: a retrospective study over a three-year period (1974-1976). *Thorac Cardiovasc Surgeon* 27:238-240
22. Sugg U, Frösner GG, Schneider W, and Stunkat R (1976) Hepatitishäufigkeit nach Transfusion von HB<sub>s</sub>-Ag-negativem und Anti-HB<sub>s</sub>-positivem Blut. *Klin Wschr* 54:1133-1136
23. Sugg U, Schneider W, Hoffmeister H-E, Huth C, Stephan W, Lissner R, and Haase W (1985) Hepatitis B immune globulin to prevent non-A, non-B posttransfusion hepatitis. *Lancet* I 1985: 405-406
24. Thetter O (1981) Fibrin adhesive and its application in thoracic surgery. *Thorac Cardiovasc Surgeon* 29:290-292

# Fibrin Glue in Open Heart Surgery

K. H. TSCHELIESSNIGG, W. STENZL, B. RIGLER, and J. KRAFT-KINZ

*Key words:* Fibrin glue, congenital heart disease, sealing of patches, leakage of chyle

## **Abstract**

New techniques of blood clotting and tissue glueing have been developed in the past few years with the aim of diminishing blood loss. In open heart surgery, caused by longer phases of extracorporeal circulation, blood clotting is often disturbed, followed by long – lasting blood trickling out of stitch channels and adhesions which have been cut through. Furthermore the impossibility of physiologically clotting vascular prostheses and patches during extracorporeal circulation means greater blood loss. It was therefore obvious to try these new techniques to diminish blood loss and operation times, on one hand, and the infection rate as a parameter of long operation times as well as rethoracotomy on the other.

In a total of 31 patients who underwent heart surgery, because of congenital heart disease fibrin glue was applied. In each case neutralization of heparin by protamin and normal clotting was waited for. After a waiting time of about 25 min after the appearance of the first blood clots fibrin glue was applied if blood trickling in suture lines or stitch channels was seen. Fibrin glue components were used in a ratio 1 to 1. The amount of fibrinogen concentrate used was  $2,2 \pm 1,3$  ml, the duration of operation procedure  $177 \pm 76$  min (means and standard deviations).

In conclusion: although fibrin glue cannot replace good technique and certainly cannot replace surgical suture, it appears to be a valuable aid under special conditions; so we highly recommend fibrin glue in open heart surgery in the abovementioned cases.

## **Introduction**

For a long time sutures have been the standard method of tissue and wound edge repair in surgery. Sophisticated suturing techniques and highly developed suture materials have not, however, always been sufficient to prevent complications. Thread fistulae and granulomas or sutures cutting into parenchymatous organs or inflamed tissues are still phenomena surgeons are all too familiar with. These factors, as well as wound dehiscence, wound edge necrosis and tissue ischemia caused by sutures placed too closely together, led to the development of various tissue sealants which originated from the basic desire for hemostasis and, at the same time, atraumatic tissue repair. New techniques of blood clotting and tissue glueing

have been developed in the past several years with the aim of diminishing blood loss [1, 2, 4, 5, 6, 7, 9, 11, 12, 13].

In open heart surgery, caused by longer phases of extracorporeal circulation, blood clotting is often disturbed, followed by long-lasting blood trickling out of stitch channels and cut-through adhesions. Furthermore, the impossibility of physiologically clotting of vascular prostheses and patches during extracorporeal circulation means greater blood loss. It was therefore obvious to try these new techniques to diminish blood loss and operation times, on one hand, and the infection rate as a parameter of long operation times as well as rethoracotomy on the other.

### **Material and Methods**

The composition and use of fibrin glue (Beriplast) are shown in Tables 1 and 2. This glue is composed of two components:

- a) highly concentrated human fibrinogen and
- b) bovine thrombin.

**Table 1.** Composition of fibrinogen Concentrate (Beriplast) dissolved in 1 ml solvent

Substance	Human fibrinogen Factor XIII	65–115 mg/ml 40–80 U/ml
Total protein content:	115–232 mg/ml	
Solvent:	aprotinin solution with 1000 KIU/ml	
pHlevel:	about 6.7	
Stabilizer and other components:		
L-Arginine hydrochloride		8–16 mg
L-Isoleucine		9–17 mg
Sodium-L-hydrogen glutamate H <sub>2</sub> O		7–13 mg
Sodium chloride		10–20 mg
Sodium citrate 2H <sub>2</sub> O		3– 8 mg
Human albumin		5–15 mg

No preservatives

**Table 2.** Composition of thrombin-calcium component

Bovine thrombin, lyophilizate (dissolved in 1 ml calcium chloride solvent)		
Bovine fraction with a thrombin activity of 1.5 – 4.0		400 – 600 IU
Sodium citrate 2H <sub>2</sub> O		1.0 – 5.0 mg/ml
Sodium chloride		1.5 – 8.0 mg/ml
Calcium chloride (40 mmol/l)		5.8 mg/ml
<i>Calcium chloride solvent (40 mmol/l)</i>		
1. Bottle with 2.5-ml solvent contains:		
a) Active component:		14.7 mg
calcium chloride 2H <sub>2</sub> O		
b) Other components:		2.5 ml
Water for injection		

In the case of contact of these both components fibrinogen is transformed to fibrin. To stabilize this polymerizate to fibrinogen, factor XIII is added. To dissolve component (a), which is the lyophilizate fibrinogen, 1000 units aprotinin is added. The second component is 400–600 units bovine thrombin dissolved in 1 ml calcium chloride. Within 1 min an opalescent gray tough-elastic glue film was formed. In the case of more severe bleeding fibrin glue was washed up before clotting. In these cases a collagen tampon was useful. The collagen tampon, saturated with the fibrinogen component, was applied and fibrinogen in the network of this collagen tampon transformed to fibrin.

### ***Patients***

Fibrin glue was applied in a total of 31 patients who underwent heart surgery because of congenital heart disease (Tables 3, 4). In each case neutralization of heparin by protamin and normal clotting was waited for. After a waiting time of about 25 min after the appearance of the first blood clots fibrin glue was applied if blood trickling in suture lines or stitch channels was seen. Fibrin glue components were used in a ratio of 1 to 1. The amount of used fibrinogen concentrate was  $2.2 \pm 1.3$  ml, the duration of operation procedure  $177 \pm 76$  min (means and standard deviations).

**Table 3.** Indications for fibrin glue

Sealing up suture lines in coarctations and aortotomies in the case of aortic valve replacement	5
Sealing of anastomoses in palliative shunt surgery	2
Sealing up patches in the right ventricular outflow tract in the case of infundibular pulmonary stenoses	8
Sealing up of chyle leakages	6
Fastening of the pleura parietalis against the thoracic wall in the case of extrapleural ligation of the duct	9
Sealing of lung fistulas	2

**Table 4.** Patients

Congenital vitia	
Aortic coarctation	5
Open ductus Botalli	9
Goretex hunt in the case of pulmonary atresia	2
Foramen Sekundum defect	2
Sinus venosus defect	1
Ventricular septal defect	2
Foramen Sekundum defect + pulmonary stenosis	1
Tetralogy of Fallot	7
Total AV channel	1
Transposition of the great arteries	1

In some cases fibrin glue was used in the case of extrapleural ligation of a persistent ductus arteriosus Botalli in neonates and premature infants; six times it was possible to seal up an intraoperatively seen chyle leakage after eventual dissection of the thoracic duct. After ligation of the duct, fibrin glue was applied between the pleura parietalis and the thoracic wall to prevent extrapleural pneumothorax and/or hemorrhage. Pulmonary outflow tract patches in the case of tetralogy of Fallot, pericardial patches in Transposition of Great Arteries (TGA), or conduits in the Fontane procedure are characterized by long bleeding times because of the impossibility of physiological clotting with Dacron prostheses during extracorporeal circulation. Fibrin glue application diminished intra- and postoperative blood loss significantly.

## ***Results***

In each case hemostasis on anastomoses, patches and suture lines was achieved. Hemorrhage from sealed surfaces and suture lines was not seen. Follow-up in over 600 patients showed non A non B hepatitis in 20 cases (3.33%) between 42 and 60 days postoperatively. Seventeen patients of these 20 were recruited from 19 patients who needed rethoracotomy because of hemorrhage. In the case of coronary artery disease a postoperative follow-up in over 200 cases showed no significant increase in graft embolization.

## ***Discussion***

Fibrin glue is employed in cardiovascular surgery mainly because of its hemostatic and sealing effect. Bleeding from needle tracts or diffuse oozing can be adequately controlled using fibrin glue together with collagen fleece as a carrier material. This technique has proven especially effective in the case of bleeding areas where access is difficult. It can be applied even when, for different reasons, suturing is impossible.

The elasticity of solidified fibrin sealant is a special advantage when sealing vascular prostheses and patches. Recent results have shown that fibrin glue is ideally suited for sealing highly porous vascular prostheses in operations involving partial heparinization. Furthermore, fibrin glue is used by some authors for sealing large-pore double Velour knitted prostheses implanted under extracorporeal circulation. A substantially reduced risk of postoperative bleeding and shorter operation time are invariably emphasized by the authors [15].

Blood clotting with high concentrate fibrinogen means imitating the end phase of physiological blood clotting [3, 7]. From the fibrin monomere a polymere is first formed, which is transformed to a stable fibrin net by added factor XIII. To prevent fibrinolysis aprotinin is enclosed. The fibrin film obtained is characterized by high adhesion. So, for instance, after experimental blood clotting on the liver with fibrin glue, portal pressures of about 300 mm Hg showed no insufficiency on glued areas [10]. It seems important to emphasize that in each case the aprotinin concentration was 1000 units/ml as recommended by the producer. In contrast to other forms of tissue glueing, fibrin glue contains substances which can be found only in the living



organism: A toxic reaction of this form of blood clotting is unknown [1, 2, 10]. Fibrin is directly transformed to granulation tissue. After application of fibrin glue the question of a possible transmission of hepatitis is of great importance. However, one has to take in to consideration that in our patients different amounts of blood intra- and postoperatively were given. The risk of transmission of hepatitis with one blood transfusion is given as up to 5.3% in literature [8, 14]. Simultaneous giving of clotting factor concentrates is increasing this percentage considerably [6]. The 3.33% incidence of hepatitis seen in our patients therefore seems to be in the expected range, a fact which makes the transmission of hepatitis by fibrin glue unlikely.

In conclusion: Although fibrin glue cannot substitute for good technique and certainly cannot replace surgical suture, it appears to be a valuable aid under special conditions; so we highly recommend fibrin glue in open heart surgery in the above-mentioned cases.

## References

1. Auvert I, Kelemen ZS, Weisgerber G (1975) Applications de la colle hemostatique GRF en chirurgie. *Nouv Presse med* 4:733-734
2. Göber I, Meissner K (1970) Zur Versorgung experimenteller Leberläsionen durch Acrylkleber. *Acta chir Austriaca* 6:146-148
3. Lindner A, Elliott M, Holzer F (1980) Die Optimierung des Fibrinogen-Thrombin-Gemisches. *Winer klin Wschr* 92 Suppl 709
4. Matras H, Jesch W, Kletter G, Dinges HP (1978) Spinale Duraklebung mit Fibrinkleber Wien, *klin Wschr* 90:419-425
5. Rauchenwald K, Urlesberger H, Henning K, Braun F, Spängler HP, Holle J (1976) Anwendung eines Fibrinklebers bei Operationen am Nierenparenchym. *Aktuelle Urologie* 7:209-215
6. Rossiter SJ, Miller G, Raney A, Oyer P, Reitz B, Stinson E, Shumway NE (1979) Hepatitis risk in cardiac surgery patients receiving factor IX concentrates. *J Thorac Cardiovasc Surg* 78, 203-207
7. Scheele I, Herzog I, Mühe E (1978) Anastomosensicherung am Verdauungstrakt mit Fibrinkleber. *Zbl Chir* 103:1325-1336
8. Silver D, Blood transfusions and disorders of surgical bleeding. In Sabiston, DC (Hrsg.) *Textbook of Surgery*, WB Saunders, Philadelphia – London – Toronto 1976, S 131 ff
9. Spängler HP (1976) Gewebeklebung und lokale Blutstillung mit Fibrinogen, Thrombin und Blutgerinnungsfaktro XIII. *Wien klin Wschr* 88 Suppl 49
10. Staindl O (1977) Die Gewebeklebung mit hochkonzentriertem humanem Fibrinogen am Beispiel der freien autologen Hauttransplantation. *Arch Oto Rhino Laryrn* 217:219-228
11. Spängler HP, Braun F, Holle H, Moritz E, Wolner E (1976) Die lokale Anwendung von Fibrinogen und Kollagen zur Blutstillung in der Herzchirurgie *Wien med Wschr* 126:86-89
12. Stenzl W, Höfler H, Tscheliessnigg KH, Hermann W, Höllner G, Dacar D (1982) Blutstillung an der Leber durch Gewebeklebung. Vergleich zweier Mehrkomponentenkleber. *Zbl Chir* 107:1557-1563
13. Stenzl W, Rigler B, Tscheliessnigg KH, Dacar D, Beitzke A (1983) Treatment of postoperative chylothorax with fibrin glue *Thor cardiovasc surgeon* 31:35-36
14. Sugg U, Huth R, Lissner R, Hoffmeister HE, Schneider W (1983) Incidence of post transfusion hepatitis in patients with open heart surgery. *Thoracic cardiovasc Surgeon* 31, Suppl I, 13
15. Walterbusch G, et al (1982) Clinical experience with fibrin glue for local bleeding control and sealing of vascular prostheses. *Thorax cardiovasc Surg* 30:234-235

# The Uses of Fibrin Sealant in Cardiac Surgery

W. STENZL, K. H. TSCHELIESSNIGG, D. DACAR, F. IBERER, and B. RIGLER

*Key words:* Fibrin sealant, application technique, hepatitis, cardiac surgery

## ***Abstract***

Fibrin sealant was applied during surgery for acquired heart disease for hemostasis on anastomoses, patches and suture lines and for epicardial fixation of artocoronary saphenous bypass grafts. A survey of various techniques of fibrin glue application is given with special regard to cardiac surgery. In 1983, fibrin sealant was used in 121 patients during surgery for acquired heart disease. Postoperatively, hepatitis B was observed in five cases and non A non B hepatitis in two cases; the total incidence of hepatitis being 5.8%. A causal relationship between the use of fibrin glue and the incidence of hepatitis seems to be very unlikely, as all seven patients had received blood transfusions and four of them had been given clotting factor concentrates. It is concluded, that, although fibrin glue cannot replace the surgical suture, it may decrease the risk of postoperative bleeding.

## ***Introduction***

From 1976, when the experimental and clinical application of fibrin sealant was first described [2], it has been increasingly used in all fields of cardiac surgery. Having used fibrin glue for experimental and clinical purpose from 1978, we now apply it predominantly for hemoastasis on suture lines, anastomoses, prostheses, and patches as well as for hemostasis after extensive pericardial adhesiolysis at reoperations. In coronary surgery we use fibrin adhesive for epicardial fixation of saphenous bypass grafts.

## ***Technical Considerations***

### ***Hemostasis***

Fibrin sealant may be used for the securing of anastomoses, provided there is no or only minor bleeding, as substantial hemorrhage would cause a washing-off of the sealant. In technically difficult anastomoses in coronary surgery, when anastomotic leakage can be expected after declamping of the aorta, fibrin sealant may be applied during the cardioplegic arrest phase, at a time when the anastomosis is still dry. The

location of anastomotic leakage can be facilitated by a cardioplegic reperfusion of the graft after the anastomosis has been completed. Minor leakage can be eliminated by fibrin glue, whereas, in major leaks, cardiac arrest facilitates an additional suture. Application of fibrin sealant during the cardioplegic arrest phase is advantageous also at reoperations when major bleeding from dissected adhesives can be expected after opening the aortic clamp.

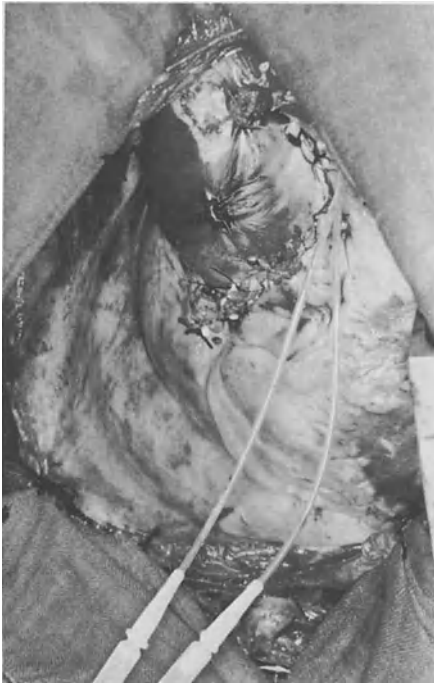After declamping of the aorta, fibrin sealant will be possibly washed off by the oozing hemorrhage. In this instance, fibrin glue should be used together with collagen fleece. It is widely recommended to press the fibrinogen and thrombin-soaked fleece against the oozing surface. With this technique, however, consolidation of the fibrin glue will occur too quickly in most cases. The sealant substances may have coagulated before the glue-containing collagen fabric has been applied to the oozing surface. To avoid premature coagulation of the fibrin glue, we first apply the fibrinogen component unilaterally to the collagen fleece. After the fleece has been pressed to the oozing surface, the thrombin component is poured onto the fibrin-soaked fleece. It penetrates and induces consolidation of fibrin within the collagen fabric. To improve the security of hemostasis, a layer of fibrin sealant may be applied afterwards above the fibrin-collagen plug.

Alternatively, the collagen fleece may be pressed against the oozing surface. The two components may be injected separately via two small catheters into the space between the collagen fleece and tissue. With both techniques it is, in our opinion, recommendable to press the fleece to the tissue for at least 60s. Gloves and instruments should be wet to avoid undesired stickiness of these utensils.

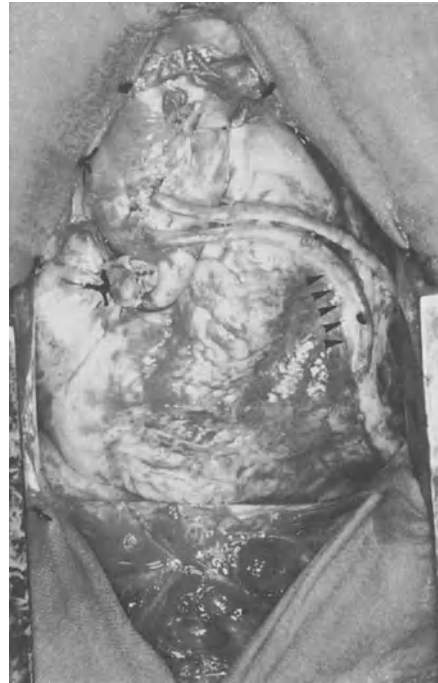At reoperations, when fibrin sealant was not applied previously during cardioplegic arrest, we usually wait for the termination of heparinization and for the occurrence of blood clots. Continuing hemorrhage at locations which are easily accessible can be treated as described above. However, access to bleeding sites posterior to the heart can be difficult, especially when the atria and ventricles are dilated. In these cases, the space between the posterior heart and the pericardium can be filled up with fibrin glue. For this purpose, we use two vena cava infusion catheters, which are attached by two ligatures at the tip (Fig. 1). The fibrinogen and thrombin components may be applied to inaccessible locations on the cardiac and pericardiac surface by way of these catheters.

### *Epicardial Graft Fixation*

In coronary bypass surgery during cardioplegic arrest it may be difficult to estimate the appropriate length of the venous transplant as dislocations of the sites of the aortovenous and venocoronary anastomoses can be observed after termination of ECC. A venous graft which is too long or slightly twisted may be fastened to the pericardium in a safe position to prevent kinking due to displacement after closing of the thoracotomy. With fibrin glue it is feasible to fix the venous graft on the epicardial surface in the desired curve, which is not as easy when surgical sutures are used instead (Fig. 2).



**Fig. 1.** Filling up of the posterior part of the pericardial cavity with fibrin adhesive. The catheters are attached by two ligatures near the tip



**Fig. 2.** Epicardial fixation of aortocoronary bypass grafts with fibrin sealant (*arrows*)

### *Incidence of Serum Hepatitis*

When plasma derivatives are used, eventually the question of the risk of serum hepatitis is raised. From this aspect we have performed a retrospective investigation in 121 patients, in whom fibrin sealant was applied during surgery for acquired heart disease from 1 January to 31 December 1983 (Table 1). Fibrin glue was applied when oozing hemorrhage was observed 15 min after administration of protamine chloride. Hepatitis was considered in patients in whom SGPT (serumglutamate-pyruvate-transaminase) levels were elevated 150% above normal values on at least two occasions 14 – 180 days after the operation [6]. Of the 121 patients, hepatitis B was

**Table 1.** Applications of fibrin sealant in 1983

Coronary surgery	66
Mitral valve replacement and anuloplasty	15
Closed mitral commissurotomy	9
Aortic valve replacement	26
Aortic and mitral valve replacement	5
<b>Total</b>	<b>121</b>

observed in five cases and non A non B hepatitis in two cases, the total incidence of serum hepatitis infection being 5.8%. All the patients who developed postoperative hepatitis were treated with at least two blood transfusions (350 ml each); in four cases clotting factor concentrates were administered additionally because of serious postoperative blood coagulation disorders.

### **Discussion**

A potentially elevated risk of serum hepatitis infection is a major argument against the use of plasma derivatives, such as fibrin sealant, in surgery. However, our observations do not support the assumption that the risk of serum hepatitis infection may be actually increased by application of fibrin sealant. After open heart surgery, the risk of hepatitis infection is about 5–6% [5]. The incidence of 5.8% of hepatitis infection that we observed is within that range.

Furthermore, treatment with clotting factor concentrates, which was necessary in four of our patients, increases the risk of hepatitis infection even more [6]. Therefore, the possibility of hepatitis infection because of application of fibrin sealant seems to be very unlikely [1]. In contrast to other well-known surgical adhesives, such as cyanoacrylate glue or gelatin-resorcine-formaldehyde glue (GRF glue), fibrin sealant does not cause toxic alterations of adhering tissue [4]. In the present paper we have described a few techniques to apply fibrin sealant as effectively as possible. Although fibrin sealant certainly cannot replace the surgical suture it may help to solve special surgical problems especially when the use of sutures has proved futile [1, 4]. In conclusion, fibrin sealant seems to increase the safety of hemostasis and thus to contribute to the decrease of postoperative bleeding complications.

### **References**

1. Borst HG (ed) (1982) Workshop on fibrin seal in cardiovascular surgery Thor cardiovasc surgeon 30:195-242
2. Spängler HP, Braun F, Holle H, Moritz E, Wolner E (1976) Die lokale Anwendung von Fibrinogen und Kollagen zur Blutstillung in der Herzchirurgie. Wien Med Wschr 126:86-89
3. Stenzl W, Höfler H, Tscheliessnigg KH, Hermann W, Höllerl G, Dacar D (1982) Blutstillung an der Leber. Vergleich zweier Mehrkomponentenkleber. Zbl Chir 107:1557-1563
4. Stenzl W, Rigler B, Tscheliessnigg KH, Dacar D, Beitzke A (1983) Treatment of postoperative chylothorax with fibrin glue (case report) Thor cardiovasc surgeon 31:35-36
5. Sugg U, Huth R, Lissner R, Hoffmeister HE, Schneider W (1983) Incidence of post transfusion hepatitis in patients with open heart surgery. Thor cardiovasc surgeon Suppl I, 13
6. Sugg U, Schneider W (1980) Hepatitisrisiko von Plasmaproteinderivaten. Dtsch Ärzteblatt 77:2545-2548

# The Use of Fibrin Sealant and Fibrin Sealant Combined with Antibiotics in Cardiovascular Surgery

A. HAVERICH, T. WAHLERS, G. WALTERBUSCH, and H. G. BORST

*Key words:* Fibrin sealant, cardiac surgery, bleeding control, sealing of vascular prostheses, fibrin sealant and antibiotics

## ***Abstract***

From 1978 to April 1985, fibrin sealant was applied in a group of 756 patients undergoing extracorporeal circulation, whenever conventional suturing methods were impossible, difficult or dangerous. The success rate was 97%. Fibrin sealant combined with antibiotics was proved to be potentially helpful for use with vascular and cardiac valve prostheses in infected areas.

In addition fibrin presealed woven or knitted grafts were inserted in 138 patients undergoing extracorporeal circulation, in which 127 underwent cardiac procedures. The failure rate was less than 5%. Fibrin adhesive has become a universally effective and reliable method of bleeding control. Fibrin presealed knitted prostheses are expected to replace woven fabric in the future because of its known poor healing qualities.

## ***Introduction***

Tissue gluing appears to be an interesting alternative to conventional suturing for control of bleeding [4] and pulmonary leakage [13, 17, 18, 21] and for reapproximation of tissue in aortic dissection [12, 14]. Fibrin gluing was first introduced into cardiovascular surgery by Spängler and coworkers in 1976 [1, 15, 16]. Fibrin glue differs from synthetic glues because it imitates a biological process. It is effective in the presence of systemic anticoagulation during extracorporeal circulation [17, 20] and/or coagulopathies and does not require perfectly dry surfaces. Also it is useful for fixation of coronary artery bypass grafts and in combination with antibiotics. This report summarizes our experience with the adhesive as a hemostatic agent for bleeding control and for presealing vascular prostheses. In addition, the potential for using fibrin seal combined with antibiotics is discussed.

## ***Material and Method***

Fibrin adhesive consists of commercially available concentrated frozen cryoprecipitated or lyophilized fibrinogen of human origin, which is prepared for use by either warming or dilution, respectively. The material is activated by thrombin (500 NIH

units/ml), calcium chloride (40 mmol/l) and the antifibrinolytic agent aprotinin (3000 NIH/units/ml). Using the fibrin adhesive as a hemostatic agent, only a small amount of fibrinogen is applied to a piece of collagen fleece or sponge; the activator is dripped onto the material, which is pressed on to the bleeding side for approximately 1 min. Alternatively, components can be sprayed on to oozing surfaces for control of bleeding. For sealing vascular prostheses, the fibrinogen is smeared onto the surface of the stretched fabric and subsequently the thrombin solution is massaged into the graft.

## Results

In our patient group we have used presealed woven grafts, double Velour knitted grafts, and plain knitted grafts. The average amount of fibrinogen used for bleeding control was 0.8 ml (range 0.5 – 4 ml). Presealing prosthetic fabric required a mean of 1.3 ml (range 0.5 ml – 6 ml) of adhesive. If the fibrin sealing was used combined with antibiotics, 2 g antibiotic dry substance was mixed up with the thrombin solution. Subsequent application of the adhesive was identical to conventional administration.

Fibrin glue has been used in a total of 380 bleedings in the high-pressure system (Table 1). There were only 13 failures (3.4%). The adhesive was used for arterial bleedings from aortic cannulation sites, aortotomies and coronary bypass anastomoses.

In the low-pressure system, the adhesive was used in 376 cases and failed in only 1.9% of the applications (Table 2). Fibrin gluing appeared especially helpful in pediatric cardiac surgery for sealing suture lines in the atria, the caval veins, the right ventricle and the pulmonary artery including puncture hole bleeding from PTFE patches. In addition, the adhesive was effective in every case of diffuse epimyocardial bleeding resulting from separation of pericardial adhesions and in venous hemorrhages occurring at the sites of exposure of the coronary arteries.

Low-porosity, woven Dacron-grafts were presealed with fibrin glue and implanted in 99 patients under full heparinization and extracorporeal circulation. There was no incidence of early or late bleeding from the prosthetic fabric (Table 3). High-porosity knitted prostheses were used in 39 patients (Table 4) undergoing extracorporeal circulation. Except for two cases the sealing was successful. One of the failures was caused by delayed leakage occurring in the only non-Velour graft implanted.

**Table 1.** Use of fibrin adhesive for bleeding control in the high-pressure system

	No. of patients	No. of failures
Aorta	211	10
CAB proximal	65	2
CAB	93	1
IV	11	–
Total	380	13 (3.4%)

CAB; coronary artery bypass; LV, left ventricle

**Table 2.** Use of fibrin adhesive for bleeding control in the low-pressure system

	No. of patients	No. of failures
IVC, SVC, atrium	105	1
Coronary veins	39	–
RA, PA	27	3
RV patch (PTFE)	22	3
Epi-/myocardial	90	–
Fixation of CABG	93	–
Total	376	7 (1.9%)

IVC, inferior vena cava; SVC, superior vena cava; RA, right atrium; PA, pulmonary artery; RV, right ventricle; CABG, coronary artery bypass graft

**Table 3.** Results of fibrin presealing of woven grafts during ECC

	No. of patients	No. of failures
Aortic arch	11	–
Ascending aorta	63	–
RV-PA conduit	11	–
RV patch	14	–
Total	99	–

ECC, extracorporeal circulation; RV, right ventricle; PA, pulmonary artery

**Table 4.** Results of fibrin presealing of knitted grafts during ECC

	No. of patients	No. of failures
Ascending aorta	14	1 <sup>a</sup>
RV-PA conduit	6	1
RV patch	14	–
LV patch	5	1
Total	39	2 (5,1%)

ECC, extracorporeal circulation; RV, right ventricle; PA, pulmonary artery; LV, left ventricle;  
<sup>a</sup>Delayed leakage occurred in the only non-velour graft



**Table 5.** Results of fibrin presealing of knitted grafts (with heparin)

	No. of patients	No. of failures
Descending aorta	42	1
Thoracoabdominal aorta	20	–
Ruptured	5	2
Infrarenal aorta	105	1
Ruptured	32	2
Total	204	6 (2.9%)

Two hundred and four knitted prostheses were implanted for descending aortic replacement, thoracoabdominal or infrarenal aortic replacement. Partial intravenous heparinization was used in all cases. Out of these, six grafts, which were primarily sealed with fibrin glue, showed transprosthetic blood loss (Table 5). In all these cases, severe hypovolemic shock symptoms due to ruptured aneurysms had preceded graft implantation.

Combined use of antibiotics with fibrin sealant was used in five cases of infected aneurysms of the infrarenal aorta. The rate of reoperation in this group was only 20%, with an overall mortality of 20% compared with a reoperation rate of 67% and mortality of 83% in patients treated conventionally by extra-anatomical bypass procedures and aortic resection. Furthermore, fibrin glue combined with antibiotics was applied in five patients undergoing cardiac valve replacement for bacterial endocarditis. In all cases, large annular abscesses were filled with glue prior to occlusion of the conduits. In one case, recurrent endocarditis occurred, while in the remaining four patients an infective process could be healed.

### ***Discussion***

Hemostatic gluing has been an interesting alternative to suturing ever since the introduction of synthetic tissue glues. Although most bleeding complications in cardiovascular operations can be controlled by conventional methods, such trials often result in continuing hemorrhage and circulatory depression. However, adhesives have been of little value in cardiovascular operations until now, because of their dependence on absolutely dry surfaces. In contrast to synthetic adhesives, fibrin glue, using a biological system, represents a reliable alternative for solving these problems. Optimal concentrations of the components of the glue have been studied in detail, as has the addition of substance to inhibit fibrinolytic activity. Fibrin gluing is now employed routinely whenever suturing is impossible, difficult or dangerous. However, it may also be used to save waiting time for spontaneous hemostasis.

The method is most effective for control of oozing but it should also not be overextended in situations where brisk arterial bleeding sites are reserved for surgical closure. Fibrin glue has been applied in prophylactic sealing of suture lines and of puncture holes in PTFE patches. In addition, aortocoronary bypass grafts may be fixed on the cardiac surfaces to prevent any kinking of the graft (Table 1).

The use of fibrin adhesive and presealing vascular prosthetic fabric appeared logical in view of the fact that even tightly woven material remained mandatory in the presence of full heparinization and extracorporeal circulation. Fibrin presealing, therefore, is now the preferred method for sealing woven prostheses and has also reduced the blood loss in complex cardiovascular procedures involving insertion of prosthetic material. Fibrin sealing of knitted grafts has resulted in superior healing characteristics of the prostheses. This has been proven histologically in animal studies in which woven and knitted tubes have been inserted [2, 13].

Finally, the combination of fibrin sealing and antibiotics represents a potentially helpful method of graft preparation for use in infected areas. Results appear to be improved compared with conventionally treated patients regarding the incidence of reoperation and mortality. Furthermore, the combined use of fibrin sealant and antibiotics may be a better treatment of mycotic aneurysms within the aortic root. For this mode of application, further studies must be performed for systematic evaluation. In summary, we think that the spectrum of application of fibrin glue in cardiovascular surgery has been widened due to the good results obtained with this method during the initial 5 years of routine application in Europe.

## References

1. Spängler HP, Holle H, Braun, F (1973) Gewebeklebung mit Fibrin Wr Klin Wschr 85, 827-829
2. Haverich A, Maatz W, Walterbusch G (1982) Evaluation of Fibrin Seal in animal experiments Thorac Cardiovasc Surg 30:215
3. Haverich A, Walterbusch G, Borst HG (1981) The use of fibrin glue for sealing vascular prostheses of high porosity. Thorac Cardiovasc Surg 29:252
4. Borst HG, Haverich A, Walterbusch G, Maatz W (1982) Fibrin adhesive: an important hemostatic adjunct in cardiovascular operations J Thorac Cardiovasc Surg 84:548
5. Haverich A, Walterbusch G, Borst HG (1983) Abdichtung poröser Gefäßprothesen unter Teil-Heparinisierung und extrakorporaler Zirkulation Angio 5:215-220
6. Walterbusch G, Saathoff M, Haverich A, Mlasowsky B (1983) Die Abdichtung poröser Gefäßprothesen – Eine Gelegenheit zur lokalen Antibiotikaapplikation? Angio 5:239-244
7. Lange U, Jenkner J (1983) Erfahrungen bei der Verwendung von Humanfibrinkleber zur Abdichtung von Gefäßprothesen Angio 5:221-223
8. Deyerling W, Haverich A, Potel J, Hetzer RA (1984) Suspension of fibrin glue and antibiotic for local treatment of mycotic aneurysms in endocarditis an Experimental study. Thorac Cardiovasc Surg 32:369-372
9. Conte JE, Cohen SN, Roe BB, Elashoff RM (1972) Antibiotic prophylaxis in cardiac surgery Ann Int Med 76:943-949
10. Wahlers Th, Haverich A, Borst HG Die Fibrinklebung und der Fibrinantibiotikumverbund in der Herz- und Gefäßchirurgie. Neue Techniken in der operativen Medizin Aachen, Springer Verlag 1986, 79-82
11. Talkington C M, Thompson IE (1982) Prevention and management of infected prostheses Surg Clin North Am 62:515-530
12. Akrami R, Kalmar P, Pokar H, Tilsner V (1978) Abdichtung von Kunststoffprothesen beim Ersatz der Aorta im thorakalen Bereich Thoraxchirurgie 26:144-147
13. Ben Sanchar G, Nicoloff DM, Edwards JE Separation of Neointima from Dacron graft causing obstruction J Thorac Cardiovasc Surg 82:268
14. Guilmet D, Bachet J, Goudot B, Laurian C, Gigou F, Bical O, Barbagelatta M (1979) The use of biological glue in acute aortic dissection. A new surgical technique: Preliminary Clinical Results. J Thorac Cardiovasc Surg 77:516-521
15. Spängler HP (1976) Gewebeklebung und lokale Blutstillung mit Fibrinogen, Thrombin und Blutgerinnungsfaktor XIII. Wien Klin Wochenschr 88/49:1-13

16. Redl H, Schlag G, Dinges HR, Kuderna H, Seelich T Background and methods of fibrin sealing biomaterial, G D Winter, D F Gibbons, H Plenk, eds. Chichester, 1982, John Wiley & Sons Ltd. pp 669–676
17. Borst HG, Haverich A, eds (1982) Fibrin seal in cardiovascular surgery. Proceedings of a workshop. *Thorac Cardiovasc Surg* 30:195–224
18. Cooley DA, Romagnoli A, Ailam DJ, Bossart AI (1981) A method of preparing woven Daeron aortic grafts to prevent interstitial hemorrhage. *Cardiovascular Diseases Bull Texas Heart Inst* 8:48–52
19. Bethea MC, Reemtsma K (1979) Graft hemostasis, An alternative to preclotting *Ann Thorac Surg* 27:374
20. Köveker G, de Vivie ER, Hellberg KD (1981) Clinical experience with fibrin blue in cardiac surgery. *Thorac Cardiovasc Surg* 29:287–289
21. Huth C, Seybold-Epting W, Hoffmeister HE (1982) Local hemostasis with fibrin glue (Tissucol) after Intracardiac repair of retralogy of Fallot and transposition of the great arteries (TGA). *Thorac Cardiovasc Surg* 30/I:30

# Fibrin Seal (Tisseel/Tissucol) in Paediatric Cardiothoracic Surgery. The Experience of the Hospital for Sick Children, Great Ormond Street, London

M. J. ELLIOTT, M. R. de LEVAL, and J. STARK

*Key words:* Fibrin seal, open-heart surgery, tracheal surgery, paediatrics

## ***Abstract***

Over the last 5 years Tisseel has become an established part of our armamentarium. We have previously reported our preliminary experience and now update those data. Tisseel has been used increasingly for the prophylaxis of haemorrhage control rather than for treatment of established haemorrhage. Since 1980, Tisseel has been utilised in 85 patients with a variety of paediatric cardiac surgical problems, and in 72 of the 85 (85%) excellent haemostasis was achieved. In ten patients (11%) a good result was achieved, and in only three patients (4%) was an unsatisfactory result achieved. One of these was early in our experience, and the remaining two were caused by the application of Tisseel to relatively severe *established* haemorrhage. Tisseel has also been used to seal serous leak from a Gore-tex graft. In our experience, Tisseel has represented a major advance in the safety of paediatric cardiothoracic surgery and may now be considered an essential part of certain procedures, particularly, for example, the arterial switch and repair of truncus arteriosus.

## ***Introduction***

Since we reported our preliminary experience with Tisseel [1], it has become an established part of our armamentarium. This paper reports our total "Tisseel" experience to date, and describes our current philosophy of its application.

## ***Material, Patients and Methods***

The basic method of utilisation of Tisseel has been laid down by the manufacturers and described in our previous publication [1]. Since that time, however, there have been some modifications in our practice. Increasingly, we use Tisseel in a 'preventive' manner, applying its two components to completed suture lines in blood vessel walls *before* blood is allowed to flow through those vessels. The Tisseel and activator are usually applied using the Duplojet, (Immuno Ltd, Arctic House, Rye Lane, Dunton Green, Nr. Sevenoaks, Kent, England), but without the use of collagen fleece. For 'established' haemorrhage, however, Tisseel is usually applied *with*

collagen fleece, often in association with the pharmacological hypotension we have already described [1]. We have not used spray application of Tisseel since it is not yet licensed in this country.

Tisseel was utilised entirely at the discretion of the surgeons in our unit (the three co-authors). It was employed either to *prevent* anticipated haemorrhage, usually at sites which would subsequently become inaccessible, or to *treat* established haemorrhage not readily or safely controlled by simple additional suture techniques. Details of the use of Tisseel and the patients in whom it was utilised were recorded and subsequently tabulated.

The results of Tisseel application have been classified as *excellent* (bleeding completely controlled), *good* (bleeding reduced but not completely stopped) and *unsatisfactory* (when other techniques were required adequately to reduce bleeding). Clearly this represents a subjective observation of the surgeon. Since 1983 all preparation of Tisseel has been carried out using thermal beds provided by the manufacturers. This has ensured adequate mixing of the two components.

Since 1980, Tisseel has been utilised in 85 patients (47 since August 1983). The operations to which these patients were subjected are listed in Table 1. The *sites* of application of Tisseel are listed in Table 2; clearly, several patients required the use of Tisseel in a number of different sites. By far the commonest indication for the use of Tisseel in our hands has been in patients requiring extracardiac conduits ( $n=43$ ), many of whom were also "reoperations". Most of the conduits we use are fresh, antibiotic sterilised aortic homografts which occasionally require extension with a prosthetic tube. Our preference has been to use knitted Dacron, presealed with Tisseel as recommended by Haverich [2], to prevent haemorrhage through this highly porous material. We do not use woven Dacron because of the unacceptable incidence of fibrin-peel-induced obstruction [3]. Twenty-three patients underwent "Dacron sealing" in this way, and Tisseel was used in a further 18 for prevention of anastomotic leak.

**Table 1.** Operations in which Tisseel was used

Operation	No. of patients
Extracardiac conduit insertion	43
Reoperations (other than conduit insertion)	13
Arterial switch operation	10
Repair of tetralogy of Fallot	4
Interrupted aortic arch repair	3
Repair of total anomalous pulmonary venous drainage	2
Repair of anomalous origin of left coronary artery	2
Fontan operation	2
Septation	1
Repair of supra-valvar aortic stenosis	1
Recoarctation repair	1
Aortic root replacement	1
Resection of tracheal stenosis	1
Bronchotomy for bronchial adenoma	1
<b>Total</b>	<b>85</b>

**Table 2.** Sites of Tisseel application

Site	Number <sup>a</sup>
Suture line (aorta, pulmonary artery, coronary artery)	25
Conduit	41
(presealing)	(23)
(anastomoses)	(18)
Pulmonary artery reconstruction patch	7
Heart surface	7
Gore-tex patch	4
Bleeding near LAD coronary artery	2
Serous leak from Gore-tex shunt	1
Hilar collaterals near phrenic nerve	1
Stump of divided ductus arteriosus	1
Stump of subclavian artery after Gore-tex shunt avulsion	1
Tracheal anastomosis	1
Bronchotomy	1

<sup>a</sup> Several patients had application of Tisseel at more than one site

Tisseel was used in 13 other reoperations of various types, accounting for six of the seven applications to the heart surface.

Tisseel has found a particular niche in the arterial switch operation. By its very nature, this procedure results in long suture lines tucked away in subsequently inaccessible corners. Haemostasis has been achieved with Tisseel in ten such patients. There was a variety of other applications of Tisseel, as listed in Tables 1 and 2. Particular mention should be made, however, of its use in sealing massive serous leak from a Gore-tex shunt (application followed clamping of both ends) and for preventing air leak in pulmonary and tracheobronchial surgery.

Tisseel was used to seal suture lines preventively in 12 patients and after bleeding was established in a further 13. It was used "prophylactically" in all but five of the conduit anastomoses.

## Results

The results of the application of Tisseel are shown in Table 3, from which it can be seen that, in the majority of patients (72/85; 85%), excellent haemostasis was

**Table 3.** Results of Tisseel use

	Haemostasis		
	Excellent	Good	Unsatisfactory
1980–Aug 1983	31	6	1
Aug 1983–Dec 1985	41	4	2
Total	72	10	3

achieved. Ten patients (11%) had a good result with Tisseel and in all of those patients bleeding was eventually controlled with a second application of Tisseel, usually in association with collagen fleece.

Three patients (4%) had unsatisfactory results from the use of Tisseel. The first patient was early in our experience when we were unfamiliar with the technique. The remaining two incidences of poor results have occurred recently. In both patients an arterial switch operation had been performed and Tisseel had been applied to bleeding points on the "aortic" suture line *after* the vessel had been reperfused. In neither case did Tisseel control the haemorrhage, despite additional pharmacological hypotension.

In all patients in whom Tisseel was used preventively ( $n=25$ ) to seal long, inaccessible or conduit suture lines an excellent result was achieved.

### ***Discussion***

Our data have demonstrated conclusively that Tisseel is of value in controlling haemorrhage and air leak in paediatric cardiothoracic surgery. Further it has clearly been of maximum benefit when used prophylactically rather than to treat established haemorrhage. It would be naive to suggest that Tisseel is necessary in every case; clearly it is not. Suture lines which are easily accessible, low pressure, "non-critical" and not close to other vital structures (e.g. coronary arteries, phrenic nerve) rarely, if ever, require prophylactic application of Tisseel in our experience.

The aim of the paediatric cardiac surgeon is, by surgery, to effect a safe correction of the congenital heart defect. There is a traditional reticence to utilise techniques of haemostasis additional to normal suture methods. All surgeons like to think their suture lines are perfect. Mostly ours are. But, given the increasingly complex procedures which we employ on ever smaller children (e.g. the arterial switch), can we be so complacent? Experience with these types of procedures shows that although haemorrhage from a suture line is unusual, when it occurs it can be extremely difficult to control. The risks of prolonged periods of haemostasis with concomitant manhandling at the end of a long bypass are well known. Since we have shown that Tisseel seems especially effective as a prophylactic agent, we now believe that it should be employed as such in all paediatric cardiac surgical procedures in which bleeding, were it to occur, would be difficult to control because of problems of access, haemodynamic instability or proximity of other vulnerable structures. Our subjective impression is one of considerable time (and worry) saving when Tisseel has been used prophylactically; this has been particularly noticeable in arterial switch procedures, in repair of the truncus arteriosus and complex reconstructions of pulmonary arteries. We have no doubt that prevention is better than cure in such critically ill children. However, bleeding does occur and Tisseel, as we have shown, is a useful addition to the methods available for its control.

We have not limited our use of Tisseel to the management of haemorrhage. Its use as an "air sealing" agent is well known, but its application for the treatment of serous leak from a Goretex graft is worthy of separate mention. Such serous leak is very rare. It was first reported by Damus in 1984 [4] in two Korean children who had undergone systemic to pulmonary shunts of the modified Blalock type. Both grafts

required subsequent surgical removal. We have seen a similar case, but observed the serous leak at the time of initial surgery, as did Quagebeur in Leiden, Holland (personal communication). In both these latter two cases the serous leak was abolished by temporary isolation of the Gore-tex graft and sealing with Tisseel [5]. The grafts continue to function well.

### ***Conclusion***

On the basis of our experience with Tisseel, we feel that it is now an established weapon in the surgeon's armamentarium. It should be used prophylactically whenever any anticipated haemorrhage would be difficult to access or dangerous to suture, or when haemodynamic instability is present. It may be considered an essential part of certain procedures, for example the arterial switch and repair of the truncus arteriosus. Tisseel is also of value in the treatment of haemorrhage, especially in association with collagen fleece and/or pharmacological hypotension. Tisseel can control air leak from bronchi and serous leak from Gore-tex grafts. In our opinion, Tisseel represents a major advance in the safety of paediatric cardiothoracic surgery.

### ***References***

1. Stark J, de Leval MR (1984) Experience with fibrin seal (Tisseel) in operations for congenital heart defects. *Ann Thor Surg* 38:411-413
2. Haverich A, Borst H G (1980) Fibrin glue for treatment of bleeding in cardiac surgery. In: Bircks W, Ostermeyer J, Schulte H D (eds). *Cardiovascular Surgery*. New York: Springer-Verlag, p 621
3. Agarwal K C, Edwards W D, Feldt R H et al (1981) Clinicopathological correlates of obstructed right-sided porcine-valved extracardiac conduits. *J Thorac Cardiovasc Surg* 81:591
4. Damus P S (1984) Seroma formation after implantation of Gore-tex vascular grafts in cyanotic children. *J Thorac Cardiovasc Surg* 88:310-311
5. Maitland A, Williams W G, Coles J T, Freedom R M, Trussler (1985) A method of treating serous fluid leak from a PFTA Blalock-Taussig shunt. *J Thorac Cardiovasc Surg* 90:791-793



# Experience with Fibrin Glue (Tissucol/Tisseel) in Vascular Surgery

G. VERCELLIO, M. COLETTI, and G. AGRIFOGLIO

*Key words:* Fibrin glue, abdominal aortic aneurysm, femorodistal bypass, arteriovenous fistulas

## ***Abstract***

We consider fibrin glue a useful aid in vascular surgery. It has proven particularly helpful as a hemostatic and tissue sealant agent. Fibrin glue has been used by authors to control difficult bleeding on vascular anastomoses, especially on small and calcified vessels, to obtain hemostasis in heparinized patients or in those with coagulopathies, to permit the use of highly porous vascular prostheses even in anticoagulated patients, to control residual bleeding after embolization and surgical resection of angiodisplasias and to obtain the thrombosis of an expanding abdominal aortic aneurysm in a very high risk patient. Fibrin glue is considered an effective aid, in many and various instances decreasing the need for blood transfusions and shortening operating time.

## ***Introduction***

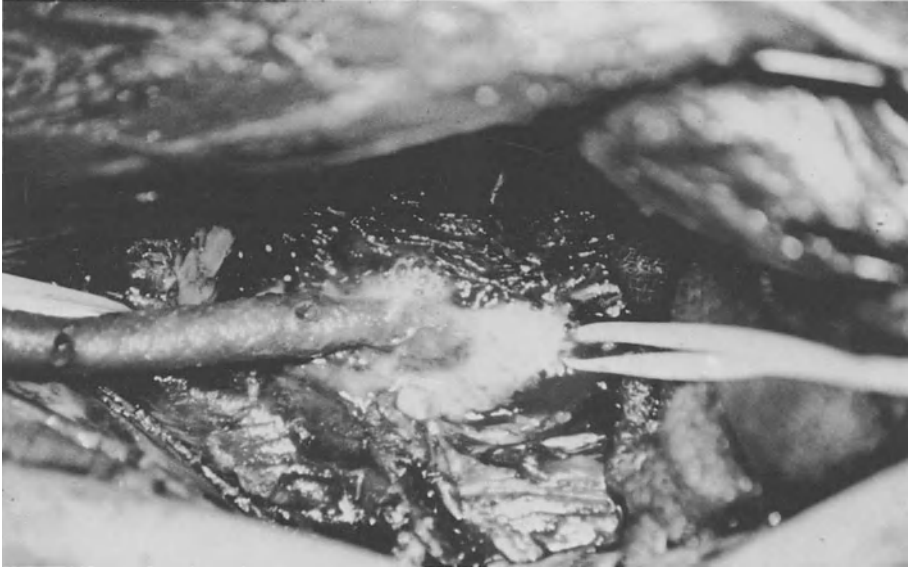An experimental study, carried out 5 years ago, in the Research Laboratory of the Institute of Vascular Surgery of Milan University, examined the properties of fibrin glue in vascular surgery as a preliminary approach.

Using Tissucol, replacement of the infrarenal aorta of the rat by bovine microprostheses of about 1.5 mm in caliber, performed with a reduced number of stitches (ranging from one to four), became easier and quicker, without modifications in the reparative process at the anastomotic level.

Afterwards our laboratory experience was transferred to the critical field of vascular surgery as femorodistal bypass procedures. In fact there is not a great difference between microsurgery and the technique required in selective revascularization of the tibial arteries.

## ***Case Histories***

In our opinion the best arterial substitutes, for infragenicular grafting, in the case of an unsuitable saphenous vein, are biografts such as the umbilical vein or the new bovine heterografts (Solcograft p); Solco, Basle (Fig. 1).



**Fig. 1.** Fibrin glue supported distal anastomosis in a femoroperoneal bypass using bovine heterograft

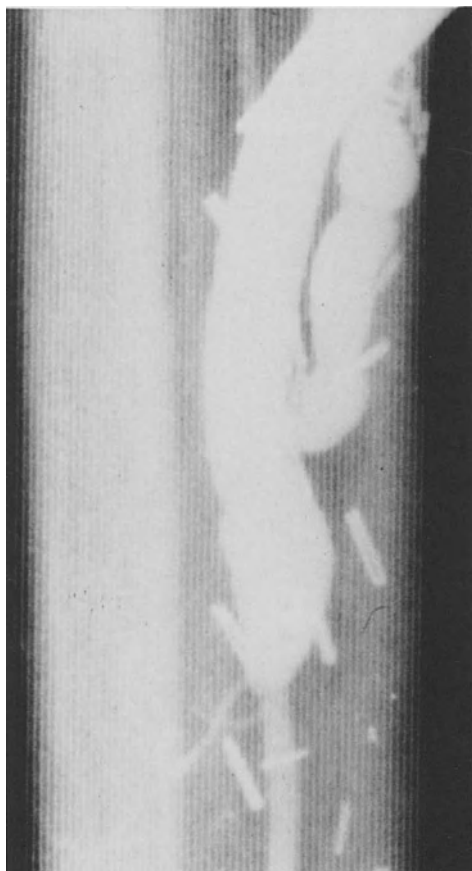The wall of these prostheses is very frail and also the wall of a tibial or peroneal vessel can be frail and often calcified: therefore, fibrin glue in many instances can provide a perfect seal of distal anastomoses in which any additional stitch could cause a stenosis.

When in the case of very high peripheral resistances arteriovenous fistula is performed, the site of the suture on the vein is, then, even more useful (Fig. 2). Outside of the distal anastomoses in femorotibial bypass, in our experience, the opportunity to use the glue to support vascular anastomoses is very limited; this happened in some cases after thromboendarterectomies (TEAs) performed in a subadventitial plane or in the case of a very frail wall of the neck of aortic aneurysms (in this instance we prefer a Teflon-supported anastomosis).

With regard to prostheses, sealing of Dacron grafts, mostly in the high-porosity grafts, could be obtained with Tissucol, in the case of incomplete or ineffective preclotting, or when the decision to employ a Dacron graft was taken after heparin administration, or finally in the case of chronic or acute hemorrhagic disorders. Recent studies carried out by Borst on fibrin glue coated prostheses show that there is no decrease in effective healing porosity.

The facility to convert a high-porosity graft to a zero-porosity graft in few minutes, in the case of real necessity, demonstrates the versatility of the glue and reduces the indications for the use of the new, rather expensive collagen-coating grafts.

On the other hand, PTFE often employed just to avoid preclotting in aortoiliac or axillofemoral grafting, in high-risk patients, sometimes requires fibrin glue on the suture line to seal the holes of the stitch needles.



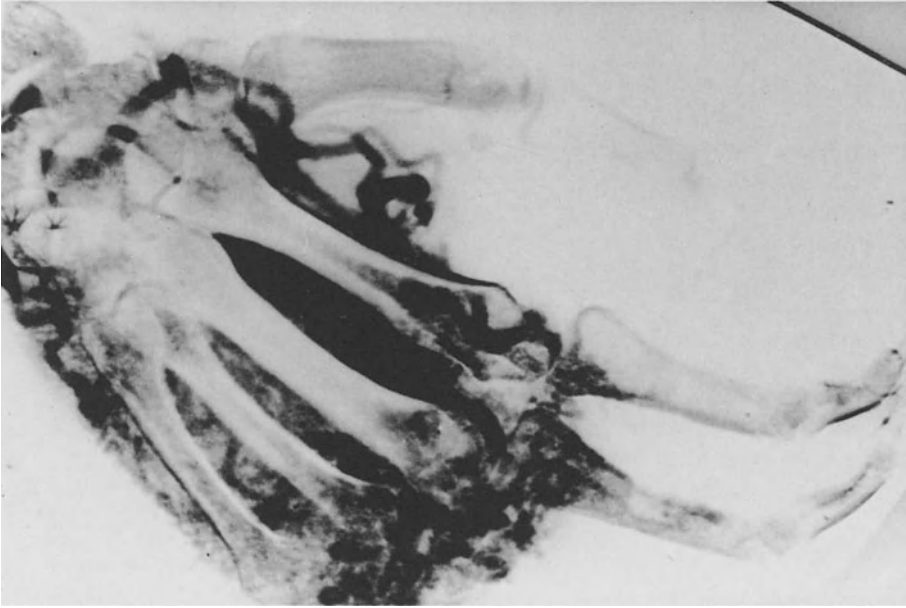
**Fig. 2.** Arteriovenous fistula at the site of distal anastomosis (as in the previous case)

Vascular malformations with arteriovenous fistulas is another critical field of vascular surgery (Fig. 3). Embolization and surgical resection of the angiodysplasia, often performed in one session, is our technique of choice.

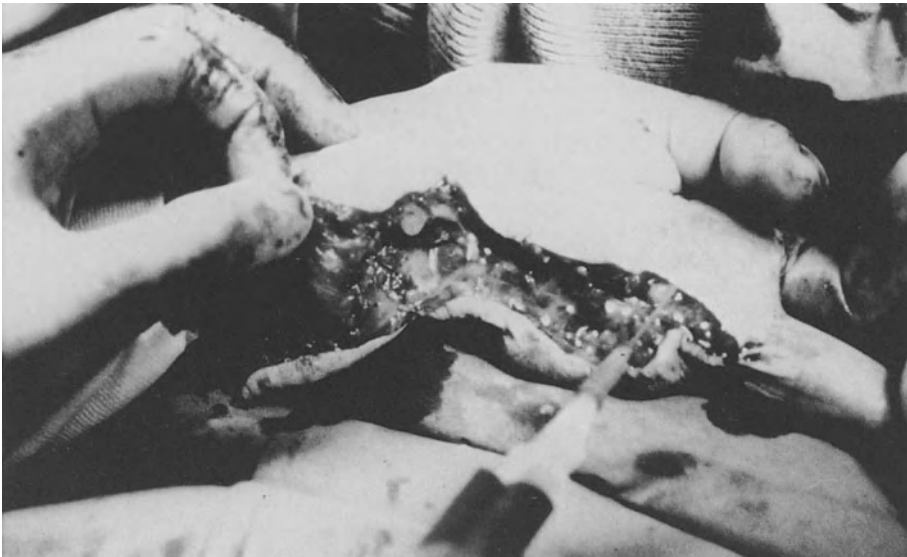Residual bleeding during surgery when embolization was not complete and effective was controlled by means of Tissucol (Fig. 4).

We have no experience of the use of Tissucol as an embolizing material in vascular malformations. We employed Tissucol, as an embolizing material, to obtain the thrombosis of an expanding abdominal aortic aneurysm, as an alternative procedure, in a very high risk patient. Risk factors were: age 84 years, neoplasm of a kidney, and previous irradiation.

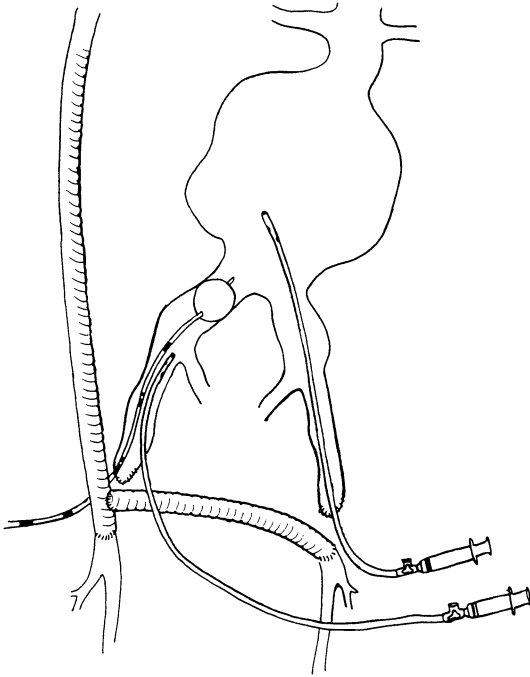
After an axillobifemoral bypass, thrombosis of the aneurysm was carried out, blocking up the flow through the hypogastric arteries with balloon catheters and injecting 6 ml Tissucol into the aneurysm (Fig. 5).



**Fig. 3.** Angiodysplasia of the hand with arteriovenous microfistulas



**Fig. 4.** Disarticulation of the fourth and fifth metacarpals; bleeding controlled by Tissuecol



**Fig. 5.** Axillobifemoral bypass and embolization of an expanding abdominal aortic aneurysm in a high-risk patient using Tissucol

### ***Discussion and Conclusions***

For its hemostatic properties fibrin glue could appear to have been developed just for vascular surgeons; on the other hand vascular surgeons are too accustomed to a refined technique to consider the glue the solution to any surgical mistake, to be put everywhere and to seal any hole. Nevertheless there is no doubt that Tissucol in many different situations can be an effective aid and in some instances enables the surgeon to avoid the so-called vascular disasters. Comparison with other experiences will define the role of this material in the armamentarium of vascular surgery.

### ***References***

1. Borst HG, Haverich A, Walterbusch G, Maatz W (1982) Fibrin adhesive: an important hemostatic adjunct in cardiovascular operations. *J Thorac Cardiovasc Surg* 84: 548-53
2. D'Angelo DA, Vercellio G, Coletti M, Carini A (1982) Impianti sperimentali di etero-innesti vascolari bovini con uso di Tissucol in microchirurgia. *Ort e Traum Oggi* Vol. 2-1
3. Vercellio G, Castelli P, D'Angelo DA, Cattaneo M (1984) Bovine heterograft: experimental study in microsurgery. *Angiology*, Plenum Publishing Corporation 824-828
4. Vercellio G, Lorenzi G, Carlesi R, D'Angelo DA, Coletti M (1984) Esperienze con la bioprotesi di Dardik nella rivascolarizzazione degli arti inferiori. *Il Policlinico sez chirurgica* 91: 622-624
5. Vercellio G, Lorenzi G, Losa S, Agrifoglio G (1985) Treatment of peripheral congenital arterio-venous fistulas. *J Cardiovasc Surg* 26: 168-170

# Application of Fibrin Glue for Prevention of Bleeding After Ascending Aorta Aneurysm Replacement

J. SADOWSKI, A. DZIATKOWIAK, R. PFITZNER, W. TRACZ, B. KAPELAK,  
and K. TRACZYŃSKI

*Key words:* Aortic homografts, vascular valved prostheses, fibrin glue, ascending aorta aneurysm, annuloaortic ectasia

## ***Abstract***

From 1982 to March 1985, 40 patients were operated on for aneurysm of the ascending aorta. Dissection of the aorta was diagnosed in 20 patients and emergency surgery was carried out. In 28 cases a homogeneous aortic valve with ascending aorta was implanted. In 12 patients a vascular valved prosthesis (conduit) was used. In all of these prosthetic procedures the suture lines were covered with fibrin glue (Tissucol, Immuno AG, Vienna). The application of this covering method significantly reduces bleeding during the procedure and after the operation.

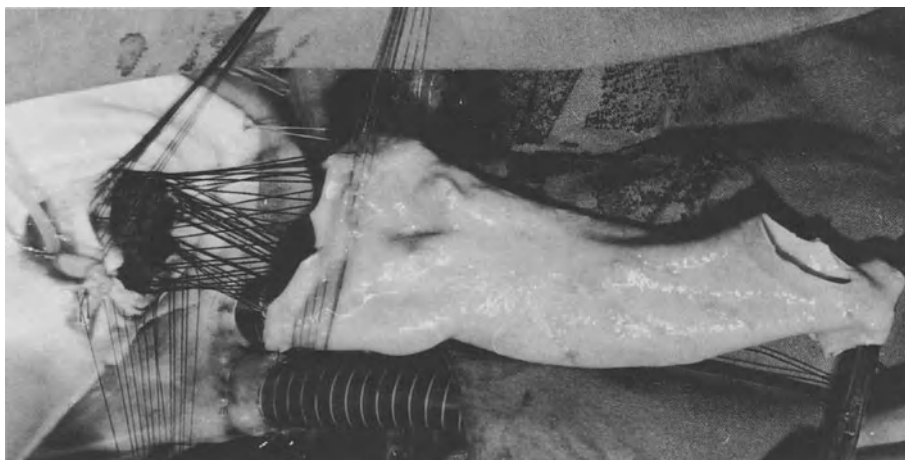
## ***Introduction***

In surgical treatment of the ascending aorta aneurysm the problem lies not only in suture technique but also in the possibility of massive bleeding after declamping. A long cardiopulmonary bypass time, application of heparin and the use of synthetic grafts may cause the disturbances of hemostasis. A decreased number of thrombocytes and lowered concentration of thrombin and fibrinogen causes bleeding through the prosthetic wall and across the suture lines [2]. In these cases it is useful to administer biological glue which contains hemostatic agents and collagen fibers [3, 4, 5].

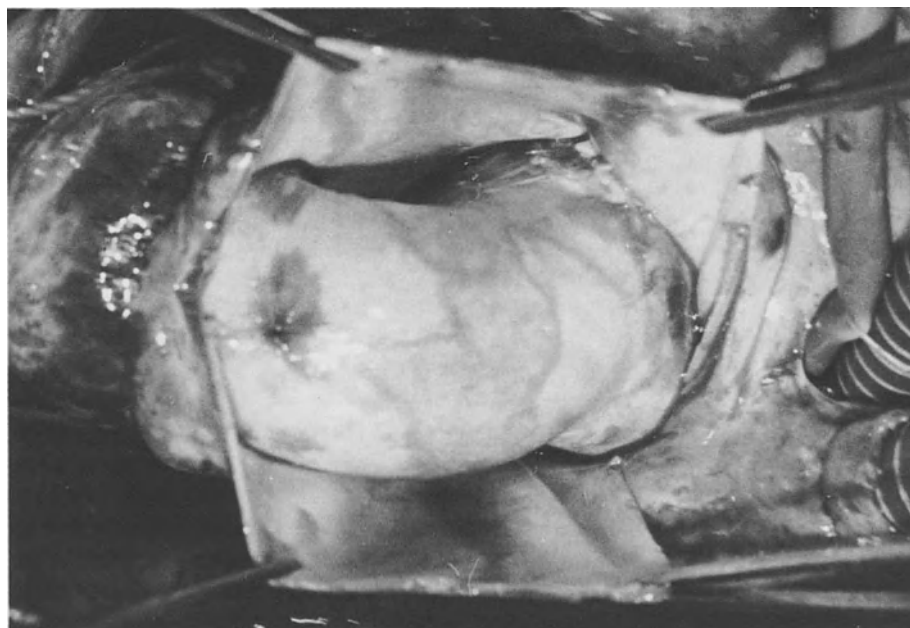## ***Material and Method***

From 1982 to March 1985 40 patients were operated on for aneurysm of the ascending aorta. There were 34 male and 6 female patients aged 15–60 years (mean 40 years). In 16 patients Marfan's syndrome and in 11 acquired aortic valve malformation were diagnosed. In eight cases atherosclerotic aneurysm was detected while four revealed aneurysm of the sinus of valsalva. In one case isthmus coarctation besides the ascending aneurysm was discovered. In 28 patients dissection of the ascending aorta was found (type II in 15 cases and type I in 13 cases according to De Bakey). Twenty-five patients were in NYHA class IV, 14 in class III and only 1 in class I. Twenty patients had to undergo emergency surgery.

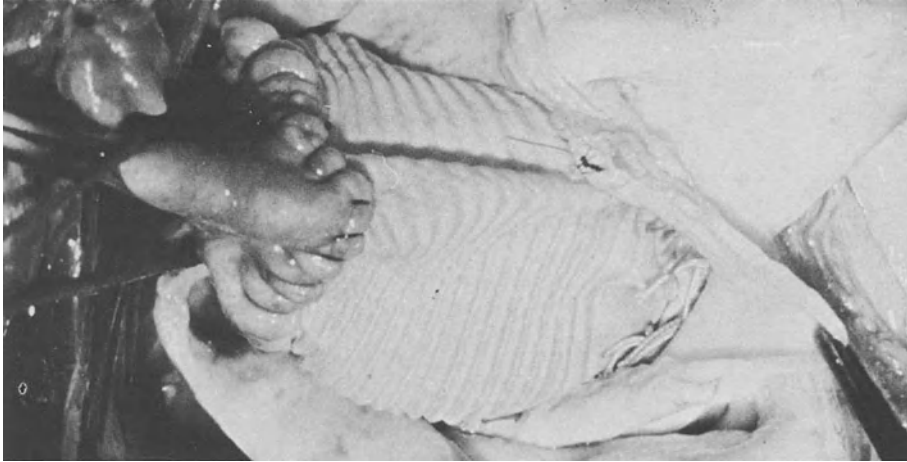
Total cardiopulmonary bypass with general (28°C) and local (11°C) hypothermia was administered in all the cases with iliac artery cannulation. St. Thomas' cardioplegic solution was used. Antibiotic sterilized allogeneous aortic graft was used in 28 patients for replacement of the ascending aorta aneurysm with reimplantation of coronary arteries (Figs. 1, 2). The valved Björk-Shiley vascular prosthesis (conduit) was used in seven patients (Fig. 3) and the separate Dacron graft in five patients.



**Fig. 1.** Replacement of ascending aorta aneurysm with reimplantation of the coronary arteries



**Fig. 2.** Replacement of ascending aorta aneurysm with reimplantation of the coronary arteries



**Fig. 3.** Valved Björk-Shiley vascular prosthesis

The prosthetic aorta and valved conduit were preclotted by the patients' nonheparinized blood and the suture lines were coated with fibrin glue. After aorta declamping the prosthesis and the suture lines were sufficiently tight with almost no bleeding. The sites, mainly coronary anastomoses, were additionally swabbed with the fibrin glue wherever some bleeding occurred. These "loci minoris resistentiae" should be routinely covered with fibrin glue before aorta declamping and restoration of circulation. We found this approach, besides the meticulous suture technique, very profitable:

### ***Results***

From among 40 patients operated on there were four perioperative deaths, due to left ventricular failure. The remaining 36 patients were examined aortographically and showed normal homograft or prosthetic aorta with proper coronary arteria anastomoses. There was no clinical evidence of any postoperative disturbances due to the tissue glue used.

### ***Discussion***

The main problem of surgical treatment of the ascending aortic aneurysm, which has usually been major bleeding of transprosthetic and transsuture lines, was minimized and almost disappeared on fibrin glue administration.

This can also be achieved with the use of homogeneous ascending aorta for aneurysm replacement [1]. The previous method of graft preclotting with nonheparinized patients' blood is now replaced by swabbing of the graft with tissue glue. Nevertheless, the ascending aorta homograft or valved vascular prosthesis may cause major bleeding at the sites of "end-to-side" or "side-to-side" coronary ostia



anastomoses [6]. The meticulous suture technique and the swabbing of graft prosthesis and suture lines with fibrin glue prevents the bleeding after declamping of the aorta.

### ***References***

1. Dziatkowiak AJ, Pfitzner R, Sadowski J, Tracz WD, Koziorowska B, Marek E (1985) Aortic root replacement using antibiotic sterilized "fresh" homografts-modification of annulus enforcement. Proceedings of the International Symposium on Cardiac Bioprostheses, 21–23 May 1985, London
2. Kalmar P, Krebber HJ, Pokar H, Tilsner V (1982) Bioadhesives in cardiac and vascular surgery. *Thorac cardiovasc Surg* 30, 230–231
3. Köveker G, Vivie ER, Hellberg KD (1981) Clinical Experience with fibrin glue in cardiac surgery. *Thorac cardiovasc Surg* 29, 287–289
4. Köveker G (1982) Clinical application of fibrin glue in cardiovascular surgery, *Thorac cardiovasc Surg* 30, 228–229
5. Walterbusch G, Haverich A, Borst HG (1982) Clinical experience with fibrin glue for local bleeding. Control and Sealing of Vascular Prostheses. *Thorac cardiovasc Surg* 30, 234–235
6. Wolner E (1982) Fibrin gluing in cardiovascular surgery. *Thorac cardiovasc Surg* 30, 236–237

# Experience with Fibrin Glue in Vascular Surgery

W. SIMMA and H. HESSE

*Key words:* Arterial occlusive disease, revascularization, Dacron prostheses, preclotting with fibrin glue

## ***Abstract***

Stimulated by the experience especially of traumatological and cardiac surgeons with fibrin glue (Immuno, Vienna) this substance has been tested and used for preclotting of bifurcation prostheses.

In 211 cases operated on for artery sclerotic disease of the aorta, the iliac arteries and the peripheral vessels, preclotting of the Dacron prostheses was done with fibrin glue.

With no additional loss of time an absolutely bloodtight prosthesis can be achieved. The considerable advantages of this method are: A marked reduction of blood loss, the possibility of full heparinization of the patient from the very beginning of the operation onwards and above all the fact that in the case of a ruptured aortic aneurysm the prosthesis is immediately sealed tightly.

Up to now our experience has shown excellent healing of prostheses so treated and absolute reliability as regards stability and tightness of the graft.

## ***Introduction***

The development of a tissue glue ready for use and therefore easily applicable (Immuno, Vienna) initiated its widespread use in all surgical specialities. Not only the traumatologists but very quickly the cardiac and vascular surgeons also began to appreciate the value of the substance [2–6].

Fibrin glue proved to be an ideal product for sealing knitted Dacron-Velour prostheses, the method practised in our department for the past 4 years with few exceptions [4].

## ***Material and Methods***

Within a 4½-year period (1. Febr. 1981–31. July 1985) 790 vascular reconstructive procedures were performed at the surgical department of the General Hospital Vöcklabruck. In 211 cases fibrin-sealed Dacron prostheses were implanted. This group includes six aortic arch reconstructions:

Aortic arch syndrome	6
Transsternal	3
Extrathoracic	3
Carotidosubclavian bypass	7

Three patients were operated on by a transsternal approach, the proximal anastomoses being made onto the ascending aorta; three patients underwent an extrathoracic reconstruction.

In seven patients subclavian-carotid-bypass procedures were carried out, in one case bilaterally.

The indications and the choice of the recipient vessels are as follows:

Abdominal aortic aneurysm	35
Iliac artery stenoses or occlusion	89
Distal anastomoses	
External iliac artery	18
Common femoral artery	19
Profundal femoral artery	87
Additional procedures	
Renal artery reconstruction	7
Superficial femoral artery reconstruction	8

Eighty-nine patients were operated on for iliac artery stenoses or occlusions, 35 for abdominal aortic aneurysms. Seven patients underwent an additional renal artery reconstruction. The distal anastomoses were performed onto the external iliac artery in 18 patients, 19 times onto the common femoral artery, and in 87 patients on to the profundal artery. In most cases unilateral or bilateral profundaplasties were additionally performed. In eight patients a reconstruction of the superficial femoral artery was necessary in the same session.

Twice a unilateral aortofemoral bypass was performed transperitoneally; in 15 patients an axillobifemoral, in two an axillounilateral, and in 9 a femorofemoral crossover bypass was performed. Four times an iliacofemoral bypass was carried out. Nine patients underwent a femoral-popliteal reconstruction, the distal anastomoses beyond the knee joint. In 36 cases iliac or femoral-crural grafts were implanted in an extraanatomical position. With one exception the distal anastomoses were performed onto the anterior tibial artery:

Aortofemoral	2
Axillobifemoral	15
Axillounilateral	2
Femoro femoral crossover	9
Iliacofemoral	4
Femoropopliteal	9
Iliacofemoral-crural	36

## **Results**

All the prostheses were completely bloodtight within 3 min after application of the fibrin glue. When any bleeding occurred – always at the site of the stitch holes – it

stopped spontaneously or after application of a small amount of fibrin glue. In three patients an intraoperative thrombosis of one limb of the bifurcation prosthesis occurred which had to be thrombectomized. In the postoperative phase no prosthesis bleeding occurred. In all but two patients an uneventful postoperative course could be observed. Of these two patients, in the first an EXS prosthesis and in the second the right limb of a bifurcation prosthesis had to be removed because of graft infection. The latter patient was lost due to an aortoduodenal fistula. In several patients 3–6 months postoperatively liver function tests were performed with negative results. Clinically no patient presented with symptoms of hepatitis.

### ***Discussion***

As one can see from our patient material fibrin glue was mainly used to seal bifurcation prostheses [4]. Here in particular the advantages of preclotting a Dacron prosthesis with fibrin glue are evident [1]. This technique reduces blood loss significantly; secondly, full heparinization of the patient is possible from the very beginning of the vascular procedure, avoiding intraluminal thrombosis, which can provoke peripheral embolism. Thirdly, as well as an enormous time saving – the whole procedure takes 5 min – the formation of extraluminal hematomas, a potential source of infection, can be minimized.

The main indication for sealing a prosthesis with fibrin glue is given in the case of a ruptured aortic abdominal aneurysm. In a situation like this the conventional preclotting procedures often fail due to blood coagulation disturbances from massive blood transfusions.

Equally problematical is the so-called defibrinating syndrome, where sudden prosthesis bleeding occurs after ideal primary preclotting. This situation can easily be controlled by the application of fibrin glue.

A final comment concerning the cost: The various primary bloodtight prostheses which are available (Goretex, Hemoshield) cost nearly double the price of the common Dacron-Velour grafts, even when one adds the cost of fibrin glue.

The simple and quick technique of sealing a prosthesis with fibrin glue and even more important the intra- and postoperatively uneventful course in almost all our patients as far as the grafts were concerned mean this technique of preclotting the prostheses with fibrin glue has become our standard method.

### ***References***

1. Hagmüller GW, Naskef BE, Müller HM, Denck H (1984) Zur Abdichtung von gestrickten Gefäßprothesen: Alternativverfahren zum herkömmlichen Preclotting. *Angio Archiv* Bd 6, 167–171
2. Haverich A, Borst HG (1981) Die Anwendung des Fibrinklebers in der Herz- und Gefäßchirurgie. In: "Mikrozirkulation und Prostaglandinstoffwechsel. Neues über Fibrinogen, Fibrin und Fibrinkleber". G Blümer u. S Haas (Hrsg), FK Schattauer. Verlag Stuttgart New York, 291–298
3. Rupp G, Haas S, Stemberger A, Blümel G (1979) Klinische Erfahrungen mit Kleben von Sehnenrupturen. *Langenbecks Arch Chir* 349, 351–353

4. Simma W, Hesse H, Krenmayr E, Finsterbusch W, Grasl G, Rupp G (1982) Zur Technik der Abdichtung von Bifurkationsprothesen mit Fibrinkleber. *Angio Archiv* Bd 3, 38–40
5. Spängler HP (1976) Gewebeklebung und lokale Blutstillung mit Fibrinogen, Thrombin und Blutgerinnungsfaktor XIII. *Wt Klin Wschr* 88, Supp. 49, 1–18
6. Tilsner V, Kalmar P, Pokar H (1980) Anwendung des Fibrinklebers zur Verhinderung von Blutungskomplikationen nach Operationen thorakaler Aneurysmen. In: "Fibrinogen, Fibrin und Fibrinkleber", 259–261, 23. Tagung Dtsch Arbeitsgem Blutgerinnung. K Schimpf (Hrsg) FK Schattauer Verlag Stuttgart New York

# Simulation of Wound Healing in Cell Cultures Given that Fibrin Sealant Is Present

R. P. FRANKE, U. DAUER, W. MÜLLNERS, R. FUHRMANN, and C. MITTERMAYER

*Key words:* Wound healing, fibrin sealant, co-cultures, human endothelial cells (HEC), fibrocytes/fibroblasts, cell proliferation

## ***Abstract***

In vivo fibrinogen, fibrin and the degradation products may play an important role for example in peritonitis and in ARDS. Formation of edema and of fibrosis might be due to the effects of these substances. In co-cultures of human endothelial cells and fibrocytes/fibroblasts we want to elucidate the role of fibrinogen, fibrin and the degradation products under wound healing conditions. It turns out that these substances may influence proliferation of cells in co-culture adversely in a dose-dependent manner.

## ***Introduction***

Pflüger and Redl [1] show the advantages and problems with the application of fibrin sealants in surgery. A serious problem might be the stimulation of fibrocytes/fibroblasts (F) with fibrin or fibrin degradation products (FDP) and, consequently, fibrosis. This process may be dependent on the total amount or the concentration of fibrin deposits, which leads to the question of how much fibrin sealant should be applied under different surgical conditions.

Fibrin and FDP not only influence F, they also stimulate, for example, proliferation of human hemopoietic cells, as was shown by Hatzfeld et al. [2]. In addition to these phenomena there is a general stimulation of fibrinogen biosynthesis through fibrinogen fragments D and E as confirmed by Bell et al. [3] and presumably similar effects through fibrin fragments.

One of our main research topics is the implantation of artificial vessel prostheses, and this implantation comprises a typical wound healing situation with the above phenomena. We wanted to know what consequences this has for endothelial cells under these circumstances.

The implanted artificial vessel becomes part of a pathophysiological organization process which can result in

- rapid sequestration of the prosthesis, sometimes accompanied by highly infectious states necessitating relaparotomy
- scar formation, which might occlude the prosthesis in the course of weeks or years, or
- the scar process comes to a standstill while the artificial vessel is still in function.

Comparing histologies obtained from previously implanted prostheses, one can see that the luminal sides of the vessels are coated by thick fibrin layers which contain many monocytes and F. At the anastomoses of the prostheses we find structure-like circular thickenings of the vessel walls caused by F. There are only a few endothelial cells accidentally contacting the fibrin-coated prostheses.

But we can assume that there are frequent intimal lesions which are covered by thrombocytes and fibrin clots later closing the intimal wound through migration and proliferation of endothelial cells. Cellular activities cannot be examined easily in animal models since there are too many complex reactions overlaying the more basic reactions of a given cell type. This kind of research should be performed with human cell cultures, for example.

There is already some evidence from experiments with cell cultures that shows the effect of fibrin on cultured vascular endothelial cells. Kadish et al. [4] and Busch and Gerdin [5] related disorganization of endothelial cells after application of fibrin deposits. Dang et al. [6] outlined that the D-fragment of fibrinogen causes disorganization of endothelial cells. This type of research can be performed with confluent monocultures in the presence or absence of the substances under consideration. But it is also possible to observe confluent co-cultures of at least two cell types in the presence or absence of the substances mentioned above. This research can be performed in wounded cell layers of the mono- or co-culture type where certain parts of the cell layers have been removed by means of specially cut razor blades. Alongside the wounds caused by the razor blades one can see enhancement of cellular proliferation activities. It is important to note that the experiments should be done with constant levels of plasmin plasminogen [7] and thrombin [8], since these substances seem to interfere with the effects of fibrin.

## ***Material and Methods***

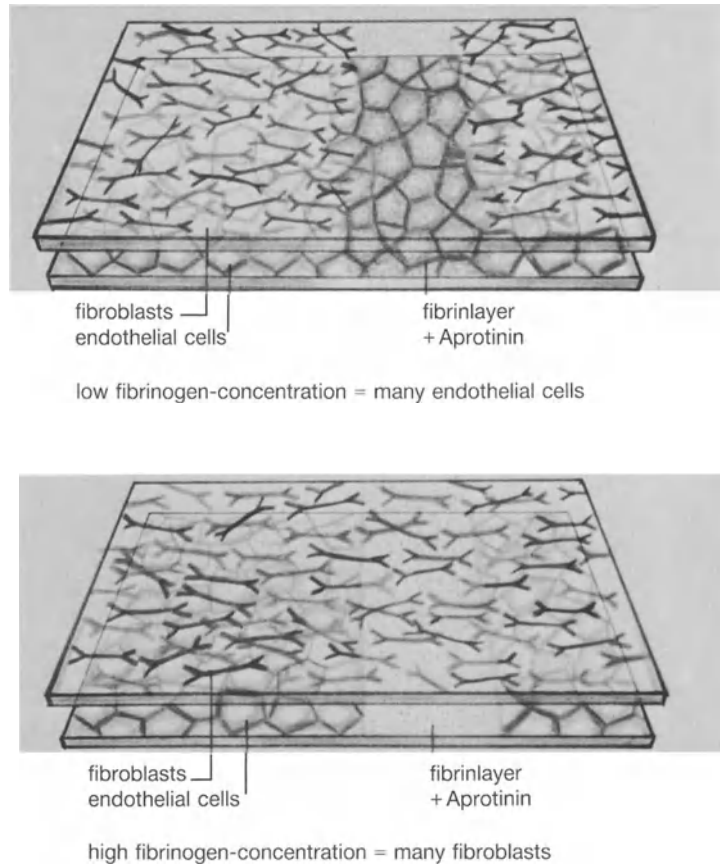
### *Clotting Proteins*

We used fibrin layers which were part of a fibrin sealant system (Tissucol 2 ml, Immuno AG, Heidelberg) according to [1]. The final composition of the fibrin layers differed with regard to fibrin contents since we started the clotting procedures with different fibrinogen concentration: 2 mg/ml; 4 mg/ml; 10 mg/ml.

### *Cell Cultures*

We used human umbilical cord endothelial cells (HUVEC) of the third passage which were cultured in medium TC 199 supplemented with 20% human serum pool and with growth factor (ECGF, 50 ng/ml). Human F-cultures were derived from foreskin preparations (third passage; split ratio 1:3) and cultured in the same medium with another growth factor supplement (FGF, 50 ng/ml).

*Figure 1* shows the experimental concept. Cells are grown on precoated rectangular coverslips to confluency. Then the just confluent cultures are wounded by sterile razor blades in such a way that cell strips 5 mm broad are scraped away by the blade.



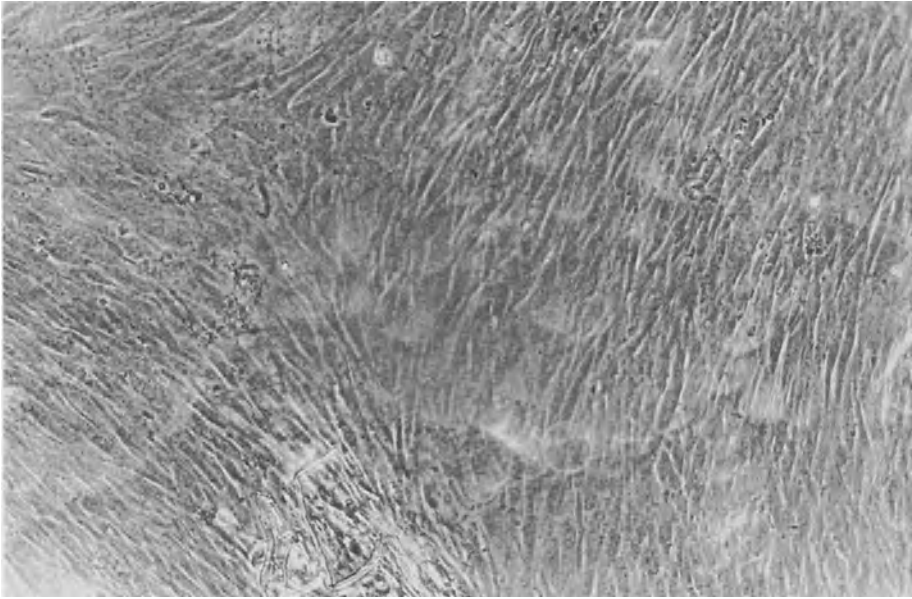
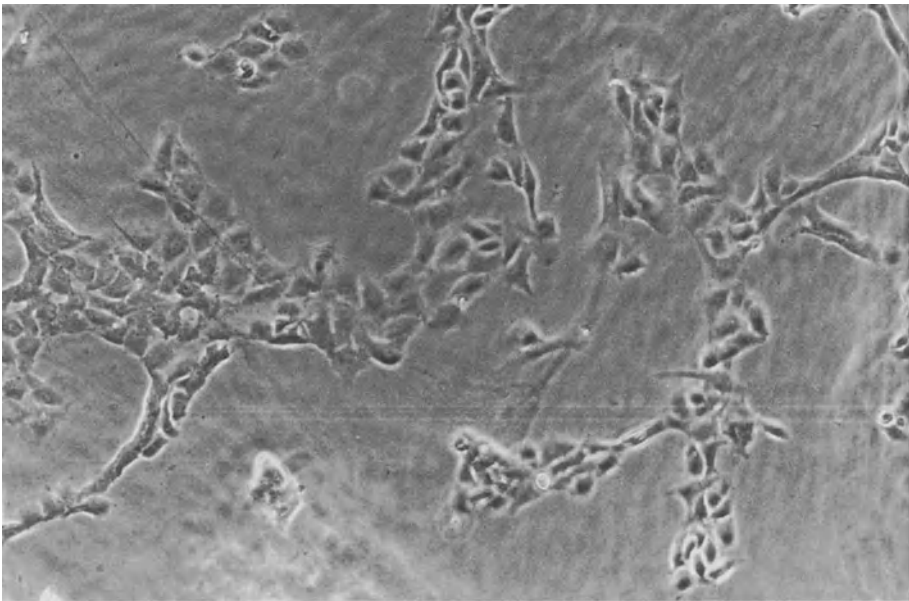
**Fig. 1.** Experimental system of wounded co-cultures with fibrin sealant

Now these uncovered areas are sealed by freshly prepared fibrin sealant as described above. In wounding experiments the HUVEC cultures as well as the F cultures were razor treated whereas only one culture received fibrin sealant. Four minutes after applying fibrin sealant, sandwiches consisting of two different cultures were formed by covering the underlying fibrin-sealed culture with a nonsealed culture in such a way that the cell-covered side of HUVEC culture faced the cell-covered side of F-culture with the cell wounds opposing one another.

### *Light Microscopy*

The cell cultures were fixed 48 h after incubation in 4% formalin for 12 h and then examined in phase contrast microscopy. Three different persons from our lab were asked to count the cells in 40 given sections from each wound region with the help of a  $20\times$  objective.



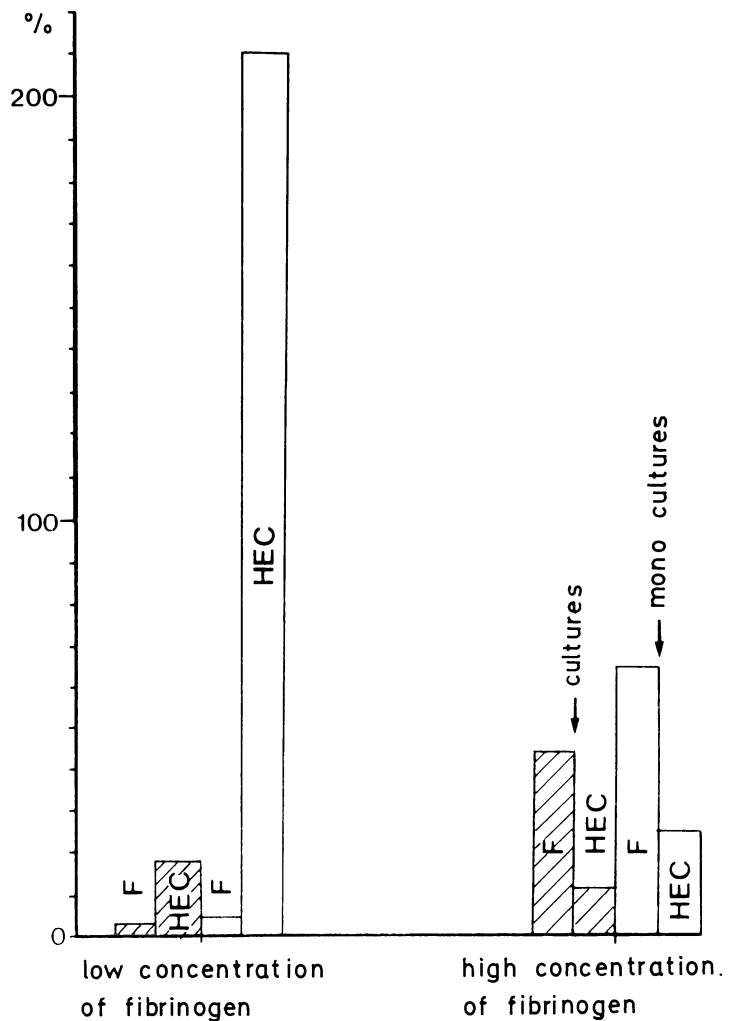
**a****b**

**Fig. 2 a, b.** Wounded section 48 h after application of Tissucol 2 ml/Immuno AG with a fibrinogen concentration of 4 mg/ml and after fixation (12 h) with 4% formalin. *a* With the focus in the F-plane we see densely packed F. *b* With the focus in the HUVEC plane we see less but moderately dense HUVEC. Unstained phase contrast microscopy. x 240

Each type of experiment was carried out three times. For control we used confluent monocultures of HUVEC and F which were wounded alike and each of which was fibrin sealed. The cells of these cultures were detached after 48h by a mixture of EDTA-Trypsin and then counted in a Coulter Counter. All preparations were made under laminar flow conditions.

### Results

As shown in greater detail in [9], Figure 2 shows a typical result of an experiment with a fibrinogen concentration of 4mg/ml. In different focal planes of the same



**Fig. 3.** Results of wounding experiments 48h after application of fibrin sealant with fibrinogen concentrations of 2 mg/ml and 10mg/ml. The results of mono- and co-cultures are shown in percent of controls being wounded cultures after application of fibrin sealant with a fibrinogen concentration of 4 mg/ml.

wound section you find on the one hand the densely packed F (Fig. 2a) and on the other hand a moderately numerous subconfluent layer of HUVEC (Fig. 2b). In Figure 3 the results of experiments of this type are shown together. All results are related to the outcome of medium-concentration experiments (fibrinogen concentration: 4 mg/ml). It is evident that with fibrinogen concentrations as low as 2 mg/ml there is a markedly enhanced proliferation stimulation of HUVEC in comparison to F in monocultures as well as co-cultures. It is, however, important to realize the differences in proliferation stimulation of HUVEC in monocultures as compared to co-cultures. It is interesting, too, that almost no proliferation of F is observed with this fibrinogen concentration.

The outcome of experiments with elevated levels of fibrinogen concentration (10 mg/ml) is quite different. While the general level of proliferation is diminished in all of these experiments, there is only a marginal proliferation of HUVEC whereas proliferation of F takes place at a much higher rate.

### ***Discussion***

There is evidence that in vivo fibrinogen, fibrin and the degradation products may play an important role, for example, in peritonitis and in ARDS. Formation of edema and of fibrosis might be due to the effects of these substances. These reasons make investigations in this field necessary.

Moreover we are interested in reactions of different human cell types on fibrin-coated xenografts. With the reported effect of these materials being adverse, we designed an experimental concept which might help to clarify whether the reported effects really existed or resulted simply from experimental conditions utterly alien to the in vivo situation. Though cells under cell culture condition up to now exhibit slightly altered phenotypes as compared to cells in vivo, we feel that our experimental system shows some similarity to a typical wound healing situation. Under these circumstances we think it important that we could show dose-dependent adverse effects of fibrin on HUVEC and on F. These effects might carry interesting aspects for the application of fibrin sealants since it might enable us, for example, to avoid unwanted fibrosis by effective dose control of fibrin.

With such a complex system, however, it takes some time to perform all the experiments necessary to rule out time and dose dependence and then to raise the degree of complexity, if necessary, by adding blood cells, for example.

### ***References***

1. Pflüger H, Redl H (1982) Abbau von Fibrin-Kleber in vivo und in vitro (Versuche an der Ratte), *Z Urol Nephrol* 75: 25–30
2. Hatzfeld JA, Hatzfeld A, Maigne J (1982) Fibrinogen and its fragment D stimulate proliferation of human hemopoietic cells in vitro. *Proc Natl Acad Sci USA* 79: 6280–6284
3. Bell WR, Kessler CR, Townsend RR (1983) Stimulation of fibrinogen biosynthesis by fibrinogen fragments D and E. *Br J Haematol* 53: 599–610

4. Kadish JL, Butterfield CE, Folkman J (1979) The effect of fibrin on cultured vascular endothelial cells. *Tissue Cell* 11: 99–108
5. Busch C, Gerdin B (1981) Effect of low molecular weight fibrin degradation products on endothelial cells in culture. *Thrombosis Res* 22: 33–39
6. Dang CV, Bell WR, Kaiser D, Wong A (1985) Disorganization of cultured vascular endothelial cell monolayers by fibrinogen fragment D. *Science* 227: 1487–1490
7. Fenselau A, Kaiser D (1978) Plasmin plasminogen inhibition of growth to cultured endothelial cells. *Fed Proc* 37(2): 913
8. Laposata M, Dohnarsky DK, Shin HS (1983) Thrombin-induced gap formation in confluent endothelial cell monolayers in vitro. *Blood* 62: 549–556
9. Franke RP, Dauer U, Müllners W, Fuhrmann R, Mittermayer C (1986) Simulation des Wundverschlusses mit Fibrinkleber in Zellgewebekulturen. In: Reifferscheid M (ed) *Neue Techniken in der operativen Medizin*. Springer, Berlin Heidelberg New York Tokyo

# Subject Index

- Adriamycin 9, 10
- Air leak 63–67
- Angiogenesis 5
- Antibiotics 23, 68–75, 147, 185–190
- Antimycotics 75
- Aortocoronary bypass 183
- Aortofemoral bypass 155–158
- Application 13–25
- Aprotinin 16, 41, 42, 44, 50
- Aortic aneurysm 196–200, 201–204
- Arteriovenous fistulas 196–200
  
- Blood loss 143–147, 164–175, 205
- Bronchal fistula 68–75
- Bronchopleural fistula 121–125, 126–129
  
- Cardiopulmonary bypass 143–147
- Cerclage 52
- Chylothorax 66–67
- Coagulation 3
- Collagen 3, 5, 7, 10
- Collagen fleece 22, 23, 104, 128, 148–151, 153, 181–184, 191
- Congenital heart disease 161, 164–175, 176–180, 191–195
- Conization 52
- Coronary bypass 152–154
- Cross linkage 14, 30
- Cryoprecipitate 28
  
- Dogs 121–125
- Duploject 69, 85, 153, 160, 191, 199
- Duploject System 16, 17
  
- Endoscopy 19, 68–75, 89–93, 95–101, 107–114, 115–120, 121–125, 126–129
- Endothelial cells 209–215
- Esophagus surgery 137–140
  
- Factor XIII 6, 7, 14, 23, 37
- Femoral distal bypass 196–200
- Fibrinolysis 16, 42
  
- Fibrinotherm 69, 85
- Fibroblasts 4, 5, 6, 7, 32, 33, 36
  
- Grafts (woven vs. knitted) 185–190
- Granulation tissue 6, 7, 8
- Granulocytes 4, 5, 46
- Growth factor 4, 5
  
- Hemostasis 191–195
- Hepatitis 51–59, 179, 183–184
- Heterograft (bovine) 196–200
- Histology 98
- Hydroxyproline 8
  
- Leakage (esophagus) 137
- Lung biopsy 65
- Lung cysts 78–81
- Lung resection 63–67, 102–106
- Lysis 39–50
  
- Macrophages 4, 5, 39, 47
- Malignant pleural effusion 130–136
- Mediastinoscopy 115–120
- Microapplication 16, 17
  
- Patches (sealing of) 159–163
- Pediatric surgery 76–77
- Phagocytosis 15
- Pigs 126–129
- Platelets 3
- Pleurodesis 89–93, 102–106, 107–114, 130–136
- Pneumothorax 65, 89–93, 95–101, 102–106, 107–114, 115–120
- Premixing 17, 19
- Preparation 13
- Prosthesis (preclotting, sealing of) 185–190, 205–206
  
- Oxycellulose 148–151
  
- Radioactive 40–50
- Radioactively labelled fibrinogen 95–101
- Rat 196
- Rethoracotomy rate 164–175

- Sleeve resection 82–87
- Spongiosa (decalcified) 121–125
- Spray 17, 19, 20, 21
- Spray system 69, 89, 96, 121, 147, 155–158, 186
- Sternal closure 70
- Suture lines (sealing of) 185–190, 191–195, 197, 201–204
  
- Tensile strength 14, 15, 30
- Tetralogy of Fallot 164–175
- Thoracic duct 66–67
- Thrombin 6
- Tracheal anastomosis 71, 82–87
- Tracheal resection 82–87
  
- Tracheobronchial surgery 82–87
- Transposition of great arteries 164–175, 191–195
- Truncus arteriosus 191–195
  
- Vascular suture lines 143–147, 148–151, 153, 159–163
  
- Wound healing 3–12, 209
- Wound repair 3–12
- Wound secretion 157
  
- X-ray 24